

**Atlas and text-book of topographic and applied anatomy / by Oskar  
Schultze ; edited with additions by George D. Stewart.**

**Contributors**

Schultze, Oskar, 1859-1920.  
Stewart, George D.  
Augustus Long Health Sciences Library

**Publication/Creation**

Philadelphia ; London : W. B. Saunders & Co., [1905], ©1905.

**Persistent URL**

<https://wellcomecollection.org/works/bgbr7p46>

**License and attribution**

This material has been provided by This material has been provided by the Augustus C. Long Health Sciences Library at Columbia University and Columbia University Libraries/Information Services, through the Medical Heritage Library. The original may be consulted at the the Augustus C. Long Health Sciences Library at Columbia University and Columbia University. where the originals may be consulted.

This work has been identified as being free of known restrictions under copyright law, including all related and neighbouring rights and is being made available under the Creative Commons, Public Domain Mark.

You can copy, modify, distribute and perform the work, even for commercial purposes, without asking permission.

**wellcome  
collection**

Wellcome Collection  
183 Euston Road  
London NW1 2BE UK  
T +44 (0)20 7611 8722  
E [library@wellcomecollection.org](mailto:library@wellcomecollection.org)  
<https://wellcomecollection.org>



COLUMBIA LIBRARIES OFFSITE  
HEALTH SCIENCES STANDARD



HX00008729

Atlas & Text=Book  
of Topographic & Applied  
Anatomy

---

Schultze=Stewart



QM 531

Sch 1

Columbia University  
in the City of New York

COLLEGE OF PHYSICIANS  
AND SURGEONS



Reference Library

Given by

Mrs. William Grosvenor.

· ROBERT · GROSVENOR ·


















Digitized by the Internet Archive  
in 2010 with funding from  
Open Knowledge Commons

<http://www.archive.org/details/atlastextbookoft00schu>



ATLAS AND TEXT-BOOK  
OF  
TOPOGRAPHIC AND APPLIED  
ANATOMY

BY  
OSKAR SCHULTZE  
PROFESSOR OF APPLIED ANATOMY IN WÜRZBURG

EDITED, WITH ADDITIONS, BY  
GEORGE D. STEWART, M.D.  
PROFESSOR OF ANATOMY AND CLINICAL SURGERY IN THE UNIVERSITY AND BELLEVUE HOSPITAL  
MEDICAL COLLEGE, NEW YORK

*With 25 Colored Illustrations on 22 Lithographic Plates,  
and 89 Text-cuts, 60 in Colors*

PHILADELPHIA AND LONDON  
W. B. SAUNDERS & COMPANY  
1905

---

Copyright, 1905, by W. B. Saunders & Company.

---

PRESS OF  
W. B. SAUNDERS & COMPANY  
PHILADELPHIA



## EDITOR'S PREFACE.

---

The distinguishing feature of Prof. Oscar Schultze's "Topographic Anatomy" is that it contains the essentials of regional anatomy and omits the exceptional or relatively unimportant details. While it does not claim to contain all the important facts of regional anatomy, it may justly claim that all the facts contained have important medical and surgical bearings. Presenting these in a graceful, forceful, and brief manner, it avoids the tedium of those books which, attempting to include everything, become more cumbrous and even less practical than the larger text-books on systematic anatomy. The editor's task has been to make the text conform to English and American nomenclature and to add occasional notes which are duly bracketed and signed. The translation of the German text has been done with admirable clearness and accuracy by Dr. W. Hersey Thomas.

Having already found favor in Germany, it is hoped and believed that a like reception awaits it in America, and that it will here again realize the author's wish to make a book for those who are or who will be doctors.

*May 15, 1905.*





## PREFACE.

---

This book is not written for the anatomist, but for him who wishes to become a physician. It is the expression of my method of instruction in anatomy which, assisted by renewed clinical studies, I have proved to be most practical for medical students. No claim is made for anatomic completeness, and I am fully aware that many anatomic details that are of importance to the physician have been omitted. As it is my earnest wish to supply the practising physician with a foundation in anatomy without being too prolix, I shall be indebted to my colleagues for any suggestions they may have to offer in this respect; it is the natural wish of every author to have an opportunity of supplying the defects in his work.

To the undergraduate, who holds the first place in my heart, I would say, "Think anatomically if you wish to become a physician." In the first half of your medical studies at the university you learned to know the structure and development of your body. Guided by lower forms of life, you gained a correct conception of your own place in nature. You have been taught to admire the worth of the body which will later be entrusted to your care when it has become diseased. As you go to the bed of suffering every moment will show you the value of your knowledge of anatomy, and you will see that its employment must form the foundation for accurate diagnosis. You should consequently strive to think anatomically if you wish to be a good physician.

To the publishers I express my thanks for their constant aid and assistance. The artist, Mr. Schmitson, has proved his artistic sense in the production of the illustrations. A small number of the pictures has been admirably executed by the artist, Mr. Hajek. I am also indebted to Professor Stöhr, who kindly placed the anatomic collection at my disposal. The greater portion of the dissections from which the illustrations have been made were of my own preparation. The employment of His's models was of the greatest value to me in those instances in which original dissections were wanting.

O. SCHULTZE.





## LIST OF LITHOGRAPHIC PLATES.

PLATE	FACING PAGE
1. The base of the skull seen from within. The various bones are indicated by different colors. Upon the left side the places of exit of the cranial nerves are colored yellow, the places of entrance of the most important arteries red, and the foramina for the chief veins blue. Upon the right side the weak areas at the base are outlined in red.....	22
2. The external muscles, arteries, veins, and nerves of the face.....	26
3. The base of the brain with the twelve cranial nerves and the cerebral arteries.....	36
4. A median sagittal section of the head. Frozen section.....	56
5. A cross-section of the neck at the level of the thyroid cartilage. Frozen section.....	62
6. A posterior view of the opened head, neck, and trunk of a man. The greater portion of the brain has been removed; the spinal cord and spinal nerves as well as the viscera and diaphragm may be seen in situ. From a Leipsic model from nature (His).....	96
7. A posterior view of a dissection of the thoracic, and of a portion of the cervical viscera. The relation of the bronchi, arteries, and veins at the hilus of the lungs. From a Leipsic model from nature (His).....	98
8. <i>a.</i> A dissection of the mediastinum seen from the left; almost the entire left half of the thorax has been removed and the left lung has been cut away at its root. <i>b.</i> The mediastinum seen from the right. Formalin preparations from a child.....	104
9. An anterior view of the heart. The parietal pericardium has been incised and reflected. Formalin preparation.....	106
10. The vessels and nerves of the mediastinum and their relation to the cervical viscera. The first illustration represents the structures as seen from the left, while the second shows them as seen from the right. Formalin preparation.....	112
11. The position of the thoracic and abdominal viscera of a boy. Anterior view. From an accurate Leipsic model made from an original dissection (His).....	120
12. The position of the thoracic and abdominal viscera of a boy. Posterior view. From the model of Plate 11.....	120
13. The position of the thoracic and abdominal viscera of a boy, seen from the left and from the right. From the model of Plate 11.....	122
14. The position of the abdominal viscera of a boy. Anterior view. The lungs, the heart, and the anterior half of the diaphragm have been removed; the small intestine has been cut away at the root of the mesentery. From an accurate Leipsic model made from an original dissection (His).....	128
15. The position of the kidneys, pancreas, spleen, duodenum, and colon as seen after the removal of the liver, stomach, and transverse colon. From the model of Plate 14.....	128
16. The position of the thymus gland, heart, liver, stomach, spleen, and intestines of a fifteen-year-old girl as seen from the left. The left lung has been removed. From a Leipsic model from nature (His).....	130
17. The position of the pylorus, cardia, large intestine and spleen of a fifteen-year-old girl. A deeper layer of the model of Plate 16.....	136
18. The position of the liver (a portion), duodenum, pancreas, left kidney, and cecum of a fifteen-year-old girl. A deeper layer of the model of Plate 16.....	138
19. The male pelvic outlet as seen from without. From a Leipsic model from nature (His) with the vessels and nerves sketched in.....	144
20. The female pelvic outlet as seen from without. From a Leipsic model from nature (His).....	146
21. A median sagittal section of the male pelvic region. From a Leipsic model from nature (His).....	148
22. A median sagittal section of the female pelvic region. From a Leipsic model from nature (His).....	151





## LIST OF FIGURES.

FIG.	PAGE
1. The skull with the three largest sensory nerves of the face and the middle meningeal artery..... <i>facing</i>	18
2. A cross-section of the calvarium .....	18
3. The skull with the closed frontal sinuses exposed by chiselling away the outer table and the diploë .....	19
4. The right frontal sinus opened from in front.....	20
5. The skull of the newborn seen from above and behind.....	21
6. A cross-section of the layers of the scalp and of the cranium.....	25
7. The layers of the scalp, the cranium, and the membranes of the brain..... <i>facing</i>	28
8. The sinuses of the dura mater. The calvarium has been removed with the exception of a central arch of bone so that the processes of the dura mater have been left intact..... <i>facing</i>	28
9. The base of the skull with the cranial nerves, as seen after the removal of the brain. Upon the left side the dura mater has been left in place and the tentorium cerebelli incised so that it is possible to look into the posterior cerebral fossa. Upon the right side the dura has been removed and the places of exit of the nerves are visible at the base of the skull..... <i>facing</i>	32
10. The Gasserian ganglion (ganglion semilunare) which has been exposed in the middle cerebral fossa by the removal of the dura mater..... <i>facing</i>	34
11. A frontal section in the region of the cavernous sinus..... <i>facing</i>	34
12. A frontal section through the posterior portion of the head (frozen section). Anterior view. The section strikes the falx cerebri, the falx cerebelli, and the tentorium cerebelli in such a way that the cranial cavity seems to contain four apparently separate compartments, in which may be seen the two cerebral and the two cerebellar hemispheres .....	36
13. Craniocerebral topography (after Krönlein and Frieriep). Explanation in the text.....	37
14. The relations of the vessels and of the facial nerve within and beneath the parotid gland. The gland has been divided by a vertical incision..... <i>facing</i>	40
15. A frontal section of the bony orbits, of the nasal cavities, and of the maxillary sinuses.....	43
16. A frontal section of the head through the orbital cavities and the maxillary sinuses (frozen section)..... <i>facing</i>	44
17. A horizontal section of the head in the plane of the palpebral fissures (frozen section). The plane of section passes through the orbits in such a way as to show the entire length of the optic nerves as well as a portion of the optic chiasm. The cerebellum lies in the posterior cerebral fossa and is covered by the tentorium cerebelli, which has been left intact. In the incisura tentorii may be seen the cross-sections of the two cerebral peduncles; the entire cerebrum has been removed.....	47
18. A portion of the skull in which the outer wall of the maxillary sinus has been removed in order to show its communication with the nasal cavity and the relations of the dental alveoli to the floor of the sinus. The alveoli have been perforated from below.....	51
19. The lateral wall of the left nasal cavity. Almost the entire middle turbinated bone has been excised in order to expose the structures and orifices situated beneath it. A piece has been removed from the anterior portion of the inferior turbinated bone. The original borders of these turbinated bones are indicated by dotted lines. The superior turbinated bone is intact. The orifices of the left sphenoidal and frontal sinuses are shown by arrows..... <i>facing</i>	52
20. The sublingual region in a dissected median sagittal section. The tongue has been displaced downward after incision of the oral mucous membrane..... <i>facing</i>	52
20 A. View of adult mouth (modified from Spalteholz) .....	55
21. The pharynx, opened longitudinally from behind, with the three anterior communications: with the nasal cavities, with the mouth, and with the larynx .....	58
22. A sagittal section through the mastoid process, the external auditory meatus, and the glenoid fossa..... <i>facing</i>	60



FIG.	PAGE
23. The temporal bone with the exposed tympanum, tympanic antrum, and mastoid cells. The relations of the facial nerve, internal jugular vein, and internal carotid artery to the wall of the tympanum may be seen. The different areas have been colored yellow, blue, and red respectively..... <i>facing</i>	60
24. The anterior cervical region. (The hypoglossal nerve has been displaced slightly downward.)..... <i>facing</i>	64
25. The submaxillary and carotid triangles..... <i>facing</i>	66
26. A median sagittal section of the neck (formalin preparation)..... <i>facing</i>	68
27. The supraclavicular region. The sternocleido-mastoid and the infrahyoid muscles have been removed... <i>facing</i>	70
28. The infraclavicular region..... <i>facing</i>	70
29. The axilla and the lateral thoracic wall..... <i>facing</i>	74
30. A posterior view of the shoulder with the quadrangular and triangular spaces..... <i>facing</i>	76
31. A model of the shoulder-joint and its bursas. The two bursas communicating with the articular cavity as well as the joint itself are colored blue. The non-communicating subdeltoid bursa is represented in red. From a Berlin model..... <i>facing</i>	78
32. A cross-section through the middle of the arm. (Hardened in formalin.)..... <i>facing</i>	78
33. The region of the elbow. (The musculospiral nerve has been drawn up from the depths and made to assume a more superficial position.)..... <i>facing</i>	80
34. A longitudinal section through the region of the elbow and the humero-ulnar articulation (frozen section)..... <i>facing</i>	82
35. The anterior aspect of the forearm above the wrist. The ulnar artery and nerve have been made visible by displacing the tendon of the flexor carpi ulnaris..... <i>facing</i>	84
36. A cross-section through the middle of the forearm..... <i>facing</i>	84
37. The muscles, nerves, vessels, and tendon-sheaths of the palm of the hand. The tendon-sheaths are colored blue. The carpal canal has been opened by dividing the anterior annular ligament..... <i>facing</i>	86
38. Diagrammatic representation of the joints of the hand.....	86
39. Cervical ribs. The seventh cervical vertebra (indicated by the figure 7) articulates with a small cervical rib upon the left, and with a complete cervical rib upon the right which reaches to the sternum. The figures 1 and 2 indicate the first two thoracic vertebrae.....	91
40. A thorax deformed by lacing (after Merkel).....	92
41. A sternum with a foramen in the lower portion of the body of the bone.....	93
42. The anterior thoracic wall seen from within. The pleura has been removed..... <i>facing</i>	94
43. The right intercostal region. In the upper of the three intercostal spaces represented the pleura is still intact; in the second it has been removed; in the third, the internal intercostal muscle as well as the pleura has been taken away..... <i>facing</i>	94
44. The diaphragm and the inferior half of the pericardium seen from above. Formalin preparation (child).....	98
45. A diagrammatic representation of the projections of the heart, of the pleural limits, and of the lungs upon the anterior thoracic wall. The lung is indicated by yellow, and the pleura by red, lines. The lungs are represented in a state of moderate distention so that their borders correspond to a position midway between deepest expiration and deepest inspiration..... <i>facing</i>	100
46. A diagrammatic representation of the projections of the pleural limits, of the lungs, and of the bifurcation of the trachea upon the posterior thoracic wall. The lung is indicated by yellow and the pleura by red, lines..... <i>facing</i>	100
47. The median surface of the right lung. } From plaster casts (His)..... <i>facing</i>	102
48. The median surface of the left lung. }	
49. A view of the dorsal surface of a frontal section of the thorax.....	105
50. A cross-section of the thorax at the level of the nipples. (The right lung is somewhat enlarged at the expense of the left one).....	107
51. The dorsal half of a frontal section of the pericardium with the large vessels. An opening has been made in the posterior wall of the pericardium so that the esophagus is exposed. Formalin preparation.....	109
52. The anterior thoracic wall with the pericardium and the diaphragm seen from within. The dashed and dotted lines represent the anterior pleural limits; between them, at the level of the fifth left costal cartilage, is the site for aspiration of the pericardial cavity (formalin preparation).....	110
53. A cross-section of the thorax at the level of the tracheal bifurcation (frozen section). The left lung was diseased at its apex and diminished in size as a whole; the right lung was correspondingly enlarged.....	111
54. The pharynx, esophagus, trachea, and aorta seen from behind..... <i>facing</i>	114



## LIST OF FIGURES.

13

FIG.	PAGE
55. A diagrammatic representation of the communications between the superior and inferior vena cavæ and the portal vein..... <i>facing</i>	122
56. The inferior half of the anterior abdominal wall as seen from within. The pelvis is shown in frontal section. The greater portion of the peritoneum has been left intact, but portions of it have been removed upon the right from the internal abdominal ring, upon the left from the epigastric vessels, the lateral umbilical ligament, and the vas deferens, and in the middle line from the median line from the median umbilical ligament..... <i>facing</i>	124
57. In the left iliac fossa the layers of the abdominal wall are shown, the dissection exposing the sigmoid colon. The recti muscles are divided and the urinary bladder has been made visible above the symphysis without injuring the peritoneum. Upon the right side there is an internal inguinal hernia..... <i>facing</i>	124
58. The inferior half of the anterior abdominal wall with the hernial regions as seen from within and above. At the site of the femoral ring is the sac of a femoral hernia. The internal inguinal fossa is limited internally by a sharply bordered fold ( <i>falx inguinalis</i> ), which belongs to the transversalis abdominis muscle. (Frozen formalin preparation.).....	124
59. First diagram for the representation of the peritoneum. The bursa omentalis is outlined in red, the remaining portion of the peritoneal cavity in blue..... <i>facing</i>	126
60. Second diagram for the representation of the peritoneum. As in Fig. 59, the bursa omentalis is outlined in red..... <i>facing</i>	126
61. The porta hepatis, the pancreas, the duodenum, the kidneys, the spleen, and the suprarenal bodies with their vessels. (Formalin preparation.)..... <i>facing</i>	132
62. A cross-section of the trunk at the level of the xiphoid process of the sternum.....	132
63. The liver, seen from below..... <i>facing</i>	134
64. The position of the structures at the porta hepatis..... <i>facing</i>	134
65. The left kidney seen from in front..... <i>facing</i>	140
66. The right kidney seen from in front..... <i>facing</i>	140
67. Anterior view of the relations of the right kidney..... <i>facing</i>	140
68. Anterior view of the relations of the left kidney..... <i>facing</i>	140
69. A cross-section of the abdomen in the inferior renal region.....	141
70. A sagittal section of the female pelvis with the anteroposterior pelvic diameters.....	144
71. The bladder, the ureters, and the seminal vesicles exposed from behind by a frontal section of the pelvis. Upon the left side there is an external inguinal hernia. Upon the right side the peritoneum has been almost entirely removed..... <i>facing</i>	148
72. The relation of the ureter to the uterine artery and to the cervix and vagina. The left half of a specimen in which a median section of the female pelvic viscera has been made. The broad and round ligaments have been incised and the uterus displaced upward and backward..... <i>facing</i>	153
73. The lateral pelvic wall of the female. The posterior layer of the broad ligament has been incised at the side of the recto-uterine pouch. The uterus, with the tube and ovary has been displaced anteriorly and the rectum has been pushed posteriorly..... <i>facing</i>	153
74. A diagrammatic representation of an anterior view of the hip-joint. The attachment of the capsular ligament corresponds to the linea intertrochanterica (red). The weaker portions of the capsule are colored yellow. A detailed description will be found in the text..... <i>facing</i>	155
75. A diagrammatic representation of a posterior view of the hip-joint. The attachment of the capsular ligament (red line) is situated above the intertrochanteric crest. The weak areas in the posterior portion of the capsule are colored yellow..... <i>facing</i>	155
76. A diagrammatic representation of the lacuna musculorum, of the lacuna vasorum, and of the femoral ring..... <i>facing</i>	155
77. The subinguinal region with the vessels and lymphatic glands lying upon the deep fascia..... <i>facing</i>	157
78. The topography of the deep gluteal region..... <i>facing</i>	157
79. The anterior femoral region..... <i>facing</i>	159
80. The exposure of the femoral artery before its entrance into Hunter's canal..... <i>facing</i>	159
81. The subperitoneal exposure of the external iliac artery. Below Poupart's ligament the femoral vessels have also been exposed..... <i>facing</i>	159
82. A cross-section above the middle of the thigh..... <i>facing</i>	161
83. The popliteal space..... <i>facing</i>	163



## LIST OF FIGURES.

FIG.	PAGE
84. The knee-joint after the injection of a blue mass into the articular cavity; the bursas communicating with the joint are also filled with the blue injection. The non-communicating bursas have been injected with a red mass. From a Berlin model.....	<i>facing</i> 163
85. The nerves and vessels upon the anterior aspect of the leg and foot .....	<i>facing</i> 165
86. A cross-section through the upper half of the leg.....	<i>facing</i> 165
87. The plantar aspect of the foot. The flexor brevis digitorum muscle has been divided and portions have been cut out of the flexor longus digitorum, adductor hallucis, and flexor brevis hallucis muscles.....	<i>facing</i> 167
88. A frontal section of the talocrural and talocalcaneal articulations.....	<i>facing</i> 169
89. A diagrammatic representation of the joints of the foot.....	<i>facing</i> 169



## CONTENTS.

	PAGE		PAGE
THE HEAD.....	17	The Contents of the Thorax.....	99
The Cranial Region.....	17	The Mediastinum.....	104
The Cranium.....	17	Review Questions.....	117
The Scalp.....	24	THE ABDOMEN.....	118
The Membranes of the Brain.....	28	The Abdominal Wall.....	118
Craniocerebral Topography.....	35	The Peritoneum.....	125
Questions.....	38	The Contents of the Abdomen.....	128
The Facial Region.....	39	Review Questions.....	142
The Face.....	39	THE PELVIS.....	143
The Orbital Cavity.....	42	The Pelvic Walls.....	143
The Nasal Cavity.....	48	The Pelvic Cavity in the Male.....	147
The Oral Cavity.....	54	The Pelvic Cavity in the Female.....	150
The Organ of Hearing.....	59	Review Questions.....	154
Questions.....	60	THE LOWER EXTREMITY.....	155
The Neck.....	61	The Region of the Hip.....	155
THE UPPER EXTREMITY.....	72	The Thigh.....	159
The Shoulder.....	72	The Region of the Knee.....	162
The Upper Arm.....	77	The Leg.....	165
The Region of the Elbow.....	79	The Foot.....	168
The Forearm.....	81	Review Questions.....	171
The Hand.....	84	INDEX.....	173
Questions.....	88		
THE THORAX.....	89		
The Thoracic Wall.....	89		





# TOPOGRAPHIC AND APPLIED ANATOMY.

## THE HEAD.

The study of the practical anatomy of the head has for its essential foundation a knowledge of the bones of the skull (Fig. 1). The cranium, surrounding the brain like a capsule, is distinguished from the face, which holds relation to the beginnings of the intestinal and respiratory tracts and to important sense-organs, particularly to the organ of vision. The external boundaries between the cranium and the face are formed by the superior margin of the orbit, the zygoma, and the external auditory meatus. In conformity with these divisions of the skull, the head is subdivided into a cranial region and a facial region.

### THE CRANIAL REGION.

#### THE CRANIUM.

The cranium is formed by the following bones:

- (a) Four single bones: (1) The occipital, (2) the sphenoid, (3) the ethmoid, (4) the frontal.
- (b) Two paired bones: (1) The parietal, (2) the temporal.

Portions of some of these bones are also found in the facial group, the greater portion of the ethmoid, for example. The relations of these bones become clearer if we remember that the broad sagittal ring formed by the single bones is open above and is converted into a closed chamber by the broad frontal ring of the paired bones, which is open below. The superior or arched portion of the cranium is known as the *vertex* or *vault*, while the inferior or flatter portion is called the *base* of the skull. The plane of the base of the skull dips posteriorly and forms the chord, so to speak, of the large arc of the cranial vault.

The *thickness of the cranium* is of great importance, particularly with reference to the prognosis of injuries. It varies with age, with the individual, and above all with location. Between the extremes of the so-called paper-skulls, scarcely two millimeters thick, and those skulls which are called hypertrophic, measuring one centimeter or even more in thickness, there are many intermediate degrees. The average thickness of the cranial vault is five millimeters. Disregarding the thin portions of the base (see page 22), a knowledge of which is particularly important for the understanding of fractures in this situation, local thinnings of the skull are produced:



FIG. 1.—The skull with the three largest sensory nerves of the face and the middle meningeal artery.

(1) By abnormally developed Pacchionian depressions, situated chiefly near the median line of the cranial vault and due to marked proliferation of the villi of the arachnoid, that is, the Pacchionian bodies (see page 33). These proliferations may lead to perforation of the bones, even appearing beneath the scalp as small tumors which are reducible upon pressure; or, in rare instances, they may cause the bone to bulge, producing palpable, immovable, and hard bony enlargements (in contradistinction to sebaceous cysts of the scalp which originate in the sebaceous glands and are movable upon the underlying bone). (2) By the middle meningeal artery (see page 29), which is deeply imbedded on the inner surface of the cranial wall, sometimes, however, reaching almost to the outer surface of the cranial vault or even perforating the external table and producing marked external hemorrhage when injured. (3) Rarely by varicose dilations of the diploic veins (see below), which lead to atrophy of the bone, and also by the sphenoparietal sinus (see page 32), which may be deeply imbedded in the cranial vault somewhat posterior to the coronal suture. (4) By increasing age, which makes the skull considerably

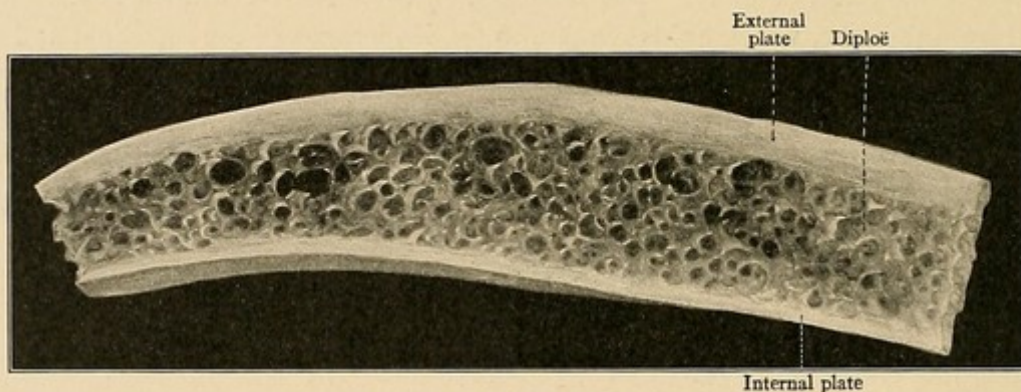


FIG. 2.—A cross-section of the calvarium.

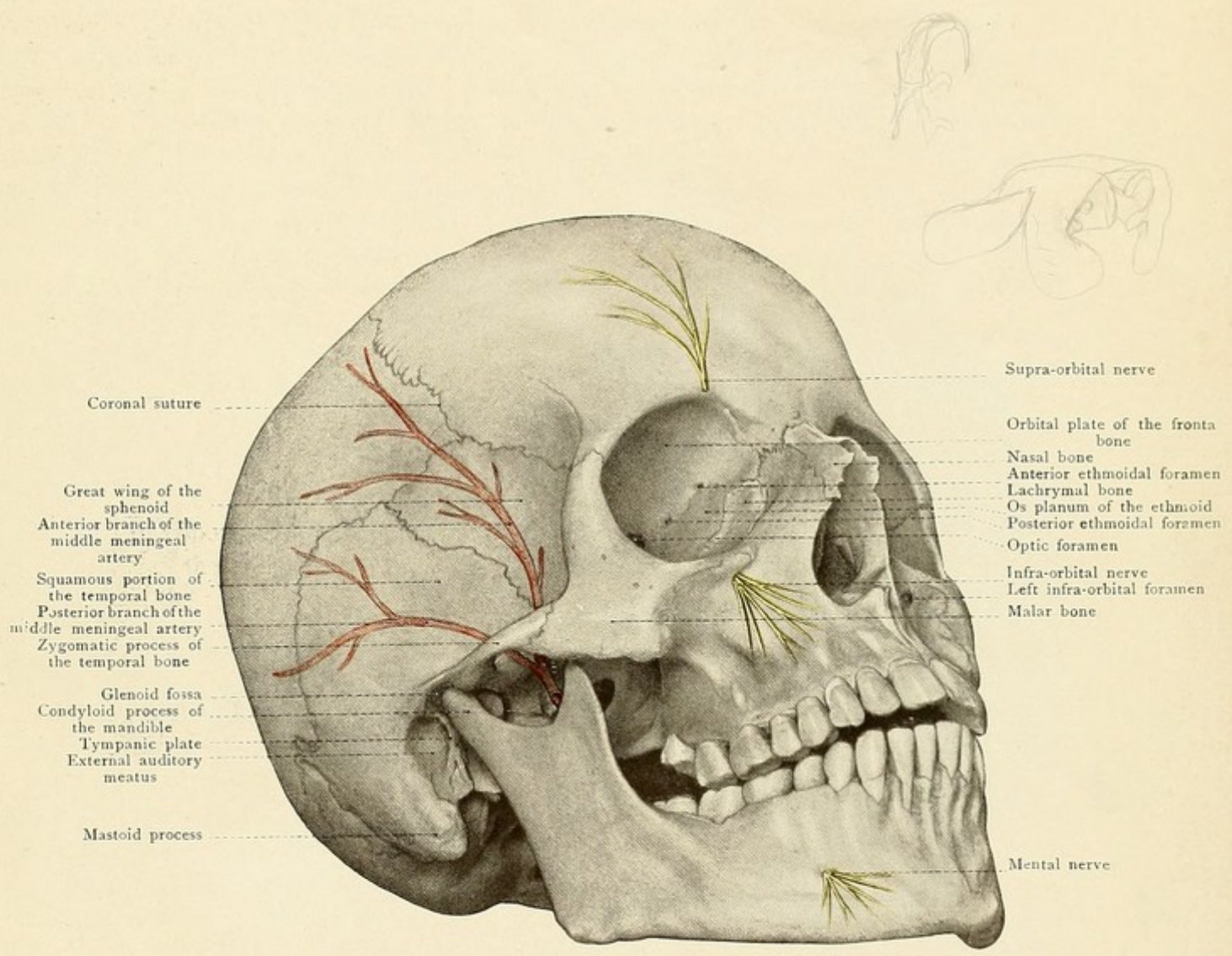
thinner, lighter, and more fragile, so that places which were previously thin (*e. g.*, the orbital plate of the frontal, the lachrymal, the os planum of the ethmoid, the posterior cranial fossa, the inner wall of the maxillary sinus) are converted into foramina by absorption.

The sawed cross-section of the vertex reveals two compact layers of bone which enclose a stratum of spongy tissue. The *external plate*—averaging 1.5 mm. in thickness—as well as the *internal plate*—about 0.5 mm. thick—have numerous fine pores for the passage of the periosteal vessels. There is no sharp line of division between either table and the enclosed diploë, which is filled with red bone-marrow. Fractures of the inner table, such as the so-called stellate fractures, or splinterings of the inner table without concomitant injury of the outer table are not due to a greater brittleness of the inner table, but to its thinness and to its shorter radius of curvature.

The *venous blood* of the bone collects in the *diploic veins* which are situated in canals in the diploë. The diploic veins are divided into the frontal, anterior temporal, posterior temporal, and occipital. They are subject to considerable variation, and hemorrhage from them after injury



Fig. 1.



Coronal suture

Great wing of the sphenoid  
Anterior branch of the middle meningeal artery

Squamous portion of the temporal bone  
Posterior branch of the middle meningeal artery  
Zygomatic process of the temporal bone

Glenoid fossa  
Condylod process of the mandible  
Tympanic plate  
External auditory meatus

Mastoid process

Supra-orbital nerve

Orbital plate of the frontal bone  
Nasal bone  
Anterior ethmoidal foramen  
Lachrymal bone  
Os planum of the ethmoid  
Posterior ethmoidal foramen  
Optic foramen

Infra-orbital nerve  
Left infra-orbital foramen  
Malar bone

Mental nerve





is not of great importance. In opening the skull with the chisel or in trephining no attempt is made to avoid them.

At the thin places in the cranium, such as the squamous portion of the temporal bone, the bottom of the posterior cranial fossa, etc., the diploë is absent and the two tables are in contact with each other. The diploë may also undergo more or less atrophy in the aged.

In the frontal bone the two tables become widely separated on either side of the glabella enclosing the *frontal sinuses*, which, next to the maxillary sinuses, are the largest of the accessory air-cavities in communication with the nose (see Fig. 3). Between the inner table and the anterior wall of the frontal sinus there is still a thin layer of diploic tissue, while the inner (posterior) wall of the frontal sinus is formed by the inner table. The frontal sinuses are paired cavities and are separated by a bony septum which is not often situated exactly in the median line. Incomplete septa projecting inward very frequently make these sinuses multilocular, in which case they may attain an enormous size. The sinus opens into the middle nasal fossa (see Fig. 19), but the orifice can rarely be sounded from the anterior nares during life. In the dreaded catarrh of the frontal sinuses with subsequent empyema, it consequently follows that relief must be given by chiseling through the bone above the supraorbital margin, never forgetting that the anterior wall of the sinus is much thicker than the posterior one (see Fig. 4). After this has been done, an attempt may be made to re-establish the normal communication with the nasal cavity from above. The opening of the frontal sinus from without may lead to a subcutaneous emphysema of the frontal region, since the air from the nasal chambers gains access to the subcutaneous tissues of the forehead. Large frontal sinuses frequently extend posteriorly into the roof of the orbit. The severe pain attendant upon catarrhal inflammation of the frontal sinus is explained by the rich supply of the lining mucous membrane from the nasal nerve.

The *fontanelles* are membranous portions of the vertex of the fetus and of the newborn at the junction of several bones where ossification takes place at a comparatively late date. We distinguish two single and two paired fontanelles (see Fig. 5).

The single fontanelles are the most important:

1. *The large or frontal fontanelle.*—This is diamond-shaped, and in the new-born is situated

between the still ununited halves of the frontal bone and the two parietal bones. Like the frontal

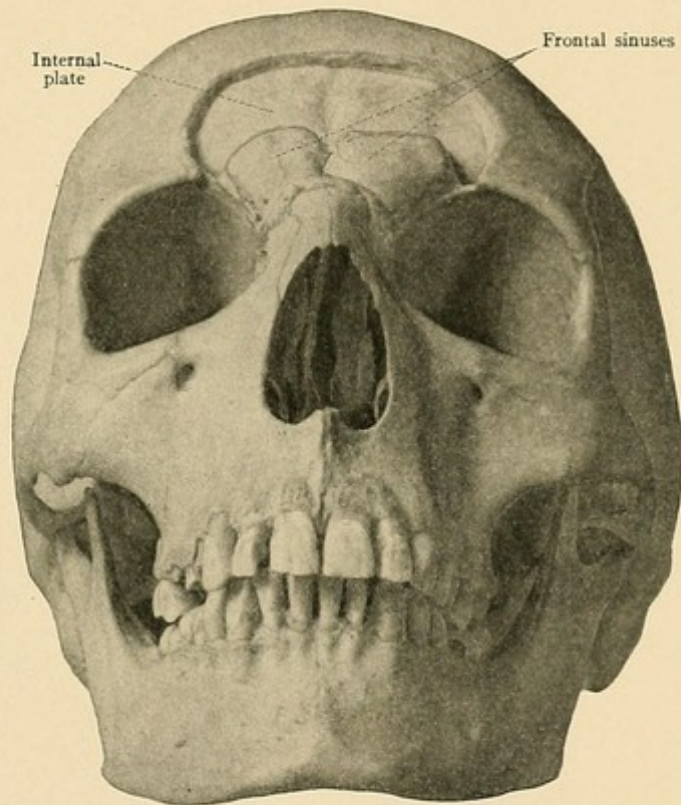


FIG. 3.—The skull with the closed frontal sinuses exposed by chiseling away the outer table and the diploë.



suture, it does not close until the second year, but may remain open for a much longer period. During the birth of the child it is utilized by the obstetrician to determine the position of the head.

2. *The small or occipital fontanelle.*—This has the shape of an obtuse-angled triangle and lies between the highest point of the occipital bone and the two parietal bones. During birth this fontanelle is usually closed, but the physician can nevertheless recognize it by the fact that the compression of the child's skull pushes the occipital bone beneath the edges of the parietal bones.

The paired fontanelles, less important and usually closed at birth, are:

1. The *antero-lateral fontanelle*, between the frontal and parietal bones on the one side and the great wing of the sphenoid and the squamous portion of the temporal on the other.

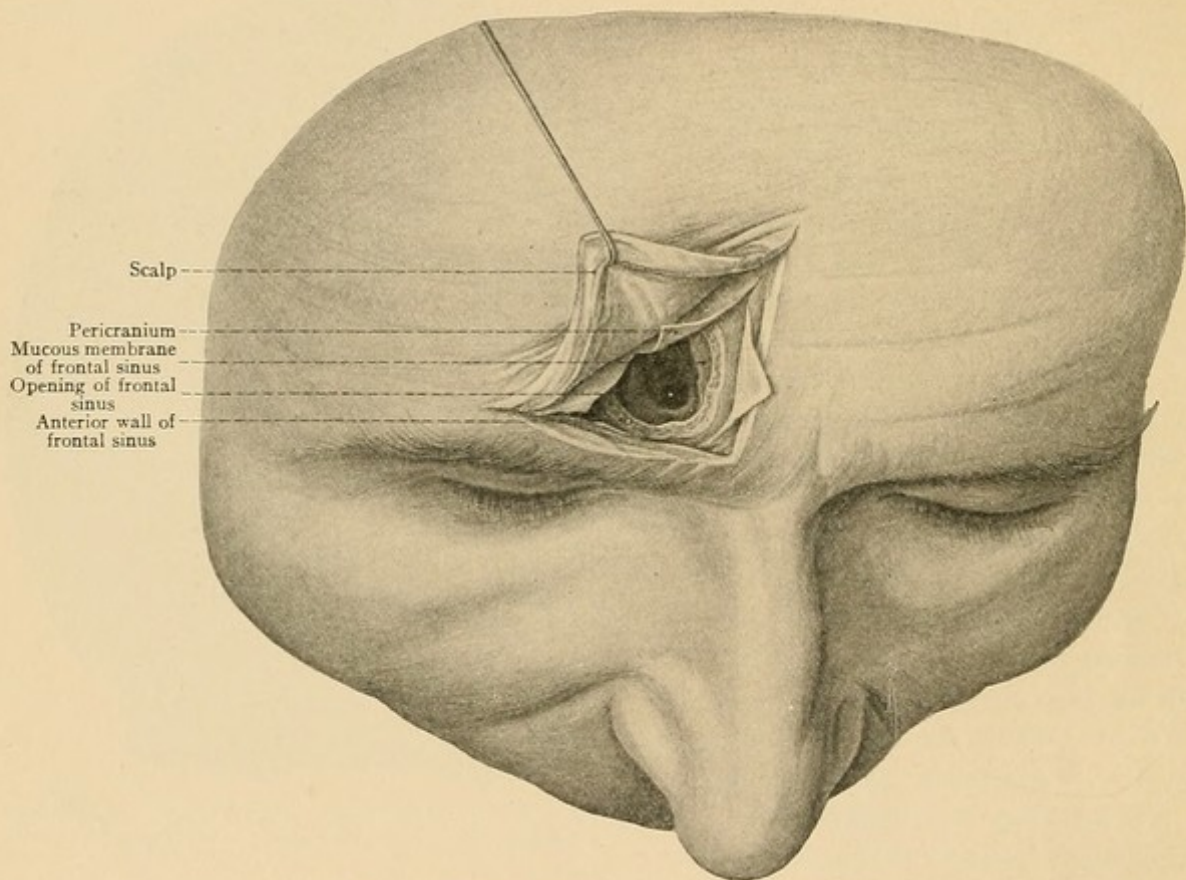


FIG. 4.—The right frontal sinus opened from in front.

2. The *postero-lateral fontanelle*, between the mastoid portion of the temporal, the parietal, and the occipital bones. In the new-born a fissure extends from this fontanelle into the occipital bone, which has been falsely attributed to the effect of traumatism, but which really marks the original boundary between that portion of the occipital bone which is laid down in cartilage and that which is laid down in membrane.

The occurrence of *supernumerary sutures* and *Wormian bones* in the vault of the skull is of considerable importance from a practical, and particularly from a medico-legal, standpoint, since they have been mistaken for fractures. Among these may be mentioned the frequently persistent



frontal suture, the numerous Wormian bones in the lambdoid suture, the so-called fontanelle-bones occurring in the paired and in the single fontanelles, and the interparietal bone, which corresponds to that portion of the occipital bone which is laid down in membrane.

The **base of the skull** is formed by the following bones: The frontal, the ethmoid, the sphenoid, the temporal, and the occipital.

The *points of exit of the twelve cranial nerves* from the base of the skull (indicated in Plate 1 by yellow) are: (1) The cribriform plate of the ethmoid which lodges the olfactory bulb and which gives passage to the olfactory filaments on their way to the nasal fossa. (2) The optic foramen for the optic nerve (and the ophthalmic artery arising from the internal carotid). (3) The sphenoidal fissure for the oculomotor, trochlear, ophthalmic division of the fifth, and the abducent nerves. (4) The foramen rotundum for the superior maxillary division of the fifth nerve. (5) The foramen ovale for the inferior maxillary division of the fifth nerve. (6) The

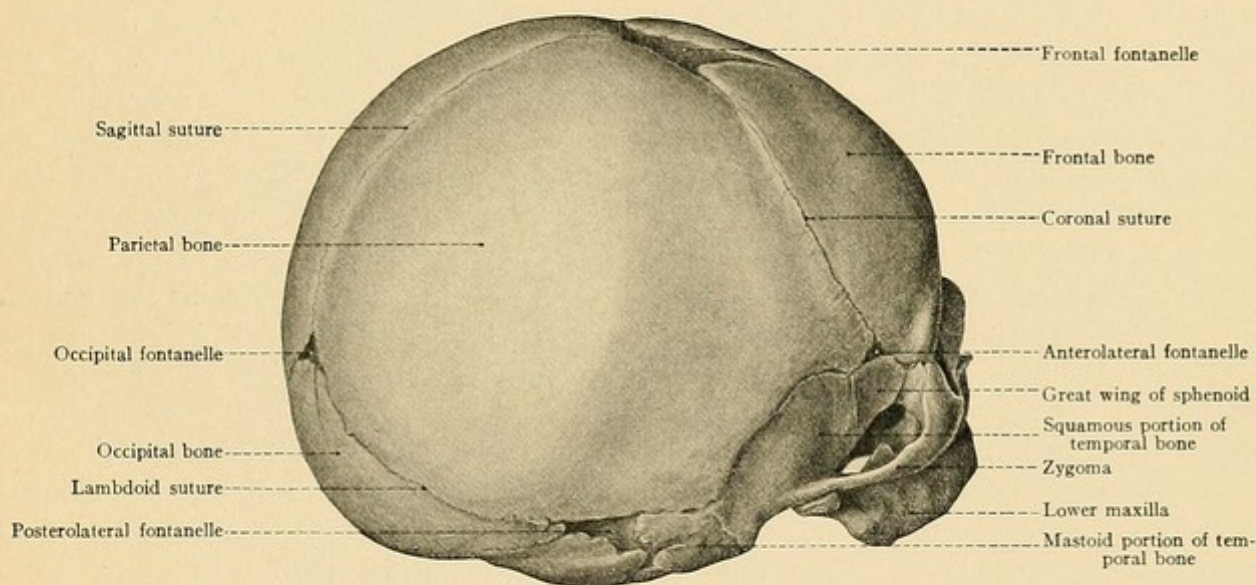


FIG. 5.—The skull of the new-born seen from above and behind.

internal auditory meatus for the facial and auditory nerves. (7) The jugular foramen, anterior portion, for the glossopharyngeal, vagus, and spinal accessory nerves [in the order named from before backward between the inferior petrosal sinus in front and the lateral sinus behind.—ED.]. (8) The anterior condyloid foramen for the hypoglossal nerve.

The *points of entrance of the main arteries* (designated in Plate 1 by red) are: (a) To the brain: The foramen magnum for the two vertebral arteries (11) from the subclavian, and the carotid canal in the petrous portion of the temporal bone for the internal carotid (9). (b) To the dura mater, *i. e.*, to the internal periosteum of the cranial vault and to the vault itself: The foramen spinosum in the great wing of the sphenoid for the middle meningeal branch of the internal maxillary artery (10).

The *venous blood* from the brain is collected in the cerebral sinuses and leaves the cranial



## PLATE 1.

The base of the skull seen from within. The various bones are indicated by different colors. Upon the left side the places of exit of the cranial nerves are colored yellow, the places of entrance of the most important arteries red, and the foramina for the chief veins blue. Upon the right side the weak areas at the base are outlined in red.

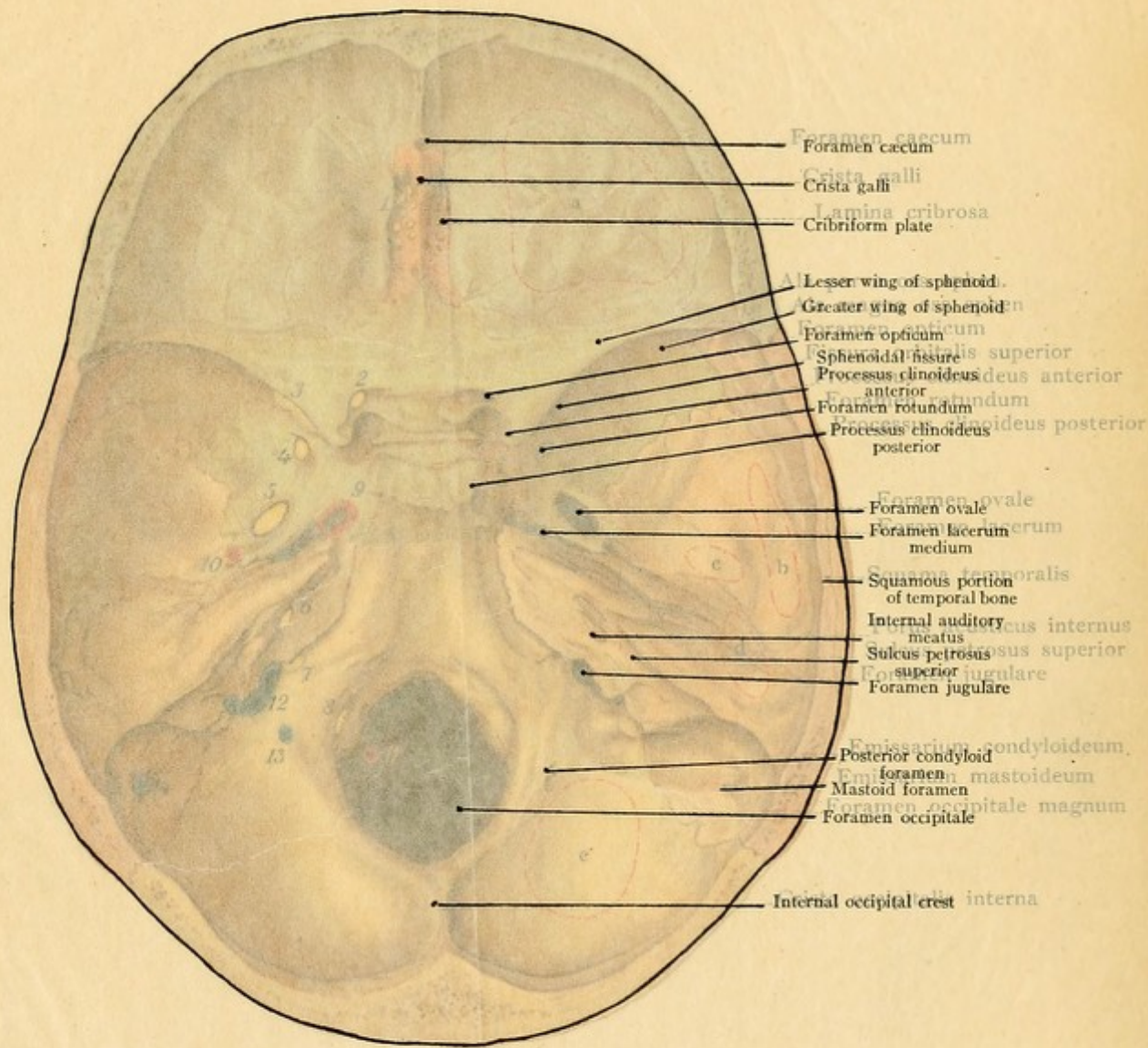
cavity through the posterior compartment of the jugular foramen (designated in the illustration by blue, 12).

Our attention should also be directed to the *emissary foramina* (*Santorini*), which are apertures in the cranium giving passage to venous connections between the external veins of the head and the cerebral sinuses. The blood in the emissary veins passes from within outward, so that these veins relieve the cerebral sinuses, particularly when the intracranial blood-pressure is increased. This explains the *rationale* of the withdrawal of blood from the scalp for the purpose of relieving intracranial congestion (for example, behind the ear in the region of the mastoid emissary). [Through them infection is sometimes carried from the surface—as in the case of erysipelas and other inflammatory diseases of the scalp—to the sinuses, causing thrombosis or meningitis.—ED.] The emissary foramina are subject to very great variations. We distinguish: (1) *The parietal foramen* to either side of the sagittal suture in a line connecting the parietal eminences. It leads to the superior longitudinal sinus and may be absent upon one or both sides. (2) *The mastoid foramen* for the vein connecting the occipital veins with the lateral sinus (it also transmits a meningeal branch of the occipital artery to the dura mater). This foramen is above the base of the mastoid process, two finger-breadths behind the external auditory meatus, and is the largest and most constant of all the emissary foramina (see Plate 1, 14). When the jugular foramen, the normal point of exit for the venous blood, is narrowed (as in a rachitic closure of this foramen, for example) the mastoid foramen is so much enlarged that it is sufficient to allow the venous blood to escape from the cranial cavity. (3) *The posterior condyloid foramen*, in the condyloid portion of the occipital bone, connects the deep veins of the neck with the lateral sinus (see Plate 1, 13). (4) *The occipital foramen* in the external occipital protuberance. This is insignificant and frequently replaced by numerous small foramina which transmit connections between the occipital veins and the torcular Herophili.

The practical study of the base of the skull with the foramina for the passage of the nerves and vessels is important not only on account of the neuralgia and paralyses following bone-disease, but also in the diagnosis of basal fractures, intracranial tumors, and the extension of disease of the middle ear to the cranial cavity. In view of the fact that the modern surgeon operates upon the base of the skull from within [as well as without.—ED.] the cranial cavity, an exact knowledge of the topography of this region is most essential.

Those *portions of the base which are thin or relatively weak*, on account of the presence of numerous foramina, are particularly predisposed to fractures and injuries in general. They are indicated in Plate 1 by dotted lines and are found in the following situations. In the anterior cranial fossa: The cribriform plate of the ethmoid bone and the orbital plate of the frontal bone (*a*), particularly in the depressions which lodge the frontal convolutions. In the middle cranial fossa: The base of the great wing of the sphenoid with the foramina rotundum, ovale, and spinosum; over the glenoid fossa of the temporal bone (*c*); the tegmen tympani (*d*) or roof of the middle ear (see page 59) and (very important from a practical standpoint) the squamous por-

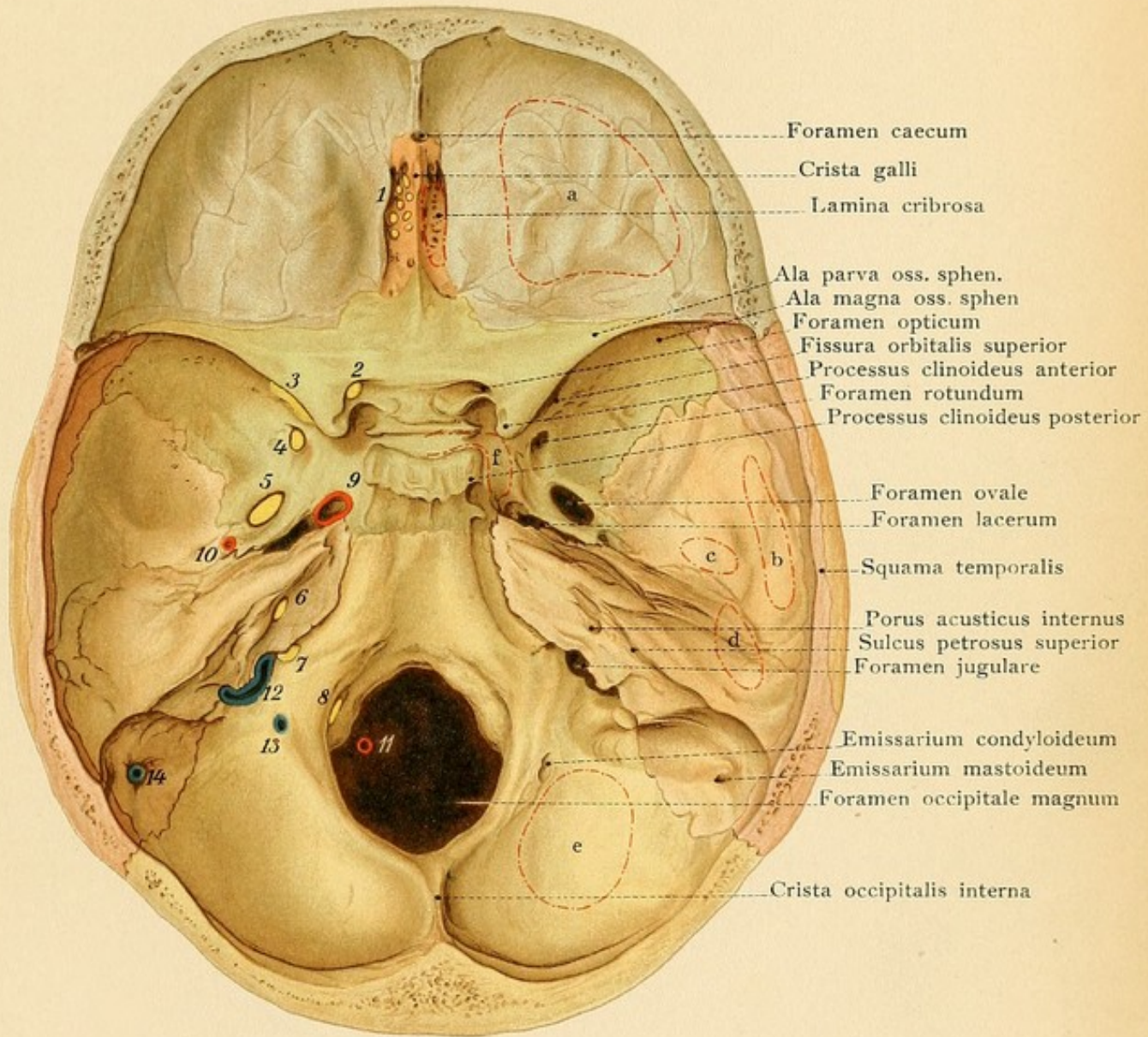












Foramen caecum

Crista galli

Lamina cribrosa

Ala parva oss. sphen.

Ala magna oss. sphen.

Foramen opticum

Fissura orbitalis superior

Processus clinoides anterior

Foramen rotundum

Processus clinoides posterior

Foramen ovale

Foramen lacerum

Squama temporalis

Porus acusticus internus

Sulcus petrosus superior

Foramen jugulare

Emissarium condyloideum

Emissarium mastoideum

Foramen occipitale magnum

Crista occipitalis interna





tion of the temporal bone (*b*). The floor of the sella turcica and the lateral walls of the body of the sphenoid bone should also be mentioned here, as they are thin walls of the large sphenoidal sinuses (*f*) (see page 52). In the posterior cranial fossa the bone is thinnest at the bottom of the fossa (*e*). The osseous layer separating the lateral sinus from the mastoid cells is often very thin, and this is a fact of great practical importance (see page 59).

*Particularly strong portions of the base* are to be found: In the median line: the crista galli, the clivus [*i. e.*, the body of the sphenoid between the dorsum sellæ and the basilar portion of the occipital.—ED.], the internal and external occipital protuberances, and the internal and external occipital crests. Laterally: the great wing of the sphenoid, with the exception of its base, and the anterior and middle parts of the petrous portion of the temporal bone with the cochlea and labyrinth.

From the preceding statements it will be observed that the middle cerebral fossa is relatively the weakest and therefore predisposed to fractures which often involve the nerves passing along the base of the brain in this situation (see page 32 and Fig. 9). If the thinness of the orbital roof is appreciated (see Fig. 16), it will be readily understood how easy it is for a punctured wound to pass the eyeball, perforate the roof of the orbit, and penetrate into the frontal lobe of the brain.

Although injuries of the brain are generally accompanied by injuries of the surrounding bones, a study of the base of the cranium shows that it is possible for a fine-pointed instrument to enter the orbit, pass through the sphenoidal fissure or the optic foramen, and injure the brain without producing a fracture of the bone.

It will also be understood that fractures of the cribriform plate of the ethmoid (*i. e.*, the nasal roof) may lead to hemorrhage from the nose, and that cerebrospinal fluid may escape through the nose if the membranes of the brain are lacerated. The same thing may occur in fractures of the middle fossa, where, after laceration of the wall of the sphenoidal sinus which opens into the superior meatus of the nose (see page 53, Fig. 11, Fig. 19, and Plate 4), there is not only an escape of cerebrospinal fluid, but where even a rapid and fatal nasal hemorrhage has been observed from a rupture of the internal carotid artery which lies in close relation with the wall of the sinus (see pages 31 and 34). If the line of fracture strikes the optic foramen, the ophthalmic artery may give rise to a large effusion of blood into the orbit [producing a subconjunctival ecchymosis, more rarely exophthalmos.—ED.]. The escape of blood or cerebrospinal fluid from the ear presupposes a fracture of the tegmen tympani and a laceration of the drum-membrane [the blood coming from the vessels of the tympanum or from one of the neighboring sinuses.—ED.], or the blood may come from the sigmoid sinus, reaching the middle ear by way of the air-cells in the mastoid process (see page 31 and Fig. 22). In this case blood from the posterior cranial fossa may escape from the nose or mouth, consequently a fracture of any of the three cranial fossas may cause a hemorrhage from the nose, for it must be remembered that with an intact drum-membrane, the blood poured out into the middle ear may reach the nasal or oral cavity through the Eustachian tube and escape from the nose or mouth (see Plate 4 and Fig. 19).

[Cerebrospinal fluid escapes from the ear when, in addition to the fracture of the petrous bone and tear of the tympanic membrane, there has occurred a rent in the dura and arachnoid or their prolongations into the internal auditory meatus through which the subarachnoid space communicates with the tympanum. A serous discharge derived from the mastoid cells or consisting



of blood-serum may escape through a torn tympanic membrane after injury without fracture; it is, however, of relatively infrequent occurrence and scanty.

After fracture of the posterior cranial fossa ecchymosis is sometimes observed in the posterior triangle of the neck.

Fractures of anterior fossas may be accompanied by disturbances of the sense of smell, those of the temporal bone by disturbance of hearing or páralysis of the facial nerve.

It must not be forgotten that in the comatose or very young, blood from the nose or mouth may be swallowed and afterward vomited or passed at stool.—ED.]

In the region of the sella turcica there is only a relatively thin plate of bone separating the sphenoidal sinus from the cranial cavity, and tumors originating in this sinus may encroach upon the cranial cavity and lead to compression of the brain or of the nerves situated at its base. The same is true of tumors proceeding from the ethmoidal cells, since these spaces are separated from the cranial cavity only by a thin plate of the frontal bone on either side of the cribriform plate (see Fig. 16).

#### THE SCALP.

The greater portion of the skin of the cranial region is covered with hair (see Figs. 6 and 7) and differs in many respects from the skin in other portions of the body. It is not only specially rich in sebaceous glands, which claim the attention of the practitioner as the starting-point of many cutaneous diseases as well as of sebaceous cysts, but the customary layer of loose subcutaneous tissue, giving the skin its mobility, is absent in this situation. In its place there is present a firm subcutaneous stratum infiltrated with fat, which is directly continuous with the subcutaneous tissue of the eyes and lids, thus explaining the readiness with which erysipelas of the scalp extends to these parts. This subcutaneous stratum, together with the overlying skin (epidermis and corium) and the underlying occipitofrontal aponeurosis, forms a firm layer, usually spoken of as the "scalp," which may be readily torn away from the external periosteum or pericranium before opening the cranial cavity. The scalp is bound down to the vault of the skull by such a very loose and movable connective tissue, the *subepicranial tissue*, that it may be readily pushed back and forth with the hand, or even by voluntary muscular contractions in some individuals. The skin and the occipitofrontalis muscle, the tendinous portion of which bears the name *galea aponeurotica*, are firmly attached to each other by tense connective-tissue fibers (retinacula) which pass transversely through the subcutaneous stratum.

The *occipitofrontalis muscle* is composed of a muscular and of a tendinous part. The muscular part consists of an anterior, of a posterior, and of a lateral portion. The anterior portion, the frontalis (see Plate 2), arises from the supraorbital margin and the skin of the eyebrows; the posterior portion, the occipitalis, takes origin from the superior curved line of the occiput; the lateral portions may be supposed to consist of the rudimentary *attrahens*, *attollens*, and *retrahens aurem*, which are attached to the auricle. The tendinous portion is firm and dense upon the vertex, but loses these characteristics at the side of the skull, where it overlies the temporal fascia and is attached with it to the zygoma or is continuous with the parotid and masseteric fascia below.

The dense subcutaneous tissue and the firm connection of the skin with the aponeurosis upon



the one hand, and the laxity of the subepicranial tissues upon the other, are responsible for the fact that cutaneous wounds, in which the aponeurosis is not divided, do not gape, in contradistinction to cutaneous wounds in other regions. Gaping occurs only when the aponeurosis, and consequently the entire thickness of the scalp, has been divided. Wounds at right angles to the direction of the fibers of the occipitofrontalis gape more than those made in a sagittal direction. Owing to the dense connective tissue intimately uniting the skin and galea aponeurotica, and the consequent loss of elasticity, large cutaneous defects cannot be covered, since it is impossible to bring the edges of the wound together. In contrast to effusions of blood in the loose subepicranial tissue, ecchymoses in the dense subcutaneous tissue are not very extensive, but give rise to circumscribed swellings.

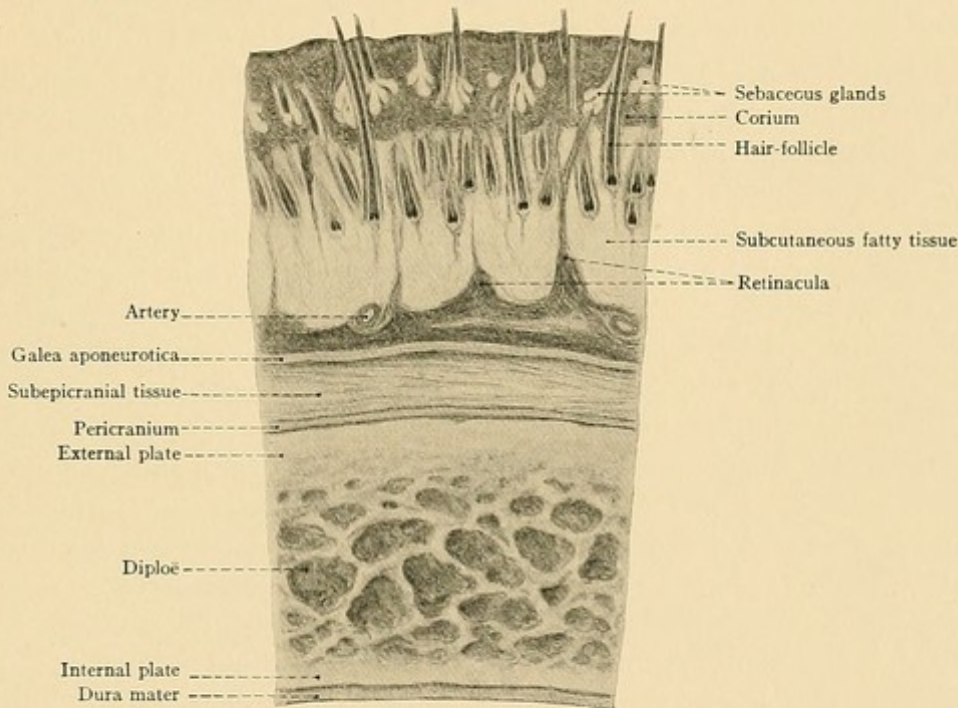


FIG. 6.—A cross-section of the layers of the scalp and of the cranium.

The same condition of affairs is noted in purulent inflammations, since suppuration in the scalp does not become diffuse, while suppuration beneath the scalp may continue to extend until its progress is arrested at the supraorbital margins, the zygoma, and the superior curved line of the occiput. In such cases an early and deep incision is necessary, since spontaneous perforation through the firm and dense scalp is not to be expected.

The scalp is more liberally supplied with blood than any other cutaneous area. In this situation, in contrast to the usual relation, large vessels are found in the subcutaneous connective tissue. These arteries are so firmly imbedded in this dense tissue that it is quite difficult to pick them up with a hemostat after division, and the hemorrhage must frequently be arrested by suture. The arterial anastomoses are so numerous that they form a large-meshed network of arteries which is spread out upon the galea aponeurotica (see Plate 2). Every portion of the



## PLATE 2.

The external muscles, arteries, veins, and nerves of the face.

scalp is supplied with blood from all sides, and the practical application is that even very large cutaneous flaps with small pedicles will readily heal when replaced in their proper position. The arteries also give off numerous branches to the cranium.

The **arteries of the scalp** (see Plate 2) originate partly from the internal, but chiefly from the external carotid. The temporal and occipital branches are so large that in rare instances they have been known to produce a fatal hemorrhage.

The branches of the external carotid artery are:

1. The *superficial temporal*, the direct upward continuation of the external carotid. It passes upward covered by the parotid gland behind the ramus of the jaw, runs over the zygoma, and, at a varying distance (usually about one centimeter) above the zygoma, divides into an *anterior or frontal branch* and a *posterior or parietal branch*. The other main branches, varying somewhat in their point of origin, are the transverse facial (passing forward beneath the zygoma and upon the masseter muscle) and a smaller artery, the orbital (running above the zygoma to the external canthus of the eye). The pulsation of the temporal artery may be palpated in front of the tragus, where the vessel leaves the parotid gland, and where it may be ligated.

2. The *occipital artery*, one of the two posterior branches of the external carotid, passes backward beneath the posterior belly of the digastric muscle, grooves the mastoid portion of the temporal bone behind the mastoid process (this groove is frequently absent), ascends between the muscles of the neck, pierces the fibrous origin of the trapezius to one side of the median line [at junction inner and middle thirds of superior curved line.—ED.], and runs upward upon the occipitofrontalis muscle. It has no large branches bearing special names which are distributed to the scalp. If the mastoid and parietal foramina are well developed, this artery gives off a mastoid and a meningeal branch which run through these foramina and supply the dura mater.

3. The *posterior auricular artery*, the other and smaller of the two posterior branches of the external carotid, runs upward in front of the mastoid process behind the ear and is covered by the posterior auricular muscle.

The branches furnished by the *internal carotid* come out of the orbit from the ophthalmic artery. They are small vessels which possess additional interest from their anastomoses with the branches of the external carotid. They are:

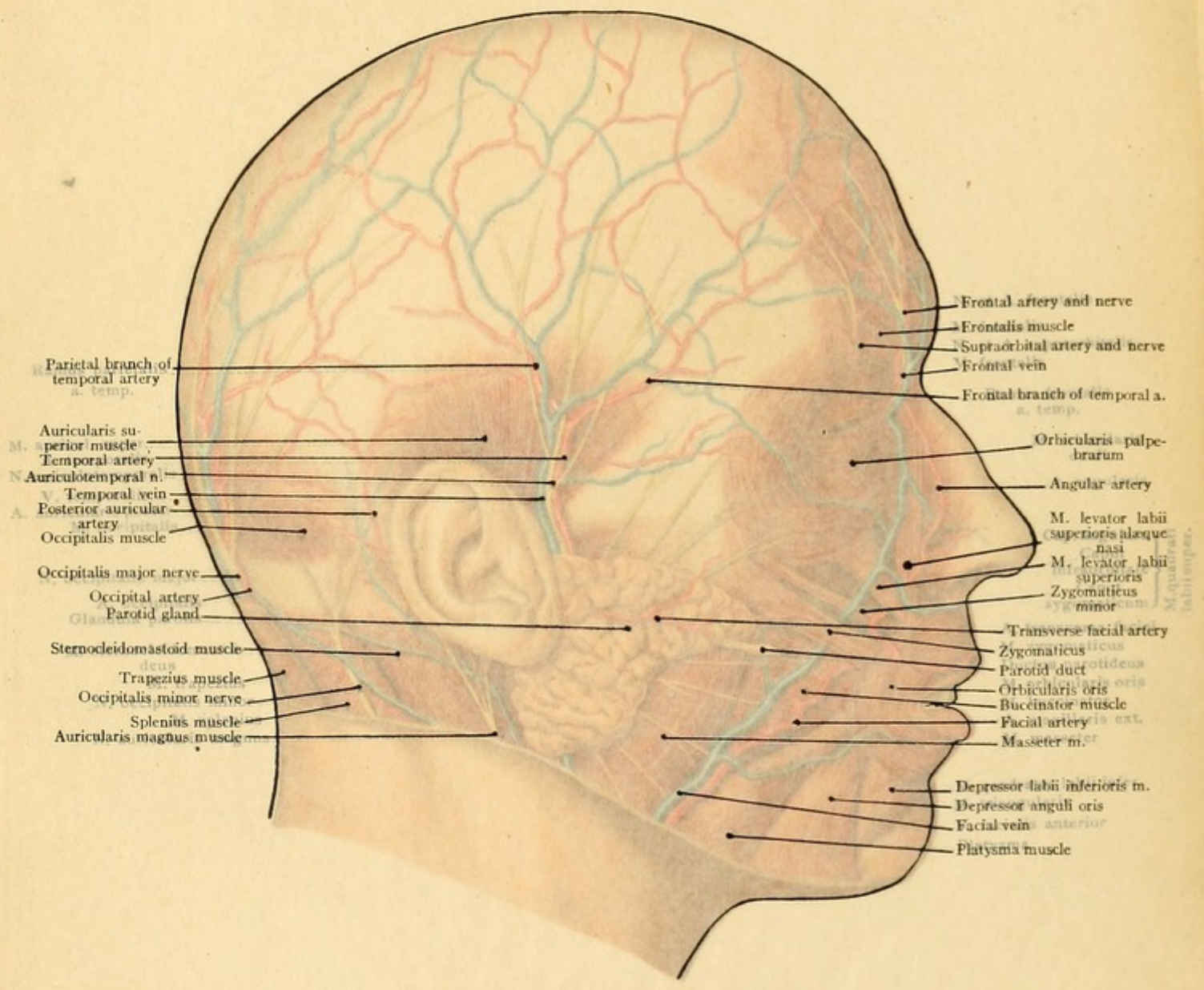
1. The *frontal artery*, passing upward through the frontal notch alongside of the root of the nose.

2. The *supraorbital artery*, external to the preceding vessel, which runs through the supra-orbital notch or foramen to reach the skin of the forehead.

**Veins.**—Only the larger venous trunks accompany their corresponding arteries; the remaining venous branches form a large-meshed network upon the galea aponeurotica. They acquire special importance from their connection with the interior of the cranial cavity through the emissary foramina and from the fact that they receive numerous tributaries from the cranium. We observe:

1. The *frontal vein*, frequently single (the "vein of anger"), which is found in the frontal





Parietal branch of temporal artery a. temp.

M. Auricularis superior muscle

N. Auriculotemporal n.

V. Temporal vein

A. Posterior auricular artery

Occipitalis muscle

Occipitalis major nerve

Occipital artery

Parotid gland

Sternocleidomastoid muscle

Trapezius muscle

Occipitalis minor nerve

Splenius muscle

Auricularis magnus muscle

Frontal artery and nerve

Frontalis muscle

Supraorbital artery and nerve

Frontal vein

Frontal branch of temporal a. temp.

Orbicularis palpebrarum

Angular artery

M. levator labii superioris alaeque nasi

M. levator labii superioris

Zygomaticeus minor

Transverse facial artery

Zygomaticeus

Parotid duct

Orbicularis oris

Buccinator muscle

Facial artery

Masseter m.

Depressor labii inferioris m.

Depressor anguli oris

Facial vein anterior

Platysma muscle

M. quadratus labii superioris



PLATE 2.

The external muscles, arteries, veins, and nerves of the face.

scalp is supplied with blood from all sides, and the practical application is that even very large cutaneous flaps with small pedicles will readily heal when replaced in their proper position. The arteries also give off numerous branches to the cranium.

The arteries of the scalp (see Plate 2) originate partly from the internal, but chiefly from the external carotid. The temporal and occipital branches are so large that in rare instances they have been known to produce a fatal hemorrhage.

The branches of the external carotid artery are:

1. The superficial temporal, the direct upward continuation of the external carotid. It passes upward covered by the parotid gland behind the ramus of the jaw, runs over the zygoma, and, at a varying distance (usually about one centimeter) above the zygoma, divides into an anterior or frontal branch and a posterior or parietal branch. The other main branches, varying somewhat in their point of origin, are the transverse facial (passing forward beneath the zygoma and the masseter muscle) and a smaller artery, the orbital (running above the zygoma to the external angle of the eye). The pulsation of the temporal artery may be palpated in the temple where the vessel leaves the parotid gland, and where it may be ligated.

2. The occipital artery, one of the two posterior branches of the external carotid, runs upward beneath the posterior belly of the digastric muscle, goes over the posterior border of the mastoid process (this groove is frequently absent), pierces the fibrous origin of the trapezius to the junction of the inner and middle thirds of superior curved line.—(Fig. 1) and runs upward under the trapezius muscle. It has no large branches bearing special names which are of importance to the scalp. If the mastoid and parietal foramina are well developed, this artery gives off a meningeal branch which runs through these foramina and supplies the dura mater.

The posterior auricular artery, the other and smaller of the two posterior branches of the external carotid, runs upward in front of the mastoid process behind the posterior auricular muscle.

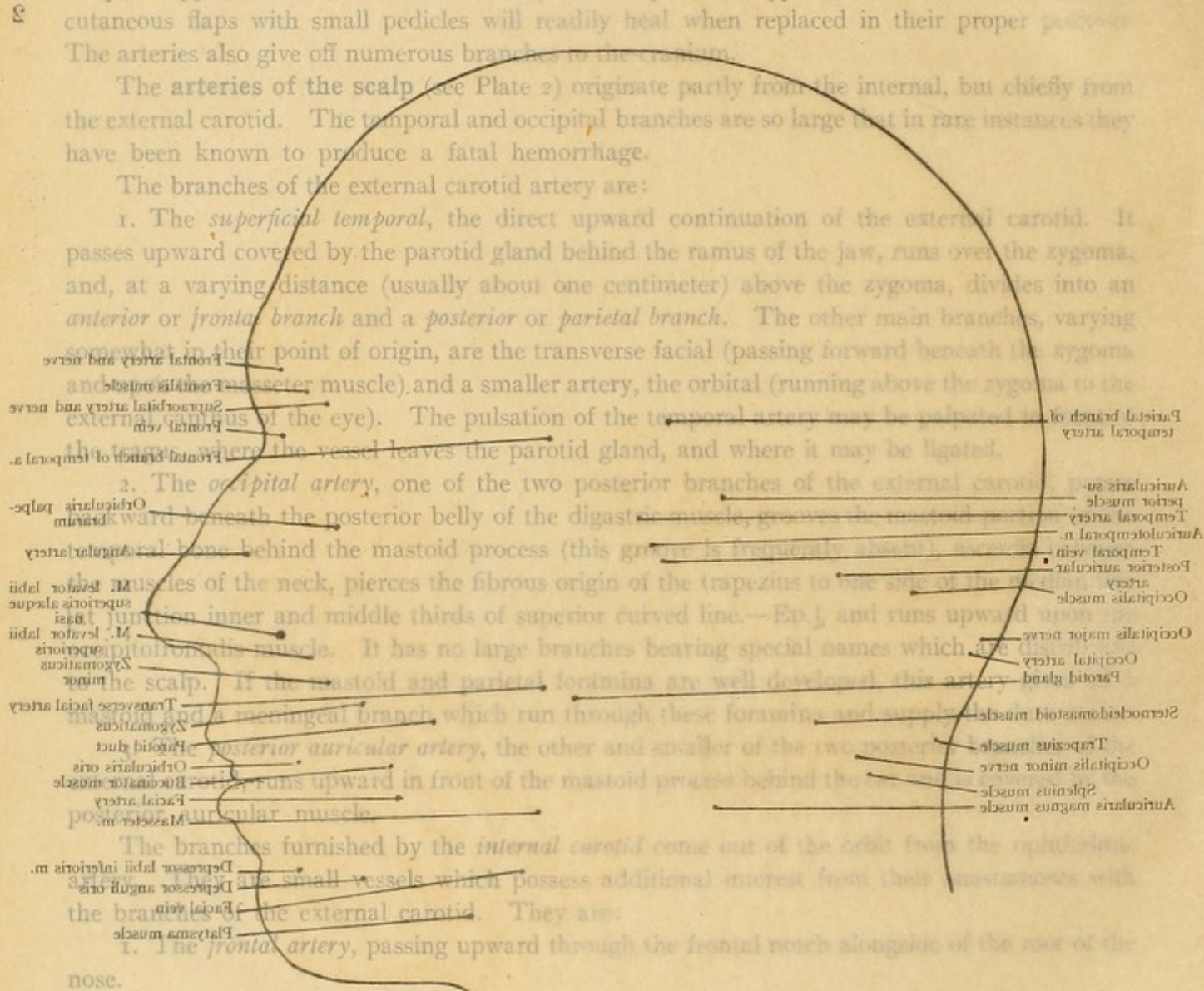
The branches furnished by the internal carotid come out of the orbit from the ophthalmic artery. They are small vessels which possess additional branches from their anastomosis with the branches of the external carotid. They are:

1. The frontal artery, passing upward through the frontal notch along the root of the nose.

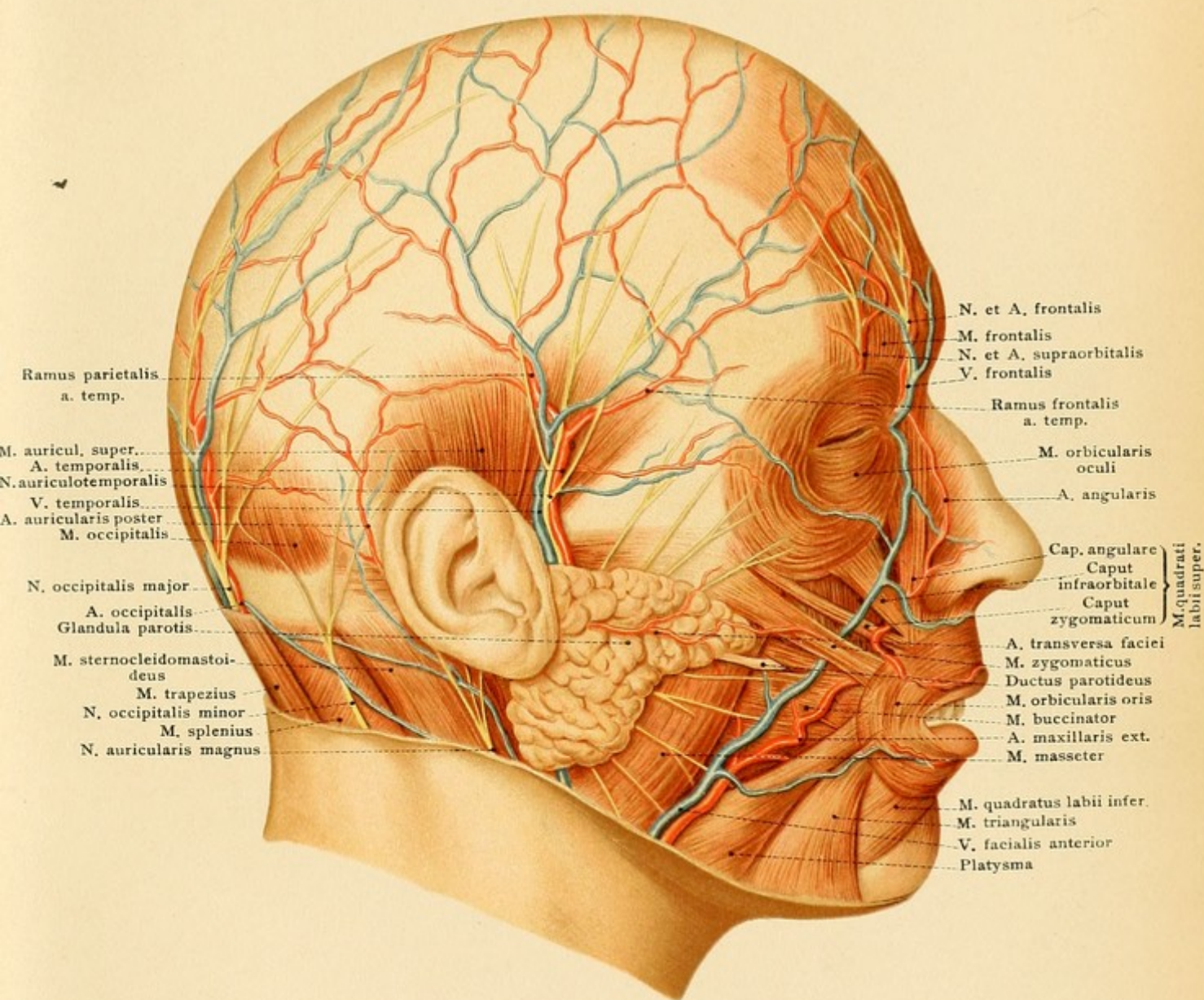
2. The supraorbital artery, external to the preceding vessel, which runs through the supra-orbital notch or foramen to reach the skin of the forehead.

Veins.—Only the larger venous trunks accompany their corresponding arteries; the remaining venous branches form a large-meshed network upon the galea aponeurotica. They acquire special importance from their connection with the interior of the cranial cavity through the emissary foramina and from the fact that they receive numerous tributaries from the cranium. We observe:

1. The frontal vein, frequently single (the "vein of anger"), which is found in the frontal













region and usually empties into the angular vein. [The angular vein communicates with the ophthalmic vein and through it with the cavernous sinus; it thus favors the extension of infection from the face or orbit to the interior, particularly in erysipelas.—ED.]

2. The *temporal vein*, usually situated behind the artery of the same name. It unites with the internal maxillary to form the temporomaxillary vein.

3. The *posterior auricular vein*, draining the region supplied by the artery of the same name. It assists in the formation of the external jugular vein.

4. The *occipital vein*, which empties into the external jugular vein. [It generally receives the mastoid emissary vein, one of its tributaries receives the parietal emissary vein and occasionally an emissary vein from the torcular Herophili opens into it (Cunningham).—ED.]

[The veins of the scalp are also, through the diploic veins, connected with the veins of the dura mater and the venous sinuses. Similar connections are established by small veins which pass from the pericranium directly through the bones, and particularly through the intersutural membranes.—ED.]

The important **lymphatic vessels**, through which inflammations extend to the scalp, are situated:

1. Anteriorly in the middle line of the forehead passing down alongside of the nose to the lymphatic vessels of the face and to the submaxillary lymphatic glands.

2. Laterally along the temporal and posterior auricular arteries and passing to the lymphatic glands of the parotid region and to those behind the ear. (This lymphatic vessel is particularly affected by syphilis.)

3. Posteriorly along the occipital artery and running to the occipital lymphatic glands upon the origin of the trapezius.

There are no lymphatic glands upon the cranial vault.

**Nerves** (Plate 2).—Only the sensory nerves of the scalp are of interest to the practitioner (the motor filaments to the occipitofrontalis muscle are supplied by the facial nerve). They are furnished partly by the trifacial and partly by the cervical nerves. The following distinct branches should be mentioned:

1. The *supratrochlear* (a branch of the frontal from the ophthalmic division of the fifth) is found above the inner canthus of the eye, one centimeter from the median line at the supraorbital margin, where it leaves the orbit to reach the skin of the forehead.

2. The *supraorbital nerve* (also a branch of the frontal from the ophthalmic) is larger than the preceding and frequently divides into two branches as it runs over the supraorbital margin. It passes upward through the *supraorbital foramen* or notch, which is palpable 2.5 centimeters from the median line [at junction of inner and middle thirds of upper margin of the orbit.—ED.], and which is the landmark for locating the nerve in supraorbital neuralgia. In performing *neurectomy* upon this nerve the orbit is entered from the supraorbital margin, the orbital contents are pushed downward, and the nerve is sought as far back as possible immediately below the orbital periosteum (the so-called "periorbita") upon the levator palpebræ superioris muscle. In this manner a long piece of the nerve may be excised.

3. The *auriculotemporal nerve* (from the inferior maxillary division of the trifacial) accompanying the temporal artery, frequently being situated between this vessel and the vein, and passing to the skin of the temporal region.



FIG. 7.—The layers of the scalp, the cranium, and the membranes of the brain.

FIG. 8.—The sinuses of the dura mater. The calvarium has been removed with the exception of a central arch of bone, so that the processes of the dura mater have been left intact.

4. The *occipitalis minor nerve* from the cervical plexus, and
5. The *occipitalis major*, the nerve of cervical neuralgia, not a branch of the cervical plexus but a dorsal branch of the second cervical nerve. It usually perforates the fibrous origin of the trapezius in company with the occipital artery and immediately divides into several branches which ascend to the vertex.

The exposure of the nerve is difficult, as it is imbedded in dense connective tissue and the pulsations of the occipital artery, the most frequently recommended guide, are often not distinctly palpable.

The external periosteum of the skull, the *pericranium*, is relatively thin in comparison with the internal periosteum (dura mater). It is very vascular and is not closely attached to the bones except at the sutures, where it becomes continuous with the outer layer of the dura mater constituting the inter-sutural membrane. During childhood the pericranium lies loosely upon the skull-cap, and in cephalhæmatoma neonatorum it is frequently stripped up from the bones (particularly from the parietal) as far as the surrounding sutures.

In flap-like wounds of the scalp the pericranium is easily stripped up from the bone [except at the sutures, where it is firmly attached.—ED.] in association with the overlying tissues. It receives its blood-supply chiefly from the vessels of the scalp, but a portion of it is also furnished by the perforating branches of the lateral or endosteal layer of the dura mater (see page 29). [The pericranium differs from the periosteum of other bones in that it may be removed for a considerable area without producing necrosis, due to the fact that the cranial bones are in large part nourished by vessels from the outer layer of the dura.—ED.]

#### THE MEMBRANES OF THE BRAIN.

The *dura mater* is of twofold importance: (1) For the skull; (2) for the brain.

1. The *dura mater* forms the internal periosteum of the cranium. Since it is responsible for the growth in thickness of the bone, we find it intimately adherent to the cranial vault during childhood, while in the adult after this growth is completed, the cranial cavity may be opened and the calvarium removed, leaving the *dura mater* and the underlying brain intact. Even then, however, the numerous vessels passing from the *dura* into the bones are torn across. In general the *dura* is more intimately attached to the base than to the cranial vault, the adhesion being most firm at the cribriform plate of the ethmoid, the sella turcica, the clivus, and the petrous portion of the temporal bone [which in part explains the infrequency of extra-dural collections of blood and pus at these situations.—ED.]. If the excised *dura* is placed in water, numerous vessels are seen upon its outer surface, while the inner surface seems smooth and contains only capillary ramifications. It is a fact that no vessels pass from the *dura* to the brain. It is completely separated from the underlying *pia mater* by the subdural space, which is filled with lymph. The importance of the *dura* as a periosteal layer is also distinctly demonstrated by the occasional ossification of this structure. [By most authorities the *dura mater* is said to consist of two layers,



Fig. 7.

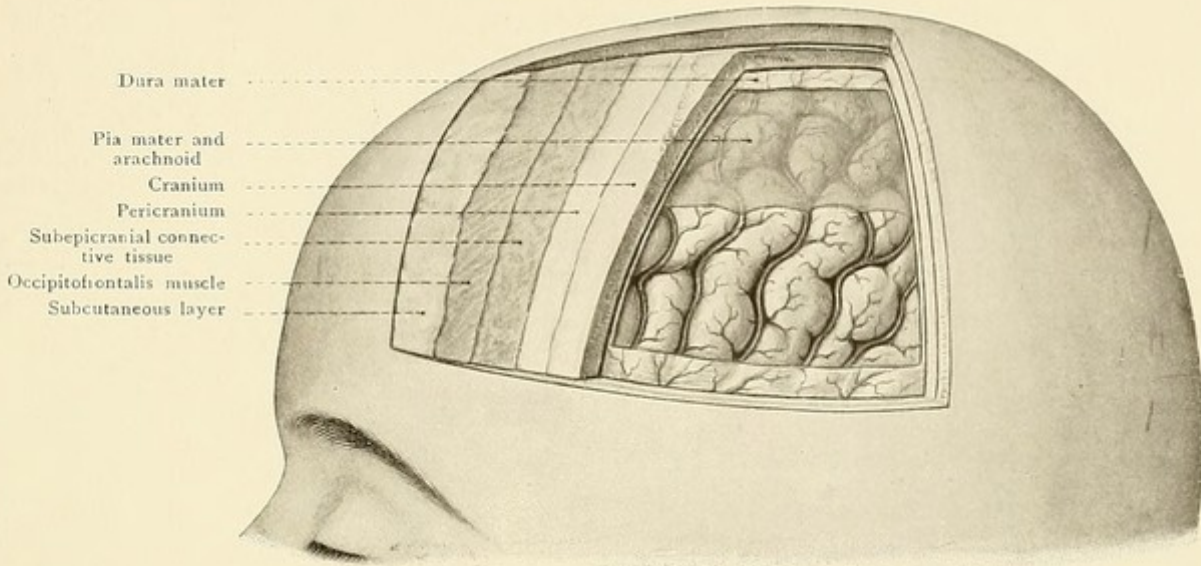
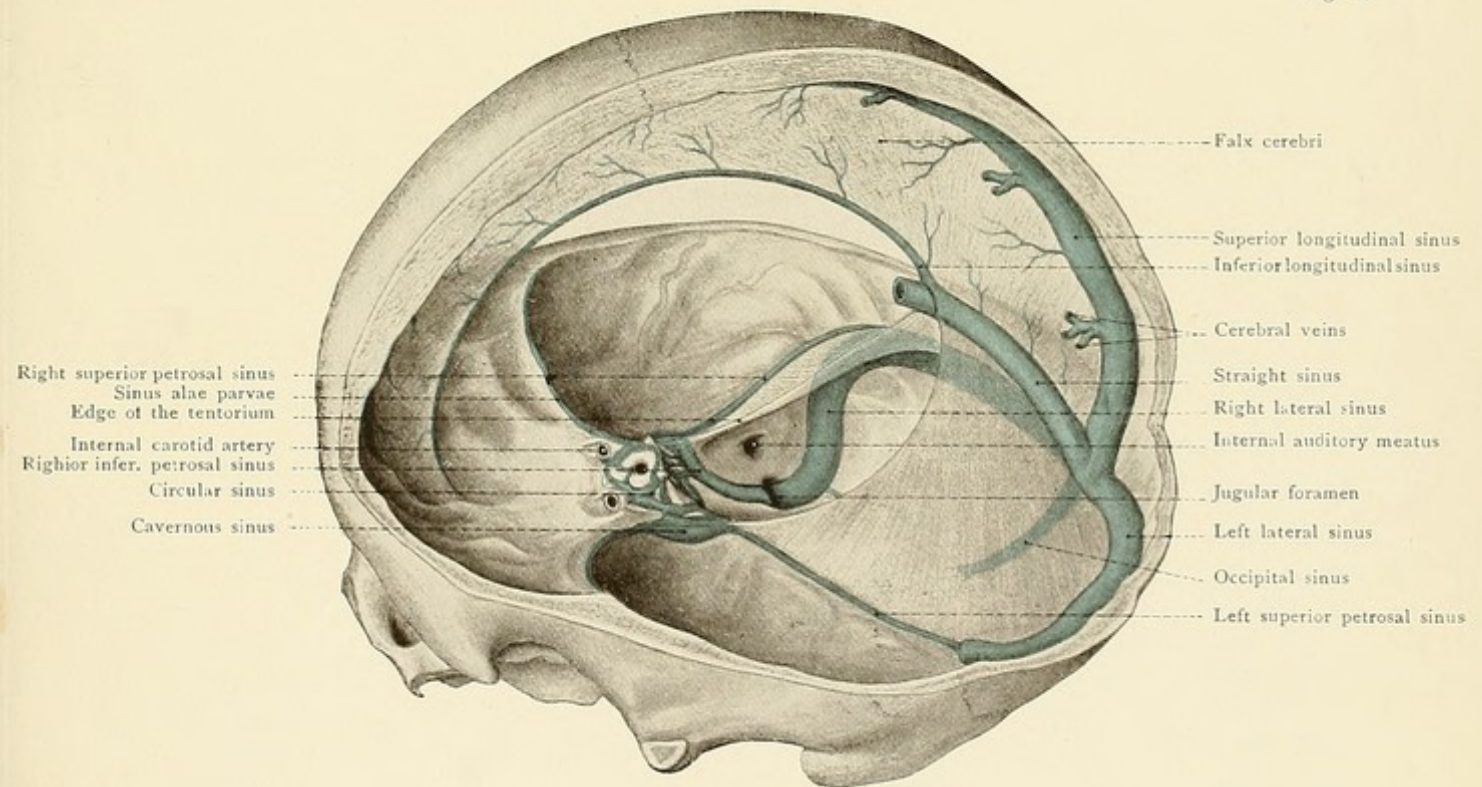


Fig. 8.





the size of the head, behind the external angular process. The posterior branch is exposed by making an opening on the same line where it is bisected by a vertical line from the posterior border of the mastoid process. It must not be forgotten that a trephine opening which has failed to exactly locate a given structure may be easily enlarged and thereby rendered effective by the use of the rongeur.—ED.]

2. The dura mater serves the brain as a supporting and protective envelope. From its inner layer it sends partitions or processes between certain of the brain divisions. These are: (1) *The falx cerebri* (Figs. 8, 9, 12, and 16), which separates the cerebral hemispheres and extends from the crista galli to the internal occipital protuberance and the upper surface of the tentorium cerebelli. (2) *The tentorium cerebelli* (see Fig. 17), which separates the occipital lobes of the cerebrum from the upper surface of the cerebellum and is adherent to the superior margin of the petrous portion of the temporal bone, continuing as far forward as the anterior and posterior clinoid processes of the sphenoid bone. Its posterior attachment corresponds to the course of the lateral sinus. If it is desired to remove the cerebellum together with the cerebrum, the insertion of the tentorium at the petrous portion of the temporal bone must be previously divided, since the cerebellum cannot pass through the opening which transmits the cerebral peduncles (see Fig. 17). (3) *The falx cerebelli*, a process of dura mater which, varying somewhat in its formation, runs along the internal occipital crest corresponding to the fissure between the cerebellar hemispheres (see Fig. 12). The sella turcica and the contained hypophysis cerebri are covered by a portion of dura mater known as the *diaphragma sellæ*, which is perforated by the infundibulum. This infundibulum is easily torn in removing the brain.

The dura mater is of additional importance to the brain since it receives the return blood, which is collected in the venous sinuses and conducted to the jugular foramen. The *sinuses* are more or less rigid canals situated in the dura between its outer and inner layers. They are lined by a prolongation of the lining membrane of the veins, are destitute of valves, and do not collapse when injured. Such injuries easily occur with injuries to the cranium; but they are relatively free from danger, since the hemorrhage is easily checked and cases are exceptional in which air gains access to the vascular system from an opened sinus. A more dangerous injury is the complete internal perforation of a sinus with effusion of blood into the subdural space and the symptoms of cerebral compression. In trephining, care is of course taken to avoid the sinuses. From a practical standpoint the following three sinuses are the most important:

1. *The superior longitudinal sinus*, holding the most exposed position along the insertion of the falx cerebri (see Figs. 8 and 12). At the internal occipital protuberance, the location of the torcular Herophili, it unites with the lateral, the occipital, and the straight sinuses. [This sinus increases rapidly in size from before backward. It receives veins from the scalp through the parietal foramina, from the diploë, the dura mater, and the hemispheres of the cerebrum. Those from the cerebrum run into the sinus from behind forward opposite to the direction of the blood-current, piercing the sinus wall very obliquely (Deaver). Its position is indicated by a line drawn over the median line of the vertex from the root of the nose to the external occipital protuberance.—ED.]

2. *The lateral sinus*, the median portion of which is called the *sigmoid sinus*, is situated in a furrow in the bone (see Figs. 9 and 22). This furrow is very often particularly deep upon the



right side. The fact that it is frequently separated from the mastoid cells by only a thin plate of bone (see page 59) is of great practical importance, since the sinus not infrequently becomes involved (sinus thrombosis) from suppuration extending into the mastoid cells from the middle ear. The external guide for the sinus is a point on the mastoid process, two centimeters behind the posterior margin of the external auditory meatus. The posterior border of the mastoid process is frequently employed as a landmark, but it cannot be utilized in all cases, as the varying size of the bony prominence and its digastric groove of inconstant depth may give rise to error. It may cause the operator to go too far forward and consequently to strike the petrous portion of the temporal bone. [The term "lateral sinus" should be restricted to that portion of the sinus between the external occipital protuberance and the posterior inferior angle of the parietal bone; the remainder of the sinus, to the jugular foramen, is known from its tortuous course as the *sigmoid sinus*. According to Wolsey, the genu of the sigmoid sinus—the part most frequently involved in middle-ear inflammations—is convex forward, reaches to a point  $\frac{1}{8}$  to  $\frac{1}{4}$  of an inch behind a coronal plane through the posterior border of the external osseous meatus, and is on the level of the upper part of the meatus. An opening may be made into the genu at a point half an inch behind the posterior wall of the bony meatus between the levels of its roof and floor, where the more superficial part of the sinus is within  $\frac{1}{4}$  or even  $\frac{1}{2}$  of an inch of the surface and is therefore placed much less deeply than the antrum.—ED.]

3. The third of the most important sinuses is the *cavernous sinus*, situated to either side of the body of the sphenoid bone [continuous with the ophthalmic veins in front, dividing into superior and inferior petrosal sinuses behind, and communicating by means of the circular sinus.—ED.]. It gains additional interest since it surrounds the internal carotid artery. As it is separated by only a very thin plate of bone from the sphenoidal air-cells communicating with the nasal cavity (see Fig. 11 and page 53), we can understand why fatal hemorrhage from the nose has been observed as the result of *rupture of the sinus and carotid artery* after fractures of the base of the skull. An injury to the carotid artery in the sinus, which is also possible from a penetrating wound through the sphenoidal fissure, may lead to the formation of an arterio-venous aneurysm and to a subsequent stasis in the superior ophthalmic vein of the orbit (see page 46) which empties into the sinus through the sphenoidal fissure. This symptom, known as *pulsating exophthalmos*, is due to the fact that the pulsations of the carotid artery are transmitted to the engorged venous spaces and displace the eyeball anteriorly.

[Cavernous sinus thrombosis most frequently follows inflammatory affections of face or upper lip, the extension taking place through facial, nasal, and ophthalmic veins. Thrombosis also occurs—but less frequently—through the supraorbital or frontal veins, through the sphenoparietal sinus, and from the pterygomaxillary region through the vein of Vesalius. This sinus is placed between the two layers of dura mater, is intimately related to the Gasserian ganglion, and may, during operations on the latter, become a source of some danger and great annoyance from bleeding, sometimes preventing the completion of the operation.—ED.]

The other sinuses are: The *inferior longitudinal sinus*, in the concave lower margin of the falx cerebri; the *straight sinus*, at the attachment of the falx cerebri to the tentorium; the *superior* and *inferior petrosal sinuses*, along the superior and posterior borders of the petrous portion of the temporal bone respectively; the *circular sinus*, composed of the two transverse venous con-



FIG. 9.—The base of the skull with the cranial nerves, as seen after the removal of the brain. Upon the left side the dura mater has been left in place and the tentorium cerebelli incised so that it is possible to look into the posterior cerebral fossa. Upon the right side the dura has been removed and the places of exit of the nerves are visible at the base of the skull.

nections between the cavernous sinuses; the *sphenoparietal sinus* (sinus alæ parvæ), running along the lesser wing of the sphenoid, ascending behind the coronal suture with the anterior branch of the middle meningeal artery, and occasionally imbedded in a very deep bony groove, to reach the superior longitudinal sinus; and the *occipital sinus*, in the attached border of the falx cerebelli.

In addition to the cerebral veins, the sinuses also receive the diploic veins, the internal auditory veins from the internal auditory meatus, the meningeal veins, the superior ophthalmic veins, and the emissary veins (see page 22).

**Nerves.**—After the removal of the brain, which is necessarily preceded by a division of the cranial nerves, the latter structures may be observed while they are still within the dura mater at the base of the skull (see Fig. 9). A number of them, the optic, the facial, and the auditory nerves, for example, disappear at the same place at which they leave the cranial cavity. Others, however, pass into or through the dura and pursue an intradural or a subdural course for a varying distance before they leave the skull. This is particularly the case with the nerves in the middle cranial fossa, which on account of their course are therefore most likely to be affected by fractures of the base (see page 23). The oculomotor and the abducent nerves, for example, perforate the dura at the anterior extremity of the tentorium, but do not leave the cranial cavity until they reach the sphenoidal fissure. The abducent nerve perforates the dura upon the clivus, but does not leave the skull until it reaches the sphenoidal fissure, consequently having the longest subdural course of any of the cranial nerves. The trunk of the trifacial nerve disappears beneath the edge of the tentorium in the posterior cranial fossa and forms the semilunar ganglion, which is lodged in a depression near the apex of the petrous portion of the temporal bone in the middle cranial fossa. This ganglion is covered by the dura mater, and the three branches of the trifacial cannot be dissected until the dura has been removed (see Figs. 9 and 10). When very obstinate trifacial neuralgia makes it necessary to attack the ganglion through the temporal region, carefully elevating the temporal lobes of the cerebrum, the structures most endangered, in addition to the middle meningeal artery (which may be ligated), are the cavernous sinus and the carotid artery. The extirpation of the ganglion is followed not only by sensory changes, but also by a unilateral paralysis of the muscles of mastication, since the small motor root in intimate relation with the ganglion is also removed. Unpleasant symptoms of cerebral compression are not infrequently observed after the operation.

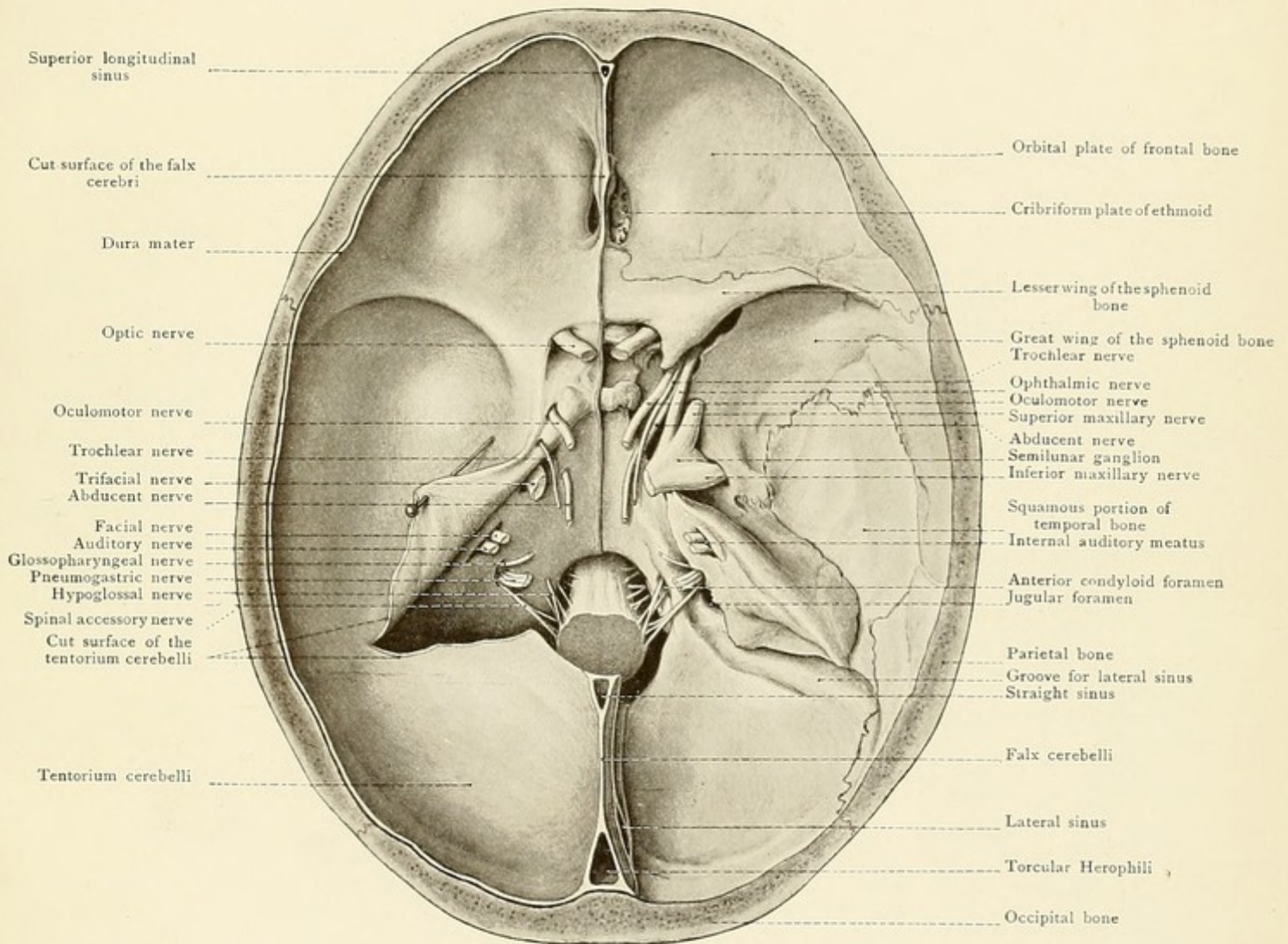
The relations of the nerves in the middle cranial fossa to the cavernous sinus and to the internal carotid artery are best shown by a frontal section (see Fig. 11).

The abducent nerve lies upon the internal carotid within the sinus, while the illustration distinctly shows the oculomotor, the trochlear, and the first and second divisions (ophthalmic and superior maxillary) of the trifacial within the wall of the sinus.

Fractures or caries of the base of the skull may involve one or more of the cranial nerves, and the symptoms produced by the affected nerve may furnish conclusions as to the site of the lesion.



Fig. 9.









The nerves most apt to give rise to symptoms are the *facial* (paralysis of the muscles of expression) and the *auditory* in fracture or caries of the petrous portion of the temporal bone, the *abducent* and the *oculomotor*, and more rarely the *trochlear*, the *trifacial*, and the *optic*. Tumors situated at the base of the skull may press upon the nerves having a subdural or an intradural course and consequently lead to more or less severe pressure-symptoms dependent upon the particular nerve affected.

Under certain circumstances olfactory or visual disturbances may point to the presence of a tumor in the anterior cranial fossa; symptoms of pressure upon the semilunar ganglion and disturbances of the muscles of the eye may likewise indicate a growth in the middle cranial fossa. If the trunk of the trifacial is pressed upon before it perforates the dura, and if the facial and hypoglossal nerves are compressed at the base of the skull, we are justified in locating the lesion in the posterior cranial fossa, while symptoms pointing to the pons or cerebellum would demand the same localization. Since the division of the fifth cranial nerve into its three branches takes place within the cranial cavity, any one of these branches may be affected by diseases of the inner surface of the base of the skull.

The *arachnoid membrane* (the second of the brain membranes) (see Fig. 7) is separated from the dura by the subdural space. The *pia mater* is separated from the arachnoid by the subarachnoid space which is filled with the cerebrospinal fluid. Numerous trabeculæ pass across this subarachnoid space and form an intimate connection between the arachnoid and pia, particularly at the convexities of the cerebral convolutions. While the non-vascular arachnoid bridges over the sulci between the convolutions, the pia mater carrying the ramifications of the blood-vessels dips into the sulci and is intimately attached to all portions of the surface of the brain. In several places, particularly at the base of the brain, there are comparatively large spaces between the arachnoid and the pia, and these are known as the *cisternæ sub-arachnoideales*. There is no communication between the subdural and the subarachnoid space, but the subarachnoid space freely communicates with the ventricles of the brain [through an opening in the roof of the fourth ventricle, and also at the extremity of the descending horn of the lateral ventricle.—ED.].

It consequently follows that the cerebrospinal fluid in the ventricles may be drawn off after the subarachnoid space has been opened.

The arachnoid membrane, particularly in the vicinity of the superior longitudinal sinus, possesses variously formed *villi*, groups of which may be seen projecting into the interior of the sinus or its lateral recesses when this venous channel has been laid open. They act as normal places of drainage for the cerebrospinal fluid. When they become hypertrophied they form the *Pacchionian bodies*, which are lodged in the Pacchionian depressions (see page 18).

The larger branches of the cerebral vessels are found in the subarachnoid space. Effusions of blood in this space come either from the cerebral vessels or from the vessels of the dura, in which latter case, a rupture of the arachnoid must, of course, have taken place (see page 29). The relation of the arteries to definite portions of the base and to definite cranial nerves (see Plate 3) makes it clear that aneurysm of these arteries must produce definite localizing symptoms of cerebral compression.

The *arterial supply of the brain* is furnished by the vertebral and internal carotid arteries



FIG. 10.—The Gasserian ganglion (ganglion semilunare) which has been exposed in the middle cerebral fossa by the removal of the dura mater.

FIG. 11.—Frontal section in the region of the cavernous sinus.

which form the circle of Willis, situated in the subarachnoidean space at the base of the brain in the region of the interpeduncular space (see Plate 3).

The *vertebral artery*, soon after its origin from the subclavian (see Fig. 27), enters the foramen in the transverse process of the sixth cervical vertebra, passes through the transverse processes of all of the overlying cervical vertebrae, runs toward the median line in the groove upon the upper surface of the posterior arch of the atlas, perforates the posterior occipito-atlantal ligament and the dura, and reaches the anterior surface of the medulla oblongata, at the superior boundary of which it unites with the vessel of the opposite side to form the *basilar artery*. This artery lies in the basilar groove of the pons, and at its superior margin divides into two terminal branches, the posterior cerebral arteries.

The *internal carotid artery*, commencing at the bifurcation of the common carotid at the level of the upper margin of the thyroid cartilage, gives off no cervical branches, but ascends to the base of the skull along the lateral wall of the pharynx. It is separated from the external carotid artery by the styloglossus and stylopharyngeus muscles. It pursues a curved course through the carotid canal of the petrous portion of the temporal bone (see Fig. 23), the concavity of the curve being directed anteriorly. This leads us to remark that fatal hemorrhage has been observed from the internal carotid artery in cases of caries of the petrous portion of the temporal bone. After leaving the carotid canal the vessel passes across the middle lacerated foramen in the carotid sulcus at the side of the body of the sphenoid bone and is enclosed in the cavernous sinus. It then ascends to the optic foramen, where it describes a short curve, convex forwards, from which is given off the only branch not supplying the brain, the *ophthalmic artery*, which, together with the optic nerve, enters the orbital cavity through the optic foramen. After penetrating the dura, the internal carotid artery reaches the base of the brain at the angle between the optic nerve and the optic tract, where it divides into two main branches, the anterior and middle cerebral arteries.

The chief branches of the vertebral and basilar arteries which supply the brain are:

1. The *posterior inferior cerebellar artery*, from the vertebral to the lower surface of the cerebellum.
2. The *anterior inferior cerebellar artery*, from the basilar to the lower surface of the cerebellum.
3. The *superior cerebellar*, which arises from the basilar at the anterior margin of the pons and ramifies upon the superior surface of the cerebellum.
4. The *posterior cerebral arteries*, the two terminal branches of the basilar. This vessel is separated from the superior cerebellar at its origin by the oculomotor nerve and supplies the occipital lobe and the greater portion of the temporal lobe. It is connected with the internal carotid by the *posterior communicating artery*.
5. The *internal auditory artery*, which reaches the internal ear through the internal auditory meatus.

The vertebral artery also gives off lateral spinal branches in the neck which pass into the



Fig. 10.

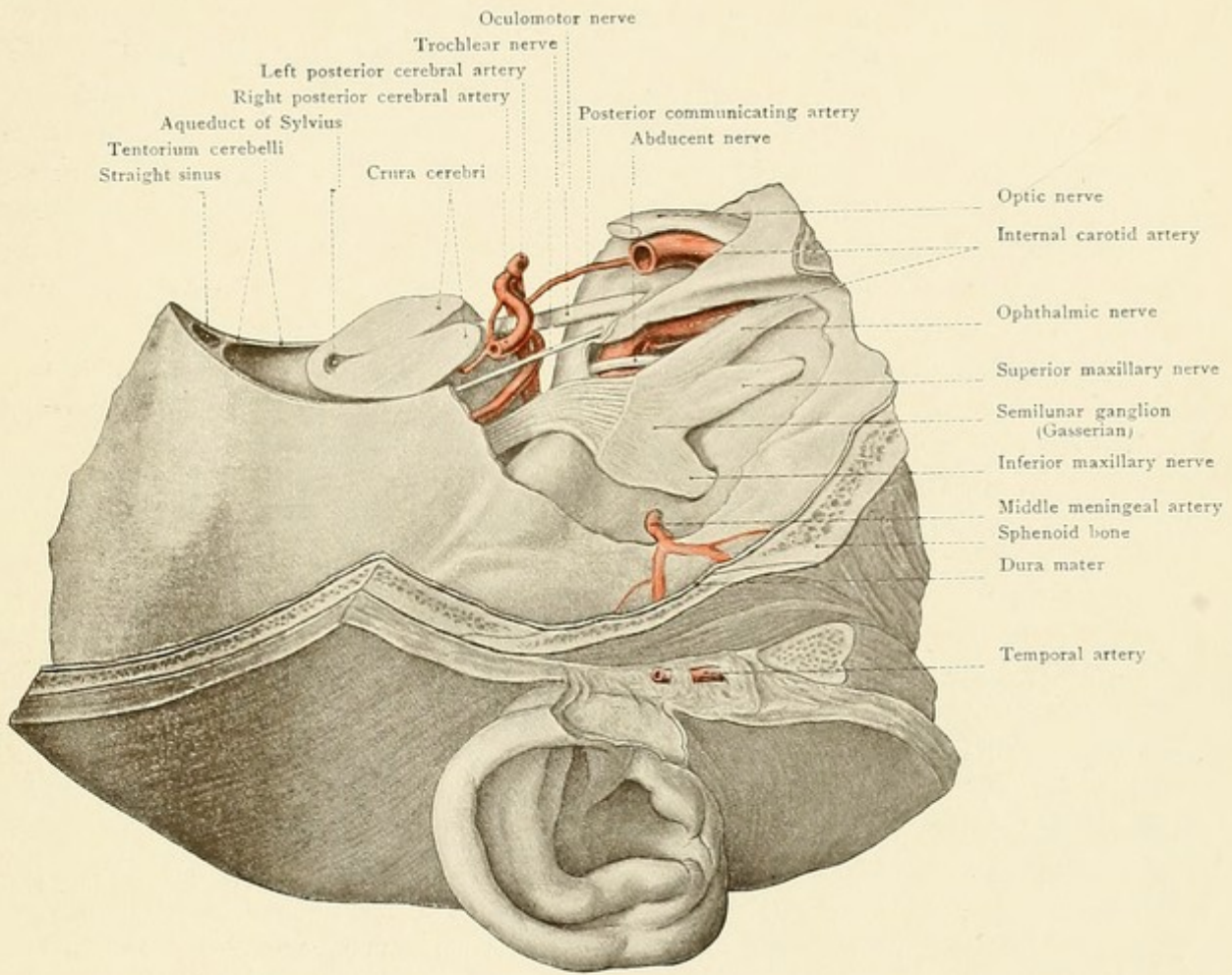
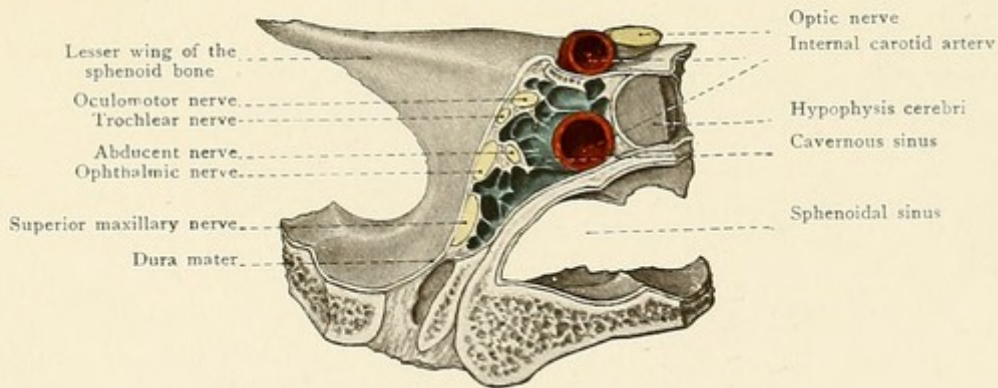


Fig. 11.









vertebral canal through the intervertebral foramina, meningeal branches to the dura mater in the posterior cerebral fossa, and the anterior and posterior spinal branches to the spinal cord and its membranes.

The internal carotid artery supplies the brain with:

1. The *anterior cerebral artery*. It passes inward over the dorsal surface of the corresponding optic nerve and then forward, approaching the artery of the opposite side, with which it is connected by the anterior communicating artery. The vessels winding around the genu of the corpus callosum pass backward, supplying the corpus callosum, and ramify upon the median surface of the cerebral hemispheres.

2. The *middle cerebral artery*, which runs in the fissure of Sylvius, supplying the frontal, parietal, and temporal lobes as well as the island of Reil.

3. The *anterior choroid artery*, passing posteriorly along the optic tract to the descending horn of the lateral ventricle to enter the choroid plexus.

4. The *posterior communicating artery*, which has been previously mentioned.

#### CRANIOCEREBRAL TOPOGRAPHY.

The *tentorium cerebelli* (see Figs. 2, 9, 17, and Plate 4) divides the cranial cavity into two closed spaces which communicate with each other through the incisura tentorii. The larger anterior space includes the anterior and middle cranial fossas and lodges the cerebrum; the small posterior space—the posterior cranial fossa—contains the cerebellum, the pons, and the medulla. A frontal section through the back part of the head, posterior to the incisura tentorii (see Fig. 12), reveals four separate compartments having apparently no connection with each other, since the falx cerebri, the falx cerebelli, and the tentorium form a cross-like partition which separates the hemispheres of the cerebrum and cerebellum. The plane of such a cross-section will be better understood after a study of other illustrations (Fig. 9, Plate 4). The following relations will be made more clear to the mind of the reader by looking at the base of a skull (see Fig. 9 and Plate 1).

The *anterior cranial fossa* lodges the frontal lobes of the cerebrum; the marked development of the juga (ridges) cerebralia and of the impressiones digitatæ on the thin orbital plate of the frontal bone are due to the orbital sulci and gyri respectively. In the median line the olfactory bulb rests upon the cribriform plate of the ethmoid and gives off the olfactory filaments to the nasal cavity.

The *middle cranial fossa* contains the temporal lobes. Its posterior and lateral portion bears an important relation to the roof of the middle ear (tegmen tympani). This is the situation at which abscesses develop in the temporal lobes as the result of suppurations in the middle ear. Another important situation in the middle cranial fossa is located anteriorly near the median line, where the large semilunar ganglion is found with its three main divisions (see page 32). The posterior border of the lesser wing of the sphenoid corresponds to the deep fissure of Sylvius situated between the frontal and temporal lobes. The optic chiasm, giving off the optic nerves, is situated anteriorly in the narrow median portion of the middle cranial fossa. Further posteriorly, the hypophysis cerebri is imbedded in the sella turcica.



## PLATE 3.

The base of the brain with the twelve cranial nerves and the cerebral arteries.

The incisura tentorii transmits the so-called *isthmus cerebri*, which is formed ventrally by the crura and dorsally by the corpora quadrigemina. The occipital lobes of the cerebrum rest upon the tentorium; the lower surface of the tentorium covers the upper surface of the cerebellum, the hemispheres of which fill the deepest portions of the posterior cranial fossa (*fossæ occipitales*). The pons lies upon the upper two-thirds of the clivus, its anterior border almost

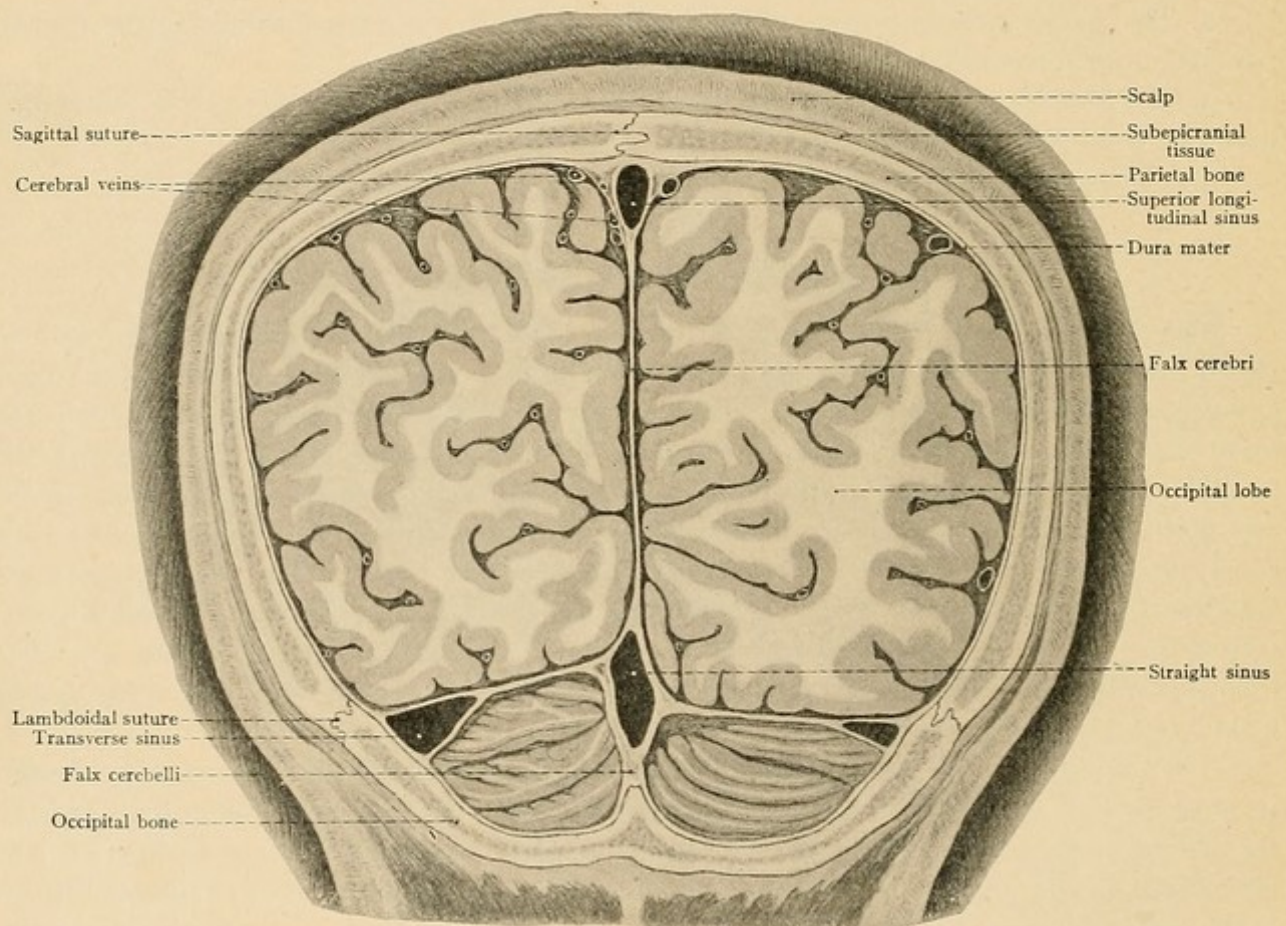


FIG. 12.—A frontal section through the posterior portion of the head (frozen section). Anterior view. The section strikes the falx cerebri, the falx cerebelli, and the tentorium cerebelli in such a way that the cranial cavity seems to contain four apparently separate compartments, in which may be seen the two cerebral and the two cerebellar hemispheres.

reaching to the dorsum of the sella turcica. The lower third of the clivus, as far down as the foramen magnum, lodges the anterior portion of the medulla oblongata which extends to the upper margin of the posterior arch of the atlas. A median sagittal section (see Plate 4) shows that the pons and medulla assume an almost vertical position. It should also be observed that the cerebrum is much more exposed to external injuries than is the better protected cerebellum.

As it is occasionally necessary to open the cranial cavity and expose definite regions of the



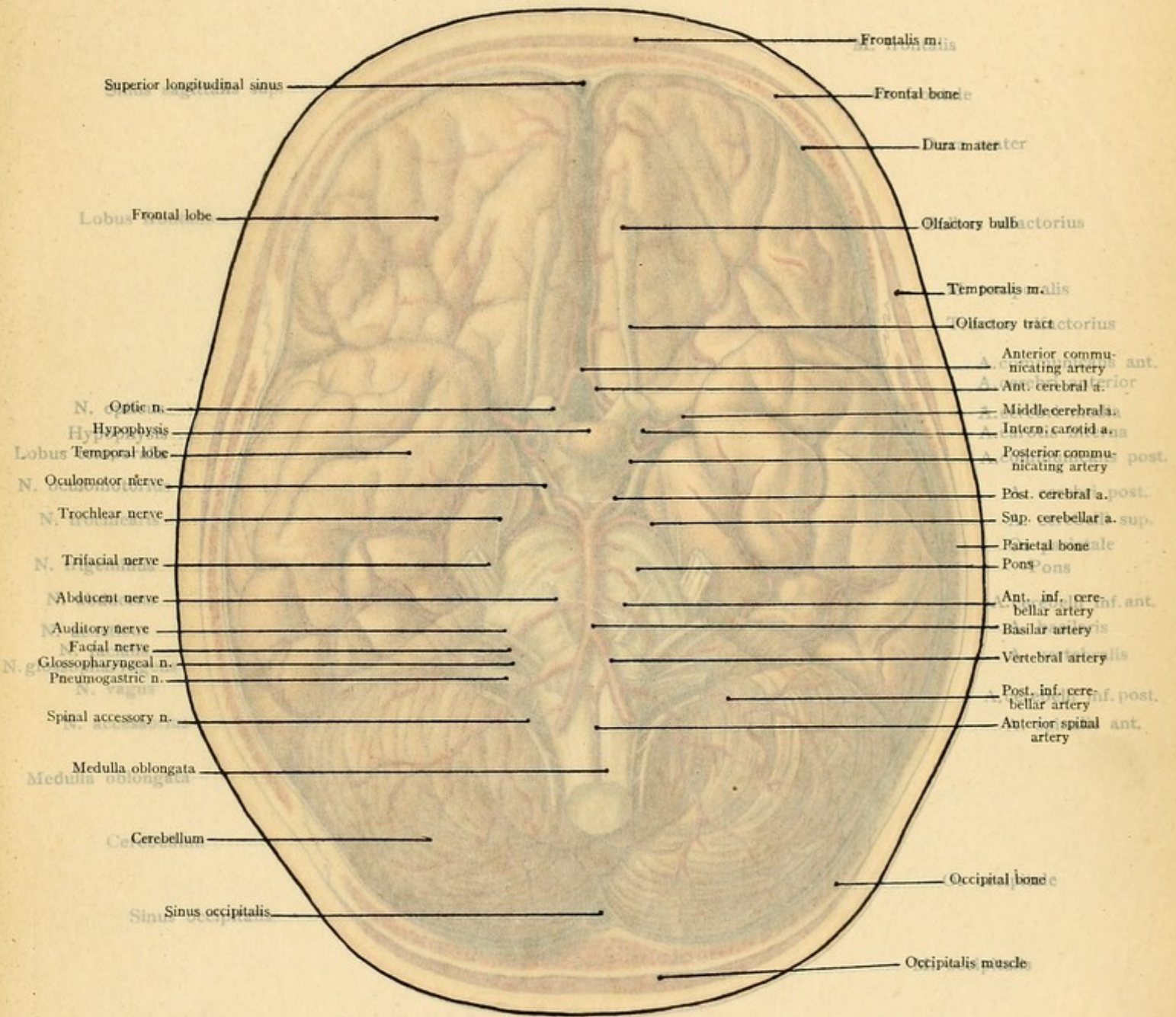




PLATE 3.

The base of the brain with the twelve cranial nerves and the cerebral arteries.

3

The incisura tentorii transmits the so-called *isthmus cerebri*, which is formed ventrally by the crura and dorsally by the corpora quadrigemina. The occipital lobes of the cerebrum rest upon the tentorium; the lower surface of the tentorium covers the upper surface of the cerebellum, the hemispheres of which fill the deepest portions of the posterior cranial fossa (fossae occipitales). The pons lies upon the upper two-thirds of the clivus, its anterior border almost

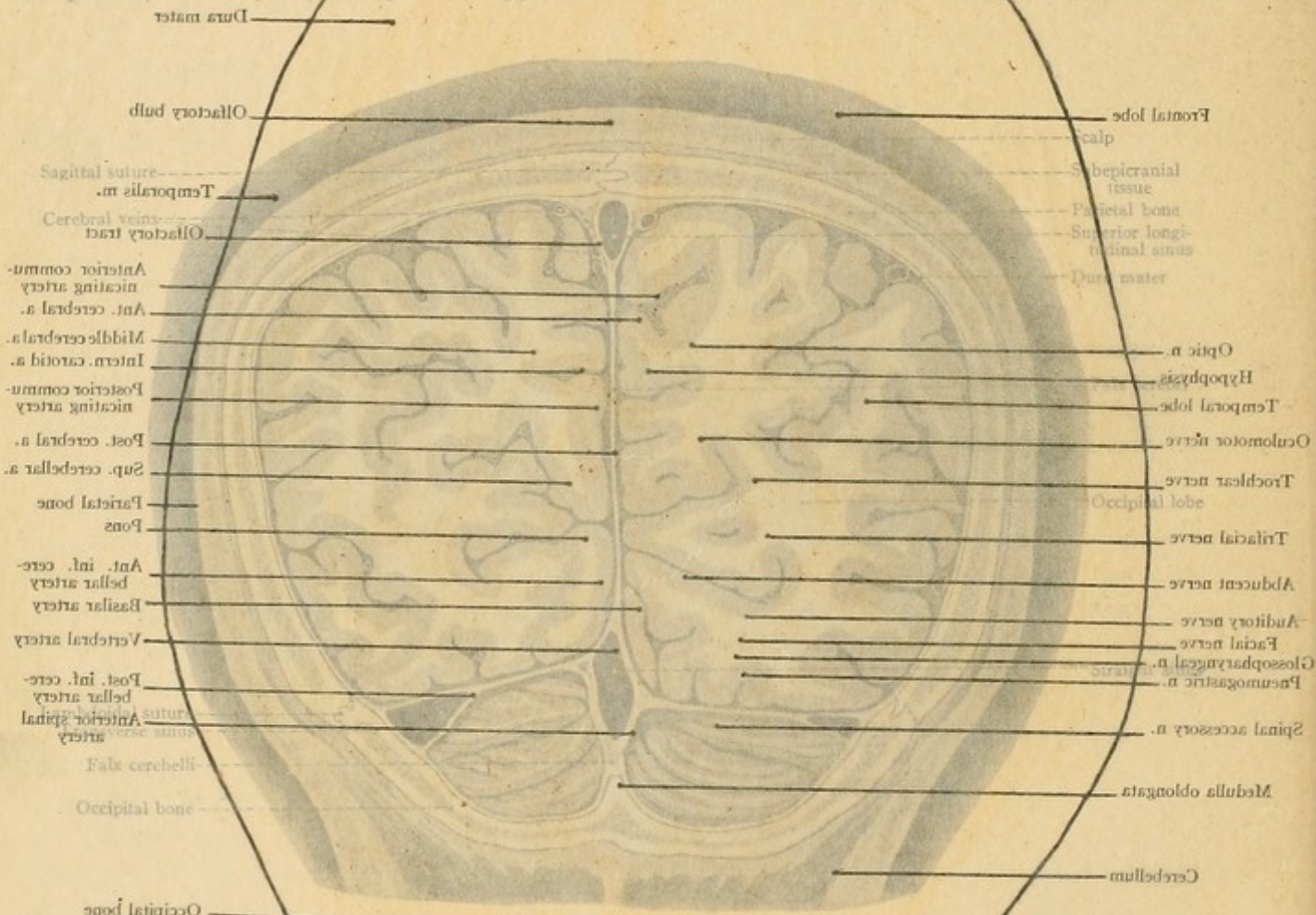
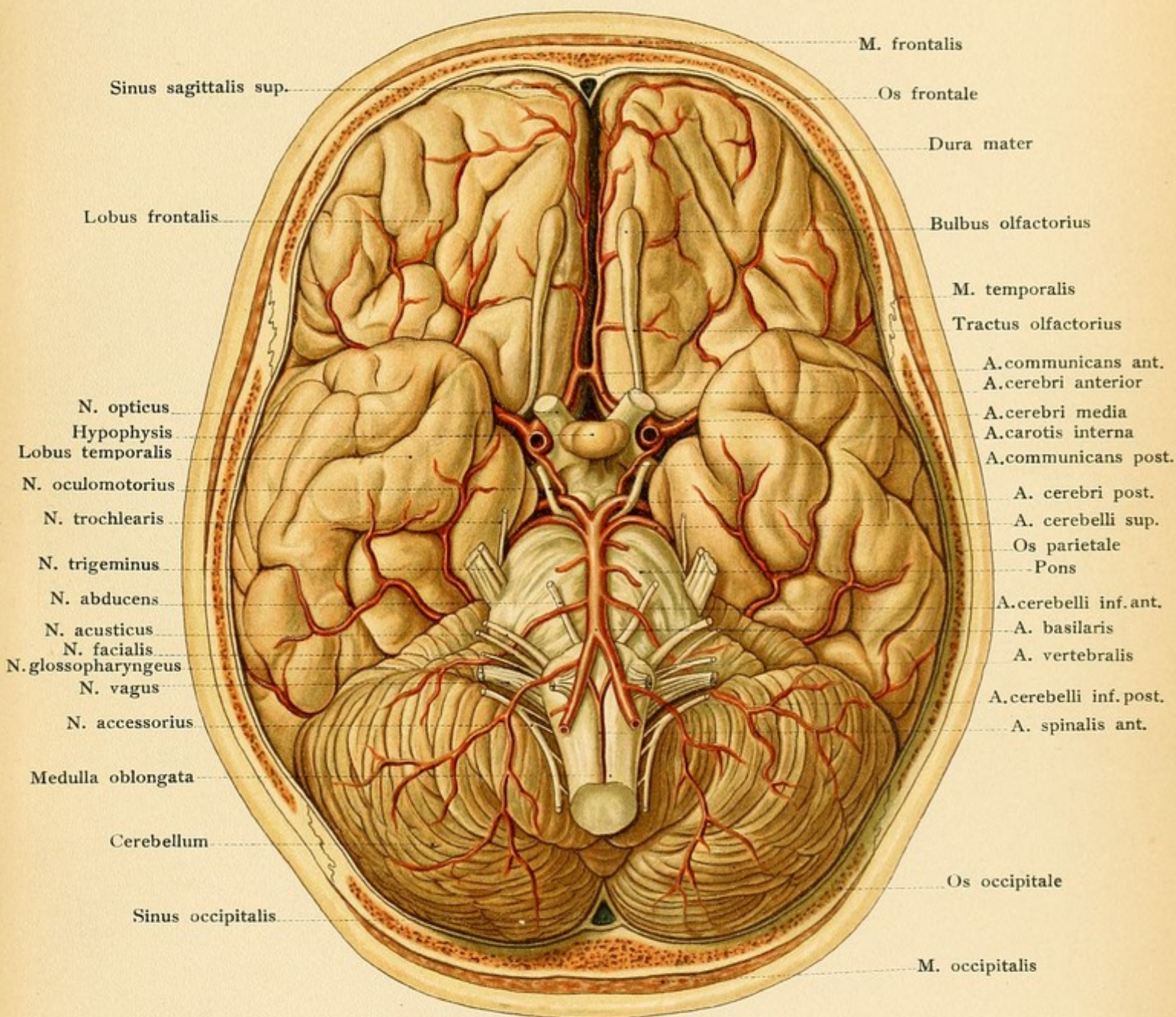


FIG. 12.—A frontal section through the posterior portion of the head (frozen section). The section strikes the falx cerebri, the falx cerebelli, and the tentorium cerebelli in such a way that the cranial cavity seems to contain four apparently separate compartments, in which may be seen the two cerebral and the two cerebellar hemispheres.

reaching to the dorsum of the sella turcica. The lower third of the clivus, as far down as the foramen magnum, lodges the anterior portion of the medulla oblongata which extends to the upper margin of the posterior arch of the atlas. A median sagittal section (see Plate 4) shows that the pons and medulla assume an almost vertical position. It should also be observed that the cerebrum is much more exposed to external injuries than is the better protected cerebellum.

As it is occasionally necessary to open the cranial cavity and expose definite regions of the











cerebral surface (in cases of cerebral abscess, tumors, and operations upon the cortex), the surgeon needs certain lines as aids in the localization. In consequence of the manifold variations in the shape of the skull, these lines are not absolutely accurate in all cases, but they nevertheless furnish indispensable guides. An exact topographic localization is never possible until the surgeon has made an extensive opening in the skull and exposed the cerebral surface. Krönlein recommends the following lines (see Fig. 13):

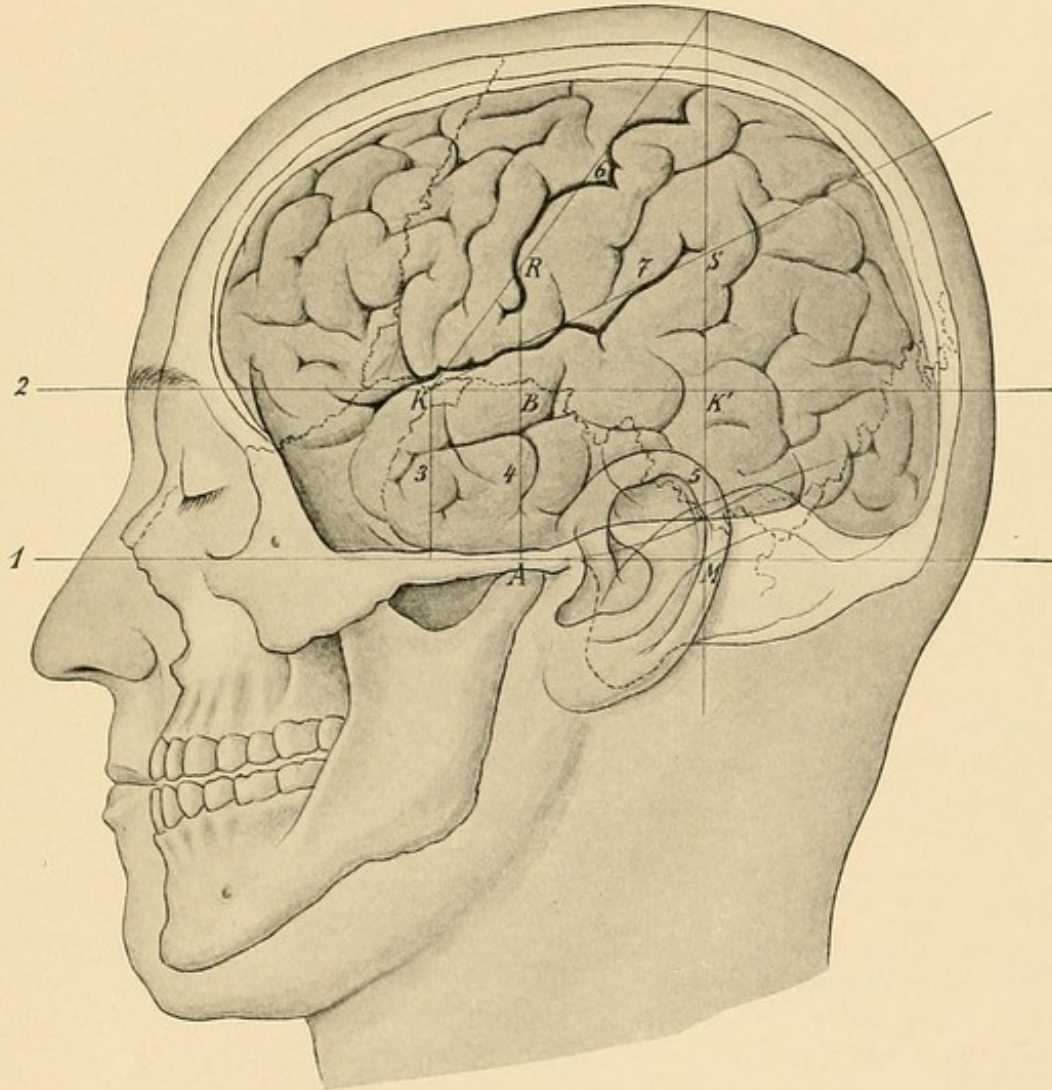


FIG. 13.—Craniocerebral topography (after Krönlein and Froriep). Explanation in the text.

1. The *base-line* (horizontal line, ear-orbit line) through the infraorbital margin and the upper border of the external auditory meatus (*Reid's base-line*).
2. The *superior horizontal line* through the supraorbital margin, parallel to the base-line (line of Krönlein).
3. The *anterior vertical line*, at right angles to the base-line at the middle of the zygoma.



4. The *middle vertical line*, at right angles to the base-line from the condyloid process of the mandible.

5. The *posterior vertical line* at right angles to the base-line from the most posterior portion of the base of the mastoid process.

If the point of intersection of the anterior vertical with the superior horizontal line is connected with the point where the posterior vertical line strikes the vertex [that is, the antero-posterior median line of the vertex.—ED.], we have:

6. The *linea Rolandi*, corresponding to the fissure of Rolando.

If the angle formed by the superior horizontal line with the line of Rolando is bisected and the bisecting line is extended to the posterior vertical line, we have:

7. The *linea Sylvii*, corresponding to the fissure of Sylvius.

The following is an explanation of the letters in Fig. 13:

K, Junction of the horizontal with the vertical limb of the fissure of Sylvius.

S, Upper end of the fissure of Sylvius.

R, Lower end of the fissure of Rolando.

K and K', indicate the two trephine openings of Krönlein for the anterior and the posterior branches respectively of the middle meningeal artery (see page 29). The rectangle ABK'M corresponds to the area resected by v. Bergmann as a preliminary step to operative measures in the middle cerebral fossa.

#### QUESTIONS.

How should the frontal sinus be opened in order to reach its communication with the nasal cavity?

What fontanelles are felt in the head of the new-born?

How may subcutaneous emphysema be produced after the frontal sinuses have been opened?

To what extent may the withdrawal of blood from the scalp—from behind the ear, for example—aid in diminishing increased intracranial blood-pressure?

Which cranial nerves are, as a result of their course, particularly apt to be affected in basal fractures and compressed against the base by tumors? What is characteristic of this course?

From what situation in the face is it possible to wound the brain without a concomitant injury of the cranial bones?

Is the escape of blood or cerebrospinal fluid from the nose, in cases of basal fractures, of any value in localizing the seat of the fracture? If not, why? What vessels may be involved?

Where are the places at the base of the skull which are pushed against the brain by tumors growing from the sphenoidal sinus or from the ethmoidal cells? Find these places in the illustrations.

What difference exists between the skin of the scalp and the scalp proper, and how is the movability of both affected by their anatomic structure?

Why is it that cutaneous wounds of the scalp do not gape while wounds involving the entire scalp do?

Why is it impossible to close large cutaneous defects in the scalp by uniting the edges of the wound?

What are the characteristics, dependent upon anatomic structure, of an effusion of blood or of a suppuration in the scalp? Beneath the scalp?

Why does the skin of the scalp bleed more profusely after injury than that of any other cutaneous area? Why do large flaps in this situation adhere more readily than elsewhere?



Where may the pulsations of the temporal artery be felt?

In what situations may neurectomy of the supraorbital and of the occipitalis major nerves be performed?

Into what cleft-like spaces may the blood be poured from a wound of the middle meningeal artery?

What are the locations of the trephine openings for both branches of the middle meningeal artery?

How is access to the lateral sinus best gained from the exterior? What is the relation of the lateral sinus to the mastoid cells?

What is the explanation of the symptom of pulsating exophthalmos?

How is the semilunar ganglion best exposed from the outside of the skull, and what neighboring structures are thereby endangered?

Which cranial nerves and which large arteries are endangered in fractures or caries of the petrous portion of the temporal bone?

Which lobe of the brain lies upon the tegmen tympani? Why is it important to know this?

## THE FACIAL REGION.

### THE FACE.

The skin of the face, on account of its thinness and vascularity, furnishes the physician with an important diagnostic aid in forming a conclusion as to the general condition of his patient (redness, paleness, cyanosis). In contrast to the skin of the scalp (see page 24), it possesses great movability, which, together with its vascularity, markedly favors the performance of plastic operations. The connection of the skin with the muscles of expression is a further characteristic demanding attention. Effusions of blood into the loose subcutaneous tissue spread diffusely, so that sharply circumscribed swellings are not observed after contusions; in dropsy the entire face may be swollen. [Because of its vascularity facial wounds, even when much lacerated and contused, heal rapidly.—ED.]

The bony framework of the face, the facial skeleton, is composed of the fourteen facial bones. Six of these are paired: the superior maxilla, the palatine, the malar, the nasal, the lachrymal, and the inferior turbinated bones. The remaining two are single bones, the inferior maxilla and the vomer. The bones as well as the large portion of the ethmoid entering into the facial skeleton should be reviewed in a systematic text-book and with specimens; the same is true of the muscles of expression and of mastication.

**Arteries.**—Disregarding the branches which extend into the face from the vessels of the cranial region, the four main trunks particularly supplying the face are:

1. The *facial artery*, from the external carotid (see Plate 2).
2. The *internal maxillary artery*, one of the terminal branches of the external carotid.
3. The *ophthalmic artery*, from the internal carotid (see Plate 18).
4. The *lingual artery*, from the external carotid (see page 64).

In addition to these vessels, there are some small branches of the temporal artery, such as those passing to the parotid gland and to the auricle, as well as the transverse facial artery below, and the orbital artery above, the zygoma (Plate 2).

The *facial artery* in the neck runs in the submaxillary triangle, imbedded in the substance of the submaxillary gland [imbedded in a groove on the posterior end of the submaxillary gland, which



FIG. 14.—The relations of the vessels and of the facial nerve within and beneath the parotid gland. The gland has been divided by a vertical incision.

separates it from the more superficial facial vein (Cunningham).—ED.], and crosses the border of the jaw at the anterior margin of the masseter muscle. At this point the pulsations of the vessel may be felt and, in a given case, hemorrhage may be temporarily arrested by pressure against the jaw-bone. The artery then pursues a more or less sinuous course upon the buccinator and levator anguli oris muscles and reaches the side of the nose, where it anastomoses, as the *angular artery*, with the dorsalis nasi artery coming out of the orbit from the ophthalmic. It also forms variable anastomoses with the buccal and infraorbital branches of the internal maxillary. In the neck the vessel gives off the *ascending palatine artery*, frequently an independent branch of the external carotid, which ascends between the styloglossus and stylopharyngeus muscles to the muscles of the palate and pharynx, giving off a tonsillar branch (see page 57); the *submental* is another cervical branch which passes forward below (*i. e.*, on the outer surface of) the mylohyoid muscle and is covered by the submaxillary gland. In the face the artery gives off the *superior* and *inferior coronary arteries* which supply the mucous membrane of upper and lower lips and anastomose in the median line with their fellows of the opposite side.

The *internal maxillary artery*, one of the terminal branches of the external carotid, arises in the substance of the parotid gland behind the neck of the condyle of the lower jaw and passes to the sphenomaxillary fossa. The branches worthy of mention, in addition to those supplying the muscles of mastication, are the *inferior dental* (passing through the inferior dental canal in company with the nerve of the same name and escaping from the mental foramen), the *middle meningeal* (see page 29), the *infraorbital* (passing through the infraorbital canal with the nerve of the same name to make its exit at the infraorbital foramen), the *superior alveolar* to the teeth of the upper jaw, the *posterior palatine* and the *pterygopalatine* to the palate (nasopharynx) (through the foramina of the same name), and the *sphenopalatine*, which passes through the sphenopalatine foramen to the nasal cavity.

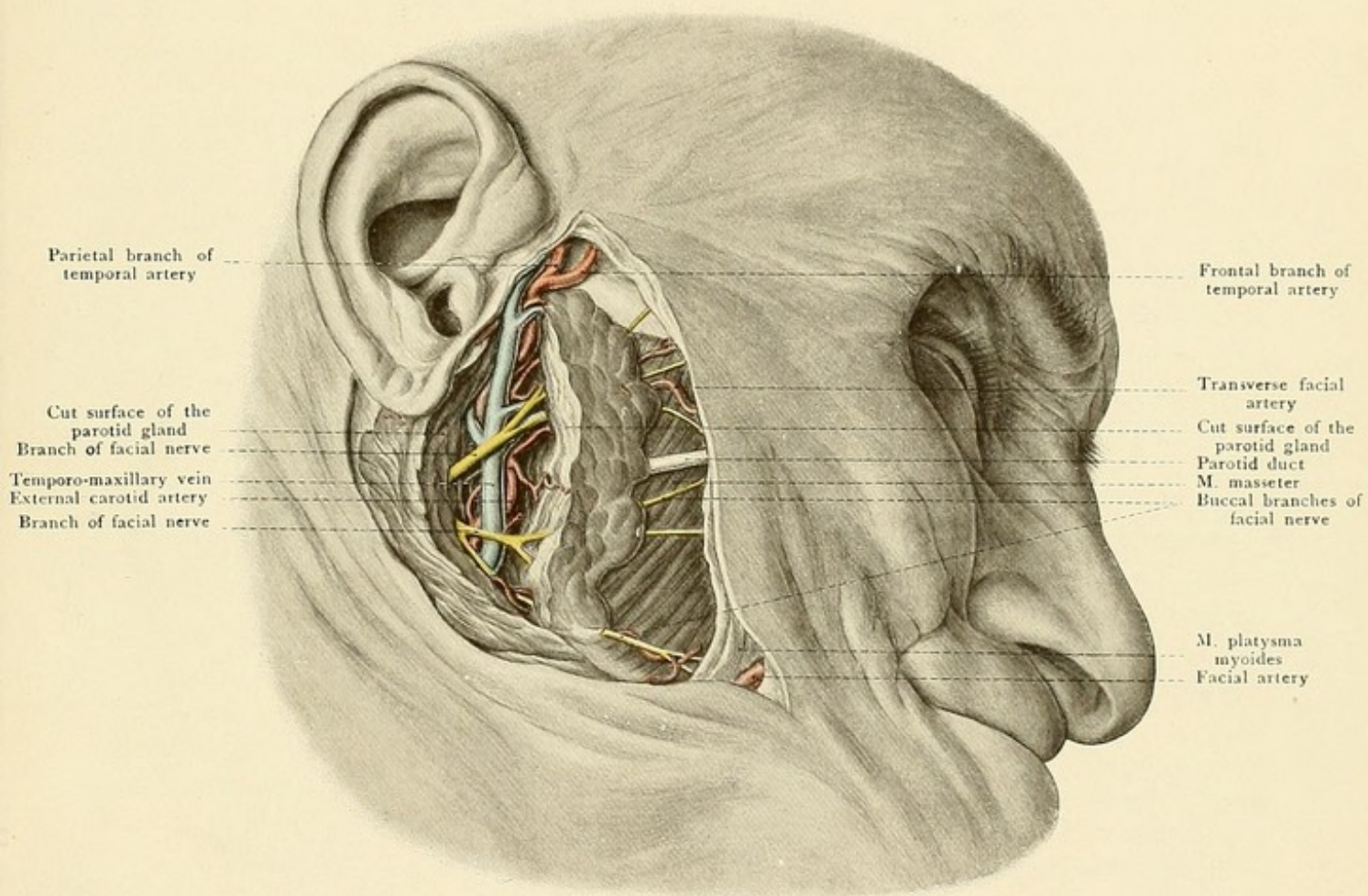
The chief **vein** of the face is the *facial*, which commences as the *angular vein*, formed by the union of frontal and supraorbital veins (see Plate 2). It is situated behind the facial artery and, though superficial to this vessel, passes beneath the zygomaticus major muscle to the angle of the jaw, where it unites with the anterior division of the temporo-maxillary vein to form a trunk which empties into the internal jugular. The *temporo-maxillary vein* is formed in the substance of the parotid gland by the union of the temporal with the internal maxillary, the latter vessel receiving blood from the pterygoid plexus in the sphenomaxillary fossa. [It divides at the lower part of the parotid gland into an anterior division, joined by the facial, and a posterior, which with posterior auricular makes up the external jugular vein.—ED.] The ophthalmic veins are described upon page 46.

The **nerves** of the face, in addition to those supplying the posterior portion of the cranial region (see page 27), are:

Sensory: 1. The *infraorbital nerve*, the termination of the superior maxillary (second division of the fifth), making its exit from the infraorbital foramen. The superior maxillary nerve reaches the orbit through the sphenomaxillary fissure and runs forward as the infraorbital nerve



Fig. 14.



Parietal branch of  
temporal artery

Frontal branch of  
temporal artery

Cut surface of the  
parotid gland  
Branch of facial nerve  
Temporo-maxillary vein  
External carotid artery  
Branch of facial nerve

Transverse facial  
artery  
Cut surface of the  
parotid gland  
Parotid duct  
M. masseter  
Buccal branches of  
facial nerve

M. platysma  
myoides  
Facial artery







in the sulcus and canal of the same name in the roof of the maxillary sinus (see Figs. 11 and 16). Neurectomy is sometimes demanded for the relief of severe neuralgia in this region. The nerve may be resected above the second bicuspid tooth at the infraorbital foramen, but it is better to make an incision down to the bone parallel to and below the infraorbital margin, elevating the orbital contents with a spatula, and resecting the nerve as far back as possible in the infraorbital fissure, after which the peripheral portion may be torn out through the infraorbital foramen. [The infraorbital foramen is about one-third of an inch below the lower margin of the orbit, opposite the junction of inner and middle thirds of this margin, and can usually be easily located with the finger.—ED.] In this operation the alveolar branches to the teeth of the upper jaw are, of course, torn away from the excised portion of the nerve. The nerve may also be exposed at the infraorbital foramen from the vestibulum oris. Since the infraorbital nerve runs in the relatively thin roof of the maxillary sinus (see Figs. 15 and 16) care must be taken to avoid injury to the sinus, which may lead to subcutaneous emphysema of the orbit. Air entering the orbit in this manner may cause exophthalmos. [When it is deemed necessary to expose and resect *Meckel's ganglion* as well as the infraorbital nerve, this is best accomplished by trephining the anterior wall of the maxillary sinus, opening the bony canal of the infraorbital from beneath, and trephining the posterior wall of the sinus, thus opening the sphenomaxillary fossa. The ganglion is slightly below the main trunk of the nerve and in intimate relation with the terminal branches of the internal maxillary artery. By this route the superior maxillary division of the fifth nerve may be easily followed to its exit from the foramen rotundum.—ED.]

The *inferior dental nerve*, a branch of the inferior maxillary division of the fifth, passes through the inferior dental canal, supplies the teeth of the lower jaw, and makes its exit at the mental foramen below the second bicuspid tooth to be distributed to the skin of the chin (see Fig. 1). This nerve is also occasionally resected, the mental foramen being exposed from the vestibulum oris or by direct incision of the overlying structures. In addition to this, the nerve may be exposed by chiseling open or by trephining the infraorbital canal between the angle of the jaw and the coronoid process.

The important *motor* nerve of the face is the *seventh cranial* nerve, the facial nerve. Its course in the petrous portion of the temporal bone (entrance at the internal auditory meatus, exit at the stylomastoid foramen) and its not infrequent involvement in caries or fracture in this situation have been previously mentioned (see page 32). After its exit from the bone, the nerve soon imbeds itself in the parotid gland, from the anterior border of which its numerous branches pass to the facial muscles (see Fig. 14). The nerve may be exposed at its exit from the stylomastoid foramen by entering behind the styloid process to the inner side of the mastoid process.

The **parotid gland** covers the posterior part of the masseter muscle as well as the temporomaxillary articulation and a considerable portion of its substance extends deeply into the retro-mandibular fossa, bounded in front by the ramus of the jaw and behind by the external auditory meatus and the mastoid process. The *parotid duct*, frequently in relation with a *socia parotidis*, passes anteriorly across the masseter and perforates the buccinator muscle to open into the mouth opposite the second upper bicuspid tooth. The orifice of the duct may be made accessible for probing by introducing the finger into the angle of the mouth and drawing the cheek away from the teeth.



The relation of the parotid gland to the retromandibular fossa furnishes sufficient explanation for the pain produced by mastication when the gland is inflamed and swollen. Since the parotid extends inward toward the pharynx it will be readily understood that large tumors proceeding from the parotid gland cause dysphagia from compression of the pharynx. The proximity of the external auditory meatus explains the occasional perforation of parotid abscesses into this canal.

In operative procedures upon the parotid gland it is rather difficult to avoid dividing branches of the facial nerve, the resulting paralysis usually being of a temporary character. It should be remembered that the trunk of the facial nerve enters the parotid gland from above and behind, at a point on a level with the base of the lobule of the ear. In total extirpation of the gland it is scarcely possible to avoid injuring the trunk. In operations penetrating deeply into the retro-mandibular fossa, it is important to remember that the external carotid artery, as well as numerous veins (particularly the temporo-maxillary), are in close relation with, or imbedded in, the median surface of the gland. [The temporo-maxillary vein and the external carotid artery usually traverse the substance of the gland, the vein being superficial to the artery and deeper than the facial nerve.—ED.] Still more deeply are found the internal carotid artery and the internal jugular vein.

#### THE ORBITAL CAVITY.

The shape of the bony orbit may be compared to that of a four-sided hollow pyramid, the base being situated at the margin of the orbit and the apex at the optic foramen. [The inner walls are almost parallel; the outer walls if prolonged backward would meet in almost a right angle. The depth of the orbit is from  $1\frac{3}{4}$  to 2 inches.—ED.] It should be carefully studied from a skull.

The *upper wall* is formed by the very thin orbital plate of the frontal bone (see Figs. 1 and 16) and a small posterior portion by the lesser wing of the sphenoid. Externally beneath the zygomatic (external angular) process is the *lachrymal fossa*, which lodges the lachrymal gland; internally is a small depression, the *jovea trochlearis* (occasionally also a *spina trochlearis*), for the attachment of the pulley of the superior oblique muscle. In the supraorbital margin toward the inner side [near the junction of the inner and middle thirds.—ED.] is the *supra-orbital notch* or *foramen* for the passage of the nerve and artery of the same name.

The *inner wall* is formed by the lachrymal bone, the os planum of the ethmoid, and posteriorly by a portion of the lateral surface of the body of the sphenoid. Anteriorly is a depression for the lachrymal sac (and duct) (*fossa saccilachrymalis*), bounded by the inner extremity of the supraorbital margin (*crista lachrymalis anterior* of the superior maxilla) and by the lachrymal crest of the lachrymal bone (*crista lachrymalis posterior*); from this point a sound may easily be passed downward into the nasal duct which opens into the inferior meatus of the nose. Further posterior on the inner wall [between the os planum of the ethmoid and the orbital plate of the frontal.—ED.] are situated the anterior ethmoidal foramen, communicating with the cranial cavity, and the posterior ethmoidal foramen, leading to the posterior ethmoidal cells.

The *lower wall* is formed by the orbital surface of the superior maxilla containing the infraorbital groove and canal, which terminates anteriorly beneath the lower margin of the orbit at the infraorbital foramen and transmits the artery and nerve of the same name (see Figs. 1 and 16).



[The bony roof of this canal is usually deficient behind.—ED.] The external portion of the lower wall is formed anteriorly by the orbital process of the malar bone; the orbital process of the palate bone also aids in forming the most posterior portion of the floor.

The *outer wall* consists anteriorly of the orbital process of the malar bone, posteriorly of the orbital surface of the great wing of the sphenoid, and above and anteriorly of the zygomatic (external angular) process of the frontal bone. This surface presents the small temporomalar canals for the temporal and malar branches of the orbital nerve.

In addition to the optic foramen, which transmits the optic nerve and the ophthalmic artery, another communication between the bony orbit and the cranial cavity is furnished by the sphenoidal fissure (transmitting the oculomotor, the trochlear, the ophthalmic, and the abducent nerves and the ophthalmic vein). The spheno-maxillary fissure (for the infraorbital

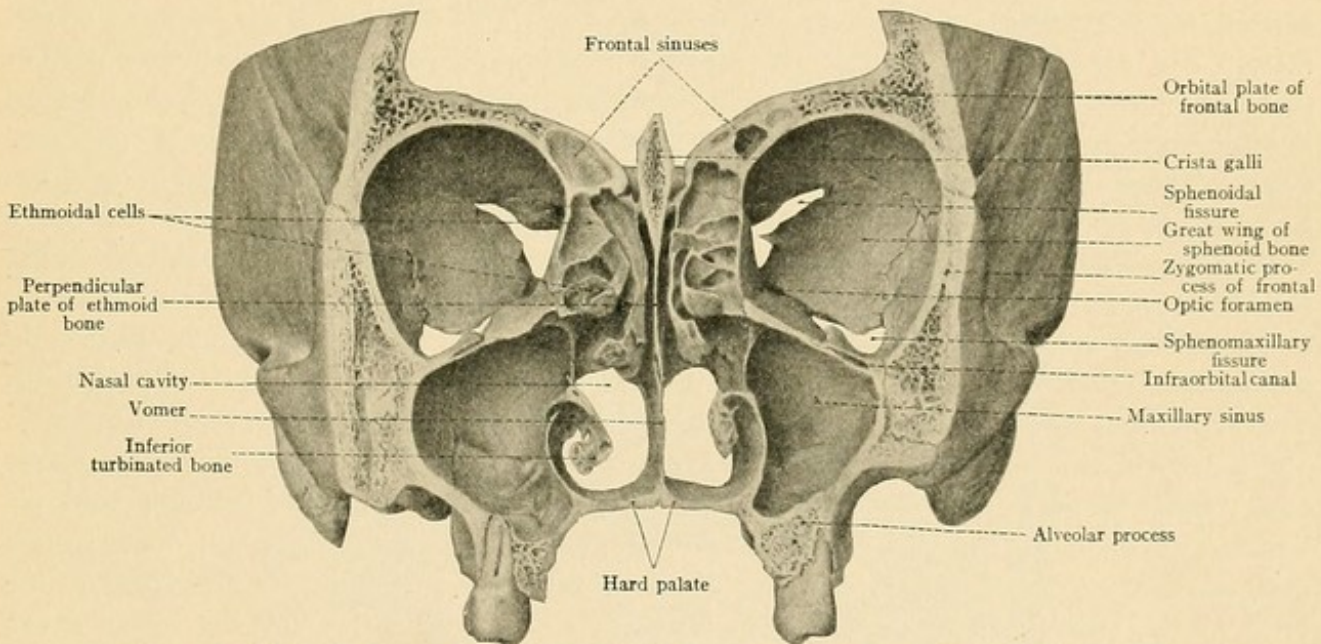


FIG. 15.—A frontal section of the bony orbits of the nasal cavities and of the maxillary sinuses.

vein) communicates in its anterior portion with the temporal fossa; the posterior portion is in connection with the spheno-maxillary fossa. [In this fissure are found the infraorbital artery as well as the vein, the superior maxillary division of the fifth nerve, the orbital branches of the same nerve, and twigs from Meckel's ganglion.—ED.]

The external wall of the orbit is the strongest. The other walls are weaker and are consequently thereby predisposed to perforation.

Since the floor of the orbit is the roof of the maxillary sinus and the os planum in the inner wall covers in the ethmoidal cells, it will be understood that when these walls are perforated, the air from these accessory cavities may enter the orbit and cause emphysema and exophthalmos. This may also be occasionally observed after perforation of the orbital roof, since the frontal sinus frequently extends into the upper wall of the orbit, in rare cases as far as the optic foramen (see Fig. 15). The relatively thin bony laminae separating the orbital cavities from the



FIG. 16.—A frontal section of the head through the orbital cavities and the maxillary sinuses (frozen section).

anterior cranial fossa, the ethmoidal cells, the maxillary sinus, and the frontal sinus, furnish an explanation for the fact that tumors growing from these adjoining regions may invade the orbit, displace the eyeball, and endanger the orbital contents.

The periosteum lining the orbit is known as the *periorbita*.

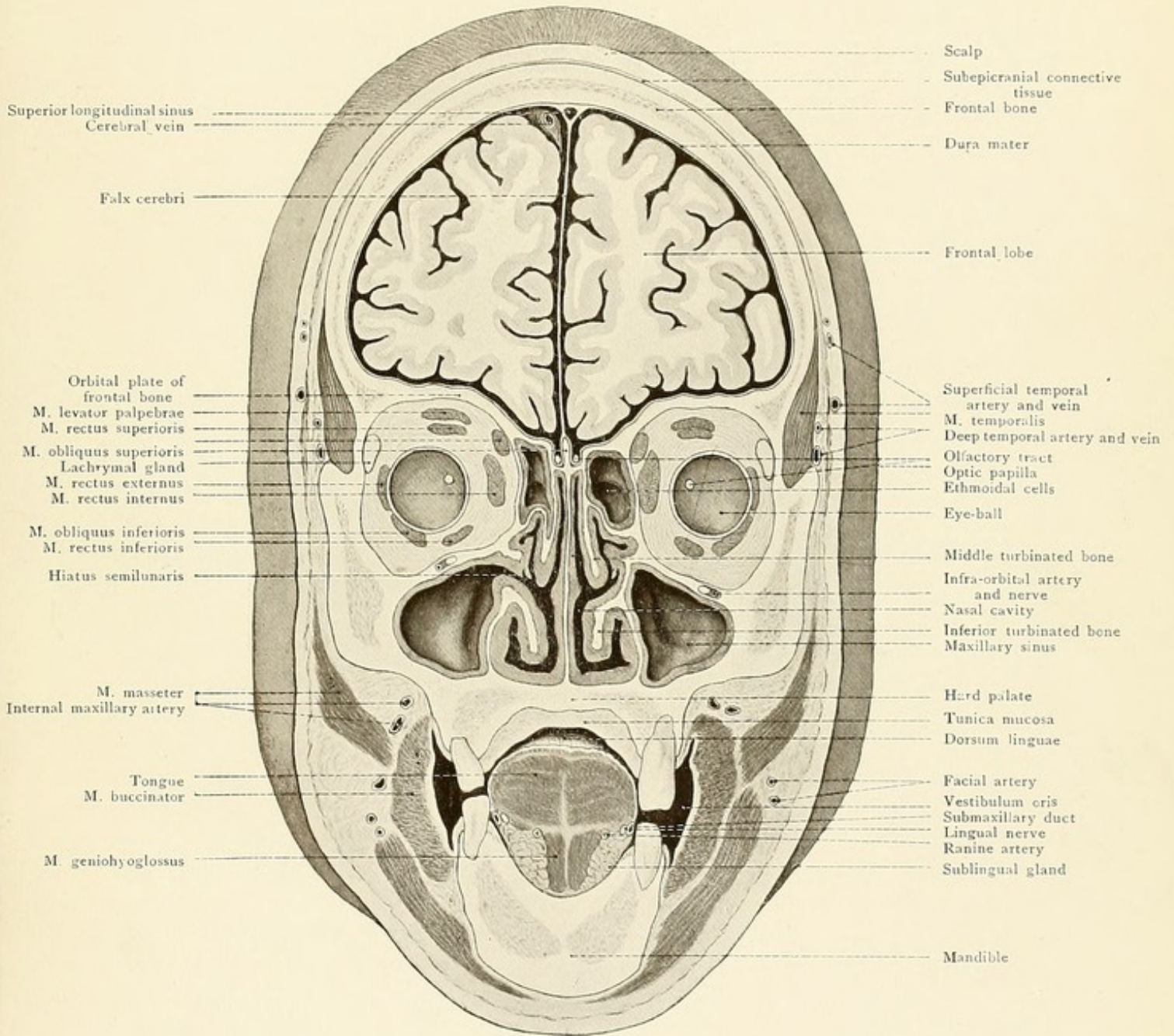
The *eyelids* are formed from cutaneous folds which grow over the protruding eyeball during fetal life and become temporarily adherent along the line of the palpebral fissure. At this fissure the skin is continuous with the mucous membrane lining the inner surface of the lid (palpebral conjunctiva) which is reflected to the eyeball at the fornix to pass anteriorly to the corneal margin as the ocular conjunctiva. Foreign bodies gaining access to the conjunctival sac occasionally become firmly lodged in the conjunctival fornix. The orbicularis palpebrarum muscle lies immediately beneath the skin, which possesses no subcutaneous fat. This muscle extends over the orbital margin and consists of an orbicular portion, of a palpebral portion, and of a lachrymal portion [the tensor tarsi—Horner's muscle.—ED.], the latter being a small bundle of fibers passing behind the lachrymal sac. The eyelids receive a certain degree of solidity from the plates of connective tissue of the so-called tarsal cartilages, which are better developed in the upper than in the lower lids. In the upper lid this cartilage contains thirty to forty, in the lower lid, twenty to thirty *Meibomian glands*, alveolar structures closely related to the sebaceous glands, which open at the anterior margin of the lid and consequently upon the external cutaneous surface. They occasionally lead to the formation of retention cysts and abscesses (stye, hordeolum). In front of the orifices of these glands, at the margin of the lids, the cilia are arranged in two or three rows. Their abnormal growth toward the eyeball leads to the disturbances of trichiasis and distichiasis. The tarsal ligament or orbital septum [palpebral ligaments of English authors, who apply the term "tarsal ligaments" to the bands which attach the inner and outer extremities of the tarsal cartilage to the superior maxilla and malar bone respectively.—ED.] is a dense lamina of connective tissue extending in a frontal plane from the periosteum of the edge of the orbit to the ciliary margin of the tarsal cartilage. It serves to close off the orbital cavity from the eyelids and may offer a certain degree of resistance to the extension of inflammations from within outward or in the opposite direction. This orbital septum is pierced by the vessels and nerves passing from the orbit to the frontal region.

When the lids are closed, the *conjunctival sac* is a slit-like space bounded by the palpebral conjunctiva, the orbital conjunctiva, and the anterior surface of the cornea. It is deepest at the middle of the eyelid, so that if the line of the fornix were projected upon the eyelid it would form a circular line the diameter of which would extend from the external to the internal canthus. The palpebral conjunctiva is more or less rich in leukocytes and small lymphatic nodules which occasionally furnish the starting-point for trachoma. It is so firmly adherent to the tarsal plate that there is no pathologic condition in which it is separated from this structure. This is in marked contrast to the ocular conjunctiva, which is so loosely attached to the eyeball that it may be pinched up into folds with the forceps; it is easily separated from the eyeball by inflammations and hemorrhages and occasionally overhangs the corneal margin.


The *lachrymal gland*, situated in the lachrymal fossa of the frontal bone, consists of a larger



Fig. 16.









superior portion and of a smaller inferior portion, the latter not always being sharply defined. The convex surface of the gland is in relation with the fossa, and the anterior border of the gland extends to the supraorbital margin, so that it may be readily exposed above the external canthus by an incision along the supraorbital margin dividing the skin, the orbicularis palpebrarum muscle, and the tarsal ligament. The lachrymal gland may also be reached through the fornix conjunctivæ without making a cutaneous incision. The *lachrymal ducts*, about ten in number, empty into the fornix above the external canthus of the eye. The two *lachrymal canals*, the inferior being somewhat broader and shorter than the superior, are about 0.5 millimeter in diameter, but they are so elastic that they may be dilated with sounds to three times this diameter. They commence at the inner ends of the palpebral margins in the *puncta lachrymalia*, which the reader may easily see in his own eye with the aid of a mirror. These puncta are situated at the summit of small elevations known as the *lachrymal papillas*. They dip into the lacus lachrymalis and take the tears from this situation to the lachrymal sac, which is lodged in a deep groove formed by the lachrymal bone and the nasal process of the superior maxillary. The upper portion of the lachrymal sac is in intimate relation with the lower end of the frontal sinus, thus explaining the occasional occurrence of purulent dacryocystitis in purulent inflammations of the frontal sinus. The *nasal duct*, a direct continuation of the lachrymal sac, runs downward in a canal of the same name to empty into the inferior meatus of the nose. The direction of this duct is not directly downward, but somewhat inward and backward, being subject to slight variation.

The most important part of the orbital contents, the *eyeball*, does not completely fill the orbital cavity. It lies in the anterior broad portion of the orbit in such a way that when the individual looks straight ahead, the center of the cornea is in a vertical line connecting the middle points of the upper and lower orbital margins. The optic nerve, entering at the optic foramen, runs approximately in the long axis of the orbit to the posterior surface of the eyeball, which it reaches some millimeters to the nasal side of the posterior pole. During this course, the nerve, surrounded by a sheath of dura and pia mater, does not run in a straight line, but in certain slight curves which vary even in carefully made sections. These small curves are probably not of much importance to the physician, but they may be important to the physiologist. With good fortune, a horizontal frozen section may strike both nerves in the same plane and show their entire course (Fig. 17).

The space between the eyeball, the optic nerve, and the periorbita is filled by the orbital fat, the voluntary muscles of the eye, the blood-vessels, and the nerves.

The *orbital fat* is separated from the eyeball by the capsule of Tenon, forming a socket in which the motions of the eyeball take place. Between the capsule and the bulbus oculi there is a capillary lymphatic space, the *spatium interjasciale* (Tenoni) or *space of Tenon*. In the vicinity of the cornea the capsule of Tenon gradually disappears in the connective tissue overlying the sclerotic coat. The ocular muscles must consequently perforate this capsule of Tenon before they become inserted into the sclerotic coat; the same is true of the vessels and nerves which enter the eyeball behind the equator. [To reach the insertions of the muscles into the sclerotic it is therefore necessary to cut two layers, the ocular conjunctiva and the capsule of Tenon.—ED.]

All of the *muscles of the eye* (see Figs. 16 and 17), with the exception of the inferior oblique, arise from the circumference of the optic foramen. As they pass forward they form a partly open hollow pyramid, the base of which is situated at about the equator of the eyeball. The



*superior, external, inferior, and internal recti muscles* are inserted into the corresponding portions of the *bulbus oculi* (globe of the eye) in front of the equator by means of flat, white, glistening tendons, in such a way that the average distance between the insertion into the sclera and the corneal margin is 7.7 millimeters for the superior, 6.9 millimeters for the external, 6.5 millimeters for the inferior, and 5.5 millimeters for the internal rectus. The long tendon of the *superior oblique muscle* is fixed by its pulley to the fovea trochlearis and passes beneath the superior rectus to be inserted behind the equator upon the upper surface of the eyeball between the attachments of the superior and external recti. The *inferior oblique muscle* arises from the floor of the orbit behind the central portion of the infraorbital margin. It runs outward and backward beneath the inferior rectus and is attached posterior to the equator, at a point midway between the insertion of the external rectus muscle and the point of entrance of the optic nerve. The *levator palpebræ superioris* almost completely covers the superior rectus and its fibers radiate to the tarsal cartilage of the upper lid. [It arises from the under surface of the lesser wing of the sphenoid.—ED.] The tendons perforate the capsule of Tenon after the fascia of the muscles has become adherent to this structure. It consequently follows that the tendinous insertions of the muscles into the eyeball may be divided from the conjunctival sac (in strabismus operations), without fearing that a complete retraction of the muscles will take place. [After enucleation of the eye the muscles through this attachment to the capsule of Tenon may provide motion to the stump and thus to an artificial eye.—ED.]

The *ophthalmic artery*, the only branch of the internal carotid not supplying the brain, is given off from the last curve of the carotid, the convexity of the curve being anterior (see page 34). It passes into the orbit through the optic foramen, in company with the optic nerve, and is situated outside and below this structure. The artery then runs inward between the optic nerve and the superior rectus and along the superior oblique muscle. It escapes from the orbit beneath the trochlea and divides into its terminal branches, the *dorsalis nasi* (anastomosing with the angular artery, the terminal branch of the facial) and the *frontal artery*. The other branches of the ophthalmic are: the *lachrymal*, to the lachrymal gland and externally to the lids; the *supra-orbital*, the largest branch, situated just beneath the periorbita and passing out of the orbit through the supraorbital notch or foramen; the *anterior and posterior ethmoidal*, running through the foramina of the same name; the important arteries of the interior of the eye, the *long and short ciliary*; and the small important terminal branch, the *arteria centralis retinae*. The vessel also gives off muscular branches.

The *veins of the orbital cavity*, occasionally leading to exophthalmos as a result of venous stasis, unite to form two pronounced trunks. The *superior ophthalmic vein*, the larger of the two, is situated at first at the inner side of the orbit; it passes outward between the optic nerve and the superior rectus and empties into the cavernous sinus through the sphenoidal fissure. At the inner canthus this vessel anastomoses with the angular vein (from the facial) and with the frontal vein (see Plate 2). The *inferior ophthalmic vein* arises in the central portion of the floor of the orbit and empties partly through the sphenoidal fissure into the cavernous sinus and partly through the sphenomaxillary fissure into the region drained by the facial vein. This inferior ophthalmic vein may be absent. Valves are not present in any of these veins.

The *nerves of the orbit*, in addition to the optic, are the sensory first division of the trifacial,



the *ophthalmic*, with its three branches, and the nerves supplying the ocular muscles—the *oculomotor*, the *trochlear*, and the *abducent*. All these nerves, except the optic, enter the orbit through

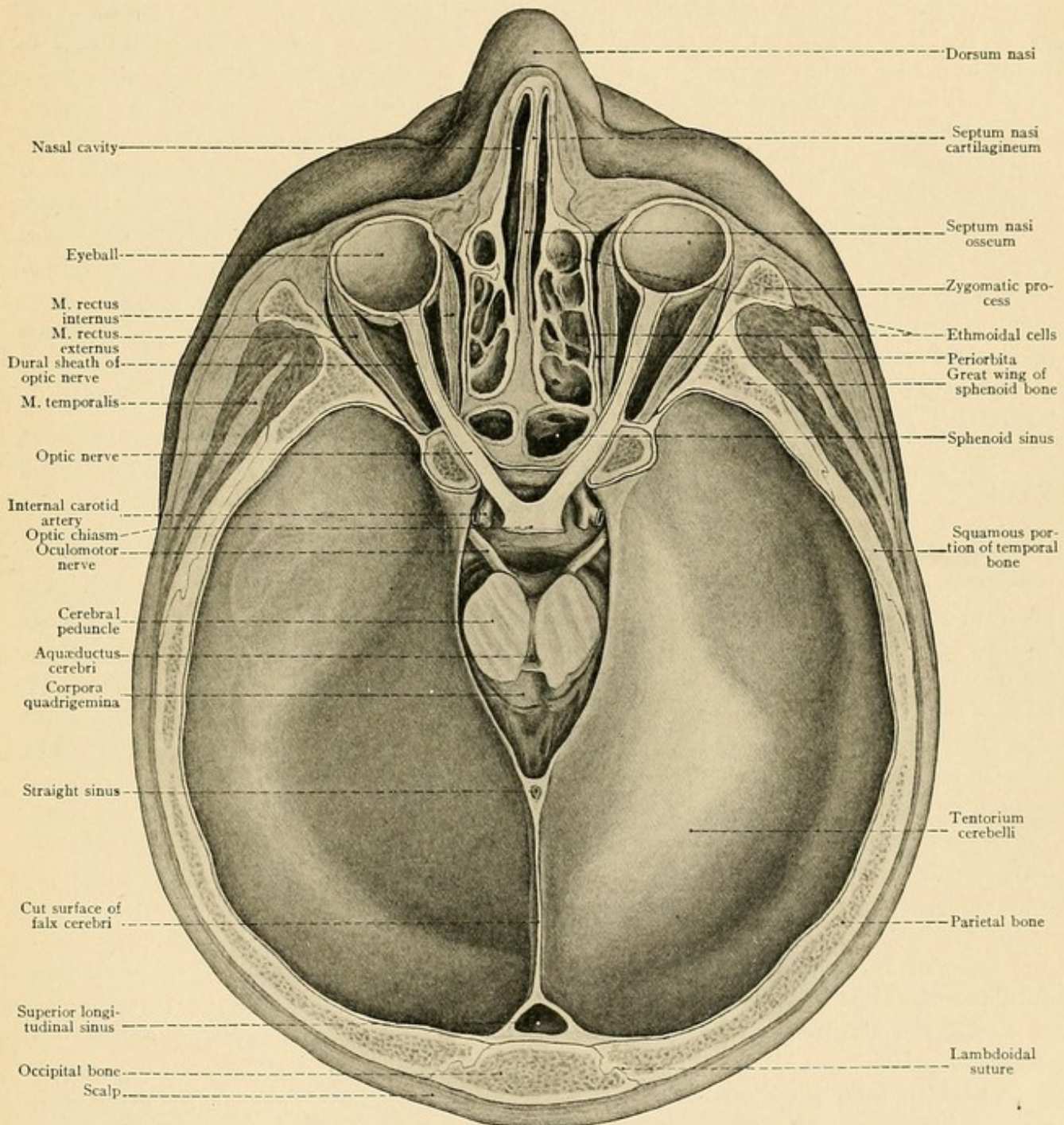


FIG. 17.—A horizontal section of the head in the plane of the palpebral fissures (frozen section). The plane of section passes through the orbits in such a way as to show the entire length of the optic nerves as well as a portion of the optic chiasm. The cerebellum lies in the posterior cerebral fossa and is covered in by the tentorium cerebelli, which has been left intact. In the incisura tentorii may be seen the cross-sections of the two cerebral peduncles; the entire cerebrum has been removed.



the sphenoidal fissure. The most superficial nerve, and the one first exposed beneath the periorbita after chiseling open the orbit from the frontal cavity, is the frontal branch (upon the levator palpebræ superioris) of the ophthalmic nerve, which has already been mentioned in the section upon the scalp. The second branch of the ophthalmic nerve, the *lachrymal* (to the lachrymal gland), is also superficial, while the third branch, the *nasal nerve*, passes internally between the posterior portion of the superior rectus muscle and the optic nerve, gives off the long ciliary nerves to the eyeball, and divides into the infratrochlear, the anterior ethmoidal, and the posterior ethmoidal nerves. The *trochlear nerve* runs along the upper and inner portion of the orbit to the superior oblique muscle. The *abducent nerve*, situated to the outer side of the optic nerve in association with the nasal nerve, passes to the external rectus muscle. All of the remaining ocular muscles are supplied by the oculomotor nerve, which divides before it enters the orbit into a superior division, for the levator palpebræ superioris and the superior rectus, and into an inferior division, for the internal rectus, the inferior rectus, and the inferior oblique.

The small *ciliary ganglion* is situated in the posterior portion of the orbit external to the optic nerve. Its roots and branches should be reviewed in a systematic anatomy. We also find within the orbit, but outside of the periorbita, two branches of the superior maxillary division of the trifacial, the small temporomalar nerve and the important infraorbital nerve.

#### THE NASAL CAVITY.

The nasal cavities are paired structures, the bony framework of which is open anteriorly at the *apertura pyriformis* (anterior nares) and posteriorly at the *choanæ* (posterior nares). The apertura pyriformis is formed by the lower margin of the nasal bone and by the margin which separates the facial from the nasal surface of the superior maxilla. The choanæ are bounded by the posterior edge of the vomer, by the pterygoid process of the sphenoid, and by the horizontal plate of the palate bone.

The roof of the bony fossa is formed by the nasal bone, by the thin cribriform plate of the ethmoid transmitting the olfactory filaments, and posteriorly by the body of the sphenoid, whose anterior as well as inferior surfaces project into the nasal cavity, diminishing the vertical diameter of this cavity to the extent of the vertical diameter of the body of the sphenoid. The sphenoid body contains the two sphenoidal sinuses. A pointed instrument may be driven into the brain from the nasal cavity, through the cribriform plate of the ethmoid, without using a great deal of force.

The *floor of the nasal fossa*, when the individual looks straight ahead, slopes gently downward and backward and is slightly concave from side to side. It consists of the palatal process of the superior maxilla and of the horizontal plate of the palate bone, which are united in the transverse palatine suture.

The *inner wall*, or the vertical septum separating the two nasal fossas, is usually deflected more or less to one side; this displacement is occasionally so marked that the affected nasal cavity is greatly narrowed or even obliterated. These deflections of the septum are due to disturbances of growth, and are to be differentiated from those occasionally produced by tumors, which grow into the nasal fossa from the base of the skull through the cribriform plate of the



ethmoid and dislocate the septum toward the healthy side. The osseous septum is composed of the *perpendicular* plate of the ethmoid bone and of the *vomer*. The alæ of the vomer articulate with the lower surface of the body of the sphenoid; its lower border rests upon the nasal crest of the hard palate, the posterior free border divides the two choanæ, and the superior portion of the anterior border of the bone is united with the perpendicular plate of the ethmoid. Anteriorly the septum is completed by the *triangular cartilage*.

The structure of the *outer wall* of the nasal fossa is complicated by the presence of the turbinated bones and of the orifices of the numerous accessory cavities (see Fig. 19). Above and in front are the nasal bone, the nasal process of the superior maxilla, and the lachrymal bone; behind these are the nasal surface of the superior maxilla with the large orifice of the antrum of Highmore, the lateral masses of the ethmoid with the superior and middle turbinated bones, and, still further posterior, the vertical plate of the palate bone and the pterygoid process of the sphenoid. The inferior turbinated bone, articulating with the inferior turbinated crests of the superior maxillary and palate bones, is an independent bone (one of the six paired bones of the face).

The inferior meatus is situated between the floor of the nasal cavity and the inferior turbinated bone; the middle meatus is between the inferior and middle, and the superior meatus is between the middle and superior turbinated bones. The meatuses communicate with the main portion of the nasal cavity beneath the overhanging turbinated bones; they run from before backward, and are shorter and narrower as we pass from below upward.

The nasal cavity communicates with the mouth through the bony anterior palatine canal, which commences as a double foramen on the nasal floor, one foramen being situated to either side of the nasal septum, and ends as a single foramen in the anterior portion of the oral surface of the hard palate. The canal for the nasal duct passes down from the orbit to open into the inferior meatus. The nasal fossa communicates with the cranial cavity through the numerous foramina in the cribriform plate of the ethmoid (for the olfactory filaments) and with the sphenomaxillary fossa through the sphenopalatine foramen (for the sphenopalatine artery and the superior nasal and naso-palatine nerves).

The wide orifice of the antrum of Highmore in the isolated superior maxillary bone is considerably encroached upon during life by the articulation and imposition of neighboring bones. These bones are the perpendicular plate of the palate bone, the inferior turbinated bone with its maxillary process, and the uncinatè process of the ethmoid.

[Above and from before backward the outer osseous wall is made up by the nasal bone, nasal process of the superior maxilla, lachrymal bone, lateral mass of ethmoid, and the orbital process of the vertical plate of the palate bone. Below and from before backward the outer wall is made up of the nasal aspect of the body of the sphenoid, the vertical plate of the palate, and the inner plate of the pterygoid process of the sphenoid bone.

The nasal aspect of the body of the superior maxilla presents the opening leading into the antrum of Highmore (superior maxillary sinus). This opening is partially closed in by bone and mucous membrane. The lower half is completely closed by the maxillary process of the inferior turbinated and the maxillary process of the vertical plate of the palate bone. Above, the antral opening is partially closed by the uncinatè process of the ethmoid bone passing down from before backward in a curved direction to articulate with the ethmoid process of the inferior



turbinate bone. This divides the upper portion of the antral opening into two parts, of which the posterior half is usually closed in by mucous membrane, while the anterior part presents the normal opening leading into the superior maxillary sinus. These openings lead from the antrum into the middle meatus.—ED.]

The *skin of the nose*, though movable upon the underlying bones, is so firmly adherent to the nasal cartilages that cutaneous defects cannot be closed by approximating the edges of the wound, and the scars following such defects do not undergo very marked contraction. In the vicinity of the alæ the skin is particularly rich in sebaceous glands, which through the retention of their secretion and the occasional appearance of the *demodex folliculorum* may lead to the formation of "black-heads" (comedones). At the nostril the skin with its hairs (*vibrissæ*) and sebaceous glands is continued into the nasal cavity, the glands and hair gradually disappearing, but the epidermic character being maintained as far as the region of the anterior nares. This portion of the nasal cavity is known as the *vestibulum nasi*.

The *olfactory region* is the only portion of the nasal mucous membrane containing olfactory cells; it covers the superior turbinated bone, occasionally a small region of the middle turbinated bone, and the opposite portion of the septum. The mucous membrane of the respiratory region is devoid of a submucous layer and adheres directly to the periosteum. It is predisposed to swellings on account of the cavernous tissue, which is especially developed upon the free borders of the inferior and middle turbinated bones. The mucous membrane also lines the accessory cavities, becoming much thinner and losing almost all of its glands as it passes in through their orifices.

There are no large *arteries* of surgical importance within the nasal cavity. Marked hemorrhages, usually of capillary or venous origin, are consequently controlled by plugging. The largest artery is the *sphenopalatine*, a branch of the internal maxillary, which passes from the sphenomaxillary fossa through the sphenopalatine foramen to the outer and inner walls of the nasal chamber. The other arteries are the small anterior and posterior ethmoidal (from the ophthalmic) and the anastomoses of the facial and of the palatine arteries in the region of the alæ of the nose.

The *veins* of the nasal cavity are particularly well developed; they form superficial and deep plexuses as well as the cavernous tissue upon the turbinated bones. The *ethmoidal veins* (accompanying the arteries of the same name) empty into the superior longitudinal sinus. The veins of the nose are also connected with the veins of the cranial cavity through the cribriform plate of the ethmoid; the foramen cæcum transmits an emissary vein in the child but not in the adult. The connection of the veins of the nasal cavity with those of the brain explains the relief afforded in a severe headache after bleeding from the nose.

The *nerves* of the nasal cavity, disregarding those of special sense, the olfactory filaments (see page 21), are the sensory nerves supplying the mucous membrane and proceeding from the first and second divisions of the trifacial. The *nasal nerve* is given off from the ophthalmic or first division of the trifacial, passes through the anterior ethmoidal foramen, pursues a short subdural course in the cranial cavity, and runs through the cribriform plate of the ethmoid toward the *vestibulum nasi*; it gives off an external branch which reaches the skin of the nose below the lower border of the nasal bone. The main nervous filaments come from the sphenopalatine



ganglion in the spheno-maxillary fossa and pass through the spheno-palatine foramen as the *superior nasal* and *naso-palatine nerves* to the lateral and median walls of the nasal cavity. The naso-palatine nerve runs upon the septum as far as the foramen of Scarpa. When the surgeon operates in this deep region, he has other things to think about than this little nerve.

The *maxillary sinus* or *antrum of Highmore* is the largest of the accessory cavities of the nose. It is separated from the orbit by the orbital plate of the superior maxilla and extends posteriorly, entirely filling the body of this bone. Upon the floor of the sinus the sockets of the molar teeth frequently produce elevations, or the apex of the tooth-socket opens directly into the antrum so that the tip of the root is covered only by the mucous membrane of the sinus. This is the situation

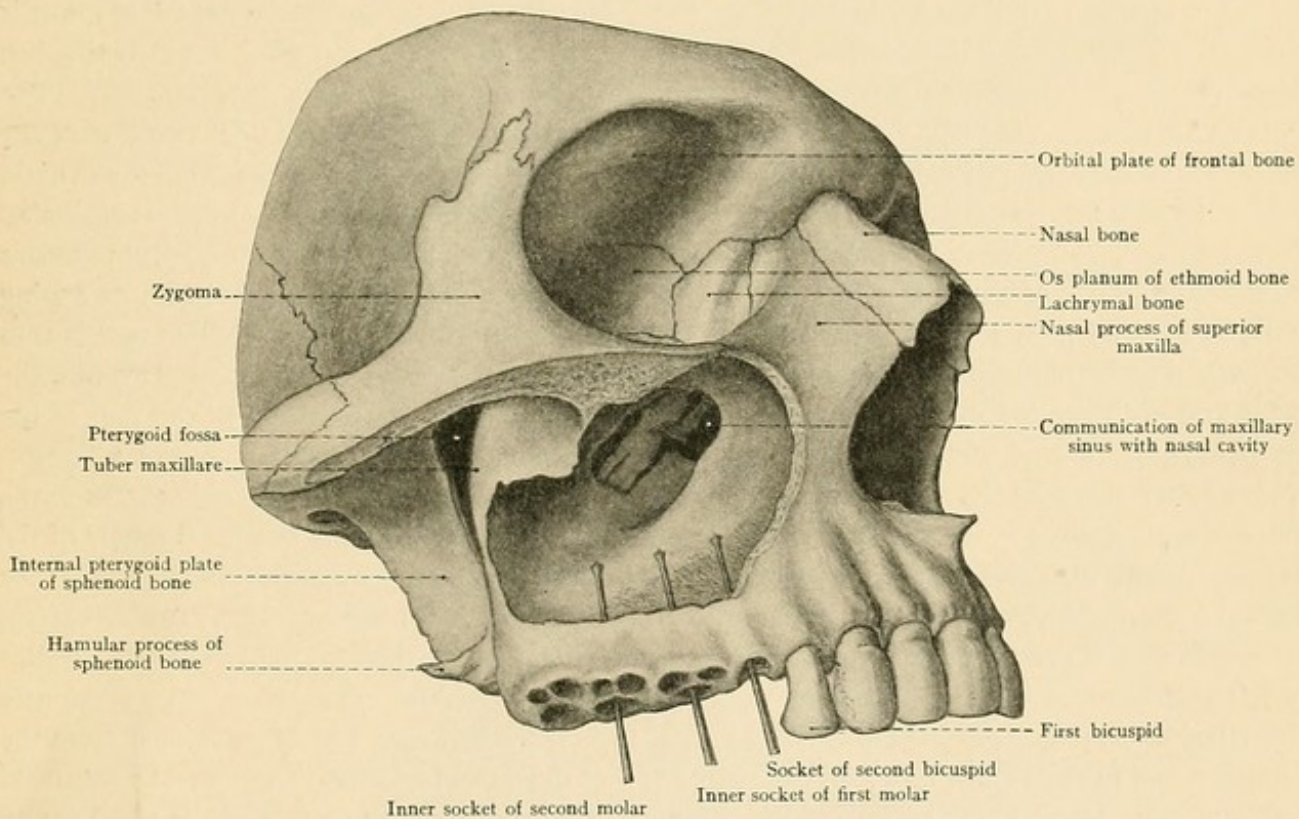


FIG. 18.—A portion of the skull in which the outer wall of the maxillary sinus has been removed in order to show its communication with the nasal cavity and the relations of the dental alveoli to the floor of the sinus. The alveoli have been perforated from below.

in which diseases of the roots of the back teeth occasionally lead to inflammations and purulent collections in the maxillary sinus. Since the orifice of the sinus is situated so high up (see Figs. 15 and 16) that it is inadequate for drainage, in such cases the sinus must be opened at its most dependent portion. A tooth is extracted and the floor of the sinus perforated through the alveolus to allow of the evacuation of the contents of the sinus. Fig. 18 shows the relation of the sockets of the back teeth to the floor of the maxillary sinus, the outer wall of which has been removed by the chisel. It will be seen that the inner sockets of the first and second molar teeth are the ones most favorably situated for the performance of this operation.



FIG. 19.—The lateral wall of the left nasal cavity. Almost the entire middle turbinated bone has been excised in order to expose the structures and orifices situated beneath it. A piece has been removed from the anterior portion of the inferior turbinated bone. The original borders of the turbinated bones are indicated by dotted lines. The superior turbinated bone is intact. The orifices of the left sphenoidal and frontal sinuses are shown by arrows.

FIG. 20.—Sublingual region, shown on a median section. The mucous membrane has been divided and the tongue is turned downward.

Another method of opening the sinus is to go through its inner wall, *i. e.*, through the thin outer wall of the nasal fossas below the inferior turbinated bone (see Figs. 15 and 19). An incision may be made through the cheek and the anterior wall of the sinus chiseled open below the infraorbital foramen. The fourth method of attacking the sinus is to chisel through its anterior wall above the alveolus from the vestibulum oris [*i. e.*, through the canine fossa external to the elevation caused by the canine tooth.—ED.] (see Fig. 16). The orifice of the maxillary sinus is situated beneath the middle turbinated bone and cannot be distinctly seen until this structure has been removed. Attempts to reach this concealed orifice in the living are usually fruitless. [The normal opening into the maxillary sinus is usually found near the most dependent portion of the hiatus semilunaris and under cover of the middle turbinated bone.—ED.] In addition to the main orifice, there is frequently an accessory opening at or beneath the margin of the middle turbinated bone (see Fig. 19). Since the inner wall of the maxillary sinus is formed by only a thin osseous lamina and partly by mucous membrane alone, it will be readily understood that tumors arising within the sinus (carcinomata, for example) grow inward into the nasal fossa. The roof is thin also and may be perforated by tumors originating in the sinus; these tumors may grow into the orbit and dislocate the eyeball. In such cases the infraorbital nerve running in the roof of the sinus may be affected and give rise to neuralgic symptoms. Such symptoms may also be produced by a fracture of the superior maxilla, in which the air from the sinus may gain access to the subcutaneous tissues of the cheek or to the orbital cavity and cause emphysema. Tumors of the maxillary sinus may also displace the anterior wall of the cavity and grow toward the face. If they extend posteriorly, they reach the sphenomaxillary fossa, and from here they may, under certain circumstances, invade the pharynx or grow into the cranial cavity through the base of the skull.

The *frontal sinuses* are also of importance to the physician. They have been previously described upon page 19. Fig. 4 shows the right frontal sinus, which has been opened from the forehead and in the depths of which the entrance into the nasal fossa may be seen. In catarrhal inflammations leading to a closure of the communication between the sinus and the nasal cavity (see page 19), the sinus may be opened in this manner and the contracted orifice dilated. In the nasal cavity this orifice is situated below the middle turbinated bone in the middle meatus at the highest portion of the slit-shaped infundibulum (see Fig. 19). During life it is usually impossible to probe this orifice from the nostril.

[By removing the anterior end of the middle turbinated bone it is possible to pass a probe into the naso-frontal duct or infundibulum. By keeping the end of the probe pressing against the turbinated side we avoid the likelihood of entering into the anterior ethmoidal cells, which form Y-shaped diverticuli leading from the naso-frontal duct.—ED.]

The paired *sphenoidal sinuses* are situated in the most posterior portion of the roof of the nasal cavity and very close to the base of the skull. The superior wall, situated in the region of the sella turcica, is very thin, and tumors growing from the sinus may consequently easily extend



Fig. 19.

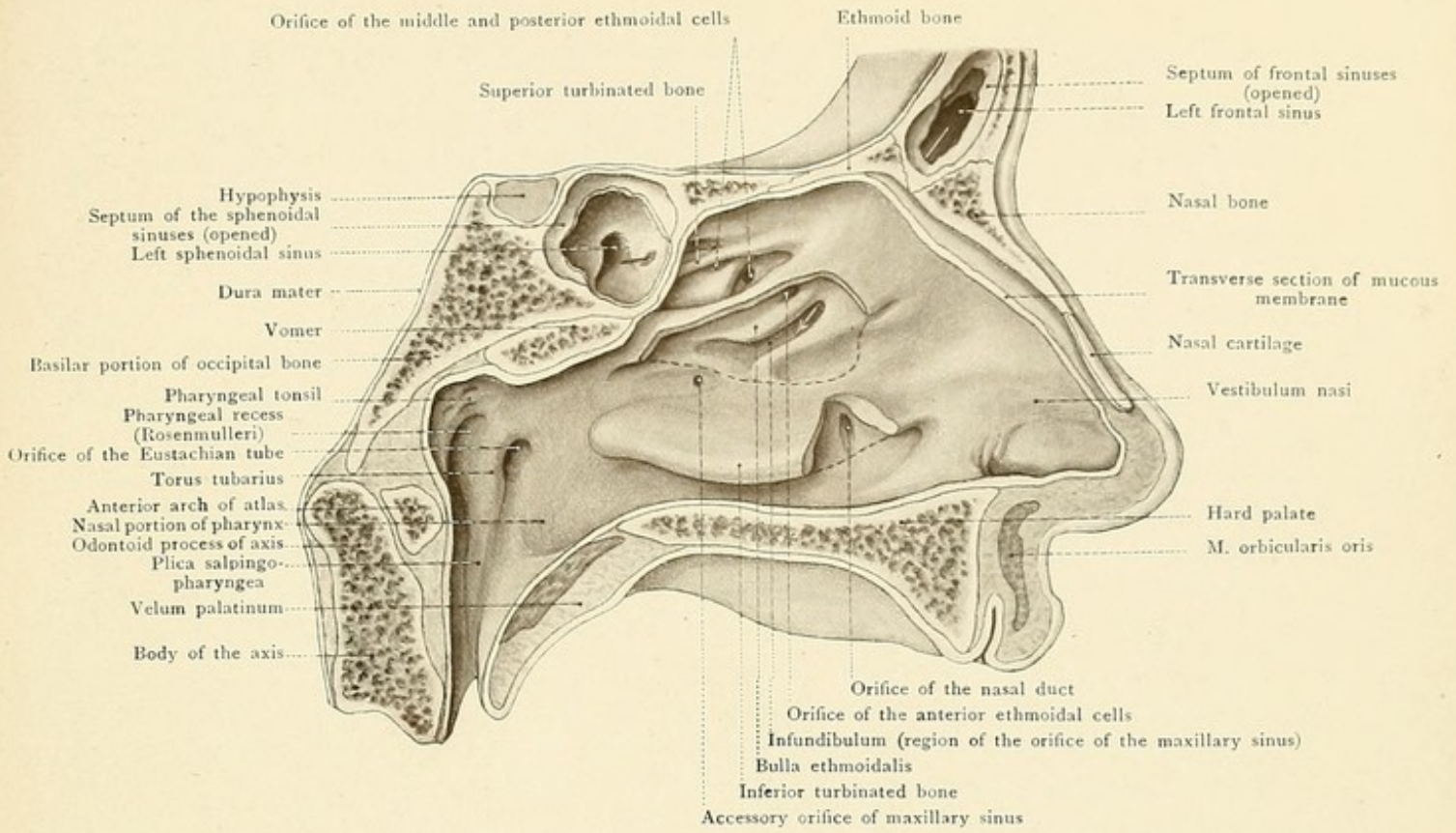
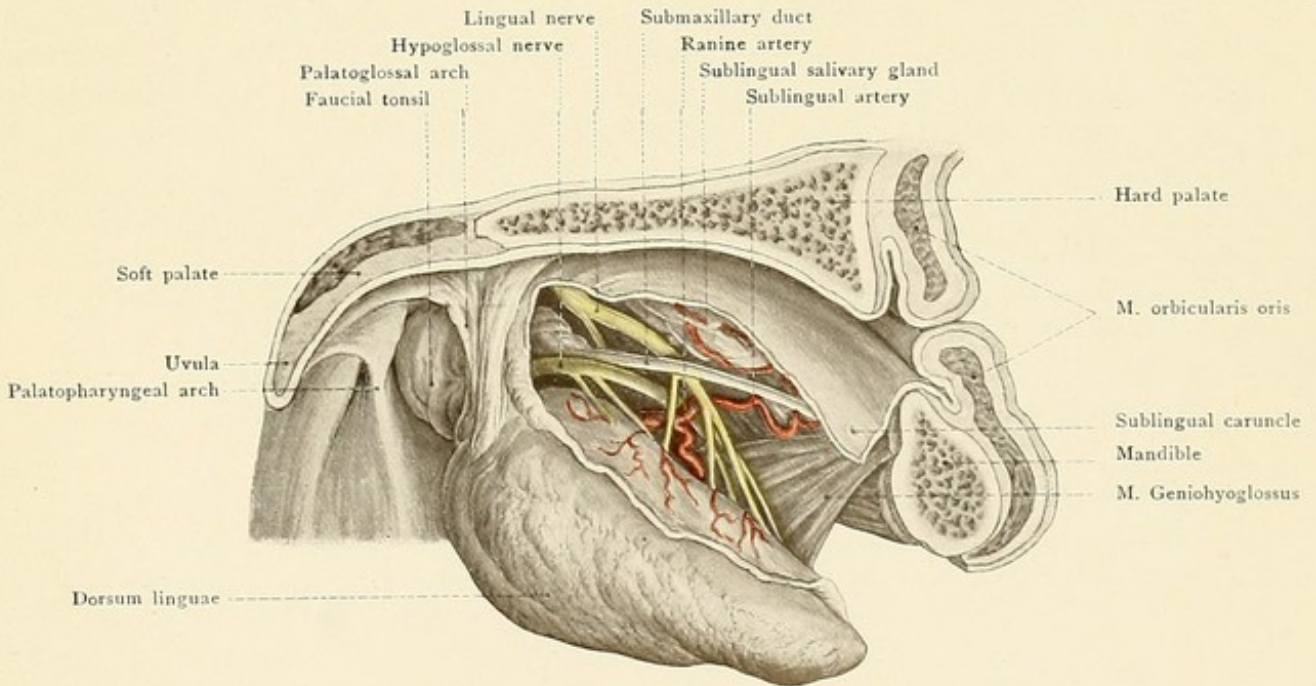


Fig. 20.









toward the base of the brain. The relation of the sinus to the internal carotid artery, which may lead to fatal hemorrhage from the nose, has been already mentioned (see page 31). The opening of the sinus into the nasal cavity is in the so-called sphenothmoidal recess, behind and above the superior turbinated bone; the orifice of the sinus, as is the case in the antrum of Highmore, is situated near its roof (see Fig. 19).

The air-cells of the lateral masses of the ethmoid bone, which occupy the upper portion of the outer wall of the nasal fossa (see Figs. 15, 16, and 17), have previously been described (see page 43), and it will readily be understood that this spongy partition between the orbital and nasal cavities may easily disappear as the result of the pressure of tumors growing into the orbit from the ethmoidal cells or from the nasal fossa. The openings leading to the ethmoidal cells are to be found upon the outer wall of the nasal fossa. In Fig. 19 the middle turbinated has been removed close to its attachment, so that the long slit-like infundibulum is exposed, passing from below upward and forward. In the anterior portion may be seen a probe which has been introduced into the frontal sinus. The normal orifice of the maxillary sinus is situated further posteriorly in the depth of the infundibulum. The entrance to the infundibulum is also designated as the *hiatus semilunaris*. [This is incorrect to call the entrance to the infundibulum the hiatus semilunaris. The hiatus semilunaris is a groove in the maxillary side of the middle meatus and runs from the naso-frontal duct above downward and backward; and since the anterior extremity of the middle meatus leads into the infundibulum, the hiatus semilunaris is simply a recess from the middle meatus beginning at the naso-frontal duct. The anterior ethmoidal cells, as well as the antral opening, open into the middle meatus *via* the hiatus semilunaris. Overhanging the hiatus semilunaris is a large ethmoidal cell called the *bulla ethmoidalis*. This cell or cells open into the middle meatus near the attached border of the middle tubinated bone at about its middle.—ED.] The ethmoidal cells usually bulge out prominently above this hiatus, forming the *bulla ethmoidalis*, and above this is the orifice of the anterior ethmoidal cells. The middle and posterior ethmoidal cells, on the contrary, open into the superior meatus. Sometimes there is still a fourth turbinated bone at a higher level, in which case the middle ethmoidal cells may open into the superior meatus and the posterior ones between the third and fourth turbinated bones.

In Fig. 19 a portion of the inferior turbinated bone has also been removed, exposing the orifice of the *nasal duct*. During life it is accessible from the nostril, but it may be probed from above to much better advantage. More worthy of note is the fact that access to the orifice of the Eustachian tube may be gained through the naso-pharynx (see Fig. 19 and Plate 4). It lies 0.5 centimeter behind the posterior extremity of the inferior turbinated bone, and is bounded posteriorly by the *torus tubarius* (an enlargement produced by the underlying tube), which may be easily located with a probe. The orifice of the Eustachian tube is six or seven centimeters from the nostril; one centimeter behind the torus tubarius is the *fossa of Rosenmüller* (*recessus infundibuliformis*), which may catch the end of the probe when an attempt is made to pass this instrument from the nostril into the tubal opening through the inferior meatus.

A study of the illustrations of the outer wall of the nasal fossa (see Figs. 15 to 19, Plate 4) will show that a chronic catarrh may extend into the Eustachian tube, into the frontal and maxillary sinuses, and posteriorly into the pharynx. Tumors proceeding from the nasal fossa may grow



through the choanæ toward the naso-pharynx and into the mouth, into the maxillary sinus, into the ethmoidal cells, into the orbit, and also through the sphenopalatine foramen into the sphenomaxillary fossa, whence they may extend outward into the temporal fossa or through the sphenomaxillary fissure into the orbit. Catarrh or new-growths in the lateral wall of the nose may lead to disturbances in the vicinity of the nasal duct.

#### THE ORAL CAVITY.

As the function of the oral cavity is to aid in the ingestion of food, it is not surrounded by bony walls to the same extent as the nasal fossas, but its boundaries are formed in many places by movable and distensible soft parts [see Fig. 20 A.—ED.]. The bony support is furnished by the hard palate and by the inferior maxillary bone, with their alveolar processes containing the teeth. The dividing-line between the mouth and the pharynx is known as the *isthmus of the fauces*. It is bounded below by the sulcus terminalis (commencing at the foramen cæcum and dividing the dorsum from the root of the tongue) and laterally and above by the palato-pharyngeal arch and the uvula (see Fig. 21). The roof of the mouth is formed by the hard and soft palates; it is covered by a thick mucous membrane, rich in glands and fat, which is immovable on account of its firm attachment to the periosteum. The mylohyoid muscle is to be looked upon as the floor of the mouth, although posteriorly the oral contents seem to extend into the neck without there being any sharp dividing-line. [Abscesses or tumors above the mylohyoid project into the mouth, those below present in the neck.—ED.]

We differentiate the vestibule (*vestibulum oris*) from the oral cavity (*cavum oris*).

The *vestibule* is a horseshoe-shaped cleft between the mucous membrane of the cheeks and lips and the teeth (see Fig. 16). If the finger is introduced into the vestibule and pushed backward, when the teeth are closed, it strikes upon the hard anterior margin of the ramus of the mandible, and the tip of the finger may be passed into the mouth (*cavum oris*) through the space between the ramus of the mandible and the last molar tooth. If the denture is perfect, this space is the only communication between the vestibule and the oral cavity (with the exception of the narrow slits between the teeth), and, in cases of trismus, it may be utilized for the introduction of liquid food, if a more favorable route has not been furnished by the loss of one or more teeth. If the tip of the index-finger is placed against the anterior border of the ramus and the teeth are firmly pressed together repeatedly, the anterior margin of the contracting masseter muscle may be distinctly felt. The orifice of the *parotid duct* (Stenson's) is situated opposite to the second upper molar [about 4 mm. below the reflection of the mucous membrane from gums to cheek.—ED.]; although small, this duct may be probed in the living subject (see page 41).

The marked elasticity of the lateral and anterior walls of the vestibule allows us to palpate the rows of teeth throughout their entire extent; it also makes it possible to recognize the altered position of the mandible in anterior dislocations of this bone. Under certain circumstances the maxillary sinus may be opened through the vestibule (see page 52).

The contents of the oral cavity, as well as the region between the mouth and the pharynx, should be studied as far as possible in the mouth of the reader with the aid of a hand-mirror and strong sunlight. If the tongue is raised, the *frænum linguæ* may be seen in the median line,



and to either side will be observed the sublingual folds, which project in varying degrees in different subjects. These folds are due to the upper margins of the sublingual glands, and to their inner side the submaxillary ducts may be exposed (for the extraction of salivary calculi, for example). The posterior portion of the sublingual gland lies upon the mylohyoid muscle, while the remainder of the gland is closely related to the inner surface of the mandible, where it produces the sublingual fossa of varying depth. The numerous invisible orifices of the gland are situated upon the sublingual folds. The sublingual gland frequently possesses a larger duct [ductus

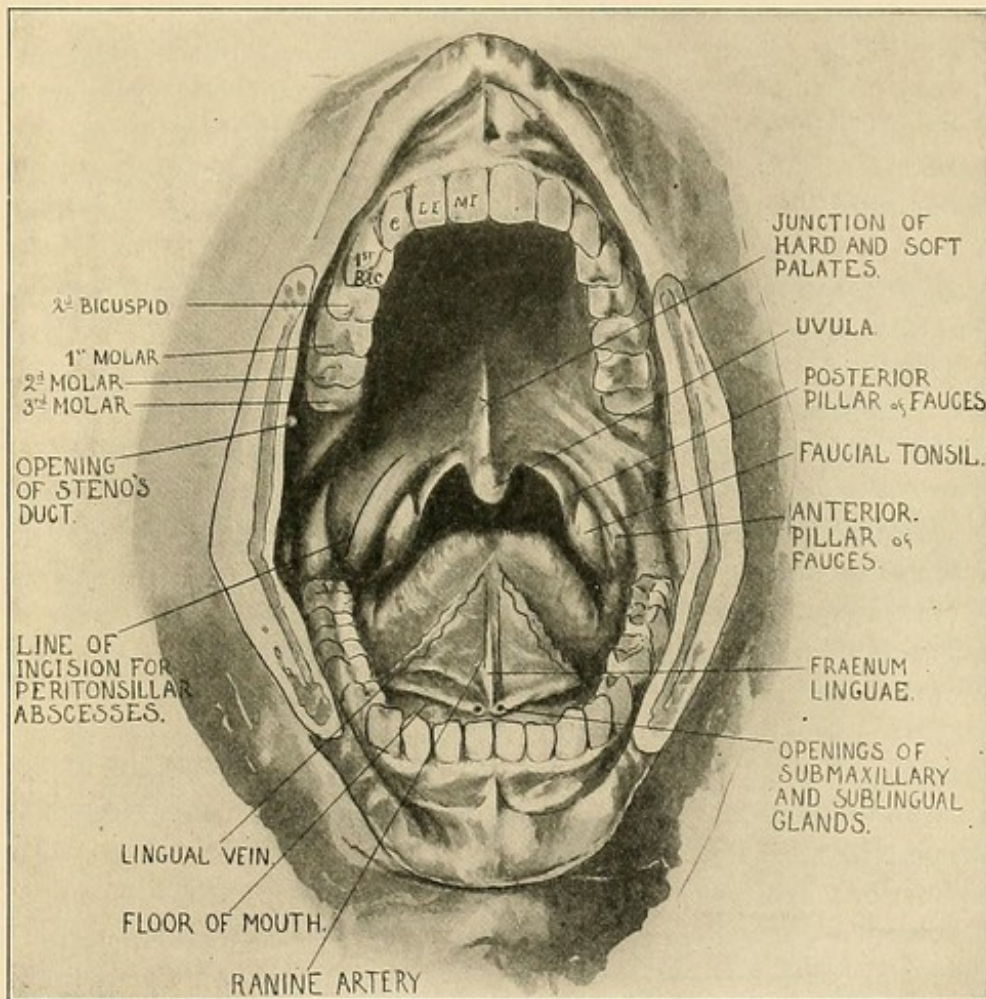


FIG. 20A.—View of adult mouth (modified from Spalteholz): M.I., Middle incisor; L.I., lateral incisor; C, canine tooth; 1st Bic., first bicuspid tooth (Eisendrath).

major Rivini or duct of Bartholin; according to Cunningham, this rarely exists in man.—ED.] which may unite with the submaxillary duct or have an independent orifice. The opening of the submaxillary duct (Wharton's) may be recognized, with the naked eye, in the *sublingual caruncle* at the anterior extremity of the plica sublingualis. [This duct and the lingual nerve lie beneath and to the inner side of the sublingual gland; the nerve on its way to the tongue crosses the duct on its inferior aspect opposite the anterior border of the hyoglossus muscle.—ED.]



## PLATE 4.

A median sagittal section of the head. Frozen section.

[Congenital dermoid cysts are frequently found in the floor of the mouth at its junction with the base of the tongue. Retention cysts of the mucous glands, of Wharton's duct, or the ducts of the sublingual glands are called *ranula*. Congenital cysts or fistulas due to incomplete closure of the thyroglossal duct—which extends from the foramen cæcum of the tongue to the isthmus of the thyroid—are always mesial; when developed from the upper part of the duct, they present in the mouth; those arising from the lower end present in the neck below the hyoid bone.—ED.]

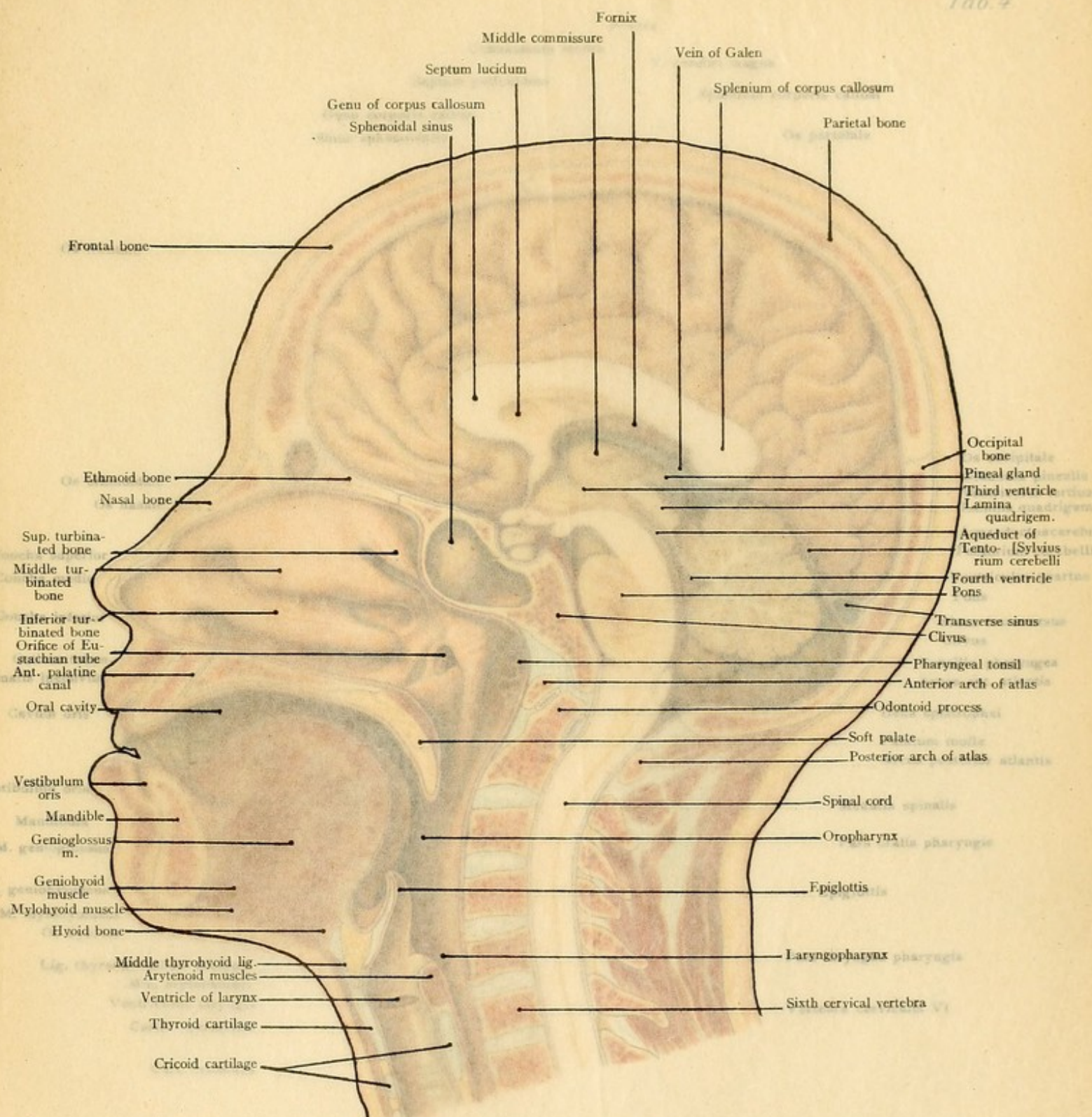
The **tongue**, the largest organ in the mouth, lies in contact with the palate when the mouth is closed. Its base reaches to the epiglottis. A median section (Plate 4) shows that a swelling of the tongue may force the epiglottis down upon the entrance of the larynx in such a manner that tracheotomy must be performed. It will also be understood that a paralysis of the muscles from profound narcosis will allow the tongue and epiglottis to fall back so that respiration is interfered with.

The *lingual artery* supplies the tongue with blood. This vessel arises in the neck from the external carotid (see page 64), passes above the greater cornu of the hyoid bone beneath the hyoglossus muscle, and, as the *ranine artery*, pursues a tortuous course in the tongue between the inferior lingualis and geniohyoglossus muscles. Although it gives off the *dorsalis linguæ*, running upward to the root of the tongue to supply the circumvallate papillas, the chief branch is the *sublingual artery*, which runs anteriorly beneath the sublingual gland to reach the gums of the incisor teeth. Above and to either side of the frænum, the artery is relatively superficial, and may be caught by a deep suture for the purpose of checking hemorrhage. There are no marked anastomoses between the arteries of the two sides. In the posterior portion of the tongue the artery is so imbedded in the soft lingual musculature that it may be impossible to control serious hemorrhage from operative procedures by ligation in the wound, and it becomes necessary to ligate the vessel in the neck.

The *lingual branch of the glossopharyngeal nerve* supplies the circumvallate papillas [that is, the posterior part of the tongue, with both gustatory and common sensory fibers.—ED.]; it is not very large and possesses no surgical importance. The sensory nerve of the tongue, the lingual branch of the inferior maxillary, which also receives gustatory fibers for the fungiform papillas from the chorda tympani, may be easily exposed beneath the mucous membrane at the side of the tongue in the neighborhood of the second molar tooth (see Fig. 20). This nerve runs over the submaxillary duct and is also accessible in the neck in the depths of the submaxillary triangle (see page 65). [According to Cunningham, Wolsey, and others, the nerve runs beneath the duct.—ED.] The motor nerve, the *hypoglossal* (see page 64), is more deeply situated [that is, from the floor of the mouth.—ED.] beneath the sublingual gland. The *inferior dental branch of the superior maxillary division of the fifth* may also be easily exposed in the mouth before it enters the inferior dental canal by means of the same incision as that for the lingual nerve. It may also be attacked by dividing the skin and masseter muscle and trephining the ramus of the jaw.

The numerous *lymphatic vessels* of the tongue lead to the submental and submaxillary lymphatic glands, which are consequently involved early in affections of the tongue.





- Frontal bone
- Ethmoid bone
- Nasal bone
- Sup. turbinated bone
- Middle turbinated bone
- Inferior turbinated bone
- Orifice of Eustachian tube
- Ant. palatine canal
- Oral cavity
- Vestibulum oris
- Mandible
- Genioglossus m.
- Geniohyoid muscle
- Mylohyoid muscle
- Hyoid bone
- Middle thyrohyoid lig.
- Arytenoid muscles
- Ventricle of larynx
- Thyroid cartilage
- Cricoid cartilage
- Sphenoidal sinus
- Septum lucidum
- Genu of corpus callosum
- Middle commissure
- Fornix
- Vein of Galen
- Splenium of corpus callosum
- Parietal bone
- Occipital bone
- Pineal gland
- Third ventricle
- Lamina quadrigem.
- Aqueduct of cerebellum
- Tentorium cerebelli
- Fourth ventricle
- Pons
- Transverse sinus
- Clivus
- Pharyngeal tonsil
- Anterior arch of atlas
- Odontoid process
- Soft palate
- Posterior arch of atlas
- Spinal cord
- Oropharynx
- Epiglottis
- Laryngopharynx
- Sixth cervical vertebra



Foraniz

Middle commissure

Vein of Galen

Septum lumbatum

A median sagittal section of the head. Frozen section.  
Genia of corpus callosum  
Sphenoidal sinus  
Tarsal bone

[Congenital dermoid cysts are frequently found in the floor of the mouth at its junction with the base of the tongue. Retention cysts of the mucous glands of Wharton's duct, or the ducts of the sublingual glands are called *ranula*. Congenital cysts or fistulas due to incomplete closure of the thyroglossal duct—which extends from the foramen cæcum of the tongue to the isthmus of the thyroid—are always mesial; when developed from the upper part of the duct, they present in the mouth; those arising from the lower end present in the neck below the hyoid bone.—ED.]

The **tongue**, the largest organ in the mouth lies in contact with the palate when the mouth is closed. Its base reaches to the epiglottis. A median section (Plate 4) shows that a swelling of the tongue may force the epiglottis down upon the entrance of the larynx in such a manner that tracheotomy must be performed. It will also be understood that a paralysis of the muscles from profound narcosis will allow the tongue and epiglottis to fall back so that respiration is interfered

The **lingual artery** supplies the tongue with blood. This vessel arises in the neck from the external carotid (see page 64), passes above the greater cornu of the hyoid bone beneath the hyo-

glossus muscle, and, as the *ranine artery*, pursues a tortuous course in the tongue between the anterior lingual and geniohyoglossus muscles. Although it gives off the *arteria lingualis*, which runs upward to the root of the tongue to supply the circumvallate papillas, the chief branch is the *sublingual artery*, which runs anteriorly beneath the sublingual gland to reach the gums of the lower jaw.

Above and to either side of the frænum, the artery is relatively superficial, and may be caught by a deep suture for the purpose of checking hemorrhage. There are no marked anastomoses between the arteries of the two sides. In the posterior portion of the tongue the artery is so

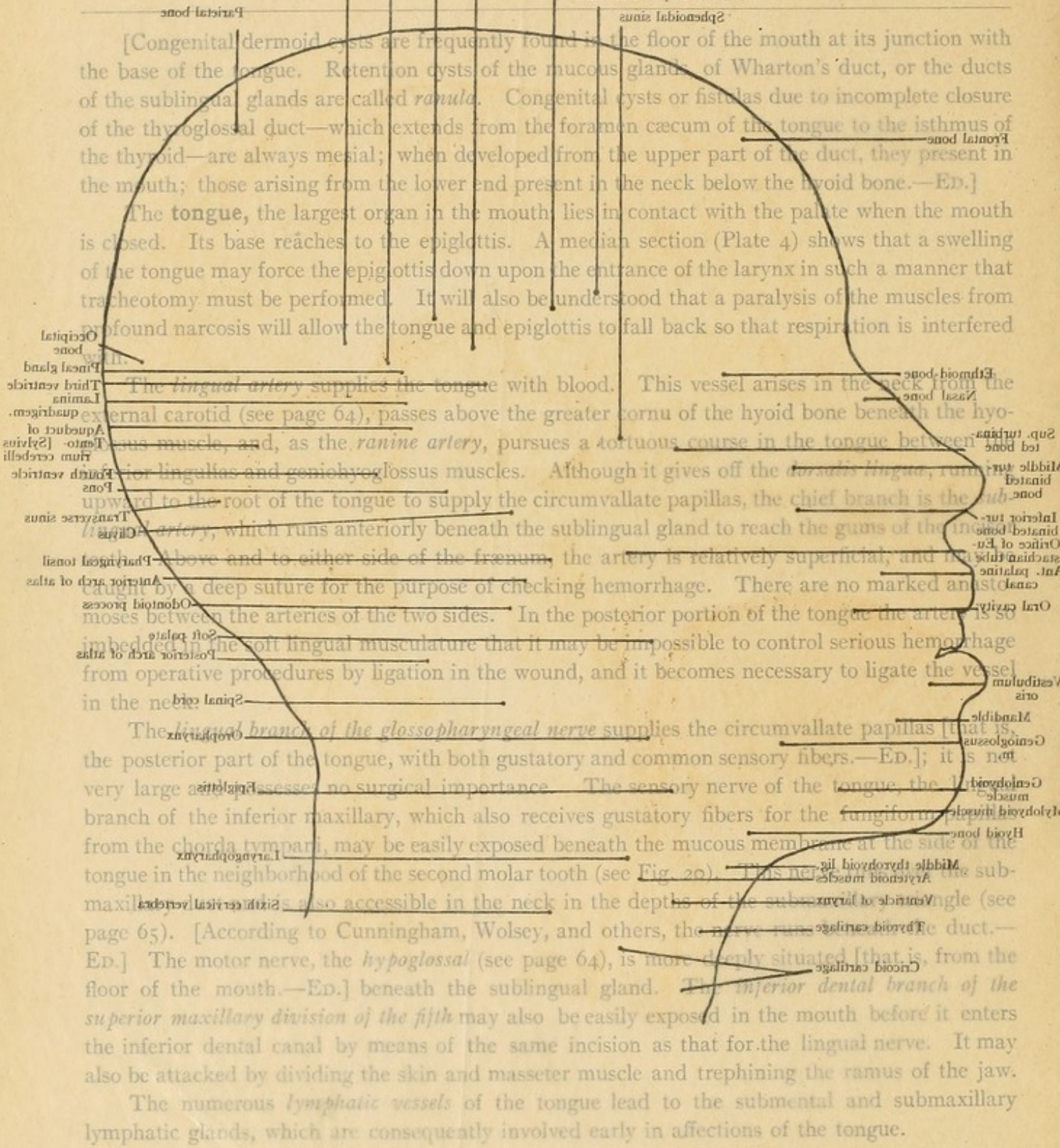
imbedded in the soft lingual musculature that it may be impossible to control serious hemorrhage from operative procedures by ligation in the wound, and it becomes necessary to ligate the vessel in the neck.

The **lingual branch of the glossopharyngeal nerve** supplies the circumvallate papillas of the posterior part of the tongue, with both gustatory and common sensory fibers.—ED.; it is very large and possesses no surgical importance. The sensory nerve of the tongue, the *lingual branch of the inferior maxillary*, which also receives gustatory fibers for the

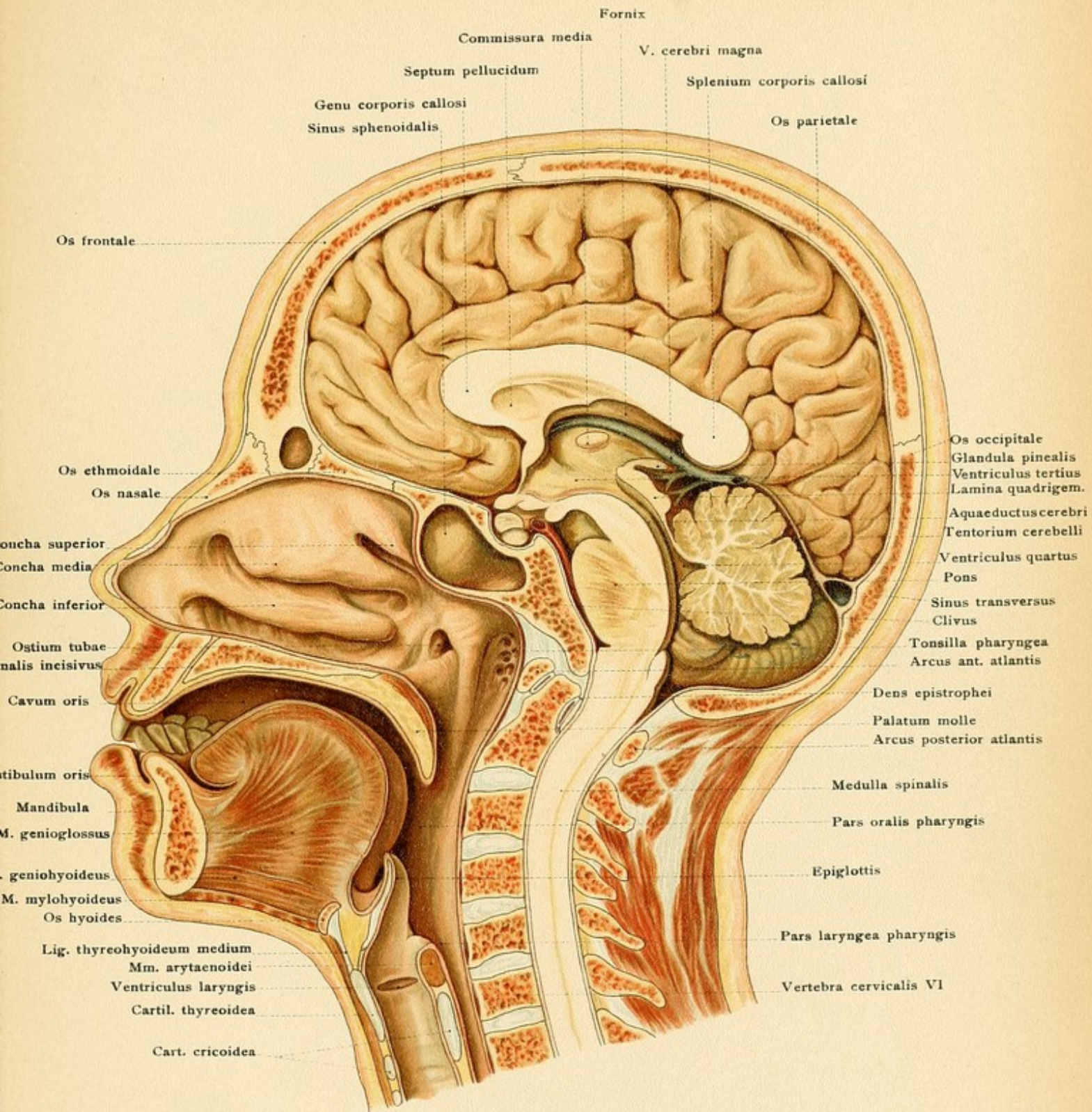
circumvallate papillae from the *chorda tympani*, may be easily exposed beneath the mucous membrane at the side of the tongue in the neighborhood of the second molar tooth (see Fig. 20). This nerve is also accessible in the neck in the depths of the submaxillary triangle (see

page 65). [According to Cunningham, Wolsey, and others, the nerve runs in the *thyroid cartilage*.—ED.] The motor nerve, the *hypoglossal* (see page 64), is more deeply situated [that is, from the floor of the mouth.—ED.] beneath the sublingual gland. The *inferior dental branch of the superior maxillary division of the fifth* may also be easily exposed in the mouth before it enters the inferior dental canal by means of the same incision as that for the lingual nerve. It may also be attacked by dividing the skin and masseter muscle and trephining the ramus of the jaw.

The numerous *lymphatic vessels* of the tongue lead to the submental and submaxillary lymphatic glands, which are consequently involved early in affections of the tongue.













In the posterior portion of the oral cavity may be seen the soft palate with the uvula, the *palato-glossal* and *palato-pharyngeal arches*, and, between the latter structures, the more or less prominent *jaucial tonsil*, which is frequently the seat of simple or diphtheric inflammation. Both the soft and the hard palates receive their blood from the terminal branches of the descending palatine artery, which is given off from the internal maxillary in the sphenomaxillary fossa, passes downward through the posterior palatine canal, and makes its exit at the posterior palatine foramen. [In repairing cleft palate it is necessary, in order to avoid hemorrhage and to maintain the nutrition of the flaps, to preserve these vessels. The incision is therefore made close to the alveolar borders outside the vessels.—ED.] Other branches of the posterior palatine artery pass through the accessory palatine canals. The posterior and accessory palatine canals also transmit the descending or palatine branches (anterior, middle, and posterior) of the sphenopalatine ganglion.

The normal **tonsil** (see Fig. 20 and Plate 4) projects but slightly, if at all, above the level of the surrounding mucous membrane, and, as it is situated in the niche between the palatine arches, it is visible to a different degree in different subjects. The surface of the tonsil is dotted by the apertures of numerous crypts. In consequence of its great tendency to become inflamed and swollen, its relation to the isthmus of the fauces is particularly important. The swelling leads not only to dysphagia, the tonsils sometimes meeting in the median line, but also to a more or less marked constitutional depression. It is clear that diseases of the tonsils may extend along the upper surface of the soft palate to the choanæ (posterior nares) and to the Eustachian tubes, and downward into the pharynx and larynx. The operation of tonsillotomy, so frequently performed upon children, is often followed by active hemorrhage which may be difficult to arrest. This is due to the tonsillar branch of the ascending palatine artery (from the facial), or, if the incision has penetrated very deeply, to the trunk of the ascending palatine itself. Occasionally a particularly severe hemorrhage is observed, in which case the "slashing" operator may not only have removed the tonsil but also the styloglossus and stylopharyngeus muscles and lacerated the facial artery, which is separated from the tonsil by these muscles. The internal carotid artery is quite distant and is not endangered in tonsillotomy, although fatal hemorrhage has been observed as the result of a tonsillar abscess ulcerating into this vessel.

The **pharynx** is situated behind the oral cavity and passes into the neck without any sharp line of demarcation. If the pharynx is incised posteriorly, it will be seen to have a threefold communication. The upper portion, attached to the base of the skull, opens anteriorly into the nasal fossas through the choanæ, and is known as the *pars nasalis pharyngis* (*naso-pharynx*). Its lower boundary is formed by the soft palate, which is in apposition with the dorsal wall of the pharynx during deglutition, and so divides the *pars nasalis* from the middle portion of the pharynx, the *pars oralis*. The orifice of the Eustachian tube is found in the *pars nasalis* directly behind the posterior extremity of the inferior turbinated bone (see page 53 and Fig. 19). It is bounded posteriorly by the torus tubarius (Eustachian cushion), the prominence due to the trumpet-shaped end of the Eustachian tube, from which point the salpingo-pharyngeal fold (see Fig. 19 and Plate 4) may be seen running downward. The pocket-like *fossa of Rosenmüller*, or pharyngeal recess, is situated behind the torus tubarius, and nearer the median line may be seen the *pharyngeal tonsil*, which varies in size in different individuals and extends into the fossa of



FIG. 21.—The pharynx, opened longitudinally from behind, with the three anterior communications: with the nasal cavities, with the mouth, and with the larynx.

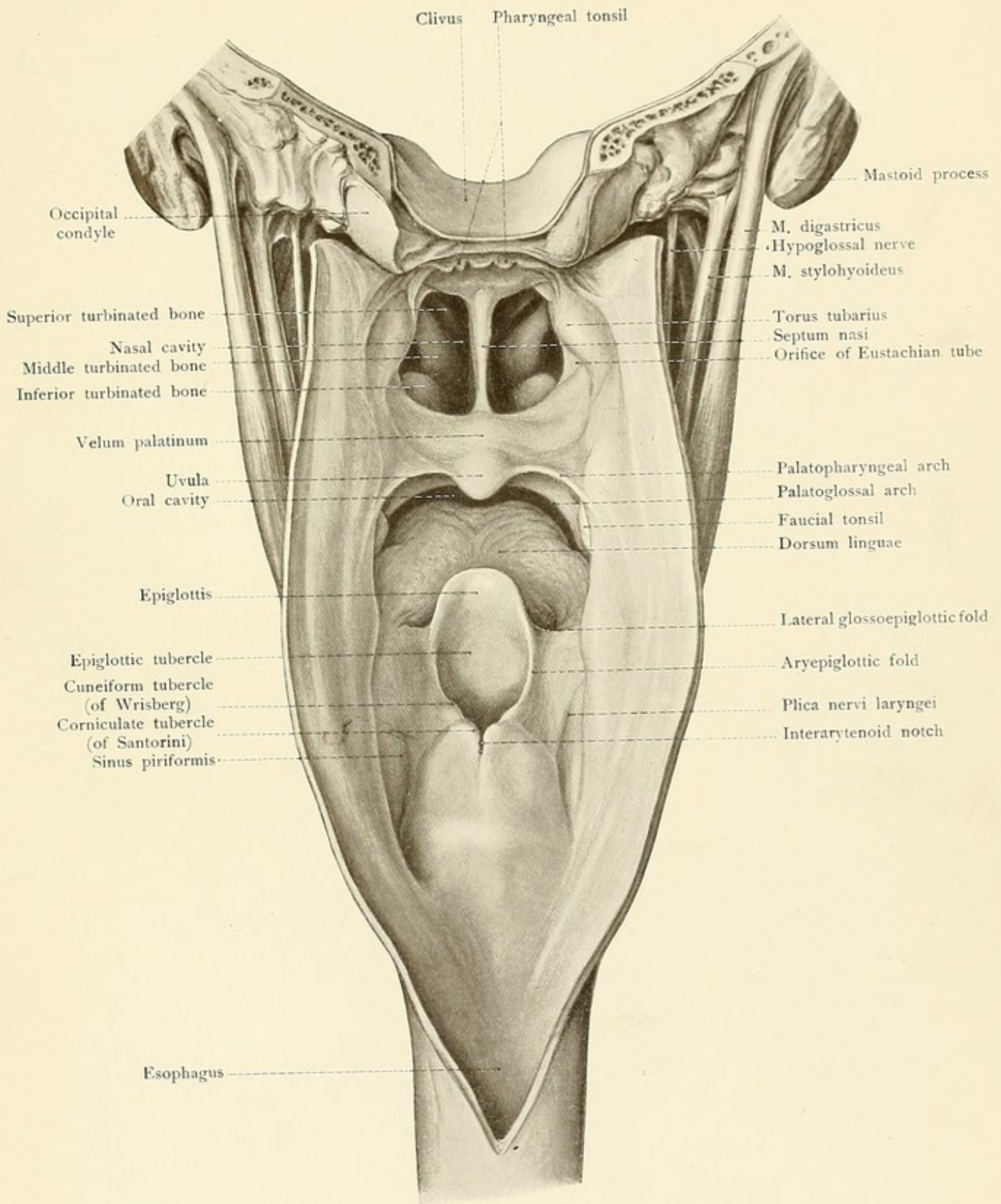
Rosenmüller. It lies upon the firm base furnished by the occipital bone at the base of the skull, a relation which is favorable for the extirpation of this tonsil. Diseases of the pharyngeal tonsil, particularly the proliferations of childhood, may involve the middle ear through the Eustachian tube and lead to suppuration in this situation.

The *pars oralis* communicates anteriorly with the mouth through the isthmus of the fauces. A study of a median section (Plate 4) will make it clear to the reader that, although unpleasant to the living subject, the finger may be introduced into the mouth and passed above the soft palate, palpating its upper surface, the vomer, the surroundings of the choanæ, and the posterior pharyngeal wall with the pharyngeal tonsil. It will also be understood that in the so-called posterior rhinoscopy, a mirror introduced behind the soft palate will show the choanæ and the turbinated bones as seen from behind.

The *laryngeal portion* of the pharynx (*pars laryngea*) is below the *pars oralis* and leads anteriorly into the larynx. It extends to the level of the sixth cervical vertebra, where the pharynx ends and the esophagus commences. The *aditus ad laryngem* (superior aperture of the larynx) is bounded above by the edge of the epiglottis and laterally by the *aryepiglottic (aryteno-epiglottic) folds*, in which the more or less prominent cuneiform and corniculate tubercles (formed by the underlying cartilages of the same name) may be seen with the laryngoscope. Posteriorly in the median line, the laryngeal entrance ends at the *interarytenoid notch*, the seat of predilection for the slit-like erosions of chronic laryngitis and for tubercular ulcers. The pharyngo-epiglottic folds extend from the pharynx to the border of the epiglottis. The *pyriform sinuses* are situated internal to the *alæ* of the thyroid cartilage, and in their upper portions may be seen a fold of mucous membrane (*plica nervi laryngei*) produced by the underlying superior laryngeal nerve.

A loose connective tissue, rich in lymphatic vessels and containing several lymphatic glands at the level of the upper cervical vertebrae, connects the posterior wall of the pharynx to the prevertebral fascia, which is separated from the spinal column by only the thin layer of the prevertebral muscles (*longus capitis et colli* muscles). During the act of deglutition the pharynx moves upon this loose connective tissue (see Fig. 26). This tissue is the seat of *retropharyngeal abscess*, which may produce dysphagia and dyspnea by pressing upon the pharynx, the choanæ, the soft palate, the laryngeal entrance, and the trachea. When these abscesses are favorably located, they may be opened from the oral cavity. Since this loose connective tissue accompanies the esophagus into the thoracic cavity, it forms a path along which a retropharyngeal abscess may extend downward into the mediastinum, come in contact with the pleura, and either break into the pleural cavity (see Plate 8, b) or lead to pericarditis by extending to the pericardium (see Fig. 51). The relation of the pharynx to the cervical vertebrae makes it possible to diagnose vertebral fractures and dislocations by inspection and palpation through the oral cavity; for example, from the relation of the anterior arch of the atlas to the posterior pharyngeal wall (see Plate 4) it is clear that when the atlas is dislocated anteriorly it may be recognized as a hard prominence in the posterior pharyngeal wall. It will also be readily understood that diseases of the cervical vertebrae (such as caries) may lead to retropharyngeal abscess or to perforation and







Handwritten notes or text on the left side of the page, appearing as a list or series of entries.

Handwritten notes or text on the left side of the page, appearing as a list or series of entries.

Handwritten notes or text on the left side of the page, appearing as a list or series of entries.

Handwritten notes or text on the right side of the page, appearing as a list or series of entries.

Handwritten notes or text on the right side of the page, appearing as a list or series of entries.

Handwritten notes or text on the right side of the page, appearing as a list or series of entries.

Handwritten notes or text on the right side of the page, appearing as a list or series of entries.

Handwritten notes or text on the right side of the page, appearing as a list or series of entries.



the extrusion of pieces of bone into the pharynx. The median sagittal section illustrated in Plate 4 shows that tumors proceeding from the anterior surface of the cervical vertebrae, from the clivus, or from the body of the sphenoid meet with little resistance in the direction of the pharynx, and may grow through the choanæ into the nasal fossas and then extend into the accessory nasal cavities or through the cribriform plate into the cranial cavity; they may also push down the soft palate and grow toward the mouth.

#### THE ORGAN OF HEARING.

The cartilaginous meatus is bounded anteriorly by the parotid gland, and tumors and inflammatory swellings of the gland may consequently lead to a narrowing of the auditory canal. The anterior wall of the bony meatus is formed by the thin *tympanic plate of the temporal bone*. This tympanic plate is the partition between the temporo-maxillary articulation and the external auditory meatus (see Fig. 22), through which affections of this joint may extend into the meatus. This bony plate is occasionally fractured and displaced into the meatus when the condyle of the jaw is driven backward by a blow upon the chin. The posterior wall of the bony meatus varies greatly in thickness; it is often nothing more than a thin lamella of bone, so that the cells of the mastoid process are in close proximity (see Fig. 22). If pus is present in these cells and an early external opening is not provided, it may break into the auditory canal. The transverse diameter of the middle ear or *cavum tympani* is very small, so that the external wall (the drum-membrane) is only about two millimeters from the internal wall (the promontory), and as a result of inflammatory processes the drum-membrane may become adherent to the promontory.

The thin roof of the tympanic cavity (the *tegmen tympani*), situated in the middle cranial fossa, also covers a portion of the so-called *attic or epitympanic recess*, a large space which connects the tympanum with the mastoid cells. This is the important path by which suppurations in the middle ear so often extend into the cells of the mastoid antrum. The outer wall of the mastoid process must then be opened, since it is rarely so thin that the pus may perforate externally spontaneously and gravitate along the sternocleidomastoid muscle. The thinness of the *tegmen tympani* (see Fig. 23) explains the possibility of the destruction of the bone by middle-ear suppurations and the escape of pus beneath the dura mater or the extension of the inflammation to the meninges by way of the vascular canaliculi. If the suppuration extends to the brain, an *abscess* is formed in the temporal lobe which rests upon the *tegmen tympani* (see page 35). Fig. 22 distinctly shows another, though practically less important, relation of the mastoid process. It will be observed that the lateral sinus passes in the immediate vicinity of the mastoid process. This explains the extension of suppurative inflammations of the middle ear to the lateral sinus (sinus thrombosis, pyemia) and through the diseased wall of the sinus to the cerebellum, producing a cerebellar abscess. These important conditions may be best understood by a study of the base of the skull.

Fig. 23 also shows three other important relations of surrounding structures to the middle ear:

1. In the region colored yellow, the facial canal, enclosing the facial nerve, projects more or less into the tympanic cavity. In this situation the wall of the canal is thin, often transparent,



FIG. 22.—A sagittal section through the mastoid process, the external auditory meatus, and the glenoid fossa.

FIG. 23.—The temporal bone with the exposed tympanum, tympanic antrum, and mastoid cells. The relations of the facial nerve, internal jugular vein, and internal carotid artery to the wall of the tympanum may be seen. The different areas have been colored yellow, blue, and red respectively.

and occasionally even perforated, so that the nerve is covered only by the tympanic mucous membrane. Inflammations of the middle ear may consequently affect this nerve and produce a facial paralysis. It is not surprising that the nerve may also be involved in caries of the petrous portion of the temporal bone.

2. Caries in this situation has led to fatal hemorrhage from the internal carotid artery. The vessel is enclosed in the carotid canal in the petrous portion of the temporal bone (see page 34) and, in the region colored red in the illustration, is separated from the tympanic cavity by only a thin bony lamella. If this plate is broken, as in a fracture of the base of the skull, the blood poured out into the tympanic cavity may break through the membrana tympani and escape from the ear or it may go through the Eustachian tube and appear anteriorly at the mouth or nose (see Plate 4).

3. The *jugular fossa*, situated on the lower surface of the petrous portion of the temporal bone and accommodating the superior bulb or sinus of the internal jugular vein, is frequently so deep that the inner and lower walls of the middle ear are correspondingly thin and transparent or even perforated. This place was quite thick in the specimen from which the illustration was made. It has been colored blue.

#### QUESTIONS.

Why is it that contusions of the face are not followed by circumscribed swellings, as is the case in the scalp?

Where may the pulsations of the facial artery be palpated?

How would you proceed in order to expose the infraorbital and the inferior dental nerves?

Which large accessory nasal cavity is endangered in neurectomy of the infraorbital nerve?

How may the place of exit of the facial nerve be exposed at the base of the skull?

What is the explanation of painful mastication and dysphagia in diseases of the parotid gland?

What nerve and what vessels are endangered by operations upon the parotid gland?

Which of the four walls of the orbit is the strongest? How may emphysema of the orbit and exophthalmos be produced by fracture of any of the other three walls? What cavities are situated above, below, and to the inner side of the orbit, and what is the direction of growth of tumors originating in these cavities?

How may the lachrymal gland be easily exposed?

What is the relation of the frontal sinus to the lachrymal sac?

Why is it that a complete retraction of the orbital muscles need not be feared after the division of their tendinous insertions in strabismus operations?

Through what thin portions of the base of the skull may the base of the brain be most easily injured?

Through what portion of what bone may tumors of the base of the skull grow into the nasal fossas with comparative ease?

What is the explanation of the relief afforded in headache by a pronounced nasal hemorrhage?



Fig. 22.

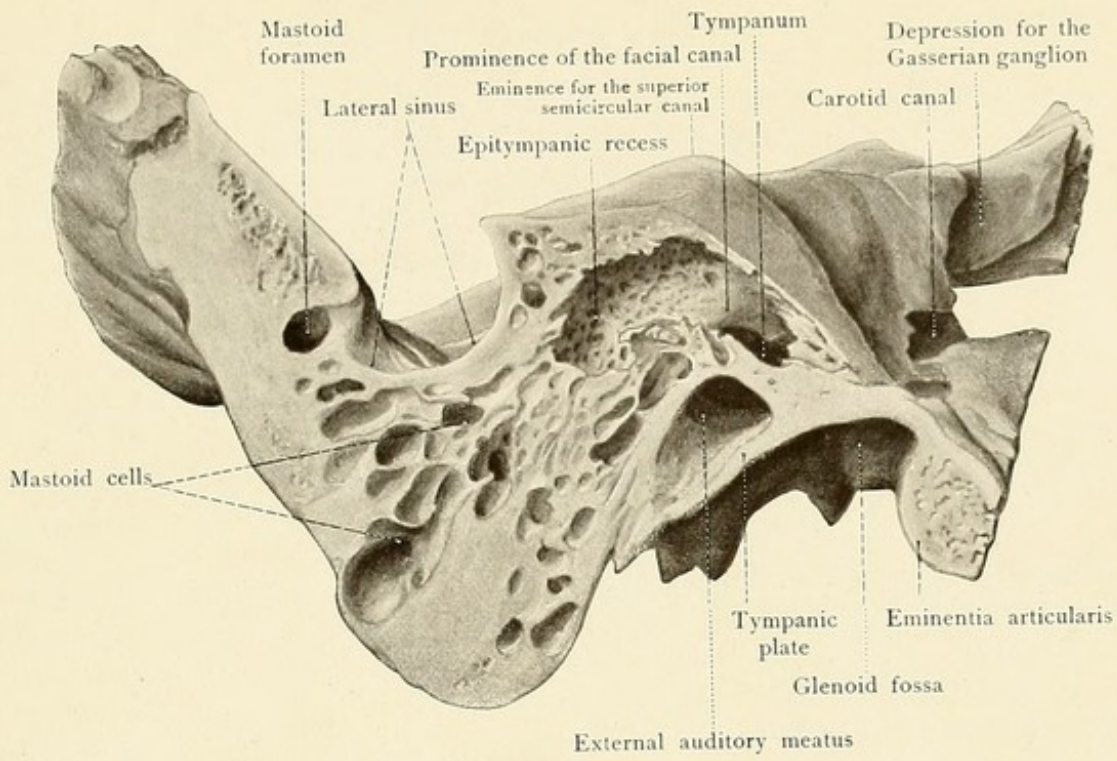
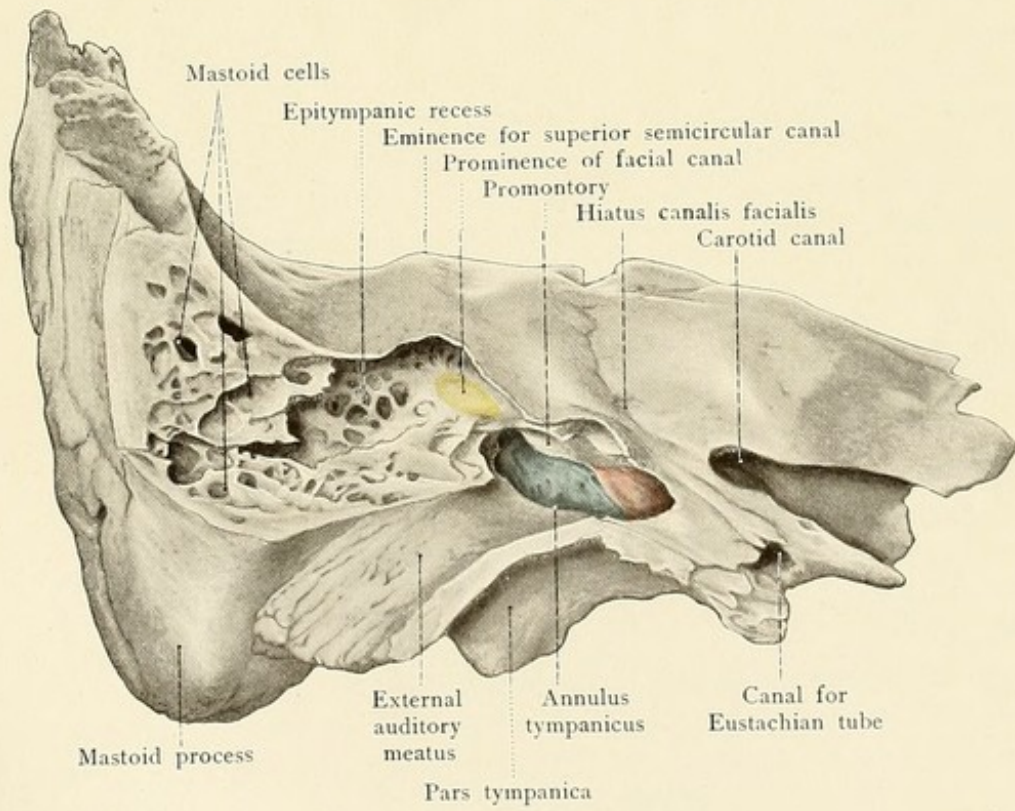


Fig. 23.









What are the four ways of opening the maxillary sinus and which is the simplest in empyema of this cavity?

What situations will tumors of the maxillary sinus reach when they grow inward, upward, forward, or backward, and what neighboring organs may be thereby affected?

Where should the frontal sinus be opened and what is the location of its opening into the nasal fossa?

What large vessel may be ruptured and produce a fatal hemorrhage from the nose and what is the route taken by the blood in such a case?

What mass of bone and what accessory cavities of the nose are encroached upon when tumors from the nasal fossas invade the orbit?

How may the pharyngeal orifice of the Eustachian tube be reached from the nostril and what should be noted in carrying out this procedure?

Where is the orifice of the parotid duct in the vestibulum oris and where is there a normal communication between the vestibule and the oral cavity, which may be utilized for feeding under certain circumstances?

Where may the submaxillary duct be easily opened in the living subject?

In what situation in the oral cavity may hemorrhage from the lingual artery be controlled by suture?

In what situation in the oral cavity may the lingual nerve be exposed? The inferior dental nerve?

What arteries may give rise to pronounced hemorrhage in tonsillotomy?

By what route may diseases of the pharyngeal tonsil extend into the middle ear?

Where do retropharyngeal abscesses arise and by what path may they gravitate into the chest and produce pleuritis and pericarditis?

Where may diseases of the cervical vertebrae be diagnosticated from the mouth?

How do tumors and swellings of the parotid gland affect the external auditory meatus?

What relation is important for the anterior, and what one for the posterior wall of the bony meatus?

By what route may suppuration in the middle ear lead to an abscess in the temporal lobe, and by what other route may a cerebellar abscess be produced?

In middle-ear disease, what nerve may give rise to symptoms of paralysis and why?

In what manner may a sudden fatal hemorrhage from the ear, nose, or mouth occur in the course of middle-ear disease?

---

## THE NECK.

The neck may be regarded as a passageway for important organs on their way from the head to the trunk and from the trunk to the head, and contains, in a comparatively small space, an unusually large number of structures which are situated in the anterior and lateral cervical regions. It is consequently a portion of the body which claims particular attention from the physician.

The neck is bounded above by the lower margin of the jaw, by the mastoid process, and by the superior curved line of the occiput. Its lower boundary is formed by the upper margin of the sternum (or sternal notch), by the sternoclavicular articulations, by the clavicles, by the acromial processes, and by a line drawn from the latter to the spinous process of the vertebra prominens (the seventh cervical). These boundaries should be seen and felt by the reader in his own neck and in the necks of others. The student should also observe the prominence caused by the sternocleidomastoid muscle (particularly when the head is turned to one side), the anterior



## PLATE 5.

A cross-section of the neck at the level of the thyroid cartilage. Frozen section.

border of the trapezius muscle, the more or less deep fossa supraclavicularis major above the clavicle, the jugular fossa above the upper margin of the sternum, and the fossa supraclavicularis minor, which is distinctly seen above the sternoclavicular articulation only when there is a marked interspace between the two heads of the sternocleidomastoid muscle. The latter is one of the rarer situations for ligating the common carotid artery (according to Zang) and the area for auscultating venous murmurs in the internal jugular vein. The external jugular vein, visible through the skin when well filled, may be distinctly outlined by making compression upon its terminal portion at the outer side of the sternocleidomastoid muscle [just above the clavicle.—ED.]. This causes the vein to become greatly distended, and it may consequently be avoided in operative procedures upon the neck.

The palpation of those portions of the respiratory apparatus which are situated anteriorly is of particular importance. Starting at the angle of the thyroid cartilage (*pomum adami*) at the *incisura thyroidea superior*, the *hyoid bone* may be palpated posteriorly as far as the greater cornua, and the hyoid bone should be distinctly differentiated from the upper border of the thyroid cartilage by placing the thumb and index-finger of one hand upon the region overlying the thyrohyoid membrane. Below the thyroid notch may be felt the blunt anterior edge of the *thyroid cartilage* leading downward to the ring of the *cricoid cartilage*, which is connected to the thyroid cartilage by means of the rigid and distinct middle cricothyroid ligament (*ligamentum conicum*). Below the cricoid cartilage is the first tracheal ring, and still lower down, provided that it is well developed, the *isthmus of the thyroid gland* may be palpated. The pulsations of the common carotid artery may be easily felt beside the larynx at the inner border of the sternocleidomastoid muscle. The subclavian artery is deeply situated in the larger supraclavicular fossa; the vessel runs over the first rib and its pulsations are not always to be distinctly palpated. If the arm is drawn downward, the subclavian artery may be compressed against the first rib for the purpose of avoiding or controlling hemorrhage from a more peripheral region.

As is shown by a cross-section (Plate 5), the soft parts of the neck are arranged in such a manner that the supporting framework of the cervical vertebrae is surrounded by muscles, the great mass of which is located posterior to the vertebral column, while anteriorly there are only the weak *prevertebral* and the *scalene muscles*. This osseous and muscular mass is covered by the prevertebral fascia and united by a loose connective tissue with the so-called *vascular* and *visceral columns*, which are almost completely covered in by the anterior cervical muscles (the sternocleidomastoid and the hyoid muscles). The single viscera of the visceral column, composed of the cervical portions of the digestive and respiratory tracts (the pharynx and esophagus, the larynx with the hyoid bone and trachea), are situated in the median line between the paired vascular columns, consisting of the carotid artery and the internal jugular vein together with the vagus nerve. This grouping of the soft parts forms the foundation for the further comprehension of this region. The visceral column, as the reader may readily discover in his own neck, is easily moved upon the anterior surface of the vertebral column. Tumors situated in the lateral portions of the neck consequently easily displace the larynx, the trachea, and the esophagus



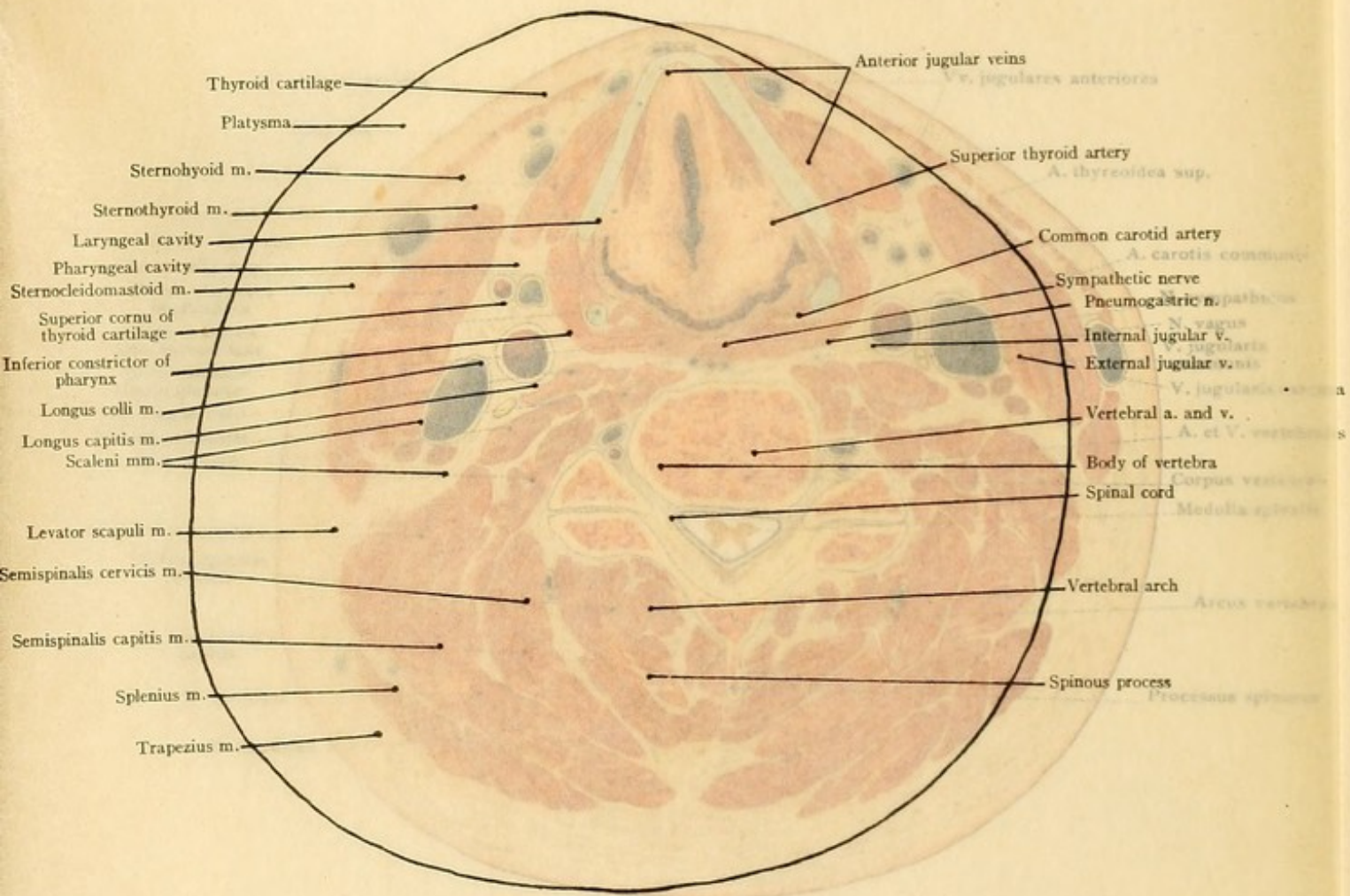





PLATE 5.

A cross-section of the neck at the level of the thyroid cartilage. Frozen section.

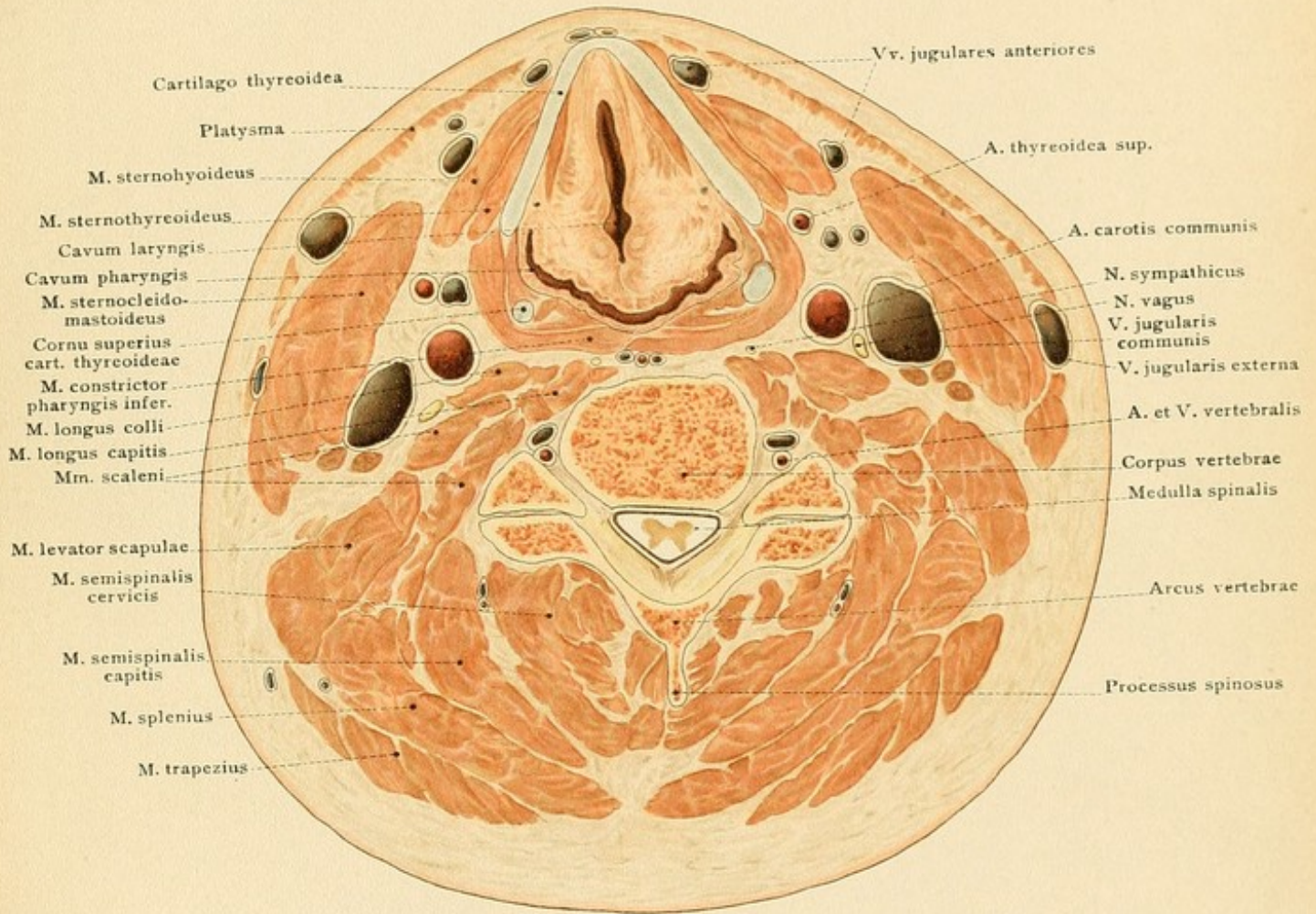
border of the trapezius muscle, the more or less deep fossa supraclavicularis major above the clavicle, the jugular fossa above the upper margin of the sternum, and the fossa supraclavicularis minor, which is distinctly seen above the sternoclavicular articulation only when there is a marked interspace between the two heads of the sternocleidomastoid muscle. The latter is one of the rarer situations for ligating the common carotid artery (according to Zang) and the area for auscultating venous murmurs in the internal jugular vein. The external jugular vein, visible through the skin, may be distinctly outlined by making compression upon its terminal portion at the outer side of the sternocleidomastoid muscle just above the clavicle. —Ed.] This causes the vein to become greatly distended, and it may consequently be avoided in operative procedures upon the neck.

The palpation of those portions of the respiratory apparatus which are situated anteriorly is of great importance. Starting at the angle of the thyroid cartilage (commonly called the Adam's apple) at the upper border of the thyroid gland, the *hyoid bone* may be palpated posteriorly as far as the *thyroid cartilage* by placing the thumb and index-finger of one hand upon the region over the *thyroid cartilage* and the *hyoid bone* should be distinctly differentiated from the upper border of the *thyroid cartilage* by means of the rigid and distinct middle cricothyroid ligament (*ligamentum conicum*). Below the cricoid cartilage is the first tracheal ring, and still lower down, provided that it is well developed, the *isthmus of the thyroid gland* may be palpated. The pulsations of the common carotid artery may be easily felt beside the larynx at the inner border of the sternocleidomastoid muscle. The subclavian artery is deeply situated in the larger supraclavicular fossa; the vessel runs over the first rib and its pulsations are not always to be distinctly palpated. If the arm is drawn downward, the subclavian artery may be compressed against the first rib for the purpose of avoiding or controlling hemorrhage from a more peripheral region.

As is shown by a cross-section (Plate 5), the soft parts of the neck are arranged in such a manner that the supporting framework of the cervical vertebrae is surrounded by muscles, the great mass of which is located posterior to the vertebral column, while anteriorly there are only the weak *prevertebral* and the *scalene muscles*. This osseous and muscular mass is covered by the prevertebral fascia and united by a loose connective tissue with the so-called *vascular and visceral columns*, which are almost completely covered in by the anterior cervical muscles (the sternocleidomastoid and the hyoid muscles). The single viscera of the visceral column, composed of the cervical portions of the digestive and respiratory tracts (the pharynx and esophagus, the larynx with the hyoid bone and trachea), are situated in the median line between the paired vascular columns, consisting of the carotid artery and the internal jugular vein together with the vagus nerve. This grouping of the soft parts forms the foundation for the further comprehension of this region. The visceral column, as the reader may readily discover in his own neck, is easily moved upon the anterior surface of the vertebral column. Tumors situated in the lateral portions of the neck consequently easily displace the larynx, the trachea, and the esophagus













toward the opposite side, and swellings of the visceral column soon lead to pressure symptoms from the adjacent vessels and nerves.

The *skin* of the anterior cervical region is firmly adherent to the underlying platysma myoides muscle, the relation being similar to that existing between the skin of the scalp and the occipitofrontalis. The skin consequently follows all of the movements of the platysma and, corresponding to the direction of the muscular fibers, may be lifted up in large folds running particularly in the vertical direction. The movability of the skin specially adapts it to the performance of plastic operations.

The *arrangement of the muscles* in the anterior and lateral portions of the neck renders possible a regional subdivision which is of practical value in the living subject. The inner margins of the sternocleidomastoid muscles, which converge from the mastoid processes to the upper edge of the sternum, together with the border of the lower jaw, form the *anterior cervical region* (see Fig. 24). The outer margin of the sternocleidomastoid, the anterior margin of the trapezius, and the upper border of the clavicle bound the *lateral cervical region*. The anterior cervical region is subdivided into a small *suprahyoid*, and into a larger *infrahyoid region* by the hyoid bone and the posterior belly of the digastric muscle (see Fig. 24); both of these regions may be further subdivided into a single *median region* and into a *lateral paired region*. The *submental region* lies above the hyoid bone and is bounded upon either side by the anterior belly of the digastric muscle; to either side of the submental region is found the submaxillary region or triangle (containing the gland of the same name), formed by the lower border of the jaw and the two bellies of the digastric muscle. In the central portion of the infrahyoid region is a small diamond-shaped space between the hyoid bone and the upper margin of the sternum and bounded laterally by the inner margins of the sternohyoid and sternothyroid muscles; this important area is known as the *median cervical region*. The lateral portion of the infrahyoid region bears important relations to the vessels and nerves of the neck and is called the *carotid triangle*; it is bounded by the posterior belly of the digastric, by the anterior margin of the sternocleidomastoid, and by the anterior belly of the omohyoid.

**The Carotid Triangle.**—In the carotid triangle (see Figs. 24 and 25) the pulsations of the *common carotid artery* may be easily felt at the anterior margin of the sternocleidomastoid muscle at the level of the larynx. The carotid artery may be exposed in this situation by an incision made parallel to the anterior margin of the sternocleidomastoid and the vessel may be ligated through this incision (the point of election, according to Cooper). This most favorable situation corresponds to the level of the anterior tubercle upon the transverse process of the sixth cervical vertebra (the carotid tubercle), which may be felt when the anterior margin of the sternocleidomastoid muscle has been exposed; it also corresponds to the level of the middle cricothyroid ligament. [The anterior belly of the omohyoid crosses the vessel at the level of the cricoid cartilage.—ED.] The common carotid artery ascends from the lower angle of the triangle, frequently concealed beneath the margin of the sternocleidomastoid muscle, and divides into the external and internal carotid at the upper margin of the thyroid cartilage [opposite the lower border of the third cervical vertebra.—ED.]. The internal carotid artery is normally covered in the first part of its course by the external carotid. [Strictly speaking, the external carotid in the first part of its course is internal, that is, nearer the median line, and anterior to the internal carotid.—ED.] To the outer side of

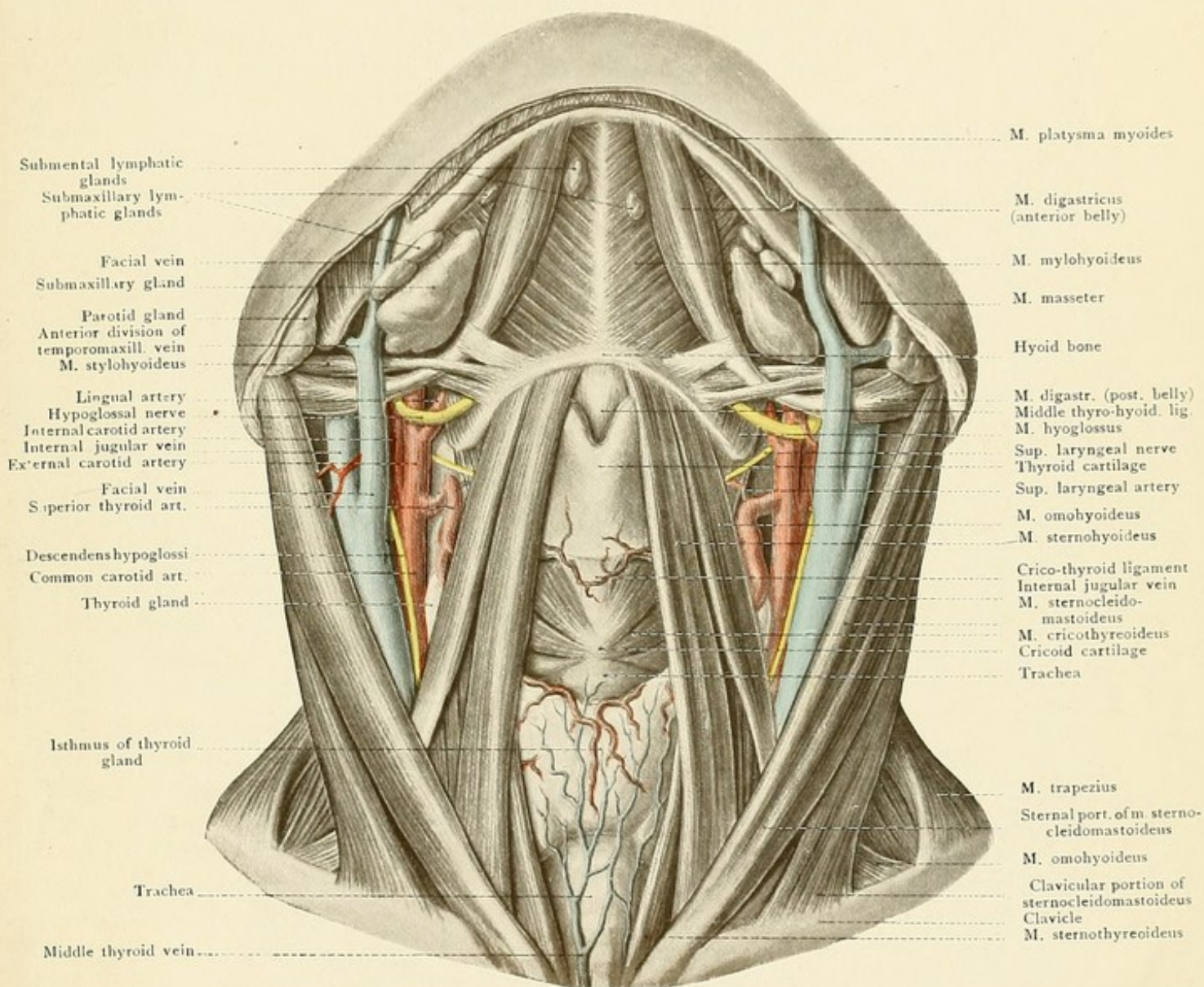


FIG. 24.—The anterior cervical region (the hypoglossal nerve has been displaced slightly downward).


the common carotid artery is situated the internal jugular vein, which when well filled with blood partly overlies the carotid, so that the artery is more deeply placed than the vein. Behind and between these two vessels, and enclosed within their common connective-tissue sheath, the vagus nerve (see Figs. 25 and 27 and Plate 5) runs downward to the upper opening of the thorax. When the great vessels of the neck are injured, this nerve is also easily involved; it should be carefully avoided in ligation of the carotid. The good operator should also spare the *descendens hypoglossi nerve* (see Figs. 24 and 25), which runs downward upon the carotid sheath, although its division is not followed by important symptoms. This small nerve, together with branches from the second and third cervical nerves, forms the *ansa hypoglossi*, from which the infrahyoid muscles receive their motor branches. One or two superior thyroid veins may run almost transversely across the carotid (see Fig. 27) and also aid in rendering the ligation of the vessel more difficult. At the margin of the omohyoid muscle may be seen the thyroid gland, which projects into the carotid triangle to a varying extent, dependent upon the degree of its development. The *superior thyroid artery*, the first branch of the external carotid, runs downward to this gland in an arched and tortuous direction. It gives off the small superior laryngeal artery, which, together with the sensory superior laryngeal nerve from the pneumogastric, enters the larynx through the thyrohyoid membrane below the greater cornu of the hyoid bone. The *lingual artery* is given off from the external carotid above the superior thyroid; it runs anteriorly and soon disappears beneath the hyoglossus muscle to supply the tongue. It must sometimes be ligated to control hemorrhage after injuries to the tongue or for the purpose of preventing hemorrhage during operations for lingual carcinoma. The vessel may be easily exposed by an incision just above the greater cornu of the hyoid bone; after dividing the skin, the platysma, the deep fascia, and the hyoglossus muscle, the artery will be found in the angle between the posterior belly of the digastric muscle and the greater cornu of the hyoid bone. The artery may also be ligated further anteriorly in the submaxillary triangle. Just above the lingual artery (and often arising with it from a common trunk) is given off the third of the three anterior branches of the external carotid—the *facial artery*. This is the largest vessel in the submaxillary triangle (see page 65), and it enters this region by passing beneath the posterior belly of the digastric and the stylohyoid muscles. The other branches of the external carotid in the carotid triangle are the ascending pharyngeal artery, passing upward and inward to the base of the skull, and the occipital artery, which runs upward and backward (see Plate 2). The carotid artery is accompanied by a chain of deep cervical lymphatic glands which frequently become diseased. Abscesses originating within these glands may point along the vessels until they reach the connective tissue of the mediastinum, from which situation the pus may extend in various directions.

The *hypoglossal nerve*, the motor nerve of the tongue, is found in the upper portion of the carotid triangle; it passes forward in a curved direction, the convexity being downward, crosses the external carotid and then the facial artery, and enters the submaxillary region in company with the lingual vein by passing underneath the posterior belly of the digastric muscle. The esophagus and the lower portion of the pharynx may be reached through the carotid triangle by an incision made along the inner margin of the sternocleidomastoid muscle (see page 67).











**The Submaxillary Triangle.**—The submaxillary triangle, which is reached by following the course of the hypoglossal nerve and the facial artery, is bounded by the lower margin of the jaw and by the two bellies of the digastric muscle. After the removal of the skin, platysma, and deep fascia we find that the largest structure in this region is the *submaxillary gland* (see Figs. 24 and 25), which may even be visible through the skin in markedly emaciated individuals. The fascia covering the gland is rather firm and offers a certain resistance to the spontaneous external rupture of glandular abscesses. The *submaxillary lymphatic glands* are situated along the lower margin of the jaw and the upper margin of the submaxillary salivary gland, some of them being partly imbedded in the latter structure. Since these glands, like those situated nearer the median line (the submental lymphatic glands), receive the lymphatics from the face, they may easily be affected in diseases of the face (such as labial carcinoma) and require extirpation. The submaxillary gland receives numerous branches from the *facial artery*, which runs from behind forward in this triangle. This vessel is imbedded in the substance of the submaxillary gland and leaves the cervical region at the anterior border of the masseter muscle, where it lies directly upon the margin of the jaw. The chief branch of the facial artery in this region is the *submental*, which is covered by the gland and runs toward the chin upon the mylohyoid muscle; it is accompanied by the small mylohyoid branch of the inferior maxillary nerve (motor). At the angle of the jaw the *facial vein* is joined by the anterior division of the temporo-maxillary vein (see Fig. 24). [This union, according to Cunningham, usually takes place a little below the angle of the jaw.—ED.] If the submaxillary gland is lifted up, the submaxillary duct may be seen anteriorly in the depths of the triangle as it disappears beneath the mylohyoid muscle; still deeper and at a higher level the lingual nerve is in relation with the submaxillary gland and the small submaxillary ganglion. The comparatively small *glossopharyngeal nerve* is found near the pharynx, deeply situated between the styloglossus and stylopharyngeus muscles; it passes beneath the tonsil to end in the circumvallate papillae of the lingual mucous membrane.

The **median cervical region** is situated beneath the hyoid bone and extends to the upper margin of the sternum. It is bounded above and to the outer side by the inner margins of the sternohyoid muscles, and below and to the outer side by the sternothyroid muscles, presenting a narrow triangular surface in this situation (see Fig. 24). The greatest breadth of this narrow region is about two centimeters and it is situated approximately midway between the hyoid bone and the sternum. In this important region the trachea is covered only by skin and fascia. Incised wounds of the trachea are consequently common in this region, particularly in cases of suicide, and the physician, under certain circumstances, must rapidly perform tracheotomy in this situation in order to save the life of his patient. The structures which may be palpated through the skin at this place (see page 62) are responsible for the subdivision into the following regions: the hyoid region (hyoid bone), the subhyoid region (the thyrohyoid membrane or ligament), the laryngeal region (the larynx), the thyroid region (the thyroid gland), and the suprasternal region (just above the sternum).

In the **subhyoid region** the respiratory tract cannot be entered by simply dividing the middle thyrohyoid ligament (see Figs. 24 and 26). Behind the ligament there is a relatively thick mass of fat, which extends for about one centimeter in the sagittal plane and is limited posteriorly by the hyoepiglottic ligament, passing from the epiglottis to the hyoid bone, and by the attached end of



FIG. 25.—The submaxillary and carotid triangles.

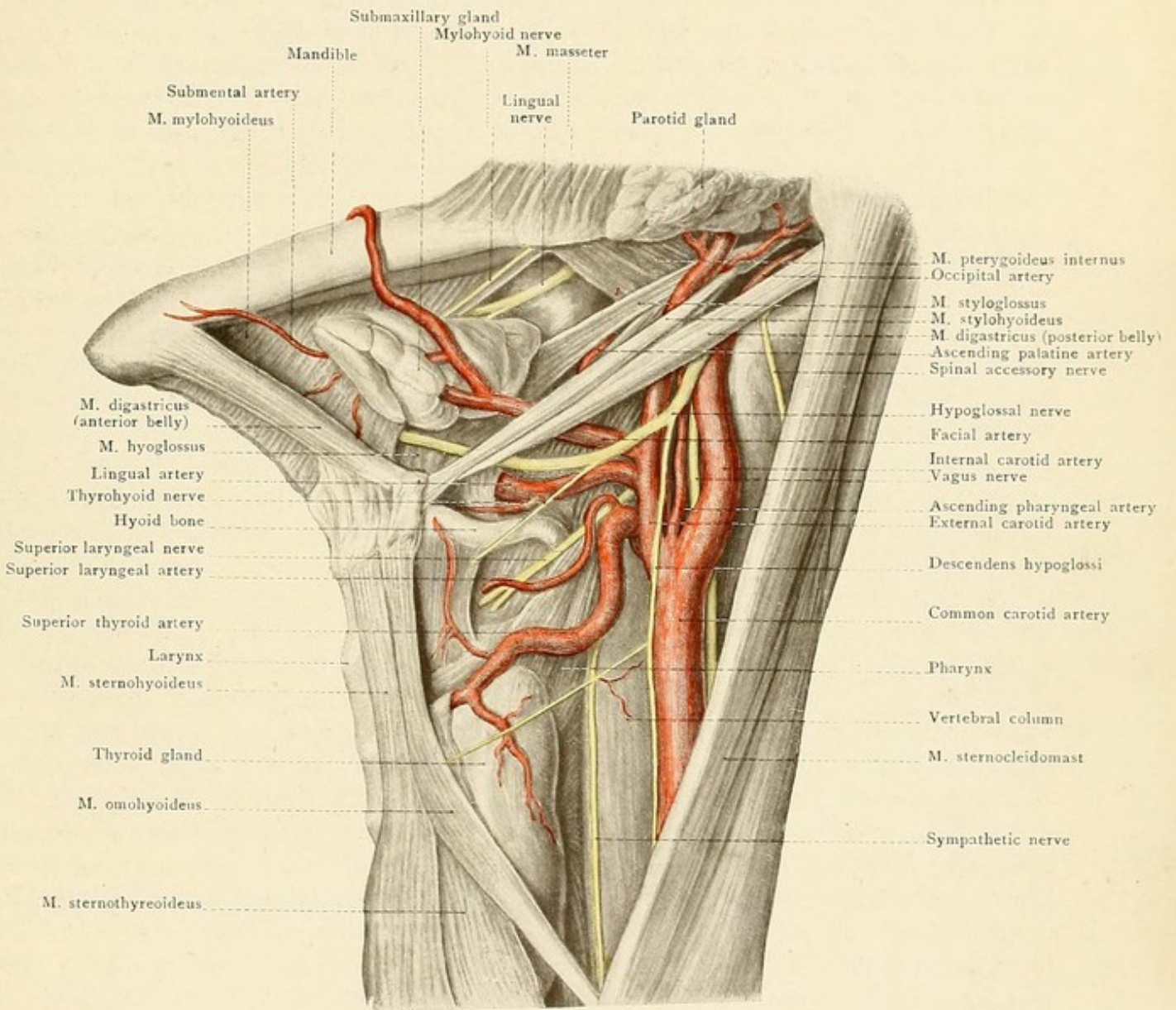
the epiglottis. This mass of fat produces the so-called *epiglottic tubercle*, which projects into the vestibule of the larynx. It will be seen that this fatty tissue is not particularly adapted for operative procedures. As a result of laryngitis, abscesses occasionally form in this mass of fat, which may be evacuated externally by an incision through the thyrohyoid ligament. The subhyoid region is broadest at its lower boundary, which is formed by the thyroid notch. In the median line there is an inconstant bursa situated between the thyrohyoid membrane and the sternohyoid muscle; it extends upward beneath the hyoid bone and occasionally leads to the development of *hygromata*. There is also a bursa lower down over the angle of the thyroid cartilage.

The largest portion of the **laryngeal region** is taken up anteriorly by the thyroid cartilage, which causes the hard projection (in the male) known as the Adam's apple. The thyroid cartilage is connected to the cricoid cartilage by the tense crico-thyroid ligament (or ligamentum conicum). This is the situation in which the larynx may be most easily opened below the vocal cords. The incision may be carried upward, dividing the thyroid cartilage (thyrotomy), or downward, dividing the cricoid cartilage (cricotomy). The small cricothyroid artery, lying upon the cricothyroid ligament, possesses no special surgical importance. A median sagittal section (see Fig. 26) shows that abscesses resulting from perichondritic processes affecting the arytenoid cartilages and the lamina of the cricoid cartilage, which form the posterior wall of the larynx, may rupture anteriorly into the larynx, (producing respiratory disturbances) or posteriorly into the laryngeal portion of the pharynx (causing dysphagia). Perichondritis of the anterior wall of the larynx (the thyroid cartilage and the ring of the cricoid cartilage) may lead to the formation of abscesses which either point anteriorly beneath the skin or rupture into the laryngeal cavity.

The narrow **thyroid region** is situated just below the laryngeal region and corresponds to the isthmus of the thyroid gland, which is in relation with the upper tracheal rings and frequently touches the cricoid cartilage. In children the isthmus of the thyroid gland usually extends to a higher level than in adults, but it does not reach beyond the cricoid cartilage; it is also more firmly fixed to the trachea in the child than in the adult. When high tracheotomy is performed, the isthmus must be separated from the trachea by blunt dissection and pushed downward, so that the incision for the introduction of the tracheal tube will not injure the thyroid gland. The performance of this operation is not infrequently complicated by the presence of a middle lobe of the thyroid gland, which often extends up to the hyoid bone. It is situated either exactly in the median line or somewhat to one side. The thyroid gland, covered by the sternothyroid and sternohyoid muscles, extends laterally into the carotid triangle and comes in contact with the lowest portion of the pharynx and the commencement of the esophagus. From the position of the thyroid gland it is clear that thyroid swellings and tumors must lead, first of all, to pressure-symptoms from the trachea with changes in the tracheal cartilage, and then to involvement of the large vessels and nerves of the neck. The *inferior laryngeal nerve* runs upward behind the thyroid gland between the trachea and the esophagus and should be carefully avoided in the extirpation of goiters, as injuries of this nerve are followed by paralyses of the laryngeal muscles of the same side. The trachea is situated considerably more deeply below than above the thyroid gland. This fact in itself complicates the performance of tracheotomy in this situation (low tracheotomy), and



Fig. 25.









additional reasons for the comparative infrequency of this operation are furnished by the numerous intercommunicating veins which pass downward from the thyroid gland, as the thyroid plexus, to empty into the middle thyroid vein, a tributary of the left innominate vein (see Fig. 24). The *inferior thyroid veins* take origin in numerous radicles from the isthmus and lateral lobes of the thyroid. Passing downward, the left empties into the left innominate vein, the right into the junction of right and left innominate veins. Frequent anastomoses between the veins of the two sides may result in a rather intricate plexus in front of the lower cervical portion of the trachea. Sometimes this anastomosis results in the formation of a single inferior thyroid vein, which usually empties into the left innominate vein, but may empty into the right.—ED.] The line of incision is also occasionally crossed by an anomalous thyroidea ima artery from the arch of the aorta.

The **trachea** begins at the lower border of the larynx, where the pharynx ends and the esophagus commences. This is at about the level of the sixth cervical vertebra. The trachea bifurcates into the two bronchi within the thorax (see page 114) opposite the fourth dorsal vertebra [or the upper border of the fifth.—ED.]; a cervical portion and a thoracic portion of the trachea may therefore be differentiated, the dividing-line being situated at the first dorsal vertebra. The cervical portion of the trachea may be further subdivided into three parts—that beneath the thyroid gland, a short portion above the gland, and a longer portion below it. As the trachea passes backward as well as downward, it constantly becomes further removed from the skin of the neck, through which it may be reached with comparative ease above the thyroid isthmus. Below the isthmus the trachea is covered by the veins of the thyroid plexus and by a varying amount of fat in the jugular fossa. When the head is held erect, the trachea consequently does not pursue a vertical course, but one that is directed from above downward and slightly backward. In children the trachea is covered above the sternum by the thymus gland, which projects above the upper opening of the thorax to a greater or less extent.

The **esophagus** is situated posterior to the trachea and commences opposite the cricoid cartilage about 15 centimeters from the incisor teeth [about six inches.—ED.]. It deviates somewhat to the left of the median line, projecting slightly beyond the left side of the trachea; esophagotomy for the removal of foreign bodies is consequently best performed by making the incision along the inner border of the left sternocleidomastoid muscle. The skin, platysma, and fascia are divided, the edge of the sternocleidomastoid is drawn to the outer, and the larynx, trachea, and thyroid gland to the inner side. The inferior thyroid artery must sometimes be ligated; particular care should be taken to avoid the inferior laryngeal nerve, which runs in the groove between the trachea and the esophagus. The same incision will serve for the evacuation of those retropharyngeal abscesses which cannot be reached through the mouth, and also for the ligation of the inferior thyroid artery. The esophagus, like the pharynx, is fixed to the vertebral column by loose connective tissue (see Fig. 26) which offers no great resistance to the downward extension of retropharyngeal abscesses. Swellings and tumors of the lymphatic glands situated alongside of the esophagus may lead to esophageal stenosis; suppurations in these glands or in the thyroid gland may rupture into the esophagus. The narrowing of the esophageal lumen at the level of the cricoid cartilage is described upon page 115. The esophagus is only loosely attached to the trachea by connective tissue. Running upward to the



FIG. 26.—A median sagittal section of the neck (formalin preparation).

larynx between the trachea and the esophagus are the two motor laryngeal nerves, the inferior or recurrent laryngeal nerves (see page 67).

In the middle line of the neck there is occasionally a *superficial median vein*. As a rule, however, the more or less prominent *anterior jugular veins* lie to either side of the median line in the anterior cervical region. They commence in the mental region, run downward upon the infrahyoid muscles, and pass beneath the origin of the sternocleidomastoid muscles to empty, together with the external jugular veins, into the subclavian vein. In the median line above the sternum the two veins are united by a transverse vein (the *arcus venosus juguli*) which is endangered in the operation of low tracheotomy. The left innominate vein (see page 112) only exceptionally projects above the upper margin of the sternum, and consequently is not usually endangered in operative procedures. The external jugular vein runs downward upon the sternocleidomastoid muscle in the lateral cervical region, and during life is often visible through the skin (see page 62). Below the ear it anastomoses with the *posterior division of the temporo-maxillary vein*; it collects the blood from the occipital and posterior auricular veins and empties into the subclavian vein above the clavicle to the outer side of the attachment of the sternocleidomastoid muscle (where it may be compressed—see page 62). If the tendon of the sternocleidomastoid is divided above the clavicle for torticollis, care should be taken to avoid injuring the external jugular vein. The origin of this muscle from the sternum and from the clavicle also conceals the more deeply situated vessels of this region. The common carotid artery may be ligated between the two heads of the muscle, but on account of its depth in this situation the vessel is reached with much greater difficulty than at the level of the cricoid cartilage (see page 62). There is little danger of wounding the common carotid artery in the operation for torticollis. If we penetrate between the two heads of the sternocleidomastoid muscle, we come upon the *internal jugular vein*; this must be pushed outward, and the sternohyoid and sternothyroid muscles inward, to expose the *common carotid artery* (see Fig. 27). The vagus nerve must be carefully avoided (see page 64).

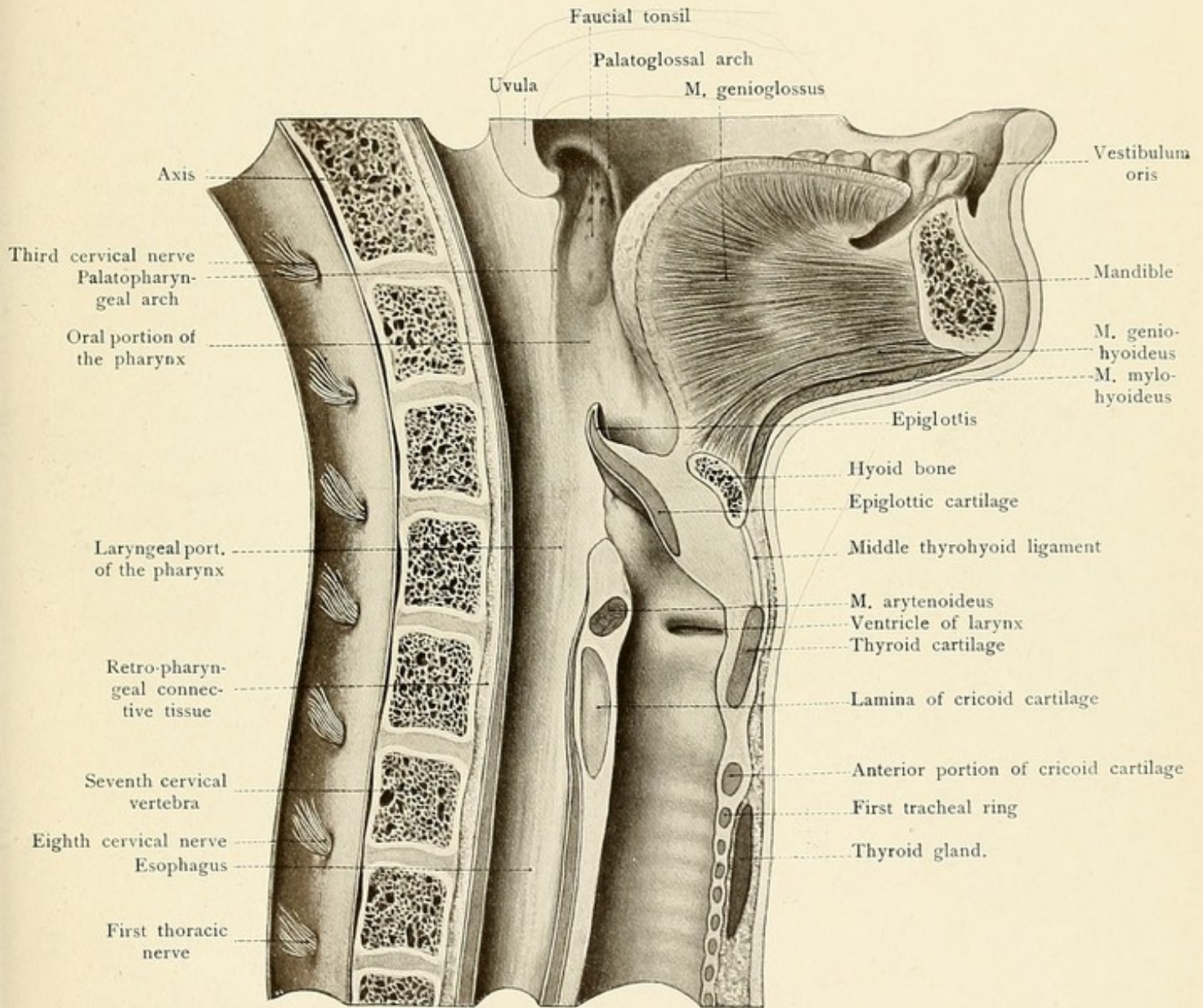
In the **lateral cervical region** the majority of the nerves originating in the *cervical plexus* are visible at the posterior margin of the sternocleidomastoid muscle, while the plexus itself, formed by the anterior divisions of the four upper cervical nerves, is concealed by this muscle. The following cutaneous nerves may be seen:

1. The *occipitalis minor nerve*, which runs close to the insertion of the sternocleidomastoid muscle to the lateral portion of the occipital region. It may be superficially or deeply placed, is often double, and frequently inosculates with the occipitalis major nerve (see page 28).

2. The *auricularis magnus nerve*, larger than the preceding and appearing below it at the margin of the sternocleidomastoid muscle. It runs directly upward to the ear upon the sternocleidomastoid muscle, supplies the skin of the auricle, that of the anterior and posterior auricular regions, and also the cutaneous lining of the external auditory meatus. It frequently divides into an anterior and a posterior branch.

3. The *superficialis colli nerve* (dividing into a superior and an inferior branch) runs anteriorly at right angles to the sternocleidomastoid muscle and pierces the platysma in order to reach the skin. It is divided, usually at the anterior margin of this muscle, in exposing the great vessels of the neck. Its upper branches inosculate with the cervical branches of the facial nerve.











4. A considerable number of *supraclavicular nerves* run downward in the region of the supraclavicular fossa, some of them passing downward anteriorly and posteriorly over the sternum and the acromion; they supply the skin of the superior thoracic region and of the shoulder.

The *spinal accessory nerve*, after perforating and supplying the sternocleidomastoid, leaves the posterior margin of this muscle and runs obliquely downward and outward in the space between the splenius and the levator anguli scapulæ to the trapezius muscle. [The spinal accessory nerve enters the deep surface of the sternocleidomastoid about one and a half inches or less below the tip of the mastoid process; perforating the muscle, it emerges at or a little below the middle of the posterior border. A line from midway between the angle of the jaw and the tip of the mastoid through the middle of the posterior border of the sternocleidomastoid continued across the posterior triangle to the anterior edge of the trapezius at the level of the seventh cervical spine sufficiently indicates its course.—ED.] This muscle is also directly supplied by branches of the cervical plexus which may be found lower down in the posterior triangle. In the neighborhood of the supraclavicular fossa the posterior belly of the omohyoid muscle appears beneath the posterior margin of the sternocleidomastoid and runs downward and outward to disappear beneath the clavicle. Together with the clavicle and the posterior margin of the sternocleidomastoid, it bounds the small *subclavian triangle* (*trigonum omoclaviculare*). In lean individuals the omohyoid muscle may often be seen when the hyoid bone and larynx are elevated during the act of deglutition.

In the depths of the lateral cervical region (see Fig. 27) above the clavicle, and forming, so to speak, the floor of this triangle, may be seen the *scalene muscles*. The anterior scalene muscle passes from the transverse processes of the third, fourth, fifth, and sixth cervical vertebrae to the scalene tubercle of the first rib; the middle scalene muscle runs from the transverse processes of all of the cervical vertebrae to the outer surface of the first rib. These two muscles form the typical *scalene slit* or *scalene triangle*, the apex of which is directed upward and the base downward. Behind these muscles is the posterior scalene muscle, which extends from the transverse processes of the fifth, sixth, and seventh cervical vertebrae to the outer surface of the second rib. Above the scalene muscles is the *levator anguli scapulæ*, arising from the transverse processes of the four upper cervical vertebrae and inserting into the superior angle of the scapula, and the *splenius capitis et cervicis*, which arises from the ligamentum nuchæ and the spinous processes of the first to the sixth dorsal vertebrae and is inserted into the mastoid process and the transverse processes of the first two or three upper cervical vertebrae.

The *supraclavicular lymphatic glands* are grouped above the clavicle; they receive the lymph from the back of the neck as high up as the ear and are frequently diseased, particularly in tuberculosis.

If the sternocleidomastoid muscle is removed, the previously concealed continuation of the vascular and nervous trunk is exposed as it passes downward toward the clavicle. A still better view is obtained if the clavicle, or at least its sternal half, is also removed. By this procedure we expose the first rib, and consequently the dividing-line between the neck and the thorax, since the dome of the pleura with the contained apex of the lung extends upward beyond the first rib. Passing downward upon the right side, we come to the *innominate artery*, which divides into the *right common carotid* and the *right subclavian* behind the upper margin of the sternum. [This



FIG. 27.—The supraclavicular region. The sternocleidomastoid and the infrahyoid muscles have been removed.

FIG. 28.—The infraclavicular region.

division takes place approximately behind the right sternoclavicular articulation.—ED.] Upon the left side these two vessels arise separately from the arch of the aorta behind the junction of the first rib with the sternum in this region; they are also covered by both portions of the sternocleidomastoid muscle, by the sternoclavicular articulation, and by the origins of the sternohyoid and sternothyroid muscles. The *common carotid artery* gives off no branches, and, after crossing beneath the omohyoid muscle, appears beneath the inner margin of the sternocleidomastoid. The *subclavian artery* passes out of the thoracic aperture to the inner side of the dome of the pleura (which encloses the apex of the lung), describes an outward curve, the convexity of which is directed upward, passes behind the anterior scalene muscle, and runs over the first rib in the subclavian groove (the lower broad portion of the scalene slit). The artery consequently reaches the supraclavicular fossa, where its pulsations may be more or less distinctly felt, and then passes beneath the middle of the clavicle and the subclavius muscle, below which it is known as the axillary artery. With the exception of the posterior scapular, all of the branches of the subclavian artery are given off before the vessel passes between the anterior and middle scalene muscles. These branches lie upon the small portion of the artery which is deeply situated behind the clavicular portion of the sternocleidomastoid muscle and are covered by the subclavian vein and its junction with the internal jugular. The branches are:

1. The *vertebral artery* (see page 34).

2. The *internal mammary artery* (see page 93).

3. The *thyroid axis*, which immediately divides into:

(a) The *inferior thyroid artery*. This is usually the largest division of the thyroid axis. It runs upward and then inward upon the vertebral column behind the common carotid artery, supplies the pharynx, esophagus, trachea, and larynx (inferior laryngeal artery), and reaches the posterior surface of the thyroid gland.

(b) The *ascending cervical*, which is often very small and runs upward upon the origins of the scalene muscles.

(c) The *transversalis colli*, which passes through the supraclavicular fossa transversely across the scalene muscles and in front of the brachial plexus to the trapezius muscle.

(d) The *suprascapular*, which is frequently an independent branch of the subclavian artery. This vessel runs slightly downward to the upper margin of the scapula and is concealed beneath the clavicle; it passes over the transverse ligament of the scapula to reach the supraspinous fossa and then skirts the neck of the bone and enters the infraspinous fossa. It supplies the supraspinatus and infraspinatus muscles and anastomoses with the subscapular branch of the axillary artery (see page 74 and Fig. 30).

4. The *costocervical axis*, a short trunk which passes posteriorly and divides into:

(a) The *superior intercostal artery* (see page 96) for the first one or two intercostal spaces, and

(b) The *deep cervical artery*, which runs posteriorly over the neck of the first rib to supply the deep muscles of the neck and back.



Fig. 27.

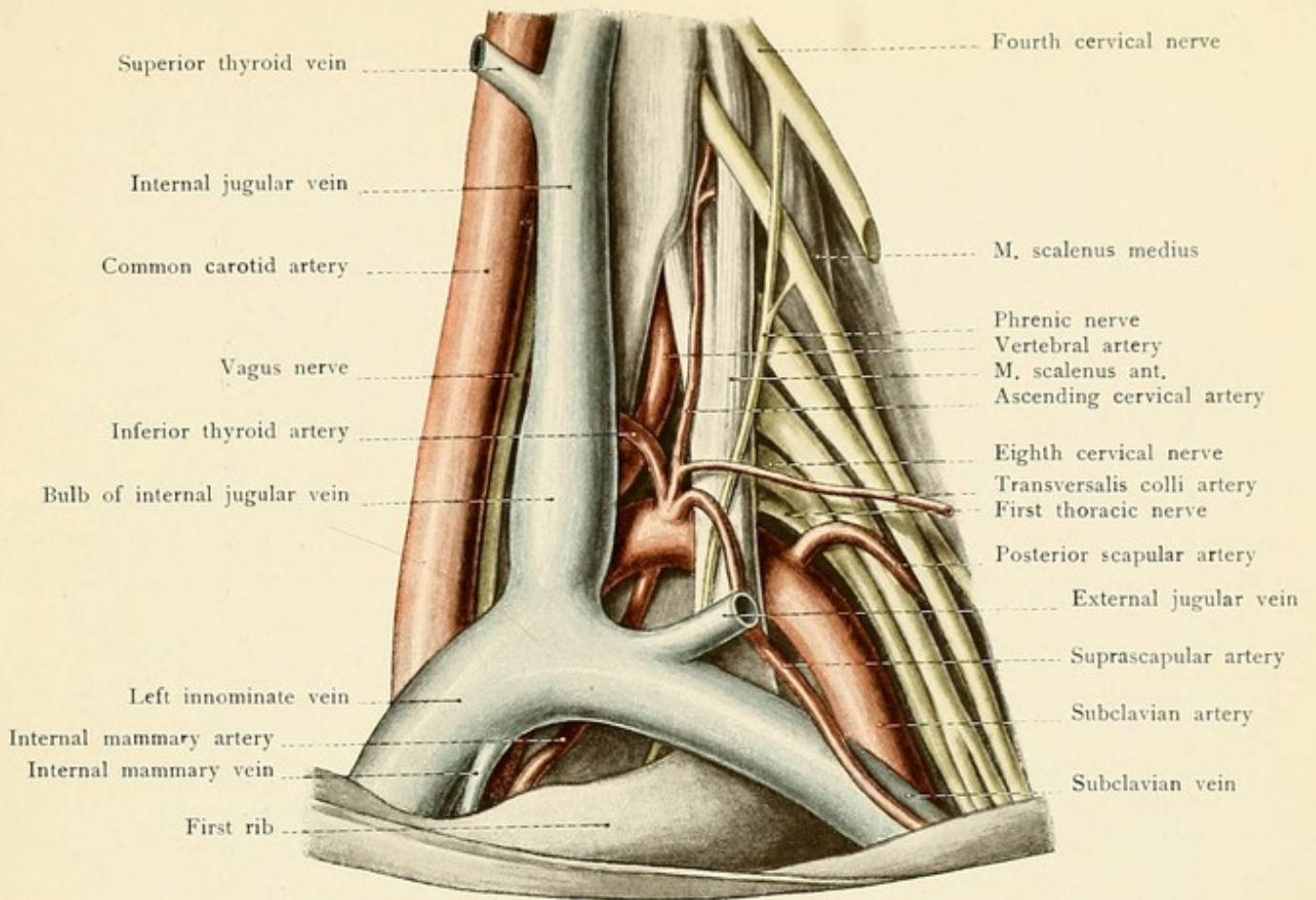
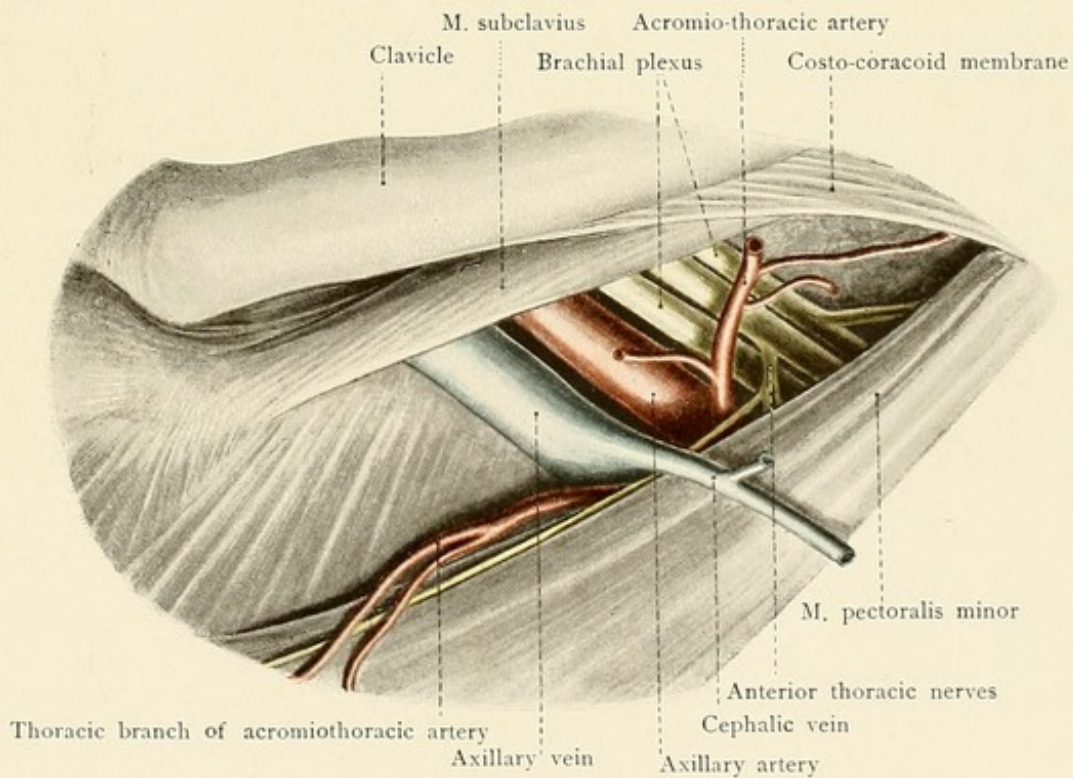


Fig. 28.









As the subclavian artery leaves the scalene triangle, or while it is still within this space, it gives off

5. The *posterior scapular artery*, which passes between the trunks of the brachial plexus and runs parallel to the transversalis colli (by which vessel it is occasionally replaced) beneath the insertion of the levator anguli scapulæ, where it subdivides into an ascending and a descending branch.\*

In ligating the subclavian artery as it passes over the first rib, the posterior scapular, the suprascapular, and the transversalis colli arteries must be carefully avoided. Special attention must also be paid to the external jugular vein, which should be divided between two ligatures to avoid the entrance of air emboli. The deeper we penetrate in this region, the more it behooves us to remember that the pleural sac projects above the superior aperture of the thorax (see page 101).

The *internal jugular vein* is external to the common carotid artery and, as in the carotid triangle, partly overlies this structure; behind the sternoclavicular articulation it unites with the subclavian vein to form the innominate vein. The lower more or less dilated portion of the internal jugular vein is known as the *inferior bulb of the vein*. The subclavian vein lies in front of and somewhat below the artery of the same name (in Fig. 27 the outer portion of the vein has been displaced slightly upward), the two vessels being separated by the insertion of the anterior scalene muscle. This vein receives the external jugular, the anterior jugular (frequently a tributary of the external jugular), the acromiothoracic, the suprascapular, and the posterior scapular veins.

The *cervical plexus*, formed by the anterior divisions of the four upper cervical nerves, lies upon the origins of the muscles forming the floor of the lateral cervical region and is covered by the sternocleidomastoid muscle.

The small anterior division of the first cervical nerve communicates particularly with the superior cervical ganglion and forms a loop with the second cervical nerve, from which the muscles of the neck receive their branches. Muscular branches are also given off by the second cervical nerve (to the levator anguli scapulæ, for example). This nerve, and frequently the third cervical as well, gives off the fine filaments which pass anteriorly and unite with the descendens hypoglossi to form the ansa hypoglossi. The *occipitalis minor* (see page 68) usually arises from the loop connecting the second with the third cervical nerve. The *auricularis magnus* (see page 68) and the *superficialis colli* (see page 68) are given off from the third or from the loop connecting the third with the fourth cervical nerve; the *supraclavicular nerves* are given off from the fourth or from the third and fourth cervical nerves, while the *phrenic* (see page 104) usually originates exclusively from the fourth cervical. There is a communicating branch connecting the fourth cervical nerve with the brachial plexus, the large roots of which may be seen in the upper portion of the scalene triangle above the subclavian artery. The phrenic nerve runs downward upon the anterior scalene muscle and enters the thoracic cavity by passing between the subclavian artery and vein (see Plate 8).

\*The author's nomenclature and description of the branches of the subclavian artery differ considerably from most English versions. This is not of great importance, however, when one considers the wide variations exhibited by the structures themselves.—ED.



## QUESTIONS.

- How may the external jugular vein be made distinctly visible in the neck of the living subject?
- Where may the pulsations of the common carotid and subclavian arteries be felt?
- Where is the most favorable place for making compression upon the subclavian artery?
- What nerve is to be carefully avoided in the ligation of the subclavian artery?
- What bone serves as a landmark in the exposure of the lingual artery in the neck?
- What relations exist between the face and the submaxillary lymphatic glands?
- What situation is best adapted for opening the larynx? What situation is least adapted?
- Where may abscesses rupture which originate in the posterior laryngeal wall and extend posteriorly?
- Where is high tracheotomy performed? Where is low tracheotomy performed? Which operation is more easily performed and why?
- What anomaly of the thyroid gland may complicate the performance of high tracheotomy?
- How may the esophagus be exposed in the neck and what nerve is thereby endangered?
- What organs may be compressed by enlargements of the thyroid gland?
- What nerve may be injured in thyroidectomy and what will be the result?
- Where are the important groups of the cervical lymphatic glands situated?
- Where should a stethoscope be placed to hear venous murmurs in the internal jugular vein?
- What artery may be ligated in this situation?

---

 THE UPPER EXTREMITY.

## THE SHOULDER.

The shoulder is bounded above by the clavicle, by the acromion, and by a line drawn from the acromion to the spinous process of the seventh cervical vertebra. The lower boundary of this region is formed by the insertions of the pectoralis major and latissimus dorsi muscles. The clavicular portion of the *pectoralis major* arises from the sternal extremity of the clavicle, the sternal portion from the anterior surface of the sternum and of the six upper ribs, and the abdominal portion (inconstant) from the anterior layer of the sheath of the rectus abdominis; the tendon of the pectoralis major is inserted into the anterior bicipital ridge of the humerus. The *latissimus dorsi* arises from the spinous processes of the lower six dorsal and of all of the lumbar and sacral vertebrae, from the crest of the ilium, from the posterior lamella of the lumbar fascia, and from the outer surfaces of the lower ribs; the tendon of the latissimus dorsi is inserted into the posterior bicipital ridge. The characteristic prominence of the shoulder is formed by the head of the humerus and by the overlying *deltoid muscle*, which arises from the acromial end of the clavicle, from the acromion, from the spine of the scapula, and from the infraspinous fascia and is inserted into the deltoid tubercle of the humerus. Through the deltoid muscle may be more or less distinctly felt the *head of the humerus*, with the greater and lesser tuberosities, and the intervening *bicipital groove* containing the long tendon of the biceps. The bicipital groove determines the direction of Langenbeck's incision for resection of the shoulder-joint. To the inner



side, covered by the edge of the deltoid muscle, may be felt the *coracoid process*. This is situated slightly to the outer side of the groove, between the pectoralis major and the deltoid, which contains the cephalic vein and widens out as it passes up toward that portion of the clavicle which is more or less free from muscular attachments. In this situation is the *intraclavicular fossa*, the region for ligating the first portion of the axillary artery. In lean individuals the sharp margin of the costocoracoid ligament may be palpated in this fossa as it runs toward the coracoid process. At the acromial end of the clavicle is the *acromioclavicular articulation*, which feels like a short narrow groove running in a sagittal direction. The parts which have been named should be palpated in normal individuals, so that the changed relations present in dislocations of the shoulder-joint may be recognized with certainty.

**The Anterior Region of the Shoulder.**—After dividing the skin, the platysma, the ends of the supraclavicular nerves, and the thin fascia covering the groove between the pectoralis major and the deltoid, we may easily find the *cephalic vein*, which runs upward from the external bicipital groove accompanied by the humeral branch of the acromiothoracic artery (see page 95); it passes inward above the tendon of the pectoralis minor, perforates the costocoracoid membrane, and empties into the *axillary vein*. If the deep fascia is removed, the narrow space between the upper border of the pectoralis minor and the *subclavius muscle* is exposed. The *pectoralis minor* arises from the outer surfaces of the second to the fifth ribs and is inserted into the coracoid process; the *subclavius* arises from the junction of the first rib with its cartilage and is inserted into the under surface of the acromial extremity of the clavicle (see Fig. 28). If we follow the cephalic vein, we come to the *axillary vein*. To the outer side of this vein are the cords of the *brachial plexus*, and between these two structures and somewhat posteriorly is the *axillary artery* just after it has passed over the first rib. This is the usual situation for the ligation of this vessel. In order to expose the artery the plexus must be displaced outward and the vein inward. The structures endangered are the acromiothoracic artery (acromial, thoracic, and descending branches), and the anterior thoracic nerves which supply the pectoralis major and minor muscles. An independent thoracic branch (the superior thoracic) is occasionally given off by the axillary artery. The vessels and nerves pass beneath the clavicle, the position of the artery corresponding to about the middle of the bone. The relation of the vessels and nerves to the clavicle explains the fact that in fractures of this bone they may be more or less lacerated or compressed by the downward displacement of the acromial fragment. [Laceration or compression of the nerves and vessels following fractures is much less frequent than might be supposed, owing to the fact that the subclavius muscle acts as a cushion.—ED.] The plexus is more frequently involved in these injuries than are the vessels. As the nerve-trunks are nearest to the shoulder-joint, they are the first structures to be compressed in the subcoracoid dislocation, in which the head of the humerus is drawn inward and presses them against the ribs. This dislocation may also injure the circumflex nerve (see page 75 and Fig. 30) which runs around the surgical neck of the humerus. A corresponding compression of the vessels and nerves may also be observed in those fractures of the surgical neck of the humerus in which the upper end of the lower fragment is so frequently displaced inward and the arm is held in a position of abduction. As the vessels are situated at a greater distance from the head of the humerus, they are less likely to be involved than are the nerves.



FIG. 29.—The axilla and the lateral thoracic wall.

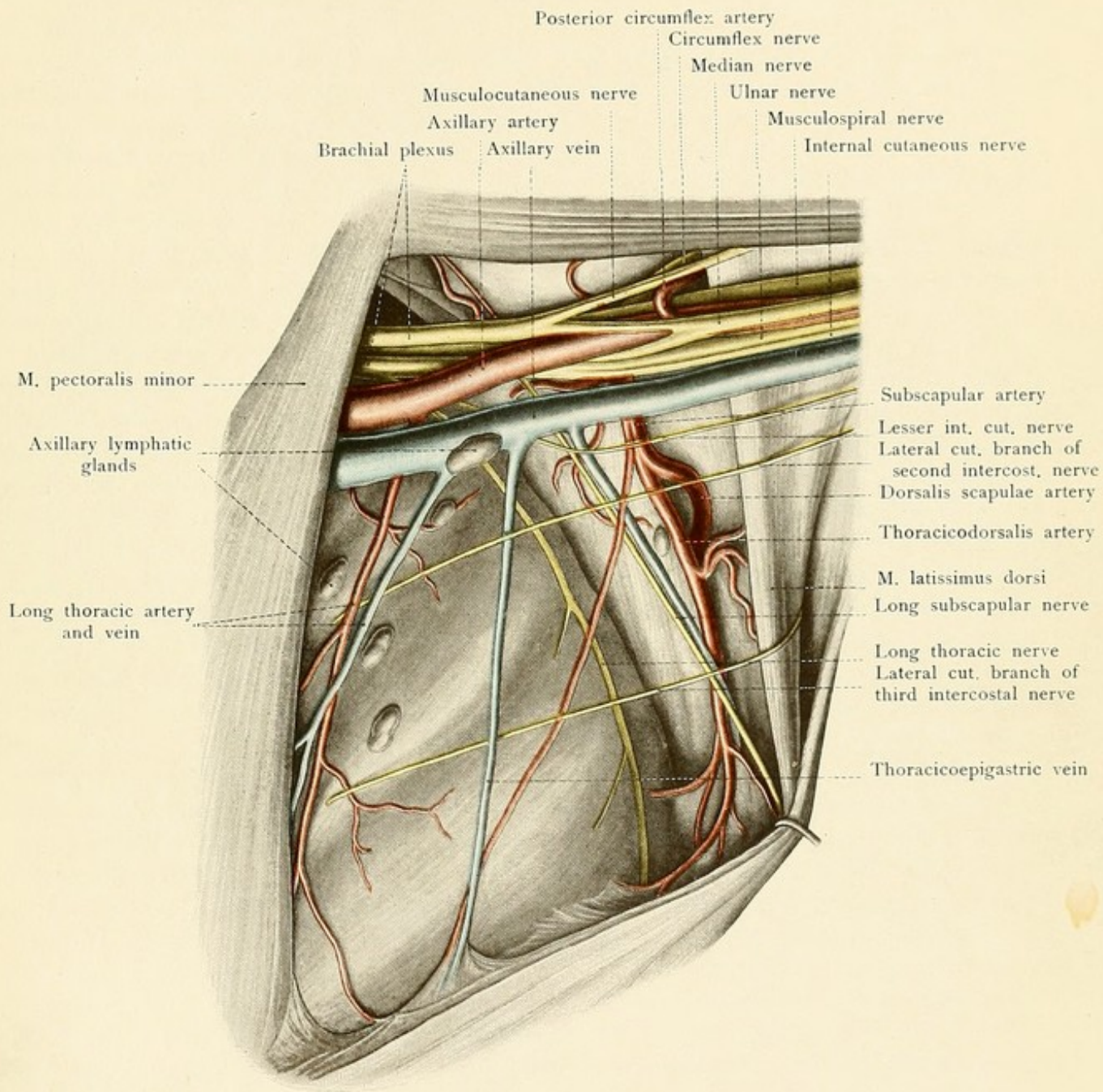
**Axilla.**—At the lower border of the subclavius muscle the vessels and nerves for the upper extremity pass into the space known as the *axillary cavity*. This cavity is situated above the axillary fossa, formed by the skin, and is a pyramidal space containing vessels, nerves, fat, and lymphatic glands. We differentiate an apex, situated at the coracoid process [in most English text-books the apex is said to be between the first rib, clavicle, and upper border of the scapula, thus opening into the neck and permitting the passage of certain structures from the neck to axilla.—ED.], a base, formed by the skin of the axillary fossa, and four walls. The anterior wall is formed by the pectoralis major and minor muscles. The inner wall corresponds to the upper portion of the lateral wall of the thorax with the overlying serratus magnus muscle. This muscle arises from the outer surfaces of the upper eight or nine ribs and is inserted into the vertebral border of the scapula. Eight or ten *lymphatic glands* are more or less closely related with this wall in the neighborhood of the three upper intercostal spaces (see Fig. 29); they are connected with the lymphatic vessels of the breast and of the arm. Great care must be exercised in removing these glands, as they are closely related to the vessels and are particularly apt to be adherent to these structures when degenerated. The surgeon has to deal with these glands particularly in carcinoma of the female breast (see page 95). The posterior wall is formed by the subscapularis and the teres major muscles which overlies the anterior surface of the scapula. The subscapularis arises from the subscapular fossa and is inserted into the lesser tuberosity of the humerus; the teres major arises from the axillary border of the scapula and the infraspinous fascia and is inserted, together with the tendon of the latissimus dorsi, into the posterior bicipital ridge. The outer wall is formed by the shoulder-joint and by the surgical neck of the humerus; these structures are covered by the short head of the biceps and by the coracobrachialis.

The *axillary artery* is in relation first with the posterior and then with the outer wall of the axillary cavity. The pulsations of the vessel may be distinctly felt to the inner side of the prominence caused by the coracobrachialis muscle; this is the situation in which the artery may be most safely ligated by elevating the arm and keeping close to the border of the muscle. The vessel is comparatively close to the shoulder-joint and is sometimes torn across in dislocations or in attempts at their forcible reduction. The branches of the axillary artery are:

1. The *acromiothoracic* (see page 95).

2. The *subscapular*, which arises from about the middle of the axillary and consequently at the mid-point between the clavicle and the lower border of the pectoralis major muscle, in which latter situation the axillary becomes the brachial. The subscapular artery divides into two chief branches, the *dorsalis scapulæ* and the *thoracicodorsalis* [the continuation of the subscapular]. The *dorsalis scapulæ* runs over the external border of the scapula to the dorsal surface of this bone, supplies the surrounding muscles, and anastomoses freely with the suprascapular branch of the subclavian. This is the main path for the collateral circulation when the blood-current in the axillary artery is interfered with or when this vessel is ligated. The *thoracicodorsalis* is the largest vessel of the lateral thoracic wall (see page 96). It runs down the axillary border of the scapula, under cover of the edge of the latissimus dorsi, and particularly supplies the teres major, the latissimus dorsi, and the serratus magnus muscles.











3. The *long thoracic*, an inconstant branch, which arises above the subscapular (see page 95) and is situated in front of the thoracic dorsalis.

4. The *anterior circumflex*, a small branch which runs outward over the anterior surface of the neck of the humerus.

5. The *posterior circumflex*, a large branch which arises beside the preceding one, passes through the quadrangular space (see page 76) close to the bone to run posteriorly with the circumflex nerve and, like it, to particularly supply the deltoid muscle. As the vessel is closely related to the neck of the humerus, it must be carefully treated in resection of the shoulder-joint. If the operation is strictly subperiosteal, the elevator being always directed toward the bone, the vessel will escape injury.

The *axillary vein*, like the subclavian, is situated in front and to the inner side of the artery; it consequently covers the artery to a varying extent, dependent upon the degree of its distention. It is only in exceptional cases that the axillary vein is double.

**Brachial Plexus.**—Just beneath the clavicle the trunks of the brachial plexus, with the exception of a few small branches, are situated to the outer side of the vessel. Beneath the pectoralis minor muscle these trunks form three cords which are so arranged about this portion of the artery that we may differentiate an outer, an inner, and a posterior cord. The outer and inner cords supply chiefly the skin and muscles of the flexor surface, while the posterior cord supplies the extensor surface. A more detailed study of the axilla shows that the outer cord gives off the *musculocutaneous* nerve and the *outer head of the median*. From the inner cord arises the *inner head of the median* which, together with the outer head, surrounds the axillary artery like the prongs of a fork; the inner cord also gives off the *ulnar*, the *internal cutaneous*, and the *lesser internal cutaneous nerves*. From the posterior cord arise the *circumflex*, the *musculo-spiral*, and the *subscapular nerves*.

Of the other branches of the brachial plexus there is one which is of particular importance from a surgical standpoint; this is the *long thoracic*, the motor nerve of the serratus magnus muscle. It lies directly upon the serratus magnus, in association with the thoracicodorsalis artery, and is covered by the edge of the latissimus dorsi; it is not particularly exposed to injury in operations in the axillary cavity. The comparatively superficial *long* or *middle subscapular nerve* running to the latissimus dorsi is more easily injured, and its division is followed by paralysis of this muscle. [Note: The long thoracic nerve is related to the thoracico-dorsal artery only in the lower part of its course; the long (middle) subscapular is in close relation to this vessel.—ED.] The other two subscapular nerves supply the teres major and the subscapularis muscles and are more deeply situated. The *suprascapular nerve*, which runs through the suprascapular notch to the dorsal surface of the scapula and supplies the supraspinatus and infraspinatus muscles, is more rarely divided by the knife of the surgeon; the nerve filaments supplying the levator anguli scapulæ and the rhomboid muscles are also rarely injured.

**Posterior Region of the Shoulder.**—The arrangement of the muscles in this situation forms a typical topographic picture which is of importance for the exposure of the deep vessels and nerves of this region. The deltoid and teres major muscles have been previously described. The *supraspinatus muscle* arises from the supraspinous fossa; it passes beneath the acromion and the trapezius muscle and is attached to the greater tuberosity of the humerus. The *infra-*



FIG. 30.—A posterior view of the shoulder with the quadrangular and triangular spaces.

*spinatus muscle*, partly covered by the deltoid, passes from the infraspinous fossa to the greater tuberosity of the humerus. The *teres minor*, in relation with the lower border of the preceding muscle, runs from the axillary margin of the scapula to the greater tuberosity of the humerus; its lower border is approximately parallel to the upper border of the *teres major* muscle. Since both of these muscles are crossed by the long tendon of the triceps (which lies behind the *teres major*, but in front of the *teres minor*), as shown in Fig. 30, it will be seen that two spaces are formed, a quadrangular space and a triangular space.

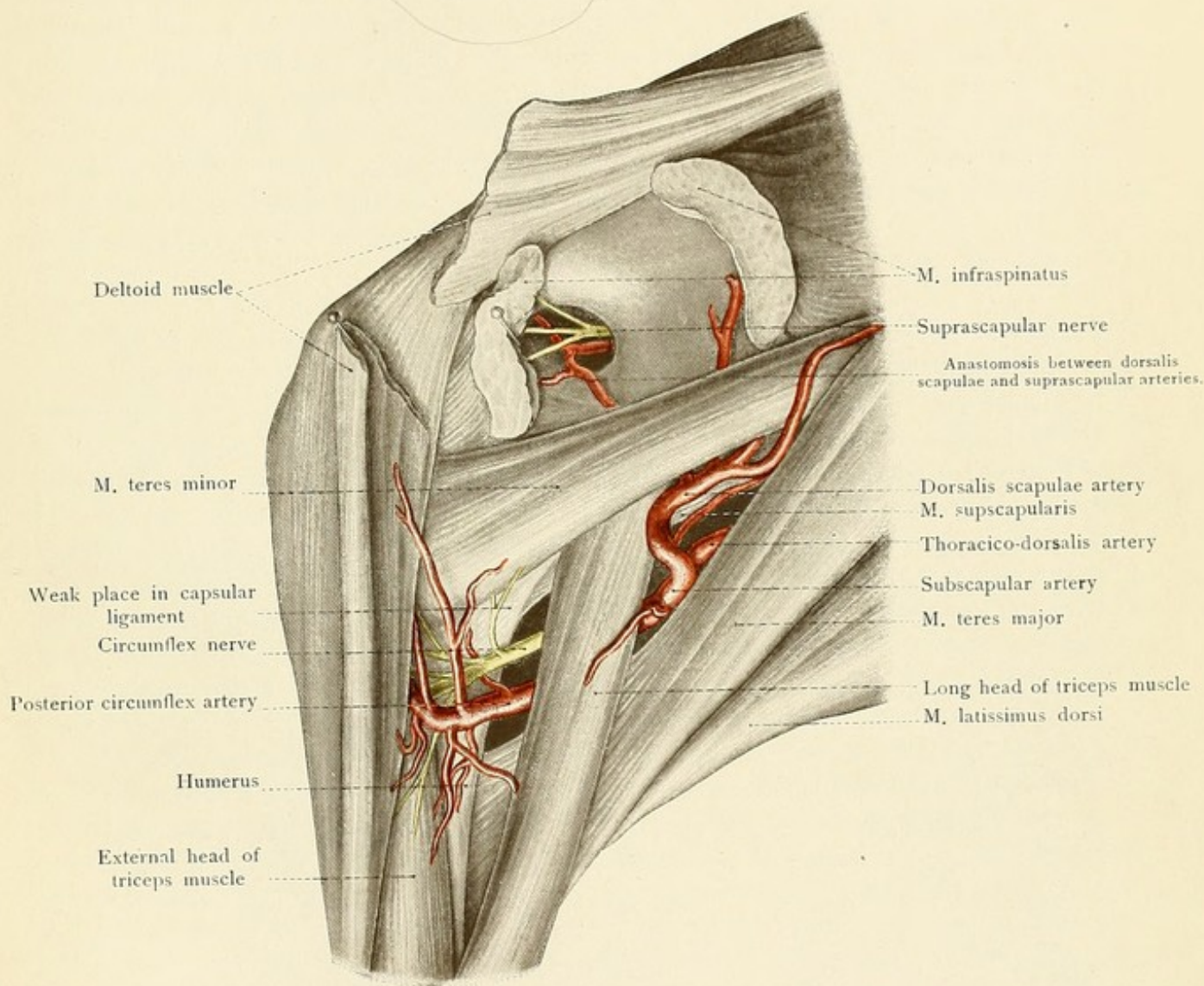
1. The *quadrangular space* is bounded by the neck of the humerus, by the *teres minor*, by the *teres major*, and by the long head of the triceps (see Fig. 30). Within this space, the axillary artery may be exposed from behind; the posterior circumflex artery and the circumflex nerve may also be seen as they pass into the substance of the deltoid from the inner surface of the muscle (see page 75).

2. The *triangular space* is bounded by the long head of the triceps and by the *teres major* and *minor* muscles. In this space may be seen one of the two terminal divisions of the subscapular artery, the *dorsalis scapulae* (see page 74). This vessel turns around the axillary border of the scapula to its posterior surface, where it is covered by the *infraspinatus* muscle, and runs upward to anastomose with the *suprascapular* artery below the root of the acromion (see page 74). This anastomosis forms an important collateral path after occlusion of the axillary artery. If the axillary artery is followed downward along the inner side of the humerus, it will be seen to emerge as the *brachial* artery below the united tendons of the *latissimus dorsi* and *teres major* muscles. In the triangular slit between the humerus, the long tendon of the triceps, and the external head of the triceps, the *brachial* artery gives off the *superior profunda*, which runs posteriorly and accompanies the *musculospiral* nerve.

**Shoulder-joint** (Fig. 31).—This joint has the widest range of motion of any joint in the body. The articulation is formed by the head of the humerus and the glenoid cavity of the scapula. The humeral head is covered by cartilage and the articular surface of the glenoid cavity is enlarged (deepened) by the *glenoid ligament*. As a consequence of the incongruity between the two articular surfaces, the head of the humerus projects far beyond the edge of the glenoid cavity.

The *lax capsular ligament* passes down from the circumference of the glenoid cavity and is attached, anteriorly, to the anatomic neck of the humerus (*i. e.*, the groove bounding the articular cartilage); posteriorly, to the bone somewhat below the anatomic neck. It bridges over the *bicipital groove* (*sulcus intertubercularis*) which lodges the long tendon of the biceps. This structure is enclosed in a tubular reflection of the synovial membrane, the *vagina mucosa intertubercularis*, which is the deepest portion of the joint when the body is held erect and which is often markedly distended by exudate when the shoulder-joint is inflamed. The greater and lesser tuberosities are outside of the joint. The synovial membrane is also reflected beneath the insertion of the *subscapularis* muscle, forming the *bursa mucosa subscapularis*. This is the weakest portion of the capsular ligament; it is the place where the head of the bone leaves the capsule in the common *subcoracoid* dislocation. A second weak place is to be found in the deepest part of the joint between the margins of the *subscapularis* and the *teres minor* muscles (see Fig. 30).











Although almost the entire capsule is surrounded and strengthened by the insertions of muscles, this place is not covered by any muscle, and through it occurs the dislocation which is second in frequency, the subglenoid or axillary dislocation.

A large bursa, which does not communicate with the joint, is also situated beneath the deltoid muscle (*subdeltoid bursa*) and may extend beneath the acromion. This bursa, when diseased, may be mistaken for an effusion into the shoulder-joint. The capsular ligament possesses but one important strengthening band, the *coracohumeral ligament*, which arises from the outer edge of the coracoid process and radiates in the capsule toward the greater tuberosity of the humerus. The joint is well protected above by the strong *coracoacromial ligament*, which extends from the acromion to the posterior surface of the coracoid process. It prevents the head of the bone from slipping upward, this displacement being possible only when a fracture of the overhanging acromion is present.

### THE UPPER ARM.

Upon the anterior or flexor surface of the arm the prominence of the *biceps muscle* may be easily palpated; to either side of this prominence are the outer and inner *bicipital grooves* respectively [indicating the inner and outer edges of this muscle. The term "bicipital groove" is usually applied by English authors to the bony groove in the humerus which contains the long tendon of the biceps.—ED.]. The pulsations of the brachial artery may be palpated at the inner margin of the muscle. The bicipital prominence becomes more pointed as it passes upward, and finally disappears beneath the edge of the pectoralis major muscle at the so-called anterior axillary fold. This portion corresponds to the short head of the biceps and to the coracobrachialis muscles. High up to its inner side may be seen, or at least felt, the pulsations of the axillary artery. This is the place of election for the ligation of this vessel (see page 73). In the upper portion of the internal bicipital groove the chief branches of the brachial plexus accompany the artery and may be palpated for a varying distance downward into the arm.

The comparatively thin deep fascia of the arm sends off the external and internal intermuscular septa, which are attached to the external and internal condyloid ridges respectively and extend downward as far as the epicondyles. They separate the biceps, brachialis anticus, and coracobrachialis muscles, which are situated anteriorly, from the posterior extensor mass of the triceps muscle. The *biceps muscle* arises by a long head from the supraglenoid tubercle within the shoulder-joint (see page 76), and by a short head from the apex of the coracoid process; it inserts into the tuberosity of the radius. The *brachialis anticus muscle*, situated beneath the biceps, arises from the anterior aspect [*i. e.*, inner and outer surfaces.—ED.] of the humerus, below the insertion of the deltoid muscle, and from the intermuscular septa, and is inserted into the coronoid process of the ulna. The origin of the *coracobrachialis muscle* is from the coracoid process in common with the short head of the biceps, and its insertion is at about the middle of the internal border of the humerus. The long head of the *triceps* arises from the infraglenoid tubercle of the scapula; the inner head arises from the posterior surface of the humerus below the musculospiral groove; the outer head commences above the musculospiral groove, which it bridges over, and arises from the outer surface of the bone and from the external intermuscular septum. These three heads are inserted into a common tendon which is attached to the olecranon.



FIG. 31.—A model of the shoulder-joint and its bursæ. The two bursæ communicating with the articular cavity as well as the joint itself are colored blue. The non-communicating subdeltoid bursa is represented in red. (From a Berlin model.)

FIG. 32.—A cross-section through the middle of the arm (hardened in formalin).

In the internal bicipital groove, about at the junction of the lower with the middle third of the arm, there is an opening in the deep fascia, which is known as the *hiatus basilicus*, for the passage of the basilic vein and the internal cutaneous nerve. In the external bicipital groove the cephalic vein runs upon the deep fascia (see page 73).

The *brachial artery* runs beneath the deep fascia in the internal bicipital groove; it is accompanied by two veins, the inner of which receives the basilic vein. Higher up, the *venæ comites* unite to form a single vein, either before reaching the axilla or, more rarely, after entering into this region. Disregarding the muscular branches, of which the bicipital is particularly large, the main branches of the brachial are:

1. The *superior profunda artery*, which accompanies the musculospiral nerve about the posterior surface of the humerus, in the musculospiral groove, between the outer and inner heads of the triceps muscle. It ends at the outer side of the humerus, where it is accompanied by a cutaneous branch of the musculospiral nerve, and descends behind the external intermuscular septum to reach the anastomotic arch above the olecranon (*rete articulare cubiti*). The posterior articular branch of this vessel runs downward in the posterior portion of the arm in the substance of the inner head of the triceps muscle.

2. The *inferior profunda artery*, usually a long vessel, which accompanies the ulnar nerve to the olecranon, where it empties into the *rete cubiti*.

3. The *anastomotica magna artery*, which arises near the division of the brachial in the region of the elbow. It runs transversely inward across the *brachialis anticus* muscle and passes posteriorly to the *rete cubiti*.

The *median nerve* is the most superficial of the three chief nerves in the upper arm. At first the nerve lies to the outer side of the brachial artery, it then passes in front of the vessel, and, while still above the elbow, takes a position to the inner side of the artery. The nerve consequently crosses the artery, and is to be felt lying upon the vessel, if the *panniculus adiposus* is not too well marked. The nerve is often situated beneath the artery, particularly in those cases of so-called high division of the brachial in which the artery divides in the upper arm into two parallel branches, one of which usually runs over and the other under the nerve. If the artery first exposed is comparatively small, and if it lies upon the median nerve, a search should always be made for a second artery. The median nerve gives off no branches in the upper arm.

The *ulnar*, the second great nerve of the arm, lies internal to the artery, but gradually becomes more distant from the vessel. It pierces the internal intermuscular septum at the lower third of the arm and reaches the space between the internal condyle and the olecranon. The ulnar nerve also gives off no branches in the upper arm.

The *musculospiral*, the motor nerve of the extensor muscles, is at first behind the artery. It enters the musculospiral groove, running upon the surface of the humerus between the outer and inner heads of the triceps muscle, and at the lower part of the arm passes into the region of the elbow between the *supinator longus* and *brachialis anticus* muscles. As the nerve lies directly



Fig. 31.

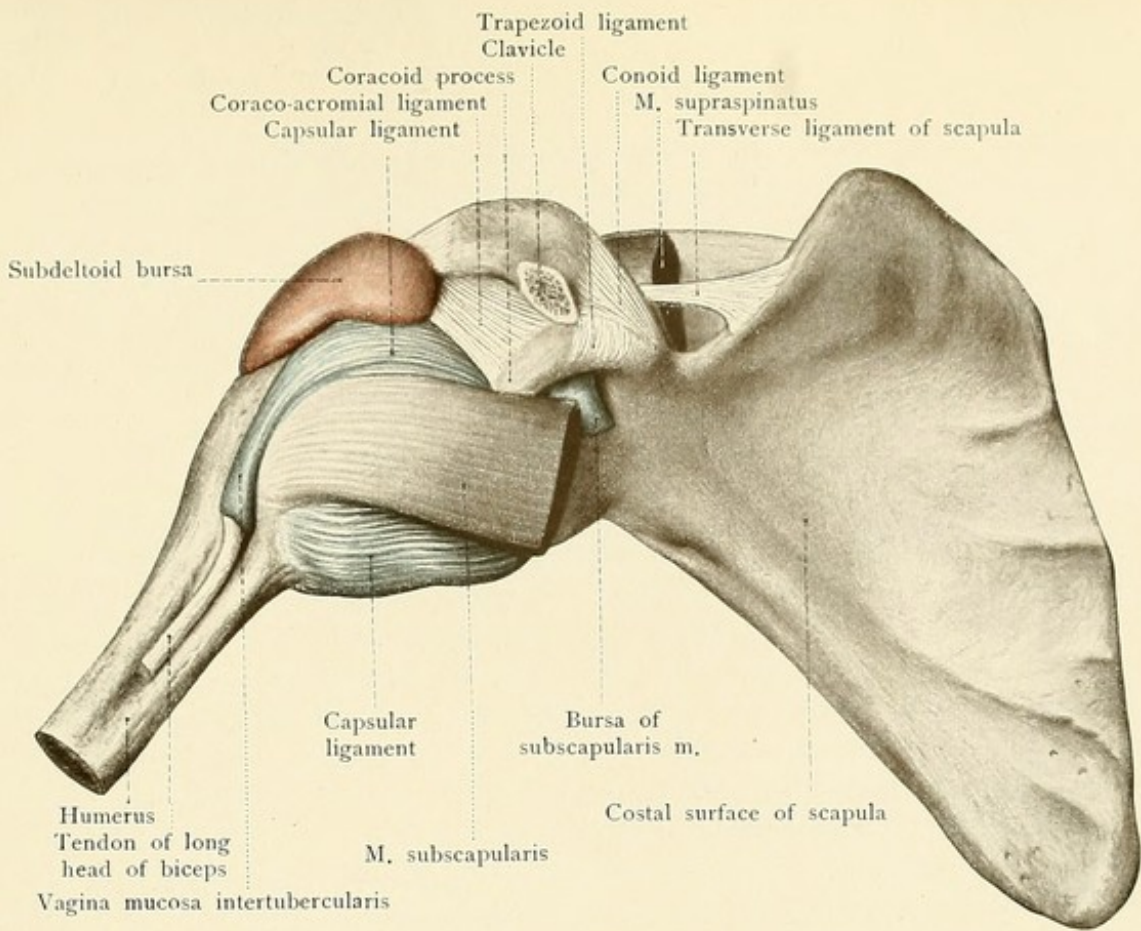
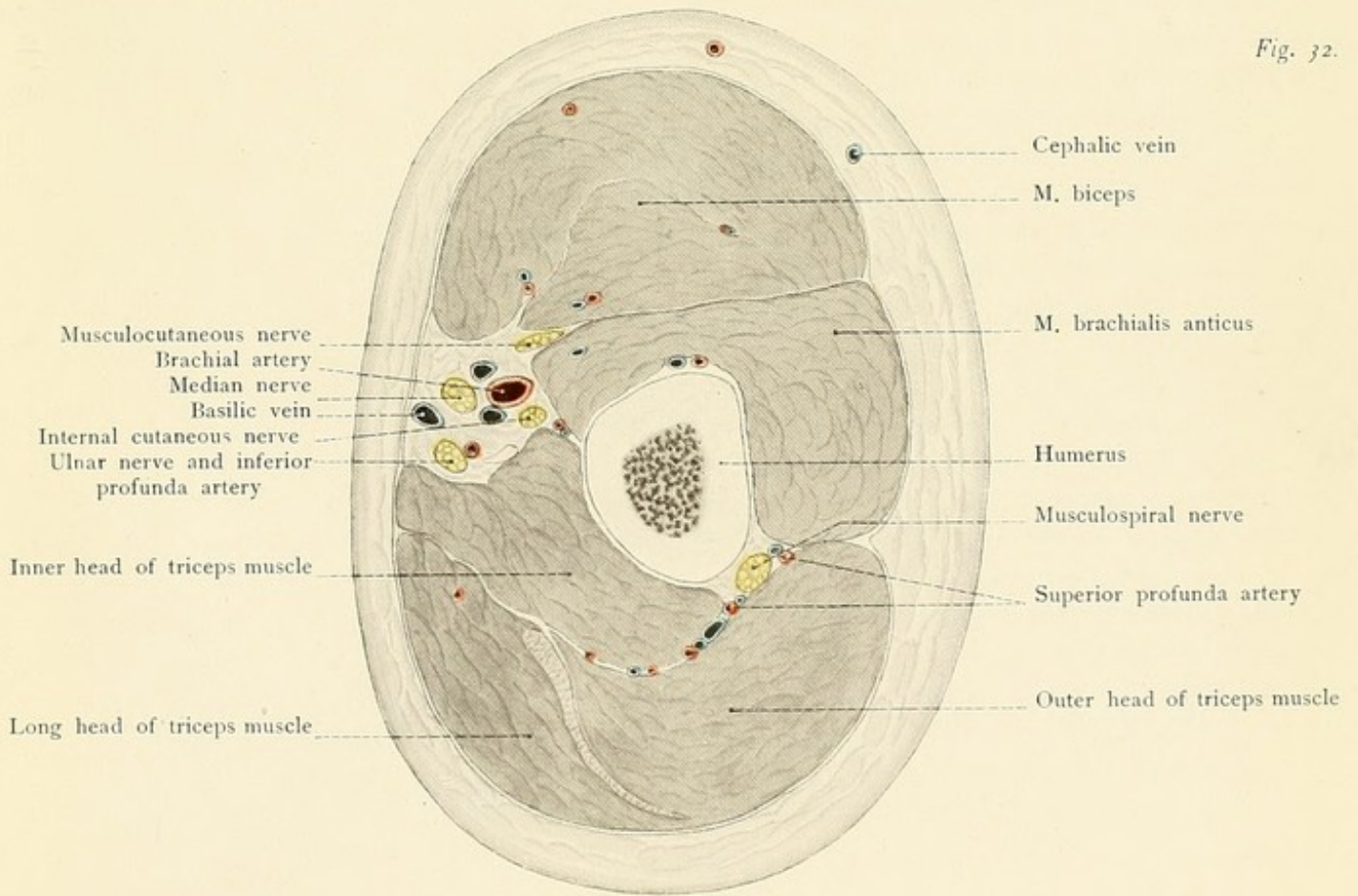


Fig. 32.









upon the humerus, it is endangered in fractures of this bone; it is also sometimes included in the callus of a uniting fracture and causes corresponding symptoms. In operative procedures upon the bone the nerve must be carefully avoided. Paralysis of the nerve is manifested by disturbances of function of all of the extensor muscles of the upper extremity (inability to extend the hand and the fingers, wrist-drop) as well as by sensory disturbances of the extensor surfaces of the arm, of the forearm, and of the radial half of the back of the hand.

### THE REGION OF THE ELBOW.

If the elbow is flexed in the living subject, there may be felt upon the flexor surface the strong *tendon of the biceps*, from which the sharply defined bicipital fascia radiates toward the ulnar side (see Fig. 33). The other landmarks which may be palpated are the *external* and *internal epicondyles* and, running upward from these points, the *external* and *internal condyloid ridges*. Posteriorly is the *olecranon*, and, to either side, the depressions which are more or less distinctly marked when the arm is extended. These depressions at the margin of the olecranon mark the points at which the cavity of the elbow-joint may be most easily and directly reached from behind (by aspiration, for example). In effusions into the joint these depressions become less distinct or even replaced by prominences. When the forearm is extended, the tip of the olecranon is in a line connecting the two condyles; when the forearm is flexed, the tip of the olecranon is about one centimeter lower. It is important to observe this normal relation, since the tip of the olecranon passes above this line in backward dislocations of the ulna and in fractures of the olecranon. Between the olecranon and the skin there is a *subcutaneous bursa* (see Fig. 34) which occasionally may lead to the development of a hygroma, particularly in individuals who support themselves upon their elbows while at work (miner's elbow). Somewhat higher up, within the tendon of the triceps muscle, there is another bursa (*bursa intratendinea olecrani*). If the forearm is moved slightly, the articulation between the external condyle and the head of the humerus may be felt, as may also the head of the radius, which will be found to rotate during the movements of pronation and supination. To the inner side of the olecranon, and running in a groove upon the humerus, the *ulnar nerve* may be easily palpated. If it is pushed about under firm pressure for a short time, the effect will be experienced in the hand. Upon the flexor surface the *cutaneous veins* may be more or less distinctly seen. They are the *cephalic vein* upon the radial side, the *basilic vein* upon the ulnar side, and the *median cubital vein*, the vein of phlebotomy and transfusion, which runs in an oblique direction from the cephalic up to the basilic vein. If the median vein, running upward upon the flexor surface of the forearm, divides, we speak of a *median cephalic* and of a *median basilic vein*. The transverse furrow which becomes visible upon flexion of the forearm is situated at the level of the epicondyles and two centimeters higher than the joint.

Beneath the thin skin of the flexor surface and lying upon the deep fascia, which is reinforced by the bicipital fascia, are two *cutaneous nerves*. Upon the ulnar side is the *internal cutaneous nerve*, which pierces the deep fascia at the hiatus basilicus (see page 78) and usually divides into two branches. The posterior branch reaches the extensor surface at the internal condyle; the anterior branch usually runs beneath the median cubital vein (or the median basilic vein) and passes downward upon the flexor surface as far as the wrist-joint. The *musculocutaneous nerve*



FIG. 33.—The region of the elbow. (The radial nerve has been drawn up from the depths and made to assume a more superficial position.)

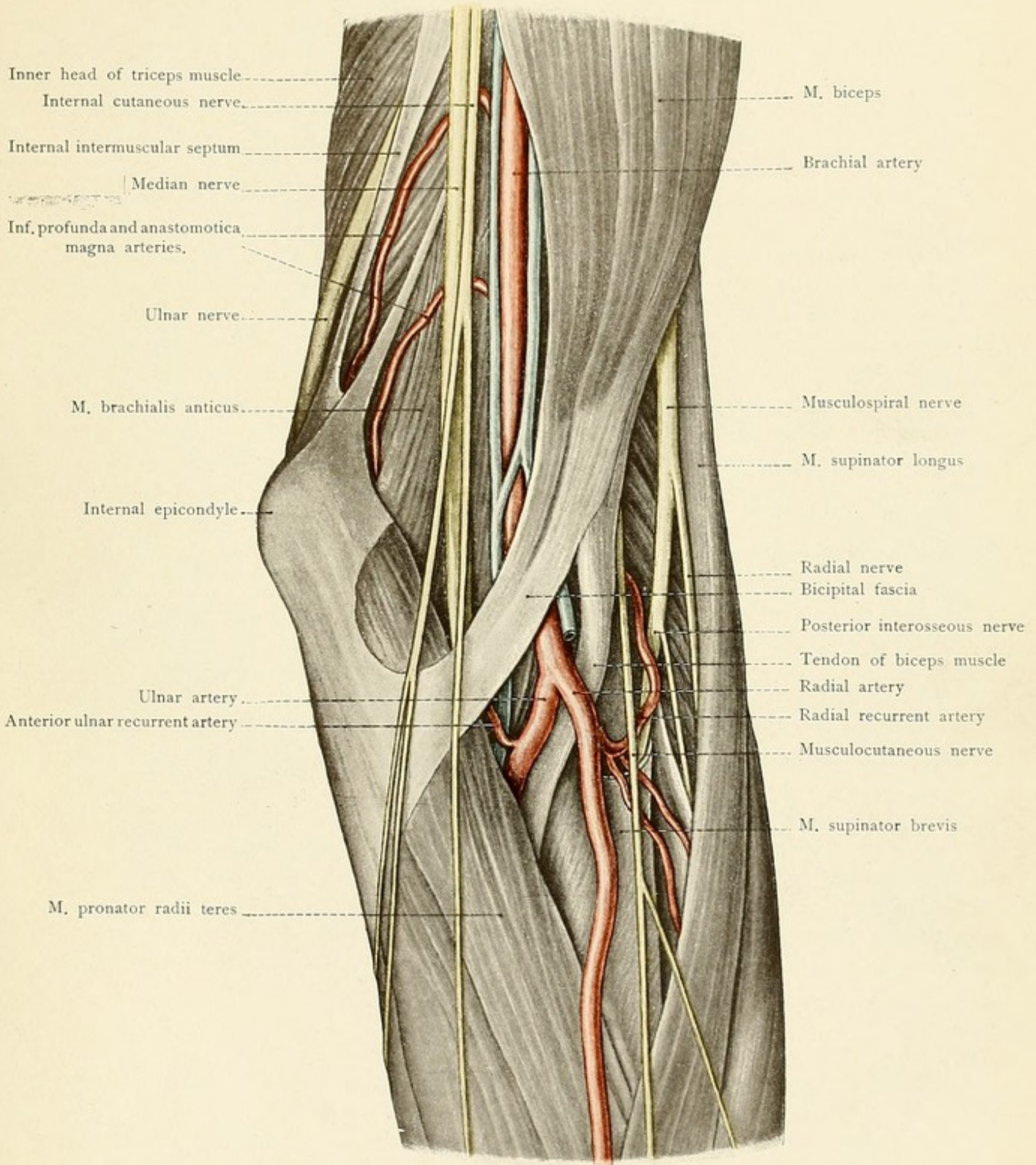
pierces the deep fascia in the external bicipital groove to the inner side of the cephalic vein, passes partly over and partly under the median cubital vein (or median cephalic vein), and runs downward to the wrist. At the bend of the elbow there is a constant and marked anastomosis between the median cubital vein and the deep veins of this region.

Removing the deep fascia and leaving the bicipital fascia behind, we obtain a view of the lower boundary of this region, which is formed upon the ulnar side by the edge of the pronator radii teres muscle, and upon the radial side by the inner border of the supinator longus muscle. The *brachial artery* is easily exposed. At the lower end of the internal bicipital groove it passes beneath the bicipital fascia, lies to the inner side of the bicipital tendon, and divides in front of the tendon of the brachialis anticus into its two terminal branches, the radial artery and the ulnar artery. The artery is accompanied by *venæ comites*. In this situation it is separated from the median cubital vein by nothing but the deep and bicipital fasciæ, and should consequently be carefully avoided in phlebotomy or transfusion into the vein. In the ligation of the artery care should also be taken to avoid unnecessary injury to the median cubital vein, which should be pushed to one side. If the incision is made too far to the inner side, the median nerve will be exposed, and the artery is consequently to be sought for to the outer side of the wound. In this region the brachial artery gives off no special branches, but vessels are given off almost immediately by its two terminal divisions. The relative position of these terminal divisions is best demonstrated by a sagittal frozen section (see Fig. 34), which shows that the radial is at first more superficial than the ulnar artery. In the bend of the elbow the radial artery gives off the *radial recurrent*, which ascends upon the supinator brevis muscle toward the musculospiral nerve to supply the rete articulare cubiti. The ulnar artery also assists in the formation of this articular anastomosis by giving off the anterior and posterior recurrent branches which frequently arise by a common trunk. The anterior ulnar recurrent artery anastomoses with the *anastomotica magna* from the brachial; the posterior ulnar recurrent artery passes upward in the groove between the olecranon and the internal condyle and anastomoses with the *inferior profunda* from the brachial.


A knowledge of the relations of the three main *nerves* of the arm is important for all operative procedures in the neighborhood of the elbow-joint. The *median nerve*, the motor nerve for all of the flexor muscles of the forearm (except the flexor carpi ulnaris and the ulnar half of the flexor profundus digitorum), is situated beneath the bicipital fascia to the inner side of the brachial artery. This nerve reaches the forearm by piercing the pronator radii teres, but gives off some muscular branches before entering this muscle. The *ulnar nerve* is to be found upon the extensor surface alongside of the olecranon (see page 78). In this situation the ulnar nerve is to be particularly avoided in the resection of the elbow-joint from behind. The nerve passes between the origins of the flexor carpi ulnaris, coming from the internal epicondyle and from the olecranon, reaches the deep surface of this muscle, which it supplies, and runs downward upon the flexor side of the forearm. The *musculospiral nerve* is quite deeply situated in the outer portion of the bend of the elbow, but may be easily exposed in the groove between the supinator



Fig. 33.









longus and the brachialis anticus muscles. After supplying the supinator longus and the extensor carpi radialis longior and breviar muscles, the nerve divides above the external condyle into the radial (a sensory branch) and the posterior interosseous (a motor branch for the extensor muscles of the forearm).

The **elbow-joint** is composed of three articulations:

1. The trochlear surface of the humerus with the greater sigmoid cavity of the ulna.
2. The capitellum of the humerus with the cup-shaped depression on the head of the radius.
3. The lesser sigmoid cavity of the ulna with the circumference of the head of the radius.

The first articulation is for flexion and extension, the third is for rotation (pronation and supination), and the second permits not only of flexion and extension, but also of rotation. All three articulations are surrounded by a common lax capsular ligament, which is attached anteriorly above the coronoid and radial depressions, excluding the epicondyles, and posteriorly above the olecranon fossa, which is also situated within the joint. To either side of the olecranon the *capsular ligament* forms small diverticula which are situated beneath the cutaneous depressions visible in this situation in the living subject (see page 79). The capsular ligament is attached to the edges of the greater and lesser sigmoid cavities of the ulna in such a way that the apex of the coronoid process and the olecranon are within the articular cavity; this ligament is also inserted into the neck of the radius so that the head of this bone is entirely within the joint.

The capsular ligament is reinforced by three other ligaments:

1. The *internal lateral ligament*, which radiates from the internal epicondyle to the edge of the greater sigmoid cavity of the ulna.
2. The *external lateral ligament*, which runs downward from the external epicondyle, some of the fibers surrounding the neck of the radius and being inserted into the anterior and posterior margins of the lesser sigmoid cavity of the ulna.
3. The *orbicular ligament*, which enforces the capsule in a circular manner about the neck of the radius and is inserted into the anterior and posterior margins of the lesser sigmoid cavity of the ulna. The external lateral and orbicular ligaments form practically one continuous band of connective tissue.

As the large superficial and deep vessels of this region are situated in front of the elbow-joint, it follows that marked subcutaneous or deep extravasations of blood may result from a backward dislocation of both bones, and particularly from that form which is due to hyperextension. In this dislocation the median nerve is necessarily lacerated, as it is also in front of the articulation. The importance of the relation of the ulnar nerve to the joint has been already emphasized (see page 80).

## THE FOREARM.

The musculature of the forearm surrounds the radius and ulna and their connecting interosseous membrane in such a way that both bones may be felt through the skin, the ulna throughout its entire extent and the radius in the lower two-thirds of the forearm. Upon the flexor surface in the median line above the wrist may be seen more or less distinctly the tendon of the palmaris longus muscle (although it is sometimes absent), to the outer side of which the tendon of the



FIG. 34.—A longitudinal section through the region of the elbow and the humero-ulnar articulation (frozen section).

flexor carpi radialis is visible. The "pulse" of the radial artery may usually be felt just to the outer side of this tendon. The pulsation of the ulnar artery is scarcely, if at all, perceptible, since this vessel is covered by the border of the flexor carpi ulnaris muscle (see Fig. 35). The tendon of this muscle may be palpated and the incision for exposing the artery may consequently be easily located.

**Muscles.**—The muscles of the forearm should be reviewed in detail from a systematic anatomy. The flexor group may be subdivided into a superficial and a deep layer, each consisting of four muscles. All of the superficial flexors originate from the internal condyle. The pronator radii teres is inserted into the outer surface of the middle of the radius. The flexor carpi radialis is attached to the base of the second metacarpal bone. The palmaris longus radiates into the palmar fascia. The flexor carpi ulnaris, the ulnar origin of which extends downward to the lower third of the bone, is inserted into the pisiform bone, the unciform process of the unciform bone, and the base of the fifth metacarpal bone.

There are *four deep muscles* upon the flexor surface. The flexor sublimis digitorum arises by two heads from the internal condyle of the humerus and from the anterior surface of the radius and is inserted by means of four tendons into the second phalanges of the fingers. [This muscle arises by three heads, one from the inner condyle of the humerus, one from the inner margin of the coronoid process of the ulna, and one from the radius.—ED.] The flexor profundus digitorum arises from the upper two-thirds of the anterior surface of the ulna [also from inner surface.—ED.] and from the interosseous membrane and is inserted by means of four tendons into the terminal phalanges of the fingers. The flexor longus pollicis arises from the anterior surface of the radius, from the interosseous membrane, and by a small muscular slip from the internal condyle and is inserted into the terminal phalanx of the thumb. The pronator quadratus, situated above the wrist, arises from the anterior surface of the ulna and is inserted into the anterior and outer surface of the radius.

The extensor muscles are subdivided into a radial group and a dorsal group.

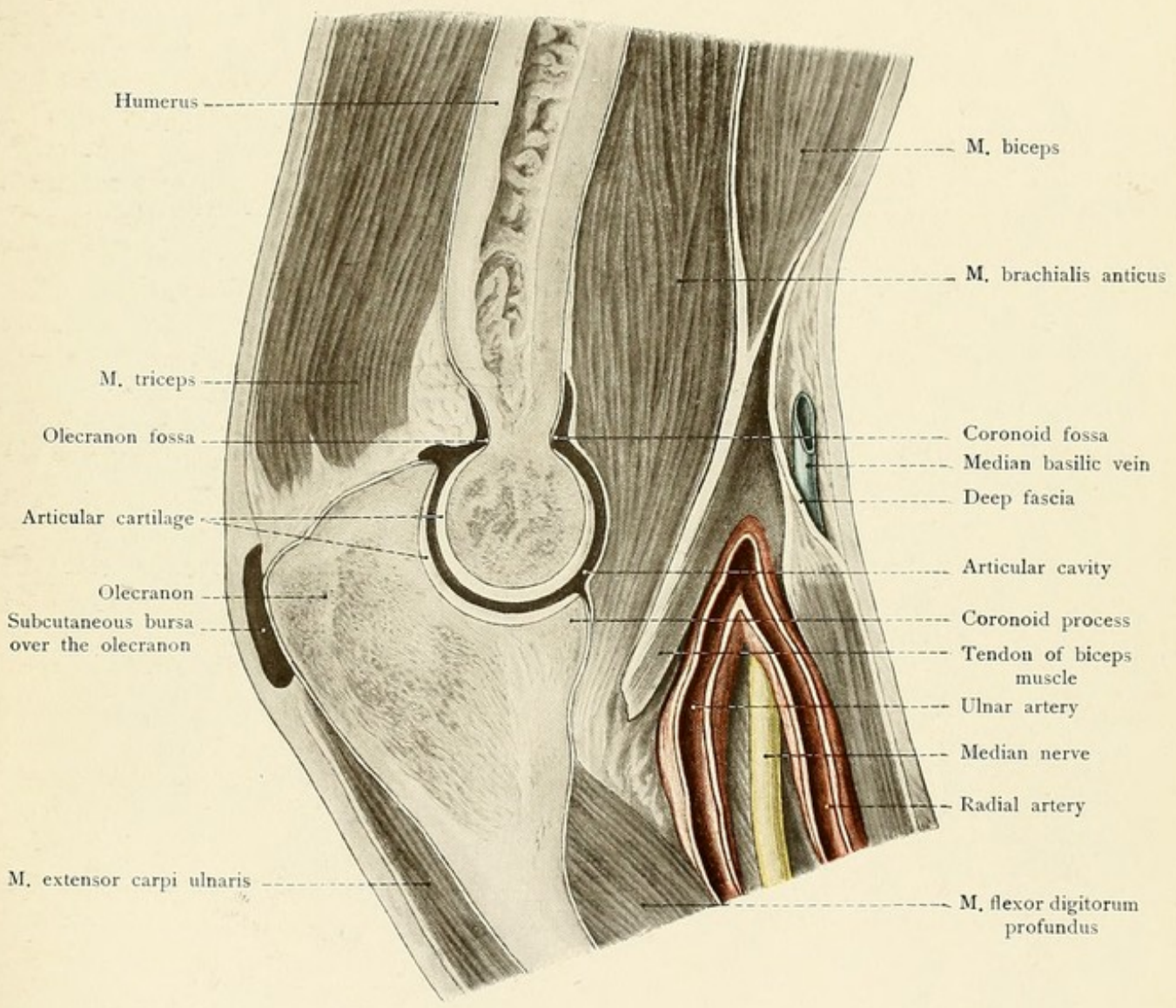
The radial group consists of four muscles, which arise from the external condyle and from the humerus above this point. The supinator longus is inserted into the styloid process of the radius. The extensor carpi radialis longior runs to the dorsal surface of the base of the second metacarpal bone. The extensor carpi radialis brevior goes to the dorsal surface of the base of the third metacarpal bone. The supinator brevis, originating also from a ridge upon the ulna, passes over the radius and is inserted above and below the tuberosity upon its anterior surface.

The dorsal group of extensor muscles, like the flexor group, may be divided into a superficial and a deep layer. The superficial layer consists of three muscles. The extensor carpi ulnaris arises from the external condyle, from the deep fascia of the forearm, and from the posterior border of the ulna, and is inserted into the base of the fifth metacarpal bone. The extensor communis digitorum arises from the external condyle and from the deep fascia of the forearm and is inserted by means of four tendons into the dorsal aponeuroses of the fingers. The extensor minimi digiti arises from the external condyle and furnishes a second tendon to the little finger.

The deep layer of the extensor muscles arises from the dorsal surfaces of the ulna, radius, and



Fig. 34.









interosseous membrane. They consist of four muscles which may be subdivided at the middle of the forearm into an ulnar and a radial pair of muscles. The ulnar pair is composed of the extensor indicis, passing to the terminal phalanx of the index-finger (both the index and little fingers consequently having two extensor tendons), and of the extensor longus pollicis, which is inserted into the terminal phalanx of the thumb. The radial pair is composed of the extensor brevis pollicis, which is inserted into the base of the first phalanx of the thumb, and of the extensor ossis metacarpi pollicis, which is attached to the base of the metacarpal bone of the thumb. The muscles should also be reviewed in transverse section (see Fig. 36) and the different groups in the illustration may be outlined by variously colored pencils.

**Arteries.**—The *radial artery*, the more superficial of the two main arteries of the forearm, passes over the tendon of the pronator radii teres muscle and is covered at first by the supinator longus muscle. The radial nerve runs to the radial side of the radial artery, though at some distance from the vessel, and is also covered by the supinator longus muscle (see page 84). Above the wrist the radial artery is so superficial that in ligating the vessel it is frequently sought for at too great a depth. Below the middle of the forearm the artery appears from beneath the border of the supinator longus and runs downward between the tendons of the supinator longus and flexor carpi radialis muscles. Just above the wrist the vessel passes to the radial side of the hand (see Fig. 37). With the exception of the radial recurrent (see page 80), the radial artery gives off no large branches in the forearm.

The *ulnar artery* becomes deeply situated immediately after its origin; it passes beneath the pronator radii teres and runs upon the flexor profundus digitorum in a line corresponding to the continuation of the brachial. Above the wrist the vessel lies beneath the border of the flexor carpi ulnaris muscle and is covered by two layers of deep fascia which must be divided before ligating the vessel. The ulnar nerve is situated immediately to the ulnar side of the vessel. In contrast with the radial artery, the ulnar always remains upon the flexor side of the forearm and passes into the hand at the radial side of the pisiform bone, where it may also be exposed and ligated with comparative ease. The main branch is the common interosseous artery, which divides immediately after its origin into the anterior and posterior interosseous. The anterior interosseous artery runs downward upon the anterior surface of the interosseous membrane to the upper margin of the pronator quadratus, where it passes to the dorsal surface to the arterial anastomosis at the back of the wrist (rete carpi dorsale). The posterior interosseous artery passes through the interosseous membrane to the extensor surface, is smaller than the anterior interosseous, and also ends in the rete carpi dorsalis.

**Nerves.**—The relations of the three great nerves of the arm in this situation must also be considered. The *median nerve* perforates the pronator radii teres, runs between the flexor sublimis and flexor profundus digitorum, supplying the neighboring muscles, and escapes from beneath the flexor sublimis digitorum above the wrist (see Fig. 35), where it may easily be exposed, to the radial side of the tendon of the palmaris longus [or is found directly beneath this tendon.—ED.]. In this situation the nerve is occasionally injured in suicidal attempts, in wounds of the vessels, or by sabre-cuts. Such injuries are followed by paralysis of the opponens pollicis muscle and by a loss of sensation upon the radial side of the palm (see page 87). The branch supplying the deep flexors ends in the *anterior interosseous nerve*, which runs upon the interosseous mem-



FIG. 35.—The anterior aspect of the forearm above the wrist. The ulnar artery and nerve have been made visible by displacing the tendon of the flexor carpi ulnaris.

FIG. 36.—A cross-section through the middle of the forearm.

brane with the anterior interosseous artery to the pronator quadratus muscle. A small palmar branch passes alongside of the tendon of the flexor carpi radialis to the skin of the palm. Paralysis of the median nerve is followed by a loss of radial flexion (flexor carpi radialis) and of flexion of the fingers (flexor sublimis and profundus digitorum); the thumb is extended and adducted (the adductor pollicis is supplied by the ulnar nerve). The *ulnar nerve*, after reaching the deep surface of the flexor carpi ulnaris, gradually approaches the ulnar artery and comes in relation with its ulnar side at about the middle of the forearm. It lies between the flexor profundus digitorum and the flexor carpi ulnaris and, below the middle of the forearm, divides into a large anterior branch, which follows the ulnar artery (see page 83), and a smaller posterior branch, which reaches the back of the hand by passing beneath the flexor carpi ulnaris. Paralysis of the ulnar nerve is followed by a loss of ulnar flexion of the hand (flexor carpi ulnaris) and by an impairment of motion of the terminal phalanges of the fingers upon the ulnar side (flexor profundus digitorum). The *musculospiral nerve*, while still in the region of the bend of the elbow, divides into the motor posterior interosseous nerve and the sensory radial nerve. The posterior interosseous nerve pierces the supinator brevis, and at the lower border of this muscle (upon the extensor side of the forearm) gives off numerous branches which ramify between the superficial and deep groups of muscles and supply all of the extensors in the forearm. The radial group of muscles is supplied by the nerve before its entrance into the supinator brevis. The continuation of the nerve runs upon the interosseous membrane as a small branch which reaches the back of the wrist. The *radial nerve* is at first covered by the supinator longus; about a handbreadth above the wrist it passes beneath the tendon of the supinator longus to the extensor side and to the dorsal surface of the hand. If the musculospiral nerve is injured (for example, by an injury of the soft parts of the upper arm or by a fracture of the humerus), there is, in addition to the loss of motion of the extensors and of the muscles of the radial group, a loss of sensation upon the extensor surfaces of the upper arm, of the forearm, and of the radial half of the back of the hand (see page 78).

### THE HAND.

The dividing-line between the forearm and the hand is easily determined in the living subject by locating the styloid processes of the radius and ulna. The line connecting these two processes corresponds to the wrist-joint, and if it is desired to disarticulate the hand or excise the wrist-joint, the knife must be introduced immediately to the distal side of these processes.

Upon the palmar surface of the base of the hand may be seen and felt the hand prominences produced by the *eminentiæ carpi radialis* and *ulnaris*. The eminentia carpi radialis is formed by the tubercle of the scaphoid and by the ridge of the trapezium; the eminentia carpi ulnaris is formed by the pisiform bone and by the unciform process of the unciform bone. These eminences are united by the anterior annular ligament which converts the deep groove lying between them into the important *carpal canal*. When the thumb is abducted, a marked prominence appears



Fig. 35

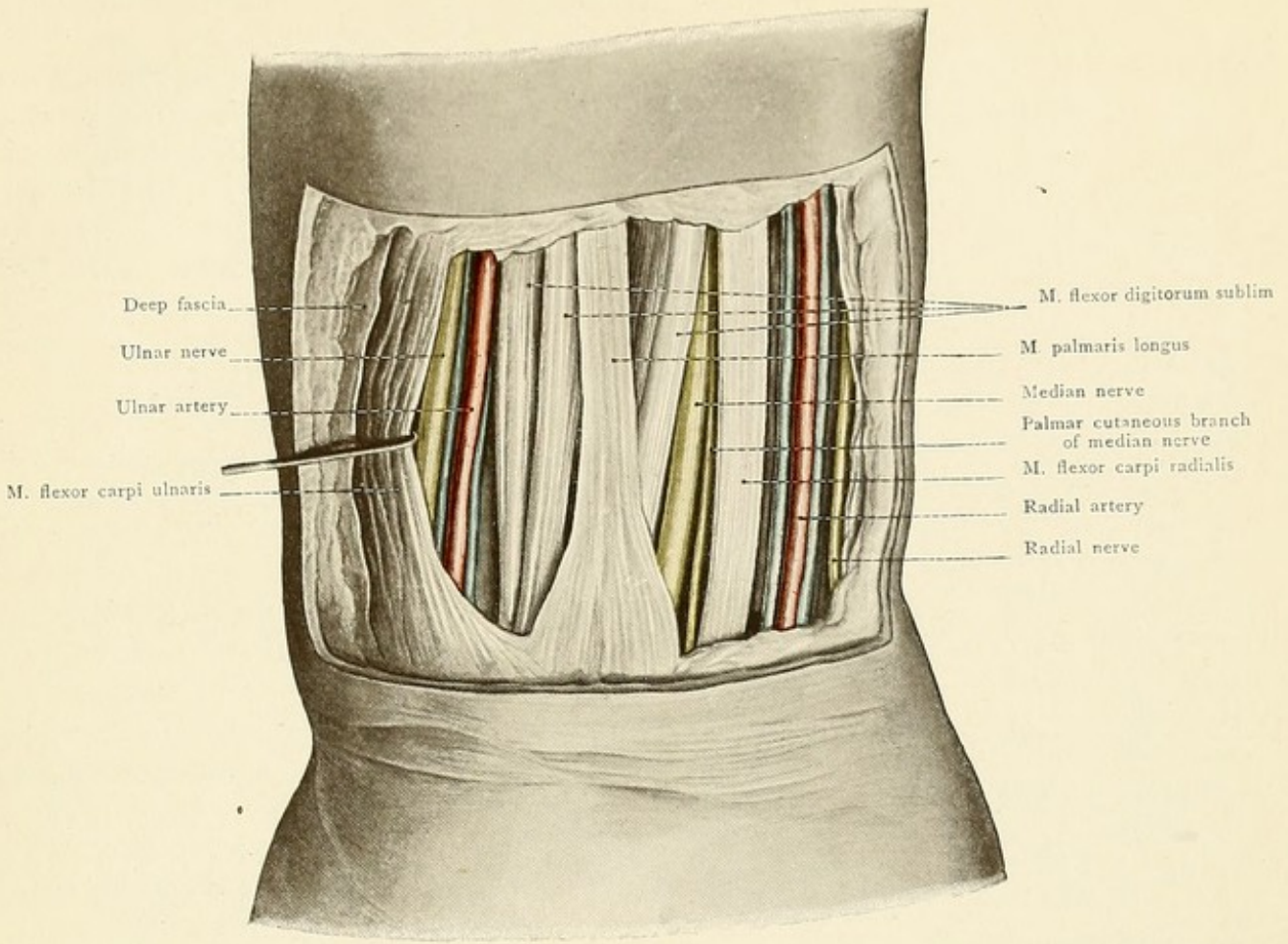
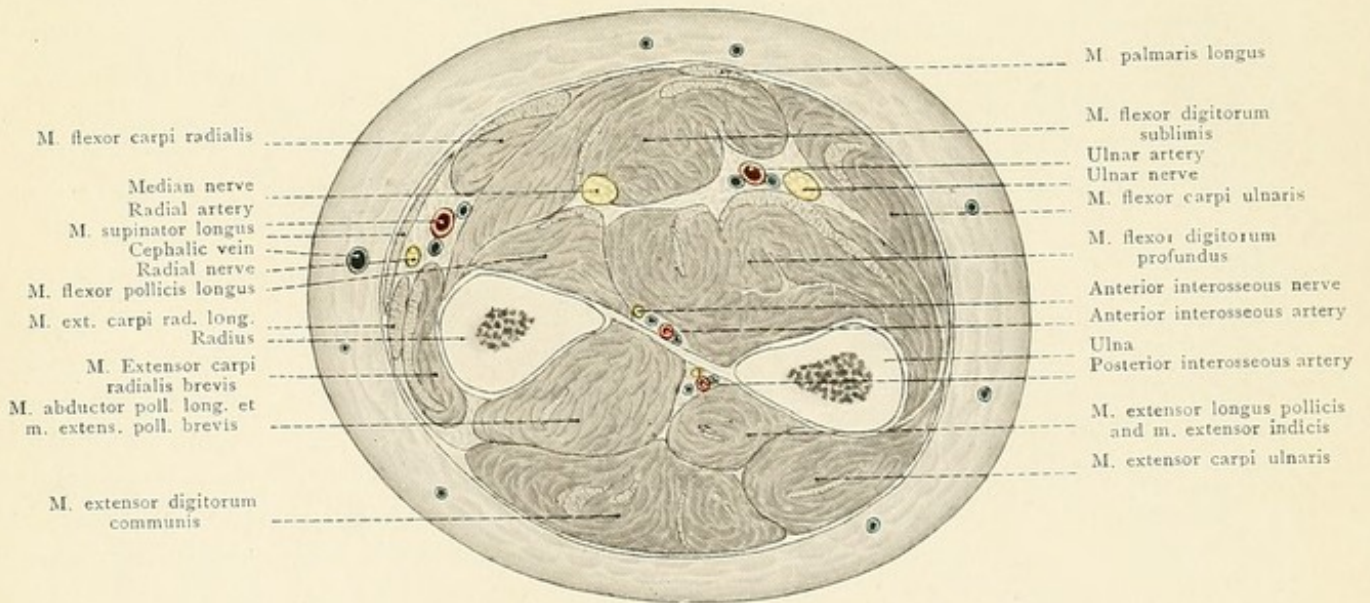


Fig. 36









upon the radial border of the base of the hand, which is produced by the tendons of the *extensor ossis metacarpi pollicis* and *extensor brevis pollicis* muscles. Two centimeters posterior to these tendons may be easily seen and felt the tendon of the *extensor longus pollicis* on its way to the thumb. These prominences are separated by a fossa, the so-called *tabatière* or "snuff-box," which holds an important relation to the course of the radial artery (see page 86). Upon the dorsal surface of the hand may also be noted the network of subcutaneous veins and the extensor tendons which become more prominent when the fingers are moved. As the extensor tendons approach the wrist they disappear from view, since they enter their sheaths in this situation.

Upon the dorsal aspect of the hand the metacarpal bones and the phalanges may be easily palpated, while the palmar surface of these structures is well covered by the soft parts. If the dorsal surface of the base of a slightly flexed finger is palpated by the thumb and index-finger of the other hand, the metacarpophalangeal joint and the thick base of the first phalanx may be easily recognized. In the closed fist the line of this metacarpophalangeal joint is one centimeter below (*i. e.*, towards the nail) the most prominent portion of the knuckle, and the same statement holds for all of the interphalangeal joints. This is something that must be felt, if disarticulations are to be performed at these joints *lege artis*. If the hand is not too fat, the joint between the trapezium and the first metacarpal bone (saddle-joint) may be palpated at the base of the thenar eminence by following the course of the metacarpal bone with the finger. If the hand is laid palm downward upon a table and the finger is passed backward in the groove between the second and third metacarpal bones, it reaches the "dorso-radial" fossa (Rotter), which is filled out during dorsal flexion of the hand by the tendons of the *extensor carpi radialis longior* and *brevior*. The location of this fossa is important for operative procedures (dorso-radial incision of Langenbeck for resection of the wrist-joint).

The *palmar fascia* radiates from the tendon of the *palmaris longus* and is situated beneath the subcutaneous fat of the palm. It is the fascia which is responsible for Dupuytren's finger contraction. Together with the tough skin of the palm, it forms a dense layer of tissue which resists the spontaneous perforation of inflammatory processes deeply situated in the palm. It divides into five slips which are adherent to the skin at the bases of the fingers and of the thumb; in hands which are not too lean, the skin of the interdigital folds forms small elevations which are due to the projection of the subcutaneous fat between these slips. The transverse ligament runs between and connects the slips passing to the four fingers. The fascia is considerably thinner over the thenar and hypothenar eminences.

The deep fascia of the forearm is reinforced over the wrist-joint by transverse fibers which form the *anterior* and *posterior annular ligaments*. The latter is of interest to the practitioner on account of its relation to the extensor tendons. The posterior annular ligament passes transversely from the styloid process of the radius to the styloid process of the ulna and forms six compartments for the tendons by giving off septa to the radius and ulna. These compartments or tendon-sheaths, though much less frequently affected than the palmar compartment (see page 87), are occasionally the seat of tendovaginitis. Passing from the radial to the ulnar side the compartments are as follows: (1) For the tendons of the *extensor ossis metacarpi pollicis* and of the *extensor brevis pollicis*; (2) for the tendons of the *extensor carpi radialis longior* and *brevior*; (3) for the tendon of the *extensor longus pollicis*; (4) for the tendons of the *extensor communis*



FIG. 37.—The muscles, nerves, vessels, and tendon-sheaths of the palm of the hand. The tendon-sheaths are colored blue. The carpal canal has been opened by dividing the anterior annular ligament.

FIG. 38.—Diagrammatic representation of the joints of the hand.

digitorum and of the extensor indicis; (5) for the tendon of the extensor minimi digiti; and (6) for the tendon of the extensor carpi ulnaris. The second and third compartments are frequently combined to form a single sheath.

The anterior annular ligament connects the eminentia carpi radialis with the eminentia carpi ulnaris and forms the roof of the *carpal canal*. This canal transmits the flexor tendons of the fingers (flexor sublimis and profundus digitorum and flexor longus pollicis) and the median nerve, which pass into the palm of the hand. The *median nerve* lies upon the tendons immediately beneath the ligament. The *ulnar nerve* and *artery*, however, pass into the hand over the anterior annular ligament to the radial side of the pisiform bone. At the lower end of the radius, distal to the insertion of the supinator longus, the radial artery passes from the flexor to the extensor side, between the styloid process of the radius and the scaphoid bone. It passes beneath the tendons of the extensor ossis metacarpi pollicis and extensor brevis pollicis into the *tabatière* or "snuff-box" (see page 85), and then runs beneath the tendon of the extensor longus pollicis to reach the space between the first two metacarpal bones. The vessel then leaves the back of the hand and passes into the palm between the heads of the first dorsal interosseous muscle. During this course the radial artery, in addition to branches to the *rete carpi dorsale* and *volare* [that is, the vascular network on the dorsal and palmar surfaces of the wrist.—ED.], gives off two vessels which vary considerably in size:

1. The *superficialis volæ*, which is often absent, though frequently as large as the continuation of the radial. It leaves the radial at the styloid process of the radius and passes over the origins of the short muscles of the thumb to unite with the ulnar artery and form the superficial palmar arch. This branch is covered only by the skin and a thin fascia (and sometimes also by a few slips from the muscles of the thumb), and, when well developed, is a dangerous vessel on account of its exposed position. In some individuals its pulsations may be seen through the skin.

2. The *princeps pollicis*, which passes between the muscles of the ball of the thumb to the palmar surface and gives off three digital branches to supply both sides of the thumb and the radial side of the index-finger.

The terminal portion of the radial artery anastomoses with the deep branch of the ulnar and forms the *deep palmar arch*, which is situated upon the bases of the metacarpal bones. This arch gives off the *palmar interosseous arteries*, which are usually small in size and pass distally between the bases of the first phalanges to empty into the digital branches of the superficial arch. If the superficial arch and some or all of its digital branches are poorly developed, the palmar interosseous arteries are larger and furnish the digital arteries for the fingers.

The *ulnar artery*, in contrast to the radial, always remains upon the flexor side of the forearm. After giving off the anterior and posterior carpal branches, it passes over the anterior annular ligament to the radial side of the pisiform bone. In the palm of the hand it gives off a deep branch and then unites with the *superficialis volæ* from the radial to form the *superficial palmar arch*, which is situated immediately beneath the palmar fascia. From the superficial palmar arch



Fig. 37.

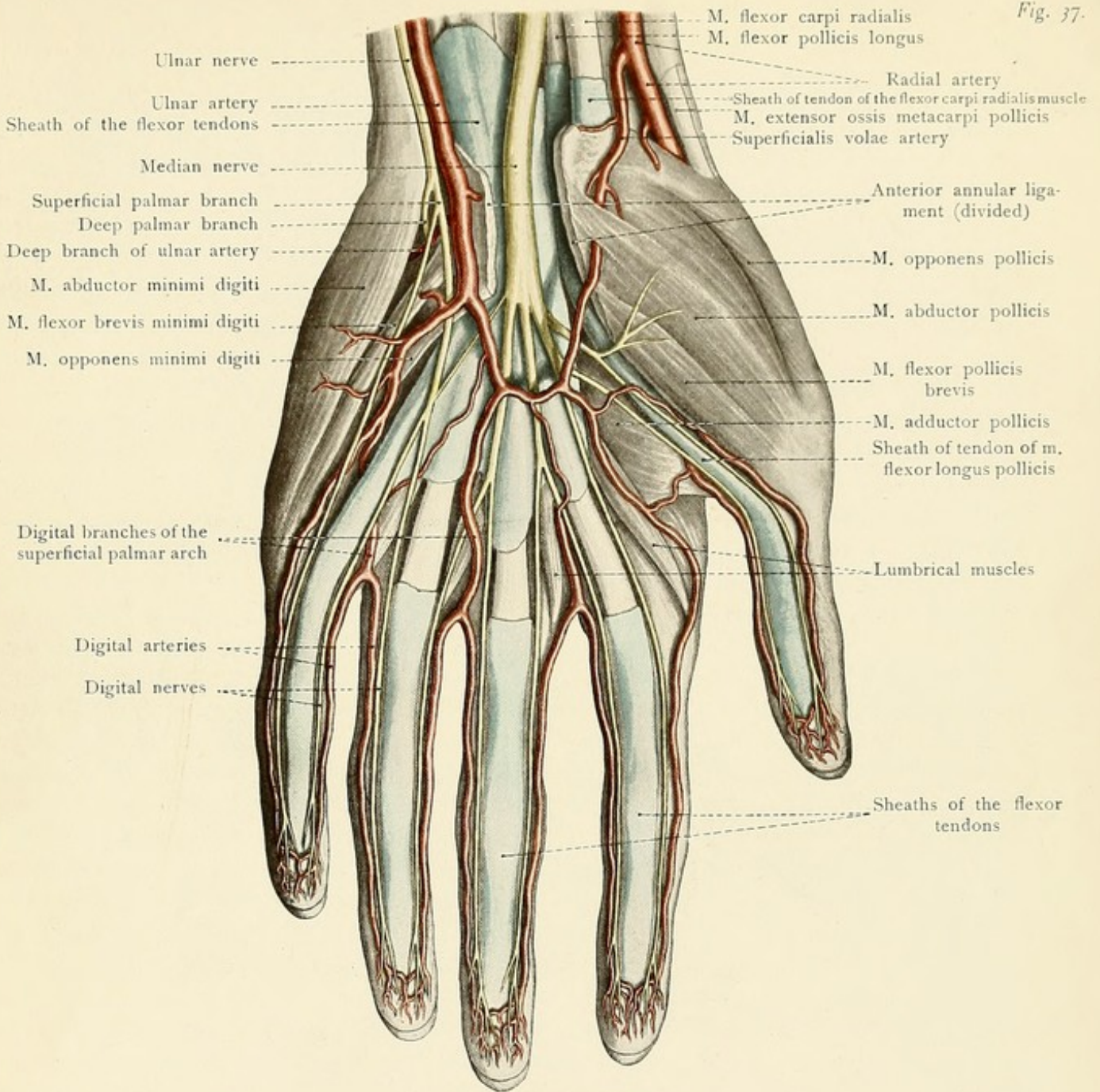
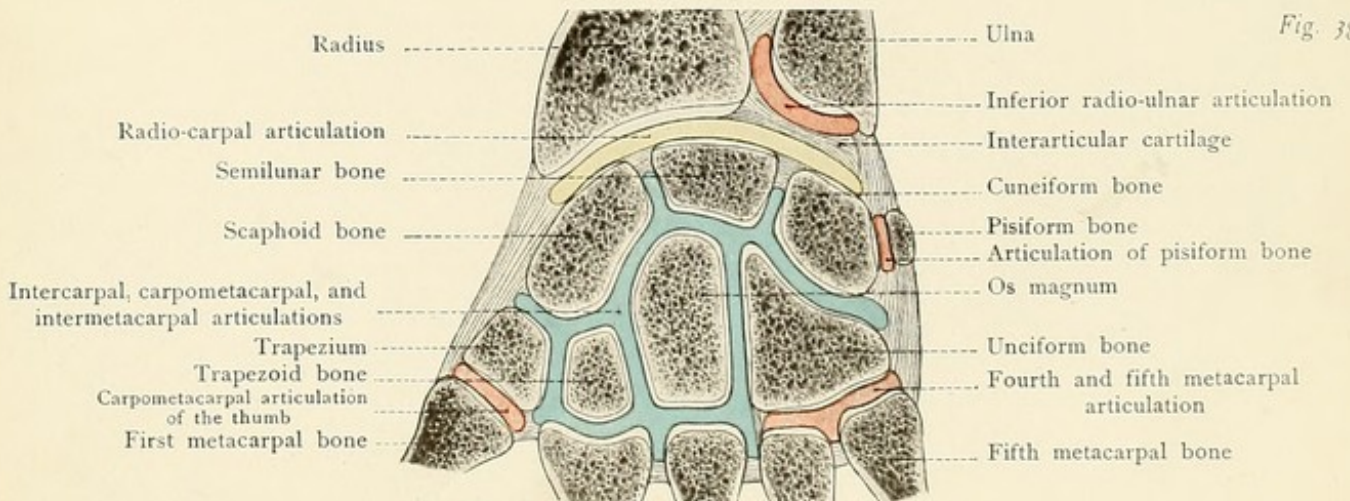


Fig. 38.









arise all of the digital branches for the fingers, with the exception of the three furnished by the *arteria princeps pollicis*. The convexity of the superficial palmar arch barely reaches to the middle one of the three lines which diverge from the base of the index-finger to the ulnar border of the hand.

The *median nerve* lies upon the common sheath of the flexor tendons and passes through the carpal canal in company with these structures (see page 86). It gives off seven digital branches which supply the palmar surfaces of the thumb, index, middle and radial side of the ring fingers and inosculate with the digital branches of the ulnar nerve. With the exception of the adductor pollicis, the muscles of the thumb are also supplied by the median nerve.

The *ulnar nerve* is situated to the inner side of the ulnar artery, passes into the hand to the radial side of the pisiform bone, and immediately divides into a superficial palmar branch, for the ulnar side of the ring finger and for both sides of the little finger, and a deep palmar branch, which follows the deep branch of the ulnar artery and accompanies the deep palmar arch, supplying the muscles of the hypothenar eminence, all of the interosseous muscles, and ending in the adductor pollicis muscle. There are no motor nerves upon the dorsal surface of the hand. The dorsal cutaneous branch of the ulnar ends in sensory filaments which supply the ulnar half of the back of the hand. In this situation these filaments inosculate with the radial nerve, which furnishes sensory branches for the radial half of the back of the hand (see page 84).

In the palm of the hand there are three synovial sheaths for the tendons, in addition to a small unimportant one for the terminal portion of the tendon of the flexor carpi radialis:

1. The common large synovial sheath for the tendons of the flexor sublimis and profundus digitorum. This extends about two centimeters above the anterior annular ligament (toward the forearm); exudates to the proximal side of the ligament may consequently make themselves manifest by the presence of a superficial swelling.

2. The synovial sheath for the tendon of the flexor longus pollicis. This also commences to the proximal side of the anterior annular ligament and envelops the tendon almost to the very point of its insertion into the terminal phalanx of the thumb. It frequently communicates with the common synovial sheath of the flexor tendons of the fingers beneath the anterior annular ligament.

3. The individual tendon-sheaths of the index, middle, ring, and little fingers, each one of which envelops one of the superficial and one of the deep flexor tendons. As a rule, the tendon-sheath of the little finger is directly continuous proximally with the common sheath of the flexor tendons of the fingers.

It follows that *tenosynovitis*, resulting from injuries or inflammations of the fingers, finds a favorable path for its extension toward the forearm, particularly when situated in the thumb and little finger. As the tendon-sheaths of the little finger and of the thumb are continuous with the common synovial sheath at the wrist,\* we can readily understand the occurrence of those cases in which an inflammation extends through the palm from the thumb to the little finger, or in the reverse direction. Clinical observations show that the individual tendon-sheaths of the index, middle, and ring fingers are occasionally also continuous with the common synovial sheath.

As there are no tendon-sheaths upon the backs of the fingers, and since the sheaths of the

\* The sheath for the thumb is less frequently continuous than is that for the little finger.—ED.



extensor tendons are not continued into the fingers, tenosynovitis occurs much more rarely upon the dorsal than upon the palmar surface.

The following articulations may be differentiated at the wrist:

1. The *radiocarpal articulation* or wrist-joint, between the radius and the distal surface of the interarticular fibrocartilage on one side, and the scaphoid, semilunar, and cuneiform bones upon the other.

2. The *inferior radio-ulnar articulation* between the sigmoid cavity of the radius and the head of the ulna. This joint is completely separated from the preceding one.

3. (a) The *intercarpal articulations*, between the carpal bones; (b) the *carpometacarpal articulations*, between the second row of the carpal bones and the metacarpal bones; (c) the *intermetacarpal articulations*, between the lateral articular surfaces of the bases of the metacarpal bones. These three sets of articulations usually possess a common synovial membrane; the carpal bones are joined together by the tense interosseous ligaments. The synovial cavity of the joint between the unciform and the fourth and fifth metacarpal bones is occasionally separated from the large synovial cavity of the carpus.

4. The *articulation between the pisiform and the cuneiform bones*.

5. The *articulation of the metacarpal bone of the thumb with the trapezium* (saddle-joint). In disarticulating at this joint care must be taken to avoid injuring the articulation between the trapezium and the second metacarpal bone, as such an injury would open up the common synovial cavity of the carpus.

The following ligaments should be noted:

1. The external lateral ligament, from the styloid process of the radius to the scaphoid bone.  
2. The internal lateral ligament, from the styloid process of the ulna to the cuneiform bone.  
3. The anterior ligament, in front of the wrist-joint, from the lower end of the radius to the scaphoid, semilunar, and cuneiform bones and to the os magnum.

4. The posterior ligament, behind the wrist-joint, from the lower end of the radius to the scaphoid, semilunar, and cuneiform bones.

5. The *ligamentum carpi radiatum*, on the anterior surface of the carpus, which connects the os magnum with the surrounding bones.

A transverse section of the finger recalls the fact that the tendons of the superficial and deep flexors run in a common sheath upon the palmar surface, and that there is no such sheath upon the dorsal surface. Upon the back of the finger the extensor tendon becomes continuous with the dorsal aponeurosis. The larger vessels and nerves are situated upon the palmar surface, while the smaller ones are upon the dorsal surface. The nerves of the palmar surface are nearer the median line of the finger than the digital arteries, which anastomose freely at the pulp of the finger. The palmar nerves of the fingers also supply the dorsal surfaces of the terminal phalanges, which are not reached by the small dorsal nerves.

#### QUESTIONS.

Beneath what portion of the clavicle does the subclavian artery pass?

What important structures may be compressed in a fracture of the clavicle or of the neck of the humerus or by a subcoracoid dislocation of the shoulder?



In what cases are the lymphatic glands of the axilla of particular interest to the surgeon and why?

What muscle aids in the location of the axillary artery?

What is the most important anastomosis between the branches of the axillary and subclavian arteries?

What nerves are endangered in cleaning out the axillary cavity (in mammary carcinoma)?

What two bursæ communicate with the shoulder-joint?

Where are the two weak places in the capsular ligament of the shoulder-joint?

What bursa, when diseased, may be confused with an exudate in the shoulder-joint?

Where may the pulsations of the brachial artery be felt?

What nerve of the upper arm is involved first in affections of the humerus (by a fracture, for example)?

In what situations may the elbow-joint be most easily opened?

What is the normal relation of the olecranon to the epicondyles of the humerus?

Where may the ulnar nerve be palpated about the elbow?

What nerve is to be particularly avoided in resection of the elbow-joint?

What effect must hyperextension of the elbow with backward dislocation of both bones have upon the large vessels and nerves?

Between what tendons may the radial pulse be felt at the wrist, and why is the pulsation of the ulnar artery scarcely, if at all, perceptible in this situation?

What symptoms are characteristic of paralysis of the musculospiral, median, and ulnar nerves, and how are these symptoms explained by the distribution of the nerves?

Why do inflammations of the tendon-sheaths of certain fingers (which ones?) extend into the forearm more readily than similar inflammations in other fingers?

Why is tenosynovitis more common upon the palmar than upon the dorsal surface?

## THE THORAX.

### THE THORACIC WALL.

The *external boundaries* of the thorax are easily defined in the living subject.

The *upper boundary* of the thorax is formed anteriorly in the median line by the upper margin of the sternum, laterally by the clavicles, and posteriorly by lines drawn from the acromion processes to the spinous process of the seventh cervical vertebra (vertebra prominens).

The *lower boundary* of the thorax is formed anteriorly in the median line by the xiphoid process of the sternum, laterally by the costal margins, and posteriorly by lines drawn from the lowest point of the costal margins (near the axillary lines) to the spinous process of the eleventh dorsal vertebra.

The *internal boundaries* of the thorax, *i. e.*, the planes separating the thoracic space\* from

\*The space surrounded by the thoracic wall and situated above the diaphragm is improperly designated as the "thoracic cavity." As a thoracic cavity (like an abdominal cavity) does not exist, it would be better to avoid this expression altogether. The space surrounded by the thoracic wall—the thoracic space—contains three cavities: two pleural cavities and a pericardial cavity. The surgeon, and sometimes the anatomist, frequently speaks of an opening into the thoracic cavity (from an injury, for example), by which is meant an opening into the pleural and pericardial cavities or into one of these three cavities.



the contents of the neck and abdomen, do not correspond with the external boundaries; they are more difficult to determine in the living subject.

The upper boundary of the thoracic space in the erect position and during expiration lies in a horizontal plane which passes through a point four centimeters above the middle of the upper margin of the sternum. This plane passes through the intervertebral disc between the last cervical and the first dorsal vertebra. It is about two centimeters above the center of the clavicle, so that the physician may examine a portion of the thoracic contents above this bone.

The *lower boundary* of the thoracic space is formed by the diaphragm, the arched dome of which, during expiration, is at the level of the fourth intercostal space in the right mammary line and a fingerbreadth lower in the left mammary line at the upper margin of the fifth rib.

The physician, as well as the anatomist, needs certain definite vertical and horizontal lines for the purpose of defining the positions of the organs of the thoracic cavity in health and in disease.

The vertical lines are: The *mammary line*, passing through the nipple [the position of the nipple is so variable that the *mammary line* should be abandoned in favor of the mid-clavicular line; the latter starts from a fixed and easily determined point, passes usually slightly internal to the nipple, and in normal subjects is continuous with the Poupart perpendicular drawn from the mid-point between the symphysis pubis and the anterior superior spinous process and used by many writers in delimiting the abdominal regions.—ED.]; the *sternal line*, along the margin of the sternum; the *parasternal line*, midway between the mammary and sternal lines; and the *axillary line*, which passes downward from the highest point of the axillary fossa (also known as the middle axillary line). The *anterior axillary line* passes vertically downward from the point at which there appears the prominence caused by the lower margin of the pectoralis major as it leaves the thoracic wall; the *posterior axillary line* extends vertically downward from the corresponding point of the latissimus dorsi. The *costoclavicular line* is drawn from the sternoclavicular articulation to the end of the eleventh rib and is employed to determine the normal position of the spleen. The *scapular line* passes through the inferior angle of the scapula. These lines are supplemented by the *anterior* and *posterior median lines*.

The *horizontal lines* are furnished by the intercostal spaces. At the upper portion of the sternum, the *sternal angle* (angle of Ludwig) may be seen and felt as a transverse elevation. It corresponds to the synchondrosis between the manubrium and the gladiolus and to the attachment of the second costal cartilage. In this manner the second intercostal space may be easily located and the remaining intercostal spaces may be defined by firm palpation from above downward and backward. The importance of these localizing lines is clear; for example, the apex of the normal heart (apex-beat) is situated in the fifth intercostal space between the mammary and the parasternal lines. The third intercostal space is the broadest, then follow the first and the second; all of the other intercostal spaces are narrower, the last one being the narrowest. The intercostal spaces are broader anteriorly than posteriorly, for which reason penetrating injuries from behind (a gunshot wound, for example) are more frequently complicated with injuries to the ribs than are similar wounds from in front.

[Anteriorly the thorax is divided into the following regions: Supraclavicular, that portion above the clavicle; infraclavicular, between the clavicle and the third rib; mammary, between



the third and sixth ribs; and inframammary, below the sixth rib. Laterally the sixth rib divides the area into two regions, axillary above and infraaxillary below. Posteriorly the space above the spine of the scapula is known as the suprascapular; that below as the infrascapular; that between the vertebral borders of the scapula as the interscapular.—ED.]

*Supernumerary ribs* occasionally occur. The supernumerary rib proceeding from the last cervical vertebra (Fig. 39) is of practical importance only when it extends to the first rib or to the sternum. In these cases the subclavian artery is placed unusually high up, since it runs over this supernumerary rib (as it ordinarily does over the normal first rib) in a shallow groove. The pulsation of the artery may consequently be easily seen or felt above the clavicle. In from five to ten per cent. of such cases this anomaly produces symptoms (violent neuralgias and paresthesias, or thrombosis and aneurysm) which demand operative interference.

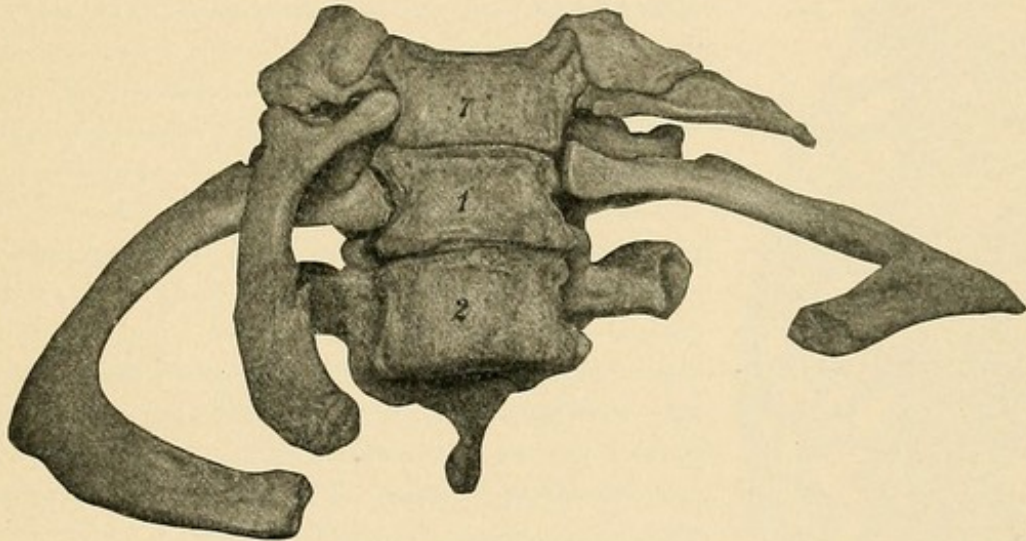


FIG. 39.—Cervical ribs. The seventh cervical vertebra (indicated by the figure 7) articulates with a small cervical rib upon the left, and with a complete cervical rib upon the right which reaches to the sternum. The figures 1 and 2 indicate the first two thoracic vertebrae.

**Inspection and Palpation of the Thorax.**—In a male subject in whom the origins of the pectoralis major muscles are well developed, a broad shallow furrow may be seen over the sternum. At the upper end of the sternum this anterior median furrow passes into the suprasternal notch; at the lower end of the sternum it is continuous with the so-called *scrobiculus cordis* or pit of the stomach.\* In the latter fossa, which may be quite deep, the xiphoid process may project anteriorly or may have an inward curve endangering the liver. The sternal angle, or the angle of Ludwig, as already stated, may be more or less prominent at the junction of the manubrium and the gladiolus; it corresponds to the attachment of the second rib and furnishes the starting-point for counting the intercostal spaces. In the female the anterior median furrow (the bosom) is produced by the presence of the mammary glands. The *nipple* is situated at the level of the

\* Both of these designations are bad, since neither the heart nor the stomach, but the liver, is situated beneath the abdominal wall in this location.



fourth rib or of the fourth intercostal space. The *posterior median furrow* extends downward from the vertebra prominens. It is produced chiefly by the prominences of the long muscles of the back. In this furrow may be felt (or seen in emaciated subjects) the spinous processes of the dorsal vertebrae. The clavicles may be easily outlined, as may also their thickened sternal ends and the sternoclavicular articulations. The *infraclavicular fossa* (Mohrenheim's fossa) is situated below the junction of the middle and outer thirds of the clavicle and corresponds to the groove between the pectoralis major and deltoid muscles; it is more distinct in individuals in whom there is a marked deviation between the borders of these muscles. In the bottom of this fossa the *costocoracoid ligament* may sometimes be felt, running approximately parallel with the clavicle. To the outer side of this ligament is the *coracoid process*, covered by the edge of the

deltoid muscle. Passing the finger outward along the clavicle we reach the *acromion*, and posteriorly we may palpate the *spine* and the *internal and inferior angles of the scapula*. Below the spine of the scapula may be felt the eighth, ninth, tenth, and eleventh ribs. The edge of the pectoralis major leaves the anterior thoracic wall and forms the anterior axillary fold; posteriorly the edge of the latissimus dorsi muscle runs upward and forms the posterior axillary fold. Below the axilla may be more or less distinctly seen the serrations of the serratus magnus muscle which interdigitate with those of the external oblique and latissimus dorsi muscles. If the trapezius muscle is put upon the stretch by drawing down the shoulder, its edge may sometimes be seen, in lean subjects, passing to the spinous process of the twelfth dorsal vertebra.

**The Bony Thorax.**—The bony thorax is the firm framework of the chest and is shaped like a truncated cone with the base downward and having a longer frontal and a shorter sagittal diameter. The superior aperture of the thorax is inclined anteriorly; its boundaries are formed by the upper margin of the sternum, by the first pair of ribs, and by the upper margin of the first dorsal vertebra. The relative shortness of the sagittal diameter of this opening should be well borne in mind. The inferior aperture of the thorax is much larger; its boundaries are formed by the xiphoid process of the

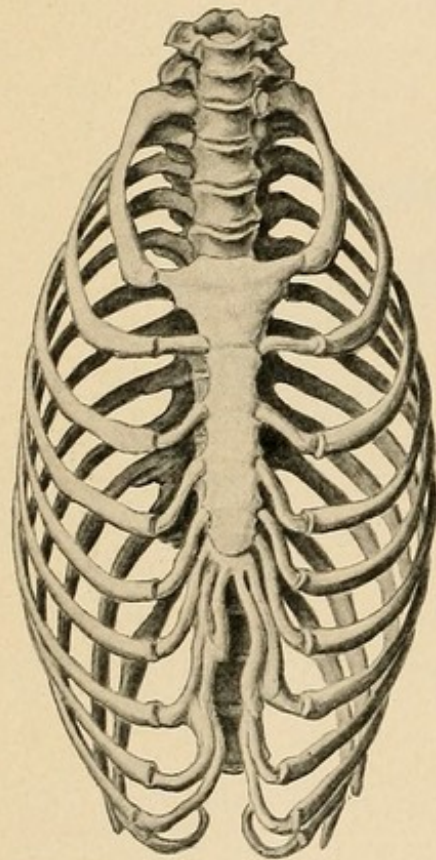


FIG. 40.—A thorax deformed by lacing (after Merkel).

sternum, by the costal margin, by the free ends of the eleventh and twelfth ribs, and by the body of the twelfth dorsal vertebra. The inferior aperture, unlike the superior one, lies in two planes which form an angle, the apex being downward, at the lowest portion of the costal margin.

The bony thorax is not firm enough to resist temporary or permanent changes of shape, which may be produced as the result of pressure from without or from within. The deleterious effects of pressure from without are particularly in evidence as a result of tight lacing (Fig. 40), against which it is the duty of the mother and of the physician to exert a sturdy and continuous opposition. Since the lower portion of the bony thorax surrounds some of the abdominal organs,



it follows that injudicious lacing is injurious to the thoracic and abdominal viscera. Transitory pressure from without, however, may be very great without overcoming the normal elasticity of the bony thorax.\* Severe crushes of the chest may produce a laceration of the heart, of the lungs, and of the liver without a concomitant fracture of the bony thorax. As a result of the relative increase of lime salts, fractures of the bones of the thorax become more common with advancing age. Prominence of definite portions of the bony thorax, arising from pressure from within, may be produced by cardiac hypertrophy, by aortic aneurysm, by tumors, and by pleuritic exudates. Localized flattenings and depressions may be brought about by pulmonary tuberculosis and by old pleuritic adhesions. Other deformities of the chest are: The chicken breast of rachitis, in which the sternum projects anteriorly;† the thoracic deformities of spinal curvature (kyphosis and scoliosis); the flattened and narrow chest of phthisis, corresponding more with the position during expiration; and the barrel-shaped chest of emphysema, corresponding rather with the position during inspiration.

**Sternal Region.**—In the sternal region the skin is but slightly movable and the underlying connective tissue contains but little fat. In the male the region is abundantly covered with hair. The deep fascia is but poorly developed, as is also the case over the pectoralis major. The greater the development of this muscle, the nearer are its origins to the median line, and the more marked is the anterior median furrow.

The sternum is covered by the sternal membrane which is formed by the fibers of the capsular ligaments of the sternocostal joints radiating into the periosteum. The bone is characterized by the slight development of the outer compact layers and by the preponderance of the spongy substance. Pressure-atrophy is consequently easily produced by tumors growing from within the chest or by aortic aneurysms. Mediastinal abscesses may rupture through a sternal foramen (Fig. 41), the presence of which is dependent upon a developmental disturbance. These foramina, like the very rare congenital fissures of the sternum, are also important from a medico-legal standpoint, since a comparatively slight trauma may produce a severe injury, particularly of the heart and of the great vessels. The synchondrosis which usually lasts throughout life between the manubrium and gladiolus is so firm that in fractures of the sternum (rare) in this vicinity pieces of bone almost always remain attached to the manubrium or gladiolus.

The important artery of this region, the *internal mammary*, ramifies only in the thoracic and abdominal walls, although it gives off small branches (such as the mediastinal and thymic

\* Circus performers apparently suffer no discomfort from having some one hammer upon an anvil placed upon the chest.

† The chicken breast stands in contrast to the rare funnel breast, in which the sinking in of the body of the sternum is combined with a projection of the xiphoid process and of the costal margin.

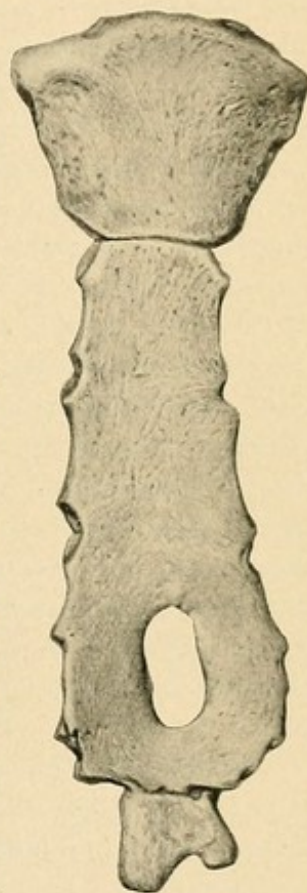


FIG. 41.—A sternum with a foramen in the lower portion of the body of the bone.



FIG. 42.—The anterior thoracic wall seen from within. The pleura has been removed.

FIG. 43.—The right intercostal region. In the upper of the three intercostal spaces represented the pleura is still intact; in the second it has been removed; in the third, the internal intercostal muscle as well as the pleura has been taken away.

arteries) and the *comes nervi phrenici artery*, which runs upon the pericardium in company with the phrenic nerves. The artery arises as the first branch of the subclavian, crosses the sternoclavicular joint, and runs downward on the inner surface of the thoracic wall, one centimeter from the margin of the sternum, to the sixth intercostal space, where it divides into its terminal branches, the *musculophrenic* and the *superior epigastric* arteries (the latter anastomose with the inferior (deep) epigastric from the external iliac). The most important branches are the *anterior intercostal*, which anastomose with the intercostal arteries from the aorta, and the *perforating*, which pass anteriorly between the costal cartilages and are of considerable size in the female during lactation. In the exposure of the internal mammary artery from without in the second, third, or fourth intercostal spaces, the following structures are divided: The skin, the superficial fascia, the deep fascia, the pectoralis major muscle, the intercostal fascia, and the internal intercostal muscle. From within, the artery is covered only by the pleura; to the inner side of the artery there is usually a single vein. Lower down the *venæ comites* lie to either side of the artery, and the vessels are separated from the pleura by the *triangularis sterni* muscle (Fig. 42). Injuries of the artery in the upper intercostal spaces are consequently more apt to lead to effusions of blood into the pleural cavity (hemothorax) than similar injuries lower down. The deep position of the artery makes it necessary to always bear in mind the possibility of hemothorax after injuries in this region, even when the external hemorrhage is slight. Although the vessel is so well protected that it is not frequently injured, many a person has bled to death into the pleural cavity because the hemorrhage was not recognized. Upon the left side an injury of the artery in the fourth or fifth intercostal space may lead to hemorrhage into the pericardial cavity, since in this situation the vessel lies upon the pericardium instead of upon the pleura.

At the upper margin of the sternum the relation of the sternoclavicular articulation to the large vessels and to the contents of the superior aperture of the thorax (see Plates 11, 13, and 16) must be borne in mind, particularly with reference to the backward dislocation of the sternal end of the clavicle. In this dislocation the sternal end of the clavicle may press backward upon the subclavian artery and vein, the common carotid artery, the internal jugular vein, the trachea, and the esophagus, and lead not only to compression of the vessels but also to dyspnea and dysphagia.

**The Lateral Thoracic Wall.**—The *mammary gland* of the male is practically devoid of interest. The *mammary gland* of the female lies upon the pectoralis major between the third and seventh ribs and possesses from fifteen to twenty secretory ducts which converge toward the nipple and have dendritic ramifications. In opening mammary abscesses (after mastitis) the incisions should consequently be made to radiate from the nipple in order to avoid injuring these ducts.

The *arteries of the mammary gland* reach their most marked development during the height of lactation. They originate from three sources: (1) From the perforating branches of the internal mammary artery in the upper five intercostal spaces, but particularly in the second and



Fig. 42.

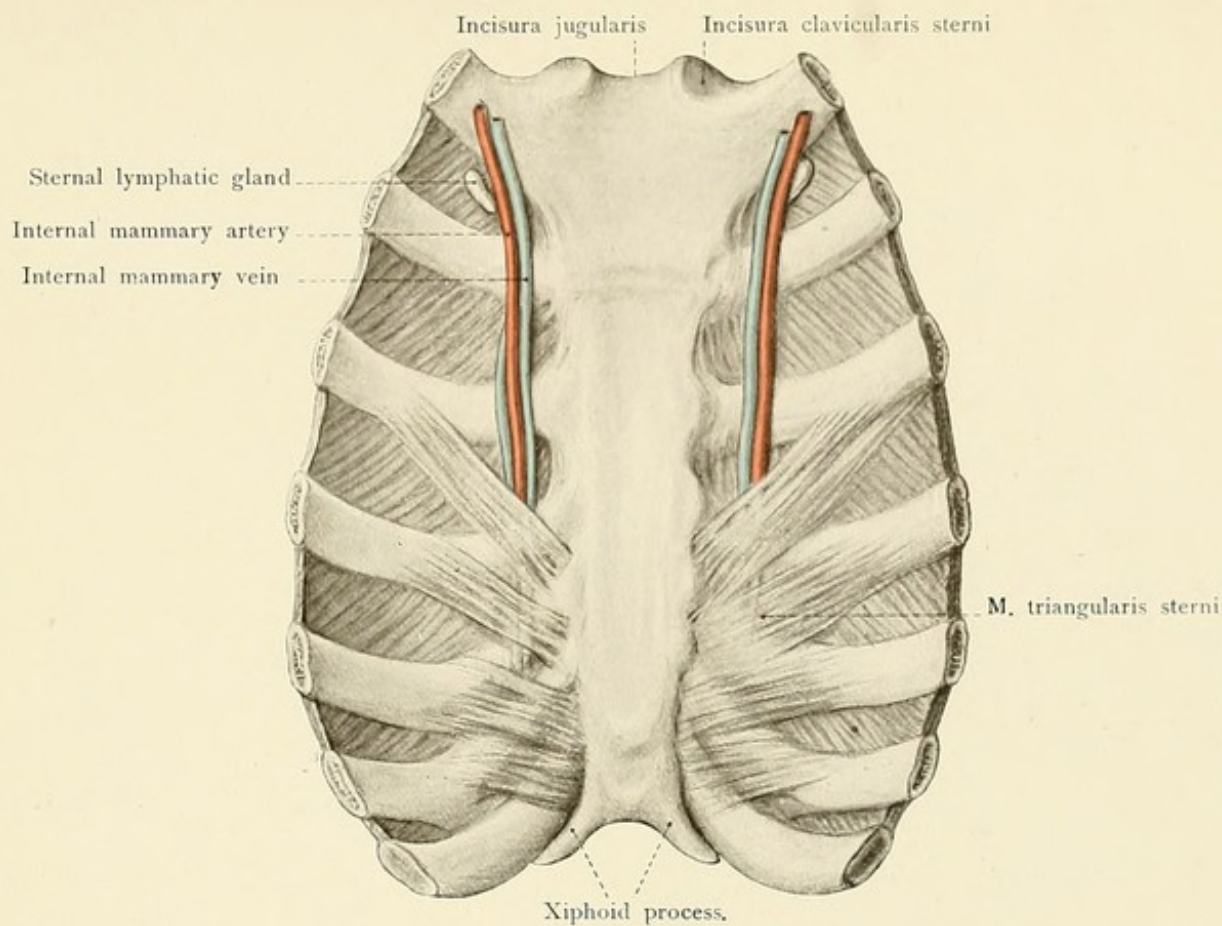
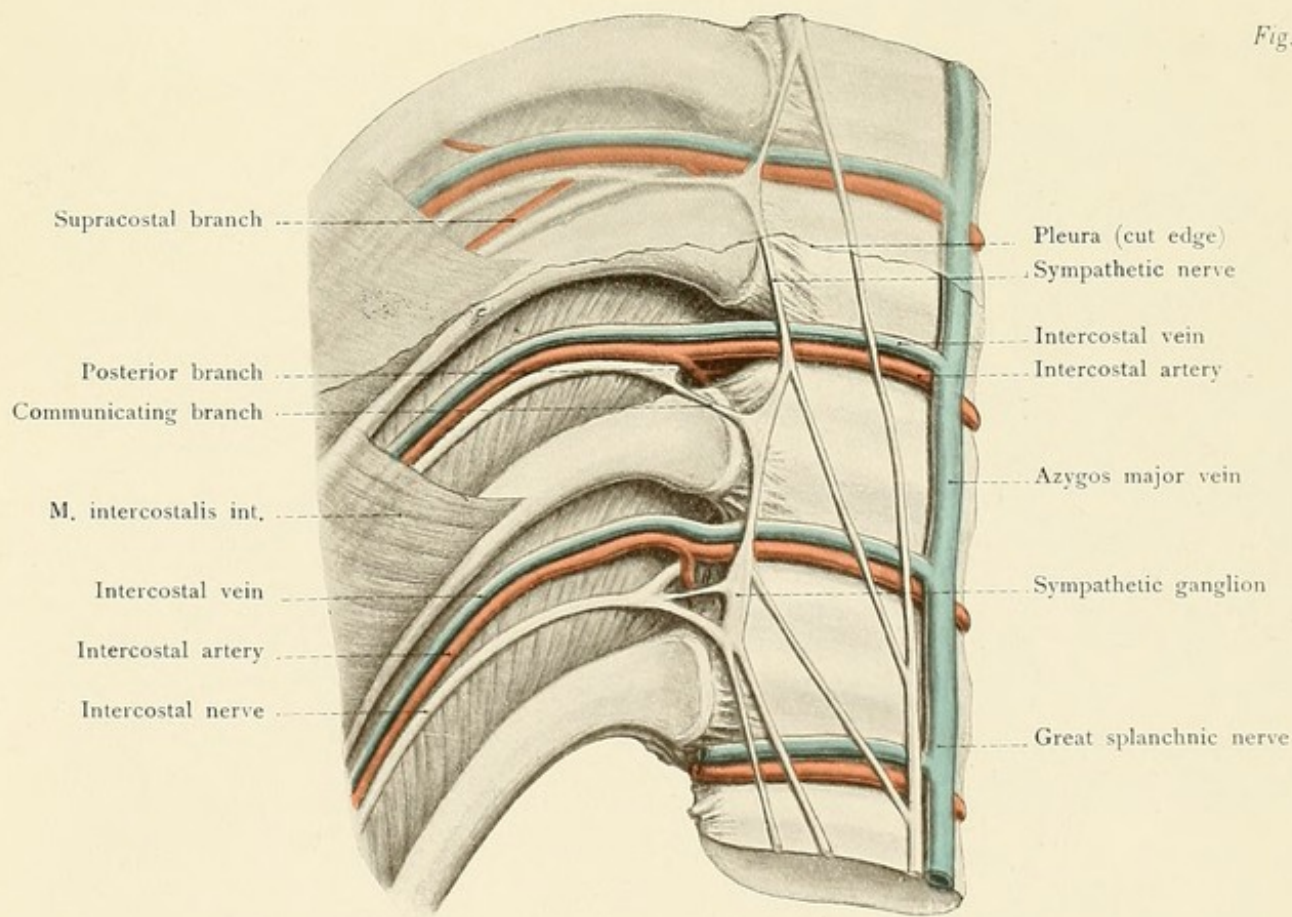


Fig. 43.









third; (2) from the long thoracic branch of the axillary artery; (3) from the perforating branches of the upper intercostal arteries. The deep veins accompany the arteries; the subcutaneous veins form a large-meshed network and, in the female, may frequently be seen through the skin. They form the *plexus venosus mammillæ* (circulus venosus Halleri) about the nipple and empty above into the external jugular vein; they also empty into the long thoracic, thoracico-epigastric, and internal mammary veins.

The *lymphatic vessels* of the mamma are very numerous and form superficial and deep networks. The greater portion of the lymph drains into the axillary lymphatic glands.\* These glands are involved in affections of the mammary gland of the same side, and they are consequently removed together with the breast. In rarer cases they also become involved in affections of the opposite mammary gland, since the lymphatic vessels of both breasts anastomose in the median line. A portion of the lymph passes internally to the intercostal lymphatic vessels and in this manner reaches the lymphatic glands of the thoracic space.

The deep *nerves* of the gland accompany the larger lactiferous ducts and are much less numerous than the cutaneous nerves. The cutaneous nerves are furnished partly by the supra-clavicular branches of the cervical plexus, but chiefly by the anterior and lateral cutaneous branches of the second to the sixth intercostal nerves. The connection between the second and third lateral cutaneous branch (intercosto-humeral nerve) and the lesser internal cutaneous nerve explains the occasional occurrence of pain radiating to the region of the elbow or still lower in diseases of the mammary gland (tumors, neuralgia of the mammary gland). In the extirpation of the mammary gland and the diseased axillary tissues the following structures should be particularly avoided: the axillary artery and vein, the long thoracic artery, the subscapular artery, the long subscapular nerve (division produces paralysis of the latissimus dorsi muscle), and the long thoracic nerve (division is followed by paralysis of the serratus magnus muscle):

The arteries of the lateral thoracic wall are external and internal.

The external surface of the lateral thoracic wall is supplied chiefly by the branches of the axillary artery (Fig. 29). The following vessels should be noted:

1. The *acromiothoracic artery*, which lies beneath the infraclavicular fossa, where the vessel, together with its numerous branches, is endangered in the ligation of the first portion of the axillary. The vessel arises at the upper margin of the pectoralis minor and immediately divides into a number of branches. The pectoral branches ramify in the muscles of the chest; if such a branch arises from the axillary higher up (comparatively rare) it is known as the superior thoracic artery. The acromial branch runs transversely outward, perforates the deltoid muscle, and ends in the anastomosis over the acromion. The descending or humeral branch accompanies the cephalic vein in the groove between the pectoralis major and deltoid muscles.

2. The *long thoracic artery*, which arises from the axillary beneath the pectoralis minor muscle. The artery leaves the outer border of this muscle and runs downward to the fifth or sixth intercostal space, somewhat posterior to the margin of the pectoralis major, upon the ser-

\* The lymphatic gland which is usually first involved in carcinoma is situated beneath the border of the pectoralis major muscle upon the third serration of the serratus magnus (third rib). The lymphatic glands extend upward beyond the axillary vein and beneath the clavicle, in which position their removal is necessarily difficult. Posteriorly, the glands accompany the subscapular artery and the nerves of the same name.



## PLATE 6.

A posterior view of the opened head, neck, and trunk of a man. The greater portion of the brain has been removed; the spinal cord and spinal nerves as well as the viscera and diaphragm may be seen *in situ*. From a Leipzig model from nature (His).

ratus magnus muscle, which it supplies. This artery varies in size and is often absent. The mammary branches of this vessel have been previously mentioned. The long thoracic nerve, for the serratus magnus muscle, does not run with the artery but somewhat posteriorly [that is, in the angle made by the inner and posterior walls of the axilla.—ED.], covered by the latissimus dorsi muscle.

3. The *subscapular artery*, the largest branch of the axillary, arises to the outer side of the long thoracic artery at the axillary border of the scapula. It is covered by the latissimus dorsi muscle and is not endangered by operative procedures in the axilla until they penetrate beneath the margin of this muscle. One of the terminal branches, the *thoracodorsalis*, runs onward in the continuation of the main trunk, as the largest artery of the lateral thoracic wall, between the serratus magnus and latissimus dorsi (and teres major) to supply these muscles. The other terminal branch, the *dorsalis scapulae*, passes posteriorly through the triangular space (see page 76) to reach the dorsal surface of the scapula.

The arteries running upon the internal surface of the thoracic wall are known as the *intercostal arteries*. These vessels originate from three sources:

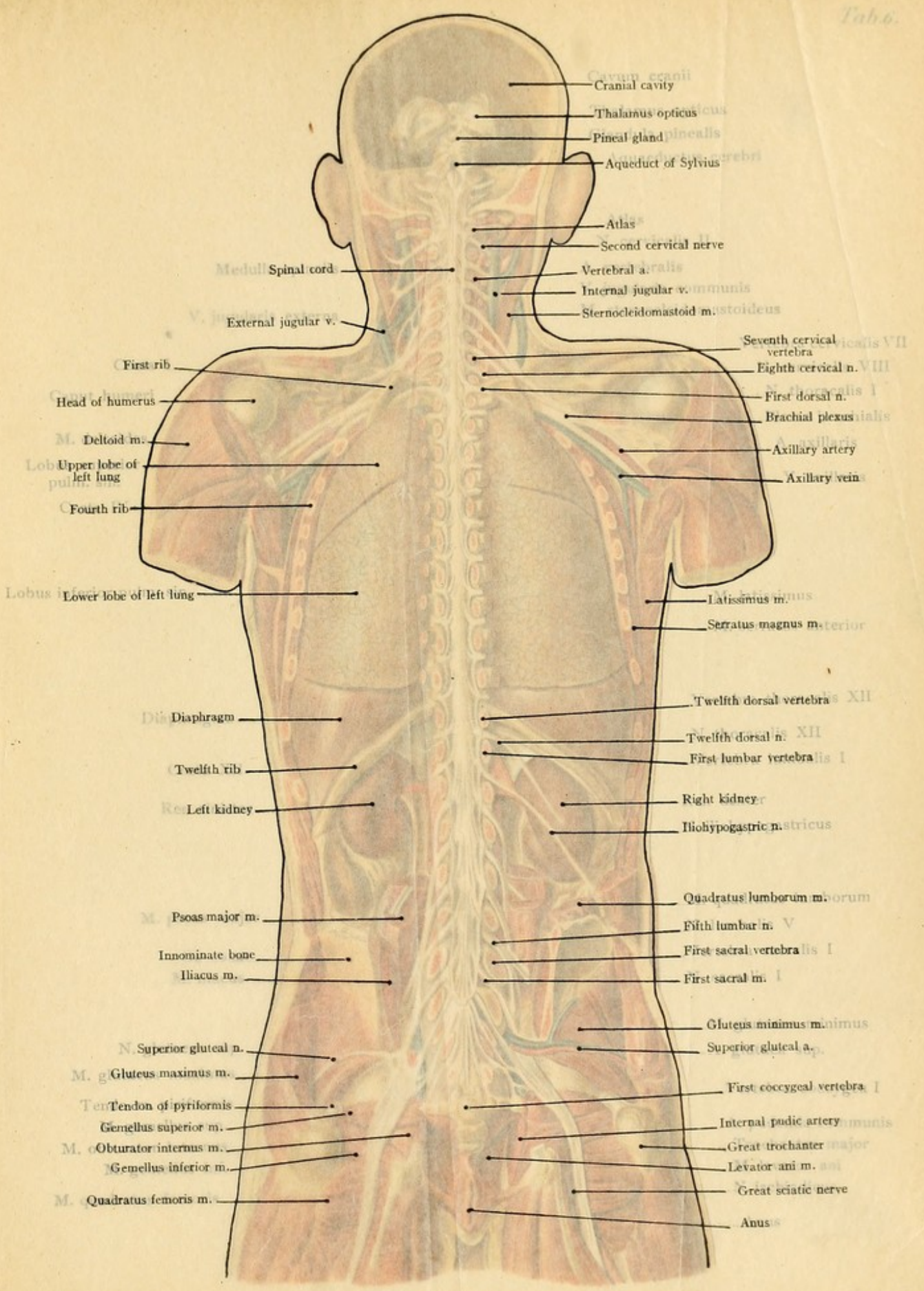
1. From the costocervical trunk of the subclavian (see page 70) is given off the small *superior intercostal artery*, which descends beneath the pleura in front of the necks of the first two ribs and supplies the two upper intercostal spaces.

2. The thoracic aorta gives off *nine intercostal* branches, for the third to the eleventh intercostal spaces inclusive, and a tenth branch for the lower margin of the twelfth rib. These vessels arise from the dorsal surface of the thoracic aorta. As the aorta lies to the left side of the vertebral column, the right intercostal arteries are longer than the left ones. The vessels of the right side pass over the vertebra toward the right and are situated behind the esophagus, the vena azygos major, and the right sympathetic nerve. The shorter vessels of the left side are behind the vena azygos minor and the left sympathetic nerve. At the necks of the ribs the arteries give off posterior branches which run backward and divide into a spinal branch, entering the vertebral canal through the intervertebral foramen and supplying the spinal cord, and a muscular and cutaneous branch. The continuation of the artery or the anterior branch, usually designated simply as the *intercostal artery*, runs in the intercostal groove along the inferior border of the rib, at first being covered only by the pleura, and then passes anteriorly between the internal and external intercostal muscles; it sends a small branch to the upper border of the rib below, gives off cutaneous branches which appear externally (with mammary branches, see page 94), and anastomoses with the anterior intercostal branches of the internal mammary artery.

3. The *anterior intercostal* branches of the internal mammary artery, which pass backward and anastomose with the aortic intercostals. These vessels run in the upper six intercostal spaces, the lower six being supplied with corresponding branches by the musculophrenic artery.

The intimate relation of the intercostal arteries with the intercostal grooves, which furnish them with an external bony protection, explains the following statements: (1) Injuries of the





Cavum cranii  
Cranial cavity

Thalamus opticus

Pineal gland

Aqueduct of Sylvius

Atlas

Second cervical nerve

Vertebral a.

Internal jugular v. communis

Sternocleidomastoid m.

Seventh cervical vertebra

Eighth cervical n. VIII

First dorsal n. I

Brachial plexus

Axillary artery

Axillary veins

Medull. Spinal cord

External jugular v.

First rib

Head of humerus

M. Deltoid m.

Lob. Upper lobe of left lung

Fourth rib

Lobus Lower lobe of left lung

Latissimus m.

Serratus magnus m. anterior

Diaphragm

Twelfth dorsal vertebra XII

Twelfth rib

Twelfth dorsal n. XII

Left kidney

First lumbar vertebra I

Right kidney

Iliohypogastric n. stricus

M. Psoas major m.

Quadratus lumborum m. posterior

Innominate bone

Fifth lumbar n. V

Iliacus m.

First sacral vertebra I

First sacral m. I

N. Superior gluteal n.

Gluteus minimus m.

Superior gluteal a.

M. g. Gluteus maximus m.

First coccygeal vertebra I

Tendon of pyriformis

Internal pudic artery

Gemellus superior m.

Great trochanter major

M. o. Obturator internus m.

Levator ani m. ani

Gemellus inferior m.

Great sciatic nerve

M. q. Quadratus femoris m.

Anus



PLATE 8.

A posterior view of the head and neck of a man. The greater portion of the face has been removed; the eye, ear, nose, and mouth are shown as they appear in the living subject. The Leipzig model from which this drawing was made is in the possession of the Anatomical Museum of the University of Leipzig.

ratus magnus muscle, which it supplies. This artery varies in size and is often... mammary branches of this vessel have been previously mentioned. The long... for the serratus magnus muscle, does not run with the artery somewhat posteriorly... in the angle made by the anterior and posterior walls of the axilla.—Ed.] covered by the... mus dorsi muscle. Sternoideomastoidei m. External jugular v. First rib Head of humerus Deltoid m. Upper lobe of left lung Fourth rib

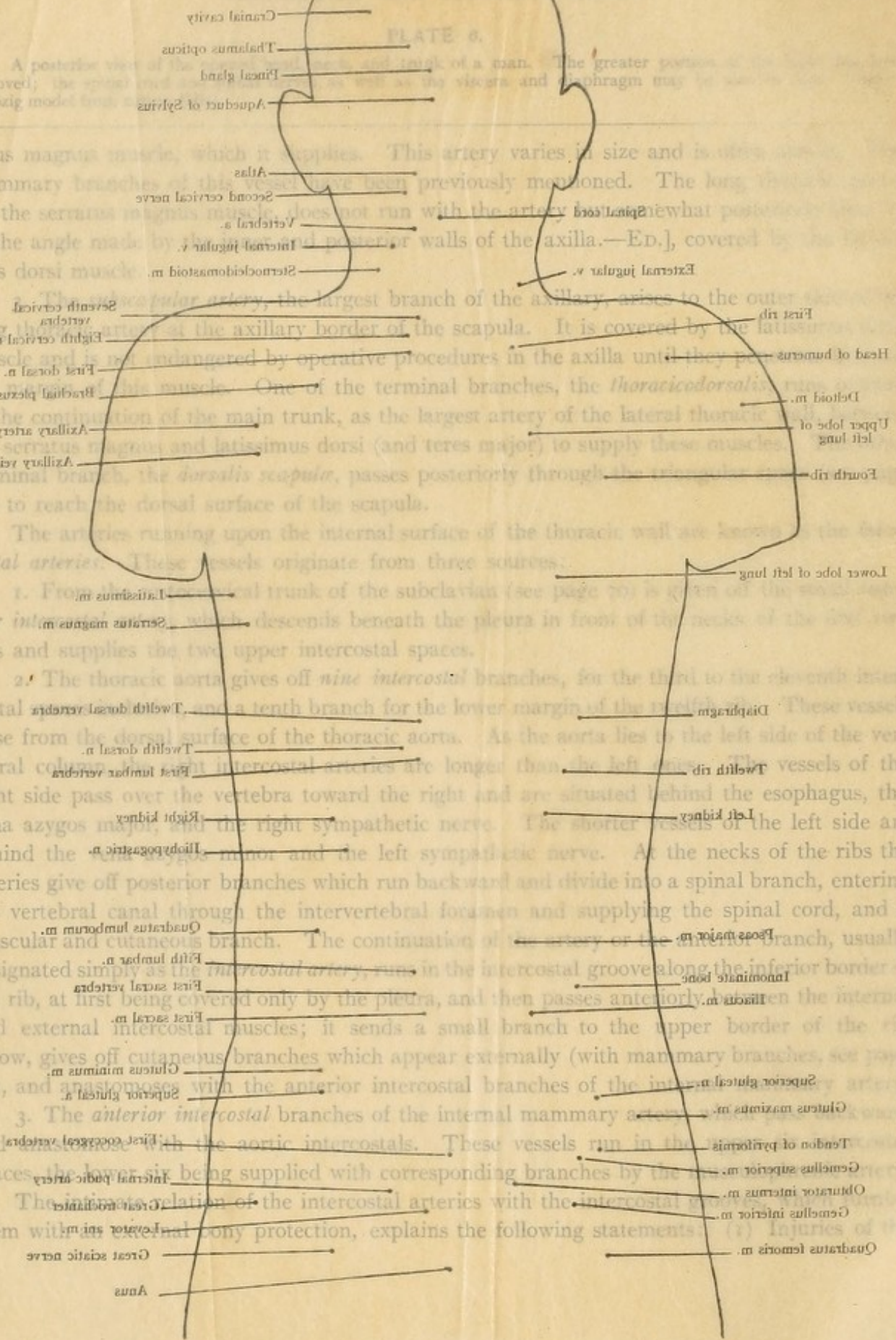
The axillary artery, the largest branch of the subclavian, arises to the outer side of the long thoracic muscle at the axillary border of the scapula. It is covered by the latissimus muscle and is not endangered by operative procedures in the axilla until they pass the serratus magnus muscle. One of the terminal branches, the thoracicodorsalis, runs in the continuation of the main trunk, as the largest artery of the lateral thoracic wall, the serratus magnus and latissimus dorsi (and teres major) to supply these muscles. A terminal branch, the dorsalis scapulae, passes posteriorly through the transverse process of the seventh cervical vertebra to reach the dorsal surface of the scapula.

The arteries running upon the internal surface of the thoracic wall are known as the *intercostal arteries*. These vessels originate from three sources: 1. From the anterior trunk of the subclavian (see page 70) is given off the *anterior intercostal artery*, which descends beneath the pleura in front of the necks of the six upper ribs and supplies the two upper intercostal spaces.

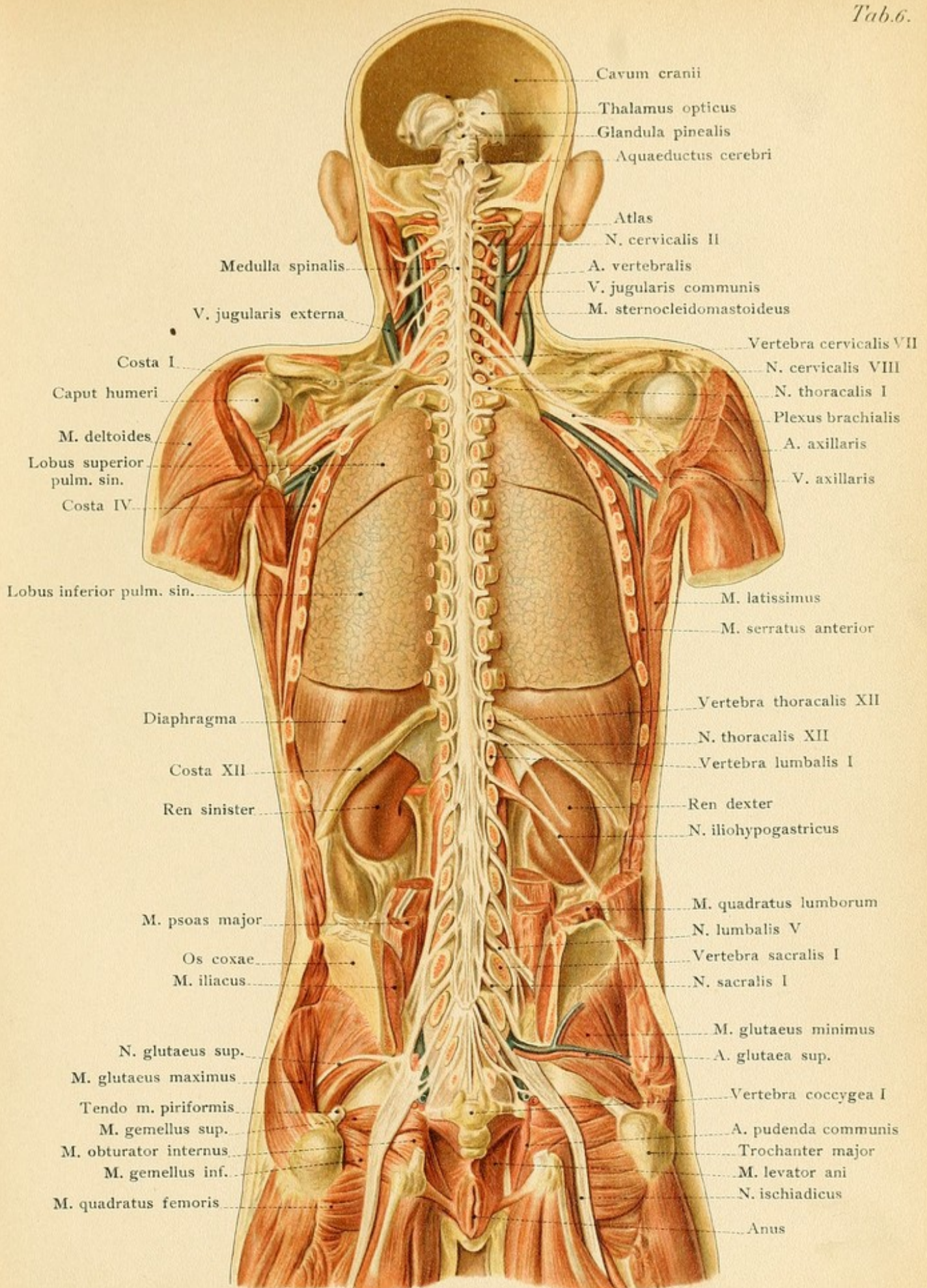
2. The thoracic aorta gives off *nine intercostal branches*, for the third to the seventh intercostal spaces and a tenth branch for the lower margin of the twelfth rib. These vessels arise from the dorsal surface of the thoracic aorta. As the aorta lies to the left side of the vertebral column, the right intercostal arteries are longer than the left ones. The vessels of the right side pass over the vertebra toward the right and are situated behind the esophagus, the vena azygos major, and the right sympathetic nerve. The shorter vessels of the left side are behind the vena azygos minor and the left sympathetic nerve. At the necks of the ribs the arteries give off posterior branches which run backward and divide into a spinal branch, entering the vertebral canal through the intervertebral foramen and supplying the spinal cord, and a muscular and cutaneous branch. The continuation of the artery or the anterior branch, usually designated simply as the *intercostal artery*, runs in the intercostal groove along the inferior border of the rib, at first being covered only by the pleura, and then passes anteriorly between the internal and external intercostal muscles; it sends a small branch to the upper border of the rib below, gives off cutaneous branches which appear externally (with mammary branches, see page 94), and anastomoses with the anterior intercostal branches of the internal mammary artery.

3. The *anterior intercostal branches* of the internal mammary artery anastomose with the aortic intercostals. These vessels run in the intercostal spaces the lower six being supplied with corresponding branches by the *anterior intercostal arteries*. The *anterior intercostal arteries* run in the intercostal spaces the lower six being supplied with corresponding branches by the *anterior intercostal arteries*. The *anterior intercostal arteries* run in the intercostal spaces the lower six being supplied with corresponding branches by the *anterior intercostal arteries*.

The intimate relation of the intercostal arteries with the intercostal spaces and their position in relation to the ribs and the pleura, explains the following statements: Great sciatic nerve Anus













intercostal arteries without concomitant injuries of the ribs are rare. (2) In resection of a portion of a rib, the arteries should be carefully avoided by shelling out the bone from the periosteum (subperiosteal resection) and exercising great care at the lower costal margin. (3) In opening the pleural cavity the instrument should be introduced in the middle of the intercostal space, avoiding the margin of the rib. (4) In fractures of the rib the artery may occasionally be lacerated; in rare cases the internal intercostal muscles and the pleura may also be torn and a fatal effusion of blood take place into the pleural cavity (hemothorax). (5) It is usually necessary to resect a portion of a rib in order to expose the intercostal artery from without.

On account of the free anastomosis of the anterior and posterior intercostal arteries, it is possible in compression or stenosis of the thoracic aorta (by tumors, for example) for the blood from the inner surface of the thoracic wall to gain access to the aorta below the site of the compression through the dilated internal mammary artery and the anastomoses between the ribs.

The *veins* of the thoracic wall consist of those which accompany the arteries and are called by the same names (intercostal veins, Fig. 43) and of the cutaneous veins. The costo-axillary veins are situated over the upper intercostal spaces and allow the blood from the intercostal veins to pass into the axillary vein. The thoraco-epigastric veins are also of importance; one of these, the *vena thoraco-epigastrica tegumentosa longa* (Braune), runs in the anterior axillary line and forms a subcutaneous connection between the femoral and axillary veins.

The *sensory nerves* of the thoracic wall are furnished from several sources. The region near the posterior median furrow is supplied by the posterior branches of the dorsal nerves, the skin of the infraclavicular region obtains its nerve-supply from the supraclavicular branches of the cervical plexus, and the remainder of the thoracic wall is provided with sensation by the intercostal nerves. The intercostal nerves (Fig. 43) are the anterior divisions of the dorsal spinal nerves. Alongside of the vertebral column they run upon the inner surface of the external intercostal muscles immediately beneath the pleura and are consequently exposed to irritation in inflammation of this membrane. At the angle of the rib, where the free border of the internal intercostal muscle commences, they pass between and supply the two intercostal muscles, and follow the lower margin of the rib, being situated below the intercostal artery. Their proximity to the ribs explains the occasional occurrence of neuralgic pains in costal fractures. In the lateral region of the thorax they give off the lateral cutaneous nerves which subdivide into an anterior and a posterior branch (read the description of the nerves of the mammary gland). Anteriorly, beside the sternum, their terminal branches pass between the costal cartilages to the skin of the sternum region as the anterior cutaneous nerves.

The *motor nerves* of the thoracic wall, with the exception of the intercostal nerves supplying the intercostal muscles and the branches to the long muscles of the back, are branches of the brachial plexus. This plexus receives almost the entire anterior division of the first dorsal nerve. This nerve is situated in the thorax at the point where it passes over the neck of the first rib, and is occasionally compressed by tumors (aortic aneurysm) and gives rise to violent pains in the arm. The long thoracic nerve, which is given off from the brachial plexus and runs upon the serratus magnus muscle, and the long subscapular nerve (for the latissimus dorsi muscle), which accompanies the subscapular artery, have been previously described (see pages 75 and 76). The branches for the pectoralis major and minor and for the subclavius muscles are



## PLATE 7.

A posterior view of a dissection of the thoracic, and of a portion of the cervical viscera. The relation of the bronchi, arteries, and veins at the hilus of the lungs. From a Leipzig model from nature (His).

occasionally encountered in the infraclavicular fossa in ligating the first portion of the axillary artery (see page 73 and Fig. 28).

**The Inferior Boundary of the Thorax.**—The *diaphragm* forms a muscular dome-shaped partition which constitutes the inferior boundary of the thorax. The right side of the dome, which covers the liver, projects upward more markedly than does the left side. The central tendon is flatter and has a more restricted range of motion during respiration (review the lumbar, costal, and sternal portions of the muscle with their origins). The structures passing through

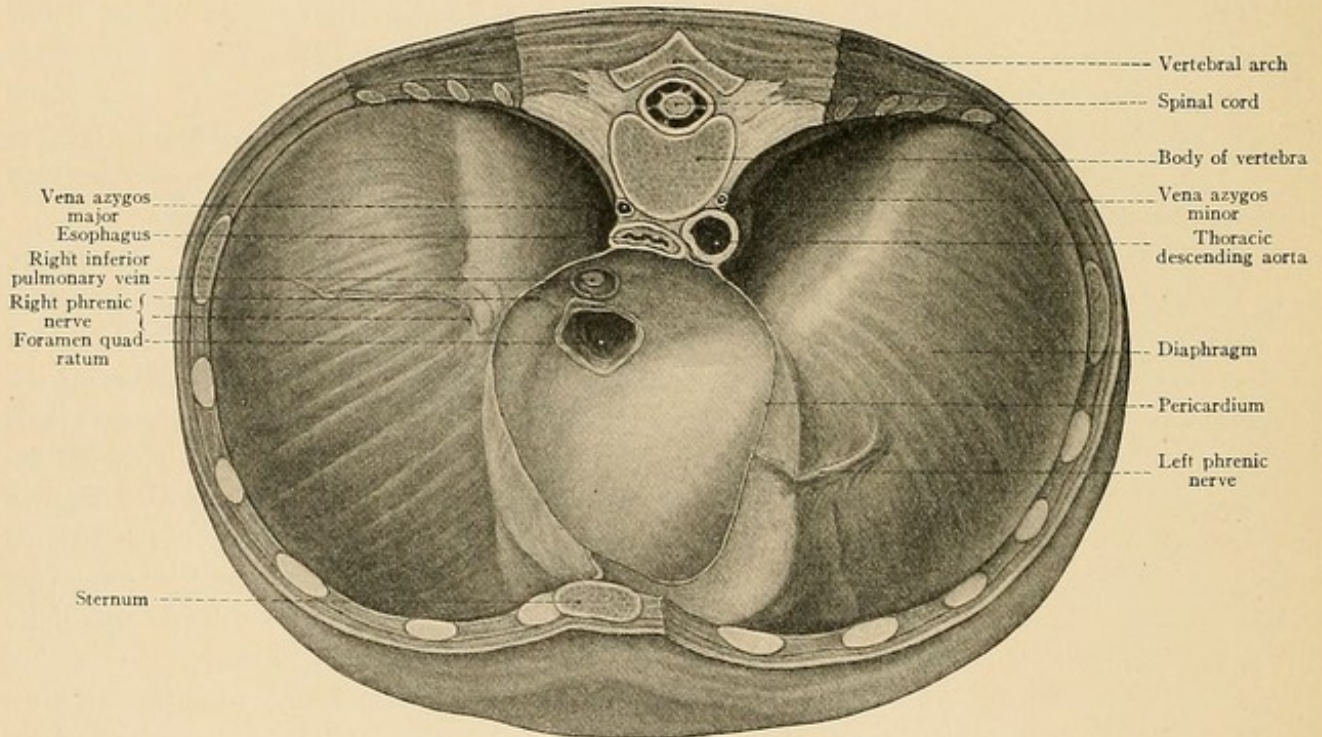


FIG. 44.—The diaphragm and the inferior half of the pericardium seen from above. Formalin preparation (child).

the diaphragm from above downward are: the descending aorta through the aortic opening; the esophagus and the pneumogastric nerves through the esophageal opening; the splanchnic nerves, from the sympathetic, between the crus mediale and the crus intermedium of the lumbar portion; the sympathetic nerve itself between the crus intermedium and the crus laterale of the lumbar portion; and the superior epigastric artery, from the internal mammary between the sternal and costal portions (the so-called fissure of Larrey). The structures passing through the diaphragm from below upward are: the inferior vena cava (accompanied by a filament from the right phrenic nerve), through the foramen quadratum in the right side of the central tendon; the vena azygos major (on the right side) and the vena azygos minor (on the left side), accom-



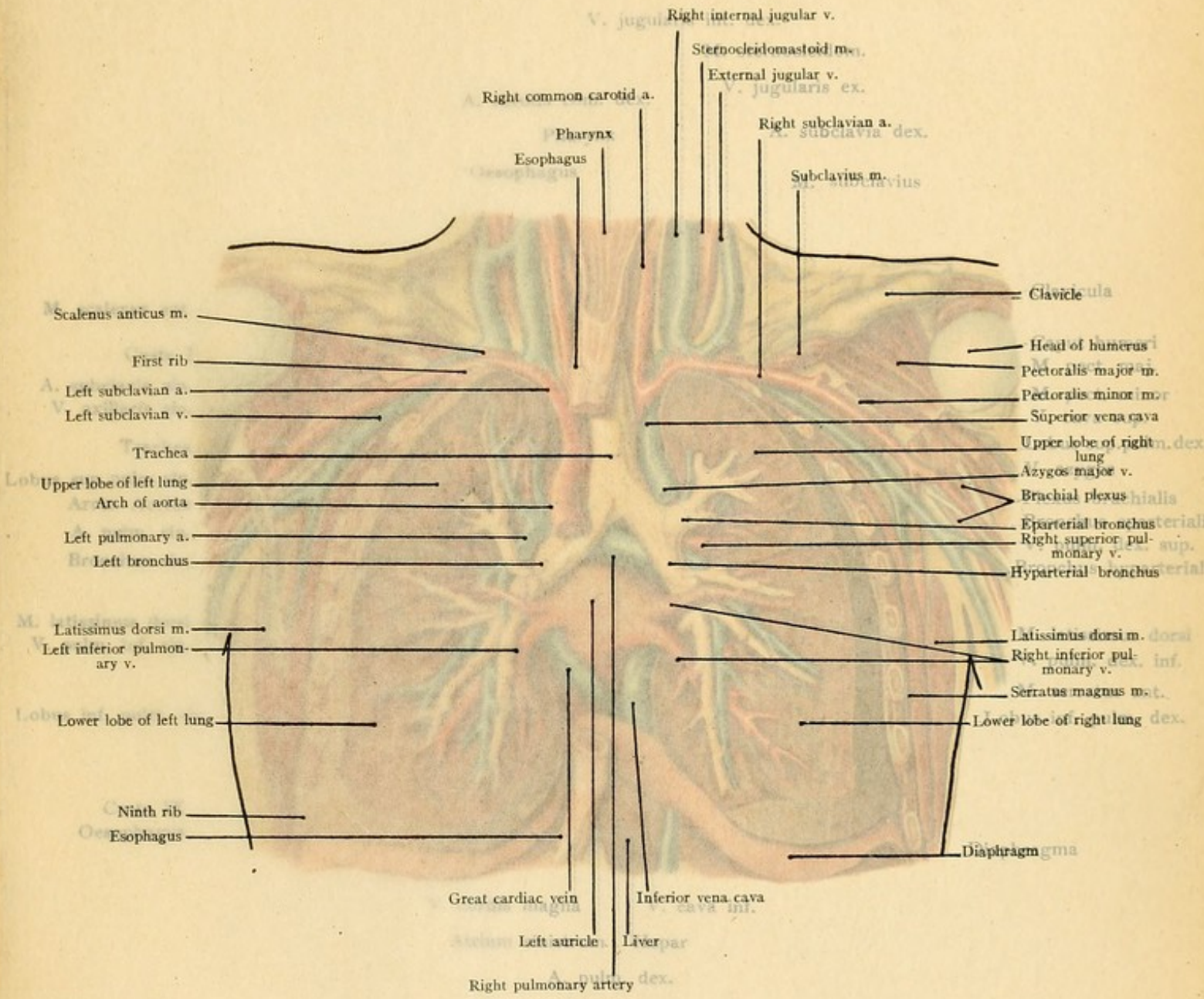
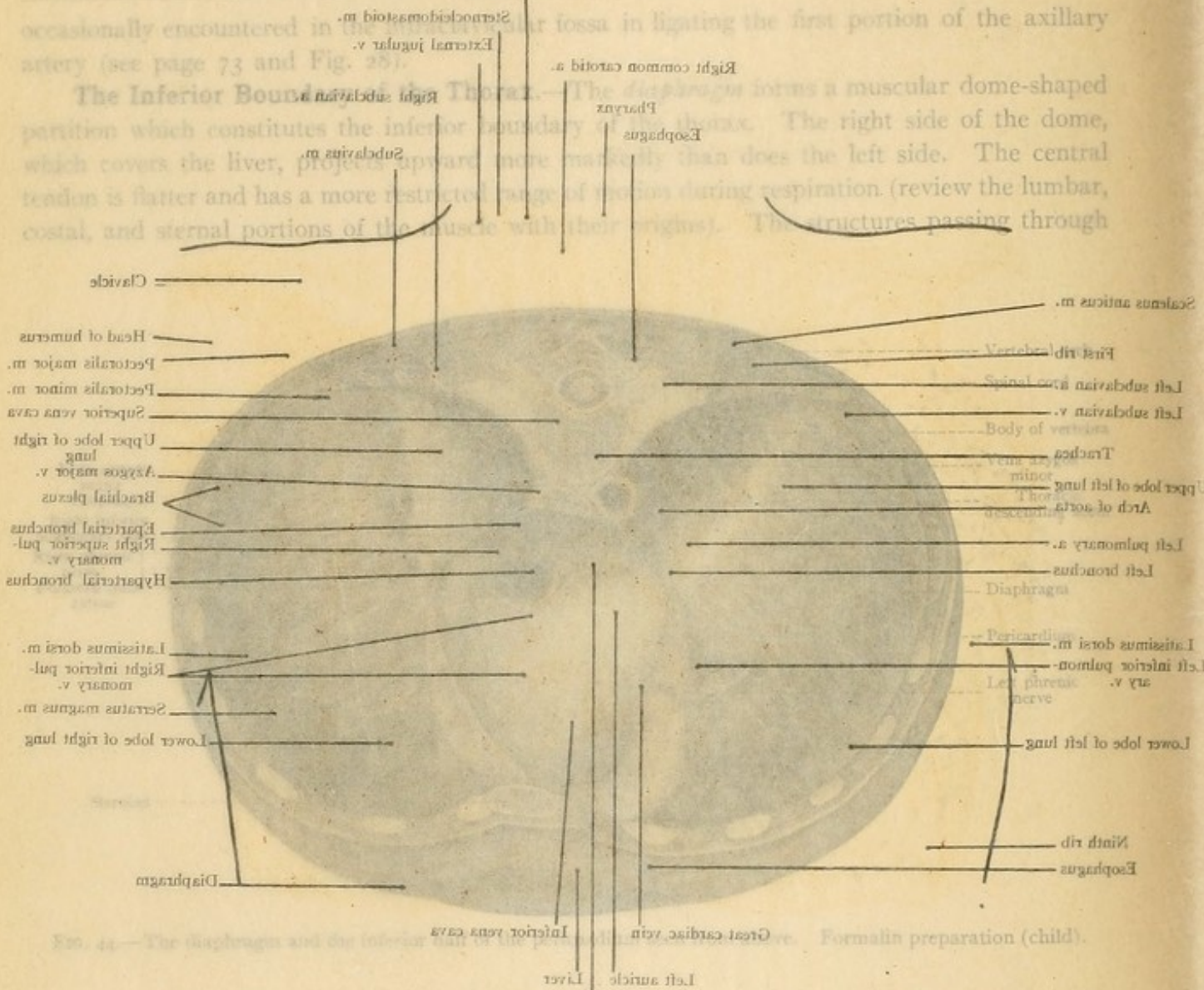




PLATE 7.

A posterior view of a dissection of the thoracic and of a portion of the cervical viscera. The relation of the bronchi, arteries, and veins at the hilus of the lung. From a Leipzig model from nature. (Black.)

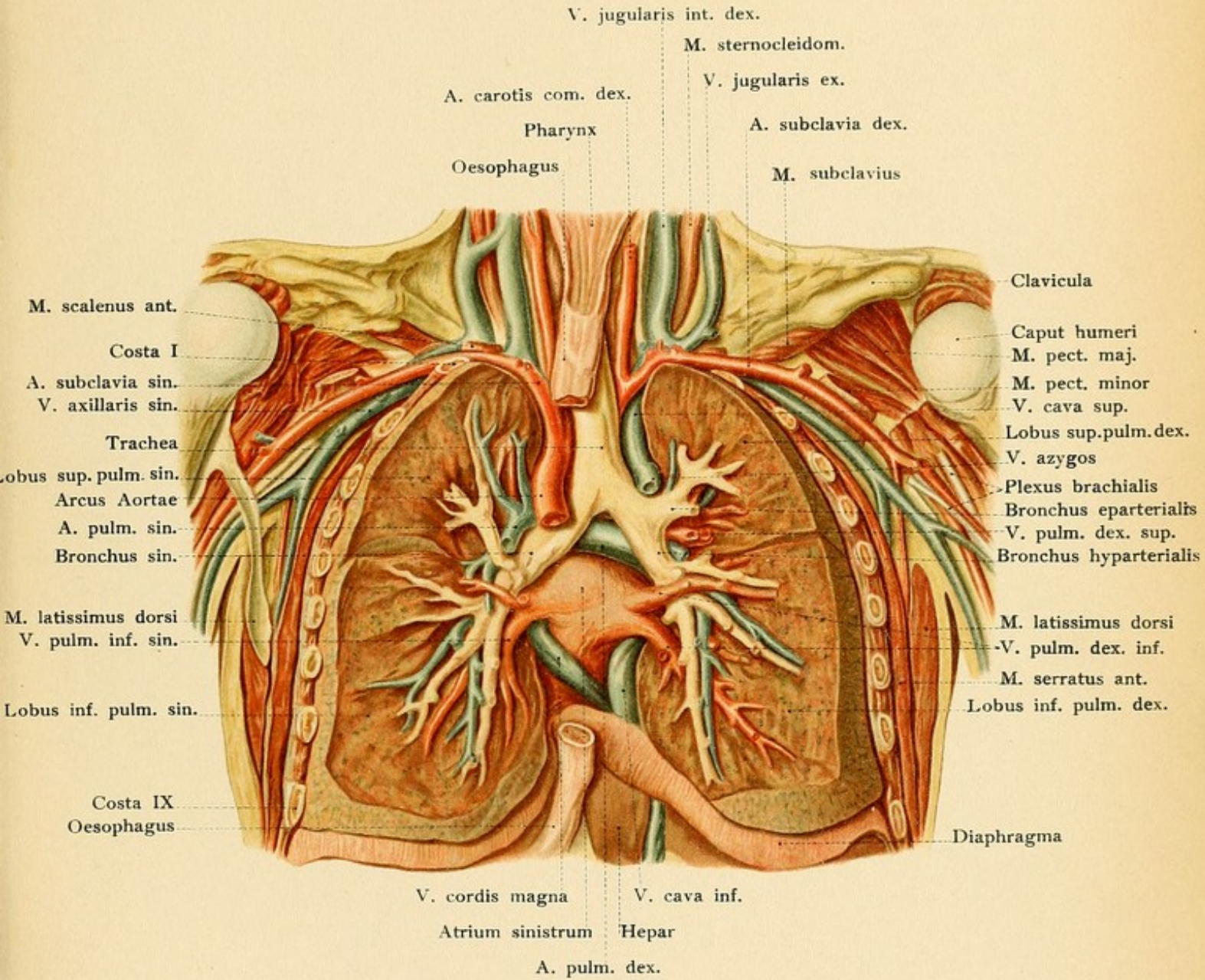


occasionally encountered in the axillary fossa in ligating the first portion of the axillary artery (see page 73 and Fig. 25).

The inferior boundary of the thorax.—The diaphragm forms a muscular dome-shaped partition which constitutes the inferior boundary of the thorax. The right side of the dome, which covers the liver, projects upward more markedly than does the left side. The central tendon is flatter and has a more restricted range of motion during respiration (review the lumbar, costal, and sternal portions of the muscle with their origins). The structures passing through

the diaphragm from above downward are: the descending aorta through the aortic opening; the esophagus and the pneumogastric nerves through the esophageal opening; the splanchnic nerves, from the sympathetic, between the crus mediale and the crus intermedium of the lumbar portion; the sympathetic nerve itself between the crus intermedium and the crus laterale of the lumbar portion; and the superior epigastric artery, from the internal mammary between the sternal and costal portions (the so-called fissure of Larrey). The structures passing through the diaphragm from below upward are: the inferior vena cava (accompanied by a filament from the right phrenic nerve), through the foramen quadratum in the right side of the central tendon; the vena azygos major (on the right side) and the vena azygos minor (on the left side), accom-











panying the splanchnic nerves through the lumbar origin (*crura*) of the muscle; the thoracic duct, through the aortic opening; and the superior epigastric veins through the fissure of Larrey.

The *arteries* supplying the upper surface of the diaphragm are the *comes nervi phrenici* (pericardio-phrenic artery, see Plate 8, a) and the musculophrenic, one of the two terminal branches of the internal mammary. The blood-supply of the lower surface of the diaphragm is furnished by the phrenic arteries, which arise from the aorta in the aortic opening or from the celiac axis.

The *phrenic nerves* from the cervical plexus may be easily found in the neck upon the anterior surface of the scalenus anticus muscle. In the chest they run upon the pericardium and are covered by the pleura mediastinalis (Plate 8). The diaphragm also receives branches from the seventh to the twelfth intercostal nerves.

The central portion of the upper surface of the diaphragm is adherent to the pericardium; the lateral portions are attached to the pleural sacs (diaphragmatic pleura). The pericardial sac is in relation with the central tendon, but also extends to the left over the muscular portion of the diaphragm (Fig. 44). Since the left lung is not so voluminous as the right, the left diaphragmatic pleura is not so extensive as the corresponding layer upon the right side.

*Diaphragmatic hernias* are produced when abdominal viscera pass into the thorax through the diaphragm. They may be congenital or acquired. The favorite site for such hernias is in the vicinity of the esophageal foramen, in which the esophagus, in contrast to the aorta and vena cava, is fixed by only a loose connective tissue. Such hernias are usually left-sided, since the liver is situated immediately below the right dome of the diaphragm. They may contain the stomach, the omentum, the large intestine, the small intestine, the spleen and other viscera. The peritoneum, which lines the under surface of the diaphragm, is protruded into the thorax and, together with the pleura, forms the sac of the hernia. Such a hernial sac is wanting when one of the abdominal viscera enters the thoracic cavity through a complete tear in the diaphragm; this is the condition of affairs in the majority of cases of diaphragmatic hernia. There have been individuals in whom the stomach has been situated above the diaphragm for many years.

As the inferior vena cava is firmly fixed in the foramen quadratum, a marked left-sided pleural exudate may, by pushing the heart over to the right, bend the vena cava to almost a right angle. This may produce symptoms of cerebral anemia, unconsciousness, or even death. At the same time, symptoms of venous stasis will appear in the lower extremities. It should also be remembered that the diaphragm reaches much lower at the vertebral column than anteriorly at the sternum, so that horizontal penetrating wounds may open the abdominal cavity in front and a pleural cavity behind (see Plate 13).

## THE CONTENTS OF THE THORAX.

The greater portion of the inner surface of the thoracic wall is lined by the **pleura**. This forms two sacs or cavities, the right and the left *pleural cavities*, which are completely separated from each other and almost entirely filled by the right and left lungs. The lungs are so closely applied against the pleural surface that injuries of the pleura without concomitant injury of the lung are comparatively rare. The pleura lining the inner surfaces of the ribs and the inter-



FIG. 45.—A diagrammatic representation of the projections of the heart, of the pleural limits, and of the lungs upon the anterior thoracic wall. The lung is indicated by yellow, and the pleura by red lines. The lungs are represented in a state of moderate distention, so that their borders correspond to a position between deepest expiration and deepest inspiration.

FIG. 46.—A diagrammatic representation of the projections of the pleural limits, of the lungs, and of the bifurcation of the trachea upon the posterior thoracic wall. The lung is indicated by yellow and the pleura by red lines.

costal spaces is designated as the *costal pleura*, while that situated upon the upper surface of the diaphragm is known as the *diaphragmatic pleura*. The costal pleura forms the outer wall of the pleural cavity, while the diaphragmatic pleura forms its floor. The inner wall is known as the *mediastinal pleura*; it extends in a sagittal plane from the vertebral column toward the sternum, and in these situations becomes continuous with the costal pleura. The *costo-mediastinal sinus* is situated anteriorly at the junction of the costal and the mediastinal pleuræ. The *costo-phrenic sinus* (Fig. 49) is formed by the reflection of the costal pleura upon the diaphragm. The sinuses are complementary spaces for the accommodation of the margins of the lungs during inspiration. During respiration the lungs glide inaudibly upon the smooth inner surface of the pleura. If inflammatory exudates are deposited upon the pleura, however, the physician may hear friction sounds through the thoracic wall.

Owing to the thinness of the thoracic wall, pathologic changes in the breathing space or in the lung-tissue or abnormal collections in the pleural sacs may be recognized by typical variations from the normal pulmonary sounds. The pleural cavity may contain air, entering through an external wound, but more frequently through a bronchus after injury to the lung (pneumothorax), a serous transudate (hydrothorax), pus (empyema), or blood (hematothorax).

The costal, diaphragmatic, and mediastinal pleuræ together form the *parietal pleura*, in contradistinction to the *visceral pleura*, which is intimately adherent to the surface of the lung. The two layers are continuous with each other at the root of the lung.

The *mediastinal pleura* is best studied by removing the lateral walls of the thorax, together with the costal pleura, and taking out the lungs by cutting through their roots (and also through the small and insignificant ligamentum latum pulmonis, which runs downward from the root of the lung to the diaphragm). It will then be seen that the two mediastinal pleuræ form a partition between the two pleural cavities which is not exactly in the median line and which extends from the vertebral column to the sternum. This is the *mediastinum*.\* It consists of the two layers of the mediastinal pleura and of the space enclosed between them. Superiorly, where the mediastinal pleura becomes continuous with the costal pleura above the superior aperture of the thorax, the mediastinal contents become continuous with the structures of the neck; inferiorly, the mediastinum is fixed to the diaphragm.

The dome of the pleura extends upward posteriorly to the level of the upper margin of the first thoracic vertebra, and slopes down anteriorly to the upper margin of the first costal carti-

\* Among the old anatomists the word "mediastinum" was equivalent to "partition"; for example, *mediastinum auris-membrana tympani*. As the diaphragm is a horizontal partition between the thorax and abdomen, so is the *mediastinum* a vertical partition in the thorax. It is formed by the two layers of mediastinal pleura, which barely touch at any point, but which enclose a space completely filled by many organs. A "mediastinal cavity" consequently has no existence.



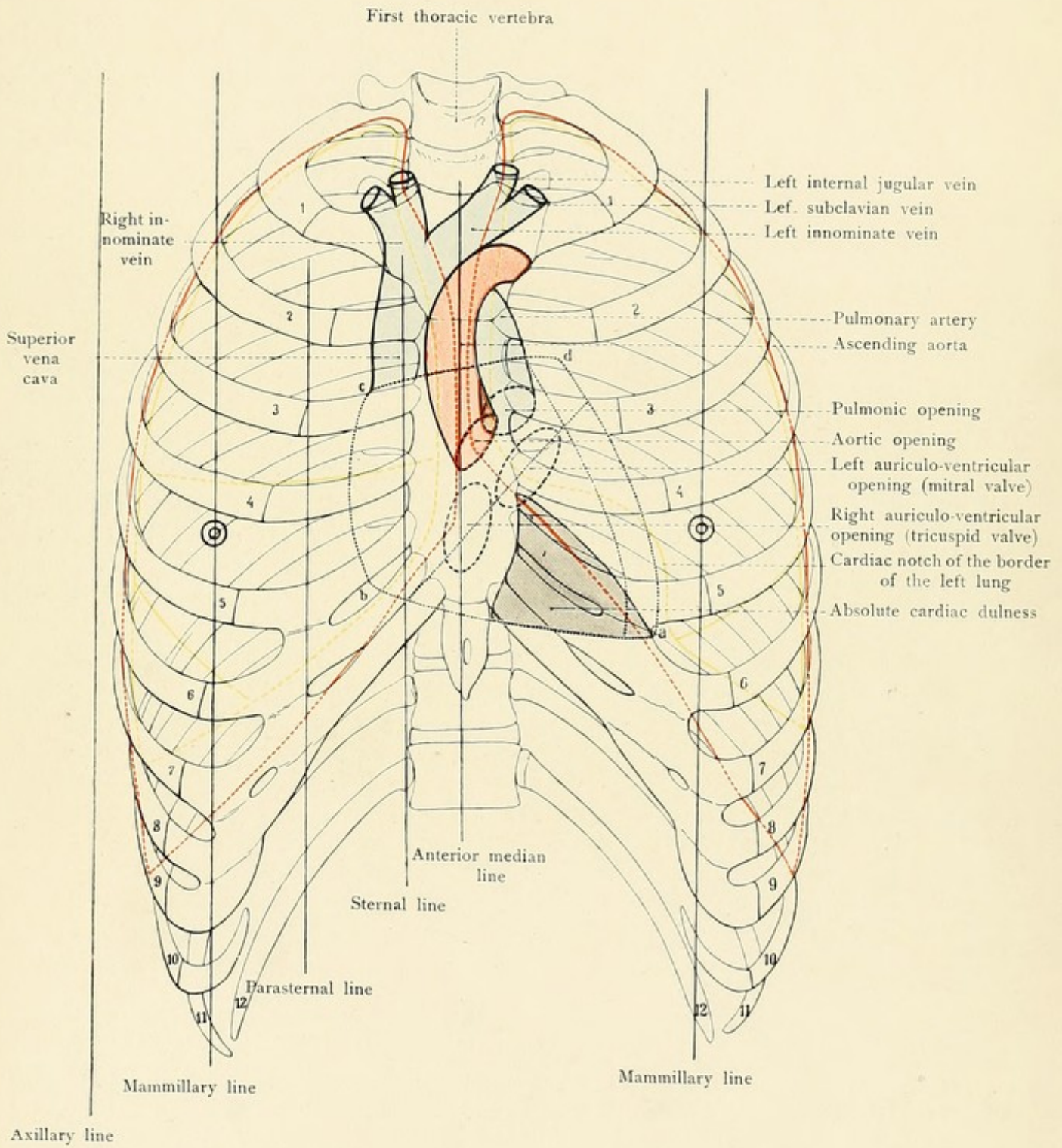
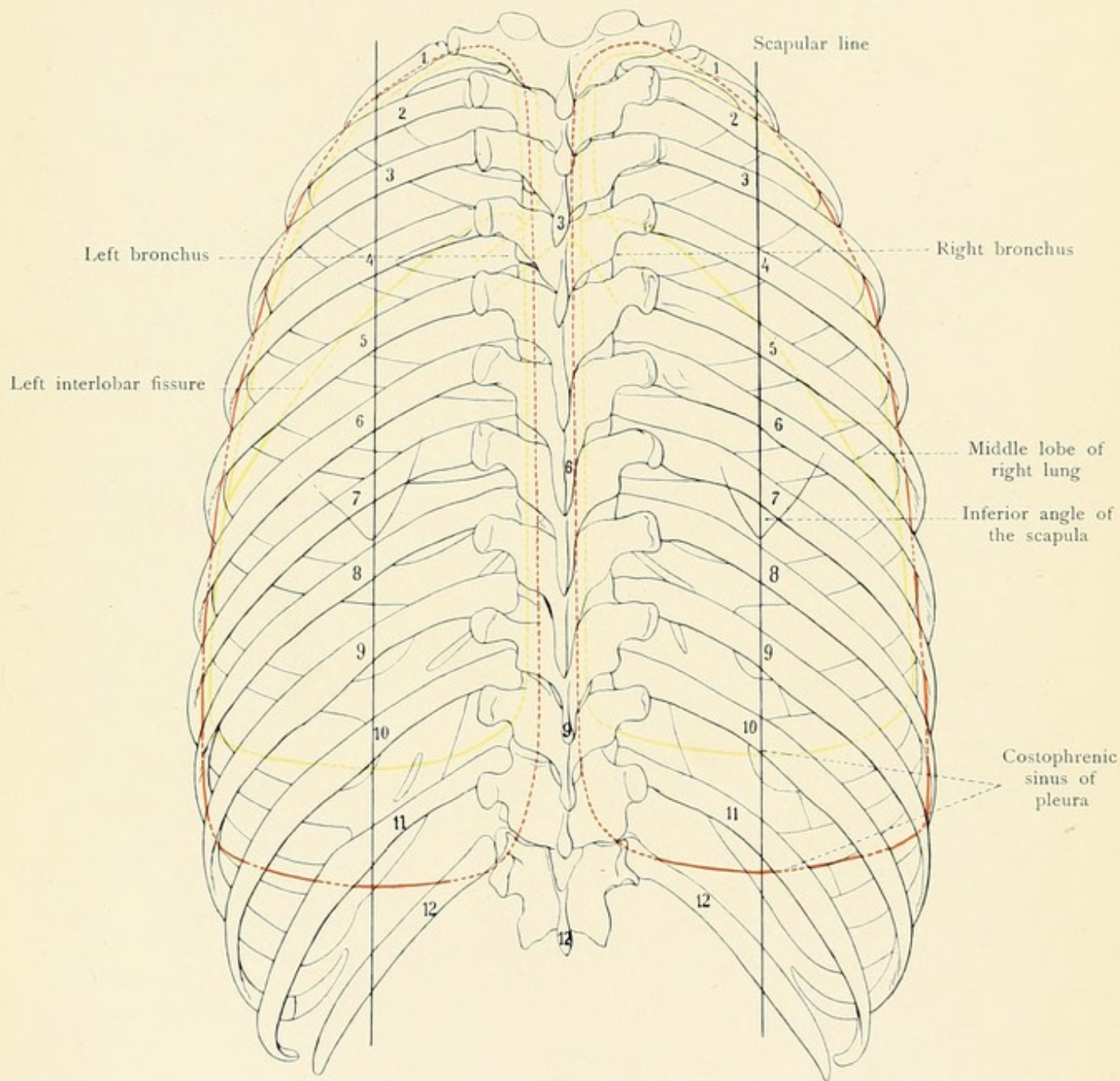








Fig. 46.









lage. The highest point of the pleural dome, projected upon the anterior surface of the body, is situated 3.0 centimeters above the anterior extremity of the first rib.

The *pleural limits* are those situations in which the three chief portions of the parietal pleura become continuous with each other. In addition to the dome of the pleura, containing the apex of the lung, the anterior and the inferior limits of the pleura are of importance in medical examination. The anterior pleural limit is at the deepest portion of the costo-mediastinal sinus and corresponds to the situation in which the costal pleura is reflected posteriorly behind the sternum to become the mediastinal pleura. The inferior pleural limit is at the lowest portion of the costo-phrenic sinus. As the lung almost completely fills the pleural cavity, the pleural limits during inspiration practically coincide with the anterior and inferior pulmonary margins. Inferiorly the pleural cavity extends almost to the origins of the diaphragm. In figures 45 and 46 the pleural limits are indicated by red lines. Upon the right side the pleural limit commences anteriorly at the middle of the sternoclavicular articulation, runs toward the median line, which it follows downward to the sixth rib, passes outward along the lower border of the sixth rib, crosses the seventh rib in the mammary line, reaches the lower border of the ninth rib in the axillary line and the eleventh rib in the scapular line, and strikes the twelfth rib at the vertebral column. [The relations of the pleura to the twelfth rib are of importance to the surgeon especially in connection with operations on the kidney. When this rib is not abnormally short, the pleural reflection crosses it opposite the outer border of the erector spinæ muscle, hence an incision may be carried deeply as far as the angle formed by the twelfth rib and the outer border of the erector spinæ without entering the pleura. When, however, the twelfth rib does not reach the outer border of the erector spinæ, an incision carried upward into the apex of the angle between this muscle and the eleventh rib is almost certain to wound the pleura. Internal to the outer edge of the erector spinæ the pleural reflection lies below the level of the twelfth rib and not infrequently descends as far as the transverse process of the first lumbar vertebra.—Cunningham's "Text-book of Anatomy."] Upon the left side the pleural limit extends anteriorly almost to the median line, and passes outward at the level of the fourth rib, so that at the seventh costal cartilage it is about five centimeters distant from the anterior median line in the horizontal direction. The left pleural limit then follows about the same course as upon the right side, but extends a trifle lower in the axillary line. The importance of these relations will be referred to in the description of the pericardium. The pleural limits vary, to a certain extent, in different individuals. When one lung is diseased, it is frequently observed that the pleural sac containing the healthy lung extends beyond the normal limits as a result of the vicarious employment of this lung (Fig. 50).

The lowest portion of the costo-phrenic sinus is not completely filled by the lung, even in deep inspiration. As a matter of fact, the diaphragm is in contact with the inner thoracic wall in this region during quiet respiration. When there is an abnormal collection of fluid in the pleural cavity, the diaphragm may be pressed downward and away from the thoracic wall; if the fluid is removed by tapping (thoracocentesis), however, the diaphragm rises again and comes in contact with the thoracic wall as before. In this manner the puncture may become occluded and hinder the withdrawal of the fluid. It consequently follows that, as a general rule, the operation should not be employed below the sixth intercostal space in the posterior axillary line. In the back the puncture may be made as low down as the ninth intercostal space. The absorp-



FIG. 47.—The median surface of the right lung. From plaster cast (His).

FIG. 48.—The median surface of the left lung. From plaster cast (His).

tion of inflammatory exudates is made possible by the great number of lymphatic vessels in the pleura. The remains of such exudates are frequently found at postmortems as opacities and thickenings of the pleura as well as in the form of cicatricial and firm adhesions between the parietal pleura and the surface of the lung. In such cases the lung is said to be adherent.

The topographic relations of the pleural cavities and of the lungs to the abdominal organs situated immediately beneath the diaphragm are of great importance. These relations are described upon pages 128-133, 138, and 139.

**The Lungs.**—The apex of the lung fills the dome of the pleura and consequently extends above the superior aperture of the thorax (Fig. 45, Plates 11 and 13); the concave base rests upon the diaphragm. The costal surface of the lung lies against the inner surfaces of the ribs and of the intercostal spaces (*i. e.*, against the costal pleura); the diaphragmatic surface or base is in contact with the diaphragmatic pleura. The third or mediastinal surface forms the boundary of the mediastinum and is hollowed out to accommodate the heart. The anterior sharp margin is lodged in the costo-mediastinal sinus; the inferior margin, which is also sharp, is directed toward the costo-phrenic sinus. The posterior convex margin is surrounded in the region of the angles of the ribs by the pulmonary sulci of the thorax (Figs. 50 and 53). At the root of the lung (hilus pulmonis) upon the mediastinal surface, the arteries of the bronchi enter, and the veins leave the viscus (Figs. 47 and 48).

Each lung is divided into two lobes by a deep fissure (*incisura interlobaris*) which pursues an almost symmetrical course upon the two sides. It passes upward and backward from the hilus, runs forward over the costal surface to the lower pulmonary margin, crosses the base anteriorly, and ascends to the hilus along the mediastinal surface. In the left lung this fissure separates the upper from the lower lobe. In the right lung the fissure runs more directly downward than upon the left side. While the fissure strikes the lower margin of the left lung about a fingerbreadth to the outer side of its anterior extremity, it reaches the lower margin of the right lung about a handbreadth to the outer side of the corresponding point. In the right lung there is a second fissure, which runs from the hilus over the mediastinal surface, crosses the anterior border of the lung, and passes horizontally along the costal surface to join the *incisura interlobaris*. It forms the upper boundary of the small middle lobe, which is present only upon the right side and varies greatly in its development. In the anterior border of the left lung there is a notch (*incisura cardiaca*) the concavity of which is directed toward the median line. In the hilus the branches of the pulmonary artery are the highest structures; below these are the bronchi, with the exception of the eparterial bronchus to the right superior lobe, which is situated higher up. The veins are partly below and partly in front of the bronchi (Figs. 47 and 48).

If the lungs are hardened *in situ* and the neighboring vessels are well injected, the following grooves may also be noted: the grooves for the superior vena cava and for the vena azygos major upon the right lung; the grooves for the left subclavian artery, for the arch of the aorta, and for the descending aorta upon the left lung.

The *respiratory changes* in the position of the lung are most distinctly manifested at the



Fig. 47.

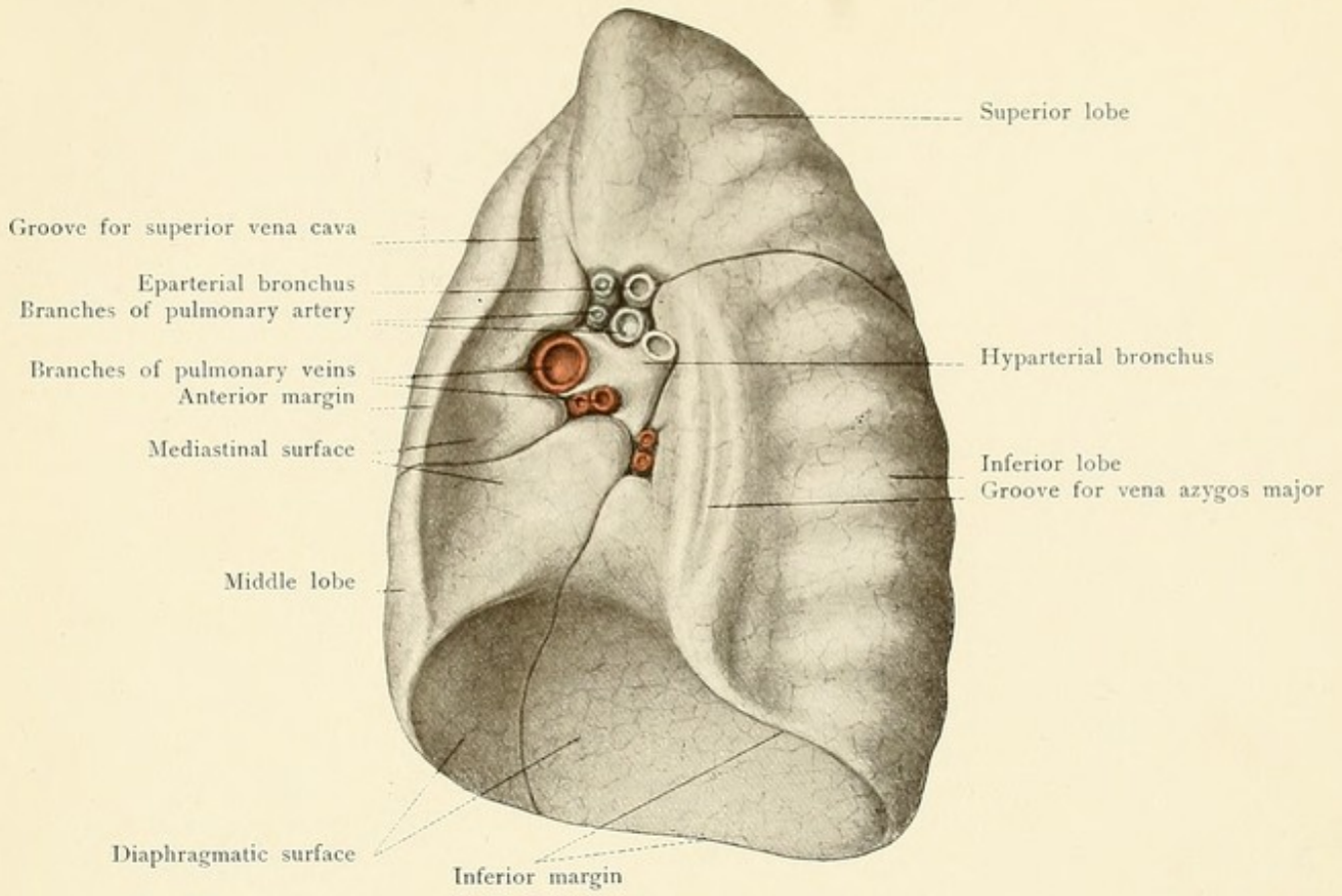
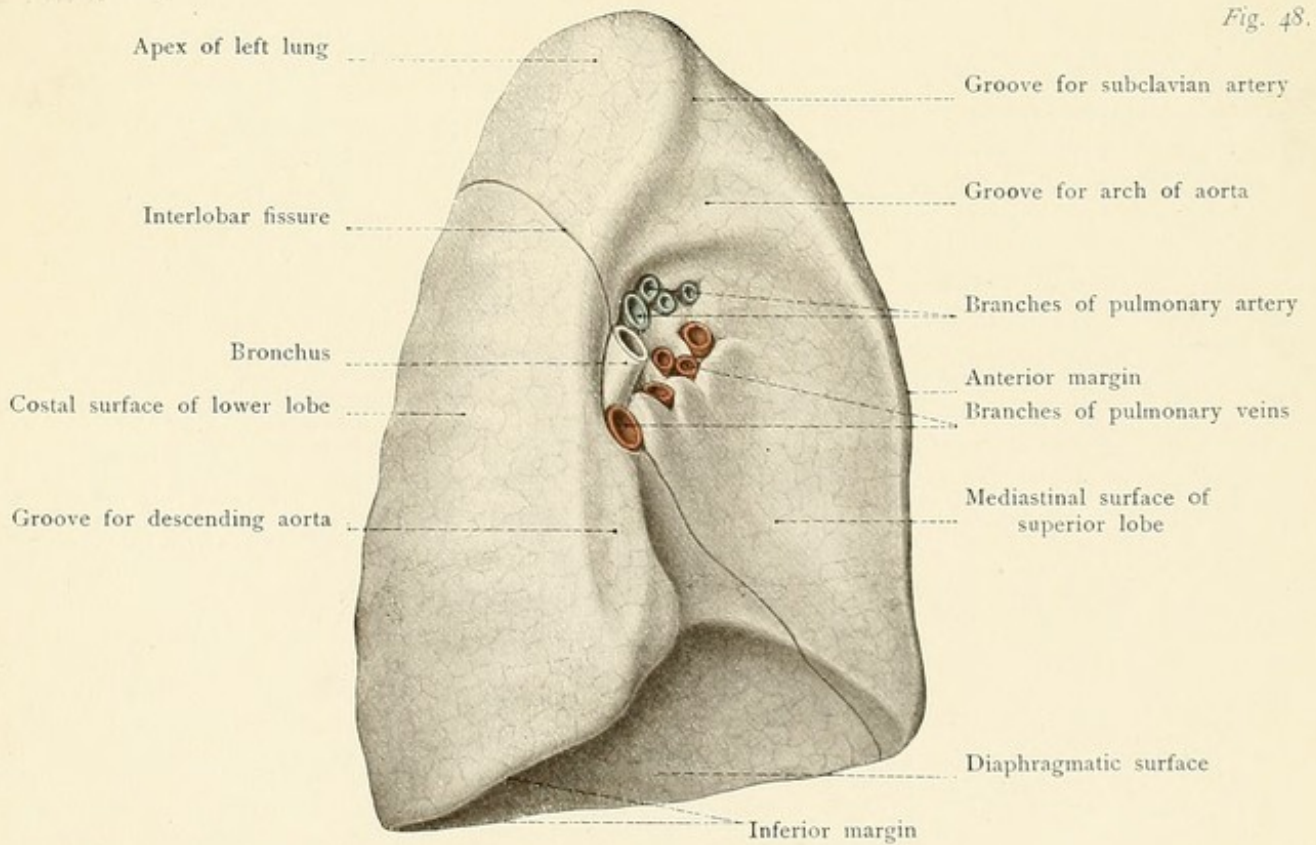


Fig. 48.









anterior and inferior pulmonary margins. The movement of the anterior margin is due to the anteroposterior expansion of the lung (costal breathing); the inferior margin moves on account of the vertical expansion of the lung (diaphragmatic breathing).

During expiration the anterior margin of the right lung extends from the attachment of the second costal cartilage along the right sternal margin to the lower border of the fifth rib. The inferior margin is situated in the mammary line at the sixth rib, crosses the seventh rib in the axillary line and the ninth rib in the scapular line, and reaches the vertebral column at the level of the spinous process of the tenth dorsal vertebra. The anterior border of the left lung runs from the attachment of the second rib to the upper border of the fourth rib somewhat external to the left sternal margin. From the fourth intercostal space it deviates outward, forming the cardiac notch (*incisura cardiaca*), approaches nearer to the sternum in the fifth intercostal space, and becomes continuous with the inferior pulmonary margin at the sixth chondrocostal articulation. From this point the inferior pulmonary margin passes outward and backward as upon the right, but at a slightly lower level, although this is of no clinical importance. During deep inspiration the anterior margins of the lungs correspond to the pleural limits. The right lung consequently extends somewhat beyond the median line, while the left one barely reaches it. This is the situation in which the two lungs are in closest proximity, being separated only by a very narrow portion of the mediastinum. The inferior margin runs obliquely outward and downward from the sternal line at the lower border of the sixth rib. In the mammary line it is at the level of the upper border of the seventh rib, crosses the eighth rib in the axillary line and the tenth rib in the scapular line, and reaches the vertebral column at the level of the spinous process of the eleventh dorsal vertebra. [The lungs in the midaxillary line are probably a little lower than here stated, reaching the eighth rib in expiration, the ninth in inspiration.—ED.] The posterior boundary between the superior and inferior lobes (*incisura interlobaris*) is indicated upon both sides of the chest by the *interscapular line*, which is drawn between the two inner extremities of the scapular spines with the arms hanging vertically downward. This line also indicates the level of the hilus. The lungs cannot be percussed posteriorly for a handbreadth to either side of the vertebral column, since the long muscles of the back, situated in the dorsal grooves of the thorax, hinder the transmission of auscultatory phenomena. Upon the left side the lateral boundary between the upper and the lower lobe is furnished by the fifth or the sixth rib; anteriorly, along the left sternal margin, only the upper lobe is present. Upon the right side the middle lobe is situated anteriorly and anterolaterally below the fourth rib. Even during deep inspiration the anterior margin of the left lung does not completely fill the costo-mediastinal sinus in the region of the cardiac notch. The middle and the inferior lobes rest upon the diaphragm upon the right side; upon the left side only the inferior lobe is in relation with the diaphragm.

If the diaphragm is pushed upward by tympanites, by ascites, or by abdominal tumors, the inferior pulmonary margin will be found at a higher level than usual. When the volume of the lung becomes greatly increased, as in emphysema, the inferior pulmonary margin extends downward beyond the normal limit. It should also be mentioned that the inferior margin of the lung is more easily determined by percussion upon the right side, since the pulmonary resonance passes directly into the hepatic dulness, while upon the left side the stomach cannot always be differentiated from the lung by typical differences in the percussion-note.



## PLATE 8.

a, A dissection of the mediastinum seen from the left; almost the entire left half of the thorax has been removed and the left lung has been cut away at its root. b, The mediastinum seen from the right. Formalin preparations from a child.

## THE MEDIASTINUM.

After the removal of the lateral thoracic walls and of the lungs, the mediastinum is exposed from both sides (see Plate 8). Upon the cut surfaces of the roots of the lungs may be seen the divided bronchi, pulmonary arteries, and pulmonary veins, which pass from the mediastinum into the lungs.

The contents of the mediastinum are most numerous where the two pleural sacs are most widely separated in the median line. This is the case behind the sternum, where the heart is situated within the *pericardium* between the two layers of mediastinal pleura. If the anterior thoracic wall is also removed by dividing the sternal attachments of the mediastinum, and if the two layers of mediastinal pleura are slightly reflected backward, the pericardium may be easily exposed. If the pericardium be opened and the heart excised it will at once be appreciated that the two pleural cavities and the lungs, together with the pericardium and heart, occupy almost the entire thoracic space. In addition to the heart and the pericardium the contents of the mediastinum include: the remains of the *thymus gland*, a large portion of the *trachea* with its bifurcation, many large and small vessels and nerves, the *esophagus*, lymphatic vessels including the *thoracic duct*, and many important *lymphatic glands*. These structures are bound together by a loose connective tissue which becomes directly continuous with the loose connective tissue of the neck and furnishes a path along which inflammations (suppurations, abscesses) may easily extend from the neck into the mediastinum through the superior aperture of the thorax.

The chief contents of the mediastinum may be seen through the mediastinal pleura after the removal of the lungs, if the membrane retains its normal transparency and has not become opaque and thickened by inflammation. The contents become still more distinct if the two mediastinal layers are removed.

Upon the *right side* may be seen: portions of the heart through the pericardium (during childhood, at least), the superior vena cava, the phrenic nerve (upon the superior vena cava and running upon the pericardium to the diaphragm), the *comes nervi phrenici*, the vena azygos major and its termination in the superior vena cava, the right intercostal vessels, the esophagus, the vagus nerve, the right sympathetic and splanchnic nerves, and the lymphatic glands at the root of the lung.

Upon the *left side* the visible structures are: the heart with the left phrenic nerve, the *comes nervi phrenici*, the descending aorta, the left subclavian artery, the left internal mammary artery, the left innominate vein\* receiving the termination of the vena azygos minor,† the vagus nerve, the left sympathetic nerve, the left intercostal vessels, and numerous lymphatic glands.

In children the thymus gland may be seen from either side; it is situated in front of and above the heart.

\* Erroneously designated as V. Cava sup. in the plate.

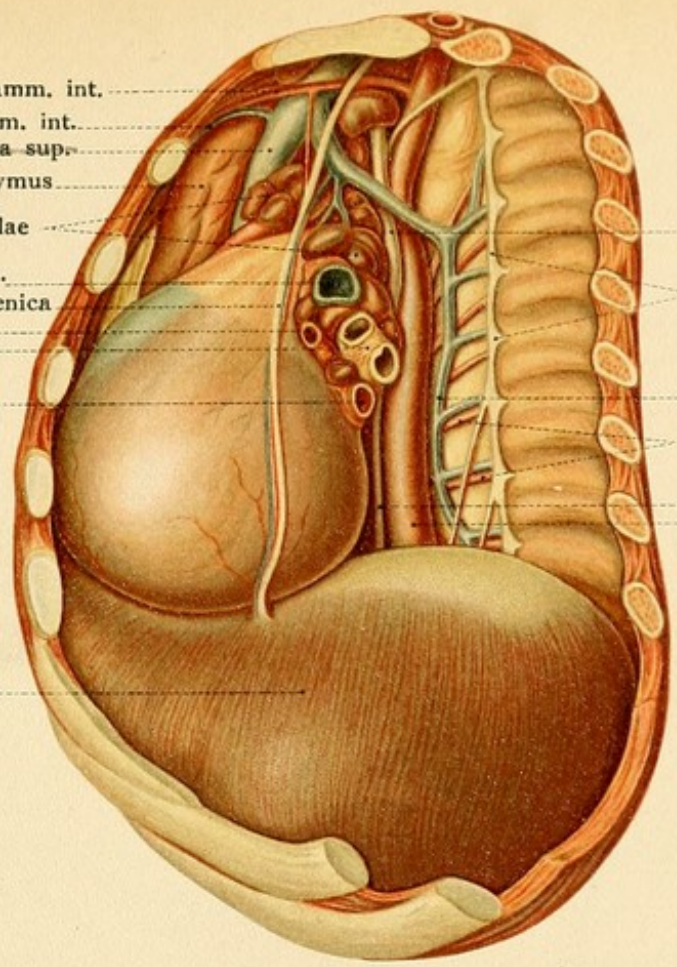
† In Plate 8, a, the vena azygos minor (vena hemiazygos) joins a very large superior intercostal vein (see page 117).



*left*

*left movement*

A. mamm. int.  
V. mamm. int.  
V. cava sup.  
Thymus  
Lymphoglandulae  
A. pulmonalis sin.  
N. phrenicus et Vasa pericardiacophrenica  
V. pulm. sup. sin.  
Bronchi  
V. pulm. inf. sin.

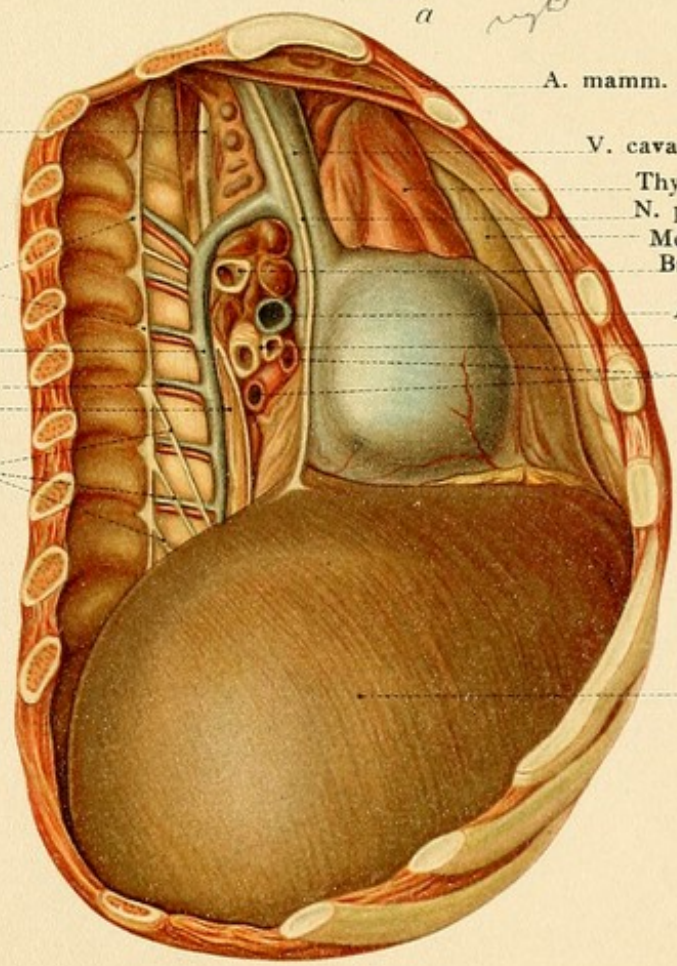


N. vagus  
N. sympathicus  
V. hemiazygos  
Aa. intercostales  
Oesophagus  
Aorta descendens

Diaphragma

*a right*

N. vagus  
N. sympathicus  
V. azygos  
Vasa intercostalia  
Oesophagus  
Nn. splanchnici



A. mamm. int.  
V. cava sup.  
Thymus  
N. phrenicus dex.  
Mediastinum  
Bronchus eparterialis  
A. pulm. dex.  
Bronchi hyparteriales  
Vv. pulmonales dex.

Diaphragma

*b*







Our chief interest in the mediastinum is naturally directed toward the heart, the methodical examination of which in the living by percussion and auscultation is one of the most brilliant and permanent results of the medical art.

The study of the position of the heart should be preceded by a thorough study of the structure of the organ.

**The Position of the Heart.**—For our purpose I will designate as the *cardiac axis* a line drawn from the apex of the heart to the root of the aorta. Take an ordinary pointed lead-pencil in the hand and assume that it represents the cardiac axis. Hold this "axis" vertically over

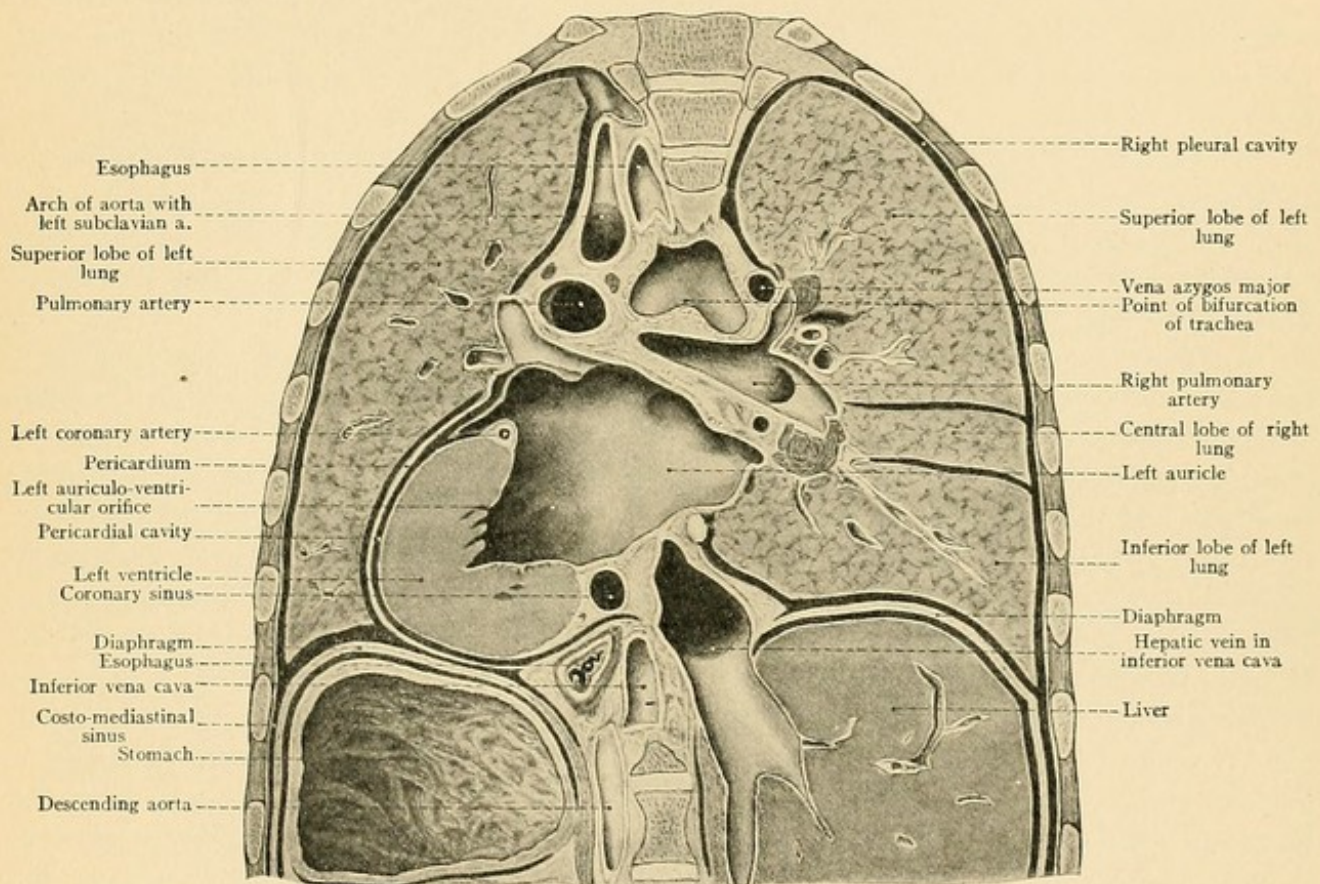


FIG. 49.—A view of the dorsal surface of a frontal section of the thorax.

the middle of the sternum with the apex downward, under the supposition that the right (venous) heart is in the right half and the left (arterial) heart is in the left half of the body, and that the intermediate septum is exactly in the median line. Now consider the four following points and carry out the movements of the axis with the lead-pencil.

1. The axis is not placed vertically, but obliquely, so that the apex (point of lead-pencil) is directed to the left and the base (blunt end of lead-pencil) to the right.

2. The axis, and consequently the entire heart, is pushed to the left, so that the median plane of the body does not correspond to the median plane of the heart, but passes through this



## PLATE 9.

An anterior view of the heart; the parietal pericardium has been incised and reflected. (Formalin preparation.)

---

organ in such a manner that two-thirds of the heart are upon the left side of the body and one-third is upon the right.

3. The apex of the heart touches the inner surface of the anterior thoracic wall and the base approaches the vertebral column. The anterior surface of the heart is consequently also directed upward and the posterior surface rests upon the diaphragm.

Clearly note that after these three deviations of the cardiac axis from the position originally assumed, the cardiac septum is still at right angles (but not in the sagittal plane) to the front-plane of the body, and that equal portions of the right and left sides of the heart would be visible from in front.

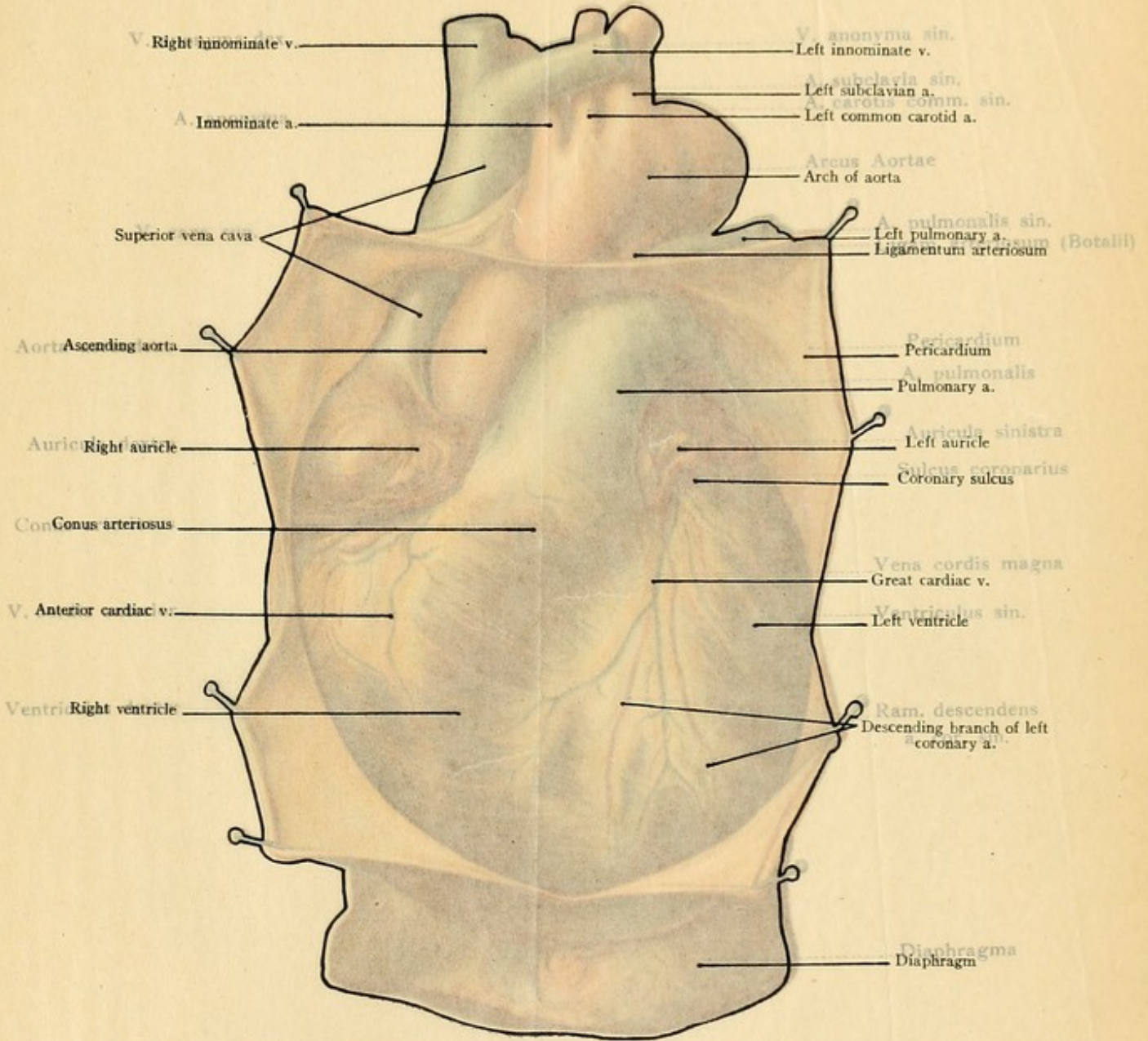
4. The heart is now rotated upon its axis in such a manner that the greater portion of the right heart is directed anteriorly (and superiorly) while the greater portion of the left heart is situated posteriorly (and inferiorly). As a result of this rotation the cardiac septum is no longer at right angles to the frontal plane, but lies more nearly in the frontal plane itself, as is best shown in frozen sections (Fig. 50).

It follows that the auricles at the base of the heart are situated superiorly and nearer to the dorsal surface, while the ventricles are nearer to the thoracic wall. Injuries of the ventricles are consequently comparatively more frequent than injuries of the auricles. As a further consequence of the position of the heart, a horizontal penetrating wound may enter the ventricle anteriorly and the auricle posteriorly. Since the ventricles are in contact with the inner surface of the thoracic wall, their pulsations may be felt in the epigastrium (beneath the xiphoid process), when there is marked cardiac hypertrophy. The right ventricle is the most anterior portion of the heart, the right auricle is directed toward the right, the left ventricle toward the left, and the left auricle is quite posterior (Fig. 50). In looking at the heart from in front, the following structures are visible (Plates 9 and 16): the right ventricle with the origin of the pulmonary artery (*comes arteriosus*), a narrow zone of the left ventricle, the anterior extremity of the left auricular appendix, a goodly portion of the right auricle, and the right auricular appendix. Each auricular appendix is situated over the arterial trunk originating from the opposite ventricle.

In examining an excised heart the various structures may be best located by looking first at the anterior surface of the viscus.

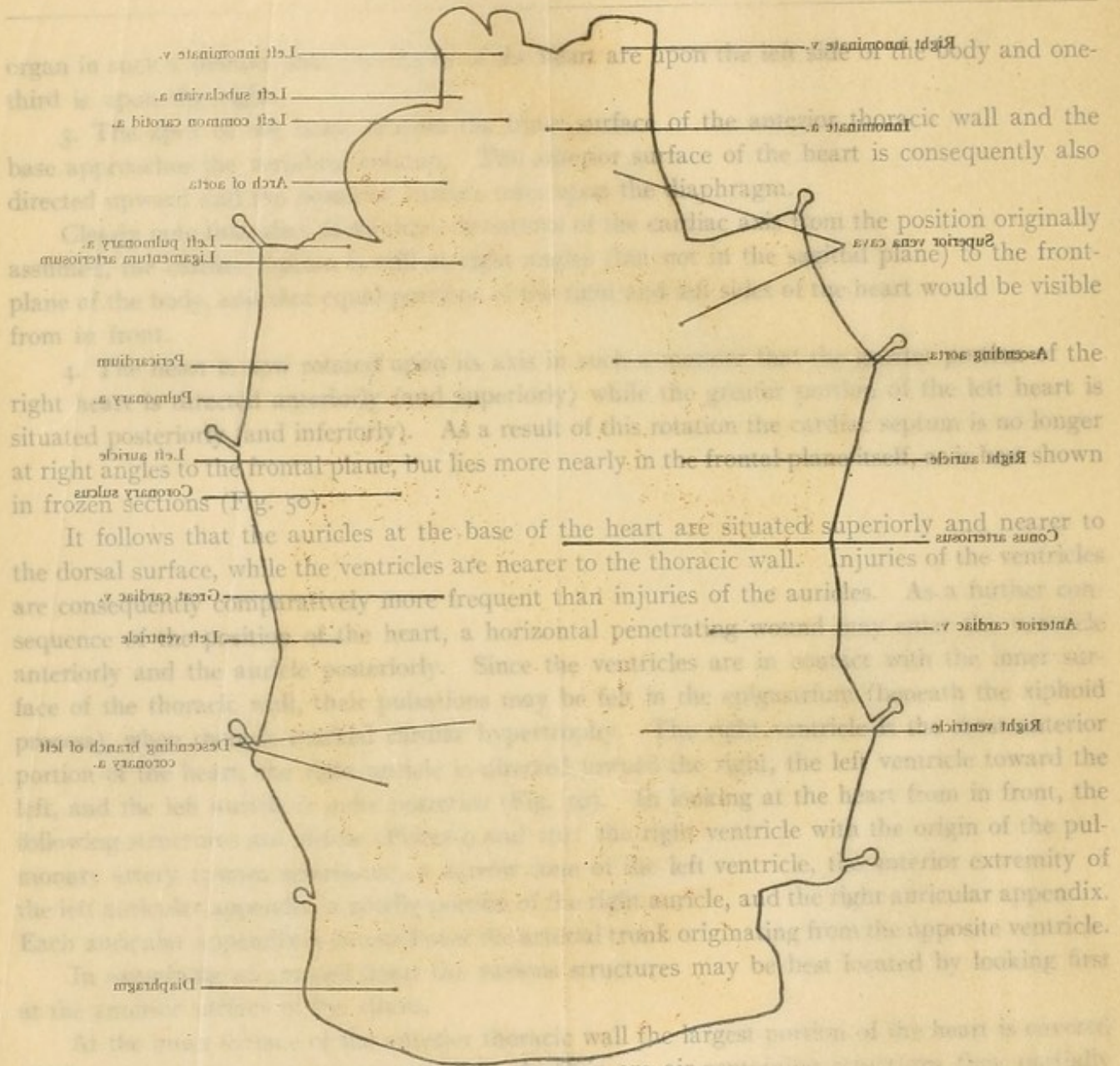
At the inner surface of the anterior thoracic wall the largest portion of the heart is covered by the two anterior pulmonary margins. As they are air-containing structures they partially mask the dull note obtained by percussion over this portion of the cardiac area (deep cardiac dulness). A small portion of the heart lies directly against the inner surface of the thoracic wall and is not covered by pulmonary tissue; over this area the trained ear recognizes the so-called *absolute cardiac dulness* upon percussion. It is clear that this area must be diminished when the lungs are distended (by emphysema, for example), and that it will be increased when the edges of the lungs are drawn or pushed to one side (by a hypertrophied heart, for example) (see Fig. 50). It is consequently important for the physician to be acquainted with the normal







9 An anterior view of the heart after the pericardium has been incised and reflected. (Formalin preparation.)



It follows that the auricles at the base of the heart are situated superiorly and nearer to the dorsal surface, while the ventricles are nearer to the thoracic wall. Injuries of the ventricles are consequently comparatively more frequent than injuries of the auricles. As a further consequence of the position of the heart, a horizontal penetrating wound would pass anteriorly and the angle posteriorly. Since the ventricles are in contact with the inner surface of the thoracic wall, their pulsations may be felt by palpation in the intercostal spaces. In looking at the heart in front, the right ventricle with the origin of the pulmonary artery is on the right, the left ventricle toward the left, and the left auricle in front. The right auricle is on the right, the left auricle on the left, and the right auricular appendix. Each auricle has a large ear-shaped appendage, the auricular appendix, which may be best located by looking first at the auricle. The largest portion of the heart is covered by the pericardium, which is a double-layered structure. As they are air-containing structures they partially collapse when the heart is removed from the chest. The pericardium is attached to the thoracic wall by the pulmonary ligament; over this area the chest wall is called *scutum cardiacum*. It is clear that the chest wall is diminished in thickness when the lung is displaced by emphysema, for example, or when the edges of the lungs are drawn or pushed to one side (as a pneumothorax, for example) (see Fig. 50). It is consequently important for the physician to be conversant with the normal











extent of this area of cardiac dulness. The projection of the entire heart upon the anterior thoracic wall is also worthy of note.

The projection of the heart upon the anterior thoracic wall is indicated by the following lines upon the external surface:

1. The *inferior cardiac line* commences in the fifth left intercostal space midway between the mammary and parasternal lines (at the cardiac apex\*), passes obliquely upward to the right, and ends at the lower border of the fifth right costal cartilage, two centimeters from the sternal margin.

2. The *right cardiac line* commences at the termination of the inferior cardiac line, runs directly upward at a distance of two centimeters from the sternal margin, and ends at the upper border of the third right rib.

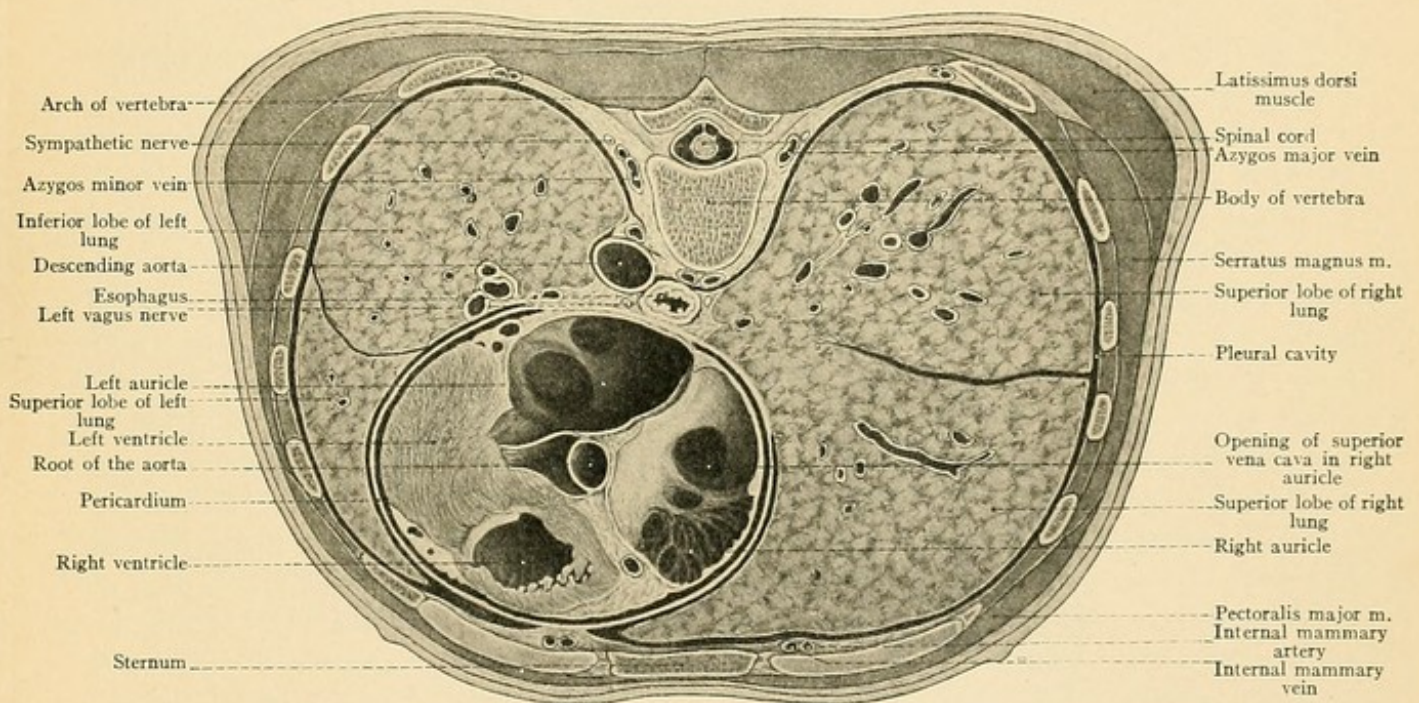


FIG. 50.—A cross-section of the thorax at the level of the nipples. (The right lung is somewhat enlarged at the expense of the left one.)

3. The *superior cardiac line* (not indicating any sharp cardiac boundary) commences at the termination of the right cardiac line and runs to the middle of the second left intercostal space, where it ends at a point three centimeters distant from the sternal margin.

4. The *left cardiac line* commences at the termination of the superior cardiac line and runs downward to the cardiac apex.

The *transverse cardiac line* should also be borne in mind; it commences where the inferior cardiac line crosses the lower border of the sixth right costal cartilage and ends at the point of

\* The cardiac apex, as well as the apex-beat, is higher in children, sometimes being situated in the fourth intercostal space; it is lower in the aged, where it may be found in the sixth intercostal space.



intersection of the left cardiac line with the upper border of the third left rib. The auriculoventricular orifices are situated beneath this line. The area of absolute cardiac dulness (colored black in Fig. 45) is bounded upon the right by a line drawn from the lower border of the sternal attachment of the fourth left costal cartilage along the left sternal margin to the lower border of the seventh left costal cartilage; it is bounded upon the left by a line commencing at the origin of the right boundary and extending to the cardiac apex. The area of absolute cardiac dulness has no sharp inferior limit on account of the neighboring hepatic dulness.

The *auriculoventricular orifices* are situated beneath the transverse cardiac line. The tricuspid orifice is between the insertions of the left fifth and the right sixth rib behind the lower end of the sternum; the mitral orifice is in the upper third of the transverse cardiac line. The pulmonary orifice is covered by the sternal end of the third left costal cartilage; the aortic orifice is posterior to the pulmonary orifice and is behind the sternum at the level of the third intercostal space.

For physical reasons the areas for auscultating these valves do not correspond accurately with the projections of the valves upon the anterior thoracic wall.

**Pericardium.**—The heart does not lie exposed within the mediastinum, but is situated within the pericardium. The pericardium with its contents is placed between the two layers of mediastinal pleura in such a way that it projects more toward the left than toward the right pleural cavity. It will be remembered that the left pleural cavity (and the left lung) is smaller than the right one, and that the mediastinal surface of the left lung is more concave than that of the right lung. That portion of the mediastinal pleura which is reflected over the pericardium is also known as the *pleura pericardiaca*. Together with the pericardium it forms a thin lamella which may be lifted up from the heart, and which is not so thick, at least during childhood, but that the individual portions of the heart may be seen and felt through it. In making an autopsy the pericardial pleura and the pericardium are usually described as “the pericardium.”

The intimate relation of the pericardium and pleura in this situation is of great practical importance, since inflammations of the pericardium may easily extend to the pleura and, upon the other hand, a pleurisy may be followed by a pericarditis. The pleural cavities and the lungs are separated from the pericardial cavity and the heart by only a thin septum. It will therefore be readily understood that diseases of the lung (such as tuberculosis) may extend to the pleura and to the pericardium. The septum may even be perforated, so that pus from the pleural cavity (in pyothorax) or air from an opened pulmonary cavity may enter into the pericardium (pyopericardium, pneumopericardium).

The lower surface of the pericardium is firmly attached to the diaphragm (see page 99).

In the pericardium, as in the pleura, we differentiate a parietal layer (usually called simply “the pericardium”) and a visceral layer. Above the base of the heart the parietal layer is reflected upon the great vessels, so that the superior vena cava, as well as a large portion of the aorta and of the pulmonary artery, are situated within the pericardium and are covered by the visceral layer. The visceral pericardium is as firmly adherent to the heart as is the visceral pleura to the lung. The visceral pericardium in this situation is also known as the epipericardium.

Within the pericardium, the ascending aorta and the pulmonary artery are firmly united by connective tissue and surrounded by a common sheath of visceral pericardium. The index-



finger may consequently be passed behind both of these structures into the *sinus transversus pericardii*, which is bounded anteriorly by the posterior surface of the pulmonary artery and of the aorta, and posteriorly by the anterior wall of the auricles (consisting chiefly of the left auricle). The aorta and the pulmonary artery are the only vessels around which the finger may be passed after the pericardial sac has been opened. None of the other vessels possess a complete covering of visceral pericardium at their cardiac extremities, but they are all more or less distinctly visible

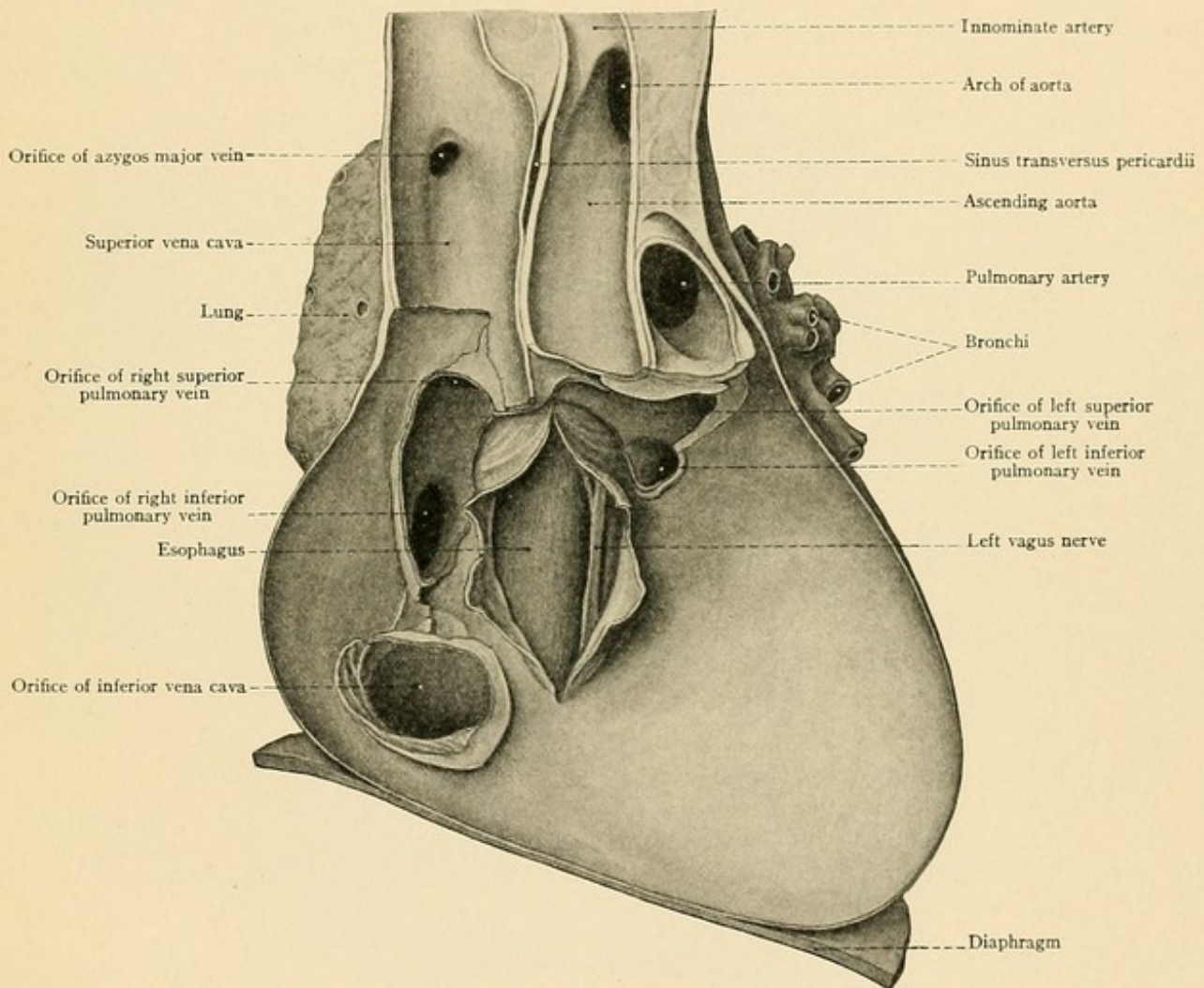


FIG. 51.—The dorsal half of a frontal section of the pericardium with the large vessels. An opening has been made in the posterior wall of the pericardium so that the esophagus is exposed. (Formalin preparation.)

in the pericardium. From in front, the superior vena cava may be seen high up and to the right alongside of the aorta; the inferior vena cava is visible when the heart is pushed upward and to the left; the left pulmonary veins are exposed by holding the heart upward and to the right by means of its apex; the right pulmonary veins are scarcely to be seen because they are covered by the right auricle. By moving the heart about in this manner it will be seen that it is suspended in the pericardial cavity by the great vessels. The removal of the heart may consequently be



accomplished by simply dividing all of the large vessels. When this is done, the posterior wall of the pericardium with the lumina of the blood-vessels is distinctly visible (Fig. 51). The posterior pericardial wall possesses no reflection of mediastinal pleura, but is directly in contact with the loose connective tissue of that portion of the mediastinal space which is situated behind the heart (see Fig. 50). In this location the structure nearest to the heart is the esophagus, which often forms a slight prominence in the pericardial sac, and which may always be palpated through the pericardium in the dead subject and easily exposed (Fig. 51).

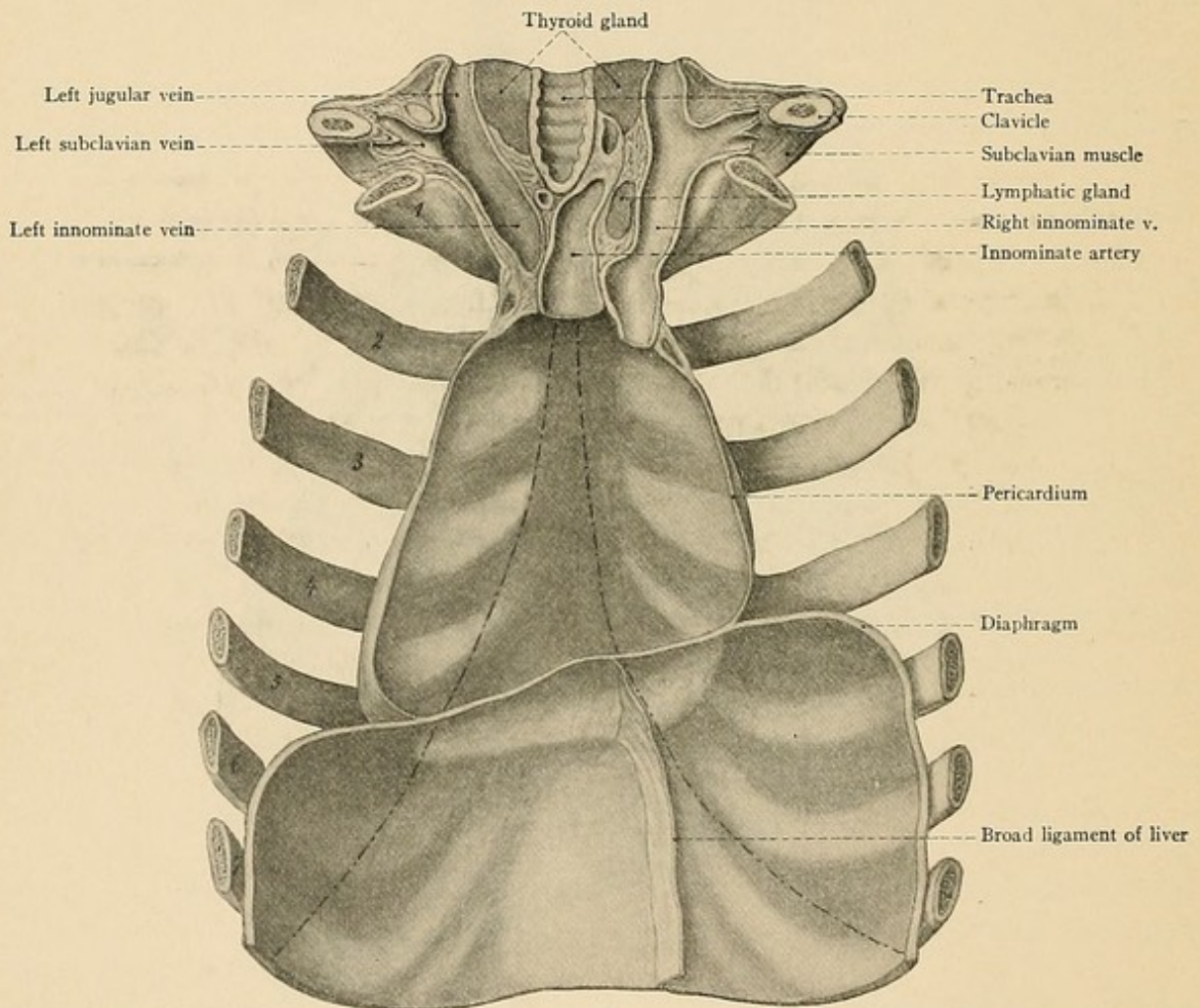


FIG. 52.—The anterior thoracic wall with the pericardium and the diaphragm seen from within. The dashed and dotted lines represent the anterior pleural limits; between them, at the level of the fifth left costal cartilage, is the site for aspiration of the pericardial cavity. (Formalin preparation.)

It is at this point that the deposition of a considerable quantity of pericardial exudate may press upon the esophagus and produce dysphagia. By irritation of the vagus nerve (Fig. 51) pericarditis in this situation may also cause vomiting, hiccough, and paralysis of the vocal cords. This practical and important relation will be referred to again when we discuss the esophagus in detail.



Not less important is the fact that a comparatively small area of the pericardium is in immediate contact anteriorly with the inner surface of the thoracic wall. This place is situated where the two anterior pleural limits diverge close to the left sternal border from the fifth to the seventh costal cartilage. In withdrawing fluid from the pericardial cavity it is best to make the puncture in the fifth intercostal space close to the sternal margin. If the puncture is made further to the left, there is danger of injuring the left pleural sac.

A knowledge of the relation of the pericardium to the thoracic wall is also necessary when it is desired to open retrosternal abscesses or to remove tumors from behind the sternum by a partial resection of this bone, since the pleural and pericardial cavities should not be clumsily nor unnecessarily opened.

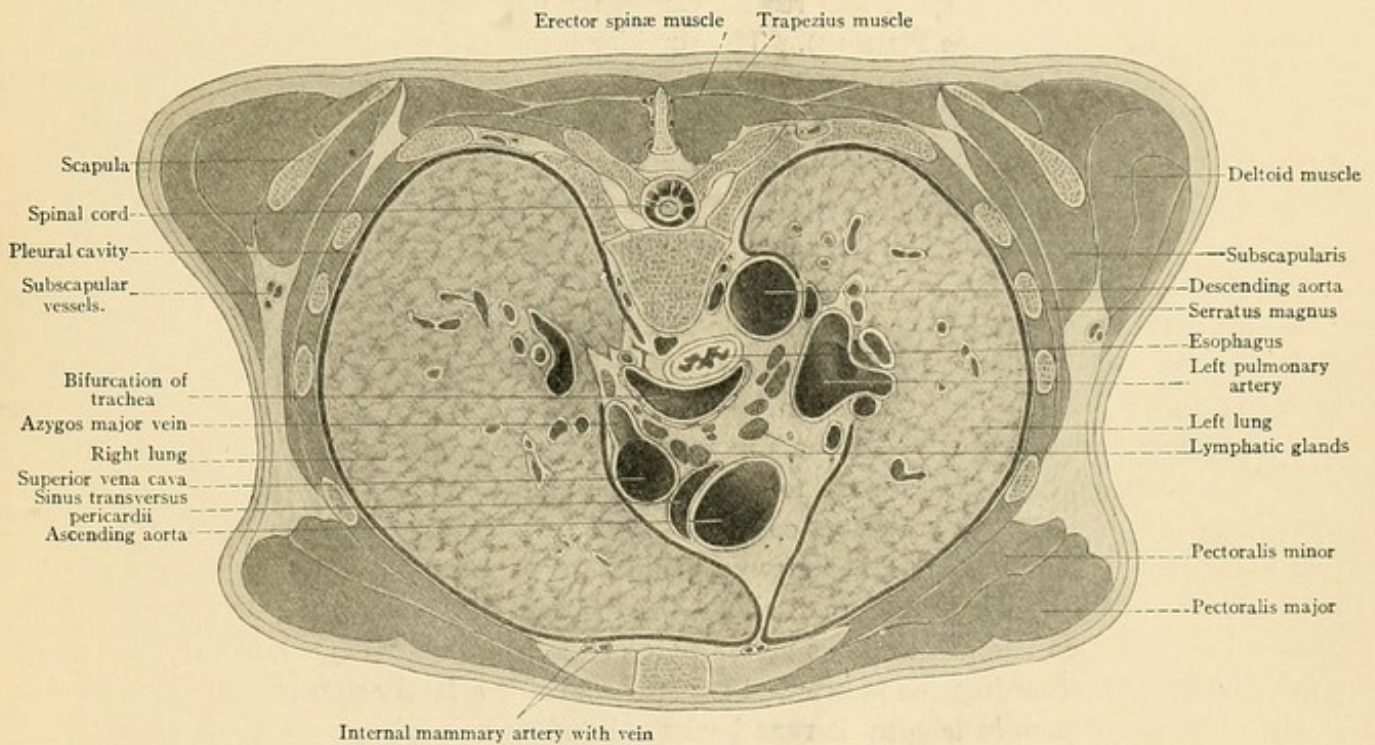


FIG. 53.—A cross-section of the thorax at the level of the tracheal bifurcation (frozen section). The left lung was diseased at its apex and diminished in size as a whole; the right lung was correspondingly enlarged.

Since the mediastinum is not a rigid partition between the two pleural cavities, but rather a movable and elastic septum, as is necessary for costal breathing, it is clear that when a pleural cavity is distended by abnormal contents (pyothorax, pneumothorax) or when one lung requires more space than normally belongs to it, the mediastinum together with the heart will be pushed toward the opposite side. This may be recognized by the physician by the displacement of the cardiac dulness. A left-sided pleural exudate, for example, may push the right border of the normal cardiac dulness far beyond the right margin of the sternum. If the lung becomes contracted, as in cirrhosis, and adherent to the mediastinal pleura, the mediastinum will be drawn toward the same side, and the opposite lung, when healthy, may undergo a compensatory enlarge-



## PLATE 10.

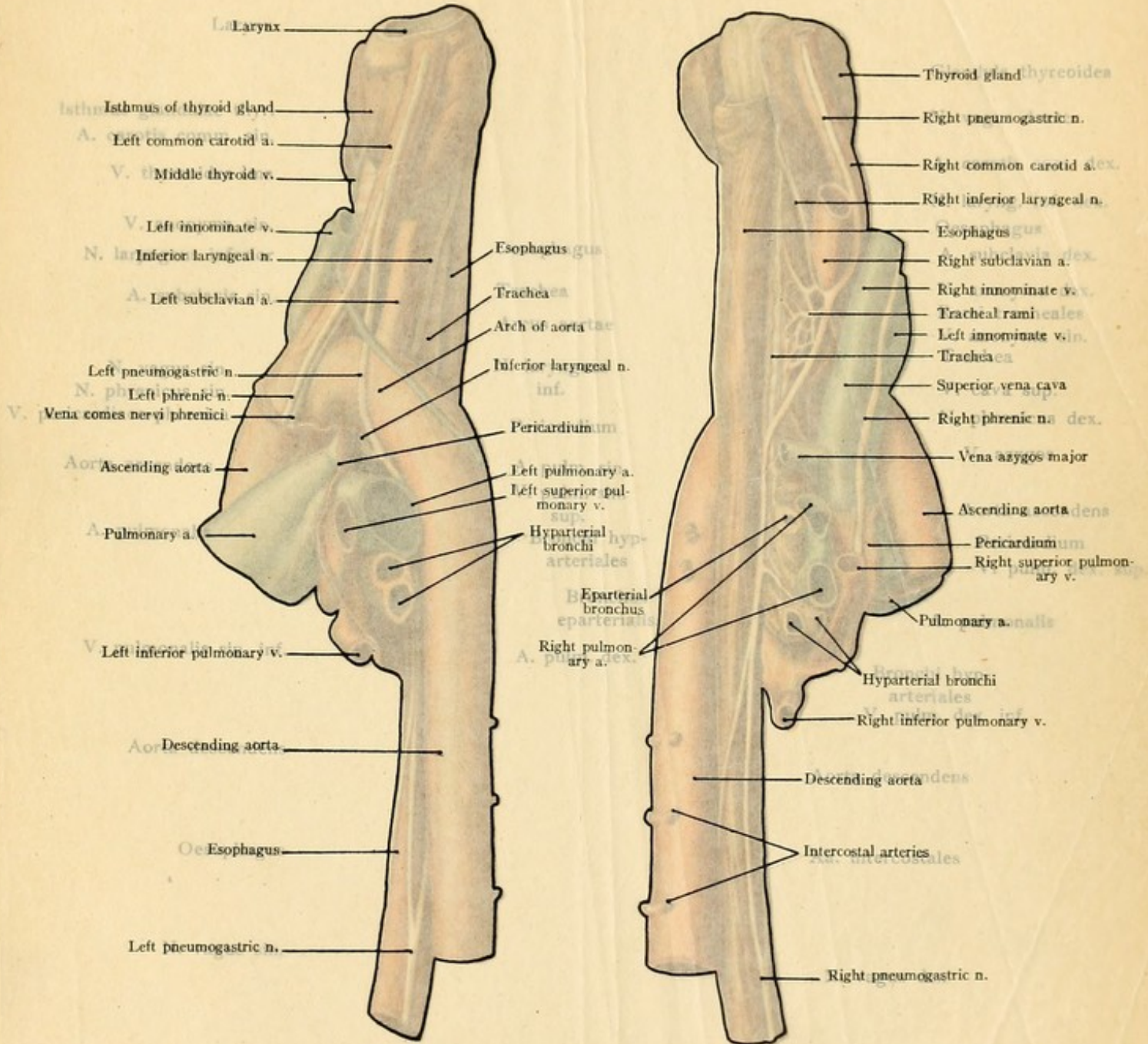
The vessels and nerves of the mediastinum and their relation to the cervical viscera. The first illustration represents the structures as seen from the left, while the second shows them as seen from the right. (Formalin preparation.)

ment. In this manner the cardiac dulness may be displaced to the left beyond the mammary line, by a contraction of the left lung and of its pleural cavity.

**The Thymus Gland.**—Immediately behind the sternum, enclosed between the two layers of the mediastinal pleura and extending upward toward the neck, are found the remains of the thymus gland, which usually have undergone fatty degeneration, but which still retain their original bilobed structure. During childhood the grayish-red gland may be seen glistening beneath the pleura. If the layers of the mediastinal pleura are dissected back, we penetrate further into the mediastinal space and readily expose the superior *vena cava* with the superimposed right *phrenic nerve* (see Plate 10). The superior vena cava produces a deep groove upon the median surface of the right pulmonary apex (see Fig. 47). It arises at the level of the sternal insertion of the first rib upon the right by the junction of the longer left with the shorter right innominate vein, and is easily injured by a penetrating wound close to the right sternal margin. Each *innominate vein* is formed behind the corresponding sterno-clavicular articulation by the union of the internal jugular with the subclavian vein. The left innominate vein does not project above the superior margin of the sternum (see page 68); it receives the middle thyroid veins. The vena azygos major (see page 116, Figs. 49 and 51, and Plates 7 and 8) passes from the vertebral column over the right bronchus to empty into the superior vena cava posteriorly just before this vessel enters the pericardium.

**The Ascending Aorta.**—The ascending aorta is situated within the pericardium to the left of the superior vena cava; still further to the left is the pulmonary artery. To avoid confusing the aorta with the pulmonary artery, a common mistake of the tyro, it should be clearly noted that the commencement of the aorta crosses behind the pulmonary artery, so that the aorta, although arising from the left ventricle, is situated to the right of the pulmonary artery and is the middle vessel of the three great trunks at the base of the heart. Aneurysms of the ascending aorta frequently rupture into the pericardial cavity, producing a fatal hemorrhage. This vessel is about six centimeters in length; it runs backward and downward toward the left and then forward, upward, and to the right [by English authors the ascending aorta is described as running forward, upward, and to the right—ED.], so that it gradually approaches the inner surface of the thoracic wall. The origin of the aorta is at the level of the upper border of the sternal attachment of the third left costal cartilage, six centimeters behind the sternum; at the level of the first intercostal space it is, however, only two centimeters behind the sternum [*i. e.*, behind the right margin of the sternum—ED.]. The right convex border of the aorta extends to the right sternal margin. It is in this situation that aneurysms of the ascending aorta are particularly prone to press forward the anterior thoracic wall and rupture externally; they may also occasionally perforate into the right pleural cavity. Such an aneurysm may press upon the superior vena cava on the right and cause symptoms of venous stasis in the region drained by this great trunk; it may press upon the pulmonary artery on the left and lead to a hypertrophy of the right ventricle (Plate 9). Rupture into both of these vessels has also been observed. The most im-

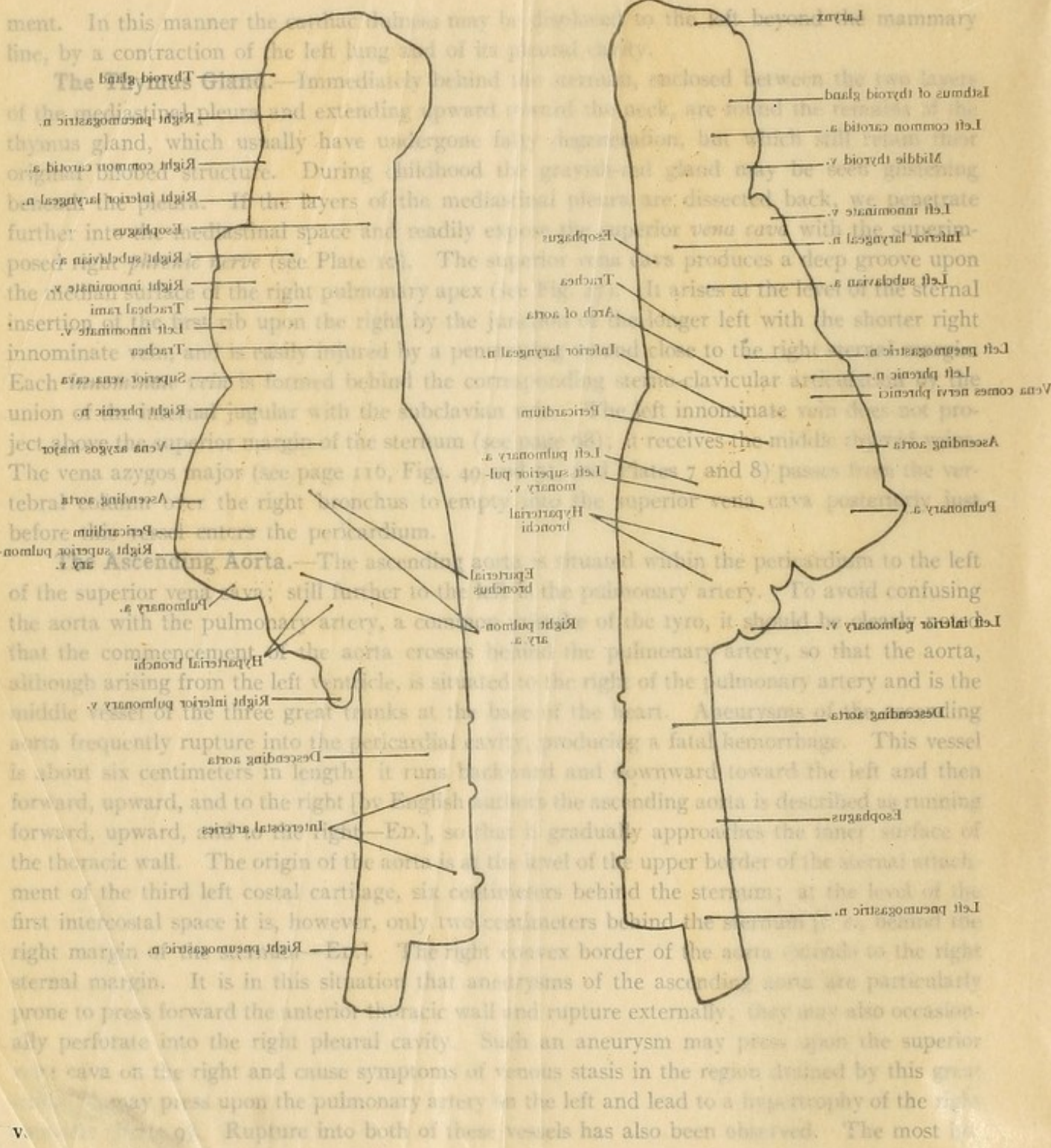




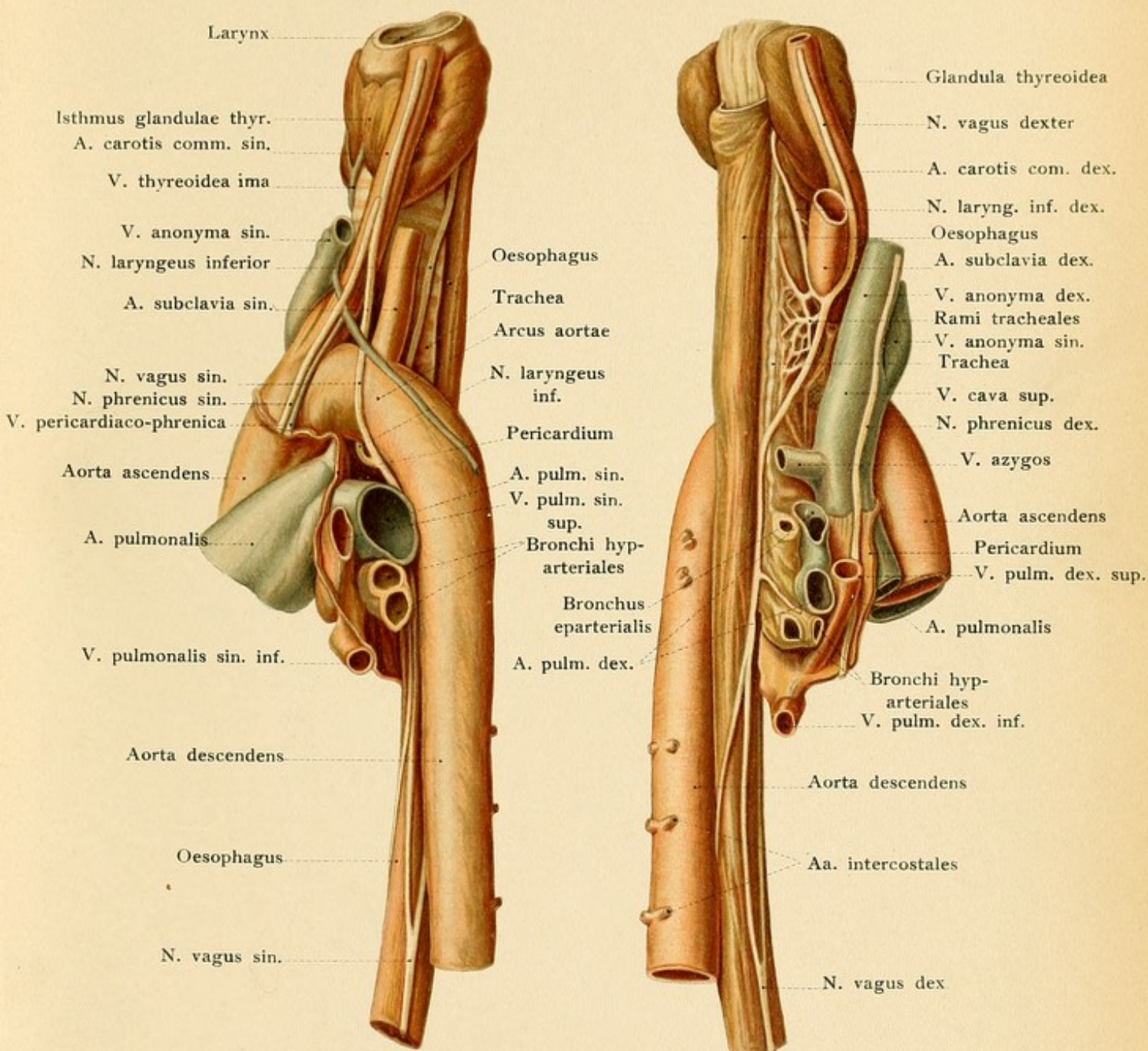


The vessels and nerves of the mediastinum and their relations to the cervical viscera. The first illustration represents the structures as seen from the left, while the second shows them as seen from the right. (Formalin preparation.)

10













portant branches of the ascending aorta are the *coronary arteries*, which arise from the right and left aortic sinuses (sinuses of Valsalva). The right coronary artery runs backward in the right coronary groove (between the auricle and ventricle), and then downward in the posterior interventricular groove to the cardiac apex. The left coronary artery immediately divides into an anterior branch, which passes downward in the anterior interventricular groove, and a transverse branch which runs in the left coronary groove.

**The Arch of the Aorta.**—The arch of the aorta commences at the origin of the innominate artery and extends to the left side of the body of the third or fourth dorsal vertebra, where it becomes the descending aorta. It runs over the root of the left lung in an approximately sagittal direction (Fig. 53) and, in contrast to the ascending aorta, continually becomes more distant from the anterior thoracic wall. The left innominate vein lies in front of the upper convex margin of the aortic arch and passes obliquely downward and to the right in front of the origins of the three main branches of the aorta,—the innominate, the left common carotid, and the left subclavian arteries. The aortic arch does not extend upward beyond the sternal attachment of the first rib; its highest point is situated at about the level of the center of the manubrium. From the course of the aortic arch it follows that the innominate artery is nearest to the anterior thoracic wall, the left common carotid is further removed, and the left subclavian is the most distant of the three vessels. The left subclavian artery projects into the upper portion of the dome of the pleura and produces the *subclavian groove* upon the apex of the left lung (see page 102 and Fig. 48). The *left inferior laryngeal nerve*, a branch of the left pneumogastric, passes backward and upward around the aortic arch (see page 68 and Plate 10). It is the motor nerve of the larynx, and is often compressed by aortic aneurysms, producing one of the first symptoms of this affection—a paralysis of the left vocal cord. Aneurysms of the aortic arch may produce: venous stasis of the head, of the neck, and of the left upper extremity by pressing upon the left innominate vein or its tributaries (Plate 9); deficient ventilation of the lungs (dyspnea) by pressure upon the trachea, or only of the left lung by pressure upon the left bronchus and the left pulmonary artery; paralysis of the left vocal cord by pressure upon the left inferior laryngeal nerve, the motor nerve of the muscles of the interior of the larynx; and dysphagia, from pressure upon the left pneumogastric nerve and upon the esophagus. Such aneurysms may rupture (Plate 7) into the trachea and left bronchus (hemoptysis) or, if the aneurysm is situated posteriorly, into the esophagus (hematemesis). The comprehension of all the preceding possibilities will be facilitated by a careful study of Plate 10.

**The Thoracic Descending Aorta.**—The thoracic descending aorta extends from the left side of the body of the third or fourth dorsal vertebra to the aortic opening in the diaphragm, in which situation it has usually reached the median line. After the removal or displacement of the left lung the aorta may consequently be seen through the mediastinal pleura at the left side of the vertebral column (Plates 8, a, and 17). The esophagus is at first upon the right side and then in front of the vessel (Fig. 54) with which it is united by loose connective tissue. The intercostal arteries arise from the posterior surface of the aorta (see page 96); there are nine pairs for the lower nine intercostal spaces and one pair for the lower border of the twelfth rib. In addition to these vessels, there are many small visceral branches which are not particularly



FIG. 54.—The pharynx, esophagus, trachea, and aorta seen from behind.

important from an operative standpoint; these are the bronchial, the esophageal, the pericardiac, the mediastinal, and the diaphragmatic.

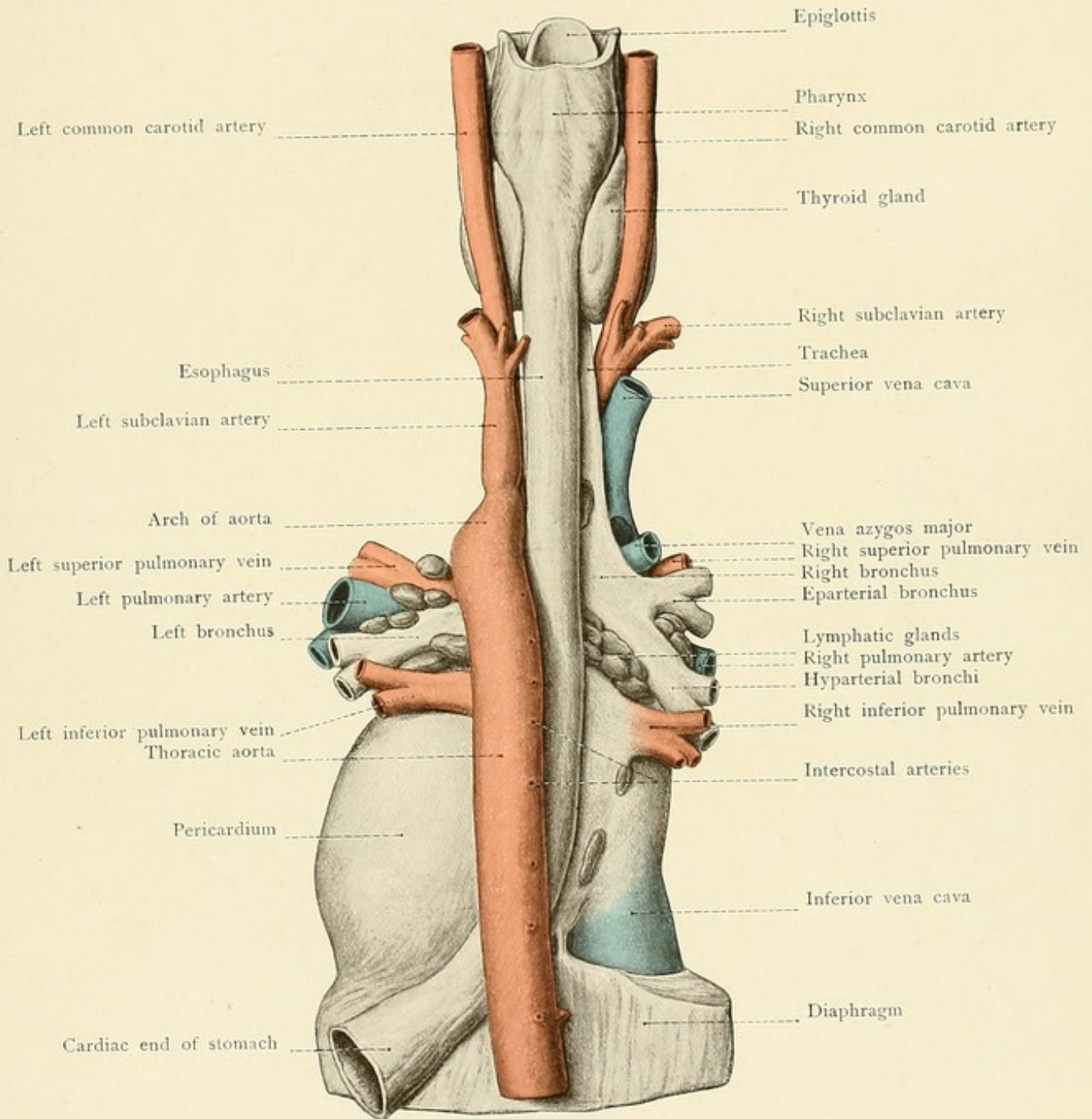
Large aneurysms of the descending aorta occasionally erode the vertebrae and adjacent ribs and appear in the back alongside of the vertebral column, where they may simulate abscesses. In such cases disagreeable symptoms are produced by pressure upon the intercostal nerves and upon the spinal cord.

**The Pulmonary Artery.**—The pulmonary artery is united with the ascending aorta by connective tissue (see page 108) and is situated almost entirely within the pericardium. The ascending aorta is upon the right side of the vessel. The pulmonary artery extends from the sternal insertion of the third left costal cartilage to that of the second, and is consequently most easily reached through the second left intercostal space. The vessel, at its origin, is only two centimeters distant from the anterior thoracic wall; it runs backward, upward, and somewhat toward the left and, after a course of about five centimeters, divides outside of the pericardium into a right and a left branch. From the bifurcation, or from the commencement of the left branch, the *ligamentum arteriosum* passes to the concavity of the aortic arch. This structure is the remains of the fetal ductus Botalli, which may remain patulous in rare cases. The right branch of the pulmonary artery runs transversely behind the ascending aorta and the superior vena cava to the hilus of the right lung; the left branch is shorter and passes in front of the descending aorta to the left lung.

The *pulmonary veins* (double on both sides) are designated as superior and inferior, the superior vein lying also more anteriorly and the inferior vein more posteriorly. The right superior pulmonary vein is situated behind the termination of the superior vena cava in the right auricle; behind this vein are the right pulmonary artery and the right bronchus. The right inferior pulmonary vein lies between the right bronchus and the termination of the inferior vena cava in the right auricle. The superior left pulmonary vein is found in front of the left bronchus and the inferior left pulmonary vein is below the left bronchus.

**The Trachea.**—The portion of the trachea situated within the mediastinum—*i. e.*, the thoracic portion, in contradistinction to the cervical portion (see page 51)—corresponds to that part of the trachea which extends from the lower border of the last cervical vertebra to the fourth dorsal vertebra. In the latter situation the trachea divides into the right and left bronchus. The point of bifurcation, when projected upon the posterior thoracic wall, is situated in the line connecting the inner extremities of the scapular spines (interscapular line); this point corresponds to the level of the spinous processes of the third dorsal vertebra, in which situation we auscult respiratory murmurs originating within the trachea. Corresponding with the greater volume of the right lung, the right bronchus is larger than the left and runs more in the direction of the trachea; it is consequently more vertical than the left bronchus. For these reasons foreign bodies in the trachea pass more readily into the right than into the left bronchus. The aortic arch runs backward over the left bronchus (Plate 7); the vena azygos major passes from behind forward over the right bronchus to empty into the superior vena cava (Plates 7 and 8, b). The lower end of the trachea is behind the aortic arch; above the arch, the trachea is found in the











angle between the innominate and left carotid arteries. The esophagus runs behind the trachea and is displaced somewhat to the left (Fig. 54).

The angle of the tracheal bifurcation is filled by a varying number (twenty to thirty) of *lymphatic glands* which follow the bronchi as far as the hilus of the lung and are usually markedly pigmented. They frequently become diseased (particularly in tuberculosis), producing swellings, unusually firm adhesions, and perforation with the escape of pus into the trachea and the bronchi (Fig. 54). Some of these same lymphatic glands are in relation anteriorly with the posterior portion of the pericardium which is not covered by the mediastinal pleura, and their diseases may consequently extend to the pericardium. These lymphatic glands are also of practical importance on account of their relation to the esophagus (see below, Plate 8, and Fig. 54).

The trachea is more or less movable in the loose connective tissue of the mediastinum, although its walls are rather rigid from the presence of the tracheal rings. It may be pushed to one side by mediastinal tumors, or even absolutely occluded, particularly when the tumor compresses the trachea against the vertebral column.

**The Esophagus** [lies partly in the neck, partly in the thorax; in the neck it begins at the level of the cricoid cartilage in front of the sixth cervical vertebra.—ED.].—Upon entering the thorax the esophagus is behind and somewhat to the left of the trachea (Plates 10 and 11, and Fig. 54) and is attached to the vertebral column by loose connective tissue. The esophagus crosses the tracheal bifurcation behind the origin of the left bronchus, in which position it is situated to the right side of the aorta where the aortic arch ends and the thoracic aorta commences. It descends along the right side of the aorta, covered by the right mediastinal pleura, passes in front of the aorta, and, after going through the esophageal opening (in front and somewhat to the left of the aortic opening), ends in the cardiac extremity of the stomach three centimeters below the diaphragm (see Fig. 54). The esophagus may consequently be exposed within the mediastinum from the right pleural cavity above and from the left pleural cavity below; in the latter situation it is in front of the aorta. This is also the portion of the esophagus which is covered anteriorly by the pericardium (Fig. 51).

The esophagus possesses three *narrow portions*: (1) At the cricoid cartilage, in the neck, where the contraction of the inferior constrictor of the pharynx may offer a definite resistance to the passage of a sound; (2) at the level of the tracheal bifurcation; (3) at the esophageal opening in the diaphragm. The first narrowing is about 15 centimeters from the incisor teeth; at the second narrow portion, which is about 25 centimeters from the incisor teeth, the esophagus is in relation anteriorly with numerous lymphatic glands (bronchial glands, see Fig. 54). The distance between the third narrowing and the incisor teeth is about 40 centimeters, and it is most frequently the seat of stricture (in carcinoma of the cardia). In addition to these constrictions, there are others which have recently claimed the attention of anatomists, but it remains to be seen whether they are of any practical importance. [The average length of the esophagus in the adult is 10 inches (25 centimeters); the distance from the incisor teeth to its commencement is 6 inches; to the point or level where it is crossed by the left bronchus, 9 inches; to the esophageal opening of the diaphragm, 14 to 15 inches; to the cardiac orifice of the stomach, 16 inches.—Stiles, in Cunningham's "Anatomy."]

Foreign bodies which have entered the esophagus or pharyngeal ulcerations (carcinoma)



may perforate: into the trachea or into the left bronchus, into the aortic arch or into the descending aorta, into either of the pleural cavities, or into the pericardium. In this manner air may enter the pleural cavity from the mouth (pneumothorax) and also the pericardium (pneumopericardium) as a result of the perforation of a cancer of the esophagus. Stenosis of the esophagus may be produced by the pressure of an aortic aneurysm, by enlargements of the bronchial lymphatic glands at the tracheal bifurcation, by carcinoma of the lung or of the pleura, and by tumors in the posterior portion of the mediastinum. Cicatricial contraction of the bronchial lymphatic glands may lead to the formation of the so-called traction diverticula, which are most commonly found in the anterior wall of the esophagus. The mucous and muscular coats of the esophagus are united by a very loose submucous connective tissue; suppuration may extend widely between these layers, and foreign bodies or sounds may perforate the mucosa and make false passages.

[The *veins*, especially at the lower end, may be enormously dilated and varicose in case of obstruction to the portal circulation, owing to nature's attempt to create a collateral circulation between the veins of the stomach and those of the esophagus (emptying into azygos and pericardiac veins), giving rise, if a rupture occurs, to severe hemorrhage (hematemesis).—Eisendrath.]

In the lower portion of the mediastinal space the esophagus is accompanied by the two *pneumogastric nerves*, which pursue a different course upon the right and the left sides (Plate 10). The right pneumogastric nerve enters the mediastinum in front of the right subclavian artery. After giving off the right inferior or recurrent laryngeal nerve, it passes to the right side of the innominate artery; it then runs alongside of the trachea and behind the right bronchus to the esophagus, which it accompanies through the esophageal opening. The left pneumogastric nerve reaches the left side of the aortic arch between the left common carotid and the left subclavian arteries, gives off the left inferior laryngeal nerve (passing backward and upward around the aortic arch), and runs behind the left pulmonary artery and left bronchus to the esophagus. (The visceral branches of the pneumogastric and its communications with the sympathetic plexuses should be reviewed in a systematic anatomy.)

The *pneumogastric nerves* descend behind the roots of the lungs, and when the pleura is intact they may both be seen above these structures. The *phrenic nerves* run downward to the diaphragm beneath the mediastinal pleura and between it and the pericardium; they are accompanied by the *comes nervi phrenici* (branches of the internal mammary artery). The phrenic nerves arise from the cervical plexus and pass through the superior aperture of the thorax between the subclavian artery and vein (see page 71).

The remaining contents of the mediastinum are the paired vessels in front of the vertebral column, the vena azygos major and vena azygos minor (hemiazygos), and the thoracic duct.

*The Vena Azygos Major.*—In the abdominal cavity beside the lumbar vertebra, the vena azygos major is connected with the lumbar veins, and through these with the inferior vena cava (see page 122). The vessel enters the thorax through the right crus of the diaphragm, ascends along the right side of the vertebral column (Plates 8 b and 14), receives the intercostal veins, passes over the right bronchus at the third dorsal vertebra, and empties into the posterior portion of the superior vena cava (Fig. 51). By its communication with the inferior vena cava it renders



possible a collateral circulation in the posterior thoracic wall when this vessel is occluded, so that the blood from the lower half of the body may reach the heart through the superior vena cava.

*The Vena Azygos Minor (Hemiazygos).*—This vein is subject to considerable variation (Plates 8, a, and 14). Situated at the left side of the vertebral column, it receives blood from the left intercostal veins and runs across the ninth dorsal vertebra to empty into the right azygos vein. When there is a second communication with the right azygos vein, at a higher level, we speak of a vena hemiazygos superior and of a vena hemiazygos inferior. This vein is frequently connected with the superior vena cava by a vessel which passes transversely across the aortic arch and is known as the superior intercostal vein (Plate 8, a, where this vein is very large, and Plate 10).

*The Thoracic Duct.*—The thoracic duct arises from the receptaculum chyli at the first or second lumbar vertebra and is subject to many variations, in its method of division and plexus formation (Plate 14). It is the main trunk of the lymphatic system and accompanies the aorta through the aortic opening in the diaphragm. The duct runs in the areolar tissue between the aorta and vena azygos major and then ascends behind the esophagus. Above the third dorsal vertebra it gradually approaches the left side, is covered by the aortic arch, and at the level of the seventh cervical vertebra passes anteriorly between the left common carotid and subclavian arteries to empty into the left innominate vein. [According to some authors, the highest part of the duct reaches to the level of the transverse process of the extra-cervical vertebra. According to Stiles, this is one inch vertically above the inner end of the clavicle. Its relation to the inner border of the scalenus anticus should be kept in mind in all operations in this vicinity.—ED.]

The thoracic portion of the *sympathetic nerve* may be seen through the costal pleura to the outer side of the corresponding azygos vein (Plate 8). It passes into the thorax, forming the inferior cervical ganglion in front of the head of the first rib; the first thoracic ganglion is situated anteriorly to the head of the second rib, and the remaining ten ganglia are in front of the heads of the lower ribs. It runs in front of the intercostal nerves, with which it is connected by visceral and communicating branches, and also in front of the intercostal arteries. The sympathetic nerve, in addition to the branches to the cardiac plexus and to the lung, gives off the greater and lesser *splanchnic nerves*, which run inward and downward, pass through the diaphragm, and end in the celiac plexus. These nerves arise by roots from the sixth or seventh to the eleventh thoracic ganglia and, in consequence of their white medullated fibers, may usually be seen through the pleura as they lie in front of the vertebral column.

#### REVIEW QUESTIONS.

Why are penetrating wounds entering the intercostal spaces from behind more commonly associated with injuries to the ribs than corresponding wounds through the anterior thoracic wall?

What large artery may be influenced in its course by the presence of a cervical rib? What may result from this anomalous relation?

What is the practical result of the preponderance of spongy tissue in the sternum?

Into which three large cavities (and in which situations) may a hemorrhage take place after an injury of the internal mammary artery?

What compression symptoms may follow a posterior dislocation of the sternal end of the clavicle?



In carcinoma of the mammary gland, how would you explain the involvement of the lymphatic glands, not only of the same but also of the opposite side?

How would you explain pain in the upper arm in a case of mammary carcinoma?

What practical results may be deduced from the position of the intercostal arteries?

Why are diaphragmatic hernias more common upon the left side? Where is the seat of predilection for such a hernia?

Which large vessel may be injuriously affected, at its passage through the diaphragm, by a large pleuritic exudate?

How do you explain the rarity of injuries of the pleura without concomitant injuries of the lung?

Along what path may inflammations in the neighborhood of the cervical viscera easily extend into the mediastinum?

Why are injuries of the ventricles of the heart more common than injuries of the auricles?

What are the practical results of the relation of the esophagus to the pericardium?

Where is the most favorable location for tapping the pericardial sac?

What is the anatomic explanation of the influence of disease of the lungs and of the pleural cavities upon the extent of the cardiac dulness and upon the position of the heart?

Into which cavity will a ruptured aneurysm of the ascending aorta usually empty?

What vessel to the right and what one to the left will be compressed by such an aneurysm?

What structures may be affected by aneurysms of the aortic arch?

What is the explanation of the occurrence of a paralysis of the left vocal cord in aneurysm of the aortic arch?

Why do foreign bodies, which have gained access to the larynx, pass more readily into the right than into the left bronchus?

Where are the three narrow portions of the esophagus and how far are they from the incisor teeth?

What is the most probable cause of a fatal hemorrhage after swallowing a pointed instrument or in a case of esophageal carcinoma?

In what manner may an affection of the esophagus lead to pneumothorax or pneumopericardium?

What practical facts must be remembered in reference to the very loose character of the submucous tissue of the esophagus?

What vein may, under certain circumstances, transmit the blood from the lower half of the body to the heart when the circulation is disturbed in the trunk of the inferior vena cava? What path does the blood take in such a case?

## THE ABDOMEN.

### THE ABDOMINAL WALL.

The superior external boundary of the abdomen, the dividing-line between the abdomen and the thorax, is formed by the inferior aperture of the thorax (see page 92), which may be both seen and palpated. The inferior external boundary, the dividing-line between the abdomen and the pelvic and femoral regions, is furnished by the iliac crests, the groins (corresponding with Poupart's ligament), and the symphysis pubis. The internal boundaries, or the lines of separation between the abdominal cavity and the thoracic and pelvic cavities, do not correspond with the external ones. The dome of the diaphragm extends far above the inferior aperture of



the thorax and the upper limit of the abdominal cavity; the diaphragm consequently corresponds with the lower limit of the thoracic cavity. The abdominal cavity also extends downward below the external boundary, formed by the iliac crests, and, although there is really no sharp demarcation between the abdomen and pelvis, we designate the linea terminalis (pelvic brim), the dividing-line between the true and false pelvis, as the inferior boundary of the abdominal cavity.

**Inspection and Palpation.**—Inspection and palpation reveal a number of superficial landmarks. The anterior median furrow of the thorax, passing into the scrobiculus cordis (see page 91), is continued downward in the direction of the linea alba, and in spare muscular individuals may be traced to the navel or even to the mons Veneris over the symphysis. To either side of this median furrow may be observed the prominences caused by the recti muscles, the external margins of which may be located by the presence of more or less distinct shallow grooves. [The linea semilunares are represented by slightly curved lines from the tip of the ninth costal cartilages to the pubic spines.—ED.] The furrows running transversely across the prominences of the recti muscles correspond to their tendinous intersections; the portions of muscle situated between these tendinous intersections are occasionally so prominent that they may simulate tumors (lipomata). [Occasionally, particularly when there is tenderness beneath, they simulate intra-abdominal tumors.—ED.] None of these landmarks are visible in the female, on account of the abundance of subcutaneous fat; during pregnancy the anterior median line of the abdomen is rendered visible by the formation of pigment in the skin over the linea alba. With the subject in the dorsal position, the vertebral column and the pulsations of the abdominal aorta may be palpated if the abdominal walls are relaxed and not too thick.

Upon the dorsal surface the posterior median furrow is continued downward over the spinous processes to the sacrum and terminates in the shallow fossa which is designated as the *sacral triangle*. The posterior surface of the sacrum may be felt in this region and, lower down, the slightly movable coccyx. The palpating finger may be passed along the iliac crest to the anterior superior spine of the ilium, and from here along the groin, upon Poupart's ligament, to the horizontal ramus of the pubis and the pubic symphysis. [The posterior superior spinous processes of the ilium are palpable, usually indicated by a depression, and are on the level of the spinous process of the second sacral vertebra.—ED.]

The following *lines* are employed to divide the external surface of the abdomen into regions: A horizontal line is drawn about the chest at the level of the root of the xiphoid process and serves as a dividing-line between the chest and abdomen. A second line is drawn anteriorly connecting the two lowest points of the costal margin and running posteriorly along the lower border of the ribs to the twelfth dorsal vertebra. The *epigastric region* is situated between these two lines. The central portion of the epigastric region, bounded laterally by the costal margins, is known as the *epigastrium*; the remainder of this region forms the two *hypochondriac regions*, which contain those abdominal organs which are situated beneath the costal margins. Below the epigastric region is the *mesogastric region*, which extends downward, anteriorly to a line connecting the two anterior superior spines, laterally and posteriorly to the iliac crests. The space bounded by the line connecting the anterior superior spines of the ilium, by the groins, and by the symphysis is known as the *hypogastric region*. Lines drawn downward from the lowest



## PLATE 11.

The position of the thoracic and abdominal viscera of a boy. Anterior view. From an accurate Leipzig model made from an original dissection.

## PLATE 12.

The position of the thoracic and abdominal viscera of a boy. Posterior view. From the model of Plate 11.

points of the costal margins to the pubic spines subdivide the mesogastric region into a *central umbilical region* and two *lateral abdominal regions*; they also subdivide the hypogastric region into a central *pubic region* and two lateral or *inguinal regions*. The *lumbar regions* are in the posterior portion of the mesogastric region and extend from the spinal column to a line which represents the shortest distance between the costal margin and the crest of the ilium. [This manner of delimiting the abdominal regions differs from that adopted by English writers and even from other German authors.—ED.]

The *skin of the abdomen* is comparatively thin and movable, except at the navel; it is also very elastic, as is shown by the distention produced by tumors, ascites, or pregnancy. The so-called *striæ gravidarum* are not an absolute indication of a preceding pregnancy, since they may be produced by any distention of the abdominal integument. The fat in the subcutaneous connective tissue is often so pronounced that it interferes with the palpation of the internal organs and is a disturbing factor in the performance of laparotomy.

**Muscles.**—In contrast to the thoracic wall, the greater portion of the abdominal wall is composed of muscular tissue; the palpation of the abdomen is consequently of more importance than the palpation of the thorax. The abdominal muscles extend between the inferior aperture of the thorax, the transverse processes of the lumbar vertebrae, the iliac crest, the symphysis, and Poupart's ligament. The *rectus abdominis muscle* arises from the outer surfaces of the fifth to the seventh costal cartilages and from the xiphoid process, and is inserted into and alongside of the anterior surface of the symphysis. It is surrounded by a fibrous sheath which is complete anteriorly, but on the posterior surface of the muscle it extends only two fingerbreadths below the navel (*linea semicircularis Douglasi*), so that the only structures beneath the muscle in this situation are the thin transversalis fascia and the peritoneum. The aponeuroses of the three flat abdominal muscles are united in the median line to form the *linea alba*, which contains few blood-vessels and is consequently frequently chosen as the site of the incision for operative procedures upon the abdomen. Above the umbilicus, it is broader and thinner; while below, it is narrower and thicker. [Below the navel, owing to the fact that the recti are more closely approximated,—in the lower fourth the aponeuroses all pass in front of the recti,—the *linea alba* is often scarcely apparent.—ED.] The greater breadth above the navel is responsible for the fact that hernias of the *linea alba* are more frequent above than below this location. These hernias pass through the slit-like orifices which transmit the vessels from the underlying structures to the skin. The *external oblique muscle* of the abdomen is situated beneath the superficial fascia; it arises from the outer surfaces of the seven or eight lower ribs and is inserted into the *linea alba*, the outer lip of the iliac crest,—anterior one-half,—and Poupart's ligament. Underlying this muscle is the *internal oblique*, which arises from the lumbar fascia, from the middle lip of the iliac crest [anterior two-thirds.—ED.], and from Poupart's ligament, and is inserted into the ends of the tenth to the twelfth ribs and into the *linea alba*. [By means of its aponeurosis



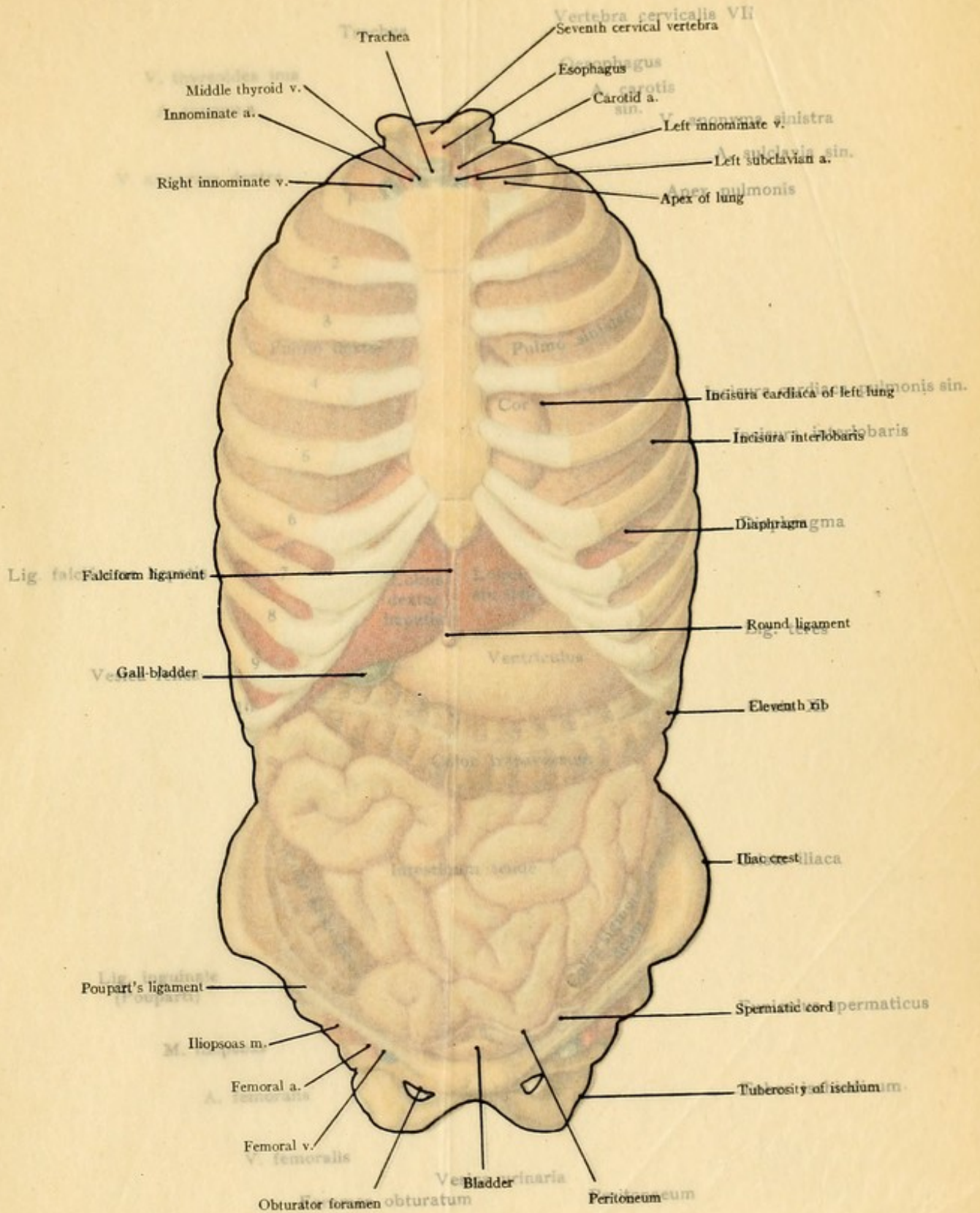




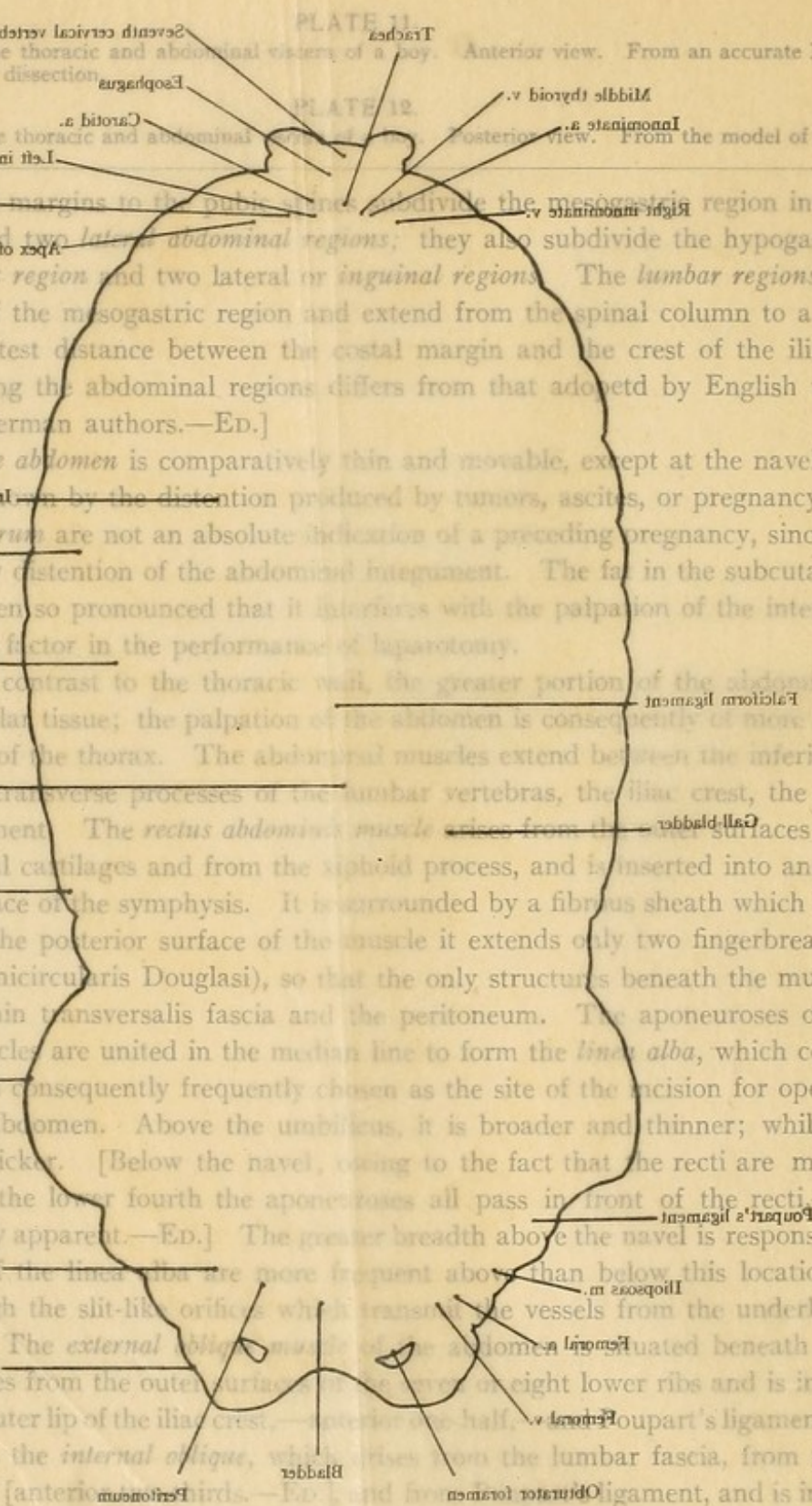
PLATE 11.  
The position of the thoracic and abdominal viscera of a boy. Anterior view. From an accurate Leipzig model made from an original dissection.

PLATE 12.  
The position of the thoracic and abdominal viscera of a boy. Posterior view. From the model of Plate 11.

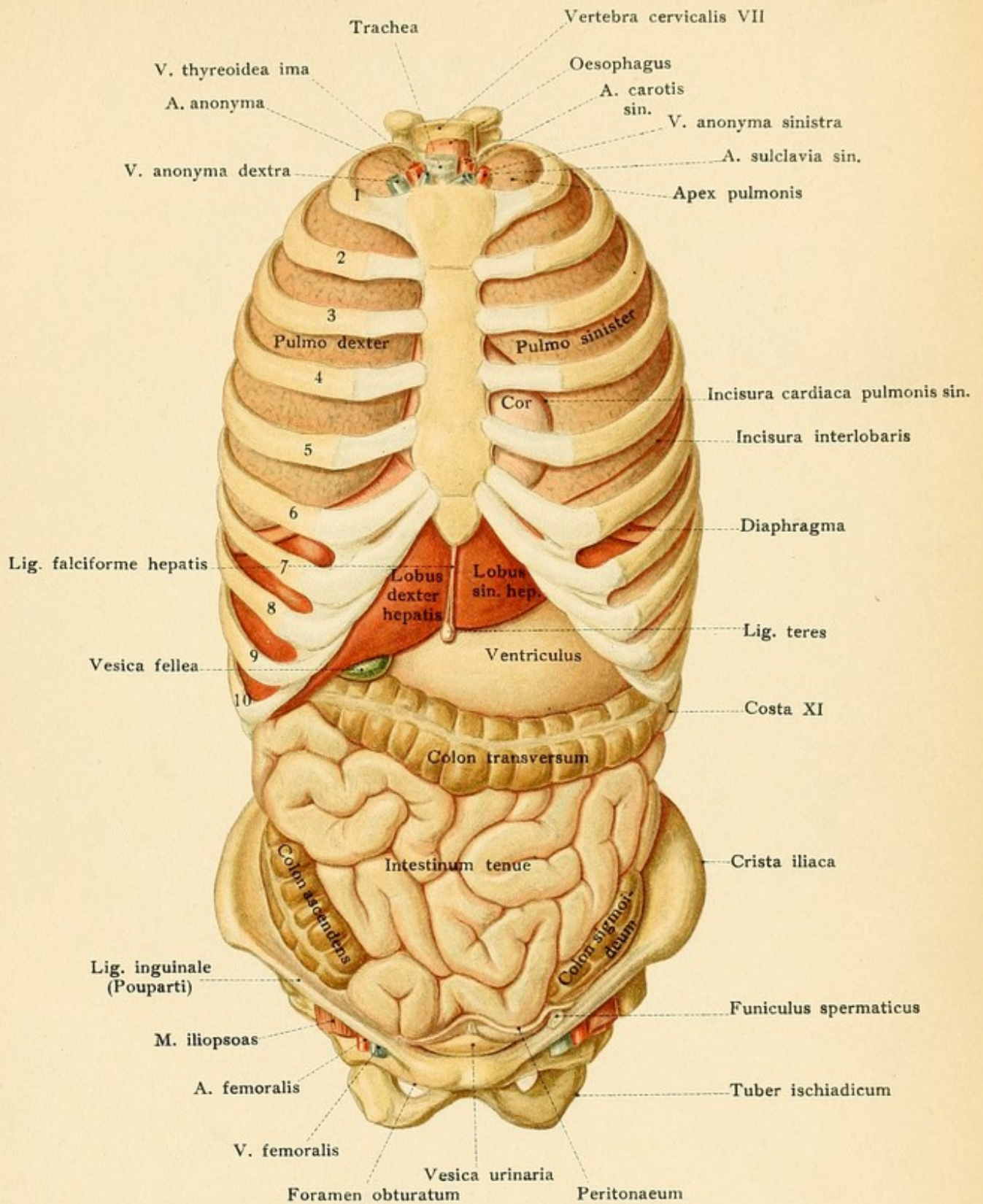
points of division of the margins to the pubic line, and divide the mesogastric region into a central umbilical region and two lateral abdominal regions; they also subdivide the hypogastric region into a central pubic region and two lateral or inguinal regions. The lumbar regions are in the posterior portion of the mesogastric region and extend from the spinal column to a line which represents the shortest distance between the costal margin and the crest of the ilium. [This manner of delimiting the abdominal regions differs from that adopted by English writers and even from other German authors.—ED.]

The skin of the abdomen is comparatively thin and movable, except at the navel; it is also very sensitive to the distention produced by tumors, ascites, or pregnancy. The so-called *striae gravidarum* are not an absolute indication of a preceding pregnancy, since they may be produced by any distention of the abdominal integument. The fat in the subcutaneous connective tissue is often so pronounced that it interferes with the palpation of the internal organs and is a disturbing factor in the performance of laparotomy.

**Muscles.**—In contrast to the thoracic wall, the greater portion of the abdominal wall is composed of muscular tissue; the palpation of the abdomen is consequently of more importance than the palpation of the thorax. The abdominal muscles extend between the inferior aperture of the thorax, the transverse processes of the lumbar vertebrae, the iliac crest, the symphysis, and Poupart's ligament. The *rectus abdominis muscle* arises from the anterior surfaces of the fifth to the seventh costal cartilages and from the xiphoid process, and is inserted into and alongside of the anterior surface of the symphysis. It is surrounded by a fibrous sheath which is complete anteriorly, but on the posterior surface of the muscle it extends only two fingerbreadths below the navel (linea semicircularis Douglasi), so that the only structures beneath the muscle in this situation are the thin transversalis fascia and the peritoneum. The aponeuroses of the three flat abdominal muscles are united in the median line to form the *linea alba*, which contains few blood-vessels and is consequently frequently chosen as the site of the incision for operative procedures upon the abdomen. Above the umbilicus, it is broader and thinner; while below, it is narrower and thicker. [Below the navel, owing to the fact that the recti are more closely approximated,—in the lower fourth the aponeuroses all pass in front of the recti,—the linea alba is often scarcely apparent.—ED.] The greater breadth above the navel is responsible for the fact that the herniae are more frequent above than below this location. These hernias pass through the slit-like orifices which transmit the vessels from the underlying structures to the skin. The *external oblique muscle* is situated beneath the superficial fascia; it arises from the outer cartilage of the tenth rib and is inserted into the linea alba, the outer lip of the iliac crest, and Poupart's ligament. Underlying this muscle is the *internal oblique muscle*, which arises from the lumbar fascia, from the middle lip of the iliac crest [anteriorly], and from the anterior foramen of the lumbar vertebrae, and is inserted into the ends of the tenth to the twelfth ribs and into the linea alba. [By means of its aponeurosis



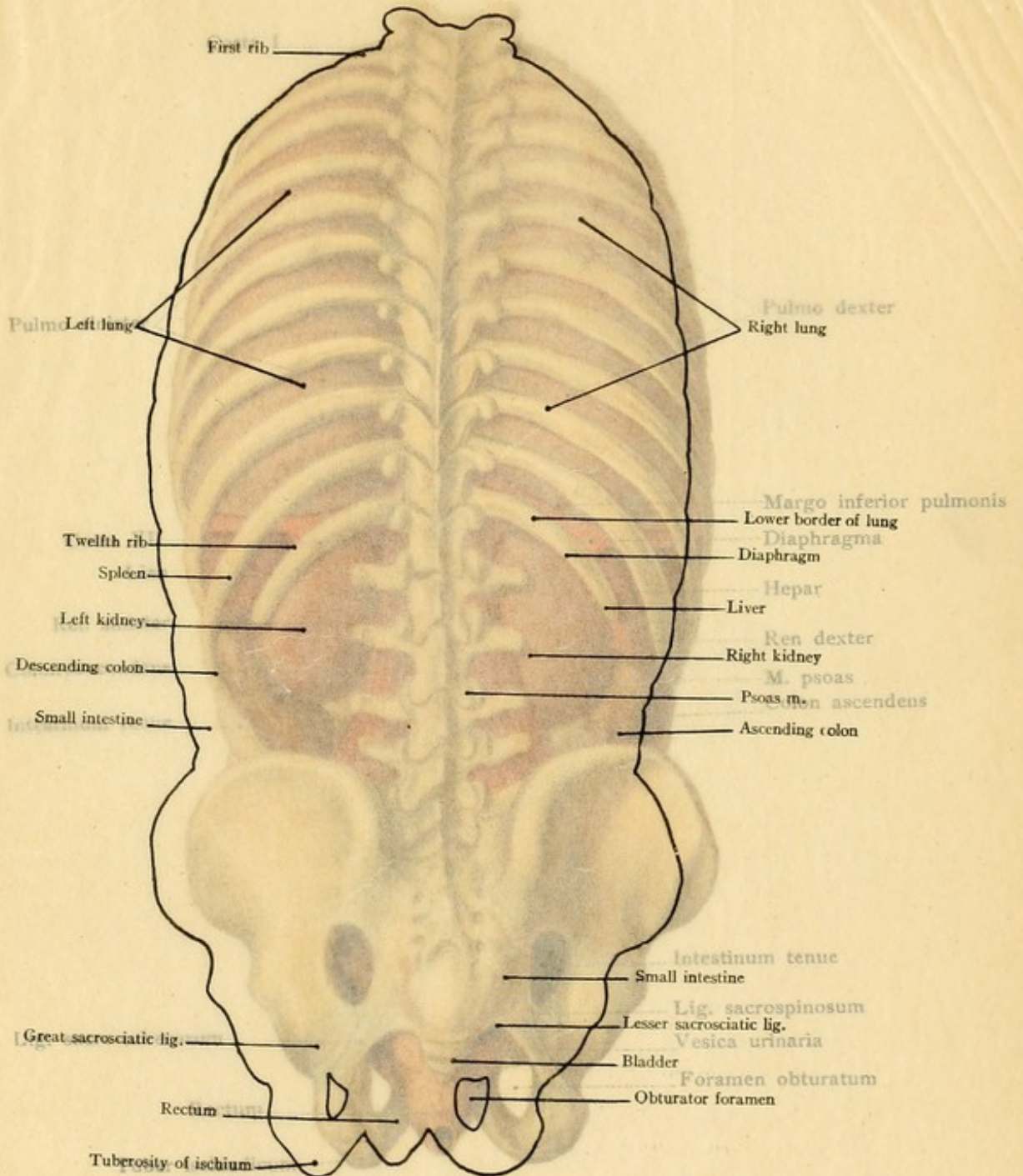




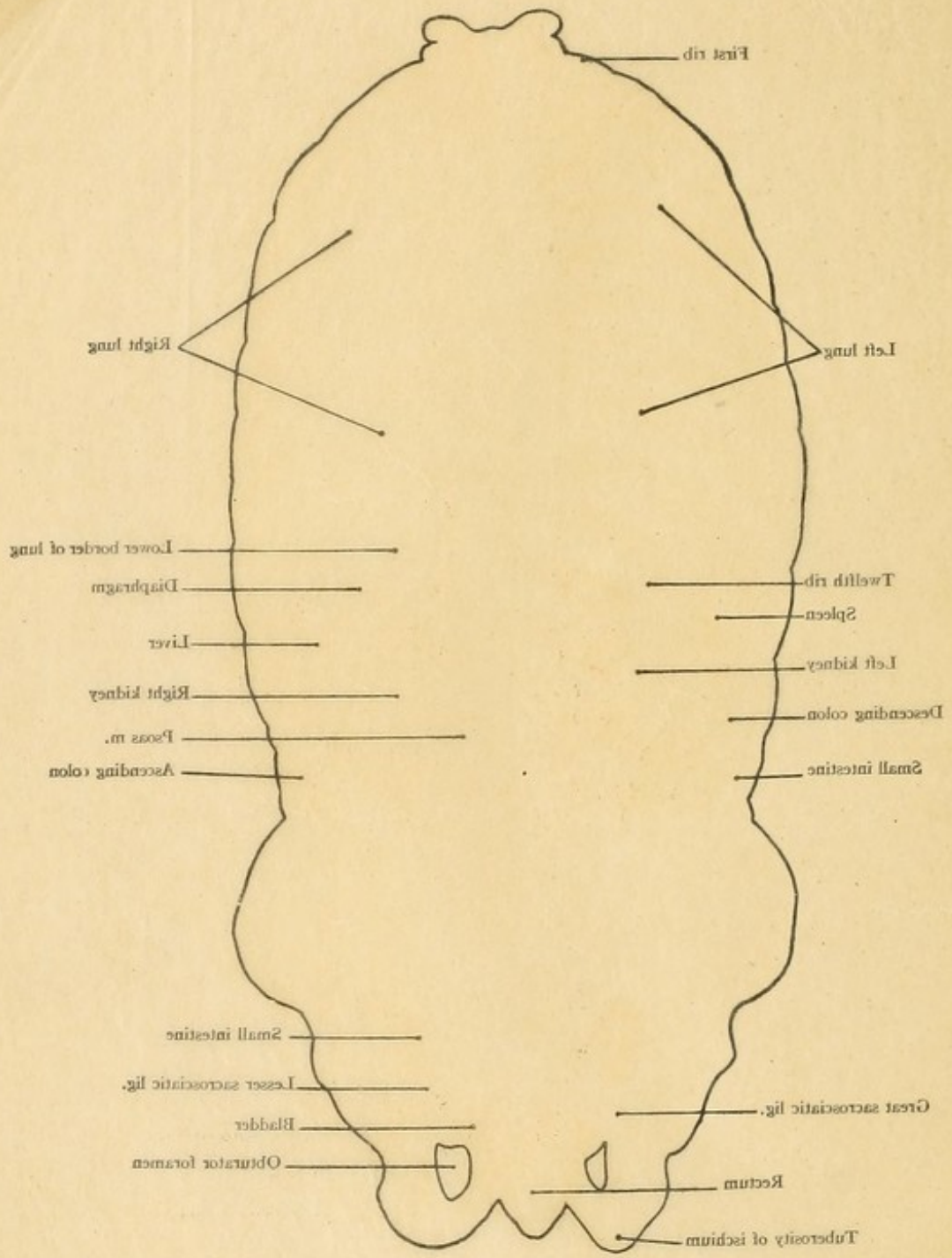




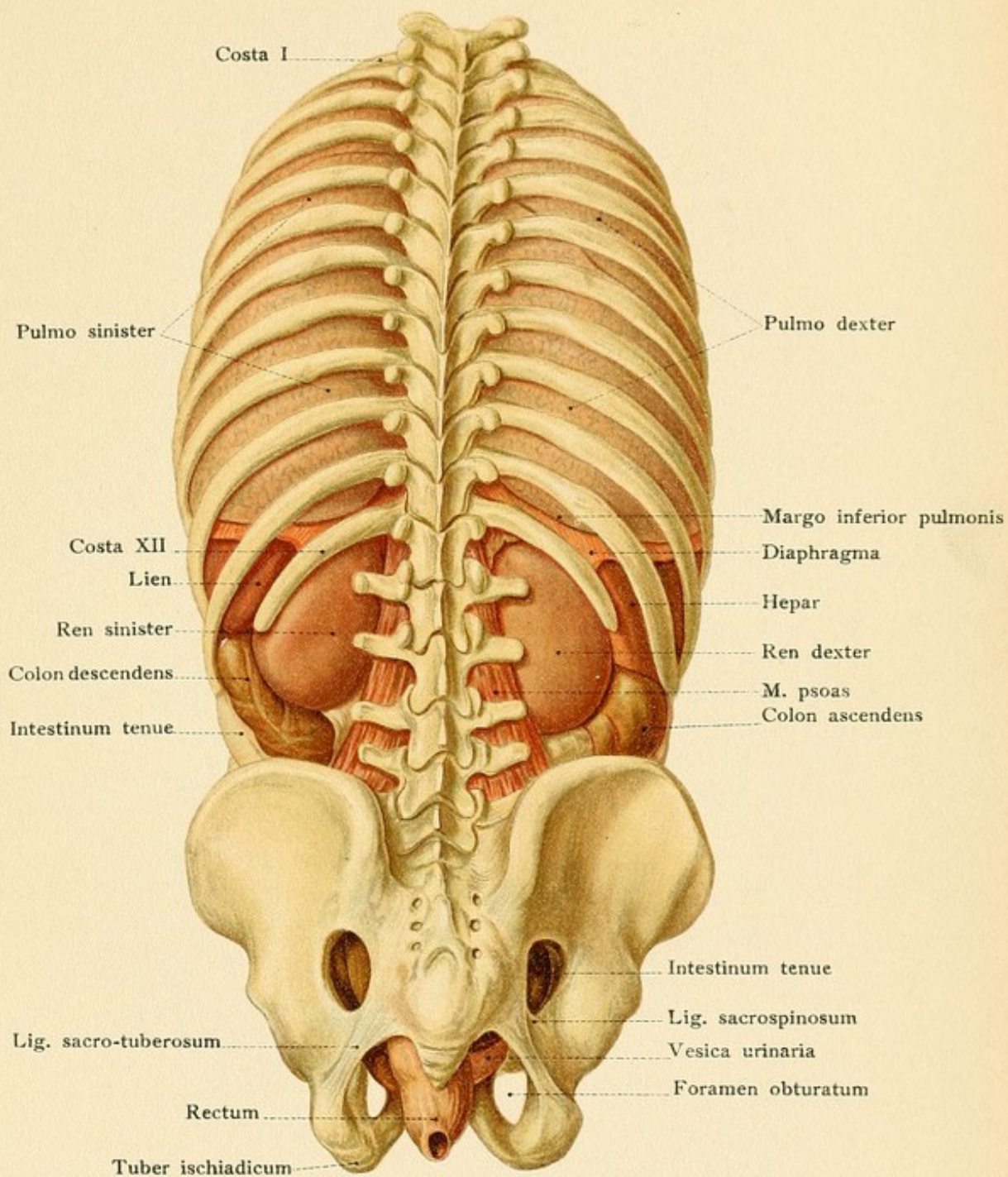


















it is also inserted into the cartilages of the eighth, ninth, and tenth ribs.—ED.] The most internal muscle is the *transversalis*, which takes origin from the inner surfaces of the six lower costal cartilages, from the deep layer of the lumbar fascia, from the inner lip of the iliac crest, and from Poupart's ligament, and inserts into the linea alba. The aponeurosis of the external oblique passes only into the anterior layer of the sheath of the rectus; that of the internal oblique runs in both layers of the sheath, and the aponeurosis of the transversalis muscle is found in the posterior portion of the sheath above the semilunar line of Douglas and in the anterior portion below it. Posteriorly alongside of the vertebral column in the lumbar region is the *quadratus lumborum muscle*, which extends between the transverse processes of the lumbar vertebrae, the last rib, and the posterior portion of the iliac crest. This muscle holds a most important relation to the kidney (see page 139). The *fascia of Retzius* varies considerably in different individuals; it seems to form a feeble continuation of the posterior layer of the sheath of the rectus. Behind this fascia, between the transversalis muscle and the peritoneum, is the *transversalis fascia*, which passes upward to the inferior surface of the diaphragm. It is thin above the umbilicus and in the umbilical region, but becomes thicker in the inguinal region and is attached to the internal lip of the iliac crest and to Poupart's ligament. Just above the umbilicus, the transversalis fascia is known as the umbilical fascia but this latter structure is subject to great variation and has received more attention than it deserves from a practical standpoint.

The **arteries of the abdominal wall** are to be differentiated as the superficial and the deep.

The superficial vessels arise from the femoral artery. They are the *superficial epigastric* and the *superficial circumflex iliac* (Fig. 77). The superficial epigastric artery is not a particularly large vessel; it perforates the fascia lata below Poupart's ligament and passes upward over this ligament toward the navel, although it does not run as far as the latter structure. The superficial circumflex iliac also perforates the fascia lata and runs parallel to Poupart's ligament to the skin in the region of the anterior superior spine of the ilium. Both arteries are of practical importance, since they supply the so-called inguinal glands.

The deep arteries are much larger. They are:

1. The *seven lowermost intercostal arteries* which run beyond the costal margin and end in the abdominal muscles.

2. The *inferior* or *deep epigastric artery* (Figs. 56 and 71), practically the most important vessel in the anterior abdominal wall, arises from the external iliac just before it passes beneath Poupart's ligament. It runs upward in a curved direction, the concavity being directed outward, passing to the inner side of the internal abdominal ring; the vessel is situated just beneath the peritoneum forming the *plica epigastrica* (see page 123 and Figs. 56 and 58). At the fold of Douglas it enters the sheath of the rectus and anastomoses freely above the umbilicus with the superior epigastric artery (see page 94). If the circulation in the descending aorta is obstructed, these anastomoses may become dilated and form a collateral path, through which the blood from the subclavian artery may pass along the inner surface of the thoracic and abdominal walls to reach the lower extremity. The course of the inferior epigastric artery corresponds to a line drawn from the junction of the inner and middle thirds of Poupart's ligament to a point one inch to the outer side of the navel. To avoid the artery in tapping for ascites or in other operative procedures the puncture should be made either to the outer side of the vessel at Monro's point



## PLATE 13.

The position of the thoracic and abdominal viscera of a boy, seen from the left and from the right. From the model of Plate 11.

FIG. 55.—A diagrammatic representation of the communications between the superior and inferior venæ cavæ and the portal vein.

in the middle of the so-called Richter-Monro line, drawn from the anterior superior spine of the ilium to the navel, or to the inner side of the vessel (Naunyn) through the rectus abdominis muscle, three centimeters from the linea alba midway between the navel and the symphysis.

3. The *deep circumflex iliac artery*, the remaining branch of the external iliac, passes outward along the iliac crest and then upward to supply the abdominal muscles; upon the iliacus muscle it anastomoses with the iliac branch of the iliolumbar artery (from the internal iliac).

4. The four pairs of *lumbar arteries* which arise from the abdominal aorta pass in front of the bodies of the first to the fourth lumbar vertebrae beneath the tendinous arch of origin of the psoas muscle, and run partly in front of and partly behind the quadratus lumborum to the musculature of the lateral abdominal wall.

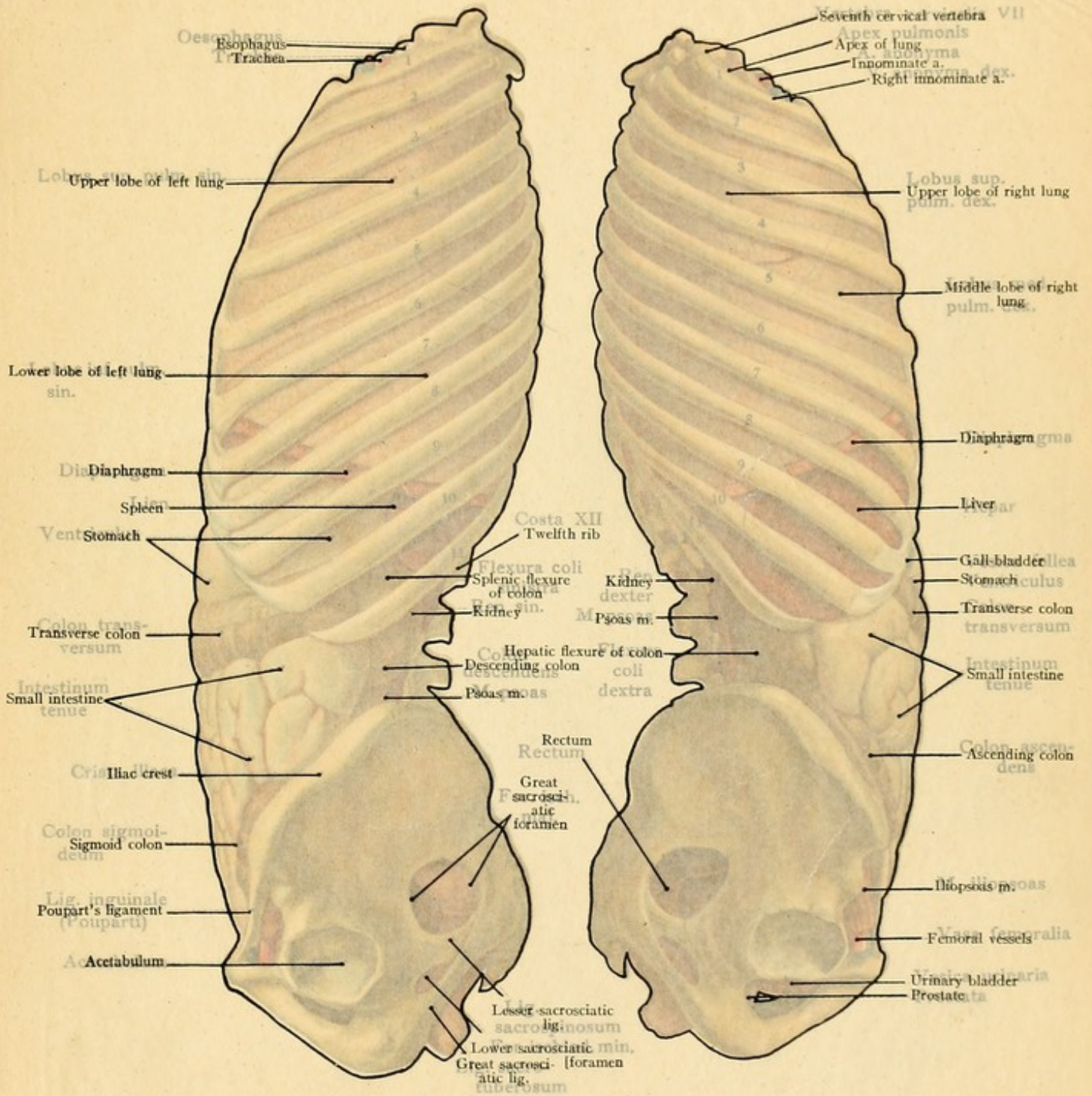
The **veins of the abdominal wall** may also be divided into a superficial and a deep set (Fig. 55).

The superficial or subcutaneous veins are the *superficial epigastric* and the *superficial circumflex iliac*; they are considerably larger than the arteries of the same name which they accompany, and empty into the femoral vein below Poupart's ligament. The superficial epigastric vein anastomoses above with the long thoracic through the thoracico-epigastric vein, and thus aids in the formation of a subcutaneous venous connection in the thoracic and abdominal walls between the axillary and the femoral veins.

The deep veins are the *venæ comites* of the inferior epigastric artery (which anastomose above with the superior epigastric branch of the internal mammary vein), the *venæ comites* of the superficial circumflex iliac artery, and the single lumbar veins (which run above their accompanying lumbar artery). The vertical anastomoses of the lumbar veins behind the psoas muscle form the *ascending lumbar veins* upon each side which give origin to the *vena azygos major* and *minor*. In this manner a venous communication is formed between the superior and inferior vena cava in the posterior portion of the body; the importance of this venous connection has been previously emphasized (see page 116). A stasis in the inferior vena cava may also make itself visible through the anterior abdominal wall, since the blood from the inferior vena cava tries to reach the superior vena cava through the dilated superficial epigastric veins.

The superficial veins of the abdominal wall form a subcutaneous venous plexus which communicates with the area drained by the deep epigastric veins by means of numerous anastomoses passing through the abdominal wall (Fig. 55). These anastomoses are also directly connected with the portal vein, on the inferior surface of the liver, by four or five small *parumbilical veins* (accessory portal branches) which pass along the round ligament of the liver. The portal vein enters the liver at the *porta hepatis* and arises from the veins of the stomach, of the intestines, of the spleen, and of the pancreas. Diseases of the liver—cirrhosis, for example—easily produce stasis in the venous radicals of the portal vein and transudation from the vessels in the organs which have just been mentioned;

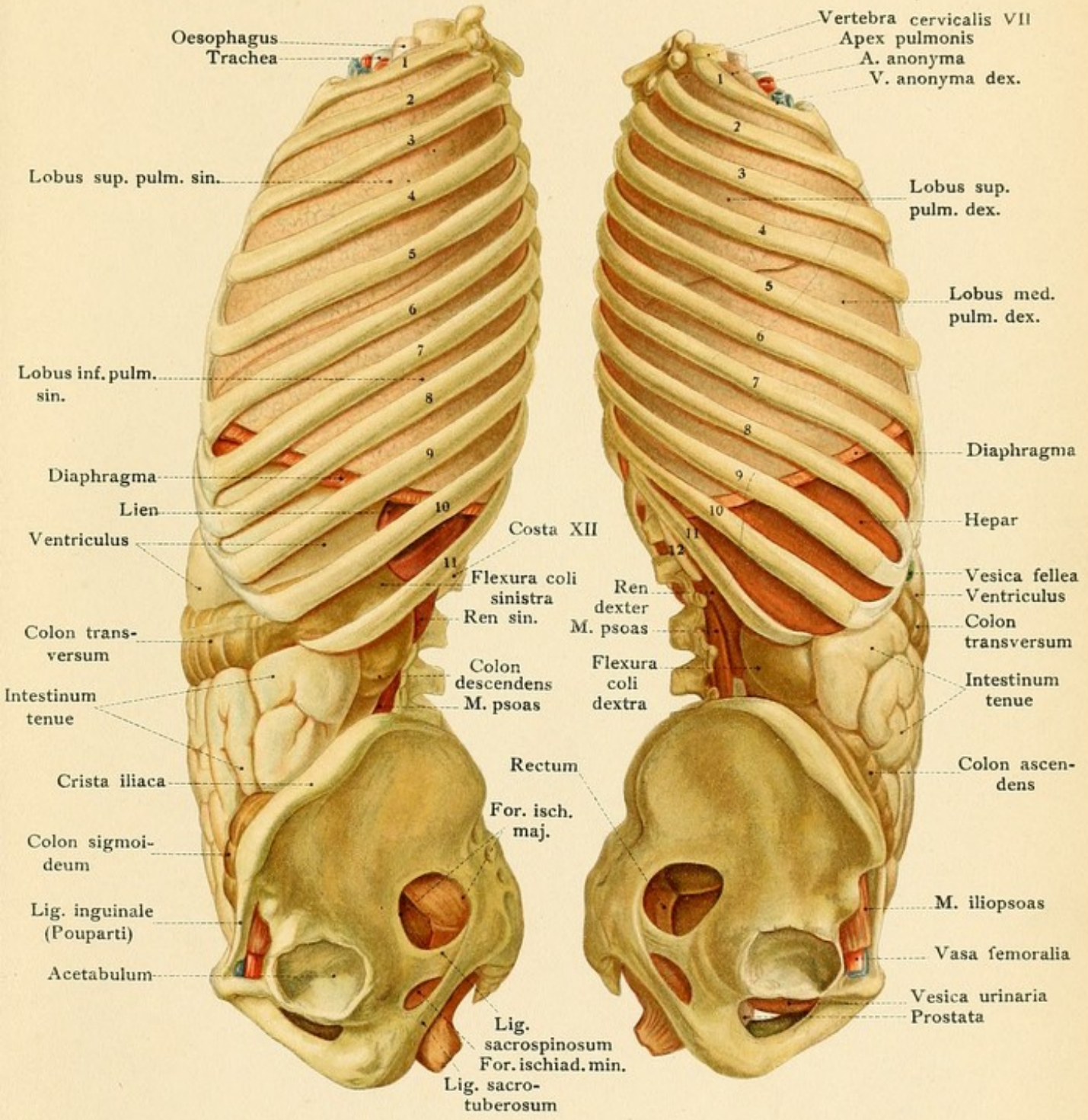








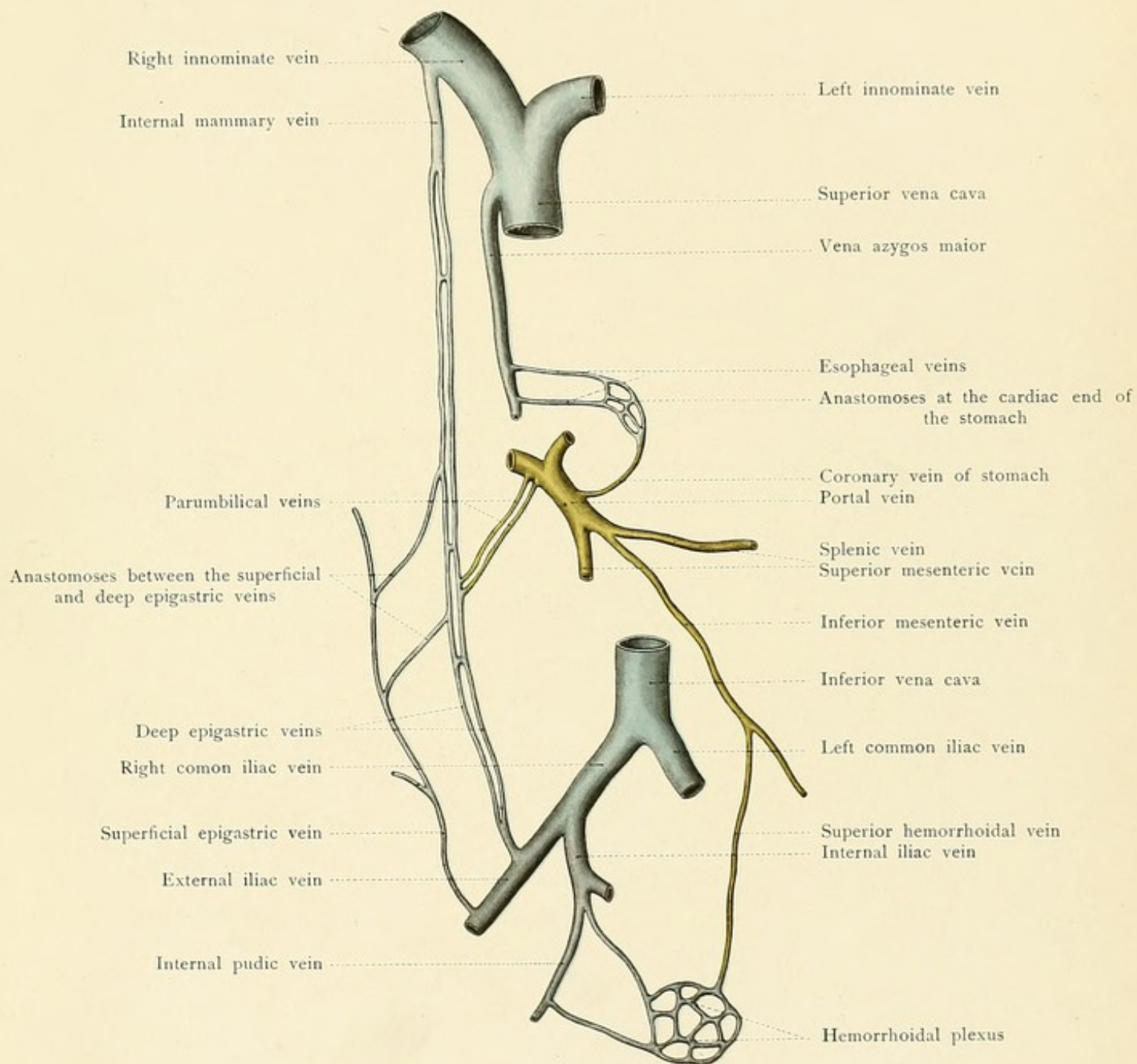


















it is in this manner that ascites is produced. In addition to ascites, there are three other symptoms or signs of obstruction, dependent upon three other sets of veins aiding in the formation of the portal circulation, which are readily understood if we are acquainted with the normal anastomoses of these veins.

1. There is a stasis in the venous *hemorrhoidal plexus*, in the neighborhood of the rectum, from which the blood passes through the superior hemorrhoidal vein to the inferior mesenteric and thus reaches the portal vein. In this manner hemorrhoids are produced. From this same plexus the blood flows through the middle and inferior hemorrhoidal veins into the internal pudic vein and finally reaches the inferior vena cava.

2. There is passive congestion of the lesser curvature of the stomach and of the lower end of the esophagus due to stasis in the *coronary vein of the stomach*. This may lead to dilatation of the veins (esophageal varices) and even to rupture of these vessels with a consequent hæmatemesis; it is possible, however, for the blood in the esophageal veins to flow into the vena azygos major.

3. As a result of passive congestion and dilatation of the *parumbilical veins*, the veins of the abdominal wall also become dilated; these veins are partly arranged in a radiating manner about the umbilicus, and the so-called caput Medusæ is thus produced. [The Talma-Morrison operation for the relief of cirrhosis, whereby the great omentum is caused to form adhesions and venous connections with the abdominal wall, is based on this venous anastomosis.—ED.]

The **nerves of the abdominal wall** are the terminal portions of the six lower intercostal nerves, which pass beyond the costal margin and reach the rectus abdominis between the flat abdominal muscles. In addition to these there are the *ilio-hypogastric* and the *ilio-inguinal nerves* from the lumbar plexus. All these nerves supply the muscles of the abdominal wall and give off lateral and anterior cutaneous branches. There are also a number of nerves from the lumbar plexus which are situated between the muscles of the posterior abdominal wall (iliopsoas, quadratus lumborum, transversalis) and the peritoneum. They are the *external cutaneous*, the *genitocrural*, and the *anterior crural nerves*. The external cutaneous nerve runs transversely across the iliacus muscle toward the anterior superior spine of the ilium. The genitocrural nerve subdivides into a crural branch, to the skin of the subinguinal region, and a genital branch, passing through the inguinal canal to the cremaster muscle. The anterior crural nerve is easily found in the iliac fossa between the psoas and iliacus muscles and, with the exception of the sciatic, is the longest nerve of the lower extremity (see page 161). [Pleuritic pain, particularly when located low and near the diaphragm, is often referred to the abdominal wall along the terminations of the lower intercostal nerves, and is sometimes mistaken for abdominal disease.—ED.]

The topography of the *inner surface of the anterior abdominal wall*, under normal tension, is of great importance for the proper understanding of inguinal and femoral hernia (Figs. 56 to 58). The peritoneum is reflected over a number of underlying cords and thus forms folds which have received special names. In the middle line the *plica umbilicalis media* passes upward from the bladder to the navel; it is produced by the ligamentum umbilicale medium, the urachus of fetal life, which is situated beneath the peritoneum. To either side of the bladder, the obliterated remains of the hypogastric arteries, the ligamenta umbilicalia lateralia of adult life, form the *plicæ umbilicales laterales*. Still more externally are the less pronounced *plicæ epigastricæ*, which



FIG. 56.—The inferior half of the anterior abdominal wall as seen from within. The pelvis is shown in frontal section. The greater portion of the peritoneum has been left intact, but portions of it have been removed upon the right from the internal abdominal ring, upon the left from the epigastric vessels, the lateral umbilical ligament and the vas deferens, and in the middle line from the median umbilical ligament.

FIG. 57.—In the left iliac fossa the layers of the abdominal wall are shown, the dissection exposing the sigmoid colon. The recti muscles are divided and the urinary bladder has been made visible above the symphysis without injuring the peritoneum. Upon the right side there is an internal inguinal hernia.

contain the inferior (deep) epigastric artery and veins. The *vas deferens* may also be seen beneath the peritoneum and palpated as a hard cord; it is situated to the outer side of the epigastric fold. In this situation it leaves the inguinal canal to pass into the true pelvis behind the bladder. This

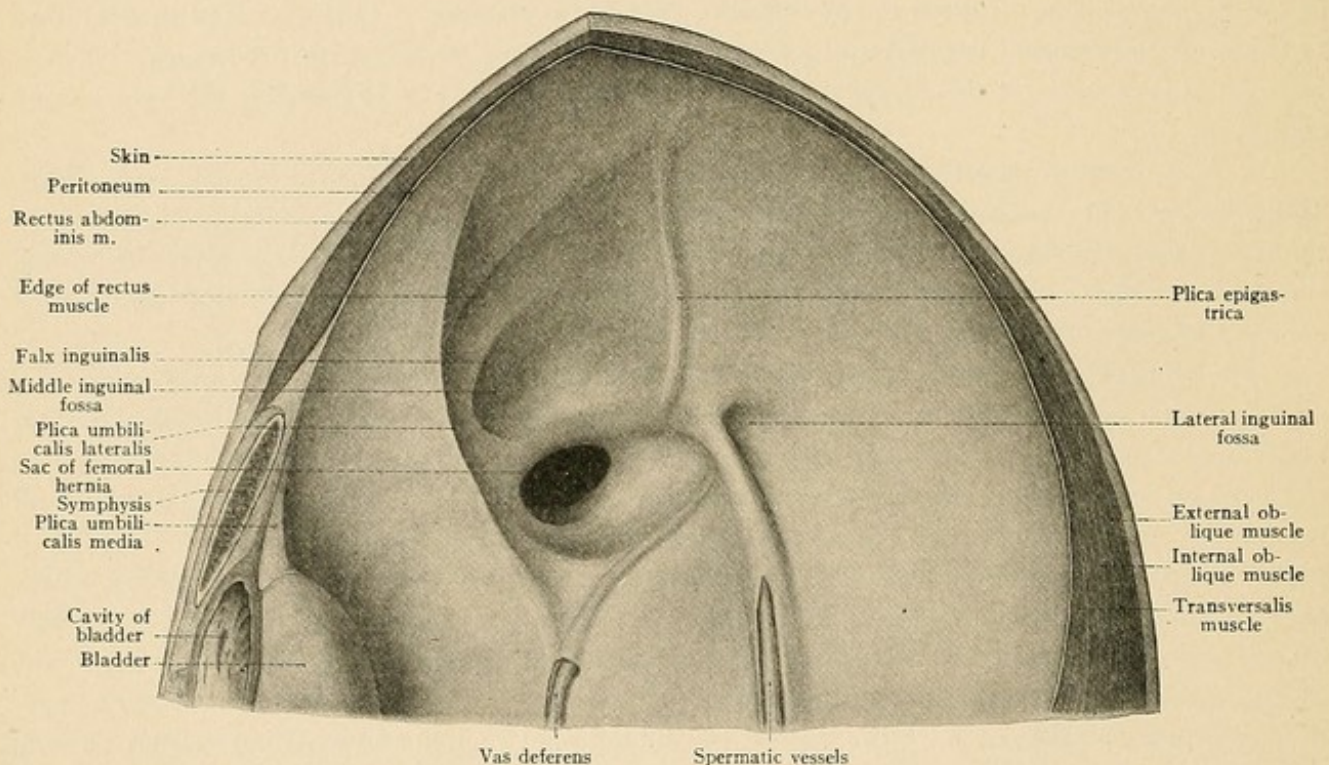


FIG. 58.—The inferior half of the anterior abdominal wall with the hernial regions as seen from within and above. At the site of the femoral ring is the sac of a femoral hernia. The interior inguinal fossa is limited internally by a sharply bordered fold (*falx inguinalis*), which belongs to the transversalis abdominis muscle. (Frozen formalin preparation.)

orifice of the inguinal canal is known as the *internal abdominal ring* in contradistinction to the external orifice, which is known as the *external abdominal ring*. At the internal ring the spermatic vessels (the spermatic artery from the abdominal aorta and the spermatic veins) also disappear in company with the vas deferens. The peritoneum closes this internal abdominal ring and forms the *external inguinal fossa* (*fovea inguinalis lateralis*), which is situated to the outer side of the deep epigastric artery. While this fossa corresponds to the abdominal orifice of the inguinal canal, the *middle inguinal fossa* (*fovea inguinalis medialis*), situated between the plica epigastrica and the plica umbilicalis lateralis, lies directly beneath the external opening of the inguinal canal. Still further to the inner side is the *fovea supravesicalis*, situated between the



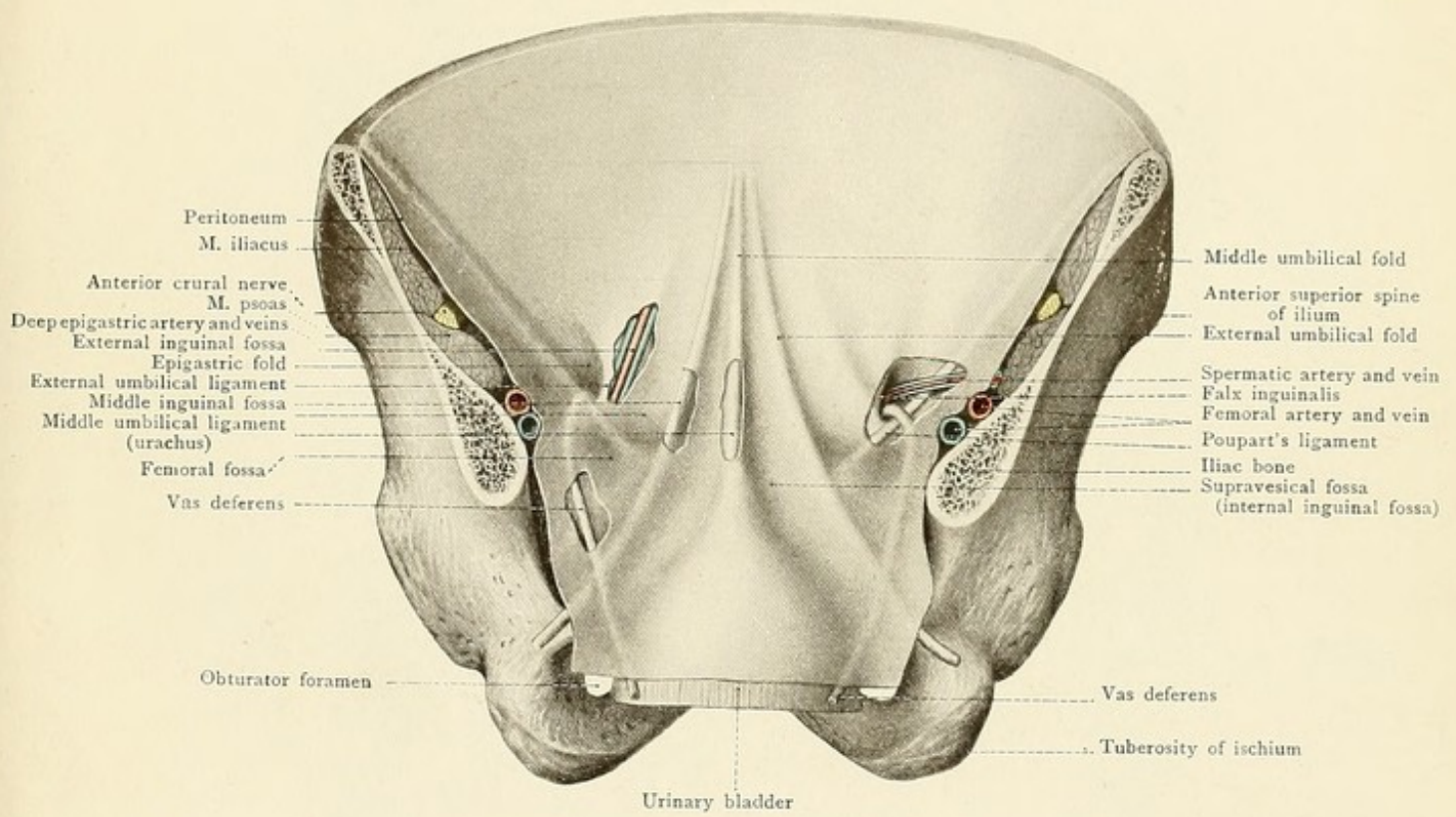
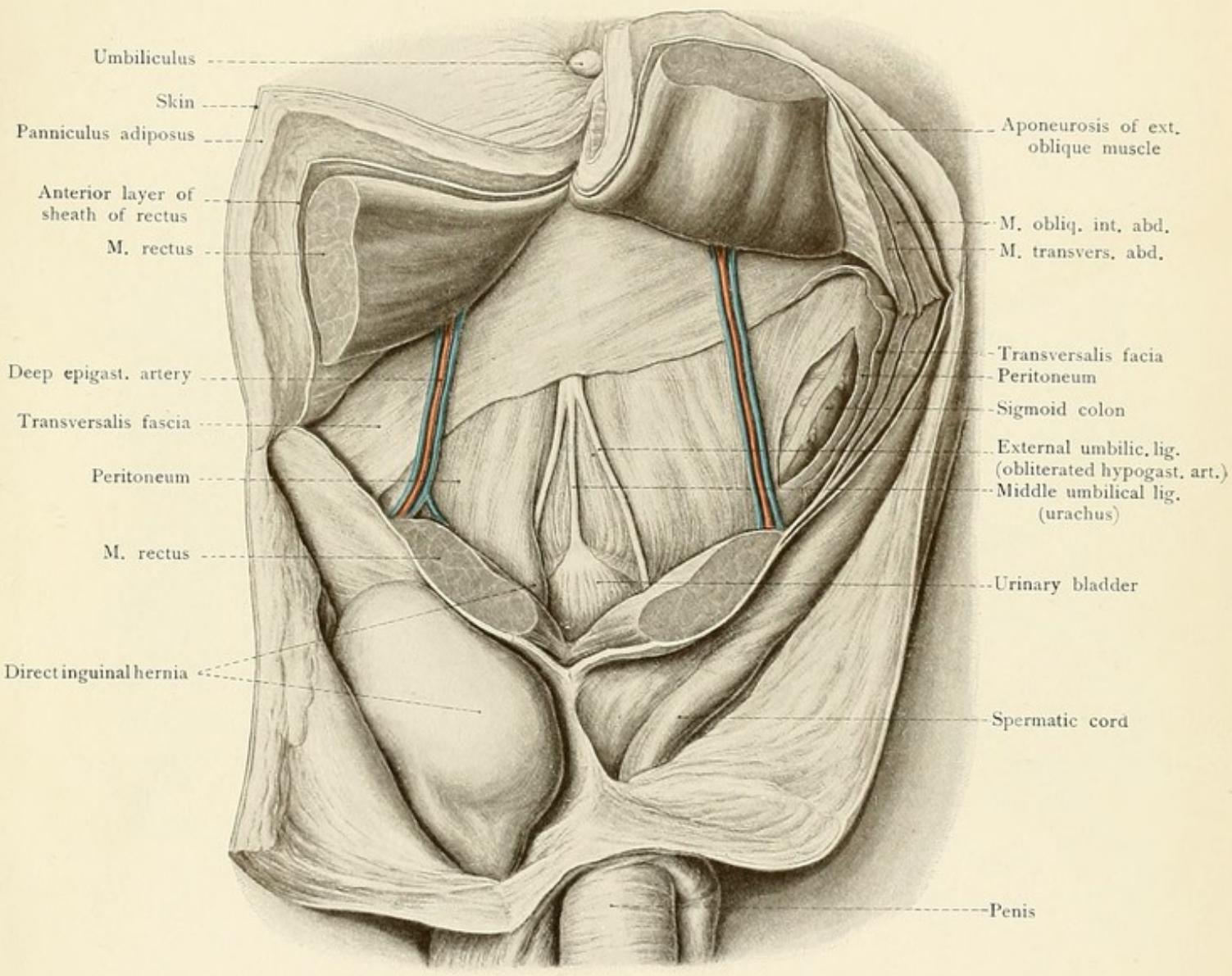








Fig. 57.









plica umbilicalis lateralis and the plica umbilicalis media. The three foveas which have just been mentioned are above Poupart's ligament and may be seen and felt upon the inner surface of the anterior abdominal wall. The *femoral fossa* (fovea femoralis) is below Poupart's ligament, opposite to the fovea inguinalis medialis. In this situation the peritoneum covers the *femoral ring* (annulus femoralis), which is also called the internal femoral ring (see page 143 and Figs. 56, 58, and 76). With the aid of Fig. 56 the reader should firmly fix in his mind that inguinal hernias pass out above Poupart's ligament, while the femoral variety makes its exit below this structure. The external inguinal fossa gives passage to the external oblique or indirect inguinal hernia; the internal inguinal fossa is the site of the internal or direct inguinal hernia. The very rare internal oblique inguinal hernia (hernia inguinalis obliqua medialis) passes out through the fovea suprapavesicalis.

### THE PERITONEUM.

The peritoneum is attached to the inner surface of the abdominal wall by loose connective tissue and is consequently more or less movable. It is also very elastic, as may be seen after recovery from ascites, pregnancy, or tumors, where the previously distended peritoneum forms no persisting folds. The relation of the peritoneum to the viscera is similar to that of the pleura to the lungs, so that we differentiate a parietal layer, covering the inner surface of the abdominal wall, and a visceral layer, reflected over the abdominal organs. If we imagine that most of the viscera grow into the peritoneal cavity from behind, it will be apparent that they are connected to the posterior abdominal wall by reflections of the peritoneum. These peritoneal duplicatures are known in general as *peritoneal ligaments*; that of the intestine is called the *mesentery*, while that of the colon is the *mesocolon*. If the ligament is very long, the organ is naturally more movable (the mesentery of the intestine, for example); while if it is short and broad, the organ is more fixed (the coronary ligament of the liver). The organs are also connected with each other by similar peritoneal ligaments or duplicatures (liver and stomach, stomach and colon). If the viscera remain against the posterior abdominal wall so that only a small portion of their ventral surfaces possesses a peritoneal covering, we say that they are situated outside of the peritoneal cavity (the pancreas and the kidneys). This relation and the following ones will be made clearer by a study of Fig. 59.

If we open the *peritoneal cavity* by an incision in the linea alba, we find behind the ligamentum duodenale\* (passing from the inferior surface of the liver to the duodenum) a foramen which is called the *foramen epiploicum*, or foramen of Winslow. This leads us into a second space, separated from the general peritoneal cavity in its course of development, which is known as the *bursa omentalis* or *lesser peritoneal cavity*, and extends downward behind the stomach, originally as far as the free border of the great omentum. In rare cases viscera (intestines) have been found projecting through a dilated foramen of Winslow into the lesser peritoneal cavity (a variety of internal hernia), and in such cases symptoms of strangulation may be produced by the constriction at the foramen of Winslow. The great rarity of this hernia is due to the protected position of the foramen and to the overlying liver.

Under normal conditions the abdominal viscera fill the abdominal cavity in such a manner

\* Better known to American and English readers as the right free edge of the gastro-hepatic omentum.



FIG. 59.—First diagram for the representation of the peritoneum. The bursa omentalis is outlined in red, the remaining portion of the peritoneal cavity in blue.

FIG. 60.—Second diagram for the representation of the peritoneum. As in Fig. 59, the bursa omentalis is outlined in red.

that they are separated only by capillary spaces; complementary spaces or sinuses, similar to those found in the pleural cavities, do not exist. These capillary spaces between the viscera are filled normally by a sparing amount of peritoneal fluid; a pathologic increase in the amount of this fluid is known as abdominal dropsy or ascites.

In the median line above the navel (Fig. 60) the parietal layer of the peritoneum passes from the inner surface of the anterior abdominal wall to the under surface of the diaphragm, which it covers as far as the openings for the esophagus and inferior vena cava. Since nothing but the thin lamina of the diaphragm separates the peritoneum from the pleura and pericardium, it will be understood that an inflammation originating in the peritoneum may pass through the diaphragm and extend to the pleura and pericardium. In the median plane the peritoneum above the navel, between the inner surface of the anterior abdominal wall and the inferior surface of the liver, forms the *falciform* or *suspensory ligament of the liver* (ligamentum falciforme hepatis), in the free posterior margin of which is situated the *round ligament* (ligamentum teres), originally the umbilical vein. From the inferior surface of the diaphragm the peritoneum passes to the posterior surface of the liver, which is in relation with the posterior abdominal wall, and thus forms the upper layer of the broad *coronary ligament* of the liver (ligamentum coronarium hepatis). The right and left free margins of this ligament are known as the *ligamenta triangularia*.\* From the upper surface of the liver the visceral peritoneum is reflected about the free anterior margin of the viscus to the inferior surface, which it covers as far as the porta hepatis, from which it passes to the lesser curvature of the stomach and to the upper portion of the duodenum, forming the anterior layer of the lesser or *gastrohepatic omentum* (ligamentum hepatogastricum and ligamentum hepatoduodenale). It then covers the anterior surface of the stomach and reaches the transverse colon in front of the greater curvature. From the transverse colon it passes downward as the anterior layer of the great or *gastrocolic omentum*, then upward from the free margin of the great omentum to the transverse colon, from which it passes backward to the posterior abdominal wall, forming the lower layer of the transverse mesocolon. Upon reaching the posterior abdominal wall, the peritoneum covers the anterior surface of the ascending portion of the duodenum. Below this region the peritoneum is reflected from the vertebral column about the small intestine, forming both layers of the mesentery. The attachment of the mesentery to the posterior abdominal wall, the *radix mesenterii*, extends downward from the left border of the second lumbar vertebra to the right sacroiliac articulation. As a result of this oblique insertion, extravasations of blood originating upon the right side of the mesentery pass into the right iliac region, while those upon the left side find an open path to the pelvic cavity. The longest portion of the mesentery is situated about twenty centimeters above the appendix, and this portion of the ileum is consequently the one most frequently found in inguinal hernia. [According to Treves, the longest part of the mesentery is found at two points, one six, the other eleven feet from the duodenum. The folds of small intestine corresponding to these may and often do reach the

\*The right and left lateral ligaments of the liver.



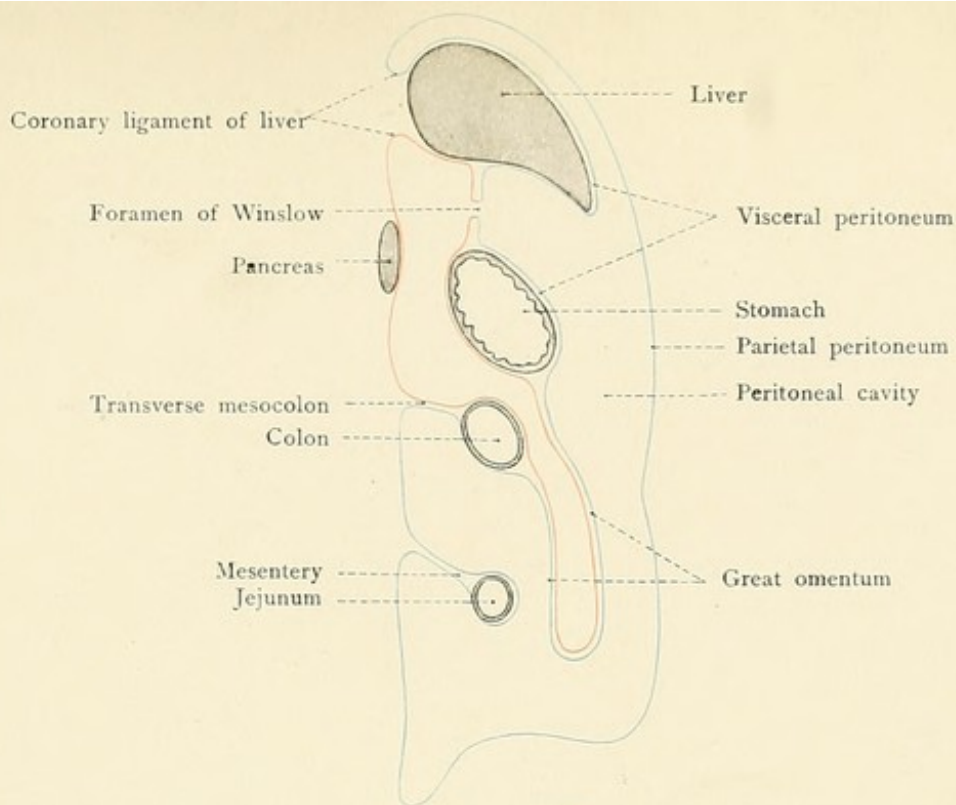


Fig. 59.

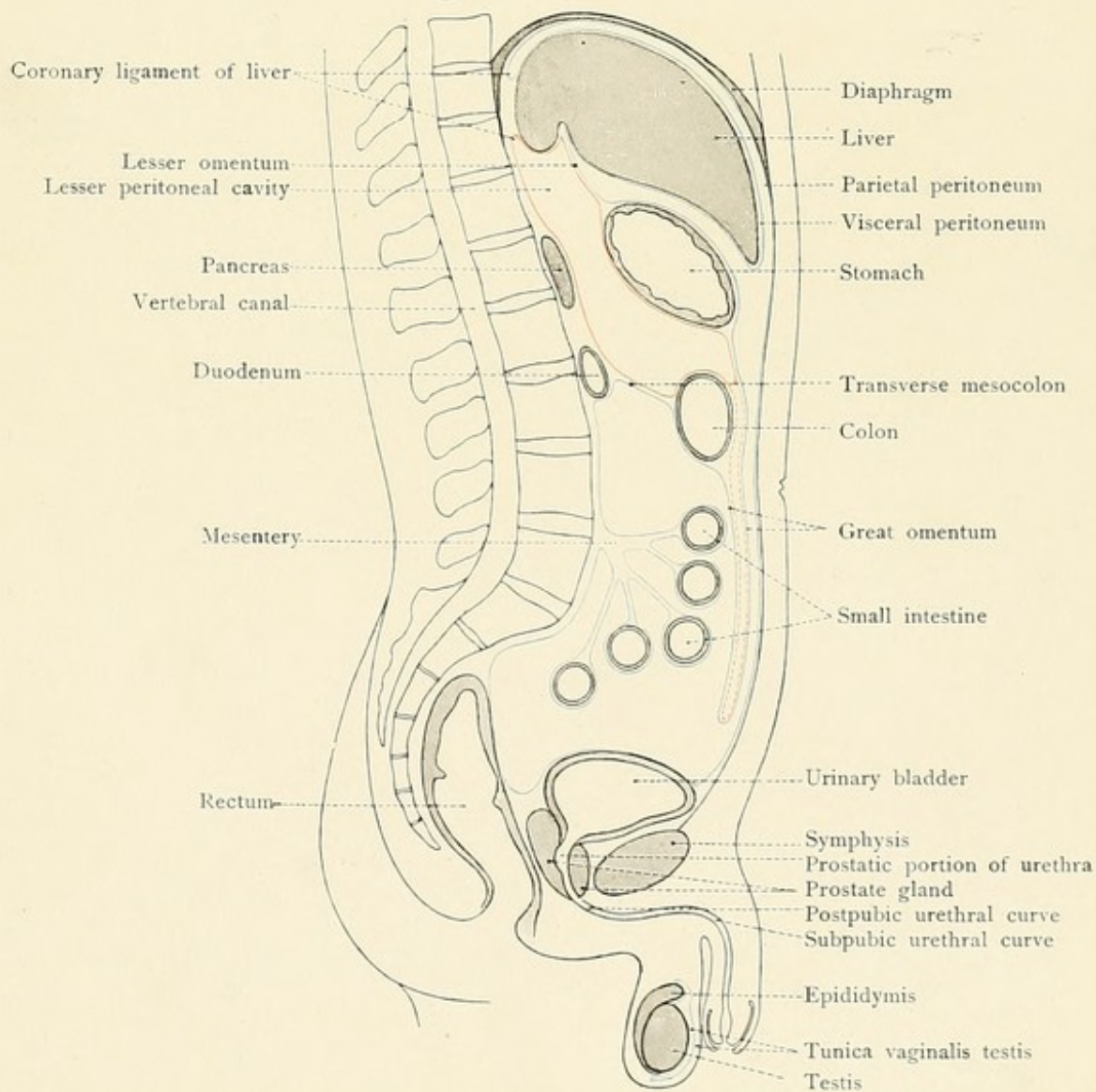


Fig. 60.







pelvis. The attachment of the mesentery for the lower end of the ileum is placed so much nearer the pelvic cavity that this portion of the bowel, even with a shorter mesentery, occupies the pelvis and is often found in an inguinal or femoral hernia.—ED.] After partly surrounding the pelvic viscera (see page 147 for detailed description), the peritoneum passes from the upper surface of the bladder to the inner surface of the anterior abdominal wall and upward to the umbilicus.

Upon the *right side* the peritoneum passes from the porta hepatis to the superior portion of the duodenum and forms the anterior layer of the *ligamentum hepatoduodenale*. There is no sharp line of demarcation between this ligament and the *ligamentum hepatogastricum*, but the *ligamentum hepatoduodenale* is thicker and contains the *ductus choledochus* in its right free border. Further to the left the *hepatic artery* is enclosed between the layers of the same ligament, while the *portal vein* passes to the liver between and somewhat behind the artery and duct. We will now trace the peritoneum through the foramen of Winslow into the bursa omentalis. This posterior layer of the peritoneum is indicated in the diagrammatic drawing (Fig. 60) by a red line. It first forms the posterior layer of the gastrohepatic omentum, then covers the posterior surface of the stomach, and passes from the greater curvature to the transverse colon as the posterior layer of the narrow *ligamentum gastrocolicum*. As a rule, the bursa omentalis does not extend into the great omentum in adult life; this portion of the peritoneum is consequently represented in Fig. 60 by a red dotted line. After the disappearance of the lumen of the bursa omentalis the anterior and posterior layers of the great omentum become adherent and the posterior layer also adheres to the anterior surface of the transverse colon; in this manner the *ligamentum gastrocolicum* is formed (compare Fig. 59 with Fig. 60). At the bottom of the bursa omentalis the peritoneum forms the upper layer of the transverse mesocolon; it then passes to the vertebral column, covers the anterior surface of the pancreas, forms the inferior layer of the *ligamentum coronarium hepatis*, and is finally reflected over the caudate lobe of the liver. If the liver is displaced upward, the caudate lobe may therefore be seen lying in the bursa omentalis, beneath the gastrohepatic omentum; it is also easy to see the pancreas through the same omentum in the posterior portion of the bursa omentalis by displacing the stomach somewhat downward. The upper portion of the duodenum also receives a peritoneal covering from the bursa omentalis which extends toward the left as far as the kidney and the spleen, where it forms the posterior layer of the *ligamentum gastrosplenicum*\* which connects the stomach with the spleen (see page 133). In Fig. 60 it is clearly shown that, in addition to the foramen of Winslow, the lesser peritoneal cavity may be opened from the front in three places: (1) Through the lesser omentum; (2) through the *ligamentum gastrocolicum*; and (3) through the transverse mesocolon. Upon the right side the peritoneum passes from the inferior surface of the liver to the anterior surface of the right kidney; it then runs to the hepatic flexure of the colon and the flexura duodeni superior and is reflected over the anterior surface and sides of the ascending colon, so that this portion of the intestine has a comparatively broad attachment to the posterior abdominal wall. In the right iliac fossa the cecum with the processus vermiformis, which possesses its own mesenterium, is usually completely surrounded by peritoneum.

Upon the left side the parietal peritoneum is reflected from the inferior surface of the duodenum to the stomach, from which it passes to the spleen, forming the *ligamentum phrenico-*

\*Gastrosplenic omentum.



## PLATE 14.

The position of the abdominal viscera of a boy. Anterior view. The lungs, the heart, and the anterior half of the diaphragm have been removed; the small intestine has been cut away at the root of the mesentery. From an accurate Leipzig model made from an original dissection (His).

## PLATE 15.

The position of the kidneys, pancreas, spleen, duodenum, and colon as seen after the removal of the liver, stomach, and transverse colon. From the model of Plate 14.

*lienale*. The spleen is almost completely enveloped by the peritoneum, which passes back to the stomach as the anterior layer of the *ligamentum gastrosplenale*. At the inferior pole of the spleen the ligamentum phrenicolicum passes from the diaphragm to the splenic flexure of the colon; this is the ligament which supports the spleen from below. After covering the splenic flexure of the colon, the peritoneum passes to the descending colon, which, like the ascending colon, possesses only an anterior and lateral peritoneal covering, so that neither colon is visible from in front after opening the peritoneal cavity. The long mesocolon of the sigmoid flexure (*S. romanum*), on the contrary, permits a wider range of motion, so that this portion of the intestine is often found in the dead subject to the right of the median line.

## THE CONTENTS OF THE ABDOMEN.

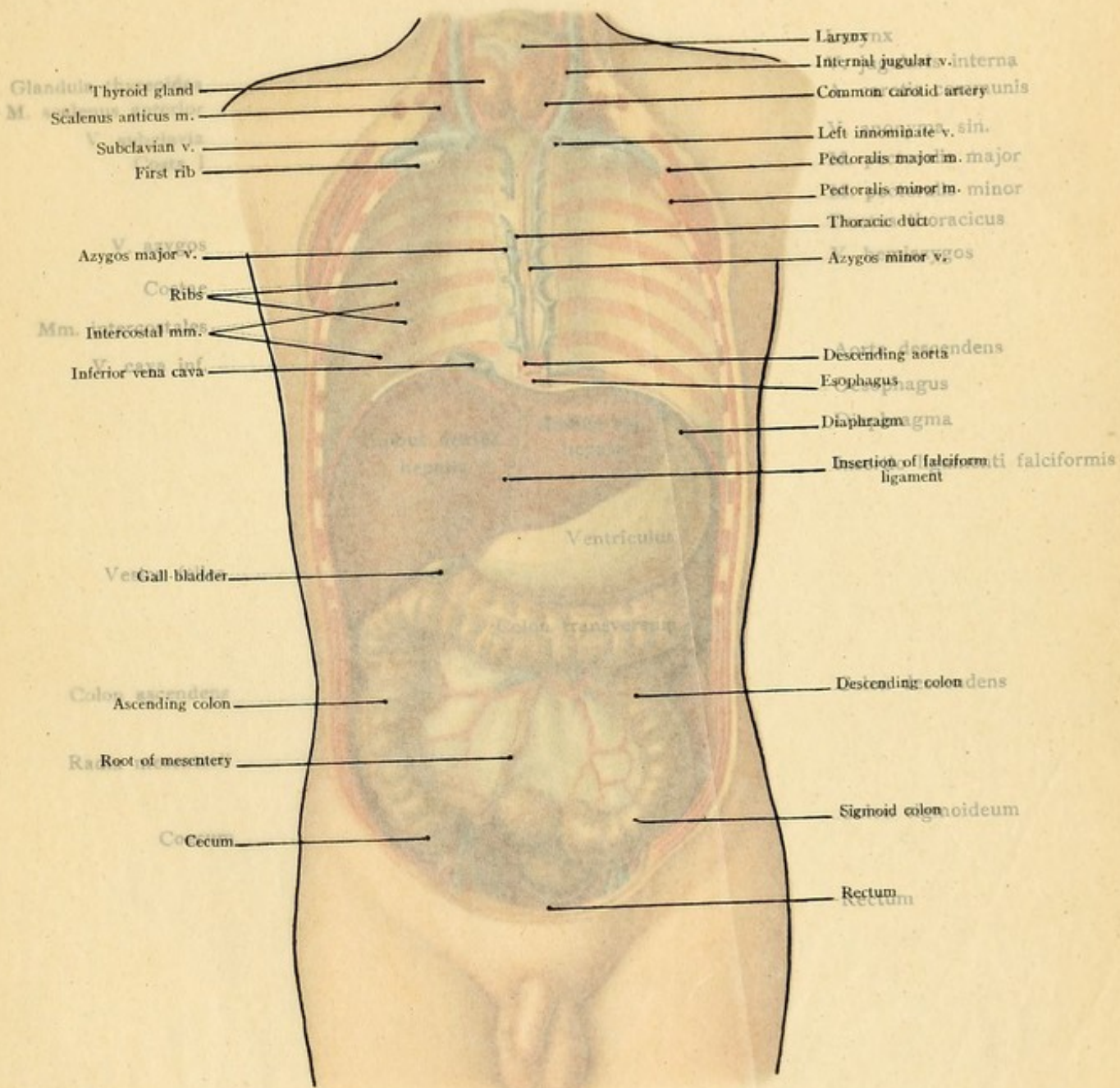
**The Stomach.**—The stomach is situated in the epigastrium and the left hypochondriac region in such a manner that only one-sixth of the viscus is to the right of the median line. The *fundus* of the stomach touches the diaphragm (Fig. 49) and borders indirectly upon the heart and the left lung; this partly explains the increased cardiac activity and accelerated respiration which are produced by the pressure of a full stomach. A large portion of the anterior gastric surface is covered by the liver. Toward the left, the fundus is in relation with the concave *facies gastrica* of the spleen (Plates 11, 13, 14, 15, and 16).

The *cardia* lies to the left of the median line at the level of the eleventh dorsal vertebra and at quite a distance (about 12 centimeters dorsalward) from the inner surface of the anterior abdominal wall (Plate 17). When projected upon the anterior surface of the body, the cardia is situated one fingerbreadth below the sternal attachment of the left seventh costal cartilage.

The *pylorus* is below and in front of the cardia (Plate 17); it lies to the right of the median line at the level of the body of the first lumbar vertebra; in the right sternal line this point corresponds to the level of the anterior extremity of the ninth costal cartilage. From the relative position of the cardia and pylorus it will be seen that the lesser curvature of the stomach pursues more of a vertical than of a horizontal direction. The *greater curvature*, the lower limit of the normal stomach, reaches to the transverse line connecting the lowest points of the ninth or tenth ribs (Plate 11); it consequently does not extend to the transverse line connecting the lowest points of the inferior aperture of the thorax. In this line is found the transverse colon, which borders upon the greater curvature (Plate 11). [The pyloric portion of the stomach is bisected by a horizontal plane, the transpyloric, which passes through the abdomen midway between the supra-sternal notch and the pubic symphysis.—ED.]

The *anterior surface* of the stomach below the lesser curvature is covered by the left, and also by a part of the right lobe of the liver. In the epigastrium, below the xiphoid process, the





Glandula Thyroid gland  
 M. Scalenus anticus m.  
 Subclavian v.  
 First rib

V. azygos  
 Azygos major v.  
 Ribs  
 Mm. Intercostal mm.  
 V. cava inf.  
 Inferior vena cava

Ves. Gall bladder

Colon ascendens  
 Ascending colon  
 Ra. Root of mesentery  
 Co. Cecum

Larynx  
 Internal jugular v. interna  
 Common carotid artery  
 Left innominate v. sin.  
 Pectoralis major m. major  
 Pectoralis minor m. minor

Thoracic duct thoracicus  
 Azygos minor v. azygos

Descending aorta  
 Esophagus

Diaphragma  
 Insertion of falciform ligament

Colon descendens  
 Descending colon

Sigmoid colon  
 Sigmoid colon  
 Rectum



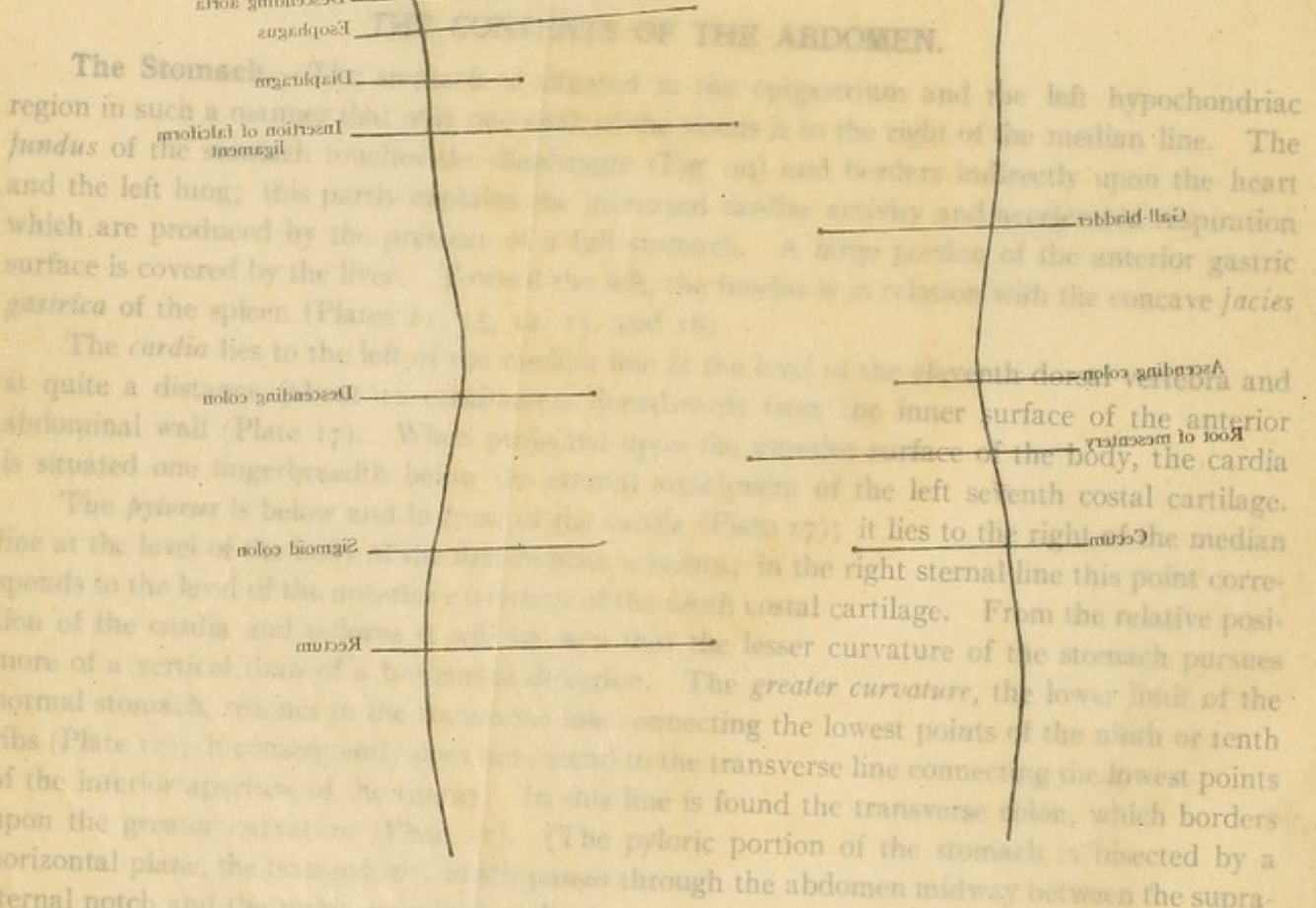
PLATE 14.

The position of the abdominal viscera of a boy. Anterior view. The lungs, the heart, and the anterior half of the diaphragm have been removed; the small intestine has been cut away at the root of the mesentery. From an accurate Leipzig model made from an original dissection (H. L.)

PLATE 15.

The position of the kidneys, pancreas, spleen, duodenum, and colon as seen after the removal of the liver, stomach, and transverse colon. From the model of Plate 14.

lienale. The spleen is enveloped by the peritoneum, which is attached to the stomach as the *ligamentum gastrosplenicum*. At the inferior pole of the spleen the *ligamentum splenicum* passes from the diaphragm to the splenic flexure of the colon; this is the *ligamentum transversocolicum*. From below: After covering the splenic flexure of the colon, the descending colon, which, like the ascending colon, possesses only a peritoneal covering, so that neither colon is free from in front after the removal of the greater omentum. The long mesocolon of the sigmoid flexure (S. romanum), or *mesocolon sigmoideum*, is that portion of the intestine is often found in the dead subject to the right of the median line.

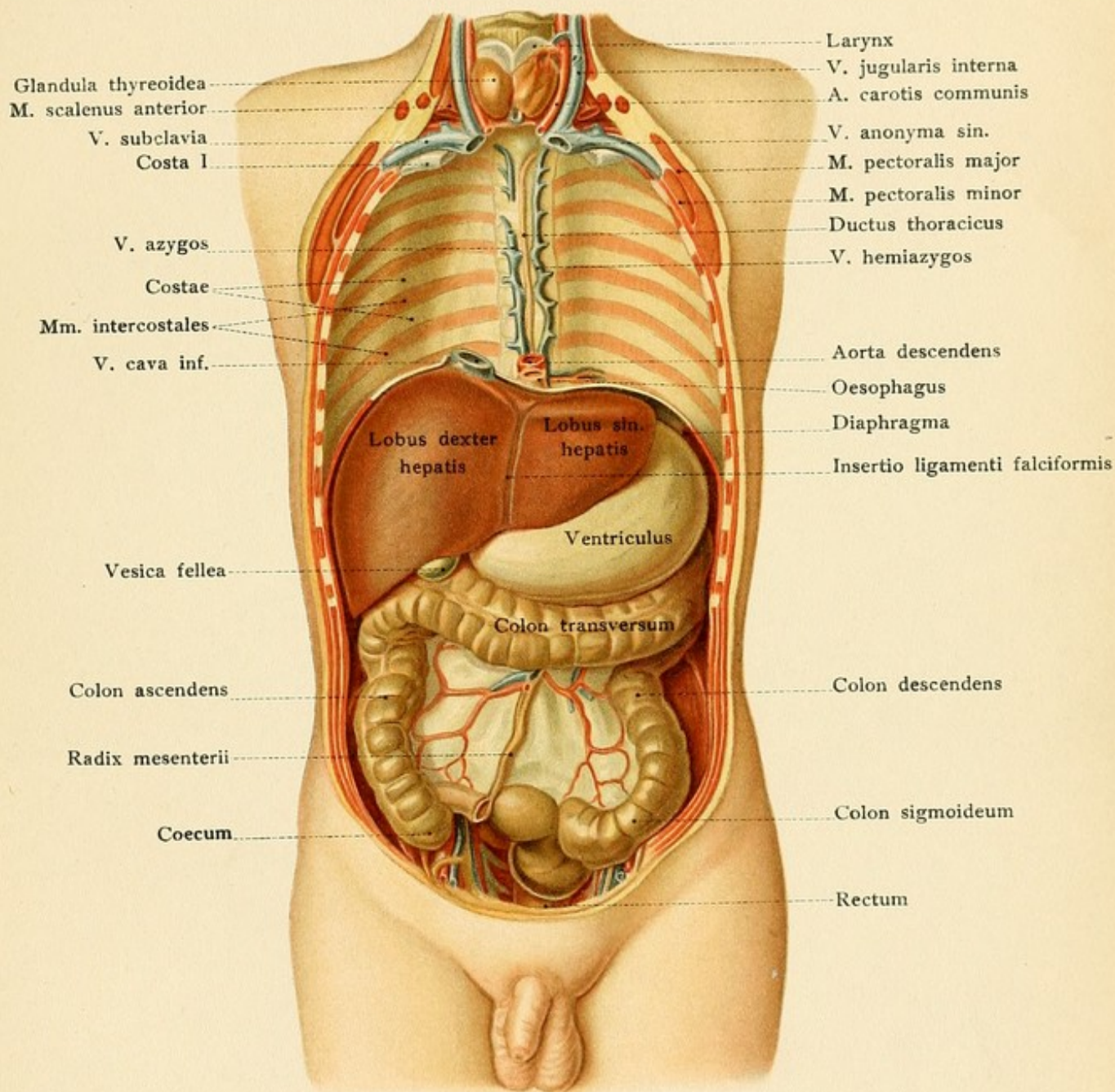


The Stomach

region in such a manner that the greater curvature is to the right of the median line. The fundus of the stomach is situated upon the heart and the left lung; this partly explains the elevation of the epigastrium and the elevation of the diaphragm which are produced by the pressure of a full stomach. A large portion of the anterior gastric surface is covered by the liver. The lesser curvature is in relation with the concave *facies gastrica* of the spleen (Plates 14, 15, 16, 17, and 18). The *cardia* lies to the left of the median line at the level of the seventh dorsal vertebra and at quite a distance from the abdominal wall (Plate 17). The *pylorus* is below and to the right of the *cardia* and is situated one fingerbreadth below the attachment of the left seventh costal cartilage. The *pylorus* lies to the right of the median line at the level of the tenth costal cartilage. From the relative position of the *cardia* and *pylorus* it is seen that the lesser curvature of the stomach pursues a curved line connecting the lowest points of the ninth or tenth ribs (Plate 17). The *pyloric* portion of the stomach is bisected by a horizontal plane, the transverse plane, which passes through the abdomen midway between the supra-sternal notch and the umbilicus (Fig. 1).

The anterior surface of the stomach below the lesser curvature is covered by the left, and also by a part of the right lobe of the liver. In the epigastrium, below the xiphoid process, the

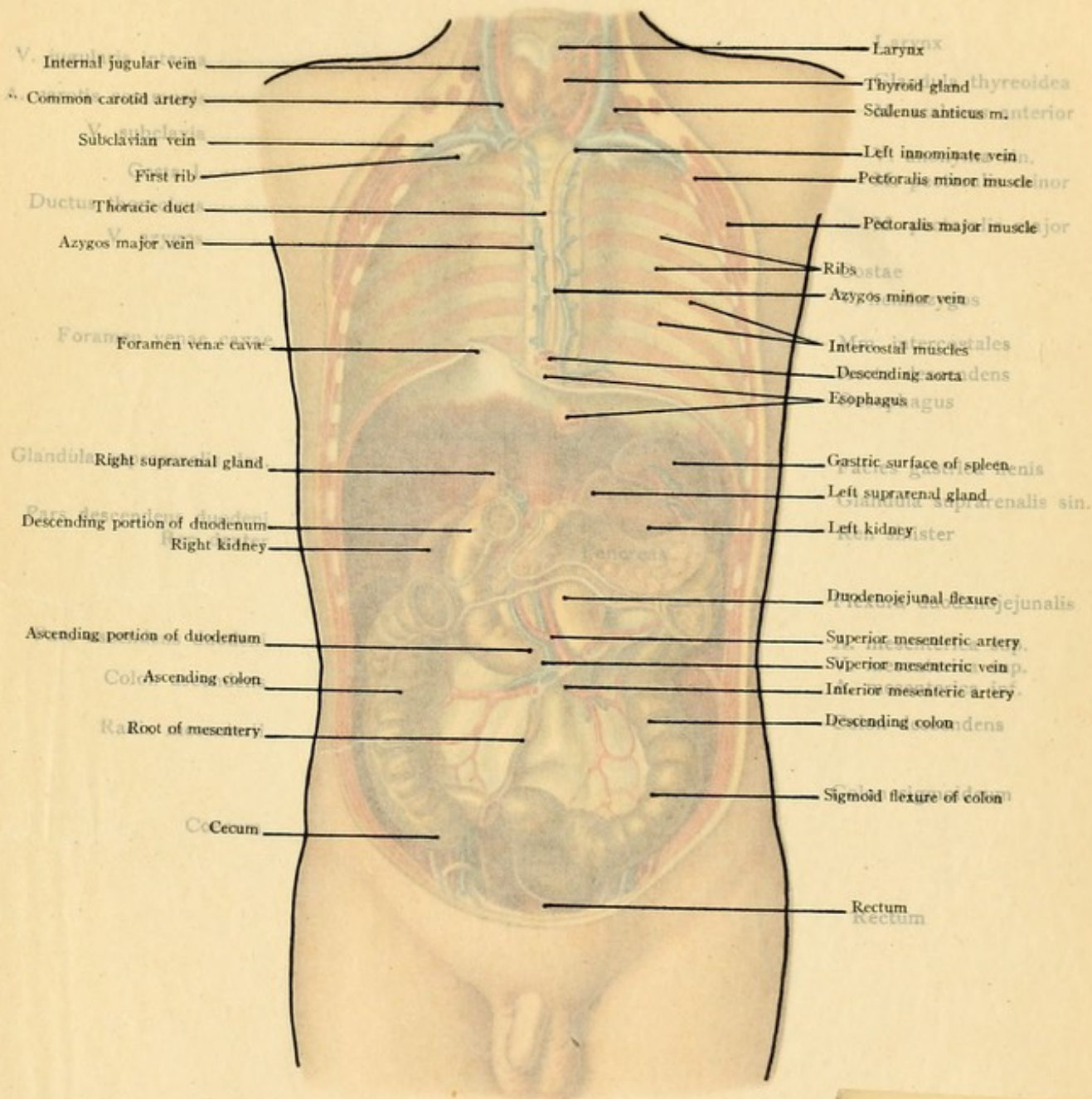




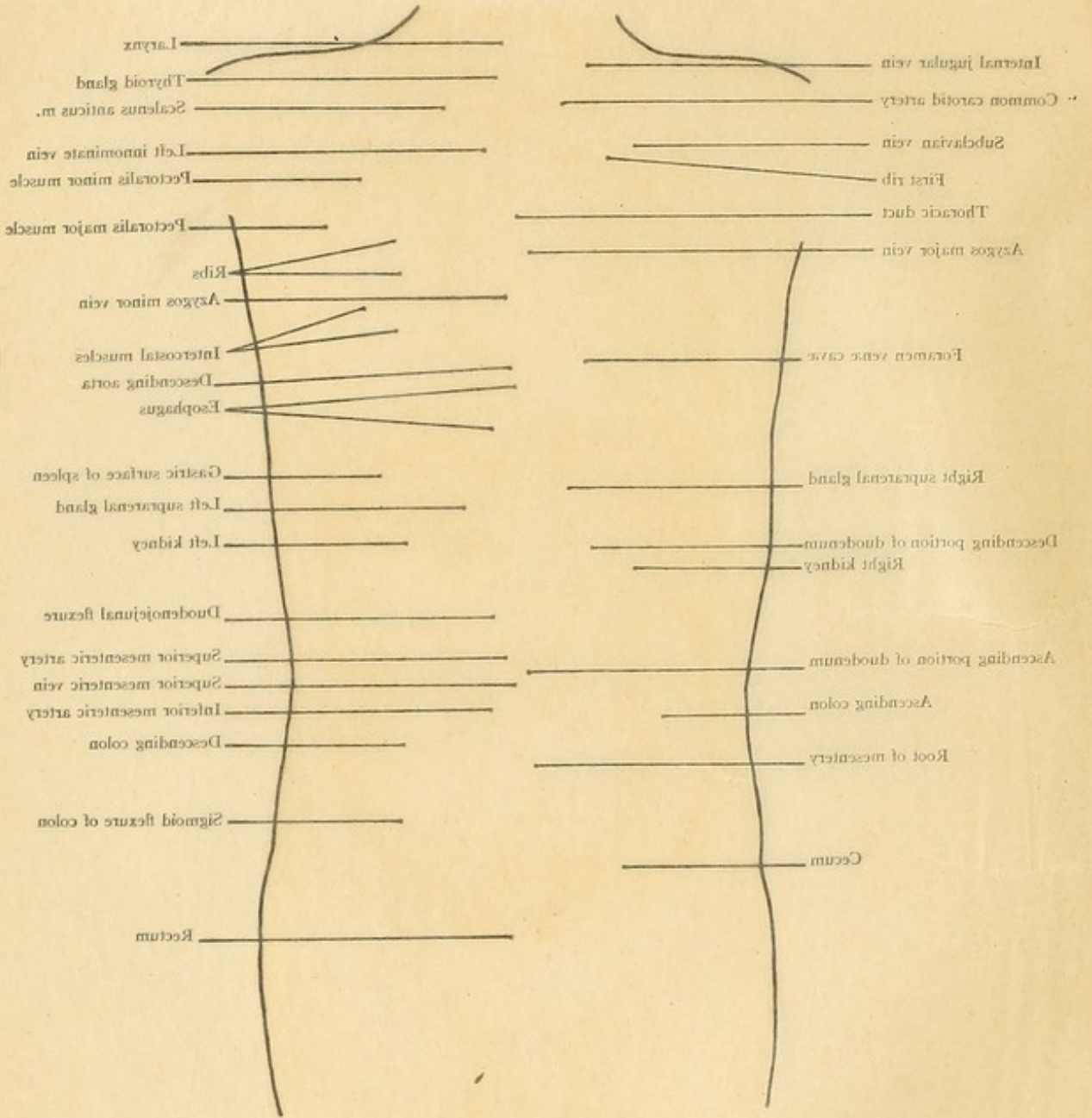




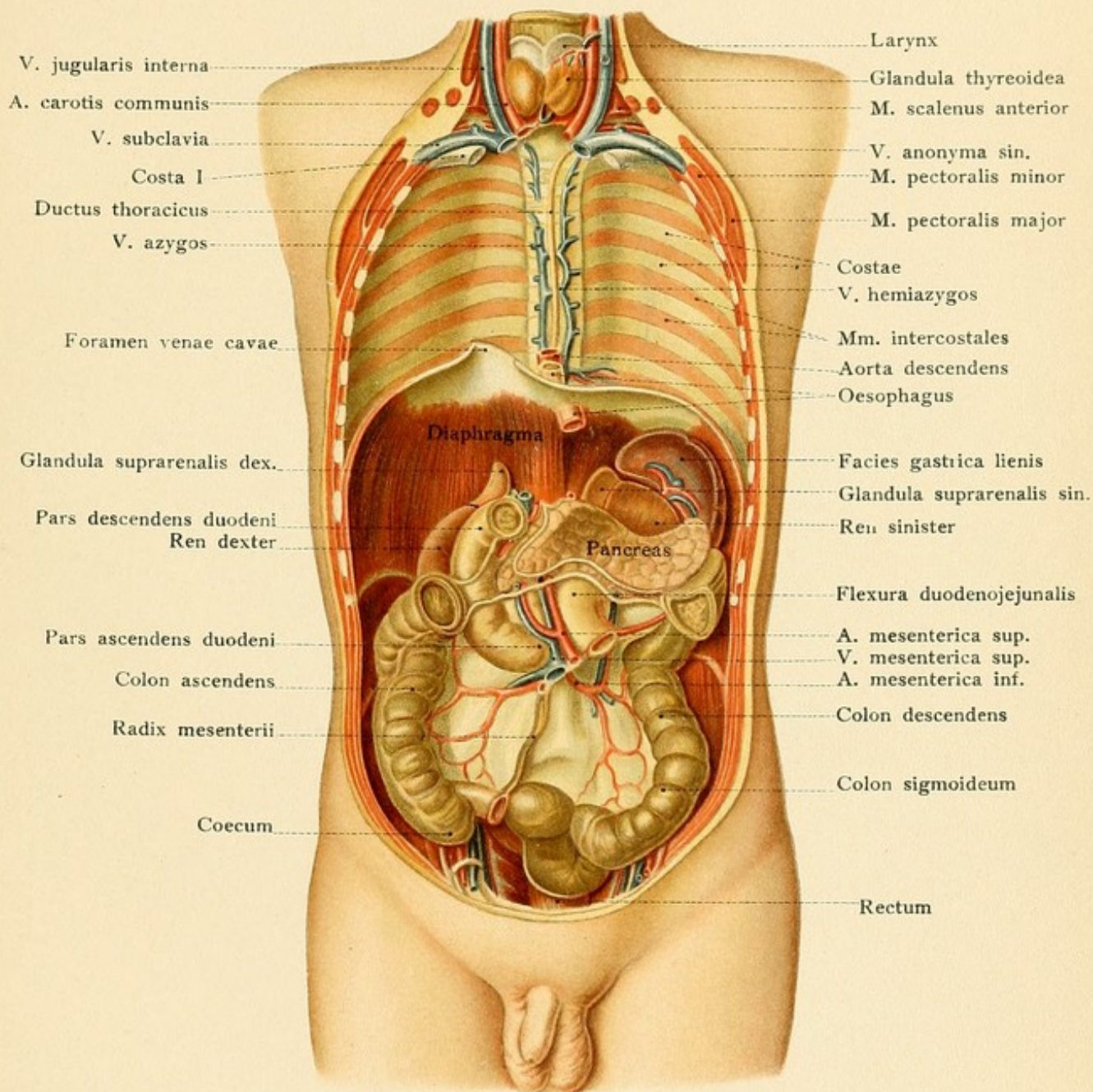


















stomach is consequently not in immediate contact with the anterior abdominal wall (Plate 11); somewhat downward and to the left, however, there is a typically formed triangular area of the gastric surface which rests against the inner surface of the abdominal wall. It is bounded to the right by the inferior margin of the liver, to the left by the eighth to the tenth costal cartilages, and below by the transverse colon. It is in this situation that gastrotomy may most easily be performed for the establishment of a fistula or for the removal of a foreign body. Beneath the costal margin in the left hypochondriac region the stomach is covered not only by the ribs and intercostal muscles, but also by the left lung, by the left pleural cavity, and by the diaphragm, so that penetrating wounds in this region may injure the pleura, the lung, and the stomach, and the gastric contents may escape into the pleural cavity. The so-called *space of Traube* is situated in the left hypochondriac region and represents that portion of the stomach which is not covered by the neighboring viscera (Plate 13, left illustration, and Plate 11). It is bounded above and to the left by the inferior margin of the left lung, above and to the right by the inferior margin of the left lobe of the liver, below and to the right by the costal margin, and posteriorly and to the left by the spleen.

The *posterior surface* of the stomach borders upon the bursa omentalis (Figs. 60 and 62) which separates it from the anterior surface of the pancreas, the *facies gastrica* of the spleen, the duodenojejunal flexure, and the upper portion of the anterior surface of the kidney.

For clinical purposes it is important to remember that the normal stomach is separated anteriorly and posteriorly from the neighboring organs by capillary spaces, but in such a manner that a direct relation and contact is a possible and more or less frequent occurrence during life. In this manner may be explained the adhesions between the stomach and neighboring organs and their manifold sequelæ in cases of gastric ulcer. After adhesions with the pancreas and to the splenic vessels running along its upper border, a fatal hematemesis may occur from the perforation of the splenic artery by a gastric ulcer. A similar ulcer may become adherent to the transverse colon and perforate into this portion of the intestine, so that there is a direct communication between the stomach and the colon; the stomach may adhere to the diaphragm and the gastric ulcer may perforate into the pleural or into the pericardial cavity. If the lung has become adherent to the upper surface of the diaphragm, the inflammatory process will spread to the lungs and the bronchi and the gastric contents may gain access to the bronchi and be coughed up. If the anterior surface of the stomach contracts adhesions with the inner surface of the abdominal wall, it is possible for the inflammation to extend to the abdominal wall and end in external perforation.

The *arteries of the stomach* all arise from the *celiac axis*, the first of the three single branches of the abdominal aorta. (Where does the abdominal aorta begin and where does it end? What are the names of the four paired parietal branches and of the three single and three paired visceral branches?) The *celiac axis* arises from the anterior surface of the aorta just below the aortic opening in the diaphragm (Fig. 61) and immediately divides into three branches, the gastric, the hepatic, and the splenic arteries. The *gastric artery* (*A. gastrica sinistra*) runs from the left to the right along the lesser curvature at the attachment of the lesser omentum. The *hepatic artery* gives off the second of the two arteries of the lesser curvature, the *pyloric* (*A. gastrica dextra*), which passes to the left from the pylorus and anastomoses with the gastric artery. The



## PLATE 16.

The position of the thymus gland, heart, liver, stomach, spleen, and intestines of a fifteen-year-old girl as seen from the left. The left lung has been removed. From a Leipzig model from nature (His).

hepatic artery also supplies the liver as it runs in the ligamentum hepatoduodenale\* as the *arteria hepatica propria* and enters the liver at the transverse fissure. The third branch of the hepatic artery, the *gastroduodenal*, divides into the superior pancreatico-duodenal artery for the head of the pancreas and the *gastro-epiploica dextra*, which passes to the left along the greater curvature of the stomach. The *splenic artery*, the third terminal division of the celiac axis, runs along the upper margin of the pancreas behind the stomach (see page 129 and Fig. 61) to the hilus of the spleen and gives off the *gastro-epiploica sinistra*, which runs to the right along the greater curvature, supplying the stomach and the great omentum and anastomosing with the *gastro-epiploica dextra*.

The *veins* of the stomach are the *gastro-epiploica sinistra* and *dextra*, running along the greater curvature, and the *vena coronaria ventriculi* along the lesser one. At the cardia, the coronary vein anastomoses with the esophageal veins, and through these with the *vena azygos major* (see page 123 and Fig. 55). All of the gastric veins empty into the portal system. The pneumogastric nerves have been described upon page 116; the left pneumogastric passes chiefly to the anterior surface, while the right one supplies the posterior surface of the stomach.

**The Liver.**—The relations of the liver, the largest organ of the abdominal cavity, are of particular importance to the physician on account of the many diseases of this viscus, of which those of the biliary passages in particular are now treated by surgical measures. The organ lies chiefly in the right hypochondrium, but also extends across the epigastrium into the left hypochondriac region (Plates 11-14 and 16).

The *upper convex surface*, divided into the right and the left lobe by the falciform ligament, is in immediate relation with the diaphragm (Plates 10, 13, and 14, and Figs. 49 and 62). Since this structure projects upward into the thorax, the greater portion of the liver is surrounded by the ribs, but the right pleural sac (Figs. 49 and 62 and Plate 14) is interposed between the liver and the thoracic wall, so that penetrating wounds which pass between the ribs and involve the liver, as a rule, open this pleural cavity. The upper surface of the liver is not only in relation with the right lung, the diaphragm being interposed, but also with the heart, with the pericardial cavity (Fig. 62), and with a portion of the left lung. Hepatic abscesses may consequently perforate the diaphragm and rupture into the pleural cavities or into the pericardium. Such an occurrence is, of course, preceded by peritoneal adhesions between the upper surface of the liver and the lower surface of the diaphragm. An abscess of the liver may also perforate into a bronchus, so that pus from the liver may be expectorated; in such a case, the inferior surface of the lung must have contracted adhesions to the diaphragm. If one of the pleural cavities becomes filled with an exudate or with air (pneumothorax), the diaphragm and the liver must be displaced downward.

The details of the *inferior surface of the liver* are very peculiar and best fixed upon the mind when the organ has been left in place. While the inferior surface of a liver which has been

\* Free edge of lesser omentum.



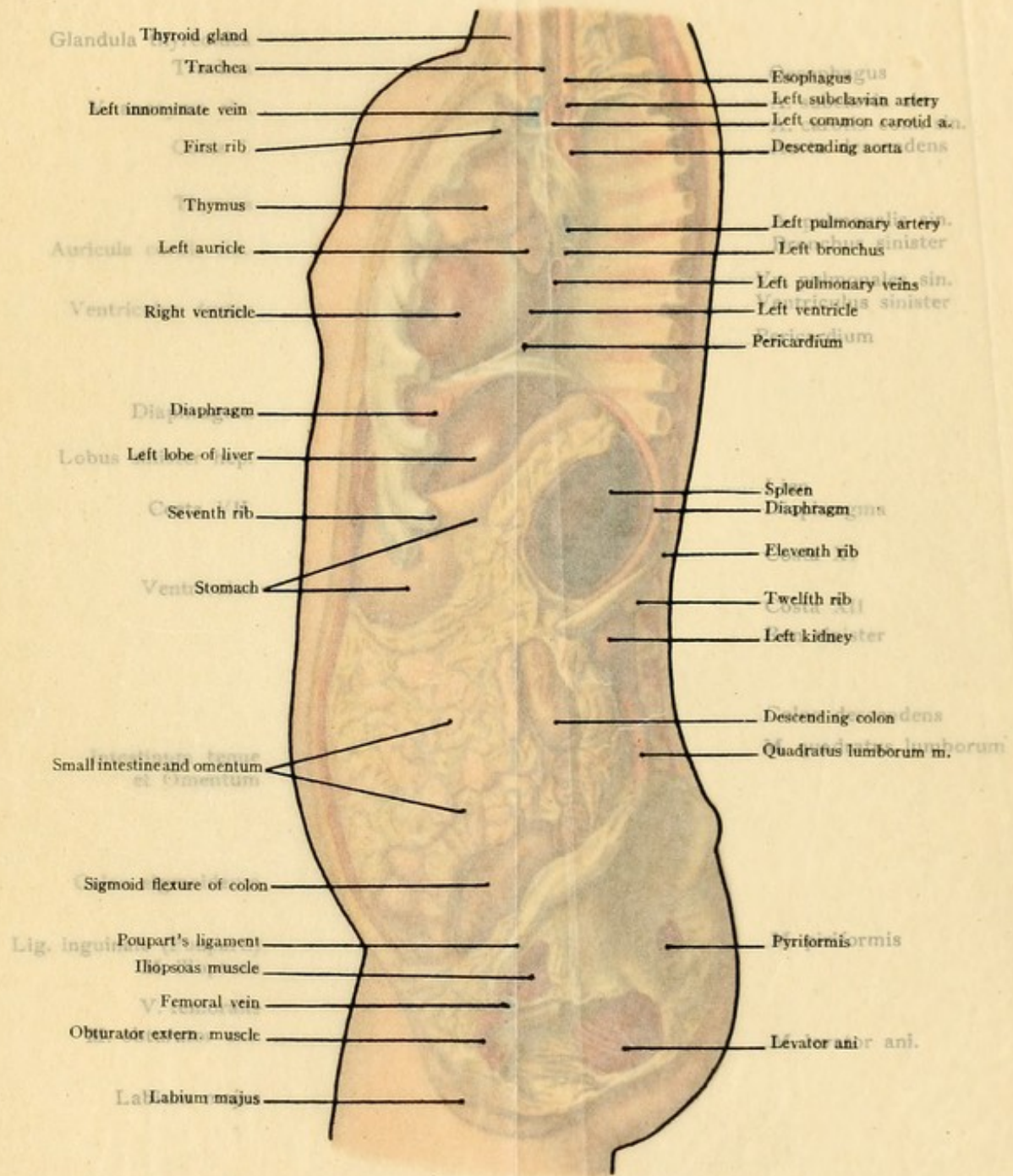




PLATE 26.

The position of the thymus gland, heart, liver, stomach, spleen, and intestines of a fifteen-year-old child from the left. The left lung has been removed. From a Leipzig model from nature (His).

16

hepatic artery also supplies the liver as it runs in the *ligamentum hepatoduodenale*\* as *arteria hepatica propria* and enters the liver at the transverse fissure. The third branch of the *arteria gastrica*, the *gastroepiploica dextra*, divides into the superior pancreaticoduodenal artery for the pancreas and the *arteria gastrica magna*, which passes to the left along the greater curvature of the stomach. The *arteria gastrica magna*, the third terminal division of the celiac axis, runs along the upper margin of the pancreas behind the stomach (see page 129 and Fig. 61) to the spleen and gives off the *arteria gastrica sinistra*, which runs to the right along the greater curvature, supplying the stomach and the great omentum and anastomosing with the *arteria gastrica magna*.

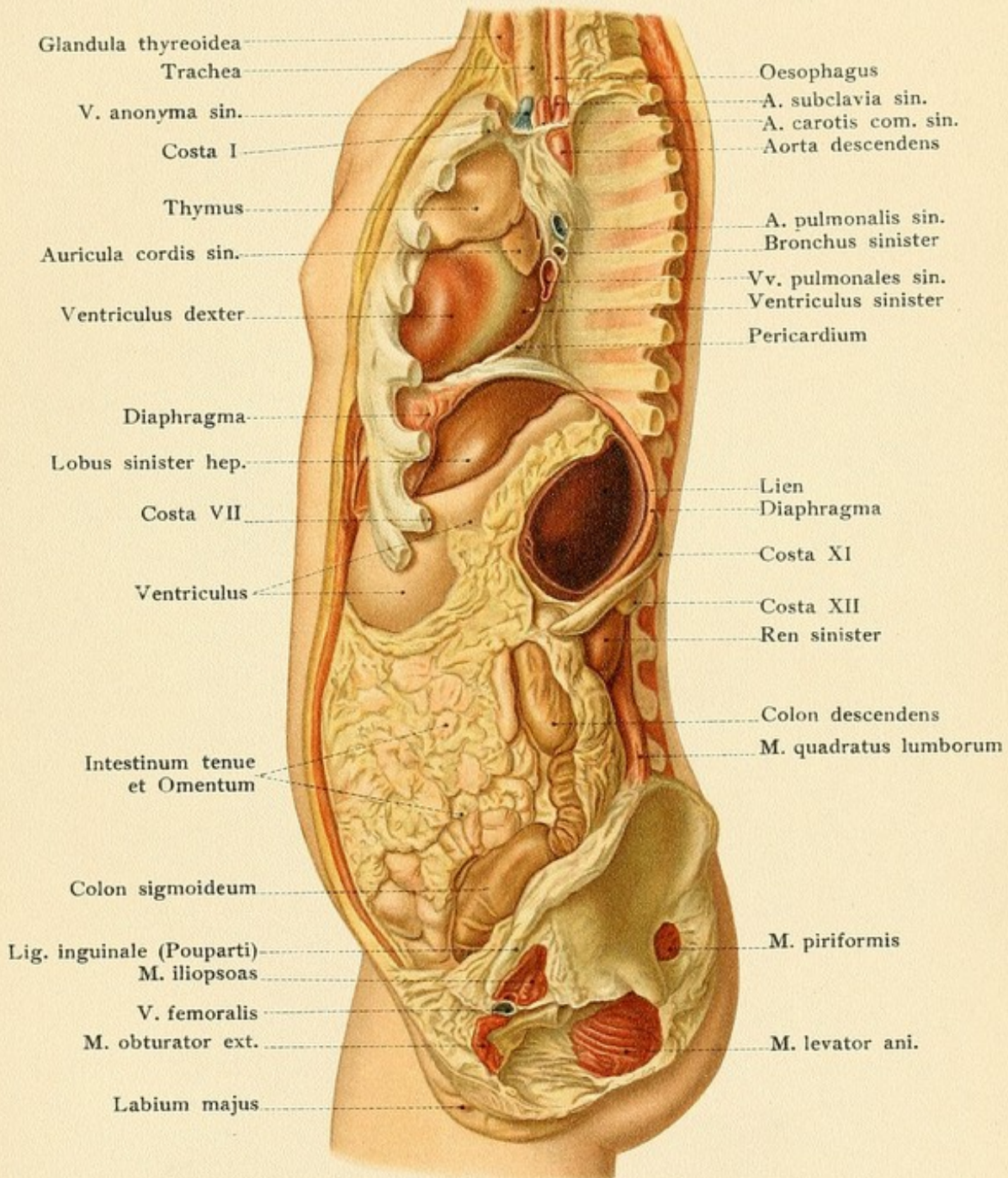
The veins of the stomach are the *gastroepiploica sinistra* and *dextra*, the *vena porta* along the greater curvature, and the *vena coronaria ventriculi* along the lesser curvature. The *vena coronaria ventriculi* anastomoses with the esophageal vein, and through the *vena porta* joins the *vena cava inferior* major (see page 123 and Fig. 55). All of the gastric veins contain the *plexus gastricus* and the pneumogastric nerves have been described upon page 123.

**The Liver.**—The relations of the liver, the largest organ of the abdominal cavity, are of particular importance to the physician, on account of the fact that the liver is situated in the right hypochondriac region (Plates 11-14 and 16). The *upper convex surface* is divided into the right and the left lobe by the *fissura falciformis* in immediate relation with the diaphragm (Plates 10, 13, and 14; Fig. 49). This structure projects upward into the thorax, the greater portion of it being situated between the ribs, but the right pleural sac (Figs. 49 and 50 and Plate 14) is interposed between the liver, as a rule, open this pleural cavity. The upper surface of the liver is in contact with the right lung, the diaphragm being interposed, but also with the heart, the *vena cava inferior* and the *vena cava superior* (Fig. 49). The *inferior concave surface* is perforated by the diaphragm and ruptured into the pleural cavity. The occurrence is, of course, preceded by peritoneal adhesions between the upper surface of the liver and the lower surface of the diaphragm. An abscess of the liver may also perforate the diaphragm, so that pus from the liver may be expectorated; in such a case, the right lung must have contracted adhesions to the diaphragm. If one of the pleural cavities is filled with an exudate or with air (pneumothorax), the diaphragm and the liver are placed downward.

The details of the *inferior surface of the liver* are very peculiar and best seen when the organ has been left in place. While the inferior surface of the liver is in contact with the diaphragm, the *vena porta* and the *arteria hepatica propria* are situated in the *ligamentum hepatoduodenale*. The *arteria hepatica propria* divides into the *arteria gastrica magna* and the *arteria gastrica sinistra*. The *arteria gastrica magna* gives off the *arteria gastrica sinistra* and the *arteria gastrica magna* anastomoses with the *arteria gastrica magna*. The *arteria gastrica magna* gives off the *arteria gastrica sinistra* and the *arteria gastrica magna* anastomoses with the *arteria gastrica magna*.

\* Free edge of lesser omentum.











removed from the body is usually flattened, on account of the doughy consistency of the viscus, the study of a liver hardened *in situ* is most instructive (Fig. 63). Particularly striking is the *impressio renalis* of the right kidney, and, in front of this, the *impressio colica* produced by the hepatic flexure of the colon. The duodenum, the pylorus, and the stomach are responsible for the impressiones duodenalis, pylorica, and gastrica, while the tuber omentale lies above the lesser curvature of the stomach opposite the gastro-hepatic omentum. In addition to these, there are the *impressio suprarenalis* of the right suprarenal body, the *impressio œsophagea*, the *fossa venæ umbilicalis* (in adult life containing the ligamentum teres, the remains of the umbilical vein), and the *fossa vesicæ jelleæ*, which lodges the gall-bladder.

At the porta hepatis the artery lies to the left, the ductus choledochus to the right, and the portal vein behind and between these structures (see page 136 and Fig. 64). The lobus caudatus (Spigelii), which is in relation with the bursa omentalis, together with the inferior vena cava, borders upon the vertebral column and is vertically placed. These parts are in relation with the so-called posterior surface of the liver. The physician directs his examination of the liver chiefly to the anterior (inferior) sharp margin, the position of which is influenced by pathologic enlargements or diminutions in size of the organ. In the axillary line the lower margin is at the level of the eleventh rib; in the right mammary line the inferior border of the liver leaves the costal margin, passes obliquely upward and to the left, crosses the median line midway between the navel and the base of the xiphoid process, and reaches the left costal margin in the parasternal line. It will be observed that the portion of the liver below the sternum is in immediate contact with the muscular abdominal wall ("scrobiculus cordis," see page 91). The gall-bladder projects slightly beyond the inferior margin of the liver and is situated in the right parasternal line, a fingerbreadth to the inner side of the point where the liver extends beyond the costal margin. The normal liver is not palpable at the costal margin in the mammary line.

If the intestines are distended with an abnormal amount of gas (meteorismus) or if the peritoneal cavity contains an excessive quantity of fluid (ascites), the liver will be pushed upward and its inferior margin will be correspondingly displaced; the liver will also press upward upon the heart and lungs.

The *gall-bladder* is in immediate relation with that portion of the inner surface of the abdominal wall which has just been indicated, and is here easily accessible to the surgeon. It may become adherent to the abdominal wall and, after inflammatory processes, gall-stones may pass through the abdominal wall so that a biliary fistula is formed which discharges bile externally. Inspection of the inferior surface of the liver and of the depressions in the vicinity of the gall-bladder (Fig. 63) shows that gall-stones or pus (empyema of the gall-bladder) may pass through the wall of the gall-bladder into the duodenum, into the colon, into the stomach, and even into the pelvis of the kidney. Such events are always preceded by peritoneal adhesions between the gall-bladder and the affected viscus.

There are a number of *lymphatic glands* in the transverse fissure (Fig. 64), enlargements of which may produce disagreeable consequences, since they may press upon the common or hepatic duct, causing biliary stasis (and even death), or compress the vessels and lead to inflammation of the portal vein (pylephlebitis).

[Several other points with reference to the anatomy of the liver may be recalled with



FIG. 61.—The porta hepatis, the pancreas, the duodenum, the kidneys, the spleen, and the suprarenal bodies with their vessels (formalin preparation).

interest: (1) The falciform ligament, which is attached to the superior surface, does not lie in the median sagittal plane of the body, but somewhat to the right; it may hinder exploration of the superior surface of the right lobe through a median incision, and to secure better access to this surface it may be necessary to cut this ligament; corresponding as it does to the umbilical fissure, it serves as a guide to the latter and therefore to the gall-bladder, which lies, of course, further to the right. (2) Subphrenic abscesses between the diaphragm and right lobe, and abscesses of the right lobe itself, are frequently more

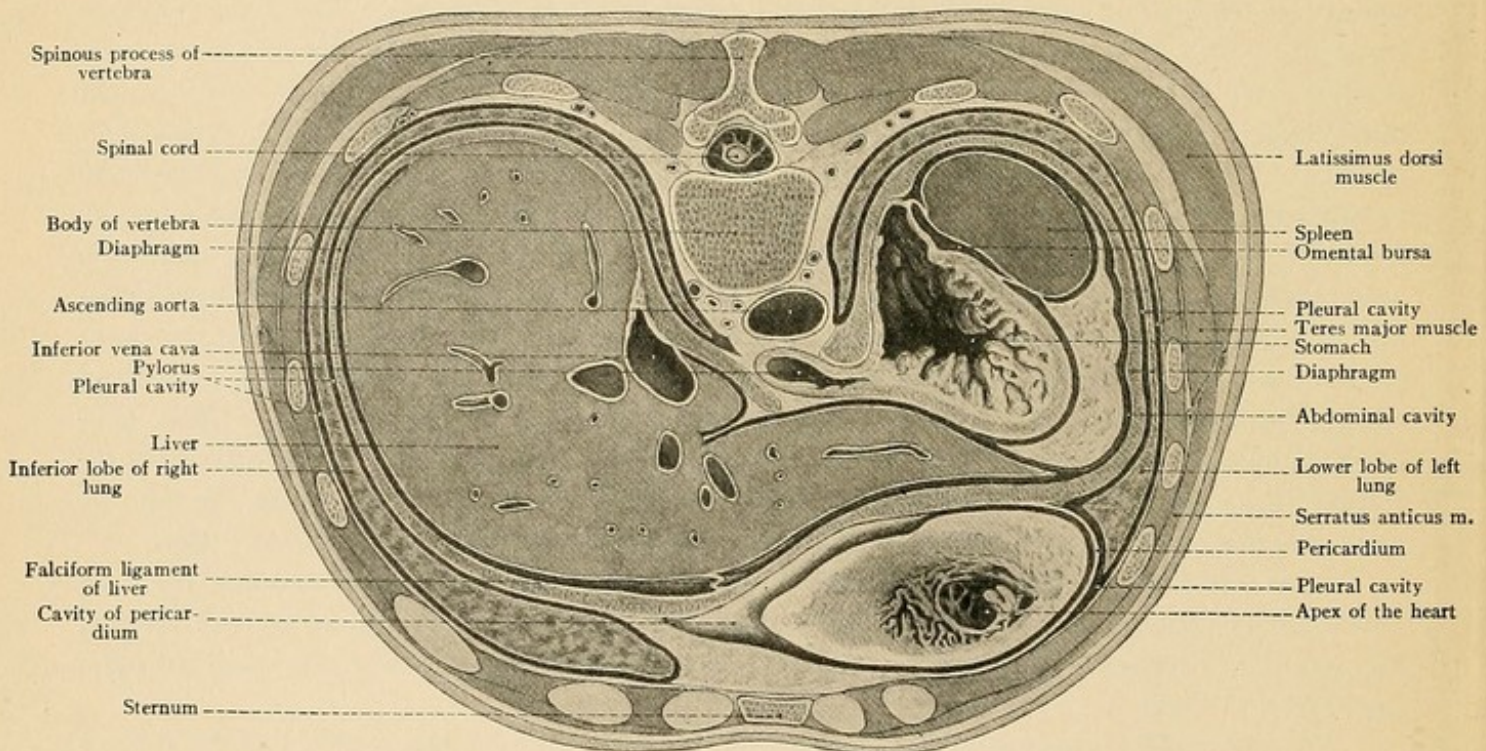
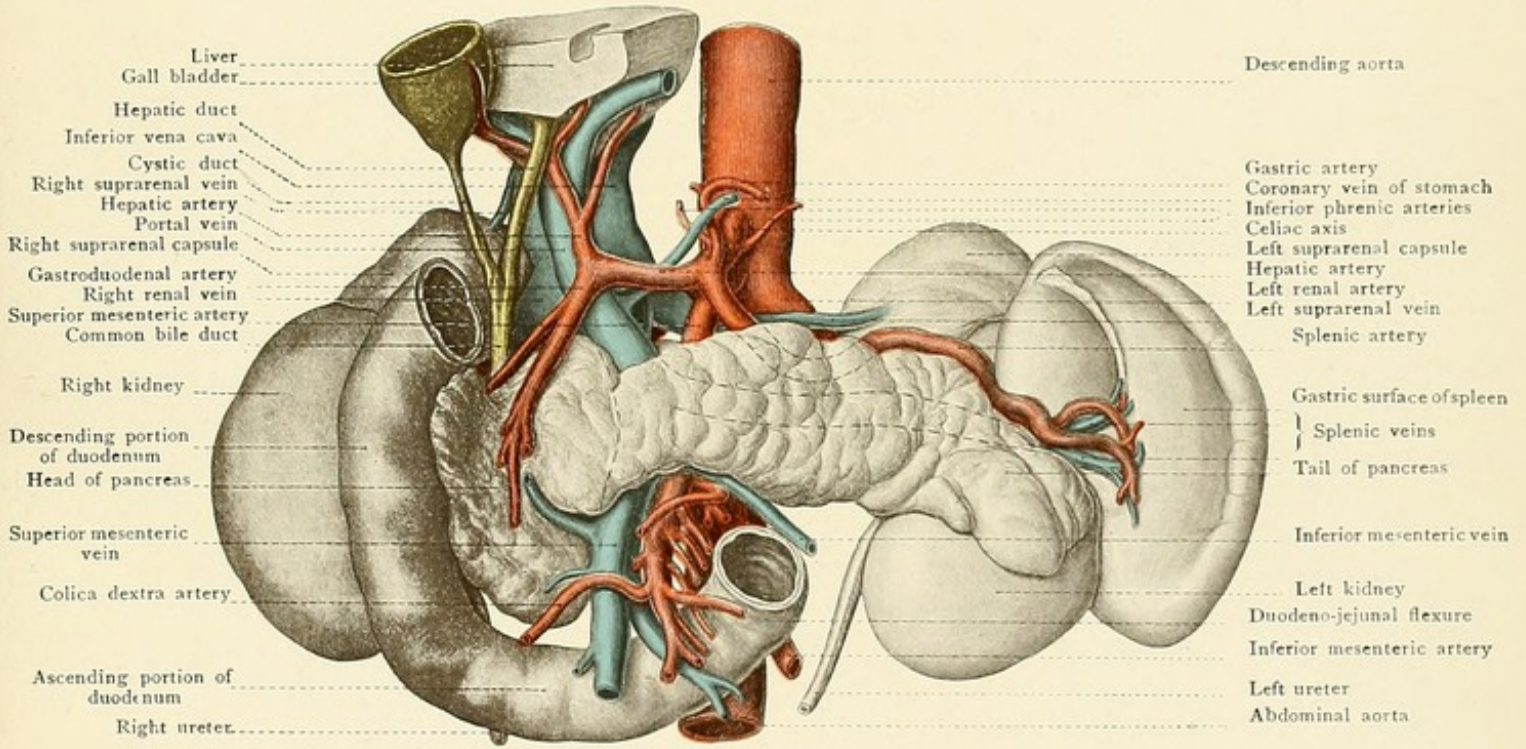


FIG. 62.—A cross-section of the trunk at the level of the xiphoid process of the sternum.

easily and safely drained by removing a rib and crossing the pleural cavity—transpleural drainage—than by the abdominal route. Particularly is this true when the abscess is pointing posteriorly and has not caused the liver to project far beneath the costal arch. (3) The gall-bladder is beneath the abdominal wall opposite the angle between the outer edge of the rectus and the ninth costal cartilage, where, when enlarged, it may be felt; its duct, the cystic, is tortuous, which, together with the arrangements of valves of mucous membrane in the calibre of the duct, prevents, as a rule, its exploration with a probe or sound. This duct joins in the portal fissure with the hepatic duct to make the common duct—*ductus communis choledochus*. The common duct in the first portion of its course lies in the right edge of the gastrohepatic omentum, the hepatic artery lying alongside and to the left, the portal vein behind and between the two. In the second part of its course it lies behind the first portion of the duodenum; in the third it is placed between





Liver  
 Gall bladder  
 Hepatic duct  
 Inferior vena cava  
 Cystic duct  
 Right suprarenal vein  
 Hepatic artery  
 Portal vein  
 Right suprarenal capsule  
 Gastroduodenal artery  
 Right renal vein  
 Superior mesenteric artery  
 Common bile duct  
 Right kidney  
 Descending portion  
 of duodenum  
 Head of pancreas  
 Superior mesenteric  
 vein  
 Colica dextra artery  
 Ascending portion of  
 duodenum  
 Right ureter

Descending aorta  
 Gastric artery  
 Coronary vein of stomach  
 Inferior phrenic arteries  
 Celiac axis  
 Left suprarenal capsule  
 Hepatic artery  
 Left renal artery  
 Left suprarenal vein  
 Splenic artery  
 Gastric surface of spleen  
 } Splenic veins  
 Tail of pancreas  
 Inferior mesenteric vein  
 Left kidney  
 Duodeno-jejunal flexure  
 Inferior mesenteric artery  
 Left ureter  
 Abdominal aorta







the second portion of the duodenum and the head of the pancreas, opening finally into the second portion of the duodenum on its inner and posterior aspect a little behind and below the middle.

(4) The relatively large size of the liver in children must not be forgotten.—ED.]

**The Spleen.**—The spleen is deeply placed in the left hypochondrium and its relations may be made clear by a description of the three surfaces of the organ. The largest or convex surface, *facies diaphragmatica*, borders immediately upon the inferior surface of the diaphragm (Plates 15 and 16 and also Fig. 62). In inflammations of the peritoneal covering of the spleen (perisplenitis) the practical clinician may occasionally hear a peritoneal friction fremitus, in this situation, produced by the respiratory movements of the diaphragm. It should, nevertheless, be remembered that the pleural cavity is superimposed upon the upper portion of the spleen in this situation (Plate 15 and Fig. 62), so that a peritoneal friction sound must not be confused with a friction rub proceeding from the contiguous pleural surfaces above the diaphragm. The interposition of the inferior margin of the lung between the spleen and the costal wall explains the fact that it is impossible to outline the upper border of the spleen by percussion (Plate 13, left). After the subsidence of an inflammation the *facies diaphragmatica* of the spleen is frequently adherent to the diaphragm. The *facies gastrica* (Fig. 61 and Plate 15) is concave and is in relation with the fundus of the stomach; upon this surface is the hilus for the entrance of the splenic artery (from the celiac axis) and for the exit of the splenic vein. Since this vein empties into the portal vein, we can easily understand the occurrence of splenic enlargement consequent upon stasis within the liver (in cirrhosis hepatis, for example). The smallest surface of the spleen is the long and narrow *facies renalis*, which is in relation with the convex border of the left kidney (Plate 15 and Fig. 61). This surface may be felt in the dead body by following the *facies diaphragmatica* posteriorly.

The most important clinical sign of most diseases of the spleen is an enlargement of the viscus, and in order to recognize this, the topography of the spleen must be known. The spleen extends from the ninth to the twelfth ribs and approaches to within two centimeters of the tenth dorsal vertebra. Its longitudinal axis passes obliquely from above and behind, downward and forward, so that the superior pole is also posterior and the inferior one is also anterior. This inferior pole extends anteriorly to a varying degree; its normal position is at about the anterior extremity of the eleventh rib (Plate 16). It is the portion of the spleen which is sometimes felt, but it is not palpable under normal conditions. If this pole can be palpated beneath the costal margin, the spleen is enlarged. The inferior pole of the spleen borders upon the splenic flexure of the colon (Plate 17); if this portion of the intestine is not filled with feces, so that it gives a tympanitic note, the splenic margin in the longitudinal axis of the viscus may be defined by percussion. If a tumor of the spleen is present, the inflated splenic flexure of the colon may be interposed between the *facies diaphragmatica* of the spleen and the diaphragm. It is, of course, impossible to determine the boundary between the spleen and the kidney by percussion; such an attempt is most likely to succeed at the inferior portion of the viscus near its posterior margin in the region of the "lieno-renal" angle (Plate 12). It will be observed that palpation is of more importance than percussion of this organ.

Although the spleen is attached to the diaphragm by the ligamentum phrenico-lienale and to the stomach by the ligamentum gastrolienale, and is also supported from below by the liga-



FIG. 63.—The liver, seen from below.

FIG. 64.—The position of the structures at the porta hepatis.

mentum phrenico-colicum, this fixation is not firm enough to hinder the occurrence of "floating spleen," which is accompanied by a stretching of these ligaments. Like the liver, the spleen may be displaced by tympanites, by ascites, or by abdominal tumors, which press the organ upward toward the pleural cavity, or by a left-sided pleural exudate which forces the spleen, together with the diaphragm, downward. An abscess of the spleen may perforate into the left pleural cavity, into the stomach, into the intestine, and even into the pelvis of the left kidney.

**The Pancreas.**—The pancreas (Plates 15, 17, and 18, and Figs. 61 and 68) may be seen and felt through the gastrohepatic omentum in the posterior wall of the bursa omentalis. It may be exposed in three ways: (1) By dividing the gastrohepatic omentum and displacing the stomach downward; (2) by dividing the ligamentum gastrocolicum (see page 113) and displacing the stomach upward; and (3) by dividing the floor of the bursa omentalis, *i. e.*, the transverse mesocolon, and reflecting upward the transverse colon and the stomach. The long flat organ is transversely situated at the level of the second lumbar vertebra; it is retroperitoneal, only the anterior portion of the viscus being covered by the peritoneum of the bursa omentalis. The "head" lies in the concavity of the duodenum (Fig. 61), but sufficient space is left for the superior mesenteric vessels to pass beneath the inferior pancreatic margin and over the ascending portion of the duodenum to reach the root of the mesentery. The tail lies upon the anterior surface of the left kidney, sometimes higher, sometimes lower, and extends to the [basal surface of the —ED.] spleen. The posterior surface is separated from the vertebral column by the crura of the diaphragm, by the inferior vena cava, and by the abdominal aorta (Fig. 69). There is a groove upon the dorsal surface of the head, which lodges the superior mesenteric artery and vein. The splenic vessels run along the upper border of the organ.

Owing to the deep position of the pancreas it is difficult to make a positive diagnosis of its diseases, such as cysts, abscesses, or tumors. The extension of such diseases to the stomach is preceded by adhesions to the posterior gastric surface within the bursa omentalis. In spite of all this, clinicians have succeeded in palpating the head of the pancreas through the abdominal walls in spare individuals. It will be readily understood that the intimate relations with the transverse colon, with the duodenum, with the pylorus, and with the transverse fissure of the liver add greatly to the difficulty of making a positive diagnosis of the diseases of the pancreas, particularly of carcinoma of the head of the viscus.

**The Duodenum.**—The duodenum (*δωδεκάδακτυλον*, because twelve inches long) extends from the pylorus to the duodenojejunal flexure and has a length of about thirty centimeters. The commencement of the pylorus is often made visible by a constriction, but it may be more surely determined by palpation of the thickening produced by the muscular tissue, which is plentiful in this situation (sphincter pylori). The *pars superior*, the shortest portion, lies to the right of the median line at the level of the first lumbar vertebra and is attached to the transverse fissure of the liver by the ligamentum hepatoduodenale [right edge of the gastrohepatic omentum.—ED.]. This ligament forms the anterior boundary



Fig. 63.

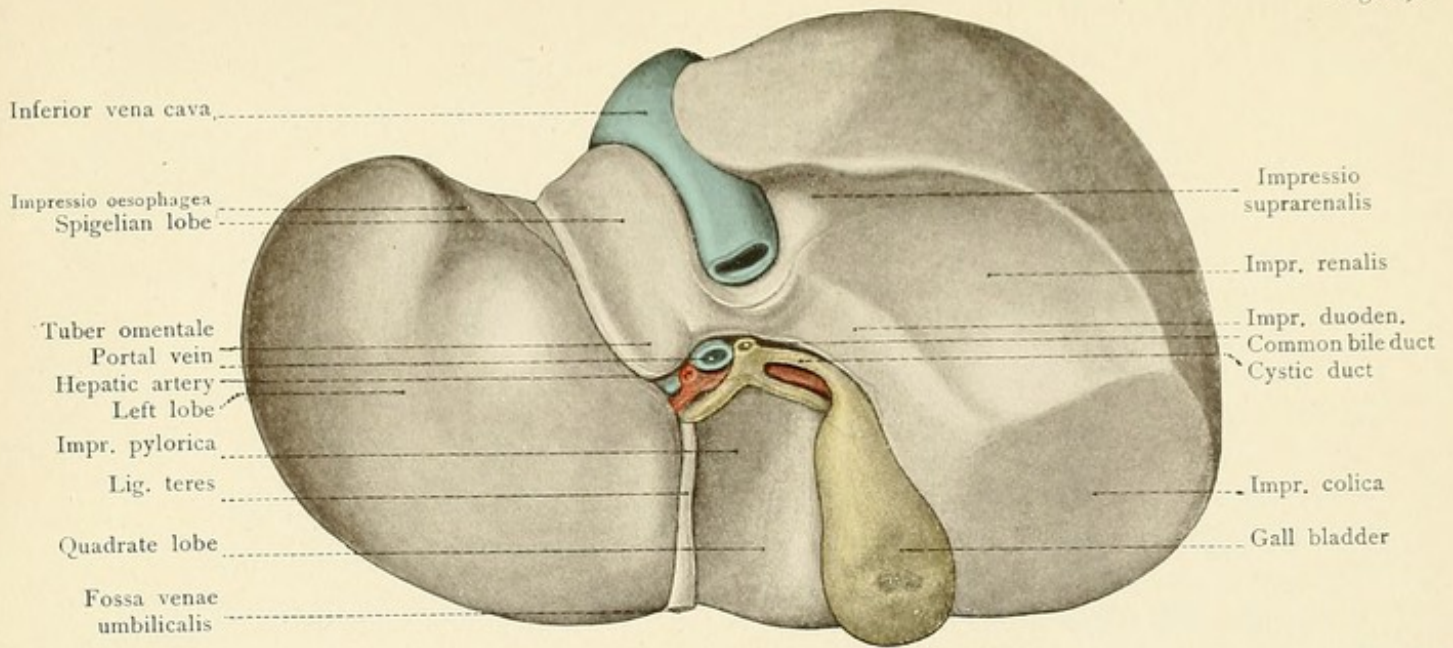
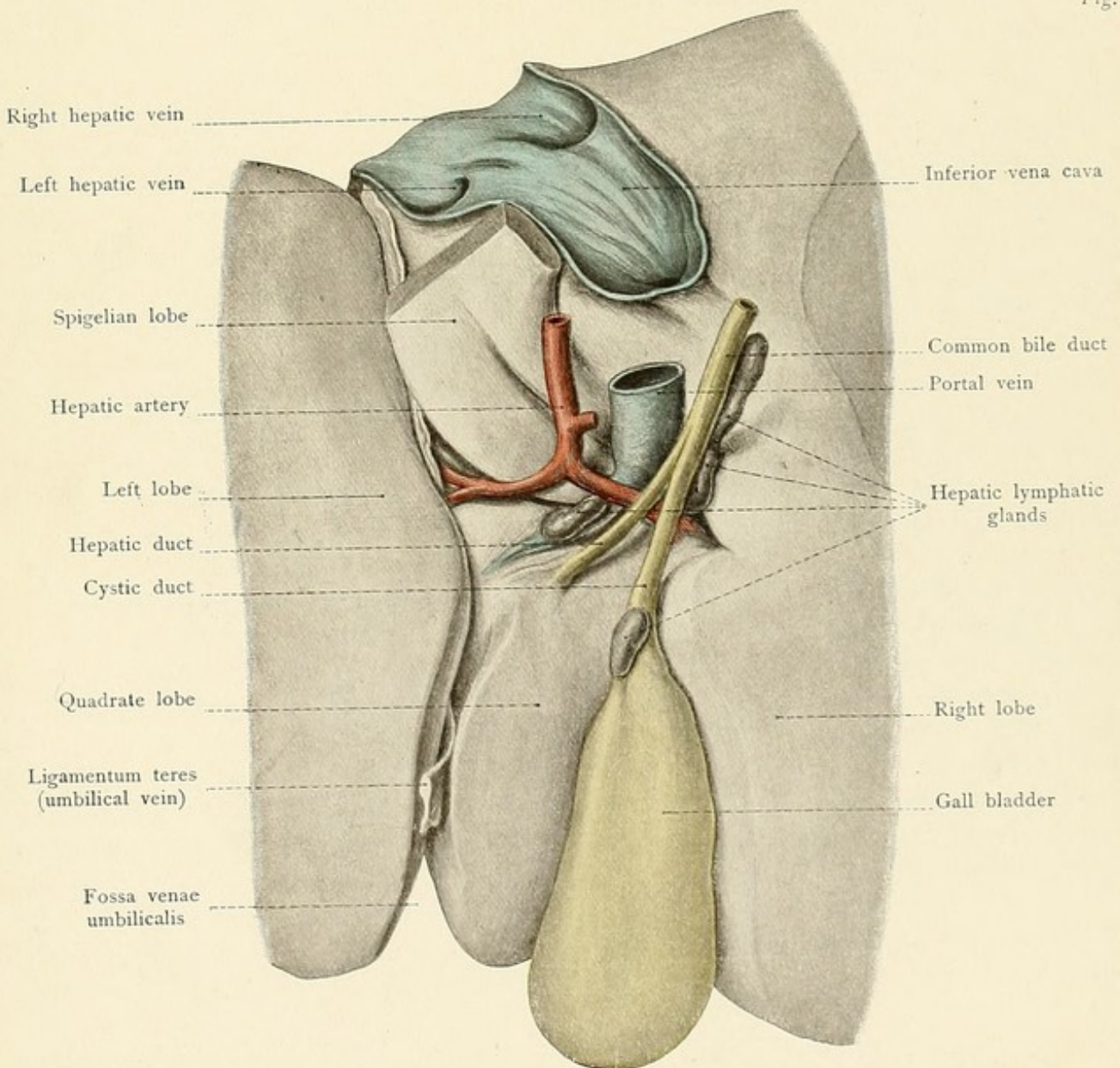



Fig. 64.









of the entrance into the bursa omentalis. The peritoneum passes from the ligament to the anterior surface of the pars superior; the posterior surface of this portion, directed toward the bursa omentalis, is also covered by peritoneum. The remaining portions of the duodenum, on the contrary, are covered only anteriorly by a peritoneal reflection, but even this is completely wanting in two narrow places, namely, at the crossing of the transverse mesocolon and at the crossing of the superior mesenteric vessels (Plate 15). When the stomach is empty, the superior portion of the duodenum runs in a frontal direction, but when the stomach is full, it lies more in a sagittal plane. It is situated just beneath the quadrate lobe of the liver. The *pars descendens* (Plates 15 and 18 and Figs. 61 and 67) lies at the right side of the second lumbar vertebra and is crossed at right angles by the transverse colon. If one desires to see the interior portion of the pars descendens, which disappears at the upper margin of the transverse colon, the transverse colon, together with the great omentum, must be reflected upward. This renders visible the duodenum, upon the posterior abdominal wall, and the region of the flexura inferior duodeni, *i. e.*, the transition of the descending into the ascending portion. The pars descendens produces the impressio duodenalis upon the right lobe of the liver (see page 131); the external convex margin of this portion of the intestine borders upon the internal margin of the right kidney (Plate 15 and Figs. 61 and 67), to which the peritoneal covering of the duodenum is reflected; the interior border is in relation with the inferior vena cava. The *pars ascendens* passes to the left, and after crossing the inferior vena cava, at the level of the third lumbar vertebra, and the abdominal aorta (Fig. 61 and Plate 18) becomes continuous with the duodenojejunal flexure at the left of the vertebral column. The root of the mesentery, running in an approximately vertical direction, crosses the duodenojejunal flexure (Plate 15) and contains the superior mesenteric artery and vein, the vein being situated to the right of the artery (see also Plate 61).

The upper portion of the duodenum is the seat of predilection for duodenal ulcers. Since this part is covered anteriorly and posteriorly by peritoneum, ulcers situated in the posterior, as well as those located in the anterior wall of the duodenum may perforate into the peritoneal cavity. (Perforating ulcers of the posterior duodenal wall open into the bursa omentalis.) Such a perforation into the peritoneal cavity may be prevented by preceding adhesions between the duodenum and the liver, the gall-bladder, or the posterior abdominal wall.

**The Small Intestine.**—The small intestine is from six to eight meters (twenty to twenty-five feet) long (jejunum about three-fifths, ileum about two-fifths of the total length) [according to English and American authors, this is reversed, the jejunum comprising two-fifths, the ileum three-fifths.—ED.], and its numerous coils fill the space below the transverse colon and the transverse mesocolon, overlie more or less the ascending and descending colon, and rest upon the iliac fossas, as well as upon and between the pelvic viscera (Plates 11 and 16). The great omentum (Plate 16; it has been removed in Plate 11) hangs down from the transverse colon, and, according to the degree of its development, separates the intestines more or less completely from the anterior abdominal wall. There is a certain regularity in the course pursued by the intestinal coils, but it is subject to great variation.

The *superior mesenteric artery*, the second of the single visceral branches of the abdominal aorta, enters the root of the mesentery at the lower margin of the pancreas (Plate 15 and Fig.



## PLATE 17.

The position of the pylorus, cardia, large intestine, and spleen of a fifteen-year-old girl. A deeper layer of the model of Plate 16.

61). This vessel supplies all of the small intestine and a considerable portion of the large intestine. Its branches are:

1. The inferior pancreaticoduodenalis, to the duodenum and the head of the pancreas;
2. The vasa intestini tenuis (arteria intestinales), about fifteen in number, running in the mesentery to the intestinal coils;
3. The ileocolic artery to the terminal portion of the ileum and to the commencement of the ascending colon;
4. The arteria colica dextra to the ascending colon;
5. The arteria colica media to the transverse colon.

This vessel consequently supplies that portion of the intestinal tract extending from the duodenum to the splenic flexure of the colon. The intestine beyond this point is supplied by the third single visceral artery, the *inferior mesenteric* (Plate 15), which arises from the abdominal aorta at the level of the third lumbar vertebra. It runs behind the peritoneum and divides into two main branches:

1. The arteria colica sinistra to the descending colon, and
2. The superior hemorrhoidal artery to the rectum. The sigmoid arteries supply the sigmoid colon.

The *portal vein* is a very large venous trunk, only three centimeters in length, which enters the liver at the transverse fissure. It receives the blood from that portion of the gastrointestinal tract which is situated between the cardia and the anus, from the pancreas, from the spleen, and from the gall-bladder, and transmits it to the liver, from which it reaches the inferior vena cava through the hepatic veins. It will be noted that the blood from the three single visceral branches of the abdominal aorta passes into the inferior vena cava by an indirect route through the liver, while the blood from the paired branches (visceral and parietal) empties directly into the inferior vena cava. The trunk of the portal vein lies in the hepato-duodenal ligament (see pages 125-127) and arises behind the head of the pancreas by the union of the splenic, the superior mesenteric, and the inferior mesenteric veins (Figs. 61 and 69). The important anastomoses of the portal system have been described upon page 122. In the region of the portal vein there are more blood-vessels compressed into a comparatively small space than in any other portion of the body (Fig. 61).

**The Large Intestine.**—The large intestine commences with the cecum and with the vermiform appendix (Plates 14 and 18), one of the most fertile regions of modern surgery. The cecum lies in the right iliac fossa upon the iliac fascia and the iliacus muscle; it extends to the left as far as the outer margin of the right psoas major muscle. Like the vermiform process, it usually possesses a complete peritoneal reflection, and is consequently in contact with the inner surface of the abdominal wall. In contrast to the ascending colon, it is a comparatively movable portion of the intestine. The posterior peritoneal covering may be wanting, however, and the cecum is then adherent to the iliac fossa. The *vermiform process* is usually freely movable, being fixed only by its own mesenterium and partly covered by the cecum. It may







The position of the pylorus, cardia, large intestine, and spleen of a fifteen-year-old girl. A deeper layer of the model of Plate 16.

17

61). This vessel supplies all of the small intestine and a considerable portion of the large intestine. Its branches are:

1. The inferior pancreaticoduodenalis, to the duodenum and the head of the pancreas;
2. The vasa intestini tenuia (arteria intestinales), about fifteen in number, running in the mesentery to the intestinal coils;
3. The ileocolica to the terminal portion of the ileum and commencement of the ascending colon;
4. The arteria colica dextra to the ascending colon;
5. The arteria colica media to the transverse colon.

This vessel consequently supplies that part of the large intestine which extends from the duodenum to the sigmoid flexure.

The superior mesenteric artery, the vasa intestini tenuia, and the inferior mesenteric artery are supplied by the third largest visceral artery, the aorta abdominalis, which arises from the abdominal aorta at the level of the third lumbar vertebra, and divides into three main branches:

1. The arteria colica sinistra to the descending colon, and
2. The superior mesenteric artery to the rectum. The superior mesenteric artery supplies the sigmoid colon.

The portal vein is a very large venous trunk, only three centimeters in diameter, which receives the blood from the small intestine, the spleen, and from the gall-bladder, and transmits it to the inferior vena cava through the hepatic portal vein.

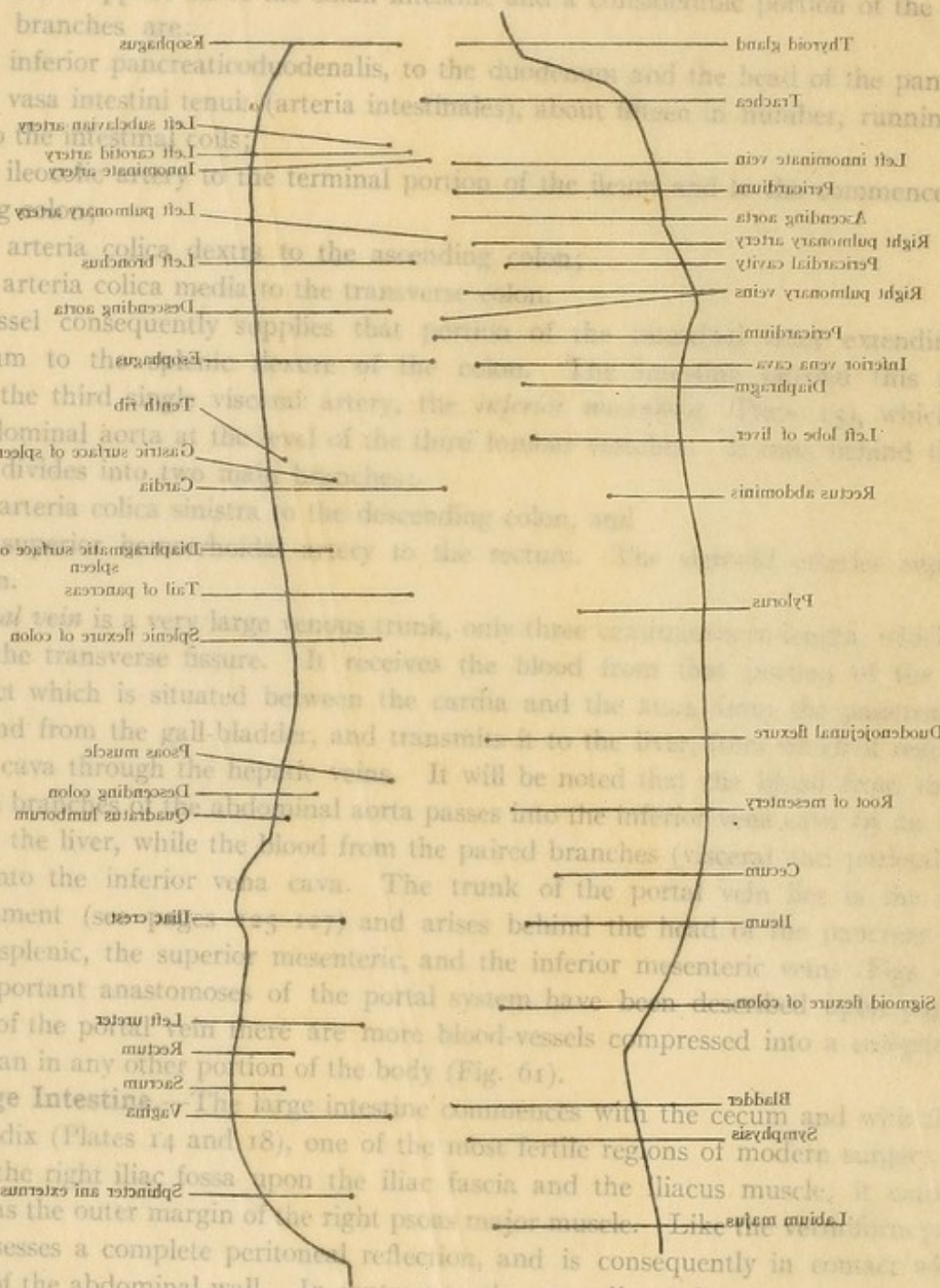
It will be noted that the superior mesenteric artery and vein pass through the single visceral branch of the abdominal aorta passes into the inferior vena cava.

The trunk of the portal vein receives the blood from the paired branches (arteries) which ties directly into the inferior vena cava. The trunk of the portal vein is situated behind the duodenal ligament (superior mesenteric) and arises behind the head of the pancreas at the union of the splenic, the superior mesenteric, and the inferior mesenteric veins.

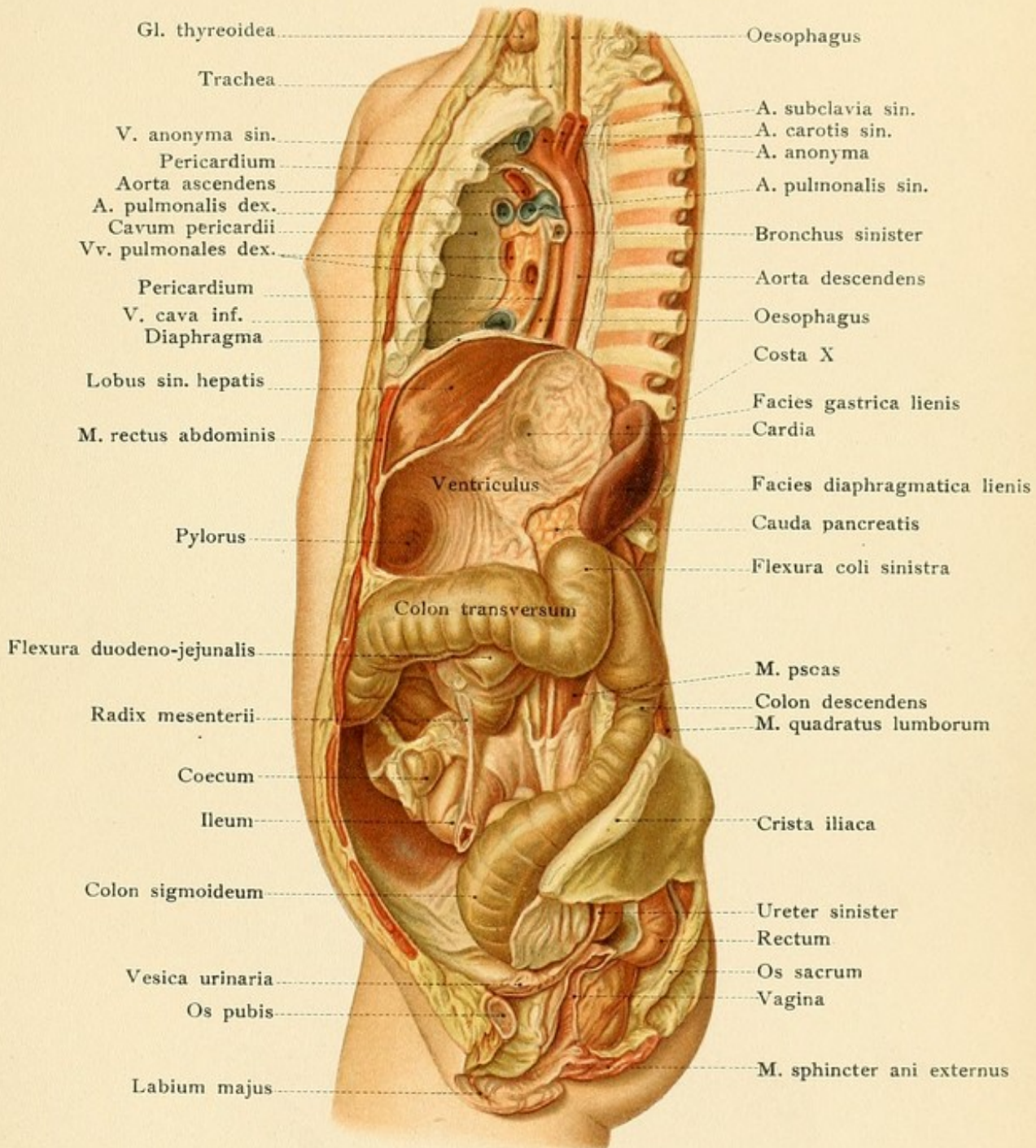
The important anastomoses of the portal system have been described in Plate 16. In the region of the portal vein there are more blood-vessels compressed into a smaller space than in any other portion of the body (Fig. 61).

The Large Intestine.

The large intestine commences with the cecum and vermiform appendix (Plates 14 and 18), one of the most fertile regions of modern surgery. The cecum lies in the right iliac fossa upon the iliac fascia and the iliacus muscle. It extends to the left as far as the outer margin of the right psoas major muscle. Like the vermiform appendix it usually possesses a complete peritoneal reflection, and is consequently in contact with the inner surface of the abdominal wall. In contrast to the ascending colon, it is a comparatively movable portion of the intestine. The posterior peritoneal covering may be wanting below, and the cecum is then adherent to the iliac fossa. The vermiform process is usually freely movable, being fixed only by its own mesenteriolum and partly covered by the caecum.













be entirely concealed behind the cecum, however, and also adherent to the posterior abdominal wall. If a foreign body is lodged in the vermiform appendix, a resulting inflammatory process may terminate in perforation. Since the appendix is completely surrounded by peritoneum, the intestinal contents may flow into the peritoneal cavity, provided that the vermiform process has not been bound down to the iliac fossa and to the neighboring organs by preceding inflammatory adhesions.

[The length and direction of the appendix are subject to great variation. According to Wolsey, the directions assumed, in the order of frequency, are as follows: (1) Retrocecal, *i. e.*, upward; (2) pelvic; (3) upward and inward; (4) variable. Allowing for variations, however, the appendix will, in the majority of cases, be found in the right lumbar region, some part of it extending frequently into the adjoining regions.

The relations of the appendix to the anterior abdominal walls are interesting and important. McBurney's point on the omphalo-spinous line ( $2\frac{1}{2}$  to 3 inches from the anterior spine and at or near the outer border of the rectus) does not, anatomically, exactly represent the base of the appendix, the latter lying somewhere in a circle two inches in diameter with the "point" as its center; it does indicate, however, with sufficient accuracy the seat of the localized tenderness in cases of appendicitis.—ED.]

The *ascending colon* (Plates 11 to 15) runs from the upper portion of the right iliac to the inferior pole of the right kidney. Below or upon this point it is continued into the transverse colon by the hepatic flexure, which produces the *impressio colica* (see page 131) upon the superimposed right lobe of the liver. The ascending colon lies upon the quadratus lumborum muscle, to the outer side of the psoas, and is covered by peritoneum only upon its anterior and lateral surfaces; its posterior surface is therefore more or less fixed to the posterior abdominal wall by connective tissue. It consequently does not seem to be freely movable and, particularly in the contracted state, is concealed anteriorly by the overlying intestinal coils. Perityphlitic abscesses are situated in the retroperitoneal connective tissue which fixes the origin of the ascending colon, and occasionally also the cecum, to the iliac fascia. From this situation the suppuration may extend in three directions:

1. Upward beneath the kidneys as far as the diaphragm;
2. Downward and inward over the iliopectineal line into the true pelvis;
3. Downward and forward beneath Poupart's ligament to the subinguinal region of the thigh.

The *transverse colon* (Plates 11, 14, and 17) commences at the hepatic flexure and runs toward the left in a slightly ascending direction until it reaches the left hypochondrium, where it is continued into the descending colon by the splenic flexure. Although the splenic flexure is somewhat higher than the hepatic flexure, we may say that the direction of the transverse colon generally corresponds to the transverse line connecting the lowest points of the costal margins (Plate 11). The transverse colon is concave above and convex below in conformity with the overlying greater curvature of the stomach. Upon the right the colon is covered by the liver and the gall-bladder, upon the left it is in contact with the inferior pole of the spleen, and the first part of the descending colon rests upon the lower portion of the anterior surface of the left kidney. The inferior margin of the transverse colon borders upon the coils of the small intestine.



## PLATE 18.

The position of the liver (a portion), duodenum, pancreas, left kidney, and cecum of a fifteen-year-old girl. A deeper layer of the model of Plate 16.

The relation to the duodenum has been described upon page 134. The long and broad transverse mesocolon should also be borne in mind, since it is responsible for the fact that the transverse colon is much more movable than the ascending or descending ones. The transverse colon is consequently in contact with the anterior abdominal wall, and, if its mesocolon is long enough, may form a loop the convexity of which is directed downward. [At either end the mesentery of the transverse colon becomes shorter, approaching the arrangement of the ascending and descending colons, which are usually without any mesentery.—ED.]

The *descending colon* (Plates 11–17) is longer than the ascending colon and commences at the left kidney. It runs downward upon the quadratus lumborum muscle, somewhat further from the median line than the ascending colon, reaches the left iliac fossa, and, after a short course toward the middle line, becomes continuous with the sigmoid colon (omega loop) at the external iliac vessels. The attachment to the posterior abdominal wall is similar to that of the ascending colon. Since the broad posterior surfaces of the ascending and descending portions of the large intestine are attached to the posterior abdominal wall by connective tissue, it is possible to open these portions of the intestine from behind without entering the abdominal cavity. This is done in the operation of lumbar colotomy when an artificial anus is made in the descending colon to the outer side of the quadratus lumborum muscle above the left iliac crest. (Find this location in Plate 16.) It should be noted, however, that these portions of the intestine may occasionally have a short mesocolon, the peritoneal reflection being almost complete, in which case the operation is very difficult to perform without opening the peritoneal cavity. The sigmoid colon is the most favorable, and the one generally preferred for the performance of this operation, in a case of rectal carcinoma, for example, where the intestine is occluded above the anus (Plates 11 and 14–18). It is situated in the right iliac region connecting the descending colon with the rectum, and is distinguished from the former by its long mesocolon. It is usually in contact with the anterior abdominal wall upon the left side above Poupart's ligament, and can be exposed and opened in this situation. This operation is necessarily preceded by a laparotomy. In making an artificial anus the opening made in the intestine must be united with the edges of the abdominal incision so that none of the intestinal contents may find their way into the peritoneal cavity. In this operation the small intestine must not be mistaken for the colon. The characteristics of the colon are that its longitudinal muscular coat is arranged into three bands or *tænia* and that it has epiploic appendages containing fat. This region is depicted in Fig. 57. [Other distinguishing features of the large intestine are: its sacculation, more fixed position,—in the case of the more movable divisions, their continuity with the parts relatively fixed,—and, as a rule, larger calibre. In addition, the large intestine is more liable to contain hardened feces. It must not be forgotten that the longitudinal bands (*tænia coli*) above referred to spread out on the lower part of the sigmoid so as to make a covering complete except for a narrow strip along either side; that is, the three narrow bands have been reduced to two wider ones, an anterior and a posterior. In the rectum these bands practically disappear.—ED.] In cutting from without inward the following structures are divided: skin,



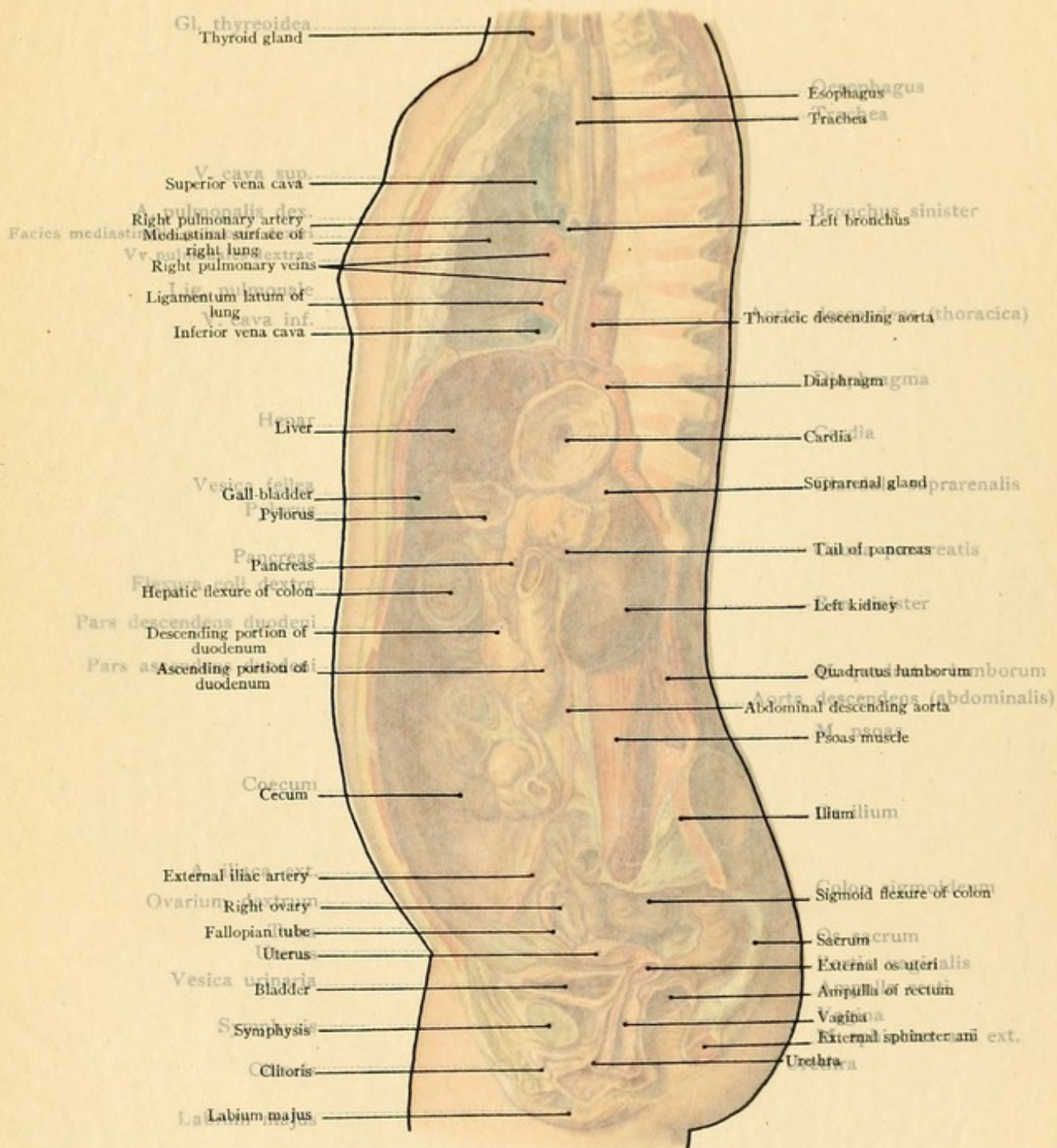




PLATE 18.

The position of the liver (a portion), duodenum, pancreas, left kidney, and cecum of a fifteen-year-old girl. A deeper layer of the model of Plate 16.

81

The relation to the duodenum has been described upon page 134. The long and broad transverse mesocolon should also be borne in mind for the fact that

the transverse colon is much more movable than the ascending or descending ones. The transverse colon is usually in contact with the anterior abdominal wall, and if its mesocolon is long enough, may form a loop the convexity of which is directed downward. At either end the mesentery of the transverse colon becomes shorter, approaching the arrangement of the ascending and descending colons, which are usually without any mesentery.—[Ed.]

The descending colon runs downward upon the posterior abdominal wall from the median line than the ascending colon, reaching the left iliac crest a short course toward the external iliac vessels. The attachment to the posterior abdominal wall is similar to that of the ascending colon.

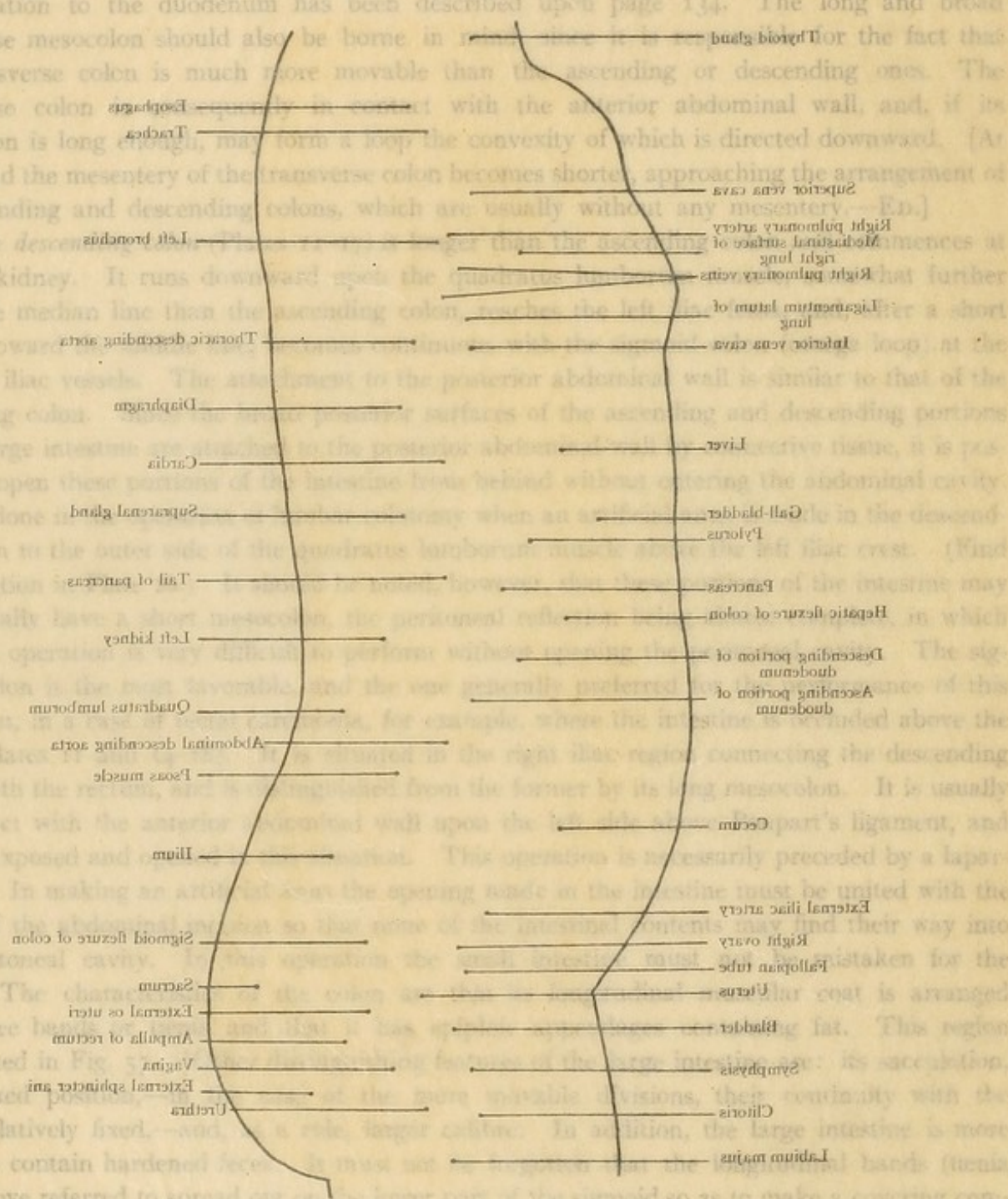
The sigmoid flexure of the colon is possible to open their points of attachment behind without entering the abdominal cavity. This is done by the sigmoid flexure of the colon to the outer side of the quadratus lumborum muscle.

occasionally has a short mesentery. In this case the operation is performed without opening the peritoneal cavity. The sigmoid flexure of the colon is the part of the large intestine which is most movable.

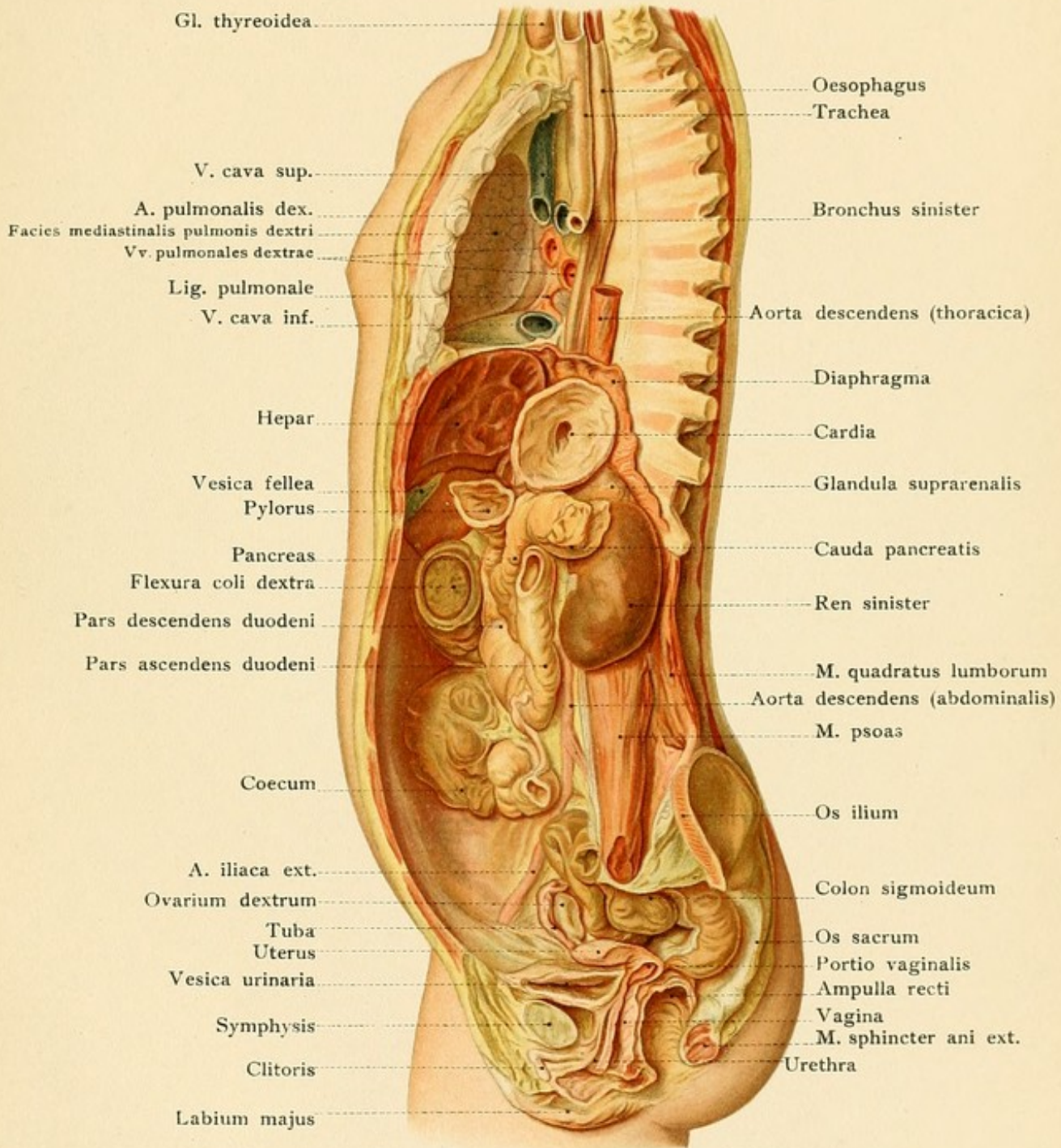
It is usually in contact with the posterior abdominal wall, and may be exposed and removed by a laparotomy. In making an artificial opening in the intestine it must be united with the edges of the peritoneum.

The sigmoid flexure of the colon is divided into three parts: the upper part, the middle part, and the lower part. The upper part is depicted in Fig. 18, and the middle and lower parts are depicted in Fig. 19.

more fixed position. The sigmoid flexure of the colon is more fixed than the other parts relatively fixed. It is liable to contain hardened feces (fecal colic) above referred to spread over the lower part of the sigmoid so as to make a covering complete except for a narrow strip along either side, that is, the three narrow bands have been reduced to two wider ones, an anterior and a posterior. In the rectum these bands practically disappear.—[Ed.] In cutting from without inward the following structures are divided: skin,













superficial fascia, the three flat abdominal muscles, the transversalis fascia, and the peritoneum. The inferior epigastric vessels should be avoided by the rule given upon page 121.

The following *peritoneal pockets or recesses*, the development of which is subject to extraordinary variations, may occasionally become enlarged, contain portions of the intestine, and, in this manner, lead to the formation of the so-called retroperitoneal hernias.

1. Recessus duodenojejunalis, to the left of the duodenojejunal flexure. It is open anteriorly and is bounded upon the right by the ascending portion of the duodenum and upon the left by the plica duodenojejunalis of the peritoneum, which contains the inferior mesenteric vein [which vein, therefore, would lie in the anterior part of the neck of a hernia occurring here.—ED.]. As a rule, it is large enough to receive the tip of the finger. It is found by reflecting the transverse colon and great omentum upward and displacing the small intestine with its mesentery to the right.

2. Recessus ileocæcalis superior, just above the ileocecal junction. The opening of this recess is directed toward the left and is bounded anteriorly by a peritoneal fold passing from the mesentery of the terminal portion of the ileum, downward and toward the right to the cecum.

3. Recessus ileocæcalis inferior, just beneath the end of the ileum. It is open toward the left and is situated between the mesenteriolum of the appendix and a peritoneal fold, the plica ileocæcalis, passing from the end of the ileum to the cecum.

4. Recessus intersigmoideus, beneath the line of attachment of the sigmoid mesocolon.

**The Kidneys.**—Each kidney has a superior and an inferior pole, an external convex and an internal concave margin, and an anterior and a posterior surface. They are situated in the lumbar region to either side of the vertebral column upon the psoas major, quadratus lumborum, and transversalis muscles, and upon the crura of the diaphragm in such a manner that the longitudinal axes of the kidneys, *i. e.*, the lines connecting the two poles, are not parallel to the vertebral column but diverge slightly as they pass downward. The transverse axis, *i. e.*, the line connecting the middle points of the two margins, is not situated in a frontal plane, but the continuations of the two axes intersect at about a right angle in front of the vertebral column, so that the anterior surface is also external and the posterior one is also internal. The convex border is the most posterior; this is favorable for the surgeon who sometimes attacks the kidney from behind, in order to open it, and, after operative procedures in its interior, sutures it together again. The kidneys extend from the lower border of the eleventh dorsal vertebra to the third lumbar vertebra; in two-thirds of the cases the right kidney is placed a fingerbreadth lower (Plates 12 and 15). The superior pole is consequently situated in the last intercostal space; penetrating wounds in this situation may therefore involve the pleural cavity (sinus phrenicocostalis) and the kidney, particularly the left kidney, which is placed somewhat higher. For this reason it is also dangerous to resect the last rib in operations upon the kidney. Abscesses of the kidney may point upward and backward, perforate the diaphragm, and rupture into the pleural cavity, or even into the lung; in such a case pus from the kidney may be expectorated. Only the anterior surface of the kidney is covered by peritoneum. The posterior surface is fixed to the underlying muscles by a connective tissue rich in fat, the so-called *capsula adiposa*. The twelfth thoracic nerve (n. subcostalis) and the iliohypogastric nerve (from the lumbar plexus) run in this fat over the posterior renal surface (Fig. 66). These nerves are



FIG. 65.—The left kidney seen from in front.

FIG. 66.—The right kidney seen from in front.

FIG. 67.—Anterior view of the relations of the right kidney.

FIG. 68.—Anterior view of the relations of the left kidney.

responsible for the neuralgic pains which accompany renal swellings and tumors and which may radiate into the thigh and into the external genitalia.

The *right kidney* is easily found by elevating the liver, the right lobe of which bears upon its inferior surface the *impressio renalis* (see page 131 and Fig. 63). To the inner side of the right kidney (Fig. 67) are the inferior vena cava, which may be compressed by renal tumors, and the descending portion of the duodenum. Renal abscesses may rupture into these structures and into the hepatic flexure of the colon which is in relation with the inferior pole of the kidney. A tumor of the right kidney may push this hepatic flexure forward so that the tumor will apparently give a tympanitic note, which will disappear when the intestine has been thoroughly emptied. The colon holds a similar relation to the left kidney.

The *left kidney* is more concealed than the right one and is not so easily located by the tyro. If the hand is pushed around the spleen until it reaches the *facies renalis* (see page 133), the left kidney may be palpated, and if the spleen is displaced upward the inferior pole of the kidney may be made to appear more distinctly in the angle of the splenic flexure of the colon (Fig. 68). The remaining portion of the kidney is in relation anteriorly with the tail of the pancreas and with the posterior surface of the stomach (in the region of the lesser peritoneal cavity). Below the pancreas, the kidney is covered by the splenic flexure and by the commencement of the descending colon (Fig. 68). The spleen rests upon the external renal margin (Plates 12 and 15 and Fig. 61).

More distant organs may also be involved by large renal tumors. If the right kidney becomes greatly enlarged, it may push the liver upward and anteriorly and interfere with the expansion of the right lung. A large left-sided renal tumor, in addition to its effect upon the stomach and the spleen, may directly compress the left lung and the heart. Owing to the firm foundation of the kidney, which is composed of strong muscles and bones, it follows that enlargements in the posterior direction are not so frequently observed as those extending forward, upward, and downward. Diseases of neighboring structures, such as hepatic abscesses, psoas abscesses, and caries of the vertebrae, may extend to the kidney.

The surgeon naturally prefers to attack the kidney from behind, since not only the kidney but also the renal pelvis is retroperitoneal. At the hilus the pelvis is the most posterior structure, then comes the artery, and anteriorly is the renal vein (Fig. 65), although variations are sometimes observed. This relation only holds for the main trunks, the terminal divisions of which are subject to manifold variations, so that large arterial branches are often observed to enter the kidney at some distance from the hilus. In all cases, however, the position of the renal pelvis, situated as it is behind the great vessels, is favorable for the removal of renal calculi from behind, as the large vessels generally escape injury. Hemorrhage from the renal vessels is retroperitoneal, as a rule; an intraperitoneal hemorrhage must be preceded by a laceration of the peritoneum. If the pelvis of the kidney becomes perforated, the urine no longer flows along its normal channel in the ureter, but forms a retroperitoneal urinary abscess upon



Fig. 65.

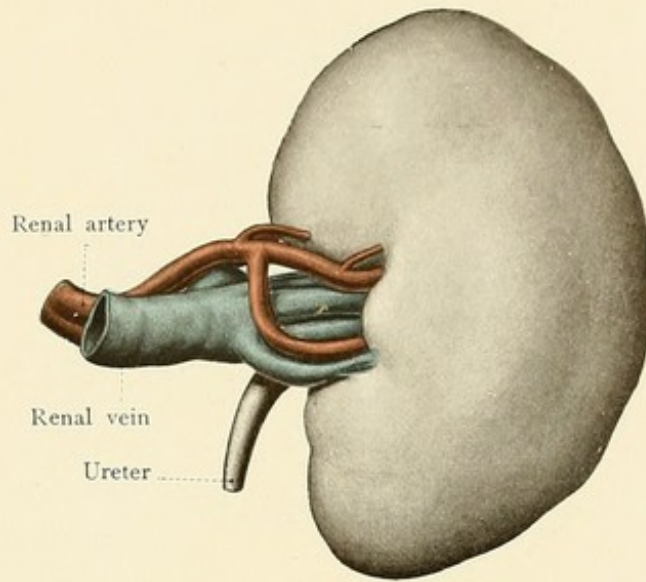


Fig. 66.

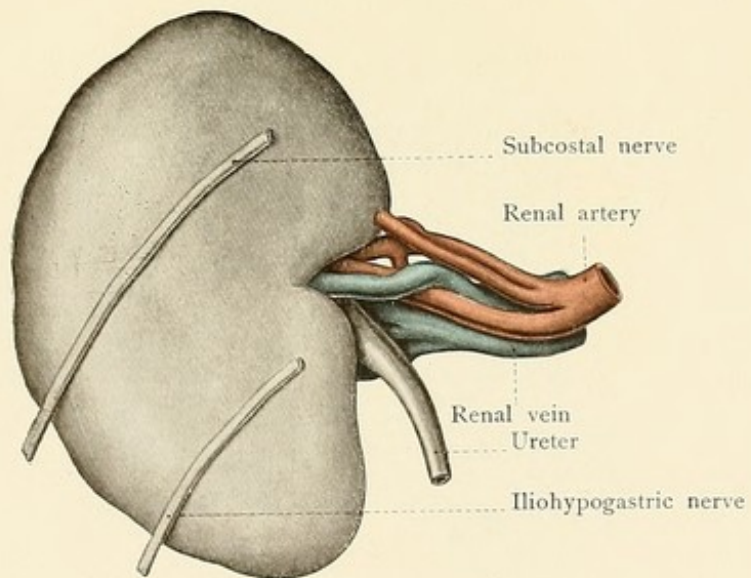








Fig. 67.

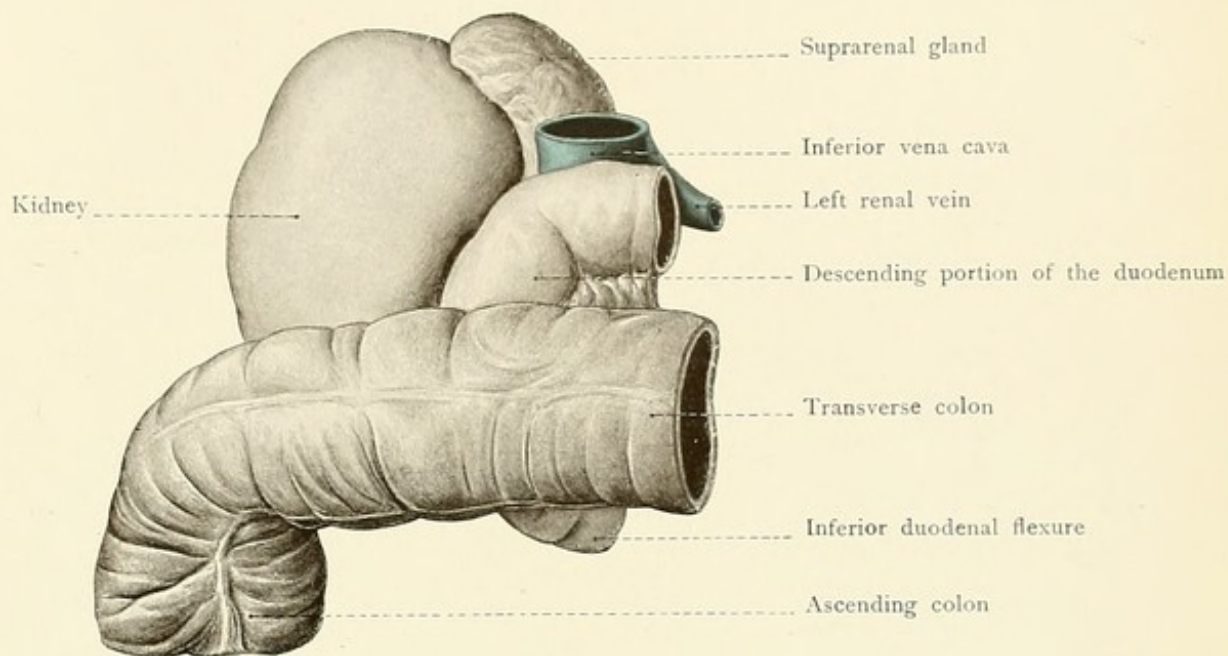
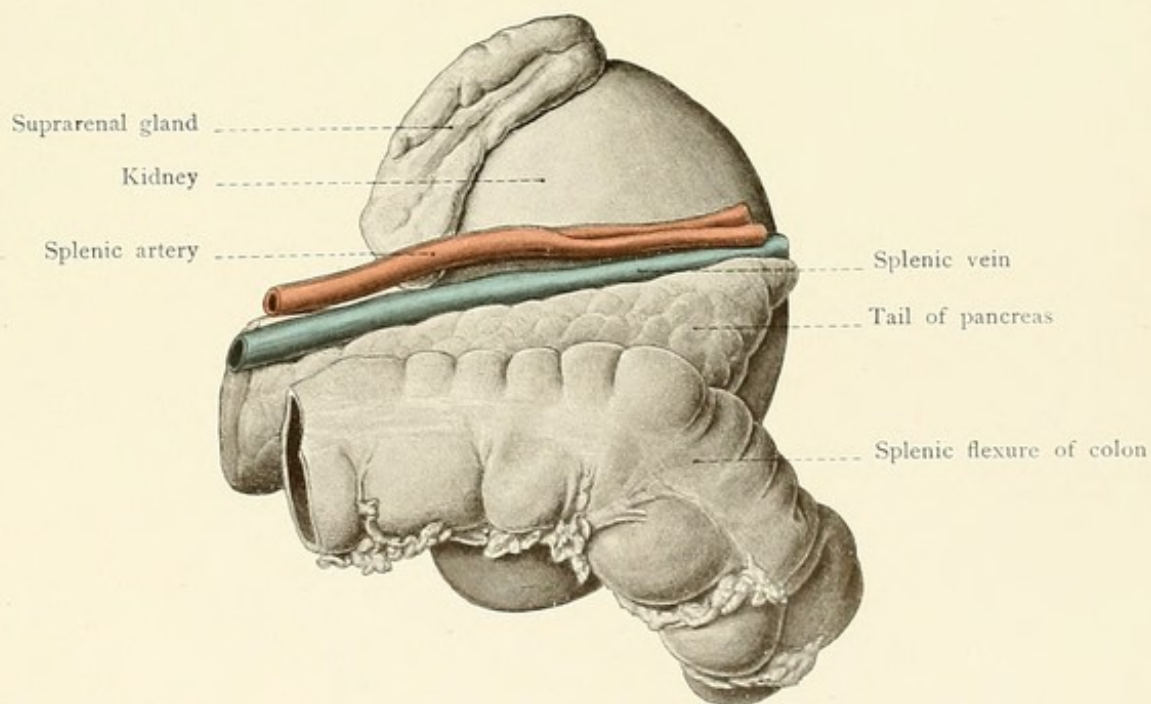


Fig. 68.









the quadratus lumborum muscle. Such perinephritic abscesses and similar ones behind the kidney may extend upward, affecting the pleura (pleurisy), or the abscess may gravitate to the iliac fossa and pursue one of a number of subperitoneal courses similar to those taken by a retrocecal (perityphlitic) abscess (see page 137).

The *method of reaching the kidney from behind* may be discerned from a study of Fig. 69. An incision is made along the outer margin of the sacrolumbalis muscle (*i. e.*, the outer portion of the iliocostalis of the erector spinæ), extending from the last rib to the crest of the ilium. After dividing the skin, the superficial fascia, the latissimus dorsi muscle, and the posterior layer of the lumbar fascia, the edge of the sacrospinalis (erector spinæ) muscle is displaced inward,

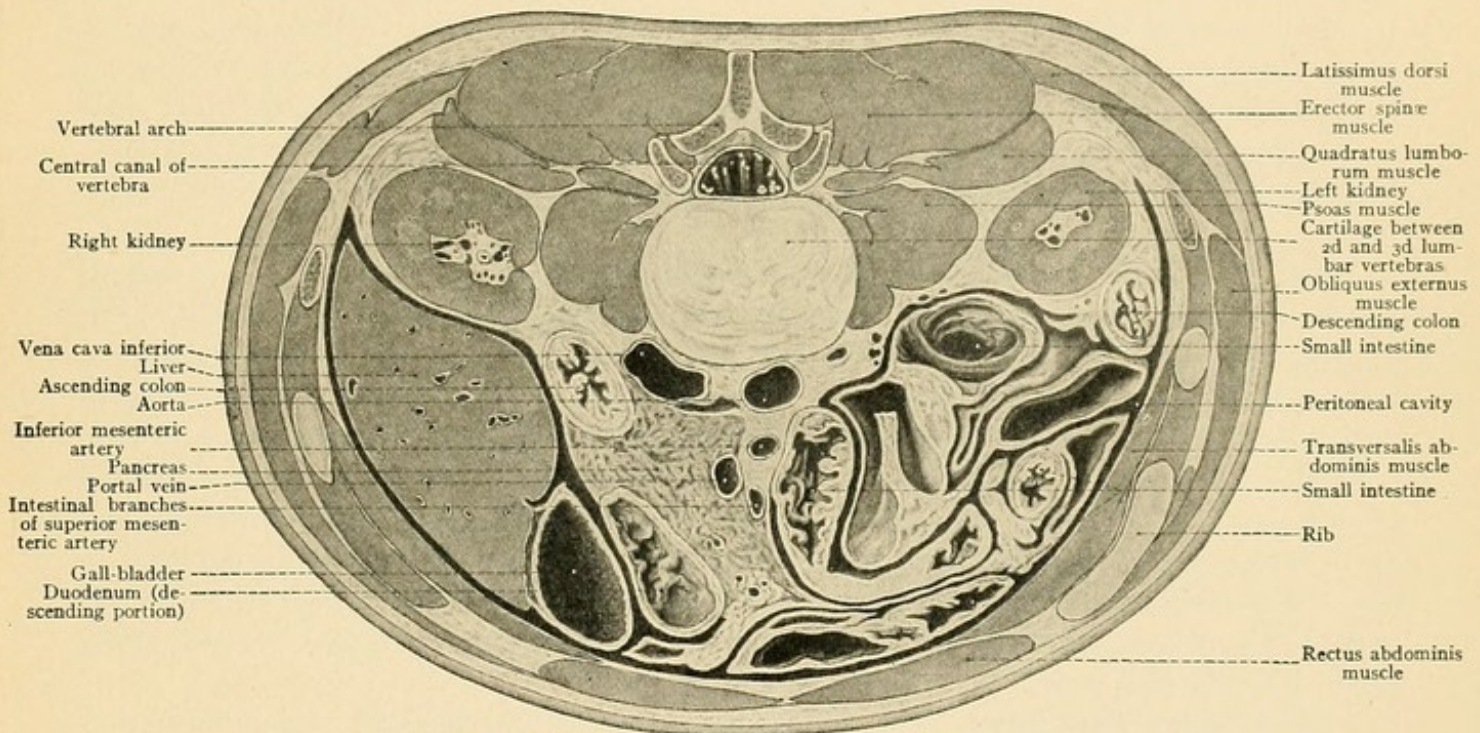


FIG. 69.—A cross-section of the abdomen in the inferior renal region

the anterior layer of the lumbar fascia is divided, and the quadratus lumborum muscle is exposed. The kidney is reached by dividing this muscle or by displacing its external border.

The *suprarenal bodies* rest upon the superior poles of the kidneys. They are also in relation with the crura of the diaphragm. The right suprarenal capsule, more frequently triangular in shape, borders upon the liver [that is, upon the posterior surface of the right lobe.—ED.] (*impressio suprarenalis*, page 131) and upon the inferior vena cava (Fig. 67); the left one is in relation with the cardia of the stomach.

The *abdominal portion of the ureter* extends from the pelvis of the kidney to the iliopectineal line of the pelvis and is situated behind the peritoneum. It runs downward and somewhat inward upon the psoas muscle, and crosses the common iliac vessels near their bifurcation. The ureter is placed in front of the vessels and may be easily exposed in this situation. The spermatic vessels are also behind the peritoneum and cross in front of the ureter at about the middle of the



psoas muscle. During its course the ureter describes a number of slight but typical curves. The descending portion of the duodenum lies upon the right ureter while the duodenojejunal flexure is superimposed upon the left one. The pelvic portion of the ureter is described upon pages 149 and 151.

**The Abdominal Aorta.**—The abdominal aorta lies directly upon the vertebral column and divides at the fourth lumbar vertebra into the two *common iliac arteries*. In thin individuals, when the intestines are empty, the pulsations of the abdominal aorta may be palpated through the belly wall, particularly if lordosis is present, as this approximates the vertebral column to the anterior wall of the abdomen. The pulsations of the aorta may also be made palpable by tumors situated behind the vessel and pushing it forward. The body of the pancreas crosses transversely in front of the aorta at the level of second lumbar vertebra; the descending portion of the duodenum passes across the vessel at a lower level. Below this situation the aorta is covered only by peritoneum and may be easily exposed. Dilatations of the abdominal aorta (aneurysms) produce pressure symptoms from the neighboring organs—from the intestines, from the liver, from the biliary passages, from the kidneys, and from the ureter (hydronephrosis).

The *common iliac artery* extends to the sacroiliac articulation and lies to the inner side of the psoas muscle. It is behind the peritoneum and, upon both sides, is situated in front of and somewhat to the left of the corresponding common iliac vein. It must occasionally be ligated, and this may be accomplished without injury to the peritoneum. An incision is made two centimeters above and parallel to Poupart's ligament (Fig. 81) through the skin, the superficial fascia, the abdominal muscles, and the transversalis fascia, exposing the peritoneum, which is pushed away from the iliac fossa as the operator follows the course of the iliac vessels upward behind the peritoneum. The external iliac artery is reached first (Fig. 81), and then follows the common iliac; in the latter situation care must be taken to avoid the ureter, which runs in front of the vessel. The incision must not be extended too far inward, as the inferior (deep) epigastric artery would then be endangered (see page 121).

**The Inferior Vena Cava.**—The inferior vena cava lies upon the right side of the abdominal aorta (Figs. 61 and 69), behind the ascending portion of the duodenum and the head of the pancreas. Before its passage through the foramen venæ cavæ of the diaphragm it is imbedded in the posterior margin of the liver (Fig. 49). For a description of the branches of the inferior vena cava the reader is referred to the text-books upon systematic anatomy.

#### REVIEW QUESTIONS.

What arterial anastomosis in the anterior abdominal wall may become the chief collateral route after an obstruction to the circulation in the descending aorta?

How would you draw a line upon the external surface of the abdomen to represent the course of the inferior epigastric artery?

How would you explain a dilatation of the veins of the anterior abdominal wall following upon a stasis in the region drained by the inferior vena cava?

What are the effects of congestion of the portal system in diseases of the liver? (In the anal, gastric, and umbilical regions.)



What are the relations of the hernial orifices of the two main forms of inguinal hernia to the plica epigastrica? What are the relations of the hernial orifices of inguinal and femoral hernia to Poupart's ligament?

What practical conclusions may be deduced from the course of the root of the mesentery?

In what three places may the great omentum be opened in order to expose the pancreas?

In what situation is the stomach immediately exposed upon opening the abdominal cavity?

How is it possible that after an injury to the stomach the gastric contents may escape into the left pleural cavity?

What is the explanation of fatal hematemesis in a case of gastric ulcer? How would you explain the expectoration of gastric contents in the same affection?

What relation explains the possibility of the rupture of an hepatic abscess into the pericardium?

What is the normal relation of the inferior border of the liver to the costal margin?

Into what neighboring organs may gall-stones from the gall-bladder perforate?

Why is it impossible to outline the upper margin of the spleen by percussion? What renders it impossible to locate the posterior margin by the same method?

What is the explanation of splenic enlargements following upon venous congestion within the liver?

What organs may be perforated by an abscess of the spleen?

In what direction may ulcers upon the anterior and those upon the posterior wall of the superior portion of the duodenum rupture?

Where does a perityphlitic abscess form and in what directions may it extend?

Why are the ascending and the descending colons adapted to the making of an artificial anus from behind?

In what locations may retroperitoneal hernias develop?

Into what cavities may a renal abscess rupture when it points upward?

What is the explanation of neuralgic pains in the thigh in tumors of the kidney?

Into what portions of the intestine may an abscess of the right kidney perforate?

Why is it more practicable to attack the pelvis of the kidney from behind than from in front?

## THE PELVIS.

### THE PELVIC WALLS.

The study of the pelvic region should be preceded by a review of the innominate bones and of the sacrum as well as by a consideration of the bony pelvis as a whole. The following designations, referable to the entire pelvis, should be thoroughly understood by the reader: The *false* and *true pelves* (separated from each other by the iliopectineal line); the symphysis pubis; the sacroiliac articulation; the promontory; the acetabulum with its articular portion (facies lunata), non-articular portion (fossa acetabuli), and cotyloid notch (incisura acetabuli); the pubic angle (in the male); the pubic arch (in the female); the obturator foramen; and the following sagittal diameters of the pelvis (Fig. 70):

1. The *anteroposterior diameter of the pelvic inlet* from the promontory to the upper margin of the symphysis (conjugata vera), about 11.0 centimeters ( $4\frac{1}{3}$  inches);



## PLATE 19.

The male pelvic outlet as seen from without. From a Leipzig model from nature (His) with the vessels and nerves sketched in.

2. The *internal conjugate diagonal*, measured in the living subject from the promontory to the lower margin of the symphysis (*conjugata diagonalis*), 12.5 centimeters (5 inches);

3. The *anteroposterior diameter of the pelvic cavity* or the width of the pelvis, from the middle of the symphysis to the middle of the third sacral vertebra, 12.5 centimeters (5 inches);

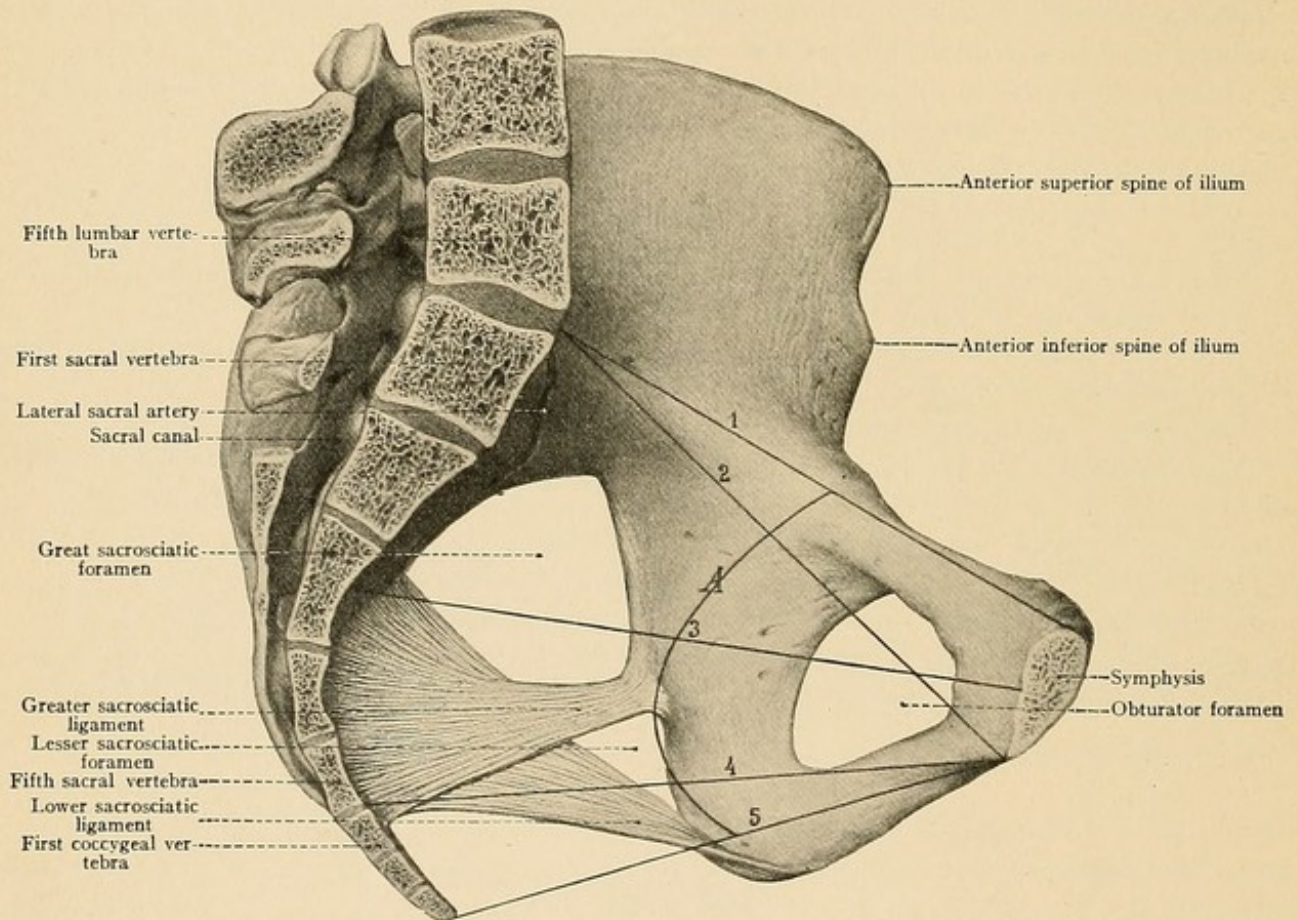


FIG. 70.—A sagittal section of the female pelvis with the anteroposterior pelvic diameters. 1, The anteroposterior diameter of the pelvic inlet (*conjugata vera*); 2, the internal conjugate diagonal (*conjugata diagonalis*); 3, the anteroposterior diameter of the pelvic cavity; 4, the anteroposterior diameter of the plane of pelvic contraction; 5, the anteroposterior diameter of the pelvic outlet; A, the pelvic axis or curve.

4. The *anteroposterior diameter of the plane of pelvic contraction*, from the lower margin of the symphysis to the intervertebral disc between the last sacral and the first coccygeal vertebra, 11.5 centimeters ( $4\frac{3}{8}$  inches);

5. The *anteroposterior diameter of the pelvic outlet* from the lower margin of the symphysis to the tip of the coccyx, 10 to 12 centimeters (4 to 5 inches). This diameter varies on account of the ability of the coccyx to become displaced posteriorly.

The *pelvic axis* (A in Fig. 70) or *pelvic curve* is the curved line which connects the middle points of the anteroposterior diameters.



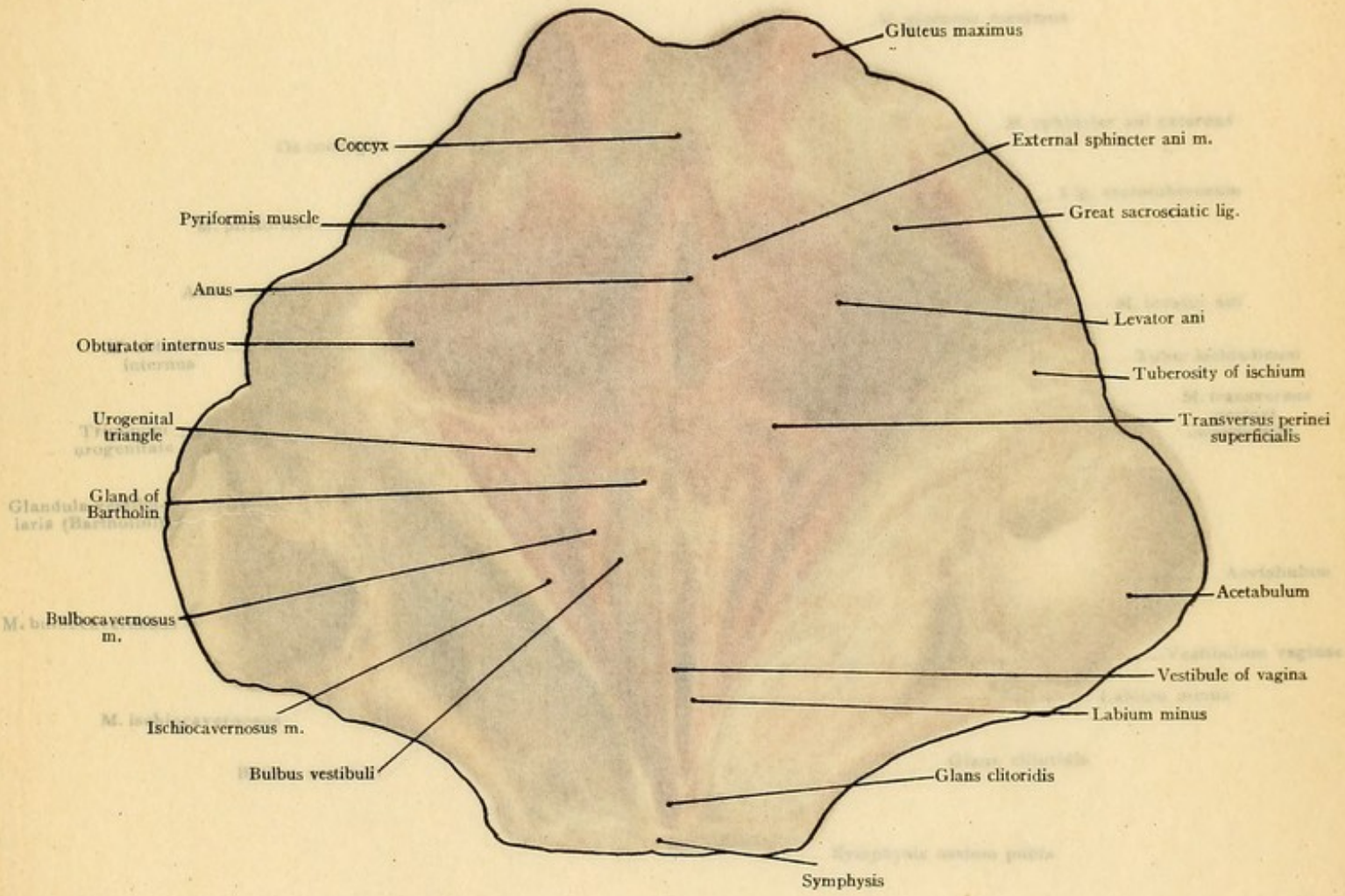


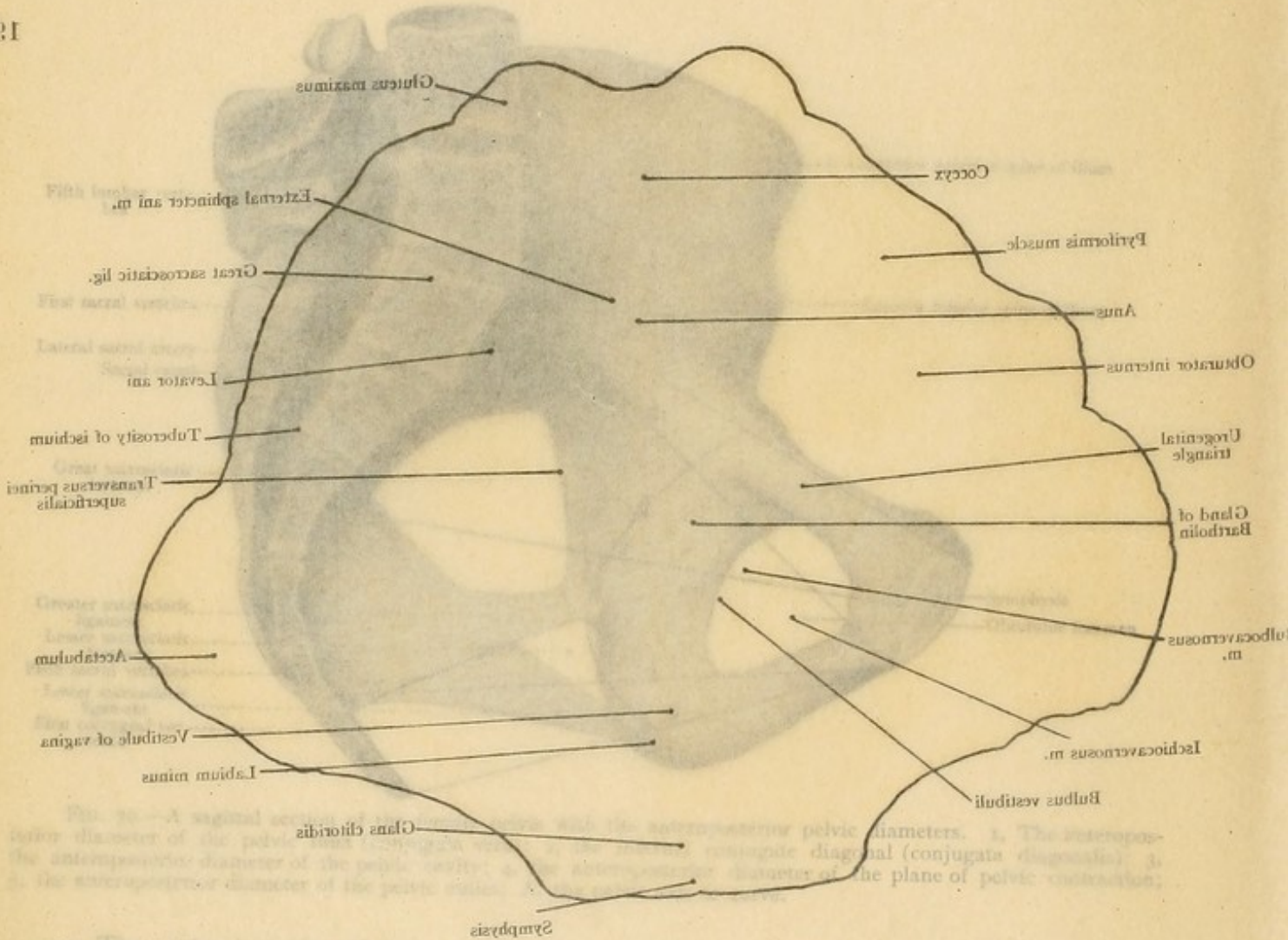


PLATE 19.

The male pelvic outlet as seen from without. From a Leipzig model from nature. The pelvic diameters are sketched in.

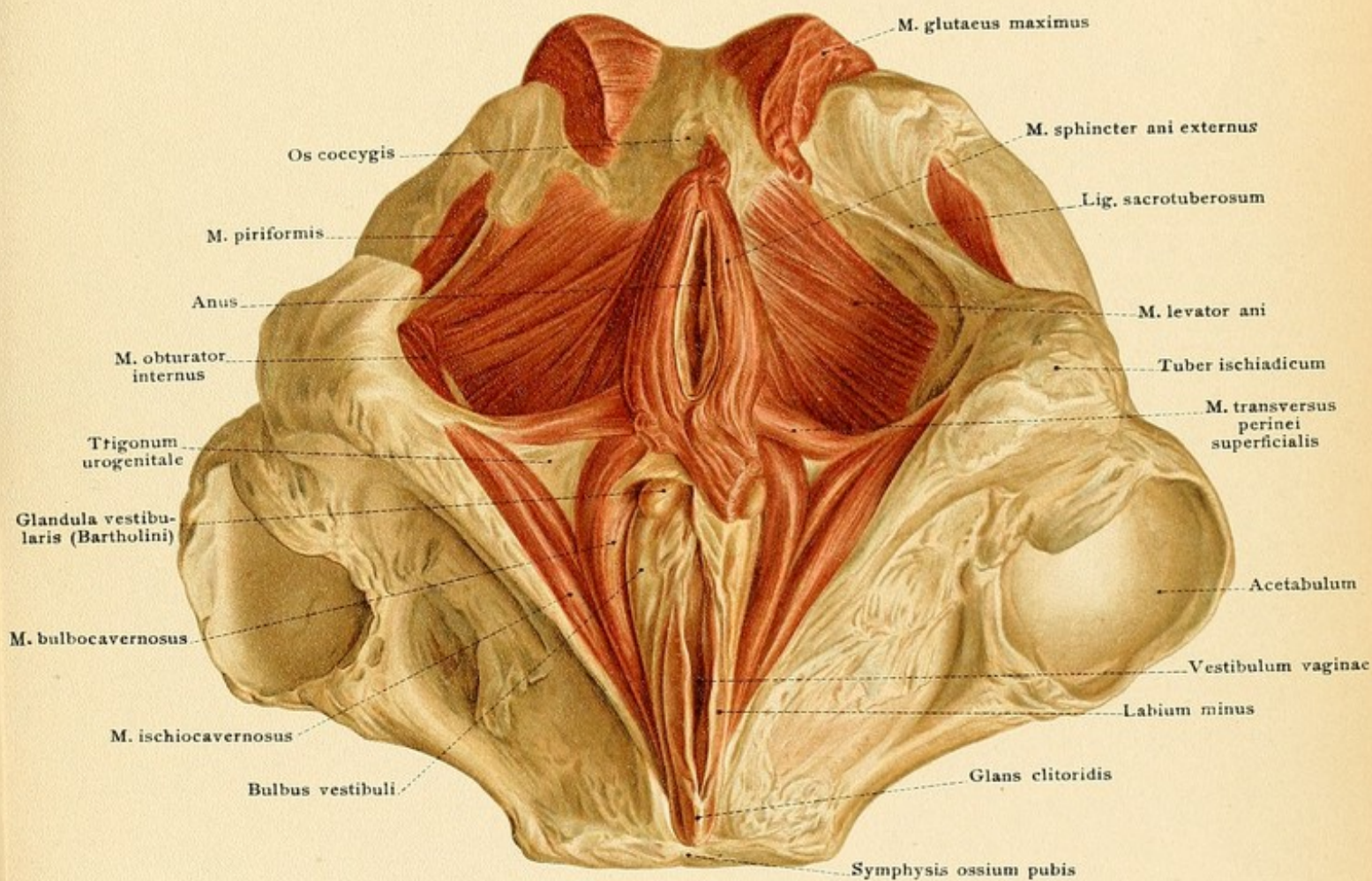
2. The *internal conjugate diagonal*, measured in the living subject from the upper margin of the lower margin of the symphysis (conjugata diagonalis), 12.5 centimeters (4 7/8 inches).
3. The *anteroposterior diameter of the pelvic cavity* or the width of the pelvic inlet from the middle of the symphysis to the middle of the third sacral vertebra, 12.5 centimeters (4 7/8 inches).

19



4. The *anteroposterior diameter of the plane of pelvic contraction*, from the lower margin of the symphysis to the intersacral disc between the last sacral and the first coccygeal vertebra, 11.5 centimeters (4 1/2 inches).
  5. The *anteroposterior diameter of the pelvic outlet* from the lower margin of the symphysis to the tip of the coccyx, 10 to 12 centimeters (4 to 5 inches). This diameter varies in a great measure of the ability of the coccyx to become displaced posteriorly.
- The *pelvic axis* (A in Fig. 70) or *pelvic curve* is the curved line which connects the middle points of the anteroposterior diameters.











The pelvic inclination is the angle between the conjugata vera and a horizontal plane (about 60 degrees). [The *obliquity of the pelvis* varies in different individuals, is greater in the female than in the male, and is increased by hip-joint disease, particularly on standing. With a normal inclination of the pelvis the sacral promontory is about 9.5 cm. ( $3\frac{4}{5}$  inches) above the upper border of the symphysis and the tip of the coccyx is  $\frac{1}{2}$  to 1 inch above its lower border.—Wolsey.] From a practical standpoint, it will be noted that, owing to the pelvic inclination, a wound passing through the abdominal wall horizontally above the symphysis may involve the filled bladder, the uterus, and the rectum, parts which are protected posteriorly by the bony pelvic wall (the sacrum).

The *true pelvis*, our "first path in life," and of more practical importance than the false pelvis, is accessible in the female to the examining finger or to the entire hand, which may be introduced into the vagina for diagnostic or operative purposes. It commences above at the pelvic inlet or superior aperture of the pelvis; the plane of this aperture passes through the iliopectineal line and is directed anteriorly; it is open below at the smaller cordiform pelvic outlet or inferior aperture of the pelvis. The plane of the latter is curved, the concavity being directed upward, since it descends from the symphysis to the tuberosities of the ischium and then ascends to the tip of the coccyx (compare the two pelvic apertures to the two apertures of the thorax, see page 92). The form of the pelvic canal is that of a truncated and inverted cone or funnel. The anterior wall of the pelvic canal is formed by the symphysis, by the two pubic rami (horizontal and descending), and by the ascending ramus of the ischium. The large *obturator foramina* are closed by the obturator membranes, only the small *obturator canal* being left open above and internally. The lateral walls are formed by the acetabular portion of the innominate bone, by the body and descending ramus of the ischium, and by the greater and the lesser sacrosciatic ligaments. The posterior wall corresponds to the sacrum and coccyx and is markedly concave anteriorly. The coccygeal vertebrae are connected by discs of fibrocartilage which render them movable, particularly in a posterior direction, as may be observed during the evacuation of a mass of hardened feces and during labor. The obstetrician is consequently justified in regarding an ankylosis of the coccygeal vertebrae as a cause of difficult delivery.

The portions of the pelvis which may be palpated externally are the posterior surfaces of the sacrum and coccyx, the tuberosities of the ischium, the iliac crests, the anterior superior spines of the ilium, and the symphysis pubis. The portions which may be palpated from the vagina and from the rectum are the concave inner surfaces of the sacrum and of the coccyx, the ischium, the pubis, and the pelvic surface of the acetabulum.

Fractures of the pelvic walls are not infrequently associated with injuries to the organs situated within the pelvis,—the urinary bladder, the urethra (particularly in the male), the rectum, the great vessels, and the sacral plexus.

The bony framework of the pelvis is strengthened by ligaments, muscles, and fascias, which better adapt it to protect the enclosed viscera, vessels, and nerves. The greater and lesser *sacrosiatic ligaments* strengthen the lateral pelvic wall and aid in the formation of the greater and lesser *sacrosiatic foramina*. The *pyriformis muscle* arises from the anterior surface of the sacrum, passes out of the pelvis through the greater sacrosiatic foramen, and inserts into the great trochanter. The foramen is almost entirely closed by the muscle, so that above and



## PLATE 20.

The female pelvic outlet as seen from without. From a Leipzig model from nature (His).

below the pyriformis there are only narrow spaces, the *suprapyriiform* and *infrapyriiform foramina*, through which important vessels and nerves make their exit from the pelvis. The lesser sacrosciatic foramen gives passage to the obturator internus muscle, which arises from the inner surface of the obturator membrane and its immediate vicinity and inserts into the great trochanter. In the upper and inner portion of the obturator membrane there is a small opening, the *obturator canal*, through which the obturator artery and nerve leave the pelvis and through which the obturator vein enters it.

At the pelvic outlet there is stretched a funnel-shaped musculo-tendinous plate, the *diaphragma pelvis*. The chief portion of the pelvic diaphragm is formed by the *levator ani muscle*. It arises from the white line (arcus tendineus) in the obturator fascia, which extends from the posterior surface of the horizontal ramus of the pubis to the spine of the ischium. In the male the muscle is inserted into the rectum and into the prostate; in the female, into the rectum and into the vagina. The closure of the inferior pelvic aperture is completed anteriorly by the musculo-tendinous plate of the *diaphragma urogenitale* (trigonum urogenitale), *triangular ligament*, which is stretched across the pubic arch. In the male the urogenital diaphragm gives passage to the membranous portion of the urethra; the muscular tissue surrounding the urethra in this situation is known as the compressor urethræ muscle. This septum is also perforated by the deep veins of the penis which enter the corpora cavernosa. In the female it gives passage to the vagina as well as to the urethra.

The pelvic diaphragm divides the larger superior from the smaller inferior portion of the pelvis. The former is the direct continuation of the abdominal cavity and, as it contains the pelvic viscera, it may be called the *visceral portion* of the pelvic space. The abdominal viscera are also found in this deepest portion of the peritoneal space, but they are kept out of the pelvis to a greater or less extent by the amount of space required by the pelvic viscera. The extravisceral portion of the pelvic space is situated below the pelvic diaphragm and between it and the inferior portion of the lateral pelvic wall (the ischium and the overlying obturator internus muscle); it is filled with fat and forms the *ischio-rectal fossas*.

In the *extravisceral portion* of the pelvic space the terminal portions of the viscera passing through the pelvic diaphragm are surrounded by the clamp-like musculature which renders possible the opening and the closing of the particular visceral canal.

The external *sphincter ani muscle* surrounds the terminal portion of the rectum in a circular manner. The superficial fibers run from before backward to insert into the tip of the coccyx. Anteriorly the fibers are continuous with the bulbocavernosus muscle in the male and with the constrictor cunni \* muscle in the female. [According to Cunningham, the most superficial fibers of the external sphincter ani decussate in front of and behind the anus; the deepest fibers are arranged in a circular direction around the canal, while between these the bulk of the muscular fibers are attached posteriorly to the coccyx, anteriorly to the central tendon of the perineum, reducing the empty canal to an anteroposterior slit on horizontal section.—ED.] The *bulbo-*

\* The sphincter vaginae.



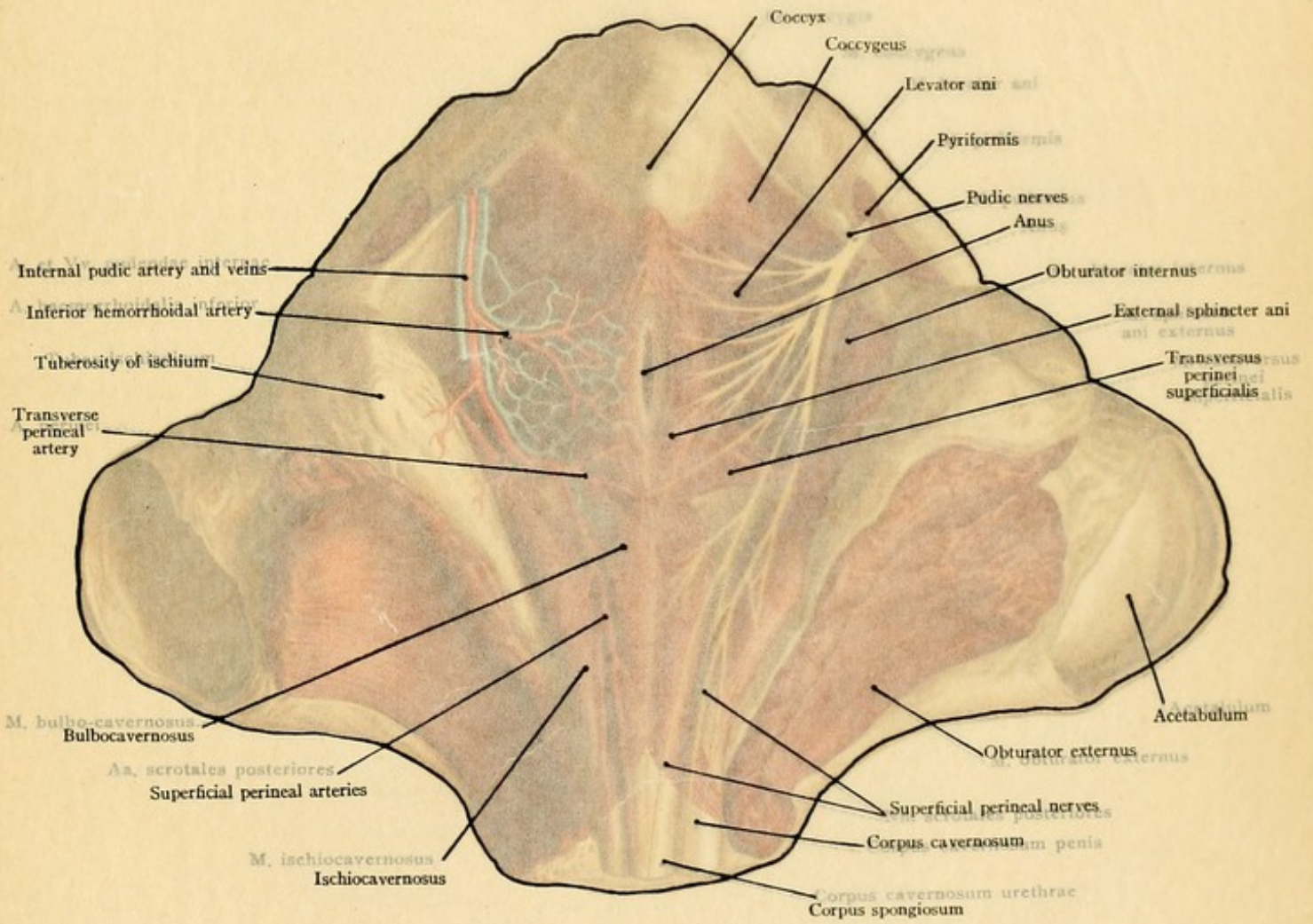




PLATE 20.

The female pelvic outlet as seen from without. From a Leipzig model from Hunter (His).

below the pyriformis there are only narrow spaces, the *suprapyriform* and *suprapyriform foramina*, through which important vessels and nerves make their exit from the pelvis. The lesser sacrosacral foramen gives passage to the obturator internus muscle, which arises from the inner surface of the obturator foramen and its immediate vessels and inserts into the great trochanter. In the upper and inner portion of the obturator foramen there is a small opening, the *obturator canal*, through which the obturator nerve and vessels leave the pelvis and through which the obturator vein enters it.

At the pelvic outlet there is the *perineal membrane*, the *diaphragm pelvis*. The *levator ani* muscle. It arises from the white line of the posterior surface of the ilium and the muscle is inserted into the lesser trochanter and into the vagina. The *pyriformis* muscle is inserted into the lesser trochanter and into the vagina. The *pubic nerve* and *anus* are also shown.

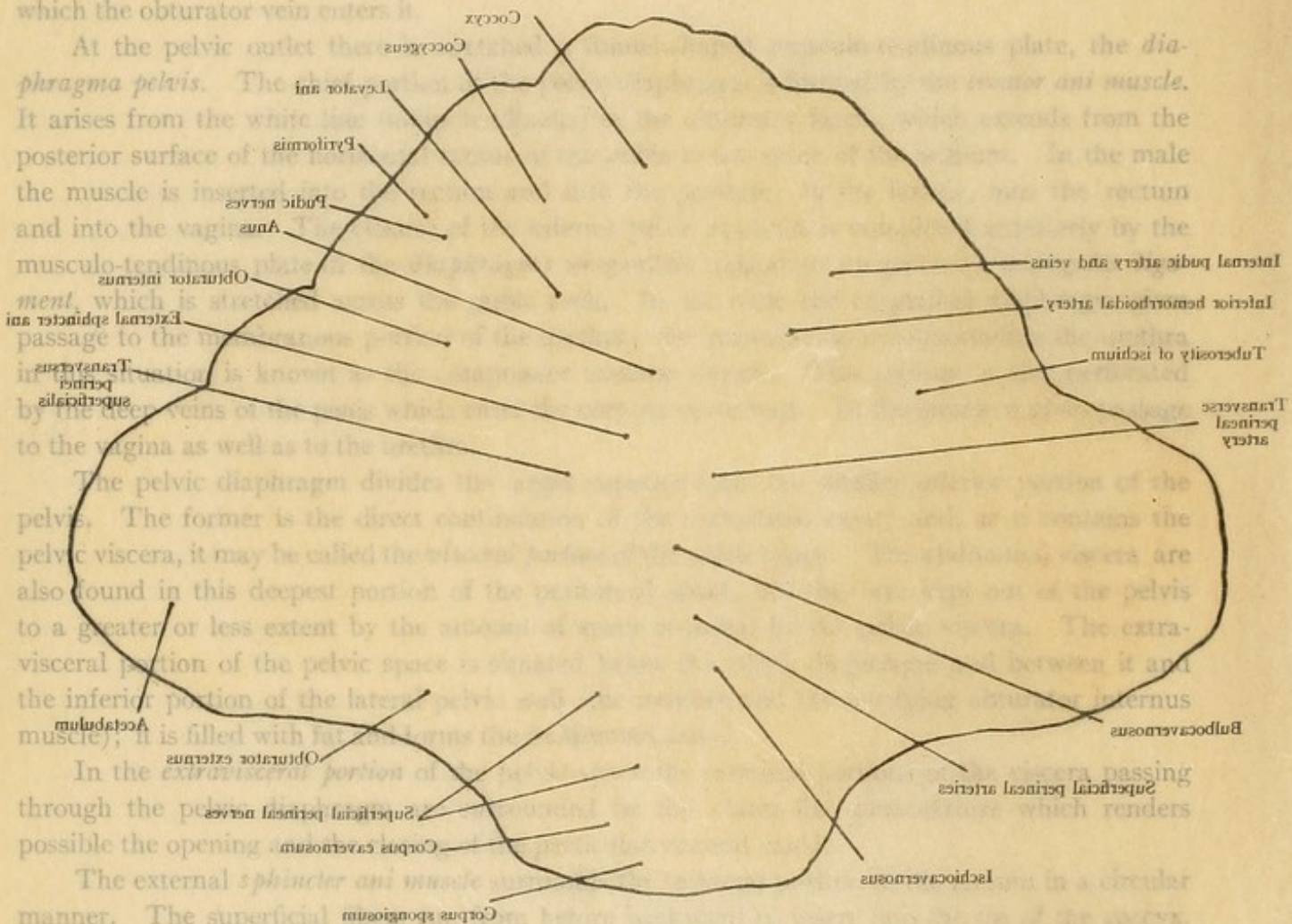
The *obturator internus* muscle is inserted into the lesser trochanter and into the vagina. The *external sphincter ani* muscle is inserted into the lesser trochanter and into the vagina. The *transverse perineal muscle* is inserted into the lesser trochanter and into the vagina. The *subcutaneous perineal pouch* is also shown.

The *pelvic diaphragm* divides the pelvic space into the *suprapelvic* and *subpelvic* spaces. The former is the direct continuation of the abdominal cavity and contains the pelvic viscera, it may be called the *intrapelvic* space. The latter is the *extrapelvic* space and contains the *ischio-cavernosus* and *bulbo-cavernosus* muscles. The *ischio-cavernosus* muscle is inserted into the lesser trochanter and into the vagina. The *bulbo-cavernosus* muscle is inserted into the lesser trochanter and into the vagina.

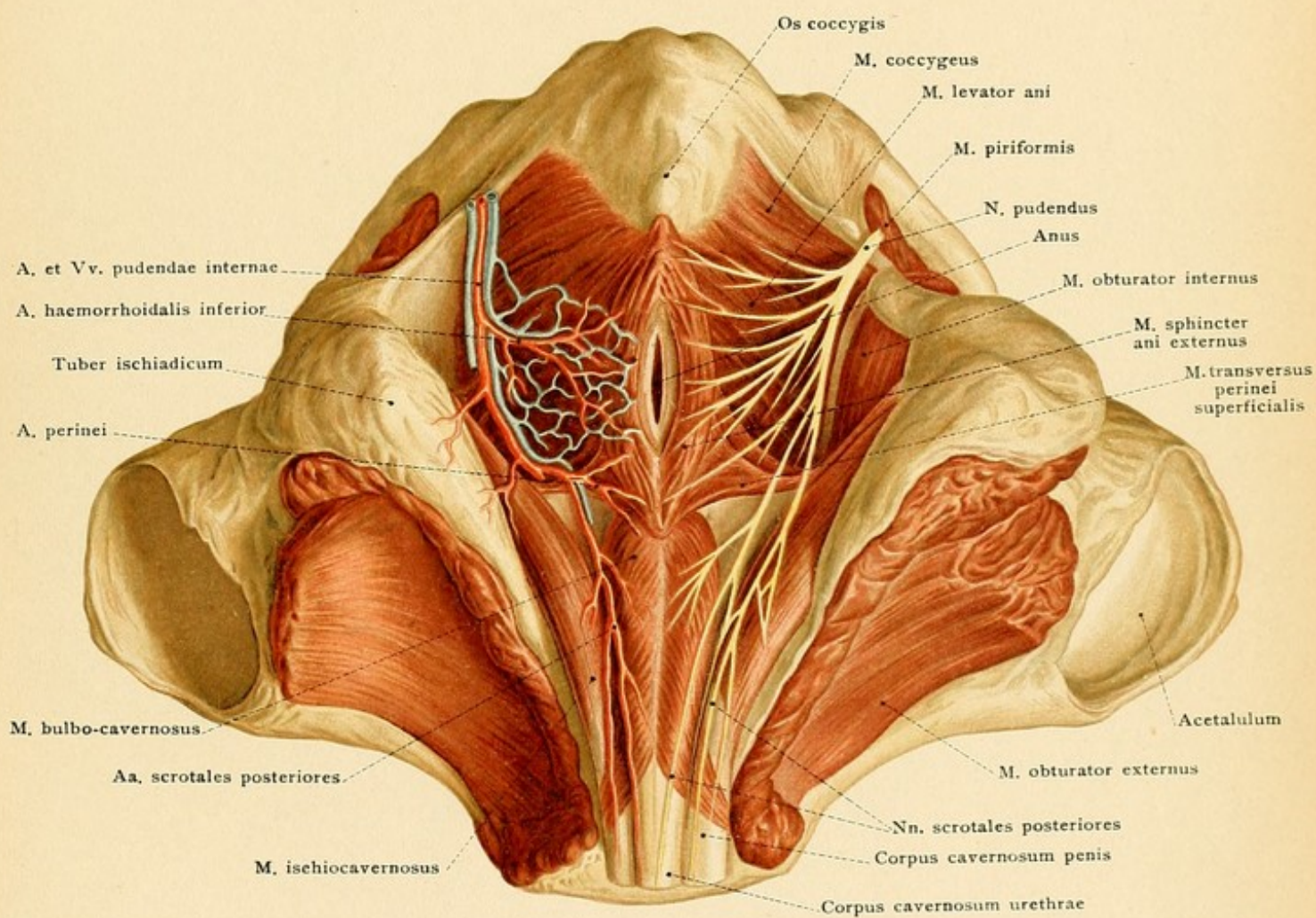
In the *extrapelvic* portion of the pelvic space the *ischio-cavernosus* and *bulbo-cavernosus* muscles are also found. The *ischio-cavernosus* muscle is inserted into the lesser trochanter and into the vagina. The *bulbo-cavernosus* muscle is inserted into the lesser trochanter and into the vagina. The *subcutaneous perineal pouch* is also shown.

The *external sphincter ani* muscle is inserted into the lesser trochanter and into the vagina. The *superficial perineal pouch* is also shown. The *ischio-cavernosus* and *bulbo-cavernosus* muscles are also shown. The *subcutaneous perineal pouch* is also shown.

\* The sphincter vaginae.













*cavernosus muscle* arises from a tendinous raphé commencing at the anus; its fibers diverge anteriorly, surround the bulb of the urethra, and run to the corpora cavernosa of the penis. The *constrictor cunni muscle* radiates anteriorly from the anus, covers the bulbi vestibuli, surrounds the entrance of the vagina, and runs over the dorsum of the clitoris. The *ischiocavernosus muscle* arises from the anterior margin of the ascending ramus of the ischium, covers the corpus cavernosum penis (or clitoridis), and radiates to the lateral and dorsal surfaces of the penis (or clitoris). The *superficial transversus perinei muscle* varies greatly in different individuals; it runs from the descending ramus of the ischium to the median line, where it becomes continuous with its fellow of the opposite side and with the bulbocavernosus muscle.

It should be clearly understood that chronic inflammations in the posterior pelvic wall, particularly those in the region of the sacroiliac articulation, may extend posteriorly to the sacral and the lumbar regions, anteriorly to the pelvic space, from which they may pass inward to the rectum, to the bladder, or to the uterus, downward through the pelvic diaphragm to the ischio-rectal fossa, or posteriorly through the sacrosciatic foramina beneath the gluteal muscles. Suppurations originating in the pelvic viscera (for example, in the prostate, in the seminal vesicles, and in that portion of the urethra situated above the urogenital diaphragm) may pass downward through the diaphragm, reach the ischio-rectal fossa, and then perforate the skin near the anus. The so-called periproctitic abscesses, originating independently in the fat of the ischio-rectal space, may also point in the same situation, and, under certain circumstances, such abscesses may be felt as swellings through the rectal wall by the finger introduced into the anus.

The vessels and nerves of the pelvic space should be recalled to memory by the aid of a text-book of systematic anatomy. The branches of the internal iliac artery in the male and in the female, and the lumbar and sacral plexuses with their respective branches, should also be reviewed.

### THE PELVIC CAVITY IN THE MALE.

**The Urinary Bladder.**—The male urinary bladder (Plate 21), when distended, takes up the greater portion of the pelvic cavity. It is in relation with the anterior pelvic wall. Its position varies with the state of distention, since the full bladder extends particularly upward and backward, although it also enlarges laterally. When empty, it barely extends above the upper margin of the symphysis; while when extremely distended, it may reach almost to the navel, compressing and displacing the small intestines situated posterior to the viscus. It consequently follows that when it is desired to enter the bladder above the symphysis, by puncture, for example, the rule is to previously distend the bladder artificially to avoid the danger of entering the peritoneal cavity (see page 127). By this route, calculi and tumors may be removed from the bladder and the urethra may be catheterized (catheterismus posterior) (retrograde catheterization). The internal orifice of the urethra is situated in the median line about three centimeters behind the middle of the symphysis. [According to Cunningham, the posterior opening of the urethra is slightly below the level of and from 2 to 2½ inches behind the upper border of the symphysis. It is easily reached through a suprapubic wound.—ED.] The inferior wall of the bladder rests upon the prostate gland. The anterior surface is connected to the pelvic wall by loose connective tissue which allows the distended bladder to ascend into the



## PLATE 21.

A median sagittal section of the male pelvic region. From a Leipzig model from nature (His).

FIG. 71.—The bladder, the ureters, and the seminal vesicles exposed from behind by a frontal section of the pelvis. Upon the left side there is an external inguinal hernia; upon the right side the peritoneum has been almost entirely removed.

*supravesical space* (cavum Retzii), which is situated above the symphysis and also is filled with loose connective tissue. The superior surface is directed upward and backward and borders upon the small intestine and the sigmoid colon. In contrast to the anterior surface, it possesses a peritoneal reflection (see Fig. 71, in which a part of this reflection is still present) which passes above the symphysis to reach the inner surface of the abdominal wall. Since the height of the bladder above the symphysis is inconstant and varies with the degree of distention of the viscus, it follows that the line of reflection of the peritoneum from the abdominal wall to the bladder is also inconstant, and is higher or lower according to whether the bladder is full or empty. If the peritoneum is irritated by an inflammation, peritoneal pains will be produced by the displacement of the peritoneum during urination. The larger portion of the lateral surfaces is also covered by peritoneum, which extends downward over the ligamentum umbilicale laterale (see page 123). The posterior and inferior surfaces rest upon the sacral curve of the rectum (see page 150). The posterior surface, at least in its upper portion, possesses a peritoneal reflection. For this reason a rupture of the posterior wall of the bladder is a more serious injury than one of the anterior wall, since the former may at once involve the peritoneum and almost surely produce a fatal peritonitis unless the surgeon interferes in time. Between the bladder and the rectum the peritoneum forms the *excavatio rectovesicalis*. Below the line of the reflection of the peritoneum from the bladder to the rectum the posterior wall of the bladder is separated from the anterior wall of the rectum by a loose connective tissue, and the *rectovesical fascia*, which also passes to the inferior surface of the bladder (in the region of the fundus). The *seminal vesicles* (Plate 21 and Fig. 71) are imbedded in this tissue and, when well developed, may extend upward as far as the line of reflection of the peritoneum from the bladder to the rectum. Between the seminal vesicles are the ends or ampullas of the vasa deferentia which unite with the ducts of the seminal vesicles to form the *ejaculatory ducts*. These parts as well as the fundus of the bladder (and occasionally vesical calculi), from their relation to the anterior rectal wall, are accessible to digital examination from the rectum. This is also most valuable in the examination of the bladder, of the prostate (particularly when hypertrophied), and of the seminal vesicles, the contents of which may, under certain circumstances, be emptied through the urethra by pressure upon the anterior rectal wall.

*The relation of the rectum to the bladder* may be utilized in practice by filling the rectum with water, or by tamponade, in order to force the distended bladder forward and upward toward the anterior abdominal wall and thus render it more accessible to operative procedures above the symphysis. [The reflections of peritoneum from the bladder to the anterior walls of the pelvis and abdomen and to the lateral walls of the pelvis rise higher and higher according to the degree of distention. As pointed out by the author, the reflection from the bladder to the rectum—posterior—however, changes but little. This reflection takes place at the level of about one inch above the prostate or a finger's length from the anus. A knowledge of this



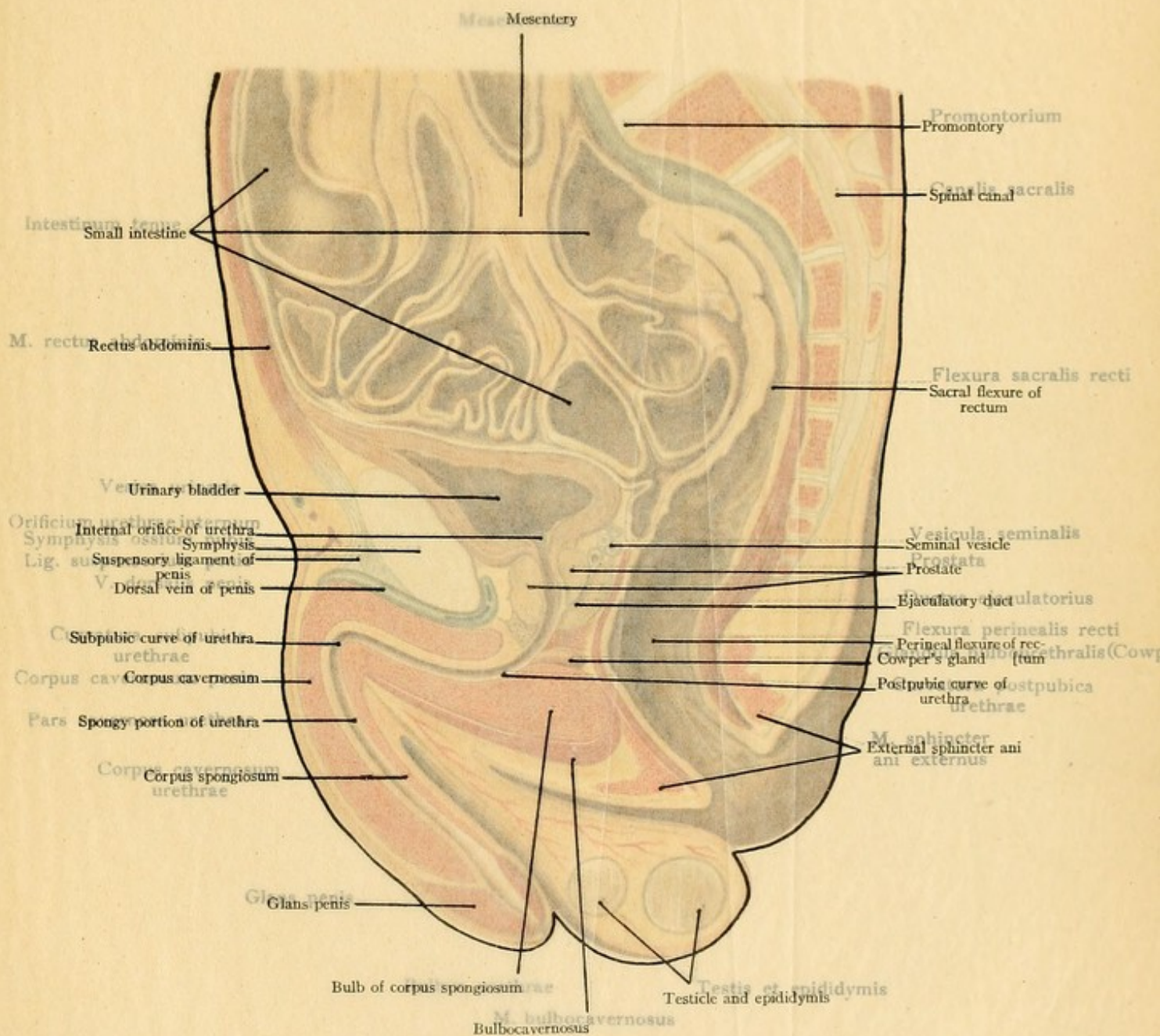
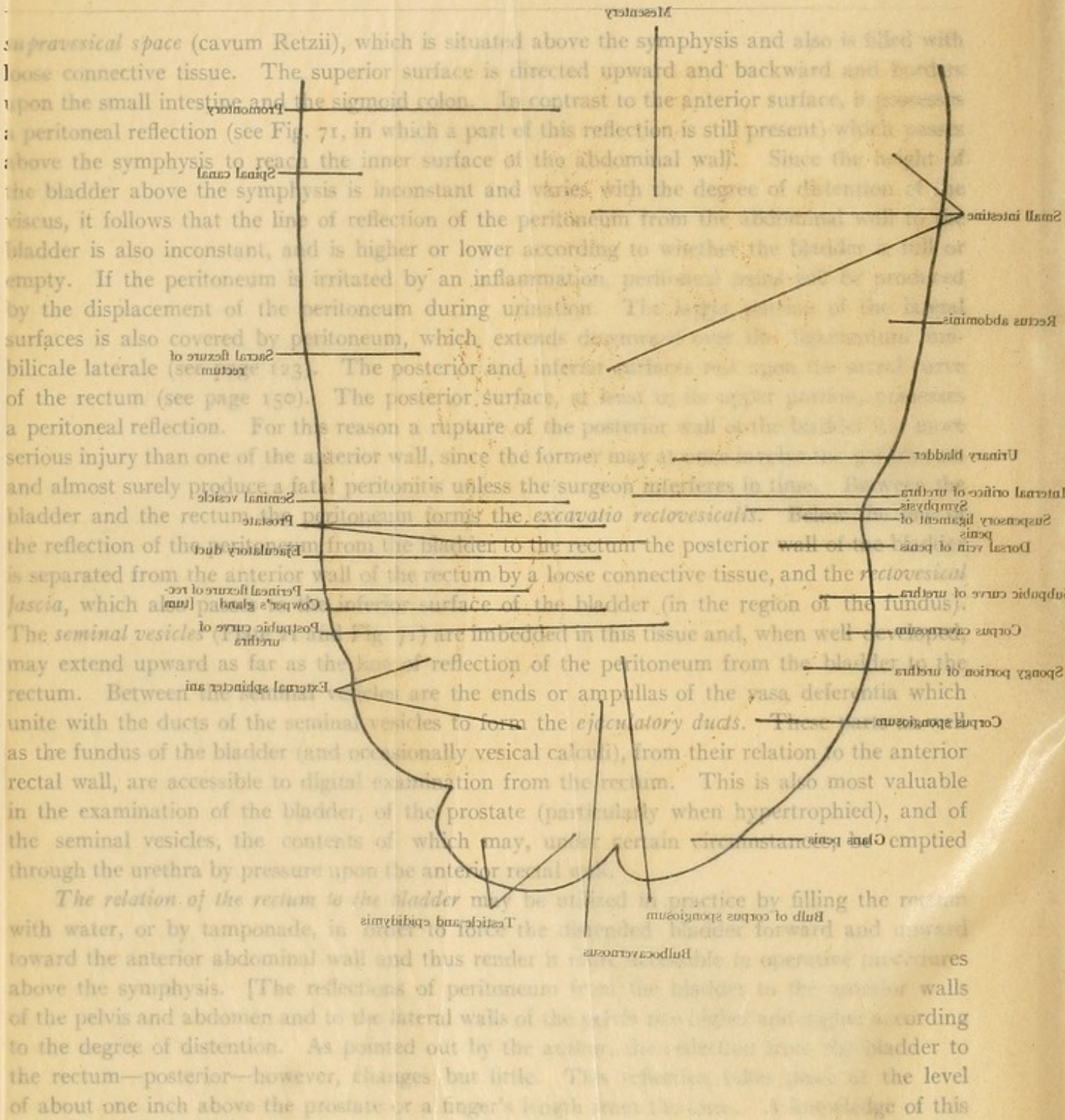




PLATE 21.

A median sagittal section of the male pelvic region. From a Leipzig model from nature (Hilf).

FIG. 71.—The bladder, the ureters, and the seminal vesicles exposed from behind by a frontal section of the perineum. Upon the left side there is an external inguinal hernia; upon the right side the peritoneum has been removed.



The relation of the rectum to the bladder may be illustrated in practice by filling the rectum with water, or by tamponade, in order to force the distended bladder forward and upward toward the anterior abdominal wall and thus render it more accessible in operative procedures above the symphysis. [The reflections of peritoneum from the bladder to the anterior walls of the pelvis and abdomen and to the lateral walls of the rectum are displaced according to the degree of distention. As pointed out by the arrow, the distance from the bladder to the rectum—posterior—however, changes but little. This distance is about the level of about one inch above the prostate or a finger's length from the urethra. A knowledge of this



Mesenterium

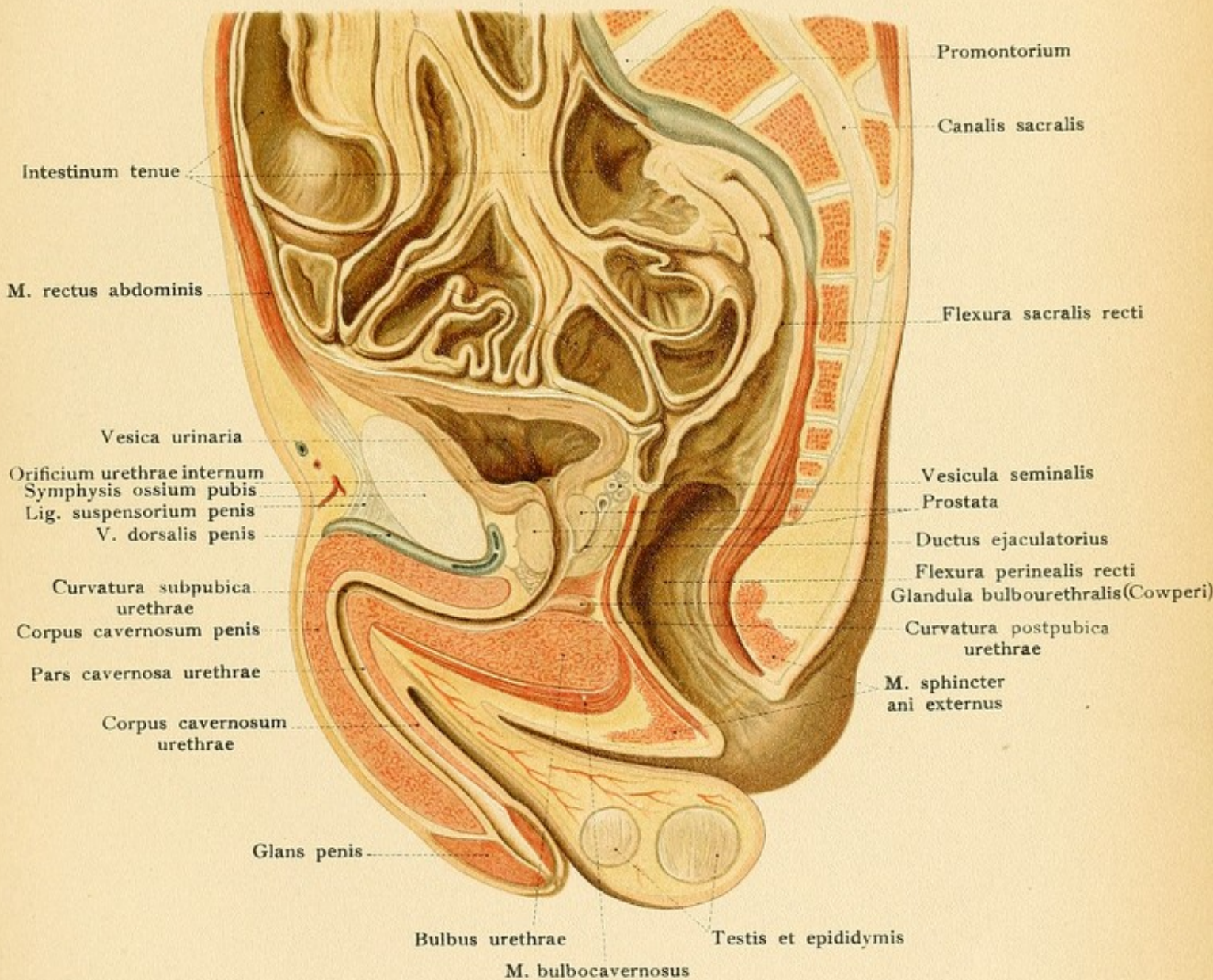
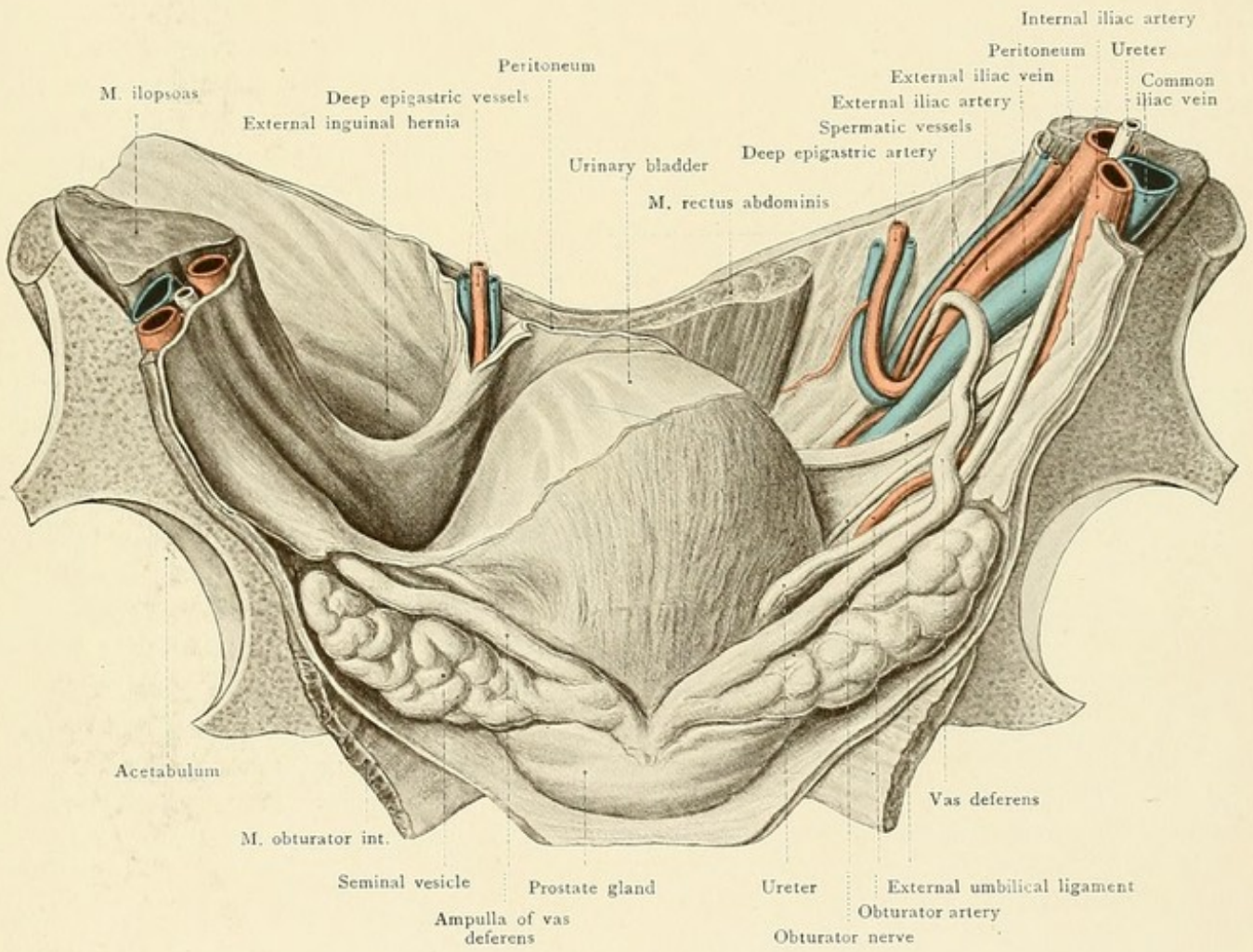








Fig. 71.









was much more important formerly, when it was the practice to enter the bladder by puncture through the anterior rectal wall, than now, when such a procedure is rarely, if ever, permissible. The posterior surface, fundus or base of English writers, and the pubic surface are scarcely changed by any degree of distention.—ED.]

**The Ureter.**—The pelvic portion of the ureter (Fig. 71), after crossing the iliopectineal line, runs beneath the peritoneum in the lateral pelvic wall along the internal iliac artery; it then passes inward and forward to the fundus of the bladder, being crossed by the vas deferens, which passes backward and inward [*i. e.*, the vas crosses on the vesical side of the ureter.—ED.]

**The Male Urethra.**—In the flaccid penis the urethra forms an S-shaped curve and is fifteen to twenty centimeters in length. The first or *postpubic curve* is situated behind the symphysis and its concavity is directed forward and upward. This curve must always be borne in mind during the introduction of a catheter, sound, or cystoscope for the purpose of diagnosis, irrigation, or internal illumination of the bladder (cystoscopy), since it does not disappear when the penis is elevated. The second or *subpubic curve* is situated beneath the symphysis, its concavity is directed downward and backward, and it disappears upon elevation of the penis. The urethra is subdivided into three portions—the prostatic, the membranous, and the spongy (*pars prostatica*, *membranacea*, and *cavernosa urethræ*). The urethra possesses three wide and two narrow places:

The three wide places are: (1) The *pars prostatica*; (2) the *recessus bulbosus*, a dilatation situated in the commencement of the *pars cavernosa*, which may occasionally catch the end of the catheter; and (3) the *fossa navicularis*, just behind the external orifice.

The narrow portions of the urethra are: (1) The *pars membranacea*, the muscular wall of which opposes the introduction of an instrument by reflex contractions; and (2) the *meatus*, behind which small calculi may become impacted after they have escaped from the bladder. [It is worth noting that, in normal urethras, an instrument which passes the external meatus may be expected to pass the other narrowed portions without difficulty.—ED.] The internal orifice of the urethra is also not infrequently narrowed and causes difficulty in urination, particularly when the middle lobe of an hypertrophied prostate presses against the orifice. [The effect of enlargement of the middle lobe of the prostate is to create a bar behind the urethra and to so change the relation that the bladder opening of the urethra does not correspond to the lowest level of that organ, as it should; the result is that the bladder cannot be completely emptied, more or less urine remaining—residual urine. It also changes the length and curve of the prostatic urethra, which must be remembered in attempting to catheterize these cases.—ED.] From the relation of the prostate to the rectum it will be understood that prostatic inflammations and abscesses may extend posteriorly and break into the rectum. The chief seat of urethral stricture is at the junction of the cavernous with the membranous portions. From the study of a median sagittal section it will be clear that the retained and decomposing urine above the stricture may give rise to inflammation and suppuration which may perforate into the rectum, into the scrotum, or through the perineum. It should also be noted that the urethra may be opened by making an incision in the perineal raphé, in the median line, and dividing the skin, the tunica dartos, the superficial perineal fascia, the bulbocavernosus muscle, and the bulbus urethræ. Finally, it should not be forgotten that in gonorrhœa the anatomic rela-



tions are very favorable for an extension of the process internally along the urethra and an involvement of the entire genito-urinary apparatus.

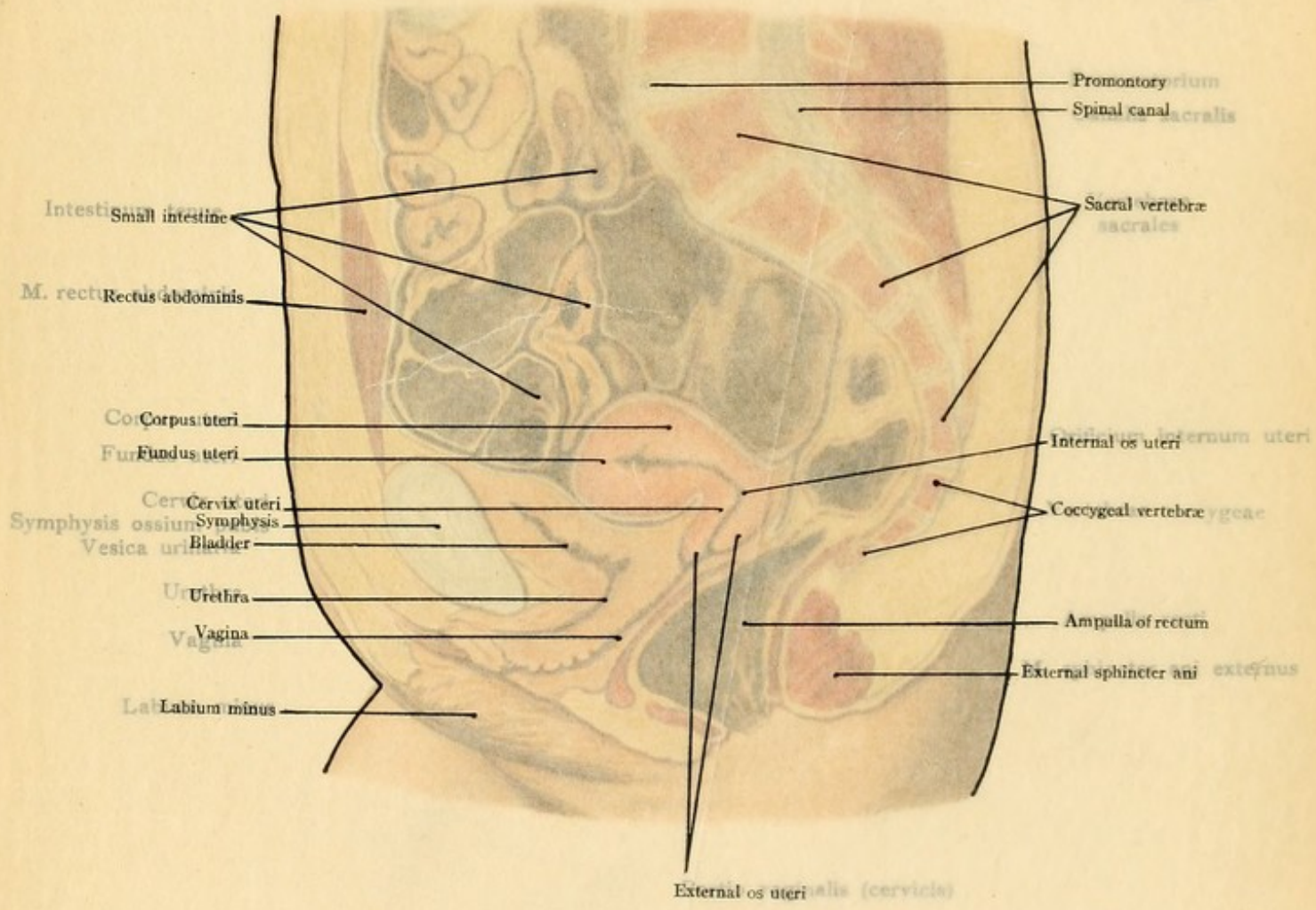
**The Rectum.**—The rectum lies behind the bladder and runs from the promontory to the anus in a double curve. The first or long curve corresponds to the hollow of the sacrum, and is known as the *sacral curve* (*flexura sacralis*). It extends to the tip of the coccyx and to the prostate, and the concavity of the curve is directed anteriorly. The second or short curve is in the perineum (*flexura perinealis*); it is convex anteriorly, only about three centimeters in length, and is surrounded by the external sphincter ani muscle. A knowledge of these curves is important for operative procedures and for the introduction of the rectal speculum. The rectum also deviates from the median line in some cases, but to so slight a degree that the variation is of no practical importance. The narrowest portion of the rectum is its termination, which is surrounded by the sphincters. Just above this is a dilatation, the *ampulla recti*, which is particularly developed posteriorly. The posterior wall of the rectum is attached to the sacrum by loose connective tissue in which are situated a number of lymphatic glands. These glands extend upward to the sacroiliac articulation; in cases of rectal carcinoma they become involved and must be removed. In this neighborhood there is also a large number of veins which anastomose with the venous hemorrhoidal plexus surrounding the anus. The perineal curve borders anteriorly upon the prostate gland. At this point rectal carcinoma may extend to the prostate, the prostate may be treated surgically through the anterior rectal wall, and prostatic hypertrophy and calculi situated in the fundus of the bladder may press upon the rectum and render defecation difficult.

The *sacral curve* may be subdivided into two sections. The inferior one is situated below the rectovesical fold and is consequently not covered by peritoneum. It borders anteriorly upon the fundus of the bladder, the ampullas of the vasa deferentia, and the seminal vesicles; these parts may therefore be involved by the extension of a rectal carcinoma. In this situation the bladder may be entered from the rectum without opening the peritoneal cavity. Only the anterior surface of the lower end of the superior portion of the sacral curve is covered by peritoneum; higher up the lateral surfaces are also covered, while at the promontory, the peritoneum almost completely surrounds the rectum and fixes it to this point by a short mesorectum. In operating high up in the rectum it must be remembered that the danger of opening the peritoneal cavity increases as we ascend. The distance between the deepest point of the rectovesical fold and the anus, measured along the anterior rectal wall, is about six to eight centimeters. The situation in which the rectum possesses a lateral peritoneal reflection is from twelve to fourteen centimeters above the anus. From the relation of the rectum to the sacrum it will be seen that this portion of the intestine may also be attacked from behind after the resection of a portion of the sacrum.

### THE PELVIC CAVITY IN THE FEMALE.

The essential difference between the relations of the pelvic viscera in the two sexes is due to the fact that the male genitalia take up less space and are situated almost entirely outside of the pelvis. In the female, however, the ovaries, the tubes, the uterus, and the vagina are pushed





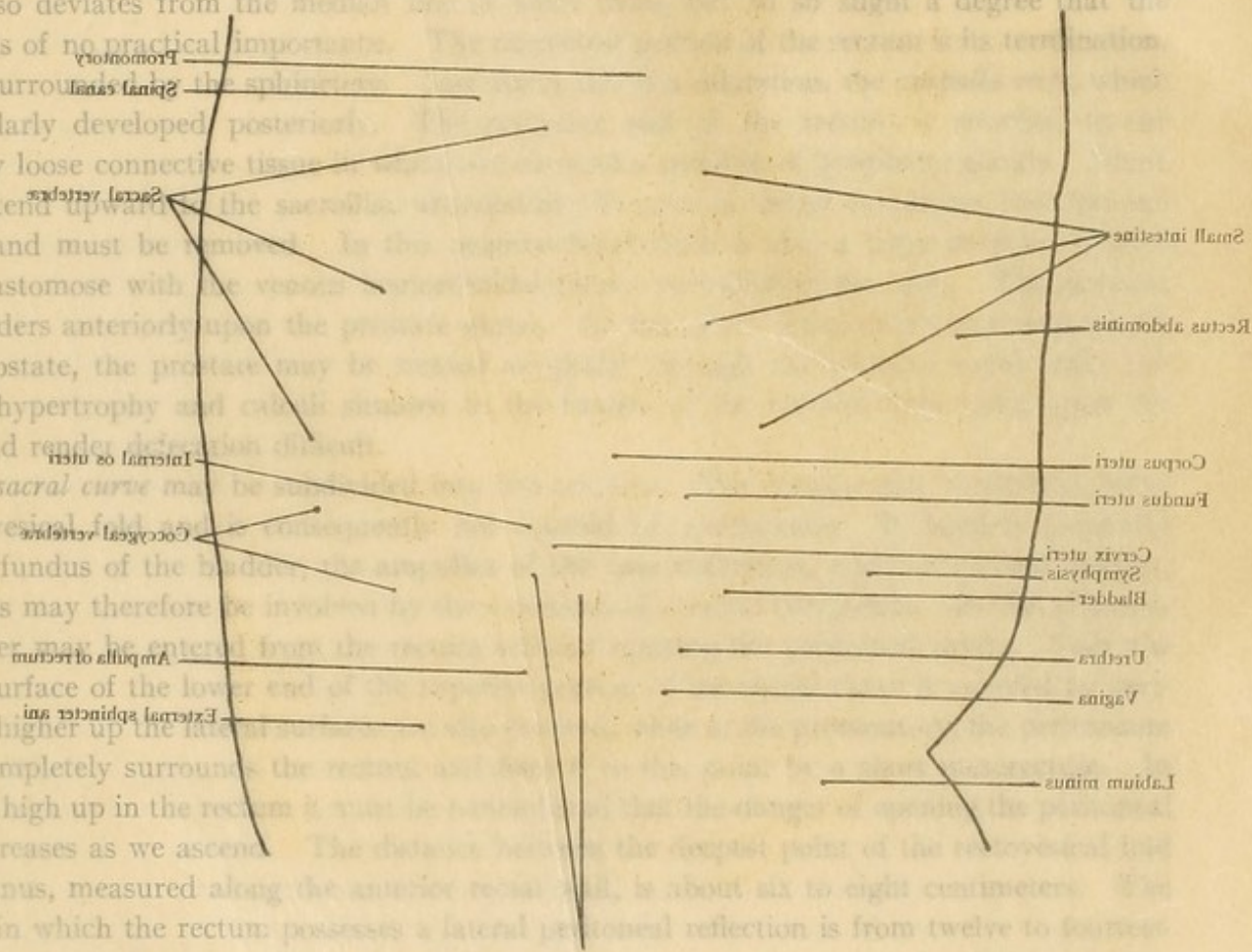


tions are very favorable for an extension of the process internally along the urethra and an involvement of the entire genito-urinary apparatus.

**The Rectum.**—The rectum lies behind the bladder and runs from the promontory to the anus in a double curve. The first or long curve commences to the hollow of the sacrum, and is known as the *sacral curve* (*flexura sacralis*). It extends to the tip of the coccyx and to the prostate, and the concavity of the curve is directed upwards. The second or short curve is in the perineum (*flexura perinealis*); it is much shorter, only about three centimeters in length, and is surrounded by the external sphincter muscle. A knowledge of these curves is important for operative procedures and for the construction of the rectal speculum. The rectum also deviates from the median line to such a slight degree that the variation is of no practical importance. The superior portion of the rectum to its termination, which is surrounded by the sphincter muscle, is particularly developed posteriorly. The rectum is attached to the sacrum by loose connective tissue. The glands extend upwards to the sacrum, which are involved and must be removed in the operation. The curve borders anteriorly upon the prostate, and to the prostate, the prostate may be enlarged by prostatic hypertrophy and cause stricture of the rectum and render defecation difficult.

The *sacral curve* may be defined as the curve of the rectum from the rectovesical fold to the coccyx. The rectovesical fold is a peritoneal reflection upon the fundus of the bladder. The coccyx is a small cartilaginous structure composed of these parts may therefore be involved in the operation. The bladder may be entered from the rectum by the anterior surface of the lower end of the rectum; higher up the lateral rectovesical fold almost completely surrounds the bladder. The distance between the point of the rectovesical fold and the anus, measured along the anterior rectal wall, is about six to eight centimeters. The situation in which the rectum possesses a lateral peritoneal reflection is from twelve to fourteen centimeters above the anus. From the rectum to the sacrum it will be seen that this portion of the intestine may also be attacked from behind after the resection of a portion of the sacrum.

The *sacral curve* may be defined as the curve of the rectum from the rectovesical fold to the coccyx. The rectovesical fold is a peritoneal reflection upon the fundus of the bladder. The coccyx is a small cartilaginous structure composed of these parts may therefore be involved in the operation. The bladder may be entered from the rectum by the anterior surface of the lower end of the rectum; higher up the lateral rectovesical fold almost completely surrounds the bladder. The distance between the point of the rectovesical fold and the anus, measured along the anterior rectal wall, is about six to eight centimeters. The situation in which the rectum possesses a lateral peritoneal reflection is from twelve to fourteen centimeters above the anus. From the rectum to the sacrum it will be seen that this portion of the intestine may also be attacked from behind after the resection of a portion of the sacrum.



### THE PELVIC CAVITY IN THE FEMALE.

The essential difference between the relations of the pelvic viscera in the two sexes is due to the fact that the male genitalia take up less space and are situated almost entirely outside the pelvis. In the female, however, the ovaries, the tubes, the uterus, and the vagina are part



















## PLATE 22.

A median sagittal section of the female pelvic region. From a Leipzig model from nature (His).

FIG. 72.—The relation of the ureter to the uterine artery and to the cervix and vagina. The left half of a specimen in which a median section of the female pelvic viscera has been made. The broad and round ligaments have been incised and the uterus displaced upward and backward.

in, as it were, between the bladder and rectum, and almost entirely surrounded by a peritoneal duplicature, the ligamentum latum (broad ligaments).

**The Bladder.**—The capacity of the female bladder is about one-fourth less than that of the male. The position of the viscus behind the anterior pelvic wall and its relation to the peritoneum are about the same as in the male. The posterior wall of the bladder, however, has quite a different topography on account of the presence of the uterus and the vagina. The larger part of the bladder (that is, of the base or fundus) rests upon the upper portion of the anterior vaginal wall (Plate 22); the top of the bladder borders upon the cervix uteri. The uterus and the bladder are united by a loose connective tissue, but between the bladder and the vagina the connective tissue forms a tense layer, the *vesicovaginal septum*. The connection between the anterior cervical wall and the posterior surface of the bladder is so firm, however, that the uterus promptly follows the movements of the posterior vesical wall produced by the varying degree of distention of the viscus. The peritoneum covers the bladder above and behind, as far as the middle of the posterior surface, from which situation it is reflected upon the uterus at the junction of the body with the cervix, forming the *vesico-uterine fold* (*excavatio vesico-uterina*). It will be observed that the bladder may be opened through the anterior vaginal wall, without injuring the peritoneum, for the purpose of removing foreign bodies (calculi) and palpating the interior of the viscus. The bladder may also be opened above the pubis (*sectio alta*), as in the male, for the treatment of vesical tumors or tuberculosis.

**The Ureter.**—As the ureter of the female enters the true pelvis, it crosses the origin of the external iliac vessels and runs downward to the outer side [in front of.—ED.] of the internal iliac artery. It then crosses over the origin of the uterine artery and passes to the inner side of this vessel (Figs. 72 and 73). In the neighborhood of the cervix the uterine artery is usually very tortuous (perhaps as a result of a past pregnancy?) and passes inward over the ureter to ascend upon the body of the uterus. Very close to this crossing the artery usually gives off a good-sized branch, the *ramus cervicovaginalis*. The ureter is imbedded in loose connective tissue alongside of the cervix. At the level of the anterior lip of the cervix the ureters approach the vaginal wall and empty into the bladder somewhat below the external orifice of the uterus. This relation of the ureter must be remembered by the operator (in vaginal hysterectomy, for example), since the ureter is not infrequently divided in this situation. During its course in the true pelvis the ureter is occasionally exposed to compression from uterine or ovarian tumors, so that retention of the urine in the ureter and in the kidney with its manifold sequelæ is possible. [According to Cunningham, the ureter near its termination is about  $\frac{3}{4}$  of an inch external to the lateral aspect of the cervix uteri.—ED.]

**The Urethra.**—The female urethra is but three centimeters in length. It is wider than in the male and so capable of dilatation that the interior of the bladder may be palpated through the urethra by the average finger. In consequence of the greater width and of the shorter length,



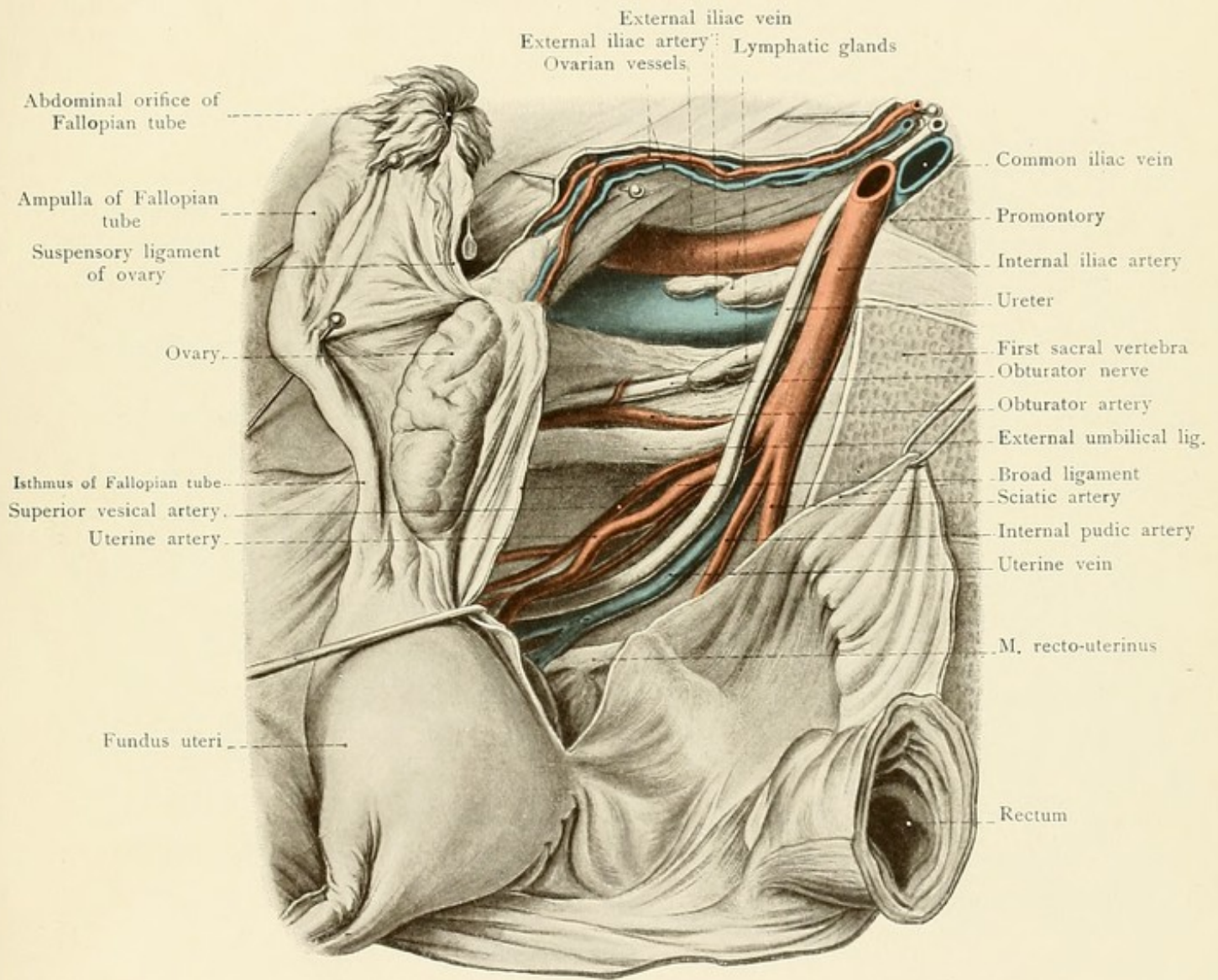
fair-sized vesical calculi may be removed through the urethra in the female more easily than in the male. Its course is almost directly forward and downward with an insignificant anterior concavity. The urethra rests upon the lower portion of the anterior vaginal wall, from which it is separated by the comparatively broad *urethrovaginal septum*. The narrowest place is at the external orifice, where the urethra opens as a sagittal slit into the vestibulum vaginæ.

**The Uterus.**—The body of the uterus projects toward the peritoneal cavity between the bladder and the rectum; it is very movable and its position is continually influenced by the degree of distention of the bladder and of the rectum. Disregarding its fixation to the vagina, bladder, and peritoneum (*ligamentum latum*), the uterus is held in its position chiefly anteriorly by the *ligamentum teres* passing into the inguinal canal and posteriorly by the recto-uterine muscles situated within the folds of Douglas. The anterior surface of the body of the uterus rests upon the bladder, although it is separated from it by the *vesico-uterine fold* of peritoneum (*excavatio vesico-uterina*). When the bladder is full, it raises the uterus to a vertical position; when the bladder is empty, the uterus sinks anteriorly. The empty and the full rectum have a similar influence upon the position of the uterus. The neck of the uterus is more fixed, and in such a way that the external os is usually at the level of the upper margin of the symphysis and the longitudinal axis of the cervix corresponds to the pelvic axis (see page 144). Since the highest point of the fundus uteri does not extend to the plane of the pelvic inlet, it follows that the normal non-pregnant uterus is always entirely within the true pelvis. The fixation of the cervix is due to its attachment to the vagina, to the connective tissue between it and the bladder, and to the recto-uterine muscles, which are enclosed in the recto-uterine folds of the peritoneum and run to the lateral walls of the rectum and to the sacrum. The position of the uterus in the dead body is no criterion for that in the living woman. The normal position is an inclination anteriorly with a more or less decided angle between the cervix and the body (normal ante flexion) which is influenced by the distention of the bladder. If no angulation is present, so that the longitudinal axes of the body and of the cervix form a straight line, we speak of *anteversion*; this condition tends to be more or less prevalent after repeated pregnancies. In the dead subject the uterus is usually displaced posteriorly, chiefly because gravitation has a better chance to act on account of the relaxed musculature and of the absence of the intra-abdominal tension. Retroversion and retroflexion are always abnormal positions.

**The Peritoneum.**—The peritoneum is reflected from the bladder to the uterus at the level of the internal os, forming the *vesico-uterine fold* (*excavatio vesico-uterina*), passes over the fundus and covers the posterior surface of the uterus as far as the upper portion of the vagina and is reflected to the rectum, forming the *recto-uterine fold* (*excavatio recto-uterina*). The peritoneum is firmly adherent to the posterior surface of the uterine body, but it is more loosely attached to the cervix. This relation of the peritoneum is of great importance for operative procedures upon the uterus and upon the vagina. It is clear that the anterior wall of the cervix may be incised toward the bladder without danger of opening the peritoneal cavity, while an incision into the posterior wall may easily open the peritoneal cavity. We may also incise the anterior vaginal wall, work upward in the loose connective tissue between the cervix and the bladder, and open the vesico-uterine pouch to reach the genital organs within the peritoneal cavity. For the same



Fig. 73.










FIG. 73.—The lateral pelvic wall of the female. The posterior layer of the broad ligament has been incised at the side of the recto-uterine pouch. The uterus, with the tube and ovary, has been displaced anteriorly and the rectum has been pushed posteriorly.

purpose the gynecologist opens the peritoneal cavity by incising the posterior vaginal fornix and entering the recto-uterine pouch. In a general way this procedure is the easier one, since it is not necessary to first separate the cervix from the bladder.

**The Vagina.**—The vagina runs from above and behind obliquely downward and forward. Its course presents a slight concavity anteriorly and it forms an inconstant angle with the cervix, which is usually a right angle in the virgin. The anterior vaginal wall is somewhat shorter than the posterior one, chiefly because the posterior wall extends higher upon the cervix than does the anterior one. The vaginal vault—*i. e.*, the circular portion of the vagina surrounding the intravaginal cervix—is lower anteriorly than posteriorly, where the fornix is deeper and where the vaginal cervix is longer. Although the anterior lip of the cervix is shorter than the posterior one, it is situated at a lower level.

The anterior wall of the vagina borders upon the bladder (with the interposition of loose connective tissue) and upon the urethra (where the connective tissue is firmer). It is consequently easy to enter the bladder through the anterior vaginal wall. Upon the posterior vaginal wall we differentiate three areas (Plate 22):

1. A small superior one, the region of the posterior vaginal vault. This portion has a peritoneal reflection and is in relation with the deepest point of the recto-uterine pouch.
2. A middle area, the longest of the three, which borders upon the sacral curve of the rectum. It is separated from the rectum by the *rectovaginal septum*, which is composed of loose connective tissue and favors the prolapse of the vagina and of the uterus.
3. A short inferior area, where the rectum becomes more distant from the vagina on account of its perineal curve. It is situated below the urogenital diaphragm, and the perineum separates this portion of the vagina and its vestibule from the lower end of the rectum. In this situation a slight perineal tear during delivery may lead to a laceration of the wall of the vestibule of the vagina, together with a varying amount of trauma to the perineal tissue and to the skin. If the tear is a complete one, the anterior wall of the rectum will also be lacerated.

What is the result, however, of a greater dilatation with laceration or of ulcerative processes higher up in the vagina? They lead to the formation of fistulas or to abnormal communications between the viscera. Anteriorly, there may be a urethrovaginal fistula between the urethra and the vagina, higher up there will be a vesicovaginal fistula, and still higher a vesicocervical fistula. In any of these conditions the urine will continually dribble from the vagina in a most troublesome manner. Posteriorly, a rectovaginal fistula may develop and feces may be passed through the vagina. Since the upper vaginal wall and the cervix are in relation with the ureters (see page 151), it is possible to have a ureterovaginal or a ureterocervical fistula.

**The Ovaries.**—The position of the ovaries in the true pelvis is partially disclosed by the designation of the parts of these flat ellipsoidal bodies. We differentiate an external and an internal surface, a superior and an inferior pole (*extremitas tubaria* and *extremitas uterina*), and an anterior and a posterior margin (*margo mesovaricus* and *margo liber*). The anterior margin corresponds to the hilus of the ovary, where the vessels make their entrance and exit.



The longitudinal diameter, which connects the tubal with the uterine pole of the ovary, is almost vertically placed; the external surface is in immediate contact with the lateral pelvic wall, at the level of the pelvic inlet, close to the inner border of the psoas muscle. The *suspensory ligament* of the ovary (ligamentum infundibulopelvicum) runs from the lateral pelvic wall to the superior or tubal pole and transmits the ovarian vessels to the ovary (Fig. 72). Posteriorly the ovary is in relation with the ureter and the uterine artery, above and anteriorly it borders upon the remains of the *hypogastric artery* (ligamentum umbilicale laterale). The position of the ovary is not absolutely fixed and is often abnormally influenced by inflammatory processes in the neighborhood. The gynecologist should be able to palpate the ovary by bimanual examination through the vagina and the anterior abdominal wall, in which procedure the vaginal finger reaches chiefly the uterine pole and the internal surface of the viscus.

**The Fallopian Tube.**—The Fallopian tube is situated in the free border of the broad ligament and cannot pursue a straight course in the restricted confines of the true pelvis. We differentiate three portions of its course: The first portion or *isthmus* passes horizontally outward from the uterus to the uterine pole of the ovary; the second portion makes a right angle with the first and runs upward from the anterior margin of the ovary to its superior pole; after making another acute turn, the third or *terminal portion* runs backward and downward and terminates at the ostium abdominale, which is directed toward the posterior free margin of the ovary.

**The Rectum.**—In the female the rectum has the same curves as those described in the male. Its anterior wall is in relation with the uterus (the recto-uterine pouch being interposed) and the vagina; the cervix may be palpated through this wall by the finger introduced into the rectum. The rectovaginal septum is composed of loose areolar tissue and is predisposed to the formation of rectovaginal fistulas after marked distention and laceration of the vagina.

#### REVIEW QUESTIONS.

How may the bladder be entered anteriorly without injuring the peritoneum?

Why are injuries of the anterior wall of the bladder (such as a rupture, for example) less dangerous than those of the posterior wall?

From what situation may we palpate and operate upon the bladder (in the male), the prostate gland, and the seminal vesicles?

How does the enlargement of the prostate gland affect the internal orifice of the urethra?

To what height may we operate upon the anterior rectal wall without endangering the integrity of the peritoneal cavity?

To what parts may a carcinoma of the rectum extend anteriorly?

From what situation may the posterior wall of the bladder be opened in the female?

Which wall of the cervix may be incised without danger of opening the peritoneal cavity, and in which wall does this danger exist?

What is the relation of the inferior extremity of the ureter to the vagina?

What peculiarity of the female urethra is of importance from a practical standpoint?

Is it easier to enter the peritoneal cavity through the anterior or through the posterior vaginal vault?

What has happened when urine dribbles from the cervix or from the vagina, and what when feces escape through the vagina?



Fig. 74.

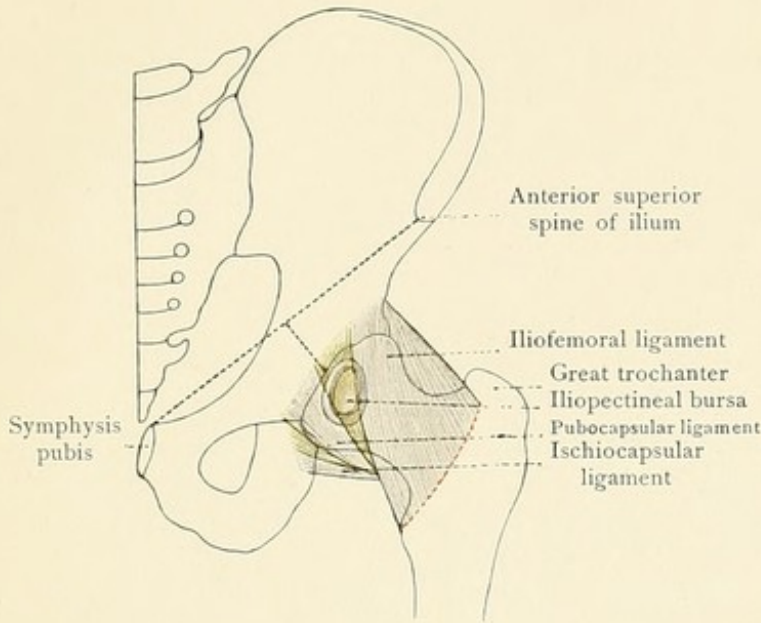


Fig. 75.

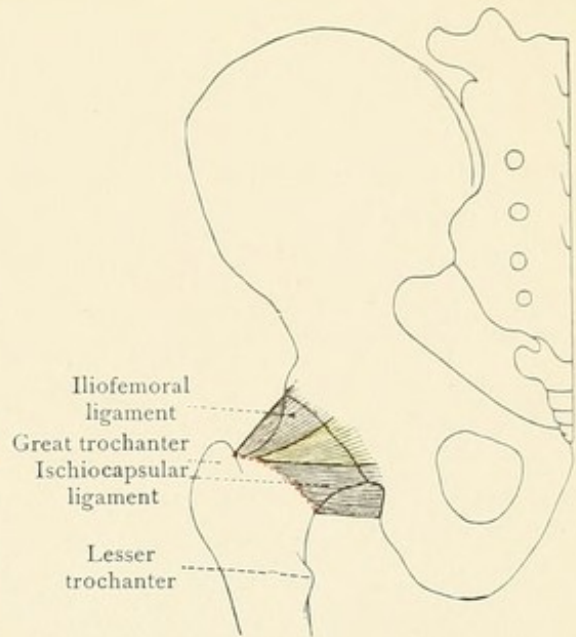


Fig. 76.

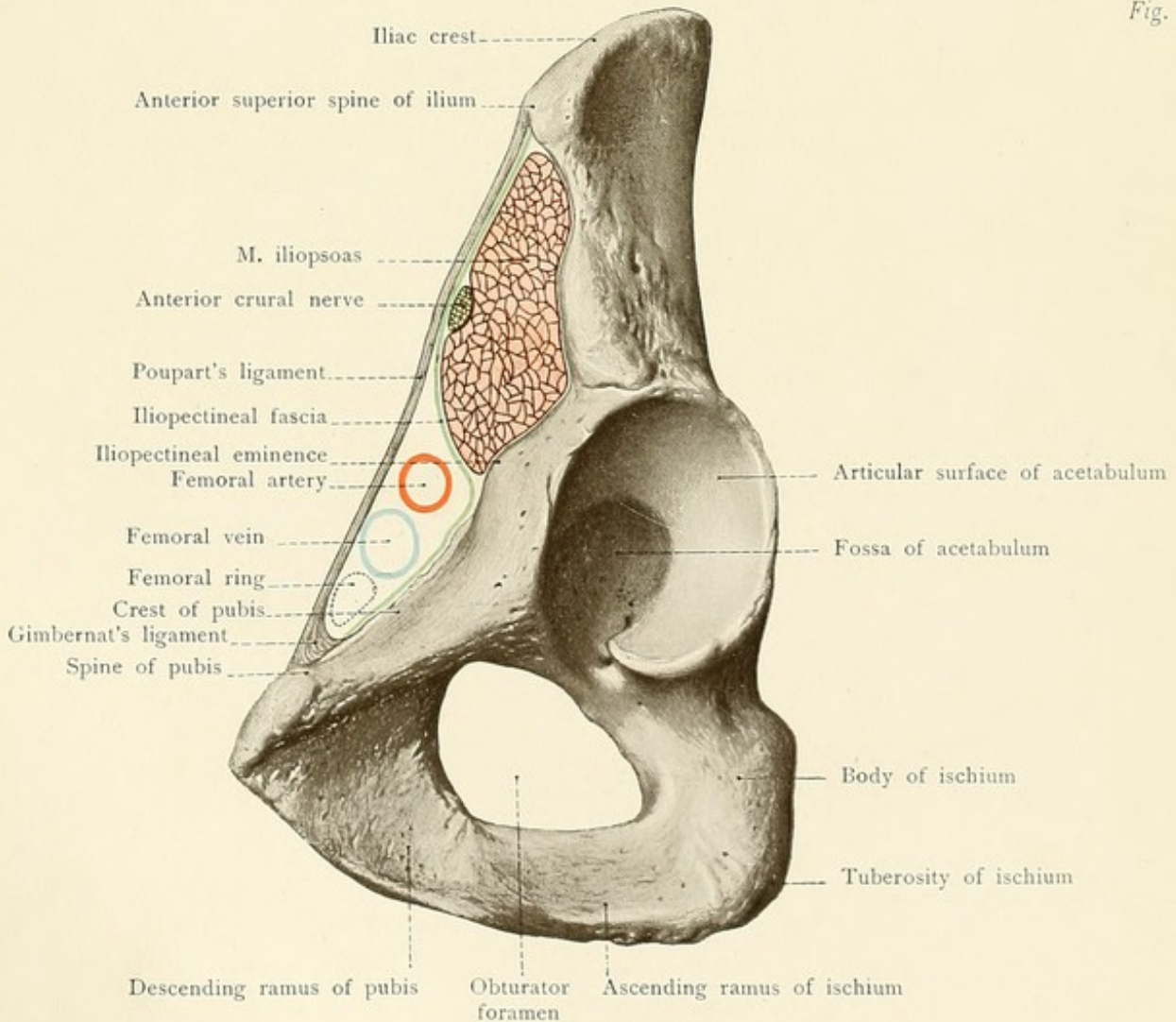








FIG. 74.—A diagrammatic representation of an anterior view of the hip-joint. The attachment of the capsular ligament corresponds to the linea intertrochanterica (red). The weaker portions of the capsule are colored yellow. A detailed description will be found in the text.

FIG. 75.—A diagrammatic representation of a posterior view of the hip-joint. The attachment of the capsular ligament (red line) is situated above the intertrochanteric crest. The weak areas in the posterior portion of the capsule are colored yellow.

FIG. 76.—A diagrammatic representation of the lacuna musculorum, of the lacuna vasorum, and of the femoral ring.

What part of the uterus may be palpated through the anterior wall of the rectum?

Where may we palpate the ovaries?

## THE LOWER EXTREMITY.

In accordance with the fact that the lower extremity is considerably larger than the upper one, we find that the vessels and the nerves of the leg are much larger than those of the arm, for which reason amputations and resections in the lower extremity are, in general, much more serious operations than the corresponding procedures in the upper extremity, and wounds of the lower extremity are also generally more dangerous than those of the upper extremity. The greater distance of the lower extremity from the heart is also in harmony with the fact that, as compared with the arm, there is a greater tendency to the development of ulcers, chronic skin diseases, edema, and dilatation of the veins from the unfavorable influence of gravitation. As the motions of the joints are more restricted than is the case in the upper extremity, we find that dislocations in this situation are of more infrequent occurrence.

### THE REGION OF THE HIP.

The boundary between the lower extremity and the trunk is furnished anteriorly by the crease of the groin, which runs from the anterior superior spine of the ilium to the region of the symphysis and corresponds in its direction to that of Poupart's ligament. Posteriorly the boundary-line coincides with the iliac crest, since the gluteal region belongs to the lower extremity. The gluteal region terminates below at the well-marked gluteofemoral crease, at the inner extremity of which may be felt the *tuberosity of the ischium*. Anteriorly the crease of the groin separates the inguinal region from the subinguinal region. Midway between the symphysis and the anterior superior spine of the ilium may be felt the pulsations of the *femoral artery* which passes beneath Poupart's ligament. In spare individuals this artery may be seen pulsating. The *lymphatic glands* situated in the subinguinal region (Fig. 77) are palpable only when abnormally enlarged. Upon the outer side of the hip the *great trochanter* may be felt beneath the skin; below this point the femur is entirely surrounded by muscles. When the thigh is flexed to a right angle, the tip of the great trochanter lies beneath a line running over the buttock and connecting the anterior superior spine of the ilium with the tuberosity of the ischium (*Roser-Nélaton's line*). Changes in the position of the trochanter (in dislocations and diseases of the hip-joint) may be recognized with the aid of this line.



**The Hip-joint.**—The range of motion at the hip is much more restricted than that of the shoulder and it is consequently much more rarely the seat of traumatic luxations. Its position is defined in the living subject by the aid of a line drawn from the anterior superior spine of the ilium to the symphysis; a line drawn at right angles to its middle point strikes the center of the acetabulum (Fig. 74). The joint is formed by the head of the femur and the *acetabulum* of the innominate bone. The central or non-articular portion of the acetabulum is not covered by cartilage and is known as the *fossa acetabuli*; this fossa is surrounded by the articular portion, which is covered by cartilage and is known as the *jacies lunata*. The head of the femur is covered by cartilage with the exception of the fovea capitis, to which is attached the *ligamentum teres*. This ligament has a broad origin from the fossa acetabuli and carries vessels to the head of the femur. It is therefore possible that after a complete intracapsular fracture of the neck the head will not undergo necrosis, but that, after becoming adherent to the socket, a false joint is usually formed. The acetabulum is further deepened at its margin by the cotyloid ligament (*labrum glenoidale*), which also bridges over the cotyloid notch (*incisura acetabuli*) as the transverse ligament. The *capsular ligament* arises from the innominate bone outside of the *labrum glenoidale*, so that the free border of this structure lies within the joint. Anteriorly it is attached to the intertrochanteric line of the femur; posteriorly, however, the ligament is inserted at a higher level at the middle of the femoral neck (see the dotted red line in the diagrammatic Figs. 74 and 75). The *trochanters* are outside of the joint. It is particularly important to note that the anterior surface of the neck is entirely within the joint, while only the superior portion of the posterior surface is intracapsular. Variations occasionally occur. The relation of the capsular attachment explains the fact that fractures of the neck of the femur are sometimes entirely intracapsular, and sometimes intracapsular anteriorly but extracapsular posteriorly—the so-called mixed fractures. It is extremely rare for one of these fractures to be entirely extracapsular. The capsule is reinforced by three ligaments:

1. The *iliofemoral ligament*. This ligament is situated anteriorly, arising from a point below and beside the anterior inferior spine of the ilium and inserting into the intertrochanteric line. It is very strong and is never lacerated in dislocations of the joint.

2. The *pubocapsular ligament*, from the body of the pubic bone to the region of the trochanter minor.

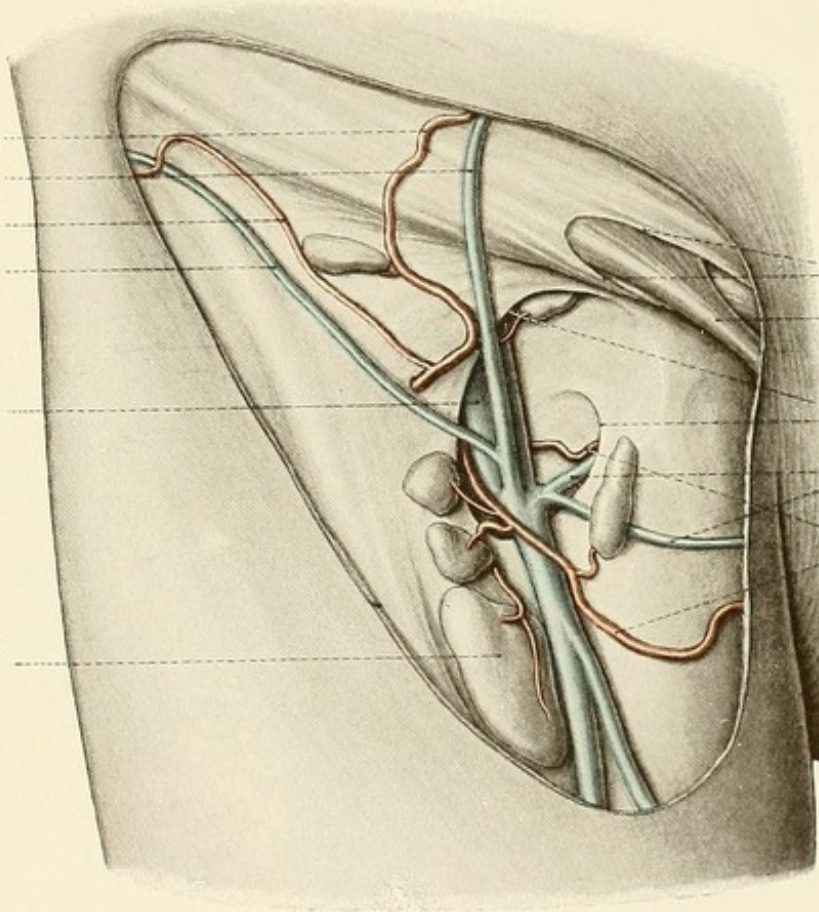
3. The *ischiocapsular ligament*, from the body of the ischium to the anterior surface of the great trochanter. Between these stronger portions of the capsule are three weak places (indicated in the diagrams by yellow), which indicate, as it were, the preformed places of exit for the femoral head in the different forms of dislocation. The posterior luxations (the iliac and the sciatic) occur at the posterior weak area, the anterior ones (obturator, infrapubic, and suprapubic) find their way out through the thin portions of the capsule situated anteriorly and internally. [The weakest portion of the capsule of the shoulder is below, while that of the hip is behind. Hence downward and forward dislocations (76 per cent.) are more frequent in the former and backward and upward in the latter (hip-joint).—Eisendrath.] The thin portions of the capsule are also important for the paths along which articular effusions tend to reach the surface. Upon the anterior weak area, between the iliofemoral and pubocapsular ligaments, there is a large bursa, the *iliopectineal bursa*, which frequently (once in ten cases) communicates



Superficial epigastric  
artery  
Superfic. epigastr. vein  
Superficial circumflex  
iliac artery  
Superficial circumflex  
iliac vein

Femoral vein

Lymphatic gland  
(enlarged)



External abdominal  
ring  
Spermatic cord

Falciform margin  
(saphenous opening)  
External pudic veins

External pudic  
arteries







Fig. 78.

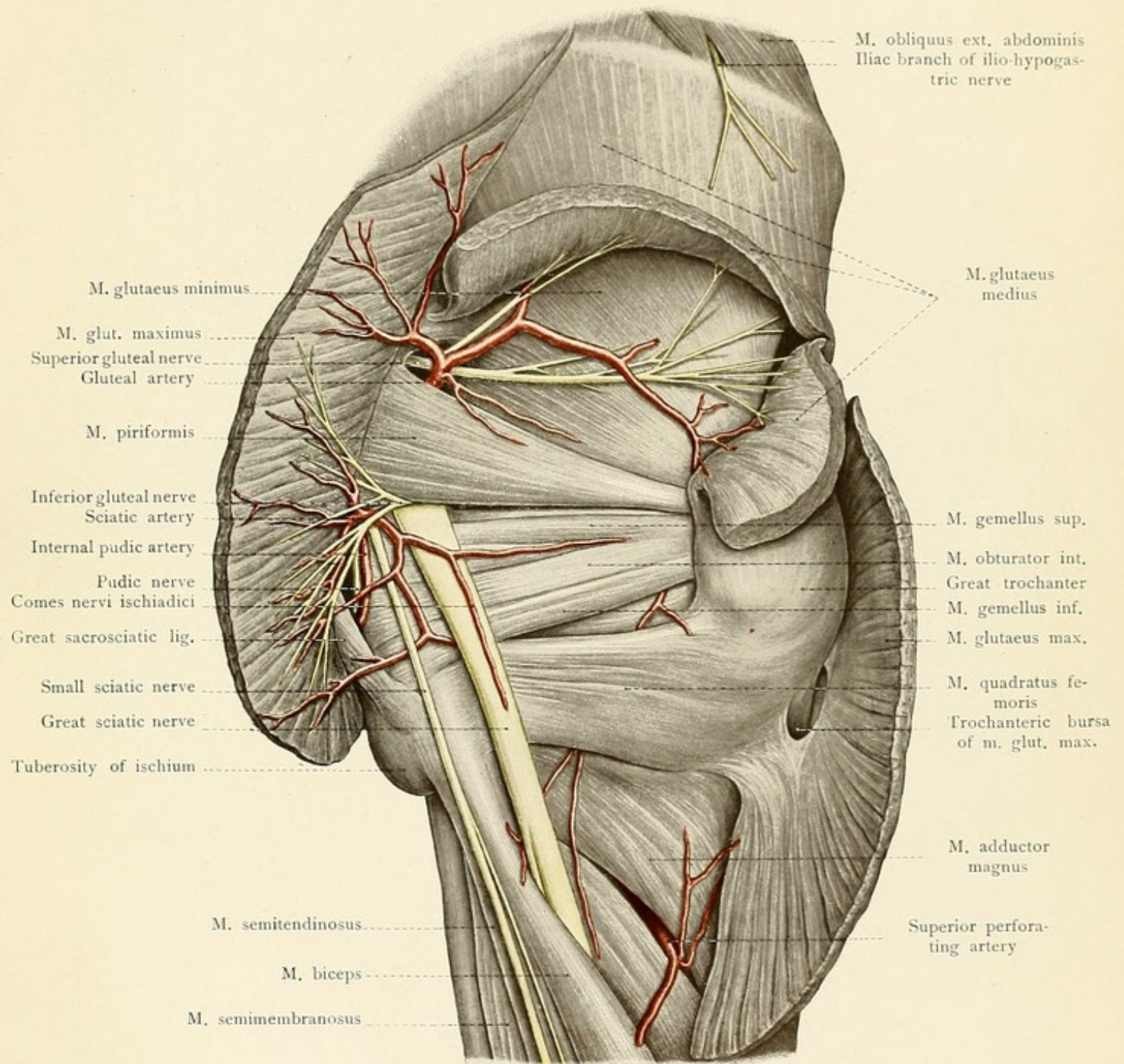








FIG. 77.—The subinguinal region with the vessels and lymphatic glands lying upon the deep fascia.

FIG. 78.—The topography of the deep gluteal region.

with the joint. Pus occasionally escapes from the joint by this route and passes beneath the psoas muscle; an iliac abscess may pass beneath Poupart's ligament and enter the joint at this point, and with particular ease, of course, when there has been a previous communication between the bursa and the joint.

As the *femoral vessels* and the *anterior crural nerve* are almost immediately in front of the joint, they are frequently involved by articular affections (for example, by pressure from an anterior dislocation); posteriorly the sciatic nerve (see page 161) is also occasionally indicated in affections of the joint.

The muscles, the vessels, and the nerves pass beneath Poupart's ligament from the iliac fossa and reach the anterior surface of the thigh according to a typical topographic arrangement (Fig. 76). This is particularly of practical importance toward the symphysis on account of the occasional occurrence of femoral hernia, which escapes beneath Poupart's ligament, in contradistinction to the inguinal variety, which passes out from the abdomen above this structure through the external abdominal ring (see page 124). The *iliopsoas muscle* passes to the thigh beneath the outer portion of Poupart's ligament, accompanied by the anterior crural nerve, and covered by the *iliac fascia* (Fig. 76). The fascia is adherent to the ligament as it passes beneath this structure, but it subsequently follows the surface of the muscle inward and is attached to the *iliopectineal eminence*. From this point the fascia passes over the pelvic margin to the thigh and, as the *iliopectineal fascia*, follows the iliopsoas and pectineus muscles behind the femoral vessels and forms the so-called deep layer (pubic portion) of the fascia lata. To the inner side of the iliopsoas muscle and its fascia there is left a second space beneath Poupart's ligament, which extends toward the symphysis as far as Gimbernat's ligament (*i. e.*, the broad reflection of the inner end of Poupart's ligament to the crest of the pubis). This space gives passage to the great vessels and is called the *lacuna vasorum*; the space beneath Poupart's ligament to the outer side of the iliopectineal fascia is known as the *lacuna musculorum*. The femoral artery is situated in the outer portion of the lacuna vasorum, and the femoral vein is placed immediately to the inner side of the artery, but it does not extend to the concave margin of Gimbernat's ligament. There is left between the vein and the margin of the ligament a small space which is filled by connective tissue and frequently also by a lymphatic gland (the *gland of Rosenmüller*). This space is the *femoral ring* (*annulus femoralis*), the place of exit of femoral hernia which pushes the peritoneum before it, passes beneath Poupart's ligament, and appears beneath the skin at the saphenous opening.

The saphenous opening (*fossa ovalis*) in the fascia lata, bounded externally by the *margo falciiformis* (Fig. 77), is closed by a thin fascia which is called the *cribriform fascia*. The *internal saphenous vein*, the varicose dilatations of which are more or less troublesome, runs up the inner side of the thigh somewhat posterior to the margin of the sartorius muscle, and passes through the saphenous opening to empty into the femoral vein. The cribriform fascia, or the adjacent portions of the fascia lata, are perforated by the superficial epigastric and superficial circumflex iliac vessels and also by smaller arterial branches on their way to supply the numerous



so-called *inguinal glands* (lymphoglandulæ subinguinales). Two arteries, the *superficial* and *deep external pudic*, also pass inward with their accompanying veins. The lymphatic glands in this region lie mostly upon the fascia, but a few of them are situated beneath it; they collect the lymph not only from the lower extremity, but also from the external genitalia. This fact explains the frequent extension of diseases of the external genitalia to these lymphatic glands. [The inguinal lymphatic nodes are divided into a superficial and a deep set. The latter are grouped around the upper end of the femoral vein. The superficial are subdivided into two groups: an upper (oblique), below and parallel with Poupart's ligament, and a lower, vertical, near the saphenous opening. The outermost nodes of the superior group receive tributaries from the buttock and lower part of the back, the innermost from the lower part of the anterior belly wall, from the urethra and penis (in the female, urethra, vulva, and lower third of the vagina), perineum, scrotum, lower and inner part of the buttocks, and the integument around the anus. The group around the saphenous opening receives the superficial tributaries from all of the lower extremity except a small area in the vicinity of the external saphenous vein, which drains into the popliteal nodes, thence to deep inguinal, and thence to external iliac, etc., without involving either of the superficial groups. Occasionally, however, the urethra, penis, vulva, lower third of vagina, scrotum, and perineum may communicate with the inferior group, and the lymphatics of the uterus, according to Gerrish, may communicate with the superior set. The practical facts in this connection are stated by Eisendrath as follows: the upper group drains the anal canal, perineum, lower portion of vagina, male and female external genitalia, and the skin of the lower portion of the anterior abdominal wall and the gluteal region. The lower set receives lymph from the entire lower extremity.—ED.]

**Muscles.**—The muscles of the hip are grouped about the external and internal surfaces of the pelvis and run to the trochanteric region of the femur. The *iliopsoas muscle* consists of the psoas major (arising from the sides of the twelfth dorsal and of the four upper lumbar vertebrae), of the iliacus (arising from the inner surface of the ilium), and of the inconstant psoas minor; it is inserted into the lesser trochanter. Opposing this muscle, we have the large muscles of the buttocks passing to the great trochanter, and also the external rotators coming from the true pelvis. The muscles of the buttocks are the gluteus maximus, medius, and minimus (Fig. 78). The *gluteus maximus* arises from the posterior surface of the ilium behind the superior curved line (linea glutæa posterior), from the outer surface of the sacrum and of the coccyx, and from the great sacrosciatic ligament, and goes to the fascia lata and to the tuberositas glutæa femoris (the rough line leading from the great trochanter to the linea aspera). Between its tendon and the great trochanter is situated the large *bursa trochanterica*. The *gluteus medius* arises from the ilium between the superior and middle curved lines (linea glutæa posterior and anterior) and runs to the outer surface of the great trochanter. The *gluteus minimus* arises from the ilium between the middle and inferior curved lines (linea glutæa anterior and linea glutæa inferior) and inserts into the anterior surface of the great trochanter. The external rotators are the pyriformis, the obturator internus, the gemelli, the obturator externus, and the quadratus femoris. The *pyriformis*, in relation with the inferior margin of the gluteus medius, passes from the anterior surface of the sacrum through the great sacrosciatic foramen to the trochanteric fossa (foramina suprapyriforme and infrapyriforme, see page 146). The *obturator*





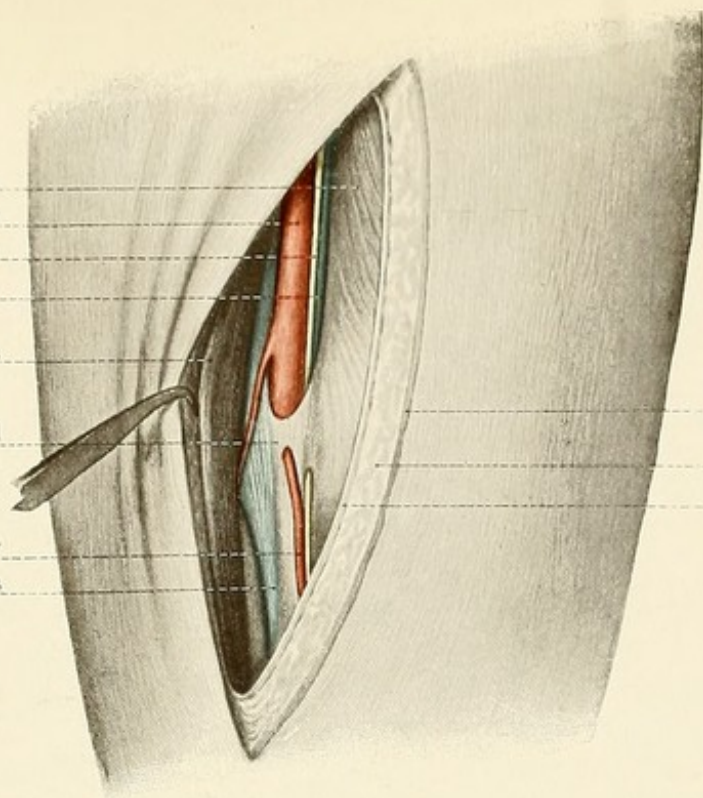






Fig. 80.

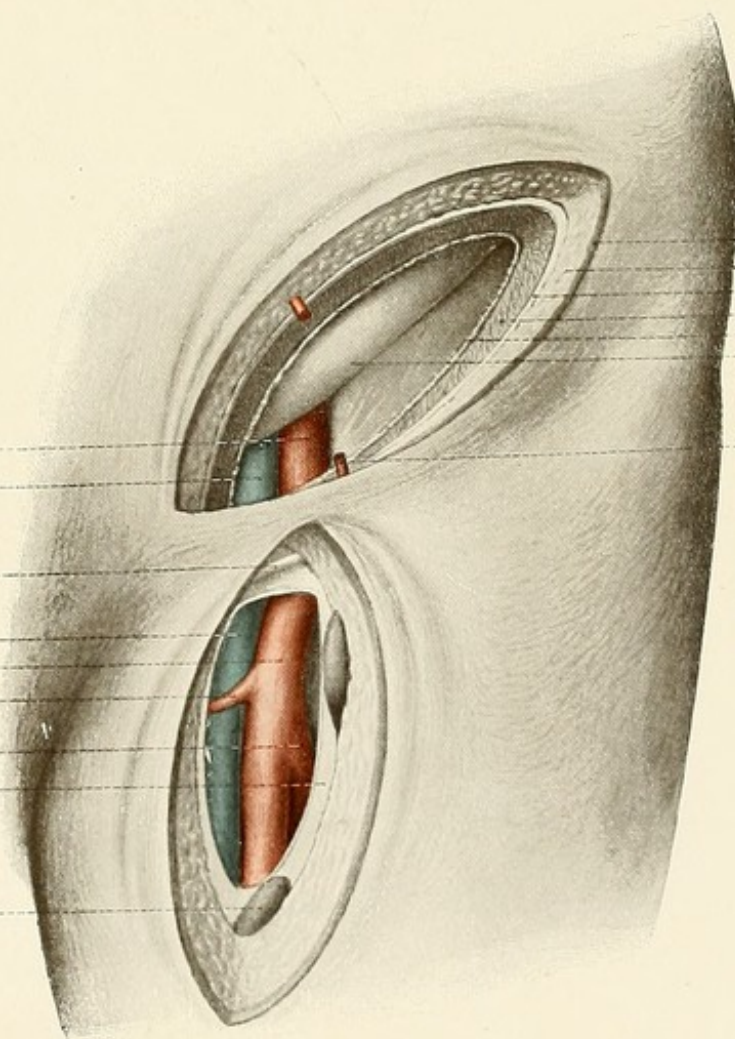
M. vastus medialis  
Femoral artery  
Long saphenous nerve  
Femoral vein (almost entirely  
concealed)  
M. sartorius  
Anterior wall of Hunter's canal  
Anastomotica magna artery  
Tendon of adductor magnus



Skin  
Subcutaneous connective tissue  
Fascia lata

Fig. 81.

External iliac artery  
External iliac vein  
Poupart's ligament  
Femoral vein  
Femoral artery  
Superficial external pudic  
artery  
Profunda femoris artery  
Fascia lata  
Lymphatic gland



Skin  
Subcutaneous connect. tissue  
Aponeurosis  
Musculature  
Transversalis fascia  
Peritoneum  
Superficial epigastric artery







FIG. 79.—The anterior femoral region.

FIG. 80.—The exposure of the femoral artery before its entrance into Hunter's canal.

FIG. 81.—The subperitoneal exposure of the external iliac artery. Below Poupart's ligament the femoral vessels have also been exposed.

*internus* takes origin from the inner surface of the obturator membrane and from the surrounding bones; it leaves the pelvis through the lesser sacrosclatic foramen and passes to the trochanteric fossa, accompanied by the superior and inferior gemelli muscles (arising from the spine and from the tuberosity of the ischium respectively). The *obturator externus* runs from the outer surface of the obturator membrane to the trochanteric fossa. The *quadratus femoris* passes from the tuberosity of the ischium to the crista intertrochanterica (linea quadrati).

After dividing the gluteus maximus at right angles to the course of its muscular fibers (Fig. 78) the inferior gluteal nerve is exposed as it leaves the pelvis through the infrapiriform foramen and radiates upward into the substance of the divided muscle. The other nerves leaving the pelvis by way of the infrapiriform foramen to reach the skin of the posterior surface of the thigh are the small sciatic, the great sciatic (the portion which subsequently becomes the peroneal nerve frequently perforating the piriformis muscle), and the internal pudic. The latter nerve immediately re-enters the pelvis, however, through the lesser sacrosclatic foramen. The branches of the internal iliac artery escaping from the pelvis below the piriformis muscle are the sciatic, chiefly supplying the gluteus maximus and giving off the comes nervi ischiadici, and the internal pudic, which is accompanied by the pudic nerve and supplies the terminal portion of the rectum, the perineum, and the external genitalia. The suprapiriform foramen is exposed by dividing the gluteus medius muscle (Fig. 78). The *gluteal artery* leaves the pelvis through this foramen; it sends a branch between the gluteus maximus and medius and gives off another below the gluteus medius. This artery is accompanied by the superior gluteal nerve, which passes over the superior margin of the piriformis and supplies the gluteus medius, the gluteus minimus, and the tensor fasciæ latæ muscles. It should be noted that one artery and one nerve leave the pelvis above the piriformis muscle, and that two arteries and four nerves pass out below this structure.

## THE THIGH.

**The Muscles.**—The muscles of the thigh surround the femur in such a manner that only the great trochanter above, the condyles below, are palpable beneath the skin. We differentiate the anterior group of extensors, the posterior group of flexors, and the internal group of adductors (Figs. 79 and 82). There is also a superficial group composed of the *tensor fasciæ latæ*, passing from the anterior superior spine of the ilium to the fascia lata, and of the *sartorius*, which arises from the anterior superior iliac spine and inserts into the tibia below the internal tuberosity and as far forward as the tibial tubercle.

The *quadriceps extensor cruris* consists of four parts: the rectus, the vastus externus, the vastus internus, and the crureus. The *rectus muscle* arises by two short tendons from the anterior inferior iliac spine and from the bone alongside of the acetabulum; the *vastus externus* springs from the great trochanter, from the outer lip of the linea aspera, and from the external intermuscular septum; the *vastus internus* takes origin from the inner lip of the linea aspera



and from the internal intermuscular septum; the *crureus* (vastus intermedius) arises from the intertrochanteric line, is covered by the rectus, and is adherent in a varying degree to the vastus externus and internus muscles. The *quadriceps* surrounds the shaft of the femur with the exception of the linea aspera and of the planum popliteum. All four portions of this muscle terminate above the knee in a common tendon which, after enclosing the patella, is inserted as the ligamentum patellæ into the tubercle of the tibia.

The three *flexor muscles* are situated posteriorly and take origin from the tuberosity of the ischium. The *biceps flexor cruris*, in addition to its long head which arises in common with the semitendinosus from the tuberosity of the ischium, has a short head from the outer lip of the linea aspera; the muscle inserts into the head of the fibula. The *semitendinosus muscle* has a long tendon which imbeds itself in a broad furrow upon the posterior surface of the semimembranosus and inserts into the tibia behind the gracilis and sartorius muscles with a broad tendon extending as far forward as the tibial crest. The *semimembranosus muscle* arises by a broad tendon from the ischial tuberosity and is inserted into the posterior surface of the internal tuberosity of the tibia.

The *adductors* are interposed between the extensors and flexors of the thigh; they arise from the pelvis and run to the inner lip of the linea aspera and to the internal epicondyle of the femur. The common tendon contains several small orifices for the perforating arteries, which run from the anterior to the posterior surfaces of the thigh, and also the large slit (*hiatus adductorius*) for the passage of the femoral vessels into the popliteal space. The *pectineus muscle* commences at the crest of the os pubis, converges toward the iliopsoas, and runs posteriorly to the linea pectinea femoris. Since it runs posteriorly with the iliopsoas muscle, a fossa is formed below Poupart's ligament, covered by the fascia lata (*fossa iliopectinea*), in which the large femoral vessels are situated (Fig. 79). It forms the deepest portion of Scarpa's triangle (trigonum femorale), which is bounded internally by the inner margin of the adductor longus and externally by the inner margin of the sartorius. The *adductor longus muscle* takes origin from the pubis below the pubic spine and is attached to the inner lip of the linea aspera. The *adductor brevis muscle* passes from the inferior ramus of the pubis to the upper third of the inner lip of the linea aspera; the *gracilis muscle* runs from the inferior pubic ramus to the tibia below the internal tuberosity, extending as far forward as the tibial tubercle; the *adductor magnus muscle*, situated most posteriorly, arises from the inferior ramus of the pubis and of the ischium as well as from the ischial tuberosity and is inserted along the entire length of the inner lip of the linea aspera and also by a strong tendon into the internal epicondyle of the femur. The *hiatus adductorius* is situated above this tendon. At the junction of the middle and lower thirds of the femur an aponeurosis is stretched across from the tendon of the adductor magnus to the vastus internus; this aponeurosis forms the anterior and internal wall (Fig. 80) of a canal ending at the hiatus adductorius, the *canalis adductorius* or *canal of Hunter*. The posterior wall of this canal is formed by the associated tendons of the adductor longus and magnus muscles and it is bounded externally by the vastus internus and the femur. This canal gives passage to the femoral artery and vein.

**Femoral Artery.**—The femoral artery (Figs. 79–82) passes beneath Poupart's ligament midway between the anterior superior spine of the ilium and the symphysis pubis and enters the fossa iliopectinea. In this situation the artery may be compressed against the underlying ilio-



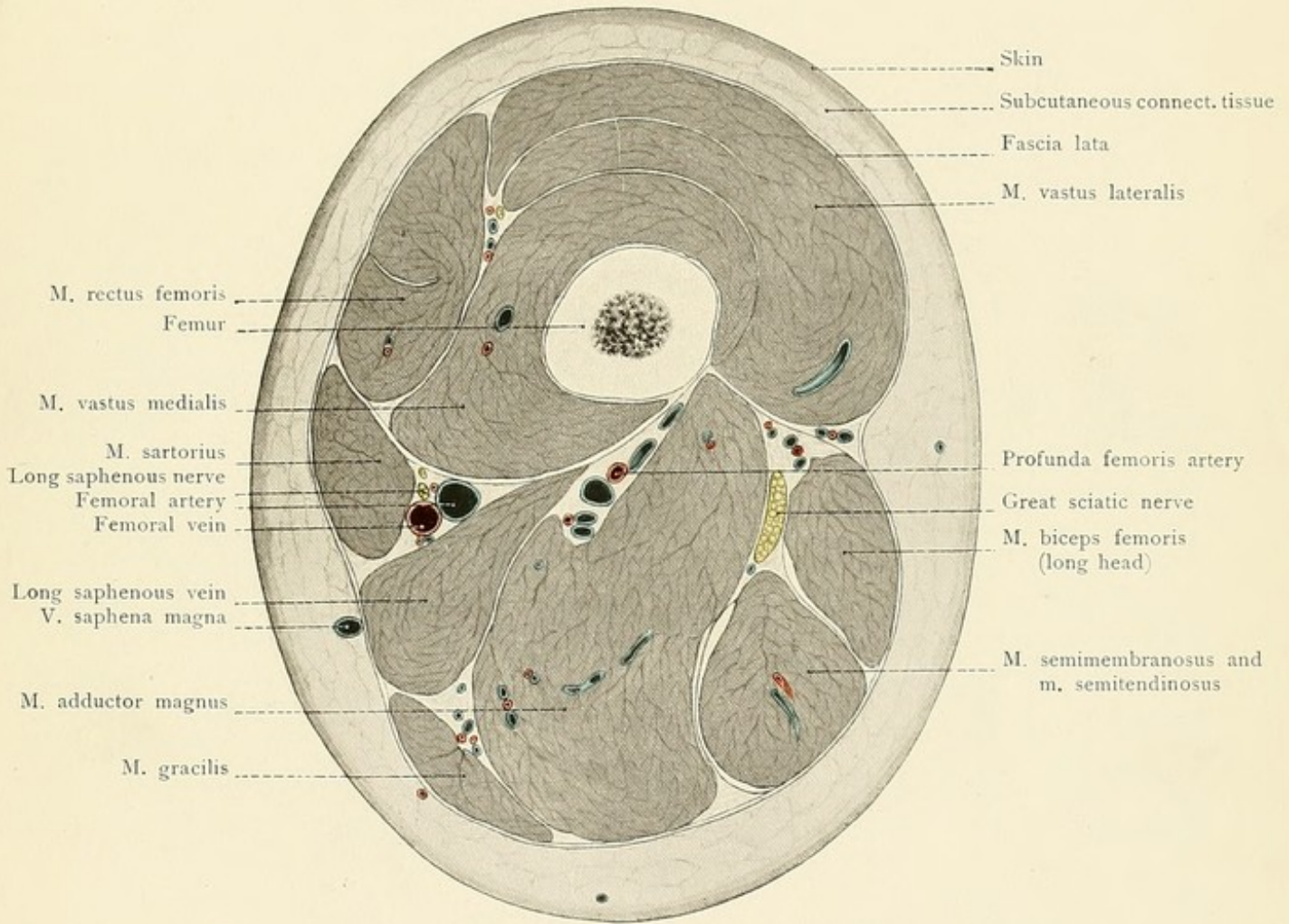








FIG. 82.—A cross-section above the middle of the thigh.

pectineal eminence; care must be taken to avoid pressing upon the vein, which is situated internally. We differentiate three portions of the artery. The *first portion* extends from Poupart's ligament to the sartorius muscle and is situated in Scarpa's triangle. In addition to the superficial vessels previously mentioned (see page 121) the femoral artery gives off the large trunk of the *profunda femoris* (Fig. 81). This vessel usually arises about three centimeters below Poupart's ligament; it may, however, commence at a higher level, and this point must be borne in mind in ligating the femoral artery. The two large *circumflex arteries* arise here as well as the three perforating arteries for the flexor surface. From the iliopectineal fossa the artery runs in the groove between the vastus internus and the adductors, covered only by the fascia lata, and then passes beneath the sartorius muscle. It consequently leaves Scarpa's triangle and enters upon the second portion of its course, which is situated below the sartorius muscle. In this situation it may be readily exposed by the aid of a line drawn from the middle of Poupart's ligament to the inner condyle of the femur and by displacing the sartorius internally. The *third portion* of the vessel is found in Hunter's canal (canalis adductorius, see page 160). Before entering the canal, or in the canal itself, the artery gives off the *anastomotica magna*, which runs to the knee-joint.

**Femoral Vein.**—The femoral vein (Fig. 79) is to the inner side of the artery above, but gradually passes behind it, so that at the entrance to Hunter's canal the vein is almost entirely concealed by the artery (Fig. 80). The nearer we approach to the knee, the firmer becomes the connective tissue between the artery and the vein, for which reason the ligation of the artery in this situation is more difficult on account of the necessary isolation of the vein.

**Anterior Crural Nerve.**—The anterior crural nerve (Fig. 79), the motor nerve for the quadriceps and the sartorius muscles, passes to the thigh through the lacuna musculorum (see page 157 and Fig. 76) to the outer side of the femoral artery and separated from it by the iliopectineal fascia. It is scarcely endangered by the ligation of the artery, and divides just below Poupart's ligament into cutaneous and muscular branches. The longest branch is the cutaneous nerve, designated as the *long saphenous* (Figs. 80 and 82), which accompanies the femoral artery to Hunter's canal; the nerve then passes through the anterior wall of the canal, runs beneath the sartorius muscle, perforates the fascia lata behind the insertion of the sartorius, and accompanies the long saphenous vein to the internal malleolus.

**Sciatic Nerve.**—The sciatic nerve, the motor nerve of the flexors, and often made familiar to the laity by sciatica, leaves the pelvis through the infrapiriform foramen (see page 146 and Figs. 78 and 82); it lies at first upon the obturator internus and the two gemelli muscles beneath the gluteus maximus, and then upon the quadratus femoris between the great trochanter and the tuberosity of the ischium. It becomes superficial at the lower border of the gluteus maximus muscle and for a short distance is covered only by the skin and fascia. In this situation the nerve is accessible to electric and surgical treatment. In order to expose the nerve the patient is placed upon the abdomen and a line is drawn from the great trochanter to the tuberosity of the ischium; an incision is now made parallel to the inferior margin of the gluteus maximus at the junction of the inner and middle thirds of this line. It must be remembered that



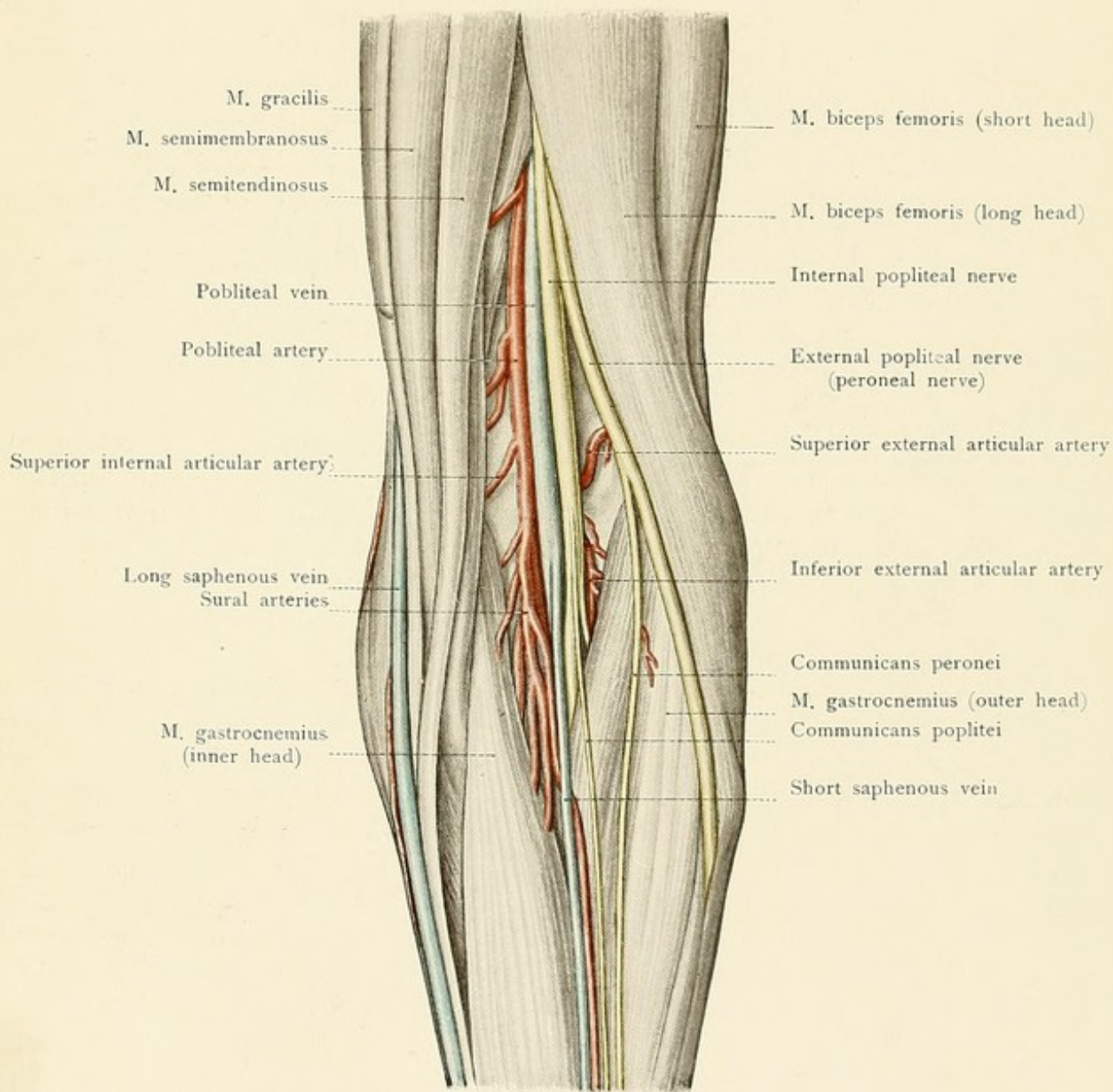
the gluteofemoral crease does not correspond with the inferior margin of the *gluteus maximus*, but that it is situated from two to three fingerbreadths above this margin. In its further course the sciatic nerve passes beneath the muscles arising from the tuberosity of the ischium, disappearing beneath the biceps, and runs downward in the middle of the posterior surface of the thigh, covered by the long head of the biceps, to reach the popliteal space. Anteriorly the nerve rests upon the adductor magnus muscle. It is surrounded by very loose connective tissue in which gravitating abscesses leaving the pelvis through the sciatic foramina may extend downward along the nerve into the popliteal space. The nerve may divide high up into its two terminal branches, the *internal* and the *external popliteal* nerves; the point of division is usually situated just above the popliteal fossa (Fig. 83). The nerve supplies the long head of the biceps, the semimembranosus, and the semitendinosus from the portion which subsequently becomes the internal popliteal nerve, and the short head of the biceps from the portion which goes to form the external popliteal nerve. The sciatic nerve also gives filaments to the adductor magnus muscle.

**Obturator Nerve.**—The obturator nerve (Figs. 71 and 73), the motor nerve of the adductors and the last branch of the lumbar plexus, runs into the true pelvis to the inner side of the *psaos* muscle, and, accompanied by the obturator artery, to the obturator canal, and divides, after its exit from the canal, into an anterior and a posterior branch. The *anterior branch* lies between the adductor brevis upon one side and the pectineus and the adductor longus upon the other; it supplies these muscles and the gracilis and ends in an unimportant cutaneous branch upon the inner side of the thigh (Fig. 79). The *posterior branch* lies beneath the adductor brevis and upon the adductor magnus and supplies the latter muscle.

### THE REGION OF THE KNEE.

In the region of the knee may be easily seen and felt the movable *patella*, imbedded in the tendon of the quadriceps and covered only by the skin and bursas (see page 165), and the *ligamentum patellæ*, which passes from the apex of the bone to the tubercle of the tibia. To either side may be felt the condyles and the epicondyles of the femur. When the knee is flexed, the patella descends so that the upper portion of the intercondyloid fossa of the femur (the trochlea) is exposed to palpation. To the outer side of the extended knee a strong band may be distinctly felt passing upward from the external epicondyle; this structure is the terminal portion of the *iliotibial band* of the fascia lata. To either side of the patellar tendon may be felt the articular space between the tibia and the femur, and, upon the outer side of the joint, the head of the fibula and the strong tendon of the biceps which passes upward from this structure. [On either side of the patella and above it are depressions; these, with the depressions on either side of the patellar ligament, disappear when there is fluid in the joint cavity. When fluid is present, the patella "floats"; which means that by pressure backward the patella may be forced in contact with the femur, but when the pressure is released it rebounds.—ED.] When the knee is flexed, the biceps tendon may be followed upward upon the posterior surface of the thigh. It forms the outer boundary of the upper portion of the popliteal fossa, the inner boundary being furnished by the tendons of the semitendinosus, semimembranosus, and gracilis. The lower portion of the diamond-shaped popliteal fossa is bounded by the origins of the *gastrocnemius muscle*.











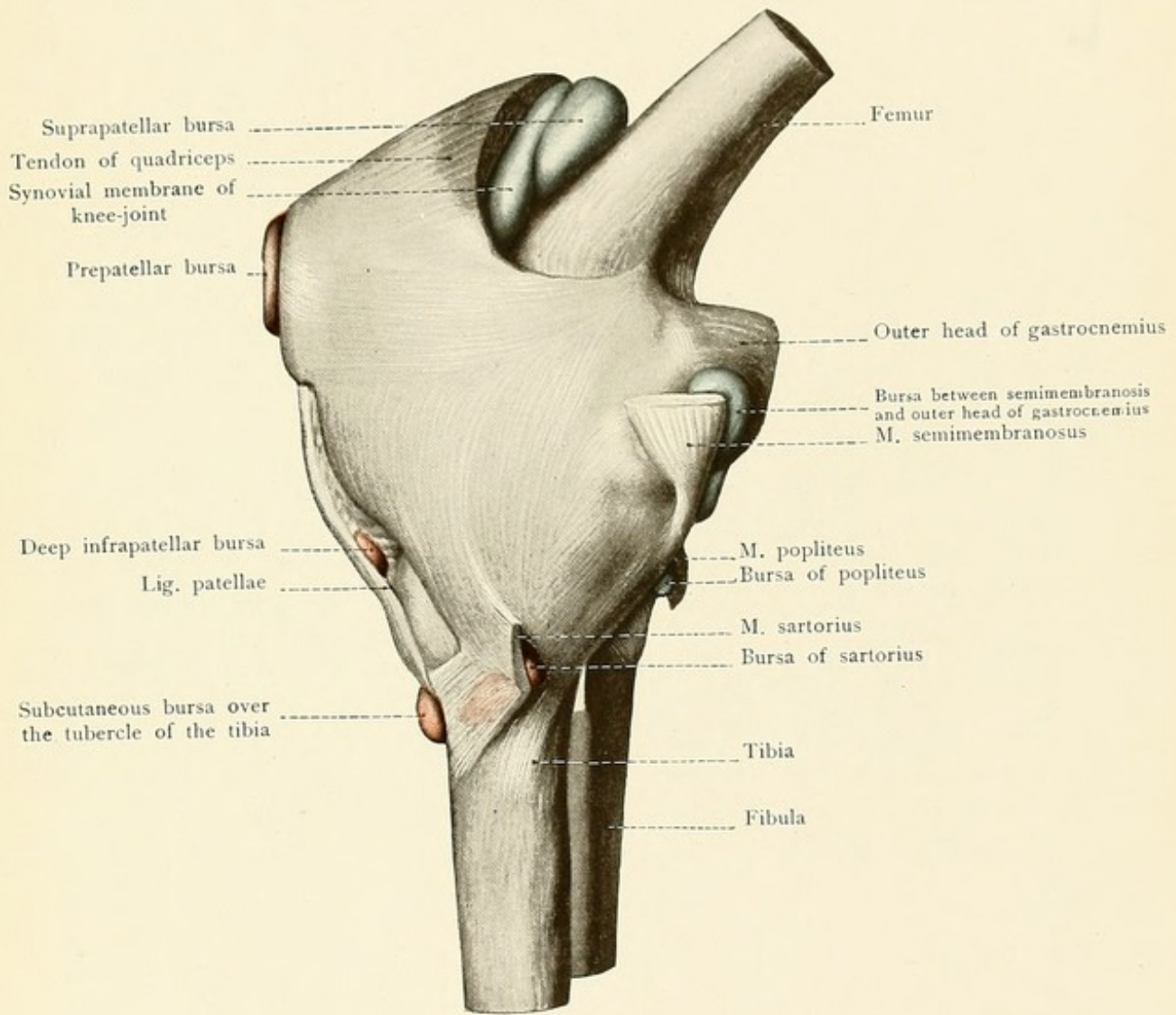








FIG. 83.—The popliteal space.

FIG. 84.—The knee-joint after the injection of a blue mass into the articular cavity; the bursas communicating with the joint are also filled with the blue injection. The non-communicating bursas have been injected with a red mass. (From a Berlin model.)

The **superficial structures** of the popliteal space are the *short saphenous vein* and *nerve* (Fig. 83). The short saphenous vein lies upon the deep fascia. It arises behind the external malleolus, runs upward upon the muscles of the calf in the furrow between the two heads of the gastrocnemius, perforates the deep fascia in the popliteal space, and empties into the popliteal vein. It usually gives off a branch which runs to a higher level and empties into the vena profunda femoris. To the outer side of the vein the *short saphenous nerve* runs downward as far as the external border of the foot. This nerve arises upon or beneath the deep fascia in the popliteal space or lower down by the union of the *communicans poplitei* (n. cutaneus suræ medialis), from the internal popliteal nerve, with the *communicans peronei* (n. cutaneus suræ lateralis), from the peroneal nerve. To the inner side of the knee is the *internal* (or long) *saphenous vein*, and somewhat posterior to this structure the *long saphenous nerve* makes its appearance beneath the tendon of the sartorius muscle (see page 161). In the median line of the popliteal space the *internal popliteal nerve* may be felt, and even seen in spare individuals, when the knee is extended; it is the motor nerve of the flexor surface and gives off branches to the heads of the gastrocnemius muscle in this situation. Somewhat deeper and closely associated with the nerve upon its inner side is the *popliteal vein*, and still deeper and more internal is the popliteal artery. The *popliteal artery* makes its appearance at the opening in the adductor magnus and lies first upon the posterior surface of the vastus internus and then upon the planum popliteum, though it is separated from this bony surface by a small quantity of fat; lower down the vessel is intimately related with the capsular ligament of the joint, so that it will be readily understood that the artery and its accompanying vein must suffer compression in posterior dislocations at the knee, and that this relation must always be borne in mind in resections of the articulation. It is also clear that in supracondyloid fractures of the lower end of the femur in which the lower fragment is tilted backward by the gastrocnemius muscle disagreeable symptoms will be produced by the laceration of the popliteal vessels and of the internal popliteal nerve. The artery finally runs upon the popliteus muscle, at the inferior margin of which it divides into its terminal branches, the *anterior* and *posterior tibial arteries*. In addition to the numerous branches to the muscles in this region, of which the large sural arteries to the heads of the gastrocnemius should be particularly emphasized, the popliteal gives off five articular arteries, which vary in size and aid in the formation of the rete articulare. There are two *superior* and two *inferior articular arteries* (an external and an internal of each), and an *azygos articular* (a. articularis genu media) which passes into the interior of the joint.

The *peroneal nerve* (external popliteal) (Fig. 83) follows the inner border of the biceps muscle and gradually becomes more distant from the internal popliteal nerve; at the head of the fibula it enters the peroneus longus muscle and immediately divides into its two main branches, the *musculocutaneous* and the *anterior tibial nerves*.

**Knee-joint.**—The study of the knee-joint (Fig. 84) should be preceded by a review of the following parts: At the lower end of the femur, the condyles, the epicondyles, the fossa inter-



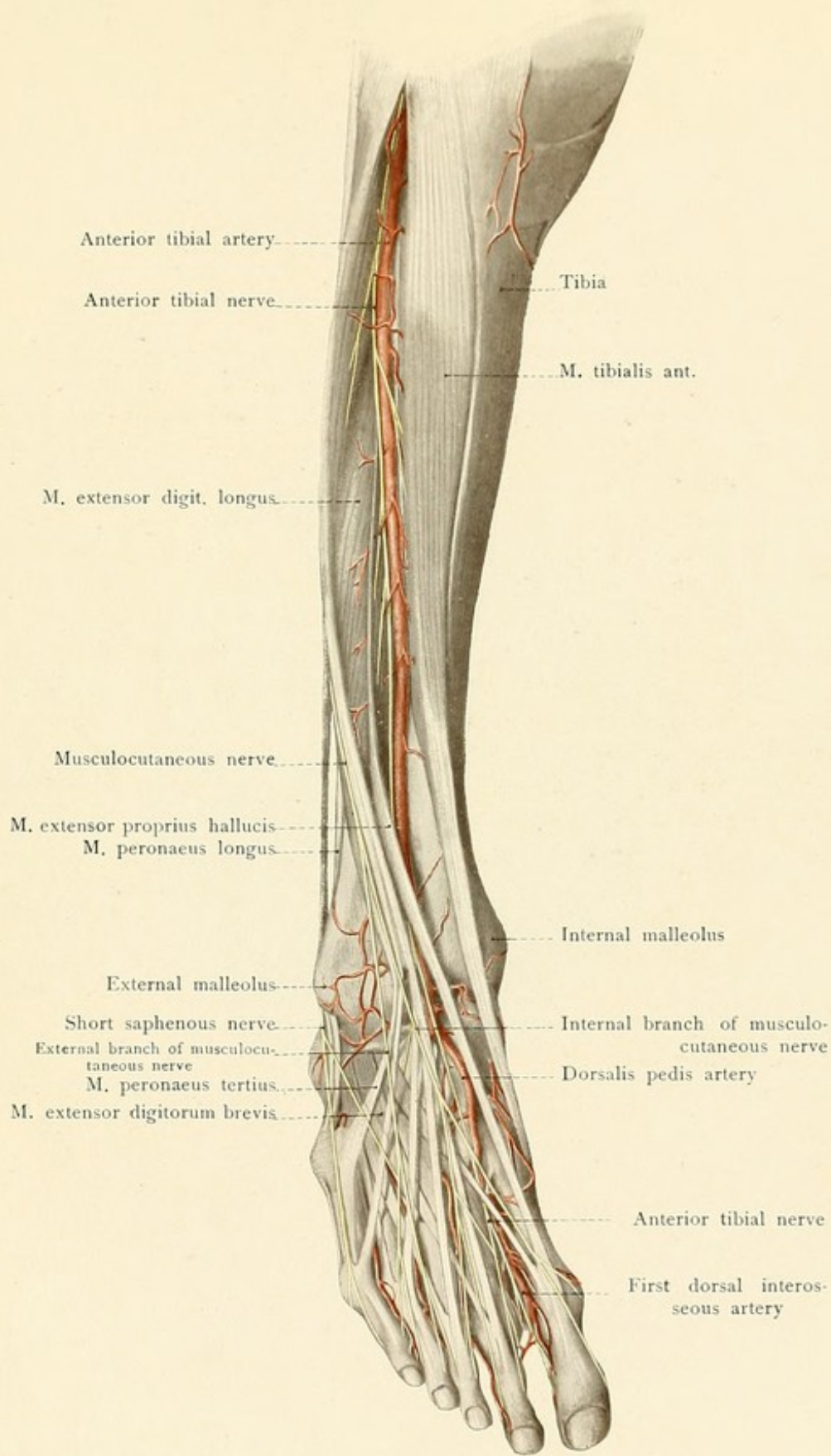
condylea, the linea intercondylea, and the facies patellaris; at the upper end of the tibia, the tuberosities with their articular surfaces, the eminentia intercondylea, the tuberculum intercondyleum anterius and posterius, and the fossa intercondylea anterior and posterior. The head of the fibula is connected to the tibia by an articulation which does not communicate with the knee-joint. The posterior surface of the patella is covered by hyaline cartilage and forms the immediate anterior boundary of the articular cavity; during flexion and extension of the joint it slides up and down upon the facies patellaris of the femur. The incongruity of the articular surfaces of the tibia and of the femur is partly compensated for by the interposition of the internal and external *semilunar cartilages* (meniscus lateralis and medialis). The external meniscus is the more sharply curved and its ends are attached immediately in front of and behind the spine of the tibia (eminentia intercondylea tibiæ). The internal meniscus is more semilunar in shape; it commences in front at the margin of the articular surface of the tibia and ends behind at the posterior intercondyloid fossa.

The *capsular ligament* is in very intimate relation with muscle-insertions which help to strengthen it. Anteriorly the tendon of the quadriceps encloses the patella and ends in the *patellar ligament* running to the tubercle of the tibia. Posteriorly are the popliteus, the origins of the gastrocnemius, and the insertion of the semimembranosus, externally the biceps runs to the head of the fibula, and internally are the three tendons of the sartorius, semitendinosus, and gracilis, forming the "pes anserinus." The capsular ligament passes from the posterior surface of the tendon of the quadriceps to the anterior surface of the end of the femur somewhat above its cartilaginous surface and excludes the epicondyles from the articular cavity. Posteriorly it is attached to the *intercondyloid line*. At the tibia the capsular ligament runs from the edge of the cartilaginous surface to the outer borders of the menisci, and to the inferior margin of the patella. At the upper and anterior portion of the articular cavity the large suprapatellar bursa is situated between the femur and the quadriceps tendon and communicates directly with the joint (Fig. 84). This bursa extends upward a distance of four to eight centimeters above the upper margin of the patella with the leg in the extended position.

The *ligaments* consist of internal, lateral, and posterior bands of connective tissue. The internal ligaments are the *ligamenta cruciata*, and they check excessive pronation. The anterior crucial ligament passes from the inner surface of the external condyle of the femur to the anterior intercondyloid fossa of the tibia; the posterior crucial ligament runs from the outer surface of the internal condyle to the posterior intercondyloid fossa. Both ligaments are united to each other by connective tissue, project into the interior of the joint from the posterior portion of the capsular ligament, and are incompletely covered by the synovial membrane. The lateral ligaments are the ligamentum collaterale fibulare (the *long external lateral ligament*), which runs from the external condyle of the femur to the head of the fibula as a comparatively independent structure, and the ligamentum collaterale tibiale (the *internal lateral ligament*), a broad fibrous radiation in the capsular ligament extending from the internal condyle of the femur to the margin of the cartilaginous surface of the tibia. Posteriorly there are two ligaments: (1) The *ligamentum popliteum obliquum*, running from the external condyle of the femur obliquely downward and inward, where it becomes adherent to the tendon of insertion of the semimembranosus muscle; (2) the *ligamentum popliteum arcuatum*, a curved fibrous band radiating from the ex-



Fig. 85.









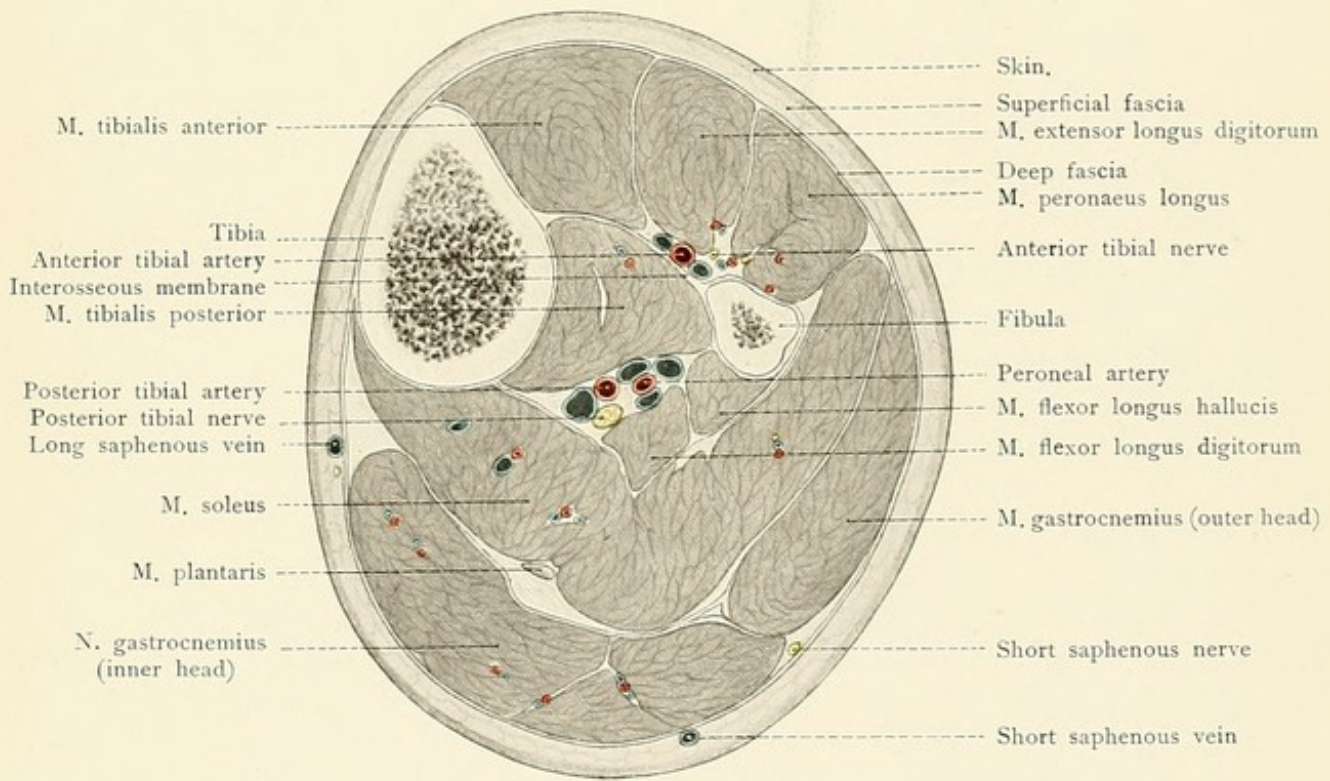








FIG. 85.—The nerves and vessels upon the anterior aspect of the leg and foot.

FIG. 86.—A cross-section through the upper half of the leg.

ternal condyle of the femur upward and inward in the capsular ligament. [The ligamentum popliteum obliquum (the ligamentum posticum Winslowii) and the ligamentum popliteum arcuatum are usually regarded as reinforcements of the posterior ligament which is attached to the femur above and the tibia below.—ED.]

No joint possesses so many bursas as the knee-joint, and diseases of the bursas are consequently more frequent here than in any other situation. The bursas communicating with the articular cavity (blue in Fig. 84) are: (1) The *bursa suprapatellaris*. (2) The bursa between the semimembranosus and inner head of the gastrocnemius muscles. In effusions into the knee-joint this important bursa is frequently demonstrable as a fluctuating tumor upon the posterior and inner aspect of the knee. (3) The *bursa of the popliteus muscle*; this may extend outward and communicate with the superior tibiofibular articulation.

The bursas not communicating with the articular cavity (red in Fig. 84) are: (1) The *prepatellar bursas*, of which three may sometimes be distinctly differentiated (*bursæ subcutanea*, *subfascialis*, and *subtendinea*); as a rule, they communicate with each other more or less. They frequently become inflamed, and such a condition should not be confounded with arthritis. (2) The *deep infrapatellar bursa*, between the ligamentum patellæ and the tibia. (3) The *subcutaneous bursa* over the tubercle of the tibia. (4) The *bursa anserina*, between the tendons of the sartorius, semitendinosus, and gracilis muscles and the tibia. The sartorius muscle frequently possesses an individual bursa which does not communicate with the bursa anserina.

## THE LEG.

The **muscles of the leg** are so arranged that the only portions of the bones which may be distinctly felt are the inner surface, the crest, and the internal malleolus of the tibia, and the head and external malleolus of the fibula. Owing to the subcutaneous position of the internal surface of the tibia, fractures of the bone in this situation are frequently made compound by concomitant injury of the integument. The extensor muscles are situated anteriorly to the outer side of the tibial crest between the tibia and the fibula. Posteriorly the curve of the calf is produced by the *triceps suræ muscle*, the tendon of which (*tendo Achillis*) may be distinctly felt in the lower part of the leg. The entire musculature may be subdivided into three groups: anteriorly upon the interosseous membrane and between the tibia and the fibula are the *extensors*; externally, the fibula is surrounded by the *fibular group*; posteriorly is the *flexor group*, which may be further differentiated into a superficial and a deep layer. The *anterior intermuscular septum*, passing from the deep fascia to the fibula, separates the extensors from the fibular group of the peronei muscles; the *posterior intermuscular septum* passes from the deep fascia to the fibula, in a similar manner, and divides the peroneal muscles from the flexor group. On the posterior aspect of the leg the deep layer of the *crural fascia* is inserted between the superficial and the deep group of the flexors.

I. *Extensor Muscles*.—(1) The *tibialis anticus* takes origin from the outer surface of the



tibia, from the interosseous membrane, and from the deep fascia, and runs to the inner margin of the sole, where it is inserted upon the plantar surfaces of the internal cuneiform and of the first metatarsal bones. (2) The *extensor longus digitorum* arises from the external tuberosity of the tibia, from the interosseous membrane, from the fibula, and from the deep fascia, and inserts by four tendons into the four outer toes; a fifth tendon runs to the base of the fifth metatarsal bone at the outer border of the foot (M. peroneus tertius). (3) The *extensor longus hallucis* arises at a lower level from the interosseous membrane between the two former muscles and runs to the second phalanx of the great toe.

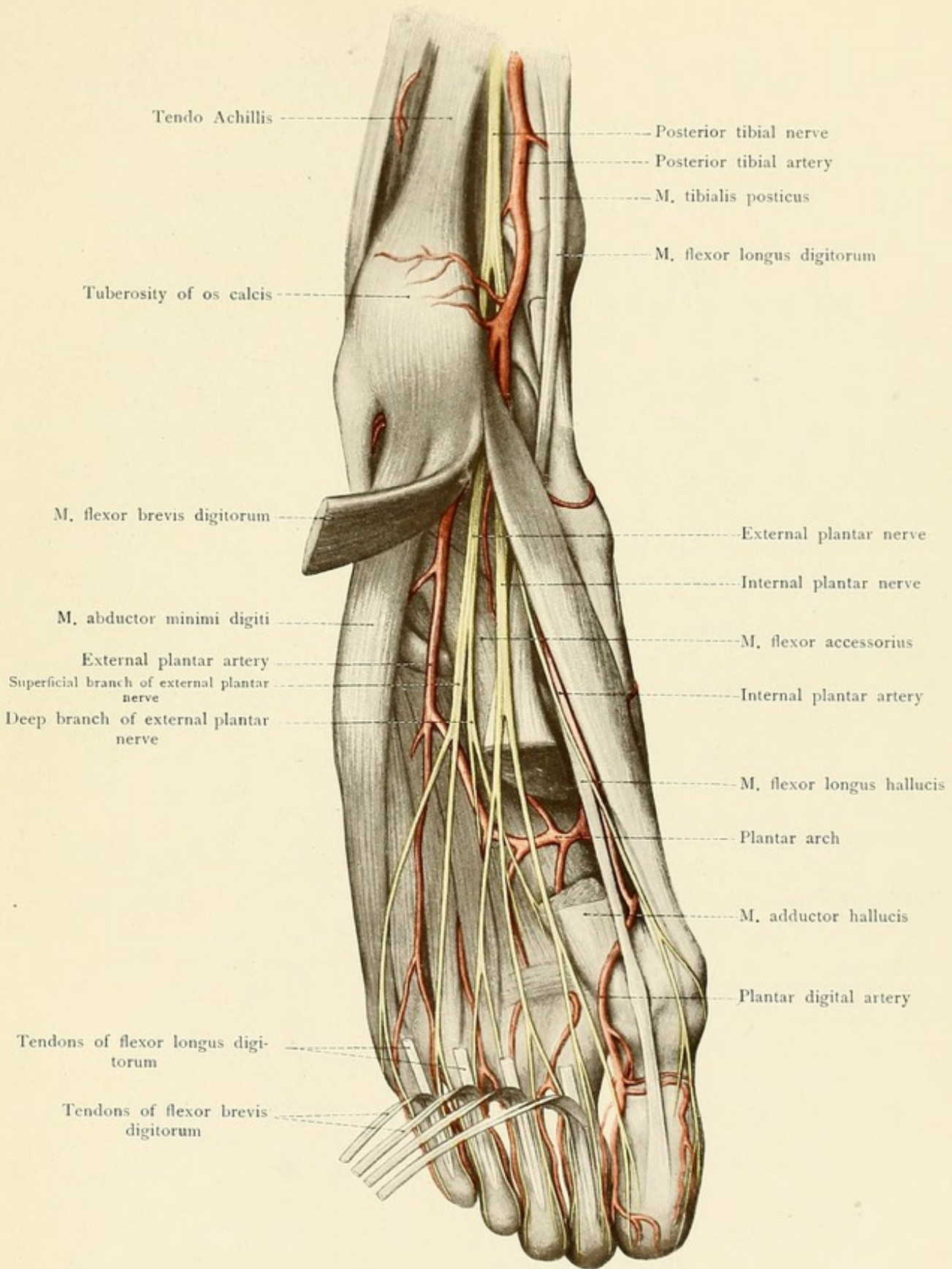
Each of the three muscles possesses an individual synovial sheath in the anterior annular ligament at the ankle.

II. *Fibular Muscles*.—(1) The *peroneus longus*. The anterior portion of this muscle arises from the external tuberosity of the tibia, from the head of the fibula, from the anterior intermuscular septum, and from the upper third of the anterior margin of the fibula; the posterior portion arises from the fibula between the head and the lower third of the bone. The tendon runs behind the external malleolus, through the groove of the cuboid bone, and passes obliquely across the sole of the foot to the base of the first metatarsal bone. (2) The *peroneus brevis*, which is covered by the preceding muscle, takes origin from the lower two-thirds of the fibula as far down as the external malleolus. The tendon crosses that of the peroneus longus and inserts into the tuberosity of the fifth metatarsal bone. The tendons of both peroneal muscles pass through a common compartment behind the external malleolus (Fig. 88), in which situation they are firmly held by two processes of the crural fascia designated as retinacula.

III (a) *Superficial Flexors* (the muscles of the calf).—(1) The *gastrocnemius* arises by two heads from the bone above the femoral condyles; in the middle of the leg the muscle becomes continuous with the tendo calcaneus (Achillis), which inserts into the tuberosity of the os calcis. (2) The *soleus*, beneath the preceding muscle, arises from the head and upper third of the fibula and from the oblique line of the tibia and runs downward into the tendo Achillis. (3) The *plantaris*, like its analogue in the upper extremity, the palmaris longus, is an inconstant muscle. It arises from the external condyle of the femur above the outer head of the gastrocnemius and its tendon usually runs into the tendo Achillis.

III (b) *Deep Group of Flexors*.—(1) The *popliteus* runs from the external condyle of the femur and the capsular ligament of the knee-joint to the posterior surface of the tibia as far down as the oblique line. (2) The *flexor longus digitorum* springs from the posterior surface of the tibia. Its tendon crosses to the outer side of the tibialis posticus, enters the sole of the foot, passes beneath and is adherent to the tendon of the flexor longus hallucis, and divides into four tendons for the four lesser toes. These tendons are inserted in a similar manner to those of the flexor profundus digitorum in the hand. (3) The *tibialis posticus* arises from the interosseous membrane and the adjacent portions of the tibia and fibula in the upper portion of the leg between the flexor longus digitorum and the flexor longus hallucis. Its tendon, with that of the flexor longus digitorum, passes behind the internal malleolus to the inner aspect of the sole of the foot, where it is inserted into the internal cuneiform and scaphoid bones. (4) The *flexor longus hallucis* takes origin from the posterior surface of the lower two-thirds of the fibula and from the posterior intermuscular septum. Its tendon runs in the posterior sulcus of the astragalus and







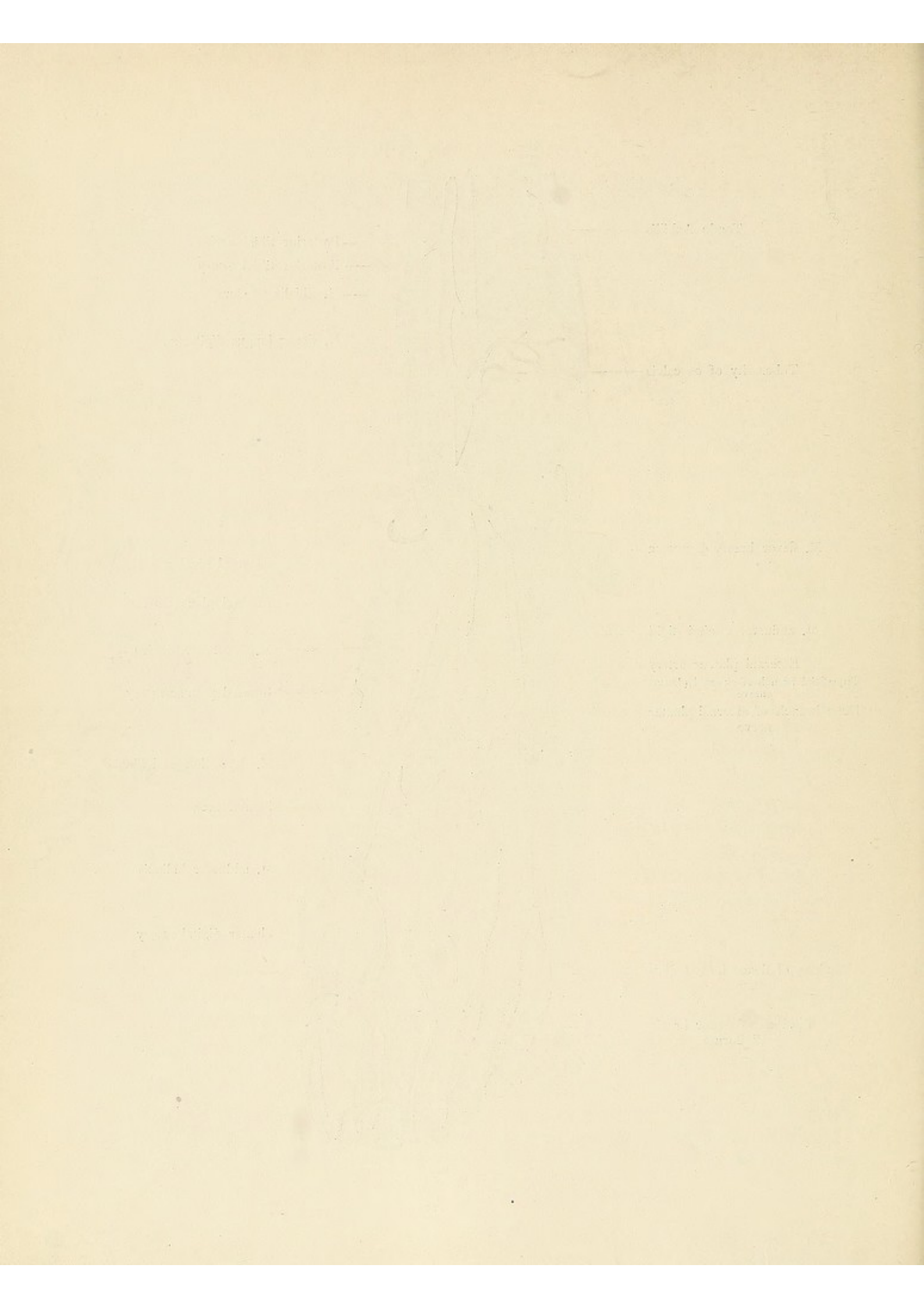




FIG. 87.—The plantar aspect of the foot. The flexor brevis digitorum muscle has been divided and portions have been cut out of the flexor longus digitorum, adductor hallucis, and flexor brevis hallucis muscles.

behind the sustentaculum tali of the os calcis to the sole of the foot, crosses the tendon of the flexor longus digitorum, and is attached to the second phalanx of the great toe. Between the internal malleolus and the tuber calcanei each of the tendons of the flexor longus digitorum, tibialis posticus, and flexor longus hallucis possesses an individual synovial sheath which is bridged over by the internal annular ligament (ligamentum laciniatum).

**Anterior Tibial Artery.**—After the popliteal artery divides into its two terminal branches at the upper margin of the soleus muscle, the anterior tibial artery (Fig. 85) gives off a small posterior recurrent branch and passes anteriorly above the upper margin of the interosseous membrane. The vessel runs downward upon the anterior surface of the interosseous membrane, being situated at first between the tibialis anticus and extensor longus digitorum muscles, and then between the former and the extensor longus hallucis. Above the malleolar region the artery lies directly upon the external surface of the tibia; it then passes beneath the anterior annular ligament and runs forward upon the foot as the *dorsalis pedis*. During life the course of the artery is indicated by a line drawn from a point midway between the tubercle of the tibia and the head of the fibula to a point upon the anterior surface of the ankle midway between the two malleoli. In addition to muscular branches, the vessel gives off the *anterior tibial artery* above, which runs upward to the anastomosis about the knee, and the *external* and the *internal malleolar arteries* below. None of the branches are of great importance from a practical standpoint. The artery is accompanied by the *anterior tibial nerve* (Fig. 85). This nerve pierces the origin of the extensor longus digitorum and runs at first to the outer side of the artery and then on top of it to the dorsum of the foot. It is the motor nerve for the three extensor muscles and for the extensor brevis digitorum upon the dorsum of the foot. The *musculocutaneous nerve* is more superficial than the preceding; it passes between the peroneus longus and brevis muscles, supplying both, pierces the deep fascia at the junction of the inferior and middle thirds of the leg, and divides, before reaching the foot, into an external and an internal branch (*N. cutaneus dorsi pedis medialis and intermedius*). In paralysis of the peroneal nerve the patient stumbles over his own toes and loses sensation over almost all of the dorsum of the foot.

**Posterior Tibial Artery.**—The posterior tibial artery (Fig. 86) runs between the soleus and tibialis posticus, beneath the flexor longus hallucis, and then between the flexor longus digitorum and the flexor longus hallucis. It is superficial and easily accessible between the tendo Achillis and the internal malleolus. In this situation it is placed to the inner side of the posterior tibial nerve and may be readily ligated. In tenotomy of the tendo Achillis the artery can scarcely be injured if ordinary care is observed. Behind the internal malleolus the vessel divides into its terminal branches—the *external* and *internal plantar arteries*. In the ligation of the artery behind the internal malleolus particular care must be taken to avoid opening the synovial sheath of the tibialis posticus, which lies immediately to the inner side of the vessel (Fig. 87). The chief branch of the posterior tibial, the *peroneal artery* (Fig. 86), arises high up, runs downward behind the fibula covered by the flexor longus hallucis muscle, and ends at the outer side of the os calcis with branches to the rete calcanei. The *posterior tibial nerve*, the



nerve for all of the flexor muscles, supplies the heads of the gastrocnemius and also the soleus in the popliteal space (Fig. 83) and runs downward to the outer side of the posterior tibial artery beneath the deep layer of the crural fascia. At the internal malleolus (Fig. 87) the nerve is deeper than the artery and closer to the tendo Achillis. Before entering the sole of the foot it divides into the *internal* and *external plantar nerves*.

### THE FOOT.

Upon the dorsal surface of the foot may be seen the *subcutaneous venous plexus*, giving origin to the short saphenous vein (accompanied by the short saphenous nerve) behind the external malleolus, and to the long saphenous vein (accompanied by the terminal ramifications of the long saphenous nerve) in front of the internal malleolus. These structures are situated in a loose connective tissue, the character of which favors the occurrence of edema. If the foot is strongly flexed dorsally, the *tendon* of the *extensor longus hallucis*, running to the great toe, springs into prominence. To the inner side of this structure may be felt the strong *tendon of the tibialis anticus*, on its way to the inner margin of the sole, the *tendons of the extensor longus digitorum* are also made prominent (Fig. 85). In dorsal flexion the tense *extensor brevis digitorum* is also palpable. In the middle of the dorsum of the foot to the outer side of the tendon of the extensor longus hallucis may be felt the pulsations of the *superficial dorsalis pedis artery*. The *tendons of the peronei*, though less prominent, may also be distinctly palpated beneath the external malleolus during dorsal flexion. In the sitting posture with the foot resting flat upon the floor, the tip of the finger may be placed in a depression upon the dorsum of the foot midway between the lower extremities of the malleoli, and in this depression the tendons may be made to glide beneath the finger. Just above this depression may be felt the lower *end of the tibia* and below it the *astragalus*; it consequently marks the highest level of the ankle-joint. In this situation swelling and fluctuation may occasionally be observed in inflammations of the articulation. At the inner margin of the sole the tuberosity of the *scaphoid bone* may be felt without difficulty, below and in front of the lower end of the internal malleolus; immediately behind this point, *Chopard's articulation* (see page 170) may be opened. At the outer margin of the sole, opposite to the scaphoid tubercle but somewhat in front of it, may be felt the tuberosity of the fifth metatarsal bone, which is just in front of *Lisfranc's articulation* (see page 170). Further anteriorly the metatarsal and phalangeal bones may be palpated upon both sides of the foot; the heads of the metatarsal bones indicate the location of the *metatarsophalangeal articulations*. In plantar flexion the heads of the phalanges may be felt upon the dorsal surface of the toes; they mark the situation of the *interphalangeal joints*.

The *dorsalis pedis artery* (Fig. 85), the continuation of the anterior tibial, passes from the anterior annular ligament along the dorsal surface of the foot in the first interosseous space. It runs anteriorly from a point midway between the two malleoli and divides at the bases of the first and second metatarsal bones into a larger branch, the *plantar digital (ramus plantaris profundus)*, passing between the first and second metatarsal bones to the plantar arch, and a smaller branch, the *dorsalis hallucis (A. metatarsæa dorsalis I)*, running forward to the web between the great and the second toes. To the outer side, the dorsalis pedis gives off the *tarsal artery (A.*



Fig. 88.

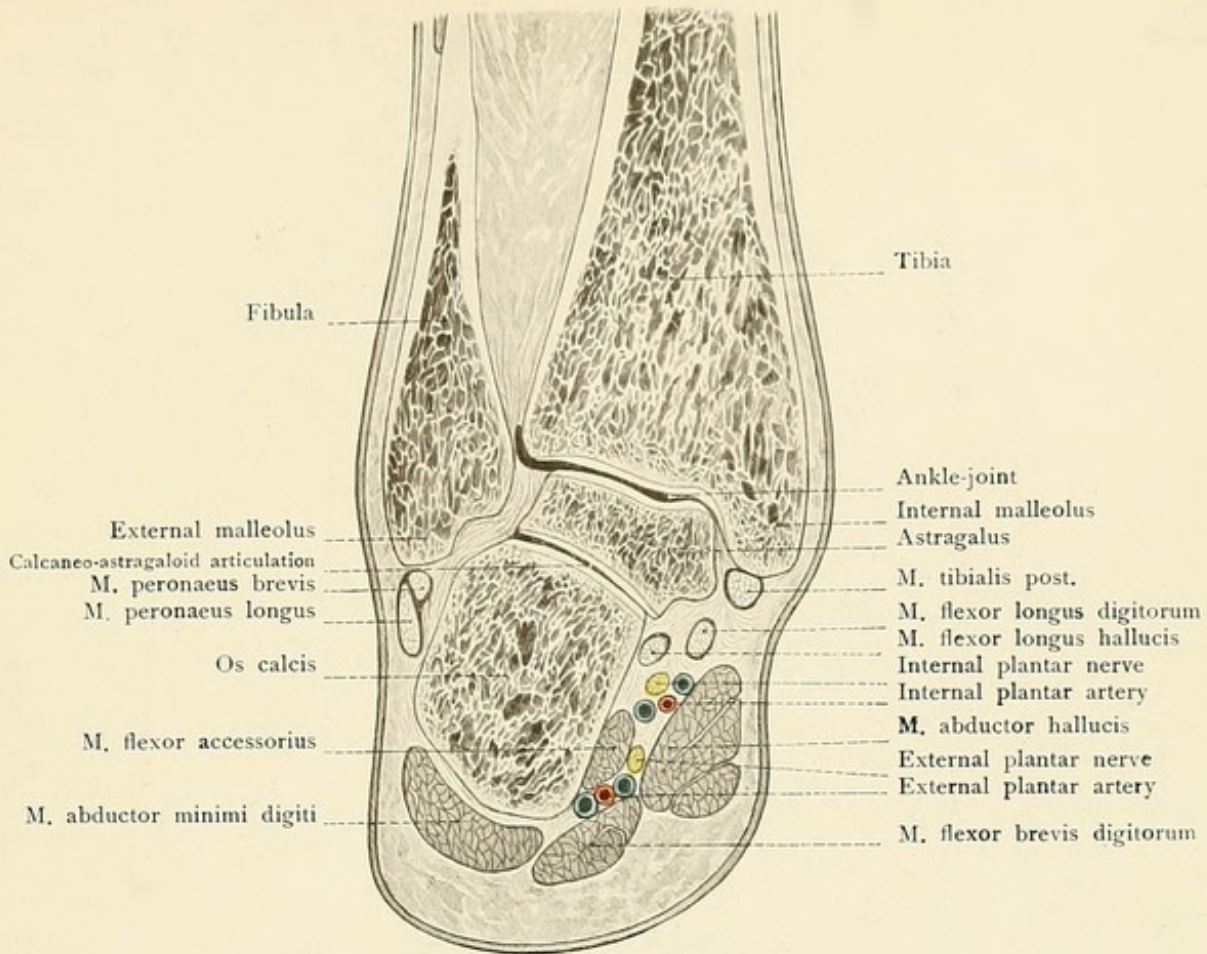


Fig. 89.

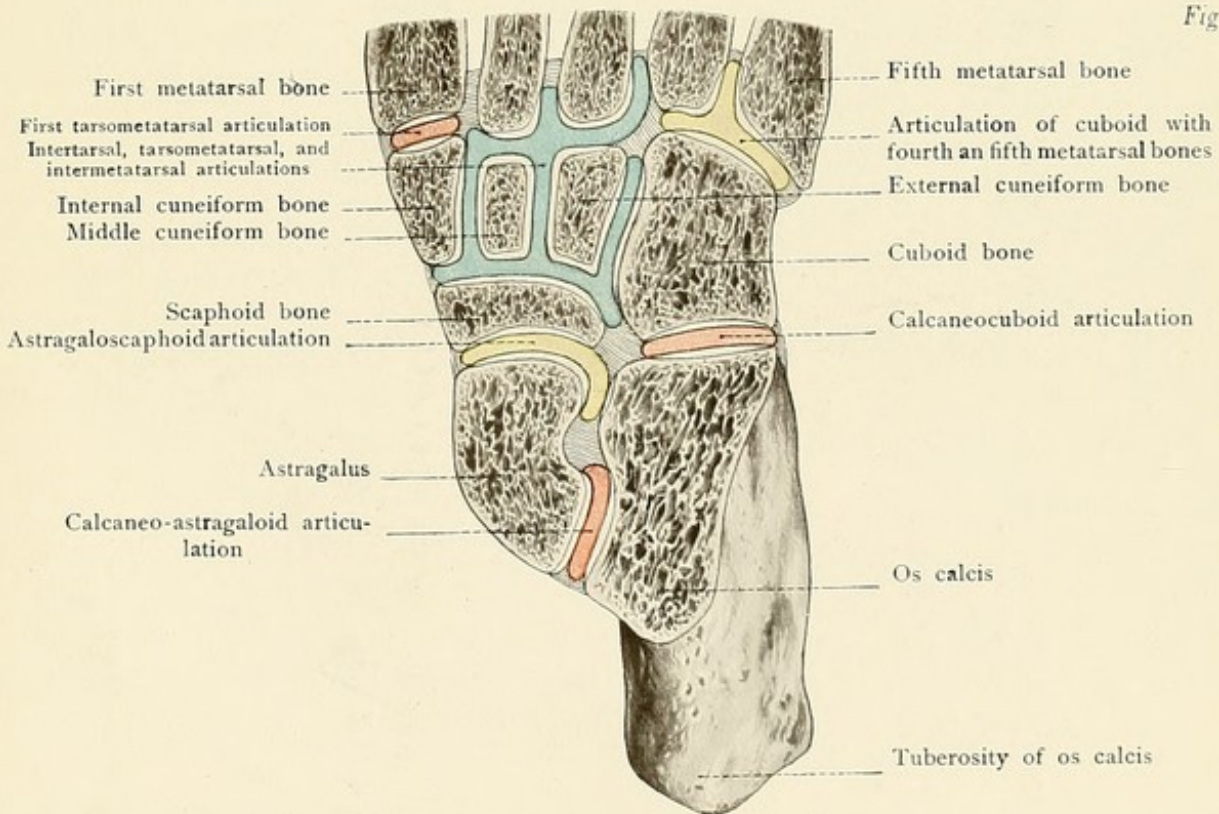








FIG. 88.—A frontal section of the talocrural and talocalcaneal articulations.

FIG. 89.—A diagrammatic representation of the joints of the foot.

*tarsæ lateralis*), passing beneath the extensor brevis digitorum and anastomosing with the next branch, the *metatarsal artery* (*A. arcuata*), which runs outward upon the bases of the metatarsal bones and gives off the dorsal metatarsal arteries for the second, third, and fourth metatarsal spaces and the corresponding sides of the toes. To the inner side, the *dorsalis pedis* gives off two or three insignificant vessels, the *Aa. tarsæ mediales*.

The *nerves of the dorsum of the foot* (Fig. 85) are: (1) The *musculocutaneous*, which divides at a higher level into an external and an internal branch (see page 167). They supply digital branches for all of the toes except the outer side of the little toe and the adjacent surfaces of the great and second toes. The latter is supplied by the *anterior tibial*; the outer margin of the dorsum of the foot and of the little toe is supplied by the *short saphenous*, which is known in this situation as the *N. cutaneus dorsi pedis lateralis*. All three nerves inosculate with each other.

**Sole of the Foot.**—Beneath the tough skin of the sole of the foot there is a thick cushion of fat which is particularly well developed posteriorly. Beneath this fat is the strong *plantar fascia*, which, like the palmar fascia, gives off five processes for the sheaths of the flexor tendons and the skin and possesses transverse trabeculæ. In the middle of the foot the fascia is considerably thicker than at the sides and covers the *flexor brevis digitorum* muscle, furnishing an origin for some of its fibers. The *external plantar artery* (see page 167 and Fig. 87) passes into the sole beneath the abductor hallucis and then runs outward between the flexor brevis digitorum and the flexor accessorius; the vessel then curves to the inner side of the foot and forms the *plantar arch* by anastomosing with the communicating branch of the *dorsalis pedis*. The plantar arch lies directly upon the bases of the second, third, and fourth metatarsal bones and upon the interosseous muscles. Anteriorly it gives off four digital branches (*Aa. metatarsæ plantares*) for the interosseous spaces and the corresponding sides of the toes, while the outer and inner margins of the sole are supplied by separate branches from the arch. The smaller *internal plantar artery* runs anteriorly to the inner side of the abductor hallucis to the great toe, where it usually anastomoses with the first digital branch (*A. metatarsæ plantaris I*).

Before entering the sole the posterior tibial nerve divides into the *external* and the *internal plantar nerves*. The external plantar nerve accompanies the external plantar artery and divides into a superficial and a deep branch (Fig. 87). The superficial branch supplies the muscles of the ball of the little toe and gives off three digital nerves to the sides of the little toe and to the outer side of the fourth toe. The deep branch follows the plantar arch into the depth of the sole and supplies the interosseous muscles and the adductor hallucis. The internal plantar nerve runs to the inner side of the flexor brevis digitorum, supplies the muscles of the ball of the great toe and the flexor brevis digitorum, and ends in seven digital nerves which supply both sides of the three inner toes and the inner side of the fourth toe.

For the **movements of the foot** there are two joints which are worthy of particular attention:

1. The *ankle-joint, or talocrural articulation* (Figs. 88 and 89), between the leg and the



astragalus; the trochlea and the lateral surfaces of the astragalus are surrounded by the articular surface of the lower end of the tibia and by the two malleoli. The capsular ligament is attached anteriorly and posteriorly to the astragalus at a slight distance from its articular surface and runs to the margins of the malleoli and of the articular surface of the tibia. The articular cavity communicates with that of the inferior tibiofibular articulation. The movements of the joint are those of dorsal and plantar flexion.

2. The *talotarsal articulation* (Figs. 88 and 89) consists of two separate portions: (a) The *posterior calcaneo-astragaloid articulation* (Artic. talocalcanea), between the posterior articular surfaces of the astragalus and of the os calcis. The capsular ligament is attached close to the margins of the articular surfaces. (b) The *anterior calcaneo-astragaloid articulation* (Artic. talonavicularis), between the middle and anterior articular surfaces of the astragalus and of the os calcis, and also between the head of the astragalus and the scaphoid bone. The capsular ligament is attached to the margins of the cartilaginous surfaces and is strengthened by the superior astragalonavicular ligament (ligamentum talonaviculare). The movement is chiefly that of pronation and supination.

The remaining joints are:

3. The *calcaneocuboid* (Fig. 89), between the corresponding articular surfaces of the os calcis and of the cuboid bone. This joint, together with the astragaloscaphoid, although separate anatomically, forms the so-called *Chopard's joint* (Artic. tarsi transversa).

4. The *intertarsal articulations*, between the remaining tarsal bones.

5. The *tarsometatarsal articulations*, *Lisfranc's joint* (the second metatarsal bone extends further posteriorly than the others). This articulation usually consists of three separate cavities (as shown in Fig. 89), of which the middle one communicates with the intertarsal articulations and with the joint between the scaphoid and the cuneiform bones.

6. The *metatarsophalangeal* and the *interphalangeal articulations*.

These articulations are strengthened by a number of ligaments. The external lateral ligament is composed of three fasciculi: The anterior astragalofibular ligament, from the external malleolus to the outer surface of the astragalus; the posterior astragalofibular ligament, from the external malleolus to a tubercle on the posterior surface of the os calcis; the calcaneofibular ligament, from the tip of the external malleolus to the outer surface of the os calcis.

The internal lateral ligament (ligamentum deltoideum) radiates from the internal malleolus to the scaphoid, astragalus, and calcaneum.

The astragalus and the calcaneum are united by the calcaneoastragaloid ligaments. Special mention should be made of the interosseous ligament which unites the anterior end of the calcaneum with the inferior surface of the neck of the astragalus. The ligamentum bifurcatum\* is situated upon the dorsal surface and unites the anterior end of the dorsal surface of the calcaneum with the cuboid and scaphoid bones.

Upon the plantar aspect the foot is strengthened by the ligaments proceeding from the os calcis and running to the scaphoid, to the cuboid, and to the bases of the metatarsal bones. The chief of these is the long plantar ligament passing from the inferior surface of the os calcis to the cuboid and to the metatarsal bones. The inferior calcaneonavicular ligament is also found in this situation.

\* Superior calcaneonavicular + internal calcaneocuboid.



## REVIEW QUESTIONS.

Where may the pulsations of the femoral artery be felt?

How may the location of the acetabulum be projected upon the surface of the body?

How does the ligamentum teres of the hip-joint manifest its importance after an intracapsular fracture of the neck of the femur?

Of what importance is the attachment of the capsular ligament of the hip for the nature of (that is, in deciding the nature of) the fractures of the neck of the femur?

Where are the weak places in the capsular ligament of the hip?

What bursa frequently communicates with the hip-joint?

From what regions do the so-called inguinal glands receive their lymph?

What landmarks aid in the location of the sciatic nerve?

What is the practical significance of the loose connective tissue accompanying the sciatic nerve?

What effect may a posterior dislocation at the knee or a fracture of the lower end of the femur have upon the popliteal vessels and upon the internal popliteal nerve?

What are the important bursas communicating with the knee-joint, and what are they which do not communicate with this articulation?

What relation must be borne in mind in exposing the popliteal artery?

Where may the posterior tibial artery be easily ligated, what synovial sheath is thereby endangered, and in the division of what tendon must the position of the artery be remembered?

How may the position of the ankle-joint be indicated externally?

What landmarks are employed to find the lines of Chopart's and of Lisfranc's articulations?







# INDEX.

- ABDOMEN, 118**  
 contents of, 128  
 external oblique muscle of, 120  
 internal oblique muscle of, 120  
 skin of, 120  
**Abdominal aorta, 142**  
 aneurysm of, 142  
 portion of ureter, 141  
 regions, lateral, 120  
 ring, external, 124  
 internal, 124  
 wall, 118  
 anterior, inner surface of, 123  
 arteries of, 121  
 external cutaneous nerve of, 123  
 inspection and palpation of, 119  
 lipoma of, 119  
 muscles of, 120  
 nerves of, 123  
 palpation and inspection of, 119  
 tumors of, 119  
 veins of, 122  
 venæ comites of, 122  
**Abducent nerve, 33, 47, 48**  
**Abscess above and below mylohyoid muscle, 54**  
 cerebellar, from suppuration in middle ear, 59  
 in brain from suppuration in middle ear, 59  
 mammary, 94  
 mediastinal, rupturing through sternal foramen, 93  
 of cervical lymphatic glands, 64  
 of fat behind thyrohyoid ligament, 66  
 of hip-joint, 157  
 of kidney, 139  
 of larynx, 66  
 of liver, 130  
 of mediastinum, 104  
 perinephritic, 141  
 periproctitic, 147  
 perityphlitic, 137  
 retropharyngeal, 58  
**Abscess, retropharyngeal, from diseases of cervical vertebrae, 58**  
 subphrenic, 132  
**Acetabulum, 156**  
**Acromioclavicular articulation, 73**  
**Acromion, 92**  
**Acromiothoracic artery, 74, 95**  
**Adam's apple, 66**  
**Adductor brevis muscle, 160**  
 longus muscle, 160  
 magnus muscle, 160  
 muscles, 160  
**Aditus ad laryngem, 58**  
**Alveolar artery, superior, 40**  
**Ampulla recti, 150**  
**Anastomotica magna artery, 78**  
**Aneurysm, aortic, 97**  
 of abdominal aorta, 142  
 of aortic arch, 113  
 of ascending aorta, 112  
 of descending aorta, 114  
**Anger, vein of, 26**  
**Angle, lieno-renal, 133**  
 of Ludwig, 90  
 of scapula, inferior, 92  
 internal, 92  
 sternal, 90  
**Angular artery, 40**  
 vein, 40  
**Ankle-joint, 169**  
**Annular ligament, anterior, 85**  
 posterior, 85  
**Annulus femoralis, 125**  
**Ansa hypoglossi, 64**  
**Antero-lateral fontanelle, 20**  
**Anteversio of uterus, 152**  
**Antrum, mastoid, suppuration in middle ear extending into, 59**  
 of Highmore, 49, 51  
**Anus, artificial, 138**  
**Aorta, abdominal, 142**  
 aneurysm of, 142  
 arch of, 113  
 aneurysm of, 113  
 ascending, 112  
**Aorta, ascending, aneurysm of, 112**  
 descending, aneurysm of, 114  
 thoracic, ascending, 113  
 stenosis of, 97  
**Aortic aneurysm, 97**  
**Apertura pyriformis, 48**  
**Apex, cardiac, 107**  
**Apex-beat of heart, 90**  
**Arachnoid membrane, 33**  
 villi of, 33  
 rupture of, 33  
**Arch of aorta, 113**  
 aneurysm of, 113  
 palmar, deep, 86  
 superficial, 86  
 plantar, 169  
**Arcuata artery, 169**  
**Arcus tendineus, 146**  
 venosus juguli, 68  
**Arm, upper, 77**  
**Arteria colica dextra, 136**  
 media, 136  
 sinistra, 136  
 hepatica propria, 130  
 intestinales, 136  
**Arterial supply of brain, 33**  
**Artery, acromiothoracic, 74, 95**  
 alveolar, superior, 40  
 anastomotica magna, 78  
 angular, 40  
 arcuata, 169  
 articular, inferior, 163  
 superior, 163  
 articularis genu media, 163  
 auditory, internal, 34  
 auricular, posterior, 26  
 axillary, 73, 74  
 azygos, articular, 163  
 basilar, 34  
 brachial, 78, 80  
 carotid, common, 63, 68, 70  
 right, 69  
 external, 63  
 internal, 26, 34, 63  
 hemorrhage from, 34, 60



- Artery, central, of retina, 46  
 cerebellar, anterior inferior, 34  
   posterior inferior, 34  
   superior, 34  
 cerebral, anterior, 35  
   middle, 35  
   posterior, 34  
 cervical, ascending, 70  
   deep, 70  
 choroid, anterior, 35  
 ciliary, long, 46  
   short, 46  
 circumflex, anterior, 75  
   external, 161  
   posterior, 75  
 colica dextra, 136  
   media, 136  
   sinistra, 136  
 comes nervi ischiadici, 159  
   phrenici, 94, 99  
 communicating, posterior, 34, 35  
 coronary, 113  
   inferior, 40  
   superior, 40  
 dental, inferior, 40  
 dorsalis hallucis, 168  
   pedis, 167, 168  
   superficial, 168  
   scapulæ, 74, 96  
 epigastric, deep, 121  
   inferior, 121  
   superficial, 121  
   superior, 94  
 ethmoidal, anterior, 46  
   posterior, 46  
 facial, 39, 64, 65  
 femoral, 155, 160, 161  
   first portion of, 161  
   second portion of, 161  
   third portion of, 161  
 frontal, 26, 46  
 gastric, 129  
 gastroduodenal, 130  
 gastro-epiploica sinistra, 130  
 gluteal, 159  
 hemorrhoidal, superior, 136  
 hepatic, 127, 129  
 hypogastric, 154  
 ileocolic, 136  
 iliac, circumflex, deep, 122  
   superficial, 121  
   common, 142  
 infraorbital, 40  
 innominate, 69
- Artery, intercostal, 96  
 anterior, 94  
 injuries of, 96, 97  
 relation with intercostal grooves,  
 96  
 seven lowermost, 121  
 superior, 70, 96  
 interosseous, anterior, 83  
 common, 83  
 palmar, 86  
 posterior, 83  
 lachrymal, 46  
 lingual, 39, 56, 64  
 lumbar, 122  
 main, of cranium, points of en-  
 trance, 21  
 malleolar, external, 167  
 internal, 167  
 mammary, internal, 70, 93  
   anterior intercostal branches of,  
 96  
   injuries of, 94  
 maxillary, internal, 39, 40  
 meningeal, middle, 29, 40  
   anterior branch, method of ex-  
 posing, 29  
   hematoma of, 29  
   injuries of, 29  
   posterior branch, method of  
 exposing, 30  
 mesenteric, inferior, 136  
 superior, 135  
 metatarsal, 169  
 metatarsæ dorsalis I, 168  
 plantaris, 169  
 metatarsæ plantaris I, 169  
 musculophrenic, 94  
 occipital, 26  
 of abdominal wall, 121  
 of diaphragm, 99  
 of face, 39  
 of forearm, 83  
 of mammary gland, 94  
 of nasal cavity, 50  
 of scalp, 26  
 of stomach, 129  
 ophthalmic, 34, 39, 46  
 palatine, ascending, 40  
   posterior, 40  
 pancreaticoduodenalis, inferior, 136  
 perforating, anterior, 94  
 pericardiaco-phrenic, 99  
 peroneal, 167  
 plantar, digital, 168
- Artery, plantar, external, 167, 169  
 internal, 167, 169  
 popliteal, 163  
 princeps pollicis, 86  
 profunda femoris, 161  
   inferior, 78  
   superior, 78  
 pterygopalatine, 40  
 pudic, deep external, 158  
 internal, 159  
 superficial external, 158  
 pulmonary, 114  
 pyloric, 129  
 radial, 83, 86  
   pulse of, 82  
 ramus cervicovaginalis, 151  
 plantaris profundus, 168  
 ranine, 56  
 scapular, posterior, 71  
 sciatic, 159  
 sigmoid, 136  
 sphenopalatine, 40, 50  
 splenic, 130  
   subclavian, 62, 70  
   branches of, 70  
   right, 69  
 sublingual, 56  
 submental, 40, 65  
 subscapular, 74, 96  
 superficialis volæ, 86  
 supraorbital, 26, 46  
 suprascapular, 70  
 tarsal, 168  
 tarsæ lateralis, 169  
 mediales, 169  
 temporal, superficial, 26  
   frontal branch, 26  
   parietal branch, 26  
 thoracic, intercostal branches of, 96  
 long, 75, 95  
 superior, 73, 95  
 thoracicodorsalis, 74, 96  
 thyroid, inferior, 70  
 superior, 64  
 tibial, anterior, 163, 167  
 posterior, 163, 167  
 transversalis colli, 70  
 ulnar, 80, 83, 86  
 vasa intestini tenuis, 136  
 vertebral, 34, 70  
 Articular artery, inferior, 163  
 superior, 163  
 Articularis genu media artery, 163  
 Articulation, acromioclavicular, 73



- Articulation between pisiform and cuneiform bones, 88  
 calcaneo-astragaloid, anterior, 170  
 posterior, 170  
 carpometacarpal, 88  
 Chopart's, 168  
 intercarpal, 88  
 intermetacarpal, 88  
 interphalangeal, 170  
 intertarsal, 170  
 Lisfranc's, 168  
 metatarsophalangeal, 168, 170  
 of metacarpal bone of thumb with trapezium, 88  
 radiocarpal, 88  
 radio-ulnar, inferior, 88  
 talocrural, 169  
 talotarsal, 170
- Artificial anus, 138  
 Aryepiglottic fold, 58  
 Arytenoepiglottic fold, 58  
 Ascites, 123, 126, 131  
 Astragalofibular ligament, anterior, 170  
 posterior, 170  
 Astragalus, 168  
 Atrophy, pressure-, of sternum, 93  
 Attic, 59  
 Auditory artery, internal, 34  
 nerve, 33  
 Auricular artery, posterior, 26  
 vein, posterior, 27  
 Auricularis magnus nerve, 68, 71  
 Auriculotemporal nerve, 27  
 Auriculoventricular orifices, 108  
 Axilla, 74  
 lymphatic glands of, 74  
 Axillary artery, 73, 74  
 cavity, 74  
 line, 90  
 anterior, 90  
 posterior, 90  
 lymphatic glands, 95  
 vein, 73, 75  
 Axis, cardiac, 105  
 celiac, 129  
 costocervical, 70  
 pelvic, 144  
 thyroid, 70  
 Azygos articular artery, 163
- BARREL-SHAPED chest of emphysema, 93  
 Bartholin, duct of, 55
- Base-line, 37  
 Reid's, 37  
 Basilar artery, 34  
 Basilic vein, 79  
 median, 79  
 Biceps flexor cruris, 160  
 muscle, 77  
 tendon, 79, 162  
 Bicipital groove, 72, 77  
 Black-heads, 50  
 Bladder, female, 151  
 male, 147  
 relation of rectum to, 148  
 rupture of, 148  
 Blood, effusions of, in subarachnoid space, 33  
 venous, from brain, 18, 21  
 Blood-supply of diaphragm, 99  
 of dura mater of brain, 29  
 of palate, 57  
 of pericranium, 28  
 of scalp, 25  
 Bone, hyoid, 62  
 metacarpal, of thumb, with trapezium, articulation of, 88  
 pisiform and cuneiform, articulation between, 88  
 scaphoid, 168  
 temporal, tympanic plate of, 59  
 Wormian, 20  
 Bony thorax, 92  
 Bosom, 91  
 Brachial artery, 78, 80  
 plexus, 73, 75, 97  
 internal cutaneous nerve of, 75  
 lesser internal cutaneous nerve of, 75  
 Brachialis anticus muscle, 77  
 Brain, abscess in, from suppuration in middle ear, 59  
 arterial supply of, 33  
 dura mater of, 28  
 blood-supply of, 29  
 middle meningeal artery of, 29  
 sinuses of, 30  
 membranes of, 28  
 nerves of, 32  
 pia mater of, 33  
 venous blood from, 18, 21  
 Breast, chicken, of rachitis, 93  
 funnel, 93  
 Breathing, costal, 103  
 diaphragmatic, 103  
 Bulbo-cavernosus muscle, 146, 147
- Bulla ethmoidalis, 53  
 Bursa anserina, 165  
 between semimembranosus and inner head of gastrocnemius muscles, 165  
 iliopectineal, 156  
 infrapatellar, deep, 165  
 intratendinea olecrani, 79  
 mucosa subscapularis, 76  
 of knee-joint, 165  
 of popliteus muscle, 165  
 omentalis, 125  
 prepatellar, 165  
 subcutaneous, 79, 165  
 over tubercle of tibia, 165  
 subdeltoid, 77  
 subfascialis, 165  
 subtendinea, 165  
 suprapatellar, 164, 165  
 trochanterica, 158  
 Buttocks, muscles of, 158
- CALCaneo-ASTRAGALOID articulation, anterior, 170  
 posterior, 170  
 Calcaneocuboid joint, 170  
 Calcaneofibular ligament, 170  
 Calcaneonavicular ligament, inferior, 170  
 Canal, carpal, 84, 86  
 Hunter's, 160, 161  
 obturator, 145, 146  
 Canalis adductorius, 160, 161  
 Capsula adiposa, 139  
 Capsular ligament of elbow-joint, 81  
 of hip-joint, 156  
 of knee-joint, 164  
 of shoulder-joint, 76  
 Caput Medusæ, 123  
 Carcinoma of esophagus, 115, 116  
 of rectum, 150  
 Cardia, 128  
 Cardiac apex, 107  
 axis, 105  
 dulness, absolute, 106  
 line, inferior, 107  
 left, 107  
 right, 107  
 superior, 107  
 transverse, 107  
 Caries of base of cranium, 32  
 Carotid artery, common, 63, 68, 70  
 right, 69  
 external, 63



- Carotid artery, internal, 26, 34, 63  
hemorrhage from, 34, 60  
triangle, 63  
tubercle, 63
- Carpal canal, 84, 86
- Carpometacarpal articulations, 88
- Cartilage, cricoid, 62  
semilunar, 164  
tarsal, 44  
thyroid, 62  
triangular, 49
- Caruncle, sublingual, 55
- Catarrh of frontal sinus, 19  
of lateral wall of nose, 54
- Cavernosa urethræ, 149
- Cavernous sinus, 31  
thrombosis, 31
- Cavum oris, 54  
Retzii, 148  
tympani, 59
- Celiac axis, 129
- Cells, ethmoidal, 53  
of mastoid antrum, suppuration in  
middle ear extending into, 59
- Central artery of retina, 46
- Cephalic vein, 73, 79  
median, 79
- Cerebellar abscess from suppuration  
in middle ear, 59  
artery, anterior inferior, 34  
posterior inferior, 34  
superior, 34
- Cerebral artery, anterior, 35  
middle, 35  
posterior, 34
- Cerebrospinal fluid, escape from ear,  
23
- Cervical artery, ascending, 70  
deep, 70  
lymphatic glands, abscess of, 64  
plexus, 68, 71  
region, anterior, 63  
lateral, 63, 68  
median, 63, 65  
vertebras, diseases of, retropharyn-  
geal abscess from, 58  
relation of pharynx to, 58
- Chest, barrel-shaped, of emphysema,  
93  
narrow, of phthisis, 93
- Chicken breast of rachitis, 93
- Choanæ narium, 48
- Chopart's articulation (joint), 168, 170
- Choroid artery, anterior, 35
- Ciliary artery, long, 46  
short, 46  
ganglion, 48
- Circular sinus, 31
- Circulus venosus Halleri, 95
- Circumflex artery, anterior, 75  
external, 161  
posterior, 75  
nerve, 75  
injury of, from subcoracoid dislo-  
cation, 73
- Cirrhosis of liver, 122  
Talma-Morrison operation for,  
123
- Cisternæ subarachnoideales, 33
- Clavicle, fracture of, laceration or  
compression of nerves and vessels  
after, 73  
sternal end of, backward dislocation  
of, 94
- Cleft palate, repairing, 57
- Coccygeal vertebrae, 145
- Colon, ascending, 137  
descending, 138  
sigmoid, 138  
transverse, 137
- Colotomy, lumbar, 138
- Comedones, 50
- Comes arteriosus, 106  
nervi ischiadici artery, 159  
phrenici artery, 94, 99
- Common carotid artery, 70  
right, 60
- Communicans peronei nerve, 163  
poplitei nerve, 163
- Communicating artery, posterior, 34,  
35
- Condylloid foramen, posterior, 22  
ridges, external, 79  
internal, 79
- Conjunctiva, palpebral, 44
- Conjunctival sac, 44
- Constrictor cunni muscle, 147
- Coracoacromial ligament, 77
- Coracobrachialis muscle, 77
- Coracohumeral ligament, 77
- Coracoid process, 73, 92
- Coronary artery, 113  
inferior, 40  
superior, 40  
ligament, 126  
vein of stomach, stasis in, 123
- Costal breathing, 103  
pleura, 100
- Costo-axillary veins, 97
- Costocervical axis, 70
- Costoclavicular line, 90
- Costocoracoid ligament, 73, 92
- Costo-mediastinal sinus, 100
- Costo-phrenic sinus, 100
- Cranial fossa, anterior, 35  
middle, 35  
fracture of, 23  
posterior, fracture of, 24  
nerve, seventh, 41  
exposure of, 41  
nerves, points of exit, 21  
region, 17
- Cranio-cerebral topography, 35
- Cranium, 17  
arteries of, points of entrance, 21  
base of, 17, 21  
caries of, 32  
fracture of, 32  
strong portions of, 23  
thin portions of, 19, 22  
tumors of, 33  
external plate of, 18  
internal plate of, 18  
thickness of, 17  
vault of, 17  
vertex of, 17
- Crease, gluteofemoral, 162
- Cribriform fascia, 157  
plate of ethmoid, fracture of, 23
- Cricoid cartilage, 62
- Cricothyroid ligament, 62, 66
- Cricotomy, 66
- Crista lachrymalis anterior, 42  
posterior, 42
- Crucial ligament, anterior, 164  
posterior, 164
- Crural fascia, 165  
nerve, anterior, 123, 157, 161
- Crureus muscle, 160
- Cubital vein, median, 79
- Cuneiform and pisiform bones, articu-  
lation between, 88
- Curvature, spinal, thoracic deformities  
of, 93
- Curve, pelvic, 144  
postpubic, 149  
sacral, 150  
subpubic, 149
- Cutaneous nerve, external, of abdom-  
inal wall, 123  
internal, lesser, of brachial plexus,  
75



- Cutaneous nerve, internal, of brachial plexus, 75  
of elbow, 79
- Cutaneus dorsi pedis intermedius nerve, 167  
lateralis nerve, 169  
medialis nerve, 167  
suræ lateralis nerve, 163  
medialis nerve, 163
- Cysts, congenital, of mouth, 56  
dermoid, congenital, in floor of mouth, 56
- DEFORMITIES, thoracic, of spinal curvature, 93
- Deltoid muscle, 72
- Dental artery, inferior, 40  
branch, inferior, of superior maxillary division of fifth nerve, 56  
nerve, inferior, 41  
resection of, 41
- Dermoid cysts, congenital, in floor of mouth, 56
- Descendens hypoglossi nerve, 64
- Diameter, anteroposterior, of pelvic cavity, 144  
of pelvic inlet, 143  
outlet, 144  
of plane of pelvic contraction, 144  
internal conjugate, diagonal, of pelvis, 144
- Diameters, sagittal, of pelvis, 143
- Diaphragm, 98  
arteries of, 99  
blood-supply of, 99  
dome of, 118  
phrenic nerves of, 99
- Diaphragma pelvis, 146  
sellæ, 30  
urogenitale, 146
- Diaphragmatic breathing, 103  
hernia, 99  
pleura, 99, 100
- Diploic veins, 18
- Dislocation, backward, of sternal end of clavicle, 94  
of elbow-joint, 81  
of hip-joint, 156  
subcoracoid, 73  
injury of circumflex nerve from, 73
- Diverticula, traction, of esophagus, 116
- Dorsal nerve, first, 97
- Dorsalis hallucis artery, 168  
linguæ, 56  
nasi, 46  
pedis artery, 167, 168  
superficial, 168  
scapulæ artery, 74, 96
- Dorso-radial fossa, 85
- Dorsum of foot, musculocutaneous nerve of, 169  
nerves of, 169
- Drum-membrane, 59
- Duct, parotid, 41
- Ductus choledochus, 127  
communis choledochus, 132
- Dulness, absolute cardiac, 106
- Duodenum, 134  
ascending part of, 135  
descending part of, 135  
superior part of, 134  
ulcer of, 135
- Dura mater of brain, 28  
blood-supply of, 29  
middle meningeal artery of, 29  
sinuses of, 30
- Dysphagia, 58, 66, 110
- Dyspnea, 58, 113
- EAR, 59  
escape of cerebrospinal fluid from, 23  
middle, suppuration in, abscess in brain from, 59  
cerebellar abscess from, 59  
extending into mastoid antrum, 59  
pyemia from, 59  
sinus thrombosis from, 59
- Ear-orbit line, 37
- Ejaculatory ducts, 148
- Elbow, internal cutaneous nerve of, 79  
miner's, 79  
region of, 79
- Elbow-joint, 81  
capsular ligament of, 81  
dislocation of, 81
- Eminence, iliopectineal, 157
- Eminentia carpi radialis, 84  
ulnaris, 84  
intercondylea tibiæ, 164
- Emissary foramina, 22
- Emphysema, barrel-shaped chest of, 92
- Empyema, 100  
of gall-bladder, 131
- Epicondyles, external, 79  
internal, 79
- Epigastric artery, deep, 121  
inferior, 121  
superficial, 121  
superior, 94  
region, 119  
vein, superficial, 122
- Epigastrium, 119
- Epiglottic tubercle, 66
- Epipericardium, 108
- Epitympanic recess, 59
- Esophageal varices, 123
- Esophagus, 67, 115  
carcinoma of, 115, 116  
foreign bodies in, 115, 116  
hemorrhage from, 116  
length of, 115  
lymphatic glands alongside, suppuration in, 67  
tumors of, 67  
narrow portions of, 115  
pneumogastric nerves of, 116  
stenosis of, 116  
suppuration of, 116  
traction diverticula of, 116  
veins of, 116
- Ethmoid, cribriform plate of, fracture of, 23
- Ethmoidal artery, anterior, 46  
posterior, 46  
cells, 53  
veins, 50
- Eustachian cushion, 57
- Excavatio recto-uterina, 152  
rectovesicalis, 148  
vesico-uterina, 151, 152
- Exophthalmos, pulsating, 31
- Extensor brevis digitorum muscle, 168  
pollicis muscle, 83, 85  
carpi radialis brevior muscle, 82  
longior muscle, 82  
ulnaris muscle, 82  
communis digitorum muscle, 82  
indicis muscle, 83  
longus digitorum muscle, 166  
tendon of, 168  
hallucis muscle, 166  
tendon of, 168  
pollicis muscle, 83, 85  
minimi digiti muscle, 82  
muscles of leg, 165



- Extensor ossis metacarpi pollicis muscle, 83, 85  
 Extravisceral portion of pelvic space, 146  
 Extremity, lower, 155  
 Exudate, pleural, left-sided, 111  
 Eye, muscles of, 45  
 Eyeball, 45  
 Eyelids, 44
- FACE, 39  
 arteries of, 39  
 nerves of, 40  
 veins of, 40  
 Facial artery, 39, 64, 65  
 nerve, 33, 65  
 region, 39  
 vein, 40  
 Facies diaphragmatica, 133  
 gastrica, 128, 133  
 lunata, 143, 156  
 renalis, 133  
 Falciform ligament, 126, 132  
 Fallopian tube, 154  
 False pelvis, 143  
 Falx cerebelli, 30  
 cerebri, 30  
 Fascia, cribriform, 157  
 crural, 165  
 iliac, 157  
 iliopectineal, 157  
 of Retzius, 121  
 palmar, 85  
 rectovesical, 148  
 transversalis, 121  
 umbilical, 121  
 Fat behind thyrohyoid ligament, 63  
 abscess of, 66  
 orbital, 45  
 Fauces, isthmus of, 54  
 Faucial tonsil, 57  
 Femoral artery, 155, 160, 161  
 first portion of, 161  
 second portion of, 161  
 third portion of, 161  
 fossa, 125  
 hernia, 157  
 ring, 125, 157  
 vessels, 157  
 Femur, fracture of, 156  
 Fibular muscles, 165, 166  
 Fifth nerve, superior maxillary division of, inferior dental branch of, 56
- Fissure of Larrey, 98  
 Fistula of mouth, 56  
 rectovaginal, 153  
 urethrovaginal, 153  
 vesicovaginal, 153  
 Flap-like wounds of scalp, 28  
 Flexor brevis digitorum muscle, 169  
 carpi radialis muscle, 82  
 ulnaris muscle, 82  
 longus digitorum muscle, 166  
 hallucis muscle, 166  
 pollicis muscle, 82  
 muscles of leg, 165, 166  
 of thigh, 160  
 profundus digitorum muscle, 82  
 sublimis digitorum muscle, 82  
 Flexura perinealis, 150  
 sacralis, 150  
 Floating spleen, 134  
 Fold, recto-uterine, 152  
 vesico-uterine, 151, 152  
 Fontanelle, antero-lateral, 20  
 frontal, 19  
 large, 19  
 occipital, 20  
 postero-lateral, 20  
 Fontanelles, 19  
 Foot, 168  
 dorsum of, musculocutaneous nerve of, 169  
 nerves of, 169  
 movements of, 169  
 sole of, 169  
 subcutaneous venous plexus of, 168  
 Foramen, condyloid, posterior, 22  
 emissary, 22  
 epiploicum, 125  
 infraorbital, 41  
 mastoid, 22  
 occipital, 22  
 of Santorini, 22  
 of Winslow, 125  
 parietal, 22  
 sternal, mediastinal abscess rupturing through, 93  
 medico-legal aspects of, 93  
 supraorbital, 27, 42  
 suprapyiform, 159  
 Foramina, infrapyiform, 146  
 obturator, 145  
 sacrosciatic, 145  
 suprapyiform, 146  
 Forearm, 81  
 arteries of, 83  
 Forearm, median nerve of, injuries of, 83  
 muscles of, 82  
 nerves of, 83  
 Foreign bodies in esophagus, 115, 116  
 Fossa acetabuli, 143, 156  
 cranial, anterior, 35  
 middle, 35  
 fracture of, 23  
 posterior, fracture of, 24  
 dorso-radial, 85  
 femoral, 125  
 iliopectinea, 160  
 infraclavicular, 73, 92  
 inguinal, external, 124  
 middle, 124  
 ischio-rectal, 146  
 jugular, 60  
 lachrymal, 42  
 Mohrenheim's, 92  
 nasal, floor of, 48  
 inner wall of, 48  
 outer wall of, 49  
 navicularis, 149  
 ovalis, 157  
 Rosenmüller's, 53, 57  
 saccilachrymalis, 42  
 venæ umbilicalis, 131  
 vesicæ fellæ, 131  
 Fovea femoralis, 125  
 inguinalis lateralis, 124  
 medialis, 124  
 supravesicalis, 124  
 trochlearis, 42  
 Fracture of base of cranium, 32  
 of clavicle, laceration or compression of nerves and vessels after, 73  
 of cribriform plate of ethmoid, 23  
 of femur, 156  
 of middle cranial fossa, 23  
 of nasal roof, 23  
 of pelvic walls, 145  
 of posterior cranial fossa, 24  
 of rib, 97  
 of sternum, 93  
 of tegmen tympani, 23  
 Frontal artery, 26, 46  
 branch of superficial temporal artery, 26  
 fontanelle, 19  
 sinus, 19, 52  
 catarrh of, 19  
 vein, 26



- Fundus of stomach, 128  
 Funnel breast, 93  
 Furrow, median, anterior, 91  
     posterior, 92
- GALEA aponeurotica, 24  
 Gall-bladder, 131, 132  
     empyema of, 131  
 Gall-stones, 131  
 Ganglion, ciliary, 48  
     Meckel's, 41  
 Gastric artery, 129  
 Gastrocnemius muscle, 162, 166  
 Gastrocolic omentum, 126  
 Gastroduodenal artery, 130  
 Gastro-epiploica dextra vein, 130  
     sinistra artery, 130  
     vein, 130  
 Gastrohepatic omentum, 126  
 Genitocrural nerve, 123  
 Gimbernat's ligament, 157  
 Gladiolus and manubrium, synchondrosis between, 93  
 Glossopharyngeal nerve, 65  
     lingual branch of, 56  
 Gluteal artery, 159  
     nerve, superior, 159  
 Gluteofemoral crease, 162  
 Gluteus maximus muscle, 158  
     medius muscle, 158  
     minimus muscle, 158  
 Gracilis muscle, 160
- HAND, 84  
     palm of, synovial sheath of, 87  
     tenosynovitis in, 87  
 Head, 17  
     of humerus, 72  
 Hearing, organ of, 59  
 Heart, apex-beat of, 90  
     position of, 105  
 Hematemesis, 113  
 Hematoma of middle meningeal artery, 29  
 Hematothorax, 100  
 Hemiazygous vein, 117  
 Hemoptysis, 113  
 Hemorrhage after tonsillotomy, 57  
     from esophagus, 116  
     from internal carotid artery, 34, 60  
     from nose, cause of, 23  
     from renal vessels, 140
- Hemorrhoidal artery, superior, 136  
     plexus, stasis in, 123  
 Hemothorax, 94, 97  
 Hepatic abscess, 130  
     artery, 127, 129  
 Hernia, diaphragmatic, 99  
     femoral, 157  
     inguinal, 125  
     inguinalis obliqua medialis, 125  
     internal, 125  
     of linea alba, 120  
 Hiatus adductorius, 160  
     basilicus, 78  
     semilunaris, 53  
 Highmore, antrum of, 49, 51  
 Hilus pulmonis, 102  
 Hip, muscles of, 158  
     region of, 155  
 Hip-joint, 156  
     abscess of, 157  
     capsular ligament of, 156  
     dislocation of, 156  
 Hordeolum, 44  
 Horizontal line, superior, 37  
 Horner's muscle, 44  
 Humerus, head of, 72  
     surgical neck of, fracture of, compression of vessels and nerves after, 73  
 Hunter, canal of, 160, 161  
 Hydronephrosis, 142  
 Hydrothorax, 100  
 Hyoid bone, 62  
     muscle, 62  
 Hypochondriac regions, 119  
 Hypogastric artery, 154  
     region, 119  
 Hypoglossal nerve, 56, 64
- ILEOCOLIC artery, 106  
 Iliac artery, common, 142  
     deep circumflex, 122  
     superficial circumflex, 121  
     fascia, 157  
     vein, superficial circumflex, 122  
 Iliofemoral ligament, 156  
 Iliohypogastric nerve, 123, 139  
 Ilio-inguinal nerve, 123  
 Iliopectineal bursa, 156  
     eminence, 157  
     fascia, 157  
     line, 143  
 Iliopsoas muscle, 157, 158
- Iliotibial band, 162  
 Ilium, superior spinous processes of, 119  
 Impressio colica, 131  
     duodenalis, 135  
     œsophagea, 131  
     renalis, 131  
     suprarenalis, 131, 141  
 Incisura acetabuli, 143, 156  
     cardiaca, 102, 103  
     interlobaris, 102, 103  
 Infraclavicular fossa, 73, 92  
 Infrapyrid region, 63  
 Infraorbital artery, 40  
     foramen, 41  
     nerve, 40  
     exposure of, 41  
     resection of, for neuralgia, 41  
 Infrapatellar bursa, deep, 165  
 Infrapyridiform foramina, 146  
 Infraspinal muscle, 75, 76  
 Inguinal fossa, external, 124  
     middle, 124  
     glands, 158  
     hernia, 125  
     lymphatic glands, 158  
     regions, 120  
 Injuries of intercostal arteries, 96, 97  
     of internal mammary artery, 94  
     of median nerve of forearm, 83  
     of middle meningeal artery, 29  
     of musculospiral nerve, 84  
 Innominate artery, 69  
     vein, 112  
     left, 68  
 Interarytenoid notch, 58  
 Intercarpal articulations, 88  
 Intercondyloid line, 164  
 Intercostal artery, 96  
     anterior, 94  
     injuries of, 96, 97  
     relation with intercostal grooves, 96  
     seven lowermost, 121  
     superior, 70, 96  
     branches, anterior, of internal mammary artery, 96  
     of thoracic aorta, 96  
     grooves, relation of intercostal arteries with, 96  
     nerves, 97  
     vein, superior, 117  
     veins, 97  
 Intermetacarpal articulations, 88



- Intermuscular septum, anterior, of leg, 165
- Interosseous artery, anterior, 83  
 common, 83  
 palmar, 86  
 posterior, 83  
 nerve, anterior, 83  
 posterior, 84
- Interphalangeal articulation, 170  
 joints, 168
- Interscapular line, 103, 114
- Intertarsal articulations, 170
- Intestine, large, 136  
 longitudinal bands of, 138  
 small, 135
- Ischiocapsular ligament, 156
- Ischiocavernosus muscle, 147
- Ischiorectal fossas, 146
- Ischium, tuberosity of, 155
- Isthmus cerebri, 36  
 of fauces, 54  
 of thyroid gland, 62  
 in children, 66
- JOINT, calcaneocuboid, 170  
 Chopart's, 170  
 interphalangeal, 168  
 Lisfranc's, 170
- Jugular fossa, 60  
 vein, anterior, 68  
 external, 68  
 internal, 64, 68, 71  
 inferior bulb of, 71
- KIDNEY, 139  
 abscess of, 139  
 hemorrhage from, 140  
 left, 140  
 method of reaching from behind, 141  
 right, 140  
 tumor of, 140
- Knee, region of, 162
- Knee-joint, 163  
 bursas of, 165  
 capsular ligament of, 164  
 internal lateral ligament of, 164  
 ligaments of, 164  
 long external lateral ligament of, 164  
 posterior ligament of, 165
- Krönlein, line of, 29, 37
- Kyphosis, 93
- LABRUM glenoidale, 156
- Laceration of vagina, 153
- Lachrymal artery, 46  
 canals, 45  
 ducts, 45  
 fossa, 42  
 gland, 44  
 nerve, 48  
 papillas, 45
- Lacuna musculorum, 157  
 vasorum, 157
- Larrey, fissure of, 98
- Laryngeal nerve, inferior, 66  
 left, 113  
 portion of pharynx, 58  
 region, 66
- Larynx, abscess of, 66  
 anterior wall, perichondritis of, 66  
 aperture of, superior, 58
- Latissimus dorsi muscle, 72
- Leg, 165  
 anterior intermuscular septum of, 165  
 extensor muscles of, 165  
 flexor muscles of, 165, 166  
 muscles of, 165
- Levator anguli scapulæ muscle, 69  
 palpebræ superioris muscle, 46
- Lieno-renal angle, 133
- Ligament, annular, anterior, 85  
 posterior, 85  
 anterior, at wrist, 88  
 astragalofibular, anterior, 170  
 posterior, 170  
 calcaneofibular, 170  
 calcaneonavicular, inferior, 170  
 capsular, of elbow-joint, 81  
 of hip-joint, 156  
 of knee-joint, 164  
 of shoulder-joint, 76  
 coracoacromial, 77  
 coracohumeral, 77  
 coronary, 126  
 costocoracoid, 73, 92  
 cricothyroid, 62, 66  
 crucial, anterior, 164  
 posterior, 164  
 falciform, 126, 132  
 Gimbernat's, 157  
 iliofemoral, 156  
 ischiocapsular, 156
- Ligament, lateral, external, at wrist, 88  
 of arm, 81  
 of knee-joint, 164  
 internal, at wrist, 88  
 of arm, 81  
 of liver, 126  
 long external lateral, of knee-joint, 164  
 of knee-joint, 164  
 orbicular, 81  
 patellar, 164  
 peritoneal, 125  
 plantar, long, 170  
 posterior, at wrist, 88  
 of knee-joint, 165  
 pubocapsular, 156  
 round (ligamentum teres), 126  
 sacrosciatic, 145  
 suspensory, of liver, 126  
 of ovary, 154  
 tarsal, 44  
 thyrohyoid, fat behind, 65  
 abscess of, 66  
 triangular, of pelvis, 146
- Ligamenta cruciata, 164  
 triangulæ, 126
- Ligamentum arteriosum, 114  
 bifurcatum, 170  
 carpi radiatum, 88  
 collaterale fibulare, 164  
 conicum, 62, 66  
 coronarium hepatis, 126  
 deltoideum, 170  
 duodenale, 125  
 falciforme hepatis, 126  
 gastrocolicum, 127  
 gastrolienale, 127, 128  
 hepatoduodenale, 126, 127, 134  
 hepatogastricum, 126  
 infundibulopelvicum, 154  
 laciniatum, 167  
 patellæ, 162  
 phrenicolicum, 128  
 phrenicolienale, 127  
 popliteum arcuatum, 164, 165  
 obliquum, 164, 165  
 posticum Winslowii, 165  
 talonaviculare, 170  
 teres, 126, 156  
 umbilicale laterale, 154
- Line, axillary, 90  
 anterior, 90  
 posterior, 90



- Line, base-, 37  
 Reid's, 37  
 cardiac, inferior, 107  
 left, 107  
 right, 107  
 superior, 107  
 transverse, 107  
 costoclavicular, 90  
 ear-orbit, 37  
 horizontal, superior, 37  
 ilipectineal, 143  
 intercondyloid, 164  
 interscapular, 103, 114  
 mammary, 90  
 median, anterior, 90  
 posterior, 90  
 of Krönlein, 29, 37  
 of Richter-Monro, 122  
 of Rolando, 38  
 of Roser-Nélaton, 155  
 of Sylvius, 38  
 parasternal, 90  
 scapular, 90  
 sternal, 90  
 vertical, anterior, 37  
 middle, 38
- Linea alba, 120  
 hernia of, 120  
 glutæa posterior, 158  
 quadrati, 159  
 semicircularis Douglasi, 120  
 semilunares, 119  
 terminalis, 119
- Lingual artery, 39, 56, 64  
 branch of glossopharyngeal nerve, 56  
 of inferior maxillary nerve, 56
- Lipoma of abdominal wall, 119
- Lisfranc's articulation (joint), 168, 170
- Liver, 130  
 abscess of, 130  
 cirrhosis of, 122  
 coronary ligament of, 126  
 inferior surface of, 130  
 lateral ligaments of, 126  
 lymphatic glands of, 131  
 size of, in children, 133  
 suspensory ligament of, 126  
 upper convex surface of, 130
- Lobus caudatus, 131
- Longitudinal sinus, inferior, 31  
 superior, 30
- Longus capitis et colli muscles, 58
- Ludwig's angle, 90
- Lumbar arteries, 122  
 colotomy, 138  
 plexus, nerves from, 123  
 regions, 120  
 veins, ascending, 122
- Lungs, 99, 102  
 adherent, 102  
 grooves of, 102  
 respiratory changes in position of, 102
- Lymphatic glands alongside esophagus, suppuration in, 67  
 tumors of, 67  
 axillary, 74, 95  
 cervical, abscess of, 64  
 in subinguinal region, 155  
 inguinal, 158  
 of liver, 131  
 of mamma, 95  
 of mediastinum, 104  
 of rectum, 150  
 of scalp, 27  
 of tongue, 56  
 of trachea, 115  
 submaxillary, 65  
 supraclavicular, 69
- Lymphoglandulæ subinguinales, 158
- MALLEOLAR artery, external, 167  
 internal, 167
- Mammary abscess, 94  
 artery, internal, 70, 93  
 anterior intercostal branches of, 96  
 injuries of, 94  
 gland, 94  
 arteries of, 94  
 lymphatic vessels of, 95  
 nerves of, 95  
 neuralgia of, 95  
 tumors of, 95  
 veins of, 95  
 line, 90
- Manubrium and gladiolus, synchronosis between, 93
- Margo falciformis, 157
- Mastoid antrum, suppuration in middle ear extending into, 59  
 foramen, 22
- Maxillary artery, internal, 39, 40  
 nerve, inferior, lingual branch of, 56  
 sinus, 49, 51
- Maxillary sinus, tumors of, 52
- McBurney's point, 137
- Meatus, 149  
 nasal, 49
- Meckel's ganglion, 41
- Median furrow, anterior, 91  
 posterior, 92  
 line, anterior, 90  
 posterior, 90  
 nerve, 78, 80, 83, 86, 87  
 injuries of, 83  
 inner head of, 75  
 outer head of, 75  
 paralysis of, 84
- Mediastinal abscess rupturing through sternal foramen, 93  
 pleura, 100
- Mediastinum, 100, 104  
 abscess of, 104  
 lymphatic glands of, 104  
 suppuration of, 104
- Meibomian glands, 44
- Membrane, arachnoid, 33  
 villi of, 33  
 drum-, 59  
 of brain, 28  
 sternal, 93
- Meningeal artery, middle, 29, 40  
 anterior branch, method of exposing, 29  
 hematoma of, 29  
 injuries of, 29  
 posterior branch, method of exposing, 30
- Meniscus lateralis, 164  
 medialis, 164
- Mesenteric artery, inferior, 136  
 superior, 135
- Mesentery, 125  
 longest part of, 126
- Mesocolon, 125  
 transverse, 138
- Mesogastric region, 119
- Metacarpal bone of thumb with trapezium, articulation of, 88
- Metatarsal artery, 169
- Metatarsæ dorsalis artery I, 168
- Metatarsæ plantaris artery, 169
- Metatarsæ plantaris artery I, 169
- Metatarsophalangeal articulation, 168, 170
- Meteorismus, 131
- Middle ear, suppuration in, abscess in brain from, 59



- Middle ear, suppuration in, cerebellar abscess from, 59  
 extending into mastoid antrum, 59  
 pyemia from, 59  
 sinus thrombosis from, 59
- Miner's elbow, 79
- Mohrenheim's fossa, 92
- Motor nerves of thoracic wall, 97
- Mouth, congenital cysts of, 56  
 fistula of, 56  
 floor of, congenital dermoid cysts in, 56
- Muscle, adductor brevis, 160  
 longus, 160  
 magnus, 160  
 biceps, 77  
 flexor cruris, 160  
 brachialis anticus, 77  
 bulbo-cavernosus, 146, 147  
 constrictor cunni, 147  
 coracobrachialis, 77  
 crureus, 160  
 deltoid, 72  
 extensor brevis digitorum, 168  
 pollicis, 83, 85  
 carpi radialis brevior, 82  
 longior, 82  
 ulnaris, 82  
 communis digitorum, 82  
 indicis, 83  
 longus digitorum, 166, 168  
 hallucis, 166  
 tendon of, 168  
 pollicis, 83, 85  
 minimi digiti, 82  
 of leg, 165  
 ossis metacarpi pollicis, 83, 85  
 fibular, 165, 166  
 flexor brevis digitorum, 169  
 carpi radialis, 82  
 ulnaris, 82  
 longus digitorum, 166  
 hallucis, 166  
 pollicis, 82  
 of leg, 165, 166  
 of thigh, 160  
 profundus digitorum, 82  
 sublimis digitorum, 82  
 gastrocnemius, 162, 166  
 gluteus maximus, 158  
 medius, 158  
 minimus, 158  
 gracilis, 160
- Muscle, Horner's, 44  
 hyoid, 62  
 iliopsoas, 157, 158  
 infraspinatus, 75, 76  
 latissimus dorsi, 72  
 levator ani scapulæ, 69  
 mylohyoid, 54  
 abscess and tumor above and below, 54  
 oblique, external, of abdomen, 120  
 inferior, 46  
 internal, of abdomen, 120  
 superior, 46  
 obturator externus, 159  
 internus, 158, 159  
 occipitofrontalis, 24  
 of abdominal wall, 120  
 of buttocks, 158  
 of eye, 45  
 of forearm, 82  
 of hip, 158  
 of leg, 165  
 of neck, 63  
 of thigh, 159  
 omohyoid, 69  
 orbicularis palpebrarum, 44  
 pectineus, 160  
 pectoralis major, 72  
 minor, 73  
 perinei, superficial transversus, 147  
 peroneus brevis, 166  
 longus, 166  
 tendon of, 168  
 tertius, 166  
 plantaris, 166  
 popliteal, bursa of, 165  
 popliteus, 166  
 prevertebral, 62  
 pronator quadratus, 82  
 radii teres, 82  
 pyriformis, 145, 158  
 quadratus femoris, 159  
 lumborum, 121  
 quadriceps, 160  
 extensor cruris, 159  
 rectus, 159  
 abdominis, 120  
 sartorius, 159  
 scalene, 62, 69  
 semimembranosus, 160  
 semitendinosus, 160  
 soleus, 166  
 sphincter ani, external, 164  
 splenius capitis et cervicis, 69
- Muscle, sternocleidomastoid, 62  
 subclavius, 73  
 supinator brevis, 82  
 longus, 82  
 supraspinatus, 75  
 tensor fasciæ latae, 159  
 teres minor, 76  
 tibialis anticus, 165  
 tendon of, 168  
 posticus, 166  
 transversalis abdominis, 121  
 triceps, 77  
 suræ, 165  
 vastus externus, 159  
 intermedius, 160  
 internus, 159
- Musculocutaneous nerve of brachial plexus, 75  
 of dorsum of foot, 169  
 of elbow, 79
- Musculophrenic artery, 94
- Musculospiral nerve, 75, 78, 80, 84  
 injury of, 84  
 paralysis of, 79
- Mylohyoid muscle, 54  
 abscess and tumor above and below, 54
- NARES, anterior, 48  
 posterior, 48
- Nasal cavity, 48  
 arteries of, 50  
 nerves of, 50  
 veins of, 50  
 duct, 45  
 fossa, floor of, 48  
 inner wall of, 48  
 outer wall of, 49  
 meatuses, 49  
 nerve, 48, 50  
 superior, 51  
 roof, fracture of, 23
- Naso-palatine nerve, 51
- Naso-pharynx, 57
- Neck, 61  
 muscles of, 63  
 skin of, 63  
 superficial median vein of, 68  
 tumors of, 62
- Nerve, abducent, 33, 47, 48  
 auditory, 33  
 auricularis magnus, 68, 71  
 auriculotemporal, 27



- Nerve, circumflex, 75  
 injury of, from subcoracoid dislocation, 73  
 communicans peronei, 163  
 poplitei, 163  
 cranial, points of exit, 21  
 crural, anterior, 123, 157, 161  
 cutaneous, external, of abdominal wall, 123  
 internal, 75  
 lesser, 75  
 of elbow, 79  
 cutaneus dorsi pedis intermedius, 167  
 lateralis, 169  
 medialis, 167  
 suræ lateralis, 163  
 medialis, 163  
 dental, inferior, 41  
 resection of, 41  
 descendens hypoglossi, 64  
 dorsal, first, 97  
 facial, 33, 65  
 fifth, superior maxillary division of, inferior dental branch of, 56  
 from lumbar plexus, 123  
 genitocrural, 123  
 glossopharyngeal, 65  
 lingual branch of, 56  
 gluteal, superior, 159  
 hypoglossal, 56, 64  
 iliohypogastric, 123, 139  
 ilio-inguinal, 123  
 infraorbital, 40  
 exposure of, 41  
 resection of, for neuralgia, 41  
 intercostal, 97  
 interosseous, anterior, 83  
 posterior, 84  
 lachrymal, 48  
 laryngeal, inferior, 66  
 left inferior, 113  
 maxillary, inferior, lingual branch of, 56  
 median, 78, 80, 83, 86, 87  
 injuries of, 83  
 inner head of, 75  
 outer head of, 75  
 paralysis of, 84  
 motor, of thoracic wall, 97  
 musculocutaneous, 75  
 of dorsum of foot, 169  
 of elbow, 79  
 musculospiral, 75, 78, 80, 84
- Nerve, musculospiral, injury of, 84  
 paralysis of, 79  
 nasal, 48, 50  
 superior, 51  
 nasopalatine, 51  
 obturator, 162  
 anterior branch of, 162  
 posterior branch of, 162  
 occipitalis major, 28  
 exposure of, 28  
 minor, 28, 68, 71  
 oculomotor, 33, 47  
 of abdominal wall, 123  
 of brain, 32  
 of dorsum of foot, 169  
 of face, 49  
 of forearm, 83  
 of mammary gland, 95  
 of nasal cavity, 50  
 of orbit, 46  
 of scalp, 27  
 ophthalmic, 47  
 optic, 45  
 peroneal, 163  
 phrenic, 71, 112, 116  
 of diaphragm, 99  
 plantar, external, 168, 169  
 internal, 168, 169  
 pneumogastric, of esophagus, 116  
 popliteal, external, 162, 163  
 internal, 162, 163  
 pudic, internal, 159  
 radial, 84  
 saphenous, long, 161, 163  
 short, 163, 169  
 sciatic, 161  
 great, 159  
 small, 159  
 sensory, of thoracic wall, 97  
 seventh cranial, 41  
 exposure of, 41  
 spinal accessory, 69  
 splanchnic, thoracic portion of, 117  
 subcostalis, 139  
 subscapular, 75  
 superficialis colli, 68, 71  
 supraclavicular, 69, 71  
 supraorbital, 27  
 neurectomy on, 27  
 suprascapular, 75  
 supratrochlear, 27  
 sympathetic, thoracic portion of, 117  
 thoracic, long, 75, 96
- Nerve, thoracic, twelfth, 139  
 tibial, anterior, 163, 167, 169  
 musculocutaneous, 163  
 posterior, 167  
 trifacial, 33  
 trochlear, 33, 47, 48  
 ulnar, 75, 78, 79, 80, 84, 86, 87  
 paralysis of, 84  
 vagus, 64  
 Neuralgia of mammary gland, 95  
 resection of infraorbital nerve for, 41  
 trifacial, 32  
 Neurectomy on supraorbital nerve, 27  
 New-growths in lateral wall of nose, 54  
 Nipple, 91  
 Nose, hemorrhage from, cause of, 23  
 lateral wall of, catarrh of, 54  
 new-growths in, 54  
 skin of, 50
- OBLIQUE muscle, inferior, 46  
 superior, 46  
 Obturator canal, 145, 146  
 externus muscle, 159  
 foramina, 145  
 internus muscle, 158, 159  
 nerve, 162  
 anterior branch of, 162  
 posterior branch of, 162  
 Occipital artery, 26  
 fontanelle, 20  
 foramen, 22  
 sinus, 32  
 vein, 27  
 Occipitalis major nerve, 28  
 exposure of, 28  
 minor nerve, 28, 68, 71  
 Occipitofrontalis muscle, 24  
 Oculomotor nerve, 33, 47  
 Olecranon, 79  
 Olfactory region, 50  
 Omega loop, 138  
 Omentum, gastrocolic, 126  
 gastrohepatic, 126  
 Omohyoid muscle, 69  
 Ophthalmic artery, 34, 39, 46  
 nerve, 47  
 vein, inferior, 46  
 superior, 46  
 Optic nerve, 33, 45  
 Oral cavity, 54



- Oral cavity, vestibule of, 54  
 Orbicular ligament, 81  
 Orbicularis palpebrarum muscle, 44  
 Orbit, nerves of, 46  
 Orbital cavity, 42  
   inner wall of, 42  
   lower wall of, 42  
   outer wall of, 43  
   upper wall of, 42  
   veins of, 46  
   fat, 45  
   septum, 44  
 Ovary, 153  
   suspensory ligament of, 154  
  
 PACCHIONIAN bodies, 18, 33  
 Palate, blood-supply of, 57  
   cleft, repairing, 57  
 Palatine artery, ascending, 40  
   posterior, 40  
 Palato-glossal arch, 57  
 Palato-pharyngeal arch, 57  
 Palm of hand, synovial sheaths of, 87  
 Palmar arch, deep, 86  
   superficial, 86  
   fascia, 85  
   interosseous arteries, 86  
 Palpebral conjunctiva, 44  
 Pancreas, 134  
 Pancreaticoduodenalis artery, inferior, 136  
 Papillas, lachrymal, 45  
 Paralysis of median nerve, 84  
   of musculospiral nerve, 79  
   of ulnar nerve, 84  
 Parasternal line, 90  
 Parietal branch of superficial temporal artery, 26  
   foramen, 22  
   pleura, 100  
 Parotid duct, 41, 54  
   gland, 41  
 Pars laryngea, 58  
   membranacea, 149  
   nasalis pharyngis, 57  
   oralis, 57, 58  
   prostatica, 149  
 Parumbilical veins, 122  
   congestion and dilatation of, 123  
 Patella, 164  
   "floats," 162  
 Patellar ligament, 164  
 Pectineus muscle, 160  
  
 Pectoralis major muscle, 72  
   minor muscle, 73  
 Pelvic axis, 144  
   brim, 119  
   cavity, anteroposterior diameter of, 144  
     in female, 150  
     in male, 147  
   contraction, plane of, anteroposterior diameter of, 144  
   curve, 144  
   inclination, 145  
   inlet, anteroposterior diameter of, 143  
   outlet, anteroposterior diameter of, 144  
   space, extravisceral portion of, 146  
     vessels and nerves of, 147  
     visceral portion of, 146  
   walls, 143  
     fracture of, 145  
 Pelvis, 143  
   diaphragm, 146  
   false, 143  
   internal conjugate diagonal diameter of, 144  
   obliquity of, 145  
   sagittal diameters of, 143  
   triangular ligament of, 146  
   true, 143, 145  
 Perforating artery, anterior, 94  
 Pericardiaco-phrenic artery, 99  
 Pericardial cavity, withdrawing fluid from, 111  
 Pericarditis, 110  
 Pericardium, 104, 108  
   relation to thoracic wall, 111  
   visceral, 108  
 Perichondritis of anterior wall of larynx, 66  
 Pericranium, 28  
   blood-supply of, 28  
 Perineal muscle, superficial transversus, 147  
 Perinephritic abscess, 141  
 Periorbita, 27, 44  
 Periproctitic abscess, 147  
 Perisplenitis, 133  
 Peritoneal cavity, 125  
   lesser, 125  
   ligaments, 125  
   pockets, 139  
   recesses, 139  
 Peritoneum, 125  
  
 Peritoneum, female, 152  
 Perityphlitic abscess, 137  
 Peroneal artery, 167  
   nerve, 163  
 Peroneus brevis muscle, 166  
   longus muscle, 166  
   muscle, tendon of, 168  
   tertius muscle, 166  
 Pes anserinus, 164  
 Petrosal sinus, inferior, 31  
   superior, 31  
 Pharyngeal recess, 57  
   tonsil, 57  
 Pharynx, 57  
   laryngeal portion of, 58  
   relation to cervical vertebrae, 58  
   tumors of, 59  
 Phrenic nerve, 71, 112, 116  
   of diaphragm, 99  
 Phthisis, narrow chest of, 93  
 Pia mater of brain, 33  
 Pisiform and cuneiform bones, articulation between, 88  
 Pit of stomach, 91  
 Plantar arch, 169  
   artery, external, 167, 169  
     internal, 167, 169  
   digital artery, 168  
   ligament, long, 170  
   nerve, external, 168, 169  
     internal, 168, 169  
 Plantaris muscle, 166  
 Pleura, 99  
   costal, 100  
   diaphragmatic, 99, 100  
   dome of, 100  
   mediastinal, 100  
   parietal, 100  
   pericardiaca, 108  
   relations to twelfth rib, 101  
   visceral, 100  
 Pleural cavity, 99  
   opening of, 97  
   exudate, left-sided, 111  
   limits, 100  
 Pleuritic pain, 123  
 Plexus, brachial, 73, 75, 97  
   internal cutaneous nerve of, 75  
   lesser internal cutaneous nerve of, 75  
   cervical, 68, 71  
   hemorrhoidal, stasis in, 123  
   lumbar, nerves from, 123  
   subcutaneous venous, of foot, 168



- Plexus venosus mammillæ, 95  
 Plica epigastrica, 121, 123  
   nervi laryngei, 58  
   umbilicalis media, 123  
 Pneumogastric nerves of esophagus, 116  
 Pneumopericardium, 108, 116  
 Pneumothorax, 100, 111, 116, 130  
 Point, McBurney's, 137  
 Pomum adami, 62  
 Popliteal artery, 163  
   nerve, external, 162, 163  
   internal, 162, 163  
   space, superficial structures of, 163  
   vein, 163  
 Popliteus muscle, 166  
   bursa of, 165  
 Porta hepatis, 122  
 Portal vein, 136  
 Posterior condyloid foramen, 22  
 Postero-lateral fontanelle, 20  
 Postpubic curve, 149  
 Prepatellar bursas, 165  
 Pressure-atrophy of sternum, 93  
 Prevertebral muscles, 62  
 Princeps pollicis artery, 86  
 Process, coracoid, 92  
 Profunda artery, inferior, 78  
   superior, 78  
   femoris artery, 161  
 Pronator quadratus muscle, 82  
   radii teres, 82  
 Prostate, enlargement of, effect on urethra, 149  
 Pterygopalatine artery, 40  
 Pubic region, 120  
 Pubocapsular ligament, 156  
 Pudic artery, deep external, 158  
   internal, 159  
   superficial external, 158  
   nerve, internal, 159  
 Pulmonary artery, 114  
   veins, 114  
 Pulsating exophthalmos, 31  
 Pulse of radial artery, 82  
 Puncta lachrymalia, 45  
 Pyemia from suppuration in middle ear, 59  
 Pylephlebitis, 131  
 Pyloric artery, 129  
 Pylorus, 128  
 Pyopericardium, 108  
 Pyothorax, 108, 111  
 Pyriform sinuses, 58  
 Pyriformis muscle, 145, 158  
 QUADRANGULAR space, 76  
 Quadratus femoris muscle, 159  
   lumborum muscle, 121  
 Quadriceps extensor cruris muscle, 159  
   muscle, 160  
 RACHITIS, chicken breast of, 93  
 Radial artery, 83, 86  
   pulse of, 82  
   nerve, 84  
 Radiocarpal articulation, 88  
 Radio-ulnar articulation, inferior, 88  
 Radix mesenterii, 126  
 Ramus cervicovaginalis artery, 151  
   plantaris profundus artery, 168  
 Ranine artery, 56  
 Ranula, 56  
 Recessus bulbosus, 149  
   duodenojejunalis, 139  
   ileocæcalis inferior, 139  
   superior, 139  
   infundibuliformis, 53  
   intersigmoideus, 139  
 Recto-uterine fold, 152  
 Rectovaginal fistula, 153  
   septum, 153, 154  
 Rectovesical fascia, 148  
 Rectum, carcinoma of, 150  
   female, 154  
   male, 150  
   lymphatic glands of, 150  
   relation to male bladder, 148  
 Rectus abdominis muscle, 120  
   externus muscle, 46  
   inferior muscle, 46  
   internus muscle, 46  
   muscle, 159  
   superior muscle, 46  
 Reid's base-line, 37  
 Resection of inferior dental nerve, 41  
   of infraorbital nerve for neuralgia, 41  
   of portion of rib, 97  
   subperiosteal, 97  
 Respiratory changes in position of lungs, 102  
 Rete articulare cubiti, 78  
   carpi dorsale, 83, 86  
   volare, 86  
 Retina, central artery of, 46  
 Retropharyngeal abscess, 58  
   from diseases of cervical vertebrae, 58  
 Retzius, fascia of, 121  
   space of, 148  
 Rib, fracture of, 97  
   resection of portion of, 97  
   twelfth, relations of pleura to, 101  
 Ribs, supernumerary, 91  
 Richter-Monro line, 122  
 Rivinus, duct of, 55  
 Rolando, line of, 38  
 Rosenmüller, fossa of, 53, 57  
   gland of, 157  
 Roser-Nélaton's line, 155  
 Rotter's dorso-radial fossa, 85  
 Round ligament (ligamentum teres), 126  
 Rupture of arachnoid, 33  
   of male bladder, 148  
 SACRAL curve, 150  
   triangle, 119  
 Sacrosciatic foramina, 145  
   ligaments, 145  
 Sacrum, 145  
 Saddle-joint, 88  
 Sagittal diameters of pelvis, 143  
 Santorini, foramen of, 22  
 Saphenous nerve, long, 161, 163  
   short, 163, 169  
   vein, internal, 157, 163  
   long, 163  
   short, 163  
 Sartorius muscle, 159  
 Scalene muscles, 62, 69  
   slit, 69  
   triangle, 69  
 Scalp, 24  
   arteries of, 26  
   blood supply of, 25  
   flap-like wounds of, 28  
   lymphatic vessels of, 27  
   nerves of, 27  
   suppuration beneath, 25  
   suppuration in, 25  
   veins of, 26  
   wounds of, 25  
 Scaphoid bone, 168  
 Scapula, angle of, inferior, 92  
   internal, 92  
 Scapular artery, posterior, 71  
   line, 90



- Scarpa's triangle, 160
- Sciatic artery, 159  
nerve, 161  
  great, 159  
  small, 159
- Scoliosis, 93
- Scrobiculus cordis, 91, 131
- Sectio alta, 151
- Sella turcica, tumors of, 24
- Semilunar cartilages, 164
- Semimembranosus muscle, 160
- Seminal vesicles, 148
- Semitendinosus muscle, 160
- Sensory nerves of thoracic wall, 97
- Septum, intermuscular, anterior, of  
  leg, 165  
  orbital, 44  
  rectovaginal, 153, 154  
  urethrovaginal, 152  
  vesicovaginal, 151
- Seventh cranial nerve, 41  
  exposure of, 41
- Sheaths, synovial, of palm of hand, 87
- Shoulder, 72  
  anterior region of, 73  
  posterior region of, 75
- Shoulder-joint, 76  
  capsular ligament of, 76
- Sigmoid arteries, 136  
  colon, 138  
  sinus, 30
- Sinus *alæ parvæ*, 32  
  cavernous, 31  
  circular, 31  
  costo-mediastinal, 100  
  costo-phrenic, 100  
  frontal, 19, 52  
    catarrh of, 19  
  lateral, 30, 31  
  longitudinal, inferior, 31  
    superior, 30  
  maxillary, 49, 51  
    tumors of, 52  
  occipital, 32  
  of dura mater of brain, 30  
  of Valsalva, 113  
  petrosal, inferior, 31  
    superior, 31  
  phrenicocostalis, 139  
  pyriform, 58  
  sigmoid, 30  
  sphenoidal, paired, 52  
  sphenoparietal, 32  
  straight, 31
- Sinus thrombosis, 31  
  cavernous, 31  
  from suppuration in middle ear,  
    59  
  transversus pericardii, 109
- Skin of abdomen, 120  
  of neck, 63  
  of nose, 50
- Skull, 17. See also *Cranium*.
- Slit, scalene, 69
- Snuff-box, 85, 86
- Socia parotidis, 41
- Sole of foot, 169
- Soleus muscle, 166
- Space of Tenon, 45  
  of Traube, 129
- Spatium interfasciale, 45
- Spermatic vessels, 141
- Spheno-ethmoidal recess, 53
- Sphenoidal sinuses, paired, 52
- Sphenopalatine artery, 40, 50
- Sphenoparietal sinus, 32
- Sphincter ani muscle, external, 146  
  pylori, 134
- Spinal accessory nerve, 69  
  curvature, thoracic deformities of,  
    93
- Spine, 92
- Splanchnic nerves, thoracic portion of,  
  117
- Spleen, 133  
  enlargement of, 133  
  floating, 134  
  inflammation of, 133
- Splenic artery, 130  
  vein, 133
- Splenius capitis et cervicis, 69
- Stasis in coronary vein of stomach, 123  
  in hemorrhoidal plexus, 123
- Stenosis of esophagus, 116  
  of thoracic aorta, 97
- Stenson's duct (parotid), 41, 54
- Sternal angle, 90  
  end of clavicle, backward disloca-  
    tion of, 94  
  foramen, mediastinal abscess rup-  
    turing through, 93  
  medico-legal aspects of, 93  
  line, 90  
  membrane, 93  
  region, 93
- Sternocleidomastoid muscle, 62
- Sternum, 93  
  pressure-atrophy of, 93
- Stomach, 128  
  anterior surface of, 128  
  arteries of, 129  
  cardiac opening of, 128  
  coronary vein of, stasis in, 123  
  fundus of, 128  
  greater curvature of, 128  
  pit of, 91  
  posterior surface of, 129  
  pyloric opening of, 128  
  veins of, 130
- Straight sinus, 31
- Striæ gravidarum, 120
- Stricture of male urethra, 149
- Stye, 44
- Subarachnoid space, effusions of blood  
  in, 33
- Subclavian artery, 62, 70  
  branches of, 70  
  right, 69  
  groove, 113  
  triangle, 69
- Subclavius muscle, 73
- Subcoracoid dislocation, 73  
  injury of circumflex nerve from,  
    73
- Subcostalis nerve, 139
- Subcutaneous bursa, 79  
  over tubercle of tibia, 165
- Subdeltoid bursa, 77
- Subepicranial tissue, 24
- Subhyoid region, 65
- Subinguinal region, lymphatic glands  
  in, 155
- Sublingual artery, 56  
  caruncle, 55  
  gland, 55
- Submaxillary gland, 65  
  lymphatic glands, 65  
  triangle, 65
- Submental artery, 40, 65  
  region, 63
- Subperiosteal resection, 97
- Subphrenic abscess, 132
- Subpubic curve, 149
- Subscapular artery, 74, 96  
  nerve, 75
- Sulcus intertubercularis, 76
- Superficialis colli nerve, 68, 71  
  volæ artery, 86
- Supernumerary ribs, 91  
  sutures, 20
- Supinator brevis muscle, 82  
  longus muscle, 82



- Suppuration beneath scalp, 25  
 in lymphatic glands alongside esophagus, 67  
 in middle ear, abscess in brain from, 59  
 cerebellar abscess from, 59  
 extending into mastoid antrum, 59  
 pyemia from, 59  
 sinus thrombosis from, 59  
 in scalp, 25  
 in thyroid gland, 67  
 of esophagus, 116  
 of mediastinum, 104
- Supraclavicular lymphatic glands, 69  
 nerves, 69, 71
- Suprahyoid region, 63
- Supraorbital artery, 26, 46  
 foramen, 27, 42  
 nerve, 27  
 neurectomy on, 27
- Suprapatellar bursa, 164
- Suprapyiform foramen, 146, 159
- Suprarenal bodies, 141
- Suprascapular artery, 70  
 nerve, 75
- Supraspinatus muscle, 75
- Supratrochlear nerve, 27
- Supravesical space, 148
- Suspensory ligament of ovary, 154
- Sutures, supernumerary, 20
- Sylvius, line of, 38
- Sympathetic nerve, thoracic portion of, 117
- Synchondrosis between manubrium and gladiolus, 93
- Synovial sheaths of palm of hand, 87
- TABATIÈRE**, 85, 86
- Tænia coli, 138
- Talma-Morrison operation for cirrhosis, 123
- Talocrural articulation, 169
- Talotarsal articulation, 170
- Tarsal artery, 168  
 cartilage, 44  
 ligaments, 44
- Tarsea lateralis artery, 169  
 mediales artery, 169
- Tegmen tympani, 35, 59  
 fracture of, 23
- Temporal artery, superficial, 25  
 frontal branch, 26
- Temporal artery, superficial, parietal branch, 26  
 bone, tympanic plate of, 59  
 vein, 27
- Temporo-maxillary vein, 40  
 posterior division of, 68
- Tendo Achillis, 165
- Tendon, biceps, 79, 162  
 of extensor longus digitorum muscle, 168  
 hallucis muscle, 168  
 of peroneus muscle, 168  
 of tibialis anticus muscle, 168
- Tendovaginitis, 85
- Tenon, space of, 45
- Tenosynovitis in hand, 87
- Tensor fasciæ latæ muscle, 159
- Tentorium cerebelli, 30, 35
- Teres minor, 76
- Thigh, 159  
 flexor muscles of, 160  
 muscles of, 159
- Thoracic aorta, intercostal branches of, 96  
 stenosis of, 97  
 artery, long, 75, 95  
 superior, 73, 95  
 ascending aorta, 113  
 deformities of spinal curvature, 93  
 duct, 117  
 nerve, long, 75, 96  
 twelfth, 139  
 space, horizontal lines of, 90  
 lower boundary of, 90  
 upper boundary of, 90  
 vertical lines of, 90  
 wall, 89  
 • lateral, 94  
 motor nerves of, 97  
 relation of pericardium to, 111  
 sensory nerves of, 97  
 veins of, 97
- Thoracicodorsalis artery, 74, 96
- Thoracocentesis, 101
- Thoraco-epigastric veins, 97
- Thorax, 89  
 bony, 92  
 contents of, 99  
 external boundaries of, 89  
 inferior boundary of, 98  
 inspection and palpation of, 91  
 internal boundaries of, 89  
 lower boundary of, 89  
 palpation and inspection of, 91
- Thorax, upper boundary of, 89
- Thrombosis, cavernous sinus, 31  
 sinus, 31  
 from suppuration in middle ear, 59
- Thumb, metacarpal bone of, with trapezium, articulation of, 88
- Thymus gland, 104, 112
- Thyrohyoid ligament, fat behind, 65  
 abscess of, 66
- Thyroid artery, inferior, 70  
 superior, 64  
 axis, 70  
 cartilage, 62  
 gland, 64, 66  
 isthmus of, 62  
 in children, 66  
 suppuration in, 67  
 region, 66  
 veins, inferior, 67
- Thyrotomy, 66
- Tibia, end of, 168
- Tibial artery, anterior, 163, 167  
 posterior, 163, 167  
 nerve, anterior, 163, 167, 169  
 musculocutaneous, 163  
 posterior, 167
- Tibialis anticus muscle, 165  
 tendon of, 168  
 posticus muscle, 166
- Tissue, subepicranial, 34
- Tongue, 56  
 lymphatic vessels of, 56
- Tonsil, 57  
 faucial, 57  
 pharyngeal, 57
- Tonsillotomy, hemorrhage after, 57
- Torus tubarius, 53, 57
- Trachea, 67, 104, 114  
 cervical portion of, 67  
 lymphatic glands of, 115  
 thoracic portion of, 67
- Tracheotomy, high, 66  
 low, 66
- Transversalis abdominis muscle, 121  
 colli artery, 70  
 fascia, 121
- Traube, space of, 129
- Triangle, carotid, 63  
 sacral, 119  
 scalene, 69  
 Scarpa's, 160  
 subclavian, 69  
 submaxillary, 65



- Triangular cartilage, 49  
   ligament of pelvis, 146  
   space, 76  
 Triceps muscle, 77  
   suræ muscle, 165  
 Trifacial nerve, 33  
   neuralgia, 32  
 Trigonum femorale, 160  
   omoclaviculare, 69  
   urogenitale, 146  
 Trochanter, 156  
   great, 155  
 Trochlea, 162  
 Trochlear nerve, 33, 47, 48  
 True pelvis, 143, 145  
 Tubercle, carotid, 63  
   epiglottic, 66  
 Tuberosity of ischium, 155  
 Tumors above and below mylohyoid  
   muscle, 54  
   of abdominal wall, 119  
   of base of cranium, 33  
   of kidney, 140  
   of lymphatic glands alongside of  
     esophagus, 67  
   of mammary gland, 95  
   of maxillary sinus, 52  
   of neck, 62  
   of pharynx, 59  
   of sella turcica, 24  
 Twelfth rib, relations of pleura to,  
   101  
   thoracic nerve, 139  
 Tympanic plate of temporal bone, 59
- ULCER of duodenum, 135  
 Ulnar artery, 80, 83, 86  
   nerve, 75, 78, 79, 80, 84, 86, 87  
   paralysis of, 84  
 Umbilical fascia, 121  
   region, central, 120  
 Upper extremity, 72  
 Ureter, abdominal portion of, 141  
   female, 151  
   male, 149  
 Urethra, female, 151  
   male, 149  
   effect of prostatic hypertrophy on,  
     149  
   narrow places of, 149  
   stricture of, 149  
   wide places of, 149  
 Urethrovaginal fistula, 153
- Urethrovaginal septum, 152  
 Uterus, anteversion of, 152
- VAGINA, 153  
   areas of, 153  
   inferior area of, 153  
   laceration of, 153  
   middle area of, 153  
   mucosa intertubercularis, 76  
   superior area of, 153  
 Vaginal vault, 153  
 Vagus nerve, 64  
 Valsalva, sinuses of, 113  
 Varices, esophageal, 123  
 Vas deferens, 124  
 Vasa intestini tenuis artery, 136  
 Vascular columns, 62  
 Vastus externus muscle, 159  
   intermedius muscle, 160  
   internus muscle, 159  
 Vein, angular, 40  
   auricular, posterior, 27  
   axillary, 73, 75  
   basilic, 79  
     median, 79  
   cephalic, 73, 79  
     median, 79  
   coronary, of stomach, stasis in, 123  
   costo-axillary, 97  
   cubital, median, 79  
   diploic, 18  
   epigastric, superficial, 122  
   ethmoidal, 50  
   facial, 40  
   frontal, 26  
   gastro-epiploica dextra, 130  
     sinistra, 130  
   hemiazgygos, 117  
   iliac, circumflex, superficial, 122  
   innominate, 112  
   left, 68  
   intercostal, 97  
     superior, 117  
   jugular, anterior, 68  
     external, 68  
     internal, 64, 68, 71  
       inferior bulb of, 71  
   lumbar, ascending, 122  
   occipital, 27  
   of abdominal wall, 122  
   of anger, 26  
   of esophagus, 116  
   of face, 40  
   of mammary gland, 95
- Vein of nasal cavity, 50  
   of orbital cavity, 46  
   of scalp, 26  
   of stomach, 130  
   of thoracic wall, 97  
   ophthalmic, inferior, 46  
     superior, 46  
   parumbilical, 122  
     congestion and dilatation of, 123  
   popliteal, 163  
   portal, 136  
   pulmonary, 114  
   saphenous, internal, 157, 163  
     long, 163  
     short, 163  
   splenic, 133  
   superficial median, of neck, 68  
   temporal, 27  
   temporo-maxillary, 40  
     posterior division of, 68  
   thoraco-epigastric, 97  
   thyroid, inferior, 67  
 Vena azygos major, 112, 114, 116, 122  
   minor, 117  
   cava, inferior, 142  
     superior, 112  
   coronaria ventriculi, 130  
   hemiazgygos, 104  
   thoraco-epigastrica tegumentosa  
     longa, 97  
 Venæ comites of abdominal wall, 122  
 Venous blood from brain, 18, 21  
 Vermiform appendix, 137  
   length and direction of, 137  
   relations to anterior abdominal  
     walls, 137  
   process, 136  
 Vertebra, cervical, diseases of, retro-  
   pharyngeal abscess from, 58  
   relation of pharynx to, 58  
   coccygeal, 145  
   prominens, 89  
 Vertebral artery, 34, 70  
 Vertical line, anterior, 37  
   middle, 38  
 Vesicles, seminal, 148  
 Vesico-uterine fold, 151, 152  
 Vesicovaginal fistula, 153  
   septum, 151  
 Vestibule of oral cavity, 54  
 Vestibulum nasi, 50  
   oris, 54  
 Vibrissæ, 50  
 Villi of arachnoid membrane, 33



Visceral columns, 62  
pericardium, 108  
pleura, 100  
portion of pelvic space, 146  
Vomer, 49

WHARTON, duct of, 55  
Winslow, foramen of, 125  
Wormian bones, 20  
Wounds, flap-like, of scalp, 28  
of scalp, 25

Wrist, anterior ligament at, 88  
external lateral ligament at, 88  
internal lateral ligament at, 88  
posterior ligament at, 88















---

---

**SAUNDERS' BOOKS**

— on —

**Practice, Pharmacy,  
Materia Medica, Thera-  
peutics, Pharmacology,  
and the Allied Sciences**

---

**W. B. SAUNDERS & COMPANY**

925 WALNUT STREET

PHILADELPHIA

NEW YORK

LONDON

Fuller Building, 5th Ave. and 23d St.

9, Henrietta Street, Covent Garden

---

---

**SAUNDERS' SUCCESSFUL PUBLISHING**

**A**S is well-known, the lists of most publishers contain a number of books that have never paid, and for which the publisher will never get back the money invested. Messrs. W. B. Saunders & Company would call attention to the fact that they have no such works on their list. In all the years of their business experience they have never published a book at a loss. This they confidently consider a most remarkable record, and submit the fact to the attention of the profession as an example of what might justly be called "Successful Publishing."

A Complete Catalogue of our Publications will be Sent upon Request

---

---



## AMERICAN EDITION

**NOTHNAGEL'S PRACTICE**

UNDER THE EDITORIAL SUPERVISION OF

**ALFRED STENGEL, M.D.**

Professor of Clinical Medicine in the University of Pennsylvania; Visiting  
Physician to the Pennsylvania Hospital.

It is universally acknowledged that the Germans lead the world in Internal Medicine; and of all the German works on this subject, Nothnagel's "Specielle Pathologie und Therapie" is conceded by scholars to be without question the best Practice of Medicine in existence. So necessary is this book in the study of Internal Medicine that it comes largely to this country in the original German. In view of these facts, Messrs. W. B. Saunders & Company have arranged with the publishers of the German edition to issue at once an authorized American edition of this great Practice of Medicine.

**BEST IN  
EXISTENCE**

For the present a set of 12 volumes, selected with especial thought of the needs of the practising physician, will be published. These volumes will contain the real essence of the entire work, and the purchaser will therefore obtain, at less than half the cost, the cream of the original. Later the special and more strictly scientific volumes will be offered from time to time.

**FOR THE  
PRACTITIONER**

The work will be translated by men possessing thorough knowledge of both English and German, and each volume will be edited by a prominent specialist. It will thus be brought thoroughly up to date, and the American edition will be more than a mere translation; for, in addition to the matter contained in the original, it will represent the very latest views of the leading American and English specialists in the various departments of Internal Medicine. Moreover, as each volume will be revised to the date of its publication by the eminent editor, the objection that has heretofore existed to treatises published in a number of volumes will be obviated, since the subscriber will receive the completed work while the earlier volumes are still fresh. The American publication of the entire work is under the editorial supervision of Dr. ALFRED STENGEL, who has selected the subjects for the American Edition, and has chosen the editors of the different volumes.

**PROMINENT  
SPECIALISTS**

The usual method of publishers when issuing a publication of this kind has been to require physicians to take the entire work. This seems to us in many cases to be undesirable. Therefore, in purchasing this Practice physicians will be given the opportunity of subscribing for it in entirety; but any single volume or any number of volumes, each complete in itself, may be obtained by those who do not desire the complete series. This latter method offers to the purchaser many advantages which will be appreciated by those who do not care to subscribe for the entire work at one time.

**VOLUMES SOLD  
SEPARATELY**

**SEE NEXT TWO PAGES FOR LIST**



## AMERICAN EDITION

**NOTHNAGEL'S PRACTICE**

VOLUMES NOW READY

Per volume: Cloth, \$5.00 net  
Half Morocco, \$6.00 net**Typhoid and Typhus Fevers**

By DR. H. CURSCHMANN, of Leipsic. The entire volume edited, with additions, by WILLIAM OSLER, M. D., F. R. C. P., Professor of the Principles and Practice of Medicine, Johns Hopkins University, Baltimore. Octavo, 646 pages, illustrated.

**Smallpox (including Vaccination), Varicella, Cholera Asiatica, Cholera Nostras, Erysipelas, Erysipeloid, Pertussis, and Hay Fever**

By DR. H. IMMERMANN, of Basle; DR. TH. VON JÜRGENSEN, of Tübingen; DR. C. LIEBERMEISTER, of Tübingen; DR. H. LENHARTZ, of Hamburg; and DR. G. STICKER, of Giessen. The entire volume edited, with additions, by SIR J. W. MOORE, M. D., F. R. C. P. I., Professor of Practice, Royal College of Surgeons, Ireland. Octavo, 682 pages, illustrated.

**Diphtheria, Measles, Scarlet Fever, and Röheln**

By WILLIAM P. NORTHRUP, M. D., of New York, and DR. TH. VON JÜRGENSEN, of Tübingen. The entire volume edited, with additions, by WILLIAM P. NORTHRUP, M. D., Professor of Pediatrics, University and Bellevue Hospital Medical College, New York. Octavo, 672 pages, illustrated, including 24 full-page plates, 3 in colors.

**Diseases of the Bronchi, Diseases of the Pleura, and Inflammations of the Lungs**

By DR. F. A. HOFFMANN, of Leipsic; DR. O. ROSENBACH, of Berlin; and DR. F. AUFRECHT, of Magdeburg. The entire volume edited, with additions, by JOHN H. MUSSER, M. D., Professor of Clinical Medicine, University of Pennsylvania. Octavo, 1029 pages, illustrated, including 7 full-page colored lithographic plates.

**Diseases of the Pancreas, Suprarenals, and Liver**

By DR. L. OSER, of Vienna; DR. E. NEUSSER, of Vienna, and DRs. H. QUINCKE and G. HOPPE-SEYLER, of Kiel. The entire volume edited, with additions, by REGINALD H. FRITZ, A. M., M. D., Hersey Professor of the Theory and Practice of Physic, Harvard University; and FREDERICK A. PACKARD, M. D., Late Physician to the Pennsylvania and Children's Hospitals. Octavo of 918 pages, illustrated.

**Diseases of the Stomach**

By DR. F. RIEGEL, of Giessen. Edited, with additions, by CHARLES G. STOCKTON, M. D., Professor of Medicine, University of Buffalo. Octavo of 835 pages, with 29 text-cuts and 6 full-page plates.

**Diseases of the Intestines and Peritoneum**

By DR. HERMANN NOTHNAGEL, of Vienna. The entire volume edited, with additions, by H. D. ROLLESTON, M. D., F. R. C. P., Physician to St. George's Hospital, London. Octavo of 1050 pages, finely illustrated.



AMERICAN EDITION

**NOTHNAGEL'S PRACTICE**

VOLUMES NOW READY

Per volume : Cloth, \$5.00 net  
Half Morocco, \$6.00 net**Tuberculosis and Acute General Miliary Tuberculosis**

By DR. G. CORNET, of Berlin. Edited, with additions, by WALTER B. JAMES, M. D., Professor of the Practice of Medicine, Columbia University, New York. Octavo of 806 pages.

**Diseases of the Blood** (*Anemia, Chlorosis, Leukemia, and Pseudoleukemia*)

By DR. P. EHRlich, of Frankfort-on-the-Main ; DR. A. LAZARUS, of Charlottenburg ; DR. K. VON NOORDEN, of Frankfort-on-the-Main ; and DR. FELIX PINKUS, of Berlin. The entire volume edited, with additions, by ALFRED STENGEL, M. D., Professor of Clinical Medicine, University of Pennsylvania. Octavo of 700 pages, with text-cuts and 13 full-page plates, 5 in colors.

**Malarial Diseases, Influenza, and Dengue**

By DR. J. MANNABERG, of Vienna, and DR. O. LEICHTENSTERN, of Cologne. The entire volume edited, with additions, by RONALD ROSS, F. R. C. S. (ENG.), D. P. H., F. R. S., Major, Indian Medical Service, retired ; Walter Myers, Lecturer, Liverpool School of Tropical Medicine, Liverpool ; and ALFRED S. GRUNBAUM, M. D., F. R. C. P., Lecturer on Experimental Medicine, University of Liverpool, Eng. Octavo of 700 pages, with 7 full-page lithographic plates in colors.

**Diseases of Kidneys and Spleen, and Hemorrhagic Diatheses**

By DR. H. SENATOR, of Berlin, and DR. M. LITTEN, of Berlin. The entire volume edited, with additions, by JAMES B. HERRICK, M. D., Professor of the Practice of Medicine, Rush Medical College. Octavo of 800 pages, illust.

**Diseases of the Heart**

By PROF. DR. L. VON SCHROTTER, of Vienna ; PROF. DR. TH. VON JURGENSEN, of Tübingen ; PROF. DR. L. KREHL, of Greifswald ; and PROF. DR. H. VIERORDT, of Tübingen. The entire volume edited, with additions, by GEORGE DOCK, M. D., Professor of Theory and Practice of Medicine and Clinical Medicine, University of Michigan, Ann Arbor. Octavo of about 1000 pages, with 72 text illustrations and 6 colored plates.

**SOME PRESS OPINIONS****London Lancet** (*Typhoid volume*)

"We welcome the translation into English of this excellent practice of medicine. The first volume contains a vast amount of useful information, and the forthcoming volumes are awaited with interest."

**Journal American Medical Association** (*Tuberculosis volume*)

"We know of no single treatise covering the subject so thoroughly in all its aspects as this great German work. . . . It is one of the most exhaustive, practical, and satisfactory works on the subject of tuberculosis."

**Medical News, New York** (*Liver volume*)

"Leaves nothing to be desired in the way of completeness of information, orderly arrangement of the text, thoroughgoing up-to-dateness, handiness for reference, and exhaustive discussion of the subjects treated."

**EACH VOLUME IS COMPLETE IN ITSELF AND IS SOLD SEPARATELY**



---

# Anders'

# Practice of Medicine

Sixth Revised Edition—Recently Issued

---

**A Text-Book of the Practice of Medicine.** By JAMES M. ANDERS, M. D., PH. D., LL. D., Professor of the Practice of Medicine and of Clinical Medicine, Medico-Chirurgical College, Philadelphia. Handsome octavo, 1295 pages, fully illustrated. Cloth, \$5.50 net; Sheep or Half Morocco, \$6.50 net.

### SIX EDITIONS IN SIX YEARS

The success of this work as a text-book and as a practical guide for physicians has been truly phenomenal, six large editions having been called for in as many years. The rapid exhaustion of each edition has made it possible to keep the book absolutely abreast of the times, so that Anders' Practice has become justly celebrated as the most up-to-date work on practice. In this edition Malaria, Yellow Fever, Bacillary Dysentery, Cholecystitis, and the use of the X-rays in Diagnosis and Treatment have been fully discussed, incorporating the results of the most recent investigations. Among the new subjects introduced are Paratyphoid Fever, the Fourth Disease, Trypanosomiasis, Orthostatic Albuminuria, Transcortical Aphasia, Adiposis Dolorosa, and Amaurotic Family Idiocy, particular attention being paid to clinical character, diagnosis, and treatment.

---

### PERSONAL OPINIONS

---

**James C. Wilson, M. D.,**

*Professor of the Practice of Medicine and of Clinical Medicine, Jefferson Medical College Philadelphia.*

"It is an excellent book—concise, comprehensive, thorough, and up-to-date. It is a credit to you; but, more than that, it is a credit to the profession of Philadelphia—to us."

**A. C. Cowperthwait, M. D.,**

*President Illinois Homeopathic Medical Association.*

"I consider Dr. Anders' book not only the best late work on Medical Practice, but by far the best that has ever been published. It is concise, systematic, thorough, and fully up-to-date in everything. I consider it a great credit to both the author and the publishers."

**Bulletin of the Johns Hopkins Hospital**

"The success of this work is well deserved. . . . The sections on treatment are excellent and add greatly to the value of this work. Dr. Anders is to be congratulated on the continued success of his text-book."



# Pusey and Caldwell on X-Rays in Therapeutics and Diagnosis

---

**The Practical Application of the Rontgen Rays in Therapeutics and Diagnosis.** By WILLIAM ALLEN PUSEY, A. M., M. D., Professor of Dermatology in the University of Illinois; and EUGENE W. CALDWELL, B. S., Director of the Edward N. Gibbs X-Ray Memorial Laboratory of the University and Bellevue Hospital Medical College, New York. Handsome octavo of 625 pages, with 200 illustrations, nearly all clinical. Cloth, \$5.00 net; Sheep or Half Morocco, \$6.00 net.

**RECENTLY ISSUED—NEW (2d) EDITION, REVISED AND ENLARGED  
TWO LARGE EDITIONS IN ONE YEAR**

Two large editions of this work within a year testify to its practical value to both the specialist and general practitioner. Throughout the work it has been the aim of the authors to elucidate the practical aspects of the subject, and to this end the text has been beautifully illustrated with clinical pictures, showing the condition before the use of the X-rays, at various stages of their application, and the final therapeutic result obtained. Details are also given regarding the use and management of the apparatus necessary for X-ray work, illustrating the descriptions with instructive photographs and drawings. In making the revision the histories of the cases cited have been brought down to the present time.

---

## OPINIONS OF THE MEDICAL PRESS

---

**British Journal of Dermatology**

"The most complete and up-to-date contribution on the subject of the therapeutic action of the Röntgen rays which has been published in English."

**Boston Medical and Surgical Journal**

"It is indispensable to those who use the X-rays as a therapeutic agent; and its illustrations are so numerous . . . that it becomes valuable to every one."

**New York Medical Journal**

"We have nothing but praise for this volume, the combined work of two authors than whom no one is better fitted by training or experience to write in his individual field."



---

## Sahli's Clinical Diagnosis

---

**Clinical Diagnosis.** By PROF. H. SAHLI, of Bern. Edited, with additions, by FRANCIS P. KINNICUTT, M. D., Professor of Clinical Medicine, Columbia University, N. Y.; and NATH'L BOWDITCH POTTER, M. D., Visiting Physician to the City Hospital and to the French Hospital; and Consulting Physician to the Manhattan State Hospital, N. Y. Octavo of 1100 pages, profusely illustrated.

### READY SOON

Dr. Sahli's great work, upon its publication in German, was immediately recognized as the most important work in its field. Not only are all methods of examination for the purpose of diagnosis exhaustively considered, but the explanation of clinical phenomena is given and discussed from physiologic as well as pathologic points of view. The examinations of the stomach, sputum, feces, urine, and blood are exhaustively treated. In the chemical examination much attention is directed to describing methods; and this is done so exactly that it will be possible for the clinician to work according to these directions. This American edition will contain all the new matter of the second German edition, with which it will simultaneously appear.

---

## Friedenwald and Ruhrah on Diet

---

**Diet in Health and Disease.** By JULIUS FRIEDENWALD, M. D., Clinical Professor of Diseases of the Stomach, and JOHN RUHRAH, M. D., Clinical Professor of Diseases of Children, College of Physicians and Surgeons, Baltimore. Octavo of 689 pages. Cloth, \$4.00 net.

### JUST ISSUED

This work contains a complete account of food-stuffs, their uses, and chemical composition. Dietetic management in all diseases in which diet plays a part in treatment is carefully considered, the articles on diet in diseases of the digestive organs containing numerous diet-lists and explicit instructions for administration. The feeding of infants and children, of patients before and after anesthesia and surgical operations, and the latest methods of feeding after gastro-intestinal operations are all taken up in detail. The subject of nutrient enemata is given completely with recipes and full instructions as to technic.



# Rolleston on the Liver

---

**Diseases of the Liver, Gall-bladder, and Bile-ducts.** By H. D. ROLLESTON, M. D. (CANTAB), F. R. C. P., Physician to St. George's Hospital, London, England. Octavo volume of 794 pages, fully illustrated, including a number in colors. Cloth, \$6.00 net.

**ENTIRELY NEW—JUST ISSUED**

This work covers the entire field of diseases of the liver, and is the most voluminous work on this subject in English. Dr. Rolleston has for many years past devoted his time exclusively to diseases of the digestive organs, and anything from his pen, therefore, is authoritative and practical. Special attention is given to pathology and treatment, the former being most profusely illustrated both with pictures of the gross appearances and with microphotographs. There are also a number of exceptionally beautiful and accurate colored plates. Dr. Rolleston's work will become the authority on diseases of the liver.

---

# Boston's Clinical Diagnosis

---

**Clinical Diagnosis.** By L. NAPOLEON BOSTON, M. D., Associate in Medicine and Director of the Clinical Laboratories, Medico-Chirurgical College, Philadelphia. Octavo of 549 pages, with 320 illustrations, many in colors. Cloth, \$4.00 net.

**A NEW WORK—JUST ISSUED**

The clinical examination of sputum, feces, blood, etc. has assumed such an important place in practice that a thorough knowledge of the significance of chemic and microscopic laboratory findings becomes absolutely necessary to successful therapeutics. Dr. Boston here presents a practical manual of the clinical and laboratory examinations which furnish a guide to correct diagnosis, giving only such methods, however, which can be carried out by the busy practitioner in his office as well as by the student in the laboratory. The chapter on Serum Diagnosis is particularly complete.



GET  
THE BEST

# American Illustrated Dictionary

THE NEW  
STANDARD

Third Revised Edition—Recently Issued

**The American Illustrated Medical Dictionary.** A new and complete dictionary of the terms used in Medicine, Surgery, Dentistry, Pharmacy, Chemistry, and kindred branches; with over 100 new and elaborate tables and many handsome illustrations. By W. A. NEWMAN DORLAND, M. D., Editor of "The American Pocket Medical Dictionary." Large octavo, nearly 800 pages, bound in full flexible leather. Price, \$4.50 net; with thumb index, \$5.00 net.

**Gives a Maximum Amount of Matter in a Minimum Space, and at the Lowest Possible Cost**

**THREE EDITIONS IN THREE YEARS—WITH 1500 NEW TERMS**

The immediate success of this work is due to the special features that distinguish it from other books of its kind. It gives a maximum of matter in a minimum space and at the lowest possible cost. Though it is practically unabridged, yet by the use of thin bible paper and flexible morocco binding it is only  $1\frac{3}{4}$  inches thick. The result is a truly luxurious specimen of book-making. In this new edition the book has been thoroughly revised, and upward of fifteen hundred new terms that have appeared in recent medical literature have been added, thus bringing the book absolutely up to date. The book contains hundreds of terms not to be found in any other dictionary, over 100 original tables, and many handsome illustrations, a number in colors.

## PERSONAL OPINIONS

**Howard A. Kelly, M. D.,**

*Professor of Gynecology, Johns Hopkins University, Baltimore.*

"Dr. Dorland's dictionary is admirable. It is so well gotten up and of such convenient size. No errors have been found in my use of it."

**Roswell Park, M. D.,**

*Professor of Principles and Practice of Surgery and of Clinical Surgery, University of Buffalo.*

"I must acknowledge my astonishment at seeing how much he has condensed within relatively small space. I find nothing to criticize, very much to commend, and was interested in finding some of the new words which are not in other recent dictionaries."



# Stevens' Materia Medica and Therapeutics

---

**A Text-Book of Modern Materia Medica and Therapeutics.** By A. A. STEVENS, A. M., M. D., Lecturer on Physical Diagnosis in the University of Pennsylvania. Handsome octavo volume of 663 pages, Cloth, \$3.50 net.

## JUST ISSUED—THIRD EDITION, REWRITTEN AND ENLARGED

Since the appearance of the last edition of this book such rapid advances have been made in Materia Medica, Therapeutics, and the allied sciences that the author felt it imperative to rewrite the work entirely. All the newer remedies that have won approval by recognized authorities have been incorporated, and their therapeutic properties fully discussed, thus bringing the book absolutely down to date. The work includes the following sections: Physiologic Action of Drugs; Drugs; Remedial Measures other than Drugs; Applied Therapeutics; Incompatibility in Prescriptions; Table of Doses; Index of Drugs; and Index of Diseases; the treatment being elucidated by more than two hundred formulæ.

---

## OPINIONS OF THE MEDICAL PRESS

---

### University Medical Magazine

"The author has faithfully presented modern therapeutics in a comprehensive work . . . and it will be found a reliable guide and sufficiently comprehensive for the physician in practice."

### Bristol Medico-Chirurgical Journal, Bristol

"This addition to the numerous works on Therapeutics is distinctly a good one. . . . It is to be recommended as being systematic, clear, concise, very fairly up to date, and carefully indexed."

---

## Monro's Manual of Medicine

Just Issued

Manual of Medicine. By THOMAS KIRKPATRICK MONRO, M. A., M. D., Fellow of, and Examiner to, the Faculty of Physicians and Surgeons, England; Glasgow Physician to Glasgow Royal Infirmary, Glasgow, etc. Octavo volume of 901 pages, illustrated. Cloth, \$5.00 net.



---

## Hatcher and Sollmann's Materia Medica

**A Text-Book of Materia Medica:** including Laboratory Exercises in the Histologic and Chemic Examination of Drugs. By ROBERT A. HATCHER, Ph. G., M. D., of Cornell University Medical School, New York City; and TORALD SOLLMANN, M. D., of the Western Reserve University, Cleveland, Ohio. 12mo of 411 pages. Flex. leather, \$2.00 net.

### JUST ISSUED—A NEW WORK

This work is a practical text-book, treating the subject by actual experimental demonstrations. Part I. comprises a guide to the study of crude drugs, both official and unofficial. In Parts II. and III. the histologic and chemic examinations of drugs are considered in a scientific, yet clear and simple manner.

---

## Eichhorst's Practice

**A Text-Book of the Practice of Medicine.** By DR. HERMANN EICHHORST, University of Zurich. Translated and edited by AUGUSTUS A. ESHNER, M. D., Professor of Clinical Medicine, Philadelphia Polyclinic. Two octavos of 600 pages each, with over 150 illustrations. Per set: Cloth, \$6.00 net; Sheep or Half Morocco, \$7.50 net.

### Bulletin of Johns Hopkins Hospital

"This book is an excellent one of its kind. Its completeness, yet brevity, the clinical methods, the excellent paragraphs on treatment and watering-places, will make it very desirable."

---

## Bridge on Tuberculosis

**Tuberculosis.** By NORMAN BRIDGE, A. M., M. D., Emeritus Professor of Medicine in Rush Medical College, in affiliation with the University of Chicago. 12mo of 302 pages, illustrated. Cloth, \$1.50 net.

### Medical News, New York

"Thoroughly representative of our practical methods of diagnosis and treatment of the disease."



# Thornton's Dose-Book

**Dose-Book and Manual of Prescription-Writing.** By E. Q. THORNTON, M. D., Assistant Professor of Materia Medica, Jefferson Medical College, Phila. Post-octavo, 362 pages, illustrated. Flexible Leather, \$2.00 net.

## Second Edition, Revised and Enlarged

In the new edition of this work, intended for the student and practitioner, additions have been made to the chapters on "Prescription-Writing" and "Incompatibilities," and references have been introduced in the text to the newer curative sera, organic extracts, synthetic compounds, and vegetable drugs. To the Appendix, chapters upon Synonyms and Poisons and their antidotes have been added, thus increasing its value as a book of reference.

**C. H. Miller, M. D.,**

*Professor of Pharmacology, Northwestern University Medical School, Chicago.*

"I will be able to make considerable use of that part of its contents relating to the correct terminology as used in prescription-writing, and it will afford me much pleasure to recommend the book to my classes, who often fail to find this information in their other text-books."

---

## Barton and Wells' Thesaurus

**A Thesaurus of Medical Words and Phrases.** By WILFRED M. BARTON, M. D., Assistant to Professor of Materia Medica and Therapeutics, Georgetown University, Washington, D. C.; and WALTER A. WELLS, M. D., Demonstrator of Laryngology, Georgetown University, Washington, D. C. 12mo of 534 pages. Flexible leather, \$2.50 net; with thumb index, \$3.00 net.

"We can easily see the value of such a book, and can certainly recommend it to our readers."—BOSTON MEDICAL AND SURGICAL JOURNAL.

---

## Mathews' How to Succeed in Practice

**How to Succeed in the Practice of Medicine.** By JOSEPH M. MATHEWS, M. D., LL.D., President American Medical Association, 1898-'99. 12mo of 215 pages, illustrated. Cloth, \$1.50 net.

---

## Jelliffe's Pharmacognosy

**Just Issued**

An Introduction to Pharmacognosy. By SMITH ELY JELLIFFE, PH. D., M. D., Professor of Pharmacognosy and Instructor in Materia Medica and Therapeutics in Columbia University (College of Physicians and Surgeons), New York. Octavo of 265 pages, illustrated. Cloth, \$2.50 net.



---

# Gould and Pyle's Curiosities of Medicine

---

**Anomalies and Curiosities of Medicine.** By GEORGE M. GOULD, M.D., and WALTER L. PYLE, M.D. An encyclopedic collection of rare and extraordinary cases and of the most striking instances of abnormality in all branches of Medicine and Surgery, derived from an exhaustive research of medical literature from its origin to the present day, abstracted, classified, annotated, and indexed. Handsome octavo volume of 968 pages, 295 engravings, and 12 full-page plates.

**Popular Edition: Cloth, \$3.00 net; Sheep or Half Morocco, \$4.00 net.**

As a complete and authoritative Book of Reference this work will be of value not only to members of the medical profession, but to all persons interested in general scientific, sociologic, and medicolegal topics; in fact, the absence of any complete work upon the subject makes this volume one of the most important literary innovations of the day.

**The Lancet, London**

"The book is a monument of untiring energy, keen discrimination, and erudition. . . . We heartily recommend it to the profession."

---

## Saunders' Pocket Formulary

**Just Issued—New (7th) Edition—With 460 New Formulas**

---

**Saunders' Pocket Medical Formulary.** By WILLIAM M. POWELL, M.D., author of "Essentials of Diseases of Children"; Member of Philadelphia Pathological Society. Containing 1831 formulas from the best-known authorities. With an Appendix containing Posological Table, Formulas and Doses for Hypodermic Medication, Poisons and their Antidotes, Diameters of the Female Pelvis and Fetal Head, Obstetrical Table, Diet-list, Materials and Drugs used in Antiseptic Surgery, Treatment of Asphyxia from Drowning, Surgical Remembrancer, Tables of Incompatibles, Eruptive Fevers, etc., etc. In flexible morocco, with side index, wallet, and flap. \$1.75 net.

**Johns Hopkins Hospital Bulletin**

"Arranged in such a way as to make consultation of it as easy as possible. It is remarkable how much information the author has succeeded in getting into so small a book."



---

# Sollmann's Pharmacology

Including Therapeutics, Materia Medica, Pharmacy,  
Prescription-writing, Toxicology, etc.

---

**A Text-Book of Pharmacology.** By TORALD SOLLMANN, M. D., Assistant Professor of Pharmacology and Materia Medica, Medical Department of Western Reserve University, Cleveland, Ohio. Handsome octavo volume of 894 pages, fully illustrated. Cloth, \$3.75 net.

## A NEW WORK—RECENTLY ISSUED

This work aims to furnish a scientific discussion and definite conception of the action of drugs, as well as their derivation, composition, strength, and dose. The author bases the study of therapeutics on a systematic knowledge of the nature and properties of drugs, and thus brings out forcibly the intimate relation between pharmacology and practical medicine.

**J. F. Fotheringham, M. D.**

*Prof. of Therapeutics and Theory and Practice of Prescribing, Trinity Med. College, Toronto.*

"The work certainly occupies ground not covered in so concise, useful, and scientific a manner by any other text I have read on the subjects embraced."

---

# Butler's Materia Medica Therapeutics, and Pharmacology

---

**A Text-Book of Materia Medica, Therapeutics, and Pharmacology.** By GEORGE F. BUTLER, PH. G., M. D., late Prof. of Materia Medica and of Clinical Medicine, College of Physicians and Surgeons, Chicago, Octavo, 896 pages, illustrated. Cloth, \$4.00 net; Sheep or Half Morocco, \$5.00 net.

## FOURTH EDITION, REVISED AND ENLARGED

In this new edition the chapters on Organo-therapy, Serum-therapy, and cognate subjects have been enlarged and carefully revised. An important addition is the chapter devoted to the newer theories of electrolytic dissociation and its relation to the topic of pharmacotherapy.

**Medical Record, New York**

"Nothing has been omitted by the author which, in his judgment, would add to the completeness of the text, and the student or general reader is given the benefit of latest advices bearing upon the value of drugs and remedies considered."



**The American Pocket Medical Dictionary. 4th Ed. Recently Issued**

THE AMERICAN POCKET MEDICAL DICTIONARY. Edited by W. A. NEWMAN DORLAND, M. D., Assistant Obstetrician to the Hospital of the University of Pennsylvania. Containing the pronunciation and definition of the principal words used in medicine and kindred sciences, with 64 extensive tables. Flexible leather, with gold edges, \$1.00 net; with thumb index, \$1.25 net.

"I can recommend it to our students without reserve."—J. H. Holland, M. D., *Dean of the Jefferson Medical College, Philadelphia.*

**Vierordt's Medical Diagnosis. Fourth Edition, Revised**

MEDICAL DIAGNOSIS. By DR. OSWALD VIERORDT, Professor of Medicine, University of Heidelberg. Translated from the fifth enlarged German edition by FRANCIS H. STUART, A. M., M. D. Octavo, 603 pages, 104 wood cuts. Cloth, \$4.00 net; Sheep or Half Morocco, \$5.00 net.

"Has been recognized as a practical work of the highest value. It may be considered indispensable both to students and practitioners."—F. Minot, M. D., *late Professor of Theory and Practice in Harvard University.*

**Cohen and Eshner's Diagnosis. Second Revised Edition**

ESSENTIALS OF DIAGNOSIS. By S. SOLIS-COHEN, M. D., Senior Assistant Professor in Clinical Medicine, Jefferson Medical College, Phila.; and A. A. ESHNER, M. D., Professor of Clinical Medicine, Philadelphia Polyclinic. Post-octavo, 382 pages; 55 illustrations. Cloth, \$1.00 net. *In Saunders' Question-Compend Series.*

"Concise in the treatment of subject, terse in expression of fact."—*American Journal of the Medical Sciences.*

**Morris' Materia Medica and Therapeutics. Sixth Revised Edition**

ESSENTIALS OF MATERIA MEDICA, THERAPEUTICS, AND PRESCRIPTION-WRITING. By HENRY MORRIS, M. D., late Demonstrator of Therapeutics, Jefferson Medical College, Phila. Post-octavo, 250 pages. Cloth, \$1.00 net. *In Saunders' Question-Compend Series.*

"Cannot fail to impress the mind and instinct in a lasting manner."—*Buffalo Medical Journal.*

**Williams' Practice of Medicine****Just Ready**

ESSENTIALS OF THE PRACTICE OF MEDICINE. By W. R. WILLIAMS, M. D., formerly Instructor in Medicine and Lecturer on Hygiene, Cornell University; and Tutor in Therapeutics, Columbia University, N. Y. 12mo of 456 pages, illustrated. *In Saunders' Question-Compend Series.* Double number, \$1.75 net.

**Brockway's Medical Physics. Second Edition, Revised**

ESSENTIALS OF MEDICAL PHYSICS. By FRED. J. BROCKWAY, M. D., late Assistant Demonstrator of Anatomy, College of Physicians and Surgeons, N. Y. Post-octavo, 330 pages; 155 fine illustrations. Cloth, \$1.00 net. *In Saunders' Question-Compend Series.*

"It contains all that one need know on the subject, is well written, and is copiously illustrated."—*Medical Record, New York.*

**Stoney's Materia Medica for Nurses****Just Issued  
Second Revised Edition**

MATERIA MEDICA FOR NURSES. By EMILY A. M. STONEY, Superintendent of the Training School for Nurses at the Carney Hospital, South Boston, Mass. Handsome 12mo volume of 300 pages. Cloth, \$1.50 net.

"It contains about everything that a nurse ought to know in regard to drugs."—*Journal of the American Medical Association.*

**Grafstrom's Mechano-therapy****Just Issued  
Second Edition, Enlarged**

A TEXT-BOOK OF MECHANO-THERAPY (Massage and Medical Gymnastics). By AXEL V. GRAFSTROM, B. Sc., M. D., Attending Physician to Augustus Adolphus Orphanage, Jamestown, N. Y. 12mo, 200 pages, illustrated. \$1.25 net.

"Certainly fulfills its mission in rendering comprehensible the subjects of massage and medical gymnastics."—*New York Medical Journal.*



### Jakob and Eshner's Internal Medicine and Diagnosis

ATLAS AND EPITOME OF INTERNAL MEDICINE AND CLINICAL DIAGNOSIS. By DR. CHR. JAKOB, of Erlangen. Edited, with additions, by A. A. ESHNER, M. D., Professor of Clinical Medicine, Philadelphia Polyclinic. With 182 colored figures on 68 plates, 64 text-illustrations, 259 pages of text. Cloth, \$3.00 net. *In Saunders' Hand-Atlas Series.*

"Can be recommended unhesitatingly to the practicing physician no less than to the student."—*Bulletin of Johns Hopkins Hospital.*

### Lockwood's Practice of Medicine.

Second Edition,  
Revised and Enlarged

A MANUAL OF THE PRACTICE OF MEDICINE. By GEO. ROE LOCKWOOD, M. D., Attending Physician to the Bellevue Hospital, New York City. Octavo, 847 pages, with 79 illustrations in the text and 22 full-page plates. Cloth, \$4.00 net.

"A work of positive merit, and one which we gladly welcome."—*New York Medical Journal.*

### Salinger and Kalteyer's Modern Medicine

MODERN MEDICINE. By JULIUS L. SALINGER, M. D., late Ass't Prof. of Clinical Medicine, Jefferson Medical College; and F. J. KALTEYER, M. D., Demonstrator of Clinical Medicine, Jefferson Medical College. Handsome octavo, 801 pages, illustrated. Cloth, \$4.00 net.

"I have carefully examined the book, and find it to be thoroughly trustworthy in all respects and a valuable text-book for the medical student."—*Sam'l O. L. Potter, Formerly Professor of Principles and Practice of Medicine, Cooper Medical College, San Francisco.*

### Keating's Life Insurance

HOW TO EXAMINE FOR LIFE INSURANCE. By the late JOHN M. KEATING, M. D., Ex-President of the Association of Life Insurance Medical Directors. Royal octavo, 211 pages. With numerous illustrations. Cloth, \$2.00 net.

"This is by far the most useful book which has yet appeared on insurance examination."—*Medical News.*

### Corwin's Physical Diagnosis. Third Edition, Revised

ESSENTIALS OF PHYSICAL DIAGNOSIS OF THE THORAX. By A. M. CORWIN, A. M., M. D., Professor of Physical Diagnosis, College of Physicians and Surgeons, Chicago. 220 pages, illustrated. Cloth, flexible covers, \$1.25 net.

"A most excellent little work. It arranges orderly and in sequence the various objective phenomena to logical solution of a careful diagnosis."—*Journal of Nervous and Mental Diseases.*

### American Text-Book of Theory and Practice

AMERICAN TEXT-BOOK OF THE THEORY AND PRACTICE OF MEDICINE. Edited by the late WILLIAM PEPPER, M. D., LL. D., Professor of the Theory and Practice of Medicine and of Clinical Medicine, University of Penna. Two handsome imperial octavos of about 1000 pages each. Illustrated. Per volume: Cloth, \$5.00 net; Sheep or Half Morocco, \$6.00 net.

"I am quite sure it will command itself both to practitioners and students of medicine, and become one of our most popular text-books."—*Alfred Loomis, M. D., LL. D., Professor of Pathology and Practice of Medicine, University of the City of New York.*

### Stevens' Practice of Medicine. Sixth Edition, Revised—Recently Issued

A MANUAL OF THE PRACTICE OF MEDICINE. By A. A. STEVENS, A. M., M. D., Professor of Pathology, Woman's Medical College, Phila. Specially intended for students preparing for graduation and hospital examinations. Post-octavo, 556 pages; illustrated. Flexible leather, \$2.25 net.

"An excellent condensation of the essentials of medical practice for the student, and may be found also an excellent reminder for the busy physician."—*Buffalo Medical Journal.*











QM 531

Schulze

Johannh.

Seite 1  
cop. 2.



