Practical surgery for the general practitioner / by Nicholas Senn.

Contributors

Senn, Nicholas, 1844-1908.
Augustus Long Health Sciences Library

Publication/Creation

Philadelphia : W.B. Saunders, 1901.

Persistent URL

https://wellcomecollection.org/works/k4z32x4t

License and attribution

This material has been provided by This material has been provided by the Augustus C. Long Health Sciences Library at Columbia University and Columbia University Libraries/Information Services, through the Medical Heritage Library. The original may be consulted at the the Augustus C. Long Health Sciences Library at Columbia University and Columbia University. where the originals may be consulted.
This work has been identified as being free of known restrictions under copyright law, including all related and neighbouring rights and is being made available under the Creative Commons, Public Domain Mark.

You can copy, modify, distribute and perform the work, even for commercial purposes, without asking permission.

wellcome collection

Wellcome Collection
183 Euston Road
London NW1 2BE UK
T +44 (0)20 7611 8722
E library@wellcomecollection.org
https://wellcomecollection.org

COLUMBIA LIBRARIES OFFSITE
HEALTH SCIENCES STANDARD
HX64051579
RD31 Se52 1901 Practical surgery fo

S. A. Spilman, M. D.
Ottumwa, Ia.

RD 31 Se 52

Columbia University
in the City of New York
COLLEGE OF
PHYSICIANS AND SURGEONS
LIBRARY

S. A. Spilman

July 1st 1901.

Digitized by the Internet Archive
in 2010 with funding from
Open Knowledge Commons (for the Medical Heritage Library project)

http://www.archive.org/details/practicalsurgery00senn

COLUMBIA
UNIVERSITY
MEDICAL LIBRARY

Practical Surgery

For the General Practitioner

BY

NICHOLAS SENN, M.D., Ph.D., LL.D.

Professor of Surgery, Rush Medical College, in affiliation with the University of Chicago; Attending Surgeon to the Presbyterian Hospital; Surgeon-in-Chief, St. Joseph's Hospital; Professional Lecturer on Military Surgery, University of Chicago; Surgeon-General of the State of Illinois.

With 650 Illustrations, many of them in Colors

PHILADELPHIA AND LONDON

W. B. SAUNDERS & COMPANY

1901

Copyright, 1901, by W. B. Saunders & Company

Registered at Stationers' Hall, London, England

RD31
Se52

PRESS OF
W. B. SAUNDERS & COMPANY
PHILADELPHIA

THIS BOOK

IS RESPECTFULLY DEDICATED BY THE AUTHOR

TO

LEVI C. LANE

Professor of Surgery in the Cooper Medical College, San Francisco

The erudite scholar, the popular and successful teacher, the eminent author, and the pioneer of modern surgery on the Pacific slope

AND TO

THE GENERAL PRACTITIONERS OF THIS COUNTRY

for whose interests and instruction the work has been written

PREFACE.

THIS book is not intended to cover the whole field of surgery. Its contents are devoted to those sections of surgery that are of especial interest to the general practitioner. Injuries and acute surgical diseases usually first come under the treatment of the general practitioner, and as the fate of the patient often depends on the efficiency of the first aid rendered, it is evident that the attending physician should be thoroughly trained and competent in everything that pertains to emergency work. The average medical student is more interested in surgery than in medicine, and the surgical training he receives ought to qualify him to treat all kinds of emergency cases with credit to himself and with benefit to his patients. Neglect and mistakes made in this department of professional work are often difficult to balance and correct later. The general practitioner should never lose interest in the surgical work that naturally belongs to him, and should endeavor to keep abreast of the advances and improvements that are constantly being made. His surgical field, although limited, is yet a very important one, and fraught with great responsibilities. He must be familiar with surgical diagnosis, and must acquire sufficient surgical technic to enable him to act wisely and safely in all surgical cases in which immediate action is an absolute necessity to the preservation of life or to the protection of the patient against remote disastrous complications.

The physician who is qualified to practise emergency surgery should never forget that he must keep himself in readiness to respond to an urgent message, and in doing so he adopts and follows the motto of this book: "*Semper paratus.*"

Familiar with the needs of the general practitioner as a surgeon, the author has aimed to simplify and lighten his often trying work by limiting the scope of the book to a discussion of only those subjects that come within the legitimate sphere of the daily routine work of every practising physician. He has taken the liberty to quote freely from his own experimental and literary productions on all occasions where it appeared to him advisable to do so. Some of the subjects have been treated at great length, for which no other apology is made than their great clinical and surgical importance to the general practitioner. Intestinal surgery is given a prominent place, and the consideration of this subject is based on the operative experience of the author for a quarter of a century.

The text is profusely illustrated, with the hope that this feature will add to the value of the book as a guide in practice. Sixty-four of the original illustrations, a number of them colored, were made by Mr. C. F. W. Eberhard, who is entitled to much credit for his excellent work. Many of the illustrations are original, and others have been selected from sources not readily accessible to the average practitioner.

As books of reference utilized in the preparation of this work, the following deserve special mention: von Esmarch, "Handbuch der Kriegschirurgischen Technik"; von Esmarch and Kowalzig, "Chirurgische Technik"; von Bruns, "Die Lehre von den Knochenbrüchen"; Hoffa, "Lehrbuch der Fracturen und Luxationen."

The material for the sections on Military Surgery and Gunshot Wounds was gathered from the author's observations and experiences during the Greco-Turkish and Spanish-American wars.

Much credit is due to the publishers for their liberality in illustrating the book so profusely, and to Dr. Charles Adams for careful proofreading.

CONTENTS.

CHAPTER I.

PAGE

EMERGENCY AND MILITARY SURGERY 17

CHAPTER II.

TRAUMATIC SHOCK 28

CHAPTER III.

GENERAL ANESTHESIA 40

Chloroform Anesthesia, 44—Preparations for Anesthesia, 45—Accidents during Narcosis, 50—Artificial Respiration, 53—Ether Anesthesia, 56—Local Anesthesia, 58—Schleich's Solution, 61—Eucain, 61.

CHAPTER IV.

PROPHYLACTIC HEMOSTASIS 62

Elevation, 63—Elastic Constriction, 64—Special Localities for Elastic Constriction as a Prophylactic Hemostatic: Hip-joint, 73—Shoulder-joint, 81—Head, 81—Manual Compression of the Aorta, 82—Digital Compression, 84—Preliminary Ligation of Arteries in their Continuity, 85—Temporary Ligation of Arteries, 86—Galvanocautery and Thermocautery, 88—Angiotripsy, 88—Spanish Windlass, 89—Ecraseur, 89.

CHAPTER V.

TREATMENT OF HEMORRHAGE 90

Classification, 91—Spontaneous Arrest of Hemorrhage, 94—Symptoms and Diagnosis, 95—Treatment, 96—Vessel Suture, 122—Arterial Invagination, 126—Torsion, 127—Forcipressure, 128—Actual Cautery, 128—Hot Water, 129—Steam, 130—Cold, 131—Acupressure, 131—Aseptic Tamponade, 131—Wound Suture, 132—Electricity, 133—Styptics, 133—Hemorrhage from Bone, 134—General Treatment, 134.

CHAPTER VI.

WOUNDS 142

Incised Wounds, 145—Lacerated Wounds, 147—Contused Wounds, 148—Stab Wounds, 150—Punctured Wounds, 150—Gunshot Wounds, 152—Poisoned Wounds, 152—Repair of Wounds, 153—Primary Intention, 154—Secondary Intention, 156—Wound Infection, 157—Prevention of Infection, 164—Operating Room, 164—Hand Disinfection, 169—Disinfection of Field of Injury, 172—Sterilization of Instruments, 174—Aseptic and Antiseptic Dressing Material, 180—Antipyogenic Agents, 184—Antiseptics, 186—Acetate of Aluminum, 187—Alcohol, 188—Boric Acid, 188—Bromin, 188—Camphor, 189—Carbolic Acid, 189—Chloral Hydrate, 190—Chlorid of Lime, 190—Chlorid of Sodium, 190—Chlorid of Zinc, 190—Chromic Acid, 191—Corrosive Sublimate, 191—Creasote, 192—Creolin, 192—Formic Aldehyd, 192—Hydrogen Peroxid, 194—Iodin, 194—Iodoform, 194—Juniper, 196—Lysol, 196—Peruvian Balsam, 196—Potassium Permanganate, 197—Resorcin, 197—Salicylic Acid, 197—Salol, 197—Sulphurous Acid, 197—Thymol, 197—Tinctura Benzoini Composita, 198—Turpentine, 198—Antiseptic Solutions, 198—Carbolic Acid Solution, 201

PAGE

—Bichlorid of Mercury Solution, 201—Acetate of Aluminum Solution, 202—Thiersch's Solution, 202—Boric Acid Solution, 202—Chlorid of Zinc Solution, 203—Normal Salt Solution, 203—Aqua Binelli, 203—Permanganate of Potash Solution, 203—Antiseptic Powders, 203—Iodoform-boric Powder, 204—Borosalicylic Powder, 204—Antiseptic Salves, 204—Antiseptic Pomade, 204—Borosalicylic Ointment, 204—Lister's Boric Acid Ointment, 204—Chloral Hydrate Ointment, 204—Unguentum Credé, 205—The Mechanical Treatment of Wounds, 205—Position, 206—Suturing, 206—Fixation Dressings, 213—Compression, 214—Drainage, 214.

CHAPTER VII.

GUNSHOT WOUNDS 218
Diagnosis, 220—Prognosis, 224—Treatment, 229—First-aid Package in Military Surgery, 231—Arrest of Hemorrhage on the Field, 244—Permanent Hemostasis, 249—Shock, 252—Primary Dressing of Wound, 252—Immobilization of Injured Joints and Fractured Limbs, 253—Transportation of Sick and Wounded, 253—The Surgeon's Work at the Field-hospital, 254—Craniectomy, 254—Laparotomy, 254—Amputation, 254—Resection, 255—Wounds of the Skull, 255—Trephining for Traumatic Abscess of the Brain, 256—Treatment, 259—Wounds of the Neck, 259—Wounds of the Chest, 261—Wounds of the Abdomen, 273—Symptoms, 276—Diagnosis, 277—Treatment, 278—After-treatment, 285—Wounds of the Spine, 285—Wounds of the Nerves, 288—Wounds of the Arteries, 290—Wounds of the Kidneys, 291—Symptoms and Diagnosis, 293—Prognosis, 294—Treatment, 295—Wounds of the Urinary Bladder, 297—Symptoms and Diagnosis, 298—Prognosis, 299.

CHAPTER VIII.

RUPTURE OF THE URETHRA 302
Prognosis, 304—Treatment, 305.

CHAPTER IX.

FRACTURES 309
Frequency, 310—Pathologic or Pseudofracture, 311—Classification, 320—Causes, 326—Mechanism of the Exciting Causes, 327—Symptoms and Diagnosis, 332—The Röntgen Ray in the Diagnosis of Fractures, 343—Symptoms Following Fractures, 344—Serious Complications of Simple Fractures, 346—Callus Production, 351—Detached Fragments in the Restoration of the Continuity, 357—Prognosis, 362—General Treatment, 365—The First Duties of the Surgeon, 366—Reposition of the Fracture, 368—Immobilization, 371—Position, 372—Remote Consequences, 389—Excessive and Defective Callus Formation, 390—Defective Callus Formation, 392—Stiffness and Ankylosis of Joints, 394—Atrophy of the Limbs, 396—Thrombosis and Embolism, 396—Gangrene, 397—Fat Embolism, 398—Hemorrhage, 398—Central Nervous System, 399—Prolonged Dorsal Recumbency, 399—Painful Callus, 400—Paralysis, 400—Delayed Union and Pseudarthrosis, 400—Vicious Union, 410.

CHAPTER X.

SPECIAL FRACTURES 411
Fractures of the Neck of the Femur, 412—Colles' Fracture, 475—Fractures of the Skull, 486—Symptoms, 488—Prognosis, 490—Treatment, 491.

CHAPTER XI.

COMPOUND FRACTURES 505
Old Statistics, 507—Recent Statistics, 508—Etiology, 511—Diagnosis, 513—Pathology, 514—Prognosis, 517—Treatment, 519—Primary Amputation, 519—Gunshot Fractures, 554.

CHAPTER XII.

PAGE

DISLOCATIONS 568

Etiology and Mechanism, 569—Pathology of Recent Dislocations, 571—Symptoms, 575—Treatment, 578—Dislocations of the Shoulder-joint, 586—Anterior Dislocations, 587—Downward or Subglenoid Dislocation, 597—Posterior or Retroglenoid Dislocation, 597—Dislocations of the Elbow-joint, 599—Dislocation of Both Bones of the Forearm, 600—Dislocations of the Ulna, 609—Dislocations of the Radius, 610.

CHAPTER XIII.

EXPLORATORY PUNCTURE, SUBCUTANEOUS AND PARENCHYMATOUS MEDICATION, PARACENTESIS, AND DRAINAGE OF SUPPURATING JOINTS 614

Exploratory Puncture, 617—Paracentesis, 620—Drainage of Suppurating Joints, 629.

CHAPTER XIV.

ASEPTIC CATHETERIZATION 632

CHAPTER XV.

EMERGENCY OPERATIONS ON THE AIR-PASSAGES 640

Intubation of the Larynx, 640—Laryngofissure, 643—Tracheotomy, 644.

CHAPTER XVI.

EMPYEMA 651

Diagnosis, 653—Surgical Treatment, 654.

CHAPTER XVII.

PERITONITIS 662

Anatomic Classification, 663—Pathologic Classification, 667—Bacteriologic Classification, 669—Clinical Classification, 672—Treatment of Septic and Suppurative Peritonitis, 676—Ectoperitonitis, 676—General Septic Peritonitis, 677—Perforative Peritonitis, 692—Circumscribed Peritonitis, 696—Hematogenous Peritonitis, 700—Visceral Peritonitis, 701—Pelvic Peritonitis, 702—Puerperal Peritonitis, 703—Subdiaphragmatic Peritonitis, 704.

CHAPTER XVIII.

APPENDICITIS 705

Size, Location, and Blood Supply of the Appendix, 706—Etiology, 707—Pathology, 712—Symptoms and Diagnosis, 720—Treatment, 723.

CHAPTER XIX.

INTESTINAL OBSTRUCTION 737

Frequency, 737—Acute Intestinal Obstruction, 739—Chronic Intestinal Obstruction, 743—Medical Treatment, 744—Operative Treatment, 758.

CHAPTER XX.

ENTEROSTOMY 761

Enterotomy, 764.

CHAPTER XXI.

COLOSTOMY 765

CHAPTER XXII.

ABDOMINAL SECTION 770

Preparations for the Operation, 774—Anesthesia, 775—Incision, 776—Intra-abdominal Examination, 777—Operative Treatment of

PAGE

the Obstruction, 783—Intestinal Anastomosis, 783—Laparo-enterotomy, 797—Enterectomy, 797—Direct Treatment of Obstruction in Strangulation by a Band or Diverticulum, Flexion, or Adhesion of the Intestines, 802—Toilet of Peritoneal Cavity, 806—After-treatment, 807.

CHAPTER XXIII.

ENTERORRHAPHY 808
Lateral Enterorrhaphy, 818—Circular Enterorrhaphy, 819—Omental Grafting, 821—Murphy Button as a Substitute for Circular Enterorrhaphy, 826—Intestinal Anastomosis and Lateral Implantation, 826—Directions for Preparing Bone-plates, 828—Jejuno-ileostomy, 829—Ileocolostomy, 833—Ileorectostomy, 839—Colorectostomy, 840—Invagination Suture, 841.

CHAPTER XXIV.

ANATOMICOPATHOLOGIC FORMS OF OBSTRUCTION 847
Volvulus, 850.

CHAPTER XXV.

ANATOMICOPATHOLOGIC FORMS OF OBSTRUCTION (*Continued*) 866
Flexion, 866—Adhesions, 870—Bands and Diverticula, 872—Internal Hernia, 883—Invagination, 885—Etiology, 889—Symptoms and Diagnosis, 893—Pathology of Acute Invagination, 894—Pathology of Chronic Invagination, 897—Treatment, 898—Impaction by Foreign Bodies, 912—Enterolithiasis, 914—Treatment, 918—Intestinal Concretions, 920—Parasites, 922—Fecal Obstruction, 924—Nonmalignant Stenosis, 925—Tumors, 961—Benign Tumors, 961—Intraperitoneal Myofibroma of the Rectum, 964—Malignant Tumors, 968—Obstruction from Compression, 974—Dynamic Obstruction, 975—Obstruction after Abdominal Section, 980.

CHAPTER XXVI.

STRANGULATED HERNIA 983
Etiology, 983—Symptoms and Diagnosis, 985—Prognosis, 988—Treatment, 989.

CHAPTER XXVII.

INTESTINAL FISTULA 1004
Etiology, 1005—Treatment, 1011—Pathologic Anatomy, 1012—Surgical Treatment, 1014.

CHAPTER XXVIII.

RESECTION OF JOINTS 1024
General Directions for Joint Resection, 1030—Resection of Special Joints, 1033.

CHAPTER XXIX.

AMPUTATIONS AND DISARTICULATIONS 1059
Indications for Amputation, 1060—General Technic of Amputation, 1065—Amputation of the Upper Extremity, 1081—Amputation of the Arm, 1086—Exarticulation of the Entire Upper Extremity, Including the Scapula and Clavicle, 1088—Amputation of the Lower Extremity, 1089—Amputation of Toes, 1089—Disarticulation of all the Toes, 1091—Amputation Through the Metatarsus, 1091—Mediotarsal Disarticulation, 1092—Malgaigne's Subastragaloid Disarticulation, 1094—Syme's Amputation Through the Ankle-joint with Excision of the Malleoli, 1094—Pirogoff's Amputation, 1094—Amputation of the Leg, 1096—Amputation of the Thigh, 1105—Disarticulation at the Hip-joint, 1105.

INDEX 1107

PRACTICAL SURGERY

PRACTICAL SURGERY.

CHAPTER I.

EMERGENCY AND MILITARY SURGERY.

EMERGENCY surgery may be defined as the application of manipulations or the performance of operations in the treatment of accidents or life-threatening affections amenable only to prompt surgical interference. Emergency surgery is the surgery of the general practitioner. Every physician qualified to practise his profession should have the necessary knowledge and manual dexterity to perform, at a moment's notice and with the simplest instruments and limited assistance, all life-saving operations in all cases demanding prompt action to meet the urgent indications. In large cities the medical practitioner can secure the services of a professional surgeon without much loss of time, but occasionally he will be confronted by a case in which he has to act promptly in order to save life. Nevertheless, the mass of general practitioners throughout the country are frequently thrown upon their own resources, and must be prepared to perform the most difficult operations when the loss of time necessary to secure surgical aid would jeopardize the life of the patient.

A fair percentage of the practice and income of the village and country practitioners consists of, and is derived from, emergency work. The average medical student is more interested in surgery than in medicine, and I am sure the surgical training he receives ought to qualify him to practise emergency surgery with credit to himself and benefit to his patients. As a rule, most of the accident cases and acute surgical diseases requiring prompt operative treatment first come to the attention of the general practitioner, who often determines, by the first aid rendered, the fate of the patient. Neglect and mistakes made in such instances are often difficult to balance and correct later. The general practitioner must be familiar with surgical diagnosis, and must acquire surgical technic sufficiently to act timely, wisely, and safely in all surgical cases in which immediate interference is an absolute necessity to save life or to protect the patient against remote disastrous complications. No physician should receive his diploma or practise his profession unless he is fully qualified to meet these requirements. Surgery must often be practised not as a matter of choice, but of necessity. Perhaps the best definition ever given of a surgeon is that expressed

in the words of Sir Spencer Wells : "A surgeon is a physician who can operate."

The profession of our country at this time is suffering from two great defects : physicians are too exclusively physicians, and surgeons are too exclusively surgeons. These defects must be remedied if our profession is to reach the highest standard of efficiency and utility. The medical man must take postgraduate instruction in surgery and subscribe for, read, and study surgical literature if he wants to be just to his high calling and honest to his clients. On the other hand, the surgeon, if he wants to practise his art with success and credit to himself and his craft, must pursue an opposite course. One-sided reading, learning, and working are harmful in the practice of our profession, and are responsible for many blunders in the practice of men who devote their time and attention exclusively either to medicine or surgery. There should be no such thing as exclusive specialty in our profession. There are, and should be, specialists, but such specialists should be well versed in the principles of medicine and surgery, as without such knowledge their work is unsatisfactory and often dangerous. A successful specialist must, above all things, be a doctor if he wants to make any claim upon the profession or command the confidence of the public. Emergency cases occur everywhere and at all times. They are the cases that interest the public most, and a rush is made for the nearest physician's office, the inmate being expected to respond at once and render the necessary aid. Every physician thus peremptorily summoned is expected to be master of the situation and do what is necessary. Such cases often come to our recent graduates who are not overburdened with engagements. Many an eminent practitioner owes his early success to prompt and intelligent treatment of such cases. On the other hand, many a young physician has injured his professional career by his early unfavorable experience with such cases. Again, many a practitioner of long experience and with a lucrative practice, but who failed to keep step with the progress of surgery, has found his practice gradually melting away and passing into the hands of younger and more competent men because of his shortcomings in emergency work.

If, as stated before, life and limb in accident cases often depend on the manner in which the first aid is rendered, the importance of emergency work becomes apparent. Every graduate in medicine must be qualified to do satisfactory service in emergency cases, regardless of the position he may occupy in the profession or the branch of medicine or surgery he may have chosen for his vocation. If this is the case, it is evident that this department of surgery should receive more time and attention in the curriculum of our medical colleges and postgraduate institutions. The student should first receive thorough instruction in surgical diagnosis. This part of his education can not be obtained from reading and lectures with a sufficient degree of thoroughness to enable him to interpret in-

telligently the signs and symptoms at the bedside. This branch of the teaching must be largely of a clinical nature. The actual contact with patients, systematic and thorough examination under the supervision of the teacher, will prove of more practical value in the recognition of the nature of injuries and disease than any amount of book-knowledge. In my own college work I devote one-third of the term of nine months to surgical diagnosis, an equal amount of time to emergency surgery, and the balance of the term is occupied by demonstrating regional surgery. Few of the graduates become professional surgeons, hence it is a loss of valuable time to dwell at too great length and detail on the description and demonstration of many of the major operations that few will have the inclination or opportunity to perform. The few who are desirous to devote themselves to surgery exclusively must acquire the necessary proficiency later by hospital work and postgraduate instruction. It is a serious mistake for any recent graduate to limit his work to surgery exclusively. A surgical career should be preceded by general practice for a period of at least five years. It is the business of every medical college to educate physicians in such a way as to make them competent to do ordinary surgical work; it is not expected to produce professional surgeons. No student should be permitted to graduate who is not familiar with the principles of surgery, surgical diagnosis, fractures and dislocations, and who has not a comprehensive knowledge of the treatment of wounds and the technic of emergency operations. In Rush Medical College, in which I have the honor to teach surgery, I describe in detail all emergency operations and perform them on the cadaver. After this has been done each student performs every one of these operations under the supervision of a competent corps of demonstrators. The ground is thus gone over twice in a systematic way, supplemented repeatedly in the clinics. Orthopedic appliances, minor surgery, and bandaging constitute separate departments in charge of two assistant professors. The students make their own splints and dress every fracture, using manikin, cadaver, or the living subject for this purpose. They are taught how to sharpen and take care of instruments. Hemostasis, suturing, and the dressing of wounds receive special attention.

Many clinical teachers are not happy unless they can perform capital operations at every clinic; they are anxious to show what modern aggressive surgery can accomplish and what they can do. The teacher of clinical surgery often forgets that he is teaching, and simply operates. The average medical student has the profoundest respect and admiration for such a teacher, but finds, when thrown on his own resources, that he has learned but little. The ideal clinical teacher imparts his knowledge to the students, and utilizes to greatest advantage that kind of clinical material which will come under the care of the general practitioner.

Emergency work and minor surgery are the subjects in which

students must be made to take a keen interest, and which should occupy a liberal share of the time devoted to didactic and clinical teaching of surgery. Emergency work demands special preparation, as it is work which must be done on the spur of the moment, without an opportunity of making special preparations. Besides the acquisition of the necessary theoretic and practical knowledge, the physician who succeeds the best in the practice of this part of his profession is the one who is also in possession of a liberal amount of what is ordinarily known as common sense. Many highly educated physicians prove failures as practitioners because they lack this natural gift, while others, less learned and less studious, succeed because they were born with a special aptitude for the profession. Hard study and constant application may, in the course of time, balance this disadvantage, but they will never entirely overcome it. Good common sense is of special importance in the successful practice of emergency surgery. Emergency cases require immediate attention, as there is no time to consult text-books and often no opportunity to obtain a consultant or to secure intelligent assistance. *Semper paratus* is the key-note to success in the practice of this department of surgery. Emergency work implies hasty, and yet careful, work. What is to be done must be done at once. The excitement which often surrounds such cases should not disturb the calmness of the physician. The physician is calm, self-possessed, and confident if he is conscious that he is master of the situation.

Originality and ingenuity are qualities essential to the successful practice of emergency work. The physician who can perform difficult operations with the least number of instruments, without assistance, and who can extemporize the dressings out of the simplest materials, is the one who will never be at a loss when unexpectedly confronted by a difficult case. Quickness of perception, ready resource, decision and promptness of action, characterize the successful emergency surgeon. The physician who is qualified to practise accidental surgery successfully never forgets that he must keep himself always in readiness to respond to an urgent message. The few instruments necessary for this purpose are kept in a faultless condition in a canvas cover. His emergency bag contains an ample supply of dressing material, antiseptics in tablet form, reliable ligature and suture material, anesthetics, stimulants, and a small medicine case ; a hypodermic syringe, a good supply of rubber tubing, and a Davidson's syringe complete the most necessary outfit.

As military surgery consists largely of emergency surgery under the most trying circumstances, it may not be out of place to discuss here briefly—

The Qualifications and Duties of the Military Surgeon.—That every military surgeon should be well trained in emergency work must be taken for granted. His surgical work in the field is limited almost entirely to the treatment of accidental wounds.

He is seldom called upon to perform major operations for any other indication. In this country, owing to the small standing army, a large part of the medical service devolves upon physicians from civil life, and our experience during the Spanish-American war has demonstrated many of the shortcomings of those men who too suddenly exchanged their civil for a military practice.

Nearly five months of continuous service with the army in the camp and field have afforded me an excellent opportunity to make a practical study of the subject. This time was spent in Camp Tanner, Springfield, Ill.; Camp George H. Thomas, Chickamauga, Ga.; Camp Wikoff, at Montauk Point, L. I., and the Cuban and Porto Rican campaigns. The first four weeks were occupied in Camp Tanner, where I assisted in the capacity of surgeon-general of the State in the organization of the State troops. This service brought me into closer contact with the National Guard of Illinois than at any time before. A physical and professional examination in which I took part brought out the shady as well as the sunny side of the qualifications of the medical officers of my State. The result of my experience here convinced me that the average National Guard surgeon is a faithful doctor, with more than average professional ability, but, with few exceptions, lacking the necessary military training in performing satisfactorily his administrative duties. This is a part of his education that has been sadly neglected in the past and should receive more attention in the future. Very few States make provision for physical examination of the medical officers, consequently some of them have entered the service totally disqualified for participating in an active campaign. Two of the candidates for the volunteer service from the National Guard of Illinois were rejected on this ground.

The exacting and often onerous duties of the military surgeon in time of war require special qualifications to prepare and fit him for his work. He is not only expected to be well versed in theoretic and practical knowledge of everything pertaining to the practice of medicine and surgery, but he must be endowed with qualities both of mind and body upon which he can rely when engaged under the most trying circumstances. In field work he has often to perform the most difficult tasks with very limited resources. In such instances good common sense and deliberate action go much further in accomplishing what is desired than the finest scholarship and the most profound logical reasoning. The man who can in a few moments extemporize a well-fitting splint out of the simplest materials, and perform with the contents of an ordinary pocket-case the most difficult operation, will do vastly better work on the battlefield than most professors of surgery and the most brilliant operators in civil practice. The surgeon who understands the principles and practice of good cooking is of more service to the troops than the one who can repeat, word for word, the contents of the most exhaustive treatise on materia medica and therapeutics. The med-

ical officer with a full knowledge of hygiene and sanitation and endowed with the faculty of making a rational, practical use of it is preferable to the most expert clinician, as in military practice it is more important to prevent than to treat disease, no matter how successfully and scientifically the latter may be conducted. The all-around medical officer must be a good mechanic: he should know how to use the carpenter's and blacksmith's tools, how to row and sail a boat, how to make a raft, and occasionally he will have reason to be thankful if he has learned how to pack a mule and drive an ambulance team. His miscellaneous knowledge of matters and things entirely outside of his legitimate province will be constantly drawn upon from different sources, and the more he knows and is willing to impart, the more he will be useful and popular. The man who enters the medical department of the army under an impression that he is only expected to treat wounds, set broken bones, and prescribe for the ordinary camp ailments makes a serious mistake and will surely be a disappointment to himself and to those he is expected to serve.

Physical Condition.—The ideal military surgeon in possession of the necessary mental and physical qualities to make him such is seldom seen. The most active brains are often found in frail bodies. I have often seen in civil life surgeons of great reputation struggling with disease or its effects, or the victims of some congenital or acquired defects, who were wonders in the operating amphitheater in spite of some disability. I have seen, more than once, the saddest of all spectacles in professional life—a surgeon himself the subject of an incurable disease muster into service every particle of his reserve strength to perform a critical operation with the view to saving the life of another. Achievements of this kind are possible in private practice, but are entirely out of the question in military service. The physical condition of the military surgeon must be as nearly perfect as possible. A physical examination as thorough and as painstaking as in the case of a private can only decide upon the necessary physical qualifications of candidates for commission in the medical service. For good reasons this rule is followed in the selection of medical officers for the regular army, and there is no ground why the same requirements should not be exacted in the National Guard. During my service at Chickamauga, Montauk, and at the front, I saw more than one volunteer surgeon who ought to have been excluded from the service for physical disability. During a campaign the loss of a single medical officer may prove a great disaster. Of all commissioned officers, the surgeon is the most indispensable. The vacant place of a line officer can be filled at a moment's notice without any serious loss to the service; not so with the surgeon. His position is one requiring special training, and one that can not be filled without crippling the medical service at some other point. For this, if for no other, reason the medical officer must be in sound health and able to cope successfully with

the hardships of a campaign. In battle and during the prevalence of an endemic or epidemic disease the medical officer is the one above all others whose strength and endurance are taxed to their utmost extent. His services are required by day and by night. He has no rest, and unless in possession of an iron constitution his strength fails him and he becomes, if not a fit subject for the hospital, at least a physical wreck, who, if he persists in continuing his work, will often do more harm than good. A number of such instances came to my personal notice during the Cuban campaign. A medical officer should not only be in full possession of health and all that this implies, but he should have been in training to endure hardships of all kinds from early childhood. He need not necessarily be an athlete, but he should be able to walk twenty miles a day or ride forty without fatigue, and then be ready to do a night's work should an emergency demand it. The dancing-halls and club-houses are poor training-schools for a successful military career. The labor and hardships encountered in hunting are best calculated to prepare the body for a life of great activity and privation. Frugal living will not only prove conducive to the maintenance of health, but will be the best means of initiating the surgeon to the uncertainties of the commissary department when on the march or in the field.

Let every one who chooses a military career dispense with unnecessary clothing and luxuries during early life, in order to accustom and adapt himself for his life-work, which in time of war will bring the inevitable amount of vicissitudes and even of suffering. The medical officer must be a good horseman, which here not only implies a good rider, but includes a knowledge of the usual ailments of horses, the treatment, feeding, and care of the animals. To sum up, the military surgeon must be a man of vigor, made so by birth and training, with as few requirements in his habits of living as possible, in order that he may resist to the highest degree the influences of climate and disease, and prepare himself for the hardships and privations incident to active warfare.

Mental Qualifications.—A proper and adequate preliminary education is exacted of every surgeon in the regular army; without it he is not permitted to pass the medical examination. Statistics show that a large percentage of the candidates are dropped at this stage of the examination. This is a reflection on the system of medical examination which continues to prevail in our country. About the only evidence of proficiency the National Guard surgeon in most of our States is required to show is his diploma. It makes but little difference where the diploma was obtained. Evidences of a satisfactory preliminary education are not required in most of the States. In consequence of so easy an entrance into the medical service of our State troops many of the men who receive commissions are illiterate. By hard postgraduate work they often become good physicians, but they seldom, if ever, make up for the early

defects of their education, which seriously interfere with a successful military career. Is it to be wondered at that when such shortcomings are discovered by their colleagues and officers of the line, they do not command the respect to which their commissions should entitle them? The reports made out by such men speak for themselves, and appear as black stains upon the department they represent. The elevation of the standard of medical education by most of the medical schools throughout the country will gradually wipe out this blemish, but it will be many years before all the diplomas can be accepted as sufficient proof that their possessors are entitled to recognition by the medical department of the different States. Let us hope that a speedy and radical reform may be instituted in the different States which will accomplish the desired object, and which will make the commission of a medical officer of greater import in showing a higher degree of preliminary and professional proficiency than the diploma of any of our medical colleges. This is a desideratum for the realization of which every one interested in the success and usefulness of the National Guard should willingly use his influence.

Fortunately, there are no specialties in military practice. The medical education of a military surgeon must be of the most liberal and broadest kind. His practice is so varied that he may have to be physician, surgeon, oculist, aurist, etc., the same day. The sphere of the regular army surgeon serving at a post includes in addition obstetrics, gynecology, and diseases of children. Every military surgeon must be an expert in physical diagnosis and examination of the eye and ear. He must know something about dentistry: he must know how to extract teeth and how to put in a temporary filling in a carious tooth that can be saved. He must be familiar with neurology, the use and application of electricity as a diagnostic and therapeutic resource. In camp and field he is limited to his own resources in the diagnosis and treatment of all kinds of injuries and diseases. He must, therefore, be well equipped with a thorough knowledge of everything pertaining to surgery and medicine, and is often called upon to represent the different specialties. No amount of preliminary and professional education will make the military surgeon an efficient officer unless he is possessed of an inborn aptitude for the profession. He must be able to apply and make use of his knowledge. Many men of great learning never become successful practitioners. Their store of knowledge fails them when they come to apply it. The military surgeon in camp and field must be a man of quick perception. He must be able to recognize malingering as well as disease. In an emergency he must be in readiness to act intelligently at a moment's notice. Hesitation is dangerous both to the patient and the reputation and good standing of the surgeon. Indecision creates mistrust, procrastination, disaster. Quick decision and prompt action are the essential prerequisites of successful emergency work. Successful action, however,

must be preceded by thoughtful, systematic preparation. The most successful surgeon is the one who adopts and follows the watchword, *semper paratus*. He should never be caught napping. Careful preparation makes prompt action possible. The successful surgeon makes his plans ahead, and supplies himself with the necessary outfit, medicines, dressing materials, and instruments before the emergency arises, and when it does so, he is fully prepared to meet it. A lack of forethought and systematic preparation accounts for many shortcomings of medical officers in the field and camp, with the necessary evil consequences for those intrusted to their care.

Military Spirit.—Any one who adopts the medical service of the army as a life vocation will be disappointed unless he does so imbued with a proper military spirit. The military surgeon must be a military man and an integral part of the army if he wants to do justice to his calling and the department he represents. I fear it is a lack of the proper military spirit in some of the medical officers in the regular army that is responsible for a well-recognizable cleft between them and the officers of the line and field. If this is true in the regular army, it is only too obvious in the National Guard. The rank of the medical officers and their standing in military and social circles suffer when they are regarded and treated as ordinary doctors. The West Point graduate, educated at the expense of the Government, too often forgets that it takes more hard work and a longer time to make a good doctor than an officer. The officers of the National Guard, holding commission by the grace of their Governor, do not realize sufficiently that their military surgeons have spent a small fortune and five years in acquiring a knowledge of their profession. They seem to forget, or at any rate often ignore, that when they go into camp or in the field they do so at a great personal and pecuniary sacrifice. Their absence from home, even for a short time, may cause a break in their practice difficult to repair. The medical officer is entitled to recognition as a military man, and if this is not accorded to him voluntarily, he must resort to measures that will enforce it. The lack of military dignity on the part of the medical staff is due largely to a lack of the proper military spirit in the members which compose it, and to too great a familiarity between the surgeons and the officers and men. The correction of these evils can not be undertaken too soon, and when accomplished, will add much to the dignity, influence, and efficiency of the medical department of the army and State troops.

The medical officer who has enjoyed the advantages of an early military training in a military academy or in the National Guard is the one best qualified to enforce military rules and assert the dignity of his position.

Punctuality.—The busiest men have always the most time to perform a duty or to meet an engagement at the appointed time. This rule holds good in all walks of life. The drones are always behind. In military life punctuality means everything, and from

this exaction the medical officer should never be excluded except for special and well-founded reasons. In the regular army there is a way of disciplining the medical as well as other officers in coming to time in the performance of definite duties and in making out the reports. My long experience in the National Guard service has taught me, occasionally in a painful way, that the surgeons are often entirely oblivious to the matter of time, especially when called upon to make out and transmit the regimental reports. It is the men who put off for to-morrow what should be done to-day, and who meet their engagements at one o'clock or thereafter instead of at twelve, who fill the lives of their superior officers with misery and disappointment. The men that accomplish the most are always ready and on time. The medical officers must be made to understand that a due regard for punctuality in performing their duties, in meeting appointments, and in making out and forwarding reports is one of the most essential features of a successful military career.

Courage.—It is still the general belief that in times of war the military surgeon is exposed to less danger than the soldiers and officers in command. That this is not so is shown by the statistics of all wars. Although the position of the military surgeon is behind the fighting-line, he is usually near enough to the enemy when serving in the front to be reached by stray bullets and bursting shells. The number of surgeons killed and wounded in the performance of their duty in rendering first aid is by no means small in any war of magnitude. In active warfare, however, the greatest danger to the surgeons is to be found in their constant exposure to contagious and infectious diseases, which follow large armies in all climates and during all seasons of the year. To enter a yellow-fever camp to my mind calls for more courage than to lead and command the troops in the battle-field. Disease always claims more victims than bullets, and this was especially true of the war with Spain. The nation worships the heroism of those who fell before Santiago, but much less is said of the vastly greater number stricken down by disease, and who have lost their lives from disease, often after prolonged and intense suffering. To the credit of the medical officers of this and other wars it must be said that they showed no fear, either in facing the enemy or, what is vastly worse, disease. When yellow fever made its appearance among the troops around Santiago, every man remained at his post and faced the danger without flinching. Men from the North who had never seen the disease accepted the detail for duty in the fever hospitals without a word of complaint. The medical officer must be endowed with more than ordinary courage to face the many dangers that surround him on all sides during a campaign. Patriotism begets heroism, and I make a well-founded claim for both for the medical profession represented in the army.

Personal Habits.—The old adage that "It is easier to preach

than to practise" is a familiar one, and should be made to apply with the same force to doctors as to preachers. The first and most important duty of the military surgeon is to prevent disease. This can often be done more effectively by example than by talking or issuing orders. The military surgeon must guard the camp against disease. He is looked upon, and must be regarded by those under his care, as the one above all others who can give them advice in matters pertaining to their health. He is expected to do this by example as well as by teaching. He must become a permanent object-lesson in inculcating the importance of cleanliness in person and in dress. His tent should be the cleanest and most orderly in camp. Temperance in eating and drinking can be taught more successfully by action than by words. A military surgeon under the influence of liquor will do more harm in encouraging the vice of intemperance than can be undone by weeks of lecturing. Profanity is prevalent in every camp, and while it is not the duty of the surgeon to supplant the chaplain in suppressing it, it should receive no encouragement by his example. In his conduct toward the men the surgeon should be firm and dignified, yet kind and sympathetic, especially to those in need of his professional services. An impetuous nature and an irritable temper create a rebellious spirit, which it is difficult to control by the most energetic measures. Proper questions should be answered willingly and with sufficient clearness and at adequate length to furnish the desired information, and not gruffly and snappishly, as is occasionally done without any reason or provocation. Overwork and a poor digestion are poor excuses for treating a subordinate in an undignified, ungentlemanly manner. The military surgeon must be known in camp as a gentleman, not only by the officers, but by every man under his charge, if he expects to be respected and to do justice to his high calling and responsible position.

The Military Surgeon in War.—The true qualities of the military surgeon are crystallized and best shown during an active campaign. It is in war that his ready resources will come to the surface and will be subjected to the severest tests. It is in battle and during the prevalence of devastating diseases that his moral courage and physical endurance will be most severely tried. It is under such circumstances that the troops will reap the greatest benefits from the skill, diligence, fortitude, and ready resources of the medical officer. The surgeon who can extemporize an operating table in the field, who can secure asepsis with the use of the camp kettle, soft soap, and carbolic acid or sublimate, and who can perform the most difficult operations with the simplest and fewest instruments, with little or no assistance, is the one who will accomplish the most and who will obtain the best results in the field.

CHAPTER II.

TRAUMATIC SHOCK.

TRAUMATIC shock is a subject of great importance and concern to every practical surgeon. He observes this condition frequently, either as the immediate result of an injury or of an operation. We are forced to admit that very little has been added to our knowledge of shock since the writings of Jordan, Pirogoff, and Groeningen. The experimental work done so far and the clinical observations made afford us but an incomplete insight into the nature and etiology of shock. It remains for the experimental investigators of the future to forge the key to unlock this mysterious complication of injuries, accidental or intentional. As the clinical field has been fairly well exhausted without any striking new results being obtained, it must be left to experimental work to furnish the necessary information regarding the nature of traumatic shock. With a full knowledge of the essential of this common complication of all grave injuries we shall be in a better position to devise more efficient prophylactic measures, and to produce, select, and apply more successful therapeutic resources.

The term **shock** originated in England, where this earliest of all wound complications first appears to have attracted attention. In that country it was made the subject of special study by Travers, Jordan, and Savory. Pirogoff described what is now generally known and understood by the word shock as traumatic torpor or wound stupor. The conceptions of writers on shock are at variance in reference to the nature of that condition. I say condition, for uncomplicated shock can not be regarded as a disease. Savory describes shock as a paralyzing influence on the action of the heart, due to a sudden and severe injury of the nerves. Jordan defines it as a peculiar condition of the animal organism, characterized by arrest of all functions, caused by a severe influence upon the central organs or a considerable portion of the peripheral distribution of the nervous system. Fischer, in his classic treatise on shock, attributes it to weakness of the heart's action caused by a reflex vasomotor paralysis, whereby the large abdominal vessels are engorged with blood, and the surface, heart, brain, and other organs are correspondingly ischemic. Guthrie, the distinguished military surgeon, who had an enormous experience with gunshot wounds, has this to say of shock : " A certain constitutional alarm or shock follows every serious wound, the continuance of which excites a suspicion of its dangerous nature, which nothing but its subsidence and the absence of symptoms peculiar to the internal part presumed

to be injured should remove. The opinion given under such circumstances should be very guarded, for if this symptom of alarm should continue, grave fears may be entertained of hidden mischief." Leyden is of the opinion that the brain does not participate in shock, and the mind remains clear—stupor, coma, and delirium are rarely present. Blum interprets shock as an arrest of the heart's action, due to reflex irritation of the pneumogastric nerve. Groeningen believes that the spinal cord is the part of the central nervous system principally involved in the production of symptoms which characterize shock. He says: "The spinal cord up to its point of origin from the brain is suddenly overwhelmed, and can only regain its vitality after a complete rest." Stevenson, in his recent work on military surgery, alludes to shock in the following language: "It is characterized by prostration or collapse, which sets in almost immediately after an injury sufficient in intensity to inhibit the action of the vasomotor nerves."

From the foregoing definitions and opinions of shock it is clear that the elucidation of this subject is in need of future study and investigation. The confusion is increased by the discussions on *delayed or protracted and local shock*. Mr. McLeod affirms that he has seen several cases of delayed shock. F. H. Hamilton never met with such an example, except where some visceral lesion or the rupture of a large blood-vessel has accompanied the accident. Very few, if any, surgeons at the present time would be willing to admit that they had ever seen a case of secondary shock. The symptoms that led some of the older surgeons to describe delayed, protracted, or secondary shock resulted not from the immediate effects of the injury or operation, but from other wound complications, such as acute sepsis, internal hemorrhage, or fat embolism. Pirogoff was the first one to describe local shock—"*la stupeur locale*." Groeningen defines it as peripheral shock and as closely allied to what is more commonly observed as reflex paralysis. Berger has seen in some cases a complete hemianesthesia. The anesthesia is so complete that operations can be performed without causing pain. Local shock is most noticeable in recent cases of gunshot wounds. Immediately or soon after the wound has been received, the injured limb can be freely handled and the wound explored without a word of complaint on the part of the patient, who may not be suffering to any extent from general shock. The injured limb is cool, skin wrinkled and of a pale bluish color, sensation nearly or entirely abolished, and the patient often complains of a sensation of prickling and numbness. Local shock was frequently observed among the wounded at Santiago.

Etiology.—From what has been said it is evident that the complexus of symptoms known as shock is the result of the immediate effect of the injury. In the absence of hemorrhage it could only be explained by assuming a permanent or temporary paralysis of a reflex origin. As the maximum symptoms appear at once, and

almost instantly upon the receipt of the injury, we can safely exclude any toxic or mechanical agent circulating in the blood as a cause of shock. Individual susceptibility to shock plays an important rôle in the etiology of this complication of injuries. The resisting power of the lower animals to the immediate effects of injuries varies greatly, and bears a direct relation to the degree of development of the nervous system. The lower the scale of development of the nervous system, the greater the resistance to injuries of all kinds. The tenacity of life that belongs to many species of amphibia is almost proverbial. The heart of a decapitated turtle continues to beat twenty-four hours or more after severing the brain from the body. Every hunter is familiar with the variable results of the same injuries in different animals. The alligator, bear, and wild turkey are hard to kill. Unless some vital organ is injured, these animals are almost sure to make their escape. The delicate, nervous rabbit is an easy prey, and is often bagged after receiving a comparatively slight injury. The sturdy mallard duck can not be stopped unless mortally wounded, while the sensitive snipe and woodcock give up the struggle for life upon the receipt of insignificant injuries. In man the condition of the nervous system constitutes an important element in determining the degree of shock. A high-strung, nervous temperament, hereditary or acquired, constitutes an important predisposing cause to shock. A sedentary occupation requiring much mental labor is another element conducive to the occurrence of shock from comparatively slight injuries.

Debilitating diseases and mental worry or anxiety operate in the same manner. It has been observed that in warfare homesickness and defeat do more to favor the production of shock than the privations incident to service in the field. Outdoor life, a sufficient amount of physical exercise, plain diet, abstinence or moderate use of stimulants, are best calculated to increase the resistance to shock in the case of injury or operation. There can be no question as to the influence of nationality in being either favorable or antagonistic to shock. Civilization increases the susceptibility to shock. The North American Indian and the negro are much less liable to shock than the descendants of the European races. The surgeon has no means of foretelling the immediate effects of an operation, as he is unable to determine beforehand the individual susceptibility to shock. The general condition and appearance of the patient can not be relied upon in estimating the immediate effects of an operation or injury. An apparently healthy, robust man may suffer more from shock than a delicate woman would from the same injury or operation. Much remains to be learned concerning the state of the nervous system in favoring or resisting shock. We know that shock is liable to occur in proportion to the degree of irritability of the nervous centers. Under similar circumstances it is pronounced in the adult, light in children without stormy

manifestations, and grave in the aged. The disparity in the individual susceptibility is so great that the same causes do not always produce the same clinical picture.

Experimental research has contributed much to explain the etiology of shock, but much remains to be accomplished in the same direction. The experiments of Goltz have shown that death in frogs results from arrest of the heart-beat in the diastole by making tapotement (tapping) over the region of the stomach. If the experiment is made short of permanently arresting the heart's action and this organ resumes its function, it remains small and pale and receives during the diastole only a small quantity of blood; hence the general circulation stagnates even if the heart continues to contract. If the animal recovers, it requires half an hour before the circulation is restored. Goltz attributes the cardiac inefficiency to a temporary paralysis of the tonus of the vessels, caused by the concussion of the abdominal viscera from the blows over the abdomen.

Later, however, he came to the conclusion that the vascular paresis is not limited to the abdominal viscera injured by the tapotement, but that it affects all the blood-vessels. It was demonstrated by experiment that concussion of the entire body gave rise to the same vascular paralysis. His experiments proved likewise that the veins, as well as the arteries, are affected by the paralysis. These experiments would tend to prove that shock is the result of a reflex paralysis of the vasomotor nerves, caused by a traumatic concussion of a part of or the entire body. The peripheral anemia present in shock is the result of accumulation of blood in the large internal vessels. Besides concussion, thermal, chemic, and toxic agents are known to produce shock.

G. W. Crile's experiments on dogs did not correspond in their results with those of Goltz. In my presence he made several demonstrations by opening the abdomen of the anesthetized animal, either beating or even crushing the solar plexus without affecting the curve made by the kymograph, while a direct blow against the heart always resulted in a sudden depression of the arterial tension. The ether anesthesia may do much toward the prevention of shock. Regnier and Richet produced some of the symptoms of shock in rabbits by injecting into the peritoneal cavity from five to twenty-five grains of boiling water or one grain of a solution of chlorid of iron. Death of the animal ensued in from twelve to twenty-four hours, and was always preceded by a marked reduction of the body-temperature. If the animals were brought under the influence of chloral before the experiment, life was prolonged, a consequence which they attributed to a diminution of the excitability of the spinal cord, due to the action of the chloral. Strong electric irritation of the peritoneum and intestines continued for an hour did not produce shock, nor did it affect the temperature. Boise does not believe in the theory

that shock results from vasomotor paralysis. He explains shock by assuming a hyperirritation of the entire sympathetic system, and, as a result, stimulation of the vasomotors, contraction of the arterioles, and a spasmodic action of the heart.

Gutsch's experiments on rabbits show that mechanical irritation of the peritoneum and intestines is productive of shock. He believes that the terminal nerve filaments subjected to mechanical insults cause a reflex paralysis through the splanchnic nerves, producing depression of the nervous centers. Loss of heat during abdominal operations, advanced as a potent and common cause of shock by Wegner, he regards as only one of the many causes of shock. He found in rabbits that firm compression of a segment of intestinal coils reduced the frequency of the pulse from 168 to 120, and on another occasion from 162 to 108, and after temporary increase in its volume it became small and feeble. In the frog, handling of the stomach and intestines caused reflex paralysis of the heart in from three to six seconds.

Bezold and Bever found that section of the splanchnic nerve was followed by accumulation of blood in the paralyzed abdominal vessels, more especially the veins, while the vessels not damaged by the nerve section were found to contain a comparatively small quantity of blood. The other nerves of the blood-vessels appear to exercise but little influence in regulating the circulation. It seems, then, that in shock the reflex influence centers principally on the splanchnic nerve. Reflex paralysis caused by trauma has been exhaustively investigated on the basis of large clinical material by Weir Mitchell, Morehouse, and Keen. Crushing injuries of the extremities, caused by railway accidents and machinery, furnish the largest percentage of grave cases of shock. Concussion and contusion of the thorax, abdomen, and testicles and fractures, dislocations, and contusions of fingers are injuries that are always followed by more or less shock. Unnecessary severe handling of the ovaries during an abdominal operation is occasionally followed by severe shock (Goodell). Fatal shock has been observed in cases of severe contusion of the testicle (Fischer, Schlesier). Intestinal perforation, pathologic and traumatic, not infrequently gives rise to severe shock. In some cases of acute intestinal strangulation symptoms of shock set in, and unless the obstruction is relieved promptly, may result in death. The pulse is feeble and rapid; the surface cold and cyanotic. The shock in such cases appears to be caused by the intense effect of the intestinal irritation on the splanchnic nerve, causing shock in the same manner as Goltz's experiments.

The shock is not always proportionate to the severity of the injury. Comparatively slight injuries in persons whose nervous system is predisposed to shock may give rise to dangerous symptoms, and grave injuries not infrequently are attended by a mild degree of shock. As a rule, gunshot, punctured, stab, and incised

wounds do not produce shock to the same extent as lacerated and contused wounds. Crushing injuries involving large nerve-trunks are known to give rise to the severest form of shock. The old-fashioned round and conic lead bullets produced more severe shock than the small-caliber jacketed bullet. During the Greco-Turkish war and the late Spanish-American war it was repeatedly observed that grave injuries inflicted by the small-caliber bullet very often were unattended by any very severe general shock. The absence of severe shock was particularly noticeable in many cases of penetrating wounds of the chest, abdomen, and large joints. Wounds of the lower extremities produce greater shock than similar wounds of the upper extremities, and, as a rule, the shock is greater the nearer the injury is to the trunk. Guthrie cites two instances in which the intensity of the shock was out of all proportion to the palpable damage caused by the bullet, and led to the suspicion of additional injuries, which could not be recognized at the time. In both cases the autopsy verified the suspicion. In one case the injury was very severe, but shock was almost entirely absent. "A soldier at Talavera was struck in the head by a twelve-pound shot, which drove some bone into, and some brain out of, his head; he was walking about, complaining but little, immediately after the accident, although he died subsequently." Shells or grape-shot are especially likely to produce severe shock, although many exceptions occur. During the battle before Santiago a sergeant of the regular army was struck by a shrapnel from a bursting shell. At the moment he was injured he believed that the shell hit his right hip before it exploded some distance from him. A few moments later he noticed a swelling about the size of a child's fist above the trochanter. He kept on firing and did active duty during the whole campaign. Five weeks later an abscess developed in that locality and ruptured spontaneously. In the surgical wards of Montauk I removed, a few days later, a round lead ball the size of a hazelnut from near the ilium, in the gluteal region. This somewhat severe injury not only failed to produce any shock, but did not even incapacitate the man from doing his share in finishing the fight and the campaign. The rule, the larger the shot, the greater the shock, has also its exceptions. Pirogoff removed a six-pound cannon-ball from the thigh of a soldier, who walked a few steps although the femur was fractured, and found him suffering but little from shock. Large missiles produce shock in passing close by the body without touching it. Many authenticated cases of this kind are on record. Pirogoff saw a soldier who was killed in this manner. A heavy bomb passed in close proximity, and he fell unconscious and soon died. A careful examination failed to detect any evidences of injury. Postmortem negative: brain congested but not apoplectic.

The danger of shock from operations has been greatly diminished by the use of anesthetics. Although operations were per-

formed more rapidly before anesthetics were employed than they are now, shock was a much more common and severe complication than it is at present. Pirogoff lost two cases of amputation of the thigh on the table from shock before he used anesthetics. The fatal moment came in both cases at the time the bone was severed with the saw. Death was preceded by rigidity of the limbs, deadly pallor of the face, dilated pupils, and a staring look of the eyes. While anesthesia has greatly diminished the danger of shock from operations, we have reason to believe that many of the deaths which have occurred on the table since anesthetics have been almost universally employed, and which have been attributed to their use, have resulted from shock.

Symptoms.—One of the characteristic clinical features of shock consists in the appearance of the maximum symptoms almost instantaneously after the infliction of the injury, which distinguishes it from all wound complications that otherwise closely resemble shock. The clinical picture is complete from the very moment the symptoms of shock set in. In marked shock the patient is absolutely helpless and takes no notice of what is going on around him; he does not realize the gravity of his condition; the face is pale and apathetic; the skin of the forehead is thrown into folds; the nostrils are dilated, and a staring look into the distance at once attracts attention. The eyes are sunken and the eyelids half closed, giving to the eyes a meaningless, staring expression. The pupils are dilated and respond sluggishly to light. The skin and visible mucous membranes are pale, and hands and lips are slightly cyanotic. The surface is cold and bathed with a clammy perspiration, which is especially marked on the forehead and eyelids. The general sensibility is markedly diminished. Although severely injured, the patient can be examined and moved, often without a word of complaint. The patient makes efforts to move the limbs only on urgent and repeated requests, and the movements are sluggish and limited. As a rule, the sphincters remain intact. The scanty urine removed from the bladder by the use of the catheter presents nothing abnormal. The pulse is almost imperceptible, small, thread-like, and often irregular or intermittent. The arteries are small and lack normal resistance. Occasionally the pulse is reduced in frequency to fifty or even fewer beats a minute. The same slowness of the pulse can be artificially produced in animals by irritation of the cut ends of the splanchnic nerve. In such cases the irritation of the splanchnic is transmitted to the pneumogastric, or some other center inhibiting the action of the heart (Bernstein). A similar irritation may be transmitted to the center of respiration. The mental faculties are not impaired. The patient responds to questions slowly but rationally, in a feeble and often somewhat husky voice. Wounds can be examined without causing any pain, he making complaint only when some large exposed nerve-trunks are touched. The patient often complains of a feel-

ing of chilliness, a sense of fainting, and prickling and numbness of the extremities. The respirations are irregular, sometimes deep and sighing; at other times long and deep inspirations alternate with very superficial, frequent, hardly perceptible respiratory movements. The special senses remain intact. Nausea, vomiting, and singultus are prominent symptoms.

The surface temperature is subnormal, as is ascertained by touch and verified by the use of the thermometer. During the revolution in Paris, after the Franco-Prussian war, Redard made the first reliable thermometric observations in cases of shock. He found the general temperature subnormal in all the cases examined—fifty in number. He ascertained that the reduction in body-temperature corresponded with the size of the bullet—that is, the larger the missile, the greater the shock and the lower the temperature. About the same time Demarquay made similar observations and came to the same conclusions. During the months of March and April he examined thirty-eight cases in the hospitals of Paris, and always found the temperature subnormal. Like Redard, he found a similar reduction of temperature in extensive burns. The symptoms enumerated are associated with shock, but they are modified by the temperament of the injured persons, the environments, and the degree of shock. While the mind is usually clear, in some cases we observe incoherence of speech and thought. Shock so changes the general appearance of the patient that it is often difficult to recognize him.

Some writers continue to describe a form of shock characterized by excitement, but it is questionable if such a variety of shock ever occurs as a primary complication of injuries; it is more probable that it follows the torpid form and constitutes the stage of reaction in certain persons who are the subjects of an excitable nervous temperament. It is known as *erethic* shock, and was described by Travers as prostration with excitement.

In this form or stage of shock the expression of the face indicates indescribable fear and distress. The patient is restless and tosses about wildly, moans and cries and complains of difficulty in breathing and of a sense of impending death. He can not be consoled, refuses to be comforted, and acts like an insane person. The mind is clear, but is occupied largely by the fearful suffering. The visible mucous membranes are pale; the face, on the other hand, is flushed, the forehead hot, the eyes sunken, but unusually brilliant, the pupils contracted. The extremities are cold and numb, but not to the same extent as during the torpid stage. Thirst is a distressing symptom and is difficult to satisfy, as fluids administered are ejected as soon as they reach the stomach. All movements are made hastily and in a nervous manner, attended by trembling. Fibrillary contractions, especially of the muscles of the face, are frequently observed. The pulse is small, frequent, almost imperceptible. The respirations are rapid and superficial. Fischer claims that a patient recovering from torpid shock may gradually pass into the erethic variety, and vice versâ.

Diagnosis.—In pronounced shock it is usually not difficult to make a diagnosis if the patient is seen soon after the injury. The symptoms are characteristic and can not be mistaken in such cases. Occasionally, however, it is difficult to make a differential diagnosis between shock and syncope or cerebral concussion, and as the treatment must depend upon a correct and early diagnosis, the surgeon must study the symptoms both individually and collectively to enable him to make a correct diagnosis.

Cerebral concussion is closely allied to shock, but can be distinguished from it by the unconsciousness of the patient, always present, and by the slow, regular, full pulse. The part injured and the nature of the injury will also aid in making a differential diagnosis between these two conditions.

It is more difficult to differentiate between shock and syncope. They differ in degree and duration more than in kind, says Travers. Syncope is caused by strong mental impressions, violent physical exercise, loss of blood, pain, etc., while shock is produced by trauma, independently of the effects of pain and loss of blood. Syncope is attended by at least momentary loss of consciousness, and it is a much more acute and evanescent condition than shock.

Shock has frequently been mistaken for hemorrhage and hemorrhage for shock. These two wound complications are most liable to be confounded with each other in practice, as many of the symptoms are common to both of them. In making the differential diagnosis it is important to study the nature of the injury and to make the necessary examination to detect the presence and location of occult hemorrhage. In shock the maximum symptoms of the full clinical picture present themselves immediately after the receipt of the injury. In hemorrhage the symptoms increase in intensity progressively, and their severity bears some relation to the amount of blood lost. Convulsions usually precede death from hemorrhage, while they are absent in fatal shock. The most complicated cases from a diagnostic standpoint are those in which shock and hemorrhage take part in the production of prostration. If the symptoms of shock present themselves immediately after the injury, as they always do, and after the patient rallies again increase in severity, the probability of the existence of hemorrhage is great. The same suspicion must be entertained if the temperature continues to fall after the symptoms of shock are fully developed.

Prognosis.—In fatal cases of shock death ensues in from a few minutes to several hours. If the symptoms of shock continue for more than six hours, it is very probable that hemorrhage or serious visceral lesions are present, and that the continuance of the prostration is due to either or both of them. There are certain symptoms in grave cases of shock that may be relied upon in predicting a fatal termination. A very low temperature is such an indication. Basing his conclusions on an extensive clinical experience, Redard made the statement that "the wounded whose tem-

perature falls below 96.8° F. usually die." A similar result may be expected if reaction does not set in under appropriate treatment in the course of a few hours.

Loss of power in swallowing is considered a particularly unfavorable symptom, indicating, according to Mansell Moullin, an inhibition of the glossopharyngeal center. Uncomplicated shock is followed by reaction within eighteen hours, and if this fails to take place during this time, it never occurs (Cheever). In prolonged shock it becomes necessary for the surgeon to examine carefully for complications, more especially for hemorrhage and visceral lesions, to guide him in formulating the prognosis and in adopting and applying the appropriate therapeutic measures.

Pathology.—In death from shock the postmortem findings, aside from the injury which produced it and the evidences of great vascular disturbances, are negative. The peripheral vessels are small and contain but little blood, while the large abdominal vessels, arteries, and veins are found constantly distended with blood. In a horse that died from shock caused by a fall Grebe found an enormous plethora of the abdominal organs which had given rise to hemorrhagic infarcts in the intestinal coats and hemorrhages into the stomach and intestines. Shock causes cerebral anemia, but the sinuses and veins are often found engorged with blood. In death from shock caused by a blow against the epigastrium autopsy revealed distention of the superior longitudinal sinus and a moderate venous hyperemia of the brain and spinal cord. In case of recovery from shock it is not unusual to find secondary lesions caused by the intense vascular disturbances which are constant in shock, and which are proportionate to the severity of the shock. Keen, Mitchell, and Morehouse reported seven cases of paralysis due to injuries received in the Civil War, in each of which the paralyzed part was distant from the injured limb and not in direct venous communication. Similar cases have been described by Barlow, Benedikt, Rumke, and Schwan. Leyden is of the opinion that in such cases the paralysis is a neurotic complication—that is, the extension of infection from the seat of injury to the spinal cord and its meninges or an indirect extension by metastasis. There is, however, good ground for the belief that paralytic complications as a consequence of shock occur as the result of vascular disturbances or as remote manifestations of reflex inhibitory influences. In several cases of pernicious anemia it has been shown by competent observers that a direct etiologic connection could be traced between shock and the development of the blood disease soon after the injury was sustained. In a number of adults suffering from shock following a fall from a height albumin and casts were detected in the urine. The urine cleared up after from two to four days. In several cases autopsy showed the lesion of acute parenchymatous nephritis. As none of the cases suffered from head injury, the influence of a cerebral reflex could not be surmised, and

therefore a direct reaction of the force upon the kidney structure or intense vascular engorgement, must be assumed as the immediate cause of the renal complication. The results of the experiments of Galeozzi to show the existence of a direct etiologic connection between shock and septic infection proved negative. Nevertheless, it can not be denied that the serious vascular disturbances which take place in shock may act as a potent determining cause in the subsequent development of the infective process, by furnishing a *locus minoris resistentiæ* for the localization, growth, and dissemination of pyogenic microbes.

Treatment.—In the treatment of shock it is as important to know what not to do as what to do. As shock is frequently the result of injuries that demand operative treatment, the question necessarily arises as to what is the most opportune time for the performance of the operation. With few exceptions writers on surgery condemn operation during shock. Advocates who were in the past in favor of primary operation during shock were Paré, Wiseman, Larrey, and McLeod. Larrey says: "I have lost a great number of soldiers, because, although operated upon within the first twenty-four hours, yet the operation had been performed too late. It is then demonstrated that the commotion, far from being a contra-indication to primitive amputation, ought to decide the surgeon in its favor. The effects of commotion, far from being aggravated, diminish and disappear insensibly after the operation." Duboys, who served in America during the war of the Revolution, states that "American surgeons amputated at once and lost but few, but that the French delayed and lost many." It must not be forgotten that these surgeons came to their conclusions at a time when anesthetics were not in use. Anesthesia adds to the danger of the operation in such cases. Pirogoff is not in favor of operations during shock, and advises that in case an operation is urgently demanded it should always be performed without anesthesia. At the present time the consensus of opinion of almost all operators of experience is opposed to operations that can be postponed until the patient has rallied from the immediate effects of the injury. The severing of a limb nearly detached, the ligation of blood-vessels, and other emergency work that can be done in a few moments without an anesthetic would not add to the existing shock and would be considered good surgery.

In performing important operations, and especially operations that are apt to be prolonged and which involve important organs, the surgeon should resort to proper prophylactic measures with a view of diminishing the liability to shock. As long ago as 1880 Stephen Smith advocated alcohol for this purpose. He administered whisky every hour, in doses large enough to produce slight intoxication before the anesthetic was administered and the operation performed. He found that patients thus prepared could be anesthetized without much excitement and were less liable to suffer

from shock. I have been in the habit for years of preparing patients for grave operations by administering two ounces of whisky by the stomach or rectum an hour before the time set for the operation, and by injecting $\frac{1}{30}$ of a grain of strychnin hypodermically a few minutes before anesthetizing the patient. I am satisfied that these prophylactic measures have been of great value in minimizing the danger from the anesthesia and the shock incident to the operation. It is likewise important to prevent loss of heat and to favor peripheral circulation by enveloping the body and limbs in warm blankets during the operation. The experiments of Dudley P. Allen have demonstrated sufficiently the value and importance of this precaution against shock.

The treatment of shock is purely symptomatic. Rest in the recumbent position, the external application of dry heat to the body and extremities, the inhalation of nitrite of amyl, and the administration of stimulants, such as alcohol, camphor, coffee, and tea, constitute the usual routine treatment of shock. The danger of causing burns must not be lost sight of in applying heat. Hot bottles and bricks, frequently employed for this purpose, must be wrapped in flannel to guard against so undesirable a complication. As alcoholic stimulants, hot red wine and rum, whisky, or brandy punch deserve the preference. If spirits are used, an ounce should be given every fifteen to thirty minutes until reaction is established. In the gravest cases the remedy that will act most promptly is nitrite of amyl by inhalation. This drug is a powerful heart and vascular stimulant, and will produce an impression in a few moments, thus bridging over the most critical period for the administration of stimulants with a more lasting effect. Copious rectal enemata of hot normal salt solution are always valuable and should never be neglected in the treatment of pronounced shock. Subcutaneous or intravenous infusions of the same solution have had an extensive trial in the treatment of shock, and with the most encouraging results. Crile has experimented with the blood pressure in shock produced by manipulation and irritation of the various tissues and organs of the body, and favors the treatment by intravenous injections of warm saline solutions, along with a dilute solution of strychnin slowly injected into the rubber tube of the infusion apparatus. Opium is contraindicated in the treatment of uncomplicated shock. If the patient can not swallow, or if nausea and vomiting interfere with the administration of stimulants, resort to subcutaneous and rectal injections becomes a necessity. Groeningen recommends digitalis as a vascular stimulant.

In the erethistic stage of shock opiates are indicated, but their use requires caution. Subcutaneous injections of sterilized camphorated oil can be relied upon as a valuable cardiac stimulant. Three or four hypodermic syringefuls administered every fifteen minutes until indications of reaction set in is the rule to be followed in the use of this drug. Electric stimulation of the phrenic nerves and artificial

respiration are indicated in desperate cases. Goltz found that abdominal tapotement in animals is less dangerous if the peripheral nerves of the extremities are subjected to intense irritation; hence the value of sinapisms and electricity as therapeutic agents. Inhalation of oxygen recommends itself as a rational remedy when life is threatened by shock, particularly in cases in which the respiratory function is threatened. In shock absorption of drugs administered by the stomach or rectum, or even if injected into the tissues, is always slow, as has been shown by the experiments of Rogers and Brown-Séquard; hence care is necessary to guard against cumulative reaction during the recovery of the patient. The experiments just alluded to seem to indicate that absorption is retarded, owing to a diminished or suspended interchange between the blood and the tissues. The therapeutic value of strychnin in the treatment of shock is doubtful. Experiments on animals have demonstrated that this drug can not be relied upon in shock. Contejean explains this by the fact that in animals in a state of shock artificially produced the spinal cord is seen to be anemic—not supplied with sufficient blood to convey the remedy to this center of innervation. Gscheidlen has shown that the extract of the Calabar bean is a potent stimulant of the splanchnic nerves. Under its influence the intestinal peristalsis is diminished, as well as the abdominal plethora. Further experiments are necessary to establish the therapeutic reliability of this powerful remedy in the treatment of traumatic shock.

CHAPTER III.

GENERAL ANESTHESIA.

General anesthesia is justifiable during all major operations, and in facilitating painful and prolonged examinations for diagnostic purposes. There can be but little doubt that this, one of the greatest blessings of modern surgery, has frequently been employed unnecessarily. In the performance of minor operations of short duration the risks incident to the administration of a general anesthetic are frequently not balanced by the benefits to be derived from it. *It is the abuse, and not the legitimate and proper use, of general anesthetics that is open to criticism at the present time.* Some surgeons seldom perform an operation, however insignificant it may be, without placing the patient under the influence of a general anesthetic; while others frequently perform operations of short duration without it. The proper course to pursue is to choose the happy mean between these two extremes.

Local anesthetics have narrowed to a considerable extent the

indications for the employment of general anesthetics. Most of the operations on the eye and minor operations in other parts of the body that can be completed in a few minutes no longer warrant general anesthesia. Although the mortality from general anesthetics is small,—probably less than 1 in 1000,—the fact can not be ignored that every full anesthesia brings the patient dangerously near the dividing-line between life and death; in other words, the life of every anesthetized patient is always in danger. It must also not be forgotten that many deaths from general anesthetics have occurred during the performance of insignificant operations, and it is when accidents of this kind occur under such circumstances that the remorse of the operator is greatest and the reproach of the relatives of the victim most bitter. I have personal knowledge of a case of resection of the knee-joint successfully performed, by a very able and painstaking surgeon, the patient, nevertheless, dying from the effects of the anesthetic, administered for the second time when the surgeon wished to remove the sutures.

Gurlt's statistics up to 1893, based on 157,815 war cases, show 53 deaths, or one in 2900. Of these fatal cases, we find one death from chloroform in every 2899 cases; chloroform with ether, one in 41,181; ethyl bromid, one in 4588; pental, one in 199. No deaths are reported from ether and the A. C. E. mixture. That these statistics are reliable no one would dispute. More deaths undoubtedly occur from the use of anesthetics than we find reported in the current medical literature or through personal communications, to say nothing of the many deaths caused by the remote consequences of the toxic effects of the anesthetics. If the whole truth were known, it is safe to say that at least one death occurs in every 1000 cases of general anesthesia, either in consequence of the primary or the secondary toxic effects of the anesthetic. One death from ether occurred in my own practice.

The administration of a general anesthetic *is comparatively safe in the hands of the expert; it becomes a dangerous weapon when left to the inexperienced.* The administration of an anesthetic requires skill, experience, caution, foresight, and prompt and efficient action when untoward alarming symptoms appear. Every medical student should receive careful instruction in anesthetization, and should be given the advantages of an ample practical training, under the supervision of a competent instructor, before his graduation. This part of his instruction can not be learned from text-books and lectures —it must be obtained by actual experience in the operating room. (In Rush Medical College this part of the surgical teaching has been placed in charge of a special instructor, under whose watchful care and safe guidance each member of the graduating class is required to administer anesthetics a sufficient number of times to make him proficient in this part of his surgical acquirements.)

Very few physicians are safe anesthetizers. This lack of familiarity with a most responsible duty, one they are so often called upon to

perform, is largely due to the imperfect, fragmentary instruction of this important part of their medical education, an evil that can not be remedied too soon.

Besides inexperienced anesthetizers, adulteration of the anesthetics is responsible for many accidents. *The anesthetic must be pure.* A few manufacturing firms have earned a well-deserved reputation in producing anesthetics of unquestionable purity, and they deserve the patronage of the profession. *Every physician should be competent to detect impurities and to reject all preparations that do not satisfy his tests.* In eliminating all sources of danger, it also becomes necessary to subject all patients to be anesthetized to a thorough physical examination, to ascertain their physical condition and to enable the physician to select the safest anesthetic. Visceral affections of the blood-vessels, heart, lungs, bronchial tubes, and especially of the kidneys, should be ascertained by a careful physical examination and urine tests. Except in cases in which delay would be dangerous, the condition of the kidneys should always be determined by an examination of the urine.

The selection of the anesthetic is a matter of great importance. Ether narcosis is preceded and attended by increased intravascular tension and capillary congestion, more especially in the capillaries of the brain and bronchial tubes. Chloroform is a decided sedative, and its full effect is characterized by a marked cerebral anemia. *It is not good practice to rely on one anesthetic in all cases. The choice of the anesthetic should be made to correspond with the patient's physical condition.*

Statistics have proved beyond all reasonable doubt that, on the whole, chloroform is more dangerous than ether. In our country professional and popular opinion is more favorable to ether than to chloroform, and on this account, if for no other reason, it has always been the anesthetic of choice. But there are conditions that would render the use of ether more dangerous than chloroform. The best results are secured by keeping in mind the physiologic action of both anesthetics, and on this ground selecting the cases. (In Rush Medical College Clinic every case is carefully examined before deciding upon the anesthetic.) In the absence of contraindications chloroform is used in all operations on the skull, brain, stomach, kidney, air-passages, and lungs. Chloroform is also always used in patients the subjects of atheroma, arteriosclerosis, or affections of the bronchial tubes, lungs, and kidneys. I have seen so many cases of bronchitis, pneumonia, and nephritis from ether that I have learned to avoid this anesthetic in all cases of preexisting disease which might be aggravated by the irritating and stimulating effect of this anesthetic. In prolonged operations—that is, operations requiring more than an hour—I am very partial to a primary chloroform narcosis, followed by ether. This mixed anesthesia has two distinct advantages, in that the patient is brought under the influence of the anesthetic quickly, without much saliva-

tion, retching, or vomiting, and the depressing effect of chloroform is avoided by substituting ether for it after full anesthesia has been reached. *Mixed anesthetics should be avoided, such as mixtures of chloroform and ether, chloroform and alcohol, and the A. C. E. mixture of Billroth, as in the event of the appearance of untoward symptoms the anesthetizer can not always know to which of the constituents to attribute them, and consequently his actions are necessarily uncertain and perhaps contrary to what should be done.*

In bloody operations on the face and mouth, as in operations for harelip, carcinoma of lips and face, excision of the maxillæ and tongue, the anesthesia should not be complete. The narcosis is carried to the stage of insensibility so far as pain is concerned, but the patient should remain sufficiently conscious to respond to questions and to cooperate with the surgeon in clearing the mouth of blood, and thus prevent more effectually its entrance into the air-passages. Since I have adopted this course I have had no occasion to perform preliminary tracheotomy for any operation above the larynx. The usefulness and efficiency of such a "talking" partial anesthesia are increased by administering, half an hour before anesthetization is commenced, two ounces of whisky or brandy in a little sweetened water, and in very nervous patients, ¼ of a grain of morphin is given subcutaneously fifteen minutes later. Patients thus anesthetized will often manifest pain and remonstrate during the operation, but have little or no recollection of it after consciousness returns. *It is a mistaken idea that children are more immune to the toxic effect of chloroform than adults.* I have seen alarming symptoms attending chloroform narcosis more frequently in children than in adults. Age, then, should constitute no criterion in the selection of the anesthetic. The experience and reliability of the anesthetizer must be taken into consideration in making the final choice between ether and chloroform. *Ether is safer than chloroform in the hands of the untrained and careless assistant.* It is a great source of comfort to the operating surgeon when he has the satisfaction of knowing that the anesthetic is being given by a watchful, conscientious, experienced physician, who takes no interest in the operation, but whose whole attention is absorbed by the patient whose life for the time being rests in his hands. No matter how competent the anesthetizer may be, the surgeon should never lose sight of his patient, no matter how trying the operation, as he is the one, after all, who should feel that he takes the place of his patient during the stage of unconsciousness.

In emergency surgery the administration of the anesthetic must often be intrusted to nonprofessional assistants, and it is in such cases that the surgeon feels most keenly his responsibility to his patient and watches with unceasing care the progress of the anesthesia. He is on the lookout for signs of danger, and when they do appear, he meets them in person at the proper time. Under such circumstances ether is the anesthetic of choice unless visceral

lesions incompatible with its safe use furnish positive contraindications. Every emergency bag should contain both anesthetics, as occasionally in persons with certain idiosyncrasies the first few inhalations of chloroform sometimes cause alarming symptoms, and the safety of the patient demands a change to ether. In other cases, when it is next to impossible to procure full anesthesia with ether, a change to chloroform produces, in a short time, the desired effect.

Chloroform Anesthesia.—It is under this heading that the preparations to be made for anesthesia, and the accidents met and their treatment, will be discussed.

Chloroform was introduced as an anesthetic by Simpson, in 1847. It is a heavy, colorless, clear, volatile fluid, with the chemic formula $CHCl_3$. Its odor is not disagreeable, and when inhaled the vapor is absorbed very rapidly by the mucous membrane of the air-passages. It is a strong poison, which, when introduced into the circulation by inhalation or otherwise, produces a paralytic effect on the ganglia cells of the brain and spinal cord, and in toxic doses results in arrest of respiration and of heart action. The paralysis appears to advance in the brain in an anteroposterior direction, first arresting consciousness and terminating in suspension of the function of the medulla oblongata, with its immediate consequence, arrest of respiration. It was formerly believed that death from chloroform was usually due to paralysis of the heart, but the results of the investigations of the Hyderabad Commission, as well as more carefully made clinical observations, have shown that the toxic effect of chloroform is manifested first by its paralytic effect on the center of respiration. This is a very important discovery, as it teaches a valuable lesson in its administration as an anesthetic—that is, to pay more attention to disturbances of respiration than of the organs of circulation as incipient manifestations of its poisonous action. *So long as the functions of the respiratory organs are not seriously impaired by its action, no serious results are to be apprehended. On the contrary, any serious disturbances of respiration are a sufficient warning for the exercise of extraordinary care* to ward off danger from this source. Temporary suspension of respiration and cyanosis are conditions that must always be dreaded and that call for additional care in the further use of the anesthetic.

As has been mentioned before, chloroform, to be safe, must be pure. It is the impure, adulterated article that is most liable to give rise to toxic symptoms and death. Chloroform should contain no alcohol and no ether, no methyl combinations (which are shown by a black color on adding concentrated nitric acid), no free chlorin (shown by the bleaching effect), no acids (exhibited by turning blue litmus-paper red). The odor test of Heppe consists in pouring a few drops of chloroform on Swedish filter-paper; if a sharp, rancid odor remains after evaporation, it is proof of the presence of impurities.

One great objection to chloroform as an anesthetic at night in a room lighted by gas is the fact that decomposition of the vapor results in the production of a very irritating gas, which, by its action on the mucous membranes of the air-passages, causes distressing cough and a bronchial irritation that may remain for a long time. The effect of this gas can be avoided to a certain extent by opening the windows and filling the room with steam. I was informed by a medical officer of the Civil War that some of the more alarming symptoms of chloroform narcosis—great excitement and cyanosis—can be avoided by adding one dram (4 gm.) of nitrite of amyl to one pound of chloroform. This mixture was used very extensively at that time, with the most satisfactory results. I have used the mixture very frequently, and have observed that the addition of nitrite of amyl certainly has a good effect on the capillary circulation, cyanosis being much less frequently seen than when chloroform alone was used. At the same time the depressing effect of the chloroform on the heart was noticeably diminished.

Preparations for Anesthesia.—In emergency work anesthetics must often be given without any elaborate preparations, owing to the urgency of the case. When time permits, everything should be done to make ample preparations for all possible emergencies. The stomach should invariably be empty, as vomiting is likely to be provoked by the anesthetic, and the food ejected might enter the air-passages, causing immediate death from asphyxia; or, if this danger is passed over, an aspiration pneumonia is a more remote complication. If the anesthetic has to be given on a full stomach, the patient should be turned on one side, with the head in a dependent position during the act of vomiting, so as to favor the ejection of the food from the mouth. The bowels and bladder should be evacuated, the former by cathartics and enema, the latter, if need be, by aseptic catheterization. All unnecessary clothing must be removed, especially such as would interfere with the free movements of the chest and abdomen. The cavity of the mouth must be inspected, and all foreign substances, such as artificial teeth, gum, food, chewing tobacco, etc., removed. The patient is placed on the operating table, with the head on the same level as the body, or slightly elevated on a small pillow, or, what is still better, a firm compress. Upon a small stand or chair at the head of the operating table, and within easy reach of the anesthetizer, are placed all articles needed during narcosis—ether, chloroform, hypodermic syringe charged with a solution of $\frac{1}{30}$ of a grain of strychnin, granules of digitalis, $\frac{1}{100}$ of a grain, capsules of nitrite of amyl, wash-basin, tongue forceps, a four-ounce bottle of whisky or brandy, a two-ounce bottle of vinegar, an electric battery, a chloroform mask, an ether cone, a sponge holder armed with a sea-sponge or small gauze compress, and a number of towels or napkins.

Everything being in readiness for the narcosis, the patient is placed on the table in the recumbent dorsal position, and the sur-

face of the body not exposed during the operation well protected by woolen blankets, so as to prevent unnecessary and perhaps dangerous loss of body-heat during the operation. The temperature of the room should not be lower than 75° F., and not higher than 85° F., according to the general condition of the patient, the nature and probable duration of the operation. The skin exposed to the caustic action of chloroform is covered with oil, vaselin, butter, cream, or any other fatty substance. The anesthetizer takes his place at the head of the table, seated on a chair or stool of convenient height. *The patient's mind must be diverted as much as possible from the ordeal before him.* This is neither the time nor the place to talk about danger or death. A proper understanding in regard to the probable outcome of the operation must have been reached between surgeon and patient ere this. *This is the time to lift the cloud of doubt, to make room for the bright sunshine of faith, hope, and confidence.* A few words of encouragement are well calculated to inspire confidence, which will do so much to lighten the labor of the anesthetizer and to shorten the stage of excitement.

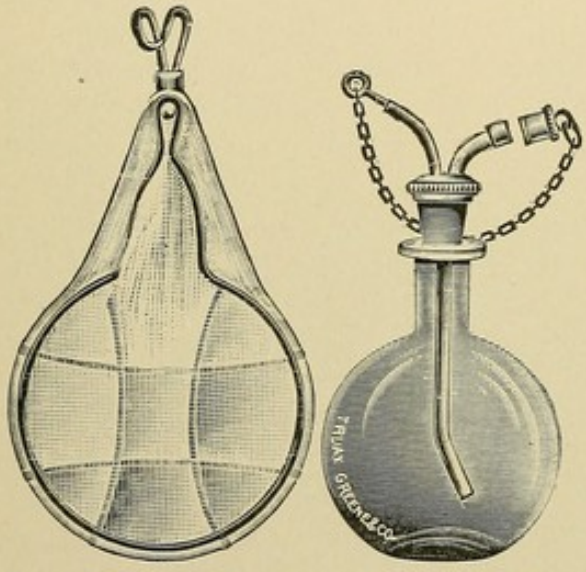

Fig. 1.—Von Esmarch's chloroform inhaler and chloroform bottle.

The mental condition of the patient has an immense influence in hastening or retarding complete anesthesia. The patient who is fearful and lacks faith and confidence will require a much larger quantity of the anesthetic than if the opposite mental conditions prevail. With the exception of a few words of assurance, no conversation should be carried on between the patient and the anesthetizer after the narcosis has commenced. Silence must be strictly enforced. Anxious relatives and useless bystanders should be excluded. Tying of hands or feet or strapping the body on the table must be avoided, as such brutal procedures savor of the time of the Inquisition and institutions for punishment, and have a depressing, if not a revolting, influence on the patient. One or two persons can always control the patient should he become violent. The masks of von Esmarch and Schimmelbusch are excellent media for the administration of chloroform. They are cheap and, what is still more important, clean, as the gauze can be changed every time they are used. The wire frame also can be sterilized by boiling. I have devised an inhaler that can be used for the administration of both chloroform and ether (Fig. 3). It consists of an open cone made of nickel-

plated copper wire, which can be molded into any shape, with a ring over it that holds the towel or napkin in place. If chloroform is used, the cone is covered with gauze, held in place by the ring; if ether is administered, the towel or napkin is made to cover only the side of the cone, a gauze or sea-sponge being placed in the opening, and upon this the ether is dropped continuously until the anesthesia is complete.

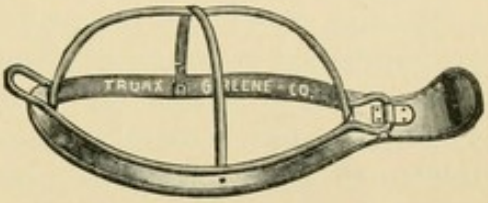

Fig. 2.—Schimmelbusch-von Esmarch inhaler.

An ideal anesthetization is characterized by a good beginning and a happy termination. The secret of success lies in the manner in which it is commenced and the degree of care exercised during its continuance. The most common blunder made by the incompetent anesthetizer is to place the mask on the face and then pour on the chloroform in a stream, strangling, almost suffocating, the patient from the beginning. The anesthesia must be commenced slowly, almost insidiously, without any strangling or great discomfort to the patient. A few drops of chloroform are poured on the mask or, in the absence of such, on a handkerchief folded once or twice and held, for a few minutes at least, four inches from the face, when it is brought gradually nearer,

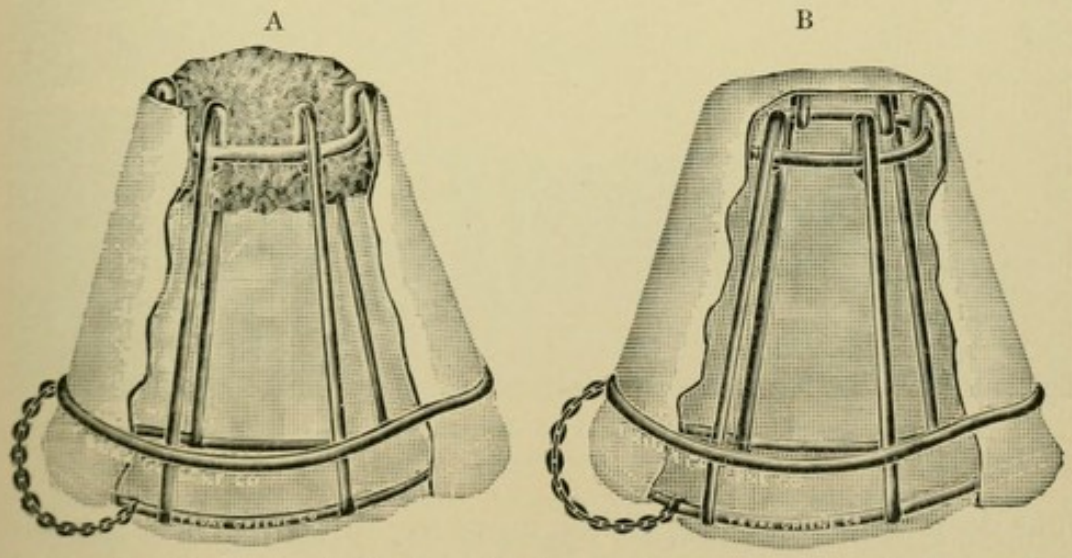

Fig. 3.—Senn's ether and chloroform inhaler; mask open to exhibit wire framework: A, Prepared for ether; B, prepared for chloroform.

but not in contact with the face, until the patient has become accustomed to the irritating effects of the vapor. Chloroform should never be *poured* on the mask: the supply must be exclusively by the *drop method.* Esmarch's bottle or an ordinary bottle loosely corked with a strip of gauze between the cork and the neck of the bottle answers the purpose excellently for this ideal method of administering chloroform.

As soon as the mask has been brought in contact with the face,

the chloroform is dropped upon it continuously, as an abundance of air passes through the loose meshes of the gauze or handkerchief, thus diluting the vapor of the anesthetic and furnishing the necessary amount of oxygen. It is during the beginning of the narcosis that the patient's mind should be occupied and concentrated upon something foreign to the procedure he is undergoing. This can be accomplished in one of two ways: he is asked to count slowly until consciousness is lost, or is requested to hold one of the upper extremities in a vertical position. The loss of consciousness in the latter instance is announced by dropping of the helpless limb. This stage of anesthesia will suffice for short operations and when it is intended to operate under partial anesthesia. If the administration of the anesthetic is not forced, but conducted by the gradual, insidi-

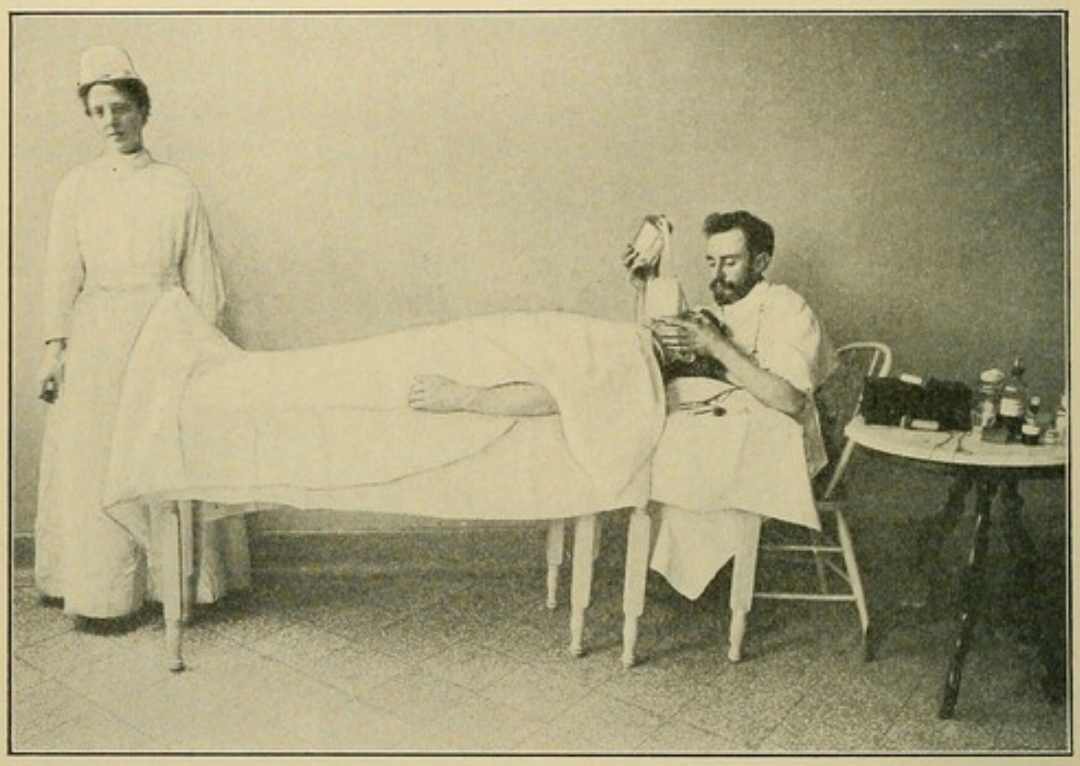

Fig. 4.—Proper position of patient and anesthetizer, and stand for the anesthetics and accessories.

ous drop method, adding a drop every five to ten seconds, patients are usually rendered unconscious in from eight to twelve minutes without much struggling or resistance.

All complicated inhalers are useless and more dangerous than the simple mask or plain handkerchief. Patients who are very apprehensive, fearful, excited, and whose confidence can not be secured, are greatly benefited by an injection of $\frac{1}{4}$ of a grain of morphin ten to fifteen minutes before the anesthesia is commenced, combined, in the case of potators or persons greatly debilitated by disease or the effects of hemorrhage, with a rectal enema of two ounces of spirits, diluted with warm saline solution. In such persons preliminary treatment of this kind diminishes or modifies

favorably the stage of excitement, the terror of the anesthetizer, and of the bystanders. After a few inhalations the patient usually experiences sensations of a pleasant nature, breathing is accelerated, the pulse becoming fuller and more rapid. Temporary suspension of respiration at this stage is not uncommon, but breathing is resumed on making the request. Crile has shown by his experiments that disturbances of respiration during the early stage of anesthesia are remedied very promptly by elevating the head and chest of the patient, while during the later stages the reverse position is more useful. Women, children, persons greatly debilitated, and adults of exemplary habits often pass insensibly into complete anesthesia.

Usually, however, complete anesthesia is preceded by a stage of excitement of variable duration. It is during this stage that the anesthetizer feels keenly the weight of his responsibility. The patient shouts, prays, swears, sings, cries, laughs, or fights, according to his temperament, habits, religious belief, occupation, or social position in life. Tonic and clonic spasms, irregular respiration, and cyanosis are some of the alarming symptoms of this stage. A turbulent stage of excitement may be confidently expected in persons of plethoric disposition and intemperate habits. This stage may subside in a few moments or may continue for ten or fifteen minutes, even for a longer time. Under the continued administration of chloroform by the drop method the excitement and convulsive movements gradually subside, and the narcosis passes into the stage of tolerance, or full anesthesia. This is announced by muscular relaxation, snoring, puffing of the cheeks, and complete loss of consciousness and sensibility. The last reflexes disappear upon the surface of the cornea, mucous membrane of the nose, and in the rectum. The pupil is contracted, the eyeballs make asymmetric movements, the pulse becomes smaller, softer, and more rapid. The body-temperature and blood pressure are diminished, the respirations become more rapid and shallow, and all tissue changes are diminished. This is as far as it is advisable and safe to carry the effect of the anesthetic. It is when this stage has been reached that the assistant who takes more interest in the operation than in the welfare and safety of the patient commits the grossest blunders and places the life of the patient in jeopardy by continuing to pour chloroform on the mask. If the anesthetic is continued without interruption, the paralyzing effect reaches the medulla oblongata, respiration is arrested, the heart ceases to beat—occurrences announced without any other premonitory symptoms than sudden dilatation of the pupils.

The disappearance of the corneal reflex is an indication that the anesthesia has reached the limits of safety, and the further use of the anesthetic must be suspended until there are indications of its return. *Dilatation of the pupils is always a signal of great danger and a strong and unmistakable reminder that the effects of the*

anesthetic have been carried beyond the limits of safety. The administration of the anesthetic must be immediately suspended until the pupils contract and the corneal reflex returns.

Grave symptoms and accidents are most likely to happen in the hands of inexperienced anesthetizers, in nervous, excitable persons, the weak and anemic, obese persons, and subjects suffering from organic disease of the heart, lungs, or kidneys, potators, and the habitual users of opium, chloral, and cocain.

Accidents during Narcosis.—One of the common first ill effects of the anesthetic is a disturbance of the function of respiration. During the first few inhalations the patient often holds his breath, and respiration is renewed by asking the patient to breathe. In other cases the vapor of chloroform provokes a distressing cough, but the cough usually subsides as the anesthesia proceeds. The subjects of bronchitis, pulmonary tuberculosis, and pleuritis are most likely to suffer from this ill effect of the anesthetic. The best way to avoid this untoward effect is to administer the anesthetic from quite a distance and very slowly in the beginning.

Prolonged expiration, interrupted by short inspirations, is objectionable because it interferes with a free entrance of the vapor into the bronchial tubes and consequently retards the complete anesthesia. The regularity of respiration in such cases is usually

Fig. 5.—Husson's sponge holder.

restored by talking to the patient or by a light blow on the chest. Should these fail, raise the body.

Vomiting may occur during any of the stages of narcosis, especially when the stomach of the patient is not empty. A rapid narcosis, by causing salivation, hawking, and coughing, is most likely to produce vomiting during the early stage of the anesthesia. Vomiting may again be produced by the swallowing of the profuse saliva mixed with chloroform or ether. If vomiting is provoked, the head must be turned to one side and on a level below that of the body, to prevent entrance of foreign substances into the air-passages. An abundance of mucus and saliva in the pharynx often provokes vomiting, in which case the removal of the irritating material with the sponge holder is the best and most successful method of preventing or arresting it. Vomiting from a neurotic source can be arrested, according to Joes, by making digital compression of the pneumogastric and phrenic nerves immediately over the sternal articular end of the clavicle. After each attack of vomiting the cavity of the mouth should be cleared of food, mucus, and saliva by wiping with the sponge, towel, or handkerchief before resuming the inhalation of the anesthetic.

If, in spite of all precautions, food should find its way into the air-passages, an immediate tracheotomy may become a necessity. In such an event the trachea above the isthmus of the thyroid gland should be opened by one incision, the trachea being held immovably between the thumb and index-finger of the left hand. A sudden arrest of respiration, which during the beginning of the narcosis is usually overcome by attracting the attention of the patient by talking to him, may become of the most serious import during the subsequent stages of the narcosis. After a few stertorous respirations and stormy, convulsive muscular movements, the rima glottidis is closed by muscular spasm, the abdominal wall makes a few inspiratory contractions, sinks in, and remains board-like. The maxillary bones remain in close contact, and the tongue is displaced upward and backward in such a way that the passage to the larynx is narrowed to an extent incompatible with a normal supply of air to the respiratory passages. The superficial veins of the forehead, temples, and face become turgid, the face purple, and the lips cyanosed. The pulse, at first slow, becomes rapid, and lastly almost imperceptible.

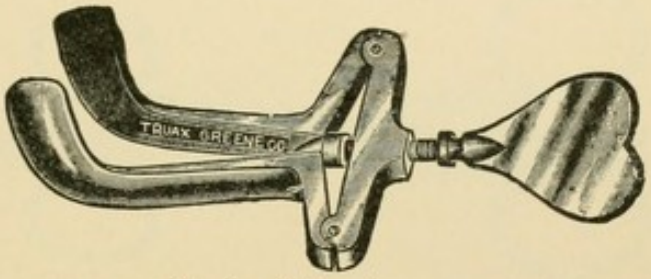

Fig. 6.—Heister's gag.

The cause of approaching asphyxia in such cases is spasmodic contraction of the muscles and larynx. Prompt action is necessary to restore the embarrassed circulation. The mouth must be opened, and this can be done most expeditiously with Heister's or Henrotin's gag; the tongue is grasped and drawn forward with forceps of special construction, or if such are not on hand, with a pair of mouse-toothed hemostatic forceps. My tongue forceps (Fig. 10) combine an infrapressure with a supratenaculum blade, the combination serving to hold a tongue with the least possible injury to the mucous surfaces. The under blade is oval in form, and contains an ovoid fenestra with its sharp angle at its distal end; the faces of the blade margins slant toward the center, giving to the whole blade a slightly concave form. The hooked portion of the blade is about six millimeters in length, and is bent at a right angle to the long axis of

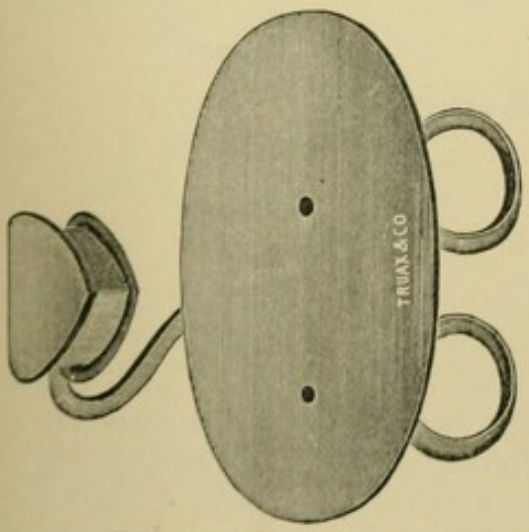

Fig. 7.—Henrotin's gag.

the instrument. The width of the lower blade is seventeen millimeters, and of the fenestra ten millimeters. The instrument is of light construction and is 5½ inches in length. On drawing the tongue forward the air-passage is cleared and the anesthesia continued with additional care. In cases in which the methods just advised can not be employed, and other and more prompt measures must be resorted to, Kappeler has suggested two valuable procedures intended to restore respiration, both of which have been extensively adopted and have been proved to be most satisfactory. The first procedure consists in elevating the lower maxilla, and with it the base of the tongue, epiglottis, and hyoid bone. The method of accomplishing this is well shown in figure 11. The same object is secured by standing in front of the patient and using the four fingers of both hands in the form of a hook, and applying them above the angle of the jaw, making traction in a forward direction.

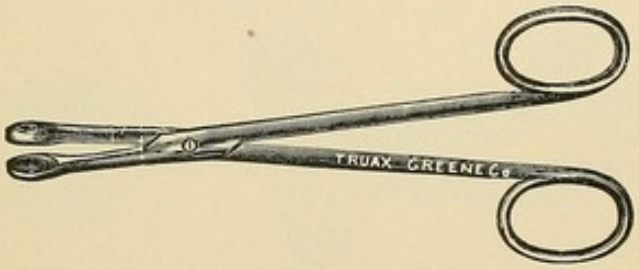

Fig. 8.—Von Esmarch's tongue-holding forceps.

In practising this procedure the mouth should not be opened to any extent, for if this is done, the base of the tongue is not lifted forward, but upward, which would interfere with the free ingress of air into the air-passages. Some care is necessary in making the

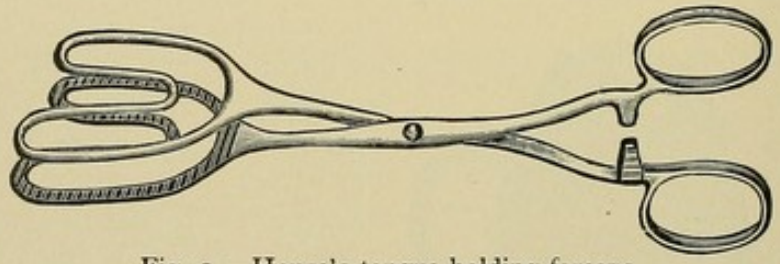

Fig. 9.—Houze's tongue-holding forceps.

manipulations, as otherwise some swelling of the temporomaxillary joints and parotid glands is liable to follow as an unpleasant remote complication. The second suggestion of Kappeler, in such cases where the tongue is difficult of access, consists in the use of a sharp tenaculum, with which the hyoid bone is transfixed through the intact skin, which is then drawn forward, and with it the base of the tongue and epiglottis, thus affording free entrance of air into the lower tract of the respiratory passage with the jaws set.

Fenger has recently elaborated this method of relieving the embarrassed respiration, due to the same cause. If, in relieving the mechanical difficulties interfering with the free entrance of air by the means described, respiration is not promptly restored, the wiper must be used to free the supralaryngeal space of mucus or

blood, which, in such an event, directly causes the mechanical obstruction to the entrance of air. Should this fail to afford the expected relief, a rapid tracheotomy and direct artificial respiration through it according to Fell's method constitute the *dernier ressort* to reestablish the suspended respiration. If respiration is not restored upon the removal of mechanical impediments, as is so often the case when the narcosis is carried beyond safe limits, artificial respiration must be resorted to promptly and continued until respiration is reestablished or all hope of restoring life has vanished. While this is being done, an assistant maintains the patency of the respiratory tract by employing a mouth gag or hemostatic forceps to separate the jaws, and by holding the tongue well forward by forceps or by a ligature passed through the median line near the tip of the organ. While artificial respiration is being made, the foot of the table is elevated so as to incline the body, with the head downward, at an angle of 45 degrees.

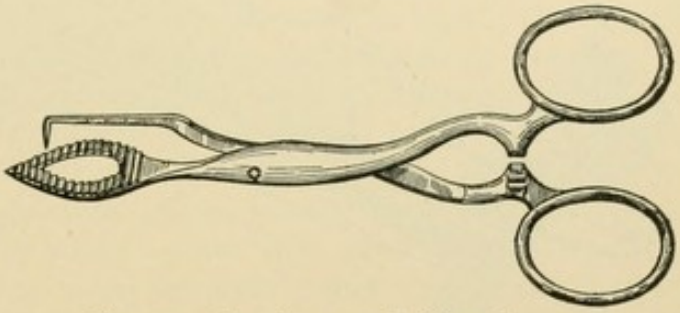

Fig. 10.—Senn's tongue-holding forceps.

The one who makes artificial respiration stands behind the head of the patient, grasps both elbows, with the arms extended, and by traction brings the arms to the side of the head so as to expand the chest-wall to its utmost. Then the movement is reversed by bringing the arms, with forearms flexed, to the sides of the chest, which is then forcibly compressed for the purpose of forcing out from the air-passages as much as possible of the contained air. These movements must be made deliberately and not spasmodically. This is Sylvester's method, the only one of the many methods of artificial respiration that have been suggested which is entitled to confidence in such cases. The respiratory movements are repeated eighteen to twenty times a minute, resembling in this respect normal respiration. Nothing is gained by increasing the frequency.

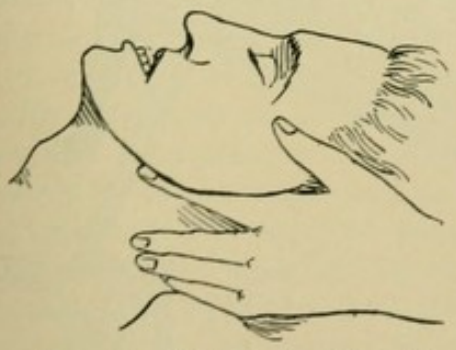

Fig. 11.—Method of pushing the lower jaw forward to prevent obstruction to breathing.

The success of artificial respiration depends on the thoroughness with which every movement is made. If respiration is not restored promptly, there is no reason for despair, as success has followed efforts continued for half an hour or more. The efforts

should be continued for at least half an hour unless unmistakable evidences of death make their appearance and warrant suspension of further efforts at resuscitation.

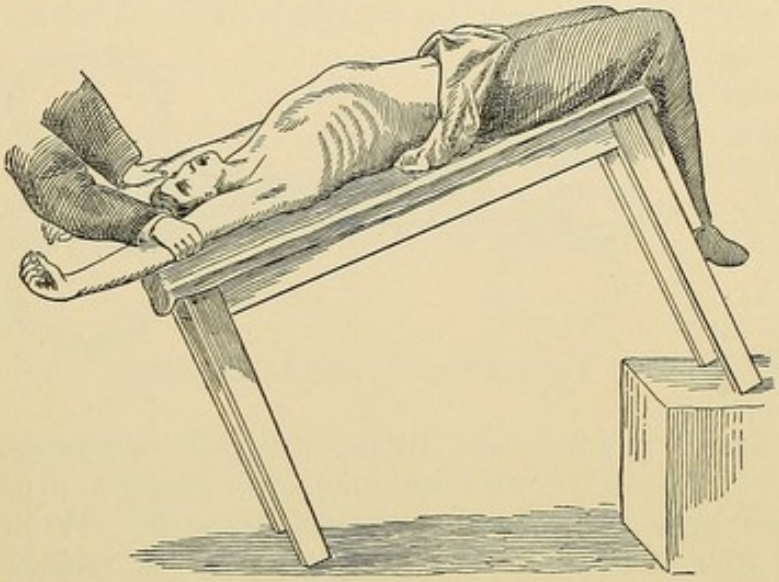

Fig. 12.—Sylvester's method of performing artificial respiration.

During the time attempts are being made to restore respiration, other means of counteracting the toxic effect of chloroform are employed. The most potent physiologic antidote of chloroform is strychnin. Horatio C. Wood advises heroic doses. In adults the first dose should not be less than one-sixth of a grain by subcutaneous injection. This may be safely repeated in ten or fifteen minutes if the nervous centers do not respond to the first dose. Inhalations of nitrite of amyl stimulate the heart's action and are well calculated to relieve the stagnant capillary circulation. Slapping the chest with a towel wrung out of cold or hot water and rubbing of the extremities are valuable agents in accomplishing the same object. Faradization of the phrenic nerve (Duchenne, von Ziemssen) is another valuable resource in restoring respiration temporarily suspended by the toxic action of chloroform on the respiratory center. The two electrodes are applied, one on each side of the neck over the clavicle, at the outer border of the sternocleidomastoid muscle.

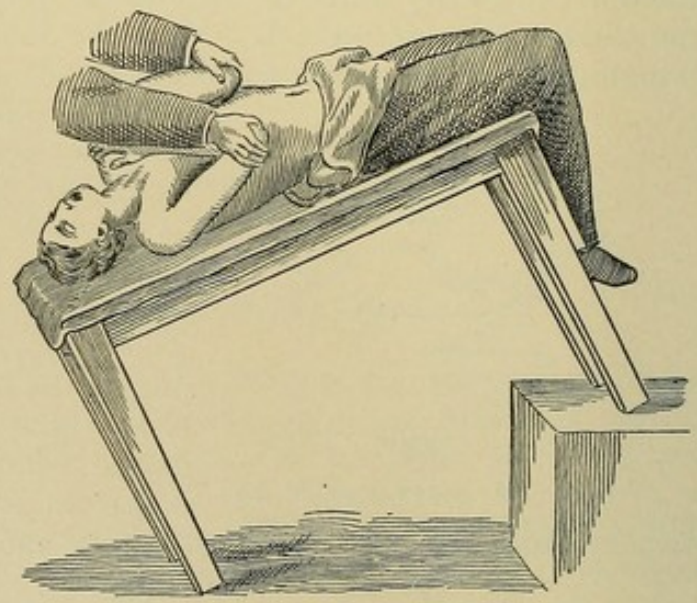

Fig. 13.—Sylvester's method of performing artificial respiration.

Although the immediate cause of death from chloroform is generally its toxic action on the center of respiration, alarming and

fatal complications may set in which are directly referable to its depressing effect on the heart muscle. Such accidents occur usually when least expected, and with a suddenness that is appalling. In a moment the color of the face is changed to a deadly pallor; the pupils dilate and do not respond to light; the corneal reflex disappears; the lower jaw drops, cadaver-like; the pulse is either very small, rapid, and flickering, or imperceptible; the heart-sounds are inaudible; bleeding in the wound ceases; respiration, although shallow and irregular, may continue for a short time until it ceases after a few spasmodic efforts, similar to those observed in a dying person. Such a terrible scene is fortunately very rare, and when it does occur, it is most frequently met in anemic patients and in those the subjects of organic disease of the heart. Nevertheless, it may occur in persons in perfect health, more especially if they are apprehensive, nervous, and excited before the operation.

Prompt action is urgently indicated in all cases of anesthesia in which heart depression follows as one of the toxic effects of the anesthetic. Inversion of the body, suggested first by Nélaton in 1861, is the first measure to be performed in such cases. To accomplish this in the shortest possible space of time the foot-end of the operating table is elevated to an angle of at least 45 degrees. This position relieves the existing cerebral anemia, and by doing so the heart center, and the heart likewise, is stimulated by the increased supply of blood. The patient is, at the same time, placed most favorably for artificial respiration, which becomes necessary if there is, as is so often the case, an inhibition of the respiratory function. Heart stimulants by hypodermic injection are always indicated. Of these digitalis, strychnin, alcohol, camphor, and coffee will prove most effectual. Tincture of digitalis or digitalin, the former in half-dram doses, the latter in doses of from $\frac{1}{100}$ to $\frac{1}{50}$ of a grain every ten or fifteen minutes until reaction takes place, will prove most successful. In very grave cases it should be combined with strychnin in decided doses. Camphorated oil, administered in the same way, in doses of two or three syringefuls, is a very powerful cardiac stimulant and entitled to confidence in such cases. Alcohol in the form of whisky, brandy, cognac, or rum, can be given at short intervals by subcutaneous injections or by the rectum. The application of dry heat to the extremities and trunk should never be neglected. Friction with hot cloths is a potent vascular stimulant and will be useful in aiding the other remedies in restoring the general circulation.

Heart massage, as advised by König, will accomplish much in stimulating the organ to renewed action. The one who attends to this part of the resuscitation of the patient stands on the left of the patient and makes compression with the ball of the right thumb between the apex-beat and the left margin of the sternum. The compressions should be firm and rhythmic, at the rate of 120 a minute, and should be continued until return of the pulsations in

the carotid artery is noticeable and the pupils contract. Intravenous infusion of normal salt solution will undoubtedly yield encouraging results in desperate cases.

The treatment outlined must be continued until the pulse at the wrist returns in fair volume and the pupils contract. In fatal cases the treatment should be continued for a sufficient length of time to satisfy the operator and those who are later called upon to investigate the cause of death, that everything known to science was done to restore the patient to life.

Ether Anesthesia.—Sulphuric ether, $C_4H_{10}O$, was introduced as a general anesthetic by Jackson and Morton in 1846. The first operation under ether anesthesia was performed in the Massachusetts General Hospital, and the sponge used is one of the many precious relics in medicine and surgery carefully preserved in that institution.

Ether for anesthetic use should contain no alcohol, water, acetic acid, sulphuric acid, or fusel oil. If the purity of the ether is questionable, tests for these substances should be made. Ether is one of the most volatile of all liquid substances, and the vapor is quickly absorbed by the mucous membrane of the air-passages. The odor of the strong vapor is pungent, and when the vapor is brought in contact with mucous surfaces, it produces a marked irritation and hypersecretion.

The physiologic effect of ether is closely allied to that of chloroform, differing, however, from the latter in that the intracranial blood supply is rather increased than diminished under full anesthesia and it is less likely to cause depression of the heart's action. The ultimate toxic effects on the brain and spinal cord are almost identical with those of chloroform, and hence its use demands the same preliminary preparations and precautions during its administration.

The disadvantages of ether as compared with those attending and following the administration of chloroform consist in the well-known profuse salivation, coughing, vomiting, and greater hyperemia of important internal organs. While the immediate mortality of ether anesthesia is less than that of chloroform, there is but little doubt that the difference would be more than balanced by the greater number of deaths from complications following its use, such as ether bronchitis and pneumonia and ether nephritis. I have seen a number of such cases in my own practice, and have knowledge of others that occurred in the practice of my colleagues, cases in which there could be no doubt that the deaths were caused by complications resulting from the remote irritating or toxic effects of ether. Such remote causes of death attributable to the anesthetic must necessarily occur most frequently in the practice of surgeons who use ether exclusively, and who do not look for or ignore the contraindications for its employment. It is equally certain that deaths, immediate and remote, from ether anesthesia occur

with greater frequency when the anesthetic is given quickly and carelessly than when administered slowly and carefully by an expert. It is a very serious mistake to administer pure ether vapor from the very beginning, as is done by many, with the expectation of hastening the narcosis. All such attempts are productive of intense irritation of the upper air-passages, profuse salivation, coughing, and very often vomiting and violent attempts to secure relief by removing the cone.

It has been claimed that a certain amount of ether is necessary to produce anesthesia, and that the sooner it reaches the circulation, the prompter the narcosis. Those who support this view are of the opinion that in ether anesthesia the admixture of air is not only unnecessary, but that it retards the narcosis without increasing its safety. Such arguments are no longer tenable. *The safest way to administer ether is to proceed slowly and dilute the vapor with a liberal admixture of air. All cones made of impermeable material should be avoided.* The mask devised by me is constructed on the principle of administering ether well diluted with atmospheric air continuously. All complicated devices for ether inhalation should be avoided, as enough air should be admitted to dilute the vapor sufficiently to diminish its irritating qualities and to supply the blood with a sufficient quantity of oxygen so long as the patient remains under the influence of the anesthetic.

The best ether inhaler is an open cone made of a starched towel or stiff paper placed over a wire framework. The opening in the apex of the cone should be at least three inches in diameter and loosely packed with a sponge, loose gauze, or a small handkerchief. The absorbent material is saturated with ether from the inside of the cone. The cone must be held at least six inches from the face, and as the patient becomes accustomed to the odor of the ether it is brought slowly nearer, until it rests evenly on the surface and close enough to prevent the entrance of air underneath it. This part of the anesthetization should be done without causing any great struggling on the part of the patient, after which the cone remains in place until the anesthesia is complete. The ether is poured on the absorbent material in small quantities, through the perforation in the cone, at intervals of ten seconds, thus continuing the inhalation from the beginning until the completion of the anesthesia without interruption unless symptoms arise which necessitate temporary suspension.

It is a very common experience when anesthesia is progressing favorably that when the cone is removed for the purpose of adding a new supply of ether, a sense of suffocation, as soon as the cone is applied to the face, brings with it a renewal of the disagreeable manifestations aroused during the beginning of the etherization.

It must not be forgotten that ether is a highly inflammable substance, and on this account special care must be exercised in its use in operations by the aid of lamplight and in the use of the

Paquelin cautery near the ether cone. Accidents during ether narcosis are met by the same treatment as has been described under the head of Chloroform Anesthesia. The subject of general anesthesia may be summarized briefly as follows:

Proper preparation of patient; adequate supply of the different antidotes and means of restoring suspended respiration; pure anesthetics and slow, continuous inhalation; dilution of the vapor with a liberal supply of air; unremitting vigilance and prompt, efficient, and persistent treatment when unfavorable or alarming symptoms make it necessary to interrupt the anesthesia.

Local Anesthesia.—A safe local anesthesia is the ideal condition under which to operate, as it relieves the operator from all anxiety regarding the dangers incident to the administration of a general anesthetic. Much progress has been made during the last decade in enlarging the field for operations and in intensifying the degree of anesthesia, but most of the major operations are performed in localities not adapted for local anesthesia and require too long a time to come within the practical range of local anesthetics. For these reasons it is more than doubtful that local anesthesia will ever entirely displace general anesthesia. The temporary suspension of the function of the brain during most of the capital operations is a benefit to the patient and a source of comfort to the surgeon.

Local anesthesia is a desideratum that has been sought for years. The first efforts in this direction consisted of firm pressure on the main nerve-trunks of the part operated upon, which was expected to interrupt, at least to a certain extent, peripheral impressions. This was aided in some cases by circular constriction, which increased the anesthetic effect of compression by retarding or arresting the circulation in the field of operation. This primitive method of procuring local anesthesia did something in the way of diminishing pain. The next step in the same connection consisted in making use of cold as a local anesthetic. This agent came into use from the well-known fact that in tissues partly or completely frozen sensation is suspended. Ice alone applied for a sufficient length of time produces a decided local anesthetic effect which includes the whole thickness of the skin. The degree of cold is increased, and its anesthetic properties intensified, by mixing common salt with crushed ice. The ice and salt should be well mixed and applied in a gauze bag or in a towel. As soon as the skin is whitened by the cold, an incision can be made through it with little or no pain. This is one of the simplest and at the same time most efficient procedures for preventing pain in excising small tumors of the skin and in incising superficial abscesses.

The next advance made in the use of local anesthetics consisted in the substitution of highly volatile fluids for ice. Richardson used sulphuric ether in the form of a spray. An ordinary hand spray answers an excellent purpose. Under the action of the spray

the skin is partly frozen in a very few seconds, and a small incision can be made without causing any pain. The anesthetic area in this method of local anesthesia is small, as the spray must be concentrated for the purpose of producing the anesthetic degree of cold. During the local reaction from the freezing process the patient experiences a prickling pain in the part, which can be relieved to some degree by immersion in warm water. More effective than ether are the chlorids of methyl and ethyl. The first is applied to the skin in a compress saturated with it and held against the part to be frozen. The area of anesthetization is regulated in this instance by the size of the compress, possessing in this respect a decided advantage over the ether and chlorid of ethyl spray. This local anesthetic was introduced by Bailly. Chlorid of ethyl is so volatile that it boils at the temperature of the body. For local anesthesia it is

Fig. 14.—Small glass tube of chlorid of ethyl.

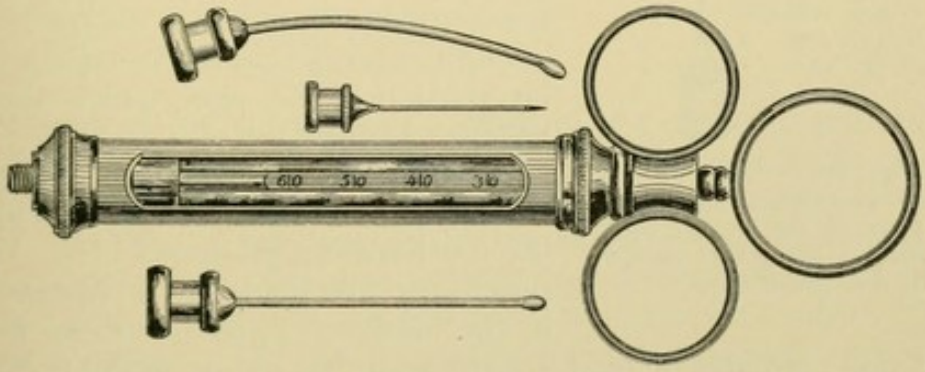

Fig. 15.—Lewis' needles and syringe for infiltration anesthesia.

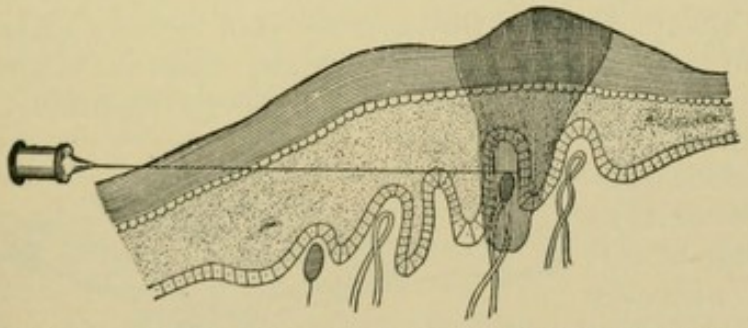

Fig. 16.—Infiltration anesthesia. The syringe point stops at the papillary layer, and the fluid lodges in the skin itself (Van Hook).

put up in glass tubes (Bengué), with a neck supplied with a metallic attachment from which the spray escapes under body-temperature on removing the metallic cork (Fig. 14). In using the spray the tube is held for a few moments in the hollow of the hand, when the cork is removed and the spray begins. The indications for the use of the chlorid of ethyl spray are the same as for the ether spray.

Cocain (Koller) is one of the most recent and useful of local anesthetics. Applied to mucous surfaces in solution of from 2 to 10 per cent. it produces a complete superficial anesthesia in from three to five minutes. It is used most extensively in ophthalmic work and in operations upon the mucous membrane of the nose, pharynx, larynx, and external genitals. The surface must be carefully cleansed before the solution is applied. It has no effect on the intact skin. To procure anesthesia of the skin it is necessary to inject the solution *into* it, and not *under* it, as is so often done. If a certain area of skin is to be anesthetized, the injections are to be made with a hypodermic syringe with a fine point, under the strictest precautions, using, in preference, a fresh solution, the asepticity of which can be depended upon. The needle-point is entered obliquely, and enough fluid is injected to raise a circular portion of the skin, which then resembles a blister.

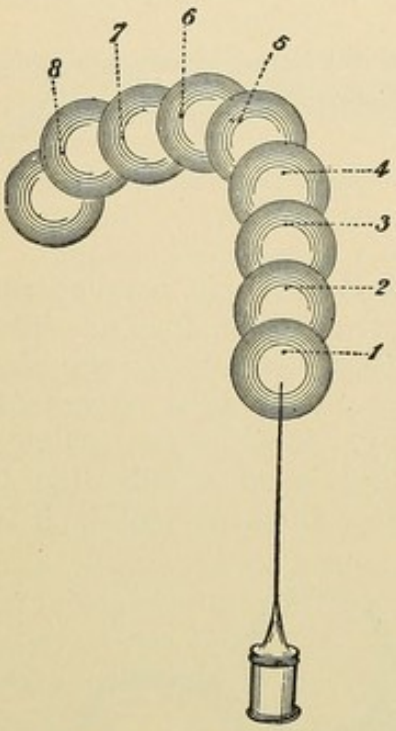

Fig. 17. — Showing how the successive wheals are raised, the point of the syringe being inserted at the points marked by the dots (Schleich).

Tension is an important element in the anesthetization of the skin, as well as the local anemia produced by it. These punctures are made in a straight line if the incision is to be made in this direction ; circular or oval, according to the nature of the operation, and sufficiently close together so that the different centers of local anesthesia touch each other. After the first puncture is made, the needle is always inserted through the skin already anesthetized.

Cocain is no indifferent drug. Many cases of severe intoxication and a few deaths from its use have been reported. In operations requiring extensive cocainization it is well to constrict the blood-vessels, wherever this can be done, by elastic constriction, so as to guard against its early and free entrance into the circulation. The toxic effects of cocain are manifested by pallor, dizziness, fainting, headache, and delirium, symptoms which should always place the surgeon on guard and which demand immediate suspension of its further use. To relieve the condition nitrite of amyl must be administered by inhalation,

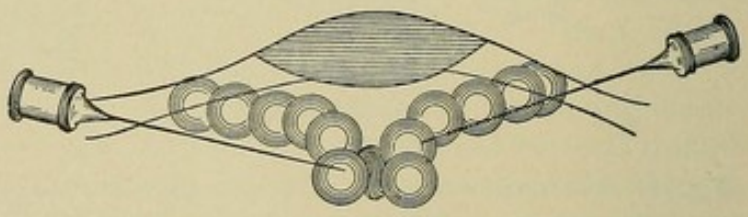

Fig. 18.—Showing mode of injecting the fluid under an abscess (Schleich).

to be followed, if the patient does not rally promptly, by subcutaneous injections of strychnin and alcohol by the mouth or rectum.

For subcutaneous use the cocain solution has been displaced almost entirely by Schleich's infiltration method. This method consists in the use of cocain and morphin in small doses, in normal salt solution sufficient in amount to produce the necessary degree of tension and local anemia. Schleich recommends the following solutions, which are known as No. 1, 2, and 3, according to their strength.

Schleich's Solution.—

No. 1, Strong.—Cocain muriate,	0.2	gm.	(3 gr.)
Morphin muriate,	0.025	gm.	($\frac{2}{5}$ gr.)
Sodium chlorid,	0.2	gm.	(3 gr.)
Sterilized water,	100	c.c.	($3\frac{2}{5}$ fl.oz.).
No. 2, Normal.—Cocain muriate,	0.1	gm.	($1\frac{1}{2}$ gr.)
Morphin muriate,	0.025	gm.	($\frac{2}{5}$ gr.)
Sodium chlorid,	0.2	gm.	(3 gr.)
Sterilized water,	100	c.c.	($3\frac{2}{5}$ fl.oz.).
No. 3, Weak.—Cocain muriate,	0.01	gm.	($\frac{1}{6}$ gr.)
Morphin muriate,	0.025	gm.	($\frac{2}{5}$ gr.)
Sodium chlorid,	0.2	gm.	(3 gr.)
Sterilized water,	100	c.c.	($3\frac{2}{5}$ fl.oz.).

To each of the solutions two drops of a 5 per cent. solution of carbolic acid may be added if they are intended for stock solutions, to preserve them in a more nearly perfect antiseptic state.

Of the No. 1 solution as much as 6½ fluidrams may be injected during one operation; of the No. 2 as much as $3\frac{2}{5}$ fluidounces; and of No. 3 even a pint has been used with safety. The normal solution is the one generally used, the strong and weak solutions being applicable only in exceptional cases.

In infants and children a general anesthetic is preferable to local infiltration by Schleich's method. Injections of cocain solution into any of the mucous passages, more particularly the urethra, are attended by great danger of intoxication, and, on the whole, are objectionable on this account. In operations extending beyond the skin the infiltration is repeated as often as required, always bearing in mind the quantity of the solution used. In this manner many tedious operations, such as thyroidectomy (Kocher), can be performed almost painlessly.

Eucain.—Eucain has recently come largely into use as a substitute for cocain as a local anesthetic. It is claimed, and apparently for good reasons, that it produces local anesthesia as satisfactorily as cocain, without depressing the action of the heart, one of the great disadvantages of cocain. Eucain A, the first preparation used, was found unreliable, and has given place to eucain B, which in a 2 per cent. solution injected along the line of the cutaneous nerves produces complete local anesthesia. A syringeful of a 2 per cent. solution (twenty minims) is injected into the subcutaneous tissues in three or four places, and the syringe is again filled and

used to moisten the wound or inject if necessary—forty minims in all. Anesthesia is produced almost instantly, and lasts at least half an hour—long enough to perform minor operations.

CHAPTER IV.

PROPHYLACTIC HEMOSTASIS.

THE intelligent selection and employment of appropriate and efficient prophylactic measures are as important and of as far-reaching value in surgery as in medicine. The surgeon who is in possession of the necessary degree of knowledge to anticipate certain unfavorable results in the case of accidental injuries and of operations, and who employs timely and rational treatment calculated to prevent them, is the one who is master of the situation and who will benefit his patients to the greatest extent; his work will be a credit to himself and to the profession to which he belongs.

Hemostasis and the prevention of wound infection are the two subjects in prophylaxis in which the modern surgeon is most deeply interested. The wounded are safe in the hands of the surgeon who knows how to prevent and arrest hemorrhage, and who is familiar with the technic of antiseptic and aseptic precautions. Emergency surgery deals necessarily largely with hemostasis and the prevention of wound infection. Every practitioner of medicine should be fully conversant with these subjects if he expects to merit the confidence of his profession and of his clientele. Prophylactic hemostasis has been developed to a wonderful degree of perfection during the last quarter of a century. The numerous resources for the prevention of hemorrhage that are at our disposal at the present time have contributed much toward the development of modern aggressive surgery. They have converted the bloody operating theater into an almost bloodless dissecting room. They have enabled surgeons to perform operations of which they never dreamed before they came into use. For the time being they transform the part to be operated upon into a bloodless cadaver. Anesthesia and prophylactic hemostasis have largely done away with the necessity of reckless, rapid operating. With the patient anesthetized and the part to be operated upon rendered bloodless, the surgeon can now proceed slowly and carefully, imitating the anatomist in making a difficult dissection in all cases in which great care and delicacy are required in the performance of the operation. The surgeon who is familiar with the use of the various prophylactic hemostatic resources will perform operations from which others not in possession of such knowledge would shrink. The best surgical work is done by men who can perform

the most difficult operations with the least possible sacrifice of blood. Bloodless operating not only saves valuable tissue for the patient, but it places the operator in a position to apply with advantage his knowledge of anatomy to the utmost extent in the treatment of injuries and in the removal of diseased tissue the presence of which furnishes the indication for the operation.

The simplest prophylactic hemostatic agent is elevation.

Elevation.—The influence of the force of gravitation on the blood supply of a limb becomes apparent by placing the arm in different positions. If one of the upper extremities is allowed to hang by the side of the body and the muscles are fully relaxed, the veins

Fig. 19.—Elevation of the upper extremity in the treatment of hemorrhage.

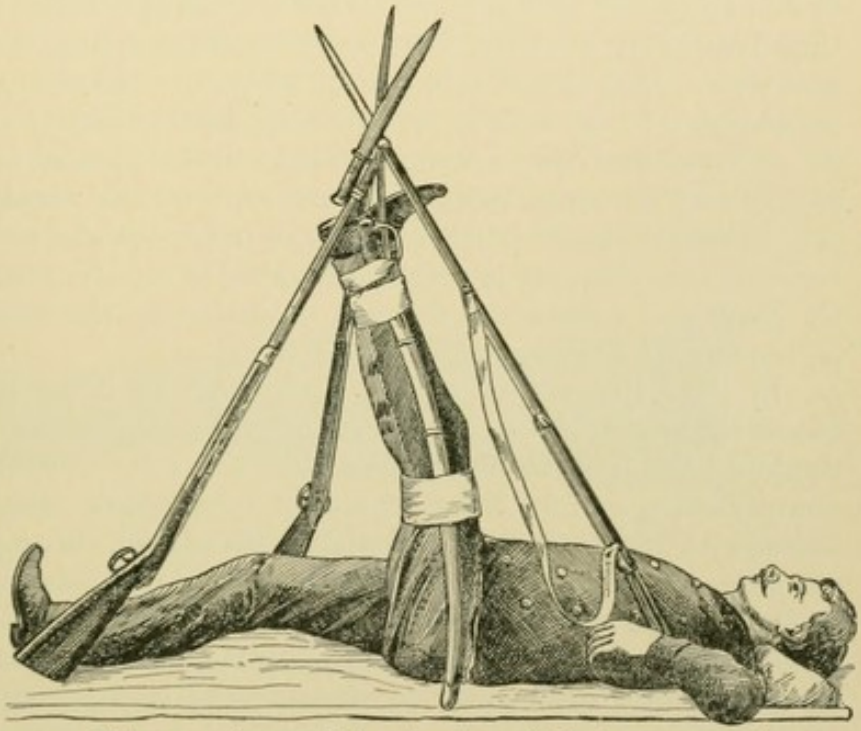

Fig. 20.—Gun-stack for elevation of the lower extremity.

become turgid, the capillaries distended, the volume and force of the radial pulse are markedly increased, and a sense of fullness and weight is experienced. If the arm is now elevated and held in the vertical position (Fig. 19), within a few minutes the cyanosed appearance of the skin vanishes and gives way to pallor, the overdistended veins collapse and are no longer visible, the radial pulse loses much of its volume and force, and the sense of weight and fullness is promptly relieved. The arterial blood supply to the elevated limb is diminished and the return of venous blood favored—vascular conditions best calculated to relieve the capillary engorgement.

Elevation is not only a valuable hemostatic agent in preventing and arresting hemorrhage from the vessels of the extremities,

but it can also be resorted to with advantage in the treatment of wounds or in operations upon the skull and pelvis. Elevation of the head has a potent influence in diminishing the blood supply to the scalp and cranial contents, and is always resorted to in performing operations upon the skull. Trendelenburg's position is a valuable prophylactic hemostatic resource in operations upon the pelvic organs. The same degree of elevation with the body in the ventral position should be made use of in extirpating the rectum, as it exerts a marked influence in minimizing venous hemorrhage.

Elastic Constriction.—Some form of elastic constriction is now generally practised in rendering bloodless the part that is injured or that is to be operated upon. As is the case with nearly all great discoveries, attempts in the same direction foreshadowed the labors of von Esmarch, but it required the genius and influence of that distinguished surgeon to perfect the procedure and to give it a permanent and wide place in the practice of surgery. Elastic constriction in some form, in preventing or arresting hemorrhage in the treatment of wounds and the operative removal of diseased tissues, is so simple and so satisfactory a procedure, and the means required are so accessible, that it is now in almost universal use, and the different forms of tourniquets heretofore employed for the same purpose are for good and substantial reasons regarded by the modern surgeons as objects of antiquity.

In 1852 Clover was on the very verge of being the inventor of bloodless surgery. In a case of hip-joint amputation, Joseph Bell rendered the limb to be removed bloodless by elevation and elastic compression, and for the purpose of temporarily displacing a large volume of blood from the general circulation, brought the opposite limb into a hanging position and made circular constriction at its base. He applied the circular constriction on the wrong side, according to the practice at the present time. The constrictor was tightened only sufficiently to obstruct the venous circulation, so as to exclude temporarily as much blood as possible from the general circulation. At the completion of the operation the patient's pulse became feeble, but improved on removing the constriction and on the return of the excluded blood into general circulation. A very ordinary case led von Esmarch to devise elastic constriction as a prophylactic hemostatic resource. The case was one of acute swelling of a finger caused by the wearing of a finger-ring. With a strong thread he made compression below the constriction, winding the thread tightly around the finger from its tip as far as the ring, placing the turns close to one another, and then passed the thread through the ring, and, on making traction laterally, removed the ring without any difficulty.

When elastic constriction was first introduced as an aid to the surgeon, its inventor aimed at rendering the tissues on the distal side of the constrictor perfectly bloodless by applying compression with an elastic bandage from the periphery of the limb to the point

of constriction. This part of the technic of "bloodless" operating is not only unnecessary, but harmful. It has been shown that under a justifiable degree of compression the part can not be rendered absolutely bloodless. P. Bruns made careful experiments to determine the amount of blood contained in an extremity after amputation under elastic constriction without elastic compression. He found that the leg and foot of an adult only contained 146 c.c. of blood. If elastic compression is used, about 70 per cent. of this amount is saved. The cases are therefore exceptional in which the surgeon should resort to elastic compression for the purpose of saving so small a quantity of blood. Besides, elastic compression employed in the operative treatment of a recent injury or of an infective inflammation might force pathogenic microbes from the wound or the inflammatory focus into the general circulation, thus adding a general to a local infection, with all the additional risks incident to such a condition. In operations for malignant disease—carcinoma or sarcoma—it might force tumor-cells into the surrounding tissues, or through the lymphatics or blood-vessels into the general circulation, thus causing local, regional, or general dissemination of the disease. These two sources of danger are not

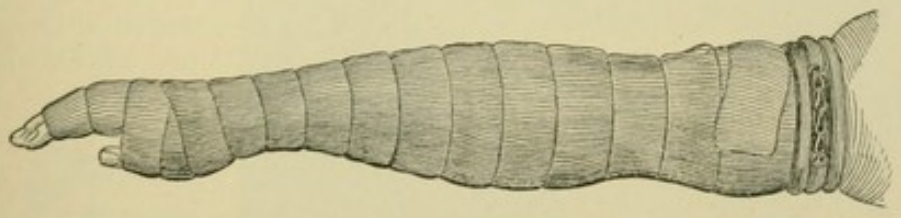

Fig. 21.—Esmarch's method of applying elastic constriction.

imaginary, but real, and every surgeon with a large experience can recall instances in which elastic compression could be made answerable for the diffusion of an inflammatory process or the dissemination of malignant disease. Fortunately, Lister's experiments on the horse have demonstrated that for all practical purposes bloodless operations can be made without the use of the elastic bandage by simply holding the limb in a vertical position for a few minutes prior to the application of the elastic constrictor. Exceptions to this rule are furnished by operations for large aneurysms subjected to treatment by excision, where elastic compression, if it can be made use of, will become the means of saving a large amount of blood and will, in addition, facilitate every step of the operation. Ordinarily, the necessary degree of bloodlessness is secured by holding the limb in a perpendicular position for five minutes, when elastic constriction is applied above the part to be subjected to operative interference. If an anesthetic is used, elevation of the limb and the application of the elastic constrictor should not be done before the patient is thoroughly under the influence of the anesthetic, as muscular relaxation is a material aid in bringing about

the desired degree of local anemia. Local anemia can be further increased by rubbing the limb firmly in the direction of the venous current.

The Elastic Constrictor and its Application.—Elastic constriction of the fingers, toes, and penis can be made efficiently and safely by using elastic bands, such as are for sale by stationers. Two or three turns of the band are ample, and instead of tying it in a knot or loop it is much better, when the necessary degree of constriction has been reached, to cross the band and apply a pair of hemostatic forceps at the point of crossing. In constricting the limbs above the base of the fingers and toes Esmarch's constrictor is the one usually employed. It consists of a strong band of rubber an inch in width, on one end of which is attached a chain and on the other a hook. Some surgeons have been in the habit of using a small, solid-rubber cord or rubber tubing of small size as an elastic tourniquet. Both of these forms of elastic constrictor are objectionable, as in either instance linear constriction is made, which, particularly if the force employed be excessive, as is so often the case, is so liable to cause temporary or even permanent damage to some of the important tissues interposed between the skin and the underlying unyielding bone. The compression should cover a surface at least two inches wide, in order to distribute the pressure over a larger area, in which event important structures are more likely to escape injury.

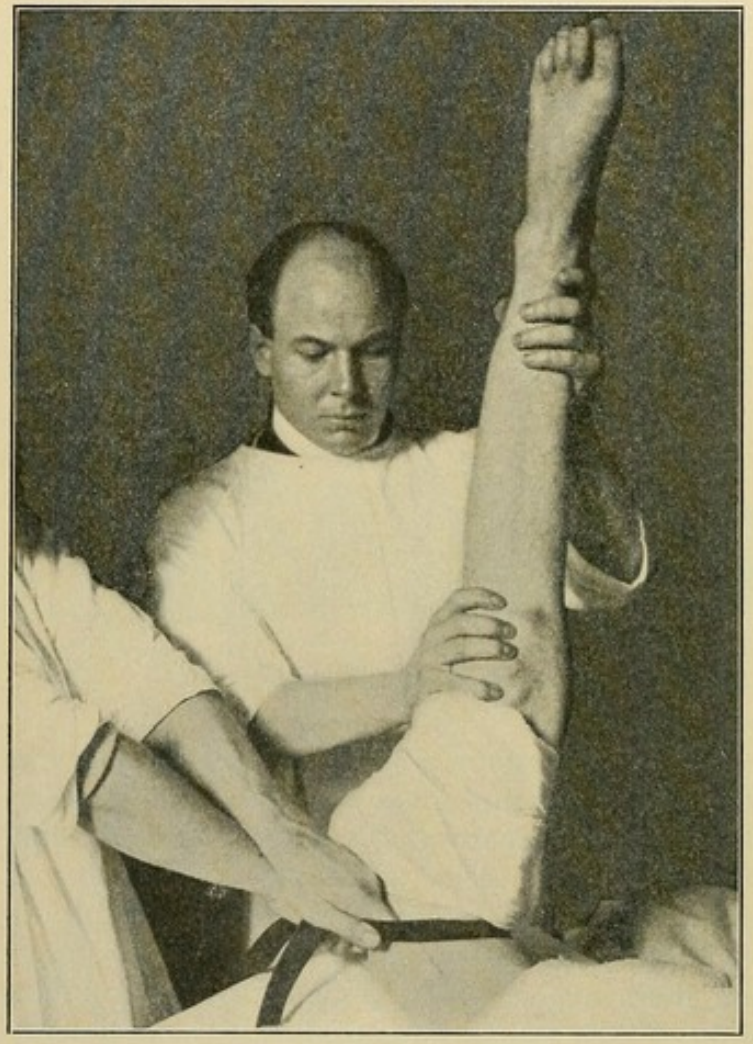

Fig. 22.—Proper method of applying the elastic constrictor.

Aside from Esmarch's constrictor, the best elastic tourniquet consists of a strong band of rubber-webbing bandage at least two

inches in width, of which never fewer than two turns are applied side by side. In the absence of such material a soft-rubber tube one-half an inch in diameter, an ordinary rubber bandage, or an elastic suspender should be used. The constrictor should be applied at a point where the large nerve-trunks are amply protected by a thick cushion of muscle tissue—that is, near the base of the

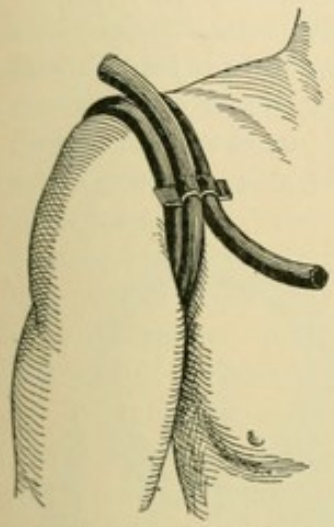

Fig. 23.—Elastic constriction of upper extremity (after Seydel).

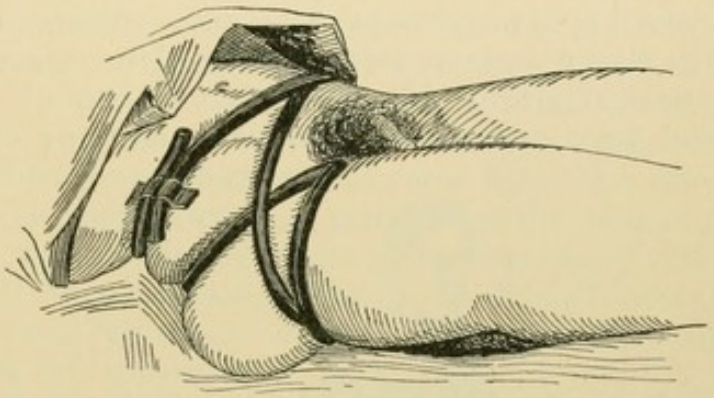

Fig. 24.—Elastic constriction of lower extremity (after Seydel).

Fig. 25.—Elastic constriction of thigh.

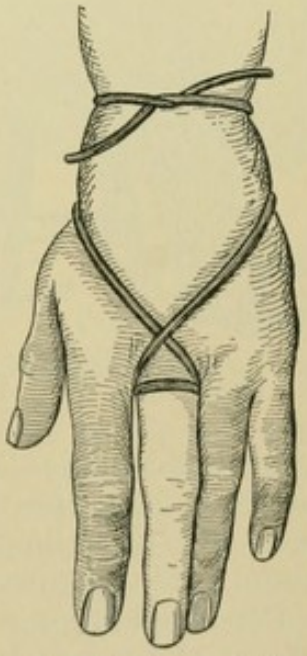

Fig. 26.—Elastic constriction of finger.

limbs. As soon as the limb has been drained of its blood to the requisite extent by position and massage, the constrictor is applied with sufficient firmness to interrupt at once both the arterial and venous circulations. Simple as this advice may sound, it is nevertheless true that frequent mistakes are made in properly applying

the constrictor, even in well-regulated clinics. The limb must be held immovably by an assistant (Fig. 22). The middle of the constrictor is applied where constriction is first to be made, and is grasped with the forearms crossed in such a manner that the two hands are not more than four inches apart. It is of the utmost importance that the pressure should first be made on the side of the limb where the principal blood-vessels are located. If pressure is made first on the opposite side of the limb, the superficial veins are constricted first, and before the arterial circulation is interrupted the limb, when fully constricted, presents a cyanotic appearance, caused by an intense passive venous stasis. If, on the other hand, the elastic pressure is applied in such a manner as to intercept the principal arterial blood supply first, venous return in the superficial veins is not interfered with until the circular constriction is completed, and the limb below the constriction is then comparatively bloodless, and remains so after the application of the constrictor.

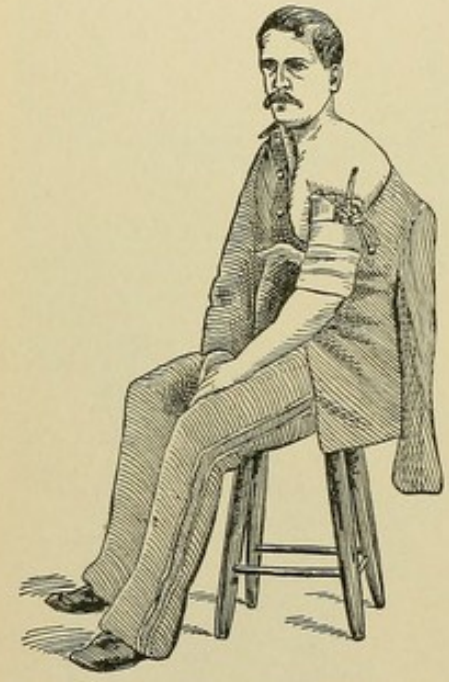

Fig. 27.—Suspender constriction of arm.

Some tact and experience are necessary in determining the force required to interrupt quickly and completely the arterial and venous circulations. Elastic pressure is deceptive, and it is much more frequently the case that too much pressure is made than the reverse. Less force is required, of course, when the main blood-vessels are near the surface and close to a bone than when a thick layer of muscles is interposed between skin and blood-vessels, or between blood-vessels and the underlying bone. Pressure beyond the required degree, especially if continued for an hour or more, is liable to result in injury of muscles and nerves, and should be carefully avoided. Instead of using the chain or tying the constrictor in a knot it is better, after encircling the limb at least twice, to cross the constrictor and fasten it between the blades of a heavy hemostatic forceps.

For how long is it safe to exclude the circulating blood from a limb by elastic constriction? This is an exceedingly important practical question. Clinical experience can not be relied upon exclusively in giving a satisfactory answer. There are cases on record in which elastic constriction in accident-cases was continued for from seven to twelve hours without having caused gangrene, but the cases are more numerous in which a much shorter period of elastic constriction has resulted disastrously. The danger of gangrene from elastic constriction is, of course, much greater when

employed for the purpose of arresting traumatic hemorrhage than when used as a prophylactic hemostatic in the operative treatment of chronic affections. Unimpaired general health and normal blood-vessels are conditions most compatible with the safety of prolonged constriction. With a view to throwing additional light on the element of time in the use of elastic constriction I made, a number of years ago, sixteen experiments on dogs. The exclusion of the circulating blood from the limb below the constriction was absolute in every instance. The constriction was made either above the elbow- or the knee-joint. It was made with rubber tubing a quarter of an inch in diameter, with which the limb was encircled at least twice, and tied with sufficient firmness to interrupt both the arterial and the venous circulation completely. As the constriction appeared to produce considerable pain, the animals were kept fully under the influence of morphin, which was administered subcutaneously, usually in divided doses. The length of time the constriction was

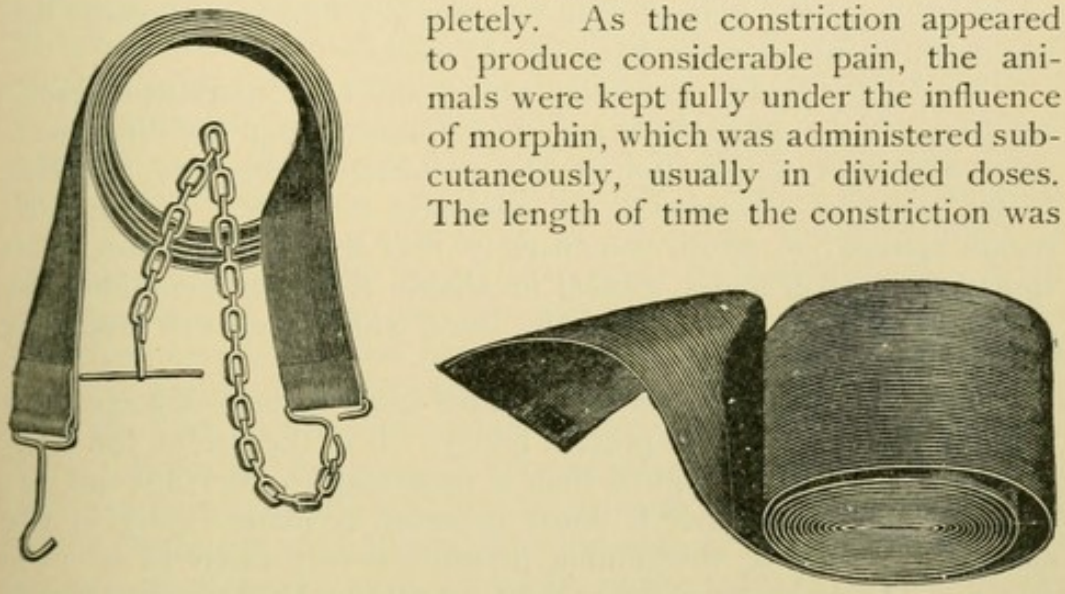

Fig. 28.—Von Esmarch's elastic constrictor, with strap and chain.

continued varied from two hours and a half to twenty-six hours. Only in one case did the experiment result in gangrene:

"Medium-sized female dog; constricted May 9th, 8.40 A.M. Constriction above elbow by three turns of tubing tightly drawn and tied. Removed May 10th, 1.10 A.M. Time of constriction, seventeen hours. Palm incised before removal of constrictor; yields a little dark, fluid, venous blood. In ten minutes blood becomes somewhat lighter in color, but does not flow freely. In twenty minutes pulse could be detected, but was very indistinct. Leg greatly swollen; soft parts appeared to be nearly divided subcutaneously at point of constriction. One and one-third grains of morphin injected in divided doses.

"May 11th, swelling of limb the same.

"May 14th, swelling stationary; entirely useless; begins to show discoloration.

"May 15th, gangrene complete."

The experiments demonstrated sufficiently that in most of the

animals where constriction was continued for more than three hours the limb was either useless or the animal walked lame for a number of days. This temporary disability of the limb was undoubtedly occasioned not by pain, but by injury to the constricted muscles. In the case in which loss of function was continued for several weeks there can be but very little doubt that the pressure produced at the same time a nerve-lesion, retarding recovery until a sufficient time had elapsed for regeneration of the nerve to have taken place. In the median nerve removed after the experiment in which the constriction was continued for twenty hours, the essential histologic nerve elements at the point of constriction could not be identified, and the nerve-fibers on the distal side showed all the appearances of far-advanced degeneration. The animal which was subjected to constriction for the longest time—twenty-six hours—recovered full use of the limb after the lapse of six weeks.

Temporary loss of muscular power and nerve paralysis resulting from elastic constriction are, undoubtedly, often the direct outcome of a faulty application of the constrictor, improper selection of the point of constriction, or excessive pressure. The experiments referred to show conclusively that firm constriction, continued for several hours, almost invariably results in diminution or suspension of the function of the limb, which does not disappear for several days or weeks.

Functional disturbances that yielded in the course of a few days were undoubtedly due to muscle injury. If in the use of the constrictor more force is applied than is necessary to interrupt the circulation, and particularly if linear pressure is made, injury of the muscles exposed to this undue pressure is very likely to be produced. The same can be said of injury to the nerves from a similar cause. Of several cases of nerve paralysis which occurred in my practice, the two following were typical in every respect:

The first case was a young man who was the subject of necrosis of the radius. Elastic constriction was made just above the elbow-joint, and at a point where the musculospiral nerve is almost subcutaneous. The operation lasted about an hour. The next day it was noticed that the patient was unable to extend the hand. The function of the nerve was destroyed as completely as though it had been divided. Massage and electricity were employed at the end of the second week, but no signs of improvement were observed before the expiration of two months, and function was not fully restored at the end of three months. During this time muscular atrophy was noticeable. With the restoration of nerve function muscular nutrition set in, and eventually the use of the hand and forearm was restored to perfection.

The second case was a student suffering from extensive necrosis of the tibia. Elastic constriction was applied just above the knee-joint. The disease involved nearly the entire shaft of the tibia. The skin-flaps were turned inward into the deep gutter and fastened

with aseptic bone-nails. The margins of the flaps necrosed, and the extensive cutaneous defect was replaced by a slow process of granulation, cicatrization, and epidermization that required several months to complete the healing process. Soon after the operation it became apparent that the function of the peroneal nerve had been destroyed by the elastic constriction. Electricity and massage proved of no avail in restoring nerve function, as the paralysis remained complete two years after the operation. I have reason to believe that if the elastic constriction in these cases had been made at the base of the limbs instead of at the localities mentioned, in all probability the nerve injury might have been avoided.

With a view to preventing injurious pressure on important nerves from elastic constriction it is necessary to constrict only with sufficient firmness to interrupt the arterial and venous circulations. Moreover, the pressure should not be linear, but distributed over a circle at least two to four inches in width. The last requirement is best attained by using a wide band, or if an elastic tube or cord is used, the limb should be encircled several times, each turn drawn with uniform force and arranged in such a manner as to compress with equal firmness a wide circle, thus exerting the same effect on the tissues underneath as pressure made by a wide band. If, for any reason, the constriction can not be made at a point where the principal nerves are well protected by a thick layer of muscles, a thick compress of gauze should be placed between the constrictor and the limb, in order to protect the nerves against injurious pressure. From the foregoing it may be inferred that it would not be safe to continue elastic constriction for more than three or four hours in the treatment of accidental hemorrhage. The question of time is an important matter, more especially to the military and the railway surgeon. In emergency cases we must calculate the time when we are in a position to substitute for elastic constriction more direct measures for the arrest of hemorrhage.

In the use of Esmarch's constrictor in arresting hemorrhage that threatens life, more especially on the battle-field, it is not necessary to distinguish between venous and arterial hemorrhage. It was the consensus of opinion of the members of the military section of the Berlin International Medical Congress that it is no longer wise nor practical to differentiate between arterial and venous hemorrhage in rendering the first aid to the wounded on the battle-field or in a case of accidental hemorrhage elsewhere ; that the one point that must be taught the soldier, the brakeman, and the conductor is that, if hemorrhage is so profuse as to threaten life before medical aid can be summoned, it should be at once arrested by elastic constriction,—by a suspender if nothing else is at hand,—applied invariably on the proximal side of the seat of injury.

The constriction must be made with sufficient firmness to arrest completely both the arterial and venous circulations, as has been repeatedly emphasized. By applying the constrictor with just

sufficient firmness to diminish the arterial circulation without interrupting it, the venous hemorrhage is increased. It is by overloading the tissues with venous blood by imperfect constriction that gangrene is invited and venous hemorrhage increased. Experimental research has shown that an ischemic condition and elastic constriction for two hours or more are liable to produce an unfavorable influence on the karyokinetic process in the tissues deprived of blood for that length of time. This is a sufficient proof that prolonged constriction retards the healing process. Necrobiosis, slow healing, and necrosis of the margins of the wound are some of the remote consequences which follow prolonged constriction of a limb. A well-recognized disadvantage of elastic constriction as a hemostatic measure is increased parenchymatous hemorrhage. The profuse capillary oozing which so often follows the removal of the constrictor is undoubtedly, at least in part, due to a temporary vasomotor paresis caused by the constriction. This result is minimized most successfully by keeping the limb in an elevated position at the time the constrictor is removed, and by maintaining the vertical position without interruption for at least six hours. The intravascular tension is reduced to a minimum by elevation of the limb, and this condition is most conducive to the formation of a minute thrombus in each of the small vessels, capillaries, arteries, and veins cut during the operation.

Another exceedingly useful resource in diminishing unnecessary loss of blood, after all visible vessels have been tied and the constrictor has been removed, consists in making firm pressure against the wound surface. This can be most effectually done by using a gauze compress wrung out of a hot normal salt solution, which is firmly held against the wound with one or both hands. After an amputation, for instance, all the principal vessels should be sought for and tied before the constrictor is removed, and the limb held in a vertical position. A compress is then placed against the wound surface, the flaps brought over it, and firm compression made over the end of the stump with both hands for at least five minutes. The compress is then lifted away, and spurting points are caught with hemostatic forceps and tied. In obstinate cases an application of peroxid of hydrogen serves an excellent hemostatic purpose, and does not interfere with primary healing of the wound. The importance of a recourse to prophylactic hemostatic measures is proportionate to the size and number of the blood-vessels which must unavoidably be severed in an operation. Thus, in amputation of the extremities, without special precautions, the immediate risk to life from hemorrhage is greater the nearer the amputation approaches the trunk. While a finger, a toe, or even a hand or a foot might be amputated without the use of a tourniquet or elastic constrictor without incurring any immediate risk to life from the loss of blood, such a procedure in amputation at the shoulder-joint or hip-joint would jeopardize life on the operating table.

The general condition and age of the patient have their influence in determining the necessity for a resort to the most painstaking prophylactic hemostatic precautions. The healthy and robust tolerate the loss of blood much better than patients worn out by disease or deprivations or excesses of any kind. The subjects of acute septic processes are peculiarly liable to suffer severely from the loss of any considerable amount of blood. Infants, children, and the aged do not bear the loss of blood so well as young adults and persons of middle age, and hence when injured or subjected to operative intervention, special precautions must be employed in guarding against the loss of blood. Elastic constriction has been applied to different parts of the body where constriction, as described above, would be impracticable.

Special Localities for Elastic Constriction as a Prophylactic Hemostatic.—In variously modified forms the great principle of elastic constriction as a prophylactic hemostatic resource has been applied over the entire surface of the body and many of the internal organs when the seat of direct operative interference. Vascular tumors and operations on the gastro-intestinal canal and uterus furnish familiar examples. In all injuries and operations upon the extremities below the shoulder- and hip-joints we have now in Esmarch's elastic constrictor, or any of its substitutes, a reliable measure with which we can absolutely control hemorrhage temporarily and thus minimize the loss of blood. In disarticulation at the hip- and shoulder-joints it must be modified to adapt itself to the anatomic conformation of the respective localities.

Hip-joint.—The various attempts made in the past to control hemorrhage in amputations at the hip-joint furnish material for an interesting and useful study. We must be free to admit that this subject constitutes by no means a closed chapter. The first attempts were directed toward rendering the limb bloodless by compression of the aorta near its bifurcation. Tourniquets for this purpose were invented by Pancoast, Esmarch, Syme, Tiemann, Signorini, Lister, and Brandis. This method of rendering the operation bloodless is uncertain, as the compressor may become displaced during sudden movements of the patient. Further, it is open to the serious objection that, when efficiently applied, it cuts off the arterial circulation from nearly one half of the body, a circumstance attended by no inconsiderable immediate risk to life from sudden vascular engorgement of important internal organs. In several cases in which this instrument was used severe venous hemorrhage was encountered. An additional objection to the employment of this instrument is the fact that organs interposed between the abdominal wall and the spine, against which the pressure is made, may be injured. Digital compression of the femoral or external iliac artery, a method of controlling hemorrhage inaugurated by Abernethy, is unreliable, as fingers are very apt to slip during the manipulation of the limb,

and in that it does not cut off the blood supply from the remaining large arterial trunks of the limb.

The next step in the development of the technic of bloodless amputation at the hip-joint was devised by Mr. Davy, and consists in instrumental compression of the common iliac artery against the pelvic brim. The instrument consists of a smooth rod or cylinder of hard wood or metal, from eighteen to twenty-five inches in length, and terminating in a conic blunt extremity. The directions given for the use of this instrument are the following: "Oil having been injected into the bowel, the conic or larger end of the lever is introduced into the rectum, and is passed in the direction of the vessel to be compressed. The surgeon, feeling the end of the instrument through the abdominal wall, directs it to the common iliac as it lies on the pelvic brim. The handle of the instrument is now carried to the thigh of the opposite side, and is then raised so that it may act as a lever, for which the anus serves as a fulcrum." This method is not only unreliable, but is inapplicable in cases where no mesorectum exists, and has more than once caused serious damage to the bowel. For these reasons it was never generally adopted and has now fallen into well-merited disuse.

Preliminary ligation of the common femoral artery was advocated by von Volher, Puthod, Moublet, Larrey, Delpech, Orten, A. Cooper, Blandin, Velpeau, Roser, Roux, and Boyer. Von Volher, Larrey, and Roser tied, at the same time, the femoral vein. Scultetten proposed preliminary ligation of the external iliac artery. Against preliminary ligation were arrayed Lalouette, Abernethy, B. Bell, Richter, Guthrie, Baffos, Langenbeck, S. Cooper, Pelikan, Béclard, Dupuytren, von Walther, Krimer, Bryce, and Lenoir. Preliminary ligation of the femoral vessels and digital compression do not render the operation sufficiently bloodless, and can not be relied upon in cases in which the loss of several ounces of blood would imperil the life of the patient. Pirogoff, von Pitha, and Volkmann advised ligation of the principal vessels in the incisions made in forming the flaps, prior to their division. Out of 39 cases of preliminary ligation 11 died, while of 29 treated by digital compression 17 recovered, showing that the former procedure is less effective than digital compression. In three cases the profunda had a high origin, and the object of the preliminary ligation was not fully realized. Linhart lost one case by hemorrhage from the branches of the hypogastric artery. Beck had a death from secondary hemorrhage at the point of ligation. E. Rose does not rely on digital compression, preliminary ligation of the common femoral, or constriction, but ties each vessel twice before cutting it. This method requires more time than it is prudent to allow for the performance of an operation which is attended by so much risk from shock. Péan operated in a somewhat similar manner, but relied on hemostatic forceps instead of ligatures to control the bleeding during the operation, which saves much valuable time. Soon after the introduction by von Esmarch

of the bloodless method of operating by elastic constriction, it was applied by this surgeon, in a modified form, to disarticulation at the hip-joint. He gave the following original directions:

"In high amputations of the thigh the tube is tightly wound once or twice around the limb, just below the flexure crease of the thigh, the ends are crossed above the groin, passing around over the posterior surface of the pelvis, and are finally hooked together by the chain across the abdomen (Fig. 24). A firmly rolled linen bandage may also be laid over the iliac artery, directly above Poupart's ligament, as a pad, and tightly pressed upon the artery by several figure-of-eight turns of a strong rubber bandage." Mr. Jordan Lloyd employed for the same purpose a common calico roller, which was applied over the external iliac artery, over which was placed a strip of black india-rubber bandage about two yards long, which was doubled. The center of this bandage rested between the tuberosity of the ischium and the anus, and the ends, drawn tight enough to arrest the circulation completely, were firmly held at a point corresponding to the center of the iliac crest on the side to be operated upon. In order to prevent slipping away of the band from the compress these were fastened together with a safety-pin. By this method of compression Mr. Lloyd expected to prevent hemorrhage from all the vessels on a level with the hip-joint. The prevention of hemorrhage by this method rests largely in the hands of the assistant, and, consequently, can not be relied upon under all circumstances. In disarticulation of the thigh through an external or anterior racket incision, elastic constriction as heretofore practised has been very unsatisfactory indeed, and main reliance was placed on dividing the tissues quickly after disarticulation, seizing and tying the principal vessels.

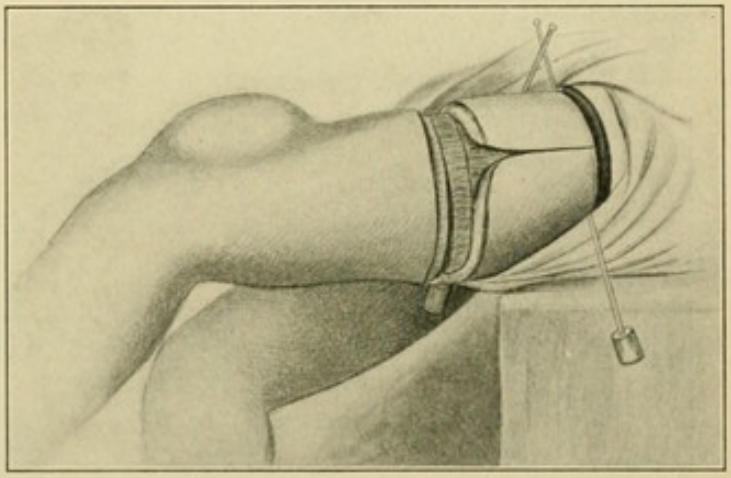

Fig. 29.—Wyeth's bloodless amputation at the hip-joint; the pins and rubber tubing applied; circular and longitudinal incisions for skin-flap.

One great obstacle to the use of elastic constriction in this operation has been the slipping of the constrictor. For the purpose of preventing this accident the thigh below the constrictor has been transfixed by long needles or skewers. Trendelenburg transfixes the thigh by a single stout steel needle passed in front of the neck of the femur and beneath the large vessels. Mr.

Myles thrusts a steel skewer straight through the thigh from before backward. The needle is made to enter just below Poupart's ligament, and to the outer side of the femoral artery it passes to the inner side of the neck of the femur, and emerges a little above the gluteal fold. A rubber cord in the form of a figure-of-eight is passed around the projecting ends of the skewer. Wyeth uses two strong mattress needles to prevent slipping of the constrictor. The point of one is inserted an inch and a half below, and to the inner side of, the anterior superior spinous process of the ilium, and is made to traverse the muscles, passing about half-way between the great trochanter and the iliac spine, external to the neck of the femur, and emerging from just behind the trochanter. The second

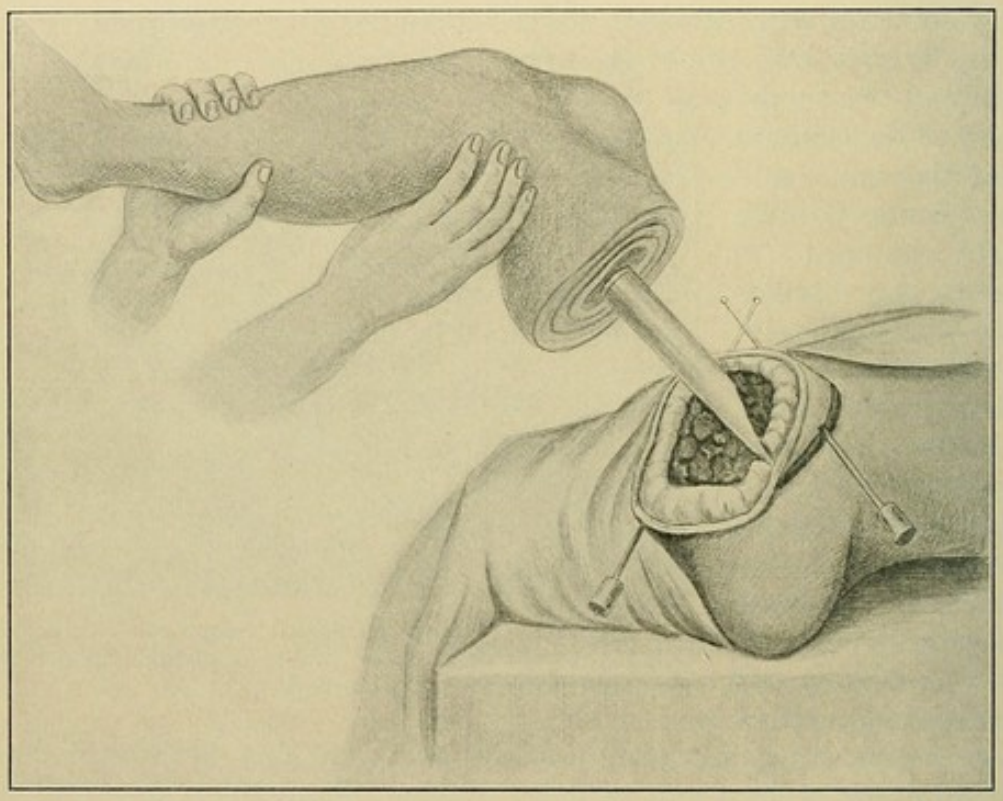

Fig. 30.—Wyeth's bloodless amputation at the hip-joint; cuff of skin and subcutaneous fat turned back; muscles divided at level of small trochanter; bone partly stripped, and large vessels exposed for deligation.

needle is entered an inch below the level of the groin, internal to the saphenous opening, and passes through the adductors, the point coming out about an inch and a half in front of the tuberosity of the ischium. A piece of strong rubber tubing, one-half an inch in diameter, and long enough when tightened to go five or six times around the thigh, is now wound very tightly around and above the fixation needles and tied. The elastic constrictor and needles are removed as soon as the circular amputation is completed and the principal blood-vessels have been tied, whereupon the proximal end of the femur is removed (Fig. 30).

Wyeth's method of controlling hemorrhage in amputation at

the hip-joint has had an extensive trial, particularly in this country, and, on the whole, has given great satisfaction. To me, however, it appears immaterial whether one or two needles are employed, as the object of their use is simply to prevent slipping of the constrictor, which is fully accomplished by using one needle or skewer. Elastic constriction, as just described, has two disadvantages which detract from its utility in emergency surgery : (1) Needles or skewers are not always at hand ; (2) enucleation of the proximal end of the femur is a very difficult task, owing to the shortness of the fragment. The method is better adapted for high amputation of the thigh than for disarticulation at the hip-joint. For the purpose of further simplifying prophylactic hemostasis for disarticulation at the hip-joint I have modified elastic constriction, which narrows the requirements down to a piece of rubber tubing long and strong enough to constrict the base of the thigh after preliminary disarticulation. The cardinal points of this method are : (1) Preliminary dislocation of the head and isolation of the upper portion of the femur from attached soft tissues through an external straight incision ; (2) elastic constriction of the thigh below the pelvis until amputation has been completed and the principal vessels have been tied.

A straight incision about eight inches in length is made directly over the center of the great trochanter and parallel to the long axis of the limb, extending about three inches above the upper border of the great trochanter. When the knife reaches the great trochanter, its point should be kept in contact with the bone the whole length of the remaining part of the incision. The margins of the wound are now retracted, and any spurting vessels, such as the circumflex arteries, secured by applying pressure forceps. During this and the remaining steps of the operation the body is drawn down so that the pelvis rests upon the lower edge of the table, in order that the thigh can be manipulated freely by the assistant who is intrusted with this work (Fig. 31). The trochanteric muscular attachments are now severed close to the bone with a stout scalpel. The clearing of the digital fossa and the division of the tendon of the obturator externus require special care. The thigh is now flexed, strongly adducted, and rotated inward, when the capsular ligament is divided transversely at its upper and posterior aspect. The remaining portion of the capsular ligament is severed, while the thigh is brought back to a position of slight flexion, after which it is rotated outward, and, if possible, the ligamentum teres is cut. If this can not be done, the head of the bone is forcibly dislocated upon the dorsum of the ilium by flexion, adduction, and rotation inward of the thigh. After dislocation has been effected, the trochanter minor and the upper part of the shaft of the femur are cleared by using scalpel and periosteal elevator alternately. At the completion of this part of the operation the femur is in a position of extreme adduction, and the upper portion projects some distance from the surface of the wound.

During the operation, so far, if the surgeon has kept in close contact with the bone and has used the knife sparingly and the periosteal elevator freely, the hemorrhage has been very slight—much more so than if this part of the operation had been reserved for the last, as is done in von Esmarch's and Wyeth's methods. Elastic constriction is now applied in the following manner: The limb is brought down in a straight line with the body, the thigh is slightly flexed so as to push the upper free end of the femur forward into and beyond the wound, when a long stout hemostatic

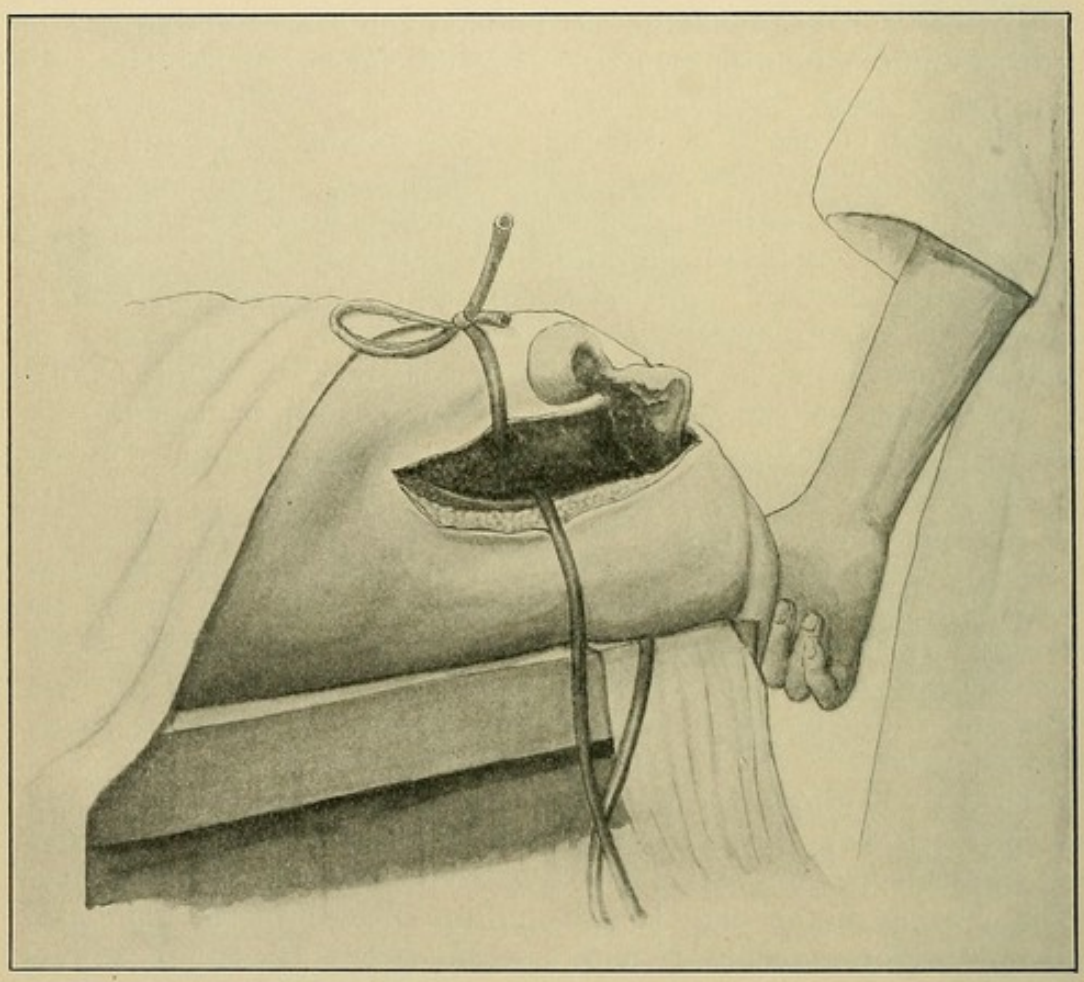

Fig. 31.—Senn's method of performing bloodless amputation at the hip-joint. Dislocation of head of femur and upper portion of shaft through straight external incision. Elastic constrictors in place, the anterior one tied.

forceps is inserted into the wound behind the femur and on a level with the trochanter minor when in a normal position. The instrument is then pushed inward and downward two inches below the ramus of the ischium and just behind the adductor muscles. As soon as the point can be felt under the skin in this location, an incision is made through the skin, about two inches in length, through which the instrument is made to emerge. After enlarging the tunnel made in the soft tissues by dilating the branches of the forceps, a piece of aseptic rubber tubing three-quarters of an

inch in diameter and about three or four feet in length is grasped with the forceps in the middle and is drawn along the tunnel as the forceps are withdrawn, whereupon the rubber tube is cut in two at the point where it was held by the forceps. With one half of

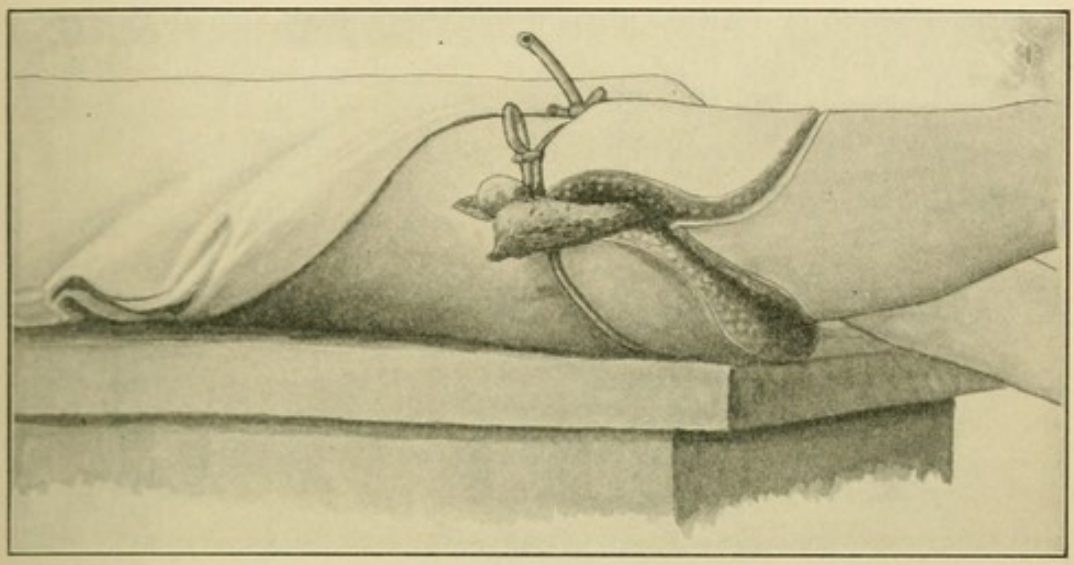

Fig. 32.—Elastic constriction completed by constricting the posterior segment of the thigh. Flaps formed including all the tissues down to the muscles.

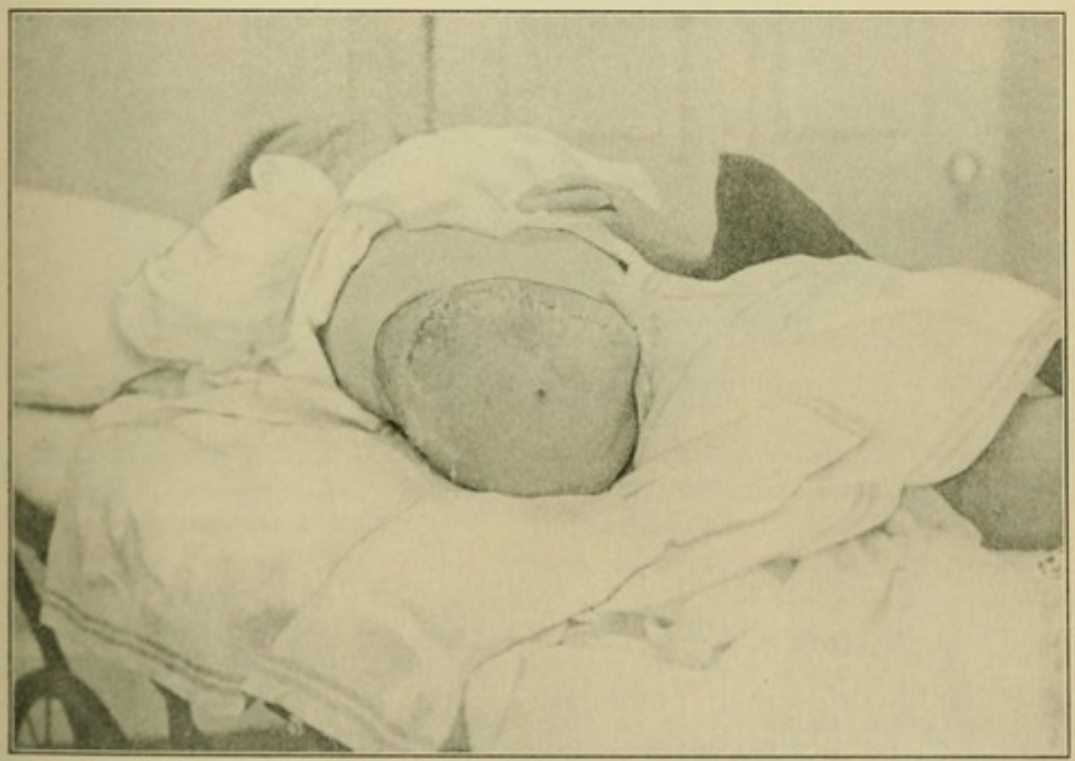

Fig. 33.—Stump after disarticulation at the hip-joint. Long posterior cutaneous flap (Clinic, Rush Medical College).

the tube the anterior segment of the thigh is constricted sufficiently firmly to intercept both the arterial and venous circulations completely. Before the constrictor is tied the limb should be held in

the vertical position for a sufficient length of time to render it practically bloodless. The elastic constrictor is either tied or, still better, after having secured the necessary degree of constriction, it is held with a pair of forceps at the point of crossing. The posterior segment of the thigh is constricted by the remaining half of the tube, which is drawn sufficiently tight behind, when the ends of the tube are made to cross each other and are brought forward and made to include the anterior segment, when they are again firmly drawn and tied, or otherwise fastened, above the first constrictor. As the anterior segment of the thigh contains the principal blood-vessels, this method of applying the posterior constrictor

Fig. 34.—Amputation completed. Vessels readily accessible for ligation.

furnishes an additional security against hemorrhage from the large vessels when cut during the amputation. After the principal blood-vessels have been tied, the posterior constrictor is removed and additional bleeding points are secured before the anterior constrictor is removed. Surface compression with a compress wrung out of a hot normal salt solution is a valuable aid in minimizing the hemorrhage after the removal of the constrictors. As this method of controlling hemorrhage does not require the presence of a skilled assistant, it will prove of special value in emergency cases. The operation can be performed with the instruments contained in every pocket-case. Should an elastic tube not be at hand, the constric-

tion can be made in a satisfactory manner by substituting for it a cord made of sterile gauze, tightened with a lever of some kind, as is done in applying the ordinary Spanish windlass.

Shoulder-joint.—Elastic constriction with the aid of one or two transfixion pins can be made use of in controlling hemorrhage in disarticulation at the shoulder-joint. The transfixion must be made on the proximal side of the glenoid cavity of the scapula. A mattress or straight steel needle is made to traverse the tissues in an anteroposterior direction, in such a way that it will pass between the axillary vessels and the neck of the scapula. In obese persons it is well enough to give an additional support to the elastic constrictor by transfixing the skin on the scapular side of the acromion process. Since much tissue must be included in

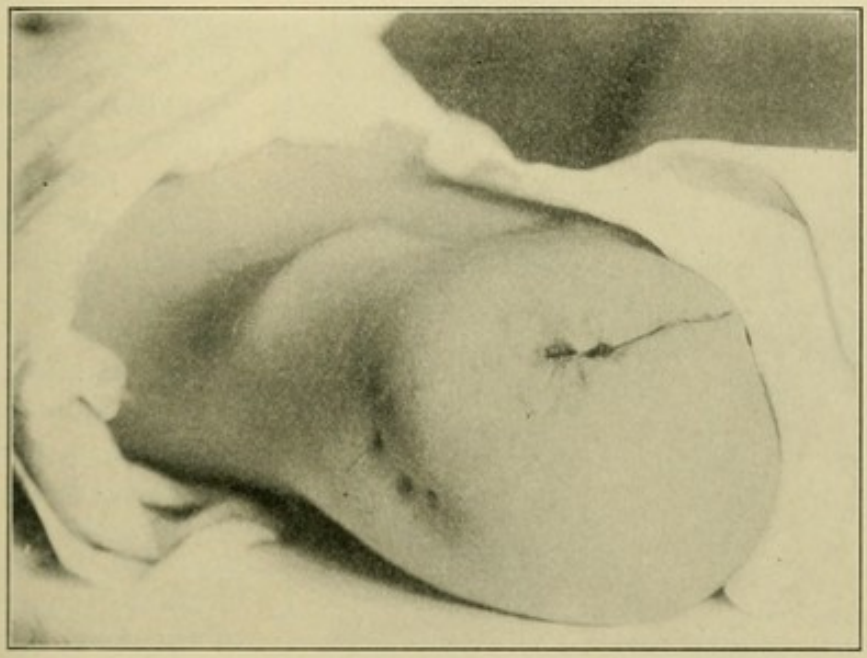

Fig. 35.—Stump after disarticulation at the hip-joint. Anteroposterior cutaneous flaps (Clinic, Rush Medical College).

the constrictor, at least two turns are necessary to insure the requisite degree of constriction. In amputations at the shoulder-joint elastic constriction can, however, often be dispensed with by resorting to preliminary ligation of the axillary artery, which can readily be done in the wound after making the deltoid flap. The accompanying vein should invariably be tied before cutting it if elastic constriction is dispensed with, as a failure to observe this precaution would result in unnecessary loss of blood and might possibly give rise to air embolism.

Head.—In extensive operations on the skull and in the removal of diffuse vascular tumors of the scalp elastic constriction of the head renders great aid in limiting the hemorrhage. A narrow, strong rubber band or a piece of stout rubber tubing long enough to encircle the head twice is best adapted for this purpose. The

circular constriction is made on a level with the occipital protuberance and at a point in front corresponding with the upper margin of the eyebrows. If the constrictor is properly applied, no transfixion pins are required (Fig. 36).

In the removal of a limited racemose aneurysm or circumscribed angiomatous tumors elastic constriction can be efficiently applied to include the desired area by the use of transfixion pins. At least four pins are required, and if the territory is a large one, more are necessary. In operations on the scalp for these indications each pin is placed in a locality where vessels of large size lead to the part to be removed. All the tissues down to the bone are included in the transfixion, and each pin is made to traverse an inch or more of the tissues. The transfixion must be made at a safe distance from the growth to be removed, and must include healthy tissue. With a rubber band or small rubber cord or tubing, elastic constriction of the tissue included by each pin is made by applying it in a figure-of-eight. When this has been done, circular constriction of the field of operation is made by including all the pins in the constrictor to interrupt the circulation in all vessels leading to and from the tumor (Fig. 37). After the removal of the tumor all visible blood-vessels are tied before removing the common constrictor. Later hemorrhage is arrested carefully after the removal of each of the pins. By following this plan the hemorrhage is never profuse, and can be arrested step by step as the pins are withdrawn. In the absence of pins of special construction large safety-pins answer an excellent purpose in securing the benefits of elastic constriction anywhere upon the surface of the body.

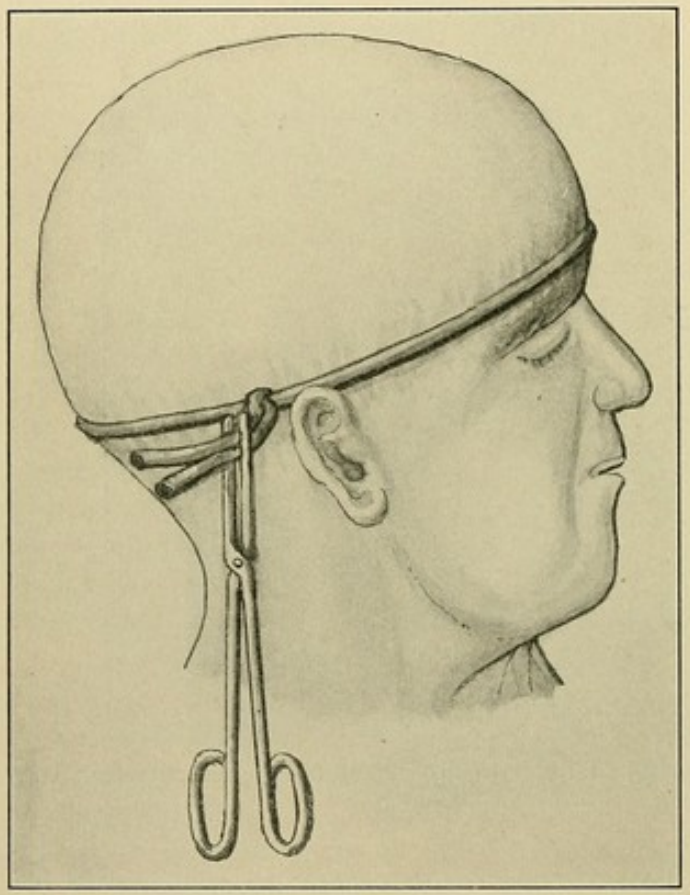

Fig. 36.—Elastic constriction of the skull.

Manual Compression of the Aorta.—For more than fifteen years Macewen has resorted to manual compression of the abdominal aorta for preventing hemorrhage during operations involving

large blood-vessels that are under control by this prophylactic hemostatic resource. In disarticulation at the hip-joint, by this method of controlling hemorrhage he never lost more than two ounces of blood from the proximal vessels. It has also proved of great service in operations upon the pelvic organs attended by severe hemorrhage. His method is as follows: "As the patient lies on his back on the table, the assistant, facing the patient's feet, stands on the left side of the table on a line with the patient's umbilicus. He then places his closed right hand upon the patient's abdomen, a little to the left of the middle line, the knuckles of the index-finger just touching the upper border of the umbilicus, so that the whole closed hand will embrace about three inches of the distal extremity of the aorta above its bifurcation (Fig. 38). The assistant then standing upon his left foot, his right foot crossing his left and resting upon the toes of the right,—an attitude commonly assumed by public speakers,—leans upon his right hand and thereby exercises the necessary amount of pressure. With the index-finger of the assistant's left hand the weight necessary for the purpose can easily be estimated by the effect produced upon the flow of blood through the common femoral, at the brim of the pelvis. Whenever the flow of blood through the femorals is absolutely arrested, the abdominal aorta is sufficiently controlled, and no further weight ought to be applied."

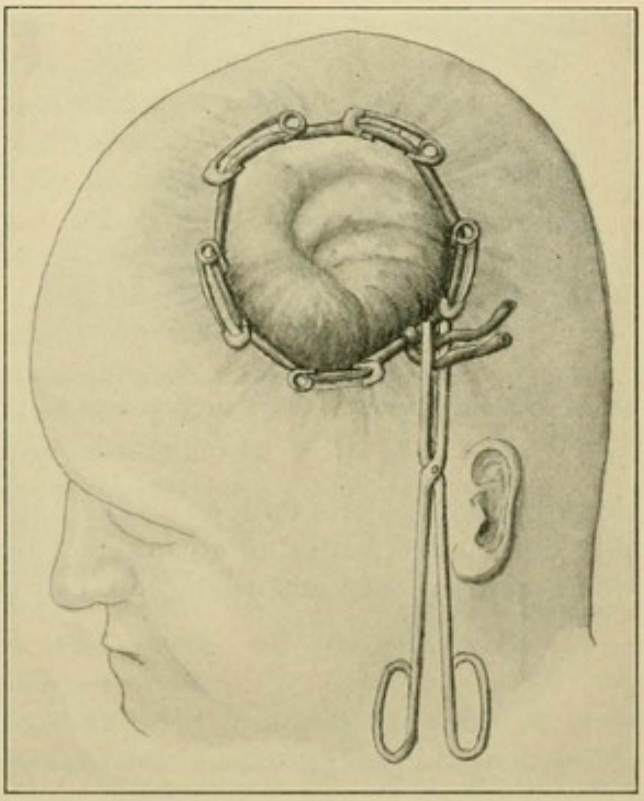

Fig. 37.—Elastic constriction of the surface with the aid of transfixion pins, applicable in the removal of large vascular tumors.

A large experience has shown that assistants performing this office can keep up the compression for the necessary length of time without undue fatigue. If the patient should cough or vomit, the pressure must be increased. As in all cases requiring compression of the abdominal aorta as a prophylactic or therapeutic measure, the time required is short. It is reasonable to hope that this method will take the place of instrumental compression, as the manual pressure can be regulated with precision to the require-

ments, and consequently is less liable to cause visceral injuries, and, at the same time, is more reliable in controlling the hemorrhage.

Digital Compression.—Digital compression is a ready prophylactic and therapeutic hemostatic resource in controlling and arresting hemorrhage anywhere below the axillary space of the upper, and below Poupart's ligament of the lower, extremity. With one or more fingers the principal blood-vessel is compressed against the underlying bone (Figs. 39 to 41). Digital compression is resorted to when quick action is required and an elastic constrictor is not at hand. The compression must be continued uninterruptedly until the bleeding vessel can be tied or pressure can be replaced by elastic constriction or the antiseptic tampon. The finger or fingers which perform this duty must not be removed for a moment so long as compression is needed, and when fatigued, can be supported by the fingers

Fig. 38.—Macewen's method for compression of the abdominal aorta ("American Text-book of Surgery").

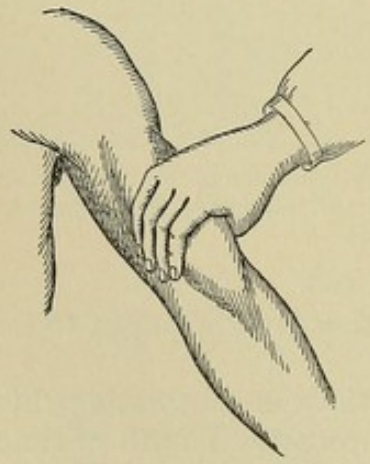

Fig. 39.—Digital compression of the brachial artery.

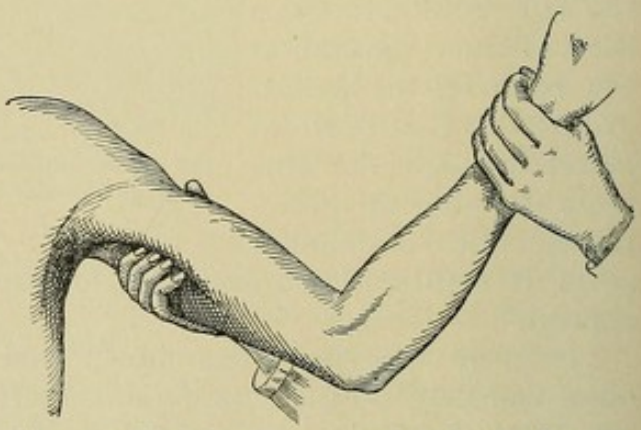

Fig. 40.—Digital compression of the brachial artery.

of the other hand rather than risk change of hands. If, for instance, one thumb is used to compress the femoral artery, the disengaged thumb can be placed over it and compression made con-

jointly or alternately. Compression of the subclavian and iliac arteries by this method is occasionally relied upon, but can not be efficiently maintained for any considerable length of time.

Preliminary Ligation of Arteries in their Continuity.—The ligation of a principal artery in its continuity for the purpose of controlling hemorrhage from its branches in performing an operation on the distal side of the ligature is practised less frequently since the rapid development of the technic of hemostasis during the last two decades. Ligation of the common carotid artery preliminary to removal of tumors in the nasopharynx, the pharynx, and in the parotid and submaxillary regions, is seldom performed now, since by the use of hemostatic forceps we are better prepared to deal promptly with the hemorrhage in the wound. Prophylactic ligation of the common carotid can not always be relied upon in guarding against profuse hemorrhage in such cases, more especially in the removal of tumors from the nasopharynx, and it is a procedure which in itself is often fraught with danger. In the removal of a nasopharyngeal tumor of large size I have resorted to preliminary ligation of the left common carotid, and yet the patient died from the immediate effects of the hemorrhage, notwithstanding the operation was performed with the utmost speed and local hemostatics were promptly employed. In persons advanced in years or the subjects of atheromatous arteries, preliminary ligation of the common carotid artery must be resorted to with great reserve, as it is apt to result in paralysis or even death. In a case of malignant tumor of the neck requiring partial excision of the common carotid artery and the internal jugular vein in its removal, the patient died in less than forty-eight hours from the immediate effects of the cerebral anemia. In another case preliminary ligation of the common carotid artery was followed by hemiplegia on the opposite side, from which the patient gradually recovered only at the end of six months. Preliminary ligation of the subclavian artery is the only hemostatic resource in controlling the hemorrhage during the removal of the entire upper extremity, inclusive of scapula and clavicle. Under such circumstances ligation of the subclavian vessels is an easy task after free exposure by elevation of the clavicle after disarticulation from the sternum. In disarticulation of the shoulder-joint preliminary ligation of the axillary artery and vein can be done, without any technical difficulties, through the wound, after making the deltoid or external flap.

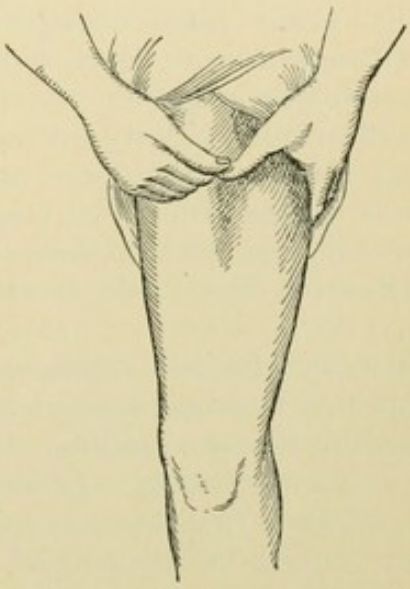

Fig. 41.—Digital compression of the femoral artery.

Transperitoneal ligation of the iliac arteries has recently received much attention from surgeons in the discussion of prophylactic hemostasis. Since Trendelenburg's position has come into general use in difficult cases of pelvic surgery, intraperitoneal ligation of the iliac arteries has become a legitimate surgical procedure, both as a prophylactic and therapeutic hemostatic resource. In injuries in which it becomes necessary to tie any of the iliac arteries, either for the purpose of preventing or of arresting hemorrhage, the intraperitoneal operation is preferable to the extraperitoneal route, with the exception, perhaps, of tying the lower portion of the external iliac artery. The extraperitoneal operation has not always terminated extraperitoneally, and many cases have been recorded, and more remain unrecorded, in which the ligature, owing to the depth of the wound and the difficulties encountered in its application, has included important structures, such as the ureter and accompanying iliac vein. Such mishaps are responsible for many of the failures. Transperitoneal ligation of the iliac arteries has been a subject of careful investigation by Dennis and S. K. Morton. The latter author has recently given the statistics of 29 operations. Of the 29 cases, 22 recovered and 7 died. Of the fatal cases, not one was due to abdominal complication. In 5 cases the common iliac was ligated, and of these 1 died, death being caused by gangrene. Of the 9 cases of ligation of the internal iliac, 2 died. The external iliac was tied 15 times, with 4 deaths. Lange tied the common iliac by the intra-abdominal route the first time in 1883. The internal iliac was ligated by Leroy McLean in 1872, and M. Richardson tied the external iliac in 1886.

Trendelenburg's position is essential in performing this operation, as it obviates extensive evisceration in finding and securing the vessel in any part of its course. The abdomen should be opened by making McBurney's muscle-splitting incision. For the common and internal iliac the median incision is preferable. The parietal peritoneum is incised over the vessel where the ligature is to be applied, and, after tying the ligature, the peritoneal incision is closed with a few catgut sutures. In urgent cases, however, this part of the operation can be omitted, with a view to saving time, without any detrimental results.

Temporary Ligation of Arteries.—The temporary ligation will, in all probability, take the place, in the near future, of preliminary ligation. The exclusion of blood from a limited segment of an artery for a short time is not incompatible with the patency of the lumen of the vessel at the point of temporary constriction, provided the intima is not injured. My experiments on animals have demonstrated that a double ligature placed half an inch apart can remain for twenty-four hours without interfering with the subsequent complete restoration of function of the temporarily excluded part of the artery. Only one of the many experiments with this special point in view will be quoted :

"*Experiment 25.*—Left femoral artery of goat. Double ligature of coarse catgut. Removal of ligatures twenty-four hours after operation. Animal killed nine days after ligation. On removal of the ligatures circulation not interrupted. Ligated portions of vessel considerably smaller. Lumen not obliterated. Inner walls of vessel at the seat of operation studded with minute patches of exudation material, the product of recent end-arteritis."

In operations on the pharynx, parotid, and submaxillary regions for the removal of large tumors in cases in which profuse hemorrhage is expected, it has been my practice for many years to expose the carotid artery on a level with the upper border of the thyroid cartilage, and to surround the common carotid with a catgut ligature, which is to be used as a temporary or permanent ligature, as the results of the operation might indicate. Such provision against hemorrhage is a great comfort to the surgeon, and in the event of sudden profuse hemorrhage, constitutes a prompt and efficient aid in controlling or arresting it. The use of the temporary ligature as a prophylactic hemostatic has recently received much favor in the practice of Schönborn, Senger, and Riese. There can be little doubt but that it will be made use of in abdominal and pelvic operations, and in disarticulation at the hip-joint as a substitute, in appropriate cases, for the permanent ligation of the common iliac artery and its branches.

Percutaneous Temporary Ligation of Arteries and Veins.—The prevention of hemorrhage by percutaneous ligation of arteries and veins is not a common practice, but is applicable in exceptional cases. Percutaneous ligation of the common femoral artery has been proposed as a proper precaution for preventing hemorrhage during disarticulation at the hip-joint. It would be difficult to prove the superiority of such a procedure over digital compression of the femoral artery. This prophylactic hemostatic measure may prove to be of value in the removal of vascular tumors by cutting off the blood supply to the part to be removed during the operation. Nicaise made use of percutaneous ligation of veins for preventing profuse hemorrhage during the removal of very vascular malignant tumors of the mammary gland, and found that it proved useful in lessening the amount of hemorrhage. Percutaneous ligation of arteries and veins will always prove useful in the removal of vascular growths when elastic constriction can not be applied. The percutaneous ligature should be permitted to remain *in situ* until the ligated vessel has become permanently obliterated—that is, from two to seven days, according to the anatomic character and size of the ligated vessel. In most of these cases it is advisable to interpose a small compress of aseptic gauze between the ligature and the surface of the body, which will not interfere with the constriction of the vessel and at the same time protect the skin against the harmful effects of linear pressure.

Galvanocautery and Thermocautery. — The galvanocaustic loop, so strongly advocated years ago by Middeldorpf as a prophylactic against hemorrhage in the removal of vascular growths, has become an almost obsolete surgical procedure since the introduction of the different kinds of hemostatic forceps and other efficient local means of guarding against hemorrhage. No modern surgeon has any use for the galvanocautery in the prevention of hemorrhage.

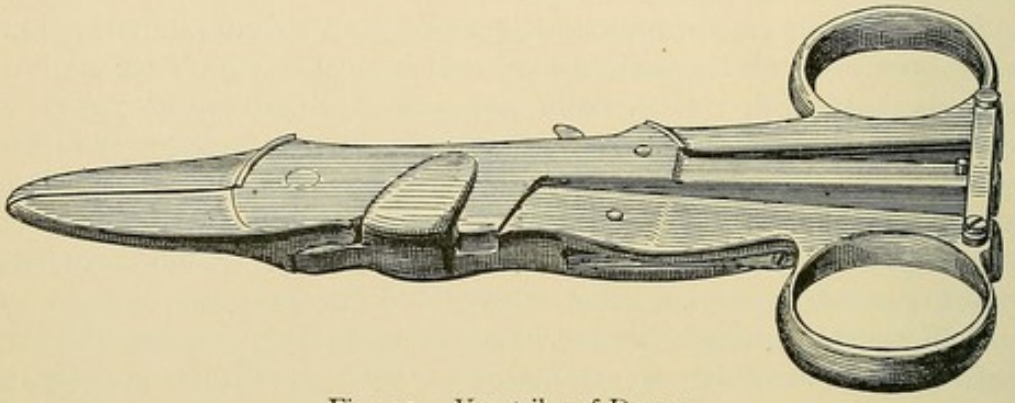

Fig. 42.—Vasotribe of Doyen.

During the time the galvanocaustic wire was a popular resource in preventing hemorrhage during the performance of operations upon very vascular tissues many surgeons were disappointed in its use for this purpose. While the red-hot wire in cutting its way through the tissues was found reliable in preventing hemorrhage from capillaries and small venous and arterial vessels, it did not prove successful in rendering bloodless operations in which vessels of any considerable size had to be divided. The Paquelin cautery retains

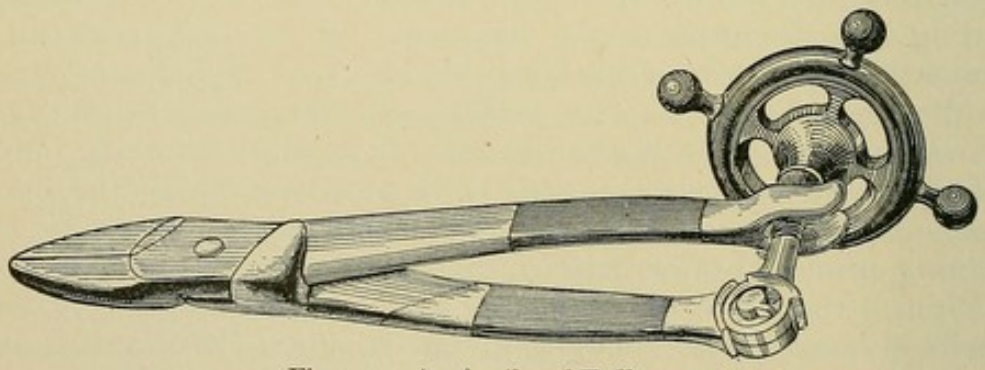

Fig. 43.—Angiotribe of Tuffier.

its reputation in the removal of tumors from very vascular organs, such as the liver, spleen, and kidney, or in making incision into the same for various pathologic indications. When used for such purpose, the knife-point of the instrument should be heated to a dull red heat only, as a white heat largely detracts from its hemostatic effects.

Angiotripsy.—The most modern prophylactic hemostatic resource is angiotripsy, as devised and practised by Tuffier and Doyen.

The principle is an old one, represented by the écraseur, but its application in the modern form is new. It consists in the use of strong forceps which crush the tissues and vessels that come into the grasp of its jaws, thus creating conditions which prevent bleeding and render the use of ligatures superfluous. This method of controlling hemorrhage has given excellent satisfaction in performing vaginal hysterectomy, and will undoubtedly be applied to some other regions of the body as a substitute for elastic constriction and other local means of guarding against unnecessary loss of blood. This procedure presents many advantages over other local hemostatic prophylactic measures in all instances where the field of operation is limited to vessels of small size, and where the crushed tissues are not exposed to any risk of infection.

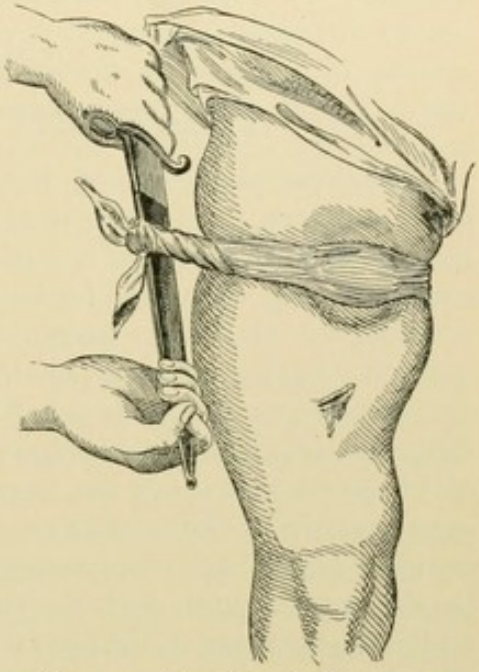

Fig. 44.—Spanish windlass.

Spanish Windlass.—This is a good substitute for the prevention as well as the arrest of hemorrhage in emergency and military surgery when no elastic constrictor is at hand (Fig. 44). A handkerchief is tied loosely around the limb at the point where constriction is needed, and is tightened by passing a stick, a hemostatic forceps, or a bayonet underneath it, and tightening it to the requisite extent by twisting. The effect of the circular compression is increased by placing a pad over the artery.

Écraseur.—As a prophylactic hemostatic the écraseur is mentioned to complete the account of the prevention of hemorrhage. Chassaignac carried the use of this instrument so far that he resorted to it in some cases as a substitute for the knife in amputations. It is seldom, if ever, employed at the present time.

CHAPTER V.

TREATMENT OF HEMORRHAGE.

SKILFUL treatment of hemorrhage is an infallible criterion of good surgery. The aptitude of a surgeon for his profession can readily be estimated by the prompt selection and the proper application of the different hemostatic resources in the treatment of unexpected alarming hemorrhage. Dieffenbach has well said: "From the behavior of a surgeon in cases of severe hemorrhage are we able to judge of what metal he is made." Profuse hemorrhage alarms the professional as well as the layman. The sight of blood pleases only the pervert; it is as distressing to the surgeon as it is to the spectator. Goethe says that "blood is a very peculiar juice," and every surgeon is more than willing to subscribe to this poetic and realistic definition of the life-giving fluid, with which he becomes so familiar from day to day during his walk of life. The mechanical measures employed in the management of hemorrhage have at all times constituted subjects of special interest to the surgeon, whose function it is to treat all kinds of accidents, and invade the body in search for, and to remove or correct, affections within the reach of curative or palliative surgical treatment. Presence of mind, a steady hand, prompt action, an accurate knowledge of anatomy, familiarity with the various hemostatic agents, and clear ideas on the process of obliteration of blood-vessels are prerequisite conditions for success in the treatment of the most frequent and, at the same time, the most alarming emergency which presents itself to the surgeon—hemorrhage. Ignorance, hesitation, and timidity in the event of sudden, unexpected, and alarming hemorrhage only too often mean death; while, on the other hand, the exercise of skill founded on knowledge is often the means of saving human life under the most desperate circumstances. To the benefit of suffering humanity, fear of hemorrhage has deterred pretenders from performing bloody operations, which has left the cultivation of the field of operative surgery to men of skill and science. Perhaps no branch of surgery has reached a higher degree of perfection than the treatment of injuries and diseases of blood-vessels. The bold operations that have characterized the present era of surgery owe their inception and their legitimacy largely to the added resources and improved methods of preventing and arresting hemorrhage.

The surgeon who is perfectly familiar with the modern prophylactic and therapeutic hemostatic resources, and who has the aptitude and necessary dexterity to apply them promptly and properly

when needed, is the one best prepared for efficient emergency work. A thorough knowledge of the technic of modern hemostasis, a quick selection of the appropriate agent for each individual case, and promptness of action characterize the modern operator and the successful general practitioner in the management of emergency cases. The fear of blood, from which no surgeon or practitioner is entirely free, can be overcome, in part at least, by the consciousness of being able to grasp the situation quickly and being in possession of the various hemostatic resources and the necessary knowledge to apply them promptly and intelligently.

Classification of Hemorrhage.—For scientific and practical reasons, hemorrhage has been classified according to its source into: (1) Arterial; (2) venous; (3) capillary.

1. The hemorrhage is **arterial** if the left side of the heart or any of the arteries is injured or cut. The blood is of a bright red color, and escapes from the wound in jets—that is, the stream is not continuous. The jets are synchronous with the heart's action and the arterial wave. The size of the stream corresponds with the lumen of the divided artery or the size of the heart or vessel wound. Clean-cut wounds give rise to profuse bleeding, while contused and lacerated wounds, even if the injured vessel is of considerable size, are known to antagonize hemorrhage, as the crushed or lacerated tissues diminish or prevent mechanically the escape of blood and, by the formation of a thrombus, furnish the best possible conditions for spontaneous arrest of hemorrhage. A limb may be torn from the body by a cannon-ball or crushed by a railway train without any considerable loss of blood. A limb may be disarticulated at any of its joints by a traction injury, such as a machinery accident, without causing any serious loss of blood. If an artery is put on the stretch, the intima gives way first, and the cuff thus formed by the retraction of the torn intima at once narrows the lumen of the vessels. If the force is continued and the remaining tunics are severed, the shreds formed from the outer two coats do their share in mechanically preventing the escape of blood and in determining the speedy formation of a thrombus. Needle puncture of the ventricles and any of the large arteries is not attended by any danger of hemorrhage, as the small tunnel formed on withdrawing the needle is at once made impervious by the displaced muscle and connective-tissue fibers resuming their former relations. Stab wounds made with a narrow blade occasionally heal without surgical intervention and without the subsequent development of an aneurysm, by the formation of a minute white mural thrombus sealing the intima wound, and by healing of the balance of the visceral wound by tissue proliferation from the connective tissue. Recent experiments and experience in military surgery have demonstrated beyond all possible doubt that the small-caliber jacketed bullet inflicts wounds more closely allied to incised than to contused wounds, and consequently, when the wound involves blood-vessels of any magnitude, the risk

of hemorrhage is greater than from similar wounds made by the large-caliber leaden bullet.

2. **Venous hemorrhage** is recognized by the dark color of the blood and the continuous stream as the blood escapes from the injured vessel. The blood stream is sometimes incompletely interrupted in wounds of the large veins at the base of the neck and the axillary spaces, locations in which the respiratory movements influence the force of the venous current. The same is true of wounds of any of the large intracranial sinuses. The stream is diminished or partly interrupted during inspiration, and reaches its maximum volume and velocity at the end of the expiratory movements and during coughing and vomiting, acts which always increase intravenous pressure. The flow of blood from a vein wound is also influenced by arterial pulsations if the injured vessels lie upon or are in close contact with an artery of considerable size. In such instances the stream is continuous, but varies somewhat in intensity with the arterial pulsations. Position has a potent influence on venous hemorrhage : the dependent position favors it ; elevation frequently controls it completely. The influence of the force of gravitation on venous hemorrhage is seen in the most striking and convincing manner in wounds of the superior longitudinal sinus.

For the purpose of ascertaining the conditions which induce air embolism and which aggravate or diminish hemorrhage in wounds of the superior longitudinal sinus, I made a series of experiments a number of years ago on dogs and horses. A detailed account of only one of these experiments will be given here, as it furnished conclusive evidence as to the influence of the position of the head in determining either air embolism or hemorrhage.

"*Experiment 4.*—Horse, fourteen years old, in good condition. This experiment was made for the special purpose of confirming the suspicions already gained that the force of gravitation constitutes the most important factor in determining the admission of air into an open sinus of the dura mater ; consequently no anesthetic was used, but the animal was securely held by a bit, and the operation was performed without any difficulty while the animal was in a standing position, with the head elevated. With the trephine and chisel an oval opening about two and a half inches in extent was made over the longitudinal sinus. After all oozing had ceased, the sinus being fully in view, its anterior wall was incised transversely. The edges of the wound immediately retracted, forming a diamond-shaped opening through which blood escaped in moderate force, but not nearly so copiously as on previous occasions when the animals were in the prone position.

"During the first inspiration after the sinus was opened air entered with a loud gurgling or lapping sound, and in applying the ear over the apex of the heart a loud, churning sound was heard, synchronous with the movements of the organ. During expiration

air-bubbles were seen to escape from the proximal end of the sinus. As soon as the head was lowered the hemorrhage became very profuse, but air never entered as long as the animal's head was held in this position. As soon as the head was elevated, however, hemorrhage either ceased entirely or was, at least, greatly diminished, but air was sure to enter during inspiration. These manœuvers were repeated a number of times, and always with the same results. As the amount of air that was aspirated increased the respirations became more labored, and indications of cyanosis became apparent. An attempt was now made to close the sinus wound by sutures, and in this way arrest the hemorrhage. Three catgut sutures were passed through both edges of the wound, but on attempting to approximate its margins every one of them tore through the tissues before the edges were in apposition, proving conclusively that transverse wounds of the longitudinal sinus can not be closed by suturing, owing to the unyielding nature of the tissues. The external wound was completely closed by the continuous suture, and a firm, graduated, antiseptic compress applied over it controlled the bleeding. The wound healed by primary intention. The defect in the skull remained permanent. The animal was killed four weeks later. The trephine opening was filled in with cicatricial tissue. The proximal end of the sinus, just behind the trephine opening, contained one large granulation thrombus. Cicatricial tissue filled almost the entire lumen of the sinus. Anteriorly the sinus was somewhat contracted and smooth; no thrombus or evidences of tissue proliferation were found here. The circulation was apparently restored by the formation of a new channel or dilatation of a preexisting one; this new sinus was located to the left of the median line. The lateral sinuses were very much enlarged. Hemorrhage from any of the large veins of the extremities will cease spontaneously by placing the limb in a vertical position, while when the limb is placed in a hanging position it may endanger life."

3. The so-called surface, or parenchymatous, oozing is largely of **capillary** origin, but not entirely so, as many of the smallest veins and arteries, the bleeding points of which can not be seen, furnish an important source of this form of hemorrhage. The blood is therefore partly venous and partly of arterial origin. The oozing while in progress is continuous and usually distributed diffusely over the surface of the wound, but is most troublesome where the capillary vessels are numerous. In amputations parenchymatous hemorrhage from the medullary tissue is frequently encountered, owing to the delicate structure of the walls of the small blood-vessels, the absence of muscular tissue, and the limited amount of firm connective tissue. Capillary hemorrhage is to be feared in wounds of soft vascular organs, such as the liver, spleen, and kidneys. It is most profuse in hemophilic subjects and in patients suffering from sepsis or organic disease of organs which impedes

the circulation, such as valvular disease of the heart, pulmonary emphysema, cirrhosis of the liver, varicosity of the veins, etc. In a case of very profuse and obstinate capillary hemorrhage following amputation of the leg that came under my observation, subsequent microscopic examination of the muscle tissue revealed extensive degenerative changes incident to the presence of encysted trichinæ as the cause of the troublesome parenchymatous oozing. Under ordinary circumstances capillary hemorrhage is arrested spontaneously by the formation of a minute thrombus in the cut end of the vessels. Thrombus formation is effected most speedily and effectively in cases in which the coagulability of the blood is not impaired, and when the tissues of the wound and the structure of the vessels are favorable to retraction of the cut ends from the surface.

Spontaneous Arrest of Hemorrhage.—Nature's resources in effecting spontaneous arrest of hemorrhage consist in the formation of a coagulum which mechanically blocks the wound and the diminution of intravascular pressure, both conditions which favor thrombus formation. Cessation of hemorrhage without surgical intervention depends largely on the caliber of the vessel injured, the structure of the vessel-wall, the degree of intravascular pressure, and the size and nature of the vessel wound. Complete transverse wounds of a large vessel, such as the common carotid artery or the internal jugular vein, made with a sharp instrument, bleed most freely and present the most unfavorable conditions for spontaneous hemostasis. Incised lateral wounds of the large vessels not only bleed more freely than lacerated wounds of the same size, but also present more unfavorable conditions for effective spontaneous hemostasis by thrombosis. Perhaps the most unfavorable conditions for thrombus formation are to be found in pathologic vessel defects as they occur in ulcer of the stomach, typhoid ulcers, and occasionally in tubercular abscesses the seat of secondary mixed infection with pus-microbes. The degree of intravascular pressure has a most important bearing on spontaneous arrest of hemorrhage. It may be stated as a rule, to which there are few, if any, exceptions, that the greater the intravascular pressure, the greater are the difficulties to be overcome in the arrest of the bleeding by thrombus formation. Cohnheim says: "When a defect or gap is produced at any point in the vascular system, all resistance ceases there, and the blood will, in consequence, flow toward it and escape through the aperture with an energy which naturally is greater the higher the pressure prevailing in the part of the vascular system involved. A thrombus, once established, obstructs the lumen of the blood-vessel injured just so long as its adhesion to the orifice of the wound is sufficient to resist the intravascular pressure."

It is for these reasons mainly that hemorrhage from vein wounds is arrested spontaneously more frequently and promptly than arterial hemorrhage. In profuse hemorrhage, particularly if

a large blood-vessel is the principal source, no attempt at spontaneous arrest of hemorrhage takes place until, by the loss of blood, the force of the heart's action is sufficiently reduced to diminish intravascular tension to a degree compatible with thrombus formation. It is on this account that the administration of stimulants is absolutely contraindicated in the treatment of hemorrhage until the bleeding has been arrested by ligation or otherwise, or by the formation of a thrombus sufficiently firm and adherent to resist effectually the increasing intravascular pressure following the use of stimulants. It would appear justifiable, in cases of internal inaccessible hemorrhage, to resort to abstraction of blood for the purpose of reducing intravascular pressure as low as is compatible with the circulation, for the purpose of aiding spontaneous arrest of hemorrhage by thrombosis. Such therapeutic intervention in the treatment of apoplexy, for instance, to prove beneficial must be had recourse to immediately or soon after the hemorrhage has commenced. It would probably be worse than useless after a sufficient quantity of blood has escaped to produce complete hemiplegia and coma. Thrombus formation, upon which everything depends in the spontaneous arrest of hemorrhage, takes place promptly when the normal coagulability of the blood has not been impaired, and when the vessel wound is torn and ragged, as is the case in lacerated and crushed wounds, and when intravascular pressure is at a minimum either as a normal condition in vein wounds or when it has been rendered so in arteries by the effects of the injury or loss of blood. When blood leaves the current and comes in contact with cut, crushed, or lacerated tissues, the intrinsic tendency to coagulation manifests itself, and under favorable circumstances a thrombus forms and hemorrhage ceases. During reaction from the depression incident to the loss of blood, a soft, recent thrombus is often washed away and hemorrhage recurs and continues until the intravascular pressure is again sufficiently reduced for thrombus formation to occur. It is in such cases of relapsing internal hemorrhage that surgeons are occasionally led astray in making a correct diagnosis, mistaking hemorrhage for shock. In permanent arrest of hemorrhage by thrombus formation the lumen of the vessel, temporarily blocked by the adherent thrombus, ultimately becomes obliterated in the same manner and by the same process as after ligation. The thrombus serves the purpose of a temporary framework for the granulations which spring from the intima and the connective tissue, and is ultimately removed and the lumen of the vessel permanently obliterated by the resulting intravascular scar.

Symptoms and Diagnosis.—The symptoms and diagnosis in external hemorrhage are easily understood. A careful analysis of the symptoms is often required to differentiate correctly between internal hemorrhage and shock, as these two conditions are associated with injuries and operations and frequently resemble each

other very closely. Time is an important element in determining the gravity of the symptoms in hemorrhage. The loss of blood under high pressure from a large vessel near the brain or heart is followed by alarming symptoms almost from the commencement of the hemorrhage. The loss of a pint of blood in two or three minutes produces a much more profound impression than the loss of three times that amount by gradual oozing. The constitutional symptoms make their appearance quickly and in a marked manner in profuse hemorrhage from the large intracranial vessels, the sinuses, and the middle meningeal artery. The acute cerebral anemia thus produced is characterized by a deadly pallor of the face, cold extremities, dilated pupils, loss or huskiness of voice, rapid, small, quivering pulse, shallow, rapid respiration, frequently interrupted by yawns or deep sighs, rushing, roaring noise in the ears, failing eyesight, nausea, and restlessness. These are the symptoms that distinguish acute anemia from hemorrhage, and if death follows, it is often preceded by slight convulsions. If the loss of blood is more gradual, the pupils become widely dilated, the eyes staring, the face and lips assume a wax-like appearance, the pulse is small and fluttering, breathing is rapid and irregular, the surface is cold, and the forehead is bathed in a clammy perspiration. In gradual hemorrhage these symptoms increase in gravity with the amount of blood lost; in other words, the symptoms are progressive, a circumstance which it is important to remember in distinguishing between hemorrhage and shock, as in the latter condition the maximum symptoms appear at once. In shock consciousness is retained, although it may be somewhat impaired. In grave cases of hemorrhage the patient falls into syncope and remains unconscious until reaction sets in. Vomiting and distressing thirst are prominent symptoms in acute anemia from gradual hemorrhage. In cases of hemorrhage into any of the three large cavities of the body the conclusions drawn from the general symptoms must be verified by a careful study of the local symptoms. In intracranial hemorrhage the loss of blood is slight, and the diagnosis must be based on the focal symptoms, which in apoplexy and hemorrhage from the middle meningeal artery and its branches enable us not only to recognize the existence of the accident, but we are also able to locate the extravasation. In hemorrhage into the pericardium the heart-sounds are distant, and percussion reveals the typical increased pericardial dullness. Hemothorax is recognized by the usual signs that indicate the existence of fluid in the free pleural cavity and by displacement of the heart. The accumulation of any considerable quantity of blood in the peritoneal cavity gives rise to physical signs that can not easily be mistaken, more especially if the patient is placed in different positions in recumbency.

Treatment of Hemorrhage.—A full mastery of the technic of modern hemostasis is an essential prerequisite to successful surgery.

Careful hemostasis is not only necessary to guard against loss of blood, but it is likewise indicated to place the injured part in the best possible condition for an ideal healing of the wound. The presence of blood in a wound not only interferes with a speedy and satisfactory healing, but furnishes, at the same time, two predisposing conditions for infection—tension and a culture-medium for the growth of pathogenic microbes. Extravasated blood is always a dead substance, and should be regarded and treated as such by the surgeon. Tension is always a harmful element in a wound, as it is not only a source of pain, but it also exerts a deleterious influence on the circulation and nutrition of the tissues upon which we must depend in effecting a repair of the wound. Our present methods of establishing drainage do not always succeed in preventing harmful tension from the accumulation of blood and serum in the wound, hence the necessity of securing complete hemostasis before suturing a wound. Few, if any, open wounds are absolutely aseptic. Living tissues exercise a certain degree of inhibitory influence on a limited number of pathogenic bacteria. On the other hand, extravasated blood serves the purpose of a nutrient medium, and, as such, becomes an important indirect cause of infection. The most important hemostatic resource in the possession of the surgeon of to-day is the aseptic ligature.

Aseptic Ligature.—To Ambroise Paré (1517–1590) surgery owes a great debt of gratitude, not as the discoverer, but as the first and most devoted champion of the ligature. Through his influence and untiring zeal the ligature gradually found its way into popular favor, and displaced the barbarous treatment by styptics and cautery. He applied the ligature with the aid of a needle, and purposely included more or less of the soft tissues surrounding the vessel, with the idea of securing a better hold for the ligature, and thus guarding more successfully against secondary hemorrhage. He removed the ligature as soon as healthy granulations covered the exposed portion of the vessel. He used the ligature with a view simply to approximate the inner walls of the vessel for a sufficient length of time to enable union to take place, when its further presence was considered useless and even detrimental. Later, the direct ligature came into general use. Besides this change, no great innovations were made in the preparation or use of the ligature until the epoch-making researches of Joseph Lister, thirty years ago. The old septic ligature did its deadly work for more than three hundred years. It is within the memory of many surgeons who are active to-day when the ligature was expected to become eliminated spontaneously in the course of two or three weeks or had to be removed by surgical intervention. As long as the ligature remained in the tissues the patient was in danger of secondary hemorrhage. Every surgeon of the Civil War is painfully aware of the frequency with which secondary hemorrhage occurred after gunshot injuries or after any capital operation. A certain amount of suppuration was always

necessary for the spontaneous elimination of the ligature, and the septic processes incident to such an occurrence always interfered with ideal obliteration of the ligated vessel and healing of the wound by primary intention, and, besides, brought with it the dangers of secondary hemorrhage, sepsis and pyemia. Billroth reported 23 cases of ligation of large arteries after gunshot wounds, and of this number secondary hemorrhage occurred in 7, or 30.4 per cent. Porta collected 600 cases of ligation of large arteries, and of this number 75, or 12.5 per cent., were followed by secondary hemorrhage. Pilz has published a table of ligation of the common carotid artery where the operation was done 158 times for hemorrhage; of these cases 35, or 33.5 per cent., suffered from secondary hemorrhage, which proved fatal in 16, or 15 per cent. How different the results to-day! We have lost all fear of ligating veins, which terrorized surgeons as long as the septic ligature was in use. An artery is ligated, the ligature is cut short, the wound heals by primary union, and permanent obliteration of the ligated portion of the vessel is the rule, and secondary hemorrhage almost unknown. The aseptic ligature, wherever and whenever it can be applied, has almost entirely displaced all other hemostatic agents, and is now universally acknowledged as the safest and most reliable measure in securing provisional and definitive closure of arteries and veins. Like all important improvements, it has met with opposition, but a more extended trial has silenced criticism.

In his first communication to the profession on this subject Lister alludes to the advantages of the aseptic ligature as follows: "If the antiseptic ligature be employed, it merely inflicts a wound or injury upon the vessel, without introducing any permanent cause of irritation. The injured part, therefore, becomes repaired after the manner of a subcutaneous wound, without passing through the process of granulation and suppuration which is induced by the employment of the ordinary septic ligature." It may now be truly said that some form of aseptic ligature is used at present by almost every surgeon, and that while the merits of the aseptic treatment of wounds are still questioned by a few, no one conversant with modern surgery would use the ordinary ligature without a sense of neglect or actual guilt. Perhaps no other surgical procedure has ever enjoyed the confidence of the whole profession throughout the civilized world to the same extent as the aseptic ligature. This universal faith in the reliability and safety of the aseptic ligature is only a natural outgrowth of the superior results following its use. Protracted suppuration in wounds, the result of retained ligatures, secondary hemorrhage, and suppurative inflammation of the ligated vessels and its many immediate and remote complications have almost entirely disappeared under the use of the aseptic ligature. Nussbaum has well said: "Catgut is without doubt Lister's greatest discovery." And, again: "How pleasant it is to cut the ligatures short and leave them unconcerned to their fate in the

wound! In ovariotomies, etc., their value can not be overestimated. The manner in which catgut adheres to an artery, forming connections with it and the surrounding tissues, assisting at the same time in forming a firm ring around the coats of the vessel, is an exceedingly welcome occurrence, guarding against secondary arterial hemorrhage in ligating in the continuity of a vessel, and rendering even the application of a ligature in close proximity to a large collateral branch devoid of danger. All this silk can not do." Before the introduction of antiseptic surgery suppuration at the seat of ligation was almost a necessity. As suppuration interfered seriously with the hyperplastic processes in the tissues of the arterial tunics, secondary hemorrhage was of frequent occurrence, because the adhesions between the surfaces of the intima were not always sufficiently firm to resist the intra-arterial pressure at the time of the separation of the ligature. On this account it was deemed absolutely necessary by the older surgeons, in deligating an artery in its continuity, to apply the ligature at least an inch distant from the next collateral branch, so as to secure a thrombus of sufficient length to resist the blood pressure. But the length of the thrombus did not always protect the patient against secondary hemorrhage, as the septic endarteritis left the thrombus loose, which, on cutting through of the ligature, was only too often swept away before the blood current.

Ligating a blood-vessel under strict aseptic precautions presents the following advantages: (1) The ligature remains undisturbed in the wound, being either removed by absorption or becoming encysted after having fulfilled the purpose of a provisional hemostatic. (2) Speedy obliteration of the lumen of the vessel takes place by proliferation of new tissue from the endothelial and connective-tissue cells, independently of thrombus formation; in fact, thrombosis is often wanting. The constricted portion of the vessel does not necrose; it is infiltrated, like the catgut, with living tissue. In all operations with the aseptic ligature the small size of the intravascular clot and its total absence, as is frequently noted, are in remarkable contrast with the results observed after the use of the ordinary septic ligature.

The importance of the thrombus as an active agent in the definitive closure of vessels has vanished before the brilliant results obtained with the aseptic ligature. The safety of the aseptic ligature does not depend on rupturing the intima, as was claimed for the ordinary ligature. All that is required of the aseptic ligature in the way of a mechanical agent to insure obliteration of a blood-vessel is to approximate and hold in contact the intact intima for a sufficient length of time for the definitive closure to be effected by the formation of a minute transverse scar immediately underneath or in close proximity to the ligature, and firm enough to resist the blood pressure. More than ten years ago I demonstrated, by a long series of experiments on different animals, that a reliable

intravascular scar will form in a very few days independently of the formation of a thrombus. In one series of experiments cicatricial obliteration of blood-vessels between two ligatures was studied, emptying the intervening portion of the blood-vessel completely of the contents. In all these experiments the vessel sheath was always laid open to the extent of an inch or more, and the artery or vein completely isolated to the same distance, when two ligatures were placed underneath the vessel. The proximal end of the artery was tied first, and the distal side of veins. The vessel was made bloodless by placing the second ligature in close contact with the first, and by making traction on both ends, and sliding the loop to the required distance, when the return of blood was prevented by an assistant who compressed the vessel firmly between the thumb and index-finger until the ligature was tied. If any doubt remained as to the bloodless condition of the intervening space, these manipulations were repeated before tying the second ligature. In tying the ligatures it was the aim not to injure the intima, but simply to approximate its inner surfaces. The ligatures were usually applied about half an inch apart. From the many experiments made, only three will be cited.

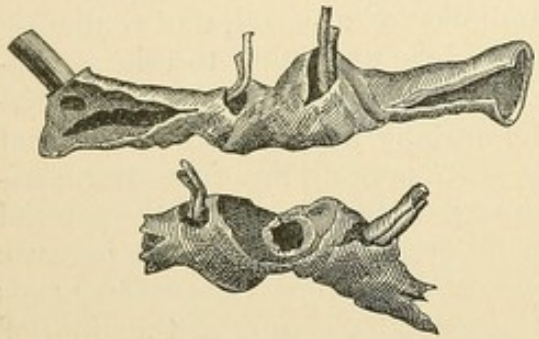

Fig. 45.—Specimen in experiment No. 4.

"*Experiment 4.*—Right femoral artery of sheep tied with coarse catgut. Animal killed seven days after operation. Proximal thrombus extending to next collateral branch, three-fourths of an inch above the ligature; nonadherent and only partly filling the lumen of the vessel. Distal thrombus minute. Intervening portion of vessel filled with an adherent mass of granulations.

"Ligatures softened and covered by granulation tissue. On removing central ligature, lumen of vessel was found to be completely and firmly obliterated by direct adhesions between the granulating surfaces of the intima (Fig. 45)."

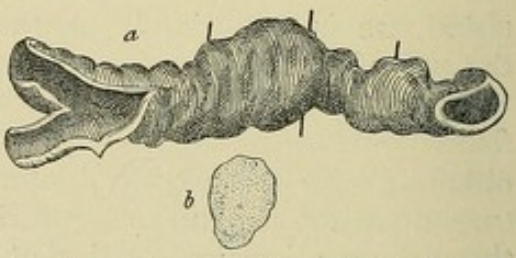

Fig. 46.—Specimen in experiment No. 18: *a*, Obliterated vessel; *b*, cross-section.

This experiment would tend to prove that the lumen of an artery the size of the femoral is securely obliterated between two ligatures in seven days, without the intervention of a blood-clot. Single ligations of vessels of similar size have shown, after the lapse of the same time, a minute intravascular scar at the point of ligation firm enough to resist the intra-arterial pressure.

"*Experiment 18.*—Left femoral artery of sheep tied with coarse braided silk. Distal ligature just above profunda. Animal killed fifty days after operation. Ligatures encysted. On the proximal side the artery was obliterated to a distance of one-eighth of an inch above the ligature. Profunda pervious. Intervening portion converted into a solid cord of connective tissue in which, on transverse section, the remains of the artery could still be recognized (Fig. 46)."

The same speedy process of definitive obliteration of the lumen of the veins takes place after exclusion of the blood for a limited period of time, as is shown by the following experiment:

"*Experiment 48.*—Double ligation of the internal jugular vein of sheep, intervening empty portion an inch in length. Silk ligatures were removed three days after operation. Animal killed twenty-seven days after ligation. Circulation arrested at seat of ligatures. Peripheral clot narrow, partially adherent, one inch in length. At the seat of operation about two lines of the vessel converted into a solid string of connective tissue (Fig. 47)."

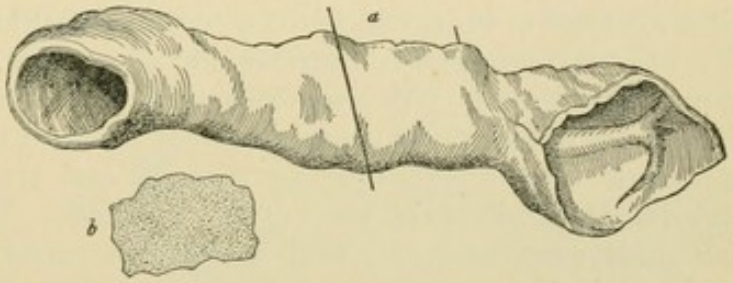

Fig. 47.—Specimen in experiment No. 48: *a*, Obliterated vessel; *b*, cross-section.

Intravascular Cicatrization after Ligation.—I found, in my experiments on arteries, that in thirty-four cases the presence of a proximal thrombus is mentioned thirty-one times, against ten in the distal portion of the artery. In four of the experiments it is noted that only a peripheral thrombus formed in seven cases, in which the thrombus was found only on the proximal side of the ligature. In most of the cases the thrombus was quite minute, seldom filling the entire lumen of the vessel, and never adherent to the intima. A notable exception was afforded by the experiment on a horse, where an immense proximal and distal thrombus formed in the right common carotid artery, filling the entire lumen of the vessel, extending on the proximal side to near the subclavian artery, and on the peripheral to beyond the bifurcation of the vessel. In the specimens derived from twenty-one experiments on veins I was never able to find even a trace of a thrombus on the proximal side of the ligature, while the presence of a distal thrombus was noted eleven times, or in a little more than 50 per cent. of all the cases.

These experiments furnished the most favorable opportunities to study the process of cicatrization underneath the proximal ligature, independently of a thrombus, as the presence of a clot was excluded in every instance. With the exception of the specimen

obtained from the horse, the thrombi in veins were usually small in size and seldom adherent over any considerable surface. Only in exceptional cases, both in arteries and veins, did the thrombus reach as far as the nearest collateral branch. The results of these experiments make it obvious that the time-worn rule laid down in most of our text-books on surgery of but a few years ago, which directs the operator to apply the ligature in such a manner as to leave a space of one inch or more between the ligature and the nearest collateral branch for the purpose of insuring the formation of a thrombus, is wrong, both in theory and practice, and should no longer be observed as a guide in deciding upon the point for ligation. The aseptic absorbable ligature can be applied near a collateral branch without incurring any risk whatever of secondary hemorrhage, provided the wound is aseptic and remains so after the operation. The first attempt at obliteration of a blood-vessel after ligation is manifested in the connective tissue of the adventitia and the paravascular connective tissue. As early as twenty-four hours after ligation the isolated portion of the vessel between the two ligatures has become adherent to the surrounding tissues, and the swollen adventitia overlaps and hides the loop of the ligature. The connective tissue becomes very vascular, and undergoes rapid transformation into embryonic tissue, being converted in a few days into granulation tissue, which completely surrounds and embraces the ligatures, the intervening portion, and the vessel ends very much in the same manner as the provisional callus incloses the ends of a fractured bone.

This investing capsule of new connective tissue was found present in every specimen, and in many instances was of remarkable size and strength. The thickest portion of this paravascular capsule always corresponded to the locality which had been subjected to the greatest amount of traumatism—that is, the side of the vessel toward the incision. As soon as definitive closure of the vessel had taken place the capsule diminished in size, until, after a period of three months, it did not exceed the diameter of the ligated vessel.

The contraction that belongs to all cicatricial tissue manifests itself also in the spindle-shaped mass of connective tissue which forms around vessels after ligation, and renders material assistance in the process of final obliteration by compressing the vessel, thus diminishing its lumen. In all my experiments in which union of the incision occurred without suppuration the intervening portion of the vessel was found covered by granulation tissue as early as the third day, and the fibrous capsule was always firmly adherent to the vessel. Through the medium of this connective-tissue capsule the ligated ends of the vessel always formed firm adhesions with the surrounding structures, the artery, vein, and nerve often being enveloped by one common capsule, as may be seen well illustrated in figure 48.

The process of repair initiated in the adventitia proceeds by continuity of tissue in a central direction toward the lumen of the vessel, until the connective-tissue proliferation perforates the endothelial lining of the intima, an event which initiates the formation of the endovascular cicatrix. Simultaneously with the appearance of the granulation process in the intima and the appearance of new vessels from the adventitia the endothelial cells assume an active part in the process of cicatrization, the new tissue elements mingling with the connective-tissue product and assisting them in the formation of the internal or definitive scar. Cicatrization begins always underneath and in the immediate vicinity of the ligature. This fact receives a satisfactory explanation by assuming that the greatest amount of traumatism is inflicted at this point, and that, by interrupting the circulation in the vasa vasorum by the ligature, an active engorgement is produced which accelerates tissue changes and the formation of new vessels. At the same time the inner surfaces of the intima are here brought into accurate and uninterrupted contact.

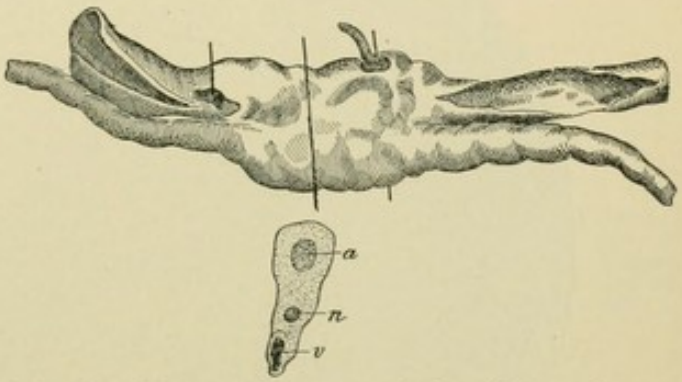

Fig. 48.—Common fibrous capsule for obliterated artery (*a*), vein (*v*), and nerve (*n*).

In my experiments on arteries three days was the shortest period of time in which a narrow, firm cicatrix formed underneath the proximal ligature. In the experiments on veins the condition of the vessel was always examined underneath the proximal ligature, inasmuch as any changes in the tunics and lumen of the vessel at this point had to be attributed to the tissues themselves, independently of a blood-clot, as the intervening portion was always made bloodless, and a thrombus was never found on the proximal side of the ligature. In one of the specimen I found, on the fifth day, a firm, circular cicatrix underneath the ligature. The intervening portion of the vessel was carefully examined at times ranging from six hours to ninety days after the operation. This portion of the vessel, although deprived of all vascular supply, never necrosed unless suppuration followed the operation. Nutrition was derived from the paravascular tissues until the interrupted circulation in the vasa vasorum was restored, when the vessel tunics were again brought into a condition capable of assuming active tissue proliferation. In many of the specimens it was noted that the walls of the intervening portion were found thickened, which would certainly indicate that the tissues did not remain in a passive condition, but were actively concerned in the work of tissue proliferation.

The earliest time at which granulation tissue was found upon the free surface of the intima was seven days in the case of arteries, and three days in veins. The formation of the cicatrix in the lumen of the vessel always began near the ligatures, the material filling the folds of the intima often forming distinct bridges connecting the highest points of adjacent ridges. The amount of granulation material in the lumen of the vessel appeared to vary; in some specimens the lumen presented a stellate shape, the surfaces of the intima adherent, with a minimum amount of new tissue between them, while in other specimens a cylindric mass of new connective tissue occupied the interior of the vessel. Complete obliteration of the

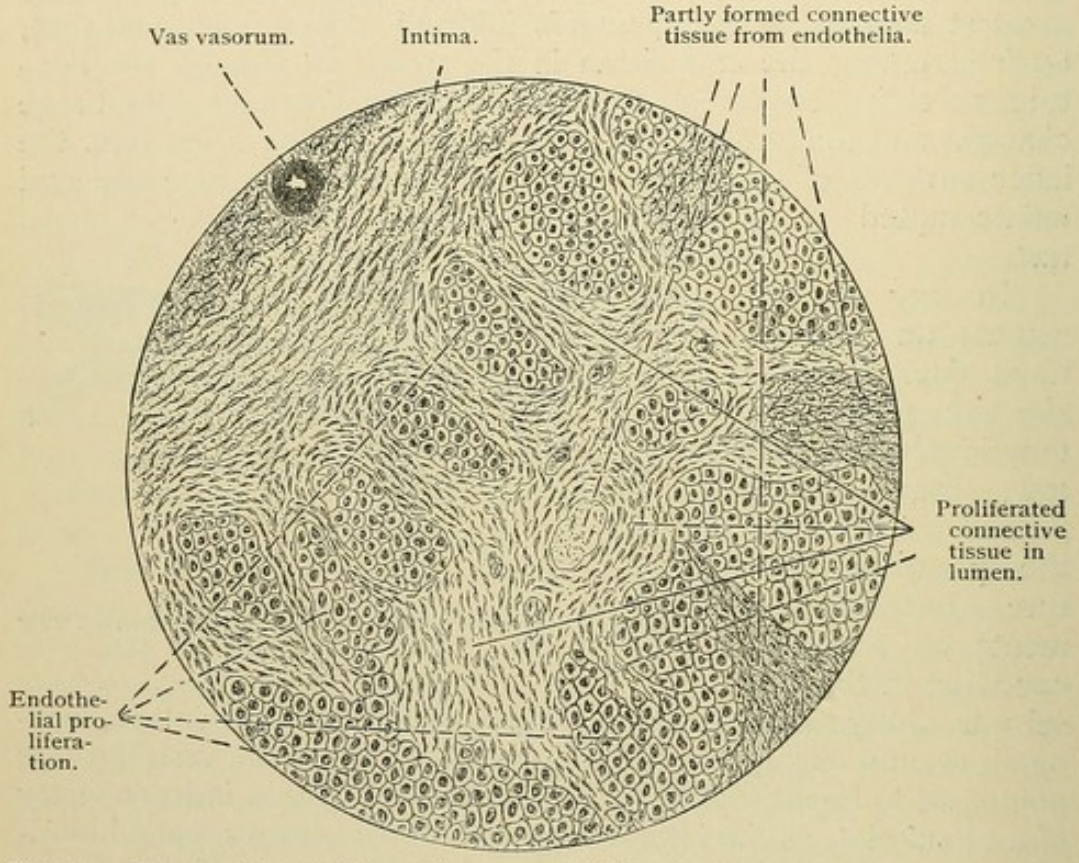

Fig. 49.—Cross-section of obliterated artery, exhibiting the histologic appearances of the intravascular scar (× 240).

intervening portion took place in the femoral artery in thirty-five days, in the carotid in thirty-nine days, and in the internal jugular vein in twelve days.

As cicatrization advances the original structures of the tunics disappear, the endothelia are transformed into connective tissue, and between the paravascular cicatrices the elastic and muscular tissues undergo degeneration and are ultimately removed by absorption.

The final effects of the ligature are obliteration of the lumen and conversion of all the tunics of the vessel into a solid cord of connective tissue, which, again, is subject to various degrees of atrophy. The histologic processes of endovascular cicatrization

in my experimental work were studied by making transverse sections through the intervening portion, equidistant from the ligatures.

Figure 49 represents the inner border of the wall of the femoral artery and a part of its lumen. The open lumen of a vas vasorum can be seen near the intima. From the intima projections of connective-tissue proliferation are seen to penetrate into the lumen of the vessel, pushing before them the endothelial lining, and perforating it at different points, subsequently forming a network of connective tissue in the interior of the vessel. In the meshes of this network are seen masses or nests of new endothelial cells, products of the preexisting endothelial cells. At certain places these new

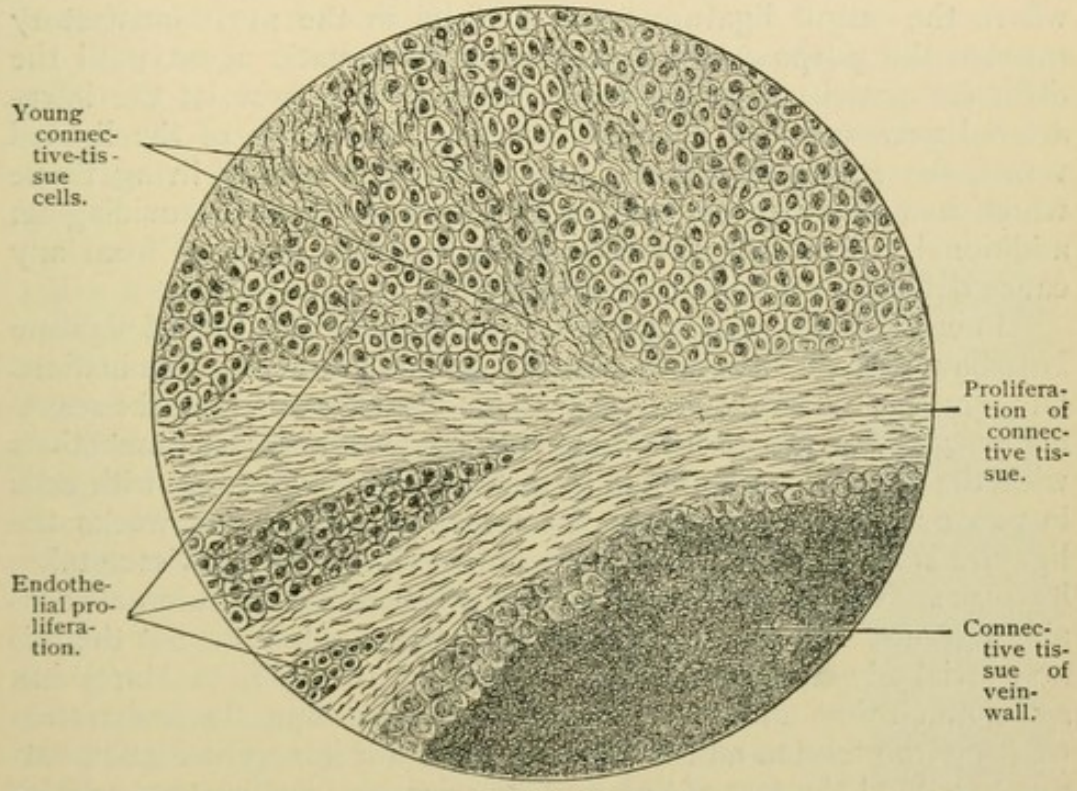

Fig. 50.—Histologic structure of intravenous scar, right internal jugular vein, forty-nine days after ligation. Transverse section between ligatures (× 240).

endothelial cells present an oval or spindle-shaped form, assumed during their transformation into connective tissue. The vasa vasorum send blood-vessels into the lumen, filled with embryonic tissue in various stages of development.

Figure 50 shows the intima and a portion of the granulation thrombus which has permanently closed the lumen of the vessel. The microscopic appearances are almost identical with those of the arterial specimen. Both of these illustrations furnish the best possible demonstration of the manner in which the intravascular cicatrix is formed from the connective tissue and endothelia. The macroscopic and microscopic examinations of the specimens seem to demonstrate in a most conclusive manner that the intravascular scar

after ligation is the exclusive product of connective tissue and endothelial proliferation. A detailed account of the obliterative processes following ligation of blood-vessels has been given, but I deem an accurate and comprehensive knowledge of this subject essential to a proper appreciation of the purpose and uses of the ligature.

Ligature Material.—The results of my experiments, as well as the literature on the subject, tend to prove that all kinds of ligatures, provided they have been made aseptic, always become encysted in aseptic wounds. All ligatures, however, that permanently resist absorption destroy the continuity of the vessel, and on this account, instead of adding strength to the paravascular cicatrix, weaken the vessel-wall at the seat of ligation. I have never observed a single instance in hospital or private practice where the catgut ligature failed to fulfil in the most satisfactory manner the purposes of a provisional hemostatic agent until the definitive cicatrix had become sufficiently firm to resist the intra-arterial pressure. In place of severing the tunics of the ligated vessel, the catgut ligature is gradually displaced by living tissue which increases the resisting capacity of the vessel, providing an additional safeguard against secondary hemorrhage, if from any cause definitive obliteration is retarded.

In enumerating the superior advantages of the catgut ligature Nussbaum says: "The most careful microscopic examinations have shown that catgut increases to a considerable degree the resisting power of an artery in forming firm connective-tissue connections with the vessel." The fibers of the catgut are infiltrated with cells in two or three days, and in the course of two to four weeks the ligature is removed by absorption and a ring of living tissue takes its place. Catgut is the material usually employed as an absorbable ligature. Some surgeons prefer kangaroo tendon, but there is no special advantage in using this material. Dr. H. O. Marcy has spent much time and used his genius in perfecting the preparation of kangaroo tendon and in introducing it for general use, but catgut has stood the test of time and experience and will retain its well-deserved place in surgery and command the confidence of the profession. The two kinds of ligature material now in general use are the animal absorbable ligature and silk.

Sterilization of Silk.—Many prominent surgeons, after an unfavorable experience with catgut, have gone back to the use of silk as a ligature material. The most influential champion of the silk ligature at the present time is Kocher. He abandoned the use of catgut a number of years ago because, with all the care that could possibly be taken in its preparation and use, many of the wounds suppurated, and he was able to trace the source of infection to the catgut. He now uses silk exclusively, and after an extensive experience is satisfied with the results. Kocher sterilizes silk by first immersing it in ether for twenty-four hours for the purpose of removing the fat, after which it is boiled for twenty minutes in a

solution of corrosive sublimate, 1 : 1000. As an extra precaution he reboils it for ten minutes before every operation. The removal

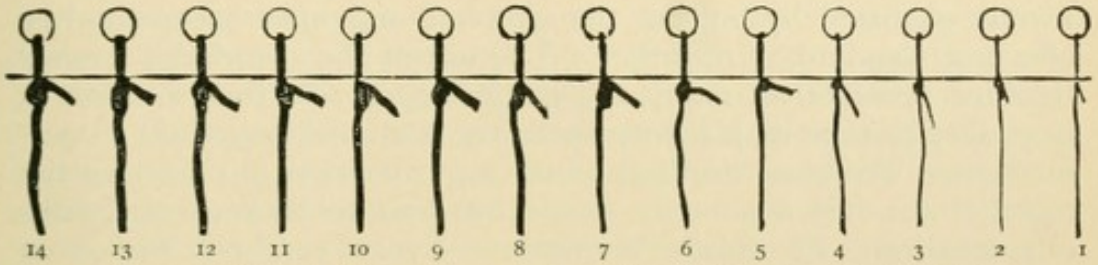

Fig. 51.—Showing the approximate sizes of both twisted and braided silk.

of fat may be an advantage in preparing the silk for sterilization by boiling, but it is not essential.

Silk can be rendered sterile by exposing it to the action of steam under high pressure for twenty minutes, or by boiling for thirty minutes in a normal salt or soda solution. It can be kept sterile and ready for use in absolute alcohol. It should be wound on glass plates with the sharp margins ground off, and be at least six inches in length. In hospitals and for office use glass jars with reels are convenient for the preservation of the silk ligatures. For emergency use the silk can be carried in sealed sterile envelops of convenient size.

Fig. 52.—Truax's bottle containing three sizes of catgut.

Sterilization of Catgut.—The sterilization of catgut has occupied the time and attention of bacteriologists and surgeons since Lister's first efforts by immersion in carbolized oil. It is safe to state that notwithstanding the great improvements which have been made, the process is still far from being perfect. Lister's crude method of rendering catgut aseptic has been variously modified during the last thirty years. Different methods have been devised, and nearly all antiseptic substances have been employed in the preparation of catgut. The very fact that so many different methods have been recommended is the very best and most convincing proof that none of them has proved entirely satisfactory. Kocher abandoned the use of his juniper catgut. Carbolized, sublimated, and chromicized catgut have been used very extensively, but every surgeon knows from actual experience that not infrequently wound infection can be traced to imperfect sterilization of the material. Dry sterilization of catgut seemed to become the general procedure a few years ago, but extensive trial has shown that it can not be relied upon in rendering the material absolutely safe for practical use.

The many failures of catgut as an aseptic suture and ligature material as heretofore prepared are responsible for the substitution of silk for catgut in the practice of many surgeons. Silk can be readily sterilized by boiling, the simplest and quickest method of effecting absolute sterilization. The use of the absorbable animal ligature presents so many advantages over silk that all that is necessary to take its place permanently is a reliable method of sterilization. The ideal sterilization of catgut consists in rendering the material not only absolutely sterile, but also mildly antiseptic, without impairing its tensile strength. Every surgeon has been anxiously looking for a method by which catgut could be prepared so that it could be sterilized by boiling without impairing its strength. Fortunately, this expectation has been realized. Experiments have shown that catgut and leather immersed for forty-eight hours in a 2 to 4 per cent. solution of formalin undergo an unknown chemic change which alters their texture in such a way that the tensile strength is not impaired, but rather increased, by



Fig. 53.—Ignition tube with ligatures wound on bobbins.



Fig. 54.—Ignition tube with ligatures wound on spools.

boiling. The commercial catgut is subjected to the action of formalin without any previous preparatory treatment of the raw material.

Hofmeister's Method.—Hofmeister, who has done such excellent service in perfecting the formalin preparation of catgut, gives the following most recent method:

1. The catgut is wound on a glass plate with slightly projecting edges, so that the gut is free from the sides of the plate and exposed to the circulation of the boiling and flowing water. The ends of the gut are fastened through holes in the plate.

2. Immersion for from twelve to forty-eight hours in aqueous solution of formalin, 2 to 4 per cent.

3. Immersion in flowing water for at least twelve hours to free the gut from the formalin.

4. Boiling in water for from ten to thirty minutes. Ten to twelve minutes answer the purpose fully, as all microbes and

spores are destroyed by exposure to boiling heat for that length of time.

5. Hardening and preservation in absolute alcohol containing 5 per cent. of glycerin and $\frac{1}{10}$ of 1 per cent. of corrosive sublimate. Experiments on animals have proved that catgut thus prepared is absorbable, though not so quickly as the ordinary material. One of the essential conditions of success in this method of catgut sterilization is to wind the gut quite tightly around the glass plate during the process of sterilization.

Senn's Modification of Hofmeister's Method.—The first attempts to sterilize catgut by Hofmeister's method under my own direction were made at St. Joseph's Hospital, Chicago, by the sister in charge of the operating room. The result of experience led to modification of the procedure in several ways. Instead of glass plates, ordinary glass abdominal drainage-tubes have been employed, upon which the gut is wound quite tightly. These perforated glass drains have been found an excellent substitute for the plates. An ordinary large test-tube would answer the same purpose. The remaining directions given by Hofmeister were followed to the letter. Numerous inoculations with fragments of catgut prepared by this method in sterile gelatin invariably gave negative results. The catgut is as strong as the raw material, and the knot is less liable to unloosen than when the ordinary material is used. It was also found that the formalin catgut could be reboiled almost any number of times without impairing its strength.

Catgut to be safe should not only be absolutely sterile, but should contain a sufficient quantity of a mild, but efficient, antiseptic to render it unfit as a culture-medium for pathogenic microbes. Hofmeister accomplishes this object by immersion in an alcoholic solution of corrosive sublimate. Others have used carbolic acid. Both of these antiseptics unduly irritate the tissues and increase the primary wound secretion, effects which can not fail to interfere to a certain extent with an ideal healing of a wound by primary intention.

The valuable and interesting experiments made recently by Lauenstein leave no doubt that it is almost next to impossible to secure an absolutely aseptic condition for the field of operation by any of our present methods of disinfection. We are forced to admit that nearly every wound inflicted by the surgeon's knife contains some pathogenic microbes, notwithstanding that the strictest aseptic precautions may have been carried out. The experiments made by Ewald have also furnished positive evidence that sterile catgut often contains a sufficient quantity of an unknown toxic substance, which, by its destructive action upon the cells engaged in the regenerative process, transforms them into pus-corpuscles, resulting in the production of a limited aseptic suppuration and the formation of sterile pus. Undoubtedly many of the stitch abscesses that occur in the practice of painstaking aseptic surgeons have such

an origin. These experimental researches force upon us the conclusion that catgut should not only be sterilized, but that it should be made sufficiently antiseptic at least to inhibit the growth of, if not destroy, the pyogenic microbes which enter the wound during the operation or which may reach it later through the circulation. In this part of the preparation of catgut I have modified Hofmeister's method by substituting iodoform for the corrosive sublimate.

This modification I deem of special importance in emergency work, in which we must take it for granted that most of the wounds are infected. After boiling the deformalized catgut for from twelve to fifteen minutes, it is cut into pieces of convenient length, tied into small bundles containing from six to twelve threads, when it is immersed and kept ready for use in the following mixture: Absolute alcohol, 950; glycerin, 50; iodoform (finely pulverized), 100 parts. The alcohol dissolves part of the iodoform. The bottle containing the catgut should be kept closed with a well-fitting glass cork, and should be shaken well every few days to bring the iodoform into contact with the threads. The catgut can be kept in this mixture for a long time without losing its strength. One of the valuable properties of iodoform applied to a recent wound is to diminish the amount of primary wound secretion. It does not destroy pus-microbes, but it inhibits their growth when present in limited numbers. Catgut prepared by this method has been in use, exclusively, for nearly two years in St. Joseph's and the Presbyterian Hospitals, and in Rush Medical College Clinic, with the very best results.

Kocher's Method.—This method consists in depriving the catgut of its fatty matter by treatment with ether, after which it is sterilized by immersion in oil of juniper for from two to twenty-four hours, according to the size of the catgut.

Alcohol Sterilization.—Répin and Saul rely on sterilization by boiling the catgut in alcohol. Schäffer has improved this method and recommends boiling the catgut for fifteen minutes in a solution consisting of 1 gm. of corrosive sublimate, 30 c.c. of water, and 170 c.c. of alcohol. Catgut thus prepared is preserved in 95 per cent. alcohol.

Von Bergmann's Method.—After removing the fat by immersion in ether for from twenty-four to forty-eight hours, according to the size of the gut, place the gut in a 1 per cent. solution of corrosive sublimate dissolved in 80 parts of alcohol and 20 parts of water, and shake the vessel frequently.

Johnston's Method.—Mr. Johnston, of the Jefferson Hospital, Philadelphia, recommends the following process:

First, steep the gut in the best ether for from twenty-four to forty-eight hours, then transfer it directly into a mercuric bichlorid mixture, consisting of 40 grains of corrosive sublimate and 200 grains of tartaric acid in 12 fluidounces of 95 per cent. alcohol.

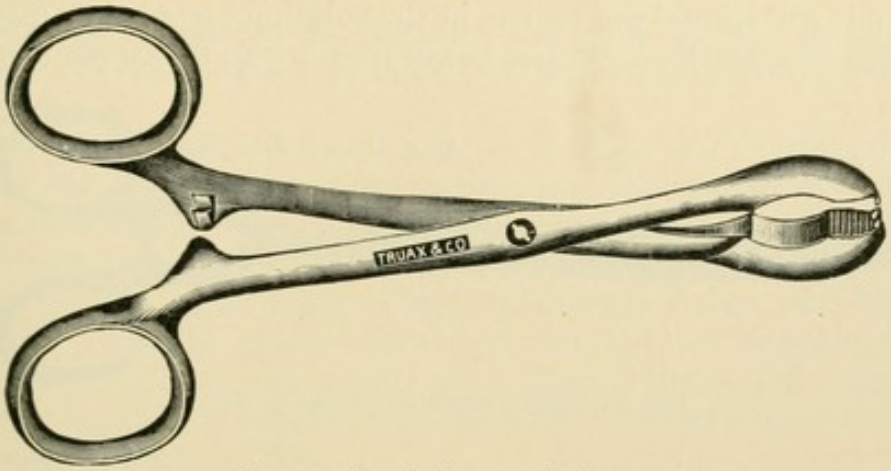

Fig. 55.—Senn's hemostatic forceps.

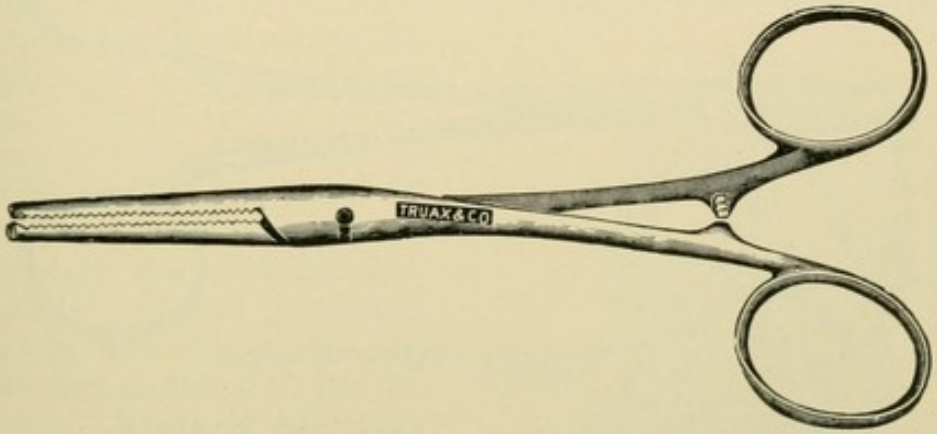

Fig. 56.—Kocher's hemostatic forceps.

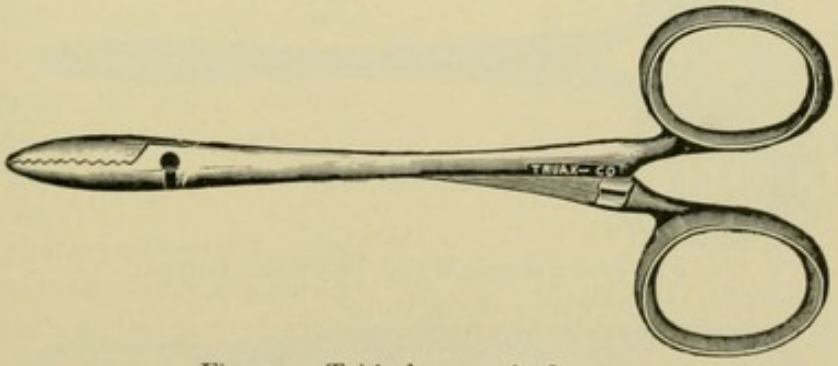

Fig. 57.—Tait's hemostatic forceps.

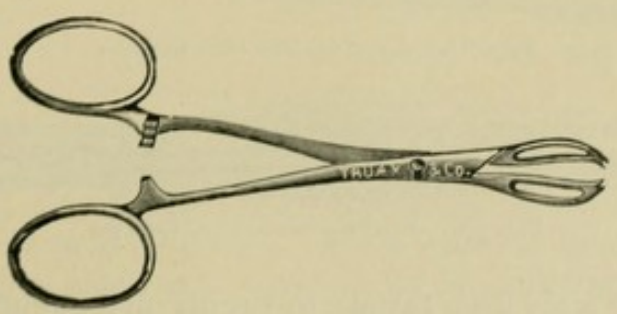

Fig. 58.—Little's hemostatic forceps.

Very fine gut should not remain in the solution longer than from five to seven minutes, the next size larger from ten to fifteen minutes, and



Fig. 59.—Etheridge's hemostatic forceps.

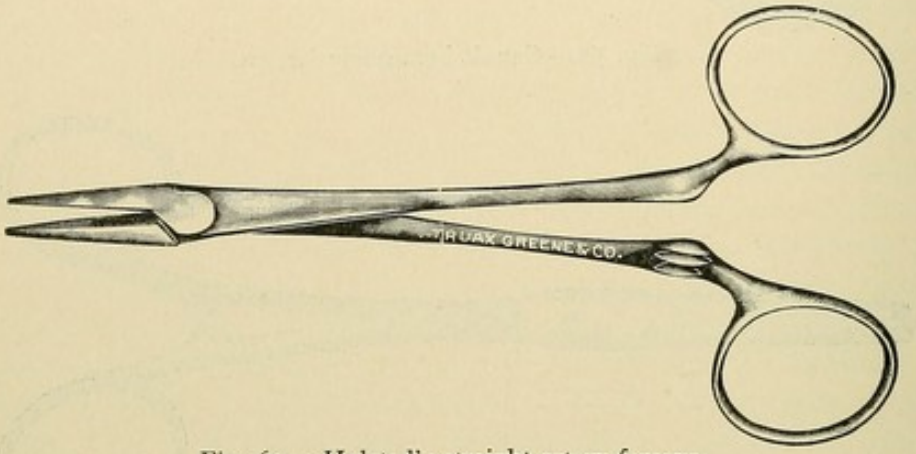

Fig. 60.—Halsted's straight artery forceps.

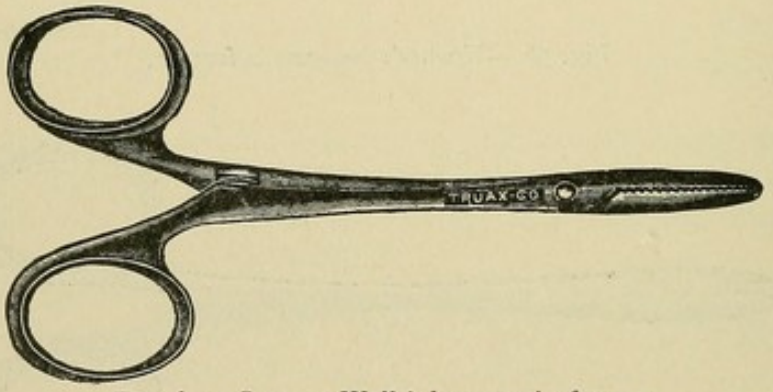

Fig. 61.—Spencer Wells' hemostatic forceps.

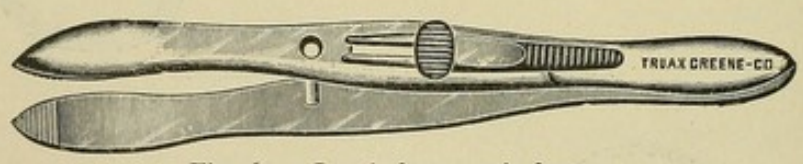

Fig. 62.—Luer's hemostatic forceps.

Fig. 63.—Fricke's hemostatic forceps.

the two largest sizes from twenty to twenty-five minutes. Gut thus prepared is then kept ready for use by immersing it in a solution

of palladium chlorid, in the proportion of $\frac{1}{16}$ of a grain to a pint of alcohol. Keen speaks very highly of the reliability of catgut thus prepared.

Horsehair and silkworm gut are seldom used in tying blood-vessels, but they are excellent suture materials and are prepared in the same manner.

Preparation of Horsehair.—Wash the horsehair thoroughly in hot water and potash soap. Place the threads in line, and fasten at one end. Wrap in gauze and boil for ten minutes in a solution of carbonate of soda 1 per cent.; then rinse in hot water. After this process boil for ten minutes in clear water. Preserve in solution of mercuric alcohol 1 : 1000.

Application of Ligature.—A liberal supply of hemostatic forceps is always a source of comfort to the surgeon, and should constitute the most important part of the contents of every emergency case. A hot controversy between Koeberlé and Péan in reference to the priority of using hemostatic forceps for temporary and definitive hemostasis finally furnished enough information to accredit the former with the invention. Koeberlé has used his "pinces hemostatiques" since 1865. Péan's forceps were not made until three years later. Koeberlé's first publication on this subject appeared on September 8, 1868, in the "Gazette des Hôpitaux."

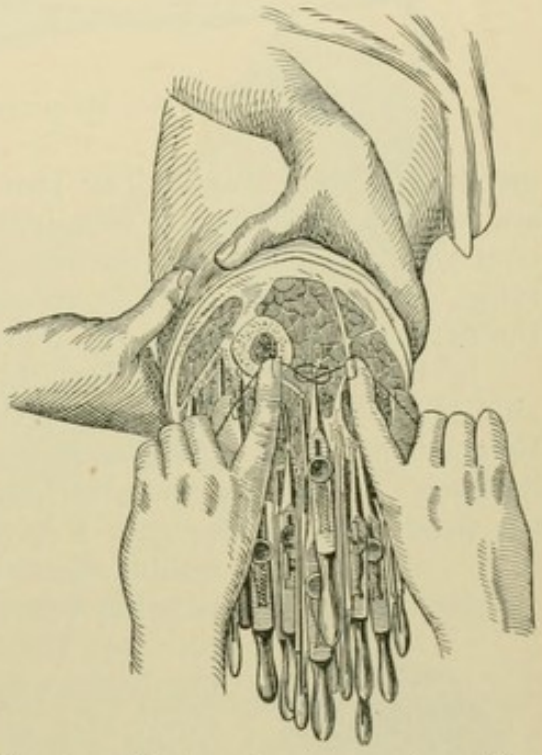

Fig. 64.—Showing the manner of applying the ligature to cut end of a vessel (Esmarch).

Of the many modifications of hemostatic forceps for ordinary use, I have a decided preference for Kocher's instrument. It is light and has a sure grasp. For abdominal and pelvic operations forceps of special size and construction are occasionally required, especially by surgeons who are accustomed to forcipressure as a substitute for the ligature.

In applying a ligature to a wounded blood-vessel the bleeding point is grasped with hemostatic forceps, and the ligature applied and tied at a safe distance from the vessel wound to insure a firm and permanent hold (Fig. 64). In the case of small vessels, especially in deep wounds, it is occasionally found impossible to secure enough tissue with a hemostatic forceps to tie the ligature so that it will not slip after removal of the forceps. In such cases the sur-

geon avails himself of the old-fashioned artery hook instead of the forceps (Fig. 66). With the sharp hook enough tissue is grasped with the bleeding vessel so that on slight traction a small cone is made and the ligature thrown around its base and firmly tied under the instrument. In some wounds and localities it is sometimes difficult, if not impossible, to tie the vessel above the grasp of the instrument, the end of which is included in the ligature on tying it. It is in such cases that a second forceps will often overcome the

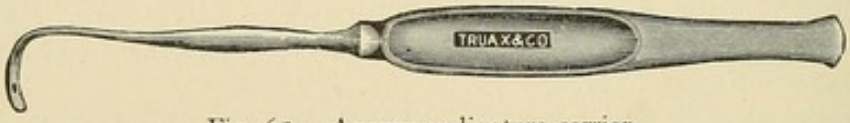

Fig. 65.—Aneurysm ligature carrier.

Fig. 66.—Minor operating tenaculum.

mechanical difficulties. The two forceps applied closely together are separated sufficiently to constitute at the grasping ends a cone over which the ligature readily glides into its proper place. On tying, one pair of forceps is removed, and the ligature is tied with the necessary firmness on the removal of the second forceps.

In ligating small arteries and veins it is seldom that we are able to apply the direct ligature, more or less of the surrounding tissues being included in the grasp of the forceps, and later in the ligature. In ligating the principal arteries after amputation above the wrist- and ankle-joints I have made it a practice to apply a double direct ligature. The artery and accompanying vein should be isolated from the surrounding tissues to the distance of one-third or one-half an inch, when the artery is tied separately at a safe distance from the cut end, and the second ligature, including the vein, is applied from a few lines to one-third of an inch higher up. In this manner a limited bloodless space is secured between the ligatures, furnishing an ideal condition for speedy obliteration of the lumen of the vessel by intravascular cicatrization. I have followed this practice for fifteen years and have never been mortified by the occurrence of secondary hemorrhage. In direct ligation of arteries the ligature should be tied only with sufficient firmness to approximate the intima; it is needless and often harmful to rupture any of the tunics of the vessel. To accomplish this a simple square knot should be made, as by so doing it is much easier to graduate the force necessary to accom-

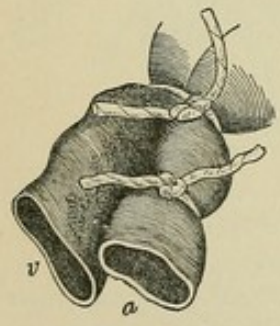

Fig. 67.—Double ligation of artery (*a*), upper ligature including the accompanying vein (*v*).

plish the desired object than by tying in the customary manner. The ligature ends should not be cut too close to the knot, as by so doing the knot might loosen and the ligature give way.

One of the rules invariably given by authors for the tying of arteries in their continuity was to make a small opening in the sheath of the vessel, just of sufficient size to permit passing the ligature needle around it. It was feared that a freer opening in the sheath and a more extensive isolation of the vessel would lead to necrosis of its tunics on account of the cutting-off of the vascular supply. That this idea still prevails is evident from some of the more recent text-books on surgery. Lidell calls special attention to this point in the following language: "The risk of sloughing, however, arises mainly from isolating the artery too much, or from separating it too extensively from its sheath while dissecting to expose it, or while preparing to pass a thread around it, whereby the

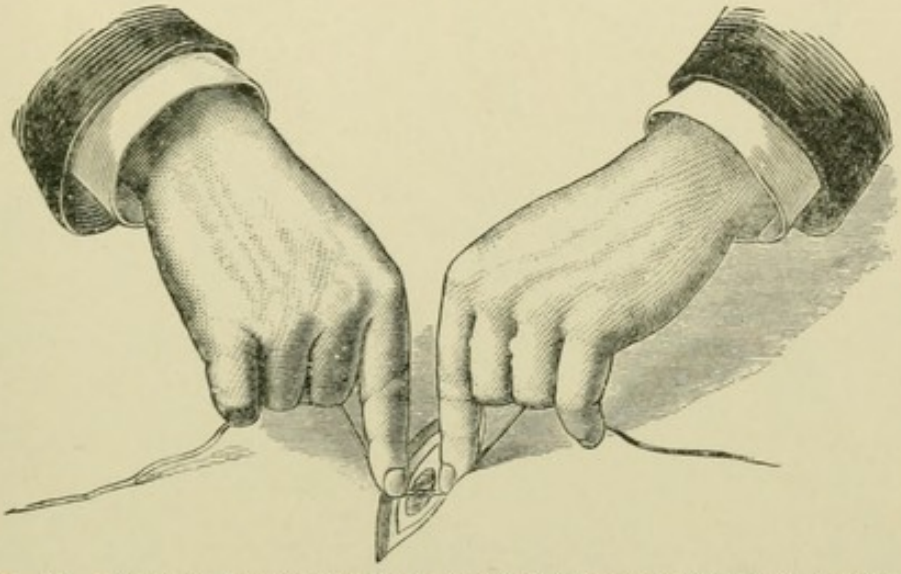

Fig. 68.—Manner of tightening the ligature in ligating an artery in its continuity (MacCormac).

minute vessels which nourish its coats are too extensively destroyed; hence the dangerousness of passing a spatula or the handle of a scalpel under the artery, and of dragging it out of its bed when tying it." These words of caution were in place as long as the septic ligature was in use. *All these fears are unfounded when operating under aseptic precautions, with the employment of the absorbable aseptic ligature.*

In experimental work I isolated the arteries and veins from their sheaths for an inch or more, and dragged the vessel near to the surface of the wound in applying the second ligature, and yet I never observed any sloughing except occasionally in the cases where the operation was followed by suppuration. Much harm has been done by ligating an artery through a small opening in its sheath. Nerves, veins, ureters, and other important structures have not infrequently been unknowingly and unintentionally in-

cluded in the ligation. By laying the sheath open freely such

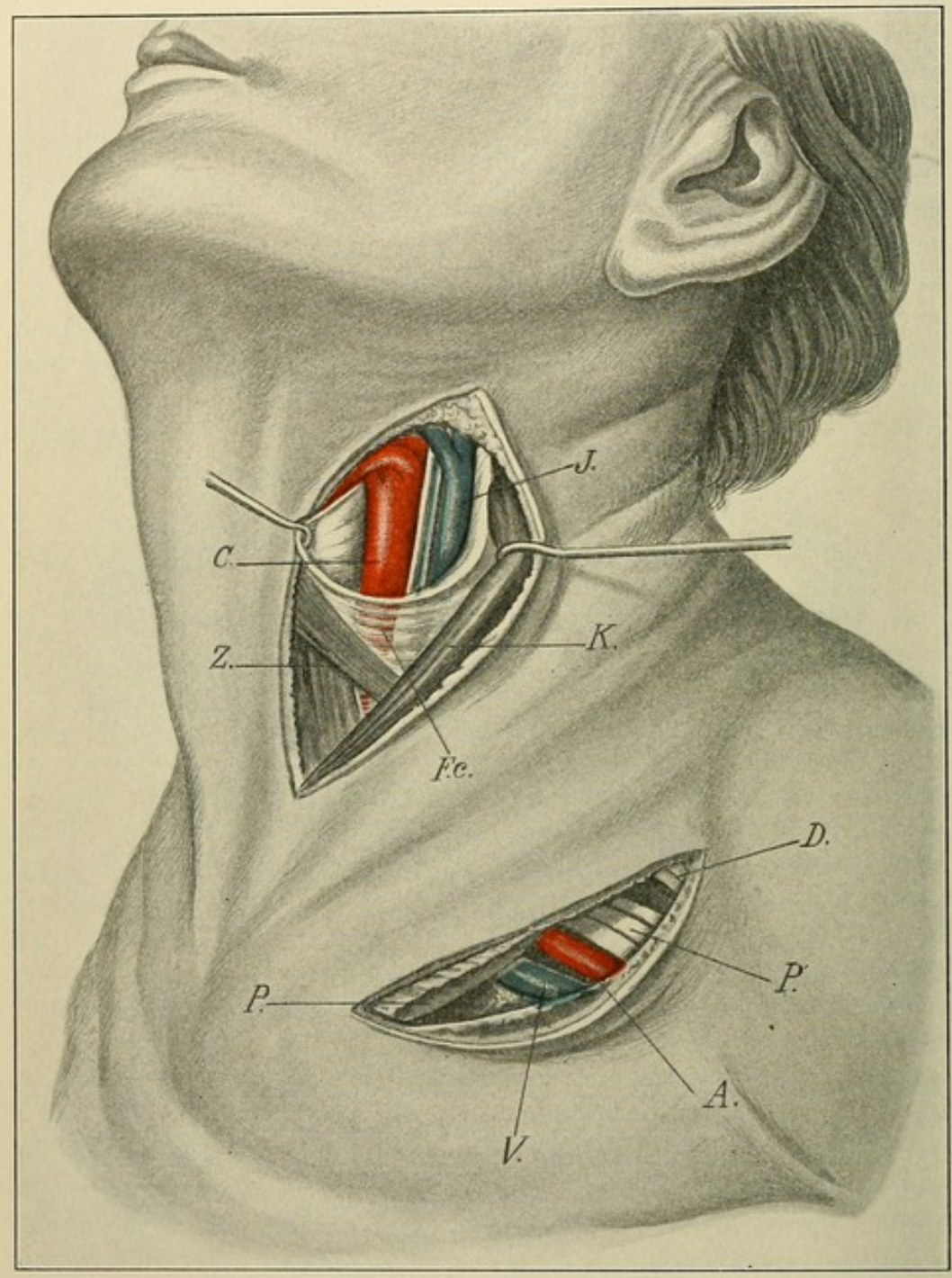

Fig. 69.—Ligation of the common carotid and subclavian arteries: (1) Exposure of the carotid artery in the neck. The sternomastoid muscle (*K*) is retracted outward; the deep layer of the cervical fascia (*F.c.*) is divided, and the common carotid artery (*C*), the jugular vein (*J*), the vagus nerve, and the descending branch of the hypoglossal nerve are thus brought into view. The bifurcation of the common carotid into the internal and external carotid is also discernible. The origin of the thyroid from the external carotid, which in the illustration is situated abnormally far outward, has been freed by dissection.

(2) Exposure of the subclavian artery below the clavicle. The pectoralis major muscle (*P*) is divided in the direction of the cutaneous incision to the deltoid muscle (*D*). Below the former the subclavian artery (*A*) is visible between the vein (*V*) and the brachial plexus of nerves (*P'*) (after Zuckerkandl).

accidents are avoided, and no harm to the ligated portion of the

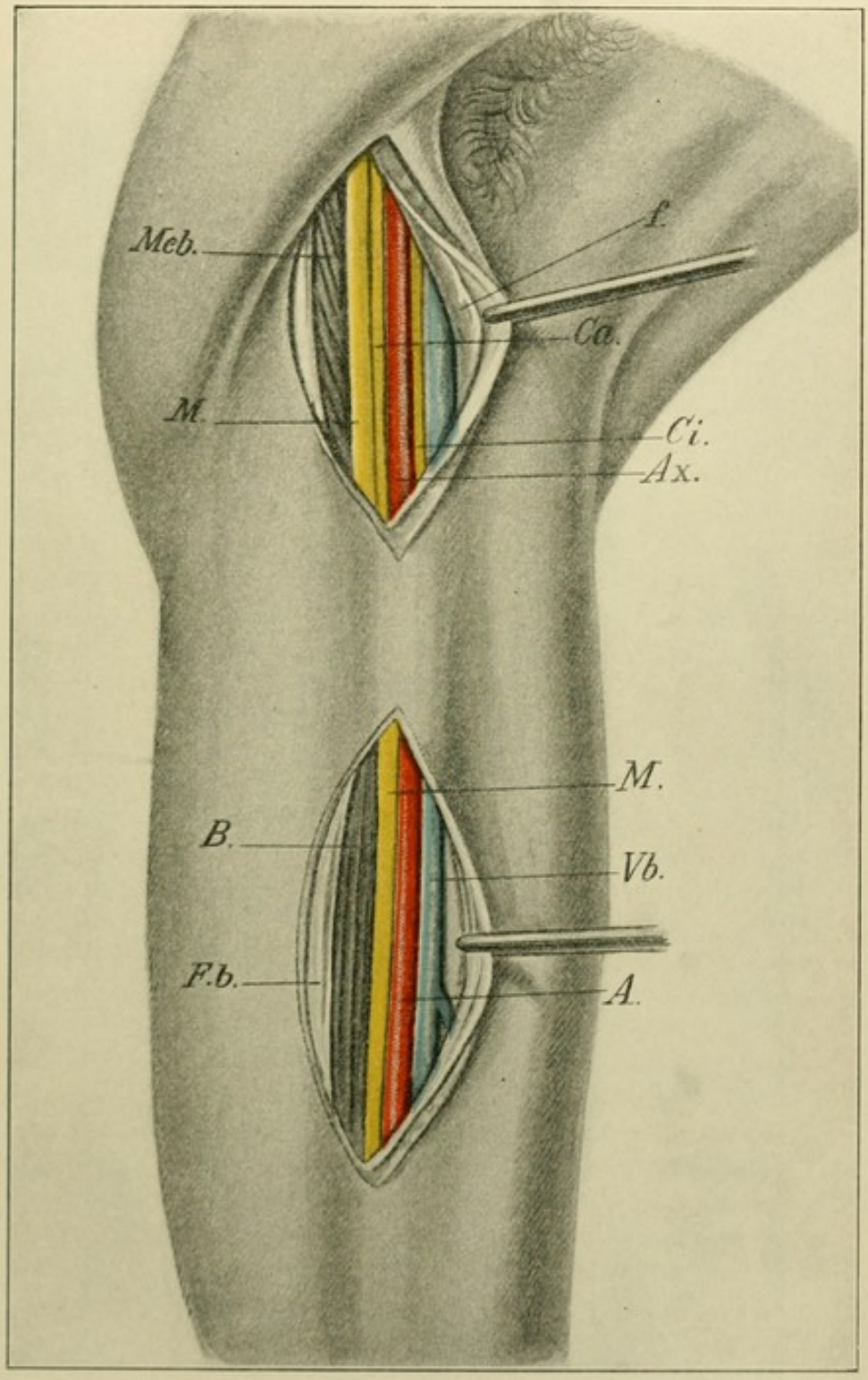

Fig. 70.—Exposure for ligation of the axillary and brachial arteries: *Mcb*, Coracobrachialis; *f*, inner portion of the fascia of the upper arm; *M*, median nerve; *Ci*, lesser internal cutaneous nerve; *Ca*, greater internal cutaneous nerve; *Ax*, axillary artery; *B*, biceps; *Fb*, brachial fascia; *A*, brachial artery; *Vb*, brachial vein (after Zuckerkandl).

vessel results if the aseptic ligature is used and applied under strict

aseptic precautions. The sheath of the vessel should be laid open freely, so that the operator can not only feel, but *see* what he is

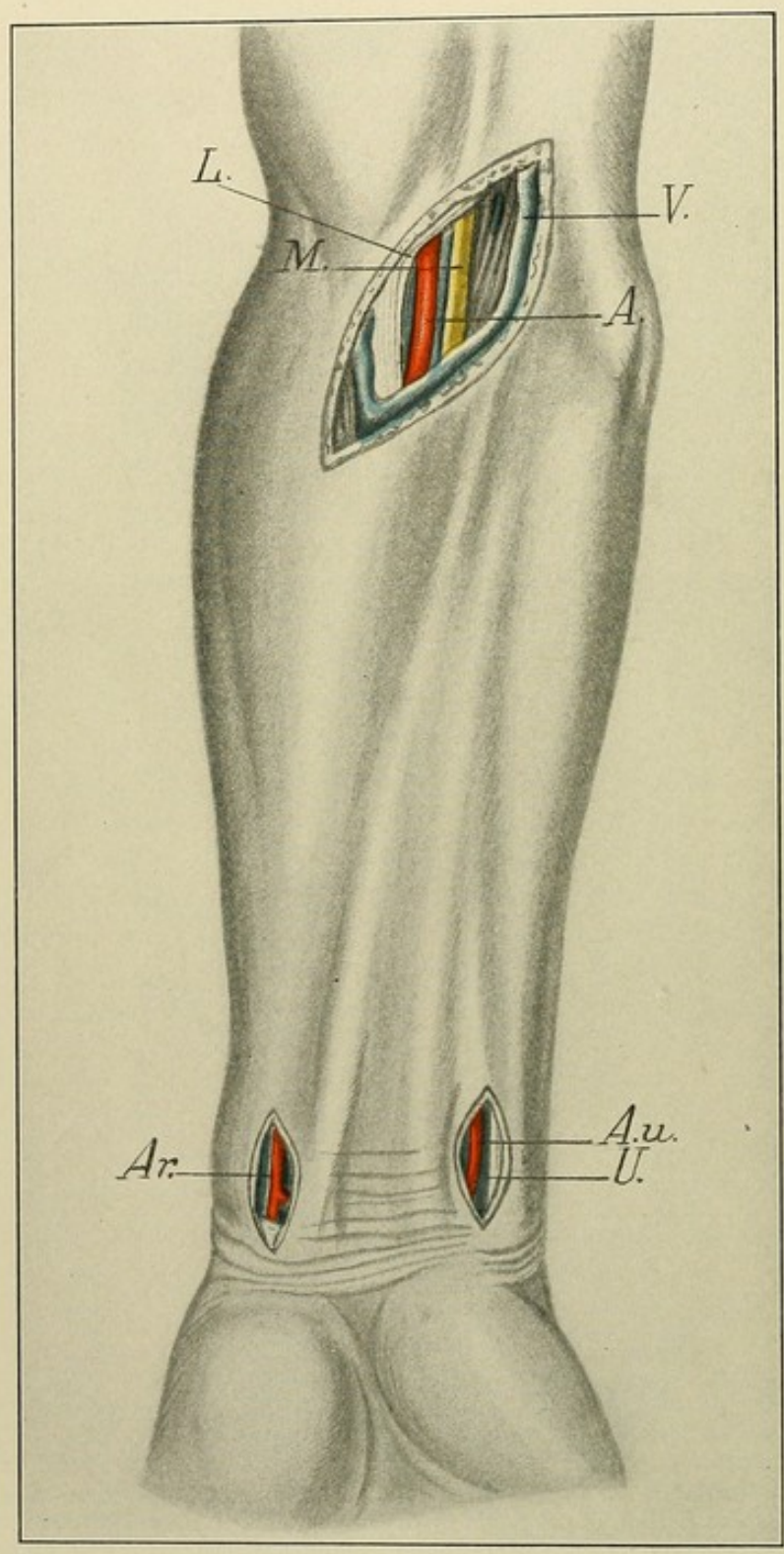

Fig. 71.—Exposure of the cubital, radial, and ulnar arteries: *L*, Transverse section of the aponeurosis of the biceps muscle; *A*, cubital artery accompanied by veins; *M*, median nerve; *V*, cubital veins; *Ar*, radial artery; *Au*, ulnar artery at the inner side of the tendon of the internal ulnar muscle (*U*) (after Zuckerkandl).

doing, for in pursuing this course there is less harm done than by operating in the dark.

The double catgut ligature may be resorted to with advantage

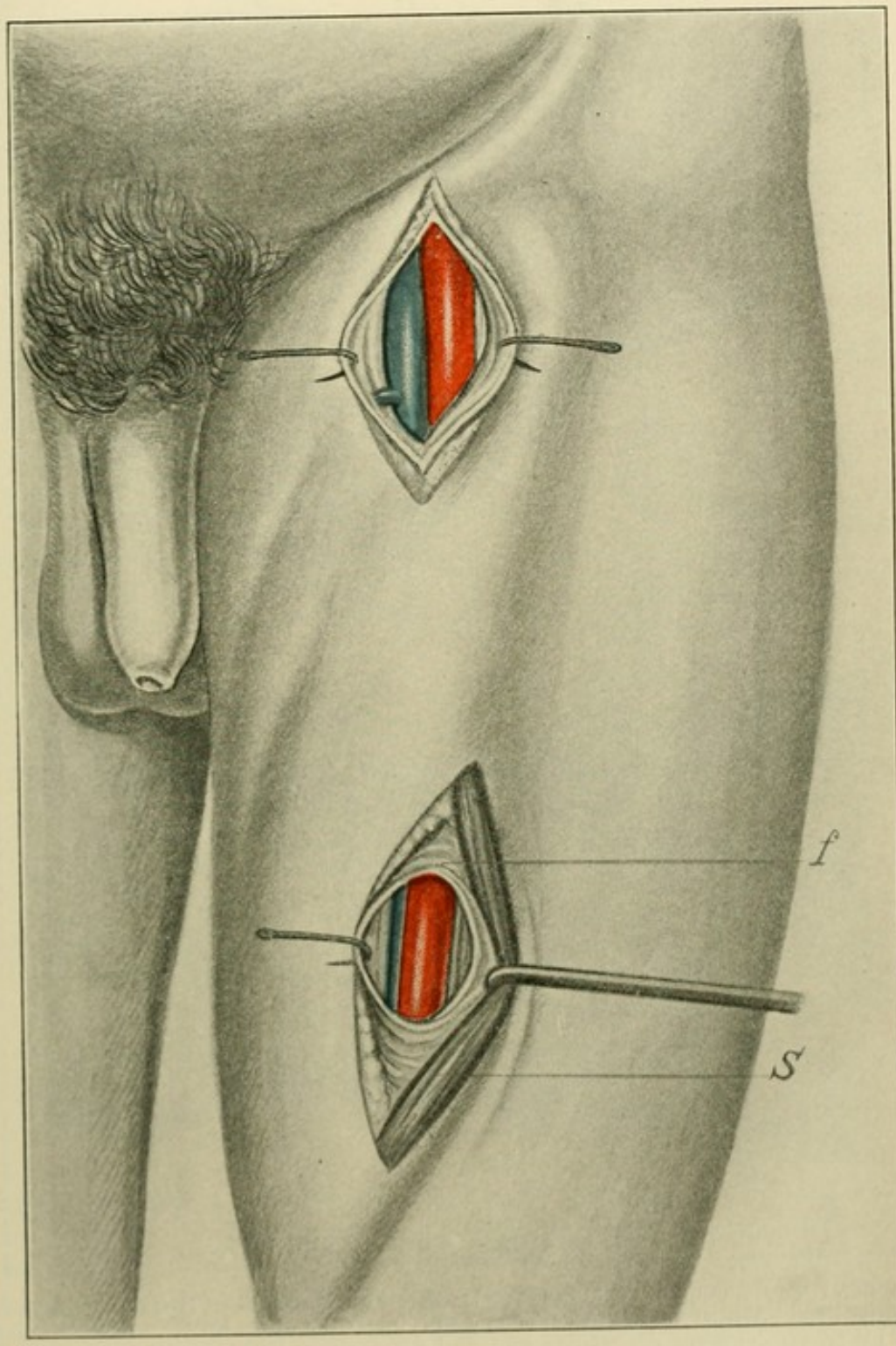

Fig. 72.—Exposure of the femoral artery. Below Poupart's ligament, in the opened sheath of the vessels, are to be seen, upon the median side, the femoral vein, and upon its outer side, the femoral artery. In the middle of the thigh the sartorius muscle (*S*) is drawn outward, the deep layer of the fascia being divided, and the artery is exposed, with the vein behind it (after Zuckerkandl).

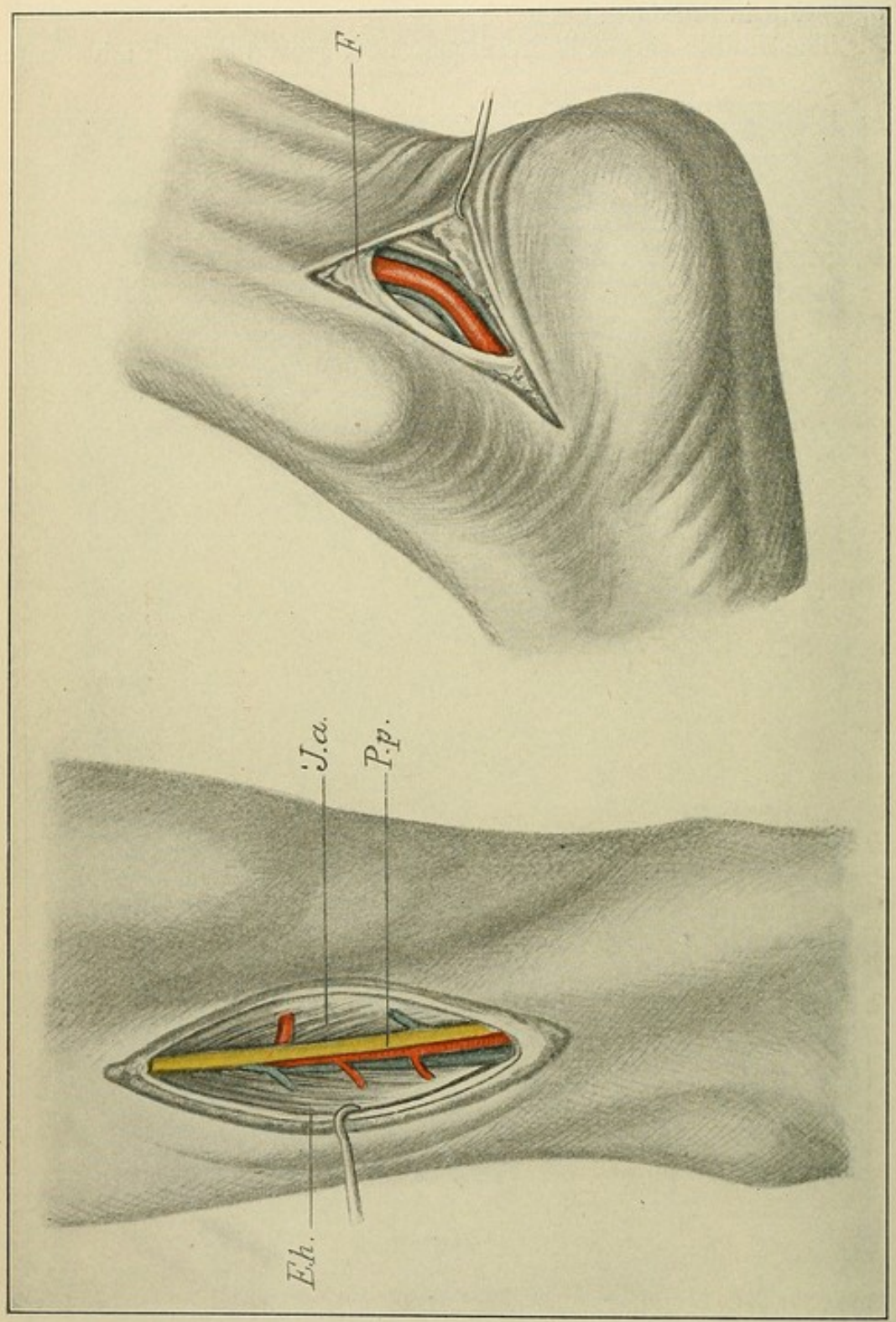

Fig. 73.—Exposure of the anterior and posterior tibial arteries: (1) Exposure of the anterior tibial artery of the left leg. The fascia is opened, and the tibialis anticus muscle (*Ja*) is retracted toward the median line, and the extensor hallucis (*E.h.*) toward the outer side. In the interval between the two muscles the deep peroneal nerve (*P.p.*) comes first into view, and behind it the artery surrounded by veins.

(2) Exposure of the posterior tibial artery behind the internal malleolus. The tortuous artery, accompanied by two veins, is visible beneath the divided fascia (*F*) (after Zuckerkandl).

in the human subject in ligating large vessels in their continuity, more especially if the operation is done near a large collateral branch, as it approximates the inner surfaces over a larger area and thus furnishes a more extensive surface for speedy cicatrization. The experiments on the veins have taught me another important and practical lesson—viz., their tolerance to traumatic insults of all kinds, provided the seat of injury remains aseptic. In not one of the cases was death produced by the operation, although in a few of the animals both the jugular and femoral veins were tied at different times. Progressive phlebitis, embolism, or pyemia was never observed. Like the peritoneum, veins may be contused, torn, lacerated, cut, punctured, burned, and ligated with impunity if infection is avoided. Veins are exceedingly prone to infection, but if infection can be prevented, their injuries are repaired with wonderful rapidity. As regards the time required for definitive obliteration to take place, the results of experiments would indicate that in the case of arteries of the size of the carotid or femoral from four to seven days are necessary, while in the internal jugular vein the same object is accomplished in three or four days.

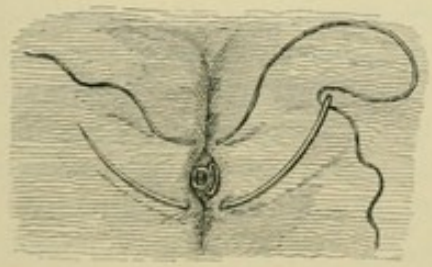

Fig. 74.—Indirect ligation of an artery or a vein.

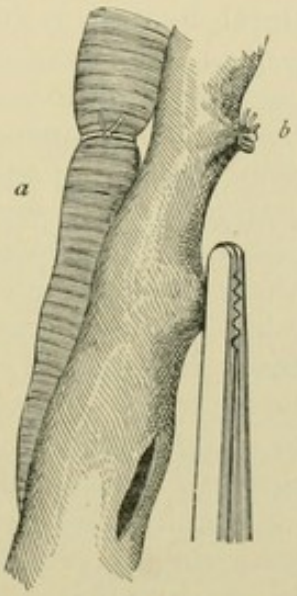

Fig. 75.—Method of controlling hemorrhage by ligation (after Esmarch): *a*, Artery ligated; *b*, lateral ligation of vein.

Intermediate Ligation—Ligation en Masse.—Ambroise Paré and all the older surgeons were in fear of a too early separation of the ligature, and aimed to guard against secondary hemorrhage as the result of such an occurrence by including adjacent tissues, thus protecting the vessel against undue pressure. The object of this practice was simply to apply the ligature as a provisional mechanical agent to arrest the flow of blood in a vessel, without any theory as to the manner in which permanent closure of the vessel took place. The ligature was passed underneath with a needle, with points of entrance and exit some distance from the vessel, and firmly tied. This method was originally practised by Paré, and through his influence and example it was adopted by all the prominent surgeons until nearly the end of the eighteenth century, when

Jones and his followers introduced the direct ligation. Since the definitive closure of vessels after ligation has been made an object of study and experiment, this method of ligation has been abandoned, and is only resorted to in exceptional cases where isolation of the vessel or vessels is impossible from the nature or location of the wound. At the present time we employ for this purpose a round, well-curved needle armed with catgut, and frequently resort to it in arresting hemorrhage from scalp wounds, meninges, brain, omentum, mesentery, and vessels near bones in performing amputation.

Lateral Ligation.—Since suturing of vessel wounds has become a common practice in appropriate and well-selected cases, it has almost entirely displaced lateral ligation, formerly frequently employed in small wounds of large veins. The lateral ligature is not to be thought of in the treatment of wounds of the arteries, intracranial sinuses, and large vein wounds. The only indication for the lateral ligature is furnished by small wounds of large veins, and even in such cases it is perhaps less safe than suturing. In small vein wounds it usually, however, answers the purpose very well. Fine silk is preferable to catgut. The best way to apply the lateral ligature in such cases is to pick up, with a sharp tenaculum, both lips of the wound, and, by making slight traction, make a small cone of the wounded side of the vein, the base of which is then firmly tied with fine silk, which must be made to cut its way deeply into the tissues to guard against slipping of the ligature.

Vessel Suture.—The arrest of hemorrhage short of ligation must be regarded as a decided advancement in surgery. The ligature at once and permanently intercepts the circulation, which may lead to gangrene if the wounded vessel is the principal artery at the base of an extremity, and the danger from this source is enhanced if the accompanying vein is involved in the injury or is subjected to ligation, as was advised by B. von Langenbeck, Braun, and others. Niebergall opposes Braun's advice, recommending, in case it becomes necessary to ligate the common femoral vein, ligation of the artery at the same time, with a view of reducing the danger from gangrene. He maintains that the arterial pressure in such cases is necessary to restore the collateral venous circulation. Clinical experience adds weight to this opinion. In twenty-five cases in which the femoral vein was ligated alone, gangrene did not follow once. Simultaneous ligation of both vessels in twenty-four cases resulted in gangrene fourteen times. Suturing of vessel wounds should take the place of the ligature only in case the size of the vessel is such that the sudden arrest of circulation would cause gangrene of a limb or of some important organ—as, for instance, when the vessel wound involves the carotid artery, internal jugular vein, or the subclavian, axillary, and femoral arteries and veins.

Suturing is only applicable to comparatively small wounds, for when the wound is large, the narrowing of the lumen of the vessel

by suturing would be almost equivalent to ligation, with the probability that the obstruction would soon become complete by the subsequent formation of a thrombus. In all vessel wounds where no serious consequences are likely to follow the sudden interruption of circulation, the ligature is indicated. The experiments of Gluck made upon animals for the purpose of demonstrating the value of vessel suture have yielded practical results. He has shown that vein wounds will heal promptly after suturing or closure by means of aluminum clamps, without obliteration of the lumen of the vessel. He places great stress on the importance of bringing the intima in accurate and uninterrupted contact. In his valuable monograph on this subject he refers to the cases of vein wounds treated by suturing by Billroth, Schede, and others, and the cases of successful suturing of arterial wounds by Israel (common iliac) and Zoege-Manteuffel (femoral artery).

Suture of Arteries.—A few years ago suture of arterial wounds was not thought of, as success was deemed beyond the realm of possibility. The intravascular pressure and the constant motion caused by the arterial waves were considered incompatible with the healing of such a wound. Another great objection was the well-founded fear of the formation of a thrombus at the seat of injury; and even if such a feat had been considered possible, it was expected that the scar would later yield and furnish the starting-point of an aneurysm. Although a few apparently well-authenticated cases of successful suturing of arterial wounds have been reported, we can not say at the present time that the latter objections have no foundation. Collateral circulation is sometimes established so rapidly that it is not always possible to determine from the condition of the peripheral pulse whether or not the lumen of the vessel at the seat of injury remained patent without direct evidence furnished by examination of the specimen. All the alleged successful cases of this kind are of comparatively recent date, and we have not sufficient proof of the reliability of the scar in guarding against a remote traumatic aneurysm. Additional experimental researches and a larger clinical material are necessary to establish arterial suture as a reliable hemostatic resource.

There can be but little doubt, however, that it will secure for itself a permanent place in surgery in the treatment of small wounds of large arteries, where for good reasons the consequences of ligation are feared. The late Heidenhain was instrumental in bringing this subject prominently before the profession. In the removal of the axillary contents for malignant disease, a longitudinal wound in the axillary artery was made by his assistant, who used the scissors too freely. The edges of the wound were picked up with dissecting forceps, and the opening was closed with fine catgut sutures inserted with a round intestinal needle. In tying the sutures the lumen of the vessel was only slightly narrowed. A section of the axillary vein was intentionally excised, owing to the extent of the

disease. The pulsations of the artery continued, and six months later the patient was in excellent condition. Heidenhain does not approve of inverting the margins of the wound and sewing only the adventitia and media, as has been recommended by others, but he advocates bringing the endothelial surfaces in contact by approximating the intima. He includes in the sutures all the vessel tunics. Villar and Branchet exclude the blood from the injured portion of the vessel by digital compression, and make use of a second row of sutures, which include the sheath of the vessel and the overlying adipose tissue. These authors, as well as von Horoch, Jassikowski, and Burci, use fine silk, a round needle, and include in the first row of sutures only the adventitia and media. Israel doubts the propriety of suturing arterial wounds when the vessels are atheromatous, but Heidenhain claims that this pathologic condition does not furnish a contraindication to suturing. Two cases of arterial suturing are reported by Durante. In one case the injured vessel was the posterior tibial artery, in the other, the axillary. Stafanjew sutured a wound of the femoral by using four sutures, which included only the adventitia. Three months later the lumen of the vessel appeared to be patent. In another case he incised the femoral artery for the removal of an embolus in a case of endocarditis. The wound was sutured in a similar manner. Nineteen days later the patient died, and examination of the sutured vessel showed that the lumen was open at the point of suturing and the vessel wound healed. It seems to me that in closing an arterial wound by suturing the example of Heidenhain deserves special consideration, as his method of closing the wound brings each one of the vessel tunics in contact and places the tissues in a condition for an ideal repair, leaving at the same time the inner surface of the wound in a condition least likely to be followed by thrombosis.

Fine catgut is the best material for vessel suture, as it leaves no foreign substance either in the lumen or in the wall of the vessel beyond the time necessary for the presence of an adequate mechanical support. An additional row of sutures, as recommended by Villar and Branchet, adds to the strength of the wounded arterial wall, and is an additional safeguard against hemorrhage and aneurysmal dilatation. Longitudinal wounds are better adapted for treatment by suturing than transverse wounds. If, in the latter case, the wound involves more than one-third of the circumference of the artery, an attempt at suturing must be regarded as a questionable procedure. Suturing is only applicable to incised wounds. Gunshot and lacerated wounds must be treated by ligation regardless of their location and size.

Suture of Veins.—Suture of veins has a much wider field of usefulness than artery suture, owing to the slight or negative intravascular pressure. The larger the wounded vein, the more urgent are the indications for the use of the suture in place of the ligature.

A sufficient number of well-authenticated cases of successful vein suture are now on record to prove that lateral wounds can be sutured and will heal without obliteration of the lumen of the vessel by thrombus formation. Tichow made thirty experiments on sixteen dogs. He made longitudinal and transverse wounds, and in some of the experiments cut away a part of the vein-wall. The wounded portion of the vein was made bloodless by placing a silk ligature above and below the wound. The ligature was drawn sufficiently tight around the vein, and the ends were crossed, but not tied, and held with hemostatic forceps. As suture material he gives the finest silk the preference over catgut. In two cases in which catgut was used secondary hemorrhage occurred, while this mishap never took place in wounds sutured with silk. He usually made use of the continuous suture, and if, on removal of the ligatures, hemorrhage occurred at a point, an additional suture was inserted and tied. Like Schede, he does not consider approximation of the intima as essential to success. In transverse wounds it is necessary to place the sutures closer together than in longitudinal wounds. Suppuration appeared to inflict no damage on the vein or interfere with the healing of the wound. This immunity to septic intravenous complications in suppuration at the seat of suturing is probably more marked in dogs than in the human subject. Specimens were examined in from one to thirty-three days after the operation. In thirty cases thrombosis occurred eight times. In the course of time the sutures were always found in the perivascular scar; they never traveled in the direction of the lumen of the vessel. During the healing process a small mural thrombus was always formed over the inner surface of the wound. Wounds of nearly all the larger veins have been successfully sutured.

Nicaise successfully treated a wound of the innominate vein by this method a number of years ago. While removing a large fibrosarcoma of the thyroid gland he cut the internal jugular vein at its junction with the subclavian. As it was found impossible to apply a ligature that would have arrested the hemorrhage, he closed the wound by means of Lembert sutures, with a permanently successful result. Schwyzer recently sutured a lateral wound of the superior and inferior mesenteric vein, cut during an operation for the removal of a malignant tumor of the transverse colon, which, owing to its extension to adjacent organs, necessitated partial excision of the stomach and pancreas, besides an extensive colectomy. His patient made a speedy and uneventful recovery.

In suturing a vein wound it is necessary to render the wounded part of the vessel bloodless by the use of two temporary ligatures, which are applied only with sufficient firmness to interrupt the circulation. The constriction is best effected by the use of hemostatic forceps instead of tying, as has been suggested by Tichow. Fine catgut would appear to be as serviceable as silk, and, as an additional safeguard, a second row of paravascular sutures

might be employed. The strictest aseptic precautions must be resorted to, for the purpose of guarding against septic thrombophlebitis and its disastrous immediate and late consequences.

Sinus Suture.—Of the intracranial sinuses, the superior longitudinal sinus is the only one that occasionally can be sutured successfully when the wound is not too large and the cranial defect is sufficiently extensive to render the wound accessible for suturing. Wounds of the remaining sinuses are best treated by antiseptic tamponade or implantation of a fragment of aseptic sponge. In my experiments on animals I found it extremely difficult to suture transverse wounds of the superior longitudinal sinus, and my experience led me to the conclusion that arrest of hemorrhage by suturing in such cases is only possible in case the wound is small. The difficulty in closing transverse wounds consists in approximating the margins. The margins of the wound retract, the opening of the sinus assumes a diamond shape, and the sutures are liable to tear through the tissues on tying them. This is what happened in one experiment. The longitudinal sinus in a horse was cut transversely for the purpose of studying the conditions that determined air embolism. The wound margin retracted at once, converting the transverse incision into a diamond-shaped opening. After the necessary information had been obtained, an effort was made to close the wound by suturing. "Three catgut sutures were passed through both edges of the wound, but on attempting to approximate its margins, every one of them tore through the tissues before the parts were in apposition, proving conclusively that large transverse wounds of the longitudinal sinus can not be sutured, owing to the nature of the tissues and the intrinsic tendency to marked retraction."

In suturing longitudinal wounds of this sinus the conditions are more favorable: there is less retraction, and the margins of the wound can be brought and held in contact by sutures. In such cases it is, however, preferable to use fine silk in place of catgut, as the wall of the sinus is thicker and firmer than the vein coats, and more force must be overcome in closing the wound. A small, round, sharply curved needle must be selected for the insertion of the sutures, as the cranial defect through which the operation must be performed is usually a limited one. The sutures should include all the tissues with the exception of the intima.

Arterial Invagination.—Attempts have been made to substitute arterial invagination for the ligature in wounds of large arteries not amenable to successful treatment by suturing. Dr. J. B. Murphy has made a series of very interesting experiments to demonstrate the feasibility and safety of such a procedure, and the results have been such as to justify further research. He invaginates the proximal into the distal end, and secures the invagination by from four to six fine catgut sutures. In many of the experiments the lumen of the vessel became occluded by thrombus forma-

tion, while in some the experiment appears to have proved successful. In two cases of stab wounds of the femoral artery the same surgeon performed arterial invagination with success. Whether or not in these cases the lumen of the vessel remained patent, or whether the vigorous peripheral circulation followed in consequence of the development of a speedy and efficient collateral circulation, it would be difficult to prove. The idea is an excellent one, and the subject deserves further experimentation and investigation. With the information at hand at this time, few surgeons would have the courage to substitute invagination for the ligature in the treatment of wounds of arteries of the size of the axillary or femoral.

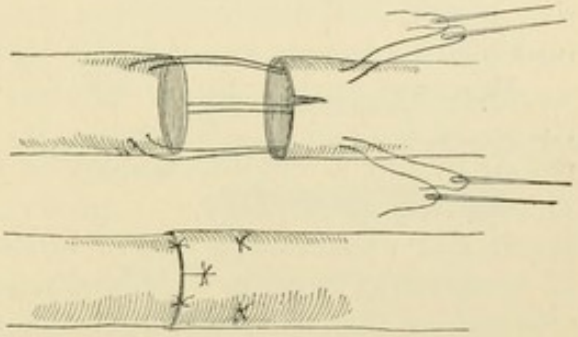

Fig. 76.—Method of suturing a blood-vessel by invagination (Murphy).

Torsion.—The arrest of hemorrhage by torsion (Fig. 77), once so popular, has given way largely to the use of the modern aseptic ligature. Wherever and whenever a ligature can be applied, torsion is no longer practised except for arresting bleeding from small vessels in case it is deemed objectionable to make use of numerous ligatures—as, for instance, in performing plastic operations. Torsion arrests hemorrhage by tearing the tunics of the end of the bleeding vessel if the vessel is large, or by twisting the surrounding tissues around the bleeding point if the vessel is small.

In performing torsion of a large vessel the end should be isolated for half an inch at least, the isolated portion grasped transversely with a pair of hemostatic forceps, and the projecting end grasped in its long axis with another forceps, which is then twisted around its axis until the tissues are torn sufficiently to form a mass of shreds, strong and intricate enough to act as a substitute for the ligature. If a vessel can be thus treated, it is certainly sufficiently accessible to apply a ligature, and there seems to be no excuse to rely on it as a permanent hemostatic resource except in the absence of reliable ligature material. Torsion of small vessels can only be practised effectually if the vessel is embedded in firm connective tissue; it is worse than useless in attempts to arrest hemorrhage from fragile vascular organs, such as the spleen, liver, and kidneys. The bleeding point is

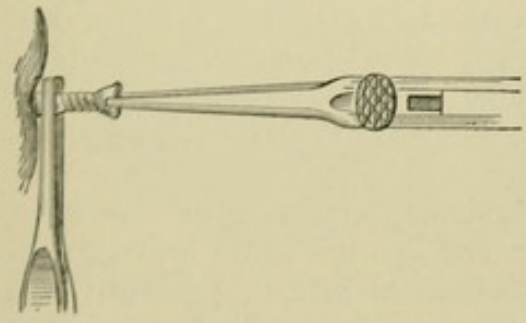

Fig. 77.—Proper method of performing torsion.

Hamilton recommended water heated to near the boiling-point, and did not observe any retarding influence from its use on the healing of wounds. John Hunter advised a temperature at which the hand could be immersed without great discomfort. This direction in determining the hemostatic temperature of water can be relied upon as safe in practice. The immediate effect of the action of water at this temperature is to contract the bleeding blood-vessels and, at the same time, form a thin film of coagulated albumin on the surface of the wound, upon which the hemostatic action largely depends. In place of plain water it is better to use a hot normal salt solution, as the hemostatic effect is the same and the saline solution has a more beneficial effect on the tissues than plain sterilized water. Hot saline solution has a wide field of usefulness in arresting parenchymatous oozing, and its use rather expedites than retards ideal healing of the wound. The hemostatic effect is increased by pouring the hot solution in a large stream from a pitcher at some height over the surface of the wound. The use of the hot solution of salt is frequently combined with surface compression, in which case the gauze compress is saturated with the solution heated to the requisite hemostatic temperature.

Steam.—Steam has recently been used to some extent as a substitute for hot water as a hemostatic agent. It is not probable that it will take the place of hot water to any considerable extent for this purpose. A tea-kettle is as good a utensil as any in making use of this form of heat, as the escaping steam from the spout can be applied to the bleeding surface without doing any damage to parts that should be avoided. It is of special utility in arresting troublesome parenchymatous oozing. Its application should be continued until a thin film of coagulated albumin covers the surface.

Snegirew has used steam for a number of years as a hemostatic, more especially in operations upon the uterus. He uses it in the following manner: After the uterus has been dilated, a fenestrated catheter is inserted into the cavity. In the lumen of the instrument passes a smaller tube which is connected with a steam generator. The steam has a temperature of 212° F. After the steam has been applied for from one-half to one minute, its caustic and hemostatic action begins, and the surface of the wound is covered with a thin layer of coagulated albumin. The action of the steam is almost painless. He first tested the hemostatic properties of steam on the lower animals, and the results obtained led him to an extensive use of it in his operative work. Jaworski fully corroborates the views of Snegirew. He removed portions of the liver, kidney, lungs, and uterus in animals, relying on hot steam exclusively in arresting the profuse hemorrhage from these vascular organs, with the result that very little blood was lost. He has made use of it in his practice in resection of the knee-joint, excision of the mammary gland for carcinoma, removal of different kinds of tumors in other localities, and operations on the uterus, with the most gratifying results.

Cold.—Cold in any form has the same effect on the blood-vessels as its counterpart, heat—that is, it produces contraction of the blood-vessels, to which action its hemostatic properties must be attributed. As it does not coagulate albumin, its power of arresting hemorrhage is inferior to that of heat. Cold enjoyed an enviable reputation as a hemostatic among surgeons and the laity for a long time, but the indications for its employment at the present time are quite limited. It is absolutely contraindicated in cases of hemorrhage complicated by shock, and it should not be used after acute anemia has occurred, as its extensive and prolonged use might counteract prompt reaction after the hemorrhage has been arrested. The employment of cold in arresting hemorrhage is indicated in plethoric persons with an unimpaired heart muscle; also in cases of hemorrhage from inflamed surfaces if it is deemed advisable to arrest the bleeding. Cold is employed in the form of ice, cold water, and spray. Ethyl chlorid spray has been used with benefit in arresting obstinate hemorrhage after extraction of teeth. After cleaning out the blood-clot, the cavity is frozen, and later packed with a 10 per cent. solution of antipyrin (Da Costa) or tincture of hamamelis (A. E. Hind).

Acupressure.—Simpson's method of arresting hemorrhage by acupressure, once so popular, has for good reasons become almost, if not entirely, obsolete. Wherever the acupressure needle can be applied efficiently the hemorrhage can be arrested by the direct or indirect ligature or by aseptic tamponade.

Aseptic Tamponade.—Aseptic tamponade arrests hemorrhage by uninterrupted surface compression with an aseptic tampon which remains *in situ* until the bleeding vessels have become obliterated at the point of compression by thrombosis and intravascular cicatrization (Figs. 80 and 81). The aseptic tampon has a wide range of usefulness in arresting troublesome surface bleeding, and occasionally is relied upon in arresting hemorrhage from vessels of considerable size when the vessel wound is not accessible, or can not readily be made so, to more direct measures. Wounds of any of the intracranial sinuses that can not be sutured should be tamponed with a strip of iodoform gauze, which is left in the wound for three or four days, by which time the sinus on each side of the tampon will be found permanently obliterated by a firm thrombosis, rendering the further use of the tampon unnecessary. If only a small tampon is required, iodoform gauze should be used; if a large tampon is required, especially in the case of children, the aged, and in persons the subjects of renal disease, iodoform gauze is used sparingly, and

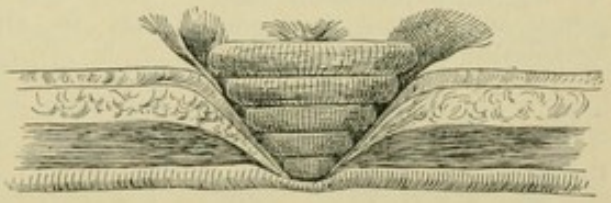

Fig. 80.—Conic aseptic tampon compressing an artery.

the bulk of the tampon is made up of sterile gauze, as a large iodoform gauze tampon might lead to grave, if not fatal, intoxication. The Mikulicz tampon is the ideal one if the bleeding space is large, as is often the case in abdominal and pelvic operations. It consists of a mantle or pouch of iodoform gauze, to the center of which is tied a silk ligature to facilitate its removal. The interior of the pouch is packed with strips of sterile gauze until the necessary degree of pressure is secured. The silk ligature is brought out over the packing, and the pouch is tied with a strip of gauze. When the tampon is removed, the pieces of gauze are extracted, the silk ligature secured, and when the pouch is empty, it is removed by making traction on the silk ligature. In using the tampon in this manner there is no danger of leaving pieces of gauze in the wound. If the ordinary tampon is used, it is made of one piece of gauze, to guard against forgetting or overlooking a piece of gauze in the wound. If the tampon is used to control hemorrhage from a vessel of considerable size, it is made in the shape of a graduated compress, the apex resting against the point where pressure is needed—that is, the bleeding vessel. Under such circumstances the aseptic tampon not only serves the useful purpose of a hemostatic, but, at the same time, acts as an efficient capillary drain.

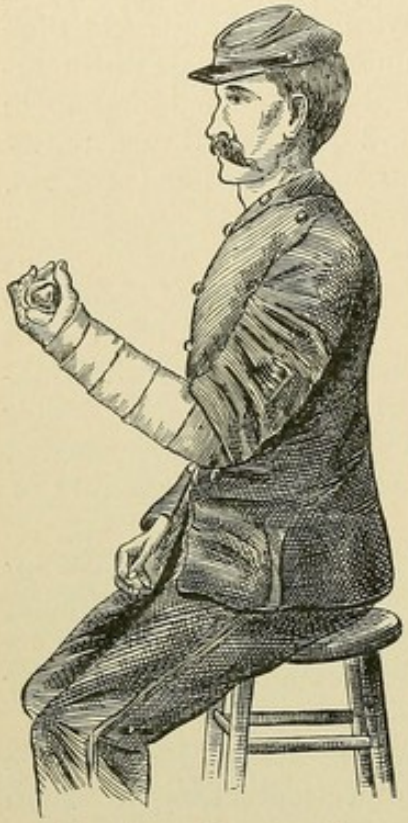

Fig. 81.—Wound of deep palmar arch treated by aseptic tamponade; dressing complete.

Wound Suture.—The buried absorbable aseptic suture is not infrequently relied upon as a hemostatic in arresting parenchymatous hemorrhage. It takes the place of the indirect ligature in controlling hemorrhage from bleeding points, and, by coaptating the wound surfaces, furnishes the most favorable condition for the formation of minute thrombi which arrest the hemorrhage by occluding the cut ends of the bleeding vessels. According to the depth of the wound, from one to several rows of sutures are made. Suturing for such an indication must be done with a round, curved needle and fine catgut. Points that bleed freely should be included in the sutures. Accurate coaptation of the wound surfaces secured by this method of suturing will usually obviate the necessity for drainage, as the formation of dead spaces is prevented and the parts are placed in an ideal condition for speedy union by primary intention.

Electricity.—The profuse capillary hemorrhage which so often follows the removal of the elastic constrictor, used either for prophylactic or therapeutic purposes, constitutes one of the disadvantages of the bloodless method of operating. Riedinger attributes this often troublesome sequela of elastic constriction to temporary muscular paralysis. He has found the use of electricity the most reliable means in limiting the parenchymatous oozing. After the operation is completed all visible vessels are ligated. A large aseptic sponge, connected with the electrode of a strong induction apparatus, is placed over the surface of the wound, while a second sponge, connected with the other electrode, is held on the side of the wound, and for a minute the current is employed, when the elastic constrictor is removed. In this manner the capillary hemorrhage is reduced to a minimum.

Styptics.—The modern technic of hemostasis has fortunately limited the use of styptics to exceptional cases. The styptics in such common use in the past—astringent preparations of iron, alum, tannin, and other vegetable astringents—are incompatible with a speedy and ideal wound healing, and should be avoided whenever arrest of hemorrhage is possible with agencies less disturbing to the process of repair. All styptics are more effective when applied to the bleeding surface on a pledget of gauze or cotton and combined with pressure. All styptics owe their hemostatic properties to their power of coagulating albuminoid substances, including the formation of an intravascular thrombus in the cut ends of the bleeding vessel. One of the best styptic applications is the old-fashioned adhesive resin gauze of Lister, in the meshes of which has been rubbed finely powdered tannin. This styptic application was in great favor with Billroth. Instead of the tannin the salt of persulphate of iron or powdered alum can be used. The styptic solutions of iron preparations, the tincture of muriate of iron, and the solution of persulphate of iron (liquor ferri persulphatis) remain popular styptics with the profession.

Oil of turpentine is an old and a reliable local hemostatic in many cases of troublesome hemorrhage from a limited surface, as after excision of the tonsils. Saese has used it with success in arresting hemorrhage after tooth extraction, by tamponing the cavity with cotton saturated with turpentine. He has also employed it with benefit internally in emulsion in doses of five drops every hour in hemorrhage from the kidneys and bladder.

Ferripyrin is a combination of chlorid of iron and antipyrin, and has been used with success in 20 per cent. solution in the clinic of Jurasz in arresting troublesome epistaxis. A pledget of cotton is saturated with the solution or sprinkled with the powder and is applied to the bleeding surface. This preparation does not cauterize, and acts at the same time as a mild local anesthetic. Frohmann has used the same hemostatic in arresting hemorrhage in more than one hundred cases of tooth extraction, with the most

gratifying results. Schaeffer has recommended ferripyrin in gynecologic and obstetric practice as an efficient and reliable hemostatic.

Antipyrin has been shown by the experiments of Park on animals to possess valuable hemostatic properties. It was found that it is at the same time a decided antiseptic. He recommends a 5 per cent. solution to be used in the form of a spray by compress or by injection. It has been employed in the treatment of free surface bleeding, and recommends itself more especially in the treatment of obstinate epistaxis.

Hemorrhage from Bone.—Troublesome hemorrhage from bone must be met by special remedial agents, as ligation and most of the other hemostatic resources referred to are inapplicable in such cases. Bleeding from bone in craniectomy, necrotomy, resection, and amputation from vessels of considerable size is often encountered and frequently proves obstinate. The middle meningeal artery is occasionally found in a complete bony canal, and when injured, the bleeding can be arrested by crushing the bone around the bleeding point with strong forceps or by spiking the canal with an aseptic bone or ivory nail. Should such nails not be at hand, a sterilized toothpick or match can be used for the same purpose. As wood is not absorbable, the nail must be left long enough to facilitate its subsequent removal. Rapin resorted to ordinary shoe-pegs in arresting hemorrhage from bone in a case of resection of the rectum by Kraske's method. From the resected surface of the sacrum the bleeding was promptly arrested by driving aseptic pegs into the bone at points from which the bleeding was profuse. From one to six nails usually suffice in such cases. The nails are extracted after the completion of the operation, but if the hemorrhage returns, they are again employed in the same manner. Riedinger employed the catgut tampon in a case of troublesome hemorrhage from the tibia after amputation of the leg. An artery of considerable size in the dense compacta was the source of the bleeding. The lumen of the vessel was tamponed with pieces of catgut that were inserted parallel to each other until the space was plugged sufficiently to arrest the hemorrhage. The use of such an absorbable tampon recommends itself very highly in arresting hemorrhage from large vascular spaces in the cut surface of the bone. The needle point of the Paquelin cautery at a dull heat is an important hemostatic resource in arresting hemorrhage from bone. The eschar created does not interfere with a satisfactory healing of the wound. If the bleeding is from small vessels in the spongy structure of the bone, compression of the spongiosa by striking it with a metallic hammer, forceps, or blunt end of a chisel will usually succeed in arresting the parenchymatous bleeding.

General Treatment.—Very little can be expected from general treatment until the hemorrhage is arrested by local measures. The administration of stimulants of any kind is absolutely contraindicated until the hemorrhage is under control. *Any treatment calculated to*

increase the heart's action and to intensify the intravascular pressure must be carefully avoided as a source of danger by aggravating the hemorrhage and by antagonizing nature's resources in effecting spontaneous arrest of hemorrhage. In some instances where the source of hemorrhage can not be reached, it would appear rational to pursue an opposite course and diminish intravascular tension and the force of the heart muscle by a timely resort to the use of the lancet. *Stimulation is in place and urgently called for when the patient is much prostrated from the loss of blood, and further bleeding has been guarded against by effective hemostasis.* In such cases the use of hot wine, or the more concentrated alcoholic stimulants, given in decided doses at short intervals, is best calculated to establish speedy and satisfactory reaction. The body-heat must be carefully preserved in such cases by the use of dry heat applied to the extremities, and in grave cases, to the entire length of the trunk. If the patient is seriously prostrated, camphor, digitalis, and strychnin will prove valuable in restoring the tone of the vascular system. Ergot has been used for a long time as an internal hemostatic in arresting traumatic and pathologic hemorrhage in cases in which local hemostasis can not be resorted to, owing to the source of the hemorrhage or the general condition of the patient. As ergot diminishes the caliber of the arterioles, not only of the affected part, but all over the body, it is difficult to comprehend its *modus operandi* in arresting hemorrhage. From the physiologic action of this drug and an extensive clinical experience it is fair to conclude that its use has done more harm than good when administered for the purpose of arresting hemorrhage. Its more legitimate use is in the treatment of uterine hemorrhage caused by inertia of the organ. Ergot acts as a vasomotor constrictor by its centric action upon the vasomotor centers. Its use should be restricted to the treatment of hemorrhage from capillary vessels, more especially in cases where the capillary oozing is due to vasomotor paresis. In such cases it exercises a dominant influence on the area of capillaries thus affected, and its specific action exerts a curative influence on the vasomotor nerves or unstriped muscle-fibers in the bleeding territory (Hare). Acetate of lead has been used for a long time as an internal remedy in the treatment of hemorrhage from the lungs and the gastro-intestinal canal, but it is reasonable to assume that the arrest of the bleeding in most instances resulted spontaneously or was favored by the opium which is usually combined with this drug when given as a hemostatic. Of all internal medicines, perhaps the most reliable is oil of turpentine, given in five-drop doses in emulsion at short intervals. The mineral acids, especially the sulphuric, so much in vogue but a short time ago in the general treatment of hemorrhage are seldom prescribed now, as it is well known that they have no influence whatever in controlling hemorrhage by increasing the coagulability of the blood or by favoring thrombus formation at the seat of injury.

gratifying results. Schaeffer has recommended ferripyrin in gynecologic and obstetric practice as an efficient and reliable hemostatic.

Antipyrin has been shown by the experiments of Park on animals to possess valuable hemostatic properties. It was found that it is at the same time a decided antiseptic. He recommends a 5 per cent. solution to be used in the form of a spray by compress or by injection. It has been employed in the treatment of free surface bleeding, and recommends itself more especially in the treatment of obstinate epistaxis.

Hemorrhage from Bone.—Troublesome hemorrhage from bone must be met by special remedial agents, as ligation and most of the other hemostatic resources referred to are inapplicable in such cases. Bleeding from bone in craniectomy, necrotomy, resection, and amputation from vessels of considerable size is often encountered and frequently proves obstinate. The middle meningeal artery is occasionally found in a complete bony canal, and when injured, the bleeding can be arrested by crushing the bone around the bleeding point with strong forceps or by spiking the canal with an aseptic bone or ivory nail. Should such nails not be at hand, a sterilized toothpick or match can be used for the same purpose. As wood is not absorbable, the nail must be left long enough to facilitate its subsequent removal. Rapin resorted to ordinary shoe-pegs in arresting hemorrhage from bone in a case of resection of the rectum by Kraske's method. From the resected surface of the sacrum the bleeding was promptly arrested by driving aseptic pegs into the bone at points from which the bleeding was profuse. From one to six nails usually suffice in such cases. The nails are extracted after the completion of the operation, but if the hemorrhage returns, they are again employed in the same manner. Riedinger employed the catgut tampon in a case of troublesome hemorrhage from the tibia after amputation of the leg. An artery of considerable size in the dense compacta was the source of the bleeding. The lumen of the vessel was tamponed with pieces of catgut that were inserted parallel to each other until the space was plugged sufficiently to arrest the hemorrhage. The use of such an absorbable tampon recommends itself very highly in arresting hemorrhage from large vascular spaces in the cut surface of the bone. The needle point of the Paquelin cautery at a dull heat is an important hemostatic resource in arresting hemorrhage from bone. The eschar created does not interfere with a satisfactory healing of the wound. If the bleeding is from small vessels in the spongy structure of the bone, compression of the spongiosa by striking it with a metallic hammer, forceps, or blunt end of a chisel will usually succeed in arresting the parenchymatous bleeding.

General Treatment.—Very little can be expected from general treatment until the hemorrhage is arrested by local measures. The administration of stimulants of any kind is absolutely contraindicated until the hemorrhage is under control. *Any treatment calculated to*

increase the heart's action and to intensify the intravascular pressure must be carefully avoided as a source of danger by aggravating the hemorrhage and by antagonizing nature's resources in effecting spontaneous arrest of hemorrhage. In some instances where the source of hemorrhage can not be reached, it would appear rational to pursue an opposite course and diminish intravascular tension and the force of the heart muscle by a timely resort to the use of the lancet. *Stimulation is in place and urgently called for when the patient is much prostrated from the loss of blood, and further bleeding has been guarded against by effective hemostasis.* In such cases the use of hot wine, or the more concentrated alcoholic stimulants, given in decided doses at short intervals, is best calculated to establish speedy and satisfactory reaction. The body-heat must be carefully preserved in such cases by the use of dry heat applied to the extremities, and in grave cases, to the entire length of the trunk. If the patient is seriously prostrated, camphor, digitalis, and strychnin will prove valuable in restoring the tone of the vascular system. Ergot has been used for a long time as an internal hemostatic in arresting traumatic and pathologic hemorrhage in cases in which local hemostasis can not be resorted to, owing to the source of the hemorrhage or the general condition of the patient. As ergot diminishes the caliber of the arterioles, not only of the affected part, but all over the body, it is difficult to comprehend its *modus operandi* in arresting hemorrhage. From the physiologic action of this drug and an extensive clinical experience it is fair to conclude that its use has done more harm than good when administered for the purpose of arresting hemorrhage. Its more legitimate use is in the treatment of uterine hemorrhage caused by inertia of the organ. Ergot acts as a vasomotor constrictor by its centric action upon the vasomotor centers. Its use should be restricted to the treatment of hemorrhage from capillary vessels, more especially in cases where the capillary oozing is due to vasomotor paresis. In such cases it exercises a dominant influence on the area of capillaries thus affected, and its specific action exerts a curative influence on the vasomotor nerves or unstriped muscle-fibers in the bleeding territory (Hare). Acetate of lead has been used for a long time as an internal remedy in the treatment of hemorrhage from the lungs and the gastro-intestinal canal, but it is reasonable to assume that the arrest of the bleeding in most instances resulted spontaneously or was favored by the opium which is usually combined with this drug when given as a hemostatic. Of all internal medicines, perhaps the most reliable is oil of turpentine, given in five-drop doses in emulsion at short intervals. The mineral acids, especially the sulphuric, so much in vogue but a short time ago in the general treatment of hemorrhage are seldom prescribed now, as it is well known that they have no influence whatever in controlling hemorrhage by increasing the coagulability of the blood or by favoring thrombus formation at the seat of injury.

Stypticin, one of the most recent hemostatics, is hydrochlorid of cotamin, the base of the opium alkaloid narcotin. It is a yellow, inodorous, bitter powder, and is usually given in doses of ¾ of a grain from five to eight times a day. In severe cases three grains or even more can be safely administered. It can also be given in 10 per cent. solution in the form of deep intermuscular injections. It is said to combine sedative with the hemostatic properties. It has been given a very extensive trial in the Innsbruck Gynecologic Clinic, and the results obtained were of an encouraging nature.

In the treatment of hemorrhage in hemophilic patients specific medication is always indicated. Inhalations of carbonic dioxid gas have proved eminently successful in such cases. Wright found that in a boy with very severe hemophilia the coagulation period of the blood exceeded fifty-four minutes at a temperature of 18.5° C. After two-gram doses of calcium chlorid it was diminished to twenty-five minutes; after a further similar dose, to thirteen and a half minutes. At a later period the normal duration of coagulation was fourteen minutes, but after administering 20.6 gm. of the calcium chlorid this was reduced to six and three-fourth minutes. Copious rectal enemata of hot normal solution of salt prove useful, after hemorrhage has been arrested, in maintaining the action of the heart and in relieving the torturing thirst. After the hemorrhage has been arrested and the immediate sources of danger from the loss of blood have been met, the general treatment consists in restoring as speedily as possible the normal quantity and quality of the blood. Rest, concentrated, nutritious diet, and the administration of some preparation of iron are indicated. The preparations of iron best calculated to correct the acute anemia are the carbonate, tartrate, citrate, and the tincture of the muriate. It is questionable whether the use of bone-marrow or any of its preparations has any positive influence in inaugurating or favoring the process of hematogenesis. During the after-treatment it is very important to protect the patient as far as possible against any incidental diseases, as the impoverished condition of the blood constitutes a pathologic condition that would be sure to exercise an unfavorable influence on the complicating disease. For the same reasons any serious operative intervention should be postponed in the absence of urgent indications until the patient has fully recovered from the immediate and remote effects of the hemorrhage.

Autotransfusion.—Autotransfusion, the temporary intravascular displacement of the blood to the essential vital organs by mechanical means, is one of the most important and valuable therapeutic resources in all cases after the hemorrhage has been arrested, and when life is threatened from the loss of blood. It should be resorted to in all cases requiring saline infusion in some form. It meets the urgent indications in the shortest time, and is best calculated to sustain the heart's action until the surgeon has time to secure and apply more permanent therapeutic measures.

Nélaton was the first one to call attention to autotransfusion as a life-saving procedure. John Hunter bandaged the extremities from the periphery to the base and made circular constriction with a muslin bandage. Gamgee's observations, made on healthy persons used as subjects for the experiments, proved that if one or both of the lower extremities be rendered bloodless by Esmarch's method (Fig. 82) the heart's action was increased, a result which he attributed to increased intracardiac and intravascular pressure caused by the temporary displacement of the blood and lymph from the constricted extremities.

Autotransfusion is indicated in all cases of loss of blood after hemorrhage has been arrested and the general symptoms indicate an embarrassment of the general circulation, as shown by great pallor, dilated pupils, a rapid, feeble pulse, and impaired respiration. Autotransfusion is made by temporarily excluding the circulation from one or more extremities. A certain amount of autotransfusion can be secured by elevating the foot of the bed so as to incline the body at an angle of at least 45 degrees. In making

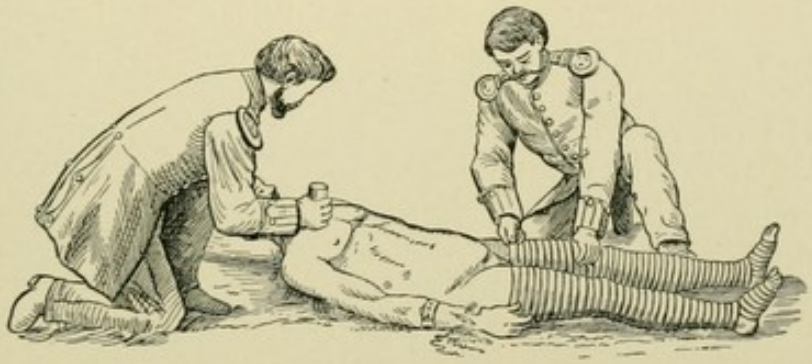

Fig. 82.—Autotransfusion (Esmarch).

autotransfusion proper, the extremity to be constricted must be placed and held in a vertical position long enough to render it practically bloodless,—that is, from three to five minutes,—when its base is constricted with an elastic band, tube, or cord in the same manner as has been described under the head of prophylactic hemostasis. In this manner, according to the severity of the symptoms, one, two, or all of the extremities are excluded from the circulation long enough to gain sufficient time for the employment of more permanent therapeutic measures. It is perfectly safe to exclude a limb from the circulation for at least two hours. Whenever it becomes necessary to maintain the essential intravascular tension by this procedure for a longer period, the limbs can be alternately constricted.

Transfusion.—The results of experimentation, as well as a large clinical experience, do not sustain the hopes entertained concerning the therapeutic value of transfusion in cases in which life is placed in jeopardy by hemorrhage. This applies with equal

force to the transfusion of whole blood from any of the lower animals and man, as well as the use of defibrinated blood. Direct transfusion is attended by so much risk from thrombosis and embolism that it is seldom resorted to at the present time. Fever and hematuria are such constant sequelæ of transfusion that we are forced to the conclusion that the transfused blood, either whole or defibrinated, plays the part of a foreign substance which is destined, if the patient survives the ordeal, to become eliminated through the various routes designed for such function. It is questionable if in successful cases the transfused blood is of more use in saving life than an equal amount of the normal saline solution which has at the present time taken the place almost entirely of transfusion and infusion of defibrinated blood.

Saline Infusion.—The intravenous infusion of milk has only a historic interest at this time. It has been shown conclusively that death from hemorrhage takes place in consequence of a loss of intracardiac and intravascular pressure, incompatible with the function of the circulatory organs. It has also been ascertained by experiments and an extensive clinical experience that the circulation can be maintained by increasing the intravascular tension to the required degree by substituting for the blood lost an equivalent quantity of normal salt solution. The solution usually employed is a $\frac{6}{10}$ of 1 per cent. solution of chemically pure chlorid of sodium. The solution can be extemporized by dissolving a teaspoonful of salt in a pint of sterile water. Szumann recommends the addition of carbonate of soda.

Szumann's Saline Solution.—

Sodium chlorid,	6 parts
Sodium carbonate,	1 part
Distilled water,	1000 parts.

The value of a rather high temperature of the saline infusion was demonstrated conclusively by Dawbarn's experiments on dogs. He used the kymograph, a giant sphygmograph, to determine the effect on the blood pressure in using solutions of different temperatures. He is of the opinion that the temperature should not be lower than 120° F. It has been shown that a temperature of 160° F. is necessary in order to coagulate any of the albuminoid ingredients of the body. A thermometer in emergency practice is not always available, and it has been shown that a sufficient degree of accuracy in determining the proper temperature of the solution to be used is obtained by means of the hand. A temperature of the solution at which the hand can be immersed without much discomfort is the one adapted for making an intravenous infusion. The saline infusion can be administered by three different routes, according to the urgency of the symptoms—by the rectum, hypodermically, and directly into one of the larger veins. The rectum absorbs the salt solution very promptly, more rapidly than plain water, and in cases in which the symptoms are not grave this is the proper route to

select. From one to two quarts of the solution can be given every two or three hours until the necessary degree of intravascular tension has been reached. In graver cases the solution is administered subcutaneously, infusing from a pint to a quart at a time, and

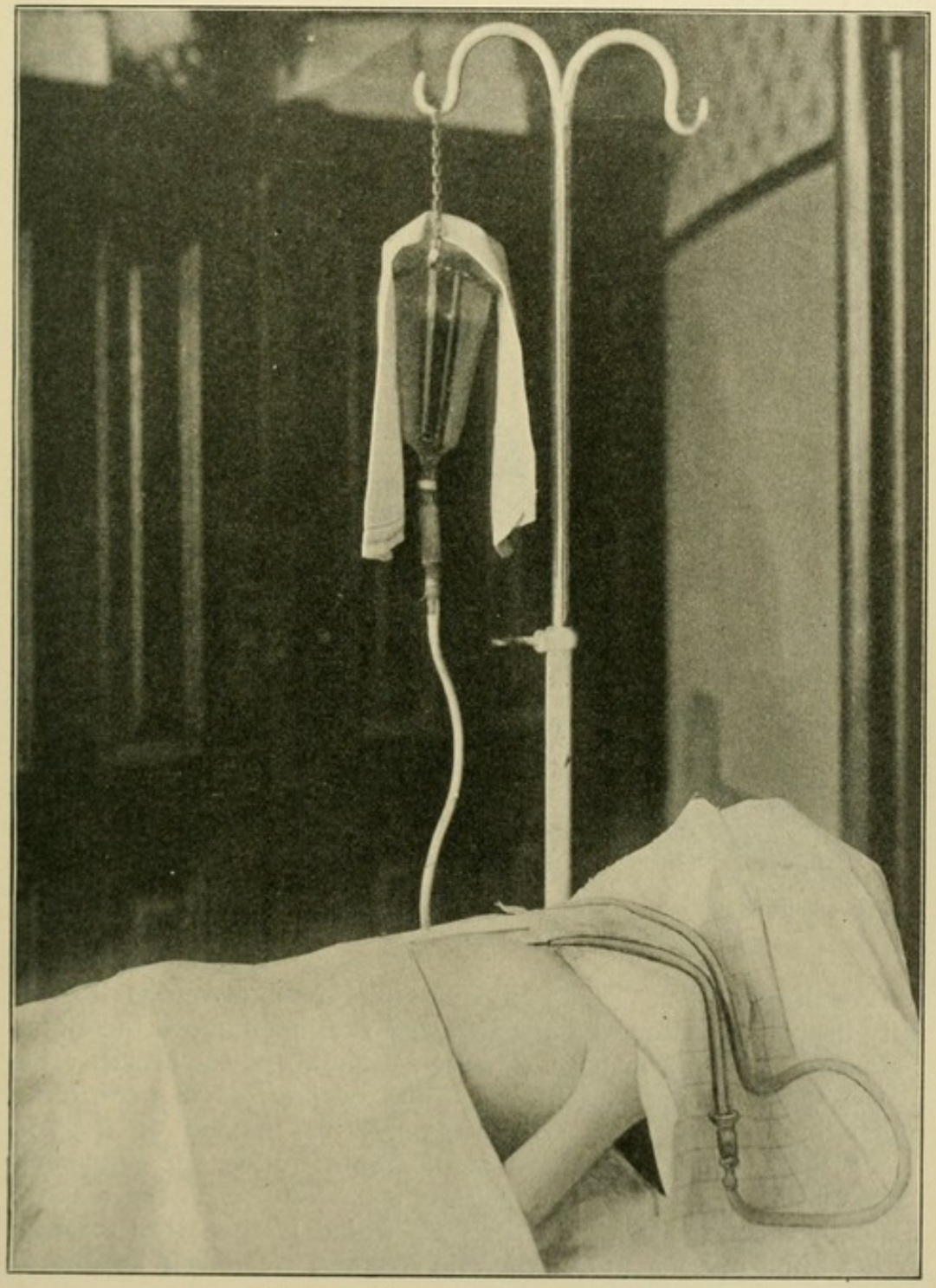

Fig. 83.—Subcutaneous saline infusion.

repeating the procedure every hour or two until a sufficient quantity has been used. All that is necessary for making the subcutaneous infusion are a small trocar and an irrigator to which a piece

of rubber tubing from four to six feet in length is attached. In the absence of an irrigator any kind of a vessel can be used, the fluid being infused by siphonage. For the puncture, localities are selected where the subcutaneous tissue is abundant and loose, as the mammary and interscapular regions, the abdomen, or the inner surface of the thigh (Fig. 83). If the infusion is repeated, a new locality is selected at each sitting. The point of puncture should be properly disinfected, and the trocar must be rendered sterile by boiling. The rubber tube is filled with the solution before it is connected with the cannula, after which the reservoir is held or suspended from three to six feet above the point of puncture. The diffusion of the fluid through the connective-tissue spaces is hastened by pressure and kneading. The puncture is sealed with collodion after removal of the cannula. In grave cases the intravenous route is the one that will yield the quickest and most reliable results.

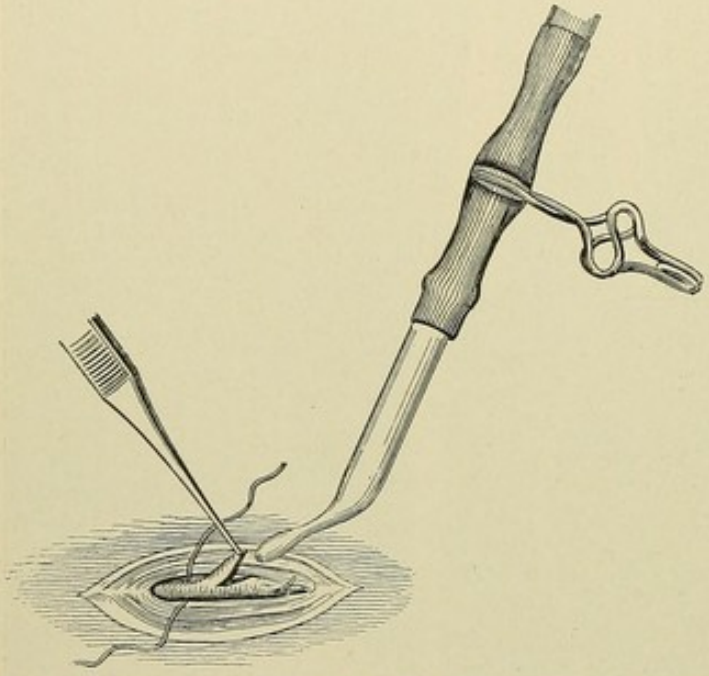

Fig. 84.—Intravenous saline infusion. Manner of incising vein and inserting glass tube.

In amputations and in other operations where large veins are wounded the injection can be made through the wounded vein. Nothing is gained by making an intra-arterial in place of an intravenous infusion. Ordinarily the median basilic vein is selected to receive the solution. The flexor side of the elbow region is carefully disinfected, after which a bandage is applied above the elbow sufficiently tight to obstruct the circulation in the superficial veins in the same manner and for the same purpose as in performing phlebotomy. The vein is then exposed by making an incision over it long enough to afford ample room during the remaining steps of the operation. The incision is made to reach the adipose tissue, between the skin and the vein, which is then torn through with a blunt instrument and the vein exposed. The vein is isolated rapidly, and two fine catgut ligatures are placed underneath it. One of the ligatures is tied at the lower angle of the wound. The vein above this ligature is then incised obliquely, making an opening large enough to admit the cannula or glass tip of the infusor. The second ligature is then drawn over it tightly enough to pre-

vent the escape of blood; its ends are crossed and held by an assistant until the infusion is completed, when it is used as a ligature above the wound. The infusion is made slowly and continued until the character of the pulse indicates that the necessary degree of intravascular pressure has been reached. From one pint to more than a quart of the solution is required in all cases that warrant the choice of the intravenous route. If in the course of an hour the patient does not rally, the intravenous infusion is repeated, or perhaps during this time a sufficient quantity of the saline solution can be introduced by the subcutaneous or rectal route, to obviate the necessity of reopening the vein.

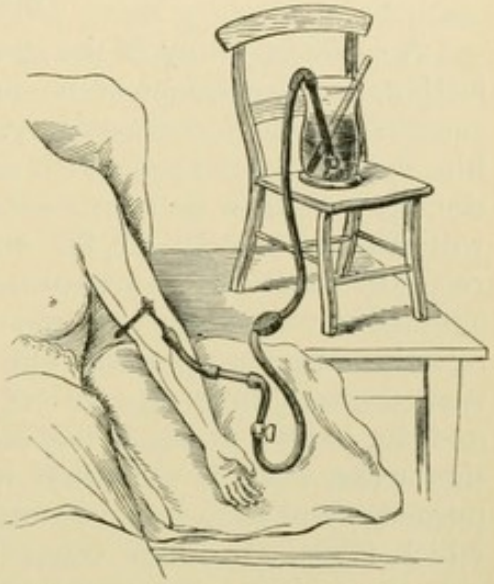

Fig. 85.—Manner of making infusion.

The employment of the saline solution as a substitute for direct transfusion or infusion marks one of the recent and greatest advances in surgery, and as such deserves a most extended recognition on the part of the profession. The procedure is so simple and the results are so gratifying that no patient whose life is in danger from the loss of blood should be left for any length of time without a recourse to saline infusion by one or more of the routes indicated. Intraperitoneal infusion, for reasons not necessary to enumerate, has been relegated to the past, having been superseded entirely by intravenous, subcutaneous, or rectal infusion.

CHAPTER VI.

WOUNDS.

A CAREFUL study of the etiology, nature, manner of healing, infection, and treatment of wounds is an essential prerequisite to the successful practice of surgery. The surgeon's daily work brings him constantly in touch with wounds which he either inflicts intentionally or which he is expected to treat. The success of his work will depend largely on his ability to minimize by his efforts the reparative work of the tissues injured, and to protect the patient against immediate and remote complications. Less than fifty years ago the surgeon assumed but little responsibility when he undertook the treatment of a recent wound, because both the profession and the public, as the result of experience and observation from the time when wounds were first inflicted and dressed, expected suppuration, and they had become accustomed to the frequency with which infected wounds, regardless of their location and size, gave rise to erysipelas, progressive phlegmonous inflammation, purulent edema, sloughing, gangrene, sepsis, pyemia, and hospital gangrene. Dupuytren's pessimistic confession, "Je le pansay, Dieu le guérit," expresses well the total helplessness of the surgeon in protecting wounds against infection before Lister raised the curtain which for several thousand years had held in utter darkness the mystery of wound infection. Many earnest attempts had been made to penetrate this veil, but all in vain until the microbic nature of the different wound complications became established through the epoch-making researches of Pasteur, Lister, Ogston, Koch, and their numerous coworkers and followers.

Judging from the present standpoint of wound infection, it is not surprising that formerly so few wounds healed by primary intention, but rather it appears almost miraculous that so many of the injured escaped with their lives. All the large hospitals became death-traps in which patients often lost their lives from insignificant injuries and the most trivial operations. We can imagine the feelings of the surgeons when they saw their patients die from erysipelas following a small scalp wound, or found themselves powerless to prevent death from sepsis or pyemia after the removal of a fatty tumor or the extirpation of a ganglion from the tendon sheaths; and yet such terrible experiences were by no means rare. If we recollect that even ordinary cleanliness in those days was often foreign to surgical practice, we can readily understand that the life of every patient the subject of an open injury was in danger, and that in all probability in many instances the danger was rather increased than

diminished by surgical intervention. At the present day the rehearsal of such scenes makes us shudder, and a sense of horror is felt when we follow the footsteps of the surgeon of fifty years ago.

Hand disinfection was not known at that time; we can see him operate with hands ornamented by precious rings, with finger-nails untrimmed, and the ominous death-dealing black line underneath. We observe him take his instruments, used but recently in performing an amputation for purulent edema, from a velvet-lined case, and, without any preparation whatever, use them again in excising a carcinomatous breast. Probably the same sponges that had done service in dressing an ulcer of the leg are used in wiping the bleeding surface. The only fluid that is brought in contact with the wound is cold water of doubtful source, and in a basin that has made its rounds from patient to patient. Watch him tie the bleeding vessels. He has no hemostatic forceps; with a sharp hook he picks up a cone of tissue with the bleeding vessel in the center. A few silk ligatures, which he waxed thoroughly before he commenced the work, are lying on the stand close by. He grasps the nearest one and applies it to the base of the cone, and ties with all the force at his command, crushing the tissues underneath the thread, which soon lies knotted and buried underneath the little pyramid of devitalized tissue; one end is cut short to the knot, the other is left hanging out of the wound. After hemorrhage has been controlled the wound is again sponged and closed with a few points of suture of the same material, and a cold-water compress constitutes the dressing.

There are many surgeons still living who operated in the manner just described. Does it seem strange that such wounds suppurated? Does it not appear stranger that so many injured and operated upon, after a long struggle with secondary hemorrhage, suppuration, and fever, finally escaped with their lives? The chills, the feverish brow, the dry tongue, the parched lips, the feeble, rapid pulse, the muttering delirium, the swollen, edematous limbs, the faces disfigured beyond recognition by erysipelas, the streams of pus, and the ravages of hospital gangrene seen on all sides in the crowded insanitary hospitals of but one generation ago have happily nearly disappeared, and are seldom seen as unwelcome and unexpected visitors in our modern hospitals. The surgeon of to-day, if he does his duty before as well as during an operation, can perform the gravest operations without fear of rendering his nights hideous by the ringing of the doorbell by messengers summoning him to arrest secondary hemorrhage or to combat the stormy symptoms announcing the beginning of a grave form of wound infection. What a contrast in the methods and results of the surgery of our day with that of our forefathers! To-day we can say with Nussbaum, "*The fate of the wounded rests in the hands of the one who applies the first dressing.*" If this is true, and there are few, if any, who would not indorse the correctness of this state-

ment by word and action, it is plain that the marvelous improvements in the treatment of wounds have brought upon the surgeon additional grave responsibilities.

The innovations that have made surgery what it is at the present time consist mainly in placing at the disposal of those who practise the art, ways and means to guard effectually against wound infection. A clear conception of the nature and conditions of life of the living agents that cause infection, their source and mode of entrance into wounds, and their action on the tissues is essential to the acquirement of a clear understanding of the methods employed in preventing infection. In standing guard for a recent wound, the surgeon has to contend with foes that are invisible to the naked eye and that approach the wound from all sides. If he expects to do effective duty, he must be familiar with the location of the enemy, his strength and source of supply, and make the attack at the right time and in the right place. The surgeon must be on the offensive if he expects to win, as a defensive course means a desperate struggle and often an ignominious defeat. Our weapons are numerous and variable,—the methods of warfare manifold,—but the object of them all should be to destroy or render harmless the enemy before he takes possession of the wound. The modern science of bacteriology is the surgeon's handbook on tactics in conducting such warfare, and unless he is perfectly familiar with its contents, his movements will be uncertain and his attacks haphazard, firing at an enemy ambushed in a jungle. The surgeon must know the sources of danger and know how to avoid them.

It is my purpose to discuss in this section open wounds, intentional and accidental, with special reference to the methods of modern treatment. The classification of wounds has a direct bearing on the course of treatment that should be pursued. The size of the wound should not be made a standard to determine the risk incident to the injury and the degree of care necessary in its treatment, as large wounds often heal promptly, and small wounds may result in dangerous complications. We see to-day some of the results of the old methods of wound treatment in cases in which the injury is treated by laymen or by physicians who do not appreciate the importance of resorting to painstaking aseptic precautions in the treatment of insignificant accidental wounds. Golebieski has recently published an article in which he reports the more or less serious results following slight injuries of the hand and fingers, which were at first treated by the patients. In all, 70 cases are reported. Of 13 injuries of the thumb, permanent disability resulted in 60 per cent., and the average loss of time during treatment was thirty-three weeks. Recovery of perfect function of the hand resulted in 9 out of 15 cases, but the average duration of treatment was twenty weeks. It is superfluous to quote further from this source; the serious and even fatal results that sometimes follow slight injuries are well known to

all who are familiar with the practice of large out-patient departments and dispensaries. In view of such facts it seems strange that physicians do not take better care of themselves; the very men who are familiar with the risks that often attend slight injuries and are most exposed by constantly coming in contact with all kinds of pathogenic microbes are often the most careless. Every physician certainly owes it to himself and to those possibly dependent upon his life and labor to keep in mind the serious cases of infection which are so common in our profession, and to disinfect carefully and protect even the slightest abrasions. It is well known that slight injuries of the hands and feet are followed by tetanus more frequently than large wounds, and the only explanation for this is that such wounds are too frequently neglected by the patients or, when a physician is called, they do not receive the attention their importance demands. The usefulness of thousands of fingers is lost annually from slight injuries and careless treatment. Insignificant penetrating wounds of the knee-joint and other large joints have filled many graves, have resulted in the loss of many limbs, and have left innumerable ankylosed joints and useless limbs. It may be said that no wounds are too large to be despaired of, and none too small to be overlooked or neglected. Any trauma that results in a loss of continuity of the skin creates an infection atrium through which pathogenic microbes may find their way into the tissues and through the lymphatics and general circulation to any part of the body. It is the duty of the surgeon to protect all such surfaces of absorption against the entrance of microbes until, by a process of repair, the continuity of the injured surface has been restored. The numerous lymphatic channels in the skin render superficial wounds liable to streptococcus infection, with all the possibilities which may arise from such, and for this reason should never be overlooked or slighted. From an etiologic standpoint wounds are classified into (1) incised, (2) lacerated, (3) contused, (4) stab, (5) punctured, (6) gunshot, and (7) poisoned.

1. **Incised wounds** are inflicted by sharp cutting instruments. The best examples are furnished by wounds inflicted by the surgeon's knife. The surfaces of the wound are smooth and bleed freely in consequence of the division of numerous vessels by a clean cut. In large wounds the margins retract freely if any of the muscles have been divided to any extent transversely, otherwise the amount of gaping will depend on the size and depth of the wound and the degree of elasticity of the severed tissues. The extent of the injury can be ascertained more readily and with a greater degree of accuracy in incised than in any other kind of wounds, as the injured tissues are open to inspection and palpation, and the trauma is limited to the line of the cut or incision. They are also more easily disinfected than wounds made by penetrating or blunt implements. Foreign bodies are seldom overlooked, and the free bleeding does its share in the mechanical removal of

microbes and infected substances. Incised wounds present also the most favorable conditions for the accurate coaptation of the same anatomic structures by mechanical means—suturing, position, compression, and immobilization. It is in the mechanical treatment of such injuries that the careful surgeon exercises his skill, with a view to obtaining an ideal functional result by uniting, with buried absorbable sutures, tendon to tendon, nerve to nerve, muscle to muscle, fascia to fascia, and skin to skin, and by placing the injured part in a position that will minimize the tension on the deep

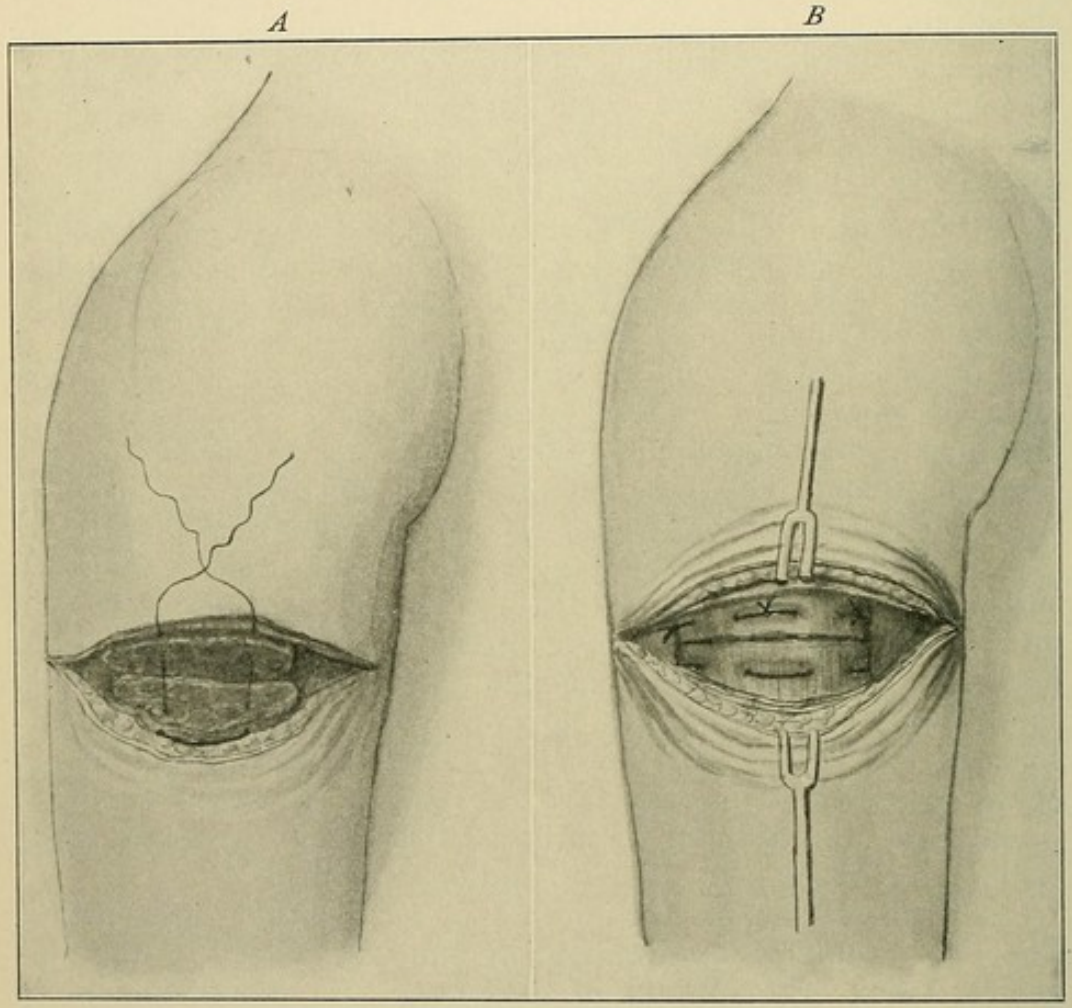

Fig. 86.—Muscle suture: *A*, Transverse wound of biceps muscle, showing marked retraction of muscle-ends and mattress suture in place; *B*, muscle suture completed.

sutures and immobilize it for the purpose of securing rest until the process of repair has advanced sufficiently to obviate the necessity for further use of mechanical supports. Recent incised wounds seldom demand drainage if by the use of buried sutures and other mechanical measures the formation of so-called dead spaces can be prevented. The time required for the healing of an aseptic incised wound depends largely on the degree of vascularity and compactness of the injured tissues. Wounds of the face, lips, tongue, and scalp heal in a remarkably short time, while wounds of the trunk

and extremities above the hands and feet require a much longer period. It is important to remember this in estimating the time for the removal of sutures. In wounds of the first-named localities the sutures can often be safely removed at the end of from three to five days, while in the latter locations they must remain two or three times as long to fulfil the indications for which they were employed.

2. **Lacerated wounds** are made by tearing caused by traction force. The most familiar illustrations of this injury are furnished by machinery accidents and wounds resulting from dragging.

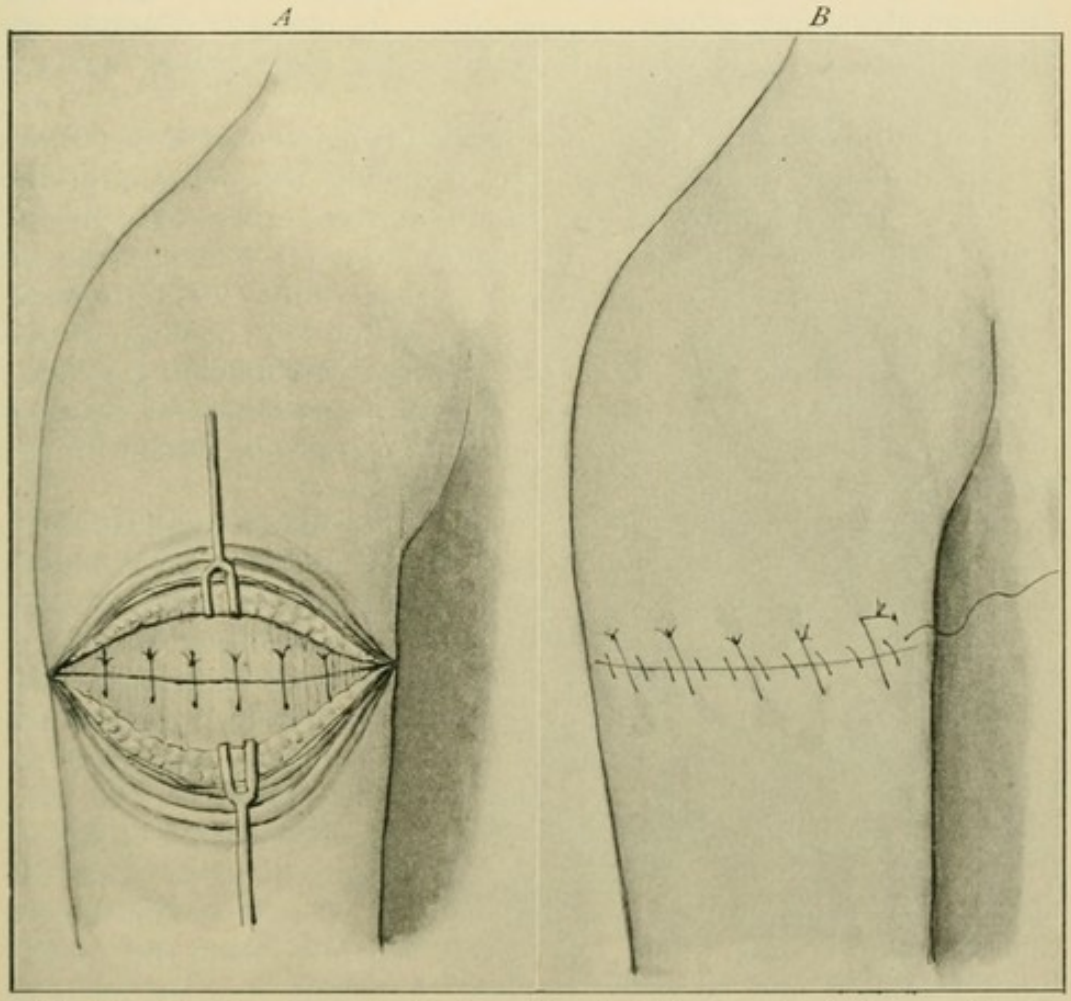

Fig. 87.—Muscle suture: *A*, Suturing of sheath of biceps: *B*, suturing completed.

Hemorrhage in such cases is slight, even when vessels of the size of the femoral or axillary artery are torn across. It is often difficult to determine, even on careful examination, the extent of the injury and the parts involved, as the size of the external wound does not always correspond with the extent of the subcutaneous injury. It is in such cases that the surgeon must seek for peripheral manifestations indicating the existence of injury to important vessels and nerves.

Large nerves may be torn across or otherwise seriously injured

some distance from the wound, and complications of this kind are often overlooked unless careful examination is made at the time in reference to nerve function below the wound. An artery, by traction force stopping short of a complete transverse tear, may become subsequently impermeable by laceration of the intima, an accident that can be recognized, or at any rate suspected, by an enfeebled arterial circulation below the injury, and, as has been shown by von Wahl, by a bruit over the seat of the torn intima. Torn wounds are irregular in their outline—the margins of the skin are ragged and frequently inverted. Muscles, tendons, and fascia yield at the point of least resistance, and the planes of laceration of the different structures seldom correspond. As lacerated wounds are always caused by accident, they must be regarded as infected wounds and treated as such.

The buried suture has only a limited field of usefulness in the treatment of lacerated wounds. By trimming the margins of the torn skin, and by removing torn tissue hopelessly destroyed by the injury underneath it, the surgeon makes attempts to transform, as nearly as he can, a lacerated into an incised wound, for more effective suturing, and with a view to expediting the healing of the wound and with the expectation of securing better functional results. In the majority of cases drainage becomes a necessity, as primary disinfection is less reliable and as suturing can not be done with the same degree of accuracy as in incised wounds.

3. Contused wounds are the result of the direct application of blunt force to the seat of injury. Wounds made by kicks, blows, or the passage of a wheel of any kind of vehicle, from a light buggy to a railway car, present the most familiar illustrations of injuries of this kind. The appearance of a contused wound depends on the size of the vulnerating implement and the degree of force with which it is applied, the character of the soft tissues injured, and their relation to the underlying bone. The force that produces the contusion not infrequently causes more or less laceration if it strikes the injured part obliquely, when the resulting wound presents the appearances of a contused lacerated wound. It is in such instances that the skin is often found extensively separated from the underlying lacerated and contused tissues. Crushing injuries, such as are produced in railway accidents, are contused wounds of the highest degree, in which not only the soft tissues are almost pulpified, but the bones are likewise comminuted—crushed into small fragments. The skin is likely to be the structure principally involved if the wound is inflicted where it lies almost directly upon the bone, as is the case with the scalp, the skin over the spine of the tibia, the bony prominences near joints, the crest of the ilium, or the surface of the sacrum. In other localities the extent of injury to the skin is often very deceptive in estimating the size and gravity of the injury, owing to its great elasticity, as is the case in crushing injuries of the limbs. Contused wounds are most liable

to infection, as the vulnerating implement usually conveys into the wound foreign material,—infected substances,—and its effect on the tissues is such as to destroy their vitality over a greater or less extent, and reduces the power of resistance to infection of the adjacent tissues.

As in lacerated, so in contused wounds, the surgeon is often compelled to judge the extent of the injury by a careful examination of the functional disturbances of muscles, nerves, and vessels below the seat of the injury, or in the territories near it supplied with these structures, which may be involved at the seat of trauma. From a practical standpoint, every contused wound must be considered as an infected wound. Foreign bodies must be searched for and removed; tissues that have lost their vitality in consequence of the immediate effect of the injury must be removed. Energetic primary disinfection is an urgent necessity. As a rule, very little can be done in the way of diminishing the size of the wound by suturing. Drainage is always indicated. Unless the wound is a small one, healing at best is delayed, and ultimately takes place by massive granulations that result in the formation of an irregular scar which in size seldom indicates even approximately the extent of the original wound. The functional result is usually far less satisfactory than that which follows an incised wound in the same locality and of the same size, for reasons that are too obvious to require mention. Hemorrhage is slight or almost entirely absent in contused wounds, as the blood-vessels implicated in the wound are crushed, a condition best adapted for the prevention and spontaneous arrest of hemorrhage. If any of the large intracranial sinuses are involved in the injury, hemorrhage may be profuse and require prompt interference on the part of the surgeon, as in such instances the contusion of the

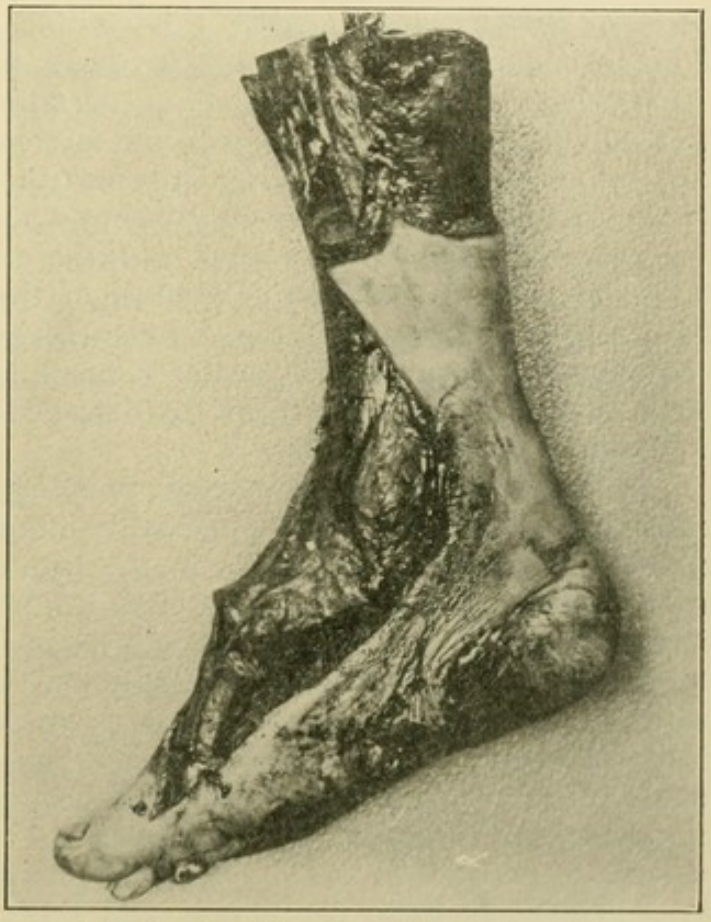

Fig. 88.—Crushing of foot by a railway injury.

soft tissues seldom succeeds in obliterating the lumen of the injured vessel.

4. Stab wounds are produced by the penetration of the tissues by the blade of a knife, scissors, saber, or any other narrow, sharp instrument. They are characterized by the small size of the wound at the point of entrance of the vulnerating instrument and, unless the implement has transfixed the injured part, by their unknown depth. In width and length they correspond in size to the portion of the blade that penetrated the tissues. If vessels of any considerable size are injured, troublesome hemorrhage takes place and traumatic aneurysm frequently follows as an immediate or remote complication. The latter result is more liable to occur if an artery is punctured or only severed in part. Stab wounds involving any of the large blood-vessels may result in death in a very short time. Hemorrhage is often internal, as in penetrating wounds of the chest implicating the internal mammary and intercostal arteries, and when the deep epigastric artery is cut in penetrating wounds of the abdomen. Stab wounds differ from gunshot wounds in that the bones are seldom injured to any extent, with the exception of the cranial bones and ribs in penetrating wounds of the skull and chest, and the greater frequency with which hemorrhage is encountered. In stab wounds of the skull, chest, abdomen, and in the vicinity of large joints, it is often difficult to determine whether or not the wound is a penetrating one.

In the absence of symptoms pointing to a visceral injury sufficiently grave to demand operative interference, the treatment should be directed exclusively to the prevention of infection by appropriate aseptic precautions. Stab wounds are straight and, as a rule, clean, and usually heal rapidly under the most conservative treatment. It is always well to secure and examine the instrument with which the injury was inflicted, as in the event of the knife-blade striking a bone, a part of the blade may break off and remain undetected in the tissues. If the knife can not be found, and such an accident is suspected, the Röntgen ray is the safest and most reliable diagnostic resource. Digital exploration and probing are inadmissible, as these procedures add little to our knowledge of the extent and gravity of the injury and always increase the risk of infection. If it becomes necessary to resort to surgical intervention for the purpose of instituting direct treatment of injury to vessels, nerves, or any of the internal viscera, the wound canal is enlarged sufficiently by incision to give ready access to the cut vessel, nerve, or injured organ to meet the existing local indication. In the absence of any such indications the first-aid dressing is applied under the usual aseptic precautions, and must remain in place until the wound is healed or symptoms indicate the existence of infection.

5. Punctured wounds, such as are made by needles, pens, pen-holders, pencils, bayonets, etc., are characterized by slight hemor-

rhage, limited destruction of tissue, and the frequency with which the foreign body that made the wound breaks off and remains in the tissues. The tissues through which the penetrating substance passes are seldom cut or torn to any considerable extent, as they yield to the advancing body, creating space by temporary displacement. After the extraction of the foreign substance the tissues resume their former normal relations, and the wound becomes closed, or nearly so, the line of puncture and its immediate vicinity being infiltrated more or less with extravasated blood. Vessels and nerves are seldom injured sufficiently by the penetrating body to require special interference. The surgeon takes advantage of this well-known clinical fact, and in important localities, where deep abscesses are to be opened or counteropenings must be made, resorts to tunneling of the tissues with a pair of locked hemostatic forceps rather than to the free use of the knife, as he knows that by puncturing the tissues in this manner important vessels and nerves will escape injury. Punctured wounds often lead to tetanus when the implement with which the puncture is made carries with it dirt, and, what it so often contains, the bacillus of tetanus. Punctured wounds of the skull and of any of the large joints are often followed by the most disastrous inflammatory complications, owing to the difficulties encountered in attempts at primary disinfection. Large punctured wounds very often heal promptly and with very little functional impairment. A case is now under my observation in which the base of the thigh was completely transfixed by a buggy shaft. The metallic point of the shaft entered the inner surface of the thigh, passed between the femoral artery and the femur, outward, forward, and upward, and made its exit below Poupart's ligament, about two inches below the anterior superior spinous process of the ilium. The accident was sustained in a runaway, and the force was so great that the shaft broke two or three feet from its end, requiring considerable force to extract the foreign body, which completely transfixed the thigh. Hemorrhage was very slight, but the shock was severe. The surfaces of the wounds of entrance and exit were disinfected, and the wounds freely dusted with borosalicylic acid, and the usual dry antiseptic dressing applied. No attempt was made to disinfect the large tubular wound. Very little temperature, swelling, and pain followed the accident. Both wounds healed under one dressing, and although the muscles were badly lacerated, the functional result was almost perfect, notwithstanding the man was nearly sixty years of age and quite obese.

In the treatment of punctured wounds the first indication that presents itself is to look for the foreign substance that made the puncture, and which so often remains in the tissues. If found, it is of course to be extracted. Metallic substances and glass can be accurately located by the X-ray. Needle-points, splinters of wood, and glass, if near the surface, can be located by digital pal-

pation, and if this can not be done, the tenderness on pressure serves as a valuable guide in locating and removing them. If infection follows a punctured wound, early incision and drainage become necessary to prevent the formation of a diffuse abscess. Very frequently when this occurs a foreign substance that was not suspected, much less sought for, is discovered in the abscess.

6. Gunshot wounds will receive separate consideration elsewhere, but in this connection it must be said that they differ materially from lacerated, contused, stab, and punctured wounds anatomically, as well as from a practical standpoint. The bullet, which travels with much greater force and velocity than the implements that inflict the wounds we have already described, carries before it all the tissues, including bone, producing a tubular wound, surrounded by a zone of contused tissue. The small-caliber jacketed bullet causes less contusion than the old-fashioned round or conic ball of lead. The wound of exit is usually larger and more ragged than the wound of entrance. *The modern bullet makes a straight wound; deflection seldom takes place, and when it does occur, it is at great range. A bullet wound should never be probed, either for diagnostic or therapeutic purposes. In the light of modern surgery bullet wounds have become a* noli me tangere *to the surgeon.* In recent cases operative interference becomes necessary in case of profuse hemorrhage only, or when complicating visceral lesions demand it. The best results are obtained when the surgeon concentrates his energies and skill in protecting the wound against infection by an efficient first-aid dressing.

7. Poisoned wounds are classified separately from punctured wounds, not because they differ from them in their appearance and the manner in which they are inflicted, but because they become dangerous to life by the insertion into the wound of a preformed poison with the vulnerating body. Dissection wounds, the stings of poisonous insects, and the bites of venomous snakes, reptiles, and rabid animals furnish familiar instances of what is understood by poisoned wounds. The injury in itself is usually insignificant; the danger lies in the introduction into the wound of the preformed poison. Antiseptic measures, employed with the intention of guarding against infection of any other kind of wound, are of no value in the treatment of such cases. In poisoned wounds the surgeon directs his first attention to the extraction or neutralization of the specific poison, and by mechanical measures to guard against its absorption into the general circulation. Circular constriction on the proximal side is made to prevent absorption; the wound and its contents are excised to effect mechanical removal of the poison, or the wound is cauterized, or, finally, chemic agents are employed locally to neutralize the poison or to render it harmless. In the case of bites from rabid animals Pasteur's prophylactic treatment is the one that has been found most reliable in preventing the reproduction of the disease in man, as well as in animals.

REPAIR OF WOUNDS.

As immediate union of wounds never takes place in any part or tissue of the body, we are prepared to assume and prove that every wound heals by the interposition between the divided parts of a greater or smaller amount of new tissue. The new cells which fill in the gap are derived from the preexisting cells from the surface of the wound and its immediate vicinity by a process of indirect cell-division recently described as karyokinesis (Figs. 89 and 90).

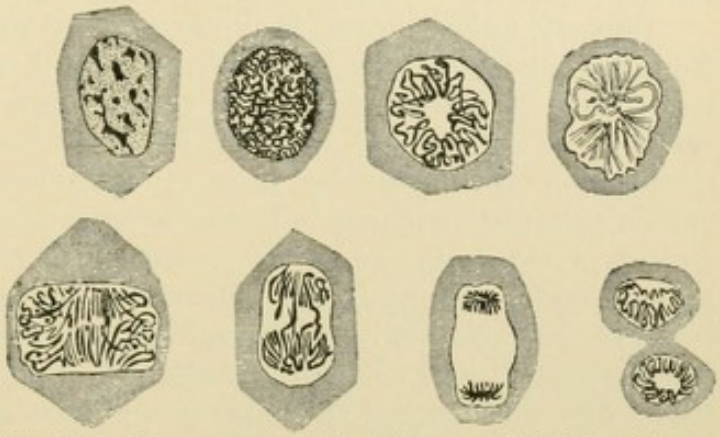

Fig. 89.—Forms assumed in indirect cell-division (Green, from Flemming).

In vascular tissue, repair of a wound means union between the divided tissues of similar anatomic structures, and restoration of the interrupted circulation by the formation of new collateral blood-vessels. If the wound remains aseptic and the surfaces of the wound are kept in accurate coaptation, the healing is accomplished in a short time and by the production of a minimum amount of new tissue. A similar wound, with great loss of tissue, precluding the possibility of bringing the parts in apposition by mechanical measures, must necessarily heal by the formation of a large amount of granulation tissue, the process of repair in both instances being the same, the difference being mainly in the length

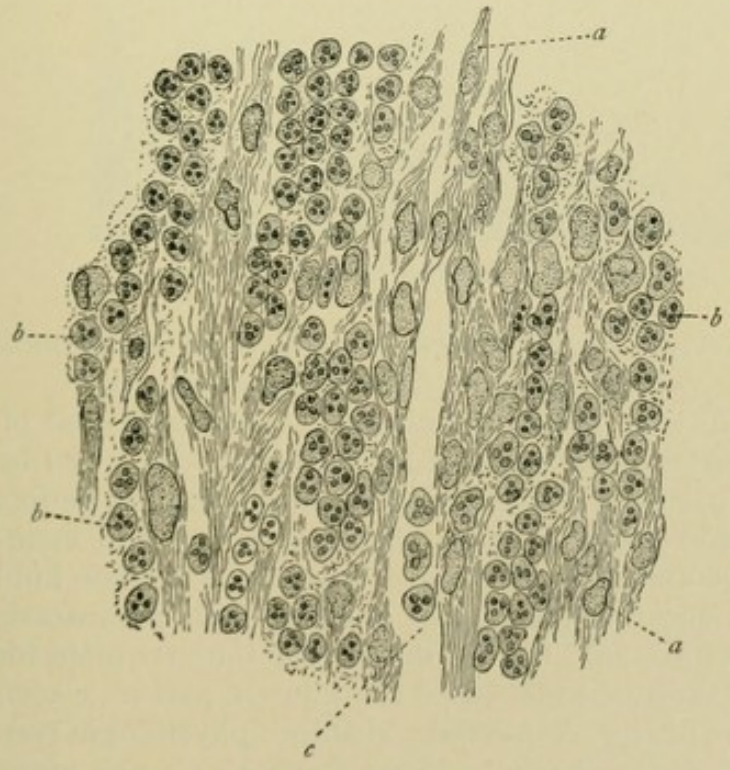

Fig. 90.—Process of repair of a wound: *a*, *a*, Cells forming connective tissue; *b*, *b*, *b*, leukocytes; *c*, newly formed blood-vessels (Keen and White).

of time required to complete the healing process and the quantity of new material necessary for this purpose (Fig. 91). In both instances it may be said that the wound healed by **primary intention.** *Healing by primary intention takes place in all wounds in which all the new material produced is utilized in the process of repair.*

Primary union means an uninterrupted process of construction from the time the wound is inflicted until it is completely repaired, regardless of time and the amount of new material required to restore the interrupted continuity. If the wound can be sutured throughout and heals by primary intention, it does so without visible granulation tissue. If the wound can not be closed, owing to loss of substance or other conditions contraindicating approximation of its margins, the defect or gaping part of the wound becomes covered with visible granulations before it can heal. The best functional and cosmetic results are obtained in aseptic wounds that admit of suturing throughout and that heal by primary intention. *Ideal wound healing consists in restoration of the continuity of*

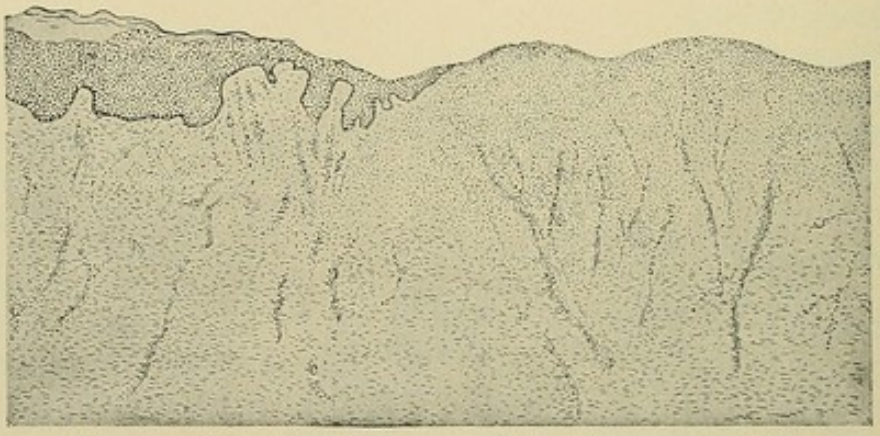

Fig. 91.—Wound healing by granulation (Keen and White).

all the anatomic structures severed, by the interposition of a minimum amount of new tissue, and by return of function ad integrum.

This description of what should be aimed at in the treatment of a recent wound intimates what is required of the surgeon when he undertakes to assist nature's resources in accomplishing so perfect a result. The surgeon's duty is clear: he must secure and maintain asepsis; he must unite by mechanical measures the same kind of tissues by careful suturing; he must secure perfect hemostasis before closing the wound, and, finally, during the time required for the healing of the wound he must place the injured part in a condition approaching as nearly as possible absolute physiologic rest. *The surgeon must not forget that each tissue furnishes its own material in the ideal repair of a wound, and that substitution of a material from other tissues necessarily yields faulty functional results.* It is of the utmost importance to unite by careful suturing, which often implies the use of the absorbable buried suture, nerve to nerve, tendon to tendon, muscle to muscle, bone to bone, periosteum to

Left margin of wound healing by first intention on the third day: *a*, Epidermic layer, showing cells undergoing karyokinesis; *b*, leukocytes accumulating on the edge of the wound; *c*, blood-clot filling dead space—commencing "organization"; *d*, vein from which leukocytes are emigrating.

periosteum, fascia to fascia, mucous membrane to mucous membrane, peritoneum to peritoneum, and skin to skin. Too much stress can not be placed on the most pedantic manner in which a recent wound should be sutured. Care and time spent in this part of the treatment are always well repaid. Some of the most brilliant operators are neglectful of this part of their work. The most successful surgeon is the one who not only knows how to make wounds, but who appreciates the importance of aiding the process of repair by careful suturing.

The macroscopic and microscopic appearances of granulating surfaces are nearly identical in all the tissues. A denuded bone covered with granulations presents a similar appearance to a granulating surface of any of the soft tissues. Even the embryonic cells of which the granulations are composed, as long as they remain in this state, furnish, from their microscopic appearance, no indications, or only remote ones, as to their histogenetic source and ultimate physiologic destination. Differentiation takes place during their further development toward the completion of the healing process. The bulk of all granulation tissue is derived from the connective tissue, as this mesoblastic structure is diffused throughout the entire body and, with the exception of the central nervous system, is found in almost every organ. In the nervous system it is represented by an almost similar tissue,—the neuroglia,—which performs the same rôle in repair of injuries and defects of the brain and spinal cord. A wound or defect covered with granulations presents a velvety appearance, each tuft or papilla representing a separate loop or network of new capillaries. The new capillaries spring, in the form of buds, from existing capillaries near the surface of the wound, and form connections with similar loops on the opposite side during the healing process, in this manner reestablishing the vascular connections between the two wound surfaces. In wounds that heal rapidly the existence of most of the new blood-vessels is a short one. With the beginning of cicatrization they disappear rapidly, and comparatively few of them remain as permanent structures as a system of collateral vessels that restore indirectly the loss of continuity between the divided vessels.

Prompt avascularization of the scar is one of the best indications that the process of healing has terminated in a satisfactory manner. The transformation of embryonic into permanent fixed tissue-cells is known as cicatrization. In tissues endowed with great vegetative powers and a high degree of physiologic adaptation even large defects are replaced by tissue that resembles to perfection—anatomically, histologically, and physiologically — the injured pre-existing tissue. This is the case in injuries involving considerable loss of substance in bone, tendons, and peripheral nerves. In other tissues endowed with less reparative energy—as, for instance, the muscular fiber—a slight separation results in the formation of cicatricial tissue between the anatomic structure which it is the intention

to unite. *By cicatrization, therefore, is understood the completion of the healing process, the term not necessarily implying the formation of a permanent scar. The ideal healing of a wound culminates in the formation of a union which effects a physiologic restitution of the injured part.* As a rule, it can be stated that the result will be satisfactory in a reverse ratio to the amount of granulation tissue produced or required in the process of repair. A wound of the external surface of the body can be said to have healed after the completion of epidermization. In accordance with the general law of succession of cells, epidermization takes place exclusively by proliferation of preformed epithelial cells, and consequently the process begins at the margins of the skin and spreads continuously over the granulating surface. It appears first as a delicate, bluish-pink pellicle. New epithelial cells possess ameboid movements, and when detached from the epithelial matrix, may wander some distance and form permanent attachments, in such an event an independent center of epidermization being established. The irregular projections of the new skin over the granulations, so frequently observed during the healing of wounds by granulation, are undoubtedly often due to such migration of epithelial cells. The granulations in the immediate vicinity of the zone of epidermization become reduced in size, the blood-vessels become smaller and are fewer in number, and the underlying fibroblasts are rapidly converted into connective tissue. In wounds healing by open granulations new papillæ are formed in the new skin, because the capillary loops atrophy downward and become the papillary vessels.

Union by secondary intention takes place in wounds in which suppuration precedes the process of repair. In a suppurating wound the embryonic cells that are destined to become transformed into new tissue are exposed to the destructive action of pus-microbes and their toxins, their protoplasm is destroyed, and they become one of the biologic sources of pus-corpuscles. The cells on the surface of the wound, being most distant from the vascular supply, possess the least power of resistance to the action of pyogenic microbes, and on this account, as well as from the greater number of pus-microbes on the surface of the wound than in the deeper tissues, they are converted into pus-corpuscles. As long as suppuration remains active the superficial layer of granulation cells is destroyed, and as soon as other embryonic cells take their place, the process is repeated; thus the healing of the wound is indefinitely delayed. When a favorable change takes place in the wound, either spontaneously or from the employment of antiseptic measures, suppuration is diminished, the granulations become firmer and more vascular, and cicatrization and epidermization now progress in a satisfactory manner and terminate in healing of the wound by secondary intention. So favorable a change in the condition of the wound can readily be accounted for by the employment of such agents as are known to destroy the microbic cause

of the suppuration when brought in contact with the wound. In such a case we would naturally expect that with the removal, destruction, or rendering inert of the pus-microbes the embryonic cells would remain attached to the point where they were produced, and would soon be converted into tissue resembling the matrix that produced them. Spontaneous cessation of suppuration, and with it the conversion of a surface covered with dead material into a healthy granulating surface, would indicate that the virulence of the pus-microbes had become diminished, that the soil was no longer congenial for their reproduction, or, finally, that the resistance on the part of the tissues to their pathogenic action had become increased. That tissue resistance has a potent influence in neutralizing and modifying the toxic action of micro-organisms has been observed clinically and demonstrated experimentally. Besides the important matter of time and the dangers incident to suppuration, wounds that heal by secondary intention as a rule leave a larger scar, and the functional results are less satisfactory than those following healing by primary intention. The surgeon must exercise his skill and focus his attention on meeting the indications presented by the infection before he can render efficient service in aiding the process of repair. After suppuration has abated, much can be done in expediting the healing process by secondary suturing, position, and the use of strips of adhesive plaster over a small aseptic dressing with a view to approximating the margins of the wound. The cases best adapted for secondary suturing are those in which suppuration has ceased and the granulations have become small and firm—in short, wounds in which cicatrization has commenced.

WOUND INFECTION.

The mystery of wound infection was cleared up by the discovery of the essential microbic cause. Bacteriology, one of the most recent and progressive of modern sciences, has demonstrated most conclusively that all inflammatory wound complications are caused by the presence of pathogenic micro-organisms. As in the case of nearly all infectious diseases, years before the specific pus-microbes were discovered living organisms were found in pus and were described and believed to be the essential cause of suppuration. In 1865 Klebs discovered, in the tubuli uriniferi in cases of pyelonephritis following suppurative cystitis, between the pus-cells, small, round cocci which he believed produced the infection. In 1872 the same author published the results of his researches on septic wound diseases during the Franco-Prussian war. In this work he again referred to the micro-organisms that he had previously described, and showed that they existed in the tissues and organs the seat of suppurative inflammation before pus had formed. He also showed how these micro-organisms enter the circulation and become the direct cause of distant infective processes. Even at that time

he insisted that as long as the cocci remained only in the tissues at the point of infection, they produce only local inflammation or necrosis, but as soon as they enter the general circulation fever and other symptoms of septic infection arise.

A. Ogston, the discoverer of pus-microbes, published the result of his researches in 1881. This patient investigator examined the

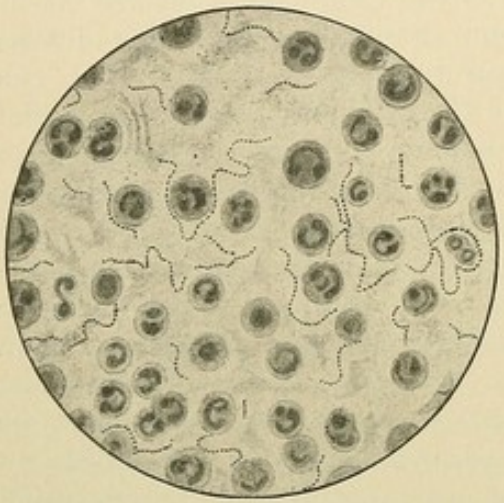

Fig. 92.—Streptococcus pyogenes (Jakob).

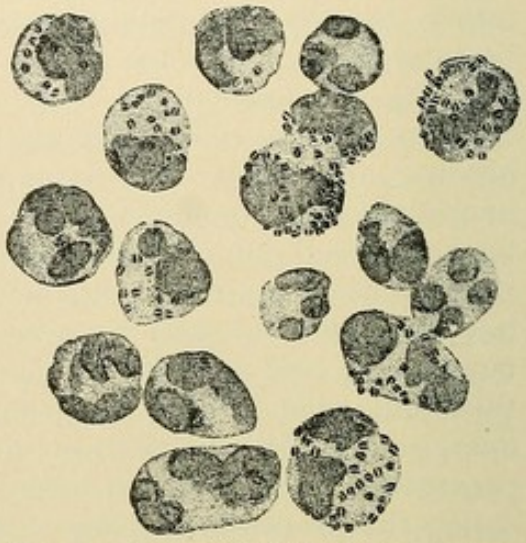

Fig. 93.—Gonococci in leukocytes; cover-glass preparation of gonorrheal pus.

pus of 69 abscesses for micro-organisms, and found in 17 of them a chain coccus (streptococcus); in 31 cocci that arranged themselves in groups that resemble a grape (staphylococcus), and in 16 both of these forms were present. In cold abscesses he failed to find either of these micro-organisms. He also ascertained that these two kinds of microbes differed in their manner of diffusion

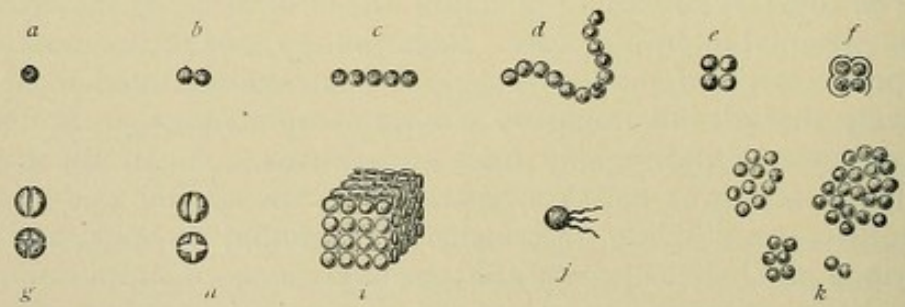

Fig. 94.—Diagram illustrating the morphology of the cocci: *a*, Coccus or micrococcus; *b*, diplococcus; *c*, *d*, streptococci; *e*, *f*, tetracocci or merismopedia; *g*, *h*, modes of division of cocci; *i*, sarcinæ; *j*, coccus with flagella; *k*, staphylococci (McFarland).

in, and action on, the tissues, as the streptococcus, following the lymph-channels and connective-tissue spaces, was seen to be the cause of diffuse suppurative processes, while the staphylococcus was found by him only in the pus of circumscribed abscesses, an observation fully confirmed by subsequent observations.

Julius Rosenbach took up the work where Ogston left it, and as

the fruit of a number of years of patient study and research published his classic work in 1884 ("Micro-organismen bei den Wund-infections-Krankheiten des Menschen"). Rosenbach's work has served as a basis for all researches on suppurative inflammation since that time. Rosenbach availed himself of the advantages offered by the improved technic of bacteriologic work founded by Robert Koch, as he cultivated the different pus-microbes upon solid nutrient media, and pointed out the difference in the macroscopic appearances of the cultures of the different kinds of pus-microbes, which enabled him to differentiate between them without the use of the microscope. He discovered the staphylococcus pyogenes aureus, the micrococcus pyogenes tenuis, and three kinds of bacillus saprogenes.

Passet should be mentioned next in the long list of distinguished names of original investigators who have made the bacteriology of infection and suppuration an object of special study. He discovered and described the staphylococcus citreus, the staphylococcus cereus albus, and the staphylococcus cereus flavus, and from a perirectal abscess he cultivated the bacillus pyogenes fœtidus. The bacillus pyocyaneus was described by Gessard and Charrin. The gonococcus, the specific microbe of gonorrhea, was discovered by Neisser in 1879. Fehleisen discovered the streptococcus of erysipelas in 1883. The identity of the garden-earth bacillus discovered by Nicolaier with the bacillus of tetanus was demonstrated in Koch's laboratory, April 10, 1887, and in 1889 Kitasato succeeded in obtaining a pure culture by exposing the inoculated nutrient medium to hydrogen gas instead of to atmospheric air.

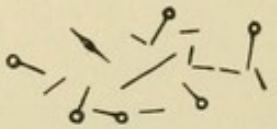

Fig. 95. — Bacillus tetani; cover-glass preparation from culture by Kitasato.

Fig. 96. — Bacillus pyocyaneus (× 700) (Flügge).

The bacillus coli commune, discovered by Emmerich in 1885 and so constantly found in the intestinal canal, has been detected so often in abscesses as the sole microbic cause of suppuration that it deserves classification with the pus-microbes. The pyogenic effect of the streptococcus of erysipelas is doubted by many, as it is well known that uncomplicated erysipelatous inflammation seldom, if ever, terminates in suppuration. The bacillus and diplococcus of pneumonia under certain circumstances may give rise to suppurative inflammation and abscess formation, as both of these microbes have been found in the pus of abscesses in different organs and parts of the body. Councilman proved by his experiments that certain chemic substances—metallic mercury, turpentine, and croton oil—produce suppuration. Abscesses caused in this manner are circumscribed and their contents are sterile, and if injected into living tissue, the result is always negative. It has also been demonstrated by Grawitz and de Bary that the toxins derived from the different

kinds of microbes produce a similar effect, and it is probable that the pus-microbes are less concerned in the destruction of cell protoplasm than their product, the toxins.

The etiologic relation of pus-microbes to infection and suppuration has been well established by experimentation and clinical observations. Experiment has shown that some form of pus-microbes is always found in the pus of acute abscesses; all the microbes which have been mentioned as possessing specific pyogenic properties have been cultivated upon artificial nutrient media, and the cultures injected into the tissues of animals susceptible to pyogenic infection have produced suppurative inflammation. It is seen, therefore, that all requirements set down by Koch in establishing the causative relation between a certain microbe and a definite disease have been fully met. Clinically we know that intentional wounds heal by primary intention if the necessary preparations are made and directed toward preventing the entrance of pathogenic microbes into the wound. The surgeon must recognize the well-established fact that infection and suppuration practically never occur without pus-microbes. *No kind or amount of injury can give rise to suppuration independently of the essential microbic cause of infection.* It is plain that the surgeon's daily work consists largely in a constant warfare against microbes. The prevention of wound infection is his daily occupation. If he is successful in this part of his undertaking, the hardest battle has been fought: the wounded are safe in his hands, and his operative work becomes a source of pleasure and gratification to him and a blessing to his patients.

Pus-microbes, the essential cause of wound infection, appear to be almost omnipresent, while others are diffused over a more limited area, their existence being dependent upon certain conditions of the soil or temperature. Water as a medium of diffusion and as a vehicle for the entrance into the organism of pathogenic microbes is of greater interest to the physician than to the surgeon. The superficial layer of the soil contains most of the disease germs and spores, as they are deposited upon it from the air, and carried into it by water that contains them, the soil in the latter instance serving the purpose of a filtering substance. For the surgeon, direct infection with microbes of the soil has acquired new interest through Nicolaier's discovery that the bacillus of tetanus has here its natural habitat, and from the well-known circumstance that the bacillus of anthrax is known to multiply in the soil of pastures that have been inhabited by animals suffering from this disease.

Of all media that serve as carriers of microbes, the atmospheric air is the most important, because it is present everywhere, and no one can exclude himself from it. In a dry state pathogenic germs move with the currents of air and attach themselves again to the solid or fluid substances with which they come in contact. Although most of the microbes under ordinary circumstances do not reproduce themselves outside of the body, their resistance to heat and

cold, moisture and dryness, is so great that they often retain their disease-producing qualities for an indefinite period of time. After their entrance into the body and after meeting with a proper nutrient medium, they exert their specific pathogenic qualities. It is well known that microbes that have been carried upward by currents of air descend by virtue of their own weight. When the air is in a quiescent state, the lower strata contain microbes in greater abundance than the upper. Klebs found that in the Campagna districts, near Rome, an elevation of three meters afforded perfect immunity against malaria. Soyka made some observations on currents of air as vehicles for the diffusion of microbes in the laboratory at Prague. He came to the conclusion that very slight currents convey microbes from the margins of drying fluids, while Naegeli asserted that a current of considerable force is necessary to effect such transportation, and that the raising of the particles into the air by the current was greatly influenced by the force of adhesion that exists between the particles and the surface to which they adhere. Every surgeon is anxious to prevent atmospheric disturbances in the room where an operation is to be performed, and aims to secure quiescence by closing the windows and doors some time before the operation is commenced, for reasons that become obvious from the foregoing. For the same reasons the operating room should be swept and dusted the day before, and the microbes held in suspension precipitated and attached to the floor by spray, steam, or by sprinkling the walls, floor, and ceilings with an antiseptic solution.

While air is an important medium of diffusion of microbes, wound infection can not often be traced to this source. Lister's spray, devised for the special purpose of destroying microbes floating in the air surrounding the field of operation, has had its day, and is seldom seen at the present time. *All substances brought in contact with a recent wound and which have not been rendered surgically clean by sterilization may become the carriers of pathogenic microbes, and of these the hands, sponges, sutures, ligatures, syringes, instruments, and dressings have been the most fruitful sources of infection.* Even if the surgeon should not know the name of a single microbe, if he takes it for granted that minute living plants that are everywhere and attached to everything are the essential cause of wound complications, he would naturally seek for ways and means to prevent their entrance into the wound, and would recognize the necessity of sterilizing everything that is to be brought in contact with the wound. Fortunately, the intact skin furnishes almost a perfect protection against the entrance of pus-microbes into the tissues. No wound is too small and none is too large to serve as a gateway or infection atrium for the entrance of pus-microbes into the tissues.

Not all individuals are equally susceptible to the pathogenic action of pus-microbes. We observe the same difference of behavior toward pus-microbes among the lower animals. The deli-

cate rabbit and guinea-pig respond very promptly to injections of pure cultures, while the hardier dog and cat are very resistant to pyogenic infection. We recognize in man a hereditary and an acquired susceptibility to the action of pus-microbes. Again, we observe a great difference on the part of the various tissues to pyogenic infection. Dense vascular tissues, such as we find in the tongue, lips, and cheeks, possess a maximum intrinsic power of resistance to infection, while the medullary tissue of bones, the synovial membranes, and the adipose and loose connective tissue are extremely susceptible to the action of pyogenic microbes.

The normal mucous membrane of a healthy bladder is very resistant to pus infection, but the paralyzed bladder is very easily infected. The nature of the wound plays an important part in the etiology of infection. It is more difficult to infect an incised than a lacerated or contused wound, and it is for this reason that the surgeon does as little tearing as possible during an operation. For the same reason he attempts, whenever feasible, to transform, as nearly as possible, a lacerated or contused wound into an incised wound. One of the most important indirect causes of infection is the primary wound secretion, which, if permitted to accumulate in the wound, serves as a nutrient medium for the microbes that may have found entrance into the wound, and which without such a culture substance might have remained harmless. It is for the purpose of rendering the soil barren that we resort so frequently to drainage in the treatment of wounds where the primary wound secretion is apt to be profuse, or when, from the nature or location of the wound, the formation of a so-called dead space or spaces can not be avoided by suturing or other mechanical measures. Wound infection is a complicated process, and the surgeon must strive not only to guard against the entrance of the essential cause, but must aim at the same time to prevent those conditions that are known to favor the reproduction of microbes in the organism, as few wounds are entirely aseptic.

Of the nonsuppurative wound infections, erysipelas, erysipeloid, and tetanus furnish the most striking examples. Fehleisen demonstrated the direct etiologic relationship between the streptococcus erysipelatis and the nonsuppurative acute dermatitis known as erysipelas, by isolating the microbe, by cultivating it outside of the body, and by reproducing the disease in animals and in man by inoculations with pure cultures. When the streptococcus of erysipelas finds its way into the lymphatics of the skin through a wound, or perhaps a slight abrasion, in sufficient number and virulence, it produces a rapidly spreading acute inflammation of the lymphatics and skin of short duration. The streptococcus multiplies in the tissues with wonderful rapidity, but its life is short, for it perishes as speedily as it was produced. The lymph-channels and connective tissue of the inflamed skin are densely packed with what appears under the microscope as an almost pure culture of the

microbe. Wherever the streptococcus finds its way, an intense non-suppurative inflammation is the result. The disease-producing qualities of the streptococcus are soon exhausted, and resolution takes place at the point of invasion, while the disease continues progressively in the periphery of the infected territory. The microbe is most virulent in the tissues of the skin most recently affected, and it is from such places that the tissue fluids are taken for inoculation experiments. The streptococcus grows most luxuriantly in gelatin at body-temperature. Fehleisen inoculated the ears of rabbits, and the first local signs of reproduction of the disease appeared at the point of inoculation in from twelve to twenty-four hours. Inoculations for therapeutic purposes in the treatment of inoperable malignant disease were made, with similar positive results. The time intervening between the inoculation and the development of the first general and local symptoms varied from fifteen to sixty-one hours. The results of these inoculations have shown that the period of incubation of this disease is a short one. We can now understand the local and general spread of erysipelas before the antiseptic era in hospitals and communities by sponges, instruments, hands, clothing, etc., from wound to wound and from patient to patient.

Another nonsuppurative surgical infectious disease that furnishes convincing proof of its microbic origin is tetanus. The key that unlocked the microbic nature of this somewhat strange wound complication was furnished by Carle and Rattone in 1884. These investigators produced tetanus in a rabbit by injecting pus obtained from a wound of a tetanus patient. A year later Nicolaier discovered a microbe in garden-earth which, when injected subcutaneously into mice, rabbits, and guinea-pigs, invariably caused tetanus. Kitasato isolated the same microbe from mixed cultures by cultivation in an atmosphere of hydrogen gas, and for the first time obtained a pure culture, which, when injected into animals susceptible to tetanus, invariably produced the disease.

Tetanus appears in animals in twenty-four hours after the injection of a pure culture, and a fatal termination may be expected under all the symptoms characteristic of tetanus in man in the course of two or three days. In tetanus the action of the microbe on the tissues is entirely different from that of erysipelas. In the latter disease the streptococcus is always present in the tissues affected, and its rapid multiplication in the body is an important element in the extension of the infection. In tetanus the bacillus does not appear to multiply to any extent in the body, but its presence can usually be determined in the wound secretion or in the tissues at the point of inoculation. The tetanic spasms extending in more or less rapid succession to the different muscular groups, according to the acuity of the disease, are caused by the action of the toxins at a distance from the seat of infection, which find their way through the fluids of the body to remote parts. It is on this account that operative treatment holds out so little prospect of arresting the disease,

as even the amputation of an entire limb would not eliminate the toxins that have invaded the central nervous system. Any of the toxins isolated by Brieger—tetanotoxin, spasmotoxin, and the muriate of toxin free from any bacilli—can produce tetanic convulsions and death. As the tetanus bacillus is an anaerobic microbe, it remains harmless on the surface of the wound and must enter the tissues deeply before it can exert its specific pathogenic action. The conditions necessary for the growth of the tetanus bacillus readily explain why tetanus is met much more frequently as a complication of punctured and contused than of incised wounds.

Infection of wounds with the bacillus of tuberculosis is extremely rare, as only a very few well-authenticated cases of this kind are on record. Large wounds do not furnish the conditions necessary for the localization, growth, and reproduction of the tubercle bacillus. Tubercular infection is more likely to take place through slight, neglected abrasions and small punctured wounds.

Prevention of Wound Infection.—The discussion of the subject of prevention of wound infection constitutes the most important chapter in any modern book on the practice of surgery. It is a subject with which every general practitioner should be perfectly familiar, as it furnishes the key to successful emergency work. The different methods directed toward obtaining asepsis have undergone great changes, and no uniformity in this regard is found among the surgeons of to-day, but the object to be obtained remains the same—viz., *to secure an aseptic condition for the wound and for everything which is brought in contact with it. Although methods may vary, the principles upon which they are based are the same, and they are to the effect that asepsis can only be secured by disinfection of the wound and its environments, the field of operation, the hands of the surgeon and assistant, and sterilization of everything that is brought in contact with the wound—instruments, sponges, sutures, ligatures, drains, and dressing material.*

OPERATING ROOM.

Since antiseptic treatment has come into general use, an immense amount of money and a great deal of genius have been expended in the construction and equipment of operating rooms in all the large hospitals. Nations, charitable and educational institutions, have vied with one another in taking the lead in making the necessary improvements. Many of the operating theaters in our large modern hospitals have been built at an enormous expense, and have been furnished with the most elaborate facilities for aseptic work. It must not be forgotten, however, that the earliest and most brilliant victories in antiseptic surgery were scored in old, infected hospitals and in old-fashioned operating theaters, where hospital gangrene, erysipelas, suppuration, sepsis, and pyemia had reigned supreme for years. This was notably the case in von

Nussbaum's clinic at Munich. Before antiseptic surgery was introduced, according to Lindpaintner nearly 80 per cent. of those operated upon were attacked by hospital gangrene. Erysipelas was common. The most insignificant wounds suppurated. Deaths from sepsis and pyemia were of daily occurrence. With the introduction of antiseptic surgery all these wound complications disappeared as if by magic. It is doubtful if the results obtained by Volkmann in the old clinic have been improved upon since the palatial new clinic has been erected. *A splendid operating room with elaborate facilities for asepsis is desirable, but not essential to obtain the best results.* The Rush Medical College amphitheater, with a capacity for holding 600 students, is anything but a modern operating room, and yet, notwithstanding that the surgical clinics are attended by from 400 to 500 students, infection during operations for aseptic conditions is the exception, primary wound healing, the rule. The wonderful results that crown the surgeon's work to-day are not due so much to the modern improvements in the operating room as to the more intelligent and efficient assistance.

The trained nurse must not be forgotten when we come to investigate the causes that have contributed to modern surgical success. *It is the trained nurse who performs the most difficult and painstaking task when she prepares for an operation.* How many operators are there who are competent and willing to look after all the details necessary to make adequate preparations for an important operation? *It is the trained, conscientious nurse of to-day who fights more than one-half of the battle, and who, as a rule, receives so little credit for her work.* The trained nurse is to be found in every operating room at the present time, and it is she who hands the surgeon the faultless knife when everything is in readiness to begin the operation. *Take away the trained nurse from the operating room, and the surgeon's work will become more laborious, time-consuming, and less satisfactory.* If I had the choice of operating in the most elaborate operating theater without a trained nurse, and in the kitchen of a farmer's house with one, I would not be long in deciding in favor of the latter, and I am confident that the patient would be benefited by the preference. A long experience with assistants and general practitioners has satisfied me that they can not be relied upon in looking after the many little details so essential in making preparations for a major operation. This part of the surgical work is woman's special sphere. Her pride and satisfaction in the success of an operation are equal to those of the operator. Her knowledge of household duties prepares her admirably for such work. Her keen sense of duty, her quick eye and sensitive ear, her delicate hands and fingers, and her appreciation of cleanliness make her what she is—*the surgeon's right hand.* It is fortunate that these trained nurses no longer limit their life-work to large cities. The time is not distant when they will be found in every village and hamlet throughout the country, where

the general practitioner will be benefited by their invaluable assistance. *It is with the aid of the trained nurse that the general practitioner will regain the surgical work that rightfully belongs to him.* The modest little hospitals that are springing up in all the smaller cities, and which, as a rule, are conducted by trained nurses, are institutions that can not fail to exert their influence in the respective communities to stimulate and advance the surgical work of the general practitioner. I have personal knowledge of a number of such hospitals in which excellent surgical work is done, within proper limits, by men who do not pose as surgeons. Each

Fig. 97.—Kitchen converted into operating room.

one of these institutions, if properly managed, is a blessing to the sick and injured of that community and a benefit to the profession. *A plain little operating room, presided over by a trained nurse, will enable many physicians to treat injuries and perform operations creditably that they would hesitate to undertake without such facilities.*

Before antiseptic surgery was practised hospitals were in bad repute, and many surgeons preferred to perform the more difficult operations in private houses, believing that the hospital air was responsible for the many wound complications. Pirogoff fought in vain against hospital gangrene and purulent edema in the great hos-

pitals of St. Petersburg, while in the hovels of the poor the results of his operations were much more satisfactory. It is not difficult to understand how the old hospitals at that time became breeding-places for infection. The congregation of so many septic cases and the lack of even ordinary cleanliness could not fail to infect every nook and corner of the sick-rooms. In most of the large hospitals at the present day there are at least two operating rooms, one for aseptic and the other for septic cases. Such an arrangement is most desirable, and greatly diminishes the responsibility of those who have charge of the operative work. In hospitals with only one operating room the aseptic cases should be disposed of first, and after the day's work the room must be subjected to thorough dis-

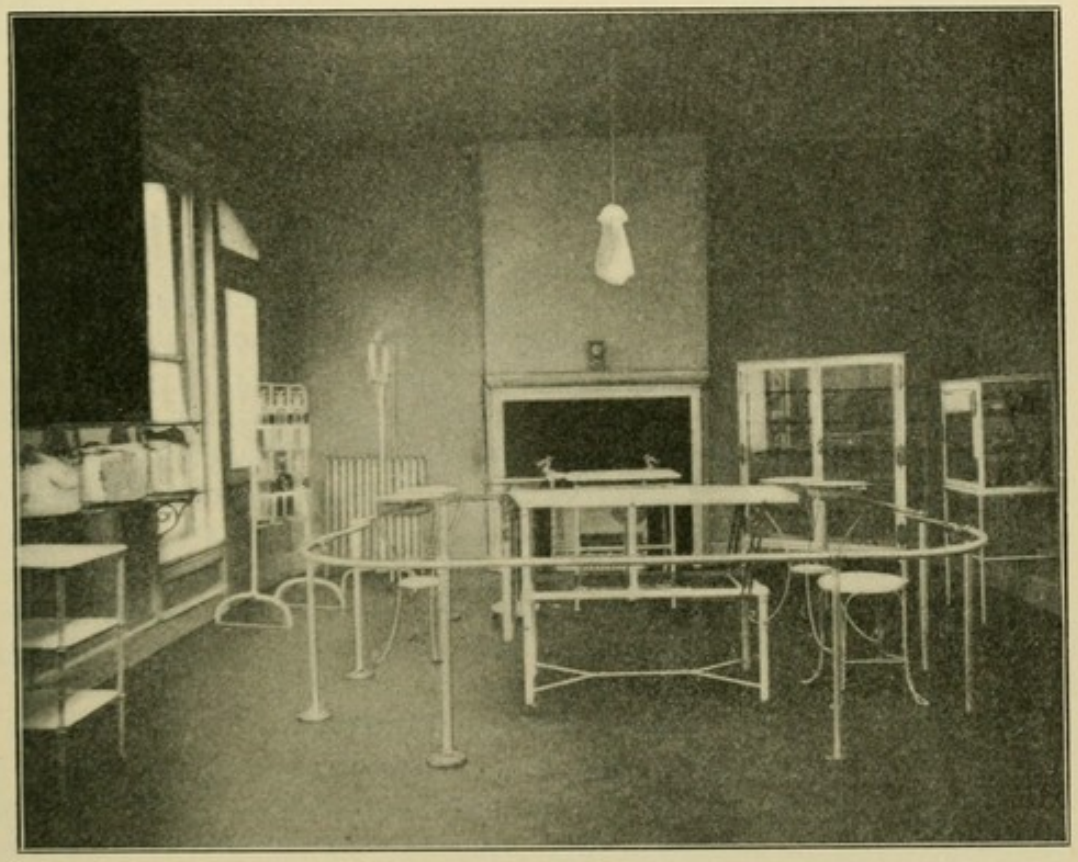

Fig. 98.—Modern operating room, St. Joseph's Hospital, Chicago.

infection. The room should be so constructed that the walls, ceiling, floor, and utensils can be readily cleaned in a mechanical way. Everything that might be in the way of effective cleaning must be removed from the room.

In private homes a room is to be selected that is least frequented, and very often the kitchen will recommend itself as the best room for this purpose. Carpets, curtains, pictures, and all unnecessary furniture must be removed. Ceiling, doors, floor, walls, windows or blinds, and all objects in the room must be scrubbed thoroughly with hot soda solution, to be followed by scrubbing with a solution of corrosive sublimate, 1 : 1000, or carbolic acid (5 per cent.). The

air of the room must receive proper attention, especially in large cities and in small, badly ventilated houses. The microbes developed upon the surface of the earth find their way in limited number into the lower strata of the atmospheric air by currents of wind that carry with them visible dust. Naegeli showed, a quarter of a century ago, that microbes are transported through the air through the medium of dry dust, never from fluid organic media in which they grow. Dry air contains more microbes than moist air, because more dust is suspended in it, which serves as a carrier for the microbes. Rain carries with it microbes from the air to the surface and purifies the atmosphere. Nature's process should be imitated in the operating room. The microbes floating in the air should be precipitated by moisture in the form of steam or spray ; by doing so the air is purified and the microbes become attached to the moist floor, which should be kept moist until the operation is completed. For the cleansing of wall-paper E. Esmarch has recommended rubbing with bread, and his advice is based on the results of carefully made experiments. Whenever possible, the room should be prepared the day before the operation, after which windows and doors are closed. In emergency cases this can not be done, but the atmosphere can be moistened with steam in a very short time during and after the mechanical and chemic cleaning of the room and its contents. The kitchen table can be converted into an operating table that will answer every purpose, by placing upon it a blanket properly folded and covering the same with a clean sheet. The kitchen stove does excellent service in sterilizing everything that can be sterilized by heat—wash-basins, pans, water, instruments, etc. Napkins and towels that are to be used during the operation, and the sterility of which is doubtful, should be boiled for five minutes in soda solution. Sterile water, hot and cold, and in sufficient quantity, must be kept in readiness, as well as sterile vessels for its use during the operation. I have entirely abandoned the use of simple sterilized water in surgery, and have substituted for it the normal salt solution, which can be easily extemporized by adding a teaspoonful of pure table salt to each quart of sterilized water. An active, efficient nurse can prepare any room in a few hours so that it will be safe to perform any operation, by making liberal use of hot soda solution, hot water and potash soap, antiseptic solutions, and steam. For major prolonged operations the temperature of the room should be kept at not less than 75° F. Warm blankets, bottles filled with hot water, or warm bricks must be in readiness to supply the necessary heat in operations upon feeble patients, or in cases in which shock is liable to set in as the immediate effect of the operation. A hypodermic syringe, strychnin tablets, capsules of nitrite of amyl, alcoholic stimulants, ether, and chloroform must be kept within easy reach of the anesthetizer.

A word in reference to the care of brushes, which are so useful in all attempts at hand and surface disinfection. Brushes may be

used repeatedly and on different patients if they are thoroughly disinfected and properly taken care of after each operation. None of the substitutes proposed for brushes has ever found its way into general favor. Wood-fiber and gauze sponges have been suggested, but their efficiency has fallen short of the brushes. The surgical brush should not be painted or varnished. The bristles or vegetable fibers should be stiff. After use, the brushes should be thoroughly cleansed with hot water and soap, sterilized by boiling for one minute, and then immersed either in a 5 per cent. of carbolic acid or in a 1 : 1000 bichlorid of mercury solution ready for use. Brushes treated in this manner are absolutely sterile, and remain so as long as they are kept in the antiseptic solution. New brushes are sterilized by exposing them to live steam for thirty minutes, or by boiling them in soda solution for from five to ten minutes.

Before hand disinfection is commenced coats are laid aside and the sleeves rolled up securely above the elbows, when the operator and his assistants are ready for the operating room. Should gowns not be on hand, clean night-shirts answer as excellent substitutes, and in the absence of such, a clean sheet may be wrapped around the chest and abdomen and fastened by safety-pins. Towels can be used in the same manner for the arms. As microbes attach themselves much more readily to woolen fabric than to linen or calico, the nurse will always wear a calico dress and over it an aseptic gown after she has made the necessary preparation for asepsis. If during the operation the hands of any one connected with the operation become contaminated, they should be again disinfected by washing in a strong antiseptic solution, after which they should be immersed for a few moments in normal salt solution, which must always be kept within easy reach of the operator, to be used whenever the hands become bloody.

HAND DISINFECTION.

Ample experience has demonstrated that infection by contact is to be feared much more than infection by microbes suspended in the air. It is generally conceded that operation wounds are most frequently infected by contact with the hands of the operator or his assistants. The risk of infection increases with the number of assistants, and this statement applies with special force to new and inexperienced assistants, as is the case in college clinics in our country in which the assistants serve for only three or four months at a time. Since Eberth discovered numerous bacteria in normal perspiration in 1875, it has been found that the surface of the body is inhabited by a whole flora of pathogenic microbes. They are most numerous upon the hairy parts of the skin, in the folds and crevices, in the outlets of the glandular appendages, and especially in the subungual spaces of the fingers. Bordini's statement that the people of each country and section of country may carry on their surface special varieties of microbes indigenous to such local-

ities is more real than imaginary ; and it is possible that each trade or occupation may bring with it microbes of a special sort. Fürbringer found that after working in the garden, notwithstanding that he washed his hands thoroughly in the usual way, the bacilli of garden-earth clung to his hands for several days, and after working in the laboratory for several days in making urine examinations, the micrococcus ureæ could be demonstrated on the surface of the hands a number of days later. The mouth in a normal condition swarms with a variety of pathogenic microbes. In the genitals of the female Winter found bacteria as far as the internal os, also in the upper respiratory tract and the distal portion of the urinary passage. It is certain that pyogenic microbes inhabit the skin of all human beings, regardless of nationality or geographic location. Welch discovered a microbe in the skin, which he called staphylococcus

Fig. 99.—Green soap in collapsible tube.

Fig. 100.—Ordinary vegetable-fiber hand-brush.



Fig. 101.—Plain steel nail-cleaner.



Fig. 102.—Glass brush-box with cover.

epidermidis albus, and which he believes is usually the cause of stitch abscesses.

Careful hand disinfection is an essential prerequisite to clean aseptic surgery. The force of this statement is well understood and appreciated by every surgeon of experience, but, from what is only too often seen, is not sufficiently comprehended by the mass of the profession. I have more than once seen an excuse for hand disinfection preparatory to an operation, in the shape of washing the hands for a few moments, with the wedding-ring in place, in a basinful of water containing a few drops of carbolic acid, as the only effort to prevent infection by hand contact. *No amount of washing, even in reliable strong antiseptic solutions, will suffice to destroy the microbes lodged upon and in the skin without a preliminary mechanical cleansing with hot water and potash soap.* The fatty sub-

stances that always cling to the surface of the skin and about the orifices of the outlets of the gland-ducts protect the microbes against the action of the most potent antiseptic solution. The hands of the surgeon are to be feared most, as he is constantly engaged in the handling of suppurating affections. *A careful hand disinfection is necessary not only in aseptic cases, but should not be neglected in pus cases, as suppurating wounds may become more infected by unclean hands.* A suppurating wound may become infected with erysipelas, and putrefactive infection may complicate erysipelas, and, finally, a purulent edema may develop, one of the most dangerous forms of infection.

Hand disinfection is a difficult problem in surgery. Some surgeons are of the opinion that this can be accomplished in a mechanical way by washing with hot water and soap and a diligent use of the brush. Kümmel's experiments have shown conclusively that by this procedure the hands are not made sterile. Kümmel and Fürbringer made the first scientific investigations concerning hand disinfection, and their conclusions hold good to-day. Kümmel found that if the hands are washed and brushed for five minutes in warm water and potash soap, followed for two minutes by scrubbing either with chlorin water or a 5 per cent. solution of carbolic acid, that the disinfection is complete. Impressions on gelatin cultures of the fingers thus cleansed remained sterile. The same result was not obtained by using a 3 instead of a 5 per cent. solution of carbolic acid. Fürbringer recommended alcohol for the removal of fatty material preparatory to the immersion of the hands in the antiseptic solution. He recommends the following procedure :

1. After the finger-nails have been carefully trimmed and cleaned, wash the hands in warm water with potash soap, and brush for from three to five minutes.

2. Dry with sterile towels and attend to finger-nails once more.

3. Scrub the hands for one minute with 80 per cent. alcohol, and finally immerse in an antiseptic solution.

Alcohol has become very popular for hand disinfection everywhere, and the universal testimony is in its favor. Some employ ether in its place ; others, turpentine. All these substances are excellent solvents for the fatty material, and prepare the way for a thorough chemic disinfection. It must be admitted, however, that the chemic disinfectants play a subordinate rôle in hand disinfection, and that they only become useful after a thorough cleansing of the hands by mechanical measures. *Reliable hand disinfection does not depend so much on the kind of antiseptic used as on the pedantic manner in which the attempt is made.*

Time is an important element in the preparation of the hands. This is especially so in emergency work. In urgent cases the surgeon frequently hastens the procedure to an extent incompatible with thorough disinfection. He should, however, remember, when urged to proceed by patient or bystanders, that it is inexcusable,

almost criminal, to touch a recent wound with hands that are not surgically clean. *More is lost by hasty action than by the delay caused in an earnest attempt to prevent infection by disinfecting the hands. Dirty hands have destroyed more lives than all the implements of warfare.*

The following method has been found very satisfactory in von Bergmann's clinic and elsewhere:

1. The hands and forearms are scrubbed thoroughly with warm water and potash soap for at least one minute.

2. The surface is rubbed dry with aseptic towels or gauze. All folds and subungual spaces receive special attention, a metallic nail-cleaner being used for the latter location.

3. For another minute the skin is rubbed vigorously with a sterile gauze sponge saturated with 80 per cent. alcohol.

4. Scrubbing and irrigation with a 1 : 1000 solution of corrosive sublimate completes the disinfection.

In important operations I have relied for several years on turpentine in preparing the surface for the antiseptic solution. After cleansing the hands and forearms in the manner described, the surface is bathed with turpentine for at least one minute, using the brush in cleaning the finger-nails, which should always be cut short and well trimmed. Warm water and potash soap are again used to remove the turpentine, after which the surface is ready for the efficient use of the antiseptic solution. As the antiseptic substance should be removed from the hands, rubbing with pure alcohol and finally washing in a normal salt solution complete the procedure. Turpentine does not damage the skin so much as alcohol, and removes fatty matter more thoroughly than any other substance, and, as experiments have shown, is a potent antiseptic in itself. The experiments of Lauenstein have demonstrated how difficult it is to disinfect the skin. In 169 aseptic operations he removed a piece of skin from the field of operation prepared by different methods and implanted it upon gelatin, and in every instance the experiment yielded a positive result. Perhaps one of the best proofs that all known methods of hand disinfection have their defects is the present quite extensive use of rubber gloves, advocated by Halsted, Mikulicz, Fenger, and other surgeons who have had a long and rich experience in the operating room. It is easy to foresee that this practice will never become general, even in the clinical amphitheaters, to say nothing of the practice of the general practitioner. The rubber gloves impair the delicate tactile sense of the fingers, are expensive, easily torn, and furnish a soothing poultice for the conscience when the surgeon fails to prepare his hands properly. There is no doubt but that future research and investigations will succeed in simplifying hand disinfection, and that a procedure will eventually be devised that will dispense with any and all excuses for wearing gloves in the operating room.

It is needless to say that the hands of the assistants and

nurses should be prepared with the same care as those of the operator.

DISINFECTION OF FIELD OF OPERATION OR INJURY.

The methods of hand disinfection just described are applicable for the preparation of the field of operation or the seat of injury. One great advantage is offered here that can not be made use of in hand disinfection, and that is the employment of the razor as a mechanical agent for the removal of septic material. Next to soap and hot water the razor is most important in disinfection of the surface of the skin preparatory to the application of the antiseptic solution. The razor not only removes hair, but also scrapes away the superficial layer of the epidermis, softened and macerated by scrubbing with hot water and potash soap. In operations of choice the skin may be properly prepared for a more efficient use of the razor and brush by applying to the surface to be prepared a soft-soap poultice for a few hours. This preliminary measure to macerate the skin is of special importance in preparing the scalp, scrotum, hands, and feet for operation. One of the commonest faults in preparing the surface for operation is that the disinfection is not carried far enough. For instance, in the treatment of compound fractures of the skull it is not an unusual practice to limit the shaving and disinfection to the site of the wound. *In all operations on the skull the whole scalp should be shaved and disinfected.* Women usually protest against such a procedure, but when informed that this is done as much for cosmetic as for surgical reasons, the objections are overcome. Every patient can expect a fair growth of hair before he recovers from the effects of the injury or operation. Disinfection for an amputation of the breast should include the whole chest and the shoulder and arm on the side of the breast to be removed. In abdominal operations the whole abdomen, including the pubic region and the chest as far as the breasts, must be prepared. In amputations of the leg, the leg from the seat of injury or disease and the thigh must be shaved and disinfected. In amputations of the thigh, the pelvis on the corresponding side is included in the preparation. In operations for hernia, the abdomen as far as the umbilicus, the scrotum, penis, and the groin constitute the field of operation requiring disinfection.

In operations of choice the disinfection should be made the day preceding, and the field of operation covered with a compress wrung out of a hot antiseptic solution, either a 2.5 per cent. of carbolic acid, or a 1 : 1000 solution of bichlorid of mercury ; moisture and heat are retained by applying around the compress a ring of absorbent cotton and over it gutta-percha tissue or waxed paper, and the whole held in place by a gauze bandage. The disinfection is repeated after the patient is under the influence of the anesthetic and before he is placed on the operating table. In emergency operations the disinfection is done after the patient has been placed

under the influence of the anesthetic, to avoid delay and prevent one of the causes of shock.

Disinfection of mucous surfaces is still more difficult than of the skin. As a rule, complete asepsis can not be secured by any of the methods in use at the present time, and in consequence of the incomplete disinfection we are generally forced to abandon all attempts to obtain primary union of the wound throughout. Irrigation of the vagina or rectum with any of the more potent antiseptic solutions has no effect whatever on the bacteria, and, besides, by doing so we incur the immediate risk of serious, if not fatal, intoxication by the rapid absorption from the mucous surfaces of the toxic agent contained in the solution. In the disinfection of mucous surfaces mechanical measures must be relied upon in preparing the parts for the operation, followed by the use of mild nontoxic solutions, such as Thiersch's solution or a saturated solution of boric acid.

STERILIZATION OF INSTRUMENTS.

Aseptic surgery has necessitated a great change in the manufacture of surgical instruments. All attempts at ornamentation have been abandoned. The beautifully carved handles and blades that adorn the pages of the old works on surgery have become objects of curiosity, and are to be found only in museums and in the shops of dealers in antiquities. The modern surgical instruments



Fig. 103.—Senn's emergency operating case.

are made as plain and smooth as possible. Knives and retractors are made of one piece of steel, all inches and crevices being avoided whenever possible. Scissors and forceps are made so that the two parts may be readily separated and joined again. Another great improvement noticeable in the instruments used to-day is their smaller size and more delicate construction. The old-fashioned sword-like amputation knife is seldom seen now, as any amputation can be done with a medium-sized scalpel, since surgeons have abandoned the transfixion methods. *The best surgeons need the fewest instruments.* Very few instruments are required to perform any operation, provided the selection is made with care and the oper-

ator is familiar with their use. During one of my visits to the veteran laparotomist, Professor Koeberlé, I was shown an instrument case that would have found ample room in any moderate-sized hip-pocket, and I was informed that it contained all the instruments ever needed in his abdominal work. Tait and Price perform the most difficult operations with the contents of an ordinary pocket-case. The surgeon should, from the beginning of his career, endeavor to do his work with as few instruments as possible. With two knives, a pair of dissecting forceps and retractors, a dozen hemostatic forceps and needles, a pair of straight and a pair of curved scissors, a silver catheter, a chisel, a saw, and an Esmarch's constrictor most of the emergency operations can be performed. The old-fashioned velvet-lined instrument cases and pocket-cases have been laid aside and replaced by canvas covers. Handles for blades of different sizes and many-bladed knives should not be used. Several years ago I made a selection of instruments for emergency work. The instruments are placed in a canvas cover, and the name of each instrument is stamped with indelible ink on the place where it belongs. Two canvas cases go with each outfit, so that they can be disinfected by boiling in soda solution and used alternately. As dust and, with it, microbes would find their way through the canvas to the instruments, an outside leather case was added as an additional protection.



Fig. 104.—Boeckmann's combined instrument and dressing sterilizer.

The first attempt at sterilization of instruments consisted in immersing them in a solution of carbolic acid, but the result soon showed that this method was not reliable. Nussbaum boiled them in a 5 per cent. solution of carbolic acid. The edge of cutting instruments is seriously damaged by the carbolic acid in concentrated solution, and, besides, the thinnest film of a greasy substance protects the microbe against the germicidal action of the acid. Dry heat and steam were next used, but it was soon found that the former could not be relied upon, while the latter method damaged the

instruments by rusting. Steam sterilizes much quicker than dry heat, and exposure of from fifteen to twenty minutes usually suffices. The necessary apparatus for this method of sterilization is usually not in possession of the general practitioner. The cheapest and probably the most practical steam sterilizer for the physician's use is the one devised by Dr. E. Boeckmann, of St. Paul. The great defect of sterilization of instruments by steam is that the instruments become rusty in a very short time. The time required—on an average from thirty to forty minutes—also constitutes a serious drawback in emergency cases. Steam under pressure is more effective than flowing steam. Redard first recommended compressed steam for the sterilization of instruments in 1888, and at that time invented a small autoclave. The whole procedure consumed forty-five minutes. The general practitioner is in need of a simpler method. Sterilization by boiling suggested itself next. Miquel recommended glycerin heated to 140° C., and Tripier and Arloing boiled the instruments in olive oil. Glycerin gives off a very disagreeable odor in a boiling state, and oil leaves a coating of fat on the surface of the instruments.



Fig. 105.—Boeckmann's sterilizer, showing arrangement for boiling instruments.

Boiling water is the least objectionable and most effective medium of instrument sterilization. Davidsohn proved by his experiments that water at boiling temperature completely sterilizes the instruments in five minutes. Boiling in plain water rusts steel instruments, and this is especially the case if the instruments are immersed before the temperature is raised to the boiling-point. It has been known for a long time, and Davidsohn again recalled the fact, that rusting of instruments in boiling water can be prevented by the addition of an alkali. Experiments showed that a 1 per cent. solution of carbonate of soda is best adapted for the sterilization of instruments by boiling. The addition of soda intensifies the disinfecting power of boiling water. Boiling soda solution is the most powerful germ destroyer known applicable in practice. Schimmelbusch ascertained that ordinary pus-microbes are destroyed in two or three seconds in boiling soda solution, and the spores of anthrax in two minutes. The addition of a tablespoonful of ordinary washing soda to a quart of water is all that is required to obtain the best solution in general practice for the sterilization of instruments by boiling. The simplicity of this procedure and the ease with which it can be put in operation in any

place have commended this method to the profession. All that is required is a metallic vessel, water, soda, and fire, all of which can be obtained in any household. During the operation the instruments should be kept in a normal salt or soda solution. After the instruments have been used they should be brushed thoroughly with hot water and soap, after which they are wiped dry with a sterile towel or gauze, and, after wiping them once more, they are returned to their proper places in the aseptic canvas cover. In emergency cases the instruments can be sterilized by boiling in soda solution without removing them from the canvas cover.

Aseptic Sponges.—Nussbaum has well said: "The disinfection of hands, instruments, and sponges is the most important thing in the whole antiseptic treatment of wounds."

Fig. 106.—Jar of aseptic sponges.

For many years the surgeons sought for a cheap and safe wiping material for wounds. Sea-sponges, so extensively used before antiseptic precautions were known, have been regarded with great suspicion since. Nussbaum did not entertain the fear of the sponge to the same extent as most of his contemporaries, and had no hesitation in placing himself on record to that effect. He believed that infected sponges could be sterilized and made safe by washing them thoroughly with hot water and potash soap and by immersing them for one or two minutes either in 5 per cent. solution of carbolic acid or a 1 : 1000 solution of bichlorid of mercury. This favorable view of the employment of sea-sponges in every-day surgical practice would find few, if any, supporters to-day, as it is well known that the indiscriminate use of sponges in different operative procedures is attended by many risks that can not be avoided even after what might appear to us as thorough antiseptic treatment of the sponges after each operation. Sea-sponges have been discarded to a great extent, but they can not be entirely dispensed with, as they serve a most useful purpose in operations in the cavity of the mouth, resection of the upper maxilla, staphylorrhaphy, partial resection of the pharynx, amputation of the tongue, and many abdominal and pelvic operations. Some surgeons have claimed that disinfection of sea-sponges is an easy matter. Nussbaum quoted Kümmel's convictions when he expressed himself on this subject, but extensive clinical experience has shown that this is not so. Thorough cleansing and prolonged

immersion in a strong antiseptic solution are necessary for their sterilization. It is for this reason that surgeons have found it necessary to use certain sponges, preserved in glass jars containing the solution and bearing a label indicating the operating day (Fig. 106). Used in this manner the sponges are thoroughly washed after each operation, and remain in one of the strong antiseptic solutions for a week. Even after such prolonged immersion anthrax bacilli and other micro-organisms enveloped by fat have been found in an active condition in the sponges.

Ordinary commercial formalin affords a convenient means for the complete sterilization of sea-sponges. After the sponges have been freed from foreign matter, washed, and dried in the usual way, they are to be placed in wide-mouthed glass jars with well-ground glass stoppers and a sufficient quantity of the formalin poured over them to moisten them thoroughly. A portion of the fluid settles in a layer at the bottom, while formaldehyd gas and watery vapor fill the upper part of the jar, penetrating every fiber of the sponge. After two or three days they are ready for use. When wanted, the sponge is removed from the jar with forceps, to avoid injury of the hands, and well rinsed in warm, not hot, sterile water to remove all the formalin, which is injurious to the tissues. They should then be placed in warm normal salt solution for use. Experiments made by Colonel W. H. Forwood, U. S. A., in 1892 with dirty sponges from the dead-house and kitchen at the Barnes Hospital, Washington, D. C., proved the effectiveness of this method. The usual laboratory tests showed no living organism after forty-eight hours in formalin solution of 40 per cent. formaldehyd. Six years' constant use of sponges prepared in this way in the practice of Colonel Forwood has given perfect results, without a single case of infection from that source. The formalin does not impair the hygroscopic qualities, neither does it injure the texture of the sponges.

Sterilization of sponges in a solution of permanganate of potash, 1 : 500, has been found quite satisfactory. After thorough cleansing and washing they are kept in this solution for twenty-four hours, and are subsequently bleached by treating them in a 1 per cent. solution of sulphate of soda, to which is added 8 per cent. of muriatic acid. They are then again washed and kept ready for use in a 5 per cent. solution of carbolic acid. Even after so tedious a process of disinfection Frisch found 20 per cent. of the sponges prepared by this method in Billroth's clinic somewhat defective from a bacteriologic standpoint. Sponges can not be made sterile by dry heat, steam, or boiling without great damage to their texture. According to Schimmelbusch, the following procedure has yielded the most satisfactory results : The sponges of good quality are first carefully cleansed, to rid them of foreign material of any kind, after which they are kept for some time in cold water, and are occasionally squeezed and kneaded. Sponges that have been used

are thoroughly washed, first in cold, and then in warm, water. The sponges are then squeezed dry, placed in a bag, and immersed in a boiling 1 per cent. solution of soda. As sponges can not be boiled without destroying their usefulness, the kettle containing the boiling solution is taken from the fire shortly before the sponges are immersed. After remaining in the solution for half an hour they are sterile, and after being squeezed dry the soda is washed out in cold sterile water, when they are immersed in the antiseptic solution, where they remain ready for use. Before their use the antiseptic is washed out in cold sterile water. Schimmelbusch found that sponges containing anthrax bacilli were absolutely sterile after immersion for ten minutes in the hot soda solution.

During the operation the blood is washed out in warm normal salt solution as often as becomes necessary. After the operation they are washed in soda solution and again immersed in a 5 per cent. solution of carbolic acid for a week. After use in septic cases it is advisable to throw them away. During a laparotomy or other

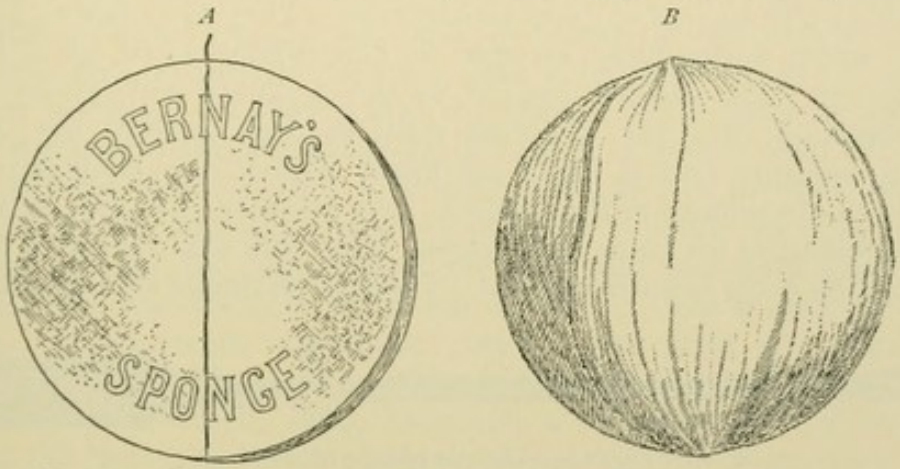

Fig. 107.—Bernay's sponge: *A*, Natural size; *B*, dropped in water.

operations, when the wound is a deep one, as in resection of the hip-joint, cleaning out of the axilla, etc., if sponges are used, they should be counted before and after the operation, for the purpose of guarding against leaving any of them in the wound. The same precaution is necessary in the use of gauze compresses as substitutes for sponges.

Sponges have become a more important feature in the operating room since surgeons have abandoned irrigation of recent wounds. Some form of sponge is now relied on almost exclusively in cleaning the wound of blood. Many substitutes have been suggested for the sea-sponge in surgery. All wiping material used in place of sponges must be hygroscopic, sterile, and inexpensive. Pledgets and small compresses of gauze are used most extensively at the present time, both in hospital and private practice. The gauze should be cut evenly into pieces of convenient size with a large pair of tailor's scissors; when loosely rolled or folded they bear a resemblance to small sponges. As these gauze wipers are thrown

aside as soon as they become saturated with blood, a large number must be kept on hand in performing extensive and bloody operations. Dr. Bernay, of St. Louis, uses discs of aseptic compressed cotton as substitutes for sponges. The cotton, properly prepared, is subjected to several hundred pounds of pressure, cut in circular form with a die, and presented for use in the shape of a compressed disc about $\frac{1}{16}$ of an inch in thickness, and of two sizes: the small 1¼ inches, and the large 1½ inches, in diameter (Fig. 107). The absorbing power of these cotton sponges is much higher than that of gauze, ordinary absorbent cotton, or sea-sponge. They absorb twelve times their weight of fluid. These sponges were used quite extensively during the Spanish-American war and gave good satisfaction. They recommend themselves more particularly for use in emergency work, as a large number of them can be carried in the ordinary emergency bag. An objection, however, presents itself to their general use, as in wiping wounds cotton fibers are liable to become detached and remain undiscovered in the wound. As cheaper, but less satisfactory, substitutes for gauze and cotton, moss and wood-wool in small gauze bags have been employed. From a technical standpoint sea-

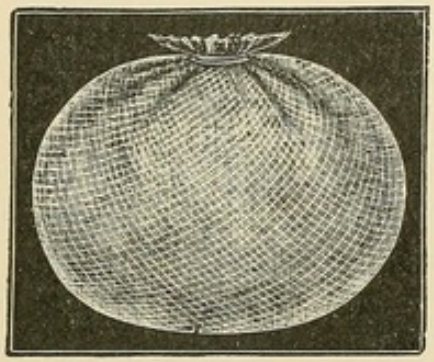

Fig. 108.—Gauze sponge.

Fig. 109.—Hart's sponge holder.



Fig. 110.—Sims' sponge holder.

sponges deserve preference; their great hygroscopic capacity, elasticity, and pliability are unexcelled. On the other hand, asepsis is more uncertain when they are used repeatedly. Good sponges are expensive, and sponges of poor quality are inadmissible in modern surgical practice.

ASEPTIC AND ANTISEPTIC DRESSING MATERIAL.

The modern wound dressing is intended to protect the wound against infection after the surgeon has completed his work. One of the great advantages of the dressings as they are applied to a recent wound to-day is that the first dressing remains until the wound is healed, thus securing for the injured part rest during the entire process of repair. The old methods of wound dressing with cold-water compress, lint, charpie, salves, plasters, and poultices often

made an hourly, and certainly a daily, change necessary. This could not fail to disturb the wound, causing pain, and often preventing necessary sleep. The full import of the advances made in wound dressing is not yet fully realized by the public in general, as they have become imbued with the necessity of frequent change of dressing, the result of a practice that dates back to the time when wounds were first made and treated. The belief in healing salves and balsams still prevails. Many patients whose wounds are not dressed every day feel that they are neglected, and regard with envy the nearest neighbor whose septic wounds receive daily attention. The salve-box, spatula, baskets of lint and charpie, pewter syringes, and slop-buckets that made their regular daily rounds through all hospitals less than a quarter of a century ago have happily disappeared from the surgical arena, never to return. The ideal dressing material is hygroscopic sterile or antiseptic gauze. For years surgeons were in the habit of impregnating the gauze with some antiseptic. The antiseptics that have been employed most extensively for this purpose are carbolic acid, bichlorid of mercury, iodoform, salicylic acid, cyanid of mercury, and boric acid. Lister's original gauze was made by forcing into the meshes of the gauze a hot mixture composed of crystallized carbolic acid one part, resin five parts, and paraffin seven parts. The resin was used to prevent evaporation of the carbolic acid, and the paraffin to make the dressing adhesive. Later the bichlorid of mercury and iodoform gauze, prepared after the formula proposed by Bruns, had a very extended trial. Hygroscopic antiseptic cotton came into use later, and remains popular with the profession to the present time. Jute, oakum, moss, earth, sand, sawdust, wood-wool, and filter-paper have all been tried, but of these only moss and wood-wool have given sufficient satisfaction for the continuation of their employment, especially in the hospitals of Germany.

Romberg has made some very interesting experiments to determine the hygroscopic capacity of the following dressing materials. He took ten grams of each, weighed them again after complete saturation, and arrived at the following results.

Ten grams of dressing material weighed when fully saturated:

	GRAMS.		GRAMS.
1. Hygroscopic cotton,	250	6. Peat,	82
2. Cell-fabric cotton,	230	7. Poplar sawdust,	73
3. Wood-fabric cotton,	150	8. Jute,	70
4. Wood-wool,	106	9. Pine sawdust,	53
5. Gauze,	96	10. Coal-ashes,	21

According to Fehleisen, cotton absorbs twice, and according to Neuber three times, as much as gauze. In this country, with few exceptions, gauze and cotton constitute the materials which are relied upon in dressing a recent wound requiring an absorbent dressing. Superficial small wounds and wounds that do not secrete do not require an absorbent dressing. Such wounds are sealed hermetically with collodion. The best way to seal such a

wound is to apply a strip of iodoform gauze that slightly overlaps the margins of the wound, and then brush collodion over it; the next layer is a little larger, and is again sealed in place with collodion, and over this a third strip again overlapping the second is placed and saturated with collodion, and finally a thin layer of absorbent cotton is fastened in a similar manner over the last piece of gauze. The crust that forms seals the wound hermetically and should not be removed until the wound is healed. To facilitate the removal of the crust and to guard against stitch abscesses it is advisable to bury the sutures under borosalicylic powder before applying the collodion crust. Medicated gauze is not used to the same extent as formerly. In the dressing of wounds that have been drained and that are expected to secrete profusely, borosalicylic acid dusted into the meshes of the gauze is one of the most efficient antiseptics in preventing putrefaction of the wound secretions in the dressings. Gauze and cotton used as dressing materials must be rendered hygroscopic and sterile, and in dressing aseptic wounds the material must be dry. In such cases the dressing is expected to absorb the wound discharges and to act as a filter for the microbes from without. The dressing must be absorbent and occlusive. In size it must vary with the dimensions of the wound and the amount of wound secretion to be expected. It is a very common mistake to make the dressing too small. It should be made to extend a safe distance from the wound and to include the whole disinfected field. The gauze must be applied loosely and not in layers, as loose gauze absorbs more freely and can be made to fill in irregular surfaces much more readily than by using gauze in the form of compresses. Around and over the gauze is placed a thick cushion of absorbent cotton, and the dressing is confined in place by a gauze roller instead of the ordinary muslin roller. I long ago abandoned the muslin bandage in the dressing of all wounds. The gauze roller, from two to four layers in thickness, is more elastic, and as it is hygroscopic and sterile, it constitutes a part of the dressing. The best iodoform gauze is sterile gauze into the meshes of which iodoform is dusted. To fix the iodoform in the gauze the latter should be moistened with sterile water before it is iodoformized.

The general practitioner should obtain his dressing material from some reliable manufacturing firm, but in important operations it is advisable to resterilize, as Schlange and others found bacteria in antiseptic gauze that was obtained from different sources in the open market. The surest way to sterilize the dressing material is by steam; steam sterilization can be relied upon in rendering the material absolutely sterile. The steam to be effective must be saturated—that is, all air must be removed and replaced by steam; consequently the sterilization must be done in a closed space. The Boeckmann sterilizer is the one which the general practitioner will find most economic, convenient, and effective, as it is constructed

upon the principle that oversteam is more powerful in penetrating the dressing uniformly than understeam. Preliminary heating of the material is important in rapid sterilization. Lister aimed to exclude bacteria from the dressing by applying over it mackintosh cloth; others have used gutta-percha tissue, waxed paper, or a thin sheet of rubber for the same purpose. This part of the dressing has been abandoned, as it is the intention now to keep the dressing dry, thus securing one of the conditions retarding germ growth. Neuber long ago emphasized the importance of dry dressings in the treatment of recent wounds. The most recent method of dressing is no longer an occlusive dressing, in the sense in which Lister and Volkmann used this term. The microbes from without have free access to the dressing, but the material of which it is composed, especially the cotton over and around the gauze, constitutes an efficient filter.

In the absence of proper dressing material in emergency work the surgeon can extemporize a dressing that will answer the purpose from an aseptic standpoint. Linen sheets, towels, napkins, etc., can be made hygroscopic and sterile by boiling for ten minutes in soda solution, after which the soda is washed out in sterile cold water. By forcible wringing it is made practically dry, and of the material thus prepared wipers, bandages, and gauze can be made. Cheese-cloth can be prepared in the same manner. If time permits, the drying of the material can be completed by placing it on sterile pans for a few minutes in the oven of the kitchen stove. If the dressing becomes saturated with blood or serum at any particular point, it is not necessary to remove it, as was formerly done. The saturated area should be dusted freely with borosalicylic powder, and a cushion of absorbent cotton applied over it and held in place by a gauze bandage. In the absence of more urgent indications the dressing should remain until the drainage-tube has been removed—at the end of the second to the fifth day. The wounded part, if it is one of the extremities, should be placed in an elevated position, at an angle of 45 degrees, for at least twelve to twenty-four hours, and properly immobilized. Splints are not used as frequently as they should be in the treatment of wounds of the soft tissues. Immobilization of the part injured or operated upon constitutes an important part of the wound treatment, as it aids the sutures in maintaining the wound surfaces in uninterrupted contact, and secures rest, an essential condition in the speedy and satisfactory healing of the wound. A few turns of the plaster-of-Paris bandage over the dressing will often answer the purpose, and, at the same time, will also prove of great service in keeping the dressing in close contact with the skin and guarding against its displacement. In large wounds of the lower extremities a splint will be found necessary to insure rest for the wounded part. The first dressing remains as long as it answers the indications for which it was applied, or until the drain must be removed or indications of infection present themselves. In a

wound that has not been drained it remains until the sutures must be removed,—that is, a week or two, according to the size and nature of the wound,—unless signs and symptoms of infection necessitate earlier interference. Frequent unnecessary changes of the dressing interfere with the conditions necessary for an ideal wound healing, and always expose the wound more or less to post-operation infection.

In wounds that have been drained and that secrete profusely, the dressing soon becomes saturated, especially in places to which the fluid drains most frequently, and unless the surgeon acts promptly, the dressing may become a source of infection by microbes from without, the wound secretion answering the purpose of a nutrient medium for their reproduction and dissemination. One of two things becomes necessary, either to remove the dressing and replace it by another, or to disinfect the surface of the saturated area and apply over it a hygroscopic aseptic compress of cotton. If the saturation appears soon after the dressing is applied and is extensive, the former course is the safer one to pursue. In the latter case the moist surface is freely sprinkled with the borosalicylic powder, and a compress of absorbent cotton is applied and held in place by a gauze bandage. For the purpose of minimizing the quantity of wound fluids it becomes necessary to secure complete hemostasis, to apply a large absorbent dressing, and to keep the wounded part in an elevated position for at least from twelve to twenty-four hours. If an early change of dressing becomes a necessity, it is sometimes advisable not to expose the wound, by leaving a limited part of the dressing over it and covering it well with the new dressing. Severe pain in the wound and indications of the existence of infection always demand removal of the entire dressing to enable the surgeon to inspect the wound and seek for and remove the cause of pain. Should the wound be found infected, the necessary changes in its treatment should be instituted to meet the indications presented by the infection. Renewal of the bandage over the dressing often becomes necessary to insure accurate contact between it and the surface of the skin.

ANTIPYOGENIC AGENTS.

After Pasteur's discovery in 1860 of the causes of putrefaction, surgeons rapidly made use of the knowledge thus gained in their work to combat wound infection. Lemaire was the first one to practise antiseptic surgery knowingly and intentionally, but his clinical observations were insufficient, and the principle was lost in France. Neudörfer planted the new idea in Germany and Gamgee in England. Lister combined the ideas of others, and, after reducing them to a scientific whole by his own untiring work, laid the foundation of a new era in surgery.

The first efforts directed toward the prevention of wound infection consisted exclusively in the use of chemic agents that were

known to be destructive to animal and vegetable life. The atmosphere was regarded as the most important medium for the diffusion of the micro-organisms that were supposed to be suspended in the air, and were regarded as the cause of the putrefactive processes in infected wounds. Lister's spray and the occlusive dressings were the outcome of this very theory regarding the cause of wound infection. Bacteriologic researches since that time have demonstrated the microbic cause of nearly all of the infective processes that the surgeon is called upon to treat. It has been shown, further, that the danger of wound infection arises more from contact than from the microbes suspended in the lower strata of the atmospheric air. The value of the use of chemic disinfectants as antipyogenic agents has been greatly overestimated, and their place has been largely taken by mechanical cleansing and the employment of heat as a germ destroyer. Many surgeons at the present time exclude from their practice the use of all so-called bactericidal agents and achieve good results. Very few surgeons, indeed, continue the practice of irrigating fresh wounds with antiseptic solutions, a very common procedure during the early history of antiseptic surgery. Experimental research as well as clinical observations have demonstrated conclusively that irrigation of a recent wound with any of the stronger antiseptic solutions is not only superfluous, but harmful, as it increases the amount of wound fluids and damages the tissues exposed to the direct action of the antiseptic used. In the treatment of recent injuries and in making preparations for aseptic operations antipyogenic measures are employed at the present time more for the purpose of preventing the ingress of pathogenic microbes into the wound than with the intention of destroying them after they have entered the wound. With such an object in view the employment of antiseptics has a wide range of usefulness that will probably never be entirely abandoned. Different ways and means are now resorted to in the struggle against microbes that threaten every recent wound. Among these we may enumerate :

1. Mechanical measures calculated to remove bacteria by washing, scrubbing, scraping, and shaving.

2. Bactericidal agents which destroy the microbes by heat or chemic action.

3. Inhibitory remedies which do not kill the microbes, but which destroy their power of reproduction in the tissues.

4. Antitoxic agents which prove useful by neutralizing the toxins without exerting any particular destructive effect on the microbes that produced them.

5. The employment of remedies not directed against the microbes or their toxins, but which are intended to antagonize their pathogenic action by increasing the resistance of the tissues and the body.

The mechanical removal of microbes from the hands, the surface of the body, and instruments constitutes the most important anti-

pyogenic measure in the treatment of recent wounds and in making preparations for an aseptic operation. Mechanical cleansing of everything that is to be brought in contact with the wound prepares the way properly for subsequent disinfection and sterilization. The importance of this part of the technic of asepsis can be readily appreciated and fully understood since the tangible cause of infection is known to consist in the presence in the wound of minute living vegetable organisms. The simple cleansing with warm water and potash soap is the preparatory act of each disinfection, and the most pedantic cleanliness on the part of the surgeon and his assistants constitutes three-fourths of what is essential to the prevention of infection. A high temperature in the form of dry heat, steam, or boiling water is relied upon almost exclusively at the present time in effecting sterilization, and alcohol, carbolic acid, and bichlorid of mercury are the antibactericidal agents most frequently resorted to for hand and surface disinfection.

Toussaint and Chauveau have demonstrated by their experiments that it is possible to render anthrax bacilli harmless by exposing them to a temperature of from 40° to 55° R. Exposure to this temperature does not destroy the bacilli, but deprives them of their pathogenic properties. Since that time mitigated cultures have been employed as therapeutic agents in the treatment of divers infective diseases. The researches of Behring and Kitasato have shown that blood-serum under some circumstances possesses the property of destroying certain bacterial products outside and inside of the animal body. It has been ascertained further by Charrin that the toxins of the bacillus pyocyaneus are capable of creating an immunity in rabbits and dogs against the ordinary pus-microbes. Among the infective wound diseases in man there is only one—hydrophobia—which may be prevented after infection has occurred by the employment of an antitoxic remedy. This antitoxin was obtained by Pasteur from the spinal cord of rabid rabbits, made safe and effective as a prophylactic therapeutic agent by a process of mitigation consisting in a somewhat complicated process of desiccation of the fresh material. Iodoform, the most reliable antibacillary remedy known at the present time in the local treatment of tubercular affections uncomplicated by pyogenic infection, does not destroy the bacillus of tuberculosis, but exerts an inhibitory action and neutralizes its toxins. It is undoubtedly to the latter effect that it owes its decided therapeutic properties.

ANTISEPTICS.

Antiseptics are all chemic substances that have been used to destroy or render harmless pathogenic microbes that are known to be causes of infection. *Asepsis is the precious, hard-earned reward for faithful antiseptic labor.* The first bactericidal agent employed in surgery for the purpose of destroying the cause of wound infection was carbolic acid. It still holds an enviable place among the anti-

septics in use at the present time, but a long list of substitutes has been introduced into practice, numbers of which have proved themselves formidable competitors. The virtues of the different antiseptics have been ascertained experimentally by the treatment of pure cultures. Silk threads contaminated with pure cultures and exposed to the action of the different antiseptics have formed the basis for such experiments. It was soon ascertained that the spores are much more resistant to the action of antiseptics than the microbes themselves. The surgeon has to deal with these spore-bearing microbes,—the bacillus of anthrax, tuberculosis, and tetanus,—and always takes the spore-bearing microbes into consideration in selecting the antiseptic and in grading its strength in the treatment of the diseases to which they give rise. The sporeless microbes most frequently met in surgical practice are the ordinary pus-microbes, the staphylococcus, the streptococcus pyogenes, the streptococcus erysipelatis, the bacillus mallei, the bacillus of diphtheria, and the colon bacillus. Of all known microbes, the anthrax bacillus and its spores are most resistant to all germ-destroying agents, and hence this microbe is usually taken as a standard in estimating the bactericidal properties of the different antiseptics employed in surgical practice. It must not be forgotten that the same organism under different circumstances varies considerably in its resisting power.

Difficulties are encountered in testing the antiseptic properties of different chemic substances, as unless great care is exercised, some of the antiseptic solution used for disinfection is conveyed with the contaminated thread to the culture-medium. Geppert, for the purpose of eliminating this source of fallacy, chemically neutralized the antiseptic employed before transferring the thread to the nutrient medium.

In the fifth edition of his classic treatise, "A Guide to the Antiseptic Treatment of Wounds," published in 1887, von Nussbaum discussed eighty antiseptics that had come into use up to that time. The list has grown materially since then, but a visit to any of the large hospitals would furnish ample proof of the fact that but few of the many antiseptics proposed have stood the test of experience. The well-known toxic properties of the two most reliable antiseptics—carbolic acid and corrosive sublimate—have induced surgeons to seek for and use antiseptics that would be less objectionable and at the same time similarly efficient in the prevention of infection. The antiseptics entitled to confidence are the following, arranged in alphabetic order :

Acetate of aluminum is a nontoxic and highly valued antiseptic. It can be used in large quantities without fear of intoxication or local irritation. Pinner has shown that a 2½ per cent. solution arrests the development of microbes in twenty-four hours. As it injures instruments and roughens the hands, it is not used in operations. Its use is almost entirely limited to the treatment of

infected wounds, either in the form of a hot, moist compress wrung out of a saturated solution, or for continuous irrigation. For the latter purpose it has no equal. A 1 per cent. solution can be made by mixing twenty-four grams of alum and thirty-eight grams of acetate of lead with one quart of sterile water. In the treatment of suppurative arthritis, suppurating compound fractures, and extensive phlegmonous inflammation permanent irrigation with a saturated solution is absolutely safe and most effective.

Alcohol.—Alcohol is a reliable antiseptic, and as such is used at the present time the world over. Its antiputrefactive effect has been demonstrated for a long time in the museums in the preservation of organic material of all kinds. The antiseptic properties of wine and the different concentrated alcoholic liquors of all kinds depend on the amount of alcohol they contain. Its external use is not attended by any danger from absorption in toxic quantities, through the skin or granulating surfaces, by prolonged or extensive application, and it is therefore applicable for hand and surface disinfection under all circumstances, regardless of the age and general condition of the patient. Additional advantages are that it is obtainable in almost all localities, and does not lose its antiseptic properties by age, as is the case with many of the more potent antiseptics. It is generally used in full strength. Its solvent action on fatty substances enhances its disinfecting power.

In his last paper on hand disinfection, read before the American Surgical Association in 1899, Kocher makes the statement that alcohol is the only antiseptic he uses, and there are many other surgeons who have the same degree of confidence in its disinfecting quality. In my practice also the local use of alcohol has been found very effective in the treatment of erysipelatous inflammation and other forms of acute superficial lymphangitis.

Boric acid is a mild, nontoxic antiseptic. It is soluble in water in the proportion of 3.5 : 100. It was introduced into surgery as an antiseptic by Lister. In combination with salicylic acid it constitutes one of the antiseptics in Thiersch's solution, which has a most extended field of usefulness in surgery. Thiersch's solution is composed of salicylic acid 2 parts, boric acid 12 parts, and water 1000 parts. Boric acid in powder is frequently used in dry dressings for recent wounds ; in solution it serves as a mild disinfectant for mucous cavities, as a local application by moist, hot compress in the treatment of infected wounds, and as a valuable, clean substitute for poultices in the treatment of dermatitis and phlegmonous inflammation.

Bromin is a powerful antiseptic, and was used quite extensively in the concentrated form during the Civil War in the treatment of hospital gangrene. A solution of ¼ of 1 to 1 per cent. made with potassic bromid is a valuable deodorant and disinfectant in the treatment of moist gangrene and profuse suppuration when used as an antiseptic in moist dressings or for irrigation or injection.

Camphor.—Camphor preparations have been used for a long time as preservatives. The antiputrefactive action of camphor is generally recognized. Gangrenous ulcers improve rapidly under the local use of pulverized camphor. It is a potent cardiac stimulant, and one of the most reliable of the long list of antaphrodisiac remedies.

Carbolic acid is intimately associated with the origin and development of antiseptic surgery, as it was the first antiseptic used by Lister, and no other antiseptic has been able to displace it entirely. In the concentrated form its action is caustic. The strength of the solutions employed has varied from 1 to 5 per cent. It is a strong poison. It is rapidly absorbed from the mucous surfaces and more slowly from the skin. The rapidity with which it is absorbed by mucous membranes and serous surfaces contraindicates its use in the rectum, peritoneal and pleural cavities, and vagina. During the time the carbolized spray constituted so important a part of the antiseptic technic many cases of severe intoxication, and not a few deaths, occurred from its use in that manner. Copious irrigation of large wounds with strong carbolic acid solutions and the prolonged use of moist carbolized compresses have not infrequently been followed by similar results. The smoky urine so frequently seen when carbolic acid was in daily use was a familiar demonstration to every surgeon of the rapid absorption of this antiseptic through mucous membranes, skin, wound, and ulcerated surfaces. Children, the aged, and patients suffering from renal disease are particularly susceptible to the toxic effect of carbolic acid. I am familiar with a case in which death resulted in a few hours from acute intoxication from the application of pure carbolic acid to a small wound inflicted by a dog, the patient being a young boy. Dilatation of the pupils, striking pallor, subnormal temperature, cyanotic lips, an extremely rapid paralytic respiration, and a feeble pulse are the most prominent symptoms of acute carbolic acid intoxication. Some persons are extremely susceptible to the toxic action of carbolic acid, and as the existence of such an idiosyncrasy can not be predicted, caution in the employment of this antiseptic is always necessary. In young children, marasmic subjects, and persons the subjects of renal disease it should not be used to any extent. For general use the strength of the solution should not exceed 2½ per cent. I have seen serious results, and in one case death, follow injection of a few drops of pure carbolic acid into the sac after tapping for hydrocele. Carbolic acid has also, under certain unknown conditions, a decided local toxic effect. Gangrene of a finger has been repeatedly seen after the local use of carbolic acid in the treatment of trivial affections or insignificant injuries. Another very distressing result of the local use of carbolic acid, even when a weak solution is used, is acute dermatitis. This ill effect has been attributed by Nussbaum and others, so long as the original Lister gauze was in use, to the action of resin or paraffin, but acute in-

flammation of the skin has been seen following the application of carbolized solutions since the adhesive gauze has been abandoned. If the surgeon decides to use carbolic acid as an antiseptic, it becomes an important duty on his part to be on guard for signs or symptoms that announce the incipient stage of general or local intoxication, and in such an event at once to remove what can be secured of the antiseptic and substitute for it a safer one.

Chloral hydrate is an antiseptic of some value in the treatment of chronic irritable ulcers. Concentrated solutions act as caustics. For a moist antiseptic dressing a 1 per cent. solution will answer a useful purpose, possessing antiseptic and anodyne properties.

Chlorid of lime was used by Nussbaum in the treatment of wounds as early as 1860, and the results were better than those from any other remedy. Chlorin water retains its reputation in counteracting putrefaction in the treatment of foul ulcers and sloughing, fetid, open carcinoma. Chlorid of lime is still preferred by some surgeons to any other antiseptic for hand disinfection. After washing and cleansing the hands in the usual way, a crystal of sulphate of soda is placed on the palm of one hand, and, after rubbing the moistened surfaces for some time, the rubbing is continued by using chlorid of lime, after which the hands are cleansed in sterile water. R. F. Weir is a strong advocate of this method of hand disinfection.

Chlorid of sodium in the strength of normal blood-serum is a very mild antiseptic, and has at the present time the most extensive use in the treatment of recent wounds. The normal salt solution, $\frac{7}{10}$ of 1 per cent., is now in constant use for cleansing recent wounds and the field of operation, and has, for good reasons, almost entirely taken the place of sterilized water in the operating room. This solution does not damage the tissues like sterile water, and consequently its contact with recent wound surfaces does not interfere with an ideal process of repair.

Chlorid of zinc is one of the strongest caustics, and as such has been used for a long time in removing malignant and other tumors. Lister recommended an 8 per cent. solution for the disinfection of infected wounds, and for such an indication its employment has proved more successful than that of any other antiseptic. I have always used a 10 per cent. solution, and have found it to be the most valuable antiseptic for secondary disinfection. The solution is applied to the surface of the wound after thoroughly cleansing and drying it with a cotton swab, with which every nook and corner is brushed over gently, so that the solution comes in contact with the whole infected surface. Enlargement of the wound often becomes necessary for a more thorough application of the antiseptic, and this is more especially important in the secondary disinfection of an infected compound fracture. As a solution for recent wounds it has been used in the strength of $\frac{1}{5}$ of 1 per cent. to 5 per cent., but since antiseptic irrigation of recent

wounds has been abandoned, chlorid of zinc is seldom used in aseptic operating rooms.

Chromic acid is said to be twenty times stronger as an antiseptic than sublimate, and ten times stronger than carbolic acid, and yet it has not found its way to any extent into surgical practice. Its most extensive use has been in the preparation of catgut, which by its action is made more durable, as was first shown by Lister.

Corrosive sublimate is the mercurial preparation that has had the most extended use and that has given the best satisfaction as an antiseptic in the practice of surgery. Koch called attention to the potent antiseptic properties of bichlorid of mercury by his experiments, which demonstrated that the bacillus of anthrax is destroyed by a solution of 1 : 20,000 of water, and the growth of the same microbe is inhibited by a solution of 1 : 300,000 of water. Von Bergmann introduced it first as a surgical antiseptic, and the classic paper of Kümmel secured for it a speedy and extensive trial by the profession in all countries where antiseptic surgery is practised.

Corrosive sublimate is incompatible with all metallic substances ; it has therefore never been used for the sterilization of instruments, and for the same reason the solutions must be kept in glass, porcelain, japanned, or wooden vessels. It is one of the most potent antiseptics known, but, unfortunately, it is at the same time also a very dangerous poison. Like carbolic acid, it is readily absorbed through mucous membranes and even through the intact skin. It is never used in disinfecting mucous passages, and care is necessary in its use for hand and surface disinfection. The health of many surgeons has been permanently impaired by the frequent use of strong solutions for hand disinfection, and many severe intoxications have resulted from its local use in the treatment of wounds. Its use is contraindicated in the case of infants and young children and in patients the subjects of advanced renal disease. Its local toxic effects are manifested by itching, burning sensations, and dermatitis, which often extends beyond the surface to which the solution was applied, and frequently terminates in the formation of blisters.

The symptoms that denote general intoxication consist in dizziness, restlessness, prostration, vomiting, inflammation of the mucous membrane of the mouth, bleeding from the swollen gums, salivation, bloody diarrhea, colitis, proctitis, tenesmus, nephritis with fatty degeneration and calcification of the tubuli uriniferi, which in many instances have resulted in death. As soon as the first symptoms of local or general intoxication appear, the further use of the remedy must be promptly suspended and as much of the antiseptic as can be reached must be removed, and in its place a milder and safer preparation substituted. The gastro-intestinal irritation must be allayed by appropriate remedies and a milk diet combined with egg-albumen.

For hand and surface disinfection a solution of 1 : 1000 of water

is usually used. It is advisable to color the solution with anilin blue, so that it can not be mistaken for water. In my practice the carbolic acid solution is colored a light red with eosin, and the normal salt solution yellow by adding a few drops of the tincture of curcuma.

Corrosive sublimate has been used very extensively in catgut preparation and in the manufacture of antiseptic gauze and cotton. When brought in contact with the alkaline wound secretions it enters into a chemic combination with the albumin, forming an inert albuminate of mercury. With a view to preventing this chemic change Laplace recommended the addition to the bichlorid solution of tartaric acid in the following proportions: Bichlorid of mercury 1 part; tartaric acid 5 parts; water 1000 parts, a formula that has been extensively adopted and that has given great satisfaction. The toxic effect of the bichlorid is diminished by adding to the solution chlorid of sodium, which favors the formation of albuminate of mercury and increases the hygroscopic capacity of the dressing material. Distilled or at least soft water must be used for the solution. For the more ready and accurate preparation of the solution Angerer devised tablets composed of fifteen grains each of bichlorid of mercury and chlorid of sodium, colored with eosin, which are admirably adapted for military and emergency practice. For ordinary use in aseptic surgery a solution of 1 : 1000 is usually employed, although the prolonged use of a much weaker solution, 1 : 5000, will answer the bacteriologic requirements.

Creasote.—Creasote had been used to a considerable extent in the treatment of wounds before carbolic acid was known. It was used with signal success during the Civil War in the treatment of hospital gangrene. It is a very potent antiseptic, but has been almost entirely displaced by carbolic acid in surgical practice.

Creolin, like carbolic acid, is a product of coal-tar, and has been used as a substitute for the latter. It was claimed that it possessed all the virtues of carbolic acid minus its toxic effects. These assertions are not supported by experience, and it is seldom used in surgery at the present time. Mixed with water it forms a milky fluid. As a local application it is used in the strength of 1 or 2 per cent.

Formic Aldehyd ($CH_2O = HCOH$).—Formic aldehyd was first obtained by Hoffmann by the slow combustion of methyl alcohol ($CH_3 . OH$), brought about by a spiral of platinum wire ($CH_3 . OH + O = H_2O + HCOH$). It was also produced by distillation of barium or calcium formate,

$$Ba(COOH)_2 = BaCO_3 + HCOH.$$

Formic aldehyd is a gas at ordinary temperatures. On standing it gradually polymerizes into paraformaldehyd, a crystalline solid consisting of three molecules of the aldehyd condensed into one molecule,

$$3CH_2O = C_3H_6O_3.$$

Formic aldehyd is soluble in water and alcohol. It occurs com-

mercially as formalin, representing its aqueous solution, containing 40 per cent. of the aldehyd.

Formalin when exposed, even at ordinary temperatures, will give off formaldehyd vapors. On allowing formalin to evaporate, either with the aid of heat or without, its vapor will condense and deposit solid paraformaldehyd (polymerized formaldehyd) upon surrounding objects, such as cotton, gauze, bandages, etc.

By the spontaneous evaporation of the paraformaldehyd it is again split up or converted into the gaseous formaldehyd, to act antiseptically upon contiguous objects. Hence formalin has been recommended to the surgeon for cleansing, disinfecting, and deodorizing sponges with a 1 per cent. solution of formaldehyd (10 parts of the 40 per cent. of formalin to 390 parts of water). For cleansing the hands, instruments, etc., a similar solution is recommended. It answers admirably for the preservation of anatomic preparations, as the action of formalin, whether upon living or dead organism, produces a hard, leathery compound with all albuminoid substances. Liebreich emphasizes the use of formalin in the form of vapor for the disinfection of clothing in closed receptacles.

Formalin is regarded as a nontoxic mercuric chlorid (bichlorid of mercury). It is not only to be preferred on account of this nonpoisonous property, but also, by its great penetrability when applied in the gaseous state, as a disinfectant, the vapor having nearly the density of air.

Formalin, when used to disinfect rooms, is regarded as more efficient than carbolic acid, sulphurous acid, chlorin, and bromin. A noticeable fact is that formalin does not tarnish or act on metallic surfaces, and that when deposited as paraldehyd, it will evaporate gradually and thus continue disinfection in a moderate degree.

Hans Avonson ("Deutsch. med. Wochenschr.," 1892) speaks of the remarkable power of formaldehyd in resisting putrefaction, and experiments made with the bacillus of typhus, staphylococcus aureus, anthrax bacilli, etc., demonstrated that a 1 : 20,000 solution of formaldehyd inhibited their development. He found also that one drop of the aldehyd added to 10 c.c. of nutrient bouillon or to 10 c.c. of urine prevented putrefaction.

J. Shahl ("Pharm. Ztg.," 1893), speaking of his results regarding the antibacterial action of formalin and its applicability as a disinfectant, states that there is no other known substance so suitable for disinfection; that even corrosive sublimate (bichlorid of mercury) failed in his experiments to equal the extraordinary destructive power of formalin.

Formic aldehyd is not considered poisonous to human life unless breathed in large quantities and for several hours. The antidote is found in the inhalation of ammonia vapor, which at once converts the aldehyd into the odorless hexamethylenamin,

$$\underset{\text{Formaldehyd.}}{6CH_2O} + \underset{\text{Ammonia.}}{4NH_3} = \underset{\text{Hexamethylenamin.}}{(CH_2)_6N_4} + \underset{\text{Water.}}{6H_2O.}$$

As a deodorant, according to Schmidt, formalin does not disguise the odor, but unites with odorous substances chemically generating inodorous compounds. Formaldehyd is relied upon very extensively in the disinfection of operating rooms and of clothing; and formalin is a valuable antiseptic for sponge and hand disinfection.

Hydrogen peroxid is a perfectly safe and very valuable antiseptic. It is used almost exclusively in antiseptic surgery in the treatment of suppurating wounds and fistulous tracts. Applied to recent wounds its also acts as a hemostatic. Nussbaum attributes its hemostatic effect to the oxygen gas that is liberated so freely when the peroxid of hydrogen comes in contact with the blood and tissues, and which irritates the vasomotor nerves, causing a retraction of the cut ends of the vessels. It is the rapid generation of oxygen when the peroxid is poured into a suppurating cavity that effects so excellent a mechanical cleansing by forcing the pus to the surface from the most remote nooks and corners of the cavity. Injections of peroxid of hydrogen are valuable in locating abscess cavities and in determining their size after they have opened, and often materially aid in making counteropenings in localities difficult of access by distending the cavity. The same procedure can be relied upon in making a differential diagnosis between a complete and an external incomplete rectal fistula. Some caution is necessary in its use, either as a diagnostic or a therapeutic resource, and that is not to expose the suppurating cavity to too much tension by the accumulation of oxygen, as by so doing pus and pus-microbes might be forced into the surrounding healthy tissues and perchance even into the general circulation. Whenever it can be done, it is better to pour than to inject the peroxid into the suppurating wound or abscess, as by so doing the danger from harmful overdistention is entirely avoided.

Iodin has no decided antipyogenic properties, and its present use in surgery is limited almost entirely to operations for tubercular affections. In operations for tubercular glands, joints, and tendon sheaths a 1 per cent. iodin solution is the one preferred for irrigation, if this is deemed necessary, as is the case when the tubercular process for which the operation is performed has terminated in extensive caseation or abscess formation. A solution of this strength has the color of sherry wine, and when brought in contact with the wound acts as a potent tissue stimulant, exciting an active phagocytosis, so important a condition in the prevention of a local recurrence. The same solution can also be used advantageously, with sterile gauze as a moist compress, as a local application in the treatment of flabby tubercular granulations. Trichlorid of iodin in a $\frac{1}{4}$ to $\frac{1}{2}$ of 1 per cent. solution as an injection has been used with some success in the treatment of tubercular cystitis.

Iodoform.—The antiputrefactive action of iodoform was well known before this remedy was introduced into general practice by

Mosetig von Moorhof in 1880. As a deodorant, Nussbaum made use of the following formula: Iodoform 10 parts; sulphuric ether 70 parts; distilled water 200 parts, and found it most efficient in correcting the odor in cases of putrefactive infection in osteomyelitic cavities, sloughing ulcers, and ulcerating malignant tumors. Von Moorhof emphasized its antiseptic properties in the treatment of recent wounds, and on his recommendations it soon found its way into the practice of surgeons. More extensive experience soon demonstrated that its antipyogenic properties are quite limited. Rovsing showed by his experiments that pus-microbes continued to grow on nutrient media in the presence of iodoform. All surgeons, however, agree that iodoform applied to a recent wound has a most beneficial effect in diminishing the primary wound secretion, and that it exercises at least an inhibitory effect on the growth of pathogenic bacteria. Iodoform gauze has been used extensively, but at present it is seldom employed as an exclusive dressing for wounds except in special localities. Its use is continued in dressing wounds of the mouth, vagina, rectum, and it is the most desirable material for the antiseptic tampon. Iodoform holds the highest place in the treatment of open tubercular affections, and when applied directly to the tubercular lesions by intra-articular injection, it is almost a specific in certain forms of joint tuberculosis not complicated by pyogenic infection. It is useless in cases of mixed infection. For parenchymatous and intra-articular injections a 10 per cent. glycerin emulsion yields the best results. Iodoform gauze can be extemporized by sprinkling finely triturated iodoform into the meshes of moist sterile gauze. It is also an excellent preparation for rendering catgut antiseptic after it has been sterilized.

The decided toxic effect of iodoform has made surgeons cautious in its use. When Billroth first used it, he often poured two or three drams of the powder into the wound after joint resection and operations on bones, but the numerous cases of serious and even fatal intoxications that have been since recorded have taught us an important lesson. It must always be used sparingly in children and in patients suffering from organic disease of the kidneys. Some persons are also exceedingly susceptible to the local toxic effect of iodoform. A rapidly spreading violent dermatitis is not an exceptional occurrence. I have seen the inflammation start in a small accidental wound treated by iodoform, and in the course of a few days extend over the entire limb and a considerable portion of the body. The itching and burning in severe cases are very distressing. In the treatment of this complication the removal of every particle of iodoform is essential, after which the appropriate local remedies for the dermatitis are indicated. As the individual predisposition to the toxic action of iodoform can not be predicted, the amount of the remedy on first trial should be small, and on the manifestation of the first unpleasant symptoms its further use must

be suspended. Three degrees of general intoxication have been noted. The mildest form is characterized by loss of appetite, nervous depression, and melancholia, while the patients thus affected complain that everything smells of iodoform. The symptoms subside gradually, but the patient does not recover fully for several weeks. The second degree of iodoform intoxication is marked by more alarming symptoms. The patient is mentally depressed for several hours each day for from four to six weeks, does not recognize his relatives, and at times is violently delirious. Even at the end of six weeks, after the patient has apparently recovered, iodoform can be detected in the urine. After a period of quiescence of somewhat indefinite length the original symptoms reappear and continue for another period of from four to six weeks, after which the patient usually recovers, especially if he is treated by stimulants.

Terrible are the symptoms that inaugurate iodoform intoxication of the third degree. One or two days after the operation the patient loses his appetite completely and becomes delirious, the movements become slower and slower, and the speech becomes indistinct; stupor and prostration follow and terminate in death, usually after two or three days. Few, if any, recover from this grave form of iodoform intoxication. We have reason to suspect that many cases of so-called postoperation insanity were in reality cases of iodoform intoxication, and some of the deaths attributed to prolonged shock or sepsis were due to the same cause.

The many substitutes for iodoform that have come into the market do not represent the full antiseptic power and antibacillary action of this drug.

Juniper.—The berries and alcoholic preparations of the needles and wood of the *Juniperus communis* have for a long time been known for their antiseptic properties. Juniper oil is a potent antiseptic, and Kocher has recommended it for the preparation of catgut. Immersion of the raw material in the oil for twenty-four hours was relied upon in effecting its sterilization. Oil of juniper has never been used for any other purpose in antiseptic or aseptic surgery.

Lysol is a soapy fluid very closely resembling creolin chemically. Its antiseptic properties become apparent in a solution of 1 or 2 per cent. The toxic effects are much milder than those of carbolic acid, and as it does not irritate the skin, it is often employed for hand disinfection and for preparing the cutaneous surface for operation.

Peruvian balsam is one of the most valuable of the resinous antiseptics. It was used as an antiseptic in the treatment of wounds by L. A. Sayre and others long before the microbic origin of suppuration was discovered. It is a strong tissue stimulant, and will hasten the process of repair when applied to sluggish, pale, and edematous granulations. Its most beneficial effects are to be seen

in the treatment of tubercular fistulous tracts. Its curative action is enhanced by a preliminary cleansing with peroxid of hydrogen.

Potassium permanganate is a powerful deodorant and antiseptic. It has been used for a long time in solutions of varying strength to correct the odor of moist gangrene, foul ulcers, and ulcerating and sloughing malignant tumors. It has had an extensive trial in conjunction with oxalic acid in hand disinfection, a method which originated in the Johns Hopkins Hospital, and which is still in use in that institution, but is seldom practised elsewhere. This method was relied upon for nearly an entire term in the Rush Medical College Clinic in preparing the hands, but did not prove so satisfactory as alcohol, turpentine, and bichlorid of mercury.

Resorcin is soluble in water, alcohol, and glycerin. It is a safe and an effective antiseptic in solutions of from 3 to 5 per cent. Under its influence suppuration is promptly diminished. The best results are obtained by using it in the form of a hot, moist compress wrung out of a 3 per cent. solution. It has done excellent service as a local application in gonorrhea, cystitis, and various inflammatory affections of the skin.

Salicylic acid is one of the safest and most valuable of all antiseptics known. Its introduction into surgery we owe to Thiersch. It is a white, nontoxic powder that does not decompose on exposure to atmospheric air. The stability of the preparation adds to its practical therapeutic value. It has been used very extensively in the preparation of dressing materials, as it has been incorporated with nearly every substance employed as an absorbent covering for wounds. It is only slightly soluble in water; hence it has been used in the form of an emulsion (1 : 5) when a stronger preparation than a saturated solution was required. A 10 per cent. ointment with vaselin, lanolin, or glycerin is one of the best applications for the toxic dermatitis caused by corrosive sublimate and iodoform. Its solubility and antiseptic properties are increased by combining it with boric acid (Thiersch's solution). Salicylic acid is the remedy *par excellence* for occlusive dressings for stab, punctured, and gunshot wounds.

Salol contains 38 per cent. of phenol. It is insoluble in water. A few drops of a concentrated alcoholic solution added to a glassful of water make a beautiful opalescent fluid which is admirably adapted for disinfection of the teeth and mouth, probably the best preparation for preparing the cavity of the mouth for operation. Like salicylic acid, it is a desirable antiseptic for the occlusive dressing in sealing small recent wounds.

Sulphurous acid is a disinfectant of great value. Mixed with equal parts of water or glycerin it destroys all kinds of bacteria. A 10 per cent. solution is useful for hand and surface disinfection and as a deodorant.

Thymol enjoyed for some time a good reputation as an antisep-

tic in Volkmann's clinic, through the observations and writings of Ranke. It was claimed that a solution of $\frac{1}{10}$ of 1 per cent. was sufficient to protect wounds against infection. Experience, however, soon demonstrated that its antiseptic properties were feeble, and that it could not be relied upon to the exclusion of more potent antipyogenic agents in the prevention of wound infection. It forms an important constituent part of listerine, a preparation that is used quite extensively in this country, in and out of the profession, as an antiseptic. The odor of thymol is pleasant, and $\frac{1}{10}$ of 1 per cent. is an agreeable addition to boric or resorcin solutions as a cleansing solution for the teeth and mouth.

Tinctura benzoini composita is one of the best antiputrefactive preparations, and has proved most efficient in the treatment of oral wounds. If the wound, after excision of the upper jaw or after any other large intra-oral operation, is tamponed with a strip of sterile gauze saturated with the tincture, the packing may remain for a week without any putrefactive changes taking place, which is more than can be said of any other antiseptic in this particular locality. The gauze thus treated is adhesive and, if properly applied, remains in place for any desirable length of time.

Turpentine.—The resin incorporated in salves and plasters is a potent tissue stimulant, and is useful in the treatment of indolent ulcers and in repressing fungous, massive granulations. The oil of turpentine is one of the most valuable antiseptics for hand disinfection and for preparing the field for operation. It dissolves fat, penetrates the skin deeply, reaching its appendages, and can be relied upon in destroying the microbes with which it comes in contact, at the same time not irritating the skin to the same extent as alcohol, carbolic acid, or corrosive sublimate. It is the antiseptic above all others that should follow the use of hot water and potash soap to prepare the way properly for further chemic disinfection. It is, at the same time, a valuable hemostatic. In infected wounds secreting an abundance of thin pus mixed with blood days after the operation, nothing will be found more prompt in its action than the local application of turpentine.

ANTISEPTIC SOLUTIONS.

Heat is the cheapest and most reliable sterilizer. Dry and moist heat are employed almost exclusively at the present time in the sterilization of all kinds of dressing material and instruments. Antiseptic solutions must be relied upon for rendering the hands and the part injured or to be operated upon surgically clean. Our present means for procuring this condition are not sufficiently perfect to deserve the name sterilization, as it must be generally conceded that the most painstaking processes of disinfection do not succeed in procuring absolute asepticity of the skin or of any of the mucous surfaces subjected to any of the known procedures. This confession of weakness on the part of our aseptic precautions should not deter

us from making conscientious use of antiseptics in preparing the hands and the field of operation, as the nearer we approach perfection, the better will be the results. A rigid pedantic disinfection practically results in asepticity in the great majority of cases. Nearly all the antiseptics used in the operating room for disinfection are employed in the form of aqueous solutions. The alcoholic solutions are made use of for the preservation of sterilized ligature and suture material. What is required of an antiseptic solution is not only its known power to destroy or inhibit pathogenic microbes, but it must be at the same time adapted for its practical employment. The disinfection of a wound is something different from the disinfection of a contaminated silk thread, as done in the laboratory to test the potency and applicability of the different antiseptic solutions. No such direct contact of the antiseptic with the microbes can take place in wounds as in the test-tube or on the culture-plate. In the preparation of antiseptic solutions it is important to remember that the menstruum holding the antiseptic in solution, to be effective, should penetrate the tissues deeply. Koch made the statement long ago that solutions in oil are comparatively inert, as they lack the power of penetration. The same objection can be made to aqueous solutions if they are used with the object of destroying microbes enveloped in fat. Experiments have shown that the strongest solutions of carbolic acid and bichlorid of mercury are almost useless if the microbes are protected by the thinnest film of fat. If the contaminated threads are soaked in oil before exposure to the chemic disinfectants, some of the bacteria are found active after days of exposure. These experiments remind us forcibly of the necessity of a careful removal of fat by washing the part injured or to be operated upon, as well as the hands of the operator and assistants, in hot water and potash soap, and of removal of all fatty material that may have escaped the mechanical cleansing, by scrubbing with solvents of fat, such as alcohol, sulphuric ether, or turpentine before making use of the antiseptic solution. *In general practice too much importance is placed upon the germicidal action of the antiseptic solutions, and not enough attention is given to the proper preparation of the parts for the restricted and legitimate action of these solutions.*

Glycerin penetrates the tissues very readily, and should on this account always take the place of oil as a vehicle for iodoform and other substances used for intra-articular and parenchymatous injections. The chemic composition of the substance or material to be disinfected also plays an important rôle in the disinfection by chemic agents. It is not immaterial whether the bacteria are in a dry state or suspended in water, urine, blood, sputum, or feces, as the chemical employed as an antiseptic may form compounds that detract from its disinfecting power. Fat, albumin, blood, and pus constitute serious barriers to efficient disinfection by forming chemic compounds with the disinfectant. These substances offer resistance to

the full antiseptic effect of the most powerful of all antiseptics, carbolic acid and bichlorid of mercury. The antiseptic solutions that will be mentioned further on are intended, in the first place, to aid other measures in procuring for everything that is to be brought in contact with the wound and that can not be sterilized by heat, practically an aseptic condition,—that is, they are used as disinfectants, with the special object in view of preventing wound infection,—and, in the second place, they have a wide range of application in the treatment of infected wounds. As water is the vehicle usually employed in the preparation of antiseptic solutions, it is well to remember that according to Carl Fränkel the only water that is absolutely free from bacteria is that which issues from the interior of the earth; the water that evaporates from the surface of the earth and condenses in the higher cold regions of the atmosphere is also sterile, but when it descends in the form of rain or snow, it becomes contaminated by the microbes floating in the lower strata of the air. Contrary to the opinion usually held, rain-water and water from melting snow are bacteriologically not pure, and are unfit for antiseptic solutions without boiling. Well- and river-water always contains bacteria and requires boiling before it can be safely used as a menstruum for the antiseptic solutions. The degree of contamination depends on the nature of the soil and the number of people and animals inhabiting certain districts. Fortunately, most of the microbes found in water do not infect wounds. Pus-microbes, however, have been found repeatedly in spring- and river-water. Most of the pathogenic microbes not only retain their vitality in water, but they often multiply in it with surprising rapidity. Cramer ascertained that the water from the water-works of Zürich multiplied 2700 times in a few days, and Leone showed that the water from the city supply of Munich contained five microbes in each cubic centimeter; if the same water was allowed to stand for five days, they increased 100,000 times. Even distilled water is an excellent culture-medium for some kinds of saprophytes. From a practical standpoint it must be taken for granted that septic organisms can live for a long time in water, retaining their virulence and power of reproduction. It is fortunate that the same warfare is carried on between different kinds of micro-organisms in water as elsewhere, so that some of the more dangerous microbes are destroyed by saprophytic and other comparatively harmless bacteria.

From the foregoing it appears plain that well-, river-, spring-, and rain-water should not be brought in contact with fresh wounds without being sterilized. The common practice among laymen of washing wounds with water, regardless of its source, must be considered as dangerous. The only surgical use of plain water is limited to scrubbing of floors, ceiling, walls, and furniture of the operating room. The methods of filtration so far devised have not succeeded in eliminating from water all sources of infection. Filtration on a small scale through the Chamberlain-Pasteur filter

yields comparatively pure water, but in the course of time the efficacy of the filter is impaired, as at the end of four days bacteria make their appearance in the water. For surgical use water must be sterilized by heat or chemic agents. Boiling is the simplest and most reliable method of sterilization. Boiling for two minutes destroys the most resistant organisms—the spores of the anthrax bacillus. Boiling for five minutes suffices under all circumstances to render the water absolutely sterile. It should not be forgotten that boiling has no influence on the ptomains, consequently the clearest, purest water should be used and sterilized. Sterilization of water by chemicals is a slower and less reliable process. Geppert found the spores of the anthrax bacillus alive after twenty-four hours in a 1 or 2 : 1000 solution of bichlorid of mercury, which would suggest that in case chemic sterilization is relied upon, the antiseptic solution should be prepared two or three days ahead of its expected use, which is certainly out of question in emergency surgery. Water containing carbonate of lime can not be used with bichlorid of mercury, as much of the antiseptic would be lost by combination with the lime salts. If no water free from lime salts can be obtained, such a chemic change can be prevented by adding acetic or tartaric acid, or, still better, common salt, to the solution. Equal parts of the bichlorid of mercury and common salt are the proper proportion, and this is represented by Angerer's tablets. Sterilization of water by boiling can be done either before or after the addition of the antiseptic—preferably before, as some of the antiseptics, especially the bichlorid of mercury, are incompatible with metal. In hospitals and private offices sterilized water can be kept on hand in large bottles or jugs, well corked.

Carbolic Acid Solution.—Five per cent. is the standard solution. It should be colored with eosin to prevent mistakes. For hand disinfection the strong solution (5 per cent.) is used. For the disinfection of large accidental wounds and in preparing an extensive field of operation, a 2½ per cent. solution will suffice. The 2½ per cent. solution, made by mixing equal parts of the 5 per cent. solution and sterile water, is the one usually employed for washing out suppurating joints after tapping, parenchymatous injections, hot, moist antiseptic dressings, and irrigation of suppurating wounds. Carbolic acid in any form should not be used in infants and young children, and must be used with great caution in anemic marasmic subjects and patients suffering from organic disease of the kidneys.

Bichlorid of Mercury Solution.—The standard solution is 1 : 1000, which should be colored with anilin blue and properly labeled. This is the solution most generally used at the present time for hand and surface disinfection. Like carbolic acid, it is never used in the disinfection of mucous cavities or passages. For irrigation of suppurating wounds and local application by hot, moist compress the strong solution is diluted from two to five times

for the purpose of diminishing the risk of intoxication, and it is well known that a solution of 1 : 100,000 exerts an inhibitory action on pathogenic microbes. Age, complicating diseases, and the general condition of the patient must be carefully considered in searching for contraindications to the use of this potent and poisonous antiseptic. For emergency work Angerer's tablets, composed of fifteen grains each of bichlorid of mercury and common salt, with the addition of eosin as a staining material, recommend themselves for accuracy and convenience. By dissolving one tablet in a quart of boiled water a 1 : 1000 solution is extemporized, which can then be diluted to the desired strength by the addition of the requisite amount of sterile water.

Acetate of Aluminum Solution.—As has been stated before, acetate of aluminum is a nontoxic, nonirritating, mild antiseptic. Its use is limited almost entirely to the treatment of infected wounds, phlegmonous inflammation, and permanent irrigation of suppurating joints and large abscess cavities. A saturated solution can be used freely for weeks or months without any risk of intoxication whatever. Acetate of aluminum is a remedy of the utmost value in antiseptic surgery. A 1 per cent. solution can be extemporized by dissolving twenty-four grams of alum and thirty-eight grams of acetate of lead in one quart of water. A compress saturated with this solution and applied directly to the skin in dermatitis of all kinds promptly relieves the itching and burning, prevents the spread of the disease, and promotes the process of resolution. I always substitute for the dry dressing the moist aluminum compress in all wounds that are or may become infected.

Thiersch's Solution.—A combination of salicylic and boric acid makes a very efficient and safe antiseptic either in the form of powder or solution. Boric acid increases the antiseptic properties of salicylic acid. Thiersch's solution is made by dissolving half a dram of salicylic acid and three drams of boric acid in one quart of sterile water. This solution, like acetate of aluminum solution, is nontoxic and nonirritant, and is used to meet the same indications. It is safe and useful in disinfecting the mouth, rectum, and vagina preliminary to an operation. It is the solution of choice in irrigating large suppurating cavities, as is the case in empyema, suppurative peritonitis, and synovitis, and in washing out large phlegmonous abscesses. It comes next in utility to the acetate of aluminum solution for permanent irrigation. It is the antiseptic solution of choice in the surgery of infants and young children.

Boric Acid Solution.—Boric acid is a mild antiseptic, and in solution is used for indications similar to those in which Thiersch's solution is employed. Three and a half per cent. constitutes a saturated solution. Very few cases of intoxication have been reported from its use. The moist boric acid compress is an admirable substitute for the old-fashioned, filthy, germ-breeding poultice.

Chlorid of Zinc Solution.—A 10 per cent. solution of chlorid of zinc is the strongest weapon in the attempt to transform a septic into an aseptic wound. The wound must first be thoroughly cleansed and dried and the suppurating surface freely exposed, when the solution is applied with a cotton swab; after a few minutes the excess of the solution is washed away with a normal salt solution, and the wound covered with a hot, moist, antiseptic compress. The chlorid of zinc solution penetrates the tissues deeper than any of the other antiseptic solutions, and reaches the microbes some distance from the surface of the wound. Injected into the normal tissues, the same solution acts as a powerful tissue stimulant, and has been recommended by Lannelongue in the treatment of peripheral tubercular affections and for the radical cure of hernia.

Normal Salt Solution.—The normal salt solution is prepared by dissolving $\frac{6}{10}$ of 1 per cent. of chlorid of sodium in sterile water. A teaspoonful of salt to a quart of water represents approximately the strength of this solution. The solution corresponds in its degree of alkalinity to the serum of blood, and it has come into the most extensive use in aseptic surgery. In cleaning recent wounds it should always take the place of sterile water, as it does not damage the tissues like the latter. The same solution is used in the treatment of grave hemorrhage by intravenous, subcutaneous, and rectal infusion.

Aqua Binelli.—This is a 1 per cent. solution of creasote, and has proved useful in the treatment of fetid suppuration as an injection and a local application.

Permanganate of Potash Solution.—A 5 per cent. solution of permanganate of potash is a reliable germicide, and as such can be used for hand disinfection and for the disinfection of suppurating wounds. In the strength of $\frac{1}{10}$ of 1 to 1 per cent. it is a deodorant that can be employed for the disinfection of the mouth and the interior of fetid abscesses.

ANTISEPTIC POWDERS.

For dry dressings in the treatment of small recent wounds some kind of antiseptic powder is of great value in preventing infection. This is more especially true in penetrating gunshot and stab wounds. Suturing in such cases is seldom done, and primary disinfection is often out of question under the circumstances under which the injury is inflicted. The antiseptics in powder form may not destroy the microbes on the surface of the wound and the adjacent skin, but they will prove efficient in inhibiting their growth. Such wounds are treated most successfully by dusting them with a potent antiseptic powder before the dressing is applied. Antiseptic powders are also in extensive use in dusting the line of suturing, and unquestionably contribute much toward the prevention of stitch abscesses. For many years iodoform has been used almost exclusively to meet both of these indications. The odor,

expense, and comparatively feeble antiseptic properties of this drug are valid objections to its general use. It has been used in combination with boric acid, and the results have been equally as satisfactory as when the pure iodoform was used.

Iodoform-boric Powder.—

Iodoform,	100 parts.
Boric acid,	500 "

To be effective the antiseptic powder for permanent dressings should resist chemic changes to a maximum degree on exposure to atmospheric air or when brought in contact with the primary wound secretions. For several years I have made use of a combination of salicylic and boric acids, with the most satisfactory results. The following is the formula for the—

Borosalicylic Powder.—

Boric acid,	4 drams
Salicylic acid,	1 dram.

This powder is particularly well adapted for the treatment of recent gunshot wounds.

ANTISEPTIC SALVES.

The typical antiseptic dressing has reduced the use of salves in surgery to within very narrow limits. All the salves in use at the present time contain one or more antiseptics, and are employed as a primary wound dressing in the treatment of small wounds, especially of the lips and face, to protect granulating surfaces, and occasionally as a protection for skin-grafts. The French surgeons are very partial to what they call the—

Antiseptic Pomade.—

Antipyrin,	5 parts
Boric acid,	5 "
Iodoform,	1 part
Vaselin,	50 parts.

As a protection for granulating surfaces and as a dressing after harelip operations and small wounds of the face I have found the following to be very efficacious:

Borosalicylic Ointment.—

Boric acid,	½ dram
Salicylic acid,	10 grains
Glycerin ointment,	1 ounce.

Lister's Boric Acid Ointment.—

Boric acid,	3 parts
Vaselin,	5 "
Paraffin,	10 "

Chloral Hydrate Ointment.—

Chloral hydrate,		
Gum acacia,		
Powdered camphor,	of each,	5 parts
Vaselin,		50 "

The last-named ointment is a soothing application in all forms of dermatitis.

Unguentum Credé.—The silver ointment of Credé is said to penetrate the intact skin and exert its antipyogenic effect on the bacteria in the tissues. It has been used with success not only in lymphangitis of the skin, but also in deep-seated phlegmonous inflammation. It is not essential, according to Credé, that the inunction should be made directly over the affected part in order to secure its antipyogenic effect on infected processes distant from the surface of the body.

THE MECHANICAL TREATMENT OF WOUNDS.

The dangers from infection incident to any open wound have been described in detail, as well as the methods best calculated to arrest or minimize them. The mechanical treatment comes next in importance to aseptic and antiseptic precautions in the modern treatment of wounds. Without the observance of the latter, mechanical measures are of but little value in aiding nature's resources in wound healing, and have often become a source of danger, as has been abundantly shown by the experience of the past. The mechanical aids in the treatment of a wound are of the greatest importance and of signal service in cases of incised aseptic wounds, such as are made by the surgeon's knife, under strict aseptic precautions.

The mechanical treatment of a wound consists in a recourse to such measures as will bring and hold in accurate, uninterrupted contact the wound surfaces, and, at the same time, procure for the part injured a condition approaching physiologic rest, in a position best calculated to favor restitution of the continuity of the severed tissues and the reestablishment of the interrupted circulation. The first indication in securing an ideal mechanical coaptation of the surfaces that it is intended to unite is to remove all substances that would interfere with such approximation and that would otherwise be detrimental to the process of healing. Before any attempts are made to unite a wound, it must be made clean, and this includes careful hemostasis and the removal of foreign substances and tissues not adapted to the process of repair. The most painstaking hemostasis, the removal of foreign substances, and the trimming of the margins of lacerated and contused wounds are the essential prerequisites to bringing the wound surfaces in contact by mechanical means.

In the mechanical treatment of wounds it is very important to make a distinction between aseptic, suspicious, and infected wounds. It is only in wounds that we have reason to believe aseptic that we aim, by mechanical aids and with the utmost care, to bring and hold in contact all the anatomic structures of the wound for the purpose of securing wound healing in the shortest possible space of time and with the best functional results. Such wounds are the intentional wounds made by the surgeon in operating on aseptic tissues.

All accidental wounds must be regarded at least in the light of suspicious wounds, and are treated as such according to the nature of the wound, the character of the vulnerating implement, the structure of the wounded tissues, and the time that has elapsed since the injury was received and the first aid rendered. In infected wounds the mechanical treatment is limited largely to efforts to secure rest of the injured part or organ by position, splints, and bandages. No attempt is made to bring the infected surfaces in close contact, as such treatment would interfere seriously with the employment of free drainage and antiseptic solutions, so essential in transforming a septic into an aseptic wound.

Position.—Position is an important element in the mechanical treatment of all wounds. Whenever it can be done without discomfort to the patient, the injured part should always be placed in an elevated position. This diminishes the arterial blood supply to the part and favors venous return, vascular conditions best calculated to minimize parenchymatous bleeding, tension, and pain. Position is again employed in relaxing the tissues involved in the injury, a part of wound treatment that is particularly important when tendons, muscles, or nerves have been severed. A failure to place the limb in proper position is often the cause of undue tension on the sutures, unnecessary pain, and unsatisfactory healing of the wound. In wounds over the extensor side of the extremities the limb must be placed and held in the extended position by an appropriate mechanical support until the wound has healed. An opposite course is pursued if the wound involves the deep structures on the opposite or flexor side. In secondary suturing of tendons, muscles, and nerves, where the diastasis is often great, after vivifying the structures we wish to unite, accurate suturing is possible only by securing the necessary degree of relaxation by position.

Suturing.—All aseptic incised wounds extending beyond the skin should be sutured. Asepsis has made this part of the treatment of wounds almost imperative. There is no region or tissue on the surface of the body which contraindicates suturing of wounds large enough to require mechanical treatment in approximating the margins. Asepsis has made the suture safe and useful. *Careful suturing is often a tedious, but always a grateful, task. The surgeon who is careful and proficient in this part of his work is the one who will achieve the best cosmetic and functional results.* The old-fashioned interrupted suture so long relied upon almost exclusively in uniting wounds, regardless of their depth and the tissues involved, has now been supplied with a most useful ally in the form of the absorbable buried or "etagen" suture.

The absorbable buried suture meets two important indications in the modern treatment of wounds:

1. It is of the utmost practical value, in fact almost indispensable, in uniting anatomic structures of the same kind in uniting deep

wounds in which several different anatomic structures have been divided.

2. Properly employed, it is the most important agent in the prevention of so-called "dead spaces," and consequently has accomplished much in limiting the indications for drainage.

Catgut is the best material for the buried suture. Its use is indicated in all deep aseptic wounds. Reference here will only be made to two kinds of wounds where its employment furnishes the most striking illustrations of the benefits to be derived from it. Let us suppose that a recent accidental transverse wound above the wrist-joint, over the anterior surface of the forearm, requires suturing. Examination shows that the median nerve and a number of the flexor tendons have been divided. After careful hemostasis has

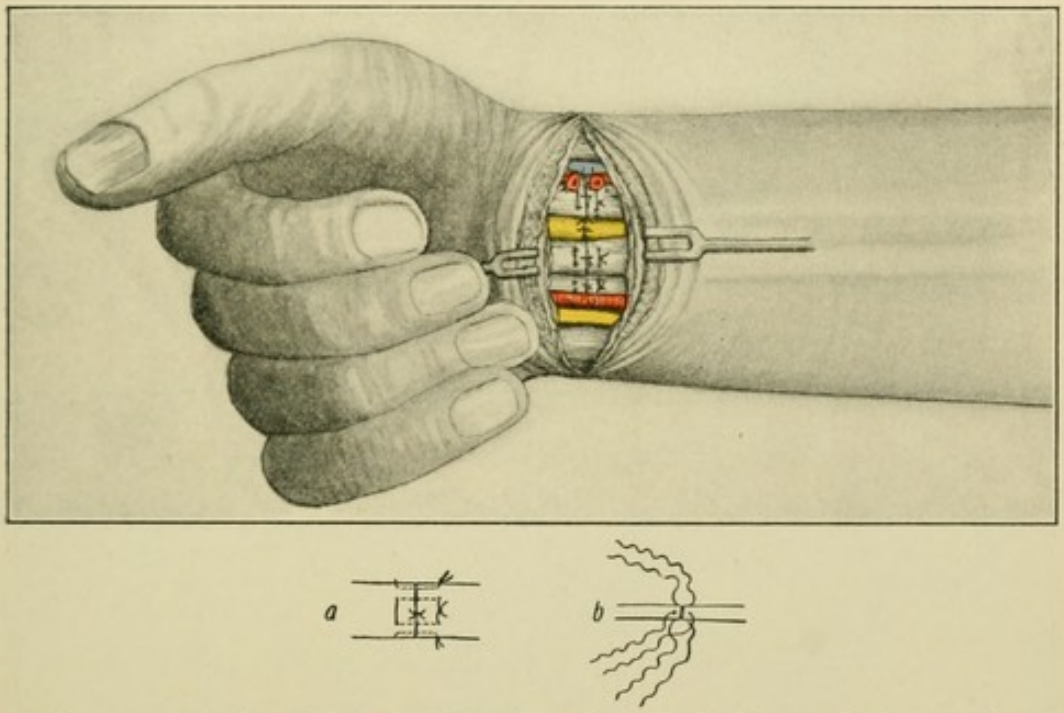

Fig. 111.—Suturing of tendons and nerves in incised wounds: *a*, Primary tendon suture; *b*, primary nerve suture.

been effected and the wound thoroughly disinfected, the surgeon proceeds to unite the severed parts separately by the use of the absorbable buried suture. The ends of the median nerve are found and united separately by two or more catgut sutures, using for this purpose a round needle and fine catgut. The severed tendons are treated in the same manner, using an ordinary round, curved surgical needle and somewhat coarser catgut in uniting the respective ends. The deep fascia is next sutured over the united nerve and tendons by inserting and tying a row of buried sutures. The skin is finally united in the usual way, the dressing applied, and the forearm immobilized with the fingers and hands well flexed.

The next object-lesson is furnished by the suturing of an abdominal wound, which is done in the following manner: The

requisite number of silkworm-gut sutures are inserted but not tied, and are made to include all the tissues, except the peritoneum. The peritoneum is sutured separately with fine catgut. Next the fascia of the recti muscles is united by a row of coarser buried catgut sutures, after which the deep sutures are tied and, finally, the skin between them is carefully united with horsehair sutures.

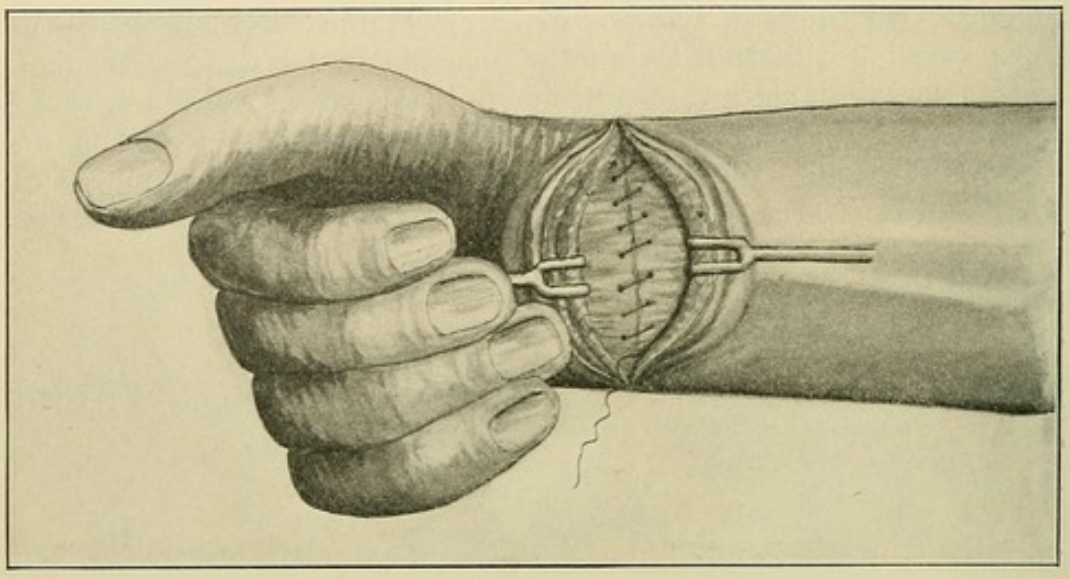

Fig. 112.—Suturing of deep fascia.

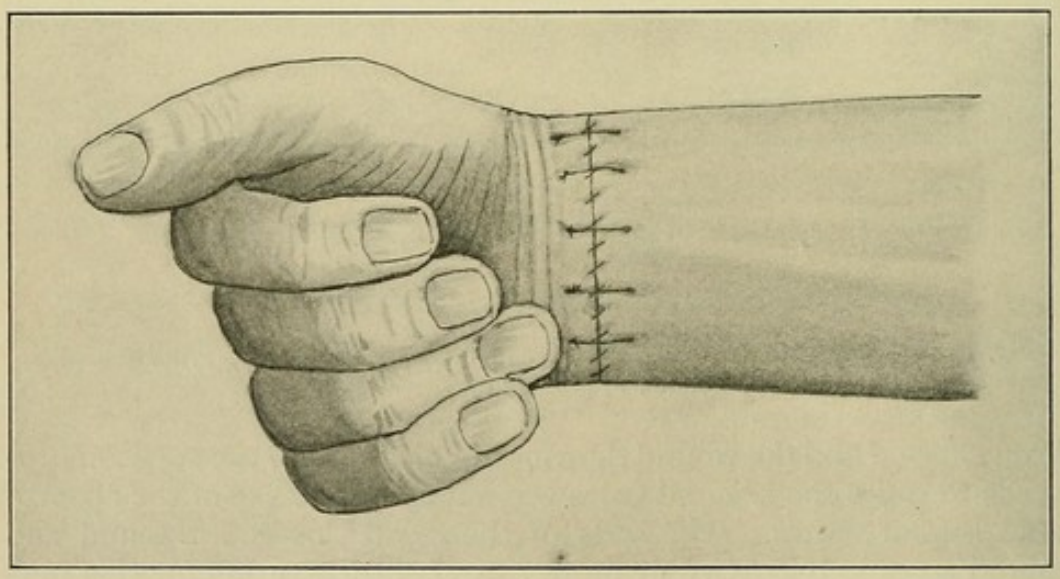

Fig. 113.—Suturing completed.

Wounds in any other part of the body that are deep enough to require the use of the buried suture are dealt with in a similar manner, the surgeon always having in view the uniting, by this mechanical resource, of similar anatomic structures, and in such a way as to guard against the formation of dead spaces. If buried sutures are used, it is well to insert the deep sutures first, leaving them untied until the deep suturing has been completed.

Another important indication for the employment of buried sutures is presented by wounds of very vascular organs, when they are occasionally employed as hemostatic agents in arresting troublesome parenchymatous hemorrhage. When employed for such a purpose, the needle must be round and well curved, the catgut be fine, and the sutures be placed close together.

Tension sutures are needed when it is found difficult to bring the wound surfaces in contact by the ordinary approximation sutures. Coarse silk is the best material for this purpose. From one to two inches are included in the suture on each side, and the sutures are removed as soon as they can be dispensed with, which is usually the case after from the third to the fifth day. The retention of such sutures for too long a time is sure to result in more or less linear pressure necrosis. Metallic wire is seldom employed

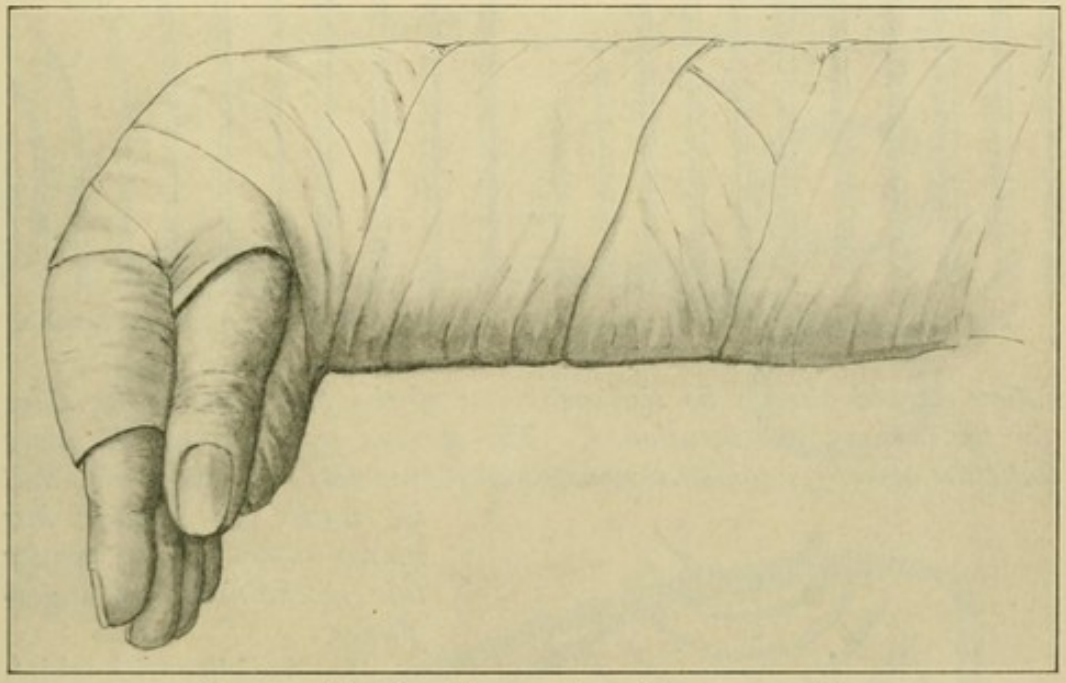

Fig. 114.—Hand and forearm dressed in proper position.

at the present time, either as tension, buried, or approximation sutures, as it does not present any special advantages over other nonabsorbable suture material, especially silkworm gut. For suturing the skin there is no better material than horsehair.

Horsehair can be readily sterilized, is elastic, is easily tied, and remains in the tissues for weeks without giving rise to the slightest irritation. It is the material of choice in the suturing of wounds made for plastic purposes. It is a very common mistake to tie the sutures too tightly. Unnecessary tension must be carefully avoided, and in tying the sutures some allowance must be made for more or less swelling of the tissues, which often takes place even in aseptic wounds. Another equally prevalent mistake is made in tying the sutures directly over the wound, where the knot

often interferes with the accurate coaptation of the skin underneath it and unnecessarily complicates the removal of the suture. *The*

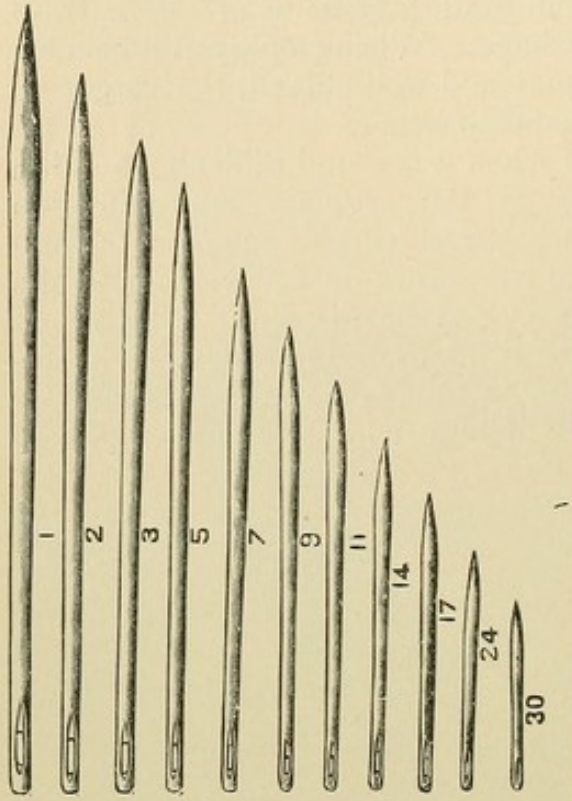

Fig. 115.—Straight surgical needles.

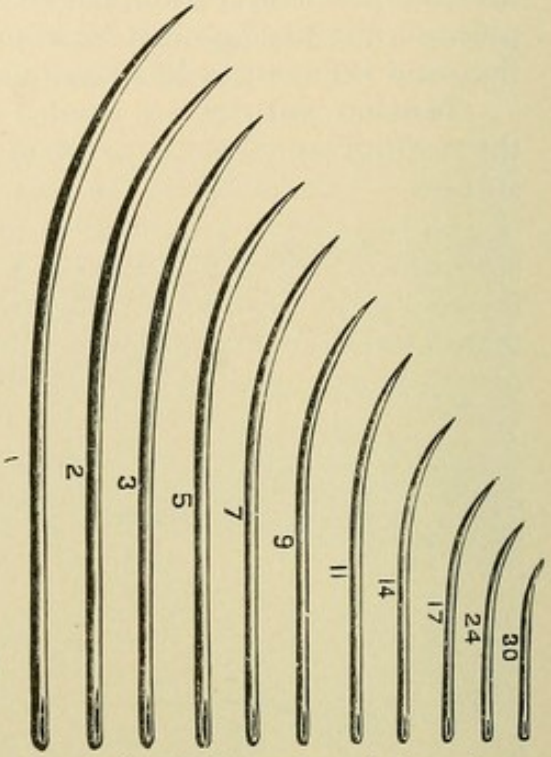

Fig. 116.—Half-curved surgical needles.

suture should always be tied near one of the punctures in the skin, for the reasons just mentioned. The sutures must remain in place until the object for which they were employed has been realized—that is, until the wound has united sufficiently to render this mechanical aid superfluous.

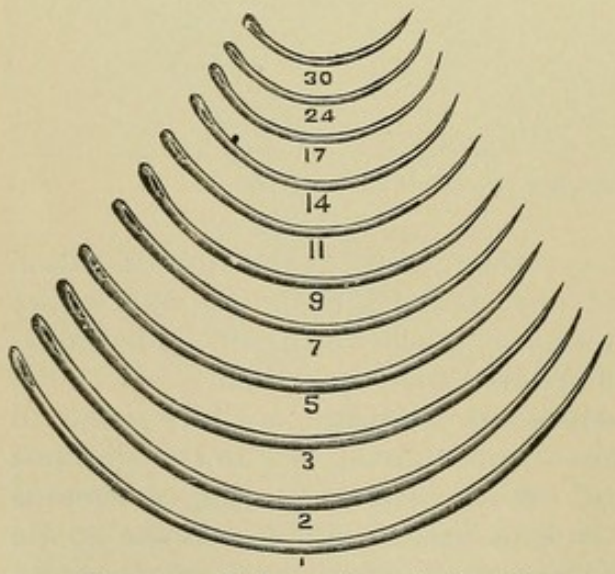

Fig. 117.—Full curved surgical needles.

The rapidity with which a wound heals depends on its size, the structure of the injured tissues, and its location. The too early removal of sutures is followed by yielding of the delicate scar, and their prolonged retention is often attended and followed by severe pain. In superficial wounds of very vascular tissue, such as the scalp, lips, skin of face, etc., their presence and support become superfluous in the course of from three to five days. The early removal of the deep sutures is especially desirable after operation for harelip and other

plastic operations. In amputations, excision of the breast, perineorrhaphy, abdominal and hernial operations it is not advisable to remove them before one or two weeks after the operation, unless special indications arise. In removing the suture the knot should be grasped with a toothed dissecting forceps, slight traction made, the sharp point of the scissors inserted underneath, and the

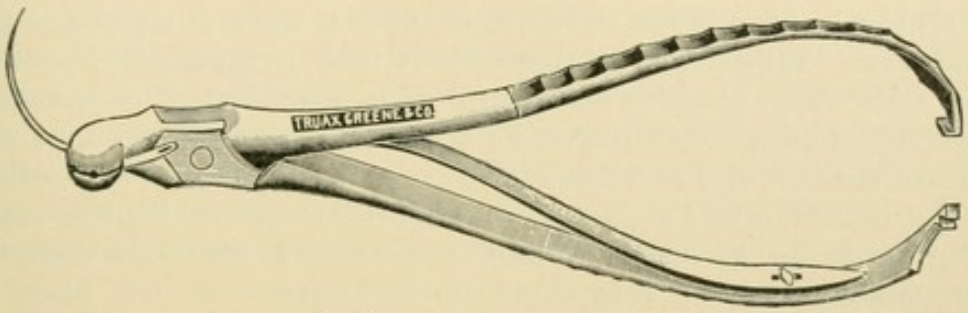

Fig. 118.—Truax's automatic needle-holder.

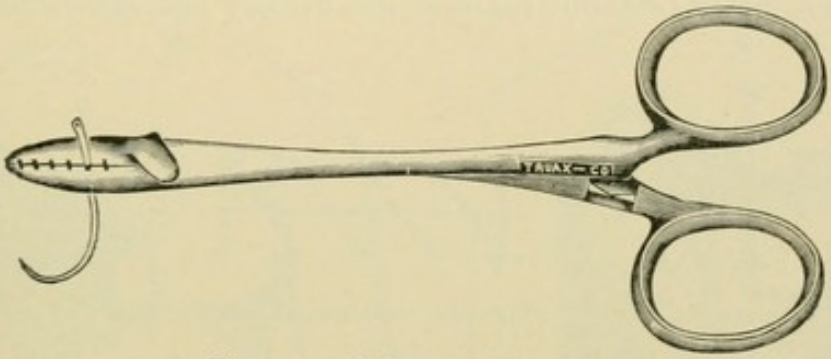

Fig. 119.—Abbé's needle-holder.

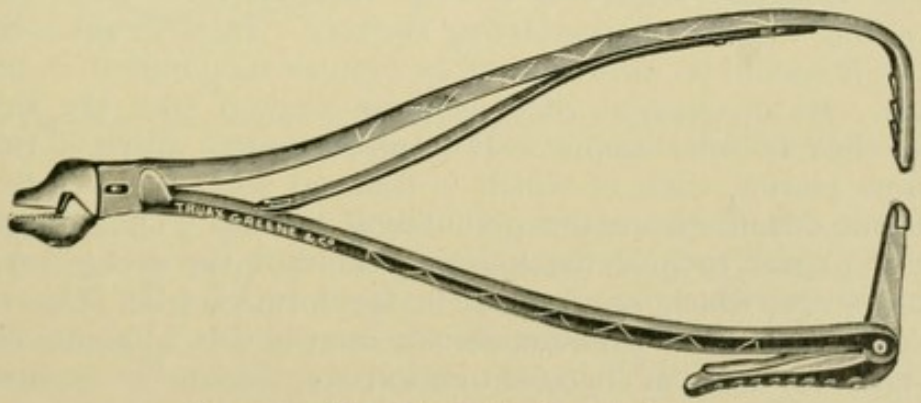

Fig. 120.—Truax's combined needle-holder.

thread cut beneath the knot and the puncture nearest to it. Silkworm gut is an excellent suturing material, but it cuts through the tissues much more readily than silk, and it is for this reason that I prefer the latter material in operations for harelip, cleft palate, and for other plastic operations. The needle-holder should be employed only in localities where the fingers can not be used in handling the needle. The Russian and Truax's needle-holders

are the best substitutes for the fingers. In suturing superficial wounds the needles used by saddlers and glovers are the best.

Secondary suturing is frequently resorted to at the present time, either for the purpose of closing aseptic wounds completely after the removal of the drain, or to unite aseptic granulating surfaces. In the former case the secondary sutures are inserted at the time the operation is performed, their ends are tied, and after the removal of the drain, the knot is cut and the sutures tied in the usual way. Wounds thus treated will heal by primary intention even if the drain remains for several days, provided, of course, that they remain aseptic. Suturing of granulating aseptic wounds can be done successfully in the usual way, and whenever it is possible, the sutures should be passed their entire length well underneath the granulating surface. This procedure prevents injury to the granulations, and the formation of dead spaces is less likely to occur. Wounds thus united heal in the same manner and in the same length of time as recent wounds, but the cosmetic and functional results, for obvious reasons, are usually less satisfactory.

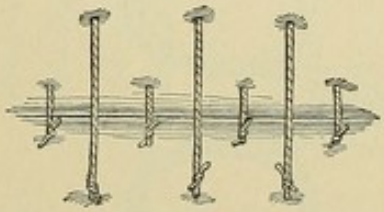

Fig. 121.—Tension and interrupted sutures.

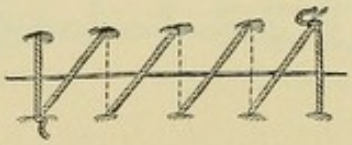

Fig. 122.—Continued suture.

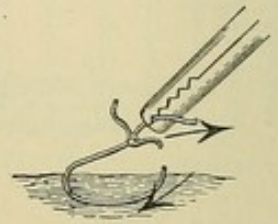

Fig. 123.—Manner of removing suture.

The **bloodless suture** is a very valuable mechanical aid in diminishing the size of granulating surfaces. In large granulating wounds it should be made use of as soon as suppuration is under control. Its mechanical effect is most marked after the wound surface has become aseptic. It is made by two strips of rubber adhesive plaster, each of which is fastened with one end to the skin some distance from the granulating border. The part of the piece of plaster to give the necessary hold on the skin is cut into narrow strips, which are applied in the form of a fan (Fig. 125). The hold on the skin can be materially increased by applying collodion and a thin film of absorbent cotton over the fan-like expansion. The wound is protected with strips of aseptic gutta-percha or protective silk, over which a dry, aseptic, small gauze compress is applied. The wound margins are then approximated as near as possible by hand pressure, and the two strips of adhesive plaster are fastened together over the gauze dressing with a safety-pin. The traction can be regulated from day to day. In large wounds several pairs of adhesive strips may be employed.

The bloodless suture, used in the manner described, not only constitutes a valuable mechanical aid in diminishing the healing

surfaces, but it also, at the same time, secures compression, so important an element in expediting cicatrization and epidermization. This mechanical support is of special value in hastening the healing of wounds that can not be sutured after excision of the breast, and in cases of retraction of the flaps after amputation.

Fixation Dressings.—The immobilization of the injured tissues is a very essential part of wound treatment, as the wound is thus placed at rest, a very important condition to a satisfactory process of healing. The necessary degree of fixation can often be attained by the dressing, but in large wounds of the neck, chest, and extremities some sort of a fixation dressing must be used to immobilize the injured part. Splints are not used so often as they should be in the after-treatment of wounds of the soft parts. Every amputation stump should be immobilized by a well-fitting and well-

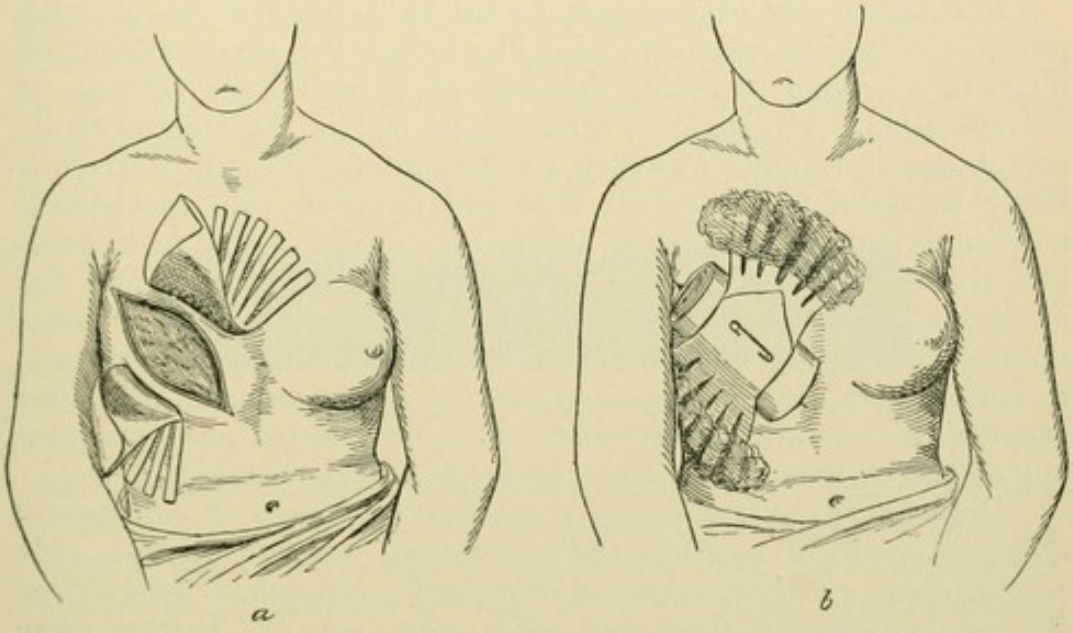

Fig. 124.—Bloodless suture: *a*, Showing shape and application of strips of adhesive plaster; *b*, dressing applied and held in place by bloodless suture.

padded hollow splint. It is an important constituent part of the first dressing, as by its use painful muscular twitchings and undue retraction of the flaps are prevented. In large wounds of the neck a few turns of the plaster-of-Paris bandage over the dressing will secure, in a satisfactory manner, fixation and rest of the injured part. Broad strips of adhesive-plaster binder or roller bandage are relied upon in immobilizing the chest and abdomen. In wounds of the extremities the plaster-of-Paris or a well-fitting anterior or posterior splint is usually employed for securing rest for the wound.

The mechanical support should be continued until the process of healing has been completed: in some cases a considerable length of time after the sutures have been removed, as a too early resumption of the use of the injured part not infrequently impairs what otherwise might have been an ideal result.

Compression.—*A moderate degree of equable, uninterrupted, prolonged compression is a mechanical condition favorable to speedy satisfactory healing of an aseptic wound.* Compression properly employed does much in aiding the sutures in bringing and holding the wound surfaces in contact. Moreover, at the same time it is well calculated to guard against the accumulation of primary wound secretion, thereby preventing swelling and tension. It also contributes much in securing rest for the wound.

Compression, as practised at the present day, is made by the hygroscopic elastic aseptic dressing, made of gauze and cotton, and held in place by a bandage, strips of adhesive plaster, or by both. The bandage for the fixation of such a dressing is made of several layers of aseptic hygroscopic gauze, as it is more elastic than the ordinary muslin or cambric roller, and hence better calculated to maintain the necessary degree of elastic pressure.

Drainage.—By drainage is meant the employment of such physicomechanical measures as will prevent the accumulation of fluids in a wound or cavity the seat of a pathologic effusion or extravasation. Drainage is a necessary evil in the treatment of recent aseptic wounds in which accumulation of blood or serum is likely to occur to an extent that will interfere with mechanical conditions necessary to insure satisfactory healing—that is, in cases in which the hemostasis is incomplete, or the mechanical aids fail in effecting and maintaining, for the necessary length of time, uninterrupted coaptation between the wound surfaces. Drainage is always indicated in the treatment of septic wounds, and after removal, by operative interference, of liquid infected products from any of the cavities of the body, preformed or pathologic.

Drainage of a recent wound is an open confession of our present imperfect means of securing and maintaining absolute asepsis. The surgeons who are most careful in their aseptic precautions and wound treatment drain least frequently, while others who are hasty in their work, and especially those who are obliged to operate with the aid of careless or inexperienced assistants, must necessarily drain often. Drainage is and will remain a common practice in the treatment of accidental wounds and in the performance of emergency operations. Accidental wounds are always infected wounds before the patients come under the care of the surgeon. It is in such cases, too, that the means of procuring asepsis are often limited, and the assistance unreliable.

Emergency operations are operations which must be performed quickly, and consequently the haste with which preparations must be made often precludes the bringing into effect of the necessary aseptic precautions. The rule still holds good : " When in doubt, drain " (Tait). Good judgment and careful consideration of conditions and circumstances are frequently required when the surgeon is to decide the important matter whether or not the safety of the patient requires drainage of the wound. Very often the life of the

patient depends on the course he adopts. *While opinions may differ in regard to the necessity of drainage in recent wounds in well-equipped operating theaters, there can be no doubt that in emergency practice, when any question arises as to the propriety of establishing drainage, the patient should be given the benefit of the doubt and drainage be employed.* To decide when and how to drain constitutes one of the most important items in the mechanical treatment of wounds.

The present methods of drainage consist of: (1) Patency of wound; (2) tubular drainage; (3) capillary drainage.

Infected, contused, and lacerated wounds are best drained by leaving them open, applying the antiseptic or aseptic dressing directly to the wound surface—that is, by resorting to the open-wound treatment under the antiseptic or aseptic compress. If the wound is very irregular, the gauze should reach the deeper recesses, so as to remove the wound fluids by capillary action. Infected and contused wounds are never sutured, but other mechanical aids are often employed to diminish the wound surface, such as bandages, strips of adhesive plaster, and splints.

The tubular drains are made of rubber, glass, or decalcified



Fig. 125.—Antiseptic soft-rubber drainage-tube bottle.

bone. Neuber introduced the absorbable tubular drain of decalcified bone for the purpose of obviating the necessity of an early change of dressing in order to remove the drain. He used tubes made of the compacta of the long bones of cattle. Trendelenburg and MacEwen made the tubes of the decalcified shafts of the long bones of birds; and Watson Cheyne made absorbable tubes of catgut. The experience with these tubes did not meet the expectations entertained, and they are seldom employed at the present time.

Glass drains retain their reputation for draining the peritoneal and pelvic cavities. The present manner of using them is to pack the lumen of the tube lightly with a strip of iodoform gauze or aseptic wicking, thus combining tubular with capillary drainage. For ordinary purposes, and especially in emergency work, the rubber drain is the one that deserves the preference. The rubber tubing can be sterilized by boiling in soda solution, and is kept ready for use in any of the strong antiseptic solutions. To be efficient it must be well fenestrated. The openings should be oval, and never wider than one-fourth of the circumference of the tube. The tube must be ample in size. It is a very common mistake to use tubes that are too small. In large wounds several drains may be required. The drain should always be placed in such a manner

as to drain the most dependent part of the wound cavity. I seldom drain through the incision, preferring to make a separate small incision at the point where drainage will be most efficient. For instance, after excision of the breast the buttonhole for the drain is made at the most dependent part of the wound, behind the line of suturing; in amputations at the base of the posterior flap, in temporary resection of the skull, in the center and base of the flap.

Every drain must be secured on the surface of the body with a safety-pin, so that the drain will never find its way beyond the sight and reach of the surgeon. This injunction may appear superfluous, but I have personal knowledge of a number of cases in which drains were lost in the wound or cavity that it was intended to drain. Such accidents will not occur in the practice of the careful physician or surgeon. The drain must correspond in length to the cavity it is expected to drain, and should never project any considerable distance beyond the surface of the skin. If the drain is too long, it becomes flexed and almost useless as a drain; or it may become bent or compressed by the dressing, causing a mechanical obstruction that interferes with the free escape of the wound secretions into the absorbent dressing. The drain must remain as long as there is anything to drain from the wound or cavity—that is, until the wound is dry or the cavity has ceased to discharge. In recent wounds drainage can usually be dispensed with after from three to five days. If at this time the wound secretions have not ceased to flow, the drain is removed, cleansed, shortened, and reinserted. *A scanty wound secretion is always a good indication of the aseptic condition of the wound, while a profuse and prolonged discharge very often means the reverse. As every change of dressing is always attended by more or less risk of wound infection, drains should never be removed unnecessarily.* An early removal of the tubular drain may become necessary in case its lumen, as so often happens, becomes blocked by a blood-clot. The blocking of the tubular drain from this cause is one of the great objections to its use, but as we have no better substitute open to fewer objections, such an occurrence must be looked for, and when found, must receive prompt attention. In draining the abdominal cavity I have been for a long time in the habit of wrapping a thin layer of iodoform gauze around the drain, for the double purpose of protecting the intestine against harmful pressure and to increase drainage by adding a capillary to the tubular drain.

In establishing through tubular drainage, the end of the drain is grasped transversely with the forceps, by the aid of which the counteropening is made. Both ends of the drain, cut short to the skin, must be secured with safety-pins. As soon as the indications for through drainage have been met, the drain is removed and each opening drained separately.

In cases in which only a small quantity of primary wound

secretion is expected, the *capillary drain* is often substituted for the tubular drain. The materials that have been used most extensively for this purpose are gauze, catgut, glass-wool (Kümmel), horsehair, silk threads, and wicking.

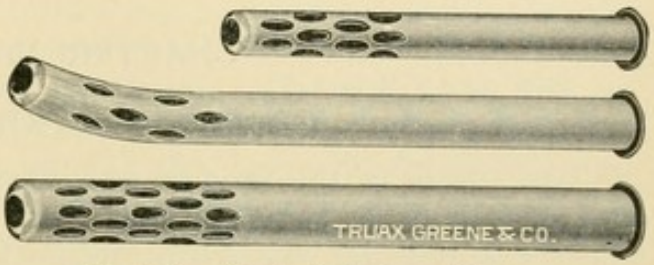

Fig. 126.—Murphy's drainage-tubes.

Capillary drainage is only adapted to the removal of primary wound fluids; it is often worse than useless in draining suppurating wounds and abscess cavities. The Mikulicz drain is a good form of the gauze capillary drain. By using a bag of gauze for the tampon, in the manner described in the chapter on Hemostasis, it is impossible to lose fragments of gauze in the wound. If the typical Mikulicz drain is not used, the gauze drain should always be made of *one* piece, which is fastened on the surface by a safety-pin. An excellent gauze drain can be made by surrounding it with a piece of protective silk, perforated at numerous points, and which is included in the pin in fixing the capillary drain. A bundle of catgut constitutes an excellent capillary drain and possesses the advantage of being absorbable, making it unnecessary to change the dressing until the wound is healed. The capillary absorbable drain is frequently employed in operations on the skull and on tubercular joints. A piece of aseptic wicking or a small bundle of horsehair or silk threads are excellent capillary drains and are frequently utilized in draining small wounds requiring a short time for drainage. It is in cases of wounds that require drainage for a short time that secondary closure of the drainage opening by secondary suturing proves so useful in securing speedy healing of the wound throughout. Tubular drainage is always necessary in draining suppurating cavities, while suppurating wounds are best dealt with by avoiding suturing or by removal of the sutures in the event of suppuration setting in, relying mainly on a large opening or openings in securing efficient drainage and in facilitating the antiseptic treatment by furnishing free access to the suppurating surfaces for the employment of antiseptic solutions.

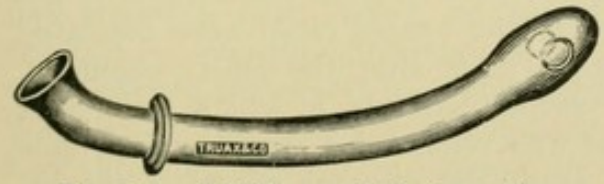
Fig. 127.—Keith's curved drainage-tube.


Fig. 128.—Tait's drainage-tube.

CHAPTER VII.

GUNSHOT WOUNDS.

THE effects of the modern small-caliber bullet on the bones and soft tissues of the body have been made the subject of extended experimental research by Bruns, Kocher, Helferich, Griffith, La Garde, A. C. Girard, and others, but as yet no uniform conclusions have been reached. The effects on the cadaver are not always the same as are those on the living body. Range and structure of the tissues greatly influence the nature of the wound. Bones are extensively comminuted if the missile is fired within a distance of 500 yards; a clean perforation with little or no splintering is made if fired within the next 500 yards, and beyond this range comminution is again almost a constant result. Our recent experience in Cuba, which embraced nearly fourteen hundred wounded, and in Porto Rico, where the number of wounded did not exceed fifty, showed that in recent cases the small tubular wound made by the Mauser bullet was surrounded by a narrow zone of contused tissue, and the wound space itself filled with either liquid or coagulated blood. A few days later the wound itself was found surrounded by an area of suggillation, which varied in extent according to the nature of the tissues and the amount of extravasation. In cases in which the bullet passed through the tissues some distance, and far from the surface of the skin, the location and direction of the wound canal were indicated by discoloration of the skin a few days after the injury occurred.

In a number of cases of aseptic wounds in which the bullet had lodged in the tissues and was removed a week or ten days later, I had an opportunity to study the remoter effects of the injury on the tissues. In all cases the swelling of the tissues at this time had almost or entirely obliterated the tubular wound, the location of which was indicated by a dark discoloration, parenchymatous extravasation, remains of fluid or coagulated blood, and a limited area of edema and infiltration. These conditions served as useful guides in following the course of the bullet. The bullet itself was usually found loose in a small cavity filled with liquid blood or bloody serum, while a more extensive zone of infiltration indicated the primary stage of encapsulation. I have no further doubt but that the new bullet will become encapsulated and remain harmless in the tissues as readily as or more so than the old-fashioned leaden bullet. Through the courtesy of Major A. C. Girard, U. S. A., I had an opportunity to examine a number of such cases in the military hospital at the Presidio, San Francisco.

Among them was a soldier recently returned from Manila, who was carrying a Mauser bullet in his pelvis, lodged on the left side of the prostate gland, and which could be distinctly felt through the rectum. Although the bullet entered the posterior surface of the left thigh, and while the soldier was in a sitting position, finally becoming arrested in its course in this locality, the patient never suffered to any extent from the injury. The bullet was well encapsulated but slightly movable, the conic end corresponding with the upper, and the blunt end with the lower, border of the prostate. No pain or tenderness were present on pressure. The total absence of symptoms prompted me to advise against its removal. The absence of any symptoms was somewhat remarkable, considering the location of the bullet and its close proximity to the rectum, always a fruitful source of infection by the bacillus coli communis.

Among the wounded of Cuba, in isolated cases late suppuration at the seat of the bullet resulted in the formation of a circumscribed abscess, a complication which aided the surgeons in locating and removing the missile. It was a surprise to us all to find that in more than 10 per cent. of all the wounded the bullet was found lodged in the tissues, a vastly greater number than we had any reason to expect. The reason for this became apparent when we began to study the condition of some of the bullets removed. A large proportion of the extracted bullets were found deformed, showing that they were deflected bullets that had struck a hard object or passed through a resisting medium before they reached the object for which they were intended. The ground upon which the battles were fought is stony and covered with trees and thick underbrush, furnishing the most favorable conditions for deflection of the bullets. Some of the firing was done at very long range, so that occasionally a spent ball was found in the soft tissues, without having injured the bones. Such a bullet is shown in figure 129. The bullet is a nickel-encased Mauser projectile of natural size; the jacket is perfect, and the bullet was removed from behind the tibia, about four inches above the ankle-joint. It entered the calf of the leg below the popliteal space, and never touched the bone.



Fig. 129.—Mauser bullet, natural size.



Fig. 130.—Mauser bullet, slightly deformed.

Figure 130 represents the same kind of a bullet; the point is flattened and mushroomed. The bullet, which was removed from the head of the tibia, was undoubtedly fired from a great distance, and the deformation was made by the resisting bone.

Figure 131 exhibits a nickel-clad bullet very much deformed. It was found lodged in the deep tissues of the thigh, about two

inches from the wound of entrance, slightly overlapping the femur near the middle of the shaft. The bullet evidently struck a stone behind its point, and was deflected before it entered the body. It was much flattened and curved. *a* shows the convex side, the point of bullet and the jacket being perfect. *b* exhibits the edge and curve of the bullet. *c* shows the concave side, exhibiting a wide rent in the jacket, indicated by the dotted lines, the lead being exposed between them.

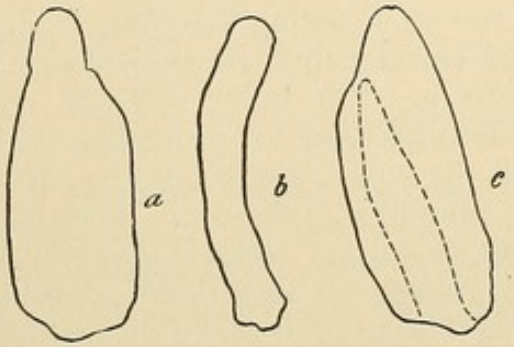

Fig. 131.—Mauser bullets much deformed.

Figure 132 illustrates the deformity of a large-caliber brass-clad bullet. As the bullet was removed from the soft tissues from a wound without bone injury, the deformity must have been caused outside of the body. The bullet is flattened on one side, from a point near the tip to near the base of the leaden core.

As the Spanish army is armed exclusively with the Mauser rifle, the weapon from which this bullet was fired must have been in the hands of a volunteer or possibly of a Cuban.

The extent of injury from bullets to any of the hollow viscera of the body is greatly influenced by their contents. The explosive effect is marked when they contain much fluid, and simple penetrating wounds may be expected when they are practically empty. These facts are of special importance in cases of visceral injuries of the gastro-intestinal canal in penetrating wounds of the abdomen. A bullet passing through the body lengthwise, as is so often the case when the soldier is in the prone position at the moment the injury is inflicted, may make a number of wounds, implicating different regions of the body. I have seen more than one instance in which three wounds of entrance and of exit were inflicted by the same bullet.

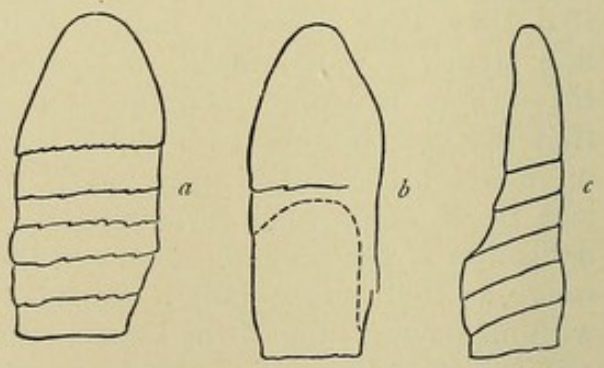

Fig. 132.—Deformation of large-caliber brass-clad bullets: *a* Exhibits the convex side; behind the last convex transverse groove the lead is exposed; *b* illustrates the flattened sides of the dotted lines; *c* shows the margin of the bullet and the location and extent of the flattening.

Diagnosis.—The diagnosis in gunshot wounds includes, besides establishing the existence of the injury, the interpretation of the existence, nature, and number of visceral lesions in the line traversed by the bullet. The latter part of the diagnostic work is necessarily uncertain when the bullet is lodged in the body. This is the case

when only one wound can be found, which is the surest indication that the bullet is lodged somewhere in the body. In such instances it is difficult and often impossible to ascertain the direction and length of the wound canal, and consequently to determine the anatomic character of the visceral lesions. The existence of two wounds is almost positive evidence that the bullet has traversed the body, in which event a straight line from the wound of entrance to the wound of exit will indicate the organs implicated in the injury. The existence of more than two wounds in a straight line is almost positive evidence that they were inflicted by the same bullet.

Probing of the wound for diagnostic purposes has become, with very few exceptions, an unjustifiable procedure. My bullet probe consists of a soft metal flexible rod, jointed in the center and tipped at each end with a porcelain bulb, one No. 22 and the other No. 38, French scale.

Heretofore, in the construction of probes with this class of tips,

Fig. 133.—Deformation of leaden bullets (natural size) (Seydel).

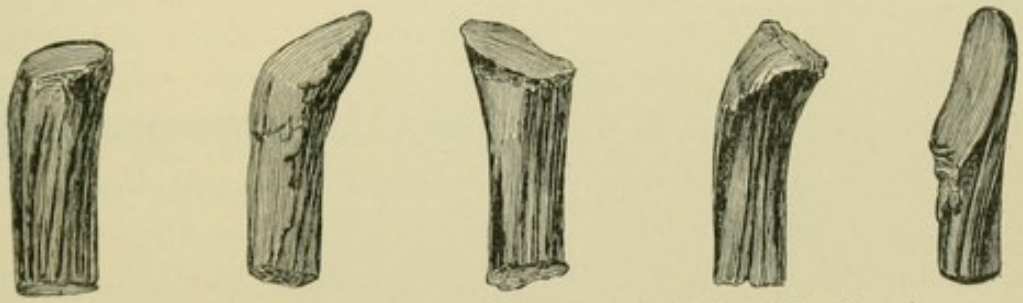

Fig. 134.—Deformation of small-caliber jacketed bullets (after Bruns).

the porcelain portion has been attached to the rod by boring or molding a hole in the former and fastening the two parts together with cement. This procedure resulted in many accidents, either from the detachment or the breaking of the porcelain bulb. After much experimenting a probe was produced with an opening entirely through the porcelain tip, the rod passing through the latter, its distal end being riveted upon the outer border of the bulb. This method of construction renders this probe perfectly safe, without in the least impairing its diagnostic value. The full length of the probe is nine inches.

In the cases in which such a course is indicated, the size of the probe should correspond as nearly as possible to the size of the lumen of the track made by the bullet. The modern small-caliber bullet will render a resort to the bullet probe much less frequent than the

bullets used in the wars of the past. Owing to its greater velocity and power of penetration, it will pass through the different parts of the body, regardless of the resistance offered by the osseous structures at a distance intended for shooting to kill. In the presence of a wound of entrance and of exit, the use of the probe is of no diagnostic value whatever, as an exploration of this kind adds nothing to our knowledge of the nature of the injury and frequently becomes a direct source of infection or a cause of renewal of hemorrhage. Search for the bullet under strict aseptic precautions is occasionally a justifiable diagnostic procedure in gunshot fractures and in penetrating wounds of the cranium and joints. It is absolutely contraindicated in penetrating wounds of the chest and abdomen. In bullet wounds of the soft parts an attempt in this direction is warranted when the surgeon has reason to believe that the bullet is located in a place favorable to its safe removal. *Probing for bullets, on the whole, has done infinitely more harm than good*



Fig. 135.—Nélaton's bullet probe.



Fig. 136.—Senn's bullet probe.

Fig. 137.—Fluhrer's aluminum gravitation probe (natural size, except the length, which is twelve inches).

in the past, and the limits of the indications for this procedure will be greatly reduced in the future.

If the location and nature of the injury make a search for the bullet and an attempt at its removal necessary, the exploration should be made systematically and under the strictest aseptic precautions.

The metal jacket of the modern bullet has largely detracted from the diagnostic value of the famous Nélaton probe, and has made the equally famous American bullet forceps obsolete as an instrument for extraction. The porcelain bulb of Nélaton's probe will, however, answer a useful purpose in following the track made by the bullet and in demonstrating the presence of foreign substances in the soft tissues. The porcelain bulb of the ordinary Nélaton's bullet probe is too small, especially in searching for bullets of large caliber. It is much easier to follow the tubular wound with a probe the porcelain bulb of which approximately corresponds in size to that of the bullet. As in instrumentation of

the urethra, a false passage is more likely to be made with a small than with a large instrument.

In searching for bullets it is of the greatest importance to bring the parts and tissues of the body as nearly as possible in the exact position they occupied at the moment the injury was received.

That no more force should be employed in using the bullet probe than in passing a catheter is simply to repeat a cardinal rule to which there should be no exceptions. Skill in the delicate manipulation of the instrument, patience, and perseverance will accomplish more than force in these cases. In exploring wounds of the brain Fluhrer's aluminum gravitation probe (Fig. 137) is the proper instrument to use. By placing the head in such a position as to make the tubular wound perpendicular, the probe, by its own weight, glides along the track until the bullet or the opposite side of the skull is reached. The latter is the case if the bullet has become deflected from that point, as was the case in a patient operated upon by Fluhrer. He then made a counter-opening in the skull, and followed again in the same manner the track made by the deflected bullet, finally succeeding in finding and extracting the missile.

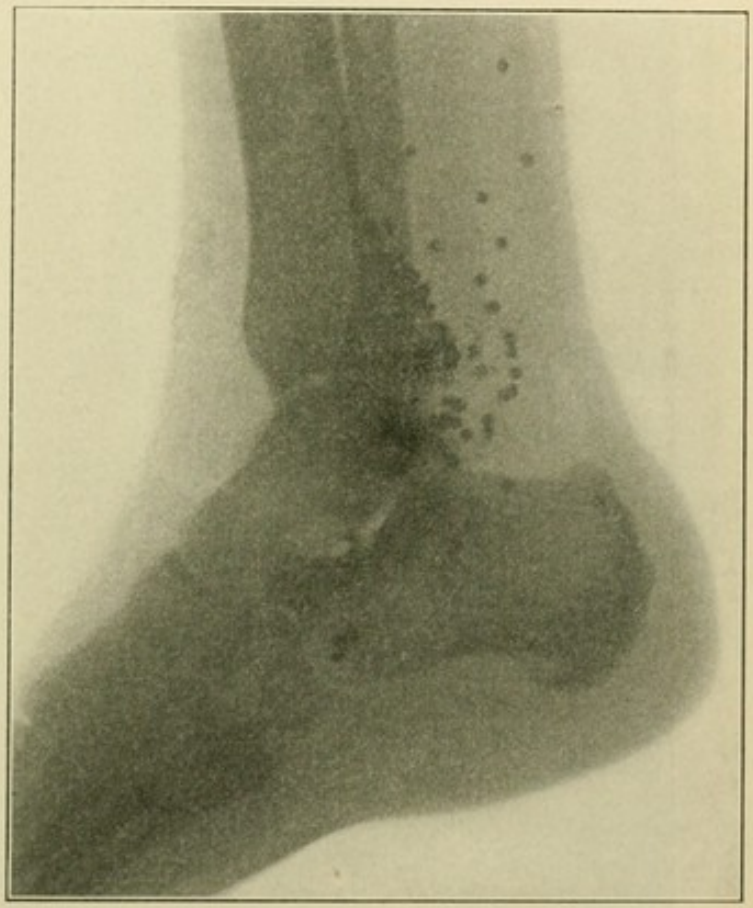

Fig. 138.—Bird shot embedded for several years in and around the ankle-joint.

Bullets that can be felt under the skin opposite the wound of entrance are extracted without exploration of the wound canal.

The use of the probe as a diagnostic instrument in locating bullets in modern military service has been almost entirely superseded by dissection and the employment of the Röntgen ray. If, from the nature of the injury and the symptoms presented, the bullet is believed to lodge in a part of the body readily and safely accessible to the knife, and it is deemed advisable and expedient to remove

it, this can often be done more expeditiously and with a greater degree of certainty by enlarging, under strict aseptic precautions, the track made by the bullet, than by relying on the probe in finding, and on the forceps in extracting, the bullet. If, as is often the case, the whereabouts of the bullet is not known, its presence and exact location can be determined without any pain or any additional risk to the patient, by the use of the X-ray. It becomes apparent, therefore, that no attempts should ever be made to find or remove

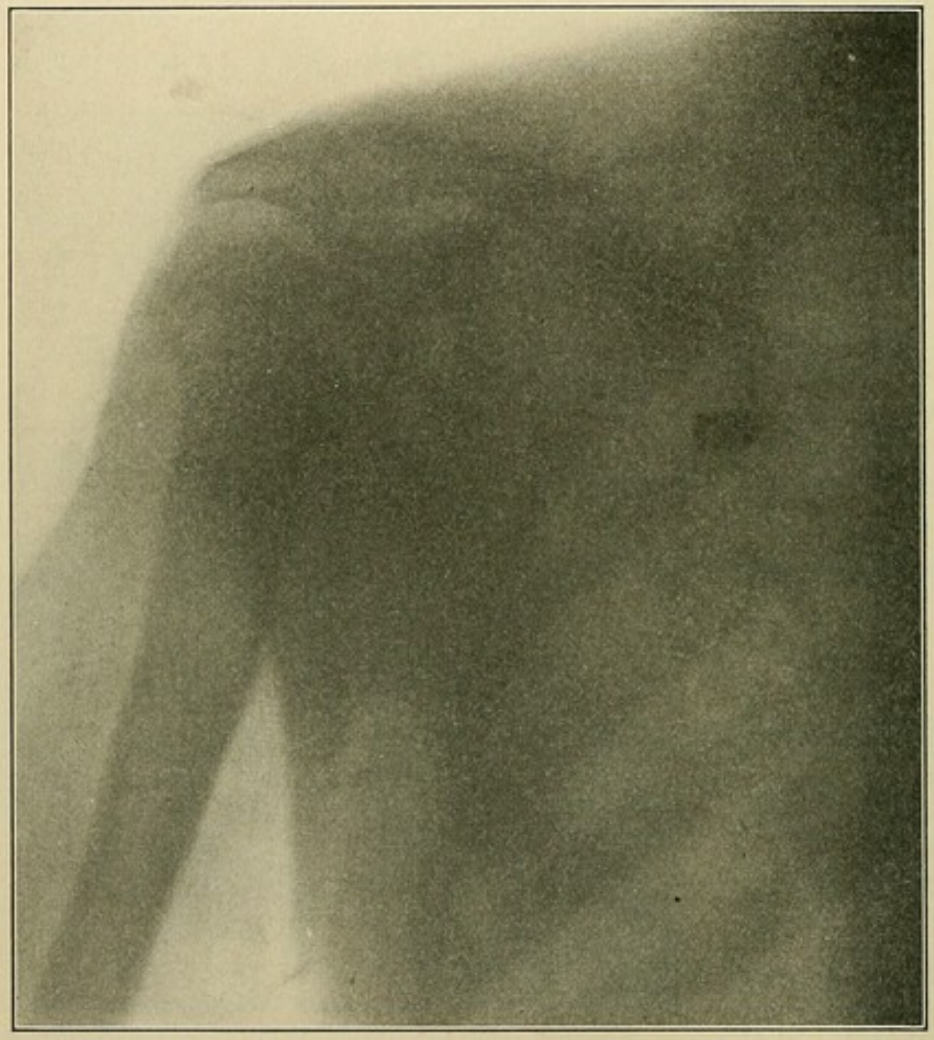

Fig. 139.—Leaden bullet encysted in the chest below the clavicle for five years.

bullets on the battle-field, as this part of the surgeon's work, if it is indicated at all, must be reserved until the surgeon can avail himself of the modern diagnostic resources and facilities for asepsis which can only be furnished by a well-equipped hospital.

All the bullets removed on board of the hospital ship Relief were located by the Röntgen ray. Dr. Gray, an expert in skiagraphy, who had charge of the scientific work of the floating hospital, was of the greatest service to the surgeons in enabling them to locate bullets and in guiding them as to the advisability of undertaking an operation for their removal. His large collection of

skiagraphic pictures will also throw a flood of new light on the effects of the small-caliber bullet on the different bones of the body. The skiagraph has enabled us to diagnosticate the existence or the absence of fracture in a large number of doubtful cases in which we had to depend exclusively on this diagnostic resource.

In fractures in close proximity to joints the X-ray has been of the greatest value in ascertaining whether or not the fracture extended into the joint. In one case of gunshot wound at the base of the thigh, in which the bullet passed in the direction of the trochanteric portion of the femur, opinions were at variance concerning the extent of injury to the bone. Some of the surgeons made a diagnosis of fracture, while others contended that there was no fracture, but believed that the bullet had made a deep groove in the anterior portion of the bone, and had possibly opened the capsule of the joint at the same time. The Röntgen ray clearly demonstrated the absence of a complete fracture and the existence of a deep furrow, with numerous fragments on each side. The X-ray apparatus also proved of the greatest practical utility in showing the displacement of fragments in gunshot fractures of the long bones, thus enabling the surgeons to resort to timely measures to prevent vicious union. The fluoroscope has added much to the diagnostic value of skiagraphy in the diagnosis of gunshot wounds and other injuries. In the light of recent experience the X-ray has become an indispensable diagnostic resource to the military surgeon in active service, and the suggestion that every chief surgeon of all army corps be supplied with a portable apparatus and an expert to use it must be considered a timely and urgent one.

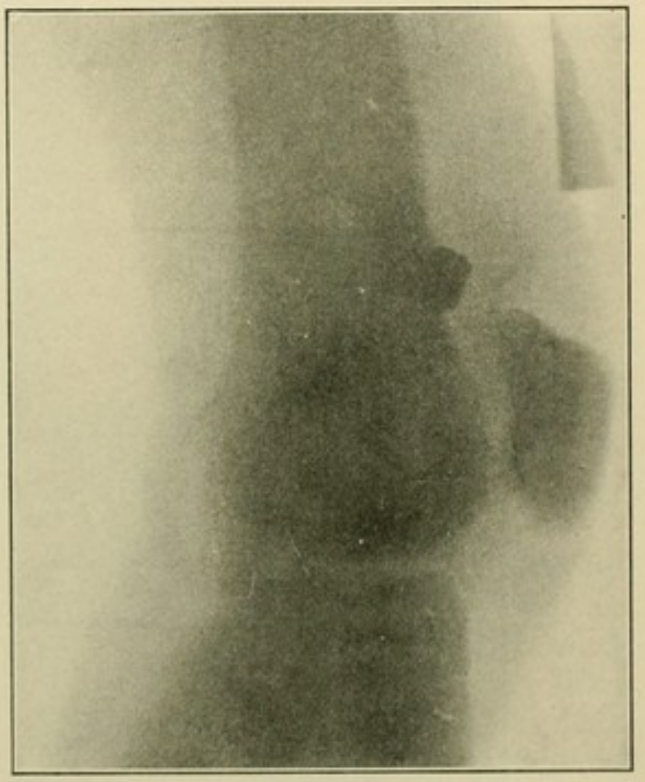

Fig. 140.—Bullet in knee-joint.

Prognosis.—The small-caliber bullet inflicts injuries that, if not fatal from its immediate effects, are favorable to successful treatment. This consists largely in the prevention of wound infection. The relative number of dead and wounded in future wars is probably well shown by our experience in Cuba. During the whole

campaign not more than 300 men were killed, while nearly 1400 were wounded. In Porto Rico the relative proportion of wounded to dead was still greater. Unless some vital organ is injured or death occurs from acute hemorrhage, the wounded man has a good chance for recovery if infection is prevented by the timely application of the first-aid dressing. Wounds of the soft parts, outside any of the large cavities of the body, heal, as a rule, by primary intention under the first-aid dressing in the course of a week or two.

As yet we have received no reliable detailed accounts of the experience of surgeons during the war that is now raging in South

Fig. 141.—Bullet in the hand, between the metacarpal bones of the index- and middle fingers.

Africa, but from the fragmentary accounts it is evident that it is but a repetition of our own experience during the Spanish-American war. A recent writer to the Netley hospital says: "Surgeon-Captain Steele, of the Militia Medical Staff Corps, who was orderly officer for the day, took me to Major Dick, R.A.M.C., in whose charge most of the surgical cases had been placed, and who kindly took me round some of the wards. Among the cases were men who had been pierced by bullets in almost every direction. Thus, there were cases in which the head had been wounded, and apparently

even the brain traversed; others were shot through the thorax, while several had been wounded in the abdomen, groin, and buttock, and in both upper and lower limbs. Shoulder- and elbow-joint had in turn been pierced. In one or two cases, of which I give brief notes, the body had been traversed literally from one end to the other. The wounds, with the exception of a very few, had almost entirely healed, and in a large number of cases had left no symptom whatever behind them. Most interesting of those with appreciable after-effects were cases of nerve injury, in which a degree of either pain or paralysis, or both, remained."

G. H. Makins, consulting surgeon with the forces in South Africa, writes as follows on the clinical signs and course of the wounds: "The actual infliction of the wound gives rise to little pain,—usually a sharp, burning sensation,—and is followed by remarkably little shock; severe shock is, in fact, uncommon, even when vital organs are struck. Omitting the cases in which a large vascular trunk is struck in a limb or in the body, external hemorrhage is slight, and even when a large trunk is implicated, it more often gives rise to intermediate or secondary hemorrhage than to severe primary bleeding. In fact, such evidence as can be obtained points to but few deaths taking place on the field from primary bleeding. Although, however, external hemorrhage is slight, interstitial bleeding into the limbs or into the cavities of the trunk during the first few hours after the injury is common, and may be severe or fatal. As will be remarked later, traumatic aneurysms are comparatively frequent. Again, the scoring or contusion of nerve-trunks gives rise to more or less complete paralysis or to severe neuralgic pain during and after the healing of the wound.

"The tendency to run an aseptic course is very marked, and deep suppuration or diffuse cellulitis is distinctly rare. This depends on the smallness of the wound, the aseptic nature of the bullet, and the fact that foreign bodies, such as pieces of clothing, are comparatively rarely introduced.

"The asepticity of the bullet is, I think, clearly demonstrated, and is probably due to the fact that the bullet, in traveling through the barrel of the rifle, obtains a completely fresh surface, and with such enters the body. As to the frequency with which portions of clothing are carried into the wound, it should be remarked that this varies considerably with the nature of the material traversed. The opening in the khaki jacket, for instance, from the hardness of the material, is usually a clean slit; but if the bullet has to traverse a flannel shirt, loss of substance and transference of this to the wound is more common, while in the case of the Highland kilt, where several layers of cloth have to be traversed, portions are comparatively frequently found in the wounds.

"The slight tendency to suppuration exhibited by the tracks is, however, I think due to some inherent character of the tissue, probably explained by the condensation and surface destruction of

the tissue resulting from the force and velocity of the bullet, since the tracks neither bleed freely at first nor do they furnish any material amount of serous discharge during the process of healing. They remain, indeed, dry throughout, and their slight tendency to suppuration is well instanced by the fact that if for any reason a deep part of a track becomes infected and suppurates, the inflammatory process shows no tendency to spread by the original wound, but comes to the surface locally.

"During the process of healing the apertures, and with them the track, gradually contract, the aperture of entry is closed by dry clot, and diminishes in size, the contused margin becoming a small black depressed spot in the center, while the aperture of exit often closes with an ordinary reddened cicatrix. When fully healed, the ends of the contracted track can be felt as two small indurated spots, often so hard as to give the impression of an included foreign body. The extreme density of the resulting cicatrix in the deeper parts of the wound is a factor of much importance, since if it involves tendons or nerves, considerable impairment of movement or signs of nerve pressure are produced. Again, a track through the muscles of the leg, for instance, will more or less tie the whole thickness of the traversed structures together from the aperture of entry to that of exit, both of which may be seen to be drawn in as dimples when the muscles are put in action. This condition naturally gives rise to much subsequent stiffness and pain on movement, and forms one of the most troublesome after-consequences in simple flesh wounds. The scars left in the situation of the two apertures are not more apparent than those resulting from a large acne pustule.

"The above description of uncomplicated flesh wounds shows that the treatment of these injuries is simple in the extreme. It has consisted almost entirely in the application of pads of dry bicyanid gauze and a little wool after the parts surrounding the openings have been washed with an antiseptic lotion, either a solution of carbolic acid or of perchlorid of mercury. Fixation, beyond that resulting from the bandaging on of the dressing, has rarely been needed. In the foregoing remarks concerning the aseptic course of the wounds considerable stress has been laid on the aseptic character of the bullet and the nature of the injury to the soft parts; but I should not neglect to add that the purity of the atmosphere and the apparently innocuous nature of the dust on the high veld, when the camp is a fresh one, must also be credited as important factors in the happy results which have been attained up to the present. It will be noted that no remark has been made as to the treatment of retained bullets, and this for two reason: first, retained Mauser bullets are uncommon; and, secondly, if not causing trouble, they are best left alone, unless they lie in very superficial positions."

Traumatic aneurysm will be more frequently observed in the

future than in the past, as the new bullet inflicts vessel wounds that bleed more profusely than similar wounds made by the large-caliber leaden bullet, and are less favorably adapted for the spontaneous arrest of hemorrhage by thrombus formation. Penetrating gunshot wounds of the skull, if the patient survives the immediate effects of the injury, are grave injuries, but not necessarily fatal, as a fair percentage of recoveries will reward early surgical intervention under strict aseptic precaution. Penetrating wounds of the chest, if the heart and large blood-vessels escape injury, usually heal by primary intention under the first dressing. Gunshot wounds of the abdomen at and above the level of the umbilicus less frequently demand operative interference and result in fewer deaths than similar wounds in the area of the small intestine. Comminuted gunshot fractures and penetrating wounds of any of the large joints not complicated by injury of large vessels and nerves are now within the range of successful conservative surgery.

The prognosis of any gunshot wound is more favorable in cases in which no probing has been done and in which the first-aid dressing was applied immediately or soon after the injury was received. Even in cases in which infection takes place the prognosis is much more favorable to-day than it was before antiseptic surgery was practised, as we are now in possession of ways and means that will enable us to ward off death from septicopyemia. This is accomplished by establishing free drainage and by resorting to antiseptic irrigation at short intervals or continuously, procedures also relied upon in limiting the indications for the performance of secondary mutilating operations.

Treatment.—The surgeon in daily practice has learned long ago that every accidental wound must be regarded and treated practically as an infected wound. In this respect the military surgeon of to-day has the advantage over his colleague in civil life, in knowing that the small-caliber bullet inflicts wounds that *per se* are more often aseptic than septic, and these are the wounds he is most frequently called upon to treat. Our recent observations in Cuba and Porto Rico have shown that the small-caliber jacketed bullet seldom carries with it into the wound clothing or any other infectious substances. Most of the wounds of the soft tissues uncomplicated by visceral injuries, which in themselves would become a source of danger, healed by primary intention in a remarkably short time. If infection followed, it usually did so in the superficial portion of the wound in connection with the skin, and, what is more than suggestive, the wound of exit was more frequently infected than the wound of entrance. This can be satisfactorily explained by the larger size of the wound and the more extensive laceration and tearing of the tissues. In many of the cases ideal healing of the wound did not occur, owing to a subsequent limited superficial suppuration of the wound. The deep tissues were seldom implicated in such cases. I have reason to believe that some of

the gunshot fractures that suppurated had such a source of infection—that is, the extension of a superficial infection to the seat of fracture.

The failures in protecting the more serious wounds against infection are attributable principally to three causes: (1) Inadequate supply of first-dressing material at all times and in all places. (2) Faulty application of first dressing. (3) Unnecessary change of first dressing.

The medical officers with the regiments and in the field-hospitals were hampered in their work by an insufficiency of proper dressing material. This was due to the haste in which the campaign was planned and finished, the difficulties encountered in transporting the hospital supplies to the front, and the unexpected large number of wounded. These reasons sufficiently explain the unavoidable lack of dressing material when and where it was most needed. The first-aid packages were more frequently found in the field-hospitals than on the person of the soldier. Many of the dressings were too small and too insufficiently secured to keep them in place in transporting the wounded from the front to the field-hospitals. As a rule, not enough attention was paid to the immobilization of the injured part, an important element in securing rest for the wound and in guarding against displacement of the dressings. It is a source of regret that plaster-of-Paris dressings were not more frequently employed in the treatment of gunshot fractures, over the primary dressing, before transporting the patients to the rear.

Another very obvious cause of infection was the too common practice of unnecessary change of dressing. The transfer of patients from one surgeon to another could not be avoided. Patients brought from the firing-line or first dressing station to the field-hospital were usually subjected to a change of dressing, and when, a few days later, they reached the General Hospital at Siboney, they had to undergo the same ordeal and often not only once, but as many times as they came into the hands of another surgeon. Patients not thus treated were dissatisfied, as the laymen are still laboring under the erroneous impression that the oftener a wound is dressed, the sooner it will heal. It is difficult to eradicate so deeply rooted and time-honored a belief, and patients will continue to clamor for a change of dressing, the good-natured, hard-working surgeons only too often complying with such unreasonable requests.

The evil of meddlesome surgery became very apparent during the brief Cuban campaign, and it has taught us an important lesson that must be heeded in the future. Our military surgeons must learn to realize more than ever the value and importance of the first-aid dressing in the prevention of wound infection. In all cases in which the first examination does not reveal the existence of complications that require subsequent operative treatment, the

diagnosis tag should convey this important instruction: "*Dressings not to be touched unless symptoms demand it.*" Such instruction is significant, and must be followed to the letter by all surgeons in subsequent charge of the patient. After the first dressing has been applied, it should not be removed except for good and substantial reasons. Much can be done in the after-treatment in the way of readjusting the bandage and in immobilizing the injured part, but the first dressing must remain unless local or general symptoms set in that would warrant its removal. Malaria and yellow fever, which crept in upon us in Cuba so insidiously, were responsible for many unnecessary changes of dressing. The appearance of fever in a wounded man naturally leads to the suspicion that there is something wrong with the wound. Many dressings were changed on this ground, but nothing abnormal was found in the wounds. A day or two later, however, the nature of the fever was recognized, and the patients were either given quinin or were sent to the yellow fever hospital, according to the diagnosis made. *Every change in dressing, more especially in military practice, is attended by risk of infection and must be scrupulously avoided, unless local or general symptoms indicate the existence of complications that demand surgical intervention.*

In detailing this it is not my purpose to cast any reflections on the work of our surgeons; on the contrary, I willingly bear testimony to the ability, faithfulness, and unselfishness with which they discharged their trying, onerous duties. A better and more conscientious group of medical officers it would be difficult to select anywhere. The results, on the whole, were excellent, but I am certain that they can be improved upon in the future by laying more stress on, and giving more attention to, the value and importance of the first-aid dressing. I wish to repeat, and in a most forcible way, the language of the late Professor von Nussbaum:

"*The fate of the wounded rests in the hands of the one who applies the first dressing.*"

FIRST-AID PACKAGE IN MILITARY SURGERY.

It is fortunate for the armed forces of the world, but unfortunate for military surgery, that no great wars have occurred since antiseptic and aseptic surgery came into general use. During the time the Franco-Prussian war was fought, the last great war since our own great civil conflict, Lister was quietly at work framing the great principles that have recast the work of the surgeon. Antiseptic and aseptic surgery has not as yet had an extensive and a fair trial on the battle-field. Carbolic acid solutions were employed to some extent by the German surgeons during the Franco-Prussian war, but Billroth's extensive observations in a number of large military hospitals led him to believe that they did not exert any special influence in the prevention of wound complications. As late as 1861, Strohmeyer, in his classic work on military surgery,

advised the use of a wet compress in the treatment of wounds on the battle-field, a method of treatment that had been in use from time to time since military surgery was practised. The only innovation was a gutta-percha tissue cover over the compress, which was used for the purpose of retaining moisture until the patient could reach the field-hospital, where the compress could be changed as often as was deemed necessary. This treatment was a decided improvement over some of the old methods, such as the common practice of stuffing the wounds with infected charpie and the barbaric use of boiling oil, but it was a step backward, judging from the present standpoint of wound infection, from the treatment of wounds by the local use of turpentine, which at one time was sanctioned and extensively practised by German military surgeons. The moist septic compress had a trial on the most extensive scale during the Civil War, and we are familiar with the results. The terrible experience with gunshot wounds by all the old methods of treatment turned the attention of military surgeons to the modern treatment of wounds as soon as it became well established in civil practice. The surgeons in civil life built the bridge across the river that separated the old from the new methods of wound treatment, and the military surgeons willingly followed the advance columns crossing it, eager and anxious to extend the benefits of the new discovery to the wounded soldier.

The wars among civilized nations have been too few and on too small a scale to perfect the technic of aseptic surgery on the battle-field ; a sufficient experience has, however, accumulated to warrant the statement that asepsis will eventually bring about as great changes in military surgery as it has already accomplished in civil practice. The first tentative efforts at practising asepsis in military surgery were made during the Russo-Turkish war. Reyher and von Bergmann, who took a conspicuous part in that campaign, promptly made known the results of their observations, and their writings laid the foundation for the modern treatment of gunshot wounds. Two things were brought out clearly during that war—viz. (1) the value of a first-aid antiseptic occlusive dressing in the prevention of wound infection, and (2) the importance of immediate immobilization of gunshot fractures.

It was during that war, too, that the too common practice of searching for and extracting bullets on the battle-field and in the hospitals was violently opposed, and strongly condemned by both Reyher and von Bergmann. The value of antiseptic and aseptic precautions in military practice has been demonstrated since that time on a limited scale in Bulgaria, Servia, Chili, Greece, Turkey, Japan, and at different points in Africa in small engagements between the British, Italian, and French troops and the natives, and lastly during the recent Spanish-American war. It is evident that aseptic military surgery will never equal in its results aseptic civil surgery, owing to circumstances over which contending armies

and governments have no control. Military surgery is and always will be emergency surgery. The difficulty in obtaining and transporting the necessary medical supplies and, in large engagements, the number of wounded, render it impossible to follow out the aseptic precautions with the same pedantic care as in private and hospital practice. Absolute asepsis in military surgery on the field is out of question, for reasons that are apparent to any one who has taken part in an active campaign. The limited experience of the past has, however, shown that the imperfect aseptic precautions that are applicable in the field have done much to minimize the horrors of war. The modern small-caliber bullet inflicts wounds that are particularly well adapted to successful treatment by a primary antiseptic occlusive dressing. All civilized nations have taken advantage of the modern treatment of wounds in their efforts to extend its benefits to military surgery. Suggestions from different sources in this direction came soon after antiseptic surgery became a generally recognized procedure. It is interesting to know what has been done in the way of recommendations for asepsis on the battle-field. Antiseptic powders, sterile and medicated cotton, gauze, wood-wool, and other hygroscopic substances have been proposed. As antiseptics iodoform, salicylic acid, carbolic acid, bichlorid of mercury, chlorid of zinc, and salol have been most frequently mentioned and used.

The many difficulties that are met in war in the transportation of medical supplies make it necessary to restrict the requirements for procuring and maintaining asepsis to so much as is compatible with the immediate demands of the principles upon which it is based; that is, asepsis on the battle-field must be attempted by the employment of the most efficient and the simplest precautions. The value of the first-aid dressing, applied behind the fighting-line by the wounded himself, by his comrades, or by members of the hospital corps, is as yet not generally admitted. Legouest, Delorme, Nimier,—French military surgeons,—do not favor the first-aid package. Chauvel does not share their view, and makes a strong plea for its general introduction into military practice. But until 1889 no such packages were in use in the French army. Patin suggested the following first-aid package: One elastic bandage, one antiseptic gauze bandage, two graduated compresses of the same material—inclosed first in paraffin paper, and, as a cover, strong paper made waterproof by linseed oil and a siccative. Bedoin proposed, as a dressing material for the first aid, filtering paper sterilized by dry heat and immersion in a 1 : 1000 bichlorid solution to which a little glycerin is added, when the paper is slowly dried. Six to eight layers are applied over the wound, besides cotton, and the dressing is held in place by a bandage. The package that he recommends for service in the field contains six sheets of aseptic filtering paper 40 cm. square, properly folded, a piece of gutta-percha tissue 45 cm. square, in which the paper is wrapped, a thin rubber bandage,

from one to one and a half meters in length, and several safety-pins. The package weighs 40 gm.

Forgue recommends iodoform and cotton as an occlusive first-aid dressing.

The first-aid package of the French army in use at the present time is quadrangular in shape, the gray cloth wrapper bearing on one side printed directions for use. It is opened by extracting the thread used in sewing the wrapper. It contains an impermeable fabric, a small cushion of sublimated jute, a sublimated gauze compress, a bandage, and two safety-pins.

Mosetig von Moorhof advises dusting the wound with iodoform, over which a gauze compress is applied, then mackintosh or some other impermeable material, which is made to overlap the gauze for at least an inch, and over this a large hygroscopic dressing and bandage.

Wein recommends iodoform gauze between two layers of hygroscopic cotton wrapped in gutta-percha tissue in a compact package. Before applying the dressing it is to be immersed in a strong solution of bichlorid of mercury or a carbolized solution, to insure absolute asepticity, when the iodoform gauze is applied next to the wound, and over it the cotton, gutta-percha, and, lastly, the retaining bandage. Langenbuch strongly advocated the closure and sealing of the wounds by suturing and adhesive plaster, a part of the field service that he wished to assign to the litter bearers. Lühe believed that this method of dealing with gunshot wounds would prove more effective if the wound were first dusted with iodoform or salicylic acid.

Port has modified the recommendations of Langenbuch in so far that he applies the adhesive plaster in the form of a Maltese cross, with a central opening the size of the bullet wound, which, when the plaster is in place, is covered with iodoform gauze and cotton, for the purpose of guarding against the retention of wound secretions. The margins of the gauze dressing are fastened to the surface with a rubber solution, and the whole is retained by strips of adhesive plaster. In 1869 von Esmarch devised the triangular bandage, with printed illustrations for its use. During the early history of antiseptic surgery he recommended balls of chlorid of zinc, jute, and, later, wipers of sublimated sawdust in gauze bags for the field service. His typical first-aid package was a later product of his fertile brain. It consists of his bandage, two compresses of sublimated gauze 10 cm. broad and 100 cm. long, each wrapped in waxed paper, and an antiseptic cambric bandage 10 cm. broad and 2 meters long. The whole package, in rubber cloth, weighs 100 gm. According to Seydl, the first-aid package of the German army in 1893 contained a sublimate gauze bandage five meters in length, two compresses of the same material, and one safety-pin, the whole wrapped in a compact form in waterproof linen cloth that is sewed into the shirt of the uniform of officers and men.

In 1855 an order was issued in England from the Medical Department, which required that a field dressing should form a component part of every British soldier's kit in active service, so as to be available at all times and in all places as a first dressing for wounds. The materials and form of the first field dressing were ordered to be as follows: Bandage of fine calico 4 yards long and 3 inches wide; fine lint 12 inches long and 3 inches wide, folded flat and fastened by four pins. It was ordered to be carried in the soldier's knapsack. During the Ashanti war, 1873–74, the dressing included a packet of lint on which a little simple ointment had been spread, inclosed in waxed paper, a triangular bandage, two safety-pins, and a small packet of ordinary pins. These articles were folded into a small flat package 4 inches by 3½ inches by 1 inch, which was covered by waxed paper. It was carried in a breast pocket, in the lining of the left side of the tunic, the pocket being made of a suitable size. Later, this package was ordered to be carried in a sewn-up pocket on the inside of the skirt of the soldier's jacket. Since 1891 the package is made up as follows: Within an outer gray, fine linen cover is a thin waterproof cambric inside cover that is rendered air-tight by being cemented at the edges. Both covers can be readily opened when necessary. The inner cover contains two safety-pins, a piece of waterproof cambric 12 inches by 6 inches, and this incloses a gauze bandage 4½ yards long, folded flat into a package 4 inches by 2½ inches; a piece of gauze 17 inches by 13 inches, also folded flat; about 160 grains of compressed flax charpie between layers of gauze. All the dressing materials are rendered antiseptic by impregnation with bichlorid of mercury 1 : 1000. The weight of the complete dressing is 2 ounces.

Metallic cases have been recommended by Majewski, Port, and others for the safe-keeping of the dressing materials. Port suggested a piece of tin that, when folded, would be about the size of an ordinary envelop, and that was to be sewed into the uniform over the region of the heart, for the double purpose of protecting this important organ against bullets and at the same time serving as a case for the dressing material.

During the Spanish-American war the Surgeon-General issued 272,000 first-aid packages to the troops in Cuba and Porto Rico and the soldiers in the home camps. Two kinds of packages were used. The one in a pale-red cover contained two antiseptic compresses of sublimated gauze in oiled paper, one antiseptic sublimated cambric bandage with safety-pin, one triangular Esmarch bandage with safety-pin. Directions printed on package: "Place one of the compresses on the wound, removing the oiled paper. In cases of large wounds open the compress and cover the whole wound. Apply the antiseptic bandage over the compress. Then use the triangular bandage as shown by illustrations on the same." The other package in a yellow cover contained the same materials and

directions, but was different in shape, somewhat larger, narrower, and thicker.

All the first-aid packages that have been described, including those furnished our own army, are too bulky for first-aid dressing in the field. The packages used during the Spanish-American war did excellent service in the field-hospitals, but there is no place in the uniform of the soldier where they would be tolerated for any length of time for the purpose for which they are intended. Longmore made the statement that during the Egyptian campaign the first-aid packages issued to the troops were used for almost everything else except as a dressing for wounds.

During my service in Camp Tanner I supplied the Illinois troops with a small first-aid package, and every soldier left the State with one of these packages sewed into the skirt of the uniform on the left side. These packages remained in place and were often made use of in the treatment of accidental wounds. No definite conclusions have been reached as to the best place for these packages on the person of the soldier. The helmet, the knapsack, the cartridge box, a hollow space in the butt of the gun, the uniform at a place over the heart, and the skirt have all been recommended as the most convenient places for carrying the packages during an active campaign. As the officers and noncombatants do not carry a gun, some place in the uniform or the accoutrement must be found where such a package can be carried without inconvenience and without coming in conflict with military regulations. It must be stored in some part of the soldier's outfit that he is not likely to throw away during a forced march or in the heat of battle. The cartridge or sword belt is about the last thing a soldier will part with, and it is for this reason that a number of years ago I made the suggestion to sew the first-aid package in the middle and upon the inner side of the belt. As the modern cartridge belt is made of canvas cloth, no difficulty presents itself in fastening the package by stitching it to its inner surface. Oiled linen cloth or thin leather would recommend themselves for the outer wrapper. To be worn in this locality without objection on the part of the soldier or the military authorities the package must be small. Large packages of any kind will never prove satisfactory. The first-aid package for use in the field must meet the following requirements:

1. The material it contains for the dressing of the wound must not only be aseptic, but antiseptic.

2. The antiseptic used must be nonvolatile and resistant to chemic changes for a long time.

3. It must contain a fixation material that will prevent displacement of the dressing after it has been applied.

4. Its size must be such as not to inconvenience the soldier or to prove a source of objection to the military authorities.

5. The dressing employed should not interfere with the free evaporation of the wound secretion.

As the quantity of dressing material must necessarily be limited in the dressing of gunshot wounds behind the fighting-line, it is evident that better results will be obtained if it is impregnated with an antiseptic substance than if it is composed simply of sterile material. Perfect asepsis on the battle-field is a happy dream that will probably never be realized. Disinfection of the wound and its immediate vicinity before the application of the dressing under such circumstances is absolutely out of question. Bullet wounds should never be touched, much less explored, before the first-aid dressing is applied.

The necessity for the use of antiseptic dressings in the treatment of recent gunshot wounds has been shown most conclusively by the ingenious experiments of Bogdan. This investigator showed, by bacteriologic experiments, that the skin of soldiers protected by the regulation clothing, when in active service, contains, on an average, to every five cubic centimeters 4429 pathogenic microbes, and he found, by further investigation, that in gunshot wounds treated by sterile dressing material the microbes increased much more rapidly than under sublimated gauze. He studied the results of twenty-two dressings after twenty-four hours, and found that under the sterile dressing the microbes had increased to 780,729, and under the sublimated gauze to 19,668, the relative proportion of increase being 4 : 176 or 1 : 44. These experiments only prove, what we would naturally expect, that the increase of microbes is diminished by the employment of antiseptic dressings in the treatment of wounds that can never be regarded as aseptic.

Carbolic acid is volatile, and is not adapted for dressings in the field. Corrosive sublimate, the most important antiseptic employed at the present time, is a very fickle chemic substance, prone to decomposition by chemic changes that destroy its antiseptic properties when incorporated in dry dressing material. Iodoform has no decided antiseptic properties, and can not be relied upon in the protection of recent wounds against infection. Salicylic acid has often been proposed from different sources as the most valuable antiseptic for the first-aid dressing. Boric acid is another stable and valuable antiseptic, but it can not be relied upon exclusively as an antiseptic in a small dressing in preventing wound infection. For years I have relied on a combination of these two antiseptics as a drying antiseptic powder as an aid in the treatment of recent wounds. The formula used is boric acid four parts, salicylic acid one part. The line of suturing is covered with a layer of the borosalicylic powder, deep enough to bury the sutures out of sight before the hygroscopic sterile dressing is applied. The primary wound secretion dissolves a part of the powder applied, and the resulting antiseptic fluid resembles in its effects very closely Thiersch's solution, which has, for good reasons, become very popular as a safe, non-irritating, and yet efficient antiseptic. Several years ago I recom-

mended the borosalicylic powder in the foregoing proportion as a valuable component part of the first-aid package, and an extensive experience has strengthened my faith in its antiseptic properties.

Fixation of the dressing by the triangular or roller bandage can not be relied upon in preventing displacement of the dressing during the transportation of the patient from the field to the hospital. The dressing must be held in place by one or two strips of rubber adhesive plaster, which must constitute an essential component part of all future first-aid packages. The size of the package must be reduced to a minimum, to do away with the most serious objections against its employment in field service, and this can be done by selecting only such materials as are essential in a primary dressing for small wounds. All primary dressings for recent gunshot wounds should be dry, and nothing must be placed in the way of free evaporation of the wound secretion; hence all impermeable covers outside of the hygroscopic dressing must be abandoned. A dry dressing is one of the very best means of preventing wound infection, and nothing should interfere with the

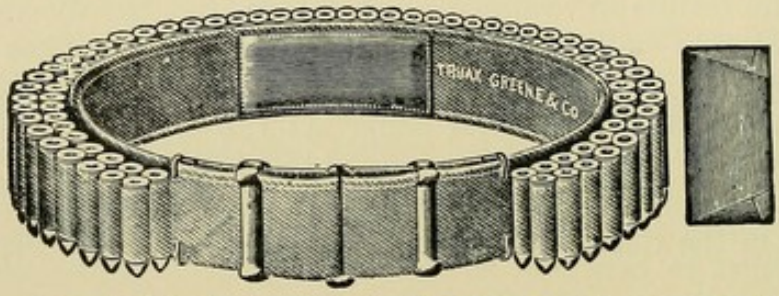

Fig. 142.—Cartridge belt with first-aid package sewed on inner surface.

conversion of the wound secretion and dressing employed in securing a dry crust, which hermetically seals the wound. Sterile absorbent cotton is far superior to gauze as a primary dressing for bullet wounds, as its hygroscopic capacity is much greater, at the same time furnishing a more efficient filter for the exclusion of microbes from the wound from without. I would suggest the following first-aid package for field use and emergency work:

A soft, flexible package, about 1¾ cm. in thickness, 6½ cm. in width, and 19 cm. in length. It consists of two drams of borosalicylic powder (4 : 1) in an aseptic fibrous paper envelop; two pieces of compressed cotton, each 2½ by 4 inches; one piece of absorbent gauze, triangular in shape, being one-half of a square yard; two safety-pins attached to the gauze; two strips of rubber adhesive plaster, each 1 inch in width and 8 inches in length. The whole, after being compressed under heavy pressure, is incased, with aseptic precautions, in a cover of thin mackintosh cloth and sealed with rubber cement. For military service the latter is included in a waterproof duck casing of sufficient width to allow the lateral margins to be stitched to the inner surface of the cartridge belt. The

weight of the package, including the duck cover, is 710 grains; without the latter, 540 grains.

In using the package the powder is applied to the wound, when the lintin is used as a compress, held in place by the strips of adhesive plaster and the gauze bandage over it. If two wounds are to be dressed at the same time, as is usually the case in modern warfare, the contents of the package are equally divided and used, which can be done without materially impairing the efficiency of the dressing. The slight hemorrhage in wounds inflicted by the small-caliber bullet will soon saturate a part of the dressing, which, by evaporation, will soon convert the antiseptic powder and the cotton into a dry antiseptic crust, the very best protection for the wound against infection.

The important question arises: Where and by whom should the first-aid dressing be applied? A number of prominent military surgeons of the present time, among them Longmore, W. Roth, Wein, and Tirok, are of the opinion that the first duty of the military surgeons when in action consists in concentrating their energies in providing for a speedy removal of the wounded from the firing-line to a place of safety. It is their belief that little or nothing can be done in the way of treating wounds until this has been accomplished. Many of the military surgeons have recently expressed themselves as being opposed to the employment of the first-aid package by any but medical men. This position will be found untenable during any great war, when the number of wounded would greatly exceed the working capacity of the limited number of surgeons. Additional and equally strong arguments against such limitation of the first-aid dressing behind the firing-line are the well-known facts that the sooner a recent wound is properly dressed, the greater is the probability of its remaining practically aseptic, and that the simple dressing proposed here can be efficiently applied by any person of average intelligence who can be made to understand and follow the imperative rule never to touch the wound. Every soldier must be taught the danger of hand contact and the importance of the first-aid dressing and its manner of application. The trained hospital corps men of the future can be intrusted with this part of the field service. I am confident that the prompt first-aid dressing applied by well-instructed hospital corps men and litter bearers will do more to prevent wound infection than the delayed dressings in skilled hands. The clothing of the patient, if allowed to remain in contact with the wound for any length of time, is a very serious source of infection, probably nearly on a par with hand contact, and the sooner the wound is protected from it by the first-aid dressing, the greater will be the chances of preventing infection. I fully agree with those who are opposed to the removal of clothing from the wounded part in the firing-line for the purpose of inspecting and dressing the wound. The wounded must be removed to a place of safety as promptly as pos-

sible. The first-aid dressing can be applied in a few moments without the removal of any of the clothing except the shoes or boots in dressing wounds of the foot or lower part of the leg. In gunshot wounds of the extremities the seam of the trousers can be sufficiently ripped to expose the wound, and the underclothing can be cut to the requisite extent to expose the wound or wounds sufficiently for the application of the first-aid dressing. The dressing is fixed in place with strips of adhesive plaster, and the retaining bandage should be applied, not under, but over, the clothing. In dressing wounds of the chest, abdomen, and pelvis the dressing and bandage are applied in a similar manner. In gunshot fractures of the extremities an extemporized fixation dressing of the simplest kind completes the first aid, and prepares the patient properly for transportation to the rear. The value of the first-aid dressing became very apparent during the Cuban and Porto Rican campaigns. One thing that was supplied liberally and timely by the Medical Department was first-aid dressings, and to this we must largely attribute the speedy healing of most of the gunshot injuries and the few wound complications which later required operative interference. In conclusion I would emphasize the following:

1. First-aid packages are indispensable on the battle-field in modern warfare.

2. The first-aid dressing must be sufficiently compact and light to be carried in the skirt of the uniform or on the inner surface of the cartridge or sword belt, so as to cause no inconvenience to the soldier or conflict with military regulations.

3. The Esmarch triangular bandage is of great value in the school of instruction; as a component part of the first-aid package it is inferior to the gauze bandage.

4. The first-aid package must contain, in a waxed aseptic envelop, an antiseptic powder, such as borosalicylic powder; two strips of aseptic lintin, 4 by 8 inches; a gauze handkerchief 40 inches square; sterilized pins wrapped in tin-foil; and between this package and the outside impermeable cover two strips of adhesive plaster 1 inch wide and 8 inches long.

5. The first-aid dressing must be applied as soon after the receipt of the injury as possible, a part of the field service that can be safely intrusted to competent hospital corps men.

6. The first-aid dressing, if employed behind the firing-line, should be applied without removal of the clothing over the injured part, and should be fastened to the surface of the skin with strips of rubber adhesive plaster, the bandage being applied over and not under the clothing.

7. The first-aid dressing must be dry, and should remain so by dispensing with an impermeable cover of any kind over it, so as not to interfere with free evaporation of the wound secretion.

8. The first-aid dressing should not be disturbed unnecessarily, but any defects should be corrected at the first dressing station.

In the remaining part of this section there will be some repetitions, but these are concise and are made with special reference to military surgery.

Two important causes were destined to bring about a radical change in the treatment of gunshot wounds as practised in the Civil War, as was taught and advised in the Spanish-American, and will be practised in future wars: (1) The modifications that weapons and projectiles have undergone since that time; (2) the introduction into general practice of aseptic and antiseptic surgery. The diminution in the caliber of the bullet, the metallic jacket, the substitution of smokeless for black powder, the greater velocity and power of penetration of the missile, are conditions and influences that must necessarily modify the character of wounds inflicted with the modern weapon. Volumes have been written on this subject by writers in all countries in which the old weapon has been abandoned and the new one introduced. Numerous experiments have been made on cadavers and on animals for the purpose of studying the effects of the modern projectile on the tissues, with a view to obtaining reliable information as to the changes that will become necessary in the rational treatment of gunshot wounds in modern warfare. Experimental investigation has done much to point out some of the changes we may expect to see in the character of gunshot wounds during coming wars, but many of the conclusions drawn from them will have to be modified after we have had an opportunity to study such wounds on a larger scale on the battle-field. There can be no question but that the living body and the cadaver represent two entirely different media in studying the effects of the modern bullet. From a practical standpoint there remains no doubt as to the following facts, which will be confirmed by future experience in the treatment of gunshot injuries inflicted with the small-caliber bullet: (1) Fewer bullets will be found lodged in the body. (2) Wounds will resemble more closely incised than contused wounds. (3) Range will have more influence in changing the character of the wound. (4) Diminished risk of infection. (5) Dangerous primary hemorrhage will be more, secondary hemorrhage less, frequent. (6) More difficult extraction of the bullet. The relative number of dead and wounded and the adaptation of the jacketed bullet to become encysted are subjects that have been fairly well elucidated during the Cuban campaign, but that must be more definitely settled by wider experience. We are better prepared to predict the influence wrought by the recent discoveries and advancements in surgery on the treatment of gunshot wounds and the fate of the wounded. The antiseptic treatment of wounds as taught and practised by the immortal Lister, and asepsis as developed by the German surgeons, with the distinguished Volkmann and Nussbaum as their leaders, are destined to minimize the remote dangers of gunshot wounds and other open injuries inflicted on the battle-field. I can safely repeat, with the late Professor von Nussbaum,

the most enthusiastic follower of Lister: "*The fate of the wounded rests in the hands of the one who applies the first dressing.*" This is the motto that every military surgeon must adopt and carry into effect. To this motto I would like to add the inflexible rule, which should never be transgressed and which, if observed without exception, will guard against one of the most fruitful sources of infection, and that rule should be: *Never probe a bullet wound on the battle-field.* The experience of the past has taught us the wisdom of adopting such a universal rule. In wounds inflicted by the small-caliber bullet the cases will be few where there is any indication for probing wounds, and in those few where the bullet has lodged in the body exploration should be absolutely prohibited until the



Fig. 143.—Immobilization of arm and forearm by fastening the sleeve to the coat near the wrist- and elbow-joints with safety-pins, and inserting hand underneath coat on opposite side between two buttons.

Fig. 144.—Mitella by fastening skirt of coat on injured side with two safety-pins, in such a position as to support the forearm in a flexed position.

patent reaches the field-hospital, where the facilities for asepsis are at hand and instruments of precision in diagnosis can be employed in locating the missile.

In the absence of grave symptoms, such as hemorrhage, the first dressing should not be disturbed until the patient reaches the field-hospital, and in many cases healing of the wound will take place without further interference. The immobilization of the injured part, particularly in cases of compound fracture of the extremities, constitutes an important part of the manifest duties of those who render first aid to the wounded. In all large engagements the supply of mechanical supports carried by the men of the hospital corps

will be exhausted long before all the wounded have received attention. Splints must be improvised. Rifles, sabers, bayonets, bark, branches of trees, shrubs, etc., the chest in fractures of the upper extremity, the opposite limb in fractures of the thigh or leg, will have to be utilized in procuring rest for the injured limb in transporting patients from the line of battle to the first dressing station. It is here that the surgeons will supplement or improve the work done by the litter bearers and hospital corps. It is for the purpose of doing away with the necessity of using splints that a German military surgeon has recently devised a litter on the plan of a double

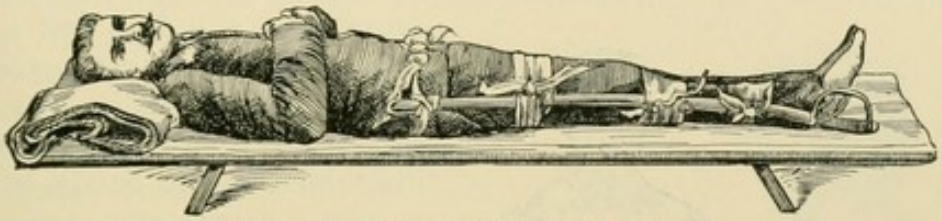

Fig. 145.—Saber splint for leg and thigh.

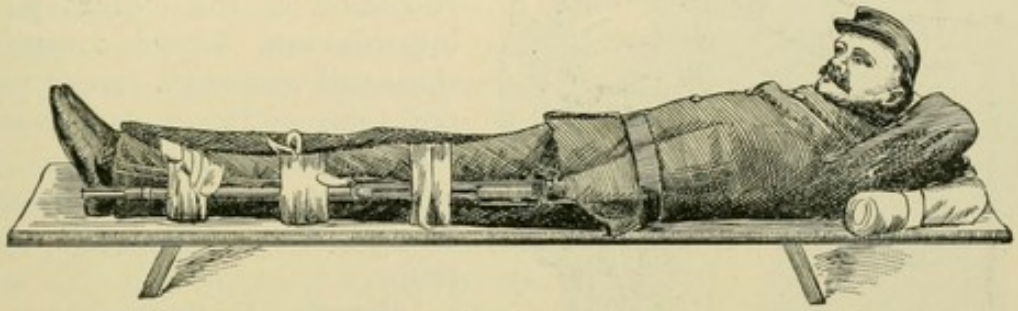

Fig. 146.—Gun splint.

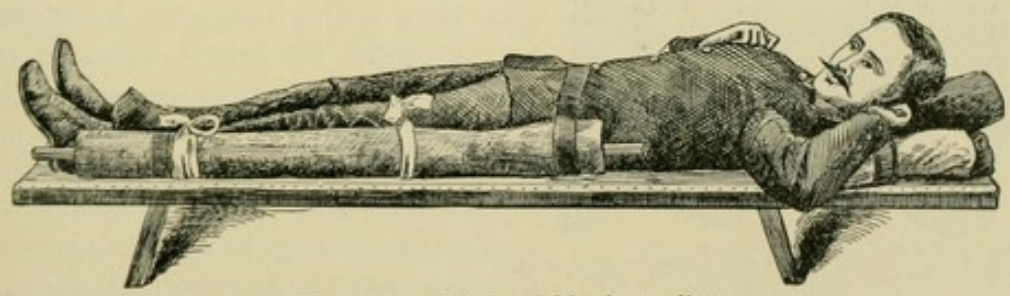

Fig. 147.—Stick and blanket splint.

inclined plane for the lower extremities, a description of which he gave before the military section of the International Medical Congress held in Moscow last summer. In the absence of a litter of such special construction the same object is attained by securing the same position for the injured limb by a roll made of a blanket, clothing, knapsack, drum, straw, etc. It is my opinion that the transportation of the wounded suffering from a fracture of the lower extremity can be done with less pain and with greater security against additional injuries if the fractured limb is placed in a flexed than if placed in a straight position. If this statement is found to

be correct by future observations, the manner of dressing such cases must undergo a material change in the future. The manner of handling, carrying, and conveying patients suffering from fracture of the lower extremity from the field to the hospital is a subject of great importance to those who have in charge the instruction of the hospital corps and company bearers.

Arrest of Hemorrhage on the Field.—Life will be placed in jeopardy and deaths will occur more frequently from internal than from external hemorrhage; in the treatment of the former little can be done on the field, and the latter class will come more frequently under the care of nonprofessional men than surgeons. Ligation of arteries on the field will prove impracticable in most instances. The company bearers and hospital corps men should be fully instructed in the details of the various hemostatic resources applicable in emergency work. Elevation of the injured part, hyperflexion, digital compression, and antiseptic tamponade are some of the measures employed that can be intrusted to intelligent and well-instructed laymen in arresting hemorrhage.

Fig. 148.—Bark splint for forearm and wire splint for arm.

Elastic Constriction.—Some form of circular constriction will, however, most frequently be relied upon in arresting hemorrhage complicating gunshot wounds of the extremities. The advantages and dangers attending this method of arresting hemorrhage must be made a prominent feature in giving instructions in first aid. The technic of the procedure, whether it consists in the use of the typical Esmarch's elastic constrictor, a pair of suspenders, or the Spanish windlass, must be fully explained and demonstrated on the living subject. The fact must be impressed that it is of great importance to render the limb that is to be constricted comparatively bloodless by elevation before the constrictor is applied. The next most important advice to be carried into effect in the use of circular constriction is to *constrict quickly and with sufficient firmness to interrupt at once and completely both the arterial and the venous circulation.* A question of immense and far-reaching importance, and one that has not as yet been definitely answered, is: How long is it

safe to continue the constriction? There must be, and there is, a limit as to length of time it is safe to exclude blood supply from living tissues. Although cases have been reported in which elastic constriction was continued for from three to twelve hours without any serious immediate or remote consequences following, yet the consensus of opinion among surgeons at the present time, I am sure, would be opposed to excluding the blood supply from an entire limb, the seat of a gunshot injury, for a longer time than three or four hours. The danger of gangrene is always greater in constricting an injured than a healthy limb. A number of years ago I made an extended series of experiments on dogs, detailed more fully elsewhere, to determine, if possible, the maximum length of time it would be safe to continue elastic constriction. The limb was invariably constricted near its base. The time varied from an hour and a half to twenty-seven hours. In a number of cases temporary incompetence of the muscles and temporary paralysis followed when constriction was continued beyond four hours, but the degree of functional disturbance was not always proportionate to the length of time. In only one instance did gangrene occur, and in this case constriction was continued for seventeen hours, while the maximum time was twenty-seven hours. This subject is of special interest to the military surgeon, as from the very nature of things, if circular constriction is resorted to as a hemostatic agent on the battle-field, a considerable length of time must necessarily intervene before the wounded reach the first dressing station or field-hospital, where it is removed and hemorrhage arrested by direct and permanent hemostatic measures. I should consider it dangerous to extend the time beyond from three to six hours, and should insist that within this limit of time the patient should be placed in charge of a surgeon fully equipped to substitute for it the ligature, aseptic tamponade, or some other direct hemostatic agent.

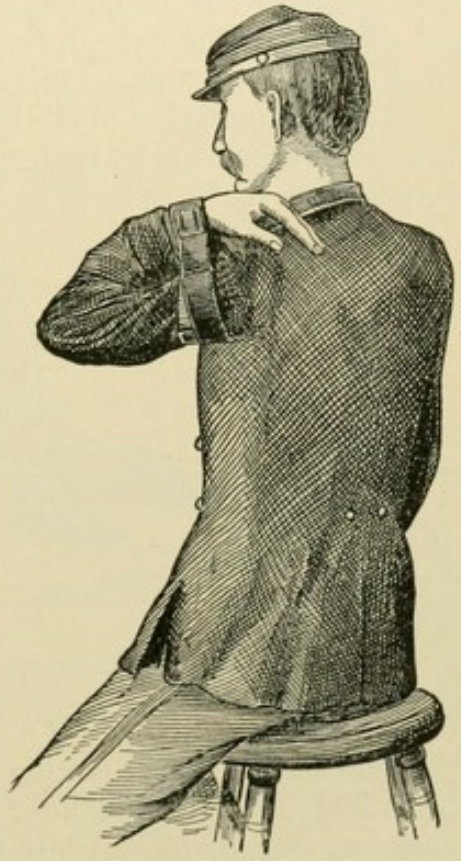

Fig. 149.—Forced flexion of forearm in arresting hemorrhage from the brachial artery opposite the elbow-joint or any of its branches below this point.

Elevation of Limb.—The force of gravitation answers an exceedingly useful purpose in arresting hemorrhage from the smaller vessels of the extremities. By placing the injured limb in a vertical position, intravascular pressure is so much diminished that sponta-

neous arrest of hemorrhage is often effected by this simple procedure, even when a vessel the size of the palmar arches is injured, but its greatest value and widest range of application will be in the treatment of venous and parenchymatous hemorrhage. The elevated position should be maintained for some time after the hemorrhage has ceased, or until more efficient measures can be employed. The manner of effecting and maintaining elevation as a hemostatic agent is shown in figures 19 and 20.

Digital Compression.—In the treatment of hemorrhage from large vessels accessible to digital compression this method offers a reliable means of controlling hemorrhage. The members of the hospital corps are familiarized with the exact location of the principal arteries of the extremities and the method of arresting hemorrhage by digital compression.

The compression must be continued uninterruptedly until the bleeding vessel can be tied, or pressure can be replaced by elastic constriction or the antiseptic tampon.

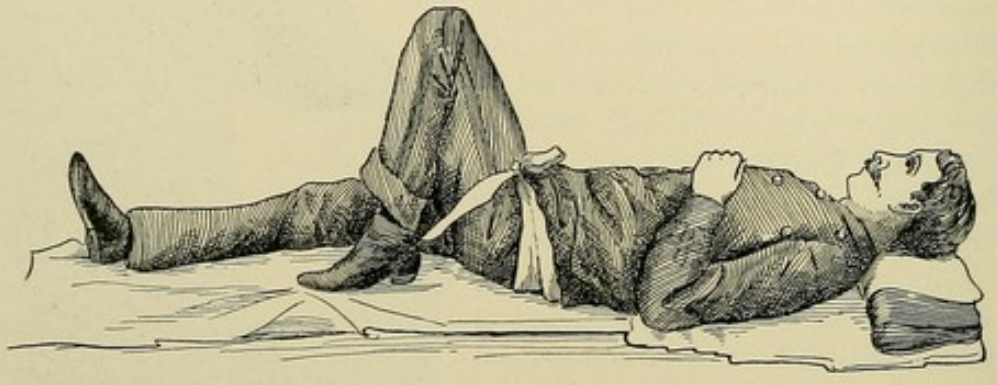

Fig. 150.—Genuflexion in the treatment of hemorrhage from the popliteal artery and its branches.

Flexion.—Forced flexion as a hemostatic agent was introduced by Adelmann. Genuflexion is a prompt and efficient method of arresting hemorrhage from the popliteal artery and its branches. Brachial hyperflexion answers the same purpose in the treatment of hemorrhage from the brachial artery from a point opposite the elbow-joint or any of its branches below this point. In making genuflexion the belt, a suspender, a gunstrap, or a triangular bandage should be passed through a slit in the shoe or boot above the heel, after which the ends are firmly tied over the base of the thigh, when it is fastened to the trousers or drawers with a safety-pin. Forced flexion of the forearm can be made with an ordinary handkerchief.

Antiseptic Tampon.—The antiseptic tampon is a convenient and very useful hemostatic agent in the treatment of accidental hemorrhage. The antiseptic package with which every soldier of civilized warfare will be supplied can be used advantageously for this purpose. It will prove of special value in the arrest of hem-

orrhage from the vessels of the scalp, face, and intercostal arteries, and in the treatment of open lacerated and saber wounds. The surface to be compressed should be dusted with the antiseptic powder contained in the package, and with the hygroscopic antiseptic material composing the remainder of the package a graduated compress is made, the apex of which is placed in contact with the bleeding vessel, and the necessary degree of pressure secured by a circular bandage, with or without the use of an extemporized splint, according to the location of the vessel or the relations of the injured vessel to the underlying bone.

Vessel injuries treated by antiseptic tamponade will seldom require ligation, as the tampon, if the wound remains aseptic, is allowed to remain until the lumen of the injured vessel or vessels becomes obliterated permanently by thrombosis and cicatrization.

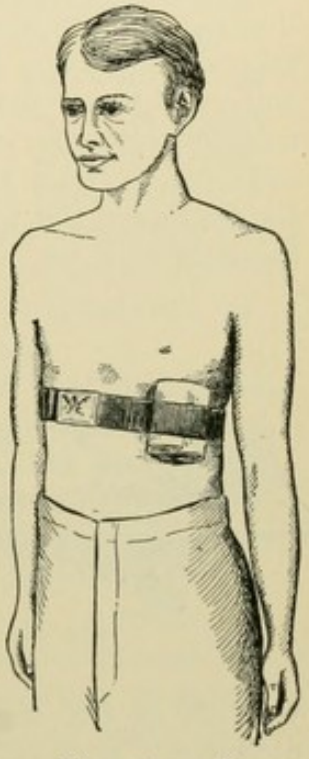

Fig. 151. — Temporary treatment of penetrating wound of chest by antiseptic tamponade and immobilization by circular compression.

Internal Hemorrhage.—The prompt and proper treatment of internal hemorrhage will constitute one of the crowning triumphs of surgery upon the battle-field. The direct treatment of the wounded vessels by early invasion of any of the large cavities of the body will be the means of saving many lives that would, heretofore, have been doomed to certain death. This part of the surgeon's work will be done at the first dressing station or at the field-hospital. What can be done behind the fighting-line in such cases to bridge over the time until such services can be rendered to the injured? In hemorrhage from the intracranial vessels caused by bullet wounds, it would be dangerous to plug the wounds of entrance and exit, as the accumulation of blood in the cranial cavity would result in death from cerebral compression. The escape of blood should be favored by inserting into the track made by the bullet a strip of aseptic or iodoform gauze. This will not only serve a useful purpose as a capillary drain, but, by bringing an aseptic foreign substance in contact with the injured vessels, the spontaneous arrest of hemorrhage by thrombosis is favored. The gauze drain should be secured on the surface of the wound with a safety-pin, and the wound or wounds protected against infection by an antiseptic dressing, retained in place by the triangular bandage. By this treatment many cases will reach the field-hospital for a timely intracranial operation. In bullet and stab wounds of the chest complicated by hemorrhage from the intercostal arteries the antiseptic tampon is the proper treatment. Packing of the tubular

wound with an antiseptic hygroscopic material will not only succeed in arresting the hemorrhage, but will serve at the same time as an efficient capillary drain and protect the cavity of the chest and its contents against infection. In hemorrhage from injuries of the organs of the chest, firm circular compression of the chest directly over the wound, already protected against infection by an antiseptic dressing, constitutes a valuable indirect hemostatic measure.

Immobilization of the chest-wall by circular compression diminishes the functional activity of the lungs, and in doing so exerts a favorable influence in arresting hemorrhage from this organ. The cartridge belt or gunstrap can be used to the greatest advantage in limiting the respiratory movements of the chest. I believe that this conservative treatment of penetrating wounds of the chest will yield better results than the injection of filtered air, absorbable aseptic solutions, or treatment by rib resection, free incision, and attempts to ligate the bleeding vessels. In penetrating wounds of the abdomen the prime indication in the future treatment of such injuries will be to prevent death from hemorrhage. Visceral

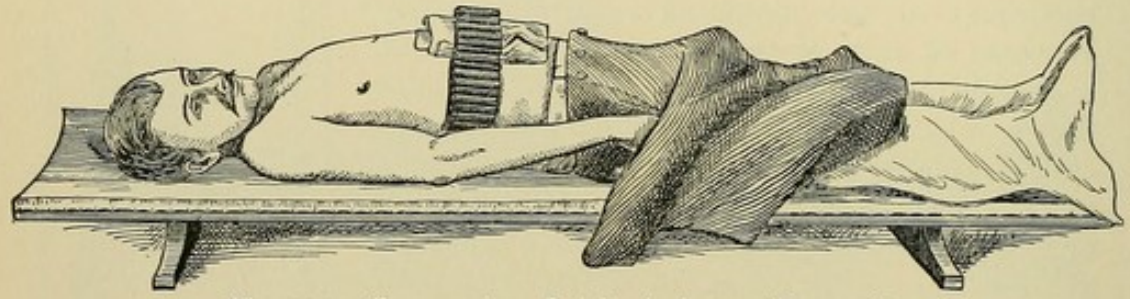

Fig. 152.—Compression of abdominal aorta (Esmarch).

wounds of the abdominal organs, notably the liver, spleen, and mesentery, usually give rise to profuse and often fatal hemorrhage. The hemorrhage is more frequently venous and parenchymatous than arterial. In my address before the Association of the Military Surgeons of the United States on one occasion, I urged the importance of early operative interference in such cases, and mentioned hemorrhage and the direct treatment of visceral wounds as ample indications to justify prompt, active interference. In injuries of vessels below the bifurcation of the abdominal aorta attempts should be made to prevent death from hemorrhage upon the battlefield by resorting to the use of compression, with a view to interrupting the circulation in the aorta above the bleeding point. Esmarch's method, shown in figure 152, can be extemporized in a few moments, as it requires no instruments of special construction and meets the indications more completely than the various instruments devised for the same purpose. The method of Brandis is equally simple and efficacious. As hemorrhage from any of the vascular organs and large vessels of the abdominal viscera requires

prompt treatment, and as in large engagements a considerable length of time will necessarily intervene between the first-aid and the permanent arrest of hemorrhage by laparotomy, and as in many instances the location of the wound is outside of the range of successful treatment by compression of the abdominal aorta, it appears to me that in such cases it would be good treatment to resort to direct and circular compression, as has been described in connection with penetrating wounds of the chest. The wound of entrance and of exit, if the latter exists, should be protected by an antiseptic dressing. Over the wound, corresponding with the yielding part of the abdominal wall, a large compress, which may be composed of a compress made of a blanket, an article of clothing, a cartridge belt, or a canteen, should be placed, and over it firm circular compression made with a belt or gunstrap. The direct compression made in the direction of the track of the bullet will do much toward diminishing the vascularity of the underlying injured parts, while the circular compression will immobilize the abdominal wall at the seat of injury and limit the movements of the abdominal organs, conditions which can not fail to materially diminish the risks of hemorrhage and to aid thrombosis, nature's resource in effecting spontaneous arrest of hemorrhage.

Permanent Hemostasis.—*Forcipressure.*—The best and most successful military surgeon is the one who accomplishes the most with the least number of instruments. Complicated instrument cases look well and make a favorable impression upon laymen, and can be used to advantage in a well-equipped hospital; they are out of place on the battle-field. The fewer the instruments in the treatment of emergency cases, the less the danger of infection. I have recently devised an operating pocket-case that contains all the instruments a military surgeon is expected to use when in active service. It contains, among the instruments needed for emergency work, seven hemostatic forceps, by the use of which he is in a position to meet the emergencies incident to hemorrhage upon the battle-field. The use of aseptic hemostatic forceps upon the battle-field will meet the indications successfully in many cases in which other hemostatic measures are inapplicable. If the bleeding vessel is so located that it can be grasped with hemostatic forceps but can not be ligated without performing a formidable operation, the forceps should be allowed to remain and should be incorporated in the antiseptic dressing, and a note be made to this effect on the diagnosis tag.

Ligation.—Ligation of blood-vessels, arteries, and veins will usually be done upon the battle-field after temporary hemostasis by other means, either at the first dressing station or, more frequently, at the field-hospital. Silk is the proper ligature material in military service. It can be sterilized repeatedly by boiling, and is, consequently, a much safer material than catgut in emergency practice. Aseptic silk in an aseptic wound invariably becomes encysted.

Catgut sterilized in Boeckmann's sterilizer and kept ready for use in sterilized envelops, as advised by Boeckmann, could be made serviceable for military surgery. As a rule, the vessel should be tied at the seat of injury by enlarging the existing wound and using it as a guide to the injured vessel. Cases, however, will present themselves in which it is impossible to apply this rule, and in which the artery must be tied in its continuity in a more accessible place on the proximal side of the bleeding point. Antiseptic precautions in the treatment of wounds and in the employment of the aseptic ligature will materially diminish, if not entirely overcome, the risk of secondary hemorrhage, which proved such a terror to the surgeons and so frequent a source of danger and death to the injured during the great Civil War. The ligature should never be tied sufficiently tight to rupture any of the tunics of the vessel. All that is necessary to obtain an ideal permanent obliteration of the vessel is to approximate and hold the intima in uninterrupted contact. If the vessel requiring ligation in its continuity is a large one, a double ligature with a bloodless space between the two ligatures is preferable, as the space interposed between them offers the most favorable conditions for an early and a permanent obliteration of the lumen of the vessel. Under aseptic and antiseptic precautions the ligation of large veins is as safe a procedure as ligation of the accompanying arteries.

Vein Suture and Lateral Ligation.—In small wounds of large veins lateral ligation and suturing with fine silk or catgut secure permanent hemostasis, with preservation of the lumen of the vein, and for these reasons should receive, in this kind of vein injuries, the preference to ligation in continuity. This method of treatment is of particular value in the case of wounds of the superior longitudinal sinus and the large veins at the base of the neck, in the axillæ and the groins, as well as the large veins in the abdominal cavity. The lateral ligature is applied by seizing the margins of the vein wound with a sharp tenaculum, and tying the base of the cone with a fine silk or catgut ligature. In suturing of vein wounds the margins are inverted toward the lumen of the vessel in the same manner as in closing an intestinal wound by Lembert's sutures.

Hot Water and Styptics.—Hot water at a temperature of from 120° to 130° F. coagulates the albumin upon the surface of the wound, and in doing so seals the orifices of small vessels; on this account it has become a popular hemostatic in arresting parenchymatous bleeding in parts and organs accessible to this method of treatment. The employment of styptics in arresting hemorrhage, on the whole, should be discountenanced, as their use interferes with an ideal healing of the wound. Their application can only come in question in the treatment of bleeding wounds of the mouth and pharynx, where antiseptic tamponade is impracticable.

Saline Infusion.—Patients who have become debilitated by hemorrhage to the extent of endangering life require restoration of

a normal degree of intracardiac and intravascular pressure by saline infusion. Transfusion of blood, whole or defibrinated, has been clinically and experimentally proved a failure in preventing death from the immediate and remote results of dangerous hemorrhage. The transfused morphologic elements of the blood do not retain their vitality, and are destined to be removed from the receiver sooner or later by elimination through some of the excretory organs. Von Bergmann and others have shown that the immediate cause of death from acute hemorrhage, subnormal intracardiac and intravascular pressure, can be avoided more successfully by substituting a physiologic solution of common salt for animal or human blood.

Every field outfit should be supplied with a definite quantity of salt, from which the solution can be prepared in a few moments. Szumann's solution is especially well adapted for this purpose. It consists of:

Natr. chlorid,	6 parts
Natr. carbon.,	1 part
Aq. destillat.,	1000 parts.

The chlorid and carbonate of soda in the foregoing proportion should be carried in every pannier, so as to be available in all cases in which a saline infusion may become necessary. The simplest apparatus for making a saline infusion is a glass or hard-rubber funnel, with two or more feet of rubber tubing and a small glass tube with a tapering point. The median basilic vein is usually selected for making the infusion.

The vein is exposed by a small incision, after having rendered it turgid by proximal compression in the same manner as in performing phlebotomy. After exposure of the vein it is incised transversely and the point of the glass tube inserted and fastened in place by a ligature previously inserted (see Fig. 84). Before inserting the glass tube, the precaution should be taken to fill it and the rubber tube with the saline solution, to prevent the introduction of air. The saline solution to be used should be heated slightly over the temperature of the blood, and infection is prevented by using only sterilized water for the solution.

The quantity of solution to be used will vary from 500 to 1500 gm., 1000 gm. being a fair average dose, and for the preparation of which the requisite quantity of the alkaline powder should be kept in readiness. If the symptoms of improvement that follow the employment of the saline infusion should come to a standstill or disappear, it may become necessary to repeat the intravenous infusion in the course of an hour or more.

The same object gained by intravenous infusions of salt solution is attained more indirectly and with greater loss of time by copious hypodermic and rectal injections.

Autotransfusion.—In threatening danger to life from hemorrhage much can be gained by autotransfusion. The exclusion from the general circulation of unessential parts of the body will often secure

for the vital organs an adequate blood supply. Autotransfusion for this purpose is secured promptly and efficiently by elastic constriction of one or more extremities at their base. This can be accomplished by Esmarch's constrictor, by suspenders, or, in the absence of elastic material, by the use of the Spanish windlass (see Fig. 44). According to the urgency of the symptoms presented, the base of one or more extremities is constricted after rendering the limb comparatively bloodless by elevation. By exclusion of the circulation from one or more extremities intravascular pressure compatible with essential functions is restored, and life is bridged over for a sufficient length of time for the employment of remedies of more lasting value.

Shock.—Next to hemorrhage, shock should receive the surgeon's attention. It is often difficult to differentiate between the symptoms produced by shock and those of hemorrhage. The non-professional assistant should be made to understand that the maximum symptoms of shock are developed almost immediately after the receipt of the injury, while in hemorrhage the intensity of the symptoms increases progressively. Even in a complete transverse tear of an artery of the size of the common carotid it requires at least five minutes to produce death from hemorrhage; in intense shock symptoms pointing to a fatal issue appear almost immediately upon the receipt of injury. Shock is the result of a reflex vasomotor paresis, and, consequently, if severe, calls for the most energetic and prompt treatment. A patient suffering from shock should be kept in the dorsal recumbent position and treated by active stimulation. Inhalations of nitrite of amyl and hypodermic injections of strychnin in doses of from $\frac{1}{15}$ to $\frac{1}{20}$ of a grain, repeated every half-hour until reaction takes place, constitute the most successful treatment. The administration of alcoholic stimulants, camphor, and ammonia is also indicated, as well as the external application of dry heat. In the transportation of patients suffering from shock the greatest care should be exercised not to subject them to any unnecessary movements, and it is of special importance that the recumbent position should be maintained until reaction is established. No operation of any considerable importance should be performed until the patient reacts from the immediate effects of the injury.

Primary Dressing of Wound.—Perfect aseptic surgery upon the battle-field is a happy dream that will probably never be realized. The bullets, as recent experiments have shown, are frequently contaminated with pathogenic microbes, and often carry with them infectious fragments of clothing and other foreign substances, as well as microbes from the surface of the injured part. Again, in large battles the number of wounded is so great and the number of those to whom their treatment is intrusted is so small that the necessary antiseptic precautions to obtain an antiseptic condition of the wound can not always be carried out. The duty

of the surgeon upon the battle-field in rendering the first aid to the wounded, after having given proper attention to the treatment of shock and hemostasis, will be to prevent subsequent contamination of the wound by protecting it with an antiseptic occlusion dressing. Shaving and disinfection of the surface in the vicinity of the wound are out of the question under such circumstances. Search for bullets and efforts to secure their removal must be postponed until the patient reaches the field-hospital, where these procedures are made possible and the attending danger of causing infection diminished by a more complete instrumentarium and more effective means of securing asepticity of the wound and its vicinity. The primary dressing on the field has been fully described in the pages devoted to the first-aid dressing in military practice (see pp. 231–240).

Immobilization of Injured Joints and Fractured Limbs.—In the case of fractures and joint injuries, the affected limb should be properly immobilized to prevent additional injury and pain during the transportation of the patient to the field-hospital. As it is impossible for the surgeons and hospital corps to carry with them upon the battle-field material for splints in sufficient quantity, they must depend upon articles that can always be found upon the battle-field in securing for the limb a proper mechanical support. A few of such extemporaneous dressings have already been shown (see Figs. 142–152).

The splint should be well padded with the blanket or articles of wearing apparel. In compound fractures and penetrating wounds of joints perfect immobilization by a plaster-of-Paris splint should be secured as soon as possible; but as this can not be done behind the fighting-line, for obvious reasons, the temporary improvised dressing should be replaced by the permanent fixation dressing at the field-hospital. Antiseptic precautions and perfect immobilization will be the most important elements in the conservative treatment of compound fractures and penetrating injuries of large joints.

Transportation of Sick and Wounded.—Increased and improved facilities for rapid transportation of the wounded from the fighting-line to a place of safety will be an essential requirement in securing the greatest amount of benefit from conservative surgery upon future battle-fields. The general introduction of the new infantry weapon will make it necessary to establish the field-hospital further away from the fighting-line than it was formerly. Unless a natural protection by a hill or deep ravine is available, it will be necessary to locate the field-hospital at least 3000 meters from the line of action. This will necessitate an improved ambulance service. The latter will be resorted to in transporting the severely wounded from the point where the first aid is rendered to the first dressing station.

A well-trained hospital corps and the use of improved litters and ambulances will be instrumental in securing prompt and easy

conveyance of the wounded from the line of duty to their destination. An efficient bicycle litter is a much-needed desideratum in the transportation of the wounded from the fighting-line to the first dressing station and field-hospital.

The Surgeon's Work at the Field-hospital.—The conservative work begun on the battle-field is continued at the field-hospital, which offers additional facilities for the practice of ideal conservative surgery. It is here that efficient measures can be employed to correct the injurious effects of profuse hemorrhage and to overcome the symptoms of prolonged shock. It is here that every serious wound will be thoroughly examined, and under strict antiseptic precautions will be subjected to the necessary treatment. It is here where permanent hemostasis will be substituted for temporary measures. It is here that the abdomen and cranial cavities will be opened for penetrating wounds requiring such intervention for the arrest of hemorrhage, the removal of foreign infected bodies, and the direct treatment of visceral wounds. It is here that permanent plaster-of-Paris splints will be substituted for the temporary fixation dressings in cases of compound fractures and penetrating wounds of joints.

Craniectomy.—Operative interference is indicated in every case of penetrating gunshot or stab wound of the cranium. The object of such operation is to secure asepticity of the wound and its environment, the removal of loose spiculæ of bone and infected foreign substances, the arrest of hemorrhage by torsion, ligation, or tamponade, and, if feasible, the removal of the bullet.

The wound of entrance is sufficiently enlarged with chisel or rongeur forceps to enable the surgeon to meet the indications for the operation. If the bullet is lodged in the interior of the skull, it may become necessary to make a circular craniectomy in the course of the bullet at a point opposite the wound of entrance, for the purpose of establishing thorough drainage and to facilitate the removal of the bullet.

Laparotomy.—The sanguine expectations as to the benefits to be derived from laparotomy on the battle-field have not been realized after ample experience. The only place where such an operation in well-selected cases is advisable and expedient is in the field-hospital.

Amputation.—The object of conservative surgery upon the battle-field, as well as in civil practice, is to obviate, whenever possible, the necessity of mutilating operations. Prompt and careful hemostasis, antiseptic precautions, immobilization of compound fractures and injured joints, and early and careful transportation of the wounded from the field-hospital to the temporary hospital are the most fruitful resources of the modern military surgeon in the prevention of complications that so often necessitated intermediate and secondary amputations in the wars of the past. A primary amputation for gunshot wound of the extremities is only justifiable

by extensive injuries of soft parts and fractures and joint wounds complicated by injury of large vessels and nerves. In other words, the indications for a primary amputation will be studied and sought for more by the character and extent of the injury of the soft tissues than the extent of the bone- or joint-lesion. In doubtful cases the patient will be given the benefit of the doubt, as under antiseptic precautions the risk to life is greatly diminished in the attempt to save a limb by conservative treatment. The conditions that will demand an intermediate or secondary amputation in cases thus treated will prove less perilous to life than in the past, an additional inducement to practise conservatism in doubtful cases.

Resection.—Primary resection for gunshot wounds of joints has, for obvious reasons, become an obsolete operation in modern military surgery. The most brilliant results have already been obtained by conservative treatment of such cases. The military surgeon will make it his duty in such instances to resort to such measures as will prevent complications necessitating secondary resection and amputation. Thorough disinfection of the wound, removal of loose fragments of bone and infected foreign substances, including the extraction of the bullet, if this is found within or in the immediate vicinity of the injured joint, gauze drainage, and immobilization of the limb in a circular plaster-of-Paris splint are the most effective measures in accomplishing this end.

I have briefly sketched in this section the essential topics that will engage the attention of the military surgeon in the future in keeping pace with the rapid advances of modern surgery, and that will enable him to extend the blessings of conservative surgery to the wounded soldier on the battle-field of the future. It behooves every military surgeon to perfect himself in the principles and details upon which his actions are based in the practice of legitimate conservatism.

GUNSHOT WOUNDS OF THE SKULL.

It is my purpose to limit my remarks under this heading to penetrating gunshot wounds of the skull. The few cases of this class of injuries that will come under the observation of the military surgeon will invariably require operative interference, provided it holds out any encouragement whatever of saving life. Gunshot wounds of the skull at close range are hopeless cases from the beginning, because the explosive effect of the bullet is such that death results in from a few minutes to a few hours after the injury, the skull being extensively comminuted and fissured and its contents greatly contused.

Von Bergmann saw a case in which the skull was broken into ninety fragments (Fig. 153). According to Pirogoff and Velpeau, isolated gunshot fractures of either the external or the internal table are very rare. Von Bergmann has described a case of fracture of the internal table resulting from a tangent bullet (Fig. 154).

Wounds of the skull inflicted in the nonexplosive range not infrequently call for operative treatment, and in a fair percentage of cases the result is favorable. I will give a few of my observations in Greece, Turkey, and Cuba illustrative of the fact that penetrating gunshot wounds of the skull are by no means always fatal, and that they do not constitute injuries incompatible with full recovery of the cerebral functions.

During the Greco-Turkish war I saw and examined the following case in Athens :

CASE 1.—*Gunshot Wound of Skull.*—The bullet entered above the orbit, and passed out of the skull in the parietal region on the same side. No operative treatment. Healing of the wounds of entrance and exit by primary intention. No focal symptoms at any time. Patient became fully convalescent.

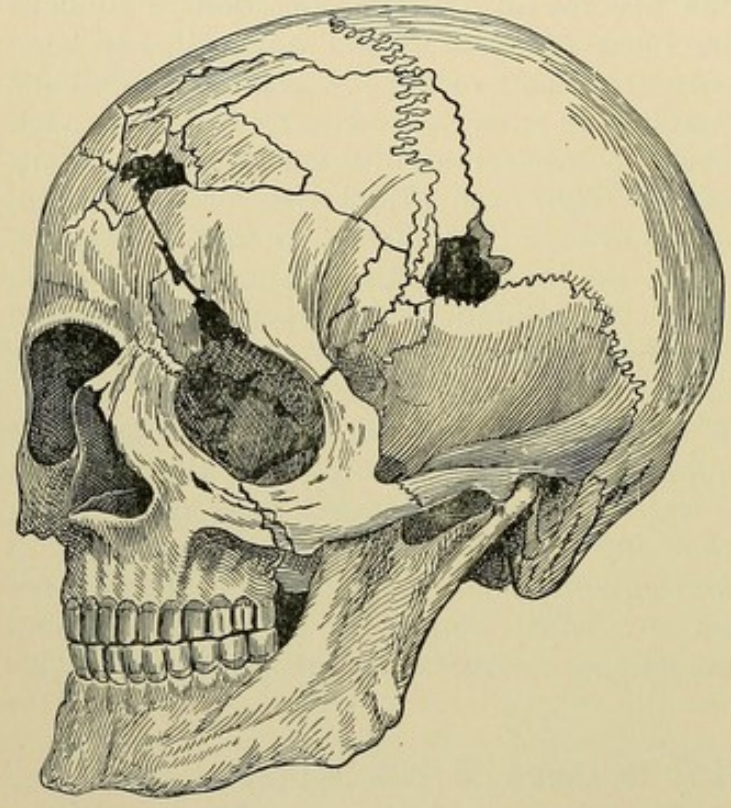

Fig. 153.—Extensively comminuted gunshot fracture of the skull (after von Bergmann).

In Turkey, during the same war, I had an opportunity of examining a number of gunshot wounds of the skull involving its contents and that recovered with and without surgical interference.

CASE 2.—*Bullet Wound of Orbit.*—Ball entered over right superciliary ridge, passed backward, outward, and downward, escaping below and in front of the external ear on the same side. Wound healed and patient wears an artificial eye with comfort.

CASE 3.—*Retrobulbar Gunshot Wound of Right Eye.*—Bullet entered orbit, passed behind the eyeball, and escaped in front of the external meatus on the same side. Traumatic optic neuritis destroyed the eyesight completely. Patient refused enucleation. There were no sympathetic complications.

CASE 4.—*Gunshot Injury of Skull.*—Primary operation. Removal of depressed fragments of bone. Wound healed, leaving a pulsating cranial defect.

CASE 5.—*Penetrating Gunshot Wound of Skull.*—Removal of loose fragments of bone. No focal symptoms. Wound healed, leaving a pulsating scar. Bullet remained in the interior of the skull. No mental symptoms.

Trephining for Traumatic Abscess of the Brain.—Djemil Pasha, of the Yildig Hospital, informed me that trephining for abscess of the brain following gunshot injuries, with lodgment of the bullet in the cranial cavity, was performed three times in the military hospitals of Turkey during the late war with Greece. In

all the cases the indications for the operation were furnished by the intracranial suppuration. In every case the abscess was found and the bullet removed. Two of the cases recovered and one died. To my own knowledge a number of gunshot wounds of the skull that survived long enough to be transported to the General Hospital at Siboney during the Spanish-American war died within twelve days after the receipt of the injury. In all the cases intracranial infection was the immediate cause of death. Encephalitis and leptomeningitis constituted the fatal complications. The beginning of the intracranial inflammation was always announced by cerebral hernia, which was proportionate in size to the extent and intensity of the inflammation. The surgical treatment resorted to in most instances proved powerless in limiting the infection. If these cases had been studied with a little more care during life, and if postmortem examinations had been made more frequently, valuable material could have been obtained for the advancement for the as yet imperfectly developed science of cerebral localization. The following cases merit attention here :

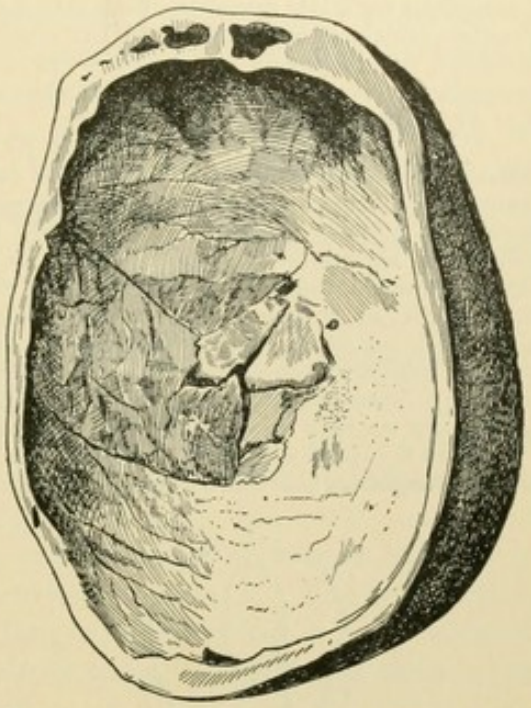

Fig. 154.—Gunshot fracture of internal table of the skull (after von Bergmann).

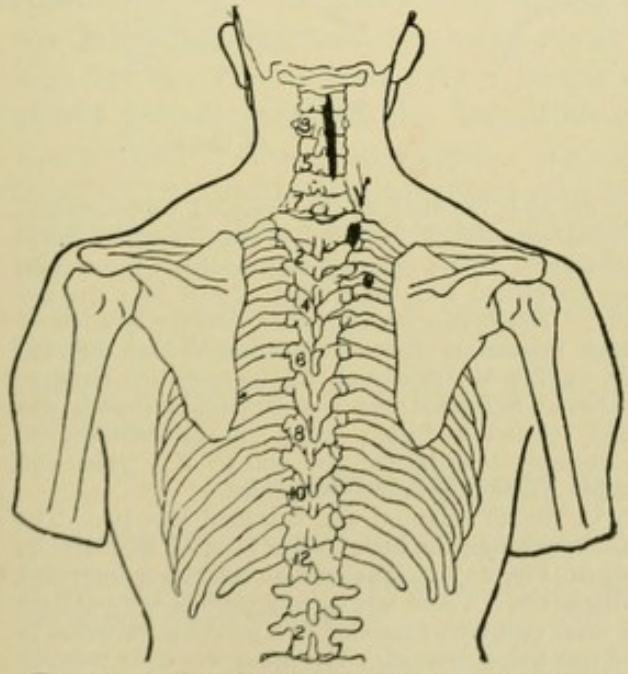

Fig. 155.—Gunshot wound of skull, neck, and chest.

CASE 6. — Fred Shockley, Company D, Tenth Cavalry, wounded July 2d. When injury was received patient was lying on his abdomen at the base of the ridge occupied by the enemy, with the head and chest extended, facing the Spanish line. This position readily explains the unusual course of the bullet, which struck the occipital base at a tangent, producing a comminuted fracture with depression; it then made a deep groove in the back of the neck, and reentered the body on a level with the first rib, to the level of the third dorsal vertebra; it then passed through the chest, and escaped

in front through the second intercostal space, a little to the left of the mammary line (Fig. 155). Soon after the injury was received he coughed up a small quantity of blood; there was no hemorrhage following this, nor were there any indications of pneumothorax, pneumonia, or pleuritis. The chest wounds healed by primary intention. At first he had convulsions for a few moments; no loss of consciousness, but clonic spasms of both arms. Intellect remained unimpaired; he had some headache, and a sensation of throbbing in the head, and there was some impairment of motion and sensation of the right leg, and complete loss of motion of the toes of the right foot; there was some pain in the eyes and slight dimness of vision.

CASE 7.—Patrick Ward, Company I, Third Cavalry, admitted from hospital at Siboney to the hospital ship Relief July 11th. Injury received probably in the same manner as in the preceding case. A large defect in the occipital bone marked the wounds of entrance and exit in the skull; the openings were enlarged by operation. The linear wound below, and extending as far as the last cervical vertebra, was undoubtedly made in following and removing the bullet. The cranial defect and the course of the bullet are outlined in figure 156. A cerebral hernia projected from the opening, and a deep-seated cerebral abscess was recently discovered, opened, and drained. In part the hernia was covered by skin. Both parietal bones were the seat of a comminuted fracture. Mental faculties were not impaired, and there were no focal symptoms. The patient lost strength rapidly, and soon succumbed to the intracranial disease.

CASE 8.—Jerome Russell, Company A, Thirteenth Infantry, was wounded July 1st. When brought on board the Relief, July 11th, a cerebral hernia of the size of a hen's

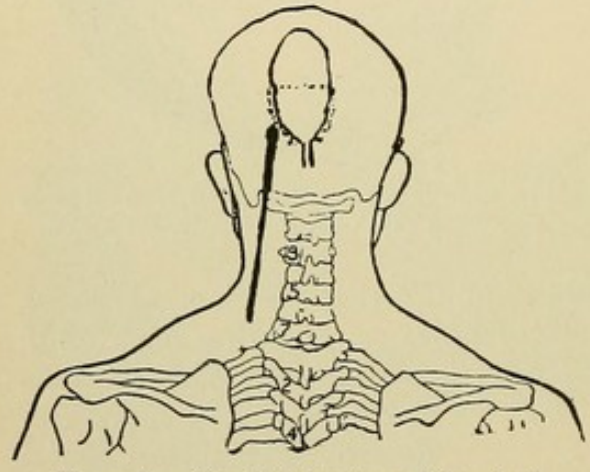

Fig. 156.—Gunshot fracture of the skull.

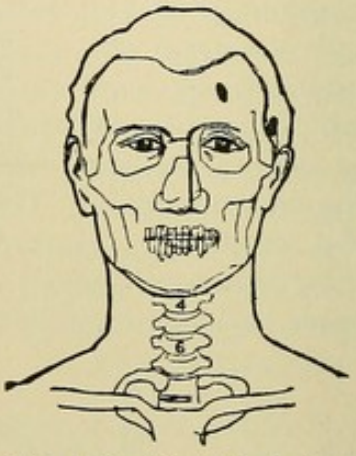

Fig. 157.—Gunshot fracture of the skull.

egg was found over the sagittal suture, an inch in front of the occipital protuberance. The wound was suppurating, and digital exploration revealed a small circular defect directly in front of the occipital protuberance. This opening was evidently the wound of entrance, and by operation had been connected with the wound of exit by a channel an inch in length and half an inch wide. The hernia corresponded with the location of the wound of exit. A number of loose fragments of bone were removed at different times. There was marked hemiplegia on the left side, and the forearm was strongly flexed and in close contact with the chest. Sensation was not impaired; speech was clear, but ideas were confused; pupils reacted to light; there was incontinence of urine, and extensive decubitus over sacrum; temperature was 100.5° F.; pulse and respiration were normal. Death occurred a few days later from sepsis.

CASE 9.—B. C. Parker, Company C, Fourth Infantry, was wounded July 1st. The bullet entered the left temporal region, comminuting the bone in that location extensively, and escaped over the left frontal eminence (Fig. 157). The cranial defect was increased by the removal of a number of loose fragments. There was quite a profuse seropurulent discharge from the wound. The only focal symptom consisted of a pricking sensation in the right foot or chest when the wound was being dressed. His mind was clear most of the time; occasionally there were slight confusion and wandering. The absence of cerebral hernia in this case is the surest indication that the infection was local.

The foregoing cases furnish sufficient proof of the facts that the remote cause of death in penetrating wounds of the skull is

almost always an intracranial infection, and that early operative interference is the best means to prevent such a complication.

Treatment.—In case a bullet has passed through the skull and its contents, the entire scalp should be shaved and thoroughly disinfected. The wound of entrance must be enlarged sufficiently to expose the perforation freely, which is then increased in size to the required extent with chisel, De Vilbiss, or rongeur forceps, to enable the surgeon to remove the loose spiculæ of bone which are frequently found driven some distance into the substance of the brain. With a long-eyed probe a strip of iodoform gauze, large enough to pack loosely the tubular visceral wound, should be inserted from the wound of entrance to the wound of exit, and the ends of the gauze drain made to project a few inches beyond the surface of each wound. Efficient capillary drainage of this kind will prevent accumulation of primary wound secretion in the interior of the skull, and will prove useful in arresting capillary hemorrhage. A large hygroscopic aseptic dressing enveloping the entire scalp and covering both wounds constitutes the dressing, and must be held in place by a few turns of a plaster-of-Paris bandage. The drain must be allowed to remain until the danger of infection is past, when it is to be removed gradually by shortening it every day or two on the side of the wound of entrance.

In case the bullet should be found lodged in the interior of the skull, the wound of entrance must be treated in the same manner and the bullet located by the careful use of Fluhrer's aluminum probe, the X-ray, or by a combination of these two diagnostic resources. A counteropening may become necessary in removing the bullet if it has reached the opposite side of the cranial cavity, or if it has become deflected or arrested in its course near the surface of the brain, provided the locality in which it has become lodged warrants operative intervention. In all visceral lesions of the contents of the skull resulting from gunshot injuries capillary or tubular drainage, or a combination of the two, is indicated and should be continued until there is no further danger of infection, hemorrhage, or accumulation of wound secretions, when the drain is to be gradually removed. The value of the Röntgen ray in locating bullets in the interior of the cranium has as yet not been definitely determined.

GUNSHOT WOUNDS OF THE NECK.

Some very remarkable recoveries following grave bullet injuries of the neck were observed in Cuba, of which the following furnish excellent illustrations :

Case 1.—Lieutenant Albert Scott, Company C, Thirteenth Infantry, on July 1st, while standing with his company at the foot of a hill, during the advance on the Spanish breastworks, received a wound in the neck. The bullet entered on the right side, just below the inferior maxillary bone, one inch in front of the angle of the jaw. The wound of entrance was a clear-cut hole about the diameter of an ordinary lead-pencil. The course of the bullet was backward and slightly downward, emerging at the back of the neck on

a level with and to the left of the fifth cervical vertebra (Fig. 158). At the moment the injury was inflicted he felt no pain in the wound, but he experienced a sensation as if he had been grasped by the wrists and thrown violently to the ground. The wound of exit was of the same size and appearance as the wound of entrance. There was very slight hemorrhage. A few minutes after he was shot he was carried from the firing-line by members of his company, and soon reached the First Division Hospital, where he remained for ten days. At the end of this time he was removed in an ambulance to the General Hospital at Siboney, a distance of seven miles, over a very rough road, and a day later was transferred to the Relief. He first became aware of the existence and location of the wound on the way from the field to the hospital. At the time he came on board the hospital ship he was voiceless, and made constant efforts to clear the bronchial tubes of mucus. There were complete paralysis of right arm and leg and partial loss of power in left arm and leg. Respiration was normal, but an almost constant spasmodic cough was present; he had no control over sphincters, and there were involuntary passages from bladder and bowels, and great debility and profuse sweating. He complained of pain all over the body. Morphin and atropin were given to subdue pain. A radiograph showed an injury of one of the cervical vertebræ, probably the fifth. Besides the first-aid dressing, he received no treatment other than complete rest and the anodyne at bedtime, which secured a good night's sleep and markedly diminished the sweating. He regained control of the sphincters and is now able to use bed-pan and urinal.

July 19th.—During the past six days there has been a decided improvement in the general condition of the patient. He is brighter in appearance, his speech is returning,

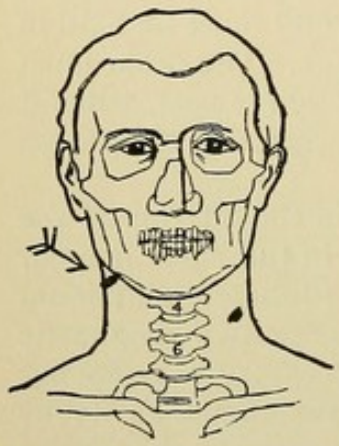

Fig. 158.—Gunshot wound of the neck.

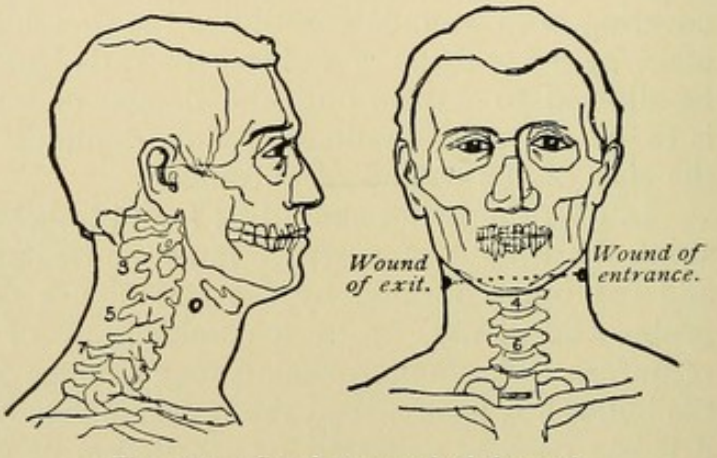

Fig. 159.—Gunshot wound of the neck.

and there is a decided improvement of motion in the right leg. The right hand is still paralyzed, but the grip of the left hand is decidedly stronger. General condition is improving rapidly.

July 21st.—Improvement in general condition continues. The external wounds healed by primary intention, and the scars are so small that they can only be seen on making a very careful inspection.

The patient was under the direct care of contract surgeon Metcalfe, who prepared the preceding clinical history.

The existence of a fracture of one of the cervical vertebræ was indicated by the clinical symptoms and confirmed by the X-ray. The concussion of the spinal cord and possibly hemorrhage into the spinal canal were the probable causes of the diffuse paralysis, but the persistence of the paralysis on the left side suggests an injury of the cervical plexus on that side, and may result in permanent loss of function in the territory supplied by the injured nerve.

CASE 2.—Oscar C. Buck, Company F, Second Infantry, was shot July 11th by a sharpshooter hiding in a tree. The bullet passed through the neck from side to side. The first and only evidence the patient had that he was wounded was bleeding from the

throat, the hemorrhage at first being quite profuse. Stiffness of the neck and pain on movement were the only symptoms complained of. The bullet entered over the sterno-cleidomastoid muscle on the left side, about two inches and a half from the mastoid process. The wound of entrance was circular and very small; the wound of exit was on the same level, but about half an inch nearer the spine (Fig. 159). Three days later a small superficial abscess formed in the wound of exit, which was evacuated by dilating the wound. Both wounds were perfectly healed by July 20th.

Judging from the course of the bullet, it is difficult to comprehend how the principal nerves and large vessels of the neck escaped injury. This is, however, one of those cases that require careful watching, as a traumatic aneurysm may develop later in the track of the bullet, which may have injured the external tunics of either of the carotid arteries.

CASE 3.—Charles F. Flickinger, Company C, Fourth Infantry, was wounded July 1st, while lying down. The bullet entered the left posterior cervical triangle, on a level with the spinous process of the fifth cervical vertebra, midway between the spine and the posterior border of the sternocleidomastoid muscle, and emerged opposite the spinous process of the seventh dorsal vertebra, equidistant from that point and the posterior border of the scapula. The patient complained of severe pain in the shoulders on attempts to move, but was free from any symptoms that would have indicated any injury to the spinal column or its contents. He was within 100 yards of the enemy when he was wounded.

I saw the following two cases in Athens during the Greco-Turkish war:

CASE 4.—Greek soldier. Bullet wound of base of neck. The bullet passed transversely through the soft tissues of the neck, behind the spinal column, and probably caused fracture of one or more of the spinous processes. The special symptoms, due to concussion which followed the injury, disappeared. Healing of the entire wound occurred without suppuration.

CASE 5.—*Gunshot Wound of the Clavicle and Scapula.*—Clavicle united by a massive callus. Bullet passed from before backward, above the large vessels and nerves. Motion of arm was greatly impaired.

The two great dangers in gunshot wounds of the neck consist in complicating wounds of the large vessels and the spinal cord. Gunshot injuries of any of the carotid arteries involving all the tunics result, with few exceptions, in death from hemorrhage on the field. Injury of any extent to the cervical portion of the cord, as a rule, proves fatal in a short time, either from a rapidly spreading leptomeningitis or later from decubitus, sepsis, or an ascending septic inflammation of the bladder, ureters, and kidneys. Wounds of the trachea or larynx may necessitate a tracheotomy. If the spine is fractured, immobilization becomes an important part of the treatment. Operative treatment in such cases may become necessary if the nature of the wound, the direction of the bullet, and the focal symptoms point to the presence of the bullet or fragments as the cause of compression.

GUNSHOT WOUNDS OF THE CHEST.

Gunshot injuries of the chest have always figured conspicuously as immediate causes of death on the battle-field and will always do so. Wounds of the heart and large vessels of the chest will never come within the range of successful surgery. Penetrating gunshot wounds of the chest are attended by a frightful mortality, owing to the physiologic importance of the organs contained in the chest cavity. Visceral injuries of the heart and large blood-vessels usually result in death in a few moments from acute anemia.

Hemorrhage into the pleural cavity and into the large bronchial tubes interferes mechanically with the respiratory functions, and frequently proves fatal in a short time. If the wounded do recover from its immediate effects, life is placed in danger by subsequent complications, which are so often caused by the hemothorax. However, the accumulation of even a large quantity of blood in the pleural cavity is not incompatible with a satisfactory recovery without operative interference, for when the blood is aseptic and remains so, its removal by absorption is accomplished in the course of time.

In gunshot wounds of the heart death is caused by heart compression on the part of the blood that accumulates in the pericardium—the pericardial tamponade of E. Rose. I shot a deer at close range with buckshot, aiming at the heart. The animal ran more than 200 yards, and was found lying dead in the brush. Postmortem revealed four wounds involving the large blood-vessels and the base of the heart, and the pericardium was distended to its utmost capacity by fluid blood. Experience during the Civil War proved that in gunshot wounds of the chest the chances for life were much better if the bullet passed through the chest than if it remained lodged in the body, an experience fully corroborated during the Spanish-American war. I saw a number of soldiers of the Greco-Turkish war, who had been shot through the chest, convalescent and in fair health a few weeks after the injury was received.

The following cases from this source are of sufficient interest to be mentioned in brief:

CASE 1.—Greek soldier, the subject of bullet wounds of the chest. Three wounds of entrance over the anterior and upper aspect of the chest. One of the bullets passed through the chest on the left side of the sternum; the point of exit was over the scapula on the same side. The other two wounds were inflicted by the contents of a bursting shell. The size of the scars indicated that the missiles were less than 38 caliber in size. No attempt was made to locate the two projectiles lodged somewhere in the chest. There was free hemoptysis immediately after the injury. The patient recovered without any grave complications setting in.

CASE 2.—*Gunshot Wound of Chest with Fracture of Spinous Processes of One or More of the Dorsal Vertebræ.*—Track made by the bullet transverse at about the junction of the upper with the middle third of the dorsal spine. The pleural cavity was not opened. The wound of entrance was on one side of the spine; incision was made for the extraction of the bullet on the other side on the same level. Spinal symptoms were well marked immediately after the injury was received, but they disappeared rapidly. Primary healing of wounds occurred.

CASE 3.—*Penetrating Gunshot Wound of Chest.*—There was only a wound of entrance; no attempts were made to find or remove the bullet. Injury was followed by empyema. Drainage was instituted without rib resection. The injured side of the chest was contracted, and respiratory movements were greatly diminished. Patient was pale and emaciated, and showed, in a marked manner, the effects of prolonged suppuration.

CASE 4.—*Gunshot Wound of Chest and Abdomen.*—Bullet entered dorsal side of chest on a level with the eighth rib, four inches from the median line, took a downward and forward course, and escaped an inch below the costal arch on the same side, at a point corresponding to the cartilage of the seventh rib. No operation performed. Bile escaped through the anterior perforation for a number of days. Wounds healed by primary intention. There were no serious inflammatory complications. Patient became fully convalescent.

The following cases came under my observation during my service in Cuba.

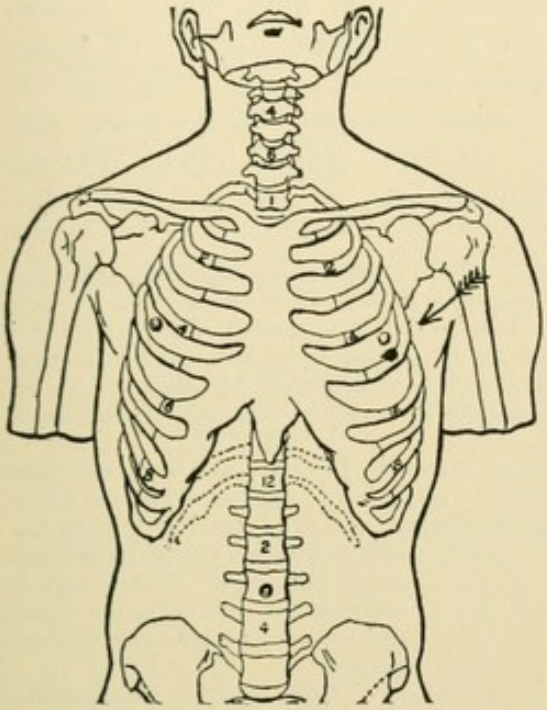

Fig. 160.—Gunshot wound of the chest.

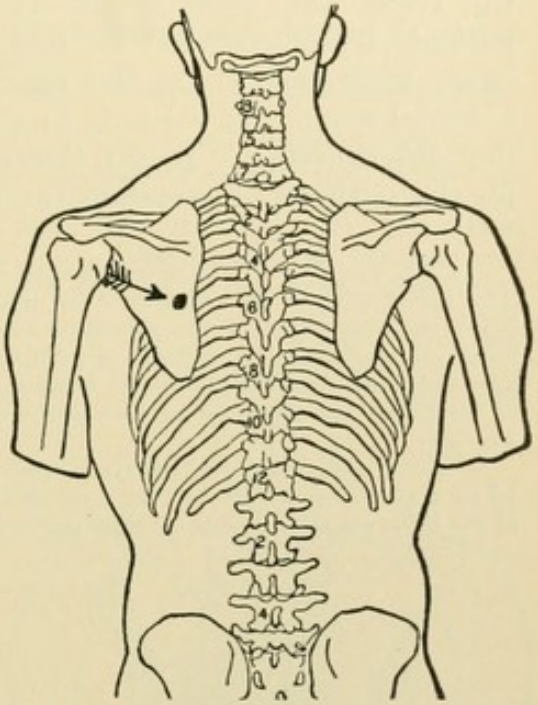

Fig. 161.—Penetrating wound of the chest.

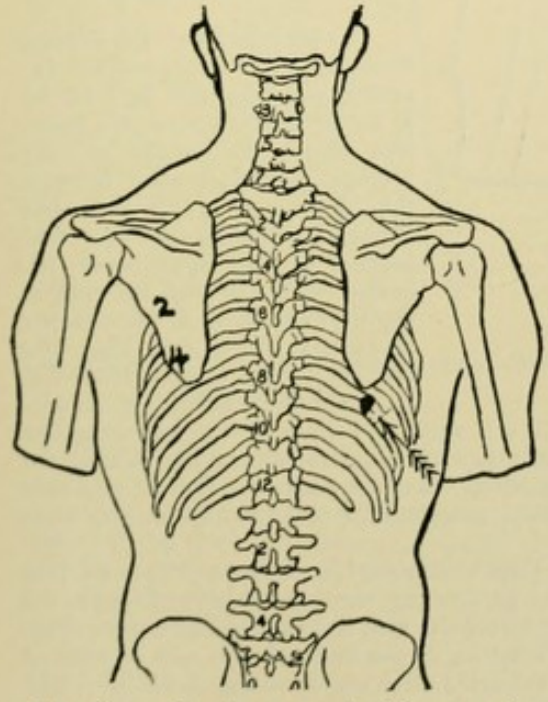

Fig. 162.—Gunshot wound of chest, neck, and mouth.

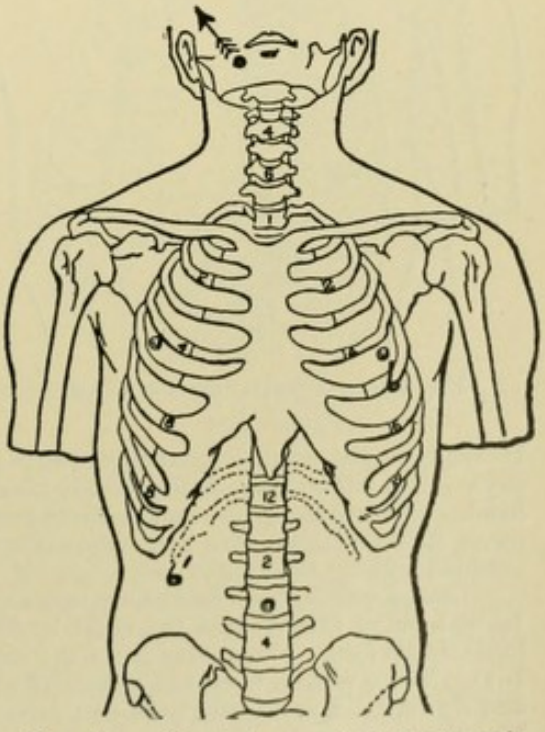

Fig. 163.—Gunshot wound of chest, neck, and mouth.

The number of cases of penetrating gunshot wounds of the

chest that lived long enough to reach the General Hospital at Siboney exceeded our expectations, and what was still more surprising was the fact that unless the hemorrhage into the cavity of the chest was copious, the symptoms were mild, some of the patients being confined to bed for a few days only. All these cases were treated on the expectant plan—*i. e.*, by dressing the external wound or wounds in the usual manner, by applying the first-aid dressing. In no instance was the pleural cavity opened for the purpose of arresting the hemorrhage.

CASE 5.—Wm. A. Cooper, Company A, Tenth Cavalry, was wounded July 1st. The bullet entered an inch below the left nipple, and escaped from the body an inch below the costal arch, in the mammary line (Fig. 160). It is questionable whether the bullet opened either the pleural or peritoneal cavity, as the injury was not followed by any symptoms referable to visceral wounds of the chest or abdomen, although the course of the bullet was such that we had reason to assume that both of these cavities had been invaded.

CASE 6.—Edward O'Flaherty, Company C, Sixteenth Infantry, was wounded July 2d by a 45-caliber ball from a bursting shrapnel. The projectile entered below the angle of the right scapula, passed through the lung, diaphragm, and liver, lodging beneath the skin in front, between the seventh and eighth ribs. Bloody expectoration followed for some time, and there was slight rise in temperature.

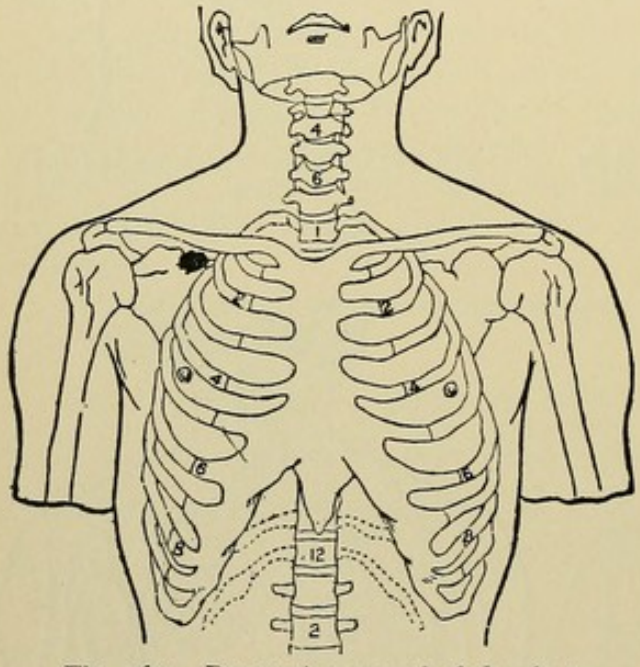

Fig. 164.—Penetrating wound of the chest.

July 12th. — Temperature normal.

July 21st.—Patient suffers but little inconvenience from his wound. No peritoneal or pleural effusion. General condition promises an early and complete recovery.

CASE 7.—John B. Senica, Company G, Twenty-second Infantry, was wounded July 1st by a bullet that entered his back, just below the angle of the scapula, passed upward through the lung, neck, and jaw, and emerged through the alveolar process of the right lower tricuspid tooth, cutting the tongue slightly, and escaped through the cheek near the mouth (Figs. 162 and 163). All wounds healed in a short time by primary intention. Hemoptysis was profuse immediately after he was shot, and slight for the following few days. The left arm was at first nearly powerless, with desquamation of the skin of the hand. The function of the arm returned gradually. In three weeks the patient was able to sit up for a short time each day. Physical examination of the chest at this time revealed nothing abnormal.

CASE 8.—Winslow Clark, Company G, First Volunteer Cavalry, was wounded July 1st by a bullet that entered the chest by first perforating the left scapula through the infraspinous fossa, three inches above the angle and one inch from the spinal border (Fig. 161). There was no wound of exit. The probable course of the bullet was downward and forward. Some hemoptysis and fever occurred, but no vomiting of blood. The hemothorax was quite extensive, and was relieved by aspiration a week after the injury was received. At the end of the third week he appeared to be convalescing rapidly.

CASE 9.—Arthur Fairbrother, Company C, Third Cavalry, sustained a perforating gunshot wound of the chest on July 1st. The bullet entered the chest just below the middle of the right clavicle (Fig. 164). There was no wound of exit. Hemoptysis

was quite profuse, followed by hemothorax. He had occasional attacks of fever, probably malarial.

July 15th.—Patient was admitted to the Relief. Wound not completely closed. On coughing, dark fluid blood escapes. The entire pleural cavity is almost filled with blood.

Two days later three pints of the same kind of blood were removed by tapping and siphonage. Sputum at this time is still bloody.

July 22d.—Patient much improved. No signs of empyema. Hemothorax diminished, but may require a second tapping.

CASE 10.— —— Scanlon, Company K, Third Cavalry, was wounded on the second day of the battle of Santiago. The ball entered the chest through the third rib, midclavicular line, on the right side, passed downward and backward, and escaped in the gluteal region on the same side, after perforating the ilium (Figs. 165, 166). The bullet must have passed through the lung, diaphragm, and liver. Hemoptysis slight, but there were distressing nausea, vomiting, and pain. He was admitted to the hospital ship Relief

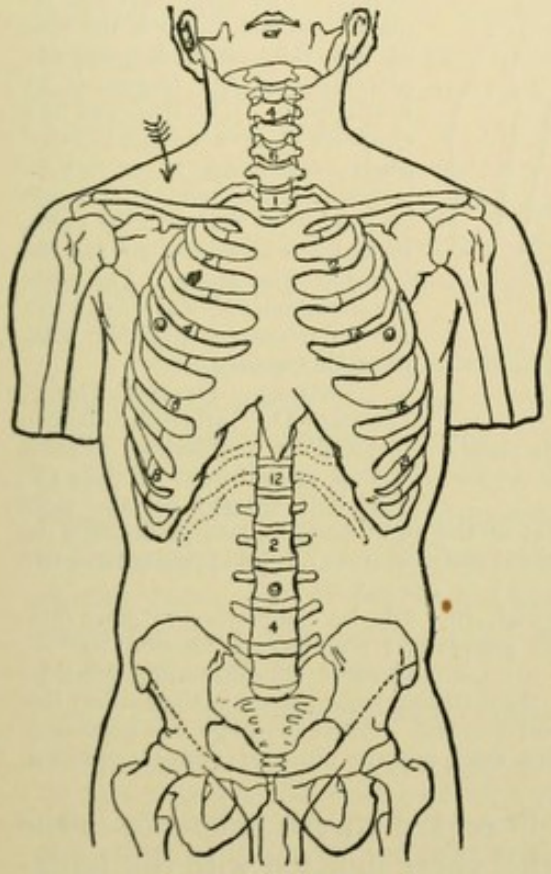

Fig. 165.—Penetrating wound of chest and abdomen.

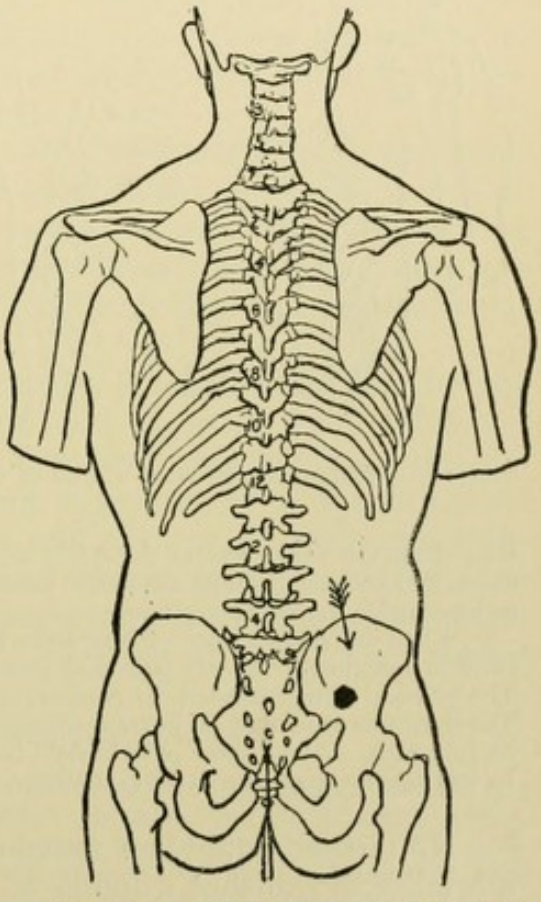

Fig. 166.—Penetrating wound of chest and abdomen.

July 15th. At that time he had a constant temperature ranging between 100° and 102° F., vomiting, diarrhea, and rapid pulse, with marked progressive emaciation. There was great pain over the liver and ascending colon; hemothorax and marked swelling in the region of the liver and abdominal cavity on the right side were present. Examination of urine negative. Owing to the great debility and pronounced anemia it was not deemed advisable to resort to laparotomy, and the patient died a few days later on the arrival of the ship in the harbor of New York.

CASE 11.—Harry Mitchell, Company C, Seventh Infantry, was wounded July 1st. The bullet entered over the right acromion process, passed through the apices of both lungs, and escaped through the second intercostal space above the right nipple. There was no hemoptysis at any time. Dry cough and a moderate hemothorax on the right side were present. He had suffered from the quotidian form of malarial fever, which yielded to quinin. A speedy and complete recovery was expected.

CASE 12.—Lieutenant John Robertson, Company G, Sixth Infantry, received a gun-

shot wound of the upper third of the right thigh at about 10 o'clock on July 1st. The profuse hemorrhage was partly controlled by an improvised tourniquet applied by an officer of the line. He was conveyed to the rear by the men of his own company, and while thus being carried, he was shot in the left breast, the bullet entering just below the left nipple and passing through the chest in an anteroposterior direction (Fig. 167). Shortly after, he was wounded a third time, the bullet grazing the inner side of the left knee. Two of the men who assisted him were killed and others took their places.

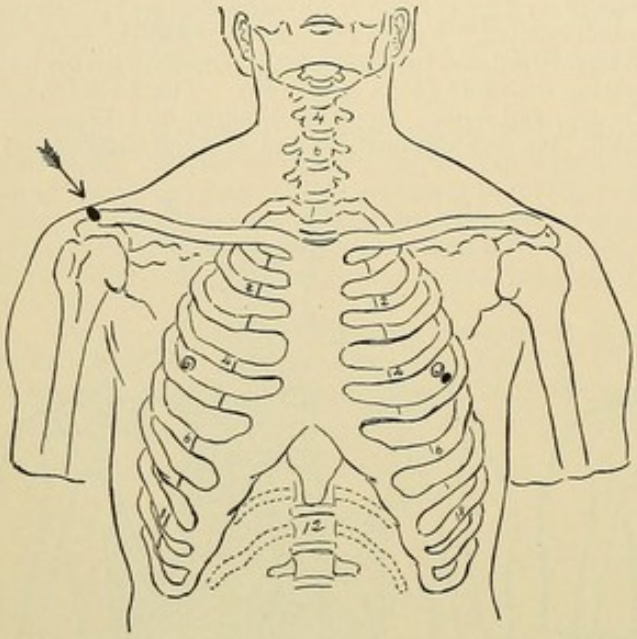

Fig. 167.—Penetrating gunshot wound of the chest.

The first dressing was applied at the First Division Hospital. The fracture of the thigh was immobilized by a long splint. From here he was sent, July 9th, to the General Hospital at Siboney, and two days later was transferred to the Relief. At this time both chest wounds were healed. The thigh wounds remained aseptic. The X-ray used at this time showed great displacement of the fragments by overlapping. The limb was now confined upon a double inclined plane, consisting of a hollow posterior splint made of the sheath of the leaf of the cocoanut palm, to which was added an anterior splint of wire gauze. The limb, thus immobilized, was suspended. No pulmonary or pleuritic complications ensued.

Case 13.—Henry T. Darby, Company D, Thirteenth Infantry, received a perforating gunshot wound of the chest on July 1st. The ball entered on the right side, above the angle and at the outer border of the right scapula, passed through the chest, and escaped through the fourth intercostal space in front on the opposite side, two inches outside the mammary line.

When the patient came on board the Relief, July 9th, he complained of great difficulty in breathing; he was pale and greatly prostrated; temperature reached 100° F. The physical signs indicated the presence of a copious pleuritic effusion on the left side. The chest was opened by an incision through the sixth intercostal space in the axillary line on July 11th. About three pints of fluid blood escaped. Gauze drainage was instituted. In this case an empyema developed after a few days, and the ultimate result is unknown.

No further doubt can remain in regard to the difference in the mortality of gunshot wounds of the chest inflicted with the large- and small-caliber bullet. The cases just related appear to prove that the danger incident to gunshot wounds of the chest made by the small-caliber projectile consists in complicating injuries involving the heart and large blood-vessels, and that in the absence of such injuries the prognosis is quite favorable. In cases in which the penetrating wound was not complicated, rapid recovery was the rule.

A very interesting study of the ultimate results of penetrating gunshot injuries of the chest from the Cuban campaign has recently been made by my former assistant during my service, now First Lieutenant Henry S. Greenleaf, U.S.A. The paper will be published elsewhere, but the author has very kindly furnished me with a copy, which I am glad to make use of here. A number of the

wounded previously reported again figure in this paper, showing that in penetrating gunshot wounds of the chest attended by marked hemothorax empyema developed more frequently than we expected, and operative treatment in such cases became a later necessity.

"To get our sick and wounded into well-established hospitals for their ultimate treatment, and away from the dangers of contagion and other unhealthy surroundings, during our late war with Spain required frequent transfers, which have left some very unsatisfactory and unconnected data for records, and might readily have led to erroneous conclusions regarding prognosis or treatment when considered under the conditions of war. There is much that would be instructive and valuable to know if we could connect the history of these cases from beginning to end, as they progressed in the different places where they were under treatment.

"For this reason it is my belief that there is much misapprehension concerning the nature of many of the gunshot wounds of the chest, especially among those under whose care they came soon after the injury was received. Several cases that looked most encouraging shortly after being wounded later developed serious complications.

"Noting one or two such instances, I began to collect the histories of as many cases as I could find recorded by the different surgeons who attended them. I have been able to collect the histories of 24 cases as they were sent in separately to the Surgeon-General's office by these surgeons, and of these, 15 recovered without complications, 3 had hemothorax without going on to formation of empyema, and 6 developed hemothorax which eventually became purulent and required operation. One out of this latter number had peritonitis and died.

"The histories of these cases were as follows:

"CASE 1.—Winslow Clark, Company G, First Volunteer Cavalry, was wounded July 1st by a Mauser bullet which perforated the left scapula through the infraspinous fossa, three inches above the angle and an inch from the spinal border. No exit. The probable course of the bullet was downward and forward into chest. There were some hemoptysis and fever, but no vomiting of blood. The hemothorax was quite extensive and was relieved by thoracentesis, performed a week after the injury was received. He recovered without further complications.

"CASE 2.—Harry Mitchell, Company C, Seventh Infantry, was wounded on July 1st by a Mauser bullet which entered over the acromion process of the left scapula, passed through the apex of the left lung, mediastinum, and right lung, and having its wound of exit in the second interspace, right nipple-line. There was no hemoptysis at any time, though a slight hemothorax developed on the right side, with some dry cough. He at that time had fever, which was promptly controlled by quinin, and his spleen was greatly enlarged. The recovery from this wound was complete without surgical interference.

"CASE 3.—Lieutenant Nair, Eighth Infantry, was wounded at the battle of El Caney by a bullet that passed through the left chest, of the exact location of which I am not informed. There was considerable hemoptysis immediately after the wound was received, which persisted for a few days. The wounds of exit and entrance healed. Later, at the general hospital at Fort Monroe, there was found flatness over the left chest, with all the signs of an effusion into the pleura. This was aspirated off and a large quantity of serosanguineous fluid withdrawn. Later this was again repeated, with the same result. Eventually signs of sapremia were present, so an incision was made and a large empyema opened into. Recovery followed this operation.

"CASE 4.—John B. Senica, Company G, Twenty-second Infantry, on July 1st was wounded by a Mauser bullet which entered the back, just below the angle of the left scapula, passed up through the lung, neck, and jaw, and emerged through the alveolar process of the right bicuspid tooth. Both wounds healed by primary intention. Just after the wound was inflicted he had profuse hemoptysis, which lasted for a few days. There were loss of power of the left arm, which disappeared gradually, and numbness and tingling in the fingers and desquamation of the skin on the left hand. While on the Relief his temperature was normal, condition generally good, and on the twentieth day after the injury he was allowed to sit up for a short time each day. When admitted to the Long Island College Hospital his temperature was 102° F.; there was considerable dyspnea. On August 2d thoracentesis yielded nothing. On August 22d the symptoms demanded a more radical operation, so two inches of rib from the seventh rib were exsected and eight ounces of pus were removed, with fragments of disintegrated clot. Recovery followed this operation.

"CASE 5.—*Report of a Case at Long Island College Hospital.*—A Rough Rider was wounded on July 1st by a Mauser bullet which perforated the right forearm and the arm, fracturing the humerus, entering the chest just below the axilla, and emerging between the seventh and eighth ribs, near their vertebral attachment, causing a compound fracture of the eighth rib, right side, at its angle, and lodging beneath the skin. On the 27th he was admitted to the hospital with fever ranging from 100° F. to 103° F., had harsh, dry cough and great dyspnea, with signs of an effusion in left pleura. Thoracentesis on July 1st yielded one pint of a serosanguineous fluid. On July 22d an incision over the eighth rib recovered the leaden core of the bullet; the incision was extended into the pleura, and two pints of purulent fluid escaped. On August 10th the seventh and eighth ribs were resected, and a large quantity of débris, clot, etc., was removed, and the jacket of the bullet was found and removed. Patient recovered.

"CASE 6.—Arthur W. Fairbrother, Company C, Third Cavalry, on July 1st was wounded by a Mauser bullet which entered just below the middle of the right clavicle, with no wound of exit. There was hemoptysis, which subsided after the first few days. Soon after this there was an irregular rise of temperature, with the beginning signs of an effusion into the right pleura and a return of the bloody expectoration. On admission to the Relief about July 12th he had a large effusion in the pleura. The wound of entrance was not completely closed, and discharged dark blood on coughing. The sputum was thick and suggested a pneumonia; temperature was very high and there was great dyspnea. Paracentesis was performed about July 20th, and about three pints of dark-red colored fluid drawn off, after which there still remained a large collection of material in the pleura, and the patient improved slightly, but only temporarily. On July 27th he was admitted to St. Peter's Hospital, Brooklyn. The wound had closed, and the patient exhibited the same symptoms as formerly, in an exaggerated form, the pleura having filled up again. An exploratory puncture was made, and an empyema was found to have developed, for which reason the resection of a rib was necessary. This was done posteriorly, and a large quantity of pus, clotted blood, and exudate was removed, and an unsuccessful search for the bullet was made. The discharge was copious for a long time, but gradually diminished, and the patient was granted a furlough on September 10th, much improved. While lying in the field-hospital in Cuba he was greatly exposed to wettings and bad climate.

"CASE 7.—Henry P. Darby, Company D, Thirteenth Infantry, on July 1st was wounded by a Mauser bullet which perforated the left arm and entered the left side of the thorax, fracturing the fourth rib in the axillary line. It penetrated both lungs and escaped from the right side of the thorax, between the fourth and fifth ribs, in the posterior axillary line. After being wounded he was subjected to considerable exposure before reaching the General Hospital at Siboney, Cuba. There, when seen on about July 10th, his temperature was about 103.6° F. Respiration was labored and very rapid, the heart was displaced well over to the right of the sternum, and there was absolute flatness over the entire left chest. Thoracentesis yielded fluid blood, only a small quantity of which could be removed. Later this became purulent, and Estlander's operation was finally necessary for his recovery.

"CASE 8.—James Scanlon, Company K, Third Cavalry, was wounded on July 2d by a Mauser bullet which entered the right side of the thorax over the third rib, in the midclavicular line, passed downward and backward through lungs, diaphragm, liver, and abdominal cavity, pierced the right iliac bone, and emerged from the gluteal region. He had but little hemoptysis. He lay in the division hospital for some time on the wet ground, and was exposed to the worst conditions of weather. On admission to the Relief he had great pain over the right chest and over the entire abdomen; nausea and vomiting, dysentery, and great dyspnea were present, and his temperature was hectic. The patient eventually died of peritonitis and pyohemothorax.

"CASE 9.—Case XVI. Mauser bullet entered the sixth interspace in the posterior axillary line, and emerged in the corresponding interspace on the opposite side. There were some dyspnea and hemoptysis, with slight effusion into the left pleura. There was no fever to indicate any purulent collection, and recovery followed without complications of any kind.

"CASE 10.—Case XV at Long Island College Hospital. Wounded by a Mauser bullet which entered over the eighth rib in the posterior axillary line, and there is no wound of exit. The bullet was never removed, and there were no resulting chest complications.

"CASE 11.—Otto Hornlein, Company C, Fourth Infantry, was wounded in left chest, but probably only superficially, without wounding the pleura. There was no hemoptysis, and the wound over the chest healed quickly.

"CASE 12.—John Taylor, Company D, Tenth Cavalry, was wounded at about 200 yards distance, the bullet entering just below the angle of the left scapula. It then lodged itself in the abdominal muscles, about two inches from the umbilicus. He had hemoptysis for several days. He made an uninterrupted recovery.

"CASE 13.—Ernest Bender, Company I, First Cavalry, was wounded through the left chest; he made a complete and uneventful convalescence. No very detailed history of his injury was received.

"CASE 14.—Edward O'Flaherty, Company C, Sixteenth Infantry, was wounded on July 2d by a 45-caliber ball from a bursting shrapnel, which entered below the angle of the right scapula and lodged beneath the skin in front, between the seventh and eighth ribs, after having traveled through the lung, diaphragm, and liver. The patient had hemoptysis for several days, with some rise of temperature, which had completely subsided in ten days from the time of injury, and no pleural or peritoneal effusion resulted. He was discharged from the Long Island City College Hospital cured.

"CASE 15.—William J. McIntyre, Company F, Seventh Infantry, was wounded by a Mauser bullet at about 500 yards range, which entered just above the middle of the clavicle, and had its exit just below the tip of the scapula. There was some hemoptysis immediately after receiving the wound, but convalescence was entirely uncomplicated and complete.

"CASE 16.—Case 7 (see 'Medical News'). Wounded by a Mauser bullet that entered the left side of the neck, one-half inch external to the median line, opposite the thyroid gland, and made its exit on the right side of the chest at the fifth rib, opposite the posterior axillary line. This fractured the clavicle at the inner third, and caused an arteriovenous aneurysm. No pulmonary symptoms other than slight hemoptysis developed, and recovery was perfect.

"CASE 17.—William A. Cooper, Company A, Tenth Cavalry, was wounded by a Mauser bullet that entered the flesh over the chest, one inch to the right of the left nipple, and made its exit one inch below the costal margin on the right side in the mammary line. It is just possible that it did not wound the pleura at all, though at a very late date the history of hemoptysis was elicited from the patient. His chest injuries healed promptly and without any resulting complications, but an intercurrent dysentery confined him to his bed for some time.

"The histories of seven other cases were secured whose wounds healed promptly without complications. These are so similar to the above-recorded cases that room is not taken to include them in this report.

"From the cases here presented we are at once impressed with the fact that while the effect of the modern gunshot injury is humane as compared with the old leaden bullet, there is a sufficient percentage that develop hemothorax and empyema greatly to modify this claim. Out of 24 cases, we have 9, or nearly 38 per cent., with most serious results. There may be many more who promptly recovered, and certainly only a very few more, if any, who had hemothorax or empyema.

"In the Santiago campaign the wounded had to be carried in ambulances, over roads that baffle description, in order to reach the hospital at Siboney, and this was done some eight or ten days after

the wounds were received. Moreover, while in the division hospitals on the San Juan River they were but poorly sheltered and subjected to very severe weather, two conditions that would most favor continued bleeding on the one hand, and infection on the other. Illustrative of this we have in cases 1, 2, 3, 4, 5, 6, 7, 8, and 9 the development of hemothorax, which in most instances was not discovered until twelve or fourteen days after the wounds were received, and it was more than likely that prior to this time they did not exist to any marked degree, but formed gradually, because of the inability to maintain perfect quiet and rest in their treatment. In three of these cases, 1, 2, and 9, the blood in the pleura was absorbed without becoming infected, and in all the others (excepting cases 6 and 8) the breaking-down of the hemothorax to form pus was a late complication. Thoracentesis showed blood only as late as the twentieth day in case 4, nineteenth day in case 5, tenth day in case 7, and in case 2 blood only when he arrived at the hospital at Fort Monroe. In each of these cases, however, operation was ultimately necessary for empyema. In all except case 6 the external wound of entrance and of exit had healed promptly and the patient had no symptoms that would indicate infection at the time of injury. Case 6 might have been no exception to this had he not had to lie on the ground exposed to wet and cold shortly after being injured. From these facts it seems evident that the cause of infection of this collection of blood in the pleura was not from the bullet directly, but that the micro-organisms gained access to this fertile soil from the wounded lung. In case 5 we find that the development of empyema after the nineteenth day was on the side opposite to the wound of entrance.

"These facts point clearly to most important suggestions in the treatment of all chest injuries in time of war. They are always to be looked upon as most dangerous wounds, especially in the eyes of the soldier himself, so that they will be handled with special care from the time of injury. The utmost care must be observed in their treatment for several weeks until all danger of further hemorrhage into the pleura is past.

"The indications for treatment are twofold: First, to guard against infection at this time, when conditions are so favorable for that serious complication; and, second, to check hemorrhage as soon as possible, for a collection of blood in the pleura or a hematocele in the lung is a most fertile ground for saprophytic invasion and acts itself as a foreign irritant. The first is met by promptly cleansing and applying the first-aid sterile dressing, and using special precautions during convalescence to prevent exposure and conditions that would lead to any general inflammation of the lungs. We know that a bronchitis, pneumonia, or any inflammatory state of the lungs renders them more favorable soil for the ever-present micro-organisms, and soon breeds them into their more virulent form, thus greatly favoring the eventual formation

of empyema or lung abscess, especially when there has been bleeding.

"The second indication is met by making it thoroughly understood, especially among the soldiers themselves, that all chest wounds are serious. The patient must be kept absolutely quiet and passive, avoid talking and active motion of any kind, and must be transferred with the gentlest care, preferably on a litter, over rough ground. The surgeon will employ the usual methods of controlling internal hemorrhages by the strapping of the injured side, the use of opium to put it to rest, the administration of internal astringents, the local use of cold, enforced use of bed-pan, etc.

"Undoubtedly we have in chest injuries a condition that calls for more extraordinary care and painstaking than other injuries of greater apparent severity, to prevent a fatal or a most serious and deforming result."

Careful investigation of these cases so remotely from the time of injury is of great value in showing that patients suffering from penetrating wounds of the chest should be handled with the utmost care, and should never be transported beyond the distance absolutely necessary, as otherwise the internal bleeding is increased. Rest constitutes an important element in the treatment of such cases. Stimulants must be withheld until the hemorrhage has been spontaneously arrested. Aspiration is contraindicated until the bleeding has ceased, as the intrathoracic compression by the extravasated blood constitutes an important hemostatic agent. The late infection in some of the cases gathered by Greenleaf can undoubtedly be explained by the prevalence of complicating intercurrent affections and the debilitating influence of the Cuban climate, together with the quality of the rations.

We have made but little progress in the treatment of penetrating wounds of the chest. Direct operative treatment of visceral wounds of the heart and lungs is always attended by imminent risk to life from pulmonary collapse. This source of danger stands in the way of direct treatment of visceral wounds of the chest. Hemorrhage from wounds of the lung is often arrested spontaneously by accumulation of blood in the cavity of the chest, causing temporary pulmonary collapse and tamponade of the tubular visceral wound by the formation of a blood-clot. Free incision of the chest-wall has been strongly advocated by several French surgeons in cases of penetrating gunshot wounds of the chest, with a view to arresting hemorrhage by ligation, tamponade, or the use of the cautery, but the profession, on the whole, for good reasons, is opposed to such heroic treatment. Unless the source of hemorrhage is one of the intercostal or the internal mammary arteries, it is advisable to rely on nature's resources, aided by such means as will favor thrombus formation in arresting the bleeding. Hemorrhage from the intercostal arteries can be quickly and effectually arrested by tamponade,

using for this purpose an hour-glass-shaped tampon of iodoform gauze in a mantle or bag of the same material (Fig. 168).

When I devised this method of tamponade for this special purpose, I had no knowledge that von Langenbeck had previously made a similar suggestion. Rest in the recumbent position, with the chest slightly elevated, is essential in aiding spontaneous arrest of hemorrhage. The internal use of veratrum viride and other heart depressants, if given early, contributes in the same direction. Fixation of the chest by a circular bandage limits the movements of the chest, and thus secures rest for the wounded organ.

A rise in the temperature during the first forty-eight hours is no indication of the existence of infection, as with few exceptions it points to a febrile disturbance caused by the absorption of fibrin ferment, the so-called fermentation fever. The production of an artificial pneumothorax or hydrothorax by the introduction into the pleural cavity of a nontoxic gas or filtered atmospheric air or sterilized water has not proved satisfactory in the treatment of intrathoracic traumatic hemorrhage. Aspiration of the contents of the chest must be postponed until spontaneous hemostasis is assured—that is, never before the third or the fifth day. In performing this operation the strictest aseptic precautions must be observed, and aspiration limited to the removal of only so much of the extravasation as will relieve the embarrassed circulation. No unnecessary suction force must be used, for fear of causing a recurrence of hemorrhage. Should later symptoms set in suggestive of septic infection, aspiration should be promptly resorted to, and if not followed by speedy improvement, no time should be lost in subjecting the patient to the same surgical treatment as is advised and practised for empyema from other causes—that is, rib resection, free incision, and drainage. *Penetrating wounds of the chest should never be explored with finger or instruments.* They constitute in recent cases a *noli me tangere* in surgery.

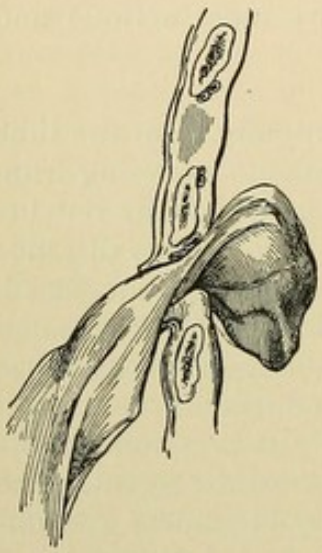

Fig. 168.—Tamponade of intercostal artery (after Von Langenbeck).

From what has been said it is clear that the best treatment in penetrating wounds of the chest consists in hermetically sealing the wound of entrance and of exit, if the latter exists, under strict aseptic precautions, immobilization of the chest by bandaging and rest, and in watching for and treating subsequent complications as they arise.

GUNSHOT WOUNDS OF THE ABDOMEN.

Modern surgery has probably done more for the successful treatment of visceral wounds of the abdominal organs than for injuries of any of the organs contained in the remaining large cavities of the body. The triumphs that have signalized the practice of civilian surgeons in the operative treatment of intra-abdominal injuries will be repeated, on a more limited scale, on the battle-field. I look hopefully for many successful results in the operative treatment of gunshot wounds in military practice, although experience so far does not seem to strengthen such an expectation. Four laparotomies for perforating gunshot wounds of the abdomen were performed in the First Division Hospital, the only ones, to my knowledge, during the Cuban campaign. All the patients died. This unfavorable experience should not deter surgeons from performing the operation in the future in cases in which, owing to the course of the missile, it is reasonable to assume that the bullet has made visceral injuries that would be almost certain to destroy life without surgical interference.

There are so many circumstances in military practice that militate against the propriety and feasibility of resorting to formidable surgical interference in such cases that it becomes necessary to restrict the indications much more than in civil practice, with a view to securing the greatest benefits for the wounded and to maintaining the good reputation of the medical service. My remarks in this section will apply almost exclusively to penetrating wounds, taking it for granted that when patients are brought to the field-hospitals, the surgeons in charge will consider it their imperative duty to make a positive diagnosis between penetrating and nonpenetrating wounds before assuming the responsibility of opening the abdomen. In the discussion of this subject I shall quote freely from the forthcoming third edition of the "American Text-book of Surgery," from the section devoted to abdominal surgery.

Sword, bayonet, and other stab wounds will diminish in frequency with the development of modern scientific warfare. The penetrating wounds of the abdomen that will come under the observation of the military surgeon will, with few exceptions, be wounds inflicted with the modern small-caliber projectile. The visceral wounds and the wounds of entrance and exit will be small —too small for digital exploration. It is perhaps superfluous to make the statement here that *a penetrating wound of the abdomen should never be probed either for diagnostic or for therapeutic purposes.* If any doubt exists as to whether or not the bullet has entered the abdominal cavity, it is far better and safer to dilate the track by the use of the knife, relying on the probe or grooved director as a guide, than to work in the dark with the probe and, by doing so, increase the possibilities of infecting the peritoneal cavity. Quite recently the assertion has been made by several prominent surgeons

that laparotomy should be performed in all cases in which it can be shown that penetration has occurred. It must, however, be admitted that, in the absence of serious visceral lesions, penetrating wounds of the abdomen are injuries from which the patients are very likely to recover without operative treatment, and that when such patients are subjected to laparotomy and prolonged search for visceral lesions, death may occur solely in consequence of the operation. It is undoubtedly true that in most cases of spontaneous recovery after penetrating gunshot wound of the abdomen the favorable termination has been due to the absence of serious visceral lesions, which some hold to be invariably present in such cases. A number of years ago I made a series of experiments on the cadaver for the purpose of demonstrating that occasionally a bullet can traverse the abdominal cavity in certain directions without producing a visceral wound that would warrant a laparotomy. The cadaver, a marasmic adult male, was placed in the erect position against a wall, and the shooting was done with a 38-caliber rifle at a distance of thirty feet. The bullet was fired in every instance in an anteroposterior direction, and invariably passed through the body. Sixteen shots were fired, and examination of the abdominal cavity, carefully made by following the track of each bullet, showed that four of the bullets traversed the abdominal cavity without injuring the stomach, intestines, or any of the large abdominal vessels. In each of these four instances the bullet entered the abdomen at or a little above the umbilical level. In all cases in which the bullet entered below the umbilical level intestinal perforations were found. Absence of visceral lesions has also been demonstrated during operations and at postmortems. During the Greco-Turkish war several cases of gunshot wounds of the abdomen recovered under a conservative plan of treatment. In nearly all these cases the bullet entered the abdomen above the umbilicus, the most favorable location for the escape of intestines from the missile, the patients being in a standing position.

Under the head of gunshot wounds of the chest I reported two cases in which the bullet at the same time invaded the peritoneal cavity, and both of these cases recovered without operative interference. I saw a number of cases of perforating wounds of the abdomen in the First and Third Division Hospitals in front of Santiago that were on a fair way to recovery without operation before they were sent home on transport ships. In most of these instances the bullet wounds were either in the umbilical region or in one of the iliac fossæ. The following case presents features of more than usual clinical and surgical interest :

CASE I.—J. F. Taylor, Company D, Tenth Cavalry, was wounded July 2d. At the time the injury was received he was in the ventral prone position. The bullet entered the left shoulder, in the infraspinous fossa, one inch below the spinous process of the scapula, and passed downward and inward, lodging under the skin in the median line, two inches above the umbilicus. Hemoptysis was considerable during the first day, when it gradually subsided. He complained of great pain and tenderness in the right

side of the abdomen. No vomiting occurred, nor were there symptoms of more than a circumscribed peritonitis. An abscess formed in the abdominal wall, which was opened July 20th and the bullet removed. From this time on the patient improved rapidly.

During the Civil War an occasional recovery from gunshot wounds in the region of the stomach and large intestine was observed, while penetrating wounds in the small intestinal area, with few exceptions indeed, proved fatal. Dr. D. R. Brower recollects distinctly a very unusual case that came under his own observation. A young soldier was admitted to the hospital who a few hours before had been shot in the region of the umbilicus. Only one wound was found, and this corresponded exactly to the umbilicus. It was thought, judging from the mildness of the symptoms, that the wound was not a penetrating one. The injury was followed by a circumscribed peritonitis, and two weeks later the bullet was found in the fecal discharges. It is possible that in this case the bullet did not penetrate the transverse colon, but found its way into it later, with the contents of a circumscribed abscess.

Wounds of the empty stomach inflicted by small-caliber bullets frequently heal without operative intervention, an observation well established by many well-authenticated cases in civil as well as in military practice. The following cases of penetrating wounds of the abdomen that recovered without primary operation came to my notice during the Greco-Turkish war:

Case 2.—*Gunshot Wound of Abdomen and Chest.*—Greek soldier. Bullet entered dorsal side of chest on a level with the eighth rib, four inches from the median line; it took a downward and forward course, and escaped below the costal arch, an inch below the cartilage of the seventh rib. No operation was performed. Bile escaped through the anterior perforation for a number of days. The wound healed without suppuration. There were no serious inflammatory complications, and the patient became fully convalescent.

Case 3.—Greek soldier. Bullet passed through the abdomen a little to the right of, and an inch above, the umbilical level. Recovery followed without operation.

Both of these cases entered the hospital a week after the injury was received.

In the military hospitals at Constantinople I found the following cases:

Case 4.—*Gunshot Wound of Right Iliac Fossa.*—Bullet entered one inch above Poupart's ligament, to the outer side of the large blood-vessels, and escaped through the perineum on the same side. Intestinal fistula remained. The use of the limb was not much impaired.

Case 5.—Volunteer, thirteen years old, received a wound of the right iliac fossa. Infection followed the injury, and resulted in the formation of a large perityphlitic abscess, which was later incised and drained. Rapid recovery ensued. The boy soldier was much emaciated and very anemic, but was able to walk about the hospital grounds.

It will be seen from the foregoing cases that the bullet traversed the abdominal cavity, either at or above the umbilical level, or one of the iliac fossæ—that is, localities occupied by the stomach or large intestine.

In two out of sixteen cases of penetrating gunshot wounds of the abdomen that came under my observation, the absence of visceral injuries of the gastro-intestinal canal was demonstrated by the use of

the hydrogen gas test, and both of these patients recovered without resort to laparotomy. Clinical experience and the result of experiment show conclusively that laparotomy should not be performed simply because a bullet has entered the abdominal cavity, but that its performance should be limited to the treatment of intra-abdominal lesions that, without operative interference, would tend to destroy life. A bullet which passes through the lower part of the abdomen from side to side or obliquely is almost sure to produce from four to fourteen perforations of the intestines, while absence of dangerous visceral complications may be inferred with some degree of probability if it crosses the abdominal cavity in an anteroposterior direction at, or a little above, the umbilical level.

Symptoms.—The general symptoms in cases of penetrating gunshot wounds of the abdomen, with the exception of those due to profuse hemorrhage, furnish very little information in reference to the existence or absence of visceral complications. Severe shock may attend a single nonpenetrating wound, and it may be absent, or at least slight, in cases of multiple perforation of the intestines. It is not an uncommon occurrence for a patient who has received a penetrating wound of the abdomen to walk several blocks, or even a number of miles, without a great deal of suffering and without showing any symptoms of shock, and yet for a number of intestinal perforations to be revealed at a subsequent operation or autopsy. Vomiting occurs quite as frequently in parietal wounds and in simple penetrating wounds as when the viscera have been injured. Vomiting of blood points to the existence of a wound of the stomach.

Pallor is present in all penetrating wounds of the abdomen soon after the receipt of the injury, and it is only more pronounced when produced, at least in part, by sudden and severe hemorrhage. Pain is a very unreliable and often a misleading symptom, as it may be moderate or almost completely absent soon after the injury has been inflicted, even when multiple perforations are present. The pulse at first is slow and compressible in all cases, and nothing characteristic in its qualities is observed even if the stomach or intestines have been wounded. Hemorrhage caused by wounds of any of the large organs, as the spleen, liver, or kidneys, gives rise to progressive acute anemia, small rapid pulse, cold clammy perspiration, dilated pupils, yawning, vomiting, and, in extreme cases, syncope and convulsions. The local symptoms are of no more value in determining the existence of visceral injuries in penetrating wounds of the abdomen than are the general symptoms that have just been enumerated. External hemorrhage is slight or entirely absent, unless an artery or a vein in the abdominal wall has been injured. The bleeding from visceral wounds gives rise to accumulation of blood in the peritoneal cavity—occult or internal hemorrhage ; this can be recognized by physical signs that denote the presence of fluid in the free abdominal cavity and by general symptoms indicating progressive

anemia: increasing pallor of the face and of the visible mucous membranes, small feeble pulse, superficial sighing respiration, and dilated pupils. Wounds of the stomach often occasion hemorrhage into this organ and hematemesis. Blood in the stools seldom follows hemorrhage into the bowels from intestinal wounds sufficiently early to be of any diagnostic value.

Circumscribed emphysema in the tissues around the track made by a bullet has been regarded as an important sign of the existence of intestinal perforation. This symptom is misleading and absolutely devoid of diagnostic value, as this condition has frequently been observed in nonpenetrating wounds of the abdominal wall resulting from the entrance of air into the loose connective tissue, or later by gas-formation as one of the results of putrefactive infection. The accumulation of any considerable quantity of gas in the peritoneal cavity can sometimes be recognized by the disappearance of the normal liver dullness, caused by the presence of gas between the surface of the liver and the chest-wall. This condition has been sought for in cases of perforating wounds of the abdomen as a diagnostic sign, and if found, has been taken as a sure indication of the existence of visceral wounds of the gastro-intestinal canal. This, however, is not always the case. Adhesions between the surface of the liver and chest-wall may have existed before the injury was received, or the amount of gas present may be insufficient to give rise to this symptom.

Diagnosis.—If a gunshot wound has penetrated the abdominal cavity and the general symptoms and local signs lead us to suspect the existence of dangerous internal hemorrhage, *no time should be lost in further efforts to make an accurate anatomic diagnosis*, as sufficient evidence has been obtained to warrant a laparotomy for the purpose of preventing death from hemorrhage by the direct surgical treatment of the visceral injuries. If no such urgent indication presents itself, it is desirable that the existence of visceral lesions demanding surgical treatment should be ascertained before the patient is subjected to the additional risk incident to a laparotomy. Since a simple penetrating wound of the abdomen is an injury from which the majority of patients recover without operative treatment, and since visceral wounds of the gastro-intestinal canal are attended by such frightful mortality without surgical interference, the practical value and importance of a correct diagnosis before deciding upon a definite plan of treatment become obvious. It is apparent that if some reliable diagnostic test could be applied in cases of penetrating wounds of the abdomen that would indicate to the surgeon the presence or absence of visceral lesions of the gastro-intestinal canal, the indications for aggressive or conservative treatment would become clear. I have shown, by experiments on animals, and later by clinical experience in the treatment of a number of cases of gunshot wounds of the abdomen, that rectal insufflation of hydrogen gas can be relied upon in demonstrating the

existence of perforations of the gastro-intestinal canal before opening the abdomen. I have shown conclusively that if the abdominal muscles are completely relaxed under the influence of a general anesthetic, hydrogen gas or filtered air can, under safe pressure, be forced from the anus to the mouth if no perforations exist, and if such are present, the gas will escape into the peritoneal cavity, where its presence can be readily detected by the physical signs characteristic of a free tympanites or by its escape through the external opening.

Theoretic objections have been made against this diagnostic test on the ground that it occasionally fails to demonstrate the existence of a perforation, and that it is instrumental in causing fecal extravasation. In reply to this I must say that it has never failed in my hands in making, by its aid, a correct diagnosis, and the fallacy of the second objection I have shown repeatedly by experiments on animals. Hydrogen gas is a nontoxic substance, endowed with valuable inhibitory antiseptic properties, and is absorbed from all the larger serous cavities and connective tissue within a few hours. Pure zinc and sulphuric acid should be used in generating the gas, which is collected in a rubber balloon holding at least four gallons. The rubber balloon used for this purpose is square in shape, and is connected with the rectal tip by means of a rubber tube six feet in length and supplied with a stop-cock near its proximal end. In applying the test an assistant presses the margin of the anus against the rectal tip, so as to prevent the escape of the gas, while another assistant forces the gas along the intestinal tube by pressing or sitting on the rubber balloon. The gas passes through the ileocecal valve under a pressure of two and a half pounds to the square inch, and is announced by a distinct gurgling sound, which can always be distinctly heard by applying the ear or the stethoscope over that region. If the rectum or colon has been perforated, the gas will not reach the small intestine, but will escape into the peritoneal cavity under less pressure than is required in rendering the ileocecal valve incompetent. As soon as the gas reaches a perforation large enough to permit its escape it will enter the peritoneal cavity and escape through the external wound, if this has been freely laid open down to the peritoneum. If the external wound is in a location that points to injury of the stomach, this organ should be insufflated through a rubber stomach-tube, and if this test proves negative, it is to be followed by rectal insufflation. It is impossible to inflate the intestines to any extent from the stomach.

Treatment.—The propriety of surgical interference in cases of penetrating gunshot wounds of the abdomen will depend upon one of three things:

1. The general condition of the patient.
2. Dangerous internal hemorrhage.
3. Wounds of the stomach or intestines large enough to permit extravasation.

If the patient is pulseless and presents other indications of approaching death, operation is unjustifiable, as it would only hasten the end, bring reproach upon surgery, and undermine the confidence in the life-saving value of the operation among the troops. Dangerous internal hemorrhage that will come to the notice of military surgeons in gunshot wounds of the abdomen will be cases in which the vascular organs of the abdomen, the liver and the spleen, or some of the larger vessels of the mesentery or omentum, have been injured. Delay in such cases is dangerous. The abdomen should be opened and the hemorrhage arrested. The symptoms are apt to be unusually severe if the hemorrhage is sudden, and progressive if the loss of blood is gradual. In the last case it may be prudent to watch the case for some time for more pressing indications, as it is well known that spontaneous arrest of hemorrhage may occur, and large quantities of aseptic blood are removed from the peritoneal cavity in a short time. Visceral lesions of the gastro-intestinal canal large enough to permit extravasation are, with very few exceptions, mortal wounds, the existence of which can leave no doubt in the mind of the surgeon that prompt resort to abdominal section offers the only chance of saving life.

Preparation of Patient.—A patient suffering from a penetrating gunshot wound of the abdomen should be properly prepared before he is subjected to laparotomy. If the stomach is filled with food, a salt-water emetic should be given, for the purpose of emptying its contents, or, better still, this can be done by the use of the stomach siphon tube. The rectum and colon must be emptied by a copious enema of warm water, to which may be added a tablespoonful of common salt. The unloading of the gastro-intestinal canal will not only facilitate the operation, but will have a favorable influence in securing subsequent rest for the injured part. A hypodermic injection of $\frac{1}{4}$ of a grain of morphin and $\frac{1}{30}$ of a grain of strychnin should be given shortly before the anesthetic is administered, as these remedies, in the doses specified, assist the action of the anesthetic, secure rest for the intestines, and sustain the action of the heart. If the patient is much prostrated, two ounces of whisky diluted with four ounces of warm water should be given by the rectum. The whole abdomen should be thoroughly disinfected. Before and during the operation the use of external dry heat will do much to prevent shock and to aid the peripheral circulation. Compresses, towels, and several gallons of warm normal solution of salt must be provided. The operator should do the work with as little assistance and as few instruments as possible, as the danger of infection in emergency work is apt to be proportionate to the number of assistants and instruments employed. Hands, instruments, suturing material, in fact everything that is to be brought in contact with the wound, must be sterilized. In military surgery silk will have the preference over catgut. A hospital tent with a floor will be an admirable operating room in all semi-

tropic climates. Anesthesia should be commenced with chloroform until the patient is under its full influence, when it should be continued with ether.

Incision.—In the majority of cases the median incision should be made, as it affords advantages that give it the preference. It should always be selected in cases of gunshot wounds of the stomach, and where the wound of entrance is located near the median line. A median incision affords most ready access in the treatment of wounds of the small intestine. If the insufflation test is used, it will sometimes prove of value in deciding upon the location of the incision. If in gunshot wounds of the upper portion of the abdomen direct inflation of the stomach through an elastic tube reveals the existence of perforation of this organ, the median incision should be selected. If rectal insufflation yields a positive result before the gas has passed the ileocecal valve, the incision should be made over the wounded portion of the colon, which is usually indicated by the course of the bullet. A wound in the transverse colon can be found and dealt with most effectually through a high median incision; perforation of the cecum or of the ascending colon calls for a lateral incision directly over the wounded organ, while a lateral incision on the left side is indicated if, from the direction of the bullet, it is evident or probable that the colon below the splenic flexure is the seat of the visceral injury. Laparotomy performed for the arrest of hemorrhage should always be done by making a long median incision, which will afford the most direct access to the different sources of hemorrhage. Very often it will be advisable to make the incision in the line of the wound of entrance, especially in cases in which a lateral incision is indicated from the location of the wound, from the course of the bullet, and perhaps from the results obtained by the insufflation test.

Arrest of Hemorrhage.—In opening the abdomen in the treatment of internal hemorrhage the surgeon undertakes a task the gravity of which it is impossible to foretell. To do the work quietly and well he must be perfectly familiar with the anatomy of the abdominal organs and their source of blood supply, and must have full knowledge of all hemostatic resources, the indications for their selection, and the details of application. Profuse intra-abdominal hemorrhage resulting from penetrating gunshot wounds of the abdomen is more frequently of parenchymatous and venous than of arterial origin. Wounds of the liver, spleen, kidneys, and mesentery give rise to profuse and often fatal hemorrhage. After opening the peritoneal cavity it is often very difficult to find the bleeding points, as the blood accumulates as rapidly as it is sponged out, and it becomes necessary to resort to special means in order to arrest profuse bleeding sufficiently to find the source of hemorrhage. One of two means should be employed: (1) Intra-abdominal digital compression of the aorta; (2) packing the abdominal cavity with a number of large sponges or gauze compresses. Intra-abdominal

compression of the aorta below the diaphragm can readily be made by an assistant introducing his hand through the abdominal incision, which in such case must be larger than under ordinary circumstances. Compression made in this manner will promptly arrest the hemorrhage from any of the abdominal organs for a sufficient length of time to enable the surgeon to find the source of hemorrhage, and to carry out the necessary treatment for its permanent arrest.

Hemorrhage from a perforated kidney may demand nephrectomy if it does not yield to tamponade. If the tampon is used, an incision in the lumbar region must be made for the removal of the tampon, and the parietal peritoneum should be sutured, so as to exclude the peritoneal cavity from the renal wound. Wounds of the liver should be sutured with catgut, cauterized with the actual cautery, or tamponed with a long strip of iodoform gauze or a typical Mikulicz tampon; in any case the gauze should be brought out of the wound and utilized as a drain.

A wound of the spleen, if the hemorrhage does not yield to ligation, suturing, or tamponade, necessitates splenectomy. Very troublesome hemorrhage is often met in wounds of the mesentery. When multiple wounds of the mesentery and visceral wounds of the stomach or intestines are the cause of hemorrhage, it is a good plan to pack the abdominal cavity with a number of large sponges, napkins, or compresses of gauze, to each of which a long strip of gauze is securely tied, these strips being allowed to hang out of the wound in order that none of the sponges or compresses may be lost or forgotten in the abdominal cavity after the completion of the operation. The sponges or compresses make sufficient pressure to arrest parenchymatous oozing as well as venous hemorrhage if they are placed at different points against the mesentery and between the intestinal coils. The sponges are removed one by one from below upward, and the bleeding points are secured as fast as they are uncovered. The ligation of mesenteric and omental vessels, both arteries and veins, should be done by applying the ligature en masse. A round needle or a Thornton's curved hemostatic forceps is the most useful instrument for this purpose. Catgut, as a rule, should not be relied upon in tying a mesenteric vessel, as it is greatly inferior to fine silk.

If hemorrhage is profuse, this must be attended to before anything is done in the way of finding and suturing the visceral wounds. Troublesome hemorrhage from a large visceral wound of the stomach or intestines is best controlled by hemming the margin of the wound with catgut or fine silk. In hemorrhage from localities not accessible to ligation and not amenable to tamponade, pressure forceps are applied and allowed to remain for from twenty-four to forty-eight hours. When used in this manner, the instrument must be long enough to be brought out of the wound, and should then be incorporated in the dressing. For facilitating the finding and removal of the instrument a strip of gauze is tied to the handle.

Search for Perforations.—A number of cases have been recorded, and I am sure many more have occurred, in which laparotomy was performed, one or more perforations sutured, and the postmortem showed that a perforation was overlooked, death resulting from extravasation and diffuse septic peritonitis. Such experiences are by no means limited to the practice of novices, but have occurred to men of large experience and in well-equipped, first-class hospitals. The handling of the entire length of the gastro-intestinal canal in a search for perforations requires time, adds to the shock of the injury and operation, and even if done by experts and with the utmost care, a perforation may escape the attention of the operator and become the sole cause of death. If the surgeon adopts this plan of detecting the perforations, the work should be done systematically. The ileocecal region is the best landmark in beginning the search. From here the small intestine may be traced in an upward direction, loop after loop examined, and the intestine returned as soon as examined so as to avoid extensive eventration, which adds greatly to the danger of the operation. The large intestine is traced from the ileocecal region downward. In one of my cases a perforation of the rectum was found low down in the pelvis, and certainly would have been overlooked if I had not used the inflation test, which promptly revealed not only its existence, but also its exact location. If the air- or gas-test has been employed with a positive result before the abdomen was opened, no difficulty will be experienced in finding the first opening. If the stomach was inflated directly through an elastic tube and the test has shown the presence of a perforation, a median incision should be made from the tip of the ensiform cartilage to the umbilicus, and the stomach be drawn forward into the wound. If no perforation is found in the anterior wall, the insufflation should be repeated, and the escaping air or gas will direct the surgeon to the perforation. Through this perforation the stomach should again be inflated in search for a second and possibly a third perforation. In searching for intestinal wounds by the aid of inflation further inflation should be suspended as soon as the lowest perforation has been found. If possible, the perforated portion of the intestine should now be brought forward into the wound, and, after emptying the intestine below the perforation as far as possible of its contents, including the gas or air, the bowel should be compressed below the perforation by an assistant, and the intestine higher up be inflated through the wound. As a matter of course, a perfectly aseptic glass tube should be inserted into the rubber tube in place of the rectal tip. The inflation should now be carried as far as the second opening, after which the first perforation should be sutured, and, after disinfecting and emptying the intervening portion of its gas, the intestine should be replaced in the abdominal cavity. Further inflation is now made through the second opening; and if a third one is found, the second is sutured, and so on until the entire intestinal canal has been thoroughly sub-

jected to the test. By following this plan extensive eventration is rendered superfluous and the overlooking of a perforation is made impossible; likewise, the objection to the test that reduction of the intestines, owing to distention with gas or air, is difficult, is overcome if the intervening sections between the perforations are emptied of their contents before suturing the wound.

Suturing the Perforations.—The materials for suturing are an ordinary sewing needle and fine aseptic silk. Catgut should be dispensed with in all intestinal work. Trimming the margins of the visceral wounds is not only superfluous, but absolutely harmful, as it requires a useless expenditure of time and may become an additional source of hemorrhage. The same can be said of the Czerny-Lembert suture. All that is required in the treatment of a visceral wound of the stomach and intestines is to turn the margins of the wound inward and bring into apposition healthy serous surfaces by the continuous or by interrupted seromuscular sutures, which should always be made to include the fibers of Halsted's submucosa. From four to six sutures to an inch will suffice. If possible, wounds of the stomach should be sutured in the direction of the blood-vessels, and transverse suturing of the intestine is necessary for the purpose of preventing constriction of the lumen. Defects an inch and a half in length on the convex side can be closed in this manner without fear of causing intestinal obstruction, while much smaller defects on the mesenteric side usually necessitate a resection, not only because the vascular supply in the corresponding portion of the intestine would be inadequate, but also because a sufficiently sharp flexion might be produced at the seat of suturing, to become the immediate mechanical cause of intestinal obstruction.

Enterectomy.—Enterectomy is often indicated in cases of double perforation and in marginal wounds of the mesenteric border. If in cases of multiple perforations it should become necessary to make a double enterectomy, and the intervening portion of the small intestine is not more than two or three feet in length, it is best to resect the same, as the immediate effect of the single operation will be less severe than that of a double resection with a corresponding double enterorrhaphy. After resection, the continuity of the intestinal canal should always be restored by a circular enterorrhaphy, using for this purpose the Czerny-Lembert suture. Strips of sterile gauze are preferable to clamps or Murphy's button in preventing extravasation during the operation. The gauze strip is passed through a small buttonhole made with hemostatic forceps in the mesentery near the intestine, and tied with sufficient firmness to prevent escape of intestinal contents.

Irrigation of the Abdominal Cavity.—This is necessary only if fecal extravasation or escape of stomach-contents has taken place, an accident that, if it has not occurred before the abdomen was opened, should be carefully avoided during the manipulation of the wounded intestines. Flushing the peritoneal cavity with warm

sterilized water or normal salt solution not only clears it of infectious material, but acts at the same time as a stimulant to the flagging circulation. The current must be sufficiently strong not only to fill the peritoneal cavity quickly, but to *flush it out.*

After completion of the irrigation the patient is placed on his side, and in this position the fluid contents of the abdominal cavity are poured out. The cavity is then rapidly dried with large sponges wrung out of a weak sublimate solution (1 : 10,000) or Thiersch's solution. Some surgeons have practically abandoned flushing of the abdominal cavity, and rely almost exclusively on sponging in removing pus and extravasated fecal material ; others are partial to leaving the physiologic solution of salt in the cavity, paying no attention to the peritoneal toilet practised with conscientious care by all surgeons only a few years ago.

Drainage.—To drain or not to drain is the all-absorbing topic among surgeons whose time and attention are engaged largely in abdominal work. I wish to place myself on record as being a strong advocate of drainage in all cases of abdominal surgery in which we have reason to believe that contamination of the peritoneal cavity has taken place by extravasation of contents of the gastro-intestinal canal or by pus. In gunshot wounds of the abdomen complicated by visceral injury the probability that infection has occurred must not be lost sight of, and the only safe course to pursue under such circumstances is to drain when you are in doubt. Cases that require irrigation should always be drained. Other indications for drainage are visceral wounds of the liver and pancreas and the existence of parenchymatous hemorrhage that can not be remedied by any of the different hemostatic measures. A glass drain reaching to the bottom of the pelvis, loosely packed with a strip of iodoform gauze, answers an excellent purpose. Occasionally multiple drains are indicated. The Mikulicz drain is to be depended upon in arresting troublesome surface oozing. Drainage must be suspended at once, or gradually, with the cessation of the primary wound secretion.

Suturing of External Incision.—Incisions through the median line are rapidly closed by one row of silk or silkworm-gut sutures, which are placed close together and include all the tissues of the margins of the wound. Incisions made in any other place are to be closed by buried catgut sutures uniting the peritoneum and muscular layer separately, and a superficial row of silkworm-gut sutures including all the tissues except the peritoneum. A large hygroscopic compress composed of sterile gauze and absorbent cotton, held in place by broad strips of adhesive plaster, constitutes the proper dressing. The sutures are removed at the end of the second week, and the patient must not be allowed to leave the bed before the expiration of the fourth week. Four weeks in bed and the wearing of a well-fitting abdominal support for from three to six months are the most reliable precautions against the occurrence of a postoperative ventral hernia. The drainage opening should be

closed with secondary sutures, inserted at the time of operation, as soon as the drain is removed, otherwise a ventral hernia will be almost sure to develop in the scar at the former site of the drainage tube.

After-treatment.—Absolute rest must be strictly enforced. Opiates must be given in doses sufficiently large to quiet the peristaltic action of the intestines. Stimulants must be used to counteract the effect of shock and to restore the vigor of the enfeebled peripheral circulation. Strict dieting must be observed for at least forty-eight hours. During this time a mixture of brandy and iced water, in small doses frequently repeated, or iced champagne, is agreeable to the patient, as it quenches thirst, relieves nausea, and exerts a favorable influence upon the circulation. If more active stimulation is called for to overcome shock and the effects of hemorrhage, whisky, strychnin, ether, musk, or camphor can be injected subcutaneously or by the rectum, while the peripheral circulation is restored by applying dry heat to the extremities and trunk. The subcutaneous infusion of one or two pints of normal salt solution is an excellent restorative and of special therapeutic efficiency in cases where the vital forces are depressed and life is in danger from the effects of hemorrhage.

Should symptoms of peritonitis set in, a brisk saline cathartic should be given at the end of forty-eight hours, as at this time the intestinal wounds will have become united sufficiently to resist the peristalsis provoked by the cathartic, while the removal of intestinal contents and the absorption of septic material from the peritoneal cavity thus attained are not only the most efficient means of averting a fatal disease, but also of placing the wounds in the most favorable condition for rapid repair. Instead of giving the saline cathartic in one dose, it is better to give it in small doses, repeated every half-hour. Sulphate of magnesia in dram doses repeated every half-hour acts like a charm and should be the cathartic of choice. Reopening of the wound and secondary flushing have done little in arresting or limiting septic peritonitis. If the case progresses favorably, liquid food by the stomach can be allowed at the end of the second day, and light solid food at the end of the first week. Under ordinary circumstances no effort is made to move the bowels until the end of the third or fourth day. If early feeding becomes necessary in marasmic or exsanguinated patients, this can be done by rectal alimentation.

GUNSHOT WOUNDS OF THE SPINE.

All cases of gunshot wounds of the spine in which the cord was seriously damaged that came under my observation in Cuba during the war with Spain either died or were the subjects of fatal complications when last seen. The immediate cause of death in such cases was either a septic leptomeningitis or sepsis and exhaustion from decubitus. Death from the former cause occurred early,

in consequence of infection of the wound and extension of the inflammation at the seat of the visceral injury along the meninges and surface of the cord.

CASE 1.—The first case of this kind I saw was at El Caney, a few days after the little city was stormed by our troops. The patient was a Spanish prisoner. I found him lying helpless on the bare stone floor of the old church. The bullet had entered over the center of the spine, at the junction of the dorsal with the lumbar vertebræ, its course being apparently directly forward. There was no wound of exit. Complete paraplegia was present below the seat of injury. The bladder was distended, reaching nearly the level of the umbilicus, and there was incontinence of urine. The neck, the trunk above the wound, and the upper extremities were rigid. There was high fever, and the pulse was rapid and small. The countenance was extremely pale and expressive of great suffering. The wound was protected by a small dirty dressing and was suppurating. I doubt not that relief by death came to him in less than twenty-four hours after I saw him.

Wounds of the spine without injury to the cord were frequently attended by temporary paralysis, varying greatly in degree and duration.

CASE 2.—George Kelly, Company C, Seventeenth Infantry. was shot July 1st, while lying in a prone position. The bullet, which was fired from a blockhouse on the summit of a hill, at a distance of about 600 yards, entered the body at a point a little below the margin and at the middle of the right ilium, emerging from the opposite side about three inches below the crest of the left ilium (Fig. 169). The patient asserted that he suffered intense pain immediately after he was shot, and that in a little more than a week after the accident he was free from pain except when he attempted to walk. The pain thus caused he referred to the sacrococcygeal joint. The wounds healed, and the absence of paralysis was the best evidence that the contents of the spinal canal escaped injury, although the bullet must have passed through the first sacral vertebra from side to side.

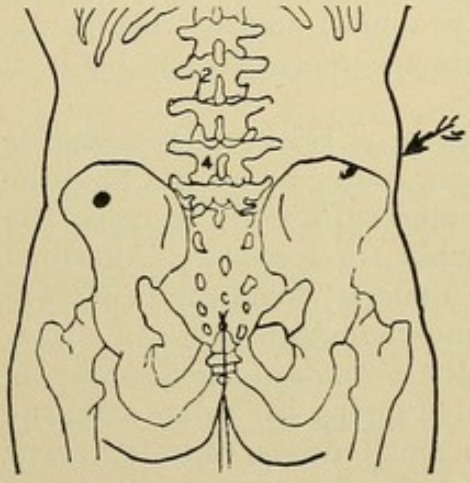

Fig. 169.—Gunshot wound of the spine.

CASE 3.—John Robinson, Company C, Twenty-fourth Infantry. The bullet entered the supraspinous fossa of the left scapula, and escaped from the right lumbar region, having perforated, in its long course, the lung, spinal cord, liver, and diaphragm. The wounds healed in ten days. Expectoration was bloody and there was complete paraplegia. Beginning extensive decubitus over sacrum and spinous processes occurred.

CASE 4.—Otto Derr, Company A, Twenty-first Infantry, was wounded July 2d. The bullet passed through the chest, from side to side, from the postaxillary line on the right side to a corresponding point on the opposite side, on a level with the seventh intercostal space. There was complete paralysis of motion and sensation below the seat of the spinal injury. The wounds healed by primary intention, but life was threatened at the time from a smouldering septic decubitus.

CASE 5.—Lewis Carlisle, Company K, Seventy-first New York Volunteers, was hit in the back by a shrapnel on a level with the third lumbar vertebra, shattering the spinous and left lateral process of the same. The missile was removed as soon as the patient reached the division hospital. As profuse suppuration set in and continued, the patient was anesthetized July 18th, and a number of fragments of bone were removed. A large abscess cavity in the right lumbar region communicated with the wound. This cavity was drained by making a counteropening in line with Simon's lumbar incision. Impaired sensation in the right leg was the most important focal symptom in this case.

CASE 6.—Charles Reardon, Company C, Sixteenth Infantry, was wounded by a fragment of shrapnel that struck him while lying down, with his shoulders raised, ready to fire. The wound was directly over the center of the spine, on a level with the fourth dorsal vertebra. The missile evidently perforated the spinal canal and injured its

contents. The foreign body remained embedded in the tissues and its location was not determined. Paraplegia was complete below the level of the umbilicus. On July 18th the patient was still alive, but an extensive moist decubitus became the direct cause of death a few days later.

The following cases came to my attention in the military hospitals at Constantinople during the Greco-Turkish war:

CASE 7.—*Gunshot Fracture of the Spinous Process at the Junction of the Dorsal with the Lumbar Vertebræ.*—Paraplegia was complete immediately after receipt of injury. Paralysis remained until laminectomy was performed. Operation was followed by prompt improvement. Patient was subsequently able to walk with the aid of crutches. Depression of the fractured vertebral arch was found to be the cause of the paralysis.

CASE 8.—*Gunshot Injury of Spine in the Lumbar Region.*—Paralysis was complete from the beginning. The wound healed, but the bullet remained in the tissues. The cord had probably been crushed by the bullet or fragments.

In gunshot injuries of the spine the first duty of the surgeon is to protect the wound against infection by the early use of the antiseptic first-aid dressing. Patients thus injured must receive more than ordinary care during their transportation to the field-hospital, to prevent additional injury to the cord by displacement of the fragments. No exploration or operation is justifiable until the patient has been conveyed to a place where asepsis can be assured. If the direction of the bullet and the symptoms presented leave no reasonable doubt of the crushing of the cord by the bullet or fragments, conservatism is the most humane course to pursue. Aseptic catheterization and prophylactic measures against decubitus constitute the most important part of the treatment. One of the best local applications to parts threatened by gangrene is the unguentum plumbi tannici. If injury to the cord can be excluded and paralysis presents itself at once and is complete immediately on receipt of the injury, it is caused either by concussion or by compression, and operative intervention must be postponed until a differential diagnosis can be made by the duration and extent of the paralysis. If symptoms of improvement manifest themselves in the course of a week or two, the suspicion of concussion is confirmed, and a conservative course of treatment is to be followed; if the reverse is the case, the propriety of cutting down upon the seat of injury must be seriously considered, and the cause of compression must be searched for and, if found, removed.

Dr. Prewitt, of St. Louis, removed a bullet from the spinal canal in the cervical region, and had the satisfaction of seeing motion and sensation return promptly after the operation. Secondary laminectomy not infrequently yields satisfactory results if the cause of the paralysis consists of a depressed arch, as was the case in case 7, or of displaced fragments. Late and gradually increasing paralysis results from hemorrhage into the spinal canal or inflammatory changes at the seat of fracture. In the former case operative intervention is superfluous, and in the latter case it is powerless to restore the function of the compressed diseased cord. If any of the bodies of the vertebræ have been comminuted, immobilization of

the spine, first by rest in bed and later by an appropriate mechanical support, is necessary in preventing aggravation at the seat of fracture and in placing the injured parts in the best condition for a speedy and satisfactory repair.

GUNSHOT WOUNDS OF THE NERVES.

Injury of any of the large nerve-trunks in gunshot wounds always constitutes a serious complication, as, owing to the nature of the wound, union without surgical intervention seldom takes place. The nerve wound may also furnish one of the indications for amputation if associated with gunshot fractures of the lower extremities. If the course of the bullet indicates the probable existence of a nerve wound, it becomes necessary on the part of the surgeon to examine closely into the degree of loss of nerve function below the seat of injury, and consequently he tests the functional disturbances of sensation as well as of motion. Nerve contusion

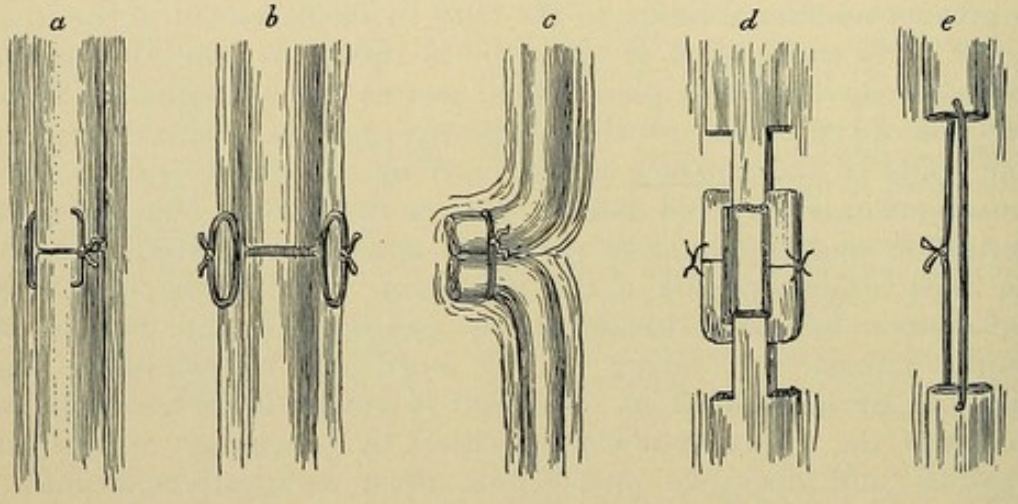

Fig. 170.—Nerve suture: *a*, Direct; *b*, perineurotic; *c*, paraneurotic; *d*, *e*, neuroplasty.

will be met less frequently in wounds made by the small-caliber than by the large-caliber bullet, while the cases of partial or complete nerve division will be of more frequent occurrence. If a nerve is completely divided, the gap between the ends, by destruction of tissue and displacement of the nerve-ends, is so great that restoration of continuity without surgical interference can hardly be expected. Partial section of a nerve by a bullet leaves a wound compatible with healing and restoration of function. Concussion and contusion of nerves by the passage of a bullet in close proximity often result in complete sudden paralysis, but function is restored in the course of from a few days to several weeks or months.

Primary nerve suture is only to be thought of if the injured nerve is readily accessible. The nerve-ends should be cut squarely with a very sharp knife or scissors, and the clean-cut surfaces united by at least three direct nerve sutures. An ordinary sewing needle armed with fine catgut may be used for this purpose.

The mechanical union can and should be strengthened by at least two paraneural sutures, and tension be avoided either by nerve stretching or position, or a combination of both of these measures in cases in which the loss of substance is extensive. It is always well to suture some of the deep tissues over the united portion of the nerve by two or more buried catgut sutures, in order to supply the nerve wound with a bed of vascular tissue.

The most serious cases of nerve injury are those in which an adjacent large blood-vessel has been wounded at the same time. If at the base of any of the extremities a gunshot fracture is complicated by a wound of the principal blood-vessel and nerve or nerves, the indications for amputation are clear, as gangrene could not be prevented in such cases by the most careful treatment of the fractured bone and vessel and nerve wounds. In the absence of a fracture it is in such cases that occasionally the patient recovers with a traumatic aneurysm and a paralyzed limb. Two cases of this kind have recently come under my observation.

CASE 1.—A robust man, thirty-five years of age, presented himself for treatment in the clinic of Rush Medical College during the winter semester, 1899. Six months before he was admitted he was shot at close range through the arm, at about the junction of the middle with the upper third on the inner side, the bullet passing in an anteroposterior direction. Hemorrhage, quite profuse and evidently arterial, was arrested by the surgeon who was called. Complete loss of motion and sensation occurred in the parts of the forearm supplied by the median and ulnar nerves. A swelling the size of a small orange developed in the track of the bullet almost immediately after the injury was received. I found marked atrophy of the muscles of the forearm, and a pulsating swelling in the line of the brachial artery and on a level with the scars following healing of the wound. Auscultation revealed a distinct bruit, loudest over the swelling. The radial pulse was decidedly smaller than on the opposite side. Superficial circulation was feeble, and the skin was quite cyanotic below the aneurysm. Sensation and motion in the territories supplied by the median and ulnar nerves were completely abolished. The musculospiral nerve was intact. Over the upper segment of the aneurysm I could distinctly feel two painful and exquisitely tender bulbous enlargements, which indicated the location of the proximal end of the divided nerves.

It was my intention when I first presented the case to the class to perform a radical operation, consisting in secondary nerve suturing and excision of the traumatic aneurysm. On second thought it became clear to me that such a procedure would almost inevitably be followed by gangrene of the forearm, as the paralysis and sudden and complete interruption of the arterial blood supply would be almost certain to suspend nutrition. I then planned another course, which consisted in attempting secondary nerve suture without interfering with the aneurysmal sac. The operation proved a very difficult and tedious one, as the nerve-ends made up a part of the wall of the traumatic aneurysm. In liberating the nerve-ends I left a part of them attached to the sac, vivified freely, and placed the sutured nerves in a position that would best facilitate the subsequent removal of the aneurysm by excision. The arm was immobilized and kept in an elevated position for twenty-four hours. The operation wound healed by primary intention, and distinct evidences of return of nerve function became apparent in less than two weeks after the operation. The operation did not interfere in any way with the blood supply to the paralyzed arm, and it is my intention, after innervation has been fully restored, to excise the aneurysm, and with the return of nerve function the second step of the operation can be performed with little or no risk of incurring gangrene.

CASE 2.—This case I had an opportunity of examining at the Presidio, San Francisco, July 9, 1899, through the courtesy of the Commander of the Military Hospital, Major A. C. Girard, U.S.A. The patient was a soldier who had recently returned from Manila. He was wounded in the battle at Malabon. The bullet passed obliquely from behind forward and outward. It entered a little below the level of the shoulder-joint, on the axillary side of the right scapula, and emerged anteriorly at the axillary base and inner border of the pectoralis major muscle. A swelling appeared over the first portion of the brachial artery almost immediately after the injury was received. Hemorrhage

from wounds of entrance and of exit was slight. Wounds healed under first-aid dressing by primary intention. Paralysis was complete immediately after he was shot. There was slight atrophy of the forearm. A swelling not larger than a walnut appeared directly over the brachial artery, in the track made by the bullet. Patient was satisfied that this swelling had been gradually diminishing in size. Pulsation was slight, and bruit feeble. On palpation the aneurysmal swelling was found to be quite hard, imparting the sensation indicative of consolidation of at least parts of its contents. Sensation was fully restored in the parts supplied by the median nerve. The ulnar side of the ring-finger was very sensitive to touch, and the little finger was anesthetic.

It was evident that in this case the paralysis of the median nerve was caused by contusion.

The ulnar nerve was injured more severely and was probably partly cut. The function in the branch that supplies the ulnar side of the ring-finger was restored, and undoubtedly represented the uncut part of the nerve. In view of the progressive improvement of innervation and the gradual diminution in the size of the aneurysm, it was advised to postpone operative treatment, if such would become necessary, for at least four or five months, as by doing so nothing would be lost and much might be avoided and gained.

GUNSHOT WOUNDS OF ARTERIES.

Death from hemorrhage from arterial wounds and aneurysms will be of more frequent occurrence in military practice since the introduction of the small-caliber weapon. The small-caliber bullet inflicts wounds more closely resembling incised wounds than those made by the large-caliber leaden bullet; consequently wounds that are more prone to hemorrhage and aneurysm formation. On the other hand, secondary hemorrhage will be less frequently observed, as wounds made by the small-bore bullet are more nearly aseptic than the wounds inflicted by the old-fashioned leaden bullet. Moreover, our means for maintaining their aseptic condition are such that infection and suppuration can be more effectually prevented.

CASE 1.—The first case of traumatic aneurysm following a gunshot wound during the Spanish-American war I saw in the General Hospital at Siboney. It was a case of gunshot wound of the subclavian artery. The swelling appeared immediately upon the receipt of the injury, and in a very short time attained the size of a large orange. The wound healed by primary intention. The supraclavicular swelling presented all the clinical aspects of a traumatic aneurysm—pulsation and bruit. The patient was sent to New York on one of the first transports, and was transferred to one of the hospitals in Brooklyn. Two months later an attempt was made to ligate the subclavian artery, but the patient died on the table from hemorrhage before the completion of the operation.

CASE 2.—Captain Mosher, Company G, Twenty-second Infantry, received a bullet wound July 1st during the advance on Santiago. Those who saw the patient first assert that the hemorrhage was severe and that the patient lost consciousness. He was removed to the First Division Hospital, and transferred. July 10th, to the general hospital. The following day he was brought on board the Relief. I examined the patient at the front five days after battle, and confirmed the diagnosis made by the attending surgeons, who had correctly interpreted the anatomic nature of the aneurysm. The wounds healed by primary union in less than two weeks. One wound was in the middle of Scarpa's triangle, and the other at the level of, and one inch posterior to, the great trochanter on the same side. From the fact that there was, as was shown by the radiograph, a piece of the jacket of a bullet in the right popliteal space, it is probable that he was wounded by a plunging fire, and that the bullet inflicted the latter wound after emerging from the wound in Scarpa's triangle. The wound in the popliteal space suppurated. Patient became very weak and anemic. In the triangle directly under the wound there was a pulsating swelling in the direction of the femoral vein, which extended to Poupart's ligament. Vein was much enlarged. Fremitus and the characteristic bruit extended to a considerable distance above and below the communicating opening between the artery and vein. Owing to the anemic and debilitated condition of the patient, it was deemed best to postpone the operative treatment of the aneurysmal varix until his general health was restored. The treatment consisted of rest and tonics. General health of the patient improved, but there was no change in the local condition. The mental state, much impaired since the

injury, gradually improved. It is possible that in this and similar cases the vessel wounds could be successfully sutured after separating them, under bloodless procedure. If this can not be done in dealing with the arterial wound, it should certainly be faithfully attempted in closing the vein wound, as preservation of the lumen of this vessel is of the greatest importance in preventing gangrene should it become necessary to ligate the femoral artery.

CASE 3.—John J. Welch, Company M, Second Massachusetts Volunteers, was wounded July 1st. The bullet entered the middle of Scarpa's triangle, three inches below Poupart's ligament, directly over the femoral artery, and escaped at a point corresponding with the gluteal crease and to the outside of the femur on the same side, perforating the base of the thigh obliquely (Fig. 171). A well-marked traumatic aneurysm developed, presenting all the physical signs characteristic of such a pathologic condition. The swelling was somewhat elongated, a little larger than a hen's egg, and did not increase in size after the patient was brought on board the hospital ship. The leg was somewhat swollen, edematous, and painful. It was decided not to interfere with the aneurysm until the patient's general health, which was considerably impaired, could be restored, and the operation performed under more favorable auspices. Digital compression in a case like this deserves a faithful trial, and if it fails, excision of the injured portion of the artery between two double ligatures constitutes the ideal treatment. As the accompanying vein is intact, if the operation is done under strict aseptic precautions, it is attended by very little risk of gangrene or other serious complications that might impair the usefulness of the limb.

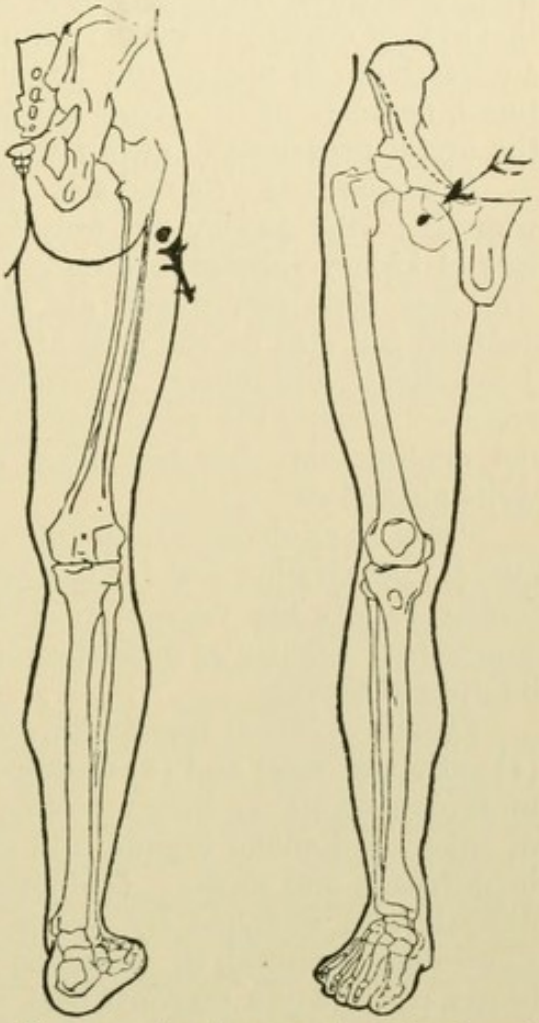

Fig. 171.—Gunshot wound of the femoral artery.

WOUNDS OF THE KIDNEY.

Injury of any part of the urinary tract is an accident that is always fraught with danger, and its early recognition and prompt treatment are often the means of averting the dangerous complications that threaten life. Hemorrhage, urinary extravasation, and sepsis are the most common sources of danger of wounds of the urinary organs, from the kidney to the meatus of the urethra.

The reparative capacity of the kidney in the healing of wounds was first shown experimentally in a satisfactory manner by Maas. He produced in the lower animals different kinds of injuries of the kidney, and found not only that the animals were quite tolerant to such traumatic insults, but that the wounds often healed promptly and without manifest disturbance of the functional activity of the organ. In limited injuries the animals recovered promptly, subsequent examination of the injured organ showing a scar and occasionally a circumscribed cyst. In grave contusions the wound healed

at the expense of the kidney substance, the organ almost entirely disappearing by cicatricial atrophy, while the opposite kidney underwent compensatory hypertrophy and assumed the lost function of the kidney destroyed by the injury and the subsequent cicatricial contraction. If any of the larger vessels of the kidney were ruptured, necrosis of the renal parenchyma followed, and injuries of the ureter occasionally gave rise to hydronephrosis.

It has been ascertained since these experiments were made that wounds of the kidney not only heal, but also that a considerable loss of kidney substance is replaced by an active process of repair. This has been determined not only by experiments on the lower animals, but also by the clinical observations of Tuffier, Kümmell, James Israel, and others. In consequence of such additional knowledge concerning the regenerative capacity of the renal tissue, partial nephrectomy has become a legitimate surgical procedure in well-selected cases.

From an etiologic standpoint, wounds of the kidney are classified into (1) penetrating and (2) lacerated or contused wounds. In the former variety the visceral wound communicates with the surface wound by a tubular or incised wound that has penetrated or cut the interposed tissues.

From a practical standpoint, such wounds are again divided into (1) extraperitoneal and (2) intraperitoneal. Of these, the latter are more dangerous, as they are often complicated by visceral injuries of other abdominal organs, and are attended by greater risk from hemorrhage and sepsis. Moreover, their surgical treatment is more difficult and attended by greater additional sources of danger. Lacerated, ruptured, or contused wounds are produced by falls, blows, passage of a wagon-wheel, etc., and are seldom accompanied by an external wound. In this class of cases the peritoneum is seldom torn, and the extravasation of blood and urine in case the capsule of the kidney is torn is entirely extraperitoneal. Wounds of the kidney caused by indirect force, according to the results of the experiments and postmortem observations of Herzog, are usually found in the region of the pelvis, while direct force is more likely to involve the convex part of the organ. The location and extent of the wound, however, vary greatly. The kidney may be torn from pole to pole and transversely, and in some instances the wounds radiate from a common center in different directions.

Anatomically, it is important to distinguish between wounds of the kidney that involve (1) the capsule, (2) the pelvis, and (3) the parenchyma. If the capsule is torn, blood and urine escape into the pararenal tissues if the parietal peritoneum is intact; and if this is punctured or lacerated, the extravasation may take place wholly or in part into the peritoneal cavity. If the renal wound communicates with the pelvis and the capsule is intact, hematuria presents itself as the main symptom of the injury. Wounds between the pelvis and the capsule, implicating only the parenchyma of the

organ, are not attended by much danger from hemorrhage, as the pressure caused by the extravasation and resistance of the capsule of the kidney limits the bleeding and the extravasation of urine.

Symptoms and Diagnosis.—In penetrating gunshot wounds of the abdomen implicating the kidney, and in severe crushing injuries, shock is a prominent and grave symptom. The severe hemorrhage present in such cases intensifies the shock. There are cases in which a blow against the lumbar region is followed by hematuria and slight renal colic. I have seen a number of such cases in which recovery appeared to be complete in a few days. The injury in such instances evidently consists in a slight tear of the kidney substance, the blood finding its way into the pelvis of the kidney through the torn uriniferous tubules, or a slight tear may extend into the pelvis and heal in a short time simultaneously with the wound of the parenchyma.

These mild cases are quite in contrast to those in which the injury is attended by severe shock and hemorrhage. Lumbar pain and tenderness accompany every kidney wound, and the pain, as in renal colic, usually extends in the direction of the ureter to the groin, testicle, and inner surface of the thigh. Frequent desire to urinate and hematuria are early and often distressing symptoms. The coagulation of blood in the bladder seriously interferes with the evacuation of this organ spontaneously or by the use of the catheter. The blocking of the ureter is also responsible for the renal colic caused by the retention of urine in the pelvis of the kidney. The coagula that escape with the urine sometimes correspond in form to the lumen of the ureter or pelvis of the kidney, in which event the kidney can safely be assumed to be the source of hemorrhage. Ordinarily, the hematuria disappears in a few days in cases that do not require operative treatment, but it may be prolonged for two to six weeks, leading to pronounced anemia, and yet recovery may take place eventually. In a few cases injury of one kidney has given rise to complete suppression of urine. Such result is generally caused by absence, atrophy, or disease of the opposite kidney, or of the wounded kidney if a horseshoe kidney.

Fever and other constitutional disturbances of a more or less violent character may occur independently of infection, and must then be attributed to fibrin intoxication. The general symptoms from this cause usually set in a few hours after the injury, while fever caused by infection is a more remote complication.

In penetrating wounds of the kidney in connection with an abdominal injury, swelling in the lumbar region may be slight or entirely absent, the blood and urine escaping into the peritoneal cavity. In the absence of such a communicating opening with the peritoneal cavity, any considerable wound of the kidney with rupture of its capsule is soon followed by a swelling in the lumbar region. A swelling that appears within a few hours after the injury is the result of hemorrhage, and the sooner it appears and the

larger it is, the more profuse is the hemorrhage and the greater is the urgency for operative interference.

The gradual increase of the swelling after the hemorrhage has ceased is caused by the extravasation of urine. The appearance of such a swelling shortly after an injury indicates the existence of a wound of the kidney, notwithstanding that hematuria may be absent. In penetrating wounds of the kidney the hemorrhage may be, in part, external, and this is more especially the case if the bullet or knife has not penetrated the abdominal cavity.

As late complications of wounds of the kidney, important from a diagnostic standpoint, must be mentioned suppurative interstitial nephritis. If a number of small abscesses become confluent large abscess cavities, they eventually lead to complete destruction of the kidney. Retention of urine in the pelvis of the kidney from ureteral obstruction by coagulated blood predisposes to the development of suppurative pyelonephritis. The extravasation of blood and urine around the kidney leads to paranephric abscesses. If, in a case of kidney wound, the primary symptoms do not warrant a resort to operative interference, the surgeon must, from day to day, search for symptoms indicating the existence of infection. When such symptoms do appear, he must again carefully consider the propriety of meeting them in time by appropriate surgical intervention, as many such patients succumb to late complications from this source.

Prognosis.—The prognosis is always grave in penetrating wounds of the kidney when the missile or knife has penetrated the peritoneal cavity. Edler collected 50 cases of gunshot wound of the kidney, and of these, 28 recovered. Of the 20 uncomplicated cases, only three died. The most frequent causes of death are hemorrhage, peritonitis, and septicopyemia. Of 12 cases of stab wounds, 7 recovered and 5 died. Bobroff ascertained the result in 141 cases of rupture of the kidney, of which number 75 recovered and 66 died.

The large mortality of wounds of the kidney will be materially reduced as soon as the importance of early operative treatment in grave cases is more generally recognized and practised. The antiseptic treatment of the complicating wound and early operations under strict aseptic precautions will do much in the prevention of death from septic complications. The modern technic of hemostasis will enable the surgeon to deal more efficiently with hemorrhage in the future than has been the case in the past. The prognosis must depend on the extent of the injury, the severity of the hemorrhage, the presence or absence of intraperitoneal complications, and the condition of the opposite kidney. A wound of a horseshoe kidney is always of grave import. If the opposite kidney is diseased or fails to assume compensatory function, death from uremia may be expected. There are cases, too, in which injury of one kidney is productive of sympathetic disease of the other,

when life is again jeopardized from a similar complication. With the appearance of septic complications the prognosis is again modified by the location and extent of the septic infection, and the general condition of the patient from the primary effects of the injury.

Treatment.—Rest of the injured organ and, if it exists, antiseptic dressing of the external wound, constitute the most important first-aid measures. If the hemorrhage is severe, the recumbent position must be enforced, the patient being disturbed as little as possible until the bleeding is under control. Probing of gunshot and stab wounds is not permissible, as little or nothing is gained in determining the location and extent of the injury, and, on the other hand, meddlesome treatment of this kind carries with it additional risks of hemorrhage and infection. As long as hemorrhage is present, stimulants are contraindicated. The administration of a full opiate is favored by the best authorities. Water by the mouth or saline solution by the rectum will prove useful in quenching thirst and in counteracting shock. The internal use of hemostatics, such as gallic acid, tannin, and ergot, is worse than useless.

If the injury is of sufficient severity to endanger life from hemorrhage, urine extravasation, or both, no time should be lost in exposing the injured kidney for direct operative treatment. The value of timely surgical aid in such cases has recently been demonstrated by Keen in his classic monograph on this subject. In penetrating wounds of the abdomen complicated by injury of the kidney, treatment by laparotomy is the proper course to pursue. If, on opening the abdomen, no other visceral lesions are found, the kidney is exposed by holding the intestines out of the way with compresses wrung out of a hot saline solution, and incising the parietal peritoneum sufficiently to give access to the wound. If the hemorrhage is severe and the pelvic part of the kidney is injured, nephrectomy should be performed at once, by lifting the kidney out of its cushion of fat, ligating the pedicle with strong silk, and cutting it at a safe distance from the ligature. Abdominal nephrectomy under such circumstances has this one great advantage, that the surgeon can satisfy himself of the presence and exact condition of the opposite kidney by direct palpation. A counteropening in the lumbar region large enough to permit free gauze drainage should always be made before closing the peritoneal wound. Washing out of the abdominal cavity with hot saline solution is most effective in removing the extravasated blood and urine, and in counteracting the depressing effects of the injury and the operation.

If the operation is performed before peritonitis has had time to develop, abdominal drainage can be dispensed with. If the bullet or knife-blade has injured the intestines or any other abdominal organ, the first duty of the surgeon is to arrest hemorrhage from the kidney or any other source by compression, until the visceral injuries have been disposed of, when the kidney is dealt with in the manner described. If the kidney wound does not furnish an ade-

quate indication for nephrectomy, it is tamponed with sterile gauze that is brought out through a lumbar incision and depended upon in arresting the bleeding and in securing free drainage. If this course is pursued, the parietal peritoneum is carefully sutured over the kidney, followed by the toilet of the peritoneal cavity. Under such conditions it is advisable to drain the peritoneal cavity long enough to avoid the immediate risks of urine extravasation, as this might occur in spite of suturing of the parietal peritoneum over the injured kidney.

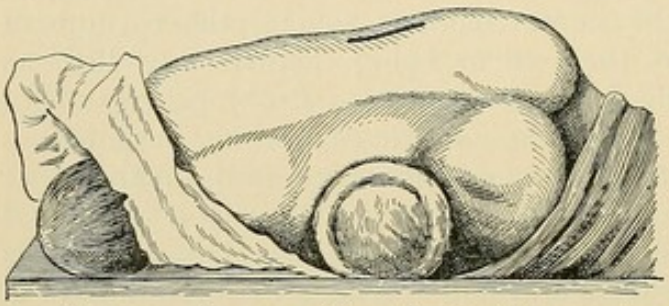

Fig. 172.—Proper position of patient for operation on the kidney, and Simon's vertical incision (Esmarch and Kowalzig).

In the treatment of all extraperitoneal wounds of the kidney, the proper route to the injured organ is through the lumbar region. Simon's vertical incision, commencing over the eleventh rib, at the outer border of the sacrolumbalis muscle, and extended downward to near the crest of the ilium, affords sufficient access to the kidney for the thorough examination and treatment of wounds that do no not involve extirpation. The capsule of fat is next incised, and the organ brought into the wound for inspection. Bleeding is arrested by suturing or tampon, the latter preferably, as suturing is often found difficult and the sutures readily tear through the capsule when subjected to tension. The external wound should be left open and packed with sterile gauze. If the kidney is injured or diseased, iodoform gauze must be used sparingly, as such patients are very susceptible to iodoform intoxication.

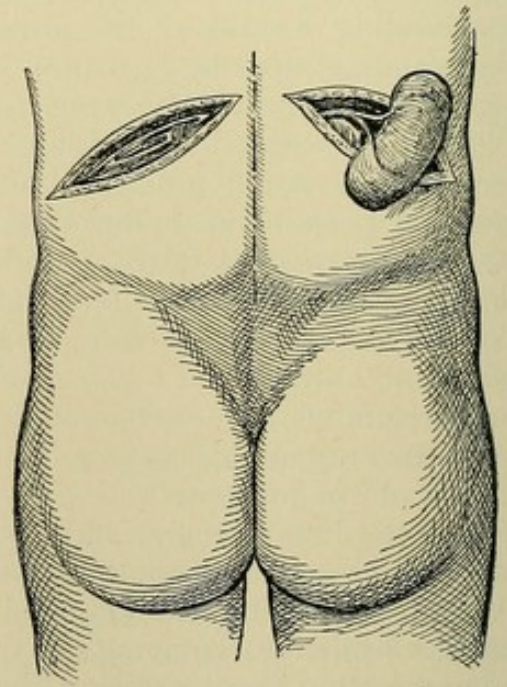

Fig. 173.—Nephrectomy through transverse incision (Esmarch and Kowalzig).

If a nephrectomy, owing to the extent of the injury or the severity of the hemorrhage, is decided upon, the vertical incision is joined by a transverse one, which is carried extraperitoneally along the lower margin of the last rib. It should be long enough to secure free access to the hilum of the kidney, the ureter, and the renal vessels. Catgut should not be relied upon in tying the pedicle, and the

latter must be cut at a sufficient distance from the ligature to prevent its slipping.

After nephrectomy, the wound is sutured and drained. The subcutaneous or rectal administration of saline solution will do much toward stimulating the function of the remaining kidney. One of the distressing conditions in wounds of the kidney with hemorrhage into its pelvis is the accumulation of blood in the bladder, which, after coagulation has taken place, is most difficult to remove. A large Nélaton catheter is inserted, and if the blood-clots do not escape, aspiration is made with a syringe. Should this fail, evacuation of the bladder by perineal section or suprapubic cystotomy must be effected without much delay. In either case the bladder must be drained until hemorrhage has ceased.

The secondary complications after injury of the kidney demand prompt surgical interference. Suppurative interstitial nephritis, pyelonephritis, and paranephric abscess must be met, as soon as discovered, by lumbar incision and nephrectomy, according to the location of the focus of infection. Secondary nephrectomy may become necessary for the removal of a kidney made useless by the injury and subsequent inflammatory complications.

WOUNDS OF THE URINARY BLADDER.

Wounds of the bladder are inflicted by the penetration of the organ by a bullet, knife, or any other implement, or by a sharp fragment of bone in fractures of the pelvis complicated by a visceral injury of the bladder, or by compression of this organ when distended. The liability to injury of the bladder from this kind of traumatism is in proportion to the size of the organ. If the bladder is empty, it is out of the way of some of the routes traversed by penetrating missiles or instruments. It would be expected, therefore, that in the majority of cases of penetrating wounds of the bladder the organ was more or less distended at the time the injury was received, and consequently escape of urine through the wound would constitute an early symptom and source of danger.

Bullet wounds may occur at any point where the missile penetrates the bony wall or soft tissues of the pelvis, but other penetrating wounds are observed most frequently in places where the bladder is covered by soft tissues only. The puncture is then made through the hypogastrium, vagina, rectum, or sacrosciatic foramen.

Rupture of the bladder by compression, as has been shown by clinical observations and the results of experiments, is almost always associated with distention. This accident is seen most frequently in persons under the influence of liquor, when injured by a fall or blow. Garrè has demonstrated that rupture of the bladder from a blow against the hypogastrium is most likely to occur when the abdominal muscles are tense. Rupture of the bladder by compression of the distended organ occurs most frequently in the posterior wall, but it may occur in almost any part of the wall, as not an in-

considerable number of cases have been recorded in which the visceral wound was extraperitoneal. If the wound is intraperitoneal, urine escapes into the free peritoneal cavity ; if it is extraperitoneal, extravasation of urine into the loose paravesical connective tissue is the immediate or more remote consequence of the injury. If the anterior wall of the bladder below the peritoneal reflection is torn, infiltration of the cavity of Retzius produces a swelling which, in shape and location, mimics very closely a distended bladder.

Symptoms and Diagnosis.—In penetrating wounds of the bladder the character of the symptoms is determined by the location of the wound. A bullet frequently inflicts two wounds, of which one may be extraperitoneal, the other intraperitoneal, or both may be intraperitoneal or extraperitoneal. In exceptional cases in which only one extraperitoneal wound exists, escape of urine through the wound furnishes sufficient evidence that the bladder is injured, and would tend to prove the absence of an additional intraperitoneal wound. Punctured wounds through the vagina or rectum may also be either extraperitoneal or intraperitoneal, according as the wound is either below or above the reflection of the peritoneum. In the former case, escape of all the urine through the wound would exclude the existence of another intraperitoneal wound ; in the latter instance, part of the urine may escape through the injured passage and part into the peritoneal cavity.

In rupture of the bladder the urine escapes either into the peritoneal cavity or into the surrounding connective tissue, according to the intraperitoneal or extraperitoneal location of the rent. If the rupture is small and intraperitoneal, and especially if the bladder is not much distended, the urine extravasation may be slight, the wound becoming blocked by adhesions a few hours after the injury. Such a condition accounts for the recovery, without surgical intervention, of two out of eighty cases of intraperitoneal rupture of the bladder reported by Stephen Smith.

The two symptoms that may be most relied upon in diagnosticating perforation or rupture of the bladder are hemorrhage and an empty bladder. An extraperitoneal wound of the bladder is characterized by the profuseness of the hemorrhage ; an intraperitoneal rupture of the posterior wall, by the escape of all the urine into the peritoneal cavity. In the former case an extraperitoneal phlegmonous inflammation is the usual result of the injury ; in the latter, physical signs pointing to the accumulation of fluid (blood and urine) in the peritoneal cavity furnish reliable, almost unmistakable, evidence of the existence of an intraperitoneal perforation or rupture. Inability to void urine and the appearance of an intraperitoneal or extraperitoneal swelling must always arouse strong suspicion of the existence of a wound of the bladder.

If any doubt remains in regard to the location of the rupture, a suprapubic incision will become an important diagnostic aid and a valuable therapeutic resource. If the extraperitoneal part of the an-

terior wall of the bladder has been ruptured, the wound is immediately discovered, and the incision at once determines the diagnosis and constitutes the proper surgical treatment. Through the visceral wound the bladder is explored for additional injuries, and if none is found, free drainage of the bladder completes the operation. If the anterior wall of the bladder is found intact, the bladder is opened extraperitoneally, and by digital exploration a wound in the posterior wall can be detected, if such exists, and the necessary radical treatment by abdominal section and suturing of the wound instituted at once.

The subjective symptoms in rupture of the bladder are often slight, and this is especially true in persons under the influence of alcohol. Probing as a diagnostic resource in gunshot and punctured wounds of the bladder must be dispensed with, as it is an

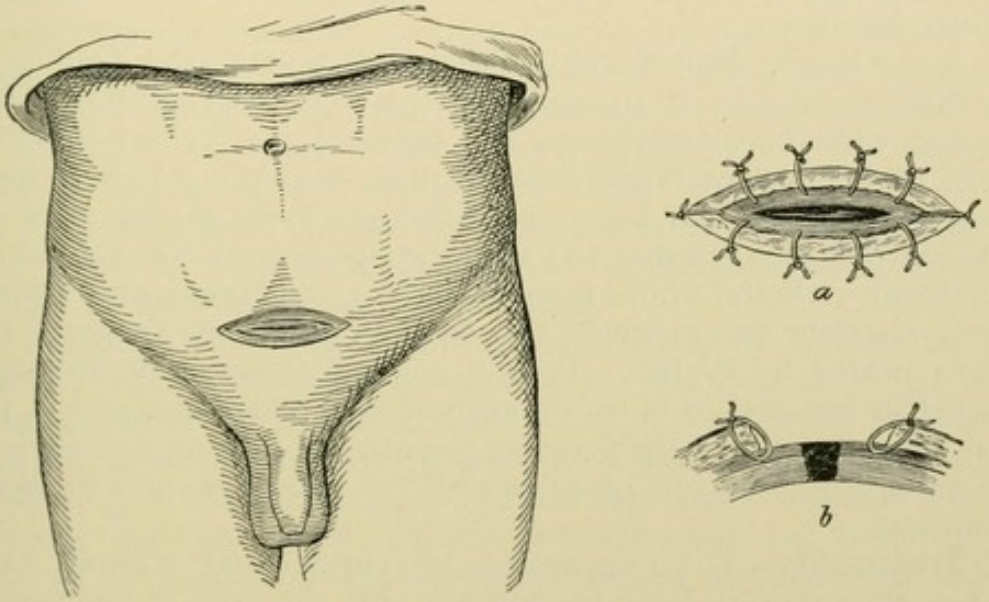

Fig. 174.—Suprapubic incision of the bladder by Bardenheuer's transverse incision; suturing of the visceral to the external wound: *a*, As seen from above; *b*, as seen in section (Esmarch and Kowalzig).

unreliable and often dangerous procedure. Inflation of the bladder with hydrogen gas or filtered air through a soft-rubber catheter was first suggested by Keen as a diagnostic aid, and in doubtful cases should always be resorted to. If the bladder is wounded, the gas or air will escape through the wound into the peritoneal cavity if the wound is intraperitoneal, or into the loose paravesical connective tissue if it is extraperitoneal. It will do no harm in either locality, and will at once confirm or correct the clinical diagnosis. Injection of a warm normal salt solution will answer the same purpose. If the bladder can not be distended by inflation or injection, the existence of a rupture or perforation has been established, and no time should be lost in resorting to the necessary operative treatment.

Prognosis.—The prognosis of wounds of the bladder, whether produced by penetration or rupture, is always grave. In default of

prompt surgical intervention the extraperitoneal wounds are followed by diffuse phlegmonous inflammation, abscess formation, sepsis, and death in the majority of cases; and intraperitoneal wounds, with few exceptions indeed, result in death from progressive septic peritonitis. The dangerous symptoms are usually delayed for a day or two, but when once developed, they progress rapidly to a fatal termination. The prognosis is vastly better in extraperitoneal than in intraperitoneal wounds, as in the former case a timely incision of the abscess following in the course of the phlegmonous inflammation may succeed in averting death from sepsis. The subsequent urinary fistula not infrequently heals spontaneously, especially when the bladder is eliminated as a reservoir for the urine for a sufficient length of time by the employment of permanent urethral or perineal drainage. The septic peritonitis which so constantly sets in a day or two after the injury in intraperitoneal wounds of the bladder is often provoked by catheterization.

According to Maltrait, of 97 cases of intraperitoneal wounds of the bladder, only one recovered after laparotomy and suturing of the visceral wound, and this case was reported by Walter, of Pittsburg, while of 76 extraperitoneal wounds, recovery is said to have taken place in 29. Rivington collected 322 cases of rupture of the bladder, of which number 183 were extraperitoneal and 119 intraperitoneal. Of the whole number, only 27 recovered, and among these was only one in which the wound was intraperitoneal—the case reported by Walter. Prompt surgical intervention has succeeded in reducing this enormous mortality materially, and is the best possible proof of the pressing necessity of making an early and a correct diagnosis, and of subjecting the visceral wound to direct treatment.

Treatment.—The experiments of Vincent and Maltrait have shown the value of early laparotomy and suturing of the vesical wound as life-saving measures in the treatment of intraperitoneal wounds of the bladder. They ascertained that laparotomy without suturing of the wound of the bladder had but little, if any, influence in preventing death from peritonitis. In intraperitoneal wounds of the bladder the abdomen should be opened under the strictest aseptic precautions as soon as possible after the accident, for the purpose of removing the products of extravasation of blood and urine and to procure free access to the visceral wound, which is then carefully sutured. After opening the abdomen, the peritoneal cavity should be thoroughly cleansed by irrigation with a warm normal salt solution, and mopped with gauze or sea-sponges. If the wound of the bladder is not readily discovered, the same solution is injected into the bladder through an elastic catheter, when the escaping fluid will indicate the existence and location of the wound. The catheter is retained in the bladder, and is fastened in position and utilized later to drain the bladder by siphonage. This is accomplished by attaching to the distal end of the catheter rubber tubing long

enough to reach from the bed to the receptacle for the urine, placed two or three feet below the level of the neck of the bladder. The distal end of the rubber tube is immersed in an antiseptic solution.

After the peritoneal cavity has been thoroughly cleansed, the perforation or rent in the bladder is sutured, somewhat in the same manner as an intestinal wound. If the margins of the wound are ragged, they are trimmed with scissors. The first row of sutures should be made with absorbable material, preferably of fine catgut, and should include all the coats of the bladder except the mucosa. The second row of sutures of fine silk is intended to bury the first row, and to bring in contact the serous surfaces. The stitches are inserted in the same manner as the Lembert stitches are inserted in suturing an intestinal wound. The stitches in both rows of sutures are placed very closely, to secure hermetic closure of the wound. After the suturing has been completed, the bladder is moderately distended by injecting normal salt solution, and if any leakage is detected, the defect is remedied by inserting additional sutures. Urethral drainage by siphonage is continued until the peritoneal surfaces have become firmly agglutinated ; that is, for at least from forty-eight to seventy-two hours. After this time it will be necessary, for a number of days, to evacuate the bladder every four hours by aseptic catheterization. Drainage of the abdominal wound for forty-eight hours is advisable.

Schlange has recently collected 32 cases of rupture of the bladder treated by operative intervention. Of these cases, 22 were intraperitoneal and 10 extraperitoneal ; of this number 17 recovered, and of these, in 10 the rupture was intraperitoneal, and in the remaining 7 extraperitoneal. In extraperitoneal wounds of the bladder drainage of the bladder by siphonage has occasionally sufficed to prevent dangerous extravasation and to effect healing of the visceral wound. It is, however, much safer not to rely on this treatment in such cases, but to resort at once to a suprapubic cystotomy, search for and, if found, make an attempt to close the wound by suturing. If this can not be done, suprapubic drainage through the operation wound should be continued until the rupture or perforation is healed.

CHAPTER VIII.

RUPTURE OF THE URETHRA.

RUPTURE of the urethra is of either traumatic or pathologic origin. Of the former, external crushing injuries and unskilful or forced catheterization are the most frequent causes. Pathologic rupture of the urethra follows usually upon the footsteps of periurethral abscess, stricture, or malignant disease of any part of the urethra. Regardless of the nature of the immediate cause, rupture of the urethra endangers life by urine retention, urine infiltration, gangrene, phlegmonous inflammation, and abscess formation. As traumatic rupture is vastly more frequent than the pathologic variety, the remarks will apply more especially to this etiologic variety of rupture of the urethra.

Traumatic rupture of the urethra is an accident that belongs to emergency surgery, and is, consequently, a subject of the greatest importance and interest to the general practitioner. It is strange, but nevertheless true, that most authors on operative surgery do not treat this subject with the necessary degree of detail and thoroughness for the instruction of the general practitioner. Terrillon, a painstaking author, classifies traumatic ruptures of the urethra anatomically into: (1) Interstitial (first degree); (2) rupture of the mucosa and submucosa (second degree); (3) rupture, either complete or incomplete, of all the coats (third degree). This classification is of very slight clinical value before operation, as a differential diagnosis is often impossible without direct inspection of the tissues exposed by the incision.

The classification of Oberst is simpler and of greater practical value. He recognizes and describes two degrees: (1) Partial rupture without destroying the continuity of the tube; (2) complete rupture, destroying the continuity of the tube, an injury that will be almost certain to be followed by urinary infiltration unless prompt surgical interference is instituted to prevent it. According to Oberst, the injury occurs in the following manner:

With the limbs separated, the person falls astride some object, which strikes the perineum. In consequence of such impact the perineum and urethra are forced against the sharp margin of the pubic arch. As the urethra is connected with this arch by the puboprostatic ligament, the injuring force is concentrated at this point. If the force is directed more to one side of the median line, the urethra is crushed against the descending ramus of the pubis. The overlying skin, which is more elastic than the urethral tissues, usually remains intact.

Oberst's conception of the *modus operandi* of the trauma has been fully corroborated by the experimental work of Terrillon. Poncet and Ollier claim that not all ruptures of the urethra are caused by direct impact against the pubis. They maintain that the force is directed against the triangular ligament, which severs the urethral roof. They made experiments by inserting bougies of soft wax into the urethra of cadavers, and then striking the perineum with force. The wax always showed impressions made by the ligament. They believe that this method of rupture applies only to the membranous portion of the urethra, agreeing with others that the bulbous portion is severed by pressure against the pubis.

Kaufmann gives the statistics of the cause of urethral rupture in 239 cases as follows: 198, or 82 per cent., were due to injuries caused by falling astride of some hard, sharp-margined object; 28, or 12 per cent., were caused by a blow upon the perineum; 9, or 4 per cent., resulted from an injury by being thrown upon the pommel of a saddle. In fractures of the pelvis, especially of the pubic portion, the deep urethra is almost invariably torn, or the escape of urine is impeded or arrested by pressure of a fragment upon the urethral canal.

In fractures of the pelvic ring, the deep urethra, with the exception of the prostatic portion, is especially liable to injury, owing to its manner of fixation by the triangular ligament. Gosselin is of the opinion that fractures of the pelvis usually result in only partial rupture of the urethra. In all the cases studied by Oberst the urethra was found completely severed in such injuries. In severe contusions of the pelvis there may be rupture by reason of momentary disjunction of the symphysis pubis. A few cases have been reported in which rupture of the urethra was caused by violent abduction of the thigh, in which case the rupture must be attributed to muscular action.

Rupture of the urethra from careless instrumentation occurs most frequently during attempts at catheterization in patients suffering from stricture or hypertrophy of the prostate. Rupture of the pendulous portion of the urethra is of very rare occurrence, and when it does take place, is due to violence sustained during erection of the penis.

It is not always possible to locate, with precision, the anatomic location of the rupture. The relative frequency with which the bulbous and membranous portions are involved is not definitely settled. Terrillon described 9 cases, 6 of the bulbous and 3 of the membranous portion. Oberst reported the results of 5 autopsies in which the rupture was found four times in the membranous and only once in the bulbous part of the urethra.

The clinical recognition of a rupture of the urethra is not difficult, but the prediction of the extent of the injury often remains uncertain. Hemorrhage from the urethra furnishes an indication of the existence of the injury, but the amount of hemorrhage is not a

criterion as to the extent of the injury. The artery of the bulb might be torn by a slight rupture, in which case the bleeding would be profuse; while, on the other hand, a complete rupture of the membranous portion often produces but slight hemorrhage. The urethral walls are elastic and retract after being severed, an occurrence that would naturally tend to arrest the bleeding. The space between the torn surfaces becomes blocked by a blood-clot, which plays an important part in the diminution and arrest of the urethral hemorrhage.

The next most important diagnostic indication of the existence of a rupture of the urethra is interference with urination. In complete rupture urination is arrested at once, as the urine that escapes from the proximal end accumulates in the wound cavity and gives rise to urinary infiltration. In incomplete rupture the urine may escape first through the natural channel, but later there may occur complete occlusion, due to para-urethral infiltration. If the rupture is interstitial, there is difficulty of micturition, due to infiltration of the urethral wall causing a temporary occlusion of the lumen of the urethra. In about 75 per cent. of all cases urine retention results from obstruction caused by the formation of a coagulum. The perineal swelling that invariably attends rupture of the urethra is caused by the extravasation of either blood or urine, or, what is more frequently the case, by both. The swelling usually involves, at the same time, the scrotum. The primary swelling is caused by the hemorrhage and increased by urine extravasation. A gradual progressive swelling, which makes its appearance some time after the receipt of the injury, is always due to extravasation of urine.

Rupture of the membranous portion of the urethra alone results in extravasation of blood and urine into the space between the two layers of the triangular ligament. In such cases the extravasation of urine can not extend beyond the rami of the pubis, the points of attachment of the two layers, without laceration of either of them. The swelling in such instances is always found in the middle line of the perineum. If the rupture occurs anteriorly to the ligament, it is always attended by great infiltration of the scrotum, and in neglected cases, the subsequent infiltration and edema extend over the anterior surface of the abdomen as far as the umbilicus, and downward along the inner aspect of the thighs. The urinary infiltration, unless promptly relieved by surgical interference, is followed by infection, gangrene, abscess formation, and sepsis.

Pain at the site of rupture and tenderness are always present, and the former is always aggravated during attempts at urination. In severe cases of urethral rupture the most prominent symptoms that present themselves soon after the accident has occurred are complete retention of urine, urethral hemorrhage, and perineal swelling.

Prognosis.—The prognosis in rupture of the urethra is largely influenced by the existence of serious complications, such as fracture

of the pelvis and the promptness and efficiency with which surgical aid is rendered. The danger of infection must always be remembered, and if infection occurs, it is very difficult, indeed, to predict the gravity of the results to which it may lead. The prognosis of a partial is always more favorable than that of a complete rupture; especially is this the case if the mucous membrane has not been injured. Kaufmann estimates the mortality of all cases at 14 per cent. Extensive urinary infiltration, gangrene, and progressive phlegmonous infiltration are some of the early complications that always add to the gravity of the prognosis.

Treatment.—The fate of a patient the subject of a ruptured urethra, either of traumatic or pathologic origin, depends on a correct early diagnosis and on the receipt of prompt surgical aid. Every general practitioner should be prepared to recognize the accident and to relieve the mechanical difficulties in the way of spontaneous urination, as tension caused by the extravasation of blood and urine is one of the principal causes of more remote serious consequences. Successful catheterization is possible only in cases in which the rupture is incomplete. In the complete variety the use of the catheter is seldom, if ever, attended with success, but serves, nevertheless, as a means of diagnosis.

The first tentative efforts in this direction to relieve the distended bladder should be made with a soft Nélaton catheter, of large or medium size, well lubricated. If this proves unsuccessful, a careful effort may be made with a metallic catheter, as with cautious manipulation of this instrument clots are more easily displaced, and entrance into the bladder thus facilitated. The utmost care must be exercised in the employment of the metallic catheter, as it is a somewhat dangerous instrument in the healthy urethra if manipulated by unskilled hands, and in the torn urethra is treacherous even in the hands of an expert. *No force must be used in its introduction; it should find its way largely through its own weight, as otherwise additional and more dangerous false passages may be made.*

In inserting the catheter it should be remembered that in the great majority of cases the wound is in the posterior wall of the urethra, in the region of the bulbous portion, and consequently the roof of the urethra should be followed instead of, as is only too commonly done, its floor. The anterior wall has been well designated by Guyon as the "surgical wall." If there is any doubt as to whether the bulbous or membranous portion is torn, it is advisable to follow the anterior wall in the bulbous portion, and the posterior wall in the membranous portion, as here the anterior wall is most frequently torn. Should catheterization prove successful, it is advisable to retain the instrument in place for a few days, as recommended by Duplay and others.

Suprapubic puncture is indicated if catheterization fails and if the physician is not prepared to perform perineal section at once. It can not be relied upon as a therapeutic resource any further than as

a palliative measure to relieve urine retention until the proper preparations can be made for the radical operation. In severe cases perineal section must be made with as little loss of time as possible. Delay in performing the operation is attended by great risks follow-

Fig. 175.—Wheelhouse's beaked straight staff.

ing the consequences of blood and urine extravasation and infection at the seat of injury. Perineal section for this injury was advocated by Chopart, Desault, and Lallemand in the beginning of the last century, and is now universally indorsed as the operation of choice. Performed under the necessary aseptic precautions, the mortality of this operation has been reduced to less than 10 per cent. External urethrotomy, perineal section, boutonnière, meet the most urgent indications in the treatment of a urethra ruptured sufficiently extensively to resist successful catheterization. The operation exposes the seat of injury to direct treatment, relieves tension by furnishing a free escape for the products of extravasation, and secures free drainage for the visceral wound, thereby minimizing the danger of infection. The operation must be performed under the most pedantic aseptic precautions, as perineal wounds implicating the urethra are noted for their great liability to infection.



Fig. 176.—Senn's retractor.

After the patient is fully under the influence of the anesthetic, he is placed on the operating table in the lithotomy position. Two assistants take charge of the lower extremities, the knees and hips being well flexed and the thighs abducted. If there is any lack



Fig. 177.—Syme's external urethrotomy staff.

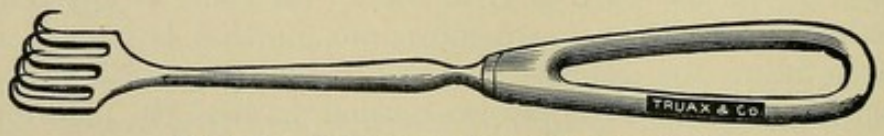

Fig. 178.—Volkmann's four-prong retractor.

of reliable assistance, it is well to tie hand and foot on each side together. A grooved staff or, in the absence of such, an ordinary urethral metallic sound is next introduced into the bladder. If however, it is found impossible to enter the bladder, as is usually the

case in complete rupture, the instrument is passed down to the seat of injury. The staff or sound so introduced serves the purpose of a reliable guide in making the incision down to the urethra and the seat of rupture. The staff or sound is held securely by an assistant, who rests his hand on the symphysis pubis. With the left hand the same assistant elevates the scrotum. The operator inserts his left index-finger into the rectum, and makes an incision in the median line, through the skin and connective tissue, and from two to three inches in length, which extends to within an inch of the anal margin. Care is necessary to avoid injuring the bulb in the upper angle of the wound. If the bulb has not been injured by the trauma, it is drawn upward with a blunt hook or the finger of an assistant, while the incision, by successive strokes of the knife, is deepened. The superficial fascia and transverse perineal muscles must be divided before the urethra is reached. The operator now feels for the groove or tip of the sound, which serves him as a guide to the seat of injury. If the rupture of the urethra is complete, the point of the instrument will be felt in the wound between the retracted ends of the urethra; if incomplete, the floor of the urethra is freely incised in order to expose the lacerated or crushed part of the urethra. If the bulb has been injured, the removal of the masses of coagulated blood will, in all probability, renew the hemorrhage, in which event hemostasis by ligation, direct or indirect, or compression by forceps or tampon, will occupy the first attention of the operator.

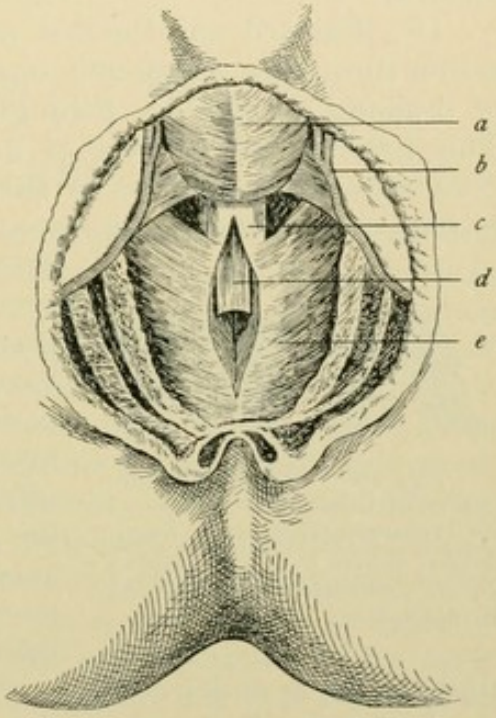

Fig. 179.—Anatomy illustrating perineal section: *a*, Bulb of urethra; *b*, pudic artery; *c*, membranous portion of urethra; *d*, grooved staff; *e*, prostate (Esmarch and Kowalzig).

The recognition of the crushed urethra is often a matter of great difficulty, but is usually made possible by the careful use of the staff or sound. If the rupture is complete, the guide in the urethra at once discloses the distal end, but the finding of the proximal end is usually very difficult, and occasionally impossible, owing to the retraction of both ends, the presence of coagula, and bruised tissue. A good light, patience and perseverance, and an accurate knowledge of the anatomic relations of the injured parts often lead to success in the most difficult cases. Forcing urine from the proximal end by compression of the bladder has been resorted to as an aid in searching for the opening, but its value in rendering such assistance

has been greatly overestimated. If, after a faithful attempt, the surgeon finds it impossible to secure the proximal end, a tubular drain the thickness of the little finger should be inserted into the wound, at a point behind the distal end, and the space between it and the wound margins packed with iodoform gauze. If the bladder is much distended, suprapubic puncture will secure the necessary immediate relief. As soon as the bladder recovers its tone the urine is expelled and escapes through the tubular and gauze drain, without any danger of extravasation occurring, and, as normal urine is practically sterile, without much additional risk of wound infection. Later it may be less difficult to find the opening during the time the urine escapes.

Dr. Brainard was the first one to suggest retrograde catheterization through a suprapubic opening in such cases for the purpose of draining the bladder through the proximal part of the urethra. This practice has its field of usefulness in desperate cases, as has been shown by a number of successful operations. If it is decided to pursue this course, the retrograde catheterization should be done through a transverse suprapubic incision (Fig. 174). If perineal section is performed before the infiltrated tissues have become infected, the urethral and perineal wounds usually heal in a remarkably short time, and the urine often escapes spontaneously through the natural channel in a few days. If infection has occurred at the time the operation was performed or follows later, free drainage is required until suppuration is under control. Stricture of the urethra as a remote result of rupture is only to be feared if the urethra has been extensively crushed, as under ordinary circumstances the resulting scar tends to widen the elongated and injured part of the urethra, as was shown many years ago by W. Roser.

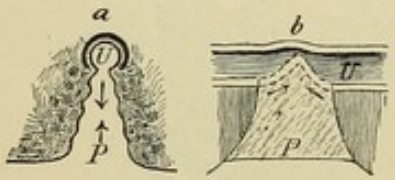

Fig. 180.—Schematic illustration of external urethrotomy: *a*, Transverse section; *b*, longitudinal section; *U*, *U*, urethra; *P*, *P*, perineum (Esmarch and Kowalzig).

It has been suggested that in complete rupture of the urethra an attempt should be made to restore the continuity of the canal at once by suturing. Kaufmann and Hägler have demonstrated experimentally that primary suture is not followed by cicatricial contraction, and frequently results in speedy restoration of the urethral channel. The results of these experiments, however, only prove that so ideal a healing is only possible in incised wounds, which in practice are the exception, contused and lacerated wounds the rule. A number of cases of successful primary suture of the torn urethra have been reported by Nogués, Pearce Gould, Boisson, Rudolph Frank, Delorme, and others. If the rupture is complete and both ends can be found and brought in contact without tension, it is always advisable to suture with catgut at least the upper half segment of the urethra, and drain the bladder through either the

urethra or the perineal wound. Bringing a portion of the ends together in such a manner prevents undue diastasis and does not interfere with free drainage of the bladder and the urethra. Moreover, it can not fail to hasten the process of repair and to improve the functional result. Incised wounds of the urethra, whether accidental or intentional, should always be sutured if the seat of injury or field of operation is aseptic and no drainage is required. Under no circumstances is it permissible to close the perineal wound throughout, as drainage of the wound for a certain length of time is always a necessity.

CHAPTER IX.

FRACTURES.

A CONSIDERABLE share of the general practitioner's work and source of income consists in the treatment of fractures. There is, perhaps, no other department of surgery in which good common sense, mechanical skill, and a thorough knowledge of the nature of the injury are more important in securing desirable results than in the treatment of fractures. Success means the building-up of a good and lasting reputation for the practitioner; failure brings reproach and a long-standing source of humiliation. Bad results following fractures have been the tombstones that have marked the termination of an otherwise successful professional career of many ill-fated, unlucky, disappointed practitioners. It is not always possible to prevent unsatisfactory results by the employment of the most modern and approved methods of treatment, but it is a source of satisfaction to know beforehand when to expect them, and to recognize early the complications that justify their prediction. Such knowledge, properly used, is an invaluable safeguard against assuming a responsibility so often unjustly charged against the practitioner in cases in which bad results are inevitable, and owing entirely to the nature of the injury and not to any defect or neglect in the treatment.

It is very evident that success in the treatment of fractures depends largely on an early and a correct diagnosis. The most flagrant mistakes in practice follow the footsteps of an erroneous diagnosis. Forcible attempts to reduce a supposed dislocation of the hip-joint in fractures of the neck of the femur are followed by consequences alike disastrous to the patient and to the reputation of the surgeon. The same can be said of fracture of the anatomic neck of the humerus mistaken for and treated as a subcoracoid dislocation of the head of the humerus. The persistent and vicious practice of establishing the existence of a fracture of the neck of the femur by searching for crepitus as the most reliable evidence of the pres-

ence of this injury has only too often resulted in converting an impacted into a nonimpacted fracture, and in doing so, removing the anatomicomechanical conditions upon which so much depends in securing repair by bony consolidation.

A correct diagnosis made, the result of the treatment is determined by the mechanical skill exercised by the surgeon and the care and attention with which he conducts the after-treatment. The most learned physicians are often the poorest mechanics. The plain country doctor, endowed with a liberal amount of good common sense and of a mechanical turn of mind, will achieve success in difficult cases far superior to that of some of the most accomplished physicians. The man who can extemporize an efficient dressing from the simplest material is often of greater benefit to his patients than the one whose brain is crammed and confused with an immense wealth of book knowledge, and who is fully conversant with the names and uses of innumerable manufactured splints devised for special fractures of every long bone in the body.

One of the lessons in the treatment of fractures that is so often forgotten or ignored by the general practitioner is that the treatment of a fracture does not always terminate with the union of the fragments by bony consolidation. The physician who takes charge of a fracture assumes a responsibility that terminates only with the restoration of the maximum degree of function compatible with the nature of the injury. This period of time necessarily varies with the location and nature of the injury from three weeks to as many years. Grave mistakes are committed daily by discharging patients with the removal of the splints at the expiration of the time necessary for the healing of the fracture by bony consolidation. Such a course is approved of and sanctioned by the public, which, as yet, is ignorant of the many difficulties that must be met in restoring function after the fracture has united. These remarks apply with special force to fractures in close proximity to or involving any of the large joints. A mutual understanding between physician and patient in the management of such cases must be effected regarding the probable ultimate result and the time and efforts necessary to reestablish the maximum obtainable functional result. Many fractured limbs are made comparatively useless by premature suspension of the after-treatment, so necessary for the restoration of function.

Frequency.—The importance of fractures becomes apparent when it is known that they constitute, as has been shown by extensive statistics, one-seventh of all kinds of injuries that come under the care of the general practitioner. Regarding the relative frequency of fractures, the statistics of the London Hospital, including 40,277 cases from 1842 to 1874, show that fractures of the upper extremities are twice as frequent as are those of the lower. Fractures of the long bones, including the clavicle, constitute three-fourths of all the fractures, while fractures of the skull

embrace only one twenty-fifth of all cases. The bones of the forearm furnish the largest contingent (18 per cent.), and the tibia and fibula come next in frequency, followed closely by the ribs and clavicle. Fractures of the scapula, spine, and pelvis occupy the lowest positions in the scale of frequency.

Men, being exposed more frequently to injuries of all kinds than women, the male sex predominates in the statistics of fractures, the proportion being, according to the estimates of different authors, about 3 : 1. This disproportion is, as would be naturally expected, most marked during the most active period of life—from twenty to forty years of age. In both sexes fractures occur most frequently from the second to the fourth decennium, a time of life during which injuries of all kinds are most liable to occur. Incomplete fractures, greenstick fractures, and traumatic epiphyseolysis are notably frequent injuries of childhood and young adults, while fractures of the neck of the femur and Colles' fracture are injuries for the occurrence of which senile osteoporosis furnishes a marked predisposing cause. Fractures of the neck of the femur are rare in persons under fifty years of age, and the increased fragility of the bones in the aged constitutes a potent influence in the production of Colles' fracture from a fall upon the hand in persons the subjects of senile marasmus.

In children fractures occur most frequently during the summer months ; in the aged, usually during the winter months, for very obvious reasons.

Before giving the classification of fractures caused by a trauma, it is necessary to refer briefly to what is understood and meant by a

Pathologic or Pseudofracture.—A pseudo- or false fracture is a solution of continuity of a bone which occurs independently of a traumatic force sufficient to fracture a bone of normal structure and resistance. Such injuries have been described as spontaneous fractures, an erroneous designation, as the fractured bone is always found the seat of disease, the break being caused by muscular contraction or an insignificant injury. The terms pseudofracture and pathologic fracture are more appropriate, as they indicate the existence of an antecedent pathologic condition at the seat of solution of continuity, and the occurrence of the latter under the influence of a slight or nonappreciable mechanical cause. Such injuries present to the physician greater pathologic and practical importance in determining the nature and origin of the original bone affection than the occurrence of the accident, which may perhaps furnish the first indication of the antecedent disease of the bone. Serious mistakes in the treatment of fracture have been made by concentrating the energies on the mechanical treatment of the pseudofracture and by failure on the part of the attendant to recognize and correctly diagnosticate the antecedent affection of the bone. The fracture, if we use the term at all, in such instances constitutes only a complication of the preexisting bone affection, which may be diffuse, involving many

or all the bones, or limited to the seat of the pseudofracture, as is the case in primary or metastatic malignant disease or localized inflammatory affections at the seat of injury. The conditions that determine the fracture are such as to justify the expression pathologic fractures, as the injury is caused by pathologic processes that destroy or weaken the bones to an extent sufficient to produce a severance of its continuity upon the slightest injury.

The fragility of the bone (osteopsathyrosis, fragilitas ossium) is a symptomatic condition incident to several affections of bone found in pathologic or pseudofractures.

Predisposing Causes.—In the enumeration of the predisposing causes of pathologic fractures **bone atrophy** should receive first mention, owing to the frequency with which it is found as the sole pathologic cause. Atrophy of bone as a diffuse or localized condition represents different pathologic processes, the nature of many of which remains unexplained at the present time. Atrophy of bone does not necessarily mean diminution in its volume A bone may become atrophic without diminution of its size by the gradual disappearance of its organic constituents, which increases its porosity and diminishes its resistance, resulting in a condition known as osteoporosis. The most conspicuous gross pathologic conditions found in osteoporotic bone are diminution in the thickness of the compacta, rarefaction or partial or complete disappearance of the spongiosa, and dilatation of the central medullary cavity and medullary spaces, which are filled with yellow medullary tissue.

One of the most frequent causes of osteoporosis and the accompanying increased fragility of bone is senile marasmus. Bones thus affected yield to slight force, and in some cases the atrophy reaches such an extent that a fracture may occur under the weight of the body or from ordinary muscular action. In aged men and women a misstep or a fall upon the great trochanter is often sufficient to produce a fracture of the neck of the femur. General osteoporosis is, however, not a constant accompaniment of old age, as it is occasionally found in persons who have not passed middle life, and is not infrequently absent or developed only to a slight extent in persons of far-advanced age. Gurlt found a few cases of pathologic fracture in persons the subjects of premature senile osteoporosis.

Another form of bone atrophy, limited to the bones of an extremity or part of an extremity, makes its appearance in consequence of prolonged enforced rest, and is then called *inactivity atrophy*. If the function of a limb remains suspended for years in consequence of paralysis or chronic disease of bones or joints, the bones eventually become extremely osteoporotic and fragile. If the causes of the atrophy set in during early childhood, the bones are not only rendered osteoporotic and fragile, but their growth is also impaired or arrested, great shortening of the limb following as an inevitable result. If the causes make their appearance after the completion of the growth of the skeleton, the bones of the useless

limb undergo eccentric atrophy, which may reach such a degree as to serve as the sole cause of a fracture that should be called pathologic. In ankylosis of the hip-joint and knee-joint following a tubercular coxitis during childhood the bones later in life are often found so fragile that they fracture or bend during careful efforts made to correct an existing deformity by manual force. The researches of Julius Wolf have shown that where bone tissue is not in static use no apposition takes place, but the reverse sets in, resorption, which leads to osteoporosis and a corresponding loss of resistance.

A very obscure form of bone atrophy is not infrequently observed, for which we must assume a trophoneurotic origin. Neurotic bone atrophy is associated with some forms of chronic inflammatory and degenerative affections of the brain and spinal cord. Pathologic fractures have been repeatedly observed as remote consequences of locomotor ataxia. Weir Mitchell was the first one (1873) who called attention to pathologic fractures as a complication of this disease. This subject later received careful and extended study by Charcot, and the number of well-authenticated cases of pathologic fractures occurring during the advanced stages of locomotor ataxia has been steadily increasing since attention has been called to the direct connection between cause and effect.

A peculiar form of great fragility of the long bones, cranium, and spine has been described in connection with progressive general paralysis of cerebral origin. As early as 1842 Davey found six pathologic fractures in a postmortem on a patient who died from this disease. In 100 autopsies Gudden found pathologic fractures in 16, and in three-fourths of these cases the fracture was multiple. In one case 14, and in another 36, fractures were found in the same subject.

Another form of fragility of bone of neurotic origin is found in connection with, and as a consequence of, arrest of development of the cerebrospinal centers. Congenital hydrocephalus and spina bifida in the lumbar region are often productive of bone atrophy to so great a degree as to give rise to pathologic fracture. Charcot regards the atrophy of bone in such cases as a result of trophoneurotic disturbances, probably caused by degeneration of the anterior horns of the gray substance of the spinal cord. Experimental researches have demonstrated that loss of innervation following nerve section, if the paralysis continues long enough, is constantly followed by atrophy or rarefaction of the bone tissue in the form of **eccentric anostosis** and substitution by the deposition of fat. Chemic analysis of the atrophic bone shows a decided diminution in the inorganic constituents, and more than double the quantity of organic material, this great increase being due largely to the deposition of fat. The union of such fractures is preceded by the formation of a voluminous callus.

Osteomyelitis as a source of pathologic fractures presents itself in two forms—diffuse and circumscribed.

In the **acute diffuse variety of osteomyelitis** pathologic fracture may occur when the entire thickness of the shaft of a long bone is destroyed by the suppurative inflammation, and the formation of an involucrum fails to take place or is retarded by extensive or complete destruction of the periosteum. Fortunately, such cases are rare, as even in total necrosis of the shaft of a long bone separation of the sequestrum is usually preceded by the formation of an involucrum strong enough to prevent the occurrence of such an accident. The bone gives way more frequently in the vicinity of the epiphyses than in any portion of the shaft (pathologic epiphyseolysis). The pseudofractures occur at a time when the line of demarcation is established between the dead and the living bone—seldom before the sixth week after the commencement of the acute attack. I have observed a number of cases of pseudofracture complicating acute osteomyelitis, and resorted to the usual mechanical treatment, always having had the satisfaction of securing restoration of the continuity of the bone by the formation of an involucrum in the course of from four to eight weeks after the occurrence of the accident.

Epiphysitis of osteomyelitic origin is another cause of epiphyseolysis. The primary inflammation and the subsequent pathologic separation of the epiphysis from the shaft are always complicated by inflammation of the adjacent joint, a fact that must be taken into careful consideration in the selection of therapeutic resources. Pathologic fracture of the epiphysis resembles very closely, in many respects, dislocation of the adjacent joint, for which it is not infrequently mistaken and treated. In acute osteomyelitis a late pathologic fracture may occur in consequence of the imperfect development of the involucrum, after the sequestrum has become separated, and is then due to fracture of the neck of the involucrum.

Circumscribed osteomyelitis figures as a very rare cause of pathologic fracture in cases in which the resulting abscess destroys the entire thickness of the shaft of the bone, or weakens it sufficiently to cause it to yield to muscular action or to efforts in raising or changing the position of the limb. A number of such cases have been recorded. The case in Verneuil's clinic furnishes a good illustration: A boy fifteen years of age suffered from an attack of acute osteomyelitis involving the lower third of the femur. Death from pyemia followed during the eighth week. Shortly before death fracture occurred at the seat of disease. Autopsy revealed, in the vicinity of the fracture, the spongiosa infiltrated with pus, the bone almost entirely destroyed in its continuity, and infiltrated with pus. The epiphyseal cartilage and periosteum were intact.

Tubercular osteomyelitis involving the epiphyseal ends of the large long bones occasionally results in pathologic epiphyseolysis. Pathologic fracture of the odontoid process of the axis has been known to produce sudden death from compression of the cord in

tuberculosis of the upper cervical vertebræ. As tuberculosis seldom attacks the shafts of the large long bones, pathologic fracture from this cause is almost unknown in this part. Spontaneous fracture from tubercular osteomyelitis is observed most frequently in the phalanges, in metacarpal and metatarsal bones, and in the ribs.

Rachitis is the most frequent cause of pathologic fracture and bending of bones in infants and young children. Pathologically, this disease is characterized by great softening of the bones, in which the entire skeleton is more or less concerned. The rachitic process consists in an abnormal development of the intermediary cartilage and periosteum, which results in the growth of an osteoid in place of normal bone substance, while the normal resorption from the medullary canal continues, gradually reducing in thickness and strength the normal compacta. The normal static evolution of the cancellated structure of bone suffers at the same time, and adds its share in diminishing the resisting power of the rachitic bones. During the acute stage of rachitis incomplete fractures, infractions, and bending of the bones occur more frequently than complete fractures.

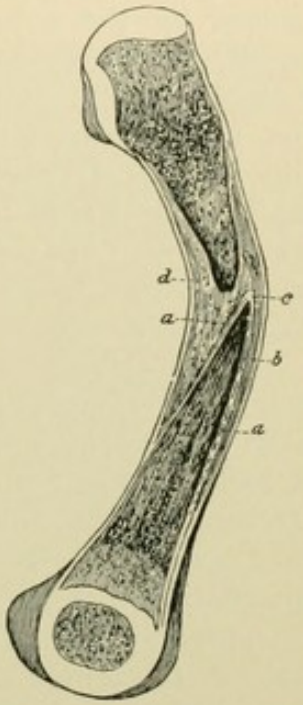

Fig. 181.—Repair of fracture of a rachitic humerus (longitudinal section): *a*, Compacta surrounding medullary canal; *b*, callus mass composed of spongy bone tissue; *c*, obliteration of medullary canal by displacement of compacta fractured on concave side, and by callus formation, which is most marked on concave side (after Gurlt).

Incomplete fractures are almost always found only on the concave side, where the slight fracturing force is most concentrated, while on the convex side the softened bone tissue and thickened periosteum preserve the continuity of the bone. Under such circumstances the bones curve often under the weight of the body or from muscular contraction, and incomplete fractures result from slight falls or in lifting the patient. The spinal column yields under the weight of the body if the child is permitted to sit for any length of time during the day, a well-marked long posterior curvature developing slowly but progressively.

Complete pathologic fracture of rachitic bones is more likely to occur during the latter stages of the disease; that is, with the beginning and during the healing process. Even in such cases the periosteum usually remains intact. The femur and humerus are most frequently affected by complete pathologic fracture of rachitic origin.

The repair of fractures in rachitic subjects is effected by the same material as the rachitic product—that is, osteoid substance—during the active stages of the disease, but with the disappearance of the disease, either spontaneously or through the intervention of medical

treatment, the osteoid callus is transformed into bone. Callus formation takes place only in the fractured part of the bone, hence in incomplete fractures on the fractured side only, which is almost invariably on the convex side of the bone. The callus is often so abundant as to contribute much in correcting the angular deformity.

Osteomalacia constitutes, in the adult, a somewhat similar predisposition to pathologic fracture to that which rachitis does in children. Osteomalacia is a disease of adults, and affects, almost without exception, only pregnant and puerperal women.

The softening and fragility of the bones in osteomalacia are caused by the substitution of osteoid material for normal bone tissue, and abnormal proliferation of the medullary tissue, with widening of the medullary spaces, processes that eventually remove the entire compacta, leaving the softened bone ensheathed by the periosteal envelop. The bones in advanced cases of osteomalacia bend rather than fracture spontaneously or under the influence of an insignificant trauma. The ribs and bones of the extremities are most frequently the seat of this disease, and the fractures usually are repaired by the formation of a bony callus.

Osteomalacia, as has been shown by Senator, may be limited to one bone or part of a bone, and then must be regarded as a local process, in contradistinction to its usual clinical manifestations. A localized form of osteomalacia in the adult has been described by Volkmann, affecting, as it usually does, the tibia and fibula, occurring occasionally as a bilateral affection and followed by bending of the affected bone under the weight of the body. It is accompanied by pain and tenderness at the seat of osteoporosis, and has been described later by Czerny as osteitis deformans. Volkmann found that in such cases the compacta over a limited extent is transformed into yielding spongiosa.

In all the inflammatory and degenerative affections of bone here described the bone and periosteum do not lose their regenerative capacity, and union of the pseudofracture or pathologic fracture by bony consolidation is not only possible, but probable. Pseudarthrosis may occur in cases in which the bone-producing tissues are extensively destroyed, as occasionally happens in suppurative osteomyelitis, both in the diffuse and circumscribed varieties. Such a termination can not be expected if the pathologic fracture is caused by either a primary or a metastatic malignant tumor.

Sarcoma, the primary malignant tumor of bone, is very apt eventually to give rise to a pathologic fracture if the tumor has a central origin. In central myeloid sarcoma of bone the preexisting bone structure is gradually destroyed by infiltration and pressure until the bone gives way under the weight of the body, or fractures on an attempt to move the limb. Periosteal sarcoma seldom gives rise to this accident, as the tumor often contains a framework of bone tissue; infiltration of the preexisting normal tissue is less marked than in central sarcoma, and pressure as an element in the causation of rare-

faction and atrophy is entirely absent. In a pathologic fracture of a bone in connection with a primary malignant tumor, the very occurrence of the fracture is almost positive indication of the central location of the tumor. Central sarcoma is found more frequently in the epiphyseal regions of the long bones than in the shaft, while the reverse is the case in periosteal sarcoma. A sarcoma in any part of the body, like carcinoma, may give rise to metastatic tumors in bone and a resulting pathologic fracture of the bone thus affected.

Carcinoma of bone as a cause of pathologic fracture always presents itself as a secondary metastatic tumor. Occasionally the patient is ignorant of the existence of the primary tumor, and after a variable period of local complaint, which is usually attributed to rheumatism and treated as such, the pseudofracture takes place and is, perhaps, the first thing that calls the attention of the physician to the malignant affection of the bone that preceded the accident. I remember a case of this kind that occurred many years ago. The patient was a woman seventy-five years of age, who had been confined to bed for a number of weeks for what she believed to be rheumatism in her left hip-joint. One morning she found she had lost the use of the limb. All the symptoms pointed to a fracture of the upper part of the femur. Suspecting the nature of the cause of the pathologic fracture, it was ascertained that a small tumor had existed in the left mammary gland for twenty years. Examination of this tumor left no doubt as to its malignant nature, a diagnosis fully corroborated by a chain of carcinomatous glands in the corresponding axillary space.

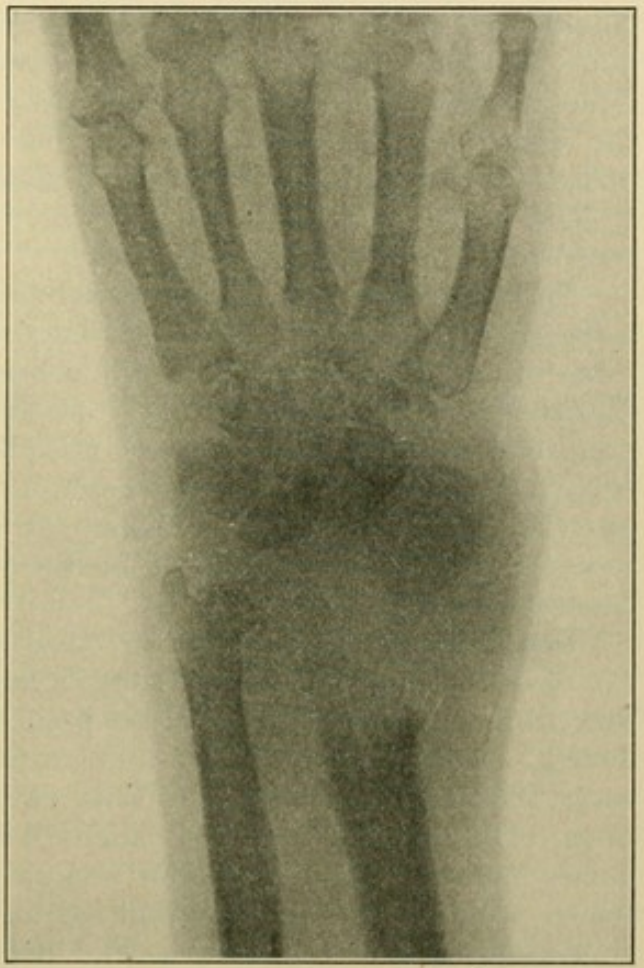

Fig. 182.—Pathologic fracture of the lower end of the radius caused by central medullary sarcoma.

Bruns collected 79 cases of pathologic fracture caused by metastatic carcinoma, and found that in 59 the primary tumor involved

the mammary gland. According to Gurlt, the uterus and vagina rank next in the scale of frequency as the seats of the primary tumor. The femur is the bone affected most frequently by metastatic carcinoma, and of the bones of the trunk, the vertebræ.

Occasionally the metastasis is very diffuse. Thomsen reports a case in which the autopsy on a patient who had suffered from carcinoma of the mamma for four years revealed numerous metastases in almost all the bones of the skeleton, which had gradually led to great deformity of the spine, chest, and pelvis, and six pathologic fractures in both femora and the left humerus.

In very rare instances pathologic fracture has occurred in carcinomatous patients independently of metastasis in the fractured bone, and must then be explained by assuming the existence of bone atrophy and fragility, caused by a general malnutrition from the effects of the carcinoma. A pathologic fracture caused by malignant disease is seldom, if ever, repaired by bony consolidation. If bony union does take place, it will give way sooner or later to extension of the disease to the callus.

Enchondroma and cysts sometimes destroy the bone tissue sufficiently to cause a pathologic fracture. Gross collected a few cases of pathologic fracture resulting from enchondroma, and found that this accident is more liable to occur in cases of central than of periosteal tumors. In 10 cases of central enchondroma fracture occurred twice, while in 63 cases of periosteal sarcoma it was observed only three times. Froriep, Nélaton, and Körte have each reported a case of pathologic fracture in which the fracture was caused by a cyst.

Echinococcus cysts of bone occupying the central medullary cavity of the long bones may cause a degree of pressure atrophy of the compacta sufficient to cause pathologic fracture. Bruns collected 11 such cases, of which number the humerus and femur were each affected four times, the tibia twice, and the spinal column once. The accident occurred usually before there was any palpable enlargement of the bone, and it was only the slight degree of force which produced the fracture that led to the suspicion of antecedent central disease of the bone. The diagnosis, as a rule, was made subsequently, during the operation for the resulting pseudarthrosis.

Syphilis is very seldom the cause of pseudofracture, considering the great prevalence of this affection. Gurlt was able to collect only 20 cases of pathologic fracture from the old literature in which a direct causative relationship could be traced between tertiary syphilis and pseudofracture. In most of these cases the humerus and clavicle were the seat of fracture, and the injury was usually produced by an attempt to use the arm in throwing or by leaning upon it. Fragility of bone has been attributed to the prolonged use of mercurial preparations, but this view is not supported by facts. In the few cases in which syphilis does figure as a cause of pathologic fracture the abnormal localized or diffuse fragility of the bone was

caused by tertiary lesions of the bone itself. Gummatous periosteitis and osteomyelitis may eventually destroy the entire thickness of the part of the bone affected.

In children hereditary syphilis not infrequently leads to pathologic epiphyseolysis. The softening of the bone occurs in the epiphyseal line, where the osteoporotic bone contains, in the dilated medullary spaces, a peculiar gelatinous material. Pathologic fractures from this cause may occur during intra-uterine life.

Scorbutus occasionally gives rise to localized bone affections which may cause a pathologic fracture. Scorbutic affections of bone sufficiently severe to destroy its continuity are found most frequently at the junction of the ribs with their cartilages. In advanced cases of scurvy complicated by osteochondritis and periosteitis of the ribs these affections are very apt to cause multiple pathologic fractures.

The causes of pathologic fracture here enumerated, many as they are, do not explain all cases. In some instances the great osteoporosity and fragility of bone presents itself as a hereditary affection for which no adequate or satisfactory explanation can be given. The strength and resisting power of bone are subject to many variations. Some persons otherwise apparently in good health inherit a strong predisposition to fractures. A large number of well-authenticated cases of this kind have been recorded. A number of persons of the same age and weight may meet with similar accidents; in some a fracture will occur, while the remainder escape with a sprain or an insignificant bruise. Hamilton treated a man fifty-three years of age for eleven fractures and two dislocations, in whose family there existed a strong predisposition to fractures. Blanchard observed the case of a girl twelve and one-half years of age who had, since the age of two years, sustained forty-one fractures from the slightest causes, among them fourteen of the right and eleven of the left leg. Among this class of cases of pathologic fractures we must include all those in which the usual causes of pseudofracture, as previously given, can be eliminated. It is probable, too, that additional research and observations will in the future, as they have done in the past, reduce the number more and more by the discovery of new causes and conditions that will throw more light on the presenile osteoporosis and fragility of bone.

In ascertaining the existence and location of a pathologic fracture, the practitioner must not rely on crepitus in conducting the examination, as by doing so much harm may be inflicted, and the information thus gained may lead to erroneous conclusions. The pathologic conditions of the bone are often such as to exclude the possibility of eliciting crepitus. Loss of function, the false point of motion, malposition of the limb, and, if there is longitudinal displacement, comparative measurements, must be relied upon in recognizing and locating the accident. Pain and tenderness are of slighter importance, from a diagnostic standpoint, in pathologic

than in traumatic fractures. The pathologic fracture is usually transverse, or nearly so, and longitudinal displacement to any considerable extent is rare, while angular deformity is almost constantly found sooner or later. In spontaneous fracture resulting from malignant disease a swelling at the seat of fracture can be detected more frequently in primary than in metastatic tumors of the bone.

Except in fractures caused by malignant disease, the prognosis concerning the repair of the injury is favorable. In many cases the process of repair appears to be favored by the osteoporotic condition of the bone caused by the general or localized affection. Speedy and often massive callus production is observed. The mechanical treatment of such fractures is attended by no special difficulties, as the tendency to displacement is less manifest than in traumatic fractures. As the trauma that completes the fracture is always slight, little or no additional swelling follows the injury, and it is safe and advisable to immobilize the limb at once by a plastic or circular plaster-of-Paris splint. The general treatment must be conducted according to the nature of the bone affection and the general condition of the patient.

Classification of Fractures.—A correct diagnosis, a reliable prognosis, and the proper treatment of traumatic fractures must be based on a rational anatomic classification.

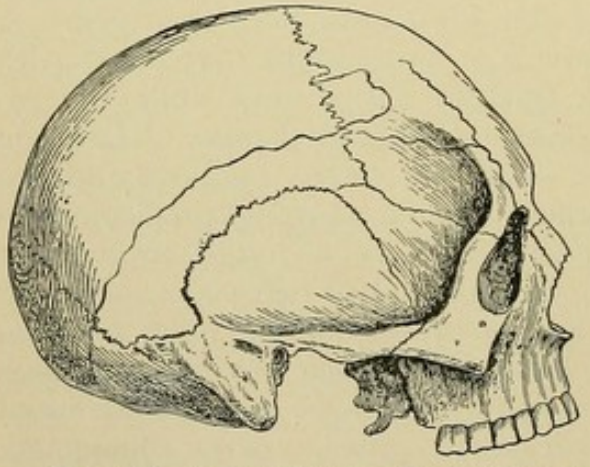

Fig. 183.—Isolated fissure of the skull, caused by a fall upon the head. The fissure crosses the coronary fissure, and involves the occipital, parietal, and frontal bones (after Bruns).

Incomplete Fracture.—A fracture is said to be incomplete when a bone is only partly broken. As compared with complete fractures, this accident is very rare. Anatomically it presents itself in the form of a fissure, infraction, depression, or in separation of a fragment of bone or an apophysis.

A *fissure* is a linear fracture and occurs either as an isolated injury or in connection with other fractures. Straight and spiral fissures of the long bones have been observed in which the continuity of the bone was preserved. Such fractures are exceedingly rare, and a correct diagnosis is seldom made. Linear fractures or fissures occur more frequently in connection with complete fractures, more especially in fractures of the skull and in gunshot fractures of the long bones. In the latter case, if the fracture is near one of the epiphyses, the fissure frequently extends into the adjacent joint.

An *infraction* is an incomplete fracture, and is represented by the so-called greenstick fracture. It is met most frequently in children

and in persons the subjects of softening of bone. If one of the long bones is the seat of an infraction, the periosteal envelop often remains intact, the bone on the fractured side is crushed to a greater or less extent, while the part of the shaft on the opposite side, owing to its great elasticity, yields, permitting a certain degree of angular deformity, which is always present and which clinically constitutes the most important diagnostic criterion. A partial fracture of a long bone by infraction is characterized by bending and more or less separation on the fractured side. The partial fracture always corresponds with the convex side of the angular deformity. If the angular deformity is slight, the accident is very likely to be overlooked.

König has described partial fracture of the neck of the femur in the aged, but it is somewhat doubtful if such an injury is compatible

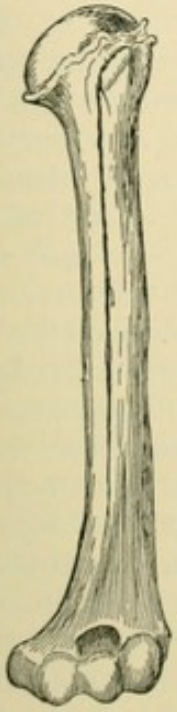

Fig. 184. — Longitudinal fissure of the humerus (after Froriep).

Fig. 185.—Spiral fissure of the tibia, seen from behind (after Bruns).

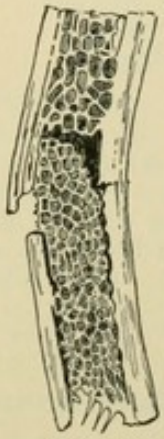

Fig. 186.—Infraction of the radius in a child twelve years of age (after Vidal).

with the senile osteoporosis and fragility, and it is more than probable that in cases thus interpreted the injury consisted of a complete fracture with impaction. Partial fractures clinically characterized by depression are represented in a most typical manner by fractures of the external table of the cranial bones, although they can occur in any other bone in which a thin compacta is supported by a bed of spongiosa. In rare cases the internal table of the skull yields to the direct application of force, the external table remaining intact, thus constituting another variety of incomplete fracture. In consequence of direct application of force a fragment of bone can be detached, or, as the result of a traction injury, the tendinous insertion of a bone or an apophysis may become separated, producing another anatomic form of incomplete fracture.

Owing to the slight degree or total absence of deformity, incomplete fractures are seldom recognized. The possibility of such an

occurrence should always be borne in mind in connection with injuries that are likely to produce such fractures, and, if need be, repeated careful examinations should be made to ascertain their existence. In doubtful cases the patient should be given the benefit of the doubt, and the injury should be treated as a fracture. The formation of a callus in the usual course of time in suspected cases will often enable us to make a positive diagnosis at a time necessary to obtain the desired functional result by appropriate treatment. In suspected fracture of the internal table of the skull the X-ray will furnish the lacking diagnostic information. In children serious functional disturbances following injuries of any of the extremities should always arouse suspicion of an incomplete fracture, and should remind the physician of the necessity of making a most scrutinizing examination, and in doubtful cases of repeating the same every few days. Conspicuous deformities and serious functional impairment of the injured limb have often been the consequence of a lack of care and attention in such cases.

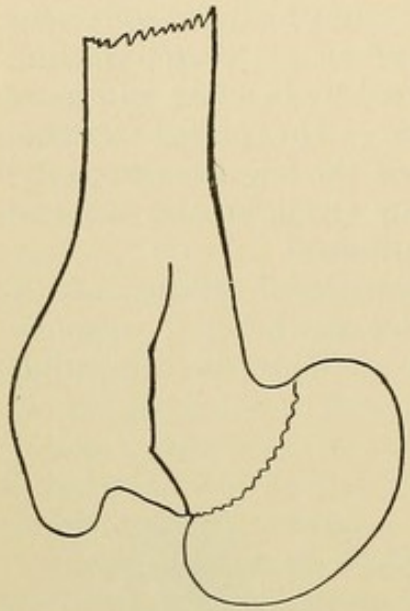

Fig. 187.—Infraction of the neck of the femur, caused by a fall from a height, which at the same time fractured the shaft of the same bone in its middle and the spine. Death after eighteen days (after Mussey).

Subcutaneous Simple Fractures.—The simple subcutaneous or closed fracture is by far the most frequent injury of bone that comes under the care of the general practitioner. The long bones are most frequently fractured, and the description of the injury will apply to them, as fractures of the skull and compound fractures are discussed elsewhere.

The line of fracture, according to its direction and shape, is described as transverse, oblique, longitudinal, dentate, and Y-shaped. Intra-articular fractures are always transverse, or nearly so. Fractures near the epiphyses are more likely to be transverse than fractures of the shaft. In infants and children transverse fractures of the shaft are common. In transverse fractures shortening is not present if the fragments do not overlap each other. Angularity at the seat of fracture is the most constant deformity and should receive the most careful attention in the mechanical treatment of the injury. In the adult the line of fracture through the shaft of any of the

Fig. 188.—Dentate transverse fracture of a rib (Bruns).

long bones is nearly always more or less oblique. The degree of obliquity is determined to some extent by the compactness of the bone and the manner in which the injury was inflicted. As a rule, it may be said the harder the bone, the more oblique the line of fracture. Fractures resulting from indirect force as a rule are more oblique than fractures caused by direct violence. The degree of obliquity has some influence in determining the amount of shortening. Longitudinal displacement of the fragments is favored by the degree of obliquity of the line of fracture, and marked shortening soon after the accident has occurred is one of the clinical witnesses suggestive of the oblique direction of the line of fracture.

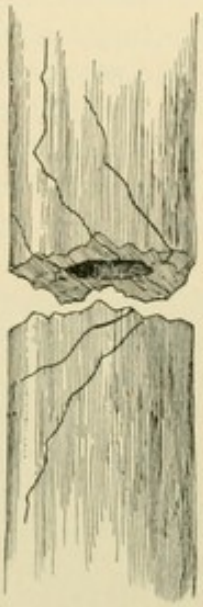

Fig. 189.—Transverse fracture of the shaft of the tibia, caused by passage of a wagon-wheel over the limb (Bruns).

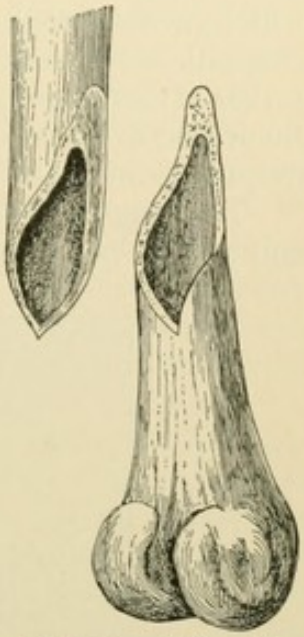

Fig. 190.—Oblique fracture of the femur; fractured ends in the form of the mouthpiece of a clarinet (Bruns).

Longitudinal fracture of the long bones has already been referred to under incomplete fractures. Although a very rare accident, it should be carefully looked for in injuries to the shaft of the

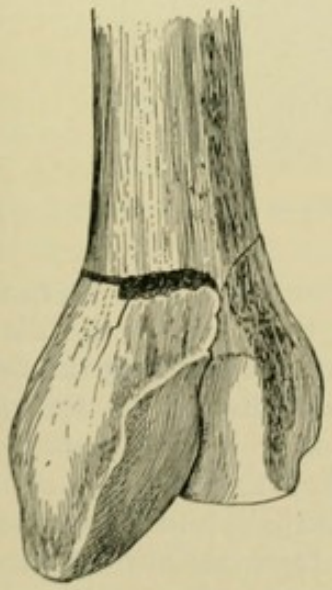

Fig. 191.—T-shaped fracture of the condyles of the femur, caused by a fall upon the knee (after Bruns).

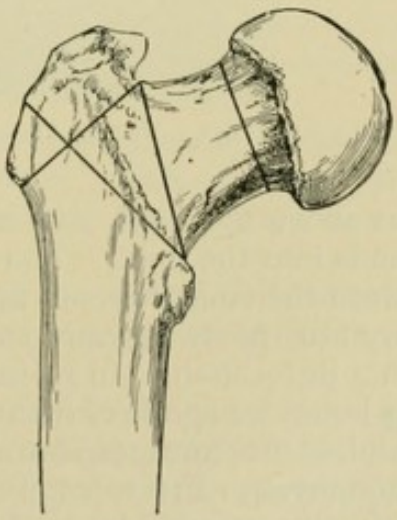

Fig. 192.—Lines of fracture of the upper extremity of the femur.

long bones sufficient in intensity to produce a fracture, yet unaccompanied by indications that point to the existence of a transverse or oblique fracture. If the fractured ends are dentate, interlocking and partial immobilization of the fragments are apt to occur, in which event crepitus and shortening are absent and the mutual coaptation between the fractured surfaces by the spicula of bone serves a useful purpose in the mechanical treatment of the fracture. Such fractures are usually more or less transverse, and occur most frequently near the articular extremities of the long bones.

The typical Y- and T-shaped fractures are found in the lower end of the femur and humerus, and consist of a fracture of the con-

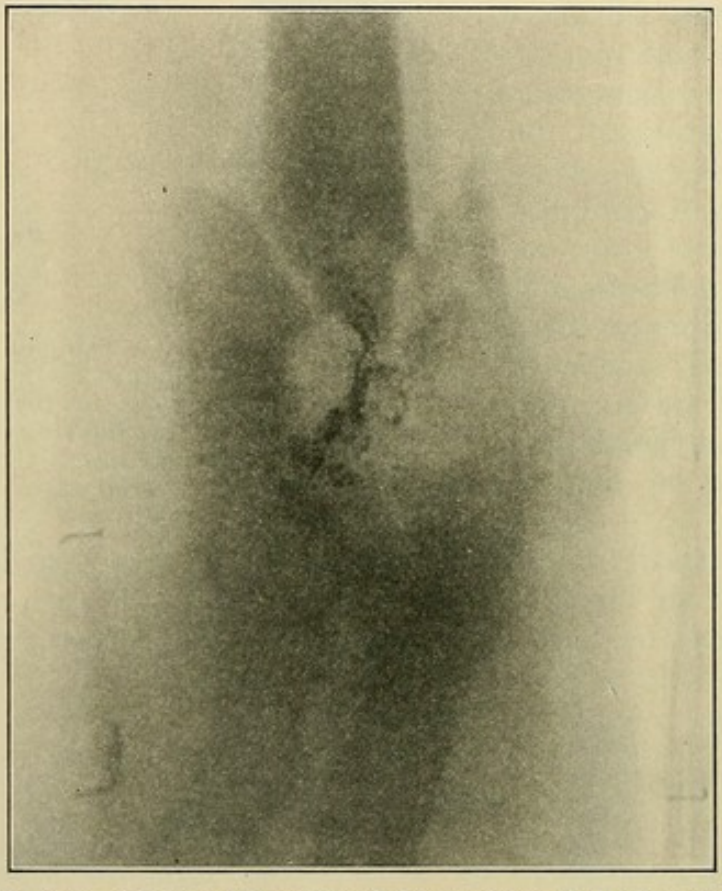

Fig. 193.—Y-shaped fractures of the condyles of the humerus.

dyles above the joint, with a line of fracture between them which extends into the joint. The widening of the bone by the diastasis between the condyles and the preternatural mobility at the seat of injury are the two symptoms that serve to distinguish this injury from a dislocation. In reference to the location of fractures of the long bones we speak of fractures of the shaft and of the neck, intercondyloid fractures, separation of an epiphysis, and detachment of an apophysis. Fractures of the shaft predominate in frequency and are usually attended by marked deformity, and when oblique, shortening is almost invariably present. Fractures of the neck of the femur and humerus are divided, anatomically, according to the

relation the line of fracture bears to the capsular ligament, into intracapsular, extracapsular, and, if the fracture intersects the capsular ligament, into partly extracapsular and partly intracapsular.

An absolute anatomic diagnosis can seldom be made. A primary para-articular swelling and decided shortening of the limb soon after the occurrence of the accident suggest an extracapsular fracture, while the opposite conditions would speak in favor of a fracture within the boundaries of the capsule. More frequently, however, the line of fracture passes through the capsule, when the symptoms are modified by the concomitant injuries of the soft tissues.

Intercondyloid fractures of the humerus and femur always implicate the adjacent joint, a complication which is clinically characterized by the appearance of a swelling in the joint, caused primarily by intra-articular extravasation of blood, aggravated later by the products of a catarrhal synovitis.

Any of the apophyses may become separated by the application of direct force or by muscular traction, and in either event one point of anchorage of one or more tendons or muscles is lost, the accident resulting in functional disturbances that point to the location and extent of the injury. The diastasis between the fragments varies according to the extent of injury of the soft tissues and the degree of isolation of the point of tendon or muscle insertion.

A traumatic epiphyseolysis consists of a transverse fracture through or near an intermediate cartilage, and is an accident that only occurs in children and young adults—that is, in persons during the bone-growing period of life. The close proximity of the fracture to joints often results in conditions that render it difficult to make a differential diagnosis between fracture and dislocation. Epiphyseolysis never gives rise to the same degree of immobility of the injured limb as dislocation, and unless the epiphysis is sufficiently displaced to permit of longitudinal displacement, shortening of the limb does not occur, and elongation of the limb is never observed. Comparative measurements are therefore of the greatest importance in differentiating between a traumatic epiphyseolysis and a dislocation.

An intra-articular fracture is one in which the line of fracture is within the limits of the capsular ligaments. This anatomic variety of fractures is limited to the neck of the femur, humerus, and radius.

A multiple fracture is one in which the same bone is fractured in different places, or where the same injury results in fracture of different bones.

A compound fracture consists of a fracture of any bone, complicated by an injury of the soft tissues, which establishes an avenue between the surface of the skin or any of the mucous membranes and the seat of fracture.

A pathologic fracture is the result of an existing disease of the bone which gives rise to a solution of continuity without or

with but insignificant trauma. The pathologic conditions that may bring about such a condition have already been enumerated and described.

A fracture deserves the qualifying term *complicated* if the frac-

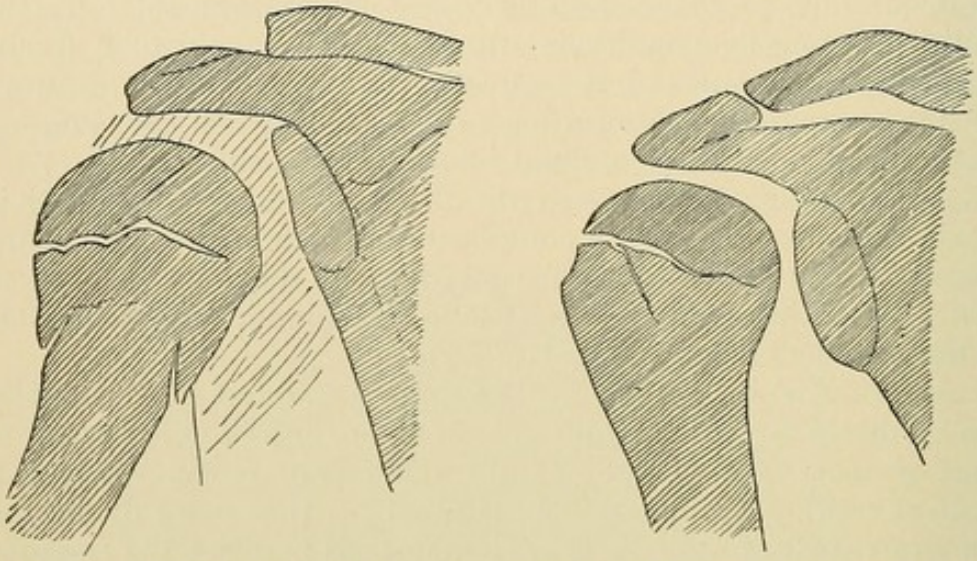

Fig. 194.—Traumatic epiphyseolysis of upper end of the humerus (after Oscar Wolff).

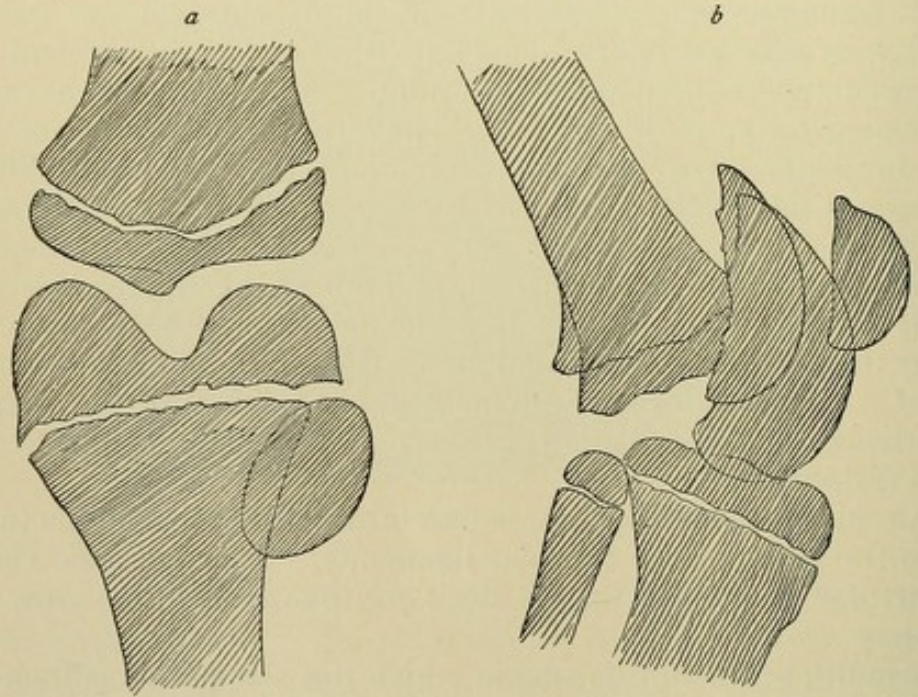

Fig. 195.—Traumatic epiphyseolysis of lower end of the femur: *a*, Lateral illumination; *b*, anteroposterior illumination (after Oscar Wolff).

ture is accompanied by an injury to any of the large blood-vessels or nerve-trunks.

A fracture is said to be *comminuted* if the bone is crushed or splintered into a number of fragments at the seat of fracture.

Causes of Fracture.—The predisposing causes of fracture con-

sist of congenital or acquired textural changes in the bone which diminish its power of resistance. The physiologic causes include structural and textural conditions that weaken the bone, but not to a sufficient degree to give rise to a pathologic fracture. These causes include age, heredity, inactivity atrophy, and the structure and function of the long bones. The two extremes, youth and old age, predispose the bones to fracture. The softness of the bones in children and the increased fragility of the bones of the aged are well-recognized predisposing causes of fracture. Trauma in children and the aged is more likely to result in a fracture than a dislocation. Dislocations occur most frequently during the active period of life, after the bones have become fully developed and before senile osteoporosis sets in. Traumatic epiphyseolysis is an injury of childhood and young adolescents, and fracture of the anatomic neck of the femur and humerus is seldom seen in persons less than fifty years of age.

Heredity as a predisposing cause of fracture means a congenital defect in the development of bone to its average physiologic standard. Some individuals, families, and successive generations are predisposed to fractures in consequence of an inborn weakness of the bones. A vigorous muscular development does not always imply that the bones have reached a similar degree of perfection of growth and resistance. In a case of suspected fracture caused by a force that, under ordinary circumstances, would not cause a fracture, it is well enough to investigate the personal and family history carefully, to ascertain the possible existence of a hereditary predisposition to fracture before the existence of a fracture is excluded, owing to a supposed inadequacy of the injuring force.

Prolonged inactivity is constantly followed by bone atrophy, which becomes a predisposing cause of fractures in proportion to the degree of atrophy. The most familiar illustrations of inactivity atrophy are furnished by permanent paralysis sustained during childhood, and ankylosis following joint tuberculosis. Manual redressement by moderate force, made for the purpose of correcting deformities, under such circumstances has not infrequently resulted in fracture.

By their structure and function the long bones are predisposed to fracture. The attachment of numerous strong muscles, the long leverage, and the frequency with which they are exposed to direct and indirect injuries explain fully why the long bones furnish the large percentage of fractures.

The pathologic causes of fractures have been already referred to, and among them the most important are sarcoma, carcinoma, rachitis, osteomalacia, osteomyelitis, paralysis of central origin, syphilis, scorbutus, and echinococcus and other cysts.

Mechanism of the Exciting Causes of Fractures.—The occurrence of a traumatic fracture presupposes the action of an adequate mechanical cause to overcome the resistance of the bone

broken. The accident is produced either by violence from without, by direct or indirect application of force, or by traction force from within—that is, by muscular contraction.

External Violence.—By far the greatest number of fractures are produced by external violence. The mechanism of the fracturing force is variable, but in all cases it must suffice in overcoming the elasticity and resisting power of the broken bone. The trauma fractures the bone either by pressure or traction, or by a combination of these two mechanical forces. As was ascertained by the ingenious experiments made by Rauber and quoted by Bruns, a much greater force is required to fracture a long bone from compression than if the bone is bent at the same time, thus combining pressure with traction. Fracture of a bone caused by bending will always take place at a point where the curve is most marked, and consequently where tension is greatest. If both articular ends are supported, the fracture takes place in the middle; if only one end is fixed, immediately in front of the point of fixation. For the same reason the fracture always begins on the convex side of the bend, as has been demonstrated so conclusively by clinical observations and, likewise, by the experiments of Bruns and Messerer. In all cases of fracture resulting from forces that cause a bending of the bone the line of fracture is transverse for an indefinite distance, when it forks in both directions, including between the branches a detached fragment of bone if both branches of the fork are completed. If only one of the oblique lines is complete, the partially detached piece of bone remains attached to the end of the bone on the side of the incomplete oblique line. If the branches of the fork are complete, the base of the triangular fragment is directed toward the concavity of the bend created by the fracturing forces the moment the accident occurred. In complete and incomplete transverse fractures the same tendency to forking of the line of fracture is seen in the form of fissures. Messerer has shown that

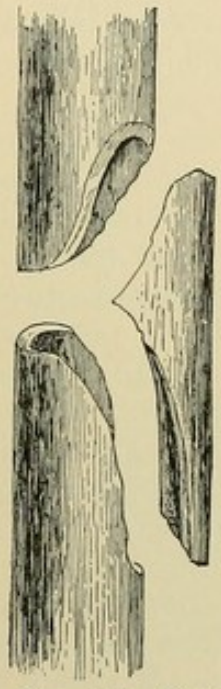

Fig. 196.—Bending fracture of the femur, with detachment of a wedge-shaped fragment on the convex side (after Bruns).

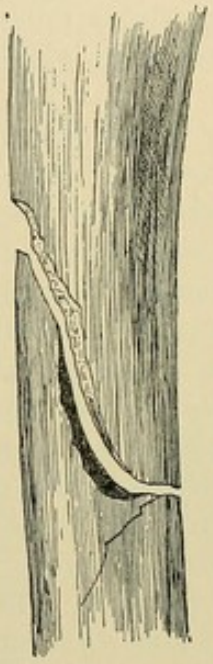

Fig. 197.—Oblique fracture of the shaft of the femur, showing an oblique fissure on the lower fragment (after Bruns).

in oblique fractures the oblique line of fracture is completed only on one side of the triangular piece of bone, the other side being indicated by a fissure. Fractures are produced either by direct or indirect force, in the former case the fracture occurring at the point where the violence is applied; in the latter, the fracturing force is transmitted through some medium to the seat of injury. Fractures caused by a fall, a blow, a kick, or by projectiles of all kinds are good illustrations of what is meant by fractures resulting from direct force if the fracture takes place at the point of impact. Fractures caused by direct violence are always attended by more injury to the soft tissues than fractures resulting from indirect force, and are more frequently compound, as the same force that causes the fracture commonly destroys, over a greater or less extent, the soft tissues between the point of impact and the seat of the fracture. Owing to the existence of greater injury of the soft parts and the greater liability to the recurrence of later complications in fractures from direct than indirect force, the prognosis is graver and the treatment more difficult in the former than in the latter class, so that the etiology of the fracture has an important bearing both on the prognosis and treatment. Comminution of the bone is more frequently caused by direct than by indirect force.

Indirect fractures occur some distance from where the force was applied, in which case the force is transmitted through the intact bone to where the fracture takes place. Fractures of the long bones by indirect force are caused usually by a fall upon the hands or feet or upon the elbows or knees. In fractures of the neck of the femur by a fall upon the greater trochanter the force is transmitted from this part of the bone through the neck of the femur, to the seat of fracture, while in fracture of the femur caused by a fall upon the foot the force is transmitted through all the bones, from the point of impact to the seat of fracture, in which event the ankle-joint and knee-joint are immobilized in the extended position by muscular contraction at the moment the fracture is produced. Much uncertainty remains in explaining satisfactorily the point of localization of the injury, as the same force may result in a fracture near where it is applied, and in other instances it is transmitted a great distance through several bones.

The mechanism of indirect fractures is a variable one. In most instances the fracture is caused by pressure from both ends of the bone, the shaft of which is then bent beyond its elastic capacity, the fracture usually taking place where the convexity of the curvature is greatest. For instance, in fracture resulting from a fall, one point of pressure is made by the weight of the body and the force of the fall, and the other by the resistance it meets, the two opposing forces resulting in the bending of the bone and, finally, the fracture. In other instances the fracture is induced by one end of the bone being fixed, the other being carried onward, at which time the bending and fracture occur in front of the fulcrum,

the fixed portion of the bone. The force is expended in a vertical direction to the long axis of the bone. Fracture of the internal malleolus by forcible adduction of the foot, and fracture of the external malleolus by forcible abduction, are the injuries typical of this mechanism of indirect fracture. Another mechanism of indirect fracture is represented by fracture of the neck of the femur by the transmission of force through the shaft of the bone. It is the only fracture produced in this manner. The neck of the femur is placed at an angle with the shaft of the bone, and the fracture is caused by the force increasing this angle beyond the elastic capacity of the bone.

Fig. 198.—Compression fracture of the scaphoid by a fall upon the palm of the extended hand.

A compression fracture of a long bone is caused by indirect force applied to both ends, without bending the bone. Such fractures are usually seen near one of the epiphyseal extremities, and the shaft of the bone is driven into the spongiosa of the articular end, the impaction being caused by a continuation of the same forces that produced the fracture. Pressure fractures from transmitted force also occur in a number of the articulations. The head of the radius, the rim of the acetabulum and glenoid cavity, and the anterior margin of the internal malleolus furnish such instances; more frequent are the traction fractures. Hyperflexion, hyperextension, and forcible lateral flexion not infrequently result in articular fracture caused by contraction made by the ligaments when these are more resistant than the bone to which they are attached. Fractures of the margins of the malleoli thus produced furnish the most familiar illustrations; many of the fractures of the vertebræ are produced in this manner.

Violent twisting of the long bones around their axes may finally cause what is known as a torsion fracture. Fractures produced in this manner are very rare, but Bruns and others have reported cases

in which the fracture was evidently produced exclusively by this mechanism. The fracture occurs at a point where the transverse resistance of the bone is weakest, and the line of fracture is spiral.

The injury of the soft tissues in indirect fractures is caused by the displacement of the fragments. If an indirect fracture is made compound, the wound is made from within outward by perforation of the skin by one or more fragments by the same force that produced the fracture.

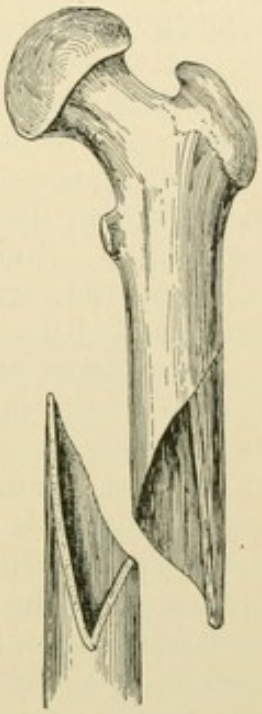

Fig. 199.—Torsion fracture of the femur (Bruns).

Muscular Contraction.—Fracture of a normal bone from muscular contraction is very rare as compared with fracture from external violence. Fracture from this cause does not exceed from 0.5 to 1 per cent. Violent contraction of the voluntary muscles, the usual involuntary muscular contraction, as, for instance, during convulsions and epileptic seizures, is the exceptional cause of fractures independently of external violence. As fractures thus produced must be considered only those cases in which other intrinsic and external causes can be excluded as the essential vulnerating force. In this group belong those fractures of bony prominences that serve as points of insertion of powerful muscles, such as the coronoid process of the ulna and inferior maxilla, the coracoid process of the scapula, the greater tubercle of the humerus, the greater trochanter of the femur, and the tubercle of the os calcis.

To the fractures caused by muscular contraction must be added certain fractures of the patella, which embrace about one-third of the whole number of fractures of this bone. Fracture of the patella from this cause occurs from violent contraction of the quadriceps extensor femoris muscle in persons who make a violent effort to retain the erect position when threatened by a fall; or muscular contraction takes place when the knee is flexed, in which case the fracture occurs in consequence of bending and traction. Of the long bones, the humerus is most frequently the seat of fracture from muscular contraction. Of 85 cases of fracture from muscular contraction collected by Gurlt, the humerus was the seat of the fracture 57 times, the femur 25 times, the bones of the leg 8 times, and the forearm 5 times. The humerus is broken usually during an attempt to throw a stone or a ball, or by a blow that fails to reach its mark. The accident occurs at the moment powerful muscles arrest further

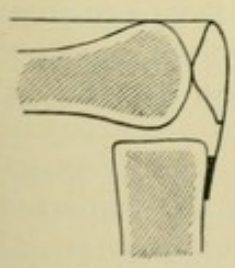

Fig. 200. — Mechanism of fracture of the patella by muscular action (Treves).

movement of the arm. In fractures of the neck of the femur caused by lifting a heavy object, muscular contraction is an important, if not the sole, element in the mechanism of the fracture. The bones of the forearm have yielded to violent pronation and supination. The head of the fibula in rare cases gives way to violent contraction of the biceps cruris muscle, while the shafts of the tibia and fibula have yielded to the combined influence of the weight of the body and muscular contraction. Ribs have been broken during severe attacks of coughing, and the cervical vertebræ may fracture during violent extension caused solely by muscular contraction. In fractures of the clavicle from muscular contraction the sternocleidomastoid, pectoralis major, and deltoid are the muscles concerned in the production of the fracture.

Symptoms and Diagnosis.—In the majority of cases the signs and symptoms that attend a fracture are so prominent that a diagnosis can be made without any special difficulties, but there are cases in which the immediate results of the injury are so obscure and ill defined that it is very difficult, and sometimes impossible, to detect the fracture. In such doubtful cases the patient should be given the benefit of the doubt, by subjecting the injured part to treatment for fracture that, if later results should exclude the existence of a fracture, will prove beneficial in the treatment of the injury of the soft tissues which in the beginning gave rise to symptoms that suggested a fracture. It is better for the patient and for the reputation of the physician that such a mistake should be made than to overlook a fracture and fail to carry into effect the necessary mechanical treatment until the nature of the injury is discovered, when it may be too late to correct the consequences of the oversight. While, as a rule, it is not difficult to determine by the signs and symptoms presented the existence of a fracture, it is not so easy to ascertain its exact anatomic location and line of fracture. This is especially true of fractures in close proximity to any of the large joints. The evil consequences that may follow an incorrect diagnosis and inaction are well shown in cases of unrecognized impacted fractures of the neck of the femur. If, in such cases, the seat of fracture is not immobilized, the impaction very often gives way in three or four weeks, at a time when the osteoporosis that precedes callus formation is sufficiently advanced to loosen the impacted fragment, separation of the fragments taking place from trivial causes. The failure to immobilize the fractured bone by an external mechanical support of some kind is largely responsible for the secondary displacement and the almost inevitable resulting nonunion.

The differential diagnosis between dislocation and fracture within or near joints is often very difficult, and frequently can only be made after a most careful and painstaking examination. Inexcusable blunders have been made in practice by mistaking fractures of the neck of the femur and of the anatomic and surgical necks of the humerus for dislocations. The additional injuries to the soft tissues

inflicted by violent attempts to reduce a supposed dislocation greatly add to the gravity of the injury and create new conditions that detract still more from the functional result, which is, as a rule, bad enough even in cases in which a correct diagnosis is made and the proper treatment employed. The diagnosis of intercondyloid fractures and traumatic epiphyseolysis calls for the most careful and systematic consideration of all the signs and symptoms, and gentle but scrutinizing examination. Gentleness and care should characterize every examination for fracture. Rough and reckless handling of the injured limb inflicts additional injuries of the soft tissues and often of the broken bone, and the information gained does not compensate for the additional trauma. *The practitioner who undertakes the treatment of a fractured limb assumes a moral and legal responsibility that can only be met by the careful employment of all known diagnostic resources in establishing the existence, location, and nature of the fracture, the presence or absence of serious complications, the adoption of a treatment based on correct mechanical principles, and unremitting attention during the after-treatment, for the purpose of securing the best obtainable functional result compatible with the nature of the injury.* In doubtful and trying cases the practitioner should avail himself of the services of at least one of his neighboring colleagues, as four eyes can often see more than two, and four hands can feel what two might fail to detect. Professional jealousy and personal interests must not come into conflict with the welfare of the patient or the reputation of the attending physician in such cases. To assist willingly and to assume the joint responsibility of the case, together with the protection of the reputation of the attending physician, should be the endeavor of the consultant who has the interest of the patient and the honor and dignity of his profession at heart.

The symptoms of fracture are divided into subjective and objective. The objective symptoms are more fully relied upon in making a diagnosis than the subjective symptoms.

Subjective Symptoms.—The three subjective symptoms that deserve the attention of the physician before he undertakes the examination are: (1) Loss or disturbance of function; (2) pain; (3) tenderness. Complete loss of function of a fractured limb is a frequent but by no means a constant symptom. In fractures of the shaft of the femur or humerus without impaction complete suppression of function is the rule; the same can be said of fractures of both bones of the leg and forearm. If only the fibula or one of the bones of the forearm is fractured, the patient may be able to walk or pronate and supinate the forearm. A number of well-authenticated cases of impacted fracture of the neck of the femur have been recorded in which the patient walked for some distance after the occurrence of the accident. In the absence of well-marked deformity loss and impairment of function can not be relied upon as conclusive diagnostic evidences of fracture, as the same may occur in consequence of injury of the soft tissues from contusion. In

the absence of injury of the soft structures sufficient in severity and extent to account for loss or impairment of function, the existence of a fracture should always be suspected and the necessary careful examination to determine its location be made.

Pain as a source of diagnostic information is of no value in the case of children, and very unreliable in the adult. Every fracture is a cause of pain, but its location and intensity do not always correspond with the location and extent of the injury. The severity of the pain depends more upon the complicating injuries of the soft tissues than upon the fracture itself. A simple fracture with little or no displacement is a comparatively painless injury, while a fracture with much displacement is usually attended by severe pain caused by the irritation of the soft tissues by the displaced fragments. Aggravation of the pain by passive motion would indicate rather a fracture than a contusion, while active motion might increase the pain due to contusion as well as to a fracture.

Tenderness is a more reliable indication of the existence of a fracture than spontaneous pain. Tenderness as a symptom of fracture is of special value in the diagnosis of fractures without much displacement, caused by indirect force. In the absence of deformity it is of little service in distinguishing between a contusion and a fracture the result of direct force, as in both instances the pain would be increased under pressure. In fractures from indirect violence a fixed point of tenderness on pressure and movements of the limb, by either active or passive motion and continued for any length of time, is a strong presumptive proof of a fracture. Fractures of the clavicle with little or no displacement and greenstick fractures in children can often be located by this symptom alone. A circumscribed fixed point of tenderness at a distance from where the injuring force was applied must therefore be looked upon as proof of the probable existence of a fracture. If such a circumscribed point of tenderness is at the same time the seat of an ecchymosis, the suspicion of the presence of a fracture is converted almost into a certainty. Fractures of the clavicle in children and fractures of the fibula, ribs, and lower end of the radius in adults are often detected by relying largely on circumscribed tenderness as the immediate, and ecchymosis as the more remote, consequence of the injury.

Objective Symptoms.—The final diagnosis of a fracture, concerning not only its existence, but also its exact location, extent, and nature, and the search for serious complications are based on a careful study of objective symptoms. The surgeon who takes the time and pains to elucidate the objective symptoms singly and collectively is the one who will be least likely to be misled in diagnosis and who will commit the fewest errors in predicting the probable result. Moreover, he it is who will obtain the best functional results as the highest reward for timely and well-conducted treatment, which, under his personal supervision, is continued so long as his services are required.

Before the objective symptoms are searched for and studied it is well to inquire into the history of the case concerning a possible predisposition to fracture, the manner in which the injury was sustained, the occurrence of a previous fracture under exceptional circumstances, the age of the patient, and the condition of the bones. An inherited or acquired predisposition to fracture will help to explain the existence of a fracture under circumstances that would ordinarily exclude such an accident. The very fact that the patient had sustained fractures before, perhaps from trivial causes, would speak in favor of such a predisposition. The extremes of life are predisposed to fractures, dislocations being comparatively rare. Traumatic epiphyseolysis is an injury that only occurs in individuals before the age of puberty. The existence of osteoporosis and softening of the bones in any part of the skeleton would indicate that a fracture might occur from causes that, under ordinary conditions, would exclude such an accident.

The objective symptoms, when properly considered, are the guide-posts that lead to a correct diagnosis. Among these, deformity is the most important. Deformity as the result of a fracture is due to a continuation of action of the force that produced the fracture, muscular contraction, and the force of gravitation. In impacted fractures of the neck of the femur the slight degree of shortening and outward rotation of the limb are caused by the crushing of bone under the same traumatic influence that produced the fracture. In fracture of the neck of the femur without impaction, the shortening of the limb and outward rotation result in consequence of muscular contraction and the weight of the limb.

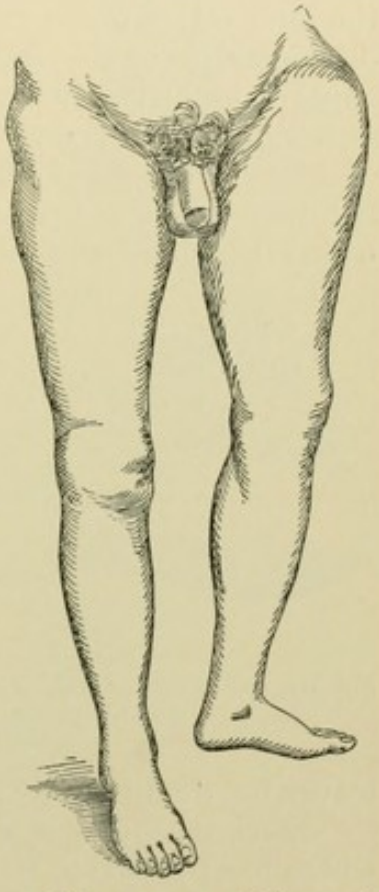

Fig. 201. — Unimpacted fracture of neck of the femur, with marked outward rotation and shortening of the limb (after Bruns).

In oblique fractures of any of the long bones the shortening is caused almost exclusively by muscular contraction. Angular deformity, which appears immediately after the injury, must be considered as one of the immediate consequences of the fracturing force. The appearance of this deformity more remotely from the time of injury is conclusive proof that the deformity was caused by the force of gravitation, or, what is oftener the case, by muscular contraction.

The displacements of the fragments are studied by making use

of inspection, measurements, comparison with the same part of the body on the opposite side, and, in exceptional cases, by akidopeirasty. The visible and palpable deformity that attends many of the fractures is often the most striking and conclusive proof of the existence of the accident. In making use of inspection as a diagnostic resource it is important to expose the same parts of the body for examination, in order to judge correctly the deviations from normal. A lack of caution in this respect has not infrequently resulted in erroneous conclusions. If the deformity is slight, a most careful examination is necessary to detect slight deviations, which is only possible by comparing the normal side or limb with the injured. An abnormal swelling at the seat of injury signifies displacement of the fragments or an extravasation of blood if it appears immediately or soon after the injury occurred. If this swelling increases rapidly in size, it indicates hemorrhage at the seat of injury; if more slowly, it would suggest progressive increase of the displacement of the fragments by muscular contraction, or slow hemorrhage and muscular contraction combined. The swelling appearing at once or soon after the injury some distance from where the force was applied, is almost a positive indication of the existence of a fracture or dislocation. The presence of a sharp fragment near the skin leaves no doubt as to the existence of an oblique fracture caused by direct or indirect violence. In some cases such a fragment which has perforated the tissues as far as the skin forms a characteristic swelling, in the apex of which the point of the fragment can be distinctly felt as a sharp subcutaneous projection. The appearance of suggillation of the skin some days after the occurrence of the accident, at a point distant from where the force was applied, is an important, but not a reliable, indication of the existence of a fracture or dislocation. In compound fractures the fragments can often be seen and felt in the wound. In such cases inspection and digital palpation enable us to make an absolute diagnosis that embraces both the presence and extent of the fracture. A wound of the soft parts is not an infallible proof either of the existence of a fracture or, in the event of a fracture being present, of its being compound. A wound of the soft tissues at the seat of injury may give rise to symptoms simulating some of the symptoms of fracture, and a wound may be caused by the

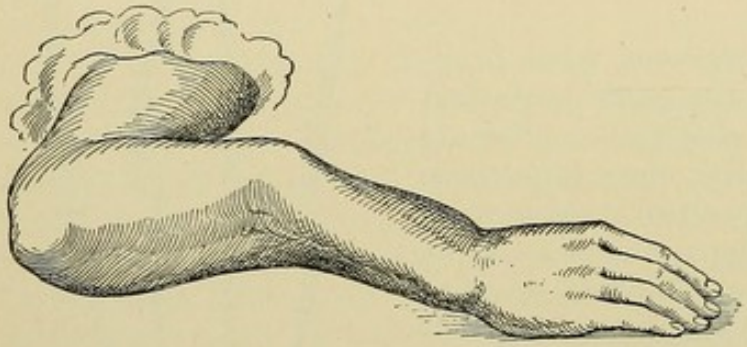

Fig. 202.—Fracture of both bones of the forearm, with marked angular deformity (after Bruns).

fracturing force over the seat of fracture without a communication having been established between it and the seat of fracture.

The displacement of the fragments in fractures of the long bones depends largely on the location of the fracture, the manner in which the injury was sustained, muscular contraction, and the action of various extraneous mechanical forces after the accident occurred. The deformities that immediately follow the accident are caused by the same mechanical force that produced the fracture and that, by its continued action, brought about displacement of the fragments. More remote deformities are usually caused by muscular contraction, loosening of impacted fractures, gravitation, and the action of subsequent outside mechanical causes. The displacements of the fragments for which the surgeon looks and upon which he relies largely in ascertaining the existence and location of a fracture of any of the long bones are lateral, angular, rotary, overriding, impaction, and longitudinal.

Fig. 203.—Transverse fracture of upper part of the radius, with marked lateral displacement.

Lateral Displacement.—Lateral displacement (dislocatio ad latus) as an isolated result of fracture is very difficult to recognize by inspection and palpation, except in case the broken bone is near the surface of the skin, when the prominence of the displaced fragment can be felt and seen. Lateral displacement in deep-seated fractures can not be determined with any degree of safety. Fractures of the clavicle, sternum, tibia, and lower end of the radius can be detected by palpating the most superficial parts of the bones. More frequently lateral displacement occurs in connection with angular deformity, in which event the existence and extent of the lateral dislocation can be determined with a greater degree of accuracy.

Angular dislocation of the fragments (dislocatio ad axem) is recognized by inspection and confirmed by palpation. It presents itself clinically in the most typical manner in fractures of the shafts

of the long bones, where it is often recognized at first sight on exposure of the injured limb. In fractures of the femur and humerus it is almost always associated with overriding and shortening of the limb, while in fractures of only one bone of the leg and forearm it is often seen as an isolated deformity. In incomplete fracture by infraction it exists as the only deformity, caused, in the first place, by the fracturing force, increased later by muscular contraction.

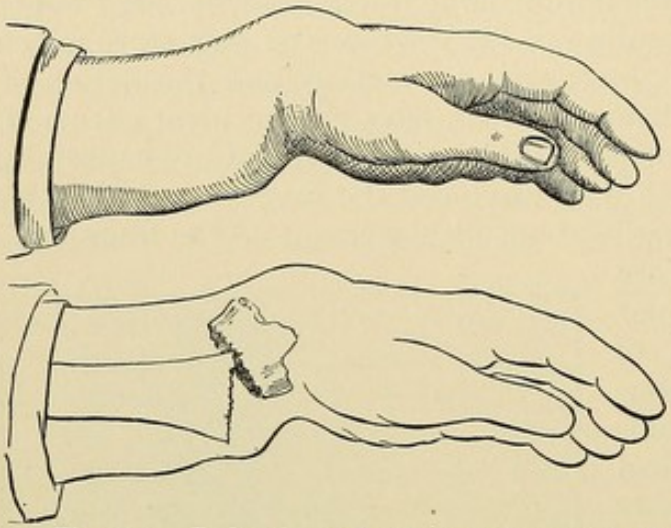

Fig. 204.—Deformity at the wrist consequent upon displacement backward of the lower fragment of the radius after fracture at its lower extremity (Levis).

Rotary displacement (dislocatio ad peripheriam) is recognized without any difficulty by comparing the two limbs and noting

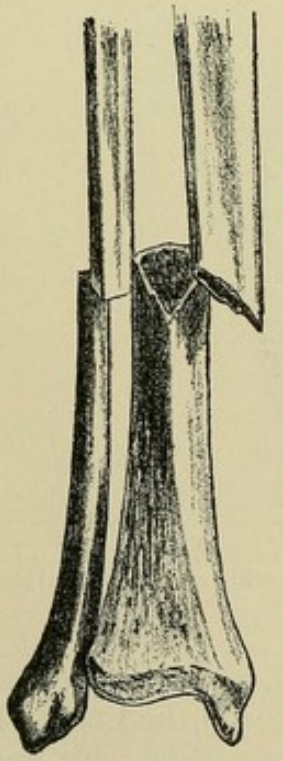

Fig. 205.—Fracture of the shaft of the tibia and of the fibula, with external rotary displacement (Hoffa).

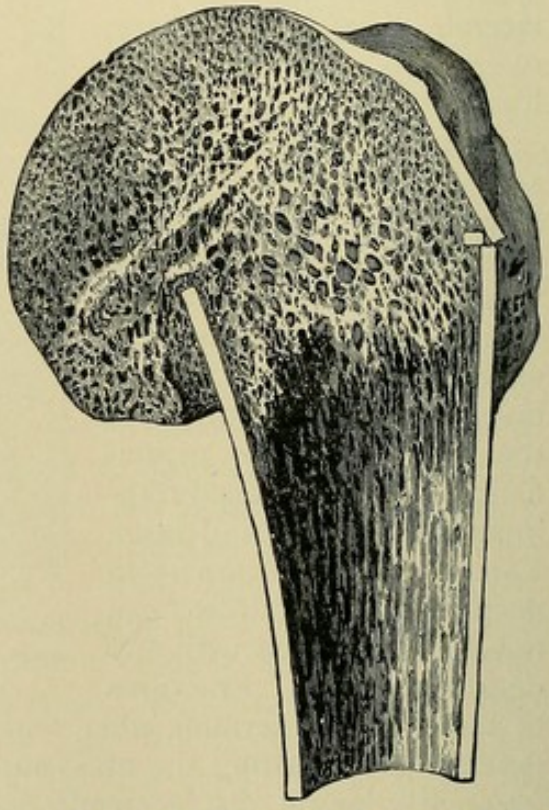

Fig. 206.—Impacted fracture of the humerus through the tuberosities (R. W. Smith).

the position of the part of the limb below the fracture. This displacement is seen most frequently in fractures of the lower

extremity, more especially in fractures of the neck of the femur with and without impaction, when outward rotation presents itself as an almost constant phenomenon, the degree of eversion being determined by the depth of the impaction and the extent of injury to the capsule of the joint.

Overriding of the fragments in fractures of the long bones is always associated with angular displacement. It is seen in the most typical form in fractures of the femur and clavicle (Fig. 207).

Impaction gives rise to abnormality of position of the limb below the seat of fracture, and results in rotary and angular deformity in proportion to the depth of the impaction. Impaction always constitutes one of the results of the fracturing force. One fragment penetrates the other at the expense of the spongiosa, which is crushed and condensed by the penetrating fragment. It occurs generally in the epiphyseal extremities of the neck of the femur and the neck of other long bones, notably the humerus and lower end of radius.

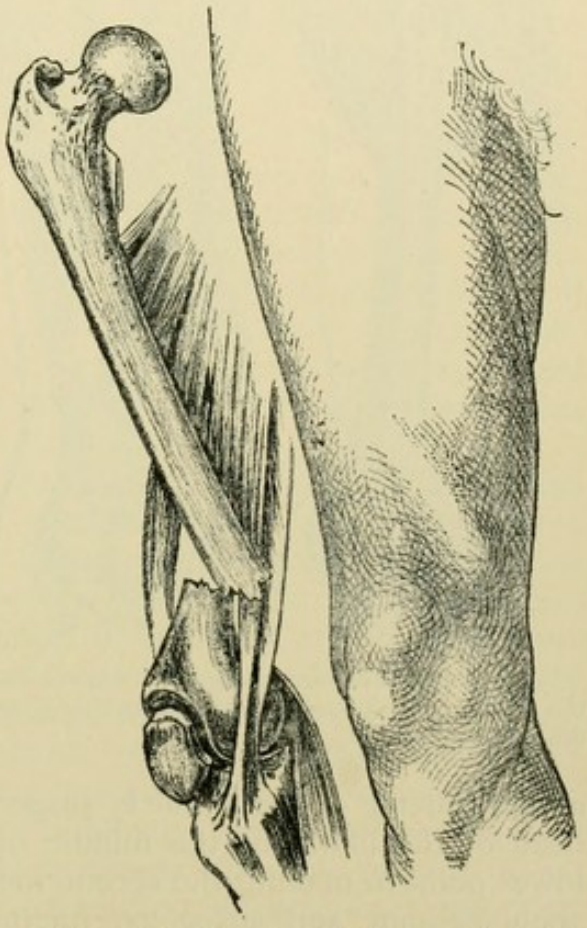

Fig. 207.—Fracture of lower end of the shaft of the femur, with overriding of the fragments and angular deformity (Hoffa).

Longitudinal displacement (dislocatio ad longitudinem cum retractione) is always associated with shortening of the limb. It can only take place when the fractured surfaces no longer furnish a mutual support—that is, when in oblique fractures there is no support between the fractured ends, and in transverse fractures when the lateral displacement is complete. Longitudinal displacement occurs in consequence of muscular contraction, which, if not antagonized by appropriate mechanical treatment, is apt to increase the extent of the shortening gradually. If the shortening is marked, it is recognized without difficulty by inspection ; if slight, its existence must be determined by measurements.

Measurements.—Mensuration is an important aid in the detection of impacted fractures and fractures in which longitudinal displacement has occurred, as well as in making a differential diagnosis

between dislocation and fracture. To avoid errors, the limbs must be placed in the extended normal position and the measurements be made on both sides, between the same anatomic landmarks that are always subcutaneous bony prominences. This diagnostic resource is of special value, and is most frequently employed in fractures of the femur and humerus and injuries and dislocations of the hip- and elbow-joints.

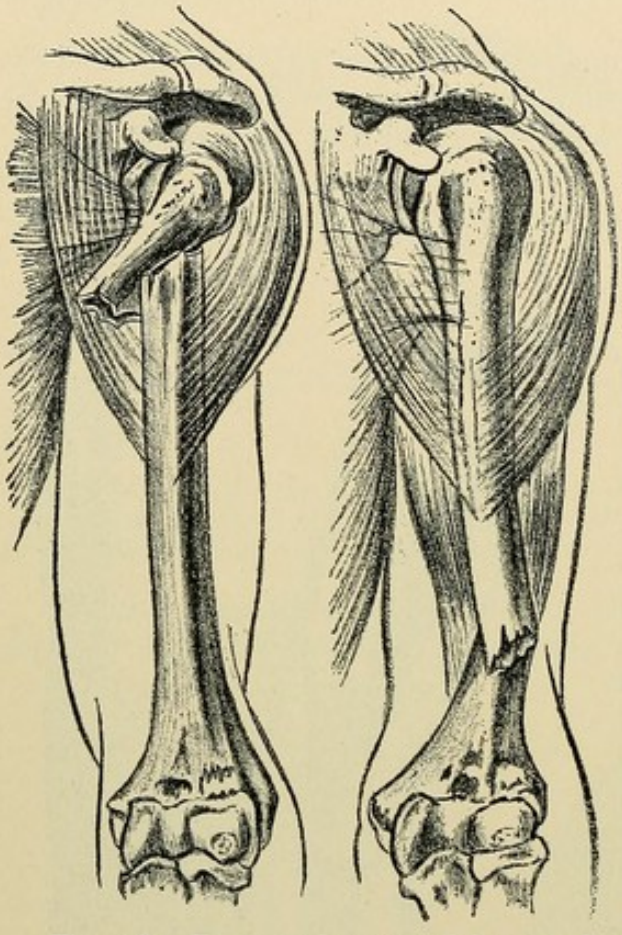

Fig. 208.—Fracture of upper and lower ends of the shaft of the humerus, with marked longitudinal displacement (Hoffa).

In making comparative measurements of the lower extremity the patient must be placed on his back upon an even, solid surface, the pelvis and limbs exposed, and thighs and legs extended and parallel to each other. In suspected fracture of the femur and injuries of the hip-joint the fixed points selected are the anterior superior spinous process of the ilium and the lower margin of the internal malleolus. If an asymmetry of the femur is suspected, the upper margin of the head of the fibula or the middle of the patella is taken for the lower point in making the second measurement. In injuries of the shoulder-joint and suspected fracture of the humerus the most

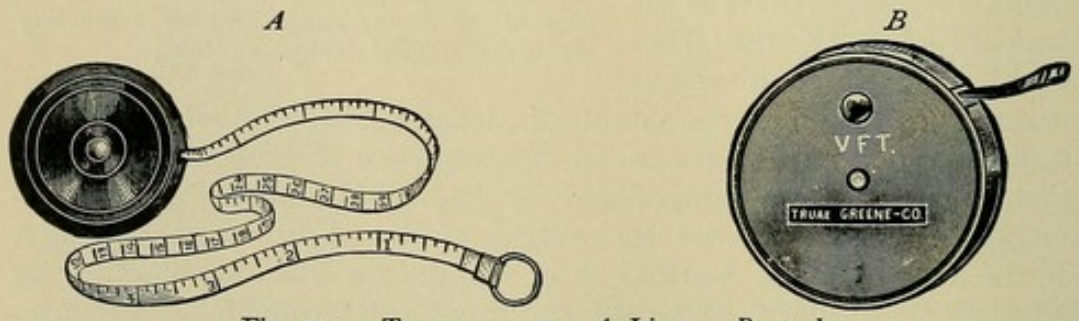

Fig. 209.—Tape-measures: *A*, Linen; *B*, steel.

prominent point of the acromion process and the head of the radius or one of the epicondyles of the humerus is the prominence selected for the measurements.

The best instrument is a steel tape-measure, but a strong thread or a thin wire will answer an excellent purpose in showing the existence, if not the exact amount, of shortening.

In measuring the upper extremities the patient should be in a sitting or standing position, with the arms resting against the sides of the chest and the forearms either extended or flexed at a right angle.

Comparison between the injured limb or part with that of the opposite side is necessary in securing accurate results from examination by inspection, palpation, and comparative measurements. The limbs or parts must be placed exactly in the same position, and during the examination the alterations that take place during changes of position are noted.

Akidopeirasty of Middeldorpf consists in making exploratory punctures with a steel needle to detect abnormalities of resistance of the tissues explored. It is acupuncture employed for diagnostic purposes, and it is occasionally resorted to in examination for fracture, in order to demonstrate lateral displacement, depression, and the presence of fissures. The needle must be made sterile by boiling in soda solution, and the puncture must be made under strictest aseptic precautions. Through the same skin puncture the tissues can be explored in different directions.

Preternatural mobility is one of the strongest proofs of the existence of a fracture of any of the long bones. This symptom is absent in impacted fractures. If abnormal motion can be detected immediately after an injury involving the continuity of a long bone, it can be relied upon in establishing the existence of a fracture. Important as this symptom is in making a diagnosis of fracture, it is not always present, hence absence of preternatural mobility would not exclude the presence of a fracture. As has just been stated, it is absent when the fragments have become impacted, and it is slight in greenstick fractures and when interlocking of the fragments has occurred, and, of course, is always absent when the fracture is incomplete. This symptom is most marked in fractures of the shaft of the humerus and femur and in fractures of both bones of the leg and forearm. In fractures of the fibula and of either the radius or ulna alone it is often found difficult to establish the existence of a fracture by relying upon this symptom alone. *In obscure cases of fracture in the neighborhood of joints preternatural mobility is one of the most reliable symptoms in making a differential diagnosis between fracture and dislocation, as it is almost without exception present in nonimpacted fractures, while impaired mobility is one of the constant features of all dislocations. Preternatural mobility and altered relations of bony landmarks are the two conditions that unerringly point to a fracture near or extending into a joint, but they do not exclude the presence of a complicating dislocation. As an unmistakable indication of fracture a new point of motion is of greater diagnostic significance than preternatural motion.* The latter symptom applies

with special force to fractures near joints, while the former is much relied upon in the search for fractures of the shafts of the long bones.

A new point of motion in the course of the shaft of a long bone established immediately after an injury leaves no further doubt concerning the existence of a fracture. If the fracture is near a joint or extends into it, it is difficult, if not impossible in many cases, to detect the new point of motion, and the injury is characterized by preternatural mobility in the region of the joint. If one or both of the condyles of the femur or humerus, or any of the subcutaneous prominences, have been fractured, a new point of motion can often be ascertained and located by grasping and moving the fragment. The search for a new point of motion must be made with care, as the examination should not result in additional injuries to the soft tissues or greater separation of the fragments. The bone or bones on the proximal side of the supposed seat of fracture are held firmly in the grasp of one hand, while with the other the limb is grasped below and moved gently in a lateral direction, when, if an angle forms between the fixed and the moving points, the necessary information has been secured and the existence of a fracture is established. Should the first effort fail, the position of the hands is changed as often as is necessary to test the continuity of the entire shaft. If the suspected fracture is near the head of one of the large bones, the new point of motion often can be found by fixing the head of the bone immovably with the left hand and by rotating the shaft with the right.

Crepitation has been regarded for a long time as one of three pathognomonic symptoms of fracture, the other two being abnormal mobility and deformity. As an indication of fracture it has been greatly overestimated in the past, and too great reliance upon it as a diagnostic resource has resulted in serious injury.

Crepitus is produced by rubbing two fractured surfaces together, when the mechanical effect produced by the friction between the two rough surfaces can often be heard as well as felt. The production of this sign of fracture by the surgeon is only possible when the fracture is complete, when impaction is absent, and when the two fractured surfaces can be brought in contact and can be rubbed against each other sufficiently to produce the necessary mechanical effect upon which the production of this sign depends—that is, a certain degree of mobility of the fragment with which the crepitation is produced. This sign is necessarily absent in incomplete and impacted fractures, and when the fragments are firmly interlocked or when they can not be brought in contact, owing to great longitudinal displacement or interposition of soft tissues. Crepitation is most distinct in fractures of the shaft of the long bones, with great mobility of the fragments. It is in such cases that patients themselves often are annoyed by the sense of crepitation on the slightest disturbance of the limb, even after the fracture has been properly

dressed and immobilized. If other symptoms are insufficient to prove the existence of a fracture, it is justifiable, by the gentlest means, to search for crepitus as an indication that the fragments have been brought in contact, thus excluding the presence of interposition of soft tissues between the fragments—a frequent mechanical barrier to union of the fracture by bony callus.

Crepitation is more frequently felt than heard, and the vibrations are often conducted a considerable distance to the hand with which one of the fragments is moved. If the fragments override each other, extension must first be made sufficiently to bring the fractured surfaces in contact, when crepitus is produced by making careful lateral or rotary movements. In fracture of the patella and olecranon process, the diastasis must be eliminated by relaxing the muscles that have caused the injury, when the fractured surfaces are brought in contact and, by rubbing them together, crepitus is elicited, provided interposition of soft tissues does not prevent it. In fractures of the ribs crepitus is sometimes produced by the respiratory movements of the chest, and can be heard by placing the stethoscope over the seat of fracture, as was first suggested by Lisfranc. *The search for crepitation should never be made unnecessarily, as in many instances this sign is absent, and in the vast majority of cases a satisfactory diagnosis can be made by a careful study and analysis of the other symptoms.*

The vibrations produced by rubbing torn ligaments together have not infrequently been mistaken for fracture crepitus, and vice versâ. Cartilage injuries, disease of tendon sheaths, subcutaneous emphysema, and blood extravasations are other conditions that have given rise to confusion and erroneous conclusions in searching for crepitus as a sign of fracture. *The greatest care is necessary in fractures of the neck of the femur and anatomic neck of the humerus in making attempts to elicit crepitus in the examination of impacted fractures. It is in such cases that search for crepitus has been followed by the most disastrous results by loosening the impaction, thus converting a fracture into an almost unavoidable pseudarthrosis, that, under ordinary care, would have united by bony consolidation.* In nonimpacted fractures of the neck of the femur the other symptoms are so apparent that a correct diagnosis can be made without searching for crepitus, and in impacted fractures the production of this sign implies loosening of the impaction, a positive diagnosis at the expense of a permanent disability. In doubtful cases it is much better to take it for granted that the fracture is an impacted one, and treat it as such for the necessary length of time, rather than insist on making a positive diagnosis, with the risks incident to such an attempt.

The Röntgen Ray in the Diagnosis of Fractures.—The X-ray is the most recent acquisition to the diagnostic resources of fractures, and in obscure cases has become almost indispensable. It is of special value in determining the existence and location of fractures near joints, and in showing the presence or absence of com-

plicating dislocations. It will also be found of the utmost value in showing the position of the fragments and the causes that interfere with their reposition, among them the interposition of soft tissues. The fluoroscope used in connection with the Röntgen apparatus will aid the surgeon in determining whether or not his efforts at reduction have been successful. If his efforts have failed, it may point out to him the obstacles which are in the way and which must be removed before the fragments can be brought in contact. In old fractures united in malposition, and in old dislocations unreduced, skiagraphy has become a very useful and often necessary procedure preliminary to efforts at reduction, as it will reveal the precise relations of the fragments in a vicious union and the exact location of the dislocated head of the bone and its relations to adjacent important structures. The information thus gained will be of material assistance in deciding upon the propriety of active interference in correcting the deformity, and in reducing the dislocation by either the bloodless or the open method. To make skiagraphy reliable as a diagnostic resource it is often necessary to make the illumination in different directions, as otherwise it may lead to serious deceptions.

Symptoms Following Fractures.—The more remote symptoms of fracture may either clear up or obscure the diagnosis.

Shock, more or less marked, is present in nearly every case of fracture. Fractures caused by direct force are, as a rule, attended by greater depression than fractures from indirect violence, owing to the existence of more extensive injury to the soft tissues, upon the extent of which shock largely depends. Pallor, fainting, a feeble pulse, later nausea and, in more serious cases, real shock, are the principal general nervous manifestations caused by fractures. Profound shock is one of the great dangers of extensive crushing injuries. Simple fractures are almost constantly followed by more or less shock.

Fever.—Independently of infection, the febrile reaction which, as a rule, sets in a few hours after the accident has occurred is caused by ferment intoxication. The fibrin ferment is a product of coagulation necrosis of the blood extravasated, and when a sufficient quantity finds its way into the general circulation, a rapid rise in the temperature and other febrile phenomena develop in rapid succession. Fermentation fever from this, as well as from any other, cause differs clinically from fever caused by microbic infection in that the fever sets in within a few hours after the accident. Although the temperature may be high, the pulse rapid, full, and bounding, the subjective symptoms are light; the tongue remains moist, vomiting and diarrhea are absent, there are no chills, appetite remains unimpaired, and the patients are seldom willing to acknowledge that they are ill. The fever is of short duration and disappears as suddenly as it came on, with the elimination of the fibrin ferment. *The amount of extravasated blood bears no relation whatever to the intensity and duration of the fever, as a small extravasation may give*

rise to a high fever that may continue for several days, and a large extravasation may exist with little or no rise in the temperature. The conditions that determine fermentation fever are as yet not well understood, and await a more satisfactory explanation by additional experimental research and more accurate clinical observations.

Local Symptoms.—With the general and local reaction the seat of fracture is very liable to undergo changes that give rise to additional symptoms. In simple fractures such changes do not occur, and if they do, only to a slight extent, when the extravasation of blood is limited, when the fragments are in accurate contact and perfectly immobilized. A copious blood extravasation, comminution and imperfect reduction, and immobilization are responsible for increase of the swelling, extensive ecchymosis, blistering of skin, and a continuation of pain. In the absence of infection a gradual increase in the size of the swelling indicates a continuation of hemorrhage at the seat of fracture and infiltration of the loose connective tissue with blood. In such cases the swelling becomes larger and more extensive soon after the injury, or, if the swelling increases in size later, it is caused by an obstructed venous circulation, and its direct consequence, edema. Very often these two pathologic conditions caused by the trauma are associated, when the limb, at and below the seat of fracture, becomes enormously swollen, the skin very tense, and blisters form, filled with a yellow or reddish serum. The appearance of such bullæ have often caused unnecessary alarm, not only on the part of the patient, but also to the physician, who regarded them as indications of the approach of gangrene. These blisters indicate impeded venous, and an embarrassed capillary, circulation, but if the principal blood-vessels have escaped injury, no fear of gangrene need be entertained. The contents of these blisters should be removed by puncture, the cuticle carefully preserved and protected by dusting with borosalicylic acid, and covered with hygroscopic sterile cotton.

Ecchymosis appears early and is most extensive if the blood extravasation is diffuse and near the surface of the skin; late, and perhaps at quite a distance from the seat of fracture, if the extravasation is underneath a firm fascia and a deep layer of uninjured muscle. In fractures caused by direct violence the ecchymosis appears early over the seat of fracture, and may be caused by the contusion of the soft parts. In indirect fractures it comes on later, over the seat of fracture or at some distance, but as an indication of fracture remote from where the fracturing force was applied. If the ecchymosis is intense, the discoloration is at first black, which, as the absorption of the coloring material of the blood progresses, fades gradually into green, deep yellow, light yellow, and finally into the normal color of the skin.

Pain.—The continuation of pain should always remind the surgeon of the necessity of investigating its cause. Instead of administering opiates, it becomes the duty of the surgeon to seek for and

remove its cause. Continuation of pain after the fracture has been reduced and dressed is a strong indication of imperfect work, either in effecting complete reduction or because of unequal harmful pressure on the part of the splints or a faulty position of the limb. The splints should be removed, the seat of fracture examined, the necessary corrections made if the fragments are found in faulty position, and if the dressing has caused the pain, the defects are remedied and the limb placed in the most comfortable position.

Serious Complications of Simple Fractures.—One of the common oversights in the examinations for fracture in the practice of most general practitioners is a failure to make a careful investigation concerning the presence of serious complications involving the principal blood-vessels and large nerve-trunks. Many grave consequences have followed simple fractures when least expected, because at the first examination no careful investigation was made regarding the condition of the principal blood-vessels and nerves. This part of the examination should never be neglected; it is superfluous in the majority of cases, but of far-reaching importance in isolated cases. The average physician is usually content with limiting his diagnostic work to the bone injury, and in so doing serious complications are occasionally overlooked that are of the utmost prognostic importance. The main artery of a limb is occasionally injured by the fracturing force, or the circulation is suspended or impaired by compression caused by displaced fragments, conditions that may result in gangrene, an occurrence for which the treatment of the fracture is more frequently blamed than the injury. Traction injuries sometimes rupture the intima of the principal artery, an accident which at once diminishes the blood supply and is followed in a short time by complete obliteration of the injured blood-vessel by the formation of a thrombus. The condition of the peripheral circulation should always be carefully noted, not only in making the first examination, but also day after day subsequently, to gain timely knowledge of vascular complications that might threaten the life of the limb and of the patient.

Rupture of large nerve-trunks by the fracturing force or indirectly by the fragments is a very serious complication, and one that is not infrequently overlooked. Such accidents are more frequently detected later than at the time the first examination is made. The physician should never complete his examination of any fracture until he has ascertained the condition of the nerves below the seat of injury. This he does by testing sensation and motion in the course of the principal nerve-trunks, thus better preparing him to render a reliable prognosis and to protect himself against unnecessary and undeserved blame.

Suppuration.—Infection of a subcutaneous fracture is an extremely rare occurrence, and in this respect the results of experimentation appear to be at variance with clinical experience. A number of experimenters have succeeded very frequently in pro-

ducing an osteomyelitis at the seat of a subcutaneous fracture, artificially produced, by injecting into the general circulation pus-microbes either before or after the injury was inflicted. The rarity with which osteomyelitis is met in subcutaneous fractures as an early or a remote complication would seem to prove that the blood and tissues of persons apparently in good health do not contain enough microbes to develop a suppurative inflammation at the *locus minoris resistentiæ* created by the fracture. A number of well-authenticated cases of complicating osteomyelitis have, however, been reported, and I recall two very interesting cases that came under my own observation. In both cases the subcutaneous fracture became infected about a week after the accident occurred. Abscess formation and limited sequestration followed and retarded the process of repair, but eventually the fracture united in a satisfactory manner. The osteomyelitis resembles, in its beginning and in its course, acute osteomyelitis without fracture, with this exception : that the pain during the early stages of the disease is less severe. A chill, followed by a rapid rise in temperature, pain, tenderness, and a rapidly forming diffuse swelling at the seat of fracture, which soon presents fluctuation, are the most important clinical features of this complication.

The inflammatory process differs from so-called spontaneous osteomyelitis in several respects, owing to the existence of the fracture. The pain is not so intense, intra-osseous tension is diminished by the fracture, and swelling of the soft tissues comes on at an earlier period, because the osteomyelitic product finds its way into the loose connective tissue through the open ends of the fragments. Finally, the absence of intra-osseous tension and the early and free escape of the product of the suppurative inflammation into the surrounding soft tissues explain satisfactorily why, as a rule, the sequestration is limited. Although such complications are very rare indeed, they must be looked for and recognized as soon as they appear, as early incision and free drainage under strict aseptic precautions will minimize the danger from pyemia and greatly limit the destruction of bone and soft tissues, together with hastening the initiation of a process of repair. Incision and drainage convert the subcutaneous into an open fracture, which should then receive the same surgical and mechanical treatment as infected compound fractures receive.

Fat Embolism.—One of the least dangerous but most frequent complications of fractures is fat embolism. Fat embolism as a complication of fracture and as a cause of sudden death was first described by Zenker in 1862. It has since been made the subject of careful clinical and experimental investigation, and numerous cases have been recorded, substantiated by carefully made postmortems.

The most elaborate description of fat embolism that serves as the basis of all writings on this subject we owe to Wiener and Scriba. Fat embolism of a slight degree and unattended by symp-

toms is, in all probability, a frequent accompaniment of fractures, especially in fractures involving the medullary canal of the shaft of a long bone. Comminution of the bone and crushing of the medullary tissue favor the occurrence of fat embolism, and are prone to give rise to grave forms which may destroy life suddenly or in a short time.

The frequency with which fat embolism occurs in fractures is best shown by the experiments made by Halm. In 13 animals he produced bone injuries under a hydraulic press, varying in intensity from a simple fracture to complete crushing of the bone, and found fat embolism of the lungs and other organs 12 times. The only animal in which it was not found was the one in which a wedge-shaped piece was removed from the femur without injury to the medulla. One of the essential conditions in the etiology of fat embolism is the presence of fluid fat, and this is produced in fractures by crushing of the medullary tissue, which liberates free fat globules. Another source of fluid fat is the fat tissue involved in the injury, which, when crushed, likewise furnishes free fluid fat. A few well-authenticated cases of fat embolism have been reported in which there was no fracture, but extensive contusion of fat tissue, from which the fluid fat was derived exclusively.

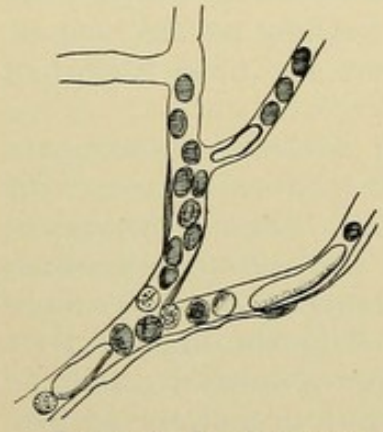

Fig. 210.—Fat globules and blood-corpuscles in capillaries (after Perls).

In fractures we find another condition that predisposes strongly to fat embolism—the wide-open lumina of the vessels of the medullary tissue. The pressure caused by the displaced fragments and by the blood extravasation, aided by aspiration of the open veins, is the principal active agent in forcing the liberated air globules into the venous circulation. The torn veins are the main avenues for the entrance of free fat into the circulation, although it has been shown that it may also gain access indirectly through the lymphatic channels. In the latter case, however, the oil globules are emulsified in the lymph-glands to an extent which, according to Riedel, renders them harmless in the general circulation. The entrance of fat into the circulation occurs soon after the injury, as the open veins are speedily blocked by coagulated blood. The oil globules that find their way into the venous circulation are arrested chiefly in the pulmonary filter of capillary vessels. In the capillary vessels the oil globules become attached to the intima, coalesce, and form larger drops which finally completely fill the lumina of the smallest capillary vessels. In the capillary network are found, between the emboli of fat, capillary vessels filled with blood. The smallest part of the fat passes the pulmonary filter and reaches the various distant organs, particularly

the kidneys, liver, spleen, brain, spinal cord, and the digestive tract, where it again blocks capillary blood-vessels.

The embolic fat acts as an aseptic plug, and does not cause inflammation, sepsis, and pyemia, as was formerly asserted. The danger from fat embolism arises solely from the mechanical obstruction of blood-vessels, and the degree of danger is proportionate to the extent of the capillary obstruction. The hemorrhagic infarcts, which are, however, not constant in fat embolism, are caused by obstruction of capillaries of considerable size, around which, from smaller engorged capillaries, rhexis takes place. Paralysis of the heart has been regarded by Bergmann and Panum as the immediate cause of fat embolism, but the very elaborate researches and numerous experiments of Scriba lead to an opposite conclusion. He has shown that extensive fat embolism has no disturbing influence on the action of the heart. If the subjects of fat embolism escape the immediate and remote consequences of obstruction of the pulmonary capillaries, the emboli are detached in the course of from eight to twelve days, and find their way into the general circulation. This may give rise to embolism in distant organs, when, in the course of time, the fat is again liberated and finds its way back into the pulmonary capillaries, again causing embolism. As these successive liberations and new embolic processes occur, the kidneys continue to eliminate fat periodically, until finally all the fat that has not already been absorbed by the tissues the seat of the different embolic processes is removed by this route.

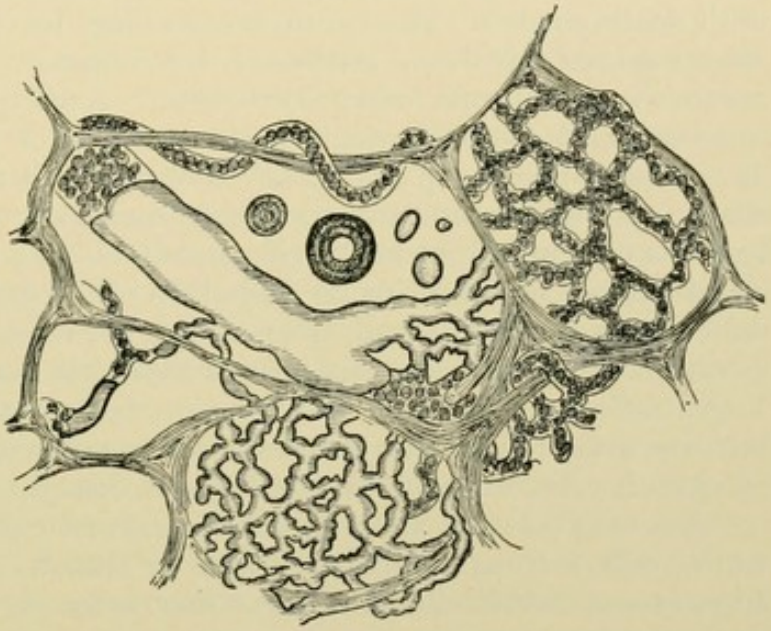

Fig. 211.—Fat embolism of the lungs, eight days after fracture of the leg. The capillary network to the right of the alveolus is filled with blood, the one below with fat; also the afferent artery. Above the artery blocked with fat are seen two air-bubbles showing several dark rings, and extravasant oil globules with plain black contour (after Perls).

The appearance of fat in the urine after injuries is an indication of the existence of fat embolism. Riedel found fat in the urine in all cases of fracture. Halm found it present in 28 per cent., and Riedel in 42 per cent., of the cases. It is only in the graver cases of fat embolism that free fat-drops appear on the surface of the urine. In most

of the cases the fat appears in the form of a cloudy, mucoid layer on the surface of urine that has been allowed to stand for some time. Under the microscope the fat is seen in the form of round, strongly refracting granules, with fine, dark contours, never exceeding in size that of half a blood-corpuscle. These granules adhere to one another or are irregularly distributed over the field.

These small drops of fat never coalesce. Scriba has shown that elimination of fat through the kidneys takes place periodically. The first appearance of fat in the urine occurs from the second to the fourth day after the accident; the second in from ten to fourteen days, and so on, at intervals of from six to ten days. In the experiments on animals a prompt and decided reduction in the temperature was observed, which reached its lowest level in from six to ten hours. In the fatal cases the temperature continued to sink until death ensued. The rise in temperature so constantly observed after fracture has been attributed by Wagner, Busch, and Bergmann to mild forms of fat embolism. Subsequent observations, however, and more particularly the results of experiments, have shown most conclusively that fat embolism has, if any, an opposite effect, and when the temperature is increased, the febrile disturbance is not due to fat in the circulation, but to a coexisting ferment intoxication. In extensive fat embolism of the pulmonary capillaries difficulty in breathing and cyanosis are the most prominent symptoms, and in fatal cases death from asphyxia may occur suddenly. If the patient survives the first invasion, later symptoms of a similar but less severe character announce a repetition of the same process or vascular disturbances caused by hemorrhagic infarcts.

A severe collapse inaugurates the gravest cases of fat embolism, which differs from traumatic shock in that it does not make its appearance *immediately, but some time after the accident.* In the fatal cases great pallor of the skin and mucus membranes, loss of strength, apathy, diminished sensibility, and, at times, convulsions and paralysis follow in succession, the paralysis finally involving the respiratory centers.

Experiments on the lower animals have shown that the danger from the presence of fat does not depend so much on the amount of fat introduced as it does on the force with which it is introduced and the time taken in injecting it. The same amount of fat injected with force *quickly* into a vein near the heart, with the result of causing immediate death of the animal, when injected into a peripheral vein *slowly* will cause no serious or remote ill results. Bruns has collected 110 fatal cases of fat embolism that have been reported in literature, but he very properly insists that in many of these cases death was the result of other complications.

The differential diagnosis between acute sepsis and fat embolism is sometimes very difficult, if not impossible. In subcutaneous fractures a differential diagnosis between these two complications is seldom made necessary. A high temperature always excludes fat

embolism as the sole or principal source of danger, and should always remind the surgeon of the necessity for searching for other complications that are responsible for the febrile disturbance. Practical experience and experiments on the lower animals have demonstrated the frequency with which bone injuries give rise to fat embolism, but they have likewise shown that death from uncomplicated fat embolism is very rare.

The only rational treatment for fat embolism, if it becomes a source of danger to life, is the administration of stimulants.

Traumatic Emphysema.—In subcutaneous fractures traumatic emphysema is caused by the entrance of air into the loose connective tissue around the seat of fracture. The fracture in such cases communicates with some part of the respiratory passage, and the air finds its way through the mucous passage by means of a connecting wound in the mucous lining, to the seat of fracture. Fractures of this kind are open fractures, but differ from fractures that communicate with a wound of the skin in that they are not exposed to contact infection, as the air which enters from the bronchial or tracheal wounds is filtered air, practically sterile. In traumatic fractures communicating with the air-passages the air is forced, during the end of the expiratory act, through the wound into the loose connective tissue, producing traumatic emphysema. Fractures of the ribs that penetrate the pleura and lungs and fractures of the larynx and trachea are most frequently the seat of traumatic emphysema.

Traumatic emphysema also occurs occasionally in connection with fracture of the bones of the face which communicate with the cavity of the mouth, the nasal cavity, the antrum of Highmore, and the frontal sinus. Traumatic emphysema accompanying fracture of the larynx is at times so extensive as to threaten life from compression of the larynx or trachea, in which case a rapid tracheotomy is urgently indicated. Emphysema following puncture of the lung by a sharp fragment of a broken rib often spreads very rapidly over an extensive surface in the loose subcutaneous areolar and intermuscular connective tissue, where it seldom does any harm. The emphysema may, however, reach through the subserous connective tissue, the interlobular connective tissue of the lung, and the mediastinum and pericardium, where it may produce distressing symptoms and even death by compression. In open fractures air may be aspirated under certain conditions which create suction, but in the majority of cases of emphysema developing in connection with compound fractures some time after the accident has occurred, the emphysema is caused by gas-formation, one of the gravest indications of infection. The gas-generating bacteria are bacilli that live on dead tissue, and the emphysema makes its appearance after the wound has become the seat of a secondary mixed infection with putrefactive bacilli.

Callus Production.—A study of callus production is an impor-

tant introduction to a consideration of the manner of repair, prognosis, and treatment of fractures.

Fractures are repaired in the same manner as wounds of the soft tissues—that is, by proliferation of preexisting cells, the product of which, in this instance, is called callus. A brief historic review of this subject will be of interest to illustrate to what extent the opinions of surgeons regarding the mode of repair after fractures have been influenced by the views they entertained as to the histologic source from which the reparative material is derived.

Galen, who wrote quite at length on this subject, regarded callus as a substance thrown out around the seat of fracture for the purpose of cementing the fragments together, without, however, becoming transformed into bone. Van Swieten claimed that the cement of Galen is changed into bone. J. L. Petit compared the healing process of bone with the repair of soft tissues.

Duhamel de Monceau attributed to the periosteum and endosteum the function of producing callus. Haller, and his prosector Detlef, believed that the periosteum took no part in the regeneration of bone, but that the callus is derived from the fractured ends of the bones, more especially the myeloid tissue. Dupuytren, from a clinical aspect, revived the theory of Duhamel, and at the same time assigned bone-producing qualities to the soft tissues around the seat of fracture. He also introduced the terms provisional and definitive callus. He claimed that the definitive callus does not make its appearance until four or five months after the injury, and that it is not complete before from eight to twelve months.

Cruveilhier did not recognize the different kinds of callus described by his teacher, and ascribed its source to the lacerated soft parts surrounding the fractured bone-ends—the periosteum, connective tissue, muscles, tendons, etc. Bransby B. Cooper defined callus as a plastic exudate from the inflamed ends of the broken bone. Lambron asserted that a broken bone can unite directly through the medium of an interfragmentary callus without the formation of a provisional callus. P. Flourens believed that the periosteum alone is capable of furnishing material for new bone. Subsequently, however, he modified his view, and made a distinction between the periosteal or permanent callus, and the temporary or muscular callus.

August Voetsch speaks of callus as the product of periosteitis. Rokitansky taught that callus is developed directly from bone and its connective tissue, including the periosteum. Bernh. Heine, who has studied this subject with great care by means of the microscope and experimentally, has come to the following conclusions: The regeneration of broken and resected bone commences, as a rule, from connective tissue. The process of regeneration is, at times, limited solely to the connective tissue of bone and periosteum, but in most cases the connective tissue of adjacent parts, more especially the muscles, contributes to it.

According to Virchow, callus is produced from connective tissue outside of the bone, as well as from myeloid tissue in the interior of bone.

Preparatory to his studies on the production of callus, Hofmokl has traced the histology of bone during fetal life. During the development of bone, cartilage cells are transformed into bone-cells. The primary marrow spaces are formed in the interior of cartilage cells, which, with their contents, are transformed into marrow spaces. The normal development of callus appears, histologically, as a return of perfect bone into its primary stage, embryonal development. The periosteum, bone, and marrow are active in the production of callus. The neighboring soft tissues assist in the process of repair only in so far that they may become converted into bone. In point of importance the callus-yielding tissues are arranged in the following order: periosteum, marrow, bone. The bone-cells take an essential part in the production of callus, since they become enlarged, multiply, and thus form marrow spaces with myeloid cells, changes that are observed very distinctly upon the surfaces of the ends of broken bone, on the periosteal, as well as on the medullary, side. Ossification invariably begins from the margins of a medullary space.

Gegenbauer takes the ground that bone is produced directly from connective tissue. Sharpey's fibers, if traced carefully, always spring from a bony point between the Haversian canals, from which point they radiate toward both sides into the lamellar systems. The fibers form networks, and at points of intersection bone-cells are produced, a deposit of lamellæ taking place around connective-tissue fibers. The intercellular substance is regarded by Gegenbauer as a product of secretion of cell elements, and not as a metamorphosis of cells, as was asserted by Waldeyer, who believed that the protoplasm of the cells is transformed, in part or in entirety, into basis substance.

Kassowitz, after a careful study of the process of ossification, has come to the conclusion that the deposit of earthy material in the fibrillary reticulum, as well as in the osteoblasts, is dependent on the condition of the circulation. The fact that the immediate neighborhood of the vessels does not ossify and that the deposition of earthy material occurs in advance of the vessels induced him to accept the theory that active circulation prevents the deposition of earthy material, while diminution of blood pressure favors ossification.

Rigal and Vignal's experimental researches on the formation of callus have an important and direct bearing on the process of repair after fractures. Their practical deductions may be summarized as follows:

If periosteum is exposed to a moderate degree of irritation, new bone is produced from the marrow beneath the point of irritation directly, without passing through the stage of cartilage. If irrita-

tion is increased by displacement of the fragments and rubbing of the soft parts, the result is cartilage beneath the periosteum, which is subsequently converted into bone. If the periosteum is completely destroyed by scraping the bone, the defect is repaired by a connective-tissue cicatrix, which somewhat resembles periosteum. If a circular piece of periosteum has been removed, and the bone is broken after cicatrization has been completed, perfect union is the result, showing that bone can unite independently of the periosteum. If the cortical layer of bone is scraped or chiseled away down to the medullary canal, the defect is replaced by a myeloid callus. If the medullary canal is not opened, the process of regeneration is slower, as a considerable period of time will elapse until the resulting rarefying osteitis opens the Haversian canals sufficiently to furnish the required amount of cellular elements from the medullary tissue for the reparative process.

It is now generally conceded that the provisional or temporary

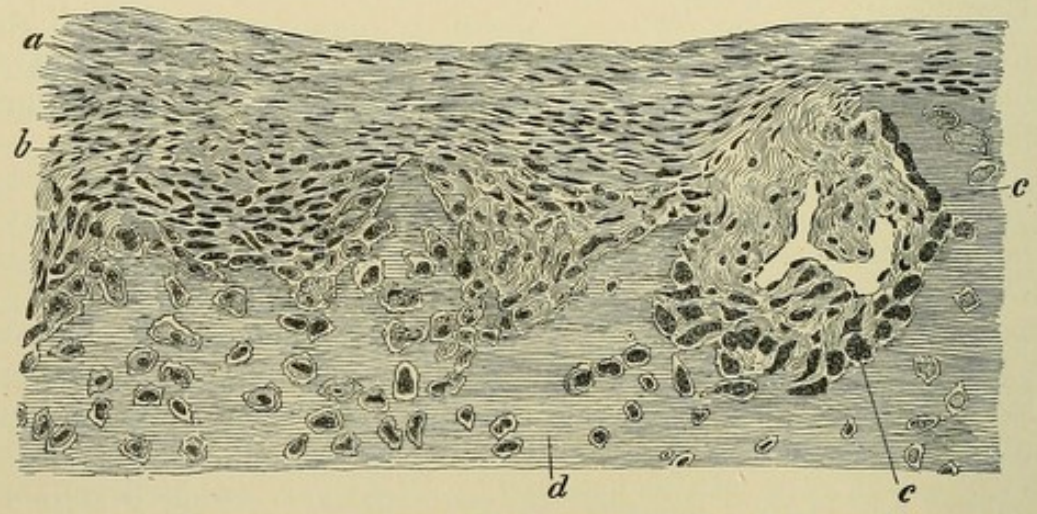

Fig. 212.—Bone production from the periosteum (× 285) : *a*, External layer, scanty in cells ; *b*, internal layer, rich in cells (osteoplastic layer of the periosteum) ; *c*, *c*, osteoblasts ; *d*, osteoid tissue (after Weichselbaum).

callus is the product of the periosteal and paraperiosteal tissues, while the definite or permanent callus is produced directly from the osteoid and myeloid tissues. The provisional callus is nature's splint, its only object being to immobilize the parts until the definitive callus firmly and permanently unites the fragments. The temporary callus is accidental, and appears earliest and most copiously where paraperiosteal tissues are most abundant and motion between the fragments is greatest ; the intermediate or permanent callus is produced later, and is most certain to take place in spongy bones. Fractures of the neck of the femur, partly within and partly outside the capsule, unite with as much certainty as fractures in other localities, in the usual way—by the formation of external and intermediate callus. In this variety of fractures an abundance of callus, sometimes bordering on deformity, designates

the exact location of fracture. In intracapsular fractures, as in fractures within any other joints, the conditions for the formation of external callus are unfavorable; hence we find in all cases purporting to be bony union imperfect, if any, attempts in this direction. Anatomy, physiology, and experimental research all tend to prove that in cases of intracapsular fracture we have all the conditions present that are necessary for the production of intermediate callus, provided the fragments are kept in accurate contact for a sufficient length of time.

From the older writings it has become apparent that the material for the repair of a fracture is derived from two sources, the periosteum and the myeloid tissue. That the periosteum takes an important, if not an essential, part in the process of bony consolidation of a fracture is shown by experiments made by Ollier. He removed the periosteal envelop of the entire circumference of the shaft of a bone in a rabbit, and, after healing of the wound, fractured the bone. The result was a very tardy union, which required eight weeks for its completion, while fractures made in animals of the same age not thus treated united firmly in two weeks.

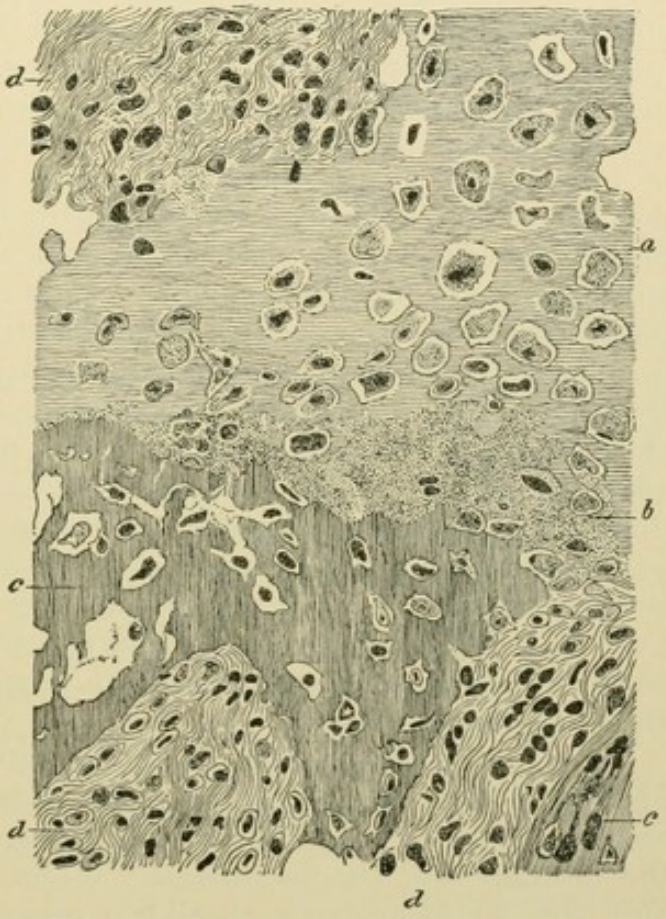

Fig. 213.—Cartilaginous and bony callus, four weeks after fracture of the coronoid process (× 285): *a*, Cartilaginous callus; *b*, beginning calcification of the cartilage and direct mass formation of the same into bone; *c*, *c*, bony callus; *d*, *d*, *d*, medullary spaces (after Weichselbaum).

Experiments have likewise shown that the medullary tissue in the central canal takes an active part in the repair of fractures of the shaft of the long bones, and that the red marrow, wherever found, is the most essential agent in the formation of the intermediary permanent or definitive callus. According to Gegenbauer, Waldeyer, and F. Busch, the medullary spaces are lined with cells that can be recognized as remnants of osteoblasts, which, when subjected to irritation, are aroused from their latent condition and

assume active tissue proliferation. Bruns proved the osteogenetic capacity of the medullary tissue by his transplantation experiments. The result was negative in 69 experiments in which he transplanted the marrow from one animal to another. Of 19 autotransplantations, 12 proved successful. The marrow was planted in localities devoid of tissue capable of producing bone; hence the bone formation that was found in places occupied by the medullary graft could have been produced only by the myeloid cells.

The histology of callus formation has not reached perfection: many gaps remain which must be filled with the results of carefully made experiments and deductions drawn from the examination of specimens from the human subject.

The yellow marrow undergoes, according to Ollier, a process of rejuvenation before the cells can take an active part in the production of bone; by disappearance of the fat-cells and proliferation of the myeloid cells the yellow marrow again resumes its embryonic appearance and juvenile activity. Authorities differ regarding the transformation of the product of proliferation from this source into bone: some claim it is transformed directly into bone; others contend that it is first converted into cartilage and later into bone, while still others claim that only the connective tissue of the marrow takes an active part in the production of bone. Bruns is of the opinion that bone formation from the product of medullary proliferation occurs in a direct manner by the formation of an osteoid substance, and by the indirect, through a preliminary stage of cartilage formation. The intra-osseous callus, from proliferation of the medullary tissue, forms in a remarkably short time, as has been shown by Bruns, Hilty, and Maas.

The intermediary callus plays the most important rôle in the process of bony consolidation. In some cases the provisional callus appears early and in abundance, but, owing to the tardiness of the formation of the intermediary callus, bony union takes place late, and sometimes not at all; in other cases the intermediary callus forms early, and the bone unites with little or no provisional callus. The osteoid material that effects the bony union is derived in part from the medullary tissue in the Haversian canals, and in part from the periosteum. The first link in the long chain of tissue changes that occur in the ends of the fragments during the process of repair is the stage of osteoporosis.

The osteoclasts prepare the way for callus formation. The increased vascularity of the bone-ends, so constantly present during this stage, stimulates the cells to renewed activity. The vascular spaces and medullary canals become enlarged, to adapt themselves to the increased vascular supply and for the reception of new cells. With the transformation of the new material into bone the stage of sclerosis sets in, which terminates with the transformation of the callus into bone and the completion of the process of repair, a function performed exclusively by the osteoblasts in the medullary tis-

sue and the periosteum. With the restoration of the continuity of the bone by bony consolidation the temporarily exaggerated nutritive processes subside, and much, if not all, of the provisional callus disappears. By a very complicated process the internal architecture of the bone is restored, in a manner analogous to that witnessed during the growth of bone. This adds strength and durability to the new tissues interposed between the fragments, and which then constitute a permanent part of the reunited bone.

The Function of Detached Fragments in the Restoration of the Continuity of a Broken Bone.—In the discussion of compound fractures great stress was placed on the importance of preserving detached fragments of bone in all cases in which there was reason to believe that the wound was or could be made aseptic. Convincing reasons were given to substantiate the wisdom of pursuing such a course. It is well known that in comminuted fractures the detached fragments do not act as foreign substances, but are incorporated in the callus and unquestionably take active part in the process of repair. It is important to follow the fate of such loose fragments of bone, more especially in connection with the subject of intracapsular fractures of the neck of the femur, radius, and humerus, fractures in which the detached head of the bone receives little or no blood supply. It is my intention to introduce here evidence to the effect that, even in the event of the detached piece of bone being entirely deprived temporarily of all blood supply, union by bony callus may be obtained if the fractured surfaces are brought at once in accurate contact and immobilized in this position until the process of repair is completed.

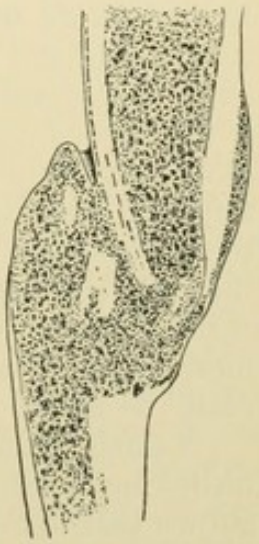

Fig. 214.—United fracture of the shaft of the femur, showing two fragments of the compacta embedded in the callus (Bruns).

In fractures of the neck of the femur the bone has usually been rendered vascular and porous by senile osteoporosis, and its medullary spaces have been provided with an abundance of myeloid tissue capable of bone production. The vessels in the red marrow, according to recent observations, are also admirably adapted to the purpose of establishing early and free collateral circulation. In 1869 Hoyer made the discovery that the small veins in the red marrow are without walls, their lumina being bounded by the parenchyma of the marrow. Most of the capillaries are also without walls. The small arteries of the marrow consist of a delicate tube of endothelium and a single layer of muscle-fibers. Rindfleisch corroborated these observations.

From this peculiar structure of the vessels in marrow, it is easy to conceive how readily the interrupted circulation could be restored through direct contact of the severed vessels, or by canalization

through the medium of a blood-clot or mass of exudation material. That intermediate callus is formed in cases of intracapsular fractures where the fragments have not been kept in contact and bony union has failed to take place is evident from examinations made of specimens where the broken surface of the upper fragment, and sometimes the connecting ligamentous band, presented well-marked spurs of hard, compact bone, a condition alluded to by many observers, but more particularly by Sir Astley Cooper and Mr. MacNamara. It has been urged against the possibility of bony union after intracapsular fractures that the upper fragment is not furnished with a blood supply sufficient to maintain nutrition, much less to produce callus. Clinical and postmortem evidence, however, tends to prove that, in the great majority of cases, the fragment retains its vitality, and in many instances where bony union has failed to take place the fractured surface shows evidence of callus production. In such cases, where the fracture was complete and the fibrous investment of the neck was completely torn across, the requisite vascular supply must have been furnished through the round ligament. If the upper fragment was not nourished from some source, it would more frequently disappear by absorption, suffer necrosis, and act as a foreign body than has been actually observed at the bedside or in the postmortem room. The establishment of collateral circulation through the ligamentum teres, in maintaining the vitality of the upper fragment after intracapsular fractures, is, unquestionably, of more frequent occurrence and of greater importance than many are ready to admit.

Taking it for granted, however, that the ligamentum teres furnishes no vessels to the upper fragment, it can nevertheless be shown that in case of impaction it can retain its vitality, assist in the formation of callus, and enter into the production of bony union. It has been known for a long time that, in compound fractures, perfectly detached splinters remain innocuous and assist in the production of bony callus without giving rise to any particular symptoms of irritation. John Hunter expressed himself as follows on this subject: "Adhesion of the detached splinters also takes place, not only in those which are attached to the soft parts, but even such as are entirely loose. (This was shown in a thigh bone in which one of the splinters had moved quite around on its axis and adhered by its outer surface to the bone.) I never examined a compound fracture without finding some of those loose pieces, which shows they must be common. Their union must be similar to that in the transplanted teeth."

Ollier and Philip Walther inform us that they have seen the disc of bone separated by the crown of the trephine, and, entirely removed, reunite with the surrounding bone when replaced.

Prince, in speaking of the drilling operation for ununited fractures, says: "When the operation results in the effusion of plastic lymph without suppuration, there are new centers of ossification in

the chips of bone cut off by the drill. These are left in the track of the drill: some of them in the soft callus between the ends of the fragments. That these minute fragments of bone become parts of the living tissue is certain; for if they did not, they would, by the offensive emanations of dead bone, excite suppuration and work their way to the exterior. The importance of these little fragments cut off by the drill as centers of ossification may have received too little attention." Cases where fragments of bone from the internal table of the skull were completely detached and yet united with the surrounding bone by permanent callus are reported by Samuel Thomas, Soemmering, B. Beck, von Bergmann, H. Demme, Cluston, Richet, Ziegler, and others.

Lossen has studied this subject in connection with comminuted fractures of the long bones, and has come to the conclusion that not all loose fragments necrose, but that in many instances they are incorporated in the callus and form part of the living bridge between the fractured ends. He is of the opinion that the vessels of the fragment unite at some point with the vessels in the lacerated district, thus establishing the circulation. In one of his illustrations may be seen a fragment, five centimeters long and one centimeter broad, completely isolated and denuded of its periosteum, which, with its wedge-shaped end, had been driven into the medullary canal. The upper end was perfectly united with the bony mass filling the medullary cavity, and its lower end could be seen alongside of the necrotic portion of the fractured bone. It can be safely taken for granted in this instance that the vessels in the medullary canal vascularized the fragment and preserved its vitality. Klebs gives a description of a similar specimen, and believes that the vitality of the medullary tissue and periosteum is sufficient to sustain the physiologic activity of isolated fragments under favorable circumstances, production of new bone taking place from the isolated transplanted fragment.

Von Bergmann describes a specimen of comminuted fracture of the femur the result of a gunshot wound during the Turko-Russian war, where a fragment 7.2 cm. long, 15 mm. broad, and 6 mm. thick had become completely detached from the soft tissues, and had been forced into the medullary cavity, where it became firmly united with the fractured ends of the bone and the intervening bony callus.

Meek'ren made a series of experiments on animals for the purpose of establishing the fact that isolated fragments of bone devoid of periosteum would, under certain favorable conditions, retain their vitality, and were capable of forming an attachment to bone through the intervention of a bony callus. He removed, by the trephine, from the skull of a dog, a disc of bone and replaced it. On the twenty-second day he found this disc firmly united by bony callus to the surrounding bone.

Flourens transplanted a piece of rib from a dog under the peri-

osteum of the tibia of the same animal, and in due time found it united by bony callus. The well-known experiments of Ollier are familiar to every surgeon, but as he placed great importance on the preservation of the periosteum as an essential condition for success in bone transplantation, they are not of great importance for our purpose. The experiments of Kosmowski, to ascertain the exact mode of repair in cases of fracture of the skull, indicate that the reparative process in general, and the union of loose splinters of bone in particular, are accomplished through the osteogenetic functions of the medullary tissue.

Of great practical importance are the experiments of Jakimowitsch. The experiments were made exclusively on the long bones of dogs, and the vascular connections of the transplanted or replanted piece of bone were demonstrated by means of gelatin injections stained with Berlin blue. To insure success, he places great importance on securing accurate apposition and perfect immobilization of the fragment by stitching the periosteum or soft parts over it, and applying elastic pressure and a fixation splint of plaster-of-Paris. The operation was always done under strict aseptic precautions.

To prove that the detached bone had become part and parcel of the living bone, some of the animals were fed on madder, after the example of J. Wolff. This staining material is deposited, during life, in the new bone in greatest abundance around the fragment, while it also follows the new vessels into the transplanted piece. In almost all the cases, after death the vessels of the limb operated upon were injected with gelatin stained with Berlin blue, which afforded an excellent opportunity to follow the course of the vessels into the transplanted or replanted piece of bone. In other instances the examination was made even more complete by decalcifying the bone and subjecting it, in numerous sections, to microscopic examination. The results of these experiments induced him to conclude that replantation and transplantation of isolated fragments of bone can be successfully performed if the detached piece retains its former relations to its immediate vicinity. Under such conditions the piece of bone becomes a living part of the bone through the medium of an intermediate callus and the reestablishment of vascular connections.

Gurlt describes and furnishes illustrations of two specimens of fracture of the femur in which a large fragment of the cortical layer near the center of the shaft had become entirely detached, and in one instance turned completely around, and yet they were found firmly attached by bony union. He states, further, that in comminuted fractures, where many loose fragments must exist, they furnish no obstacle to ready bony union.

McEwen resorted to transplantation of small pieces of bone to restore extensive pathologic defects, believing that the blood-clot between the fragments served as a medium through which the vas-

cular connection between the detached bone and surrounding tissues is established. He operated successfully upon a case of necrosis of the humerus, with extensive loss of bone substance, by transplanting into a groove made in the bone numerous wedge-shaped pieces of bone derived from the tibiæ of six rickety children, the fragments being supplied with periosteum and marrow tissue. The bone grafts retained their vitality and united with and grew with the bone.

Professor von Nussbaum has introduced transplantation of bone as a legitimate operation in surgery, for the purpose of supplying bone defect in cases of ununited fracture, and his success, as well as similar operations by several other German surgeons, certainly proves that the vitality of even compact bone is sustained by a minimum amount of blood supply through a narrow strip of periosteum.

Spongy bone, containing an abundance of marrow tissue and a rich supply of blood-vessels, is endowed with a higher degree of vitality than compact bone, and is, consequently, better adapted to enter into union with surrounding tissues in case it has become detached.

It has also been established, by way of experiment, that in animals marrow can be transferred to different parts of the body, and, if the operation is successful, the transplanted marrow will produce bone.

Baikow, Goujon, and Ollier were successful in their autotransplantation of marrow, but failed when the tissue was transferred from one animal to another. The most extensive and reliable experiments on marrow transplantation have been made by P. Bruns. He operated upon sixty chickens and six dogs. He failed repeatedly as long as he transplanted the marrow from animal to animal, but as soon as he limited his experiments to autotransplantation, he succeeded in the great majority of cases. Of 19 autotransplantations, 12 proved successful, 3 failed on account of suppurative inflammation following the operation, and in 4 the transplanted tissue was absorbed.

The operation consisted in removing cylindric pieces of marrow from the femur or tibia, from one-half to an inch and a half in length, and transplanting them under the skin of the same animal. After the fourteenth day foci of ossification could be distinctly seen, which enlarged and became confluent after the twentieth to the twenty-fourth day. Ossification was preceded by an active proliferation of spindle-shaped cells. The formation of bone took place from preexisting osteoblasts in the marrow, an observation strongly supported by Waldeyer. The yellow and red marrows were used in these experiments, and proved alike capable of producing bone in their new location.

The success that attended the transplantation of bone and medullary tissue a number of years ago has been increased by recent efforts in the same direction, and fully corroborated in the

human subject by ample clinical experience. Elsewhere I have detailed the results of my observations and experience on the same subject, which have convinced me, more than ever before, that completely detached fragments and portions of bone in aseptic environments, kept in contact with vascular surroundings, will live and take an active part in the subsequent process of repair. The success attending bone and marrow transplantation constitutes a strong argument in favor, not only of the *possibility*, but also of the *probability*, of bony union after intracapsular fractures, in the event of the fractured ends being in accurate and undisturbed contact for the requisite length of time.

The neck of the femur in a state of senile osteoporosis furnishes a number of favorable conditions for a speedy production of bony callus. It is very vascular, the compacta is attenuated, the spongiosa is exceedingly porous, and its meshes are filled with an abundance of myeloid tissue fully capable, in the event of injury, of assuming active tissue proliferation. If perfectly detached pieces of bone, devoid of periosteum, and isolated masses of marrow can be transferred to a distant part of the body, and, when properly transplanted, not only retain their vitality, but also are vascularized and produce bone, there is no reason why the upper fragment in intracapsular fractures, which is retained in its normal location, should not possess the same power of self-preservation and repair, inasmuch as it receives at least a feeble blood supply through the ligamentum teres.

In impacted fractures the bone tissue, marrow, and lacerated vessels are brought in such immediate contact that the reparative process is taxed only to its minimum extent in restoring the continuity of the bone. In these instances we have an example of bone and marrow transplantation under the most favorable conditions, and the reason such transplantation does not succeed oftener, is simply because these favorable conditions, as a rule, do not exist (unimpacted fractures) or are not maintained for a sufficient length of time (impacted fractures).

Prognosis.—The prognosis of subcutaneous fractures has reference to the preservation of life and the functional utility of the limb. The danger to life depends almost exclusively on the presence of complications, as the fracture or fractures themselves are very seldom an immediate or a remote cause of death if we exclude fractures of the skull, in which case a deep depression may in itself become a source of danger to life. As the immediate and sole cause of death in fractures of any other bones except those of the skull, must be mentioned the very rare cases of death from fat embolism. In the remaining cases danger to life may arise from complications caused by the fracturing force or by displaced fragments. In this respect fractures of the skull, vertebræ, hyoid bone, larynx, sternum, ribs, and pelvis are attended by the greatest probability of being complicated by dangerous lesions of important organs.

In crushing injuries shock enters as an element of danger to life. Wounds of large blood-vessels complicating a fracture may result in death from hemorrhage or in fractures of the skull from cerebral compression. In complicated fractures wounds of large blood-vessels and injuries of the principal nerve-trunks may become a source of danger to limb and life from gangrene. The danger to life from compound fractures lies almost exclusively in the extent and nature of the complicating wound. The antiseptic treatment as employed to-day has succeeded in reducing the mortality from this cause enormously, but the most careful treatment has not succeeded, even in the hands of the most competent surgeons and with the best facilities for securing asepsis, in reducing the mortality of compound fractures to that of subcutaneous fractures, independently of the danger arising from the wound *per se*, as the most rigid antiseptic precautions practised immediately or soon after the wound has been received do not always prove successful in averting infection. Delirium tremens and nervosum, hypostatic pneumonia, and decubitus are dangers common to open and subcutaneous fractures. Tetanus as a complication due to fracture can only occur in connection with compound fracture ; if, in very exceptional instances, it attacks a patient suffering from a subcutaneous fracture, infection takes place through a wound of the skin distant from the seat of fracture.

In compound fractures the preservation of the limb depends almost entirely upon the extent and nature of the injury of the soft tissues, instead of upon the extent of the bone injury. Primary amputation for compound fractures has become very rare, except in cases in which the limb has been rendered lifeless by a crushing injury. In subcutaneous fractures a primary amputation is seldom, if ever, justifiable, even should the injury be complicated by a wound of a large blood-vessel. In such cases it would be the duty of the surgeon to resort to ligation, if need be, and await the effect of the vessel injury on the nutrition of the limb, and resort to a secondary amputation should gangrene set in. *Examination for vessel and nerve injury is as important in subcutaneous as in compound fractures, and should never be neglected, as the only danger to the limb in closed fractures arises from this source, and unless the physician recognizes the nature of the complication early and is able to predict the probable result, the patient and his friends are only too ready to blame the treatment and not the injury should gangrene occur.*

Satisfactory union of the fracture and restoration of function are influenced by many conditions with which the physician should familiarize himself on taking charge of the case. Fractures caused by direct force, on the whole, are more serious injuries than indirect fractures. This is true of open as well as of subcutaneous fractures. The seat of the fracture has an important bearing on the process of repair and on the subsequent utility of the limb. Fractures of bones that include and protect important organs are always

serious injuries. Short and flat bones present the most favorable conditions for speedy and satisfactory union, as there is but slight tendency to displacement, union taking place almost exclusively by intermediate callus, produced by the myeloid tissue, so richly stored in the porous spongiosa. Reverse conditions are presented by fractures of the long bones when the tendency to displacement is great, and the dense thick compacta must undergo osteoporosis preliminary to the process of repair by callus formation. On the whole, fractures of the lower extremity do not yield so good results as fractures of the upper extremity, as the mechanical difficulties encountered in their treatment are much greater. Fractures of the lower extremity are likewise more dangerous to life, from incidental causes, as they require a longer period of recumbency in their treatment. Fractures of the shaft of the long bones yield better functional results than fractures of the epiphyseal extremities, owing to the proximity of the latter to joints, which are often invaded by the fracture or, at least, injured by the fracturing force. Moreover, the prolonged rest of the joint during the treatment of the fracture is prone to impair for a long time, or permanently, the function of the joint.

Fracture of one bone of the forearm or leg is followed by a better result than fracture of both bones, as in the former instance the remaining bone serves as a splint, antagonizing longitudinal displacement and securing rest for the seat of injury.

Impacted fractures, if the limb is in a useful position, heal by bony consolidation in a very short time if the impaction remains or is maintained by an appropriate mechanical support.

The prognosis as to the time of healing and to functional result is better in transverse than in oblique fractures, for the reason that, when the fragments are placed in proper position, shortening can not occur, angular deformity can be prevented by the simplest mechanical treatment, and accurate contact between the fractured surfaces is the best guarantee for a speedy union by a minimal intermediate callus. Comminuted fractures, especially such as extend into the joint, often tax the surgeon's ingenuity to its utmost in maintaining the fragments in proper position, unsatisfactory results, nevertheless, occurring in the practice of the most expert surgeons. It is also in this class of cases that, in spite of most efficient mechanical treatment, a massive provisional callus forms that not infrequently permanently impairs joint motion, and in which nerves, muscles, and tendons may become embedded—remote conditions that impair permanently the usefulness of the limb.

Diastasis, or separation of the fragments in the axis of the limb, as is the case in fractures of the patella and olecranon process, is the most unfavorable condition for obtaining union by bony consolidation without direct means of fixation. Union by a short ligamentous band, the usual result obtainable by any known methods of treatment short of operative interference, usually yields

a satisfactory, if not a perfect, functional result. Repair of fractures in children takes place very rapidly,—in one-half of the time required in adults,—and the functional results, as a rule, are better, as muscular contraction is less pronounced and correction of deformities arising from the fracture takes place more completely during the bone-growing period of life than in the adult or the aged.

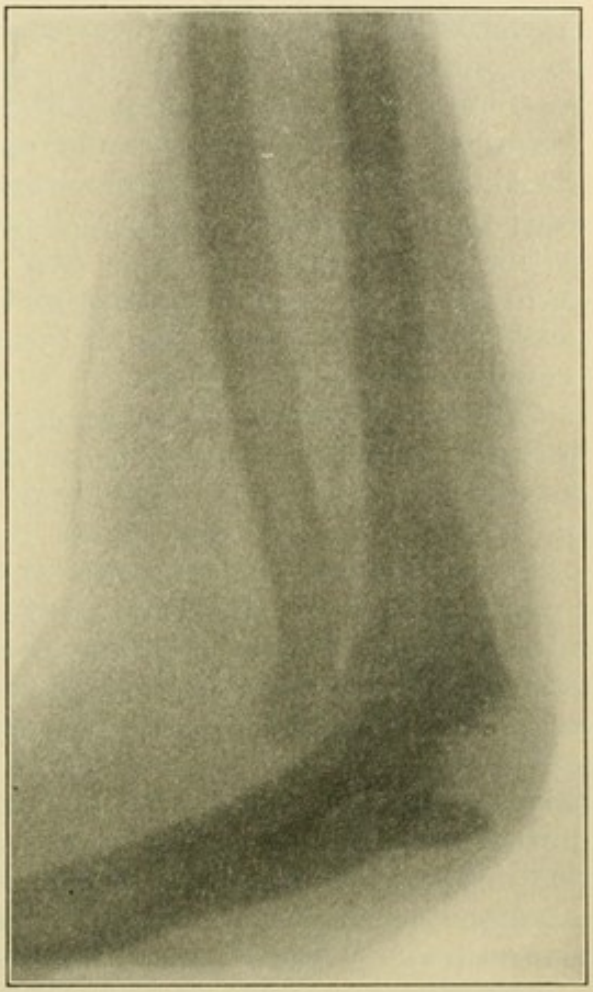

Fig. 215.—Fracture of the olecranon, with great retraction of upper fragment by the triceps muscle.

The general condition of the patient has very little bearing on the repair of fractures, as union by bony callus takes place in the weak as readily as in the strong, and in osteoporotic and softened bones as favorably as in bones of normal texture and resistance. Finally, the functional result in all cases of fractures, uninfluenced, as it is, by various conditions, depends very largely on the accuracy with which the diagnosis is made, the care exercised in effecting complete reduction, the mechanical skill employed in the treatment, and the degree of vigilance brought to bear from the time the injury was received until the maximum obtainable function compatible with the nature of the injury is secured.

GENERAL TREATMENT.

The physician who masters the principles that govern the general treatment of fractures is best prepared to apply his knowledge in the management of special cases, while the one who is familiar with prescribed rules for special cases and who loses sight of the general principles upon which they are based is very apt to make serious mistakes of omission and commission in following out the details of treatment. The successful treatment of a difficult fracture depends on a thorough knowledge of anatomy, including the mechanism of muscular action in effecting displacement of fragments, an accurate diagnosis, complete reduction of the dislocated fragments, the employment of efficient and safe methods of fixa-

tion, and constant care and watchfulness in averting complications, and, after the fracture has united, persistent efforts to restore function. The public and, it may be safely said, many members of the profession still entertain the erroneous impression that the most important functions of the surgeon consist in setting and dressing the fracture; once set and properly dressed, a good result is expected as a matter of course. The knowledge necessary to make a correct diagnosis, which should necessarily precede all attempts at reduction and fixation of the fracture, the endless difficulties in keeping the fragments in correct position, the complications that accompany so many fractures, and the persistent efforts so often necessary to restore function are seldom adequately estimated; and yet they constitute very essential features in the rational and successful treatment of fractures.

The first duties of the surgeon in the treatment of subcutaneous fractures consist in meeting the indications presented by the immediate effects of the injury, applying the first dressing, superintending the transportation of the patient, and, in fractures of the lower extremity requiring confinement in bed, in supervising the construction of a bed that will be adapted to the mechanical treatment of the fracture without exposing the patient unnecessarily to the immediate discomforts and remote consequences of decubitus. If the patient is suffering from shock, rest in the recumbent position and stimulation are relied upon in counteracting the immediate effects of the injury, while the limb is placed in a comfortable position until the patient has recovered sufficiently to permit examination and the application of the first dressing. If the patient is examined at the place of injury, a thorough examination and permanent dressing are not made until he has reached his destination, —a hospital, his home, or a boarding-house,—because during the transportation the fragments are very liable to become displaced and the permanent dressing may do more harm than good by making harmful pressure and by interfering with the free peripheral circulation. This precaution applies more particularly to fractures of the lower extremity. Fractures of the ribs, scapula, clavicle, and most of the fractures of the arm and forearm can be at once subjected to the necessary thorough examination, and if readily reduced, they are immobilized before the patient is transported. In fractures of the lower extremity above the ankle-joint it is advisable to ascertain the existence and probable location of the fracture, bring the fragments in such a position that no injury will arise from them during the transportation, and apply a provisional dressing that will immobilize the limb without exposing it to the risk of harmful localized or circular compression. In fractures of the spine even the lifting of the patient requires attention and care. Flexion of the spine and lateral deviations must be carefully avoided, as such movements might displace fragments in the direction of the cord sufficiently to cause dangerous compression, if not laceration

or crushing, of the cord. The lower extremity can be safely immobilized by wrapping a pillow or blanket around it, and by supporting it with two lateral splints tied together with just sufficient firmness practically to immobilize the fractured bone. If not at hand, a stretcher can be improvised with the aid of a blanket, a sheet, an overcoat, or one or more empty flour bags, and two poles or sticks, from two to four feet longer than the patient. Stretcher transportation is much more comfortable for the patient than riding in a wagon if the distance is not too great. If the patient is transported by wagon or railway train, he should be placed flat on his back on a mattress, with the head only slightly elevated, as this position is the one that secures relaxation of all muscles and, consequently, rest for the entire body as well as for the injured limb. In lifting patients suffering from fracture of the lower extremity upon and from the stretcher or wagon, the uninjured limb should be used as a temporary splint, as otherwise the patient's attempt to support it, or the carrier's effort to lift it, will disturb the injured limb.

The physician who has mechanical skill and good sound judgment will have no difficulty in extemporizing dressings from the simplest materials, and so conduct the transportation that the fractured bone does not become a source of danger. A fractured humerus can be safely immobilized by bandaging the arm loosely to the side of the chest, placing a small pillow or compress between the arm and the chest-wall, and putting the forearm in a sling. Patients with a fracture of both bones of the forearm can be made comfortable during the transportation by applying a well-padded splint, extending from the bend of the elbow to the base of the fingers, over either the flexor or extensor side, and placing the forearm in a sling at a right angle, half-way between pronation and supination.

A fractured rib can be immobilized by pinning the undershirt or vest tightly around the chest. As soon as the patient has reached his destination, preparations must be made for the final examination and for his comfort during his confinement. The former necessitates removal of the clothing; the latter, proper construction and preparation of the bed. In making an examination for fracture of the upper extremities, chest, and spine it is necessary to remove the clothing as far as the pelvis; in examining for fracture of the remaining bones the pelvis and lower extremities must be exposed. Removal of clothing to this extent is necessary for the purpose of making comparisons by inspection, palpation, and mensurations between the two sides. Grave mistakes in diagnosis have been committed by not taking the necessary precaution to make the examination thorough. In injuries of a serious nature the clothing should be removed by cutting or tearing the seams, as otherwise unnecessary pain is inflicted and additional injuries may be produced. Boots and shoes are removed in the same manner. In fractures of the spine and pelvis, with paralysis or

injury of the bladder or urethra, a water or air bed should be secured at once, to protect the patient against bed-sores. In fractures of the lower extremity requiring prolonged rest in bed a narrow bed with an even hair mattress on a solid level support is a very important requirement to successful treatment by continuous extension combined with fixation. A handle attached to a rope carried over a pulley fastened in the ceiling over the bed is a great convenience to the patient in changing his position. Of all the different kinds of invalid beds, Munger's gives the best satisfaction. The position of the patient can be changed, without disturbing him, by a very simple contrivance. It will prove of the greatest benefit in the treatment of fractures of the spine and neck of the femur. If the fracture of the leg or thigh is to be treated by extension, a box covered with a blanket is placed at the foot of the bed, against which the patient can rest the foot of the opposite limb to

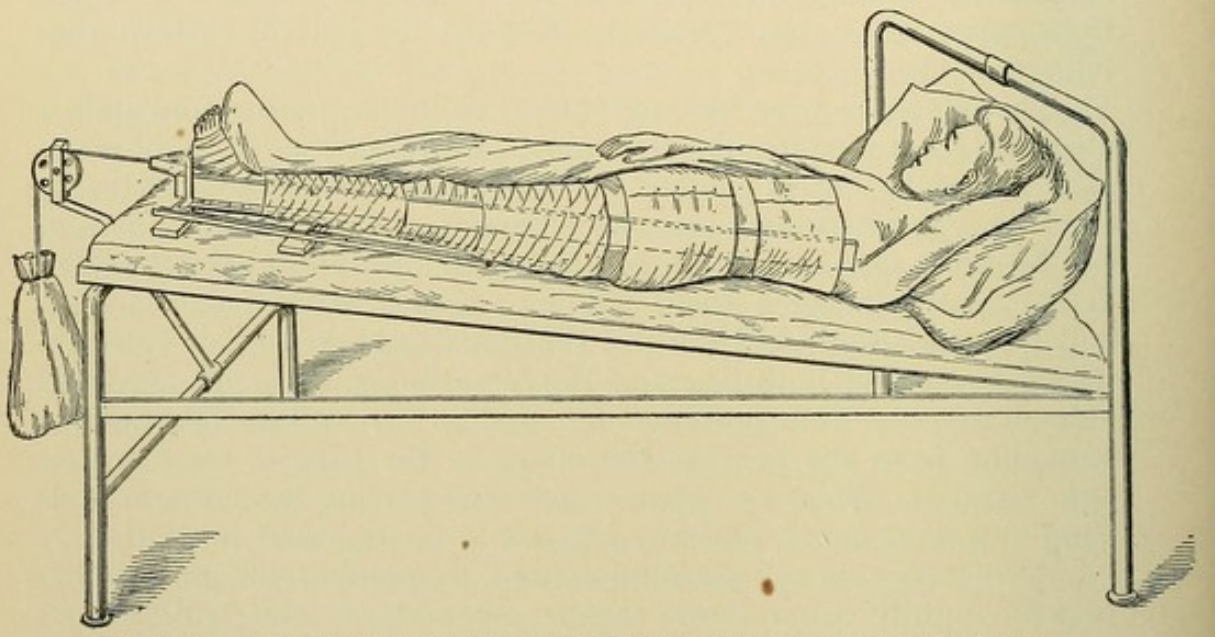

Fig. 216.—Complete permanent dressing for fracture of the shaft of the femur.

prevent the body from sliding in that direction. In all cases of fracture of the lower extremity requiring extension the foot of the bed should be raised one foot or more, for the purpose of utilizing the weight of the body for counterextension. During the time the preparations are being made for the dressing of the fracture the physician makes the final careful examination, which in doubtful complicated cases may require the use of a general anesthetic.

Reposition of the Fracture.—A diagnosis made and everything being ready for the dressing, the next duty of the physician is to reduce the fracture. Reposition or reduction of a fracture signifies the bringing of the fragments, by manual force and other expedients, into the same relative position, or as nearly so as possible, that they occupied before the injury occurred. A successful reduction has in view the correction of all deformities, and if this is accom-

plished to perfection, the normal length and position of the limb are restored. So ideal a reduction is the exception; partial, although satisfactory, reduction, the rule. In oblique fractures the shortening may be overcome completely by manual extension, but as soon as the foot or hand is released and splints are relied upon in maintaining the position of the limb, more or less shortening always occurs as the result of muscular contraction. In lateral displacement it is very difficult indeed to secure perfect contact between the fractured surfaces throughout. In rotary displacement the deformity is remedied without any difficulty, but a slight deviation may occur before the fixation dressing is applied and later. *One rule that should be invariably followed in making the reposition is to place the shaft of the broken bone in a position that will relax the strongest muscles.* For instance, in fractures of the humerus the arm should be slightly abducted and the forearm flexed, so as to relax the deltoid and biceps muscles; in fractures of both bones of the leg the knee-joint should be flexed; in fractures of the femur below the trochanters the thigh should be flexed; in fractures of the lower end of the femur much good often is gained by flexing the thigh and the leg. The effect of relaxing opposing muscles is best seen in reducing a fracture of the clavicle with marked displacement.

Besides extension and counterextension, so necessary in correcting the shortening, digital or manual compression over one fragment or both, in opposite directions, serves a useful purpose in correcting angular and lateral displacements. Pulleys and other mechanical contrivances as substitutes for manual force in the reduction of fractures have become obsolete in the practice of modern surgery. Manual force, aided, if necessary, by a general anesthetic, will, under all circumstances, serve as an efficient mechanical power to correct the displacements as far as is deemed safe and prudent. In exceptional cases one or two assistants can furnish the required traction force, while the physician aids the reduction by making pressure over the fragments where it is needed.

Extension is most efficient when made near the seat of fracture. In fractures of the arm it is made by grasping the condyles of the humerus with the arm flexed, while counterextension is made in the axilla. Elongation of the contracted powerful muscles of the thigh is effected, with the least expenditure of force, by making traction upon the condyles of the femur, with the leg half-way between flexion and extension, with perineal counterextension. In some fractures pressure alone will effect reduction, as in fractures of the ribs, scapula, and other flat bones. In greenstick fractures extension and pressure over the convex side of the angle will correct the deformity. In Colles' fracture extension of the hand and pressure against the dorsal side of the lower fragment are relied upon in correcting the angular deformity, and ulnar flexion of the hand and pressure against the lower end of the ulna in reducing the ulnar subluxation. In fractures of the patella and olecranon

the reduction consists in relaxing the muscles that have caused the diastasis, and in pressing the fragments together. In fractures of the spine forcible attempts at reduction are contraindicated, as the attempt might cause visceral injury of the cord by the moving fragments. In fractures of the skull with marked depression, with and without brain symptoms, reduction is made by elevation of the fragments by operative interference.

The success of an attempt at reduction is estimated by the degree of disappearance of the displacement. In some cases the reduction is announced by crepitation; in others the reduction may be perfect, or nearly so, without such indication. If shortening is the principal displacement to overcome, measurements should be made from time to time to ascertain when the limit of extension as a reducing force has been reached. As soon as the shortening is corrected, coaptation by pressure completes the reduction, as rotary displacement should always be corrected before extension is commenced. It is needless to say that if it is the intention to treat the fracture by continuous extension, the surface of the limb should be thoroughly prepared by shaving and scrubbing with hot water and soap, followed by washing with alcohol and the application of strips of adhesive plaster before reposition is made.

Reduction is often made with very little effort; at times it is very difficult, and at others impossible. Fractures of the patella, olecranon process, coracoid process of the ulna and scapula, and the posterior process of the os calcis can seldom be brought in accurate coaptation, and if so, the moment the fingers that coaptated the fragments are removed, more or less separation of the fractured surfaces at once occurs from muscular contraction. In intracapsular fractures the inaccessibility of the proximal fragment to direct manipulation interferes seriously with securing accurate coaptation of the fragments. Inaccessibility of the fragments in fractures of the sternum, ribs, vertebræ, and pelvis is a formidable obstacle to complete reduction. Interposition of the soft tissues between the fragments often proves an insurmountable barrier to complete reduction. Extension and rotation are not always efficient in removing the obstacle to reduction. Pressure, rubbing, and even a resort to the use of the tenotome are not always effective in removing the interposed soft tissues, and often pseudarthrosis can be prevented later only by an open operation.

Perforation of the soft tissues, including sometimes the skin, by a sharp fragment presents another difficulty in the way of a ready reduction. Extension, rotation, and forcing, under local pressure, the skin and other soft tissues, will fail in many cases to liberate the fragment. It is in such cases, too, that interposition of soft tissues between the fragments is very likely to occur should the manipulations secure reduction of the perforating bone. In difficult cases it is, therefore, justifiable to cut down upon the fragment, under strict aseptic precautions, with the intention of liberat-

ing it and of securing accurate coaptation of the fractured ends. In impacted fractures the physician must decide what course to pursue. In impacted fractures of the neck of the femur and humerus no attempt should be made to correct the malposition, as the impaction, if maintained, furnishes the best possible condition for union by bony callus, together with the best prospects for a useful limb. Extra-articular impacted fractures with considerable deformity must be treated by loosening the impaction and by bringing the fragments into proper position. This is more especially the case in Colles' fracture of the lower end of the radius, which is so often found impacted and which, if the deformity is not corrected, yields bad functional results.

In crushing injuries of the short bones, such as the vertebræ, the deformity is not improved by any attempts at reduction, owing to the destruction of tissue by the compressing force that produced the fracture.

Interlocking fractures often present a decided obstacle to reduction, which, if it can not be accomplished by extension, careful flexion, extension and rotary movements, is only effected, if persisted in, by breaking off some of the denticulated projection that locks the fracture.

Extensive comminution of the bone offers no obstacle to reduction, but as soon as manual traction is suspended, some of the fragments become displaced, and more or less shortening occurs in spite of a perfectly fitting mechanical support.

Fractures complicated by dislocation present unusual difficulties in bringing the fractured surfaces in accurate contact and in maintaining accurate coaptation by any kind of fixation dressing. Cross-position of fragments is very difficult to correct, and if extension, gentle rotary movements, and direct pressure fail, they are allowed to remain unless, by pressure, they should cause serious symptoms, when they are removed by making an open incision.

Immobilization of Fracture.—Reduction of a fracture is followed by substituting for the hands a dressing that will hold the fragments in place and immobilize them. Perfect retention and immobilization of the fragments after complete reduction constitute the ideal mechanical treatment and, if accomplished, yield the best functional results. Like reduction, perfect retention is possible only in a limited number of cases in which the fractured surfaces are such as to render material aid to the mechanical treatment in antagonizing the displacing forces. Perfect retention under any kind of treatment is almost an impossibility in oblique fractures of the shaft of the humerus and femur, and more or less longitudinal, lateral, or rotary displacement is inevitable, but under proper treatment the displacements are usually so slight as not to interfere with a perfect functional result. In transverse fractures retention and fixation of the fragments after a satisfactory reduction present no unusual mechanical difficulties, as the natural support between the

broad fractured surfaces effectually guards against shortening to any extent, and lateral and axial displacements can be prevented by very simple mechanical treatment.

Position.—All retention dressings must be applied with due regard for a correct position of the fractured limb. In selecting a proper position of the limb we must study the effect of muscular contraction as a displacing force. This is done during the reduc-

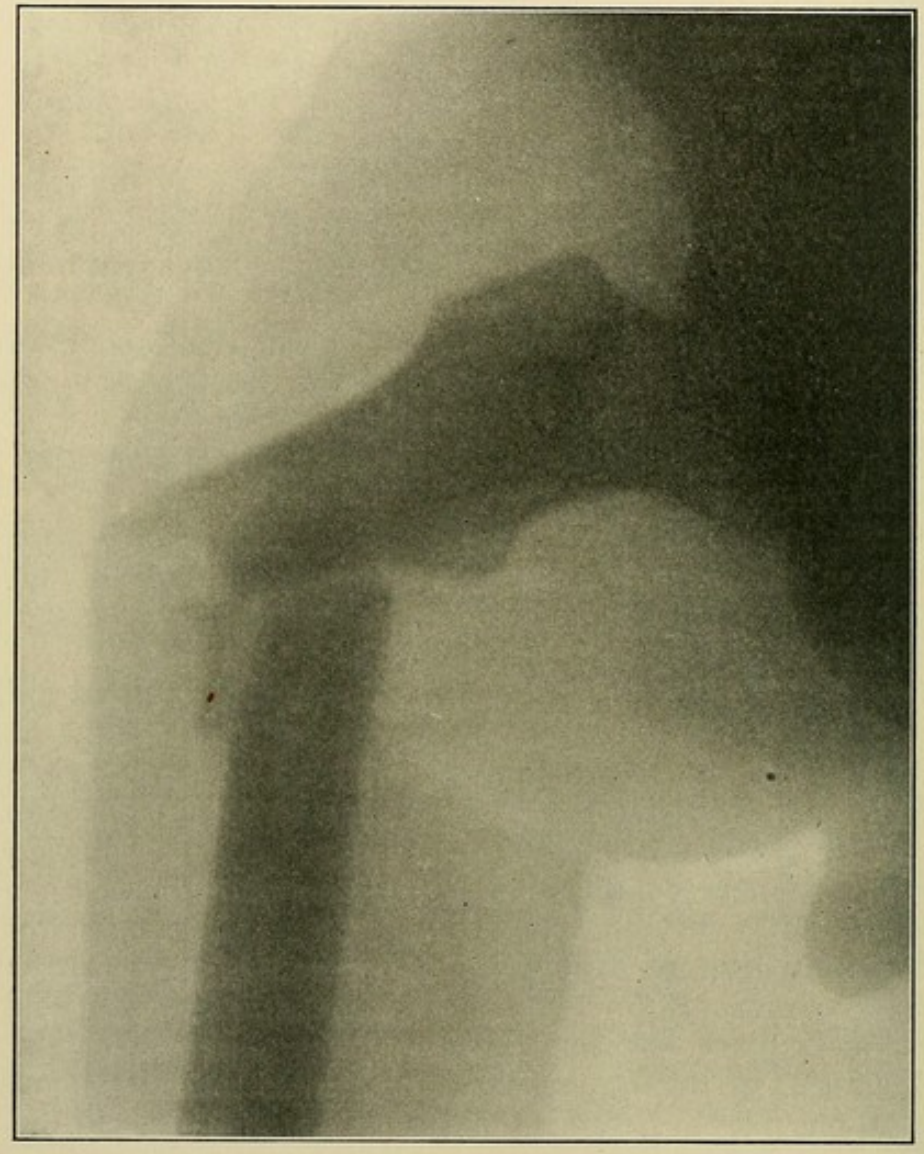

Fig. 217.—Fracture of the femur about three inches below the trochanter minor, with tilting of the upper fragment forward and outward.

tion of the fracture. In replacing the fragments muscular resistance will assert itself, and the effect of such action as a displacing force, during and after reduction, must be carefully studied. *The fractured limb must be placed in a position that will relax the principal muscles that tend to reproduce the displacements after reduction. All positions and dressings that interfere with this rule are harmful and must be scrupulously avoided.*

Much harm has been done by ignoring position as one of the

most important elements of the successful treatment of fractures. A few instances will suffice to corroborate the force and correctness of this statement. I have seen a number of cases of fracture of the femur, from one to several inches below the trochanter minor, treated by extension and fixation with the thigh in a straight position, with the inevitable results—vicious union, great angularity, and marked shortening. Extension and fixation in such cases have no control over the upper fragment, which is tilted forward and outward by contraction of the iliopsoas and gluteal muscles. The lower fragment, over which we have control, must be made to correspond with the axis of the upper, to prevent angular deformity and to secure the full benefit of extension. *Fractures of the upper end of the femur must be treated by extension on the flexed thigh in the direction of the upper fragment, with the limb placed*

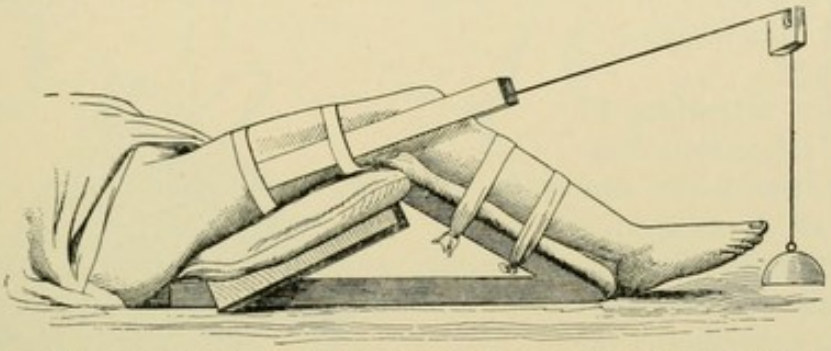

Fig. 218.—Dressing of fracture of the femur in the upper third with extension upon inclined plane (Agnew).

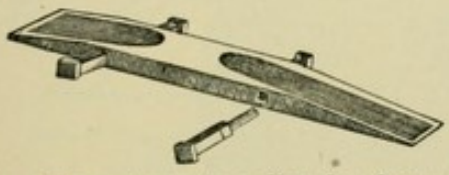

Fig. 219.—Agnew's splint for fractured patella.

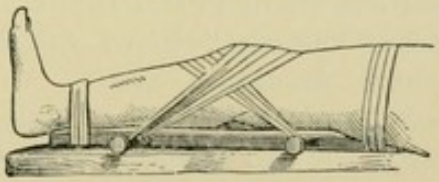

Fig. 220.—Agnew's splint applied.

upon a double inclined plane, at an angle that will bring the axis of the lower in line with the axis of the upper fragment. In fractures of the patella treated without direct fixation, the diastasis between the fragments can only be removed by relaxing the quadriceps extensor femoris muscle, which has caused it, and this can only be done by extending and elevating the limb to an angle of at least 45 degrees before local external means of retention gains any control whatever over the upper fragment. Agnew's splint with a foot-board attached constitutes the very best dressing for fracture of the patella.

In fractures of the olecranon process we must rely on relaxing the triceps muscle in bringing the fragments together, and are obliged to apply the fixation dressing with the forearm in the extended position, and to support the upper fragment in position with strips of adhesive plaster in the same manner as in fracture of

the patella. In fractures of both bones of the forearm the dressing is applied with the forearm flexed, and in a position half-way between pronation and supination, to antagonize muscle action and guard against the fragments encroaching upon the interosseous space.

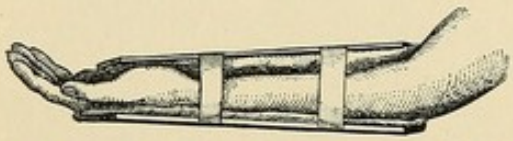

Fig. 221.—Dressing for fracture of both bones of the forearm.

In fractures of the posterior process of the os calcis the foot and knee are flexed and maintained in this position, to approximate the points of origin and insertion of the gastrocnemius and soleus muscles. The importance of muscle relaxation was recognized years ago, by Mr. Pott, as an important aid in securing retention in fractures of the leg. He relied largely on flexion of the knee-joint and lateral position of the body in bringing and holding the fragments in contact.

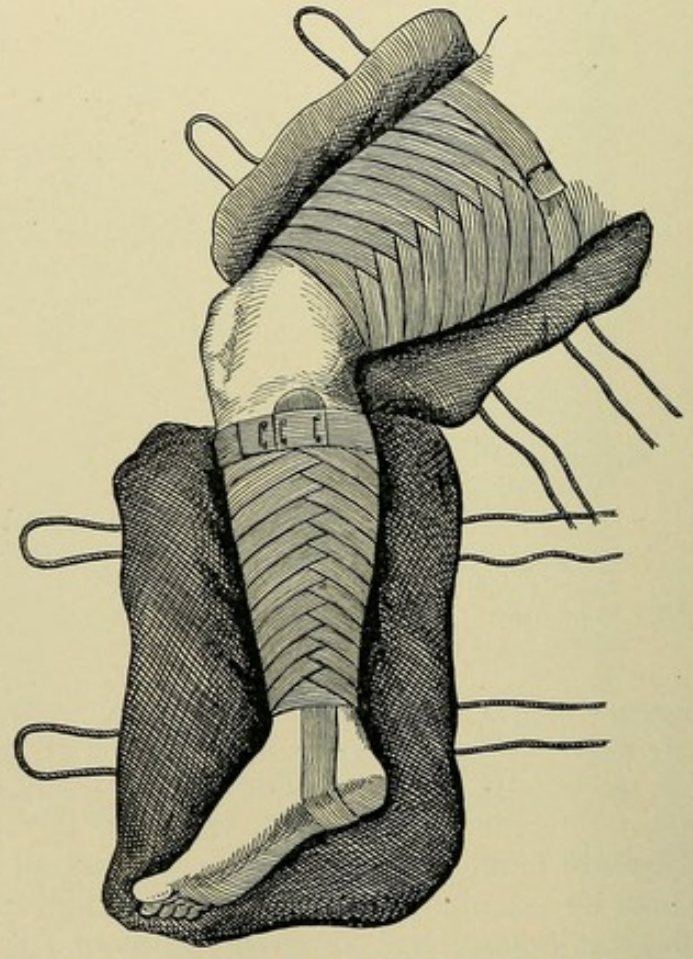

Fig. 222.—Flexion and lateral position (after Pott).

Strict attention to muscle relaxation constitutes the main object of all dressings for fracture of the clavicle. Limitation of the respiratory movements by circular compression of the chest is the principal treatment in fractures of the ribs. Provisional dressings are often employed in obtaining the full benefits of, and in maintaining for the requisite length of time, the most favorable position of the fractured limb. In fractures of the sternum, pelvis, and in many fractures of the vertebræ retention is secured almost exclusively by position. The patient is placed in the dorsal recumbent position, on a level mattress or a water or air bed, and cushions or compresses are utilized where local pressure will afford comfort or add to the fixation of fragments. In fractures of the extremities with great swelling and, perhaps, extensive blistering of the skin, position and a provisional dressing are resorted to after

reduction has been made, to maintain coaptation and retention, as well as can be done under the circumstances, until the swelling subsides, when the fragments are again carefully adjusted before a permanent dressing is applied. A permanent dressing with an unyielding circular support has often resulted disastrously in such cases. If the swelling increases in size, obstructed venous circulation and, perhaps, complete arrest of the circulation have resulted

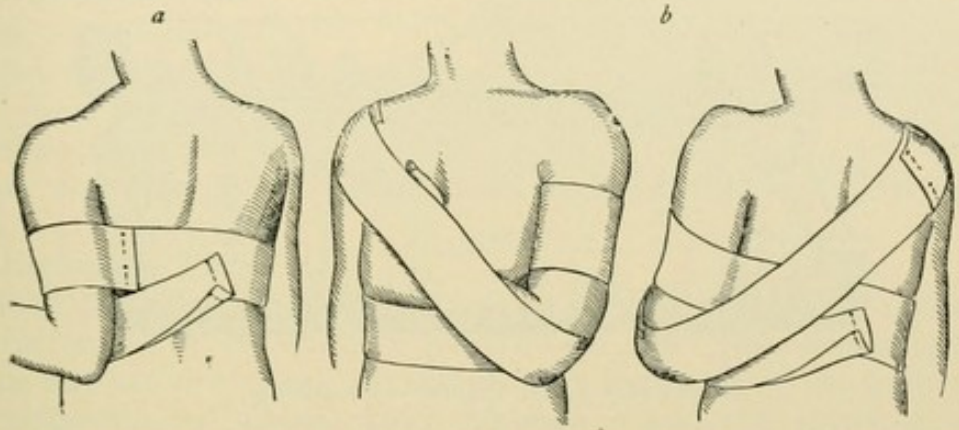

Fig. 223.—Sayre's dressing: *a*, First strip; *b*, second strip, front and back views.

in gangrene; and if the swelling diminishes in size, the mechanical support no longer maintains retention, and its presence often does more harm than good.

A provisional or temporary dressing is one that does not aim at perfect retention or fixation, owing to the existence of a wound, great swelling, or other contraindications to a permanent dressing. It is employed, in connection with position, to effect relative fixation

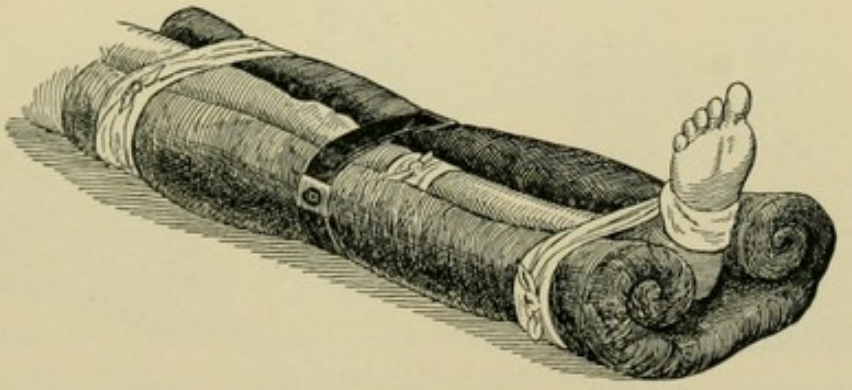

Fig. 224.—Mantle splint (von Esmarch).

compatible with the condition of the injured part or limb, and is continued until the local or general conditions warrant accurate adjustment and permanent fixation. We expect, from a provisional dressing, that it will, under no circumstances, compromise the circulation or vitality of the tissues; that it will be a source of comfort to the patient, and, combined with position, will secure for the seat of fracture at least a relative, if not a perfect, condition of rest.

Cushions containing chaff, straw, hair, bran, or sand answer an excellent purpose in immobilizing, with or without splints, either the upper or the lower extremity. If splints are used, the contents of the cushion should be elastic,—hair, cotton, wool, etc.,—to guard against harmful compression. Sand-bags molded to the surface of the limb are often relied upon as a provisional dressing. Dry earth, bran, and flour can be used for the same purpose.

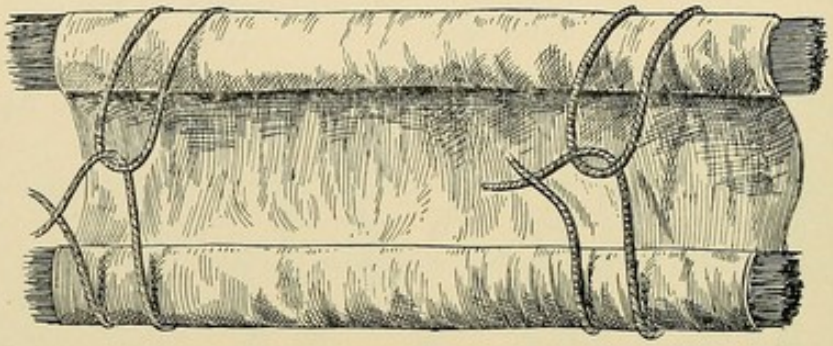

Fig. 225.—Straw splints (von Esmarch).

A cushion divided into two sections by a seam in the center is a very useful and favorite form of dressing by this method. Stromeyer's triangular cushion for the axilla and chest bandage makes an excellent provisional dressing for fractures of the humerus. A large triangular pillow, on the plan of a double inclined plane, serves well in fractures of the leg or thigh accompanied by extensive swelling.

The fracture box is seldom used in the practice of modern

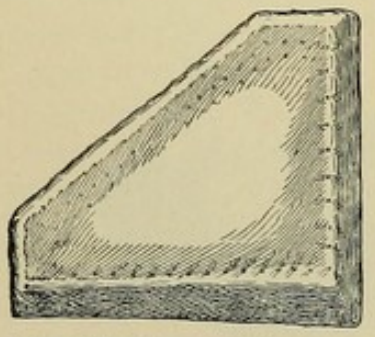

Fig. 226.—Stromeyer's arm cushion (Bruns).

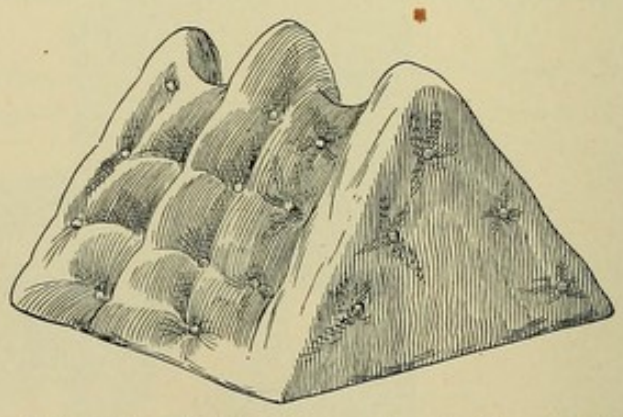

Fig. 227.—Dumreicher's wedge cushion for the lower extremity (Dumreicher).

surgery. Many forms of this apparatus have been in use, none of these, however, presenting any advantage over the original invention of Petit. The fracture box has had its day, and as there is no reason to justify a demand for its reinstatement, few physicians would feel inclined to have one made in an emergency.

The double inclined plane can be used advantageously as a substitute for the fracture box, and as this apparatus can be made

from a piece of board, two hinges, and with the simplest tools, it can be extemporized in almost any place in less than half an hour. The simplest double inclined plane consists of two pieces of board perforated at a number of points, and connected by two hinges, or, in the absence of these, two strips of leather will answer, the incline being regulated with two cords, one on each side.

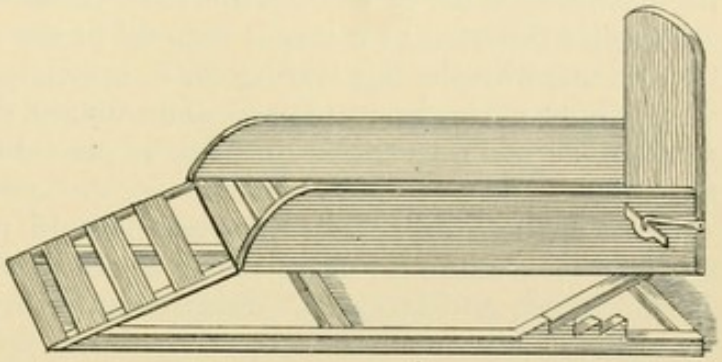

Fig. 228.—Petit's fracture box (Bruns).

Esmarch's double inclined plane, with a place cut out for the heel and a number of erect sticks on each side, is a somewhat more complicated apparatus, but has this great advantage, that the sides of the limb can be supported by pillows placed between it and the sticks, giving the limb a wider surface for support. The cut-out space serves to protect the heel against decubitus. With a bandage wound around the foot behind the base of the toes, and tied to one of the sticks on each side, the foot can be supported and held in proper position.

The double inclined plane will always remain as a valuable provisional dressing in fractures of the thigh and leg not adapted for a permanent fixation dressing, and in fractures of the upper

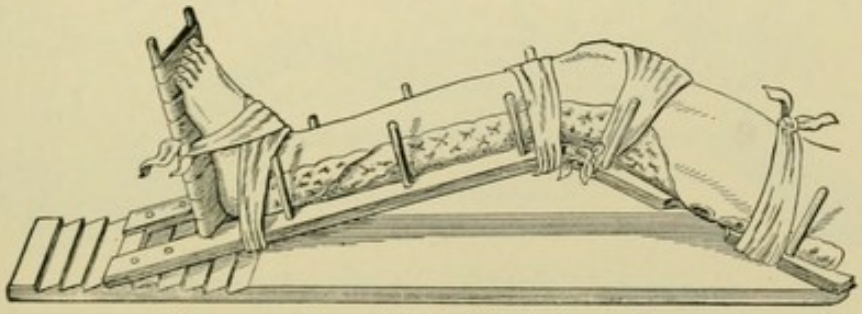

Fig. 229.—Esmarch's double inclined plane.

end of the femur, combined with extension and continued as a permanent dressing, it will secure the best results.

Suspension Splints.—In fractures of the leg and in some fractures of the thigh suspension is one of the important mechanical resources in immobilizing the fragments and securing rest for the injured limb. In fixed dressings, with and without extension, every movement of the body may disturb the fragments in the limb fixed by the stationary dressing. If the immobilized limb is suspended, it moves with the body, and disturbance of the fragments by the patient himself is less likely to occur.

The simplest suspension apparatus and one that, besides being

useful, can be extemporized anywhere and in a short time, consists of a square piece of canvas or any other strong cloth, and two sticks the length of the leg, which are sewed into two corresponding margins of the cloth. With four cords tied to the ends of the sticks and fastened to a staple secured in the ceiling above the bed the canvas, with the leg resting on it, is swung at the desired height. The patient is the best judge in determining the level at which suspension is made, as the limb must be placed in a position affording the greatest degree of comfort.

The suspension splints that have found most favor and given the best satisfaction in this country are those designed by McIntyre, N. R. Smith, and Hodgen. Smith's anterior splint has had a very

Fig. 230.—R. N. Smith's anterior suspension splint.

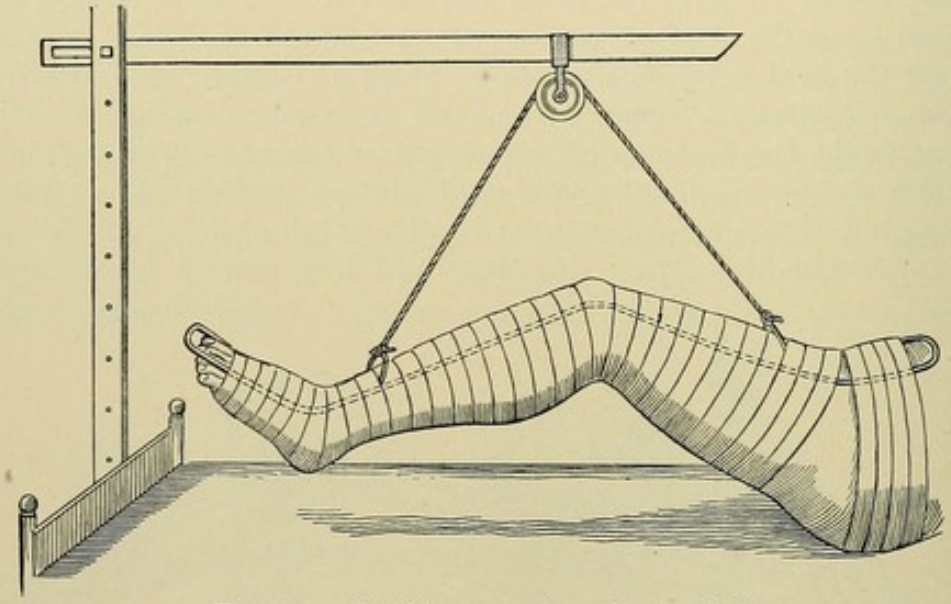

Fig. 231.—Smith's suspension splint applied.

extended and satisfactory trial, and can be extemporized from a piece of telegraph wire and adapted to each individual case. The splint is applied and suspension made as shown in figure 231. Hodgen's splint is made of the same material and is applied in a very similar manner, but suspension is combined with extension, giving it particular usefulness in the treatment of fractures of the femur requiring extension.

Ready-made Splints.—The sale of manufactured splints for the treatment of fractures has come nearly to a standstill, for surgeons have found, by sad experience, that splints, like shoes, in order to be tolerated or worn with comfort and ease must be made to fit each individual case. It would be time and labor lost should

an attempt be made here to describe the numerous splints that have been devised for special fractures. Many of these splints are evidences of deep study and careful observation, and when made for the case on which they were first used, may have answered the local indications, but when used on a second case, their unfitness must have become apparent. The defects in the surface of the splint were undoubtedly corrected to some extent by filling in empty spaces with pads and by making ridges that were calculated to fit into anatomic depressions more or less prominent by again resorting to padding. Ready-made splints might possibly fit the same limb of two individuals of exactly the same size and weight in a normal condition, but the same splint certainly could not be expected to fit the same limbs when fractured, as the location of

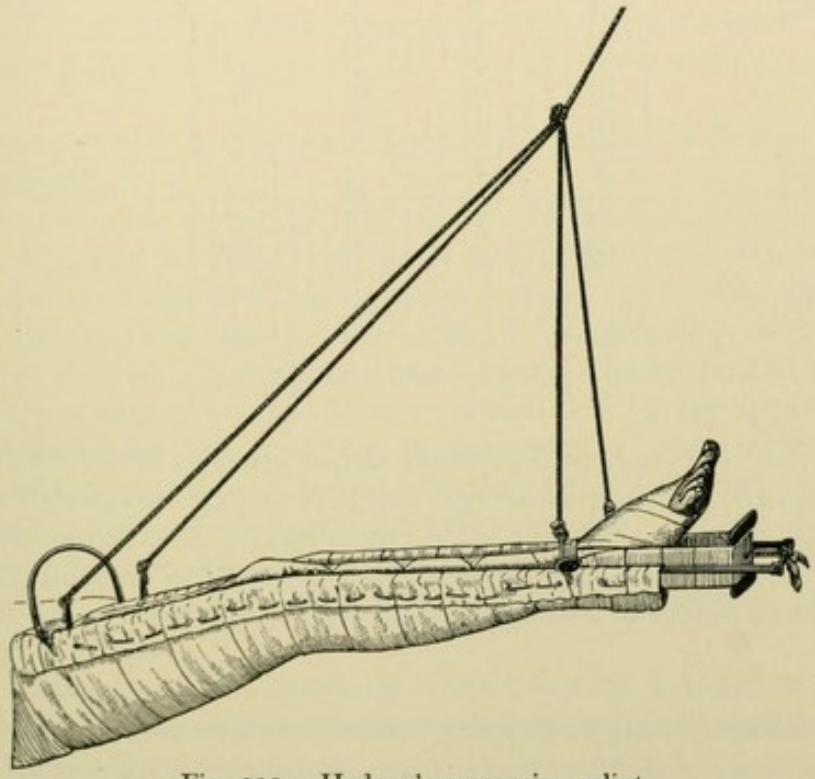

Fig. 232.—Hodgen's suspension splint.

the fracture and the degree of displacement and swelling would not be exactly alike in both instances. Splints, to fit, must be made for each individual case, and the physician who has not the mechanical ingenuity to make his own splints should not undertake the treatment of fractures. The splint should not be made until after the examination has been completed, as the location and nature of the fracture and the degree of swelling must guide the physician in making the splints.

There are two ready-made splints that every physician should keep in his office and that he should make himself. They are excellent provisional splints for different kinds of fractures, and the best permanent thigh splints in the treatment of fractures of the

femur by extension and fixation. Gooch's splint is made by pasting a thin pine board, not over one-fourth of an inch in thickness, two feet in length, and of convenient width (6 by 8 inches), upon linen or leather with flour paste or glue, and, after drying, cutting the

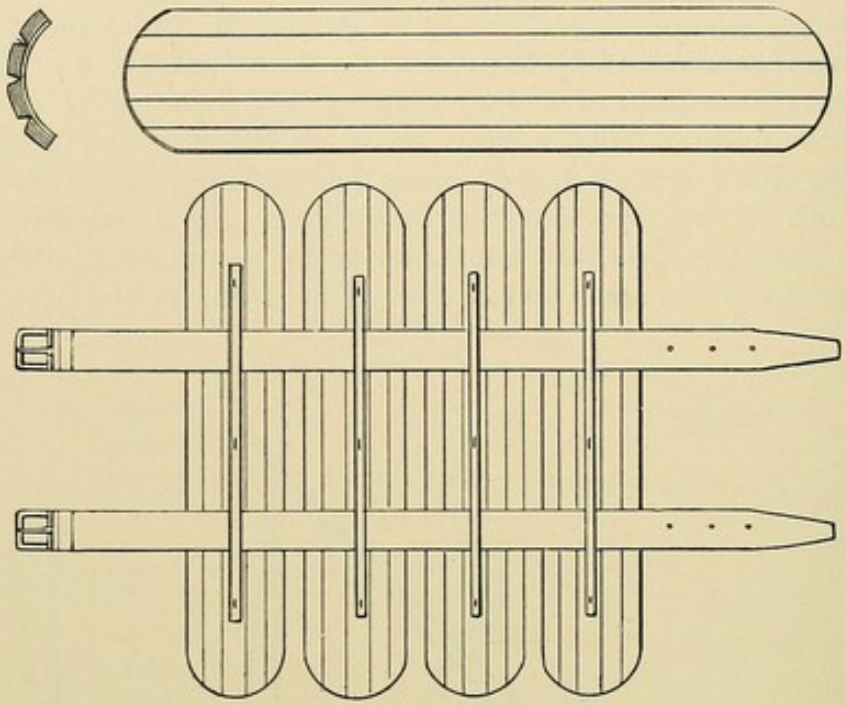

Fig. 233.—Gooch's splint.

board partly through into parallel strips about three-fourths of an inch in width. When used, the splint is cut the proper length and width and the strips are separated by breaking the remainder of the wood. Esmarch's splint answers the same purpose, but is made in a somewhat different manner. The wood, 1 ½ mm. in thickness, is



Fig. 234.—Von Esmarch's splint.

first cut into strips that are placed between two layers of cotton cloth, which is then saturated with silicate of soda solution, which holds the strips in place. The cloth between the strips can be cut with scissors, and splints of the required length and width obtained. Schnyder makes such splint material by sewing the strips of wood

between two layers of linen or cotton cloth, leaving a narrow space between them. Any of these splints, cut into proper shape, well padded, and carefully applied, is very serviceable in emergency work as well as in hospital practice, and it is a source of regret that their use has not become more general. All other splints should be made at the bedside of the patient. Thin pine board, a jack-knife, absorbent cotton, and a gauze roller will furnish the material requisite for any provisional splint. The splint must, in all cases, correspond with the width of the limb and the length that is to be immobilized. No mistakes must be made in these respects, as a narrow splint will endanger the circulation of the limb, and in case it is used for the forearm or the leg, it would determine encroachment upon the interosseous space by deviating the fragments in that direction. It must be of sufficient length to immobilize the fractured bone, as otherwise it would not effect the fixation required; if too long, it would expose the limb to unnecessary sources of unrest.

The opposite limb should serve as a model in determining the length, width, and outlines of the splint. Over bony prominences defects are made in the splint—as for the heel in posterior splints for the leg, and for the condyles of the humerus in lateral splints for fractures of the arm, and for the ball of the thumb in anterior splint for fractures of the forearm. The padding of the splint must be done with the utmost care, so that the surface of the splint will fit the contour of the limb to which it is to be applied. The best material for the padding is absorbent cotton, which is sufficiently elastic and molds itself to the surface of the limb better than any other material used for this purpose. At the same time it absorbs the moisture from the skin. If the skin is abraded or blistered, it should be dusted with borosalicylic powder before the splint is applied.

Provisional splints must be supplied with a cushion of cotton from two to four inches in thickness, in order to secure enough elasticity to allow for an increase of the swelling. The padding must correspond with the irregular spaces between the surface of the limb and the plane of the splint. The border of the splints for the forearm and leg must be raised by adding to the thickness of the padding here, so that the cotton cushion on the splint will be concave, to supplement the convexity of the limb. This part of the construction of a splint is very important, as a flat splint will make unequal pressure, producing pain, decubitus, and pressure atrophy, while, on the other hand, a splint the surface of which is supplied with a cotton cushion that fits the surface of the limb will make what is so desirable, equable support—so essential in the prevention of harmful localized points of pressure and so useful in securing muscular rest and in maintaining uninterrupted retention.

Fixation of the cotton padding upon the surface of the splint with a gauze roller is another very essential detail in finishing the

splint, and one that is so frequently omitted. If, as is so often done, the cotton is placed loosely between the splint and the limb, the padding will, in the first place, never fit, and in the second place is sure to become displaced. *The padding must be a part of the splint itself, and to make it so it must be carefully fastened to the surface of the splint with a gauze roller.* A gauze roller is preferable to a cotton roller, as it is thinner, applies itself more smoothly to the surface of the splint, and as it is hygroscopic and aseptic, permits the moisture from the skin to enter the cotton cushion, at the same time constituting a part of the aseptic dressing upon the wooden splint, which, in case the skin is abraded or blistered, is a decided advantage. The roller is first applied lengthwise over the splint, not too firmly, as in a provisional splint the padding should be elastic. After the cotton has been fastened securely lengthwise upon the splint, the roller at one corner is fixed with a safety-pin and then wound around the splint, somewhat obliquely, the whole length of it, so that the cotton is completely covered. The end of the roller bandage is then fastened with a pin to the posterior surface of the splint. Splints made according to these directions will fit the surface of the limb, and when properly fastened in position, will furnish the necessary equable mechanical support and, moreover, will not be likely to become displaced.

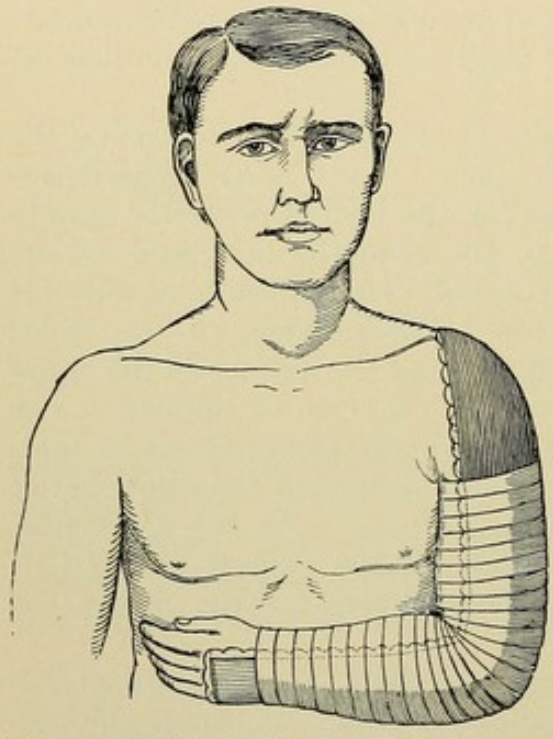

Fig. 235.—Splint for fracture of the humerus.

Provisional and permanent splints should be fixed in position by at least two strips of adhesive plaster, and over them a gauze roller. The gauze roller is more elastic than the cotton roller, and on this account should receive the preference; at the same time it is more porous, and permits freer evaporation of the moisture from the surface of the injured limb.

In all dressings, including all kinds of splints, the tips of the fingers and toes must remain exposed, as from their appearance the surgeon can judge, from time to time, the condition of the peripheral circulation, and the degree of sensation ascertained by touch and otherwise affords an insight into the condition of the principal nerve-trunks. In other words, repeated examinations of the fingers and toes by sight and touch enable the surgeon to ascertain, in time, the

existence of harmful compression on the part of the dressing, blood extravasation, inflammatory products, or displaced fragments.

In fractures of the arm the splints should include the shoulder- and elbow-joints; in fractures of the forearm they should reach from the bend of the elbow to the base of the fingers; in fractures of the femur, from the pelvis to the sole of the foot; in fractures of the leg, from the knee-joint to the base of the toes. A foot-board attached to one of the splints is an important part of the fixation dressing in all fractures of the leg, as it furnishes a support to the foot, preventing flexion, an almost constant remote condition and one so often difficult to correct after the fracture has united.

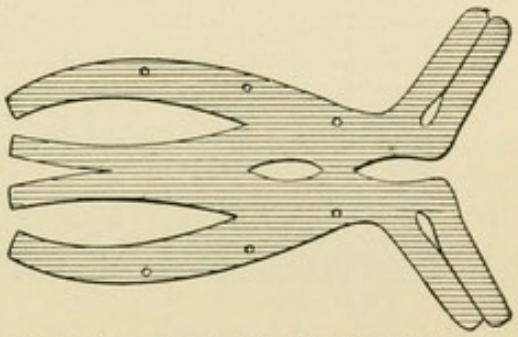

Fig. 236.—Raoult-Deslongchamp's zinc splint for fractures of the leg.

Pasteboard splints should be used only in fractures of the fingers, as their resisting power can not be relied upon in dressing a fracture of any of the long bones with marked tendency to displacement. In children the subjects of greenstick fracture they are often used as permanent splints, but it requires a long time for the pasteboard to become dry and resistant, and during this time, unless special precautions are taken, the deformity may reappear. If a plastic splint is required, plaster-of-Paris is a much more reliable material than pasteboard or leather. The same objections apply to leather splints.

Tin splints have the advantage over wooden splints in that the material can be molded to the surface of the limb, but it is extremely difficult to make it fit the irregular surface of the limb, the defects having to be corrected by padding. Sheets of zinc (No. 8, 0.4 mm. in thickness) can be cut with ordinary scissors and molded into proper shape much more easily and accurately than ordinary tin. Zinc splints and, what resembles them closely in practical utility, wire splints recommend themselves more especially as provisional splints in military and emergency surgery. Of all metallic splints, the wire splint is the safest and most useful, as it can be molded into proper shape with the hands, and the splint permits free evaporation of the perspiration. Strong wire gauze, which can be cut with a strong pair of scissors, is the best material. The edges of the

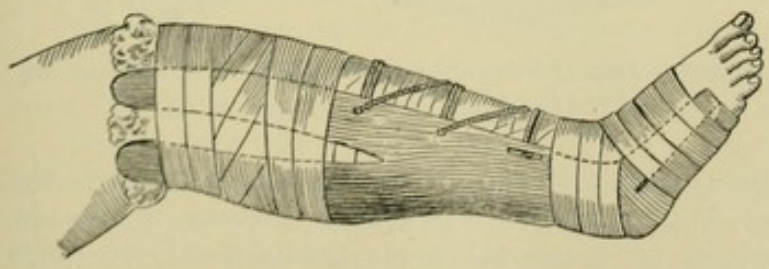

Fig. 237.—Raoult-Deslongchamp's splint applied.

splint, after it has been cut, should be bent over or covered with a hemming of cloth, to protect the skin against irritation from the cut ends of the wires.

Plastic splints, immovable and removable, have, at the present time, a wide range of application in the treatment of fractures of the extremities. The directions for making these splints, the indications for their use, and the cautions to be observed in their application will be given in detail in the chapter on Compound Fractures. Circular plastic splints are seldom used as a primary fixation dressing, except in cases in which there is nothing to fear from circular compression and when there is little or no tendency to longitudinal displacement. The immovable plastic splints are the ideal splints after the primary swelling has subsided and union is firm enough to prevent shortening. Plastic splints, like any other splints, are frequently employed as a first fixation dressing, as when properly made and applied, there is no danger from circular and

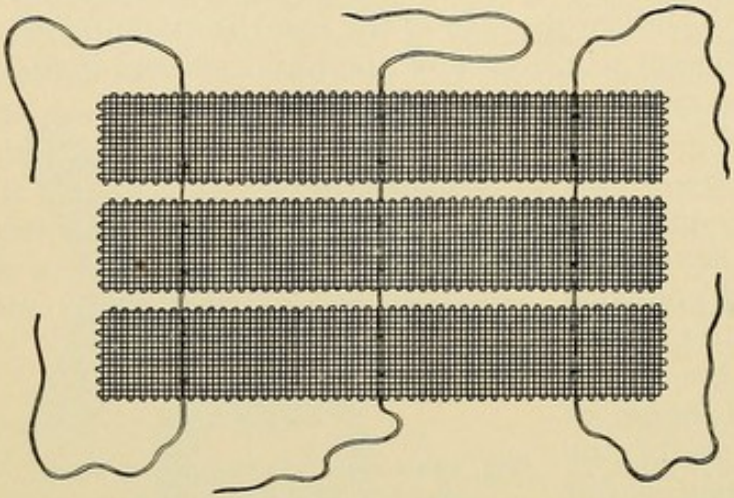

Fig. 238.—Wire splints connected with cords (Bruns).

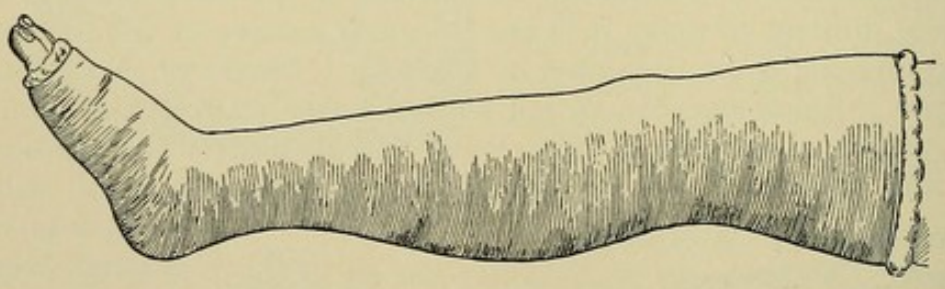

Fig. 239.—Immovable circular plaster-of-Paris splint applied for fracture of the leg (von Esmarch).

localized harmful pressure, as it can be molded accurately to the surface of the limb. When used as a provisional splint, it must be well padded with cotton or some other elastic material, to guard against harmful pressure caused by an increase of swelling at the seat of fracture. The materials in most common use for plastic splints are plaster-of-Paris, starch, pasteboard, leather, felt, gutta-percha, glue, dextrin, and silicate of soda. The material which can be molded most readily and accurately at the surface of the limb and which will, in the shortest time, pass from the plastic

into the permanent firm state is the one that will adapt itself best to the use of the surgeon. This material is plaster-of-Paris, as it is cheap, readily obtainable, easily molded, and sets in the shortest period of time. Pasteboard, leather, and felt are sometimes useful as provisional, but are not strong enough as permanent, splints when there is any considerable tendency to displacement. Gutta-percha is expensive and can not be molded with the same ease and accuracy as plaster-of-Paris. Glue, starch, dextrin, and silicate of soda are very plastic materials, but it requires hours before the material, by drying, becomes firm enough to serve the purpose of a splint. Plaster-of-Paris is the material *par excellence* for plastic splints, circular and lateral, bracketed and fenestrated, and, when ever necessary, it can be strengthened by incorporating in it strips of wood, tin, or iron.

The plaster is used by incorporating it in rollers of loosely meshed fabric, such as crinolin, organtin, or the ordinary cheese-cloth. Bandages thus prepared should be wrapped in waxed paper and stored in air-tight cases. If the plaster becomes impaired by

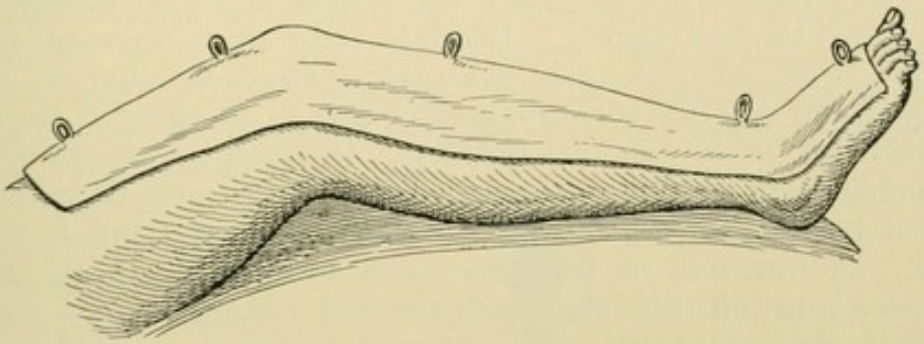

Fig. 240.—Beely's plaster-of-Paris hemp splint for fractures of the leg, with wire rings for suspension.

absorption of moisture, it may be exposed to slow dry heat until the moisture is removed. Salt, alum, or any other substances that hasten the setting of the plaster are harmful, as when the plaster sets more slowly, the splint can be molded more satisfactorily and is stronger and more durable. The circular plaster-of-Paris splint can be made removable by cutting it on one or both sides, but the fitting qualities are at once seriously impaired, and it soon becomes necessary to replace it by a new one.

Beely, who has done most excellent work in the development of removable plaster splints, has used hemp very extensively as a framework for the plaster. The fibers of hemp (from thirty to fifty inches in length) should be placed parallel in small bundles, two to three inches in width and half an inch in thickness, which are then twisted into a loose cord of the thickness of the little finger. A plaster cream is then made by mixing equal parts of warm water and plaster-of-Paris. The hemp cords are then drawn through the cream slowly, so as to saturate the meshes well, when they are laid over the limb parallel to each other and close together, until the

splint has reached the desired size. The splint should be thickest in the center. The width of the splint should correspond with one-third, never more than one-half, of the circumference of the limb. If fixation is to be combined with suspension, wire rings are placed at suitable distances from one another, in a straight line, in the center of the splint, by inserting them between the layers of the bundles of hemp.

Inclined Plane.—The use of the double and single inclined plane has been referred to in connection with position as an aid in the mechanical treatment of fractures. In some fractures of the thigh and leg the inclined plane, single or double, is often combined with splint fixation and permanent extension. The inclined plane will often accomplish more than extension, and when combined with extension, will accomplish what is so necessary in the treatment of very oblique fractures, relaxation of muscles and correction of longitudinal and lateral displacements.

Permanent extension by weight and pulley is one of the approved methods of treatment of oblique fractures of the femur and both bones of the leg. It is sanctioned by all authorities, and has yielded the best results. *Extension must always be made in the direction least likely to excite muscular contraction*—that is, *in a direction that will not come in conflict with a position of the limb calculated to favor muscle relaxation.* In fractures of the femur the influence of position on muscle relaxation must be carefully studied before deciding in what direction the extension is to be made. In fractures of the upper and lower ends of the bone extension must often be made with the limb resting upon a double or single inclined plane. *The experience gained in making the reduction will indicate to what extent position will aid extension.* My observations and experience have satisfied me that position of the limb has not been utilized to the extent it deserves to be in securing the full benefit of permanent extension. No strict rules can be laid down to guide the physician in determining upon the direction in which extension should be made. This important matter must be studied in connection with each individual case, as the location of the fracture, the line of fracture, and the degree of muscle power are varying conditions that have a direct bearing on the position in which the limb should be placed most favorable to extension.

Elastic extension with the aid of a special apparatus is sometimes resorted to, but the general practitioner will rely almost exclusively on the weight and pulley in making permanent extension. This method is employed occasionally in the treatment of oblique fractures of the forearm, but the cases are very rare, indeed, in which it becomes necessary to confine a patient with fracture of the forearm to bed for the purpose of securing the benefits of permanent extension, which then is made on the arm with the elbow flexed. I have resorted to this method of treatment in a few cases

of infected compound fractures of the humerus with signal success.

The usual method of applying extension is to fasten two strips of adhesive plaster one on each side of the limb, covering a sufficient surface to support the weight, and connect them with a cross-piece of wood below, to which the extending cord is tied. The adhesive plaster not infrequently irritates and blisters the skin, more especially in the case of children; at other times the skin is



Fig. 241.—Adhesive plaster cut for Buck's extension (Stimson).

abraded or ulcerated, when some other method of securing a hold on the limb must be devised. Lead plaster is less likely to cause irritation than the ordinary rubber plaster, and for this reason it should be used in preference to the latter. In children and in subjects with delicate abraded or diseased skin cloth instead of plaster should be used. Strips of linen are fastened with collodion, and to increase the surface for traction upon the limb, and to secure a better hold of the cloth strips on the skin, thin layers of absorbent cotton are placed along the borders and across the strips, and fastened by saturating the cotton and the cloth strips with collodion. Extension made on a plaster-of-Paris shoe or boot is objectionable, as decubitus upon the dorsum of the foot is very likely to occur. If, for any reason, this method of extension is used, the boot or shoe should be lined with a thick layer of absorbent cotton at pressure points. Extension would be combined with mechanical measures that will prevent eversion and lateral displacement. A long outer splint, reaching from the sole of the foot to the axilla, supplied with a foot-board and well padded, is frequently used to prevent eversion. A posterior splint with a foot-board and a cross-piece answers the same purpose. Two long sand-bags molded to the sides of the limb furnish a good lateral support.

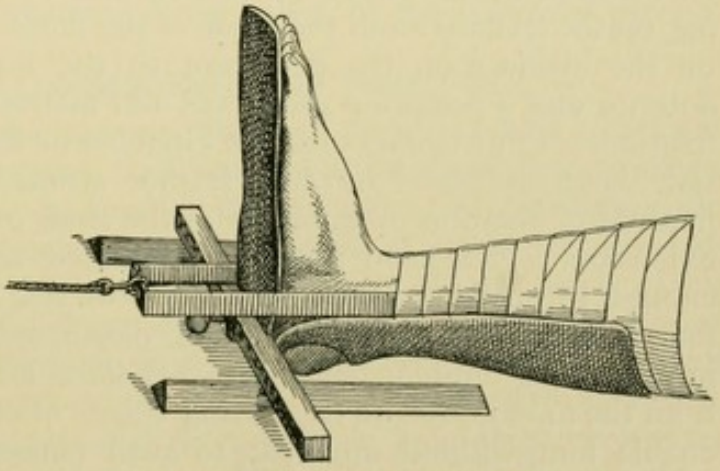

Fig. 242.—Volkmann's sliding foot-board.

Perhaps the best device yet invented to prevent eversion and for the preservation of the extending force is the sliding foot-board of Volkmann, shown in figure 242. *The pulley over which the cord*

makes the extension must correspond with the axis of the limb, or that part of the limb upon which the extension is made. This often makes the use of a second pulley necessary. The weight making the extension must necessarily vary according to the age of the patient, the amount of muscular resistance to be overcome, and the degree of longitudinal displacement to be corrected, the variation being from five to twenty-five pounds. The effect of extension must be noted from day to day, until the shortening has disappeared or has been reduced to a minimum degree. The maximum weight should never be used first. Beginning with a minimum or medium weight, it is increased as rapidly as the comfort of the patient will permit, until the object for which the extension is employed is realized, when it can be as gradually diminished. Should shortening again set in, the weight is again increased. In fractures of the femur the extension should be carried beyond the knee-joint, as prolonged and severe traction from a point below the joint often results in temporary, and sometimes in permanent, damage to the joint. The same effect of extension is realized if the strips of adhesive plaster or the extending cloth sling is carried up to and even beyond the seat of fracture, as when the extension is limited to below the knee-joint. Extension alone does not secure the necessary rest for the seat of fracture, which, in addition to the extension, should always be immobilized by lateral splints extending on the outside from the crest of the ilium to the knee-joint, and on the inside from the perineum to the same level below. An anterior and a posterior splint will add materially to the security of fixation. Four splints made of Gooch's or Esmarch's splint material, held in place by two leather straps, constitute the ideal method of fixation of fractures of the shaft of the femur treated by extension. Extension must be continued until the union is firm enough to guard against shortening,—that is, on an average of from four to six weeks,—when a circular plastic splint can be relied upon in preventing angular deformity. Besides, it will relieve the patient from the monotony and depressing effects of confinement in bed, and enable him, without any risk, to avail himself of the benefits of exercise, with the aid of crutches, and the bracing, tonic effects of outdoor air.

Malgaigne hooks and spear, the former for the treatment of fracture of the patella, the latter for oblique fractures of the leg with marked displacement of the upper fragment of the tibia forward, are no longer used, since aseptic surgery has made it comparatively safe to resort to direct means of fixation in cases in which these instruments were formerly employed.

Direct means of fixation, so strongly urged by me in discussing the treatment of compound fractures, has its rigid limitations in the management of subcutaneous fractures. The conversion of a subcutaneous into an open fracture is attended by some risk and brings additional responsibilities that the physician, and even the

expert surgeon, can ill afford to ignore. Our present means of procuring asepsis are by no means infallible, and the treatment of subcutaneous fractures by the open method of reduction and direct means of fixation by nailing or suturing must, for good reasons, be restricted to cases in which the best external mechanical treatment would be inadequate to secure a satisfactory result, to cases in which the reduction is found impossible, and, finally, to cases in which we have reason to believe that the interposition of soft tissues between the fragments is present and can not be removed by bloodless attempts. Fractures of the clavicle with marked displacement, irreducible traumatic fracture of the epiphyses, and fractures of the patella and olecranon process are some of the fractures in which the open treatment has been strongly recommended from influential sources, and which, even in the minds of the most conservative practitioners, will bring up the question of the propriety of resorting to direct means of reduction and fixation. With the necessary care in effecting reduction and maintaining retention, the cases of subcutaneous fracture justifying the open method of treatment at the present time are exceptional. Suturing of the patella in recent fractures should be limited to cases in which the ligaments of the joint are extensively implicated, in which event the direct intervention is resorted to more for the purpose of securing a satisfactory healing of the wound of the soft tissues than with a view of obtaining bony union of the fractured patella.

REMOTE CONSEQUENCES OF FRACTURE.

Ill results after subcutaneous fractures under the best treatment are by no means infrequent, and bad results attributable to careless, unskilful, or negligent treatment are not rare. In estimating the shortcomings of treatment in the latter class of cases the physician should be his own critic rather than a critic of the work of his colleagues, as he should remember that it is far easier to criticize than to prevent unfavorable results. The conduct of the patient himself often contributes to or detracts from the functional result. The same treatment pursued in a patient, confiding subject for the same injury will result more favorably than if the patient is irritable, mistrusting, and refractory. In the treatment of a fracture the patient owes a duty to the physician, as does the physician to the patient, and it is a disregard of duty on the part of the former that is as often responsible for a bad result as is ignorance or lack of attention on the part of the latter. It is the harmonious cooperation between a good patient and a skilful, careful, and attentive surgeon that overcomes obstacles in the treatment of a difficult fracture and that is usually rewarded by a satisfactory functional result. A late examination of the remote ill consequences of fracture does not always give a clear idea of the nature and gravity of the injury, much less of the difficulties encountered on all sides in its treatment. Physicians on this account should be

slow in passing judgment on the work of their colleagues, as much harm has resulted to able, painstaking, and conscientious practitioners and the profession as a whole from injudicious and uncalled-for interference in this direction.

Among the conditions that interfere with a desirable result must be mentioned, foremost,

Excessive and Defective Callus Formation.—*Callus formation depends on the abundance and functional activity of the osteoblasts in the periosteum and medullary tissue, the principal, if not the sole, histologic sources of new bone. If these callus-forming agents are in excess in number and activity, or if they are defective in number or proliferating power, the physician certainly can not be blamed for faulty callus production.* The intrinsic capacity of the fractured bone to repair itself must be taken into due consideration in a search for the many causes of faulty callus formation. Excessive traumatic stimulation of the tissues by comminution of the bone and disturbance of the fragments are important agencies in excessive callus production. Accurate coaptation of the fragments to their normal relative positions and immobilization at the seat of fracture are best calculated to limit callus production to normal requirements. Premature passive motion, imperfect reduction, and defective immobilization are the three causes attributable to faulty treatment that contribute to the formation of a massive callus, and among these premature passive motion is the most important. Physicians, as a rule, are overanxious, in the treatment of fractures near and into

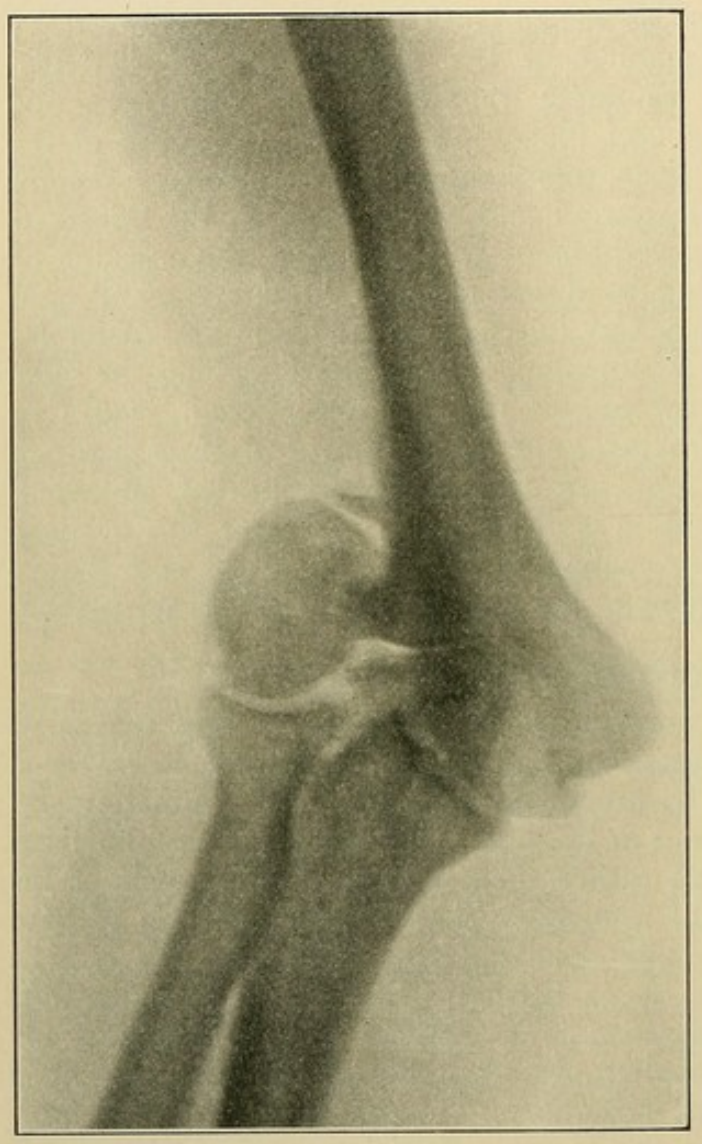

Fig. 243.—Old fracture of the lower end of the humerus; massive callus formation and ankylosis.

joints, to resort to early passive motion for the purpose of preventing stiffness or ankylosis of the joint. Passive motion made before union by bony callus has taken place always results in motion between the fragments, as the short fragment on the side of the joint can not be immobilized, and the mechanical irritation thus produced stimulates the tissues beyond the degree required for a satisfactory union. *Passive motion in fractures of the epiphyseal extremities of the long bones should invariably be postponed until the fragments have united with sufficient firmness to guard against disturbance of coaptation by the movements. Premature passive motion is one of the recognized causes of nonunion, but more frequently it impairs the functional result by being conducive to the formation of an excessive, luxuriant callus, which, by its proximity to or involvement of important joints, mechanically interferes with the restoration of the normal range of motion.*

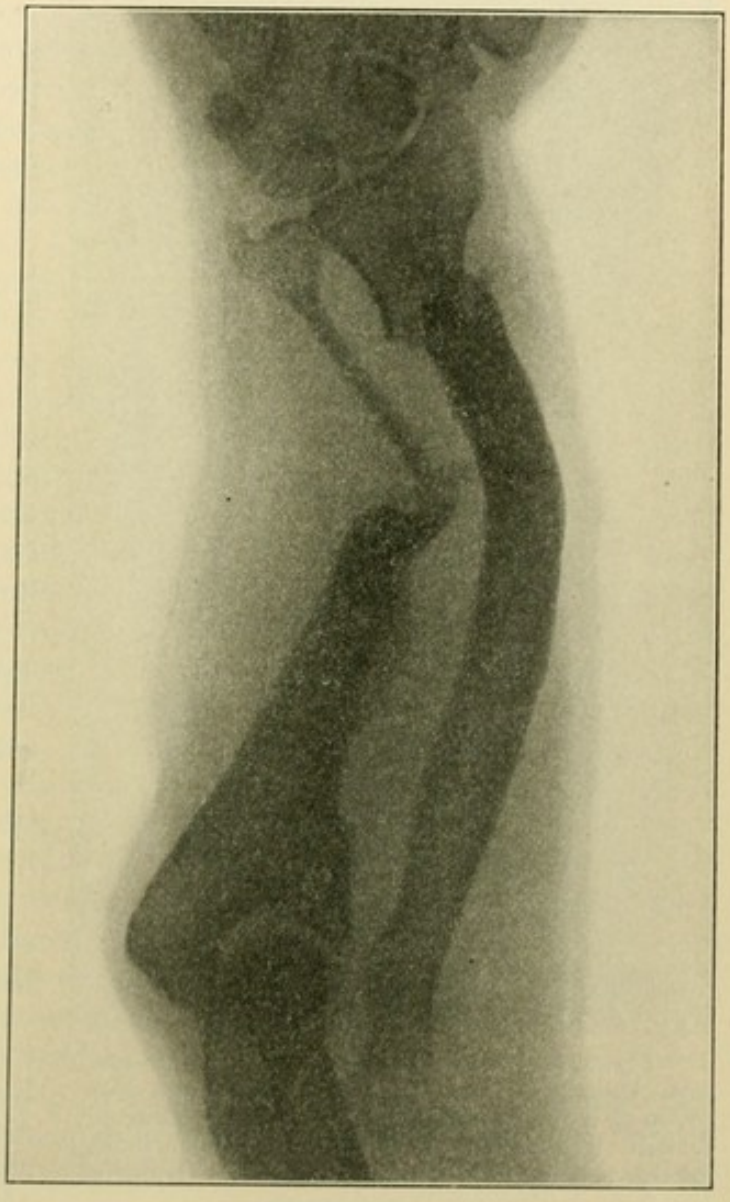

Fig. 244.—Fracture of both bones of the forearm; defective callus production and nonunion. Extreme atrophy of lower fragment of ulna. Old case.

Among the causes of excessive callus production over which the physician has no control are age, seat of fracture, and the extent of injury of the soft tissues. Callus production is likely to be in excess of normal requirements during infancy, childhood, and adolescence—that is, during the time of life when the osteoblasts are actively engaged in the development of the osseous system. Injury of the soft parts has always been considered as an im-

portant element in the production of callus. It is well known that callus formation is most plentiful on the side of the fracture where the soft tissues are most abundant. In cases of exuberant callus of fracture of both bones of the leg the callus is always most luxuriant on the flexor sides, and in fractures of the forearm it is most profuse on the anterior side. The greater vascularity on the side of the bone most profusely supplied with soft tissues has, in all probability, more to do with massive callus formation than the amount of soft tissues.

Fig. 245.—Fracture of both bones of the forearm. Union of fracture of radius in malposition. Non-union of radial fracture owing to defective callus formation. Operation by direct treatment, including wiring, restored the continuity of the bone. Illumination through plaster-of-Paris dressing.

The seat of fracture has a decided influence on the amount of callus production. Fractures in close proximity to joints, for reasons that are not fully understood, are very likely to give rise to profuse callus formation (see Fig. 243). Fractures in the epiphyseal extremities of the long bones are often fractures characterized by extensive injury to the bone, and not infrequently complicated by involvement of the adjacent joint, conditions that give rise to great vascularity, and its usual inevitable consequences, hypernutrition and great activity of cell proliferation. Premature passive motion can only aggravate these conditions, and, unfortunately, it is too often resorted to by the anxious, zealous practitioner. Incomplete reduction and imperfect immobilization are two causes of excessive callus formation that should be eliminated by judicious treatment.

Defective callus formation is one of the consequences of suppuration in compound fractures, and in simple fractures made compound by infection, occurring with or without direct operative interference. The suppurative process interferes with the func-

tional activity of the osteoblasts, and when extensive and prolonged in compound fractures, may interfere with callus formation sufficiently to prevent union by bony callus.

Suppuration retards but does not always interfere with the production of a normal or even an excessive callus. After the subsidence of the infective process, the osteogenetic tissues that remain resume their legitimate function, and eventually the fracture unites by a normal or even an exuberant callus.

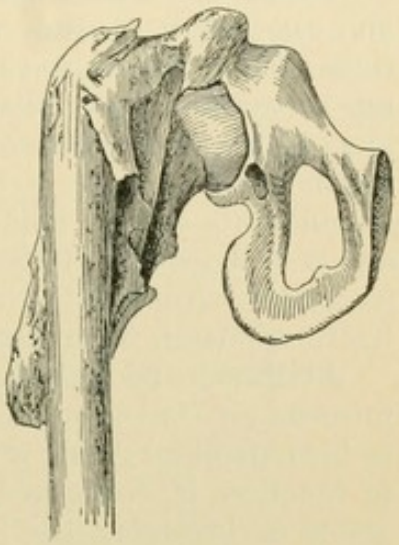

Fig. 246.—Fracture in the upper third of the femur, with great longitudinal and angular displacement, united by bony callus with the pelvis (Bruns).

Scanty covering of soft parts has always been regarded as a condition adverse to callus production. Pseudarthrosis is more likely to occur in that part of a limb where the soft tissues are scanty. It is beyond the power of the physician to eliminate this cause of defective callus formation. When this anatomic cause of defective callus production presents itself, the physician is anxious to so treat the fracture as to utilize all the remaining conditions, in order to place the fragments in the most favorable conditions for speedy and satisfactory union by bony callus. Intra-articular fractures require special care on the part of the physician to obtain union by bony callus, as the local conditions are most unfavorable for such a result. Perfect reduction and permanent fixation are the indications that have to be fulfilled to the maximum extent to overcome the anatomic conditions adverse to satisfactory callus formation.

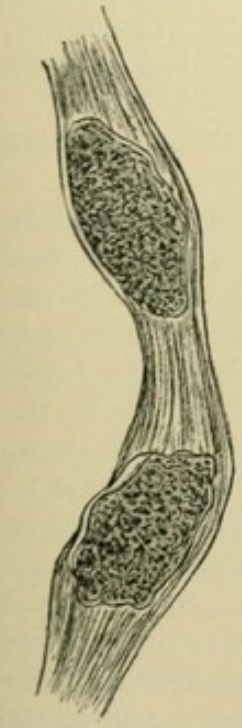

Fig. 247.—Fibrous band of union after fracture of the patella (Hoffa).

Defective local and general nutrition has been greatly overestimated as a cause of defective callus formation and nonunion. Complete lateral and extensive longitudinal displacements are serious causes of defective callus formation and nonunion, but it is astonishing to what an extent the reparative processes neutralize these unfavorable conditions. Nature's resources to remedy such conditions are best demonstrated in fractures occurring in the lower animals, where mechanical treatment is out of question. It is in cases of this kind that the osteogenetic tissues, placed in the most unfavorable condition for repair of the injury, accomplish the difficult task of restoring the continuity of the bone

by being subjected to traumatic irritation, caused by the displaced and movable fragments.

Diastasis of the fragments, as occurs in fractures of the patella and olecranon process and in nonimpacted intra-articular fractures, is a very potent cause of defective callus formation. Accurate coaptation and fixation of the fragments are conducive to ideal callus production. It seems that a certain degree of intra-fragmentary pressure is a mechanical condition favorable to tissue stimulation, as was pointed out long ago by Sir Astley Cooper, and is best seen in studying the process of repair in intra-articular fractures. Among the more common remote ill consequences of fractures stand, preeminent,

Stiffness and Ankylosis of Joints.—Every prudent practitioner protects his own reputation and avoids a source of disappointment to his patient by giving a very guarded prognosis, as far as recovery of function is concerned, in all cases of fractures situated near joints or involving the joint itself. In fractures near joints defective function is frequently one of the unavoidable permanent consequences of the injury. A change of direction of the articular surfaces, the result of malposition, excessive callus production, laceration of the ligaments, loss of points of muscle origin or insertion, are some of the more important conditions that impair the functional result. Such fractures are often complicated by dislocation, complete or partial, of one of the articular extremities, a condition not infrequently overlooked and often not completely corrected.

Instances of this kind are observed most frequently in fractures near or extending into the elbow-joint.

Bony ankylosis is, fortunately, a rare occurrence, but must be expected when the joint fracture is extensive, when it extends beyond the limits of the capsule, and especially when opposite articular extremities are fractured at the same time, when the bony callus may span the joint connecting the two bones by a bridge of new bone. If, from the nature of the injury, such a result is anticipated, the prognosis must be made accordingly. The limb is placed in the position in which it will be most useful in the event of ankylosis—that is, in fractures involving the elbow-joint the forearm is flexed at a right angle, half-way between pronation and supination; in fractures of the hip-joint the thigh is slightly flexed. This applies to fractures of the articular ends of the tibia and femur in fractures involving the knee-joint, when the leg should be slightly flexed.

Besides abnormal deviation of the articular surfaces and callus formation invading the joint, pathologic conditions affecting the soft tissues of the joint and following as a sequence of the injury may impair seriously the function of the joint. One of the common causes of stiffness of joints after fractures is intra-articular extravasation of blood. The blood in the joint acts as a foreign, aseptic, absorbable material. It is usually absorbed rapidly without causing

anything more than a temporary disturbance of function. In other cases, however, the effusion may be so copious that harmful intra-articular tension may become a source of danger to the future utility of the joint. If the blood is not absorbed promptly, its presence acts as an irritant, when the synovial membrane becomes vascular and proliferates. The new tissue from the surface of the synovial membrane infiltrates the blood-clot, and an intra-articular

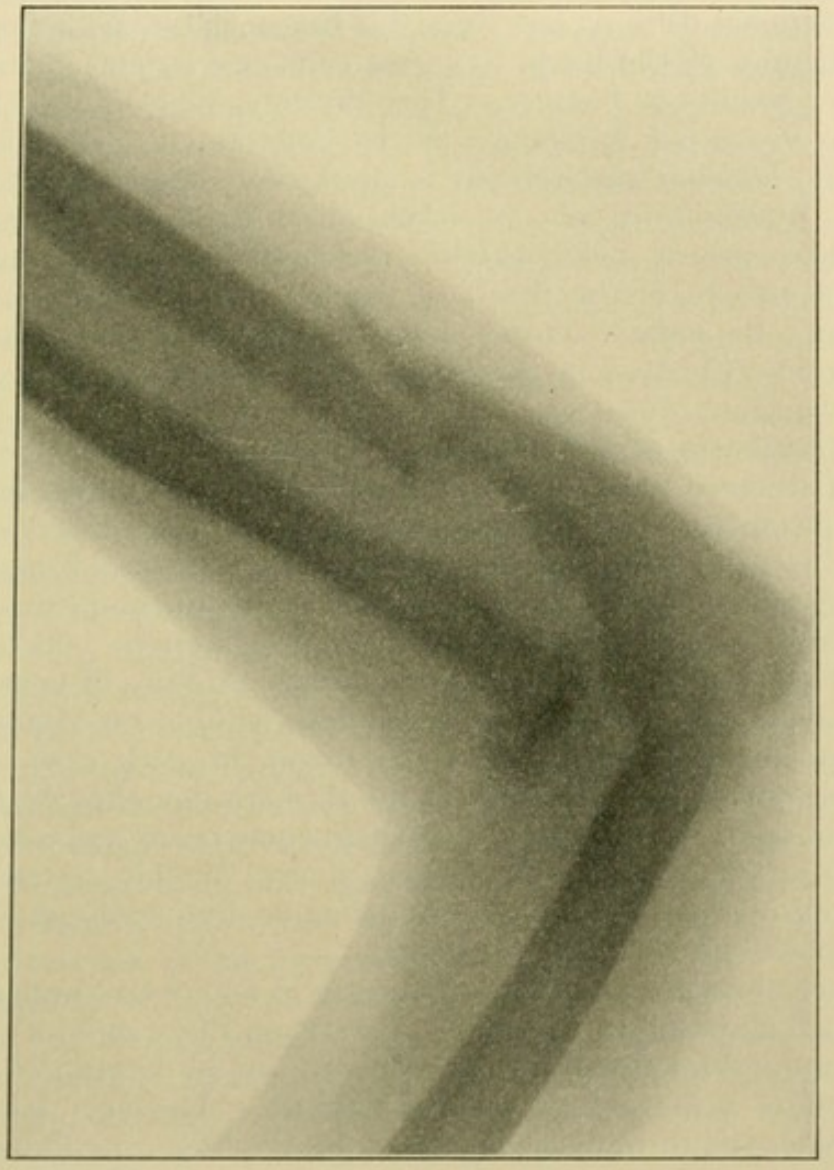

Fig. 248.—Fracture of the ulna with forward dislocation of the head of the radius.

scar or adhesions form, resulting in stiffness or fibrous ankylosis, which not infrequently remains as a permanent remote result of the fracture.

Tendovaginitis and adhesions of muscles or tendons to the callus or between themselves are among the most common causes that lead to troublesome, and sometimes to permanent, stiffness of the joint. The formation of these adhesions can not be prevented, as they follow injuries to the soft structures, tears of the tendon

sheaths, laceration of muscles, and extravasation of blood. Neglect on the part of the physician to begin the treatment of such adhesions as soon as the bone has united, and to supervise and continue the same as long as necessary, is responsible for many tardy recoveries and permanent disabilities. Active and passive motion, as soon as union is sufficiently firm to warrant the same, and systematic massage constitute the most effective course of treatment. If tendons or muscles become embedded in the callus, the functional disturbances from this cause will be permanent.

Atrophy of the limb, to a greater or less extent, is one of the constant results of fracture. The physiologic atrophy that always sets in is caused by nonuse of the limb, and is called inactivity atrophy, which disappears in a short time upon the use of the limb. Inactivity atrophy is slight unless it has been increased by harmful pressure, which is often the case. A more troublesome form of atrophy is the result of trophoneurotic influences in connection with some fractures, but this kind of atrophy is rare as compared with atrophy associated with bone and joint diseases from the same cause.

Thrombosis and Embolism.—Thrombosis of the veins at the seat of fracture must occur to a greater or less extent in almost every instance. The thrombosis of practical importance is limited to occlusion of veins large enough to cause peripheral symptoms indicating venous obstruction and to be a cause of embolism. Thrombosis and embolism are more frequently seen in infected compound than in subcutaneous fractures. A vein of considerable size may become occluded by thrombosis without producing visible external manifestations. Durodie found, in each case, in eight autopsies made from the fifth to the thirtieth day after the fracture, thrombosis of the deep veins, which, in some cases, had extended to the large vein-trunks. Bruns has shown, by his statistics, that fractures of the lower extremity are most frequently the seat of thrombosis—in 45 out of 53 cases.

Thrombosis occurs more frequently in adults and in persons of advanced age than in children. Except as the result of infection in compound fractures, thrombosis is caused by laceration or compression of veins at the seat of fracture. The vein injury that determines the thrombosis is caused by the fracturing force, by the displaced fragments, or the thrombosis follows compression that, in the majority of cases, is due to a copious extravasation in connection with the resulting diffuse edematous swelling of the soft tissues. In most of the cases in which thrombosis of large veins was found, either by external manifestations or by autopsy, it was noted that the thrombosis followed a severe contusion and a copious extravasation of blood. **Phlebitis** as a cause of thrombosis is only seen in compound infected fractures; in all other cases the thrombus formation is due to the immediate effects of the injury and their consequences. *Edematous swelling of the limb points to the*

existence of venous obstruction, caused by thrombosis of the principal vein of the limb—the axillary in the upper, and the femoral in the lower, extremity. The swelling makes its appearance usually in from two to four weeks after the injury.

Embolism is a very rare occurrence in cases of aseptic thrombosis of the veins. Sudden death from this cause is, fortunately, very rare. Virchow, in 1846, called attention to death resulting from embolism in cases of subcutaneous fractures. The case to which he referred at that time was one of fracture of the neck of the femur. Bruns has collected 35 cases of embolism complicating fracture, and of these 30 died, the diagnosis being verified in 23. The accident occurred in from the fourth to the seventy-second day after the injury, the largest number between the thirteenth and the twentieth day. In a case that came under my observation sudden death from pulmonary embolism occurred during the sixth week after the fracture. The case was one of fracture of the shaft of the femur treated by continuous extension. The bone had united, and the patient was expected to leave the hospital the next day. During the night he sat up in bed, fell back unconscious, and died in a few minutes, death being preceded by the characteristic symptoms of pulmonary embolism.

In the 23 fatal cases of embolism verified by autopsy, the embolus was found twenty times in the pulmonary artery or its branches, and three times in the right side of the heart. If the embolus does not cause death from the immediate effects of the obstructed pulmonary circulation, the patient's life remains in danger from the more remote effects of the pulmonary infarct—pneumonia and pulmonary gangrene. I remember a case of pulmonary embolism that occurred three weeks after the fracture, the patient narrowly escaping death from the immediate effects of the accident. After the acute symptoms had subsided, the patient appeared to improve steadily, when, two days later, pneumonia set in, which again threatened his life for more than a week.

Gangrene.—Gangrene of an entire limb below the seat of fracture indicates the coexistence of injury of the principal blood-vessels or arrest of the circulation by pressure caused by a displaced fragment or a faulty dressing. Gangrene from vessel injury can not be avoided, neither can it always be predicted at the time the first examination is made. Gangrene from compression should be prevented by effecting complete reduction and by resorting to all precautions to guard against harmful localized or circular compression. Localized gangrene of the skin caused by a faulty dressing may extend by the infection becoming diffuse, eventually necessitating amputation as a life-saving measure.

One cause of gangrene that is so seldom recognized at the time the first examination is made is crushing or tearing of the intima of the principal artery of the limb, the former produced by contusion, the latter by a traction injury. If the manner in which the

injury was inflicted should point to the possible existence of so serious a complication, the most thorough search for evidences of disturbance of the peripheral circulation must be made, in order to determine the existence of serious vascular complications. A decided diminution in the intra-arterial tension and feeble capillary circulation with venous engorgement are conditions that should arouse the suspicion of injury to the inner coat of the artery. Complete arrest of circulation will occur in such cases in the course of a few days, from arterial thrombosis. Simultaneous injury of the principal vein, or vein compression from blood extravasation, will hasten the gangrene and favor its rapid extension. Harmful circular compression in such instances will be productive of the most serious consequences, and must be carefully guarded against by immobilizing the limb in a way that will entirely eliminate this additional source of danger to the circulation and the vitality of the injured limb.

Fat embolism has already been discussed in connection with the immediate results of the injury, as it constitutes one of the earliest complications of fractures. It is again alluded to here because the infarcts that may occur in cases that recover from the immediate effects of fat embolism are liable to be followed by pulmonary complications. In all cases in which this result of fractures is suspected it becomes necessary to investigate the condition of the lungs repeatedly, by making a thorough physical examination from time to time, and by looking carefully for symptoms that accompany and follow pulmonary infarcts. Rapid respiration, imperfect oxygenation of the blood, cough, hemoptysis, pain, and defective respiratory movements of the affected side of the chest are the most prominent and reliable indications of the onset of pulmonary complications following an infarct from fat embolism.

Hemorrhage in subcutaneous fracture always presents itself in the form of an interstitial infiltration or extravasation. If an artery of considerable size has been completely torn by the fracturing force, or if it has been pierced or cut by a sharp fragment, the primary swelling appears rapidly. Its size will depend on the looseness or compactness of the tissues around the injured vessel. A swelling that appears very rapidly and reaches its maximum size in a short time usually indicates arterial hemorrhage. If the principal artery of the limb is the source of the bleeding, the peripheral pulse disappears and other indications of arrest of the circulation will soon make their appearance. Hemorrhage from an artery of considerable size will cause a swelling of the limb, which appears rapidly and which may interfere, by pressure, with the establishment of a satisfactory collateral circulation. The limb at the seat of fracture is swollen, the skin tense, and the superficial circulation feeble. The swelling is often so tense that fluctuation can not be detected. In hemorrhage from small arteries and veins the swelling increases more gradually in size and tension is less marked.

Puncture of an artery by a sharp fragment not infrequently is followed by the development of a traumatic aneurysm, and if the fragment should, at the same time, penetrate the accompanying vein, an arteriovenous aneurysm that will develop later will reveal the nature of the vessel injury.

Central Nervous System.—The central nervous system is liable to become implicated in fractures in the same manner and for the same reasons as in injuries of the soft tissues of similar gravity. Following the shock, the immediate effect of the injury, muscular spasms occur and add greatly to the difficulties in immobilizing the injured limb.

Delirium tremens, in persons addicted to the excessive use of alcohol, is a remote complication fraught with danger to life, and one that will tax the ingenuity of the surgeon to the utmost in devising a method of immobilizing the fracture without endangering the circulation of the injured limb. Rest in bed and immobilization of the fractured limb in a circular plastic splint with a thick lining of an absorbent elastic material, such as absorbent cotton, will constitute the safest treatment until the patient recovers from the effects of the nervous complication.

Delirium traumaticum is most likely to develop in persons with a high-strung nervous temperament, hereditary or acquired. The treatment of the fracture will be the same as in delirium tremens, until the patient regains the normal composure of the nervous system.

Prolonged dorsal recumbency frequently leads to complications that may endanger the life of the patient. In persons advanced in years or debilitated by previous disease hypostatic pneumonia is very liable to occur. Pneumonia produced by such a cause is usually masked, lacking the classic symptoms that characterize, clinically, croupous pneumonia. The disease sets in insidiously, and is very often overlooked unless the physician takes the precaution to watch for the symptoms and makes, as he should, frequent physical examinations of the chest.

Decubitus is another remote complication of fractures requiring in their treatment prolonged dorsal recumbency. The danger from this source is greatest in fractures of the spine at any age. Obesity is another predisposing cause. Under the conditions mentioned, the occurrence of this remote complication should be anticipated, and the necessary prophylactic treatment resorted to in time—an elastic bed, alternate pressure by the use of air-pillows, washing the skin with a 50 per cent. solution of alcohol, besides enforcing cleanliness. If decubitus is inevitable, the necessary care should be exercised to prevent infection of the devitalized tissues by appropriate antiseptic precautions. The skin should be thoroughly disinfected in the usual way, dusted freely with borosalicylic powder, and covered with a cushion of cotton well impregnated with the same preparation, and held in place with strips

of adhesive plaster and a gauze roller. Aseptic necrosis does not expose the patient to any risk to life, and limitation of the necrotic process can be confidently expected, while moist gangrene is noted for its intrinsic tendency to progressive extension and the danger to life from general sepsis.

Painful Callus.—A callus extending beyond the space between the fragments is likely to become a source of pain by encroaching upon the nerves in the immediate vicinity of the seat of fracture. A painful callus is, with few exceptions, an exuberant callus. Displaced fragments or an excessive callus may, by pressure and irritation, involve adjacent nerve-trunks, producing neuralgia and neuritis—complications that are characterized by pain that is usually attributed to the luxuriant callus, which in itself is painless, but which, by compression and irritation, is productive of painful affections of the nerves.

Paralysis.—Paralysis as a complication of subcutaneous fractures makes its appearance, when it does occur, either immediately after the injury, when it is caused by division, laceration, or contusion of one or more of the principal nerve-trunks by either the fracturing force or by the displaced fragments, or it sets in later in consequence of compression caused by displaced fragments or by the callus. Paralysis produced by the immediate effects of the injury should be detected at the time the first examination is made, which should always include a search for nerve injury. This is not done so often as it should be, and consequently, if days or weeks later paralysis is discovered, it is more difficult to interpret its essential cause. If, on first examination, nerve function below the seat of fracture is found intact and paralysis makes its appearance later, it is reasonable to exclude the immediate effects of the injury as an etiologic factor and connect it with displacement of fragments or compression on the part of the callus.

Delayed Union and Pseudarthrosis.—A sharp clinical and pathologic distinction must be made between delayed union and pseudarthrosis. A delayed union signifies a slow process of repair; a pseudarthrosis indicates an incapacity of the tissues to repair the injury, or the existence of mechanical difficulties that intercept the process of repair. Delayed union means a paucity of osteoblasts, a low degree of their capacity to proliferate, or abnormal retardation of the conversion of the new material into bone. It is strange, but nevertheless true, that delayed union and pseudarthrosis are most likely to occur in the vigorous adult rather than in the debilitated, marasmic, and the aged.

Pseudarthrosis presents itself, pathologically, in two distinct forms: (1) Ligamentous union; (2) interposition between the fragments of a new joint. In either event the continuity of the bone is permanently destroyed. According to Agnew's table, the relative frequency of false joints in fractures of the long bones is as follows: Femur, 155; leg, 180; humerus, 219; forearm, 76. Frac-

tures of the humerus at the junction of the middle with the lower third figure the most prominently in statistics of false joints.

A delayed union is a union that may be effected in the course of several months and even a year or more. I observed a case of fracture of the femur a year and a half after the accident, in which the fragments overlapped one another and no bony union had taken place. After the fragments were adjusted, under the influence of an anesthetic and under treatment by continuous extension and immobilization by Gooch's splints, union took place in the course of two months. As has already been stated, delayed union occurs either in consequence of slow callus formation or retardation of the transformation of the products of tissue formation into bone. The physician will exercise his patience and perseverance in the mechanical treatment of fractures that manifest such reparative defect, and his efforts will eventually be rewarded by success.

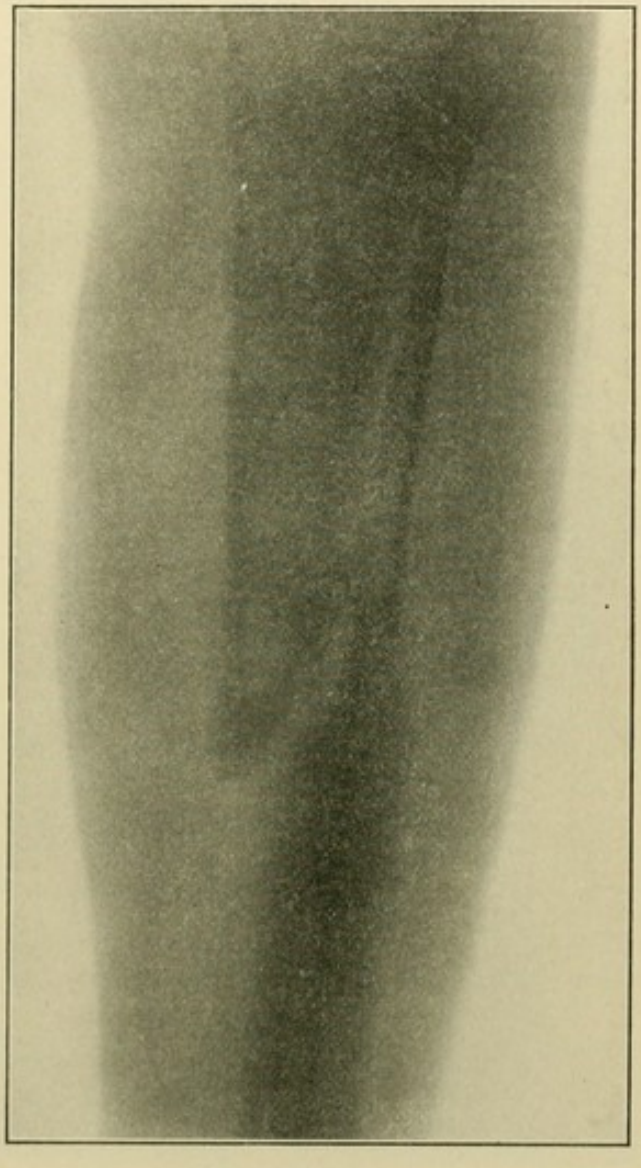

Fig. 249.—Nonunited fracture of the tibia. Anteroposterior illumination. No callus. Short ligamentous union between the two oblique fracture surfaces (Clinic, Rush Medical College).

In **pseudarthrosis** the false point of motion remains, and callus formation is inadequate or entirely wanting. Fibrous union between the fragments means either the absence of bone-producing tissues between the fragments, or a lack of intrinsic power of the new tissues to undergo transformation into bone. Bruns collected 56 cases of fibrous union, shown as such by autopsy. The femur was the seat of fracture in 22, the humerus in 18, and the forearm and leg in 8 each.

The most important cause of fibrous union is the distance separating the fragments. Fibrous union is expected in most cases of

fractures of the patella and the olecranon process. It is also the usual method of repair in intra-articular fractures of the neck of the femur and humerus without impaction. The next most frequent cause is interposition of soft tissues between the fragments. Loss of bone tissue is another important etiologic element in the failure of consolidation by bone. In fractures that heal by fibrous union the medullary cavity of the fragments becomes obliterated, the ends of the bone become more or less conic by absorption, and the length of the ligament will depend on the distance between the fragments and the degree of mobility, on the strength of the ligament, and the length of the space between the fragments. Callus formation in such cases is either entirely absent or, at least, inadequate to bridge the space between the fragments. It appears that in some cases callus production progresses to what appears as the requisite extent, when resorption of the new material takes place and the breach of continuity is repaired by the interposition of fibrous material. If the fractured surfaces are separated to any considerable extent, atrophy of the ends of the bone occurs; if they are opposite each other and in near contact, they are ground off and polished in the course of time. In some cases they are covered with cartilage, and in exceptional cases a true joint with synovial lining is interposed between the ends of the fragments, constituting a true nearthrosis. The genuine character of joint formation in such cases has been demonstrated by

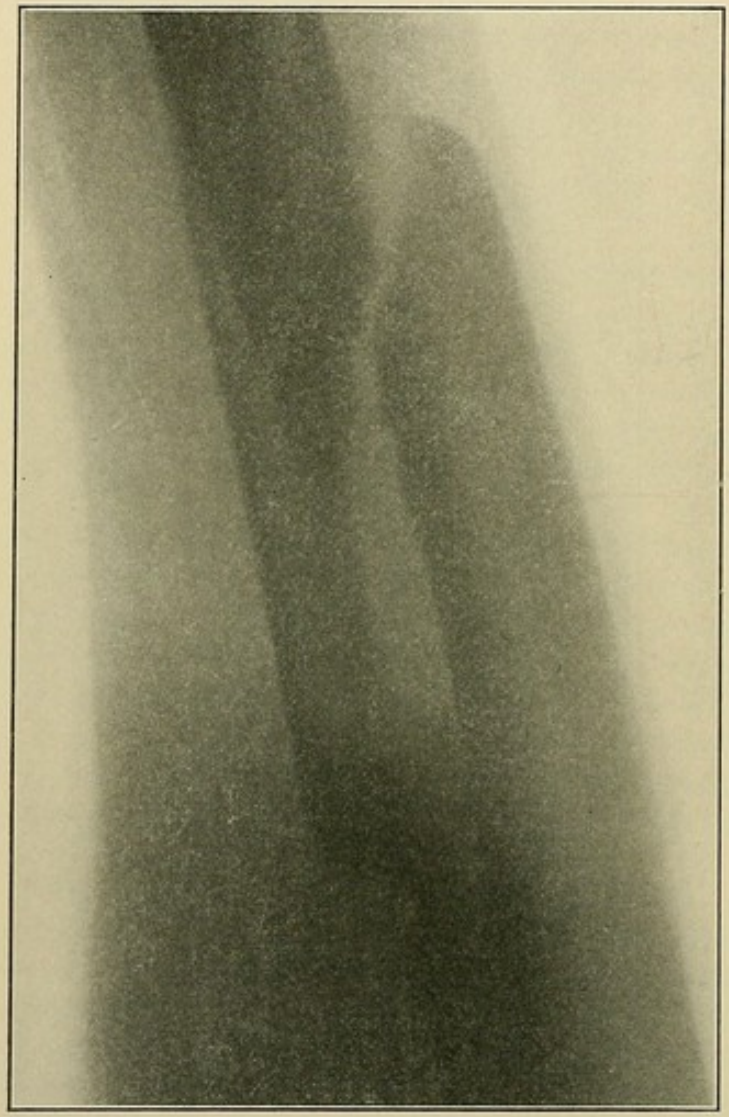

Fig. 250.—Fracture of both bones of the leg. Great shortening by overlapping of fragments. Fibula united. Fibrous union of fracture of tibia.

diseases that may affect the joints, being of the same nature and character as similar affections of normal joints, such as arthritis deformans and loose bodies. Of the latter affection of false joints, Bruns has collected seven cases, of which number the humerus was the seat of nearthrosis four times, the forearm twice, and the leg once.

Among the causes of delayed union and pseudarthrosis rickets, syphilis, pregnancy, lactation, marasmus, and acute infective diseases are usually enumerated as general influences that retard callus formation and transformation of the new material into bone. Among the local causes are included displacements of the fragments, interposition between the fragments of soft tissues and foreign bodies, defective innervation and blood supply, inflammation of the surface of the limb, and loss of bone substance. Faulty treatment contributes to such an occurrence, and among the faults must be mentioned excessive application of cold, imperfect reduction and immobilization, harmful circular compression, early passive motion, and premature use of the injured limb.

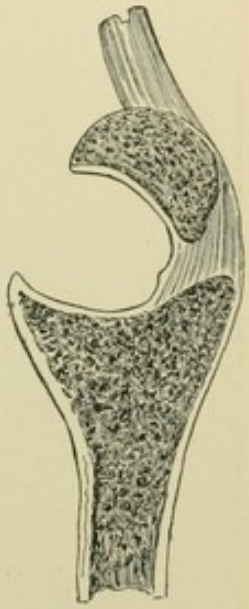

Fig. 251.—Fracture of the olecranon healed with diastasis and ligamentous union (Bruns).

The treatment of delayed union consists in removing mechanical causes that interfere with normal repair of the injury and stimulation of the tissues at the seat of fracture. If, after the expiration of the usual length of time, union by bony consolidation fails to develop, the treatment is so modified that it will be more conducive to callus formation. Active use of the limb, immobilized by an immovable dressing, is one of the simplest means to increase the vascular supply and to stimulate the process of repair. A more vigorous circulation thus produced may also prove adequate in transforming an immature callus into bone, which, without such stimulation, might possibly become absorbed or fail to undergo such metaplastic transition. If delayed union is the result of imperfect reduction, this defect must be corrected by tearing up existing adhesions and effecting accurate coaptation with the aid of a general anesthetic. Light elastic constriction above and below the seat of fracture, as advised by Dumreicher and Helferich, to secure a venous congestion of the parts in order to furnish the material for the callus, has been found useful in cases in which delayed callus formation could be attributed to a defective blood supply.

Amos Graves, of San Antonio, in his very extensive experience in emergency surgery, has resorted, for many years, to a somewhat novel procedure in stimulating the tissues to a more active process of repair. He imitates the useful effects of walking in such cases

by instructing the patient to push the fragment together somewhat violently by pounding, the limb being properly immobilized. In fractures of the forearm the blows are directed against the knuckles of the fist, the elbow resting against a firm support. In fracture of the humerus the force is applied by the patient striking the elbow against a firm support. In fractures of the leg and thigh the patient stands on the opposite limb, leaning on a chair or table, and stamping the foot of the injured limb on the floor. The sittings should be continued for from ten to fifteen minutes, and repeated frequently during the day. It is very easy to conceive how this additional treatment would favorably influence the production and development of callus, and it is so simple and safe that it recommends itself favorably to the attention of the profession. Massage is another therapeutic resource of considerable value in such cases, and if the fragments are held in proper position while it is applied, can do no harm, while the vascular stimulation and improved nutrition following its use will influence favorably the bone-producing function of the osteoblasts. Broca speaks encouragingly of the descending galvanic current as a remedy in stimulating callus production. Finally, the injection of from three to ten drops of a 10 per cent. solution of chlorid of zinc between and around the fragments is a very potent tissue stimulant, and may be tried with advantage in expediting the process of repair in delayed union.

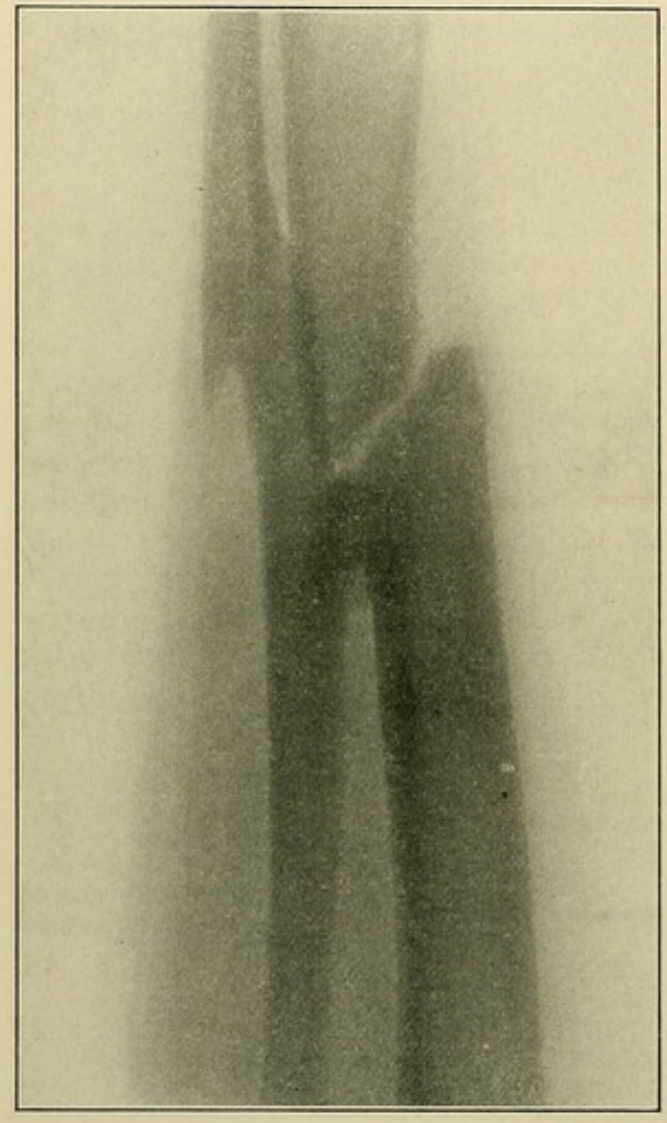

Fig. 252.—Fracture of both bones of the leg. Union of fibula with overlapping of fragments. Non-union of fracture of the tibia.

Time is a relative element in making a distinction between delayed union and pseudarthrosis. In some cases a pseud-

arthrosis is established immediately after the injury has occurred, by the interposition of soft tissues between the fractured ends, in quantity and structure calculated to furnish a permanent barrier against union by bony callus, while, as I have found, some fractures in which union was delayed for more than a year eventually united by bony consolidation. Some fractures, especially in children, unite firmly in less than three weeks, while in others the process of repair is not completed in less than from three months to a year. In all cases of delayed union it becomes necessary to search for and to correct constitutional causes by appropriate general treatment. The internal use of minute doses of phosphorus deserves a trial in case no general cause for the delayed union can be found.

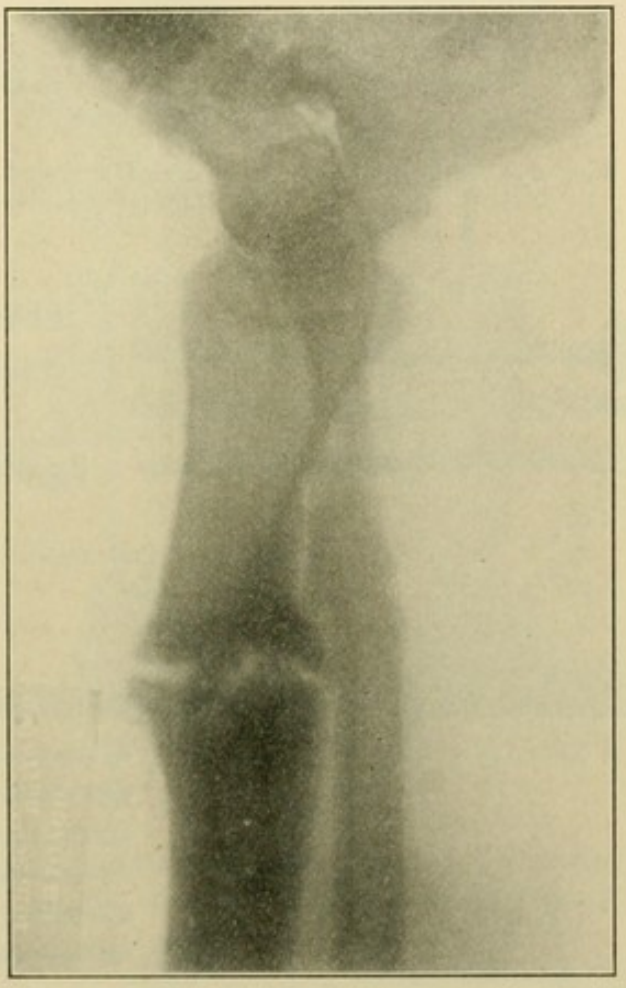

Fig. 253.—Fracture of tibia and fibula. Fibula united by bony callus. Interposition of a false joint between fragments of the tibia.

From a practical standpoint, pseudarthrosis is represented by a condition at the seat of fracture that excludes the possibility of the restoration of the continuity of the bone by bony consolidation, without active interference. In fractures of the leg and thigh that fail to unite in the expected time, the walking apparatus of H. H. Smith will not only enable the patient to walk about, but the improved local conditions arising from the active exercise will occasionally result in late consolidation by bony callus. Acupuncture and subcutaneous scarification of the ends of the fragments are seldom employed at the present time in the treatment of pseudarthrosis. The seton, so highly praised by S. D. Gross, Physick, and others, has become almost entirely obsolete as a therapeutic agent in promoting the healing of a fracture. Acupuncture, combined with the galvanic current, has been suggested and tried, but the results have not been sufficiently encouraging to claim the confidence of the modern surgeon.

One of the oldest methods of treatment of pseudarthrosis is

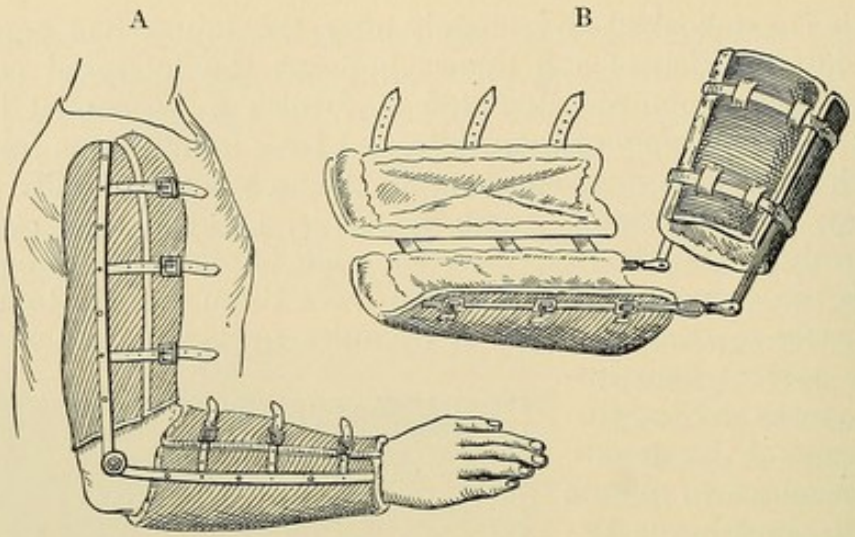

Fig. 254.—Apparatus for delayed and ununited fractures: A, For arm; B, for forearm (after H. Smith).

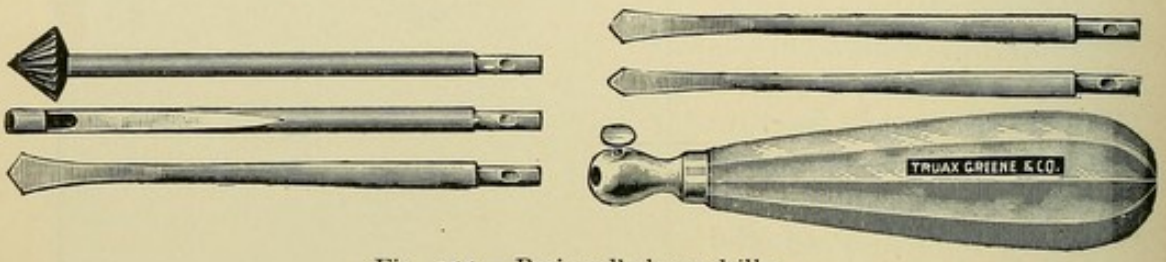

Fig. 255.—Brainard's bone drills.

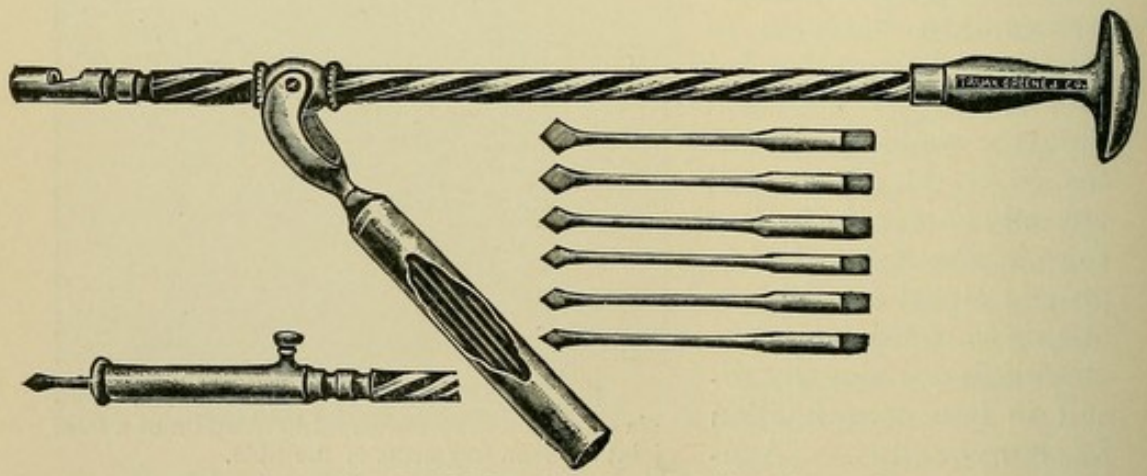

Fig. 256.—F. H. Hamilton's bone drills with guard.



Fig. 257.—Langenbeck's bone drills.

the transformation of an old into a recent fracture by manual force. Under the influence of a general anesthetic existing adhesions are torn by bending the limb at the seat of fracture in different directions, followed by rubbing the fragments together, after which they are carefully coaptated and immobilized in the same manner as a recent fracture.

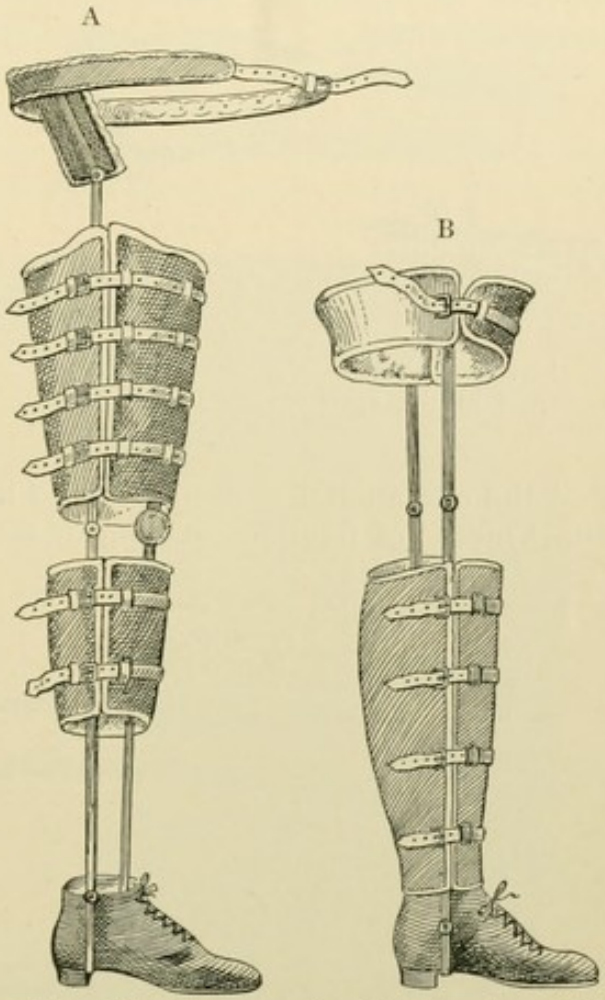

Fig. 258.—Apparatus for delayed and ununited fractures: A, For thigh; B, for leg (after H. H. Smith).

Subcutaneous perforation of the bone-ends with a drill, introduced by Daniel Brainard in 1840, has, after an extensive trial, remained as a reliable and safe operation in the treatment of delayed union and pseudarthrosis. Through the same puncture in the skin the ends of the fragments are perforated in different directions. The perforation opens up new medullary spaces and the medullary canal on one or both sides, stimulating the tissues and opening up new channels for the products of tissue proliferation in bridging the space between the fragments. The procedure is repeated every two or three weeks until the fracture promises to unite by bone, or until the attempts at effecting union by bony callus have proved unavailing.

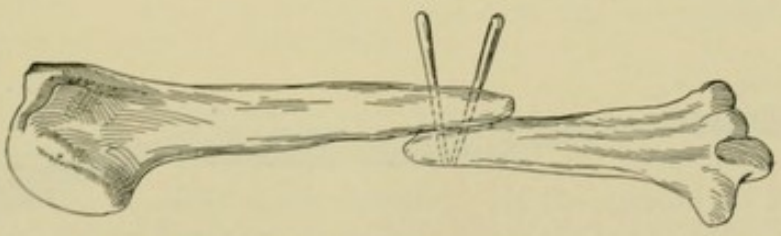

Fig. 259.—Fastening two overlapping fragments together with two ivory nails (Bruns).

In 1846 Dieffenbach recommended the use of ivory pegs, claiming that the foreign substance driven into the ends of the bone

would be more productive of callus than simple perforation—an assertion fully warranted by subsequent experience. If Brainard's drilling operation fails, it may be followed by the employment of aseptic ivory or bone nails, as the presence of the foreign substance adds another stimulus in arousing the tissues to a more active process of repair.

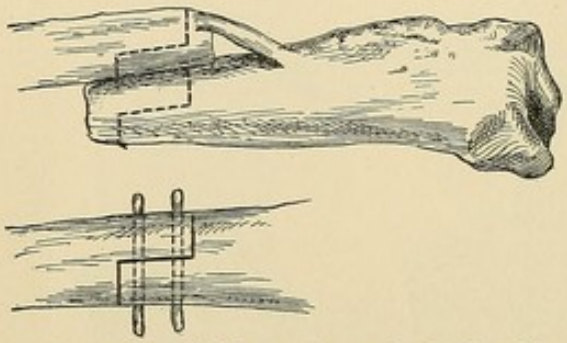

Fig. 260.—Volkmann's method of uniting fragments in the operation for pseudarthrosis (Bruns).

Direct operative interference by resection of the bone-ends was introduced by White in 1760. Since then the operation has been modified by following the resection by direct means of fixation—nailing or suturing. Aseptic absorbable

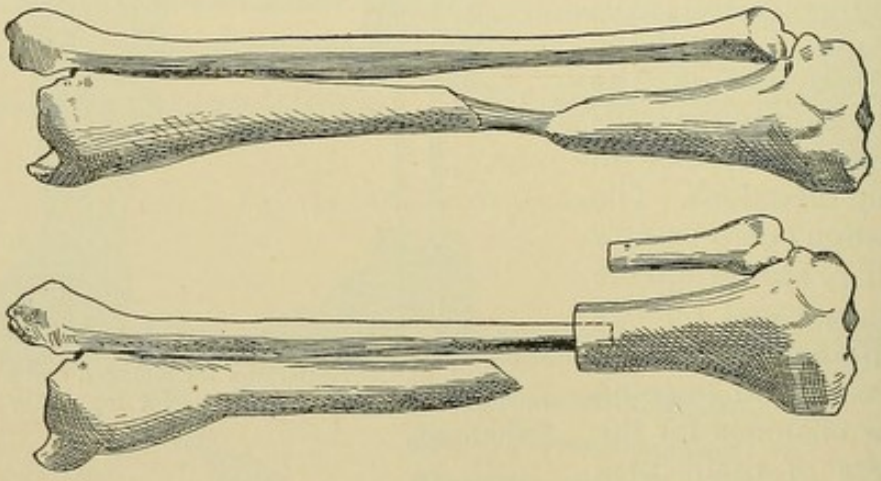

Fig. 261.—Pseudarthrosis of the tibia, with extensive loss of substance. Impaction of the lower end of the fibula into the upper fragment of the resected tibia (after Hahn).



Fig. 262.—Bone transplantation in the treatment of pseudarthrosis of the ulna (after Nussbaum).

nails of ivory or bone and sutures of silver wire or strong catgut are now used almost exclusively for fastening the vivified fragments together. *Resection should never be made by cutting the bone-ends transversely, as it is very important to sacrifice as little of the bone tissue as possible and to secure the largest bone surfaces obtainable for coaptation. The fragments should be vivified obliquely or in the shape of a step, as advised by Volkmann, and, if possible, the fragments removed in vivifying the ends should not be completely detached, but should be retained and fixed in a place where they may be utilized in the subsequent reparative process.* The methods of wiring and other means of direct fixation will be fully described in the chapter on Compound Fractures.

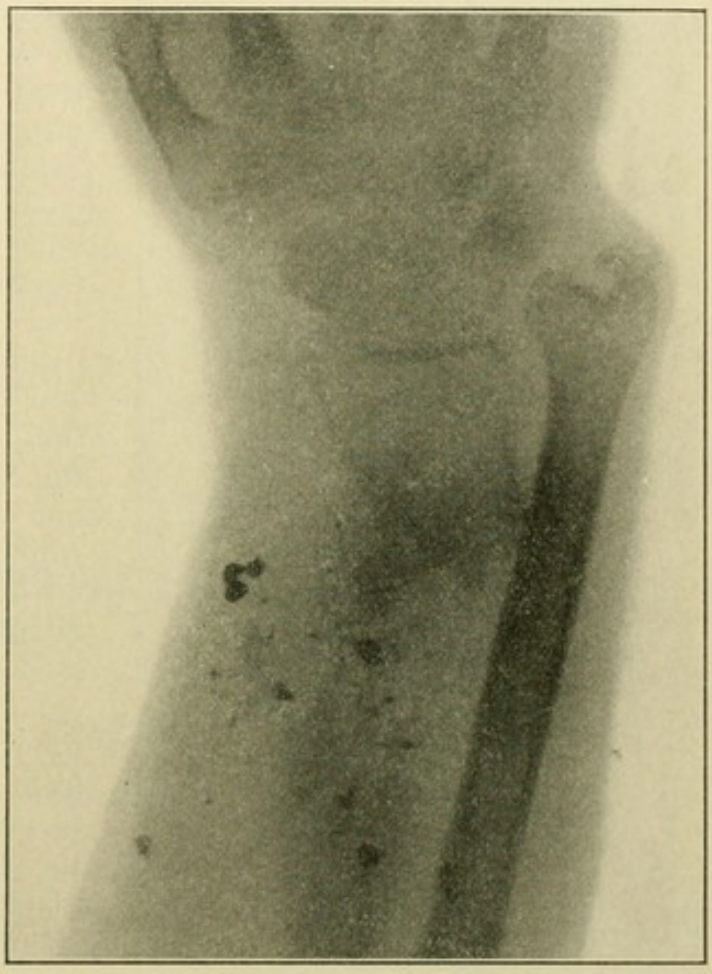

Fig. 263.—Pseudarthrosis following gunshot fracture of the radius, some of the bird shot remaining embedded in the tissues.

The exposure of a false joint for the purpose of transforming an old into a new fracture, and of substituting direct for indirect means of fixation, should only be seriously entertained after other methods have had a fair trial in securing healing of the fracture by bony callus. In some cases of fracture of the humerus or femur or fracture of two parallel bones, with great loss of substance of one, coaptation and fixation by impaction offer the best prospects of bony consolidation. If the impaction can not be maintained by an external dressing, direct fixation by wiring, nailing, or the use of the bone ferrule is indicated and will add greatly to the success of the operation.

In false joints caused by great loss of bone tissue it may become necessary to resort to transplantation of bone. Implantation of bone from any of the lower animals has invariably proved a failure. In the cases in which the operation appeared to have been successful,

and were reported as being so, the implanted bone was absorbed and replaced by new bone, produced by the osteogenetic tissues around the foreign aseptic substance. The results of experiments, as well as a large clinical material, have proved that autotransplantation is the proper method to pursue in such cases. The material for the transplantation should be taken, if possible, from the same bone, by chipping off fragments from the bone-ends, as will be described in the chapter on Compound Fractures, or, in case the operation is made on one of two parallel bones, from the bone opposite, preserving, if possible, some of the vascular connections.

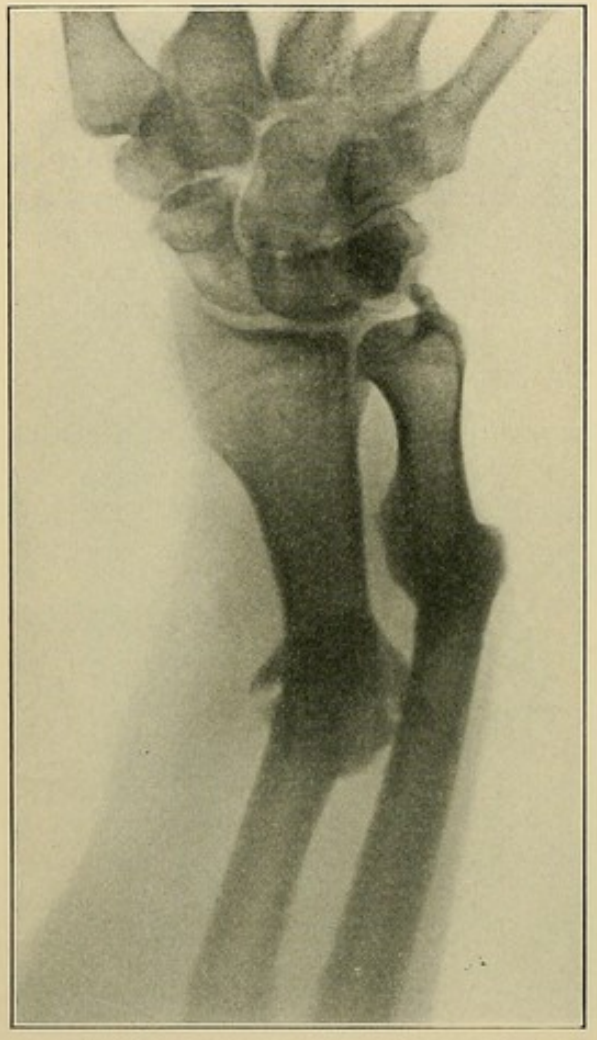

Fig. 264.—Vicious union of fracture of both bones of the forearm. Great overlapping of fragments of the radius and marked deviation toward the radial side.

The first successful bone transplantation in the treatment of pseudarthrosis was made by von Nussbaum. The ulna was the seat of fracture, and a portion long enough to bridge the space was taken from one of the fragments, with which it remained connected by a periosteal bridge. Nussbaum placed great stress on preserving vascular connection between the fragment and the bone from which it was taken in determining the success of the operation. In transplanting fragments of considerable size, every effort should be made to preserve at least a slight vascular supply; this, however, is not essential in filling in gaps of even large extent by smaller bone fragments. Preservation of the periosteum is very important, as the bone chips and vivified ends of the fragments should be furnished with a vascular bone-producing covering.

Vicious Union.—Vicious union can not always be prevented, even by the most careful and painstaking treatment, as the injuries of the soft tissues do not always permit of the most efficient mechanical measures in securing complete reduction and perfect retention. It is in such cases that the physician should resort to early efforts in correcting the malposition as soon as the condition of the soft

tissues warrants such an attempt. Manual brisement forcé often succeeds in correcting the deformity in from four to eight weeks after the injury occurred, and in delayed union several months after the accident. In vicious union with the fragments united by a bony callus, more force is required, and the osteoclast must be substituted for manual force. If the osteoclast can not be used, owing to the seat of the fracture or to the uncertainty as to where the fracture will take place, the continuity of the bone is destroyed with a chisel used through an open incision, and that section is made that offers the best local condition for the correction of the deformity by the subsequent treatment of the recent compound fracture. A linear osteotomy will suffice in some cases, while others require a wedge-shaped excision of bone, with the base of the wedge corresponding with the convex surface of the angle. In some cases subcutaneous drilling, carried to the extent of weakening the bone sufficiently to yield to manual force, or the osteoclast at the desired point, will constitute the safest and most advisable procedure in correcting the vicious union.

CHAPTER X.

SPECIAL FRACTURES.

I HAVE made an effort to describe, somewhat in detail, the general principles that should govern the treatment of fractures, upon which the physician must rely largely in the management of special fractures. Each case must be studied on its own merits, in order intelligently to meet special indications. It is my purpose in this section to consider only the fractures that present the greatest difficulties to accepted methods of treatment, and that have so often been followed by vicious union, nonunion, and unsatisfactory functional results. Preeminent among these are fractures of the neck of the femur and Colles' fracture of the lower end of the radius. The latter fracture is so frequent, and the results are so very unsatisfactory when not recognized or when improperly treated, that a repetition of what has already been said with special reference to this fracture can not be out of place.

Fractures of the neck of the femur are always dreaded by all physicians, because the results are such as often to cast a reflection on the treatment pursued, besides being a source of great disappointment to the patient. I have for a long time entertained very decided views regarding the possibility of more frequently obtaining repair by bony callus in nonimpacted intracapsular fractures by more energetic treatment—a treatment calculated to bring into action the same principles that should govern the treatment of fracture in any other locality—than by abandoning the idea of

making an attempt to carry these principles into effect in such cases, and of adopting a treatment accordingly. Fractures of the neck of the femur and Colles' fracture receive special consideration here because they serve as a useful and instructive object-lesson in illustrating the difficulties that we encounter in the diagnosis and treatment not only of these two fractures, but also of all fractures near or involving any of the large joints.

Fractures of the Neck of the Femur.—The treatment of a fracture of the neck of the femur is always a source of anxiety to the surgeon. In many instances the diagnosis is attended by unusual difficulties, and not infrequently a fracture of this kind is overlooked, even after what appears to have been a thorough examination, while at other times, for want of a correct diagnosis, patients have been submitted to a long and debilitating treatment when no fracture existed. Patients suffering from this injury are, with few exceptions, advanced in years and liable to succumb to complications incident to prolonged confinement in bed. The marantic changes in the tissues of the aged and in persons rendered prematurely old by hereditary or acquired causes are known to be antagonistic to a rapid repair of such an injury, while at the same time the anatomic conditions at the seat of fracture are such as are well calculated to retard, if not to prevent, the production of callus. With few exceptions our surgical text-books and special works on fractures continue to advance the same ideas that have been prevalent for centuries concerning the process of repair in fractures of the neck of the femur, and assert that bony union is only possible if the line of fracture is completely, or at least partially, outside of the limits of the capsular ligament. Teachers and authors are so positive in their assertions that if the fracture is entirely intracapsular a pseudarthrosis is inevitable, that many cases of partly extracapsular fractures have been treated on the expectant plan, the same as intracapsular fracture, and only too often with the same unsatisfactory result. The time has come when it is no longer admissible to make such a distinction in the lecture room, in the text-books, or at the bedside. Experience and experimental research have demonstrated that the proximal fragment, in case the line of fracture is entirely intracapsular, does not only retain its vitality, but if placed in accurate contact with the opposite fragment, either by impaction or by mechanical fixation, will take an active part in the production of callus.

In a paper read at the meeting of the American Surgical Association in 1883 I gave an account of fifty-four cases, collected from different sources, of bony union after intracapsular fracture of the neck of the femur, and in most of them the proofs in support of the assertion were so convincing that even skeptics on this subject would find it difficult to give to them a different interpretation. In the same paper were recorded the results of my own experimental work, undertaken for the special object of demon-

strating, if possible, that bony union after intracapsular fracture is so seldom obtained, not so much on account of the anatomic peculiarities of the parts involved in the fracture, as the inefficient efforts that are resorted to in its treatment, owing to the wide-spread opinion that bony union is not obtainable by any kind of treatment of nonimpacted intracapsular fractures. These experiments are introduced here as evidence of the results that usually attend fractures of the neck of the femur within the capsule treated by the old methods, as well as to show that immediate and perfect reduction and uninterrupted retention will succeed, in many cases, in securing union by bony callus yielding excellent functional results.

Experiments on Animals Made for the Purpose of Proving the Possibility of Obtaining Bony Union by Immediate Reduction and Perfect Retention.—These experiments were made with a view to obtaining reliable information concerning the following questions:

1. What is the mode of repair after nonimpacted intracapsular fracture of the neck of the femur?

2. What becomes of a bone or metallic nail when driven into the neck of the femur and retained permanently?

3. What is the effect of such nails upon the adjacent bone tissue?

4. Can we, in cases of intracapsular fractures of the neck of the femur, by immediate or direct measures, as by nailing the fragments together, obtain such accurate coaptation and retention as to secure union by bone?

A great many difficulties were encountered in performing these experiments, preeminent among them being shortness of the femoral neck and difficulty in carrying out the aseptic precautions and in providing additional means for securing immobility of the fractured bone. The operation was made painless by injecting morphin or by general anesthesia with ether. The animals used were cats, dogs, and rabbits, embracing, in all, thirty-three experiments upon thirty animals.

In the first thirteen operations the capsule of the hip-joint was exposed by a small posterior incision, and the neck was rendered more accessible by forcibly rotating the thigh inward; the bone was perforated a sufficient number of times with a small drill close to the head, and usually fractured by forcible abduction and rotation outward of the limb. The fracture, as a rule, took place with a distinct snap, and was followed by all the characteristic symptoms of fracture through the neck—preternatural mobility, shortening, and crepitus. The incision was closed with catgut sutures, and the wound covered with iodoform and salicylated cotton. In all these cases the fractured bone was replaced as nearly as possible in the normal position, and a plaster-of-Paris dressing applied, which included the pelvis and both extremities. Two of these animals died of pyemia, and in not a single instance out of the whole number

could be found, at the postmortem examination, the slightest attempt at bony union. In one instance, that of a young Newfoundland dog, the hip-joint presented evidences of severe inflammation without suppuration; the head of the femur, having necrosed, was found completely detached in the acetabulum. In some cases ligamentous union had taken place, while in others the fractured surfaces were covered with healthy granulations. In all the specimens the lower fragment had become shortened. Having satisfied myself that the antiseptic treatment could not be followed with sufficient accuracy in these cases to protect the animals against infection, it was decided to fracture the neck subcutaneously. In the next six cases, after shaving and disinfecting the hip and rotating the thigh inward and sliding the skin forward, a puncture was made down to the neck of the femur from behind with a narrow tenotome, and a drill being inserted into the passage made, the neck was divided and fractured as before. The skin retracting made the operation entirely subcutaneous. A plaster-of-Paris dressing was applied in the same manner as in the first series of experiments. No inflammation or febrile reaction followed these operations, and the postmortem examinations showed evidence of ligamentous repair. In the absence of bony union the functional result in several cases appeared remarkable. With few exceptions all the fractures produced so far were proved at the autopsy to be purely intracapsular.

In experiment No. 21 the neck was fractured subcutaneously and no retaining dressing applied. The animal was killed five weeks after operation, and an examination of the hip-joint showed that a firm and short ligament connected the fragments within the capsule. After the first three weeks little or no lameness could be detected.

Having failed in all cases so far in obtaining union by bone, it was determined to change the treatment and resort to immediate reduction and fixation of the fragments by nailing. The fracture was produced subcutaneously in the same way as in the preceding series of cases, and, after replacing the limb in its natural position and sliding the opening in the skin to a point corresponding with the center of the base of the femoral neck, the drill was introduced and a perforation made in the direction of the center of the femoral neck. An aseptic wire nail or bone peg of proper length was then driven into the perforation made by the drill, so that the outer extremity of the nail should not project beyond the surface of the bone, while the opposite end fixed the detached head of the femur. The first two animals progressed very favorably after the operation and appeared to suffer but little pain, but, unfortunately, escaped before an examination could be made to ascertain the result.

Experiment No. 24.—Young cat; fractured the right femoral neck subcutaneously, and nailed the fragments with a bone nail. Animal killed ten weeks after operation. Neck of femur almost entirely absorbed; capsular ligament thickened; vertical section

through head, neck, and upper part of the shaft shows that the head is almost in contact with the trochanteric portion of the femur. Posterior portion of neck shows line of fracture near the head and fractured surfaces in close contact, but movable upon each other. Anterior portion firmly united by a dense compact callus, the upper fragment apparently impacted into the lower; no trace of the bone peg could be found. The perforation in the trochanter major can be followed to a distance of about two millimeters. In this specimen the lower fragment as far as the capsular ligament appears to have become almost entirely absorbed, as the upper fragment remains unchanged and is almost in direct contact with the trochanteric portion of the femur. Ligamentum teres normal.

Experiment No. 25.—Adult cat; subcutaneous fracture of neck of right femur; direct transfixion of fragments with wire nail. Animal killed eighteen weeks after operation. Fracture within capsule close to the head; fragments in close contact, slightly movable upon each other, but united by a very short ligament. Nail had slipped outward, and projected from the trochanteric surface about one-third of an inch, and could be felt as a sharp point immediately under the skin. The projecting portion of the nail is invested by a firm, dense, fibrous capsule, while the implanted portion is firmly and immovably fixed in the bone. Vertical section through the head, neck, and trochanteric portion shows that almost the entire neck has disappeared by interstitial absorption, the upper fragment being nearly in contact with the trochanteric portion. The trochanteric portion has lost the greater part of its cancellated structure, its interior being filled with compact tissue; this change is conspicuous more particularly in that portion of the bone traversed by the nail. Capsular ligament thickened; ligamentum teres normal.

Experiment No. 26.—Adult, large Maltese cat; subcutaneous fracture of right femoral neck; direct coaptation of fragments with wire nail. Animal killed ten weeks after operation. Neck of femur shortened; capsular ligament thickened; ligamentum teres normal; vertical section through the upper portion of the femur shows line of fracture within capsule, with impaction of upper fragment into lower; fragments movable upon each other, but broken surfaces in immediate contact. A new compact layer of bone was formed on the outer surface of the compacta in the region of the lesser trochanter. Nail firmly embedded in bone; outer extremity on a level with compact layer of trochanter major; it is seen to traverse the trochanteric portion in a backward direction, entering the cavity of the hip-joint, and being in close contact with the posterior surface of the femoral neck, its sharp point being on a level with the highest point of the head. No inflammation in the hip-joint. During life the function of the joint appeared to be perfect. As the point of the nail was firmly fixed in the capsular ligament and impaction had taken place during the nailing process, immobility was tolerably

well attained, and there is every reason to believe that bony union would ultimately have taken place.

Experiment No. 27.—Adult Maltese cat; subcutaneous fracture of left femoral neck; direct adjustment of fragments by bone nail. Cat died of fatty degeneration of liver and kidneys five weeks after operation. Vertical section through upper portion of femur reveals line of fracture partly within and partly without the capsule. No union; fragments in good apposition; outer extremity of bone nail beneath the compacta; direction of nail downward and inward, the point terminating a little beyond the line of fracture in the neck. The saw has cut the nail obliquely at the juncture of the outer with the middle third. No evidences of inflammation or repair.

Experiment No. 29.—Adult cat; fractured neck of left femur subcutaneously, and used bone peg for nailing fragments together. Animal died of pyemia twelve days after operation. Hip-joint filled with pus; fracture intracapsular; outer extremity of nail on a level with compacta; its point was in the cavity of the joint, on a level with the foveola of the head. A piece of the posterior portion of the head is split off, an accident that occurred either in the use of the drill or in driving in the nail.

Experiment No. 30.—Adult cat; subcutaneous fracture of right femoral neck and direct transfixion of fragments by wire nail. Animal died, four weeks after operation, of pneumonia. No inflammation of joint; fracture intracapsular; fragments slightly separated, but well transfixed by nail; no callus.

Experiment No. 32.—Young cat; subcutaneous fracture of neck of right femur; direct fixation of fragments with bone peg. Animal killed four months after operation. During life, function of the joint was perfect; vertical section through the head, neck, and upper portion of shaft shows that the line of fracture must have been entirely within the capsule, as no thickening of bone or of ligament could be seen; capsular ligament normal. Accurate measurement shows only an appreciable shortening of neck; compact tissue within neck more abundant than in the opposite bone. Spongiosa restored to nearly its natural perfection. No trace of track of perforation or bone nail.

In no case was crepitation felt more distinctly than in this case, and the sudden giving way of the bone the moment it was fractured was well marked and heard by several witnesses, and as the post-mortem examination shows a perfect restoration of the continuity of the bone, it is certain that this case represents a typical and perfect recovery through union by bone after intracapsular fracture of the neck of the femur.

In all cases, twenty-one in number, where no direct means of fixation were used, there was not the slightest evidence of bony union; the best result attained was a short ligamentous band. In experiment No. 21 no retention dressing was applied, and the

result was equally as good as, if not better than, in the cases where the plaster-of-Paris dressing was used.

In all these cases the tendency to shortening was not so well marked as in man, while eversion occurred seldom, and only to a slight degree.

The weight of the limb evidently counteracted muscular action, while the conditions that produce eversion in man are absent in animals. The results obtained by immediate transfixion of the fragments stand in direct contrast to those treated by external fixation. Bony union, or union by short ligament, was the rule; non-union, the exception.

These experiments would also tend to prove that aseptic metallic nails, when implanted subcutaneously into living bone, remain firmly in its substance for an indefinite period of time without giving rise to suppuration, and from one of the experiments it will be seen that the point of the nail was within the cavity of the joint for many weeks without materially interfering with the normal function of the joint, or producing more than a slight synovitis.

Ivory and bone nails, if driven into living bone, produce an osteoplastic process, and are, on this account, not only useful in the treatment of pseudarthrosis, but are equally efficient in accelerating the reparative process in recent fractures. Aseptic bone and ivory nails in aseptic tissues are completely absorbed, the time required for absorption depending upon the vascularity of the tissues that are in immediate contact with the nail.

According to Gurlt, the time required for bony union is proportionate to the diameter of the fractured bone, being much shorter in case of slender bones as compared with those of greater diameter. It appears that the shortest time in which the slender neck of the femur in cats unites by bone is at least two months; hence it is reasonable to assume that in man the time required for bony consolidation of fracture of the femoral neck must be at least from one hundred to one hundred and twenty days. As in two of the specimens well-marked impaction occurred during the nailing process, the question arises whether the same desirable conditions could not be obtained in man by using sufficient lateral pressure at the time direct coaptation is attempted; in other words, would it not be prudent to use sufficient pressure to produce interlocking of the fragments or even artificial impaction? Interstitial absorption, as the consequence of osteoporosis, takes place to a greater or less extent in every case of fracture through the femoral neck, and precedes and accompanies the reparative process. In all cases of bony union the posterior attachment of the cervical portion of the capsular ligament was displaced outward, an occurrence that can only be explained satisfactorily by assuming that during the osteoporotic process the periosteal investment of the femoral neck is loosened and transplanted toward the femoral shaft, carrying with it the

femoral insertion of the capsular ligament. These experiments also illustrate the difficulty of transfixing the upper fragment in the process of nailing, a circumstance largely due to the diminutive size of the bone, the incomplete anesthesia, and the want of fixation of the parts in their relative normal positions previous to the operation.

Specimens of Bony Union after Intracapsular Fracture of the Neck of the Femur.—As the specimens representing bony union after intracapsular fracture of the neck of the femur are still few, and the possibility of such a method of repair is still a disputed question, I made a very thorough search of the literature on this subject, and was able to find only fifty-four well-authenticated specimens of this kind. In addition to these I desire to place on record another case that came under my own personal observation.

Bony Union after Intracapsular Fracture.—The patient was a female, aged seventy-five years, who came under my care as a hospital patient. She was in good health at the time of the accident, hence there can be no possibility that the extensive changes in the neck of the femur were the result of senile coxitis or interstitial absorption. The fracture was produced by direct violence by a fall upon the greater trochanter. Fractures of the neck produced in this manner are very apt to be impacted. Loss of function was complete immediately after the injury, and remained so for several months. The patient suffered great pain in the groin and the region of the trochanter minor, a symptom that is always indicative of injury within the capsular ligament. For the purpose of excluding asymmetry of the bones, all the long bones of both legs were measured separately, and on comparing the measurements, the injured limb was found one-half of an inch shortened. The limb was strongly everted. Gentle traction had no effect on the length of the limb. On comparing the movements of the trochanter major on both sides by rotating the limbs, it was found that the neck of the femur on the affected side was perceptibly shorter. No crepitation could be felt. As the impaction appeared to be firm, no treatment was employed except rest in bed, on a smooth, even mattress, with sand-bags on each side of the limb for support. In this position the patient remained for three months; at the expiration of this time she was allowed to walk on crutches. Three weeks after the injury the shortening gradually increased until it reached an inch and a half. The secondary shortening evidently was the result of a loosening of the impaction by the osteoporosis and absorption of some of the spongiosa of the neck of the femur; it might have been prevented by more efficient fixation of the fragments by lateral pressure, combined with immobilization of the pelvis and limb. The patient eventually was able to walk quite well with the aid of a cane. Two years after the accident she died of pneumonia. Autopsy revealed the following conditions of the joint and neck of the femur:

"The capsule of the joint, especially the upper portion, was

thickened and firm, and bridges of fibrous bands connected the line of fracture with the anterior portion of the ligament. On the anterior surface of the neck the direction of the fracture could be clearly traced from below upward and from within outward, but not extending beyond the insertion of the capsular ligament. The line of fracture is elevated and presents a serrated appearance. Posteriorly the head of the bone was in close proximity to the posterior intertrochanteric ridge. A slight depression on the articular cartilage marked the point of contact with the inner surface of the capsular ligament. Impaction had evidently taken place at the expense of the posterior compact portion of the neck. A portion of Adams' arch, which had been impacted into the lower fragment, could be distinctly seen in the spongiosa in making a vertical section. A vertical section through the neck, head, and trochanter revealed a white line of very compact bone traversing the cancellated tissue of the neck near the shaft in an oblique direction, corresponding to the line of fracture on the anterior surface of the neck. The anterior half of the specimen has been submitted to the boiling test without affecting the union of the

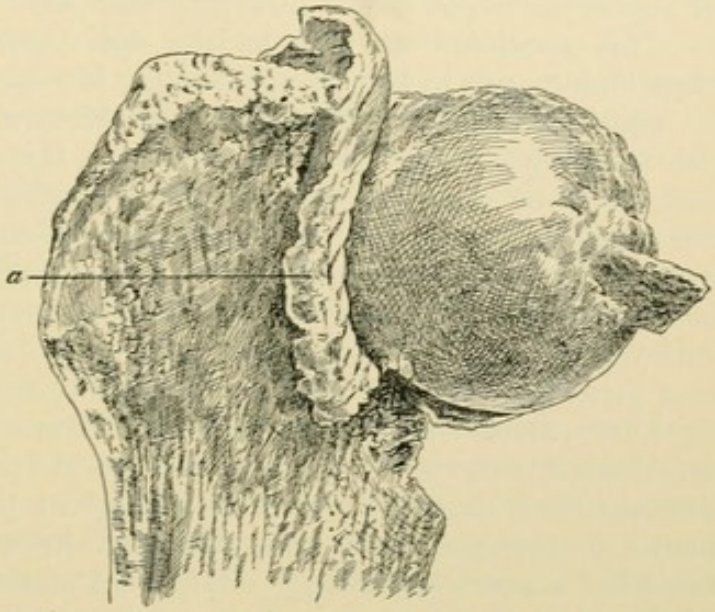

Fig. 265.—Bony union after intracapsular fracture (posterior view) : *a*, Capsular ligament.

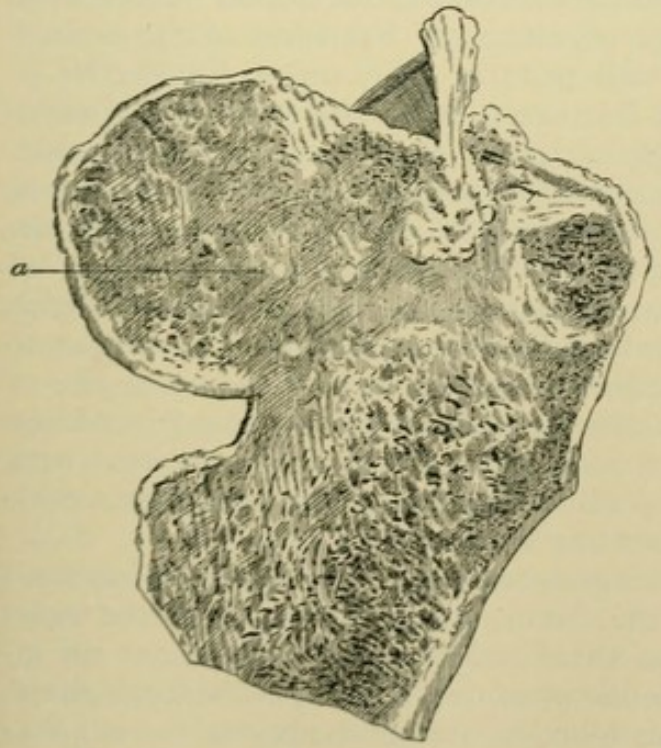

Fig. 266.—Bony union after intracapsular fracture (vertical section) : *a*, Compact plate of bone.

fragments; hence there can be no doubt as to the union by bone. The bone outside of the capsular ligament presents no sign of callus or any other evidences of injury or disease."

This specimen, as well as the specimens obtained from the experiments, are in the Army Medical Museum.

Classification of Fractures of the Neck of the Femur.—Since the teachings of Sir Astley Cooper on this subject, it has been customary to classify fractures of the cervix femoris, according to the relative position the capsular ligament bears to the line of fracture, into the intracapsular and extracapsular fractures, to which has been added a third variety, fractures partly within and partly without the capsular ligament. The mixed variety has given rise to a great deal of confusion, as some have included it among intracapsular, others among extracapsular, fractures. Since it has been ascertained that many of the fractures of the neck of the femur are impacted, those who have placed great prognostic and therapeutic importance upon this condition have made impaction the basis for a new classification—impacted and nonimpacted fractures of the neck of the femur. Among those who have supported this classification may be mentioned Cloquet, Gosselin, Duplay, Bigelow, Bryant, Hueter, and Lossen.

The distinction between impacted and nonimpacted fractures is important in a clinical, diagnostic, prognostic, and therapeutic sense, while the division into intracapsular and extracapsular fractures has a very important pathologic significance. Fractures of the neck of the femur with impaction will unite by bony union, irrespective of the location of the line of fracture, provided the impaction is maintained for a sufficient length of time. Fractures, impacted or nonimpacted, outside of the capsular ligament, will unite in the same manner as fractures in any other locality, if the fractured ends are kept in apposition and are immobilized for the necessary length of time. Fractures at the narrow part of the neck and entirely within the capsule can unite only by bone if the penetration is such as to secure apposition for a number of weeks, or if the same degree of apposition and immobilization is effected by surgical procedures. The frequency with which impaction occurs in the femoral neck and the important part it performs in the reparative process entitle it to a permanent place as a basis for classification.

When we are able to diagnosticate the existence of an impacted fracture of the neck of the femur, all efforts to locate the exact seat of fracture are worse than useless, as it could have no influence in selecting therapeutic measures, and might eventuate disastrously by abolishing the most favorable conditions for a fortunate issue. If we adopt the proposition that fractures of the femoral neck with penetration can, and often do, unite by bone, irrespective of their relative position to the capsular ligament, then the distinction between fractures within and fractures without the capsular ligament can only find a practical application in the

examination of specimens to prove or disprove the correctness of the proposition. This is the more true as, *in vivo*, all known diagnostic means have proved unreliable in locating the exact point of fracture. The sooner the profession can be convinced that intracapsular fractures also unite by bony union under certain favorable conditions, the better will it be to abandon the old classification, which has proved to be incorrect anatomically and unwarranted by pathologic facts. Practically, then, it is always important to ascertain the presence of impaction, and not to interfere with it when found; theoretically, and for the purpose of adopting therapeutic measures, it is desirable in nonimpacted fractures to locate, as nearly as possible, the seat of fracture without inflicting unnecessary violence.

In the light of recent anatomic investigation and pathologic research, and for the purpose of avoiding unnecessary confusion, it would be advisable to limit the term intracapsular to all fractures that do not extend beyond the insertion of the capsular ligament, and include among the extracapsular fractures the so-called mixed and purely extracapsular fractures. Remembering the attachment of the anterior portion of the capsular ligament, we should naturally infer that purely extracapsular fractures without further injury to the shaft of the femur, if possible at all, must be exceedingly rare. The greatest number of extracapsular fractures, as described in our text-books, belong to the mixed variety: intracapsular in front, extracapsular behind. In speaking of extracapsular fractures R. W. Smith says: "All extracapsular fractures are, in the first instance, also impacted fractures, and all impacted fractures are necessarily accompanied by a fracture traversing some part of the trochanteric region. I have omitted no opportunity of investigating this point, and have now examined, here and elsewhere, upward of one hundred specimens of the extracapsular fracture, and have found in all, without a single exception, a second fracture traversing some portion of the intertrochanteric space."

In commenting upon this paper A. C. Post suggested the substitution of the terms intracervical and extracervical for intracapsular and extracapsular, the latter designation to indicate an impacted fracture at the base of the neck with more or less injury of the femoral shaft. As under this classification intracervical fractures would include intracapsular and mixed fractures, and the term extracervical would imply the existence of a fracture rather beyond than in the cervix itself, these terms do not convey sufficiently accurate anatomicopathologic precision to recommend themselves for general adoption, although they are full of practical significance. Inasmuch as the principal object in writing this section is to prove that bony union after intracapsular fractures can take place, the terms intracapsular and extracapsular are retained, used in the sense previously suggested.

Relative Number of Intracapsular and Extracapsular Frac-

tures.—The inability accurately to locate the fracture during life and the existing confusion and uncertainty as to the meaning and application of the terms intracapsular and extracapsular in the description of specimens have rendered the statistics on this point unsatisfactory and unreliable. Although the cervix femoris may be broken at any point between the head of the femur and the intertrochanteric ridges, there are certain points where it is more liable to give way. The exact location of the fracture is determined to a great extent by the seat and degree of senile osteoporosis and the direction of the fracturing force. Senile osteoporosis, as we have seen, begins in the spongiosa and reaches its maximum degree soonest at the contracted portion of the neck; hence fracture nearest the head is most likely to take place in decrepit old people. Fractures at this point are exceedingly rare in persons less than fifty years of age, only a very few well-authenticated cases being on record. Rodet, in a series of experiments on the femur and on plaster-of-Paris casts of the upper extremity of this bone, has demonstrated the important fact that the situation and direction of a fracture of the neck of the femur may be predicted to almost a certainty by a knowledge of the direction in which the force was applied. Thus, a force acting vertically will produce an oblique intracapsular fracture; a force acting from before backward, a transverse intracapsular fracture; one from behind forward, a fracture partly within and partly without the capsule; and a force applied transversely, a fracture entirely without the capsule. Clinical evidence has repeatedly verified the correctness of these observations. The traction fractures described by Linhart, Riedinger, and Hueter, from the powerful traction of the iliofemoral ligament when the thigh is overextended and adducted, invariably fall outside of the limits of the capsule.

Bonnet believed that the line of fracture was almost always without the capsule, and Nélaton contended that in the great majority of cases he made the same observation; while many equally competent authors, among them Sir Astley Cooper, Ashhurst, and Druitt, claim that intracapsular fracture occurs more frequently in persons above fifty years of age. Of 12 specimens examined in the museum of St. Bartholomew's Hospital by Stanley, 6 were supposed to be intracapsular and 6 extracapsular. Malgaigne examined 103 specimens from different sources to determine the relative frequency of these fractures, and found that 61 belonged to the intracapsular, against 42 of the extracapsular, variety.

M. Mercier, at Bicêtre, found, in 8 autopsies, 3 intracapsular to 4 extracapsular fractures, and 1 below the trochanters; while Malgaigne himself, in the same hospital, found, in 8 other autopsies, 1 fracture below the trochanters, 5 within the capsule, and only 1 outside of it. Stimson made a postmortem examination in 6 cases, and ascertained that in 2 of them the fracture was purely intracapsular, and in 4 it was at the junction of the neck with the shaft.

Heppner gives a description of 5 cases of impacted fractures of the neck of the femur, of which number 3 were extracapsular and 2 intracapsular. Of 20 specimens of fracture of the neck of the femur in the Museum of the College of Physicians, Philadelphia, and the University of Pennsylvania examined by Agnew, 10 were within and 13 without the capsular ligament. Mussey's collection contains 12 specimens of fracture of the neck without the capsule and 10 within.

The foregoing statistics embrace 185 postmortem specimens, of which number 99 were fractures within and 86 without the capsular ligament, figures which would tend to prove that intracapsular fractures are more frequent than fractures without the capsule. It must, however, be remembered that many of these specimens were collected for a special purpose, and on that account the numbers do not represent the true proportion as it actually exists. If the statistics obtained by the examination of postmortem specimens are not reliable in ascertaining the relative frequency with which these fractures occur, the information derived from clinical observation must prove still less satisfactory in deciding this question, as the symptoms during life are not sufficiently well marked to enable the surgeon to locate the exact seat of fracture with certainty.

Billroth refers to 27 cases of fracture of the neck of the femur, of which number 13 were diagnosticated as intracapsular and 14 as extracapsular. In Dr. Hyde's table of 321 cases of fracture of the femur we find that the neck was involved 31 times; these were supposed to be located 14 times within and 17 times without the capsule.

Hamilton has recorded 84 cases of fracture of the femoral neck from his own personal observation; of these, 40 were believed to be without the capsule, and 30 were believed to be within; the remainder were undetermined. These statistics furnish 128 cases with 57 intracapsular and 71 extracapsular fractures, a majority in favor of the extracapsular variety.

Combining the figures from the museum specimens and those taken from bedside observation, we obtain 313 cases of fracture of the neck of the femur, of which number 156 were supposed to be located within and 157 without the capsular ligament.

Incomplete Fractures of the Neck of the Femur.—The structure of the neck of the femur in the aged furnishes conditions unusually favorable for the occurrence of partial or incomplete fracture. Although this form of fracture has received but little attention on the part of surgical writers, receiving at the best only brief mention, it would appear, from the cases reported during the last few years, that the accident is not so rare as has been supposed. Colles was the first to call attention to this variety of fractures as it occurs in the neck of the femur, and described three cases. J. B. S. Jackson, of Boston, described a case of incomplete fracture (fissure), the line of fracture extending from the junction of the upper border

of the neck with the head downward, to within a quarter of an inch of the inferior and internal wall of the bone. Gurlt mentions three cases. In Tournel's case the infraction occurred at the upper portion of the base of the neck, the line of fracture running from the digital fossa downward. In the case reported by P. W. King, the line of fracture was near the head of the femur. A bridge of compact tissue on the anterior and upper portion of the neck, one-third of the circumference of the compacta, remained intact. The third specimen described he found in the Pathologic Museum in Giessen. The transverse infraction affects the entire posterior half of the femoral neck about its middle, while the anterior wall is not affected. The margins of the fractured surfaces are in immediate contact.

Koenig describes two specimens. In the first the line of fracture occurred on the upper and posterior surface of the neck, near the head, with impaction of the cervical portion into the head, while the compact tissue on the anterior and inferior surface remained

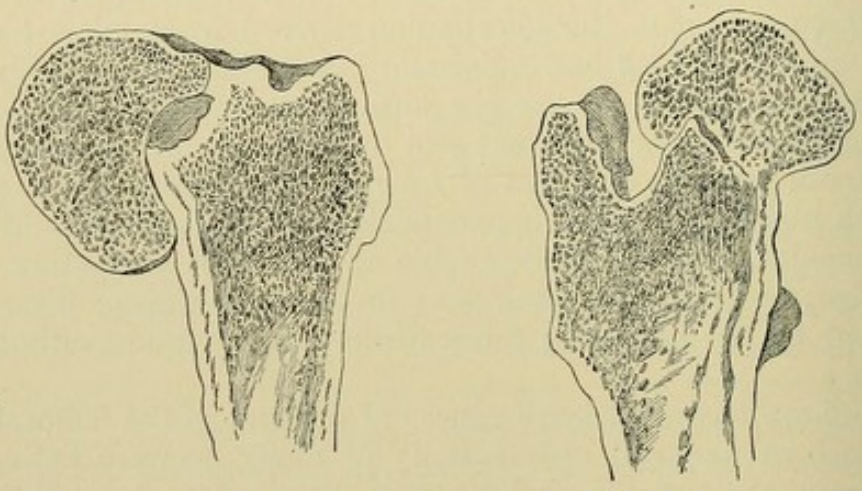

Fig. 267.—Incomplete fracture of neck of femur (Koenig).

entire. In the second specimen the line of infraction took place at the lower surface of the neck, at the most constricted point, with penetration of the apex of Adams' arch into the interior of the head, while the upper portion of the neck had yielded without being broken. These two varieties Koenig considers as representing typical forms of this fracture, the mechanism of their production being the same as in complete fractures of the neck. In the first variety, from the direction of the impaction the limb is rotated outward, while in the second form the foot remains in its natural position, but the limb is shortened in proportion to the depth of the impaction. Koenig is of the opinion that many of the cases of complete recovery after supposed intracapsular fractures were cases of incomplete fracture with impaction.

At the same meeting Billroth reported two cases in which he made the diagnosis of incomplete fracture during life; in both instances recovery was perfect.

Incomplete fractures of the neck of the femur, as well as of other bones, consist of a loss of continuity of a certain number of cancelli forming the substance of bone. It may exist in every degree, from a fracture almost complete to one in which the number of severed cancelli is so small as to elude detection by the naked eye. The location and direction of the line of infraction, as in complete fractures, must necessarily vary according to the direction in which the force that produces the fracture is applied. Stimson says: "The line of fracture is transverse and upon the concave side, and is produced by crushing, not by overbending." Incomplete fractures are repaired by the formation of intermediate callus between the fractured surfaces, which restores the continuity of the bone. The unbroken portion of the bone and periosteum serves as a perfect splint, which secures complete rest and apposition until the injury is repaired. The deformity attending this fracture is necessarily slight, and as the symptoms during life are not pronounced, the diagnosis must always remain uncertain. The cases are most likely to be mistaken for contusion of the hip; hence we should always examine the severer injuries about the hip with unusual care, and if any doubt exists, give the patient the benefit of the same, and treat the case as one of incomplete or complete fracture with impaction.

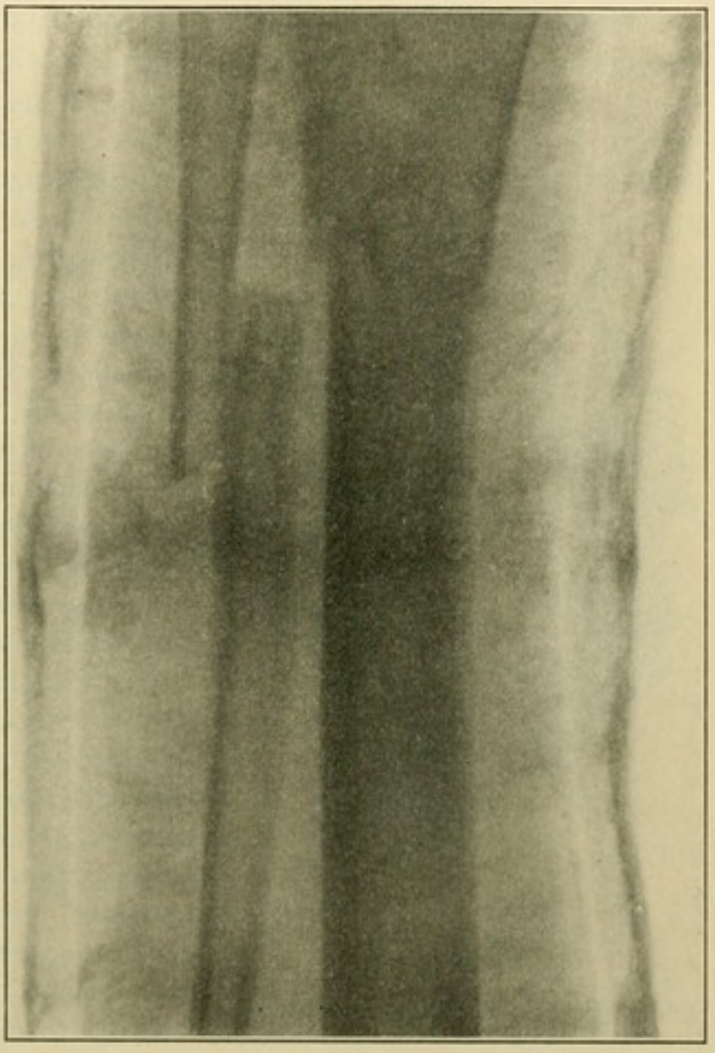

Fig. 268.—Impacted fracture of the tibia with overriding of the fragments of the fibula. The shaft of the tibia is driven into the spongy tissue of the upper fragment. Illumination through plaster-of-Paris dressing.

Impacted Fractures of the Neck of the Femur.—Impaction, penetration, implantation, and incuneation are synonymous terms,

used to designate a fracture when one fractured end is driven into the other, an occurrence that secures perfect coaptation and fixation. In some instances impaction is mutual. Impaction may be complete or incomplete, according to the tissue structure at the seat of the fracture, or the direction and intensity of the fracturing force. Impacted fractures are most frequently met in the spongy portions of the long bones and in persons suffering from osteoporosis from any cause.

These fractures have only quite recently become the object of special investigation, and are at the present time securing the attention their importance merits. Robert was the first to give a good description of impacted fracture of the neck of the femur and to explain its mechanism. He specified the following conditions that must present themselves in order to permit penetration. In the first place, the penetrating bone must have a conic shape and must be placed opposite a spongy section of bone, and must have been broken off close to the insertion of the same. The impacting force must be applied in the direction of the long axis of the incuneated bone. All these conditions are presented in fractures through the neck of the femur. Adams regarded the inner and lower compact tissue of the neck of the femur as the principal feature of impaction. The direction of the fracture through the neck being oblique from above downward, the arch is fractured in such a way that the apex, sharp and pointed, is placed opposite the loosely cancellated tissue of the shaft, into which it is driven by the same force that fractured the bone.

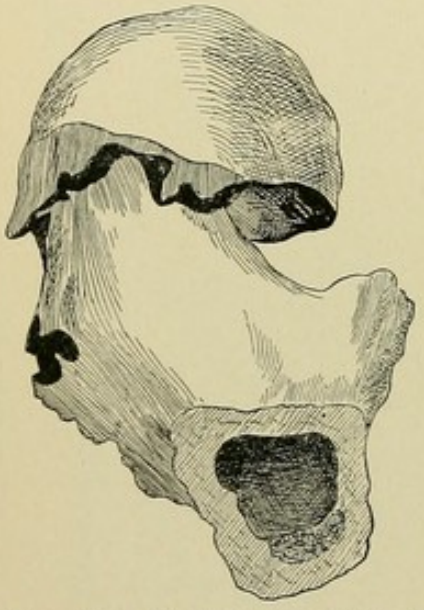

Fig. 269.—Posterior impaction of femoral neck (Bigelow).

Streubel looked upon senile osteoporosis as the main cause of impaction. It is necessary, however, that the compacta of the fractured neck should retain sufficient firmness to penetrate the bone without being comminuted. Some authors assert that impaction follows fracture in this way: that the neck of the femur gives way to indirect violence from a fall upon the foot or knee, the impaction following by the patient falling upon the trochanter. Heppner assumes that the relation existing between the neck of the femur and the trochanteric portion of the femur is the cause of impaction, and takes into special consideration the spongiosa, in which he distinguishes two distinct layers, the one possessing a greater degree of density than the other. He believes fracture at the base of the neck with impaction is always the result of force applied to the trochanter major, which expends itself at the origin

of the femoral brace and fractures the entire base of the cervix. Aside from the diminution in the obliquity of the cervix and the presence of osteoporosis, he finds another cause for this fracture in the general atrophy of the aged, rendering the trochanter major more prominent and thus more directly exposed to external violence.

This last assertion, however, is not in accord with experience, as corpulent aged females furnish the largest number of fractures of the femoral neck. Streubel made some experiments on cadavers to determine the seat of fracture on the application of direct and indirect violence. To test the effect of violence applied in the axis of the femur he amputated the thigh, and applied the force directly to the sawed surface of the femur, and succeeded only in one instance in producing an intracapsular fracture. By applying the force to the trochanter major he produced one extracapsular impacted fracture, while in all other cases the trochanter major was fractured. Heppner repeated these experiments with the same results. He then reversed the direction of the force. Taking a femur stripped of its soft parts, and resting the outer surface of the trochanter major upon a table, he struck the head of the femur with an ax, and produced, in every instance, a fracture of the neck resembling an impacted fracture. He repeated the experiment thirty times, and in five of the cases the impaction was typical. From these experiments he concluded that the fracture is produced by contre-coup, whether the force is applied to the trochanter major or through the axis of the femur. In regard to impaction of intracapsular fractures, he could find nothing in the literature on the subject of fractures of the femoral neck. Voillemier speaks of them at length, but only for the purpose of denying their occurrence. But inasmuch as he claims to have seen several specimens where the end of Adams' arch was found to terminate in the interior of the spongy portion of the head of the femur, he contradicts himself, as the description corresponds with impaction of the lower wall of the femoral arch into the head. The question at issue is not the degree of impaction, but whether it can secure mutual fixation of the fragments. In most cases only the lower

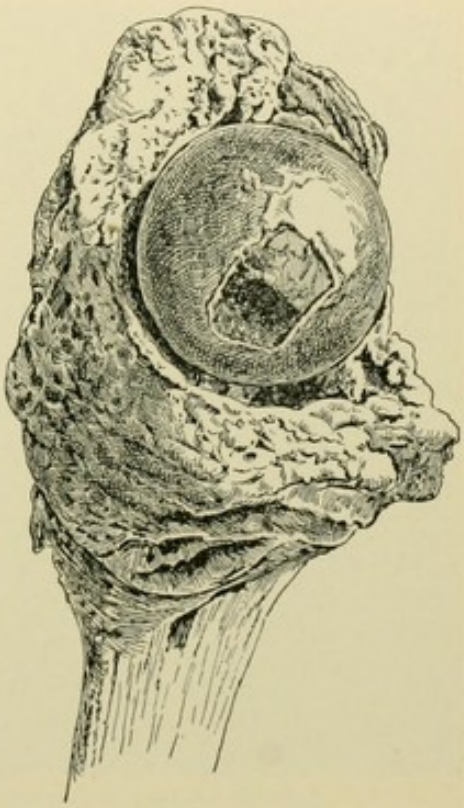

Fig. 270.—Impacted fracture of the neck of the femur at its base, exhibiting a massive extra-articular callus (after Verity).

edge of the outer fragment is impacted, but the contrary may occur, as is evident from the description given by Koenig under the head of partial fractures.

For one of the best contributions to our knowledge of impacted fractures of the neck of the femur we are indebted to Riedinger. He has studied this subject by way of experiments and examination of museum specimens. In speaking of intracapsular fractures he says that, as a rule, the lower, and more particularly the posterior, wall of the lower fragment is driven into the spongiosa of the head. As a necessary consequence of this form of impaction the head of the femur is depressed and inclines backward, sometimes to such an extent as to come in contact with the posterior intertrochanteric line. The cortical portion of the lower fragment can often be traced into the interior of the head to a distance of an inch. At the anterior line of fracture the denticulated margins retain so firm a grasp as to add materially to the firmness of the impaction.

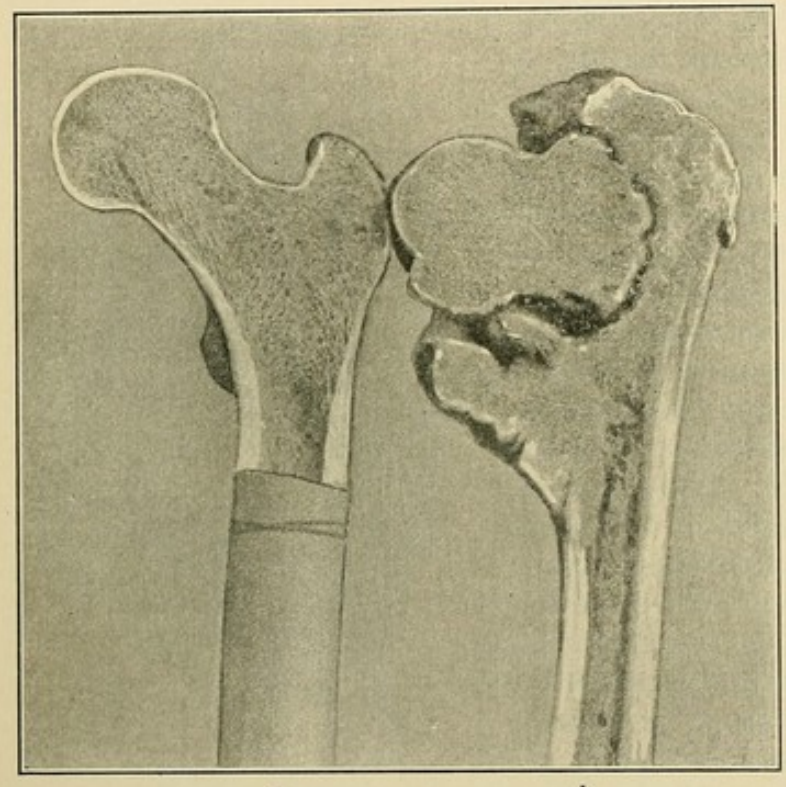

a *b*

Fig. 271.—Same specimen as figure 270 (vertical section): *a*, Vertical section through head, neck, and upper part of shaft of femur; *b*, vertical section through head, fractured neck, and upper part of shaft of femur (after Verity).

At the base of the neck of the femur the conditions for impaction are most favorable. If sufficient force is applied over the trochanter major, the neck fractures in such a way that the femoral brace is detached near its origin, and constitutes a sharp projection, which, when slightly dislocated, is placed *vis-à-vis* to the spongy tissue of the outer fragment, and is implanted into the same by the fracturing force. The upper portion of the inner fragment, although not possessed of a dense structure analogous to that of the femoral brace, follows in the penetrating process the more readily, as the whole inner fragment is wedge shaped. The spongiosa between the cortical layers forms a somewhat sharp projection. Impaction of the base of the neck is carried to its fullest extent in case the fracturing

force is sufficient to fracture also the trochanteric portion of the femur. In such instances the apex of the inner fragment splits the shaft of the femur, sometimes into a number of fragments, and presents itself on the outer surface of the bone beneath the soft parts.

Figures 270 and 271 represent a very interesting specimen. Ten days after the accident the patient from whom this specimen was obtained ran out of his burning house and received no treatment thereafter. The union is very firm, but not by bony callus.

Mr. Bryant has published a table of fourteen cases of impacted fracture of the neck of the femur, and from an analytic study of these cases he draws the following conclusions:

"1. That in all the cases the injury to the hip-joint was communicated through the great trochanter.

"2. That as a result of the injury there was more or less loss of power in the limb: in some cases it was complete, in as many the patient could rotate the limb slightly on the couch, and in two cases partial flexion of the thigh could be performed.

"3. That in all the cases immediate shortening of the injured limb was the direct result of the accident; and that this shortening was about an inch or less, and it was irremediable by extension.

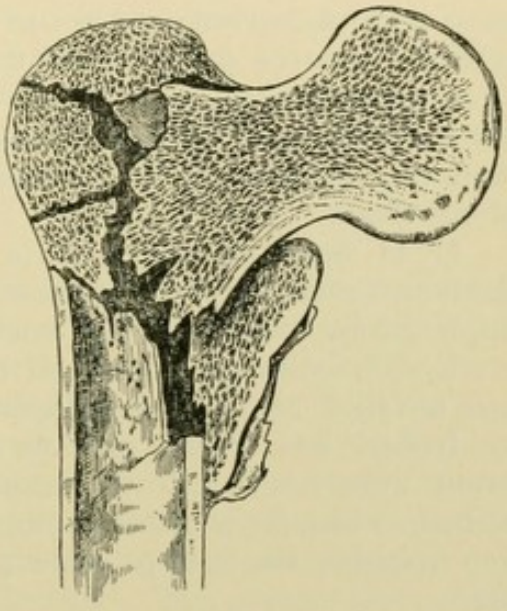

Fig. 272.—Impacted fracture at the base of the femoral neck, with fracture of the greater trochanter (Hoffa).

"4. That the foot of the injured extremity was either straight or slightly everted, although in several cases this eversion was less marked on the injured than on the sound side.

"5. That the great trochanter was placed nearer the median line of the body, and also nearer the anterior superior spinous process of the crest of the ilium than on the sound side.

"6. That the head of the femur could be made to rotate smoothly in the acetabulum, and the great trochanter moved with it.

"7. That crepitus was either absent or indistinct in all cases.

"8. That all the cases, with one exception, occurred in patients past middle age."

Bardeleben maintains that in intracapsular fractures longitudinal displacement is opposed by the untorn portion of the capsular ligament. In this fracture the ends of the fragments are often interlocked in such a manner as to prevent dislocation, and may

even enable the patient to walk on the limb for a few hours or for several days. The more important elements in retaining the fragments are, however, the presence of impaction and the untorn portions of the reflected capsule, the retinacula of Weitbrecht.

S. D. Gross believes that impaction is rare, and, when present, that it is almost exclusively extracapsular. The distance of penetration varies from a few lines to one-half or three-fourths of an inch.

Hueter places great stress on recognizing the presence of impaction. He regards the "Schenkelsporn" as the most important agent in the process of impaction. Anatomically, he distinguishes two varieties: either the upper end of the lower fragment is displaced inward, so that the termination of the Schenkelsporn penetrates the soft tissues below the upper fragment, or the lower fragment is displaced outward in such a manner that the Schenkelsporn is driven into the spongiosa of the neck.

Impacted fractures are not so frequent as nonimpacted fractures, but they are sufficiently common to impart great importance to them in diagnosis, prognosis, and treatment of fractures of the neck of the femur.

H. H. Smith believes that, in the majority of cases, the neck of the femur is fractured by indirect violence, impaction following subsequently by a fall upon the trochanter major.

R. W. Smith says that "all extracapsular fractures are, in the first instance, also impacted fractures."

Robert was of the opinion that fractures of the neck of the femur were nearly always impacted, and as such should be disturbed as little as possible to obtain the best results, as the impaction furnishes the best possible conditions for bony union to take place.

MacNamara affirms that fractures of the neck of the femur are usually impacted, the fragments being jammed into one another; the crushed cancellated tissue must be removed, rendering the process of repair tedious.

Bigelow, who has devoted a great deal of time and attention to the subject of injuries about the hip-joint, from the views he entertained as to the architecture of the femoral neck, was convinced that fracture takes place most frequently at the base of the neck, and is usually accompanied by impaction of the posterior wall. The cases present outward rotation of the limb and slight shortening, and may be followed by complete repair without lameness. Impaction at the constricted portion of the neck is not frequent. Impaction of the entire bone of the neck with inward rotation of the limb is very rare, and is hardly possible without fracture of the trochanters.

The same author, at a meeting of the Boston Society for Medical Improvement, held November 23, 1874, exhibited a specimen of a fracture within the capsular ligament with imperfect impaction

which, during life, had simulated impaction at the base of the neck, and induced him to predict a favorable prognosis. "The autopsy showed that the fracture was not through the base of the neck, but through the neck itself, close to the head, and that the fragments were 'rabbeted' together. There was motion enough to have worn away the thin walls of the neck, and to show that any bony union, had the patient lived, was not to be hoped for. In this respect it differed from Dr. Gay's case of impacted fracture into the head, where the patient, on the day of his death from pneumonia, a week or two after the accident, lifted up his leg and said that as far as that went he was getting well. Had that man lived, he would undoubtedly have had bony union and a serviceable leg. The rabbeting of the fragments was shown here very well in the present specimen. It was due to a conic mass of comparatively dense bony tissue projecting from the head fragment, which was driven into the loose cancellated structure of the portion of the neck in the shaft fragment. This dovetailing, although sufficient, while the fragments were surrounded by the capsule and soft parts, to prevent crepitus and to cause the neck and head to rotate in the socket as a whole, did not prevent such attrition of the fragments as would hinder bony union."

Koenig locates fractures of the neck of the femur near either the head or the trochanteric portion, localities that correspond to intracapsular and extracapsular fractures. From anatomic reasons, after a fall upon the trochanter major the anterior wall of the neck (the convex side) fractures first and the fractured end of the neck is directed forward. In most, if not in all, cases the wedge-shaped end of the inner fragment is implanted into the trochanteric portion, producing impaction. Adams' arch, the densest and strongest portion of the neck, penetrates the deepest. The greater the inclination of the inner fragment forward, the more extensive the impaction. As a necessary result of this impaction the head of the femur descends and approaches the posterior intertrochanteric line; the dislocation of the head in these directions satisfactorily explains the shortening and outward rotation of the limb.

Accurate statistics as to the frequency with which impacted fractures occur as compared with nonimpacted fractures are still wanting. The individual experiences of surgeons are so widely at variance on this point that a final decision can only be rendered after the accumulation of more positive knowledge from actual bedside observations and postmortem examinations. From a study of the literature it is apparent, however, that the more recent authors advance the opinion that it is of frequent occurrence. It is also evident that impaction is not limited to any particular part of the femoral neck, but that it can occur in any fracture, although the most favorable conditions for its occurrence are found at either extremity of the femoral neck. The direction and extent of impaction depend on the density of the tissues that are penetrated,

and on the direction and intensity of the fracturing force. Impacted fractures within the capsule may occur from the application of indirect violence, as the capsular ligament will offer the necessary resistance. On the other hand, impacted fractures without the capsular ligament can only take place from direct violence. It is also possible, in cases of this kind, as suggested by several authors, that a simple fracture is produced, in the first place, by force applied through the axis of the femur, and impaction occurs subsequently by a fall upon the greater trochanter.

Impaction from indirect violence would necessarily take place at the lower portion of the constricted portion of the neck, by the apex of the femoral brace penetrating the soft spongiosa of the head (Fig. 273), while if produced by a fall upon the trochanter major, the compacta of the posterior surface is also implanted into the head. Impaction outside of the capsule, from the normal position of the neck and the direction of the fracturing force, always takes place at the expense of the posterior portion of the neck, except in cases where the fracturing force is so severe as to drive the entire neck into the upper portion of the femoral shaft like a wedge, splitting the shaft into two or more fragments.

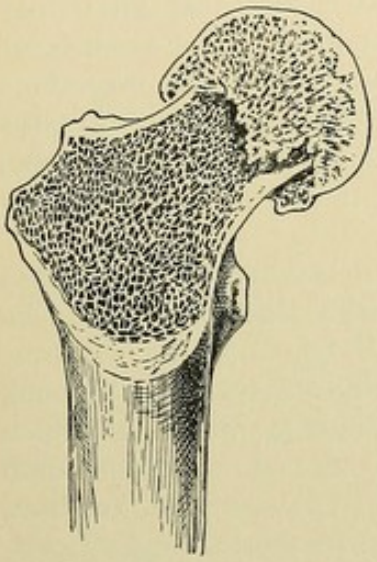

Fig. 273. — Intracapsular fracture of the neck of the femur, with deep penetration of Adams' arch into the head of the femur (Hoffa).

Impaction implies the destruction or crushing of more or less bone tissue; in case the fragments are unlocked, a vacuum is formed, which must be filled by the interposition of fluids or the adjacent soft tissues. It is well known that intracapsular fractures are often produced by very slight injuries, and it is equally certain that these are the cases that furnish the most unfavorable prospects for a good result, and the question might naturally arise, Had the violence been sufficient to produce deep penetration, would it not have enhanced the prospects for a more favorable issue? In fractures of the neck of the femur the prospects for a good result are better if the exciting cause acts with sufficient intensity to produce impaction, as this condition is the best adapted to repair by bony union.

Predisposing Causes.—Fracture of the neck of the femur is one of the rarest accidents during childhood and adult life, while after the fiftieth year it constitutes a high percentage of all fractures. Between the twenty-first and thirtieth years it constitutes $\frac{1}{91}$ of all fractures; between thirty and forty, $\frac{1}{74}$; between fifty and sixty, nearly $\frac{1}{10}$; and over seventy, $\frac{1}{3}$. The frequency of these fractures increases steadily with the advance of old age. A num-

ber of explanations have been advanced to explain this clinical fact. Thus, Richter mentions the following predisposing causes: (1) Spongy texture of neck and diminution in thickness of compact layer. (2) Diminution in the obliquity of the neck. (3) Prominence of trochanter major, by which the fracturing force is transmitted directly to the neck.

Walther assigns an important part to syphilis. Sex has also been mentioned as a predisposing cause: aged females furnish a greater number of fractures, and it has been claimed that this could be accounted for by the more horizontal position of the neck in women, owing to a greater width of the pelvis. As the strength of the neck is derived from the peculiar architectural arrangement of the spongiosa, the simple diminution of its angle would not render it more liable to fracture, as Julius Wolff has shown that, even in fractures that have healed with considerable deformity, the structure of the spongiosa is perfectly restored, in accordance with the original plan. If the neck is placed at a right angle to the shaft, it would give way more easily at the constricted portion on the application of indirect violence, while from a mechanical standpoint it ought to resist force more advantageously in case it is applied in the direction of the long axis of the neck. The predisposing cause is intrinsic, inherent in the bone itself,—a degeneration or diminution of bone tissue. All influences that affect nutrition—and that of bone in particular—hasten the degeneration of bone. Senile osteoporosis, then, is the most important known predisposing cause, a statement abundantly confirmed by clinical experience.

Exciting Causes.—Fractures of the neck of the femur are produced by:

1. Force applied in a vertical direction through the axis of the femur.

2. Force applied in a horizontal direction over the greater trochanter in the axis of the femoral neck.

3. Traction force transmitted through the capsular ligament when the limb is forcibly hyperextended, adducted, and rotated outward.

A fall upon the foot or knee will fracture the neck of the femur at its narrowest portion; and if the fracture is complete, no impaction will follow unless it takes place as a secondary occurrence from transmission of force through the greater trochanter. Most authorities who believe that intracapsular fractures are the most frequent assert that indirect violence is the exciting cause most usually encountered.

Experiments and clinical observation have shown that the majority of fractures of the neck are produced by force applied in the direction of the axis of the neck by falls upon the trochanter major. It is also an established fact that in most instances of this kind the neck gives way at its trochanteric portion, and that the

posterior wall is crushed or fractured first. Impaction takes place more frequently from direct force, with deeper penetration of the posterior than of the anterior wall of the neck.

Of thirty cases of fracture of the neck examined by Desault for the purpose of learning the exciting cause, twenty-four were produced by a fall upon the trochanter major. All the cases reported by Sabatier appear to have been produced in a similar manner. Sabatier ascribed to the prominence of the greater trochanter an important part in the production of fracture, and believed that fracture of the femoral neck does not occur in children, on account of the imperfect development of the upper extremity of the femur.

Although direct force through the axis of the neck generally expends itself near the femoral shaft, causing a fracture of the expanded portion of the neck, with posterior impaction, there are a number of cases recorded where the fracture occurred within the capsule. Intracapsular fractures produced in this manner are often impacted.

Finally, a fracture of the femoral neck may be produced by forcible hyperextension and rotation outward of the limb, movements by which the iliofemoral ligament is stretched to its utmost, and when the bone has become so fragile that it is unable to resist the traction of this powerful ligament, a fracture, the so-called traction fracture, takes place at the junction of the neck with the femoral shaft. This fracture is always extracapsular, and was first described by Linhart, and subsequently experimentally studied by Riedinger. Riedinger believes the fracture occurs before the patient falls upon the ground; comminution of the trochanter major and impaction may subsequently result from direct violence.

Symptoms of Fractures of the Neck of the Femur.—As the very highest authorities are forced to admit that during life it is impossible to locate accurately the precise seat of fracture, the necessity for considering symptoms separately under the head of intracapsular and extracapsular fracture no longer exists. In practice the greatest care should be exercised to ascertain the presence of impaction; but even impacted fractures present the most important symptoms in common with nonimpacted fractures, and they may be conveniently grouped together to prevent unnecessary repetition.

The symptoms presented by a fracture through the neck of the femur, as in any other fracture, are (1) subjective and (2) objective.

The subjective symptoms are (1) pain and (2) loss or impairment of function.

1. *Pain.*—The pain is due to the immediate effects of the traumatism, to laceration of the contiguous soft tissues, to irritation produced by the movements of the fractured ends, or to the inflammation of the bone or surrounding tissues succeeding the injury. The pain is variable—almost absent and of short duration in some cases, excruciating and continuous for months and sometimes years in others. If the fracture is located in the narrow portion of the

neck, the pain is usually referred to the groin, at about the insertion of the iliopsoas muscle; if at or near its base, it is more diffuse and referred to the seat of injury.

There has been considerable discrepancy of opinion as to the severity of the pain in fractures within, as compared with fractures without, the capsule. Sir Astley Cooper maintained that it is less severe in the former variety, while Malgaigne claimed that the reverse was true. As fractures of the narrow portion of the neck are the result of less violence than when they occur near the shaft, it is undoubtedly true that the pain attending them immediately after the injury is milder than in the latter class of injuries, while the reverse may be true during the subsequent history of the case. In impacted fractures, where the favorable conditions for bony union are not disturbed and the process of repair is instituted at once and progresses uninterruptedly, the pain, as a symptom, is referable only to the traumatism. As such, as a rule, it is severer in fractures where the greatest amount of tissue has been lacerated—that is, in extracapsular fractures.

In cases of nonimpacted fractures within the capsule, with motion of the fragments upon one another, a certain amount of inflammation develops, which is always attended by its most prominent symptom—pain. When pain the result of inflammation is present, it assumes the characteristic features, as witnessed in coxitis independent of fracture. It is then no longer a symptom of fracture, but indicates the accession of coxitis. The presence of no inconsiderable amount of inflammation has repeatedly been verified at autopsies in the form of thickening of the capsule, adhesions, and destruction of the synovial membrane and cartilage. Any attempt at motion or pressure against the greater trochanter aggravates the pain. In some old inveterate cases the pain assumes a neuralgic type, which would indicate that some of the nerves about the hip-joint were encroached upon by the displaced fragments, exuberant callus, or the products of inflammation.

2. *Loss or Impairment of Function.*—This symptom is present in all fractures of the femoral neck. As a general rule, it may be stated, it is prominent as a symptom in proportion to the degree of separation of the fragments. In impacted fractures the patients are often able not only to move the limb, but also to walk for hours, and sometimes for days. The range of motion, however, is always diminished, and the use of the limb is attended by aggravation of the pain. The impairment of voluntary movements does not depend alone on the direct loss of support, but is influenced also by the pain incident to such movements; hence this symptom will present itself in the highest degree in nervous, excitable patients. Laceration of the soft parts of the periosteum and of the capsule, in the absence of impaction, will also counteract voluntary motion, not only by allowing a greater degree of disjunction of the fragments, but likewise by increasing the pain on any attempt at motion.

In the great majority of cases the patient, as he lies in bed, is unable to raise or move the limb in any direction—it remains perfectly helpless in the position it was left in after the accident, or in which it has been left by the displacing elements. In some cases, where interlocking of the fragments exists or where a slight amount of impaction has taken place, the patient has control over a certain number of voluntary movements for a number of days, or until disjunction of the fragments takes place as a result of injudicious examination or inflammatory osteoporosis, when the limb is placed in the same condition as if no impaction had occurred.

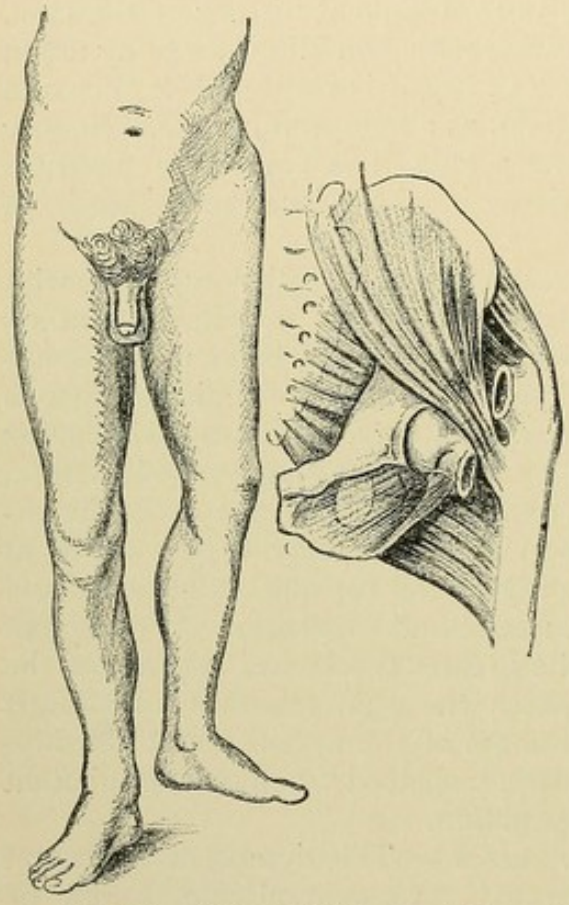

Fig. 274.—Unimpacted fracture of the neck of the femur, showing displacement of the fragments and faulty position of the limb (Hoffa).

The objective symptoms are: (1) Swelling and deformity at the hip; (2) suggillation about the hip; (3) eversion of limb; (4) shortening; (5) change of position of trochanter major; (6) either increased or diminished mobility of the hip-joint; (7) loss of tension of fascia lata between the trochanter major and the crest of the ilium.

1. *Swelling and Deformity.*—In all cases there is an appreciable fullness in the fold of the groin corresponding to the seat of fracture. This swelling is caused by the hinge-like projection of the anterior portion of the neck, effusion of blood or inflammatory products, and, lastly, by the overriding or impaction of the fragments. When impaction takes place at the base of the neck, the trochanteric portion of the femur is enlarged from implantation of the upper fragment. The swelling is larger when the fracture is located without the capsule, from the more extensive bone injury and the more copious effusion of blood.

2. *Suggillation* appears earlier and more constantly the nearer the fracture is seated to the femoral shaft. As this symptom is the result of the presence of blood at the point of fracture, it is more extensive if the hemorrhage has been severe and outside of the capsule. If the hemorrhage has been within the capsule and the capsule is ruptured at some point, the discoloration will usually

show itself along the inner side of the thigh. The same force that produced the fracture may also contuse the soft parts sufficiently to give rise to superficial discoloration independently of the fracture.

3. *Eversion.*—The lower limb in a natural condition is slightly everted, on account of the forward obliquity of the femoral neck. This normal eversion is increased during sleep, when the muscles are at rest, when they have been completely relaxed by a general anesthetic, or when their action has been permanently suspended by paralysis. In the normal condition, then, the weight of the limb effects outward rotation until arrested by muscular action or the resistance offered by the ligaments of the hip-joint. As the posterior wall of the neck is usually the seat of more extensive comminution or impaction than the anterior, and as the fracturing force, in the majority of cases, is applied in the anterolateral direction, it is only reasonable to expect that outward rotation of the limb is the rule. Until recently it has been generally taken for granted that eversion is the result of muscular contraction. In support of this view it has been suggested that, in nonimpacted fractures, it increases after the muscles have recovered their contractility.

Edmund Owen, basing his opinion on anatomic demonstrations and carefully made experiments, as well as accurate clinical observation, holds that eversion of the limb takes place independently of muscular contraction; that it is invariably the result of the impacting force or the weight of the limb, as the case may be. In intracapsular fractures it is especially true that eversion is more marked a few days after the injury, but this fact can be explained more satisfactorily from a different standpoint. In such cases the fragments are often kept in apposition by an interlocking of the broken surfaces or untorn portions of the fibrous investment of the neck. Either of those supports may give way to the constant traction from the weight of the limb, or the same result may follow reflex muscular contractions or careless handling of the limb. The great mass of muscles,—the external rotators of the hip,—after the fracture, are relaxed, from the approximation of their points of origin and insertion, and it is difficult to conceive in what way they could effect outward rotation.

Dupuytren believed that eversion may also be due to the action of the adductor muscles, and in some instances to the obliquity of the fracture itself. It is also necessary to mention that eversion is not a constant symptom. Cases have been described by reliable observers where the limb remained normal so far as the position of the foot was concerned, and in some even the reverse—inversion—occurred. Cases of fracture with inversion have been described by Ambroise Paré, J. L. Petit, Guthrie, Stanley, Dupuytren, Desault, Cruveilhier, Hamilton, R. W. Smith, and others. Desault thought that it occurred in about one case out of every four. Stanley observed one case where the autopsy showed that the fracture was

purely intracapsular, and no satisfactory explanation could be found for the inversion. Wm. Pirrie mentions a case of intracapsular fracture where the limb was not only inverted, but also strongly flexed and adducted, a position he ascribed to the tension of the iliofemoral ligament. Of the 130 cases of intracapsular fracture of the neck of the femur that came under Pirrie's observation, and where the accuracy of the diagnosis was verified by dissection, this was the only case with flexion, adduction, and rotation inward of the limb. Of the remaining number, in one case only inversion existed, the limb in other respects occupying the usual straight position. Malgaigne reports an exceedingly interesting case: "In 1833, having found the foot inverted in a fracture of the neck of the femur, I ascertained that it was easily everted and again inverted at will, and that it remained as readily in one position as in the other; *whence I concluded whatever inclination is given to the part upon the supporting plane it keeps by its own weight.*" This observation is exceedingly valuable, and would lead us to the conclusion that whenever the support derived from the cervical portion of the femur is lost, the limb will follow the natural law of gravitation, and will turn outward by its own weight, unless opposed by some special conditions at the seat of fracture or by external influences.

4. Shortening.—The significance of shortening as a symptom of fracture of the neck of the femur has received additional interest since it has been ascertained that in many persons there is normally a difference in the length of the lower extremities in the same individual. Wight, of Brooklyn, has made a valuable contribution to surgery, relating to the comparative length of the inferior extremities in the same person. His first published table comprised the results of measurements of 60 persons of varied nationalities, pursuits, and ages. In these there were 10 persons who presented perfect symmetry of length in the two legs, and 50 who showed an asymmetry varying from ¼ of an inch to 1⅜ inches. The right leg was the longer in 18, and the left in 32.

A second table comprises 42 measurements, and shows a parity of length in 13 and a difference in 29 instances, the difference varying from one-fourth of an inch to one inch. In 9 cases the right, and in 20 the left, limb was the longer. F. H. Hamilton corroborated the correctness of these results by his own researches.

These measurements not only prove that the lower limbs differ in length in a majority of cases examined, but likewise point out the importance of measuring the long bones separately for the sake of comparison when measurements are made for diagnostic purposes.

More or less shortening will take place in every case of fracture of the neck. M. Lisfranc and M. Lallemand each have reported a case where the limb was longer. It is impossible to conceive in what manner the fracture could add to the length of the limb; and still the observations undoubtedly were correct, and an explanation

can be given only by assuming that the amount of actual shortening was slight, and the patient's limbs were of unequal length. The amount of shortening depends on the degree of disjunction: the greater the longitudinal displacement, the greater the shortening. The shortening is always the direct result of muscular contraction or longitudinal displacement by impaction. In impacted fractures the maximum is reached at once, and the degree of shortening depends on the depth of penetration or mutual interpenetration of the fractured ends.

In cases of impaction the shortening remains stationary, as the fracture is not disturbed, and can increase only on the advent of inflammatory interstitial absorption. In fractures without the capsule, all resistance to muscular contraction is lost, and the maximum amount of shortening is reached as soon as the muscles have become contracted. If the capsule is intact and remains attached to the lower fragment, shortening takes place gradually by stretching of the capsular ligament. In case the fragments are held in contact by the denticulated fractured surface, shortening can proceed only after this medium of apposition has been removed, by displacement of the bones, or after inflammatory osteoporosis has removed the projecting spicula. This condition is often met in intracapsular fractures. The degree of shortening immediately after a fracture has been relied upon by some in determining the seat of fracture. Among surgeons there has been, however, such discrepancy of opinion in this respect that no reliable deductions can be drawn from this circumstance in rendering a decision.

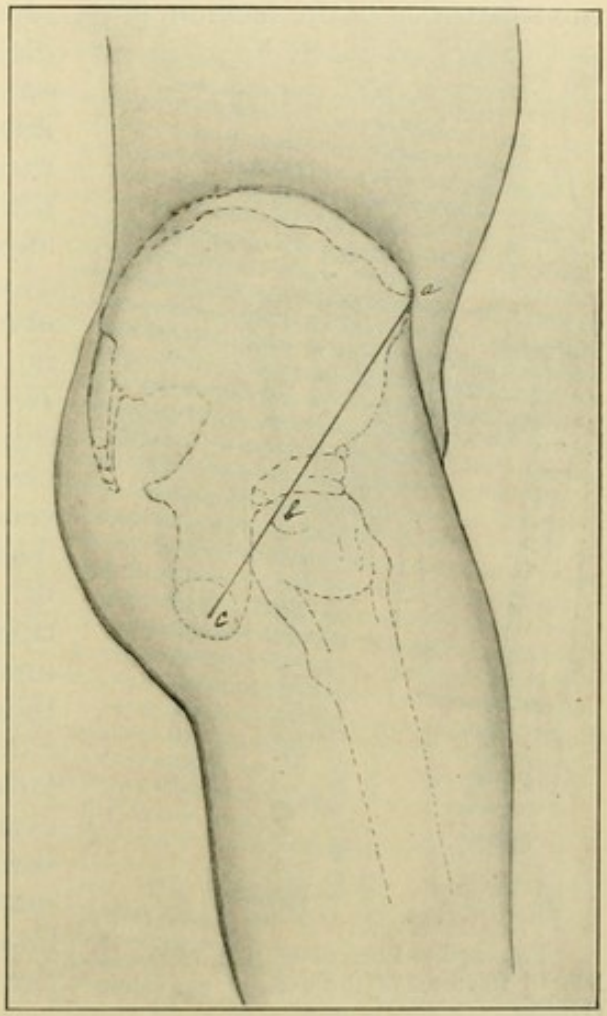

Fig. 275.—Roser-Nélaton line: *a*, Anterior superior spinous process of ilium; *b*, upper border of trochanter major; *c*, tuberosity of ischium.

Sir Astley Cooper and Amesbury claim the greatest shortening for intracapsular fractures, while Stanley, Earle, and R. W. Smith entertained an opposite view. Impaction and the integrity of the

capsular ligament are such important factors in determining the amount of shortening and the time of its occurrence that these conditions must be carefully considered in estimating the value of shortening as a diagnostic aid.

5. Change of Position of Trochanter Major.—The greater trochanter is displaced upward and backward in proportion to the extent of shortening and eversion. When shortening has occurred, its upper margin has passed above the Roser-Nélaton line, which is a straight line drawn from the anterior superior spine of the ilium to the tuberosity of the ischium (Fig. 275). This line is of the greatest diagnostic value, not only in examinations for fracture of the ilium, but also in ascertaining the existence of shortening of the limb caused by inflammatory affections of the hip-joint. In a normal condition the upper margin of the greater trochanter is on a level with the Roser-Nélaton line. In fractures of the neck of the femur the trochanter major describes a smaller arc of a circle on rotation of the femur. The diminution in the arc of circle is less in impacted fractures and when the lower fragment is not in apposition with the upper.

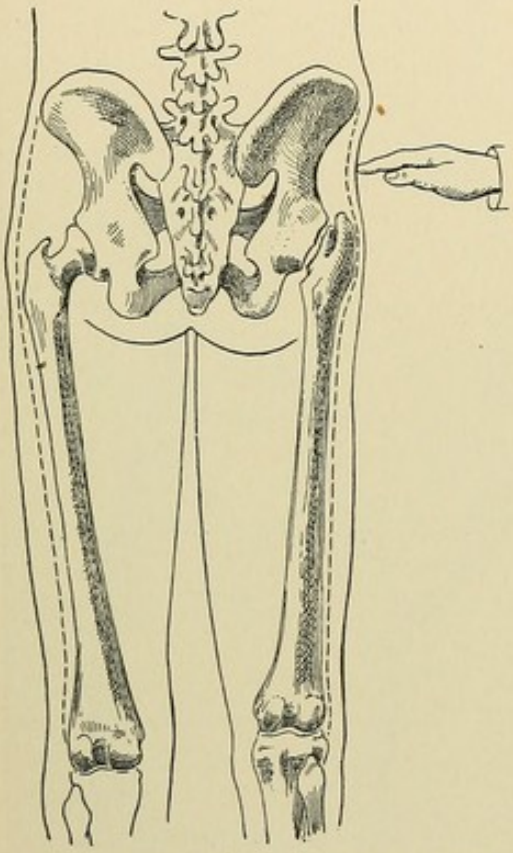

Fig. 276.—Loss of tension of fascia lata in fractures of the neck of the femur (Hoffa).

6. Alteration of Motion.—A false point of motion is always established in nonimpacted fractures. Preternatural mobility is most marked if the fracture is not impacted and located outside of the capsule. It is probably in cases of this kind that Gerdy has been able to rotate the limb outward until the toes were directed backward, and that Maisonneuve brought into requisition his test of hyperextension. If the fracture is within the intact capsule, the latter will serve as a retentive measure and limit the motion between the fractured ends. Levis discovered that in nonimpacted fractures the limb can be extended beyond its normal length. In case firm impaction has taken place, the neck has become shorter and thicker, conditions that necessarily impair the normal mobility of the hip-joints.

7. Fascia Lata.—Allis, of Philadelphia, has added another symptom that indicates fracture through the neck of the femur—namely, the existence of a relaxed condition of the fascia lata

between the crest of the ilium and the greater trochanter on the injured side, produced by the loss of resistance which is furnished by the neck when not broken. As the presence of this symptom depends on the dislocation of the lower fragment upward and inward, it is met only when such changes have taken place. The standing position is the only one in which this test can be applied (Fig. 276), as in the reclining position the muscles that make tense the fascia are relaxed.

Bezzi has called attention to a sign that he considers as pathognomonic of fracture of the neck of the femur. In examining the space between the trochanter and the crista ilii, it will be found that while on the same side the muscles occupying this region (the tensor vaginæ femoris and the gluteus medius) are tense and offer to the hand a considerable feeling of resistance, they present on the affected side a deep, well-marked depression, flaccidity, and diminution of tension from displacement upward of their points of insertion. The sign appears under the same circumstances and possesses the same significance as the one described by Dr. Allis.

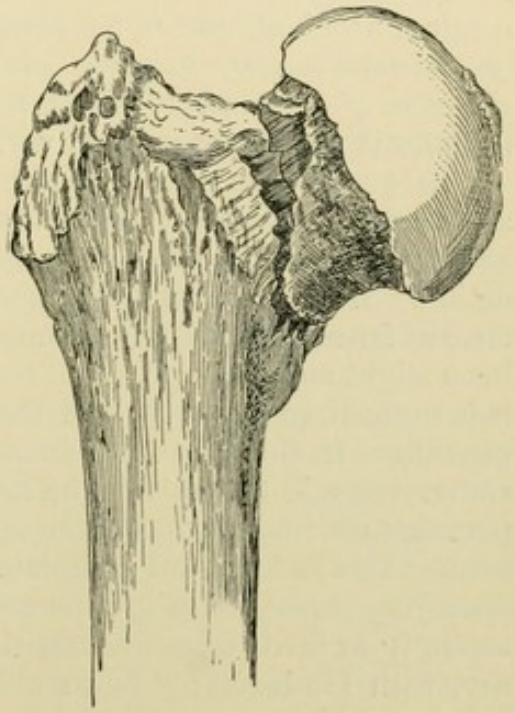

Fig. 277.—Anterior view of bony union after fracture of neck of femur (Hutchinson).

The mention of crepitus as a symptom has been omitted intentionally, as more harm than benefit has accrued from the efforts of the anxious surgeon to establish a positive diagnosis on the presence or absence of this sign. A careful study of the other symptoms will usually enable us to arrive at a correct conclusion, without exposing the patient to the risks incident to the manipulations necessary for the purpose of eliciting this symptom.

Diagnosis.—All manipulations during the examination of a supposed fracture through the cervix femoris should be performed with the utmost care and gentleness. The so-called "thorough examination," the search for positive symptoms, has been the source of incalculable mischief. In many instances careless handling of the limb has resulted in disjunction of impacted fractures or in tearing of periosteal or ligamentous bands, thus most effectually precluding possible union by bone or the formation of a short fibrous union. Years ago Davis entered his protest against such reckless examinations in the following emphatic language: "Now, while we willingly concede the importance of a correct diagnosis

in its bearings upon the successful treatment of any case, we hold that too much handling and manipulation of the limb in intra-capsular fracture is liable to eventuate in irreparable injury to the patient." Again: "When this connecting link of periosteum and capsular ligament is not severed by officious handling on the part of the surgeon in his zealous, but often mischievous, efforts to ascertain to the fullest extent the details of the injury, then we may hope for better results than have usually followed this accident."

T. Bryant's caution is equally strong: "In fact, the ordinary fracture at the base of the neck of the thigh bone is primarily an impacted fracture, the impacted bone in some cases being loosened by a second fall, in others by excess of violence received in the original accident, and *in too many by the manipulations of the surgeon in his anxiety to make out the presence of a fracture by the detection of crepitus.* Indeed, this seeking for crepitus in cases of fracture is a practice fraught with danger."

In every case of suspected fracture we should make careful search for evidences of senile osteoporosis, and ascertain, as nearly as possible, the degree of force applied and the direction of its application. If the general appearances of the patient indicate the existence of far-advanced senile osteoporosis, and if the degree of force has been slight and was applied in the direction of the axis of the femur, it is more than probable that the fracture has occurred within the capsule. If the fracturing force has been greater and was applied transversely in the axis of the femoral neck, we have reason to suspect that the fracture has taken place, at least partly, without the capsule. The sudden and complete loss of function of the limb after an injury to the hip in a person over fifty years of age speaks strongly in favor of a fracture through the femoral neck. We can say, with Hodgson: "If an elderly person, after a fall upon the hip, is unable to use the injured limb, it is very probable that a fracture of the neck of the femur has been sustained, and this is more likely to be the case if, during the fall, no such great force has acted upon the greater trochanter as would be necessary to produce a contusion sufficiently severe to render the limb useless."

Aside from a general consideration of the case, the diagnosis will depend on the presence or absence of the two most important symptoms, shortening and eversion. Many of our best surgeons depend almost exclusively on accurate measurements in rendering a diagnosis. The extent of immediate shortening will vary, according to the presence or absence of impaction, from a few lines to two inches. In impacted fractures the shortening is immediate and remains stationary, unless displacement takes place or if, during the reparative process, the femoral neck is shortened by interstitial absorption. The progressive shortening a few days after the accident is due to a loosening of the fragments that have been in mutual contact by denticulated projections, and to a gradual stretching of

untorn portions of the capsular ligament. Mr. Bryant, in speaking of the utility of his "test-line," says: "Indeed, as a proof of its use, I may add that twenty-five consecutive cases of fracture of the neck of the thigh bone admitted into my wards to the end of 1877 (the average age of the patients being seventy-four) left the hospital with union of the broken bones and useful limbs."

J. S. Wight, of Brooklyn, has written an exceedingly interesting and practical paper on diagnosis of fractures of the femoral neck, based on the report of twenty-one cases. For the purpose of avoiding errors that might accrue from asymmetry of the lower extremities, he directs that the following measurements should be taken:

"1. Inside measurements from the superior anterior spines of the ilium to the lower ends of the internal malleoli.

"2. Outside measurements from the anterior spines of the ilium to the lower ends of the external malleoli.

"3. Measurements from the tops of the greater trochanters to the lower ends of the external malleoli.

"4. Measurements from the bases of the tibiæ to the lower ends of the internal malleoli.

"5. Measurements from the superior anterior spines of the ilium to a line drawn transversely in front, between the tops of the greater trochanters."

The object of all these comparative measurements is to determine the possibility of original asymmetry of the two limbs, and to determine, so far as possible, if the injury to the hip has caused any shortening of the limb on the injured side, so that we can infer the *probability* of the existence of a fracture of the femoral neck. He gives the results of examination of twenty-one such fractures, where a diagnosis was made without eliciting crepitus. In eight of these cases there was probably impaction. The average shortening was $\frac{58}{100}$ of an inch, as shown by the inside and outside measurements. In no case of fracture of the femoral neck does he use force to elicit crepitus. He considers the other evidences of fracture as sufficient for reaching a practical conclusion. His concluding statements contain so many practical and useful suggestions that they are given in detail here:

"1. Moving the outer fragment when it is in contact with the inner fragment will generally carry the inner fragment with it, and there will be no crepitus; and when there is impaction, ordinary manipulation will not cause crepitus to be felt. Yet crepitus may, at times, be felt when there is impaction of the neck of the femur.

"2. Moving the outer fragment when it is not in contact with the inner fragment of course will not give crepitus.

"3. Hence unwarrantable force will be required in order to get crepitus in many cases of fracture of the neck of the femur, and, more than this, *an impacted fracture of the neck of the femur may be broken up by severe manipulation, and a patient that would have had*

a useful limb may be quite completely disabled for life, for an impacted fracture of the neck of the femur is the best setting of the bony fragments that a surgeon can have.

"In a suspected fracture of the neck of the femur I examine all the witnesses of fracture except crepitus, and if these witnesses agree substantially, I pronounce a verdict in favor of fracture of the neck of the femur; and if there is a doubt as to the correctness of such a verdict, I give the patient the benefit of that doubt by treating the case as if there was a fracture of the neck of the femur, and then the surgeon receives a benefit from the doubt. But if there is no fracture, the patient has had some days of needful rest and has had a contused hip well treated."

The instrument recommended is an accurate steel tape-line, with feet and inches indicated on one side, and meters and centimeters on the other side. This tape-line will not elongate under tension. It is superfluous to mention that the patient should be placed in the recumbent position, on an even surface, when the measurements are taken. It is to be hoped that the text-books of the future will say less of crepitus as a sign of fracture, and will advocate, instead, accurate methods of measurement.

Eversion of the limb is the next most reliable symptom. In impacted fractures the position of the limb depends on the direction of the fracturing force. If the force acts in the direction of the axis of the cervix and is severe, causing implantation of the whole base of the neck into the trochanteric portion of the femur, the limb will retain its natural position. If the anterior wall is impacted by force applied against the outer and posterior aspect of the trochanter major, the limb will remain in a position of inward rotation. Owing to the anterior obliquity of the neck, the usual manner of falling (forward and on the side), and the thinness of the compacta of the posterior concave surface of the neck as compared with the anterior, we would naturally infer that posterior impaction takes place in the great majority of cases. This supposition has been abundantly verified by clinical observation. Impaction, then, is usually attended by eversion. If the fracture is located within the capsule, eversion frequently will increase for a few days or weeks after the accident, from the same causes that give rise to secondary shortening. In cases of posterior impaction where the fragments remain firmly implanted during the process of repair, eversion increases from the weight of the limb and the inflammatory absorption of the impacted fragments, permitting increased rotation outward of the lower fragment. The abnormal position of the greater trochanter is also an important diagnostic sign. If we can exclude dislocation of the hip-joint upward and backward, the application of the Roser-Nélaton test may decide the diagnosis. In cases of fracture of the neck of the femur the upper border of the greater trochanter will be found above the Roser-Nélaton line, the distance corresponding with the amount of shortening. In nonimpacted

fractures the false point of motion diminishes the arc of rotation that the greater trochanter describes in rotating the limb. This symptom is mentioned simply to be condemned, as the manipulations necessary to apply this test, like the search for crepitus, have done a great deal more harm than good.

In doubtful cases, more particularly when dislocation is suspected, the patient should be carefully placed in the erect position, when the position of the limb and an examination of the contour of the hip, as well as an inspection of all the landmarks in that locality, will render material assistance in arriving at correct diagnostic conclusions. In case of doubt, if we err at all, it should be on the safe side, and we should treat the case as one of fracture. Many cases that were in a most favorable condition for bony union have been rendered hopeless by a disregard for this rule. The surgeon must ever bear in mind that the most favorable cases present the least degree of deformity, and that in our anxiety to make a correct diagnosis we sacrifice all the conditions that are essential for obtaining bony union.

In response to a circular sent by me inquiring as to the possibility of bony union after impacted intracapsular fracture, Professor A. C. Post, of New York, after replying in the affirmative, kindly wrote: "But the difficulty in proving this proposition depends on two circumstances: (1) The want of absolute determination that fracture has actually occurred, and (2) the want of opportunity to demonstrate, by autopsy, that bony union has actually occurred. It is a common thing for a person of advanced age to meet with an accident rendering him or her unable to stand or walk or to raise the affected limb from the bed. There is a certain amount of pain and lameness about the hip, with eversion of the toes and a scarcely perceptible shortening of the limb. On careful examination, without using much force neither crepitus nor abnormal motion can be detected.

"There is probable evidence, but not certain demonstration, of impacted intracapsular fracture. If the surgeon is contented with this imperfect diagnosis, he treats the case as one of fracture, and recovery takes place with a perfectly sound limb. But the proof of the fracture and reunion is incomplete. If the surgeon, in his anxiety to obtain a perfect diagnosis, moves the limb freely in all directions, he overcomes the impaction, rupturing the cervical ligament, demonstrates beyond all doubt the existence of the fracture, and effectually destroys all hope of reunion. For my part I prefer an imperfect diagnosis for the surgeon and a perfect limb for the patient, rather than a perfect diagnosis for the surgeon and a useless limb for the patient."

These remarks require no explanation. They are concise, plain, practical, and to the point. Unimpacted fractures of the neck of the femur seldom give rise to any difficulty in diagnosis; the symptoms attending them are so well marked that a correct

conclusion can be reached without causing needless suffering or sacrificing important tissues in searching for any one particular positive sign. Fractures with impaction present the same symptoms in a minor degree; their presence can usually be recognized by a careful consideration of symptoms, the elucidation of which does not necessitate the disengagement of the fragments; and, finally, if we have reason to believe that a fracture with impaction exists, although the symptoms are not sufficiently well marked to warrant the diagnosis, it is our duty to initiate the treatment in accordance with such a supposition.

Specimens of Bony Union after Extracapsular Fracture.—It is not my intention to enter into a discussion of the merits of the many specimens for which bony union has been claimed by their possessors. Many of them have been the object of the most rigid criticism, at different times and at the hands of various writers. While careful and competent men have brought their specimens to the attention of the profession as typical examples of union by bone within the capsule, equally capable observers have failed to see the evidences that justified these claims. I have tabulated only the cases reported by competent observers up to 1883, and where the diagnosis was verified by a postmortem examination. To these I have added the case that came under my own observation, described in the first part of this section.

TABULATED SPECIMENS OF BONY UNION AFTER INTRACAPSULAR FRACTURE.

No.	Name of Reporter.	Where Mentioned or Classified.	In Whose Possession.
1	Adams, R.,	Todd's "Cyclopedia," vol. II, p. 813.	Adams.
2	Adler,	"Am. Jour. Med. Sci.," April, 1873.	Adler.
3	Bardeleben,	"Lehrbuch d. Chir.," Bd. II, S. 477.	Goyrand.
4	Brulatour,	"Med.-Chir. Trans.," vol. XIII.	Brulatour.
5	Bryant,	Bryant's "Surgery," p. 843.	Guy's Hospital Museum.
6	Callender,	"St. Barthol. Hosp. Rep.," vol. I, p. 154.	
7	Chassaignac,	"Thèse inaugurale."	Van Houte.
8	Chelius,	"Handb. d. Chir.," Bd. I, S. 319.	Chelius.
9	Chelius,	"Handb. d. Chir.," Bd. I, S. 319.	Soemmering's collection.
10	Cushing,	Bigelow, "The Hip," p. 133.	
11	Earle,	"Practical Obser. in Surgery," 1823, p. 97.	
12	Fawcington,	"Am. Jour. Med. Sci.," vol. XV, p. 534.	Fawcington.
13	Field,	Amesbury on "Fractures."	Field.
14	Fischer, H.,	Personal communication.	Pathologic Museum, Breslau.
15	Fischer, H.,	Personal communication.	Ponfick.
16	Geddings,	"Am. Jour. Med. Sci.," Jan., 1847.	Geddings.
17	Gurlt,	"Knochen-Brüche," vol. I, p. 308.	Giessen Museum.
18	Hamilton,	Hamilton on "Fractures," p. 407.	Hamilton.
19	Harris,	"Am. Jour. Med. Sci.," vol. XVIII, p. 246.	Harris.
20	Holthouse,	Holmes' "System of Surgery," vol. II.	St. George's Hospital, Specimen No. 112.
21	Howship,	"Med.-Chir. Trans.," vol. XIV.	Howship.

TABULATED SPECIMENS OF BONY UNION AFTER INTRACAPSULAR FRACTURE.—(*Continued.*)

No.	Name of Reporter.	Where Mentioned or Classified.	In Whose Possession.
22	Hutchinson,	"Illustr. Clin. Surgery," vol. II, p. 8.	Leeds Hospital Museum.
23	Hutchinson,	"Museum Notes" of Jan. 23, 1870.	Museum of Trinity College, Dublin.
24	Jones,	"Med.-Chir. Trans.," vol. XXIV.	Jones.
25	Kocher,	Personal communication.	Pathologic Museum, Berne.
26	Kroenlein,	Personal communication.	Pathologic Museum, Zürich.
27	Langstaff,	"Med.-Chir. Trans.," vol. XIII.	Langstaff.
28	Maas,	Personal communication.	Pathologic Museum, Freiburg.
29	Malgaigne,	"A Treatise on Fractures," 1859, p. 555.	Musée Dupuytren.
30	March,	"Trans. Am. Med. Assoc.," 1858.	Albany College Museum.
31	March,	"Trans. Am. Med. Assoc.," 1858.	Albany College Museum.
32	March,	"Trans. Am. Med. Assoc.," 1858.	Albany College Museum.
33	Mussey,	"Am. Jour. Med. Sci.," 1857, p. 299.	Mussey.
34	Mussey,	"Am. Jour. Med. Sci.," 1857, p. 299.	Mussey.
35	Mussey,	"Am. Jour. Med. Sci.," 1857, p. 290.	Mussey.
36	Parker, W.,	Johnson, "Intracapsular Fractures," 1857, p. 28.	W. Parker.
37	Pope,	Hamilton on "Fractures," p. 407.	
38	Post,	Personal communication.	Destroyed in fire of University Medical College.
39	Riedinger,	"Studien über Grund u. Einkeilung der Schenkelhalsbrüche, 1874, Pl. XI.	Würzburg Museum.
40	Roberts,	Personal communication.	Penna. Hospital Museum.
41	Sands,	"New York Med. Record," June 1, 1869.	Sands.
42	Selden,	"Trans. Virginia State Med. Soc.," 1877.	Selden.
43	Selden,	"Trans. Virginia State Med. Soc.," 1877.	Selden.
44	Senn,	"Trans. Am. Surg. Assoc.," 1883.	Army Medical Museum.
45	Smith, H. H.,	"Princ. and Prac. of Surg.," vol. II, p. 610.	Wister and Horner Museum.
46	Smith, H. H.,	"Princ. and Prac. of Surg.," vol. II, p. 610.	Smith.
47	Smith, R. W.,	"Dublin Jour. Med. Sci.," Jan., 1873.	Trinity College Museum.
48	Smith, R. W.,	"Dublin Jour. Med. Sci.," Jan., 1873.	Trinity College Museum.
49	South,	Chelius "Surgery," by South, vol. I, p. 621.	South.
50	South,	Quoted by Hamilton, ed. 1871, p. 363.	Museum of St. Bartholomew's Hospital.
51	Spalding,	"Boston Med. and Surg. Jour.," March 4, 1858.	Spalding.
52	Stanley,	"Med.-Chir. Review," vol. XII, p. 170.	Stanley.
53	Swan,	"On Diseases of Nerves," p. 304.	Swan.
54	Zeiss,	Hamilton, "Fractures and Dislocations," 1880, p. 406.	Zeiss.
55	Zeiss,	Hamilton, "Fractures and Dislocations," 1880, p. 406.	Zeiss.

Only a description will be given here of a few undoubted specimens, for the purpose of illustrating the alterations that occur in the femoral neck during the process of repair.

R. Adams (No. 1 in table): "The round ligament was sound. The head and neck of the bone had lost their normal obliquity

and were directed nearly horizontally inward ; the cervix presented, both anteriorly and posteriorly, evidence of a transverse intracapsular fracture having occurred. The globule-shaped head was closely approximated behind and below to the posterior intertrochanteric line and to the lesser trochanter, so that the neck seemed altogether lost, except anteriorly, where a well-marked ridge of bone showed the seat of displacement and of the union of the fragments. This ridge is evidently the upper extremity of the lower fragment of the cervix. The fracture of the neck posteriorly was found to have been closer to the corona of the head than anteriorly, and the fibrosynovial fold in the former situation remained unbroken. A section has been made of the bone through

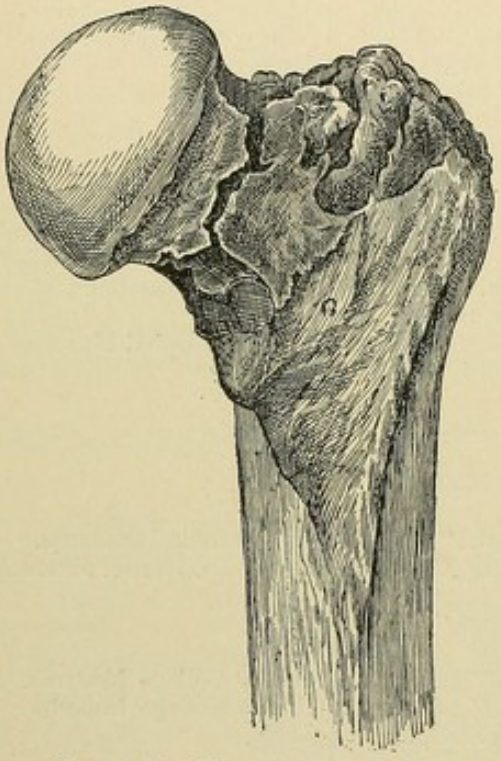

Fig. 278.—Posterior view of bony union after fracture of neck of femur (Hutchinson).

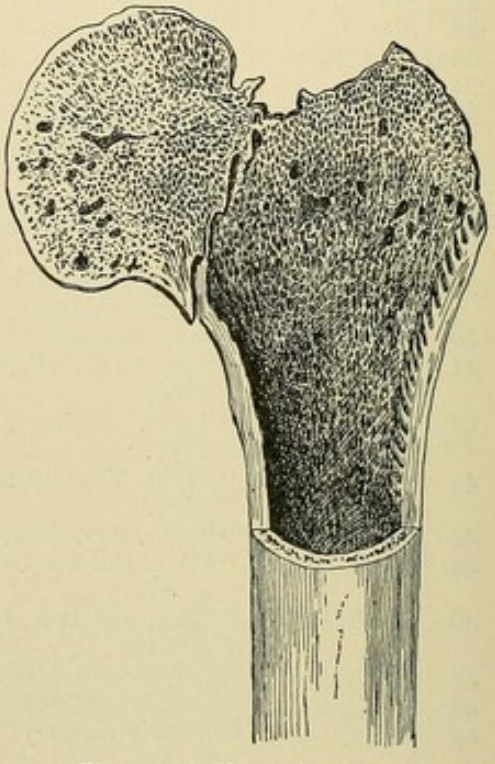

Fig. 279.—Vertical section showing bony union after fracture of neck of femur (Hutchinson).

the head, neck, and trochanter ; one portion has been subjected to maceration and boiling, and the bony union has been unaffected by these tests. Scarcely any portion of the neck can be said to have been left. The section shows the compact line that denotes the union of the fragments ; the head and shaft seem to be mutually impacted into each other, and almost the entire cervix has been absorbed ; the line of union is serrated, solid, and immovable ; the cells of the head and substance of the shaft seem to communicate freely in all places, except where the thin line of compact tissue here and there points out the seat of the welding together of the remaining portions of the head and neck of the femur."

As Mr. Adams, in his article on "Abnormal Conditions of the Hip-joint" in Todd's "Encyclopedia," took the ground that bony union was impossible, and commented unfavorably on the cases that had been reported as instances of bony consolidation, it is evident that this case must have presented convincing proof in order to change his views on this subject. The value of this specimen is enhanced by a full and clear clinical history.

Chorley's specimen, described by Jonathan Hutchinson (No. 22 in table): "The bone which supplied the illustration I now publish is one of the many treasures of the Pathologic Museum of the Leeds Hospital. The drawings were, by permission, made for me by Mr. Tuffen West, some years ago, at the time of the visit of the British Medical Association to Leeds. The specimen is the best example of union of an intracapsular fracture with which I am acquainted, and as it appears to be beyond all cavil, I have great pleasure in endeavoring to secure for it a wider recognition. The drawings show so exactly the condition of the bone that it is scarcely necessary to describe them. It will be seen that, while the transverse fracture is wholly within the capsule, and nowhere more than half an inch from the articular head, yet on the back of the cervix some fragments have been detached which pass much further out. It is worth notice, also, that in the section of the bone the edge of the lower outer layer is seen to catch in the cancellous tissue of the articular end, thus constituting a degree of impaction which, no doubt, much favored fixation and union. The specimen was obtained by the late Mr. Chorley, formerly surgeon to Leeds Infirmary, from the body of a gentleman aged seventy, whom he had attended several years before his death, with the diagnosis of fracture of the neck of the thigh bone. The treatment had been by very careful immobilization and long-continued confinement to bed. The recovery had been such that the patient had been able to walk well with a stick."

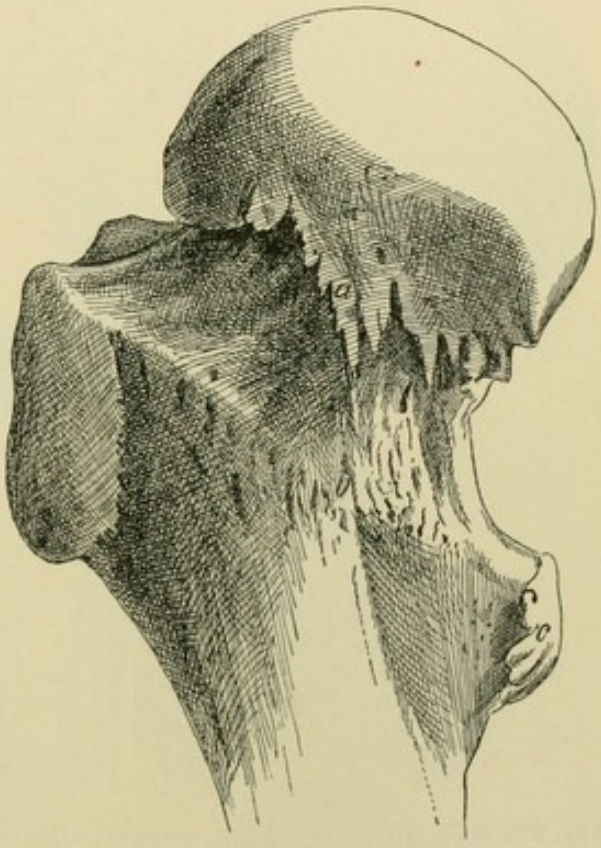

Fig. 280.—Anterior view of bony union after intracapsular fracture (Riedinger).

The well-known ability of Mr. Hutchinson is a sufficient guaranty for the genuineness of this specimen.

Riedinger's specimen (No. 39 in table): The neck of the femur is considerably shortened, and the head inclines so far backward that, superiorly, it comes almost completely in contact with the posterior intertrochanteric line. From behind, only the cartilaginous surface of the head can be seen; downward, the neck is visible to the extent of 1 cm.; above, the length of the neck is 1 ½ cm. On the anterior surface the well-marked denticulated line of fracture can be seen close to the head. Its length is 3 cm. A longitudinal section of the upper portion of the femur into an anterior and a posterior half discloses the line of fracture in the loosely cancellated tissue of the spongiosa, and more clearly shows the impaction of the lower fragment into the head, which is especially well marked in the lower cortical portion of the neck (Adams' arch). The length of the implanted portion amounts to 2 cm.

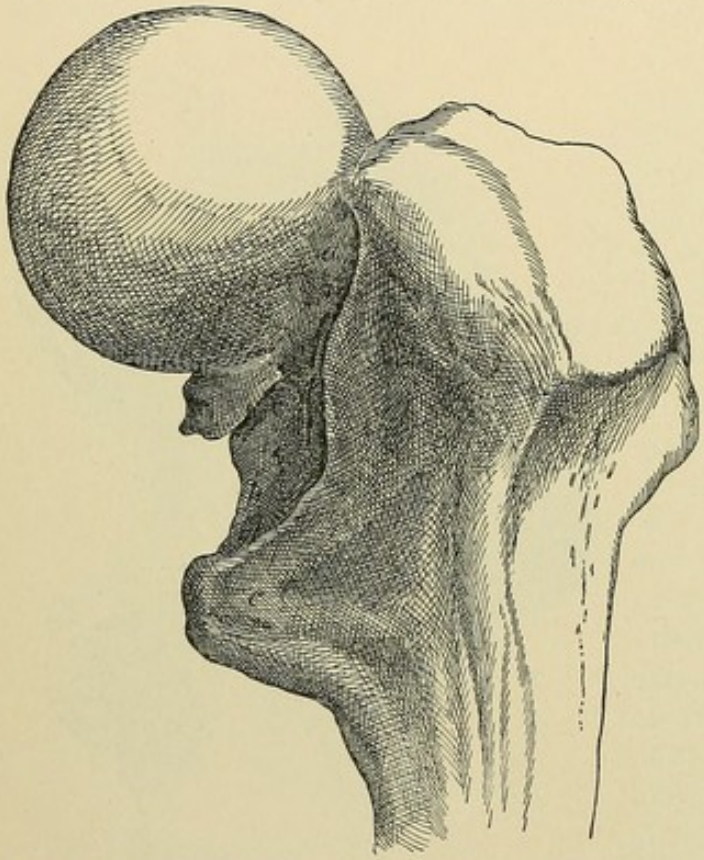

Fig. 281.—Posterior view of bony union after intracapsular fracture (Riedinger).

As Riedinger has made fractures of the neck of the femur a special study for many years, no one would for a moment doubt the correctness of his description or the authenticity of this specimen.

Gurlt's specimen (No. 17 in table): "The fracture runs obliquely through the neck of the femur; in front it is three-fourths of an inch from the base of the neck; posteriorly, a little less. The head of the bone is displaced somewhat backward and downward and is united by bone, although the line of fracture is still visible in places" (Figs. 283 and 284).

Gurlt's name occupies a foremost position among writers on fractures, present and past, and his decision admits of no appeal.

To prove the validity of any specimen, it is necessary to examine

for evidences that will warrant an affirmative reply to the following questions:

1. Has the bone been fractured?
2. Was the fracture within the capsular ligament?
3. Has the fracture consolidated by bone?

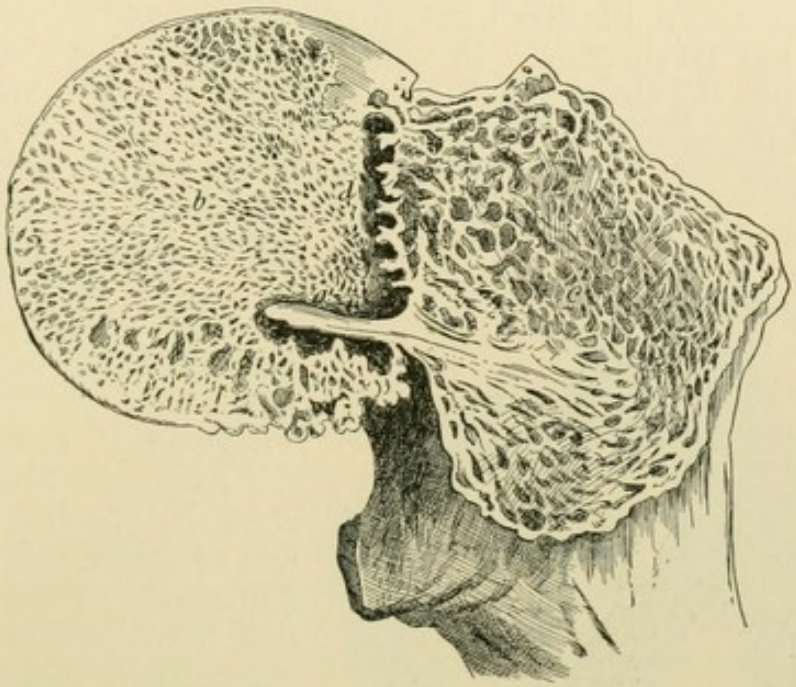

Fig. 282.—Vertical section, showing impaction with bony union after intracapsular fracture (Riedinger).

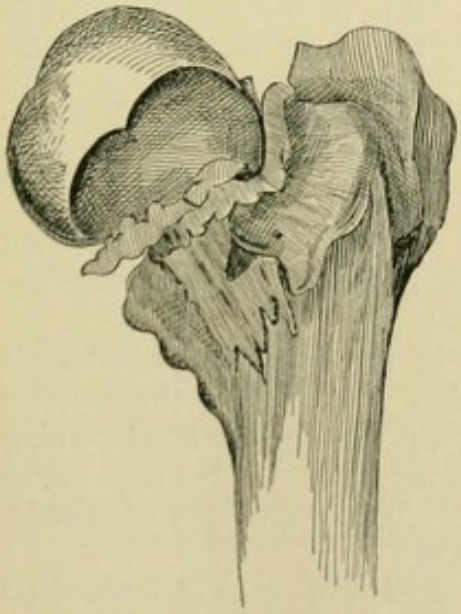

Fig. 283.—Anterior view of bony union after intracapsular fracture (Gurlt).

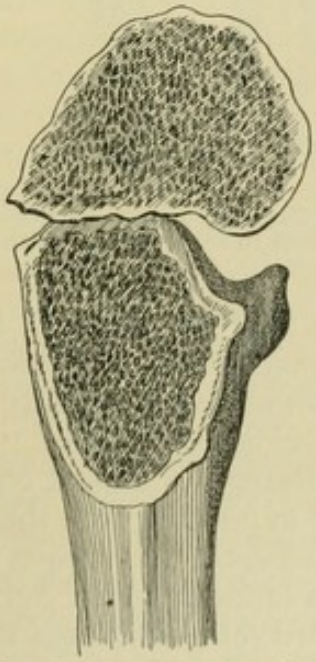

Fig. 284.—Section through neck, showing bony union within capsule (Gurlt).

The first question can arise only in specimens without a clinical history. Postmortem specimens have been brought forward as

instances of bony union, when the changes in the bone were due to other causes, as rickets and senile coxitis. In all cases of interstitial absorption without fracture the wasting of the neck takes place in a more symmetric manner; the neck may become greatly shortened, and, yielding to the vertical pressure, the head may descend to a level with the upper border of the trochanter major, but does not incline backward, as is generally the case when fracture has taken place. In senile coxitis the head is enlarged, and presents the characteristic deep depression for the round ligament; at the same time its upper and anterior surface is deprived of cartilage, and presents an eburnated appearance (Fig. 285). If rickets or senile osteomalacia has been the cause of the deformity, the disease affects both joints simultaneously. An intracapsular fracture always unites with some degree of deformity. Longitudinal sections of the specimens usually disclose the direction and extent of displacement of the fragments. From causes that have been previously enumerated, absorption of the neck is more extensive in the posterior portion of the neck than in the anterior, permitting the head to approach the posterior intertrochanteric ridge. If the fracture has been entirely within the capsule, little or no provisional callus is found over the seat of the fracture, while in senile coxitis irregular bony masses are found over different portions of the neck.

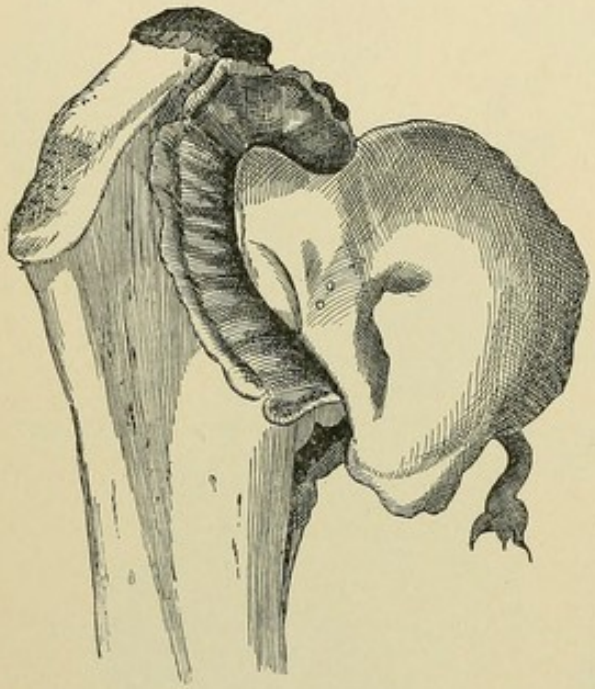

Fig. 285.—Appearance of head and neck of femur in senile coxitis (Richardson).

The writer on fracture of the neck of the femur in Eulenburg's "Encyclopedia" says: "If bony union takes place, the femoral neck disappears almost completely by absorption, the head coming nearly in contact with the trochanteric region. Little or no callus is found upon the surface of the neck." These changes are shown most admirably in the author's specimen.

Bardeleben indicates the following appearances as characteristic of union by bone after fracture within the capsule: "If it can be ascertained with certainty that a fracture has occurred during life, and on postmortem we find a bone cicatrix,—that is, a disc of dense bone through the intracapsular portion of the neck,—and if there are no other evidences of synovitis or osteitis, then we are

justified in claiming for such a case that a fracture within the capsule has united by bone."

Erichsen remarks: "When bony union has taken place, the head will usually be found somewhat twisted around, in such a way that it looks toward the lesser trochanter, owing to the eversion that has taken place in the lower fragment."

Gurlt states: "Absorption of the fragments occurs exclusively in fractures involving joints, and proceeds hand in hand with the process of repair. In some joints, as in the hip-joint, it may be so extensive that almost the entire neck is absorbed. This is more likely to be the case if the fracture is within the capsule. In such cases the head of the bone may be very near the greater trochanter, at the base of the cervix femoris. The cause of this absorption is not known."

The characteristic deformity presented by specimens of bony union of fracture through the neck of the femur corresponds to the direction of the displacing forces—shortening and eversion. The cause of the primary displacement is the fracturing force itself. The secondary displacement takes place upon the accession of osteoporosis, and is the result of softening and absorption of bone, muscular contraction, and the force of gravitation.

Exacting critics have questioned the validity of many specimens of bony union, on the ground that the fracture was not entirely intracapsular. Indeed, this argument has been the main support of all modern believers in nonunion. In all specimens of bony union the point of attachment of the posterior portion of the capsular ligament is changed: instead of being inserted near the middle of the femoral neck, it is found attached to or near the posterior intertrochanteric line, and on this account it has been asserted that the fracture extended beyond the capsular ligament. It is, however, more probable that this alteration in the attachment of the capsule admits of a more satisfactory explanation. All fractures are followed by osteoporosis in the ends of the broken bone, and this is more especially well marked in intra-articular fractures. During the osteoporotic process the periosteal covering of the bone is loosened, and readily changes its relative position to the bone during the process of interstitial absorption, and carries with it the capsular ligament with which it is intimately connected. Interstitial absorption precedes and attends the production of callus, and is most active in that portion of the bone supplied with the greatest number of blood-vessels. The upper fragment being scantily supplied with blood-vessels, absorption, if it takes place at all, occurs at a later date and progresses very slowly, while the reverse is the case in the lower fragment. The point of attachment of the capsular ligament is no indication as to the seat of fracture, as almost the entire femoral neck may disappear by absorption, and the capsule approaches the trochanteric region in proportion to the amount of bone absorbed. A more important sign

is the presence or absence of new bone upon the outside of the capsule. In intracapsular fractures little or no external callus is produced within or without the capsule, while extracapsular fractures, for obvious anatomic reasons, yield an abundance of exuberant callus, part of which at least remains permanently. The last test is to ascertain the nature of the connecting medium. This can be done by submitting the specimen to a microscopic examination or to the boiling process. In the first test the tissues at the seat of fracture will show the histologic elements of true bone in all genuine specimens. The boiling process will destroy the ligamentous union between the fragments in all doubtful cases, and is, therefore, the simplest and most certain method of demonstrating the restoration of the continuity of the broken bone.

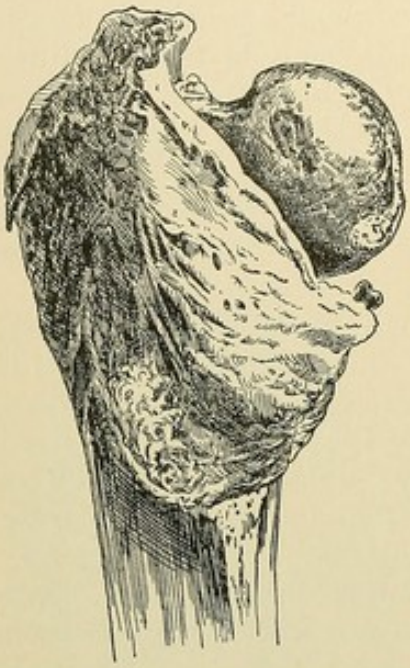

Fig. 286.—Impacted fracture of the neck of the femur at its base, exhibiting a massive extra-articular callus. Lateral view (after Verity).

In recapitulation it may be stated that the validity of a specimen is established whenever the clinical history has revealed the existence of fracture during life, and the postmortem examination has demonstrated that the fracture has been within the capsule and that the union is by bone.

Nonunion after Intracapsular Fractures.—Sir Astley Cooper enumerates the causes of nonunion under the following heads:

1. Want of proper apposition of the bones.
2. Want of pressure of one extremity of the broken neck upon the other, even though the limb preserved its length, and the fractured parts are consequently not much displaced.
3. Absence of nutrition in the head of the thigh bone.
4. Atrophy of bone.

The first cause can only apply to nonimpacted fractures where treatment has failed to keep the fractured ends in immediate and uninterrupted contact for a sufficient length of time for union by bone to take place, and as such constitutes the principal, if not the only, cause of nonunion. There is no other fracture where immobilization is so difficult to accomplish. Every movement of the body disturbs the fractured ends. No apparatus yet devised has answered the first and principal indication in the treatment of all fractures—namely, to secure perfect immobility and permanent coaptation.

Colles, who fully indorses the views of Sir Astley Cooper on the subject of fractures within the capsule, in speaking of the

causes of nonunion remarks: "However this may be, I think the difficulty of keeping the parts motionless on each other would be sufficient of itself to account for it."

Gurlt, who has studied the process of repair in fractures with the most assiduous care, says: "There is no specific tendency to nonunion in any form of fracture. If the ends of the broken bones can be kept in accurate apposition, union by bone will take place." As illustration of this statement he mentions the following fractures: Neck of femur, patella, coronoid process of inferior maxilla, coracoid process of scapula, olecranon, coronoid process of ulna, trochanter major, tuberosity of os calcis, spinous processes of vertebræ, and some of the sharp prominences of the pelvic bones.

The second cause of nonunion—want of pressure of one fragment upon the other—implies a want of apposition expressed in other words. Dupuytren and Brainard were of the opinion that oblique fractures resulted more frequently in nonunion than transverse fractures, and Dupuytren applied this rule to fractures of the neck of the femur. Experience has shown that of all fractures within the capsule, none is so prone to result in nonunion as transverse fractures through the narrowest portion of the neck. Lateral pressure applied over the trochanter major is an important measure for obtaining union by bone, but this desirable result does not follow from the fact that pressure is made, but simply because, by the pressure, coaptation and immobilization are effected.

Deficient vascular supply of the upper fragment is prominently mentioned, by almost every author, as against the probability of union by bone. On the other hand, it is generally admitted that fractures of the anatomic neck of the humerus unite by bone, and that completely isolated pieces of bone, when properly replanted or transplanted, retain their vitality and physiologic properties. It is also well known that traumatic or pathologic epiphyseolysis may be repaired by bony callus. Why should the upper fragment in intracapsular fractures, with at least a doubtful supply of blood through the round ligament, make an exception to this general rule? Simply because, in this instance, coaptation without impaction is next to impossible with the present methods of treatment. On this point MacNamara makes this statement: "I hardly think the nonunion between the ends of the bone in instances of intracapsular fracture of the neck of the femur is most frequently due to the insufficient blood supply of the head of the bone; otherwise we should more commonly meet with examples, after fractures of this kind, in which the head of the bone had become absorbed; but, as you will see in the specimen I now show you, the cancellated tissue of the head of the bone is supplied with blood through vessels passing along the round ligament and through the fibrous structure uniting it with the trochanter major."

The fractured head of the humerus, deprived of all vascular supply, unites by bone as any other fracture, because the anatomic

relations about the seat of fracture are such that coaptation is maintained without difficulty, and fractures within the capsule of the hip-joint will follow the same rule as soon as the surgeon can successfully combat the obstacles that cause displacements.

The last cause, atrophy of bone, is the weakest argument in favor of nonunion. Clinical experience furnished abundant proof that in persons suffering from fragilitas ossium, regardless of its cause, fractures not only unite, but unite very promptly. Mr. Holmes, in his "System of Surgery," quotes from Gibson the case of a youth of nineteen who had 24 fractures, and from Esquirol another with as many as 200 fractures. Earle records a case of 8 fractures in a child of ten years, and Flemming observed a case where a person suffered 53 fractures between the ages of one and one-half and twenty-five years. In all these cases union took place rapidly.

Gurlt reports a large number of similar cases. He states very distinctly that *old age does not retard the process of union, as has been erroneously supposed: the reparative process remains the same as during adult life.* Nonunion of fractures is seen more frequently in the adult than in the aged. I have seen a fracture of the femur, at the junction of the middle with the upper third, in an old, decrepit man suffering at the same time from locomotor ataxia, unite firmly by bone in less than six weeks. Fracture of the lower end of the radius is common after middle life, and invariably unites in a remarkably short time. Senile osteoporosis is a condition of bone favorable to the production of intermediate callus. Atrophy of bone facilitates osteoporosis, an event that always precedes the formation of callus.

Some authors mention still other causes of nonunion, as the presence of synovia and the absence of a nidus for the formative material. Both of these conditions remind us simply that the fractured ends are not in apposition; otherwise they have no significance in preventing union by bone.

From this short review we are not only justified, but warranted, in asserting that the only cause for nonunion in cases of intracapsular fracture is to be found in our inability to maintain perfect coaptation and immobilization of the fragments during the time required for bony union to take place.

Bony Union after Intracapsular Fractures.—In a circular letter addressed by me in 1883 to prominent surgeons in this country, England, France, Germany, and Switzerland, for the purpose of ascertaining the prevailing opinion on the subject of bony union after intracapsular fractures, this question was propounded: "In your opinion does bony union ever occur after impacted intracapsular fracture of the neck of the femur, and under what circumstances?"

To this question fifty direct replies were received. The opinions were divided as follows: Yes, 27; no, 18; doubtful, 5. It is a significant fact that the replies from professors of surgery in Ger-

man universities, five in number, were, without exception, in the affirmative, while the greatest diversity of opinion appeared to exist in our own country; at least 50 per cent. of the correspondents replied with an emphatic "no." The answers received undoubtedly reflect correctly the sentiments of the entire profession on this point. If we add the five doubtful correspondents to the eighteen negative, we have nearly 50 per cent. who do not believe it possible for bony union to take place within the capsule even under the most favorable circumstances.

The text-books and monographs on this subject were consulted with about the same result. It would then appear that nearly one-half of the profession still doubt the possibility of union by bone in cases of intracapsular fractures.

Having shown that there are no anatomic and physiologic impossibilities present to prevent osseous union after intracapsular fractures, and having referred to a number of reliable and well-authenticated cases of this kind, the opinion on this subject of a few recognized authorities will be quoted.

Sir Astley Cooper, the originator of the controversy on this subject, and who is always quoted as authority on the negative side of this question, never denied the possibility of union by bone, as is evident from what he says on page 137 of his work: "I have only met with one in which a bony union had taken place, or which did not admit of a motion of one bone upon the other. To deny the possibility of this union (bony union) and to maintain that no exception to the general rule can take place would be presumptuous, especially when we consider the varieties of direction in which a fracture may occur, and the degree of violence by which it may have been produced."

He enumerates a number of conditions that would maintain permanent apposition, and then proceeds: "Such a favorable combination of circumstances is of very rare occurrence." At the time this was written the process of repair in bone was but imperfectly understood, and the occurrence of impaction within the capsule was either unknown or its importance as an essential element for bony union was not appreciated.

Heister, nearly a century and a half ago, after explaining that the frequency of nonunion in cases of fractures of the femoral neck was owing to the difficulty of keeping the broken ends of the bone in apposition, made the following statement: "If an instrument could be invented which would keep such a limb so extended that during the cure, or at least during the first two or three weeks, it could be kept as long as the healthy one, there would be hope that the fracture could be cured more satisfactorily than has been the case heretofore." Since we have learned that the production of the intermediate callus requires months instead of weeks, Heister would have to modify his statement by greatly extending the time required for maintaining apposition.

Desault, in combating the popular idea of insufficient blood supply as a cause of nonunion, states: "The head of the bone, separated from the soft parts and attached to the acetabulum by the round ligament, receives a sufficiency of nutriment to enable it to live in that cavity, for there is no instance of its having suffered mortification in consequence of a fracture. Why, then, should it not partake of the properties of life, and particularly of the faculty of reunion, when placed in regular apposition with the body of the bone?"

The following quotation is from Syme: "But none of the arguments which have been adduced to prove the *impossibility* of osseous junction seems to be conclusive, and though the small extent and mobility of the broken surfaces, the absence of vascular tissues surrounding the fracture, and, perhaps, also the presence of synovial fluid may render the cure very difficult, it ought still to be regarded as a possible occurrence."

Richter claimed that bony union could take place in impacted fractures, or where, by careful treatment, apposition and retention were fully accomplished. He evidently was impressed with the importance of the bone-producing function of the periosteum, as he advanced the theory that, in fractures of the neck with complete rupture of the periosteum, under favorable conditions, bridges could be thrown across the line of fracture from one membrane to the other, from which bone could be produced.

Dupuytren, in criticizing the treatment adopted by the English surgeons, and alluding to the secondary displacements owing to the too early removal of retaining apparatus, makes the following remark: "But if these surgeons had adopted the practice of the Hôtel Dieu in keeping their patients in bed for eighty or even a hundred days, they would have been convinced of the practicability of reunion and complete cure without deformity." And, again: "I can only say, for my part, that if the specimens at the Hôtel Dieu are insufficient to satisfy any one who may take the trouble to examine them, I am at a loss to know what amount of evidence such skeptics would require. For my part, I regard the osseous union of intracapsular fractures as demonstrated and placed beyond doubt."

Malgaigne is a firm exponent of Sir Astley Cooper's teachings, and yet, after the most critical examination of specimens for which bony union was claimed, he is forced to acknowledge that three of them were genuine. He says: "When a fracture unites, the fragments do not undergo such enormous losses of substance as we should be forced to admit in the neck of the femur; and in Swain's case, which Sir Astley Cooper himself acknowledged as an instance of bony union, the neck of the bone had not changed its form. It was so also in Stanley's case; and, lastly, one femur (No. 188) in the Musée Dupuytren has lost nothing, either in form or volume, except as the result of very trifling displacement. I admit that

these three examples demonstrate quite positively the existence of consolidation; but I can not say the same of the rest." Loss of substance and change of direction of the neck can no longer be admitted as evidence against the existence of bony union, as they only indicate the presence of impaction, followed by interstitial absorption the consequence of osteoporosis.

N. R. Smith, in recommending his anterior splint in the treatment of fractures of the neck of the femur, expresses his convictions as follows: "This apparatus, with slight modifications, is applicable to all fractures of the femur. To none is it more appropriate, and in none has it accomplished more satisfactory results, than in fractures of the cervix, the events of which are so justly regarded as an opprobrium of surgery. So uniformly have non-union and deformity resulted, that eminent surgeons have denied that bony continuity is ever restored within the capsule. We hope to show these results are rather the consequence of insufficient treatment than defect in the reparative power of nature."

H. H. Smith advocates the possibility of bony union in the following language: "That osseous union has been seen can not reasonably be doubted, and from a careful analysis of the seat of fracture in these cases I think it is evident that there are a comparatively limited number of cases in which osseous union does occur; and I suggest that, as a general rule, based on observation, it will be found that the nearer a fracture is situated to the head of the bone, or, in other words, the shorter the upper fragment, the greater will be the possibility of osseous union; because the shorter the upper fragment, the greater the chance that the vessels which supply it with blood through the round ligament will be able to furnish it with an amount of material sufficient to enable osseous union to take place by a deposit of bone from the Haversian canals."

Samuel Solly writes: "If you can diagnose that the fracture is an impacted fracture of the cervix, then you may with tolerable confidence predict complete union and a sound limb. I have shown, by reference to the preparations in the College of Surgeons' Museum and also in our own, that fractures of the cervix within the capsule will unite, though not so frequently as those without."

Chelius claims that bony union may have been observed less frequently in England than on the Continent, on account of neglected treatment in cases diagnosticated as intracapsular fractures.

Erichsen, in discussing this subject, remarks: "In some cases, however, bony union takes place. This may happen when the cervical ligament remains intact or when the fracture is impacted."

Holthouse says: "Bony union in this fracture (intracapsular) is rare, and by some has been considered impossible; but a sufficient number of undoubted cases have now been brought to light, both in Europe and America, to place the fact beyond a doubt."

Agnew, in speaking of Astley Cooper's method of treatment of intracapsular fractures, remarks: "There have been recorded a sufficient number of cases of bony union, after what was believed to be intracapsular fracture, to justify a hope that some of the cases encountered by the surgeon may have a similar termination."

Gant expresses a similar hope: "Bony union at one time, and for many years, thought never to take place, does assuredly in some rare cases; but only, it would seem, when the capsular ligament remains entire or the fragments are impacted, whereby a due supply of blood can be speedily established."

Mr. Thomas Bryant makes use of the following language: "In the impacted fractures union ought to be looked for if the broken fragments are left alone and not loosened by a careless and too curious manipulation. In the purely intracapsular fractures union may take place—osseous in many cases, fibrous in more."

MacNamara affirms: "I believe if you can keep the parts at rest, in many cases of intracapsular fractures union of the ends of the bone will occur."

Koenig realizes the importance of impaction in the reparative process, as may be seen from his statement that intracapsular fractures heal less frequently by osseous union than extracapsular fractures, because they are less frequently impacted.

Hueter, who classifies fractures of the neck of the femur into those with and without impaction, regardless of the attachment of the capsular ligament, lays down as a rule that impacted fractures usually unite by bony union.

Stimson, in discussing the subject, advances the following as one of his arguments in favor of the possibility of bony union: "Even if we disregard all existing specimens of alleged bony union, the possibility of such union must, I think, be admitted, because of the demonstrated fact that the head preserves its vitality and has shown its ability to produce granulations and bone: the former proved by the examples of fibrous union, the latter by eburnation or condensation of its spongy tissue."

The list of witnesses who testify to the possibility of bony union after intracapsular fractures can be closed by quoting the last sentences of Jonathan Hutchinson's description of the specimen in the Pathologic Museum of Leeds Hospital. "This specimen is alluded to by Malgaigne and Hamilton as if it were of doubtful validity; but neither of them had probably seen it. I can not but hope that the publication of these life-size drawings of the bone will set at rest all skepticism as to the possible union of intracapsular fractures. I trust, also, that it may lead to greater hopefulness in the treatment of these accidents, and thus to more systematic care in securing coaptation."

With such an array of unprejudiced, honest, and conscientious witnesses before us, who unanimously and most positively testify that union by bone can, and not infrequently does, take place, we

are no longer warranted in denying its possibility. The number of well-authenticated specimens has been gradually increasing, and the knowledge derived from clinical observation and experimental investigations on this subject during the last twenty years can leave no further doubt regarding the production of bony callus in intracapsular fractures. In the interest of science and for the benefit of the patients this controversy ought to be and must be decided in favor of the affirmative, and then the profession will be prepared to seek for measures that will secure better results.

Treatment.—In no other fracture are the indications for successful treatment so difficult to meet as in fracture of the neck of the femur. Every unprejudiced surgeon is forced to admit that the usual bad result in these cases is owing more to the inefficiency of the treatment employed than to the anatomicopathologic conditions of the broken bone. The causes of nonunion are not to be found in the broken bone, but in the difficulties encountered in the treatment. All the various methods of treatment suggested and practised have failed to secure perfect coaptation and uninterrupted immobilization. In all intracapsular fractures union is effected by the production of an intermediate callus from the broken surfaces. Nature's splint, the external callus, for well-known anatomic reasons is always wanting, hence the surgeon's splint has a more important and prolonged application than in fractures.

The time required for bony union to take place in fractures of the femoral neck is an unusually long one. Gurlt fixes the time at from fifty-six to two hundred and seven days, and the average duration at eighty-four days. Dupuytren estimates the time at from one hundred to one hundred and twenty days, and states that it had been customary at the Hôtel Dieu to keep these patients in bed for from eighty to one hundred days. There can be no doubt that many cases that promised well from the beginning terminated badly from abandoning the treatment too early. It has not been an unusual occurrence suddenly to find, for want of proper precautions, at the end of the third or the fourth week a rapid increase of shortening from half an inch to an inch and a half or even more. To prevent secondary displacements, the retentive apparatus should not be removed for at least from eighty to one hundred days.

In deciding upon a course of treatment to be pursued, it is important to make a distinction between impacted and nonimpacted fractures. In impacted fractures the fragments have been placed in the best possible condition for bony union to take place, and the sole object of treatment consists simply in maintaining the mutual penetration until the reparative process is completed and the continuity of the bone restored. The physician must be satisfied with securing consolidation of the broken bone in the position in which it has been placed by the accident. *Any attempt to correct the deformity is unjustifiable and would necessarily result in loosening of*

the impaction, an event that would be followed, almost to a certainty, by nonunion, unless it were again reproduced artificially and maintained by fixation. Extension is useless in these cases.

Permanent fixation of an impacted fracture is necessary for the following reasons:

1. It maintains the impaction.

2. It prevents secondary shortening and eversion during the osteoporotic stage of the reparative process.

3. By keeping the injured parts at rest it serves as a preventive measure against the accession of arthritis and para-arthritis.

It enables the patient to leave the bed before complete consolidation of the fracture has taken place. Extension is always contraindicated in these cases, as it certainly can do no good and may result in irreparable damage by loosening the impaction. The best dressing to accomplish permanent fixation is a plaster-of-Paris bandage. To insure complete immobility of the hip-joint the bandage must include the injured limb from the toes upward, the entire pelvis, and the sound limb from the pelvis to at least as far as the knee. For the purpose of greater durability and security of the dressing a tin or wood splint can be incorporated in the plaster bandage. In the application of this bandage it is necessary to protect all prominent bony projections, more especially the trochanter major over the affected side, with salicylated cotton, to guard against excoriations; a thin layer of absorbent cotton should be applied next the skin and held in place by a gauze bandage. During the application of the bandages, and until the plaster sets, it is necessary to place the patient on a pelvic rest, such as is described by Bardeleben. During the setting of the plaster it is important to make lateral pressure over both the greater trochanters, in order to secure firm support to the broken bone.

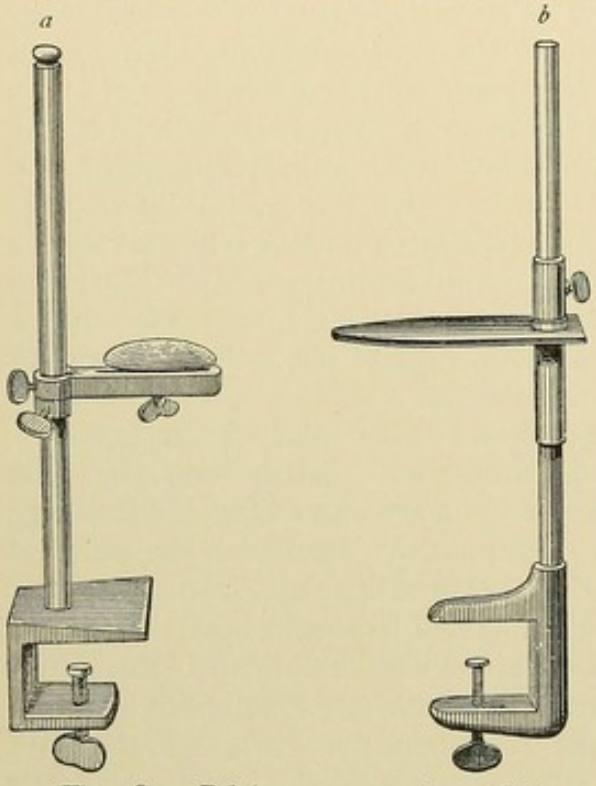

Fig. 287.—Pelvic supports, to be used in applying plaster-of-Paris dressing in fractures of the thigh and neck of femur: *a*, Von Esmarch's; *b*, von Bardeleben's.

With such a dressing the patient can be moved without fear of disturbing the fracture, and in a few days he can leave the bed, and in a few weeks can walk on crutches, if this is deemed necessary

for the purpose of preventing complications. Unless indications arise, it is advisable not to disturb the dressing until osseous union has become sufficiently firm to support the fragments. It is particularly dangerous to change the dressing in from the third to the

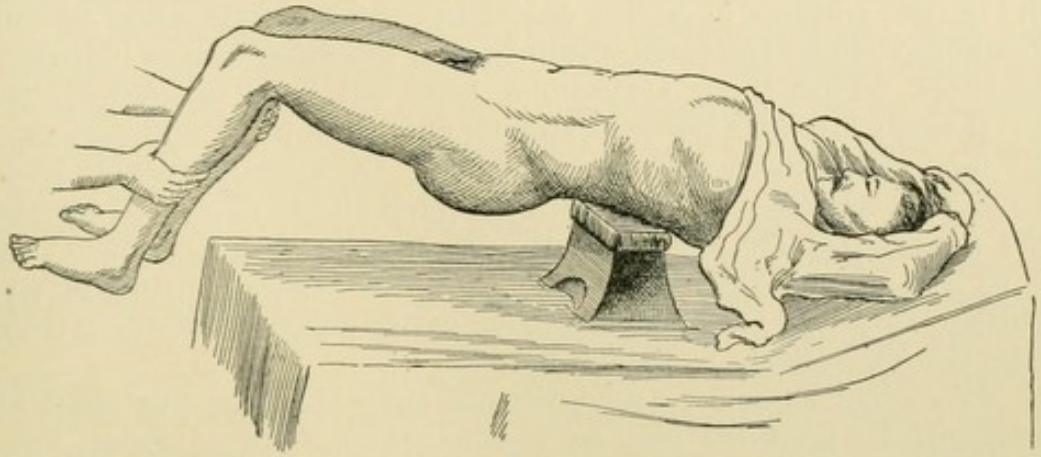

Fig. 288.—Von Volkmann's pelvic support, to be used in applying plaster-of-Paris dressing in fractures of the thigh and neck of femur (von Esmarch).

fifth week, as during this time the inflammatory osteoporosis has a tendency to loosen the fragments. A dressing of this kind is vastly superior to any splint in affording comfort to the patient and in securing the best attainable result. In very feeble and decrepit patients, where such permanent fixation is not applicable, the best plan to pursue is to place the patient in a bed properly prepared, and in a position that will prove most comfortable to the patient, most conducive to securing muscular relaxation, and most favorable toward the prevention of decubitus. With the head and chest slightly elevated, a double inclined plane, sand-bags on the sides of the limb, a pelvic belt with a compress over the trochanter major of the injured side, will contribute much toward keeping the fractured surfaces in contact. Strict attention to cleanliness and proper attention to the skin will do much toward preventing decubitus.

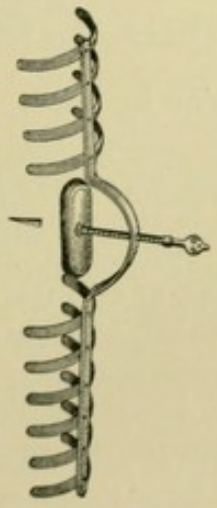

Fig. 289.—Senn's apparatus for making lateral pressure in the treatment of fractures of the neck of the femur.

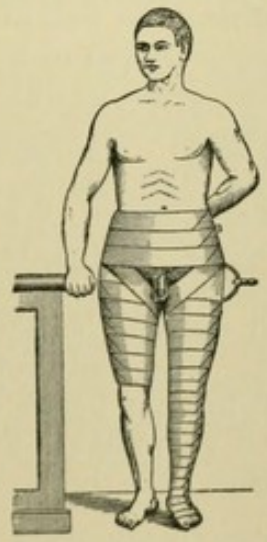

Fig. 290. — Senn's apparatus applied.

In the treatment of nonimpacted fractures the same principles

should govern us as in the impacted variety. In this class of fractures, however, another important indication arises—namely, to effect coaptation of the fractured ends; at the same time retention is more difficult to accomplish. The closer we can imitate impaction, the better are the prospects for a favorable result. If we could keep the broken surfaces in perfect coaptation and maintain retention and immobility, these fractures would heal in the same way as impacted fractures. That these indications have not been fulfilled by the usual treatment with different splints, extension by weight and pulley, and pelvic belt, nobody can deny. Even extracapsular fractures have healed, as a rule, with so much shortening as to cripple the patients for life, while the results after intracapsular fractures have almost uniformly been bad; for this reason many distinguished surgeons have abandoned all active measures, limiting their attention exclusively to palliation.

Prominent among the advocates of the expectant treatment in intracapsular fractures may be mentioned Sir Astley Cooper, Velpeau, Langlet, and Lavacherie. That the views of many surgeons on this point have undergone no material change since Sir Astley Cooper's time is apparent from more than one recent work on surgery. In Gant's "Surgery," on page 647, we read as follows: "No bony union taking place, as a rule, in intracapsular fractures of the neck of the femur, it will generally be useless to adjust the fracture and apply any retentive apparatus with a view to such union; and the more so in proportion to the years of the patient."

The older methods of treatment are well illustrated by the views of Dr. E. M. Moore, the veteran surgeon of Rochester, N. Y., who, after a long and rich experience, writes as follows:

"In case of extracapsular fracture we expect union by bone. A favorable result, with shortening from one to three inches, can be pretty well assured by simple expectation. When the intra-articular form occurs, a proper therapeusis is important. If the so-called cervical ligament remains unbroken, it becomes thickened and reinforced, and after about two months becomes strong enough to bear the weight of the patient. The limb being shortened about an inch, with foot slightly everted, no union by bone is to be expected. The possibility of such union has been strenuously denied. A few—a very few—cases have been brought forward to prove union by bone.

"From what has been stated above, it can be seen that in the condition ordinarily resulting from this accident—viz., where there has been a shortening of the neck by crushing of bone tissue—union would be impossible. But in a case of extreme rarity, where a sudden twist would snap off the neck without any crushing of tissue, it is hardly to be supposed that a bony union might not occur. Professor Senn's experiments on cats demonstrated this perfectly. But in making a fracture for experiment, just the condition described would occur. The tissue would not be crushed,

and the broken surfaces would touch. It becomes highly important to protect this ligamentous tissue, while nature is thickening and strengthening the band that will extend from the head to the neck. It has been proposed to confine the patient with a long splint to attain this object. But old age does not tolerate such confinement readily, and a fatal result might disappoint the surgeon. Still, it is wise to guard against the danger incident to the steady strain of the muscles of the thigh. The necessary restraint can be obtained by appending a weight to the limb. This can be most easily obtained by the application of adhesive plaster. The amount of weight may vary from five to fifteen or twenty pounds. It should be regulated by the sensation of the patient: that which produces the greatest comfort is to be adopted. All other restraint should be avoided, but even this must sometimes be given up, and the patient should sit up and even use crutches to maintain health. Nevertheless, the sensation of the greatest comfort to the patient is the best measure of what is necessary to antagonize the contraction of the thigh muscles.

"The same method is suitable for both forms of fracture. The strips, three or four inches in width, and long enough to reach from the groin to four inches below the foot, held in contact with the skin by a roller bandage the whole distance, and held apart at the lower end by a wooden brace so as to protect the ankles from pressure, is a simple and efficient device. To this brace a cord may be attached, which, carried over a pulley, holds the weight necessary."

This is the treatment that has been employed for years and that may be resorted to with advantage in cases in which more radical measures are contraindicated. The treatment detailed by the distinguished surgeon who has done so much in perfecting the treatment of a number of fractures has never succeeded in securing bony union in cases of nonimpacted intracapsular fractures, its sole benefit consisting in placing the capsular ligament in a favorable condition to become strengthened, and later serve as a substitute for the fractured neck in supporting the weight of the body. There are cases in which this conservative course is the only alternative—when, from the general condition of the patient or the presence of serious complications, perfect reduction and permanent immobilization are contraindicated. For such cases I recommend extension by weight and pulley, lateral support of limb by sand-bags, and pressure against the greater trochanter by compress and pelvic belt.

If the results attending the different methods of treatment have been so bad as to induce men of the highest professional attainment to abandon all active treatment, the question naturally arises, Are there any other means that are better adapted to accomplish the desired result? The inquiry as to the possible bony union after intracapsular fracture, in the light of recent researches has been decided in the affirmative, and a more practical query arises,

How can it be obtained? By what means can we keep the fragments in mutual coaptation during the process of repair? The following points suggest themselves in the treatment undertaken for the purpose of obtaining bony union in nonimpacted fractures of the neck of the femur:

1. Immediate reduction and coaptation of the fracture: if need be, under the influence of a general anesthetic.
2. Fixation with a plaster-of-Paris splint.
3. Lateral pressure.
4. Direct fixation of fragments by aseptic ivory or bone nail.

Extension by means of weight and pulley overcomes the shortening, only gradually, and seldom completely; at the same time it necessitates the recumbent position for a long time, and thus exposes the patient to all the risks and inconveniences incident to such position. If the patient is placed thoroughly under the influence of an anesthetic, muscular action is temporarily annihilated, and the limb can be extended at once to its natural length, while coaptation can be effected at the same time. If reduction is made with the patient under the influence of an anesthetic, some kind of a pelvic rest is necessary in the subsequent application of the fixation dressing. The advantages arising from immediate reduction and coaptation are the following:

1. The untorn portions of the joint structures are replaced at once in their normal relations, a procedure that can not fail to influence favorably the circulation in vessels that may have escaped injury.
2. The sharp and irregular margins of the broken surfaces act as irritants to the surrounding soft tissues; immediate reduction, by placing the bones at once in mutual coaptation, acts as a preventive against the supervention of undue irritation and inflammation in and around the hip-joint.
3. With coaptation the process of repair is initiated at once, and the blood and exudation material between the fragments act as a temporary cement substance, at the same time serving a useful purpose in reestablishing the interrupted circulation.
4. Perfect reduction and coaptation prevent muscular spasms and diminish pain.

Having reduced the fracture, retention should be maintained in a similar manner as in impacted fractures, with the exception, however, that eversion should be carefully corrected. The plaster-of-Paris splint is applied as for impacted fracture, only that over the trochanter major of the injured side a fenestra, about two inches wide and four inches long, is left open for the purpose of applying lateral pressure.

Many fractures of the femoral neck are kept from becoming displaced for a variable period of time by interlocking of the denticulated broken surfaces, a condition that has been called by Bigelow "rabbeting." Believing that the surgeon should imitate the repara-

tive resources of nature whenever it is possible to do so, it appears to me that artificial rabbeting could often be produced by lateral pressure. The fractured surfaces being placed as accurately as possible opposite each other, lateral pressure would cause coaptation and a mutual interlocking of the fragments. Lateral pressure applied with this view would be one of the most reliable means of preventing secondary lateral and longitudinal displacements. Pressure, to be effective, must be applied in the direction of the broken neck,—that is, over the trochanter major,—and in such a manner as not to interfere with the superficial circulation. Pressure with belts and strips of adhesive plaster encircling the whole pelvis can exert but little influence on the fractured bone; at the same time it impedes the superficial circulation. With the fenestrated plaster-of-Paris splint pressure can be applied directly over the trochanter major by placing a well-cushioned pad, with a stiff, unyielding back, corresponding in size to the fenestra, in the opening of the splint, and applying the necessary amount of pressure by means of a Petit tourniquet or some other similar contrivance. A small amount of pressure, if well directed, would be sufficient to retain the fragments in apposition. By removing the pad from time to time and washing the parts with dilute alcohol there would be no danger of producing excoriation. The pad could also be made smaller, and the pressure surface changed as often as necessary as an additional precaution against decubitus.

Apposition of the fractured ends could be secured and maintained with the greatest degree of accuracy by measures that are calculated to operate directly upon the fragments. Such direct treatment has been successful in other joint fractures where the usual prescribed methods of treatment had failed in effecting union by bone. In fractures of the femoral neck, however, the injured parts are so inaccessible as to exclude the propriety of any cutting operation for the purpose of exposing the fragments to view and securing apposition by direct fixation. At the same time, this injury usually occurs in a class of patients whose general condition would forbid an operation of such magnitude for such a purpose. If, however, an operation could be devised that would be devoid of immediate or remote danger to life and that would not incur any loss of blood nor add to the suffering of the patient, and at the same time would render substantial aid in maintaining permanent apposition of the fragments, then our prospects for securing better results would indeed become more encouraging. I hope that the same operation I performed so successfully on animals will prove useful in the human subject, in well-selected cases—viz., subcutaneous drilling and nailing of the fragments with an ivory or a bone nail. The observations of Volkmann and Heine have shown that driving ivory pegs into osteoporotic bones will produce an osteoplastic process and sclerosis of the bone. The operation of drilling and insertion of bone nails has been resorted to for a long

time for the purpose of promoting the formation of callus in cases of ununited fractures, and it is only reasonable to assume that the same treatment would have a similar effect in recent fractures. The operation offers no technical difficulties, and if done under strict aseptic precautions, does not expose the patient to any additional risks.

The idea of immobilizing fractures by nailing the ends of the broken bone together is not a new one. It is alluded to by David Prince in treating of the subject of ununited fractures, when he says: "Perhaps a bone might be drilled through both fragments and held in apposition by a rivet of one of these metals. The presence of the rivet after the completion of the healing process would do no harm, and if a permanent discharge should be the result, the metal could be readily removed."

As yet a discrepancy of opinion prevails as to the future fate of bone and ivory pegs when embedded in living bone. Trendelenburg operated for a very oblique ununited fracture of the femur at the junction of the lower with the middle third by fixing the fragments with an ivory peg. He had an opportunity to examine the specimen two and one-half years after the operation. The fracture was firmly united, and the ivory peg was found intact in the bone tissue, having undergone no change whatever, except that a portion that had projected into the knee-joint had become detached and was found embedded in a cyst in the interior of the joint, surrounded by giant cells.

Riedinger made similar observations. Introducing ivory or bone pegs into the bones of animals, he found them after a variable period of time either entirely unchanged or only slightly diminished in size. The diminution in size appeared to be in proportion to the vascularity of the living bone. The growth of the bones thus treated was stimulated, as was shown from an increase in their length as compared with the opposite bones.

Bidder found that by boring a hole into the spongiosa of the epiphysis of the long bones in old rabbits—into the lower end of the femur, for example—no regeneration of bone took place, the loss of substance being replaced by fibrous and myeloid tissue. In young adult rabbits a slight attempt at regeneration was manifested. The process of regeneration, however, was increased by driving ivory pegs into the perforations or by injecting iodin or lactic acid. Brainard taught that simple perforations of bone increased the formation of callus, while insertion of ivory, wooden, or metallic nails not only diminished it, but with few exceptions produced absorption of bone.

Volkmann treated a false joint of the femur by excision of the fractured ends, and immobilized the new fracture by driving a nail made of a piece of fresh bone taken from another patient into the medullary cavity of both pieces. The fracture united, and the transplanted piece was not seen again.

Riedinger's experiments on animals have shown that ivory and bone nails implanted into bone increase the nutrition of the bone, and remain without giving rise to any undue irritation, and are finally partially or completely absorbed. Metallic substances remain firmly embedded in bone; wood and rubber invariably give rise to suppurative inflammation. Clinical experience and experimental investigations have sufficiently demonstrated that bone and ivory nails, if implanted under aseptic precautions, do not act as foreign bodies, and never give rise to suppuration. They can, therefore, be safely employed in securing accurate coaptation of recent fractures, if this is deemed advisable and necessary, and is not obtainable by simpler measures. It has also been shown that these nails stimulate the bone tissue and thus materially hasten the process of repair, and are ultimately removed by absorption. The operation of direct immobilization of the fragments by means of bone or ivory nails is, therefore, particularly adapted to the treatment of intracapsular fractures whenever it is decided to make every legitimate attempt to secure union by bone. A somewhat similar operation has been performed repeatedly for the purpose of relieving the pain and functional disability in old cases of fracture of the neck of the femur followed by the formation of a false joint.

Before the introduction of aseptic surgery von Langenbeck operated by exposing the greater trochanter, and passing a silvered drill through it into the upper fragment, so as to secure apposition. The fracture was oblique and extracapsular, in an aged female. The operation was followed by destructive inflammation, hospital gangrene, and death. Lister operated in a similar manner, but under the protection of antiseptic surgery, and secured a good result by a short fibrous union. In this case, however, it appears that the upper fragment was not transfixed by the screw. Koenig repeated Langenbeck's operation under aseptic precautions and secured a favorable result. The experiments made by the author on animals have satisfied him that it is not always an easy task to find the upper fragment with the drill and perforate it at the proper point. To overcome this difficulty it has been suggested by Trendelenburg to expose the seat of fracture by a small incision from behind, and, after forcibly abducting the limb, perforate the lower fragment from within outward, and by reinserting the drill from without inward, guided by a finger in the wound, after straightening the limb, to transfix the upper fragment. A silver screw is inserted in the hole made by the drill, and the two fragments are screwed together. The screw is to be removed after two weeks. For the purposes for which we have urged the operation Trendelenburg's method is too severe and dangerous. By using bone or ivory pegs no disastrous result would follow in case the peg should miss the upper fragment and be driven into the joint.

Trendelenburg's case and my experiments on animals furnish positive proof that bone and ivory pegs driven into the interior of

joints do not give rise to any serious results. The operation of drilling the femoral neck and the subsequent insertion of the ivory peg is facilitated by placing the limb in its natural position and securing it by a plaster-of-Paris dressing. The drilling is done through the fenestra over the greater trochanter in the plaster splint, by sliding the skin and making a passage for the drill with a tenotome through the soft tissues down to the bone, at a point corresponding to the center of the base of the femoral neck, and drilling in the direction of its axis toward and into the femoral head. The length of the bone or ivory peg should correspond to the distance between the outer surface of the greater trochanter and the center of the femoral head. The advantages arising from the treatment suggested would be :

1. A perfect degree of coaptation and immobilization of the fragments.

2. The patient could be placed in any position in bed, or even be taken outdoors as soon as the dressing is applied, thus effectually preventing excoriations and the diseases incident to prolonged confinement to bed in the recumbent position.

The subcutaneous drilling and transfixion of the fragments with an aseptic bone or ivory nail must be restricted to cases in which there are no contraindications and in which bony union by such treatment can be confidently expected. Such cases are necessarily few. Obesity, great general debility, atheroma and arteriosclerosis, complicating diseases, and very old age are contraindications that must not be ignored. Direct fixation in recent fractures must be combined with immobilization of the limb and pelvis. The open operation for direct fixation must be reserved for the relief of pain and functional disability in well-selected cases of pseudarthrosis following fracture of the femoral neck. It is an operation of considerable magnitude, and should not be undertaken lightly.

An extensive clinical experience has satisfied me that direct measures of fixation are seldom called for in the treatment of recent unimpacted fractures of the neck of the femur, as the same results can be obtained by well-regulated lateral pressure in the direction of the axis of the femoral neck, combined with perfect fixation of the lower fragment upon the pelvis. The influence exercised by impaction in determining the ultimate result in fractures within the capsule of the hip-joint has been repeatedly alluded to.

Many fractures of the femoral neck are kept from becoming displaced for a variable period of time by interlocking of the denticulated broken surfaces, a condition that has been termed by Bigelow "rabbeting." Believing that the surgeon should imitate the reparative resources of nature whenever it is possible to do so, it occurred to me that artificial rabbeting could be produced in all cases by uninterrupted lateral pressure. It is not difficult to conceive that if the fractured surfaces are placed as accurately as possible in apposition, lateral pressure would effect perfect approximation and a mutual

interlocking of the fragments. Lateral pressure thus applied is one of the most efficient means in preventing secondary, lateral, and longitudinal displacements. Pressure, to be effective, must be applied in the direction of the broken neck—that is, directly over the trochanter major, and in such a manner as not to interfere with the superficial circulation. Pressure with belts and strips of adhesive plaster encircling the whole pelvis can exert but little, if any, influence on the fractured bone; at the same time it impedes the superficial circulation. In the more recent cases of fracture of the neck of the femur that have come under my observation I have pursued the following plan of treatment:

The patient is dressed in well-fitting knit drawers and a thin pair of stockings. For strengthening the plaster-of-Paris dressing over the joints, and at other points where greater strength is required, oaken shavings or strips of tin are placed between the layers of plaster. These small thin splints greatly increase the durability of the dressing without adding much to its weight. The bony prominences are protected with cotton before the plaster-of-Paris dressing is applied. The drawers and stockings furnish a more complete and better protection to the skin than roller bandages. Usually about twenty-four plaster-of-Paris bandages are required for a dressing. The fractured limb is first incased in the dressing as far as the middle of the thigh, after which the patient is lifted out of bed by two strong persons, the physician supporting the limb so as to prevent disengagement of the fragments if the fracture is impacted, and to guard against additional injuries in nonimpacted fractures. The patient is placed in the erect position, standing with his sound leg upon a stool or box about two feet in height; in this position he is supported by a person on each side until the dressing has been applied and the plaster has set. A third person takes care of the fractured limb, which is gently supported and immovably held in impacted fractures until permanent fixation has been secured by the dressing. In nonimpacted fractures the weight of the fractured limb makes autoextension, which is often quite sufficient to restore the normal length of the limb; if this is not the case, the person who has charge of the limb makes traction until all shortening has been overcome, as far as possible, at the same time holding the limb in a position so that the great toe is on a straight line with the inner margin of the patella and the anterior superior spinous process of the ilium. In applying the plaster-of-Paris bandages over the seat of fracture a fenestra, corresponding in size to the dimensions of the compress with which the lateral pressure is to be made, is left open over the great trochanter.

To secure perfect immobility at the seat of fracture it is not only necessary to include the fractured limb and the entire pelvis in the dressing, but it is absolutely necessary to include the opposite limb as far as the knee, and to extend the dressing as far as the

cartilage of the eighth rib. The splint which is represented by figure 289 is incorporated in the plaster-of-Paris dressing, and must be carefully applied, so that the compress, composed of a well-cushioned pad with a stiff unyielding back, rests directly upon the trochanter major, and the pressure that is made by a set-screw is directed in the axis of the femoral neck. The set-screw is projected by a key that is used in regulating the pressure. Lateral pressure is not applied until the plaster has completely set. If the patient is well supported and the fractured limb is held immovably in proper position, but little pain is experienced during the application of the dressing. Syncope should be guarded against by the administration of stimulants. As soon as the plaster has hardened sufficiently to retain the limb in proper position, the patient should be laid upon a smooth, even mattress, without pillows under the head, and in nonimpacted fractures the foot is held in a straight position and extension is kept up until lateral pressure can be applied. The lateral pressure prevents all possibility of disengagement of the fragments in impacted fractures, and in nonimpacted fractures it creates a condition resembling impaction by securing accurate apposition and mutual interlocking of the uneven fractured surfaces. No matter how snugly a plaster-of-Paris dressing is applied, it becomes loose in a few days, as the result of shrinkage, and without some means of making lateral pressure it would become necessary to change it from time to time in order to render it efficient. But by incorporating a splint in the plaster dressing, as shown in figure 290, this is obviated, and the lateral pressure is regulated from day to day by moving the set-screw, the proximal end of which rests in an oval depression in the center of the pad. From time to time the pad is removed and the skin washed with dilute alcohol, for the purpose of guarding against decubitus.

After-treatment.—If the application of the dressing, as just described, is a tedious, laborious, and difficult task, it will richly compensate both physician and patient during the after-treatment. I have never found it necessary to apply more than one dressing. If the fracture is properly reduced and the limb fixed in normal position in the dressing, then the only thing that requires watchful attention is the regulation of the lateral pressure. The patient can move himself in bed and can lie on the back, face, and on either side, and can be taken out of bed and, if the weather is favorable, outdoors daily if desirable, without pain or risk of displacement of the fragments. If necessary, a patient in such a dressing could be transported great distances without any immediate or remote risks. The impunity with which the patient can change his position and the benefits to be derived from outdoor fresh air are advantages that can not be obtained by any other treatment, and to them must be attributed an important influence in the prevention of a number of the fatal complications that have so often figured as causes of death in patients suffering from fractures of the

femoral neck. If the dressing has been well applied, and more especially if the precaution has been followed to protect the bony prominences with a layer of salicylated cotton, there is little or no danger of the formation of excoriations. At the expiration of from eighty to one hundred days, the time required for bony union to take place, the dressing is removed, but the patient should be cautioned not to make use of the limb until the end of the fourth or sixth month, when union will be sufficiently firm to sustain the weight of the body. As soon as the dressing is removed passive motion should be made, and the nutrition and function of the limb should be promoted by massage and, if considerable muscular atrophy is present, the use of the faradic current.

Cases of Fracture of the Neck of the Femur Treated by Immediate Reduction and Permanent Fixation.—

Case 1.—Female, aged sixty-eight, in fair general health, slipped on the sidewalk and fell upon the right hip. The examination made a few hours after the accident revealed a contusion over the trochanter major, some swelling about the region of the hip-joint, limb everted, and a shortening of 1¼ inches. The displacement of the great trochanter above Roser-Nélaton's line corresponded with the extent of the shortening. There was no impaction. Crepitus was elicited by the slightest movement of the limb. Anatomic diagnosis: Fracture of the neck of the femur partially within and partially without the capsular ligament. In this case reduction was made by placing the patient upon a pelvic rest and making extension. The limb could be brought down to within ¼ of an inch of its normal length, and in this position, with the foot in proper line, it was fixed in the plaster-of-Paris dressing, and as soon as the plaster had become firm, lateral pressure by means of the pad and set-screw was applied. The patient suffered but little pain at any time, and could roll herself in bed from one side to the other with ease. The dressing was removed after three months, when it was ascertained that bony union had been obtained, with ½ inch of shortening and the limb in good position. Passive motion and massage were now made daily, and the patient was allowed to walk on crutches. Four months after the accident she was able to walk with the aid of a cane, and three months later she required no further mechanical support. At the end of a year recovery was complete and she could walk nearly as well as before the accident.

Case 2.—Male, aged sixty-five years. Patient was somewhat anemic, and presented evidences of senile marasmus. He had fallen from a ladder for a distance of about six feet directly upon his left side. There was no external contusion, and swelling over anterior aspect of hip-joint was slight. A number of careful measurements revealed ¾ of an inch of shortening. Foot was moderately everted; no impaction. Gentle traction upon the limb and slight rotation produced crepitus. After fractured limb was incased in plaster as far as the knee, patient was made to stand with the sound limb upon a stool and was supported on each side by an assistant, while a third person made traction until the shortening was nearly corrected, and with the foot in proper position the fixation dressing was applied. Lateral pressure was applied the next day, and was kept up carefully for eighty-five days, when the dressing was removed. A thorough examination showed that bony union had taken place, and that the shortening did not exceed ⅓ of an inch. The patient used crutches for six weeks, later a cane for a few months longer, and at the end of a year he walked well without any support and with only a slight limp.

In this case the symptoms after the accident pointed to a fracture of the neck of the femur involving more of the bone within than without the capsular ligament. Only a slight amount of callus could be found behind the posterior margin of the great trochanter.

Case 3.—Female, fifty-eight years old. Senile marasmus was well marked. Patient stumbled and then fell on right side. A few hours after accident the right foot was found everted and the limb shortened ⅔ of an inch. There was no impaction. Right groin was considerably swollen, and trochanter major was displaced backward and upward. Probable seat of fracture was partly within and partly without the capsule. Reduction was effected by autoextension and traction upon the limb. After the limb was immobilized in the dressing the foot was in normal position, with apparently little or no shortening. Fixation and lateral pressure were continued for three months. On removal of the dressing the union was found firm, with ½ inch of shortening. Patient used crutches for three months. Stiffness in the hip-joint was overcome only by regular active and pas-

sive exercise and massage continued for a long time. At the end of eight months the patient was able to take care of her household, and the function of the limb was nearly restored. Measurements made at this time showed that the shortening had not increased.

Case 4.—Male, fifty years old, prematurely aged, the result of intemperate habits. Patient slipped and fell on the doorsteps, fracturing the left femoral neck. There was considerable swelling at the seat of fracture. Foot was strongly everted; shortening 1 ¼ inches; no impaction. Trochanter major was less prominent than on the opposite side, and displaced upward above Roser-Nélaton's line 1 ¼ inches. There was no impaction. On making extension and gently rotating the limb crepitus could be distinctly felt. Reduction and immobilization were performed in the usual manner. The second day the patient had an attack of delirium tremens. During the maniacal excitement he tossed about in every direction, and the nurses were kept busy preventing him from demolishing the dressing. It was during this attack that the fixation dressing and the lateral pressure gave evidence of their efficiency in maintaining uninterrupted coaptation under the most unfavorable circumstances. Under the use of narcotics the patient became rational and quiet on the third day. The dressing had to be repaired in several places. Subsequently the progress of the case was favorable. The dressing was removed after ninety days, when the fracture was found firmly united, with nearly an inch of shortening. There was considerable callus in front of and behind the trochanter. The patient was soon able to walk about on crutches, but no reliable information could be obtained as to his condition since.

Case 5.—A female, weighing nearly 200 pounds, was thrown out of a buggy and fell upon her left side. After she recovered from the immediate effects of shock she found that she could not use her left leg. Two physicians who examined the patient soon after the injury suspected a dislocation of the hip, but made no attempts at reduction. On examination the following day it was found that the foot was markedly everted, and a number of measurements made showed ½ inch of shortening. The great trochanter had been displaced beyond Roser-Nélaton's line to the same extent, and appeared to be less prominent than on the opposite side. There was no swelling in the groin or posterior aspect of the hip-joint. On gently rotating the limb the great trochanter described a smaller circle than on the opposite side, and the movements affected the head of the femur. Slight traction had no effect in diminishing the shortening. The diagnosis of intracapsular impacted fracture was based upon this symptom, and every precaution was exercised not to cause disjunction of the fragments during the examination and the application of the dressing. As it was important to maintain the impaction during the time required for bony union to take place, the patient was treated in the same manner as in the preceding cases, only that no attempts were made to overcome the shortening or to correct the other displacements. Lateral pressure was applied in a line with the axis of the outer portion of the femoral neck, for the purpose of maintaining the impaction during the stage of inflammatory osteoporosis. The dressing was not disturbed for three months, when it was removed, and the limb was found in the same position as when it was applied. The shortening had not increased. The patient was cautioned not to use the limb for another three months, and in walking to depend entirely on crutches. For a long time the movements in the hip-joint were impaired undoubtedly the result of a traumatic plastic inflammation of the structures of the joint. Passive motion and massage succeeded in restoring the normal function of the joint. At no time could any callus be felt, which must be considered as another proof that the fracture was intracapsular. At the end of a year the patient walked nearly as well as before the accident.

Case 6.—A man, sixty-five years of age, slipped on an icy sidewalk and fell in such a manner that the right femoral neck was fractured. A few hours after the accident a considerable swelling had formed in the groin. There was contusion over the great trochanter, and eversion was so marked that the outer margin of the foot rested on the mattress. A shortening of 1½ inches was revealed; no impaction. Crepitus elicited on slightest motion of limb. Diagnosis of nonimpacted extracapsular fracture of the neck of the femur was made. Reduction was accomplished by autoextension and traction on the limb. Fixation by means of plaster-of-Paris dressing and lateral pressure were made. Patient was relieved of pain as soon as the dressing had been applied, and remained in good health during the entire treatment, which was continued for seventy-five days, when the dressing was removed. Bony union with ¾ of an inch of shortening followed. A large mass of callus on each side of the great trochanter could be distinctly felt. Crutches were used for four months. At the end of a year he walked without any support and with only a slight limp.

Case 7.—A strong, healthy blacksmith was thrown from a buggy that was upset by an unruly horse. He fell in such a manner that his full weight came upon the right hip. Immediately after the fall he found that he was unable to use the right leg. He was conveyed in a carriage to his home, some three miles distant, and examination two hours

later revealed the following: Superficial abrasion of skin over the great trochanter; marked eversion of foot; shortening 1½ inches; tip of trochanter some distance above Roser-Nélaton's line; right femur 17¼, and left femur 17⅛, inches in length; crepitus on extension and rotation of the limb inward. New point of motion at seat of fracture was very evident. Pain was referred to point immediately behind the great trochanter. There was considerable swelling in the groin and behind the great trochanter. The injury was diagnosticated as an extracapsular nonimpacted fracture. Reduction by autoextension was made on the third day, and the fracture immobilized by plaster-of-Paris dressing, in which the splint was incorporated for making lateral pressure. Patient suffered but little pain after the dressing was applied. The dressing was not removed for twelve weeks, when a large mass of callus was found behind and in front of the great trochanter, which for quite a long time seemed to impair the movements of the joint. With the disappearance of the callus the functional result improved. The fracture healed by bony consolidation, with an inch of shortening. In six months he dispensed entirely with the use of crutches, and with a high sole on the right boot, to make up for the shortening of the limb, he walked with only a very slight limp. In twelve months he was able to attend to his business, even to horseshoeing, and has since, aside from the slight lameness, suffered no inconvenience from the accident.

CASE 8.—An invalid lady, sixty-one years old, while descending three low steps caught the left heel in the skirt of her dress and fell, striking on the left hip. Examination soon after revealed the following *status præsens:* Dark-blue discoloration of skin over the outer and posterior aspect of the great trochanter, and from two to three inches below the hip-joint indicated the point where the fracturing force was applied; slight eversion of foot; no swelling in groin or posterior aspect of hip-joint; tip of great trochanter ½ inch above Roser-Nélaton's line. On making measurements from anterior superior spine of the ilium to the internal malleolus no shortening could be detected, but the apparent discrepancy between the result obtained by these measurements and the Roser-Nélaton's test-line was subsequently explained by the other measurements, which showed asymmetry of the femora, the femur on the injured side being ½ inch longer than its fellow on the opposite side. Left trochanter rotated on a shorter radius of a circle than the right. Pain in the hip was increased by pressure over the great trochanter. Patient was able to elevate the limb about two feet from the bed, but all such efforts aggravated the pain. The symptoms in this case, as well as the manner in which the injury occurred, pointed directly to an impacted intracapsular fracture of the neck of the femur. In order to secure the benefits of long-continued impaction during the process of repair, immobilization of the fracture was secured by a plaster-of-Paris dressing and splint for lateral pressure. The general condition of the patient was not impaired by this kind of treatment of the fracture, and when the dressing was removed, eight weeks after its application, the limb was found in the same position as after the accident. The patient was directed to rely on crutches for a number of weeks and then to use the limb cautiously. At the end of five months she could walk without a cane and with an almost imperceptible limp.

I recommend for adoption the treatment just described in all cases where there is a reasonable hope that by it a bony union of the fracture will be obtained. It is superfluous to remark that it is not applicable in all cases of fracture of the femoral neck, and is positively contraindicated in cases of extreme obesity and debility, and in patients suffering from concomitant diseases that, in themselves, would lead to a fatal termination, in which event a purely palliative treatment, such as has been previously detailed, is the only one that the physician will institute for the purpose of securing as useful a limb as is compatible with an unavoidable pseudarthrosis of the femoral neck.

Colles' Fracture.—The importance of fracture of the lower end of the radius, first described, from an anatomic and clinical standpoint, by Abraham Colles, pertains to the frequency with which it occurs, the liability of its being overlooked, and, when recognized, the number of bad results that follow the mechanical treatment without complete reduction.

Fractures of the lower end of the radius are the most frequent, comprising 10 per cent. of all fractures. Sex and its consequences have some influence as a predisposing cause, as Morris has ascertained that in 169 cases of these fractures it occurred 114 times in women and only 55 in men. The largest number of patients were between fifty and sixty years of age. The senile osteoporosity of bone during that period of life and the greater liability to falls upon the hand will explain the more frequent occurrence of this fracture in persons advanced in years. In children and young adults the line of fracture occasionally takes place through the epiphyseal junction, in which case arrest of bone growth from the injury to this important bone-growing center in the lower end of the radius constitutes one of the most formidable remote consequences of the injury.

Professor E. M. Moore, of Rochester, N. Y., has made Colles'

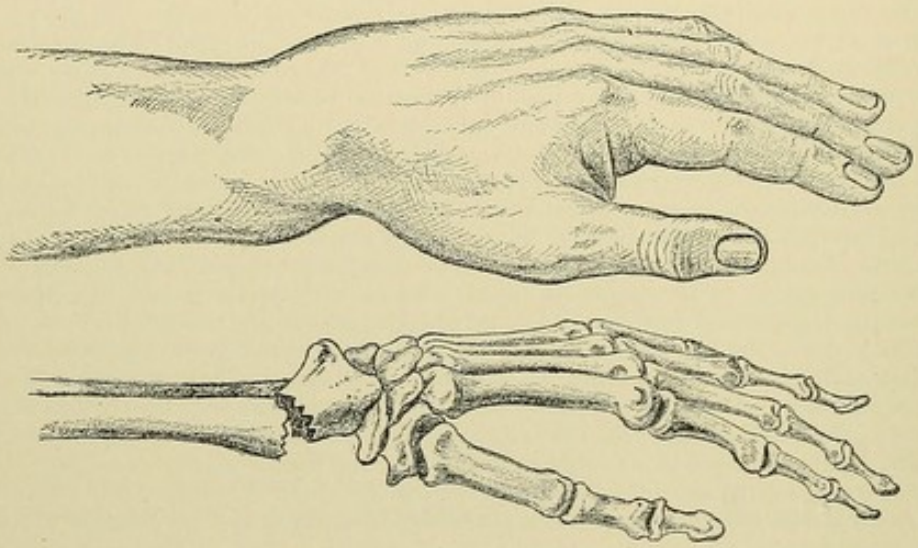

Fig. 291.—Colles' fracture, illustrating the usual seat of fracture and deformity of the wrist (Hoffa).

fracture of the radius a special study during his long and busy professional career, a work of lasting merit for which, however, he has never received the credit to which he is so well entitled. It is my desire to give to the profession the benefits of Dr. Moore's researches by inserting here the most recent views of this distinguished authority on this subject:

"Professor Colles drew the attention of the profession of his day so earnestly to a constant misunderstanding with reference to the fracture of the radius at its lower end as to have had his name indissolubly attached to it. The fracture was usually regarded as a contusion with swelling, or, if the displacement was much, as a luxation of the carpus. These errors still delude the profession, but it is to be hoped in a not very great degree. The fracture is to be found from half an inch to an inch and a half above the carpal articulation, usually at the less distance. The fragments are apt to

be somewhat interlocked, because the line of fracture is in cancellated tissue, so that it requires a little force to separate them so as to get crepitus. If this is not done, the diagnosis may be of sprain, and thus becomes a very great error.

"Perhaps the more frequent error of diagnosis is that of the carpal luxation. It may be remarked that this dislocation is exceedingly rare, and the fracture perhaps the most frequent one in the body. However, the prominence is above the articulation, and with sufficient care crepitus can be produced. The cause of this fracture is a fall upon the outstretched palm. Thus the bone is broken, and the cancellated tissue at the expanded end of the radius has its surfaces somewhat interlocked and the hand usually a little turned to the radial side of the forearm. The hand, of course, follows the radial fragment, and when well carried back, makes a curve of the anterior aspect of the hand and semi-extended fingers, which has given to it the name of the 'silver-forked fracture.' I think, however, this description is far short of that necessary to elucidate the varying conditions direct and supplementary to this accident. The fall, of necessity, has always a varying quantity of force. It may be just sufficient to produce a fracture, as described by Colles. But it may be a little more. It is obvious that when the bone is broken, the tissues attached to the ulna must bear the strain. These are the internal lateral ligament and the triangular fibrocartilage. On examining the carpal end of the ulna we find a smooth, articulating surface, flanked by a dull-pointed, bony projection at its internal border, known as the styloid process. From this the internal lateral ligament takes its rise and is inserted in the carpus. At the base of this process, and between it and the articulating surface at the end of the ulna, is a depression or pit into which the corner of the triangular fibrocartilage is inserted. When the radius is broken at the point described, the unexpended force alluded to above is all brought to bear on these two attachments connecting the hand with the ulna, directly through the ligament and indirectly through the fibrocartilage. The ulna does not articulate with the carpus, but finds a substitute for a bony socket in the fibrocartilage which originates from the side of the radius and covers the articulating surface like a hood. Both the ligament and cartilage usually give way, but sometimes the cartilage alone.

"When we inspect the anatomic arrangement, it is palpable that the fragment broken off from the radius could hardly be driven a half-inch above its normal position without a rupture of this singular ligament. It must almost inevitably give way in every fracture at this point. It has a broad insertion along the side of the end of the radius, and a narrow and weak one in the pit at the root of the styloid process. When the ligament is separated, as is almost surely done by pulling off a scale of bone or even the entire process, which is weaker than the fibrous structure of the ligament, the triangular fibrocartilage gives way at its weakest point,—the inser-

tion into the pit at the styloid,—and thus the ulna becomes dislocated. But the force may be still more, and sufficient to change the position of the end of the ulna. The scale of bone drawn from the surface of the styloid process leaves the end of the stump, brought to a sharp edge in most cases, and thus fitted to penetrate the tissues with which it comes in contact at the lower end of the forearm; the fascia has fibers running across the back of the wrist, and termed the posterior annular ligament. This unexpended force is sufficient to cause the styloid process to penetrate it and complicate the case. A still greater force, and especially if the resistance is aided by fracture of the radius above that of the Colles fracture, or a luxation of the radius at the elbow, may be sufficient to push the head of the ulna through the skin and produce a compound dislocation. Wherever there is a joint there may be a luxation, and this at a point described has been known both of the simple and compound form, but as a complication in Colles' fracture has not been observed, as far as I have been able to learn.

"The comparative frequency of these various conditions is difficult of establishment, but the X-rays have thrown light upon the diagnosis. The obscurity that has long embarrassed surgeons with reference to the treatment of the fracture has been due to the general ignorance of the complication arising from the luxation of the ulna. Mere palpation does not reveal this, and deformity is the usual result. *From my last observation I had come to the conclusion that luxation prevailed in about two-thirds of the cases, but many skiagraphs have been taken which render it probable that luxation occurs in nearly all cases, and that treatment which provides for its reduction and retention should always be practised, inasmuch as it is equally beneficial in the simpler form.* [Italics mine.]

"The very large number of appliances which have had advocates and then were found to fail in other hands testifies to the inefficiency of their methods. I think this is due to the disregard of the luxation of the ulna. I will not undertake a review of the methods of treatment proposed, as the literature is encyclopedic, as is apt to be the case where failure is the rule.

"The worthlessness of all splints was impressed upon me in the year 1870, when I made my first autopsy of this fracture. Indeed, they are a positive damage, producing an unusual, false ankylosis. *Rectification of the deformity is absolutely necessary. This must be complete. Anesthesia is called for. The whole strength of the surgeon is often required.* [Italics mine.]

"A direct pull and a rest of the ulna upon the patella of the surgeon, with a strong pull upon the hand and forearm of the patient, drawing the hand toward the ulna, is apt to rectify the deformity. But this must be as perfect as can be made. The chief guide is the position of the ulna. Before attempting reduction, the prominence of the ulna on the uninjured side should be noted. The prominence of the head of the ulna is remarkably various; we

must bring up the dislocated head on a par with the sound one. This will also bring the fractured radius in place. No splint can be more efficient than a parallel bone *in situ*. Where the fracture is nearly transverse and simple, a good result could be obtained by the mere application of a band around the wrist; but if the radius is suffering from a comminution, this can hardly be sufficient. The

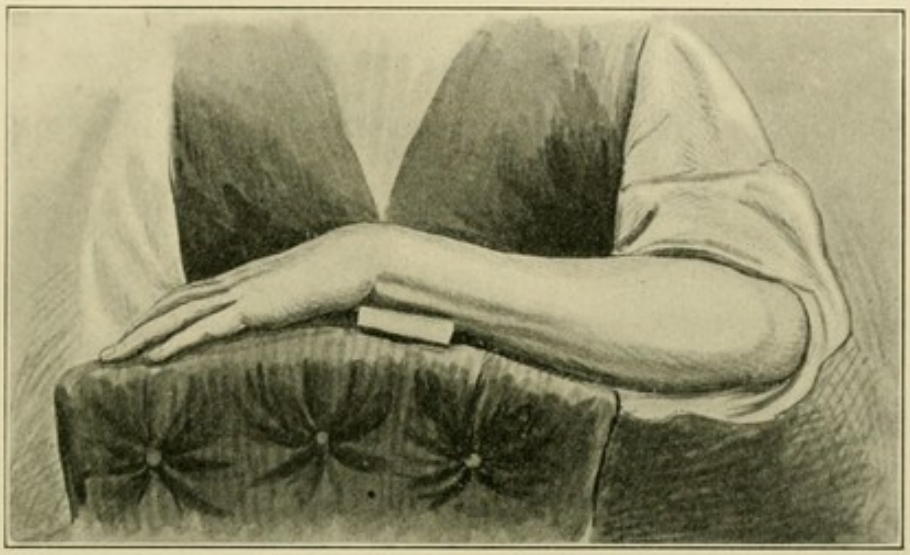

Fig. 292.—E. M. Moore's dressing for Colles' fracture. Position of roller compress.

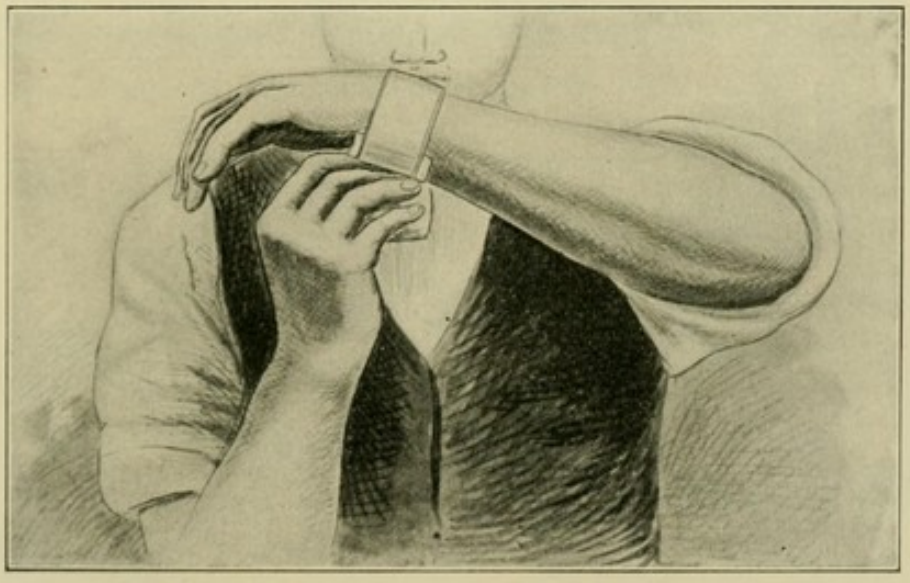

Fig. 293.—E. M. Moore's dressing for Colles' fracture. Roller with adhesive strap applied.

ulna has a tendency to displacement downward and forward, and should be held up against the fascia, which prevents it from going too far. To accomplish this a roller of cotton cloth two inches in width and about three-quarters of an inch in thickness, very firmly rolled, should be placed under the ulna, extending down its end, leaving the tendon of the flexor carpi ulnaris on the radial side. This should be secured by a strip of adhesive plaster not quite two

inches in width, which should be drawn around the wrist and roller. This strip need not be warmed, but it should be drawn firmly, and where it overlaps at the roller, should be secured by a pin. The warmth of the wrist soon secures the full adhesive property of the plaster. The tight strap might become dangerous if continued, but

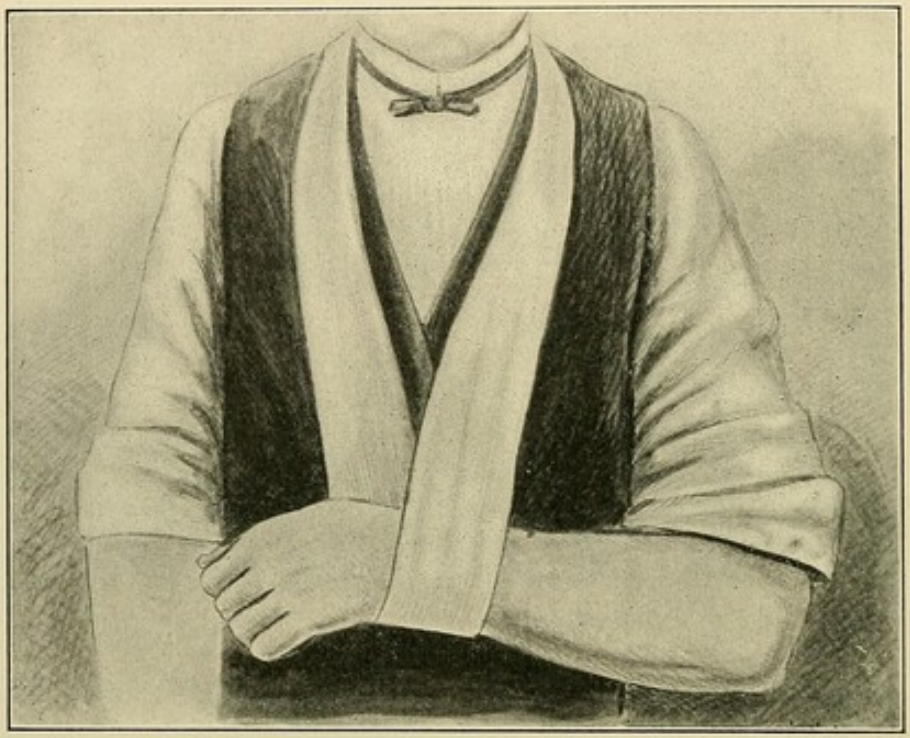

Fig. 294.—E. M. Moore's dressing for Colles' fracture. Dressing complete.

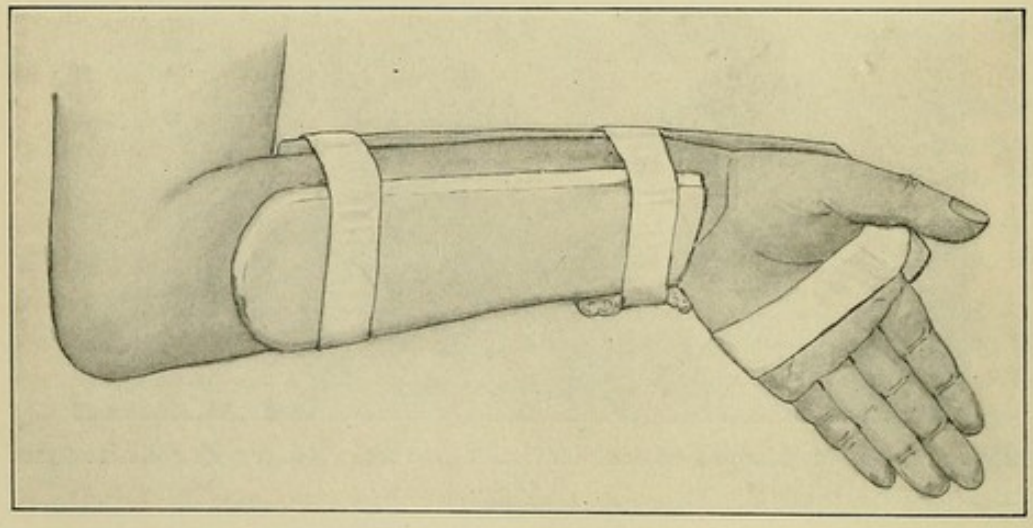

Fig. 295.—Old-fashioned pistol splint dressing for Colles' fracture.

at the end of a few hours may be cut through by inserting the point of scissors along the back of the forearm. Thus all strangulation is absolutely removed. A sling three inches wide, placed under the ulnar roller so as to bring the weight of the forearm and hand upon it, and secured around the neck, completes the dressing.

"The retention of the hand absolutely quiet, by any device, and surely if splints are used, is apt to give rise to great stiffness of wrist and fingers. But if the hand is allowed to hang down without restraint, this will not occur, and its weight is sufficient to hold the end of the ulna in its place. Any use the patient is likely to make of the hand or fingers is not apt to do harm, but rather good, by preventing false ankylosis. Three weeks is all that is necessary for treatment.

"Colles' fracture is apt to be very painful until restitution of the displaced parts is complete. When this is done, the pain and general distress rapidly subside. I have broken over many wrist bones, at times varying from a few weeks to six months after the accident, and while there is much pain and soreness from the new traumatism, in a few days the pain begins to subside, and finally disappears if the parts are successfully replaced. It is not wise to break over the bone united in a wrong position later than six months. Nature begins the process of rectification, which she is able to partially secure by rounding off the edges of the displaced bone. Of course, the radius is shortened and the end of the ulna thrust downward and forward, the end projecting about a half-inch beyond the line of the shortened radius. Sometimes the pain is severe and constant, from the strain upon a filament of the ulnar nerve. Such a condition is best treated by removing the lower end of the ulna for a half-inch. The result is remarkably gratifying. If there is a compound luxation as well as fracture, careful antiseptic precaution must accompany the reduction."

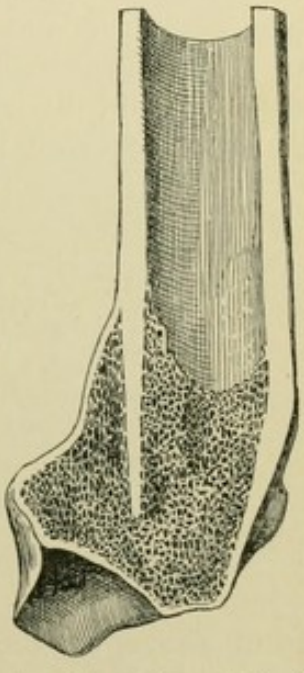

Fig. 296. — Colles' fracture, showing impaction of the upper into the lower fragment (Hoffa).

The foregoing description of the nature and treatment of Colles' fracture leaves little room for additional discussion, as Moore's conception of its mechanism and the essential points in treatment are correct and in full accord with modern surgery. As he very correctly states, the line of fracture in a typical Colles' fracture is usually nearer, seldom further, than an inch from the articular end of the bone. The line of fracture is usually transverse and oblique from the palmar to the dorsal surface, so that the dorsal side of the fragment is somewhat larger than the palmar. The fractured surface of the lower fragment is often slightly concave, that of the upper, convex. The direction in which the fracturing force is applied and the line of fracture are such as to tear the periosteum on the palmar side, while a bridge of periosteum usually connects the lower with the upper fragment on the dorsal side. If the fracturing force is continued after the bone is broken, it results in

impaction of the upper into the lower fragment, which may fissure or comminute the latter if the penetration is a deep one and the incuneated part of the bone of considerable size, acting like a wedge.

Impaction always results in more or less crushing of the spongiosa of the lower fragment. The most frequent form of impaction consists of penetration of the compacta of the upper fragment on the dorsal side into the spongiosa of the lower fragment on the opposite side, resulting not only in shortening, but also in a tilting of the lower fragment backward, displacements which, in typical cases, give rise to the silver-fork deformity. The deviation of the hand toward the radial side, caused by the fracturing force, immediately after the radius gives way, results in tearing of ligaments on the ulnar side, the triangular cartilage, and partial or complete dislocation of the lower end of the ulna. The importance of this complication has never been fully recognized by authors, teachers, and the mass of the profession.

In rare cases the line of fracture is very oblique, extending

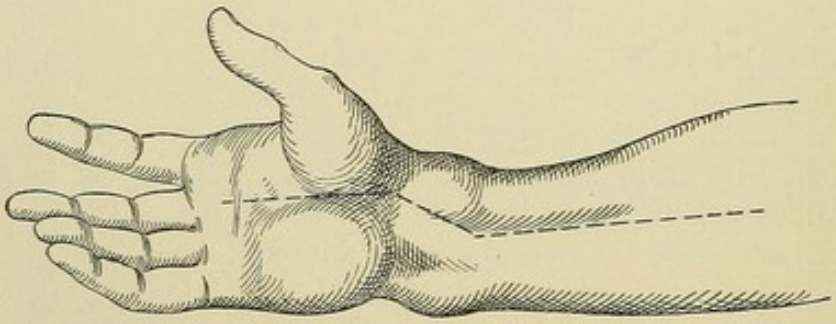

Fig. 297.—Colles' fracture, exhibiting the radial deviation of the hand.

from above, on the radial side, downward and toward the ulnar side, occasionally extending into the joint.

Besides the injuries at the lower end of the ulna we find, as further complications in this fracture, injuries of the tendon sheaths of the extensor pollicis brevis and adductor pollicis longus, with extravasation into the open tendon sheaths and the fascia surrounding them. It is in cases of this kind, when the primary swelling comes on quickly and reaches considerable dimensions, that the anatomic landmarks are often so much obscured as to render the diagnosis very difficult. With great displacement of the upper fragment toward the palmar side, serious injury of the soft tissues on this side of the fracture may still further complicate the case and add to the diagnostic difficulties.

The most important symptoms of Colles' fracture are: Pain and tenderness that correspond to the location and line of fracture and that, in the event of no displacement, serve as the only or, at least, as the most important witnesses of the existence of the fracture; when displacement to any considerable extent

has occurred, the characteristic silver-fork deformity leaves no doubt as to the location of the fracture. The degree of functional disability corresponds with the extent of the displacement. The power of the hand is diminished or almost entirely lost, and pronation and supination are impaired or entirely suspended. In the typical deformity two abnormal prominences are seen, one on the dorsal side, corresponding with the lower fragment displaced in that direction, and one on the flexor side, the palmar margin of the upper fragment. In the presence of considerable swelling of

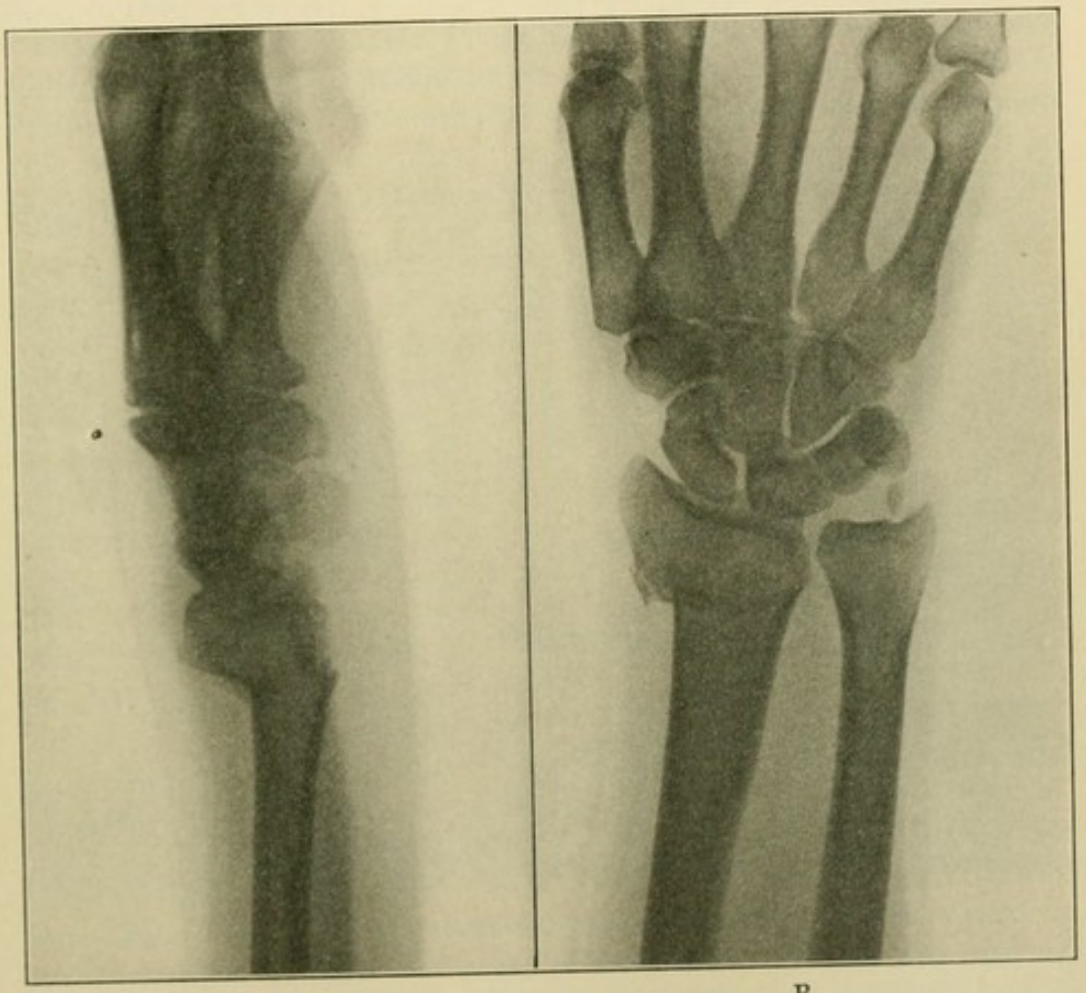

A B

Fig. 298.—A, Colles' fracture, lateral illumination; B, Colles' fracture, illumination from dorsal side.

the soft tissues these prominences are obscured, but can always be felt on making firm digital palpation. *In consequence of the radial deflection of the lower fragment the axis of the forearm corresponds with that of the long axis of the fourth metacarpal bone, a deformity that imparts to the forearm and hand the outlines of a bayonet. The normal dorsal convexity of the radius is also lost by the displacement of the lower fragment, something that can be determined even in cases in which the deformity is slight. Suggillation is most marked on the volar side. Abnormal mobility and crepitus are usually absent, owing*

to the existence of impaction to a greater or less extent. If the dorsal branch of the ulnar nerve is compressed by the preternaturally prominent head of the ulna, the patient usually makes complaint of pain along the inner side of the wrist-joint, which often extends to the fourth and fifth metacarpal interspaces and respective fingers. Paralysis in the territories supplied by branches of the median nerve below the seat of fracture is met in rare cases in which the upper fragment is displaced to any considerable extent toward the palmar side. *In sprains of the wrist-joint the pain and tenderness correspond with the location of the joint; in fractures, with a point always within a distance of from one to one and one-half inches.*

Dislocation of the carpus is an exceedingly rare injury; Colles' fracture, on the other hand, is very common. The exact location of the dorsal prominence and the location of pain and tenderness will serve a useful purpose in the differential diagnosis between these two injuries.

In reference to the prognosis it may be said that the functional result depends more on the completeness of the reduction than on the mechanical treatment calculated to maintain retention. A slight dorsal displacement often remains as an evidence of the existence of a Colles fracture in the practice of the most competent and painstaking surgeons, in consequence of more or less crushing of the spongiosa in the lower fragment. If the subluxation of the ulna is not entirely corrected at the time the reduction is made, a permanent radial displacement of the hand is the inevitable result. Even if the fracture heals with marked deformity, ultimate satisfactory restoration of function is the rule. Speedy and perfect restoration of function may be confidently expected in cases in which the nature of the injury is recognized and perfect reduction effected, and retention of the fragments in their normal position maintained until the fracture has healed by bony union. The functional result is enhanced by resorting to methods of immobilization that do not interfere with the free movements of the fingers from the moment the injury was sustained. The complicating injuries of the adjacent wrist-joint, tendon sheaths, and other important paraosteal structures must be taken into careful consideration in predicting the probable result of the injury. *Premature use of the limb, as well as too prolonged restraint, is in the way of obtaining a speedy and satisfactory functional result. The retentive dressing should never interfere with the free movements of the fingers, but the immobilization of the hand for three or more weeks*

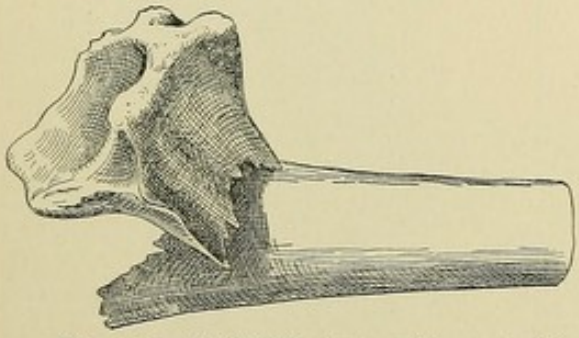

Fig. 299.—Colles' fracture, with great displacement of the upper fragment toward the palmar side (Hoffa).

constitutes an important part of the treatment most conducive to an ideal functional result. The most important part of the successful treatment of Colles' fracture is perfect reduction. It is this part of the treatment that is so often defective, owing to uncertainty of diagnosis or inefficient efforts to effect perfect reduction. In fractures in Colles' line without displacement, Sir Astley Cooper recommended, in the treatment, the employment of a compress, applied below the seat of fracture and retained with a strip of adhesive plaster, and placing the forearm in a sling in such a way that the line of fracture would correspond with the anterior margin of the mitella.

The method of reduction under the influence of a general anesthetic, described by Moore, is the one to be relied upon in Colles'

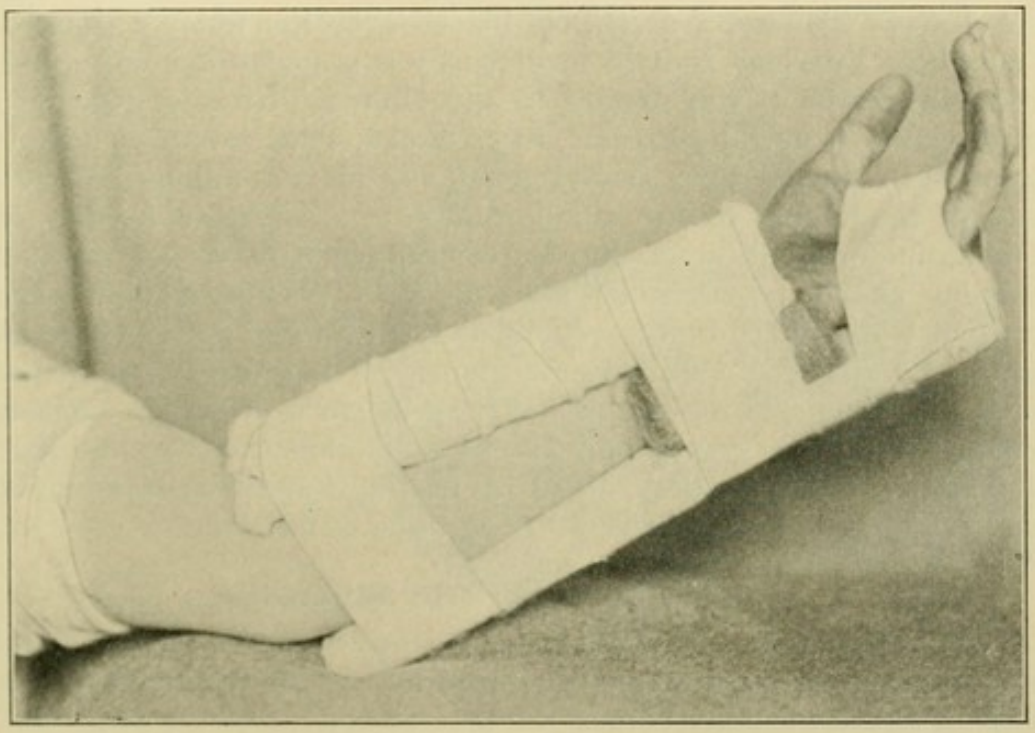

Fig. 300.—Dressing for Colles' fracture.

fracture with displacement. He has well said that it requires often the full strength of the surgeon to effect the same. Extension and counterextension, pressure, and ulnar flexion of the hand are the means by which perfect reduction should be aimed at and effected. *Imperfect reduction always means a result unsatisfactory alike to patient and physician, regardless of the care that may be exercised later in the mechanical treatment of the fracture. Without complete reduction the subsequent treatment will prove unsatisfactory in yielding an ideal functional result.*

After reduction has been effected, the next rule is to resort to retentive measures that do not interfere with the free movements of the fingers. Moore relies on compress, circular strip of adhesive plaster, and mitella in maintaining coaptation of the fragments, and

undoubtedly in his hands this treatment has yielded ideal results. The laity, as well as the mass of the profession, however, would consider such treatment short of the indications presented by the injury. Long ago I grasped the principles laid down by Moore in the treatment of Colles' fracture, but I have always deemed it advisable to support it by mechanical treatment that would immobilize the hand and thus add to the more nearly perfect immobilization of the lower fragment.

Ready-made splints of any kind are out of place here. I apply Moore's dressing, and, in addition, two well-padded splints, anterior and posterior, the former extending from the elbow to the wrist, the latter from the elbow to the base of the fingers. These are held in place by three strips of adhesive plaster, one below the thumb, the second over the lower fragment, and the third below the elbow. The second strip is placed over the ulnar compress. The whole dressing is held in place by a gauze roller extending from the base of the fingers to the elbow. This dressing will answer a most useful purpose for two weeks, when it can be advantageously replaced by a dorsal plastic splint extending from the base of the fingers to the elbow-joint. It is my opinion that, in adults, immobilization of the lower fragment by an appropriate dressing should be continued for a period of at least four weeks; in other words, until bony consolidation is firm enough to make an external mechanical support superfluous. The forearm should be placed in a sling, in a position half-way between pronation and supination, until the process of repair is completed. Active and passive motion after this time, aided by massage and faradization, are well calculated to insure speedy restoration of function.

FRACTURES OF THE SKULL.

There is, perhaps, no department in surgery in which the general practitioner is more interested than in fractures of the skull. This class of injuries usually comes for first treatment to the physician, and not to the professional surgeon. The subject is a most important one, because life and the future well-being of the patient often depend upon prompt, rational surgical treatment, based on a correct diagnosis. In the management of such cases it is important to remember that the injury that produces the fracture of the skull frequently causes, at the same time, visceral intracranial lesions, which constitute the main reason for life-saving operations. The extent of the fracture is of less consequence, so far as the fate of the patient is concerned, than the existence of complicating intracranial injuries. An extensive comminuted closed fracture of the skull without the coexistence of serious intracranial complications is an injury from which the patient recovers in the usual course of time and without any remote ill results. On the other hand, a limited fracture with rupture of the middle meningeal artery may result in death in the course of a few hours, from cerebral compression, unless

the immediate cause of death is averted by prompt operative interference.

The greatest source of danger in fractures of the skull is a complicating wound of the overlying soft tissues, which communicates with the contents of the skull through the cranial defect. A punctured fracture of the skull is always a grave injury, as of all fractures of the skull it is most likely to be followed by infection. A fracture of the skull is said to be complete if the line of fracture involves both the external and the internal table—that is, the entire thickness of the skull. In incomplete fractures of the skull only one of the tables is fractured. A vulnerating implement of limited dimensions, directed against the skull with sufficient force to fracture either the external or the internal table, results in a characteristic injury at the point of impact. If only the external table is fractured, a limited depression, corresponding in size to the circumference of the fragment, is produced by crushing of the underlying diploe. If the external table remains intact, the internal table gives way immediately underneath the point of impact, and the detached fragment is left with few or no vascular connections, acting the part of a foreign aseptic substance until it enters into new vascular connections. The existence of fracture of the internal table has recently been satisfactorily demonstrated on the living subject by the use of the X-ray. From a surgical standpoint it is important to divide fractures of the skull anatomically into fractures of the vault and base, the former being accessible to direct surgical intervention, the latter remaining largely inaccessible to direct surgical treatment.

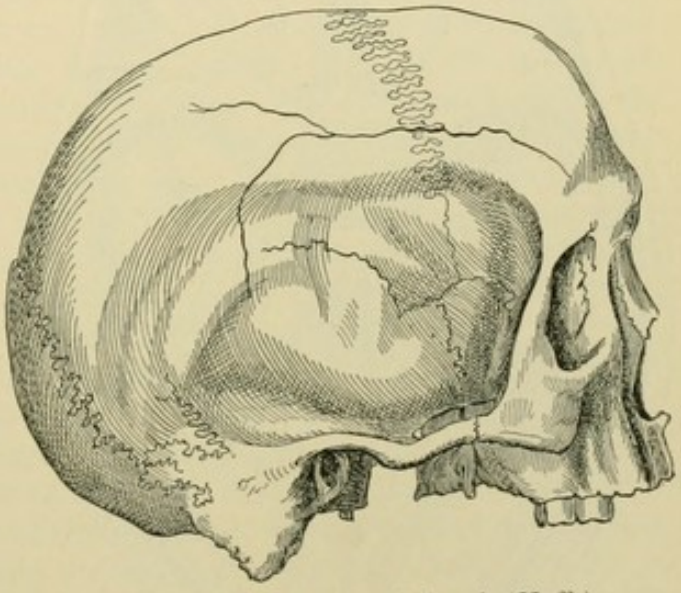

Fig. 301.—Fissure of cranial vault (Hoffa).

In fractures of the vault, the seat of injury is within range of direct examination, and the exact location, nature, and extent of the fracture can usually be determined by the signs presented. A fissure is a linear fracture, and as an isolated single injury occurs most frequently at the base of the skull, in consequence of indirect application of force. In open fractures of the vault hair and other foreign substances are not infrequently found imprisoned in the fissure, having entered at the moment the fracture occurred, the open fissure closing upon them as soon as the elasticity of the skull is

restored, the fractured bone returning to nearly its normal shape and position. A fracture may be extensively comminuted with little or no depression, and the depressed fragment of a limited fracture may give rise to grave symptoms of cerebral compression. In fissured fractures of the skull a "cracked-pot" sound is elicited on percussion. The same force that fractures the skull also causes the depression. The depressed fragment or fragments frequently correspond in size and shape to the contour of the vulnerating implement, a matter of great importance in forensic medicine. Muscular action has nothing whatever to do with the displacement of the fragments. Contusion of the scalp is occasionally mistaken for a depressed fracture, and vice versâ. The crushing of the soft tissues underneath the point of impact, and the subsequent edematous wall surrounding the contused area, in many respects resemble the appearance of a depressed fracture, and it is only by a careful examination of the local signs and by a recourse to all diagnostic resources that the surgeon is enabled to make a differential diagnosis between this condition and a depressed fracture. In contusion of the scalp the surface of the skull remains smooth and the level everywhere normal, conditions revealed by deep palpation and confirmed in doubtful cases by exploration with a stout aseptic steel needle (akidopeirasty). This diagnostic resource often is found useful in determining the existence of a depression and in locating the line of fracture. In fractures produced by contre-coup, or so-called counterstroke, the seat of injury is always at a point opposite to where the force was applied.

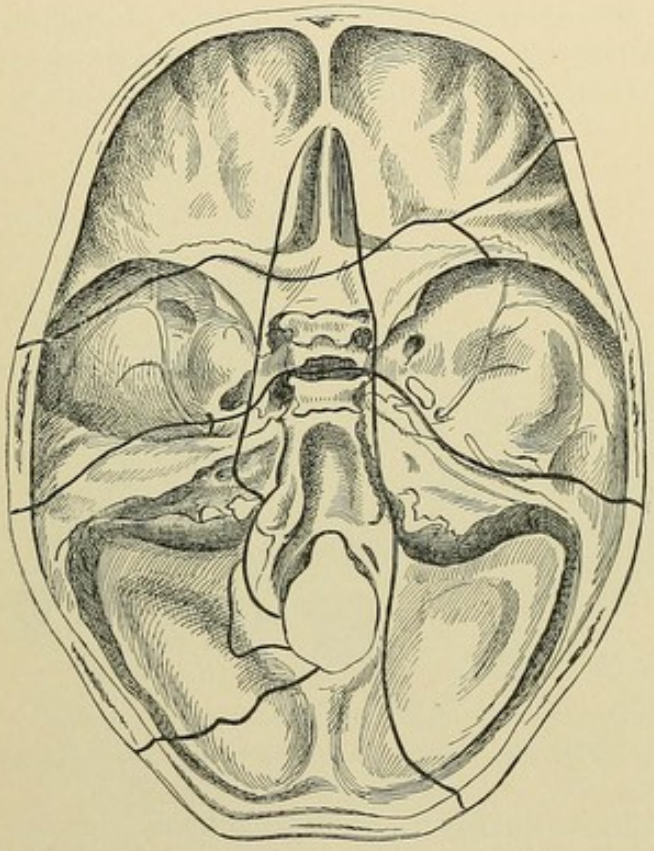

Fig. 302.—Extensive fracture at the base of the skull (Hoffa).

Symptoms.—The escape of cerebrospinal fluid through the wound or underneath the scalp is a positive evidence of the existence of a fracture and laceration of the meninges. If the cerebrospinal fluid escapes through the external meatus, it is a reliable

proof of laceration of the membrana tympani and fracture at the base of the skull. If any doubt exists as to the source of the serous discharge, a chemic test will yield results that will decide between a ruptured tympanum, followed by the escape of fluid from the middle ear, and a fracture at the base of the skull. As a rule, it is not difficult to recognize the existence of a depressed fracture of the vault of the skull, even in the absence of any brain symptoms. In fractures at the base of the skull displacement of the fragments to any considerable extent seldom takes place, except in circular fracture around the foramen magnum, and in this event sudden death from compression of the medulla oblongata by the displaced fragments, caused by either the fracturing force or, later, by the patient assuming the sitting position before union has taken place. The existence of focal symptoms is of special diagnostic value in fractures at the base of the skull. Fractures in the neighborhood of the thalamus opticus and optic tracts are sometimes followed immediately by loss of vision in one or both eyes, caused by laceration of the brain or of the optic nerves. Facial paralysis and loss of hearing immediately following the injury point to fracture of the petrous portion of the temporal bone. Hemorrhage from the nose or the nasopharynx following an injury to the skull is very suggestive of fracture at its base. Exophthalmos appearing a short time after the injury indicates fracture of the orbital plate of the frontal bone. Ecchymosis of the eyelids and conjunctiva points to a similar injury or to fracture of the sphenoid bone; and the appearance of an ecchymosis of the mastoid region several days after the accident is a late evidence of a fracture in the region of the mastoid process of the temporal bone. In gunshot and punctured fractures at the base of the skull the location and direction of the wound and the nature of the discharge must be taken into careful consideration in formulating a diagnosis, more especially in cases in which no focal symptoms are present. Fracture of the internal table of the skull as an isolated injury is recognized more frequently in the postmortem room than at the bedside. The focal symptoms and the seat of injury may suffice in locating the lesion, but the differential diagnosis between this fracture, cerebral contusion, and intracranial hemorrhage must always remain doubtful. Improved radiography may, in the future, prove to be the most important diagnostic resource in establishing the existence of this injury, as well as in the recognition of other fractures of the skull that are inaccessible to direct examination.

The cerebral lesions that so often complicate fractures of the skull sometimes aid, and at other times obscure, the diagnosis. Concussion, so constantly present if the fracture is produced by the application of blunt force, always overshadows focal symptoms, which often appear later, after the patient has recovered from the immediate effects of the injury. In punctured fractures symptoms of concussion are usually slight or entirely absent, and the focal

symptoms, if there are any, appear promptly. The existence and location of a cerebral contusion become apparent only after the effects of the concussion have subsided. The characteristic clinical feature of intracranial hemorrhage is a gradual but progressive increase in the severity of the focal symptoms as long as the hemorrhage continues; on the other hand, the maximum symptoms of concussion present themselves immediately after the injury, and of contusion as soon as the patient recovers from the effects of the concussion. In compound fractures of the cranial vault very little, if any, difficulty will be experienced in ascertaining the existence of a fracture. The escape, from the wound, of cerebrospinal fluid and brain tissue leaves no doubt as to the nature of the injury. *The examination of the wound, with a view to determining the exact location and extent of the fracture, and the search for visceral injuries must be conducted with the most pedantic care, for the purpose of guarding against wound infection. Every accidental wound must be regarded as an infected wound, but the superficial infection amenable to successful disinfection may be made deep and inaccessible by careless, reckless exploration of the wound for diagnostic purposes. The surgeon should realize to the fullest extent the additional responsibilities thrown upon him by modern aseptic surgery in the management of such cases. The fate of the patient is often decided by the degree of care exercised in the examination and treatment of the complicating wound. Recognizing the force of this statement, it is apparent that haste under such circumstances is inexcusable, if not almost criminal. No digital or instrumental examination of the wound should be made until the necessary preparations have been completed. The examination of such a wound with a dirty finger or an unclean instrument is responsible for innumerable deaths from septic intracranial affections, many of which might have been prevented by making the examination under strict aseptic precautions.* Early mistakes made in assuming charge of such cases frequently result in complications that are not amenable to later and better directed treatment. Sins of commission and omission bring the same dire results in such cases.

In every compound fracture of the skull involving the hairy scalp the examination should be preceded by shaving and disinfection of the entire scalp. The wound itself must be subjected to a superficial disinfection before it is touched. Pouring peroxid of hydrogen into the wound and flushing it with a 2½ per cent. solution of carbolic acid will prepare it properly for exploration with a thoroughly disinfected finger or sterile instruments. Foreign bodies are searched for and removed, and antiseptic irrigation is repeated from time to time as the exploration is extended. By following these directions the wound is in a condition for safe surgical intervention at the completion of the examination.

Prognosis.—The prognosis in fractures at the base of the skull is always grave, owing largely to the inaccessibility of the complicating intracranial lesions to direct surgical treatment, and, in case

the fracture is compound, to the difficulty in preventing infection through the wound from without. The danger in all fractures of the skull depends largely on the location and extent of the visceral lesions and intracranial hemorrhage, and, if the fracture is compound, infection of the wound. Wound infection is prone to result disastrously if the meninges of the brain are ruptured, as when the infection reaches the pia and surface of the brain it is very liable to spread rapidly, and as surgical treatment has only a limited control over this affection, the patient dies in a few days from septic leptomeningitis. The mortality of fractures at the base of the skull complicated by an external wound has been materially reduced by treating the wounds under antiseptic precautions as far as their nature and location will permit. The extent of brain injury has a weighty bearing on the prognosis. If the brain wound implicates important nerve centers, death may ensue in consequence of paralysis of vital nerves; on the other hand, if the wound affects less important locations, large masses of brain tissue have been lost by the injury or were later removed, without any serious immediate or remote consequences. In compound fractures the prognosis rests largely on the existence or absence of wound infection—guarded in the former case, favorable in the latter instance. It is almost impossible to predict the remote consequences of fractures of the skull. Vertigo, headache, insanity, paralysis, and epilepsy are only some of the remote results of such injuries. Experience has shown that these late complications are caused more frequently by the visceral lesions of the cranial contents than by changes in the shape of the skull or by altered dimensions in the cranial cavity, as is shown only too conclusively by the many negative results following trephining of depressed fractures in the treatment of these affections. It is very fortunate, indeed, that fractures of the skull heal by an intermediate callus almost exclusively, as the formation of an exuberant provisional callus, as found so frequently in the healing of fractures of the long bones, could not fail greatly to increase the frequency of remote complications.

Finally, it may well be said, in the language of an eminent surgeon of the distant past: "No injuries of the skull are too extensive to be despaired of, and none too slight to be ignored."

Treatment.—The mechanical treatment of fractures of the skull is limited to cases in which it becomes necessary to elevate or remove depressed fragments. Fixation of the fragments is never required, owing to the absence of displacing forces. Operative treatment further than this may become necessary for the purpose of removing foreign bodies, and exposing and subjecting to direct treatment grave intracranial lesions. Rest in bed with the head in an elevated position must be enforced in all cases until the danger arising from complications has passed, and in fractures at the base of the skull until the injury to the bone has been repaired—that is, for at least from four to six weeks. The general treatment must

have for its object the guarding against a harmful blood supply to the brain, which includes a limited nonstimulating diet, the administration of cathartics, and the application of cold to the head in the form of a cold coil or an ice-bag. The application of cold should be begun as soon as reaction has been established, and continued until the tendency to cerebral congestion has subsided. If the ice-bag becomes a source of discomfort to the patient, a moist compress is placed between it and the scalp. Mental rest is as essential as physical repose in placing the injured parts in the most favorable condition for a speedy and satisfactory repair. Absolute quietude in the room and exclusion of light during the first few days must be rigidly enforced. If the patient is unconscious, aseptic systematic catheterization must be instituted at the proper time and continued until the patient recovers control over the bladder. Bloodletting, leeching, and cupping, so constantly employed until a few years ago with the hope of diminishing the liability to intracranial infection, are no longer resorted to, since the real causes of infection have been discovered and satisfactorily demonstrated. The local treatment in fractures at the base of the skull is limited to cases in which the fracture is compound, and consists in attempts to prevent infection of the wound. If the wound consists of a ruptured tympanum, the external meatus is disinfected, dried, freely dusted with the borosalicylic powder, and lightly packed with aseptic absorbent cotton, which is removed as soon as it becomes saturated, when the meatus is repacked with fresh cotton. In fractures at the base of the skull communicating with the nasal cavities or the nasopharynx it is advisable to disinfect the mucous surface, so far as this can be done, with mild antiseptic solutions, and pack with a strip of iodoform gauze. In punctured fractures at the base of the skull, if no foreign bodies are lodged in the wound, an antiseptic dressing is applied and the wound disturbed as little as possible.

The much-discussed subject of trephining in recent fractures of the skull can be quite briefly disposed of in the light of modern surgery. It is a very old surgical procedure and has had an extended trial. During the preantiseptic era of surgery the operation was so often followed by infection of the wound and of the cranial contents that Stromeyer entered his protest against it, and most of the surgeons of his time followed his example and eliminated it from the list of legitimate operations. With the introduction of antiseptic and aseptic surgery the operation again came rapidly into favor, and at the present time the pendulum swings in an opposite direction. Many surgeons of large experience entertain decided convictions regarding the propriety and advisability of operative interference in all fractures of the vault of the skull. This extreme position is not tenable, even at the present time, as we can not always rely on the aseptic precautions absolutely to protect the wound against infection. *The surgeon who converts a closed fracture of the skull into an open one without adequate cause assumes a great respon-*

sibility. The present technic of asepsis does not furnish absolute protection against infection, even in the best-equipped hospitals, and with all the advantages to be gained from the cooperative work of well-trained and experienced assistants and nurses. If this be true of hospital practice, it is easy to imagine how much more frequently infection would occur in emergency surgery in private practice, where the facilities for asepsis are often very limited and operations have to be performed without the aid of skilled assistants. But, besides the dangers of a possible infection, there are other reasons why operative interference should not be resorted to indiscriminately in all cases of fracture of the cranial vault. Subcutaneous fractures with little or no depression are speedily repaired, and are seldom followed by cerebral disturbances of any kind that could be attributed to the fracture *per se*. It has already been stated that the remote complications of fractures are more frequently caused by complicating intracranial lesions than by the fracture itself, and it is not always possible to correct these defects by the operation, even if discovered at the time, to say nothing of injuries that are inaccessible or that are overlooked.

Conservatism in the treatment of fractures of the skull is to be recommended more particularly in the case of children. I have seen several cases of depressed fracture of the skull in children in which, under conservative treatment, the depression disappeared entirely during the second week. Spontaneous replacement of the fragments not infrequently occurs from the cerebral pressure, after the fragments become loosened by the softening and absorption of the spiculæ of bone that at first interlock the fractured surfaces.

Trephining of the skull must be reserved for the following fractures of the skull: (1) Subcutaneous fractures in adults, with marked depression; (2) subcutaneous fractures attended by focal symptoms; (3) all compound fractures, including punctured and gunshot fractures; (4) fractures, compound and subcutaneous, complicated by hemorrhage from the middle meningeal artery.

Fracture with Depression.—No surgeon would hesitate for a moment to resort to operative treatment in cases of depressed fracture of the skull in which the depression is deep enough to cause cerebral compression. The same course of treatment is indicated in cases in which the depression is marked, and in which the fracture has caused no immediate or focal symptoms. In such instances the operation is a justifiable prophylactic precaution against remote complications that, in the course of time, might develop in consequence of the irritation produced by the permanently displaced fragments. *The trephine should never be used in the elevation of a depressed fracture of the skull.* All that is necessary in the mechanical treatment of such cases is to make a cranial defect, with chisel and hammer, nearest the most depressed part of the fracture, and only large enough to permit the insertion of an elevator underneath the depressed bone, with which the fragment or fragments are

raised to their normal level. The wound is enlarged sufficiently to expose the whole depressed area, then, at a point where the depression is deepest, the margin of the cranial defect is chiseled away for the insertion of an elevator. If the fracture is subcutaneous, the seat of injury is exposed by raising a flap, with the base directed downward, and large enough to expose the whole depressed area. As the internal table is always fractured more extensively than the external, the cranial defect made with the chisel must extend somewhat beyond the margin of the depressed fragment, for the insertion of the elevator. Kocher's director is a very safe and useful instrument for this purpose. In using it as a lever the margin of the cranial defect becomes the fulcrum, the hand the power, and the depressed fragment the weight. In raising the fragment the tips of the left index- and the middle finger are placed over the depression, steadying the fragment as it is being slowly elevated. This is done for the purpose of preventing any loss of bone, and to determine with accuracy the completion of the elevation of the depression. The fragments must be raised to their normal level before the elevator is removed. *Every frag-*

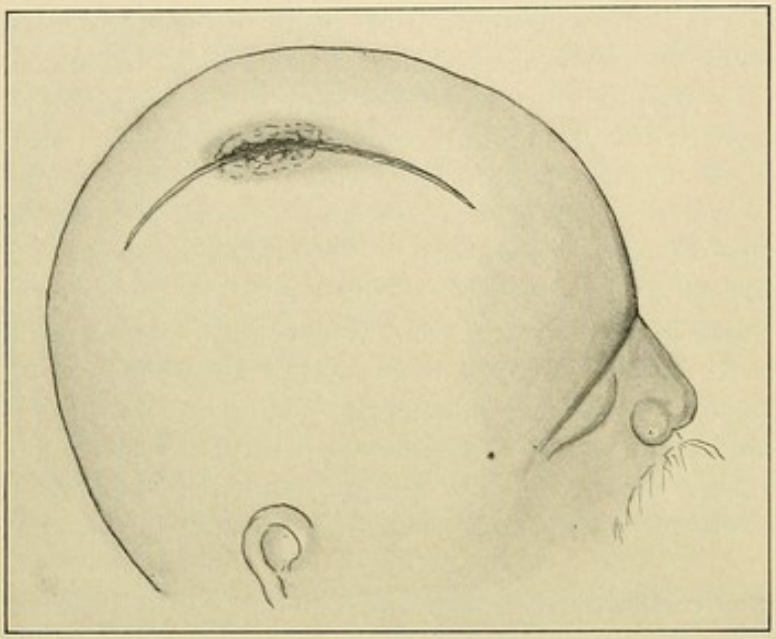

Fig. 303.—Enlarging the wound preparatory to operation for a compound depressed fracture of the skull.

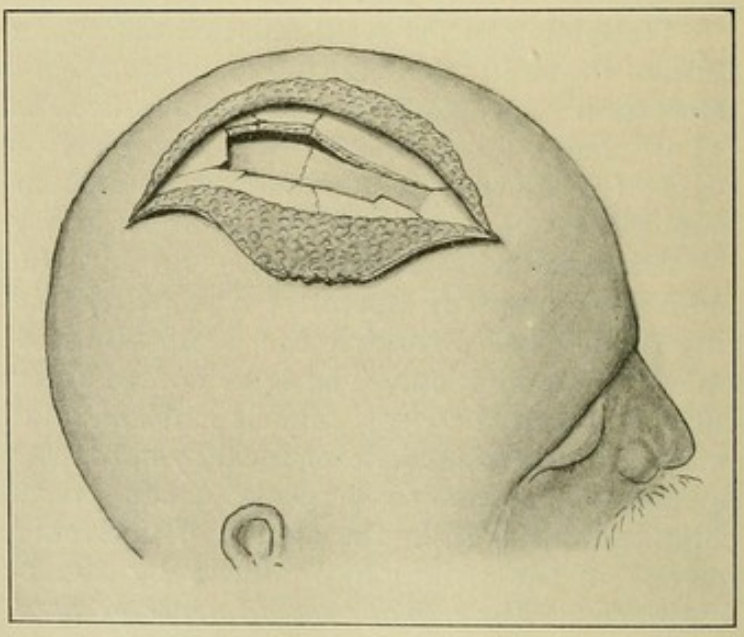

Fig. 304.—Exposure of seat of fracture.

ment, even if completely detached, must be saved and placed in proper position. If the external wound is a lacerated or crushed one, it is transformed, as nearly as can be done, into an incised wound by trimming the margins. Whenever possible, the seat of fracture is covered with the pericranium and skin. If the former is detached from the skin, it should be sutured separately with fine catgut, and the skin with silkworm-gut or horsehair. If the line of suturing corresponds with the seat of fracture, drainage should be secured

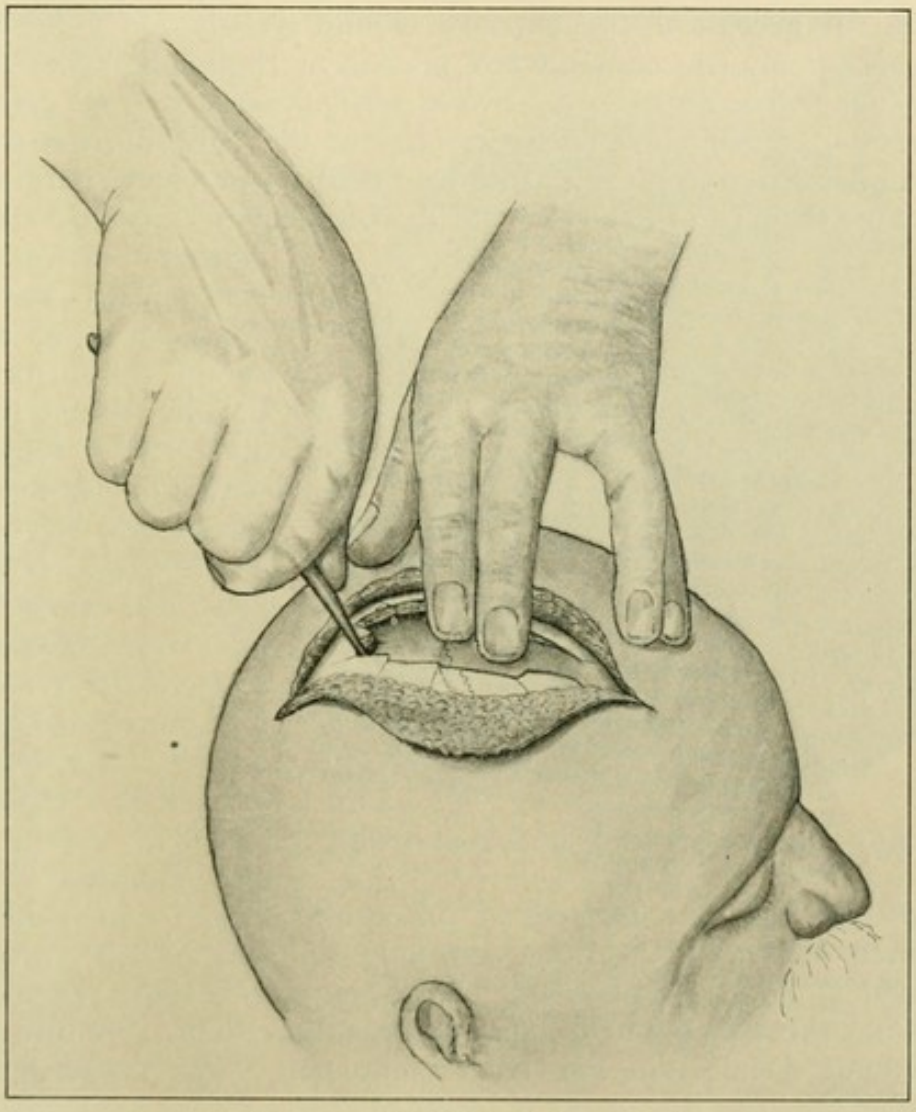

Fig. 305.—Proper method of elevation of the depression.

through a small opening made for this special purpose rather than through the wound, as it is desirable that the fragments should be covered with vascular tissue. According to the size of the wound and the length of time it was exposed to infection the surgeon resorts to either tubular drainage or capillary drainage, with strips of iodoform gauze or a small bundle of catgut or horsehair. Drainage is continued until the wound has been shown to be aseptic, or has been made so by vigorous antiseptic treatment.

Comminuted Compound Fractures.—Open comminuted fractures of the skull, inflicted usually by a blow, a kick, or a fall, present well-defined conditions for prompt and thorough surgical intervention. These injuries frequently involve the meninges and the brain itself. The scalp wound is more or less torn or contused, and almost always infected by hair, dirt, and other foreign substances. *Free exposure of the fracture is necessary to make a thorough search for foreign infected substances and to determine the extent of the fracture and the existence and nature of intracranial lesions.* If necessary, the external wound is enlarged sufficiently to expose freely the comminuted portion of the skull. *Free exposure of the fracture is also an essential preliminary step to the primary disinfection of the wound.* Every step of the procedure must be done under strict aseptic precautions. Before the wound is touched the whole scalp and the surface of the wound are disinfected. Bone-cutting instruments can usually be dispensed with, as some of the fragments are usually found loose, and can be removed with dissecting or hemostatic forceps. *If the wound is a recent one, every loose fragment should be temporarily removed and placed in a warm 2½ per cent. solution of carbolic acid for disinfection, during the time required in disinfecting the wound.* Defects of the skull owing to such injuries are often followed by serious consequences, and must be carefully guarded against by preserving every one of the loose fragments, removing them temporarily, and reimplanting them carefully after the wound disinfection has been completed. *The temporary removal of detached fragments prepares the wound for a more thorough disinfection.*

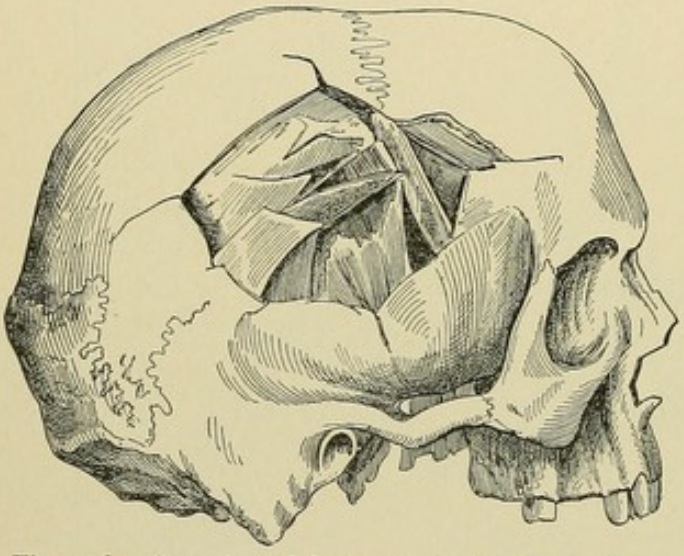

Fig. 306.—Comminuted fracture of the skull (Hoffa).

Depressed fragments are elevated with the utmost care to preserve existing vascular connections, contused brain tissue is excised, and the torn dura mater is sutured with fine catgut after the subdural hemorrhage has been arrested. Subdural capillary drainage is always necessary if the brain has been exposed by the injury. In the case of a dural defect the pericranium from the adjacent surface of the skull should be utilized in the form of a flap with which to cover and protect the surface of the brain. After the wound has been rendered surgically clean, the loose fragments are transferred

from the carbolized solution into a warm physiologic solution of salt prior to their implantation upon the surface of the dura. If the fragments are large, it is advisable to fragment them with bone-cutting forceps and reduce them to the size of the thumb-nail or smaller. The fragments are conveyed from the salt solution to the surface of the dura mater with dissecting forceps, and are planted in such a manner that the smooth surface comes in contact with the dura. If some of the fragments have been lost by the injury, the defect can be filled in with chips of bone made by cutting the remaining fragments through the diploe separating the external from the internal table. After the mosaic of fragments has been completed, the pericranium and skin are sutured over it, so as to secure for the bone chips vascular tissue on both sides. Drainage must be established where it is most needed, preferably through a separate opening in the scalp some distance from the fragments. A large hygroscopic sterile dressing, held in place by a gauze roller and a few turns of a plaster-of-Paris bandage, completes the operation. *If the wound remains aseptic, every one of the fragments will retain its vitality and will take an active part in the restoration of the continuity of the skull.*

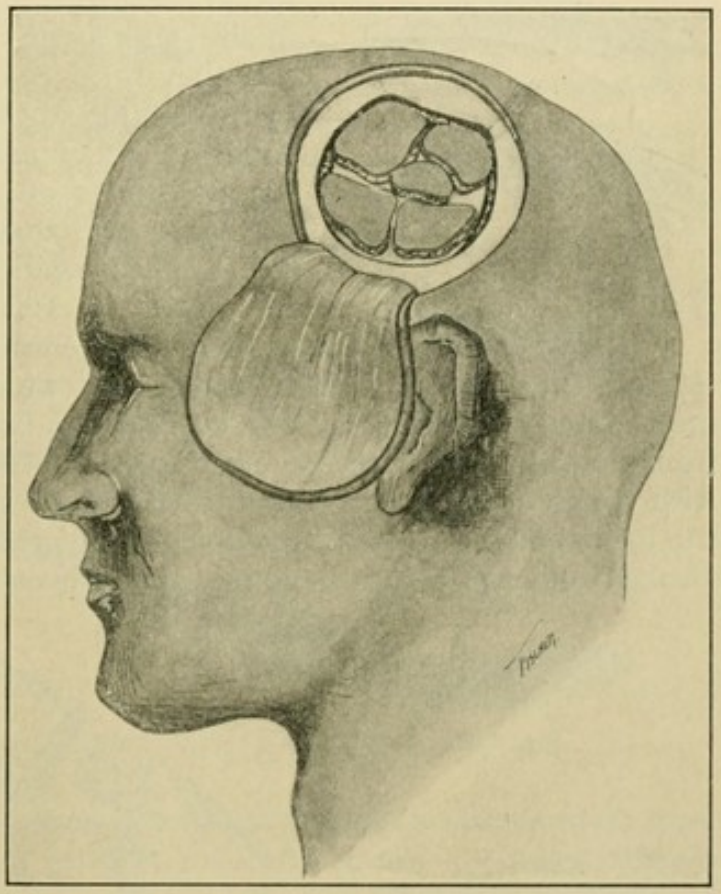

Fig. 307.—Reimplantation of fragments of bone in craniectomy for old depressed fractures of the skull and in recent fractures when the wound is aseptic.

Should the wound become infected, all the sutures should be removed, the wound opened widely, and all the loose fragments be removed and another attempt be made to render it aseptic by resorting to a vigorous secondary disinfection with peroxid of hydrogen, 2½ per cent. carbolic acid solution, or a 1 per cent. solution of formalin. Open treatment and the substitution of the warm antiseptic moist compress for the dry dressing constitute, in such an event, the appropriate after-treatment. Even in such cases nothing has been lost by an attempt to secure restoration of the

continuity of the skull by the preservation of detached fragments, their temporary removal, disinfection, and reimplantation.

Punctured and Gunshot Fractures.—Operative treatment is indicated in all cases of punctured and gunshot fractures of the skull. These injuries are almost always complicated by visceral wounds of the contents of the skull, and the vulnerating implement or bullet often carries infected substances with it into the interior of the skull. The opening in the external surface of the skull corresponds in size and shape to the weapon or missile that produced the fracture, but the internal table always fractures more extensively. Comminution is the rule, and the fragments often are driven into the substance of the brain. If a bullet passes through the skull, the wound of exit in the skull and soft tissues is larger than the wound of entrance, as when the bullet penetrates the skull from within, the external table is fractured more extensively than the internal, the conditions being the reverse from those in the wound of entrance. The smaller the instrument with which a punctured wound of the skull is inflicted, the greater the probability of a part breaking off and remaining in the wound. Broken-off knife-blades have repeatedly been overlooked, and have

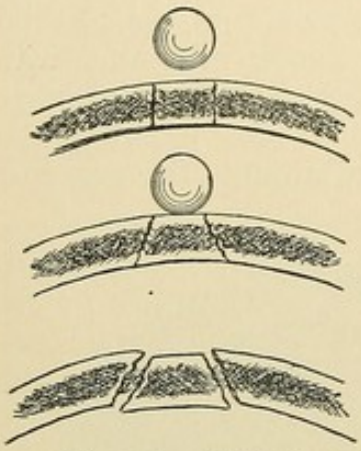

Fig. 308.—Mechanism of gunshot and punctured fractures of the skull.

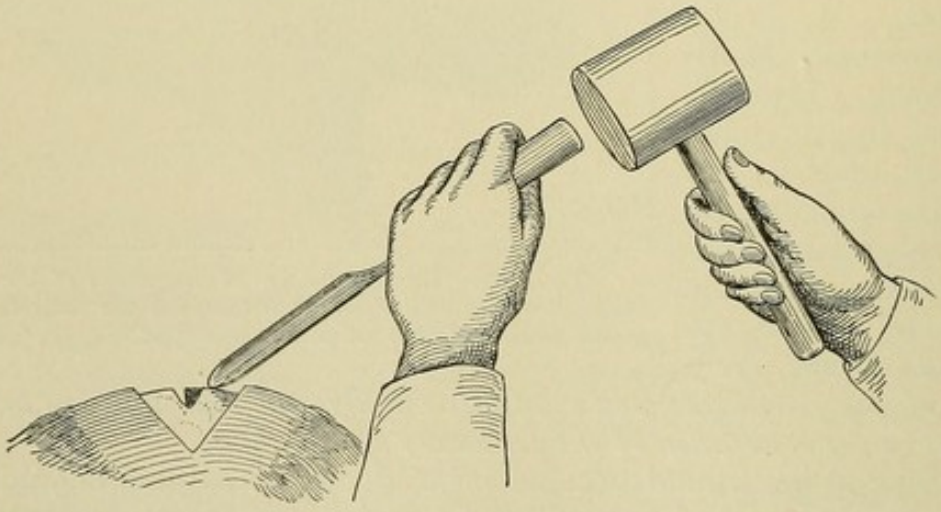

Fig. 309.—Removal of an impacted sword point with chisel and hammer (von Esmarch and Kowalzig).

remained impacted in the skull for years, until discovered at post-mortems or during operations for cerebral abscess. The point of a bayonet has been found so firmly fixed in the perforation that it could not be removed without the aid of a chisel. In every punctured fracture of the skull it becomes necessary to ascertain the

kind of instrument with which the injury was inflicted, and to examine the same to learn whether or not a part has remained in the wound. The perforation in the skull must be enlarged, to facilitate the search for foreign bodies, and to enable the surgeon to grasp and extract the detached fragments of bone. With bone-cutting forceps the overhanging external table is removed, until the openings in the external and internal tables of the skull are equal in size. Under pedantic aseptic precautions the perforation is exposed by enlarging the existing opening, or, still better, by reflecting a flap with the external wound in its center. In the absence of a foreign body in the substance of the brain, digital or instrumental exploration of the visceral wound should be abstained from, and the operative treatment limited to the arrest of hemorrhage, the removal of spiculæ of bone, and the disinfection of the extracranial wound. If foreign substances are detected in the intracranial wound, they are removed and the disinfection is extended to the limits of the part of the wound exposed to infection. Suturing of the dura and im-

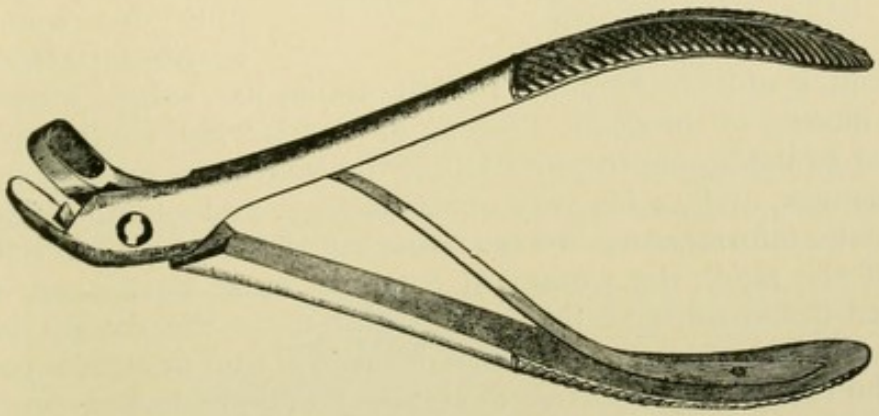

Fig. 310.—Keen's rongeur forceps for operations on the skull.

plantation of the fragments are usually impracticable in such cases. Drainage with a small strip of iodoform gauze is always indicated and should be continued until the time for infection has passed.

Gunshot fractures of the skull should invariably be subjected to operative treatment, provided this holds out any encouragement whatever of saving life. In case a bullet has passed through the skull and its contents, the entire scalp should be shaved and thoroughly disinfected. The wound of entrance must be enlarged sufficiently to expose the perforation freely, which is then enlarged with chisel and de Vilbiss or rongeur forceps, to enable the surgeon to remove the loose spiculæ of bone which are frequently found at some distance in the brain. With a long, eyed probe a strip of iodoform gauze large enough to pack the tubular visceral wound loosely should be inserted from the wound of entrance to the wound of exit, and the ends of the drain be made to project a few inches beyond the surface of each wound. Thorough capillary drainage of this kind will prevent accumulation of primary wound

secretion in the interior of the skull, and will be of value in arresting capillary hemorrhage. A large hygroscopic dressing, enveloping the entire scalp and covering both wounds, constitutes the dressing, and must be held in place by a few turns of plaster-of-Paris bandage. The drain must be allowed to remain until the danger of infection is passed, when it is removed gradually by shortening it every day or two on the side of the wound of entrance, because infection is more likely to take place here than on the opposite side.

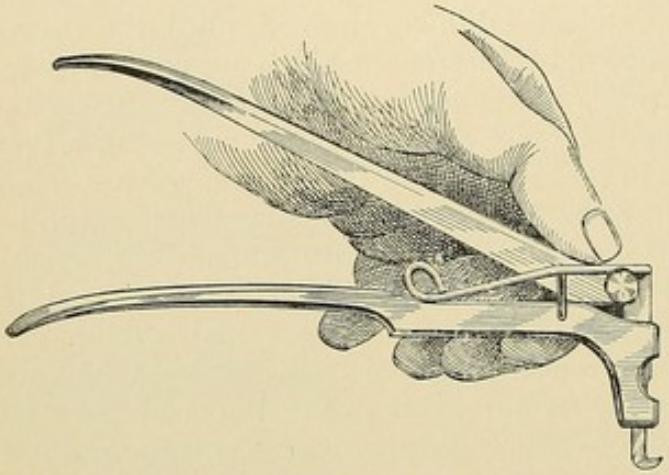

Fig. 311.—De Vilbiss bone-cutting forceps for operations on the skull.

In the presence of only one wound in gunshot fractures of the skull, it must be assumed that the bullet has lodged somewhere in the interior of the skull. Probing of a brain wound in the ordinary manner to determine the location of the bullet is a practice fraught with danger, and yields very unsatisfactory, and often misleading, diagnostic information. In case the bullet has lodged in the interior of the skull, the wound of entrance must be treated in the manner described, and the bullet located by the careful use of Fluhrer's aluminum probe. The head is placed in such a position that the tubular wound is vertical, when the gravitation probe, by its own weight, finds its way along the track until it strikes the bullet or the opposite side of the skull, in case the bullet has become deflected after impinging upon the inner surface of the skull, as happened in the famous case reported by Fluhrer. A counter-opening may become necessary in order to remove the bullet if it has reached the opposite side of the skull, or if it has become deflected or arrested near the surface of the brain, provided the locality in which it has lodged is such as to warrant operative interference. In all visceral injuries of the contents of the skull resulting from gunshot wounds, capillary or tubular drainage, or a combination of the two, is indicated and should be continued until there is no further danger of infection, hemorrhage,

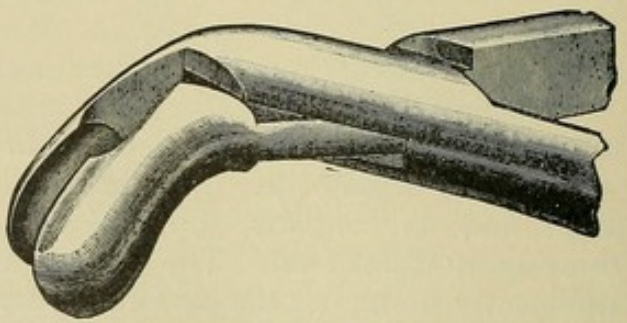

Fig. 312.—Hopkins' rongeur forceps, as modified by Weir, for operations on the skull.

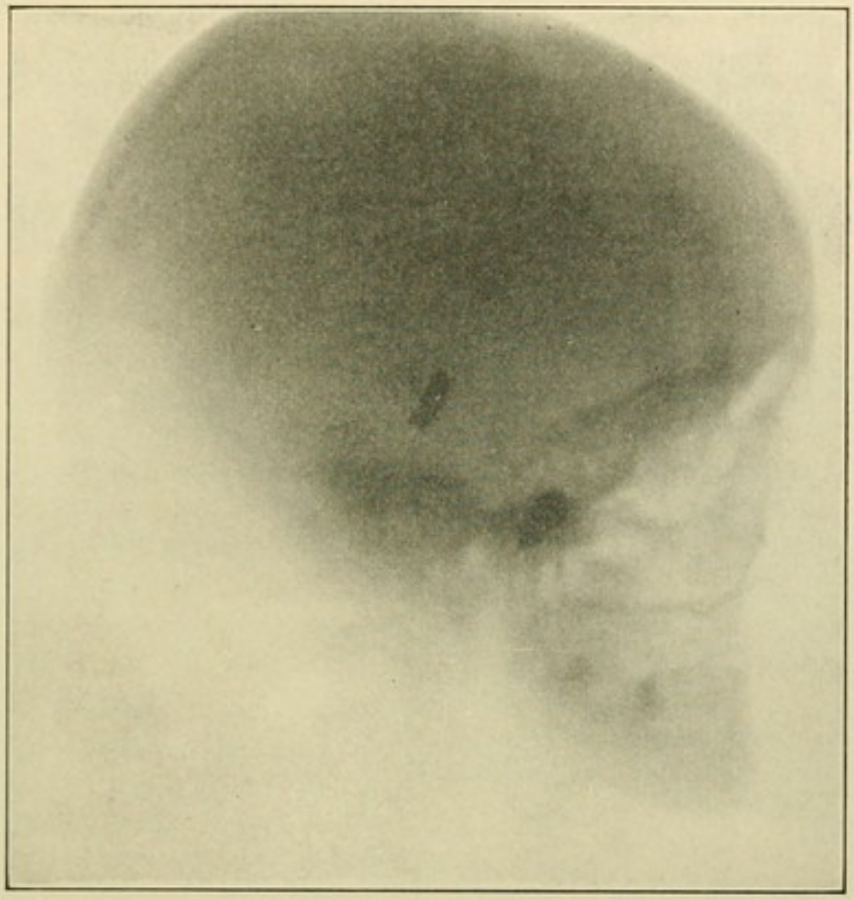

Fig. 313.—Skiagram showing part of the bullet inside and part outside of the skull. In striking the skull the bullet split and the smaller fragment entered the skull.

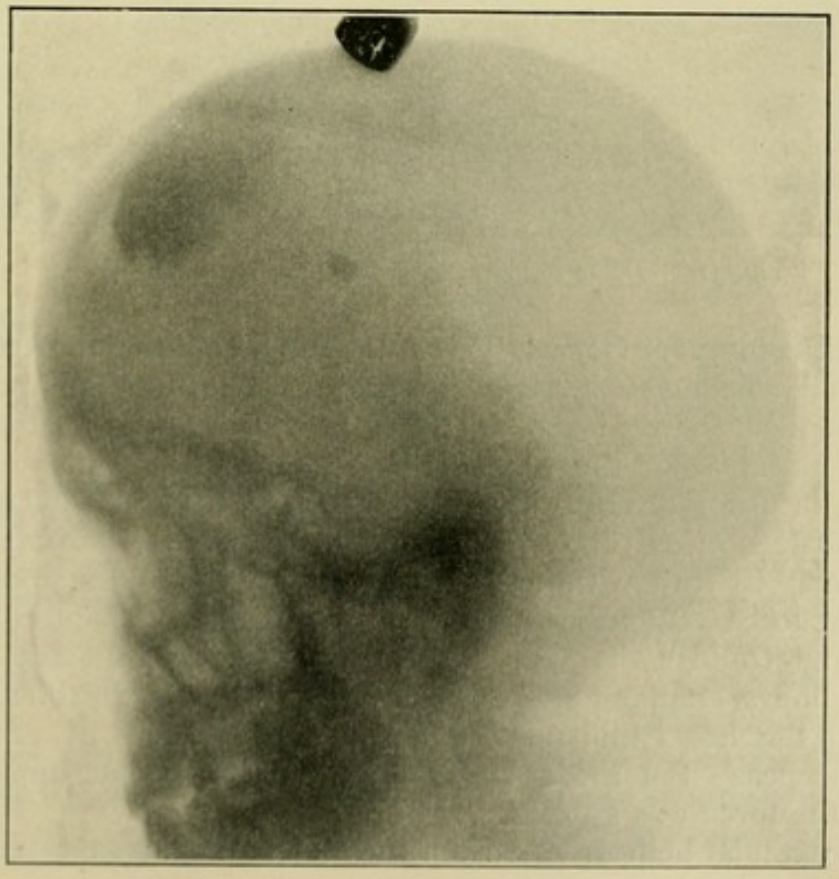

Fig. 314.—Bullet in frontal lobe of brain (lateral view).

or accumulation of wound products, when the drain is to be removed gradually. Illumination with the X-ray has finally succeeded in locating bullets in the interior of the skull, as can be seen from the skiagrams (Figs. 313, 314, and 315); in a number of cases so far reported it furnished the principal diagnostic information that enabled the surgeons to locate and remove the bullet.

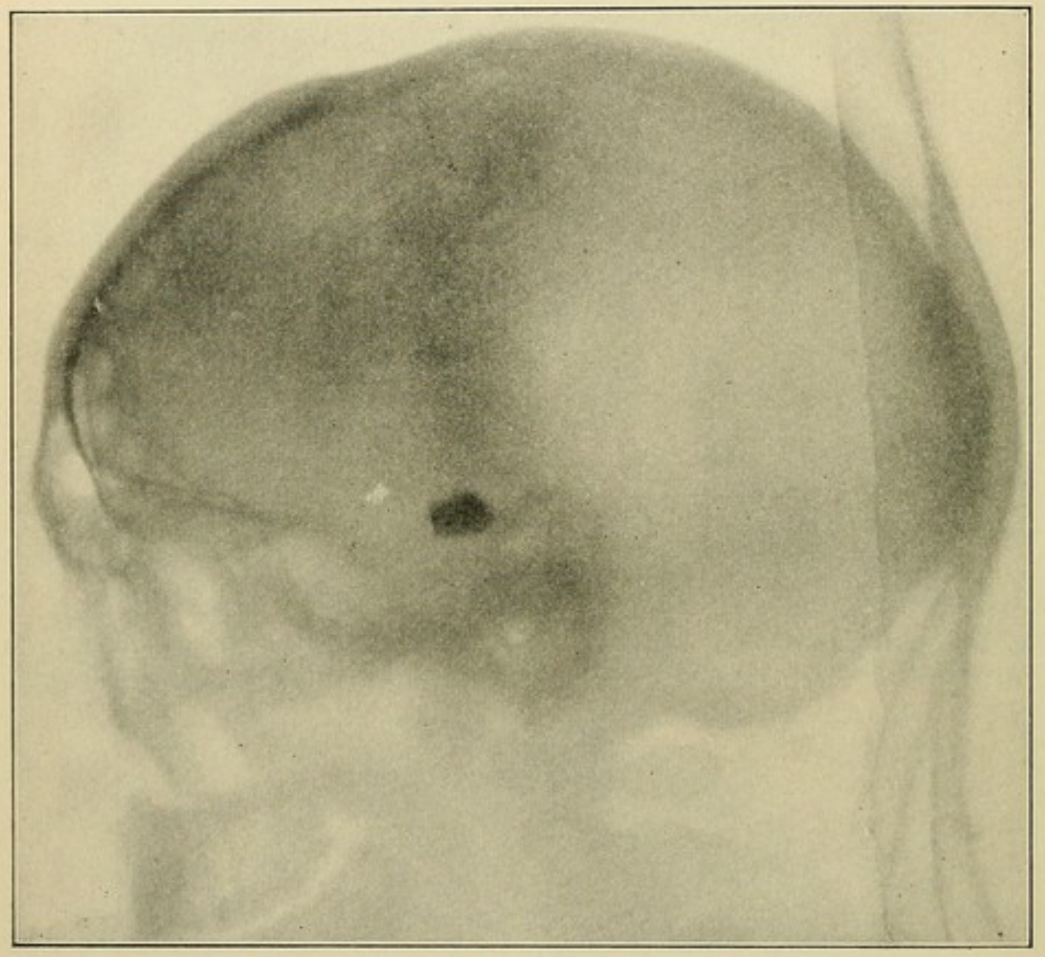

Fig. 315.—Bullet in left temporal lobe (lateral illumination).

Craniectomy for Hemorrhage from Middle Meningeal Artery.—The middle meningeal is one of the largest of the intracranial arteries, and when cut or ruptured, life is in imminent danger, either from loss of blood, when the bleeding vessel is exposed by an external wound, or from cerebral compression if the skull is intact or the extravasated blood can not escape through the fracture. This artery may be torn, without fracture of the skull, by the application of blunt force sufficient momentarily to change the contour of the skull and to tear the vessel, but, owing to the elasticity of the cranial bones, stopping short of causing a fracture. In the majority of cases the vessel injury is one of the complications of a fracture. In either case the artery may be injured at a point opposite to where the force was applied.

Intracranial hemorrhage from the middle meningeal artery gives

rise to a complexus of symptoms almost characteristic of this injury. In the absence of severe concussion or brain injury the patient is often able to walk a considerable distance before symptoms of compression set in. The hemiplegia on the opposite side develops gradually. The progressive increase in the intensity of the focal symptoms distinguishes this injury from the symptoms caused by a depressed fracture or visceral injury of the brain. After the hemiplegia is complete, loss of consciousness, stertorous breathing, dilatation of the pupils, and other indications of more diffuse cerebral compression make their appearance, and, unless prompt surgical intervention is instituted, death from acute cerebral compression is the rule. There are, however, exceptions to this rule. I have seen a case of hemorrhage from the middle meningeal artery, complicating a fracture at the base of the skull, eventually recover completely without operative treatment. The patient was unconscious for a number of days and completely hemiplegic. The paralysis gradually disappeared in the course of six months. Such cases are, however, exceptional, and do not disqualify the rule previously laid down that hemorrhage from the middle meningeal artery furnishes a positive indication for the employment of direct hemostatic measures. If the dura is intact, the extravasation will be found between it and the inner surface of the cranial bones; if the dura is ruptured, the hematoma may be

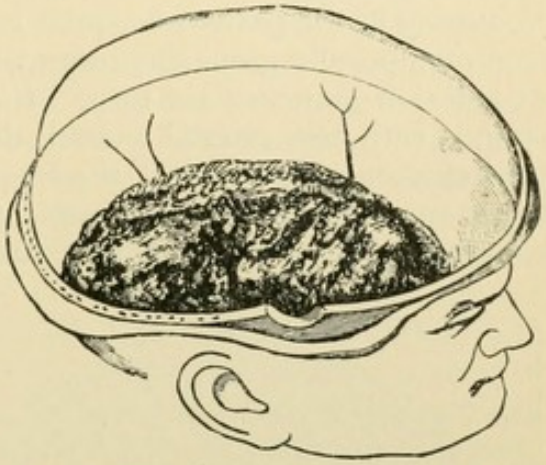

Fig. 316.—Hemorrhage from the middle meningeal artery (Jacobson).

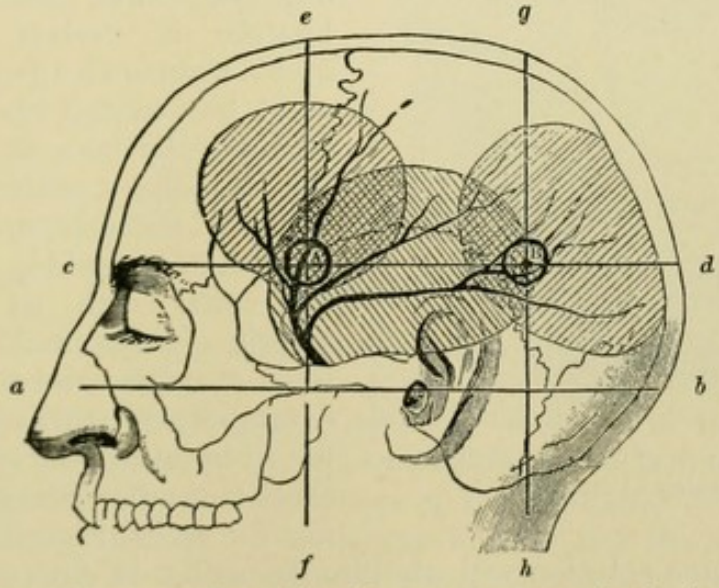

Fig. 317.—Site of trephine opening to reach clot in hemorrhage from middle meningeal artery (Krönlein): *a–b*, Horizontal line through the meatus; *c–d*, on a line with the eyebrows; *e–f*, vertical line, from three to four centimeters behind the external angular process; *g–h*, at the posterior border of the mastoid process; A, the point to reach the anterior branch, and B, that to reach the posterior branch (von Esmarch and Kowalzig).

almost entirely subdural, or if the tear in the dura is limited and opposite the bleeding point, subdural and epidural. The location of the blood-clot will depend on the part of the vessel injured: most frequently it is found in the temporoparietal region, next in frequency in the parieto-occipital region, and least frequently in the frontotemporal region, according as the main artery or the posterior or anterior branches are torn. If the fracture of the skull corresponds with the arterial wound, the bleeding vessel is exposed by the temporary removal of the fragments, and if the bleeding point is not made sufficiently accessible, the opening is enlarged with the rongeur or de Vilbiss forceps. Direct ligation is seldom possible. The best course to pursue is to pass a catgut ligature with a well-curved, round needle underneath the vessel, including some of the dural tissue, and tie carefully. If the artery is in a complete bony canal, as is occasionally the case, the ligature is useless, and hemorrhage must be arrested by crushing the bone at the bleeding point with a sequestrum forceps, or by spiking the canal with an aseptic ivory nail. Such a spike can be extemporized with a file from an ordinary crochet-needle. Boiling for from ten to fifteen minutes in a soda solution will sterilize the nail. In emergency cases a sterilized toothpick will answer a useful purpose; this has, however, this great disadvantage, that the wooden spike must be removed at the end of from forty-eight to seventy-two hours.

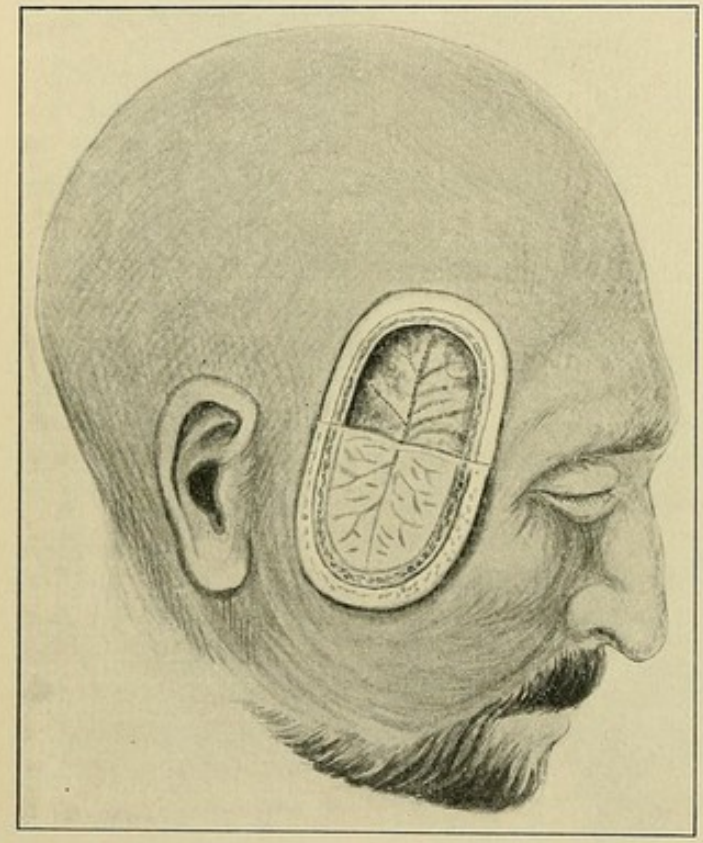

Fig. 318.—Osteoplastic resection of the skull for ligation of the middle meningeal artery.

As the free hemorrhage usually obscures the field of operation, digital compression of one or both carotid arteries recommends itself as a useful temporary hemostatic resource until the bleeding vessel has been found and tied. If the bleeding point can not be reached from the seat of fracture, or if the skull is not fractured, the main artery must be exposed and ligated in the temporal fossa.

This can be done with the greatest safety and with the best prospects of finding the vessel by making an osteoplastic resection. The flap should be at least one and one-half or two inches wide and three inches in length, with the base above the zygomatic arch. The convex border of the flap should correspond with the temporal ridge. The flap includes the skin, temporal fascia, muscle, periosteum, and bone. The operator must remember, in using the chisel, that the bone in this locality is very thin. After outlining the piece of bone to be elevated by a groove made with gouge and hammer, the internal table is fractured with a narrow, thick chisel ground on one side. The fracture at the base of the flap can be made, without much cross-cutting, by the use of the elevator. On reflecting the flap the main artery and the anterior and posterior branches are exposed, and if the bleeding point is not found, the main artery is tied. By opening the skull in the manner indicated the hematoma comes within reach and is removed before or after the artery is tied. After complete hemostasis and removal of the extravasation, the flap is sutured in place without making provision for drainage. Should hemostasis not be complete, drainage is established by making a buttonhole in the base of the flap, and by cutting away a small semicircular piece from the fractured surface of the temporarily displaced bone, and by inserting a tubular or gauze drain, or by combining tubular and capillary drainage.

CHAPTER XI.

COMPOUND FRACTURES.

Compound fractures belong to the gravest class of injuries that come under the care of the general practitioner. The responsibility of those who render the first aid in such accidents is very great, as upon prompt and intelligent action depend the preservation and future usefulness of the fractured limb, and often the life of the patient. The danger to limb and life in such cases consists usually in the presence of the wound in, and the extent of injury to, the soft parts, rather than in the fracture itself. A subcutaneous fracture with extensive comminution under appropriate treatment usually heals in a satisfactory manner, while a much less extensive fracture, complicated by a communicating wound with the surface, places the limb and life of the patient in jeopardy in case the wound becomes infected. The treatment of compound fractures must meet many and more difficult indications than that of simple fractures. The complications that are frequently met in such injuries often make it difficult to decide whether the conditions are such as to warrant conservative treatment or whether primary amputation

should be performed. If a conservative plan of treatment is decided upon, the prognosis in reference to the danger to life and as to securing a useful limb is influenced unfavorably by the existing wound.

The term compound originated in England, and is used to distinguish open from simple or subcutaneous fractures. The English and American surgeons understand a compound fracture to be one in which a communication between the medullary tissue at the seat of fracture, a tissue extremely susceptible to pyogenic infection and the external air, is established through a wound of the soft parts. A complicating wound that does not communicate with the seat of fracture does not add materially to the danger of the injury, nor does it interfere with a satisfactory process of repair of the fractured bone. The great risk of a compound fracture is infection of the exposed medullary tissue, with its immediate and remote consequences. The German and French surgeons include compound fractures under the head of complicated fractures, a term restricted in this country and in England to designate fractures complicated by injuries of the soft parts that are important in maintaining the nutrition of the limb, such as wounds of large blood-vessels and nerves. The classification into open and closed fractures, as has been recently proposed, would probably accomplish much in doing away with the prevailing confusion regarding what is meant by a compound fracture, but it requires time to make the change a general and permanent one in the countries where the profession has been brought up and educated in the term compound as applied to fractures.

In the discussion of compound fractures the remarks will apply exclusively to fractures of the long bones. The distinction between open and closed fractures is an important one, from a prognostic as well as a therapeutic standpoint, even at the present time, when the surgeon's efforts at preventing wound infection are more successful than they were a quarter of a century ago. The high degree of receptivity of the medullary tissue to pyogenic infection is well known and fully realized. Before antiseptic surgery was known, suppurative osteomyelitis followed nearly every amputation and seldom was delayed for more than ten days in compound fractures. The old museums of pathologic anatomy are overstocked with sequestra of all sizes and shapes, obtained from patients after a hard struggle for life or more frequently from the postmortem room. The innumerable deaths from pyemia in both classes of patients were caused, with few exceptions, by osteomyelitis. All wounds complicating fractures must be regarded as infected wounds, and, as can be seen from the recent statistics, the most painstaking surgeon, in a well-equipped hospital, is not always able to guard against infection by the most energetic recourse to antiseptic precautions. Antiseptic surgery has accomplished much in eliminating the dangers incident to wound infection, but we can not claim

for it absolute protection. The cases often come to the surgeon after the infection has gained a firm foothold, and the most thorough and energetic antiseptic measures are usually powerless in arresting the extension of the infection before great damage has been inflicted upon the fractured bone and the adjacent soft tissues.

Old Statistics.—The value of timely antiseptic treatment of the wound complicating compound fractures is made most apparent by comparing the old with recent statistics. What the mortality of compound fractures was before statistics were available may readily be imagined. Few escaped with their lives before surgeons knew how to immobilize a compound fracture properly. Considerable gain was made in the treatment of compound fractures after surgeons realized the importance of proper immobilization of the injured limb, but they were almost powerless in preventing wound infection until Lister announced his great discovery. Before antiseptic surgery was practised in Germany nearly 50 per cent. of all cases of compound fractures died from hospital gangrene, sepsis, erysipelas, or pyemia, and primary amputation had little influence in diminishing this enormous mortality. Volkmann publicly stated that in his own practice and in that of his predecessors the mortality of compound fractures in the Halle Clinic before the antiseptic treatment was introduced was 40 per cent. Of the last twelve cases of compound fracture of the leg that were treated on the old plan and that came under his own observation, every one died of pyemia or septicemia. Volkmann and Fränkel collected 388 cases of compound fracture of the leg from civil practice, treated conservatively under the old method, with a mortality of 32.5 per cent.

From England comes the report of Thomas Bryant, giving the results of treatment of 302 compound fractures treated in Guy's Hospital during twenty years previous to the introduction of antisepsis. Of this number, 177 were treated on the conservative plan, and of these, 39 died. In 91 cases primary amputation was performed, and of these, 57 died. Secondary amputation became necessary in 31 cases, and of these, 19 died. In all cases in which the fracture implicated any of the large joints the result was uniformly fatal. Similar experiences prevailed in France. Després treated, during the year 1872–73, 13 cases of compound fracture of the leg by applying camphor wine to the wound and by immobilizing the limb in a fracture box. Eight of these were treated throughout on a conservative plan, and of these, 6 died; of 5 treated by amputation, 4 died, so that of the whole number, 13, of compound fractures of the leg, only 3 recovered. The following year he treated 11 cases by protecting the wound with diachylon plaster and by immobilization of the limb in a plaster-of-Paris dressing, with the result that only one died, a difference in the mortality that he attributed to more perfect immobilization of the limb. During the Franco-Prussian war he saw, at Sedan, 8 gunshot fractures of the leg, of which 3 died; at Beaugency 26, of which 7 died. He believed

that the comparatively low mortality in military as compared with civil practice in such cases was due to the fact that the bullet usually passed through the limb, leaving two openings for free drainage.

We can not show much better results in our own country in the treatment of compound fractures under the old régime. Of 166 compound fractures of the large long bones treated in the Pennsylvania Hospital from January 1, 1839, to April 1, 1857, reported by Norris, 71 died. Of 30 cases treated by amputation, 20 died. During the same period of time 158 compound fractures were treated in the New York Hospital, with a mortality of 50 per cent., as reported by Lente. The fearful mortality that attended gunshot fractures of the extremities during the Civil War lives in the memory of many surgeons who are actively engaged in professional work at the present time. This mournful picture of suffering, mutilation, and death caused by compound fractures under the old treatment, as shown by the foregoing statistics, is only a partial portrayal of the actual results, as they comprise cases from the practice of experienced surgeons, and do not include the enormous material in the hands of general practitioners. Let us turn away from the sickening details, and in the light of modern surgery consider the treatment of compound fractures as reflected by recent statistics.

Recent Statistics.—Volkmann did more to develop and perfect the modern treatment of compound fractures than any other surgeon. In his classic address, delivered before the International Medical Congress, London, 1881, on "Modern Surgery," he refers to the radical changes that have taken place in the treatment of compound fractures and its results since the antiseptic treatment has been generally adopted. After giving his experience with the old treatment, he made the statement that of the first 135 cases treated antiseptically in his clinic he lost only two, one of fat embolism, and the other, a potator, of delirium tremens. In 1886 Bruns tabulated 254 cases of compound fracture, treated with carbolized preparations, from the practice of leading German surgeons, distributed as follows:

75 cases, Volkmann, 1873–77.	38 cases, Wilms, 1877–78.
60 cases, Bardeleben, 1875–78.	28 cases, Schede, 1875–77.
53 cases, Socin, 1873–79.	

Of this number, 84 involved the upper extremity, 45 were fractures of the shaft, 30 were joint fractures, and 9 were complicated cases. The lower extremity is represented by 170 cases, among them 132 of the shaft, 35 joint fractures, and 3 complicated cases. The total mortality amounted to 9 per cent. Of the 23 fatal cases, 1 died of collapse, 1 of fat embolism and hemorrhage, 7 of delirium tremens, 2 of tetanus, 4 of pyemia, and 7 of septicemia. The mortality due to septicopyemia is, therefore, reduced to 4.3 per cent., and in many of the fatal cases from this cause infection was present at the time the patients came under treatment, so that the real mortality from sepsis is reduced to 3.5 per cent. Of the 84 cases of

fracture of the upper extremity that came under treatment within twenty-four hours, 2 died, 1 of septicemia, and of 10 who came under treatment after the expiration of twenty-four hours, 2 died, only 1 of septicemia. Of the 170 open fractures of the lower extremity, 141 came under treatment during the first twenty-four hours; of these, 13 died of septicopyemia; of the 29 that came under treatment later, 6 died—5 of septicopyemia. Of the cases that came under treatment during the first twenty-hours, in 115 aseptic healing of the wound occurred. In the cases in which the first aid was rendered later, the mortality from sepsis was three times greater, and the number of aseptic wound healings was reduced one-half. In 168 compound fractures of the shaft of the long bones the fracture failed to unite in 5, and in 12 cases bony union was delayed—over ten weeks. Of the 48 cases in which large joints were involved, 32 were treated upon a conservative plan (1 died of tetanus); in 8 primary resection was done; in 2, secondary resections; and in 6 secondary amputation became necessary. The mortality from accidental wound infection amounts to 6.2 per cent.; from sepsis, 4.1 per cent. In 31 cases a good functional result was obtained, and only in 3 did ankylosis occur.

Wölfler has recently published his experience in the treatment of compound fractures in his clinic at Graz. Nineteen were admitted in a septic condition; of the remaining 88, 2 died of tetanus, and 1, a case of extensive crushing of the thigh in which amputation was objected to, succumbed to sepsis. He makes use of the term "atoxis" to describe the procedure necessary to convert an infected into an aseptic wound. M. Villars has reported another series of compound fractures from the Halle Clinic since the publication of Volkmann's paper on the same subject. The absolute mortality was 7.7 per cent., including deaths from sepsis present at the time the patients were admitted and complications occurring independently of the fracture. Of the 90 cases, 60 recovered with useful limbs and excellent union of the fracture. In 6 cases amputation, and in 3 exarticulation, became necessary to save life. The treatment, on the whole, was of the most conservative nature. The wound was seldom sutured, but direct fixation of the fragments by suturing was frequently practised. In delayed union callus formation was stimulated by steel or ivory nails driven into the ends of the bone, and circulation was increased by permitting the patients to use the limb, properly immobilized, before union by bony callus was complete.

In a valuable article Mumford gives the results of treatment of 300 cases of compound fracture in the Massachusetts General Hospital during eight years—from 1887 to 1895. He excludes from the list those cases that died within the first twelve hours and those treated by primary amputation. Of the 300 cases, 30 died—a mortality of 10 per cent.; the causes of death were: Sepsis, 10; shock, 7; delirium tremens, 6; fat embolism, 3; gangrene, 3; acute

nephritis, 1. In 171 cases the fracture was of one or both bones of the leg, with 18 deaths—a little more than 10 per cent.; the highest mortality was in fractures of the femur—25 cases with 7 deaths—28 per cent. In 50 cases involving joints there were only 3 deaths. In 20 cases secondary amputation was performed. Primary wiring of the fragments was done 27 times, and in 7 of the cases necrosis followed. These recent statistics show conclusively what antiseptic surgery has done for the treatment of compound fractures. For reasons that are not difficult to comprehend it has not succeeded, and probably never will succeed, in reducing the mortality from septic complications to *nil*, but it has already reduced it from over 50 per cent. to an average of not much over 5 per cent. While it has done so much in the way of saving life, it has perhaps done more in the prevention of mutilating operations,—primary and secondary amputations and resections,—in shortening the healing process, and in improving and increasing the functional results. Under the old treatment primary healing of the wound was the exception, even in the simplest cases. In the cases that recovered from the septic complications the fracture ultimately healed after a long siege of suppuration, and often extensive sequestration, following the traumatic suppurative osteomyelitis, accidents that could not fail greatly to retard recovery and to impair the functional results.

Compound fractures have lost their former bad reputation solely on account of the improved methods of dealing with the external wound since the introduction of antiseptic surgery by Lister. Under strict antiseptic precautions, timely employed, the majority of compound fractures heal in the same manner as simple fractures, in the same length of time, and with no more suffering and equally as satisfactory functional results. Formerly the surgeons who had become painfully aware of the great dangers arising from inflammation aimed to prevent and combat it by the employment of energetic antiphlogistics,—application of cold, restricted diet, venesection sedatives, emetics, and cathartics,—while the modern surgeon, on the other hand, scores such marvelous results by excluding or rendering harmless the direct cause of infection and by husbanding the strength and recuperative energies of the patient. Subcutaneous fractures suppurate only in exceptional cases, even when the bone is extensively splintered and the soft tissues are seriously injured. Lister, following Pasteur's researches, showed that it was not the atmospheric air, as was formerly believed, but the micro-organisms suspended in it, that produced the fermentative and putrefactive processes in the primary wound secretions. It is the antiseptic treatment of the wound that must be credited with having wrought so radical a change in the results of the modern treatment of compound fractures, and it is the surgeon who is perfectly familiar with the principles and practice of antisepsis who will be most successful in the management of such cases.

Etiology.—The manner in which a compound fracture is produced has an important bearing on the prognosis and treatment. A fracture is made compound by force acting either from within or without. Fractures that are made compound by force acting from within result usually from indirect application of force, and the wound is inflicted by one or more fragments perforating the soft tissues by a continuation of the same force that fractured the bone or bones. The force transmitted through any of the long bones to the point where the fracture takes place results in bending of the limb at the seat of fracture, and with the increasing angularity one or more fragments are forced through the soft tissues to the surface, converting, almost in the same moment, the simple fracture into a compound one.

Comminution in such cases is usually slight or entirely absent.

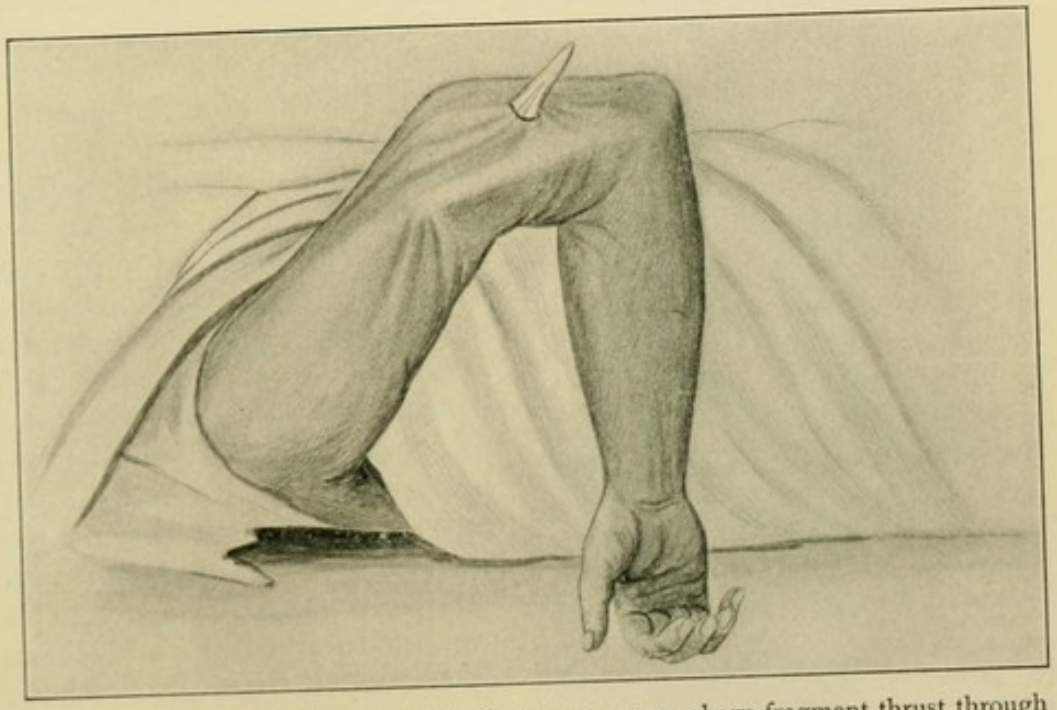

Fig. 319.—Perforating fracture of the humerus; upper sharp fragment thrust through the skin, which firmly embraces the protruding bone.

The fragment or fragments that perforated the skin may be found protruding by the surgeon when the case comes under his observation, in which event the wound, to a certain extent, is protected for a short time against infection by the mechanical barrier furnished by the displaced fragment. These are the most favorable cases, so far as the prevention of infection is concerned. In other cases the projecting fragment is replaced spontaneously or by the intervention of persons who are first brought in contact with the patient. In such instances the danger of infection is greater, as the projecting part of the bone may have become infected during the short time it was extruded, or pathogenic microbes from other sources may have entered the wound cavity through the perforation before the

patient comes under the care of the surgeon. A simple fracture may be made compound if the patient, after the accident has occurred, makes an attempt to use the limb. This was the case with Mr. Pott, who sustained a fracture that bears his name. A similar complication may occur in the subjects of simple fracture who later become afflicted with delirium of any kind. A simple fracture is occasionally made compound by decubitus from without or within, by splint pressure or great displacement of the fragments, and in rare instances by the occurrence of suppuration at the seat of a simple fracture.

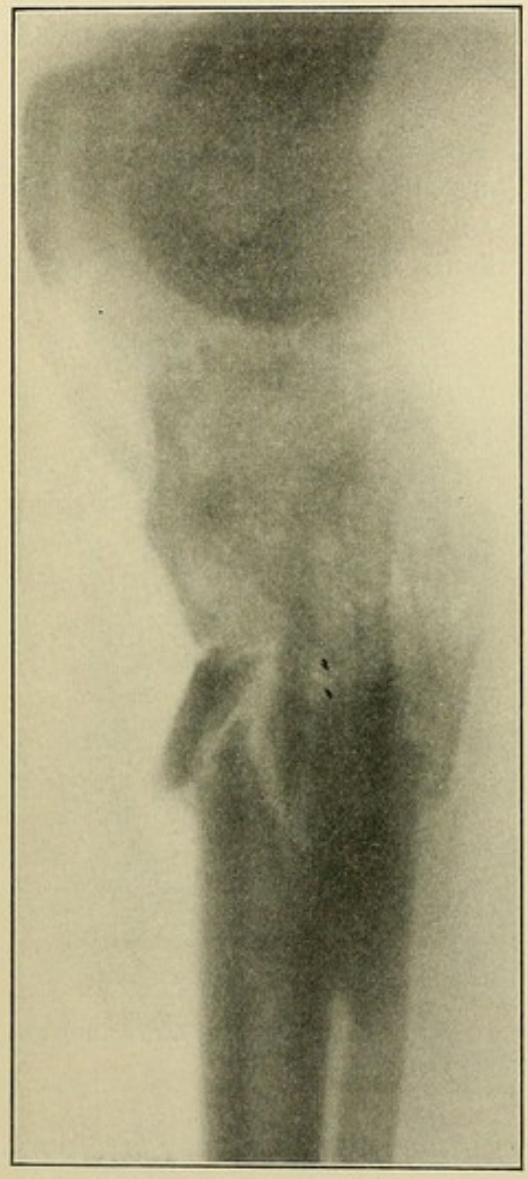

Fig. 320.—Compound comminuted fracture of the tibia from the kick of a horse.

As instances of compound fractures resulting from direct violence may be mentioned gunshot fractures and those from kicks, blows, and the passage of the wheels of a heavy vehicle of any kind. The last method of causing a compound fracture produces injuries of the gravest kind by inflicting extensive comminution of bone and serious crushing of important soft tissues. The degree of comminution caused by bullet injuries depends largely on the range from which the missile was fired. The modern small-caliber bullet causes extensive comminution within a distance of 500 yards; it drills the bone the next 500 yards; and beyond that range more or less comminution again takes place. Loss of bone tissue is sometimes sustained in perforating fractures by the breaking-off of the projecting piece of bone under the influence of the same force that produced the compound fracture. In other cases the crushing is so extensive and the external wound so large that some of the fragments are lost before the patient receives surgical attention. The lower extremities are more frequently the seat of compound fracture than the upper. According to Gurlt, the most reliable authority, 19.91 per cent. of all fractures are compound. In fractures of both bones of the leg 17.96 per cent. are compound. In

fractures of both bones of the forearm 11.68 per cent. are compound; of shaft of the femur, 7.05 per cent.; of the humerus, 6.66 per cent. The greater frequency with which fractures of the leg are compound than are those of the forearm is undoubtedly due to the fact that more simple fractures of the leg are made compound by continuation of the same force that produced the simple fracture, or by bending at the seat of fracture under the weight of the body, or on attempts to use the limb after the fracture has occurred.

Diagnosis.—The diagnosis in the majority of cases of compound fractures presents no special difficulties. If the fractured bones are exposed, or if the wound is large and the fragments are readily accessible, a glance or a touch settles the existence of a fracture and the presence of a complicating wound. *In more doubtful cases no digital or instrumental examination is justifiable in efforts to establish the compound nature of the fracture, except under strict aseptic precautions.* It is in such cases that meddlesome exploration, digital or instrumental, does great harm, because quite frequently a very thin layer of soft tissue covers the fragments; this thin *bassin du infection*, when torn, establishes an infection atrium communicating with the seat of fracture. As a rule, digital exploration should not be encouraged except it be done under strict aseptic precautions. The external wound and its environment should be thoroughly disinfected, and the examination made with a finger faultlessly aseptic. A wide experience has demonstrated the danger of exploring gunshot wounds with the probe, and this instrument has, for good reasons, become almost obsolete in the examination of recent gunshot fractures. If, after a careful examination, any doubt remains as to the compound nature of the fracture, the patient must be given the benefit of the same, and the case must be treated on principles appropriate to the doubt entertained. By following such a course nothing is lost and much may be gained.

The diagnosis in compound fractures has, however, more in view than the settlement of the existence of a wound communicating, on the one hand, with the surface, and, on the other, with the seat of fracture. It is important to ascertain the extent of communication and the location and degree of displacement of the fragments. This can be done only by making a careful inspection and digital exploration of the wound. It is equally necessary to ascertain the existence and nature of additional complications. This part of the examination has special reference to the extent of injury to the soft parts, skin, muscles, vessels, and nerves. Imperfect or superficial attention given to this part of the examination has often resulted in serious harm to the patient and in unnecessary damage to the reputation of the attendant. Crushing injuries are peculiarly deceptive in this respect. The apparently slight injury of the skin over the crushed bone, and the soft tissues interposed between

them, has often given rise to serious mistakes in prognosis and treatment. The great elasticity of the skin often permits extensive comminution of bone and crushing of the soft tissues—conditions liable to be overlooked unless the examination is conducted with the necessary degree of care and thoroughness. Injury of the intima of large blood-vessels from crushing or traction force is not infrequently present in such cases, and is manifested clinically soon after the injury has been received, not by a complete, but by a partial, interruption of the peripheral circulation. The circulation may also be threatened from compression of the principal blood-vessels, arteries, and veins, caused by one or more displaced fragments. The condition of the peripheral circulation should be studied with the utmost care, for the purpose of ascertaining the existence or absence of obstructive traumatic lesions from intravascular or extravascular causes. The condition of innervation of the limb below the seat of fracture must receive similar careful attention in formulating a correct diagnosis and in determining the existence or absence of injury to any of the principal nerves by crushing, cutting, tearing, or compression. In order to arrive at rational correct diagnostic conclusions, it is, therefore, necessary not only to establish, if possible, and without detriment to the patient, the existence of the compound nature of the injury, but it is likewise essential in the interest of the patient, as well as for the protection of the reputation of the practitioner, to establish the extent of the fracture of the bone or bones, and especially of the injury to the soft tissues.

Pathology.—The acute pathology of a recent compound fracture is characterized by the comminution of the fractured bone, so frequently present, crushing of medullary tissue, and laceration of the soft tissues overlying or surrounding the seat of fracture. Owing to the manner in which such injuries are produced, hemorrhage is seldom profuse. A certain amount of extravasation of blood, however, is always present about the fractured ends of the bones, caused by hemorrhage from the medullary tissue and from the torn or crushed tissues from the vessels injured by the fracturing force. In gunshot fractures implicating large blood-vessels the hemorrhage is usually profuse, and demands the first attention of the surgeon. If any of the large blood-vessels are severed by the sharp fragments, hemorrhage will present itself as one of the most conspicuous symptoms of the accident. If the fracture is the result of traction force, some of the large arteries may become partially occluded immediately after the accident by narrowing of the lumen of the vessel by the torn intima, a condition that later is almost sure to result in complete obliteration of the vessel by thrombus formation. The peripheral circulation may become seriously embarrassed by compression of the principal blood-vessels, caused by displaced fragments. In crushing injuries the skin may show but slight indications of the extent of injury to the bone and

the soft tissues interposed between it and the skin. The pressure and extent of injury to the principal nerves at the seat of fracture must be thoroughly investigated at the time the first examination is made. The sensation of the parts supplied by the different nerves below the seat of injury must be carefully tested for this special purpose. There is every reason to believe that this part of the examination is frequently overlooked, and it is therefore not strange that startling results will occasionally be seen when least expected, owing to the incompleteness of the first examination. Careful inspection and digital exploration under strict aseptic precautions are necessary to ascertain the presence and exact location of foreign bodies in the wound, to enable the surgeon to proceed intelligently when he undertakes the disinfection of the wound.

Fat embolism is a somewhat rare complication of fractures, but in any considerable number of cases of compound fractures reported it figures as a cause of death. It is most likely to occur in cases in which the medullary tissue is extensively crushed, but it has also been observed in isolated simple fractures. The urine should be examined daily for at least three weeks. The more fat there is in the urine, the less circulates in the blood. Rapid respiration, cyanosis, and subnormal temperature are the most reliable indications of the existence of this grave complication. Groubé reports a case of fatal fat embolism in which the first symptoms set in thirteen days after the accident. The patient was a railroad employee, the subject of multiple fractures and severe contusions which he sustained in a collision. The postmortem showed many of the pulmonary capillaries completely blocked with globules of fat. It is well known that compound fractures, as a rule, require a longer time for bony consolidation to take place than do subcutaneous fractures. The importance of furnishing bones deprived of periosteum with moisture to prevent dry necrosis, especially in the case of compound fractures, is shown by Lesser experimentally and clinically. He found, in a number of cases, the bone-ends divested of their periosteal covering weeks after the fracture occurred, presenting a white, absolutely dead appearance, with no attempt whatever at callus production or the formation of a line of demarcation. To prevent such an occurrence it is important to furnish the exposed bone with moisture—by a blood-clot or moist dressing. If this condition is developed, the superficial necrosed bone must be removed with the chisel and hammer, otherwise callus formation will be unduly delayed or perhaps entirely lacking.

The immediate infection of the wound, it may be stated broadly, may be brought about by any of the pyogenic microbes, if present in the wound in sufficient number and if of the required degree of virulence. In his experimental work on compound fractures Roncali demonstrated the presence of the bacillus œdematis maligni, the bacillus pseudo-œdematis maligni, the bacillus coli commune,

the staphylococcus pyogenes aureus, and the streptodiplococcus septicus. He describes the various phases of the infective process caused by the different pyogenic microbes. In the majority of cases a mixed infection will be found: in the gravest cases a combination of pyogenic microbes and putrefactive bacilli. Primary infection in a compound fracture usually presents itself, as in any other wound, within forty-eight hours after the receipt of the injury. The pathologic developments after infection has occurred depend largely on the nature of the microbic cause. Staphylococcus infection usually terminates in localized suppuration and limited necrosis of the ends of the fractured bone. Streptococcus infection, as either an isolated infection or in combination with staphylococcus infection, generally terminates in more diffuse phlegmonous inflammation, profuse suppuration, and more extensive traumatic osteomyelitis. Infection with any of the putrefactive bacilli in combination with the effects of pyogenic microbes results in diffuse inflammation, extensive edema, and the production of more or less emphysema and fetid pus.

The inflammatory swelling that follows so promptly in case a compound fracture becomes infected is one of the prolific causes in the production of conditions that retard the process of repair, and not infrequently necessitate intermediary or secondary amputation. The inflammatory swelling, and the tension caused by it, is often an important element in diminishing the arterial blood supply to the limb below the seat of fracture and in determining venous congestion, conditions that frequently result in gangrene. Fortunately, the traumatic osteomyelitis in such cases is usually limited to the ends of the fractured bones, but it always interferes with ideal repair, retarding callus formation, and in the majority of cases results in necrosis of greater or less extent. The secondary suppurative periosteitis that follows osteomyelitis of the same type interferes with bony consolidation at the usual time, as callus formation does not commence until the acute suppurative process has subsided. Eventually, profuse callus production usually takes place, part of which is concerned in the formation of an involucrum around the necrosed bone. If the periosteum has been extensively destroyed by the trauma, or subsequently by the suppurative periosteitis, the opening in the involucrum is generally large enough to admit of the spontaneous elimination of the necrosed bone after it has become separated from the living bone by a tedious process of granulation. If the reverse is the case, the removal of the sequestrum and the ultimate recovery of the patient depend on the timely intervention of the surgeon. A compound fracture that has become infected results in the production of pathologic changes at the seat of fracture that may eventuate at any time in relapsing attacks of osteomyelitis, in the same manner and for the same reasons as after an attack of spontaneous infective osteomyelitis. The retardation of union by bony callus in infected compound frac-

tures and the frequency of pseudarthrosis are readily explainable if we consider the important rôle that the medullary tissue is called upon to assume in the definitive repair of a fracture. Permanent enlargement of the bone is to be expected in all cases of compound fractures in which suppuration precedes the process of repair. Septic thrombophlebitis at the seat of a compound infected fracture is one of the most frequent fatal complications of such accidents, as it precedes and constitutes the direct cause of pyemia. Septic intoxication and infection, perhaps even more frequent causes of death in such cases, result from streptococcus or mixed infection.

Fig. 321.—Compound comminuted fracture of the femur. Necrosis of fractured ends and detached fragments. Death after six weeks (Bruns).

Fig. 322.—Consolidated comminuted compound fracture of the femur, with necrosed fragments embedded in the callus (Bruns).

Ferment intoxication is a frequent accompaniment of simple fractures, and usually appears in a more marked form in compound fractures. It is caused by the absorption of fibrin ferment from the extravasated blood, and is observed as an earlier complication of compound fractures than septic infection or pyemia.

Prognosis.—The danger to limb and life is determined more by the extent of injury to the soft tissues and by wound infection than by the number of fractures or the degree of comminution of the fractured bone. Extensive loss of skin, crushing of muscles, and tearing of any of the large vessels and nerves must be looked for, more especially in crushing injuries, and when present to any extent as isolated or combined injuries will often furnish ample

ground for primary amputation. In estimating the gravity of the injury a most thorough and searching examination into the condition of the soft parts is necessary, for the purpose not only of formulating a reliable prognosis, but likewise with a view to determining upon the proper treatment to be pursued. In cases of extensive crushing injuries important vessels and nerves are usually implicated to an extent incompatible with preservation of the limb.

The time intervening between the receipt of the injury and the rendering of efficient first aid has an important bearing on the prognosis, as has been shown so conclusively by the statistics of Bruns, previously quoted. The danger of infection increases with time, and is much greater after the lapse of from twenty-four to forty-eight hours after the accident, in wounds left unprotected for that length of time. The presence of dirt and of foreign substances of any kind in the wound adds to the gravity of the prognosis by increasing the danger from infection. Some surgeons take the ground, at the present time, that primary amputation should never be resorted to, as they claim that under antiseptic precautions the danger to life is not increased by delay, and that by waiting for the line of demarcation to become established, more tissue can be saved by substituting secondary for primary amputation in case a mutilating operation be made necessary by the occurrence of gangrene. This position is too extreme even at the present time. It is in just such cases that the most intelligent and rigorous antiseptic precautions will frequently fail in protecting the wound against infection, thus adding greatly to the danger to life from septicopyemia. It must also be remembered that in case the antiseptic treatment fails, the inflammatory conditions that follow infection may necessitate a higher amputation than would have been the case had primary amputation been done.

Conservatism in the treatment of compound fractures has become the rule, but there are many cases where the indications for amputation as a life-saving operation are so clear that it would be folly to ignore them and expose the patient's life to the additional risks of sepsis for the purpose of ascertaining exactly how much of the limb could be saved. The necessity for the performance of secondary amputation has very much diminished since the antiseptic treatment of compound fractures has been generally adopted, but it occasionally becomes necessary—when the septic wound complications do not yield to antiseptic treatment and life is placed in jeopardy from profuse suppuration or sepsis, and in cases in which, owing to undiscovered complications or the intensity of the inflammation, gangrene follows as an early or a late complication. From a prognostic standpoint, the general condition of the patient, his age, and his habits must be taken into careful consideration before positive conclusions are reached. A vigorous constitution and a satisfactory condition of the general health are favorable conditions when we come to estimate the gravity of the injury.

Children and young adults recover more rapidly from such injuries than persons advanced in years. Intemperance and excesses of all kinds add to the liability of infection and are apt to retard the process of repair.

Treatment.—The modern treatment of a compound fracture enjoins a heavy responsibility on the attending surgeon. Under ordinary circumstances and in recent cases he is expected to protect the wound against infection, and the patient from its serious immediate or late consequences. After eliminating the cases requiring primary amputation, two leading indications present themselves: (1) Healing of the wound; (2) repair of the fracture. Upon the results of the first examination must depend the propriety of a primary amputation. Heretofore surgeons have placed too much reliance on the extent of comminution of the fractured bone in deciding the important question, Is an amputation necessary? Experience has shown that the condition of the soft tissues is more important in determining the advisability of adopting a conservative plan of treatment. In badly complicated compound fractures it is unwise to expose the patient to the dangers of too much conservatism, because even in case the patient survives the injury and the limb is saved, it is often deformed and useless. In general, the condition of the vessels, nerves, muscles, skin, and neighboring joints should influence the surgeon in forming an opinion as to what course he should pursue.

Primary Amputation.—How the indications for primary amputation have been formulated in the past is made evident from the rules laid down by the great surgeon, Sir Astley Cooper: "If the lower extremity of the tibia be broken into small pieces, the loose portions of bone ought to be removed, and the end of the tibia be smoothed by a saw; but if, in addition to this comminution, the lower extremity of the tibia be obliquely broken and a large loose portion of bone be felt with the fingers, then it will be proper to amputate; also, if the astragalus be broken, the portions of this bone should be removed, otherwise they will separate by ulceration or occasion considerable local irritation. But if the ends of the tibia and tarsal bones, as the astragalus and os calcis, are broken, then amputation will be required." Antiseptic surgery has entirely recast these rules. Primary amputation in recent cases, in accordance with modern legitimate indications, must be restricted to cases in which the fracturing force or subsequent accidents have resulted in injuries that would be likely to lead to arrest of circulation and nutrition, and their inevitable result, gangrene. Extensive loss of skin and crushing of muscles are well established and generally admitted as legitimate indications for sacrificing the limb. The extent of vessel injury in such cases can seldom be estimated by the amount of hemorrhage, as lacerations and crushing injuries, even of large blood-vessels, seldom give rise to profuse hemorrhage. If examination should reveal a wound of an artery of the size of

the femoral or brachial, amputation is usually a justifiable procedure. If the accompanying vein is injured at the same time, the indication for immediate operation is more urgent. If the injury of vessels of this size can not be demonstrated by existing hemorrhage, inspection and digital exploration, under strict antiseptic precautions, become justifiable diagnostic procedures. The extent of vessel injury should be carefully ascertained by the condition of the peripheral circulation, as indicated by the character of the pulse, by the temperature, and by the color of the surface of the limb. If the intima of an artery of any considerable size has been torn by traction force, the peripheral pulse will be found smaller immediately after the injury, and, as has been pointed out by von Wahl years ago, a bruit can be detected on auscultation over the injured part of the vessel. It is in such instances that complete obstruction soon sets in from thrombus formation, thus interfering with a proper blood supply to the limb below the seat of fracture. The extent of nerve injury in the absence of visible or palpable injury must be estimated by ascertaining the degree of loss of innervation, both of motion and sensation, below the seat of fracture. Examination concerning vascular and nervous disturbances below the seat of injury has, as a rule, not been conducted with the degree of thoroughness necessary to estimate, with some degree of certainty, the fate of the injured limb.

In performing primary amputation the surgeon must be careful not to include in the flaps any of the tissues that have been seriously bruised or crushed. For the purpose of securing a desirable stump, and with a view to saving as much tissue as possible, it is often necessary to modify prescribed methods of amputation by taking the tissues from the side least injured. Typical amputations as described in our text-books often are not adapted to meet the local indications in such cases, and the surgeon must exercise his ingenuity and judgment to adapt the operation to the injured limb, and not the injured limb to the operation, in justice to himself and to his patient.

Treatment of Wound.—The most responsible and important part of the treatment of a compound fracture consists in properly caring for the wound. The wound treatment must necessarily vary in accordance with the manner in which the fracture was produced and the length of time that has elapsed since the injury was received. For the purpose of showing the recent advancements in this part of the treatment of compound fractures, only a few methods of wound treatment, practised generally and by the best surgeons less than half a century ago, will be described here. Sir Astley Cooper spoke very highly of healing of the wound under a scab. For this purpose he employed charpie, which was applied to the wound and which, with the blood with which it became saturated, was after a time converted into a dry crust that was permitted to remain, thus protecting the wound against late

infection from without. Trendelenburg, as late as 1873, recommended this method in strong terms, and maintained that it always succeeded in retarding suppuration for at least ten days. He believed, at that time, that the substitution of strong carbolic acid for the blood in making the crust did not materially influence for the better the healing of the wound. Cold and hot water has had an extensive use in the treatment of wounds of compound fractures. Chassaignac favored the use of his *pansement par occlusion*, sealing the wound with strips of diachylon plaster, relying on Scultet's dressing in securing fixation. A. Guérin made an advance in the right direction when he enveloped the limb in a thick layer of cotton, which he did not remove for two or three weeks, even in the event of profuse suppuration. This method of treatment was extensively practised in France during the war with Germany. Ollier improved upon this treatment by applying a fixation dressing over the cotton. Guyon sealed the wound with collodion and cotton. Continuous irrigation in suppurating compound fractures was first practised by Josse in 1834. Langenbeck favored permanent immersion in warm water. Gurlt advocated the local use of cold and a somewhat rigorous antiphlogistic treatment, including bleeding in some cases and local abstraction of blood by leeching; in cases in which the patient showed signs of depression, stimulants and the local use of poultices, warm-water compress, camphor wine, dilute creasote, turpentine, and vegetable charcoal. Larrey was partial to the use of camphor preparations in the treatment of the wound.

All these methods accomplished little in preventing wound infection except in the simplest cases. Profuse suppuration and septicopyemia continued to maintain the fearful mortality and to force the surgeon frequently to resort to secondary amputation, often in a vain effort to save life, until Lister and his early followers taught us the value of more effective prophylactic measures in guarding against wound infection. Many of the surgeons of the present day remember the first efforts, which consisted in the use of carbolized putty and carbolized oil. It required time and experience to reap the full benefits of the antiseptic treatment of wounds as applied to compound fractures. Reyher was one of the first to bring to the attention of the profession the value of the antiseptic treatment of compound fractures, combined with immobilization, in the management of gunshot wounds in military surgery. The early statistics on this subject by Reyher and von Bergmann were a revelation to every surgeon who had battled in vain for years in preventing infection in such cases. Moist antiseptic compresses have been used very extensively, and the results have been encouraging. Kocher saturated the compress with a $\frac{1}{5}$ of 1 per cent. solution of chlorid of zinc; von Bergmann used a $\frac{1}{3}$ of 1 per cent. solution of bichlorid of mercury, but most of the surgeons preferred a 2½ per cent. carbolic acid solution. Bardeleben used the

moist carbolized jute compress on a large scale and obtained good results. Thiersch recommended salicylated cotton or jute. Münnich employed, as a wound dressing, dry carbolized jute. Maas obtained the best results by subjecting the wound and adjacent parts to thorough cleansing, then irrigating the wound with either a 2½ per cent. solution of carbolic acid or a $\frac{1}{10}$ of 1 per cent. solution of bichlorid of mercury. The wound is then covered with silk protective, and dressed with corrosive sublimate, chlorid of sodium gauze.

Modern Treatment.—The antiseptic treatment of compound fractures can not be said to have reached perfection. Much has been done in simplifying and making more efficient the antiseptic measures employed in preventing wound infection since the first efforts were made in this direction, but we have reason to believe that the methods will undergo further modifications, and additional improvements be made that will materially reduce the present low mortality, and make a recourse to secondary amputation even less frequent than at the present time. Since the antiseptic treatment of compound fractures has been generally adopted, triumphant results have been reported from nearly all parts of the world. The statistics given elsewhere furnish the most convincing proof of the advancements that have been made in this department of surgery.

The modern antiseptic treatment must vary according to the nature of the wound and the manner in which it was inflicted. As a general rule, it may be stated that the first dressing decides the fate of the patient and determines the process of wound healing. The treatment of the wound is of far greater consequence than that of the fracture itself, more especially during the first two weeks. A combination of most thorough antiseptic treatment of the former, immediate and perfect reduction of the latter, followed by fixation of the fractured limb by some kind of plastic splint, yields the best results. Whenever there is any prospect of obtaining primary healing of the wound, the attempt should be most faithfully made. In punctured and gunshot fractures and when the wound is small and clean cut, the surrounding skin for a distance of several inches should be shaved and thoroughly disinfected by scrubbing with hot water and potash soap, then with alcohol, and lastly with a 5 per cent. carbolic acid or a 1 : 1000 bichlorid of mercury solution. If the bone projects from the wound, the part protruding should be included in the disinfection before reduction is made, as otherwise infection may be caused by the reduction. Such fractures must never be explored, and the wound should not be enlarged unless reduction is impossible without so doing or complications present themselves that demand it. Resection of the projecting fragment is seldom necessary, as reduction can usually be effected under the influence of an anesthetic. It is in cases of this kind and in gunshot fractures that, as a rule, the wound beneath the skin is aseptic. Suturing of such wounds should be avoided.

The wound properly disinfected, is dressed by applying an antiseptic occlusion dressing. For this purpose nothing is more efficient than a nonirritating effective antiseptic powder, composed of four parts of boric acid to one part of salicylic acid, and a compress of aseptic absorbent cotton. Cotton is preferable to gauze, as it serves as a more efficient filter, and with the powder and blood is soon converted into a dry crust that seals the wound hermetically and excludes it from the entrance of pathogenic microbes. About a teaspoonful of the borosalicylic powder is placed on the wound, and the cotton compress is applied and retained with a gauze roller, or, if there is any danger of it becoming displaced, it is fastened in place with a strip of adhesive plaster before the bandage is applied. The dressing should not be disturbed until the wound is healed, unless signs and symptoms indicate the existence of infection. Should infection follow this treatment, removal of the dressing, enlargement of the wound, counteropenings, efficient tubular drainage, energetic secondary disinfection, and substitution of the hot antiseptic compress for the dry dressing is the proper course to pursue. If wound infection does not occur, the compound fracture is practically converted at once into a subcutaneous fracture, and should be treated as such. P. Bruns recommends for similar cases a powder composed of—

Carbolic acid,	25 parts.
Colophonium,	60 "
Stearin,	13 "
Precipitated carbonate of lime,	700 "

I have, however, used the borosalicylic powder, in the proportion specified, on an extensive scale, both in civil and military practice, and have been so much gratified with the results that I can recommend it most emphatically as a local application in such cases, used in the manner described.

In lacerated and contused wounds the first and most important duty in rendering first aid is to subject the wound to an absolutely efficient and safe primary disinfection. This can be done only by first shaving and disinfecting the part of the limb that is the seat of the fracture, and, if the fracture is near a joint, as much of the adjacent part of the limb or trunk as will be covered by the large antiseptic dressing. A common error made in the management of such cases is that the surface disinfection is not extended far enough. If the wound disinfection can not be made with sufficient thoroughness without the use of an anesthetic, it is preferable to anesthetize the patient rather than neglect meeting, to the fullest extent, the most important indications in the treatment of the wound. *All such wounds must be regarded and treated as infected wounds.* The sources of infection are so numerous that few wounds, if any, escape. The vulnerating implement, the clothing, the torn skin, the exposure of the wound to dirt and air, are only some of the sources from which pathogenic microbes are introduced into the wound.

The surgeon who makes the first examination and applies the first dressing must disinfect his hands as carefully as if he intended to open the skull or the abdomen. In most instances the wound is larger underneath the skin than on the surface, and a thorough primary disinfection is out of question without enlarging the external wound sufficiently to expose every nook and corner for the direct application of the antiseptic solution. After free exposure of the wound surface the surgeon removes blood-clots, foreign bodies, and loose fragments not required in a satisfactory process of repair. If on hand, peroxid of hydrogen should now be poured into the wound; if not, antiseptic irrigation with a hot 2½ per cent. carbolic acid solution or a solution of bichlorid of mercury, 1 : 1000, should at once be commenced and continued until the wound is surgically clean. I have more faith in carbolic acid than in sublimate as a disinfecting agent in the treatment of accidental wounds, as it penetrates the tissues more deeply and leaves them in a more favorable condition for the healing of the wound by primary intention. In extensive lacerated wounds it is advisable to cut away the torn margins, converting the wound as nearly as possible into an incised wound, better adapted for successful suturing. The deeper portions of the wound can be treated in the same manner if they are covered with torn tissue that would be in the way of primary union, for the purpose of preparing the surfaces for buried sutures, which can often be employed to advantage in diminishing the size of the wound and the space requiring drainage. The *etagen*, or buried suture, of aseptic catgut is of special value in suturing vascular tissue over the detached fragments if the fracture is a comminuted one. The disinfection must extend to the seat of fracture. *All the loose fragments should be removed, disinfected in the carbolic acid solution, and immersed in a warm saline solution, ready for reimplantation after the wound has been disinfected.*

Counteropenings may become necessary for drainage if the wound is an irregular one, and dead spaces can not be avoided by buried sutures. Tubular drains well fenestrated must be employed for this purpose. The counteropenings are made by tunneling the soft tissues from the side of the wound with a pair of locked hemostatic forceps, which are pushed in the desired direction until the skin over the point of the instrument is raised in the form of a cone, which is then incised at its base on one side, and the instrument made to emerge from the wound; the drain is grasped and brought into the wound with the return of the forceps. The tube should not project further into the wound than the cavity it is intended to drain. In large wounds multiple counteropenings may become necessary. For this special purpose the drains should never be thinner than the little finger, and should not be disturbed until the time for infection to take place has elapsed—that is, for from forty-eight to seventy-two hours. *The wound itself must never be entirely closed by suturing, as drainage is always required in such cases, and*

must be maintained until all danger from infection has passed. The wound is drained, in preference, with a single strip of iodoform gauze, the projecting end of which is secured by a large, aseptic safety-pin. Two ways present themselves for dressing the wound —(1) with the dry dressing; (2) with the moist dressing. The surgeon must discriminate carefully in making the selection. The typical dry absorbent antiseptic gauze dressing is indicated in wounds that, from their size, from the time that has elapsed from the receipt of the injury to the first dressing, and from the thoroughness with which the primary disinfection was made, we have reason to expect will heal by primary intention. In applying such a dressing a few layers of iodoform gauze should be placed next to the wound, the bulk of the dressing being made of sterile gauze, and over and around it a thick cushion of absorbent cotton should be placed. The dressing should be a copious one, and should be retained in place by a gauze roller. So copious a dressing exerts an equable elastic pressure, so important an element in securing muscular rest and in holding in accurate and uninterrupted contact the wound surfaces. After the dressing has been applied and the fractured bone placed in proper position, a fixation splint of some kind should be applied over the wound dressing. In case no infection sets in the first dressing may remain in place for two or more weeks. Should the dressing become saturated with blood, the surface may be sprinkled with borosalicylic powder, and an additional layer of cotton be applied, to make an early change of dressing unnecessary. Nothing is more harmful in the treatment of a compound fracture than meddlesome surgery; the longer a dressing can remain with impunity, the greater is the probability of avoiding infection, and the better are the chances of obtaining primary healing of the wound.

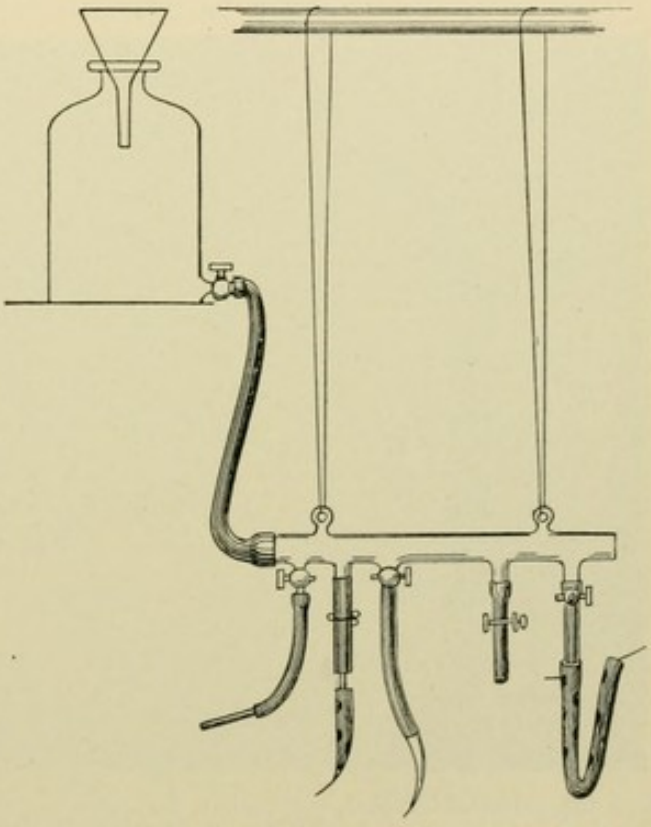

Fig. 323.—Starke's apparatus for permanent irrigation.

The surgeon can not be too watchful in the after-treatment of a compound fracture. He must, day after day, look for evidences of

infection. A rise in temperature during the first twenty-four hours usually means ferment intoxication; after that time it suggests septic infection. In fermentation fever the subjective symptoms are generally *nil;* in sepsis they correspond in intensity with the degree of intoxication. The condition of the tongue is of more diagnostic importance than the character and frequency of the pulse in discriminating between fermentation fever and sepsis. In septicemia the tongue is dry and usually brown; in fermentation fever it is moist and coated. If, from the local and general symptoms, it becomes apparent that the wound has become infected, no time must be lost in removing the dressing and in making additional provision for drainage. Secondary disinfection is generally incomplete and unsatisfactory. If the wound has been sutured, every

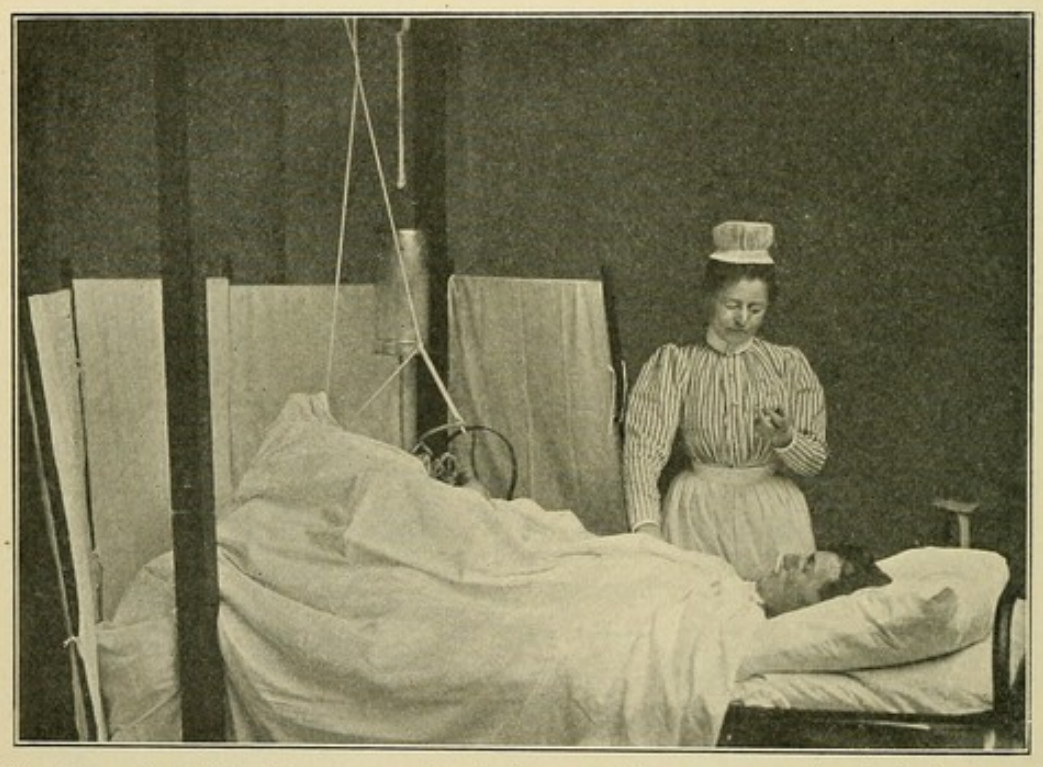

Fig. 324.—Immobilization, suspension, drainage, and permanent antiseptic irrigation of the knee-joint.

stitch must be removed and drainage established wherever it appears necessary. The moist antiseptic compress must invariably take the place of the dry dressing, and frequent antiseptic flushings become indispensable. It is advisable, under such circumstances, to replace the more energetic antiseptic solutions, such as carbolic acid and corrosive sublimate, by Thiersch's solution or a saturated solution of the acetate of aluminum, as the former, used in large quantities and at short intervals, might, and often do, result in intoxication that may prove disastrous and even fatal. The antiseptic irrigation should be preceded by the injection of peroxid of hydrogen. If suppuration does not yield promptly to this treatment, continuous irrigation with either of the mild antiseptic solu-

tions must be instituted at once, and has often, in my experience, been the means of averting death from sepsis and in preventing the necessity of a secondary amputation. Should this treatment not make a prompt impression by improving the local conditions and by ameliorating the general symptoms, the propriety of performing a secondary amputation must be considered, with a view to preventing death from septicopyemia. Continuous irrigation can be extemporized in a very simple and yet efficient manner. A piece of rubber tubing, six or eight feet in length, can be used as a siphon, or may be connected with an opening on one side near the bottom of the reservoir holding the antiseptic solution, and with one of the drains in the wound. A stop-cock or clothes-pin is used to regulate the size and force of the stream. The solution must be kept at a temperature of blood heat, or, still better, a little higher, and if more than one drain is employed, the point of irrigation is changed at certain intervals from one to the other. If many drains have been used, it is advisable to connect them with several siphon tubes so as to flush the different parts of the wound continuously. By suspending the limb, properly immobilized, and placing underneath it a rubber sheet, the fluid is drained into a vessel by the side of the bed. A compress saturated with the same solution is made to cover the wound and is to be changed several times a day. The general treatment in such cases must be stimulating and tonic, supported by a concentrated and nutritious diet. Should an adjacent joint become involved, free drainage and continuous irrigation constitute the proper local treatment. Progressive phlegmonous inflammation calls for free drainage and frequent or continuous irrigation. It is in cases of this kind that signal benefit has been derived from applying a compress saturated with a 1 : 1000 solution of either the lactate or the citrate of silver. If a secondary amputation becomes necessary, the operation must be performed through healthy tissue, at a safe distance from the infected territory.

Fig. 325.—Volkmann's dropping tube for continuous wound irrigation.

Direct Fixation of Fragments.—Attempts to immobilize the fragments by direct means of fixation would appear to be a rational course to pursue in the treatment of compound fractures. In cases in which it is apparent that the fragments can not be retained in a desirable position by the usual methods of immobilization, there is strong temptation to utilize the existing wound for the purpose of gaining access to the seat of fracture and resort to direct means of fixation. This method of treating compound fractures has many ardent supporters, but, for obvious reasons, it has failed to receive general recognition. The additional trauma sustained in uniting

the fractured bone-ends by direct measures must be taken into account before resorting to wiring or other methods of direct fixation. Such a procedure may also become an additional source of infection. Direct fixation in compound fractures, under ordinary circumstances, is absolutely contraindicated, and even at the present time should be restricted to cases in which an external fixation dressing proves inadequate to hold the fragments in a satisfactory position, and would, consequently, if relied upon, result in vicious union. The indications for operative interference in such cases would, in other words, be the same as in subcutaneous fracture of a similar nature and in the same locality. If the wound is large and the seat of fracture readily accessible, direct fixation is indicated only in cases in which the usual treatment of a similar subcutaneous fracture, by established methods, would yield an unsatisfactory functional result. The most frequent indications for some sort of direct fixation are presented by cases of extensive comminution, complicated by a large wound. It is in such instances that all the loose fragments of bone should be temporarily removed, disinfected in a warm 2½ per cent. solution of carbolic acid or a 1 : 1000 bichlorid solution, and subsequently immersed in a warm normal salt solution, in readiness for reimplantation after the wound has been thoroughly disinfected. *The temporary removal of the loose fragments enables the surgeon to complete the primary disinfection of fragments and wound with a greater degree of thoroughness, and the fragments are often removed from localities where their presence would be harmful and where they can not take part in the subsequent process of repair.* It is somewhat strange that all the modern text-books on surgery continue to insist that all loose fragments should be removed, in the face of the fact that the majority of compound fractures, under antiseptic treatment, are repaired in the same manner as subcutaneous fractures. The time has certainly come to make the attempt to preserve as many of these fragments as are necessary for a satisfactory restoration of the continuity of the fractured bone. That this can be done successfully has been demonstrated by experimentation and clinical observation. Jakimowitsch made twelve experiments on animals to determine the fate of completely detached fragments of the long bones, and in ten of them the attempt proved successful in showing that such fragments retained their vitality and again became a part of the bone during the process of repair. Sharp and conic pieces were removed subperiosteally with the chisel or saw, and were either reimplanted in their former position, or were turned over before reimplantation, so that the cortical surface was directed toward the medullary canal. After placing them in position, the periosteum was sutured over the fragment, and the wound having been sutured and dressed, the limb was immobilized. The union of the fragment with the shaft was demonstrated by stained vessel injections, prolonged feeding with madder, and microscopic examination. The

results of von Bergmann's experiments in the same direction convinced him that the loose bone fragments from animals of the same species can be successfully transplanted, but if obtained from another species, the experiment failed.

The value of autotransplantation of bone is conceded by most authorities of the present time as established, in operations upon different kinds of animals as well as upon man. That the operation proves successful in persons advanced in years as well as in children was shown most conclusively in one of my cases. The patient was a man over fifty years of age who sustained a fracture of both bones of the leg. The fibula united in the usual length of time; the fracture of the tibia, at the junction of the middle with the upper third, failed to unite. Four operations were performed for the pseudarthrosis, with no result. Much bone had been lost by these futile attempts to secure bony union, and the fragments were found separated nearly an inch, with absolutely no indications of callus formation. The fractured surfaces were vivified with chisel and hammer, and all the fragments carefully preserved in a warm normal solution of salt. Large chips of bone were taken from the anterior surface of both fragments, sufficient in number to fill in the gap between the vivified surfaces of the ends of the fragments. Periosteum and connective tissue were sewed separately over the loose pieces of bone, the wound was closed throughout and sealed, and the limb was immobilized in a plaster-of-Paris dressing. Firm bony union took place at the end of two months. The function of the limb was restored perfectly, and the patient has experienced no inconvenience of any kind since the operation, five years ago. If such a result is possible in the treatment of pseudarthrosis, there can be no impropriety in reimplanting loose fragments, in the treatment of recent compound fractures, under strict antiseptic precautions. Every surgeon is familiar with the well-established fact that large fragments of

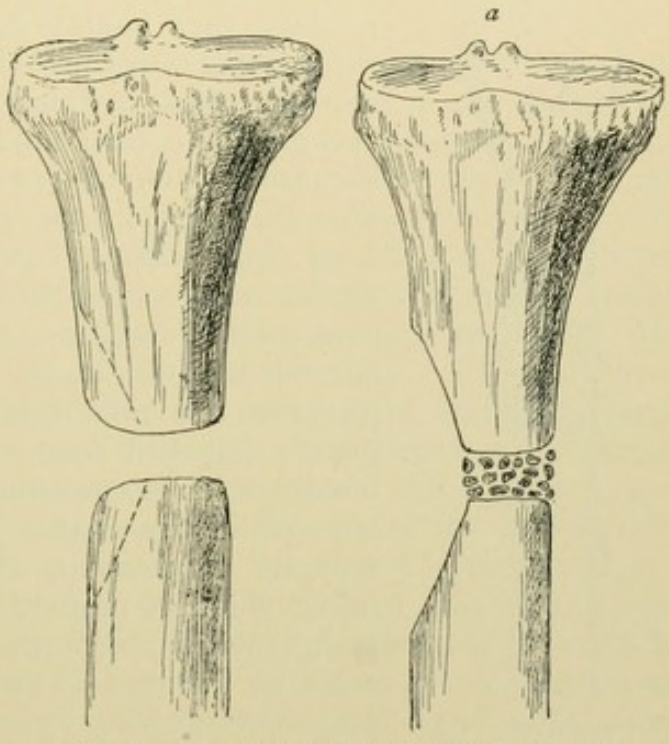

Fig. 326.—Pseudarthrosis of the tibia, with extensive loss of bone substance, following repeated operation. *a*, Successful restoration of the continuity of the bone by filling in the gap with bone chips from the fractured ends.

bone can be successfully reimplanted after operations upon the skull. The conditions for callus formation and bony union are much more unfavorable here than is the case with the long bones. For years it has been my practice, in opening the skull for the purpose of relieving the remote consequences of old fractures, to fragment the piece of bone removed with chisel and hammer into chips of the size of the thumb-nail, and smaller, and plant them upon the dura in the form of a pavement, and not in a single instance has anything been seen of these loose fragments when the wound healed by primary intention, which, with one exception, was always the case (see Figs. 303–307). The continuity of the skull was invariably restored in three or four weeks, which ought to convince the most skeptical that the fragments retained their vitality and took an active part in the process of repair. No surgeon would, for a moment, think of removing the loose fragments in a case of comminuted subcutaneous fracture, because he knows, from reading and observation, that these fragments do no harm, and that bony consolidation is the rule, regardless of the extent of comminution. In recent compound comminuted fractures I recommend making a faithful attempt, under antiseptic protection, to preserve and reimplant as many of the completely detached fragments as are necessary to restore, as far as possible, the normal length and strength of the bone. The temporary removal, separate disinfection, and immersion in warm saline solution prepare the pieces properly for reimplantation. Fragments that are reimplanted must be fastened in proper position by heavy catgut sutures or ligatures. If the space between the ends of the broken bone is large and the comminution extensive, the attached fragments must be handled with the utmost care during the disinfection and reimplantation of the loose fragments and their subsequent fixation. The reimplantation must be done in such a manner that the fragments will occupy, as nearly as possible, their former location. Drilling of the fragments must be avoided, as it will complicate the procedure and add little to the security of fixation by the ligature and suture. Different fragments can be tied together, as well as to the ends of the broken bone. If a firm support is needed, the ligature can be made to surround the parts it is intended to unite three or four times, when it is drawn tight and firmly tied. Some of the smaller fragments can be held in place by a suture including the adjacent soft parts. The periosteum must be carefully preserved and utilized in covering the fragments. *Every fragment must be*

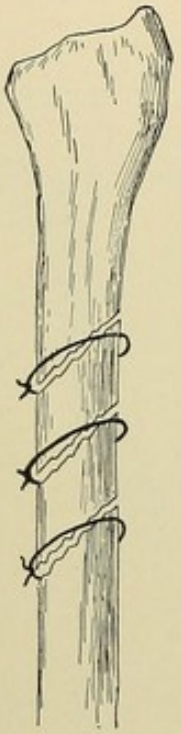

Fig. 327.—Compound comminuted fracture of the fibula; fragments fastened together with catgut ligatures.

supplied with vascular tissue on all sides, and where the periosteum is defective, the connective tissue and muscle must be used to bury the fragments by suturing with catgut. I am satisfied that if this part of the treatment of recent compound fractures is more generally adopted, excessive shortening, delayed union, and pseudarthrosis will figure less conspicuously in future statistics than they have done in the past. Should infection set in, all these fragments are removed during the secondary disinfection. If the wound remains aseptic, these fragments will accomplish much in securing a speedy and satisfactory recovery, and in yielding a desirable functional result. If much bone tissue has been lost, by either the injury or the subsequent suppurative inflammation, implantation of antiseptic decalcified or aseptic decalcified bone will render material assistance in the process of repair.

Silver wire has been extensively employed in the operative treatment of pseudarthrosis, and has had a fair trial in the direct fixation of the fragments in recent compound fractures. Lapeyade and Sicre, of Toulouse, are supposed to have been the first to use silver wire for this purpose, in 1775. The procedure appears to have been forgotten, until it was revived by Flaubert, of Rouen, who was probably the first one to use the bone suture as a means of direct fixation in the treatment of compound fractures. He used silk sutures in a case of compound fracture of the humerus. After the removal of a large detached fragment of bone the sharp-pointed ends of the bone were drilled obliquely, when a cord made of four waxed silk ligatures, twisted, was passed through the openings with a needle and firmly tied. The end of the lower fragment necrosed, and the suture made its escape from the upper fragment in from three to four weeks, but union had commenced and was subsequently completed. Kearney Rodgers, of New York, employed the bone suture first in the treatment of pseudarthrosis in 1826. It certainly seems that the time is at hand when compound fractures presenting the indications for direct fixation should be treated upon the same principles as wounds of the soft parts—viz., to bring into apposition and hold in contact by direct temporary mechanical measures the different anatomic constituents of the wound until the process of repair is completed. As soon as this method of treatment is perfected and more generally adopted, we shall hear less frequently of the many unsatisfactory remote results of these injuries, such as delayed union and pseudarthrosis, paralysis, impairment of health from long confinement in bed, excessive shortening, angular deformity, displacement by rotation, exuberant callus, and permanent injury to adjacent joints from long-continued extension. In very oblique fractures, compound as well as simple, interposition of soft tissue takes place more commonly than is generally supposed, and this condition not infrequently is the sole cause of nonunion. It is a well-known fact that long-continued extension is frequently followed by temporary, and occasionally by

permanent, injury to the adjacent joints. Overriding of fragments is frequently productive of harmful pressure upon important vessels and nerves. Displacement of fragments and imperfect immobilization are the most potent influences in the production of exuberant callus, which so often impairs the functional result and not infrequently causes remote painful affections. Displacement of detached fragments in comminuted compound fractures is often not recognized, and much less frequently corrected without direct intervention. Long-continued confinement in bed, incident to treatment of compound fractures of the lower extremities, is detrimental to the general health of the patient, and is often the indirect cause of many fatal intercurrent affections.

The evils attending the treatment, heretofore in vogue, of compound fractures can be avoided, in a measure, by resorting, more frequently than has been done, to direct fixation. *Direct treatment of the fracture, in well-selected cases, does not add to, but rather diminishes, the danger of traumatic infection, provided the operation is done with the necessary care and under the most pedantic antiseptic*

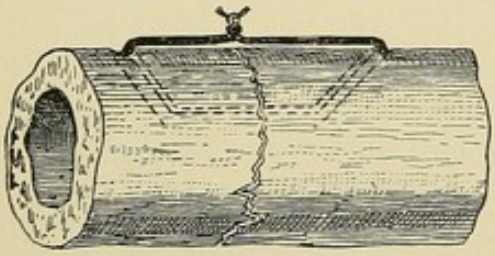

Fig. 328.—Old method of bone suture.

Fig. 329. — Improved bone suture. Transverse fracture, wire suture including entire thickness of both fragments.

precautions. It not only enables the surgeon to bring the fragments into accurate apposition and secure permanent retention, but it also makes it possible for him to disinfect every part of the wound and to arrest the hemorrhage, important elements in the prevention of traumatic infection. Moreover, it at the same time materially simplifies the immobilization of the fractured bone by an external mechanical support. Such treatment, thoroughly and conscientiously instituted, imparts a sense of security regarding the usual immediate and remote complications that is foreign to the ordinary routine treatment.

The oldest method of accomplishing direct fixation is by suture or ligature. Different kinds of metallic wire, silk, silkworm-gut, and, more recently, absorbable sutures have been employed. Silver wire is the material most frequently used, owing to its nonirritating nature and the ease with which it becomes encapsulated in the tissues. Before antiseptic surgery was practised the ends of the wire were brought out of the wound, with the intention of removing the suture as soon as the object for which it was employed was realized. Since it has been ascertained, by experiments and clinical

observation, that small aseptic bodies can be safely left in aseptic wounds, the wire was cut short to the twist, with the expectation that the suture would become encysted and remain indefinitely in the tissues without causing any disturbance. In the treatment of compound fractures by direct means of fixation the silver-wire suture is most applicable and efficient when the fracture is comminuted and there is little tendency to longitudinal displacement. In oblique fractures with a tendency to excessive shortening, the tension on the suture is great, and undoubtedly has often seriously impaired the nutrition of the part of the fragments included in the suture. For good reasons the bone suture has often been charged with causing necrosis. The old method of suturing fragments is very defective, as the suture was made to include only one side of the broken bone.

The technic of bone suture has recently been materially improved. Wille, of Denmark, uses a drill with an eye near the point

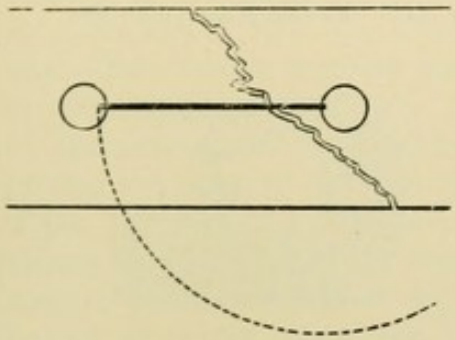

Fig. 330.—Oblique fracture sutured, showing curve in which fragment will become displaced.

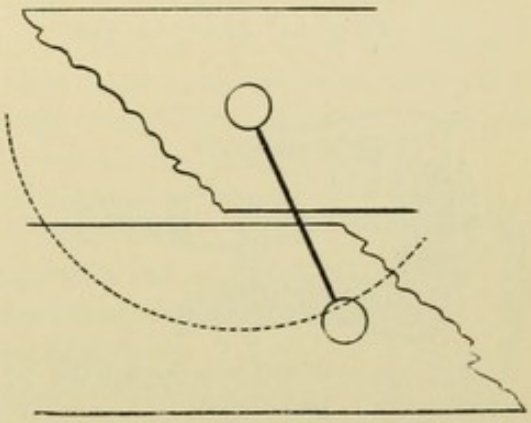

Fig. 331.—Extent of lateral and longitudinal displacement that may occur.

for the wire, which is carried with the instrument through the perforations, thus greatly facilitating the insertion of the suture, which formerly often constituted a tedious task. He has modified the old method in so far that the wire is made to include the entire thickness of the bone on both sides in wiring transverse and slightly oblique fractures. The wire is always cut short to the twist, and the twisted portion is bent down and buried through a small tear or incision in the periosteum, so that the suture is subperiosteal. The same author has also shown that, in suturing oblique fractures by this method, the suture does not prevent lateral and longitudinal displacement, as can be seen from the two accompanying illustrations (Figs. 330 and 331). The further the drill openings are apart, the greater will be the tendency to displacement. In very oblique fractures Wille advises the cutting of two grooves, with a file or saw, in the fragments, the direction of the grooves being at a right angle to the fractured surfaces, and tying the fragments firmly together

with the silver wire. If the seat of fracture is sufficiently accessible so that the drill can be applied vertically to the fractured surfaces, he drills through both fragments, and, with a hook of his own device, pulls a loop of silver wire through the perforation, cuts the wire in the center, and twists each half separately. It appears to me that in operating by this method it would be much better not to cut the wire, but to pass both ends through the loop and twist them in the same manner as in tying the Staffordshire knot.

Dollinger describes a new method of bone suture, or rather bone ligation, which he has employed in several cases where per-

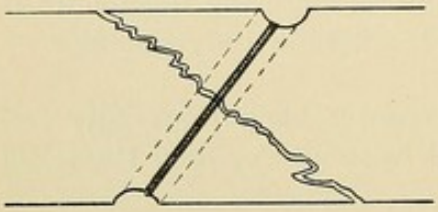

Fig. 332.—Peripheral groove for wire.

Fig. 333.—Lateral groove for wire.

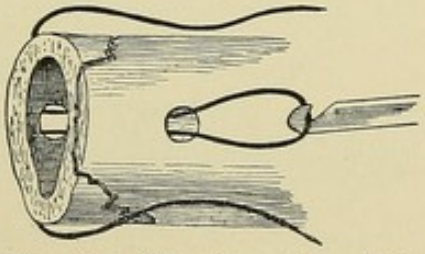

Fig. 334.—Wire drawn through the perforation.

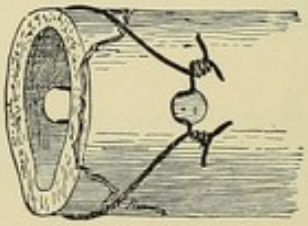

Fig. 335.—Wire cut in the center and each half twisted separately.

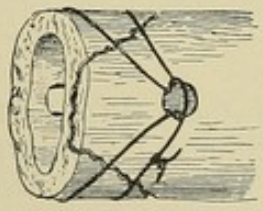

Fig. 336.—Senn's modification of twisting the wire (Staffordshire knot).

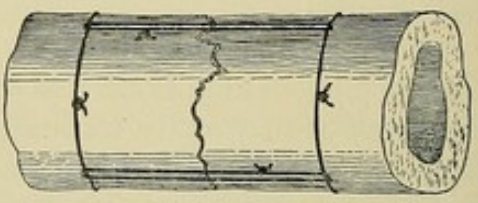

Fig. 337.—Dollinger's bone ligation as a substitute for bone suture.

foration of the bone could not easily be carried out. In one case —pseudarthrosis of the leg in a man forty-three years old—the tibia was sutured in the usual manner. The fibula was fractured in two places, the middle piece, about four inches in length, lying loose. The fragments could not be perforated without causing further separation of the periosteum. A ring of silver wire was placed around the lower part of the upper fragment, a little above the seat of fracture, and a similar ring around the upper part of the middle fragment. A piece of wire was then placed on each side of the fragments, parallel to the long axis of the bone and within

the two rings encircling the bone. The rings were then tightened up and fixed, and the longitudinal wires doubled over and their ends united on each side. The second fracture was dealt with in a similar manner. In eight weeks union by bony callus had taken place. In another case the tibia was sutured in like fashion after a piece had been resected, together with a tumor that had developed in the part. The resected ends were hard and ivory-like, and could not readily be sutured in the ordinary way.

While this method of suturing may guard effectively against diastasis of the fragments, it certainly could not prevent lateral displacement and shortening in oblique fractures, and consequently the indications for its employment are very limited. Bone is very tolerant to the presence of silver wire, and if the wound remains aseptic, permanent encapsulation of the suture is the rule. The modifications of suturing the fragments, as described, are a great improvement upon the old method, but do not set aside all the objections to the silver-wire suture in securing direct fixation. The drilling of the fragments, the passing of the wire through the perforation made with the drill, the twisting of the wire, are details that often require a great deal of time and are frequently attended by many difficulties. At the same time the necessary degree of immobilization is not attained without exposing the bone to harmful linear compression if the fracture is very oblique. While such means of direct fixation may frequently answer a useful purpose in the treatment of ununited fractures, they are not applicable in maintaining retention in very oblique recent fractures, owing to the strong muscular contractions invariably encountered in such cases.

Fig. 338.—Bruns' double metallic nail for fixation of fragments.

Metallic Spikes, Screws, Nails, and Clamps.—Among the older methods of direct immobilization of compound and ununited fractures must be mentioned the sharp metallic spikes recommended by Malgaigne, and used quite extensively in the treatment of oblique fractures of the tibia. By screw action the spike makes direct pressure against the displaced fragment. Dieffenbach transfixed the fragments with an iron nail, and applied over it, including one side of the fragments, a figure-of-eight suture. MacCormac used two strong steel needles for the transfixion of the fragments, in combination with the figure-of-eight suture. The employment of aseptic bone or ivory nails for the same purpose presents the great advantage over the metallic nails that the material used is absorbable and does not require removal, thus diminishing the danger from postoperative infection, and placing the wound in a condition for primary healing throughout.

Langenbeck's, Parkhill's, and Marks' bone clamps are ingenious devices, and may be used in well-selected cases to advantage, but

the same objections hold good against their general use that have been made against the metallic nails and spikes.

Langenbeck used two steel screws, which were driven into the fragments and were then connected by an iron bar, which effected immobilization of the fragments.

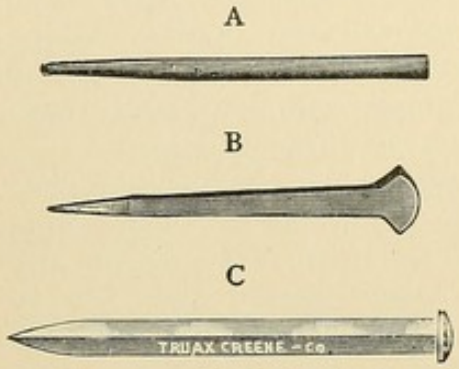

Fig. 339.—Nails for fixation of fragments: A, Ivory nail; B, horse-shoe nail; C, Gerster's metallic nail.

Ivory Cylinders and Clamps.—Volkmann and Heine inserted into the medullary cavity of the fragments ivory cylinders across the line of fracture, with a view of preventing lateral and longitudinal displacement. This method of treatment has been more fully described by Bircher, to whom it has generally been accredited. Bircher used a solid ivory cylinder. Its method of insertion and relative position to the fragments are shown in figure 340.

To prevent slipping of the ivory cylinder upward or downward, he makes a shoulder or projection at the center on one side of the

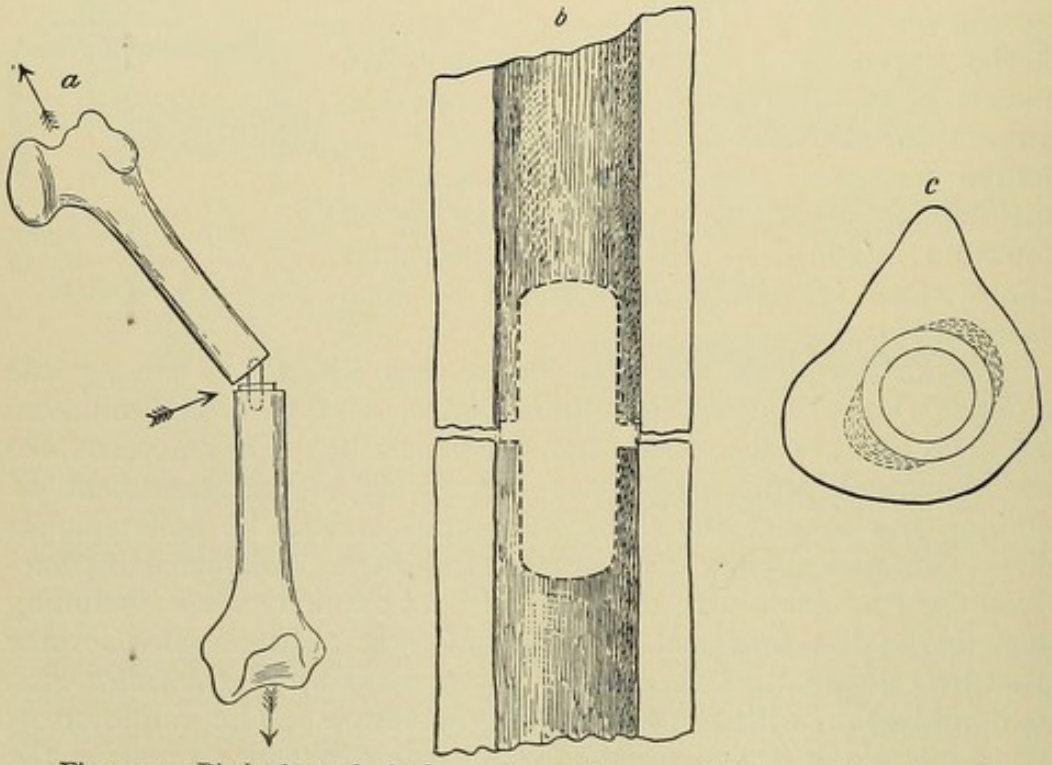

Fig. 340.—Bircher's method of retention with ivory cylinder: *a*, Direction of pressure, traction upon leg; *b*, fragments and cylinder in position (longitudinal section; natural size); *c*, transverse section, showing ivory cylinder in the interior of the medullary canal.

cylinder, which rests in a depression made with a chisel in one side of the medullary canal, as is shown in figure 341, or in a bone defect at the seat of fracture, as in figure 342.

The ivory clamp that he uses in uniting fractures of parts of bones devoid of a medullary cavity resembles the capital letter H, one bar of which rests in the channels cut on each side in the bone, while the other bar rests on the surface of the fragments (Fig. 343).

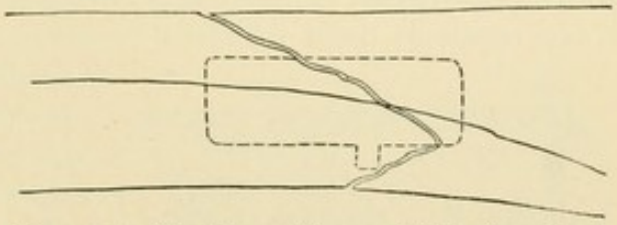

Fig. 341.—Shoulder of ivory cylinder fixed in depression of wall made with chisel.

Bircher treated five cases by these methods of fixation, four compound fractures and one subcutaneous fracture (femur) complicated by a large hematoma. In all the cases more or less suppuration followed, and the foreign body was removed as soon as firm consolidation had taken place. In every instance bony union in good position with very little shortening was secured, and the functional results were excellent. In the compound fractures infection had taken place before the treatment was commenced.

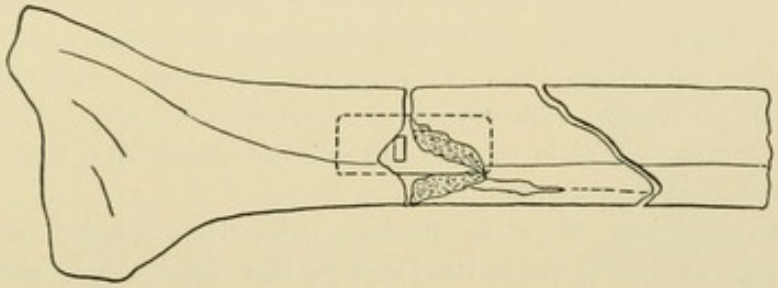

Fig. 342.—Projection resting in defect at seat of fracture.

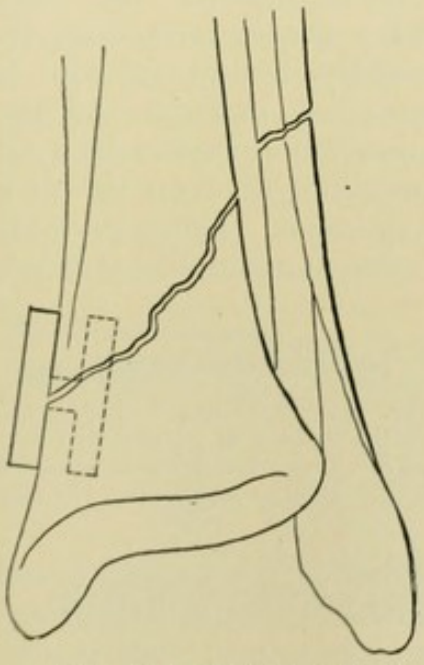

Fig. 343.—Retention of oblique fracture of lower end of tibia by ivory clamp.

Socin has given this method of treatment an extensive trial, and is pleased with the results. He has used it in pseudarthrosis caused by defective reposition or interposition of soft parts, and in many cases of compound fracture. He does not resort to the operative removal of the cylinder. The method has proved so satisfactory in his hands that he intended to extend it to the treatment of subcutaneous fractures with a strong tendency to displacement of the fragments, as in very oblique fractures of the lower third of the tibia. The method is, of course, inapplicable to fractures with comminution. The size of Bircher's cylinder is a serious objection, as the introduction of so large and solid a mass of ivory

overtaxes the absorptive capacity of the tissues, and removal by operative treatment becomes necessary, or spontaneous expulsion is almost sure to take place sooner or later. There is a limit to the absorption of aseptic absorbable substances. While aseptic ivory or bone nails driven into bone for the purpose of exciting callus formation or to serve as a temporary means of fixation will be removed by absorption in the course of time, if their immediate vicinity remains aseptic, a similar disposal of a solid ivory cylinder the thickness of the little finger could hardly be expected. Gluck's experiments with ivory joints have taught us an important lesson, and that is not to impose too much upon the intrinsic absorptive power of the tissues. Of one thing we are now certain, that the diminution in size and the ultimate removal of such bodies are not brought about by the corroding action of pus, as has been claimed by many, but by the action of living tissues.



Fig. 344.—Senn's hollow perforated intra-osseous splint.

The mechanical effect is the same, whether a solid or a hollow cylinder of ivory or bone is used. For this reason I recommended, a number of years ago, the employment of absorbable hollow, perforated cylinders of bone as intra-osseous splints. The use of such cylinders does not interfere with the early formation of the intermediate callus from the medullary tissue, a tissue so important in effecting the final bony union between the fragments. Instead of crushing the medullary tissue, as is done by the use of the solid cylinder, the lumen of the hollow cylinder is filled at once with this valuable bone-producing material and the product of tissue proliferation, and the new blood-vessels later fill the perforations, establishing a communication between the process of repair within and outside of the cylinder. The surface for absorption of the foreign substance is also immensely extended, and thereby the probability of its spontaneous removal greatly increased. Such cylinders should be made of the shaft of the long bones of young animals, such as chickens, turkeys, or rabbits. The medullary cavity can be increased in size and the compacta reduced in thickness by the use of a round file, and the lateral perforations may be made with a drill. Fenestration of the tube is an important part of its proper construction, as new bone tissue and blood-vessels can then reach, at an early stage during the process of repair, the interior of the tube from the adjacent bone-walls. The length of this intra-osseous splint will vary, according to the size of the bone and the obliquity of the frac-

Fig. 345.—Appearance of ivory nail used in the fixation of an ununited fracture of the femur seven weeks after the operation. Profuse suppuration (Bruns).

ture, from one to three inches. Displacement of the splint upward or downward need not be feared if additional immobilization is secured by an appropriate external support. Experimental research and clinical experience have demonstrated that pieces of aseptic ivory or bone of moderate size are removed slowly by absorption in aseptic tissues, a task accomplished largely by the agency of giant cells. Riedinger made experiments on animals in reference to the fate of ivory nails, fragments of bone, and other material implanted into living bone. Wood, rubber, etc., in every instance produced suppuration and were invariably eliminated. Ivory and fragments of bone, even if taken from another species of animal, produced no such result, and were gradually reduced in size and eventually disappeared by absorption. He made the observation that the speed with which the material disappeared by absorption depended largely on the degree of vascularity of the bone. In one experiment a fragment of bone that was driven into a perforation of the shaft of a long bone did not undergo absorption, except that part which projected into the medullary cavity. He ascertained, also, by his experiments that ivory or bone pegs driven into the shaft of a long bone brought about elongation of the bone. Two ivory nails inserted into the left tibia of a dog increased the length of the bone four millimeters. Similar observations were made by Aufrecht and the author in their experimental work on the same subject. Experiments and observations made so far prove conclusively that bone or ivory nails and hollow cylinders used in the direct fixation of a fracture can safely be left in the tissues with the expectation that the material will become temporarily encysted and remain harmless, and that in the course of time it will be re-

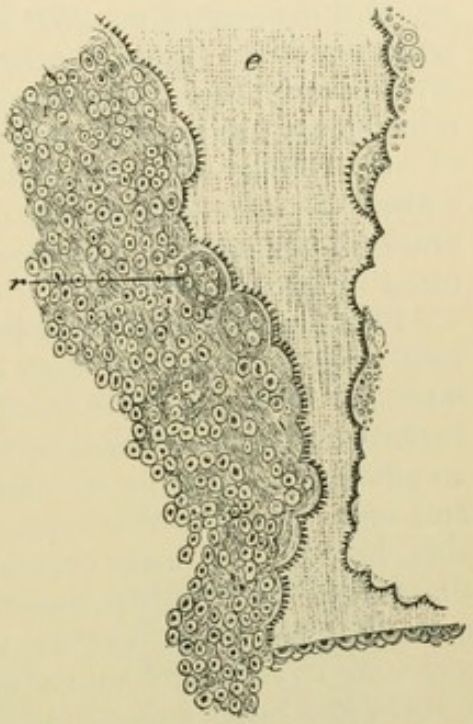

Fig. 346.—Section through partially absorbed ivory nail. The margins of the ivory (*e*) consist of lacunæ, the margins of which appear serrated. On the left margin giant cells (*r*) can be seen in some of the lacunæ (after Bidder).

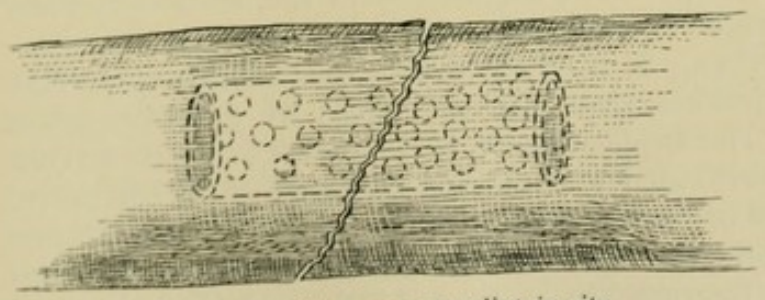

Fig. 347.—Intra-osseous splint *in situ*.

moved by absorption. They teach also that these substances are more rapidly removed by absorption when inserted into the medullary cavity, or when placed around, instead of into, the bone. My own experience has shown, to my own satisfaction, that bone is absorbed more readily and in a shorter time than ivory, and on this account the former material should have the preference in the direct treatment of fractures. Ample experience has demonstrated that a hollow cylinder of bone inserted into the medullary cavity is removed completely by absorption in the course of two or three months. The same disposition is made of a thin ring of bone, embracing and holding in mutual uninterrupted contact two or more fragments, in the treatment of compound and ununited fractures by direct fixation.

Fixation of Fragments with Bone Ferrule.—The most efficient way to prevent lateral and longitudinal displacement in oblique fractures of the shaft of the long bones is to bring the fractured surfaces in accurate contact, and to hold them in this position by an efficient absorbable circular support. The use of the silver wire and other unabsorbable suture material for this purpose is objectionable, because the linear pressure caused by the support must affect the fragments in a detrimental manner, and the circular splint, even if it become encysted, remains as a foreign body, liable at any time to become a source of irritation and remote complications. Catgut and other absorbable ligatures in many cases are not sufficiently durable to hold the parts in contact for a sufficient length of time. It has occurred to me that such fractures could be retained almost to perfection after reduction by engaging the ends of the fragments in a ferrule or ring of ivory or bone. The rough, and often denticulated, fractured surfaces, held in contact by the temporary circular splint, will bring about interlocking of the fragments, the best safeguard against undue shortening. If the fractured surfaces are smooth and interlocking of the fragments can not thus be secured, shortening and lateral displacement are effectually prevented by the ring. The broken ends grasped by the ring act in the manner of two inclined planes gliding in opposite directions, which will permit sliding of one fragment over the other only until each fragment impinges against the respective side of the ring, after which further overriding is a mechanical impossibility. Angular deformity and rotation can readily be prevented by an appropriate external support. The application of such a bone or ivory ferrule requires less time, is attended by slighter disturbance of the soft parts, and is a much easier procedure than suturing of the bone. In my experience the results that have so far attended this method of treating compound fractures have been exceedingly satisfactory, and have induced me to again present this method of direct fixation to the attention of the profession for a thorough trial.

The ferrules are made of different sizes, from fresh bone obtained from the slaughter-house or butcher-shop. For the

humerus and femur of the adult the femur of an ox should be selected; for children the same bone of a smaller animal will answer the purpose. For the tibia the corresponding bone of the animal is chosen. With a sharp saw the shaft of the bone is cut transversely, the length of the sections corresponding with the desired width of the ferrule, which will vary from one-fourth of an inch to an inch. With a round file the medullary canal is enlarged until the thickness of the bone does not exceed one-sixth of an inch; in some instances a much thinner ring will furnish the necessary lateral support. If the ferrule is longer than an inch, it should be perforated at a number of points, in order to furnish avenues through which the products of tissue proliferation and the new blood-vessels can reach the tissues in both directions, and also with the intention of facilitating the absorption of bone after the fracture has become consolidated. Ferrules made of the tibia should retain the shape of the bone, in order to adapt their lumen to the treatment of fractures of the tibia. Sterilization is effected

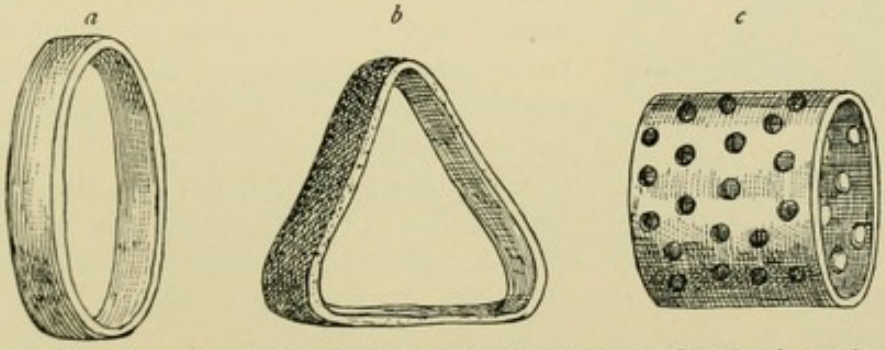

Fig. 348.—Bone ferrules for immobilizing fractures: *a*, Circular bone ferrule for humerus or femur, made of an ox femur; *b*, triangular bone ferrule for tibia, made of ox tibia; *c*, wide perforated circular bone ferrule.

by boiling, for an hour or more, in soda solution, after which the rings are kept immersed in sublimate alcohol, 1 : 1000, ready for use. Partial decalcification of the bone ferrule is an advantage. Should further clinical experience show that the bone is not sufficiently absorbable, such ferrules could be made of chromicized catgut or partially decalcified bone.

In the treatment of compound fractures the observance of the strictest antiseptic precautions, and in the operative treatment of pseudarthrosis by this method, rigid aseptic measures, must precede and accompany the direct treatment of fractures. The seat of fracture must be exposed in such a way that both fragments are readily accessible. The ferrule must be large enough so that it can be slipped over the fragments without danger of breaking it. In the majority of cases the use of a general anesthetic is indispensable for the purpose of securing complete muscular relaxation and the necessary immobility of the limb, not only until reduction is effected and the ferrule is in place, but until the whole dressing is applied and complete immobility at the seat of fracture has been

secured by a proper external mechanical support. After the seat of fracture has been freely exposed, the most accessible fragment is isolated from the surrounding tissues with as little disturbance of the periosteum as possible, when the ferrule is slipped over the fragment and pushed away from the line of fracture far enough to clear the other fragment. After reduction has been accomplished, the second fragment is engaged in the ring, which is then pushed back sufficiently to grasp both fragments securely. A reliable assistant should hold the limb securely in position, as bending at the seat of fracture might break the ring. Hemorrhage is to be carefully arrested, and if the wound is aseptic, the different tissues are separately united by buried sutures. In case of infected fractures and in fractures accompanied by troublesome oozing, free drainage must be established. Bending at the seat of fracture is prevented, and absolute immobilization secured, by a circular plaster-of-Paris dressing or plastic splints. Harmful pressure is avoided by interposing between the surfaces of the limb and splint a layer of antiseptic hygroscopic cotton, at least an inch in thickness, and localized decubitus is prevented by protecting all bony subcutaneous prominences with special care. With a view of securing perfect immobility of the fragments as early as possible, small splints of wood or metal are incorporated in the plaster-of-Paris splint in such a way as to form an unyielding bridge across the line of fracture, an important matter during the time required for the setting of the plaster. The limb, especially if it is the lower extremity, should be kept suspended in an elevated position for a number of days, in order to prevent, as far as possible, the occurrence of edema at and below the seat of fracture. If the wound has not been drained and no indications for a change of dressing present themselves, the first dressing should not be disturbed until union between the fragments is sufficiently firm to prevent displacement during the second dressing. In wounds that require drainage the dressing

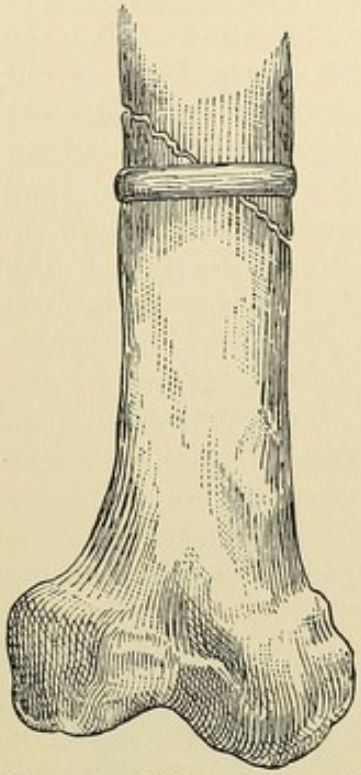

Fig. 349.—Oblique fracture of femur united by bone ferrule.

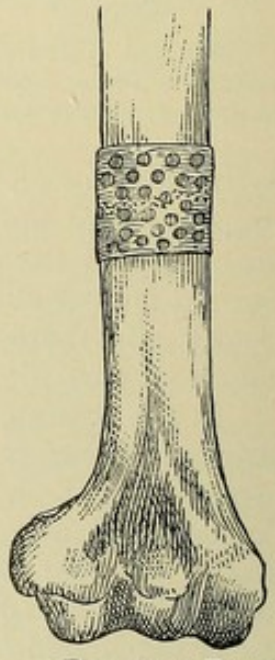

Fig. 350.—Transverse fracture of humerus immobilized by a wide perforated bone ferrule.

is changed after from two to five days, without disturbing the fixation splint. Should suppuration set in, the bone ferrule should not be removed until direct fixation has become unnecessary, when the sinus is enlarged, the ring cut on one side with bone forceps, and fractured on the opposite side by bending, when each half can be extracted separately. Loose fragments of bone, should they be present, are removed at the same time.

In comminuted fractures two rings may be employed with advantage, and, if need be, some of the smaller fragments between them can be held in proper position by catgut ligatures or sutures. All methods of direct fixation have in view the bringing and holding in contact of the fractured surfaces as accurately as possible, for the purpose of taxing the regenerative powers to a minimum, and to obtain union by bony callus with as little lateral and longitudinal displacement as is compatible with the nature of the injury.

Fixation Dressing.—Immobilization of the fractured bone by any of the methods of direct fixation can not be relied upon exclusively in securing for the seat of injury the requisite degree of rest,

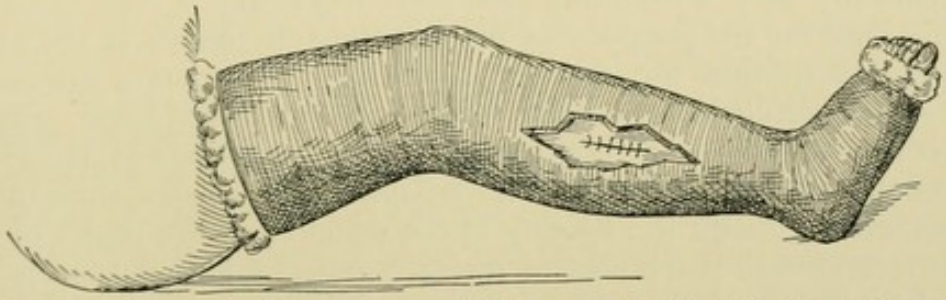

Fig. 351.—Compound oblique fracture of tibia treated by direct fixation of fragments and application of fenestrated plaster-of-Paris splint.

and in preventing more or less displacement of the fragments during the process of healing. For these reasons direct fixation should always be supplemented by some reliable external support. The immobilization of a compound fracture, with or without a recourse to direct fixation, always presents greater difficulties than the mechanical fixation of a subcutaneous fracture of the same bone and in the same locality. The swelling following a compound fracture is usually more extensive than after a simple fracture, and calls for additional precautions in guarding against harmful pressure on the part of the mechanical means that are employed to immobilize the fracture. The wound and the dressing present difficulties in the application of an external mechanical support that often tax the ingenuity of the surgeon to the utmost extent in overcoming them without impairing the efficiency and reliability of the mechanical treatment. One of the most important indications in the treatment of a compound fracture, after the wound has received proper attention, is to apply an external fixation dressing that will make allowance for the subsequent swelling, and that need not be disturbed in gaining access to and in inspecting and redressing the

wound. At the time the first dressing is applied it is impossible to predict whether or not the wound will suppurate, and the mechanical treatment must be such as to anticipate all the complications that might arise from wound infection. In recent fractures we are not in a position, even in the simplest forms and after a most thorough primary disinfection, to say positively that the wound is aseptic, and we must be governed accordingly in the treatment of the fracture. While the obstacles encountered in securing rest and correct position for the fractured bone in recent cases are many, the difficulties are multiplied manifold in the treatment of a suppurating compound fracture. In such event the wound must be exposed at short intervals or permanently, and this should be made possible without disturbing the fixation dressing. Under such circumstances no fixed rules can be laid down to guide the surgeon in efforts to maintain retention.

Much stress has been placed on the importance of the buried sutures in providing a vascular cover for the fragments in the treatment of open wounds complicating a fracture, in order to secure for partially and completely detached fragments a free vascular supply, and for the purpose of placing the soft tissues in the most favorable condition for satisfactory healing by primary intention. The same careful attention must be given the fractured bone. Every movement at the seat of fracture disturbs the relations of the fragments and affects unfavorably the adjacent soft tissues, thus interfering seriously with the healing of the wound and the repair of the fracture. Unrest at the seat of fracture inflicts additional injury on the damaged medullary tissue, and frequently results in displacement of partially detached or isolated fragments from the places in which they were brought when the fracture was reduced, and where they belong in effecting a satisfactory repair of the fracture. The first thing to be done in procuring rest for the fracture is to place the limb in proper position. Muscular attachments must be considered, and their action on the fragments must be carefully studied. A disregard of this part of the treatment is often the direct cause of displacements that can not be corrected by any external appliance. In fractures of the shaft of the femur between the trochanter minor and the junction of the upper with the middle third, if the limb is dressed in a straight position, nothing can prevent the upper fragment from tilting forward and outward, and if the fracture unites, it does so with marked angularity and considerable shortening of the limb. A fracture in this locality must be treated by immobilizing the thigh at an angle of at least 45 degrees, and extension must be made with the axis of the femur in a direction downward, forward, and outward, to correspond with the axis of the upper fragment. This is accomplished most satisfactorily by placing the limb upon a double inclined plane, and by making extension on the thigh by weight and pulley.

In fractures of both bones of the leg great lateral and longi-

tudinal displacement can often be more effectually prevented by relaxing the flexor muscles by placing the limb in Pott's position than by any kind of dressing with the limb in a straight position. After paying due attention to position in securing relaxation of powerful muscles, if any marked tendency to shortening of the limb remains, this must be counteracted by making continuous extension, usually by weight and pulley. In fractures of the thigh in the upper third the extension is made at an angle of 45 degrees, with the leg flexed. In fractures of the remaining portion of the shaft of the femur extension with the limb in a straight position usually gives the best results. In the latter case the strips of adhesive plaster should be made to reach near the base of the thigh, as by making the extension below the knee-joint for any length of time, and with sufficient force to prevent undue shortening, the ligaments are not infrequently damaged sufficiently to impair the function of the joint for a long time, and occasionally permanently. In oblique fractures of the humerus in which autoextension by the weight of the limb, and aided by splints, does not succeed in overcoming overlapping, extension by weight and pulley with the patient in bed and the limb in proper position, continued for two or three weeks, will yield the best results. If extension is employed in oblique fractures of the femur and humerus, it should be continued until the consolidation is firm enough to prevent overlapping, and the weight graded to the age of patient and the amount of muscular resistance to be overcome—generally from ten to twenty-five pounds. The necessary counterextension is made by the weight of the body, by elevating the foot of the bed. Extension is always combined with an appropriate fixation dressing, to guard against rotary and lateral displacement, and to aid the extending force in effecting muscular rest and relaxation.

The ambulatory treatment of compound fractures of any of the large long bones can not be condemned too strongly; repose of the entire body in the recumbent position is an essential prerequisite to insure complete rest of the fractured limb, and must be strictly enforced until union between the fragments is sufficiently firm to place full reliance on a fixation dressing. Another very important element in the treatment of a fracture of the long bones, particularly of fractures of the femur and humerus and fracture of both bones of the leg and forearm, is to include in the fixation dressing both adjacent joints: the knee, ankle, and foot in fractures of both bones of the leg; the knee and pelvis in fractures of the femur; the hand, as far as the base of the fingers, and the elbow-joint in fractures of both bones of the forearm; and the shoulder and elbow in fractures of the humerus. In the treatment of fractures of the spine and suppurating compound fractures of the thigh and leg Verity's suspension splint (Fig. 352) constitutes a most valuable dressing. The technical difficulties encountered in the use of an external support permitting a change of dressing of the

wound without removing it are exceedingly great, and often insurmountable. The antiseptic treatment of the wound demands the first claim on the attention of the surgeon, and immobilization of the fragments in proper position the second; but if these two indications can be met efficiently at the same time, as can often be done by direct fixation of the fragments, this method is entitled to full recognition in well-selected cases. The immobilization of the fragments has very properly been designated long ago by Billroth as the best antiphlogistic in the treatment of compound fractures.

Manufactured splints have become almost obsolete in the treatment of fractures, simple and compound. Carved, metallic, and plastic splints molded on any other model than the fractured limb can never be made to fit, and copious padding, which is often made use of to correct the mechanical defects, usually seriously

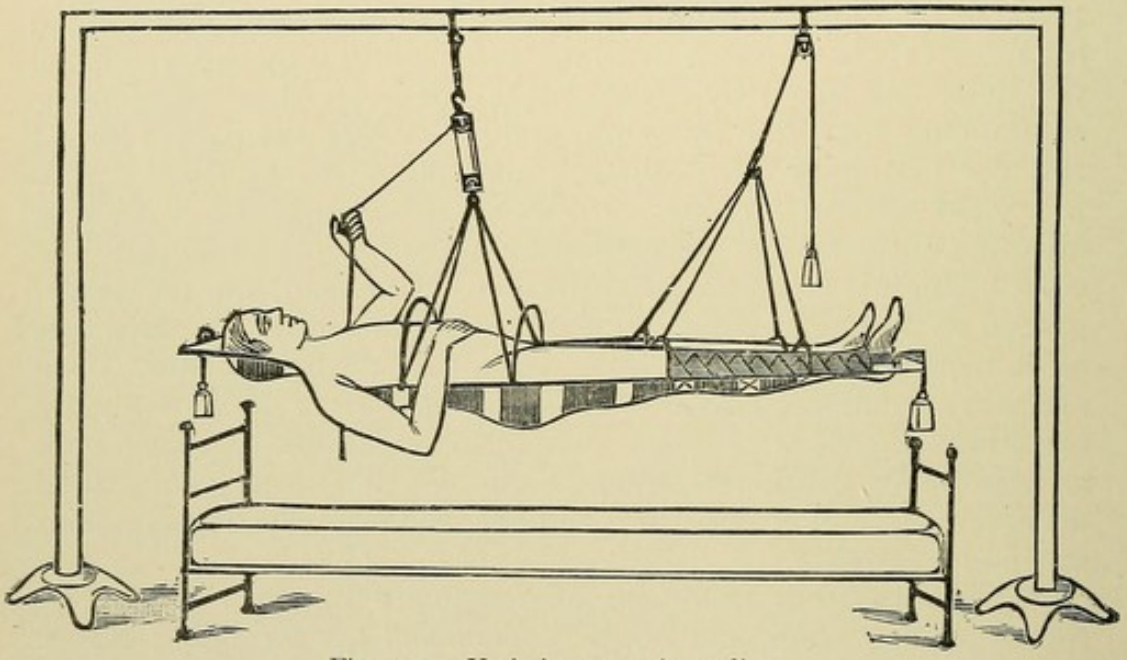

Fig. 352.—Verity's suspension splint.

impairs their efficiency in maintaining retention. Circular plaster-of-Paris dressings are absolutely contraindicated in the treatment of a recent compound fracture, a statement fully indorsed by the experience of Volkmann and P. Bruns. Bardeleben was very partial to the use of fenestrated plaster-of-Paris splints, as he was decidedly opposed to the removal of the first fixation dressing until the fracture was united. He made the fenestra large enough to secure free access to the wound, and for the application of a large moist antiseptic compress. But such splints often interfere seriously with the antiseptic treatment should the wound become infected, as the fenestra can not be made of sufficient size for the antiseptic treatment of the wound without impairing its efficiency in maintaining fixation. Different kinds of supports must be employed to meet the peculiarities of individual cases. Some form of plastic

splint serves an excellent purpose in immobilizing a recent compound fracture. Gutta-percha, felt, leather, and plaster-of-Paris are the materials that have had the most extended trial in the construction of such splints, and of these, the last is the cheapest and most valuable. Gutta-percha is somewhat expensive ; felt lacks strength ; leather takes a long time to dry, and none of them can be so accurately molded to the surface of the limb as plaster-of-Paris. Dr. Buchanan, of Pittsburg, has devised an excellent method for applying such plaster splints. He uses crinoline, cut to fit the surface of the limb accurately,—from four to eight layers,—and next

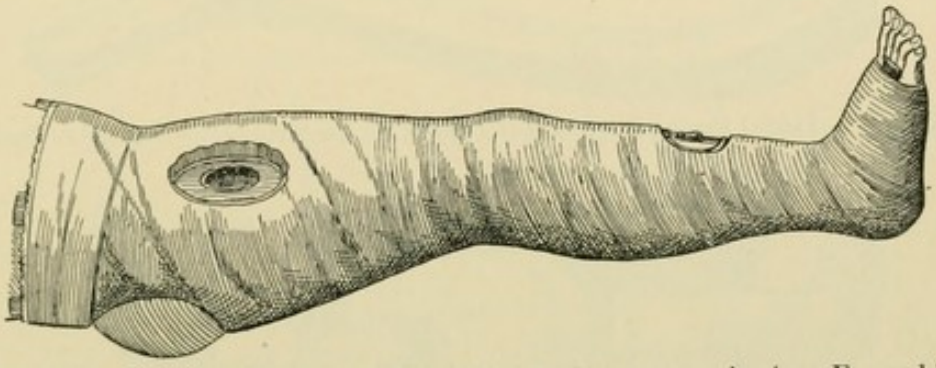

Fig. 353.—Fenestrated plaster-of-Paris splint for lower extremity (von Esmarch).

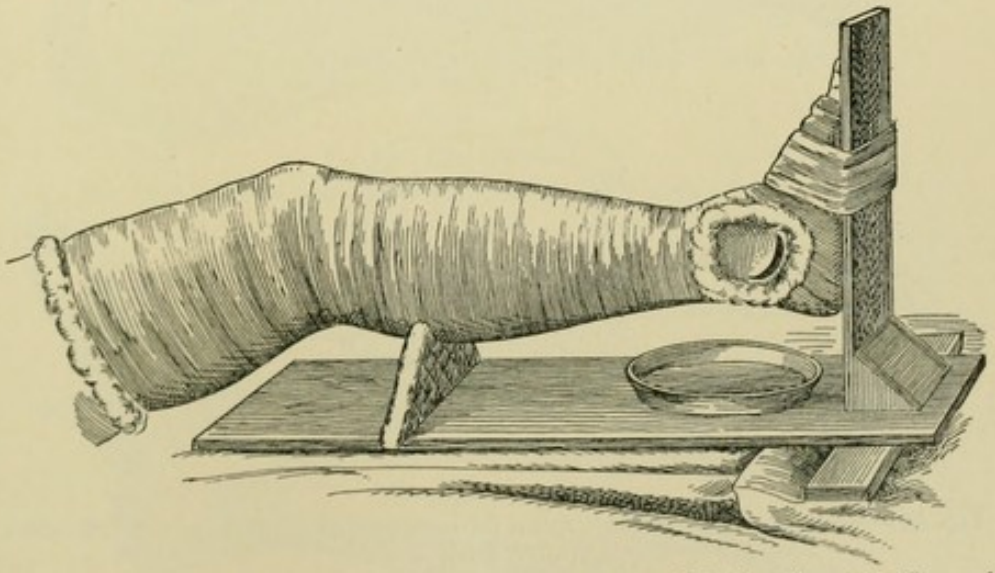

Fig. 354.—Open-wound treatment in fenestrated plaster-of-Paris splint (von Esmarch).

to the limb a layer of lintin,—a form of compressed cotton,—for the protection of the skin. After the plaster has been rubbed into the meshes of the crinoline, the different layers are fastened together by ordinary pins, which are converted into staples by a pin-stapling tool. He gives the following directions :

" 1. The plaster should be rubbed well into each layer of crinoline separately by hand.

" 2. In handling the splint, care should be taken lest the plaster be shaken out.

"3. In soaking the splint, seize the open ends, one in each hand, and immerse gently in warm water, keeping hold of the splint to prevent the plaster from being washed out of the meshes of the crinoline.

"4. Apply one splint to the limb with a roller bandage; apply the other splint to the other side of the limb with another muslin roller.

"5. In reapplying the splints, the same plan should be followed,



Fig. 355.—Dorsal hemp plaster-of-Paris splint for fractures of the leg (after Beely).

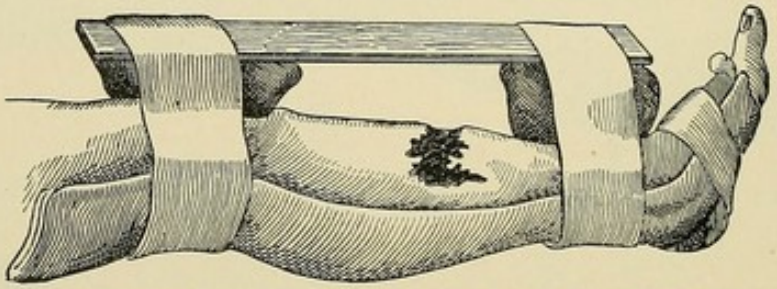

Fig. 356.—Bridge plaster-of-Paris splint (after Pirogoff).

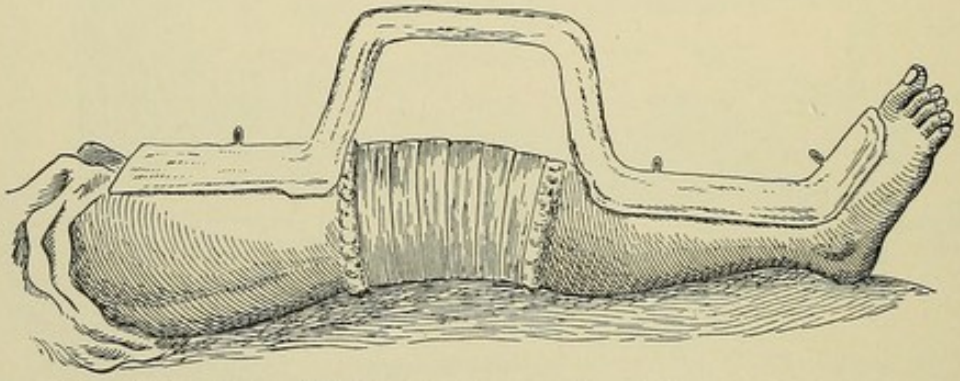

Fig. 357.—Hemp plaster-of-Paris splint for complicated fractures of the knee-joint (after Beely).

—of applying each splint with a separate roller,—so that they may fit as before and not pinch the limb in front or behind.

"6. Never use any pads, for this destroys the fit of the splints.

"7. If any points of pressure occur, cut an opening in the splint to correspond exactly with the point of irritation. This very rarely happens."

This description applies more particularly to fractures of the leg requiring two lateral splints. In fractures of the thigh two lateral or anteroposterior splints with a space of an inch or two between them, and extending from the tuberosity of the ischium to

below the knee behind, and from the groin to the same distance below, or from the crest of the ilium on the outer side, and from the perineum on the inner side to below the knee, will immobilize the femur most effectually. An outer splint, encircling one-half of the arm and extending from the top of the shoulder to below the elbow, is an excellent way in which to immobilize a fracture in any part of the humerus above the junction of the middle with the lower third. In fractures of the forearm anteroposterior splints reaching from the bend of the elbow to the base of the fingers

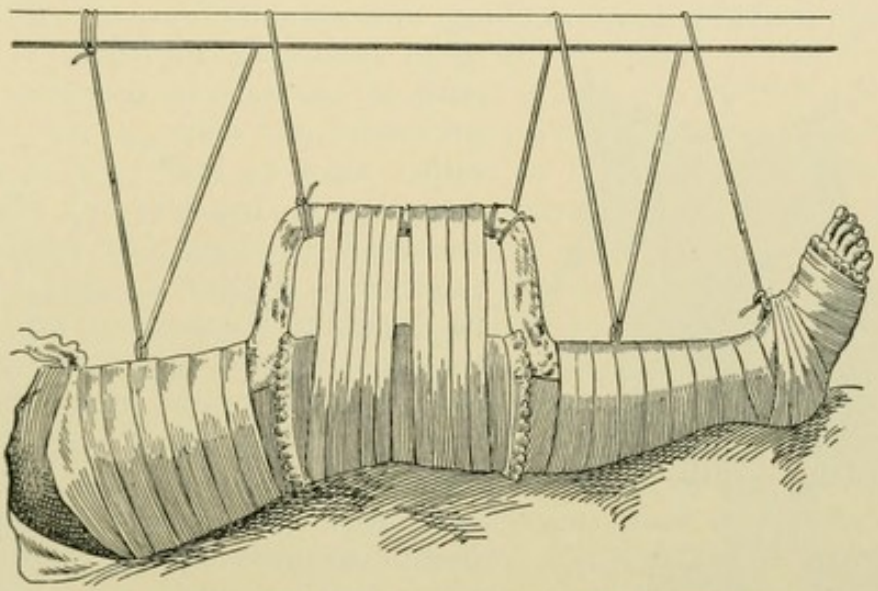

Fig. 358.—Same splint with suspension of the limb (after Beely).

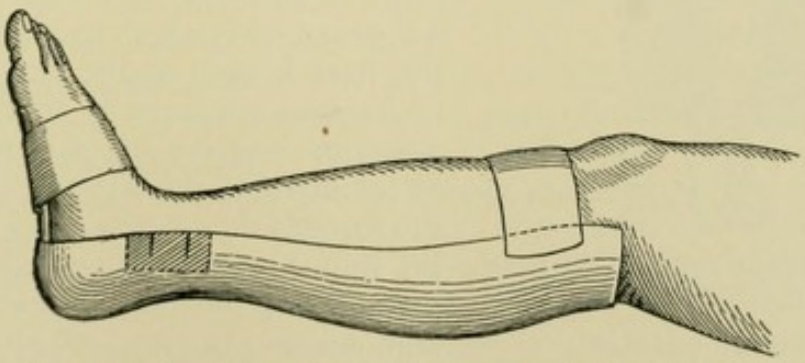

Fig. 359.—Posterior plaster splint for fractures of the leg (after Herrgott).

constitute an excellent method of fixation. In molding the splints for such fractures, care must be exercised not to make lateral pressure sufficiently to force the fragments in the direction of the interosseous space. In Colles' fracture of the radius an anterior splint will suffice. The strength of the splint is regulated by the number of layers of crinoline used. If a strong support is required, as is often the case in compound fractures, more especially in instances where only one splint is applicable, the requisite strength can easily be secured by making a double plastic splint, and interposing

between the two splints an additional metallic support, such as strips of tin, sheet-iron, aluminum, or wire. To make such splints more durable the outside surface can be covered with a coat of shellac or glue. By incorporating at the margins of the splint, at desirable points, rings or loops, suspension can be combined with fixation without any additional mechanical contrivance.

Plastic splints, as described, do not interfere with extension, which is so necessary in the successful treatment of all oblique fractures of the femur, and which is occasionally necessary in similar fractures of the humerus. Should diminution in the size of the dressing or inflammatory swelling impair the fitting qualities of the splint sufficiently to render it insecure in maintaining retention, it is preferable to make a new splint rather than to make use of pads. A splint, to be safe and efficient, should fit accurately the surface of the limb to which it is applied, so as to distribute the pressure necessary to secure fixation equally and evenly over that part of the limb. Splints that do not fit are frequently the cause of localized pressure necrosis, and often over points that it is important to preserve in an intact condition for the purpose of maintaining efficient immobilization of the fracture. Allusion in this regard to the frequency with which decubitus over the heel is seen as the direct result of harmful pressure of an ill-fitting posterior support in the treatment of fractures of the leg will illustrate the force of this statement. The plastic splints can often be relied upon throughout the entire treatment in immobilizing the fracture; more frequently, however, after the danger from infection has passed, the swelling following the accident has subsided, and the risks of overlapping of the fragments have been diminished by a beginning bony consolidation they are removed, and a circular plastic splint is substituted. The application of a well-fitting efficient circular plaster-of-Paris splint requires skill and experience. It is the novice and the surgeon devoid of any mechanical skill who are responsible for the many disastrous results following the use of the circular plastic splint, and not the method. In well-selected cases this method of fixation is the one that offers the greatest security against displacement of the fragments and is attended by the least risk. A circular

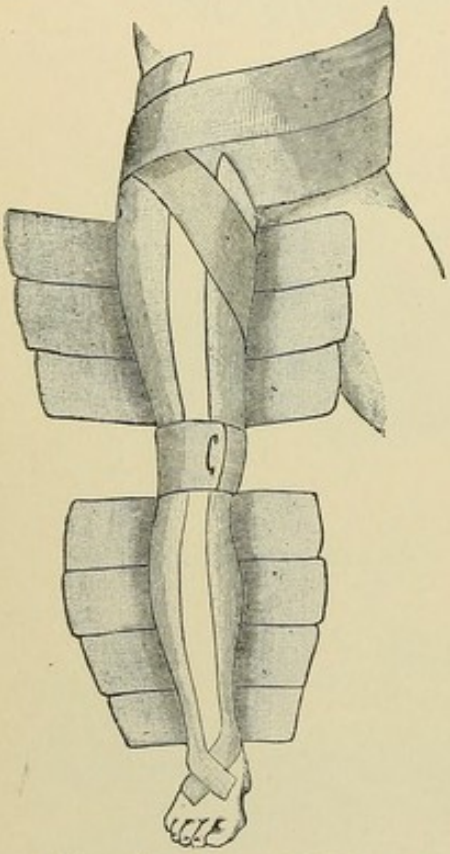

Fig. 360.—Plaster-of-Paris strips dressing for fractures of the femur (Pirogoff).

splint should always extend from the periphery of the limb, and should include the joint on the proximal side of the fracture. In fractures of the leg it must extend from the base of the toes to some distance above the knee; in fractures of the thigh, from the base of the toes, including the corresponding side of the pelvis; in fractures of the forearm, from the base of the fingers to, or, still better, above, the elbow; in fractures of the humerus it must embrace both of the adjacent joints. In cases justifying the use of the circular splint it is superfluous and harmful to interpose between it and the surface of the limb a thick cushion of cotton, as by so doing fixation is lost, and if allowed to remain until repair is completed, vicious union is the probable result. If the splint is applied smoothly and carefully from the periphery of the limb to the requisite distance on the proximal side of the fracture, the uniform circular support is the very best means of preventing swelling and of securing the necessary degree of fixation. The limb must be protected by a layer of lintin or a smooth layer of loose absorbent cotton, not more than half an inch in thickness, held in place by a gauze or flannel roller, over which the plaster bandage, immersed for the requisite length of time in warm water, is applied, beginning at the periphery and terminating at the various points just indicated. The plaster roller should be allowed to take its own course upward and downward at different angles, in order to apply it smoothly, making, at the same time, as few reverses as possible. Subcutaneous bony prominences must be protected by an additional layer of cotton. Before applying the dressing, and during the time required for the setting of the plaster, the fragments must be brought in accurate coaptation, and held in this position until the mechanical support is such as to render manual extension and fixation unnecessary. With a limb immobilized in such a manner the patient will be able to leave his bed and walk about with the aid of crutches at an early date in fractures of the leg, and somewhat later in fractures of the femur.

Unremitting watchfulness is always essential in the successful treatment of fractures. *Negligence is inexcusable and often leads to legal complications.* The fingers and toes must always remain accessible to inspection, as from their appearance the surgeon can determine the condition of the circulation, to which the patient's attention should be called in order that he may give timely warning of approaching danger from an impeded circulation caused by harmful circular constriction. In such an event no time is to be lost in relieving the pressure by cutting the splint longitudinally on one side, increasing the space in this way sufficiently to relieve the embarrassed circulation. Various instruments have been devised for this purpose, but few, if any, of them have answered the expectations of their inventors, much less those of the purchasers. The application of vinegar or acetic acid in the line of the proposed cut softens the plaster and prepares the way for an easier cutting of the splint. A

stout blade of a pocket-knife will accomplish this task as quickly and safely as the many cumbersome and expensive plaster shears or saws. A splint that has been cut longitudinally soon becomes useless as an efficient means of fixation, and must be replaced by a new one if union at the seat of fracture is not sufficiently secure to guard against overriding of the fragments.



Fig. 361.—Von Bergmann's plaster-of-Paris bandage saw.

It has been previously stated that the circular plastic splint should never be used in the treatment of a recent compound fracture. This rule, like every other, has its exceptions. These exceptions present themselves more especially on the battle-field and in the practice of railway surgeons, where the patients often have to be transported great distances from the place of injury to the nearest hospital, residence, or boarding-house. In transporting a patient the subject of a compound fracture, immobilization is absolutely necessary to prevent additional injury to the soft tissues during the journey, and no other method of fixation accomplishes this object to the same degree as does the circular plaster-of-Paris splint. When employed for this purpose, the limb should be enveloped in a thick cushion of cotton, so that no harm can result from the swelling at the seat of injury. When the patient reaches his destination, the

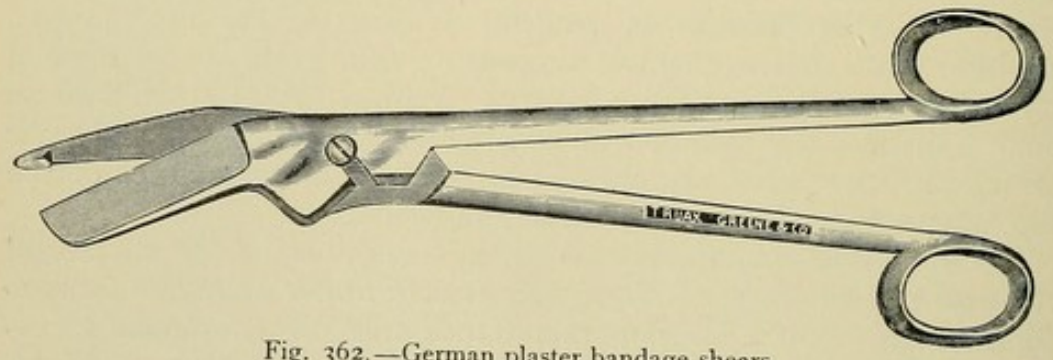

Fig. 362.—German plaster bandage shears.

circular splint should be removed and replaced by a plastic lateral splint. The value of immediate immobilization in the treatment of compound fractures in patients requiring transportation for some distance has been demonstrated by an extensive experience in military and emergency practice, and no other dressing can compare in comfort and efficiency with the circular plastic splint. The plastic splint is the splint of the future in the treatment of compound fractures; it will soon almost entirely displace the manufactured splints in the surgeon's armamentarium. Dowling has well said: "Carved and manufactured splints generally fit nobody, and are to be re-

jected as not only expensive, but damaging." Different kinds of bracketed splints have been in use since the time of Abernethy. If a splint of this kind is required, it can very readily be extemporized by connecting two plastic splints by an iron bar, curved in such a manner as to suit the locality of the wound and to adapt itself to the dressing. For good and substantial reasons the old-fashioned fracture box has almost entirely disappeared from the surgical arena in all parts of the world. The bran dressing, introduced into practice by Rhea Barton in connection with the fracture box, has met a similar fate, its place having been taken entirely by the modern antiseptic dressing. In compound fractures of the femur, when extension constitutes an essential feature in their successful treatment, Hodgen's extension or N. R. Smith's (see Figs. 232 and 230) anterior suspension splint will frequently meet the indications of the mechanical treatment better than any other method of fixation.

In review it may be stated that the mechanical treatment of

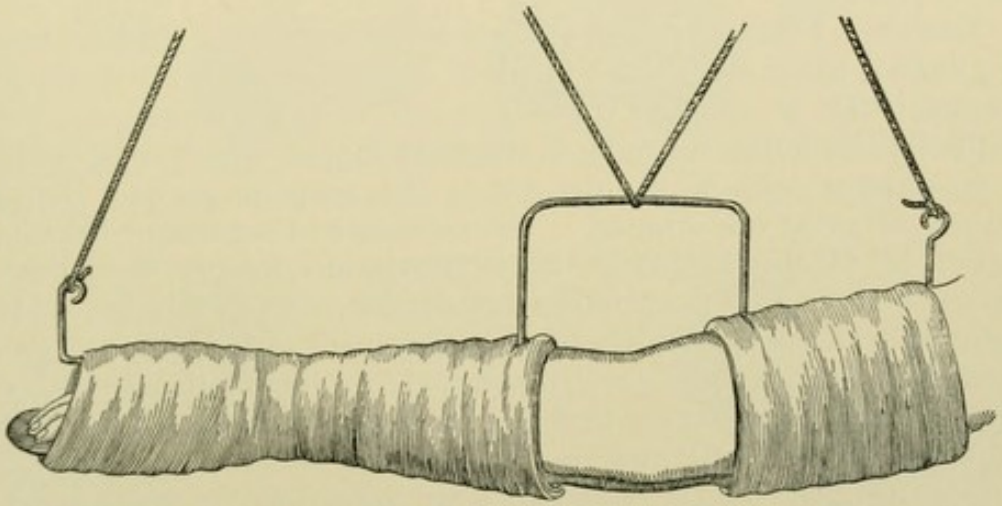

Fig. 363.—Bracketed plaster-of-Paris suspension splint for elbow (von Esmarch).

compound fractures consists of direct means of fixation in cases demanding such interference, and, if such a course is not called for by the nature of the injury, of careful reposition and fixation of the fractured bone by an efficient mechanical support, which should fit the limb with sufficient accuracy to prevent decubitus, be of sufficient strength to maintain coaptation, and should not interfere with the circulation in the injured limb. And, finally, the plastic splint is the one that accomplishes these objects with the greatest degree of certainty and with the least interference with the antiseptic treatment and dressing of the complicating wound. Immobilization of a fracture must be continued until the union is firm enough to balance muscular action, and in fractures of the lower extremities to bear the weight of the body. The length of time for bony union to take place varies much, and is dependent largely on the age of the patient, the seat and extent of the fracture, and, in compound fractures, on the condition of the wound. In children,

under favorable conditions a fracture of any of the long bones may be repaired sufficiently to dispense with any kind of fixation dressing at the end of three or four weeks, while in the adult and the aged from two to three months are often required. Harm results if the fixation splint is removed too soon, as well as if its use is prolonged beyond the necessary length of time. Secondary displacement and bending at the seat of fracture are liable to occur in the former, and muscular atrophy and stiffening of joints in the latter, case. *Active and passive motion must never be made, regardless of the location of the injury, until the fracture has firmly united, as premature efforts of this kind are more likely to provoke than prevent stiffness and ankylosis. This statement applies with special force to fractures extending into and near joints. The old teaching to the effect that in such cases ankylosis is likely to follow unless passive motion is commenced within a week or two after the injury has occurred is based upon wrong principles, and certainly has led to vicious practice.*

Gunshot Fractures.—A few remarks on the modern treatment of gunshot fractures will be in place here. Besides the ordinary characteristics of gunshot wounds, wherever the anatomic location of the injury, bullet wounds of the extremities, when complicated by fracture or joint injury, present to the surgeon special clinical features of great importance. The existence of a gunshot fracture, regardless of the extent of bone injury, no longer furnishes a legitimate indication for primary amputation. Such injuries, under appropriate aseptic and mechanical treatment, are amenable to a satisfactory repair, with good functional results, in the course of time. They are the cases that tax the ingenuity of the surgeon to the utmost in applying and maintaining the necessary mechanical support until the fracture heals by bony consolidation with the limb in a satisfactory useful position. The wound should never be probed or otherwise interfered with. It should be dressed with the borosalicylic powder and cotton compress securely fixed in place with bandage, or, still better, with strips of adhesive plaster and bandage. In gunshot fractures of the femur extension with immobilization will now, as it has for a long time, constitute the generally accepted treatment. A determined strong protest must be made against the unnecessary removal of detached and partially detached fragments of bone. If the wound remains aseptic, loose fragments of bone will not only retain their vitality, but will take an important part in the restoration of the continuity of the bone and add materially to the functional result. Débridement, more or less extensive, becomes necessary, and should be performed only in case the wound becomes infected. In such an event the loose infected fragments of bone should be removed promptly, free tubular drainage established, and the wound throughout subjected to thorough disinfection. If the ordinary measures should fail, continuous irrigation with a saturated solution of acetate of aluminum

or Thiersch's solution will very often bring about the desired results and obviate the necessity for a secondary amputation. Fixation and

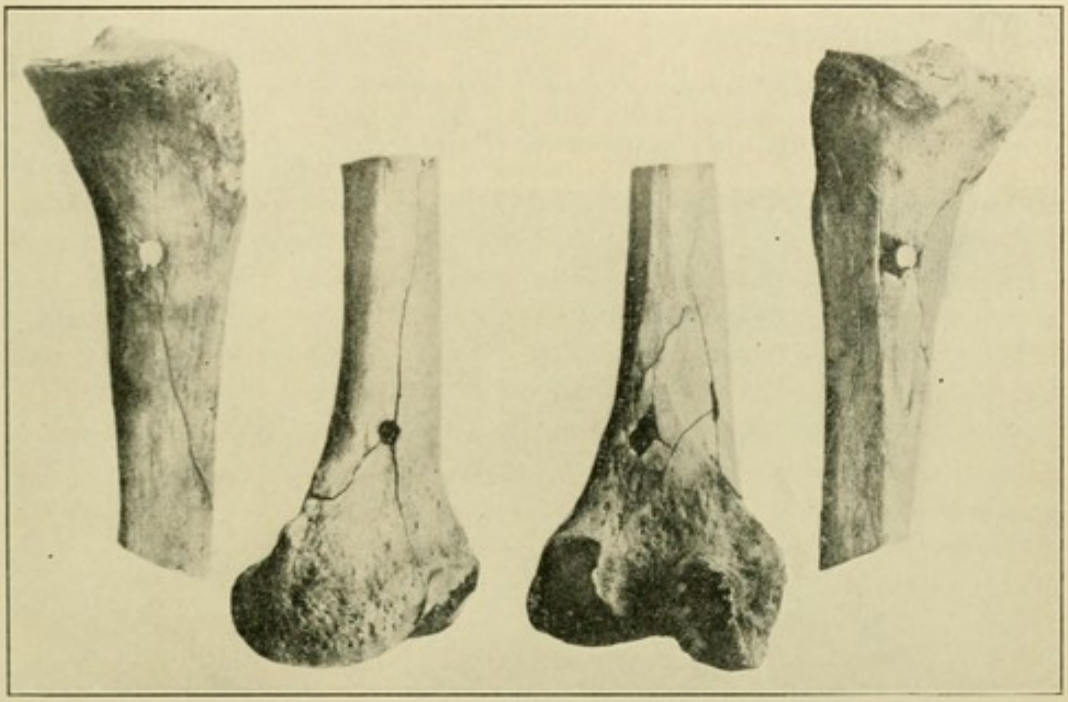

Fig. 364.—Effect of the small-caliber bullet on the shafts of the long bones (Bruns).

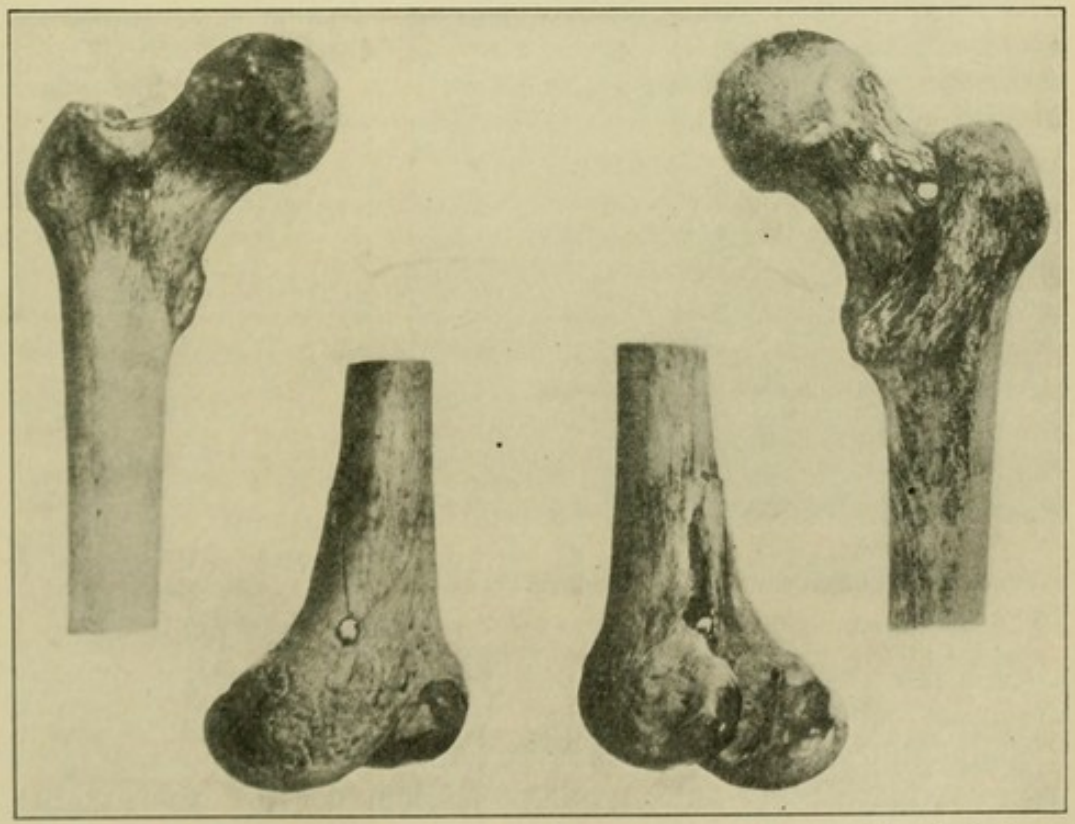

Fig. 365.—Effect of the small-caliber bullet on the epiphyseal extremities of the long bones (Bruns).

suspension in such cases will not only procure comfort for the

patient, but will answer an excellent purpose in securing and maintaining coaptation and in facilitating drainage and irrigation. As soon as the fracture has united with sufficient firmness to render extension unnecessary, the limb should be immobilized in a circular plaster-of-Paris splint, in the manner previously described, after which the patient is permitted to walk about with the aid of crutches. In gunshot fractures of the leg early immobilization in a circular plastic splint is to be advised and yields the most gratifying results. Watchful control of patients suffering from such injuries and treated by the use of the plaster-of-Paris bandage is essential in guarding against disastrous complications and in obtaining satisfactory functional results.

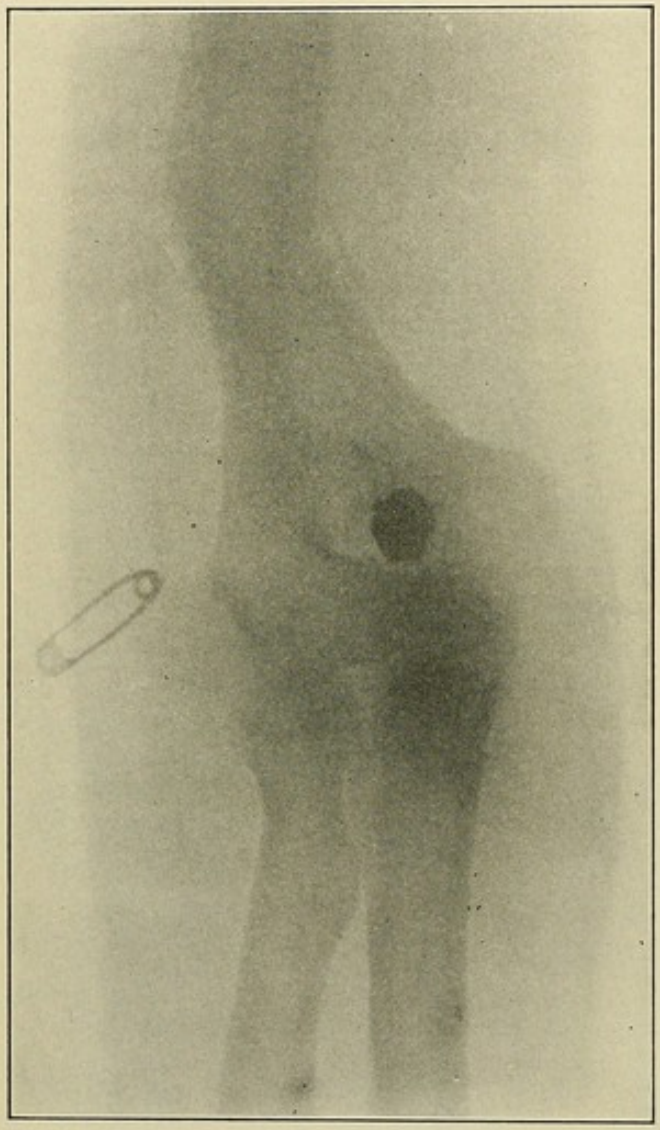

Fig. 366.—Old gunshot fracture of the lower end of the humerus; bullet embedded in the bone between the condyles.

Gunshot injuries implicating any of the large joints are now within the range of successful conservative treatment. I have seen, in the military hospitals, both in Greece and Turkey during the late war and during the Spanish-American war in Cuba and Porto Rico, gunshot wounds of the hip-, knee-, ankle-, shoulder-, elbow-, and wrist-joints, not only recover without any operative interference whatever, but in many of the cases a fair degree of motion and good use of the limb rewarded the most conservative treatment. With a view to showing what the modern treatment of gunshot fractures is capable of accomplishing in saving life and limb, I will very briefly describe a few of the many cases that came under my own personal observation in Greece, Turkey, Cuba, and Porto Rico.

The following cases came under my observation in Greece and Turkey:

CASE 1.—*Wound of Right Knee-joint.*—Received in Epirus. The bullet fractured the internal condyle of the femur, opened the knee-joint, and was removed through an incision over the outer aspect of the joint. Wound healed. Joint motion was limited, and capsule of joint was thickened.

CASE 2.—*Gunshot Fracture of Leg, with Extensive Comminution of Fibula.*—Wound received during the first week of the war. Healing by secondary intention and slow formation of callus followed.

CASE 3.—*Comminuted Gunshot Fracture of the Tibia.*—Many fragments of bone were removed soon after the injury was received, leaving a large bone defect. Wound healed. No union occurred and but slight callus production. An operation for pseudarthrosis will become necessary in the near future.

CASE 4.—*Gunshot Wound of Knee-joint with Extensive Comminution of the Internal Tuberosity of the Tibia.*—Patient was a captain in the Greek army. First dressing was applied fifteen hours after the injury was received. Wound was redressed on the sixth day. Bullet passed through the joint and escaped between the head of the fibula and the external condyle of the femur. Slight suppuration ensued. Wound now healed; capsule of the joint and para-articular tissues remained somewhat swollen and indurated. Joint motion was limited.

CASE 5.—*Gunshot Wound of Knee joint.*—The bullet perforated the external condyle of the femur, and passed out over the inner aspect of the joint. There was moderate swelling of joint, but no suppuration. Wound healed by primary intention. Recovery with fair motion of joint followed.

CASE 6.—*Cretan. Gunshot Wound of Shoulder-joint.*—Bullet passed through the head of humerus and joint from behind; point of exit below the coracoid process. Fistulous opening remained, through which a limited amount of pus escaped daily. Ankylosis not complete. Considerable atrophy of deltoid muscle, which may have been due to injury of circumflex nerve, ensued.

CASE 7.—*Gunshot Fracture of Thigh.*—Injury received four months ago. Wound healed; bone united by massive callus; limb considerably shortened and femur curved.

CASE 8.—*Gunshot Fracture of Patella, Opening Knee-joint.*—Secondary suturing of patella was done, with satisfactory result. Motion of knee-joint was greatly impaired, a condition in part due to the swelling and induration of the soft tissues that still remained. Suturing material, silkworm-gut; operator, Professor Galvani.

CASE 9.—*Gunshot Fracture of Both Bones of the Forearm.*—Bullet and loose fragments of bone were removed in the field-hospital. Wound healed. No union and no callus formation followed.

CASE 10.—*Gunshot Fracture of the Humerus.*—Bullet passed through the arm near the middle. Nerves escaped injury. Healing by primary intention occurred. No splints were used. Fixation was accomplished by bandaging arm to the side of the chest with forearm flexed and supported by the same bandage. Union by bony callus with good functional result followed.

CASE 11.—*Gunshot Fracture of Femur.*—Infection occurred. Secondary amputation was done. Osteomyelitis of the bone in the stump made it necessary to perform a second operation, which consisted in enucleating the bone. Wound still suppurated and healing slowly followed by granulation.

Gunshot Fractures in the Military Hospitals in Turkey.

CASE 1.—*Gunshot Fracture of the Humerus Implicating the Shoulder-joint.*—Bullet entered in front, passed through the head of the humerus, and escaped behind. Infection followed. Secondary resection of about three inches of the upper end of the bone was made, and pieces of clothing were removed from the wound. Posterior incision healed. Fistulous opening remained in front. Patient had very little use of arm, but his general condition was good.

CASE 2.—*Gunshot Wound of Knee-joint.*—Bullet comminuted internal condyle of femur and penetrated the joint. Extraction of bullet and atypical resection of joint were done in the field-hospital. Primary healing of the wound followed. Joint partially ankylosed, with leg in useful position.

CASE 3.—*Gunshot Wound of Knee-joint.*—Bullet located by the Röntgen ray. No suppuration occurred. Incision was made on both sides of joint and bullet extracted. Primary healing of operation wounds and almost perfect joint function resulted.

CASE 4.—*Gunshot Injury of Shoulder-joint.*—Wounds of entrance and exit were enlarged, through which comminuted fragments of the head of the humerus were removed. Wounds healed. Fair degree of motion followed.

CASE 5.—*Gunshot Injury of Shoulder-joint.*—Bullet passed obliquely through the

joint. Anterior and posterior incisions were made, through which loose fragments from the head of the humerus were removed. Operation was performed in the field-hospital. Slight infection ensued. Fistulous opening remained behind. Anterior incision healed by primary intention. Use of arm was limited.

CASE 6.—*Gunshot Wound of Shoulder-joint.*—Débridement done in the field-hospital. Wounds of entrance and exit healed rapidly. Function of joint and arm returned gradually.

CASE 7.—*Gunshot Wound of Elbow-joint.*—Bullet passed obliquely through the joint, fracturing the internal condyle of the humerus. Primary atypical resection of joint was made. Infection followed. Fistulous opening remained behind the joint. Active motion, none; passive motion, slight.

CASE 8.—*Gunshot Wound of Knee-joint.*—Primary resection was done. There was great comminution of articular ends of femur and tibia. Wounds healed without suppuration. Consolidation was not complete after two months and a half.

CASE 9.—*Gunshot Wound of Knee-joint.*—Secondary resection was done. Slight infection followed. Healing took place by granulation, with limb in good position. Bony union was quite firm.

CASE 10.—*Volunteer, Fourteen Years Old. Gunshot Wound of Shoulder.*—Bullet passed from before backward, about an inch to the inside of the surgical neck of the humerus. Wounds healed by primary intention. Little or no impairment of function of the muscles of the arm occurred.

CASE 11.—*Gunshot Fracture of the Humerus.*—Infection present. Secondary amputation was done, the stump healing by granulation.

CASE 12.—*Gunshot Fracture of Humerus.*—There was great loss of bone, caused by the injury, and later by an operation for the removal of sequestra. Although the periosteum was preserved, there was no callus at the end of two months, and a false joint was established.

CASE 13.—*Resection of the Shoulder-joint for Gunshot Wound.*—Operation wounds healed. Arm remained almost useless. Great muscular atrophy followed.

CASE 14.—*Resection of Elbow-joint for Gunshot Wound.*—Secondary operation done through posterior bayonet incision. Fistulous openings and considerable swelling of soft parts remained. Muscles of arm and forearm were much atrophied.

A glance at the foregoing report of cases from the Greco-Turkish war will suffice to show that infection and bad functional results were much more frequent on the side of the Turks, a circumstance that is plainly attributable to the more aggressive treatment that was pursued. The Greek physicians seldom interfered with the wounds, and pursued throughout a most conservative course, while the military surgeons of the Turkish army, stimulated by the example of a number of German physicians, resorted too frequently to the use of the knife, with the result that infection of the wound was a much more frequent occurrence, and the primary débridement and resection only too often resulted in delayed union, pseudarthrosis, and useless limbs. *Primary resection of a recent gunshot wound of any of the large joints has become an unjustifiable surgical procedure, and is under no circumstances permissible. The indications for primary amputation of a limb for gunshot fracture should at present be restricted to cases in which the nutrition is suspended or seriously threatened by the existence of lesions of the soft parts incompatible with the vitality of the tissues at and below the seat of injury. In cases of doubt, the soldier is entitled to the benefit of the same, and the conservative treatment should be carried to its utmost legitimate limits until the appearance of complications has demonstrated its futility, and dictates the propriety of resorting to a mutilating operation.* It is always more creditable to a surgeon to save a limb than to remove it, and the soldier is entitled to the benefit of conserva-

tive surgery as much as the civilian, and the duty of the military surgeon of the future should and will be to limit more and more the indications for primary amputation, and to resort to means and measures that further lessen the necessity for secondary amputation.

The principles that should guide the military surgeon in the treatment of gunshot wounds of joints and gunshot fractures were followed more closely and thoroughly on our side during the Spanish-American war than during any previous campaign. Probing of bullet wounds was discouraged from the very beginning and was seldom resorted to, and the first-aid dressing was relied upon largely in preventing wound infection. Primary amputation was reserved for cases in which the extent of injury to the soft tissues made it apparent that gangrene would follow as an inevitable result under any kind of conservative treatment. Very few secondary amputations were made, and only in cases in which gangrene or sepsis became an imminent source of danger to life.

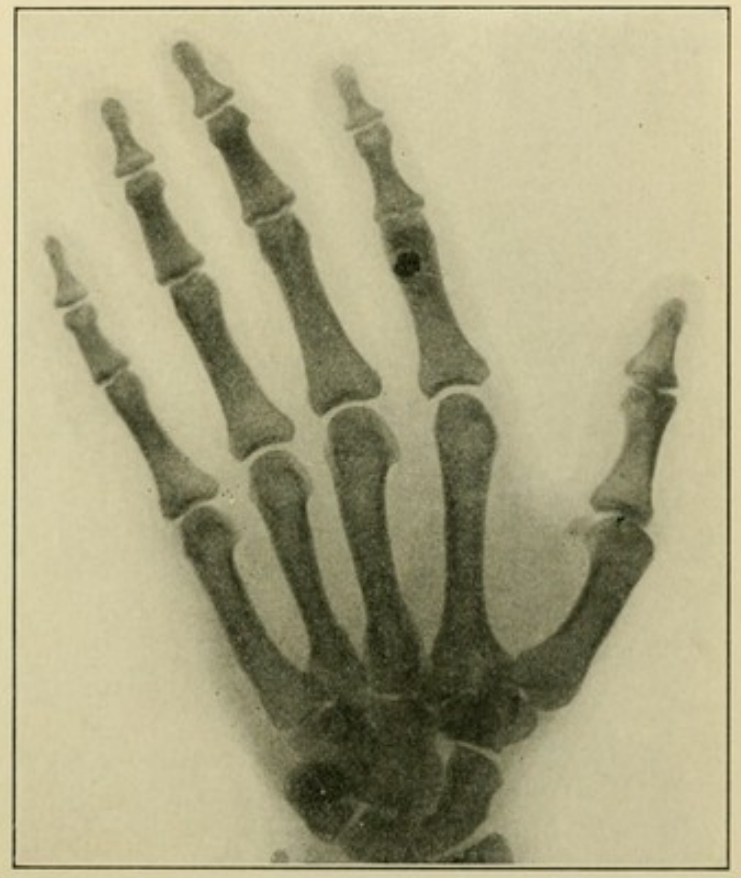

Fig. 367.—Old gunshot injury of hand; bullet embedded partly in the basal phalanx of the index-finger.

One of the first cases of gangrene I saw at the front at the First Division Hospital, in charge of Major Wood, U. S. A., was a gunshot fracture of the femur complicated by a complete transverse tear of the popliteal artery. The wound of entrance was over the inner margin of the patella, and that of exit over the lower and outer aspect of the thigh. The knee-joint and thigh were enormously swollen, and the gangrene had extended to within a few inches of the knee-joint. The pulse was rapid, and the temperature 105° F. The amputation was made at the seat of fracture, above the comminuted condyles of the femur, by making a long oval anterior and a short oval posterior flap. Notwithstanding the edematous condition of the flaps, the wound was in excellent condition three days later, and the temperature normal.

Among the wounded Spanish prisoners I found several cases of gunshot fractures badly infected, and secondary amputation became necessary in an effort to ward off death from progressive sepsis. In the majority of cases of gunshot fracture not complicated by serious nerve and vessel wounds, the results under the most conservative treatment were excellent. In the cases of compound fractures in which late suppuration occurred it was noticed that the infection usually commenced about the margins of the skin, extending in some of the cases to the seat of fracture; in others, remaining localized. There can be no doubt that late infection in quite a number of cases resulted from subsequent probing of the wound, or in consequence of unnecessary removal of the first-aid dressing.

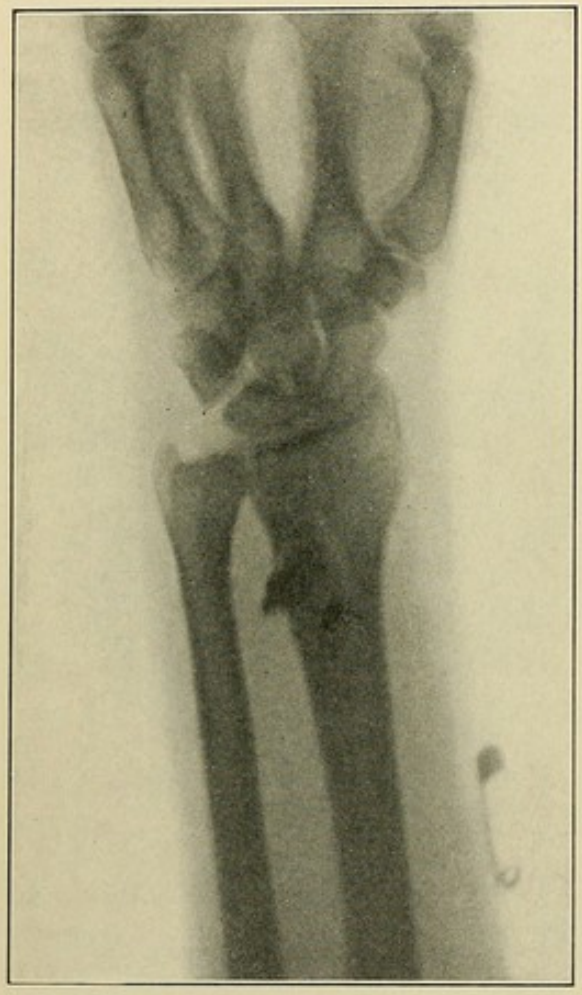

Fig. 368.—Gunshot injury of forearm; point of bullet buried in the lower end of the radius.

It is a source of regret that fixation of the fractured limbs by plaster-of-Paris splints was not more generally practised. Owing to the want of reliable plaster-of-Paris we had to resort to various kinds of splints and single and double inclined planes in effecting immobilization. We made very extensive use of the sheath of the leaf of the royal palm as a material for splints, which answered an excellent purpose, as it is light, porous, and can be made to fit the surface of the limb much better than splints made of wood. Many cases of gunshot fracture of large joints, in which one or both articular extremities were extensively comminuted by the bullet, healed in the same satisfactory and painless manner as subcutaneous injuries, with excellent functional results, such as were seldom, if ever, seen during the Civil War. The modern treatment of recent gunshot fractures can be summed up briefly as follows:

1. No probing of the wound.
2. No primary débridement.
3. Early efficient first-aid dressing.
4. Immobilization of fracture, preferably by plastic splints.

5. Immobilization combined with extension if there is a tendency to undue shortening.

6. First-aid dressing must not be removed unless this becomes necessary by the appearance of local or general symptoms that indicate the existence of wound infection.

Repair of Compound Fractures.—It is generally conceded that, all other things being equal, it takes a somewhat longer time for a compound fracture to consolidate by bony union than a simple fracture. This applies to fractures in which the complicating wound remains aseptic and heals by primary intention. The difference in the time of healing between a simple and an aseptic compound fracture depends mostly on the more extensive injury to the

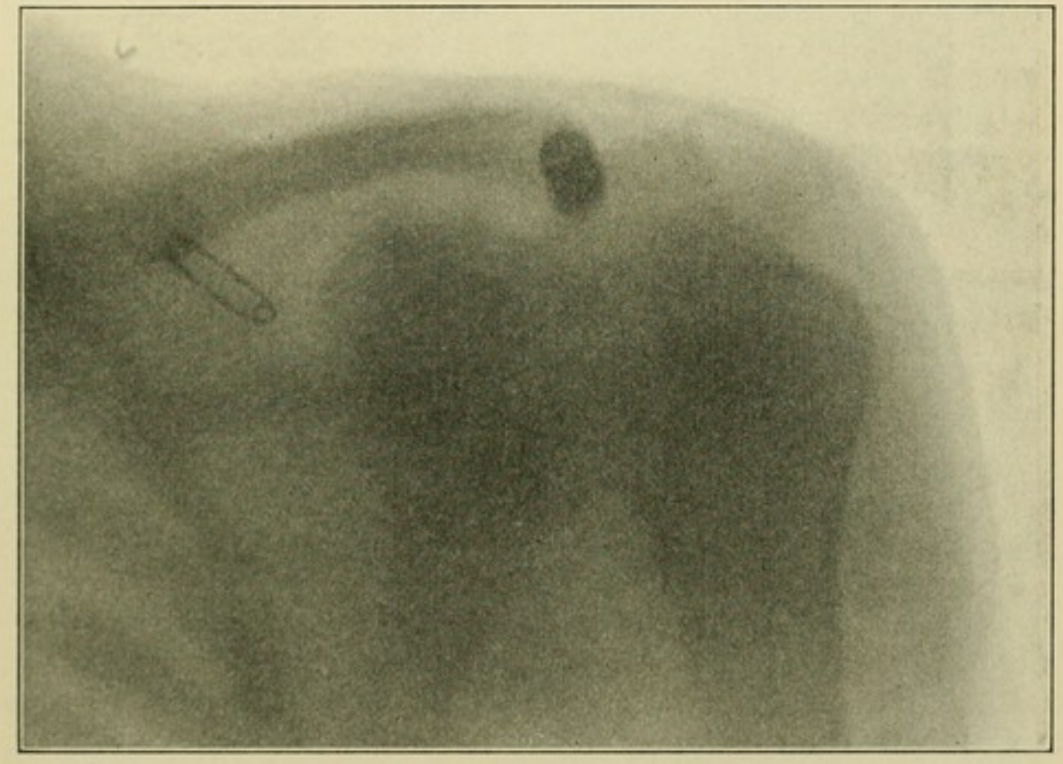

Fig. 369.—Recent gunshot fracture of the clavicle; bullet lodged in the tissues below the fracture.

soft parts in the latter, and, further perhaps, on a less perfect immobilization of the fracture, owing to the existence of an external wound. In more or less extensive crushing of the soft tissues at the seat of fracture, even if the wound remains aseptic, the vascular supply to the fragments is for some time greatly interfered with, a condition unfavorable to the speedy repair of the bone injury. Callus formation is also greatly retarded by comminution of the fractured bone. Callus formation is stimulated by the uninterrupted accurate contact between the ends of the fractured bone. A space between them filled in with detached fragments and lacerated soft tissues always constitutes a serious obstacle to a speedy and satisfactory process of repair. The removal of loose and partially detached fragments is always followed by delayed, and not in-

frequently by nonunion. If the wound and the seat of fracture become infected, delay of union follows as an inevitable consequence. Callus production does not take place to any extent until the acute suppurative process has subsided, and the necrosis of the fragments and fractured ends, which so constantly follows the osteomyelitis, creates new defects that are often repaired with the greatest difficulty by late profuse callus formation.

Infection and suppuration are, for good reasons, much feared in cases of extensive comminution, so far as callus production is

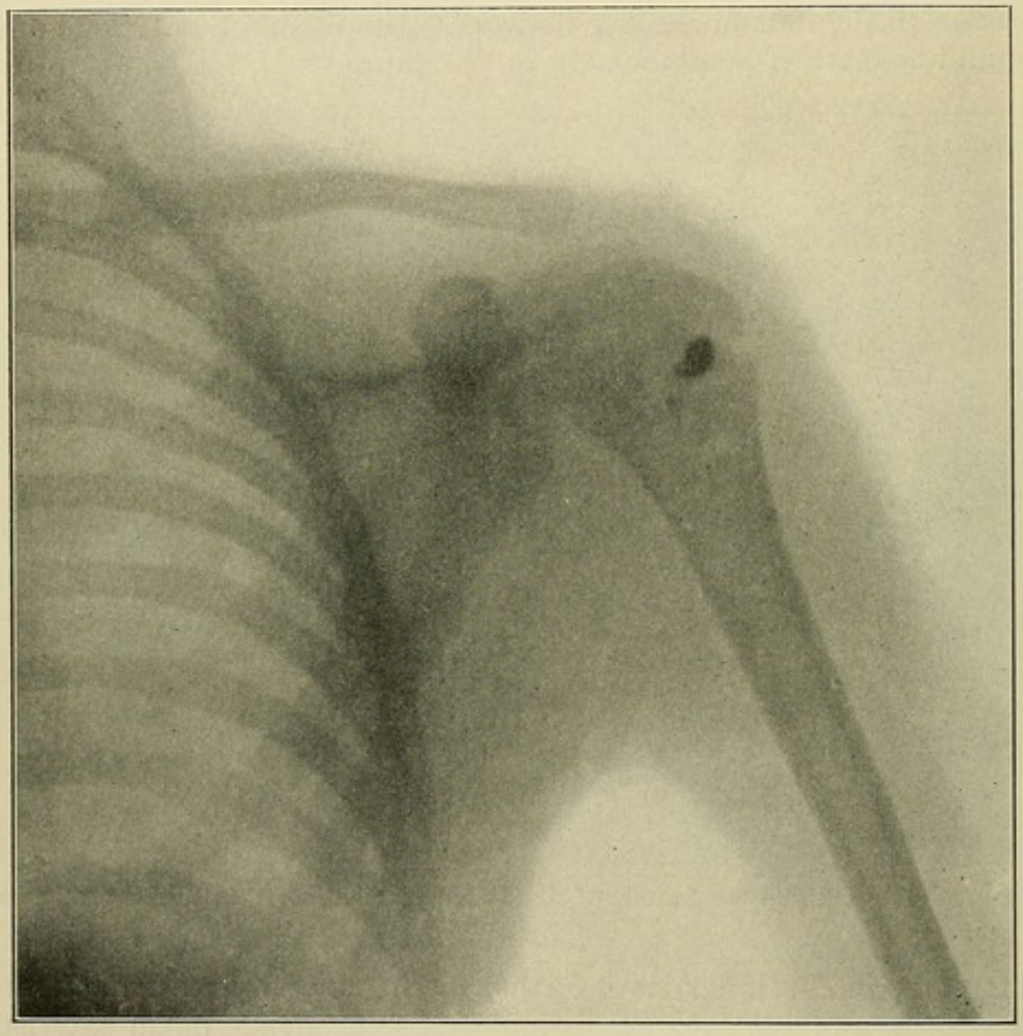

Fig. 370.—Bullet embedded in upper epiphysis of the humerus.

concerned, as all the loose fragments, and many with limited attachments, are lost by necrosis. Extensive phlegmonous inflammation of the soft tissues at the seat of fracture seriously retards repair of the fracture, aside from its destructive effects on bone by causing tension and by preventing speedy vascular connection between the ends of the fractured bone. Besides, suppuration at the seat of fracture always destroys more or less of the two bone-producing tissues—medulla and periosteum. The torn periosteum and the exposed and often crushed medullary tissue fall an easy

prey to the suppurative process, and the extent of their destruction is proportionate to the intensity and extent of the inflammatory process.

In the treatment of a recent compound fracture the surgeon must pay especial attention to the preservation of the osteogenetic tissues. Fragments, loose and partially detached, must be saved whenever possible, and the lacerated periosteum must be preserved, placed, and fixed in its proper position around the fragments; the medulla, even if crushed, may prove useful in the subsequent process of repair, and is utilized in its normal anatomic location as a valuable bone-producing agent. Bruns has made successful transplantations of bone-marrow in the lower animals, and in the light of these experiments it appears rational and judicious to preserve this tissue carefully in dealing directly with the seat of injury. *The surgeon must recognize the importance of favoring callus production in compound fractures by saving all bone-producing tissues compatible with the nature of the injury, and so place and hold them in their proper relative anatomic positions by direct or external means of immobilization with the same care and in the same manner that he would deal with wounds of the soft tissues in which different anatomic structures are involved.* It is for this reason, if for no

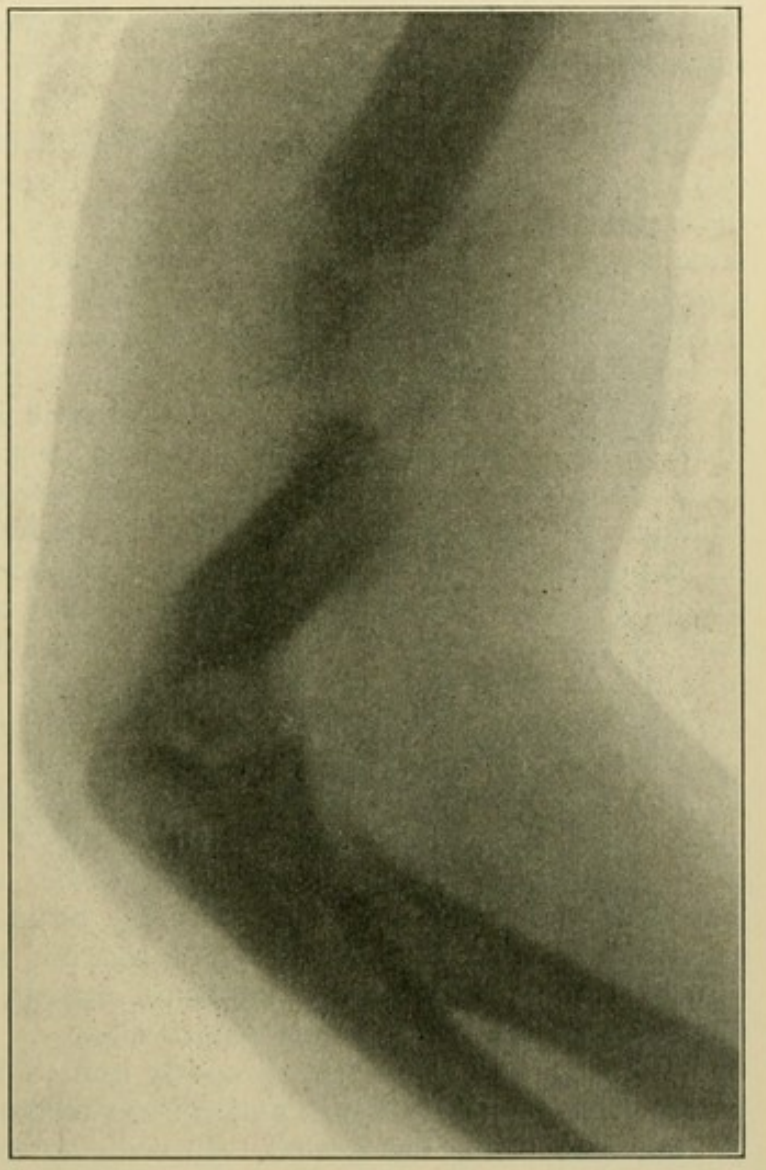

Fig. 371.—Extensive loss of bone following gunshot fracture of shaft of humerus and two unsuccessful operations for pseudarthrosis. Patient a lieutenant in United States army, wounded in the Philippine Islands (Clinic, Rush Medical College).

other, that the buried absorbable suture should be more frequently employed in the treatment of open fractures. If the wound is, or becomes, infected, the surgeon has another and important duty to perform in protecting the bone-producing tissues by establishing free and efficient drainage, and in taking the necessary steps to effect secondary disinfection by frequent antiseptic flushings or continuous antiseptic irrigation for the purpose of minimizing tension and of limiting the extension of the infection. In aseptic compound fractures repair usually takes place in the course of time by the formation of an exuberant provisional callus. Should callus formation be unduly delayed, several methods of treatment recommend themselves to stimulate the process of repair. If the wound has healed, the fragments can be rubbed together (Celsus), or the ends of the bone are drilled, according to the method devised and extensively practised with success by Brainard. Steel, ivory, and bone nails have been driven into the ends of the fragments for the same purpose by Dieffenbach. Stimulating injections between and around the fragments have likewise proved valuable in such cases. Of these, a 10 per cent. solution of chlorid of zinc (Lannelongue), injected in quantities of from fifteen to twenty-five drops, is the most reliable. If the wound remain open and the fragments are accessible, a tampon saturated with turpentine has been recommended by Mitchell Banks. Partial elastic constriction above the seat of fracture, as recommended by Dumreicher and Helferich, has a decided influence in stimulating the reparative process. Finally, the use of the limb, properly immobilized, is conducive to callus formation in the treatment of delayed union.

If a false joint develop at the seat of fracture in spite of the measures employed, direct operative treatment should be resorted to promptly, if the general condition furnishes no contraindication. The operation consists in transforming, by incision and vivifying the fragments, an old into a recent fracture, and in resorting to direct means of fixation by suturing, nailing, or by the use of intra-osseous splints, bone ferrules, or clamps. After any of these operations the limb must be properly immobilized by an efficient external mechanical support, and its use recommended as soon as the external wound has healed. In vivifying the fractured ends, as little of the bone should be sacrificed as possible, and the sections made with a view to securing as large surfaces as possible for approximation. The bone-ends should never be cut transversely, as such a procedure necessitates an unnecessary loss of bone and furnishes only limited approximating surfaces. The bone sections should be made obliquely, so that the fragments overlap each other freely, when they are immobilized by a bone or an ivory nail, a means of fixation applicable also when the vivifying is done by step sections, as advised by Volkmann, or when the fragments are dovetailed. If the bone defect is such as to preclude the possibility of direct fixation, some kind of an autoplastic operation will become

necessary to supply the seat of fracture with a sufficiency of bone-producing tissue to effect restoration of the continuity of the bone. Implantation of bone from any of the lower animals has not proved successful in such cases, and further experimentation in this direction is unwarranted in the light of the experiences of the past. Transplantation of bone from one human being to another has occasionally proved successful, but the supply of desirable tissue is always difficult to obtain, and the results are much more uncertain than those of autoplastic operations. If traumatic osteomyelitis complicates the case, the reparative process is always retarded, and the subsequent sequestration not infrequently results in bone defects sufficiently extensive to prevent union by bony consolidation. This result is more likely to occur if the periosteum is destroyed to any considerable extent by the secondary suppurative periosteitis, and by extensive paraosteal phlegmonous inflammation. It is the character of the osteomyelitis and the extent of the phlegmonous inflammation that determine the degree of danger to limb and life in such cases. In the most virulent cases streptococci are almost constantly found in the inflammatory product, and when emphysema makes its appearance, the existence of a mixed infection can safely be assumed. In the most acute and dangerous form of wound infection the fractured limb becomes enormously swollen and often emphysematous, and a superficial inflammatory blush plainly indicates streptococcus infection. The general symptoms set in quickly, and in a short time reach a degree that can leave no doubt as to the existence of progressive sepsis. It is under such circumstances that the surgeon is often in doubt as to what course he should pursue. Prompt action is necessary to cut off the further

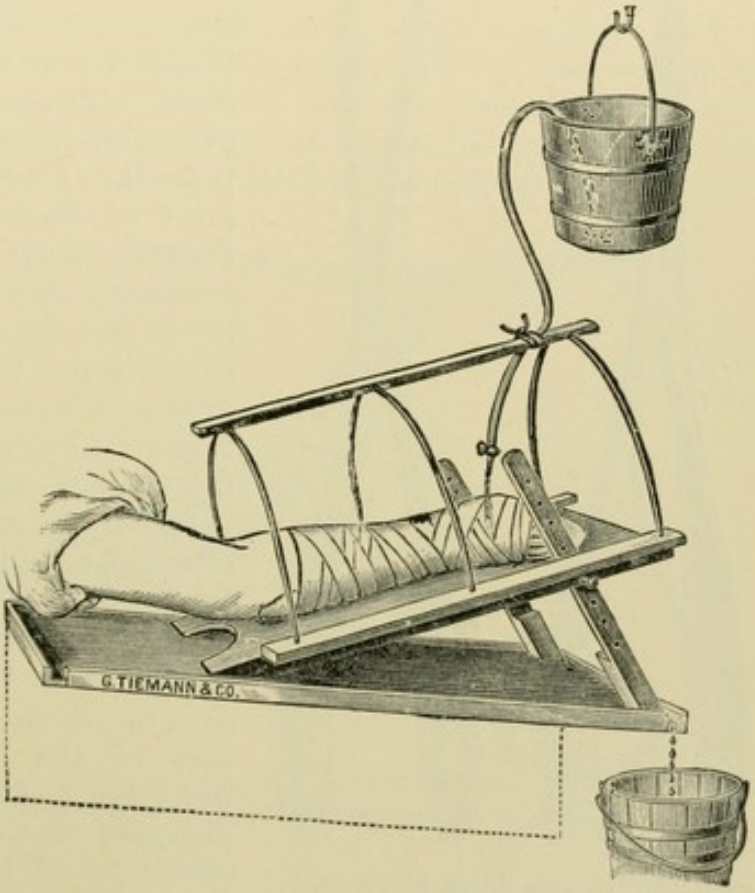

Fig. 372.—Apparatus for permanent antiseptic irrigation.

supply of septic material, either by free drainage and permanent antiseptic irrigation or by secondary amputation. Careful examination and good judgment are necessary to choose wisely between a conservative course of treatment and a mutilating operation. Each case must be judged on its own merits. The appearance of gangrene in the wound, or at a distance from it, and extensive emphysema are conditions that warrant a resort to amputation as the only means of preventing death from septicopyemia. Peripheral evidences of extensive septic thrombophlebitis indicate the same course as well as the symptoms which point to an incipient pyemia.

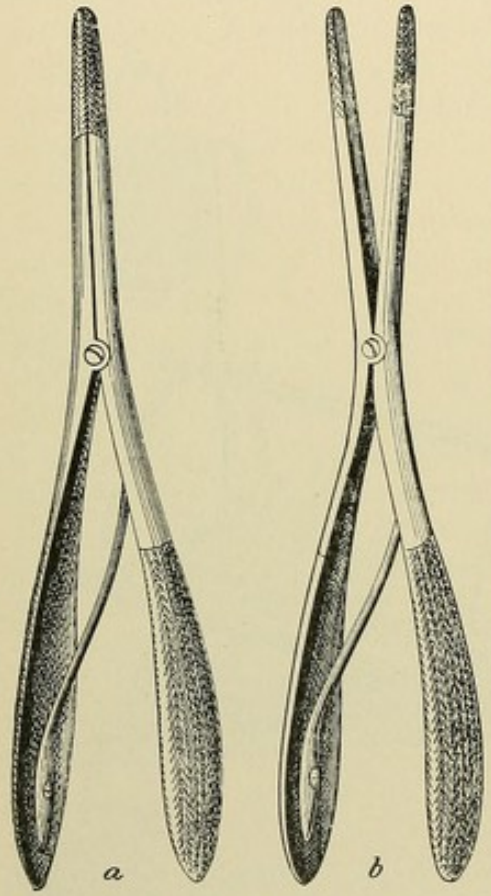

Fig. 373.—Roser's dilator for establishing drainage: *a*, Closed; *b*, open.

On the other hand, extensive phlegmonous inflammation can often be treated successfully by free drainage and continued antiseptic irrigation, with the limb properly immobilized and suspended. *Drainage, to be effective, must be thorough.* The seat of fracture must be exposed, the necessary débridement made, and from the fracture the drainage canals made by tunneling the tissues with a locked pair of hemostatic forceps of the requisite size from within outward, and the knife used only in making the counter-opening at the base of the projecting cone of skin over the point of the instrument. The tubular drains must be well fenestrated and of adequate size. Every recess of the suppurating cavity must be drained separately in a direction that will favor the ready discharge of its contents. Continuous irrigation should be made through several or all the drains, so that the septic material that is formed is promptly washed away.

The immobilization of fractures thus complicated will tax the surgeon's mechanical ingenuity to the highest degree. One of the essential conditions of the mechanical treatment consists in suspension of the fractured limb. Frequent change of the fixation splint not only causes unnecessary pain, but never fails to aggravate the existing inflammation and to inhibit incipient reparative processes. The surgeon must devote the necessary time and exercise the requisite skill to apply a fixation dressing that will require no change until the inflammatory process is under control and the swelling has subsided. Some form of a bracketed plastic splint is

best adapted to meet the mechanical indications, and, if required, this method of fixation can be combined with extension. Persistent efforts during a long struggle for limb and life are often rewarded ultimately by a satisfactory process of repair and a good functional result. Early operative interference for the osteomyelitic complication is always contraindicated. Early operations would tend rather to increase than diminish the danger from sepsis, and almost always result in pseudarthrosis. If the case yields to the conservative measures employed, the inflammatory process becomes limited, suppuration diminishes, the fever subsides, and in the immediate vicinity of the infected territory a process of repair is initiated. Under favorable circumstances the periosteum and medullary tissue assume active tissue formation, a profuse provisional callus makes

Fig. 374.—Sharp spoon.

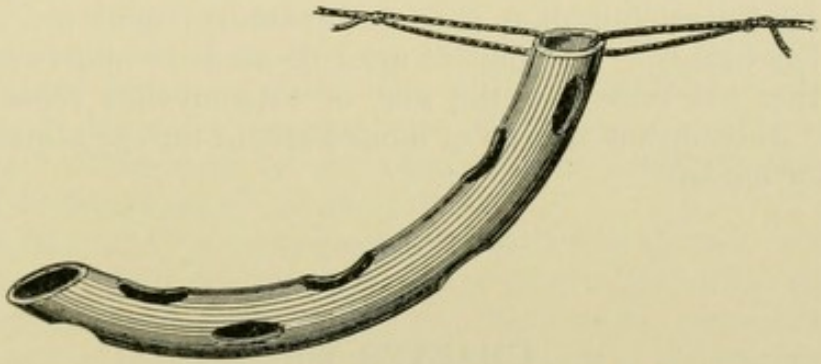

Fig. 375.—Fenestrated rubber drain.

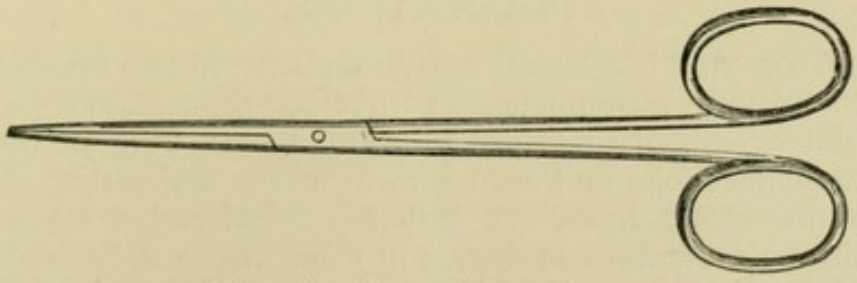

Fig. 376.—Lister's drainage forceps.

its appearance and connects, bridge-like, the fractured ends, and constitutes a more or less complete involucrum for the sequestrating bone. The external wounds heal, with the exception of one or more fistulous tracts that lead down to the necrosed bone. *Operative interference must be postponed until the fracture has united by a bony callus, and until the necrosed bone has become detached in the form of a sequestrum or sequestra, when necrotomy is performed in the usual manner.* The healing of such bone cavities is often a very tedious process. The process of final repair can be hastened and the functional result improved by packing the cavity, previously

rendered aseptic, with decalcified iodoformized bone chips. The success of this procedure depends entirely on the thoroughness with which the disinfection is made. It is necessary to remove not only the necrosed bone, but also the infected granulations lining the bone cavity and the fistulous tracts, by the vigorous use of a sharp spoon, after which the cavity and the whole wound are disinfected by pouring into them peroxid of hydrogen, and later by a prolonged irrigation with a hot 2½ per cent. solution of carbolic acid. The cavity is then mopped out with a gauze sponge, held in the grasp of a hemostatic forceps, when it is properly prepared for the implantation of the decalcified bone chips. In opening the involucrum the periosteum is carefully preserved, and after tamponing the cavity with the absorbable material, it is sutured over the cavity by a row of buried absorbable sutures, when the external wound is closed in the usual manner, leaving a small space at one of its angles for a small absorbable capillary drain consisting of a bundle of catgut. The limb must be kept in an elevated position, at an angle of 45 degrees, for at least twelve hours, to prevent undue parenchymatous oozing, and immobilization must be continued until the external wound has healed. The patient must be made to understand that a bone that has once been the seat of osteomyelitis remains predisposed to recurrent attacks of limited extent for the remainder of his or her lifetime.

CHAPTER XII.

DISLOCATIONS.

A DISLOCATION is a lateral separation between two articular surfaces, complete or incomplete. A traumatic dislocation is an injury of a joint or articulating surfaces, caused by tearing of the ligamentous connections and displacement of the articulating surfaces by the dislocating force. A pathologic dislocation takes place gradually by muscular contraction in joints made defective by disease of the ligaments or destruction of the articular ends. Partial or incomplete dislocation is common in pathologic dislocations, but very unusual in traumatic dislocations. A compound dislocation, like a compound fracture, is complicated by the existence of a wound that establishes a communication with the surface of the skin and the dislocated bone. Bilateral, double, and multiple dislocations are designations used in the same sense as in the description of fractures. Besides traumatic and pathologic dislocations, we speak of congenital dislocations when the displacement of the articular surfaces takes place during intra-uterine life in consequence of defective development of the articular ends or facets.

The nomenclature of dislocations has reference to the dislocated

member. Thus, in dislocation of the knee-joint, when we speak of an anterior, a posterior, or a lateral dislocation, we have reference to dislocation of the head of the tibia in the respective directions. The name of the joint is also usually associated with the designation of the dislocation, and we find that the text-books make use of this classification in the description of the different dislocations. The direction of the dislocation of the distal member is made use of in the anatomic description of the injury, and we are made familiar with the expressions anterior, lateral, and posterior dislocations of the knee- and elbow-joints; dislocation of the head of the humerus forward into the subcoracoid space, downward into the axilla, and backward; and of the head of the femur upward and backward upon the dorsum of the ilium; anteriorly, posteriorly into the sciatic notch, and downward into the obturator foramen.

Dislocations occur much less frequently than fractures, the proportion being about one to ten. This disproportion in the frequency of fractures as compared with dislocations has an important bearing on the diagnosis of injuries of the important joints, as in cases of doubt the existence of a fracture must at least be suspected. Dislocations of the shoulder-joint are prominent in the statistics, being followed very closely by dislocations of the elbow-joint. The lower extremity is the most frequent seat of fracture, the upper, of dislocations. *Dislocations of the shoulder-joint constitute about from one-half to two-thirds of all dislocations.*

Age has an important bearing on the etiology and location of dislocations. This accident may occur at any age, but is most frequent between the ages of twenty and thirty years—that is, a period of life exposed to the greatest risks of all kinds of traumatism. The relative frequency of this accident is greatest between forty and seventy years. In persons less than twenty years of age dislocations of the shoulder are rare; on the other hand, dislocations of the elbow, frequent. The reverse is the case during later life.

Etiology and Mechanism.—Among the predisposing causes must be included the anatomic and pathologic. The anatomic predisposing causes consist in the conformation of joints and deviation of the axis of the distal member. The shoulder-joint, owing to its anatomic conformation, is highly predisposed to dislocation, and this accounts quite satisfactorily for the very unusual frequency with which we find dislocations here as compared with any other of the important joints. Deviation of the axis of the distal member as an etiologic factor is best shown by the frequency with which dislocations occur at the elbow-joint. The deviation of the forearm outward from the axis of the humerus constitutes a potent predisposing cause of dislocations of this joint.

Among the pathologic predisposing causes must be mentioned distention of joints by effusion or extravasation, destruction or softening of the ligaments, and fractures involving joints or their vicinity. The stretching and weakening of ligaments consequent upon

prolonged intra-articular tension is one of the most potent predisposing causes of pathologic dislocation. The softening and destruction of ligaments resulting from chronic and acute diseases of joints act in a similar manner. The frequency with which dislocations of large joints are complicated by fracture reminds us of the influence of fractures as a predisposing cause of dislocation. Fracture of the upper and posterior margin of the acetabulum, if sufficiently deep and extensive, removes the support for the head of the femur. This complication is to be suspected in dislocations of the

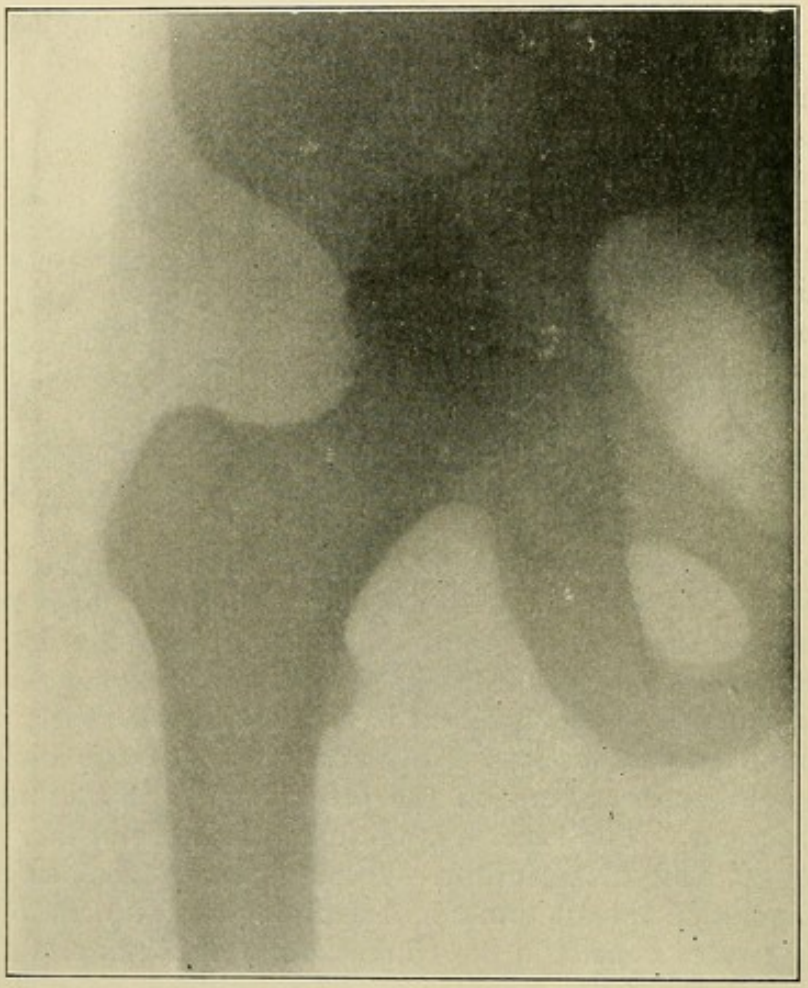

Fig. 377.—Fracture of the upper rim of the acetabulum, with partial dislocation of the head of the femur upward.

hip-joint in which the reduction can be made without any difficulty, but is followed almost immediately by recurrence of the dislocation.

Dislocations of the elbow-joint are most frequently associated with fracture, and it is here that the fracture is so often overlooked and consequently the dislocation imperfectly reduced, or, if reduced, followed by partial or complete recurrence, owing to defective treatment of the fracture. These are the cases that demand a most searching examination under the influence of an anesthetic, and the most untiring attention during the entire treatment.

The exciting causes of dislocations are external violence, applied

either directly at the seat of dislocations or at some distance, the indirect force being transmitted through the axis of the bone, and muscular action. By far the greatest number of dislocations are produced by indirect force. Dislocations from muscular contraction are rare in intact joints, and are seen most frequently in habitual dislocations where the joint surfaces and ligamentous connections have been damaged by antecedent disease or injury.

Pathology of Recent Dislocations.—One of the constant pathologic conditions in every dislocation is more or less tearing of the ligamentous connections. A dislocation can never occur short of some laceration of the soft structures that hold the articular surfaces in contact. In pathologic, congenital, and habitual dislocations the defects of the joint surfaces or destruction or relaxation of the ligaments furnish the predisposing cause, and permit a dislocation to occur in consequence of a very slight trauma, or as the result of muscular contraction. *In ball-and-socket joints laceration of the ligaments is found on the side of the dislocation, and the untorn part of the ligaments fixes the dislocated bone firmly in its abnormal position, and offers the greatest opposition to efforts at reduction.* In dislocations of the upper articular ends of the humerus and femur the head of the bone often escapes through a slit or rent in the capsule, when the neck of the bone is grasped by the margins of the tear, a condition that often effectively resists all efforts at reduction. It may be stated, as a rule, that reduction is easy in proportion to the extent of tearing of the ligaments, and very difficult and occasionally impossible when the capsule retains, to a maximum degree, its resisting power. *Physicians must learn to appreciate the practical importance of overcoming the resistance of the untorn portion of the ligaments in attempting reduction, to antagonize the most serious mechanical resistance by placing the dislocated bone in the exact position that it occupied the moment the dislocation occurred, which will always result in relaxation of the untorn portion of the ligament.* In all joints other than enarthrodial the ligaments on one or both sides are ruptured.

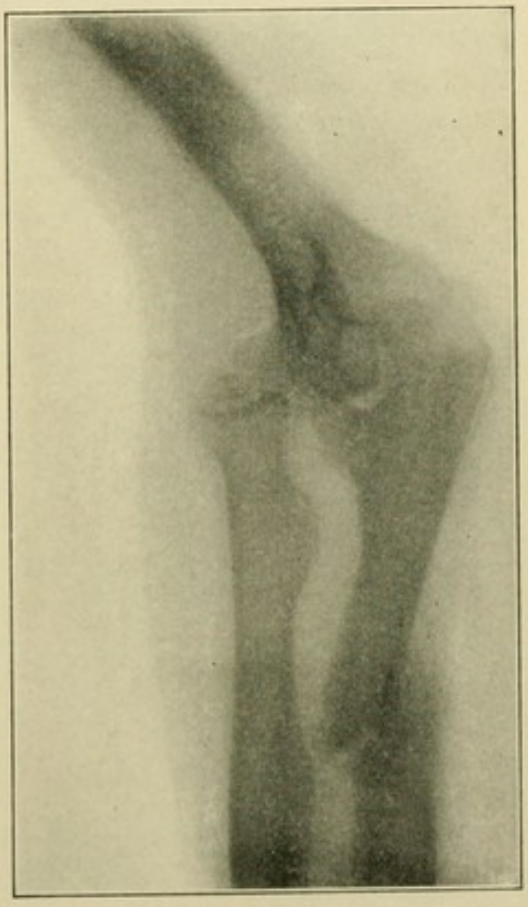

Fig. 378.—Anterior dislocation of the head of the radius, with fracture of the ulna.

In dislocations of the lower maxilla the ligaments are stretched and partially torn; the same may be the case in joints supplied with relaxed ligaments. Not enough stress has been placed on the tearing of ligaments in the reduction of dislocations. It is an injury which, if not recognized and properly treated, only too often weakens the joint permanently, and lays the foundation for habitual dislocations. After reduction has been effected, the treatment must be directed toward a satisfactory repair of the injured capsule, to restore its normal efficiency as a retentive apparatus. Premature active and passive motion interferes with ideal healing of the joint wound, and should be carefully avoided until the healing process is completed—that is, in the case of the large joints; rest, with the limb in the most favorable position to relax the torn part of the capsular ligament, must be enforced for from three to four weeks. Enforced rest beyond this time may again result in hernia, by causing inactivity atrophy.

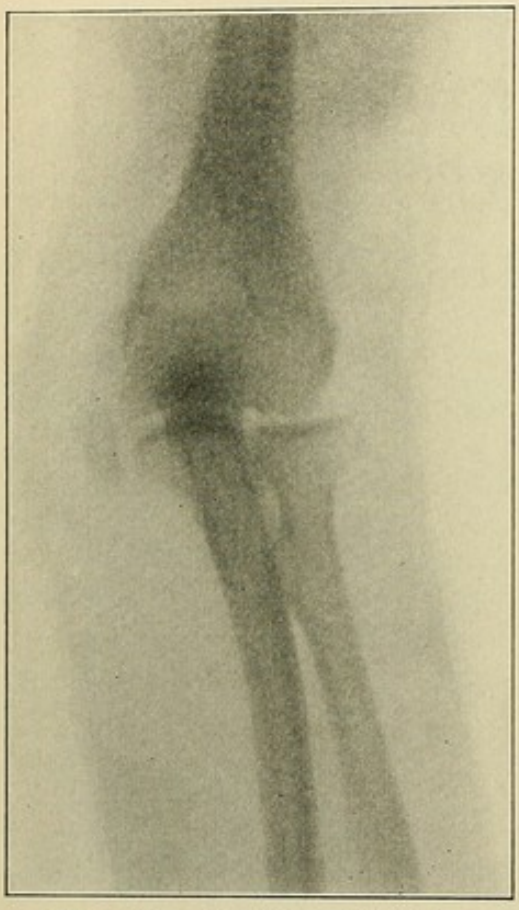

Fig. 379.—Dislocation of both bones of the forearm backward, with fracture of the internal epicondyle of the humerus. Epicondyle is displaced downward and backward.

Rupture of tendons and muscles is another important feature in the pathology of recent dislocations. The extent to which muscular action is restored immediately after the reduction will serve to indicate, to some degree at least, the presence and extent of this part of the injury. Fixation of the limb, with the injured tendon or muscle relaxed, continued until union is firm enough to warrant the removal of the mechanical support, is a very important part of the treatment in such cases.

The splitting off by traction force of portions of the rim of the acetabulum, of the glenoid cavity, the margins of the malleoli, and the condyles of the femur and humerus takes place much more frequently in dislocations than is generally supposed, and is often responsible for unsatisfactory functional results, and may furnish a serious obstacle to reduction, and often becomes the direct cause of habitual dislocation. The chipping off of subcutaneous bony prominences can usually be discovered by careful palpation, as crepitus can be elicited by rubbing the fractured surfaces together; but in hip- and shoulder-joint dislocations this method of examina-

tion will not succeed in demonstrating the presence or absence of this very important complication. It may, however, be suspected if the reduction is made with unusual ease or if it is attended by any especial difficulties, and more particularly if redislocation occurs by placing the limb in the same position it occupied the moment the accident occurred. Crepitation during the reduction and redislocation is seldom felt, and can not be relied upon in diagnosticating a marginal fracture of any of the deep joints. The existence of such a complication calls for prolonged immobilization of the joint after the reduction. Bony union between the fractured surfaces is seldom obtained, even under the most careful treatment, but if the fragment unites by the formation of a short and strong fibrous union, the function and strength of the joint are not necessarily permanently impaired by the fracture.

Every dislocation is attended by injuries of the ligaments and para-articular tissues, constituting a severe sprain, which must be properly treated after reduction has been made. Such reduction must be accomplished in a manner that is calculated not to add unnecessarily to the size of the first wound. The amount of extravasation depends on the extent of the injury to the capsule and other soft tissues. Intra-articular and para-articular hemorrhage increases the primary swelling caused by the dislocated bone, but its extent can not be estimated with any degree of accuracy before the reduction. The swelling that remains after the reduction of a recent dislocation consists of extravasated blood, the presence of which can later be recognized by the appearance of ecchymosis. If the primary swelling from this cause is large, it often obscures important landmarks upon which the physician has to rely so much in recognizing the dislocation and in satisfying himself that reduction has been effected. Secondary swelling setting in a few hours after reduction is due to effusion from the injured capsule and synovial membrane.

In some instances the dislocating force is productive of a fracture at the same time, the dislocation of what remains of the head of the bone taking place after the fracture has occurred. In the event of such an injury the dislocated bone is not immobilized to the same extent as when the entire articular end has become displaced, because the complicated injury implies extensive tearing of the capsule of the joint and a diminution in size of the articular end.

Fracture of the articular end of the bone is rare, and when it does occur, it is produced after the dislocation has occurred, and usually by a continuation of the force that caused the dislocation—that is, it is a secondary accident. Partial fracture of the rim of the socket in enarthrodial joints and evulsion of portions of the epiphyses as complicating injuries are not rare, and often constitute the principal causes of unsatisfactory restoration of function after perfect reduction and otherwise efficient treatment.

Ruptures of important vessels and nerves are the most serious complications of dislocations. These accidents are, fortunately, rare, and when they do occur, they have been produced by traction or twisting after the dislocation has taken place. Rupture of the axillary artery or any of the large branches is an accident to be feared and guarded against in attempting the reduction of old dislocations of the shoulder-joint. This accident has occurred repeatedly during such attempts, and has only too often been followed by gangrene or the formation of a traumatic aneurysm. *In using more than ordinary force in attempting the reduction of a recent or old dislocation the relation of large blood-vessels and nerves to the dislocated bone must be carefully studied, and all harmful traction on these important structures studiously avoided.* The anterior circumflex nerve is occasionally torn by the dislocating force or by the attempts to reduce a dislocation of the shoulder-joint. Such an accident is necessarily followed by permanent paralysis of the deltoid muscle. Inflammatory adhesions and the great force exerted by using the dislocated bone as a lever will occasionally produce a disastrous result when least expected.

After reduction has been made successfully, the objective and subjective symptoms are remedied promptly, and the subcutaneous injury, as a rule, is repaired quickly and satisfactorily, provided the injured parts are kept in a condition of rest a sufficient length of time. In some cases, however, perfect repair fails to obtain, owing to the extent of the injury of the soft tissues, the margins of the articular surfaces, injury to important tendons, muscles, and nerves, the amount of extravasation, and, later, effusion into the injured joint, and the development later of joint affections arising from the trauma. Active and passive motion, massage, and electricity at the expiration of three or four weeks after the injury are the most useful therapeutic resources in removing stiffness, in preventing ankylosis, and in restoring the normal range of motion and usefulness of the joint.

Unreduced dislocations are not infrequently met in neglected cases and as the result of erroneous diagnosis, impossibility of effecting reduction in recent cases, and sometimes as an unavoidable consequence of dislocation complicated by fracture.

The terms recent and old or ancient dislocations are relative in their clinical meaning. Some dislocations become old—that is, irreducible—in a few days or weeks; others can be successfully reduced by the bloodless method a year or more after the accident. Of eight or ten cases which have come under my own care, it has been my good fortune never to have failed in reducing a dislocation of the shoulder-joint three months old, while I failed in two cases of dislocation of the hip-joint after about the same lapse of time. From a trying experience every surgeon has become aware of the fact that dislocations of the elbow-joint in any direction and in all anatomic forms become irreducible in a very short time. The

head of the dislocated bone in an old irreducible dislocation soon becomes encapsulated, and if it presses against a bone surface and a certain degree of motion is preserved, a new socket forms and the limb becomes useful in proportion to the range of motion. One of the obstacles to successful reduction of an old dislocation is union of the untorn portion of the capsule with the cavity of the joint. Interposition of the torn portion of the capsule between the head of the dislocated bone and the cavity of the joint imposes another serious impediment to reduction. The encapsulation of the head of the dislocated bone in its abnormal position, and adhesions of the neighboring socket, nerves, and blood-vessels, add to the difficulties and immediate risk of forcible attempts at reduction. One of the almost hopeless conditions, so far as successful reduction and restoration of function are concerned, is furnished by a gradual but progressive obliteration of the cavity of the joint. This remote pathologic condition is established by shrinkage of the capsule—filling in of the cavity by new material and shallowing of the articular depression by atrophy of its rim.

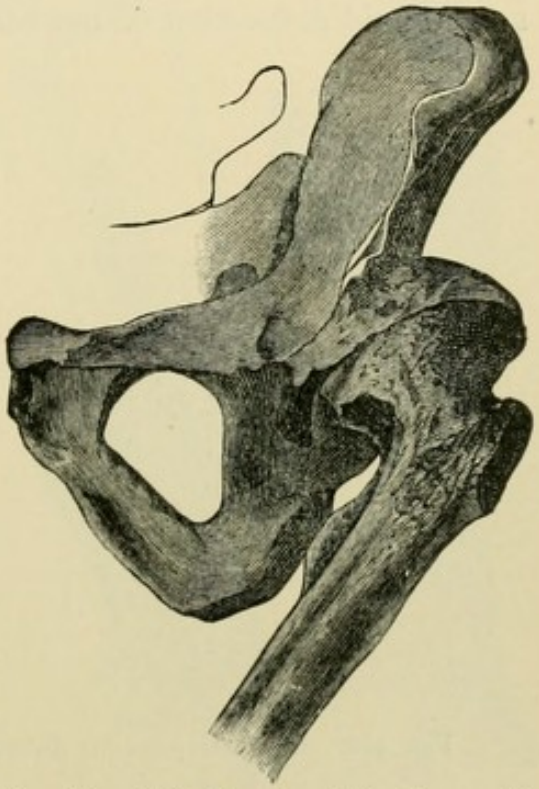

Fig. 380.—Old dislocation of the femur with very complete new acetabulum (Krönlein).

Symptoms. — The most important distinguishing features between a nonimpacted fracture and a dislocation are a false point of motion and preternatural mobility in the former, while in the latter motion is either entirely suspended or at least greatly impaired by the displacement of the bone, held firmly in its abnormal position by the untorn portion of the capsule, muscles, tendons, and fascia, changed in their relations to the dislocated bone by the alterations in their point of origin and insertion. The deformity that attends a dislocation is usually more striking and of greater diagnostic value than in fractures (Figs. 381 and 382). *In dislocations the maximum degree of deformity is seen immediately after the accident has occurred, while in fractures it is increased by muscular contraction and the weight of the limb. In dislocation the deformity is caused by the head of the dislocated bone being removed from its socket by the dislocating force, and remaining fixed and uninfluenced later by the position of the body or limb.* Deformity as an indication of the existence of a dislocation presents itself to greatest diagnostic

advantage immediately after the injury has been received, and before important anatomic landmarks become obscured by the extravasation of blood from the torn soft parts.

Deformity is frequently so well marked and characteristic as to be almost diagnostic. In posterior dislocation of both bones of the forearm, the anteroposterior diameter of the limb at a point corresponding with the condyles of the humerus is greatly increased, the limb is in a fixed extended position, and the tip of the olecranon process is seen and felt above its normal level. In dislocation of the head of the femur upon the dorsum of the ilium the marked prominence of the head of the femur in its abnormal position at once attracts attention, and the thigh is found adducted, rotated inward, and the limb markedly shortened. In a subcoracoid dislocation of the head of the humerus the acromion

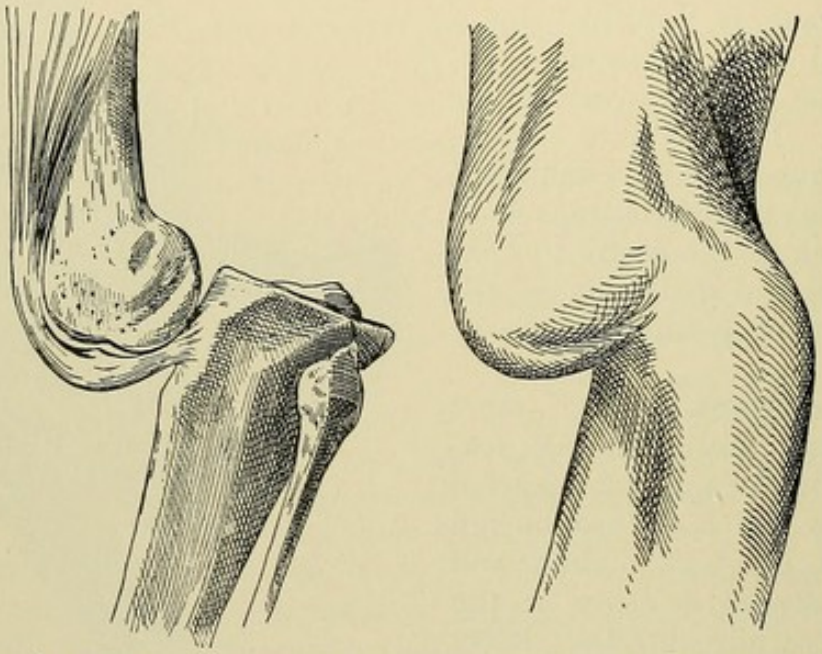

Fig. 381.—Complete posterior dislocation of the head of the tibia (Hoffa).

process is preternaturally prominent, the depression below it conspicuous, the humerus abducted and immovable, and the space below the coracoid process of the scapula made prominent by the displaced head of the humerus.

In rendering the deformity a reliable witness of dislocation, the examination must be made with the necessary care. Comparison between the same joints is necessary to detect and note abnormalities. The removal of clothing to the requisite extent must precede inspection, palpation, and mensuration, as well as to determine the degree of impairment of mobility of the injured limb. This advice may appear trivial and unessential, but it should never be lost sight of in conducting the examination. The detection of the head of a bone in an abnormal position after an injury goes far in the diagnosis of a dislocation. If we can, at the same time, determine by

inspection and palpation a vacancy in the position usually occupied by the head of the bone, and a faulty axis of its shaft, we are in possession of additional valuable corroborative evidence. The head of the femur and humerus can usually be detected in their faulty position without any special difficulty, and can be identified as such by rotating the shaft of the bone and noting the faulty position of its axis. *The altered axis of the shaft of the dislocated bone is usually mentioned as an indication of dislocation, but its diagnostic value is not made use of sufficiently or is underestimated. Abnormality of the axis of a long bone after an injury is a reliable indication of the existence of a dislocation or a fracture near the articular end. The detection of the head of a bone in a faulty position and abnormality of the axis of the shaft, combined with fixation of the limb, are three proofs that speak unmistakably for dislocation.*

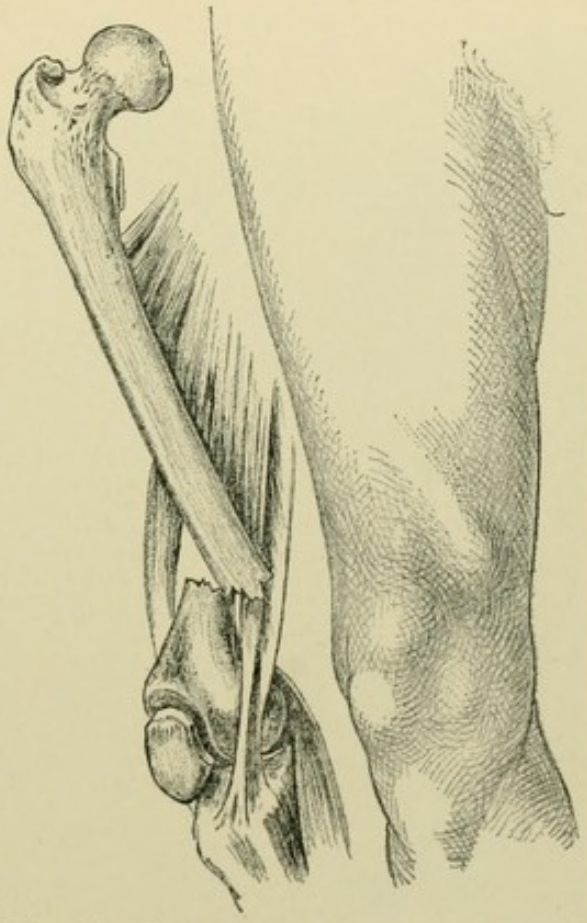

Fig. 382.—Supracondyloid fracture of the femur (Hoffa).

To determine the existence of deviation from normal of a shaft of a bone it is not only necessary to determine the abnormal position of the limb, but what is gained from inspection must also be confirmed by tracing the direction of the shaft of the bone from end to end by careful palpation, and by connecting the articular ends by a straight line drawn with a tape-measure, string, or, still better, by placing over the shaft the inflexible rule. To exemplify, in subcoracoid dislocation of the head of the humerus the faulty line of the shaft of the bone will not point in the direction of the glenoid cavity, but away from it toward the coracoid process of the scapula. Fixation of the limb in its abnormal position is one of the constant clinical features of a dislocation, and can mislead only in impacted fractures of the articular ends. In impacted fractures there is less deviation of the shaft of the bone, and the mobility of the joint is not impaired to the same extent. Comparative mensuration is always employed as a diagnostic resource in doubtful dislocations, as well as in fractures. As in fractures, fixed anatomic landmarks are selected, and the limbs should always be placed in symmetric

position. With few exceptions shortening is always found. No shortening would be expected in dislocations of the head of the radius alone. Elongation attends dislocation of the head of the humerus and femur downward, but the rarity of these accidents, compared with the frequency of the more common forms of dislocation, does not detract from the importance of the rule that shortening is an important symptom of dislocations as well as of fractures.

The altered attitude of the limb, ascertained by inspection and confirmed by palpation, aids us in suspecting the existence of a dislocation. The faulty position of the limb and the restriction of motion are due to the new relations of the head of the dislocated bone to the untorn portion of the capsule, adjacent muscles, tendons, and fascia.

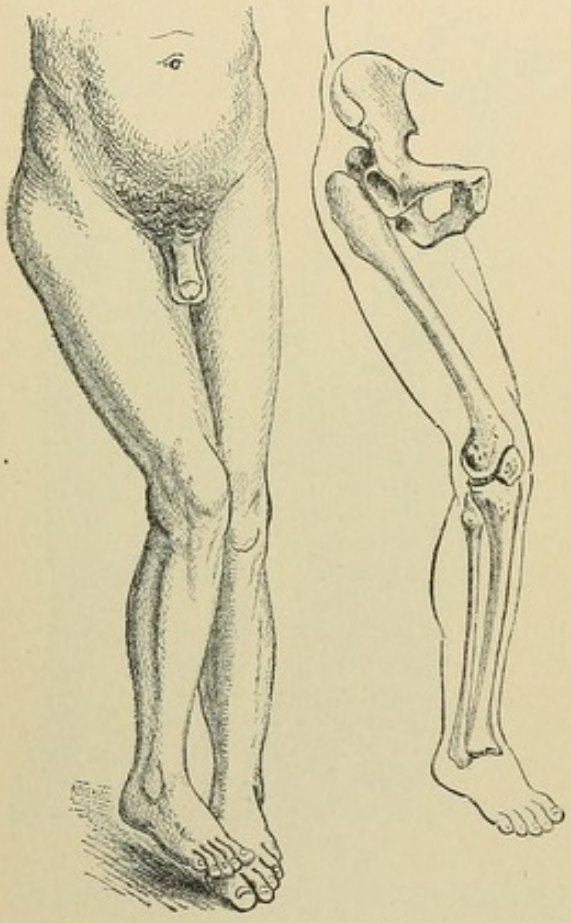

Fig. 383.—Characteristic deformity in dislocation of the head of the femur upon the dorsum of the ilium (Hoffa).

Pain is more severe than in fractures, which can readily be explained by the greater degree of harmful pressure and tension caused by the displaced end of the bone than by the ends of a fracture. The intense pain that attends and follows a dislocation is always an indication of great pressure and tension, caused by the displaced head of the bone. Pain is a distressing symptom, and is apt to become permanent if the dislocation is not reduced and the displaced end of the bone makes compression of any of the large sensitive nerve-trunks. It is a marked symptom in dislocation of the head of the humerus in the direction of the axillary plexus. In obscure cases and in cases complicated by fracture, the X-ray will demonstrate the existence or absence of a dislocation, and if a fracture exists, its location and relation to the dislocation.

Treatment.—It requires no argument in pleading for an early, correct diagnosis and prompt reduction in all dislocations. Procrastination obscures the diagnostic information, delays the relief, and retards restoration of function. The sooner a dislocation is recognized, the earlier the relief; and the sooner the reduction is effected, the better the functional results. Doubt and hesitation are utterly out of place here. If any doubt exists in regard to the

diagnosis, the sooner it is cleared away by the additional advice of consultants or the use of the Röntgen ray, the better for the welfare of the patient and the reputation of the surgeon. The malposition of fractures can often be corrected weeks after the accident without any special detriment to the patient, but the same can not be said of dislocations. Unrecognized and unreduced dislocations have been the bane of many well-meaning practitioners. In doubtful cases all diagnostic resources, including the use of a general anesthetic and the X-ray, have often been brought into requisition, and if they do not yield the desired information, it is to the credit

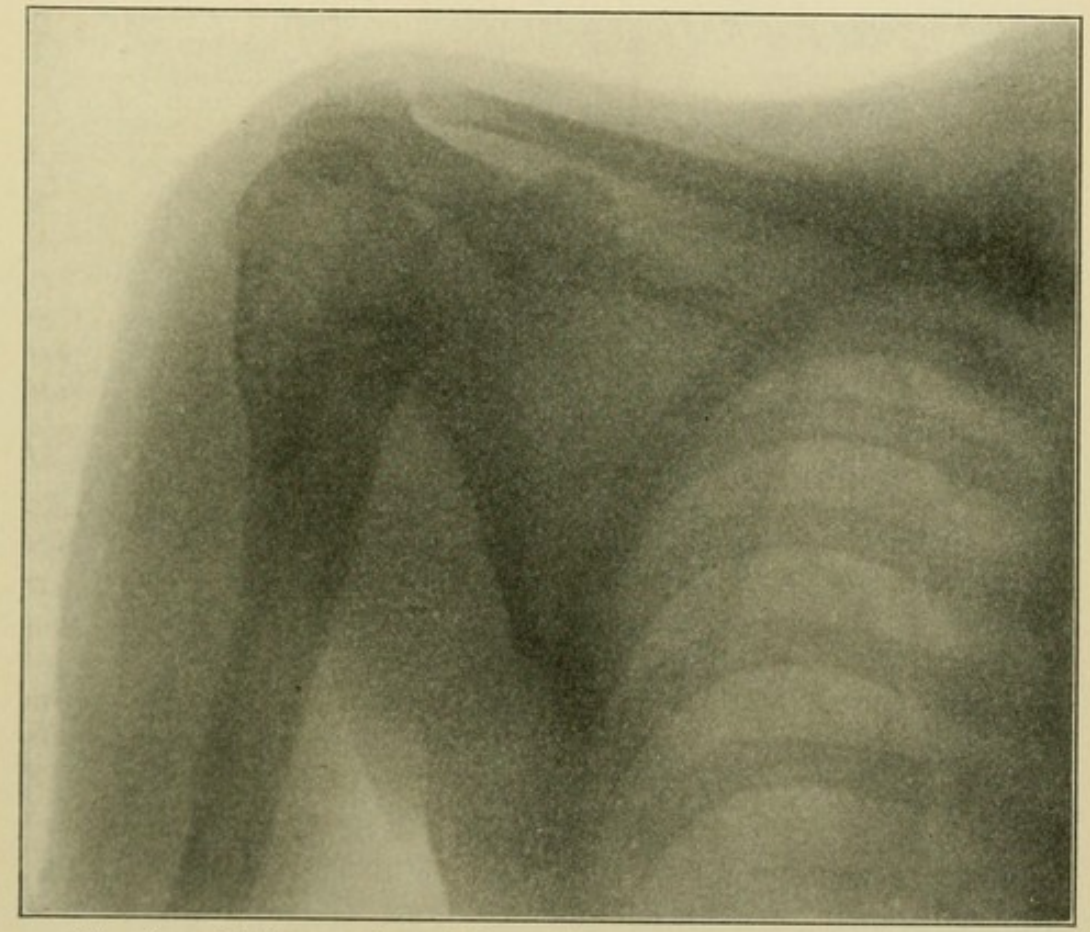

Fig. 384.—Old fracture through the surgical neck of the humerus mistaken for anterior dislocation. Marked displacement of lower fragment forward and inward. Union by massive callus in malposition. A considerable portion of the callus mass was removed to relieve pressure symptoms (Clinic, Rush Medical College).

of the physician to make the necessary open, honest admission and request counsel. It is a great mistake to shoulder the burden of an unknown weight, when relief is in sight by calling in the aid of competent colleagues. The most expert surgeon often finds himself in such a situation, and is only too willing to divide the responsibility incident to the case with one or more of his colleagues. It is certainly to be expected, therefore, that the general practitioner, with fewer opportunities for observation, would be more willing and anxious to share such responsibility. There are few things more

humiliating in surgery than to live in a community inhabited by former patients with unrecognized and unreduced dislocations. The error of two or more men in such cases receives less blame from juries, judges, and the public than the mistakes of one.

Positiveness in the diagnosis must come in advance of attempts at treatment. A correct diagnosis once made, prepares the way for successful treatment. *If the physician is able to picture to himself correctly the manner in which the injury was inflicted, the exact position of the limb at the moment the accident occurred, the location of the dislocated head of the bone, and its relations to the structures that antagonize reduction, he will have very little difficulty indeed in devising the manipulations that will enable him to effect reduction.* It is in such cases that it is wise policy to locate the resisting structures and resort to the manœuvers to overcome them with as little force as possible. Blind action is dangerous in all such cases. Shrewd strategy is better than force. Relaxation is safer and more effective than tearing; position more effectual than brutal, ill-directed force. It is said that the late Professor Brainard was once called to reduce a dislocation of the ankle-joint of a valuable horse. He made the remark that if he were conversant with the anatomy of the joint he would have no difficulty in doing what was necessary, but as he was entirely innocent of such knowledge, he refused to interfere. This was an honest confession on his part, and did more to maintain the great reputation he enjoyed as a surgeon than many of his brilliant and original operations. *An intimate knowledge of the anatomy of the joints and the points of origin and insertion of the muscles that antagonize reduction is an essential prerequisite to successful surgical intervention in dislocations, recent and ancient.* I am fully convinced that such information is not always at the disposition of the many practitioners who are called upon to diagnosticate and reduce dislocations. From necessity the average student prepares himself for his examination on anatomy, and after this trying ordeal has been passed, he only too often fails to keep abreast of this science in later life. His shortcomings in this primary branch of medicine become most apparent when he is called upon to diagnosticate and reduce dislocations.

While, as a rule, it is advisable to attempt reduction as soon as possible after the occurrence of a dislocation, actual interference may have to be postponed until the patient recovers from the immediate effects of the primary shock; more especially is this so if it becomes necessary to make use of a general anesthetic. *All methods of reduction must be based upon the recognition of the obstacles to reduction.* Muscular rigidity and contraction constitute very important elements in the fixation of the dislocated limb in its faulty position and in antagonizing the efforts at reduction. In dislocations easily reducible, muscular opposition can often be diminished or entirely overcome for the moment required for reduction by diverting the patient's attention; when the opposition from this

source is great, it can always be eliminated by a deep general anesthesia. The use of a general anesthetic enables us not only to determine with a greater degree of accuracy the exact position of the dislocated bone, but by removing muscular resistance further facilitates and simplifies the surgeon's work in replacing the bone in its normal position. Muscular relaxation as a preliminary step to reduction is especially desirable in the reduction of dislocated joints that are under the control of powerful muscles, as the hip- and shoulder-joints, and in persons of strong muscular development, while in emaciated and enfeebled persons, in children, and in the aged it can often be dispensed with.

In all dislocations the untorn portion of the capsule or ligaments plays an important rôle in fixing the displaced bone in its abnormal position and in resisting efforts at reduction. Bigelow and Gunn have made this obstacle to reduction a special study, and by careful dissections have shown how it can be best overcome. *All the different methods of reduction by manipulation are based on the now generally recognized great principle of moving the dislocated bone in such a way as to relax the untorn portion of the capsule or ligaments. This rule should never be transgressed in the reduction of a dislocation by either manipulation or traction.* As a rule, the untorn portion of the capsule is at a point opposite the location of the head of the dislocated bone. There are, however, exceptions to this rule, as, for instance, in dislocations of the shoulder-joint the head of the humerus usually finds its way out of the joint through a tear or slit on the anterior side of the capsule, but may become subsequently displaced into the axillary space, or even to a point behind the glenoid cavity. The possibility of such an occurrence should be remembered when the prescribed manipulations fail, as a change in the direction of the movement may accomplish what is so essential—relaxation of the untorn part of the capsule. If the untorn portion of the capsule is not respected in attempting the reposition, what remains of the capsule has to be torn before the bone can be replaced, thus adding unnecessarily to the injury of the soft structures of the joint. If the injured limb is placed in the exact position it occupied at the moment the injury occurred, the untorn portion of the ligamentous connections will always be relaxed, and it is in this position that necessary manipulations should always be commenced and the later movements made, with special reference to maintaining the relaxation.

Interposition between the head of the dislocated bone and the adjoining cavity of a portion of the ruptured part of the capsule occasionally constitutes a barrier to all bloodless attempts at reduction. The existence of such a mechanical obstruction is often suspected in irreducible luxations, but its actual presence can only be ascertained by exposing the joint in making the reduction by the open method.

An unusual relation of the dislocated head of the bone to certain

adjoining muscles may interfere with successful reduction. In dislocation of the head of the humerus forward the untorn portion of the subscapular muscle in rare cases is interposed between the head of the humerus and the glenoid cavity, frustrating all attempts at reduction by the bloodless methods. In typical dislocation the untorn portion of the capsule always presents itself as the most formidable obstacle to reduction ; in atypical luxations the ligamentous connections are torn so completely that no opposition is encountered from this source, in which case the influence of muscle contraction and bony prominences in the way of an easy return of the bone must be remembered in attempting reposition.

Reduction by manipulation is applicable only to typical dislocations. *Manipulation in the reduction of a dislocation consists of a succession of gentle motions communicated to the dislocated limb, by which the margins of the rent in the capsule are separated from each other, and the head of the bone is rolled back into place by aid of the untorn portion of the ligaments.*

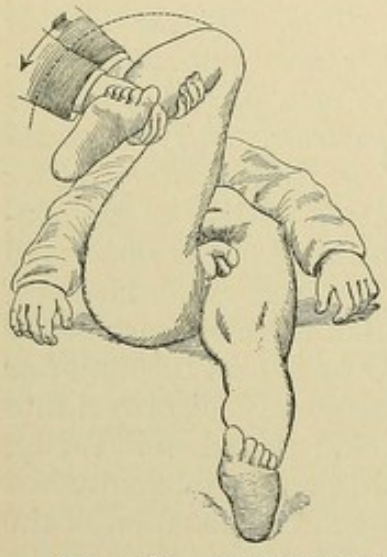

Fig. 385.—Middeldorpf's (Bigelow's) method of reduction of a dislocation of the head of the femur upon the dorsum ilii by manipulation.

The mechanism and technic of manipulation, as employed in the reduction of typical dislocations, are best shown by Kocher's method of reducing subcoracoid dislocations of the shoulder, and Middeldorpf's method of reducing dorsal dislocations of the hip-joint. The former will be fully described in the section on special dislocations of these joints. The use of a general anesthetic is usually necessary in facilitating manipulation, by securing the benefits accruing from perfect relaxation of the muscles, as well as to render the procedure painless. *The use of pulleys or other mechanical devices of great power is seldom made at the present time*, as their employment is attended by risks that should be avoided, and with very few exceptions, indeed, they can be dispensed with if the physician will locate accurately the position of the displaced head of the bone, and not forget that, with the patient fully under the influence of an anesthetic, the only serious obstacle to the reduction is the untorn portion of the capsule, and that when this is not placed on the stretch by the manipulations, the head of the bone can be rolled into place with very little force. *If considerable force becomes necessary in the reduction of recent difficult cases or old unreduced dislocations, the traction, manual or instrumental, as the case may be, must be made in a direction that will not expose important vessels and nerves to harmful trauma.* Very little is to be expected from gradual extension by weight or pulley or by india-rubber in

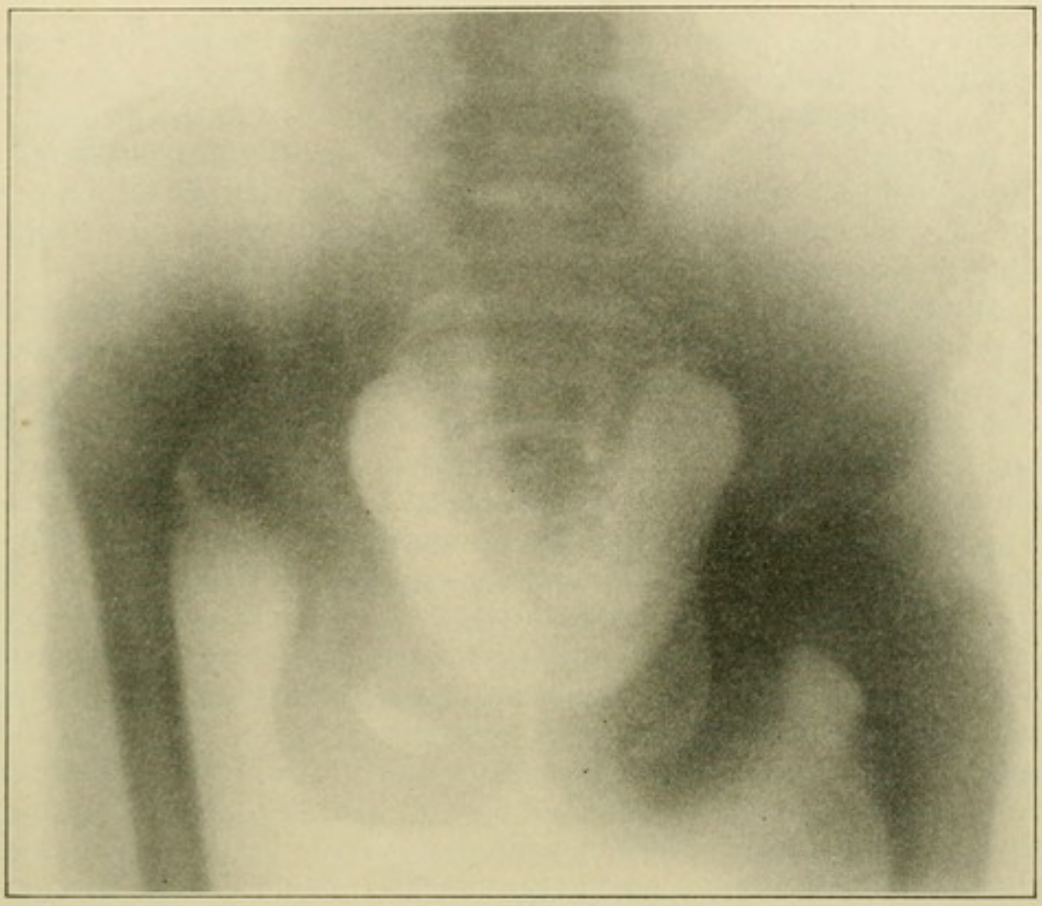

Fig. 386.—Old unreduced iliac dislocation of the femur.

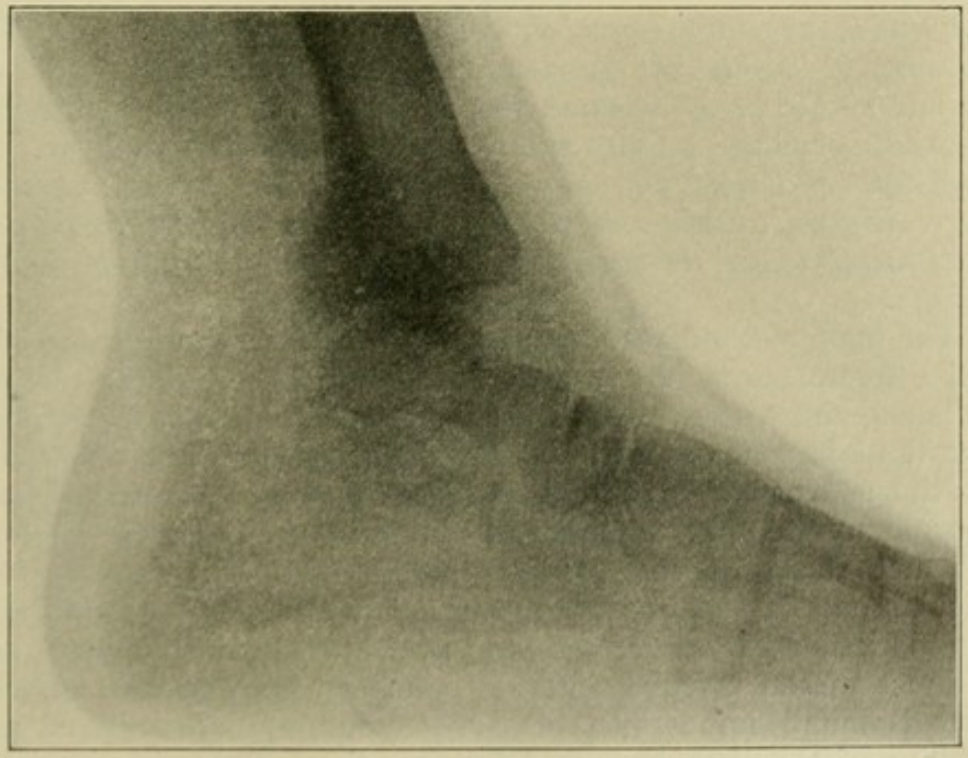

Fig. 387.—Subluxation of the foot backward.

the treatment of otherwise irreducible dislocations, both old and recent. If, after faithful attempts at reduction by the bloodless method, repeated, if need be, several times and with the assistance of at least one consultant, reduction is not successful, the propriety of resorting to the open method must seriously be considered. The probable benefits to be derived from it, as well as the immediate and remote risks that attend it, must be fully explained to the patient before proceeding.

Open Method of Reduction.—If the ordinary and safe methods of reduction fail, and the patient's general condition warrants the performance of an operation, it is much safer and the result more certain to resort to the open method than to persist in making forcible attempts, with the dangers incident to them and the uncertainty of accomplishing the desired object. Recent irreducible dislocations are usually made so by an uncertain or erroneous diagnosis. No number of manipulations or amount of traction could succeed in reducing the dislocated head of a bone separated from the adjoining socket by the interposition of soft tissues, a fragment of the torn capsule, or an adjacent muscle or tendon. There are cases, too, in which the head of a bone escapes through a slit in the capsule not large enough to permit its return by bloodless methods short of tearing off a considerable part of, if not the entire, capsule. A similar difficulty would be encountered if the head of the bone, after escaping through a rent in the capsule, should change its location, being subsequently displaced from one side of the joint to the other. Under such and similar circumstances open reduction under strict aseptic precautions inflicts less damage upon the soft tissues than would the employment of a dangerous amount of force. The exposure of a joint by an open incision always reveals the location and nature of the obstacle that resisted reduction, which, when removed, opens the way for the return of the dislocated bone. *In irreducible dislocations the open method enables the surgeon to make a correct diagnosis, locate and remove the cause of interference with reposition, and return the bone, with little or no violence, into its natural position.*

The open method recommends itself, however, more especially in the treatment of old dislocations where the bloodless method has failed, and where, owing to the length of time that has elapsed since the injury has occurred, it is deemed useless to give it a trial. It is in this class of cases that accidents of a serious nature have occurred so often in attempting reduction by the bloodless method, and that the procedure has so often failed. By exposing the articular end of the bone, ligaments, and socket by a careful dissection, important structures are protected against injury, and by direct means of reduction the bone can be replaced. If this latter is found impossible, pressure symptoms are relieved and mobility of the limb increased by resection of the head of the bone. The operation must be performed under the most pedantic

aseptic precautions, as wound infection, under such conditions, might result in very grave complications, and in the event of intra-articular suppuration, after a successful reduction, would almost be certain to impair, if not completely suspend, joint motion.

The incision is made with special reference to securing free exposure of the end of the dislocated bone and the adjacent socket, and, with another important object—the protection of important structures in the field of operation. The incisions that will be described and recommended in the chapter on Resections will be found well adapted for the operation. Good retractors, an elevator, curved scissors, hemostatic and two dissecting forceps, are the most important instruments in the direct reposition of the dislocation. Free exposure of the head of the bone, removal of interposed soft tissues, enlargement of the capsular rent, retraction of resisting muscles and tendons, are the most important preliminary steps to the reduction. In old dislocations the separation of adhesions by dissection or the use of blunt instruments is always necessary before reduction is attempted. After the head of the bone has been freely exposed and isolated, and the way to the socket cleared of all obstacles, the reduction is usually accomplished without much difficulty by rolling the head into its proper position. A certain amount of traction may be necessary before this can be done. In old cases the use of the elevator may likewise be required. After the bone has been placed in proper position, the capsule should be sutured with catgut, the hemorrhage carefully arrested, the wound closed throughout in the usual manner, and sealed with strips of iodoform gauze, a thin film of aseptic absorbent cotton, and collodion, and the limb immobilized in a position that will relieve all tension on the injured side of the capsule. In reducing a dislocation of the head of the humerus complicated by a fracture of the upper portion of the shaft of the bone, McBurney drills the fragment and inserts a hook, supplied with a handle, into the perforation, with which the necessary traction and rotation are made. After the reduction of an old dislocation, whether by the open method or by manipulation, immobilization of the limb must be continued for a longer time than after a recent case, as the more extensive injury of the capsule requires a longer time for the completion of the process of repair.

Allusion must be made to some of the more important accidents that have occurred during efforts at reducing dislocations. One of these is tearing of the skin by excessive and improperly applied traction, an injury that will not occur if ordinary care is exercised. Fracture of the bone has occurred in the practice of able and careful surgeons, and is most likely to take place when the bone has become exceptionally fragile from prolonged nonuse, as is often the case in old unreduced dislocations. I met such an instance, the case being one of subcoracoid dislocation of the humerus of long standing. The bone fractured through the surgical neck. The

injury was treated in the same manner as a recent fracture, and it was a source of comfort to learn later that this mishap rather improved the condition of the arm than otherwise. The risk of incurring such an accident is an additional argument in favor of the open method of reduction in all cases that do not yield to a safe degree of force and when there is reason to suspect that the bone is exceptionally fragile.

One of the accidents that is most feared in forcible attempts to reduce a dislocation of the shoulder is rupture of the axillary artery. Stimson has collected forty-seven cases of rupture of this vessel, caused by forcible attempts to reduce shoulder-joint dislocations, and of this number, thirty-one died. I have personal knowledge of two cases that occurred in the practice of two very able and careful surgeons. In both cases the axillary artery was tied. In one, gangrene of the whole arm supervened and an amputation at the shoulder-joint barely saved the patient's life; in the other case the dislocation remained unreduced and the patient recovered partial use of the arm.

Tearing either the subscapular or the circumflex artery during attempts to reduce anterior dislocations of the shoulder is a less serious accident, one from which the patients usually recover without operative interference. In this accident the blood supply is not threatened to the same extent as in rupture of the axillary artery. Injury of the principal nerves in the axillary space is another accident that has been produced by violent traction and severe pressure. Violence has been carried to the extent of tearing out the roots of the brachial plexus. Syncope and sudden death have occurred during attempts to reduce dislocations, more especially old ones, of the shoulder-joint. I very nearly lost two patients on the table during prolonged efforts to reduce ancient dislocations of the shoulder-joint.

The foregoing recital of the immediate complications consequent upon violent or misdirected efforts to reduce dislocations by the bloodless method should be a sufficient caution to the practitioner to use every possible precaution in averting such evils by substituting skill for excessive force. In difficult cases he should resort, under proper aseptic precautions, to the open method, rather than persist in the use of violent and too forcible traction, bending, and rotation.

DISLOCATIONS OF THE SHOULDER-JOINT.

Anatomically and functionally the shoulder-joint is more predisposed to dislocations than any other joint in the body, thus explaining why dislocations of this joint equal in frequency dislocations of all other joints. The greater exposure of men to all kinds of injury than women accounts for the greater number of dislocations of this joint among males than females, the proportion being about four to one.

Age is an important predisposing cause, as dislocations of this joint are rare in youth and old age, periods of life when, from the same force, fractures are more liable to occur than dislocations. Statistics show that the largest number occur during middle age. The left humerus is more frequently dislocated than the right. The support furnished to the head of the humerus above by the acromion process, the coracoid process, and the coraco-acromial ligament excludes a typical dislocation in that direction. A dislocation upward is very rare, and always atypical, as it is necessarily complicated by fracture of the bony roof, which covers the head of the humerus above the glenoid cavity. A primary dislocation of the head of the humerus downward into the axillary space is also a rare accident, as the capsule below the joint is enforced and greatly strengthened by the long head of the triceps muscle.

The weakest points of the shoulder-joint are in front and behind, and it is in these directions that dislocation usually occurs, so that practically all dislocations of the shoulder are either anterior or posterior. The following will give an idea of the varieties and subvarieties, and their relative frequency :

Anterior.	Subcoracoid, very common; intracoracoid, exceptional; subclavicular, very rare.
Downward.	Subglenoid, uncommon; erecta (Middeldorpf), very rare; Subtricipital (?).
Posterior.	Subacromial, rare; subspinous, very rare.
Upward.	Supraglenoid, very rare and always atypical.

Anterior dislocations, with the subvarieties, subcoracoid, intracoracoid, and subclavicular, are the luxations with which the general practitioner has usually to deal, and of these, the last two subvarieties are very uncommon, but are amenable to the same treatment as the subcoracoid. The main interest, therefore, in the discussion of dislocations of the shoulder-joint centers in the displacement of the head of the humerus forward, underneath the coracoid process of the scapula.

Mechanism of Traumatism.—Forward or preglenoid dislocation of the shoulder is caused by direct or indirect violence or muscular contraction. In the great majority of cases it is produced by indirect force, transmitted through the shaft of the humerus—usually by a fall upon the outstretched hand or elbow. The arm is brought into a hyperabducted position, and the head of the humerus is forced against the inner and lower portion of the capsule, while the highest point of the greater tuberosity rests against the upper margin of the glenoid cavity, and the surgical neck of the humerus against the acromion process. If, with the arm in this position, the force continues, the humerus becomes the lever, the margin of the glenoid cavity and the acromion the fulcrum, the head of the humerus under lever action tearing through the anterior and inferior portion of the capsule, and escaping into the axilla. The position of

the arm and the head of the humerus will now depend on the action of displacing forces after the head of the bone has escaped through the rent in the capsule. If the arm at this moment is held in the vertical position by the untorn portion of the capsule, drawn, perhaps, a little closer toward the chest by the latissimus dorsi and pectoralis major muscles, the head of the humerus is opposite the infraglenoid tubercle, with the articular surface directed downward.

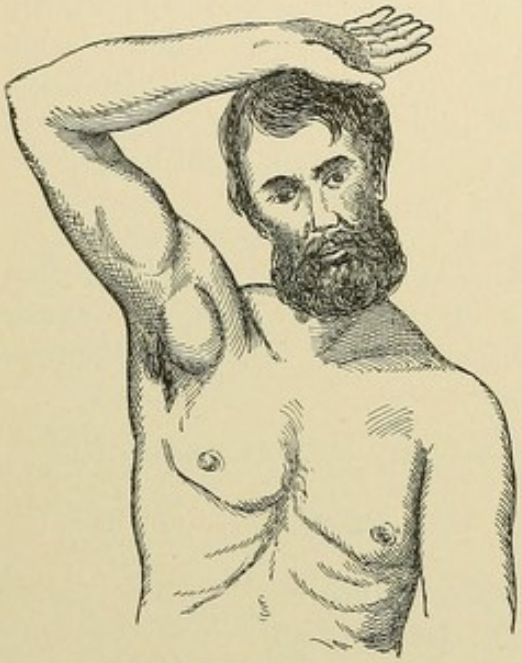

Fig. 388.—Position of arm in luxatio humeri erecta (Hoffa).

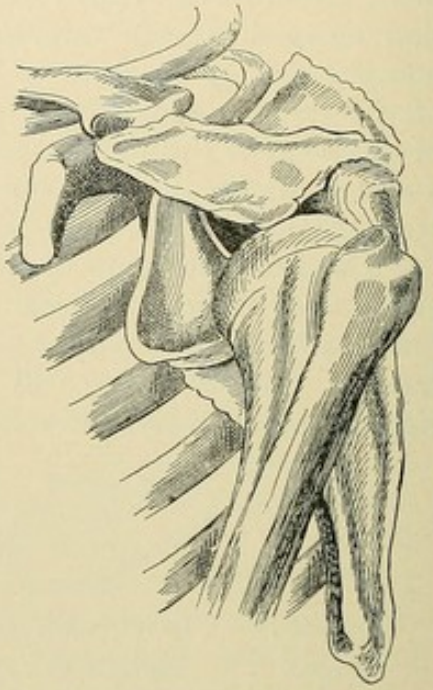

Fig. 389.—Retroglenoid or posterior dislocation of the humerus (Hoffa).

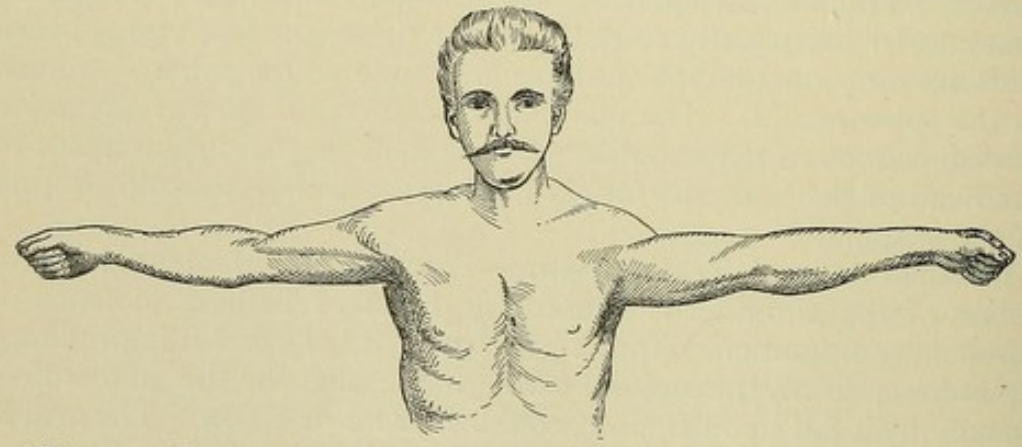

Fig. 390.—Position of arm in subclavicular dislocation of the humerus (Hoffa).

Such dislocation has been described by Middeldorpf as *erecta*, a very rare subvariety of anterior dislocation. If the head of the humerus during the secondary movement remains below the glenoid cavity, or if it moves only slightly along its inner border, a downward or infraglenoid dislocation has taken place. If, on the other hand, the head ascends higher in front of the glenoid cavity, so that it reaches the space below the coracoid

process, between the thorax and the anterior border of the glenoid cavity, as is usually the case, there results by far the most common form of dislocation—the subcoracoid subvariety of the anterior dislocations. If the head of the bone finds its way to the inner side of the coracoid process without touching any other part of the scapula, and ascends to near the clavicle, the injury is designated a subclavicular dislocation. The dislocation is called intracoracoid if the head of the humerus is displaced in the same direction, when a small portion of the articular surface remains in contact with the coracoid process. Both of these latter subvarieties are exceedingly rare, and, as has been stated before, are amenable to the same methods of reduction as the subvariety, subcoracoid.

Dislocation of a normal joint from muscular contraction is very rare, but happens occasionally by throwing movements of the arm, as in throwing stones, balls, etc. The displacing force is created in such cases by the antagonism between the deltoid muscle, which elevates the arm, on the one hand, and the great pectoral and latissimus dorsi, which draw the arm downward, establishing a pendulum action of the arm between the points of attachment of these muscles, on the other. Under forcible abduction the luxation takes place in the same manner as by indirect force transmitted through the shaft of the humerus. A blow or fall upon the shoulder may dislocate the head of the humerus forward if the force strikes the greater tuberosity, forcing the head of the bone through the weakest portion of the capsule in its anterior lower segment. The cases in which the capsule of the joint is not torn by the dislocating force are exceptional. The dislocation may be partial, but such cases are very rare.

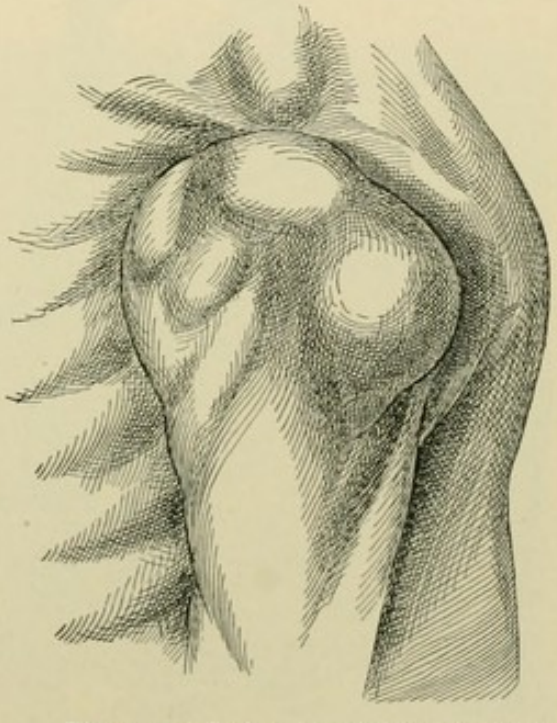

Fig. 391.—Deformity of the shoulder in retroglenoid dislocation of the humerus (Hoffa).

In subcoracoid anterior dislocations of the shoulder the dislocated head of the humerus is beneath and in contact with the coracoid process.

Pathologic Anatomy.—In subcoracoid, by far the most frequent dislocation of the humerus, the capsule is found ruptured on the anterior and inferior segment of the circumference of the joint, between the tendon of the subscapularis muscle and the long head

of the triceps. The extent of the rupture varies : it may be so large as to permit free to-and-fro motion of the head, or the margins of the slit may hug the neck of the bone so closely that reduction is impossible without direct operative interference. The untorn portion of the capsular ligament remains on the stretch so long as the bone is in its abnormal position, and is the principal factor in the immobilization of the dislocated bone. The tension is most marked in the fibers that lie on each side of the passage of the subscapularis in the capsule, and from the margin of the glenoid cavity to the small tuberosity and neck of the humerus, and especially the coracohumeral ligament. The untorn portion of the subscapular muscle may be interposed, and the capsular portion of the supraspinatus, infraspinatus, and teres minor may be torn ; the long head of the biceps is occasionally ruptured. A portion of the greater tuberosity may be found detached. The primary swelling, outside of that made up by the head of the dislocated bone, consists of extravasated blood, varying greatly in amount according to the extent of injury to the soft parts and the number and size of ruptured vessels. The muscles placed most on the stretch are the deltoid, coracobrachialis, and the short head of the biceps. The long head of the biceps, with that of the triceps, makes up a sling around the neck of the humerus. Limited traction fractures involving the bony prominences around the head of the bone are not infrequently found. Fracture of the surgical neck is a rare complication.

Fig. 392.—Subcoracoid dislocation of the humerus (Hoffa).

The larger vessels and nerve-trunks are always stretched by the head at the moment hyperabduction reaches the maximum limit, but later they escape harmful pressure by the head gliding laterally toward the inner side. With the exception of the subscapular artery, tearing of vessels of considerable size is very rare. Cyanosis of the limb is not an unusual occurrence, and is caused by compression of the large veins. The nerve injuries resulting

from the dislocation seldom give rise to permanent paralysis, with the exception of paralysis of the deltoid muscle caused by tearing of the circumflex nerve, which usually passes directly over the most prominent part of the dislocated head, and consequently is sometimes severed or permanently damaged by overstretching.

Symptoms.—It has been said that a subcoracoid dislocation can be recognized through the patient's clothing. While this may be true in some cases so far as the existence of this injury is concerned, no careful physician would be willing to base his prognosis and treatment on so superficial and often deceptive a diagnostic ground. It is necessary not only to recognize the dislocation, but also to ascertain the presence of complications if they exist. A subcoracoid dislocation must be suspected if the patient,

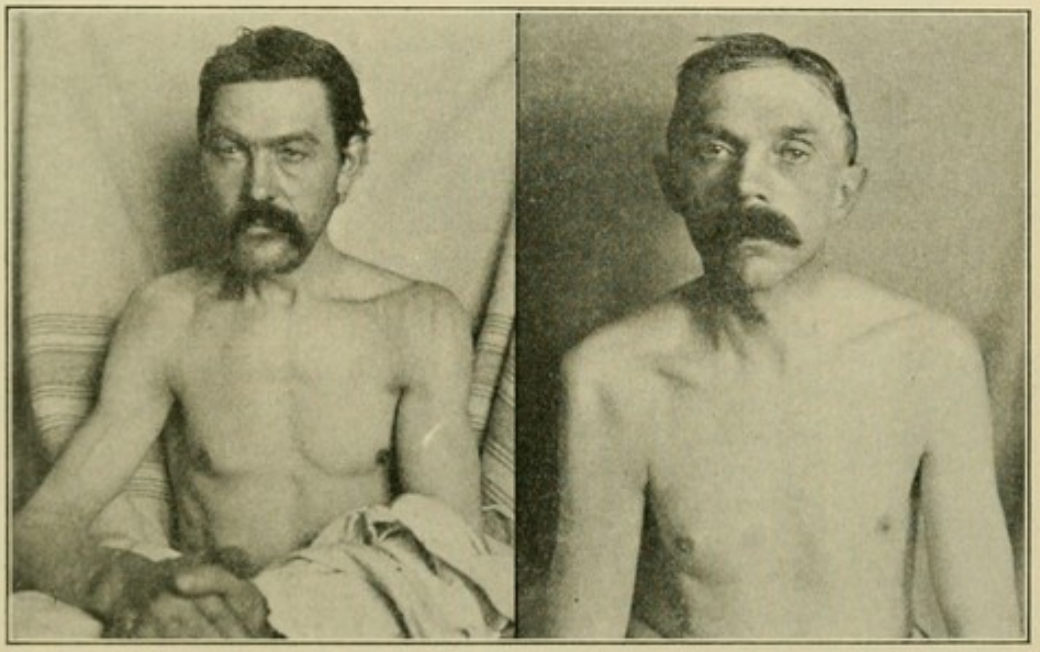

Fig. 393.—Subcoracoid dislocation of the humerus, showing deviation from the normal axis of the humerus (Clinic, Rush Medical College).

Fig. 394.—Subcoracoid dislocation of the humerus, exhibiting depression below the acromion process (Clinic, Rush Medical College).

in a standing or sitting position, inclines his head and trunk toward the injured side, and if he holds, with the healthy hand, the forearm with the arm in an *abducted* position. The elbow is always a little way from the side of the chest, and never touches the chest. The patient invariably complains of severe pain in the shoulder, and if the axillary plexus has been severely stretched or is compressed, of pain in the whole arm, numbness, and creeping sensations in the forearm and fingers.

In conducting the examination, the clothing must be removed as far as the waist, for the purpose of making the necessary comparison, by inspection, palpation, and measurements, between the impaired and the healthy side. Inspection will reveal, at once, besides the characteristic abduction and absolute helplessness of the arm, a

marked change of contour of the shoulder-joint. The acromion process is preternaturally prominent, and below it the rotundity of the shoulder has disappeared, a deep depression being seen instead. This subacromial flatness or depression is caused by the disappearance of the upper end of the humerus, which then presents itself in front of the glenoid cavity and below the coracoid process, in Mohrenheim's fossa, in the form of a firm, globular swelling, to which the movements of the humerus are imparted. The deltoid is apparently elongated, flattened, and its anterior border prominent. As the upper end of the humerus is displaced inward, the points of origin and insertion of the pectoralis major and latissimus dorsi are approximated, a condition that accounts for a folding of the skin at the lower margin of the anterior and posterior wall of the axillary space. The position of the arm is almost characteristic. The elbow is distant from the chest-wall from one to two inches, and is at the same time directed somewhat backward. The arm is almost fixed in its faulty position. It is impossible, on placing the hand over the opposite shoulder, to bring the elbow in touch with the side of the chest (test of Dugas). This test, if not infallible, is, at least, of great diagnostic value in differentiating a fracture in or near the joint from a dislocation. In palpating the region below the acromion no bony resistance can be felt.

If, in the case of a very obese patient, or in the presence of a large swelling, there is any doubt as to the absence of the head of the humerus, on making axillary palpation this doubt could be cleared up by exploration through the deltoid, half an inch below the acromion, with an aseptic steel needle (akidopeirasty of Middeldorpf). If the physician has recognized and established the presence of a faulty axis of the shaft of the humerus, pointing toward the coracoid process instead of the glenoid cavity, he has demonstrated the existence of either a subcoracoid dislocation of the head of the humerus or a fracture through one of the necks of the bone. Owing to the rarity of the latter accident as compared with the former, the probability is strongly in favor of a dislocation. If the head of the humerus can be felt in Mohrenheim's fossa instead of in the glenoid cavity, the diagnosis of dislocation becomes unmistakable. If the arm is more movable than usual and the springy condition, so constantly present in the typical form of dislocation, be absent, we may suspect avulsion of the margin of the glenoid cavity or the tuberosities of the humerus. The limb is always shortened in subcoracoid luxation. Having made a diagnosis of dislocation, the physician makes careful search for complications.

The complications that are most important to remember are fracture, rupture of blood-vessels of considerable size, and contusion or laceration of the principal nerve-trunks. The condition of the circulation of the limb below the seat of injury is inquired into, as well as any disturbances of innervation in the distribution of the principal nerve-trunks. The most prominent symptoms of sub-

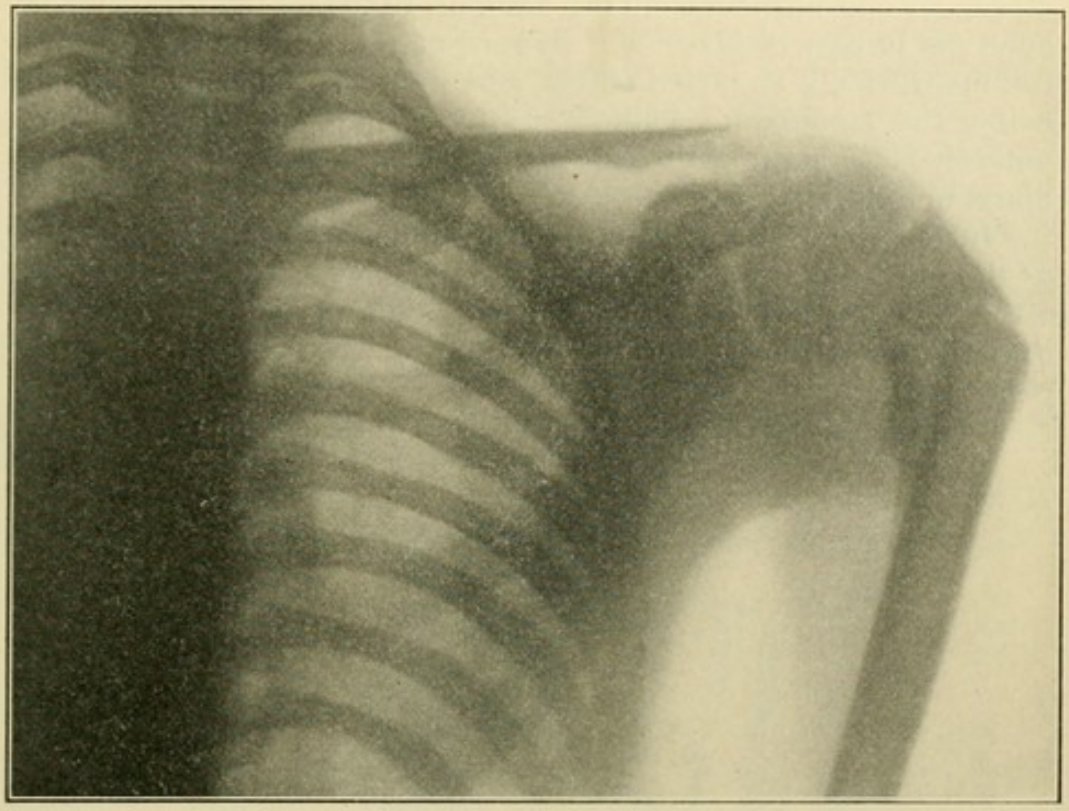

Fig. 395.—Recent fracture of the surgical neck of the humerus.

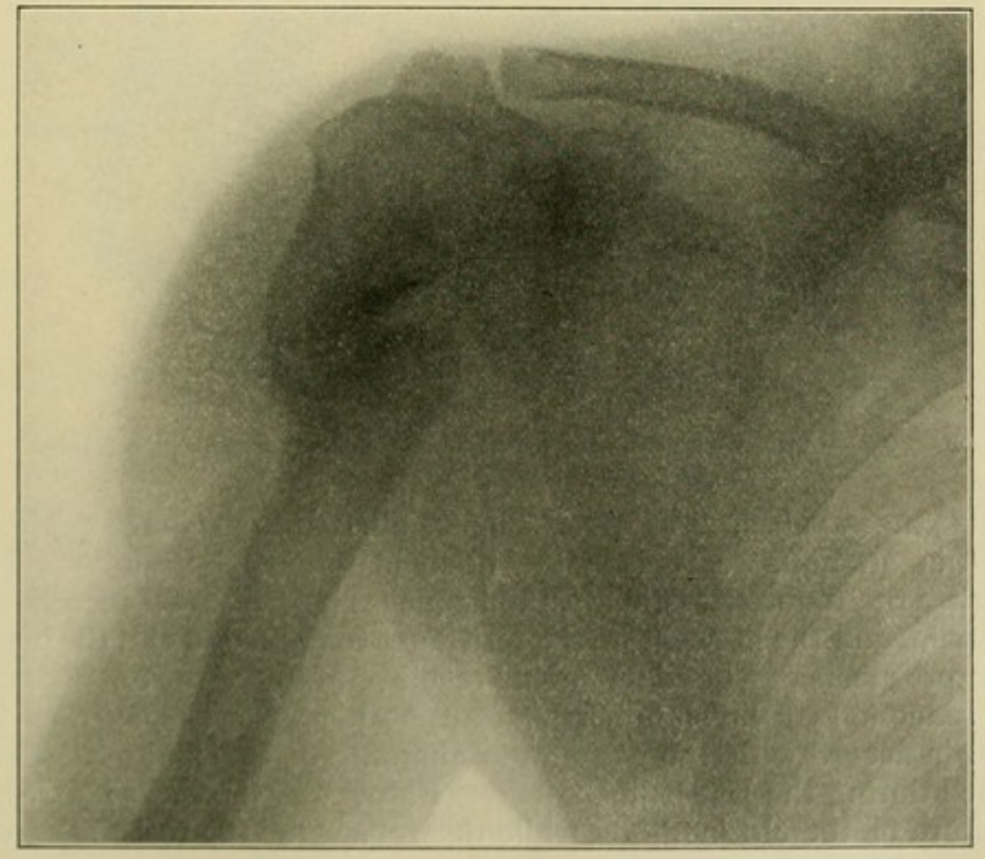

Fig. 396.—Fracture of the surgical neck of the humerus two years and a half after the accident.

clavicular and intracoracoid dislocations, as compared with subcoracoid, are further displacement upward of the head of the humerus, the more widely abducted elbow, and more flattening or depression below the acromion. Pathologically we find in such cases more extensive laceration of the capsule and more tearing of the subscapularis muscle.

In the erect form of anterior dislocation Middeldorpf mentions, as the most important diagnostic symptoms, vertical position of the arm, elbow on a level with the head, and arm flexed in such way that the dorsal surface of the hand rests on the top of the head (Fig. 388).

Treatment.—A positive diagnosis of a dislocation having been

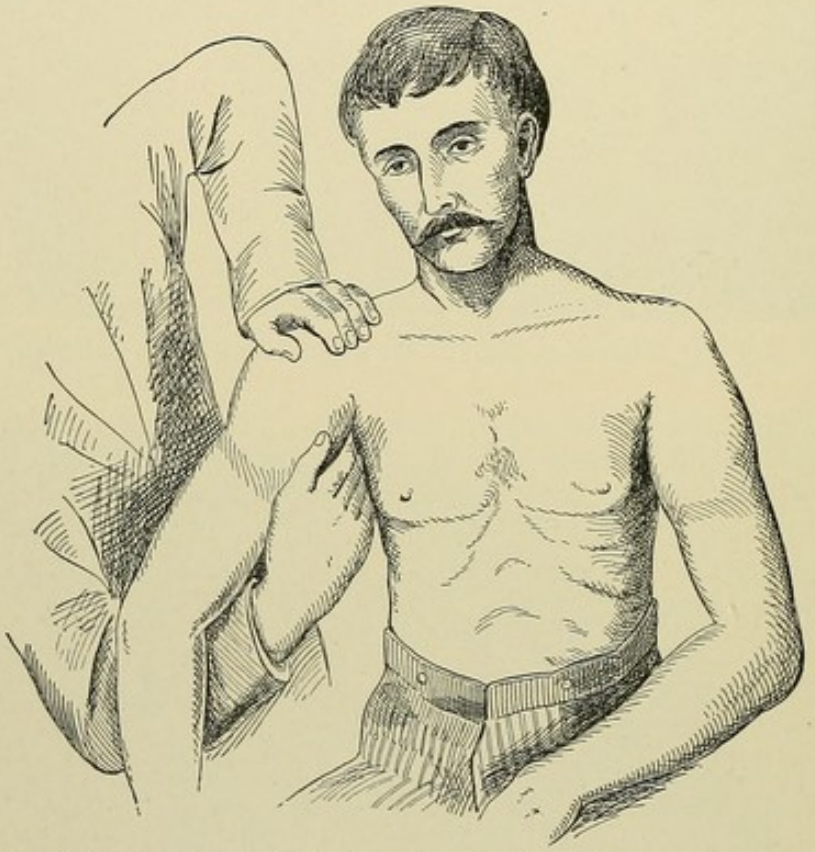

Fig. 397.—Avicenna's method of reduction of subcoracoid dislocation (Hoffa).

made, in the absence of specific contraindications no time should be lost in attempts to replace the bone in its usual position. The earlier the reduction is made, the sooner the patient will be relieved of pain, and the less will be the resistance to reduction and the better the prospects of a good functional result. Many of the old methods of reduction of the shoulder-joint are no longer in use, as they are not in accord with the pathologic anatomy of the injury as developed during the last half century. Force was the most important feature of the old methods, while due regard for the resisting structures and gentleness characterize the modern.

Forcible traction in the axis of the body, with the heel in the

axilla, a method of reduction usually attributed to Sir Astley Cooper, was known to Ambroise Paré, in whose work on surgery a very creditable illustration of this procedure can be found.

Position with manual pressure, a method devised and described by Avicenna, is safe and frequently succeeds in the reduction of subcoracoid and other dislocations of the humerus. It is well shown in figure 397.

Extension in the direction of the dislocated member, combined with counterextension by a hand over an axillary cushion and another over the acromion process, is an old method, and one which, when employed with proper care, is devoid of any great risks. It will occasionally succeed after manipulation has failed.

Extension of the limb in a vertical position, first recommended by Mothe, is attended by more risk, and if used at all, combined

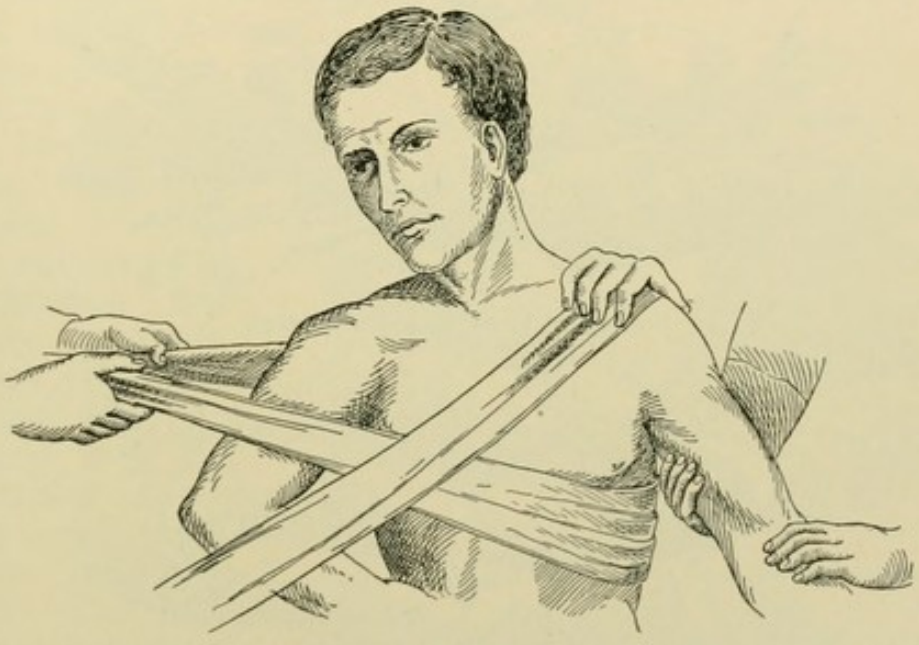

Fig. 398.—Reduction by extension in the axis of the dislocated humerus (Hoffa).

with pressure over the shoulder and in the axilla, must be made with the utmost care, to guard against injury of any of the important axillary contents.

The lever method, by using the humerus as a lever and the knee or closed fist as a fulcrum, may be tried with safety, and will occasionally succeed after other methods have failed.

The rotation method, based entirely on the principle of avoiding, during manipulation, the mechanical resistance offered by muscles and the untorn portion of the capsule, is the method above all others, as it precludes all accidents, and with few exceptions, indeed, if properly performed, proves successful. In many cases the rotation method enables the physician to reduce the dislocation easily, even without the use of an anesthetic. The rotation methods have

been devised and practised only recently. Schinzinger gives the following directions:

The patient sits on a chair. The scapula is fixed by an assistant placing his hands over the shoulder, making pressure, and at the same time grasping the bone. The physician sits on a chair opposite the patient, grasps, with both hands, the forearm, flexed at a right angle, presses the arm against the chest, and then makes outward rotation until the hand is directed outward, or even a little beyond this point, from the adducted arm. At this moment the greater tuberosity of the humerus presses against the posterior

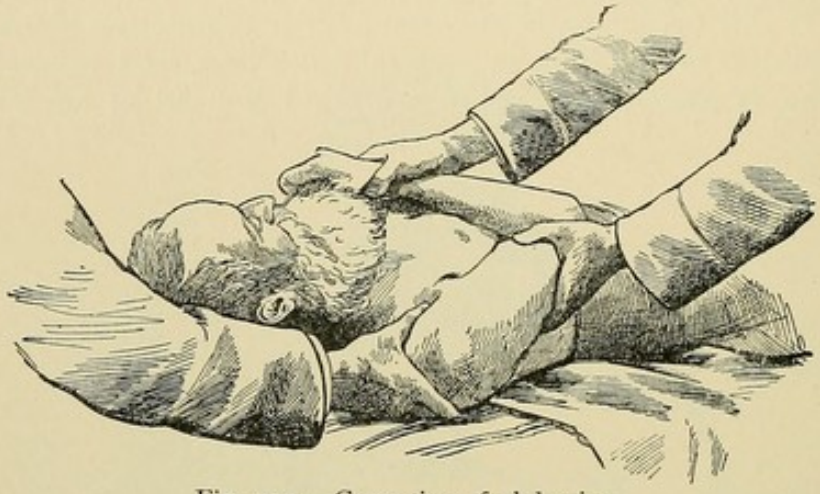

Fig. 399.—Correction of abduction.

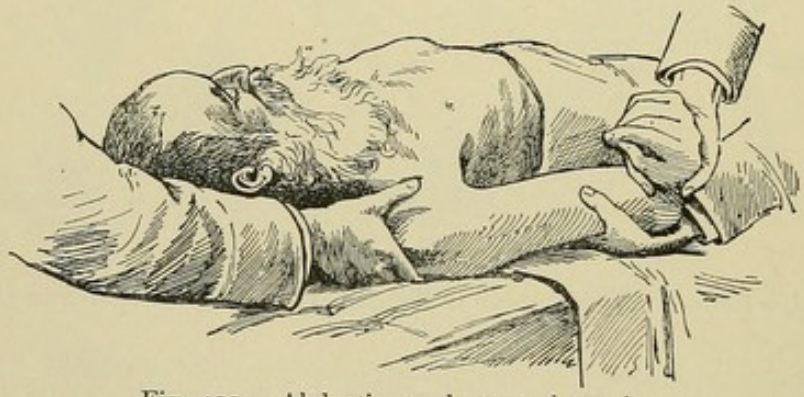

Fig. 400.—Abduction and external rotation.

border of the glenoid cavity. When this resistance is felt, the arm is raised somewhat, when rapid inward rotation is made, which rolls the head into the socket. In intracoracoid dislocations Kocher recommends adduction of the arm and outward rotation; then the arm is carried in a vertical plane, and finally rotated inward and, at the same time, carried to the side of the chest.

In subcoracoid dislocation Kocher's rotation method yields the best results, and is the one now generally accepted and practised. The reduction is made by rotation in the abduction position of the bone. He recommends that, after correction of the abduction, the arm first be abducted, to relax the coracohumeral ligament, when

outward rotation is made, followed by rapid adduction and flexion. The arm is then not only brought to the side, but also over the anterior surface of the chest. During this movement the arm is rotated inward at the same time. During the abduction and outward rotation of the arm the head of the bone rolls outward, in front of and below the acromion, and during the adduction and inward rotation it glides into position. During any of the methods mentioned manipulations by an assistant with his hand in the axilla are often of signal service.

Downward or subglenoid dislocation has already been referred to as one of the subvarieties of anterior dislocation. It is always produced by forcible abduction of the arm, and the rent in the capsule takes place in front of and below the circumference of the joint; the head remains in a fixed position below the glenoid cavity in the axilla. The lower part of the subscapularis may be torn, and the greater tuberosity is usually broken off.

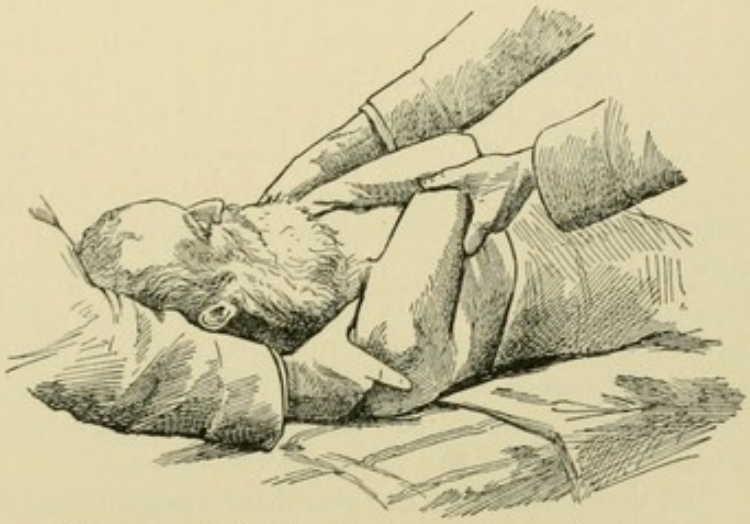

Fig. 401.—Adduction, flexion, and internal rotation.

The symptoms are very similar to those of subcoracoid dislocation, but more marked. The elbow is further from the chest, and the flattening below the acromion more conspicuous. The head of the humerus can be felt very plainly in the axilla. Reduction is usually readily effected by Kocher's rotation method, and if this should fail, traction in the direction of the dislocated member and direct pressure should be tried.

Posterior or retroglenoid dislocation is of very rare occurrence, and the subvariety, subacromial, is most frequent. It is caused by pressure of the head of the humerus outward and backward, which results in a rupture of the capsule on its outer side, and above and below, between the acromion process and the long head of the triceps. If the head of the bone is displaced backward beyond the acromion into the infraspinatus fossa, that very rare form of dislocation is produced known as infraspinous or luxatio infraspinata. Posterior dislocation is very seldom produced by a fall upon the outstretched hand or elbow; it is much more frequently caused by direct violence applied over the anterior surface of the head of the bone, driving the same backward through the rupture in the posterior portion of the capsule, either underneath the acro-

mion or into the infraspinous fossa. It is also produced by muscle action.

The arm hangs at the side of the chest in inward rotation, with elbow directed forward. The whole shoulder appears markedly broadened (Fig. 391). The coracoid process, the anterior margin of the acromion, and the coraco-acromial ligament are unusually prominent. Below the acromion, over the region of the deltoid, is a deep depression, in the bottom of which the glenoid cavity can be distinctly felt. Immediately below the acromion, or in the infraspinous fossa, the displaced head of the humerus presents itself in the form of a hard, smooth, globular swelling, which follows the movements of the arm and becomes more prominent during each anteversion. The axis of the humerus falls with its upper end outward and behind the glenoid cavity. The arm itself is only slightly abducted, in old cases abducted, rotated inward, and somewhat anteverted. In this position the arm is fixed, and any attempt at passive motion is productive of great pain. The length of the limb remains normal, or slight shortening or elongation may be present. Supination of the forearm is difficult and causes pain.

Reposition of posterior dislocations is easy. It is made by elevating the arm to a horizontal level, making slight extension, outward rotation, followed by rapid adduction, combined with pressure against the head of the humerus from behind forward. Redislocation in such cases is very liable to occur, owing to the extensive injury of the subscapular muscle, which always complicates backward dislocations. Unreduced backward dislocation greatly and permanently impairs the usefulness of the arm, much more so than do dislocations in the opposite direction.

In dislocations of the shoulder complicated by fracture near the head of the humerus reduction can usually be made by the plan devised by McBurney. Through a puncture a perforation is made in the upper fragment, deep enough to insert a strong blunt hook with a handle attachment. With this simple instrument the necessary extension and other manipulations can be made to effect reduction, aided by pressure against the bone in the direction of the glenoid cavity. After the reduction of the upper fragment, the usual treatment for fractures in that locality is instituted and continued until the fracture has united by bony callus.

Space will not permit the discussion of all special dislocations separately and in detail. I have attempted to treat the whole subject of dislocations somewhat comprehensively, and have described, at length, the different forms of shoulder-joint dislocations, with the various methods of their reduction, for the purpose of illustrating the mechanism of production and reduction of ball-and-socket joint dislocations. The descriptions given and the teachings laid down are, to a large extent, applicable to dislocations of the largest enarthrodial joint—the hip-joint. The important rôle played by the unruptured portion of the capsular ligament in resisting reduc-

tion, and the great necessity of relaxing it in attempting reduction, are perhaps even more forcibly shown here than in the shoulder-joint. The manipulations in reducing the different dislocations of the hip-joint are based on the same great principles used in relaxing the untorn portion of the capsular ligament and in replacing the head of the humerus by rotation. If the physician has ascertained the exact location of the head of the femur and that of the rupture in the capsule through which it escaped, he will have but little difficulty in planning and executing the movements necessary to overcome the resistance of the untorn portion of the capsule and in replacing the bone into the adjoining socket by rotation.

Hip-joint dislocations are rare as compared with dislocations of the elbow-joint; hence it has occurred to me that it would be more profitable for the reader to find a somewhat detailed account of dislocations of the latter joint, instead of of the hip-joint. I have seen so many cases of fracture of the neck of the femur mistaken for dislocation that I feel called upon to emphasize once more the importance of making a thorough examination in all cases of hip-joint injuries, to guard against committing so serious a mistake. *Fractures of the neck of the femur are very common as compared with dislocations; the deformity is less and the patients are usually persons advanced in years, and the violence that produced the injury is insufficient to produce a dislocation.* Fracture of the neck of the femur is generally the result of a *fall upon the greater trochanter; dislocations are produced by forces that deviate the axis of the femur sufficiently to tear the capsule at a point where the head of the bone, in consequence of such deviation, makes the greatest pressure.*

DISLOCATIONS OF THE ELBOW-JOINT.

Next to the shoulder-joint, the elbow-joint is most frequently the seat of dislocation. The complicated structure of this joint, its great functional activity, and its repeated exposure to all sorts of injuries furnish an adequate explanation for this frequency.

Dislocations of the elbow-joint are more common in children and young adults than in persons advanced in years. The elbow-joint is a typical ginglymoid, or hinge, joint of great strength, and dislocations occur only on the application of great force. The strength of the joint is increased by the many bony prominences that enter into its formation, and that are but imperfectly developed in children and young adults. About 18 per cent. of all dislocations involve the elbow-joint. Both bones of the forearm may be dislocated in all four directions, or either may be dislocated alone.

Dislocations of the elbow-joint are more frequently complicated by fractures than dislocations of any other joint. Some of the dislocations can not occur without fracture, and if such dislocations are recognized, it is safe to assume the existence of a fracture. The extent of the injury to the soft structures and the frequency

with which the dislocations are complicated by fracture, have an important bearing on the prognosis. The diagnosis is often obscure, and the treatment unsatisfactory. The X-ray will prove of the utmost utility in making the diagnosis positive in obscure cases, and the additional diagnostic information gained by the employment of this diagnostic resource will dispense with the uncertainty and hesitation that so often overshadow such cases like a dark cloud. Moreover, the information gained by the Röntgen rays will enable us to devise and carry into effect more efficient treatment and to obtain more satisfactory results.

CLASSIFICATION OF DISLOCATIONS OF THE ELBOW.

A. Dislocations of both bones of the forearm:

1. Backward, { *a*, without, *b*, with, fracture of the coronoid process.
2. Forward, { *a*, without, *b*, with, fracture of olecranon process.
3. Lateral, { *a*, outward. *b*, inward.
4. In different directions. Diverging dislocations.

B. Dislocations of one of the bones of the forearm:

1. Dislocation of the ulna backward.
2. Dislocation of the radius, { *a*, forward. *b*, backward. *c*, outward.

A. **Dislocation of Both Bones of the Forearm.**—Of all dislocations of the elbow-joint, displacement of both bones of the forearm backward is the most common.

The dislocation may be partial or complete. In a complete dislocation the lower articular end of the humerus is in front of the coronoid process of the ulna and the neck of the radius. Instead of the olecranon, the coronoid process occupies the olecranon fossa. In the incomplete form the coronoid process rests against the trochlear surface, and the head of the radius, with its margin, lies under the eminentia capitata.

Causes.—The usual cause of a backward dislocation of both bones of the forearm is a fall upon the outstretched hand, with the elbow in hyperextension or the forearm abducted. The dislocation is produced by lever action by hyperextension. When the hyperextension is carried to a point so that the tip of the olecranon impinges upon the posterior supratrochlear fossa, a fulcrum is formed upon which the articular end of the humerus is lifted forward. The force continuing, the anterior portion of the capsule is torn and the end of the bone escapes through the rent, while both bones of the forearm are drawn upward behind it by the action of the triceps and brachialis anticus muscles. This is the usual mechanism of the production of a posterior dislocation of both bones of the forearm, although Malgaigne and Stetter are of the opinion that dislocation

in the same direction sometimes takes place with the forearm hyperflexed, the dislocating force being transmitted from the hand through the bones to the capsule. Schüller has shown by his experiments that the same displacement can be produced by forcible abduction or adduction of the forearm.

In a posterior dislocation the anterior portion of the capsule and the internal and external lateral ligaments are torn. As a rule, the laceration in the internal lateral ligament is more extensive than in the external. Both epicondyles may be detached, the internal more frequently than the external. Not infrequently a fracture of the coronoid process complicates the injury. In children the line of fracture is usually at its base; in the adult more frequently only the tip is detached. Supracondyloid fracture has also been seen as a complication of this dislocation. Without exception, the brachialis anticus is found more or less torn. The vessels in the bend of the elbow are occasionally severely injured, and in a few cases the traction has been so severe as to sever the musculospiral nerve.

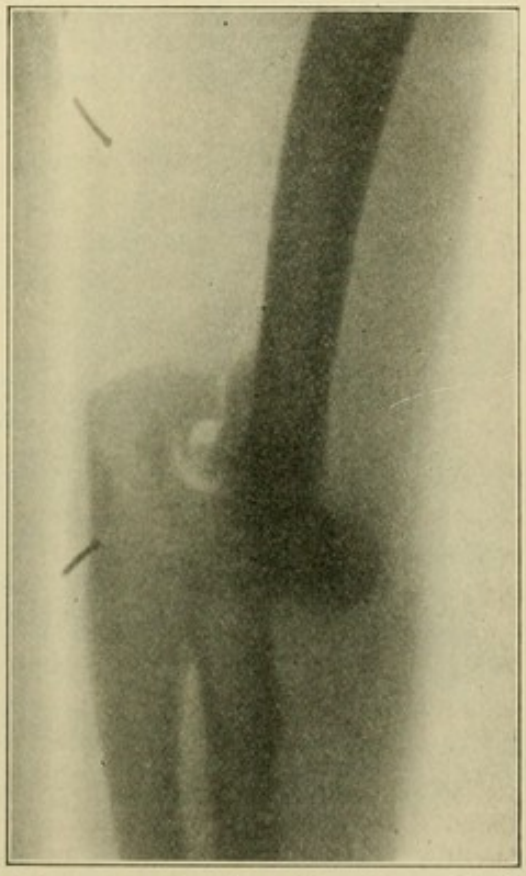

Fig. 402.—Complete dislocation of both bones of the forearm backward.

Symptoms.—The most conspicuous symptoms of posterior dislocation of the elbow are partial flexion of the forearm and absolute immobility. The displacements can be distinguished very readily in recent cases, but during the following days the hemarthrosis and reactive infiltration produce a swelling that often obscures the important landmarks. It is in such instances that the removal of the swelling by massage and the use of a general anesthetic renders material aid in making a diagnosis. If the contours of the joint are not obscured by such a swelling, the first thing that attracts attention is the marked shortening of the whole extremity. The joint is generally slightly flexed, seldom completely extended; the forearm is slightly supinated, or half-way between pronation and supination. The axes of the arm and forearm do not meet in the joint, but a little behind that of the former. *A careful study of the important landmarks, the epicondyles and tip of the olecranon, is of the utmost value, as their relative positions are always seriously altered in this form of dislocation. The anteroposterior diameter of the joint*

is always markedly increased. The tendon of the triceps is very prominent, and can be readily seen and felt in the form of a curve with the concavity directed backward. On both sides of the tendon there is a marked recession of the skin. The olecranon, the sigmoid fossa of the ulna, and the head of the radius are very prominent behind—so much so that the cup-shaped depression of the articular surface of the radius can readily be felt. The cubital fold of the elbow is displaced downward. Above it can be seen and felt a distinct and almost characteristic swelling, representing the lower end of the humerus. The relation of the olecranon to the epicondyles has been materially changed. *If the forearm is extended, the olecranon is above the epicondyles; when flexed, behind the epicondyles.* The olecranon can be satisfactorily palpated at a point from an inch and a half to two inches above the epicondyles. In rare

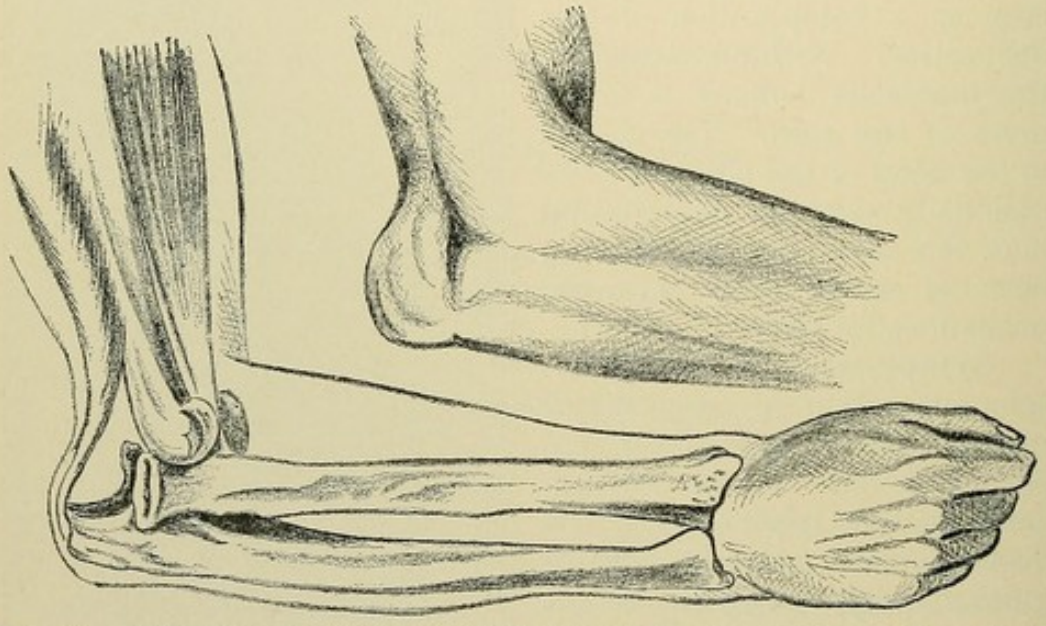

Fig. 403.—Dislocation of radius and ulna backward, showing position of the ends of the dislocated bones, deformity of elbow, and position of forearm (Hoffa).

cases the forearm is displaced slightly outward. In such cases the elongated axis of the humerus no longer strikes the ulna, but passes outward or inward of the same.

In examining into the functions of the injured joint, it is found that passive flexion and extension are reduced to within very narrow limits. In full extension lateral mobility is increased. Pronation and supination of the forearm are also materially impaired. If an attempt be made to rotate the forearm, a springy resistance is plainly recognized. Paresis, varying in location and extent, traceable to pressure on the nerves, is a common symptom. A fracture of the coronoid process must be suspected if reduction and redislocation are accomplished with ease.

The symptoms of a partial dislocation differ from those of a complete one only in degree.

Treatment.—Before any attempts are made to reduce a posterior dislocation of both bones of the forearm, it is of the utmost importance to ascertain the location and nature of the resistances. The fixation of the coronoid process in its faulty position is caused by the untorn portions of the capsular and lateral ligaments, and especially by the twisted radiating firm fascia of the forearm on the dorsal side, which extends to the muscles attached to the condyles of the humerus. Interposition of soft tissues, fragments of the torn capsule and muscles, especially the brachialis anticus, and avulsed bony prominences between the articular surfaces deserve careful attention as causes of resistance to successful reduction.

In recent cases reduction is made without any special difficulties. Aided by a general anesthetic, the reposition can often be made by pressure alone. Forced flexion is the oldest method of reduction. The forearm is flexed at a right angle, when extension is made by an assistant. While this is being done, the physician places his forearm in the bend of the elbow, which constitutes a fulcrum, over which the displaced coronoid process is lifted into its proper place, assisted by the other hand making pressure over the olecranon. The reduction is usually announced by a distinct movement and snap the moment the articular surfaces are restored to their normal relations. Instead of the forearm, the knee can be used as a fulcrum.

Fig. 404.—Reduction of posterior dislocation of both bones of the forearm by flexion and extension over fulcrum, aided by pressure (Hoffa).

Dumreicher's distraction method is more rational and successful. The patient is placed on a table. An assistant behind the patient makes counterextension by making traction on a sling placed in the axilla; a second assistant grasps the arm and assists in making the counterextension. The physician grasps the forearm above the wrist, and flexes it to a right angle, which brings the coronoid process lower down, and, by making traction upon the forearm at its base away from the body with the aid of a sling, the coronoid process is lifted still lower down. As soon as he feels that the process is liberated, the forearm is extended while extension is being

made, when reduction is generally effected, attended by indications that leave no doubt as to the result of the operation. *The most reliable of these indications is the possibility of acute flexion without opposition.*

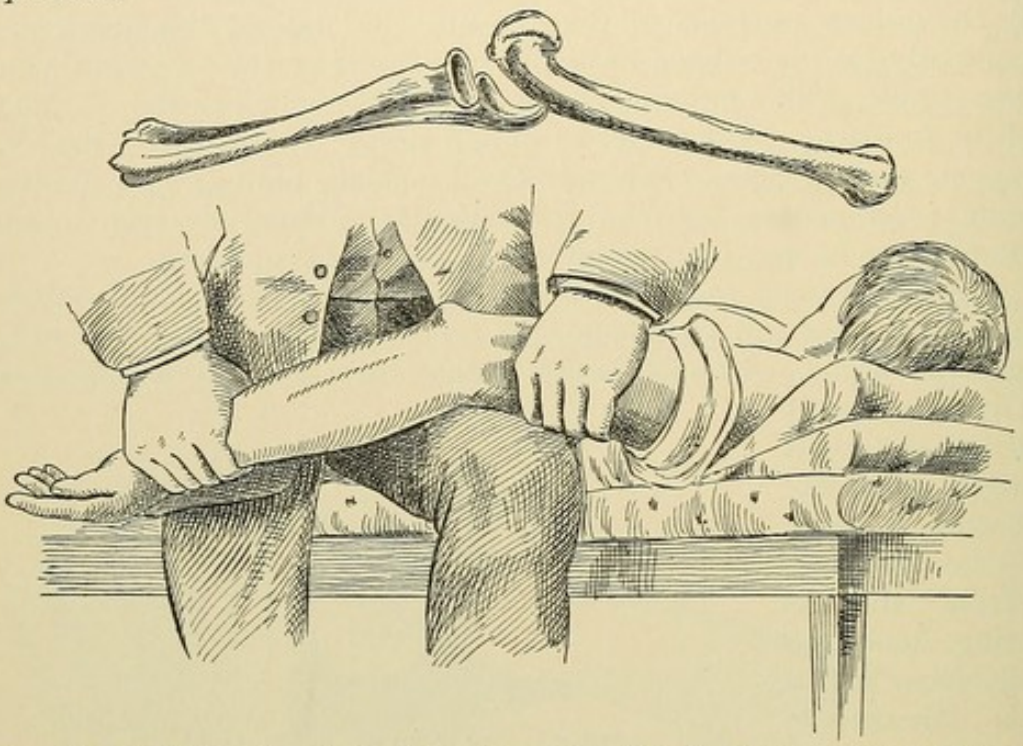

Fig. 405.—Reduction of posterior dislocation of the elbow by flexion, using the knee as a fulcrum (Hoffa).

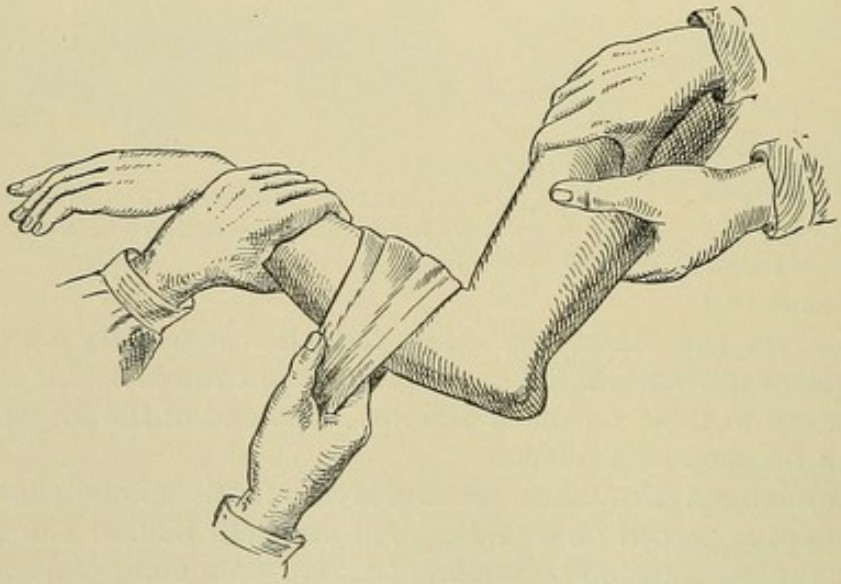

Fig. 406.—Dumreicher's method of reduction of posterior dislocation of the elbow-joint (Hoffa).

Roser has recommended hyperextension as the most effective method of reducing a posterior dislocation of the elbow-joint. With the patient in the recumbent position, the operator places the injured arm upon his knee, makes hyperextension until the arm and

forearm form an angle open behind, then makes rapid flexion combined with extension. During these movements reposition generally takes place. It is advisable to have an assistant make pressure against the tip of the olecranon process at the same time that the operator brings the forearm from the hyperextended into a flexed position.

An extensive clinical experience has demonstrated that the hyperextension method is unattended by any danger of injury to the important soft structures on the flexor side of the bend of the elbow. In old dislocations that can not be reduced, the forearm should be flexed, under the influence of an anesthetic, sufficiently to bring it into a useful position, and in some cases an arthrotomy or resection of the joint will yield a more satisfactory functional result.

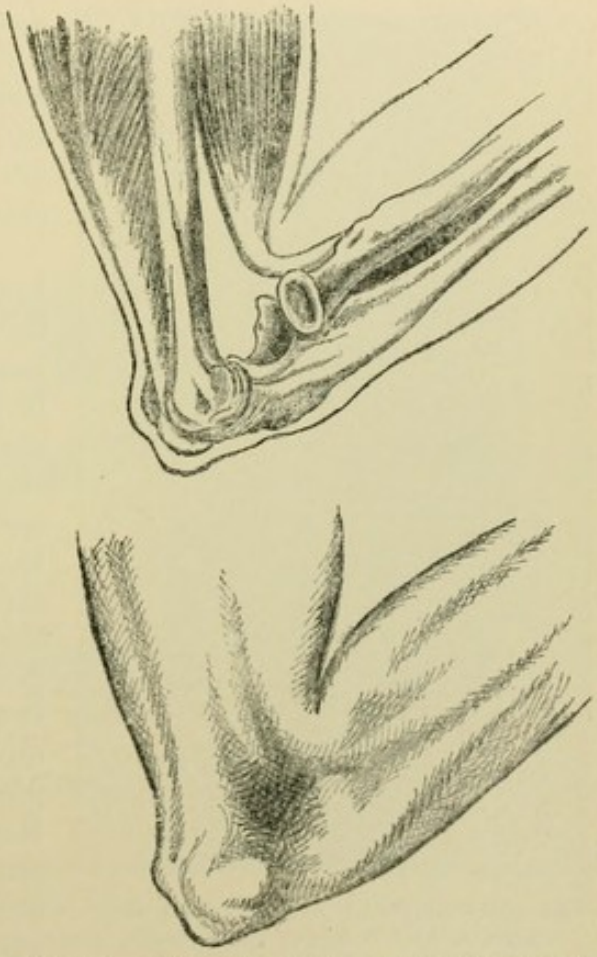

Fig. 407.—Complete anterior dislocation of both bones of the forearm (Hoffa).

Forward dislocation of both bones of the forearm is a very rare accident. Until recently only twenty-one cases of this kind had been recorded. In seven of these the dislocation was compound, and in six of these seven the olecranon was fractured. Dislocation in this direction, without fracture of the olecranon, can occur only if the dislocation occurs with the forearm in a hyperextended position. When the dislocation takes place with the forearm flexed, fracture of the olecranon process always complicates the injury.

In most cases forward dislocations are caused by direct violence inflicted upon the back of the flexed elbow. The experiments of Colson have shown that fracture of the olecranon process constitutes a frequent complication of dislocation of the elbow in the anterior direction. Streubel has shown that anterior dislocations are occasionally produced by violent rotation of the forearm upon the axis of the humerus. As in posterior dislocations, the displacement of the articular ends may be partial or complete. In incomplete dislocations the olecranon occupies only a part of the trochlea; in complete, the entire trochlea. Complete dislocation is

made possible only when the ligaments are extensively lacerated, when the tendon of the triceps is placed in a condition of utmost tension, and when the brachialis anticus is extensively torn.

Symptoms.—In incomplete anterior dislocations the forearm is elongated about an inch and a half or two inches. The anteroposterior diameter of the joint is diminished, and the olecranon is abnormally prominent. The fold on the flexor side of the joint is not appreciable. The empty fossa of the olecranon can be felt, and if the joint is not much swollen, the coronoid process can be seen and felt. On the outer side of the joint the head of the radius can be seen. Between the ulna, radius, and processus cubitalis a ring-like furrow, created by the soft tissues in a state of tension, can be seen and felt. The forearm is either extended or moderately flexed.

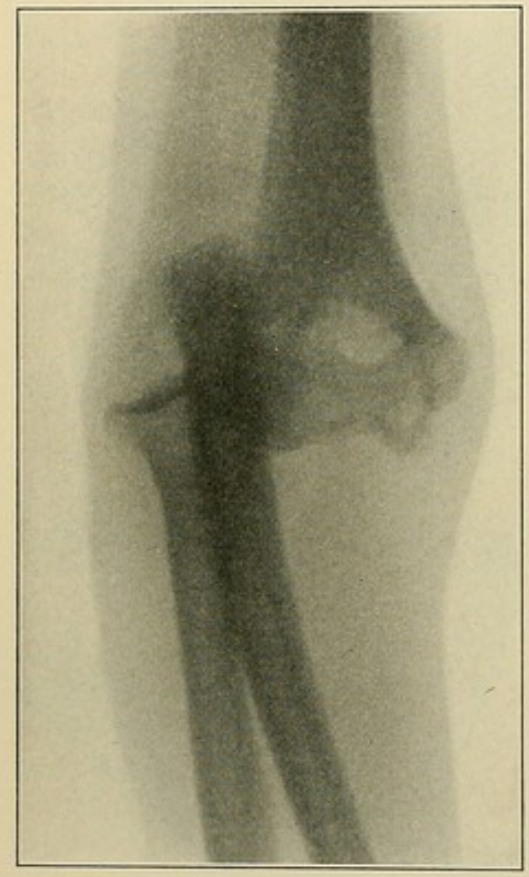

Fig. 408.—Outward and backward dislocation of both bones of the forearm.

In complete dislocations the lower end of the humerus lies behind and immediately underneath the skin. If the olecranon is fractured, the anteroposterior diameter of the joint is increased, and the forearm is slightly flexed and supinated and considerably shortened. The tip of the olecranon retains its normal position, but the base is abnormally swollen. Over the line of fracture is a deep depression. Furthermore, additional evidences of fracture present themselves. Reposition is generally easily effected. It is made by moderate extension and direct pressure from before backward, upon the ulna and radius, and from behind forward upon the lower end of the humerus. The reduction can also be accomplished by strong flexion of the forearm and backward pressure upon the dislocated ends of the radius and ulna.

Lateral luxations of the forearm are very uncommon. It has been found that lateral dislocations are usually attended by more or less posterior displacement. In the great majority of cases the dislocation is incomplete, and takes an outward direction much more frequently than the opposite. This is owing to the greater resistance offered to the dislocating force by the inner than by the outer side of the joint. The patients are usually children in whom the resistance of the joints has not been fully developed, owing to

the absence or incomplete development of the bony prominences which contribute so much to the strength of the joint.

This dislocation is caused by a fall upon the hand, with extended or moderately flexed forearm, or a fall upon the arm itself or the elbow. The mechanism of the production of the dislocation from a fall upon the hand, according to Hueter, is the same as in posterior luxations. The secondary movement in these cases is not flexion, but lateral deviation. At the moment of rupture of the capsule the body loses its support by the loss of bone contact, and the bones are displaced laterally. Violent abduction or adduction may cause lateral dislocation. If the forearm is forcibly adducted and force is applied to the inner surface of the ulna, an outward dislocation is very liable to occur, and the same forces applied in an opposite direction may result in an inward dislocation.

In complete inward dislocations the olecranon fossa lies below, and embraces the internal condyle. The radius is found in front

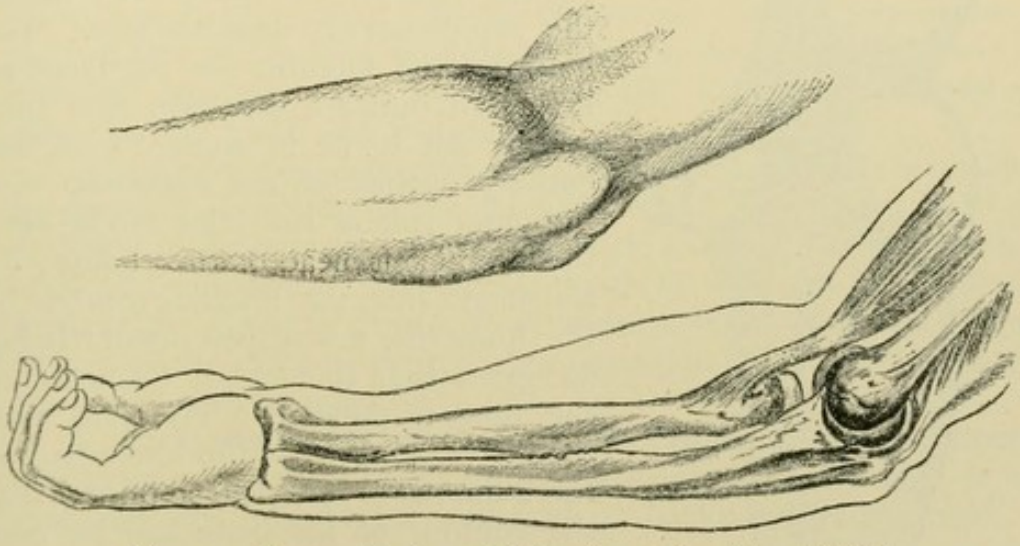

Fig. 409.—Incomplete inward dislocation of the elbow (Hoffa).

of and somewhat below the trochlea. Both lateral ligaments are torn. The forearm is pronated and lightly flexed. The olecranon and external condyle are preternaturally prominent. The head of the radius is felt below and to the inner side of its position. In incomplete inward dislocations the same symptoms, though less marked, present themselves. Flexion and extension can be made, and are not attended by much pain. In unreduced dislocations of this kind the function of the limb is not much impaired. In external luxations the internal lateral ligament is not always torn, but the internal epicondyle is frequently detached, by contraction of the flexor or pronator radii teres, or, what is more often the case, by a blow which at once relieves the traction upon the ligament.

If, in the cadaver, the internal condyle is detached, hyperextension results in outward luxation, as has been shown by the experiments of Sprengel. In both lateral displacements the capsule is extensively

lacerated in front, as well as behind, and the para-articular structures are more or less injured at the same time. Of the nerves, the ulnar suffers most. All lateral luxations are attended by severe injury to the soft structures composing the joints and the tissues outside of it.

In incomplete outward luxations of the elbow-joint the following points are to be noted: The lateral displacement takes place so far that the central longitudinal ridge of the olecranon fossa has passed beyond the outer rim of the trochlea. The radius lies partly below or entirely beyond the external condyle. The elbow is more or less flexed, and the forearm is pronated. The internal condyle is prominent, the skin being tightly stretched over it. The external condyle is very prominent, the olecranon is conspicuous, and the tendon of the biceps is curved. The head of the radius can be distinctly felt and outlined.

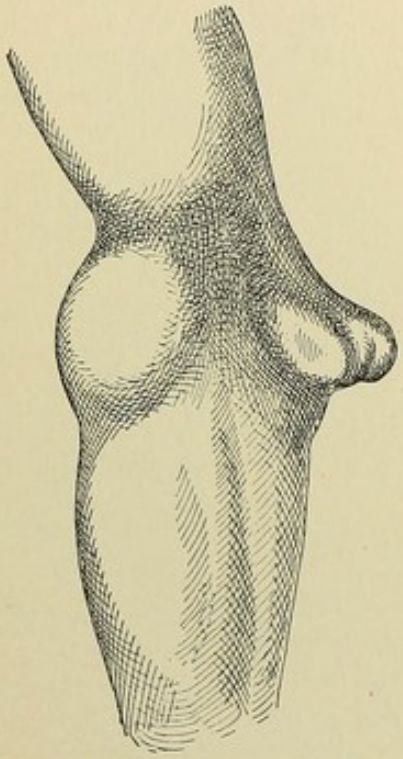

Fig. 410.—Complete outward dislocation of the elbow (Hoffa).

In complete outward dislocation the symptoms are unmistakable. The bones of the forearm are displaced so far in an outward direction that they appear not to be in contact with, but entirely outside of, the humerus. On the outer side of the joint can be seen the prominent head of the radius; on the inner side, the internal condyle of the humerus, the displacements being so great that the lateral diameter of the joint is doubled. The skin over the internal aspect of the lower end of the humerus is stretched so tightly that the contour of the bone can be very readily observed.

Three grades of outward dislocation are recognized and described. In extreme cases the bones of the forearm override the outer border of the humerus. In the complete variety the head of the radius is so prominent that the depression in the articular surface can be seen and felt. The forearm is either flexed or extended in a strongly pronated position.

Treatment.—Reposition, owing to the extensive laceration of the capsular ligament, is usually easy. In outward luxations extension is made on the hand and forearm, with pressure over the latter inward, and over the arm, outward. If this attempt does not succeed, it is very probable that either the epicondyle or the tendon of the biceps has become interposed. It is well in such cases to abduct the hyperextended forearm and follow with a rapid adduction, combined with pressure against the arm outward and the forearm inward. Instead of these manipulations the joint can be flexed, so

that the reduction can be made during hyperextension, abduction, rapid adduction, and flexion of the forearm. If the detached epicondyle interfere with the reduction after all these manœuvers, it must be removed under strict aseptic precautions.

The reposition of internal dislocations is made by extension and counterextension, with simultaneous impulsion of the articular ends by hyperextension, adduction, and flexion of the forearm.

1. Diverging Dislocations of Both Bones of the Forearm.—These dislocations are very rare, as is seen from the fact that, until quite recently, only twelve cases were recorded, and of these only one was transverse. The anteroposterior variety, the only one of practical interest, is produced by the same mechanism as produces posterior dislocations, but with the divergence of the two bones, which can occur only after extensive laceration of the interosseous ligament.

The ulna is found behind, and the radius in front of, the articular end of the humerus. In the transverse form the olecranon lies behind the epitrochlea, and the radius on the outer surface of the external condyle. The only case of this kind was observed and described by Bisell and Guersant.

Anteroposterior divergent dislocation of the elbow is produced by forcible abduction of the forearm. The elbow-joint is greatly widened in its anteroposterior diameter, and the forearm is shortened and supinated. The olecranon can be seen and felt behind the head of the radius in front. Each bone must be reduced separately. In two of the cases so far reported reduction failed, and in one only the ulna could be replaced.

2. Dislocations of One Bone of the Forearm.—Dislocations of the Ulna.—As an isolated injury, dislocation of the ulna is very rare and can take place backward or backward and inward. In incomplete dislocations the coronoid process is displaced only slightly inward and backward, over the margin of the trochlear eminence. In complete luxations the coronoid process is engaged in the olecranon fossa. In partial dislocation only the internal lateral ligament is torn; in the complete variety the annular ligament also is ruptured.

The dislocation is caused by a fall upon the ulnar side of the hand or forearm, whereby the extended arm is abducted and, the force continuing, the internal lateral ligament gives way, the displacement following. The ulna can be dislocated also by forced adduction and pronation, especially if, at the same time, force is applied to the hand in the direction of the joint, or if forward pressure is made upon the posterior surface of the humerus.

The symptoms of dislocation of the ulna resemble very much those of dislocation of both bones backward. The forearm is usually in full extension and adducted. The tendon of the triceps is preternaturally prominent, and a deep depression is seen on its inner, and a more shallow one on its outer, side. The trochlea is

prominent in front; the olecranon, behind. The inner margin of the trochlea is very conspicuous, while the internal epicondyle is somewhat obscured. The head of the radius is in its normal position or slightly displaced inward. The shallow angle on the outer side of the elbow, formed by the axes of the humerus and the bones of the forearm, is effaced, and sometimes the arm is so much adducted that a similar angle is formed on the opposite side. The ulnar side of the forearm is shortened. The forearm is not only adducted, but also markedly pronated. Flexion can not be made beyond a right angle, and is very painful; rotation of the forearm is free.

In incomplete luxations the symptoms are the same, but less pronounced. The local symptoms become more apparent and positive on rotation and abduction of the forearm when the articular surfaces between the ulna and humerus are more widely separated.

In the reduction of this dislocation it is necessary to direct the manipulations in such a way that they will dislodge the coronoid process from the articular depression, and, at the same time, relax the posterior untorn portion of the capsule. An attempt is first made by traction upon the forearm in the extended position, aided by pressure against the olecranon process, and, if the reduction does not succeed, the forearm is hyperextended, combined with traction and local pressure. In other words, the reduction is made in the same manner in which the accident occurred, the arm is hyperextended and abducted, and while the arm is rotated outward, rapid flexion is made.

Dislocations of the Radius.—Statistics have shown that luxations of the radius are more frequent than those of the ulna, as they comprise about 4 per cent. of all luxations. Dislocation of the radius as an isolated injury occurs most frequently during childhood, as in adults the radiohumeral joint becomes stronger and more secure by the greater firmness of the ligaments and complete development of the articular prominences. The head of the radius may be displaced backward, outward, and forward, and some authors claim also downward. These dislocations are very seldom produced by direct violence, as by a blow upon the head of the radius. Much more frequently they are caused by the transmission of force through the radius by a fall upon the hand or forearm. Until recently it has been claimed that dislocations of the radius occur most frequently in consequence of forced pronation.

The mechanism of the dislocation was explained thus: In extreme pronation a fulcrum is formed where the radius and ulna cross each other, and the radius then forms a lever which, at its humeral end, under the influence of the same force, ruptures the capsule and causes the dislocation. The experiments of Schüller and Löbker have shown conclusively that such lever action is never established by forced pronation in the adult and very seldom in children. Forced supination occasionally may result in partial

backward luxation of the radius if the dislocating force first tears off the epicondyle in connection with the external ligament. If the ulna is fractured in its upper third, a secondary dislocation of the radius is readily produced by hyperextension or forced pronation.

Forced pronation and supination play an important part in the production of dislocations of the head of the radius when combined with forced adduction or abduction of the forearm. If, when the forearm is extended or slightly flexed, forced pronation is made, and at the same time the arm is also strongly adducted or abducted, the annular ligament tears, or the head of the radius slips out of it below, and, after the cessation of the forced movement, presents itself in front, behind, or to the outside of the external condyle of the humerus. Forced supination combined with forcible abduction produces the same effects and the same kinds of dislocation. The production of the dislocations is favored when a fragment from the radial side of the coronoid process is broken off and the line of fracture extends to the annular ligament. Undoubtedly most of the dislocations of the head of the radius are produced by a combination of forced pronation and abduction.

The direction that the head of the radius takes after tearing of the annular ligament and capsule depends mainly on the direction of the dislocating force and the location of rupture in the capsule. If the luxation occur forward, the annular ligament is torn; if backward, the posterior portion of the lateral ligament; and if outward, not only the annular and external lateral, but also the interosseous. In children the head of the radius can also, under strong traction, slip from the grasp of the annular ligament, and, after its liberation, may become displaced in different directions.

Dislocations of the head of the radius are very often secondary to fractures of the upper part of the shaft of the ulna, coronoid process, and external epicondyle. If the dislocation is the result of the application of direct force, a part of the head of the radius is often chipped off, but as the fracture is, at least in part, extracapsular, and as there is little displacement, union by bone is the rule. Neither does the fracture materially impair the functional result if the dislocation is reduced and the necessary care exercised during the after-treatment.

Among the soft tissues that are liable to injury in dislocations of the radius outside of the ligaments must be mentioned the supinator brevis, the brachialis internus, and the musculospiral nerve.

Backward Dislocation.—The head of the radius can be felt behind the external condyle and on the side of the olecranon process, while a deep depression can be seen and felt below the external condyle. The muscles displaced by the head of the radius on its way backward hide the external epicondyle, while the internal epicondyle is very prominent. The distance between the external epicondyle and the styloid process of the radius is diminished. The forearm is abducted, and the angle at the elbow increased.

The forearm is in a position half-way between pronation and supination, and can not be extended or supinated. Reduction by direct pressure is usually successful, and, if necessary, is aided by adduction of the forearm and extension. Failure to reduce a recent dislocation is usually due to interposition of the annular ligament.

Outward Dislocation.—In some of the outward dislocations the inner portion of the head of the radius is broken off. The head of the radius is found to the outer side of the external condyle, where it appears in the form of an almost characteristic swelling, while below and behind the external condyle a marked depression can be seen in which the articular surface of the condyle can be distinctly outlined. The abnormal position of the head of the radius is determined in the most satisfactory and reliable manner by extending and flexing, alternately, the forearm, and at the same time making pronation and supination. Rotation of the forearm is not

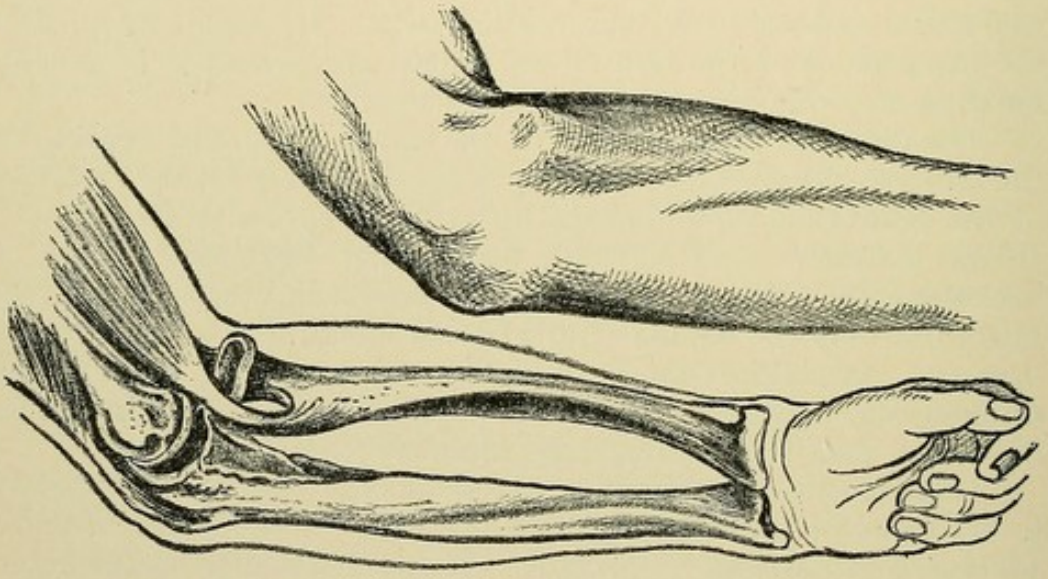

Fig. 411.—Forward dislocation of the head of the radius (Hoffa).

much impaired in outward dislocation of the head of the radius. Reduction is most readily effected by alternate adduction and abduction of forearm, aided, if necessary, by extension and direct pressure.

Dislocation Forward.—This is the most common form of dislocation of the head of the radius. It is frequently accompanied by fracture of the shaft of the ulna, caused by a fall upon the hand. The head of the radius is displaced forward and upward, where it presents itself in front of the external condyle of the humerus as a clearly visible and palpable swelling underneath the supinator brevis muscle. A distinct depression is noticeable behind and below the external condyle, in which the lateral articular depression of the ulna can be felt if the tendon of the biceps does not pass over it. The swelling in the bend of the elbow is made more conspicuous by extending the forearm. The forearm is slightly flexed,

somewhat pronated, and the patient is unable to rotate the forearm or flex it to more than a right angle. If flexion is carried further, it is arrested by the head of the radius resting against the anterior surface of the humerus. The radial side of the forearm is shortened, and pronation and supination are limited or impossible. The external epicondyle is preternaturally prominent.

Reduction is sometimes very easy, sometimes impossible. The best method of reduction of a forward dislocation of the radius is by abduction of the forearm and direct pressure. In fractures of the upper part of the shaft of the ulna this dislocation should always be looked for.

Malgaigne, Hutchinson, and Lindemann have described an incomplete anterior dislocation of the head of the radius in children. Streubel and others, however, believe that the symptoms that have been observed in such cases are due, not to a dislocation, but to interposition of the intact posterior portion of the capsule between the articular surfaces. In small children the injury is caused by lifting them by the pronated hand. The function of the arm is suspended at once, and the pain is greatly aggravated by attempts to correct the pronation. If the bone is flexed and supinated, a crackling sensation is felt. Almost immediately after such interference the child resumes the use of the arm. To guard against recurrence it is advisable to immobilize the limb, with the arm at a right angle, for at least a week.

Downward Dislocation.—Downward displacement of the head of the radius was described by Duverney in 1751. This dislocation is not generally recognized, but there is but very little doubt that such cases have occurred. It has been observed in children less than three years of age. It is caused by traction upon the hand. Tenderness in the region of the head of the radius and a space between it and the external condyle have been mentioned as the most prominent symptoms. With the exception of supination, passive motion is not much interfered with by this dislocation. Reduction is effected by forced supination, the return of the head of the radius to its normal location being generally announced by a distinct click.

CHAPTER XIII.

EXPLORATORY PUNCTURE, SUBCUTANEOUS AND PARENCHYMATOUS MEDICATION, PARACENTESIS, AND DRAINAGE OF SUPPURATING JOINTS.

THE hypodermic and exploratory needles and trocars of various sizes and shapes are instruments constructed upon the same plan, and are intended to reach the tissues underneath the skin for diagnostic purposes, subcutaneous, intra-articular, and parenchymatous medication, and to remove fluid pathologic products.

The extent to which the hypodermic syringe is now being used in the practice of every physician and surgeon makes it desirable to detail, at some length, the proper use of this instrument; the same remarks apply to the exploratory needle and trocar. Many accidents have occurred from the employment of defective needles. The breaking off of the point of a hypodermic needle in the tissues is a very unpleasant, and, to a large extent, an avoidable, accident. The

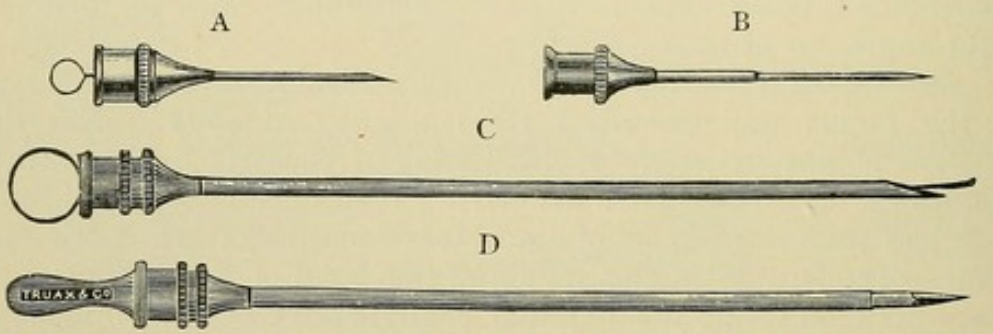

Fig. 412.—Hypodermic needle-points: A, Plain; B, reinforced; C, aspirating needle; D, hypodermic trocar.

strength and permeability of the needle must be carefully tested, and the breaking off of a perfect needle must be guarded against by cautious manipulation of the instrument and by securing, beforehand, immobility of the part to be punctured. In the case of children and excitable, nervous persons it may become necessary for an assistant to steady the patient while the physician immobilizes the part to be punctured. *Hypodermic needles and trocars can be sterilized in a reliable manner only by boiling for five or ten minutes in soda solution. Passing the needle or trocar through the flame of an alcohol lamp, dipping it into a 5 per cent. solution of carbolic acid or in pure carbolic acid or alcohol, as is so frequently done as an excuse for disinfection, can not be relied upon in effecting complete sterilization, as microbes buried in desiccated blood, secretions, fat, or dirt will escape the destructive action of the most potent chemic antiseptics.*

If the instrument is used indiscriminately among different patients, resterilization is necessary in going from one patient to another, as otherwise there is danger of transmitting disease from one patient to another. If a patient is to be subjected to subcutaneous or parenchymatous injections for any considerable length of time, he should be supplied with an instrument of his own. This is particularly necessary if he is the subject of an acute infectious disease, such as syphilis or tuberculosis. The conditions for infection in making a subcutaneous injection are not nearly so favorable as when a joint is punctured and injected, owing to the rapidity with which the absorption of fluids from the subcutaneous tissues takes place, and, with it, the rapid disappearance of the microbes introduced.

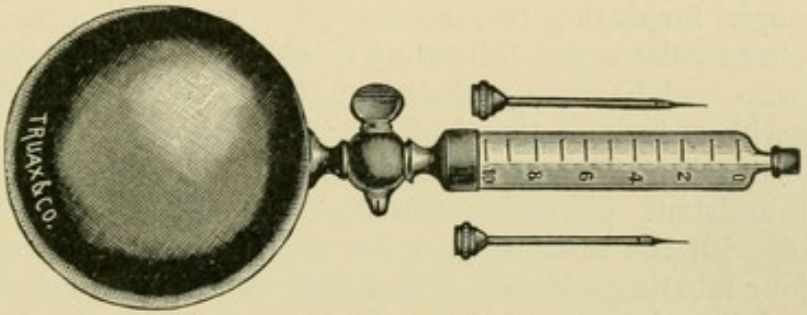

Fig. 413.—Koch's hypodermic syringe.

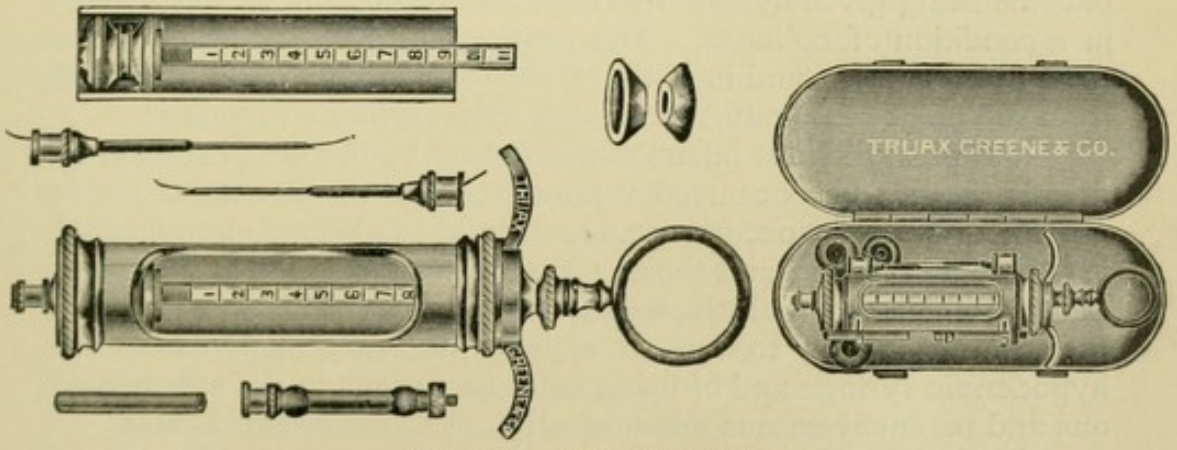

Fig. 414.—Antitoxin syringe.

The general condition of the patient has also an influence in determining infection after puncture, as the resistance of the tissues to the action of pathogenic microbes is much impaired in anemic and badly nourished subjects. The correctness of this assertion is perhaps best illustrated by what is occasionally seen in the case of morphin or cocain habitués. So long as the general health is not much impaired, the daily use of a dirty syringe may cause no serious consequences, but when the patient becomes marasmic and anemic, every puncture made with the same syringe becomes a focus of infection in the form of a furuncle or abscess. I have seen a number of such instances.

The use of a dirty hypodermic syringe has in many instances been followed by fatal sepsis. I have personal knowledge of a most distressing case of this kind. The father of a young, promising physician suffered from a painful, but in no way dangerous, affection. The son made a hypodermic injection of morphin with a syringe that he carried with him on his daily rounds. The patient died in a very few days with symptoms of the most acute form of sepsis that had its starting-point at the seat of puncture. It is unnecessary to say that the unfortunate son had failed to sterilize the needle, and that he keenly felt his responsibility when the fatal complication made its appearance. From that moment his mind became unbalanced, and he sought relief from remorse in the excessive use of alcoholic stimulants, and in a few years found what he had vainly sought for during life, peace,—in a drunkard's grave.

Bouchard relates the following incident: A male nurse in his employ who had become addicted to the use of morphin made an injection with a syringe that had not been properly sterilized, and erysipelas developed from the puncture. In the evening of the same day the assistant physician administered an injection of morphin, and, with the same instrument and without sterilization, injected four tabetic patients. The result was that in less than two days all of them became victims of a grave form of erysipelas.

Brieger and Ehrlich reported two cases of typhoid fever, the patients being given hypodermic injections of tincture of musk when in a condition of collapse. The same syringe and solution were used in both cases, and in both of them a purulent edema started from the point of puncture, to which both rapidly succumbed.

Fatal phlegmonous inflammation caused by the use of the hypodermic syringe has occurred repeatedly, and abscess formation is not an uncommon occurrence. Anthrax has been communicated in the same manner, and there are at least two well-authenticated cases in which tuberculosis was thus conveyed. These cases suffice to bring forcibly to our attention the necessity of sterilizing the hypodermic syringe and of using sterile solutions in the subcutaneous and parenchymatous administration of drugs of any kind.

Many of the fluid preparations for hypodermic use sold by druggists and wholesale manufacturers are not sterile, as has been shown most conclusively by the painstaking and extensive investigations made by Schimmelbusch and Hohl. It is fortunate that some of the solutions in common use, such as ether and saturated solution of quinin, destroy the ordinary pus-microbes at once, as has been shown by Ferrari. In a 10 per cent. solution of cocain pus-microbes were found active after two hours. In a 2 per cent. solution of morphin they were destroyed after twenty-four hours. In glycerin the staphylococci lived six days. In a 1 per cent. solution of atropin and a 0.5 to 1 per cent. solution of morphin they lived for weeks and increased in number to an extraordinary degree. These observations only tend to show the necessity of sterilizing doubtful

solutions and of preparing fresh solutions whenever it is possible to do so.

Sterilization and resterilization of prepared solutions are best done by exposure for a sufficient length of time to live steam. Contamination of ready-made solutions can be prevented to a great extent by the addition of carbolic acid, creasote, or bichlorid of mercury, even in very small quantities.

Koch's syringe is an excellent instrument for subcutaneous medication. Overlach's piston syringe can be sterilized, without damaging the instrument, by boiling. The leather piston has been almost entirely replaced by asbestos. Steel needles are damaged by dry heat, but needles made of platinum-iridium can be treated in this manner without impairing their strength.

Another precaution in the prevention of infection from needle puncture is disinfection of the skin, which should never be omitted. This can be accomplished effectually and speedily by scrubbing with hot water and soap, followed by rubbing the surface with absolute alcohol or a 5 per cent. solution of carbolic acid. If it is the intention to introduce the solution underneath the skin, a fold of the skin is raised and the needle inserted boldly into the loose connective tissue, when the fluid is injected somewhat slowly, so as to bring it in contact with a maximum surface for absorption. *In making a parenchymatous injection, the needle is inserted into the swelling or tumor, and before the injection is made, the point is withdrawn a line or two to prevent entrance of the solution directly into the circulation in case the point of the needle should have penetrated a vein.*

In making a copious parenchymatous injection, the contents of the syringe are injected slowly as the needle is being withdrawn, and as soon as the point of the instrument is near the skin, the direction of the needle is changed and another puncture made, when the syringe is detached, filled with the solution, and again connected with the needle, and the injection made as before. In this manner several syringefuls can be injected into the pathologic product through the same puncture in the skin.

The injections of a tumor or any other pathologic product to the extent just described results in more or less tension, which makes it desirable to seal the puncture hermetically with a film of cotton or collodion.

Exploratory puncture is made exclusively for diagnostic purposes, and if the pathologic product is fluid and within reach of the needle of an ordinary hypodermic syringe, this instrument answers all the requirements. Exploration of the subdural space, pericardium, pleural cavity, and more superficial accumulations of serum or blood can be done in a reliable manner by the use of the hypodermic syringe. The puncture should always be made obliquely and under strictest aseptic precautions, to guard against leakage and later infection. By making the puncture obliquely the valvular arrangement in the wall of the cavity explored will prevent extrava-

sation and serve as a mechanical barrier to the subsequent entrance of pathogenic microbes. The direction of the needle from the surface to the cavity to be explored must be determined beforehand, and when this has been done, the needle is plunged to its destination in one quick movement. As soon as resistance ceases, it is a sure indication that the point of the needle has reached the space to be explored, when aspiration is made and the result carefully noted. If the cavity contain a substance sufficiently fluid to flow through the narrow lumen of the needle, such as blood or serum, the result of the puncture will yield the desired diagnostic information. If the cavity is small and distant from the surface, it often becomes necessary to make systematic explorations by pushing the needle from the same external puncture in different directions, and making aspiration at different points as the needle is advanced or withdrawn.

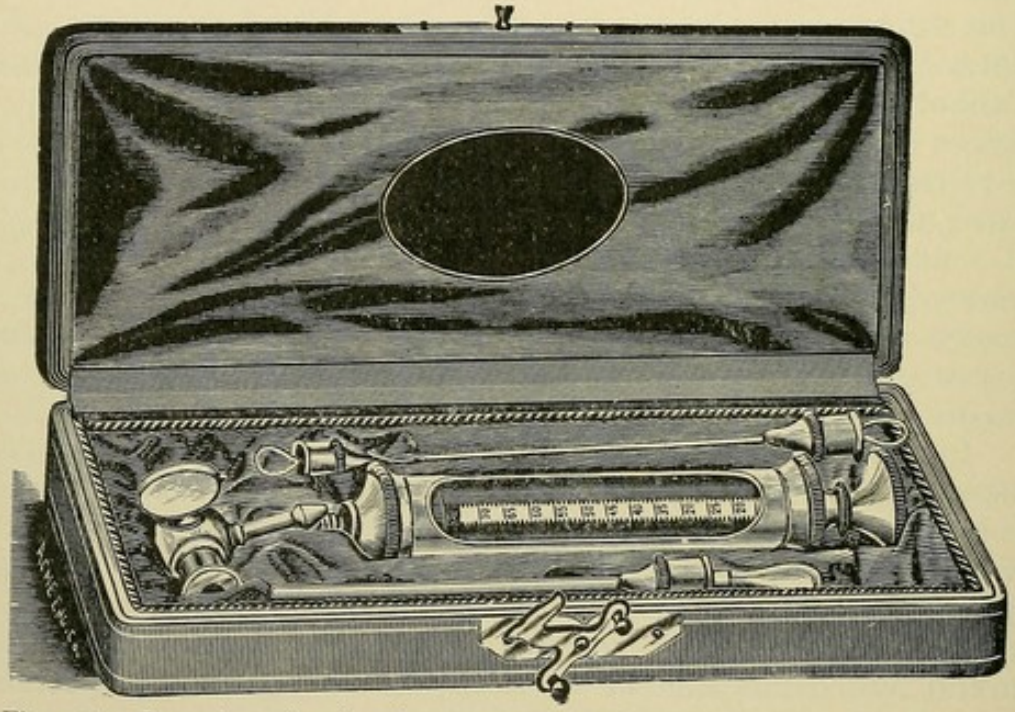

Fig. 415.—Large hypodermic syringe with stop-cock, used for exploratory purposes.

This method of exploration is the one to be recommended in treating pulmonary and cerebral abscesses. Thin, sanious pus will escape through the needle of an ordinary hypodermic syringe, but mucus, thick, creamy pus, and the contents of a tubercular abscess usually require the larger needle of an exploratory syringe to demonstrate their presence in the swelling under examination.

An exploratory syringe differs from a hypodermic syringe only in size. The glass cylinder, piston, and needles are larger. The needles vary in size from the needle of an ordinary hypodermic syringe to that of a small-sized trocar. The increased length of the needles enables the surgeon to reach fluid pathologic products beyond the range of the hypodermic syringe. Every physician should have and maintain in good condition an exploring syringe,

which is used solely for diagnostic purposes, reserving the use of the hypodermic needle for the subcutaneous or parenchymatous administration of therapeutic agents. As the exploring syringe is used almost exclusively for the demonstration of the presence and nature of pathologic products, careful disinfection by boiling in soda solution for five or ten minutes after each use becomes absolutely necessary.

In the exploration of doubtful fluctuating swellings or tumors of the abdominal cavity, the greatest care is required either in excluding the free peritoneal cavity from the line of puncture, or in making the puncture sufficiently oblique with a small needle to prevent extravasation into the peritoneal cavity. Puncture of a distended paretic intestine is attended by great risk of extravasation and should be avoided. The same caution applies to the intraperitoneal puncture of abscess cavities. Exploratory puncture of the skull for suspected hydrocephalus in young children is made with a fine needle, through existing defects in the skull, the fontanels, or patent sutures. The pericardium is punctured in the fourth intercostal space, about an inch distant from the sternal border. The pleural cavity is explored by puncturing an intercostal space over the area of dullness, obliquely from below upward and inward, in the direction corresponding with the space between the adjoining ribs. In doing so and by following the middle of the intercostal space, the intercostal vessels and nerve are avoided. Before making the puncture the patient should be placed in a proper position, either sitting or in a half-reclining posture, with the arms well elevated, to increase the width of the intercostal space. The best guide for the needle is the tip of the left index-finger, which is pushed between the ribs as far as possible. The needle is then made to rest against the radial side of the finger, and when in proper position, is pushed through the chest-wall in one movement. Even local anesthesia is unnecessary in such cases, as when the puncture is made properly and with the necessary quickness, the pain is momentary and slight. During the aspiration the needle should be held steadily in the position in which it was inserted.

In cases in which the cavity punctured is very tense, the danger of extravasation through the needle puncture is very much diminished by evacuating a part of its contents through the exploring needle. This can be done by detaching the syringe from the needle if the extravasation or inflammatory product is sufficiently thin to escape through the needle ; otherwise by aspiration with the syringe.

For good reasons the old-fashioned grooved exploring needle is almost entirely out of use and has been replaced by the tubular needle. The different kinds of aspirators in such common use but a few years ago as diagnostic instruments are seldom employed at the present time for such purpose, and for therapeutic use they have been replaced largely by the trocar and siphon.

It is to be hoped that the profession, as a whole, will soon realize the importance of strict aseptic precautions in the employment of the exploring needle as a diagnostic instrument, as its reckless and careless use in the past has but too frequently been followed by infection, and, in the case of infected swellings, mixed infection. It is an instrument of indispensable diagnostic value in many cases, but if used improperly, it becomes a dangerous weapon. The contents of the syringe in successful exploratory puncture are often subjected to microscopic and bacteriologic examination for further diagnostic information, and for this reason, if for no other and more important one, the instrument should be absolutely aseptic.

Paracentesis.—This operation consists of tapping any of the preformed cavities of the body for the evacuation of fluid. The operation is usually performed for the removal of an extravasation (blood), transudate (serum), or the product of a suppurative inflammation (pus). The evacuation of an extravasation or a transudate by this method often suffices to effect a permanent cure, while the removal of pus affords only temporary relief and must be followed sooner or later by a radical operation. The aspirator, used so extensively as a substitute for the trocar during the last two decades, is seldom employed at the present time. It is impossible to estimate

Fig. 416.—Plain trocar.

the suction force of the different aspirators, which has done so much harm in evacuating the different cavities after the removal of the positive pressure. Great vascular engorgement, hemorrhage, edema, syncope, and distressing cough are some of the complications caused by harmful aspiration, according to the nature of the cavity and its contents and the amount of suction force employed.

The proper instruments for paracentesis are trocars of different sizes, and in cases in which simple tapping is liable to be attended by the entrance of air, a piece of rubber tubing is attached to the cannula of the trocar, the fluid being evacuated by siphonage. The entrance of air after the positive pressure is removed is prevented by immersing the free end of the rubber tube in a nontoxic antiseptic solution. For this purpose trocars without shields must be used.

As punctured wounds are very easily infected, the operation must be performed under the most pedantic aseptic precautions. The trocar is sterilized by boiling in soda solution for at least from five to ten minutes. The hands and point of puncture are disinfected with the same care as is used in the preparations for any other operation. General anesthesia is never permissible, as the pain caused by the puncture is of only momentary duration, and in enfeebled or

nervous subjects can be almost entirely obviated by freezing the skin with ether or chlorid of ethyl spray. *The tunnel made by the trocar in the deep tissues should never correspond with the puncture in the skin, as otherwise subsequent leakage and infection might occur.* The tubular wound in the deep tissues is made subcutaneously by making the puncture obliquely, or by displacing the skin by drawing it to one side before the puncture is made. After the cannula is withdrawn, the puncture in the skin is sealed with collodion and a thin film of sterile absorbent cotton, which remains in place until the continuity of the skin is restored by healing of the little wound.

Hydrocephalus.—The treatment of acute and chronic hydrocephalus by tapping has not yielded encouraging results. The operation, however, is justifiable, and if performed with the requisite care, devoid of danger. In infants the lateral ventricle has been punctured with a fine trocar through the open anterior fontanel. The puncture is made far enough from the median line to avoid the superior longitudinal sinus. Not more than two ounces of the cerebrospinal fluid should be removed at one time, as the evacuation of a larger quantity is likely to result in convulsions and death. Compression of the skull should be made during and after the operation.

After the skull has become ossified, tapping can be performed only through a small cranial defect made with the chisel or trephine, but under such conditions the operation has so far yielded very unsatisfactory results. In a case of hydrops of the lateral ventricle in a young man who came under my observation, the lateral ventricle was tapped through an opening in the skull made with the chisel, and two ounces of cerebrospinal fluid were removed and an ounce of a weak aqueous solution of iodin was injected. The operation was not followed by any untoward symptoms, and resulted in permanent improvement.

Lumbar Puncture.—In 1891 Quincke introduced lumbar puncture of the spinal canal as a therapeutic measure in the treatment of serous and tubercular meningitis in children. This procedure proved very useful in a number of cases of cerebrospinal meningitis during the Spanish-American war. The patient is placed on his left side, and the lumbar segment of the spine is placed in a position of hyperextension. With a fine trocar the puncture is made below the arch of the fourth or the fifth lumbar vertebra, within half an inch of the median line. The instrument is pushed obliquely upward and inward from one to three inches, according to the age of the patient and the thickness of the soft tissues, until the subarachnoid space is reached, an event announced by the escape of cerebrospinal fluid. The same procedure is repeated on the reappearance of symptoms pointing to cerebrospinal compression.

Paracentesis Pericardii.—Puncture of the pericardium has been made a legitimate and useful surgical resource largely through the

writings of Dr. J. B. Roberts, of Philadelphia, who warmly advocated the operation at a time when the consensus of opinion was opposed to it. An effusion or extravasation in the pericardial sac sufficient in quantity to compress the heart is a source of imminent danger to life, and death from arrest of the heart's action (pericardial tamponade, E. Rose) can often be averted only by timely surgical intervention. The evacuation must be done quite slowly, through the cannula of a very fine trocar or the medium-sized needle of an aspirator. The puncture is made in the fourth or the fifth intercostal space, about an inch from the sternal border.

Thoracentesis.—Evacuation of fluid from the cavity of the pleura through a hollow needle or a small trocar is an operation known as thoracentesis. Puncture of the chest and evacuation of its fluid contents by siphonage or aspiration are indicated in

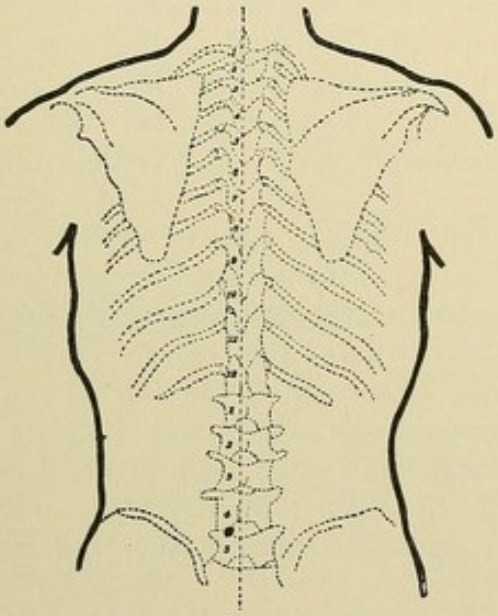

Fig. 417.—Lumbar puncture of the spinal canal.

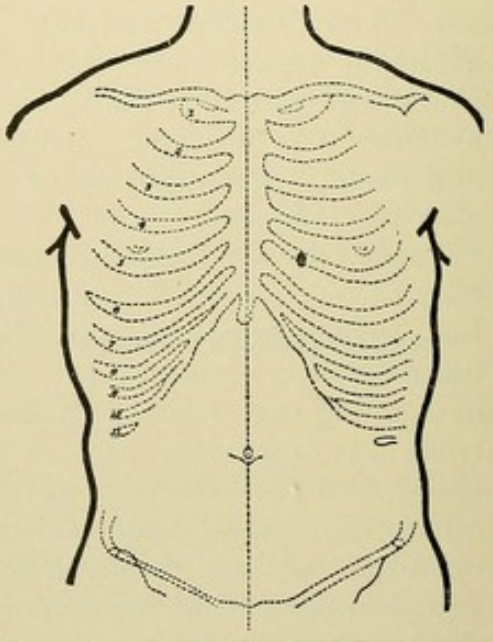

Fig. 418.—Puncture of the pericardium.

hemothorax after the hemorrhage has ceased and when the extravasation fails to disappear by absorption in due course of time, or as soon as signs and symptoms point to the existence of infection of the contents of the pleural cavity. Tapping must always be postponed until bleeding has become arrested, as the extravasation itself becomes an important aid in effecting hemostasis by pulmonary compression and the formation of a coagulum at the bleeding point. Unless the symptoms are very urgent, it is postponed until it has become evident that removal of the extravasated blood by absorption is no longer to be expected. I have seen several cases of gunshot wounds of the chest in which the entire pleural cavity was filled with blood, the dullness extending to the second rib, and yet disappearance of the blood by absorption occurred in the course of from four to six weeks.

Upon the appearance of the first symptoms of infection, tapping, under strict aseptic precautions, should be performed without delay. Early tapping and evacuation by siphonage are necessary in the treatment of serous pleuritis with copious effusion. Tapping of the chest, if properly performed, is devoid of danger and at once relieves the pulmonary compression and embarrassed action of the heart, thus placing the absorbents in a condition favorable to the return of their physiologic function. Under positive intrathoracic pressure the stream remains continuous unless interrupted by blocking of the cannula by shreds of fibrin. Should this occur, the lumen is cleared by the insertion of a sterile probe or wire; should this fail, it might become necessary to make a new puncture. With the approach of negative intrathoracic pressure the stream diminishes in size and force. During inspiration it ceases altogether, when the fluid in the basin is drawn into the tube and possibly into the cavity of the chest, to be expelled during the next expiratory movement of the chest. Serous pleuritis, in the great majority of cases, is of a tubercular nature, and if the fluid continues to accumulate in the chest after repeated tappings, much is gained and nothing risked by injecting two or three drams of a 10 per cent. iodoform glycerin emulsion through the cannula after the fluid has been withdrawn by siphonage. If the fluid is in the free pleural cavity, the puncture is made in the axillary line, usually through the sixth or seventh intercostal space.

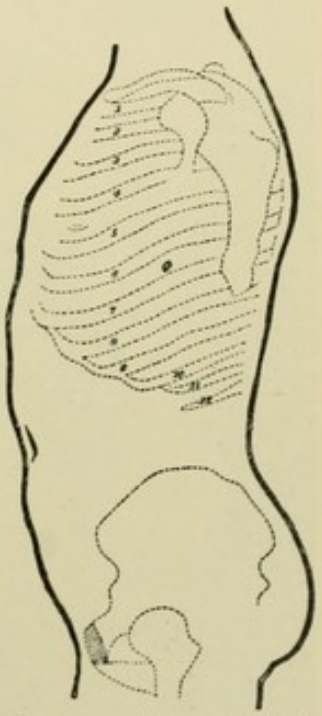

Fig. 419.—Puncture of the pleural cavity.

In circumscribed hydrothorax the center of the area of dullness is the proper place for the puncture. The arm on the affected side of the chest should be raised to the side of the head, to widen the intercostal space. If the patient is a child, a reliable assistant must hold it securely until the operation is completed. The skin is anesthetized by Schleich's infiltration method or by the freezing spray. The left index-finger is used as a guide for the needle. The tip of the finger is pressed as deeply as possible into the intercostal space, when the needle or trocar is placed along the radial side and pushed, in one movement, inward and slightly upward, so that the puncture will correspond with the direction of the intercostal space. By following these directions there is hardly a possibility of striking a rib or of injuring the intercostal nerve or vessels, mishaps that might otherwise occur.

In empyema tapping and siphonage constitute an important part of the preparatory treatment of the subsequent radical opera-

tion. Preliminary partial evacuation of the pus by this means is conducive to pulmonary expansion, and if the empyema is extensive, contributes much toward diminishing the immediate and remote risks of the subsequent radical operation. If the pleural infection is mild and the pus thin and serous, this simple and safe procedure occasionally suffices to effect a cure, more especially in the case of children. In the adult, with very few exceptions, it must be regarded in the light of a palliative measure and as a valuable preparatory procedure to incision and drainage.

Paracentesis Abdominis.—Tapping of the abdomen is now resorted to almost exclusively for the evacuation of serum in cases of ordinary ascites of high degree or tubercular hydrops. Puncture of ovarian cysts through the intact abdominal wall, formerly frequently practised, has, for obvious reasons, been almost entirely abandoned. The large trocar has given place almost entirely to the small hydrocele trocar, as it is necessary to evacuate the fluid slowly to avoid dangerous venous hyperemia and syncope.

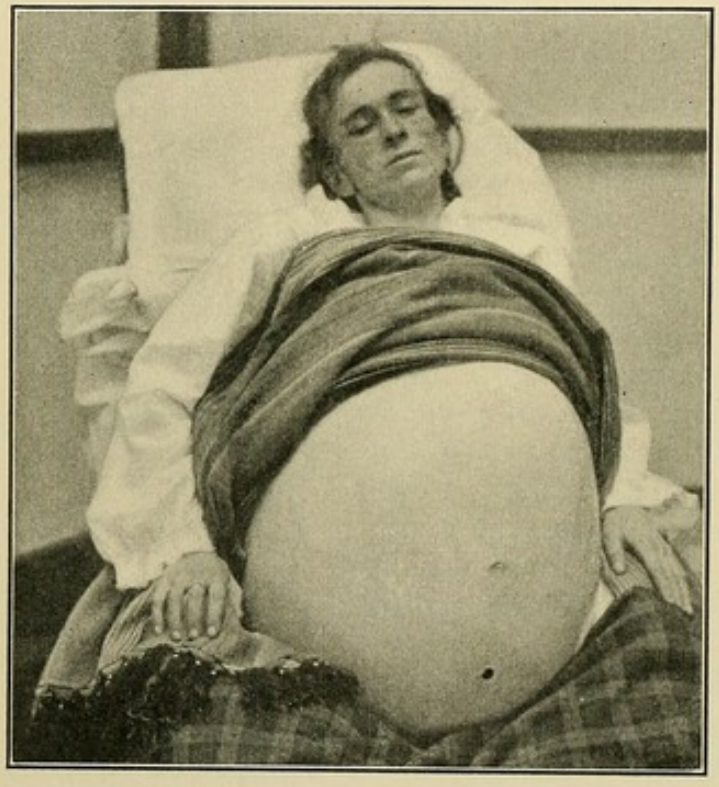

Fig. 420.—Point of puncture and proper position of patient in tapping the abdomen for ascites.

The bladder should be empty at the time the puncture is made. The patient is placed in a semi-reclining position, and the abdomen is supported by passing a towel or broad bandage twice around it, crossed in the region of the umbilicus, traction being made on the ends by an assistant standing behind the patient. The trocar is sterilized by boiling in soda solution, and the skin is well disinfected in the usual way. The puncture is made in the median line, half-way between the pubes and umbilicus. Before the puncture is made the level of the fluid is ascertained by percussion, the tympanitic space above indicating the location of the intestines floating on the fluid. With one quick movement the instrument is plunged through the entire thickness of the abdominal wall, the sudden cessation of resistance announcing that the point of the instrument has reached its destination. As the stilet is with-

drawn the fluid escapes through the cannula, and is conveyed into a receptacle by a piece of rubber tubing attached to the end of the cannula. The fluid should be withdrawn very slowly, to guard against the accidents previously referred to. As the abdomen relaxes the bandage is drawn sufficiently tight to secure the necessary mechanical pressure. Should the heart's action at any time show evidences of inefficiency, stimulants are administered, the patient is placed in the dorsal recumbent position, and the flow of fluid is interrupted until reaction is established. The sudden arrest of the stream before the evacuation is completed is caused by closure of the cannula by the omentum or intestines or a wrong direction of the cannula. As the fluid is removed, the intestines and omentum descend, when the cannula should be directed downward. If any of the abdominal contents occlude the cannula, they can be pushed backward by a sterile probe, wire loop, or catheter.

After the completion of the operation, the puncture is sealed with iodoform collodion, and the abdomen is supported by a well-fitting abdominal bandage or broad flannel roller. Rest for a day or two must be enforced. Tapping for tubercular ascites should be followed by injection through the cannula of two or three drams of iodoform glycerin emulsion. I have seen two cases of recovery from this affection by intraperitoneal iodoformization after laparotomy and drainage had failed.

Tapping of Joints.—Aseptic tapping of joints is a most useful modern therapeutic resource, as it relieves pain by removing tension, and renders the diseased joint surfaces accessible to direct medication. Every surgeon knows how easy it is to infect a joint, and consequently resorts to the most scrupulous aseptic precautions in performing the operation. The trocar should invariably be boiled in soda solution before the tapping, and the hands of the surgeon and the point of puncture should be disinfected as carefully as in the preparation for a major operation. The small trocar that accompanies my syringe for making intra-articular and parenchymatous injections is very well adapted for puncturing and evacuating any of the joints that are ordinarily subjected to this method of treatment.

To prepare the syringe for use, the rubber cap should be removed from the top of the glass cylinder, which is then filled with the fluid to be injected, after which the cap is replaced. Before making the puncture with the needle the stop-cock should be opened and the air expelled from the rubber tube and needle by filling them with the fluid. The injection should be made slowly, by steady pressure on the bulb with the cylinder in a vertical position.

Simple tapping and evacuation of the joint are performed in traumatic and pathologic hemarthrosis when the extravasation of blood is sufficient in amount to cause painful tension, or if spontaneous resorption fails to occur within the expected period of time.

After the evacuation of the blood the joint should be supported by a thick cushion of cotton, held in place by a gauze or flannel roller, and immobilized. The same procedure is applicable in the treatment of catarrhal synovitis with copious effusion. In gonorrheal synovitis and mild forms of suppurative synovitis the joint should be washed out with a 2½ per cent. carbolic acid solution. This can be done with the injection syringe shown in the illustration (Fig. 421). The joint is slightly distended with the solution, which is then allowed to escape, the same procedure being repeated two or three times. I have found this method of treatment very satisfactory in both forms of synovitis referred to. Should the joint again become distended in the course of a few days, the tapping and intra-articular disinfection are repeated. Elastic compression of the joint, immobilization, and elevation of the limb constitute an important part of the after-treatment. In gonorrheal synovitis the internal use of large doses of potassium iodid, as advised by Professor Schüller, will prove useful.

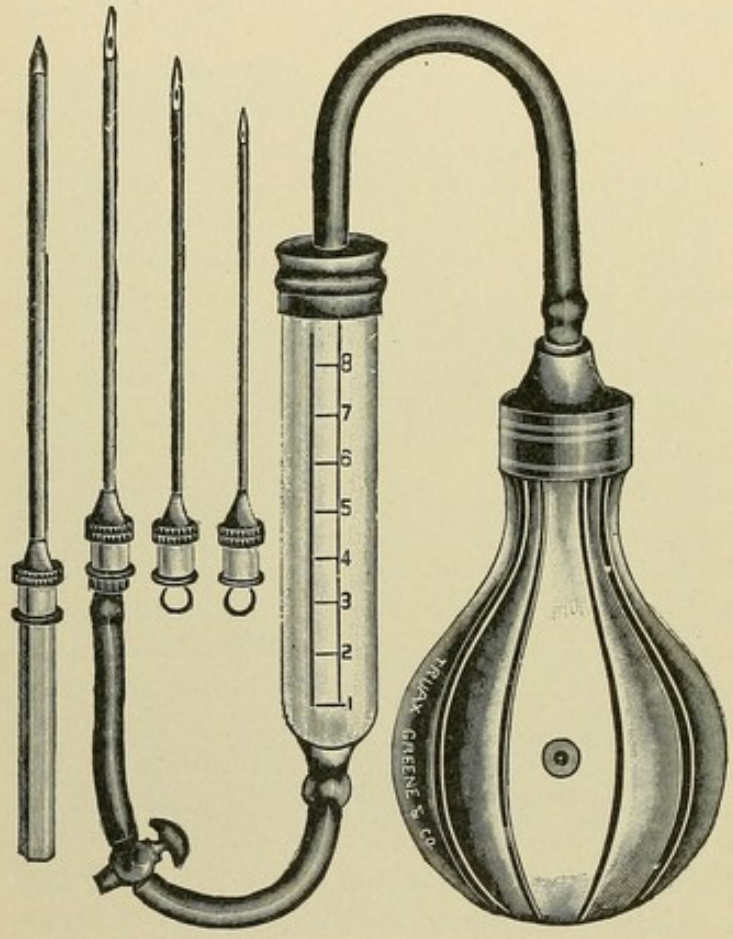

Fig. 421.—Senn's injection syringe.

Intra-articular medication after tapping has been found most satisfactory in the treatment of tubercular abscesses and synovial tuberculosis. The preparation that has given the best results is a sterilized 10 per cent. emulsion of iodoform glycerin. In injecting a tubercular abscess the puncture should not be made where the abscess wall is thinnest, but at some distance from the most prominent point of the swelling, so that the puncture will be made through healthy skin, and not through tissues reduced in vitality from the long-continued pressure and infection from beneath. Before the puncture is made the skin is drawn to one side, so that after the removal of the cannula the puncture in the deep tissues will be subcutaneous. If the joint or abscess cavity contain broken-

down tubercular products that can not be removed through the cannula, the joint or abscess should be freely incised, the interior scraped and rubbed out with iodoform gauze, the wound sutured, and then the injection be made, a plan of treatment practised with great success by Billroth.

Phelps has recently recommended, in similar cases, the application of pure carbolic acid to the diseased surfaces, followed by alcohol. He speaks in the highest terms of the curative value of this treatment. *Iodoform is useless in any form after the joint or abscess cavity has become infected with pus-microbes. Its antibacillary action is limited to uncomplicated tubercular processes.*

In tapping a joint, the cardinal rule in all cases should be to select the shortest route from the surface into the different joints, and at a point where no important structures will come into the line of the proposed puncture. The shoulder-joint is punctured from the front; the elbow-joint, between the head of the radius and the external condyle of the humerus or inner border of the olecranon process, according to which side of the joint is most extensively affected; the wrist-joint, from the dorsal surface. The best place to puncture the hip-joint is on a line drawn from the spine of the pubis to the upper margin of the greater trochanter of the femur, and at a point corresponding with the inner margin of the sartorius muscle. The knee-joint is most accessible at a point corresponding with the outer margin of the patella, near its upper border. The ankle-joint is punctured on either the tibial or fibular side from the front, care being taken to avoid important vessels and nerves.

The curative value of intra-articular injections of iodoform glycerin emulsion has been fully established by a large clinical experience. As before stated, the best results are obtained in cases in which the tubercular disease remains limited to the soft tissues of the joint. The dose must vary, according to the age of the patient, from two to four drams. As some persons are very susceptible to the toxic effect of iodoform, it is advisable to begin with the minimum dose, and, in the absence of such idiosyncrasy, increase it gradually in repeating the injections. The interval between the injections should be from one to two weeks. The most favorable indication of the curative effect of the iodoform is the transformation of the joint or abscess contents into a viscid fluid. From one to six injections will usually suffice in cases susceptible to this method of treatment. Elastic compression of the joint is beneficial, but immobilization can often be dispensed with.

Punctio Vesicæ.—Puncture of the bladder occasionally becomes necessary as an emergency operation in the treatment of retention of urine caused by rupture of the urethra, mechanical obstruction from enlargement of the prostate, or stricture. The operation is reserved for cases in which the surgeon has found it impossible to evacuate the bladder by catheterization. The route for the puncture now invariably selected is the suprapubic. For good reasons

puncturing of the bladder through the rectum has been abandoned. As the bladder is always much distended in all cases that justify evacuation by suprapubic puncture, ample extraperitoneal space will be found between the symphysis of the pubis and the reflection of the parietal peritoneum above the space of Retzius. The large needle of an aspirator, an exploring needle, or a small straight trocar can be used as a useful substitute for Fleurant's suprapubic long and curved trocar, made for this special purpose.

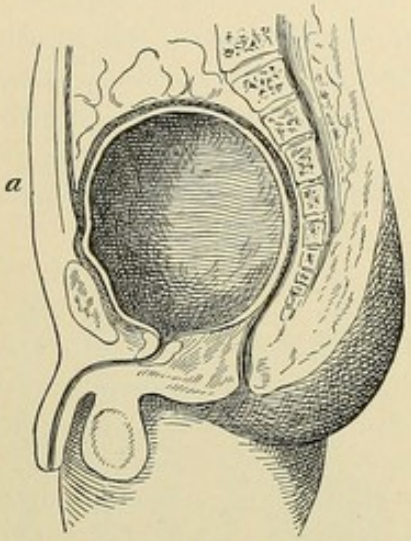

Fig. 422.—Bladder distended by retention of urine (after Fehleisen): *a*, Peritoneal reflexion.

The suprapubic region is shaved and thoroughly disinfected. The puncture is made in the median line, directly above the symphysis pubis, and the instrument is pushed backward and slightly downward until resistance ceases, when the stilet is withdrawn, followed by the escape of urine in a forcible stream. A rubber tube attached to the cannula will facilitate the emptying of the bladder. Fleurant's trocar has two cannulas, and if this instrument is used, the outer cannula is fastened in place with strips of adhesive plaster and can remain for the necessary length of time, while the inner cannula is frequently removed, cleansed, and reinserted. *The greater the distention of the bladder, the slower must be the evacuation of its contents.* The stream is interrupted from time to time by pressing the finger-tip against the end of the cannula or by compressing the rubber tube. If it is desired to maintain suprapubic drainage for a number of days and Fleurant's catheter is not at hand, a small Nélaton catheter can be inserted into the bladder through the cannula before the latter is withdrawn. If the patient is within easy reach of the physician, repeated puncture of the bladder is to be preferred to the establishment of a suprapubic fistula. The bladder can be punctured once or twice a day for a number of days without any serious consequences, provided the punctures are made under the strictest aseptic precautions. If, from the nature of the obstruction, it is deemed advisable to maintain suprapubic drainage indefinitely or permanently, it is done by performing cystostomy.

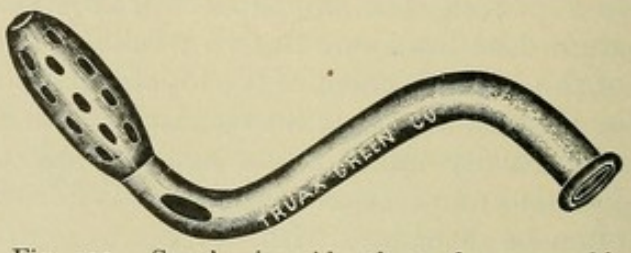

Fig. 423.—Senn's sigmoid catheter for suprapubic drainage of the bladder.

With the pelvis of the patient elevated, a transverse incision is made immediately above the pubis, three inches in length, down to

the anterior wall of the bladder. The bladder is then opened transversely an inch and a half, and the margins of the visceral wound sutured to the skin. My sigmoid catheter will be found very useful as a permanent drain in such cases.

Tapping of Hydrocele.—Tapping of a hydrocele is performed as either a palliative operation or with curative intent, if followed by the injection of from twenty to thirty drops of pure carbolic acid, tincture of iodin, or any other irritant. The puncture is made with a small trocar. *The exact location of the testicle must be determined before the puncture is made.* The swelling is grasped with the left hand, for the purpose of protecting the testicle and to render the skin tense. Visible veins are avoided. The instrument is thrust into the sac of the hydrocele, and, on withdrawing the stilet, manual compression is continued until the fluid is evacuated. If the tapping is to be followed by an injection, the cannula must not be displaced, so as to insure the entrance of the fluid injected into

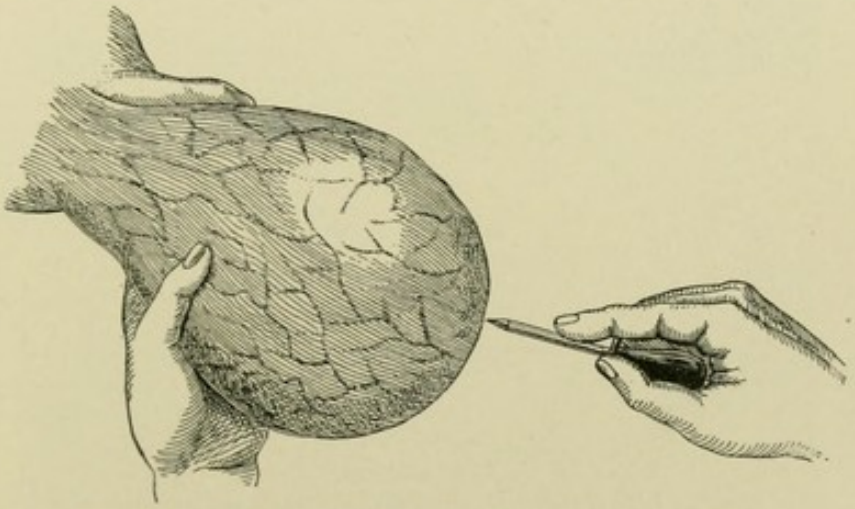

Fig. 424.—Tapping of hydrocele (Esmarch and Kowalzig).

the sac of the hydrocele, as injection of the fluid into the loose scrotal connective tissue has repeatedly been followed by necrosis and other serious consequences. The puncture is sealed with iodoform collodion, and the relaxed scrotum is properly supported.

Drainage of Suppurating Joints.—The indications for amputation for large abscesses, phlegmonous inflammation, and suppurating joints have become very few since surgeons have learned the importance of free drainage, effective antiseptic irrigation, continuous or at short intervals, and the use of the hot moist antiseptic dressing, combined with immobilization of the affected limb or part. A suppurating joint, as an isolated affection of either traumatic or pathologic origin, seldom, if ever, justifies a mutilating operation at the present time, as free incision and efficient drainage usually suffice in protecting the life of the patient from sepsis, and generally succeed in restoring the limb to a useful position. In discussing the treatment of suppurating joints by incision and drainage I have

excluded all tubercular affections of joints that require separate consideration and special treatment. The average practitioner seldom drains a suppurating joint properly. The most common mistakes made are that too small and too few incisions are made and too small drains used. No joint should be incised until the presence of pus has been demonstrated by an exploratory puncture or by local signs and general symptoms that can leave no doubt as to the existence of intra-articular suppuration. The diagnosis being established of suppurative synovitis or arthritis, which has not yielded or does not come within the range of successful treatment by tapping and intra-articular antiseptic irrigation, the following treatment recommends itself: (1) Free incisions; (2) ample drainage; (3) antiseptic irrigation with mild, nontoxic, yet effective antiseptic solutions; (4) moist hot antiseptic compress; (5) immobilization of the limb in a useful position.

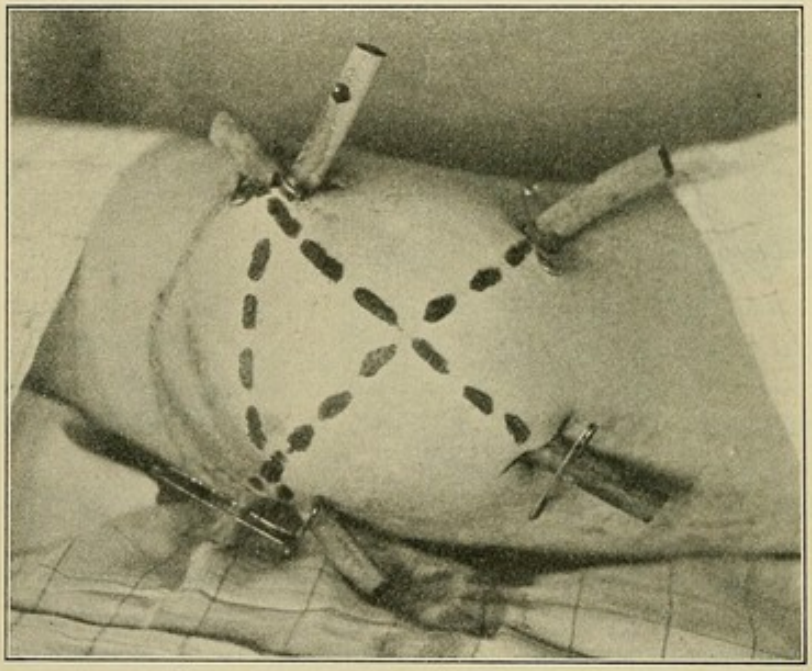

Fig. 425.—Drainage of the knee-joint.

The incisions must be made large enough to furnish space for drains of ample size, and at points where drainage is most required; they should be sufficient in number to give access to all places where retention is liable to occur. The knife must be used as sparingly as possible, as the tissues can be tunneled more safely with locked hemostatic forceps. Tubular drains should be employed exclusively. The drains should seldom be smaller than the little finger in draining any of the large joints, and often drains the size of the thumb will be required. Every drain must be supplied with a large safety-pin. For continuous intra-articular irrigation Thiersch's solution or a saturated solution of acetate of aluminum should be used. The compress of gauze should be moistened with one of these solutions, and heat and moisture be retained by apply-

ing over it an impermeable fabric, such as gutta-percha, mackintosh, oiled silk, or rubber. The limb should be invariably immobilized in a useful position by a splint that will permit local treatment of the joint without disturbing it; in many cases it will be a source of comfort to the patient to combine immobilization with suspension.

Drainage of the Knee-joint.—The knee-joint can be efficiently drained by making an incision, at least an inch in length, just above the patella on each side of the joint, and placing a drain the size of the little finger transversely. This will drain the upper recess of the synovial sac. A long pair of hemostatic forceps are then inserted through one of these openings, and passed obliquely through the joint to the opposite side of the tendon of the patella, when the point of the instrument is pushed through the tissues until the skin is raised in the form of a cone. This cone is then

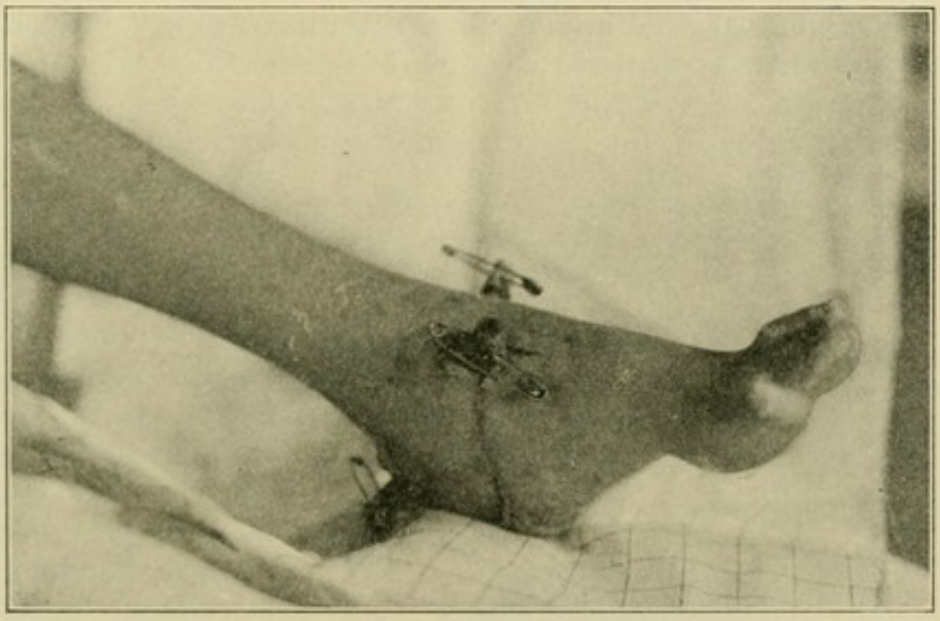

Fig. 426.—Drainage of the ankle-joint.

incised at its base, the instrument is pushed through the opening, and the blades are expanded. With a drain firmly grasped, the forceps is then withdrawn. Another drain is inserted in a similar manner and in an opposite direction from the other incision.

Drainage of the Ankle-joint.—The transverse drain is placed underneath the extensor muscles and the tibialis anticus artery and nerve by making the drainage openings immediately in front of the anterior margin of the malleoli. The anteroposterior drain is inserted by passing a hemostatic forceps from the opening on the tibial side obliquely across the joint to the fibular side of the Achilles tendon, where the counteropening is made.

The shoulder- and the hip-joint should be drained in an anteroposterior direction. Through drainage of the elbow-joint can be established by opening the radiohumeral joint, passing the forceps

across the joint, and making the counteropening just below and a little to the inner side and in front of the internal epicondyle, so as to avoid the ulnar nerve.

CHAPTER XIV.

ASEPTIC CATHETERIZATION.

Successful catheterization premises delicacy of touch, the employment of an instrument of proper construction, a practical knowledge of the structure of the urethra, and a full reliance on aseptic precautions. There is perhaps no minor surgical procedure in which the advantages arising from skill over force become more apparent than in the use of the catheter. Skill, patience, and perseverance often succeed in overcoming the most trying obstacles to catheterization in obstructive affections of the urethra, while unskilled attempts to pass a catheter through a normal urethra have often been the cause of most disastrous consequences. Some men acquire the necessary manual dexterity in the use of the catheter very readily, while others never become proficient in properly handling this instrument. Every student of medicine should be thoroughly trained in the technic of catheterization on the cadaver before he attempts to use the instrument on the living subject. False passages, hemorrhage, urinary fever, urinary infiltrations, urethritis, and septic cystitis are some of the complications that have followed reckless catheterization. Thousands of lives are lost annually from the remote consequences of infection following the use of the catheter, many of which might have been saved by a more careful handling of the instrument, combined with the most pedantic aseptic precautions. The one great rule that should govern the surgeon in the employment of the catheter is *never to use force.*

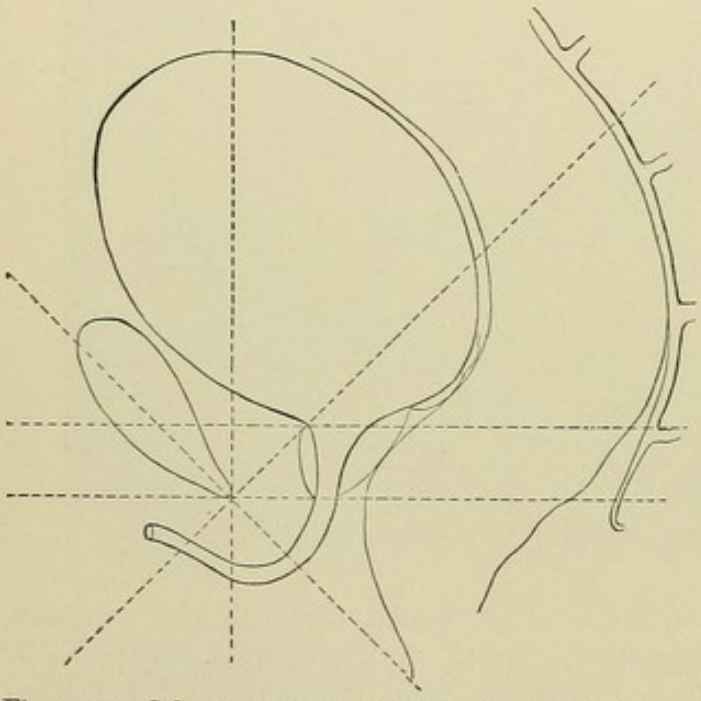

Fig. 427.—Schematic representation of urethral curve and its relation to the symphysis pubis (Tillaux).

Catheterization has become much safer since the soft-rubber catheter has largely taken the place of the metallic instrument. Traumatism of the urethra, so frequently inflicted by metallic catheters, occurs much less frequently by the use of the English catheters, and is almost entirely avoided by the employment of the soft-rubber Nélaton catheter. The French catheter is the ideal

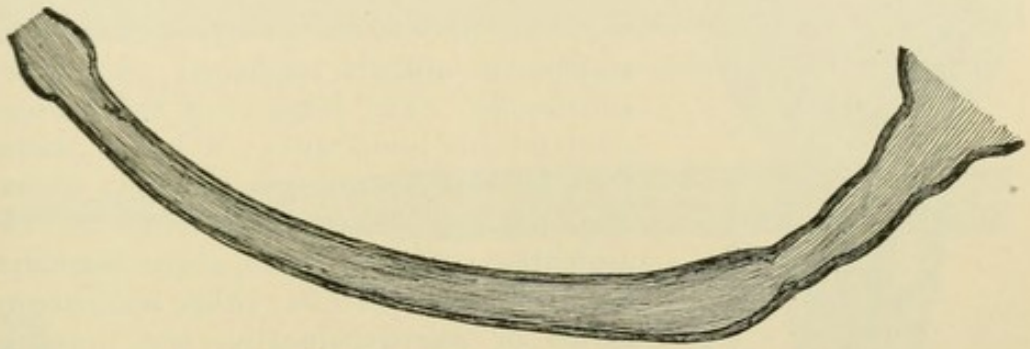

Fig. 428.—Male urethra (wax cast, after Home).

instrument in all cases in which the urethra is large enough to admit its passage. The prostatic catheter (Fig. 434) with a short, sharply bent beak will be found most useful in catheterization of patients suffering from enlargement of the prostatic gland. Kelly's glass catheter should be used exclusively in females, as it is cheap and can easily be disinfected and kept in an aseptic condition.

The most common mistake made in introducing the inflexible catheter is in following the floor instead of the roof of the urethra after the point of the instrument has passed the pubic arch. If a metal catheter is used, an instrument with a proper curve must be selected. In passing the catheter as far as the pubic arch the distal end of the instrument should not be raised more than 45 degrees from the surface of the abdomen; the half circle which it must make before the bladder is reached is then rapidly completed, a manœuver that keeps the point of the instrument in contact with the urethral roof, avoiding, in this manner, the prostate.

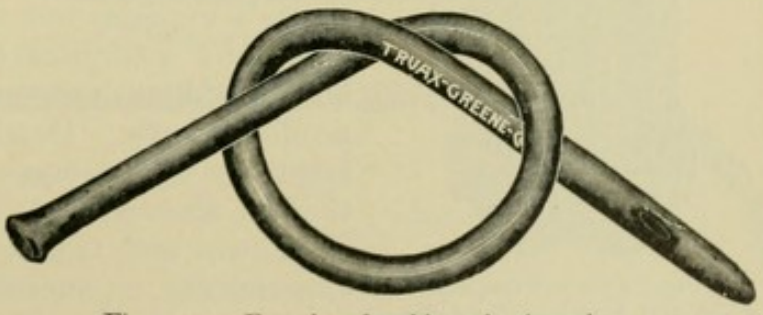

Fig. 429.—French soft-rubber elastic catheter.

Wounds and abrasions made with the catheter serve as entrance gates to the pathogenic microbes, and for this reason, if for no other, must carefully be avoided. *The normal bladder is difficult to infect; the paralyzed and diseased bladder, on the other hand, is very susceptible to infection.* In the study of the susceptibility of the

bladder to infection it is important to obtain a clear conception of the function of its mucous lining. The epithelial lining of this organ is not, properly speaking, a mucous membrane, as it is not supplied with glandular appendages, and in a normal state secretes no mucus. It is the reservoir for an excretion and not for a secretion. For this, if for no other, reason, we should, *a priori*, question its ability to absorb medicinal and other substances. The mucosa of the bladder contains no lymphatics; it lacks, therefore, all the physiologic elements necessary for absorption. Gerota, in the examination of more than sixty bladders, could not demonstrate, either macroscopically or microscopically, the presence of lymphatics belonging to the mucous membrane. The few vessels found in the submucosa of the vesical neck were identified in the lymphatics of the urethra, which extend for a short distance into the neck of the bladder, but soon enter the muscular coat. That the normal mucous membrane of the bladder is not an absorbing surface has been demonstrated by the clinical observations of Civiale and many other surgeons and the experimental work of many investigators, among them Kuss, Susiné, Alpay, Alling, Lewin and Goldschmidt, Cazeneuve, and Livon. Hottinger's experiments seem to prove that enormous quantities of poison must be introduced into the bladder of animals to produce death. Death in such cases he attributes to a process of diffusion rather than to absorption.

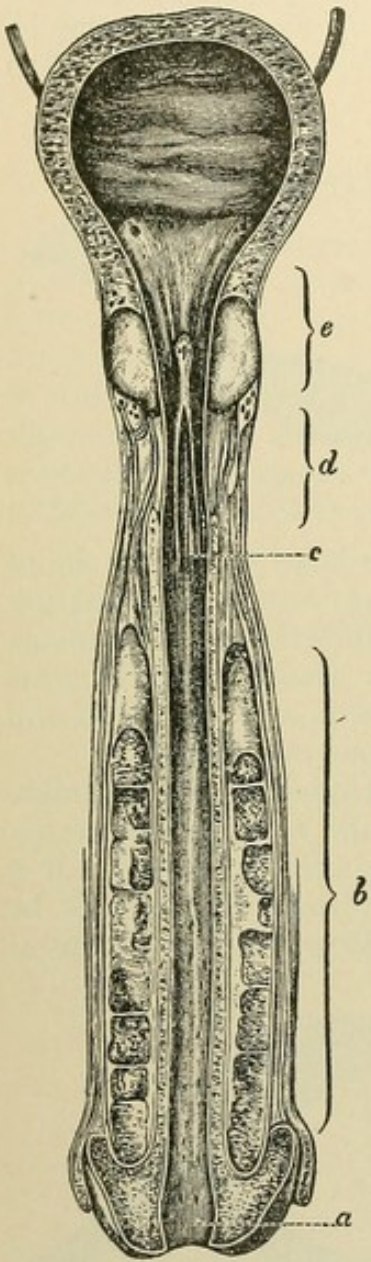

Fig. 430. — Comparative width and length of the different anatomic parts of the urethral canal: *a*, Fossa navicularis; *b*, cavernous portion; *c*, bulbar enlargement; *d*, membranous portion; *e*, prostatic portion (Finger).

Lewin and Goldschmidt made many experiments on animals, and came to the conclusion that the healthy mucous membrane of the bladder is impermeable to toxic substances, and, when absorption does take place, it is from the prostatic portion. Their experiments were made by ligating the neck of the bladder and injecting the solution directly into the bladder through an abdominal incision.

Although Pasteur ascertained, in 1860, that the decomposition of the urine outside of the body and in the inflamed bladder is

Fig. 431.—Olive-tip elastic web catheter.

Fig. 432.—Cylindric elastic web catheter.

Fig. 433.—Conic elastic web catheter.

Fig. 434.—Mercier's single-elbow prostatic catheter.

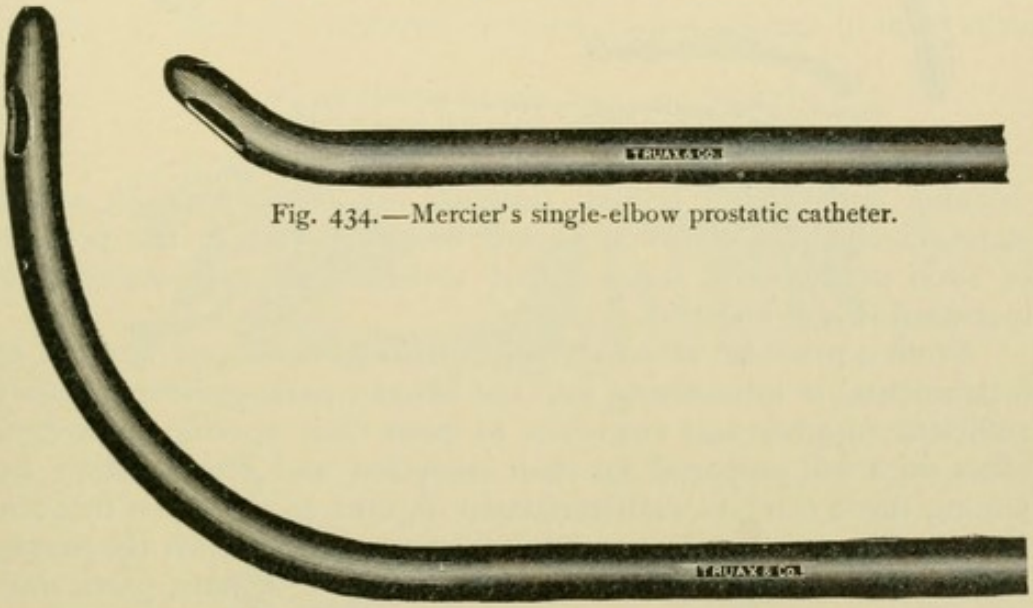

Fig. 435.—Large-curve prostatic web catheter.



Fig. 436.—Ordinary male metal catheter.



Fig. 437.—Metal prostatic catheter.

caused by the action of micro-organisms, our knowledge of the putrefactive changes of urine remains imperfect at the present time. He described the bacteriologic cause of urine decomposition, the microbe that he so constantly found, as "*une des torulacée en chapelets des très petits grains.*"

Among the predisposing causes of cystitis must be mentioned retention of urine, unrest of the bladder, abnormal urine, tumors,

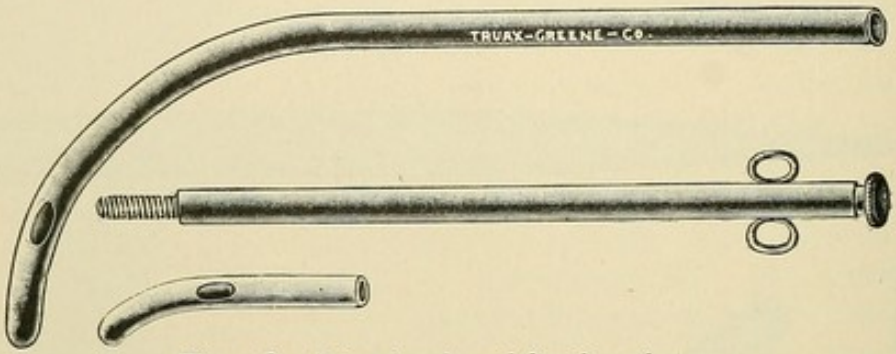

Fig. 438.—Jointed male and female catheter.

calculus and foreign bodies, pressure, exposure to cold, venous stasis, mechanical obstruction, and trauma. It is in the presence of such predisposing causes that catheterization is attended by increased risk of infection.

From a practical standpoint the exciting causes are such as are instrumental in introducing into the bladder pathogenic microbes in sufficient number and virulence to exert their specific pathogenic effect on a soil prepared for their reception and reproduction, and among these careless catheterization figures as the most frequent. Every surgeon is familiar with the frequency with which the passage of instruments into the bladder is followed by cystitis, particularly when the urethra is the seat of inflammation and in case catheterization is performed for retention of urine under any but the strictest aseptic precautions.

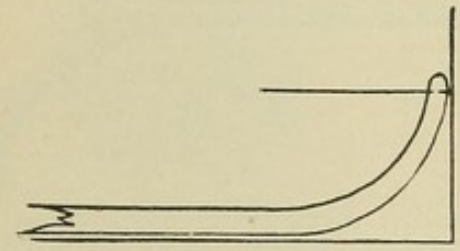

Fig. 439.—Proper curve (Van Buren and Keyes).

By continuity of surface a suppurative inflammation of the urethra may extend to the bladder without instrumental intervention. Complete sterilization of catheter and hands does not always succeed in depriving catheterization of the danger of bladder infection. Pathogenic microbes are almost constantly found in the normal urethra of healthy persons. Lustgarten and Mannaberg made a bacteriologic examination of the urethræ of eight healthy men, and found ten different kinds of micro-organisms, among them a number that are known to produce cystitis. The meatus urethræ is a favorite lodging-place for microbes. If the meatus is not disinfected before insertion of the catheter, microbes may be carried with

the instrument into the bladder sufficient in number and virulence to provoke a cystitis, provided they are brought in contact with a

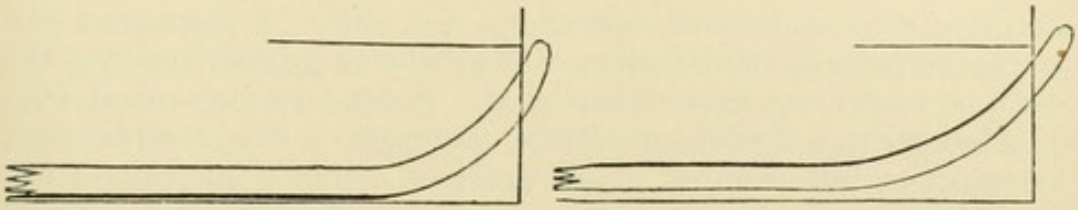

Fig. 440.—Faulty curves (Van Buren and Keyes).

soil prepared for their reception and growth by an injury or by antecedent lesions.

During a visit, a few years ago, to the obstetric wards of Professor von Winckel, I was informed that, for some time, quite a large number of recently delivered women had suffered from cystitis.

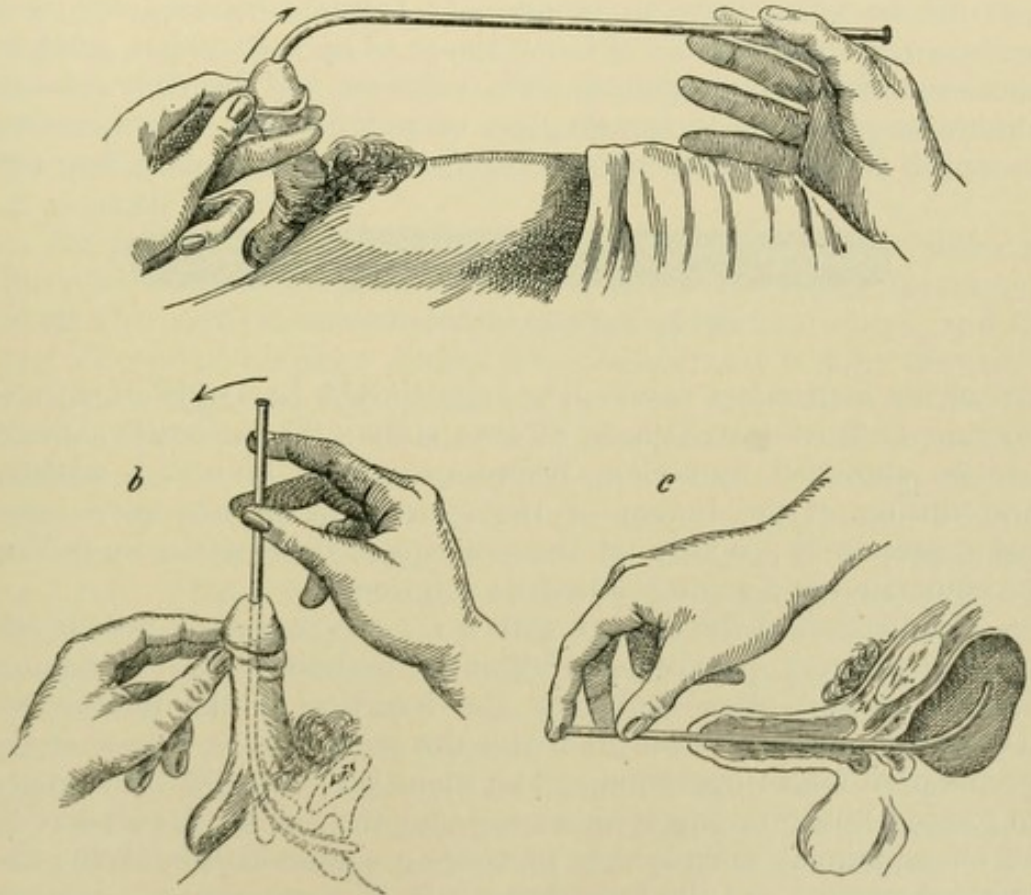

Fig. 441.—Technic of catheterization (Esmarch and Kowalzig). Manner of holding penis and catheter, and position of the same on inserting it into the meatus; *b*, position of catheter on passing prostatic portion of urethra; *c*, catheter in the bladder.

The strictest antiseptic precautions were practised in sterilizing instruments and hands, but the prevalence of this puerperal complication continued until the professor introduced an additional precautionary measure in all cases requiring the use of the catheter—namely, disinfection of the meatus with a solution of mercuric

bichlorid. From that time on cystitis from this cause disappeared from the lying-in wards.

I have seen numerous cases of cystitis following the use of the catheter after abdominal operations, but since I instructed the nurses to precede the insertion of the catheter by disinfection of the meatus, such cases have disappeared. Secondary gonorrheal cystitis following a specific urethritis, although a rare complication, does occur, but is more prone to follow a mixed infection of the urethra.

In view of the facts that it is difficult to disinfect the meatus completely, and that pathogenic bacteria always inhabit the urethra, it is necessary not only to sterilize hands and instruments, but to employ, at the same time, antiseptic precautions for the purpose of protecting the bladder against infection. The English hard-rubber catheter, covered with a coat of varnish, can not be sterilized by boiling without ruining the instrument, and chemic disinfection can not be relied upon in rendering it aseptic; consequently it is seldom employed at the present time. The soft-rubber catheter can be sterilized by boiling in soda solution, and for daily practice should be placed in an aseptic glass or metallic tube, corresponding in length to the instruments, and carried in the emergency bag and

Fig. 442.—Papier-mâché catheter case.

not in the instrument case. The tube should be large enough to contain at least instruments of four sizes. The metallic catheter can be sterilized by boiling before using it. Thorough washing and rinsing of the lumen of the instrument in hot water after using prepare it properly for the subsequent disinfection by boiling or immersion in a strong antiseptic solution.

Disinfection of the meatus with a 1 : 1000 solution of bichlorid of mercury, a 5 per cent. solution of carbolic acid, or absolute alcohol should always precede the insertion of the instrument. The hands must be disinfected with the same care as is used in the preparation for an operation. The glans penis should be wrapped in gauze, thus affording a firmer hold for the left hand, and serving as an additional safeguard in preventing contamination of the disinfected meatus and the instrument. It is customary to lubricate the instrument with some kind of fat or oil, to facilitate its insertion. Rancid fat, butter, or unsterilized vaselin are frequently used for this purpose, and there can be but little doubt that infection has often occurred from this source. Fatty material as a coating for the catheter is of advantage not only in facilitating the insertion of the instrument, but also in furnishing for the urethral microbes a mantle of an indifferent substance, and, in doing so, preventing their direct contact with the mucous membrane of the bladder.

This coating for the catheter and mantle for the microbes should be not only aseptic, but also antiseptic. The fatty material must be sterilized and made antiseptic by incorporating with it a nonirritating but efficient antiseptic. The best preparation to fulfil the indications for aseptic catheterization is sterilized vaselin, with the addition of 2½ per cent. carbolic acid or 1 per cent. of formic aldehyd. This should be kept in a collapsible metallic tube, and be carried in every emergency bag. Belfield recommends a 5 per cent. solution of boric acid in glycerin. After the catheter has been used, the coating of fat must be removed by thorough scrubbing with hot water and soap preparatory to disinfection.

The microbes enveloped by an antiseptic mantle of fat, even if they reach the bladder, will escape with the urine, and such as may remain are rendered more or less harmless by the inhibitory action of the antiseptic. The material for the lubrication of the instrument, properly selected and prepared, thus becomes an important preventive against, instead of a fruitful source of, infection, as has been only too often the case in the past. The most pedantic care in preventing infection becomes of the utmost importance in the treatment of cases requiring systematic catheterization for a long time, as is the case in paraplegia caused by injury or disease of the spine and in prostatic obstruction.

In private practice catheterization must, of necessity, often be intrusted to unskilled hands. Under such circumstances the surgeon must give explicit instructions in the use of the instrument, and the one who takes his place during his absence must acquire the requisite knowledge and skill under his personal supervision. *The Nélaton soft-rubber catheter is the only safe instrument in the hands of a layman.* The method of sterilization of the instrument and its proper care and use must be fully explained. A number of catheters must be kept on hand ready for use. It must not be forgotten that, as a rule, a large catheter passes through the urethra more readily than a small one ; this fact is often forgotten by the general practitioner. The instruments should be kept in a 5 per cent. solution of carbolic acid and suspended in a glass jar with a wide mouth and glass stopper. The glass stopper is covered with a piece of aseptic gauze to which the catheters are fastened with small safety-pins. The fluid should be changed every few days, and the catheter, after use, should be thoroughly cleansed with hot water and soap before it is immersed in the solution. Before the instrument is inserted it is rinsed in warm boiled water to free it from the carbolic acid, wiped dry with an aseptic towel, and lubricated with the antiseptic vaselin pomade squeezed from the collapsible tube. Thorough disinfection of the hands before handling and inserting the catheter must be insisted upon, as well as the preliminary disinfection of the meatus. The patient himself will often be found the one most competent and reliable to carry out the directions given by the surgeon. Trained nurses may usually be relied on for this service.

CHAPTER XV.

EMERGENCY OPERATIONS ON THE AIR-PASSAGES.

Intubation of the Larynx.—The mechanical treatment of inflammatory stenosis of the larynx by intubation was conceived and brought to its present state of perfection by the late Dr. O'Dwyer, of New York. As a substitute for tracheotomy it has yielded the most gratifying results in children less than five years of age. Successful intubation requires a full set of instruments, much practice in the technic of the operation, and constant watchfulness during the entire after-treatment. No one should attempt intubation without having received full instruction and without having acquired the necessary manual dexterity in inserting and extracting the tube quickly and safely. As a substitute for tracheotomy it has become a favorite procedure in this country, more so than in any other. This is, perhaps, due to the fact that on the continent of Europe children suffering from inflammatory stenosis of the larynx are generally taken to the hospitals, where the treatment after tracheotomy is placed in the hands of skilled assistants and experienced nurses, thus insuring better results after this operation than can be obtained in private homes, even under the most favorable circumstances. In this country the treatment of such cases is usually conducted at the homes of the patients, where intubation in children under six years of age has certainly yielded much better results than tracheotomy. Every general practitioner should make himself fully conversant with the technic of intubation, more particularly if he lives in a locality where he can not avail himself of the services of an expert. Medical colleges and post-graduate schools should make ample provision for practical instruction in intubation, to prepare the students and practitioners properly for this important part of their calling.

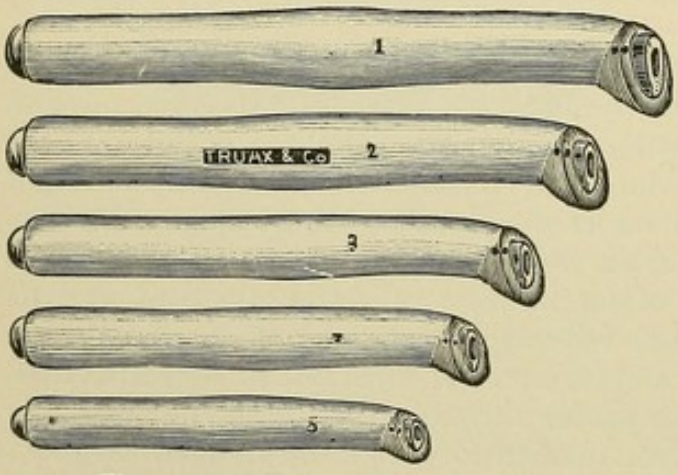

Fig. 443.—O'Dwyer's intubation tubes.

Intubation is a surgical precedure that requires for its successful performance an intimate knowledge of the anatomy of the seat of

the disease, and delicate manipulation for the insertion and removal of the tube. The directions for intubation given below are taken from the third edition of "Diseases of the Chest, Throat, and Nasal Cavities, etc.," by Professor E. F. Ingals, who has had a very extensive experience in this department of special work.

"The tube must be selected with special reference to the age of the child. A strong thread, about three feet in length, is passed

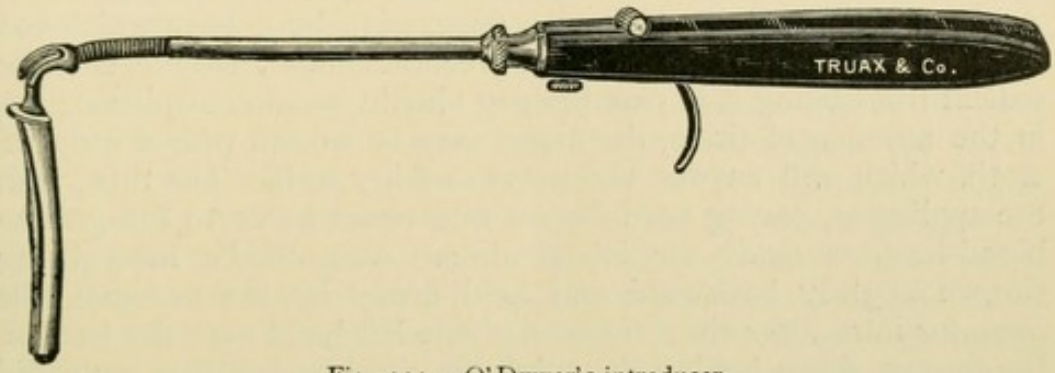

Fig. 444.—O'Dwyer's introducer.

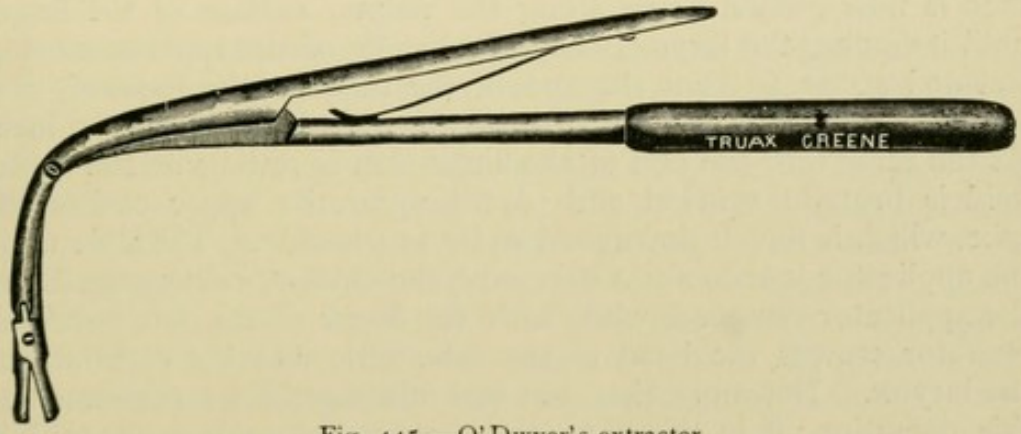

Fig. 445.—O'Dwyer's extractor.

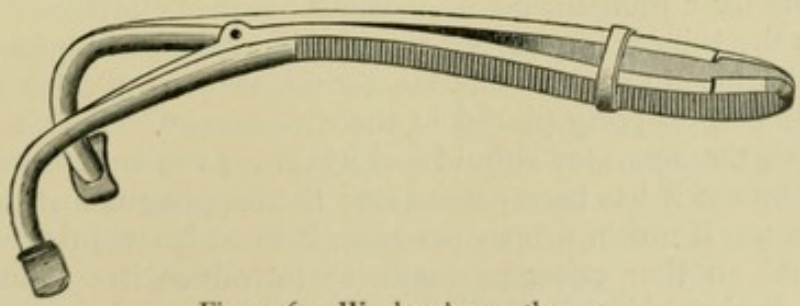

Fig. 446.—Waxham's mouth-gag.

through the eyelet in its head, and the ends are tied together. The applicator is then screwed into the obturator and this passed through the tube, ready for the operation. The short side of the tube should be placed toward the handle of the instrument, so that when introduced into the larynx, it will conform to the position of the epiglottis.

"The child, wrapped in a blanket or sheet, which is pinned closely about the neck so that its arms are pinioned, should be held in the arms of the nurse, with its head against the nurse's left shoulder. The gag is then inserted between the teeth upon the left side, and intrusted to the assistant who is to hold the head. The forefinger of the operator's left hand should be oiled or smeared with vaselin, to prevent inoculation through any abrasions upon the surface in case the disease should prove to be diphtheria. A broad metallic ring or a rubber finger-cot, the head of which has been cut off, should be slipped over the finger, to prevent the patient from biting it in case the gag should become displaced; or, in the absence of these, the finger may be wound with a strip of cloth, which will answer the purpose fairly well. The tube, with the applicator, having been dipped into warm water to bring it to blood-heat, is ready for introduction. The child's head being thrown slightly backward and held firmly by the assistant, the operator introduces the forefinger of the left hand over the base of the tongue, down behind the epiglottis, until he feels the arytenoid cartilage, upon the upper edge of which the finger rests. The tube is now guided down along the palmar surface of the finger until it reaches the larynx, when, the handle of the applicator being elevated so as to turn the end of the tube further forward, it is passed into the glottis and crowded downward about half an inch. At the same time the end of the finger that is resting on the arytenoid is brought upward and placed upon the upper end of the tube, which is forced downward so far as possible. The slide upon the applicator is then shoved forward, the obturator disengaged, and the applicator removed, while with the finger of the left hand the operator crowds the head of the tube fairly into the vestibule of the larynx. Not more than ten seconds should be consumed in this operation; if in this time the operator does not succeed in introducing the tube, it is better to withdraw it and allow the child to breathe for a moment before making another effort.

"As the tube is introduced the child generally coughs, and the respiration has a peculiar tubular sound, which indicates that the tube has been properly placed in the air-passage. If this sound is not heard, the operator should feel again for the tube, to ascertain whether or not it has been passed into the esophagus instead of into the larynx. If not in proper position, it must be withdrawn by the string and another effort be made to introduce it. If in correct position, it should be allowed to remain with the string attached for a few minutes, until respiration becomes thoroughly established and the child has finished coughing. One of the threads should then be cut near the lips, the operator's forefinger being carried down to the head of the tube to hold it in position, and the string withdrawn. The tube is left in the larynx, where it should remain for from two to six days, unless it should become partially stopped by dried mucus, indicated by difficult breathing, or unless subsidence of the

symptoms leads one to believe that the swelling has subsided and the false membrane disappeared. In many cases the tube will be coughed out as soon as the necessity for its further use ceases. When it becomes desirable to remove it, the child is placed in the same position as for its introduction, and with the index-finger of the left hand the operator guides the extractor down to the larynx, when it may be felt to strike against the end of the tube. It is then moved about gently, no force being used, until it drops into the opening of the tube; the blades are then separated and firmly held while the instrument and the tube are being withdrawn. Special care should be observed not to relax the pressure just as the tube is being turned out of the pharynx, for if this is done, the instrument will slip, and the tube may either fall back into the larynx or be swallowed. It is well to have a pair of forceps at hand for the purpose of seizing the tube in case the instrument should slip at this stage of its withdrawal. Special precaution should be taken that no pressure is made upon the head of the tube in attempting to introduce the extractor, for the tube might possibly be pushed below the vocal cords, an accident that has happened in a few cases."

Success in the operation of intubation, as in tracheotomy, is the well-earned reward of constant watchfulness during the after-treatment. One of the dangers incident to intubation in puny children is the entrance of food or drink into the air-passages if taken when the child is in a sitting position. To avoid this danger, Frank Cary, of Chicago, recommended the placing of the head of the child in Rose's position,—that is, placing the head much lower than the body,—and feeding it from a nursing-bottle or through a tube. "Soft solids may be given with the child in any position, and some children will speedily learn to swallow even fluids in the erect position; but the friends must be cautioned not to try the experiment."

Occasionally, on introducing the tube, some portion of the false membrane is forced below it into the trachea, and suffocation becomes imminent. If this occurs, the tube should be at once withdrawn, when it usually brings the membrane with it, or the latter will speedily be coughed out. If this should not occur, tracheotomy should be done at once. Because of the liability of this accident, the operator should always have his tracheotomy instruments at hand when performing intubation.

Laryngofissure.—Incision of the larynx through the anterior median line is technically called laryngofissure. This operation is applicable for the removal of benign growths and foreign bodies lodged in the interior of the larynx. The operation is not difficult, and affords free access to the interior of the larynx. If the incision is made as it should be, through the median line, the only blood-vessel of any account that falls into the line of the incision is the cricothyroid artery; this can readily be caught with hemostatic

forceps, and tied by either direct or indirect ligation. Unless the patient is very young, the operation should invariably be performed under local anesthesia by Schleich's infiltration method, as the co-operation of the patient in clearing the larynx of blood after the deep incision has been made renders a preliminary tracheotomy superfluous.

The patient is placed in the supine position, with the head well extended and the shoulders and neck resting upon a firm cylindric cushion. An assistant immobilizes the head until the operation is completed. With the head well thrown back, the larynx and upper part of the trachea become prominent and easy of access. An incision is made through the skin and superficial fascia from the upper border of the thyroid cartilage to the first tracheal ring. The thyrohyal membrane is next divided along the upper border of the thyroid cartilage sufficiently to permit the entrance of the point of the scalpel with which the thyroid cartilage, the cricothyroid membrane, and the cricoid cartilages are then divided with one sweep of the knife. If more room is required, the first tracheal ring is also divided. The cricothyroid artery is secured as soon as cut, and it is about the only vessel that requires attention during the entire operation, provided the incision is made exactly in the median line. With sharp tenacula or retractors the margins of the wound are retracted sufficiently to expose the interior of the larynx freely for the detection and extraction of foreign bodies, or for the radical removal of tubercular products or benign growths. In persons advanced in years it may become necessary to substitute the bone-cutting forceps for the knife in incising the larynx. In operations for intralaryngeal tubercular affections the use of the sharp curet is followed by the vigorous use of the Paquelin cautery to eradicate the disease more completely and to arrest the hemorrhage. At the completion of the operation the laryngeal wound is closed by a number of catgut sutures, which are made to include the perichondrium and the overlying connective tissue. The external incision is then closed throughout by suturing in the usual manner, without making any provision for drainage, as primary healing of the wound may confidently be expected.

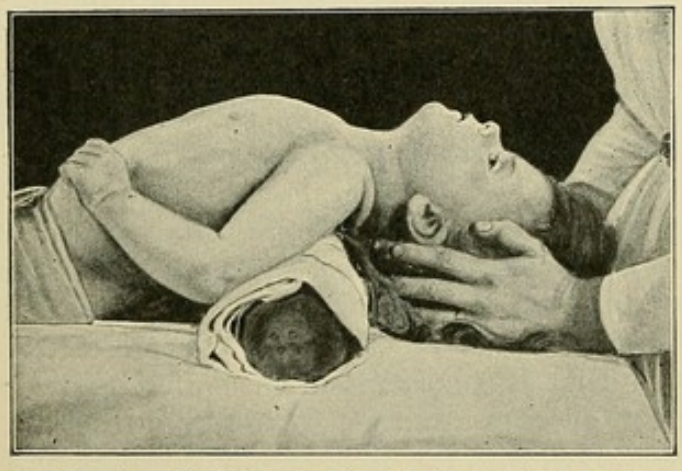

Fig. 447.—Position of patient for laryngotomy and tracheotomy.

Tracheotomy.—Tracheotomy signifies opening of the trachea at any point between the cricoid cartilage and the sternum. This

operation is usually performed as a life-saving procedure in obstructive lesions of the larynx in cases in which intubation is impracticable or has failed to procure the expected relief. Occasionally it is resorted to for the removal of tracheal growths and of foreign bodies lodged in the larynx or the bronchial tubes. The tracheal opening is made above, through, or below the isthmus of the thyroid gland. In children with thick, short necks, and in cases in which the thyroid gland is enlarged, the high operation should invariably be selected. Ordinarily the high operation should be performed, more especially by the beginner in surgery, as it is

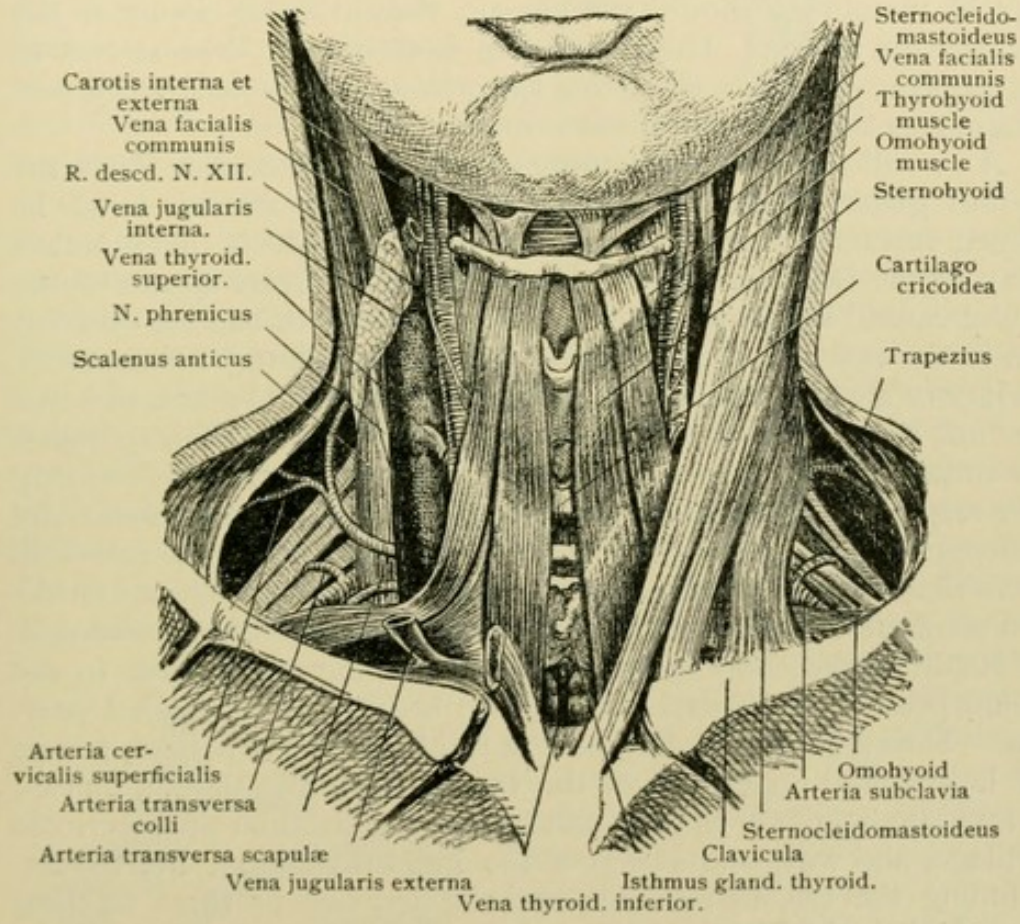

Fig. 448.—Anatomy of the neck, with special reference to the operation of tracheotomy (after Henke).

attended by fewer technical difficulties than the median or low operation.

The median operation requires preliminary double ligation of the isthmus of the thyroid gland, which is then cut between the ligatures. The ligatures of silk are passed between the trachea and the isthmus of the gland, one on each side, with an artery needle, and if such is not at hand, with an eyed probe or Kocher's hemostatic forceps. After tying firmly, the isthmus is cut between them, after which the trachea is exposed. The loss of time consumed in this preliminary step of the operation is an important item in determining

the choice of operation in cases in which the symptoms are urgent. The thermocautery can not be relied upon as a hemostatic in dividing the isthmus of the gland, and forcipressure is objectionable; hence if the median route is chosen, preliminary double ligation of the isthmus with silk furnishes the only security against troublesome hemorrhage. If the neck is long, the panniculus adiposus scanty, and the trachea prominent, the low operation presents the least difficulties and should be selected.

In children the high operation is made much easier by including the cricoid cartilage, thus substituting for the typical tracheotomy cricotracheotomy. In opening the trachea by this route the cricothyroid membrane should not be cut, thus avoiding injury to the cricothyroid artery. This membrane is elastic and will stretch to the requisite extent on retracting the cricoid and tracheal rings preparatory to the insertion of the cannula.

A so-called rapid tracheotomy should always be made above the thyroid gland. There are cases in which the trachea must be opened instantaneously by one cut—cases in which one minute's delay might result in death. Impending death from spasm of the larynx caused by the presence of a foreign body or sudden obstruction to the entrance of air from edema in inflammatory affections of the larynx are the conditions that demand immediate action and that preclude a careful dissection in opening the larynx. This operation has succeeded, occasionally, in saving a life when performed shortly after respiration has ceased, and when followed by systematic and prolonged artificial respiration. In great emergencies of this kind it would be justifiable and proper to open the trachea with one stroke of a penknife, to open the way for successful artificial respiration.

Rapid tracheotomy is performed by placing the patient in the supine position, an assistant fixing the head in the extended position. The surgeon, standing on the right side of the patient, grasps the larynx and upper part of the trachea with the thumb, index-, and middle fingers of the left hand, notes the location of the cricoid cartilage, and with one sweep of the knife divides all the tissues, including the cricoid cartilage and the first two or three tracheal rings. If the incision is made as it should be, exactly through the median line, troublesome hemorrhage need not be feared. With a view to preventing the blood from entering the bronchial tubes the head and neck are placed in a dependent position until the hemorrhage has been arrested. Nothing must interfere with a prompt resort to artificial respiration. If a cannula is at hand, it is at once inserted, using the tip of the left index-finger in the wound as a guide for the insertion of the cannula and as a wedge in separating the tracheal rings. If respiration has become suspended before or during the operation, artificial respiration must be continued as long as there is any hope of reviving the patient. If any mistake is made in this respect, it should be made on the right side, as apparently hopeless efforts are occasionally rewarded by success if they

are continued for a sufficient length of time. Tracheotomy under more favorable circumstances must be made by careful dissection, arresting hemorrhage as the operation proceeds.

In adults general anesthesia is unnecessary, as the operation can be made almost painless by Schleich's infiltration method, by injecting solution No. 2 into the skin along the proposed line of incision. After the skin and superficial fascia have been incised, the wound can be brushed from time to time with the same solution, or, what is perhaps better for this particular purpose, with a 2 per cent. solution of cocain. In children the carbonic dioxid intoxication has frequently reached such a degree at the time the operation is performed that the administration of a general anesthetic can be dispensed with. If this is not the case, chloroform should be given instead of ether, as the latter irritates the inflamed air-passages and causes profuse salivation, both very undesirable effects during a tracheotomy. The addition of nitrite of amyl to the chloroform, in the proportion of fifteen minims to four ounces, will facilitate and add to the safety of the administration of the anesthetic. The chloroform is to be administered continuously and very slowly, with an abundance of air.

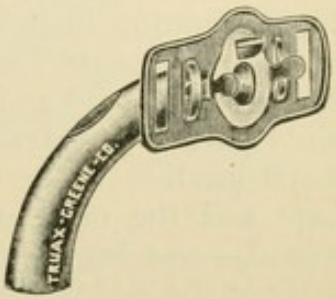

Fig. 449. — Trousseau's double tracheotomy tube.

The operation should be performed in a room the temperature of which must be at least 75° F., and it is advisable to impregnate the air with steam. The little patient should be properly prepared for the operation by fastening the arms, in the extended position, to the side of the body, with a broad towel or sheet firmly fastened with safety-pins. Proper immobilization of the arms is an important preparatory step to the performance of a tracheotomy. The next step consists in placing the child upon a narrow table, in the most convenient position, which consists in slight elevation of the chest and full extension of the neck, rendering the larynx and trachea prominent and easy of access (Fig. 447). An assistant sitting at the head of the table holds the head immovably in this position by grasping it on its sides with both hands well expanded. The operator stands on the right side of the patient, opposite his assistant.

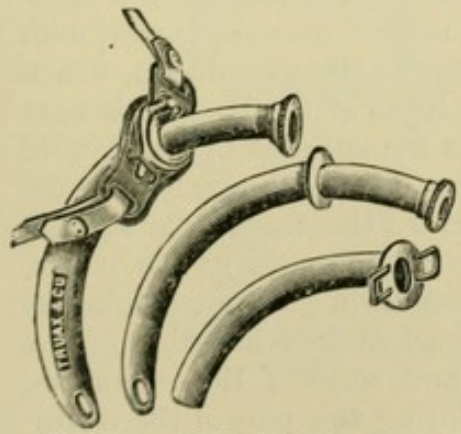

Fig. 450.—Cohen's tracheotomy tubes.

The instruments required for this operation are few: a scalpel, four hemostatic forceps, two dissecting forceps, sharp and blunt retractors, Kocher's director, a blunt hook, two sharp hooks, an aneurysm needle, and a double tracheotomy tube of proper size

constitute the necessary instrument supply; in an emergency, the operation can successfully and quickly be performed with a scalpel and two dissecting or hemostatic forceps. The Luer-Hagedorn or Trousseau's double cannula, without a fenestra, is the one in general use, and has given the best satisfaction.

Unless there are special objections presented by the case, the high operation, including section of the cricoid cartilage, is the one the general practitioner should perform, as it does not implicate the thyroid gland and involves the most prominent and most accessible part of the trachea. The operator satisfies himself of the exact location of the cricothyroid space, between the cricoid cartilage and the most prominent part of the larynx,—the pomum adami,—and begins the incision directly over this space and exactly in the middle line, extending it downward for at least two or three inches, dividing the skin and superficial fascia. The skin is stretched and the trachea fixed with the thumb and first two fingers of the operator's left hand. *The great secret in performing the operation quickly and safely is not only to begin in the median line, but also to follow the same during the remaining steps of the operation until the trachea has been reached, and to arrest hemorrhage, as it occurs, by the free use of hemostatic forceps, which not only serve well in controlling the bleeding, but to some extent also take the place of retractors.* The deep connective tissue between the sternohyoid muscles is opened between dissecting forceps and carefully divided, or, what is safer, after it has been opened, is torn with the dissecting forceps sufficiently to expose these muscles, which are then retracted. The deep fascia in front of the trachea is next severed with blunt instruments as far as the isthmus of the thyroid gland. If the gland is large and in the way, it is drawn downward with a blunt hook by an assistant. Before the trachea is opened each bleeding point is secured with hemostatic forceps, as few, if any, ligatures will be required after respiration through the cannula has been fully restored. Opening of the trachea and insertion of the cannula are the final and most important steps of the operation. Two sharp hooks are very convenient during this part of the operation. The trachea should never be incised until the rings that it is necessary to incise can be seen as well as felt. The violent movements of the trachea must be overcome for the few moments required in dividing the rings and in inserting the tube. The two sharp hooks are inserted into or under the first tracheal ring, a few lines apart, one held by the operator and the other by his assistant, when traction is made upward and forward, and, at the same moment, the cricoid cartilage and the first two tracheal rings are in-



Fig. 451.—Koenig's long tracheotomy tube.

cised in the middle line between the hooks. On making lateral and forward traction on the hooks the tracheal wound is opened for the insertion of the tube (Fig. 452 exhibits double hook). In the absence of such hooks a very useful substitute can be extemporized by passing a strong silk suture with a well-curved needle through the tracheal ring on both sides.

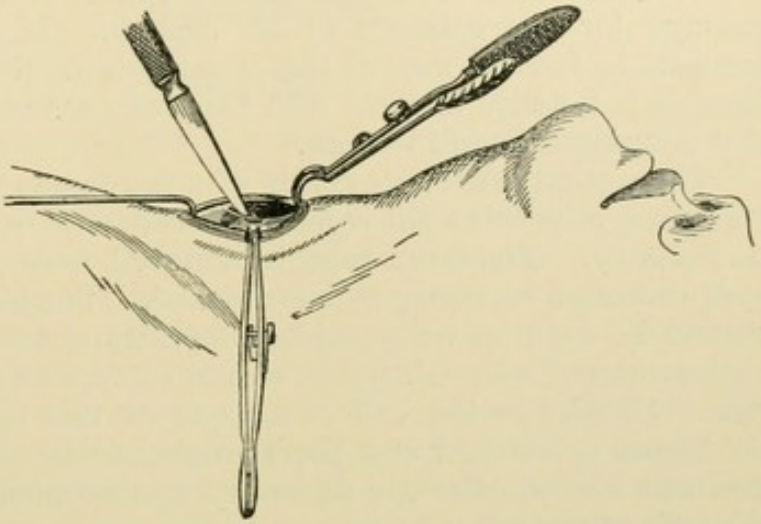

Fig. 452.—Tracheotomy; illustrating the manner in which the tracheal rings should be cut (Esmarch and Kowalzig).

In incising the trachea it is, of course, necessary to guard against injury of the posterior wall of the trachea by not penetrating the trachea much beyond the thickness of its anterior wall. It is always necessary to cut at least three of the tracheal rings. If the trachea is to be opened below the cricoid cartilage, the first three rings are incised. The general practitioner will very seldom perform median tracheotomy, as this operation necessitates cutting of the isthmus of the thyroid gland between a double ligature.

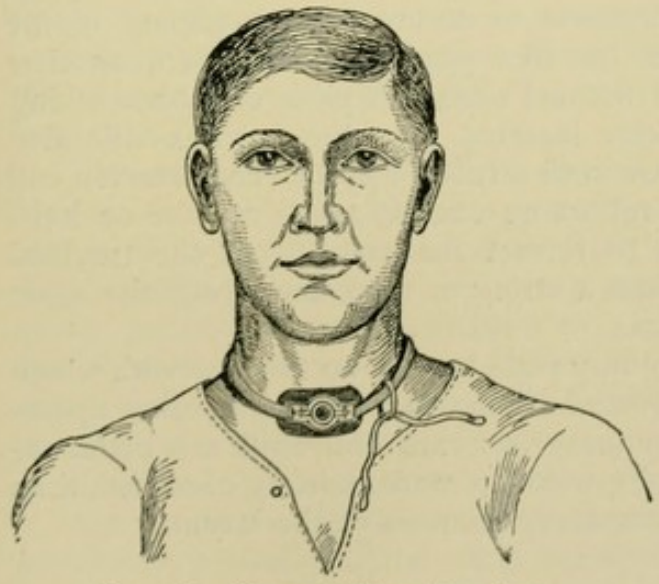

Fig. 453.—Cannula fastened in place.

The low operation is performed in the same manner as the high, except that the thyroid gland is displaced upward instead of downward by inserting a blunt hook underneath the lower border of the isthmus, the assistant making upward traction to increase the space between the gland and the jugulum of the sternum. As has been stated before, the low operation is occasionally preferable if the neck is long and the trachea prominent. After the insertion of the cannula, the surgeon's first attention is directed toward establishing free respiration through the artificial inlet. If mucus, membranes,

or blood interfere with the free passage of air in both directions, the passage in the cannula and trachea is cleared by using a feather or cotton mop made by wrapping cotton around a wire loop and moistening the same in warm salt solution. In this manner fragments of membrane and blood-clots can be removed, and the passage for the entrance of air cleared. If, on removing the hemostatic forceps, any of the vessels bleed, they are tied. The cannula is fastened in place with two tapes sewed to the shield, and tied securely around the neck.

The wound dressing consists of a few layers of iodoform gauze compress, in which a slit is made, placed underneath the shield of the cannula. The inner tube is removed from time to time, and after thorough cleansing is reintroduced. The air in the sick-room should be kept at an equable temperature, free from drafts, and kept saturated with salt water, steam, or vapor from slaking quicklime. Usually at the end of a week or two the permeability of the larynx is restored and the cannula can be dispensed with, but care and watchfulness are necessary in determining the time when it is safe to remove it.

If no cannula is at hand when a tracheotomy must be performed, some kind of a reliable substitute must be pressed into service. The first thing that suggests itself would be to cut a circular defect in two rings of the trachea, corresponding in size to the tracheal tube. Tubeless tracheotomy made in this manner was warmly advocated by the late Henry Martin, of Boston, and might be resorted to with confidence in case no proper tube could be secured. Silk threads passed through the middle tracheal ring on each side and tied behind the neck with sufficient firmness to secure enough gaping of the tracheal wound to permit the free passage of air, form another valuable substitute for the tracheal tube. A piece of rubber tubing or a large Nélaton catheter inserted into the trachea will also answer an excellent purpose until a tube of proper construction can be secured. And, lastly, retractors can be made of wire or hairpins, which can be used to retract the margins of the tracheal wound by attaching to them a string or tape, and tying the same behind the arch.

The success of tracheotomy rests largely on the care with which the after-treatment is conducted. There is, perhaps, no other operation in surgery in which unremitting care and skill are better rewarded, and negligence and ignorance more severely punished, than after tracheotomy for inflammatory stenosis of the larynx.

CHAPTER XVI.

EMPYEMA.

THE term empyema is used to designate the presence of pus in the pleural cavity; practically, it means the existence of a pleural abscess. It represents the pathologic product of either a primary or a secondary suppurative pleuritis. Suppurative pleuritis is always the result of a pyogenic infection of the pleura, sufficient in virulence to give rise to pus-formation. In the absence of traumatic causes it appears clinically and pathologically either as an isolated inflammation of the pleura or as a more or less remote complication of pneumonia. Bacteriologically speaking, suppurative pleuritis can result only from the presence in, and the specific action upon, the tissues of the pleura of pyogenic microbes in sufficient number and virulence to give rise to a suppurative inflammation. Nontraumatic suppurative pleuritis is a comparatively rare, isolated affection; in the great majority of cases it presents itself as a complication of pneumonia. Recent investigations tend to prove that the essential cause of pneumonia is either Fränkel's pneumococcus, Friedländer's bacillus of pneumonia (diplobacillus), or the streptococcus pyogenes. In rare cases the bacillus coli communis has been found as the principal, if not the sole, microbic cause of the pleural suppuration. Streptococcus pneumonia, occurring as either a primary or secondary affection, is characterized clinically by the gravity of the disease, and pathologically by the intrinsic tendency to pus-formation.

The microbes of pneumonia, discovered by Fränkel and Friedländer, are the bacteriologic agents usually found in the inflamed tissues in croupous pneumonia. Both of these microbes possess feeble intrinsic pyogenic properties, and when, during the pneumonic process, abscess formation or suppurative pleuritis sets in, the complication occurs usually as the result of a secondary or mixed infection with pus-microbes. Occasionally, however, the pneumococcus is found as the sole bacteriologic cause in the pus of empyema and more distant foci of suppuration.

Croupous pneumonia is a self-limited disease, and when febrile symptoms persist after the usual lapse of time required for the disease to complete its typical cycle, it is usually an indication that mixed infection has occurred. In this event it becomes the urgent duty of the attending physician to look for, locate, and determine, if possible, the nature of the complication in order to enable him to institute timely and appropriate therapeutic measures. Retarded resolution and continuance of fever, or reappearance of fever after

a few days of defervescence, are very suggestive of a beginning suppurative pleuritis. Many serious mistakes have been made by not subjecting patients to repeated and careful examinations during this critical stage. A progressive increase in the area of dullness, with or without a continuance of febrile symptoms, at a time when, under ordinary circumstances, resolution should have been in progress or completed, is very strong evidence of the existence of a complicating suppurative pleuritis. In suppurative pleuritis occurring as a secondary affection to pneumonia, the inflamed lung tissue is seldom involved in the suppurative process. Resolution may proceed in a satisfactory manner at the time and after the suppurative pleuritis has set in, a fact that would tend to prove that the parenchyma of the lung is more resistant to the action of pyogenic microbes than the tissues of the pleura, or that these microbes find their way more readily to the pleura than into the pneumonic focus after secondary infection has occurred.

The complicating secondary pleuritis manifests itself usually about the time the crisis is expected or a few days later. It is evident that the suppurative complication in cases of pneumonia would be likely to appear in cases in which the tissues are rendered susceptible to the action of pus-microbes, and under circumstances that would supply the bacteria for the secondary mixed infection. A corroboration of the correctness of the statement was furnished by observations at Camp George H. Thomas, at Chickamauga, during the Spanish-American war. Pneumonia of a severe type was prevalent during the spring months. It was observed that empyema occurred most frequently in parts of the camp where dust was most abundant. In some parts of the camp comparatively free from dust no cases of empyema occurred, although the sick-reports showed the usual percentage of pneumonia. It is more than probable that in most of the cases of secondary suppurative pleuritis the pyogenic microbes, which eventually attacked the pleura and caused the suppurative process, entered the lungs at the same time and in the same manner as the microbes that produced the pneumonia. The bronchitis and diarrhea that initiated the disease were plain evidences pointing in this direction. In some of the cases in which the pneumonia pursued a typical course the subsequent suppurative pleuritis was caused by a secondary mixed infection.

The limited means at Camp George H. Thomas for making a satisfactory bacteriologic examination of the inflammatory product made it impossible to ascertain, in each case, the nature of the microbic cause. In two of the cases inoculation of proper nutrient media resulted in an abundant growth of the staphylococcus pyogenes aureus. There can be but little doubt that in most, if not in all, cases the suppurative pleuritis developed in consequence of a secondary infection with pus-microbes, probably in most instances with the staphylococcus, as indicated by the clinical course of the disease and the nature of the inflammatory product.

The influence of dust in the causation of pneumonia and suppurative pleuritis acts in two ways :

1. The mechanical irritation of the bronchial mucous membrane resulting from the presence of ordinary dust renders the epithelial layer of the bronchial mucous membrane more permeable to the entrance of pathogenic microbes.

2. Pathogenic microbes, and in this case pus-microbes, are suspended in the dust and find, with it, entrance into the air-passages.

Nontraumatic primary suppurative pleuritis is the result of a hematogenous infection. The disease often comes on insidiously. It is sometimes difficult to trace the beginning of the disease ; pain in the side and a slight rise in temperature, with a gradually increasing shortness of breath, are often the only symptoms that attract the attention of the patient.

This form of the disease is due to a very mild form of pyogenic infection. The effusion takes place rapidly, and consists, at first, of a slightly turbid serum, which under the microscope exhibits only a limited number of pus-corpuscles. The pus-corpuscles, however, in time increase in number, and finally this inflammatory product consists of a thin, serous pus. Fibrinous exudates are scanty or are entirely absent. By repeated tappings I have observed the different stages of pus-formation from almost clear serum to well-marked empyema. In the more acute form of empyema the general and local symptoms are much more violent. The disease is usually initiated by a chill, followed by a rapid rise in temperature, remaining, with some daily variations, for some time, but may become normal after several days or weeks, with the pleural cavity full of pus. The absence of elevated temperature is, in such cases, as under some other circumstances, no positive proof of the absence of pus. The general practitioner usually associates pus with temperature, and by so doing mistakes in diagnosis are frequently made and timely surgical aid postponed or, perhaps, goes entirely by default. The pleuritic stitch in the side is a constant symptom in acute suppurative pleuritis, and is usually attended by a dry, hacking cough. The inflammatory product consists of more or less fibrinous exudate and pus. In some cases the fibrinous exudate is very copious, covering both the visceral and parietal pleuræ, and constituting a considerable portion of the contents of the abscess in the form of large fibrinous masses mixed with the thick, cream-like pus. This fibrinous product is invariably infected with pus-microbes, and hence, if not removed at the time the radical operation is performed, serves to maintain suppuration indefinitely.

Diagnosis.—The history of the case and the signs and symptoms presented by suppurative pleuritis are often sufficient to enable the physician to make a probable diagnosis of empyema. A positive diagnosis exacts demonstrative evidences of the presence of pus in the pleural cavity. Such indications are furnished by rupture of

the empyema into a bronchial tube and the sudden expectoration of a large quantity of pus by coughing, the escape of the chest contents between two ribs, and the formation in the connective tissue of an abscess in communication with the pleural cavity (empyema necessitatis), or by resorting to an exploratory puncture. Obliteration and bulging of the intercostal spaces over a limited area and edematous swelling of the skin are strong indications of the existence of pus in the pleural cavity, the suspicion of such a condition being strengthened by redness of the overlying skin. Displacement of the heart and liver, dullness on percussion, absence of respiratory sounds, enlargement of the affected side of the chest, and diminished respiratory movements are physical signs that point to the existence of fluid in the cavity of the chest, but they are of little value in differentiating between empyema and hydrothorax. The change in the level of the fluid, caused by placing the chest in different positions and ascertained by percussion, is more marked in hydrothorax than in empyema, because in the latter condition the copious fibrinous exudate immobilizes the lung and walls in the inflammatory product. *In the absence of positive indications of the presence of pus in the pleural cavity no operation should be undertaken without resorting to an exploratory puncture for the purpose of demonstrating the presence and exact location of the intrapleural abscess.* An exploratory puncture is attended by so little risk and pain that its employment as a diagnostic resource should never be neglected.

Surgical Treatment of Empyema.—Medical treatment has no curative influence on empyema. Internal treatment by the administration of tonics and stimulants is indicated, as in other suppurative affections, to maintain the general strength of the patient and the heart's action, but it is of no value in the removal of the inflammatory product. As soon as a positive diagnosis of empyema can be made, the old teaching, *ubi pus ibi evacuo*, is in force, and must be followed without much delay. Late diagnosis and delayed operations are responsible for many unsatisfactory recoveries, as prolonged pulmonary compression and adhesions are the most potent causes of subsequent imperfect expansion of the compressed lung. The existence of an empyema in the adult is a sufficient indication for the performance of a radical operation. Puncture and removal of the pus by aspiration may succeed occasionally in mild cases of suppurative pleuritis in the case of children ; seldom, if ever, in the adult. In the case of empyema puncture followed by drainage and permanent aspiration, as advised by Bülau, may be tried for a limited length of time, but if it fails, should be followed, without unnecessary harmful delay, by a radical operation.

Aspiration drainage is made by inserting a trocar of ample size in the axillary line at the most dependent point of the empyemic cavity, and by inserting a Nélaton elastic catheter into the lumen of the cannula after withdrawing the stilet. The catheter should fill the lumen of the instrument accurately, so that, on the removal

of the cannula, the tissues of the tunnel made by the trocar will grasp the drain, preventing leakage and the entrance of air. The drain is fastened to the surface of the chest with collodion and a few thin layers of absorbent aseptic cotton. The catheter is connected with a long piece of rubber tubing by a short glass tube, and the distal end of the rubber tube is immersed in a vessel holding an antiseptic solution and placed at the side of the bed, two or three feet below the level of the chest. When the vessel is full, its contents are poured out and it is disinfected. After emptying the rubber tube by stripping it from the glass tube in a downward direction, the distal end is again immersed in the new antiseptic solution. By siphon action the pleural cavity is gradually emptied of its contents, and so long as the siphon drainage is in good condition, reaccumulation is prevented. If the patient is manageable and of sufficient intelligence, he can leave his bed in a few days without interfering with drainage, by carrying the receptacle in a pocket below the level of the puncture (Fig. 454). In well-marked cases of empyema in the adult nothing is gained by this method of treatment. A radical operation should be performed as soon as a diagnosis can be made. Unless the signs and symptoms are conclusive, the diagnosis must be verified and the pus accurately located by an exploratory puncture. Nothing is gained and much is lost by postponing a radical operation until the accumulated pus has increased to the extent of producing serious and often irremedial compression of the lung on the affected side. The plastic exudate, which is often copious, is another source of danger in case the operation is delayed, as it creates mural adhesions unfavorable to the subsequent expansion and restoration of function of the compressed lung, and extenuates indefinitely the infection.

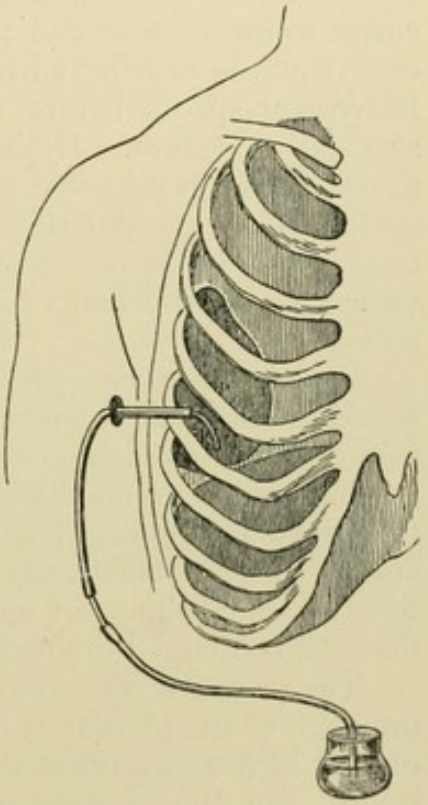

Fig. 454.—Bülau's aspiration drainage of the pleural cavity (Esmarch and Kowalzig).

In view of the pathologic anatomy exhibited by cases of empyema it must be admitted that the only rational treatment consists in opening the pleural cavity freely and in establishing efficient tubular drainage. The abscess walls in empyema are more or less unyielding, hence the provision must be made to maintain adequate drainage until, by gradual reduction in the size of the cavity by expansion of the lung, retraction of the chest-wall, ascent of the dia-

phragm, and a process of granulation and cicatrization, further drainage can be dispensed with without fear of a relapse.

Incision of the chest-wall for the liberation of pus is an ancient procedure. Hippocrates came to the conclusion that incision through an intercostal space did not furnish a sufficiently free outlet for the pus, and advised trephining of a rib over the pleural abscess as an additional mechanical means of effecting free evacuation of the contents of an empyemic cavity. This operation was later revived and given considerable prominence by Dr. Stone, of New Orleans. In children intercostal incisions and drainage will suffice; in adults with more unyielding chest-walls, subperiosteal rib resection should always be made as a preliminary step to incision of the empyemic cavity to insure free and permanent drainage. I had an extensive experience in incising and draining the pleural cavity through the intercostal spaces before rib resection became a well-established surgical procedure. Drains of metal and rubber often gave rise to great pain from pressure, and in chronic cases the painful effects of prolonged intercostal pressure were often seen in the form of extensive semilunar defects of the margins of the adjacent ribs, revealed at postmortem or subsequent radical operation by rib resection.

Koenig deserves a great deal of credit for having so persistently urged the necessity of resection of a section of a rib as an essential part of every radical operation for empyema. Rib resection does not increase the immediate risks of the operation to any extent, and the advantages gained from it in securing free and permanent drainage more than balance any additional dangers incident to the operation, by establishing an opening in the chest-wall well adapted for free and prolonged drainage.

The proper method of preparing the way for free and prolonged drainage of the pleural cavity is by subperitoneal resection of three or four inches of a rib at the most dependent part of the empyemic cavity. In the absence of contraindications the axillary line is selected for the operation, at a point corresponding to the lowest level of the suppurating cavity. It is interesting to know that every intercostal space, from the first to the last, has been recommended at different times as the most important point of attack for the operation for empyema. High operation is objectionable because it does not secure free and complete evacuation of the cavity, and an opening low down is apt to become subsequently obstructed by ascent of the diaphragm. If the empyema is not circumscribed and localized, it is important to open the chest in the axillary line, where the ribs are nearest the skin and near the base of the pleural abscess. The seat of operation must be determined beforehand by a careful physical examination and, if need be, by an exploratory puncture. In cases of extensive empyema complicated by great embarrassment of the respiratory function, it is advisable to resort to a preliminary aspiration of the chest to relieve the urgent symptoms and

to prepare the way for a more speedy and satisfactory expansion of the compressed lung. Preliminary aspiration is of special value in the treatment of large empyemic cavities. The radical operation must be performed under the most careful aseptic precautions, as the opening of large pus-cavities is attended by great responsibility; this is more especially true in empyema, as secondary infection is liable to occur unless the operation is performed under the most pedantic aseptic precautions. The whole side of the chest must be disinfected, and the instruments and drains employed must be made faultlessly aseptic. If an anesthetic is given, the greatest watchfulness is required. It is advisable to operate under local anesthesia by Schleich's infiltration method or under partial general anesthesia, and strychnin and alcohol should be administered as valuable

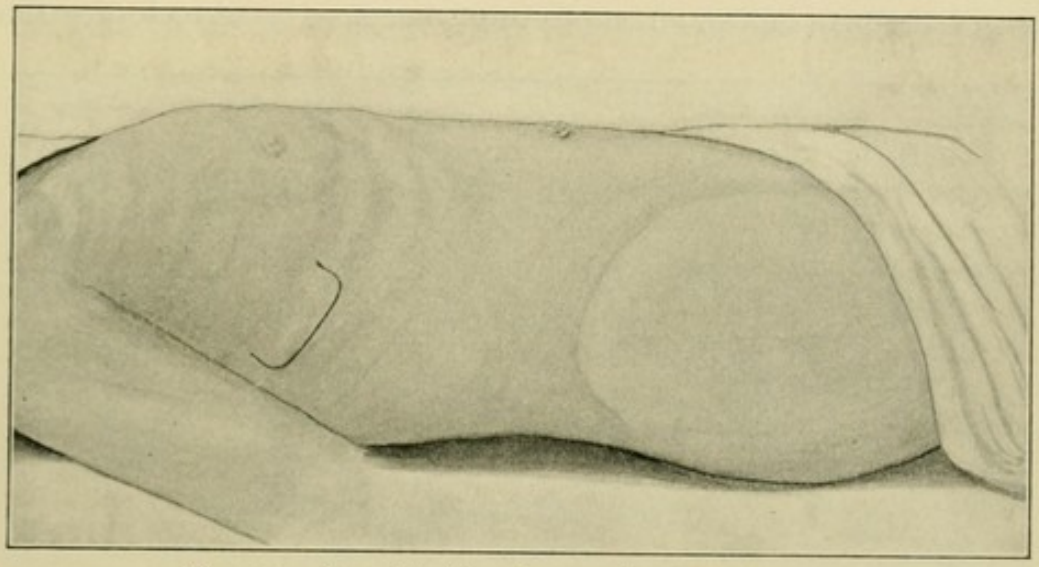

Fig. 455.—Curved incision for exposing rib for resection.

prophylactics in guarding against the immediate and remote risks of the operation.

The patient should be placed partly on the opposite side, with the chest slightly elevated, and the arm on the side to be operated upon raised to the side of the head, for the purpose of increasing the width of the intercostal spaces. In exposing the rib to be resected, I make a slightly curved incision, with the convexity directed downward, beginning the incision at a point corresponding with the upper border of the rib, carrying it in a gentle curve to the lower border, and terminating it at the upper border at a point about four inches from where it started. By reflecting the cutaneous shallow oval flap in an upward direction, the muscular covering of the rib is exposed. A straight incision over the center of the rib down to the bone, about three inches and a half in length, is then made. With an elevator the periosteal envelop, with the tissues attached to it, is then separated, taking care to lift out from its groove at the lower border of the rib the intercostal artery, with

the tissues to be reflected. The intercostal vessels and nerve are safe, provided the operator will hug the bone closely in separating the periosteum with the elevator. After laying bare the rib to the extent of at least three inches, the bone is lifted forward with the elevator and excised with a strong pair of bone-cutting forceps. Several kinds of bone-cutting forceps have been invented for this special purpose, but if the operator feels himself in need of a bone-cutting forceps of special construction, he should provide himself with an ordinary pair of pruning shears, used by gardeners and sold in every hardware store. Saws of any kind are to be avoided in making a rib resection. If the diagnosis is positive, all that remains to be done after rib resection is to make an incision with the scalpel in the center of the peritoneal trough, large enough to admit the tip of the index-finger. If any doubt remains as to the exact location of the pus cavity, an exploratory needle is used to locate the

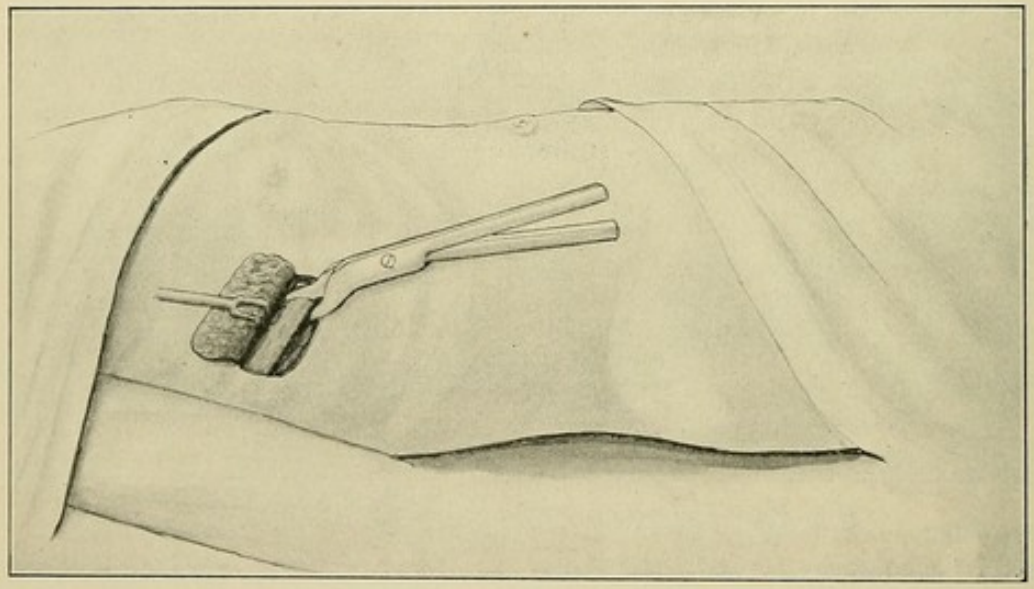

Fig. 456.—Section of rib with bone-cutting forceps.

same after the rib resection has been made. *The evacuation of the chest contents should always be done slowly; this can be accomplished most effectually by interrupting the flow of pus from time to time by plugging the pleural incision with the tip of the index-finger.* After evacuation of the pus and loose shreds of fibrinous material, the pleural cavity should be carefully examined by direct inspection and digital exploration. Reflected light is an important aid in making the visual examination. *Plastic exudates loose in the cavity and attached to either pleura must be removed as thoroughly as can be done with the finger and a small gauze sponge held securely in a sponge-holder or the jaws of a pair of long, preferably slightly curved, forceps. The membranes should be removed by mopping and not by the use of sharp instruments.* Scraping of the pleuræ with a sharp spoon is superfluous, and occasionally detrimental. In acute cases free hemorrhage often takes place from the pleural surfaces, even

after gentle efforts to dislodge the adherent fibrinous exudate. Should troublesome hemorrhage follow the procedure, packing the pleural cavity with one long strip of plain sterile gauze should at once be resorted to, as the loss of any considerable amount of blood in such cases might prove disastrous. The space below the drainage opening is packed first, and if the hemorrhage is not arrested, the remainder of the cavity is packed from above downward.

Tubular drainage is the ideal method of draining a suppurating pleural cavity. Two fenestrated tubular drains the size of the little finger and about four inches in length, securely fastened together with a large safety-pin or a stitch through each end, should be used for this purpose. This precaution is absolutely necessary, as drains have been frequently lost in the pleural cavity for want of securing with a large safety-pin. After inserting the tubular drain, the external wound is sutured in the usual manner. The curved

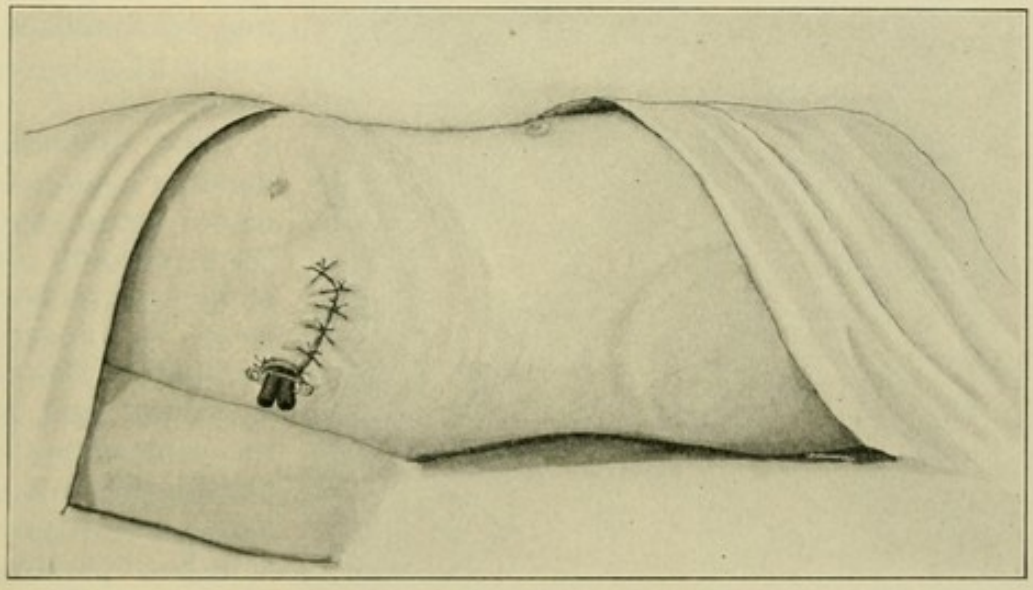

Fig. 457.—External wound partly sutured; double drain in place.

incision, as previously described, not only exposes the rib more freely than the straight incision as usually practised, but also is much better adapted for efficient prolonged drainage. It is not advisable to irrigate the cavity the day the operation is performed, and irrigation at this time is always contraindicated if the empyemic cavity is in communication with the bronchial tubes. Irrigation may become necessary later if the suppuration continues. If irrigation becomes necessary at any time, care must be exercised in the selection of the antiseptic solution; carbolic acid and corrosive sublimate in the usual strength are dangerous and should never be used. A nontoxic and yet potent antiseptic solution should be used—either a saturated solution of acetate of aluminum or Thiersch's solution. Either of these solutions is efficient as an antiseptic, and nontoxic even when used in large quantities. The value of the double drain is made more apparent when it becomes necessary to

irrigate the pleural cavity. By placing the patient on the opposite side the fluid that enters the chest through one of the tubes escapes through the other as soon as the cavity is full, thus washing it out thoroughly. By placing the patient on the affected side the cavity is emptied, when the same procedure is repeated until the solution returns clear. The solution used must always be heated to blood temperature, as irrigation with a cold solution is fraught with danger. I have seen, in the case of a child, almost fatal collapse attend irrigation of the pleural cavity with a solution at room-temperature. It required persistent and prolonged efforts to restore the suspended respiration by the administration of stimulants and artificial respiration.

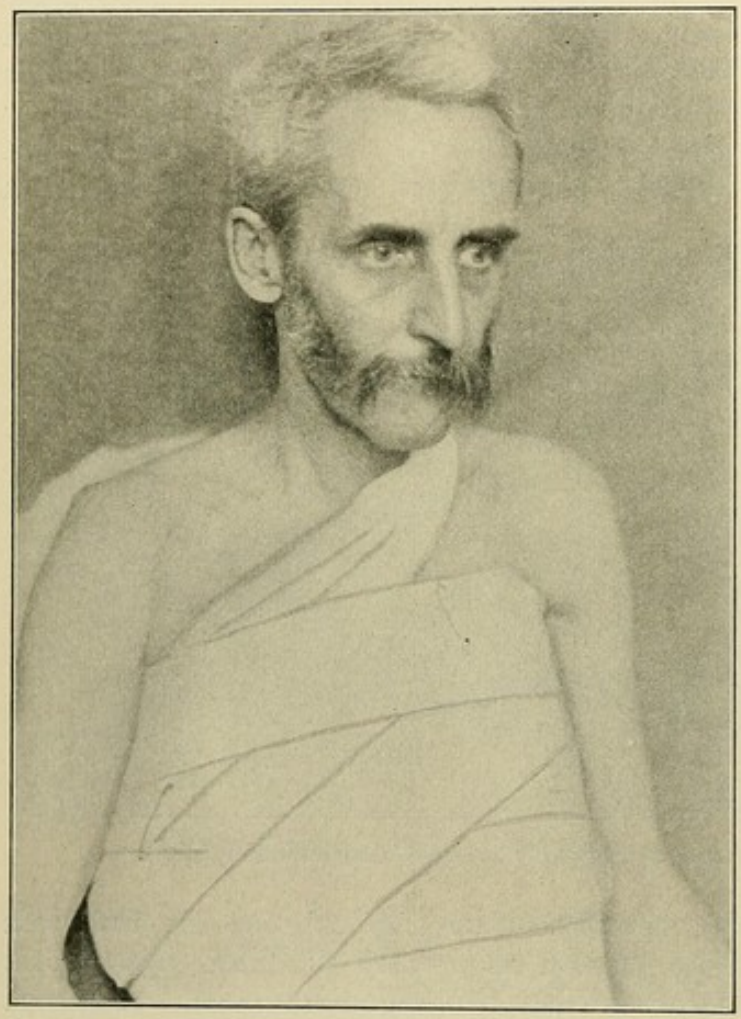

Fig. 458.—Dressing after operation for empyema.

The external dressing consists of a large and thick cushion of sterile gauze and cotton to absorb the fluid as fast as it escapes, and, at the same time, to provide the wound with a filter to prevent postoperative infection. There is no special advantage in using medicated in place of sterile absorbent material, so long as the compress is removed, as it should be, as soon as indications of saturation appear on its surface. The best way to retain the dressing in place and to prevent the entrance into the pleura of unfiltered air is to substitute for the ordinary bandage the rubber-webbing bandage, or to place over the gauze roller, over the upper and lower margin of the dressing, a band of the rubber-webbing bandage. Change of dressing and antiseptic irrigation become necessary as often as the dressing becomes saturated. For the purpose of obviating frequent changes the dressings should be at least six inches thick and cover the whole side of the chest. As the cavity dimin-

ishes in size the drains are shortened from time to time, and sooner or later one of them can be dispensed with. *Premature removal of the drain is often followed by relapse; drainage must not be suspended until the surgeon can satisfy himself by careful examination that the pleural cavity has become obliterated.* Should the lung fail to expand sufficiently in the course of a few months to place the cavity in a condition for definitive healing, Schede's thoracoplasty is the operation of choice, as Estlander's multiple rib resection has not yielded the expected results in the practice of many operators, including my own.

It is well for the surgeon to keep close watch on the size of the empyemic cavity during the after-treatment, not only for the purpose of keeping himself well informed of the progress of the healing process, but also with a view to determining the time when it is safe to abandon drainage. For a long time it has been my custom to place my patient, at stated intervals, on the opposite side, then to fill the cavity with one of the antiseptic solutions used for irrigation, then evacuate the chest by reversing the position, and measure the quantity of fluid removed. This procedure can be relied upon in giving the size of the cavity, and should be employed systematically at fixed intervals, to ascertain the proper time for the removal of the drain. Schede's thoracoplastic operation is a grave one, and should never be undertaken without clear and well-defined indications. It is attended by a degree of shock equivalent to that attending an amputation at the shoulder-joint or base of the thigh. The general condition of patients upon whom it must be performed is often such as to require the most careful preliminary preparation, in order to minimize the immediate risks. It has yielded encouraging results in cases of empyema complicating pulmonary tuberculosis, in instances in which the extent of the primary disease furnished no contraindication to the operation.

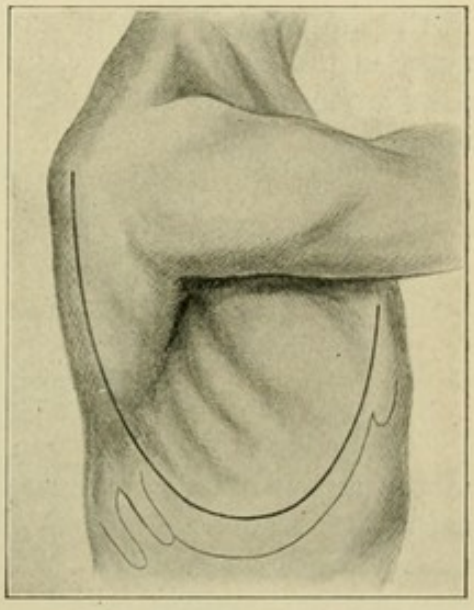

Fig. 459.—Line of incision for Schede's thoracoplasty.

The operation consists in excising the wall of the chest, including the pleura and intercostal muscles, leaving the skin and the muscles outside of the chest-wall proper in the form of a large oval flap, which is then brought in immediate contact with the collapsed lung. The incision is commenced over the anterior border of the pectoralis minor, on a level with the axillary space, and is extended downward in a curved line to the lower limit of the pleura, and

continued in a similar curve upward, between the spine and the scapula, as far as the second rib. All the soft tissues, including the scapula, are reflected upward in the shape of an enormous flap (Fig. 459). All the ribs from the second downward are detached from the cartilages with a cartilage knife or bone-cutting forceps. After incising the pleura to the same extent, the pleural cavity is freely laid open for inspection. The remainder of the thorax wall is then separated by cutting rib after rib with bone-cutting forceps, seizing and tying the intercostal arteries after section of each rib. After cleansing the cavity by mopping and the careful use of the sharp spoon and thorough disinfection, the flap is brought in position and in contact with the large wouud surface. Besides a few sutures, the external dressing is relied upon in maintaining contact of the flap with the underlying wound surface. This is the typical Schede's thoracoplasty for the treatment of large empyemic cavities. If the empyema is circumscribed, the resection of the chest-wall is made in the same manner, but to a less extent, as it would not be prudent to extend the resection beyond the limits of the suppurating cavity.

CHAPTER XVII.

PERITONITIS.

Peritonitis of a nontraumatic origin is a disease that comes most frequently under the care of the general practitioner. Modern pathology teaches us that, with few exceptions, it occurs as a secondary lesion as the result of an extension of infection from a more or less localized suppurating focus, or in consequence of a perforation in any part of the gastro-intestinal canal. Peritonitis as observed in connection with appendicitis, salpingitis, and perforating typhoid ulcer furnishes interesting clinical illustrations of the advances made in the investigation of its etiology and pathology.

Death from peritonitis usually occurs from septic intoxication. For the purpose of gaining access to and, if found, of removing or rendering harmless the original cause, and with a view to securing an outlet for the septic material from the peritoneal cavity, laparotomy has largely taken the place of the expectant treatment. Thousands of lives are saved annually by timely surgical intervention, which, under the former routine of medical treatment, would have been doomed to certain death. The progressive physician makes a careful study of every case of peritonitis and watches for indications for operation, availing himself of timely surgical aid whenever they present themselves.

Peritonitis is characterized by a complexus of symptoms, consisting of fever, rapid, wiry pulse, pain, tenderness, muscular rigid-

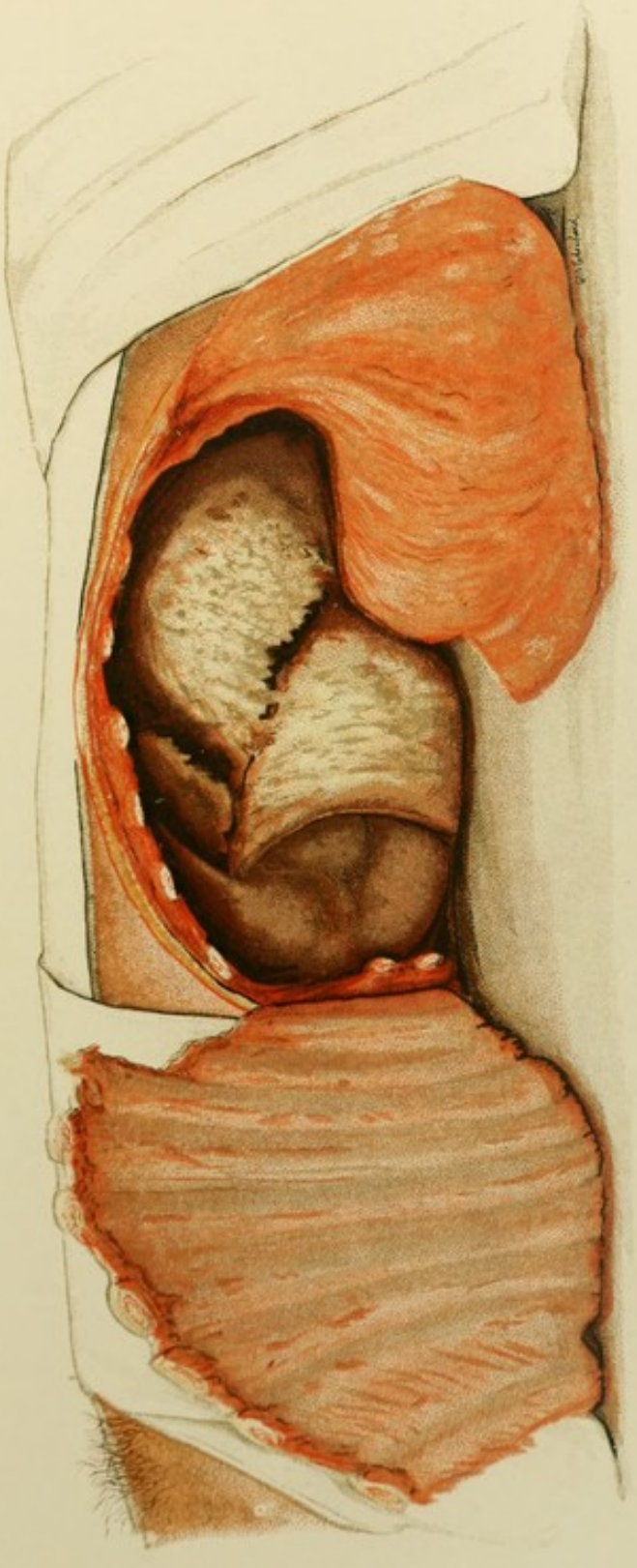

Resection of chest-wall and exposure of empyemic cavity.

ity, tympanites, vomiting, and constipation, which vary according to the extent and type of the disease. It is generally less difficult to diagnosticate the existence of the disease than to ascertain the location and nature of its primary cause.

An intelligent and systematic discussion of acute peritonitis must be based necessarily on a rational classification. A great deal that has been said and written on this subject from the distant past until the present time is worthless from a scientific as well as a practical standpoint, owing to a lack of a proper classification. The ordinary terms used to designate the different forms of peritonitis are differently interpreted and applied by pathologists and clinicians. Acute inflammation of the peritoneum is produced by so many different causes and assumes such varied clinical aspects that it is extremely difficult to formulate a satisfactory classification. A discussion of the etiology, differential diagnosis, prognosis, and treatment of acute peritonitis except upon the basis of a clear and comprehensive classification is fruitless, misleading, and usually results in the deduction of erroneous and often dangerous conclusions. The classification should include the anatomy, pathology, and etiology of the disease to be of value in rendering a correct diagnosis, a reliable prognosis, and in enabling the physician and surgeon to advise and apply effective therapeutic measures. It is especially important in the discussion of the surgical treatment of peritonitis to make a clear distinction between the different clinical forms of peritonitis, with a view to pointing out the limitation of purely medical treatment and the legitimate scope of surgical intervention.

1. Anatomic Classification.—An accurate anatomic diagnosis is necessary for the purpose of locating the inflammatory process correctly or to trace the connection between it and the organ primarily the seat of infection. During the beginning of the attack and in cases of localized peritonitis the inflammation can usually be located without much difficulty, while the reverse is often the case after the disease has become diffuse. The inflammation may commence and spread from either surface of the serous membrane, visceral or parietal.

(**a**) **Ectoperitonitis.**—An inflammation of the attached side of the peritoneum is called ectoperitonitis. As compared with inflammation of the serous surface, this inflammation of the subendothelial vascular connective tissue is characterized clinically and pathologically by intrinsic tendencies to limitation of the inflammatory process. The mechanical and anatomic conditions for the diffusion of the infection are less favorable than when the free surface of the membrane is affected. Ectoperitonitis, however, in certain localities may become quite diffuse, as when the cavum Retzii (Wm. Gruber) or the retroperitoneal space on either side of the spinal column is the seat of a suppurative inflammation. In the latter locality a paranephric or spondylitic abscess is often the cause of an extended ectoperitonitis, the extent of the disease corresponding with the size

of the subperitoneal abscess. In infected wounds of any part of the abdominal wall in which the peritoneum is exposed, but not perforated, the primary ectoperitonitis is occasionally followed by the extension of the infection to the serous surface through the lymphatics, or the direct extension of the infective process through the tissues until it reaches the endothelial lining. Peritonitis of a visceral origin is always preceded by ectoperitonitis, whether the infection reaches the peritoneal cavity through a perforation or by progressive extension of the infection from the primary focus through the tissues until it reaches the free peritoneal surface.

(**b**) **Endoperitonitis.**—What is usually spoken of and described as peritonitis is an inflammation of the serous surface of the peritoneum, which, anatomically speaking, is an endoperitonitis. Endoperitonitis not infrequently leads to ectoperitonitis and the formation of subserous abscesses. In inflammation of the serous coat of the intestine the peritoneum is always loosened and frequently extensively detached by the secondary ectoperitonitis.

(**c**) **Parietal Peritonitis.**—Inflammation of the serous lining of the peritoneal cavity is called parietal peritonitis. It may occur as a primary affection in penetrating wounds of the abdomen, but more frequently it is met with as a secondary disease in consequence of the extension of an infection from one of the abdominal or pelvic viscera, or perforation into the peritoneal cavity of a visceral ulcer or a subserous or visceral abscess. Visceral peritonitis is always associated with parietal peritonitis, and parietal peritonitis is absent in the visceral peritonitis only when the inflammation remains limited and the parietal peritoneum is protected against infection by plastic exudations or interposition of one of the abdominal organs. In the female parietal peritonitis of the pelvic floor usually follows in the course of an extension of an infective process from the internal genital organs through the lymphatics, rupture of a visceral or connective-tissue abscess into the peritoneal cavity, or leakage of septic material from the Fallopian tubes.

(**d**) **Visceral Peritonitis.**—Inflammation of the peritoneal investment of any of the abdominal or pelvic organs is known as visceral peritonitis. The inflammatory process is seldom limited to a single organ, as during the course of the disease adjacent organs or the parietal peritoneum will surely become involved. In general peritonitis the whole peritoneal sac and the serous covering of all the abdominal organs are affected. The nomenclature of visceral peritonitis is a lengthy one, as it includes all the abdominal and pelvic organs that, when the seat of a suppurative inflammation, may become the primary starting-point of an attack of localized or diffuse peritonitis. The mesentery and omentum are modified anatomic forms of the peritoneum, and when the seat of inflammation, we speak of mesenteritis and epiploitis. Peritonitis involving the serous covering of any abdominal organ, and arising in consequence of an inflammation of the organ that it invests, is desig-

nated by the prefix *peri-*, and the noun used to indicate the organ primarily affected in a state of inflammation which has given rise to the following terms: perigastritis, perienteritis, perityphlitis, periappendicitis, pericolitis, perihepatitis, perisplenitis, pericystitis, perisalpingitis, and perioophoritis.

(e) **Pelvic Peritonitis.**—Inflammation limited to the peritoneal lining of the pelvis and its contents is known clinically and anatomically as pelvic peritonitis. It is an affection almost entirely limited to the female sex, and in the majority of cases is caused by extension of gonorrheal infection from the Fallopian tubes, or a mild form of pyogenic infection from the uterus, its adnexa, or the connective tissue of the parametrium.

(f) **Diaphragmatic Peritonitis.**—Inflammation of the under surface of the diaphragm is described as diaphragmatic peritonitis, and when it assumes a suppurative type and remains limited, leads to the formation of subdiaphragmatic abscess. This acute localized form of peritonitis is usually secondary to suppurative affections of the liver and gall-bladder and perforating ulcers of the stomach and duodenum.

2. Etiologic Classification.—The classification of peritonitis upon an etiologic basis is of the greatest importance and practical value. The nature of the exciting cause frequently determines the anatomic and pathologic varieties. It likewise has a strong bearing upon the prognosis, and often furnishes positive indications as to the methods of treatment that should be adopted. Peritonitis, like every other inflammatory affection, is always the result of infection with pathogenic microbes, usually of the pyogenic variety. The etiology must consider the different avenues through which the microbes find their way into the peritoneal cavity.

(a) **Traumatic Peritonitis.**—Primary peritonitis has usually a traumatic origin—that is, the injury establishes, between the peritoneal cavity and the surface of the body or some of the hollow abdominal or pelvic organs, a communication through which pyogenic bacteria enter in sufficient number and of adequate virulence to cause an acute inflammation. Traumatic peritonitis is most frequently caused by penetrating wounds of the abdominal wall, the uterus, bladder, rectum, and lower portion of the esophagus. In some cases the penetrating wounds of the chest extend into the abdominal cavity through the diaphragm. Contusions and lacerations of the abdominal organs often cause peritonitis by extravasation of the secretions or excretions of the injured organ. Not infrequently the injury is followed by a circumscribed suppurative inflammation in the injured organ, which later is followed by diffuse peritonitis from perforation of an abscess or the injured wall of any part of the gastro-intestinal canal, in which case the peritonitis follows as a secondary affection.

(b) **Idiopathic Peritonitis.**—The occurrence of peritonitis without an antecedent injury or suppurative lesion is doubted by many.

It is an exceedingly rare affection, since pathologists and surgeons have brought, by their investigations and observations, the peritoneal inflammations with few exceptions into connection with neighboring or distant primary suppurative lesions. It is certainly much rarer than primary inflammation of the pleura and pericardium as an isolated affection. It is too early to deny *in toto* the existence of so-called idiopathic peritonitis, but future bacteriologic examinations of the inflammatory product will no doubt reveal a microbic cause in all such cases. Leyden found diplococci and streptococci in the inflammatory exudate in a case of primary peritonitis. As an isolated affection peritonitis is found most frequently in females during or soon after menstruation; it is probable that the pyogenic bacteria multiply in the blood that accumulates in the uterus, and reach the peritoneal cavity through the Fallopian tubes. It is said to have occurred in consequence of exposure to cold, and is then known as rheumatic peritonitis. Occasionally it has been observed as one of the remote manifestations of Bright's disease, pyemia, and the acute eruptive fevers.

(c) **Perforative Peritonitis.**—Perforation of an ulcer of any part of the gastro-intestinal canal, or of an abscess of any of the abdominal or pelvic organs, or of the abdominal wall into the peritoneal cavity, is by far the most frequent cause of acute peritonitis. Two important and frequent causes are appendicitis and suppurative salpingitis. If localized inflammation develops over the ulcer or abscess before perforation takes place, the general peritoneal cavity is often protected by firm adhesions before the accident occurs, and the peritonitis remains circumscribed. If, however, the contents of the gastro-intestinal canal or the abscess cavity reach the free peritoneal cavity, a diffuse septic peritonitis sets in, which usually destroys life within from twelve to seventy-two hours, unless prompt surgical treatment is resorted to. Experimental research, as well as clinical observation, has demonstrated that the intestinal wall, when paretic or gangrenous, becomes permeable to the microbes contained in the intestinal canal. In many cases of intestinal obstruction, acute and chronic, death results from septic peritonitis after the intestine has become paretic or gangrenous.

(d) **Metastatic Peritonitis.**—This form of peritonitis occurs, like other metastatic affections, in connection with a suppurative or infectious process anatomically disconnected from the peritoneum. It is rarer than metastatic pleuritis, and is seldom seen except as a pyemic lesion. In very rare cases it develops in the course of many of the acute infectious diseases, as scarlatina, smallpox, erysipelas, rubeola, and even varicella. It also occurs frequently in the course of septicemia and pyemia. Andral and Desplatz have seen it occur during attacks of acute articular rheumatism. It has also been observed in scorbutic subjects and in patients suffering from valvular disease of the heart.

(e) **Puerperal Peritonitis.**—Peritonitis occurring in connection

with septic diseases of the puerperal uterus has for a long time been known as puerperal peritonitis. The infection may extend from the endometrium through the Fallopian tubes, or may follow the lymph-channels or the thrombosed infected uterine veins. Infection through the lymphatics usually results in rapidly fatal diffuse septic peritonitis, while in thrombophlebitis there is a greater tendency to localization unless the thrombi disintegrate and cause embolism and pyemia.

(f) **Peritonitis Infantum.**—Peritonitis attacks most frequently infants, children, young adults, and women during the child-bearing period of life, but no age is exempt.

(g) **Fetal and Intra-uterine Peritonitis.**—If the disease attacks, as it occasionally does, the fetus *in utero*, it often results in death before or soon after the birth of the child; most frequently death ensues during the seventh to the ninth month of gestation. Prenatal peritonitis is frequently associated with syphilis. In most cases the disease is detected only at the postmortem; in others death, if the child is born alive, is preceded by meteorismus, icterus, and edema of the legs.

(h) **Peritonitis Neonatorum.**—Infection takes place during the first few weeks after birth through the imperfectly healed ulcerating umbilicus. It has been met with most frequently in children whose mothers were afflicted with puerperal fever. Besides peritonitis, symptoms of pyemia appear.

3. Pathologic Classification.—The pathologic conditions that characterize the different varieties of peritonitis must necessarily be considered in classifying this disease. The pathologic classification is based almost entirely upon the gross and microscopic appearances of the inflammatory exudation and transudation.

(a) **Diffuse Septic Peritonitis.**—Every acute peritonitis is septic in so far that phlogistic substances reach the general circulation from the inflammatory lesion, and in that frequently the inflammation terminates in suppuration; but the term septic peritonitis should be limited to those cases of diffuse septic inflammation in which, as a rule, death occurs in a few days, and before any gross pathologic conditions have had time to develop. It is a disease that is almost uniformly fatal with or without operative treatment, the patients dying from the effects of progressive sepsis. The claim of operators to have cured such cases by laparotomy must be accepted with a good deal of allowance. The microbes that produce this form of peritonitis are those that follow the lymph-spaces, and are rapidly diffused not only over the entire peritoneal surface, parietal and visceral, but also through the subserous lymphatic channels. The disease is observed most frequently after perforation, into the free peritoneal cavity, of an abscess containing septic pus, rupture or perforation of any of the abdominal or pelvic viscera containing septic material, gunshot or stab wounds of the abdomen with visceral injury of the gastro-intestinal canal, and occasionally as the result

of infection during laparotomy. The gravest form of puerperal fever is a diffuse septic peritonitis. The subjects of this variety of peritonitis die so soon after the beginning of the disease that at the postmortem, or, if the abdomen is opened during life, at the operation, no gross tissue changes are discovered—beyond a slightly increased vascularity, nothing is found to indicate the existence of peritonitis. The septic material, formed in large quantities and of great virulence, is rapidly absorbed by the stomata of the under surface of the diaphragm, discovered and described by von Recklinghausen.

(**b**) **Putrid Peritonitis.**—The inflammatory product in this form of peritonitis is a scanty brown or reddish-brown fetid fluid. It occurs most frequently in connection with grave forms of puerperal metritis. It is usually associated with more or less gangrene or ulceration of the organ or parts primarily affected, as uterus, intestine, or abdominal wall.

(**c**) **Hemorrhagic Peritonitis.**—The ascites which so frequently develops in consequence of malignant or tubercular disease of the peritoneum is composed of serum, frequently stained with blood, but in acute peritonitis the transudate is occasionally hemorrhagic by the tearing of vascular adhesions, and rhexis is also observed in persons suffering from peritonitis who are greatly debilitated, scorbutic, or intemperate, and occasionally when peritonitis occurs in patients suffering from typhoid fever. It is met with most frequently in the pelvis, upon the posterior surface of the uterus and vagina, and, in men, behind the bladder. The inflammatory product appears in the form of brown patches, composed of delicate and very vascular villi. These villi, from their unfavorable location, are subjected to frequent mechanical disturbances, and when injured bleed, giving rise to the so-called retro-uterine or retrovesical hematocele.

(**d**) **Suppurative Peritonitis.**—Suppurative peritonitis—that is, an inflammation of the peritoneum which results in the formation of pus—is always more or less circumscribed. This form of peritonitis is the most frequent, and is generally associated with more or less fibrinoplastic exudation. The pus is serous, seropurulent, or may reach the consistence of cream, when it is usually of a yellow color. The accumulation of pus may be so large that upon opening the abdominal cavity it may appear as though the entire peritoneal cavity and all the organs contained within were implicated; but a careful examination will almost always reveal the fact that a large part of the peritoneal cavity and many of the organs were shut out from the inflammatory process by plastic adhesions. Suppurative peritonitis must, therefore, be regarded from a practical standpoint as a circumscribed inflammation. The appearance and character of the pus are often greatly modified by the admixture of an extravasation accompanying the perforative lesion that produces the peritonitis. If the pus is thin and serous, we speak of a *seropurulent peritonitis*—it is a serous peritonitis with the formation of pus in

sufficient quantity to render the serum more or less turbid. This subvariety of suppurative peritonitis is, without exception, in combination with fibrinous exudations that tend to limit the extension of the infective process. Sedimentation of the solid constituents takes place, so that the fluid contains more of the solid constituents in the most dependent portion of the affected district.

(e) **Serous Peritonitis.**—Independently of malignant and tubercular disease of the peritoneum, circumscribed hydrops of the peritoneal cavity is caused by a very mild form of peritonitis, the pus-microbes present not being sufficient in number to produce pus. Patients usually recover rapidly from this form of peritonitis. The slight alterations of the peritoneum produced by the inflammatory process do not interfere with the transudation of serum, and resorption is effected as soon as the inflammation subsides and the normal absorptive function of the peritoneum is restored. Serous peritonitis is usually more or less complicated by fibrinous peritonitis, as fragments of fibrin are often found suspended in the fluid. The serum is generally somewhat turbid, not transparent, and grayish-yellow or reddish in color. So long as the fluid is limited in quantity it gravitates toward the most dependent parts of the abdominal cavity in the small pelvis ; when more copious, it reaches the upper portions of the peritoneal cavity, and seeks first the depression on each side of the spinal column.

(f) **Fibrinoplastic Peritonitis.**—Peritonitis in which plastic exudations are formed and pus is absent or scanty is called fibrinoplastic peritonitis. *Exudative peritonitis* and *peritonitis adhesiva seu sicca* have been used as synonymous terms for this variety of peritonitis. It is usually a secondary process, following a primary affection of one of the abdominal or pelvic organs, and denotes a comparatively mild form of infection, the extension of which becomes limited by firm adhesions. The inflammation results in a plastic exudation with little or no effusion. The character of the exudate depends on the intensity and quality of the bacterial cause. The exudation is often so copious that it has been mistaken for malignant disease. Goldberg reports two such cases. The symptoms were marked cachexia, ascites, uncontrollable diarrhea, and apparent tumor deep in the abdomen. The distinguishing features of this form of peritonitis from abdominal tumor are the less circumscribed outline, the less resistance offered, the more regular surface, and the fact that the ascitic fluid is not bloody, but serous or seropurulent. The exudation in the course of time contracts and results in strong bands of adhesion, which frequently flex and distort the organs to which they are attached, thus giving rise to another term —*peritonitis deformans.*

4. **Bacteriologic Classification.**—As the essential causes of peritonitis are always the presence and action of pathogenic microbes and their toxins upon the peritoneum, and as the character of the inflammatory process is largely influenced by the kind of

microbes that produced the infection, a bacteriologic classification is of the greatest scientific and practical importance. All pus-microbes present in sufficient number and virulence in the peritoneal cavity can produce peritonitis. Experiments as well as clinical observation have shown, however, that their action is enhanced by local conditions that favor their growth and reproduction. Injuries or antecedent lesions of the peritoneum and the presence of putrescible substances furnish such predisposing and exciting conditions.

(a) **Streptococcus Infection.**—The streptococcus pyogenes is the microbe that is most frequently found in the tissues in cases of diffuse septic peritonitis. The infection spreads so rapidly over the peritoneal surface and through the subserous lymphatics that death, as a rule, occurs from septic intoxication before a sufficient length of time has elapsed for any gross pathologic conditions to form. Absence of fibrinous exudate and effusion is the most striking negative finding at operations and necropsies. Streptococcus infection is the immediate cause of the most fatal form of puerperal peritonitis. Fränkel has found the streptococcus pyogenes in a great variety of puerperal diseases, especially in cases in which the local affection implicated the lymphatic vessels. In such cases the microbes found entrance into the pelvic tissues from abrasions of the vagina or uterus, and, by extension of the inflammatory process, the broad ligaments and the peritoneum are successively reached. After the peritoneum has once been infected, rapid diffusion takes place, and finally the diaphragm and pleuræ are implicated in the same process, and the patient dies from the effects of progressive sepsis.

(b) **Staphylococcus Infection.**—In peritonitis caused by staphylococcus infection the intrinsic tendency to localization of the disease is more marked—the inflammation results more often in circumscribed suppuration and limitation of the infective process by copious fibrinoplastic exudations. As a rule, the inflammation terminates in the formation of thick, cream-colored pus. Different forms of staphylococci are often seen in the same inflammatory product.

(c) **Pneumococcus Infection.**—It is now well known that pneumonia is produced by different microbes, but the diplococcus is found in about 80 per cent. of all cases. It is this microbe that occasionally is found as the bacteriologic cause of acute suppurative peritonitis. Weichselbaum has found the diplococcus of pneumonia unaccompanied by any other micro-organism in three cases of peritonitis. In one case the peritonitis and acute pneumonia occurred simultaneously; in the other, double pleuritis followed the peritonitis; but in the last case the peritonitis was undoubtedly primary, and, in the absence of any other microbes in the inflammatory product, must have been caused solely by the diplococcus of pneumonia.

Etheridge has described three cases of abscess of the ovary

complicated by plastic peritonitis, in the contents of which the diplococcus alone was found. Le Gendre reports a case of peritonitis in a girl of eighteen years; the pus was yellowish-green, lumpy, and of a fibrinous consistence, and contained a pure culture of the pneumococcus. The author found altogether eleven cases recorded, eight of which had been fatal. Another case is reported by Veillon. The suppuration caused by pneumococcus infection is almost invariably attended by copious fibrinoplastic exudation.

(**d**) **Bacillus Coli Communis Infection.**—The bacillus coli communis, a microbe that constantly infests the intestinal canal, is, in a fair percentage of cases, the bacteriologic cause of acute peritonitis. This microbe possesses pyogenic properties, and in intestinal paresis and perforations escapes into the peritoneal cavity and produces usually a pathologically mixed form of peritonitis—that is, suppurative and fibrinoplastic peritonitis. Of thirty-one cases of peritonitis examined by Fränkel, this microbe was found in nine. In eleven cases, seven gave mixed cultures, and in three of these the colon bacillus predominated. The same author has shown that pure cultures injected into the abdominal cavity of rabbits cause typical peritonitis.

(**e**) **Gonococcus Infection.**—In the peritoneal cavity the gonococcus produces a plastic peritonitis and sometimes localized suppuration. Salpingoperitonitis and more diffuse pelvic peritonitis are most frequently caused by gonococcus infection. "The proper character and results of the pathogenous activity of the gonorrheic microbes are, therefore, seen pure and unadulterated in the tubes. They cause purulent inflammation of the mucous membrane, but the surrounding connective tissue remains free from them. The gonorrheic tubal pus is evacuated into the peritoneum; and, whereas in other conditions the bursting of an abscess into the abdominal cavity is followed by the gravest consequences, in this case the whole process terminates with a circumscribed inflammation encapsulating the exuded pus. The cause of this difference is the varying pathogenic value of the organisms that are contained in the pus. A puerperal pelvic cellulitic abscess bursting into the peritoneum causes general peritonitis, because it contains pyogenic streptococci, which rapidly multiply in serous cavities and are capable of exerting the most deleterious effects. Gonorrheal tubal pus can not do this; its microbes do not find in the peritoneum conditions for their increase; the pus, therefore, acts as an aseptic foreign body, becomes encapsulated, and is finally absorbed" (Sinclair).

(**f**) **Tubercular Infection.**—The rapid diffusion of the tubercle bacillus in the peritoneal cavity, through either the circulation or by rupture of a tubercular abscess into the peritoneal cavity, or by extension from a tubercular salpingitis or a tubercular intestinal ulcer, occasionally gives rise to a form of acute peritonitis characterized as such, in a modified way, by the clinical manifestations that

accompany it. According to the intensity of the infection or the degree of susceptibility of the patient to the action of the tubercle bacillus, the disease assumes one of the following pathologic forms: 1. Tubercular ascites. 2. Fibrinoplastic peritonitis. 3. Adhesive peritonitis. Suppuration takes place only when the tubercular product becomes the seat of a secondary mixed infection with pus-microbes.

5. Clinical Classification.—From a practical standpoint the clinical classification is the most important. A modern clinical classification must be based on the location, causes, and pathologic types of the inflammatory process as just outlined. Upon a correct clinical differentiation between the various forms of peritonitis as seen at the bedside depends largely the adoption of a rational course of treatment. The recognition of the disease no longer completes the diagnosis for the physician, much less for the surgeon. A diagnosis for the careful physician and conscientious surgeon must include the location, extent, causation, and pathology of the disease. From the information gained from the classification already made, must be obtained the material upon which to base a clinical classification. Such classification should serve as a guide in differentiating between the cases that demand surgical intervention and the cases that can be trusted to medical treatment.

(**a**) **Ectoperitonitis.**—Abscess formation in the subperitoneal connective tissue, as seen most frequently in the pelvis in women, in the cavity of Retzius in men, and in the retroperitoneal space in both sexes, is always attended by inflammation of the outer surface of the peritoneum, and is not infrequently followed by extension of the infection through the lymphatic spaces to the free surface, and exposes the patients to the risks of perforation of the abscess into the free peritoneal cavity, septic diffuse peritonitis, and death. Such abscesses should be recognized and accurately located sufficiently early to prevent such serious complications by an extraperitoneal incision and drainage; or, if the abscess is of tubercular nature, by tapping, evacuation, and iodoformization.

(**b**) **Diffuse Septic Peritonitis.**—This form of peritonitis is characterized clinically by the gravity of the general symptoms from the very incipiency of the disease; pathologically, by the rapid diffusion of the infection over the entire serous surfaces, visceral and parietal; bacteriologically, by the presence, in most of the cases, of the streptococcus pyogenes in the inflamed tissues. Staphylococci, pneumococci, and the colon bacillus may also be the causes of rapidly spreading diffuse peritonitis. This form of peritonitis usually follows penetrating wounds of the abdominal cavity complicated by visceral injuries of the gastro-intestinal canal, contusion or laceration of any of the abdominal or pelvic organs, in rupture of an abscess or ulcer into the free peritoneal cavity, or the extension of a septic lymphangitis from any of the abdominal or pelvic organs to the peritoneum. Strict aseptic precautions have succeeded in

greatly reducing, but not entirely eliminating, the danger from this source in all operations requiring opening of the free peritoneal cavity. In genuine cases of general septic peritonitis surgical intervention is usually powerless to prevent speedy death from toxemia, while prompt surgical interference may cope successfully with the diffuse variety.

(c) **Perforative Peritonitis.**—Perforative peritonitis invariably occurs as a secondary affection, usually in connection with an ulcerative or gangrenous lesion of some part of the gastro-intestinal canal. Perforative ulcer of the stomach or duodenum, or typhoid or tubercular ulcers of the ileum, perforation or sloughing of the appendix, the different forms of intestinal obstruction, are the most frequent causes of this well-defined clinical form of peritonitis. Perforative peritonitis is manifested by the sudden onset of the disease, by diffuse pain and tenderness, rigid abdominal walls, fever, vomiting, the impossibility, by inspection, palpation, and auscultation, to ascertain intestinal peristalsis, this condition being almost positive proof of the presence of gas in the free peritoneal cavity or paresis of the distended intestines. According to my observations, meteorismus peritonei in perforative peritonitis caused by affections of the appendix is rare, while I have seldom found it absent in perforations of any other portion of the gastro-intestinal canal. According to the number and virulence of the microbes that find their way into the peritoneal cavity with the extravasation, the resulting peritonitis is either diffuse or more or less circumscribed. The colon bacillus is invariably present in the inflammatory product, but in addition streptococci, staphylococci, putrefactive bacilli, the typhoid bacillus, or bacillus of tuberculosis, according to the nature of the primary infection, may also be found.

Perforative peritonitis must be regarded and treated as a strictly surgical disease. The primary lesion must be exposed and treated as soon as a diagnosis can be made and the necessary measures applied to limit the extension of the infection and to prevent death from toxemia.

(d) **Circumscribed Peritonitis.**—A circumscribed peritonitis is an inflammation of the peritoneum during which a greater or less part of the peritoneal cavity becomes excluded from the original source of infection by the formation of plastic, visceral, parietal, or visceral and parietal adhesions. The complexus of symptoms varies according to the degree of virulence of the microbic cause, which only occasionally is overshadowed by the primary affection. The symptoms appear suddenly or are preceded by those incident to the primary disease. The severity of the pain and the extent of the muscular rigidity and tenderness will correspond with the extent of the disease. The intensity of the general symptoms is determined more by the nature and virulence of the microbic cause than the size of the peritoneal surface involved. The inflammatory focus may be limited to a very small space, or it may involve the

greater portion of the peritoneal cavity and organs that it contains. The clinical course and termination are determined largely by the nature and virulence of the primary bacterial cause, the anatomic location of the primary starting-point, and nature of environment. If the organs adjacent to the primary focus of infection are favorably located to limit the process, diffusion is frequently prevented by the formation of adhesions. This is especially true in cases where the primary infection is limited by the existence of old adhesions.

Localized peritonitis may be confined to the lesser peritoneum, particularly in cases of perforating ulcer of the stomach. More frequently it is caused by appendicitis and cecitis. A very frequent cause of circumscribed peritonitis is inflammation about the gall-bladder, uterus, Fallopian tubes, and ovaries. The localized form of peritonitis is very often overlooked during life. It can usually be detected only if a demonstrable swelling forms at the seat of inflammation. The mildest form of infection gives rise to fibrinoplastic peritonitis, which leaves temporary or permanent adhesions, but terminates without pus-formation. Circumscribed suppurative inflammation is always attended by fibrinoplastic peritonitis, the products of which and the viscera, which it involves, form the abscess wall. The microbes that produce most frequently fibrinoplastic peritonitis without suppuration are the gonococcus and the staphylococci. Circumscribed suppurative peritonitis is usually the result of infection with staphylococci, bacillus coli communis, and pneumococci. In fibrinoplastic peritonitis surgical interference becomes necessary only when intestinal obstruction is caused by the adhesions. In circumscribed suppurative peritonitis the pus should be evacuated as soon as the disease is recognized, and, if possible, by an extra-peritoneal route.

(e) **Hematogenous Peritonitis.**—In very rare instances peritonitis occurs without an injury or discoverable antecedent lesion of any of the abdominal or pelvic organs, and is then described as idiopathic peritonitis. As peritonitis is always caused by bacteria of some kind, a peritonitis that develops independently of a local source of infection is the result of an infection through the blood, and should be called hematogenous or metastatic peritonitis. It has been observed in connection with nephritis, pyemia, rheumatic arthritis, and acute exanthematous diseases.

(f) **Visceral Peritonitis.**—A localized peritonitis that can be brought in direct etiologic connection with the organ primarily affected is expressed by a compound word with the prefix *peri-* and the noun used to indicate the organ primarily affected in a state of inflammation. Thus the anatomic forms of peritonitis present themselves: Perigastritis, perienteritis, perityphlitis, periappendicitis, pericolitis, perihepatitis, perisplenitis, pericystitis (urinary and gall-bladder), perimetritis, perisalpingitis, and perioophoritis.

As the mesentery and omentum are only duplications of the

peritoneum, we have to add to the foregoing anatomic forms mesenteritis and epiploitis.

(g) **Pelvic Peritonitis.**—Pelvic peritonitis is seldom met with in the male. It is a form of peritonitis in which the female pelvic organs are the primary starting-point of infection, with extension to the peritoneum, through either the Fallopian tubes or the lymphatics of the uterus or its adnexa. It is caused most frequently by gonorrheal or puerperal infection, or develops after instrumental examination of the interior of the uterus or operations upon this organ.

(h) **Puerperal Peritonitis.**—By the term puerperal peritonitis is understood a progressive inflammation of the peritoneum occurring in consequence of an extension of an infection from any part of the genital tract in puerperal women after delivery or abortion. The infection usually takes place through the lymphatics, and in the majority of cases terminates in diffuse septic peritonitis.

(i) **Subdiaphragmatic Peritonitis.**—A peritonitis limited to the under surface of the diaphragm and any of the adjacent organs is called subdiaphragmatic peritonitis. If the inflammation remains limited and life is sufficiently prolonged, it usually terminates in the formation of a subdiaphragmatic abscess.

(j) **Chronic Peritonitis.**—With few exceptions chronic peritonitis is tubercular peritonitis. It is noted clinically by its insidious onset, its slow course, the comparative mildness of the inflammatory symptoms, pain, and tenderness, and the absence of or late pus-formation. It occurs much more frequently in the female than in the male, as the Fallopian tubes are the most frequent starting-point of the peritoneal infection. In the male, extension of the tubercular infection from the prostate and vesiculæ seminales occasionally takes place, but more frequently the primary source of infection is to be found in the intestinal canal. The disease appears as either a diffuse or localized affection. Caseation of the tubercular product takes place late or is entirely wanting. Pathologically, it presents itself either as a dry process, in which case the exudate causes firm and extensive adhesions, or a free transudation accompanies the inflammatory process and results in a diffuse or circumscribed hydrops. In the latter case the localized ascites is walled off by fibrinous exudates and adherent abdominal organs. A slight evening rise in temperature, progressive marasmus, and the existence of tuberculosis in other organs are conditions that would naturally arouse suspicion of the tubercular nature of the peritoneal affection. Abdominal section and drainage have accomplished the most in arresting the disease and in restoring health. I have confidence in tapping followed by the injection of a 10 per cent. iodoform glycerin emulsion. The first injection should not exceed three drams, as some patients are exceedingly susceptible to the toxic action of iodoform. In one of two of my cases laparotomy and drainage were resorted to several times, and each attempt was followed

by a speedy relapse. The patients were then tapped at intervals of about two weeks, and each time from three to four drams of a 10 per cent. emulsion of iodoform glycerin were injected, with the result that after two and five injections respectively, the hydrops disappeared and the patients recovered and remained in good health two and three years after the last tapping. In another case of exquisite peritoneal tuberculosis and tubercular salpingitis the disease yielded to the same treatment on laparotomy having been performed. Abdominal section and intraperitoneal iodoformization are indicated only in the hydropic form of peritoneal tuberculosis.

TREATMENT OF SEPTIC AND SUPPURATIVE PERITONITIS.

1. Ectoperitonitis.—The surgical treatment of an ectoperitonitic suppurating focus is curative and prophylactic. The prophylaxis consists in the prevention of rupture of the abscess contents into the free peritoneal cavity by an extraperitoneal incision and drainage, which ordinarily results in healing of the abscess cavity and a permanent cure. Paranephric abscesses should be treated by lumbar incision and drainage; tubercular spondylitic abscesses without fistula formation, by tapping and iodoformization; pelvic abscesses in the female, whenever practicable, by vaginal incision and drainage. If the abscess is not within reach by the vaginal route, an incision is made through the abdominal wall directly over the abscess, and in the absence of adhesions the parietal peritoneum is sutured to the surface of the abscess wall and the abscess incised and drained at once, or the incision is tamponed with iodoform gauze and the abscess opened and drained a few days later after the peritoneal cavity has been more thoroughly excluded by the formation of firm adhesions.

Suppurative inflammation of the loose connective tissue in the cavum Retzii often leads to extensive ectoperitonitis, occasionally to perforation into the peritoneal cavity, septic peritonitis, and death.

Leusser has collected forty-six such cases and has made some important investigations concerning the structure and arrangement of the tissues in the prevesical space in reference to the directions in which the pus will burrow when this space is the seat of a phlegmonous inflammation. He found that the loose connective tissue between the peritoneum and the abdominal muscles is divided into two layers by a plane of fascia that is inserted into the upper border of the symphysis. An abscess in this region may therefore be submuscular or prevesical; the former occupies the space between the fascia and the muscles and assumes an ovate outline, with the pointed extremity of the swelling directed downward; an abscess behind the fascia, a true prevesical abscess, resembles in outline the distended bladder. The prevesical abscess can be reached by rectal and vaginal examination, and disturbs the function of the bladder. The indications for prompt surgical interference are particularly

urgent when the abscess is deep,—subperitoneal,—as it is in such cases that the peritoneum is extensively involved and the danger of extensive burrowing of the pus is greatest, and perforation into the peritoneal cavity most frequently takes place. The proper treatment of an abscess in the cavum Retzii is an early and free incision made in the same manner and with the same care as in operations for stone in the bladder by the suprapubic route and extending to the anterior wall of the bladder.

2. General Septic Peritonitis.—The greatest confusion still prevails among pathologists, physicians, and surgeons in reference to what is meant by general septic peritonitis, more particularly as to the distinction between septic and suppurative peritonitis. By a general septic peritonitis is understood an inflammation of the entire peritoneal sac with the serous covering of all abdominal organs, which, as a rule, proves fatal from progressive intoxication before sufficient time has elapsed for the formation of pus or any considerable transudate, or before any marked macroscopic tissue changes have occurred. It is the result of the most virulent infection, the patients dying not so much from the effects of the inflammation as from the rapid introduction into the general circulation from the peritoneal cavity of preformed septic material. In suppurative peritonitis the primary microbic infection is less in quantity or virulence, and a sufficient length of time intervenes between the beginning of the attack and the operation or death for the formation of pus and other inflammatory products. *Every acute peritonitis is septic in so far that phlogistic substances reach the general circulation from the inflammatory lesion, and in that frequently the inflammation terminates in suppuration, but the term septic should be limited to those cases of diffuse septic peritonitis in which, as a rule, death occurs in a few days and before any gross pathologic conditions have had time to develop. It is a disease that is almost uniformly fatal, with or without operation, the patients dying from the effects of progressive sepsis.* The subjects of this variety of peritonitis die so soon after the beginning of the disease that at the postmortem, or, if the abdomen is opened during life, at the operation, no gross tissue changes are discovered. Besides a slightly increased vascularity, nothing is found to indicate the existence of peritonitis. The septic material, formed in large quantities and of intense virulence, is rapidly absorbed by the stomata of the under surface of the diaphragm, discovered and described by von Recklinghausen.

In putrid peritonitis the streptococcus infection is complicated by the presence of putrescible substances which serve as a nutrient medium for saprophytic bacteria which modify the character of the inflammatory product. It occurs most frequently in connection with grave forms of puerperal metritis. It is usually associated with more or less gangrene or ulceration of the organ or parts primarily affected, as the uterus, intestine, or abdominal wall. It is diffuse septic peritonitis that has so far proved so obstinate to suc-

cessful surgical treatment. Surgery has done much toward its prevention, but very little toward saving life after the disease has once fully developed. Careful analysis of the cases that yielded to laparotomy would undoubtedly disclose the fact that most of them were not genuine cases of general septic peritonitis, but cases of more or less localized inflammation of the peritoneum with or without suppuration. In this opinion I am supported by no less an authority than Frederick Treves, who, from a surgical standpoint, divides peritonitis into localized and diffuse. He states that the surgical treatment of the former has yielded encouraging results, but in general nontubercular peritonitis it has been phenomenally unsuccessful. After speaking of circumscribed peritonitis, the same author says: "Peritonitis in the 'small intestine area' is, on the other hand, rapidly diffused, and is as rapidly attended by septicemic symptoms. In the treatment of localized peritonitis surgery can claim to have made great advances, but in the treatment of diffuse peritoneal inflammation with marked constitutional symptoms there is little progress to record. The abdomen may be opened, washed out, and drained, and the distended bowel may be relieved of its putrescent contents by incision, but the results at the best are not brilliant, and it is evident that the treatment of this terrible complication must still incline toward that desirable prevention which is better than cure."

I have opened, drained, and washed out the peritoneal cavity in many cases of diffuse septic peritonitis and, I am free to confess, without a single successful result. All my cases died of sepsis a few hours to a day or two after the operation, in spite of heroic stimulation and, in some cases, of frequently repeated irrigation with sterilized water, normal solution of salt, or mild antiseptic solutions, such as boric acid and acetate of aluminum. On the other hand, some surgeons report a fair percentage of recoveries after laparotomy for what they call general septic peritonitis. Krecke has collected 119 cases of laparotomy in general peritonitis, the origin of which was determined in all except 18, of which 9 died and 9 recovered. In most of the cases the disease was caused by perforation. Of these, 36 followed perforation of the appendix, 12 were cases of typhoid perforation, of which 5 recovered; 12 were due to perforation from gangrene and other causes implicating the intestines. Of the gangrenous variety, not one recovered, and of the 8 others, only 3 were cured by the operation. Of traumatic cases, 3 of punctured and 1 of gunshot wound, all recovered, but of contusions only 3 out of 8 recovered. The operation saved 5 out of 13 cases of puerperal peritonitis. Lastly, a group of cases of peritonitis from various other causes yielded 3 deaths and 6 recoveries. The total result is 119 cases of general peritonitis treated by laparotomy, with 51 recoveries and 68 deaths.

A. J. McCosh ("The Treatment of General Septic Peritonitis," "Annals of Surgery," June, 1897) operated (1888 to 1895 inclu-

sive) in 43 cases of general septic peritonitis. Of these, 37 died and 6 recovered, a mortality of about 86 per cent. A free abdominal incision was made in all, and with a few exceptions irrigation was employed.

It is not easy, nor always possible, to ascertain the extent of inflammation *in vivo* by opening the peritoneal cavity, and a strong suspicion remains that at least in some of the cases that recovered the peritonitis was not general, or that the operation was performed before the entire serous surfaces were involved. Certain principles in the medical and surgical treatment of peritonitis are applicable to all forms of the disease, and the best place to discuss them is in connection with the gravest variety—acute general septic peritonitis.

Medical Treatment.—A more general discussion of the medical treatment of peritonitis is out of place here, but a few words in reference to what the surgeon should do and what he should not do in the way of medical treatment when he assumes charge of a case of peritonitis is pertinent to the subject under consideration. Stomach feeding must be abstained from entirely or limited to the administration of liquid food and stimulants. If, as is so frequently the case, nausea and vomiting are prominent symptoms, rectal enemata are of the greatest value. The distressing thirst can often be effectually relieved by high rectal enemata of warm water or normal saline solution ; if these are not tolerated, by hypodermic infusion. The therapeutic indications for cathartics and opium in the treatment of peritonitis are not definitely settled. Some favor cathartics, others condemn them and rely on opium. Mr. Tait taught us years ago the value of saline cathartics in the prevention of peritonitis and in its treatment during the incipient stage. Most practitioners have adopted his views and administer saline cathartics as soon as the first symptoms make their appearance, and certainly the results have been much better since this practice has come into more general use. It is not only clinical observation that supports Tait's teachings and practice: his views have been substantiated by experimental investigations. The experiments of Wegner prove that bacteria injected into the peritoneal cavity readily enter the blood-vessels and lymphatics and thus reach the excretory organs, notably the intestinal canal, through which they are rapidly eliminated by free catharsis.

Lawson Tait has found the most efficient treatment for septic conditions following abdominal section to be thirty or forty grains of sulphate of magnesia, repeated every hour or every other hour until the bowels move freely. Hence, when microbes accumulate in such quantities that nature unaided can not remove them, it is rational treatment to render assistance by the administration of saline cathartics to favor the process of elimination.

I have seen many cases of threatened peritonitis after abdominal section aborted by the timely administration of saline cathartics. If the stomach is intolerant, calomel in small doses, repeated hourly, and saline enemata are indicated.

One of the greatest dangers in peritonitis is rapid distention with paresis of the intestines, a condition that is provoked by opium and that can be most effectually averted by early and free catharsis. The use of cathartics is absolutely contraindicated in all cases of peritonitis caused by perforation. In such cases the use of opium is legitimate and useful, as it diminishes shock, extravasation of septic material, and its rapid diffusion over the peritoneal surface. Peritonitis, especially the septic variety, invariably depresses the heart's action, a condition that should be met by active stimulation. Shock, general debility, and, as Fritsch has shown, a weak heart increase the danger from sepsis. Strychnin, camphor, and alcoholic stimulants should be employed early and at short intervals in all cases of grave peritonitis. If these remedies are not retained by the stomach, they must be administered subcutaneously or by the rectum. The application of ice or the cold coil over the abdomen frequently succeeds in diminishing the tympanites, and should be employed to prevent overdistention and paresis of the intestines when this condition appears and the peripheral circulation warrants their use. If the heart's action is weak and the capillary circulation sluggish, hot applications are more agreeable to the patient and a better stimulant for the feeble peripheral circulation.

Operative Treatment.—There can be no difference of opinion in reference to the advisability of early operative treatment in the management of diffuse septic peritonitis. Without operation death is almost certain. An early operation may succeed in arresting further extension of infection in cases in which the disease would become general, and in diffuse cases may occasionally be the means of saving a life that, without it, would be surely lost. An early diagnosis and prompt operative interference are the conditions *sine qua non* for success. The patient should be properly prepared for the operation, not only with a view to securing absolute asepsis for the field of operation and everything that is to be brought in contact with the wound, but the necessary precautions should also be carried into effect to sustain the heart's action and stimulate the capillary circulation during and immediately after the operation. This can be accomplished by administering $\frac{1}{32}$ of a grain of strychnin, if the patient is an adult, hypodermically, and two ounces of whisky or brandy by the stomach or rectum half an hour before the anesthetic is administered. I am partial to the use of sulphuric ether as an anesthetic in performing laparotomy for this indication, as it has a less injurious effect on the already enfeebled circulation than chloroform. The body must be carefully protected against loss of heat during the administration of the anesthetic and the performance of the operation, by warm flannel blankets and bottles or rubber bags containing hot water.

The normal salt solution and antiseptic solutions that are to be used for irrigation must be kept at a temperature of from 110° to 120° F. Different kinds of drains and drainage material should be

on hand to be used as indications may arise. The handling of the patient must be done with the utmost care and gentleness.

History of Operation for Peritonitis.—For centuries abscesses that had their origin in the peritoneal cavity have been opened after they presented themselves as such upon any of the accessible surfaces. Laparotomy as a therapeutic resource in the treatment of peritonitis is of recent date. J. Ewing Mears as early as 1875 operated by abdominal section in a case of circumscribed suppurative peritonitis following childbirth. He advocated at that time surgical intervention in all cases of suppurative peritonitis. Treves reported a case of acute peritonitis treated by abdominal section in 1885, which terminated in recovery, and he recommended the operation in similar cases. During the same year Péan advocated in the treatment of septic peritonitis incision toilet and drainage of the abdominal cavity. He favored a large median incision, removal of inflammatory product with sponges and napkins, closure of wound by suturing, except a place large enough for drainage. About the same time Oberst urged energetic surgical treatment in cases of acute peritonitis. In the acutest form, however, he admitted that abdominal section and drainage were powerless in averting death from sepsis. In 1886 Lawson Tait reported two cases of acute peritonitis treated by abdominal section, of which one recovered. He advised laparotomy in all cases of peritonitis if an effusion can be demonstrated and the existence of fever indicates the pyogenic nature of the inflammatory product.

In 1889 successful laparotomies for septic peritonitis were reported by Demons, Bouilly, Dernuce, Brun, Labbé, and Routier. It is evident that in most of these cases the operation was performed for circumscribed suppurative and not for diffuse septic peritonitis.

The treatment of peritonitis by laparotomy received a new impetus when, about twelve years ago, it was found that the disease is so often produced by primary suppurative and perforative lesions of the appendix vermiformis. About the same time gynecologists began to treat suppurative lesions of the pelvis, so frequently the precursors of a similar affection of the peritoneum, upon sound surgical principles. The old dictum, *ubi pus ibi evacuo*, is now fully appreciated by surgeons and gynecologists, and is daily put in practice in the treatment of suppurative ectoperitonitis and septic and suppurative peritonitis. Future clinical experience and experimental research will make this department of surgery one of the greatest blessings to humanity.

Incision.—In the operative treatment of general septic peritonitis authorities are as yet not agreed as to the size, location, and number of incisions that should be employed in opening the abdominal cavity. In circumscribed peritonitis, the rule, to incise and drain by the shortest and most direct route, is usually followed. In perforation of any other organ except the appendix vermiformis resulting in diffuse peritonitis, the first incision should always be made at

or near the median line. The incision is made above the umbilicus if the gall-bladder, stomach, or duodenum is the seat of perforation ; below the umbilicus, in perforation of any other portion of the small intestines.

Mikulicz makes a sharp distinction in the treatment of diffuse septic and progressive fibropurulent peritonitis. In the former variety the abdominal incision should be large, the perforation closed, and the abdominal cavity disinfected and drained. In the latter the adhesions should be carefully preserved and the different pus accumulations opened and evacuated separately. Some surgeons prefer to open the abdomen some distance from the linea alba.

Ramsay gives cogent reasons why, in opening the abdominal cavity, the incision should not be made in the median line, but through the center of either rectus muscle, where the abdominal wall is thickest and strongest, and where the different layers can be sutured separately with the greatest ease, and where, for these reasons, ventral hernia is least likely to follow as one of the remote consequences of the operation. Prolonged drainage is always an important etiologic element in the occurrence of postoperative ventral hernia, and this complication is certainly less likely to follow if the incision is made through the muscular portion of the abdominal wall than through the thin fibrous linea alba.

In the treatment of diffuse septic peritonitis the incision should be at least large enough to insert the hand for the purpose of making a careful intra-abdominal exploration with a view to ascertaining the extent of the disease and to locate and, if possible, treat the primary lesion. Gill Wylie recommends, in the surgical treatment of diffuse peritonitis, an incision of this size to enable surgeons to break up all adhesions among the intestines, and to wash freely the entire cavity of the peritoneum and insert two or more drainage-tubes. The question relating to the propriety of breaking up adhesions will be discussed elsewhere, as in the form of peritonitis that is now under consideration adhesions, as a rule, are absent, or, if present, few and slight. As has been stated before, the incision should be large enough to enable the surgeon to find and treat the primary affection that caused the peritonitis.

Mr. Bowlby is of the belief that an incision below the umbilicus does not necessarily empty the peritoneal cavity. In the one case, after incising and flushing out through a subumbilical incision, he found a large quantity of gas as well as fluid remaining in the peritoneal cavity above. In cases of peritonitis resulting from perforation of a gastric or duodenal ulcer he advises two incisions (one above and one below the umbilicus), to insure complete flushing. In diffuse peritonitis incisions should be made at a number of points with a view of facilitating irrigation and of insuring free drainage. The best points will be above the pubis and above the umbilicus, and posteriorly through the lumbar region on each side ; in the female

through drainage into the vagina, by incising the Douglas culdesac, will answer an excellent purpose. A long incision, permitting the intestines to escape from the abdominal cavity and covering them with a piece of gutta-percha rubber tissue, which is sutured to the margins of the wound, a method of treatment suggested by Hadra, of Texas, is based entirely upon theoretic grounds and is too hazardous to merit a trial.

McBurney has devised an incision for operations on the appendix that reduces to a minimum the risks of a subsequent formation of a ventral hernia. "The skin incision is oblique, about four inches in length, crossing at a right angle a line drawn from the spine of the ilium to the umbilicus, and about an inch from the spine. This incision is a little to the outer side of the normal situation of the appendix. The fibers of the external oblique and its aponeurosis are not cut, but are separated with great care in the direction in which they run. When the edges of the wound of the external oblique are separated with retractors, a considerable expanse of internal oblique muscle is seen, the fibers of which cross somewhat obliquely the opening formed by the retractors. With a blunt instrument the fibers of the internal oblique and transversalis muscles can be separated without cutting more than an occasional fiber in a line parallel with their course—that is, nearly at right angles to the incision in the aponeurosis. Blunt retractors are now introduced, and these expose the transversalis fascia, which is then divided in the same line; last of all, the peritoneum is divided." This incision is an ideal one in the removal of a diseased appendix not complicated by suppurative periappendicitis. In the latter event the incision must be large enough to enable the surgeon to see what he is doing in order to avoid injuring important neighboring organs. It will be seen, from what has been said, that no fixed rules can be laid down and followed in regard to the size, location, and number of incisions to be made in opening the abdominal cavity for peritonitis. The surgeon must be guided by his own judgment and adopt plans and methods applicable to each individual case rather than follow, as is only too frequently done, a routine practice.

Eventration.—A number of surgeons favor eventration after incising the peritoneal cavity freely, for the purpose of effecting more thorough disinfection. In septic peritonitis the serous coat of the intestines is always damaged, and frequently the muscular coat is in a condition of paresis. The intestines are also usually very much distended. These conditions render them very liable to be injured and even ruptured when extensive eventration is made, to say nothing of the shock that always attends such a procedure, notwithstanding that the greatest care is exercised in protecting them with warm moist compresses.

Olshausen has called attention to the danger of eventration and prolonged exposure of the healthy intestines in abdominal

operations. He reported several cases in which adynamic ileus and death followed laparotomy that could be traced to no other cause. Gusserow recognizes the danger from these sources, and guards against them by retaining the intestines in the abdominal cavity with large flat sponges. If such baneful results follow eventration and exposure of healthy intestines, it is not difficult to conceive that the danger from the same source in laparotomy for peritonitis would be increased tenfold. The feeble circulation and the increased sensitiveness of the inflamed viscera in such cases would necessarily greatly increase the shock and aggravate the already existing intestinal paresis. If eventration is practised for the purpose of relieving the overdistended intestines, a limited part of the intestine should be brought forward in the wound. When prolapsed, the loop is incised or punctured, emptied of its contents, the visceral wound sutured, and the loop douched with hot saline solution, dried and returned. Extensive eventration is dangerous and must be scrupulously avoided.

Irrigation.—The subject of irrigation in the surgical treatment of peritonitis has been frequently discussed, but so far no positive final conclusions have been reached. Some surgeons invariably irrigate; others believe that irrigation does more harm than good, and are content to remove the inflammatory product by means of sponges. It is generally conceded that in diffuse peritonitis it is impossible, by any known methods of irrigation, to remove all the infectious material from the peritoneal cavity. In diffuse septic peritonitis the patients die from the effects of sepsis caused by the absorption of septic material from the peritoneal cavity, and the surgeon resorts to irrigation almost instinctively to diminish the danger from this source. The use of strong antiseptic solutions has been abolished, owing to the danger from intoxication resulting from the rapid absorption of the antiseptic employed and the damage that results from the irritating germicides when applied to the endothelial cells lining the peritoneal sac. Sterilized normal physiologic solution of salt, solutions of boric acid and acetate of aluminum, and Thiersch's solutions are now most frequently used in washing out the peritoneal cavity. Whatever medium is employed should be used at a temperature of from 110° to 115° F., and the stream should be sufficiently large and strong to wash out the most remote corners of the peritoneal cavity in the direction of the drainage opening or openings.

Reichel's experimental attempts to treat successfully septic peritonitis artificially produced in animals were almost entirely a failure. Irrigation of the peritoneal cavity with sublimate, chloroborate of soda, salicylic acid, etc., was useless—the animals quickly perished. Laparotomy performed for the purpose of cleansing the peritoneal cavity after the introduction of fecal matter, and prior to the development of peritonitis, according to Reichel, is not only useless, but, even in healthy animals, proved to be an injurious measure. Some-

what better results were obtained by gently sponging the peritoneal surfaces, after opening the abdominal cavity, with gauze sponges, and employing the Mikulicz gauze drain. In nine experimental cases in dogs two recoveries were obtained by this method. Reichel believes successful operative treatment is applicable only in cases of circumscribed empyema-like pus accumulations.

Delbet speaks more favorably of the results of irrigation of the peritoneal cavity in cases of general peritonitis from an experimental standpoint. He ascertained, by experiments on animals, that if the peritoneal cavity is irrigated for ten minutes with a physiologic solution of salt, toxic substances can be introduced without causing peritonitis or death from intoxication if the infection is followed by another irrigation with the same solution. He advocates the use of salt solution in operations on the abdominal cavity when contamination takes place during the operation and in the operative treatment of septic peritonitis.

Mr. Barker has found by experience that a very convenient method of flushing the abdominal cavity is to use a can with three taps, to which tubes of large caliber are attached, and thus the peritoneal cavity can be flushed from several points at once, the fluid flowing out through the original incisions. He uses fluids for flushing at 105° F.

Wiggin believes that the use of peroxid of hydrogen, followed by plenty of normal salt solution, is most beneficial in disinfecting the peritoneal cavity and in preventing adhesions. He claims that many otherwise successful laparotomies are followed by such extensive and painful adhesions that the patients are left in a worse state than before operation, and the observance of this simple rule would avoid so disagreeable a result. Continuous irrigation, so useful in the treatment of septic wounds in other localities, has been suggested in the treatment of general peritonitis. In 1894 Oscar Allis recommended in the treatment of general septic peritonitis, abdominal section, liberation of pus from all pockets by tearing adhesions, continuous irrigation, the local application of cerate to the walls of the suppurating cavities, the prone position, and to keep the wound open by tucking a rubber dam covered with cerate between the abdominal wall and the intestines on each side, with one border emerging from the incision. He believes that under a continuous system of flushing or irrigation the wash products would be made to float constantly to the surface, and be more effectually carried off than by dependent dorsal drainage. The peritoneal cavity can not be flushed continuously for any length of time, as adhesions will soon form around the drainage-tubes and between the intestinal coils.

In acute septic peritonitis, however, continuous irrigation deserves a fair trial, and its therapeutic value has recently been emphasized by the brilliant results of Laplace. The fluid to be used should be introduced into the lowest portion of the abdominal cavity

through a nonfenestrated rubber tube, and seek escape through the rubber tubes above the umbilicus and in the lumbar regions.

The propriety of tearing up adhesions for the purpose of making the irrigation more thorough is very questionable, and, as a rule, should be avoided. The so-called toilet by using sponges must be done with the utmost gentleness, if resorted to at all, as all mechanical insults inflicted on the endothelial surface are sure to aggravate the existing conditions. If it is intended to remove the fluid from the peritoneal cavity, it is better to do so by placing the patient on the side, so as to pour it out instead of removing it by mopping. If no irrigation is employed and the peritoneal cavity contains a transudate of serum or pus, the fluid should be disposed of in the same way, after which the more thorough cleansing can be effected by the gentle use of a soft sea-sponge.

Incision of Overdistended Intestine.—One of the most unfavorable conditions in peritonitis is overdistention of the intestines with gas and septic fluid material. A paretic inflamed intestine is permeable to pathogenic microbes, thus adding another fruitful source of infection to the existing septic inflammation. Death from peritonitis is the result more of rapid intoxication than of the inflammation itself. The inflammation of the visceral peritoneum of the intestines leads to paralysis of the muscular coat, rapid distention, and the escape of preformed toxins and bacteria. Boennecken's experiments have shown that the latter occurs in a remarkably short time. It is natural that surgeons should have made attempts to remove distention and unload the intestines of septic material by tapping or by making one or more visceral incisions.

Mixter advises this procedure in grave cases of general peritonitis. He recommends incision of the coils of the paretic intestines at as many points as may be necessary thoroughly to evacuate them. The intestine should be drawn out of the wound, held over a basin, incised in from one to four places, and thoroughly emptied, after which the coils should be quickly washed off with a hot saline solution, the visceral wounds sutured, the intestine returned, and the abdominal incision closed. Mixter has resorted to this procedure in nearly twenty cases, some of which recovered, and in those that died the visceral wounds were found to be tight. In some cases, particularly in those that have had an abdominal incision on the right side, I secure permanent drainage by introducing a tube into the most prominent part of the cecum and retain it as long as necessary. Through this tube the medicines and nourishment may be introduced if the stomach is not retentive. In a paper read before the Royal Medical and Surgical Society, Mr. C. B. Lockwood advocated puncture and incision of the paretic intestine in cases of diffuse septic peritonitis treated by abdominal section. Incision of the intestine for the purpose of relieving distention and evacuating septic contents was favored by Hulke, Knowsley Thornton, and Barker. In the few cases in which McCosh incised the intestine he noticed

that it did not relieve the distention for a distance of more than ten or twelve inches.

I have made visceral incisions in a number of cases in which the intestine had become paretic, and although but one of the cases recovered, I am fairly convinced that it is almost essential to success in such desperate cases. I am in the habit of placing the patient on the side and bringing the most distended part of the intestine well forward into the wound, and making a transverse incision about an inch in length opposite the mesenteric attachment. As the intestinal wall does not contract, evacuation should be secured by pouring out the contents from above and below the incision by grasping the intestine some distance from the incision and bringing it above the level of the visceral incision. By this method several feet of intestine can be evacuated through one incision. After thorough cleansing of the exposed intestinal surface with warm salt solution, the wound is sutured in the usual manner and the intestine returned. If more than one incision is made, it is not difficult to conceive that irrigation of the intestinal tract between them with a warm normal solution of salt would secure a more thorough cleansing of that part of the intestinal tract and would be a potent means of restoring intestinal peristalsis.

Drainage.—Drainage of the abdominal cavity after operations for peritonitis is an admission of the present imperfect state of surgery. It is an acknowledgment on the part of the surgeon that he has only in part fulfilled the indications for which the operation was performed; it is a confession that he was not able to accomplish what was so much needed and what he so earnestly desired—complete asepsis of the entire peritoneal cavity. With the means at our disposal at the present time drainage in the surgical treatment of peritonitis is an unavoidable evil. The question that confronts us now is not when, but how, to drain in such cases. In 1870, during the Franco-Prussian war, Marion Sims made a special study of the cause of death in cases of gunshot wounds of the abdomen. The result of his observations led him to the conclusion that, independently of shock and hemorrhage, death resulted from sepsis. He found that with few exceptions, if the bullet entered above the pelvis, the case was fatal, while similar wounds of the pelvic portion of the abdominal cavity ended in recovery. He ascribed this difference in the mortality to the circumstance that high wounds resulted in extravasation of intestinal contents which accumulated in the pelvic cavity, while in pelvic wounds the track made by the bullet served as a drainage canal. In 1872 he recommended that in all penetrating wounds of the abdomen and in operations on any of its contents drainage should be established. In ovariotomy he recommended tubular drainage through the wound and vagina, using for this purpose a large rubber drain. Very few surgeons at the present day would feel justified in opening the abdominal cavity for peritonitis and dispensing with drainage. Voices have, however, been raised

against too frequent resort to drainage, among them that of Olshausen, who says: "Drainage of the peritoneal cavity is an illusion. Drainage to be of service must be limited to the evacuation of preformed pathologic spaces."

Removal of fluid pathologic products by gentle sponging accomplishes the same object. The absorptive power of the peritoneum should be preserved as much as possible by handling with the utmost gentleness. Prolonged and rough manipulation of the intestines is productive of great shock. Drainage is always attended by the danger of putrefaction bacilli entering into the peritoneal cavity. In perforating wounds he recommends a careful cleansing, complete hemostasis, avoiding drainage in all recent cases.

Barker has largely dispensed with drainage of the abdominal cavity for suppurative lesions. He relies mainly on thorough flushing, and sutures the abdominal incision. He resorts to drainage only in the treatment of putrid abscesses caused by appendicitis. If a drain is used in exceptional cases of peritonitis, he advises its removal at the expiration of twenty-four hours.

The difficulties encountered in draining the peritoneal cavity become very apparent in following the work of Bardenheuer. He describes four methods in operation on the abdominal and pelvic cavities of women. The first method is by a T-shaped tubular drain, of which only the transverse piece is fenestrated and the vertical portion brought out behind the uterus into the vagina. The second method consisted in using two transverse drains instead of one, fastened together, of which the four ends were sutured to the pelvic floor with catgut. The third method had in view the prevention of prolapse of the intestines by using a fenestrated rubber plate above the drains, which was sutured to the pelvic peritoneum. This method proved useful for the first four to six days; after this time putrefaction of the contents of the cavity invariably set in. The subsequent removal of the plate through the vagina also proved troublesome and often deleterious. The last method consisted in the use of a catgut net with meshes six centimeters wide, sewed to the pelvic floor above the two rubber drains. The pelvic peritoneum was always united to the vaginal mucous membrane by suture. This method proved eminently satisfactory, but it is doubtful if it still remains in use in his practice; certainly it has never been generally adopted.

Methods of Drainage.—At present there are three methods of drainage in general use: (1) Tubular drainage; (2) capillary drainage; (3) a combination of tubular and capillary drainage. All these methods have their advocates and are applicable under certain circumstances. No one method of drainage will answer in all cases.

Tubular drainage: Tubular drainage is specially indicated in cases in which the abdominal cavity contains pus. The tubes employed are made of either glass or soft rubber. Keith's glass drains

answer an excellent purpose in draining the lowest portion of the abdominal cavity. They should be slightly curved at the abdominal end, so as to reach the floor of the pelvic cavity without making harmful pressure against the bladder. Frequent aspiration of the contents of the drain is necessary for the purpose of removing the fluid inflammatory product as soon as it is formed. The rubber drain answers the same purpose, but is properly accused of causing more mechanical irritation than the smooth glass tube. Prolonged tubular drainage has not infrequently caused intestinal fistula by pressure. It is for this reason that I almost invariably surround the rubber or glass tube with a few layers of iodoform gauze securely fastened to the tube. In draining the pelvic portion of the abdominal cavity I frequently use two drains the size of the little finger, one on each side, brought out through the same opening in the lower angle of the wound. In draining in the lumbar regions and through the vagina rubber drains should be employed.

Capillary drainage: Capillary drains are frequently employed as substitutes for the tubular drains, and in addition must often be relied upon as an important hemostatic resource in arresting parenchymatous oozing. Iodoform or sterilized gauze is usually employed as a capillary drain in draining the abdominal cavity for peritonitis. Bardenheuer first resorted to strips of iodoform gauze in draining the peritoneal cavity. The greatest objections to this method of drainage are the danger from iodoform poisoning if a considerable quantity of gauze is used, the difficulty of removing the gauze, and the likelihood of a ventral hernia as a legacy.

The name of Mikulicz is connected with a special method of gauze drainage of his own device, familiarly known as the Mikulicz iodoform gauze tampon or drain, which has proved of the greatest value in abdominal operations and in the surgical treatment of peritonitis. The typical Mikulicz tampon is made by taking a piece of iodoform gauze the size of a large handkerchief, to the center of which a strong piece of aseptic silk thread is stitched. When used, it is arranged as a pouch and is carried by means of a curved forceps to the bottom of the pelvis, and filled with strips of iodoform gauze, the free end of the silk thread issuing from the mouth of the pouch. When it is desired to remove the drain, the gauze strips are removed and the pouch removed by making traction upon the string. Mikulicz speaks of an iodoform gauze drain, and any surgeon who has had considerable experience in abdominal surgery can testify to the fact than when the Mikulicz drain is called for we are frequently dealing with large cavities requiring an enormous amount of gauze. It is in such cases that we must learn to fear iodoform gauze, because the cases are by no means isolated in which a gauze drain composed exclusively of iodoform gauze has been the immediate cause of death from iodoform intoxication. This is particularly liable to occur in cases in which the patient's kidneys are not functionating properly or are diseased. It is in

dealing with this class of cases that the elimination of iodoform is accomplished with great difficulty, and hence when accumulation occurs, death is liable to follow from intoxication. Again, there are persons who are extremely susceptible to the local and general toxic effects of iodoform. A very small quantity of this substance may prove fatal from intoxication. It is, therefore, advisable, in using the Mikulicz drain, to limit the iodoform gauze to an outer layer or two and pack the pouch with ordinary sterilized gauze. Drainage by using sterilized wicking has been popular in Germany for a number of years, and in many cases has answered an excellent purpose. It has never found its way to any extent into America, where gauze is employed in preference.

A most excellent method of securing capillary drainage has been described by R. T. Morris. To avoid the danger of hard and soft tubes and of unprotected gauze, he recommends wicks, which he employs in a peculiar way. The simplest wick consists of a little roll of absorbent bichlorid gauze, around which are wrapped a couple of thicknesses of Lister's protective silk. The gauze protrudes a little from each end of the cylinder, and a few small fenestræ in the protective silk allow the serum to reach the gauze elsewhere. In certain cases where injections through a tube are desirable, the soft tube can be surrounded by this wick. When a large gauze packing for the pelvis or abdomen is needed, an apron of the silk can expand over the gauze and protect against intestinal adhesions. This method of drainage possesses great advantages over ordinary tubular and capillary drainage as heretofore described, and recommends itself more especially in the surgical treatment of diffuse septic peritonitis. The prolonged contact of gauze with a serous surface is very prone to give rise to permanent adhesions, as every clinician knows. In employing gauze in draining the peritoneal cavity it is necessary to use long strips, which should be inserted some distance in different directions and brought out at the same place and fastened together with a safety-pin. Van Hook has shown by his experiments that the gauze drains more freely if the external ends of the strips are left long and placed on the side of the pelvis below the level of the wound.

Drainage must be dispensed with as soon as possible, in order to prevent adhesions and to enable the surgeon to close the incision by secondary suturing, an important precaution against the formation of a ventral hernia. The strips should be shortened, and one after the other removed as the indications for drainage disappear.

Combined tubular and capillary drainage: The simultaneous use of a tubular and capillary drain is an excellent method of securing drainage. It is made by packing loosely a glass drain of proper length and size with strips of gauze or aseptic wicking. This manner of drainage is especially useful when the inflammatory product is serum instead of pus. It does away with the annoyance and risks of removing the transudate at frequent intervals, as is neces-

sary in the employment of simple tubular drainage. If it is the design of the surgeon to resort to frequent irrigation after the operation, tubular drainage is necessary, but to this can be added capillary drainage by inserting strips of gauze into localities that would not be reached by the irrigating fluid.

Intra-intestinal Saline Injections.—The value of saline cathartics in the treatment of peritonitis in its early stages not caused by perforation and after operations for peritonitis is now generally recognized. One of the difficulties encountered in the treatment of such cases is the intolerance of the stomach to food and medicines. A. J. McCosh has succeeded in securing free catharsis and in overcoming the intestinal paresis after operations for peritonitis by injecting into the intestine saline cathartics in concentrated solution. He claims that since he has resorted to this additional procedure his results have been greatly improved. Sulphate of magnesia is injected, through a hollow needle attached to a large aspirating syringe, into the small intestine, at a point in the jejunum or in the ileum as high up as possible. A saturated solution containing from one to two ounces of the salt is used. The needle puncture is closed by a Lembert suture. This suggestion certainly appears rational and should receive a fair trial by the profession.

After-treatment.—In all cases of general septic peritonitis subjected to operative treatment the most attentive and careful after-treatment is essential to success. All such patients are prostrated from the effects of the disease and the immediate effects of the operation and require a stimulating treatment. External dry heat is an important element in counteracting the direct effects of the shock caused by the operation and in restoring the peripheral circulation. The distressing thirst is quenched most effectually by the administration of water by subcutaneous infusion or rectal enemata. Strychnin and alcoholic stimulants are best calculated to increase the force of the heart's action and the tone of the arterial circulation. Partial inversion of the body by raising the foot of the bed and autotransfusion are potent means of inducing cardiac stimulation. A well-fitting abdominal bandage applied firmly exerts a favorable influence in preventing and diminishing abdominal distention. As long as nausea and vomiting persist, main reliance must be placed on rectal feeding. Saline cathartics should be administered as soon as the stomach is in a condition to absorb them. Meteorism can often be relieved by high turpentine enemata and the use of the elastic rectal tube.

A number of cases have recently been reported in which the serum appears to have been of great value in the treatment of septic conditions in the peritoneal cavity and elsewhere. It is not probable that the serum treatment will ever displace the knife treatment of diffuse general septic peritonitis. Marmorek's antistreptococcic serum has proved a failure in the treatment of septic peritonitis. Opium should be used with great caution in the after-treatment, as it is liable to cause intestinal paresis and thus increase the danger

from autointoxication. If the peritoneal cavity has been drained with gauze, the external dressing should be changed as soon as it has become saturated. The same course of treatment is to be pursued if the combined tubular and capillary drain has been used. In cases in which tubular drainage has been established, the surgeon usually intends to follow the operation by continuous or periodic irrigation. If continuous irrigation is decided on, the normal salt solution is the one usually employed. The solution should be used at a temperature of 105° F.; the current should be small and without much force. The outflow from the peritoneal cavity should be received upon a rubber blanket, and the necessary provision made to conduct it into a receptacle near the patient's bed. This method of irrigation recommends itself particularly in cases of diffuse septic peritonitis. In suppurative diffuse peritonitis periodic flushings, repeated at intervals of two or three hours, will prove of value in removing from the peritoneal cavity the fluid products of the inflammatory process. The solutions best adapted for this purpose are a saturated solution of the acetate of aluminum, a 3 to 5 per cent. solution of boric acid, or Thiersch's solution. Between the flushings the wound and the openings of the drains are covered with the usual hygroscopic aseptic dressings to receive the discharge and to prevent secondary mixed infection with putrefactive bacilli. Drainage, when once established, should be suspended gradually and not suddenly. As soon as the peritoneal cavity and the drain canals are aseptic, the external wound should be sutured to prevent, as far as possible, the subsequent formation of a ventral hernia.

3. Perforative Peritonitis.—Perforation of the abdominal wall or of any of the abdominal organs containing septic material may give rise to general or circumscribed peritonitis; large visceral perforations usually result in general septic peritonitis; small perforations are preceded by visceral adhesions that limit the extension of the infection and inflammation and end in circumscribed peritonitis. Perforative peritonitis invariably occurs as a secondary affection, usually in connection with an ulcerative or gangrenous lesion of any part of the gastro-intestinal canal. Perforating ulcer of the stomach, duodenum, or typhoid or tubercular ulcers of the ileum, perforation or sloughing of the appendix vermiformis, the different forms of intestinal obstruction, are the most frequent causes of this well-defined clinical form of peritonitis. Penetrating wounds of the abdomen with visceral injury of the gastro-intestinal canal must be regarded in the same light as perforative lesions of the abdominal organs in the causation of peritonitis, and should hence be classified under this head from a bacteriologic as well as anatomicopathologic standpoint. Perforative peritonitis is manifested by the sudden onset of the disease, by diffuse pain and tenderness, rigid abdominal walls, fever, vomiting, the impossibility by inspection, palpation, and auscultation to ascertain intestinal peristalsis, this condition being almost positive proof of intestinal paresis or the presence of gas in the free peritoneal cavity.

According to my observations, peritoneal meteorism in perforative peritonitis caused by appendicitis is rare, while I have seldom found it absent in perforations of any other portion of the gastro-intestinal canal. According to the number and virulence of the microbes that find their way into the peritoneal cavity with the extravasation, the resulting peritonitis is either diffuse or more or less circumscribed. The colon bacillus is invariably present in the inflammatory product, but in addition streptococci, staphylococci, putrefactive bacilli, the typhoid bacillus, or the bacillus of tuberculosis, according to the nature of the primary affection, may also be found.

Perforative peritonitis must be regarded and treated as a strictly surgical disease. The primary lesion must be exposed and treated as soon as a diagnosis can be made and the necessary measures applied to limit the extension of the infection and to prevent death from toxemia. The perforation should be found and properly treated before a general septic peritonitis has had time to develop. There are exceptions to this rule in cases where the perforation is small and the extravasation has produced a limited peritonitis in a locality where it is safe to wait for abscess formation, as is often the case in the region of the gall-bladder and appendix vermiformis. Penetrating wounds of the abdomen with visceral lesions of sufficient extent to give rise to extravasation should be subjected at once to treatment by laparotomy. If at the time the operation is performed peritonitis has set in, this must receive proper attention after the visceral wounds have received the necessary treatment.

Perforating Gastric Ulcer.—Perforating ulcer of the stomach is found most frequently on the anterior wall of the stomach, near the small curvature. According to Brinton, in 85 per cent. of all cases the anterior wall of the stomach is the seat of the perforation. Perforation in this locality is followed more constantly by diffuse peritonitis than if the posterior wall is the seat of ulceration and perforation. In 75 cases of perforating ulceration of the anterior wall of the stomach collected by Eichhorst, in 64 the perforation was complete, whereas in 30 cases at the cardiac extremity escape of contents into the peritoneal cavity occurred but 12 times. When perforation of the ulcer into the free peritoneal cavity takes place, the onset of the disease is always sudden, no matter what the antecedent symptoms may have been. Shock is present in greater or less degree. Vomiting, though frequent, is not constant. Abdominal pain and tenderness increased by pressure are nearly always present; abdominal rigidity in the early stage, and distention later on, are frequently noted. The duration of the cases varies from a few hours to five days, most of them terminating in death in less than twenty-four hours.

Treatment.—Mikulicz performed the first operation for this condition in 1883. The first successful case was reported by Kriege, of Berlin. The incision should be made in the median line, from the ensiform cartilage to the umbilicus, and enlarged if necessary. A long incision is required if the operation is performed after peritonitis

has developed. In such cases suprapubic and epiumbilical drainage is required after suturing of the perforation, and free flushing of the abdominal cavity is indicated. If the posterior wall is perforated and the perforation can not be reached in the usual manner, the anterior wall should be incised and the perforation closed through the incision, after which the incision is sutured and the peritoneal cavity cleansed and the external wound closed if the peritoneal cavity has not become infected. Before suturing the perforation the stomach should be emptied through a stomach-tube or through the opening before suturing the perforation. It is not necessary to excise the margins of the ulcer, as these can be inverted in tying the Lembert sutures. Should the wall of the stomach in the immediate vicinity of the ulcer present an unfavorable condition for successful suturing, an omental flap or graft of requisite size should be sewed with catgut over the line of suturing.

E. W. Andrews treats the gastric ulcer by incision of the wall of the stomach in the direction of its lumen, and applying a ligature at the base of the cone, which answers as an excellent substitute for sutures and greatly simplifies and shortens the operation.

Barling operates after the symptoms of shock have subsided. According to his experience, the prognosis is best if the operation is performed as soon as possible after the accident has occurred. In nine successful cases collected by this author, the operation was made on an average seven and three-fourth hours after the perforation occurred; shortest interval three hours, longest ten hours. In fifteen cases that died the average time was twenty-seven hours; the shortest interval four, the longest seventy, hours. Perforation of the posterior wall of the stomach frequently gives rise to a subdiaphragmatic abscess, and when the disease resulting from the perforation has reached this stage, it must be treated in accordance with the rules that will be laid down in discussing this subject later on.

Perforating Ulcer of the Duodenum.—Much that has been said concerning perforating ulcer of the stomach applies to the same pathologic condition of the duodenum. The perforation occurs suddenly and frequently without any marked premonitory symptoms indicative of the existence of the primary disease. The direction in which the extravasation takes place depends on the location of the ulcer. Perforation into the free peritoneal cavity before any adhesions have taken place results in diffuse and rapidly fatal peritonitis. If perforation takes place into the lesser peritoneal cavity, circumscribed suppurative peritonitis ensues, which occasionally terminates in the formation of a subdiaphragmatic abscess.

Treatment.—It is only recently that peritonitis resulting from this cause has been subjected to operative treatment. Percy Dean, in 1894, performed the first successful operation. Greig Smith advises incision over the seat of perforation—that is, if the condition is suspected. If we follow this rule, the incision will be above the umbilicus and through the right rectus muscle. The ulcer is usually

in the first part, but may be in either of the other two portions. In order to expose the lesser peritoneal cavity we must split the gastro-colic omentum in part. The ulcer is simply inverted, excision being unnecessary. Drainage must always be provided for.

Perforating Typhoid Ulcer.—Perforation of a typhoid ulcer large enough for extravasation to take place into the free peritoneal cavity is a fatal accident, death ensuing in the course of a day or two. Perforation, however, does not always terminate in that way. Extravasation is often prevented by the affected part of the intestinal wall becoming attached to an adjoining serous surface, thus protecting the peritoneal cavity against infection. I have seen several cases of typhoid fever in which, about the time that perforation is most likely to occur, circumscribed peritonitis set in, which could have been caused only by a perforating ulcer, but under such favorable conditions that the patients recovered without operative intervention.

Treatment and Results.—Kussmaul was the first to perform laparotomy, excise, and suture a perforating typhoid ulcer. The operation was performed October, 1885. Luecke reports a case in which he performed laparotomy for the same indication October 22, 1885. A large perforation was found, excised, and the edges sutured. The abdominal cavity was washed out with salicylated water, the wound sutured, except a space left for a large tubular drain. The patient died in seven hours. A pint of fluid with a fecal odor was found in the pelvic cavity. Luecke, in connection with the report of this case, suggested the performance of the operation in two stages, the perforated intestine to be fastened to the abdominal wall in the wound in the first, and the direct treatment of the perforation later. In the following three years the operation was performed by Bontecou, Bartlett, and T. G. Morton with no recoveries. Van Hook reports 3 cases treated by laparotomy and suturing of the perforation, of which 1 recovered. He collected 19 cases, of which 4 recovered. He places the line of sutures parallel to the long axis of the bowel, and flushes the peritoneal cavity with a thick stream of sterilized salt solution at a temperature of from 105° to 112° F.

Wiggin collected 24 cases of perforating typhoid ulcer subjected to laparotomy, with 6 recoveries. If those cases are rejected in which the diagnosis is somewhat doubtful, there are 17 patients with 3 recoveries. The first successful result was obtained by Van Hook, the second by Netschajans, the third by Abbe. J. Price has recently reported 3 consecutive operations with as many recoveries, a surgical feat which it will be difficult to duplicate. I have performed the operation 3 times with 1 recovery. The feasibility and justifiability of abdominal section for perforating typhoid ulcer have been established, in view of the fact that all the patients who have been operated on would have died without the operation. The operation should be performed as soon as possible after the accident has occurred. The mortality will always remain great, owing to the debilitated condition of the patients and the existence of multiple ulcers.

The incision is made through the median line, between umbilicus and pubes, and at least large enough to insert a hand. The first point to be sought for is the ileocecal region, when search is made for the perforation in an upward direction, replacing the part of the bowel examined so as to prevent extensive eventration. Excision of the ulcer is unnecessary, as its margins can be inverted by the Lembert stitches, which should be placed transversely and not in the long axis of the bowel, as advised by Van Hook. Should the serous surface over any other ulcer present indications of an approaching perforation, it should be covered with an omental flap or graft fastened in place with a few points of catgut suture. Flushing of the abdominal cavity with a warm physiologic solution of salt, followed with Thiersch's solution and free drainage, is strongly indicated and should invariably be carried out. If the patient is much prostrated, Luecke's suggestion to perform the operation in two stages should receive serious consideration. If the perforation has resulted in circumscribed suppurative peritonitis, incision and drainage of the abscess cavity are indicated, leaving the perforation to heal spontaneously or to be closed by a subsequent operation.

4. Circumscribed Peritonitis.—A circumscribed peritonitis is an inflammation of the peritoneum during which a greater or lesser part of the peritoneal cavity becomes excluded from the original source of infection by the formation of plastic visceral, parietal, or visceral and parietal adhesions. The complexus of symptoms varies according to the degree of virulence of the microbic cause, which only occasionally is overshadowed by the primary affection. The symptoms appear suddenly, or are preceded by those incident to the primary disease. The severity of the pain and the extent of muscular rigidity and tenderness will correspond with the extent of the disease. The intensity of the general symptoms is determined more by the nature and virulence of the microbic cause than by the area of the peritoneal surface involved. The inflammatory focus may be limited to a very small space, or it may involve the greater portion of the peritoneal cavity and organs which it contains. The clinical course and termination are determined largely by the nature of the bacterial cause, the anatomic location of the primary starting-point, and nature of the environment. Localized peritonitis is most likely to occur outside of the limits of the small intestine area. If the organs adjacent to the primary focus of infection are favorably located for limitation of the process, diffusion is frequently prevented by the formation of adhesions. This is especially true in cases where the primary infection is limited by the existence of old adhesions. Localized peritonitis may be confined to the lesser omental cavity, particularly in cases of perforating ulcer of the stomach and the duodenum. More frequently it is caused by appendicitis and cecitis. A very frequent cause of circumscribed peritonitis is inflammation about the gall-bladder, uterus, Fallopian tubes, or ovaries. The localized form of peritonitis is very often overlooked during life. It can usually be detected

only if a demonstrable swelling forms at the seat of inflammation. The mildest form of infection gives rise to fibrinoplastic peritonitis, which leaves temporary or permanent adhesions, but terminates without suppuration. Circumscribed suppurative inflammation is always attended by fibrinoplastic peritonitis, the products of which and the viscera which it involves form the abscess wall. The microbes that most frequently produce fibrinoplastic peritonitis without suppuration are the gonococcus and the staphylococci. Circumscribed suppurative peritonitis is usually the result of infection with staphylococci, bacillus coli communis, or pneumococci. In fibrinoplastic peritonitis surgical interference becomes necessary only when intestinal obstruction is caused by adhesions. In circumscribed suppurative peritonitis the pus should be evacuated as soon as the disease is recognized, and, if possible, by an extraperitoneal route.

Acute Tubercular Peritonitis.—Tubercular peritonitis, met with in the majority of cases in the circumscribed form, occasionally presents itself as a widely diffused acute affection. The rapid diffusion in the peritoneal cavity, through either the circulation or by rupture of a tubercular abscess or intestinal tubercular ulcer into the peritoneal cavity, or by extension from a tubercular salpingitis, occasionally gives rise to a form of acute peritonitis, characterized as such in a modified way by the clinical manifestations that accompany it. According to the intensity of the infection or the degree of susceptibility of the patient to the action of the tubercle bacillus, the disease assumes one of the following pathologic forms: (1) Tubercular ascites; (2) fibrinoplastic peritonitis; (3) adhesive peritonitis. Suppuration takes place only when the tubercular product becomes the seat of a secondary mixed infection with pus-microbes. Laparotomy is now a well-established operation in tubercular peritonitis. The exact manner in which the operation exerts its therapeutic influence is not well understood.

Nannotti and Baciocchi studied the curative effect of incision and drainage for peritoneal tuberculosis experimentally produced on rabbits and dogs. The operation yielded only temporary improvement in rabbits, but usually resulted in a permanent cure in dogs. They found, soon after the operation, a decided local reaction in the periphery of the tubercle nodules, an increased phagocytosis, which in dogs brought about absorption of the tubercular product and formation of new connective tissue. Irrigation of the peritoneal cavity did not appear to add to the therapeutic effect of the operation. According to these investigators, the curative influence of the operation is to be attributed to the local reaction that it induces, and also to the fact that it increases the absorptive power of the peritoneum. I have obtained very satisfactory results in cases that resisted laparotomy and drainage, by repeated tappings and injections of from two to four drams of a 10 per cent. iodoform glycerin emulsion.

Suppurative Peritonitis.—Suppurative peritonitis—*i. e.*, an inflammation of the peritoneum that results in the formation of pus—

is always more or less circumscribed. This form of peritonitis is most frequent and is generally associated with fibrinoplastic exudation. The pus is serous, seropurulent, or may reach the consistence of cream, when it is usually of a yellow color. The accumulation of pus may be so large that upon opening the abdomen it may appear as though the entire peritoneal cavity and all the organs contained within were implicated, but a careful examination will almost always reveal the fact that a large part of the peritoneal cavity and many of the organs are shut out from the inflammatory process by plastic adhesions. Suppurative peritonitis must therefore be regarded from a practical standpoint as a circumscribed inflammation. The appearance and character of the pus are often greatly modified by the admixture of an extravasation accompanying the perforative lesion that produced the peritonitis. If the pus is thin and serous, we speak of a seropurulent peritonitis—it is a serous peritonitis with the formation of pus in sufficient quantity to render the serum more or less turbid. This subvariety of suppurative peritonitis is without exception in combination with fibrinous exudations that tend to limit the extension of the infective process. Sedimentation of the solid constituents takes place, so that the fluid contains more of the solid matter in the most dependent portion of the affected district.

Fibrinoplastic Peritonitis.—A very frequent form of circumscribed peritonitis is the one in which the inflammatory exudate is composed largely of fibrin—fibrinoplastic peritonitis. It is usually a secondary process following a primary affection of one of the abdominal or pelvic organs, and denotes a mild form of infection, the extension of which becomes limited by firm adhesions. The inflammation results in plastic exudation with little or no effusion. The character of the exudate depends on the intensity and quality of the bacterial cause. The exudation is often so copious that it has been mistaken for malignant disease. The distinguishing features of this form of peritonitis from abdominal tumor are less circumscribed outline, the lesser resistance offered, the more regular surface, and the fact that ascitic fluid is not bloody, but serous or seropurulent. The exudation in the course of time contracts and results in strong bands of adhesion that frequently flex and distort the organs to which they are attached, thus giving rise to another term, *peritonitis deformans*.

Treatment.—The surgical treatment of circumscribed peritonitis by abdominal section has yielded very encouraging results. In many of these cases the surgeon is able to reach the abscess and gain access to the primary lesion without invading the peritoneal cavity. In such instances the operation is an *oncotomy*, and should be distinguished from the operation in which the free peritoneal cavity must be invaded to reach the pus cavity, which is then an *abdominal section* in the sense in which this expression is used in surgical language. The extraperitoneal route is the operation of choice in all cases in which the abscess cavity can be safely reached and efficiently drained by this method. In circumscribed accumulations of pus in the peritoneal

cavity, in which the seat of the disease must be reached through the free abdominal cavity, the safest course to pursue is to perform the operation in two stages. The first operation then consists in suturing the parietal peritoneum to the wall of the abscess cavity, suturing the abdominal incision, with the exception of a space large enough to incise and drain the abscess cavity later. This space is packed with iodoform gauze, and two or three days later the abscess is incised and drained. If the symptoms are urgent and the operation must be completed, the contents of the abscess cavity should be removed by aspiration, after which the suturing can be more thoroughly done, when the abscess can be incised and drained with less risk of infecting the peritoneal cavity than without preliminary evacuation by the use of the aspirator. These methods of treatment are especially applicable for single pus cavities. If the disease is more diffuse, involving a number of abdominal organs, and the abdominal incision reaches at once the infected territory, pus, wherever found, must be removed by flushing or by mopping with a soft sponge. In fibrinoplastic peritonitis without suppuration no attempt should be made to tear the adhesions unless they have caused intestinal obstruction, when the new surfaces are dusted with aristol, which, as has been shown by the experiments and clinical observations of R. T. Morris, is the most efficient way to prevent recurrence of the adhesions.

Witzel admits that in cases of peritoneal sepsis, the most acute and gravest form of infection, surgical treatment is of no avail. In general and circumscribed suppurative peritonitis operative treatment is indicated. Eventration and removal of the pus with sponges are not permissible, as animals thus treated invariably died. Experiments on animals as well as clinical observation satisfied Witzel that multiple incisions, drainage, and irrigation with salt solution proved successful in thoroughly cleansing the peritoneal cavity without causing shock.

Mikulicz advises that in progressive fibropurulent peritonitis the adhesions should not be disturbed, and each abscess should be evacuated separately in order to prevent fresh infection from the liberated contents of these encapsulated foci of infection. In one case six intraperitoneal abscesses were evacuated, through as many incisions, at four consecutive operations. The diagnostic indications of such abscesses are increased resistance, tenderness, dullness, and elevated temperature. In cases of doubt an exploratory puncture should be made. The abscess cavities should be drained with iodoform gauze. Some surgeons pursue a more aggressive course and are not content in removing the fluid pathologic product, but aim to remove at the same time the fibrinous exudate. At the meeting of the French Surgical Congress Demons made a strong plea in favor of early operative intervention and the removal of fibrinous deposits. In 1883 he had under his care a woman suffering from suppurative peritonitis following suppuration of an ovarian cyst.

Her condition at the time of operation was critical. He opened the abdomen, evacuated the pus, removed the cyst, and with a rough sponge and blade of a knife scraped the entire surface of the intestine; a most satisfactory recovery followed. He deemed it advisable to scrape the inflamed surfaces, as being more efficacious and affording less risk of missing portions of the exudates. In a similar case he assisted Denucé in performing this radical method of cleansing, and the patient rapidly recovered. There are few surgeons who would to-day follow his example. Adhesions tend to limit the infective process, and should be interfered with as little as possible in the search and liberation of pus.

Körte saved six out of nineteen cases of acute general suppurative peritonitis treated by abdominal section. All cases without adhesions and peritoneal sepsis died, also all cases operated upon after the fourth day. He cautions not to separate adhesions, and is content to evacuate the pus and to establish drainage. The closure of perforations should not be attempted unless it can be done without additional risk.

5. Hematogenous Peritonitis. — The existence of primary peritonitis without an antecedent intra-abdominal direct source of infection is looked upon with suspicion by most modern pathologists and surgeons. Idiopathic peritonitis, so called, or hematogenous peritonitis, does occur, but is much more rare than similar affections of the pleura and pericardium. As a primary affection, peritonitis is found most frequently in females during or soon after menstruation. It is probable that the pyogenic bacteria multiply in the blood which accumulates in the uterus, and reach the peritoneal cavity through the Fallopian tubes. As peritonitis is always caused by bacteria of some kind, a peritonitis that develops independently of a local source of infection is the result of an infection through the blood, and should be called hematogenous or metastatic peritonitis. It has been observed in connection with nephritis, pyemia, rheumatic arthritis, and acute exanthematous diseases. In the absence of even a distant focus of infection it is plausible to assume that peritonitis in very rare cases is caused by the localization of pus-microbes derived from the circulating blood in some part of the peritoneum prepared for their reception and growth by some antecedent disease or injury. In primary peritonitis the disease is not preceded by any symptoms that would suggest the existence of an antecedent disease or injury. Hematogenous peritonitis assumes different pathologic types, resembling in this respect peritonitis produced by direct local causes.

Treatment.—The surgical treatment must be guided by the location and extent of the disease, the existence or absence of complications, and the pathologic type the disease presents at the time of operation. The absence of primary visceral disease of any of the abdominal organs is a favorable item in the prognosis and in the technic of the operation to be performed in the surgical treatment of this form of peritonitis.

6. Visceral Peritonitis.—A localized peritonitis that can be brought into direct etiologic connection with the organ primarily affected is expressed by a compound word, with the prefix *peri-* and the noun used to indicate the organ primarily affected in a state of inflammation. The inflammatory process is seldom limited to a single organ, as during the course of the disease adjacent organs or the parietal peritoneum will surely become involved. The nomenclature of visceral peritonitis is a lengthy one, as it includes all the abdominal and pelvic organs from which, when the seat of a suppurative inflammation, may come the primary starting-point of an attack of localized or diffuse peritonitis. The mesentery and omentum are modified forms of the peritoneum, and when the seat of inflammation, we speak of a mesenteritis and epiploitis. In inflammatory and traumatic affections of the abdominal walls and the abdominal and pelvic viscera, plastic inflammation of the omentum frequently constitutes the safeguard against infection of the general peritoneal cavity by firmly attaching the omentum over a threatened perforation or visceral or parietal wound, thus affording protection against infection from within and without. On the other hand, such adhesions between the different abdominal viscera and the viscera and any portion of the abdominal wall are often transformed into firm bands of adhesions which later on so frequently become a direct cause of intestinal obstruction. The surgeon to-day imitates nature's process and makes use of the omentum in covering denuded surfaces or in suturing tissues of doubtful resistance, and in covering surfaces of the gastro-intestinal canal the seat of a threatened perforation. In visceral peritonitis the primary disease frequently furnishes the special indication for which the operation is performed. Inflammation of the gall-bladder often gives rise to inflammation of the serous investment of a number of adjacent organs, resulting in succession in pericystitis, epiploitis, perigastritis, perihepatitis, and perienteritis. The removal of the original cause which provoked the primary disease furnishes the main indication in the treatment of such extensive pathologic indications.

The surgical treatment of appendicitis and its various complications is not well settled at the present time. Some surgeons advise operation in all cases in which a diagnosis of appendicitis can be made, regardless of the nature of the disease and the character of its complications. The more conservative element of the profession limits the use of the knife to cases in which there are positive indications for surgical interference. I resort to operation in all cases, during a first attack, when the symptoms point to perforation or gangrene of the appendix. The sooner the operation is undertaken under such circumstances, the better are the results. The appendix should only be sought for and removed if pus is found in the iliac fossa, when this can be done without a material increase in the immediate risks of the operation, otherwise the treatment by incision and drainage will yield the best results. In mild cases of appendicitis from 80 to 90 per cent. recover under appropriate medical treatment, and in a

fair percentage of cases the disease does not return. The gravest cases are those in which the affection of the appendix is followed by diffuse peritonitis. In the treatment of this class of cases nearly all surgeons are fully in accord with the rules laid down by McBurney. This surgeon reports twenty-four cases of diffuse peritonitis caused by appendicitis treated by abdominal section, of which number fourteen recovered. He prefers glass tubes to rubber drains. The glass tube is loosely packed with sterile gauze and inserted to the floor of the pelvis. He irrigates with a hot sterile salt solution. The incision, four to six inches in length, is made from a point near the anterior superior spine of the ilium, following the direction of Poupart's ligament, and about an inch above it. Adhesions are interfered with as little as possible. Collections of pus or seropurulent fluid are searched for and evacuated. After removal of pus with sponges irrigation is practised. If fluid is found outside of the pelvis, strips of iodoform gauze are used to drain the different spaces. At the end of from twenty-four to thirty-six hours the glass drain is removed and a strip of gauze inserted in its place. If the clinical history reveals the fact that during the first or any subsequent attack an abscess in the vicinity of the appendix has ruptured into the cecum, I should hesitate to recommend an operation, as such cases usually recover spontaneously in the course of time, while an operation for such a condition is attended by many and serious risks. I have operated in four cases, removing that part of the appendix which still remained and suturing the opening in the cecum; two of these cases recovered and two died of septic peritonitis within three days after the operation. In relapsing appendicitis an operation is indicated, particularly in cases in which the attacks set in at short intervals and with gradually increasing intensity.

In peritonitis resulting from infective lesions of the female internal genital organs,—the uterus, ovaries, and Fallopian tubes,—the organ primarily affected and the resulting intraperitoneal abscess can often be reached more safely by a vaginal than by an abdominal operation. Occasionally the combined operation will afford greater safety, more complete removal of the infected tissues and organs, and more efficient drainage.

7. Pelvic Peritonitis.—Pelvic peritonitis is seldom met with in the male. It is a form of peritonitis in which the female pelvic organs are the primary starting-point of infection, with extension to the peritoneum, through either the Fallopian tubes or the lymphatics of the uterus or its adnexa. It is caused most frequently by gonorrheal or puerperal infection, or develops after instrumental examination of the interior of the uterus or operations upon this organ. In pyogenic infection the inflammation may become diffuse, and if circumscribed, usually leads to the formation of parametritic or intraperitoneal abscesses, or pus-formation takes place in both of these localities. In the peritoneal cavity the gonococcus produces a plastic peritonitis, and sometimes localized suppuration. Salpingoperitonitis and more

diffuse pelvic peritonitis are most frequently caused by gonococcus infection. Ceppi reported the first case of laparotomy for gonorrheal peritonitis. Gonococci were found in the pus-cells. The patient recovered. Abdominal section is seldom performed for gonorrheal peritonitis during the acute stage. Opening of the abdominal cavity by this route is usually reserved for the removal of the remote consequences of the disease, and the operation usually includes the removal of the adnexa on one or both sides. An early incision through the vaginal roof into the culdesac of Douglas in the treatment of pelvic peritonitis, so strongly urged and frequently practised by Henrotin, is a rational procedure and frequently succeeds in preventing the extension of the infection and the occurrence of serious remote complications. I have in several instances incised and drained the Fallopian tube through such an incision, and in this way prevented further leakage from the tube into the peritoneal cavity, and thus directly cut off additional supply of infectious material. The treatment of large parametritic abscesses extending to the brim of the pelvis and above it, by making an extraperitoneal incision the same as is resorted to in ligating the external iliac artery, a procedure advocated by Pozzi, is preferable to a transperitoneal operation in all cases in which the abscess can be reached by this route.

Birnbaum advises, in puerperal sepsis in which a pelvic exudate has been thrown out, if continued high fever persist, drainage of the abscess as required. When fluctuation is detected, an incision is made from one to two centimeters above Poupart's ligament, and from two to three centimeters from the anterior superior iliac spine. When fluctuation is not positive, exploratory puncture is recommended; vaginal exploration and incision are indicated when the abscess is located lower down in the pelvis. We shall hear less of intestinal, vesical, and rectal fistula in the future as the remote results of pelvic peritonitis or parametritic abscesses, so soon as the profession recognizes fully the importance and necessity of timely operative interference.

8. Puerperal Peritonitis.—By the term puerperal peritonitis is understood a progressive inflammation of the peritoneum occurring in consequence of an extension of an infection from any part of the genital tract in puerperal women after delivery or abortion. The infection usually takes place through the lymphatics, which in the majority of cases terminates in diffuse septic peritonitis. In some instances the disease remains limited to the pelvic organs and their serous investment, when abscess formation, intraperitoneal and extraperitoneal, is very likely to occur. The infection in such comparatively mild forms of puerperal sepsis is usually caused by the different varieties of the staphylococcus, while the diffuse septic puerperal peritonitis is nearly always produced by the streptococcus.

Treatment.—The treatment of the localized form of puerperal peritonitis is the same as that advised in circumscribed peritonitis resulting from other causes. The foudroyant form of puerperal sepsis

proves fatal in spite of the most energetic medical and surgical treatment. The use of the antistreptococcus serum may prove of great value, and should receive an early and a fair trial. It has been suggested that early removal of the infected uterus would prevent the extension of the disease to the peritoneum and death from sepsis. A number of vaginal hysterectomies have beeen performed for this indication, but, on the whole, the results have not been encouraging. It is exceedingly difficult, and in many cases absolutely impossible, to make a sufficiently early and positive diagnosis to warrant so grave and mutilating an operation as a timely and life-saving measure. If the uterus is removed after general septic peritonitis has developed, the operation is performed too late, and death from shock and sepsis is the rule. Professor von Winckel is not in favor of resorting at once to the removal of the uterus and adnexa by the vaginal route. In cases in which the Douglas culdesac is prominent in the vagina he recommends a broad and free incision behind the uterus. If the inflammatory product is not within safe reach of a vaginal incision, he advises abdominal section. He is in favor of vaginal hysterectomy only in cases in which a double parametritis sets in after such a procedure.

9. Subdiaphragmatic Peritonitis.—A peritonitis limited to the under surface of the diaphragm and any of the adjacent abdominal organs is called subdiaphragmatic peritonitis. If the inflammation remain limited and life is sufficiently prolonged, it usually terminates in the formation of a subdiaphragmatic or subphrenic abscess. Perforating ulcer of the stomach and duodenum and abscess of the spleen and liver are the most frequent affections that precede subdiaphragmatic peritonitis. Maydl has written the most complete treatise on subphrenic abscesses, dividing them into twelve groups according to their location and the organ from which they have their starting-point. The diagnosis is usually difficult, and Maydl recommends the exploring needle very strongly as an important diagnostic resource. The abscess often ruptures in the pleural cavity, through which it is most frequently reached; the pleural cavity is sometimes found obliterated when the puncture and incision are made through the diaphragm. In cases of empyema of the pleural cavity the possible existence of a subphrenic abscess must be kept in mind.

Witthauer reports two cases of subphrenic abscess caused by perforation of the stomach that terminated fatally without operation. In the first case carcinoma of the stomach was diagnosticated, in the second the diagnosis was first made of perforating ulcer of the stomach, but was later doubted, as the usual symptoms of peritonitis did not appear. A similar case is reported by Schlesinger. Trojanow reports a case of subphrenic abscess that had its starting-point in a splenic infarct that occurred during an attack of typhoid fever. He resected the tenth rib between the axillary line and scapula, found the pleural cavity at that point obliterated, and at

once incised the diaphragm and opened and drained the abscess, in the contents of which fragments of necrosed splenic tissue were found. In cases in which the pleural cavity is not found obliterated, he advises suturing of the pleura to the diaphragm before opening the abscess. A valuable contribution to the statistics and surgery of subphrenic abscesses has recently been made by C. Beck, of New York. He reports five cases treated successfully by operative interference. Rib resection and opening of the pleural cavity usually become necessary as preliminary steps in opening a subphrenic abscess. Accurate location of the abscess and a positive diagnosis are made by exploratory puncture. As perforating ulcer of the stomach is the most frequent cause, subphrenic abscesses are more frequently located on the left than on the right side. Occasionally a spontaneous cure occurs by perforation of the abscess into a hollow adjacent organ. Maydl has shown that out of 104 cases not operated on only 6 recovered, while out of 18 cases operated on only 11 per cent. died. The satisfactory results of the operation furnish the most conclusive proof regarding its necessity and life-saving value.

CHAPTER XVIII.

APPENDICITIS.

APPENDICITIS, or inflammation of the appendix vermiformis, is now a well-recognized surgical affection, and is regarded as the primary lesion in the causation of the numerous pathologic and clinical forms of peritonitis in the ileocecal region, formerly described as typhlitis, perityphlitis, paratyphlitis, and appendicular peritonitis. Küster has recently proposed the term *epityphlitis* for appendicitis, but the latter word has gained so firm a foothold in medical literature that it will in all probability remain. According to the pathologic conditions presented by the diseased organ, we speak of catarrhal, ulcerative, obliterating, perforative, and gangrenous or sloughing appendicitis.

The successful surgical treatment of peritonitis caused by infective lesions of the appendix vermiformis constitutes the most brilliant chapter of modern aggressive surgery. The surgeons have taught physicians, by scientific research as well as by lessons learned from clinical experience, that peritonitis, in the majority of cases, is a secondary affection, and that its successful treatment depends largely upon the detection and removal of the primary cause. The present large amount of knowledge concerning appendicitis and its complications is largely the result of the work of American surgeons. The European surgeons are slow in accepting the teachings and practice as developed and promulgated in this country, but in the near future

they will have to submit to the most convincing proof—the results of clinical experience. During the last ten years so much literature on the surgical treatment of inflammatory affections of the appendix has accumulated that this subject has become somewhat threadbare and confusing. For a number of years it was customary for a certain class of abdominal surgeons to report the result of their annual work on ovariotomy; then it became the fashion to give the statistics of tubal surgery; but at the present time the appendix vermiformis is the favorite topic of discussion, and to it is assigned a liberal space in the medical press and the programs of the medical societies, both large and small.

It would be more profitable in the future for this department of abdominal surgery to write less concerning individual experience, and elaborate more thoroughly upon a pathologic basis the conditions that demand surgical interference. The surgeon must bring more convincing proof than the simple recovery from the operation —viz., the reasons for the necessity of operative intervention—in order to convince the mass of the profession of the correctness of the ground taken by a number of surgeons, that the appendix should invariably be removed when it is the seat of an infective lesion. There are exceptions to nearly all rules, and the surgery of the appendix vermiformis has not advanced sufficiently to enable us to lay down fixed rules when and when not to operate. Pelvic surgery has been degraded by the modern *furor operativus*, and the same fate threatens the surgery of the appendix. The conscientious surgeon must bring his work into consonance with the pathologic conditions that he is expected to correct or remove.

Size, Location, and Blood Supply of the Appendix.—Abnormalities in the size, location, and blood supply of the appendix have unquestionably an important bearing on the etiology of inflammation of this organ. Infective processes undoubtedly not infrequently extend from the appendix to the cecum, and from the cecum to the appendix, in the course of the vascular connection. If the appendix is flexed by displacement of any kind, the mechanical obstruction incident to such malposition would furnish a strong predisposition to appendicitis. Partial or total gangrene is often the result of thrombosis of the principal artery or vein, caused by the infective process. At my request, Dr. C. A. Parker, Demonstrator of Anatomy in Rush Medical College, made some very interesting observations on the variations in size, location, and blood supply of the appendix. The following is a brief report of his investigations:

"Observations on the Appendix Vermiformis in the Dissecting Room of Rush Medical College, Autumn and Winter Quarters, Session 1899 and 1900.

"Number observed 70—59 white, 11 black; males 56—51 white, 5 black; females 14—8 white, 6 black.

"Average length of all, 3.67 inches—white 3.61, black 4; males 3.86—white 3.72, black 5⅜; females 2.9—white 2.8, black 3.

"Longest male, 7 inches, black; 6 inches, white; female, 4½ black; 3¾ inches white.

"Shortest male, white 1¾ inches; black 3½ inches; female, white 1¾ inches; black ¾ inch.

"Number of mesenteriola observed, 65—55 white, 10 black; males 54—49 white, 5 black; females 11—6 white, 5 black.

"Number with mesentery extending the whole length of the appendix, 44—37 white, 7 black; males 36—32 white, 4 black; females 8—5 white, 3 black.

"Number of mesenteriola extending one-half the length or more, but not the whole length, 20—18 white, 2 black; males 18—17 white, 1 black; females 2—1 black, 1 white.

"Number with no mesentery, 1, female, black, appendix ¾ inch long.

"Percentage of mesenteriola extending the whole length 67½ per cent.—white 67 per cent.; black 70 per cent.; males 66½ per cent.—white 65 per cent., black 80 per cent.; females 73 per cent.—white 83 per cent., black 60 per cent.

"*Position of Appendix.*—Number of cases observed, 70—59 white, 11 black; males 56—51 white, 5 black; females 14—8 white, 6 black.

"Downward and inward from cecum, as follows: 57 cases, or 81½ per cent.

"(*a*) Cecum in normal position and appendix extending to brim of pelvis and over it into cavity, ...	40	"	" 57	"
"(*b*) Cecum normal, with appendix not extending to pelvis, but curled to right or left and lying more or less behind cecum, ...	7	"	" 10	"
"(*c*) Cecum near crest of ilium and appendix extending downward and inward over iliacus, reaching pelvis only where very long (this includes one ¾ inch long that is not put in first because it did not reach the pelvic brim),	6	"	" 9	"
"(*d*) Cecum in pelvis, ...	3	"	" 4	"
"(*e*) Cecum in scrotum in right oblique inguinal hernia and appendix at lower end, also included in hernia, ...	1 case,	"	1 3/7	"

"Upward behind the cecum, 13 cases, or 18½ per cent., as follows:

"(*a*) Cecum in normal position, ...	9 cases, or		13	per cent.
"1. Toward right side, ...	7	"	" 10	"
"2. Vertical behind cecum, ...	1 case,	or	1 3/7	"
"3. Toward left side, ...	1	"	" 1 3/7	"
"(*b*) Cecum at crest of ilium, and appendix lying on the quadratus lumborum or transversalis muscle and directed slightly to the right, ...	2 cases, or		2 6/7	"
"(*c*) Cecum in pelvis and appendix upward and toward the left and behind ileum also, ...	2	"	" 2 6/7	" "

Etiology.—Appendicitis in all its pathologic forms is essentially an infective microbic disease. Congenital and acquired conditions determine the frequency with which this remnant of a former important organ is the seat of infection and inflammation as compared with other more active portions of the intestinal canal. The embryologic processes in this location are of a complicated nature, and may have a decided influence in magnifying the susceptibility to infection. The unrest caused by the contractions of the iliopsoas muscle (Byron Robinson) may play a subordinate rôle as either a predisposing or an exciting cause. Its dependent position, its communication by an orifice, more or less constricted and often imperfectly guarded by Gerlach's valve, with that portion of the intestine in which inspissa-

tion of intestinal contents first occurs, while at the same time it is removed from the direct fecal current, are decidedly predisposing

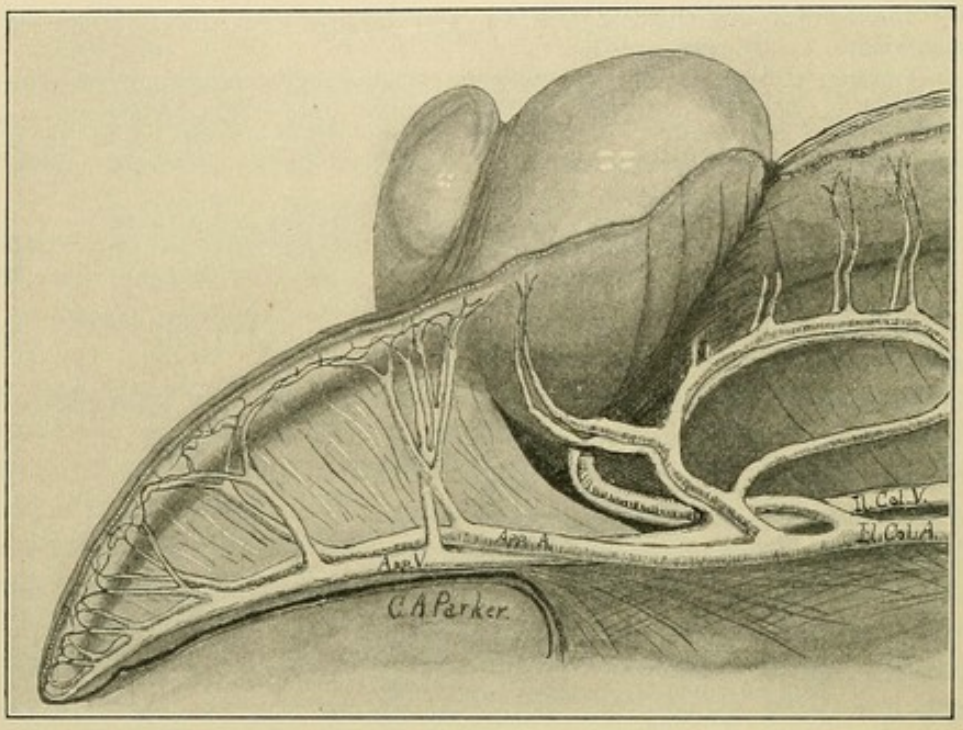

Fig. 460.—Blood supply of the appendix as found in the majority of cases.

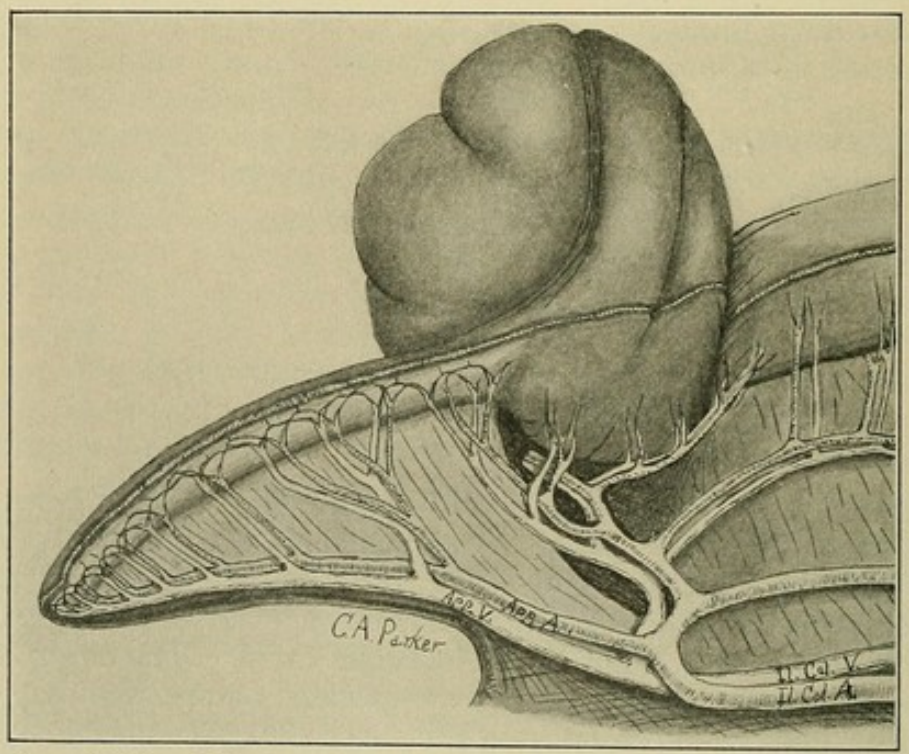

Fig. 461.—Additional blood supply to the appendix from cecal branch. Uncommon.

conditions to infection, which satisfactorily explain the frequency with which the appendix is the seat of inflammatory affections. The partial exclusion from the cecum and the frequency with which the

valve of Gerlach is found incompetent likewise explain the formation of fecal concretions, which are so often found in connection with perforative, ulcerative, and relapsing catarrhal appendicitis that they certainly must be regarded in the light of an exciting cause.

A glance at the anatomy of the appendix, as well as an examination of the most constant pathologic conditions, will corroborate the correctness of this assertion. The appendix is richly supplied with lymphatic vessels, and it is through these that infection most frequently takes place. Orth (Fig. 463) has fully described the lymphatic structures in the appendix of the rabbit, and Morris has recently alluded to the lymphatic channels of this structure as a route of infection in man.

It is not difficult to understand that an ordinary catarrhal inflam-

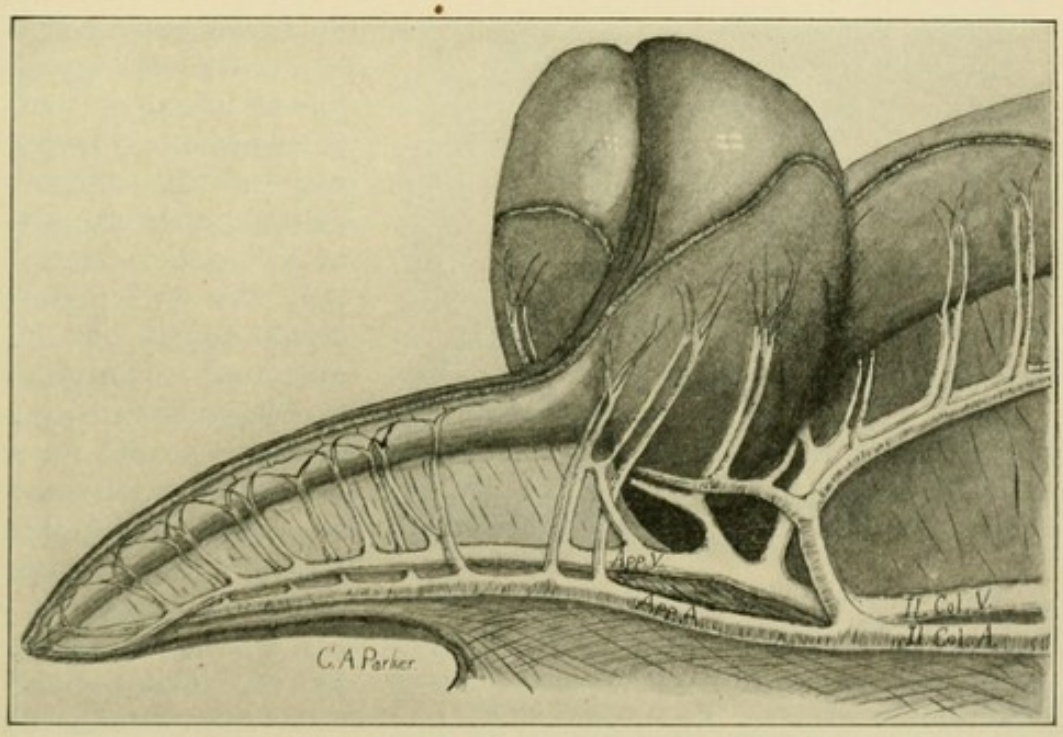

Fig. 462.—Cecal supply from appendicular artery. Rare.

mation would render the mucous membrane permeable to the passage of pathogenic microbes, rendering it possible for them to pass from the lumen of the appendix into the lymphatics, the essential cause of the inflammation thus coming in direct contact with every anatomic constituent of the wall of the appendix, its serous investment, and even the free peritoneal cavity, without any ulcerative perforation. The distribution of the microbic cause through the lymphatic route has been demonstrated by many postmortem examinations and appendices removed by operative treatment. Minute miliary abscesses have often been found in the wall of the appendix and underneath the peritoneal coat, and usually in locations formerly occupied by lymphatic channels.

It is evident that a plastic peritonitis in the vicinity of the appen-

dix can be produced by pyogenic microbes without visible pus within the appendix or its wall. The bacillus coli communis, so constantly found in the intestinal canal, even in the absence of disease, is the most constant microbic cause of appendicitis. This microbe appears to be harmless as long as the mucous membrane of the appendix is normal, but it exercises its specific pathogenic properties promptly whenever the essential *locus minoris resistentiæ* is produced by other conditions. The anatomic location of the appendix is such that retention of its secretions is likely to occur, particularly in cases in which the lumen at the proximal end has become narrowed by congenital stenosis or acquired affections of the cecal wall. From a bacteriologic aspect the appendix must be regarded as an open test-tube, and the retained stagnant secretions as a culture-medium.

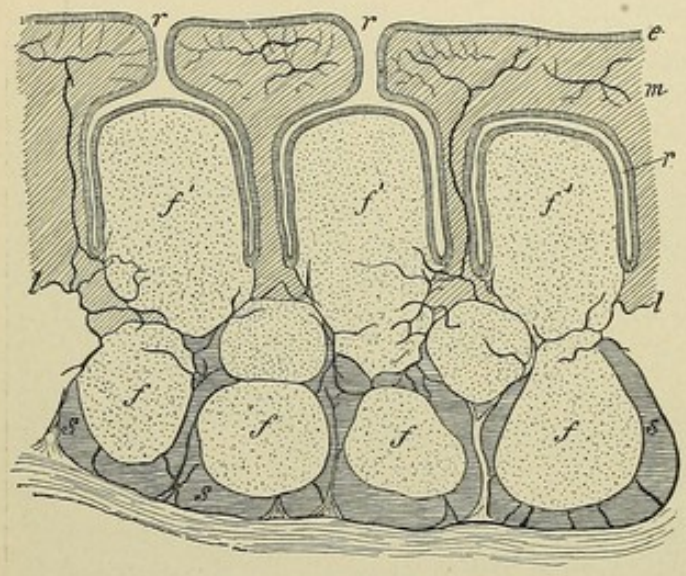

Fig. 463.—Appendix of rabbit, lymphatics injected: *f*, *f*, *f*, *f*, Outer follicles with lymph sinus, *s*, *s*, *s*; *f'*, *f'*, *f'*, inner follicles; *l*, *l*, lymph-vessels that leave the lymph-follicles; *m*, mucous membrane with dilated glands; *e*, their epithelial cells; *r*, *r*, their recesses; *r'*, recess; point of entrance does not correspond with level of section (Orth).

Pus-microbes undoubtedly enter largely into the etiology of mixed infections here as elsewhere. Intensity of the inflammation is determined more by the quantity than by the pathogenic quality of the microbes. The same cause that in one case produces a mild form of inflammation may in others determine speedy death from gangrene or perforation and acute sepsis. In the majority of cases the appendix receives its blood supply from a single branch of the ileocolic artery, which runs along the free convex border of the mesentery. This single blood supply, as well as the peculiar arrangement of the meso-appendix, accounts for the very serious disturbance of the circulation by flexion in the event of pressure produced by the cecum distended by gas or by coprostasis. Anything that interferes with the normal circulation in the appendix causes local conditions favorable to infection. The extension of a catarrhal inflammation from the cecum to the appendix is by no means a rare occurrence. A catarrhal cecitis acts in two ways in the subsequent development of a similar affection of the appendix:

1. By direct extension of the surface inflammation from the cecum to the appendix.

2. By the inflammatory swelling causing a stenosis of the cecal

end of the lumen of the appendix, with its immediate consequences —retention of the secretions, distention, and violent appendicular peristalsis, conditions favorable to infection.

The etiologic influence of foreign bodies has been greatly overestimated. It is said that foreign bodies have been found in about 4 per cent. of all operative cases, which is certainly a very high estimate. I found foreign bodies in only two cases out of a total of more than 300 operations for appendicitis. In the case of a young girl the subject of perforative appendicitis, a piece of straw was found in the abscess cavity. In the second case, a man twenty-five years of age, a pin was found in the perforation and projecting into the small abscess cavity outside of the appendix. In one of Fenger's cases of obliterating appendicitis two grape-seeds, one fecal concretion the size of a split-pea, and the husk of an oat were found in the appendix below the obstruction. Fecal concretions are found in from 15 to 20 per cent. of all cases subjected to operative treatment. Fecal concretions may remain in the appendix indefinitely without any serious consequences, as is shown by their presence at post-mortems in otherwise healthy appendices. They, however, undoubtedly serve frequently as a provoking cause.

Fecal concretions are concerned in two distinct ways in the etiology of appendicitis:

1. Their presence causes a mechanical irritation and lesions of the mucous membrane, which serve as infection atria for the entrance into the tissues of pathogenic microbes.

2. In case the appendix becomes swollen from mechanical or inflammatory causes, pressure necrosis directly over or around them may ensue, as is so often seen in perforative and gangrenous appendicitis.

No age is exempt from appendicitis, although the disease is much more frequent in the adult than at the two extremes of life. Women are less subject to the disease than men, which would seem to indicate that exposure and the more active pursuits of life exert an influence in exciting the disease. It would naturally be expected that catarrhal affections of the intestinal canal would frequently be the forerunner and direct cause of appendicitis. This is not borne out by clinical experience. Catarrhal affections are more frequent in infants and children than in the adult, and yet children are seldom attacked by appendicitis.

It was somewhat astonishing that of the many thousands of soldiers who returned from Cuba and landed at Montauk, not one case of appendicitis came to my attention that would have justified an operation. It was naturally not anticipated, among so large a body of men, almost all of them at some time during the preceding five months the victims of intestinal affections, that the appendix would escape infection so constantly. The climate, the dirt, the antecedent intestinal affections contracted in home camps and during the campaign in Cuba, should have, according to our ideas of the

nature of appendicitis, combined in exciting the disease. But such was not the case. The profession is very well aware of the fact that some surgeons who can see nothing else but appendicitis in cases in which patients complain of pain in the ileocecal region have performed laparotomy, and the cases are not few in number where, as an excuse for their error in diagnosis, they have completed the operation by removing a normal appendix. Of the three cases of supposed appendicitis sent to the surgical wards at Montauk, in only one the diagnosis proved correct, and this case was so mild a one that an operation was not deemed justifiable. One proved to be malaria and the third typhoid fever. For the purpose of showing the difficulties that surround the differential diagnosis between appendicitis and other conditions attended by pain in the regions of the appendix these cases will be related briefly :

CASE 1.—Charles W. Dyer, age nineteen, Company K, Seventh Infantry, was in the service only six weeks when he was taken sick, September 11th, and was transferred to the surgical ward three days later. The attack commenced with a chill and some fever ; the following day pain in the right iliac region set in. Bowels were constipated, there was no vomiting, but loss of appetite. He had had a similar attack a year ago. On his admission to the surgical ward there was slight tenderness over the appendix and cecum, no tympanites and no palpable swelling or muscular rigidity, and temperature was only one degree above normal. Catarrhal appendicitis was diagnosticated, complicated probably by a similar condition of the cecum. Rest in bed, liquid diet, and ounce-doses of equal parts of castor oil and sweet oil, four hours apart, until bowels moved freely, constituted the treatment under which the patient recovered in a few days.

CASE 2.—James Reid, age twenty-one, Company I, Seventh Infantry, was in the service three months when he was admitted to the surgical ward, September 1st, with the diagnosis of appendicitis. The clinical history, as well as his condition at the time of admission, warranted a change in the diagnosis from appendicitis to typhoid fever. The temperature was erratic, showing malarial complication, but the curve from day to day showed the typhoid fever part to our satisfaction. The tongue was brown and dry, with red tip and margins. Pulse was 100, and temperature at that time varied from 101° to 105° F. Abdomen was tympanitic and there was great tenderness in the right iliac fossa. Numerous rose spots appeared on the abdomen the next day. Under appropriate treatment the fever subsided gradually at the end of the third week of his illness. The great tenderness in the ileocecal region undoubtedly led originally to a wrong diagnosis, but it simply indicated in this case deep typhoid ulcers in the lower portion of the ileum.

CASE 3.—Martin G. Newman, age twenty-seven, Company C, Seventh Infantry, enlisted three months before. On leaving Santiago he began to feel ill ; with headache, anorexia, and malaria ; became worse, lost sleep, and complained of pain in the stomach : most severe on left side, under the costal arch ; bowels were constipated, tongue was pale and flabby, with indented margin. Spleen was markedly enlarged. At times he had pain in the cecal region, which disappeared promptly after the administration of a laxative. Under quinin in large doses this patient improved rapidly.

From the foregoing considerations it becomes apparent that much additional light is needed to ascertain accurately the causes that are active in exciting the infection that constitutes the essential condition of every attack of appendicitis.

Pathology.—The pathologic conditions of appendicitis vary according to the extent of the inflammation and the tissues involved. The description of the morbid anatomy must be based on a proper classification. From a practical as well as a scientific standpoint it is advisable to classify appendicitis into : (1) Catarrhal ; (2) ulcerative ; (3) obliterative ; (4) perforative ; (5) gangrenous.

1.

2.

1. Catarrhal appendicitis. Epithelial lining interrupted only in a few places; dilatation of tubular glands from inflammatory obstruction; infiltration of ductless glands and submucosa. (Transverse section.)

2. Ulcerative appendicitis. Epithelial lining completely destroyed; marked ulceration and deep infiltration. (Transverse section.)

Catarrhal Appendicitis.—This is the mildest form of appendicitis. The infection and resulting inflammatory conditions are limited to the mucous membrane and the loose submucous connective tissue. The mucous membrane is very vascular and thickened, the glandular appendages are enlarged, and the interglandular connective tissue is infiltrated (Plate 3). The tubular glands are often found considerably dilated by retained secretion. Retention of secretion is caused by the swelling of the mucous membrane, which brings with it inflammatory stenosis of the open end of the tubules. The lymph-follicles are markedly enlarged and densely packed with lymphoid cells and leukocytes. The swelling of the mucous membrane is often found most intense on the cecal side, and the inflammatory stenosis is then sufficient to give rise to obstruction to the free passage of the physiologically increased secretion from the lumen of the appendix into the cecum. It is in cases where such an obstruction exists that the retained secretions give rise to violent peristaltic action of the muscular coat of the appendix, the cause of the so-called appendicular colic.

Catarrhal appendicitis does not give rise to any severe constitutional disturbances, and the local symptoms are limited to the inflamed organ. The most prominent local symptoms are pain, very often of an intermittent type, and tenderness, limited to the appendix. The disease is usually of short duration, but is very prone to recurrence. Repeated attacks frequently result in a club-shaped distal enlargement of the appendix, from thickening of its walls and in consequence of retention of secretions from flexion or inflammatory stenosis on the cecal side. The elongation of the organ caused by chronic catarrhal appendicitis almost constantly leads to flexion and obstruction (Plate 4). The mechanical impediments to the escape of the secretions created by the chronic inflammatory process contributes largely to the maintenance of the infection and relapsing attacks. In all cases of catarrhal appendicitis the whole mucous lining eventually becomes involved, but there are usually certain points where the inflammatory infiltration is most intense and where the more remote pathologic conditions are most marked. If the cecal end of the lumen remain freely patent and the disease assumes a chronic form or relapses frequently, the lumen of the organ becomes more and more contracted and eventually is obliterated, when the mucous membrane and its glandular appendages have become destroyed by the inflammatory process and the cicatricial contraction following it.

Ulcerative Appendicitis.—Catarrhal inflammation long continued ultimately results in the formation of multiple catarrhal ulcers. In the absence of localized mechanical causes inside of the lumen of the appendix, such as foreign bodies or fecal concretions, the ulcers are usually superficial and multiple, but in the course of time their depth is increased and eventually perforation takes place. Such an occurrence is usually complicated by the existence of a mechanical obstruc-

tion on the proximal side of the ulcer. So long as the infection remains, such ulcers seldom heal, and infection, as we know, is most likely to remain in the presence of a mechanical obstruction on the cecal side. In the most favorable cases these ulcers finally heal by granulation and cicatrization, but always at the expense of the lumen of the appendix, which becomes partially or completely obliterated by cicatricial stenosis. Such strictures may be found either single or multiple in relapsing appendicitis (Plate 4). The destruction of tissue by the ulcerative process and the resulting cicatricial contraction from partial or complete healing of the ulcers are often followed by great shortening and distortion of the appendix. A circumscribed plastic peritonitis often complicates catarrhal and ulcerative appendicitis by the extension of infection to the serous coat through the lymphatics, when the peritoneal adhesions may take an important part in the process of deformation.

3. Appendicitis Obliterans.—In 1894 I called attention to a pathologic form of appendicitis in which the most conspicuous feature consists in a gradual cicatricial contraction of the lumen of the appendix, and which I termed appendicitis obliterans. Of the many cases of this form of appendicitis that have come under my observation since that time, reference will be made only to the first few which induced me to describe this distinct pathologic form of appendicitis. My views in regard to its pathology and clinical significance have not been changed since that time. The distal form of obliteration is well shown in figure 464, a specimen from Professor Fenger's collection. The pathologic processes resemble very closely a similar condition in the terminal arteries, designated here arteritis obliterans. The cases here mentioned and those of a similar nature, presented, before the operation, a complexus of symptoms that, when grouped together, will enable the physician to at least suspect, if not positively predict, this condition.

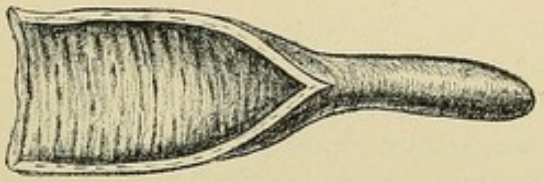

Fig. 464.—Appendicitis obliterans; cicatricial stenosis on distal side.

Case 1.—H. M. Stewart, aged twenty-six; business, bookkeeper; residence Lyons, Kan. Admitted into St. Joseph's Hospital September 30, 1893.

The patient stated that his health had been fairly good until three years ago, when he suffered from an attack of "cramps in the stomach" and pain and tenderness in the ileocecal region. This attack lasted about eight hours. Similar attacks followed at intervals of two or three months, becoming more frequent, until, during last year, they occurred from every four to six weeks. The acute symptoms would, as a rule, subside in from six to fourteen hours, to be followed by a dull aching pain in the right iliac fossa, accompanied by tenderness on pressure that would continue for from ten days to two weeks, when he would be able to resume his occupation, but more or less soreness and tenderness remained. The last attack, which was unusually severe, occurred in June. Operation was performed October 2, 1893. The appendix was found behind the cecum, directed inward and upward. It was adherent to the cecum and a loop of the ileum; mesenteriolum was shortened and much thicker than normal. The organ, when removed, measured about three inches in length and presented a peculiar club-shaped appearance, the constricted portion being on the proximal side, while the free end was bulbous. The

PLATE 4.

Macroscopic appearance of different pathologic forms of appendicitis (from drawings furnished by Dr. Maurice H. Richardson for "The American Text-book of Surgery"). 1. Obstruction from acute bending of appendix. 2. Obstruction from stenosis of appendix. 3. Dilatation of distal end of appendix; perforation by a fecal concretion. 4. Gangrene of terminal end of appendix. 5. Gangrene of nearly the whole of the appendix; fecal concretion in lumen. 6. Gangrene and distention of appendix; perforation by a fecal concretion.

wall of the free bulbous portion was much thickened. About one-third of the lumen on the proximal side was completely obliterated. The excluded part contained a viscid fluid of a brownish color. The temperature ranged between 99° and 100° F. for four days, when it reached 101.5° F. on the fifth day, after which it became normal. The patient left the hospital at the end of the fourth week.

CASE 2.—J. Barzhof, aged twenty-five. German-American; dentist; residence, Manitowoc, Wis. He entered St. Joseph's Hospital at the request of his attending physician, Dr. Pritchard, November 4, 1893. Operation on the following day. General health fair. In the summer of 1888 he was taken with the first attack, in the form of severe vomiting, diarrhea, and intense pain in the abdomen, radiating upward and downward to the right of the median line. The first seizure lasted about four days. Similar attacks occurred about four times every year. In the spring of the present year it appeared that the attacks were provoked by change in diet. Pain often more severe when stomach was empty. Dietetic treatment had no effect in preventing recurrence of the difficulty. No constipation. Last and most severe attack about September 20th. This was preceded by a somewhat hard swelling, extending from umbilicus to the right inguinal region, which was followed by a severe chill, vomiting, diarrhea, and the characteristic sharp lancinating pain, more severe in the ileocecal region. Highest temperature 102° F. The pain and tenderness in the ileocecal region never disappeared completely after this, and were relieved only by rest in the recumbent position. On opening the abdominal cavity the appendix was seen at once. It measured at least five inches in length, and was firmly attached to the caput coli and extended behind the colon. The distal bulbous end was small. A similar bulbous expansion was found near its attachment to the cecum. Between these bulbous expansions the organ was not larger than a small lead-pencil, anemic, and very dense. Owing to the length of the mesenteriolum it had to be tied in four sections. The glands in the vicinity were found much enlarged,—some of them had attained the size of an almond,—but none of them presented any evidences of caseation. Examination of the specimen after its removal showed that nearly the entire lumen had been obliterated, only a small portion on the distal and proximal side remaining patent. The open spaces contained a catarrhal, viscid secretion of a brownish color. The temperature in this case never reached 100° F., and the patient left the hospital at the expiration of four weeks.

CASE 3.—Mrs. E. A. West, aged twenty-eight, American, housewife; residence, Decatur, Ill. Entered St. Joseph's Hospital at the suggestion of the family physician for the purpose of having the appendix removed for a recurrent inflammatory affection in the right iliac region of long standing. Her mother died of pulmonary tuberculosis when patient was only six months old, and the latter has always been in delicate health. Married two years; no children. Six years ago was taken suddenly ill, with symptoms indicating peritonitis. The pain was diffuse, and of a grinding character. The acute symptoms subsided in five or six hours, but she was confined to the bed for four days. The tenderness in the right iliac region remained for a number of days. Later in the same year she had a similar attack, and during each of the succeeding four years the same experience was repeated from two to four times. Beginning with September, 1892, she had an attack each month until February, 1893—six in all. The attack in February was so severe that a physician was called for the first time. As in all previous attacks, pain passed off in a few hours, but patient was confined to bed for four or five days, and tenderness persisted for as many more days. She was never aware of the exact location of tenderness until she was examined by her physician. The last and most severe attack occurred in July of the present year, and lasted twelve days. She was attended by Dr. Bumstead, who recognized the difficulty and advised a radical operation. During the last attack the temperature reached 103° F. Vomiting and nausea were not conspicuous symptoms during any of the attacks. In the beginning of the acute exacerbations the pain was generally diffuse; later, localized in the ileocecal region. Hot applications always afforded prompt relief, and she believes that they were the means of cutting short several of the attacks. When examined after her admission into the hospital, the appendix could be felt as a firm cord, and tenderness was limited to this structure. Operation November 14th. In this case the appendix was directed downward and inward toward the pelvis; adhesions were old and firm. Mesenteriolum was very short and adherent to appendix. It was tied in several sections. About one-fourth of the lumen on the proximal side was obliterated, and the corresponding portion of the appendix was transformed into a firm fibrous cord (Fig. 465). Beyond this obliterated part the lumen was much dilated, and subdivided into two unequal portions by a thin partition composed of cicatricial tissue. Wall of appendix was much thickened and dense. Both compartments contained inspissated pus, which resembled liquefied caseous material. Lymphatic glands in the vicinity of the appendix were much enlarged and exceedingly vascular. Patient recovered without an untoward symptom.

A small stitch abscess at the end of a week gave rise to a slight elevation of temperature, and slightly retarded the healing of the wound.

CASE 4.—J. H. Croskey, aged thirty-three, American; farmer by occupation; residence, Farmer City, Ill. Entered St. Joseph's Hospital December 5, 1893. Family history good. Patient was never sick until November, 1891, when, after a hard day's work, he experienced a dull pain in right side and lower part of abdomen. He was able to sit up, but could do no work for three days, when all symptoms passed away. There was no nausea or vomiting; a little tympanites and constipation were present. He attributed the difficulty to a strain produced by lifting. The second attack in April, the following year, commenced with a sudden, sharp, intense pain, confined to the right side, in the region of the appendix. The acute symptoms continued for one month, during which time he was confined most of the time to bed, but at any time, if assisted to his feet, he could walk with the aid of a cane. During the second month he improved sufficiently to resume his work. A sense of soreness and tenderness in the ileocecal region remained. Vomiting occurred on the evening of the second day. Tympanites was absent. Diagnosis of appendicitis was made on the fourth day by the attending physician. Third attack occurred in February, 1893, and resembled the second in every respect. There remained not so much tenderness on pressure as a soreness or pain from a slight jar, as would happen when riding in a buggy when the wheel struck a stone. Could not stand perfectly erect, but would incline the body slightly forward and to the right, with feet about twelve inches apart. Examination before operation revealed tenderness in the region of the appendix on deep pressure. Operation December 8, 1893. The appendix was readily found, as it was directed forward and to the right, occupying a groove in the caput coli.

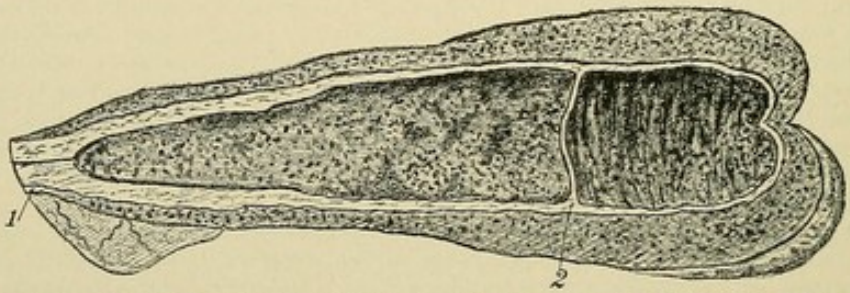

Fig. 465.—Appendicitis obliterans: 1, Proximal end completely obliterated; 2, narrow stricture dividing completely the remaining lumen into two unequal portions; great thickening of wall near distal end.

Separation from the cecum was very difficult, as the peritoneal coat of the latter appeared to be absent and the muscular coat very much attenuated. The dissection was made slowly and carefully, and mainly with the aid of blunt instruments. The mesenteriolum was incorporated so firmly in the adhesions that ligation was rendered superfluous. A number of bleeding points were ligated. The appendix, when removed, measured three inches in length, and on slitting it open it was found that about one-third of its lumen on the distal side was completely obliterated. The distal end tapered into a sharp point. The wall of the remaining portion was only slightly thickened. Mucous membrane was intensely congested. At a point about half an inch distant from obliterated part both the wall of the appendix and its lumen showed changes that indicated the first stages of the formation of a circular stricture. Mucous membrane was much thickened.

In this case the second attack of appendicitis produced an intense localized plastic peritonitis that gave rise to the extensive and firm adhesions of the appendix to the cecum, rendering the operation one of great difficulty.

CASE 5.—James McChane; occupation, farmer; aged thirty-five years; married; mother died of phthisis. Personal history: Never a very robust man. Had "ague" eight years ago, lasting three months. Regular in habits; no venereal history.

In August, 1893, the patient, while threshing wheat, was attacked with a severe paroxysm of pain in the right lumbar region. He had to stop work, but did not go to bed. He has not been able to do a day's work since, although he has not been confined to his bed. The pain was always present,—a dull aching pain,—and the least exertion aggravated the difficulty and tenderness. The pains were always referred to the same point—a few inches to the right and below the umbilicus.

The bowels were constipated, and the patient resorted to the use of enemata to relieve them. The appetite was very poor, and he lost flesh steadily. When admitted, the patient's temperature was normal in the morning, with a slight evening rise.

On physical examination, a point of tenderness was found corresponding to McBurney's point, with some induration and fixation of the head of cecum.

From the clinical history and existing symptoms it was not difficult to make an almost positive diagnosis of appendicitis obliterans before the operation. The operation was performed in the clinic of Rush Medical College. The distal end was patulous, and the proximal end completely obliterated.

The cases just reported present many clinical features in common. The age of the patients varied from twenty-five to thirty-eight. Four were males, and one was a female. In all of them the acute exacerbations were characterized by symptoms of peritonitis of varying intensity. Swelling does not appear to have been a constant feature, either during or after the acute attack. In most instances the pain was at first diffuse or referred to the epigastric region; later, localized in the ileocecal region. In most of the cases tenderness in the region of the appendix remained a long time after the subsidence of the acute symptoms, or persisted as a permanent condition. The point of tenderness varied according to the location of the appendix. The febrile disturbance during the acute attack appears to have been moderate and of short duration. Nausea and vomiting were not constant symptoms. Tympanites depended on the extent of the peritoneal involvement. The most constant and characteristic feature was recurrence of the acute exacerbations, which set in from once a year to every few weeks. As a rule, the attacks become gradually more frequent. In two out of the five cases, some of the important symptoms remained in a masked form during the intermissions. This was noted particularly in the cases in which the appendix was obliterated on the proximal side. Absence of complete intermission between attacks points to the existence of stenosis or obliterations on the proximal side.

From what has been said it will be seen that the most conspicuous symptoms of this form of appendicitis are: (1) Short duration and moderate intensity of the acute exacerbations; (2) slight or no swelling in the region of the appendix; (3) recurrence of acute attacks, varying in frequency from a year to several weeks; (4) persistence, during the intermission, of some soreness and tenderness in the part affected.

Ribbert wished to ascertain the frequency with which the appendix vermiformis undergoes obliteration, and for this purpose noted the condition of this organ in 400 postmortem examinations. He found partial or complete obliteration in 25 per cent. of these cases. He believes that this change is due to involutionary changes in the majority of cases. One reason for entertaining this idea is that this condition of the appendix is met more frequently in persons advanced in years. The influence of age is shown in the following table:

1 decennium	4 per cent.	5 decennium	36 per cent.
2 "	17 "	6 "	53 "
4 "	27 "	7 "	58 "

In favor of the inflammatory origin of appendicitis obliterans it can be said that appendicitis is a comparatively rare affection in children, and that the longer the person lives, the greater the liability to suffer from an attack. There can be but little doubt that obliteration of the appendix occasionally occurs as a congenital condition. Atresia of the lumen of this organ is probably more liable to occur during intra-uterine life than is the same condition in other parts of the gastro-intestinal canal.

Pathology and Morbid Anatomy.—Ranvers found the appendix completely obliterated in thirteen postmortem examinations. All the specimens showed evidences of circumscribed plastic peritonitis. He believed that in some of these cases perforation had taken place, and that the disease ultimately cured itself. In one specimen he found a small fecal concretion surrounded by a capsule of cicatricial tissue. The most striking morbid changes in obliterating appendicitis are found in the different tissues of the organ, and these are directly concerned in the gradual and progressive obliteration of its lumen. A stricture of the appendix, like that of any other hollow organ, may be brought about by : (1) Destruction of the mucous membrane by ulceration ; (2) infiltration, thickening, and contraction of the muscular coat ; (3) prolonged cicatricial contraction of exudates upon its serous covering ; (4) in consequence of a combination of two or more of these causes.

The obliteration is always preceded by destruction of the epithelial lining by the inflammatory processes, aided later by cicatricial contraction following the healing of the ulcerating surface by granulation. Epithelial remains in the scar tissue are finally destroyed by the progressive cicatricial contraction and avascularization.

Perforative Appendicitis.—The tissues around the appendix, particularly the peritoneum, may or may not be involved in catarrhal, ulcerative, or obliterating appendicitis. In perforative appendicitis the complicating para-appendicular affections constitute the most conspicuous part of the clinical picture. An acute necrosis of the wall of the appendix over a limited space may result in perforation within forty-eight hours, followed by circumscribed or diffuse phlegmon or peritonitis, according to the location and size of the perforation and the amount and virulence of the infective cause. Postmortem examinations have shown conclusively that, with few exceptions, perityphlitis and paratyphlitis are preceded by a primary appendicitis, so that in all acute inflammatory processes in the ileocecal region an appendicitis must be suspected as the primary cause. Every perforative appendicitis is followed by peritonitis of greater or less extent. A retrocecal phlegmonous inflammation will occur if the perforation takes place in this direction, which can occur only by the accident being preceded by a plastic peritonitis shutting out the peritoneal cavity from the focus of infection. In such an event the subsequent course of the disease is attended by signs and symptoms of acute abscess formation behind the cecum. Such an abscess may find its

way as far as the under surface of the liver, simulating a paranephric abscess, or it may reach the surface near the spine of the ilium or above Poupart's ligament. In other cases the perforation leads to a plastic peritonitis that walls off the peritoneal cavity, and the abscess, intraperitoneal from the beginning, may rupture into the cecum, a loop of the small intestine, the rectum, bladder, or vagina. The most serious consequences occur in cases of perforation with the escape of the inflammatory product into the free peritoneal cavity, in which event a diffuse septic peritonitis and death are the usual consequences unless the latter can be prevented by prompt operative interference. In case the perforation is small and a plastic peritonitis limits the escape of septic material, suppuration does not follow as an inevitable result. In such instances a hard inflammatory swelling makes its appearance, which in the course of time disappears by absorption, leaving the appendix embedded permanently in adhesions.

In relapsing appendicitis the inflammatory swelling appears toward the end of the acute exacerbation, when it diminishes in size or disappears entirely, to reappear during the next attack. Perforation may follow recurring attacks of appendicitis as the result of a chronic ulcerative process, usually in combination with a mechanical obstruction, but in the great majority of cases it presents itself clinically as an acute process, perforation taking place in from a few hours to several days from the beginning of the first symptoms. The pathologic anatomy in such cases presents, as the most conspicuous feature, a circumscribed necrosis of the wall of the appendix. If a fecal concretion is present, the perforation usually corresponds to its location, which would indicate that the pressure caused by the fecal concretion in the inflamed swollen appendix had something to do with causing the necrosis. In the absence of such a local cause we must assume that the inflammation eventuates in necrosis by obstructing the vessels in the necrosed territory.

Gangrenous Appendicitis.—In this form of appendicitis a part of, or the whole appendix is destroyed. Gangrenous appendicitis is always an acute process. The inflammation and the conditions induced by it may be so severe that gangrene takes place in the course of twenty-four hours. I have seen a number of cases of appendicitis in which laparotomy was performed in less than thirty-six hours after the appearance of the first symptoms, and found in such instances the entire organ gangrenous. The most careful examination of the specimens removed showed no evidences of perforation. In two cases of gangrenous appendicitis that recovered after the abscess ruptured into the bowel, pain and tenderness remained in the right iliac fossa, where a limited induration could easily be detected. Operation several years after the acute attack revealed about half an inch of the distal end of the appendix buried in a mass of adhesions, and entirely detached from the cecum. In both specimens the lumen of the isolated part of the organ contained a few drops of

a viscid fluid of a brownish color. The gangrenous portion in both of these instances was eliminated with the contents of the abscess, and the survival of the tip of the organ must necessarily be attributed to a separate blood supply, either through blood-vessels in antecedent adhesions or from other source aside from the principal artery of the appendix. Total gangrene of the appendix is always associated with thrombosis of the principal blood-vessel, and the complete arrest of the circulation is the direct cause of the gangrene. Malposition of the appendix, abnormality of its principal blood-vessels, and acquired conditions that interfere mechanically with the necessary blood supply are undoubtedly the most frequent and potent predisposing causes of the gangrenous inflammation. The direct immediate cause, however, is to be found in the infective process which determines the thrombosis. The veins undoubtedly are always first occluded by a progressive thrombophlebitis, which extends from the inflamed wall to the mesenteriolum, resulting finally in occlusion of the principal vein that returns the blood from the appendix and the meso-appendix. The complete arrest of the venous circulation is soon followed by thrombosis on the arterial side, complete arrest of the circulation, and the inevitable result—gangrene.

Fig. 466.—Distal portion of appendix isolated from the cecum and embedded in scar tissue after an attack of gangrenous appendicitis. The lumen contained a gelatinous substance, and a culture made from it yielded a growth of staphylococcus pyogenes albus.

Unless prompt surgical treatment is resorted to, gangrenous appendicitis leads, in a great majority of cases, to septic peritonitis and death. There are, however, exceptions to such a course. Under favorable circumstances a plastic peritonitis limits the infection, and abscess forms in which the detached gangrenous appendix is later found as part of its contents. But even under the most favorable circumstances the disease pursues a very rapid course and demands operative treatment as soon as a diagnosis can be made.

Symptoms and Diagnosis.—The symptoms of appendicitis must necessarily vary according to the pathologic forms of the disease and the absence or presence of peritoneal complications. In perforative and gangrenous appendicitis the primary affection is soon overshadowed completely by the resulting peritonitis. The local symptoms are most characteristic in the catarrhal and obliterating varieties. In such cases the pain is usually referred at first to the region of the umbilicus, for the reason, as has been suggested, that during the early stages of the embryologic development of the intestinal canal the appendix is found in that locality. In this respect the appendix furnishes an analogy to the testicle, in which, when the seat of a painful affection, the pain is referred, in part, at least, to a point occupied by the organ during embryonic life. Others believe that this distant pain is caused by a reflex implication of the great

sympathetic ganglia situated in that region. The characteristic pain of appendicitis corresponds with the location of the organ, the attached portion of which is found almost invariably, as was pointed out by McBurney, on a line drawn from the anterior superior spinous process of the ilium to the umbilicus, and about half-way between these two points. This is McBurney's point, so constantly referred to in the discussions on inflammatory affections of the appendix and their operative treatment. This point corresponds with the cecal end of the appendix, while the organ itself may be found displaced in almost any direction and any part of the abdominal cavity. The appendix has been found in the pelvis, in the region of the sigmoid flexure or of the umbilicus, and even under the surface of the liver, but its origin from the cecum is almost constant and corresponds with McBurney's point.

Tenderness is a more important diagnostic evidence than pain. In the absence of peritonitis the tenderness is limited to the inflamed organ and serves as a guide to its location. In catarrhal and obstructive appendicitis the pain is often colicky, and has been referred to exaggerated peristalsis (Morris), constituting the so-called appendicular colic. The inflammatory swelling incident to appendicitis varies in size and character according to the amount and nature of the inflammatory product.

The normal appendix can seldom be outlined by palpation, which is contrary to what has been asserted by Edebohls and others. *It is usually found difficult to locate the slightly enlarged appendix by palpation, and the absence of a palpable swelling does not exclude the presence of a catarrhal appendicitis.* If the appendicitis has given rise to a circumscribed peritonitis, a hard and tender swelling, variable in size, indicates the exact location of the diseased organ. If the appendix is located behind the cecum, as is so often the case, a swelling of considerable size may elude palpation. Owing to the tenderness and rigidity of the abdominal wall, it is extremely difficult to detect fluctuation if suppuration has taken place unless the abscess is large or has reached a stage where it has resulted in a marked bulging of the abdominal wall. So far as palpation is concerned, a large retrocecal intraperitoneal abscess often very closely simulates an extraperitoneal abscess. *Muscular rigidity is a prominent clinical feature of appendicitis, and, as a rule, it is proportionate to the severity and extent of the complicating peritonitis. Retraction of the thigh is an indication of the extension of the inflammation in the direction of the sheath of the iliopsoas muscle, and is met most constantly in retrocecal suppuration.*

The treacherous nature of appendicitis becomes more suspicious in the study, at the bedside, of general than of local symptoms. The gravest cases are often initiated by a complexus of symptoms that furnish no indication whatever of the lurking danger hidden behind it, and mild cases often present themselves attended by symptoms indicative of a far graver condition than really exists. The pulse

and temperature are especially misleading, more particularly so in children. I have operated repeatedly in cases in which the constitutional symptoms were of a severe type, and found, to my utter astonishment, a plain case of appendicitis without perforation or peritonitis to any considerable extent. I have been lured into a sense of security by a temperature not far from normal and a good pulse, and found, a few days later, when forced to operate by a sudden aggravation of the symptoms, a gangrenous or perforated appendix, extensive pus-formation, or a diffuse septic peritonitis. It is the difficulty of interpreting correctly the early symptoms of appendicitis that makes it often so trying a task to decide whether to operate or to pursue a conservative course. While the initial symptoms are well calculated to leave doubts in the mind of the surgeon as to the propriety of resorting to operative interference, there can be no question as to the advisability of doing so when the symptoms increase progressively in intensity. *If the temperature continues to rise and the pulse increases in frequency after the first twenty-four hours, it is safe to assume that the appendicitis has resulted in complications that warrant operative treatment.* The same can be said of a gradually increasing tympanites. Vomiting is a frequent, but by no means a constant, symptom. The disease is often preceded and accompanied by constipation, but the reverse may be the case.

In the differential diagnosis between appendicitis and the affections resembling it the greatest care is required, as healthy appendices have been repeatedly removed for symptoms caused by other diseases, and many cases of appendicitis have been overlooked and treated for other affections when, perhaps, operative treatment was urgently indicated. The most important symptoms upon which to base the diagnosis of appendicitis are the following : Pain and tenderness in the region of the appendix, fever, muscular rigidity, tympanites, vomiting, and very often either constipation or diarrhea. Another circumstance important to remember is that the attack is usually ushered in suddenly without any premonitory symptoms. In the grave forms of the disease progressive aggravation of symptoms is to expected, although sometimes the acute symptoms diminish in severity after a few days, and a lull precedes the subsequent more stormy and progressive symptoms.

Typhlitis in many respects very closely resembles appendicitis, but the rarity of this disease as compared with appendicitis must be remembered in making the differential diagnosis between these two acute inflammatory affections in the ileocecal region. Typhlitis is usually attended by coprostasis, and the existence of a doughy swelling in the cecal region during the beginning of the attack speaks strongly in favor of typhlitis. If any doubt exists, the administration of a laxative and a high enema will often promptly confirm or correct the diagnosis.

Tuberculosis of the cecum is a chronic affection and lacks most of the clinical features that characterize appendicitis.

It is more difficult to differentiate between some forms of mechanical intestinal obstruction and appendicitis. As a rule, in intestinal obstruction the constipation is absolute, vomiting persistent, and the intestinal peristalsis violent. Appendicitis is always attended by more or less rise in the temperature, tenderness in the region of the appendix—symptoms that are absent in intestinal obstruction.

Intestinal catarrh caused by the ingestion of indigestible food often manifests itself by symptoms that might suggest an appendicitis, and the diagnosis is often uncertain, as it is well known that acute indigestion frequently precedes appendicitis. The *diarrhœa crapulosa* and the gaseous distention of the intestines almost from the beginning of the attack are strong evidences in favor of acute indigestion and against appendicitis. Castor oil in laxative doses will decide the diagnosis in a few hours.

Renal colic has been mistaken for appendicitis, and vice versâ. The passage of a renal calculus is attended by the most excruciating pain along the ureter, and frequently by retraction of the testicle on the corresponding side. Examination of the urine will prove of great diagnostic value in making the differential diagnosis between these two affections. Renal colic does not give rise to fever, and is not attended by any symptoms indicative of intestinal or peritoneal irritation. The passage of a biliary calculus is inaugurated by intense paroxysmal pain in the upper right segment of the abdomen, which radiates to the back or shoulder of the same side, and chills and vomiting are the rule. If the obstruction lasts for any length of time, jaundice appears, which, if any doubt remained, sets this aside.

In the female ovaritis and salpingitis add to the difficulty in establishing the diagnosis of appendicitis. Combined vaginal and abdominal palpation is to be relied upon in making a differential diagnosis between these two inflammatory affections of the female internal organs of generation and appendicitis.

Treatment.—The rational treatment of appendicitis must depend entirely on the anatomicopathologic form of the disease. The views of the profession on this subject at the present time might be divided into three categories: (1) Exclusively surgical; (2) exclusively medical; (3) medical treatment, as a rule, surgical treatment in cases in which the indications for an operation are clear. Extreme doctrines are seldom tenable, and one-sided exclusive practice is never safe. There are few rules without exceptions, and this is particularly applicable to the practice of medicine and surgery. It would be difficult to find a physician to-day, no matter how well informed and eminent he might be, who would feel that he had discharged his duty to his patients suffering from appendicitis by making a diagnosis and then handing them over to the surgeon for operative treatment. There are only a few surgeons who make the claim that appendicitis is a purely surgical disease, and who resort

invariably to the knife as soon as the disease is detected. The men who hold and defend this view argue that if an early diagnosis is made and an operation promptly performed, the chances for life are better than under conservative treatment and late operations, should subsequent complications make them necessary. Such an argument is contradicted in the most forcible manner by the well-known clinical fact that from 80 to 85 per cent. of all cases of acute appendicitis recover under judicious medical treatment. On the other hand, the claim can again be made that of these cases, an unknown percentage is liable to suffer from subsequent attacks. There can be but little doubt that a person who has passed through an attack of appendicitis is predisposed to subsequent attacks. The percentage of those who suffer relapses remains undetermined, but every practitioner has seen no inconsiderable number of cases where patients remained in perfect health throughout the remainder of their lifetimes, so far as the appendix was concerned. I have seen my share of cases of acute appendicitis recover completely and permanently under medical treatment. It has been my experience that relapses are more likely to occur in the more chronic and milder forms of appendicitis, including the catarrhal and obliterating varieties. The greatest doubt in the mind of the conscientious physician arises when confronted by a case of acute appendicitis during the first attack, and attended by stormy symptoms. It is in such cases that careful observation and good judgment are required to determine what to do and to decide when to operate in case the medical treatment is deemed inadequate to meet the existing indications. *The medical treatment, however, has an important place in the management of every case of appendicitis, and should never be ignored.*

A diagnosis of appendicitis having been made, the first thing that suggests itself is to place the patient upon an appropriate diet. Solid food of any kind must be absolutely forbidden, and liquid food reduced to a minimum; in fact, for the first few days it is advisable to abstain entirely from stomach feeding. If vomiting is a conspicuous symptom, nothing but cold or hot water, in small quantities frequently repeated, or ice pills should be given to quench the thirst. If nothing is retained by the stomach, normal saline solution can be administered by the rectum or by subcutaneous infusion. So long as the stomach remains irritable and the temperature continues high, even liquid food will do more harm than good. Kumiss, milk-whey, barley- or rice-water, and thin flour soup will be retained more readily than any other kind of liquid food, and should be given the preference over milk and broths as articles of diet during the acute stage. The appendix being a part of the intestinal canal, it is important to influence favorably peristaltic action by limiting the diet to articles of food that are digested and absorbed in the upper portion of the digestive tract. Much harm is done by administering food that should be withheld, under the belief that the patient's failing strength demands it. Instead of benefiting the

patient, reckless feeding aggravates the disease and increases the danger from perforation and peritonitis. Much has been said in favor of and against the use of laxatives in the treatment of appendicitis. A laxative is a two-edged sword that must be handled with care in the treatment of this disease. *Laxatives must never be given if there are any indications that perforation has taken place. If perforation and gangrene can be excluded and the bowels are constipated, a laxative is indicated as soon as a diagnosis of appendicitis can be made.* The best laxative is castor oil in tablespoonful doses every three hours until the bowels move freely. Some physicians prefer to combine it with olive oil, claiming that the latter is a soothing application to the inflamed surface. If, after the second or third dose, the desired effect is not produced, a rectal enema, not to exceed a quart, and containing besides soap two tablespoonfuls of castor oil or glycerin, should be used to aid the laxative in procuring a free movement of the bowels. *In the absence of positive indications the evacuation of the intestinal canal, and especially the cecum, during the early stages of the disease is one of the most important therapeutic resources.* Free catharsis acts beneficially not only by eliminating pathogenic bacteria from the seat of the disease, but also, at the same time, is the best possible means to secure for the inflamed part what is so much needed—rest, by quieting the intestinal peristalsis.

Opium, the remedy employed so freely and constantly in the treatment of peritonitis but a few years ago, is used to-day with the greatest reserve, especially during the beginning of the attack. Many physicians are entirely opposed to any kind of opiates in the treatment of appendicitis. The objections to the routine use of opium are well founded. This drug and all of its preparations aggravate the intestinal paresis, increase the tympanites, and by so doing favor the development of pathogenic microbes and their migration through the paretic intestinal wall. There is, however, one well-defined and clear indication for the use of the opium, and that is perforation. One of the most important agents for the diffusion of septic material in the peritoneal cavity after perforation has taken place is intestinal peristalsis. *The moment perforation has taken place, all influences must be brought to bear to quiet intestinal peristalsis and to limit the escape of septic material into the free peritoneal cavity.* These objects are attained more nearly by abstaining from the use of laxatives and stomach feeding and by resorting to opium, than by any other known methods of treatment. By securing rest for the intestines and the perforated organ the most favorable conditions are created for the localization of the infection and protection of the free peritoneal cavity by plastic exudates around the focus of primary invasion.

Perforative peritonitis is a surgical affection, and should be regarded and treated as such the moment the accident has taken place, but, unfortunately, the physician is not always summoned at

this opportune time, and a certain length of time must necessarily elapse before the necessary preparations for the operation can be made. This time must be utilized to the utmost advantage in securing the benefits of rational medical treatment.

Operative Treatment.—Even the most conservative surgeons are fully in accord with the progressive physicians advocating early operative interference in perforative and gangrenous appendicitis. Hesitation in such cases only aggravates the danger, and delayed operations have often to deal with complications beyond the reach of successful surgery. The difficulty met here is an early positive diagnosis. If we were in a position to recognize, by infallible signs or symptoms, the existence of a perforation, there would be little difficulty in convincing the patient and the profession of the necessity of an immediate operation. *It is this uncertainty in the diagnosis during the early stages of the disease that is responsible for many unnecessary operations on the one hand, and dangerous delays on the other. Perforative appendicitis should be treated by laparotomy within twenty-four hours after the accident has occurred, because if this period of time is allowed to elapse without active interference, owing to the uncertainty of the diagnosis or unavoidable delay, the peritoneal infection may have reached an extent beyond the limits of a successful operation.*

Early Operations for Appendicitis.—By early operations should be understood a resort to laparotomy within twenty-four hours after a first attack of appendicitis. It is important to make a distinction between early and late operations from a pathologic as well as a technical standpoint. If the operation is performed within the limit of time named, no, or but slight, adhesions are found, there will be no pus, and the mesentery and base of the appendix will be in a favorable condition for amputation and safe disposal of the stump. Early operations are always made in a typical manner—that is, the free peritoneal cavity is invariably opened and the diseased appendix is removed through a comparatively small opening. In all early operations the appendix can be removed without any special difficulties, and by doing so the diseased organ and, with it, the primary source of infection are eliminated. The abdomen is opened by McBurney's muscle-splitting method, which usually secures ample room for the removal of the inflamed organ. The first incision is made about four inches in length, two inches from Poupart's ligament, and parallel with the fibers of the external oblique muscle, and equidistant from McBurney's line. The external oblique muscle is next divided by penetrating the muscle with the point of the scalpel in the upper angle of the wound, and cutting in the direction of the fibers until the lower angle is reached. The incision is made with greater accuracy if the knife is followed by the tip of the left index-finger, thus spreading the wound as the incision is enlarged. The margins of the wound are now retracted sufficiently to expose the internal oblique to the requisite extent. With the

knife and a blunt dissector an opening is made in the middle of the wound in the internal oblique muscle, in the direction of its fibers,

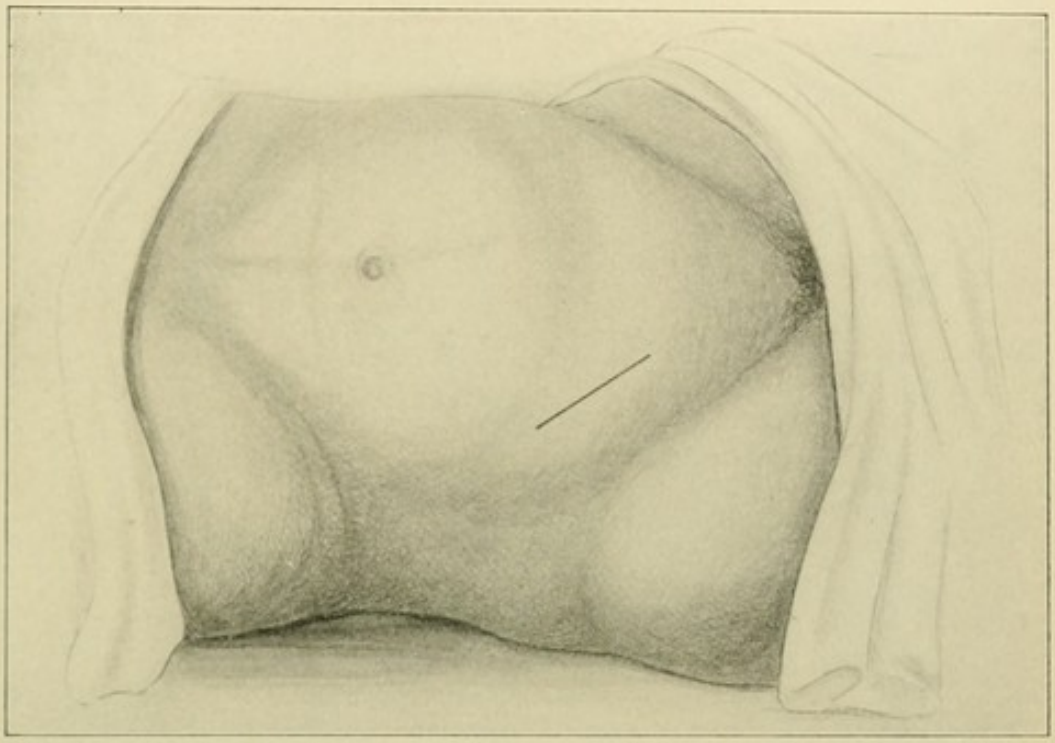

Fig. 467.—Opening the abdomen for the removal of the appendix by McBurney's muscle-splitting incision. External incision.

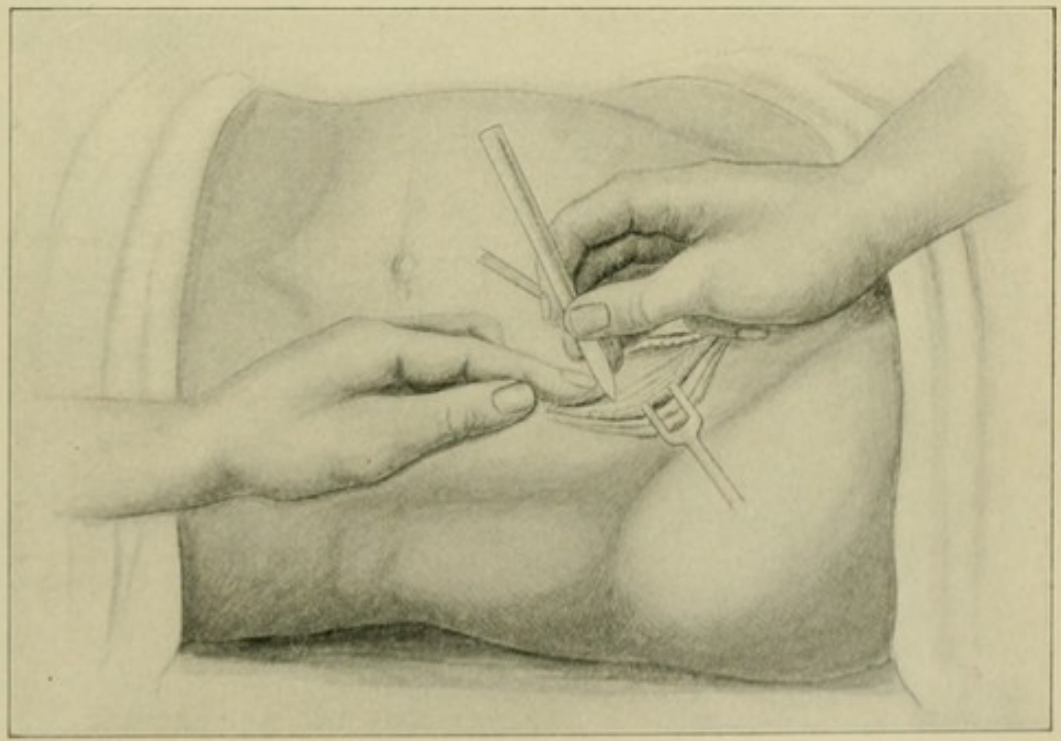

Fig. 468.—Manner of cutting the external oblique muscle in the direction of its fibers.

when the wound is enlarged by inserting the tips of both forefingers, which are then used in dilating the wound to the desired

extent. With blunt retractors the margins of the wound in the internal oblique are then retracted, and the remaining structures

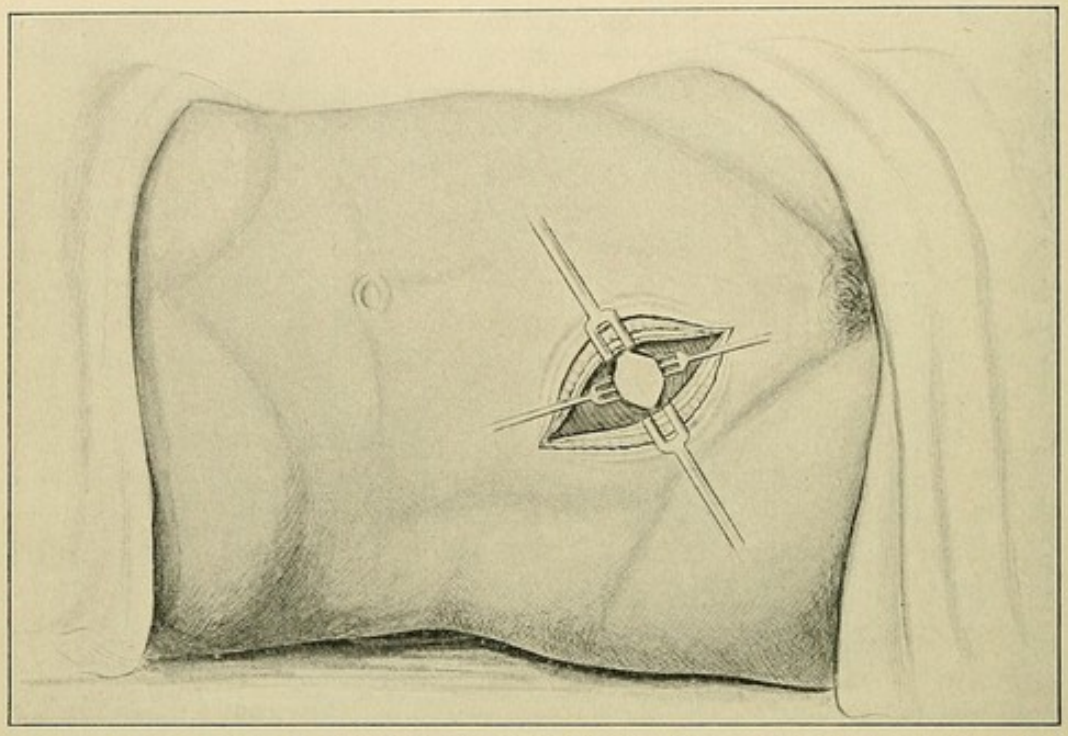

Fig. 469.—Internal oblique muscle divided in the direction of its fibers, largely by the use of blunt instruments and index-fingers; remaining structures ready to be incised between two dissecting forceps.

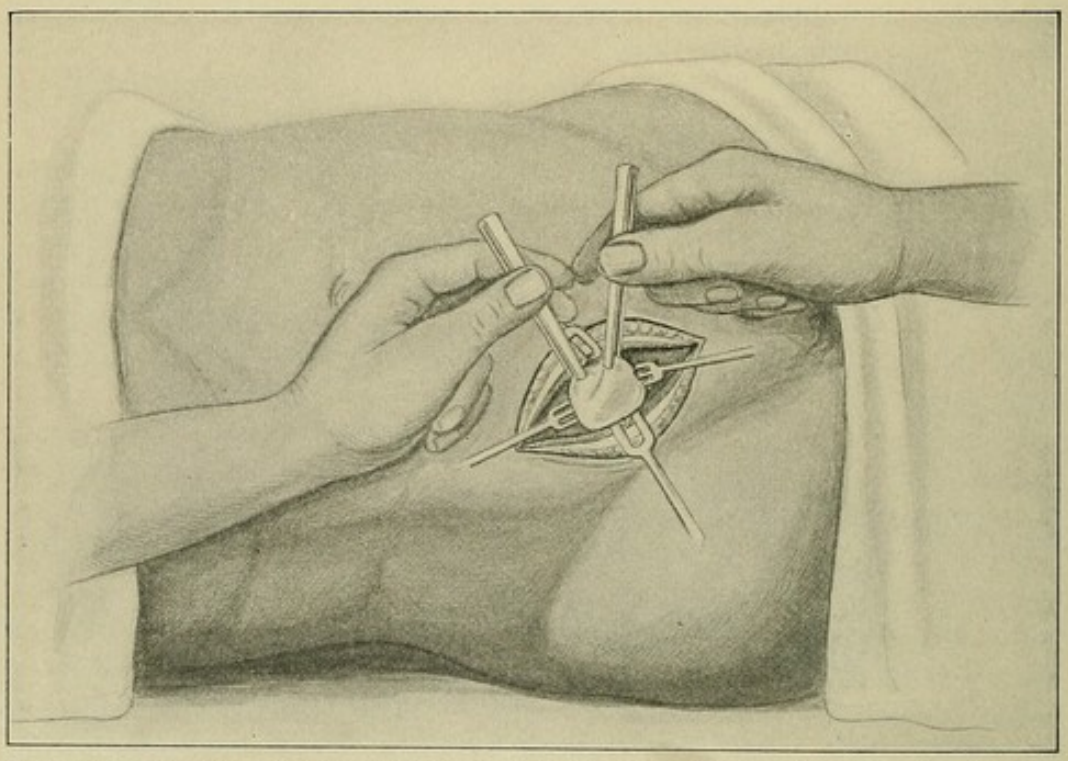

Fig. 470.—Incision of transversalis fascia and peritoneum between two dissecting forceps.

divided between two dissecting forceps. Care is necessary in completing the incision not to include in the grasp of the forceps an

intestinal loop, an accident that occurred in one of the cases in my practice. As soon as the peritoneal cavity has been opened, the omentum usually presents itself in the wound. By inserting the tips of the index-fingers the peritoneal opening is enlarged sufficiently to locate, bring forward, isolate, and remove the diseased appendix.

One of the great advantages of McBurney's muscle-splitting incision is that only slight damage is inflicted upon the muscular part of the abdominal wall, and consequently, if the wound is properly closed, there is very little liability incurred to the

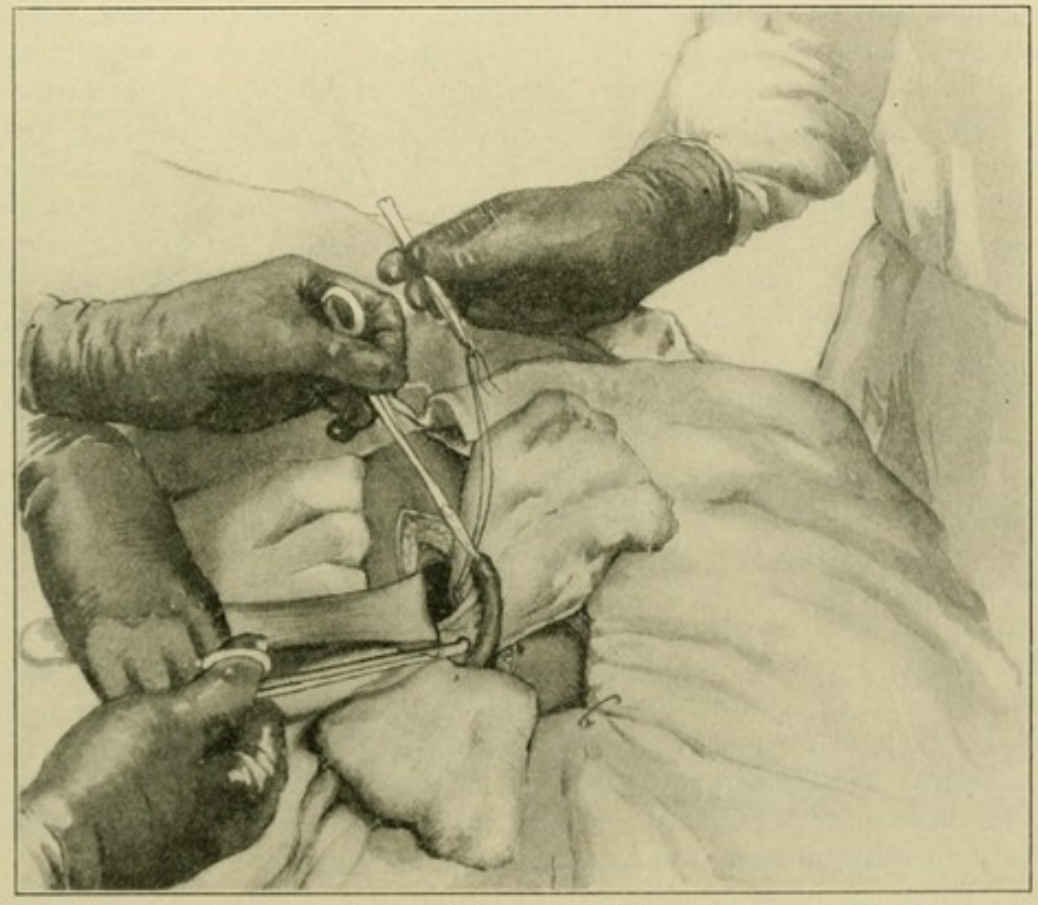

Fig. 471.—Tying off the mesenteriolum (McBurney).

formation of a ventral hernia as a remote consequence of the operation; this latter can not be said of operations in which the incision is made by cutting the abdominal muscles freely, without regard to the direction of their fibers. The opening, made as described, is generally large enough in recent cases for the radical removal of the diseased appendix. The next step in the operation consists in finding the appendix. This may be easy or difficult, according to the location of the organ. If the appendix is in front of the cecum, it is readily found and easy of access. If it is located to the inner or under side of the cecum, which is more frequently the case, it requires more time and patience to expose it.

In searching for the appendix it is necessary first to find and identify the cecum, the longitudinal band in front of which serves as an unerring guide to the base of the organ. The longitudinal band is not only relied upon in serving as a guide to the cecal end of the appendix, but it also serves as a reliable landmark in differentiating between the large and a loop of the small intestine. Should a coil of small intestine present itself on opening the peritoneal cavity, it is pushed, with the omentum, toward the median line, and is held out of the way during the remaining steps of the operation by a strip of aseptic gauze securely fastened in the jaws of a hemostatic forceps. As soon as the cecum is found, the longitudinal band is looked for and followed in the direction of the caput cæci, which always leads to the base of the appendix. As soon as the appendix has been located, the free peritoneal cavity is protected by packing with a strip of sterile gauze, again secured on the outside with the forceps. It is necessary to keep the gauze packing in place until the appendix has been removed and the stump properly disposed of, to prevent peritoneal contamination by extravasation from the perforation during the manipulation of the appendix in performing this part of the operation, and later from the cut end of the stump. After the appendix has been made accessible from base to apex, its mesentery is tied, preferably with fine silk. The location of the principal artery from the free border of the mesenteriolum varies greatly, as well as its size and length. If the mesenteriolum is short, one ligature applied near the base of the appendix will suffice; if it is long, two ligatures may be required. The tissues close to the appendix are tunneled either with locked hemostatic forceps, which are then used in carrying the ligature through the opening, or the artery needle, armed with fine silk, is used in applying the ligature. The tying must be done slowly and in steady jerks, so as to make the ligature cut its way deeply into the tissues in order efficiently to secure the vessels and to guard against slipping of the ligature. The mesentery is cut close to the appendix from tip to base, when the appendix is ready for amputation.

Three methods of amputation recommend themselves with special reference to proper disposal of the stump. The simplest method is by cutting through the base of the appendix near the cecal wall with one stroke of the scissors, as advocated and so extensively practised by Deaver. The head of the cecum just above the base of the appendix is grasped with the thumb and index-finger of the hand in such a way as to prevent fecal extravasation through the cecal opening until the wound is securely sutured, and also for the purpose of fixing the cecum during the amputation of the appendix and suturing of the resulting visceral wound. The small wound in or near the cecal wall is closed by sutures of fine silk inserted with an ordinary sewing needle in the same manner as in closing any other intestinal wound by suturing. Usually two Czerny and from three to six Lembert sutures will suffice. This

method of removing the appendix is a most excellent one, and should be followed in all cases in which the condition of the tissues can be relied upon in furnishing the necessary support for the sutures.

The next method consists in making a peritoneal circular cuff, with which the wound can be covered after the amputation of the appendix—in other words, subserous amputation of the appendix. A circular incision is made through the peritoneal coat, half an inch from the cecum, and with dissecting forceps the peritoneum is reflected as far as the cecum, where the appendix is tied with fine catgut at the base of the peritoneal cuff, and amputated at a safe distance below. The point of an aseptic toothpick is dipped into pure carbolic acid and applied to the mucosa below the ligature,

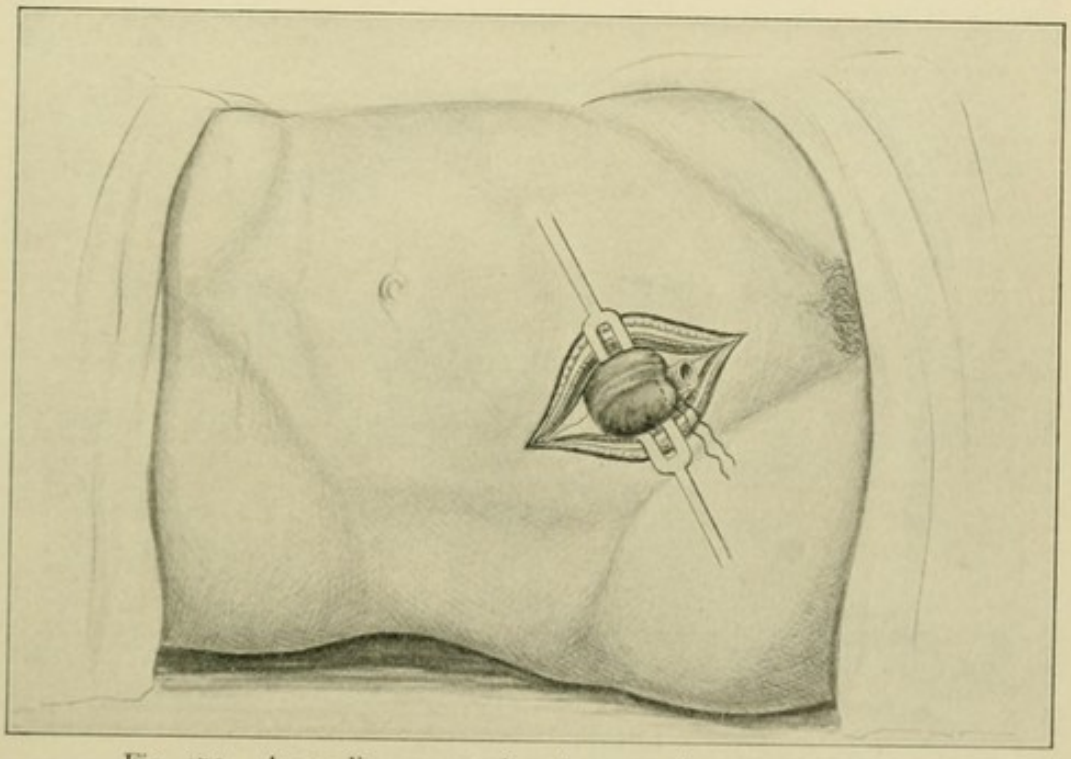

Fig. 472.—Appendix amputated, and purse-string suture in position.

and after the excess of acid has been removed by holding a small gauze sponge for a few moments against the cauterized surface, the peritoneal cuff is sutured over the stump with two or three firm catgut sutures, which are tied after inverting the margins of the cuff. I have dealt with the diseased appendix a sufficient number of times to have become convinced of the safety of this procedure.

The third and most recent method of amputation of the appendix that deserves the confidence of the profession is the one devised by Doyen. Doyen's method consists in grasping the base of the appendix with a pair of strong hemostatic forceps, and making sufficient pressure to crush the muscular and mucous coats, leaving a depression where the ligature of catgut is applied which includes only the serous coat. The appendix is amputated below the liga-

ture, and the circular strip of mucous membrane in the stump is either excised or cauterized with carbolic acid. As a matter of additional safety, the stump is buried by three or four Lembert sutures of fine silk. Very often the stump of the mesenteriolum can be utilized as a covering for the stump by fastening it over the stump with two or three seromuscular sutures of fine silk. Another safe method of burying the stump is by the purse-string suture. With a needle armed with fine silk, fine seizures are made, including all the coats minus the mucosa, when, on tying the suture, the stump is covered by drawing the serous surfaces over it.

Any of these three methods is applicable in early operations for the removal of the appendix, and in making the selection the

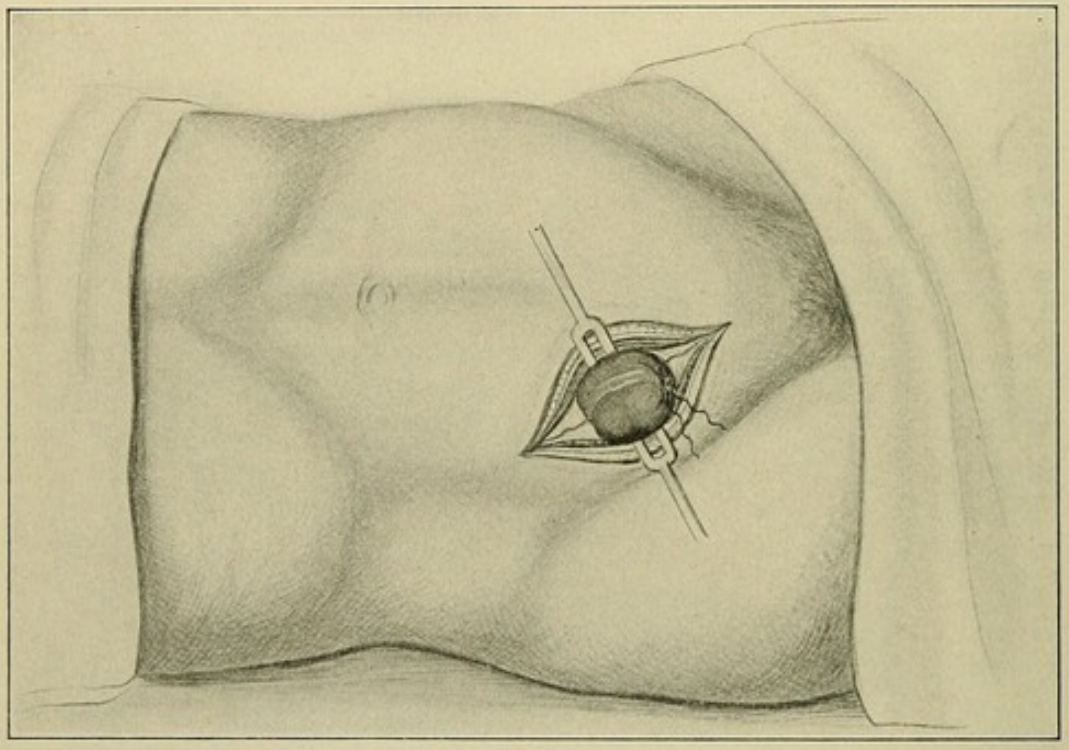

Fig. 473.—Stump buried by tying of the purse-string suture.

surgeon will be guided largely by the condition of the tissues at the site of amputation. In recent cases of appendicitis subjected to laparotomy, flushing of the exposed part of the peritoneal cavity, even in the event that perforation has taken place, is not only superfluous, but harmful. If peritoneal contamination has taken place, from a dram to half an ounce of peroxid of hydrogen is poured into the space from which the appendix was removed, previously well walled off by gauze packing, after which the surface is carefully cleansed by mopping with a gauze sponge.

In all operations for perforative appendicitis drainage is positively indicated, as we have no assurance that any amount of local disinfection has succeeded in eliminating the pyogenic infection. The gauze strip or strips used in protecting the peritoneal cavity

against infection are brought into the lower angle of the wound, and, as an additional precaution, a tubular drain is inserted into the place occupied by the appendix, which is secured on the surface of the wound with a large safety-pin. The peritoneal wound is sutured with fine catgut, leaving sufficient space for the combined tubular and capillary drain. The external oblique muscle is sutured separately to the same extent with coarser catgut. The deep sutures of silkworm-gut include everything outside of the peritoneum, and are tied as far as the drainage opening; the two lowest sutures are left in position untied, but knotted at the end, until after the removal of the drains, when the remainder of the wound is closed by tying the secondary sutures. McBurney's incision can be drained for two or three days with hardly any risk of the subsequent formation of a ventral hernia if the wound is closed by secondary suturing after the removal of the drain.

A large hygroscopic sterile dressing is necessary if the wound is drained, and the dressing is held in place by one or two broad strips of adhesive plaster and gauze roller. If the wound is sutured throughout, a small dressing similarly retained or an iodoform gauze collodion crust will protect the wound against postoperative infection.

It is a uniform rule, to which I make no exceptions, for me to enforce the recumbent position for four weeks after the operation, and, as an additional precaution against the formation of a ventral hernia, I provide my patients before resuming the erect position with a well-fitting abdominal bandage, which is directed to be worn during the day for at least three months.

Intermediate Operations for Appendicitis.—If, during a first grave attack of appendicitis, a radical operation is not performed within the first twenty-four or forty-eight hours, complications are most likely to occur the presence of which may demand an operation as a life-saving measure. The two complications that most frequently necessitate a recourse to an intermediate operation during the active progress of the disease are progressive septic peritonitis and abscess formation. If the primary attack is mild from the beginning or is made harmless, as far as life is concerned, by the encapsulation of the appendix by a localized plastic peritonitis, an intermediate operation is contraindicated. If, on the other hand, the symptoms become progressively aggravated and life is placed in jeopardy from a rapidly spreading septic peritonitis or the formation of an intraperitoneal abscess, an operation becomes a matter not of choice, but of necessity. Both the general and local conditions combine in frequently modifying the technic of early operation. The prostration of the patient and the tympanites make it often necessary to complete the operation as quickly as possible.

The main objects of the intermediary operations are to reach the focus of infection, establish free drainage, and disinfect the area of infection. Attempts to find and remove the diseased appendix under

such circumstances are justifiable only when this can be done without increasing the danger from the extension of peritoneal infection. The leading indication in such cases is to save life by arresting or limiting the intraperitoneal infection. To accomplish this, the most direct route to the seat of infection must be followed, and the peritoneal cavity beyond the limits of the infection must be protected against contamination, as far as possible, by mechanical and chemic means. If, on opening the abdominal cavity in the usual manner over the appendix, it is found that the peritoneal surface has become extensively involved and there are no indications of limitation of the infection by plastic adhesions, the efforts must be directed particularly to limiting further extension of the infective process. If the perforated or gangrenous appendix can be reached without any special difficulty, it is removed in the manner previously described. The opening in the abdomen made by muscle splitting is often too small to deal efficiently with the peritonitis, in which case it is enlarged to the requisite length. Washing out of the accessible area of inflamed peritoneal cavity with a hot saline or Thiersch's solution is recommended by many surgeons whose experience in this department of surgical work is extensive. If the peritonitis has resulted in intestinal paresis and extensive tympanites, evacuation of the distended intestinal coils is an absolute necessity. This can be done in one of two ways: (1) By the formation of an intestinal fistula by a left inguinal enterostomy. (2) By visceral incision of the distended intestine, pouring out of its contents, injecting into the bowel a saturated solution of sulphate of magnesia (one ounce), suturing of wound, and returning the bowel into the peritoneal cavity.

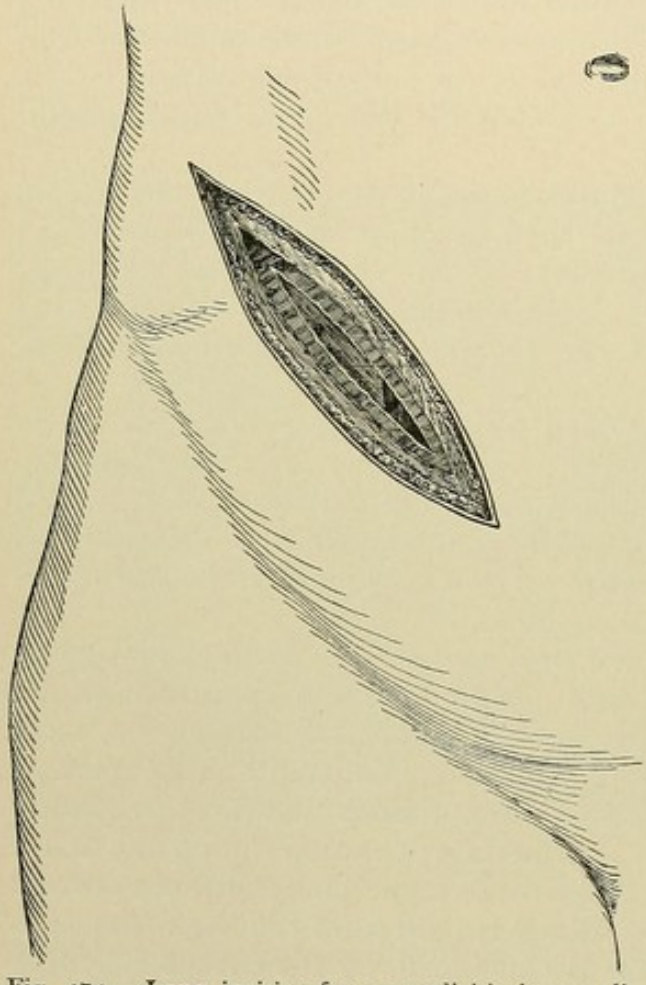

Fig. 474.—Long incision for appendicitis in complicated cases (Kocher).

If it is decided to relieve the intestinal distention by the formation of a temporary intestinal fistula, the left groin should be selected,

in order to bring the fecal fistula far enough away from the operation wound to protect it from subsequent infection from this source, as the first incision is always needed for free drainage. If the peritonitis has become diffuse, extensive tubular and gauze drainage is required. It is advisable in such cases to leave the abdominal incision unsutured, relying upon gauze in preventing prolapse of the small intestine and cecum. A hot moist antiseptic compress over the wound answers a better purpose than a dry dressing. Active stimulation is necessary to support the flagging circulation and to combat the general effect of the septic infection. If the infection is more localized and has resulted in the formation of pus, the principal object of the operation is to furnish a free outlet for the inflammatory product. The use of the exploring syringe in locating the abscess through the intact abdominal wall is unreliable and often dangerous. The exploring needle is occasionally required in locating an abscess after the abdomen has been opened, and can then be used without risk ; the information derived from its employment in this manner is often of great value in guiding the surgeon in finding and opening the abscess cavity. If the abscess is found immediately underneath the abdominal wall, the operation is a very easy one, and unless the appendix can be found and removed without exposing the free peritoneal cavity to risks of infection, it is completed by evacuating the contents of the abscess cavity, pouring into it peroxid of hydrogen, and establishing free tubular drainage. The drain should be at least the size of the index-finger, well fenestrated, and secured with a safety-pin. A dry sterile dressing is applied as a protection against mixed infection. If suppuration continues, daily disinfection with peroxid and irrigation of the cavity with a mild warm antiseptic solution constitute the most important part of the after-treatment. Such cavities often heal in a short time, and permanently, even if the appendix is not removed. A persistent fistula, with or without the escape of intestinal contents, indicates a communication with the interior of the appendix as the result of a perforation or partial sloughing, and may require a secondary operation for the removal of the organ.

If, on opening the abdomen through the free peritoneal cavity, the abscess is found behind the cecum, the surgeon has the choice between two procedures :

1. Packing the wound with gauze in such a way that in the course of a few days the free peritoneal cavity is shut out from the wound by adhesions, and the abscess behind the cecum is made readily accessible to a second extraperitoneal operation (Sonnenburg).

2. The peritoneal cavity is protected by gauze, which is allowed to remain, and the abscess is at once opened and drained. *In such cases the appendix should not be looked for, much less should attempts be made to remove it.* Prolonged drainage always creates a predisposition to the subsequent formation of a ventral hernia.

Late Operations for Appendicitis.—These operations include all

cases in which abscesses need to be opened weeks and months after the acute symptoms have subsided, and in relapsing appendicitis. In the former case, if it is possible, the abscess is always opened and drained by the extraperitoneal route, reserving the removal of the diseased appendix for a secondary operation should this become necessary by persistence of a fistulous tract or by recurring attacks of pain.

Operative interference is always justifiable in relapsing appendicitis after the second attack. The operation is easier, safer, and more successful if it is performed after the cessation of acute symptoms—that is, during the interval. It may be easy or extremely difficult. If the attacks point to the catarrhal form of the disease, the appendix is usually found enlarged, very muscular, free, and can be removed without any special difficulty, regardless of its location. If the attacks appear in the form of circumscribed plastic peritonitis, the appendix is generally found embedded in a mass of scar tissue, and its removal becomes an extremely difficult task. *It is in such cases that I have, for a number of years, resorted to subserous enucleation of the organ.* This is done by first reaching its cecal end, when the peritoneal coat is incised in the long axis of the organ, and, with Kocher's director or a pair of blunt-pointed scissors, the enucleation is made from the base to the tip of the appendix. Hemorrhage is avoided by incising the peritoneum opposite the mesenteric border. With a fine catgut ligature the enucleated appendix is ligated near the cecum, and amputated at a safe distance below the ligature. The exposed mucous membrane of the stump is cauterized with carbolic acid, and the peritoneal envelop is sutured over the stump with two or three fine catgut sutures.

In all operations for relapsing appendicitis the peritoneal cavity is protected against infection by gauze packing, and this is particularly necessary in cases in which small peri-appendicular abscesses are exposed during the isolation or enucleation of the appendix.

I have come to the conclusion that surgical interference is attended by more than the usual amount of risk in cases in which the clinical history points to abscess formation and rupture of the abscess into the cecum during the first attack. Such cases should not be interfered with unless the urgency of the symptoms demands it, because the intrinsic tendency is to an ultimate permanent recovery, and the risks incident to the operation are such as to caution the surgeon against hasty action. In all operations in which pus is found, disinfection of the bed occupied by the appendix and free drainage for a day or two, at least, are urgently indicated.

CHAPTER XIX.

INTESTINAL OBSTRUCTION.

A SURGICAL subject of mutual interest both to the physician and surgeon, but more particularly to the general practitioner, is intestinal obstruction. The pathologic and mechanical conditions that may intercept the fecal current, in part or completely, are so manifold, the symptoms are often so obscure, and the treatment, on the whole, is so unsatisfactory, that such cases nearly always give rise to doubt, misgivings, and not infrequently to hesitation in the minds of the most experienced practitioners. Every one who undertakes the treatment of a case of acute intestinal obstruction feels most keenly the responsibility that he assumes, the difficulties encountered in making an early pathologic and anatomic diagnosis, and the uncertainty that awaits the fate of his patient. It is in cases of this kind that we are always willing and anxious to avail ourselves, where it can be done, of the knowledge, diagnostic skill, and sound advice of one or more of our colleagues, to aid us in correctly interpreting the symptoms at the bedside, and in adopting a course of treatment best calculated to meet the pathologic conditions that have interfered with or completely suspended function in a certain part of the intestinal tract. The general practitioner in isolated communities, far away from counsel and skilled assistance, realizes the responsibility of his position when confronted by a case of acute intestinal obstruction. He knows that the ultimate result always depends on an early correct diagnosis and a rational treatment based on the same. How many professional men are there who are willing to assume the sole responsibility in such a case, and who are in possession of the requisite degree of moral courage to act in accord with their convictions? It requires courage based on knowledge to perform laparotomy in a case of acute intestinal obstruction, with the aid of a lamp or by candle light, in the kitchen or in a small bedroom, without skilled assistance; and yet modern surgery makes such demands on the general practitioner, so situated, in cases in which death would be the inevitable consequence without operative interference.

The importance of intestinal obstruction from a medical as well as a surgical aspect, and the difficulties encountered in its early diagnosis and rational treatment are the apologies offered for giving this chapter, in a book intended for the general practitioner, the prominence that, in my estimation, it deserves.

Frequency.—An examination of the statistics of Leichtenstern shows that, external herniæ and malignant tumors being excluded,

one death from intestinal obstruction takes place in every 300 to 500 deaths from all causes in hospital practice. This statement is based upon the records of the late Dr. Brinton, of London, and a number of large hospitals on the European continent.

Hilton Fagge has shown, from an examination of the records of 4000 autopsies in Guy's Hospital, from 1854 to 1868, that 54, or about ¼ of 1 per cent., were cases of intestinal obstruction.

Heusner, from his own investigations regarding the frequency of intestinal obstruction, maintains that annually out of every 100,000 individuals, from 5 to 10 suffer from this affection, and that one out of every 300 to 500 deaths is attributable to this cause. These statistics show the importance of intestinal obstruction in its medical and surgical relations, and it is eminently proper that this subject should receive the most careful and detailed treatment in a work on emergency surgery, as all operations for intestinal obstruction come within the legitimate scope of emergency work, with which every general practitioner should be perfectly familiar and competent to undertake.

Intestinal obstruction—ileus of the German authors—is a complete or partial arrest of the intestinal contents, due to either mechanical or dynamic causes. In mechanical obstruction the lumen of the bowel becomes impermeable by impaction, invagination, twist, constriction, compression, or flexion—the mechanical causes contributing obstacles to the passage of intestinal contents above the seat of obstruction. Dynamic obstruction is produced by causes (inflammation, defective or suspended innervation, muscular atony) that diminish or arrest peristalsis in a portion of the intestinal canal, of greater or less extent, resulting in accumulation of the intestinal contents in the affected part of the bowel, such accumulation then becoming a secondary mechanical cause of obstruction by aggravating the existing paretic condition. It is in the latter class of cases that medical treatment occasionally proves successful, and for which surgical treatment offers so little as compared with intestinal obstruction caused by purely mechanical causes. Mechanical obstruction, if not relieved in time, always leads to dynamic obstruction by overdistention and paralysis of the intestinal wall above the obstruction, so that not infrequently a partial mechanical obstruction ultimately is followed by complete obstruction due to dynamic causes.

For diagnostic, pathologic, and practical reasons the classification of intestinal obstruction into acute and chronic is of the greatest importance. The mechanical causes that give rise to acute intestinal obstruction usually affect the intestinal canal above the ileocecal valve, while the reverse is the case in chronic obstruction. Recently attention has been called to embolism and thrombosis of the inferior mesenteric vessels as a cause of acute dynamic obstruction. Watson has collected twenty-nine cases, three of which came under his own observation. He mentions as the most important symptoms: (1) Colicky, very intense, not definitely localized, ab-

dominal pain; (2) bloody diarrhea; (3) subnormal temperature. Vomiting, if present,—and next to pain it is the most frequent symptom,—strengthens the diagnosis, as do also abdominal distention and marked prostration; but the first two or three symptoms, when occurring in combination, are the only ones that can be called in any sense characteristic. Pain is the first symptom more often than any other, and its intense character is dwelt on by several authors. In about one-sixth of the cases that came to an autopsy the examination showed that the intestinal lesion, gangrene, was sufficiently limited and well defined to permit of a successful resection of the affected part of the bowel.

The various causes that lead to intestinal obstruction will be alluded to in detail in the discussion of the different anatomic and pathologic forms of the affection.

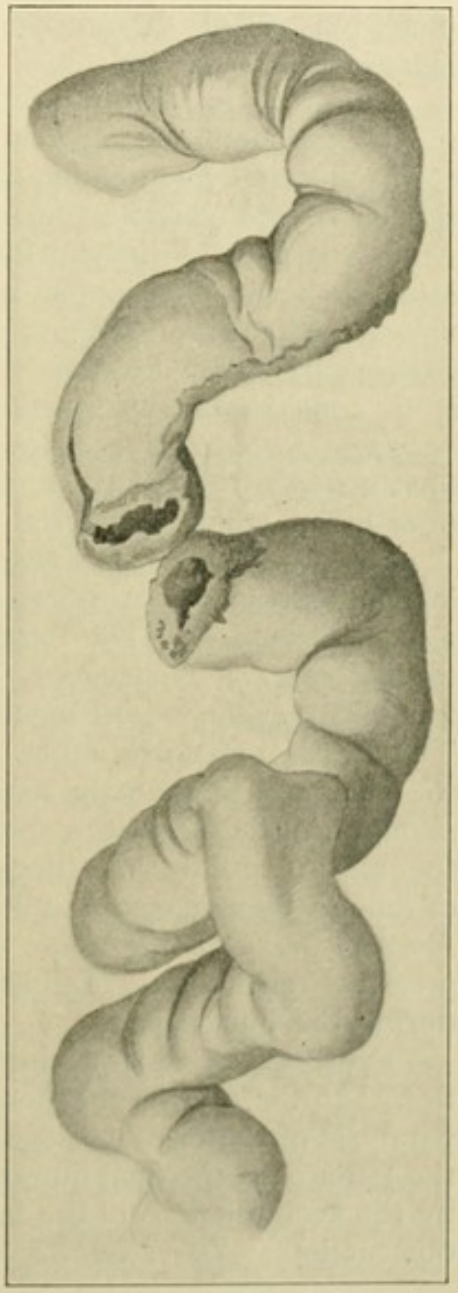

Fig. 475.—Resected intestine. Thrombosis of mesenteric vein (Elliot's case).

Acute Intestinal Obstruction.—Acute intestinal obstruction occurs without any, or with ill-defined, premonitory symptoms, by the development of a group of symptoms almost pathognomonic of this disease. The sudden arrest of the fecal passage is followed almost immediately by violent peristaltic action of the bowel above the seat of obstruction in a vain attempt to clear the intestinal tract, which, from muscular exhaustion and the increased pressure from within, due to the accumulation of intestinal contents, finally gives rise to paresis, and the textural changes that accompany great congestion in relaxed and exhausted tissues. The most prominent clinical evidences of the existence of acute intestinal obstruction consist in: *Absolute constipation, vomiting, intermittent, colicky pains*, and *tympanites*. If the obstruction is complete, as is usually the case except in the milder forms of invagination, the intestinal contents become arrested at once and completely above the seat of the obstruction, and the fecal discharges secured after the accident has occurred, by the use of

enemata or otherwise, represent only the contents of the bowel below the obstruction. The last normal movement of the bowels furnishes some indication as to the time when the obstruction occurred. In the milder forms of invagination liquid feces may pass through the narrowed lumen of the intussusceptum, and, consequently, the obstruction, for some time at least, may not be complete, but usually becomes so later by dynamic causes above the invagination.

Vomiting is present in all cases, and appears early and proves most persistent the nearer the obstruction is located to the stomach—that is, vomiting appears soon and at short intervals if the obstruction affects the upper portions of the intestinal canal, while it is usually delayed for some time and occurs at irregular intervals if the obstruction is located near or below the ileocecal valve. Attacks of vomiting are most likely to occur soon after the paroxysmal attacks of pain. The character of the material ejected is of considerable diagnostic value. Sooner or later the vomiting becomes fecal, and the lower down in the intestinal tract the obstruction is located, the more marked are the fecal appearance and odor of the vomited material.

Colicky Pains.—The pain that attends intestinal obstruction is intermittent, and is produced by and corresponds in time with the violent peristalsis. The location of the pain is little or no indication of the seat of obstruction—at first it is usually referred to the umbilical region, regardless of the nature or seat of the obstruction. The strong peristalsis takes place in the small intestine area, and the character of the pain, as well as its location, rather indicate the situation of the intestines above the obstruction than the location of the obstruction itself. Between the paroxysms of pain a sense of relief is experienced and continues until the next attack sets in. *Pressure does not aggravate the pain;* on the contrary, firm diffuse pressure relieves it. Tenderness is seldom a marked symptom during the intervals.

Tympanites is a sign common to peritonitis and intestinal obstruction. In the former affection it appears in consequence of muscular paralysis of the intestinal wall, resulting from the inflammation; in the latter it is the final outcome of the mechanical distention caused by the accumulation of the intestinal contents above the seat of the obstruction. *The intestine above the obstruction is always found extremely vascular, distended, and fragile; below the obstruction, pale, contracted, and firm. In intestinal obstruction the tympanites is caused exclusively by distention of that part of the intestinal canal above the obstruction.*

Kader has studied, by numerous experiments upon animals, the causes and varieties of distention of the bowel noticed in intestinal obstruction, and has come to the following conclusions:

The distention is due to interference with the circulation of the wall of the intestine or to obstruction by, and decomposition of, the

contents of the intestinal canal above the obstruction. In the first case the bowel-wall becomes thickened, infiltrated with blood, paralyzed, and finally gangrenous, while the intestine is filled with bloody serum and gas, distending it to two or three times its original diameter. In the second class the bowel-wall is not much altered, excepting some paralysis coming on after several days' duration of the obstruction, and, in chronic cases, the compensatory hypertrophy of the muscular coat, while the distention is less marked. Peritonitis, however, will cause the first-described changes to occur even when the circulation of the bowel is not directly involved. If, therefore, the circulation of a loop of bowel is affected by the same cause that obstructs its lumen, we shall have a localized distention and threatening gangrene of the wall, which will occur so early that it can often be recognized before general distention is present. Tympanites is slight or absent if the obstruction is high up in the intestinal canal; marked if it affects the intestinal tract at or below the ileocecal region. Owing to imperfect occlusion of the lumen of the bowel, it is often moderate or slight in many cases of invagination as compared with other forms of obstruction in the same locality. Intestinal distention and tympanites of the free peritoneal cavity can be distinguished by the relation of the liver dullness to the tympanitic area. In the former case the liver dullness is displaced in an upward direction; in the latter event it disappears, unless the organ has become previously immobilized by adhesions or by the presence of gas between the surface of the liver and the chest-wall.

The symptoms that have just been described are those most relied upon in differentiating between intestinal obstruction and peritonitis, a disease that it often simulates very closely. There are other symptoms that must be taken into careful consideration in excluding the latter disease.

The pulse in intestinal obstruction is at first slow and full, becoming small and frequent as prostration and septic intoxication set in, while in peritonitis the pulse is rapid, small, and wiry almost from the beginning of the attack. The temperature remains normal or nearly so in the absence of complication, while in peritonitis it is increased; or, in the gravest cases, subnormal, with the appearance of the other early symptoms. *Rigidity of the abdominal muscles indicates peritonitis, and is never a prominent symptom in intestinal obstruction uncomplicated by peritonitis.* Limited ascites speaks in favor of intestinal obstruction and against acute peritonitis, as has been shown by Gangolphe and Carl Bayer. The former surgeon, as early as 1893, directed attention to what he considered as a new sign, by means of which he thought internal strangulation might be distinguished from other forms of intestinal obstruction. Bayer has called especial attention to limited ascites as an important sign in distinguishing between strangulation of the intestine and peritonitis. Gangolphe encountered a case of obstruc-

tion of uncertain diagnosis ; laparotomy gave escape to a considerable quantity of serosanguinolent fluid, similar to that found in the sac of an ordinary strangulated hernia. On exploration of the abdominal cavity the cause of obstruction was discovered in an internal strangulation of the small intestine in the foramen of Winslow. It occurred to him that the presence of such a fluid might be characteristic of internal strangulation, and so enable the surgeon to distinguish obstructions of this kind from those due to other causes. Experiments made on dogs have since confirmed this view by showing that constriction of a loop of intestine by an elastic ring results in an effusion of bloody serum, both into the peritoneal cavity and the intestine. Moreover, the quantity of the transudation is in proportion to the extent of strangulated intestine and to the intensity of the constriction. This sign is likely to be of especial value in cases of intestinal obstruction in the female, as the presence of ascites in the abdominal cavity may readily be determined by vaginal examination even where the amount of the effusion is limited.

In making a probable differential diagnosis between intestinal obstruction and peritonitis, it is also important to remember the location and character of the pain. In obstruction, as has been stated, the pain is intermittent and almost always referred, at least during the beginning of the attack, to the umbilical region ; on the other hand, in peritonitis it is constant, aggravated during increased peristalsis, but never entirely absent except in cases of peritoneal sepsis, and the seat of pain corresponds with the part of the peritoneum affected. Exquisite tenderness over the inflamed peritoneum is a constant symptom in peritonitis ; it is usually absent in intestinal obstruction. Before coming to positive diagnostic conclusions, it is extremely important to study carefully the clinical history, and to analyze carefully, collectively, and separately the existing symptoms and the order in which they made their appearance. The most difficult cases, from a diagnostic standpoint, are those in which peritonitis is followed by intestinal obstruction, or intestinal obstruction by peritonitis—that is, the coexistence of both affections.

As in strangulated hernia, the symptoms of acute intestinal obstruction are sometimes masked, and their intensity does not correspond with the gravity of the case. Briggs, of Sacramento, has related a very instructive case of this kind. The case was one of acute obstruction from band constriction, and terminated in death from gangrene. The symptoms were so mild that three days after the supervention of complete obstruction and two days' vomiting, the patient traveled thirty-five miles, and the following day walked two miles. The operation, performed on the fourth day after the manifestation of the first symptoms, showed the cause of obstruction to be a band of constriction under which the bowel had been caught in such a manner that two sections, eight and six

inches in length, had become gangrenous, and between these a portion of intestine three inches in length had remained in a good condition. Resection and circular enterorrhaphy were performed, but the patient died two and a half hours after the operation. If, in this case, the operation had been done early,—that is, before gangrene occurred,—it would have been a comparatively easy matter, and the patient would, in all probability, have recovered, as the obstruction could have been removed readily and permanently by simple division or excision of the constricting band.

In contrast with this case we find occasionally, during operations for intestinal obstruction attended by stormy symptoms, pathologic conditions that do not account for the severity of the symptoms. If the tympanites is not extensive, very important diagnostic information can often be obtained by resorting to rectal insufflation of air to the extent of ballooning of the bowel below the obstruction, indicating, approximately at least, the probable anatomic location of the obstruction. Even the most expert surgeons, after resorting to all known diagnostic resources, not infrequently fail in making a correct ante-operation diagnosis. Obalinski proposed abdominal section in thirty-eight cases of intestinal obstruction from almost every possible cause. In about 50 per cent. the diagnosis, both as to location and character of the obstruction, was proved to be accurate. He is of the opinion, in which every surgeon fully coincides, that, even by a resort to all the modern diagnostic aids, an accurate diagnosis is possible only in about one-third of the total number of cases. In the remaining number, when symptoms point to obstruction, but, with our present means of diagnosis, we are unable to make a positive diagnosis, he is in favor of an early exploratory incision through the median line—an opinion sanctioned by most of the surgeons at the present time.

Chronic Intestinal Obstruction.—In chronic intestinal obstruction the mechanical impediment to the passage of feces is progressive—that is, the constriction or compression of the bowel is due to causes that gradually diminish the lumen of the bowel. The intrinsic causes of this clinical form of obstruction are usually cicatricial stenosis, malignant tumors, and the extrinsic inflammatory exudates or tumors, both malignant and benign.

The symptoms usually develop very slowly as the occlusion becomes more complete. In other cases the chronic process which results in obstruction does not give rise to any, or but slight, symptoms until acute symptoms announce the presence of an obstruction. During the early part of the affection the bowel above the seat of obstruction undergoes compensatory hypertrophy, dilatation taking place very slowly unless the chronic suddenly merges into the acute form—an event that is always announced by a complexus of symptoms characteristic of acute or subacute obstruction. Chronic obstruction is more frequently met in persons advanced in years, and the seat of obstruction is usually

located in some part of the large intestine. *One of the earliest indications of the existence of a chronic obstruction is diarrhea, caused by a catarrhal inflammation of the mucous membrane above the obstruction.* It is in cases of this kind that a careful inquiry into the clinical history will usually reveal the fact that irregularity of the bowels—diarrhea alternated by constipation—was present a long time before the patient sought medical advice. Repeated and well-directed questions will frequently result in a statement by the patient to the effect that the stools, when solid, have for some time been smaller in caliber than normal, or flattened. Besides diarrhea, usually alternated by constipation, the most prominent clinical features of chronic intestinal obstruction are attacks of colicky pains, gradually increasing tympanites, and visible intestinal coils during the paroxysmal pains. The colicky pains have the same meaning as in acute obstruction—exaggerated intestinal peristalsis, vain attempts to overcome the gradually increasing mechanical obstruction. The tympanites during the early stages of chronic intestinal obstruction is often temporary, always attended by paroxysmal pains, and relieved by the free passage of gas and liquid intestinal contents. The attacks of pain and tympanites usually come on at irregular intervals, and, as a rule, increase in intensity with each successive attack.

One of the most important signs of intestinal obstruction, both acute and chronic, so long as the muscular coat of the intestine remains active, is the appearance of intestinal coils in the small intestine area during the stormy attacks of exaggerated intestinal peristalsis. In obese persons this sign is absent, owing to the thickness of the abdominal wall. Whenever this sign makes its appearance, it precludes peritonitis, and is an almost infallible indication of the existence of some kind of intestinal obstruction. *In infants and young children chronic intestinal obstruction usually indicates chronic invagination; in young adults, cicatricial stenosis or compression of the intestine by a tumor; in persons advanced in years, malignant disease.*

Medical Treatment.—With very few exceptions, indeed, mechanical obstruction of the intestines is amenable to successful treatment only by early operative interference. In such cases medical treatment is unavailing, and the time lost in experimenting with it adds to the gravity of the case and increases the difficulties to a successful subsequent operation. Medical treatment offers some encouragement in cases of intestinal obstruction due to dynamic causes. According to the statistics of Curschmann, Goltdammer, and Bülau, about one-third of the cases of intestinal obstruction met in general practice can be saved by well-planned internal medication, and we have reason to assume that most of these cases are due to dynamic obstruction; consequently two-thirds of all the cases belong from the very beginning to the surgeon, and must be subjected, at the earliest possible moment, to direct treatment of the mechanical con-

ditions that cause the obstruction. It is in doubtful cases, in which it is difficult or impossible to differentiate between obstruction due to mechanical and obstruction due to dynamic causes that medical treatment deserves a tentative trial, but always in consonance with the significant motto, *nil nocere*. In dynamic obstruction more persistent efforts are not infrequently crowned by success.

Several things must never be neglected in all cases of intestinal obstruction, regardless of its cause: (1) Suspension of stomach-feeding; (2) efforts to move the bowels by copious enemata; (3) lavage of the stomach.

Attempts at stomach-feeding always aggravate the intestinal peristalsis, and consequently provoke retching and vomiting, conditions that can not fail in exerting a harmful influence upon the cause of obstruction, whether this be of a mechanical or dynamic nature. *Stomach rest constitutes an important* element in modifying favorably the intestinal unrest by limiting the intestinal contents. Food and water in sufficient quantities must be supplied by rectal enemata after the large intestine has been thoroughly cleared out by a copious enema. If this method of alimentation has to be continued for a long time and the rectum has become irritable, the nutrient enemata should be administered through the elastic rectal tube, so as to utilize the colon as an absorbing surface. Peptonized milk and beef and albumin of egg in normal salt solution are the best preparations for rectal alimentation. The system is to be supplied with the requisite amount of water, which can be done most speedily and satisfactorily by using the normal salt solution in place of plain water, as it is absorbed much more quickly and causes less irritation.

Evacuation of the colon by *copious rectal injections* is resorted to almost instinctively in every case of intestinal obstruction. This procedure is of therapeutic value by emptying the bowel of its contents and in increasing peristaltic action below the obstruction. The capacity of the large intestine in adults is at least four quarts, and this is the amount that should be administered. Soapsuds, with the addition of a tablespoonful of common salt and four tablespoonfuls of castor oil, is a very common and useful combination for a simple laxative enema. Some prefer glycerin to oil; others use a solution of sulphate of soda or magnesia. A fountain syringe holding a gallon of fluid is the best apparatus for administering the enema. If the rectum is very irritable, it is necessary to press the margins of the anus closely against the rectal tip until the desired amount of fluid has been administered. The knee-chest or elbow position will materially facilitate the administration of a copious enema. If, for any reason, this position can not be employed, the patient should be placed with the pelvis elevated on the right side, and kept in this position until the injection is expelled by the violent peristalsis which the injection provokes.

Lavage of the stomach is a very important therapeutic resource

in all cases of intestinal obstruction. The accumulation of intestinal contents above the seat of obstruction acts deleteriously in several ways:

1. It causes violent peristaltic action of the intestine above the seat of obstruction.

2. It exhausts the patient's strength by causing persistent retching and vomiting.

3. It is one of the causes that produce distention of the intestine.

4. It favors fermentative and putrefactive changes in the intestine by the fluid serving the purpose of a nutrient medium for pathogenic micro-organisms. In my experiments on animals, where I made complete obstruction I never witnessed such persistent vomiting as in man. I attributed this difference to the fact that animals thus treated refuse, as a rule, both food and drink, and that the intestinal canal, in proportion to the size of the abdominal cavity, is much shorter than in man. Patients suffering from acute intestinal obstruction should abstain from taking either food or drink, as digestion and absorption are almost, if not completely, suspended, and the accumulation of fluids can not fail in aggravating the symptoms.

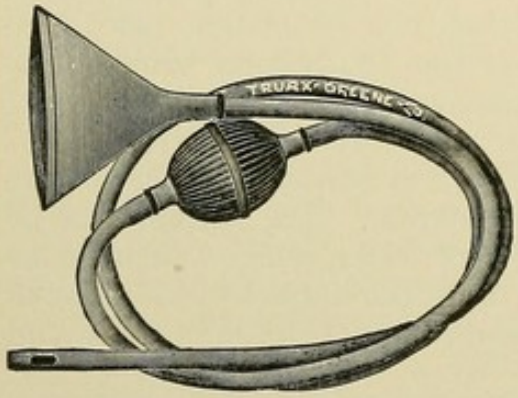

Fig. 476.—Soft-rubber stomach-tube with funnel and exhaust bulb.

Kussmaul has introduced a new and exceedingly valuable therapeutic measure in the treatment of intestinal obstruction in the use of the elastic stomach-tube. By the siphon action of the tube, gas and fluid contents of the stomach and upper portion of the intestinal canal are evacuated, and thus abdominal distention is relieved and the hydrostatic pressure in the intestine above the obstruction diminished. He claims for this measure the following advantages: (1) Intra-abdominal tension is diminished, and thus the first condition secured for the correction of the mechanical difficulties that have caused the obstruction. (2) It relieves the distention of the bowel above the seat of obstruction, and consequently also the pressure of the intestines against each other, a condition that can not fail to impair peristaltic action. (3) Finally, what is most important, by evacuating the accumulated contents it diminishes the violent peristalsis. He reports the case of an adult where an intestinal obstruction, due to an invagination, had lasted twenty-three days, and that yielded to daily irrigations of the stomach. A portion of the intussusceptum sloughed and was found in the stool. The patient died later of peritonitis, which may have started from the seat of invagination.

Bardeleben, in a paper on the treatment of acute intestinal obstruction, praises the utility of irrigation of the stomach as a palliative means, but speaks at the same time of the danger incident to the employment of such a temporizing measure, as too much valuable time may be lost before a curative treatment is adopted. He reports a case in which irrigation afforded such absolute relief that the operation was postponed until it could no longer be of any avail. Kuester expects from irrigation of the stomach prompt palliative effects, but warns not to persist with it in cases where the seat and cause of the obstruction can be ascertained. Hahn looks upon it as a curative agent only in cases where the obstruction is due to coprostasis in the large intestine, and he claims that in such cases irrigation of the colon would lead more promptly to the desired result.

Schlegtendal claims that lavage of the stomach in the treatment of intestinal obstruction fulfils a threefold therapeutic indication: (1) It prevents distressing symptoms; (2) it alleviates them when they are present; (3) in some cases it cures the disease.

Rehn maintains that irrigation of the stomach, as devised by Kussmaul, in the treatment of intestinal obstruction not only empties the stomach of its contents, but also evacuates a certain portion of the intestinal canal above the seat of obstruction. In two cases of intestinal obstruction where this expedient was resorted to after the abdominal cavity was opened he observed that a considerable portion of the dilated intestine was emptied of its contents.

Heusner states that by this means many liters of intestinal contents can be removed, pain is relieved, eructation and vomiting are controlled, peristalsis is quieted, the function of the stomach is restored, and suitable nourishment can be taken and assimilated, thus maintaining strength and life until the cause of obstruction is removed spontaneously or through the intervention of surgery. Madelung has called attention to the necessity of resorting to irrigation of the stomach prior to the administration of an anesthetic in operations for intestinal obstruction, as without such precaution there is danger, during the attacks of vomiting that are almost sure to be provoked by the anesthetic, of fluid entering the trachea, causing suffocation or, later, pneumonia.

As an aid in the treatment of intestinal obstruction due to mechanical causes, irrigation of the stomach should always be systematically practised every four to six hours, but as a curative measure it should never be relied upon. I have always combined emptying of the stomach with irrigation, using large quantities of warm water rendered antiseptic by the addition of salicylated soda or hypophosphite of soda. The washing out of the stomach with a harmless and efficient antiseptic solution has a decided beneficial effect in preventing fermentative and putrefactive changes in the intestinal contents above the seat of obstruction.

The use of cathartics, as a rule, can not be condemned too strongly. They may prove useful in isolated cases of dynamic obstruction in which the muscular coat of the affected intestine is in a condition able to respond to the stimulation of the cathartic, but such cases are rare, and it requires great diagnostic skill to make a safe selection of cases. If it is deemed advisable to resort to cathartics, calomel and the saline preparations deserve the preference. Twelve grains of calomel and half a dram of bicarbonate of soda rubbed together with a little sugar and divided into twelve powders is a prescription that deserves consideration. The powders should be given at intervals of half an hour or an hour, and if the desired result is not realized, a saline cathartic will be in place. A teaspoonful of sulphate of magnesia in saturated solution every hour or two will act promptly if such a result is compatible with the nature of the obstruction. Not more than eight doses should be used. Seidlitz powders and effervescing citrate and sulphate of magnesia are excellent preparations in such cases. Opium has a place in the treatment of acute intestinal obstruction, as it eases pain, quiets the stormy peristalsis, and contributes much toward securing rest for the intestines and toward preparing the patient properly for the operation. It is always contraindicated in chronic obstruction, as in these cases operative treatment is always indicated as soon as a diagnosis can be made.

In all cases of intestinal obstruction, but more particularly in the chronic form, uniform firm support of the abdomen affords relief to the patient, and is one of the best means of preventing rapid distention of the intestine above the seat of obstruction. Fixation and equable compression are resorted to in other parts of the body as the best known means for controlling muscular spasm. It is only reasonable to expect that the same measures should prove useful in retarding, if not preventing, the violent peristalsis in cases of intestinal obstruction, and especially in preventing overdistention of the intestine. Equable compression of the abdomen should be made before great distention has occurred. Uniform compression of the abdomen is best secured by padding the iliac regions with absorbent cotton and then enveloping the body from the pubes to the tip of the sternum with broad strips of adhesive plaster, which should be made to overlap each other.

Distention of the colon with fluids will often prove useful as a diagnostic as well as a therapeutic aid, more especially in cases of invagination. This procedure has been employed with the intention of utilizing the hydrostatic pressure as a means of correcting the mechanical difficulties that have given rise to the obstruction. This method of treatment and diagnosis brings up the much-disputed subject concerning the permeability of the ileocecal region to rectal injections of fluids and air or gases. The majority of those who have studied the subject, clinically or by experiment, make the positive assertion that the ileocecal

valve is perfectly competent, and effectually guards the ileum against the entrance of both fluids and gases forced into the rectum; others insist that it is permeable only in exceptional cases; and but a few claim that its resistance can be overcome by a moderately safe degree of pressure.

Heschl made a number of experiments on the cadaver, and satisfied himself that the ileocecal valve serves as a safe and perfect barrier against the entrance of fluids from below. In testing the resisting power of the coats of the intestine, he found that the serous coat of the colon gave way first to overdistention, while the remaining tissues yielded subsequently to a somewhat slighter pressure.

Ball has found that in the adult one quart of water injected by the rectum will reach the cecum, but that the entire capacity of the large intestine is from four to five quarts. He is of the opinion that in the living body fluid can not be forced beyond the ileocecal valve, although ancient and modern experimenters claim to have succeeded in doing so in the cadaver. He affirms that when the rectum and colon are distended by air, the ileocecal valve is rendered incompetent and the air passes into the small intestine.

Cantani is a firm believer in the permeability of the ileocecal valve to fluid by rectal injections. In one instance he treated a case of coprostasis by an injection of a quart and a half of oil by the rectum, and an hour later a part of the oil was ejected by vomiting. He advises that the intestinal tract above the ileocecal valve should be utilized as an absorbing surface in cases requiring rectal alimentation, and when in a diseased condition, should be treated by topical applications.

Behrens concluded from his experiments that it required the insufflation by the rectum of more than a quart in volume of air to reach the ileum through the ileocecal valve. In his experiments he had no difficulty in overcoming the competency of the ileocecal valve by rectal insufflation of air.

Debierré made numerous experiments on the cadaver to test the permeability of the ileocecal valve to rectal injections of fluids or insufflation of air. The results that he obtained were not constant. In some subjects the valve proved permeable only to air; in others, to both air and water, while in some no air or fluids could be forced into the ileum by any degree of force. When the intestine was left *in situ*, the valve was found less permeable than when it had been removed from the body. He attributes the different degrees of competency of the valve to variations in the anatomic construction of the valve. If both lips of the valve are equal in length, or if the lower lip is longer, the valve was found impermeable. It proved permeable in cases where the lower lip was shorter, contracted, and smaller than the upper. In the last instance the advancing volume of fluid or air lifted the upper valve, while in the former structure of the valve the margins of the lips of the valve

were approximated, perfectly shutting off all communication between the colon and the ileum.

Mr. Lucas enumerates the following objections against forcible rectal injections of water as a means of reducing an invagination :

1. Owing to its weight, it exerts much too strong lateral pressure for the intestine safely to bear, and he has found it easy to rupture the bowel after death by forcing in water.

2. Should reduction have been accomplished, the contact of a large quantity of water with the large bowel is apt to increase the tendency to diarrhea. He claims, very properly, that gas, on the other hand, is a natural occupant of the intestinal canal, and, while its pressure is of the gentlest, its presence excites no unnatural peristaltic action. He administers an anesthetic to the point of relaxation before the inflation is attempted.

Dawson made a number of experiments on the cadaver, and came to the conclusion that when the ileocecal valve is in a normal condition, it effectually guards the small intestine against the ingress of fluids from below.

Illoway devised a force pump that he strongly recommends for the purpose of forcing water beyond the ileocecal valve in case the obstruction is located above that point. He reports four cases treated by this method, three of which recovered.

Battey believed that the ileocecal valve is permeable to the passage of fluids forced into the colon if the patient is anesthetized.

Insufflation of air by the rectum in the treatment of intestinal obstruction has been known since the time of Hippocrates. Gorham was the first to resort to this method of treatment in England. In comparing the effects of enemata to air insufflation, he says : "But the effect is totally different when air is used ; its freedom from all irritating qualities, its elasticity and expansibility, give it a decided preference over enemata."

In a paper read before the Surgical Section of the Washington International Medical Congress, I detailed the results of a large number of experiments made on dogs to determine, to my own satisfaction, the extent to which the ileocecal valve is permeable to fluids forced from below. In three cases where fluid was forced beyond the ileocecal valve the postmortem revealed multiple lacerations of the peritoneal investment of the large intestine in two of them, while the third animal sickened immediately after the experiment was performed, and died eight days later from the effects of the injury inflicted.

These experiments, combined with clinical experience, leave no further doubt that, practically, the ileocecal valve is impermeable to fluids from below, and that for diagnostic and therapeutic purposes it is unsafe and unjustifiable to attempt to force fluids beyond the ileocecal valve. In two cases of ileocecal invagination in children less than two years of age I succeeded in reducing the bowel by

steady hydrostatic pressure while the little patients were under the influence of an anesthetic and held in the inverted position. In both instances the invagination had existed for two or three days. We should, *a priori*, expect that air and gases, on account of their lesser weight and greater elasticity than water, could be forced along the intestinal canal with less force, and for that reason alone, if for no other, should be preferred to water in cases where it appears desirable to distend the intestine below or above the ileocecal valve for diagnostic or therapeutic purposes.

Rectal Insufflation of Hydrogen Gas and Air.—Hydrogen gas is the lightest of all known gases. I have demonstrated by my experiments that this gas is nontoxic, nonirritant when injected into the connective tissue and into large serous cavities, and is rapidly removed by absorption. Distention of the entire gastro-intestinal canal with this gas by rectal insufflation, both in man and animals, was never followed by any immediate or remote ill effects. Accurate experiments to determine the force requisite to render the ileocecal valve incompetent by insufflation of air or gas had previously not been made, and as it is exceedingly important to obtain accurate information on this subject, I made a number of inflations in animals and man, estimating at the same time the pressure under which it was made, with either a mercury gage or a manometer such as is used by gas-fitters and plumbers. The gas was collected in a four-gallon rubber balloon, and the inflation made by compressing the balloon. The manometer or mercury gage was connected by means of rubber tubing with the rectal tube on one side and the rubber balloon on the other. Numerous experiments showed that when the gas was forced through the opening of a stop-cock, the lumen of which was about the size of a knitting-needle, compression equal to 200 pounds (90 kilograms) would never register more than two and one-half to three pounds of pressure to the square inch. In the living subject the escape of gas from the rectum was prevented by an assistant pressing the margins of the anus firmly against the rectal tube. A number of experiments made for the special purpose of measuring the resisting capacity of the ileocecal valve to the entrance of gas from the cecum into the ileum showed that in a normal condition the valve in a healthy adult person is overcome by rectal inflation under a pressure varying from one and a half to two and one-fourth pounds (0.6 to 1.2 kilograms). This amount of pressure is not sufficient to injure any of the coats of a healthy intestine in any part of its course. As the result of numerous observations on man and animals, it can be stated that when the inflation is made slowly and continuously, there is less danger of inflicting injury than when it is done rapidly or interruptedly. When the patient is placed fully under the influence of an anesthetic, the ileocecal valve yields to a lower pressure than when the abdominal muscles are in a state of rigidity, as this interferes with the requisite degree of distention of the cecum which is necessary to effect

the separation of the margins of the valve. A rubber balloon holding four gallons (twenty liters) is the simplest, safest, and most efficient apparatus for making rectal insufflation both for diagnostic and curative purposes.

Another series of experiments on dogs was made for the purpose of determining the degree of pressure required to force hydrogen gas from anus to mouth—the whole length of the gastro-intestinal canal. In all the experiments the pressure fell rapidly after the ileocecal valve had been opened, but it had again to be increased before the gas reached the stomach and escaped through the stomach-tube. It usually required one-half to one pound more pressure to force gas through the entire length of the alimentary canal than when it had to be forced through only the ileocecal valve. Whenever it becomes necessary to conduct the hydrogen gas a considerable distance along the intestines or through the entire alimentary canal, it is exceedingly important to proceed slowly with the inflation, as under slow gradual distention, half a pound (0.2 kilogram) of pressure to the square inch of surface will accomplish in time a great deal more without doing harm than four times this amount of pressure if the force is applied quickly and only for a short time. In the dog, rectal insufflation of hydrogen gas made under a pressure of one-quarter of a pound, if made very slowly and uninterruptedly, the abdominal walls being completely relaxed by an anesthetic, will not only overcome the resistance offered by the ileocecal valve, but will prove sufficient to force the gas through the whole length of the alimentary canal.

Experiments made on different portions of the gastro-intestinal canal when in a healthy condition and removed soon after death proved that laceration did not take place under a pressure of less than eight pounds, and often it had to be increased to twelve pounds. It was found that the resisting power of the intestinal wall is nearly the same throughout the entire length of the canal, and in a normal condition yielded to a diastaltic force of from eight to twelve pounds of pressure. When rupture took place, it occurred either as a longitudinal laceration of the peritoneum on the convex surface of the bowel, or as multiple ruptures from within outward at the mesenteric attachment. The former result followed rapid, and the latter slow, inflation. The superiority of hydrogen gas or air inflation over injections of liquids in the mechanical treatment of intestinal obstruction is apparent. Liquid injections can not safely be forced beyond the ileocecal valve, and even in distending the entire colon by liquids a great deal more force is required than by insufflation with hydrogen gas or air. Insufflation of hydrogen gas or air is a valuable means of diagnosis in locating the seat of obstruction before tympanites has set in, and therefore best adapted at a time when most needed—during the early stage of intestinal obstruction. If the colon dilates uniformly from the sigmoid flexure to the cecum, the obstruction must be sought for higher up in

the intestinal canal. The passage of gas through the ileocecal valve, rendered incompetent by the distention of the cecum, is always attended by a characteristic gurgling or blowing sound, which is always heard more distinctly by applying the ear or stethoscope over the ileocecal region. Not infrequently the sounds are so loud and distinct that they can be heard at a distance of several feet. If the gas passes the ileocecal valve under a pressure not in excess of that required to overcome it in a state of health, and if, after inflation, a thorough examination of the ileocecal region by inspection, palpation, and percussion reveals nothing abnormal, the search for the obstruction is continued by inflating the small intestine slowly and making frequent examinations of the abdomen to ascertain the height to which inflation has been made and to study the relative position of the different abdominal organs. Inflation is also a useful diagnostic resource in locating the obstruction during laparotomy for intestinal obstruction. The intestine below the seat of obstruction is always empty, collapsed, and anemic as compared with the portion above the obstruction. When the obstruction is located high up in the intestinal canal and the tympanites is extensive, the empty portion of the small intestine has by compression become displaced and is often not readily found. In such cases the distention of the bowel from below will indicate to the surgeon at once the location and length of the intestine below the seat of the obstruction, and will enable him to search for the obstruction from below upward. The manipulation of the healthy intact portion of the intestinal canal in the search for the obstruction is by far a less hazardous procedure than the handling of the distended portion above the obstruction rendered paretic, exceedingly vascular, and much softened by the obstruction. In cases where we suspect the presence of a perforation, inflation with hydrogen gas or air will demonstrate not only its existence, but also its location. Invagination is rare above the ileocecal valve, and its location can be determined by inflation with hydrogen gas or air, and, if resorted to early, it may prove the means of effecting reduction. In ileocecal and colonic invagination slow and persistent distention of the colon with hydrogen gas, with the patients completely under the influence of chloroform, is the safest and most efficient means of effecting reduction, and should always be resorted to whenever these conditions are recognized or even suspected. Rectal inflation as ordinarily practised, by forcing air into the rectum with bellows or a Davidson's syringe, is not devoid of danger, as the force employed can not be accurately regulated or estimated.

Bryant has collected twenty cases of invagination treated by inflation, in three of which it produced rupture of the bowel below the invaginated portion, while in a fourth the child died in collapse shortly after the inflation. He does not look upon inflation as a proper and safe method of treatment in cases of acute invagination, and in the subacute form it should be resorted to only within the

first three days, because later on changes in the bowel are almost certain to have taken place which would render this measure fruitless and probably dangerous.

Knaggs reports the particulars of eight cases of invagination where forcible distention of the bowel by air or water was the cause of rupture or other serious injury to the bowel. These cases show that this method of treatment is attended by great risk to children less than one year of age, as six of the eight cases in which harm resulted were children less than eight months old. In Symond's case the abdomen was opened at once after the rupture had taken place, and the rupture was sutured. The child, however, was too exhausted to rally from the operation, but at the necropsy the sutured wound was found closed.

Metallic instruments should never be used. A case recently came under my observation where a physician attempted to dilate a stricture of the large intestine with a metallic instrument. He perforated the bowel below the sigmoid flexure, and the patient died in less than twenty-four hours from shock and peritonitis.

Tubage is occasionally resorted to as a diagnostic and therapeutic resource. If a rectal tube (Fig. 477) is not available, a large Nélaton catheter or the stomach-tube will serve as a useful substitute. Force should never be used during the insertion of the tube, and the procedure is much facilitated and made more effective by placing the patient in the knee-chest position. Some authors suggest the introduction of a rectal tube in the treatment of obstruction below the ileocecal valve, as first practised by O'Bierne, and claim that with it they have reached the cecum, but Treves assures us that he has made numerous experiments on the cadaver and has never succeeded in passing it further than the sigmoid flexure. Kelly has recently shown that by placing the patient in proper position his sigmoidoscope can be passed into, if not beyond, the sigmoid flexure by careful manipulation of the instrument.

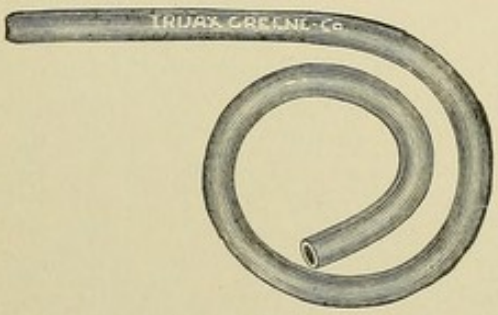

Fig. 477.—Plain elastic rectal tube.

The legitimate indications for tubage of the colon are the following:

1. Detection and location of obstruction below the sigmoid flexure.

2. To relieve gaseous distention of the colon.

3. To administer high nutrient enemata in cases where it becomes necessary to maintain the strength of the patient by this method of feeding.

Manual exploration of the rectum as a means of diagnosis was devised and first practised by Simon. This method of exploration

is applicable only in the adult. Simon and his numerous followers claim that the hand can be introduced sufficiently far to enable the surgeon to palpate most of the abdominal organs. Nussbaum asserts that he has felt more than once the tip of the sternum with the hand employed in the manual exploration by the rectum.

Wagstaff places great stress on the importance of manual exploration by the rectum as a diagnostic measure, as appears from one of his conclusions: "That the causes of obstruction can generally be determined by the history of present and past illnesses and by thorough external examination, and that manual exploration by the rectum is certainly the greatest advance in our means of diagnosis." The glowing accounts of the value of this method of exploration were soon followed by the report of disastrous consequences, such as rupture of the bowel and permanent loss of function of the sphincter muscles. Manual exploration by the rectum should be undertaken only by surgeons with small slender hands, and the examination should be made with the patient fully under the influence of an anesthetic, and always with the utmost care and gentleness. This method of examination will enable the surgeon to ascertain the location and nature of obstructions below the sigmoid flexure, the existence of volvulus at the sigmoid flexure, and to determine the presence of pathologic conditions in the pelvis that might have caused the obstruction. As a therapeutic measure this procedure can be employed in the removal of foreign bodies or an enterolith within reach of the hand, and in the reduction of some cases of intussusception in the adult where the invaginated portion of the bowel has passed beyond the sigmoid flexure.

Taxis and massage have a limited range of usefulness in the treatment of noninflammatory dynamic intestinal obstruction—that is, when procedures are to be restricted entirely to cases in which the obstruction is caused by atony of the bowel-wall, usually the result of long-standing coprostasis.

Hutchinson advocates what he terms *abdominal taxis* under an anesthetic. By abdominal taxis he means a thorough kneading of the abdomen, with inversion of the patient, shaking him, tossing him in a blanket, and a variety of rough performances, the object being to dislodge the bowel or untwist the volvulus. At the same time he advises large enemata and cathartics. If these means do not lead to the desired result, he waits and keeps the patient on a low diet, and administers opium or belladonna internally, and subsequently repeats the abdominal taxis. He reports a number of cases successfully treated by this method. It is doubtful if any surgeon at the present time could be found who would be willing to subject his patients to such primitive treatment as advised by Hutchinson. In most forms of intestinal obstruction such treatment is not only unscientific and useless, but attended by great risk to life, as the violent movements would not only aggravate the mechanical difficulties that have caused the obstruction, but might produce rupture

of the distended intestine, and could not fail in causing exacerbation of the vascular disturbances.

Streubel succeeded, in a boy eleven years of age suffering from intestinal obstruction due to the impaction of a mass of cherry-stones above the ileocecal valve, in removing the cause of obstruction by submitting the swelling to gentle massage frequently repeated.

Marotte gives an account of a case of acute intestinal obstruction that had lasted for some days when fecal vomiting set in, and in which the usual internal treatment with opiates and chloroform afforded no relief, which was promptly cured by palpation of the abdomen, made for the purpose of locating the seat of obstruction. The patient experienced a sensation at the time as though the obstruction had given way, and soon afterward had a number of evacuations in which a gall-stone the size of a walnut was found. This author refers to five cases of intestinal obstruction caused by the presence of gall-stones, collected by Fauconneau-Dufresne. One of these cases came under the observation of Mayo. In this case the gall-stone was also dislodged by palpation, followed by cessation of the symptoms of obstruction and recovery of the patient. The remaining four patients died. In cases of fecal accumulation in any portion of the large intestine from the cecum to the sigmoid flexure, unattended by inflammation and giving rise to symptoms of obstruction, and not amenable to irrigation of the colon, massage and taxis should be made while the patient is under the influence of an anesthetic, so as to enable the operator to break up the mass and to force it onward in the interior of the bowel to a point where the peristaltic action is more active.

Puncture of the intestine is not countenanced by surgeons at the present time as a remedial measure in the treatment of intestinal obstruction, but the general practitioner, in exceptional and well-selected cases, will have occasion to make use of it; consequently a few remarks on this much-abused semi-medical subject will not be out of place here.

Advanced cases of intestinal obstruction are always attended by great distention of the bowel on the proximal side of the obstruction, a condition that causes increased intra-abdominal pressure. The tympanitic distention of the abdomen may be so great as to destroy life by the suspension of important functions from mechanical pressure. The diaphragm is pushed upward so far that death may ensue from asphyxia, or the circulation is so far impeded by compression of the heart as to cause death from syncope. Great distention of the intestines on the proximal side of the obstruction also aggravates the mechanical difficulties which have caused the obstruction, as the distended bowel under such circumstances forms numerous flexions which interfere with the free passage of its contents as far as the obstruction; at the same time, the distended coils may render the bowel less permeable at the seat of obstruction by compres-

sion. The anxiety with which surgeons look upon extensive tympanites following the course of intestinal obstruction is universal; hence it is only natural that for a long time it has been customary to make attempts at affording relief by puncturing the distended bowel through the abdominal wall. A small trocar was usually employed for this purpose, and since the introduction of the hypodermic needle and the aspirator, a hollow needle of one of these instruments has been used. Cases have been reported where repeated punctures not only afforded relief, but finally led to a permanent cure. In some instances the cannula of a trocar after puncture was allowed to remain until a fecal fistula had been established. An intestine distended to the extent of giving rise to distressing and dangerous intra-abdominal pressure is always in a paretic condition, unable to expel its contents, and whatever escapes through a needle or the cannula of a trocar, is expelled by the contraction of the abdominal wall. This applies not only to the liquid, but also to the gaseous contents. I have repeatedly satisfied myself during operations on the living subject, and in animals where the obstruction was caused artificially, that mere puncture empties only a limited space—not more than from six to eight inches on each side of the puncture. If aspiration is practised at the same time, the effect is doubled; further evacuation is arrested by flexions among the distended coils and valvular closure of the collapsed segment of the intestine at the terminus of the evacuated area. The recorded results of puncture of the intestine represent largely only the successful cases, while the numerous failures seldom find their way into literature. Puncture of a healthy intestine with a needle of moderate size is never followed by extravasation, as the irritation incident to the puncture always produces muscular contractions that start from the point of puncture and at once obliterate the canal made by the needle. Puncture of a paretic intestine is always attended by great risk of extravasation, as the muscular coat has lost its tonicity, and the track of the needle or trocar is slower in closing or remains permanently patent. Numerous cases have been reported where a mere needle puncture gave rise to escape of fecal contents into the peritoneal cavity. As the removal of the tympanites is the means, only in exceptional cases, of removing the cause of obstruction, and as the puncture of a distended paretic intestine is never devoid of risk of causing fecal extravasation, the legitimate indications for puncture of the intestine are extremely limited. If employed at all, puncture is applicable only to cases where no mechanical obstruction is present and where the rapid distention of the abdomen in itself constitutes an imminent source of danger. Puncture should never be resorted to with a view to removing liquid contents; its use should be limited to the evacuation of gases. For this purpose one of the smaller needles of an aspirator should be used. The point of the needle should be sharp, so that it can readily be passed through the intestinal wall. The needle should always be disinfected thoroughly

by boiling in soda solution. The puncture should be made at the most prominent point, and the instrument pushed boldly forward until all resistance is overcome. As soon as the gas escapes, the intra-abdominal pressure should be increased by gentle and uniform compression of the abdominal walls. As soon as gas ceases to escape, aspiration should be made and continued as long as anything can be evacuated and until the needle is withdrawn, but not at the time it is withdrawn. Should it be possible to ascertain the location and direction of the part of the intestine to be punctured, it is advisable to make the puncture obliquely in the long axis of the bowel, so as to guard more effectually against extravasation.

Electricity, properly applied, and especially in conjunction with scientific massage, is a valuable remedy in the treatment of intestinal obstruction caused by atony and relaxation of the muscular coat of a noninflammatory origin. It is worse than useless in dynamic obstruction of an inflammatory nature and in obstruction caused by permanent mechanical conditions.

Operative Treatment.—Since laparotomy for other indications has became an established and frequently practised procedure, a number of the bolder and more aggressive surgeons have resorted to direct measures for the relief of intestinal obstruction, but, like all serious operations for otherwise incurable and fatal affections, its general application has met with strong opposition not only by the laity, but also by the profession. The appalling mortality that has attended the operation in the hands of even the most competent surgeons has been quoted in the discussions of this subject in medical societies as a sufficiently strong argument in favor of nonoperative interference. In this regard the history of laparotomy for intestinal obstruction is only a repetition of the history of ovariotomy. During the early practice of the latter the mortality was so great that the operation was condemned and denounced as a deliberate murder by some of the ablest and most influential surgeons. Men who had the moral courage to perform ovariotomy in the face of such bitter opposition only too often reaped a harvest of reproach for having performed their duty toward their patients. Yet in spite of all opposition the good work progressed until, by an improved technic, and more especially by the introduction of antiseptic surgery, ovariotomy in the hands of experts has become one of the safest operations in surgery. To accomplish this, hundreds of lives were sacrificed that thousands might be saved. The early ovariotomists operated only on patients worn out by the disease, and often the subjects of additional serious visceral lesions caused by the prolonged intra-abdominal pressure, the reason for this being the great mortality that attended the operation. To-day the danger incident to opening the abdominal cavity under proper aseptic precautions is so slight that patients suffering from ovarian tumors are encouraged to have them removed as soon as their presence can be diagnosticated,

at a time when the general health remains unimpaired—a change of practice that has still further reduced the mortality of ovariotomy. The mortality of laparotomy for acute intestinal obstruction will be reduced to that of other intraperitoneal operations as soon as surgeons will recognize the importance of operating early, before the patient's strength has been wasted by the disease, and before the parts involved in the operation have undergone irreparable textural changes.

The mortality of abdominal section in the treatment of the different forms of intestinal obstruction will always be great, because the conditions that have caused the obstruction are often an intrinsic source of danger. In others the removal of the obstruction necessitates an intestinal resection that in itself is a vastly more serious operation than the removal of an ovarian tumor. Intestinal obstruction, irrespective of its cause, is always followed by a series of consecutive pathologic changes that, independently of the partial or complete interruption of the passage of intestinal contents, tends to destroy life. The dilatation of the intestinal tube on the proximal side of the seat of obstruction may give rise to such a degree of abdominal distention as to destroy life from suspension of important function by mechanical pressure. In acute obstruction the violent peristalsis on the proximal side of the occlusion causes an increased afflux of blood to the portion of bowel the seat of exaggerated physiologic function, which, after cessation of peristaltic action, remains as an intense venous and capillary engorgement. During the paretic stage the blood-vessels in the intestinal wall have lost their extravascular support, hence transudation and exudation readily take place into the paravascular tissues, which, combined with the capillary stasis attending this stage of the inflammatory process, often result in gangrene. The intestinal wall in a state of inflammation becomes permeable to pathogenic micro-organisms, which are always present in the intestinal canal, and which, after passing through the entire thickness of its walls, enter the peritoneal cavity and induce septic peritonitis—a frequent immediate cause of death. These facts are cogent reasons for adopting surgical measures in all cases of intestinal obstruction due to mechanical causes as soon as a probable diagnosis can be made. If this were done, the two greatest sources of immediate danger attending and following laparotomy,—shock and septic peritonitis,—if not entirely avoided, at least would be less likely to occur, and the tissues the seat of operation would be in a favorable condition for direct treatment and repair. An abdominal section in the treatment of intestinal obstruction is always necessarily attended by some shock, and it is therefore of the utmost importance to perform the operation at a time when the organs of circulation and the nervous system are still in a condition to resist successfully the immediate effects of the operation. Death from septic causes can be avoided only by operating at a time when the intestinal canal at the seat of obstruction and on its proximal side is

still in a condition capable of resisting infection and of undergoing a satisfactory process of repair in case it becomes necessary to incise or resect during the operation. The statistics of operations for intestinal obstruction will improve as soon as we shall be able, by improved methods of diagnosis, to make an early positive diagnosis and to adopt in the treatment positive surgical measures before the prospects of a recovery have been rendered improbable, if not impossible, by days and weeks of useless, and worse than useless, internal medication. True intestinal obstruction, whatever its cause may be, is as strictly a surgical affection as strangulated hernia, and remediable only by the same kind of surgical treatment. Physicians should recognize this fact and should call a surgeon into counsel as soon as a probable diagnosis of intestinal obstruction can be made. To let a patient die of the consequences of a removable cause of obstruction without an operation is a reflection upon the advances of modern aggressive surgery. The difficulties that surround the diagnosis and the present imperfect technic of the operative procedures in cases of intestinal obstruction are not only responsible for the heretofore late operations, but also, to a great extent, for the many failures. Ways and means for more accurate diagnosis will have to be devised by more careful clinical observations and by experimental research; while new and improved methods of operation must be devised and their merits and safety tested by experiments on animals. I am convinced that accurate experimental work of this kind will render essential information in the diagnosis of the obscure causes of obstruction, and will point out more clearly the indications for operative treatment, while improved methods of operation will have to be studied exclusively in this manner. The obstacles that the surgeon encounters in the diagnosis and treatment of many cases of intestinal obstruction often appear insurmountable, but they will be greatly diminished in the future by facts that will be revealed by the results of experimental investigation. Abdominal surgery was founded and developed on American soil, and in the part referring to the treatment of intestinal obstruction ample scope is left for the exercise of the genius and perseverance of the younger members of the profession in this country, who would do honor to the memory of our McDowell, our Sims, and our Gross by honest, faithful, unselfish, original work.

CHAPTER XX.

ENTEROSTOMY.

THE formation of a fecal fistula in the treatment of intestinal obstruction was first recommended by Louis in 1757, and was first successfully performed by Renault, of Joinville, in 1787, and later by Maisonneuve. Nélaton revived the operation in 1840. In a memoir published in 1845 Maisonneuve returned to the subject and boldly advocated the propriety of resorting to this operation in cases where complete obstruction is clearly established, whether from a foreign body, the formation of strictures, tumors, invagination, or whatever the cause might be, provided enteritis had not taken place or that the alarming symptoms—tympanites, stercoral vomiting, etc.—had not resulted in gangrene. Nélaton taught that, by opening the abdomen in the right iliac region and seizing the first distended coil that might present itself, the surgeon, almost without exception, would, by suturing the bowel to the margins of the wound and incising it, establish the fistula near the ileocecal region. The selection of the site of operation and, to a certain degree, its technic as performed to-day, are the same as were proposed by Nélaton, and consequently the operation continues to bear the name of this distinguished surgeon.

Nélaton's right iliac enterostomy is indicated in intestinal obstruction when the patient's general condition is such as to contraindicate a radical operation by laparotomy. *It is the duty of every practitioner to perform it in all cases in which, from lack of assistance, the extent of the tympanites, or the prostrated condition of the patient, laparotomy is out of question. Enterostomy is a life-saving effort, and as such no patient should be allowed to die without giving him the possible benefits of the operation.*

By following the directions given by Nélaton,—and no better advice has since been offered,—the surgeon has no means of selecting the most desirable place in the intestine for making the opening. The only rule laid down by the text-books, and the only one applicable in such a case, is to secure in the wound and open the first distended loop that presents itself. It not infrequently happens that the opening is made far above the seat of the obstruction, an occurrence that is attended by two immediate sources of danger: (1) Physiologic exclusion of a large portion of the intestinal canal, which, in the event of the patient's recovery from the operation and the cause of obstruction remaining permanent, is followed by marasmus which in itself may prove the cause of a subsequent fatal issue. (2) The portion of the intestine between the artificial opening and the seat of the obstruction, being the part that has suffered most from the

effects of the obstruction, remains distended and continues to exert the same deleterious effects as before the operation. These objections should restrict the indications for enterostomy as much as possible, but the practitioner meets with many cases of intestinal obstruction advanced beyond the legitimate limits of a radical operation, in which the operation will occasionally save a life that otherwise would be lost. The operation can be performed in less than twenty minutes, without assistance, with the contents of a pocket-case and without a general anesthetic. Patients in whom this operation is indicated are not in a condition for the safe administration of a general anesthetic. Schleich's infiltration method will suffice in rendering the operation painless or nearly so. Strychnin by subcutaneous injection and alcohol by the rectum should always be given fifteen minutes to half an hour before the operation. After the skin has been cocainized, an incision about three inches in length is made, about two fingers' breadth above and parallel with Poupart's ligament, commencing on a level with the iliac spine. The muscular layers are then anesthetized by a second infiltration, when the external oblique is divided in the direction of its fibers to the same extent, the wound is retracted, and the fibers of the internal oblique and transversalis are separated with blunt instruments. The remaining structures, including the peritoneum, are picked up between two dissecting forceps and incised sufficiently to insert the tips of both index-fingers, when the opening is enlarged by stretching. The first distended knuckle of small intestine that presents itself in the wound is then sutured to the parietal peritoneum, using for this purpose a small, curved, round needle and fine silk. The intestine is anchored in such a manner that its long axis corresponds with the direction of the external incision. The stitches are placed sufficiently close together to prevent the fluid feces that are evacuated later from reaching the peritoneal cavity. The operation should expose an oval space of the bowel about an inch in length and three-fourths of an inch in width. The external wound is diminished in size by suturing to the same extent, when the intestine is incised transversely and the center of each margin of the wound fastened to the skin on opposite sides by one or two sutures of silk inserted with an ordinary surgical needle. The entire thickness of the margin of the visceral wound is included in each one of the external stitches.

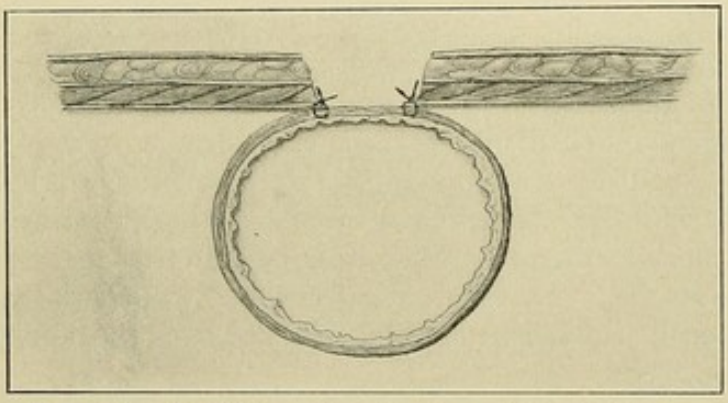

Fig. 478.—Right iliac enterostomy; peritoneal sutures.

Considerable gas and liquid feces will escape with some force, but the amount is often disappointing to the operator. The escape of gas and the flow of feces will increase with the return of peristaltic action on the diminution of the intra-intestinal tension. The employment of elastic catheters contributes but little to the intestinal evacuation. Before the bowel is incised, the sutured portion of the wound should be sealed with collodion and cotton, and the surrounding surface of the skin covered with vaselin or some other fatty substance to protect it against the irritating action of the fecal discharges. The use of a drain is superfluous and often harmful. An absorbent loose dressing, held in place by a bandage, constitutes the dressing.

Witzel has suggested that the intestinal fistula should be made

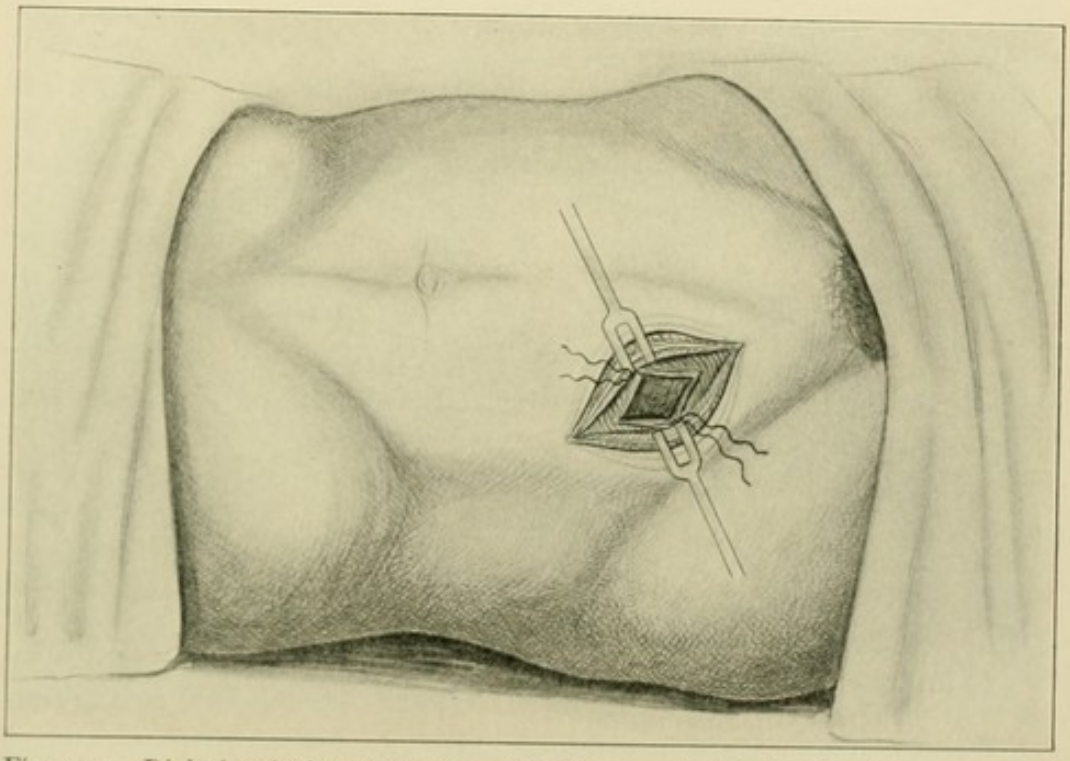

Fig. 479.—Right inguinal enterostomy. Operation completed, showing the two external sutures uniting the margins of the intestinal wound with the skin.

oblique in the same manner as in his operation for gastrostomy. Mikulicz argues that such an oblique fistula will close spontaneously after the object for which it was made has been accomplished. If this expectation can be realized, one of the greatest objections to this operation—a permanent fistula—will be removed. If the patient recovers and the obstruction is not relieved spontaneously, a radical operation can be performed later, with a good prospect of success, and the intestinal fistula is closed at the same time or later. If after developments make it plain that the obstruction itself can not be removed, the intestinal fistula remains permanently as an unavoidable evil unless the continuity of the intestinal tract can be established by a lateral anastomosis.

Enterotomy is the operation that has in view the removal of the mechanical obstruction through an incision of the bowel, followed by immediate closure of the wound by suturing. If the operation is made on any part of the large intestine above the rectum, it is called *colotomy*. The indications for this operation are furnished by impaction of the lumen of the bowel by foreign bodies that can not be dislodged by less formidable treatment, or by pedunculated benign tumors, such as adenomata and submucous lipomata. *The visceral incision should always be made transversely, and never in the long axis of the bowel, as is usually recommended, because transverse wounds can be more readily sutured than longitudinal wounds, and the operation is less liable to be followed by stenosis of the bowel.* The

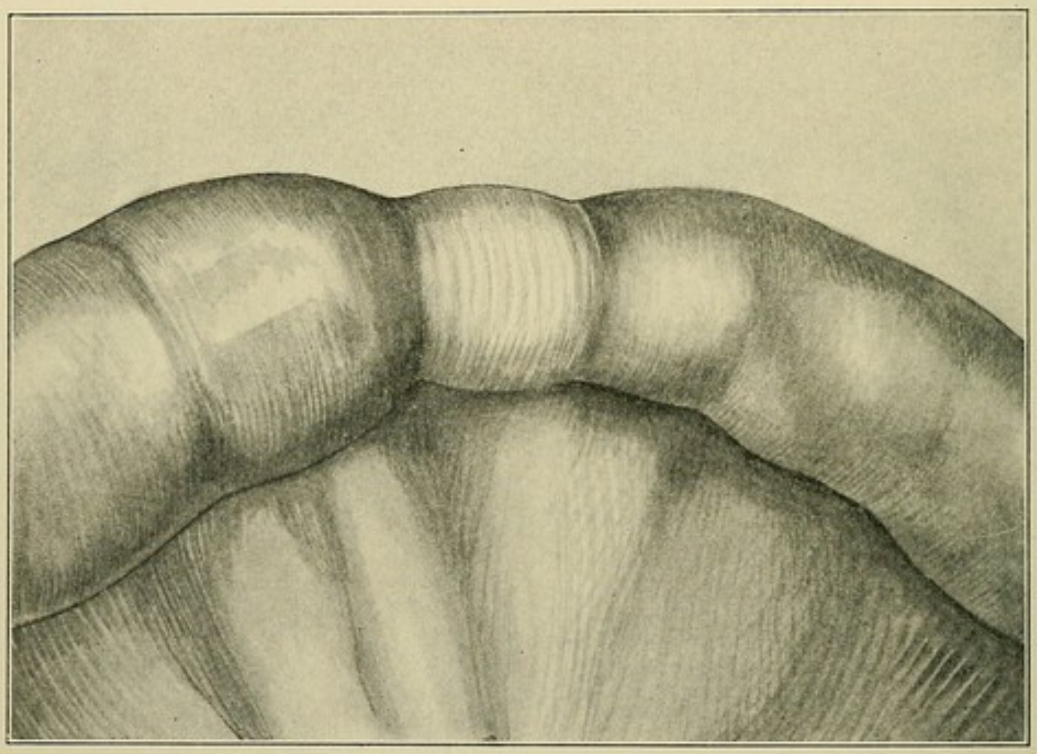

Fig. 480.—Obstruction of the jejunum due to gall-stone, showing the contraction of the muscular fibers of the intestine upon the stone, which is smaller in diameter than the lumen of the gut (Mixter's case; three-quarters size).

only exception to this rule is in cases in which intestinal obstruction by impaction from a foreign body or pedunculated benign tumor is complicated by the presence of a cicatricial stricture. In such an event the incision is made longitudinally, opposite the mesenteric attachment, and the wound is closed transversely in the same manner and for the same reasons as in performing the operation for non-malignant stricture of the pylorus, according to the method devised by Heineke and Mikulicz.

In removing an obstructing pedunculated tumor from the lumen of the intestine the pedicle is transfixed with a needle armed with fine silk, both halves are tied separately, and the tumor is excised at a safe distance from the ligatures, when the visceral wound is

closed in the usual manner. In the removal of mural tumors of a benign nature not sufficiently pedunculated to admit of the use of the ligature, enucleation is the proper procedure. All bleeding points in the bed of the tumor are tied, after which the wound is carefully disinfected and closed transversely by suturing the mucous membrane and submucous fibrous coat transversely with either fine catgut or silk before closing the visceral incision by Lembert stitches.

CHAPTER XXI.

COLOSTOMY.

THE operation of establishing an artificial anus in any part of the colon is now generally known as colostomy instead of colotomy, as was the case until quite recently. It is intended to meet the same indications as enterostomy in cases in which the obstruction is located in any part of the large intestine below the cecum, and in which a radical operation is inapplicable, owing to the nature of the obstruction or the general condition of the patient. It has become a generally recognized surgical procedure as a palliative and life-prolonging operation in cases of inoperable malignant disease and extensive cicatricial stricture in any part of the bowel below the sigmoid flexure. If the artificial anus is established at a point corresponding with the cecum, the operation should be called *typhlostomy;* if it involves, as it generally does, the sigmoid flexure, *sigmoidostomy*. Sigmoidostomy has come into favor of late as a preliminary operation to excision of the rectum for malignant disease. In extensive disease of the rectum necessitating the removal of the sphincter muscles the formation of a permanent artificial anus in the left inguinal region has been favored by a number of surgeons of large experience. The operation can be performed in one or two sittings, according to the general condition of the patient. It is argued, and for good reasons, that an inguinal anus is a less objectionable evil than a sacral anus.

Colostomy will always retain a legitimate place in operative surgery as a palliative and life-prolonging procedure in the treatment of malignant stenosis of the lower portion of the colon, and in cases of inoperable carcinoma of the rectum. The recent advances in abdominal surgery have rendered the old-fashioned lumbar operation almost obsolete. Amussat's operation has few, if any, stanch advocates at the present time. It has held its place in surgery in England probably longer than in any other country, but is hardly ever performed in Germany, and seldom in our own country. The immediate risks to life of inguinal colostomy, properly performed, are very small. Allingham has performed the operation 68 times,

with only 2 deaths, and those were cases of complete obstruction. Cripps reports 45 cases with only 1 death ; this also was a total obstruction case. Edwards has resorted to it in 16 cases, with 1 death ; Reeves reports 65 cases without a death. Goodsall had 22 consecutive recoveries. These statistics, collected by Strauss, show a death-rate of less than 2 per cent.

Cripps has called special attention to the value of temporary typhlostomy in the treatment of complete obstruction of the large intestine. He advises, first, that in all cases if copious enemata have failed, and neither the exact site nor the cause can be ascertained, the abdomen should be opened on the left side, over the sigmoid flexure ; if this part of the bowel prove to be below the obstruction, the wound should be closed and the cecum exposed on the opposite side. Secondly, he advises that a small opening should be made in the distended cecum after stitching it to the parietal peritoneum, and that this opening may be ultimately enlarged or permanently closed, according to the nature of the obstruction, as shown by the subsequent progress of the case. There are cases in which these suggestions may prove of value, but ordinarily we are able, by resorting to the modern diagnostic resources, to make a reliable anatomicopathologic diagnosis if the obstruction is located below the cecum ; consequently, the necessity for establishing a fecal fistula below the ileocecal valve can arise only in exceptional cases.

Colostomy as a palliative operation is usually resorted to in cases of chronic obstruction below the ileocecal junction due to malignant disease, cicatricial stenosis beyond the reach of more conservative treatment, chronic irreducible invagination, and internal fecal fistula not amenable to a radical operation.

The modern operation is performed by opening the peritoneal cavity in the right or left iliac region, according to the part of the large intestine that is the seat of the obstruction, and one of the principal objects of the operation is to terminate the intestinal canal at the artificial anus so as to secure absolute physiologic rest for the affected portion of the bowel below the artificial anus. If it is the intention to establish a fecal fistula only, the operation is performed in the same manner as has been described under the head of Enterostomy. The incision is made a little longer and with special reference to avoiding injury to the muscular fibers.

Maydl's technic of anchoring the intestinal loop in the wound is the one most generally adopted at the present time in establishing an artificial anus in the left inguinal region. In the majority of cases the abdomen is opened in the manner indicated for the operation in the left inguinal region. The external incision is made from three to four inches in length and a finger's breadth above the external half of Poupart's ligament. The external oblique is divided in the direction of its fibers, and the internal oblique and transversalis are opened to the requisite extent by blunt instruments, after which the perito-

neum is divided between two dissecting forceps. The fibers of the different muscles must be carefully preserved, to guard against prolapse of the artificial anus later. If the obstruction is located below the sigmoid flexure, there is no difficulty in finding, identifying, and bringing forward into the opening this part of the large intestine, which is usually supplied with a long mesentery. The longitudinal band and the manner of distribution of the blood-vessels serve as reliable landmarks in distinguishing the large from the small intestine. In obese subjects it is sometimes found difficult, if not impossible, to bring the intestine sufficiently forward to anchor it safely in the wound by the aid of Maydl's bridge. If this is the case, suturing must be relied upon in holding the loop in the wound and in securing the necessary degree of flexion. Ordinarily, the sigmoid flexure is drawn forward into the wound until its mesenteric attachment is on a level with the external incision. Through a slit made in the mesentery close to the intestinal wall with a pair of locked hemostatic forceps is inserted a hard-rubber cylinder or piece of glass tubing the size of a lead-pencil, four inches in length, and wrapped in a layer or two of iodoform gauze. This device holds the intestine in the wound and prevents its return into the abdominal cavity. By means of two Lembert stitches placed on each side of the prolapsed loop and below the bridge, the two limbs of the flexure, in so far as they lie in the abdominal wound, are sewed together so as to make and maintain an acute flexion, so essential a feature in intercepting the fecal current completely. Some care is necessary in preventing a partial twist or volvulus of the bowel before anchoring it in the wound. If this can not be done with a sufficient degree of certainty by following each limb with the finger, the necessary information can readily be obtained by inflating the bowel from the rectum, or by the insertion of a rectal tube or bougie. It is anything but a source of satisfaction for the surgeon to find, on opening the bowel, that the contents, contrary to his expectations, are escap-

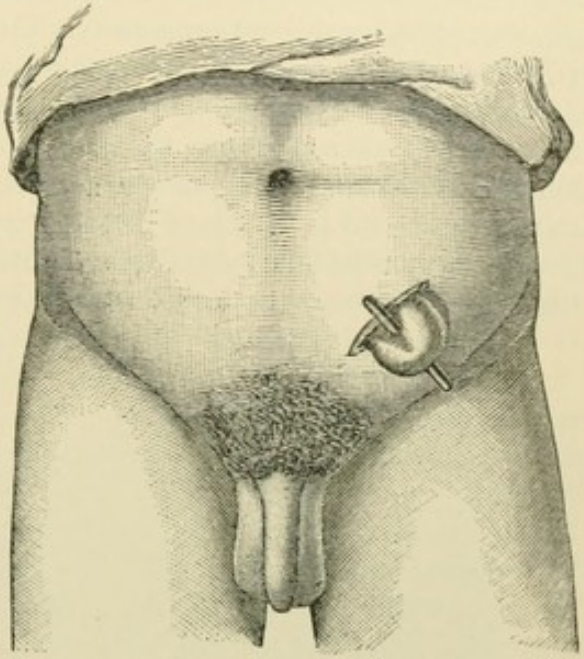

Fig. 481.—Maydl's left inguinal colostomy.

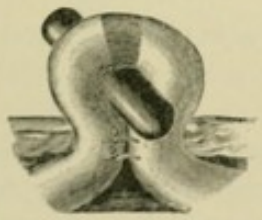

Fig. 482.—Sigmoid flexure brought forward into the wound, and the two limbs of the loop united by two sutures below the bridge.

ing from the lower instead of the upper end. The base of the intestinal loop is next sutured to the parietal peritoneum with at least six fine catgut or silk sutures. This precaution is taken to prevent prolapse of the small intestine should the patient vomit during or soon after the operation, and also to serve as an additional safeguard against peritoneal contamination should it be deemed advisable to complete the operation. Maydl regarded this part of the operation as unnecessary, but a case in my own practice in which such prolapse occurred has taught me the importance of this procedure. The angles of the abdominal incision are sutured sufficiently so that the external wound is in close contact with the intestine, but without giving rise to harmful circular constriction. A small circular dressing of iodoform gauze and cotton is sealed with collodion to the base of the loop and adjacent skin to protect the wound against infection. A piece of gutta-percha tissue, four to six inches square, with a small central opening to receive the apex of the intestinal cone, is fastened to the base of the prolapsed bowel and skin with collodion. If the symptoms are urgent, the bowel is divided transversely over the bridge with the knife or, preferably, with the Paquelin cautery, to the extent of from one-third to one-half of its circumference. If the symptoms are not severe, it is safer to postpone the visceral incision for from twenty-four to forty-eight hours, when it can be made almost painlessly without the use of a general or even a local anesthetic.

Drains inserted into the bowel do more harm than good. Drains were inserted into each end of the bowel by König and Hahn, leaving the bowel in such a condition that both ends could be flushed freely; but this can be done with equal facility without drains. Madelung advises that in cases in which it becomes necessary to establish a permanent artificial anus the bowel should be completely cut across and the lower end closed, but this is objectionable, as it interferes with proper cleansing of the excluded portion of the bowel.

The modern operation of colostomy is indicated in cases of congenital atresia of the rectum when the bowel can not be readily reached from below; also in cases of carcinoma of the sigmoid flexure or of the rectum not amenable to a radical operation. Finally, the operation might become necessary in irreducible colic invagination in which, for anatomic reasons, resection or anastomosis can not be done.

If it is the intention to establish a permanent artificial anus and the progress of the case is satisfactory, the bowel can be cut through completely in two or three weeks, the bridge serving a useful purpose as a guide in making this incision; a few sutures will serve to secure the cut proximal end to the skin. Should the artificial anus be only a temporary one, the incision in the intestine is made in a longitudinal direction. When it has become desirable to close the artificial opening, the bridge is removed, after which the bowel

retracts and the opening often closes without any further treatment. If the adhesions are too firm for this, they are removed and the bowel is sutured and returned into the peritoneal cavity. Lauenstein accomplishes the same object in establishing an artificial anus without the bridge, by suturing first the peritoneum to the skin, thus lining the external incision by peritoneum, then drawing out a loop of intestine, and closing the parietal wound by sutures passing through the mesocolon of the prolapsed portion of intestine, which is thus fastened in the abdominal incision ; next the serosa of each limb of the prolapsed loop is stitched through its entire circumference to the parietal peritoneum.

An interesting discussion has arisen lately in Germany in regard to a step in the operation of colostomy that was described by Knie.

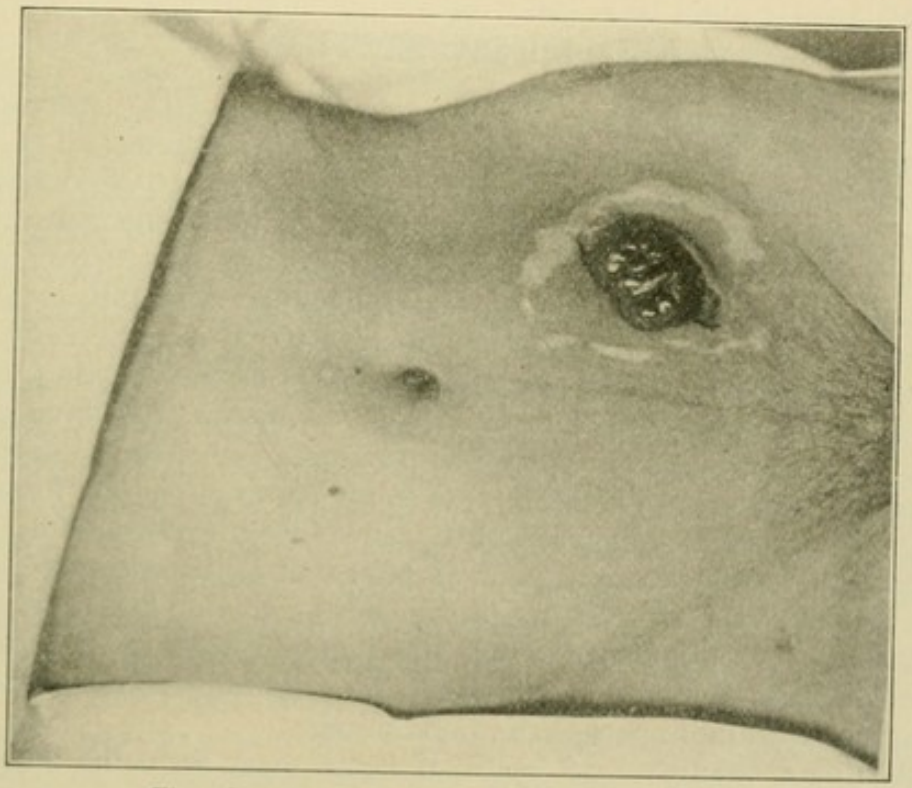

Fig. 483.—Artificial anus after Maydl's operation.

So far the operation has been done only on dogs. It consists in opening the abdomen transversely in the region of the transverse colon, stitching the peritoneum to the edges of the wound, drawing out the colon, making a slit in the mesocolon near the gut with a blunt instrument, and closing the abdominal wound with two or three sutures, which are passed through the slit in the mesocolon. The object of this is to secure a loop of the colon outside of the abdominal cavity. This loop is to be stitched carefully at each side to the edge of the (now) two additional openings, after which it is to be opened by an incision, or, if the symptoms are not urgent, the incision is postponed for a few days until the peritoneal cavity has been shut off by adhesions. As a general thing, Lauenstein's operation

will be found simplest and should receive the preference in ordinary cases.

If the artificial anus is made for an incurable condition, it would appear advisable to divide the bowel completely when it is first opened, and fasten each end to the skin by sutures separately, leaving a bridge of skin three-quarters of an inch wide between them.

CHAPTER XXII.

ABDOMINAL SECTION.

A RADICAL operation in the treatment of intestinal obstruction embraces the fulfilment of two principal indications: (1) The removal or rendering harmless of the cause of obstruction and (2) the immediate restoration of the continuity of the intestinal canal. To meet the first indication the cause of the obstruction must be found, its nature determined, and, whenever advisable or practicable, it is removed, a step in the operation that may be very easy or may demand a most formidable and serious undertaking, more especially in cases where the pathologic conditions that have given rise to the obstruction are of such a nature as to constitute in themselves an imminent or remote source of danger—as, for instance, malignant disease or gangrene of the bowel from constriction. Abdominal section in the treatment of intestinal obstruction has so far been attended by a fearful mortality, owing to the fact that most operations were performed when the patients were in collapse or when the parts involved in the obstruction had undergone advanced and often irreparable pathologic conditions.

Ashhurst tabulated 57 cases of laparotomy for acute intestinal obstruction from other causes than intussusception, from which it will be seen that only 18 terminated favorably, so that at that time the mortality of laparotomy in cases of intestinal obstruction other than intussusception was over 68 per cent. Most of these operations were performed without aseptic precautions.

Schramm has collected 190 cases of intestinal strangulation treated by laparotomy, including 3 cases observed by himself in the practice of Mikulicz. He alludes to the difficulties encountered in the diagnosis of these cases, and pleads in favor of early operative interference. Of this number 64.2 per cent. died, the mortality before the antiseptic treatment of wounds being 73 per cent., and since that time 58 per cent. The cause of obstruction and the death-rate attending each kind may be gleaned from the following table:

Invagination	27 times,	8 cured,	19 died.
Bands or intestinal diverticula	49 "	13 "	36 "
Adhesions	16 "	7 "	9 "
Reduction *en masse*	11 "	6 "	5 "
Torsions	10 "	1 "	9 "
Knotting of bowel	12 "	4 "	8 "
Internal strangulation	12 "	4 "	8 "
Foreign bodies	7 "	4 "	3 "
Neoplasms	38 "	16 "	22 "
Unknown causes	8 "	4 "	3 "

Curtis has collected a large number of cases of intestinal obstruction treated by abdominal section since the year 1873, consequently since the antiseptic treatment of wounds was introduced. His first table shows a total of 328 cases, with 102 recoveries and 226 deaths, the percentage of mortality being 68.9—a higher percentage than that of Schramm's collection. His third table shows that in 101 cases the failure of the operation was due directly to the unfavorable condition of the patient, who was in a dying state in 8 cases. In the majority of the cases with complications, 41 in all, the fatal result was also really due to the condition of the patient, for the existence of peritonitis or gangrene of the bowel at the time of operation shows that there had been too much delay in resorting to operative measures, and most of these cases died a few hours after operation. In 28 cases the cause of obstruction was not found or could not be removed, and in 11 the reports are so defective that the cause of death can not be ascertained from them. Of the remaining 45 fatal cases, 13 died of shock; in three cases the unusual length of the operation was probably the direct cause of death, and in 17 cases sepsis, probably due to the operation, was the cause of death. In 12 cases the cause could not be definitely learned, but as death followed in most of them within twenty-four hours after the operation, it was probably shock and exhaustion. In 247 cases where the cause of obstruction was removed, the mortality was only 62.7 per cent.; while in 47 in which it was not done, the mortality was 86.4 per cent. In 41 cases where the obstruction consisted of invagination, volvulus, adhesions, bands, and internal incarceration, in which the obstruction was not removed, not a single one recovered, although in 16 an artificial anus was made.

The greatest mortality attended cases where from any cause suturing of the bowel was made, attaining the extreme point of 86.6 per cent. in 45 cases. The necessity for a short operation is well shown by the cases collected by Curtis, which give a mortality of 57 per cent. in 190 cases in which the operative interference was limited to relieving the obstruction without wounding the bowel, while it rose to 73 per cent. in 15 cases in which it became necessary to establish an artificial anus after the obstruction had been removed, and to 83 per cent. in 48 cases in which the bowel had to be sutured. In all these cases the true danger lay in the long duration of the operation, for death resulted from the immediate effects of the operation in most of them.

Improved aseptic precautions, a better technic, and prophylactic measures against shock have done much to reduce the former alarming mortality of abdominal section for intestinal obstruction, as is shown by a more recent paper on this subject by Obalinski, based on 110 cases operated upon by himself. Although in some of these cases the operation was done as a last, almost forlorn, hope, 38 recovered. Those who oppose operative interference often quote Goltdammer and others who believe that surgery has done but little in saving life in such cases. Goltdammer treated 50 cases of intestinal obstruction in the Bethany Hospital, at Berlin, on the expectant plan and by the use of large doses of opium, and of these, 15 recovered. There can be but little doubt that in most of the cases that recovered the obstruction was the result of dynamic and not mechanical causes. The uncertainty of the diagnosis and the recoveries attributed to internal treatment have done much to maintain the high mortality of surgical interference by causing a delay of the operation until the complications arising from the obstructions have become the most formidable causes of danger to life.

The statistics given show the value and importance of an early operation, as sometimes delay of only a few hours will bring complications that not only necessitate more time in their removal, but will, at the same time, require a resection or an anastomosis, which, had the operation been done at an earlier date, might have been obviated. The older text-books on surgery always cautioned the practitioner to postpone the operative treatment of a strangulated hernia for a certain length of time, which was often consumed in vain attempts at reduction; consequently the old statistics of herniotomy present a high mortality when contrasted with recent operations. This striking contrast was brought about not solely by an improved technic or by the introduction of antiseptic surgery, but it is largely owing to the modern teaching that it is dangerous to delay an operation, if the strangulation is not relieved by gentle taxis persisted in not for hours and days, but only for fifteen minutes, and at the utmost for half an hour. Modern surgery recognizes the safety of an early operation for strangulated hernia, and the results that have been obtained have demonstrated the wisdom of the change in practice. Vain and prolonged attempts at reduction of a strangulated hernia aggravate the causes that have produced the strangulation and hasten the pathologic changes in the strangulated intestinal loop that arise from the strangulation. If delay is dangerous in a case of strangulated hernia, what can we expect of a laparotomy for intestinal obstruction when postponed until the patient has been exhausted or the local conditions necessitate complicated operative measures? In strangulated hernia the destructive changes in the constricted intestinal loop affect, by continuity and contiguity, primarily only a limited peritoneal surface, while in intestinal obstruction the seat of obstruction is in direct communication with the entire peritoneal cavity, which becomes the seat of a rapidly fatal

septic inflammation if gangrene or perforation has caused the inflammation. A recent intestinal obstruction due to a change of visceral relations, such as flexion, volvulus, and invagination, if subjected to operative treatment before consecutive pathologic changes have occurred, would offer but little difficulty to mechanical correction of the displacement, and, as in such cases the intestinal tube would be in a healthy intact condition, the danger of the operation would not be greater than that of an ordinary ovariotomy. Enough has been said in favor of an early operation in all cases where the signs and symptoms indicate the existence of an obstruction that does not yield to milder measures. Intestinal obstruction is a surgical lesion in every sense of the word, and should be treated from the very beginning upon common-sense surgical principles. To temporize with such cases by the administration of uncertain drugs must be looked upon as evidence of ignorance or unpardonable timidity. The treatment of a case of intestinal obstruction upon the expectant plan until gangrene or perforation has taken place, which, if submitted in time to proper surgical treatment, might have been relieved by one stroke of the scissors, should be considered as gross negligence for which the modern aggressive physician and surgeon can offer no justification or apology. The future progress of abdominal surgery will conquer the difficulties that now surround the diagnosis and treatment of intestinal obstruction. Experimental research and more careful and accurate clinical observation will solve the difficult problems that now surround us in this as yet imperfectly explored field of surgical labor. Laparotomy for intestinal obstruction should not be undertaken by every tyro in surgery. The one who undertakes it should be master of the situation, familiar with every detail of the technic of different operative procedures, and fully conversant with the manifold complications with which he may be confronted. Every possible contingency must be fully considered before the abdomen is opened, as this is an operation where unnecessary hesitation and loss of time weigh heavily in the balance on the side of failure. Like other abdominal operations, laparotomy can not be mastered in the lecture-room or even under the tuition of experienced surgeons. Those who expect to perform this operation must, in the first place, have a perfect knowledge of the structure and relations of all the abdominal organs in conditions of health and disease, and must acquire the necessary operative skill on the cadaver, and then, what is still more important, should make the more important operations on the living animal. It is not necessary or even desirable that every physician should become a laparotomist, but practitioners distant from medical centers should interest themselves in this branch of surgery and prepare themselves to meet such emergencies. Unlike a patient suffering from an ovarian tumor, patients affected with acute intestinal obstruction can not be transported great distances, and as loss of time leads to disastrous consequences, it is not always possible to secure

from a distance the services of a surgeon versed in abdominal surgery, and for such contingencies every physician should hold himself in readiness.

The technic of intestinal resection, anastomosis, and suturing can be acquired by operations on the fresh intestines of dead animals. Unnecessary experiments should not be made on the living animal, as this would be an unpardonable cruelty: a few operations on the living intestine will suffice to prepare the physician properly for emergency operations of this kind.

Preparations for the Operation.—The most careful and perfect preparations should be made for the operation. The presence of at least three reliable and intelligent assistants is an absolute necessity. As an eventration may become necessary and exposure of the intestines to a cool atmosphere is productive of shock, an equable temperature of from 80° to 85° F. should be maintained in the operating room from the beginning to the end of the operation. Opinions among operators may still differ as to the wisdom or even propriety of using antiseptics in a healthy peritoneal cavity, but no one at the present day would have the courage to oppose the use of *strictest aseptic precautions in securing an aseptic condition for everything that will come in contact with the wound of the peritoneal surfaces.* The operating room must be cleared of everything, leaving the walls and floor bare, and the whole of its interior surface washed with a strong solution of sublimate or carbolic acid. The table and stands are disinfected in a similar manner. The blankets, if not perfectly aseptic, can be covered with linen sheets. Heat is the most reliable, safest, and cheapest sterilizer, and can be used for the disinfection of towels, napkins, instruments, and wash-basins. *The operator must satisfy himself of the aseptic nature of everything that is to be used inside the peritoneal cavity.* The abdomen of the patient and the operator's and assistants' hands are rendered aseptic by washing with potash soap and warm water, and afterward with a 1 : 1000 solution of sublimate. The water used for solutions and sponges is sterilized by boiling. For the protection of prolapsed intestine, compresses of aseptic gauze or napkins are better than sponges, and the temperature of the parts is maintained, not by pouring warm water on the compresses, but by removing them and applying new ones wrung out of warm saline solution. The danger of using corrosive sublimate solution within the peritoneal cavity is well shown by Kümmell's experience. He made nine laparotomies, using for the sponges a 1 : 5000 solution of sublimate, and all the patients recovered without an unpleasant symptom. Then he met with two cases of sublimate intoxication in succession after having used the same strength of the solution. One of the patients died on the fourth day, and the postmortem revealed intestinal lesions characteristic of acute mercurial poisoning. The other patient recovered after a lingering illness, during which the symptoms of mercurial intoxication were well marked. He cautions against the use of sublimate in debili-

tated, anemic individuals or in patients suffering from renal disease. In cases where the peritoneal cavity is in a healthy aseptic condition, the use of any of the stronger antiseptics is contraindicated. Several gallons of hot sterile saline solution in an aseptic vessel must always be provided, as this solution is now the one generally relied upon for the sponges, compresses, and for flushing the abdominal cavity in cases requiring it. For the cases where septic peritonitis, suppuration, gangrene, or perforation exists, a 2 per cent. solution of boric acid or a saturated solution of salicylic acid (0.3 per cent.) should be kept in readiness for flushing the abdominal cavity. Bands of rubber or fine rubber tubing should always be on hand, as well as a good assortment of aseptic silk, well-prepared catgut, glass drains, Murphy's button, decalcified perforated bone or vegetable plates, and a full complement of needles and forceps. Stimulants and means to make autotransfusion must never be absent, as prompt interference when symptoms of shock make their appearance may prove the means of restoring the force of the circulation until reaction can be established by other measures.

Weir suggests the administration of a hypodermic injection of from $\frac{1}{100}$ to $\frac{1}{80}$ of a grain of atropin and a large rectal enema of brandy before the anesthesia, for the purpose of increasing the force of the heart's action. Subcutaneous injection of strychnin and a quart of hot saline solution administered by the rectum half an hour before the anesthetic is given will prove valuable in minimizing the shock of prolonged operations. During the operation the peripheral circulation is best kept up by placing the patient on a rubber bed, filled with hot water, and in the absence of such a contrivance by applying to the extremities warm blankets or rubber bags or bottles filled with hot water.

Anesthesia.—A number of American surgeons have recently expressed a preference for chloroform to ether as an anesthetic in abdominal operations, as it is less likely to produce vomiting before, during, and after the operation. Another serious objection to the use of ether, especially in persons advanced in years, is the frequency with which bronchitis is produced when this anesthetic is used exclusively. The use of chloroform, however, is also not free from objection. The depressing effect of this anesthetic on the action of the heart is well known, and as the force of the circulation is almost without exception seriously impaired in these cases, its prolonged use might result in dangerous consequences. The best course to pursue is to follow the use of chloroform by ether. The addition of fifteen minims of nitrite of amyl to four ounces of chloroform diminishes in a marked degree the depressing effect of the latter. The retching and bronchorrhea are prevented by placing the patient first under the influence of chloroform, and the deleterious effects of the prolonged use of this agent are avoided by keeping up the narcosis during the operation with ether. From the time the first incision is made until the abdominal wound is closed the patient

must be kept profoundly under the influence of the anesthetic, inasmuch as any interruption will cause an unnecessary delay in the operation and may result in complications that are not easily remedied. Irrigation of the stomach should always precede the administration of the anesthetic, as evacuation of the stomach, by preventing vomiting, will guard against the entrance of foreign material into the larynx and trachea, which might produce asphyxia during the narcosis or pneumonia later.

Incision.—Differences of opinion still exist among surgeons as to the size and location of the abdominal incision. The advocates of eventration argue in favor of a long incision through the median line. Kümmell advises that it should be carried from the ensiform cartilage to the pubis, for the purpose of affording free access to every part of the abdominal cavity; while, on the other hand, a number of distinguished surgeons, among them Madelung, Czerny, and Obalinski, are in favor of a small incision. Polaillon advocates lateral incision in opening the abdomen for the relief of intestinal obstruction in all cases where the seat of obstruction can be reached more directly by such incision. He also claims that in cases where extensive meteorismus is present, the distended intestines are more prone to prolapse and are more difficult to return through a median than through a lateral incision. He thinks that this is due to a lesser degree of intra-abdominal pressure in the iliac than the middle abdominal region, and that in the former the muscular fibers keep the margins of the wound in contact. He opens the abdomen in the ilioinguinal region by an incision parallel with the fibers of the external oblique muscle, and, if occasion requires, it can be made sufficiently large to permit exploration of the abdomen by the introduction of the whole hand. In lateral laparotomy exploration is less easy, but this operation is indicated in all cases of localized obstruction, circumscribed adhesion, or when any symptoms render it probable that the obstruction exists in one or the other side of the abdominal cavity. In case a distinct swelling, the probable seat of the obstruction, can be detected in the ileocecal region, the ascending or descending colon, as will probably be the case in ileocecal and colic invagination, volvulus of the sigmoid flexure and tumors of the cecum and colon, the incision should be made over the most prominent part of the swelling, as such a course affords the most ready access to the seat of obstruction and greatly facilitates the operative procedures that may become necessary. In reference to these points J. Greig Smith regards it as only less than a surgical calamity to perform median laparotomy for obstruction in the colon, since in the majority of cases it must, he says, be supplemented by a transverse or lumbar incision. In making a lateral incision muscular fibers must be respected, and whenever the size of the incision permits, the knife is used as sparingly as possible, substituting muscle splitting for a clean incision.

In all other forms of intestinal obstruction and in all cases where

it is found impossible to ascertain the nature and location of the obstruction, the incision should be made through the median line. Not much time should be consumed in making the external incision. With successive strokes of a sharp scalpel the tissues are rapidly divided until the subperitoneal layer of fat is reached. This is picked up and nipped between two toothed forceps; when the peritoneum comes into view, it is seized and divided in a similar manner. The incision is then enlarged as circumstances may require, by introducing the left index- and middle finger into the peritoneal cavity, and dividing the tissues with a blunt-pointed bistoury or scalpel between them. Hemorrhage is arrested as it occurs by applying hemostatic forceps to the bleeding points, which in most instances obviates the application of ligatures. In reference to the size of the incision, this will vary in accordance with the difficulties that are encountered in locating the seat of obstruction and in removing the cause or causes that have produced the occlusion; with few, if any, exceptions it must be large enough to admit the introduction of the whole hand. As a rule, it may be stated that the ease of diagnosis increases with the size of the incision, and the danger that attends searching in the dark for the seat of obstruction more than overbalances the slight increase of risk incident to a large incision. Intra-abdominal manual exploration through a small incision is, in most instances, an unreliable diagnostic measure, as the cause of obstruction may be of such a character as entirely to elude such method of examination. It is a well-known fact that the location of the seat of obstruction, even in the postmortem room after a full abdominal section, has sometimes been found a difficult task. A large incision shortens the operation by facilitating the intra-abdominal examination, and the operative treatment of the obstruction and the immediate risks of the operation are diminished in proportion to the shortening of the time required in its performance.

Intra-abdominal Examination.—The first and most important object of the external incision is to enable the surgeon to make a satisfactory intra-abdominal examination. Unless a positive diagnosis has been made beforehand, the first incision is an exploratory one. Exploration of the abdomen for the purpose of locating the obstruction and ascertaining its nature is a more difficult procedure than in cases of abdominal tumors, and on this account the first, or exploratory, incision must be made at least large enough to enable the surgeon to combine ocular inspection with manual exploration.

Smith says: "The best guide to the seat of operation is not manual exploration, but visual examination, assisted, if necessary, by extrusion of bowel."

The surgeon must bear in mind that in nine out of ten cases of intestinal obstruction the cause is located in the lower portion of the abdominal cavity, below the umbilicus, and that in the great majority of these cases it will be found in either the right or left inguinal region.

Bryant lays down the rule that in all abdominal operations for intestinal obstruction, when the seat of obstruction can not readily be found, the surgeon should find the cecum, since it will prove to be his best guide. If this be distended, he will at once know that the cause of obstruction is below ; if it be found collapsed or not tense, the obstruction must be higher up. The naked-eye appearances of the intestine that presents itself in the incision will serve a useful purpose in deciding whether it belongs to the part of intestine above or below the seat of obstruction. In all cases of intestinal obstruction the bowel above the seat of obstruction is dilated and congested, while below the obstruction it is empty, pale, and contracted (Plate 5). The contents of the presenting loop, if distended, will also indicate whether it is near or distant from the obstruction ; if near, it will probably contain fluid feces and gas ; if distant, only gas. If the obstruction is located in the lower portion of the small intestine or in any portion of the colon, without exception a distended loop above the obstruction presents itself in the wound.

Fowler has called attention to the fact that in all forms of intestinal obstruction the empty contracted portion of the intestine corresponding to the part below the obstruction is always found in the pelvis, and that it may be most easily reached toward the right side. He explains this on the supposition that during the violent and continued peristalsis and gradual distention of the bowel above the obstruction the smaller and less active portion of bowel below, after expelling its contents, is forced downward into the pelvis, while the distended, and therefore specifically lighter, portions rise to the surface. The pelvis also is too small to hold a distended loop. If the seat of obstruction can not readily be found by manual exploration of the regions where it occurs most frequently, two methods of further examination present themselves: The presenting bowel is drawn forward into the wound and systematically examined step by step as it glides through the fingers of the surgeon, who replaces the loops as they are examined. This method of examination is safe and practicable only when the distention of the intestines is moderate and the intra-abdominal pressure not extensive, so that loop after loop can be drawn forward, examined, and returned without injury to the intestine. If this method of examination is selected, it would be advisable to secure the portion of intestine first examined near the wound by passing a strip of gauze through its mesentery, so that in case the obstruction is not found in one direction, the examination in the opposite direction can be made without passing the portion already examined again through the operator's hands. Mikulicz attains the same object by an assistant's holding the first knuckle that appears against one of the angles of the wound, while the operator examines and immediately returns coil after coil until the obstruction is found. During the examination prolapse of the intestines is prevented by an assistant, who

Contrast in the appearance of the intestine above and below the seat of obstruction. Partial evisceration by long incision. Contracted, pale, empty intestinal loop grasped by hand below obstruction.

PLATE 5.

guards the opening with an aseptic compress, and thus, as inspection is progressing, unnecessary exposure of the intestines is prevented.

For the purpose of avoiding eventration and its evil consequences in cases of intestinal obstruction with great distention of the abdomen, Madelung has recently described a new method of dealing with the distended intestines. He makes a comparatively small incision through the median line, and brings the first distended knuckle of intestine that presents itself into the wound, and, by passing two fixation ligatures through the mesentery near the bowel and making traction upon them, draws it forward sufficiently far until both limbs of the loop can be ligated with a strip of aseptic gauze at a point corresponding to the external surface of the wound. The patient is now placed on his side, and the prolapsed loop is incised over the convex surface and its contents evacuated. The gauze ligature is slowly loosened, so as to prevent flooding of the wound with intestinal contents by too forcible escape of the fluid contents. When the spontaneous escape ceases, a Nélaton catheter is introduced into the incised bowel, for the purpose of facilitating the escape of intestinal contents. Fifteen minutes are spent in efforts aimed at evacuation of the distended paretic intestine, during which time anesthesia is suspended in order to effect still further evacuation of the bowel above the seat of obstruction by the contraction of the abdominal muscles. After all discharge has ceased, the visceral wound is cleansed and sutured and the ligatures on each side of the wound are tied so as to prevent undue tension upon the sutures after the bowel has been replaced. The ligatures are left hanging out of the wound, to serve as guides to the incised part of the bowel after the completion of the intra-abdominal examination. The abdominal incision is now enlarged, the intestine drawn forward, and careful search made for the obstruction. If this is not found, the incised loop of bowel is brought into the wound, the sutures of the visceral wound and the two ligatures are removed, and an artificial anus is established by stitching the intestinal wound to the margins of the external wound, suturing the portion not required for this purpose.

While Madelung's procedure can not fail in facilitating exploration of the abdomen by diminishing intra-abdominal pressure, it is questionable if the room thus gained is a sufficient recompense for the time lost and the additional risks incident to an intestinal wound in a place where it is not required. If a laparotomy is decided upon in the treatment of an intestinal obstruction, it is made for the distinct purpose of finding and removing the obstruction; hence if the patient's strength is such as to warrant this treatment at all, the surgeon should not close the abdomen with the principal object of the operation unaccomplished. How difficult it is to find the obstruction in some cases is well shown by Madelung, who, in several cases where the seat of obstruction could not be located during life, requested the pathologist when he

made the postmortems to locate the obstruction by introducing his hand through an incision, allowing him from ten to twenty minutes for the exploration; in every instance he failed to find or locate the obstruction within the specified time. When the ordinary methods of examination through an incision large enough to permit the introduction of the hand prove inadequate in locating the obstruction, after a search of from ten to twenty minutes it is useless and unwise to persist in pursuing the same course. Such cases should be dealt with by resorting to eventration. This method of exploration was first suggested by Harber in 1872, and practised by Kümmel in 1885. The large incision that he advocates is necessarily followed by prolapse of the distended intestine, and enables the surgeon to examine rapidly and accurately every portion of the intestinal canal, with a view to locating the obstruction with little or no risk of inflicting injury during the examination. The greatest objection that has been urged against it is that it is sometimes exceedingly difficult to replace the intestines, even after the cause of obstruction has been removed, as the paretic intestines are slow in regaining their normal peristaltic action, and that during the attempts at replacement the intestines are often injured. The proper way to effect replacement is to follow Kümmell's advice, and instead of making direct compression, to resort to protection of the intestines by covering the whole mass with a warm moist aseptic compress, the margins of which are tucked in under the abdominal incision; in this way the bowels are protected against the injurious effects of irregular direct pressure, and are guided back into the abdominal cavity as the wound is closed by tying the sutures already in place from above downward. If uniform, diffuse, gentle pressure fails in replacing the intestines, then the margins of the abdominal incision should be lifted with blunt hooks, an expedient that renders material aid in effecting replacement. I have found, in a number of cases, that partial inversion of the body is a material aid in effecting reduction of the prolapsed intestines. Should the obstacles be so great as to frustrate all attempts at replacement, it is better to resort to incision and evacuation of the most distended portion of the prolapsed bowel, which can be done with greater safety and more marked effect than by the plan devised by Madelung. An overdistended paretic intestine is always a source of danger in the abdominal cavity. An intestinal wall in such a condition is permeable to pathogenic microbes. Unloading of its contents relieves tension, removes preformed toxins and pathogenic microbes, and is best calculated to restore peristaltic action. Greig Smith strongly advocated operative evacuations of intestinal contents in cases of obstruction where distention is a marked feature. Mere overdistention of the intestinal walls is a potent factor in the production of obstruction; physical and physiologic causes combine to render an overdistended bowel incapable of propelling its contents. The operation is not complete unless this condition be corrected.

According to the nature of the case, Smith pointed out that the measures adopted should be one of the following:

(1) Simple evacuation of contents with immediate suturing and reduction of the bowel. (2) Evacuation with drainage for several hours or days, and subsequent closure and return of the loop. (3) Evacuation with permanent drainage.

In peritonitis, attended as it usually is by dynamic obstruction, Mixter recommended, a number of years ago, free incision and evacuation of the overdistended intestine. He recommends that the distended intestines be drawn out of the wound, held over a basin, incised in from one to four places, and thoroughly emptied, after which they should be quickly washed off with hot saline solution, sutured, and returned, and the abdominal incision closed. He has made use of this method in nearly twenty cases, a number of which recovered, and in those that died the wounds were found impermeable to air and fluids.

McCosh has found, from his experience, that after evacuation of the intestine by incision, injection of a saturated solution of sulphate of magnesia has a decided effect in restoring peristalsis and in diminishing the mortality of the operation. At least from six to eight feet of intestine can be evacuated through a single incision by pouring out its contents. In doing so the intestine below and above the incision is elevated, and the contents are poured out from each side. If the intestine is distended for a greater distance, two or more incisions must be made. The visceral incision should always be transverse and at least an inch in length, and at a point directly opposite the mesenteric attachment. The wound is sewed by one row of Lembert sutures placed closely together. The practice of McCosh of injecting into the intestine from one to four drams of magnesium sulphate in concentrated solution will prove as effective in restoring peristalsis of the intestine made paretic from obstruction as in cases of overdistention of the bowel from dynamic causes.

The value of free evacuation of the overdistended obstructed bowel is well shown by a case that recently came under my observation. The patient was a woman forty-eight years of age, the mother of eight children, the last being an infant ten months old. She stated that she had suffered during the last year from constipation, but had always been promptly relieved by cathartics. Ten days before her admission into the hospital symptoms of acute intestinal obstruction appeared, which increased in intensity until fecal vomiting supervened the day before she entered the hospital. She had been treated by high injections and irrigation of the stomach—the former had no effect, but the latter afforded great relief. The patient was well nourished, and her general appearance gave rise to no suspicion of malignant disease in any of the organs. She had passed nothing by the rectum since she was taken ill, and the retching and vomiting were persistent. The abdomen was uniformly and enormously distended; upon the surface of the abdominal wall the out-

lines of some distended coils of intestine could be distinctly seen. The tympanitic distention of the abdomen interfered with respiration, the respiratory movements being shallow and rapid, the lips cyanosed, and the extremities cold. Examination per vaginam and rectum revealed nothing as to the seat and nature of the obstruction. Percussion and palpation of the abdomen yielded the same negative results. Laparotomy was performed under the most careful aseptic precautions. The stomach was irrigated, and chloroform was used as an anesthetic. The operation was performed with the patient upon a rubber bed filled with hot water. The first incision was made half-way between the umbilicus and pubes, and large enough to permit the introduction of the hand. As soon as the peritoneal cavity was opened a loop of small intestine, distended to three times its natural size and intensely congested, presented itself. This was pushed aside, and similar loops made their appearance. The hand was then introduced, and it was found that the cecum and entire colon were also enormously distended, which proved that the obstruction was located low down in the colon or in the upper part of the rectum ; but the most careful attempts by manual exploration failed in furnishing any clue as to the location or nature of the obstruction. The incision was enlarged upward an inch above the umbilicus and downward to the pubes, for the purpose of effecting complete eventration. Two assistants caught the intestines in warm moist aseptic compresses as they prolapsed, and as the abdominal cavity was nearly empty, it was possible to explore with ease the sigmoid flexure, where was found the seat of the obstruction. The carcinomatous obstruction was finally located at the junction of the colon with the rectum. As resection in this locality was impossible, and for the same anatomic reasons an anastomosis could likewise not be made, it became necessary to establish an artificial anus in the left groin. The sigmoid flexure was pushed into an inguinal incision and sutured in position. Reposition of the distended intestines by the ordinary methods failed. The patient was now placed on her side, and one of the most distended loops was grasped, held over a basin, and punctured with a trocar, while the remaining intestines remained covered with the warm compresses. As the escape of gas and fluid feces through the cannula was very slow, transverse incision an inch and a half in length was made in the paretic distended intestine. As the bowel did not contract, the escape of contents was very slow, and it became necessary to resort to pouring out of the contents, as it were, by seizing the bowel several feet above and below the incision and elevating it, a large quantity of fluid feces being literally thus poured out. When no further evacuation could be effected, the visceral wound was closed by the continuous suture, and after the loop was thoroughly disinfected, the bowels were returned without further difficulty. The abdominal incision was closed in the usual way, only that two tension sutures were added as a matter of precaution. After the

abdominal wound was closed and dressed, the colon, which had been stitched into the inguinal wound, was incised, and the margins of the incision were separately stitched to the sides of the external wound. A considerable quantity of gas and fluid feces escaped. The vomiting ceased after the operation, and the patient rallied under the effects of stimulants. The abdominal distention had diminished greatly the next day, and disappeared almost completely on the second day. The patient's general condition continued to improve until the tenth day after the operation, when symptoms of collapse set in, which persisted until she died on the following day. The postmortem showed that the median incision had healed with the exception of the skin, and that the artificial anus had served as a perfect outlet for the intestinal contents. The small intestine was restored to its normal size, the incision had healed, the fine silk suture being completely embedded. The cause of the recent diffuse septic peritonitis was traced to perforation of a small abscess behind the carcinoma. The constriction caused by the carcinoma had reduced the lumen of the bowel so much that it was permeable only to the tip of the little finger.

Reference will again be made to the subject of chronic causes giving rise to acute obstruction. This case also illustrates the importance of establishing the artificial anus, when such a procedure can not be avoided, not in the laparotomy wound, but in the right or left inguinal region. When eventration is practised, it is essential to furnish the prolapsed and dilated intestine with an artificial covering that should act as nearly as possible as a substitute for the abdominal parietes. This is best accomplished with warm compresses wrung out of a hot saline solution in the hands of one or two reliable assistants. After the surgeon has found the obstruction, it becomes necessary to demonstrate the permeability of the remaining portion of the intestinal canal, as it has happened that after a successful removal of an obstruction patients have died because a second obstruction was overlooked. Of course, in such cases the search for additional obstructions must be extended below the obstruction, which has been found and removed. A valuable test for ascertaining the permeability of the remaining portion of the intestinal canal is furnished by rectal insufflation of hydrogen gas or air. In cases where, after eventration, it is not possible to find the obstruction by examination of the distended portion of the intestine, the contracted empty portion below the obstruction can be brought into sight by the same means, and a search for the obstruction made from below upward by examining the bowel as it becomes inflated until the seat of obstruction is reached.

OPERATIVE TREATMENT OF THE OBSTRUCTION.

Intestinal Anastomosis.—The results of postmortem examinations and clinical experience have shown how difficult it is in many cases to find the obstruction, and this is more especially the case when

the general condition of the patient is such as to forbid free evisceration.

What shall be done if the obstruction can not be found after all diagnostic resources have been exhausted? Shall we establish an artificial anus and leave the patient to the inevitable fate of remaining a sufferer from this loathsome condition the remainder of his lifetime should he recover from the operation? Under such circumstances the surgeon assumes a great responsibility in establishing an artificial anus high up in the intestinal canal, even as far as the immediate effects of the operation are concerned. The paretic bowel below the seat of the artificial outlet unable to empty itself of its contents constitutes an immediate and remote source of danger, as it leaves that portion of the bowel between the new opening and the obstruction in the same condition as before the operation, and permanent exclusion of a considerable portion of the intestinal canal alone may subsequently destroy life by progressive marasmus. In such cases I should advise the following plan of treatment: The empty bowel below the seat of obstruction, if not already found, should be inflated per rectum with hydrogen gas or air, the highest portion of the inflated bowel drawn forward into the wound, and two rubber bands passed through its mesentery, about four inches apart, and held in place by an assistant. The surgeon now locates, as near as he can, the lowest portion of the bowel on the obstructed side, which is also brought forward into the wound and similarly secured. The bowel on the proximal side is incised on the convex surface to the extent of an inch and a half; through this incision the contents are evacuated as far as possible, after which all four rubber bands are tied, and the bowel on the distal side is incised in a similar manner.

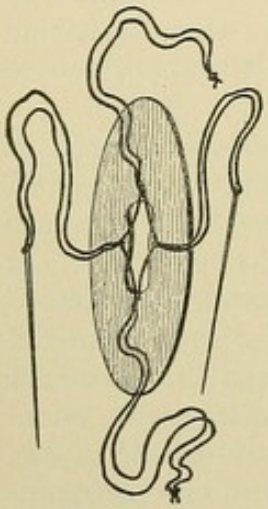

Fig. 484.—Senn's decalcified perforated bone-plate for anastomosis.

The continuity of the intestinal canal is then restored by uniting the two visceral wounds by the use of Mûrphy's, Ramonge's, or Frank's anastomosis button, absorbable bone-plates or vegetable discs, or, what will be the most common practice of the future, by suturing. If the anastomosis is made by approximation plates, the wounds are enlarged to the requisite extent and one of the plates is inserted into each, and with a round needle the margin of the wound on each side is transfixed with a lateral suture. After the plates and sutures are in place, the loops are thoroughly disinfected, and the serous surfaces, to the extent of the size of the plates, are lightly scarified with the point of a needle, when the wounds are placed *vis à vis*, and the corresponding four threads tied together with sufficient firmness to secure perfect coaptation of the serous

surfaces. The sutures are cut short, and their ends buried as deeply as possible by pushing them in between the approximated surfaces with a director or blunt scissors. A few superficial stitches of a continued suture will enhance the safety of the operation. In this manner an anastomosis is established, with the exclusion of probably only a small portion of the intestinal tract.

After uniting two intestines by approximation plates in the formation of an intestinal anastomosis, it appears at first sight as though, on the slightest distention of the intestines, leakage of gas or fluid contents would take place between the serous surfaces. That this fear is unfounded has been proved satisfactorily by a number of experiments. The intestines of animals recently killed were used, and an anastomosis was made between the lower portion of the ileum and the colon. The colon was tied below the new opening, and fluid forced into the ileum on the proximal side. The pressure was measured by a mercury gage. It was found that no leakage occurred under a pressure of two pounds to the square inch continued for thirty seconds. As even in cases of great intestinal distention the pressure can never reach this degree, leakage from mechanical or physical causes will never take place from the new opening. The margins of the visceral wounds act like valves, and when the serous surfaces are kept in contact by the plates, prevent the escape of gas or fluids into the peritoneal cavity. The safety and practicability of this operation has been abundantly demonstrated by experiments on animals and by a number of operations on the human subject. The operative treatment of the obstruction will depend upon the location, extent, and nature of the cause. If it is decided not to remove the obstruction, either on account of its intrinsic harmless character, aside from its mechanical effect, or on account of its extent, in which case the removal would

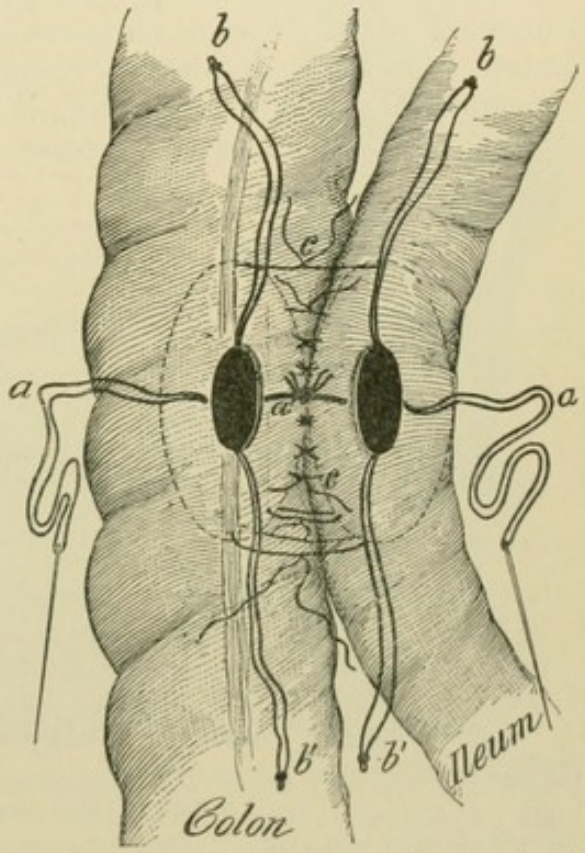

Fig. 485.—Ileocolostomy with decalcified bone-plates, showing plates in position, one in the ileum, the other in the colon: *a*, *a*, *a*, Lateral or fixation sutures passed through the margins of the wound, *a* to be tied to *a*; *b*, *b*, *b'*, *b'*, end or apposition sutures to be tied, *b* to *b* and *b'* to *b'*; *c*, posterior or seromuscular sutures (Keen and White).

be an imminent source of danger to life, or if, after removal, a recurrence in the near future appears inevitable, an anastomosis is established between the intestine above and below the obstruction by lateral apposition with decalcified perforated bone-plates. By this operation the continuity of the intestinal canal is restored, with permanent exclusion of the seat of obstruction. In cases of multiple cicatricial stenoses as a cause of obstruction, intestinal anastomosis, for instance, would be a vastly more safe operation than resection and circular enterorrhaphy, and would secure equally well the restoration of the continuity of the intestinal canal. In cases of carcinoma of the intestine with extensive infiltration of the lymphatic glands, a resection, followed by circular enterorrhaphy, must always constitute a hazardous procedure, and even if it proved successful, an early recurrence of the disease would be inevitable. Under

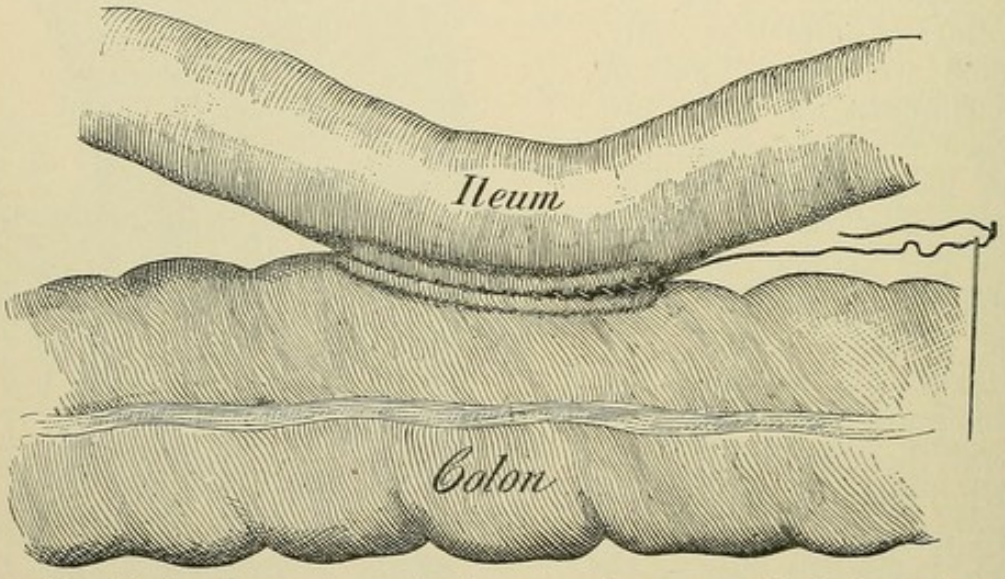

Fig. 486.—Showing the anterior continued seromuscular suture as the final step in ileo-colostomy (Keen and White).

such circumstances it is advisable to establish, in preference, an intestinal anastomosis that will effectually exclude the cause of obstruction, alleviate suffering, and prolong life.

The opponents of laparotomy in cases of acute intestinal obstruction have urged as one of the principal reasons for their opposition that the dilated inflamed intestine above the obstruction is not in a condition to undergo reparative processes when the operation demands a solution of continuity in this part of the intestinal tract. Circular enterorrhaphy under such circumstances is a very dangerous procedure for two reasons: (1) It becomes necessary to unite bowel ends of unequal size. (2) The inflamed intestine has undergone textural changes ill adapted for suturing, as the sutures readily cut through the softened tissues. A number of clinical observations have shown that the failures that have attended circular enterorrhaphy in such cases are not due to a lack of healing capacity on the part of the inflamed end of the bowel,

but to the mechanical difficulties that are encountered in the approximation and retention of the bowel ends, and the danger of the cutting through or yielding of the sutures. It can be stated, on the contrary, that in case septic peritonitis does not exist, the vascularity of the bowel above the seat of obstruction constitutes a favorable condition for rapid union. To demonstrate the correctness of this assertion I made the following experiments:

EXPERIMENT 1.—Dog, weight fourteen pounds. The whole abdomen was shaved and thoroughly disinfected, and while the animal was under the influence of ether a small incision was made in the left iliac region, and a loop of intestine drawn forward and ligated with a band of iodoform gauze, the ligature being tied with sufficient firmness to cause complete occlusion; the intestine was then returned and the wound sutured. Seventy-three hours later the dog was again etherized and median laparotomy performed. Distended vascular loops of the intestine came into the wound, which were pushed aside and the hand introduced, which, being passed toward the left inguinal region, at once came in contact with the ligated portion, which had formed adhesions to the parietal peritoneum and neighboring intestinal loops. The adhesions were separated, and the ligated loop was drawn out of the wound. Above the ligature the bowel was at least one and a half times larger than immediately below the seat of obstruction, very vascular, and contained gas and fluid feces. The degree of dilation diminished from below upward. The seat of obstruction was eight inches above the ileocecal valve, and the gauze ligature was covered with a thick layer of plastic lymph. The obstruction was left, and the continuity of the intestinal canal restored by an ileocolostomy with perforated decalcified bone-plates. The animal, which was not vigorous before the experiment was made, appeared much prostrated and died twenty-four hours after the operation. The necropsy showed that the bowel above the constriction had to a great extent recovered its normal size and color. The two intestines where anastomosis was made were firmly adherent, the groove between them corresponding to the length of the plates filled in with plastic lymph. The new opening was permeable. No leakage occurred at point of operation under hydrostatic pressure and no peritonitis.

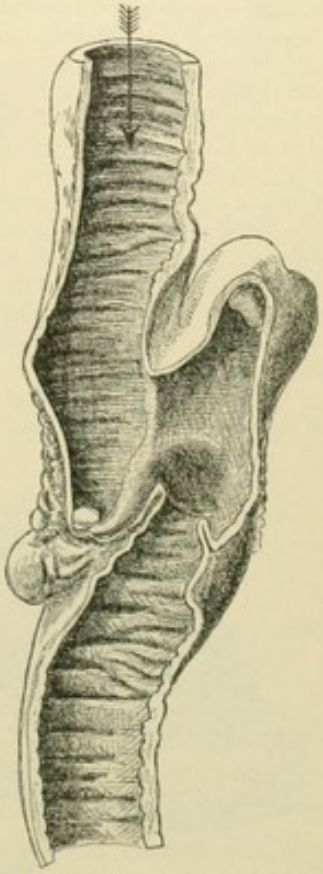

Fig. 487.—Lateral anastomosis in dog, with Senn's plates; sixty-three days. The arrow indicates the direction of the flow through the bowel. It will be noticed that the anastomosis still remains lateral. One blind end—that of the upper bowel—has contracted more than the other (two-thirds size) (after Edmunds and Ballance).

EXPERIMENT 2.—Dog, weight twenty-four pounds. Obstruction was produced in a similar manner as in preceding experiment. Seventy-five hours later operative treatment of obstruction by laparotomy was instituted. The seat of obstruction was again readily found by manual exploration of the abdomen. The bowel above seat of constriction was at least twice the normal size and highly congested. Peristaltic action sluggish, responding very slowly and imperfectly to mechanical irritation. Gauze band buried under a ring of plastic lymph, which, bridge-like, united the bowel below and above the constriction. As the obstruction was located about the middle of the ileum, an ileoileostomy by lateral apposition with decalcified perforated bone-plates was made, leaving the gauze band undisturbed. The incision into the bowel above the seat of obstruction showed that all the coats were thickened and softened, while below the obstruction only the mucous membrane was in a state of catarrhal inflammation. About eight inches of the bowel, including the seat of constriction, were excluded by the operation. The animal showed no signs of suffering or illness after the operation, and when killed, after the expiration of twenty-one days, was in excellent condition. During this time the appetite was good

and fecal evacuations were normal. Gauze band was completely encapsulated, and close to it was an acute flexion of the bowel; excluded portions were adherent to each other along convex surface; bowel above constriction was about one-third larger than below. New openings admitted the tips of two fingers.

EXPERIMENT 3.—Dog, weight twenty-eight pounds. Laparotomy performed seven days after complete obstruction had been caused by ligation of small intestine with gauze band through a small wound in the left inguinal region. Moderate tympanites present. Obstruction was found sixteen inches above the ileocecal region. Peristaltic action was almost suspended in bowel above obstruction—normal below. The intestine above the constriction was dilated to twice its normal size, exceedingly vascular, containing solid fecal masses, fluid feces, and gas; below, empty, contracted, and anemic. Exclusion of six inches of the intestine at seat of obstruction and restoration of continuity of intestinal canal by ileoileostomy with decalcified perforated bone-plates. After operation the function of the intestinal canal was normal and the appetite good. The animal was killed eight days after operation. No peritonitis occurred; there was adhesion of omentum to the line of abdominal incision. Gauze band was completely covered by a plastic exudation, and there were a number of adhesions between adjacent intestinal loops. Point of operation was situated in the center of a horseshoe-shaped loop of intestine, which was found to be the excluded portion. Intestine above obstruction was about one-fourth larger in size than below. Excluded portion of bowel was empty. At seat of anastomosis a mass of straw and hair had accumulated on proximal side. New opening was large enough to admit two fingers.

EXPERIMENT 4.—Dog, weight thirty-four pounds. There was complete obstruction of small intestines by ligation with gauze band through a small wound in the left iliac region. Operative treatment by laparotomy instituted one hundred and twenty hours later. This animal vomited several times shortly before the operation. Bowel at seat of obstruction was adherent to adjacent intestines. Obstruction was readily found and brought into the incision. Intestine above constriction was twice its normal size, dark purple in color, and the tissues were swollen and very much softened. Below constriction the bowel was empty, collapsed, pale, and only the mucous membrane was in a state of catarrhal inflammation. The dilated bowel contained gas and fluid feces. Peristaltic action in this part was nearly suspended, the response to mechanical irritation being slow and imperfect. Below the obstruction the function of bowel remained unimpaired. As the occlusion was only four inches above the ileocecal valve, it was found impossible to limit the anastomosis to the ileum, consequently the continuity of the bowel was restored by an ileocolostomy, uniting the ileum just above the obstruction with the colon above the cecum, using the perforated approximation plates. The gauze band was left *in situ*. The animal showed no untoward symptoms after the operation, and was killed twenty-one days later. During this time appetite was good and intestinal function normal. A number of adhesions were found at site of operation between adjacent intestinal loops. Gauze band was completely encysted. Some crude material, as straw, hair, and fragments of bone, was found on the proximal side of new opening. Anastomotic opening was large enough to admit tips of two fingers; union between approximated portions of intestine was so complete that it presented all around the appearance as though their peritoneal surfaces were continuous.

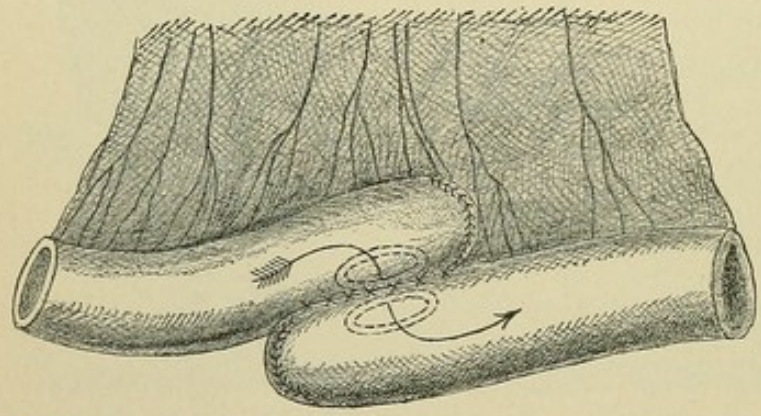

Fig. 488.—Lateral anastomosis as a substitute for circular enterorrhaphy after enterectomy (after Baracz).

These experiments show conclusively that in acute obstruction, even after seven days, the bowel above the obstruction is capable of undergoing a rapid reparative process, and that adhesive union takes place as early as, if not earlier than, in operations upon a normal

intestine. The experiments likewise prove the greater safety of anastomosis by lateral apposition with decalcified perforated bone-plates than of resection and circular enterorrhaphy in restoring the continuity of the intestinal canal. Anastomosis after resection of intestinal obstruction can be made in the same manner between the proximal and distal parts after the resected ends have been closed by invagination and a few stitches of the continued suture, as when the obstruction is not resected, but excluded.

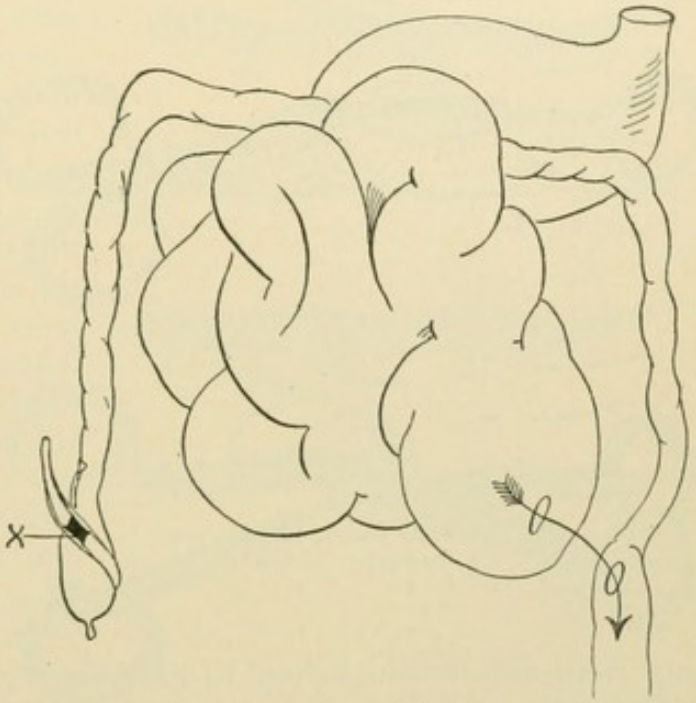

Fig. 489.—Intestinal anastomosis for congenital atresia of ileum. Ileosigmoidostomy (after Wanitscheck).

In cases of congenital atresia of the small intestine, most frequently met with in the upper portion, anastomosis should always take the place of circular resection, as the operation can be done in less than twenty minutes, an exceedingly important matter as far as the immediate effects of the operation are concerned in infants, at the most only a few days old. In cases where such a congenital defect is suspected, the abdomen should be opened in the median line, being careful not to cut through the umbilicus, when the seat of obstruction can be readily and rapidly located by inflation of the stomach and rectum with hydrogen gas or air. It is necessary to inflate from both directions, as in some cases the atresia is multiple.

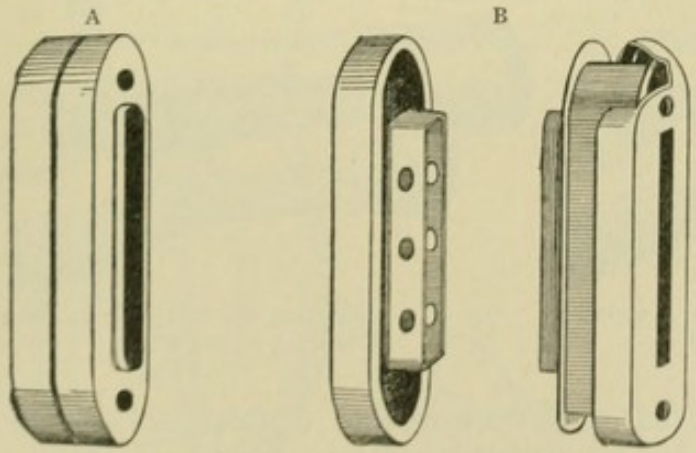

Fig. 490.—Murphy's oblong anastomosis button: A, Closed; B, open.

The anastomosis button of Murphy has had an extensive trial as a substitute for suturing in performing gastro-enterostomy and intestinal anastomosis, and many surgeons of large experience speak of it in the

highest terms. Czerny, who has had an enormous experience in suturing, recommends it very highly and has used it with excellent success on a large scale. The surgeon who intends to make use of it should supply himself with a full set, and should use only buttons of faultless make. Half of the button is inserted into each opening, and fixed in place by purse-string suture. After uniting the two halves, on joining the wounds the serous surfaces over the margin of the button should be united by the continued suture of fine silk as an additional security.

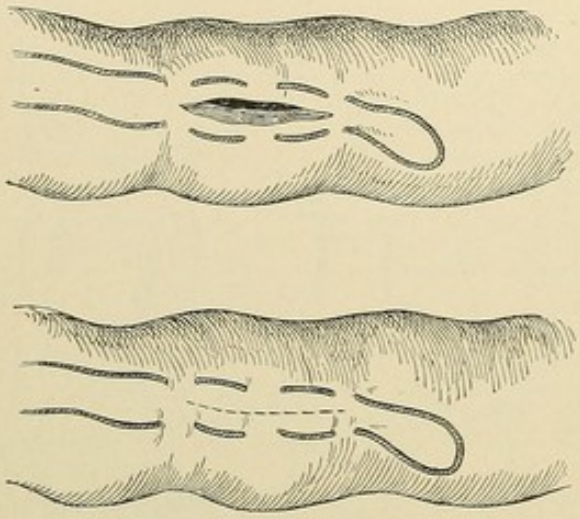

Fig. 491.—Showing size of incision and retaining sutures for Murphy button in lateral anastomosis.

Two objections present themselves against the general adoption of the button as a substitute for suturing —viz.: (1) The danger arising from the button failing to pass the intestinal canal, remaining as a source of irritation or possibly acting later as a mechanical cause of obstruction. (2) The limited inclusion of the margins of the visceral wounds between the two halves of the button and the pressure necessary to keep them in contact always give rise to marginal sloughing and occasionally to perforation. The danger from the latter source is always greater in uniting diseased than healthy intestine. The risks just alluded to are much less in using absorb-

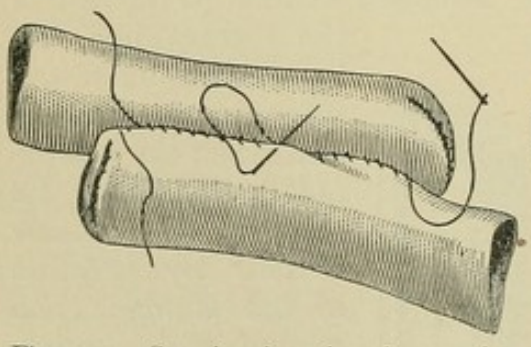

Fig. 492.—Suturing intestines in apposition before incision (Abbe).

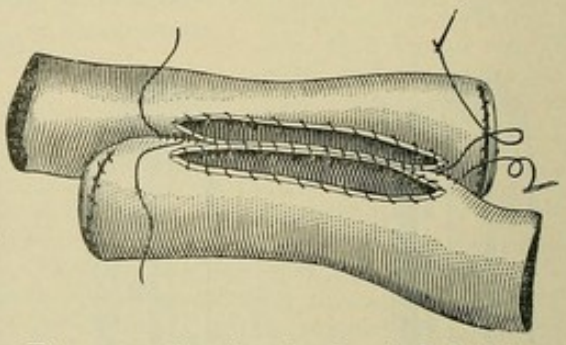

Fig. 493.—Showing the four-inch incision and sewing of the edges.

able approximation plates or the absorbable coupler devised by J. Frank. The time is not far distant when the suture will take the place of all such mechanical devices. This will be especially true of emergency work, which often limits the surgeon to needle and thread in establishing a communication between the intestine above and below the obstruction. The fewer the requirements in such cases, the better will the operator be prepared to accomplish what

is necessary. The principal reason that induced me to substitute the perforated decalcified bone-plates for sutures in performing intestinal anastomosis was to shorten the time of operation, and, consequently, to minimize the danger from shock. A more extensive experience with needle and thread has greatly modified my views in this regard. I now believe, with H. Braun, that the suturing can be completed in twenty-five minutes, which previously, with less experience, required twice that length of time. I have made many gastro-enterostomies and intestinal anastomoses by suturing during the last five years, and the time occupied by this part of the operation seldom

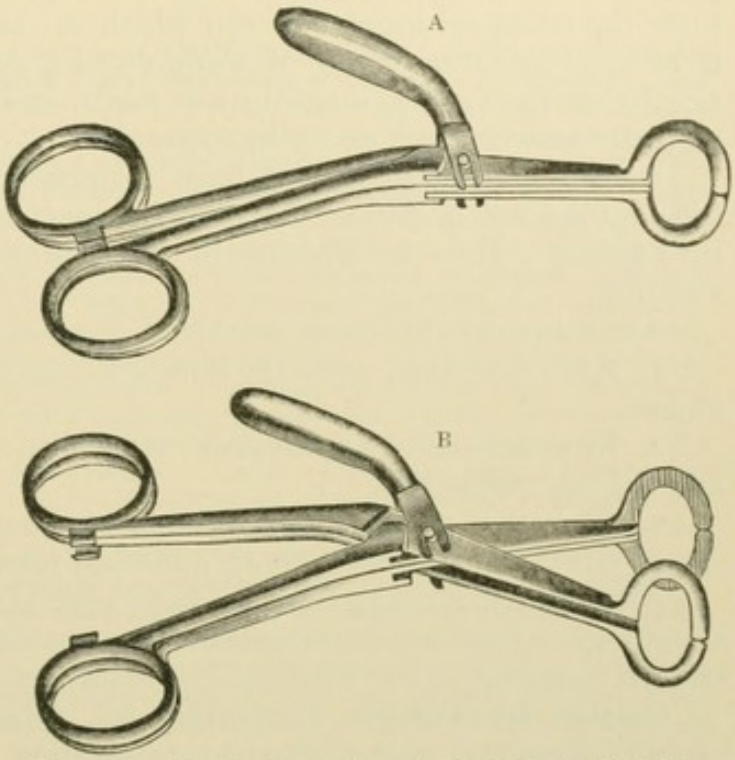

Fig. 494.—Laplace's anastomosis forceps: A, Closed; B, open.

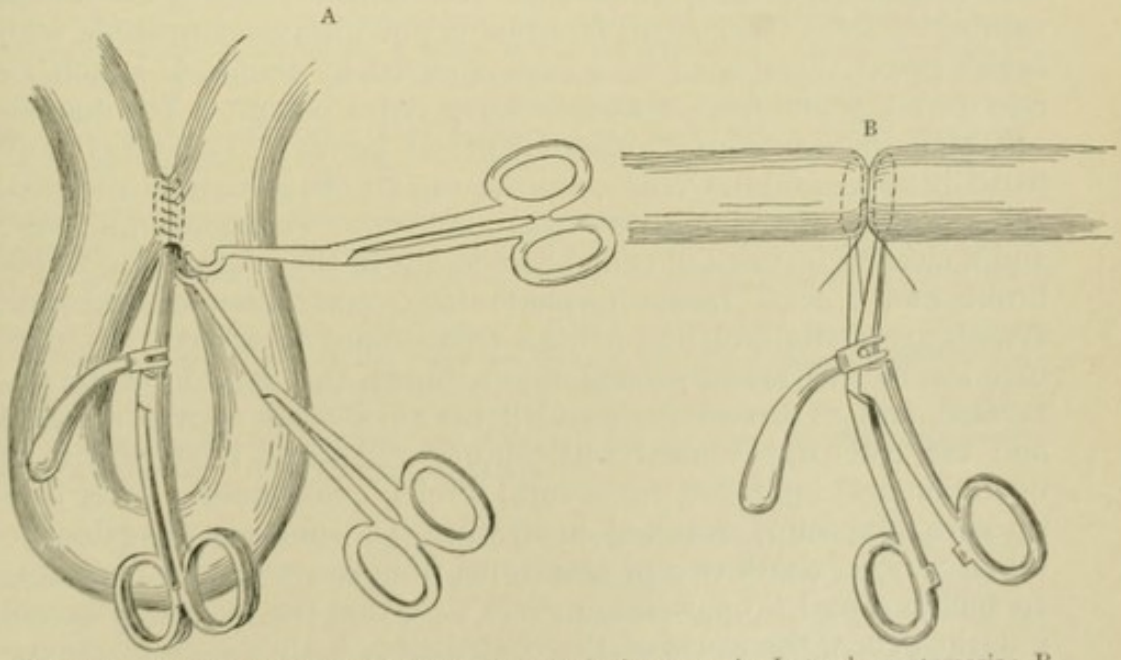

Fig. 495.—Application of Laplace's anastomosis forceps: A, Lateral anastomosis; B, circular enterorrhaphy.

exceeded more than from twenty to thirty minutes. In performing

intestinal anastomosis by suturing, the visceral incisions should be at least three inches in length, and united by Lembert, Czerny-Lembert, or Halsted's quilt suture. It is always necessary to unite the intestinal loops between which an anastomotic opening is to be established by a row of seromuscular sutures on the convex side before the visceral incisions are made, and to exclude intestinal contents between two gauze ligatures.

Intestinal anastomosis has been materially simplified and made safer by the use of the very ingenious anastomosis forceps devised by Laplace. It is an instrument of great value also in circular suturing.

According to H. Braun, intestinal anastomosis is indicated:

1. After resection, when the lumina of the ends are very unequal in size.

2. Firm adhesions of intestinal coils with the adjacent surfaces and among themselves.

3. Resection of the lowest portion of the ileum.

4. Great narrowness of both intestinal lumina.

Allusion has already been made to several other indications that should give preference to intestinal anastomosis over resection and circular suturing in the treatment of intestinal obstruction.

Partial Physiologic Exclusion by Anastomosis.—In some cases of intestinal obstruction the restoration of the continuity of the intestinal canal by resection and circular enterorrhaphy would necessitate the removal of several feet of the intestine when the cause of obstruction in itself constitutes no intrinsic source of danger, and when recovery would be more likely to take place by the substitution of anastomosis for resection. That resection of a number of feet of the small intestine is not always compatible with health is well illustrated by a case reported by Baum, in which he removed 137 cm. from a woman forty years of age. The patient was suffering from strangulated femoral hernia. Taxis was only partially successful. On opening the sac an offensive fluid escaped, and a portion of the omentum was removed. Peritonitis followed, and a swelling formed in the abdomen above the crural ring, which broke and a fecal fistula formed; rapid emaciation ensued, and symptoms of strangulation made a laparotomy necessary. A mass of intestine was found twisted into a bunch that could not be unraveled, and as it was surrounded by an abscess, it was resected and the ends were united with sutures. Patient recovered from operation and improved for several weeks. Six months later progressive marasmus resulted in death. The autopsy revealed no other cause of death except marasmus from too extensive resection. In such a case I proposed, ten years ago, that the twisted adherent intestinal coils, the cause of the obstruction, if they present no evidences of gangrene, should be left and permanently excluded from the fecal circulation by making an anastomosis with approximation plates between the bowel leading to and from the obstructing mass.

A case somewhat similar to Baum's, but under less favorable circumstances, recently came under my care where this plan of treatment was adopted.

Strangulated Hernia; Resection of Gangrenous Portion; Additional Obstruction by a Mass of Adherent Intestinal Loops; Restoration of Continuity of Intestinal Canal by Anastomosis.—The patient was a brewer, thirty years of age, who had had an inguinal hernia for several years, but never wore a truss. On lifting a heavy weight the swelling became suddenly enlarged, followed by symptoms of acute strangulation. The attending physician overlooked the hernia and treated the patient for gastritis. Eight days after the attack he was admitted into the hospital. At this time symptoms of acute diffuse peritonitis were well marked. The pulse was rapid and feeble, the extremities were cold, the abdomen was tympanitic and excessively tender on pressure, and there was stercoraceous vomiting. The hernia was as large as a child's fist, and the skin covering it was discolored and edematous. It was plain enough that gangrene had occurred, and that in consequence of this peritonitis had developed. The patient was given $\frac{1}{120}$ of a grain of atropin hypodermically before chloroform was administered. On opening the sac fecal matter escaped and a large mass of discolored omentum presented itself. The sac was irrigated with a weak solution of sublimate, and the omentum was drawn forward and wrapped in a small compress of gauze. The entire loop of intestine was gangrenous and perforated on the convex surface at its highest point. The parts were again irrigated before the inguinal canal was laid open by incision. The omentum was now drawn downward until a healthy portion was reached, when it was ligated in several parts and cut off. The intestine was separated from its attachments to the inguinal canal, and the gangrenous part, about eight inches in length, was excised after having previously guarded against fecal extravasation by applying a rubber ligature on each side. Examination of the abdominal cavity at this time showed recent peritonitis. In drawing down the proximal end of the bowel it was found that it was but little distended, hence search was made for an additional obstruction higher up, which was found in the shape of a mass of intestinal coils twisted in every conceivable shape and so firmly adherent that all attempts at unraveling had to be abandoned. The intestine above this point was enormously distended, showing that the bunch of adherent intestines had caused a second obstruction. Excision of from three to four feet of intestine under these circumstances was not to be thought of, as the patient would certainly have died on the table. It was decided to leave the obstruction and establish a communication between the intestine on the distal and proximal side of the obstruction. Both resected ends were closed by invagination and a few stitches of the continued suture. By lateral apposition with decalcified perforated bone-plates an anastomosis was established between the distal collapsed end and the dilated bowel on the proximal side of the obstruction. Before the approximation sutures were tied, the intestinal contents were evacuated as far as possible. The whole peritoneal cavity was flushed with sterilized water, carefully dried, drained, and the wound sutured. The toilet of the peritoneum was made with a sponge wrung out of a 1 : 2000 solution of sublimate. The hernial sac was excised, and the stump fastened in the inguinal canal by the deep suture used in closing the external wound. Duration of operation, less than an hour. The patient rallied from the operation, but succumbed to the peritonitis at the end of twenty-four hours. Postmortem: On removing the sutures the sac-walls were found agglutinated by plastic lymph. Drainage-tube was surrounded by a thick layer of plastic lymph and coils of intestine that completely shut out the abdominal cavity. Only about half of the omentum remained. The part of intestine where anastomosis was made was found in the pelvis, lying against the concave surface of the sacrum, surrounded by numerous recent adhesions. The new opening was twelve inches above the ileocecal valve. Adhesion between the serous surfaces, held in approximation by the plates, was sufficiently firm to prevent leakage under strong hydrostatic pressure. The opening was patent.

My experiments on animals have demonstrated that physiologic exclusion of a certain portion of the intestinal tract is a less dangerous operation than excision. The appearances of the specimens also tend to prove that so long as any of the contents of the intestines reach the excluded portion, the peristaltic or antiperistaltic action in that part is effective in forcing it back into the active current of the fecal circulation. If the excluded portion again becomes

permeable, it resumes its physiologic function and again takes an active part in the processes of digestion and absorption; if the obstruction remains permanent, it undergoes progressive atrophic changes.

These experiments were made and the results reported in 1887. As extensive resection of the intestines is always attended by great immediate and remote risks to life, I concluded at that time to study the subject of sudden deprivation of the system of a great surface for digestion and absorption by leaving the intestine, but excluding permanently a certain portion from participating in the function of digestion and absorption—in other words, by resorting to physiologic exclusion.

These experiments were also made to determine the tissue changes that would take place in the bowel thus excluded, and to learn if, under such circumstances, accumulation of intestinal contents would become a source of danger, as had been feared by the older surgeons. The complete interruption of passage of intestinal contents either by section and closure of the bowel or by making an intestinal obstruction of some kind, and the restoration of the continuity of the physiologically active portion of the intestinal canal, were established by suturing of the proximal end of the high section with the distal end of the lower section, or by implanting the proximal end into the bowel lower down, the intervening portion of the intestinal tract in either case thus becoming the excluded portion.

For the purpose of illustrating the therapeutic value of physiologic exclusion of the intestine in the treatment of certain forms of intestinal obstruction in which it is impossible or impracticable to remove the mechanical cause, reference will be made here to only a few of the experiments and their results.

EXPERIMENT 37.—Dog, weight thirty-five pounds. The ileum was divided just above the ileocecal region, and both ends of the bowels were closed. Ileocolostomy was done by making an incision about an inch and a half in length on concave side of ileum, forty-four inches above the division, and a similar slit on convex side of ascending colon, and uniting these wounds by Czerny-Lembert sutures, thus excluding from the intestinal circulation forty-four inches of the bowel. The day after the operation the feces contained blood. During the progress of the case it was frequently noted that the stools were thin, sometimes liquid. Appetite remained good, and animal was well nourished at the time of killing, twenty-five days after operation. Abdominal wall was well united. The omentum and a few intestinal loops were adherent to inner surface of wound. The excluded portion was contracted to more than one-half of its usual size, was atrophic, and not nearly so vascular as remaining portion of intestinal canal. The two blind ends were adherent to each other and to adjacent loops. The excluded portion contained in its blind end a few sharp fragments of bone. The new opening between the ileum and colon, about the capacity of the lumen of the ileum, was surrounded by a prominent margin of mucous membrane that somewhat resembled the ileocecal valve, to which still remained attached about ten of the deep sutures. The coats of both bowels at points of approximation were thickened by inflammatory exudation.

EXPERIMENT 38.—Young cat. The ileum was divided about thirty inches above the ileocecal region. The distal end was closed, and the proximal end was laterally implanted into the convex side of the transverse colon, where it was fixed by a double row of sutures. Before implantation the continuity of the peritoneal surface was procured by drawing the peritoneum, with a fine catgut suture, over the denuded space left after detachment of the mesentery. Although the animal partook freely of food, progressive

marasmus set in, to which the cat succumbed eleven days after the operation. Abdominal wound was completely healed. Union of implanted ileum with colon was perfect and there was no peritonitis. Excluded portion was empty. Bowel above implantation was somewhat dilated.

EXPERIMENT 40.—The entire ileum was excluded in a cat by dividing the intestine at its junction with the jejunum, closure of distal end, and making a jejunocolostomy by implantation of the proximal end into a slit of the transverse colon at a point opposite the mesocolon. The cat remained in good condition until killed, fifteen days after operation. No vomiting occurred, and movements from bowels were normal. Abdominal wound was completely closed. There was no peritonitis, and jejunum at point of implantation was firmly united. New opening in colon was the size of the lumen of the ileum. Excluded portion was empty, contracted, and anemic.

EXPERIMENT 41.—Large mastiff. The small intestine was divided six and a half feet above the ileocecal region, the distal end closed, and the proximal end implanted into an incision of the transverse colon large enough to receive it at a point opposite the mesocolon. Suturing was done exclusively with fine silk. For three weeks the dog appeared quite well, ate well, and the discharges from the bowels were normal. From this time the emaciation, which commenced soon after the operation was done, began to increase rapidly, the animal began to refuse food, and died of marasmus thirty-two days after operation. There was no peritonitis. Excluded portion was empty and reduced one-half in size. The coats of the bowels were very much attenuated, and the vessels hardly half the normal size. Only three feet and five inches of the small intestine remained for physiologic action. New opening in colon was sufficiently large to permit the introduction of the index-finger as far us the first joint. On slitting open the colon the point of juncture with the jejunum upon the inner surface was marked by a slight ridge of mucous membrane that bore a faint resemblance to the ileocecal valve.

For some reason that it is difficult to explain satisfactorily, in animals where the same length of intestine was physiologically excluded, as in the resection experiments, the appetite never became so voracious and the remaining portion of intestine did not undergo the same degree of compensatory hypertrophy as in the excision experiments. Theoretically, two explanations might be advanced: first, in shortening the intestinal canal by resection an extensive vascular district is cut off by ligation of the mesentery, and it is but reasonable to assume that the circulation in the remaining branches of the mesenteric artery would be increased, and consequently the functional activity of the organs supplied by them augmented; secondly, in cases of physiologic exclusion by lateral apposition it is possible that at least some of the fluid contents reached the excluded portion, from which a certain amount might still have become absorbed. The exclusion was complete, or nearly so; hence we must conclude, from the postmortem appearances, that in nearly every instance the excluded portion presented an atrophic, contracted condition and was only sparingly supplied with blood-vessels. From a practical standpoint these experiments teach us that a limited portion of the intestinal canal can be permanently excluded from the processes of digestion and absorption in proper cases by operative measures, without incurring any risk of fecal accumulation in the excluded part. These experiments demonstrate also that physiologic exclusion of a certain portion of the intestinal tract is a less dangerous operation than excision, and that in certain cases of intestinal obstruction, where excision has been heretofore practised, it can be resorted to as a substitute for this operation in cases where excision is impracticable or where the pathologic conditions

that have caused the obstruction do not in themselves constitute an intrinsic source of immediate or remote danger to life. The post-mortem appearances of the specimens of these experiments tend to prove that as long as any of the contents of the intestines reach the excluded portion, the peristaltic or antiperistaltic action in that part is effective in forcing it back into the active current of the intestinal circulation.

Complete Physiologic Exclusion.—At the time the experiments on partial physiologic exclusion were made, a few attempts to render the exclusion complete were instituted, but it soon became apparent that this was incompatible with the life of the animal without establishing a fistulous opening communicating with the excluded segment of the intestine. In the few experiments made, both ends of the excluded portion were closed by suturing and the continuity of the remaining portion of the intestinal canal was restored by circular enterorrhaphy. The results were in every instance very similar to an experiment of the same kind reported by F. Mall.

Halsted and Mall's experiment:

"A large dog was operated upon by Dr. Halsted to isolate a loop of intestine. The ends of the separated loop were sutured together by Lembert's method, and the two remaining cut ends of the intestine were likewise stitched together so as to reestablish the continuity of the alimentary canal (Halsted, *loc. cit.*, p. 7). The dog made an easy recovery after the operation, and appeared perfectly well until February 1st, when he gradually began to sink. On February 9th the dog was very weak and apparently dying. It was therefore decided to make an exploratory operation. Upon opening the animal it was found that the loop was enormously distended with fluid. The loop was removed, and now could be more carefully examined. The suture had healed very nicely, so that the isolated loop formed an oval with a continuous lumen. Peculiar vermicular waves were now seen to pass around the loop. A pipet manometer was introduced, and although the waves still continued, there was no variation in the fluid in the tube, although the least pressure on the intestine showed that the manometer was not plugged. The oval formed by the loop measured in the long diameter 15 cm., and in the short diameter 11½ cm., while the diameter of the intestine was from 4½ to 5 cm. There were 375 c.c. of dirty, black-colored fluid within the loop, which was full of bacteria and epithelial cells and did not convert starch into sugar.

"*Microscopic Examination of the Walls.*—The muscle layers are hypertrophied, the longitudinal muscle being thicker than the circular, and the muscularis mucosæ is also enormously thickened, showing that the longitudinal layers have thickened more than the circular. The muscle-fibers are greatly thickened and contain many vacuoles, especially about the nuclei. There is a great scarcity of nuclei in the fibers, which is in inverse proportion to the hypertrophy of the layers, more frequent in the muscularis mucosæ than in the longitudinal coat, and more frequent in the longitudinal than in the circular. It is very natural that the coat which is most thickened should contain most nuclei, but even in the most thickened coat, the muscularis mucosæ, the nuclei are less frequent than normal. The villi are very rich in leukocytes, and the capillaries are well filled with the same—suggesting inflammation. The lower ends of the crypts are dilated and irregular, but at no point are they found breaking through the muscularis mucosæ. The stratum granulosum does not show a smooth outline, and is filled with many fine granules which often appear to be micrococci."

Later complete physiologic exclusion with the formation of a fistulous opening communicating with one or both ends of the excluded portion came to the notice of the profession through the writings of European experimenters. Modified in this way, the operation is occasionally indicated when the obstructing portion of

the intestinal canal thus excluded is amenable to successful topical treatment, as may be the case in more or less diffuse intestinal tuberculosis with or without stenosis. Practically, however, the same therapeutic benefits are derived from partial physiologic exclusion, which does not imply the necessity for the establishment of one or two intestinal fistula, always a source of disappointment and discomfort to the patient.

Laparo-enterotomy.—Enterotomy has already been referred to as a surgical therapeutic resource in the treatment of intestinal obstruction from impaction by abdominal section.

Incision of the bowel for the removal of obstruction during laparotomy is indicated when the obstruction is due to the presence of a foreign body, a concretion, an enterolith, or a pedunculated benign polypoid tumor. In the removal of a foreign body, a concretion, or an enterolith not amenable to removal by submural crushing or fragmentation with a needle, the incision for extraction should not be made over the seat of impaction, as this part of the intestine has undergone changes unfavorable to the satisfactory healing of the visceral wound. It is much better in such cases to make the incision in a healthy part of the intestine, an inch or two below the impaction, and then crush the foreign body by instruments introduced through the incision, if it can not be extracted safely without fragmentation. The removal of a nonmalignant pedunculated polypoid tumor is to be accomplished by making an incision on the convex surface of the bowel large enough to admit of dragging the tumor through it, after which the base of the pedicle is transfixed by a double ligature and tied, the tumor cut off, and the wound closed in the usual manner.

Enterectomy.—Enterectomy is indicated when the obstruction is due to a malignant tumor, if it is possible to remove the disease completely; also for the removal of benign tumors that can not be excised by enterotomy, and in all cases where gangrene has been caused by constriction, compression, or overdistention. Carcinomatous stenosis is met with most frequently in the large intestine, while the causes that result in gangrene are most common above the ileocecal valve. For malignant disease resection should be done if the entire tumor and all infected glands can be removed completely and with safety. Even if, on account of loss of substance, circular enterorrhaphy can not be made in such cases, the continuity of the intestinal canal can be restored by lateral implantation or by lateral apposition with decalcified bone discs. Immediate circular enterorrhaphy after resection for intestinal obstruction has always been attended by a great mortality, for reasons mentioned elsewhere. In a series of thirty-five resections of the large intestine that Weir collected when symptoms of obstruction indicated the operation, the mortality amounted to 100 per cent. Reichel has also shown that resection of the small intestine for conditions giving rise to obstruction gave a mortality of 75 per cent., whereas in secondary resec-

tion for an artificial anus the mortality is reduced to 37 per cent., a statement that is supported by Makins in his report of 15 deaths in 39 resections for artificial anus. If, after the resection is made, a primary circular enterorrhaphy is not made, Hahn recommends, so as to preserve the advantages of a clean wound and yet to allow the escape of feces, that the intestine should be closed tightly around a rubber tube, which is left projecting some distance for this purpose.

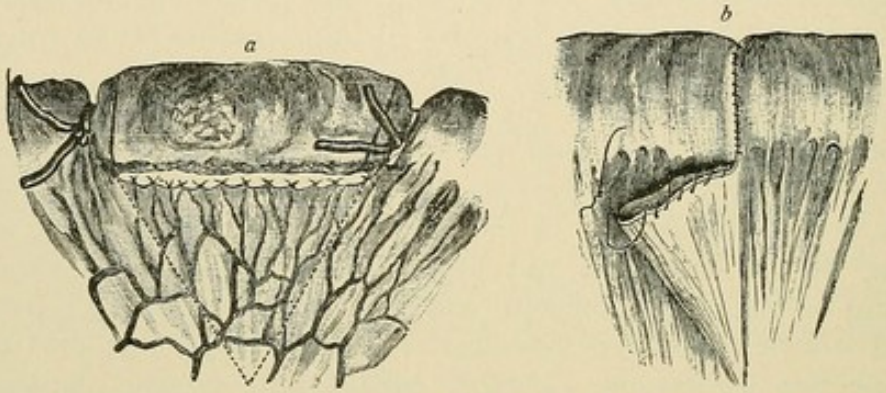

Fig. 496.—Enterectomy: *a*, Constriction of bowel on both sides beyond the limits of resection; manner of ligating mesentery; line of incision; *b*, suturing of intestine and mesentery (after Kocher).

In the removal of a tumor of the cecum with partial resection of the intestinal wall it may be advisable to follow the example of Porter in restoring the continuity of the intestinal canal by suturing. In his case a part of the circumference of the cecum, including a portion of the ileocecal valve, was resected for the cure of a fecal fistula. The wound was closed by slitting up a portion of the ileum from the seat of resection and uniting the margins of this

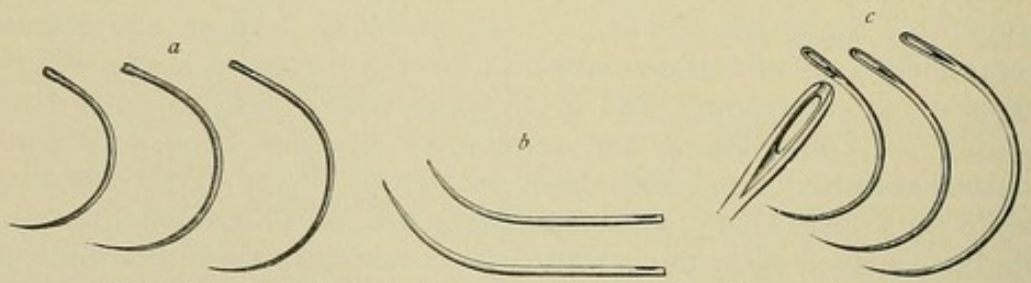

Fig. 497.—Intestinal needles: *a*, Kelly's; *b*, Frank's; *c*, Mayo's.

wound with the resected surface of the cecum. The patient recovered.

In cases where the lumina do not correspond, it is advisable to follow the suggestion first made by Wehr in performing pylorectomy—viz., to cut the end of the narrower part of the bowel not transversely, but sufficiently obliquely so that the circumference of the oblong opening will correspond to the lumen of the larger end of the bowel. The obliquity should always be made at the expense of the convex portion of the bowel, so as to interfere as little as possible with the vascular supply from the mesenteric side. If the

obliquity of the incision should not equalize sufficiently in size the two lumina for suturing, the difference can be corrected by incising longitudinally the convex side of the small end.

Madelung, in resecting the bowel, makes his incisions somewhat obliquely in the same direction, for the purpose of guarding more effectively against gangrene on the convex side of the bowel after circular enterorrhaphy. In very extensive resection of the colon, where the possibility of circular suturing is precluded on account of the impossibility of approximating the cut ends, an artificial anus should never be established, as no subsequent treatment could restore the continuity of the intestinal canal. Two such cases were reported by Hahn. It is possible that, in the future, experimental research will prove the practicability of restoring such defects by a plastic operation consisting of transplantation of a corresponding portion of the small intestine between the separated ends, a procedure that would necessitate circular suturing at three different points. Until it has been shown that some such plan is feasible, the surgeon must content himself with establishing an anastomosis between the closed proximal and distal ends by lateral anastomosis. The latter procedure offers all the advantages to be derived from approximation and keeping in uninterrupted coaptation a large serous surface, with immobilization of the parts it is intended to unite during the process of repair. In circumscribed gangrene due to decubitus and involving not more than one-half of the circumference of the bowel, affecting its lateral or convex surfaces, such as is caused by constriction by a narrow band, resection is not necessary. After the constriction has been removed, the gangrenous spot is turned inward and is covered by suturing the adjacent healthy margins of the bowel over it. The serous surfaces unite rapidly, so that perforation during the separation of the gangrenous part is prevented by union of the serous surfaces over it. When a whole loop or a number of loops of the intestine present evidences of gangrene from constriction, the indications for resection are clear as affording the

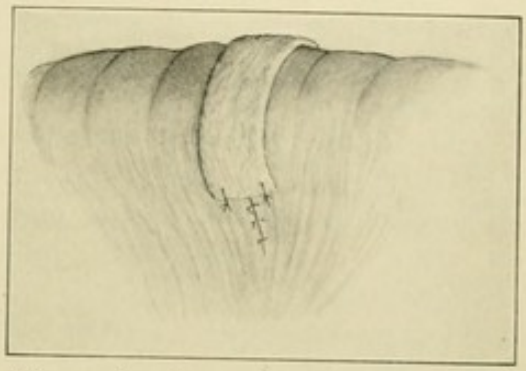

Fig. 498.—Omental graft over line of suturing after circular enterorrhaphy.

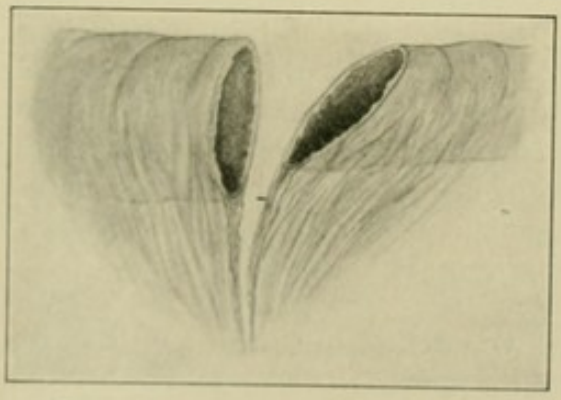

Fig. 499.—Oblique section of smaller end of intestine to equalize the lumina of the cut ends.

only possible chance of preventing death from sepsis or perforation. Unfortunately, in such cases septic peritonitis has usually set in before the operation is performed, and it becomes necessary, after the resection has been made and the continuity of the intestinal canal restored by approximation plates, to treat the peritonitis by flushing the abdominal cavity with warm saline solution and disinfecting with some mild antiseptic, as a one-third per cent. solution of salicylic acid, as advised by Mikulicz. Drainage in such cases becomes a necessity.

The different kinds of intestinal clamps used for the purpose of preventing fecal extravasation are more harmful than useful. They endanger the vitality of the intestinal wall from compression, and are always in the way of the hands of the operator. In safety and efficiency they can not compare with strips of gauze or a rubber band passed through a tunnel made in the mesentery near the bowel with a locked pair of hemostatic forceps, and tied only with sufficient firmness to guard against the escape of fecal contents. The points of constriction must be at a safe distance from the lines of resection, and before tying the constrictors the part to be resected should be carefully emptied. The mesentery should not be excised, as was formerly done, but should be tied with fine silk in small sections before the resection is made (Fig. 496).

It still remains an open question to what extent resection of the small intestine can be performed with impunity. It is true that Koeberlé, Kocher, and Baum have successfully removed respectively 2.05 m., 160 cm., and 137 cm. of the small intestine in the human subject, but, while two of the patients do not appear to have suffered any ill effects in consequence of the removal of so large a surface for digestion and absorption, in Baum's case death, which supervened six months after the operation, was attributable clearly to marasmus, brought about by the extensive intestinal resection. As in a number of pathologic conditions of the intestinal canal, as multiple strictures, gangrene, and multiple gunshot wounds, where the wounds are large and in close proximity, it may become necessary to resort to extensive resection, it becomes an important matter for the surgeon to know how much of the intestinal tract can be removed without any immediate or remote ill consequences.

The immediate danger attending such an operation is the traumatism, which, of course, will be proportionate to the length of the piece of intestine removed, while the remote consequences are due to impairment of the function of digestion and absorption caused by the shortening of the intestinal canal. With a view to obtaining additional light on these important questions I made a number of experiments in 1887. Only a few will be related, for the purpose of presenting points of great interest.

EXPERIMENT 28.—Dog, weight thirty-six pounds. Mesentery was tied in several sections with catgut ligatures; ileum was divided just above the ileocecal valve; six feet of the small intestine were excised, and the ends united by Czerny-Lembert sutures. On

the third day the fecal discharges were bloody. Although the appetite remained good and the dog was allowed to eat as much as he desired, he lost several pounds in weight during the first week. On the third day the abdominal wound opened, as the sutures had cut through, necessitating resuturing. After this time the wound healed kindly. There were three or four fluid fecal discharges during twenty-four hours. The character of the discharges remained the same, and several microscopic examinations made at different times revealed the presence of free undigested fat. The dog was kept busy eating most of the time, and although the most nourishing food was furnished, he emaciated to a skeleton. He was killed one hundred and sixty-one days after the operation. Marasmus was extreme, and hardly a trace of fat could be found anywhere in the tissues. Stomach was enlarged to three or four times its normal size, and distended with food. A slight thickening of the wall of the gut indicated externally the site of suturing, and the lumen of the bowel at this point was slightly diminished in size. At point of operation a loop of intestine was found adherent and somewhat contracted. The remaining portions of the small intestine, only forty-five inches in length, seemed to have undergone compensatory hypertrophy, as the coats were much thickened and exceedingly vascular. At the seat of suturing the mucous membrane presented a slight circular prominence. Pancreas, liver, and spleen were normal in size and appearance.

EXPERIMENT 29.—Medium-sized adult dog. Mesentery was tied in several sections, and eight feet and two inches of the small intestine, from ileocecal region upward, were excised and the ends sutured in the usual manner. On the following day the dog vomited, and blood was seen to escape from the abdominal wound. Death followed three days after operation. The abdominal cavity was filled with fluid and coagulated blood, which, on closer inspection, was found to have escaped from one of the stumps of the mesentery where the catgut ligature had slipped off.

EXPERIMENT 30.—Scotch terrier, weight ten pounds. Mesentery was ligated in parts with catgut ligatures, the ileum was divided four inches above the ileocecal region, fifty inches of the small intestine were excised, and the continuity of the intestinal canal was restored by the usual method of suturing. Some difficulty was experienced in suturing, as the lumen of the upper end was considerably larger than that of the lower. Until four weeks after the operation the dog, although eating well, seemed to become more and more emaciated. After this time he gained somewhat in weight until killed, forty-seven days after the resection. During the whole time the feces were either fluid or only semisolid, and at different times contained free undigested fat. Appetite was most of the time voracious. There were no adhesions to abdominal wound. Omentum was adherent to visceral wound and to bowel. The site of operation was indicated by a slight depression on the surface of the bowel. On palpation, a ring-like thickening was felt, corresponding to the united ends of the bowel. Bowel above seat of resection was somewhat enlarged. On cutting into the bowel the point of union was indicated by a circular prominence of mucous membrane. Nine of the deep sutures were found still attached to the mucous membrane. The entire tract of the small intestine that remained measured only two feet and ten inches in length.

EXPERIMENT 31.—Adult Maltese cat. The mesentery was tied in five sections with catgut ligatures corresponding to twenty-nine inches of the ileum which were excised. Previous experience in circular enterorrhaphy had proved that perforation is most likely to take place on the mesenteric side of the bowel, where, on account of the triangular place made by the reflections of the peritoneum, the muscular coat is not covered by serous membrane. To obviate this difficulty continuity of the serous covering of the ends of the bowel before suturing was secured by drawing the peritoneum over this raw surface by a fine catgut suture. The mesentery was detached only to a sufficient extent to apply the second row of sutures. The fine catgut suture, to approximate the edges of the peritoneum, must be applied near the margin of the divided end of the bowel, so that the knot will not interfere with the accurate coaptation of the serous surface between the deep and superficial row of sutures. This modification of circular suturing was adopted for the first time in this case. Although the animal manifested no untoward symptoms and the appetite remained good, the marasmus was progressive until the time of killing, twelve days after the excision. Abdominal wound was not completely united. Intestinal wound, which was two inches above the ileocecal region, was completely healed. The sutured surface was adherent to loop of bowel, which caused a sharp flexion. Intestine above this point was somewhat dilated and partially distended with fecal accumulation. Slight contraction of the lumen of bowel by circular bulging of mucous membrane, in which most of the deep sutures remained fixed. The postmortem appearance points to partial obstruction at point of flexion; remaining portion of small intestine measures only twenty-one inches in length.

EXPERIMENT 32.—Medium-sized Maltese cat. Mesentery was tied in sections, thirty-four inches of the small intestine were excised, and the divided ends were united in

the same manner as in the preceding case, special care being taken to secure an uninterrupted peritoneal surface for divided ends before suturing. Appetite remained good, but progressive marasmus, which appeared at once, continued and proved the direct cause of death twenty-one days after the excision. Abdominal wound was firmly united. There was no peritonitis. Visceral wound was completely united, and intestine at site of operation was covered with adherent omentum.

EXPERIMENT 35.—*Excision of Entire Colon and Two Inches of Ileum in a Cat.*—A triangular piece was excised from distal end to narrow the bowel sufficiently so that its lumen should correspond to that of the ileum. The ileum and rectum were then united by Czerny-Lembert sutures. The animal never rallied from the prolonged operation, and died of shock two hours later.

The results of these experiments speak for themselves. In all cases of extensive resection of the small intestine where the resected portion exceeded one-half of the length of this portion of the intestinal tract where the animals survived the operation, marasmus followed as a constant result, although the animals consumed large quantities of food. The experiments on partial enterectomy illustrate conclusively that for wounds of the convex side of the intestine, where, from the nature of the injury, transverse suturing is impossible, longitudinal approximation and suturing can be safely done, provided at least one-half of the lumen of the bowel can be preserved. If the stenosis is carried beyond this point, there is great danger that the inflammatory swelling following the operation will still further narrow the tube and lead to the most serious consequences, due to intestinal obstruction, and place the visceral wound in the most unfavorable condition for the healing process.

Partial enterectomy on the concave side of the bowel for a defect of any considerable size is never admissible, as it is sure to be followed by gangrene or pathologic flexion of the bowel.

Direct Treatment of Obstruction in Strangulation by a Band or Diverticulum, Flexion, or Adhesion of the Intestines.—The most favorable cases of intestinal obstruction for laparotomy are those where the obstruction is due to constriction from a narrow ligamentous band. The history of such cases usually points to an antecedent attack of localized peritonitis. One or more of the adhesions during the course of time are drawn out into a band, under which the intestine is caught, and strangulation takes place in the same manner as in strangulated hernia. These are the cases of intestinal obstruction which, if left alone, almost without exception result in death; if submitted to an early operation, they are cured by one stroke of the scissors. If the strangulated loop presents no evidences of gangrene and no signs of decubitus are found at the point of compression, the strangulation is relieved by cutting the bands, and, for the purpose of preventing a recurrence of the strangulation from the same cause, it is necessary to trace the band to its points of fixation and resect it between two ligatures. A diverticulum of the small intestine, remnants of the vessels of the vitelline duct, or the appendix vermiformis have often been found as a cause of constriction when the free extremity of these structures had become adherent to some

fixed point, and it is always necessary to make a close examination of a constricting band before resorting to cutting instruments, as a mistake in recognizing the true anatomic character of the obstructing cause might lead to serious results. A narrow appendix may be tied and resected the same as a ligamentous band when the stump is properly cared for, but when the obstruction is caused by a diverticulum, greater care must be exercised in removing the cause of obstruction. Many of the diverticula which have been met with as a cause of obstruction were nearly as large at their base as the intestine with which they were connected, and in such instances it would be unsafe to rely upon a ligature at the resected end in effecting permanent obliteration, as cutting through the ligature might be followed by perforation and death from septic peritonitis a few days after the apparent recovery of the patient. The proximal end of such a resected diverticulum must be closed with the same care and in the same manner as an intestinal wound of the same size from other causes. If the obstruction is found to be due to flexion, the mechanical difficulty must be corrected by separating the adhesions, as the apex of the flexion is generally, if not always, adherent to some fixed point. After this has been done, the proper shape and contour of the bowel should be restored and its permeability tested by pushing the contents beyond the flexed part, if this can be done without meeting with resistance, and if the condition of the intestinal wall at the site of flexion presents no serious textural changes, the intestine is returned and the abdominal incision closed. As the concavity of the flexion is usually directed toward the mesenteric attachment, the vascular disturbances are most marked on the convex surface of the bowel, and if gangrene or perforation has taken place, it is found at this point. In either of these events it would become necessary to liberate the intestine by separating the adhesions, and then resort to a V-shaped excision on the convex side of the intes-

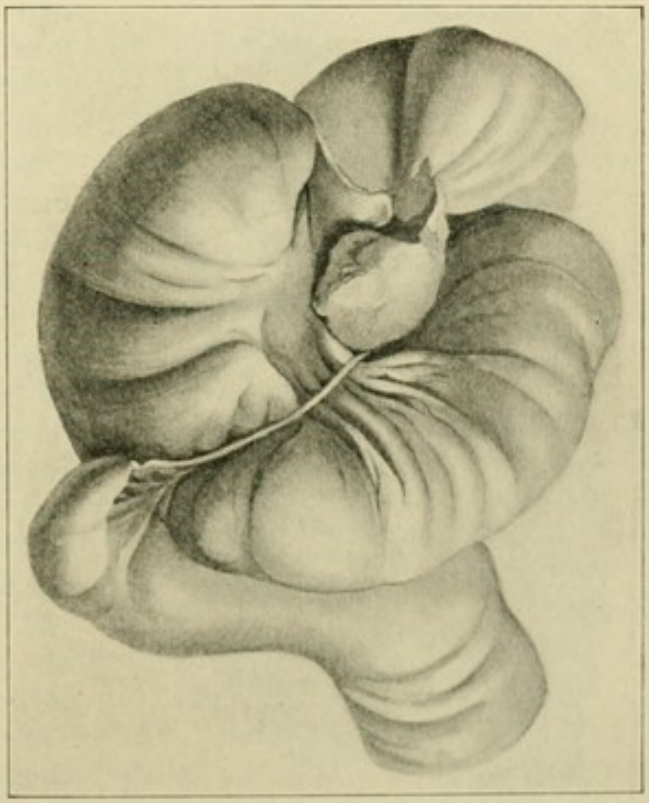

Fig. 500.—Strangulation by Meckel's diverticulum (Warren Museum).

tine. The portion to be excised must be of sufficient size to include the diseased tissue and to enable the surgeon to rectify the malposition by suturing.

Immobilization of a considerable portion of the intestinal canal by a large blood-clot and extensive parietal and visceral adhesions may give rise to symptoms of intestinal obstruction. When intra-abdominal hemorrhage is followed by a complexus of symptoms indicative of the presence of intestinal obstruction, the abdomen should be opened and the coagulated blood removed by sponging and flushing of the peritoneal cavity with hot saline solutions, and the recurrence of the same condition prevented by arresting further hemorrhage. A form of visceral adhesion between coils of intestines massed into a bunch has already been described as a cause of intestinal obstruction. If this condition has lasted for several days and the adhesions have become firm, it is absolutely impossible to unravel the bowel without running the risk of inflicting numberless and perhaps irreparable injuries. In such instances excision of the mass, followed by circular enterorrhaphy or anastomosis between the intestine above and below the obstruction, as previously described, present themselves as the most appropriate methods of treatment. Each of these operations is applicable to special cases and adapted to meet particular indications. Thus, if any of the embedded coils should present indications of incipient gangrene, resection must be done. If no such textural changes are present, intestinal anastomosis should be preferred, as by it the obstruction is removed indirectly, and the portion temporarily excluded, after subsidence of the inflammation and absorption of the adhesions, may again become permeable and resume its physiologic functions.

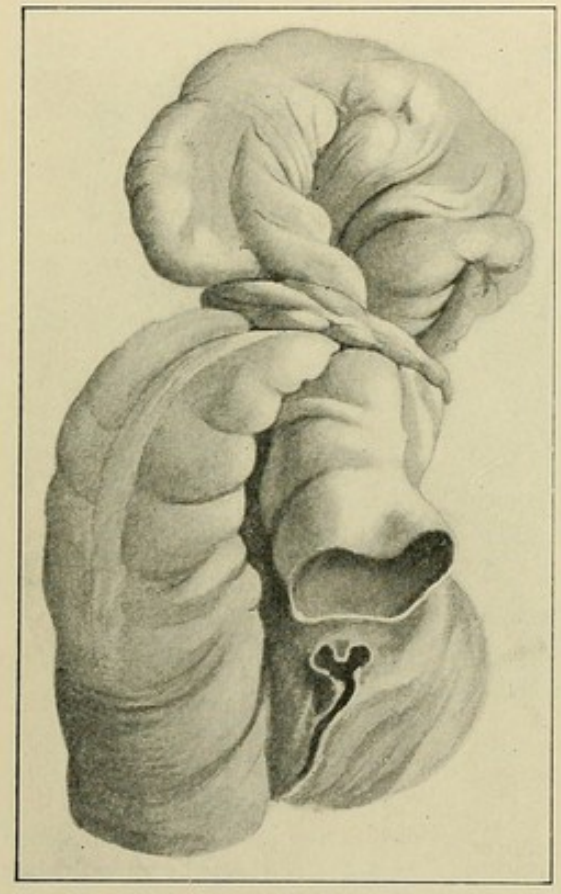

Fig. 501.—Strangulation by appendix vermiformis (Warren Museum).

Circumscribed parietal adhesions as a cause of intestinal obstruction are most commonly met with in the pelvis, and on account of the greater frequency of pelvic inflammation in the female, occur more frequently in women than in men. Pelvic intestinal adhesions produce obstructions in two distinctly different ways: (1) An adhe-

rent intestine becomes flexed or twisted by the peristaltic action of the free portion, and obstruction results from sudden or gradual stenosis of the lumen of the bowel. (2) A portion of intestine becomes fixed at each end by adhesions, and a loop is caught under it, when obstruction is caused in the same manner as by ligamentous bands.

The only case of intestinal obstruction after ovariotomy that occurred in my experience was produced in this manner. The pedicle was tied and its surface cauterized. No untoward symptoms until the end of the third week, when symptoms of intestinal obstruction appeared suddenly and increased in intensity in spite of irrigation of the stomach and high rectal injections. Patient died two weeks later. The postmortem showed that a loop of the lower portion of the ileum had become adherent to the surface of the pedicle, and that the mesentery constituted the second fixed point; under this loop another loop four inches in length had slipped from above downward, and had become incarcerated in this position. The intestine below the obstruction was perfectly empty, while above it it was enormously dilated and exceedingly vascular as far as the duodenum.

Quite a number of similar cases have been reported by different operators. In old cases of pelvioperitonitis and salpingitis, the cause of a subsequent attack of intestinal obstruction is frequently traceable to intestinal adhesions and the formation of ligamentous bands. In the separation of such old adhesions the greatest care must be exercised not to tear the bowel, as both the parietal and visceral peritoneum may have been transformed into a cicatricial mass which it is not safe to separate by tearing. The separation must be done by careful dissection, which, for the sake of safety, is done rather at the expense of the parietal than the visceral tissues. Defects of the peritoneum thus caused or made during other abdominal operations should be covered by suturing, by laying the omentum over it, or, if need be, by omental grafts, to prevent a recurrence of such complication. The parietal peritoneum is so loosely attached almost everywhere that it yields sufficiently to cover a defect at least two inches in width by suturing, and whenever this can be done, it should not be neglected, as surfaces denuded of peritoneum are liable to become permanently adherent to adjacent abdominal viscera. If larger defects are to be covered, the peritoneum can be cut in the shape of flaps, which can be readily mobilized and sutured. When the omentum is within reach, this should be utilized in covering the defect.

A number of years ago I made a series of experiments on animals that demonstrated that when a piece of parietal peritoneum three to four inches square is removed and not restored in some of the above-mentioned ways, permanent adhesions form between the denuded place and the organ that comes in contact with it. Another series of experiments that it would be too tedious to describe in full were made to show that peritoneal defects that can not be restored by

suturing or covering with omentum can be treated successfully by transplantation of an omental or peritoneal graft. In some of the experiments a piece of peritoneum four inches square was removed from each side of the abdominal wall at corresponding points, and was transplanted to opposite sides and sutured to the margins of the wound with catgut. All these experiments proved successful. Omental grafts answered the same purpose, and in only one instance did the graft fail to unite throughout, and here one of its margins projected into the median abdominal incision, which did not unite by primary union. Infection of this margin led to gangrene of the graft and septic peritonitis.

Toilet of Peritoneal Cavity.—If everything that has come into contact with the abdominal cavity during a laparotomy for intestinal obstruction has been rendered aseptic by the most scrupulous antiseptic precautions, and the local conditions found have caused no infection and no soiling of the peritoneal cavity with intestinal contents during the operation, the abdominal cavity is aseptic after the operation and can be closed after the removal by gentle sponging of any blood that may have collected. Unnecessary exposure of the intestines should always be most carefully guarded against by hot compresses around the incision during intra-abdominal exploration, and by keeping the intestines constantly covered by warm compresses as long as they are outside the peritoneal cavity, for the purpose of preventing infection by floating microbes and to guard against loss of heat during the operation. The case is, however, entirely different when the parts concerned in the obstruction have caused intraperitoneal sepsis at the time the operation is undertaken, or when, during its performance, in spite of all care to prevent it, the peritoneal cavity has become contaminated by fecal extravasation. Under these circumstances the peritoneal cavity should be flushed with gallons of hot saline solution or a saturated solution of salicylic acid. The end of the glass tube or rubber tubing of the fountain syringe should be held in different parts of the abdominal cavity, especially in the deepest portion of the pelvis and the lumbar regions, so as to direct the current of the antiseptic solution out of and not into the peritoneal cavity. After the abdominal cavity has been cleansed by flushing, it is dried by sponging. In such cases drainage should never be omitted. The closure of the external incision when intra-abdominal pressure is excessive is greatly facilitated by covering the intestines with a napkin or thin compress of gauze, which is tucked underneath the margins of the wound all around. All the sutures should be introduced before any of them is tied. When all the sutures are in place, they are tied from above downward. If tension is considerable, it is necessary to add two or more button sutures, which are passed only down to, but not through, the peritoneum, and are removed as soon as the tympanites disappears. A copious aseptic dressing, held in place by a firm abdominal bandage, completes the operation.

After-treatment.—Uniform equable support of the abdomen, by strapping and bandages over the antiseptic absorbent dressing, furnishes efficient support to the distended abdominal walls and the paretic intestines, and is not only grateful to the patient, but is an important aid in relieving the distress due to distention and peristalsis. In all operations for intestinal obstruction efforts should be made to empty the bowel, not only at the seat of obstruction, but as far as it can be done, as such immediate evacuation constitutes one of the elements of success.

J. Greig Smith states distinctly that "No case of operation for intestinal obstruction is properly concluded until the distended bowels are relieved of their contents." One of the most favorable symptoms after a successful operation for intestinal obstruction is a spontaneous action of the bowels, as it not only proves the permeability of the intestinal canal, but is also an evidence that peristaltic action has been restored. The retention of fecal material in the distended paretic intestines after operation for intestinal obstruction is a condition that not only retards recovery, but is in itself a grave source of danger. Through the sympathetic nerves the distended intestine exerts a most depressing effect on the cerebrospinal centers, while the putrefactive changes that are constantly going on in the stagnant intestinal contents must be a constant source of intoxication, and, at the same time, the migration of septic micro-organisms through the paretic walls threatens life from septic peritonitis.

Symptoms of shock are met by the administration of strychnin subcutaneously, stimulants by the rectum, intravenous or subcutaneous saline infusions, and stimulation of the peripheral circulation by dry heat applied to the surface of the trunk and extremities.

Mr. Tait has taught us the value of cathartics in the prevention of peritonitis after abdominal operations. Would it not be rational to follow his example in the after-treatment of operations for intestinal obstruction? Surgeons have repeatedly made the observation that the paretic intestine above the seat of obstruction will respond slowly but surely to mechanical irritation, and it is logical to conclude that the same effect would be produced by the administration of a brisk saline cathartic. *Dangerous as the use of cathartics necessarily must be before the obstruction is removed, so beneficial may their judicious employment be after the continuity of the intestinal canal has been restored by operative treatment.*

Thirst is quenched by sips of hot water, fragments of ice, and saline rectal enemata. Stomach-feeding is absolutely contraindicated for the first forty-eight or seventy-two hours, during which time rectal alimentation is relied upon exclusively. Absolute rest in the recumbent position must be enforced until the visceral and abdominal wounds have healed. The administration of copious laxative enemata is permissible for the purpose of assisting the saline cathartics to restore peristalsis, provided the seat of strangulation was above the ileocecal valve.

CHAPTER XXIII.

ENTERORRHAPHY.

INTESTINAL suturing is technically called enterorrhaphy. From a practical standpoint intestinal suturing is divided into (1) lateral and (2) circular. Lateral enterorrhaphy is intended for the closure of gunshot, stab, cut, and punctured wounds of such size and so located that in closing them by sewing, the lumen of the injured part of the intestine remains sufficiently large for the free passage of intestinal contents, and without interfering with the necessary blood supply to the injured tissues or the corresponding segment of the bowel. Intestinal suturing is also resorted to by the lateral method in closing pathologic perforations of limited dimensions and tears made during abdominal and pelvic operations, and after partial enterectomy for trauma or the removal of pathologic products or extraction of foreign impacted bodies from the lumen of the intestines by enterotomy. In selecting the cases for lateral suturing the surgeon must exercise the greatest caution in determining the exact location and extent of the intestinal defect and its influence on the blood supply of the injured or diseased segment of the bowel. *On the concave side of the intestine only incised and small punctured wounds are amenable to successful lateral enterorrhaphy, as wounds or perforations involving any considerable part of the mesenteric attachment interrupt the blood supply to the convex side of the bowel sufficiently to incur danger from gangrene, and the suturing of a mesenteric wound involving the bowel-wall to any considerable extent is very liable to result in stenosis* from flexion to a degree which may become a cause of mechanical obstruction. In this connection only two of a number of experiments made by me will be quoted to illustrate the danger incident to lateral suturing on the mesenteric side, and the treatment of large defects on the convex side by the same procedure.

EXPERIMENT 2.—Large, full-grown cat. On the concave side of the bowel, about the middle of the ileum, a semilunar piece of the wall of the intestine with the corresponding mesentery was removed and the wound closed parallel with the long axis of the bowel, which diminished the diameter of the lumen of the bowel to about one-eighth of an inch. It was noticed during the operation that the convex surface of the bowel over an area corresponding to the partial excision presented a cyanosed appearance. The animal died on the fourth day after operation, and the whole segment of the sutured bowel was found gangrenous, but no fluid in the abdominal cavity.

EXPERIMENT 3.—Adult, large cat. In this case a segment of the ileum was emptied of its contents, and, before cutting away a semilunar piece from the convex surface, a back-stitch continuous suture was applied on the inner margin of the proposed line of incision, which left about one-third of the lumen of the bowel. After excision of the semilunar piece the margins of the cut surface were turned inward and covered with serous surface by a continuous catgut suture. Several small passages occurred after the operation, but the animal died on the fourth day with symptoms of intestinal obstruction.

The visceral wound was found healed, but the lumen had become so narrow from the inflammatory swelling of the tunics of the bowel that it was entirely inadequate for the passage of intestinal contents, and as a result of this operation the bowel had become considerably dilated above the point of operation.

These experiments illustrate conclusively that in wounds of the convex side of the intestine, where, from the nature of the injury, transverse suturing is impossible, longitudinal approximation and suturing can be safely done, provided at least one-half of the lumen of the bowel can be preserved. If the stenosis is carried beyond this point, there is great danger that the inflammatory swelling following the operation will still further narrow the tube and lead to the most serious consequences, due to intestinal obstruction, and place the visceral wound in the most unfavorable condition for the healing process.

Experiment 2 shows the great danger of interference with the blood supply from the mesentery in longitudinal suturing of wounds on the concave side of the bowel, as such a procedure is invariably followed by gangrene of the corresponding segment of bowel on the convex side.

Circular enterorrhaphy is the procedure by which the continuity of the intestinal canal is restored after complete division of the bowel or after excision of a greater or less section for injury or disease. Circular enterorrhaphy is the ideal method of accomplishing this object in all cases in which time and the general condition of the patient permit. The various mechanical devices that have been brought to the attention of the profession during the last twelve years were intended mainly as time-saving measures. As compared with the suture and anastomosis and lateral implantation, they have come into wide-spread use as substitutes for circular suturing in cases in which the cut ends of the intestine can not be united by this method, owing to the extent of the defect, fixation of the parts to be approximated by adhesions, or too great difference in the size of the lumina to be united.

A study of surgical literature brings the conviction that the successful treatment, by direct operative intervention, of injuries and surgical affections of the intestinal tract is one of the most brilliant achievements of modern surgery. Less than fifty years ago many of the most famous surgeons regarded the direct treatment of wounds of the intestines as a *noli me tangere*, under the belief that nature's resources would prove more successful in saving the life of the patient than the surgeon's efforts in closing the wound by artificial means. The intentional infliction of an intestinal wound by the surgeon for the purpose of correcting mechanical difficulties anywhere in the intestinal canal and the removal of life-threatening affections by operative procedure are operations that have been seriously discussed and extensively practised only during the last twenty-five years. It is advisable and profitable, during the present time, which has witnessed such wonderful advancements in surgery,

to make occasionally a halt in the restless search for new discoveries and novel operations to take a retrospective view of what has been done in the past in certain departments of surgery that have recently been subjected to such complete revolutionary changes. No part of abdominal surgery has undergone more radical changes than the intestinal suture, and in none is the contrast greater between the ancient and modern methods.

The history of the intestinal suture is full of interest to the student of surgical literature. It is replete with stupendous ignorance, clever mechanical ingenuity, patient experimental research, and the careful application of pathologic knowledge to the treatment of injuries and diseases of the intestinal canal. From an anatomico-practical standpoint the history of the intestinal suture can be divided into three epochs: (1) ancient, (2) modern, and (3) recent. The ancient history extends back from Lembert (1826) to the time of Celsus. The modern history commenced with the researches of Lembert, which proved that healing of intestinal wounds takes place most constantly and speedily if the serous surfaces are brought and kept in contact by the sutures. The third period was initiated by the introduction of the aseptic suture by Lister, and will necessarily extend far into the future. We have reason to believe that the technic of intestinal suturing remains an unfinished chapter, and that the ideal method of uniting intestinal wounds has yet to be devised.

In the presidential address on "Enterorrhaphy: Its History, Technic, and Present Status," delivered by me before the Association of Military Surgeons of the United States in 1893, and published in the transactions for the same year, I gave a complete history of the intestinal suture and its substitutes up to that time, with fifty-four figures illustrating the same. A great many new sutures and mechanical appliances have been devised and described since, but none of them marks any decided improvement in the technic of enterorrhaphy.

The axiom of successful intestinal suturing, "peritoneum to peritoneum," established by Lembert, holds good to-day, although several attempts have been made to undermine its force. In 1895 the late distinguished author and abdominal surgeon, J. Greig Smith, raised his voice in opposition to its universal acceptance and application in practice. He changed his views in consequence of what he observed in the healing of wounds after enterostomy or colostomy. He found the adhesions firmer and more permanent between a serous and raw surface than between two apposed serous surfaces. He argued strongly in favor of uniting a serous to a raw surface in effecting permanent fixation of any of the intra-abdominal organs. The two closing sentences of one of his last valuable contributions to abdominal surgery express clearly his conviction on this subject:

"Senn went some way toward serofibrous approximation

when he suggested scratching of the apposed peritoneal surfaces. I should like to see it carried further, either into actual denudation of one serous surface or actual outfolding of both serous surfaces so as to get a flange-stitch, or by removal of a ring of mucous membrane and enveloping the intact gut by the muscular and serous coats (Jessett-Robinson). And this is one purpose of my writing now, to suggest further experiments in intestinal surgery to test the question whether seroserous apposition with infolding is really the best method of joining divided bowel. A cautious application of accidental results has convinced me that, over the greater part of the field of abdominal surgery, seroserous junction is not the best ; extended experience must show whether the same rule holds good with regard to intestinal surgery. If the proof in this case goes against the general principle, I think it is more likely to be on mechanical than on pathological grounds."

Reasoning from the same point of view, Kummer advocated the removal of a ring of mucous membrane by excision or scraping as a preliminary step to circular suturing. This practice, however, has found but few imitators, and the law, "serosa to serosa," continues in force at the present time in uniting intestinal wounds by suture or any of its substitutes.

The sutured serous surfaces appear to become attached to each other before the completion of the operation, as will be seen from the paper of F. Mall on "Healing of Intestinal Sutures." He describes a specimen of "suture of a few hours' standing." "The serous coats that are in apposition are closely stuck together. It has been noticed frequently by Dr. Halsted and myself that this union takes place before the operation is completed. In a double resection, as in this case, the suture first made was always examined before finally closing the abdominal cavity. In pulling the edges of the wound apart, a fibrinous substance would have to be torn in order to separate the edges. There are in this substance very few leukocytes, and under favorable circumstances primary union takes place." What the author understands by primary union is somewhat vague, as organic union without granulation and vascularization is no longer considered within the range of possibilities.

I made a series of experiments with the aim of studying the effect of chemic and mechanical irritation of the peritoneum in the reparative process after intestinal operations. The chemic substances used were the tinctures of iodin and muriate of iron, and mechanical irritation was made by scarifying the peritoneum with the point of an aseptic needle. The scarification was made deep enough to reach the subserous vascular tissues. It was expected that, by bringing the blood-vessels on both sides in closer contact, the process of repair would be hastened, besides securing tissue stimulation from the mechanical irritation caused by the procedure. Only two of the experiments will be quoted here :

EXPERIMENT 104.—*Triple Ileo-ileostomy by Perforated Decalcified Bone-plates.*—Three internal fistulæ were made between the adjacent loops of the ileum, about six inches apart. In operation No. 1 approximation of intact serous surfaces; in operation No. 2 the serous surfaces were painted with tincture of iron over an area corresponding to the size of the plates; in operation No. 3 the serous surfaces over the same extent were brushed with pure tincture of iodin. The animal was killed forty-eight hours after operation, and the following conditions were noted: No general peritonitis. All the plates firmly in place, coaptating the serous surfaces accurately, the swelling of the tunics of the bowel serving only to enhance their efficiency. At No. 1 adhesions quite firm, flexion of bowel, and marked injection of serous surfaces. At No. 2 no adhesions between serous surfaces. The peritoneal surfaces to which the tincture of iron had been applied appeared stained, almost black, and at some points the serous coat was destroyed. At No. 3 peritoneal surfaces stained dark brown, adhesions firm, and an abundance of plastic lymph even beyond the margin of the plates.

EXPERIMENT 105.—*Double Ileo-ileostomy by Approximation Plates and Omental Grafting.*—Operation No. 1, approximation of ileum to ileum by perforated decalcified bone-plates; serous surfaces intact. Operation No. 2, similar operation six inches higher up, uniting the same loops, but painting the serous surfaces with pure tincture of iodin. Operation 3, cut off a piece of omentum two inches wide and sufficiently long to encircle the entire bowel. After scarifying the bowel and the omental graft on one side, the scarified surfaces were brought in contact, and the graft fixed in its place by two fine catgut sutures passed through the mesentery and both ends of the graft. Animal killed forty-eight hours after operation. All plates firmly in place At No. 1 adhesions firm. At No. 2 dark-brown discoloration of surface to which the iodin had been applied; agglutination over the whole surface. Under hydrostatic pressure the adhesions first gave way between the two plates where the iodin had been applied, showing conclusively that chemic irritation of serous surface does not hasten the adhesive process, while it may, and probably does, expedite the definitive healing. At No. 3 omental graft firmly adherent to the entire circumference of the bowel and beginning vascularization of the graft around its margins.

In all these experiments the postmortem examinations showed no evidences of diffuse peritonitis. In most of the cases the inflammatory process was limited to the portion of the bowel interposed between the plates. Without exception the adhesions formed were firmest, and the definitive healing was initiated first where scarification was performed, results that clearly demonstrate the fact that the reparative process between serous surfaces that it is intended to unite is hastened by traumatic irritation. Traumatic irritation by scarification of the peritoneal surface with the point of an aseptic needle is the most potent means to provoke a circumscribed plastic peritonitis, and is followed within a few hours by a copious exudation of plastic lymph, which, like a cement substance, mechanically agglutinates the coaptated serous surfaces. The same measure, by destroying the continuity of the nonvascular layer of the peritoneum, brings at once in contact the vascular network of both sides of the bowel, and opens up a direct route for the new vessels, an important element in the rapid healing of the visceral wounds. Chemic irritants, by destroying the endothelial layer of the peritoneum, rather retard than favor early adhesion and union between the coaptated bowels, and should therefore not be resorted to in intestinal surgery with a view to hasten the reparative process.

The value of scarification as a means of expediting the healing process and in securing firm permanent adhesions can no longer be questioned, and while neither essential, nor perhaps even necessary, in intestinal suturing, it never does harm and may accomplish much

good. It should, therefore, never be neglected in abdominal surgery when the operator undertakes to fix permanently, by broad adhesions to the abdominal wall, any of the pathologically displaced organs.

Needles for intestinal suturing must be round. A delicate, long, ordinary sewing needle is best adapted for this purpose. Curved round needles must be kept on hand, and will come into use when the intestinal ends to be united can not be brought well forward into the abdominal incision (Fig. 497).

The best suturing material is fine aseptic silk. There is some advantage in using iron-dyed silk. Maunsell is very partial to horsehair, carefully selected and properly prepared. This material has not been used with the frequency it merits. Horsehair is elastic to some extent, and causes absolutely no irritation in the tissues, a matter of considerable importance in using the seromuscular stitch, which comes in such close contact with the mucous membrane and the intestinal contents, full of pathogenic microbes. Some surgeons rely on catgut, but there is no special advantage in the use of absorbable sutures in sewing intestinal wounds, to say nothing of their greater liability to give way and to become a direct or indirect source of infection.

The emergency surgeon should be familiar with the different kinds of sutures that are in use at the present time and the different methods of using them, and he must be, at any rate, an expert in handling the needle in making the seromuscular or Lembert stitch. Most of the stitches devised since the time of Lembert are only modifications of his stitch. Lembert was the first one who taught that in closing an intestinal wound the wound margins should be inverted, and that the needle should not penetrate into the interior of the bowel, so that when the sutures are tied, the serous surfaces included in the stitches are brought and held in contact. Lembert emphasized the importance of including only the peritoneum in the sutures, and hence, for a long time, Lembert's suture has been known as the serous or peritoneal suture, in contradistinction to the ancient sutures, which included all the coats of the intestinal wall. The peritoneum is a very delicate structure, and does not offer the necessary resistance to give the sutures a safe support, and probably Lembert himself always included more or less of the muscular coat in suturing intestinal wounds. Even the older text-books insist on including in the Lembert stitch a part or the entire middle tunic of the intestinal wall. The muscular coat itself yields under the suture if the intestine is distended, and surgeons were eager to include in the suture a firmer and more resistant tissue. Clason has shown, by his anatomic studies, that the submucosa of the small intestine consists of two distinct layers of connective-tissue fibers, which, according to the tension of the intestine, cross at more or less acute angles, run spirally around the intestine, and make the submucosa much like the "Indian puzzle." These connective-tissue

fibers are in great part white fibrous tissue bundles. Halsted was the first one to call attention to this important tissue in connection with the intestinal suture. With the point of the needle these firm connective-tissue bundles can be distinctly felt, and a sufficient number of the fibers are included in the stitch by lifting them up on the point of the needle. It requires considerable practice on the part of the student to recognize this important layer of the intestinal wall when he first begins to use the needle. Fresh intestines from dogs or pigs furnish the best material for acquiring a reliable practical knowledge of the technic of this part of enterorrhaphy. The suture is placed so close to the mucous membrane that the inexperienced, untrained physician, in his endeavor to secure a firm hold for the suture, will not infrequently penetrate the mucous membrane or its glandular appendages.

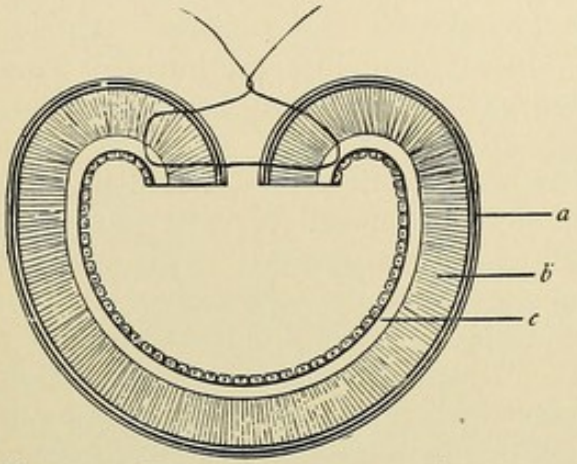

Fig. 502.—Lembert's suture: *a*, Serous coat; *b*, muscular coat; *c*, submucous fibrous layer.

Including the entire thickness of the intestinal wall is attended by much risk of the escape, by capillary attraction, of septic material into the peritoneal cavity in sufficient quantity and virulence to provoke septic peritonitis. Inclusion in the stitch of one or more of the follicles is less likely to be followed by such an immediate disastrous consequence, but it opens up another source of danger and creates an obstacle to a speedy healing of the intestinal wound. "The tearing into the crypts, as mentioned by Dr. Halsted, suffices, no doubt, to start a peritonitis. But it also gives the crypt a chance to return to its embryonic type and to grow out of its proper domain, thus giving an additional cause why the mucosa should not be pierced. It may possibly be that these cells, when once fully liberated, could do considerable damage" (F. Mall). *The Lembert stitch, in whatever form it is used, must include all the structures of the intestinal wall minus the mucosa.*

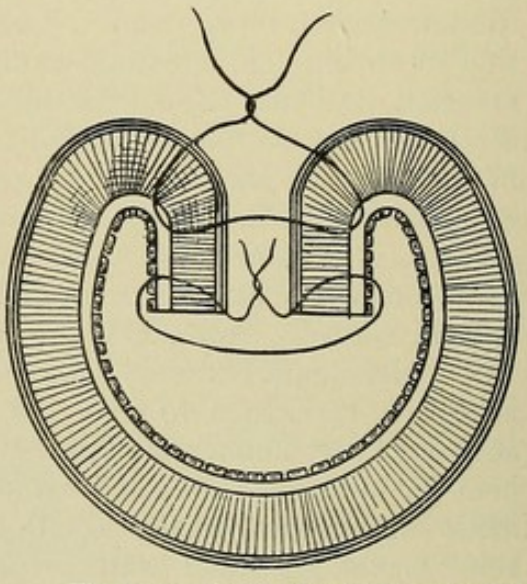

Fig. 503.—Czerny-Lembert, or double intestinal, suture. The deep sutures include all the coats except the peritoneum.

Another rule of great importance bears on the manner in which the Lembert stitch should be tied: *The interrupted Lembert stitch must be tied by making an ordinary square knot, and only with sufficient firmness to approximate and hold in contact the serous surfaces, so as to avoid harmful linear compression.* Simple as this rule may appear, it is certain that it is often ignored and that more frequently the stitches are tied too tightly than otherwise.

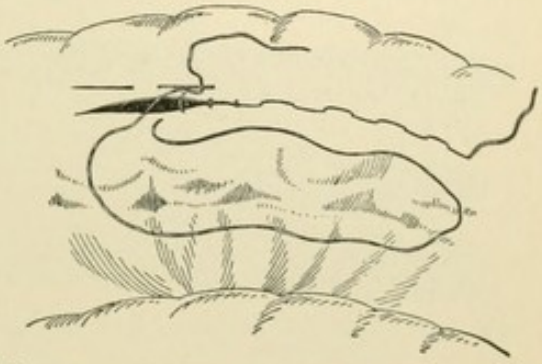

Fig. 504.—Cushing's "right-angled" continuous suture.

The stitches should be placed sufficiently close together to render the line of suturing impermeable to gases and fluids—that is, from six to eight to every inch. Too great inversion of the margins of the wound must be avoided, as it may result in obstruction, but serous surfaces to be brought in contact must be wide enough for a speedy and sufficiently broad union to take place. The amount of tissue included in each stitch and the extent of inversion of the wound margins must be determined largely by the size of the wound and of the injured intestine and the condition of the tissues included in the sutures. The continued Lembert stitch is frequently employed in reinforcing deep Czerny stitches and the different appliances used as substitutes for suturing. It should never be used in place of the interrupted suture where one row of sutures is relied upon in closing an intestinal wound or in making a circular enterorrhaphy. The continued suture can not be relied upon in regulating the coaptating force with the same degree of accuracy as when the interrupted sutures are used, and in the event that one stitch should give way, adjacent stitches are often loosened sufficiently to give rise to extravasation and its consequence, peritonitis. Halsted's quilt suture and Cushing's right-angled suture are excellent modifications

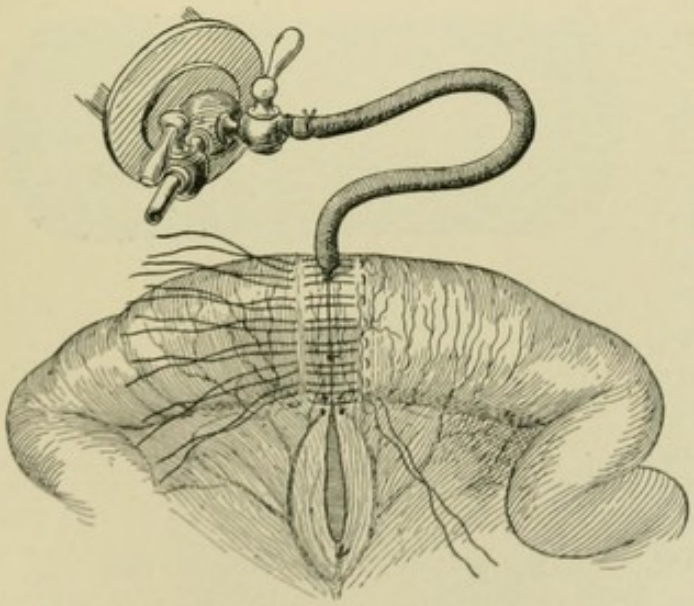

Fig. 505.—Halsted's mattress suture and inflatable bulb for circular enterorrhaphy.

of Lembert's seromuscular stitch. The surgeon of limited experience will, however, do well to make use of the simplest procedure and rely in his work in preference on the Lembert suture, interrupted or continued. The Mitchell-Heamner mesenteric suture is a very important aid in circular enterorrhaphy in approximating the serous surfaces on the mesenteric side.

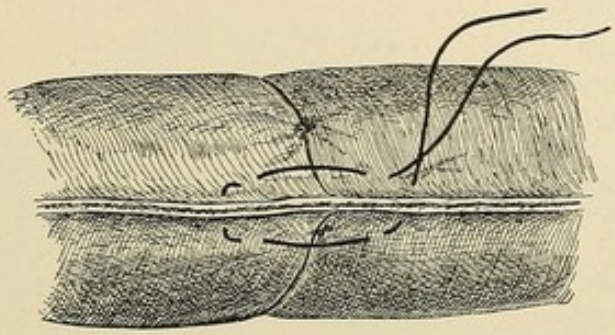

Fig. 506.—Mitchell-Heamner mesenteric suture.

In circular enterorrhaphy, if time permits two rows of sutures, deep and superficial, the Czerny-Lembert method is one that offers the greatest safety and one that is mastered with the fewest difficulties. *The deep, or Czerny, stitches include all the coats of the intestinal wall minus the peritoneum. Each stitch includes a small cone of tissue of each wound margin, the base of which is directed toward the line of union* (Fig. 503). It would be unsafe to include the peritoneum in the deep row of sutures, as by capillary attraction or oozing intestinal contents might find a way between the two rows of sutures or enter into the peritoneal cavity. The inflatable bulb and Laplace's anastomosis forceps render valuable aid in performing intestinal suturing. One of the first, if not the first, inflatable bulb for circular suturing was devised by F. Reder (Fig. 507).

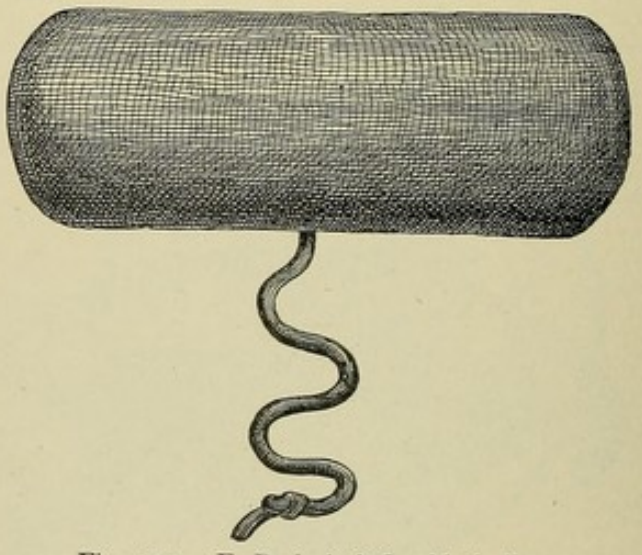

Fig. 507.—F. Reder's inflatable bulb.

The healing of intestinal wounds has been made the subject of very extended investigation by a number of diligent experimenters, and the results can be summarized from the conclusions drawn from his own work by F. Mall, in the paper previously referred to. I take the liberty to make use of a few of the illustrations that accompany his paper and that exhibit very clearly the different stages of the reparative process :

" 1. An immediate fibrinous union of the serous surface.

" 2. A destruction of the protruding parts between the two flaps of mucosa. This destruction is brought about in two ways :

(*a*) by necrosis and (*b*) the destroying power of those crypts that have returned to their embryonic type.

"3. Regeneration of the mucous membrane. Soon after the

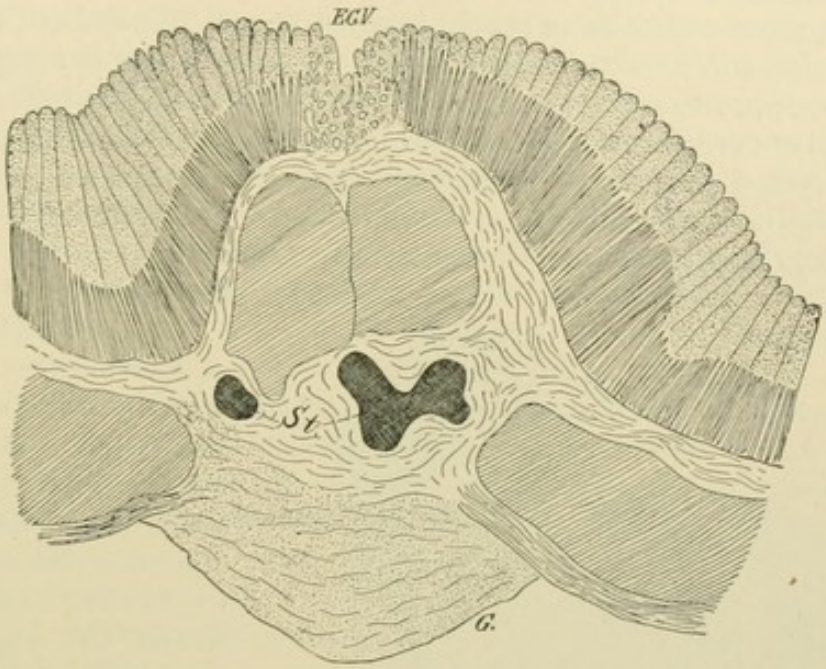

Fig 508.—Repair of intestinal wounds. Suture of twenty-four days (× 9 times) (after Mall): *G.*, Granulation tissue; *E.G.V.*, regenerated glands and crypts; *St.*, stitch.

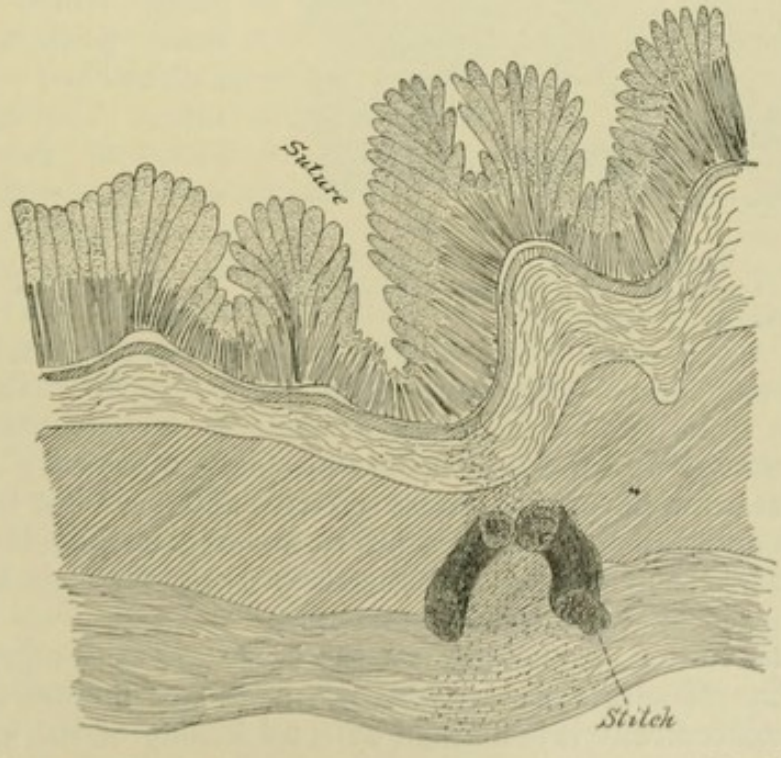

Fig. 509.—Intestinal suture of sixty-four days (× 9 times) (after Mall).

intestine is sutured, the cut ends of the mucous membrane are destroyed. The bases of the crypts, however, seem to be more

resistant and soon show many karyokinetic figures within the epithelial cells. The multiplication of cells in this portion, which is probably only an exaggeration of the normal process, soon causes this layer to spread in all directions. These cells cover the whole surface within their reach, besides sending cystiform invaginations into the tissue. This growth continues until it meets cells from the opposite side, when, of course, it can not continue. The epithelial covering at once sends invaginations into the tissue, which are converted into crypts, between which newly formed villi arise and grow into the lumen of the intestine. If the conditions are favorable, the mucous membrane is fully regenerated at the end of three weeks.

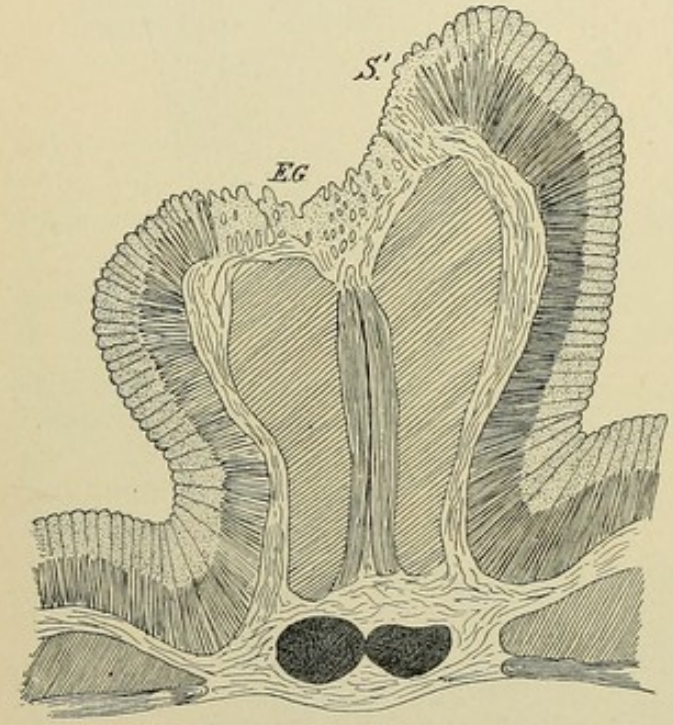

Fig. 510.—Intestinal suture of twenty-four days (× 9 times) (after Mall): *S'.*, Projecting submucosa; *E. G.*, embryonic glands.

"4. Straightening of the suture. During the fourth week the stitches begin to loosen their hold in the submucosa, thus allowing the intestine to straighten out. While the regeneration of the mucosa is taking place the submucosa of one side is being united by fibrous tissue with the submucosa of the other. The straightening of the suture now allows the ends of the muscle coats to be arranged in a straight line, besides placing the embryonic mucosa under a greater pressure, thus favoring its maturation. Before the straightening is complete there is a regeneration of muscular tissue, most marked in the muscularis mucosæ.

"The stratum fibrosum is most resistant and does not begin to regenerate until the sixth week. Up to this time its edge is marked by a sharp border, which, during the sixth week, becomes less defined and projects across the line of suture.

"At the end of two months all the coats are fully regenerated and the line of suture can hardly be made out microscopically, while macroscopically it is marked by a thickening of the intestinal walls."

Lateral Enterorrhaphy.—The sewing of a lateral intestinal wound presents no special difficulties. Usually one row of Lembert stitches will suffice. If the injury or disease has resulted in any con-

siderable defect of the intestinal wall, the wound must be sutured transversely, as longitudinal suturing would in many cases result in narrowing of the bowel to an extent that might cause intestinal obstruction. A defect of an inch to two inches on the convex side of the bowel can be sewed transversely without causing a stenosis or flexion incompatible with the free passage of intestinal contents. If the tissues of the margins of the defect are in a condition that has materially damaged their resisting power, it will become necessary to make a double row of Lembert stitches—the first row of interrupted sutures, the second of the continued suture. If the tissues can not be relied upon in furnishing the necessary support for the sutures, a piece of the omentum should be fastened over the line of suturing with a few superficial stitches as an additional precaution against perforation and extravasation.

Circular enterorrhaphy consists in uniting, by suturing, the two ends of an intestine completely severed. Many writers and surgeons continue to call this method of restoring the continuity of the intestinal canal **end-to-end anastomosis,** which certainly gives a wrong impression of what is accomplished by the suturing. End-to-end junction of the intestine is done quickly and safely by the Czerny-Lembert double suture. The deep or Czerny stitches, including all the tissues except the peritoneum, are inserted and tied first all around, where they are buried by a row of Lembert stitches, interrupted or continuous. Before suturing is commenced each end of the bowel should be beveled at the expense of the convex side, as by doing so there is less danger of the sutures causing stenosis, and the liability to marginal gangrene on the convex side is also diminished. If the lumina of the bowel are unequal in size, as is usually the case in making resection for intestinal obstruction, the obliquity should be greatest on the side of the small end. The greatest care is required on the mesenteric side, as it is here where perforations occur most frequently in consequence of a faulty technic. The reflexion of the peritoneum on each side at the mesenteric attachment leaves a small triangular space containing the principal blood-vessels that supply the intestine with its branches. It is this point that requires special attention.

In applying the Czerny sutures the first one should approximate the two spaces. The second suture is placed at a point opposite, on the convex side, so as to divide the wound margins at once into two equal halves. The remaining sutures are then inserted and tied in such a way that the wound margins are equally distributed. The ends of all the deep sutures should be cut short to the knot, as all these sutures are intended to cut their way through the tissues, being cast off into the interior of the intestine and eliminated with the fecal discharges. If the ends are left unnecessarily long, they do harm by retarding the elimination of the suture after it has accomplished the object for which it was designed; they likewise interfere with accurate coaptation of the serous surfaces by the

second row of sutures, and, finally, by capillary attraction, they may become the medium of the entrance into the peritoneal cavity of pathogenic bacteria from the intestinal canal.

The first two Lembert stitches are inserted and tied on the mesenteric side, and must bring accurately together the peritoneal reflection on each side. This is a very important step in circular enterorrhaphy, and one that is frequently ignored, and, if so, there is the greatest danger of the occurrence of a perforation at the little point where the line of suturing is devoid of peritoneum. The Mitchell-Heamner stitch (Fig. 506) accomplishes the same object of turning in the mesenteric border, but as it transfixes the mesentery at two points, it might endanger the circulation in the included vessels, more especially if the suture should be tied too tightly. Students and practitioners must learn to correct this little defect of the peritoneal investment of the intestines by giving special attention to the mesenteric attachment in performing circular enterorrhaphy. All Lembert stitches that are aseptic and remain so become permanently encysted and remain harmless in the tissues. If any of these stitches include the mucous surface of the bowel, even to a slight extent, such a favorable disposal is not to be expected; on the other hand, perforation, abscess formation, and peritonitis, even at a late day, may mar the result of the operation.

The emergency surgeon must become accustomed to perform a circular enterorrhaphy quickly and safely without any special appliances to facilitate the insertion and tying of the sutures.

In 1892 F. Reder, of Hannibal, Mo., described and used his rubber bulb, which was made in three sizes and could be inflated through a small rubber tube in the center. Five years later Halsted described a very similar bulb in his paper on "Inflated Rubber Cylinders for Circular Suture of the Intestine"; and it seems that some other surgeons have made very similar discoveries before and after. Such bulbs may prove advantageous if the bowel-ends are not readily accessible; otherwise their use often implies an unnecessary loss of time.

Unquestionably, the most valuable aid to intestinal suturing, in making either an anastomosis or a circular suture, has recently been devised by Ernest Laplace (Fig. 494). It consists of a pair of forceps of very ingenious construction, which he describes, with their use, as follows:

"The forceps consists of two parts, which are really hemostatic forceps, curved into a semicircle on each side; only held together by means of a clasp, they open as two rings. They are opened within the intestine and serve the same purpose as Senn's rings or any other ring that has been devised, bringing serous membrane to serous membrane. Accurate suturing is the operation of the present. Therefore if these forceps are within the gut and sutures are applied, as they would be with the help of Senn's rings, it follows that sutures are introduced all around, except where the for-

ceps penetrate the parts that are sutured. The suturing being done, the forceps are released by loosening the clasp and then withdrawing the forceps out of the small opening: first one half, then the other, when the operation is finished by a stitch or two. This forceps will serve for the operation of end-to-end anastomosis and also of lateral anastomosis."

The inventor demonstrated the use of his instrument before the last meeting of the American Surgical Association, and every member present was impressed with the value of this aid in all kinds of gastro-intestinal work requiring suturing.

Halsted's quilt stitch (Fig. 505) is of special value in cases in which the tissues of the bowel at the seat of suturing have undergone changes that have diminished their firmness and resistance, caused by contusion, inflammation, or distention. It is in such instances that the surgeon has reason to fear that, notwithstanding the suturing has been done with the utmost care, leakage or perforation might occur. Nature often provides a safeguard against such occurrences by the formation of adhesions between the line of suture and the abdominal wall or adjacent viscera. Such adhesions often correct the defects of the mechanical union in preventing diffuse peritonitis, but not infrequently become later a source of danger by causing intestinal obstruction. It was for the purpose of preventing such occurrences in suturing intestines with defective walls that I made, twelve years ago, experiments on omental grafting, being desirous, if the experiments proved successful, of furnishing the line of suturing with a band of living tissue that would guard against extravasation and the formation of parietal and visceral adhesions. It is somewhat strange that omental grafting was not attempted soon after Reverdin and Thiersch demonstrated the feasibility of transplantation of skin, a much more highly organized structure. In abdominal surgery the operator often meets with so many peritoneal defects that should be covered with a similar structure that omental grafting, if shown to be feasible, certainly would be desirable. The conditions for grafting in the abdominal cavity are vastly more favorable than on the surface of the skin, and the results of my experiments, which will be introduced here, leave no further doubt concerning the practicability and advisability of omental grafting in cases in which, after intestinal suturing, lateral or circular leakage is feared, as well as in cases of large peritoneal defects, for the purpose of preventing dangerous visceral adhesions.

Omental Grafting.—Under the head of circular enterorrhaphy mention is made of transplantation of omental flaps after uniting the two ends of the bowel by suturing or invagination, with a view of securing an additional safeguard against perforation during the process of repair. A number of experiments are described where the procedure was practised with different results. After a few days the omental flaps were found firmly adherent and vascular around the whole circumference of the bowel, constituting a ring

of living tissue outside the line of suturing. In all these cases the proximal end of the flap remained in connection with the omentum, and care was taken to cut the flap in such a manner that some vessel of considerable size should furnish the necessary vascular supply. I was well aware that plausible objections could be entered against this method, in that the connecting bridge between the bowel and the omentum might become subsequently a cause of intestinal obstruction by making traction upon the bowel, thus causing a flexion, or by becoming a band of constriction for some loop of intestine. For the purpose of obviating such remote consequences another procedure was practised which can be properly designated as omental grafting. It is a well-known fact that implantations of aseptic substances into the peritoneal cavity have frequently been done without any immediate or remote ill effects, and there was every reason to expect that a large, completely detached aseptic omental graft, in an aseptic abdominal cavity, would be well tolerated, and would soon become adherent to the subjacent peritoneal surface, and thus afford an additional safeguard against perforation and the disastrous consecutive result—perforative peritonitis—during the time required for the healing of the intestinal wound. In the following experiments the grafts used were from one and a half to two inches in width, and of sufficient length to encircle the bowel completely. The free ends were made to project a few lines beyond the mesenteric attachment, and were fixed by two fine catgut sutures, each of which embraced the corresponding angles of the graft and the mesentery. The stitches were made in the direction of the mesenteric vessels, so that in tying no vessel should be included in the suture. In these experiments dogs were used exclusively.

EXPERIMENT 106.—Three pieces of omentum, two inches wide and sufficiently long to encircle the bowel, were completely detached and grafted as follows:

1. Graft simply laid over the bowel corresponding to the lower portion of the ileum and fastened in its place on mesenteric side by two fine catgut sutures.

2. Serous surface of bowel about six inches higher up scarified and graft applied to this surface and fixed in the same manner.

3. About six inches still higher up bowel treated in the same way, and one of the serous surfaces of the graft also freely scarified.

The graft was scarified on the side which was to be brought in contact with the bowel. Fixation of graft by two catgut sutures on mesenteric side. Animal killed thirty-six hours after operation. All the grafts adherent, slightly contracting the bowel at the three different places. On separating the adhesions the subjacent serous surface was very vascular and denuded of its endothelial layer. Firmness of adhesions increases in proportion to the extent of scarification done, being least firm at No. 1, firmer at No. 2, and firmest at No. 3, where both coaptated serous surfaces had been scarified. At Nos. 2 and 3 the plastic lymph was freely supplied with new blood-vessels. The vascularization was most conspicuous on the mesenteric side.

EXPERIMENT 107.—Two omental grafts planted around the ileum in the same manner as described above. At No. 1 both the bowel and the inner side of the graft were scarified; at No. 2, only the serous surface of the bowel. Animal killed forty-three hours after operation. Stump of omentum adherent to abdominal wound and intestines. No peritonitis. At No. 1 graft firmly adherent over the entire extent. A slight extravasation of blood between the graft and the bowel. Beginning vascularization of interposed plastic lymph. At No. 2 also firm adhesions and beginning vascularization of the plastic exudation. Both of the grafts appeared to be stained with the coloring material of the blood.

EXPERIMENT 108.—Planting of two omental grafts around the ileum, about eight inches apart. At No. 1 both the bowel and one side of the omental graft were scarified. At No. 2 only the serous surface of the bowel was treated in this manner. Animal killed six days after the operation. Both grafts firmly adherent throughout and freely supplied with blood-vessels, the largest of the new vessels being on the mesenteric side. The omental stump adherent to the portion of bowel between the grafts, where a flexion has been made from this cause.

EXPERIMENT 109.—In this experiment omental grafting was done at two points around the lower portion of the ileum. At one point the serous surfaces were left intact; at the other both the peritoneal surface of the bowel and the omental graft were freely scarified. Animal remained perfectly well and was killed eight days after operation. No signs of peritonitis. Both grafts formed a thin vascular layer around the entire circumference of the bowel and firmly and evenly united throughout. Vascularization was more marked where scarification had been done. On attempting to separate the grafts it was difficult to find and define the line of union between the omentum and the underlying bowel, as the union was very intimate and firm.

In all these experiments the grafts retained their vitality, and in a few hours became firmly adherent to the intestinal surface with which they had been brought in contact. Scarification of the serous surface has also been found in these experiments an exceedingly valuable measure in hastening the process of adhesion, granulation, and vascularization. By planting grafts side by side, with and without scarification, it was possible to determine with accuracy the beneficial influence exerted by this procedure in favoring the reparative process, and without a single exception it was observed that where scarification was done, the adhesions were firmer and vascularization more advanced. The postmortem examinations appeared to demonstrate that the firmness of the adhesions and the degree of vascularization were in direct proportion to the extent of traumatic irritation of the peritoneum, being always most marked in cases where both the bowel and the under surface of the graft were scarified, and least where intact peritoneal surfaces were brought into apposition. As soon as the omental grafts were cut off from the omentum they were placed in a 1 : 2000 solution of corrosive sublimate, kept at the temperature of the body in order to secure for the graft a perfectly aseptic condition, until everything was in readiness for the transfer of the graft to its new location. A warm saline solution will probably be better adapted for immersion of the omental graft. Before planting the graft it was carefully dried by pressing it between gauze or sponges wrung out of the same solution. The scarifications of the serous surfaces should be made only sufficiently deep to give rise to a very slight oozing, as when hemorrhage is more profuse there is danger of the formation of a clot between the graft and the bowel, which, if it does not ultimately prevent union between the coaptated surfaces, must necessarily interfere with the formation of early and firm adhesions. Omental grafting can not fail in becoming an established procedure in many abdominal operations. After suturing a large wound of the stomach or intestines, a strip of omentum should be laid over the wound and fastened in its place by a few catgut sutures. After circular enterorrhaphy in cases in which the tissues of the bowel have been damaged by injury or disease, the operation should be finished by covering the circular wound by an omental

graft about two inches wide, which should be fixed in its place by two catgut sutures passed through both ends of the graft and the mesentery. Omental grafting should also be resorted to in repairing peritoneal defects in visceral injuries of the abdominal organs, and in covering large stumps after ovariotomy or hysterectomy, where the pedicle is treated by the intra-abdominal method.

Scarification of the serous surfaces included in the sutures and omental transplantation and grafting are modern surgical resources that hasten the process of repair and materially diminish the risk of extravasation. These means should be resorted to when, owing to the damaged condition of the tissues, the sutures can not be fully relied upon. The experiments described have shown conclusively that scarification of the peritoneum at the seat of coaptation hastens the formation of adhesions and the definitive healing of the intestinal wound.

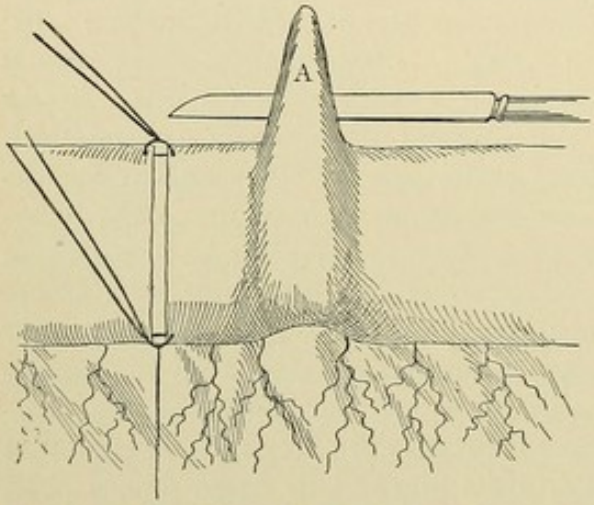

Fig. 511.—Maunsell's method of circular enterorrhaphy: A, Longitudinal section (about an inch and a half long) with tenotomy knife of that portion of the larger segment of bowel that is opposite to its mesenteric attachment. This opening should be made about an inch from the severed end of the larger segment of bowel; its length depends on the size of the intestine to be invaginated. In performing this part of the operation pinch up the coats of the intestine between the finger and thumb and divide with a tenotomy knife or pair of scissors.

Omental grafts, from one to two inches in width, and sufficiently long to encircle the bowel completely, retain their vitality, become firmly adherent in from twelve to eighteen hours, and are freely supplied with blood-vessels in from eighteen to forty-eight hours.

Omental transplantation or omental grafting should be done in every circular resection or suturing of large wounds of the stomach or intestines in all cases requiring an additional security, as this procedure favors healing of the visceral wound and affords an additional protection against perforation.

The most important and practical modification of circular enterorrhaphy, as ordinarily practised, has been described by H. Widenham Maunsell. Bring the ends of the bowel together with two temporary sutures passed through all the coats of the intestine. The long ends of these sutures are left intact. One is placed at the mesenteric attachment and the other exactly opposite. These temporary sutures secure the complete peritoneal covering of the mesenteric attachment of both segments, help to maintain the proper relative position and accurate coaptation of the two cut ends, and facilitate their subsequent invagination through the opening in the

larger segment of the gut. A slit is made on the convex side of the larger segment, an inch or so from the cut end, and large enough for the invaginated ends of the divided bowel to be dragged through by the long ends of the temporary sutures. When they are accurately sewn together all around, they may be pulled back into their normal position. The edges of the longitudinal slit made in the bowel should be well turned in and brought together with a continuous suture passed through the peritoneal and muscular coats only. By this simple device the perfect union by suture of a complete transverse section of the bowel, with its circumferential peritoneal surfaces in exact position, and all the knots of the sutures on the inside, can be accomplished. From figure 513 it may be seen that the peritoneal surfaces are in accurate apposition all around. While an assistant holds the ends of the temporary sutures, the surgeon passes a long, fine, straight needle, armed with a stout horsehair or very fine silkworm gut, through both sides of the bowel, taking a good hold (quarter of an inch) of all the coats. The suture is then hooked up from the center of the invaginated gut, divided, and tied on both sides. *In this way twenty sutures can be placed* rapidly in position with ten passages of the needle (see Fig. 514). The temporary sutures are now cut short, and the bowel is then pulled back. The longitudinal slit is then closed in the usual manner, completing the operation.

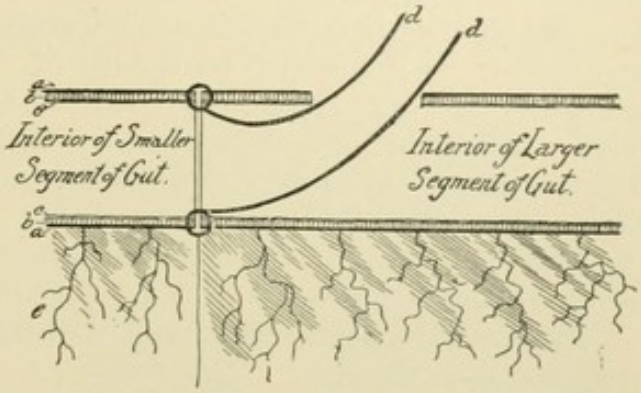

Fig. 512.—Maunsell's method for longitudinal section of intestine: *a*, Peritoneal coat; *b*, muscular coat; *c*, mucous coat; *d*, temporary sutures passed into the bowel and out through the longitudinal slit made in the larger segment of bowel; *e*, mesentery.

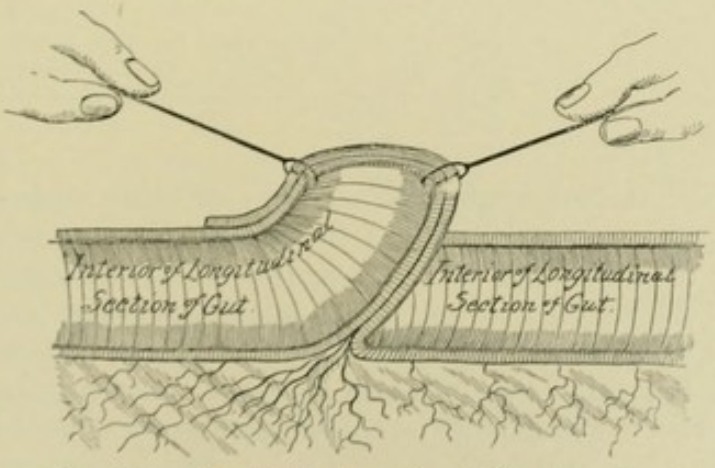

Fig. 513.—Longitudinal section of intestine, showing the relative position of the different layers of the bowel invaginated at the longitudinal slit.

Maunsell's method has been favorably received by the profession and has yielded most excellent results. The use of horsehair in place of silk is undoubtedly a great advantage in performing this

operation, as the danger from leakage by capillary attraction is much less and the elasticity of the sutures hastens their elimination.

Murphy Button as a Substitute for Circular Enterorrhaphy.—Of all the appliances as a substitute for suturing of intestinal wounds, the Murphy button has been used most extensively and has yielded the best results. The utility of this device is most apparent in retaining the continuity of the bowel after resection, when the operation has to be finished as rapidly as possible. A full set of buttons of faultless construction should be kept on hand. The manner of using the button is so well shown (Fig. 516) that a description would be superfluous.

Frank's coupler of decalcified bone will undoubtedly come into more general use after a more extensive experience.

Intestinal Anastomosis and Lateral Implantation.—There are conditions that give rise to intestinal obstruction that can not be

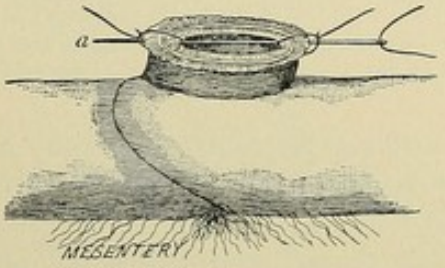

Fig. 514.—Maunsell's method. Invaginated intestine, showing the two peritoneal surfaces in juxtaposition all around: *a*, Needle passed through both sides of the bowel, including all the coats—introducing two sutures with one passage of the needle.

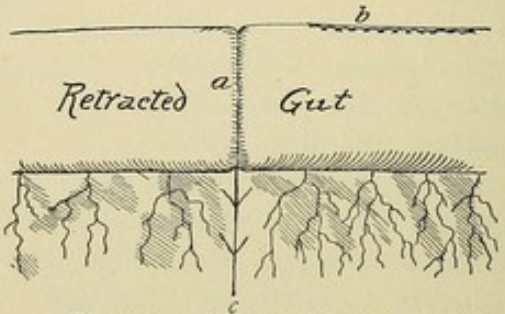

Fig. 515.—Maunsell's method, intestine reduced: *a*, Line marking junction of both ends of bowel, the peritoneum well turned in and the sutures and knots all inside of the bowel, making an almost invisible air- and water-tight joint; *b*, longitudinal slit in bowel, sewn up with continuous suture; *c*, sutures in the mesentery; seldom necessary to insert more than one or two.

removed without imminent immediate risk to life; or, after resection, the two bowel-ends can not be joined by suturing. In such cases modern surgery comes to our aid in restoring the continuity of the intestinal canal by making an intestinal anastomosis by lateral apposition or implantation. The experiments related below were made prior to 1887, and most of them before I accidentally found an account of two cases of anastomosis by Maisonneuve in one of the old volumes of "Rust's Magazine." The operation had been entirely forgotten, and was never mentioned in the current medical literature until it was revived by my experimental work.

Intestinal Anastomosis.—By an intestinal anastomosis is understood a condition of the intestinal canal where, on account of an obstruction or complete occlusion, the intestinal contents are directed into a segment of the bowel below the seat of obstruction or occlusion through a fistulous opening between the bowel above and below the seat of partial or complete occlusion. The idea of

establishing such a communication between the bowel above and below the seat of obstruction originated with Maisonneuve, who, without testing the new procedure first on animals, operated on two cases, but as the result in each case was fatal, he seems to have become discouraged and abandoned the operation, and never published the communication on this subject which he had in preparation. In the Surgical Society of Paris, his proposition met with violent opposition from his contemporaries, who argued that the excluded portion of the intestine would become the seat of fecal accumulation, which, even if the operation was a success, would subsequently destroy the life of the patient. The subject was revived in 1863 by Hacken, who, under the direction of Adelmann, made some experiments on dogs. For a long time the operation was completely forgotten, until E. Hahn, of Berlin, very recently alluded to it again in commenting on his two cases of excision of the colon where circular enterorrhaphy could not be performed, and where an artificial anus was established. Both patients recovered from the operation, but all attempts to close the preternatural opening proved futile. The results of my experiments have shown conclusively that the fear of accumulation of feces in the excluded portion of the intestine—that is, the intervening portion containing the seat of obstruction and extending on each side as far as the new opening by

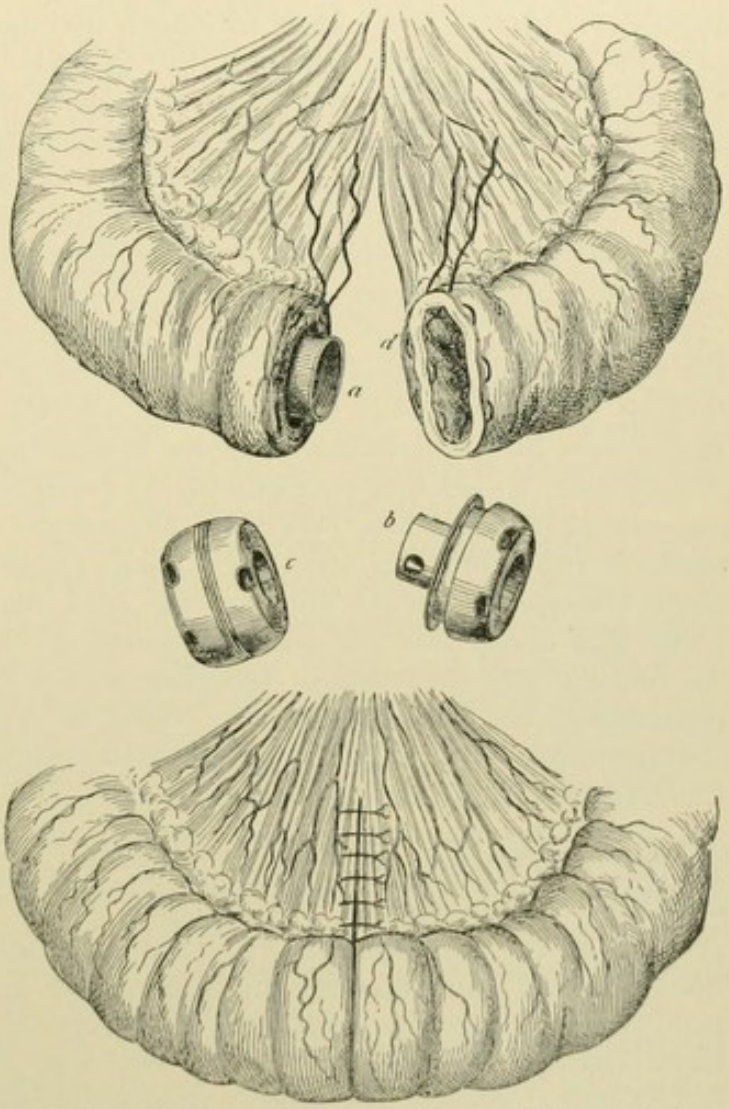

Fig. 516.—Resection of intestine: *a*, *b*, The two halves of the button; *c*, the two portions clamped together; *d*, introduction of the sutures for holding each half of the button in place. The lower figure shows the completed union of the intestine by the Murphy button; the slip in the mesentery has been closed by linear union (after Zuckerkandl).

which the anastomosis has been established—is unfounded. If this objection can be laid aside, it becomes evident that the operation of making an intestinal anastomosis has a great future, and will soon become the recognized procedure in the treatment of intestinal obstruction, and as a substitute for circular suturing in some forms of injuries or diseases of the intestines that require excision.

The first experiments were performed by making an incision an inch and a half to two inches in length through the convex surface of each bowel, and by suturing the wounds together by Czerny-Lembert sutures. The results soon showed that the operation was attended by the same dangers as suturing after circular resection—that is, gangrene of the margins of the bowel and perforation. Dr. M. E. Connel, Superintendent of the Milwaukee County Hospital, suggested the use of perforated plates for making the lateral apposition in place of suturing. A few crude experiments were made with perforated discs of lead, wood, gutta-percha, and leather, and the results soon satisfied us of the expediency and greater safety of uniting the intestines in this manner. Although the first experiments were very imperfect and faulty in technic, almost every animal recovered. In the first experiments no needles were used. Around the oval perforation four catgut or silk sutures were tied; a slit was made in the bowel on the convex side, parallel with its axis and large enough to permit the passage of a plate about an inch in width and about two and one-half inches in length. After making the incision and introducing the plate above and below the seat of obstruction, the two wounds were brought into apposition and the corresponding strings tied together with sufficient firmness to bring the flattened surfaces into accurate coaptation. The threads were cut short, and the ends pushed inward out of sight. Experience showed that although the apposition was good, a tendency was observed on the part of the margins of the wound to evert on account of the bulging of the mucous membrane. For this reason the operation was modified by arming the lateral threads with a needle with which the margin of the incision about the middle of the wound was transfixed. This proved a step in the right direction, as the lateral sutures completely prevented eversion of the margins of the wound, at the same time fixed the plates in their position, and, further, at once transformed the longitudinal slit into an oval foramen of sufficient size for the free passage of intestinal contents. After many trials with different kinds of materials for the plates the conclusion was reached that decalcified or partially decalcified bone-plates, preserved after the decalcification in pure alcohol, served the best purpose.

Directions for Preparing Bone-plates.—The compact layer of an ox's femur or tibia is cut with a fine saw into oval plates, one-fourth of an inch in thickness, two and one-half to three inches in length, and an inch in width. The plates are then decalcified in a 10 per cent. solution of hydrochloric acid, changed every twenty-

four hours until they have become sufficiently softened to be bent in any direction without fracturing. After decalcification they are washed by letting water flow over them for from three to six hours, so as to remove the acid. The plates are then covered with porous paper and compressed between two pieces of tin until they are perfectly dry. If, during the process of drying, the plates are not compressed between two smooth surfaces, they become distorted by warping. The hardened plates are next drilled several times in a straight line in the center, and the openings enlarged and connected with a file, until the perforation is ⅝ inch in length and about ⅛ to ⅙ inch in width. The sharp margins of the plate and perforations are removed with a file. With a fine drill the four perforations for the sutures are made near the margin of the oblong perforation—one at each end and one at each side. For preservation the plates are kept in absolute alcohol. When the plates are to be used, they are washed in a 2 per cent. solution of carbolic acid, and the threads or sutures attached by threading two fine sewing needles, each with a piece of aseptic silk twenty-four inches in length, which are tied together. The threads are then fastened to the surface of the plate by another thread, passing through the perforations in the shape of a loop, and fastened at the back.

Anastomosis between the stomach and small intestines is called gastro-enterostomy; between the jejunum and ileum, jejuno-ileostomy; between the ileum and ileum, ileo-ileostomy; between ileum and cecum, ileotyphlostomy; between ileum and colon, ileocolostomy; between ileum and sigmoid flexure, ileosigmoidostomy; between colon and colon, colocolostomy; between sigmoid flexure and rectum, sigmoidorectostomy; between colon and rectum, colorectostomy.

The experiments were made to relieve an artificially produced intestinal obstruction, a fact that may account to some extent for the high mortality of the operations. The very high death-rate from the operations done by suturing was unquestionably largely due to defective technic and inexperience.

Jejuno-ileostomy.—In this operation some form of intestinal obstruction, either complete, by division of the bowel and closure of both ends, or partial, by making a volvulus, invagination, or flexion in the vicinity of the juncture of the jejunum with the ileum, was first established and then an intestinal anastomosis made by establishing a communication between the bowel above and below the obstruction. Before the perforated approximation discs were used this was accomplished by making an incision an inch and a half or two inches in length through the convex surface of the bowel above and below the obstruction, and uniting the wounds by a double row of sutures. An operation of this kind usually lasted over an hour, while the rapid operation of coaptation by perforated discs seldom took more than fifteen minutes.

Jejuno-ileostomy by Suturing.

EXPERIMENT 56.—Large cat. Invagination of ileum into ileum in a downward direction, and fixation of intussusceptum to neck of intussuscipiens by two fine catgut sutures, to prevent spontaneous reduction. Intestinal anastomosis by establishing an opening an inch in length; suturing by Czerny-Lembert method. The animal never recovered from the shock of the operation, and died in less than twenty-four hours. Length of intussusceptum two inches, which, after the removal of the sutures, could not be reduced by traction, as the bowel was firmly constricted by the neck of the intussuscipiens and recent adhesions had formed. No peritonitis; suturing found perfect.

EXPERIMENT 57.—Dog, weight sixty-five pounds. Intestinal obstruction by making acute flexions in upper portion of ileum, and fixation of loops of intestine by fine catgut sutures. Intestinal anastomosis between jejunum and ileum by incision and double suturing. The animal died on third day, with symptoms of perforative peritonitis. On close examination, one of the superficial approximation sutures had been passed through the whole thickness of the wall of the bowel, and it was here that perforation had taken place. Recent diffuse peritonitis.

EXPERIMENT 58.—Dog, weight seventeen pounds. Descending invagination of ileum into ileum; length of intussusceptum three inches; fixation by two catgut sutures. Formation of intestinal anastomosis between the bowel above and below the invagination by incision and double suturing. Animal died on third day with symptoms of perforative peritonitis. Abdominal wound not united. Adhesions at point of operation quite firm. Diffuse general peritonitis from a perforation that had been made by a sharp fragment of bone above the new opening. Intussusceptum not gangrenous.

EXPERIMENT 59.—Dog, weight, twenty-three pounds. Intestinal obstruction was made by producing a volvulus in the upper part of the ileum. Restoration of continuity of intestinal canal by making a jejuno-ileostomy by lateral apposition and double suturing. Day after operation intestinal discharges were bloody; after this time, normal. Animal in perfect health when killed, sixty-seven days after operation. The volvulus was found in same condition as after operation; the intestinal loop was empty, atrophied, and adherent to adjacent loops of intestine. Bowel above seat of obstruction and as far as the new opening empty. Intestinal tract above and below the obstruction presented no indication of the presence of an obstruction. New opening oval in shape and as large as the lumen of the bowel at that point.

EXPERIMENT 60.—Large Maltese cat. Intestinal obstruction by making two flexions in ileum, about eighteen inches apart, after this portion had been cleared of its contents. Flexions made by doubling the bowel toward its convex side and fixing it in this position by fine catgut sutures. Jejuno-ileostomy by lateral apposition and suturing. Vomiting day after operation; stools scanty the first few days, and later complete obstruction. Died nineteen days after operation. Wound completely united; no general peritonitis; flexions remained; bowel between them contained a slight amount of fecal matter. Bowel some distance above the new opening very much dilated, pointing to obstruction above new opening. On tracing the intestinal canal from above downward this obstruction is seen to consist in acute flexion of the bowel by firm and extensive adhesions. New opening sufficiently large to admit the tip of the index-finger, and around the margins of the opening most of the deep sutures remain attached.

EXPERIMENT 61.—Large cat. Obstruction made by two flexions in the ileum, their apices being united by catgut sutures. Intestinal anastomosis made by a jejuno-ileostomy. For eleven days the animal remained in good condition, when symptoms of perforative peritonitis manifested themselves, and death ensued two days later. External portion of wound not united. Numerous omental and intestinal adhesions. Flexions retained and their apices adherent to each other by firm band of adhesion. Excluded portions above and below the obstruction empty. Two small perforations at point of suturing on anterior surface of bowel; remaining portion of wound firmly united. New opening sufficiently large to admit tip of index-finger. Death from perforative peritonitis.

EXPERIMENT 62.—Large Newfoundland dog. Descending invagination of ileum into ileum to the extent of six inches; fixation of intussusceptum by two catgut sutures. Permeability of intestinal canal restored by making a jejuno-ileostomy; wounds united by a double row of sutures. Intestinal discharges normal throughout. No rise in temperature. When killed on the twentieth day, general condition as good as before operation. Abdominal wound completely united; no peritonitis; omentum adherent at site of operation. Invagination had reduced itself, and its location was marked by an acute flexion caused by extensive adhesions. No accumulation of intestinal contents in excluded portions. The new opening at least two inches in length, a few of the deep sutures remaining attached to its margins. This opening was partially obstructed by a mass of hair and fragments of bone. On passing a stream of water from above downward

the fluid passed through an opening in the center of this mass into the lower portion of the ileum, but not through the portion that was invaginated. After this mass was removed the fluid was found to pass through the portion that was invaginated as well as through the new opening.

The many failures which attended jejuno-ileostomy and ileo-ileostomy by lateral apposition and suturing led to the use of perforated approximation discs. A great contrast was observed in the animals operated upon by these two methods. The operation by suturing required usually more than an hour, and almost all the animals showed more or less symptoms of shock after its completion, and not a few succumbed to its immediate effects, while the operation by approximation plates could always be finished within twenty minutes; consequently the animals never suffered seriously from the immediate effects of the operation. The first experiments were made somewhat carelessly and with crude material, and yet it was observed that the healing process progressed more favorably and was accomplished in a shorter time than after suturing. The approximation discs brought into uninterrupted contact large serous surfaces without impairing the vascular supply; at the same time they secured for the parts destined to become united an essential condition for rapid wound healing—rest—by serving the useful purpose of splints.

EXPERIMENT 63.—Dog, weight fifteen pounds. Ileum was completely divided at its junction with the jejunum, and both ends of the bowel closed by invagination and three stitches of the continued suture. An incision was made on convex side of bowel, about two inches from the closed ends, and a heavy perforated lead plate, to which six catgut sutures were fastened around the oval perforation, was introduced into the lumen of the bowel of each closed end, all the catgut sutures being brought out through the incision. The two wounds were brought opposite each other and the six sutures tied. The serous surfaces of the two intestines over a surface corresponding to the size of the lead discs were thus brought into accurate apposition. The sutures were cut short, and the ends buried as deeply as possible. The condition of the animal remained excellent until the time of killing, seventy-five days after operation. Omentum adherent to wound; large intestine distended with normal feces. Bowel above and below point of operation normal in size and structure. New opening between ileum and jejunum large enough to admit the little finger to second joint. Bowels firmly united by a broad surface. Above the communicating opening a double flexion of the bowel was found that apparently had done no harm.

EXPERIMENT 64.—Dog, weight eighteen pounds. Operation done in the same manner as in the last experiment, only that instead of lead the discs were made of sole leather, and the sutures used were linen in place of catgut. For a few days the temperature was higher than normal and appetite diminished. After fourth day the animal appeared to be in excellent condition and remained so for three weeks, when the appetite failed and occasional attacks of vomiting set in. These symptoms remained more or less prominent until the time of killing, thirty-nine days after operation. Omentum adherent to abdominal wound; extensive intestinal adhesions at site of operation; union between intestines perfect. On incising the bowel it was found that the plates had sloughed through and had passed along the distal portion of the bowel, leaving an opening the size of the plates, the margins of which had almost completely cicatrized. The two leather plates, still held together by the linen sutures, were found three feet lower down in the ileum, where they had become embedded in a mass of hair, straw, and fecal matter, and quite firmly impacted, causing complete obstruction of the bowel. The intestine above the seat of obstruction was enormously dilated, while below the seat of impaction it was empty and contracted. Large intestine likewise empty and contracted. The cause of the illness was evidently due to intestinal obstruction, produced by the impaction of the large enterolith, in the center of which the leather discs were found.

EXPERIMENT 65.—Dog, weight ten pounds. In this instance the bowel was

divided near the junction of the jejunum with the ileum, both ends closed, and its continuity established by incising the convex surface of both ends and approximating the wounds by two perforated bone-plates tied together by silk ligatures. The animal died fourteen days after operation. During the last few days symptoms of intestinal obstruction were present. Abdominal wound completely united. Numerous intestinal adhesions at site of operation. Bone-plates still *in situ* and firmly fixed. On proximal side perforation of bone-plates completely closed by hair and fragments of bone, giving rise to complete intestinal obstruction. The bowel above this point was greatly dilated, while on distal side it was empty and contracted. Adhesions between the two intestinal surfaces included by the bone-plates firm. Intestinal obstruction by a mechanical arrest of portion of the intestinal contents above the proximal plate caused death before a more efficient communication could be established by sloughing through of the bone-plates.

EXPERIMENT 66.—Dog, weight thirty pounds. Ileo-ileostomy by dividing the ileum near its center, closing both sides, and, after incising both ends on convex surface, brought wounds in apposition by perforated plates of cross-grained walnut wood, which were tied together with silk sutures. The dog remained in perfect health and was killed eighteen days after operation. External wound completely united. Plates had become detached, leaving a communicating opening two inches in length. Blind ends of bowel empty ; no trace of plates could be found.

EXPERIMENT 67.—Dog, weight twenty-four pounds. Double ileo-ileostomy. Ileum divided transversely five inches above ileocecal region, and both ends closed by invagination and three stitches of the continued suture. Lower and upper ends of bowel were again brought into communication by incision on convex side and lateral apposition of wounds by means of perforated approximation plates of *decalcified bone*, hardened in alcohol. The plates were fastened together by four silk sutures, the threads being brought out of the incision, tied, and cut short. Above this point a loop of the ileum was made by bringing the convex surfaces into apposition after incision at two points, and introducing perforated gutta-percha plates, which were retained in place by four silk sutures. No fever or symptoms of obstruction followed the operation. Animal killed thirteen days later. External wound firmly united. No evidences of peritonitis or intestinal obstruction. First operation left a communicating opening large enough to admit the little finger. The silk ligatures that had become detached from the plates had embedded themselves. The decalcified bone-plates had disappeared, and no trace of them could be found in any portion of the intestinal canal lower down. The second operation was thirty inches higher up. Gutta-percha plates remained *in situ*, although somewhat loosened by the gradual disappearance of the intervening tissues by pressure atrophy. Adhesions between the two surfaces of the bowel firm and extending a little beyond the line of approximation. The perforation in the proximal plate almost completely closed by an accumulation of hair. The entire ileum normal in size and appearance.

EXPERIMENT 68.—Dog, weight fifty-four pounds. Transverse section of ileum thirty inches above the ileocecal region, and closure of both ends in the usual manner. The two closed ends were overlapped four inches and brought into communication by two longitudinal openings, which were approximated by being buttoned together with a shuttle-shaped button, nearly one and one-half inches in length, the sides being lead plates and the shaft a rubber tube through which the anastomosis was established at once. As the margins of the intestinal wounds showed a tendency to evert, a fine catgut suture was inserted on each side embracing only the peritoneal coat. Only for two or three days after the operation did the dog not appear to be well. Killed twenty-three days after operation. Omentum adherent to abdominal wound, which was firmly united. Omental adhesions to intestine at site of operation. Intestinal anastomosis thirty inches above the ileocecal valve. Proximal blind end of bowel five inches in length, adherent to distal end, considerably dilated, and contained fragments of bone and other crude substances. Approximation button *in situ* and quite firmly fixed. A fragment of bone partly fills the lumen of the rubber tube. Coaptated peritoneal surfaces firmly adherent. The obstruction of the communicating tube had given rise to dilatation of the bowel above the point to twice its natural size, while below the seat of partial obstruction the intestine appeared empty and contracted.

EXPERIMENT 69.—Small dog. In this experiment the ileo-ileostomy was made by lateral apposition by perforated approximation plates of partially decalcified bone tied together by four catgut sutures. The lateral sutures were passed through the *margins of the wound* near its border, a modification of the usual procedure that not only fixed the plates firmly in their places, but also prevented ectropion of the mucous membrane, and insured free patency of the new opening by retracting the margins of the wound so that the longitudinal slit is at once transformed into an oval shape. The animal showed no unfavorable symptoms, and was killed twenty-nine days after operation. Dog well nourished. External wound united. Omentum adherent to wound and intestines. The prox-

imal blind end of bowel contained one of the bone-plates, which showed signs of softening and disintegration. The bone-plate in the distal end had been passed with feces previously. The new opening perfect and sufficiently large to equal in size the lumen of the bowel.

EXPERIMENT 70.—Dog, weight twelve pounds. Made ileo-ileostomy the same as in the last experiment, using decalcified, perforated bone-plates, which were tied together with four catgut sutures, the lateral ones being passed through the margins of that wound. An omental flap was used to cover the sides of the bowel where approximation had been made. This flap was retained by two fine catgut sutures. No unfavorable symptoms. Animal killed twenty-three days after operation. Omentum adherent to distal blind end. Omental flap in position and firmly adherent. Site of operation fourteen inches above ileocecal region. Both bone-plates had disappeared and no trace of them could be found. Some hair had collected in the blind proximal end. New opening large enough to admit the index-finger.

Jejuno-ileostomy and ileo-ileostomy by apposition with decalcified perforated bone-plates in cases of complete obstruction of the bowel artificially produced is an operation almost devoid of danger. Partially or completely decalcified bone-plates hardened in alcohol remain firm for a sufficient length of time to answer the purpose of retentive measures until firm adhesions have formed between the serous surfaces held in approximation by them. Until it was ascertained by experiment that the plates would undergo softening and disintegration in the course of a few days, catgut sutures were used to hold them in place with the expectation that the plates would become detached and escape with the intestinal contents as soon as the sutures would give way. Experience, however, has shown that aseptic silk threads are preferable to catgut, as they can be tied with greater accuracy and the knots will never become loosened, while the approximation discs disappear completely by softening and disintegration in a few days. Approximation plates of unabsorbable material, as lead, wood, leather, bone, and gutta-percha, fastened together by silk or linen sutures, remain *in situ* until the interposed tissues disappear by pressure atrophy, and the opening that results corresponds in size to the dimensions of the plates. In the first experiments the plates were tied together by six sutures, but it was found that four sutures answered the same purpose. As a rule, the plates were about two and one-half inches in length, and their width corresponded to one-third of the circumference of the bowel. The greatest advantage to be found in the method of restoring the continuity of the intestinal canal by lateral apposition by approximation discs consists in the fact that the point of contact is always made on the convex surface of the intestines, so that the means employed to secure coaptation do not interfere with the blood supply from the mesenteric vessels. As this method requires much less time than any form of circular enterorrhaphy and has been followed, almost without exception, by recovery, it recommends itself strongly as a substitute for the latter procedure in many cases where loss of time constitutes an important factor in the issue of the case, or where, from other causes, circular suturing appears impossible or impracticable.

Ileocolostomy.—As the ileocecal region is frequently the seat

of intestinal obstruction, it becomes desirable to devise some definite plan of operative treatment in cases where the cause of obstruction is not amenable to removal, with a view to establishing the continuity of the intestinal canal, thus avoiding the necessity of resorting to the formation of an artificial anus. To accomplish this object two distinct methods were followed: (1) Division of the ileum, with closure of distal and implantation of proximal end into colon. (2) Division of ileum, closure of both ends, and lateral apposition of proximal end with colon, and the formation of an intestinal anastomosis by suturing or approximation discs.

Ileocolostomy by Implantation.

EXPERIMENT 71.—Dog, weight thirty-eight pounds. Intestinal anastomosis by implantation of the ileum into colon. The ileum was divided transversely just above the ileocecal region, and the distal end closed by invagination and three stitches of the continued suture, and dropped back into the abdominal cavity. A longitudinal incision, in size corresponding to the lumen of the ileum, was made in the ascending colon at a point directly opposite the mesenteric attachment, and the proximal end of the ileum was then fixed in this opening by Czerny-Lembert sutures. Only slight febrile reaction followed the operation. The appetite remained good, and the discharges from the bowels were normal. The animal was in excellent condition when killed, thirty-three days after operation. Few circumscribed omental adhesions to abdominal wound, which was completely closed. Peripheral portion of ileum presents a conic appearance, and was found adherent to, and of the same length as, the appendix vermiformis. Implantation had been done about the middle of the colon. Union at point of suturing perfect; apparently no interruption of continuity of peritoneal surface. The new opening into colon a little smaller than the lumen of the ileum. Around the margins of this opening, which somewhat resembled the ileocecal valve, six of the deep silk sutures remained attached. Above the new opening the colon and the cecum were found empty and somewhat atrophic. Lower portion of the ileum and of the colon below the new opening appears normal in size and structure.

In the remaining experiments the implantation was made by lining the proximal end of the ileum with a narrow flexible rubber ring, which was retained in place by a continued catgut suture, embracing the free margin of the bowel and the lower margin of the rubber ring. The implantation was made by two catgut sutures (invagination sutures), threaded each by two needles and passed at opposite points from within outward through the upper margin of the ring and the entire thickness of the bowel, while the needles were passed through only the serous and muscular coats of the colon. After both sutures were in place gentle traction upon all of the ends brought the end of the ileum into the incision in the colon, and the walls of the colon were drawn over the end of the ileum to the points where the needles emerged from the ileum, making really a limited invagination. When in proper position, the serous surfaces of the colon and ileum over a surface corresponding to the width of the rubber ring were in accurate coaptation after the two sutures were tied. Only in exceptional cases was it found necessary to apply one or two additional superficial coaptation sutures. As in circular enterorrhaphy, so in these cases, the elastic pressure on part of the rubber ring rendered material assistance in maintaining accurate coaptation, while at the same time it secured rest for the sutured parts, and kept the new opening freely patent for the escape of intestinal contents into the colon. This operation did not require one-fourth of the time consumed in making an implantation by Czerny-Lembert sutures.

EXPERIMENT 72.—Dog, weight fifty pounds. Division of ileum eight inches above ileocecal region; distal end closed by invagination and three stitches of the continued suture. Proximal end lined with rubber ring and implanted into incision of ascending colon by two catgut invagination sutures. The dog did not appear to do well after the operation, and died on the fifth day. Abdominal wound not united. Partial separation of implanted bowel and diffuse septic peritonitis from perforation.

EXPERIMENT 73.—Dog, weight thirty-five pounds. Ileum divided twelve inches above ileocecal region, distal end closed, and proximal end lined with flexible rubber ring and implanted into an incision in the transverse colon and retained by two invagination sutures of catgut. An omental flap an inch and a half in width was placed over the junction of the two intestines and fixed in its place by two catgut sutures. No unfavorable symptoms after operation. Animal, when killed, eighteen days later, in excellent

condition. Omentum adherent to abdominal wound, which was firmly united. Omental flap adherent all round. Colon above new opening ten inches in length, completely empty, contracted, and atrophic. New opening oval in outline and as large as the lumen of the ileum.

EXPERIMENT 74.—Dog, weight sixteen pounds. Division of ileum, closure of distal end, and implantation of proximal end into an incision of the colon by rubber ring and two invagination sutures of catgut. As the inverted portions of the colon showed a tendency to evert, two additional retaining sutures of fine catgut were used, which secured perfect coaptation throughout. An omental flap was laid over the junction of the intestines and fixed in its place by one catgut suture. The dog remained in good condition, appetite unimpaired, and discharges from bowels normal. Killed thirteen days after operation. Abdominal wound firmly united. Omentum adherent to wound. A number of adhesions between coils of intestine. Ileum somewhat dilated above the new opening. Omental flap in place and adherent. Union between ileum and colon perfect. A long, sharp fragment of bone was found lodged just above the new opening, its lower end partially occluding its lumen. The dilatation of the lower portion of the ileum was evidently due to partial obstruction from the presence of the foreign body in the new opening.

EXPERIMENT 75.—Dog, medium size. Section of ileum two feet above the ileocecal region; closure of distal end in the usual manner; implantation of proximal end into colon by rubber ring and two invagination sutures of catgut. No omental flap. Animal remained well and was killed forty-three days after operation. Omentum adherent to abdominal wound. Distal end of ileum conic in shape, the extremity presenting a cup-shaped depression which was filled with cicatricial material. Omentum adherent at ileocecal region and at site of operation. Union between the bowels perfect, and their serous surfaces appeared to be continuous over the line of junction. The new opening from the colon admitted the little finger, and was surrounded by a prominent ridge of mucous membrane that resembled the ileocecal valve.

EXPERIMENT 76.—Dog, weight fourteen pounds. Division of ileum a few inches above ileocecal valve; distal end closed by invagination and three stitches of continued suture. Implantation of proximal end into colon by rubber ring and two catgut invagination sutures. Over the junction of the two intestines an omental flap was placed, which was retained by a catgut suture. The animal showed no unfavorable symptoms, and was killed twenty-three days after operation. Omental flap retained and firmly adherent throughout. Point of implantation three inches above cecum; union between the two intestines firm throughout. New opening corresponded in size to the lumen of the ileum, and was surrounded by a prominent ridge of mucous membrane that appeared to be derived from the invaginated portion of the ileum.

EXPERIMENT 77.—Ileum divided a few inches above ileocecal region, and, after closure of distal and proximal ends, was implanted into the colon in the usual manner by means of rubber ring and two invagination sutures of catgut. Animal died on the third day after operation. Wound partially united; a considerable quantity of serosanguinolent fluid in the abdominal cavity. Ileum almost completely separated from colon, and the portion that had been invaginated showed signs of gangrene. Rubber ring had disappeared; death from perforative peritonitis. In this case there was reason to believe that the rubber ring that was used was too large, and that the gangrene and separation were due to injurious pressure.

Ileocolostomy by Lateral Apposition.—Anastomosis by this method was made after producing an intestinal obstruction of some kind at or near the ileocecal region, and then by bringing the ileum above the seat of obstruction, in communication with the colon below the point of obstruction by making an incision an inch and a half to two inches in length in both intestines at a point opposite the mesenteric attachments, and uniting the wounds either by a double row of sutures or by perforated decalcified bone discs. The first experiments were all made by suturing, but, as in a circular enterorrhaphy, it was found by experience that perforation not infrequently occurred along the track of one of the sutures, in some instances several days after the operation, at a time when union had taken place by firm adhesions. These unfavorable results led to the use of the approximation discs.

EXPERIMENT 78.—Dog, weight twenty-five pounds. The ileum was withdrawn from the abdomen through an incision in the linea alba, and, a loop being emptied of its contents, acute flexion was made just above the ileocecal region by approximating the serous surfaces of the convex side for an inch and a half by five catgut sutures. Two longitudinal incisions of equal size were made, one in the ileum, six inches above the flexion, and the other in the ascending colon, three inches above the cecum. The visceral wounds were carefully united by Czerny-Lembert sutures, using silk for the deep interrupted sutures, and fine catgut for the superficial continued sutures. No untoward symptoms were observed after the operation; appetite remained unimpaired, and fecal discharges were normal. The dog was killed thirty-seven days after operation. Animal well nourished. No evidences of peritonitis. Bowel above point of obstruction nearly empty, and somewhat contracted as far as the new opening. Flexion permeable to a stream of water. Slight omental adhesions to bowel at site of operation; union firm throughout. Lumina of nonexcluded portion of bowel normal in size above and below the flexion. Serous surfaces at point of junction appeared perfect and continuous. On slitting open the colon opposite the new opening, its outlines were seen to be marked by a prominent ridge of mucous membrane to which a number of the deep sutures remained attached. The opening was large enough to admit the tip of the middle finger. The excluded portions of the colon and the cecum were somewhat contracted and atrophic and contained only a very small quantity of fecal matter.

EXPERIMENT 79.—Medium-sized cat. About two inches of the ileum were invaginated into the colon through the ileocecal valve, and the intussusceptum stitched to the neck of the intussuscipiens by two fine catgut sutures. Continuity of the intestinal canal restored by incising the ileum above the obstruction and the ascending colon below the free extremity of the intussusceptum, and uniting the wounds by a double row of sutures. The invagination caused no serious disturbance, and the animal remained in good health, being in excellent condition at the time of killing, one hundred and sixty-two days after operation. A number of adhesions between the folds of the intestines near the site of operation. At point of junction of the two intestines the peritoneal surface presented a glistening and continuous surface. New opening an inch and a half in length, oval in outline, and located five inches above the ileocecal region. Two inches below the opening the invagination remained in the shape of a circular thickening of the bowel with a narrowing of its lumen to more than one-half of its normal size. A close inspection of the specimen showed that no gangrene had occurred, but that the intussusceptum had undergone atrophy. A stream of water passing along the ileum in a downward direction escaped through the invaginated portion and through the new opening, the stream from the latter being at least three times larger than the one through the intussusceptum. Excluded portion of ileum and colon empty and very much atrophied and contracted. Below the new opening the colon and rectum contained normal feces in considerable quantity.

EXPERIMENT 80.—Young cat. Ileocecal invagination; length of intussusceptum four inches, and in order to prevent spontaneous disinvagination the bowel was fixed in its position by two fine catgut sutures. Ileocolostomy below the lower end of the intussusceptum by lateral apposition and suturing. Animal died on the fourth day after operation. Abdominal wound united. Diffuse peritonitis from perforation at site of suturing. Length of intussusceptum reduced from four inches to two inches and a half. It was found impossible to effect reduction by traction on account of firm adhesions at neck of intussuscipiens. No gangrene.

EXPERIMENT 81.—Adult, large dog. Intestinal obstruction was produced by making two sharp flexions near the ileocecal region by folding the bowel on its side and fixing it in this position by fine catgut sutures; the apices of the flexions were sutured together so as to render the obstruction more complete. Intestinal anastomosis was established by lateral apposition and suturing. Physical condition of dog remained good throughout; appetite and evacuations normal. Killed thirty-one days after operation. No peritonitis; a number of omental adhesions at point of operation. Flexions quite sharp, rendering the bowel nearly, if not completely, impermeable at this point. Perfect union between bowels, with some thickening of their walls by inflammatory exudation. New opening oval in shape, an inch and a half in length, a few of the deep sutures still remaining attached to its margins. Excluded portion of bowel empty and somewhat atrophic.

EXPERIMENT 82.—Dog, weight thirteen pounds. Obstruction of the bowels made by an acute flexion four inches above the ileocecal region, retained by four catgut sutures. Intestinal anastomosis by an opening an inch and a half in length, which brings into communication the ileum above the obstruction and the descending colon. The animal showed no untoward symptoms, and was killed forty-one days after operation. A number of intestinal folds agglutinated by adhesions; no evidences of diffuse peritonitis. Where the flexion had been made, the loop of intestine is connected by a broad band of

adhesion, which gives to the bowel a horseshoe-shaped appearance. Intestine below the seat of flexion contained a small amount of hardened feces. Colon and cecum above the new opening nearly empty and greatly contracted. Line of suturing somewhat thickened. New opening oval in outline and about an inch in length, surrounded by a corrugated elevation of mucous membrane. A stream of water passed through the bowel from above downward readily escaped through the new opening, while only a small stream could be forced through the flexion.

EXPERIMENT 83.—Dog, weight twenty-seven pounds. A volvulus was made six inches above the ileocecal region by rotating an empty loop of the intestine once around its axis and fixing it in this position by three catgut sutures. Intestinal anastomosis between the ileum above the volvulus and the descending colon by lateral apposition and suturing. For four days after the operation the evacuations from the bowels contained blood; after this time the stools were normal. Dog in excellent condition when killed, thirty-one days after operation. No signs of diffuse peritonitis. The portion of bowel that constituted the volvulus adherent, contracted, and empty. Water could be readily forced through this part of the bowel. Cecum and colon above new opening empty and contracted. Size of new opening larger than the lumen of the ileum, its margins surrounded by a prominent ridge of mucous membrane to which a few of the deep sutures still remained attached. In this experiment nearly the entire colon was excluded, consequently the fecal discharges were quite frequent and fluid or semifluid in consistence.

EXPERIMENT 84.—Dog, weight seventeen pounds. Two inches of the ileum were invaginated into the cecum. Ileocolostomy, by uniting the ileum with the transverse colon by suturing. The animal appeared quite ill after the operation, and died on the fifth day after having manifested well-marked symptoms of peritonitis. Abdominal wound not united. Only partial union between the intestines at point of junction. Diffuse septic peritonitis from perforation.

In at least two experiments that are not here reported the animals died of shock a few hours after operation. In a number of other experiments the operation was followed by more or less shock, but the animals, without receiving any special treatment, rallied after from six to twelve hours. The symptoms referable to the immediate effects of the operation were due to the length of time required in applying a double row of sutures in uniting the visceral wounds, a step in the operation that always required from thirty minutes to an hour. These experiments only corroborate the statement previously made that the excluded portion of the intestinal canal, including the obstruction, does not become the seat of fecal accumulation, but undergoes atrophy after free intestinal anastomosis has been established between the intestine above and below the seat of obstruction. Experiments 68 and 69 furnish most striking proof that the danger of gangrene in cases of invagination is greatly diminished by establishing an early intestinal anastomosis, as when this is done the violent peristalsis is promptly arrested by furnishing a new outlet to the intestinal contents; at the same time, the serious consequences resulting from pressure and distention above the obstruction are likewise promptly averted. In cases of intestinal anastomosis where nearly the entire colon has been excluded, the fluid contents of the small intestine reach the rectum at once, and cause frequent fluid fecal discharges, an occurrence that does not appear to impair the general health of the animal. The new opening should be made of adequate size, so that its lumen will at least correspond to the lumen of the bowel above the obstruction.

Ileocolostomy by Perforated Approximation Discs.

EXPERIMENT 85.—Dog, weight twenty pounds. The ileum was completely divided three inches above the ileocecal region, both ends closed by invagination and three stitches

of the continued suture. A communication was established between the proximal extremity and the colon by making an incision into the ileum on convex side near the closed end, and introducing through this opening a perforated decalcified bone-plate. A similar opening was made into the ascending colon opposite its mesenteric attachment, through which a perforated plate of wood was introduced. To each plate were tied four catgut sutures. The lateral sutures were passed through the margins of the wound. After the plates and sutures were in place, the wounds were brought in contact and the four sutures tied, which coaptated the serous surfaces of both bowels over an area corresponding to the size of the plates. The animal remained apparently well for two days, when symptoms of peritonitis set in and death occurred five days after operation. Diffuse peritonitis. Union at point of operation incomplete, which resulted in a perforation. Discs had disappeared. As the catgut sutures were quite fine, it is more than probable that partial separation of the plates occurred before adhesions had taken place between the serous surfaces of the coaptated bowels, which resulted in perforation and death from diffuse septic peritonitis.

EXPERIMENT 86.—Dog, weight fifteen pounds. Invagination of colon into colon to the extent of two inches. Intestinal anastomosis by making an ileocolostomy by lateral apposition of the ileum to colon below invagination, using perforated hard-rubber plates, which were tied together by four catgut sutures, the lateral sutures being passed through the margins of the wound. After tying the sutures it was found that at one point the margins of the wound showed a tendency to evert; consequently a fine catgut suture was passed through the peritoneum only and tied. The animal did not appear bright the day after the operation, but subsequently showed no signs of suffering. Killed twenty-four days after operation. Abdominal wound firmly united. Omentum adherent to wound and at point of operation. The invagination was partially reduced. The bowel at this point was curved in the shape of a horseshoe, but permeable to a stream of water. Excluded portion of colon tortuous and atrophic. Cecum contained a small quantity of fluid feces. Plates could not be found. New opening sufficiently large for free passage of intestinal contents.

EXPERIMENT 87.—Dog, weight fifteen pounds. Ileum divided transversely fifteen inches above the ileocecal region; both ends closed in the usual manner. Ileum and colon approximated by decalcified perforated bone-plates, which were tied together by four catgut sutures, the lateral ones transfixing the margins of the wound. On the second day the evacuation from the bowels contained traces of blood. Animal killed eighteen days after operation. Abdominal wound completely healed. Omentum adherent to wound. Numerous adhesions between the intestinal folds. Proximal blind end of ileum had been changed into a pouch-like form and contained a mass of hair and fragments of bone. One very sharp spiculum of bone had nearly perforated the intestine. New opening corresponds in size to the lumen of the ileum.

The operations of lateral apposition of ileum to colon by perforated approximation discs have shown that it is unsafe to rely upon catgut as a suturing material, as when fine catgut is used coaptation is not maintained for a sufficient length of time for adhesions to take place, and coarse catgut, when tied, interferes with accurate approximation, as the knots, after tying, mechanically separate the serous surfaces. It is advisable to use removable plates and to tie with silk. The results of ileocolostomy made by approximation discs have not been so favorable as after jejuno-ileostomy or ileo-ileostomy, and in repeating the operation on man it would be indicated, after bringing the intestines in apposition by tying the four sutures, to apply a number of superficial sutures for the purpose of still further guarding against the escape of gas or fluid contents into the peritoneal cavity. The plates, when properly fixed in their places and tied together with sufficient firmness, not only coaptate an extensive area of serous surfaces, but also, at the same time, secure perfect rest for the parts that it is intended to unite until firm adhesions have formed.

Clinical experience since these experiments were performed has

shown that intestinal anastomosis by lateral apposition can be made by suturing quickly and safely, preference being given to the plates or Murphy's button only in cases in which the intestinal wall is in such a condition that safe suturing would be precluded—that is, when it is extremely thin, softened by inflammation, or damaged by contusion. In lateral implantation the rubber ring can safely be dispensed with, and invagination may be effected by making traction on the two invagination sutures, completing the fixation by a row of Lembert stitches closely placed. In making an ileocolostomy it is well to unite the mesentery of the implanted part of the ileum with the mesentery of the colon by a separate stitch as an additional means of fixation. Maunsell implants the ileum into the colon in the same manner as in his method of performing circular enterorrhaphy. As the method appears easy and of practical value, his directions are here quoted:

"Invaginate the cut end of the ileum attached to the cecum and sew it up with a continuous suture.

"Make a slit on the convex surface of the colon sufficiently long to just receive, with very slight constriction, the cut end of the ileum; secure with two temporary sutures, leaving the ends long.

"Make a slit in the colon an inch higher up or an inch lower down in the cecum, whichever is most convenient for the invagination.

"Pass a dressing forceps through the slit, and seize the two ends of the temporary sutures.

"Drag the invaginated cut end of the ileum and its corresponding opening in the colon out through the slit.

"Suture carefully all round, and pull back to its normal position.

"Sew up the longitudinal slit with a continuous suture."

Ileorectostomy.—In cases of intestinal obstruction due to inoperable conditions low down in the colon it becomes necessary to establish an intestinal anastomosis between the ileum and the rectum, in order to avert the necessity of making an artificial anus—in other words, to perform an ileorectostomy. The operation can be made in the same way as establishing a communication between the ileum and the colon by lateral implantation, by lateral apposition and double suturing, or by lateral apposition by the Murphy button or by perforated decalcified bone-plates. The operation is, however, more difficult, because the rectum is not so accessible as the colon, and from the greater vascularity of the bowel the incision is more liable to give rise to troublesome hemorrhage. While the slight hemorrhage from an incision into the small intestine and the colon is usually promptly arrested by suturing or compression by the approximation discs, the bleeding from the wound of the upper portion of the rectum not infrequently requires the application of one or more catgut ligatures before it is safe to unite the wounds. During the operation traction must be made upon the rectum in an upward direction so as to lift the upper portion of the bowel out

of the pelvis. In both of the experiments described below the wounds were united by Czerny-Lembert sutures:

EXPERIMENT 88.—Dog, weight ninety pounds. Invagination of colon into colon for two inches, and suturing of intussusceptum to neck of intussuscipiens by four fine silk sutures to prevent spontaneous disinvagination. Ileum incised in a parallel direction for an inch and a half on convex side, and this wound united with a similar incision in the rectum on its anterior surface by a double row of sutures. For the purpose of immobilizing the sutured intestines an additional fine catgut suture was applied above and below the place of suturing, embracing only the peritoneal and muscular coats of the intestines. On the third, fourth, and fifth days the fecal discharges contained blood and mucus. On the sixth day the abdominal wound partially opened, and a considerable quantity of seropurulent fluid escaped. Death seven days after operation. Abdominal wound not united. Diffuse purulent peritonitis. Numerous intestinal adhesions. Invagination retained; adhesions between the intussusceptum and intussuscipiens; no gangrene; perforation at point of operation.

EXPERIMENT 89.—Cat, weight seven pounds. Ileorectostomy by lateral implantation. The ileum was cut across transversely an inch above the ileocecal valve, and the distal end closed by invagination and three stitches of the continued suture. The proximal end was transplanted into a longitudinal incision on the anterior surface of the upper portion of the rectum by Czerny-Lembert suture. With the exception of an occasional slight rise in temperature, no serious disturbances were observed during the progress of the case. The evacuation of the small intestine directly into the rectum appeared to increase the peristaltic action of the rectum, as the fecal discharges were fluid and frequent. Animal killed twenty days after operation. Abdominal wound completely united. No peritonitis. A few folds of the small intestine and the omentum adherent to the wound. Insertion of ileum into rectum in an oblique direction; union at point of junction complete throughout; intestinal coats at this point somewhat thickened. Peritoneal surface smooth and continuous from one bowel to the other. New ileorectal opening corresponded in size to the lumen of the ileum; margins of this opening consisted of a ridge of mucous membrane to which a row of the deep sutures remained attached. Excluded portion of large intestine empty and contracted. Rectum contained a small quantity of fluid feces.

Colorectostomy.—Among the many possibilities in the operative treatment of intestinal obstruction, a condition might be met with where the seat of obstruction is located low down in the colon, perhaps in the sigmoid flexure, and where it might be impossible or impracticable to remove the cause of obstruction, it becoming necessary, in such a case, to restore the continuity of the intestinal canal by establishing a communication between the permeable portion of the colon and the rectum. Such an anastomosis can be made, as in ileocolostomy, by lateral implantation, lateral apposition by the Murphy button, perforated approximation plates, or by double suturing. For want of time one experiment only was made, and although the animal died of the immediate effects of the operation, the local conditions at the site of operation found after death show that colorectostomy in selected cases is not only a justifiable and feasible operation, but, whenever it can be done, is also always preferable to the formation of an artificial anus. As the operation by lateral apposition requires much less time than lateral implantation, it should be preferred to the latter procedure, and should be done in this locality in preference with the Murphy button and a few superficial sutures.

This operation has recently been described as a new one, but I conceived the idea twelve years ago and carried it into effect in the experiment given below:

EXPERIMENT 90.—Medium-sized cat. Incision through the linea alba; colon cut transversely in the middle third and the distal portion, and the rectum cleared of its contents by injecting a stream of warm water from the cut end downward, a procedure that could be well accomplished only after forcible dilatation of the sphincter ani muscles. The distal end was closed in the usual manner. The rectum was drawn upward, and an incision made into its anterior wall large enough to correspond with the lumen of the colon. Into this opening the proximal end of the colon was implanted by two rows of sutures. During the latter part of the operation, which lasted over an hour, the animal was seized by convulsions that continued for several hours, and finally subsided under the administration of whisky given hypodermically. The symptoms of shock, however, continued, and death occurred thirty-six hours after operation. Numerous omental adhesions; closed end of bowel congested; peritoneal surfaces adherent; colon and rectum at point of implantation adherent.

In cases where the obstruction is located some distance from the rectum and where it would be impossible to approximate the permeable portion of the colon with the rectum, the entire colon must be excluded and the continuity of the intestinal canal restored by ileocolostomy or ileorectostomy. In all cases of intestinal anastomosis where the communication is made in the lower portion of the colon or the rectum, the sphincters of the anus should be rendered temporarily incompetent by stretching, for the purpose of guarding against overdistention of this part of the bowel during the time required for the healing process between the united intestines.

Invagination Suture.—Another method of effecting a speedy and comparatively safe end-to-end junction is by my modification of Jobert's invagination suture:

According to Madelung, the ingenious method of circular suturing devised by Jobert was practised in only four cases, and two of the patients are known to have recovered. A number of years ago I was forced to resort to resection of a part of the small intestine in a very complicated case of ovariotomy, and resorted to this method. Although the patient died forty-eight hours after the operation from causes outside of this complication, the bowel was found permeable and quite firmly united, and, had the patient lived, there is but little doubt the result of the resection and suturing would have been satisfactory. In Jobert's method the invagination sutures must be looked upon as a source of danger, as they were made to traverse the entire thickness of the wall of the bowel, and the material used was silk. It has been claimed that in this method the invaginated portion of the bowel becomes gangrenous, as in cases of invagination from pathologic causes. This claim has arisen from a theoretic, and not from an experimental, standpoint. In cases of invagination the intussusceptum carries with it the mesenteric vessels intact in the form of an arch, which, by constriction at the neck of the intussuscipiens, is prone to become strangulated, an event that is followed by edema and inflammatory swelling of the invaginated portion, which rapidly tends to complete venous stasis and gangrene. In circular suturing by Jobert's method the intussusceptum has no vascular connection with the intussuscipiens. The vascular arch is interrupted, and consequently the danger arising from venous obstruction is almost completely obviated. My experiments will show that

gangrene of the invaginated portion, as a rule, does not occur, and my modification of Jobert's method consists essentially in the use of a thin elastic rubber ring for lining the intussusceptum to prevent ectropion of the mucous membrane, to protect the mucous membrane of the bowel against injurious pressure from the suture, to keep the lumen of the bowel patent during the inflammatory stage, and to assist in maintaining coaptation of the serous surfaces; and, further, the substitution of catgut for silk as invagination sutures.

The operation is performed as follows: The upper end of the bowel, which is to become the intussusceptum, is lined with a soft, pliable rubber ring made of a rubber band, transformed into a ring by fastening the ends together with two catgut sutures. This ring must be the length of the intussusceptum,—from one-third to half of an inch,—and its lower margin is stitched by a continuous catgut suture to the lower end of the bowel, effectually preventing the bulging of the mucous membrane, a condition that is always difficult to overcome in circular suturing. After the ring is fastened in

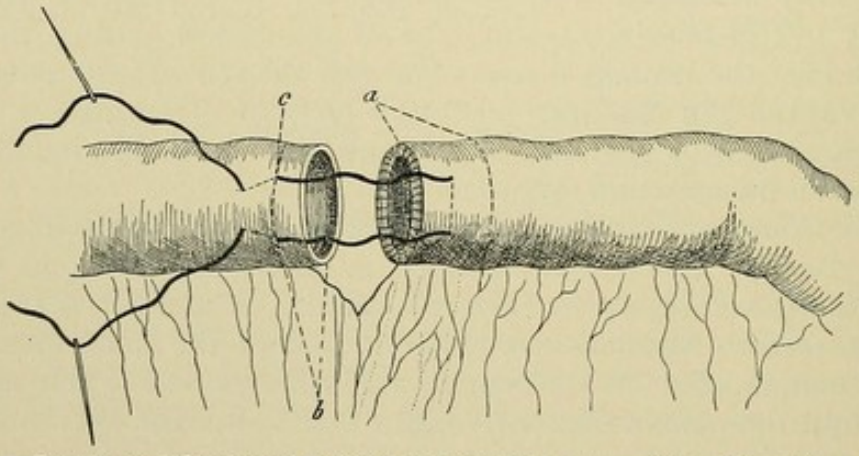

Fig. 517.—Senn's modification of Jobert's invagination suture (after Baracz): *a*, Upper end lined with soft-rubber ring; *b*, invagination sutures in place; *c*, lower end.

its place, the end of the bowel presents a tapering appearance that materially facilitates the process of invagination. Two well-prepared fine juniper catgut sutures are threaded, each with two needles. The needles are passed from within outward, transfixing the upper portion of the rubber ring and the entire thickness of the wall of the bowel, and always equidistant from each other. The first suture is passed in such a manner that each needle is brought out a short distance from the mesenteric attachment, and the second suture on the opposite convex side of the bowel. During this time an assistant keeps the opposite end of the bowel compressed, to prevent contraction and bulging of the mucous membrane. The needles are passed next through the peritoneal, muscular, and connective-tissue coats at corresponding points, about one-third of an inch from the margins of the opposite end of the bowel, and when all the needles have been passed, an assistant makes equal traction on the four strings, and the operator assists the invagination by turning in

the margins of the lower end evenly with a director, and by gently pushing the rubber ring completely into the intussuscipiens. The invagination accurately made, the two catgut sutures are tied with only sufficient firmness to prevent disinvagination should violent peristalsis follow the operation. This is their sole function. The invagination itself effects accurate, almost hermetic, sealing of the visceral wound. The intestinal contents pass freely through the lumen of the rubber ring from above downward, and escape from below is impossible, as the free end of the intussuscipiens secures accurate valvular closure. After a few days the rubber ring becomes detached, and, by giving way of the catgut sutures, is again transformed into a flat band that readily passes off with the discharges through the bowels. The invagination sutures of catgut are gradually removed by substitution on the part of the tissues, hence the punctures in the bowel remain closed either by the catgut or by the products of local tissue proliferation ; thus extravasation is prevented. In the first experiments three invagination sutures were used, but it was found, by experience, that two are just as efficient in making and retaining the invagination. No superficial or peritoneal sutures were used in any of the cases, sole reliance being placed upon the invagination to maintain approximation and coaptation. The mesenteric attachment, both of the intussusceptum and intussuscipiens, was separated only a few lines, to enable invagination without too much narrowing of the lumen of the intussuscipiens.

EXPERIMENT 42.—Dog, weight fifteen pounds. Three invagination sutures were used. The ileum was cut completely across, at a point about three feet above the ileocecal region. Depth of invagination one inch. For two days after operation a slight rise in temperature; no symptoms of obstruction during the whole time. Animal in good condition when killed, two weeks after operation. Omentum adherent at point of operation as well as on adjacent loop of intestine. Union between intussusceptum and intussuscipiens firm ; no signs of gangrene. Narrowest portion of lumen of bowel was large enough to pass the little finger to second joint. An enterolith composed of fragments of wood, bone, etc., in the center of which the straight rubber band, which had been the rubber ring, was found just above the seat of operation. No distention of the bowel above this point. Bowel considerably flexed at seat of invagination, this condition being evidently brought about by inflammatory adhesions.

EXPERIMENT 43.—Dog, weight twenty pounds. Section of bowel and invagination with rubber ring the same as in the foregoing experiment. In subsequent history no mention is made of any symptom of obstruction, but for the last few weeks it was noticed that the dog began to emaciate. He died suddenly eighty-one days after the operation. Diarrhea was a prominent symptom toward the last. No adhesions and no peritonitis. An enormous enterolith, composed of all kinds of crude material and again holding in its center the rubber band, was found just above the invagination. Bowel at this place considerably dilated. Intussusceptum firmly adherent; a false passage admitting the tip of the little finger had been made on one side, between it and the intussuscipiens. Death in this case was evidently produced by the enterolith. In this, as in the last, case, the invagination was made at least an inch in length, and the collection of the crude, indigestible material, which the dog must have eaten in large quantities, around the detached rubber ring gave rise to the enterolith. The wall of the bowel surrounding the foreign body was not only dilated, but also greatly thickened. It is a well-known fact that even a moderate degree of stenosis of the bowel in dogs is liable to give rise to the formation of an enterolith, as the crude material that these animals swallow becomes arrested, and, by constant accretions of the same kind of material, the enterolith forms and continues to increase in size until its presence causes catarrhal inflammation and finally intestinal obstruction.

It is quite possible that the lower end of the intussusceptum in the last case became

impermeable during the inflammatory stage, and that the false passage was formed on this account by perforation on one side of the intussusceptum, an accident that was plainly traceable to too deep invagination.

EXPERIMENT 44.—Dog, weight forty pounds. This experiment is interesting only from the fact that it shows that it is possible to make a mistake in the direction of the invagination, even after the operation has determined with accuracy which is the ascending and descending end of the bowel, and to show the disastrous consequences that must necessarily follow such a technical mistake. The invagination was made in the usual manner, with rubber ring and three catgut sutures. The animal appeared to be quite ill the day following the operation, and on the next day the thermometer showed a rise in temperature to 104.2° F. On the third day the dog died, with well-marked symptoms of perforative peritonitis. Recent peritonitis with some agglutinations of intestines. Considerable quantity of serosanguinolent fluid in the peritoneal cavity. To the utter astonishment of all, it was found that an ascending invagination had been made. Circular gangrene of intussusceptum and complete separation of ends were found. The rubber ring remained *in situ* still attached to the intussuscipiens by the catgut sutures, which had become somewhat softened. The invagination had decreased considerably by the traction caused by the peristalsis and by the pressure of the intestinal contents from above the obstruction, and the extensive gangrene of the bowel was undoubtedly determined to a great extent by these causes.

EXPERIMENT 45.—As an illustration of another source of danger due to faulty technic, the next experiment will prove of practical interest. Medium-sized dog. Circular enterorrhaphy was done with the rubber ring two feet above the ileocecal valve. In making the invagination it was noticed that the ring was too large, as it was seen that it caused too much pressure. Thinking that the parts might adapt themselves to this pressure, the bowel was replaced and the abdominal wound closed. The dog died thirty-six hours after the operation. Abdominal wound not united; omentum and intestines adherent to each other and at point of operation. The circumscribed gangrene of the intussuscipiens was evidently entirely due to pressure on part of the rubber ring. The intussuscipiens was much swollen, a condition that materially aggravated the pressure caused by the rubber ring. With the following experiment two new departures were inaugurated—viz., the inserting of two sutures instead of three, thus still further shortening the time required for performing the operation; and the using of Nothnagel's test in determining the direction in which the invagination should be done. In all the remaining experiments of circular enterorrhaphy that were made only two catgut sutures were used. Until now it was always necessary to find one of the extremities of the small intestine for the purpose of determining which was the afferent and which the efferent end of the tube, so as to make the invagination in the right direction, a procedure that often required considerable time and brought additional risk by increasing the shock of the operation and the danger of traumatic infection.

EXPERIMENT 46.—Dog, weight thirty pounds. Circular section of ileum and immediate enterorrhaphy by invagination with rubber ring and two catgut sutures. Intussusceptum invaginated not more than a quarter of an inch. A few days after the operation stools mixed with blood; no other unfavorable symptoms. Animal killed fourteen days after operation. Wound united firmly. A number of omental and intestinal adhesions. A small abscess in mesentery at point of operation. No obstruction of any kind. On opening the bowel the walls at site of operation were very thick, corresponding to the three intestinal coats, which had become considerably attenuated. The inner surface shows the point of junction of the intussusceptum with the intussuscipiens in the shape of a circular ring of mucous membrane. The most contracted portion is large enough to admit the little finger.

EXPERIMENT 47.—Dog, weight fifteen pounds. Section of ileum and circular enterorrhaphy with rubber ring and two catgut sutures. Depth of invagination, one-third of an inch. No unfavorable symptoms after operation. Animal killed after seven days. Wound completely united. Firm union of visceral wound; no gangrene of intussusceptum. Rubber ring retained *in situ* by catgut sutures, which are easily torn. Upper end of ring matted with hair. No obstruction. Lumen of bowel somewhat contracted by a circular ridge of mucous membrane, which indicates the junction of the two invaginated ends of the bowel.

Nothnagel's Test.—In making an end-to-end junction by invagination it is very important to determine which is the proximal and which the distal end, as the former is always invaginated into the latter. In the absence of other indications or means this differ-

entiation can be accomplished with some degree of positiveness by resorting to Nothnagel's test.

In experimenting upon animals for the purpose of studying the functions of the intestinal canal in health and disease Nothnagel made the discovery that when the salts of potash are brought in contact with the serous surface of the bowel, circular constriction takes place, and when the peritoneal surface is touched with a crystal of common salt, ascending peristalsis is produced. The sodic chlorid test was applied in sixteen cases, and by subsequent anatomic examination Nothnagel's observations were corroborated in fifteen cases. In the remaining case, where a wrong conclusion was drawn, the error might have been due to a faulty observation, or, perhaps, the observation was not continued for a sufficient length of time. If, in the human subject, these observations could be verified, it would be of great practical importance to surgeons in operations on the intestinal canal whenever it becomes necessary to determine which is the ascending and which the descending part of the bowel.

In circular enterorrhaphy, as in cases of intestinal wounds of any kind, the ideal of any operation should be to bring in continuous uninterrupted apposition a large surface of serous membrane, without, at the same time, interfering with the vascular supply of the parts that it is intended to bring together for permanent union by cicatrization. If, in employing the Czerny-Lembert sutures, more than a few lines of the margins of the bowel are inverted and included between the two rows of sutures, there is great danger of causing primary traumatic stenosis by the projecting circular ring in the lumen of the bowel. The narrowing of the lumen of the bowel must be as great, if not greater, than after invagination. That the second row of sutures has often been the cause of gangrene of the inverted margin of the bowel would not be difficult to prove by many postmortem records and specimens. By invaginating to the depth of a quarter or third of an inch, accurate coaptation of the corresponding serous surfaces between the intussusceptum and intussuscipiens is secured, and this coaptation is made more secure and effective by the elastic pressure exerted by the rubber ring. This method of coaptation furnishes a large peritoneal surface for immediate union by cicatrization. With perhaps one exception, all the experiments have shown that when catgut is used for invagination sutures none of the failures was attributable to their presence. On the inner side of the bowel the rubber ring is drawn against the puncture, and would thus furnish a mechanical protection against the escape of fluids of the invaginated portions, which finally appear only as a prominent ridge of mucous membrane on the inner surface of the bowel, the remaining coats having completely or nearly disappeared by retrograde metamorphosis and absorption. In the healing of all wounds one important condition for an ideal result is rest. The rubber ring in the intussusceptum secures this important

condition for the invaginated portion, as the elastic pressure must overcome peristaltic action and secure for this segment of the bowel, as near as possible, absolute physiologic rest. The danger of stenosis after invagination is greatest as soon as inflammatory swelling makes its appearance,—a day or two after the operation,—and the rubber ring is again in the right place to prevent any undue swelling by affording a gentle support for the invaginated portion, which can not fail in preventing undue venous engorgement and edema, which would otherwise follow the invagination. It serves both the purpose of a splint and an elastic bandage. After union of a bowel by invagination with a rubber ring peritoneal sutures are superfluous, as the invagination itself most effectually prevents any escape of intestinal contents by the valvular action of the invaginated portion; at the same time the serous surfaces are kept in permanent and uninterrupted contact by the elastic pressure on the part of the rubber ring.

Although the experiments have demonstrated the safety of the catgut invagination sutures in operating upon dogs, the same innocuity might not attend operations after intestinal resections for obstruction, as in such cases the coats of the bowel are almost without exception very much attenuated, and consequently the danger of extravasation along the needle punctures would be increased. Very recent trials have proved that invagination after circular resection can be done with the rubber ring with facility and probably greater safety by dispensing with the invaginating sutures and adopting the following plan: The lower end of the intussusceptum is lined with a soft-rubber ring about one-quarter to one-third of an inch in width, and with a lumen of sufficient size to afford free transit to the intestinal contents. The lower margin of the ring is stitched to the end of the intussusceptum by a continued fine catgut suture. The ends of the bowel are now brought in contact and fastened together with four catgut sutures that are placed equidistant from one another. Invagination is now made by gently pushing the ends of the bowel in opposite directions, being careful to push the ring sufficiently deep so that its upper margin is grasped by the neck of the intussuscipiens. A few superficial sutures are applied simply for the purpose of preventing disinvagination: the four catgut sutures act as invagination sutures, and at the same time prevent ectropion of the mucous membrane of the lower end of the bowel during and after invagination. With proper facilities and good assistance a circular enterorrhaphy can be made in this manner in ten minutes without using invagination sutures; and by using not more than four retention sutures, the blood supply to the inverted portions is not impaired, and at the same time the two ends of the bowel have been joined together by a large surface of peritoneum, which is held in accurate contact for rapid union by granulation and cicatrization.

The advantages that are derived from covering a sutured intestinal wound by an omental flap are self-evident. The procedure is

simply an imitation of nature's process in protecting the peritoneal cavity against perforation and in hastening the healing of the visceral wound. An adherent omentum secures rest for the part to which it has become attached. As the omental flap becomes firmly adherent before definitive healing of the visceral wound has taken place, it furnishes additional protection, and, in the event of a small perforation, it guards against perforative peritonitis by mechanically preventing the entrance of pus into the peritoneal cavity. Should pus reach the omental flap after it has become firmly adherent, it is not very probable that perforation would take place through the two layers of peritoneum furnished by the adherent omental flap, and the subsequent healing of the perforation of the bowel would be most likely to take place. Allusion to this subject has already been made under the head of Omental Grafting.

CHAPTER XXIV.

ANATOMICOPATHOLOGIC FORMS OF INTESTINAL OBSTRUCTION.

In the introductory section stress was placed on the importance of the classification of intestinal obstruction into acute and chronic; this was done rather from a practical than from a scientific standpoint. But an exclusive reliance on such a differentiation at the bedside will not infrequently lead to faulty practice, as a chronic obstruction may give rise to slight symptoms until suddenly the clinical picture of acute obstruction is developed; on the other hand, in acute obstruction under expectant treatment the stormy symptoms may subside, to be followed by manifestations indicating the existence of a chronic obstruction. A scientific classification of intestinal obstruction remains a desideratum to be accomplished by future experimentation and pathologic and clinical investigations. A step in the right direction was initiated by von Wahl, who aimed to base the classification on the pathologic conditions of the obstructed portion of the intestine itself. Following this suggestion, his assistant, W. von Zoege-Manteuffel, proposes the following schema:

I. STRANGULATION OBSTRUCTION.

Pathologic Changes.	Clinical Symptoms.
1. Localized tympanites; distention of strangulated loop.	1. (*a*) Asymmetries on the abdomen. (*b*) Localized resistance.
2. Ischemic paralysis of the strangulated loop.	2. Complete rest of loop lying against abdominal wall; no peristalsis.

In this category are included:

1. Volvulus, twists.
2. Obstruction from bands and diverticula.
3. Incarceration in preformed spaces—internal hernia.
4. Invagination.

II. OBTURATION OBSTRUCTION.

Pathologic Condition.	Clinical Symptoms.
1. Tympanites caused by accumulation of intestinal contents above obstruction.	Appreciable asymmetry, palpable resistance in obstruction of the large intestine. In obstruction of small intestine diffuse tympanites.
2. (*a*) No considerable disturbance of circulation.	(*a*) Peristalsis visible or palpable.
(*b*) Hypertrophy of muscular coat above obstruction in the chronic form when the large intestine is affected.	(*b*) Peristalsis strong.

To this group belong:

1. Strictures.
2. Twist around the axis of the intestine.
3. Obstruction from tumors and foreign bodies.
4. Compression by tumors from without, etc.

A glance at the foregoing schema will convince any one that a clearer classification of intestinal obstruction is greatly needed in order to harmonize the views of physicians and surgeons and so furnish them with a more reliable guide in formulating rational plans for the treatment to be pursued. For the physician it is most important to differentiate, as early as possible, between mechanical and dynamic obstruction—in other words, to separate the cases into medical and surgical; for the surgeon it is imperative that he should know the nature and location of the mechanical obstruction before he resorts to the knife. For these reasons it has been deemed advisable to discuss the different forms of intestinal obstruction from an anatomicopathologic standpoint. While the different pathologic forms of chronic and acute obstruction present many features in common, the clinical picture is usually materially modified by the anatomic location of the obstruction, and certainly when this location can be determined before the abdomen is opened, the surgeon is better prepared to outline beforehand the operative treatment that is to be pursued. The experience of Curschmann, Naunyn, Goltdammer, and other distinguished physicians has shown that about one-third of all cases of intestinal obstruction will recover under rational internal treatment, and these are the cases that, with few exceptions, are due to dynamic causes. It seems, then, that about one case in three has a chance of recovery without operation under medical treatment. Dynamic obstruction is due most frequently to peritonitis; next in frequency, to reflex intestinal paralysis; and, finally, to intestinal spasm—enterospasm.

It is not always easy or possible to differentiate between dynamic and mechanical obstruction; there are, however, certain symptoms that are very significant of each and that must be studied with the greatest care. Peritonitis is characterized by diffuse tympanites, tenderness, fever, rapid, wiry pulse. Fever is not constantly present in peritonitis, as in the gravest forms the temperature is not infrequently subnormal. Vomiting, so constant a symptom in both the mechanical and dynamic forms of obstruction, often becomes fecal in peritonitis when the inflammation and adhesions of the intestinal

wall result in dynamic obstruction. Dynamic obstruction due to intestinal paralysis without inflammation is of rare occurrence, and its nature is as yet very imperfectly known. It is probable that some of the cases of intestinal obstruction after laparotomy have such an origin. Heidenhain reports from the Greifswald clinic three cases of enterospasm out of thirty cases of intestinal obstruction. All recovered. In one, laparotomy was performed, but no obstruction was found. In all the cases the existence of a local irritation was considered as the cause of the localized spasm. He refers to similar cases in the practice of James Israel and Körte. In all cases of obstruction due to enterospasm or paralysis without inflammation the constitutional symptoms were not severe, a clinical feature of great importance as compared with mechanical obstruction or obstruction due to inflammation. No surgeon questions the fact that in very rare cases a slight invagination or volvulus is corrected spontaneously or by rectal inflation, but these cases are, to say the least, exceptional. We are, therefore, forced to the conclusion that all cases of mechanical obstruction are surgical affections from the very beginning, and must be treated as such within from twenty-four to forty-eight hours if the patient is to receive the benefits from an early operation to which he is entitled. Irregularity of the contour of the abdomen, localized tympanites and resistance, absolute interception of gas and fecal matter, visible or palpable intestinal peristalsis, and fecal vomiting are some of the symptoms most relied upon in differentiating mechanical from dynamic obstruction. The pulse at first is but little affected. In volvulus the pulse has been frequently reduced to less than sixty (Heidenhain). Fecal vomiting is seen not infrequently during the latter stages of peritonitis. Arrest of intestinal contents is often incomplete in invagination. Visible or palpable peristalsis is more constant in obstruction from obturation, strictures, twists, impaction from tumors and foreign bodies, or obstruction from compression.

The clinical symptoms most characteristic of strangulation obstruction, volvulus, band constriction, internal hernia, and invagination are appreciable asymmetry of the abdominal surface, localized resistance, paresis of the strangulated loop lying against the abdominal wall, and the absence of stormy peristalsis. The clinical history is of much import in searching for the nature and location of the obstruction. Age, sex, antecedent abdominal affections, previous condition of the fecal discharges, and the general physique of the patient must all be taken into careful consideration before the symptoms presented at the bedside are analyzed and classified.

The weak side of intestinal surgery to-day is the uncertainty of diagnosis; the surgeon must often shoulder the responsibility imposed upon him by the present status of modern aseptic surgery of seeking light in doubtful cases by resorting to an exploratory incision, and then acting in accordance with what is revealed by inspection and palpation.

Volvulus.—Volvulus constitutes a well-defined and definite anatomic form of intestinal obstruction. This term is used to designate that form of impermeability of the intestinal canal that results from twisting or rotation of one or more loops of the bowel about its mesenteric axis.

Frequency of its Occurrence.—Volvulus, as compared with some other forms of intestinal obstruction, is quite rare, constituting about 4 per cent. In 1541 cases of obstruction from different causes collected by Leichtenstern and analyzed with special reference to the anatomic cause of the obstruction, after deducting 178 due to carcinoma, 33 cases only were due to twisting of the bowel, including twists of both the sigmoid flexure and the ileum. The same author also gives the result of his examinations of 76 cases of volvulus that he has collected, and of this number the lesion was found in 45 cases in the sigmoid flexure, in 23 cases in the ileum, and in 8 cases in the jejunum and ileum combined (Plate 6).

Predisposing Causes.—Volvulus occurs more frequently in the male than in the female, the proportion being about four to one. A larger mesentery in the male and more violent exertions are the probable causes that explain this difference. It is met more frequently in persons advanced in years, the average age being about fifty; no age, however, is exempt, and it has been observed as a congenital affection.

G. Fischer found a most interesting specimen of congenital volvulus in a child that died, three days after birth, with symptoms of intestinal obstruction. An operation for imperforate anus was made soon after the child was born. The postmortem showed intestinal atresia and volvulus. The narrowing of the intestine commenced at the middle of the ileum, and from there extended the whole length of the intestinal canal. In some places the intestine was represented by a solid cord; in other places the lumen was reduced to the size of a quill. The appendix was found attached to the contracted colon at a point where it was slightly dilated, but without a sign of a cecum. About the middle of the contracted portion of the small intestine a loop had become twisted twice around its mesenteric axis, and showed distinct evidences of strangulation. No indications of intra-uterine peritonitis.

Volvulus can occur only when the mesentery of the bowel is of abnormal length, and is, therefore, most frequently met in the segments of the intestinal tract normally provided with a long mesentery, as the sigmoid flexure and the lower part of the ileum.

Volvulus of the cecum can occur only when it is supplied with a mesentery common with the ileum—that is, in the event of an arrest of development in which the mesenteric plate of the cecum does not become attached to the posterior abdominal wall. Dreike found such a common mesentery quite frequently in postmortems made on children in the orphan asylum at Mosthon, and von Zoege-Manteuffel found in the literature twenty cases of volvulus of the

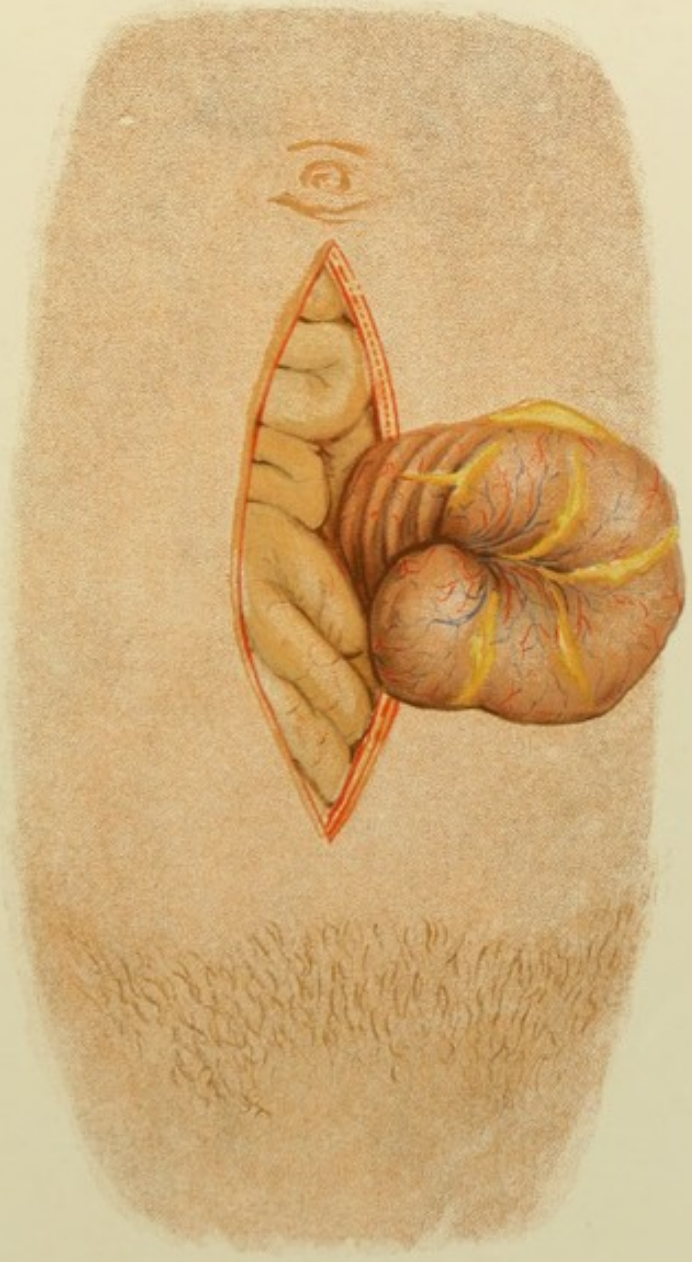

Volvulus of sigmoid flexure. Twist one and one-half around mesenteric axis. Great distention and vascularity of twisted loop.

cecum, and four additional cases that came under his own observation. Of these four cases all were treated by laparotomy, three recovering, but the fourth dying of peritonitis, which had set in before the operation was performed.

James Israel calls special attention to contracting mesenteritis as a predisposing cause of volvulus of the sigmoid flexure. In several cases he found that the mesocolon of the sigmoid flexure had been narrowed so much from this cause that the limbs of the flexure were brought almost in contact at the base of the volvulus. As to the immediate or exciting cause, he believes that distention of the bowel plays an important part. If the distention is on the proximal side, the upper limb is thrown around the rectal portion. "*Type rectum en arrière*" (Potain), while the reverse, "*Type rectum en avant*," takes place if the distention is on the opposite side. In one of his cases the latter form could be traced to a high enema.

I found it almost impossible to produce and maintain a complete volvulus in dogs and cats, owing undoubtedly to the shortness of the mesentery. The volvulus was experimentally produced by rotating a loop of intestine one and a half or two times around its axis, and retaining it in this position by a number of fine sutures, which were applied in places at the base of the volvulus, where fixation was most required.

EXPERIMENT 11.—Dog, weight twelve pounds. A loop of the ileum eight inches in length was brought out through a small incision, and the tubes turned around their axis twice and the twist maintained by two catgut sutures. The constriction was sufficiently firm to cause considerable venous engorgement in the twisted loop. The dog manifested no unpleasant symptoms after the operation. The specimen was not obtained, as after a few days the dog ran away.

EXPERIMENT 12.—Medium-sized adult cat. In this case the volvulus was made by twisting a loop of the ileum about four inches in length twice around its axis, and retaining it in this position by a number of fine silk sutures. Vomited several times during the first day. The first three days, in taking the temperature in the rectum, the thermometer when taken out was bloody. The first two days the temperature was normal, followed by an increase to 104.6° F. and 103.2° F. respectively, the two succeeding days; then it became normal. No constipation; appetite good throughout the whole time. Animal killed twenty-two days after operation. Abdominal wound completely united; no peritonitis. Volvulus remains as after operation, with the exception that where the bowel had been flattened by the twisting it had, at least partially, resumed its tubular form. Serous surfaces where approximated had become firmly adherent at point of constriction; size of bowel considerably diminished. The twisted loop contained liquid feces. Connecting the specimen with the faucet of a hydrant, water could be forced through, but on increasing the force of the current the peritoneum ruptured extensively in a longitudinal direction to point of partial obstruction.

These experiments are interesting, inasmuch as the primary constriction produced in making and maintaining the volvulus, which was sufficient to cause venous engorgement in the twisted loop, must have been of only short duration, the disappearance of the effects of constriction being undoubtedly due to the gradual yielding of the sutured parts; while the faulty axis of the twisted loop was maintained by the sutures, the circulation improved and remained in a sufficiently vigorous condition adequately to nourish the most distant portions of the volvulus. While it was found difficult during life to force fluid through the specimen of a volvulus, propulsion

of the intestinal contents by peristaltic action was carried on in a satisfactory manner, as the bowel above the volvulus was not dilated and contained no abnormal amount of fluid, and the animal manifested no symptoms indicative of intestinal obstruction.

That the relation of the length of the intestinal canal to the mesentery exerts some influence in the causation of volvulus has been well shown by Küttner. He ascertained, from his anatomic researches, that in persons who subsist almost exclusively on coarse vegetable food, as is the case with most of the peasants in Russia, the small intestine measures from twenty to twenty-seven feet in length, while in persons of German birth the length varies between seventeen and nineteen feet. The same author has also shown that volvulus is much more frequently met in Russia than in Germany. As the mesenteric attachment to the posterior abdominal wall must be nearly the same in all individuals, so far as its extent is concerned, the occurrence of volvulus will be favored in proportion to the length of the intestinal canal. The nearer the two bars of an intestinal loop approach each other, the narrower the mesentery and, therefore, the greater the risk of rotation about its axis from causes that disturb the peristaltic movements. Sudden or gradual elongation of the intestinal canal from distention, as we observe it in cases of intestinal obstruction and peritonitis, furnishes one of the mechanical conditions upon which the production of volvulus depends, by disturbing the normal relations that exist between the length of the intestines and their fixed points of attachment. It is not uncommon to find, in postmortem records of persons who have died of peritonitis, mention of volvulus as a secondary condition, and in cases of intestinal obstruction it is by no means rare to find the same condition as a secondary occurrence on the proximal side of the primary occlusion.

I have met volvulus in two of my abdominal sections, where this lesion could be accounted for only by attributing it to elongation of the intestines from distention. In one case it followed a strangulated hernia. The patient was a young man who had suffered for a week from a strangulated inguinal hernia. On opening the sac the strangulated loop was found to be gangrenous; the incision was therefore enlarged in an upward direction, and the bowel brought down until healthy tissue was reached. The part of the intestine leading downward was collapsed, while the portion on the proximal side was only moderately distended. As this amount of distention did not explain the general diffuse tympanites, it was deemed necessary to search for an additional cause of obstruction higher in the intestinal canal. The abdomen was opened by enlarging the incision in an upward direction. About one foot above the seat of strangulation a mass of intestinal coils was found twisted upon their mesenteric attachments and firmly adherent. Above this secondary obstruction the intestines were enormously distended and very much congested. In this case the distention of

the intestine, commencing at the internal inguinal ring, had caused elongation of the bowel, which in turn resulted in volvulus, giving rise to a speedy aggravation of the symptoms of obstruction. That the volvulus was not of long standing was evident from the fact that the adhesions were recent, and limited to the part of the intestine implicated in the twist.

In my second case the volvulus formed after perforation of a typhoid ulcer. The patient was seen three days after the perforation had occurred, and at that time the symptoms pointed rather to volvulus than to perforation and peritonitis. The abdomen was opened and the volvulus readily found. A number of loops of the small intestine had undergone a complete twist around the mesenteric axis, and showed evidences of strangulation, and were at the same time enormously dilated. The diffuse septic peritonitis that was present had been caused by perforation of a typhoid ulcer a few inches above the ileocecal valve. The perforation was closed by suturing, the volvulus corrected, and the abdominal cavity flushed with a weak solution of salicylic acid. The patient never rallied fully from the shock, and died a few hours after the operation.

Nieberding has recently called attention to another cause of volvulus. He has reported a case that occurred in Bumm's practice, where, after an ovariotomy, a volvulus of the small intestine occurred that proved fatal after a few days. During the operation the omentum, which was adherent to the cyst, was separated and a portion excised. The necropsy showed that the raw surface of the omental stump had formed an adhesion to a loop of the small intestine, and above the fixed point a volvulus was found. He reported another and somewhat similar case that had come under his own observation. A large cystosarcoma of the left ovary was removed in a woman twenty-nine years of age. Before closing the wound it was noticed that the omentum was so short that the intestines could not be covered by it in the region of the incision. At the end of the second day symptoms of acute obstruction set in, the temperature remaining normal. As the symptoms increased in gravity and the ordinary treatment proved fruitless, the wound was opened, and a loop of intestine was found adherent to the left margin of the incision, and after this separated a volvulus was detected. The bowel was untwisted and its contents forced into the segment further down, beyond the seat of obstruction, the detached loop pushed beyond the reach of the abdominal wound, and the abdomen closed. The day after the operation the intestinal canal appeared to be permeable, gas escaping per rectum, but evidences of peritonitis set in and the patient died with symptoms of collapse.

From the foregoing considerations it is apparent that the following three mechanical conditions favor rotation of the intestine about its mesenteric axis:

(1) Long mesentery; (2) physiologic or pathologic elongation of the bowel; (3) intestinal adhesions to the abdominal wall.

Exciting Causes.—Among the exciting causes of volvulus Küttner mentions, as the most important, unequal distribution of intestinal contents and exaggerated peristalsis. He never observed peritonitis in any of his cases, even if life was prolonged for five or six days. He asserts that the complicated forms of knotting of the intestines, which are still described in the text-books as rare but distinct forms of obstruction, are only varieties of volvulus. Grawitz asserts that the immediate cause of volvulus is to be found in an accumulation of intestinal contents above a constricted portion of bowel; that the distended portion of intestine above the seat of constriction undergoes elongation, and that this elongated portion then rotates around its axis. Henning firmly ligated the intestines of animals, and injected water above the seat of obstruction. In the small intestine the distended and elongated coils above the ligature always showed a tendency to rotate upon their vertebromesenteric axes, thus producing a volvulus. In the large intestine, on account of the shortness of the mesenteric attachment, the same experiment caused rupture of the bowel before a volvulus could be produced. These experiments furnish positive evidence that volvulus of the large intestine can not occur when the mechanical conditions described as predisposing causes are absent. Henning collected a number of cases of volvulus scattered through the literature on this subject, where, in the postmortem description of the twisted bowel, it was distinctly stated that the lumen of the intestine was narrowed by some form of acquired or congenital stenosis, which is only another proof in support of the statement that elongation of the bowel constitutes one of the most important conditions in the causation of this form of intestinal obstruction. Violent peristalsis, caused by intestinal indigestion, some form of chronic obstruction, or some kind of violent exertion in which the abdominal muscles are especially concerned, is usually the immediate cause of the torsion.

Spontaneous Reposition.—We have reason to believe that a violent peristalsis not infrequently produces a volvulus, but when the bowel and its mesentery are of normal length, spontaneous reduction occurs as soon as the peristaltic wave has passed. Such a condition gives rise to abdominal pain and a temporary disturbance of the fecal movement. In animals in which volvulus was produced artificially by twisting an intestinal loop completely around its axis and fixing it in this position by suturing, complete obstruction was never produced, and it was usually found, subsequently, that partial reposition had been effected by gradual yielding of the sutures and adhesions. The conditions are entirely different when both the intestine and the mesentery are abnormally long, under which circumstances spontaneous reposition seldom, if ever, takes place. In such cases the mechanical obstruction caused by the twist is soon followed by dynamic obstruction in the segment of bowel constituting the volvulus, caused by the pathologic conditions

arising from the strangulation. The mechanical constriction that takes place at the point of rotation produces paresis, venous engorgement, edema, and gangrene. These secondary conditions are followed by distention of the intestine and accumulation of intestinal contents, which can not fail to aggravate the mechanical difficulties that initiated the obstruction.

Symptoms and Diagnosis.—Primary volvulus is of sudden occurrence, and when located anywhere above the ileocecal valve, is usually attended by severe pain and other symptoms of acute obstruction. Vomiting is a prominent symptom in volvulus of the small intestine, but is often entirely absent when the colon is the seat of the twist.

Poppert reports a case of volvulus of the sigmoid flexure, which had become twisted 180 degrees around its mesenteric axis, where vomiting never occurred from the beginning of the attack to the fatal termination. He also refers to the statement made by Roser, that in cases of volvulus of this portion of the colon, vomiting is a late symptom, or may be entirely wanting. Treves found that this symptom was absent in three out of twenty cases of volvulus that he collected.

In Poppert's case it was shown during life, by the introduction of an elastic tube through which the organ was washed out, that the stomach was empty or nearly so. In volvulus of the sigmoid flexure the pain is often referred to the umbilical region, and not to the seat of the obstruction. A circumscribed area of tenderness over the surface corresponding to the circumference of the twisted loop is an early and well-marked symptom. A volvulus once fully developed gives rise to complete obstruction, the violent peristalsis above the seat of obstruction aiding in rendering the occlusion more complete. Diffuse peritonitis is never met with in cases of volvulus unless it has developed in consequence of gangrene or perforation. Localized plastic peritonitis is, however, of frequent occurrence, commencing in the twisted mesentery and extending from that to the intestine. Such adhesions in cases where a number of loops are implicated in the volvulus, or where knotting of the intestine has taken place, frequently offer serious difficulties in effecting reposition, and, after successful reposition, tend to reproduce the volvulus unless provision is made by special measures against such an occurrence. The occurrence of gangrene of the twisted loop is announced by a small, rapid, feeble pulse and other symptoms indicative of septic intoxication. Professor von Wahl has called special attention to an important early diagnostic sign in cases of strangulation and volvulus. Schweninger's experimental investigations have shown that meteorismus first takes place in the constricted or twisted loops of the bowel, and von Wahl has in a number of cases been able to make a positive diagnosis of volvulus by percussion, by which he located a circumscribed area of tympanites, which, on opening the abdomen, was found to correspond to the site of the

twisted and dilated loop. As volvulus occurs usually in some portion of the colon or the lower portion of the ileum, its exact location can be readily determined by rectal insufflation of hydrogen gas or air. This diagnostic measure is of the greatest importance and value before general tympanites has set in. If the volvulus is located at the sigmoid flexure, only a small quantity of gas can be introduced, and after the distention of the colon below the seat of obstruction, the localized tympanites due to the volvulus will be found a little higher up in the abdomen, the twisted loop of the bowel having been pushed in an upward direction by the distended colon. If the cecum is the seat of the volvulus, the insufflation can be continued until the entire colon is fully distended, but the gas can not be forced into the small intestine. The effect of the insufflation under such circumstances will be to widen the abdomen without increasing its prominence. If the volvulus is situated above the ileocecal valve, the gas will rush from the colon into the ileum with an audible blowing or gurgling sound, and the distention of the lower coils of the small intestine will cause the hypogastric region to become more prominent.

In recapitulation it may be said that the most important symptoms and signs upon which a probable or positive diagnosis can be based are the following: (1) Suddenness of attack; (2) absolute obstruction; (3) localized area of tympanites; (4) permeability of intestinal canal to rectal insufflation of hydrogen gas or air as far as the seat of obstruction. The localized swelling, tympanites, and tenderness over the twisted intestinal loop are symptoms of the utmost value soon after the accident has occurred; later these symptoms are overshadowed and obscured by the more diffuse tympanites caused by the distention of the bowel above the obstruction.

Prognosis.—A fully developed volvulus—that is, a half to two complete twists—taking place in a portion of the intestine predisposed to such an occurrence by congenital or acquired causes is never corrected without direct mechanical assistance, and, if left to itself, invariably results in death within a short time from intestinal obstruction, gangrene, or septic peritonitis. The acuteness of symptoms and the immediate danger to life increase as the volvulus approaches the upper portion of the intestinal canal. Death results either from exhaustion, owing to the incessant vomiting and defective nutrition, or from the pathologic changes that occur in the twisted portion of the bowel; the latter consist in gangrene affecting the entire loop or circumscribed gangrenous spots at the point of greatest pressure, resulting in perforation and septic peritonitis. As the gangrene is the result of pressure or strangulation, its rapid occurrence may be expected when the twist is tight—that is, when the intestinal loop has been rotated once or twice around its mesenteric attachment. Death from any of these causes may occur in a few days, and life is seldom prolonged for more than a week.

Treatment.—A violent peristalsis is not only one of the causes

of volvulus, but also a condition that seriously aggravates the local and general conditions after the accident has occurred, one of the first indications of treatment should be to place the bowel as nearly as possible in a condition approaching physiologic rest. No food should be introduced into the stomach, and thirst should be quenched by small pieces of ice. If the vomiting is severe, or if this symptom is absent and there is reason to believe that the stomach is not empty, washing out of the organ by means of a flexible tube is indicated, this simple procedure being often followed by immediate and great relief. The peristalsis is quieted by the administration of some preparation of opium, and if this is not retained by the stomach, morphin is administered hypodermically. The bowel below the volvulus is evacuated by copious injections, which should be given while the patient is placed in Hegar's knee-chest position. The patient is to be nourished exclusively by rectal enemata. Are there any known means by which reposition can be effected without opening the abdomen? Jonathan Hutchinson, whose views concerning the utility of laparotomy in the treatment of intestinal obstruction are, to say the least, exceedingly pessimistic, in a paper on "Records of Intestinal Obstruction, with Especial Reference to Symptoms and Treatment" ("Archives of Surgery," vol. I, No. 1), again calls attention to the value of his method of performing abdominal taxis in the treatment of intestinal obstruction, irrespective of a probable or positive anatomic diagnosis. His method is described as follows: "The first point in abdominal taxis is the full use of an anesthetic, so as to obliterate all muscular action, repeatedly kneading the abdomen, pressing its contents vigorously upward, downward, and from side to side. The patient is now to be turned on his abdomen, and in this position to be held up by four strong men, and shaken backward and forward. This done, the trunk is to be held uppermost, and shaking again practised directly upward and downward; while in this position copious enemata are to be given. The whole proceedings are to be carried out in a *bona fide* and energetic manner. It is not to be merely the name of taxis, but the reality, and patience and persistence are to be exercised. The inversion of the body and succussion in this position are on no account to be omitted, for they are possibly the most important of all. I do not think that I ever spend less than half or three-quarters of an hour in the procedure."

As Mr. Hutchinson mentions no exceptions, so far as the nature of the obstruction is concerned, we have reason to believe that he advises taxis, as described, in the treatment of volvulus. Taxis has a limited field of useful application in some forms of intestinal obstruction, but in the treatment of volvulus it must be looked upon not only as a useless, but also as an exceedingly dangerous, performance. It is difficult to conceive in what manner such gymnastic exercises could effect reposition, while it is easy to understand in what manner the different movements would increase the rotation.

Furthermore, volvulus is rapidly followed by textural changes that weaken, and finally destroy, the intestinal walls; and hence taxis, as advised and practised by Mr. Hutchinson, would expose the patient to the imminent risk of producing a rupture of the bowel, without promising the shadow of a hope that reposition would be accomplished. Only one mechanical measure suggests itself as offering any inducements in effecting the reposition of volvulus short of laparotomy. Rectal insufflation of hydrogen gas or air has already been referred to as a diagnostic measure. In some cases of volvulus the rotation of the bowel around the vertebromesenteric axis is often less than one complete circle, and before the loop has become considerably changed by the twist, a reduction might be effected by dilating and elongating the bowel below the seat of obstruction, thus bringing the same causes to bear that have produced the displacement, but in an opposite direction. In the majority of cases the twist is made by violent peristalsis on the proximal side, the "*Type rectum en arrière*," and then the distention of the bowel below the volvulus would have, in the absence of adhesions, a decided influence in correcting the torsion. This method of reduction should be practised with great care, and is, of course, applicable only in recent cases, before the appearance of general tympanites and before the bowel has undergone serious tissue changes in consequence of the strangulation. If this comparatively harmless procedure fails in accomplishing the desired object, laparotomy should be performed at once, as every hour of delay increases the danger and diminishes the prospect of a favorable issue by operative interference. Statistics show a fearful mortality of operations done for the relief of obstruction from volvulus simply because they were performed too late. Oettingen has collected five cases of volvulus treated by the formation of an artificial anus with the result that all the patients died. Of the cases treated by laparotomy, six recovered and thirteen died. The cause of death in these cases was generally due, not to the operation, but to pathologic changes in the bowel caused by deferring surgical interference too long. Laparotomy, undertaken early in the treatment of this form of intestinal obstruction, will show better results in the future. If reposition of the twisted bowel is accomplished by direct measures at a time when the general tympanites is not excessive and the twisted loop has not undergone irreparable tissue changes, the prospects of a speedy recovery are as good as after any other intra-abdominal operation. Early diagnosis and early treatment by laparotomy are the requirements that will insure success in the treatment of volvulus.

Of the operative treatment Treves says that simple laparotomy is an unpromising procedure, but that in future he will make the incision in the median line, puncture the bowel, and attempt its reduction; if this fails or the result appears unsatisfactory, he will evacuate the involved bowel through an opening in the summit of

the flexure, unfold the volvulus, and establish an artificial anus, using the opening first mentioned for that purpose. The advice here given I should like to modify by the following suggestions: (1) Never to puncture the bowel. (2) Substitute intestinal anastomosis for the formation of an artificial anus. (3) Evacuate not only the twisted loop, but also the bowel for some distance on the proximal side. The strictest antiseptic precautions are urgently indicated in the surgical treatment of volvulus, more particularly if the operation is performed before gangrene or perforation has occurred, as in such cases the surgeon has to deal, in the majority of cases, with an aseptic peritoneal cavity. The stomach and intestine below the seat of obstruction should be thoroughly evacuated before the anesthetic is administered.

Incision.—A median incision should always be preferred, even if it has been determined beforehand that the volvulus is located at the sigmoid flexure. The first incision is made sufficiently long to permit the introduction of the hand, for the purpose of making a brief manual exploration of the abdominal cavity, with a view to determining the existence and exact location of the volvulus. If the cecum is found distended, it is positive proof that the volvulus is located at the sigmoid flexure. A brief examination of the sigmoid region, if the volvulus is located here, will show that the bowel composing the volvulus is more distended than the remaining portion of the colon, and the twist in the mesentery can usually be felt and recognized without any difficulty. In cases of volvulus above the ileocecal region the colon will, of course, be found collapsed and empty.

If the probable diagnosis of volvulus has been confirmed by this manual exploration, or if, after the examination of the most important landmarks in determining the location of the obstruction, no positive conclusions can be reached, no time should be lost in enlarging the incision sufficiently to permit of ready evisceration. As the intestines are usually found greatly distended, it is of the greatest importance to support them well and to keep them covered with moist warm aseptic compresses (saline solution), so as to prevent injury, especially at the points where they come in contact with the sharp margins of the abdominal incision. The twisted portion of the bowel, on account of its greater degree of distention, will be among the first loops to escape, and it is thus made easily accessible to direct treatment.

Reposition of Volvulus.—Intra-abdominal reposition of a volvulus is not a feasible procedure, hence the necessity of making a large incision and bringing the twisted bowel within reach of sight and direct manipulation for the purpose of dealing more efficiently and safely with the displacement. The danger incident to a few moments' exposure of the intestines is more than counterbalanced by the risks that attend attempts at replacement through a small wound with the abdomen often distended to its utmost by dilated

intestines with congested and fragile walls. Reduction is easily accomplished in recent cases without adhesions, and it is not difficult if the adhesions are of recent date. The intestinal loop is rotated in an opposite direction from that of the twist, until the unfolding is completed. As a rule, the segment of bowel of which the volvulus is composed contains but little solid or fluid matter, but is distended to its utmost by gas that has been generated within it by putrefactive or fermentative changes since the accident occurred. If there is any difficulty encountered in the unfolding of the distended loop, it is advisable to empty the bowel on the convex side by a transverse incision, at least an inch in length, as through such incision not only the twisted portion, but the intestine above the seat of obstruction, can also be emptied of its contents—a matter of great importance in such cases. After the bowel has been washed out with a warm solution of salicylated water or saline solution further escape of intestinal contents is prevented by an assistant compressing the wound during the time the surgeon is engaged in correcting the twist. It is absolutely necessary to incise the bowel in every instance where the abdomen is opened for the purpose of reducing a volvulus. Before the incision is made it may be necessary to place the patient on his side, to enable the operator to draw the bowel beyond the rest of the intestinal coils, so that, after the incision has been made, the intestinal contents can escape into a receptacle without coming in contact with the prolapsed intestines. This position is to be maintained until the intestinal contents that have accumulated about the seat of obstruction can be poured out through the incision. This pouring-out process is accomplished by seizing the highest loop that it is deemed necessary to evacuate, and, by raising it, pouring the contents by the force of gravitation from loop to loop until the incision is reached. It is an excellent plan not only to evacuate as much as possible of the intestinal contents, but also to resort to irrigation of the bowel through the incision with a saline solution. Such thorough evacuation of the bowel at and above the seat of obstruction accomplishes three desirable objects: (1) It facilitates the replacement of the intestines into the abdominal cavity. (2) It directly unloads the distended paretic intestine, and thus favors the return of peristaltic action. (3) It exerts a potent influence in preventing putrefactive and fermentative changes in the intestines after the operation. Before the bowel is returned the incision is closed in the usual manner by Czerny-Lembert sutures. If one or more circumscribed points of gangrene are found, they should be buried by suturing over them healthy peritoneum. The bowel is then returned, with a fair expectation that after removal of the strangulation the gangrene will not extend. If large portions of the intestines or the entire loop show evidences of gangrene, enterectomy has become an unavoidable evil. If, as is usually the case in such instances, the patient is in a collapsed condition, no time should be lost in the restoration of the

continuity of the intestinal canal by circular enterorrhaphy, as the same object is attained in a much shorter time by closing both ends of the intestine and making a lateral anastomosis.

Intestinal Anastomosis.—Cases may occur where it will be found impossible to unfold the volvulus without tearing the bowel, and the question arises, Is it best to resect and suture the ends of the intestine, or to leave the volvulus and establish a communication between the intestine above and below the obstruction? Mr. Hutchinson (*op. cit.*) reports such a case. A soldier, aged forty-six, in good health, who was in bed in the hospital after removal of a fatty tumor, two days after operation complained of pain in the back and abdomen. He had not left the bed since the operation. The following day the pain was less; slightly nauseated; constipation; injections and laxatives produced no effect, excepting to increase the sickness. On the fifth day after the attack the retching and vomiting were persistent and distressing. On the seventh day the abdomen was distended and coils were visible. The symptoms became more and more threatening, until death occurred on the tenth day after the commencement of the attack.

"*Autopsy.*—Three inches above the ileocecal valve a coil of small intestine was found twice twisted round a portion of the mesentery, and the canal of the bowel was thus completely obstructed. There were no recent inflammatory changes about this part of the intestine, but from the dense and contracted condition of the bowel where twisted, it must have been for some time narrowed at this point. When I moved aside the coils of intestine which lay in front of the obstruction,—more or less adherent amongst themselves by means of old and tough peritoneal bands,—and when I endeavored to, and after some sorting of the parts succeeded in unrolling the twisted canal, *I was glad not to have attempted the operation during the life of the patient, for it would have been impossible.* [Italics my own.]

"*Criticism.*—It seems not improbable that in this case some old adhesions favored the formation of the twist. It may be alleged that an early operation would have found the unravelment not so difficult; but then it must be remembered that the early symptoms were but slightly marked. The case was not considered a serious one until seven days had passed. It is in order to illustrate the vagueness of the early symptoms that I have quoted this case."

It is difficult to appreciate the reasons for self-congratulation on the part of Mr. Hutchinson for not having made an attempt to save the life of this patient by surgical interference. The result might have been better, and certainly could not have been any worse. The time will come, and is not far distant, when as much blame will be attached to a surgeon who will look on as an idle spectator at the bedside of a patient whose life is in danger from intestinal obstruction as now falls upon an obstetrician who permits a parturient woman to die undelivered. But supposing that unravelment would have been found impossible or impracticable, two plans of treatment were still left for the operator to pursue, and either of them might possibly have become a life-saving measure. As the bowel presented no evidences of gangrene, resection was not to be thought of, but the continuity of the intestinal canal might have been restored by intestinal anastomosis with permanent exclusion of the volvulus from the fecal circulation. Or, if the operator had

no faith in this procedure, he could at least have made an artificial anus above the seat of obstruction. An intestinal anastomosis between the intestine above and below the volvulus by means of decalcified perforated bone discs or a Murphy button can be done in a few minutes, and at once restores the continuity of the intestinal canal. If such a procedure is chosen in the treatment of an irreducible volvulus, it becomes necessary to make provision for a permanent outlet of the contents of the isolated segment of the intestine that constitutes the volvulus, as the obstruction of both ends of this portion may prove to be permanent. This can be accomplished by making a second anastomosis between the apex of the volvulus and an adjoining intestinal loop, in preference to a loop below the seat of obstruction. Such a procedure will establish, with but little additional risk, a permanent fistulous opening between the twisted portion of the bowel and the fecal circulation,

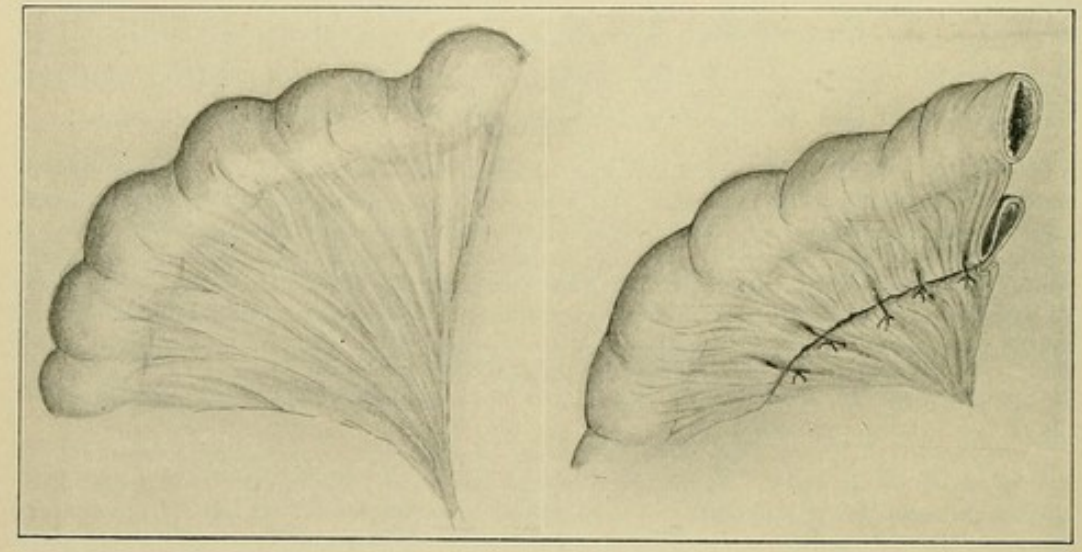

a *b*

Fig. 518.—*a*, Showing long mesentery of sigmoid flexure; *b*, shortening of mesentery after reduction of a volvulus by duplication and suturing.

and will prevent any danger that might arise from overdistention and perforation should the obstruction caused by the volvulus remain permanent. In making intestinal anastomosis the lateral apposition should be preceded by thorough evacuation and disinfection of the intestine. In order to hasten plastic adhesions the serous surfaces that are to be coaptated should be freely scarified.

Shortening of Mesentery.—After the reduction of a volvulus has been accomplished by operative measures it is desirable to protect the patient in the future against a possible recurrence of the same accident in the same place. As an elongated mesentery plays the most important rôle in the production of volvulus, this can be done in a few moments with certainty and safety by shortening the mesentery. Resection of the mesentery is out of the question, as such a procedure would in all probability result in gangrene of a corre-

sponding portion of the intestine. Shortening of the mesentery, however, can be effected by folding the mesentery upon itself in a direction parallel to the bowel, and suturing the apex of the fold to the root of the mesentery. By this method the floating bowel is firmly anchored, and a recurrence of the volvulus is made impossible. The indications for flushing the abdominal cavity and for establishing drainage are the same as in laparotomy for other forms of intestinal obstruction. I have successfully resorted to this method of preventing a relapse in two cases, and as an illustration of the procedure will insert here a brief history of the first one.

The patient was a man, sixty-three years of age, a carpenter by occupation. He had never suffered from any bowel complaint except occasional attacks of constipation that always yielded to mild laxatives. On the morning of October 6th, while walking around in his room, he was suddenly seized with a severe pain in the middle and lower part of the abdomen. He sought rest in the recumbent position and the pain gradually subsided. At this time the appetite was impaired, but there was no nausea or vomiting. Toward evening he felt somewhat distressed in the abdomen, a circumstance which he attributed to flatulency, as he felt relieved after loosening his clothing. The following morning he awoke free from pain, but on rising the pain returned. He remained quiet all day and suffered only an occasional attack of colicky pain. He rested well during the night, and on the third morning he was again free from pain. He ate a light breakfast and started to resume work at his shop. On his way, however, the pain returned. On reaching his destination the severity of the pain increased and he returned home. The pain yielded to rest, but the abdomen became more distended. The fourth day he was again able to be about. As the bowels had not moved since the beginning of the attack, he took a dose of rhubarb in the evening. As the cathartic did not act by the following morning he took an enema, which brought away a small quantity of fecal matter. The following two days the pain became severer and the distention of the abdomen greater; there was nausea, but no vomiting. He did not consider himself sufficiently ill to call a physician until October 12th. The physician diagnosticated some form of intestinal obstruction, and sent the patient to the hospital to be placed under surgical treatment. Examination at this time showed that the temperature was normal; pulse 90, soft, and compressible; copious eructations, but little nausea and no vomiting. According to his statement, he had not had a proper movement of his bowels since the attack, and no flatus passed per rectum. Abdomen enormously distended and tympanitic over the entire surface; contour of intestinal coils visible at a number of places. It was evident that the obstruction was located low down in the colon, probably in the sigmoid flexure, and it was surmised, from the history of the case and the symptoms presented, that it was caused by either a volvulus or a circular carcinoma. Laparotomy was advised, and as the patient at once gave his consent, it was performed the following day, October 13th, about noon. After he came into the hospital the nurse administered two ounces of castor oil in one dose without any appreciable effect being produced.

Operation.—As the patient was suffering at the same time from a chronic bronchial catarrh, chloroform was used in place of ether as an anesthetic. The temperature of the room was kept at 85° to 90° F. The most careful aseptic preparations were made, and during the operation rigid aseptic measures were carried out. The abdomen was opened by a median incision half-way between the umbilicus and pubes, and sufficiently large to permit introduction of the hand. Intra-abdominal manual exploration showed, in the first place, that the cecum was greatly distended; consequently the examination was continued by exploring the sigmoid region. Below the sigmoid flexure the colon and upper portion of the rectum were found completely empty and collapsed. The sigmoid flexure could be distinctly felt, and was enormously distended and twisted around its mesenteric axis. The twist in the mesentery could be distinctly felt. No time was lost in useless attempts to effect reduction. The incision was enlarged in an upward direction to three inches above the umbilicus. As the intestines escaped, they were covered with hot, moist aseptic compresses and carefully supported by two assistants. The small intestine was greatly distended and extremely vascular; the visceral peritoneum had lost its glistening appearance. The colon had become so much distended and elongated that the transverse portion, in the shape of a horseshoe, was found displaced in a downward direction to near the pubes. The sigmoid flexure was twisted around its mesenteric axis in one complete twist. The twisted portion of the mesentery was the seat of a limited plastic

peritonitis that had resulted in adhesions. The part of the bowel constituting the volvulus measured at least eighteen inches in circumference, and its walls appeared to be of the thinness of parchment paper. Reposition was very easily effected by simply turning the bowel in an opposite direction to that of the twist until the normal position was restored. Peristaltic action appeared to be almost completely suspended, both in the large and the small intestine. It would have been mechanically almost impossible to return the intestines into the abdominal cavity without producing serious injury, perhaps complete rupture, of the bowel; hence an incision an inch in length was made into the colon, where the distention was the greatest. The incision was made parallel to the long axis of the bowel, and directly opposite its mesenteric attachment. The part of the bowel that had been twisted contained, besides gas, only a very small amount of fluid fecal matter. The incision did not empty more than this part of the bowel. As a large amount of fluid feces had accumulated above the seat of obstruction, this was evacuated by the "pouring-out process" previously described, and in this manner almost the entire colon was emptied. The incised portion of the bowel was drawn well forward, and held in this position by an assistant during the entire time required for unloading the bowel, and thus soiling of the intestines and abdominal cavity was prevented. As far as it could be readily done the intestine was subsequently washed out with warm salicylated water. The wound was closed with two rows of silk sutures. The mesentery of the volvulus was at least eight inches in length, and was shortened more than one-half by the method previously described. Replacement of the intestines was now accomplished without any difficulty, and, after drying the peritoneal cavity with sponges wrung out of warm sterilized water, the external incision was closed in the usual manner. No drainage. The customary antiseptic compress, composed of iodoform gauze and salicylated cotton, was applied, and the abdominal walls were well supported with adhesive strips. Outside of the adhesive strips a layer of common cotton was applied, and over this a snugly fitting binder. Duration of operation nearly an hour and a half. The patient recovered rapidly from the immediate effects of the operation. At 8 o'clock in the evening temperature was 100.5° F., pulse 110. Free movement of bowels; feces liquid, dark colored, and of a very offensive odor. Complained of no pain, but a sensation of soreness in the abdomen.

October 14th.—Temperature 99.5° F., pulse 90. During the night had four fluid passages of the same offensive character. So far the patient had not been allowed any food by the mouth. Thirst was relieved by giving water in small quantities and frequently repeated. In the evening the patient felt so well that during a brief absence of the nurse he got out of bed and walked around the room.

October 15th.—Temperature and pulse normal. Imprudence on part of patient did not seem to have resulted in any harm. From this time on the patient was allowed liquid food, and after the lapse of another week was placed on the ordinary hospital diet. With the exception of a small parietal abscess the recovery was not marked by any untoward symptoms. The patient left the hospital three weeks after the operation in perfect health.

So far as I am aware no recurrence has taken place in either of the cases of mesenteric duplication after volvulus reduction.

Ventrofixation is the usual procedure resorted to by surgeons for the purpose of guarding against a recurrence. It may be urged against this practice that the parietal adhesions often give way, and in other instances are drawn out gradually into long cords that may become another cause of mechanical obstruction besides the partially liberated loop, which again may become twisted.

Enterostomy is always contraindicated in the treatment of volvulus, as all the cases thus treated collected by H. Braun, eight in number, died. Enterostomy or colostomy may become a useful procedure after reduction or resection of the volvulus by laparotomy when the intestine on the proximal side is much distended and paretic. Lennander reports two cases of this kind treated by laparotomy, reposition, and typhlostomy, and suggests that in all cases of obstruction of the large intestine an artificial anus should be established in the cecum if it become evident, after washing with a physiologic salt solution, that the intestine does not possess a nor-

mal power of contraction. Even in resection with immediate suturing of the intestine, as in cancer, the surgeon should be prepared to establish an anus in the cecum if, owing to the degree of strangulation, the portion of the intestine beyond has not been thoroughly emptied. The example of James Israel may be followed in some cases with advantage in regard to the necessity of establishing an artificial outlet from the part of the intestine constituting the volvulus. In a case of volvulus of the sigmoid flexure he found the tympanites limited to the sigmoid at the time laparotomy was made, and, being fearful that the peristaltic action would not be restored, he sutured the center of the paretic portion of the bowel into the abdominal wound; as the next day the symptoms of obstruction increased, he incised the bowel. For a short time the feces escaped through the artificial anus; later, *per vias naturales*, after which the artificial anus closed spontaneously. He believes that this method of dealing with the paretic bowel also prevents recurrence of the volvulus.

Enterectomy is indicated in all cases in which the volvulus exhibits indications of gangrene. Very few successful cases of enterectomy for volvulus have so far been reported. Braun reports a successful resection of a volvulus of the sigmoid flexure with the formation of an artificial anus.

Schlange resected successfully 135 cm. of the ileum for gangrene the result of volvulus. The intestine showed unmistakable signs of incipient gangrene, and the mesenteric veins corresponding with the section of the intestine removed were all thrombosed. The resected ends were united by circular suturing and the bowel returned. The wound was tamponed with iodoform gauze that embraced the line of suturing. The tampon was removed on the third day, when the wound was lightly packed with a strip of iodoform gauze for seven days longer, it then being closed by secondary suturing. The recovery was rapid, and several weeks after the operation the patient presented all the appearances of perfect health and unimpaired nutrition.

Enterectomy for a gangrenous volvulus is one of the most serious of all abdominal operations, and any surgeon who is so fortunate as to save a life by this operation deserves the highest credit. The patients suffering from this stage of volvulus are always in a critical general condition and exposed to many sources of infection. If the patient is much collapsed, or becomes so during the operation, the formation of an artificial anus becomes necessary to save time. If it can be done, the two ends of the bowel should be sewed together on the mesenteric side, and fixed together by suturing in the abdominal incision. In the event of recovery, the continuity of the intestinal canal can be later restored with little risk to life. If circular suturing after resection, in cases that warrant the attempt, can not be done, anastomosis in some form comes to our aid and dispenses with the necessity of establishing a permanent artificial anus. It is

in such cases, too, that the suggestion made many years ago by me might find a useful application. This suggestion was to the effect of implanting a section of the small intestine to fill in the gap between the two bowel ends, an operation that would necessitate the making of three circular enterorrhaphies. The suggestion has also been made, to meet a similar contingency after resection of the sigmoid flexure, to close the proximal end by invagination and sutures, and implant the rectal end into a slit in the lower portion of the ileum, thus excluding the remaining portion of the colon from the fecal circulation.

C. Bayer proposes, in similar cases, to implant into the defect a loop of the lower portion of the ileum, establish a communication between both ends by anastomosis, and, finally, unite the two limbs of the loop by a third anastomotic opening, an operation that, under favorable circumstances, appears rational and justifiable.

CHAPTER XXV.

ANATOMICOPATHOLOGIC FORMS OF INTESTINAL OBSTRUCTION (Continued).

FLEXION and adhesions are occasionally met with as the sole cause of mechanical obstruction, and the former is usually the remote consequence of the latter. Flexion gives rise to intestinal obstruction by the formation of a spur on the mesenteric side, which, when sufficiently well developed to encroach upon the lumen of the bowel, usually intercepts the fecal current by its mechanical action.

Adhesions without distortion of the bowel may cause intestinal obstruction by suspending peristalsis by mural fixation.

FLEXION.

As many instances are on record where flexion of the bowel constituted the cause of intestinal obstruction, this condition was artificially produced in animals either by making a partial enterectomy by removing a wedge-shaped piece from one side of the bowel or by bending the bowel upon itself acutely and fixing it in this position with catgut sutures.

EXPERIMENT 8.—Dog, weight sixty pounds. A wedge-shaped piece of the wall of the ileum was removed from the concave side, with a corresponding portion of the mesenteric attachment, and, after arresting the bleeding by tying several vessels with catgut, the wound was closed transversely by two rows of sutures. The excised piece measured one inch at its base, and the apex reached as far as the median line of the bowel. Immediately after excision the convex portion of the bowel, which had become acutely flexed by uniting the wound, presented a livid, congested appearance, and, after the sutures had been tied, the cyanosis increased. The area of disturbance of the circulation corresponded to the width of the base of the excised portion. About fourteen inches from this place a similar piece was excised from the convex side of the bowel, and the

wound closed in the same manner. At this point the flexion was only slight, the mesenteric portion forming the prominence of the curve. On the third day the temperature rose to 105.6° F., and on the following day the animal died with symptoms indicative of perforative peritonitis. On opening the abdomen diffuse general peritonitis was found, together with numerous adhesions. Gangrene and perforation were found on the convex side directly opposite the first operation. Second visceral wound closed and lumen of bowel at this point somewhat contracted, but permeable to fluids.

EXPERIMENT 9.—Large adult cat. A triangular piece measuring one inch at its base and the apex reaching a little beyond the middle line of the bowel was removed from the convex side of the ileum, and the wound closed transversely by Czerny-Lembert sutures. After closure of the wound the bowel presented an obtuse angle at point of partial resection, the apex being formed by the mesenteric portion. The stools were bloody the second day after operation. The animal remained in excellent condition until it was killed, forty-three days after operation. Adhesions of loops of small intestine to abdominal wound and of omentum and adjacent intestines at point of operation were found. The extent of flexion was found somewhat diminished, yet the concavity on the convex side of the bowel was well marked. The size of the bowel above and below the point of operation was equal, showing that the flexion had not acted as a cause of obstruction. On opening the bowel a pouch-like bulging was found on the mesenteric side, which appeared to compensate for the narrowing caused by the artificial stenosis. Two of the deep sutures still remained attached to the inner surface of the bowel.

EXPERIMENT 10.—Large adult cat. In this case a loop of the middle portion of the ileum, four inches in length, was acutely flexed in such a manner that the peritoneal surfaces of the convex side were brought in contact, and in this position the bowel was fixed by a number of fine catgut sutures. No symptoms pointing toward intestinal obstruction were observed, and the animal was killed sixteen days after the operation. The wound was found completely united, and signs of peritonitis were absent. The angle of flexion had somewhat diminished, but otherwise the bowel was adherent in position left after operation. The bowel presented no dilatation above nor contraction below the flexion, showing that complete permeability of the canal at the point of flexion was quickly restored.

The partial excision on concave side of bowel in experiment 8 illustrates the danger of suturing wounds in this locality where the blood supply from the mesentery is likewise impaired, as gangrene of the remaining portion of the bowel is almost certain to take place. In all wounds on this side of the bowel more than half an inch in length there is also another great danger that attends transverse suturing—viz., stenosis, which may become the cause of intestinal obstruction. As the small intestine naturally describes quite a large curve, with the concavity on the mesenteric side, closure of a wound involving this portion of the bowel gives rise to acute flexion, which, at least, during the process of healing, must cause more or less obstruction, until, by yielding of the opposite portion of the intestinal wall, an adequate dilatation of the caliber of the tube has taken place. A considerable portion of the wall on the convex side of the bowel can be removed and sutured transversely until the bowel has been transformed into a straight tube, and a wound an inch in length will make but a slight flexion, which furnishes no serious mechanical obstacle to the passage of the intestinal contents. In this connection the question arises: Does simple flexion, even if acute, without diminution of the lumen of the bowel, give rise to symptoms of obstruction? I have made numerous flexions when performing operations for establishing intestinal anastomosis, and in most instances satisfied myself, by examination of the specimens, that fluids passed them without great difficulty. If the bowel at the point of flexion re-

main free, certain portions of its wall will yield to pressure of the fluid intestinal contents, and gradually the lumen of the bowel will become restored. If, on the other hand, the entire circumference of the bowel at the point of flexion has become fixed and immovable by inflammatory adhesions or other pathologic products, a compensating dilatation becomes impossible, and the flexion becomes a direct and serious cause of obstruction.

Every pathologist who has carefully examined the intestinal canal of persons who have succumbed to acute peritonitis must have noticed the presence of numerous flexions caused by visceral and parietal adhesions, and yet such patients seldom exhibited well-marked symptoms of intestinal obstruction during life. I have observed the same conditions in animals during my experimental work on the intestinal canal, and seldom found that simple flexion gave rise to intestinal obstruction. In recent cases of flexion, of course, the circumference of the lumen of the bowel at the point of flexion is equal in size to that above or below the obstruction. The obstruction in such cases is not caused by stenosis, but by compression of the distal limb of the flexion by the intestinal contents in the proximal portion, thus causing a valvular closure not at, but just beyond, the seat of flexion. This is more likely to take place if the apex of the flexed portion of the bowel is adherent at some fixed point, as in this case compensatory dilatation of the intestinal wall at a point corresponding to the apex of the flexion can not take place. When a flexion has existed for a long time without having given rise to symptoms of obstruction, it finally may cause occlusion by a cicatricial stenosis at the seat of flexion, due to a circumscribed plastic inflammation and cicatricial contraction of the inflammatory product. Such a case came under the observation of Obalinski. A boy, eighteen years old, had suffered from typhoid fever eight months before the attack of intestinal obstruction set in. Some time before the acute symptoms appeared he suffered from pain in the abdomen, which gradually increased in intensity until the clinical picture of obstruction was well marked. On the eighth day after the attack the abdomen was opened by a median incision. Distended and collapsed intestinal coils came within easy reach. The obstruction consisted of a rectangular flexion of the small intestine caused by a pseudoligament the size of a lead-pencil. After division of this band and straightening the bowel, it was seen that the bowel was considerably contracted at the point of flexion by a circular cicatrix, but as it was permeable, nothing further was done. The boy was discharged cured four weeks after the operation. That the pressure of intestinal contents in the proximal bar is exerted mainly upon the spur that forms in acute flexions between the two bars is well shown by a specimen described by Birkett, where an intestinal anastomosis was established spontaneously by ulceration between the approximated adherent tubes at the point of compression, so that the intestinal contents passed

directly from one intestine to the other through this "fistula bimucosa" instead of traversing the loop. The patient was a man, aged fifty-eight, who, six months before his death, had presented a strangulated hernia that had been reduced by taxis. When the flexion is very acute, the spur formed by the apex of the approximated walls of both bars acts like a valve in closing the lumen of the distal bar under the influence of the hydrostatic pressure from the accumulation of intestinal contents above the seat of flexion. Nicaise has reported a typical case of this kind. A man, aged twenty-five years, was operated upon for strangulated hernia five years before the attack of intestinal obstruction. Since the herniotomy he had suffered frequently from attacks of vomiting and constipation with abdominal pain. The last attack was so severe that enterotomy was performed. He died the next day. The necropsy revealed an acute flexion that had become permanent by old adhesions. The flexion was so acute that the mucous membrane at its apex constituted a kind of valve across the lumen of the bowel. After liberation of a flexed bowel the seat of an intestinal obstruction, it becomes a step in the operation to resort to such prophylactic measures as may appear necessary to prevent a return of the malposition, and to cover, as far as possible, the peritoneal defects that have been made during the separation of the loop. Winslow reports a case in point. In this case a loop of the small intestine was found firmly adherent in the pelvis over an area of six inches, and sharply flexed. After it was carefully detached it was found denuded of peritoneum over a small space. The continuity of the peritoneal surface was restored by applying a number of sutures transversely to the long axis of the bowel. It is distinctly stated that this portion of the bowel was deeply congested, hence the seat of the textural changes consequent upon the obstruction. In most cases of flexion that have been described in connection with intestinal obstruction, the flexed bowel was found either in the pelvis, near the internal inguinal rings, or in the ileocecal region, localities where localized peritonitis is most frequently met with. If, after the reduction of a strangulated hernia, the replaced loop of intestine is or becomes the seat of a plastic peritonitis, it forms an attachment to the abdominal parietes or viscera with which it comes in contact. In case the adhesion thus formed remains firm and is not drawn out in the form of a band, or if a flexion form by the free portion of the bowel changing its relative position, the two bars of the flexion thus formed, when in close contact and the seat of the same plastic inflammation, become adherent and the flexion becomes permanent. If the continuity of the bowel can not be restored by separation of the adhesions in the operative treatment of obstruction caused by flexion, and the tissues at the seat of obstruction present no evidences of gangrene, an anastomosis between the two bars of the flexion should be made in preference to resection and circular suturing. Another equally safe and efficient

operation in such cases consists in longitudinally incising the bowel on the convex side over the apex of the flexion to the requisite extent, increasing its lumen, and connecting the spur by transverse suturing in the same manner as in the Heineke-Mikulicz operation for pyloric stenosis. Circumscribed spots of gangrene can be excised and the wound sutured transversely to the long axis of the bowel, as this will cause no stenosis and will tend to correct the faulty position of the bowel. As in cases of constriction by bands, if it is found difficult to separate the adhesions, no attempt should be made to liberate the bowel until a rubber ligature has been applied to each bar of the flexion. This precaution is taken to prevent fecal extravasation should the bowel be ruptured during the separation.

ADHESIONS.

Many abdominal surgeons have published their experience in reference to the occurrence of intestinal obstruction after laparotomy. A number of cases of intestinal obstruction that occurred soon after ovariotomy were found to have been caused by extensive parietal adhesions of the intestines, hence the question of how such adhesions are to be prevented has been discussed.

P. Mueller has advised that in difficult ovariotomies adhesions of the intestines among themselves and with the abdominal wall should be prevented by avoiding external compression by bandages and by filling the abdominal cavity with a physiologic solution of common salt (0.7 per cent.). For the purpose of limiting peritoneal absorption he suggests that the solution should be introduced from time to time and finally should be withdrawn through the drainage-tube.

Olshausen has found in all the cases of intestinal obstruction after ovariotomy which occurred in his practice that the obstruction was caused by adhesion of an intestinal loop to the surface of the stump. Mueller's prophylactic treatment he considers rational, especially in cases where the operation is attended by considerable hemorrhage. Schatz holds that visceral and parietal adhesions of the intestines after ovariotomy are a much more frequent condition than is generally believed. He is of the opinion that serious consequences do not necessarily follow such condition. Gusserow asserts that adhesions which have produced no symptoms are frequently found on making a second laparotomy in the same patient.

Kaltenbach has for some time used a 1 : 6000 solution of sublimate in place of carbolic acid solution, and since he has made this change he has not observed a case of intestinal obstruction in fifty-four consecutive laparotomies, while of twenty-four cases where carbolic acid was used, he lost two cases from intestinal obstruction. Kruckenberg attributes to the use of sublimate an influence in causing plastic adhesions, and asserts that since he has abandoned this agent he has had no cases of intestinal obstruction after ovariotomy. Sänger's experiments appear to prove that for the formation of a

firm and permanent adhesion only one wounded surface is necessary. Schwarz believes that parietal adhesions along the internal surface of the abdominal wound are of frequent occurrence, because intestinal loops are caught in the furrow of peritoneum along the line of suturing, where an additional irritation is met with on the part of the sutures.

Martin, as early as 1865, reported two cases that illustrate one of the dangers that follow puerperal pelvioperitonitis. In one case the peritonitis followed a manual separation of the placenta. The patient made a rapid recovery, but six weeks later symptoms of acute intestinal obstruction developed from which the patient died on the fourth day. On postmortem the cause of obstruction was found to be a firm pseudomembranous band that connected the anterior surface of the cecum with a coil of the small intestine. In the second case a metroperitonitis followed a normal delivery, but yielded, however, to proper treatment on the fifth day. During the seventh week after delivery symptoms of acute intestinal obstruction set in, and the disease proved fatal after a few days. A similar condition as in the first case was found at the postmortem.

Hirsch presents at length the results of his observations and researches on intestinal obstruction after ovariotomy due to one of three causes: (1) Adhesions of an intestinal loop to abdominal incision and occlusion from the traction of the cicatrix. (2) Aseptic plastic peritonitis which, by causing extensive adhesions, results in immobilization of a considerable portion of the intestinal canal, which leads to coprostasis and complete obstruction. (3) Impaction of an intestinal loop between a pedicle, treated by the extraperitoneal method, and the abdominal wall. Sir Spencer Wells reported eleven deaths from this cause in 1000 cases of ovariotomy. Usually the obstruction occurs soon after the operation, but several years may elapse before the accident takes place. The symptoms are the same as in obstruction from other causes.

The prognosis in cases of obstruction from intestinal adhesions is extremely unfavorable. Of the fourteen cases collected by me, only one recovered after secondary laparotomy. In view of the great mortality that attends this, the most serious complication after laparotomy, it is exceeding important to resort to proper prophylactic measures in all cases of intra-abdominal operations. In the first place, when the operation is done in an aseptic peritoneal cavity, all irritating antiseptic solutions should be kept from coming in contact with the peritoneum, as their local irritant action might produce a plastic peritonitis. The peritoneum should not be unnecessarily bruised or sponged, as a slight traumatic irritation may be productive of a circumscribed adhesive inflammation. Finally, it should be the aim of the surgeon to restore, if possible, the continuity of the peritoneal surface should any defects be found during the operation. Adhesion of the intestines to the abdominal incision can be prevented by spreading the

omentum carefully over the intestines the whole length of the incision. Limited defects can be readily closed by suturing. The cut surface of the pedicle after ovariotomy should be covered by stitching the peritoneum over it. The stump after supravaginal amputation is treated in a similar manner. Parietal and visceral defects not amenable to suturing can be covered with an omental graft, which is stitched to the margins of the defect with catgut sutures. In cases of intestinal obstruction due to extensive adhesions after operations or to attacks of circumscribed peritonitis, it is essential to resort to early operative treatment; this consists in separating the adhesions and in restoring peritoneal defects as far as possible for the purpose of guarding against similar attacks in the future. After the intestine has been liberated, it is advisable to place the detached portion in some part of the abdominal cavity where a similar condition is less likely to occur.

BANDS AND DIVERTICULA.

Strangulation caused by constricting bands or diverticula results in a complexus of symptoms that resembles the clinical picture of a strangulated hernia.

I made the following experiments for the purpose of studying the effects of circular constriction upon the circulation of the isolated constricted loop of bowel. In all cases where the constriction was made with a gauze band, this was tied with the same degree of firmness in all, so as to determine whether the same degree of strangulation would produce identical results.

EXPERIMENT 4.—Adult cat. A loop of bowel about the middle of the ileum, six inches in length, was tied with a band of aseptic gauze with sufficient firmness to cause slight congestion, but without interfering with a free arterial supply, as the arteries in the ligated portion continued to pulsate freely. The day after operation a few small fecal discharges stained with blood occurred. The cat died forty-eight hours after the operation. No rise in temperature was observed, and death was evidently caused by collapse from perforation. The loop of bowel showed gangrene on convex side, equidistant from the point of strangulation, and a small perforation that had given rise to diffuse septic peritonitis. The whole visceral and the parietal peritoneum were uniformly affected, and the peritoneal cavity contained a considerable quantity of serosanguinolent fluid.

EXPERIMENT 5.—Large adult cat. A loop of the ileum of the same length was tied in a similar manner and with the same degree of firmness. The animal absolutely refused food until the eighth day. Rise in temperature occurred on the second and third days. There was only one fecal discharge on the second day. The animal was killed eight days after operation. The abdominal wound was completely united, and there was no peritonitis. Four inches of bowel below the point of constriction showed that partial reduction had taken place. The gauze band was found completely covered with adherent omentum and a thick layer of plastic lymph that formed a complete bridge connecting the intestine above and below the ligature. The ligated portion showed no evidence of defective circulation, and no ulceration underneath the ligature. The obstruction was complete, as no fluid could be forced through the bowel, and in proof that the same condition existed during life, it was found that the bowel above the constriction was considerably dilated, while below the strangulation it was empty and contracted.

EXPERIMENT 6.—Large Maltese cat. A loop of ileum six inches in length was tied in a similar manner. On the third day feces were passed stained with blood. On the same day the temperature, which had remained nearly normal until this time, rose to 105° F., and on the following day the animal died, having manifested symptoms of perforative peritonitis for twenty-four hours. Abdominal wound was united, and there

were evidences of recent diffuse peritonitis. The abdominal cavity contained several ounces of seropurulent fluid. Bowel above constriction was distended with fluid contents; below the obstruction, empty and slightly contracted. The greater portion of strangulated loop was found gangrenous and adherent to adjacent loops of bowel. Perforation had taken place in the middle of the loop on the convex surface, showing that gangrene had occurred first at this point and had extended from here toward the ligature.

EXPERIMENT 7.—Adult dog, weight twenty-six pounds. In this case an opening was made in the mesentery through which a loop of the small intestine six inches in length was pushed. With sutures this opening was made sufficiently small so that its margins produced slight strangulation. The dog remained perfectly well after the operation, and was killed on the twenty-second day. Abdominal wound had healed completely, and there were no signs of peritonitis. On searching for the seat of obstruction it was found that spontaneous reduction had taken place, the site of perforation in the mesentery being indicated by a recent cicatrix.

The postmortem appearances in these cases demonstrate clearly that the gangrene was not produced by the primary mechanical strangulation, but that it depended upon consecutive pathologic changes in the loop or its vessels. In experiment No. 5 the primary strangulation was fully as great as in the preceding experiment, and yet gangrene did not occur, and we have positive proof that vascular engorgement in the ligated portion was less intense from the fact that partial reduction took place. In all cases where gangrene resulted it must have been from an obstruction to the return of blood through the veins, rather than from deficient arterial blood supply. If defective arterial blood supply had been the immediate cause of the gangrene, we would have found gangrene of the entire loop more constantly, while every specimen illustrated that gangrene always commenced at a point where the return of venous blood met with the greatest resistance—viz., on the convex surface in the middle portion of the loop. As in cases of hernia or in any other form of intestinal strangulation where a firm constricting band surrounds the loop of bowel, the danger of complete strangulation is increased if, by the peristaltic action, additional portions of the intestine are forced through the ring; and the immediate cause of the gangrene is always referable to obstruction to the return of venous blood, which leads rapidly to edema, complete stasis, and moist gangrene in that portion where the venous circulation is most seriously impaired. Violent peristalsis under such circumstances always aggravates the existing conditions, and is often the precursor of symptoms of complete strangulation. In such cases opiates act favorably by arresting peristaltic action, and in so doing may avert gangrene by preventing the causes that otherwise would have led to complete venous stasis.

Ligamentous bands resulting from old adhesions are usually found in parts of the abdominal cavity most frequently the seat of peritonitis—viz., in the pelvis and the ileocecal region. Their formation can generally be traced to a broad parietal adhesion that, by the peristaltic action of the free portion of the intestine, has become elongated and often narrowed to a delicate cord. It becomes a cause of obstruction when the migrating or free end

forms an attachment to some fixed point, which then renders the band tense and unyielding, and in case a loop of intestine becomes ensnared underneath it strangulation takes place in the same manner as in strangulated hernia, the constricting cord by its pressure causing venous engorgement below the constriction, and by the increased peristaltic action of the proximal limb of the loop forcing intestinal contents into, but not through, the constricted loop. As in hernia, an intestine may have become adherent and fixed underneath such a band for an indefinite period of time without strangulation taking place as long as the immediate causes of strangulation are absent. Any causes that disturb the mechanical relations still further in such a case, as a fall, lifting, coughing, the administration of an active cathartic, etc., may bring on an acute attack of intestinal obstruction. The history of cases of intestinal obstruction due to the presence of a ligamentous band frequently discloses an attack of peritonitis through which the patient passed perhaps years before, and as frequently describes one of the above-mentioned proximate causes as preceding the attack of intestinal obstruction. A displaced neck of a hernial sac may cause obstruction in the same manner as a ligamentous band. Kurz treated such a case successfully by laparotomy. The patient, a man thirty-three years of age, had been the subject of a small inguinal hernia for several years that did not cause much inconvenience, when symptoms of acute intestinal obstruction set in, and the inguinal canal, when carefully examined, was found empty. The symptoms of obstruction were very grave, including a subnormal temperature and fecal vomiting at the time the operation was performed. Digital exploration of the ileocecal region through a median abdominal incision led to the discovery of a ring in which the colon had become ensnared. Reduction by moderate traction was found impossible, and it was found necessary to incise the ring at two points, when the bowel, which was deeply congested, was readily withdrawn. The ring was found displaced four inches from the internal ring. The patient made a rapid and satisfactory recovery. In other instances the contents of the hernia,—either the omentum or the intestinal loop,—when in a condition of plastic inflammation, may lead to the formation of a ligamentous band when either of these structures becomes attached near the internal ring, the adhesion that forms lengthening out until it is attached to some other fixed point. Obre described the postmortem appearances of such a case. The strangulated loop had wandered to near the xiphoid cartilage; while between it and the inguinal ring a cord seventeen inches long was found. A band of constriction can also be formed by the margins of an opening in the mesentery or omentum in which a loop of intestine can become strangulated. In such cases it becomes necessary, after reduction has been effected, to close the opening by sutures to prevent a possible relapse of the obstruction from the same cause. An adherent portion of omentum in the

course of time may become a cause of internal strangulation. In operating for intestinal obstruction caused by constricting bands it is always necessary, after relieving the point of constriction first found, to search for additional bands, as it is not unusual to find more than one. Obalinski made a laparotomy for intestinal obstruction on the third day after the appearance of acute symptoms. On introducing his hand through a median incision, he felt in the right iliac region distended and empty coils, and, by tracing the latter in an upward direction, found as the cause of obstruction two bands, each the size of a goose-quill, extending from the cecum to the abdominal wall, between which a loop of intestine thirty centimeters in length had become strangulated. Both bands were ligated and divided. Bowels moved on the fourth day, and patient was discharged cured in two weeks.

Fowler has met with two cases where, at the autopsy, a second band was found close to the divided one.

Another frequent location for the formation of bands is in the umbilical region, where the remains of the umbilical artery may become a cause of constriction. Polaillon opened the abdomen in a young man by lateral incision on the right side for intestinal obstruction one week after the appearance of the first symptoms. As the patient was the subject of an inguinal hernia, both inguinal canals were examined by digital exploration through this incision, but nothing was found to explain the obstruction. The incision was enlarged and the whole hand introduced, and, after careful exploration, a falciform fold was found to the left of the median line, which extended from the left inguinal ring toward the umbilicus. Between the band and the abdominal wall a sac was found that contained numerous coils of intestine. The whole intestine was carefully examined, and finally an empty loop about ten inches in length was found. The cause of strangulation was the peritoneal band, reduction having taken place by the introduction of the hand. The band was not divided for fear of hemorrhage. The patient recovered after a slight attack of peritonitis.

Intestinal obstruction by a constricting band furnishes the simplest and most favorable conditions for early operative treatment by abdominal section. Without prompt surgical treatment a fatal termination is almost inevitable, as death results either from the mechanical effects of the obstruction or the constriction produces gangrene under the sharp margin of the band, followed by perforation and death from septic peritonitis. An operation undertaken before the strangulation has caused great abdominal distention and serious textural changes by pressure or constriction would be almost sure to be rewarded by success. Two cases of intestinal obstruction caused by ligamentous bands reported by Bull illustrate, in a most striking manner, the importance of early operative interference. Both cases were treated by laparotomy, and the difference in the results obtained was plainly traceable to the length of time that had intervened be-

tween the onset of the disease and the operation. In the first case the operation was delayed until the eleventh day, and during the separation of the band a gangrenous spot in the bowel gave way, followed by fecal extravasation. The circumscribed gangrenous patch was excised, making a wound an inch in length, and parallel to the long axis of the bowel, which was closed with twelve Lembert sutures. Death twelve hours after operation. In the second case laparotomy was performed under almost identical circumstances, but the strangulation had existed only six days. In this case the operation was limited to the removal of the cause of obstruction, as the constricted bowel had not undergone irreparable damage. The patient recovered. The operative treatment of the obstruction in this form of intestinal strangulation is usually not attended by any difficulties. The band of constriction, whatever its location or mode of origin, is traced to both fixed points of attachment and excised between two ligatures. This not only relieves the strangulation, but prevents a possible recurrence of a similar attack from the same cause. In some instances, however, the local conditions may be more complicated. Reali met with a case where it was found impossible to liberate the intestine from a constricting band; he divided the intestine at the point of constriction, and reunited the ends again by circular suturing, his patient recovering. If on careful examination the conditions at the seat of constriction are such as to make it probable that the intestine is the seat of gangrene from compression underneath the band, or that the separation of the band from the intestine is not readily accomplished, no attempts should be made to liberate the intestine until measures have been employed to guard against fecal extravasation in the event of the bowel being ruptured. This precaution consists in emptying the intestine on each side of the constriction to a distance of from two to four inches by displacing its contents in its interior between the thumb and index-finger and applying a rubber ligature, which is passed through the mesentery with a pair of hemostatic forceps. The ligatures are not removed until the bowel has been liberated, and if it is injured or presents evidences of gangrene, not until its continuity has been restored by suturing or excision or by establishing an anastomosis after resection.

From a surgical standpoint in the causation and treatment of intestinal obstruction the appendix vermiformis must be looked upon as a diverticulum. The appendix vermiformis may become a cause of obstruction when it is of abnormal length and supplied by a long mesentery, and when it is transformed into an unyielding band by fixation of its free extremity to some firm point by adhesive inflammation. Treves reports such a case. A boy, six years of age, who had suffered frequently from attacks of constipation lasting from a few days to a week or fortnight, was seized with violent pain in the abdomen, besides exhibiting other symptoms of acute internal strangulation. On the fourth day the pain was referred to the iliac

region, where a resonant swelling could be located. As the usual means proved of no avail, laparotomy was performed on the fifth day. About twelve inches of the small intestine were found to be tightly strangulated by an abnormal appendix vermiformis, whose free end had become fixed to the iliac fossa, forming a complete ring through which the small intestine had slipped and became strangulated. Strangulation was relieved by division of the ring. Patient had not a single bad symptom after the operation. Excision of the appendix vermiformis, when the cause of obstruction, should always be practised with a view to preventing a similar attack from the same cause. As in such cases the process has undergone elongation by traction, it is sufficient to apply a ligature near its base and then remove it by excision.

Quite a number of cases of intestinal obstruction are on record where the obstruction was caused by a diverticulum, and in a num-

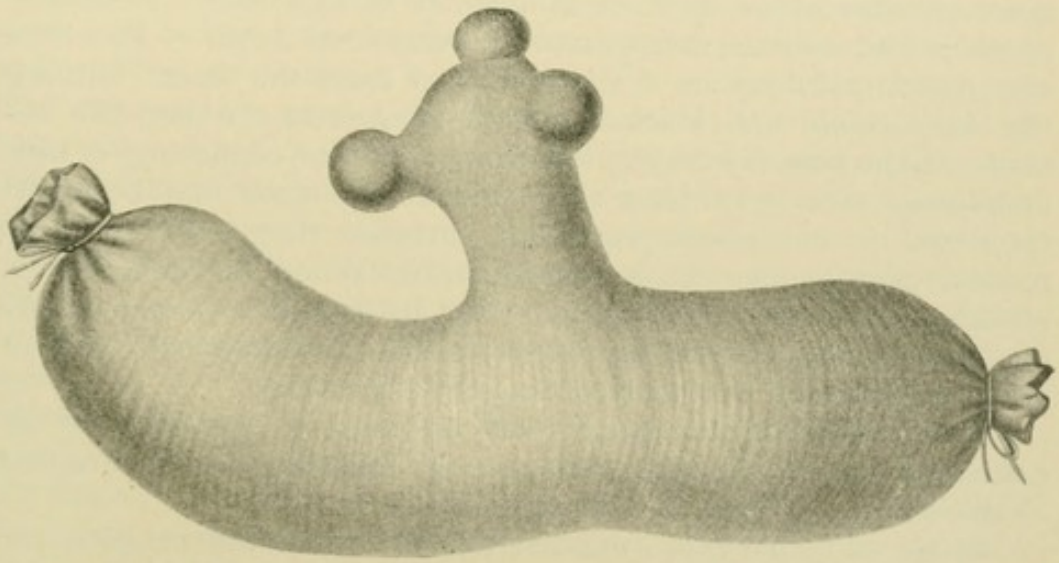

Fig. 519.—A Meckel's diverticulum of the small intestine (Lebert).

ber of these cases the strangulation was successfully treated by laparotomy. To the same class belong bands, the remains of obliterated omphalomesenteric vessels.

In 1851 Parise published his paper on a new cause of strangulation, in which he claimed that he was the first one to show that strangulation may take place from constriction by a diverticulum. The same year Bonvier described a case where a diverticulum of unusual length, springing from the ileum three feet above the ileocecal valve, encircled a loop of the small intestine so firmly as to give rise to complete obstruction. Where the diverticulum joined the ileum the lumina of both were equal in diameter, but the diverticulum tapered toward its end, ending in a bifid extremity that was adherent to intestinal coils. Omentum and abdominal wall furnished the unyielding points. The constriction was not very firm, and

reduction could have been readily effected had an abdominal section been made.

Meckel's diverticulum, as a remnant of fetal life, occurs in about 2 per cent. of individuals. Osler reports finding 12 in 550 autopsies. It is of interest because it is occasionally a cause of intestinal obstruction. Fagge believes that obstruction takes place from diverticula as frequently as from all other bands. Diverticula are found in the lower third of the ileum, usually about three or four feet from the ileocecal valve. The duct is accompanied by the omphalomesenteric vessels.

"Early in the second month closure of the plates forming the abdominal wall divides these canals into an extra-abdominal segment and an intra-abdominal portion. Both segments atrophy with the establishment of placental circulation, the remains of the former being found as a cord lying in Wharton's jelly in the umbilical cord. The intra-abdominal portion passing from ileum to umbilicus sometimes remains as an open canal (fistula) or as a cord. It usually ruptures and entirely disappears. It may form a cyst. The duct may remain patulous for a short distance from the ileum, forming the *diverticulum ilei* (Meckel's), with sometimes the cord-like remains of the vessels hanging free from its tip or connecting it with umbilicus; with or without these the diverticulum may be found connected to mesentery, omentum, intestine (large or small), or parietal peritoneum. Such connection has almost universally been considered of inflammatory origin; but by reports of examinations of various specimens Fitz demonstrates that not infrequently it is an omphalomesenteric vascular connection" (Putnam).

Lamb has made an analysis of 185 cases of this remnant of embryonic life, which, tabulated, give the following result in regard to the location of Meckel's diverticulum.

In 39, or 21 per cent., the diverticulum was found between the ileocolic valve and one foot above the valve. In 20 cases, or 10 per cent., it was one or two feet above the valve. In 22 cases, or 12 per cent., it was from two to three feet. In 4 cases, from three to four feet; in 8 cases, from four to five feet; in 4 cases, from five to six feet; in 1 case, ten feet above—in all, 98 cases of the 185 cases reported. In 62 other cases no measured distance was given, but the ileum is stated or implied. These, added to the 98, make 160, or 86 per cent., in which the diverticulum was without doubt in the ileum. Twenty-one cases remain in which the anomaly was in the jejunum or duodenum; duodenum, 7 cases; jejunum, 14.

Fitz, in an exhaustive article on "Persistent Omphalomesenteric Remains," has collected all material facts pertaining to Meckel's diverticulum with especial reference to its influence as a cause of intestinal strangulation. As a result of a careful study of this subject, he has come to the following conclusions:

1. Bands and cords as a cause of acute intestinal obstruction are second in importance to intussusception alone.

2. Their seat, structure, and relation are such as frequently admit their origin from obliterated or patent omphalomesenteric vessels, either alone or in connection with Meckel's diverticulum, and oppose their origin from peritonitis.

3. Recorded cases of intestinal obstruction from Meckel's diverticulum, in most instances at least, belong in the foregoing series.

4. In the region where these congenital causes are most frequently met with an occasional cause of intestinal strangulation—the vermiform appendix—is also found.

5. It would seem, therefore, that in the operation of abdominal section for the relief of acute intestinal obstruction not due to intussusception, and in the absence of local symptoms calling for the preferable exploration of other parts of the abdominal cavity, the lower right quadrant should be selected as the site for incision. The vicinity of the navel and the lower three feet of the ileum should then receive the earliest attention. If a band is discovered, it is most likely to be a persistent vitelline duct—*i. e.*, Meckel's diverticulum—or an omphalomesenteric vessel, either patent or obliterated, or both these structures in continuity. The section of the band may thus necessitate opening the intestinal canal or a blood-vessel of large size. Each of these alternatives is to be guarded against, and the removal of the entire band is to be sought for, lest subsequent adherence prove a fresh source of strangulation.

According to Schröder, a diverticulum is supplied with a mesentery only when it springs from the lateral aspect of the intestine or near the mesenteric attachment. Diverticula on the convex surface of the bowel are free and supplied with vessels from the intestinal wall (see Fig. 519). Meckel found, in several specimens, a valve at the junction of the diverticulum with the bowel, and in one instance Phoebus found the opening of the diverticulum into the bowel crossed by a bridge of tissue connecting its margins. The so-called false diverticula always form on the concave side of the bowel, and are hernial protrusions, their walls being composed of peritoneum and mucous membrane.

Meckel's diverticulum may become a cause of obstruction when the free end becomes attached to a fixed point, when it becomes a constricting band if a loop of intestine is ensnared underneath it.

In 23 cases collected by Cazin and 19 by Treves the attachments were as follows:

Near the umbilicus	10
" inguinal ring	1
" femoral ring	1
To the small gut	9
" cecum	3
" colon	1
" mesentery	17

Greenhow observed a case where a coil of the ileum had slipped through a slit in the mesentery of a diverticulum, which in this case contained omphalomesenteric vessels, and had become strangulated

in this position. Sometimes a number of congenital diverticula are found in close proximity, and at times associated with other congenital defects of the intestine.

Moore exhibited to the Pathological Society of London the intestines of a man aged forty, showing three diverticula in the first three feet of the small intestine, and a congenital stricture at the commencement of the jejunum. The diverticula were each an inch long and about as much in diameter, and were on the mesenteric side of the intestine. Their walls consisted of all intestinal coats, and were not mere hernial protrusions. As long as the free end of a diverticulum remains unattached, strangulation from this cause can not take place. Strangulation can occur only when both extremities are fixed, either as a congenital condition or when later the free end becomes adherent to some fixed point. Harris showed a specimen of intestinal strangulation taken from a man, aged twenty, to the Pathological Society of Manchester. There was a whipcord-like adhesion, about an inch and a half long, stretching from the tip of Meckel's diverticulum to the mesentery of the lower part of the ileum, and through the aperture so formed a loop of the lower part of the bowel had become strangulated. There had also been a twist of Meckel's diverticulum, which had ruptured near its base, and death ensued from acute peritonitis consequent upon fecal extravasation. That the danger of perforation and peritonitis from strangulation by a Meckel's diverticulum is greater than when the obstruction is caused by a ligamentous band is shown by another case reported by Heiberg. The patient was a woman, forty years of age, who died in a few days from an acute attack of intestinal obstruction. At the necropsy he found a diverticulum seven inches in length thirty inches above the ileocecal region, which constricted a loop of the ileum twenty-one inches in length. The free end of the diverticulum had passed between its base and the intestine, and it was found here, with its terminal end somewhat dilated. The softened wall of the diverticulum was found perforated at one point, which had given rise to fecal extravasation and septic peritonitis. A somewhat similar mechanism of strangulation by a diverticulum was described by Concato. A man, otherwise in perfect health, was attacked by acute intestinal obstruction and died on the fourth day. A loop of the small intestine was found constricted by a diverticulum located several feet above the ileocecal valve, the free end of which had insinuated itself between the junction of the diverticulum with the intestine and constricted bowel, thus forming a firm knot around the bowel. That in most cases where a diverticulum causes an obstruction the free end has found a firm point of attachment is well shown by the cases tabulated by Cazin. He collected thirty cases of intestinal obstruction caused by a diverticulum, and of this number, in twenty-five the free end was found adherent. A diverticulum may give rise to symptoms of intestinal obstruction without directly interfering with the fecal circulation. Such a case has been reported by

Doran. A boy, four years old, died on the fourth day after an attack of what resembled acute intestinal obstruction. At the necropsy a diverticulum the size of a pear and containing a pea was found at the junction of the ileum with the jejunum. The foreign body had caused ulcerative inflammation and perforation of the diverticulum, and death from perforative peritonitis. The diverticulum was supplied with a mesentery, and its walls were composed of all the tunics of the bowel.

Southey alludes to another variety of obstruction caused by a diverticulum—viz., contraction of the intestine at a point where the diverticulum is given off. He gives a description of two such specimens. In one the diverticulum formed a band the size of a goose quill, and extended from a point two feet above the ileocecal valve to the abdominal wall, two inches below the umbilicus. The ileum just above the diverticulum was so constricted as to admit only the tip of the little finger, and at the point of constriction the coats of the intestine, both muscular and mucous, were ulcerated through, the continuity of the intestine being preserved only by the thickened peritoneum. In the second case the bowel, at a point about eighteen inches above the ileocecal valve, was abruptly constricted to a diameter of about half an inch, and a diverticulum five inches long, having a caliber large enough to admit the little finger, passed from the intestine and was attached at its extremity to the umbilicus. In this case death was hastened by acute diffuse peritonitis. That not all constricting bands are the remains of the vitelline duct requires no argument in speaking of the operative treatment of obstruction from constriction by bands, but the possibility of mistaking a peritoneal fold inclosing unobliterated umbilical vessels for an ordinary cicatricial band must be remembered, and the necessary sections of the band made between ligatures. If Meckel's diverticulum is found to be the cause of obstruction, this appendage should always be resected in the same manner as the appendix. Weir recommends, in the excision of a constricting diverticulum, to apply a ligature, and, after cutting it off, to stitch the peritoneal surface over the divided muscular and mucous coat, but when the diverticulum is nearly of the same diameter as the intestine from which it springs, such a course would not afford ample protection against perforation.

Clutton related a case of intestinal obstruction caused by a diverticulum, successfully treated by operation, to the Clinical Society of London. The patient was a boy aged ten years, who had suffered on several occasions from colicky pains lasting for two or three days, and always terminating with a copious evacuation from the bowels. This attack commenced with vomiting and great pain in the abdomen, which persisted in spite of opium treatment for four days, when he was brought into the hospital and at once submitted to an operation. On opening the abdomen through the linea alba a collapsed portion of bowel was soon found, and on bringing it to the surface a tight, ring-like cord could be felt and seen to be the cause of

strangulation. The cord was divided between two pairs of forceps, and each end was tied with a catgut ligature. This step of the operation relieved the bowel from strangulation. On making an investigation as to the nature of the band divided, it was found that one of the ligatures was situated at the extreme end of a diverticulum two inches in length, and the other was placed upon the wall of the same loop of intestine at a distance of about six inches. A portion of the bowel about three inches in length between these two points of attachment was the part strangulated, and was of an extremely dark color, with a deep sulcus at each side. The boy made an uninterrupted and rapid recovery.

Clutton explained the condition as follows: "The vitelline duct had become obliterated at the umbilicus and set free from the abdominal wall, but, remaining patent toward the ileum, the lower end had become a pouch-like diverticulum from the intestine. This diverticulum terminating in a pointed extremity or cord, part also of the vitelline duct, which had been obliterated and remained floating about among the intestines till it became attached to the bowel in contact with it. The bowel between the two points of attachment had slipped beneath the cord which united them, and, being unable to extricate itself, had become strangulated."

Maas reports a case of diverticulum of unusual size that, by its dimensions, caused symptoms of obstruction by compressing the rectum. The patient was a boy fourteen years of age, whose abdomen began to enlarge soon after birth, and continued to do so until a year before he came under treatment. During the last year the abdomen became so much distended that respiration and circulation were seriously impaired. The bowels moved frequently, but the stools were scanty and thin. The abdomen was enormously distended and tympanitic on percussion. No solid tumor could be detected. An enema brought away a large quantity of fecal matter. Some dullness on percussion on left side remained. A rectal tube introduced could be felt apparently over the tumor, under the abdominal wall, hence a diagnosis was made of congenital hydronephrosis on left side, or cystic degeneration of the kidney. An exploratory puncture in the left lumbar region evacuated fecal matter. A median abdominal section revealed a swelling covered by a large plexus of veins. The exploration was not carried any further, and the wound was closed. The patient manifested no symptoms of peritonitis, but soon became dyspneic and died quite suddenly soon after. The autopsy showed that the swelling was an immense diverticulum from the upper part of the rectum, containing fourteen quarts of liquid feces. The enormous cavity communicated with the rectum at the posterior inferior part of the pouch. Kölliker and Maas believed this diverticulum to be of congenital origin, resulting from arrested development of the blastodermic layers.

Poppert reports an exceedingly interesting case of acute intestinal obstruction from a Meckel's diverticulum, where, on account

of the debilitated condition of the patient, he made an enterostomy in the right iliac region. The patient improved after the operation, and soon after the bowels moved spontaneously and continued in this condition daily until the fistula was closed by operation, when symptoms of obstruction reappeared that necessitated reopening of the fistula. As the symptoms of obstruction did not subside completely, a median abdominal section was made, and, by following the intestine from the fistula in a downward direction, the strangulation by an adherent diverticulum was found fifty centimeters lower down and in the right lumbar region. The diverticulum was divided between two catgut ligatures. The patient made a good recovery, and the fistula was later successfully closed by a second operation.

Another interesting case of intestinal strangulation caused by a Meckel's diverticulum and successfully treated by laparotomy is reported by McGill. The patient was a man aged thirty years, who had suffered from acute intestinal obstruction for nine days. The abdomen was very much distended at the time of operation. As the seat of obstruction could not readily be found by intra-abdominal palpation, partial extrusion of intestines was allowed to take place, but as soon as three feet of the small intestine had escaped, the junction of the distended with the empty intestine came into view. At this point a Meckel's diverticulum, much dilated and about six inches in length, passing downward and forward, was seen to be attached to the fundus of the bladder. A loop of collapsed intestine passed under the diverticulum, the obstruction being caused by the twisting of the bowel at the point where the diverticulum was attached. Slight traction proved efficient in releasing the bowel from the grasp of the diverticulum, and as soon as this was accomplished, the empty portion of the bowel became filled with the intestinal contents. Nothing was done to the diverticulum. On the tenth day a small fecal fistula formed at the lower angle of the wound. This continued for two weeks, when the discharge ceased and the patient recovered without any further untoward symptoms. The author believes that this is the first recorded case where the free end of the diverticulum had its attachment to the fundus of the bladder. There can be but little doubt that the fecal fistula in this case was caused by a perforation of the diverticulum, an accident that might have proved fatal if extravasation had taken place into the peritoneal cavity, and that might have been avoided had the diverticulum been removed, which would also have protected the patient with certainty against a possible recurrence in the future of obstruction from the same cause.

INTERNAL HERNIA.

Internal hernia has been seen, recognized, and studied more frequently at autopsy than in the operating room. An internal hernia is a hernia in which an intestinal loop becomes incarcerated or strangulated in a physiologic or preformed pouch or pocket. The

two spaces where this accident is most liable to occur are the foramen of Winslow and the duodenojejunal fossa—cavum Treitzii. In the former location the hernia, as a rule, is larger than in the latter, owing to the difference in the size of these two normal spaces. Other spaces of less importance and rarely the seat of internal hernia are in the region of the sigmoid flexure and cecum.

The only successful operation for strangulated internal hernia so far reported was performed by Sonnenburg. Although the exact

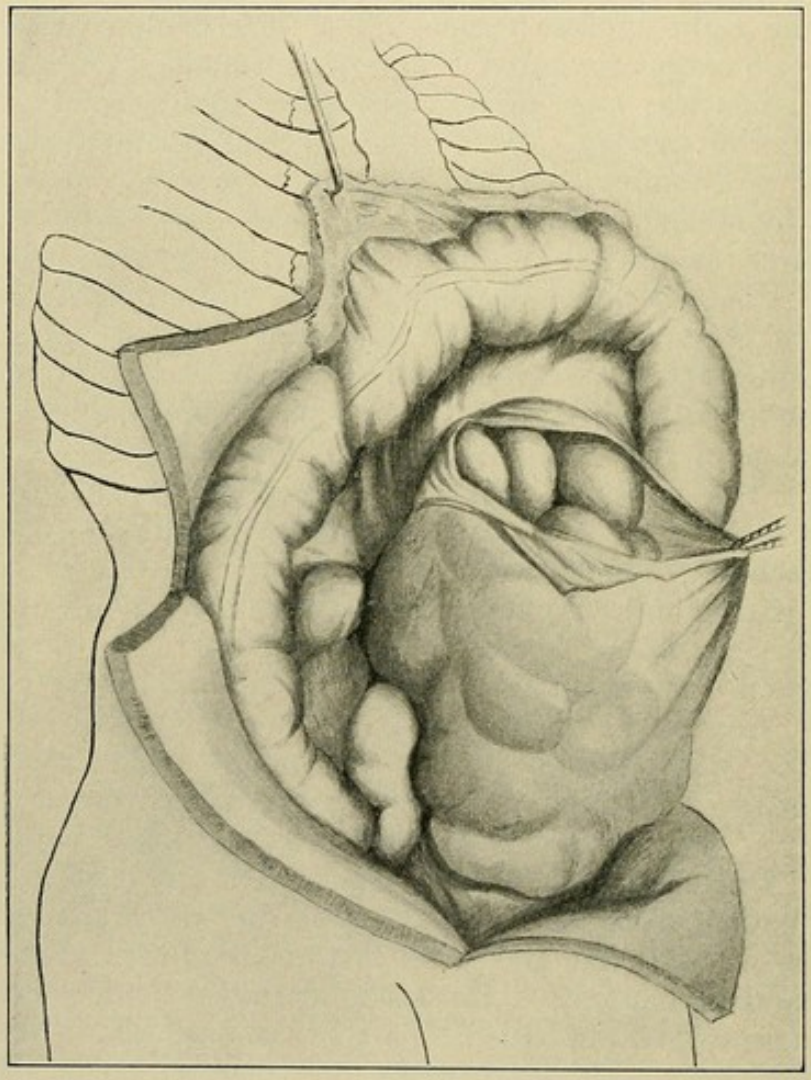

Fig. 520.—Hernia into the fossa duodenojejunalis (after Cooper).

location of the hernial sac could not be demonstrated at the time the operation was performed, the clinical symptoms, the size and condition of the strangulated loop, left but little doubt that it was a hernia of the duodenojejunal fossa.

No *intravitam* diagnosis has ever been made in internal strangulated hernia. Herniæ of the foramen of Winslow and of the duodenojejunal fossa have much in common. In both locations the upper portion of the small intestine usually constitutes the hernial contents. The pain is referred to a point half-way between the ensiform carti-

lage and umbilicus, and a little to the left of the median line. During the early stages of strangulation a tympanitic tender swelling can be felt in that location if the hernia is large, but this swelling soon becomes indistinct or disappears entirely by distention of the intestines above the seat of obstruction. Herniæ in the right and left iliac fossæ are even more obscure in their clinical manifestations. Early treatment by abdominal section is the only treatment that offers any hope whatever of saving life. A long median incision and partial evisceration are necessary to secure access to the hernia and for its direct treatment.

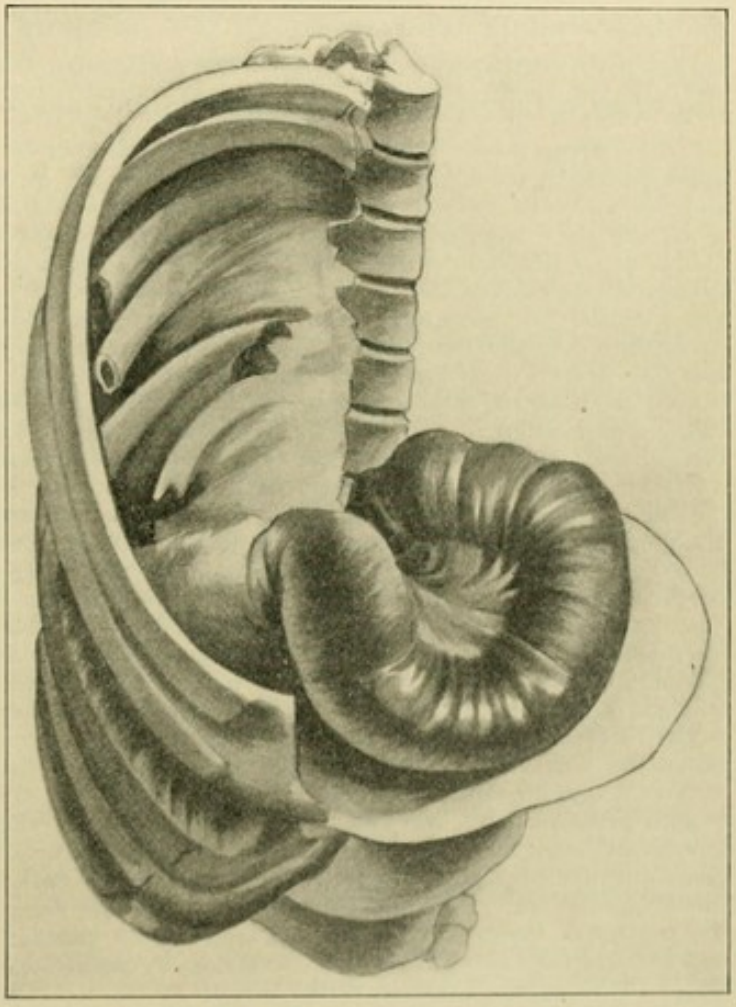

Fig. 521.—Diaphragmatic hernia (after Cooper).

INVAGINATION.

By invagination or intussusception is understood a telescoping of one section of the intestine into another, with very few exceptions in a downward direction. From a surgical standpoint invagination is the most important form of intestinal obstruction. Leichtenstern and Leubuscher have made careful experimental studies to explain the mechanism and pathologic conditions that give rise to this kind of intestinal obstruction, but in the following experiments this part of the subject was ignored, and the invaginations were made by direct manipulation. It was found impossible to make an invagination at any point so long as the bowel was in a condition of contraction; consequently it was always found necessary to wait until the peristaltic wave had passed by, or to cause relaxation by firm pressure continued for several minutes. Usually it was found easy to produce an invagination of the bowel, when in a state of relaxation, by indenting one side of the bowel, and pushing the pouch forward with a blunt instrument until the entire lumen of the intestine had passed

into the section of the bowel below. After this was accomplished, further invagination was readily effected by manipulation, consisting in pushing the intussusceptum and intussuscipiens gently toward each other. After it was ascertained by experience that disinvagination frequently takes place spontaneously, the intussusceptum was sutured to the neck of the intussuscipiens for the purpose of maintaining the invagination. But even this expedient did not always succeed in retaining the malposition, as spontaneous reduction was observed in several of these cases. These experiments would certainly tend to prove that temporary invagination is of rather frequent occurrence, and may account for many painful bowel disorders of short duration in infants and children.

EXPERIMENT 13.—Adult cat. The lower portion of the ileum and the cecum and upper portion of the colon were drawn forward into an incision through the linea alba, and five inches of the ileum were pushed into the colon through the ileocecal valve, when the parts were replaced and the abdominal wound closed. For six days the animal had a temperature from 102.6° to 105° F., and suffered from tenesmus. The stools contained mucus and blood. After the sixth day the symptoms due to invagination subsided, and were replaced by symptoms of peritonitis. The animal was killed twenty-two days after operation. There was great emaciation. The abdominal wound had united completely and there were evidences of diffuse purulent peritonitis. The disease had evidently commenced in the ileocecal region, as at this point the pathologic changes were found most advanced. There was complete spontaneous reduction of the invagination, and the colon was greatly distended and intensely congested.

EXPERIMENT 14.—Large adult cat. Invagination was made in the lower part of the ileum. Length of intussusceptum, three inches. For nine days the scanty fecal discharges contained mucus, and at times blood. On the ninth day the temperature registered 105° F. There was absolute refusal of food, and only occasional vomiting; death occurred on the thirty-third day after invagination. Abdominal wound healed. There was small ventral hernia, but no peritonitis. Apparently the greater portion of the intussusceptum had disappeared by sloughing, and the subsequent healing process had produced an acute flexion at the neck of the intussuscipiens. Firm adhesions occurred between the peritoneal surfaces in the concavity of the flexion, nearly an inch in length. Above this point the intestine was enormously dilated and distended with fluid contents. Below the obstruction the bowel was found contracted and empty. Water could not be forced through the obstruction from either direction. On slitting open the bowel in a longitudinal direction it was found that the lumen at the point of flexion was contracted to such an extent that only a fine probe could be passed. On the concave side of the flexion the mucous membrane presented a prominence marked by a number of longitudinal ridges. These folds had undoubtedly acted like valves in completely preventing the passage of intestinal contents, and later of the injection of water. Death in this case resulted from intestinal obstruction caused by cicatricial contraction after the sloughing of the invaginated portion of the bowel.

EXPERIMENT 15.—Adult cat. Two inches of the ileum were invaginated into the colon and fixed by two fine silk sutures at the neck of the intussuscipiens. For two days after the invagination the stools were scanty and contained mucus and blood. On the third day the abdominal cavity was reopened by an incision along the outer border of the right rectus muscle, and the invaginated bowel was drawn forward into the wound. No peritonitis followed. The bowel at point of operation was very vascular, and the neck of the intussuscipiens was covered with plastic exudation. The sutures were removed, and the rectum and colon distended with water for the purpose of effecting reduction. As soon as the colon had become thoroughly distended, the adhesions gave way with an audible noise, and complete reduction followed in such a manner that the portion last invaginated was first reduced. After reduction had been accomplished, the injection was continued to test the competency of the ileocecal valve. As soon as the cecum was well distended the fluid passed readily through the valve into the small intestine, showing that the valve had been rendered incompetent by the invagination. The force required to overcome the adhesions in the reduction of the invagination was sufficient to rupture the peritoneal covering of the large intestine in three different places, the rents always taking place parallel to the bowel. The animal died on the following day with symptoms of diffuse peritonitis.

EXPERIMENT 16.—The ileum was invaginated in a cat a few inches above the ileocecal region in an upward direction to the extent of two inches. At the time the invagination was made the intussuscipiens contracted firmly. In consequence of this a tear occurred in its peritoneal covering in a direction parallel to the bowel. The stools were few and scanty. On the fourth day the animal died of perforative peritonitis. Abdominal wound had not united, but the peritoneal wound was closed by omental adhesions. Spontaneous reduction of half an inch of the invagination had taken place. Reduction by traction was found impossible on account of firm adhesions about the neck of the invagination. Recent diffuse peritonitis caused by two perforations, one at the neck of the intussusceptum on the mesenteric side, and the other a little to one side of this one and on the proximal side of bowel. The perforation resulted from beginning sloughing of the invaginated portion of the bowel. About two inches above the invagination the bowel was acutely flexed toward the mesenteric side by recent firm adhesions. Flexion was undoubtedly caused by circumscribed plastic peritonitis and increased peristalsis.

EXPERIMENT 17.—Large adult cat. Descending invagination of the ileum to the extent of two inches in the upper portion of this part of the bowel was made. On the second and third days the scanty discharges from the bowel were bloody. Temperature from the second day after operation varied between 103.4° F. and 105.4° F. Death occurred from perforative peritonitis on the seventh day after invagination. Abdominal wound was found united. Recent diffuse peritonitis resulted from a perforation at the neck of the invagination on the mesenteric side. There were gangrene of intussusceptum and partial separation, which had again caused a sharp flexion of the bowel at the neck of the invagination. Above the seat of obstruction the bowel was dilated and distended with fluid contents; below, empty and contracted.

EXPERIMENT 18.—Young cat. Invagination of ileum into ascending colon to the extent of three inches. For a week after operation there was frequent tenesmus, followed by mucous discharges mixed with blood. The temperature during this time varied from 102.6° to 105° F. After this the animal improved, and was in good condition when killed, fourteen days after operation. Abdominal wound was found united, and there were no omental adhesions or peritonitis. Firm union had taken place between the serous surfaces. No dilatation of bowel occurred above seat of obstruction. Intussusceptum was not gangrenous, its lumen being about the size of an ordinary lead-pencil. It was found impossible to reduce the invagination by traction or by forcible injection of fluid from below. When the traction was increased, the peritoneal surface of the neck of the intussuscipiens ruptured in a longitudinal direction.

EXPERIMENT 19.—Large, adult cat. Six inches of the ileum were invaginated into the colon. Frequent bloody discharges occurred until the third day, when the abdomen was reopened and the neck of the intussuscipiens exposed to sight, so as to observe directly the mechanism of disinvagination by rectal injection of water. As soon as the colon was well distended, the adhesions at the neck of the intussuscipiens began to give way, and complete reduction followed, as the adhesions gave way under the pressure from below. The abdominal wound was again closed and dressed in the usual manner. The animal recovered completely from the operation, and was killed twenty-four days after the first operation. Abdominal wound was well united. In the ileocecal region numerous adhesions were found around the portion of the bowel that had been invaginated and subsequently reduced.

EXPERIMENT 20.—Invagination of colon into colon was commenced about the middle of the bowel and advanced as far as the cecum. On the second day bloody discharges occurred from the bowels. Animal was killed five days after operation. External wound was united only on peritoneal side, and invagination was completely reduced. Localized plastic peritonitis was limited to the portion of the bowel that had been invaginated; otherwise the peritoneum and intestines were in a healthy condition.

EXPERIMENT 21.—Cat. Invagination of colon into colon to the extent of four inches was made. The subsequent symptoms indicated the existence of invagination only for a short time, and, after they had subsided, were followed by evidence of peritonitis. Death occurred on the nineteenth day after the invagination. Abdominal wound was well united. There were evidences of diffuse purulent peritonitis, and the under surface of the diaphragm was covered with a plastic lymph. Although sought for, no perforation could be found in the disinvaginated bowel, but as the peritonitis appeared to have started at the site of operation, it is probable that infection took place through the paretic walls of the disinvaginated bowel.

EXPERIMENT 22.—Same kind of invagination made in a cat as in the preceding case. For two days the stools were frequent, scanty, and contained mucus and blood. After this the animal remained in good condition until it was killed, thirty-five days after the invagination. The abdominal cavity showed no trace of inflammation. The invagination was completely reduced, and the entire colon presented a normal appearance.

With the exception of experiment No. 16, the invagination was always made in a downward direction. In the case of ascending invagination, gangrene of the intussusceptum and perforation resulted in death from diffuse peritonitis on the fourth day, after partial spontaneous reduction had taken place. In experiments No. 15 and No. 19, both cases of ileocecal invagination, complete reduction was effected by distention of the colon with water; in the first case the force required to accomplish this result was sufficient to produce multiple longitudinal lacerations of the peritoneal surface of the distended bowel, which undoubtedly were responsible for death, on the following day, from diffuse peritonitis; while in the second case no such accident occurred and the animal recovered, although the abdominal wound was reopened for the purpose of observing the mechanism of reduction by this method of procedure. In one case of ileocecal invagination, experiment No. 18, the intussusceptum remained *in situ* after the invagination, and became so firmly adherent to the intussuscipiens that even in the specimen reduction by traction was found impossible. In this case, although the lumen of the invaginated portion barely permitted the introduction of an ordinary lead-pencil, no symptoms of obstruction were manifested during life, and the bowel above the invagination was not found dilated after death. In experiment No. 14 the sloughing of the intussusceptum led to cicatricial contraction of the bowel and flexion at the site of invagination, conditions that resulted in death from obstruction twenty-three days after invagination. The great dangers that attend sloughing of the invaginated portion are circumscribed gangrene and perforation of the intussuscipiens at the neck, and death from perforative peritonitis, as illustrated by experiments No. 16 and No. 17. Experiment No. 16 illustrates that ascending invagination, should it occur, is not more likely to be reduced spontaneously than the more common form of descending invagination. These experiments also demonstrate conclusively that the danger attending the invagination increases the higher it is located in the intestinal canal, being greatest when it is situated high up in the tract of the small intestine, and gradually less as the ileocecal region is approached. The ileocecal form is less dangerous, as spontaneous reduction is more likely to take place, and gangrene of the intussusceptum, when it occurs, does so at a later period, after firm adhesions about the neck of the intussuscipiens have formed, a condition that is well adapted to prevent perforation. Of the three invaginations of the colon, experiments No. 20, 21, and 22, complete spontaneous reduction took place in all of them from the first to the fourth day, and in only one of them was the result fatal—in experiment No. 21, where purulent peritonitis, either from infection through the operation wound or, what is more probable, through the damaged wall of the colon, occurred and was the cause of death on the nineteenth day after the invagination. Experiments No. 15 and 19 prove both the danger and the utility of distention of the

colon in cases of ileocecal and colic invaginations. As a rule, the longer the invagination has existed, the firmer the adhesions, and consequently the greater the danger of relying too persistently on this measure in reducing the invagination. In resorting to this expedient in the reduction of an ileocecal invagination it is of the greatest importance to relax the abdominal wall completely by placing the patient fully under the influence of an anesthetic; further, in order to add to the distending force as much as possible by gravitation, the patient should be inverted and the injection should always be made very slowly and with requisite care, to prevent rupture of the peritoneal coat by rapid overdistention. When the obstruction is located beyond the ileocecal valve, no reliance can be placed upon this measure, as can be seen from the following experiments made to determine the *permeability of the ileocecal valve to fluids injected per rectum:*

EXPERIMENT 23.—While completely under the influence of ether, an incision sufficiently long to render the ileocecal region readily accessible to sight was made through the linea alba of a cat. An incision was made into the ileum just above the valve, and by gently retracting the margins of the wound, the valve could be distinctly seen; water was then injected per rectum, and as the cecum became well distended, it could be readily seen that the valve became tense and appeared like a circular curtain, preventing effectually the escape of even a drop of fluid into the ileum. The competency of the valve was overcome only by *overdistention* of the cecum, which mechanically separated its margins, and thus allowed a fine stream of water to escape into the ileum. The insufficiency of the valve was clearly caused by great distention of the cecum. That such a degree of distention is attended by no inconsiderable danger was proved by this experiment, for upon immediately killing the cat and examining the colon and rectum, a number of longitudinal rents of the peritoneal coat were found.

EXPERIMENT 24.—In this experiment a cat was fully narcotized with ether, and while the body was inverted, water was injected per rectum in sufficient quantity, and with adequate force, by means of an elastic syringe, to ascertain the force required to overcome the resistance offered by the ileocecal valve. Great distention of the cecum could be clearly mapped out by percussion and palpation before any fluid passed into the ileum. As soon as the competency of the valve was overcome, the water rushed through the small intestine, and, having traversed the entire alimentary canal, issued from the mouth. About a quart of water was forced through in this manner. The animal was killed, and the gastro-intestinal canal carefully examined for injuries. Two longitudinal lacerations of the peritoneal surface of the rectum over an inch in length were found on opposite sides of the bowel.

EXPERIMENT 25.—This experiment was conducted in the same way as the foregoing one, only that the cat was not etherized. More than a quart of water was forced through the entire alimentary canal from anus to mouth. The animal was not killed, and lived for eight days, but suffered the whole time with symptoms of ileocolitis. A postmortem examination was not made in this case, although the symptoms manifested during life leave no doubt that they resulted from injuries inflicted by the injection. It will thus be seen that in the three cases where fluid was forced beyond the ileocecal valve, in two of them the postmortem examination revealed multiple lacerations of the peritoneal coat of the large intestine, while the third animal sickened immediately after the experiment was made, and died eight days later from the effects of the injuries inflicted. The injection of water beyond the ileocecal valve in the treatment of intestinal obstruction must therefore be looked upon in the light of a dangerous expedient, and should never be resorted to.

Rectal insufflation of hydrogen gas or air is the only direct mechanical agent that should be employed in recent acute and chronic invagination, with a view to effecting reduction short of the use of the knife.

Etiology.—Invagination as an isolated uncomplicated affection

is notably a disease of infancy and childhood. In adults and the aged it is often complicated by intestinal tumors or stenosis, conditions that take an important part in the invagination.

In regard to the age of patients suffering from invagination, it may be said that 50 per cent. of all cases occur in persons under ten years of age. According to Heusner, in children invagination is the cause of obstruction in three-fourths of the cases of intestinal obstruction. If every case of invagination were tabulated, it would be seen that one-fourth of the whole number would be children under one year of age. The acute form is most frequent in the young, and the chronic variety between the ages of twenty and forty.

Leichtenstern has studied the mortality that attends invagination, and in 557 cases in which the termination was known, the result was as follows :

Age.	Total Mortality.	Mortality of Cases without Elimination of Gangrenous Portion.
1 year	88	86
2 years	82	
2–10 "	72	80
11–20 "	63	86
21–40 "	63	82
41–50 "	63	80
51–60 "	71	
More than 60 years	77	

From this table it will be seen that the mortality up to the age of forty increases with the diminution of the age of the patients, being greatest in infants and children, in whom the invagination usually pursues an acute course.

A long mesentery furnishes an anatomic predisposing cause, and violent or irregular peristalsis is undoubtedly the most potent exciting cause. Whether, during the process of invagination, that section of the bowel that becomes the intussusceptum is telescoped into a relaxed section of the bowel adjacent by active peristalsis, or whether the intussusceptum is aspirated, as it were, into the intussuscipiens, is a question that has not been fully determined. It is probable that intussusception may, and does, take place in both ways.

No effort will be made here to elaborate upon the views entertained by different authors and experimenters concerning the mechanism of the ordinary forms of invagination, but from a surgical aspect it is important to allude to some of the physiologic conditions that produce the invagination, and at the same time complicate the treatment. Mr. Bellamy has described the case of a very rare form of intestinal obstruction, due to invagination of a portion of the small intestine in the walls of the rectum, successfully treated by abdominal section. The obstruction had been complete for nine days. The patient was a female who had been subject to obstinate constipation, and on three occasions the retention of fecal matter had given rise to serious symptoms, which,

however, had always yielded to ordinary means. On admission into the hospital a hard swelling could be felt in the left iliac fossa, in the region of the inguinal canal and sigmoid flexure. Manual examination of the rectum disclosed an obstruction in the upper part of this portion of the intestine. As the symptoms of obstruction became urgent and failed to yield to ordinary treatment, abdominal section was performed by enlarging the incision upward and obliquely outward, having previously exposed the left external inguinal ring, which had been the seat of an old hernia. On introducing the hand into the abdomen it was ascertained that the swelling in the iliac region was composed of a knuckle of small intestine that was obviously invaginated in the anterior aspect of the first part of the rectum, and, in addition, there were felt what appeared to the touch to be bands of organized lymph, stretching across in the same place, and probably the result of a former circumscribed peritonitis. The operator introduced his right hand into the rectum and pushed the prolapsed mass upward and toward his left hand, which was in the pelvic cavity, at the same time breaking down the adhesions and gently drawing out the knuckle from its imprisoned position and freeing it from the peritoneal fold. The symptoms of obstruction subsided promptly, and the patient, after having passed through a mild attack of peritonitis, made a complete recovery. In examining the literature of the subject Bellamy had been unable to find any case where abdominal section had been performed for a similar condition, although Lockhart described this form of hernia, stating, however, that he had never known an operation to be necessary.

The cause of a chronic invagination is often a tumor attached to the inner surface of the bowel. The tumor, by its weight, drags the portion of intestine to which it is attached into the segment of bowel below, the descent of the intussusceptum being often very slow. In these cases the tumor is always found attached to the apex of the intussusceptum. Invagination caused by tumors is most frequent in the large intestine, as these are more frequently the seat of tumors than the intestinal canal above the ileocecal valve.

Tuffier reports a case of invagination operated on by Marchand that is of special interest on account of the rare condition found, which had led to the invagination. The patient was a woman forty-three years of age, who had suffered from a gradually increasing intestinal obstruction. Rectal examination revealed a tumor that had dragged an upper segment of the bowel with it into the rectum. Marchand opened the abdomen in the left inguinal region, and found an invagination of the sigmoid flexure into the rectum. Reduction was found impossible. An artificial anus was established after the method of Littré. Death followed on the fifth day. The necropsy showed diffuse peritonitis, which, in the small pelvis, had assumed a suppurative type. The sigmoid flexure was found invaginated to the depth of six centimeters; the serous surfaces were adherent,

and gave way only to considerable traction force. A pedunculated lipoma was attached to the apex of the intussusceptum.

Kulenkampff reports a case of a woman, aged thirty-nine years, who had suffered from incomplete obstruction of the bowels with bloody discharges from the anus for six months. During the progress of the disease a mass that was thought to be a polypus could be felt in the rectum. This proved to be a papilloma (probably malignant) that originated in the sigmoid flexure, and had been the cause of the invagination of that part of the colon into the rectum. The entire mass, including the intussusceptum, was removed through the rectum. An adherent coil of intestine was accidentally wounded, and the wound was at once closed by suturing. The operation was followed by an aggravation of the symptoms of obstruction; on the tenth day laparotomy had to be performed, and an artificial anus was established in the left groin. The patient recovered, but the fecal fistula remained.

Bryant related the case of a woman, aged seventy-four, who had been suffering from obstruction due to invagination for fourteen days. He suspected the existence of a growth, and this, after much difficulty, was found, drawn down, and removed, the patient making a rapid and perfect recovery.

Barker, in a case of invagination of the rectum due to adenoid epithelioma of that part of the bowel, succeeded in drawing down and excising the affected part and in reducing the invagination. The patient recovered completely. Three similar cases had been treated previously in the same manner, two by Verneuil and one by Kulenkampff, only one of them recovering.

The case reported by Nicolaysen is of special interest as illustrating the course to be pursued when it becomes necessary to resect a portion of the intestine with the tumor. The patient was a woman forty-nine years of age, who had suffered from troublesome constipation and painful defecation for a year, due to chronic invagination of the sigmoid flexure of the colon into the rectum, produced by an epithelioma. Through the rectum a tumor could be felt that, by traction, could be drawn down to the anus. The diagnosis made was carcinoma of the colon and invagination of the colon into the rectum. The patient could produce the invagination at will. The extirpation was made by pulling the tumor downward beyond the anal orifice. The healthy mucous surfaces two and one-half centimeters above the base of the tumor were circumscribed by a row of silk sutures that were carried through the entire thickness of both intestinal walls. The tumor was excised one centimeter below the sutures; only one artery had to be tied. Posteriorly and on the left side of the circular wound the divided mesocolon could be seen. The wound was accurately united by a superficial continued suture. As soon as the bowel was replaced it retracted as far as the upper portion of the rectum. The patient recovered after fifteen days, and reported herself well at the end of two and a

half months. The intestinal tube removed measured 6.5 cm. Under the microscope the tumor showed the typical structure of cylindric-celled epithelioma.

Claudot has given an accurate description of a specimen of double invagination in a patient who had died with symptoms of intestinal obstruction. The first invagination was 80 cm. below the pylorus, the second two meters further down, the latter consisting of an invagination of the ileum into the colon, the intussusceptum having advanced nearly the entire length of the ascending colon. The upper invagination showed evidence of gangrene, of which no sign could be seen in the lower, and for this reason it is probable that the upper invagination occurred first. Intestinal hemorrhage was one of the prominent symptoms during life in this case.

At a meeting of the Pathological Society of London, Power demonstrated a specimen of double intussusception obtained from a child five months old. One intussusception, two inches in length, was in the ileocecal region; the other, one inch in length, in the transverse colon. The latter was an ascending invagination. Both invaginations showed adhesions between the serous surfaces, and consequently must have been antemortem conditions.

Symptoms and Diagnosis.—Treves asserts that 30 per cent. of all forms of intestinal obstruction, exclusive of hernia and congenital malformations, are cases of invagination. The same author recognizes clinically four forms. The ultra acute is very rare and terminates fatally in twenty-four hours; the acute, lasting from two to seven days, constitutes about 48 per cent. of all cases of invagination; the subacute, lasting from seven to thirty days, about 34 per cent.; and the chronic, lasting over thirty days, occurs about eighteen times out of every 100 cases. As far as the operative treatment is concerned, it is exceedingly important to classify all cases into acute and chronic, as in the former class the symptoms appear with great violence, and the pathologic changes at the seat of invagination come on so rapidly that death is inevitable unless efficient surgical treatment is resorted to before the tissues at the seat of invagination have undergone changes incapable of repair. In the chronic form the symptoms are never so urgent and the adoption of early radical measures is not so positively indicated. Of the anatomic forms of the cases collected by Treves, 30 per cent. were enteric; 18 were colic; 44 were ileocecal; and 8 were ileocolic. The enteric forms are most common at the lower part of the jejunum and are small. The colic forms are mostly to the left of the transverse colon. The latter, as a rule, belong to the chronic form of invagination.

Leichtenstern calls an invagination ileocecal when the ileocecal valve is pushed forward and forms the apex of the intussusceptum, and ileocolic when the ileum is pushed through the valve. The invagination always increases at the expense of the intussuscipiens.

In examining 479 cases of invagination in reference to the anatomic location of the lesion, he gives the following figures:

Ileocecal	212
Ileum	142
Colon	86
Ileocolic	39
	479

Symptoms of intestinal obstruction in infants and children, unattended by fever during the incipiency of the attack, must always arouse well-founded suspicions of invagination. In adults and the aged, vague intestinal symptoms preceding an attack of intestinal obstruction should tend to call our attention in the same direction. Except in the most acute forms, obstruction from invagination differs clinically from the other forms in that the obstruction is seldom complete, the lumen of the intussusceptum being sufficiently patent to permit the passage of gas and liquid feces. Partial obstruction is a conspicuous clinical feature of chronic invagination. Unless the obstruction is complete, the tympanites is either entirely absent or, at any rate, not extensive. The most reliable diagnostic evidence of invagination is a sausage-shaped swelling, which can often be satisfactorily felt and outlined by palpation through the intact abdominal wall, or, if the intussusceptum has reached the rectum, by digital examination. The existence of mucus and streaks of blood in the scanty fecal discharges, and the tenesmus, if the invagination is colic, are very important symptoms in differentiating invagination from other forms of intestinal obstruction and appendicitis. Rectal inflation of air is a very valuable diagnostic resource in establishing not only the existence, but also the anatomic location, of the invagination. Active peristalsis above the obstruction is a conspicuous symptom in the chronic variety of invagination.

Pathology of Acute Invagination.—The pathologic changes in the acute form of invagination are chiefly of two kinds: (1) Obstruction of the bowel; (2) strangulation of the intussusceptum. Both of these results may be absent in the chronic form. The obstruction is not only due to the narrowing of the lumen of the bowel by the invagination, but also to the swelling of the invaginated portion caused by the constriction of the blood-vessels supplying the intussusceptum at the neck of the intussuscipiens. In cases of chronic invagination, where no such vascular engorgement is present, the lumen of the intussusceptum remains sufficiently large for a free passage of the intestinal contents, and no symptoms of obstruction are observed. In a number of experiments on animals where invagination was artificially produced no symptoms of obstruction were observed, and when the animals were killed, weeks or months after the invagination had been made, the lumen of the intussusceptum was not larger than an ordinary lead-pencil, and yet the bowel on the proximal side was not dilated, but somewhat hypertrophic. The greatest danger after invagination has taken place

Ileocolic invagination, showing tip of appendix projecting from the neck of the intussuscipiens.

arises from the constriction of the intussusceptum at the neck of the intussuscipiens. The acuity of the symptoms is always proportionate to the severity of the strangulation at this point. *The circular constriction interferes with the return of venous blood from the intussusceptum, and is followed by edema, complete stasis, and gangrene of the constricted portion.* An acute invagination becomes irreducible by ordinary means within a few hours on account of the appearance of edema in the intussusceptum. If the strangulation is less intense, the passive congestion precedes a plastic inflammation of the serous surfaces held in apposition, and adhesions form that again oppose or render a reduction impossible. In cases where gangrene of the invaginated portion follows within a few hours or days after the invagination, no adhesions form between the serous surfaces. Adhesions at the neck of the intussuscipiens and throughout the extent of the invagination may form soon, and they may be absent after six weeks in the chronic variety. Adhesions are met with in about 80 per cent. of chronic cases and 40 per cent. of acute ones. In acute cases a fatal termination usually takes place from perforation at the neck of the intussuscipiens, followed by septic peritonitis. Numerous cases have been reported where a spontaneous cure was effected by sloughing and elimination of the intussusceptum. This favorable termination is possible only if the continuity of the intestine is restored at the neck of the intussuscipiens by firm unyielding adhesions before the proximal end of the intussusceptum has become gangrenous, or if the line of demarcation is below the neck. Gangrene usually commences at the apex of the intussusceptum and travels in the direction of the neck. That sloughing and elimination of the intussusceptum are not always followed by recovery becomes evident from a study of 149 cases collected by Leichtenstern where this occurred. Out of this number 61 died and 88 recovered, a mortality of 41 per cent. Separation of the gangrenous intussusceptum usually takes place in acute cases in from the eleventh to the twenty-first day, and in children somewhat earlier than in adults. The length of the slough corresponds with the length of the invaginated portion, and cases are on record where recovery followed after the elimination of five or six feet of intestine. According to Treves, spontaneous elimination occurs in about 40 per cent. of all cases. The frequency with which it takes place in the different anatomic forms varies, being 20 per cent. in the ileocecal form, 28 per cent. in the colic form, and 61 per cent. in the enteric form, so that it is most rare in the most common variety. The frequency of elimination of the gangrenous part increases with the age of the patient, being least common in infants on account of the rapidly fatal course of the disease in them, and most frequent in patients advanced in life.

Birch-Hirschfeld gives an accurate postmortem description of a child two years of age who had recovered from a double invagination by sloughing and elimination of the intussusceptum, and died

four months later of measles. At the necropsy it was found that the lower portion of the ileum, the cecum, and the appendix vermiformis were absent. A circular cicatrix in the lumen of the bowel showed where separation had taken place; upon the serous surface at the same point a circular depression indicated the site where separation had occurred. The second invagination had evidently been in the colon at the junction of the ascending with the transverse portion, as a similar cicatrix was also found in this locality. The cures after spontaneous elimination of the intussusceptum are often more apparent than real, as such an ideal restoration of the intestinal canal as described by Birch-Hirschfeld is but rarely effected. Kuettner has followed up the history of several of these cases, and has found that not an inconsiderable number of them die later of perforation and peritonitis. Stricture of the intestine has also been observed as a sequel in some of these cases.

Gerry reports such a case. The invagination was acute, and after three weeks a portion of the small intestine 17½ inches in length passed per anum, followed later by a number of smaller fragments. Soon after the apparent recovery had taken place symptoms of obstruction again set in, due to the formation of a stricture at the point where spontaneous resection had taken place. The patient died seven months after the invagination from the effects of obstruction. At the necropsy a circular stricture was found in the upper part of the small intestine, with loss of several feet of the intestine by sloughing, a fistulous communication between the small intestine and the descending colon, and chronic peritonitis.

Hassler relates a very instructive case of intestinal obstruction following invagination and sloughing of the intussusceptum, which occurred in the practice of Brahmann. The patient was a boy, aged fifteen, who suffered from acute invagination in March, 1892. Four weeks after the attack a piece of gangrenous intestine was discharged with the stool, the discharge being followed by apparent recovery. Two months later symptoms of obstruction returned. At this time a swelling the size of a hen's egg could be felt in the lower part of the ileum. Laparotomy was performed. The obstruction was found at the swelling. By pressure, fluid feces could be forced from the proximal into the distal part of the intestine. The opening, however, appeared to be small. As the proximal end was not in a favorable condition for resection and suturing, the affected part of the bowel was brought forward into the wound, where it was fastened. Two days later the bowel was opened above the seat of obstruction. Two weeks subsequently enterectomy and circular suturing were done. Recovery followed without any untoward symptoms. The specimen showed that at the time the resection was made the lumen of the bowel was completely obliterated by cicatricial contraction. The swelling immediately below the stricture had the shape and appearance of a polypus, but on careful examination proved to be the remnant of the intussusceptum.

It will be seen, from the foregoing, that very little reliance can be placed on nature's resources in reestablishing the permeability of the intestinal canal in invagination, as even in the most favorable cases the temporary relief following sloughing of the invaginated portion is so frequently followed by cicatricial stenosis and flexion.

Pathology of Chronic Invagination.—In cases of chronic invagination the symptoms are identical with those of intestinal stenosis from other causes. The constriction at the neck of the intussuscipiens is not sufficient in degree to arrest the circulation in the invaginated portion, consequently gangrene does not take place. The seat of the invagination and the bowel on the proximal side become the seat of hyperplastic changes resulting from the chronic congestion that attends the lesion and from the increased peristalsis that is maintained by the chronic obstruction. Adhesions do not form with the same rapidity in the subacute variety, and reduction is often possible weeks and months after the accident has occurred. The chronic form of invagination is very often caused by a pedunculated, interstitial, or circular tumor, in which case the tumor always forms the apex of the intussusceptum. Sloughing is of rare occurrence.

Pohl has described an interesting specimen of chronic invagination taken from a man sixty-two years of age who suffered from two attacks of intestinal obstruction eleven years apart. The second attack proved fatal after an illness of eleven days. The postmortem appearances indicated that the invagination that was found had existed for eleven years, and that the second attack was due to an aggravation of the mechanical difficulties at the seat of invagination, and that had given rise to ulcerative inflammation of the mucous membrane lining the intussusceptum, perforation, and suppurative peritonitis. The intussusception was located in the lower portion of the ileum. The intussuscipiens was thirty centimeters in length, its muscular coat hypertrophic, the mucous membrane thickened and very vascular, and some of its folds adherent to the inclosed intestine; on the posterior wall, near the mesenteric attachment, two perforations were found. The intussusceptum was twenty-four centimeters in length, and its mucous membrane was extensively ulcerated; old and firm adhesions were found at the neck of the intussuscipiens. The mesentery of the ileum throughout, but especially at the seat of invagination, was much thickened. The ileum above obstruction was dilated, and its walls were thickened.

Leichtenstern reports a case of chronic invagination that presents a number of interesting points. The attack was brought on by indiscreet diet, and was attended by well-marked symptoms, tenesmus, and liquid stools mixed with mucus and blood. The patient lived for eleven weeks. After the first few days the stools were normal in size and consistence. Recurring colicky pains, often very severe, constituted the most troublesome and important symptom. A swelling in the region of the transverse colon could always be felt, but

became firmer and more circumscribed during the attacks of colic or after a prolonged examination by palpation. The necropsy revealed an ileocecal invagination, the lowest portion of which consisted of the point of entrance of the ileum into the colon, the inner cylinder of the cecum and ascending colon, and the outer cylinder or sheath of the transverse colon. All the parts involved in the invagination were the seat of hypertrophic changes.

Treatment.—Invagination sufficient in extent and duration to give rise to intestinal obstruction is, from the very beginning, as much a surgical affection and requires as prompt surgical interference as a strangulated hernia. The physician must become a surgeon or must avail himself of the services of one as soon as a diagnosis can be made. There is no form of intestinal obstruction that offers a better prognosis than intussusception if rational surgical treatment is resorted to within a few hours after the accident has occurred ; and no other form is sooner followed by more dangerous complications than acute invagination. As invagination is produced by exaggerated or irregular peristalsis, and the descent of the invaginated portion often takes place with great rapidity, the first indication that presents itself in the treatment is to quiet the intestinal contractions. This can be done most speedily by washing out the stomach, by suspending stomach-feeding, and by administering opium, preferably the resin or tincture. If the opiate can not be given by the mouth, it should be administered by the rectum or subcutaneously. Of course, great caution is necessary in the use of this drug in infants and young children. The next step in the treatment consists in the employment of such mechanical measures as are likely to prove useful in effecting disinvagination without a formal operation.

Early recognition of the existence of invagination is of the greatest importance for successful treatment, as the prospects for successful reduction by ordinary surgical means diminish with the development of secondary pathologic conditions at the seat of invagination. Many of the artificial invaginations in animals previously described were reduced spontaneously within a few hours, and in order to study the effects of invagination it was necessary to resort to suturing at the neck of the intussuscipiens in order to retain permanently the invaginated portion. Reduction was resisted after a time either by the swollen, edematous intussusceptum or by the adhesions at the neck of the intussuscipiens, or between the serous surfaces throughout the invaginated portion of the bowel. From these observations we must conclude that reduction by gentle but efficient distention of the bowel below the invagination would succeed in the majority of cases if this procedure were practised before either of the two principal conditions that cause irreducibility has had time to make its appearance. As soon as the existence of an invagination is suspected, the large intestines should be emptied of their contents by the administration of a large enema, the patient

being placed in Hegar's position. After this has been done, the patient should be placed thoroughly under the influence of an anesthetic, so as to facilitate the next step in the treatment by

Rectal Insufflation of Hydrogen Gas or Air.—As gas can be readily forced beyond the ileocecal valve, this method of treatment is applicable in the treatment of invagination in any portion of the intestinal canal, and as distention of the intestine below the seat of obstruction may prove successful in correcting the mechanical difficulties due to other causes, it should be resorted to both as a diagnostic and therapeutic measure in the beginning of all cases of intestinal obstruction if a correct diagnosis can not be made without it. The *modus operandi* of this surgical resource was witnessed in an animal on the third day after the invagination had been made, by opening the abdomen and exposing to sight the seat of invagination before the insufflation was made. In this instance two inches of the ileum were invaginated into the colon and fixed by two fine silk sutures at the neck of the intussuscipiens. On the third day the abdominal cavity was reopened by an incision along the outer border of the right rectus muscle, and the invaginated bowel drawn forward into the wound. The bowel at point of operation was very vascular, and the neck of the intussuscipiens was covered with plastic exudation. The sutures were removed, and the rectum and colon were distended with gas for the purpose of effecting reduction. As soon as the colon had become thoroughly distended, the adhesions that had formed gave way with an audible noise, and complete reduction followed in such a manner that the part last invaginated was first released. As the force necessary to rupture the adhesions and to reduce the bowel produced no injury of any kind to the intestine below or at the seat of invagination, this experiment would tend to prove that insufflation can be practised successfully in cases of invagination of several days' duration.

The rectal insufflation of hydrogen gas or air in the reduction of an invagination should always be made under the influence of an anesthetic administered to the extent of complete muscular relaxation. The pressure upon the rubber balloon should be uninterrupted, and should never exceed two pounds to the square inch. Disinvagination is effected by inflation by two distinct forces. In the first place, the steady elastic pressure of the gas distends the bowel between the sheath and the returning cylinder, which makes traction upon the neck of the intussuscipiens, while the column of gas, by its pressure against the apex of the intussusceptum, acts as a direct reduction force. In order to accomplish the desired mechanical effect, the inflation must be made slowly and continuously, as when this is done there is less danger of rupturing the bowel than when rapid inflation is made under the same pressure, but with interruptions, and the object of the inflation is more surely realized. The return of the gas is prevented most effectually by an assistant pressing the margins of the anus against the rectal tube.

A small female gutta-percha syringe makes the best rectal tube. A sudden diminution of pressure indicates either that disinvagination has been effected or that a rupture of the intestine has occurred. It is exceedingly important that the surgeon should satisfy himself of the existence of a rupture if this accident has occurred. The best way to recognize the accident is to continue the inflation under a pressure of not more than a quarter to half a pound to the square inch. If the invagination has been reduced, the intestine above it will become gradually distended by the gas, and the distention of the abdomen takes place first over the middle of the abdomen and above the pubes, ascending gradually as the inflation is continued in an upward direction. If the intestine has been ruptured, the gas escapes into the peritoneal cavity, and the existence of the accident is proved by the appearance of a uniform free tympanites, with disappearance of liver dullness. In a recent case there is no danger of rupturing the bowel under a pressure of two pounds to the square inch, and in cases where the tissue of the intestine yields under this pressure, a laparotomy is the only proper remedy, and the occurrence of the accident renders the indication for the performance of the operation imperative without adding materially to its danger.

Massage.—It is very natural that massage should have had a limited trial in attempts to reduce invagination. Herder reports two cases successfully treated by this procedure. Both patients were infants, one fourteen days old and the other eight months old. In one the invagination reached the splenic flexure of the colon ; in the other the intussusceptum had advanced as far as the sigmoid flexure. The manipulations consisted of inserting the little finger of the left hand into the rectum, and placing the middle finger of the other hand upon the abdominal wall, at a point that would bring the invaginated portion between both fingers. Pressure was made from left to right, and the swelling, which could be distinctly felt, was reduced in size. Repetition of the procedure at different times finally resulted in disinvagination and recovery. Marie succeeded in reducing the invagination in a third case by limiting the manipulations to the outside of the abdominal wall. External massage may prove useful in aiding rectal insufflation in the reduction of recent invaginations, and in such cases deserves a trial.

Colostomy.—Two indications for colostomy might arise in the treatment of colic invagination : (1) In acute cases, when the general symptoms are so grave as to contraindicate a laparotomy. (2) In irreducible chronic cases, when the lower portion of the colon is invaginated into the upper part of the rectum, where it is impossible to make a resection or anastomosis by lateral apposition. According to the location of the invagination, the operation is made in either the right or the left iliac region, in the former instance the opening being made in the cecum, and in the latter, in the descending colon.

Dubois reports a case of intussusception where the invaginated portion could be felt in the region of the sigmoid flexure, through the abdominal wall. Colostomy was performed above the seat of obstruction, and the patient not only recovered, but four months later the permeability of the intestinal canal was restored spontaneously, but the artificial opening had not closed.

A case of chronic invagination of the colon complicated by a circular carcinoma below the sigmoid flexure recently came under my observation. When the patient was admitted into the hospital, the obstruction was complete. The abdomen was enormously distended, and the apex of the intussusceptum could be felt very distinctly a few inches above the anus, presenting a hard, nodular mass, with an opening not large enough to permit the insertion of the tip of the index-finger. The patient's general condition was critical, hence no effort was made to correct or remove the invagination. A left inguinal colostomy afforded prompt relief. Spontaneous reduction of the invagination commenced soon after the operation, and was completed two weeks later.

Enterostomy.—In irreducible iliac and ileocecal invagination an enterostomy should be made only when the patient is in such a collapsed condition that more radical measures are inadmissible. As in the majority of cases the invagination is below the ileocecal valve, the artificial opening should be made in the right iliac region. Should the invagination be located higher up in the intestinal canal and an empty collapsed coil of intestine present itself in the opening, it should be pushed aside and search made for a distended loop. An enterostomy is justifiable even when the patient is in an almost pulseless condition, as this operation is attended by little, if any, shock, and can be done in a few minutes and, if necessary, without an anesthetic. Emptying the bowel above the seat of obstruction will bring relief by removing the abdominal distention and by favorably influencing the invaginated part by diminishing the hydrostatic pressure above the obstruction, which is in itself a potent means of maintaining vascular engorgement.

Langenbeck saved the life of a patient suffering from invagination of the colon by an enterostomy. The invagination had advanced so far that the apex of the intussusceptum could be felt in the rectum. He performed Nélaton's operation, and the patient recovered. Nine months after the operation both the invagination and the artificial anus remained.

Laparotomy.—Remembering that the general mortality of invagination is 70 per cent., and in children less than eleven years of age spontaneous cure by elimination of intussusceptum does not exceed 12 per cent., it becomes plain that in cases where reduction is not accomplished by rectal inflation a laparotomy is indicated in all instances where the general condition of the patient is such as to justify active procedure. It is true that the experience of the past in the operative treatment of invagination is not such as to inspire

confidence, but it must not be forgotten that almost without exception the abdomen was opened only as a last resort after the patient had been completely prostrated by the disease or after the invagination had given rise to irreparable local conditions. Instead of discouraging operative interference, the statistics collected so far furnish the best possible argument in favor of early operations where simpler measures have failed.

Ashurst brought together, with more or less detail, the histories of 13 cases in which laparotomy had been undertaken for the relief of intussusception. Of this number 5 recovered and 8 died. As the result of a study of his cases, he arrived at the conclusion that the operation is not admissible in patients less than one year of age, as all operations to that date done in children less than a year of age proved fatal. He also advises against an operation when the symptoms present, and particularly the existence of intestinal hemorrhage, render it probable that the tightness of the intussusception will lead to sloughing of the invaginated portion, as he claims that under these circumstances an operation would almost surely fail, while there is a fair hope that separation of the invaginated mass may lead to spontaneous recovery. Experience has shown that a cure by spontaneous elimination of the intussusception seldom, if ever, takes place in very young children and infants; consequently the hopelessness of the situation in such cases where legitimate efforts at reduction have failed can be advanced as the most logical reason in favor of operative treatment, as the patient and surgeon have nothing to lose and everything to gain.

Knaggs, after reporting an unsuccessful case of abdominal section for invagination that occurred in his own practice, gives the results of 37 operations, including his own. Of this number 8 recovered and 29 died. In many of these cases peritonitis had set in before the operation was performed, and this condition, and not the operation, was answerable for the subsequent fatal issue.

Sands tabulated the records of 21 cases of laparotomy for intussusception, 8 of which have occurred since the publication of Ashurst's paper. Of 20 cases in which the result of the operation is given, 7 recovered and 13 proved fatal, thus showing a mortality of 65 per cent. After a study of these cases he came to the conclusion that the prognosis after operation is also influenced by the age of the patient: thus, of 12 cases of two years old or under, 3 recovered and 9 died. Of 7 cases sixteen years old or over, 4 recovered and 3 died, showing that the mortality is greater in infants than in adults. Sands remarks, very properly, that the mortality depends more on the condition of the intestine than on the age of the patient. In taking all cases together he has found that the mortality of the operation is 14 per cent. in the easy cases, and 91 per cent. in the difficult ones.

The largest number of operations for invagination has been collected by Braun. He tabulated 51 operations that were performed

since 1870—that is, operations done under antiseptic precautions. Of this number, 11 patients were cured and 40 died. In 27 of these cases disinvagination was effected, and in 24 it was not; of the former, 18 were children and 9 were adults. Four children recovered, while 14 died. Seven adults lived and 2 died. Resection of the invaginated portion was practised 12 times, with only 1 recovery. An artificial anus was established in 9 cases, followed by death in every instance.

Treves gives the general mortality in 133 recorded cases as 72 per cent.; when reduction was easy, it was 30 per cent., and when difficult, 91 per cent. No one can look over these tables without noticing that the mortality was greatly influenced by the local conditions, as when the reduction was easy it was greatly lowered. This fact alone should convince us that laparotomy should be resorted to without delay as soon as a faithful attempt at reduction by rectal insufflation has demonstrated that reduction can not be accomplished in any other way. The operation should be done as a first, and not as a last, resort. As in cases of strangulated hernia, the obstacles to reduction become more persistent as time advances, and the danger is augmented in proportion to the time that elapses until reduction is attempted. In reference to the time when the operation should be done, a protest must be entered against unnecessary delay and the positive statement be made that it should be done as soon as it has been shown that reposition can not be effected by rectal insufflation. The age of the patient should not enter into consideration in deciding upon the propriety of an operation. Sands operated successfully upon an infant only six months of age, where the ordinary treatment by injection and inflation had been only partially effective in accomplishing disinvagination. The cecum and appendix vermiformis and a small portion of the ileum remained firmly fixed in the sheath, and it required considerable traction force to release them.

As could be expected, recent statistics place abdominal section in the treatment of invagination in a much more favorable light than heretofore. In 1895 Rydygier reported 75 abdominal sections for invagination, which material embraced all of the cases since Braun's statistics, and extended over a period of twenty years,—from 1875 to 1895,—with a mortality of 75 per cent. in acute cases and 25.9 per cent. in chronic cases. A year later the statistics gathered by F. H. Wiggin showed a mortality of only 22 per cent. In 1897 C. L. Gibson published the results of treatment and mortality of 239 cases of acute intussusception, in which the mortality was estimated at 53 per cent. His tables are extremely valuable in showing the influence of time in determining the result of operative interference. He says:

"The mortality, according as the condition was found to be reducible or otherwise, is in direct proportion to the duration of symptoms. Of 99 reducible cases, 38 died, a mortality of 38 per

cent., while in the remaining 50 cases, in which reduction could not be performed, the mortality was 82 per cent., or more than double. As table IV shows how the proportion of nonreducible cases rose steadily after the first day, it requires no further demonstration that an early intervention is necessary for reduction and cure of the intussusception by virtue of its being reducible."

Recent results seem to indicate that timely surgical interference will bring invagination—the form of intestinal obstruction that has destroyed more lives than all the other varieties combined—within the reach of successful treatment with results on a level with those we now achieve in strangulated hernia.

The incision, without exception, should be made in the median line, as it furnishes the most ready access to the invagination, and enables the operator to apply the various surgical resources with the greatest facility. For special indications a lateral incision can be made later. If the swelling has not been previously located by palpation or insufflation, it is usually not difficult to find the seat of obstruction. As soon as the invaginated part has been found, it should be brought into or as near to the wound as possible for careful examination, as the future action of the surgeon will be guided by the local conditions of the invaginated bowel. If, on examination, no evidences of gangrene are found, efforts should be made to effect reduction.

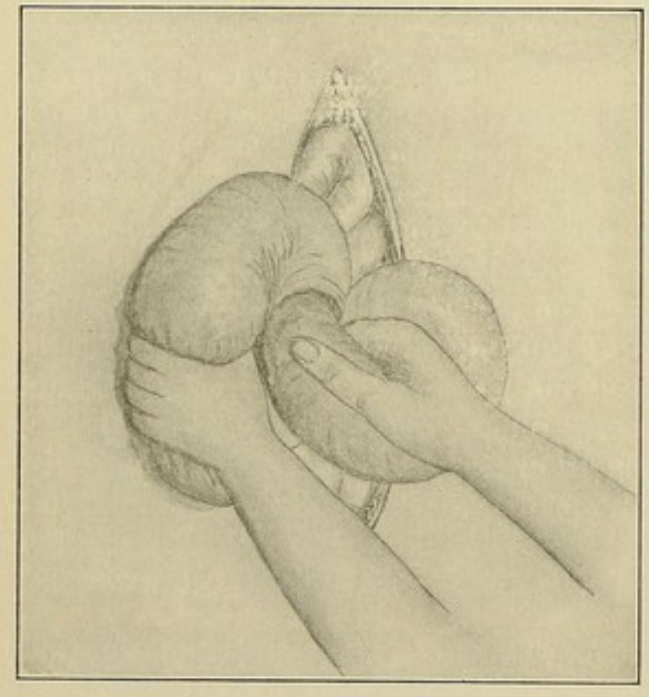

Fig. 522.—Senn's method of performing taxis in reducing an invagination.

Disinvagination.—In recent and especially acute cases, the difficulties that resist reduction are not to be sought in the presence of adhesions as often as in the *swollen edematous intussusceptum.* The same measures should be used to facilitate reduction as in the preliminary treatment of a phimosis or paraphimosis. *The edema and inflammatory swelling should be removed before any efforts at reduction are made. This can be readily accomplished by steady and uninterrupted manual compression of the invaginated portion.* As soon as the swelling has been reduced in this manner, reduction is attempted by making gentle traction upon the bowel above the neck of the intussuscipiens (Fig. 522), aiding the reduction by grasping the bowel below firmly with the left hand, and pressing against the

apex of the intussusceptum. Should this fail, inflation is practised, and as soon as the bowel between the returning cylinder and the sheath has become expanded, taxis is repeated in the same manner. If this manœuver fails to effect reduction, Rydygier directs that reduction should be facilitated by inserting the finger between the intussusceptum and the intussuscipiens, for the purpose of breaking up adhesions. Any one who has had much experience with such cases must have observed that the neck of the intussuscipiens grasps the bowel very tightly, and that any such efforts as the introduction of a finger would be almost certain to result in rupture of the bowel. If the treatment as just directed does not effect reduction, the presence of adhesions must be suspected. These should be broken up not by the introduction of the finger, but by inserting and passing around the bowel a Kocher's director or a small probe. When the adhesions have been severed, the efforts at reduction by traction, pressure, and inflation are repeated.

Roser has suggested that after reduction has been effected the invaginated portion should be sutured to the abdominal wall, for the purpose of preventing reinvagination. Under proper treatment it is not very likely that reinvagination will take place, and such fixation might subsequently result in another form of intestinal obstruction. Reinvagination can positively be prevented by shortening the mesentery at the point of invagination by folding it upon itself in a direction parallel to the bowel, and maintaining it in this position by a few catgut sutures.

Should the bowel present any indications of seriously impaired nutrition, it must be fastened in the wound with strips of iodoform gauze, until time has decided upon the safety of its replacement into the abdominal cavity, when the external incision can be closed by secondary suturing.

Intestinal Anastomosis.—In 1887 I recommended intestinal anastomosis in cases in which the invagination is irreducible, and claimed at that time that upon relieving the obstruction the pathologic conditions that so constantly threaten life would recede. This method of dealing with the invagination must, of course, be limited to cases in which there are no indications of gangrene or perforation.

Should repeated attempts at reduction fail, one of two courses of treatment may be pursued: (1) The establishment of an intestinal anastomosis; (2) resection of the invaginated portion with or without circular enterorrhaphy. Resection of the invaginated portion, especially if the invagination is extensive, is a very grave undertaking, as it involves the removal of important parts and requires a long time for its execution, a matter of vital importance in these cases; on these accounts it should never be resorted to unless the invaginated parts show evidences of gangrene.

An intestinal anastomosis between the bowel above and below the invagination by suturing, Murphy button, or decalcified perfor-

ated bone discs can be made in a short time, and at once restores the continuity of the intestinal canal. As soon as the hydrostatic pressure above the obstruction has been removed by this operation, the danger of gangrene is diminished, and the bowel may again become permeable by a subsequent spontaneous reduction or by elimination of the intussusceptum. If the invagination remain permanently, it does no particular harm, as the obstructed portion has been excluded by the anastomosis and subsequently undergoes atrophic changes. In cases where the intussusceptum has advanced beyond the sigmoid flexure, it would become necessary, after ligation, to

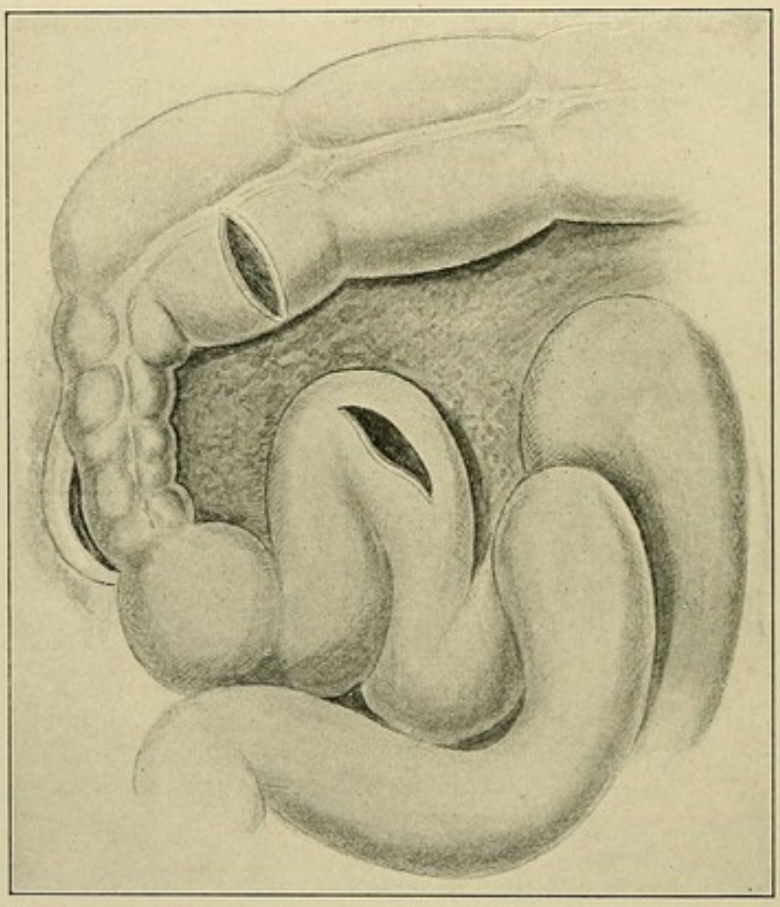

Fig. 523.—Bayer's case of irreducible ileocolic invagination successfully treated by ileocolostomy.

remove a part of it through the lower incision, in order to render the bowel permeable below this point. I have demonstrated, to my entire satisfaction, the therapeutic value of this operation on the lower animals.

Korcynski reports an exceedingly interesting case where intestinal anastomosis was established spontaneously in a case of invagination, followed by a cure. The patient was forty-one years of age, and the symptoms of obstruction had lasted for six weeks, but were completely relieved by the new opening. The existence of such an opening could readily be verified by digital exploration of the rectum. After the symptoms of obstruction had subsided, the

exclusion of a part of the intestinal tract could be ascertained by insufflation of the rectum, which at once produced a tympanitic distention of the middle of the abdomen without distention of the colon. A similar but small communication was found on postmortem, as in the case reported by Gerry, previously referred to.

Two successful cases of intestinal anastomosis for irreducible invagination have recently been reported. Both operations were performed in 1893. H. Braun treated a case of chronic ileocecal invagination successfully by making an ileocolostomy. The patient was a man who had suffered for several months with symptoms of chronic obstruction. More than twenty centimeters of the ileum were found invaginated into the colon. An anastomosis was established between the ileum above the obstruction and the transverse colon. The patient recovered, and although the invagination remained, it caused no further difficulty.

The second case is reported by C. Bayer (Fig. 523), of Prague, who made an ileocolostomy in a case of irreducible ileocolic invagination. The patient was a girl, eight years old, and the invagination was of a subacute nature. In making the anastomosis he transversely incised the colon below, and the ileum above, the obstruction, for a distance of 3½ cm., as is shown in the illustration. The recovery was somewhat retarded by the formation of a mural abscess.

Extra-abdominal Treatment of Invaginated Portion.—In irreducible invagination with indications of gangrene, and when the patient's condition does not warrant total resection, the best course to pursue is to bring the invaginated portion into the abdominal incision, fasten it in position with a few catgut sutures and strips of iodoform gauze, and open the bowel above the obstruction, either at once or one or two days later. Should the patient recover, secondary resection and circular enterorrhaphy can be done later with a fair prospect of success.

Total Resection.—The only indication for total resection of the invagination is furnished by gangrene, provided the general condition of the patient is such as to warrant the performance of so grave an operation. The extent of the gangrene is immaterial in reference to the advisability of making a resection, as a small gangrenous spot necessarily would lead to perforation and death from septic peritonitis unless this radical measure is adopted. The resection must always include the entire intussusceptum, but not necessarily the entire sheath. The first evidences of gangrene upon the external surface of the bowel appear about the neck of the intussuscipiens; and when the invagination is extensive and the lower portion of the sheath presents a healthy appearance, it is necessary only to resect the neck of the intussuscipiens, and the intussusceptum, which, after division and isolation about the neck, can be drawn out and removed. The bowel above and below the proposed points of section should be tied with a rubber band to prevent fecal extrava-

sation during the operation. The mesenteric attachments must be tied in small sections with fine silk ligatures, as tying in larger sections or with catgut is liable to be followed by hemorrhage. After the resection has been made, it becomes a serious question how to proceed further. Shall the continuity of the intestinal canal be restored at once by suturing, or shall an artificial anus be established? When the resection involves the ileum above and the colon below, it is exceedingly difficult to restore the continuity of the intestinal canal by circular enterorrhaphy on account of the difference in the lumina of the bowel to be united. As ileocecal invagination is the most common form, it is evident that, as a rule, some other plan must be followed. Under these circumstances one of two methods of procedure can be chosen. The colon at the point of division is inverted to the extent of an inch or more, and closed by making a few stitches of the continued suture, which should embrace only the serous and muscular coats, and the iliac end is implanted into a slit, corresponding in size to the circumference of the bowel, made in the colon on the side opposite to the mesocolon, at a point just below the closed end. Fixation is most effectually secured by a rubber ring and two inversion sutures, as described in the section on Lateral Implantation, to which should be added, as a matter of precaution, a superficial continued suture. If lateral implantation can not readily be done, an equally efficient method consists in closing both ends and establishing the continuity of the intestinal canal by lateral apposition, in the same manner as has been described under the head of Intestinal Anastomosis. Restoration of the continuity of the intestinal canal after resection of an invaginated bowel by lateral implantation or lateral apposition requires much less time than a circular enterorrhaphy, and both operations secure better conditions for definitive healing than circular enterorrhaphy; on these accounts, therefore, they should, under these and similar circumstances, be preferred to the latter procedure.

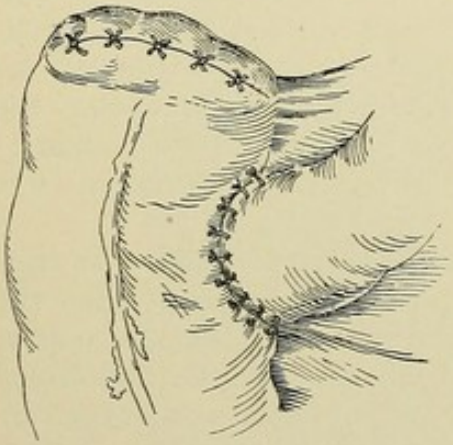

Fig. 524.—Lateral implantation (McCosh).

In cases of colic invagination requiring an extensive resection, approximation of the two ends is not possible on account of the distance they are separated from each other and the comparatively slight immobility of this part of the intestine. In such a case lateral implantation is impracticable for the same reasons. The choice lies between lateral apposition and the establishment of an artificial anus; the latter should never be made, as in case of recovery of the patient the fecal fistula would remain as a permanent condition without any prospects of an ultimate cure. The

continuity of the intestinal canal can be restored at once in these cases by making an ileocolostomy, or a colocolostomy by lateral apposition, according to the location or extent of the resection.

Wassiljew reports a very interesting case of resection for invagination that ultimately terminated in recovery. The patient was a man, aged twenty-five years, who was seized with abdominal pain and vomiting. As the symptoms of obstruction did not yield to ordinary treatment, laparotomy was performed on the second day. On opening the abdominal cavity a swelling was readily detected in the right hypogastric region. This swelling was drawn forward, and was found to be an extensive invagination of the ileum into the colon. As reduction could not be accomplished, an elastic ligature was tied around the bowel in two places, and the ileum and mesentery were divided. Then the invaginated portion was readily withdrawn, and about seventeen inches were resected. The abdominal cavity was washed with a solution of sublimate, and the cut ends of the bowel were fixed by sutures to the abdominal wound. Much gas and fecal matter escaped when the ligatures were united. During the sixth week an operation was performed for the cure of the artificial anus. About six inches more of the intestine were resected, and the cut ends united by Czerny's suture. On the third day the bowels moved, but on the fifth day the fecal discharges again escaped through the wound. The different attempts to close the fistulous opening failed. Digital exploration showed that a spur was beginning to form. To this spur a pressure forceps was applied; it fell off on the third day. Ultimately the fistula closed.

Resection of Intussusceptum.—In 1891 I proposed resection of the intussusceptum as a substitute for total resection in cases of irreducible invagination in which the intussuscipiens was found in a condition warranting such an attempt. The following method was recommended: Incise the intussuscipiens longitudinally over the convex side, two inches or more from the neck, and to a sufficient extent to give easy access to the intussusceptum near the neck. Ligate the intussusceptum here with a strong rubber cord, amputate at a safe distance below, and extract through incisions. Make a similar visceral incision in the bowel above the neck, and establish an anastomosis by uniting the incisions by suturing, Murphy button, or decalcified bone-plates. Disinvagination of the stump is impossible if the rubber ligature is tied with sufficient firmness, and the continuity of the intestinal canal is at once restored by the anastomosis. By the time the ligature cuts its way through the tissues, the serous surfaces will have become firmly united.

In 1892 Barker devised what he considered a new operation, calculated to obviate the necessity of resecting the intussuscipiens in cases of irreducible invagination. He places a ring of sutures around the neck, so as to fasten together the intussuscipiens and intussusceptum; then he incises the former, generally longitudinally. Through this incision the intussusceptum is divided just below the

neck and removed. A few sutures through the edges of the folds of the intussusceptum control the bleeding. The visceral incision is then closed in the usual manner.

Barker claims that the operation requires much less time than the customary resection and suturing, but the operation is liable to be followed by further invagination. In two cases operated upon

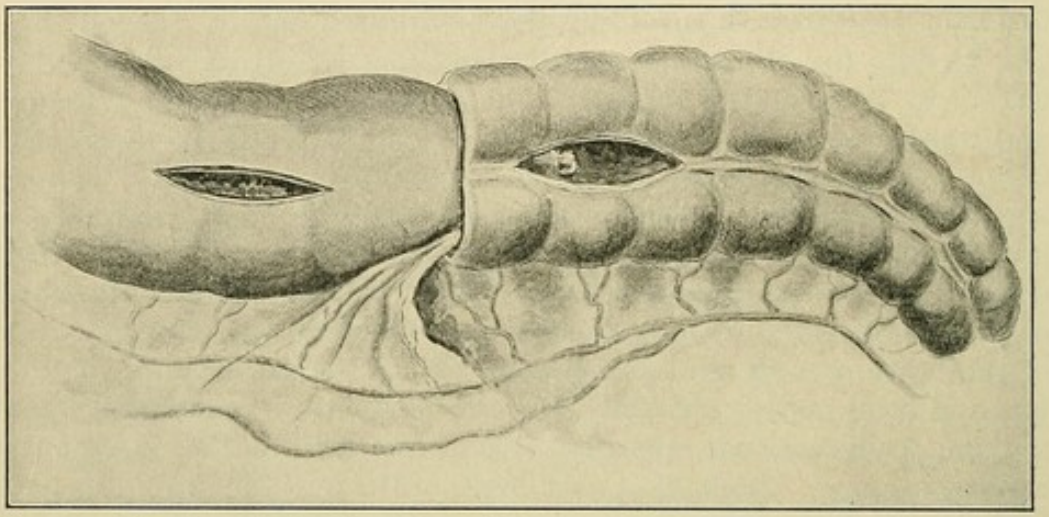

Fig. 525.—Senn's method of resection of the intussusceptum, and establishing an anastomosis between the intestine above and below the neck of the intussuscipiens.

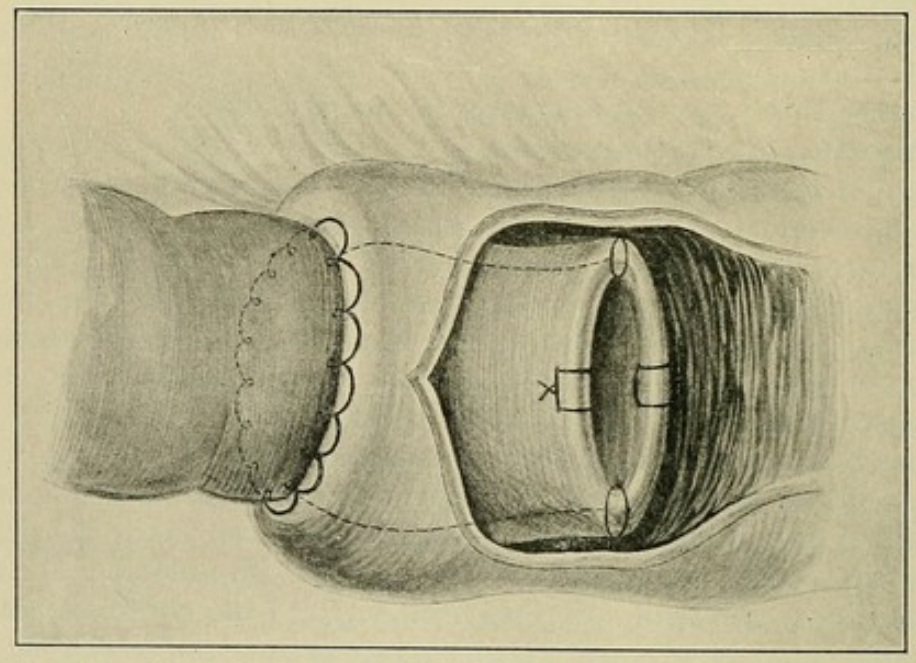

Fig. 526.—Rydygier's method of resection of the intussusceptum.

by Barker, the patients' general condition was so bad that they died of shock shortly after. In performing the same operation, Rydygier proceeds as follows:

Attach invaginated portion to the neck of the intussuscipiens by a running suture (Fig. 526). Incise sheath on convex side, below the neck, longitudinally; amputate invaginated portion; suture cut end,

especially of the mesenteric portion, for the arrest of hemorrhage; extract the resected portion through incision, or, if long and accessible, by the rectum from below; suture the incision; close the abdomen.

Maunsell removes the invaginated portion in the following manner: "Gently withdraw the intussusceptum until its neck appears outside the slit in the intussuscipiens. Transfix the base with two fine, straight needles armed with strong horsehair, chromicized catgut, or fine silkworm-gut. Now amputate the intussusceptum a quarter of an inch clear of the needles, so as to leave a fair stump beyond them. Transfixing the neck of the intussusceptum previous to its amputation prevents it from flying back inside, and insures the proper relative position of the different layers of the bowel previous to sewing them up. Having amputated the intussusceptum, pass the needles through, and pick up the suture in the middle of the invaginated bowel, divide it, and suture the bowel on both sides; leave the ends of the four sutures long, so as to hold the cut ends of the bowel in position until it is completely sutured up circumferentially. Now cut off the long ends of the sutures, apply Wölfler's mixture, blow over with iodoform, and withdraw the bowel. It only now remains to sew up the longitudinal slit with a continuous suture."

Which one of the operations that have been devised for resection of the intussusceptum will prove most successful will have to be determined by future experience. The one proposed by me can be made in the shortest space of time, and at once secures a free passage for the intestinal contents through the anastomotic opening.

Amputation of Intussusceptum through the Rectum.—In cases of colic invagination with prolapse of the bowel from the anus, Mikulicz has described a new operation for the removal of the invaginated portion. The prolapsed bowel is transfixed with two ligatures, which are used for steadying the bowel during the operation. The intussuscipiens is then cut transversely, about one or two centimeters from the anal fold. Step by step the tissues are divided, the hemorrhage being arrested as it occurs. After division of the serous coat, any intestinal loops that may be found in the peritoneal pocket are replaced, whereupon the serous coats of the outer and inner cylinders are united with interrupted sutures. When this has been done, the anterior half of the intussusceptum is cut across, after which the walls of both bowels are united with deep sutures embracing all coats. In the same manner the posterior half of the intestinal tubes is carefully divided and sutured. The hemorrhage from the mesentery must be arrested promptly. The sutures are first cut long, so that they can be used to hold the parts in position. If the two ends of the bowel vary so much in size that exact suturing can not be done, the space that can not be closed is packed with a strip of iodoform gauze. The after-treatment consists in securing rest for the sutured bowel. All dressings and irrigation of the rectum are superfluous and might even prove harmful.

A very simple operation for rectal invagination with prolapse of the intussusceptum was successfully performed in two cases by von Volkmann. Both were children, aged one and three years respectively. The operation was performed by inserting the index-finger into the intussusceptum as far as the anus, when sutures were introduced with a short curved needle, using the tip of the index-finger as a guide in such a manner as to shut off the peritoneal cavity before the prolapsed portion was amputated on a level with the anus below the line of suturing. In one of the cases the insertion of the finger caused a rupture of the invaginated portion to the extent of two centimeters, an accident to which von Volkmann called special attention. After amputation of the bowel hemorrhage was carefully arrested, and the mucous membrane of the anus accurately united with the mucous membrane of the upper portion of the bowel by suturing. On completion of the operation the bowel retracted, so that the line of suturing was above the anus. Both patients made a rapid and permanent recovery.

IMPACTION BY FOREIGN BODIES.

The term intestinal occlusion, in the strict sense of the word, is applied most appropriately to that form of obstruction where the lumen of the bowel is occupied and completely or partially closed by a foreign body or an enterolith. A foreign body introduced into a healthy bowel, even if it completely fill its lumen, does not necessarily produce intestinal obstruction, as the healthy intestine is capable of dilatation to a sufficient extent to furnish an outlet to fluid intestinal contents between the wall of the bowel and the foreign body. The following experiments were made for the purpose of studying the effect of the presence of a foreign body of sufficient size to interfere with the passage of intestinal contents, and also with a view to ascertaining if the exclusion of peristaltic action of a certain limited segment of the intestine could produce intestinal obstruction. The operations were performed under strict aseptic precautions, and the abdominal incision was always made through the linea alba. The animals were fed on the coarsest kind of food, and, as a rule, their appetites were not impaired by the operation.

EXPERIMENT I.—Dog, weight thirty-four pounds. The ileum was drawn forward into the abdominal wound and an incision made about an inch in length on the convex surface, about twelve inches above the ileocecal valve, and through this opening a stiff rubber tube, four inches in length and three-quarters of an inch in diameter, was inserted in a downward direction. The rubber tube distended the bowel so thoroughly as to produce a limited longitudinal rupture of the peritoneal coat. The tube was pushed forward as far as the ileocecal valve, when the intestinal wound and the peritoneal rent were sutured. The visceral wound was covered with an omental graft that was sufficiently long to embrace the entire circumference of the intestine, and was fixed in its place by two catgut sutures that were passed through the mesentery and both ends of the graft. The intestine was now thoroughly cleansed, dried, and returned, and the abdominal wound closed. The tube was passed per rectum in sixty hours. No symptoms of obstruction were observed during this time, and the animal remained in perfect health until killed, twenty days after the operation. The intestinal wound was recognizable upon the external surface of the bowel by a ridge that consisted plainly of a portion of

the omental flap; the remaining portion had evidently disappeared by absorption—at least it had become invisible to the naked eye. The interior surface of the bowel along which the rubber tube had to pass on its way out of the body presented nothing abnormal.

EXPERIMENT 2.—Dog, weight twenty-four pounds. In this instance the incision in the bowel was made eighteen inches above the ileocecal region, and instead of a rubber tube, a glass tube three and three-quarter inches in length and half an inch in diameter was introduced and pushed along the bowel until its distal end was within six inches of the ileocecal valve. Omental graft was made over the visceral wound. No symptoms followed. The tube was passed in sixty-eight hours. The dog was killed fifty-seven days after operation. The intestinal canal was found throughout healthy, and the omental graft had almost completely disappeared.

EXPERIMENT 3.—Dog, weight sixty-two pounds. Incision of bowel was made twelve inches above ileocecal region, and of sufficient size to permit the insertion of a glass tube five-eighths of an inch in diameter and six inches in length, which was pushed in a downward direction to within an inch of the ileocecal valve. The tube filled the lumen of the bowel completely, but produced no tension in the walls. No symptoms appeared. One month later the abdomen was again opened, and the tube was found in the descending colon. The abdomen was closed, and the tube was passed per rectum four days later.

In these experiments hollow tubes were used, and it might be claimed that intestinal obstruction was not produced because the fluid intestinal contents could pass through the lumen of the tube. The effect of the peristaltic action of the bowel in that portion occupied by the tube was certainly eliminated as far as the fecal circulation is concerned, and yet no symptoms of obstruction during life, were observed, and the postmortem appearances indicated that no obstruction had existed during life. It is certainly surprising that the peristaltic action of the intestine should be able to force a rigid tube of such length and dimensions as was used in the last two experiments through the ileocecal valve into the colon.

In the following experiments the foreign body introduced was of such a structure that in case it filled the entire lumen of the bowel it would, of necessity, produce intestinal obstruction, unless a space for the passage of intestinal contents should be created between the foreign body and the intestinal wall by dilatation of the bowel.

EXPERIMENT 4.—Dog, weight thirty-four pounds. Intestine was incised at the junction of the ileum with the jejunum, and the closed end of the barrel of a glass female syringe, six inches in length and half an inch in diameter, was inserted in a downward direction. The animal never showed any untoward symptoms, and as the syringe was not found in the fecal discharges, the animal was killed six weeks later, when it was ascertained that it must have passed at some previous time through the normal outlet, as it could not be found and the intestine presented a normal appearance throughout.

EXPERIMENT 5.—Dog, weight sixty pounds. In this experiment the incision in the bowel was made thirty inches above the ileocecal valve, and through it was inserted, with considerable force, a glass female syringe six and one-half inches long and three-quarters of an inch in diameter, with a metal cap, which considerably increased its diameter at this point. The piston of the syringe projected one inch and a half from the cap. The perforated end of the syringe was directed downward. Visceral wound protected with a circular omental graft. For the first few weeks the animal appeared to be in a good condition, and the fecal discharges were normal. Later the appetite became impaired, and during the last few days obstinate constipation appeared. The dog was killed forty days after the insertion of the foreign body. At this time the syringe could be plainly felt through the abdominal wall. The syringe was found in the ascending colon, having passed through the ileocecal valve. The ileocecal region was distended, and the bowel at this point was partially obstructed by a mass of straw, hair, fragments of bone, etc., for a distance of about ten inches. Above this point the bowel was considerably dilated and contained liquid fecal matter. Several ulcerations were found in the portion of ileum traversed by the syringe. The lowest ulcer was about an inch and a half in length and

half an inch in width, reaching as far as the ileocecal valve, and apparently of recent date. The next ulcer, about one inch longer, but of the same width, was found six inches higher up. This ulcer presented a granulating surface and beginning cicatrization. The third point of ulceration, in an advanced stage of cicatrization, was twelve inches above the ileocecal valve. These ulcers were evidently of a traumatic origin and were undoubtedly caused by friction of the intestinal wall against the projecting point of the piston in the attempts of the bowel to propel the foreign body by increased peristaltic action. In this case the intestinal obstruction commenced with the accumulation of solid material on the proximal side of the syringe, being in reality not caused by the foreign body, but by the coprostasis. Had this latter condition not developed, the foreign body would undoubtedly have been expelled spontaneously as in the former experiments.

These experiments furnish positive proof that a foreign body of sufficient size to fill the entire lumen of a healthy intestine above the ileocecal valve causes no obstruction, and that when obstruction takes place in such instances it is caused by tissue changes in the intestinal wall arising from prolonged contact with the foreign body.

The intestines of man can, of course, not be compared with those of the dog in power and capacity to propel foreign bodies. The intestinal walls in the dog are much stronger and the canal is much shorter. It is, however, somewhat surprising that so large a foreign body as the Murphy button has not more frequently become impacted, and that it is so seldom a cause of intestinal obstruction. In the human subject the passage of foreign bodies through the intestinal canal is favored by a milk and bread or potato diet. It is claimed that such a diet proves beneficial by covering the irregularities of the surface of the foreign body with a thin, smooth incrustation which diminishes the irritation caused by the passage of the foreign body and also the risk of arrest by mural fixation or impaction. The Murphy button is smooth and hollow in the center, and consequently admirably adapted for passage through the intestinal canal.

Enterolithiasis in man is due, in the great majority of cases, to the impaction of a gall-stone or the formation of an enterolith in the lumen of the bowel, the nucleus of which is usually a gall-stone. It has been a disputed question in what way a gall-stone of sufficient size to give rise to obstruction could enter the intestinal canal. Rokitansky asserted that a calculus the size of a hen's egg may pass through the bile-ducts. It is now generally believed that, as a rule, at least, such large concretions can escape from the gall-bladder only by ulceration through its walls, or that a gall-stone of smaller size, after it has passed through the bile-ducts, subsequently becomes larger by the formation of concentric concretions during its retention in the intestinal canal. In reference to the frequency of this form of obstruction, Leichtenstern has found that in 1541 cases of intestinal obstruction with different causes tabulated by himself, in 41 it was produced by gall-stones.

I operated on a middle-aged woman who was suffering from acute intestinal obstruction, and found, as the cause of the obstruction, a gall-stone as large as an English walnut firmly impacted in the ileum a few inches above the ileocecal valve. The gall-stone

was removed by enterotomy, and the patient made a speedy recovery.

Campenon reports two cases of intestinal obstruction caused by impaction of a large gall-stone treated by laparotomy. One recovered, and the other died of peritonitis, caused, as he believed, by separation of adhesions between gall-bladder and intestines during the operation.

Körte operated four times for obstruction caused by gall-stone; two of the patients recovered and two died. In all the cases the foreign body was found firmly impacted and the symptoms were very severe. Enterotomy was made by incising the bowel longitudinally, and after extraction of the gall-stone the wound was sutured. Lindner operated on a similar case and, from the clinical history, he had reason to believe that the gall-stone had been at least six months in the intestinal canal before it gave rise to obstruction.

Israel is of the opinion that impaction is not always the cause of obstruction in such cases, as in one of his operations he found the gall-stone loose in the intestine. König made a postmortem on a similar case, and believes that obstruction is sometimes produced by the foreign body in its descent, by causing, as it were, an invagination of the mucous membrane. In other instances the foreign body may produce irritation and enterospasm.

Wising collected 51 cases of intestinal obstruction caused by the presence of a biliary calculus, with the result that only in 24 of them could the anatomic condition of the gall-bladder be ascertained. In 18 of these the postmortem appearances showed that the calculus had entered the intestine from the gall-bladder by a process of ulceration, and only in 3 cases it appeared as though the calculus had passed through the common bile-duct. In 33 cases the jejunum was 12 times and the ileum 21 times the place of obstruction. In the 21 cases where the calculus was impacted in the ileum the seat of obstruction in 2 was in the middle, in 6 in the upper half, and in 12 in the lower half of this portion of the intestine. Icterus was observed only in 8 of the 51 cases. The prognosis is always very grave, as of the 51 cases, 38 died. In 25 fatal cases death occurred 14 times between the sixth and the eighth day, while in isolated cases it did not occur until from the ninth to the twenty-eighth day, and one patient died from perforative peritonitis after two months. Taking all cases of obstruction from gall-stones, it may be stated that the seat of obstruction is located in the lower portion of the ileum in 50 per cent. of the cases. The upper part of the jejunum is the next most frequent site of obstruction, and in a few the gall-stone becomes impacted in the duodenum, at the site where it has ulcerated through the walls of the gall-bladder and intestine. In 32 cases collected by Leichtenstern, the gall-stone occupied the duodenum and jejunum in 10 cases, middle of ileum in 5 cases, and lower part of ileum in 17 cases. Treves is of the opinion that gall-stones causing intestinal obstruction ulcerate directly into the intes-

tine. He had collected 48 cases of obstruction due to gall-stones. In the majority of cases direct evidence of ulceration between the gall-bladder and duodenum was to be obtained. The gall-bladder was entirely disorganized in a case in which the gall-stone was supposed to have traversed the biliary ducts. When impaction takes place high up in the intestinal tube, tympanites may be entirely absent and the symptoms point rather to the existence of pyloric stenosis than to intestinal obstruction. The higher the location of the impaction, the greater the probability that the calculus attained its size within the biliary passages, and that it entered the intestine by a process of ulceration. In some cases the communication between the gall-bladder and the duodenum remained at the time of death, showing that perforation had taken place only recently. Wising has reported such a case. The patient was a woman seventy years of age, who had never suffered from biliary colic or jaundice. The attack of intestinal obstruction was acute, fecal vomiting being an early symptom; slight icterus and little tympanites were present, and death followed on the fifth day. At the necropsy a biliary calculus seven centimeters in length and ten centimeters in circumference was found firmly impacted in the ileum. The intestine on the proximal side was found greatly distended, and of a color suggesting incipient gangrene, while the bowel below the obstruction was pale and contracted. The gall-bladder was ulcerated and contracted by cicatricial tissue communicating with the duodenum by a perforation above the common bile-duct. A smaller communication was also found between the gall-bladder and the transverse colon. Shattock mentions a case under the care of Dr. Bristowe, in which the remains of the gall-bladder, which was very small, communicated directly with the intestine.

In some cases the pathologic conditions within and around the gall-bladder show evidences that go to prove that perforation had taken place long before the development of the intestinal obstruction. In such cases the gall-stone must have occupied the intestinal canal for a variable period of time without having given rise to obstruction, the intestinal contents passing between it and the intestinal wall in the same manner as in the experiments previously detailed. In some cases the gall-stone becomes encysted and symptoms of obstruction are not produced until the size of the stone has increased by the addition of concentric layers of concretion. Harley reported a case where a gall-stone became encysted in the duodenum. Woodbury reports a case that came under the observation of Dr. T. H. Andrews, of a woman sixty years of age, who was suddenly attacked with symptoms of acute intestinal obstruction without having previously suffered from any disorder of the biliary passages. She died on the seventh day. A concretion the size of an English walnut was found firmly impacted in the upper portion of the jejunum. Upon section the concretion was seen to consist of a brown, friable, cortical substance, enveloping a dense, white crystalline body as

large as a cherry, which was evidently cholesterin. It appears that in this case a small gall-stone that had passed through the bile-ducts without producing symptoms was in some way retained high up in the intestine, and served as a nucleus for the formation of an enterolith of sufficient size to give rise to intestinal obstruction.

Barlow reports the case of a woman fifty-seven years of age who had symptoms of gall-stone for a year. She suddenly developed an acute intestinal obstruction from which she died. About the center of the ileum there was found a biliary calculus the size of a walnut, partially sacculated. In some rare cases the obstruction is caused by the retention of numerous calculi in a circumscribed portion of the bowel. Metcalfe presented to the New York Pathological Society a specimen taken from a man fifty-four years of age, in which the duodenum was occupied by numerous gall-stones in such a way as to give rise to complete obstruction. A calculus may attain great size before it becomes impacted. Smith observed a case of acute intestinal obstruction that proved fatal on the fifth day, and where the postmortem revealed the cause to be a biliary calculus measuring 4½ by 2½ inches in circumference, which was found impacted in the jejunum, thirty inches below the pyloric orifice of the stomach. Clark relates the case of a woman fifty-eight years of age who died of acute intestinal obstruction. Two large gall-stones were found impacted immediately above the ileocecal valve, each of which was one inch in length and four inches in circumference, and together weighed one and one-quarter ounces. The stones were composed of cholesterin and coloring material of bile. The intestine was perforated at the seat of impaction, and a number of small gall-stones were found in the peritoneal cavity. The biliary passages were dilated and thickened, but the gall-bladder appeared to be normal in size and structure and not adherent to the duodenum; jaundice had never existed. Eight months previous to the last illness she had a similar attack of obstruction, and at that time a firm swelling could be felt in the right hypochondriac region. This and the next case illustrate that the great danger of impaction of a gall-stone consists of textural changes of the intestine at the site of impaction. Meymott's patient was a woman forty-seven years old, who died after a short illness during which symptoms of intestinal obstruction were well marked. At the necropsy a gall-stone composed of cholesterin, and weighing 400 grains, was found impacted in the ileum, four inches above the ileocecal valve. At the seat of impaction circumscribed gangrene and perforation had taken place.

Fagge, in his excellent paper "On Intestinal Obstruction," gives an account of a case which he examined, where, in a woman sixty-nine years of age who had died with symptoms of intestinal obstruction, a gall-stone measuring 4½ inches in its largest circumference and 2½ inches in its smallest was found impacted in the jejunum, thirty inches below the pyloric orifice of the stomach. The stone had passed from the gall-bladder into the duodenum through a per-

foration, firm adhesions having prevented its escape into the peritoneal cavity. In two other cases to which the same author refers the patients suffered from intestinal obstruction, and recovery followed after the evacuation of gall-stones of immense size. In cases terminating by spontaneous recovery he believes that perforation takes place into the colon. That the danger is not always passed when a large biliary calculus enters the colon directly through a perforation of the gall-bladder is well illustrated by a case reported by Bourdon, where the calculus became lodged in the sigmoid flexure, producing there an inflammation that proved fatal. In a number of cases recovery took place by discharge of the calculus *per vias naturales* even after the symptoms had pointed to complete obstruction. The largest stone which has been successfully passed was 3½ inches in circumference. Pye-Smith narrates a case that would tend to show that in cases of intestinal obstruction due to the presence of a biliary calculus a spontaneous cure is possible even after the symptoms have continued for a number of days. The patient was a female seventy-eight years of age, who had never suffered from jaundice and gave no history of biliary colic. She had always been very constipated; obstruction finally ensued, and after some temporary relief became complete. By external palpation no swelling could be felt. On rectal examination, however, the finger could just reach a smooth, hard, movable tumor, and it seemed probable that there was malignant disease of the colon. After thirteen days' complete obstruction, however, a large gall-stone was passed, and the patient recovered quickly, and has subsequently remained free from the trouble.

The clinical history of intestinal obstruction by gall-stones will often reveal attacks of biliary colic and peritonitis, which will serve to cause the physician to at least suspect obstruction from an impacted gall-stone.

Treatment.—Copious hot laxative enemata are always indicated in the treatment of intestinal obstruction by impaction of a foreign body. Israel relates a case in which this treatment was followed by the expulsion of a gall-stone that had become impacted and had given rise to severe symptoms of obstruction. Castor oil in cathartic doses may prove effectual in recent cases. Enterospasm caused by the presence of a foreign body may yield to the administration of opiates.

Foreign bodies when impacted in the intestine set up inflammation, and this may go on to gangrene and perforation, and so it can be explained how cathartics under such circumstances are more likely to do harm than good. If impaction has taken place near the ileocecal valve or in the colon, large injections and massage may be tried, provided symptoms of severe inflammation or gangrene at the site of impaction are absent. In the great majority of cases, however, the local lesions at the site of impaction are of such a nature at the time surgical aid is summoned that nothing short of a

laparotomy will promise any hope of success. It will be well for the surgeon not to place too much importance on the presence of tympanitic distention of the abdomen in these cases as an indication for the necessity for an abdominal section, as this sign may be entirely absent if the impaction is located high up in the intestinal tract; if the impaction is in the lower part of the ileum or colon, an operation should not be postponed until such distention has taken place. After the abdomen has been opened in the median line and the seat of obstruction determined, the course to be pursued will depend upon the pathologic conditions at the seat of impaction. As the mucous membrane in contact with the foreign body is always first to suffer in consequence of the impaction, puncture and incision should be avoided at this point. As the cases must be few where such a stone, even soon after impaction has taken place, can be pushed along the intestinal canal and through the ileocecal valve into the colon, submural crushing of the stone should be practised when attempts at distant displacement have failed, and when the condition of the intestinal wall is such that no fear need be entertained that gangrene or perforation will take place. The stone should never be attacked at the seat of impaction, but should be pushed in an upward or downward direction, and then removed, if possible, by breaking it up by manual pressure, or, if this fail, the method suggested by Tait, of passing in a needle obliquely through the intestinal wall and attacking the calculus in this manner, may be tried. A stout steel needle, such as is used for electrolysis, is best adapted for this purpose. The needle should always be introduced obliquely through the intestinal wall, an inch or two below the impaction, in order to secure healthy tissue for the seat of puncture. After the stone has been crushed and the débris within the bowel has been pushed into a healthy segment of bowel below, the puncture in the serous coat should be closed by drawing the peritoneum over it with a fine superficial suture, for the purpose of guarding against leakage. When efforts at submural crushing or fracturing of the enterolith have failed and it is deemed necessary to excise it, it is also advisable to push the foreign body within the bowel in an upward or downward direction sufficiently far to bring it to a perfectly healthy portion of the intestine, as the healing process of the visceral wound made for its extraction would proceed more satisfactorily here than where the tunics of the intestine have been damaged in consequence of the impaction. If the stone can not be displaced and the incision must be made through an inflamed intestinal wall, a graft of omentum should be placed around the intestine after suturing the visceral wound, so as to cover the wound, and its ends fastened together by two sutures passed through the mesenteric attachment. Such a procedure will place the visceral wound in the very best condition for healing, and will furnish an additional safeguard against subsequent perforation. If the intestine at the site of impaction shows evidences of gangrene, or if perforation

has already taken place, no efforts should be made to extract the stone, as under such circumstances the surgeon is compelled to resect that portion of intestine in which the stone is imprisoned. As patients presenting such conditions are always more or less collapsed, it becomes of the greatest importance to finish the operation as rapidly as possible; consequently after the resection has been made in the usual manner the continuity of the intestinal canal should be restored by an operative procedure that can be executed without unnecessary loss of time. As the bowel above the seat of obstruction is always found greatly dilated, circular enterorrhaphy for this reason alone would be a difficult, if not an impracticable, task; hence both ends of the intestine should be invaginated to the extent of an inch, and the invagination maintained by three or four superficial stitches of the continued suture, and the continuity of the intestinal canal restored by making an incision an inch in length in each closed end of the bowel, on the convex surface, about two inches from the sutured extremity, and lateral apposition of the wounds secured by decalcified perforated bone-plates. The last method should always be preferred to circular enterorrhaphy in uniting the bowel after resection under such circumstances, as the extensive and secure coaptation of serous surfaces greatly enhances the chances of early union between the coaptated bowels, and at the same time establishes a communicating opening equally serviceable as after circular suturing.

Intestinal Concretions.—We have already seen that a small gall-stone, when retained for a sufficient length of time in the intestinal canal, may become the nucleus for an intestinal concretion that, by the addition of concentric layers, gradually increases in size until it fills the lumen of the bowel, and, after impaction, gives rise to intestinal obstruction. Enteroliths causing obstruction have been described, in which a variety of foreign bodies have been found as nuclei.

Cloquet divides the concretions found in the alimentary canal into two classes. The first includes enteroliths in man and bezoars in animals, both being the result of calcareous deposits secreted by the parietes of the intestines. The second class comprises abnormal masses, such as solids (animal or vegetable hairs that have escaped the process of digestion, and agglomerate to form ægagropilæ), pulverulent substances, and foreign bodies, such as stones of fruit, biliary calculi, and hardened feces. He described an enterolith that formed around a pin as a nucleus by deposits of phosphate of lime, and that had become arrested in the cecum, where it caused the death of the patient. In another case he found that the nucleus was composed of an ivory pessary that had perforated the bowel on one side and the bladder on the other; the perforation in the bowel was covered by a concretion of phosphate of lime, while the part in the bladder was incrusted with uric acid.

Aberle reported a case where chronic intestinal obstruction was caused by the presence of thirty-two enteroliths, each of which was composed of a concretion in concentric layers around a cherry-stone as a nucleus. The concretions had collected in the colon and were successfully removed by rectal injections and cathartics. A chemic examination of the concretion showed that it was composed of phosphate of lime and a considerable quantity of fat, animal glue, and traces of cholesterin.

Schoor described an enterolith that for five years had given rise to pain, first in the ileocecal region and later in the left inguinal region, and was finally discharged spontaneously. It measured 4½ inches in length and 2.9 inches in width and weighed 44.9 gm. On making a section of it it was found that the central portion, or nucleus, was composed of a triangular piece of bone around which, in concentric layers, the concretion was arranged. A chemic examination of the concretion showed that it was largely composed of phosphate of ammonia and magnesia, the remaining part of it consisting of vegetable fibers, coloring material of bile, cholesterin, and chlorid of sodium.

Virchow made a careful chemic and microscopic examination of an enterolith that had caused symptoms of obstruction in a woman, but that was finally expelled after another severe attack of colica stercoralis. The stone measured 5 cm. in length and 8.5 cm. in its greatest circumference. On making a section through its center it was seen to be composed of a plum-stone surrounded by a shell 2 cm. in thickness, made up of concentric layers of crystalline bodies held together by a brownish mass. Chemic analysis showed that the shell was composed largely of phosphate of ammonia and magnesia.

In Friedländer's case the obstruction was due to the impaction of an enterolith in the ileum, 30 cm. above the ileocecal valve. It was composed of shellac. The patient was a cabinet maker, and it is said that the apprentices of this trade not infrequently consume the alcoholic solution of shellac used for varnishing; in the stomach the alcohol is absorbed and the shellac is deposited. In this case the stomach contained a large number of the same kind of concretions.

At the meeting of the Congress of German Surgeons in Berlin, in April, 1880, Langenbuch showed some large concretions, some of which he had removed by enterotomy in a patient who had suffered from repeated attacks of intestinal obstruction. As the symptoms became more urgent and failed to yield to simpler measures, abdominal section was performed in the median line, and the operator, without much difficulty, found a swelling in the jejunum, laid open the intestine, and removed the mass of concretions, which completely filled the lumen of the bowel. Vomiting continued, and the patient died a few hours after the operation. The necropsy revealed a second mass in the pyloric region of the stomach, larger

than the first. Virchow examined the concretions and found that they consisted almost exclusively of organic substances, and especially of the derivative of the biliary acids known as dyslysin.

The surgical treatment of intestinal concretions is the same as in cases of impacted gall-stone.

Parasites as a Cause of Intestinal Obstruction.—A few cases of intestinal obstruction have been recorded where the obstruction was caused by a mass of ascarides that interfered with the passage of intestinal contents in the same manner as an enterolith. Halma-Grund refers to a patient ten years of age who came under his care suffering with the characteristic symptoms of acute intestinal obstruction, followed by hemorrhage from the bowels, collapse, and death. The necropsy revealed, as the cause of obstruction, a mass of ascarides, eighteen in number, which completely filled the lumen of the ileum. At the site of impaction an ulcer was found, showing an eroded vessel that had been the source of hemorrhage.

Saurel's patient, twenty-three years of age, suffered from symptoms that resembled closely an attack of intestinal obstruction. A swelling could be felt to the left of the umbilicus. Two ascarides were thrown up during a severe attack of vomiting. Anthelmintics were administered and injections given without any effect, and the patient died in collapse. The necropsy revealed the cause of obstruction to have been a mass of ascarides that was firmly impacted in the lower part of the ileum.

Pockels was called to attend a patient who had suffered for some time from an intra-abdominal swelling the size of a hen's egg, which could be distinctly felt below and to the left of the umbilicus. A purge of male-fern and jalap expelled 103 ascarides, after which the swelling disappeared and the patient's health was completely restored.

Stepp has recorded an instance in a boy, aged four, who died with symptoms of acute intestinal obstruction an hour and a half after medical aid was summoned. The postmortem showed that the intestine was completely obstructed by a twisted mass of some forty or fifty round-worms, lodged just above the ileocecal valve. The ileum contained some thirty-five more higher up, and there were a few in the stomach and esophagus. The mother of the child had given the patient some worm medicine a few days before the acute attack, and Stepp thinks that the worms, weakened by the medicine, were dislodged in numbers by the violent peristalsis set up by an injudicious diet afterward, and so rolled down in a tangled mass too large to pass the ileocecal valve.

Paul Simon, of Nancy, reports the case of a child, eleven years of age, who had been suffering with symptoms of intestinal obstruction for seven days. The most prominent symptoms were obstinate vomiting and, on several occasions, hemorrhage from the bowels. The abdomen was tympanitic, very tender to the touch, and a swelling could be felt immediately below the umbilicus, which was pain-

ful on pressure. As the ordinary treatment afforded no relief, an artificial anus was established in the right iliac region. A large quantity of fluid feces escaped, followed by immediate collapse of the distended abdomen; the day following seven living ascarides were discharged in a mass, and a little later an eighth. The next day the bowels moved freely through the natural passage. Santonin treatment resulted in the escape of three additional ascarides. The artificial anus was closed, and the child made an uninterrupted recovery. This is the first case of operative treatment of intestinal obstruction for this kind of occlusion.

Two other cases have been recorded in which intestinal obstruction of parasitic origin was relieved by operative treatment. Rocheblanc's case was a girl nine years old. The symptoms had existed for four days previous to the operation. Injections and cathartics proved of no avail. The child complained of violent pain, which became more and more aggravated in the region of the transverse colon. Opium had no effect on the vomiting and pain. The abdomen was distended and excessively tender, but an area of dullness could be made out corresponding to the transverse colon, and a mass could be distinctly felt. In view of the increasing intensity of the symptoms, operation was decided upon, and a median incision made from the xiphoid cartilage to the umbilicus. The seat of obstruction was found in the transverse colon, at the junction of the left and middle third, and consisted of a plug, conveying to the examining finger the sensation of a bunch of pack thread. Gentle manipulation succeeded in unrolling the mass and distinguishing three lumbricoid worms. With careful massage they were pushed along as far as possible toward the sigmoid flexure, when the abdominal incision was closed. Four hours after the operation the child felt completely relieved of pain and vomiting had ceased. A spontaneous stool occurred, and an injection was followed by several abundant movements of the bowel and the reestablishment of appetite. On the third day calomel and santonin caused the expulsion of the three lumbricoids, after which the child recovered rapidly.

The presence of blood in the stools in children suffering from intestinal obstruction, if invagination can be excluded, is a strong indication of the parasitic nature of the obstruction. The obstruction itself is undoubtedly caused more by the irritation provoked by the parasites, abnormal peristalsis, and textural changes in the intestinal walls than occlusion from impaction. Enterotomy will seldom become necessary, as the mass of parasites can usually be unraveled and pushed downward into the healthy portion of the bowel without a visceral incision.

When the surgeon is called upon to treat a case of intestinal obstruction in a child, such a cause should be borne in mind, as in a case of this kind a timely anthelmintic remedy, followed by a brisk cathartic and a high enema, may prove efficient in removing the cause of obstruction. If such treatment should prove unavail-

ing, no time should be lost in resorting to operative treatment by abdominal section.

Fecal Obstruction.—Fecal obstruction is almost without exception met with only in the large intestine, and here in preference in the cecal region or in the sigmoid flexure. Cases have been reported where a congenital abnormal dilatation of some part of the colon predisposed to this affection. The acquired form of dilatation that attends all cases is the result of prolonged overdistention resulting in paresis of the distended segment of the bowel. It occurs more frequently in women than in men, and in persons advanced in years and leading a sedentary life.

Boys de Loury has collected a number of cases of retention of feces in the cecum and colon that finally gave rise to inflammation at the seat of impaction and intestinal obstruction. Among them was one observed by Nélaton, where the fecal swelling occupying the cecum and ascending colon, by pressure against the under surface of the liver and gall-bladder, caused icterus. The icterus and symptoms of obstruction disappeared promptly after the removal of the fecal accumulation by cathartics. Retention of feces after a time produces more or less acute enteritis, attended by tympanites, pain, and dyspnea. The patients usually have been constipated for a long time, constipation sometimes alternating with diarrhea. The retained feces become inspissated, hard, and form mural concretions, the middle often remaining tunneled for the passage of fluid feces. The masses are molded, and, when thrown off, often describe in accurate outline the contour of the bowel. Distention of the bowel often takes place to an enormous extent. Cruveilhier found, on making a necropsy on an old man, the transverse colon dilated so that it measured 35 cm. in circumference. The cecum was even more dilated and was the size of a child's head. In one of my cases of periodic accumulation of feces in the sigmoid flexure the patient would return for treatment only at a time when symptoms of obstruction set in, and every time he presented himself the swelling would occupy almost the entire space in the abdomen below the umbilicus. Mechanical removal of the fecal accumulation, followed by massage and the use of the faradic current and galvanism, had no effect in diminishing the size of the bowel or in preventing the periodic accumulation of feces. If the cecum alone is the seat of impaction, it often presents the appearance of a circumscribed swelling that may be and has been mistaken for an ovarian tumor, abscess, or carcinoma. The retained mass constitutes an irritant that sooner or later causes a catarrhal and ulcerative enteritis, which extends to the remaining tunics and is occasionally the direct cause of perforation and local or diffuse peritonitis. In some instances the inflammation extends to the connective tissue around the intestine, and an abscess forms without an antecedent perforation. The distended bowel gradually becomes paretic, and the local and general symptoms are aggravated. One of the most important diagnostic

points consists in making pressure over the swelling in chloroform narcosis, when the fecal mass is indented, leaving a permanent depression at the point of pressure. Diarrhea alternated by constipation is a very frequent symptom. If the impaction is within reach, the removal should be accomplished by the use of a scoop, assisted by copious injections. If the bowel at the seat of impaction has lost its contractility, cathartics are entirely useless, and if it is in a state of inflammation, positively harmful. In such cases gentle massage, electricity, and high injections are indicated.

Perforation and suppurative inflammation in the connective tissue surrounding the bowel must be met by prompt surgical treatment. In cases where all ordinary measures fail in removing the fecal accumulation, and the symptoms of obstruction continue unabated, it would be not only justifiable, but good surgery, to cut down upon the distended bowel, break up the mass within, and push it along to a portion of the intestine below, where peristaltic action has not been impaired. In rare cases, where the intestinal wall presents pathologic conditions that would contraindicate such a course of treatment, it may become necessary to resort to colotomy and the removal of the fecal mass through the wound. According to circumstances, either close the visceral wound by suturing, or establish a temporary artificial anus by suturing the visceral into an abdominal incision in the corresponding iliac region.

Nonmalignant Stenosis.—Congenital.—Congenital narrowing of the bowel varies in degree from a slight contraction to complete atresia. The experiments on artificial stenosis of the intestines referred to previously have shown that, when the lumen of the small intestine is diminished one-half in size by partial enterectomy and suturing of the wound in a direction parallel to the long axis of the bowel, the function of the bowel is not impaired and obstruction does not occur, but if the stenosis is carried beyond this point, there is great danger of obstruction arising from accumulation of solid intestinal contents on the proximal side of the stenosis. The same holds true of congenital stenosis of the small intestine. Even if the narrowing is considerable, no serious symptoms are produced until some foreign bodies collect above the seat of constriction and cause obstruction from occlusion.

Not all cases of intestinal obstruction developing soon after birth are to be attributed to congenital atresia of the intestine. Chiari made a postmortem examination in a child that died seven days after birth with symptoms of obstruction. Atresia of the intestine was found fifteen centimeters above the ileocecal valve; a defect of the intestine five centimeters in length had been caused by an intrauterine invagination; and the gangrenous intussusceptum was found lower down in the bowel.

Lægg reports an exceedingly interesting case where a congenital stenosis of the ileocecal opening led to chronic obstruction, dilatation of the ileum, and finally to perforation into the ascending colon.

A female twenty-six years of age was admitted into the hospital in April, 1858. She stated that since she was five years of age she suffered from occasional attacks of colic—perhaps five times during a year—attended by constipation and vomiting. After such an attack eight years ago a number of cherry-stones passed with the feces. Recently the attacks became more frequent, and the last was so severe that she found it necessary to seek admission to the hospital. When admitted, she presented many symptoms of obstruction. In the right iliac fossa on percussion a dry crackling sound could be heard and felt. In a few days she again passed a few cherry- and plum-stones and felt relieved. She was given five gutta-percha pills, which never passed through. She left the hospital improved, and was not seen again until six years later. At this time she again suffered from well-marked symptoms of intestinal obstruction, and during the first few days vomited a number of cherry- and plum-stones and a black round mass that, on cutting, was believed to be one of the gutta-percha pills that she had taken six years before. Below the umbilicus the same crackling sound could be heard and felt as before. The symptoms of obstruction gradually became worse, and a few weeks after admission she died. At the necropsy the entire colon was found empty and contracted, the ileum very much dilated—so much so that the lower portion measured seven inches in circumference. On opening it fluid feces and a few fruit-stones escaped. Ileocecal orifice contracted so that it would admit only a No. 9 catheter. Above the ileocecal valve a communicating bimucous fistulous opening the size of a quarter of a dollar had formed between the colon and ileum, and a little above this point another but smaller opening had formed in the same manner by adhesion and perforation. In the small intestine a pint of cherry-stones was found, all of them covered with a black crust that, on examination, proved to contain iron. This author could find in literature only six cases of nonmalignant stenosis of the ileocecal opening. In Schroeder van der Kolk's case the opening was even smaller, and in the lower portion of the ileum, which was enormously dilated, a large mass of cherry-stones and fragments of bone were found.

Bourdon observed another case of congenital stenosis of the ileocecal orifice, as narrated by Dor. The patient was a man, thirty-two years of age, who had suffered for a month from pain in the abdomen, nausea, and vomiting. The bowels were moved with difficulty by cathartics. On examination nothing could be found except a doughy condition of the middle portion of the abdomen, where percussion revealed also a certain degree of dullness. He remained two weeks in the hospital without any improvement being noticeable, when he left, but returned two days later. At this time an irregular uneven swelling could be distinctly felt in the right groin. The swelling rapidly increased in size, and the patient died in a few days of peritonitis. At the necropsy the small intestine

was found very much distended, and the colon and rectum were contracted and empty. Just above the ileocecal valve the ileum was distended to the size of a fetal head, and adherent to the posterior abdominal wall, mesentery, and intestinal coils. The walls of this pouch were thickened and of a brown color. When opened, it was found to contain 120 plum-stones and 92 leaden bullets. The ileocecal valve was nearly closed, and was permeable only to fluids. The patient had probably swallowed the bullets to overcome obstinate constipation. In all these cases of congenital stenosis no symptoms were caused by the congenital defect until the foreign bodies that collected above it finally produced death from complete intestinal obstruction or perforative peritonitis. The clinical history in each case points distinctly to aggravation of the obstruction by the occurrence of coprostasis above the seat of stenosis.

Occlusion of Duodenum in a New-born Child.—Porak and Bernheim describe a case where a woman was delivered at the eighth month of a sickly female child. There was hydramnion, and over six pints of fluid came away during labor. There were two small fibrous deposits in the placenta. On the first day the child vomited dark matter, each attack of vomiting coming on about three-quarters of an hour after nursing. On the third day, as no meconium had passed, imperforate rectum was suspected; but a sound could be passed for over two inches beyond the anus. An enema was given, and a little meconium came away, but the vomiting continued, and the infant died on the fifth day. The stomach was found much dilated; the lower part of the large intestine was full of meconium, but the remainder of the intestinal canal was nearly obliterated. The stomach communicated by a contracted orifice, apparently the pylorus, with a blind pouch that had no connection of any kind with the remainder of the intestine, which terminated above in a blind extremity close to the pancreas, which opened into it. In a similar case, reported by Crooks in 1828, the pancreatic duct opened into the pouch connected with the stomach. Luton described, in 1855, a third case where that pouch communicated with the blind end of the intestine by a ligament. There was a similar breach of continuity between the large and the small intestine. No trace of peritonitic bands could be seen in Porak and Bernheim's case.

Treatment.—The surgical treatment in adults the subject of congenital stenosis sufficient in degree to cause intestinal obstruction consists in removing the impacted substances through an incision above the stenosis, and, after clearing the bowel of its contents, uniting it with a similar incision in the bowel below the obstruction by lateral apposition with decalcified perforated bone-plates, thus establishing a free communication between the bowel above and below the obstruction, and, at the same time, permanently excluding from the intestinal circulation the functionally useless and contracted portion of the intestine. Excision and restoration of the continuity of the intestinal canal by circular

enterorrhaphy can be thought of only in case perforation has taken place.

If the stricture is single and narrow, the lumen of the bowel is restored by enteroplasty, after the method of Heineke-Mikulicz for pyloroplasty.

In infants born with a complete intestinal atresia or a stenosis incompatible with bowel function, surgical interference must be instituted at once. If the general condition of the little patient is such as not to admit of abdominal section, enterostomy is indicated as a life-saving operation. Under such circumstances this operation is very uncertain in its result, as the obstruction is often located high up in the intestinal canal, and, should the patient recover, death from marasmus would be certain in a short time unless a secondary operation is performed in time to restore the continuity of the intestinal canal.

In 1887 Tischendorf saved an infant by this procedure. Enterostomy was performed on the sixth day after birth for what appeared to be an intestinal obstruction involving the upper portion of the intestinal canal. The symptoms of obstruction disappeared at once, but the child died three weeks later from intestinal disturbance and soor. The obstruction at the postmortem was found twenty-five centimeters above the ileocecal valve, and consisted in a complete atresia of the ileum, which was converted into a string not larger than ordinary twine. The part of the intestine between the fistula and obstruction, a distance of twenty centimeters, was dilated and filled with meconium.

J. Bland Sutton was able, from the symptoms presented, to diagnosticate an imperforate ileum in a child shortly after birth, and relieved the symptoms of obstruction by making an artificial anus. The child was first seen forty-eight hours after birth, when the abdomen was found distended and the child vomiting; it had passed nothing by the anus but mucus. The anus was normal, and a catheter could readily be passed into the bowel for many inches. As the child retained milk for a time, imperforate duodenum was excluded. The abdomen was explored with the expectation of finding an imperforate ileum. The congenital defect was found at a point about eighteen inches above the ileocecal valve. The distal end of the ileum was somewhat shrunken and separated from the proximal end by a gap an inch across. The upper culdesac was dilated with meconium and congested; this was removed, and the end of the intestine stitched to the abdominal wound. Meconium and gas escaped freely, the child rallied and took food, and the case promised to go well; but about six hours later the child suddenly expired. This was a favorable case for restoring the continuity of the intestinal canal by lateral anastomosis, as the lumina of the two ends of the bowel were very unequal in size, thus rendering circular enterorrhaphy after resection difficult, if not impossible; moreover, lateral anastomosis would have taken less time than the formation

of an artificial anus. Sutton is of the opinion that congenital stenosis or atresia of the duodenum usually, if not always, will be found just above the opening of the bile-duct, and in the ileum in that part where the primitive alimentary canal is in communication with the yolk-sac by means of the vitelline duct, as in the case he reported.

In infants enterectomy for any congenital obstructive defect of the intestinal canal is contraindicated, and treatment by abdominal section and intestinal anastomosis should always take the place of resection and circular enterorrhaphy, as the operation can be done in a shorter time and is attended by less immediate risk to life. Felix Franke operated by this method on a child two days old. Intestinal obstruction was complete. A left lateral incision was made, as it was believed that the obstruction was located in the descending colon or sigmoid flexure. Dilated vascular coils of the small intestine appeared in the wound, which terminated in a blind end where the intestine was lost in a small but permeable cord. An anastomosis was established between the blind end and the contracted part of the bowel, about 10 cm. from the seat of obstruction. The symptoms improved after the operation, but on the third day collapse suddenly set in and the child died in a few hours. Postmortem revealed leakage and diffuse peritonitis. One of the sutures had given way, and the fatal complications were traceable directly to this cause.

Wanitschek made an intestinal anastomosis for a congenital obstructive defect in a child four days old. The abdomen was opened the entire length of the linea alba. The small intestine, much dilated, vascular, and hypertrophic, presented itself at once, and could be traced into the left iliac fossa, where it terminated in a blind pouch. Cecum and appendix were normal in location, but contracted, as well as the colon. An anastomosis was made between the culdesac of the small intestine and the sigmoid flexure. The child never recovered from the immediate effects of the operation, and died in the evening of the same day. The postmortem showed that about four centimeters of the lower portion of the ileum consisted of a cord, which was found attached to the cecum.

Acquired or Cicatricial.—Cicatricial stenosis of the intestines is one of the remote consequences of deep ulcerative lesions, such as are caused by dysentery, typhlitis stercoralis, tuberculosis, and ileotyphus. The cicatrix that forms during the reparative stage of the ulceration contracts slowly and gives rise to stenosis and chronic intestinal obstruction. As in cases of congenital stenosis, the obstruction often becomes complete and gives rise to acute symptoms when foreign bodies or solid feces become impacted above the seat of constriction. Not infrequently the causes that have led to cicatricial stenosis are located at the same time or appear successively in different parts of the intestine, consequently producing also multiple strictures.

Sharkey presented to the Pathological Society of London a specimen of multiple strictures of the ileum taken from a woman thirty-three years of age, who had suffered frequently from indigestion and vomiting. The immediate cause of death was facial erysipelas. The lower two-thirds of the small intestine exhibited numerous ulcers apparently healed. They were so near together and produced such marked constriction that the appearance of a succession of pouches was simulated. There were no distinct evidences of tuberculosis in the intestine or any of the other organs. In the discussion that followed the demonstration of this specimen Treves spoke of other somewhat similar recorded cases in which typhoid fever and tuberculosis seemed to be excluded. Treves has described another cause of cicatricial stenosis. He has met with such cases in patients who suffered from a strangulated hernia when the prolonged compression during the strangulation had produced a circumscribed gangrene of the mucous coat. In all the recorded cases the patients appear to have recovered well from the hernial trouble, and, after a varying time, gradually to have developed symptoms of cicatricial stenosis of the small intestine.

The most frequent cause of cicatricial stenosis of the intestines is tuberculosis. The healing of a typhoid ulcer is seldom followed by cicatricial contraction. In the large intestine dysentery is often the cause of ulceration, which later leads to contraction. Strictures of the rectum, in the great majority of cases, are syphilitic or gonorrheal in their origin. Intestinal tuberculosis deserves a thorough consideration in connection with acquired cicatricial stenosis.

Frequency of Intestinal Tuberculosis.—Intestinal tuberculosis is a very common complication of pulmonary and miliary tuberculosis. It is not often met with as a primary affection. In 1000 tubercular subjects examined postmortem in the Pathological Institute at Munich between the years 1886 and 1890, only one case of primary intestinal tuberculosis was noted, while in 566 cases secondary intestinal tuberculosis was seen.

That the disease occasionally occurs as a primary affection can no longer be doubted; the results of an enormous clinical experience and thousands of necropsies furnish a substantial verification of this fact. There can, however, be but little doubt that in many cases of tuberculosis of the intestine in which the clinical features point only to this organ as the sole seat of disease, careful search would reveal old, perhaps latent, tubercular foci in some other part of the body. The prudent surgeon selects for his operative work only the cases in which he has reason to believe, from the clinical history and the signs and symptoms presented, that the disease is limited and confined largely, if not entirely, to the intestinal canal.

Etiology.—Primary tuberculosis of the intestinal canal is the result of infection from without by the ingestion of food contami-

nated with the essential cause of the disease, the bacillus of tuberculosis, usually in the form of tubercular milk and meat. The secondary form is caused by autoinfection by the entrance of tubercular sputa into the intestinal canal. The lymph-follicles and Peyer's patches furnish the most favorable anatomic conditions for the localization and growth of the tubercle bacillus. Klebs believes that the introduction of infection into the intestinal canal by the swallowing of sputa in phthisical patients is a frequent cause of intestinal tuberculosis. He discovered two tubercular ulcers in the stomach of a patient who had died of pulmonary tuberculosis. The supposition that intestinal tuberculosis is caused often by the ingestion of tubercular food or sputa is supported by the experiments of Malin, Parrot, and Bonley, who found that animals fed with the expectorations of consumptives died of tuberculosis; while Chauveau, Bollinger, and others succeeded in producing intestinal tuberculosis by feeding animals susceptible to the disease with fragments of tubercular lungs or with raw tubercular meat. The experiments of Gerlach, Zürn, and Klebs demonstrated the dangers attending the use of milk from tubercular cows. In these experiments it was noted that the disease commenced in the form of an intestinal catarrh, and that the extension of the tubercular infection began through the mesenteric glands before the development of diffuse miliary tuberculosis. W. Zinn observed a man twenty-nine years of age who, in the course of nine weeks, died of acute miliary tuberculosis. The autopsy showed that the miliary tuberculosis had its origin in a mass of caseous tubercular mesenteric glands. No other old tubercular deposit could be found. In the intestine, at a point corresponding to the diseased glands, was found the scar that followed the healing of a tubercular ulcer. The ulcer was evidently the primary lesion that led to tubercular lymphadenitis, and finally death followed from reinfection of the body from the tubercular glands long after the intestinal ulcer had healed. General infection in this case took place through the thoracic duct. Wyss found, in seventy-one postmortems on children, three instances of undoubted primary intestinal tuberculosis. In one case, a girl five and three-quarter years of age, who had died of diphtheria, a solitary tubercular ulcer was found in the ileum, with extensive tuberculosis of the mesenteric glands. No trace of tuberculosis could be detected in any other organ. Upon inquiry it was ascertained that the child had been fed on milk almost exclusively for some time before she contracted diphtheria. In the other two cases the disease could be traced to the same cause.

Intestinal tuberculosis is found most frequently in children and young adults, although no age is entirely exempt. In the language of Virchow: "The predisposition to tuberculosis, the hereditary vulnerability, resides in the tissues, and the younger and more incompletely developed these are, the more readily will the vulnerability manifest itself in the presence of exciting causes." This

may explain the special frequency of intestinal tuberculosis in children and in subjects affected by antecedent inflammatory affections of the intestinal mucous membrane.

Baumers first called attention to intestinal tuberculosis in children, which has been known as tabes s., phthisis mesaraica, febris mesaraica, febris xanthus infantum, and intestinal scrofula. Intestinal tuberculosis in children results in early and extensive infection of the mesenteric glands, from which reinfection usually terminates life by miliary tuberculosis. Secondary tuberculosis appears to be more frequent in adults than in children. In children intestinal tuberculosis is met with in from 30 to 40 per cent.; in the adult, in from 60 to 70 per cent. The local predisposing lesion, although important in determining localization, is not essential, as the tubercle bacilli can penetrate the intact mucous membrane.

In six of Czerny's cases subjected to operative interference the patients were between twenty-five and fifty years of age, the average age being thirty-nine. In four of the cases tuberculosis was hereditary, in two cases the disease followed typhoid fever, and in one it was preceded by an acute attack of parametritis. In three of the cases the intestinal disease was complicated by pulmonary tuberculosis, and in one by diffuse miliary tuberculosis. In one case the infection occurred by the rupture of a tubercular adnexal abscess into the intestine, and in another the intestinal tuberculosis was complicated by actinomycosis.

Clinical experience has shown that intestinal tuberculosis pursues a more benign and chronic course in the adult than in children, and consequently the primary form of intestinal tuberculosis amenable to successful surgical treatment is met with most frequently in young adults and persons of advanced age, seldom in the case of infants and young children.

Infection from the blood is undoubtedly of quite common occurrence in primary and secondary intestinal tuberculosis. The most favorable cases for successful surgical intervention are those in which a localized predisposing lesion furnishes an infection atrium for the entrance of tubercle bacilli into the tissues. These are the cases in which characteristic solitary or multiple tubercular ulcers develop that manifest an intrinsic tendency to heal, and in which an operation finally becomes a necessity after symptoms of obstruction indicate the existence of a cicatricial stenosis.

Pathology.—Intestinal tuberculosis presents itself clinically and pathologically in the form of a chronic catarrhal or ulcerative enteritis. The inflammation that follows the tubercular infection is characterized by a series of pathologic processes common to all tubercular affections, influenced and modified, however, by the structure and function of the tissues involved. The primary seats of infection are the glandular appendages of the mucous membrane, the lymph-follicles, and Peyer's agminated glands. The mode of infection resembles typhoid fever in many respects. The lower

portion of the ileum and the ileocecal region are the most frequently infected, although any portion of the intestinal canal may be involved primarily or by extension. Of six cases of intestinal tuberculosis reported by Schiller that were operated upon by Czerny during a period of four years, the disease involved the ileocecal region four times and the descending colon twice. In all cases of cecal tuberculosis operated upon by Czerny, the ulceration was limited on one side by the ileocecal valve; the mucous membrane of the cecum was extensively ulcerated, presenting elevations, depressions, and polypoid excrescences between the ulcers; the cecal wall was much thickened and indurated. The

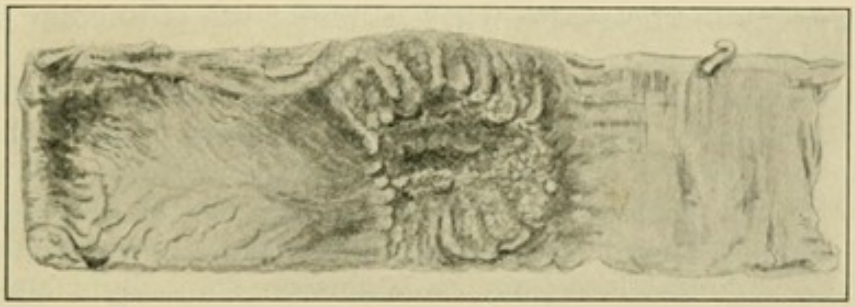

Fig. 527.—Diffuse annular tubercular ulcer of ileum (Pathological Museum, Rush Medical College).

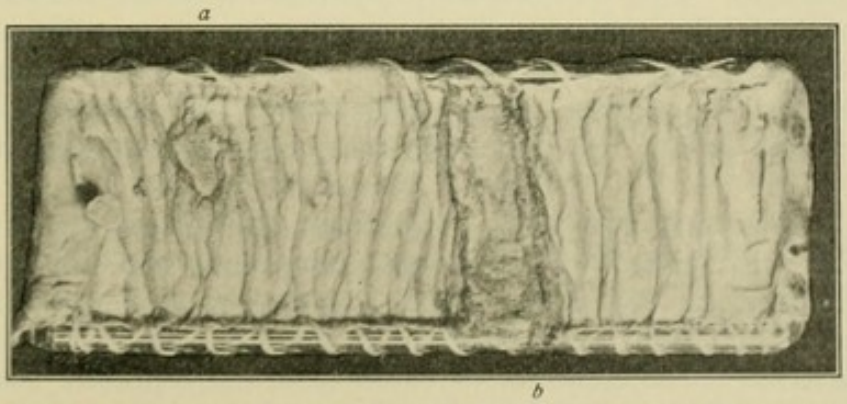

Fig. 528.—Tubercular ulcer of ileum (Pathological Museum, Rush Medical College): *a*, Round tubercular ulcer; *b*, narrow circular tubercular ulcer.

lumen of the cecum was usually found contracted, the stenosis being the direct cause of the intestinal obstruction. In one case the mechanical impediment was found to be a sharp flexion at the insertion of the ileum into the cecum. In one case the contracted lumen of the cecum was divided by a band of cicatricial tissue. The bowel below the obstruction was, as is always the case, nearly empty, reduced in size, and anemic, while on the proximal side reverse conditions existed, which facilitated circular suturing after excision. In acute cases, such as are observed in children and that seldom come to the notice of the surgeon, the disease is usually diffuse and often implicates a large section of the intestinal canal above the ileocecal valve. Tuberculosis is likely to attack a portion

of the intestinal canal subjected to mechanical irritation, as is the case in hernia.

A number of cases of tuberculosis of hernia have been reported. Bruns adds one new case to those previously published. In these 13 cases the hernial sac was attacked 10 times, and in 7 it alone was the seat of disease. This, together with other conclusions, substantiates the belief that "tuberculosis of hernia" may occur as a primary disease; generally, however, it is associated with peritoneal tuberculosis.

It appears, from the present literature on the subject, that tuberculosis in the ileocecal region and the colon is usually a disease of adults, although there are a few cases on record in which the intestinal canal at and below the ileocecal region was affected in children not more than ten years of age.

Reclus has called attention to the rapidly increasing number of cecal tuberculosis cases that have been operated upon. The cases of Bouilly, Terrier, Hartmann, Reynier, Broca, Roux, Salzer, Billroth, and Hochenegg, the anatomic researches of Duguet, Spillmann, Hérard, Cornil, and Hanot, and the more recent descriptions of Pilliet and of Le Bayou, have thrown some light upon this hitherto but little recognized affection. This disease may manifest itself as a localized tuberculosis without infiltration and as a purely local disease. This suffices to place this intestinal lesion among the surgical tuberculoses. From the moment it is a limited focus and this focus is accessible, in such favorable circumstances intervention is legitimate. The greatest number of cases of cecal tuberculosis so far reported have been over twenty-five years of age.

It seems that two distinct anatomicopathologic forms may be described, associated with different symptoms—the one a fibrous and the other an ulcerating variety; moreover, these may be combined, or there may be noticed many intermediate stages between the varieties. The majority of cases thus far reported have been characterized by an abundant tissue proliferation, which imparted to the swelling much of the aspects of carcinoma. The inflammatory mass is almost always found freely embedded in plastic adhesions, and it is difficult, if not impossible, to outline the anatomic landmarks of the parts involved. Ordinarily the lesions are most marked around the ileocecal valve. The appendix is generally affected and constitutes a portion of the inflammatory mass.

The second or ulcerated form may present thickening of the peritoneum and adhesions around the intestinal loops, but these have not the remarkable hypertrophy of the other form; on the contrary, the ulcerative process predominates, and the mucosa has often completely disappeared, especially at the site of the ileocecal valve. Ulceration often leads to abscess and fistula formation. The fistulous openings are frequently multiple.

Cornil believes that in such cases the primary infection takes

place in the appendix vermiformis, more especially when it is the seat of a fecal concretion or foreign body.

The tubercular infection may take place in the upper portion of the intestinal canal. Claude made a postmortem on a man thirty-three years of age who had died of pulmonary tuberculosis. He found tubercular ulcers in the upper portion of the duodenum; four other ulcers were found in the ileum. He attributed the intestinal disease to infection from the blood. During life this patient never showed any symptoms referable to the intestinal canal. The tubercular nature of the intestinal affection was established by histologic and bacteriologic examinations.

The entire length of the intestinal canal is seldom affected by tuberculosis, and in the exceptional instances when this is the case, the disease pursues a rapidly fatal course. It has already been stated that intestinal tuberculosis always begins in the lymph-follicles or Peyer's patches. The tubercular process is at first submucous, and reaches the surface only after degeneration and ulceration have taken place. The glands become swollen, and can be felt under the epithelial lining as small hard nodules which present a grayish color before caseation sets in. With the onset of caseation the swelling increases in size and assumes a yellowish color. As soon as the overlying epithelial lining is destroyed, softening of the inflammatory product and ulceration set in. The primary ulcer is small and round, with yellowish margins. At the time the crater-like defect takes place the mass is not larger than a hempseed. Such small ulcers may heal, but more frequently progressive extension takes place in the direction of the blood-vessels. In Peyer's patches the appearance of sieve-like defects can be seen during the early stages of the disease, which Rokitansky described as primitive tubercular ulcerations. They constitute the evolution stage of secondary tubercular ulcers. Even in superficial ulcers tubercles can constantly be found between the muscular fibers. By confluence and progressive infection the surface defects increase in size. Not infrequently remnants of intact mucous membrane remain between the different points of ulceration. The shape of the ulcer is variously modified by the confluence of several ulcers. The most extensive ulcers are found in the cecum, colon, and terminal portion of the ileum.

The intrinsic tendency of intestinal tubercular ulcers is to increase in size in the direction of the blood-vessels,—that is, transversely to the long axis of the bowel (see Figs. 527 and 528),—a pathologic feature that was first pointed out by Rokitansky. The tubercular infection follows the lymph sheath of the blood-vessels. Through the lymphatics the infection extends to the serosa, upon the surface of which miliary tubercles are often found over an area corresponding in extent to the base of the ulcer. The mesenteric glands are infected through the same channels (Plate 8). In children the mesenteric glands are often affected without an antecedent

intestinal lesion. In such cases the tubercle bacilli penetrate through the mucous membrane and enter the lymphatic system without producing a demonstrable surface lesion, or infection takes place by the way of the general circulation. Infection through the mucous membrane undoubtedly is often determined by catarrhal enteritis, which damages the epithelial lining and prepares the way for invasion from the intestinal canal.

Extension of the ulcer in the muscular coat occurs by progressive extension of the ulcerating process and by diffusion of the infection through the lymph-channels. As soon as the serous coat is reached, secondary plastic peritonitis is the almost constant result. Usually the peritonitis is limited to the affected portion of the bowel, between which and the adjacent viscera firm adhesions are formed. In exceptional cases the peritonitis becomes profuse without perforation. More frequently, however, the diffuse tubercular peritonitis is caused by the rupture of a peri-intestinal tubercular abscess. Perforation of a tubercular ulcer is often prevented by early and firm adhesions. In one of the cases reported by Rindfleisch the intestine was found perforated at five different points without causing diffuse peritonitis, owing to the existence of firm adhesions. Perforative peritonitis is so rare in intestinal tuberculosis that Leube saw but 2 cases during his service in the clinic at Erlangen. Leudet reports 6 cases that occurred in his practice, which were due to tubercular affection of the appendix. Eisenhardt found perforation in 28 out of 566 cases of intestinal tuberculosis examined postmortem. Extension of the disease to other parts and organs frequently takes place through the lymphatic system.

Tubercular lymphadenitis is a frequent and, in long-standing cases, a constant concomitant pathologic condition, as was first pointed out by Schüppel and Rindfleisch. The observations occurring during operations made for intestinal tuberculosis and the results of postmortem examinations combine to show that retrograde metamorphosis of the inflammatory product of the tubercular glands takes place very slowly. I have repeatedly seen tubercular mesenteric glands as large as a hazelnut that had not undergone any decided cheesy degeneration. Coagulation and caseous degeneration, however, occur in the course of time, but liquefaction and abscess formation in and around tubercular mesenteric glands are of rare occurrence. Infiltration and thickening of the intestinal wall occur most frequently and reach the maximum height in cases in which the tuberculosis is located in the ileocecal region or colon. In these localities the disease is most commonly primary, a fact that would explain its chronicity and comparatively benign nature. When the tubercular process affects this part of the intestinal canal, the resultant swelling is often of larger size and has very often been mistaken for malignant disease. In such instances the intestinal wall has been found several centimeters in thickness.

In acute cases of intestinal tuberculosis the ulcers manifest little

Tuberculosis of the small intestine involving the lymphatic glands of the corresponding section of the mesentery (Lebert).

or no tendency to repair. In chronic cases an attempt at healing or complete healing is the rule. Eisenhardt, in examining the post-mortem records of 566 cases of intestinal tuberculosis, found that healing was completed in only 10, while in 25 instances the ulcers were only partly healed.

Attempts at cicatrization are frequently seen, but very often while healing is going on in one part of the ulcer, progressive infection and destruction are witnessed in another portion. The healing of a tubercular ulcer of large size requires an enormous quantity of new material, which is composed largely of new connective tissue. The scar tissue always evinces a tendency to contraction, which leads to stenosis and flexion. If the ulcer is circular, healing is attended by contraction of the lumen of the bowel, which finally leads to intestinal obstruction. If only one side of the circumference of the bowel is ulcerated, healing will result in contraction and flexion. The healing of several tubercular ulcers gives rise to the development of multiple strictures, which have been found by several surgeons in operations for intestinal obstruction. Progressive cicatricial contraction may eventually result in almost complete obliteration of the lumen of the bowel. In one of Scheuer's cases the stricture at the time the intestinal resection was performed for obstruction was so narrow that it admitted only a probe three millimeters in size. The healing of intestinal tubercular ulcers is seldom followed by complete recovery, as all such patients are liable later to intestinal obstruction and reinfection from the tubercular mesenteric and retroperitoneal glands.

Symptoms.—Intestinal tuberculosis may run its entire course from beginning to end without any symptoms that would point to the intestinal canal as the principal seat of the disease. Tubercular ulcers of the intestines are often found at autopsies without the slightest evidence of their existence during life. That an isolated tubercular ulcer of the intestine may exist without causing symptoms before perforation occurs is shown by a case reported by Baumgarten. A young soldier in almost perfect health died suddenly of perforative peritonitis. The postmortem revealed, as the cause of the peritonitis, a solitary perforated ulcer the size of a penny in the lower portion of the ileum. Microscopic examination of the tissues demonstrated the tubercular nature of the ulcer. No evidence of tuberculosis was found in any other organ of the body.

In other cases the symptoms are misleading. Thus, Leonhardi-Aster recorded a case of intestinal tuberculosis that presented all the clinical features of pernicious anemia, the intestinal symptoms being masked by the progressive anemia, for which no cause could be assigned until the necropsy revealed the characteristic pathologic lesions of intestinal tuberculosis. In cases of diffuse acute intestinal tuberculosis the most important and prominent symptoms point to the existence of an intestinal catarrh. Profuse diarrhea is seldom absent, the stools being copious and liquid. Colicky pains referred

to the umbilicus, slight tenderness on deep pressure, progressive emaciation, and more or less rise in temperature, especially toward evening and during the night, are symptoms well calculated to arouse suspicion in regard to the probable tubercular nature of the intestinal disease. Enlarged mesenteric glands can often be palpated through the thin and relaxed abdominal wall. In some cases enlarged mesenteric and retroperitoneal glands can be detected by vaginal or rectal examination. The severity of the diarrhea is attributable more to the existence of the complicating intestinal catarrh and increased peristalsis than to the ulcers themselves. Pulmonary tuberculosis, as well as tuberculosis of any other important organ, often overshadows and masks the intestinal complication. In all cases of pulmonary tuberculosis attended by diarrhea that does not yield to the ordinary treatment, we have reason to assume the existence of intestinal tuberculosis. In primary intestinal tuberculosis the early symptoms set in insidiously; the disease is usually mistaken for an ordinary intestinal catarrh, and is regarded as such until the negative results obtained from the treatment induce the physician to make a more thorough investigation of the case. The suspicion of the tubercular nature of the intestinal disease is materially strengthened if it can be ascertained that the patient has made unsterilized milk a staple article of diet.

The frequent presence of traces of blood in the stools is decidedly suspicious. If the ulcers are located in the small intestine, the blood is intimately mixed with the stools; if in the large intestine, the extravasated blood often forms a coating for the otherwise well-formed fecal masses. Pus in the stools is found, as a rule, only when the tubercular process involves the lower portion of the large intestine. In the small intestine the pus that forms on the surface of the ulcers is speedily washed away with the intestinal discharges, and, on the other hand, pus-formation is checked by the peptic action of the intestinal juice, which acts as an efficient antiseptic. Bamberger has called attention to the character of the stools in intestinal tuberculosis, which, according to this authority, frequently contain transparent particles of mucus resembling frog spawn or boiled sago grains. These masses of mucus are probably formed in, and are discharged from, the lymph-follicles of the intestinal mucous membrane, the structures primarily affected by the tubercular process.

Virchow places less diagnostic importance on the presence of this pathologic product, which he believes has often been mistaken for partially digested starch.

The partial or complete healing of a tubercular ulcer of considerable size is usually announced clinically by the appearance of a complexus of symptoms that indicates the existence of chronic intestinal obstruction, caused by the cicatricial stenosis that so constantly attends and follows the healing of a tubercular ulcer. Intermittent colicky pains in the umbilical region, diarrhea alternated

with constipation, and perhaps occasional attacks of vomiting, are the most prominent clinical manifestations in such cases. Chronic intestinal obstruction from this cause, as well as from other causes, often terminates in an acute attack. In rare cases the chronic obstruction presents few or no symptoms until symptoms of acute obstruction set in, when operation or autopsy reveals the presence of an old cicatricial stenosis that has not been suspected before the abdomen is opened.

The formation of a chronic abscess in the ileocecal region, or in any part of the abdominal wall, in connection with intestinal symptoms of long standing, always suggests the probable existence of a tubercular intestinal ulcer. I have always observed these in the ileocecal region, over the ascending colon, and in one case in the umbilical region. These are the cases in which, prior to the perforation of the ulcer, adhesion takes place, excluding the peritoneal cavity, and is followed by the formation of a mural tubercular abscess. In more than one case the tubercular nature of the abscess and its intestinal origin were predicted before the abscess was opened. A fecal fistula is sure to follow the opening of such an abscess. The granulations lining the abscess cavity may for a time prevent the escape of intestinal contents, but in the course of a few days or weeks the granulations give way and the fecal fistula appears. If the disease is attended by plastic peritonitis to any considerable extent, the inflammatory exudate may often be distinctly outlined by palpation.

Voehts calls attention to a condition of diagnostic value, often met with in such cases, in the form of indurated plates in the peritoneum of almost cartilaginous hardness. Such areas of induration are not only found in the ileocecal region or along the course of the colon, but also in Douglas' fossa. In the pelvis these indurations may grow to actual exudates of considerable size, which in women might be mistaken for diseased adherent ovaries or tubercular Fallopian tubes.

In four out of six cases operated upon by Czerny a diagnosis of probable intestinal tuberculosis was made before the operation was performed. The diagnosis was based largely upon the clinical history, which indicated the existence of a cicatricial stenosis in the ileocecal region; the presence of a swelling that, on percussion, yielded a dull, tympanitic resonance, and that was movable and only slightly tender on pressure; and the periodic abdominal pains caused by exaggerated intestinal peristalsis, as described by Czerny, König, and Benoit.

The anatomic location of the stricture is indicated by clinical phenomena that deserve careful study and analysis. Stenosis of the duodenum above the entrance of the bile-duct gives rise to the same symptoms as stenosis of the pylorus, but below this point it is not only attended by symptoms that simulate the latter affection, but it also obstructs the entrance of bile into the intestinal canal.

The most important condition that characterizes duodenal stenosis below the bile-duct is the constant presence of bile in the chyme and repeated ejections of the fluid by vomiting. On the other hand, in three clinical observations, Boas showed that fluid taken from the stomach contained not only bile, but also pancreatic juice. The contents of the stomach possessed all the chemic properties of duodenal chyme.

Duodenal differs from pyloric obstruction also by the absence of a corresponding dilatation of the stomach, by the absence of the products of fermentation of the stomach-contents, and by the absence of sarcinæ and yeast-cells. No distinction can be made between obstruction in the lower portion of the duodenum and the upper part of the jejunum. Vomiting of large quantities of bile indicates duodenal obstruction, while the ejected material assumes more and more the character of feces the lower the location of the obstruction. In eight out of twelve cases of duodenal obstruction collected by Gerhardi and Hagenbach the disease was due to carcinoma, cysts, or hemorrhage of the pancreas. The search for the pancreatic juice in the stomach-contents is important. A number of well-authenticated cases of tuberculosis of the duodenum have been placed on record, and there is no reason to doubt that in isolated cases the ulceration might heal with the usual remote conditions following cicatricial stenosis and intestinal obstruction. If the cicatricial stenosis involves the ileocecal region or any part of the colon, the usual symptoms indicative of intestinal obstruction in these portions of the intestinal tract will develop. Diarrhea is the most constant symptom in such cases. In far-advanced cases extensive tympanites, fecal vomiting, and complete interruption of the fecal current at the point of obstruction complete the clinical picture of intestinal obstruction.

Diagnosis.—The diagnosis of secondary tuberculosis of the intestines presents few difficulties if the primary disease is well marked and if the organ affected is readily accessible to examination. Pulmonary phthisis generally precedes and attends secondary intestinal tuberculosis. In women, tuberculosis of the internal genital organs occasionally constitutes the primary affection, and extension takes place to the intestinal canal either through the lymphatic channels or, as in one of Czerny's cases, by rupture of a tubercular abscess into the intestinal canal. In cases of primary intestinal tuberculosis an early correct diagnosis is seldom made. There are other ulcerative affections of the intestines that in many respects resemble intestinal tuberculosis. Councilman reports a case of extensive and deep ulceration of the lower portion of the ileum, complicated by stricture of the rectum, which terminated in death from perforation and gangrenous periproctitis, and in which typhoid fever and tuberculosis could be safely excluded as causes. At the postmortem, ulceration of the ileum was found, with invasion of the tissues by colon bacilli. Some of the ulcers presented the appearance of an

acute process; others were of a chronic nature. Numerous bacteria, both short rods and micrococci, were found in the superficial necrosed tissue, in some places extending into the cellular infiltration in the submucosa. These microbes did not seem to stand in any direct etiologic connection with the pathologic changes. I recently had under observation for several months a case of chronic diarrhea that had resisted all remedial measures. The patient was a man about thirty years of age, very anemic and greatly emaciated. No hereditary tendency to tuberculosis and no cause could be ascertained that might have produced the chronic intestinal catarrh. Examination of the lungs and other important organs failed to locate a tubercular focus. The mesenteric glands could not be felt on palpation and rectal examination. The stools were frequent and liquid. The pain was slight and referred to the umbilical and hypogastric regions.

Intestinal tuberculosis was suspected. Carbonate of guaiacol and salicylate of bismuth were administered internally, and the colon was washed out daily with a copious enema of warm salt solution. On many different occasions the stools were examined for tubercle bacilli, but none could be found. Myriads of colon bacilli and micrococci were invariably found. The absence of tubercle bacilli in the stools and the marked improvement that followed the treatment leave but little doubt that this was a case of intestinal ulceration caused by infection with the colon bacillus.

Bacteriologic examination of the feces in suspected cases of intestinal tuberculosis should never be neglected, as it often furnishes positive proof of the tubercular nature of the disease. Tubercle bacilli, when present in the feces, in which they may be demonstrated by the same methods as in sputum, are indicative of intestinal tuberculosis, providing that they are observed upon repeated examination and that clinical symptoms are present that point to the intestines as the seat of disease, as otherwise they may be referable to swallowed tubercular sputa.

The best way to find the bacillus is to dilute the feces with distilled water and to prepare and strain the deposit after centrifugation. Sawyer urges the importance, in cases of suspected intestinal tuberculosis, of examining the mucus collected from the rectum, just above the sphincter ani, for bacilli. When found, particularly on the surface of fissured stools, these clusters of bacilli are of diagnostic value, and may be relied on to indicate tubercular processes in the intestinal tract. He has thus found them in several cases when they could not be found in the sputum, or when sputum could not be obtained.

If the tubercular enteritis has progressed to the formation of cicatricial strictures, the differential diagnosis between intestinal obstruction from this cause and other inflammatory affections that result in ulceration and cicatricial stenosis is always difficult and sometimes impossible. In such cases a probable diagnosis must

rest on a careful study of the clinical history and search for tubercular foci in other organs.

Congenital Stricture.—Congenital stenosis of the intestinal canal may appear as a single or multiple congenital defect, may affect any portion of the intestinal canal, and may cause no symptoms until long after birth. Intestinal stricture occurring in infants, children, and young adults, without any history of the existence of an antecedent ulcerative lesion, is quite frequently of a congenital origin.

Traumatic Stricture.—If, in cases of intestinal obstruction from a stricture, the clinical history shows that the patient has been the subject, in the past, of an injury to the abdomen, it should be borne in mind that the stricture may be the direct result of the trauma. Such strictures are occasionally caused by a blow on the abdomen. Mygind reports such a case. Intestinal resection was performed, six months after the accident, for symptoms of obstruction, and the patient recovered.

Traumatic strictures may result from laceration of the mucosa or from plastic peritonitis. In the former variety the lesion of the mucous membrane would be likely to simulate more closely tubercular enteritis than the peritonitic form. In both instances, however, the catarrhal enteritis complicating the chronic obstruction would present some clinical features in common with tubercular enteritis.

Stricture Following Strangulated Hernia.—It has been known for a number of years that intestinal stricture occasionally develops after the reduction of a hernia by taxis or operation. The stricture is such cases is caused by a circular necrosis of the mucous membrane, resulting from the pressure by the strangulation. The elimination of the necrosed tissue is followed by ulceration, and the healing of the circular ulcer finally leads to cicatricial contraction and intestinal stenosis. Garrè first described intestinal stricture as one of the remote results of a strangulated hernia. He made the observation that in some cases of strangulated hernia the mucous membrane of the bowel at the point of constriction becomes necrotic and is cast off as a slough. The circular defect heals by granulation, and the resulting scar leads to circular constriction.

In his first case the symptoms of obstruction necessitated a laparotomy, which was performed nine weeks after the herniotomy. The patient was twenty-seven years old, and the subject of a preperitoneal inguinal hernia. Intestinal resection to the extent of forty-one centimeters was made, and the continuity of the bowel restored by circular enterorrhaphy. The patient recovered. Examination of the specimen removed showed that the ulcerated surface had not entirely healed. At one point the ulceration extended as far as the peritoneum.

Ravult reports a case of double cicatricial stricture of the small intestine that caused death from acute intestinal obstruction. Several years before the last illness the patient was operated upon suc-

cessfully for strangulated hernia. The acute attack of intestinal obstruction resulted fatally in a few days. The necropsy revealed two strictures eight centimeters apart; the segment of bowel between them was distended by gas. Above the stricture on the proximal side the bowel was greatly distended and vascular, while the intestine below the second stricture was contracted, empty, and pale. The strictures were undoubtedly the result of sloughing, ulceration, and scar formation, consecutive pathologic conditions caused by harmful circular constriction by the neck of the hernial sac. The time of appearance of symptoms of obstruction in this form of intestinal stenosis varies from a few days to a year or more. Pitt records a case of femoral hernia in which symptoms of obstruction appeared five days after the reduction of the strangulated hernia, while in Garrè's case the symptoms of obstruction did not set in until nine weeks after the relief of the strangulation by taxis.

The possibility of the existence of a cicatricial stricture due to such a cause must be remembered in cases of intestinal obstruction in which the clinical history refers to strangulated hernia relieved either by taxis or operation.

Stricture Following Healing of Typhoid Ulcer.—The healing of typhoid ulcers is very rarely followed by cicatricial stenosis. Treves made a very careful search for stricture of the intestine caused by typhoid ulcer, and was able to find only one well-authenticated case. Typhoid ulcers, as a rule, heal rapidly, and much of the tissue destroyed is reproduced by the reparative process, leaving only a minimum quantity of connective tissue, while the healing of a tubercular ulcer is attended by the formation of an abundance of connective tissue that subsequently undergoes progressive cicatricial contraction. The locations for the stricture are the same in typhoid and tubercular ulcers.

Syphilitic Stricture.—Among the multiform visceral lesions caused by tertiary syphilis are to be noted intestinal strictures. According to Rieder, the lesions causing the obstruction are most frequently met with in the upper part of the small intestine. Syphilitic stricture is not caused by ulceration, but by the production of new connective tissue in the submucosa and later in the other coats. The symptoms attending syphilitic intestinal stricture indicate the existence of a mechanical obstruction without the existence of a previous ulceration, as is the case in tubercular stricture.

Ovarian Tumor.—The differential diagnosis between a tubercular stricture and intestinal obstruction caused by certain anatomicopathologic forms of ovarian tumor is attended by many difficulties. In one of Czerny's cases of ileocecal tuberculosis the swelling was mistaken for an ovarian tumor by the attending physician. Veit has shown that in women the differential diagnosis between tuberculosis of the ileocecal portion of the intestinal tract and ovarian tumor that has extended to the mesocecum and mesocolon is always extremely difficult and often impossible.

Malignant Stricture.—The two causes that give rise to intestinal obstructions most likely to be mistaken for each other are cicatricial stenosis following tubercular ulcer and malignant stricture. The ileocecal region is the favorite locality for both of these affections. In intestinal obstruction due to either of these causes the clinical history is characterized by a complexus of symptoms pointing to chronic obstruction, and in either case involvement of the mesenteric and retroperitoneal lymphatic glands is sure to occur sooner or later. Tubercular strictures are found most frequently in persons below middle age, while carcinoma is more likely to occur in persons of advanced age. The reverse may, however, be the case, as intestinal tuberculosis may attack the aged, and intestinal carcinoma may occur in young adults. The detection of a tubercular focus in another organ and the discovery of tubercle bacilli in the stools will furnish evidences of the tubercular nature of the obstructive lesion, and will exclude the probability of the existence of malignant disease.

Surgical Treatment.—The foregoing heading may appear somewhat strange and out of place to the general practitioner and the surgeon who have not kept fully abreast with the great advancements that have been made during the last decade in the diagnosis and surgical treatment of localized lesions of the intestinal tract. Our increased knowledge of the location, nature, and clinical tendencies of accessible tubercular affections has opened a wide and fertile field for successful surgical intervention. There is hardly an organ in the body that, when the seat of a localized tubercular process, has not been exposed and subjected to direct treatment with a fair expectation of removing or limiting the further extension of the disease. The medical treatment of tuberculosis in its various forms at the present time is not much in advance of that of fifty years ago. The numerous specifics invented and vaunted in different parts of the world have all fallen by the wayside, and the old-fashioned remedies are again taking their place. Leaving out the local measures, we have to rely, in the treatment of such cases, largely on diet, change of climate and occupation, outdoor air, and the administration of those remedies known to exercise a favorable influence in improving digestion, nutrition, and assimilation, and thus indirectly antagonize the ravages of the disease.

Powerless as we remain to-day in the successful systemic treatment of tuberculosis, it is a source of gratification to know that great improvements have been made in the local treatment of accessible tubercular lesions. The intestinal canal is one of the last territories opened up for successful surgical invasion. All the work done in this department of surgery dates back but a few years. The results obtained by the surgical treatment of localized intestinal tuberculosis are such as to encourage further efforts in this direction. The number of cases operated upon so far remains a small one, and it is my intention to bring these cases to the attention of the pro-

fession of this country and to describe the different operative procedures that have been employed by different operators with the same aim in view—to remove the diseased tissue, or to render the affected portion of the bowel accessible to direct treatment, or to place it in a more favorable condition for the spontaneous healing of the tubercular ulcers.

The remarks will be limited to localized primary tuberculosis of the intestinal canal, illustrated by cases amenable to successful surgical treatment. Diffuse primary tuberculosis of the intestines remains, for the present, a surgical *noli me tangere*. Surgical intervention is also contraindicated in secondary intestinal tuberculosis in all cases in which the primary disease, usually pulmonary tuberculosis, is far advanced and constitutes in itself an imminent source of danger to life. There are, however, cases of primary intestinal tuberculosis in which timely radical measures prove successful in eliminating the disease permanently and in restoring normal intestinal digestion and absorption. The attention of the mass of the profession must be called to the necessity of a more careful and thorough examination of chronic inflammatory affections of the intestinal tract, for the purpose of making an early and correct diagnosis, and with a view to selecting appropriate cases for timely surgical treatment. The internist and the surgeon must cooperate with each other in the future development of this, one of the most recent departments of successful surgical intervention.

The cases operated upon for intestinal tuberculosis will be referred to under the headings of the different operative procedures:

1. Abdominal Section and Iodoformization.—Every surgeon is familiar with the curative effects of abdominal section and drainage, with or without iodoformization, in cases of peritoneal tuberculosis. The *modus operandi* of this method of treatment has never been fully and satisfactorily explained, but the fact remains that it has proved eminently successful in the majority of such cases. There can be but little doubt that the local application of iodoform adds to the therapeutic value of this method of treatment. In one of the cases that recently came under my observation abdominal section and drainage were resorted to on two different occasions, but the tubercular hydrops returned. Tapping and the injection of from two to four drams of a 10 per cent. iodoform-glycerin emulsion, repeated six or eight times at intervals of from one to two weeks, finally succeeded in effecting a cure, and the patient was in perfect health when last seen, more than a year after the last tapping. Future observations will undoubtedly prove that peritoneal tuberculosis is more frequently caused by infection from primary intestinal lesions than has been heretofore supposed.

It is not strange that the same treatment should occasionally prove equally useful and efficient in certain cases of intestinal as in peritoneal tuberculosis. Nové-Josseraud made a laparotomy on a child twelve years old for a swelling the size of an adult's fist in

the region of the cecum. The incision demonstrated the existence of extensive tuberculosis of the cecum and adjacent portions of the ileum and ascending colon. The affected parts were not interfered with, except that they were wiped gently with iodoform gauze and dusted with a thin film of iodoform, and yet the operation was followed by a speedy and permanent recovery.

This method has a limited application in the treatment of intestinal tuberculosis when the disease is too extensive for more radical measures and no obstructive lesion is indicated by the symptoms or discovered at the time of operation. Iodoformization and capillary drainage with iodoform gauze for a few days would seem to be indicated in such cases.

2. *Enteroplasty*.—Plastic operations are indicated in solitary circular strictures following the healing of a tubercular ulcer and constituting the cause of intestinal obstruction. In narrow circular strictures an operation similar to that devised by Heineke-Mikulicz for pyloric cicatricial stenosis will yield the most satisfactory operative and functional results. The stricture is divided on the convex side of the bowel and the incision carried sufficiently far into healthy tissues on each side of the stricture, in a direction parallel to the long axis of the bowel, and the visceral wound closed transversely by two rows of sutures of fine braided silk, thus restoring the lumen of the bowel to its normal size. The operation is a plastic one, using healthy tissue from both sides of the stricture, with which the lumen of the bowel is restored to its physiologic requirements. As the sutures have to overcome considerable resistance in closing the wound, they should be inserted and tied from each angle of the wound toward the center, and at least two rows are required. If much tension on the sutures is anticipated, the quilt suture of Halsted should be relied upon for the outer or seromuscular sutures.

Péan performed such an operation for cicatricial stenosis of the ileocecal valve following the healing of a tubercular ulcer. He made the abdominal incision above and parallel to Poupart's ligament. The bowel was tied above and below the constriction with a rubber cord passed through a slit in the mesentery. The intestinal wall was incised at the level of and at each side of the strictured valve for a distance of three inches. After washing out the opened segment of the bowel with a 1 per cent. solution of carbolic acid, the cicatricial tissue was excised. This being done, the two extremities of the intestinal wound were brought together by means of forceps. The incision, which was first longitudinal, soon took the form of a lozenge, two sides of which were represented by the edges of the small intestine, and the other two by those of the large intestine. Bringing the forceps nearer together the incision became transverse, and in this position the edges were sutured in the usual way. The patient recovered and remained in good health at the time the report was made.

3. Enterectomy.—The most radical treatment of intestinal tuberculosis, in appropriate cases, is resection, followed by circular suturing. Resection is indicated in isolated intestinal tuberculosis as long as the swelling is movable and the disease gives rise to symptoms of obstruction; if, however, the disease is no longer limited to the organ primarily affected, or if it is complicated by advanced pulmonary or general tuberculosis, entero-anastomosis should take the place of a radical operation. Experience has shown that it is neither essential nor even necessary to add to the gravity of the operation by attempts to remove the products of regional infection. After removal of the primary focus of infection the lymphatic tuberculosis usually comes to a standstill, although cases have been recorded in which later reinfections occurred from this source.

Diffuse glandular tuberculosis in such cases is beyond the reach of safe surgery. Caseous glands in the mesentery, corresponding with the portion of the intestine excised, should be removed by including the mesentery in the excision. So far excision has been performed only in cases in which the tubercular lesion gave rise to intestinal obstruction. The results of this operation will be greatly improved in the future when intestinal resection will be performed as soon as a localized tubercular lesion can be diagnosticated, and before the patient's general condition has been seriously impaired by the mechanical obstruction.

Intestinal resection has been most frequently performed for tuberculosis in the ileocecal region. A number of cases, however, have been recorded in which the seat of the disease was the small intestine. Dr. Rudolph Matas made a successful enterectomy for intestinal stricture following the healing of a tubercular ulcer involving the upper portion of the jejunum. The patient made a rapid and permanent recovery (personal communication).

König reports five cases of stricture of the intestine caused by cicatricial contraction of tubercular ulceration, all treated by laparotomy and resection of the intestine, with circular enterorrhaphy. Two of the patients died: one from exhaustion, the other from the giving way of a suture, an accident that resulted in leakage and diffuse peritonitis. He believes that this pathologic form of cicatricial stenosis is much more frequent and more easily recognized than has hitherto been thought. He has met with this affection most frequently in persons between twenty and thirty years of age, and especially in those suffering from other tubercular lesions. He has made a careful investigation of such cases and found that the clinical history usually reveals a chronic cause, frequent attacks of colic with constipation, tympanites, visible peristalsis, and peculiar splashing and musical sounds, ending with a sound that resembles that of fluid driven forcibly from a syringe. The disease invariably produces great emaciation and anemia. In spite of the feebleness of the patients, König thinks surgical interference advisable, espe-

cially as the ulceration is probably still progressing in part of the cicatricial contraction, and often the tubercular disease elsewhere is not far advanced.

Treves made a resection of the intestine for tubercular stricture, and united the bowel-ends by the use of Murphy's button. The patient made a satisfactory recovery.

Sachs reports the following case of resection for intestinal tuberculosis: A woman, aged forty-one, had suffered for a long time from constipation, and for two years had had loss of appetite and gradually increasing marasmus and debility. On examination a hydronephrosis of the right kidney was discovered, and also a swelling in the right iliac fossa, which was supposed to be of a malignant nature. Laparotomy was performed, when the right iliac fossa was found to be occupied by a hard swelling the size of an adult's fist. Surrounding the ileum was a band of contracted fibrous tissue with tubercular granulations in some places. The diseased parts were resected, and the two ends of the intestine joined together by circular enterorrhaphy. The patient recovered and was in a satisfactory condition several weeks after the operation. On examination of the specimen removed the ileum was seen to be surrounded by a band of scar tissue and granulations. At the junction of the ileum with the cecum there was a large tubercular mass that extended to the mesenteric glands. The mucous membrane of the cecum was replaced by tubercular granulations that extended into the muscular coat, and on microscopic examination were seen to consist of epithelioid and giant cells. He collected thirteen cases of resection of the ileocecal portion of the intestinal canal for tuberculosis, of which eleven recovered.

Zahlmann reports a case of tubercular stricture of the intestines removed by Tage Hansen, of Denmark. The patient, a girl aged seventeen years, had been previously treated for tuberculosis of the phalanges of the fingers and toes. For one and a half years she had exhibited signs of stricture of the intestines, and at the laparotomy the entire cecum, with the adjacent parts of the ascending colon and ileum, were found to be the seat of an inflammatory mass that had produced a stricture an inch and a half in length, of a diameter corresponding to that of a lead-pencil, while the walls were nearly an inch in thickness. Six inches of the ileum, the entire cecum, and four inches of the ascending colon were removed. The healthy ends of the ileum and colon were united by means of Lembert sutures, the difficulty in adapting the different lumina to each other being overcome by dividing the ileum by an oblique section at the expense of the convex side. The patient recovered and remained in good health at the time the report was made, six months after the operation.

Of five cases of intestinal tuberculosis in which the cecum and colon were the seat of disease, and in which Czerny resorted to resection and circular suturing, two died of peritonitis and one of

hemoptysis after complete recovery from the operation. In one case the peritonitis was caused by leakage through one of the needle punctures, and in the second the perforation occurred in consequence of abscess formation in the line of suturing. The patient died from the effects of peritonitis, septicopyemia, and metastasis five weeks after the operation. In one case the operation proved successful, but was followed by rapid generalization of the tubercular process, an observation fully corroborated by Wahlländer and Wolff, who have called special attention to the diffusion of tubercular processes after intervention for what appeared as localized affections. In one case of secondary tuberculosis following rupture of a tubercular adnexal abscess into the intestine circular suturing after excision was found impossible, and consequently an artificial anus was established, with an excellent functional result. Among the cases operated upon by Czerny and reported by Rindfleisch are several in which the remote results of operations for intestinal tuberculosis have since been ascertained. In the case of a woman thirty-four years of age, operated upon in 1886, nothing definite could be learned as to the subsequent history. In the case of an ileocecal resection performed in 1888 on a man thirty years of age, death resulted three years later from pulmonary tuberculosis. The post-mortem revealed tubercular ulcers in the colon and small intestine, with miliary tubercles on the peritoneal surface, and cheesy mesenteric glands. No information could be had in the case of a man fifty-four years of age, subjected to ileocecal resection, but the operation appeared to have exerted no influence in checking the progress of the pulmonary affection. A man twenty-six years of age died of pulmonary tuberculosis two years after the operation. A woman twenty-two years of age was in good health four years after the operation. A man thirty-one years of age was found in excellent health four years after the operation, having gained during this time twenty-three pounds in weight. This patient suffered only occasionally from catarrh of the colon, the attacks being of short duration. These cases go to prove that resection for intestinal tuberculosis in well-selected cases yields satisfactory remote results, while the reverse is true if the operation is performed under adverse conditions.

Rentier resected the entire cecum for tuberculosis, and united the bowel-ends by means of Murphy's button. Death occurred on the sixth day after the operation. The lumen of the button, which remained *in situ*, was completely blocked by feces. Additional tubercular ulcers were found in the jejunum.

Caminiti-Vinci reports the case of a man aged twenty-four, without any tubercular family history, who for the last nine months had suffered from severe pain in the left superior quadrant of the abdomen, aggravated after meals; no diarrhea or vomiting. In the affected region an ill-defined swelling could be felt, descending slightly with inspiration, and rather painful on palpation. The

patient not improving under medical treatment, was operated upon March 8, 1896. The omentum was found thickened, hard, and adherent to the small intestine for about ten centimeters; this was excised, as were also about thirty centimeters of the intestine itself, with its mesentery and glands. The bowel was united by circular suturing. The patient recovered and remained in good health four months after the operation. Macroscopic and microscopic examination proved the tubercular nature of the disease in the parts removed.

Courtillier reports the case of a boy twelve years of age operated upon by Broca for tuberculosis of the cecum. The entire cecum was resected and the ileum united with the ascending colon by circular suturing. The patient recovered from the operation and remained in perfect health for three years, when a fecal fistula appeared at the site of operation. Operation for closure of the fistula was followed by death. The autopsy showed the small intestine in a perfectly healthy condition, but the disease had reached the ascending colon and was complicated by tuberculosis of the left lung.

Durante has resected the cecum for tuberculosis five times. He calls attention to the difficulties presented relative to making an early diagnosis. Intermittent diarrhea for from two to six years is a conspicuous and almost constant symptom. For a long time the general health is not much impaired. Symptoms of progressive cicatricial stenosis finally appear. In one case he was able to ascertain from examination of the specimen that the tubercular process had its primary starting-point in the appendix. Of the five cases, four lived and were in good health from five to seven years after the operation. In one case relapse was due to incomplete removal of the infected tissues. He regards the prognosis as favorable after complete extirpation of the affected portion of the intestine.

Emil Müller resorted to resection in two cases of tubercular stricture of the intestine. In the first case the disease extended over the lower part of the ileum, cecum, and ascending colon, to within an inch of the right colic flexure. In the second case the operation was performed extraperitoneally. After opening the abdomen by lateral incision the colon was made movable by excising the external layer of the mesocolon, when the diseased portion of the intestine was brought forward into the wound. The inner layer of the mesocolon was sutured to the inner margin of the incision, and the peritoneal cavity on the outer side of the bowel was shut out with an iodoform gauze tampon. After six days the affected portion of the intestine was extirpated extraperitoneally. The continuity of the intestinal canal was restored by circular suturing, which could be done without invading the excluded peritoneal cavity. The external wound was sutured and drained. The patient recovered rapidly without any untoward symptoms, and was discharged from the hospital with his health restored.

To what extent operative procedure can be carried with ultimate recovery in true cases of intestinal tuberculosis is well shown by a case reported by Körte. The patient, a man twenty-five years of age, was operated upon in 1891 for acute suppurative peritonitis. The following year, March 16th, the appendix was removed. In August of the same year a swelling developed along the course of the cecum and ascending colon. August 27th the cecum and ascending colon, nearly as far as the hepatic flexure, were excised. Healthy tissue was not reached. An artificial anus was established. The microscope demonstrated the tubercular nature of the intestinal affection. The enterotome was used without any benefit. In November twenty-one centimeters of the colon were resected. The end of the colon was invaginated and sutured, and an entero-anastomosis established between the colon and the lower portion of the ileum. A fecal fistula followed the operation. In February, 1893, Dieffenbach's enteroplasty was performed, but proved unsuccessful. In May a loop of the small intestine was implanted into the sigmoid flexure. For two weeks there were normal evacuations per rectum; then a fecal fistula formed. July 3d what was left of the colon was permanently and completely excluded by closing both ends. Regular evacuations by rectum followed. July 23d the excluded colon was resected. Patient recovered. Subsequent treatment was with iodoform gauze packing. The fecal discharge from the fistula was always liquid, but as soon as it passed through what remained of the colon the stools became natural. Only one case of resection for intestinal tuberculosis has come under my own observation.

Tuberculosis of the Cecum and Ileum.—Resection of cecum and eighteen inches of the ileum with corresponding portion of mesentery. Restoration of continuity of intestinal canal by lateral anastomosis with the aid of decalcified bone-plates. Recovery; return of the intestinal affection, and death six months after operation. The patient was a spare man of medium height, thirty-seven years of age, and a farmer by occupation. He was unaware of the existence of any hereditary taint or predisposition to tuberculosis or malignant disease in the family. His health was excellent prior to August 16, 1887. On that day he was taken suddenly ill with an attack of vomiting, without any obvious cause, which lasted for six hours. The patient insisted that toward the last he vomited fecal matter. He recovered rapidly and remained in comparatively good health until the following October, when he suffered from a similar attack of four hours' duration. This time he experienced a sharp pain in the ileocecal region, and soon after felt a distinct swelling in that locality. From this time on until March, 1889, the pain recurred periodically, the intervals becoming shorter, until pain became almost continuous, with few and incomplete remissions. During this time he suffered also a great deal from flatulence. The bowels were inclined to be loose, but the general health was not seriously impaired. Since March, 1889, diarrhea became a prominent symptom, the stools being liquid, but showing no trace of blood or mucus. Pain increased in severity and was more constant, and was always partially relieved by the free escape of gas per rectum. At the time he entered the hospital (October 9, 1889) he had lost forty-five pounds in weight. Examination at this time revealed the existence of a hard, nodulated, fixed swelling in the ileocecal region, and tympanites in the hypogastric and umbilical regions. Distention of the colon by rectal insufflation of hydrogen gas made the swelling more prominent and defined. There was not much tenderness on pressure. Digital exploration of the rectum yielded a negative result. Marasmus and anemia were well marked. For the last seven months the patient had from four to six liquid discharges daily from the bowels. Appetite was impaired. There was slight rise in the evening temperature, and the pulse-rate was from eighty to ninety a minute. From the history of the case, and more

especially from the character and location of the swelling, a probable diagnosis of tuberculosis of the cecum was made. As the usual medical treatment, which had been pursued for months, afforded but temporary relief, the consent of the patient and his friends to an operation was readily obtained. Laparotomy was performed on the day of his admission into the hospital. The abdomen was opened by an incision from near the middle of Poupart's ligament to a point half-way between the anterior superior spinous process of the ilium and umbilicus. On opening the abdomen the swelling at once came within easy reach. Examination showed that the swelling involved the entire circumference of the cecum, and its immobility suggested that it was intimately connected with the retroperitoneal tissues by inflammatory adhesions. The lower portions of the ileum and cecum were emptied by displacing their contents, and each part was intrusted to an assistant, who was instructed to prevent fecal extravasation by digital compression until the completion of the anastomosis. The ascending colon was divided about two inches below the margin of the swelling and the ileum near its junction with the cecum ; both sections showed that the visceral incisions had been made through healthy tissue. The bleeding vessels were tied with fine silk ligatures. Several large, partially caseous glands were found in the retroperitoneal space behind the cecum, and enucleated in one large mass with the cecum and a portion of peritoneum which was adherent to the glands. After the removal of the cecum it was noticed that the mesentery of the lower portion of the ileum contained several enlarged glands ; consequently, after preliminary ligation, it was excised with eighteen inches of the ileum. During the whole operation a small compress was kept in the abdominal cavity to prevent prolapse of the small intestine and to guard against infection. After all hemorrhage had been carefully arrested, both ends of the bowel were closed by invagination and a few stitches of the continuous suture ; the first stitch was made to transfix the mesentery at the point where it was invaginated into the bowel. Medium-sized perforated decalcified bone-plates were used in making the ileocolostomy by lateral approximations. An incision about two inches in length near the closed ends of both intestines was made at a point opposite the mesenteric attachment, and into each opening a bone-plate was inserted ; the lateral sutures, armed with a needle, were passed about an eighth of an inch from the margin of the visceral wound, from within outward, at a point half-way between the angles of the wound, and in such a way as not to include the peritoneum. The surfaces of the bowel corresponding to the part covering the plates were freely scarified with an ordinary sewing needle. The visceral wounds were now brought *vis-à-vis* in such a manner that both closed ends were directed downward, in this way bringing together the free surfaces of the colon and ileum. Before any of the plate sutures were tied a number of Lembert sutures were applied posteriorly, so as to approximate the serous surfaces along the margin of the plates, thus affording additional security in maintaining coaptation. The posterior pair of approximation sutures were now tied with sufficient firmness to hold the parts in contact without sufficient pressure to cause gangrene, after which both pairs of sutures not armed with needles were tied. During the tying of these sutures it is of the greatest importance that an assistant keep the plates accurately and closely pressed together. The last to tie was the second anterior pair of transfixion sutures, and as this was being done the bowel on each side was carefully pushed in between the plates with a probe. After all the approximation sutures were tied, it remained only to apply a few Lembert sutures on the anterior side. After the exposed parts were disinfected and dried, the bowel was returned into the abdominal cavity and anchored near the wound with a silk suture, at a point opposite the anastomotic opening ; the suture was made to embrace the parietal peritoneum on one side and the mesentery on the other. The abdominal incision was sutured throughout ; no provision was made for drainage. The subsequent history of the case was uneventful. The highest temperature registered was on the third day, when it reached 101.5° F., but returned to normal on the fourth day. During the first two days liquid food was administered by rectum. After that time the patient was allowed milk, beef-tea, and raw eggs, and after another week he was given the ordinary hospital diet, which he relished. The bowels moved several times a day, the passages gradually becoming normal in color and consistence. The external wound healed by primary intention with the exception of a small place where a stitch abscess formed at the end of the first week. At the ninth day half of the plate in the colon passed per rectum, and the following day the remaining half, together with the plate from the ileum with the sutures attached, was found in one of the stools. The patient left his bed on the twenty-eighth day after the operation, and three days later he returned to his home. At the time he left the hospital nothing abnormal could be felt in the right iliac fossa, and there were no pain and no tenderness on pressure. He gained rapidly in flesh and strength, and when I saw him again, during the latter part of January, 1890, he weighed nearly as much as before he was taken ill. Since the operation he has had no pain, no diarrhea, and the discharges from the bowels once or twice a day

were normal in every respect. At this time, however, a small hard swelling was discovered behind the colon at a point above where the ileum had been attached. This swelling was regarded as a recurrence of the disease along the chain of lymphatics behind the peritoneum, but no evidence of a return of the disease in the bowel could be found. In the course of a few months the patient died from the effects of the recurrent disease without any symptoms of obstruction.

It is a source of regret that a second radical operation was not performed, as repeated operations have finally yielded radical results. The specimen removed represents the entire cecum, a number of cheesy mesenteric and retroperitoneal glands, eighteen inches of the ileum, with the corresponding mesentery. A few small tubercular ulcers were found in the lower portion of the section of the ileum removed. The tubercular process had evidently started in the cecum, which it involved in its entire circumference. The walls of the cecum had become greatly thickened by the infiltrations. The lumen of the ileocecal valve was not larger than an ordinary lead-pencil, and the interior of the cecum, near the valve, presented a number of deep excavations resulting from the breaking down and ulceration of the tubercular mass. The ileum for a considerable distance was the seat of a well-marked compensatory hypertrophy, the thickening of its walls being due to an increase in muscular fibers, a result that so constantly follows progressive intestinal stenosis. The presence of numerous caseous mesenteric and retroperitoneal lymphatic glands, the character of the ulcers, and microscopic examination of the diseased tissues removed proved the tubercular nature of the inflammatory process.

From the accumulated experience of the past in the treatment of intestinal tuberculosis by resection it becomes evident that this operation is indicated in all cases in which the disease is sufficiently circumscribed to admit of complete removal, and the general condition of the patient is such as to entitle us to the hope that the operation will not prove fatal by its immediate effects. It is in such well-selected cases that enterectomy will yield far better results than any other operative procedure, as it has for its object the complete eradication of the disease, thus protecting the patient against reinfection from this source.

Partial Physiologic Exclusion of Affected Portion of Intestinal Canal by Entero-anastomosis.—Ten years ago I made a series of experiments on the lower animals for the purpose of demonstrating the value of partial physiologic exclusion of the intestine by entero-anastomosis in the treatment of certain localized affections not amenable to resection. The results of the experiments proved that the excluded portion undergoes atrophy and is placed in a condition approaching physiologic rest. In none of the experiments did the excluded portion become the seat of fecal accumulation.

In the introduction to this section the statement was made: "As extensive resections of the intestine are always attended by great risks to life from trauma, it was decided to study the subject of sudden deprivation of the system of a more or less extensive surface

for digestion and absorption, by eliminating or diminishing the cause of death from this source, by leaving the intestine, but by excluding permanently a certain portion from participating in the functions of digestion and absorption; in other words, by resorting to physiologic exclusion. These experiments were also made to determine the tissue changes that would take place in the bowel thus excluded, and to learn if, under such circumstances, accumulation of intestinal contents would take place and constitute a source of danger, as had been feared by the older surgeons."

The results of the experiments, as well as clinical experience since that time, have shown conclusively that this fear is unfounded. In speaking of the results of the experimental work and its application in intestinal surgery, the following statements were made in connection with the same subject: "The exclusion was complete, or nearly so; hence we must conclude from the postmortem appearances that in nearly every instance the excluded portion presented an atrophic, contracted condition, and was only sparingly supplied with blood-vessels. From a practical standpoint these experiments teach us that a limited portion of the intestinal canal can be permanently excluded from the processes of digestion and absorption in proper cases, by operative measures, without incurring any risk of fecal accumulation in the excluded part. These experiments demonstrate also that physiologic exclusion of a certain portion of the intestinal tract is a less dangerous operation than excision, and that in certain cases of intestinal obstruction where excision has heretofore been practised it can be resorted to as a substitute for this operation in cases where excision is impracticable or where the pathologic conditions that have caused the obstruction do not, in themselves, constitute an intrinsic source of immediate or remote danger to life. The postmortem appearances of the specimens of these experiments tend to prove that as long as any of the contents of the intestines reach the excluded portion, the peristaltic or antiperistaltic action in that part is effective in forcing it back into the active current of the fecal circulation."

Since that time entero-anastomosis has become a well-established operation, and has proved of signal success in the treatment of limited intestinal tuberculosis, complicated, as it so often is, by cicatricial stenosis. The operation effects two desirable objects in the treatment of such cases: (1) It relieves the symptoms of intestinal obstruction; (2) it secures rest for the part affected. I have had an opportunity of performing entero-anastomosis in two cases of intestinal tuberculosis.

Intestinal Tuberculosis Complicated by Acute Intestinal Obstruction Caused by Cicatricial Stenosis.—Ileo-ileostomy; recovery; patient in almost perfect health two years after the operation. The patient was a boy sixteen years of age, a member of a healthy family, free from any predisposition to tuberculosis or malignant disease. He had never been seriously ill and was in the best of health,—weight, 140 pounds,—when he was attacked with colicky pain, which he referred to the umbilical region, December, 1895, the pain continuing for two days. He recovered from this attack and remained in fair

health until December 18, 1896, when he was again seized with severe pains of a colicky nature in the abdomen, which continued until he entered the hospital. Bowels had not moved for two days prior to his present illness. Vomiting, which soon became fecal, and absolute constipation followed by great tympanites came on in rapid succession. The attending physician made a diagnosis of intestinal obstruction and resorted to the usual treatment, including the use of high rectal enemata, with little or no relief. When he was admitted into St. Joseph's Hospital, March 1, 1896, he had lost forty pounds. He was very anemic, and the emaciation was pronounced. The abdomen was enormously distended, and visible intestinal coils could be distinctly outlined. Temperature was normal, pulse small and 100 a minute. There had been no free movements from the bowels since the attack. There were frequent attacks of vomiting, at times fecal in character. Rectal examination yielded no information regarding the anatomic location or nature of the obstruction. The day after his admission into the hospital, after thorough preparatory treatment, laparotomy was performed. The abdomen was opened in the median line, half-way between the umbilicus and pubes. Intestinal coils were enormously distended and exceedingly vascular, protruded at once from the wound, and were carefully protected with compresses wrung out of a hot physiologic solution of salt. One of the first things noticed was the existence of numerous enlarged mesenteric glands. Some of them were the size of a hazelnut and presented distinct evidences of beginning caseation. The visceral as well as the parietal peritoneum was studded with innumerable tubercle nodules. The existence of peritoneal and glandular tuberculosis was at once made evident. In searching for the seat of the obstruction the distended intestine was traced in a downward direction, the intestinal loops being replaced as soon as examined so as to prevent extensive eventration. In reaching the lower part of the ileum, the obstruction was found about twelve inches above the ileocecal junction, in the form of a tight circular stricture. Above this point the intestine was uniformly distended and very vascular, while below the obstruction the intestine was empty, contracted, and pale. An ileo-ileostomy was made by establishing an anastomotic opening between the lower part of the distended ileum and that part of the ileum between the obstruction and the cecum. Before the visceral incisions were made the serous surfaces of the convex side of the intestinal loops which were to be united were sutured together with a row of Lembert stitches, extending a little beyond the intended limits of the incisions. On incising the proximal distended loop the bowel was drawn well forward, the patient placed on his right side, and as much of the intestinal contents as could be poured out was evacuated through the incision. After incising the empty loop to the same extent the mucous membrane was sutured all around, and finally a row of anterior serous stitches completed the operation. The parts exposed were thoroughly cleansed, dried, and lightly dusted with iodoform, after which the intestines were returned and the external incision closed in the usual manner. The patient recovered promptly from the immediate effects of the operation. The incision healed throughout by primary intention. The bowels moved freely the day after the operation. The tympanites diminished rapidly and disappeared entirely in the course of a week. For a few days the stools were copious and liquid; later, once a day and normal in color and consistence. Rectal feeding was continued for four days; later, liquid food was given by the stomach, followed by solid food at the end of the first week. The patient left the hospital in excellent condition March 30, 1896. A letter from his physician received two years after the operation states that he is in perfect health, having gained twenty-seven pounds in weight.

Careful search for tuberculosis in other organs was made, with negative result. The tubercular nature of the intestinal affection in this case was obvious from the simultaneous existence of peritoneal and lymphatic tuberculosis. The entero-anastomosis relieved the obstruction promptly and placed the affected organs in a condition for spontaneous healing of the tubercular lesions. The patient was placed upon the prolonged internal use of guaiacol, which may have contributed to the remarkable result of the operation.

Tuberculosis of the Cecum and Ascending Colon, Complicated by Tuberculosis of the Urinary Organs.—Ileosigmoidostomy; death from exhaustion forty-eight hours after operation. The patient was a man thirty-eight years of age, who was admitted into the Presbyterian Hospital November 6, 1897. His health began to decline four years ago, when symptoms of chronic cystitis developed. For a long time the urine contained pus

and at times blood. In February, 1896, he had a chill, followed by fever and pain in the region of the right kidney. A swelling developed below the costal arch on the same side and soon reached as far as the crest of the ilium, and to within an inch or two of the median line on the left. The temperature ranged between 102° and 104° F. for five days. A second chill occurred a few days later, followed by slight jaundice, which continued for a few days. The swelling was diagnosticated as an abscess, which was incised in front at a point half-way between the last rib and the crest of the ilium. On cutting through the abdominal wall the distended kidney presented itself and was incised, about a pint of pus escaping. The cavity was washed out and drained. For some time urine escaped through the drainage opening. Three weeks after the operation feces escaped through the opening, and the fecal fistula has remained since that time. At the time the patient entered the hospital he was very anemic and greatly emaciated. Examination of the bladder and prostate left no doubt that both of these organs were the seat of a tubercular affection. Through the fistulous opening a probe could be inserted into the ascending colon. Gas and fecal material escaped through the opening daily. Action of bowels irregular, diarrhea and constipation alternating. From the cecum, in the course of the colon, a resistant swelling could be felt that extended somewhat above the fistulous opening. Examination of the lungs revealed a limited infiltration in the left apex. A slight rise in the evening temperature was an almost constant feature. The fistulous opening externally was enlarged, and a large cavity found between the skin and abdominal muscles, which was lined with fungous granulations. These were scraped out with a sharp spoon, and the cavity was thoroughly disinfected and packed with iodoform gauze. This and the subsequent operations were performed in the clinic of Rush Medical College. The scraping-out of the cavity was followed by increased fecal discharge, and in a short time the fistulous opening in the colon was large enough to insert the tips of two fingers. Carbonate of guaiacol and tonics were administered internally, but the patient continued to lose strength and flesh. Owing to the existence of formidable complications and the extent of the intestinal affection it was decided to exclude the cecum and colon, as far as the sigmoid flexure, from the fecal circulation, by performing ileosigmoidostomy.

After careful preparations the operation was performed December 20, 1897. The abdomen was opened in the median line. The cecum and ascending colon, nearly as far as the hepatic flexure, were found embedded in an extensive exudate. Numerous enlarged lymphatic glands, especially in the mesocecum and mesentery of the ascending colon. The anastomotic opening was established between the ileum, about eighteen inches above the cecum, and the sigmoid flexure. The operation was performed in the same manner as in the case of lateral anastomosis after excision, with the exception that no bone-plates were used, the visceral wounds being united by two rows of sutures. The operation was completed in less than an hour. Very little shock followed. The next day, however, vomiting and symptoms of prostration set in, the pulse became more rapid and feeble, but the temperature never exceeded 100° F. Death occurred forty-nine hours after the operation.

The clinical history in this case points to primary tuberculosis of the urinary organs, followed by intestinal and, later, pulmonary tuberculosis. A number of cases have been reported in which entero-anastomosis was performed for intestinal tuberculosis. Hofmeister reports a case of multiple tubercular strictures of the intestine treated by establishing an entero-anastomosis. The patient, a man aged thirty-two, had suffered for four years with attacks of colic accompanied by vomiting and constipation, recurring at intervals of greater or less length, the last seizures having been particularly severe. Finally the patient was taken to the surgical clinic of Bruns, at Tübingen, with all the symptoms of a marked intestinal obstruction. The operation, which was undertaken without delay, revealed ten annular strictures of the small intestine, for the most part very narrow and distributed over two meters of the bowel. The large intestine was entirely empty and contracted. Resection being out of the question on account of the debilitated general condition of the patient, an anastomosis was

made between the intestines above and below the seat of obstruction. At the very outset the distended intestine was punctured with a small trocar, to evacuate its contents. The puncture was closed with two rows of sutures. The patient improved temporarily as a result of the operation, but died the following day in sudden collapse. The autopsy revealed the fact that death had been caused by a general peritonitis. Inspection showed that the sutures inserted for the purpose of closing the puncture opening were insufficient to resist the intra-intestinal pressure by gas, and had given way, followed by fecal extravasation. Besides the ten discovered at the operation, two additional strictures were found, one near the ileocecal valve and the other a little higher up. When the strictures are multiple, the disease usually involves the ileum. Hofmeister found records of eighteen cases of multiple strictures of the intestines of a tubercular nature.

Marwedel reports a case of tuberculosis of the cecum from Czerny's clinic treated by entero-anastomosis:

The patient was a man forty-three years of age. No hereditary predisposition to tuberculosis in the family. He suffered from two attacks of localized peritonitis, probably caused by appendicitis, the first in 1870, the second in 1887. Since last attack pain and tenderness in the right iliac fossa remained. In 1891 the pain increased, attended by colicky pains in the abdomen, the latter disappearing after two or three minutes with a loud pouring sound. Bowel movements were irregular. A few weeks before his admittance into the clinic eructations and transient vomiting returned. He was treated for some time in the medical clinic by high enemata, without any benefit. He was admitted into the surgical clinic August 17, 1893. At this time, with the exception of a chronic conjunctivitis, rhinitis, pharyngitis, and a slight pulmonary emphysema, the general health of the patient did not appear to be much impaired. Cecal region was prominent, and to the right of the cecum and ascending colon, particularly the latter, a hard, cylindric swelling could be felt, extending from the iliac spine to the tip of the eleventh rib. The swelling was fixed and tender on pressure, and there was visible peristalsis of the small intestine near the cecum.

Clinical Diagnosis.—Stenosis and tumor formation in the region of the cecum and ascending colon; chronic inflammatory, perhaps tubercular, process. First operation, August 20, 1893. Vertical incision in the linea Spigelii showed infiltration of preperitoneal tissues and firm adhesions between anterior abdominal wall and ascending colon. In separating the adhesions an ulcerated portion of the colon near its middle was torn, and a quantity of pus, but no fecal material, escaped. From this opening digital exploration showed that the colon was ulcerated as far as the ileocecal valve, which induced the operator to abandon all thoughts of performing a resection. The tear in the bowel was sutured and an entero-anastomosis made. The lower portion of the ileum was distended and hypertrophied; on the other hand, the transverse colon was contracted and atrophied. These two parts of the intestinal canal were then brought into communication, and, by incision and suturing, a free anastomotic opening was established. The sutured wound of the colon was fastened to the abdominal wall with two peritoneal sutures. External incision was closed, with the exception of a space over the cecum to secure drainage, which was effected by using the iodoform gauze tampon. The diagnosis made at this time confirmed the previous suspicion of the tubercular nature of the affection. Bowels moved on the second day, after the use of an enema. A week after the operation some fecal matter was mixed with the discharge from the wound. When the patient was discharged, four weeks after the operation, the wound was healed, with the exception of a fistula, which discharged a small quantity of pus, but no fecal material. Bowels moved without the aid of cathartics or enemata. General conditions much improved. During the fall of the same year he was attacked with influenza, and at the termination of the illness the parts around the fistula became inflamed, and soon after a more copious flow of pus ensued, which became mixed with feces. He reentered the clinic November 30, 1893. The swelling in the cecal region was smaller, but firmer, than at the time of operation. There was constipation, which, when relieved by cathartics, was followed by diarrhea, some of the fecal material escaping through the fistula. At this time the fistu-

lous tract was enlarged with the knife sufficiently to enable exploration of the abscess cavity with the finger. The cavity was about the size of a walnut, partly filled with hard fecal masses, and lined with tubercular granulations. Curettage and iodoform gauze tamponade were used. After operation nearly all the feces escaped through the fistula. A third operation was performed December 7th of the same year. The old scar was incised, and the adherent ascending colon separated. During this step of the operation a small subcutaneous abscess was opened The fistulous opening was next exposed and was located near the lower end of the ascending colon, where a defect was found large enough to admit the tip of the index-finger. Exploration of the interior of the cecum revealed a large cicatrized surface. The margins of the intestinal fistula were vivified, and the opening was closed with two rows of sutures, the operation being entirely extraperitoneal. The external incision was closed, with the exception of a space large enough to bring out the iodoform gauze tampon. No unfavorable symptoms followed the operation. Normal stool followed after injection on the eighth day. Patient left the hospital on the last day of the same month, with a small fistula, but almost in perfect health, and with normal bowel movements. One year later the fistula still remained, and at times small quantities of feces escaped; otherwise the patient was in good health and had gained twenty-three pounds in weight. Czerny attributes the healing of the extensive tubercular ulcerations to the elimination of the affected part of the bowel from the fecal circulation by the ileocolostomy.

Schiller reports three cases of intestinal tuberculosis treated by physiologic exclusion of the affected part, operated upon in Czerny's clinic during a period of four years. In all cases the disease was located in the cecum and had given rise to chronic obstruction. In two cases the anastomotic opening was made between the ileum and the transverse colon, and one between the ileum and the ascending colon. In two cases the cecum was incised and the tubercular ulcers were curetted. The visceral incision was closed by suturing parallel with the long axis of the bowel. In one case the diseased appendix was excised in addition. In one the gall-bladder was extirpated at the same time for lithiasis and chronic inflammation. In all the cases the contraindications to resection were well defined. In one case the operation was done by the use of the Murphy button, which was removed from the ampulla of the rectum on the fifteenth day, after a severe hemorrhage three days previously. The pulmonary symptoms became seriously aggravated after the hemorrhage. All these cases recovered, and the patients left the hospital improved. In one case (reported *in extenso* above) a fecal fistula developed, which was sutured on two occasions with partial success.

The exclusion of the affected part of the intestine, although not complete, led to speedy healing of the ulceration, as was shown in one case at the second operation, four and one-half months later. The healing of the ulcers was undoubtedly favored by the atrophy and diminished peristaltic action, conditions that are always established in the excluded part soon after the operation.

James Israel reported to the Surgical Society of Berlin a case of tuberculosis of the cecum and ascending colon in a woman twenty years of age, which was greatly improved by establishing a communication between the ileum and the ascending colon. The disease was attended by symptoms indicative of chronic intestinal tuberculosis. Exploratory laparotomy was performed, and a probable diagnosis of sarcoma was made. The mesenteric glands were

found enlarged. Later a second operation was performed, when a swelling the size of an apple was found projecting into the ascending colon, complicated by disseminated peritoneal tuberculosis. The patient made a good recovery, gained in weight, and after seven months the swelling was reduced in size to that of a walnut.

Gessner made a laparotomy on a case in which the cecum was tubercular and had attained the size of a goose egg. The swelling was nodulated, and the serous coat studded with miliary tubercles. The obstruction caused by cicatricial stricture in the region of the ileocecal valve was relieved by an anastomosis between the ileum and the ascending colon, which was made by the aid of the Murphy button. The button was discharged per rectum on the thirteenth day. The operation was followed by manifest improvement.

A very interesting case of intestinal tuberculosis complicated by invagination came under the observation of Czerny, and is reported in detail by Marwedel.

The patient was a boy fourteen years of age, who, two months prior to his admission into Czerny's clinic, was suddenly taken ill with vomiting and severe pain in the abdomen, attended with the appearance of a swelling in the upper and right side of the abdomen. In a few days the pain subsided and the vomiting occurred less frequently. A sausage-shaped, tender swelling above the umbilicus remained. Bowels could be moved only by the use of injections. For a few days during the early part of the attack the stools contained traces of blood. On his admission into the clinic, June 2, 1894, the patient presented an anemic appearance and was considerably emaciated. There was no fever, and the lungs and heart were normal. Inspection and palpation revealed the existence of a cylindric swelling, ten centimeters in length, in the region of the transverse colon. The swelling was slightly movable and tender on deep pressure. The liver, spleen, and kidneys were normal in size and function. Under rectal insufflation the swelling increased in size, and dullness on percussion gave way to tympanitic resonance. The capacity of the colon was only three pints. The rectal injection did not increase the dullness on percussion over the swelling, and was followed by the escape of hard fecal masses. Chronic invagination of ascending and transverse colon was diagnosticated. Operation was performed June 6th. Median incision was made from xiphoid cartilage to umbilicus, and later had to be extended two inches to bring the invaginated colon forward into the wound. The swelling, the size of two fists, was composed of the cecum and ascending colon, into which the lower portion of the ileum had become invaginated. The intussusception could be traced as far as the right flexure of the colon. Reduction, owing to the presence of extensive adhesions, was found impossible, and resection was contraindicated by the debilitated condition of the patient. An entero-anastomosis between the ileum above the invagination and the middle third of the transverse colon was established by incising the previously approximated ileum and colon and suturing the visceral wounds in the usual manner with two rows of sutures. Abdominal incision was closed throughout.

The existence of a tubercular lesion of the invaginated bowel was suspected from the presence of a plastic, caseous perityphlitis. Recovery ensued without any untoward symptoms. Patient left the hospital August 9th, the swelling being much diminished in size and the bowel movements normal. A year later the patient remained in good health, and examination showed that the invagination swelling had nearly disappeared.

The tubercular complication presented itself in the form of caseous adhesions found at the time the operation was performed. The infection probably occurred from the intestinal canal. Whether the tuberculosis occurred as a primary affection or whether it appeared after the invagination had taken place would be difficult to determine. Fleiner describes two other cases of intestinal tuberculosis from Czerny's clinic, in which the pathologic conditions produced by the disease gave rise to invagination.

The cases reported furnish conclusive proof of the therapeutic value of entero-anastomosis in the treatment of intestinal tuberculosis sufficiently limited to warrant surgical interference and beyond the reach of successful treatment by more radical measures.

Complete Physiologic Exclusion.—Practical experience has demonstrated the value of partial physiologic exclusion in the treatment of certain forms of localized intestinal tuberculosis. It would be natural to assume that the therapeutic value of entero-anastomosis would be enhanced if the affected part of the bowel could be completely excluded from the fecal circulation, thus securing for the diseased tissue a condition of absolute rest. At the time I made my experiments on physiologic exclusion of parts of the intestinal canal I had this object in view, and made a number of experiments to demonstrate the possibility and practicability of the procedure. The exclusion was made by isolating a section of the intestine and closing its ends by invagination and a few Lembert sutures. The continuity of the intestinal canal was restored by circular suturing or lateral anastomosis. The results of these experiments proved unsatisfactory, as it was found that the retained intestinal secretions constituted a source of danger. A few years later Salzer modified the operation by establishing a fistula in connection with the excluded portion. This method of effecting complete physiologic exclusion has been resorted to in only a very few instances in the surgical treatment of intestinal tuberculosis.

Of the cases operated upon by this method, the one reported by von Eiselsberg is the most instructive. In a case of tuberculosis of the cecum, ascending colon, and hepatic flexure, this surgeon resorted to complete physiologic exclusion, with temporary benefit. The patient was a man thirty-five years of age, who was in good health until five years before, when a tubercular affection of the foot developed, followed soon by symptoms of acute pulmonary tuberculosis. Two years later the head of the tibia was operated upon by curettage for tubercular caries. During the healing of the wound the patient suffered from an attack of perityphlitis, from which he recovered, but the disease was followed by periodic pains, at short intervals, in the ileocecal region. During the last few months the pulmonary symptoms became aggravated and an obstinate diarrhea set in. On admission into the hospital examination revealed extensive tubercular infiltration of left apex of the lung and a cylindric swelling in the region of the cecum; the swelling was somewhat movable and tender on pressure. Operation was commenced by making an oblique incision directly over the cecum. The cecum was found smaller than normal and not adherent. The infiltration extended from the ileocecal valve to the middle of the transverse colon. The affected portion of the bowel was completely excluded, and the continuity of the intestinal canal restored by circular suturing; the resected end of the ileum had to be joined with the transverse colon. The mucous membrane at the points of section appeared to be healthy. The ends of the excluded portion were fixed in the upper and lower angles of the wound, respectively, and the balance of the abdominal incision was closed in the usual manner. From the excluded portion of the intestine mucus and pus escaped in considerable quantities. The patient improved temporarily. On the seventh day the affected part of the bowel was washed out carefully from both ends with a warm physiologic solution of salt. These irrigations proved the competency of the ileocecal valve. The flushings were found useful in diminishing the amount of the inflammatory product. The patient left his bed in three weeks. A few days later the pulmonary symptoms became more marked, and when the patient left the hospital, a week later, he was attacked with pulmonary hemorrhage, which recurred several times and from the effects of which he died two months after the operation. Diarrhea reappeared soon after the operation, and continued to the end. The persistence with which the diarrhea continued soon after the operation tends to establish the existence of the tubercular lesion of the mucous membrane beyond the limits of the operation.

Complete physiologic exclusion will, in all probability, have a very limited scope in the surgical treatment of intestinal tuberculosis, as the immediate dangers to life are almost equivalent to the risks incident to resection, and the advantages over those of partial exclusion are not sufficient to warrant a more general recourse to this procedure. There can be but very little doubt that, with an increased knowledge of the etiology and pathology of intestinal tuberculosis, surgeons will be induced to resort to operative treatment more frequently in the future, and that with further improvements in the technic of intestinal operations the surgical treatment will yield more encouraging results.

TUMORS.

A tumor may give rise to intestinal obstruction in different ways, according to its location and anatomicopathologic character. A tumor or swelling outside of the intestinal tube may cause obstruction by compression. A polypoid growth springing from the mucous or submucous tissue interrupts the fecal current either by blocking the lumen of the bowel by its size or by causing an invagination or flexion. A circular carcinoma produces a stenosis that leads to chronic obstruction, but that is frequently the indirect cause of acute intestinal obstruction, when, either by additional pathologic changes at the seat of the malignant disease or by the accumulation of foreign bodies or solid fecal masses above the seat of constriction, the fecal passage is completely arrested.

An interstitial tumor may give rise to intestinal obstruction independently of invagination or stenosis sufficient in degree to intercept the fecal current by interfering with normal peristaltic contractions. While both benign and malignant tumors are relatively frequent in certain parts of the intestinal canal, the small intestine is quite exempt, with the exception of the portion where the bile and pancreatic ducts enter the duodenum, in which locality carcinoma and sarcoma are quite common. The cecum, the sigmoid flexure, and the rectum are the portions of the large intestine most frequently the seat of tumors, both benign and malignant. In infants and children the seat of obstruction from tumors is more frequently above than below the ileocecal valve ; in the adult and aged, at and below that point.

Benign Tumors.—Benign tumors of the intestinal walls are not uncommon, but they rarely reach a size to cause danger to life, consequently the diagnosis is usually made in the autopsy room.

Benign polypoid tumors seldom attain a sufficient size to give rise to intestinal obstruction unless they cause additional mechanical disturbances, such as invagination or flexion, conditions that have already been alluded to. If the tumor alone is the cause of obstruction, it is removed by laparo-enterotomy.

Leichtenstern classifies benign intestinal tumors as follows:

1. Fibromata that originate in the submucosa and, by their

growth in the direction offering least resistance, protrude into the lumen of the bowel as fibroid polypi, which may cause intestinal obstruction by occlusion or invagination.

2. Myomata, starting in the muscularis mucosæ, in some cases very vascular (angiomyomata), in other cases more fibrous (myofibromata); the latter project into the intestine as polypi and give rise to the same mechanical disturbances as fibromata similarly located.

3. Submucous lipomata, which may present themselves as pedunculated tumors in the intestinal canal, but seldom attain a size sufficient to cause obstruction. These tumors are often multiple.

4. Mucous polypi, papillomatous or with a smooth surface.

As to the frequency of intestinal polypi of all the different histologic varieties and their anatomic location, Leichtenstern gives the following table:

Rectum (estimate too low)	75
Colon	10
Cecum	4
Ileocecal valve	2
Lower portion of the ileum (usually found by causing invagination)	30
Jejunum	5
Duodenum	2

Virchow states that myomata are rare, and, if we exclude uncertain observations, develop only into small tumors. He has found these tumors only in the small intestine. He describes a specimen from the Berlin Museum, of a tumor the size of a cherry-stone in the transverse portion of the duodenum. It was clad with mucous membrane and had undergone calcareous degeneration, and protruded into the lumen of the intestine. Microscopic examination showed that the tumor was composed of connective tissue and muscle-fibers, and that it was connected with the muscularis of the intestine.

He also states that submucous lipomata are found in the stomach, jejunum, and colon. They may become pedunculated, and the large polypi of the jejunum are usually pedunculated lipomata that push the mucosa before them and that often extend for an inch into the intestine. Innocent in themselves, they may give rise to intussusception, but Virchow does not state that they have ever caused occlusion by their size alone.

Wesener, to whom we are indebted for a careful and exhaustive review of the literature of the subject, found, in the Pathologic Museum of Giessen, a round tumor of the duodenum the size of an apple. It was located in the posterior wall of the duodenum, five centimeters above the entrance of the bile-duct; but the large mass of the tumor extended into the peritoneal cavity and protruded only slightly into the lumen of the intestine. Behind the tumor were the pancreatic and bile-ducts, which, however, were not compressed. On microscopic examination this tumor was found to be a myoma.

Wesener also found a myoma of the duodenum in the following

case : A man, fifty-five years of age, had suffered from gonorrheal cystitis and chronic polyarthritis, and toward the end of his life presented indistinct symptoms of intestinal disturbance, constipation alternating with diarrhea, and occasional attacks of copious vomiting that persisted for two or three days and then disappeared, to recur after a short time. The increasing emaciation for the last few months before the patient died caused the diagnosis of carcinoma of the stomach to be made, though neither tumor nor coffee-ground vomiting was observed. The autopsy showed a dilated stomach, together with dilatation of the pylorus and the upper portion of the duodenum, but no carcinoma. Fifteen centimeters below the pylorus a nodular tumor the size of a plum protruded into the intestine. On its apex was a depression with loss of substance, where the mucous membrane was wanting. The tumor in the duodenum was part of a larger tumor, the size of a fist, situated outside of the intestine, between the duodenum and the transverse colon, lying on the atrophied pancreas, to the head of which it was adherent. Microscopic examination showed the tumor to be a myoma that had originated in the circular fibers of the muscularis of the intestine without causing absolute obstruction. The tumor had evidently caused a certain degree of stenosis, as was shown by the dilatation of the duodenum and the stomach above.

A very interesting case of myoma of the ileum was reported by Christian Fenger, in 1894, in a very valuable paper on "Benignant Tumors of the Ileum," from which I have obtained important information.

The patient was a man seventy-five years of age. His family history was negative. General health always good until a year before, when he had occasional attacks of constipation unattended by vomiting. During the last five or six weeks bowels have moved but slightly and the stomach has refused food, or, after eating, he would experience a sense of heaviness, followed by nausea. Occasionally an hour or two after eating he vomited, sometimes fecal matter. During the last two weeks he has vomited almost every day—first the stomach-contents, then the contents of the bowels. Paroxysmal pain in the abdomen, the paroxysms becoming more frequent. No pus or blood in the feces.

Examination.—Patient in bed, old, pale, decrepit, emaciated. Abdomen not tympanitic, but when a paroxysm of pain occurred, peristaltic contraction of intestinal coils could be seen through the thin abdominal wall. No hernia and no tumor could be seen or felt. Rectal examination negative.

Diagnosis.—Chronic intestinal obstruction from carcinoma, probably of large intestine, high up in the sigmoid or in the right flexure of colon.

Operation.—An incision three inches in length was made in the median line below the umbilicus, and the peritoneum sutured to the skin. The loops of small intestine that came into view were neither injected nor dilated. Abdominal exploration revealed nothing abnormal in the rectum or colon. On examining the small intestine a small round tumor, about the size of a walnut, was felt. The intestinal wall over the tumor was somewhat thickened and movable, but the tumor could not be dislodged. Attempts in this direction caused traction upon the base of the tumor. It was situated on the side of the loop, midway between the convex border and the mesenteric attachment. The loop was emptied to a distance of five inches on each side of the tumor, and a strip of iodoform gauze pushed through the mesentery and tied, so as to exclude feces from the loop. A longitudinal incision, an inch and a half long, was made over the tumor, which was then enucleated with ease. It was smooth, cylindric, rounded, 45 mm. long and 28 mm. in diameter, clad with mucosa, dark at the rounded end, and yellowish from imbibition of bile coloring-matter from feces. As the base or pedicle of the tumor, which was 1½ cm. in diameter, extended beyond the line of incision, the latter was prolonged to the base, which was excised, leaving a transverse incision one inch in diameter.

The T-shaped intestinal wound was now united by step sutures, first a continuous silk suture from the distal end of the longitudinal to the transverse wound, and the transverse wound united by interrupted sutures passed through the mucosa only. Interrupted Lembert sutures were then introduced through the serosa and muscularis to bury the mucosa sutures, especial care being taken at the angles of the wound.

Examination of the intestine as to its permeability for feces and gases now revealed an indentation on the side of the intestine opposite to the base of the incision, indicating that one of the mucosa sutures had caught the mucosa on the opposite side of the intestine. The sutures of the transverse wound were therefore loosened, and the opposite wall of the intestine freed by division of the offending suture. The transverse wound was then reunited by mucosa and seromuscular sutures as before, and the loop flushed with sterilized water.

The iodoform gauze strips which compressed the loop above and below were removed, and the permeability of the intestine as to feces and gases again tested. It was found that the intestine was entirely permeable at the place of operation and that at the line of sutures the intestine was air-tight. The intestine was now flushed again with sterilized water. An omental flap was then made by pulling down the omentum, which was followed by the transverse colon. The omentum was not quite long enough to go around the loop without some compression, but it was brought around and sutured to both sides of the mesentery. The loop in the field of operation and the omental flap were now anchored by sutures to the parietal peritoneum at the lower border of the wound, and an iodoform gauze drain laid down to the base of the loop. The remainder of the abdominal wound was then united in the usual manner.

The operation occupied about an hour and a half. At its close the patient was in good condition; pulse 110 and strong. He made a good and uneventful recovery and is at this time, sixteen months later, well.

Microscopic examination of the tumor proved its myomatous structure.

That myoma is by no means limited to the small intestine is well shown by a case of myofibroma of the rectum that came under my observation a few years ago. The tumor had reached the size of a child's head, was pedunculated in the direction of the peritoneal cavity, and evidently subserous in its primary anatomic starting-point.

Intraperitoneal Myofibroma of the Rectum.—This case is described somewhat in detail, for the purpose of showing how difficult it is in some cases to determine beforehand the primary location and starting-point of solid intrapelvic tumors, and at the same time to point out the impossibility, by present means of diagnosis, of differentiating between intraperitoneal myofibroma of the rectum projecting into the peritoneal cavity and solid tumors of the ovary and broad ligament, and pedunculated myofibromata of the uterus. I have not been able to find a similar case in the literature, although a careful search has been made dating back for at least twenty years.

The patient was a married woman aged forty-five, the mother of seven children. A pelvic tumor the size of a walnut was accidentally discovered by her family physician, Dr. Philler, of Waukesha, while attending her for miscarriage about three years before she came under my care. The tumor at that time was felt between the uterus and rectum, and appeared to be firmly attached. For two years it caused no inconvenience and the patient remained in her usual health; at the end of this time the abdomen gradually commenced to enlarge and the patient to complain of some pelvic distress Six months later her general health began to decline, accompanied by want of appetite and considerable loss of flesh. The patient never suffered from constipation or any other symptom pointing to the rectum as the primary seat of the tumor. Menstruation normal, both as to time and quantity She was admitted into the hospital April 20, 1890, at which time she was anemic, considerably emaciated, the abdomen greatly distended by fluid, and both lower extremities and the hips edematous. A careful examination of the heart and liver revealed nothing that could account for the ascites, and with the exception of being scanty, the urine was found normal. The supposition was that the ascites was caused

either by malignant disease of one of the abdominal organs or by tubercular peritonitis. A pailful of a clear serous fluid was removed by tapping. As the abdomen was being emptied a large solid tumor became apparent, occupying the left and lower portion of the abdomen. Bimanual examination of the uterus revealed this organ to be of normal size, but displaced to the right and pushed or drawn upward by the solid tumor. It could be clearly established that no direct connection or adhesion existed between the uterus and the tumor. The right ovary could be detected in its proper location and of normal size. The left ovary could not be discovered. It was now evident that the tumor was the same that had been discovered three years before, and that, in all probability, it was the cause of the ascites. The tumor was quite movable and could be pushed from the vagina in an upward direction for several inches, and could also be rotated around its axis, but when released, would always return to the same position. The attached portion appeared to be low down in the pelvis. A probable diagnosis of a solid tumor of the ovary or broad ligament on the left side was now made, and a radical operation advised.

Laparotomy was performed April 24, 1890. Although only four days had intervened between the time of the tapping and the operation, the abdomen had again become distended by a large quantity of the same kind of fluid. An incision sufficiently large to permit the introduction of the hand was made half-way between the umbilicus and pubes. After all the serum had escaped the relation of the tumor to the uterus and its adnexa was carefully examined. The uterus was found normal in size, but displaced upward and to the right by the tumor. The right ovary, tube, and broad ligament could be readily identified, and were found to be normal in size and structure; they had no connection whatever with the tumor. The tumor was hard to the touch and evidently covered with peritoneum. No adhesions. In searching for its attachment it was ascertained that its pelvic portions became more and more contracted, until, at the deepest portions of the pelvis, near the middle line, the attached part was somewhat flattened in a vertical direction, and about three times the diameter of the first joint of the thumb. On account of the inaccessibility of the attached portion no attempt was made to remove the tumor by enucleation lest hemorrhage be encountered. It was impossible to ligate the base of the tumor without lifting it partly out of the pelvis, which was done by an assistant. It was intended to tie the contracted, attached part in three sections—the upper and lower parts by transfixion, the central portion by throwing the ligature around it after cutting the tied sections. As soon as the transfixed portions had been cut and the last ligature was to be applied, the tumor was torn out of its bed by the traction made by the assistant. Immediately upon the removal of the tumor a small quantity of fluid feces escaped into the pelvis, which was at once carefully removed with a sponge, and the surface compressed to prevent extravasation, until it could be determined what had occurred.

Upon examination of the torn surface of the tumor a strip of mucous membrane was seen, somewhat oblong in shape, about half an inch in length and one-third of an inch in width. The escape of feces left no doubt that some part of the large intestine had been injured, but some doubt existed as to the exact location of the wound. Rectal insufflation of air demonstrated that the opening was at the floor of the pelvis, at a point over the middle of the rectum, where the peritoneum is reflected forward over the bladder. A large soft-rubber tube was now inserted into the rectum as far as the sigmoid flexure of the colon, and over this, after careful disinfection of the parts which had been contaminated with feces, the opening in the rectum was closed with a number of Lembert sutures. This part of the operation was exceedingly difficult and somewhat unsatisfactory, on account of the deep location of the visceral wound. After another careful toilet of the pelvic cavity a large Keith's glass drain, surrounded by several layers of iodoform gauze, was inserted in such a manner that its distal end corresponded exactly with the sutured rectal wound. The abdominal incision, which extended from the pubes to the umbilicus, was closed in the usual manner, except at the lower angle, where enough space was left open for the capillary glass drains. The operation was necessarily a protracted one, lasting nearly two hours, and toward the latter part of it the pulse became very feeble and rapid, the patient at the same time manifesting other symptoms of shock; whisky had to be administered subcutaneously.

The patient rallied well from the immediate effects of the operation. The bladder was emptied by the use of the catheter, and small doses of opium were given to procure rest for the rectal wound. During the first forty-eight hours nothing was given by the stomach but brandy in water and beef-tea. Very little fluid escaped through the drainage-tube, but this was allowed to remain for the purpose of guarding against fecal extravasation should the rectal wound fail to heal by primary intention. A laxative was administered on the third day, and after the bowels had moved freely, the glass drain was removed and a small quantity of fluid feces escaped. The tubular wound was gently washed out by irrigation with a solution of boric acid, and the drain reinserted. The

external wound healed without suppuration, and all the sutures were removed at the end of the first week. Six days after the operation the glass tube was removed, and drainage was secured by the insertion of strips of iodoform gauze down to the rectal wound. The fecal fistula closed completely and permanently two weeks after the operation, after which the drainage opening closed rapidly by granulation and cicatrization. Ascites did not reappear after the operation, and the patient has remained in excellent health since the operation.

Description of Tumor.—The tumor weighs twelve pounds. It is somewhat irregular in outline, but, on the whole, it is nearly globular. It is covered by peritoneum, except at the base, where it was detached from the rectum. At the margins of the attached surface it is easy to trace the tumor between the mucous membrane and the peritoneal coat of the anterior rectal wall. The tumor is very dense throughout, and the cut surface presents the trabeculated structure, with multiple foci of growth, so characteristic of myofibroma. Under the microscope it can be seen that the fibrous tissue predominates, the fibers being arranged in concentric layers and wavy bundles traversing the tumor in different directions. The muscular fibers, with their elongated large nuclei, are arranged in bundles. The tumor tissue is scantily supplied with blood-vessels. The manner of attachment of the tumor, as well as its microscopic structure, leave no doubt that it is a myofibroma which started in the anterior rectal wall, probably somewhat nearer the peritoneal than the mucous coat.

That an intraperitoneal myofibroma of the rectum must be an exceedingly rare affection is evident from the fact that no similar case could be found in literature. A friend of mine, who related this case to Sänger, of Leipzig, stated that the latter had observed a somewhat similar case, but it has evidently not been published. Myofibroma of the rectum projecting into the lumen of the bowel as a polypoid growth, if not common, is at least occasionally met with. Quite a number of operations for this affection could be collected. In such cases the primary starting-point of the tumor must be near the mucous membrane, which is pushed before it and becomes the covering of the polypus. If the primary matrix of the tumor is located nearer the serous coat, the tumor projects in the direction offering the least resistance, and becomes an intraperitoneal growth, constriction and pedunculation taking place at the attached portion as the tumor enlarges within the peritoneal cavity. It might be claimed that the tumor was primarily a myofibroma of the uterus, becoming later attached to the rectum, and isolated from the uterus by progressive atrophy of the pedicle. Such an explanation is untenable in this case, because at the margin of the attached portion it is easy to trace the tumor substance between the peritoneal and mucous coats; at the same time, the surface of the uterus on the corresponding side was found intact and perfectly smooth.

In a second case I removed a myofibroma the size of a walnut from the anterior rectal wall, through an incision of the posterior vaginal wall. This tumor reached down to the mucous membrane of the rectum, but projected toward the vagina; if it had been located about two inches higher up, it would have gradually developed into an intraperitoneal tumor.

Heurtaux, of Nancy, reports two cases of myoma of the intestine that came under his own observation. In his first case the tumor had twice given rise to attacks of intestinal obstruction, the interval between the first and the second attack being nine years. At the time the third attack occurred the patient, a woman, had reached the age of fifty. This time the attack was initiated by distressing tenesmus. In the ampulla of the rectum a round detached tumor, the size of an apple, with surface incrusted with lime salts, could be felt. Under the influence of an anesthetic the tumor was extracted, and its myomatous nature was demonstrated by microscopic examination. During the first attacks the patient was examined by Germain Sée, who felt a swelling under the liver that could not be felt after the tumor was removed. Heurtaux believes that the tumor developed originally in the large intestine, at the junction of the transverse with the ascending colon, and that the pedicle gave way spontaneously.

The second patient was thirty-seven years of age, and had been

subject for three years to constipation and paroxysmal colicky pains, and for the last month tenesmus, accompanied by mucous bloody discharges. Stools normal in shape. For the last five days intestinal obstruction. Immediately above the sphincter ani an egg-shaped tumor, the size of a pear, with smooth surface, could be felt attached to the posterior wall of the rectum by a pedicle the size of the thumb. Ligation of the pedicle and removal of the tumor were followed by recovery. Microscopic examination again proved the myomatous nature of the tumor.

A few cases have been reported where the obstruction was caused by cysts. In Buchwald's case the symptoms of obstruction were acute, and laparotomy was performed on the third day. The patient was a boy who had previously been in good health. As soon as the peritoneal cavity was opened two cysts attached to the small intestine presented themselves in the wound. As the cysts had produced a sharp flexion, nine centimeters of the bowel, including the cysts, were resected and the ends united by circular suturing. Twenty-seven hours after the operation the patient died. The necropsy showed that the resected piece was taken from the jejunum, one-half meter below the duodenum. One cyst measured seventeen centimeters and the other ten centimeters in diameter. The walls of the cyst were white and very thin. The microscopic examination showed that they were composed of the same tunics as the bowel, but the mucous membrane was atrophied and contained no glands. The cysts communicated with each other and the lumen of the bowel. The latter was not diminished in size. The cysts contained a yellowish fluid having a strong odor of acetone. Under the microscope the contents showed cylindric cells in a state of fatty degeneration, cholesterin crystals, granules of leucin, fat globules, and rod-shaped bacteria, but no intestinal contents. He believes that the cysts had no connection whatever with the vitelline duct.

Kulenkampff reports the case of a child three years of age, who had suffered occasionally from colic and constipation, and was attacked suddenly with symptoms indicative of acute intestinal obstruction. Abdomen was somewhat tympanitic, but no swelling could be made out by percussion and palpation. Tenderness and slight dullness in the right inguinal region. The boy died on the second day. The autopsy revealed, as the cause of death, a cyst in the region of the cecum. The cyst was as large as a man's fist, and had thin, almost transparent walls. It showed several depressions, which gave it the appearance of being composed of three or four parts. It was located in the mesentery of the ileum, about forty centimeters above the ileocecal valve. It did not communicate with the lumen of the bowel, and contained a thin, chocolate-colored fluid. The mesentery at this point was drawn out like a string and encircled a loop of the ileum. Above this point the bowel was greatly distended. He believed, with Roth, that the cyst was congenital and had developed from a diverticulum of the ileum.

As a rule, such cysts are located on the convex side of the bowel, but in this instance it occupied a position opposite.

At first sight the cyst appeared like a greatly distended loop of the intestine. As in both these cases the cyst had produced intestinal obstruction by secondary mechanical conditions, the operative treatment of the obstruction would include the removal of the primary cause and the correction of the secondary mechanical difficulties. This would include resection of the bowel at the seat of obstruction, including the tumor and restoration of the continuity of the intestinal canal by circular suturing.

The diagnosis of a benign intestinal tumor is never made until it causes functional disturbances, and even then seldom amounts to more than the recognition of the existence of a mechanical obstruction, the nature of which is seldom, if ever, known with sufficient accuracy to permit of positive and correct conclusions. The treatment is usually directed toward the complications caused by the tumor. In operations for invagination caused by benign tumors reduction, if it succeeds, is followed by removal of the tumor. If the invagination is irreducible, the tumor constitutes a part of the intussusceptum and is included in the treatment of the same.

Pedunculated tumors in the lumen of the intestine are removed by enterotomy, and interstitial tumors by enucleation.

Malignant Tumors.—The malignant tumors are sarcoma and carcinoma, the former being found more frequently above, the latter more frequently below, the ileocecal valve. Sarcoma is more often a disease of childhood; carcinoma, of advanced age. A sarcoma in the intestine, like one in any other organ, primarily starts from an embryonal matrix of connective tissue, and hence it always has its starting-point in the wall beneath the mucous membrane, while carcinoma, being an atypical proliferation of epithelial cells, commences either in the mucous membrane or in its glandular appendages.

Sarcoma.—Sarcoma, starting primarily in the intestinal walls, is comparatively a very rare disease. Madelung has had three cases of his own and has collected eleven others. The sarcoma is generally of the small round-celled variety, but occasionally is composed of spindle-shaped cells. The tumors probably always commence in the submucous tissue, and from there extend to the remaining tissues of the bowel. The muscular layers are next attacked; then the mucous coat; rarely the peritoneum, even in those cases that terminate in death from this cause. These tumors give rise to dilatation of the intestine, and rarely, if ever, cause any stenosis of the lumen. In some cases several distinct parts of the intestine are involved simultaneously by the disease. The regional metastasis involves the mesenteric glands at an early stage, and of the distant organs, the omentum, liver, and kidneys are most frequently involved. As regards the etiology of the disease, little is known. One case was preceded by a contusion of the abdomen.

A well-authenticated case of congenital sarcoma of the small intestine has been reported by Carl Stern. The day after the birth of the child symptoms of intestinal obstruction set in, which continued until it died at the end of the fourth day. The tumor commenced at a point 132 cm. below the pylorus, and involved a section of the intestine 45 cm. in length. On slitting the intestine open the tumor appeared as a marked prominence with a wide base. Surface of tumor covered only in part by mucous membrane. The microscope showed a very vascular round-celled sarcoma, well exhibited in the accompanying illustration (Fig. 529).

Sarcoma of the intestines occurs most commonly during the third and fourth decades of life. In Madelung's statistics, the oldest patient was fifty-two and the youngest four. All were males except one. The diagnosis is always difficult and frequently doubtful. The existence of rapidly growing tumors in the abdomen, which at first are freely movable, together with progressive emaciation and loss of strength in young persons, may point to this affection.

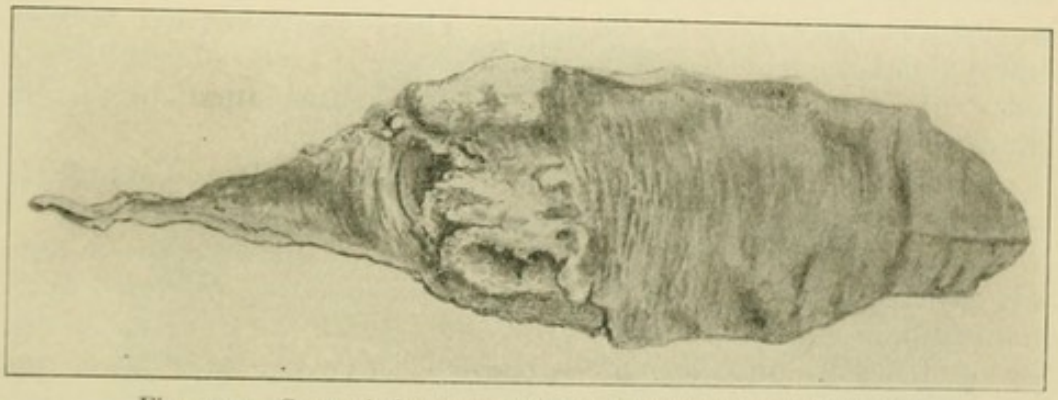

Fig. 529.—Congenital sarcoma of small intestine (after C. Stern).

Alternating diarrhea and constipation occur. The duration of life is short, the greater number dying within nine months. Little can be done in the way of treatment. If abdominal section has been performed to confirm the diagnosis, and a sarcoma is found, a radical operation is justifiable only if the disease has not extended beyond the intestinal wall and if the patient's strength promises to carry him over the immediate effects. Secondary tumors, however, appear at so early a stage of the disease that the surgeon will usually find himself under the necessity of either closing the abdomen or resorting to an entero-anastomosis, with a view to eliminating permanently from the fecal circulation the diseased portion of the intestine. Madelung made two resections, but both patients died shortly afterward. Mikulicz performed an operation for this condition; the patient left the hospital in twenty-four days, the operation wound having healed. No further observations were made on this case.

Nicolaysen reports an exceedingly interesting case of enterectomy for a sarcomatous stenosis of the small intestine. The patient

was twenty-eight years of age. A firm, nodulated, kidney-shaped tumor could be felt in the abdomen below the umbilicus. The growth was first noticed six months before, when it was as large as a hen's egg. In the morning the tumor usually could be felt under the costal arch, while during the day it descended into the hypogastric region, where it always caused more pain. As the symptoms of obstruction gradually increased in severity and did not yield to ordinary treatment, laparotomy was performed. Median incision fourteen centimeters long. It was found somewhat difficult to bring the tumor forward into the wound. The tumor occupied the mesenteric side of the bowel, and behind it a number of enlarged lymphatic glands could be felt. Eighteen centimeters of intestine, including the tumor and a triangular piece of mesentery, were excised, and the ends of the intestine united with sutures, embracing only serous and muscular coats. The proximal end was then invaginated to the extent of two centimeters, and the invagination retained with five Lembert sutures, over which the peritoneum was once more stitched with a continued suture of fine catgut. The mesenteric wound was also closed by suturing. The tumor consisted of several nodules the size of a goose egg, which had perforated the intestine. Microscopic examination of the tumor and lymphatic glands showed sarcomatous tissue. The patient recovered.

Bessel-Hagen describes a very similar specimen of intestinal sarcoma obtained by autopsy.

A boy, seven years of age, after a trauma suffered from a rapidly growing tumor in the abdomen that resulted in death from marasmus in four months. At the autopsy a large sarcoma of the jejunum was found which had perforated into the bowel by necrotic destruction of the interior of the tumor. Microscopic examination proved it to be a small, round-celled sarcoma that had originated in the submucosa of the jejunum. Multiple metastases occurred in kidneys, on back, and in the lymphatic glands. Peritonitic adhesions had caused flexion of the intestine below the tumor and dilatation of the proximal portion from obstruction thus produced. As a sarcoma of the intestine gives rise only to symptoms of obstruction and consequently comes under surgical treatment usually after extensive infiltration of the mesentery and retroperitoneal tissues has taken place, it is questionable if it is prudent to attempt a radical operation, as in case the patient recovers from the operation an early recurrence is almost inevitable. If a sufficiently early diagnosis were possible, resection could be made with a fair prospect of securing a permanent result, but if the infection has extended to the tissues around the bowel, it is more judicious to leave the sarcoma and to exclude the obstruction by an intestinal anastomosis.

Carcinoma.—In most cases of carcinoma of the intestine the disease commences in the mucous membrane, in which case the parenchyma of the tumor is composed of cells that resemble the

columnar epithelium that lines the intestinal canal. Carcinoma is found most frequently in the region of the sigmoid flexure, the

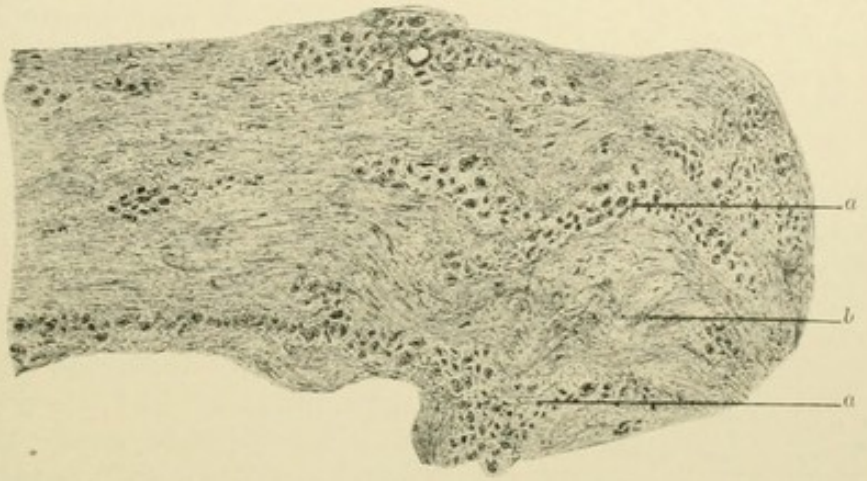

Fig. 530.—Periphery of cylindric-celled carcinoma of the cecum (× 110) (Surgical Clinic, Rush Medical College, Chicago): *a*, *a*, Rows of carcinoma cells in connective-tissue spaces; *b*, intervening connective tissue.

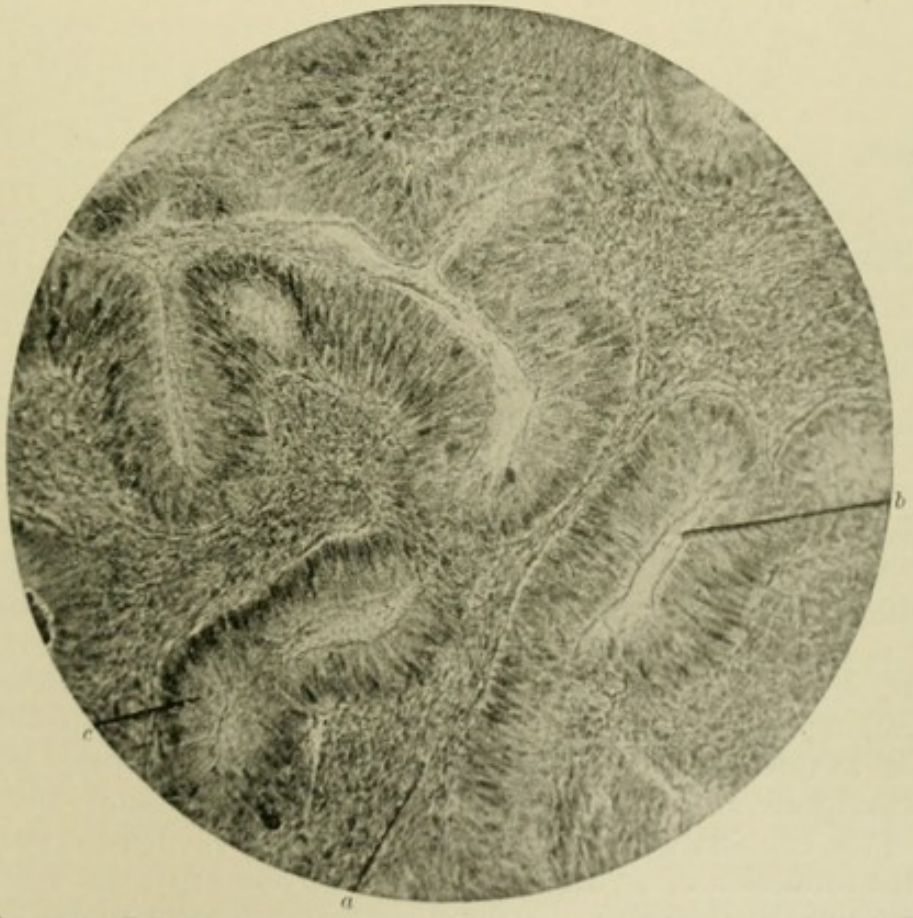

Fig. 531.—Cylindric-celled carcinoma of the rectum (× 480) (Surgical Clinic, Rush Medical College, Chicago): *a*, Connective-tissue stroma; *b*, atypical tubules of carcinoma; *c*, cylindric epithelial cells.

cecum, and rectum. A malignant stenosis may have existed for months without symptoms, when suddenly symptoms of acute

intestinal obstruction are developed, as in the case related below. In cases of acute intestinal obstruction in elderly people, where no cause for it can be found in the abdomen, a thorough rectal examination should never be neglected. During one of my visits to Zurich I was present at a very interesting autopsy made by Klebs upon one of Krönlein's patients. A few days before, a woman forty years of age was brought into the hospital presenting well-marked symptoms of intestinal obstruction which had lasted for two weeks. On examination no cause for the obstruction could be found. The abdomen was very tympanitic, rendering palpation difficult and unsatisfactory. Laparotomy was made, but as nothing could be found and the small intestine was enormously distended throughout, inguinal colostomy was performed. The operation was followed by decided relief, the abdomen collapsed, and a large quantity of feces was discharged through the artificial anus; but the patient died of exhaustion the next day. At the postmortem examination the cause of the obstruction was found twenty centimeters below the artificial anus, in the shape of a narrow annular carcinomatous stricture of the colon. In his remarks on the case Krönlein stated that he had observed four similar cases during the time he had been in Zurich. It is not unusual that such a stricture gives rise to no symptoms until suddenly evidences of complete intestinal occlusion are developed. It would be well in the future, when a similar condition is suspected, to explore, if need be, the upper portion of the rectum and lower extremity of the colon as far as accessible, by Simon's or Kelly's method, as, in case the lesion is recognized and accurately located, some of these cases will be amenable to a radical operation by excision.

The difficulties encountered in dealing with malignant tumors of the intestinal tract are made very apparent by König's experience. He gives the result of operations in 13 cases. In 3 of these only an exploratory incision was made, as it was found that removal of the tumor was impossible, owing to extensive adhesions to surrounding structures; no obstructive pressure was exerted upon the intestinal tract. In 3 other cases the tumor could not be removed, but as it produced obstruction, an artificial anus was made. Of these 6 cases 1 died of peritonitis in six days, as a result of the operation; 2 were living; 3 had died from the disease in from four weeks to three months after the operation. The remaining 7 of the 13 cases were subjected to radical operation by excision. In 5 of these the excision was followed by circular enterorrhaphy, and in 2 by the formation of an artificial anus. Of these patients, 4 died as a result of the operation. Of the 5 circular enterorrhaphies, 3 died, 1 of these being 1 of the 2 in whom an artificial anus had to be made. The surviving patient with an artificial anus died of recurrence of the carcinoma one year after operation. Of the 2 patients who recovered from the operation of resection and suture both were living—one three years after the excision of a carcinoma of

the ileum, and the other six months after removal of an obstructing section of tubercular intestine.

Such an experience by a master in surgery is certainly not well calculated to infuse courage and confidence in the average surgeon or general practitioner in dealing with intestinal obstruction due to malignant tumors. Hopeless as these cases are without operation, any rational attempts to remove the disease and, if this can not be done, to make an entero-anastomosis or artificial anus, must appear as the correct and only course to pursue. The results after operations for malignant disease are gradually improving and will continue to do so with the advancements made in diagnosis and with the improvements of the technic of intestinal operations. If a malignant intestinal tumor give rise to acute intestinal obstruction, the risks to life are diminished and the prospects of a radical operation increased by meeting the urgent symptoms by establishing an artificial anus first, and postponing the removal of the tumor until the intestines are in a better condition for such an operation. The same holds true in chronic obstruction that has resulted in great abdominal distention and intestinal paresis.

Schede is of the opinion that in cases of complete obstruction of the bowels by a malignant tumor, excision is contraindicated, as in 19 cases of intestinal resection for malignant disease, of 6 cases in which the occlusion was complete all died, while of the remaining 13, where the occlusion was only partial, but 3 died. These statistics should strongly induce us to endeavor to make a correct diagnosis before urgent symptoms have set in and to resort to operative treatment at a time when the general condition of the patient is such as to warrant a radical operation, and the local conditions at the seat of obstruction are favorable to a speedy process of repair. If, after resection of the lower portion of the colon, it is found impossible to approximate the two ends of the bowel and the distal end is not sufficiently accessible to make an intestinal anastomosis or lateral implantation, then the course adopted by Gussenbauer in one of these cases should be chosen. This patient was a man forty-six years of age, who had suffered for years from obstinate constipation. On examination he discovered a tumor the size of a hen's egg in the left hypogastric region, two fingerbreadths below a line drawn from one anterior superior spinous process of the ilium to the other. The tumor could also be felt high up in the rectum by pressing it downward into the pelvis. The abdomen was opened by an incision over the tumor parallel with the course of the descending colon. The tumor was found to occupy the most prominent portion of the sigmoid flexure, freely movable, and not attached to any of the surrounding organs. A few glands behind the affected portion of the colon were enlarged. Circular resection was made, including a corresponding portion of the mesocolon and the enlarged lymphatic glands. On account of too great loss of substance, circular enterorrhaphy could not be made, consequently

the distal end was closed by invagination and suturing and dropped into the abdominal cavity, while the proximal end was sutured into the external wound. The patient made a good recovery, and at the end of ten months the disease had not returned. Bull reports two cases of carcinoma of the sigmoid flexure where in each instance he opened the abdomen through the median line and stitched the descending colon into the wound without incising it, reserving this step of the operation until adhesions had taken place. Both patients recovered. In one of these cases he resected six inches of the colon, including the artificial anus and the tumor, twelve months later, and the patient again recovered from the operation. At the time the report was made the operator had in view a third operation for the closure of the second artificial anus, which was made at the close of the second operation. In all cases where the seat of obstruction can be located in the cecum or colon before the operation the lateral incision should be selected, as it will afford better access to the seat of obstruction than a median incision. If it is found impossible to remove the obstruction, one of two things must be done: If the bowel below the obstruction can be reached, an intestinal anastomosis is made, or the ileum is divided just above the ileocecal valve, the distal end closed, and the proximal end implanted into the bowel below the seat of obstruction. If resection can be done with a prospect of removing all the diseased tissues, it should invariably be practised as a primary radical operation, and if, on account of its extent, circular enterorrhaphy can not be done, the distal end is permanently closed, and the proximal end stitched into the wound. If the distal portion can be reached, the continuity of the intestinal canal is restored by intestinal anastomosis or lateral implantation. If the seat of obstruction can not be ascertained before the operation and exploration through a median incision locates it in the cecum, colon, or rectum, it may become necessary to make a lateral incision if a radical operation is decided upon, and when this appears impossible or unjustifiable, an intestinal anastomosis or lateral implantation can be made through the median incision. If, on account of the location of the obstruction, either of these operations is inapplicable, an artificial anus should be established in the right or the left inguinal region, and the median incision closed and dressed separately.

OBSTRUCTION FROM COMPRESSION.

Intestinal obstruction from compression of the lumen of the bowel from the outside by tumors, swellings, and inflammatory products depends in its clinical manifestations largely on the length of time required for the compressing force to develop mechanical obstruction. The slow growth of benign tumors is most likely to give rise to chronic obstruction, while malignant tumors, from their more rapid growth, give rise to mechanical obstruction by compression in a shorter time and with more speedy succession of symp-

toms. Inflammatory swellings may come on so rapidly that compression from this source may result in acute intestinal obstruction. The same is true of cases of sudden retroversion of the gravid uterus. The diagnosis in such cases is usually not difficult, as the size of the tumor is such that it can readily be located anatomically, and the clinical history will aid us in determining its nature. The treatment in such cases is directed mainly toward the removal of the cause of obstruction. In compression obstruction caused by inoperable tumors, the formation of an artificial anus is indicated as a palliative and life-prolonging operation.

Dynamic Obstruction.—A number of pathologic conditions are known to produce symptoms that so closely resemble intestinal obstruction that the abdomen has been repeatedly opened in such cases with the expectation of removing the cause of the obstruction, but no occlusion of any kind could be found. These are the cases that have caused the greatest difficulty in diagnosis, and have often brought disappointment and reproach upon the surgeon. The obstruction in these cases is not caused by a narrowing of the lumen of the intestine, but by suspension of the dynamic forces that propel the intestinal contents, and which result in accumulation of the feces and gases in the paralyzed portion of the bowel, which is followed by distention of the intestines, constipation, and obstinate vomiting, which in rare cases may become fecal. Circumscribed or diffuse paresis of the intestines is caused either by an inflammatory affection, such as peritonitis or enteritis, which produces suspension of muscular contractions in the same manner as when an inflammatory process in any other organ affects directly the muscular tissue, or the tunics of the intestines are in an intact condition, but a paralysis has resulted from reflex causes. Pitts narrates two cases in which, after reduction of a strangulated hernia, he performed laparotomy on account of persisting symptoms, and found no cause for these symptoms save that presented by the free but lifeless coil that had been liberated too late.

The contents in a paretic bowel are liable to undergo fermentative and putrefactive changes, and the gases that are developed during such changes accumulate and cause so extensive a tympanites that the latter may become a mechanical cause of obstruction.

Tympanites.—Cases of sudden death from obstruction of the intestines and stomach by rapid accumulation of gas have been reported by Dechambre, Mercier, L'Pereyra, and others. The patients were generally aged persons, or young persons during convalescence from protracted diseases.

Guéneau de Mussy, in a clinical lecture, treats of the mechanical effects of overdistention of the stomach and small intestine as a cause of intestinal obstruction. The empty portion of the intestinal tract may become impermeable from such a cause, with the inevitable result—acute intestinal obstruction. There is a well-

authenticated case on record where enormous distention of the stomach by gas produced such a result.

The lowest portion of the ileum may be compressed against the ascending colon so firmly as to become a cause of complete mechanical obstruction. Proof of the existence of such a mechanical condition is furnished in cases of extensive tympanites where the introduction of a rectal tube affords no relief. In such cases the distention increases even after death. I have also furnished experimental proof. The cadaver of a child was inflated moderately through the esophagus, after which the esophagus was tied and a tube was introduced into the rectum and its distal end immersed under water. Pressure upon the abdomen expelled the air through the rectal tube. When the experiment was repeated, but with still further distention, no air could be made to escape through the rectal tube by compressing the abdomen. On opening the abdomen with great care it was seen that the lower portion of the distended ileum was pressed against the ascending colon so firmly that the communication between them was completely interrupted. From these observations it can readily be seen how the formation of an intestinal anastomosis would frequently prove the means not only of relieving the obstruction, but also of removing its cause.

If gas is present in the peritoneal cavity as the result of putrefactive changes of the products of peritoneal inflammation, it presses the liver away from the diaphragm and the percussion dullness disappears completely when the patient lies on the back. In distention of the abdomen from the presence of gas in the intestines the diaphragm and liver are crowded upward, but the latter remains in contact with the chest-wall, and the area of liver dullness remains the same, but is displaced in an upward direction. When life is threatened by tympanitic distentions of the abdomen during the convalescence from acute diseases, the symptoms appear very rapidly and death results from mechanical compression of important organs. Puncture of the distended intestines, followed by aspiration and, if need be, repeated at short intervals, is positively indicated in such cases. There can be no doubt that in many cases of peritonitis attended by diffuse and excessive tympanites the symptoms that point to intestinal obstruction are due to the same causes,—flexions and compression,—and such cases would also be greatly benefited and sometimes cured by the same treatment.

Peritonitis.—Peritonitis may lead to symptoms resembling intestinal occlusion in different ways, according to the extent and type of the disease. In extensive plastic peritonitis the immobilization of a considerable portion of the small intestine may give rise to persistent vomiting and absolute constipation. Again, as we have just seen, arrest of the fecal circulation may be caused by the tympanites alone, while perforative peritonitis is attended by a local and general shock, which causes intestinal paresis through the sympathetic nerves. Heusner has observed that perforative peritonitis gives rise

to disturbances simulating intestinal obstruction by arresting intestinal movements. He narrates the history of two cases of this kind where the symptoms of intestinal obstruction were so prominent that laparotomy was performed. In both cases perforative peritonitis, but no occlusion, was found.

Henrot, in his classic monograph on pseudostrangulation, describes a number of cases of perforation of the gall-bladder and the processus vermiformis where the symptoms during life had pointed so strongly to the existence of intestinal obstruction that a wrong diagnosis was made by able clinicians. He also calls attention to those cases of paralytic obstruction that are often observed after herniotomy and in cases of strangulation of the appendix vermiformis and testicle. The intestinal paresis, where it is not the result of inflammation, must be looked upon as a reflex symptom.

Physical signs and symptoms are sometimes utterly inadequate to enable a distinction between acute intestinal obstruction and diffuse peritonitis to be made. In differentiating between these two conditions it must be remembered that in the absence of a swelling, absolute constipation and fecal vomiting are the most characteristic symptoms of obstruction, and that in peritonitis the pain is severe and continuous, with diffuse tenderness, tympanites, and absence of visible intestinal coils. In mechanical obstruction of the bowels the temperature, as a rule, is not above normal unless complications have set in, while in peritonitis a rise in temperature is the rule, although in some of the gravest cases it is subnormal. Many cases of supposed recovery from intestinal obstruction without operation undoubtedly were cases of dynamic obstruction, and the recovery was either entirely spontaneous or facilitated by means that assisted in the restoration of the peristaltic action. In 1851 a patient was admitted into Dupuytren's ward with well-marked symptoms of acute intestinal obstruction. This eminent surgeon gave it as his opinion that without an operation a fatal termination was inevitable, but the patient objected to the operation and was transferred to another ward, where he recovered in three days under the use of simple cathartics.

Numerous similar cases could be cited in illustration of the difficulty of differentiating in all cases between mechanical strangulation or occlusion and dynamic obstruction.

The surgical treatment of grave cases of peritonitis beyond the reach of successful medical treatment is now generally conceded and accepted, and more especially in cases in which the disease has resulted in dynamic intestinal obstruction. Abdominal section, enterotomy, evacuation of the distended paretic intestines, injection through the visceral incision of an ounce or more of saturated solution of sulphate of magnesia will occasionally save a life that otherwise would be surely doomed.

Catarrhal and Ulcerative Enteritis.—For some reasons that at present are difficult to explain simple catarrhal enteritis and circum-

scribed ulcerations of the small intestine have occasionally been the cause of rapid accumulations of gas, followed by symptoms of intestinal obstruction. Mercier has recorded a case where a patient died after a brief illness during which all symptoms pointed to the existence of intestinal obstruction, including complete constipation and fecal vomiting. The necropsy showed no stenosis or any other form of mechanical obstruction, but several large ulcers in the middle of the ileum.

Mosler reports a case of acute intestinal obstruction that followed a catarrhal enteritis, where, on postmortem, no primary mechanical obstruction could be found. The small intestine was so enormously distended that it filled the entire abdominal cavity, compressing the ascending colon so firmly as to render it completely impermeable; the transverse colon was also compressed, but to a less extent.

Zimmermann described a case of acute intestinal obstruction where, during life, the collapse came on so rapidly that it resembled cholera. The bowels remained completely constipated, and the vomiting was so severe and persistent that on the seventh day it became stercoraceous. The patient lived six weeks. At the necropsy the small intestines were found enormously distended and their walls were much attenuated. Colon was also distended. In the ileum a number of small ulcers were found that had destroyed the entire thickness of the mucous membrane. In a case of this kind Obalinsky made a laparotomy, and as he found the external surface of the lower portion of the ileum only congested, but no mechanical obstruction, he closed the external incision and the patient recovered. He believed that in this case there were typhoid ulcers that caused a functional stricture of the bowel and the symptoms that induced him to open the abdomen.

Traumatic Paresis.—Local shock the result of an injury may temporarily suspend peristalsis and cause intestinal obstruction.

E. H. King reports a case of dynamic obstruction following a contusion of the intestines, where laparotomy was made on the third day.

The patient was a boy twelve years of age, who was kicked in the abdomen by an unshod horse. The point of impact was in the middle line, just below the umbilicus. Pain and vomiting followed soon after the injury was received. Second day, pulse 120; temperature, 100.5° F.; abdomen very tender and decidedly tympanitic. Third day, symptoms much worse; temperature fell suddenly to 97° F., while the pulse increased to 140. Median abdominal section. Intestines dilated, very vascular, presented a sodden, edematous appearance, and were covered with plastic lymph. No gangrene, perforation, or sign of injury. The ileum was drawn forward into the incision and was punctured with a trocar, much gas and a pint of fluid feces being evacuated; the puncture was closed with one Lembert suture. The serum in the abdominal cavity was mopped out with a sponge, and the abdominal incision closed in the usual manner. Intestinal antiseptics were given internally to guard against subsequent distention. Drainage-tube removed on the third day. Superficial part of wound separated under tension, but was united later by secondary sutures. The patient made a rapid recovery.

There are cases on record in which the reduction of a strangulated hernia was followed by intestinal obstruction, and no gross

pathologic changes were found in the reduced loop on abdominal section or postmortem; hence it is reasonable to assume that the obstruction was caused by paralysis of traumatic origin. Opinions on this point, however, are at variance: some attribute the obstruction to paralysis, others claim that the trauma resulted in a condition of the intestinal wall that permitted the passage of microbes, causing inflammation that was responsible for the paralysis. It is in dynamic obstruction of this kind that medical treatment has met with the most encouraging results.

In several cases of volvulus in which the intestinal loop was twisted 180 degrees around its axis, but without serious pathologic changes, Heidenhain found reposition followed by temporary paralysis and persistence of the obstruction. The question arises, whether the paralysis was the result of peritonitis or vascular disturbances in the strangulated loop.

Morawek has shown, by his examination of specimens of paralytic ileus following strangulation, that the paralysis is caused by inflammation.

Borchert has seen three cases of herniotomy die with symptoms of peritonitis and obstruction, although no signs of obstruction were observed until three or four days after the operation. Postmortem showed no peritonitis. Friedländer assumed that death under such circumstances was caused by the resorption of toxic alkaloids from the intestinal canal through the damaged mucosa of the strangulated portion of the intestine.

Reichel has had a similar experience. He is, however, of the opinion that in such cases peritoneal infection has occurred by the migration of pathogenic microbes through the injured intestinal loop. Fatal peritonitis often shows no signs of inflammation on postmortem examination.

Heidenhain is of the opinion that the paralysis takes place without infection, in consequence of nutritive disturbances caused by the strangulation. He believes that passage of microbes through the damaged intestinal wall is not of frequent occurrence.

Tavel and Lanz found the serum in the hernial sac sterile in sixteen cases of external and two cases of internal hernia, and in two of the former cases the strangulation had caused gangrene.

Tietze found bacteria in the serum contained in the hernial sac in four out of nine cases of intestinal strangulation. In two cases only the serum in the peritoneal cavity could be examined and was found sterile. In three of these nine cases the intestinal loop was gangrenous and yet the serum in the hernial sac was free from bacteria. Tavel and Lanz maintain that the fibrinoplastic peritonitis found in such cases is caused by the passage of chemic products from the intestine through the injured wall.

Heidenhain advises that little or no opium should be given after herniotomy in order to prevent intestinal paralysis. Astley Cooper also opposed the use of opium in such cases. Dieffenbach admin-

istered an emulsion of castor oil after the operation. Kummell invariably gives a laxative.

Semmola has reported the case of a man, twenty years of age, of nervous temperament, in whom, after the occurrence of diarrhea, symptoms of intestinal obstruction appeared; to these ischuria was added. Ordinary treatment was without avail, and laparotomy was proposed. From the suddenness of the onset of the symptoms of obstruction after the occurrence of diarrhea; from the paroxysmal character of the pain; from coexistence of paralysis of the bladder without previous disease; and from the neuropathic tendency of the patient, a diagnosis of paralysis of the bowel was made, and the application of the constant current was recommended. The positive pole, attached to a catheter, was introduced into the rectum, and the negative pole stroked upon the abdomen in the course of the colon. The applications were made for from eight to ten minutes thrice daily. The symptoms gradually improved, and, after the ninth application, the bowels were spontaneously moved. In the course of ten days the patient was completely restored to health.

Besides electricity, high stimulating enemata, lavage of stomach, and abdominal compression constitute the most reliable expectant treatment.

INTESTINAL OBSTRUCTION AFTER ABDOMINAL SECTION.

About ten years ago Olshausen reported several cases of laparotomy in which more or less eventration became unavoidable during the operation. A few days after the operation the patients presented all the appearances of an attack of acute intestinal obstruction, and death followed in from five to ten days after the operation. Olshausen explained the symptoms during life and the fatal termination by assuming the existence of intestinal paralysis, distention of the bowel, and absorption of toxic agents from the intestinal canal. During the eventration the intestines became engorged by venous hyperemia, which in turn again was followed by exudation and transudation into the tissues of the bowel.

Sebileau reopened the abdomen in two cases of acute intestinal obstruction after laparotomy, and no mechanical occlusion or exudation of any kind, but enormous meteorism, was found. He attributes this condition to intestinal paresis and rapid accumulation of gas. The prophylactic treatment of such cases is more important than the curative. The administration of a brisk cathartic on the second or third day after the operation will usually prevent tympanitic distention of the abdomen by stimulating the paretic walls to active muscular contractions, and by removing the intestinal contents, the source of putrefactive changes. This treatment should never be postponed until the paralysis has been aggravated by overdistention, but should be resorted to either before or upon the first appearance of intestinal distention. Uniform compression of the abdomen with strips of adhesive plaster and bandage applied over the antiseptic absorbent

dressing immediately after the operation should be kept up until all danger from the occurrence of tympanites has passed. When the distention has become so great as to threaten life, the treatment should consist of the employment of such prompt mechanical measures as will diminish the intra-abdominal pressure. As the stomach may also be dilated, its contents should be removed through a flexible stomach-tube, followed by an irrigation with a harmless antiseptic solution. Tubage of the colon, followed by a turpentine enema, is used for the same purpose. If these measures fail in relieving the distention, a prompt resort to intestinal puncture with a fine hollow needle becomes imperative. This surgical resource may be repeated as often as it may become necessary to avert danger from an increasing intra-abdominal pressure.

Klotz met with 31 cases of intestinal obstruction in 569 abdominal sections for different indications; 5 of these died. This complication was observed most frequently after prolonged operations and tedious dressings and when antiseptics were used in the abdominal cavity. Since 1889, when this latter practice was set aside, only five cases of obstruction had occurred. On that account Klotz was not inclined to look on ileus as a septic affection. At necropsies or in secondary abdominal sections undertaken to relieve the obstruction, he always found coils of small intestine immobilized by great coagula. As to diagnosis, nausea on the second day was suspicious, while vomiting on the third, with no passage of flatus, undoubtedly denoted obstruction of the intestines. The way to prevent ileus was to avoid antiseptics and toilet of the peritoneum, to check completely all hemorrhage from wounded surfaces, and to regulate peristalsis of the uninjured intestine as soon as possible. This was accomplished by Seidlitz powders and enemata on the second day after operation. When occlusion had set in, Klotz washed out the stomach under high pressure, and inflated the rectum with air. The latter practice was highly recommended. When these means failed, he washed out the stomach once more, and after complete emptying of that organ he administered large doses of castor oil—up to fifty grams (over an ounce and a half). In all cases where the oil was given it was retained without vomiting, and the intestine was freed from its adhesions. In this way secondary abdominal section was avoided. Klotz did not believe that these cases were septic; there was little or no rise of temperature, and this was rare in sepsis; nor was the obstruction caused by bands of fibrin. The intestine was always found embedded in a clot and fixed to it, almost always at a point where the serous coat had been wounded.

The views concerning the proper treatment of such cases depend entirely on the opinions held regarding the cause of obstruction. Some operators favor reopening of the abdominal cavity, searching for and removing the mechanical cause of the obstruction; others, who take the ground that the obstruction is usually due to intestinal

paralysis, are in favor of a plan of treatment calculated to restore the temporarily suspended intestinal function. In the latter class of surgeons belongs Stumpf, of Munich, who has had occasion to observe two cases of paralytic ileus after laparotomy, and, inasmuch as this is one of the most formidable and dangerous complications that may supervene after laparotomy, he describes the treatment that he employed. It is an extremely interesting fact that, in one of the cases referred to, the symptoms of ileus made their appearance immediately after the intervention. The patient had barely been taken back to bed when feculent vomiting set in, which on the following day increased in frequency until it recurred every five or ten minutes. He vainly resorted to all the measures usually employed under such circumstances, and ultimately despairing of the case, contented himself with feeding the patient by nutrient enemata, which, curiously enough, were largely retained without great difficulty. From the sixth to the eighth day the grave symptoms gradually improved, and the patient was soon out of danger. He is, therefore, of the opinion that, in cases of paralytic ileus, it is useless to again open the abdomen, and that copious rectal injections, nutrient enemata, and medical treatment will prove more beneficial than operation. It is absolutely certain that the employment of asepsis, especially by dry means, materially reduces the number of cases of intestinal obstruction.

Among the most important prophylactic precautions against this grave postoperation complication must be enumerated :

Quick, but not hasty, operating ; withholding of irritating antiseptics from the abdominal cavity ; gentle and as little handling of the abdominal contents as possible ; careful hemostasis ; covering of raw surfaces with peritoneum wherever this can be done ; and an early resort to cathartics and high enemata to maintain or restore intestinal peristalsis.

CHAPTER XXVI.

STRANGULATED HERNIA.

One of the most dangerous accidents that the general practitioner is often called upon to treat is strangulated hernia. An early diagnosis and prompt action are necessary in such cases to prevent gangrene of the strangulated intestinal loop, and death from exhaustion or septic complications. If a hernia that has become strangulated contains, as it usually does, a knuckle of any part of the intestinal tract, the accident is announced and is clinically characterized by a complexus of symptoms analogous to, or at any rate closely resembling, what is observed in cases of intestinal obstruction from other mechanical causes. The symptoms are modified by the part of the intestinal canal involved in the strangulation and the degree of constriction.

An irreducible hernia attended by symptoms of incomplete obstruction is called an incarcerated hernia. The constriction in such cases is sufficient to impede the passage of intestinal contents without endangering the circulation in the incarcerated loop. In the acute form of strangulation complete arrest of the circulation and gangrene of the strangulated loop may take place in less than twenty-four hours. In the former case the obstruction is partial; in the latter, always complete. Any hernia may become strangulated regardless of its location and size. Strangulated hernia is met with most frequently in the anatomic localities most predisposed to hernia formation. Inguinal hernia constitutes 84 per cent. of all herniæ, femoral 10 per cent., and umbilical 5 per cent. Strangulated hernia, therefore, occurs most frequently in inguinal, femoral, and umbilical herniæ, while a strangulated diaphragmatic, obturator, properitoneal, etc., hernia is a surgical rarity, owing to the infrequency with which the latter anatomic forms of hernia occur. Umbilical and femoral herniæ are, on the whole, more liable to strangulation than inguinal hernia. Ventral hernia following as a remote complication of laparotomy or injury of the abdominal wall seldom becomes strangulated, owing to the yielding nature of the tissues that surround the hernial sac. The small ventral herniæ found so often in the median line, or a little to one side of it, between the ensiform cartilage and umbilicus, as a rule contain only omentum, which is seldom found strangulated, but almost always adherent to the internal surface of the minute hernial sac. These herniæ are often a source of pain and gastric and intestinal disturbance, but seldom give rise to complete obstruction and other symptoms that accompany strangulation of an intestinal loop.

Etiology.—A hernia is strangulated when, from any cause, the

intestinal loop in the hernial sac has become impermeable, usually by constriction at its neck, so that reduction is difficult or impossible, the constriction at the same time producing symptoms of obstruction and endangering the circulation in the protruded bowel. *The immediate cause of the strangulation is not, as was formerly supposed, a contraction of the hernial ring, but a sudden increase in the hernial contents. The hernial ring remains passive, and constriction takes place by an increase in volume of the structures that are embraced by it.* The more unyielding the tissues that compose the ring, and the narrower the ring, the greater is the danger of strangulation in the event of a sudden increase in the volume of hernial contents. It is for this reason that umbilical and femoral herniæ are more prone to strangulation than inguinal and ventral herniæ, the umbilical ring and Poupart's ligament furnishing greater resistance than the muscles of the abdominal wall. It is for the same reason that a small hernia becomes more frequently strangulated than a large one. The sudden increase of hernial contents occurs either in consequence of exaggerated intestinal peristalsis or because of the influence of increased intra-abdominal pressure. In the first instance the intestinal contents accumulate rapidly in the knuckle of bowel in the hernial sac, the permeability of which is always impaired more or less by the existing flexion. The intestinal loop, unable to empty the contents as fast as forced into it by the strong peristalsis, becomes distended, finally paretic, and the venous engorgement that follows as a natural sequence becomes the direct cause of the subsequent strangulation. Strangulation in such cases is preceded by intestinal disturbances that lead to violent peristalsis. These are the cases in which reduction of the hernia by taxis is greatly facilitated by the administration of a sedative dose of an opiate.

More frequently strangulation is caused by a sudden increase in volume of the contents of the hernial sac, as the direct mechanical result of abnormal intra-abdominal pressure. Laughing, coughing, vomiting, straining, lifting, a fall upon the feet, a misstep, are the most frequent causes mentioned by patients as the direct cause of the strangulation. Under such conditions the strangulation is produced by the descent of more of the intestines, thus increasing the length and volume of the intestinal loop in the hernial sac; or by the descent of a second knuckle of the bowel; or the intestinal loop is compressed by the descent of the omentum already in the sac; or the omentum is suddenly forced into the sac in addition to its former contents. The partial strangulation incident to the sudden increase in the volume of hernial contents soon becomes complete by the venous engorgement, which follows the partial strangulation as a necessary result. The next link in the chain of mechanical conditions that aggravate the strangulation is edema of the parts below the constriction. This eventually becomes the direct cause of complete venous stasis and gangrene.

Gangrene of the strangulated intestine is not the result of an inadequate supply of arterial blood, but is produced by arrest of the venous circulation by compression or thrombosis. The arterial circulation is finally suspended in consequence of complete venous stasis. Gangrene of the strangulated intestine is produced by mechanical conditions at the seat of constriction, which first embarrass and later completely arrest the venous circulation. Besides the opening through which the hernia has descended, the most frequent seat of the strangulation in all anatomic forms of hernia, constriction may take place in the neck of the hernial sac, in the sac itself by bands of adhesion, and, finally, by a twist of the intestinal loop in the sac.

The pathologic conditions produced by the strangulation vary according to the location and degree of constriction and the presence or absence of infection. If the constriction only impedes, but does not arrest, the venous circulation, transudation from the engorged capillaries takes place and the hernia becomes complicated by an acute hydrocele of the tunica vaginalis. Localized gangrene under the constricting band occurs if the pressure affects only a limited portion of the circumference of the bowel to the extent of causing pressure necrosis. Under such circumstances the necrosis is linear and corresponds in direction and width to the constricting band. If the constriction is more uniform, venous circulation is first embarrassed, later completely interrupted, and unless timely operative treatment is resorted to, gangrene of the whole loop below the point of constriction follows as an inevitable sequence.

An intestine that has been strangulated for some time undergoes textural changes that render its wall permeable to the passage of pathogenic microbes before gangrene and perforation open up a free passageway for the escape of intestinal contents into the hernial sac. Bacteriologic experiments made with the fluid in the hernial sac in cases in which no perforation or gangrene was found at the time the operation was performed have demonstrated in many instances the presence of pathogenic microbes that could have found their way into the sac only through the intestinal wall damaged by the passive venous hyperemia. If pyogenic bacteria find entrance through the permeable intestinal wall into the sac in sufficient quantity and virulence to induce suppuration, abscess formation may take place independently of gangrene and perforation. Acute suppurative inflammation of the hernial sac without gangrene is, however, a very rare complication of strangulated hernia. Acute inflammation of the sac, phlegmonous inflammation of the connective tissue outside of the sac, and emphysema are conditions that almost unerringly announce the occurrence of gangrene of the strangulated intestine.

Symptoms and Diagnosis.—In rare cases an acute strangulation is initiated by symptoms that denote shock. The patient faints, the pulse is rapid and without force, the surface of the skin

is cold and covered with a cold, clammy perspiration, and the pupils are dilated. These are the cases in which the constriction is tight from almost the very beginning of the accident, the shock being a reflex manifestation of the sudden compression and irritation of the sympathetic nerves. With the reaction the local symptoms develop in rapid succession and point to the existence of complete intestinal obstruction. Ordinarily the patient experiences a sudden pain in the hernial swelling, which at the same time becomes tender to the touch. If the patient is aware of the existence of the hernia, he suspects what has happened and makes attempts to reduce it. In doing so he discovers that the swelling is larger and much harder than usual and more painful on manipulation. In some instances the local symptoms are slight or almost entirely wanting, and if the patient is ignorant of the existence of a hernia, he usually resorts to treatment directed toward a disturbance or derangement of the intestinal canal from other causes. The constipation is absolute. The bowel movements following enemata are limited to the evacuation of intestinal contents below the seat of obstruction. Vomiting is a constant and distressing symptom, and is always aggravated by the administration of cathartics that are usually resorted to before medical aid is summoned. *The paroxysmal abdominal pain caused by the violent peristalsis is referred to the umbilical region.* As the obstruction is generally complete, the strangulated loop is impermeable to gas; consequently tympanites soon sets in and adds to the abdominal distress. At first the vomit consists of stomach-contents, followed later by intestinal contents, which, if the obstruction is low down in the intestinal canal, soon become distinctly fecal.

In all cases of intestinal obstruction it becomes the imperative duty of the attending physician to examine carefully all the hernial regions for the existence of a strangulated hernia. The patient's statement that he is not the subject of hernia can not be relied upon to exclude this cause of intestinal obstruction. If the patient is obese and the hernia small, it requires the most painstaking examination to detect the hernial swelling. This is particularly true of small femoral herniæ in obese women. If the hernial swelling is found, palpation will show that it is very tense, painful to the touch, and lacks impulse on coughing. Under moderate pressure the swelling is not reduced in size. If the strangulated loop is distended with gas, percussion reveals a tympanitic area that in size corresponds to the strangulated loop. If the swelling is large and the coverings of the sac are thin, careful manipulation of the contents of the sac may give definite information as to the character of its contents. A large mass of omentum in front of the knuckle of bowel can usually be identified by this method of examination, or, in the absence of the omentum, the strangulated loop can be traced through the intact skin in the same manner. Edema and redness of the skin over the sac are indications that gangrene has

occurred, and the existence of a subcutaneous emphysema or a general peritonitis is unmistakable evidence that the strangulation has resulted in gangrene. The existence of a hard, tender hernial swelling in cases of acute intestinal obstruction is a reliable, if not an infallible, indication that the obstruction has been caused by strangulation of the hernia.

The differential diagnosis must next be considered between strangulated hernia and other causes of intestinal obstruction, and also the following affections:

Incarcerated hernia, inflamed hernia, cryptorchism, lymphaden-

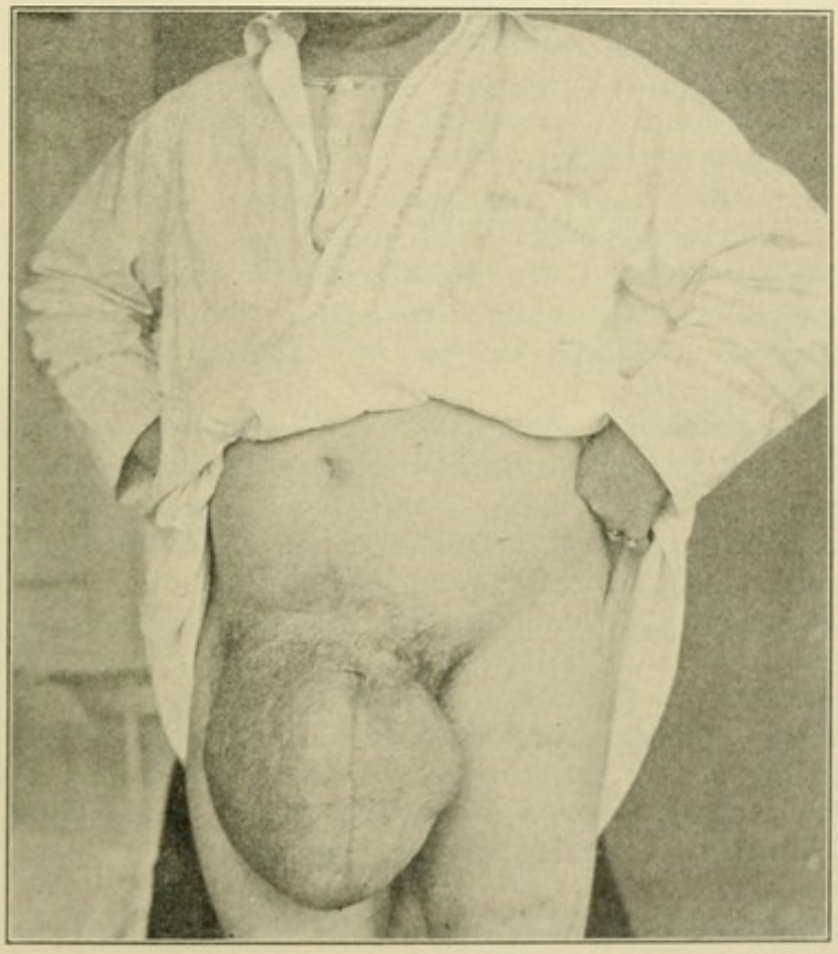

Fig. 532.—Large incarcerated scrotal hernia. Operation successful (St. Joseph's Hospital, Chicago).

itis, hematocele of the tunica vaginalis, and suppurative vaginalitis. In making a differential diagnosis between strangulated hernia and allied affections that may simulate it, it must be remembered that the most striking clinical feature of the former consists in a complexus of symptoms that points to the existence of intestinal obstruction. Intestinal obstruction from internal causes could give rise to confusion only by the coexistence of an irreducible, incarcerated, or inflamed hernia. The rarity with which such cases occur in practice would justify herniotomy as a diagnostic resource, and if the hernia can be excluded as the cause of obstruction, laparotomy for

the relief of the internal obstruction should be resorted to without delay. The patient and friends should be informed of the intent of the first operation, and the necessary preparations made for the second.

Incarcerated and inflamed herniæ do not give rise to intestinal obstruction, and the symptoms are referred to the hernial swelling exclusively.

Torsion and strangulation of an undescended testicle in the inguinal canal may produce reflex vomiting and other symptoms that might lead to the suspicion of the existence of intestinal obstruction, and the hard swelling might suggest a small strangulated hernia. The absence of the testicle from the scrotum and the sickening pain caused by pressure over the swelling would at once call the attention of the physician to cryptorchism.

Suppurative vaginalitis, either as a primary affection or following in the course of a suppurative orchitis or epididymitis, is attended by fever and the local signs of an acute inflammation. Should gastro-intestinal disturbances obscure the case, an exploratory puncture will demonstrate the nature of the swelling. The same diagnostic resource can be relied upon in making a positive diagnosis of hematocele.

Lymphadenitis in localities the favorite sites of hernia has repeatedly been mistaken for strangulated hernia and vice versâ. The differential diagnosis between a suppurative lymphadenitis in the groin and strangulated hernia is sometimes very difficult. If the inflammatory affection of the glands is multiple, a correct diagnosis can be made by establishing this fact, and, should any doubt remain, by locating the source of infection. If the inflammatory swelling is single and occupies the site of a femoral hernia, caution is necessary in resorting to the use of the knife. The possibility of the swelling being an inflamed or strangulated hernia must be borne in mind in making the incision, which in doubtful cases should be made by careful dissection in the same manner as in the operation for strangulated hernia.

Prognosis.—Under aseptic precautions herniotomy is so safe an operation that the mortality of strangulated hernia has been reduced to a minimum. The prognosis, therefore, is very favorable, provided a correct diagnosis is made and the strangulation relieved by taxis or operation before the intestinal loop has been damaged to any considerable extent. *An early diagnosis and timely and judicious interference by taxis or operation are necessary in preventing the complications that, in the past, have maintained the high mortality of strangulated hernia.* The prognosis depends entirely on the condition of the hernial contents, and this is determined largely by the time that has intervened between the occurrence of the accident and the resort to taxis or operative interference. The length of time the strangulation has existed has a direct bearing on the mortality that follows the subsequent efforts to relieve the strangulation.

But there are many exceptions to this rule. If the constriction is tight almost from the very beginning, gangrene of the strangulated intestinal loop may occur in the course of a very few hours, while under more favorable local conditions the bowel may be found viable, even when the operation for its relief has not been performed until several days after the accident has occurred. The danger from gangrene in a given space of time, all other things being equal, is greatest if the constricting band is narrow and unyielding, and if pressure is exerted directly upon the intestine. A small femoral hernia with little or no omentum in the sac is the one in which, as a rule, the circulation in the strangulated intestine is completely arrested in the shortest space of time. On the contrary, if the hernia is large, and more especially if a large elastic cushion of omentum is interposed between the constricting band and the intestine, gangrene, if it takes place, occurs as a more remote complication.

Much valuable prognostic information can be obtained from a careful study of the clinical history. If the symptoms of obstruction are acute, and the hernial swelling is very hard, and if tenderness and local pain are early and prominent symptoms, the probability of the early occurrence of gangrene is always great. If, on the other hand, the local symptoms are ill defined, vomiting and tympanites set in slowly, and the hernial swelling lacks hardness, the prognosis is correspondingly more favorable. Discoloration of the skin over the hernia and edema suggest gangrene, and this condition of the bowel can be safely predicted in the presence of emphysema. A more distant indication of the existence of the same condition of the strangulated bowel is a tendency to general capillary stasis.

Treatment.—The treatment of a strangulated hernia consists in effecting reduction as soon as possible after the strangulation has occurred, and if this fail, or if the condition of the hernial contents does not permit of such an attempt, in relieving the constriction by operative treatment and then dealing with the strangulated loop as indicated by its condition.

The medical treatment in such cases is of little avail. No modern physician would for a moment consider seriously the therapeutic value of nauseating enemata or the internal use of relaxing antispasmodic remedies, so much relied upon in facilitating taxis before herniotomy was shorn of its great mortality by the introduction of aseptic surgery. *No time should be lost in vain attempts to relieve the strangulation by a resort to drugs.*

In a recent strangulation, two things can be done with the expectation of favorably influencing the acute symptoms and of facilitating the subsequent taxis: (1) The administration of an opiate will allay the violent peristalsis above the seat of obstruction, and, by doing so, will control, to a certain extent at least, one of the causes that lead to speedy arrest of the circulation in the strangulated loop and to gangrene. (2) A high enema, properly administered, will stim-

ulate peristalsis in the intestine below the seat of obstruction, and at the same time will clear that portion of the bowel of its contents, thereby increasing intra-abdominal space, creating conditions favorable to subsequent attempts at reduction of the hernia by taxis.

Taxis.—In the treatment of a recently strangulated hernia no time should be lost in effecting reduction by taxis. By the term taxis here is meant the reduction of a hernia by methodic manipulation without instruments. Taxis is indicated in all cases in which, from the time that intervened between the occurrence of the accident and the attempt made at reduction, gangrene would not be expected to take place, and in cases in which the general and local symptoms would suggest a similar favorable condition of the strangulated bowel. *In doubtful cases it is safer to resort at once to herniotomy, rather than to assume the risks of reducing by taxis a strangulated loop that, when returned into the abdominal cavity, might become the cause of a septic peritonitis.*

Taxis is performed as follows: The patient is placed in the recumbent dorsal position, with the pelvis well elevated and the thighs and legs flexed, to relax the abdominal muscles and the constricting band or ring. According to the size of the hernia, compression is made with the finger-tips or the whole right hand. With the thumb and index-finger of the left hand compression is made of the intestinal loop, omentum, or both, below the constricting ring, in such a way as to empty the contents of the strangulated loop first. If the hernia is not reduced after a short attempt, the hernial swelling is grasped firmly with the right hand, when traction is made, combined with lateral movements; while the sac and its contents are on the stretch, the thumb and index-finger of the left hand are again employed in emptying the intestinal contents by compression, kneading, and stroking in the direction of the hernial canal. In reducing an umbilical hernia, the pressure is directed toward the umbilical ring; in inguinal hernia, in the direction of the inguinal canal; in femoral hernia, at first downward, toward the saphenous opening, and later in the direction of the crural canal. In difficult cases Trendelenburg's position will prove useful in performing taxis. The manipulations must be made systematically and without interruption, and the force used should never be sufficient to endanger the strangulated loops, the walls of which, even if not gangrenous, may have suffered sufficiently from the effects of the strangulation to diminish materially their resistance to pressure. *Reckless taxis has resulted in rupture of the bowel, and such an accident has almost always been followed by death, even in cases in which herniotomy was afterward performed.* Such an accident should never occur in the practice of a careful physician, and if reduction under gentle force does not take place, the failure is a sufficient indication for the immediate performance of herniotomy.

Reduction is often facilitated by the application of cold, either in the form of an ice-bag or ether spray. In difficult cases general

anesthesia is always required, and must be carried to the extent of complete muscular relaxation, as an incomplete anesthesia will be found more harmful than useful. In the absence of contraindications chloroform deserves the preference to ether. How long is it safe or advisable to continue taxis? It is easier to answer this question now than it was twenty-five years ago. *No harm should ever result to the hernial contents from taxis.* It is difficult to fix the time limit with precision. The length of time it is safe to continue the manipulations will depend largely on the degree of strangulation, the condition of the hernial contents, and especially on the amount of force used in attempting the reduction. The experienced physician will be able, after a few gentle efforts, to decide whether or not it is advisable to prolong the taxis. He will be guided in this matter by the effects of the pressure and manipulations on the size and consistence of the swelling. If the hernial swelling is reduced in size and becomes softer, it would indicate that the contents of the intestinal loop have been reduced and that successful reduction of the hernia will follow by a continuance of the manipulations. If the size and hardness of the hernia are not diminished after a gentle trial for ten or fifteen minutes with the patient fully under the influence of an anesthetic, it is a waste of time and detrimental to the patient to persist in the efforts, and herniotomy should be performed without delay. The patient should be informed beforehand that, in case taxis fails, herniotomy will be performed during the same narcosis; the necessary preparations should be made for the operation. After successful taxis, rest in bed and an absolute diet should be enforced for at least twenty-four hours, and before the patient leaves his bed he must be supplied with a well-fitting truss.

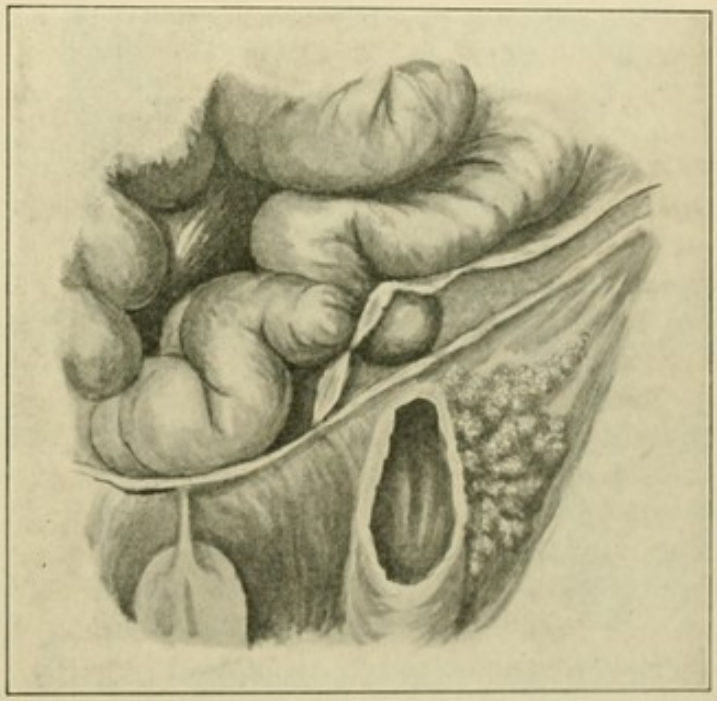

Fig. 533.—Reduction of femoral hernia, strangulation remaining (after Marcy).

If the symptoms of obstruction are not relieved by the reduction, one of the following causes must be suspected: Return of injured or gangrenous bowel, peritonitis, reduction of hernia *en masse*, a second

strangulated hernia. If a second strangulated hernia can not be found, laparotomy is the only recourse for the detection and treatment of the remaining cause or causes of the persistent obstruction.

Herniotomy.—Herniotomy is the operation resorted to for the relief of a strangulated hernia by cutting the constriction. As the sac of a hernia is a part of the parietal peritoneum, and as the modern operation almost always includes opening of the sac, it invariably implicates the peritoneal cavity. The operation is a laparotomy, and should, from a practical standpoint, be regarded as such. It consists in opening a protruding pouch of the parietal peritoneum, and deals with one or more of the abdominal organs more or less damaged by the constriction. The same pedantic preparations must be observed and carried into effect to guard against peritoneal infection as in performing a laparotomy through the intact abdominal wall for other indications. The hernial regions are hard to disinfect; consequently special care is necessary to prepare the field of operation with the requisite degree of thoroughness.

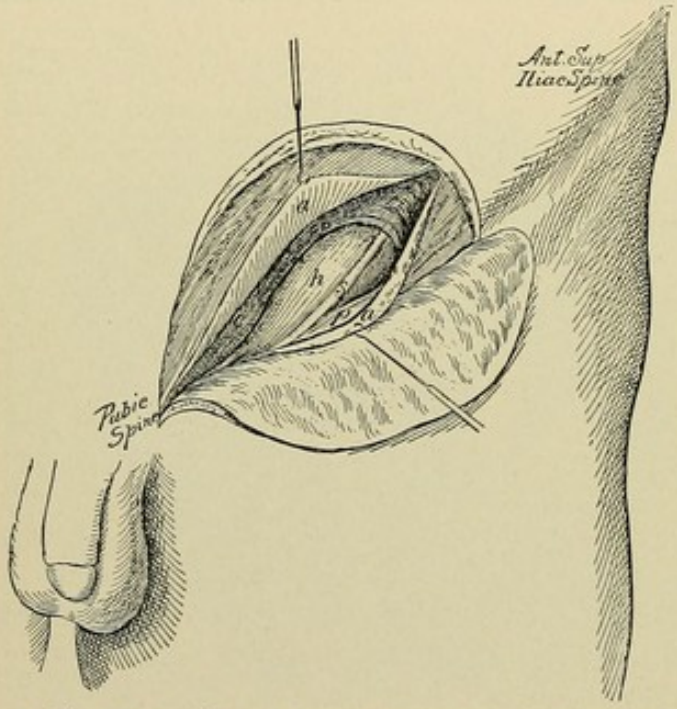

Fig. 534.—Curved incision, exposing the inguinal canal: *p*, Poupart's ligament; *a*, *a*, aponeurosis of external oblique reflected; *c*, conjoined tendon; *h*, hernial protrusion; *s*, spermatic cord.

Herniotomy is indicated when taxis fails and when gangrene of the strangulated loop is suspected. The facility with which the operation can be performed and the different important structures identified depends much on the size and shape of the external incision. The external incision must be ample, and of such shape as to expose the coverings and the sac freely; it must be made as far away from the external genitals as possible. Curved incisions afford more space than straight incisions. For nearly five years I have made curved instead of straight incisions in the operations for the radical cure of both inguinal and femoral herniæ, and as the result of quite an extensive experience, I recommend similar incisions for the operative relief of strangulated hernia. For exposing the inguinal canal, the incision is commenced over Poupart's ligament, at a point half-way between the anterior superior spinous process of the ilium and the spine of the pubes, and is carried obliquely upward

and inward on a level with the internal inguinal ring. In a gentle curve it is then continued to the inner side of the inguinal canal, and finally is terminated over the spine of the pubes. The skin and superficial fascia included by the horseshoe-shaped incision are then reflected in the form of a flap as far as Poupart's ligament, exposing the pillars of the inguinal canal freely to sight and touch. In the operations for femoral hernia the beginning and terminal points of the incision are the same, but the curve is directed downward and the incision is extended to the lower border of the saphenous opening.

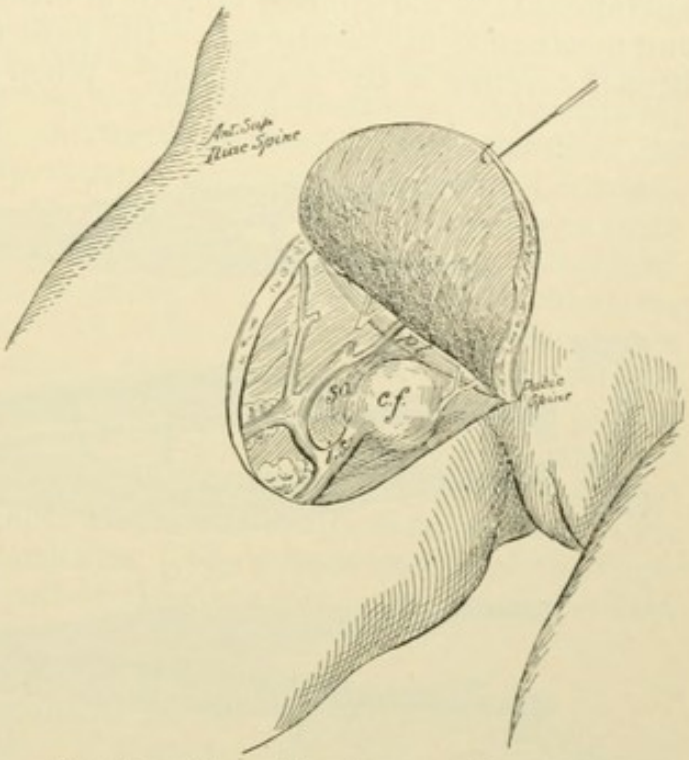

Fig. 535.—Femoral hernia exposed by reflecting oval flaps: *p.l.*, Poupart's ligament; *c.f.*, cribriform fascia overlying hernial sac; *so*, saphenous opening; *i.s*, internal saphenous vein.

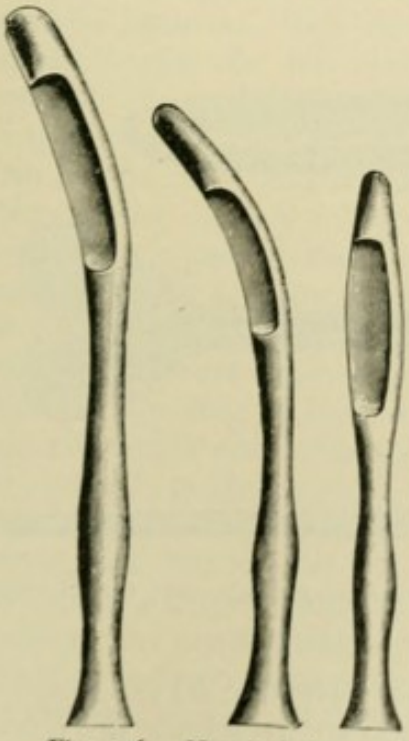

Fig. 536.—Hernia knives.

By making the incisions as described, the most important part of the field of operation is exposed freely without the use of retractors; the line of incision is as remote from the external genitals as possible, and the deep sutures relied upon in closing the hernial canal are covered by normal elastic skin instead of by scar tissue, as is the case if a straight incision is made directly over the inguinal or crural canal. Having exposed the hernial region by reflection of the cutaneous flap, the remaining layers of the hernia are picked up one after the other between two dissecting forceps, and carefully divided. It is not always easy or possible to distinguish between the different layers, but as long as the tissues are grasped and lifted up with dissecting forceps, carefully identified and divided, the hernial con-

tents are safe. The dissecting forceps is a safer and more useful instrument than the grooved director in making the deep dissection and in exposing the hernial sac. The most important layer of the hernial covering is the peritoneum. When this has been reached,

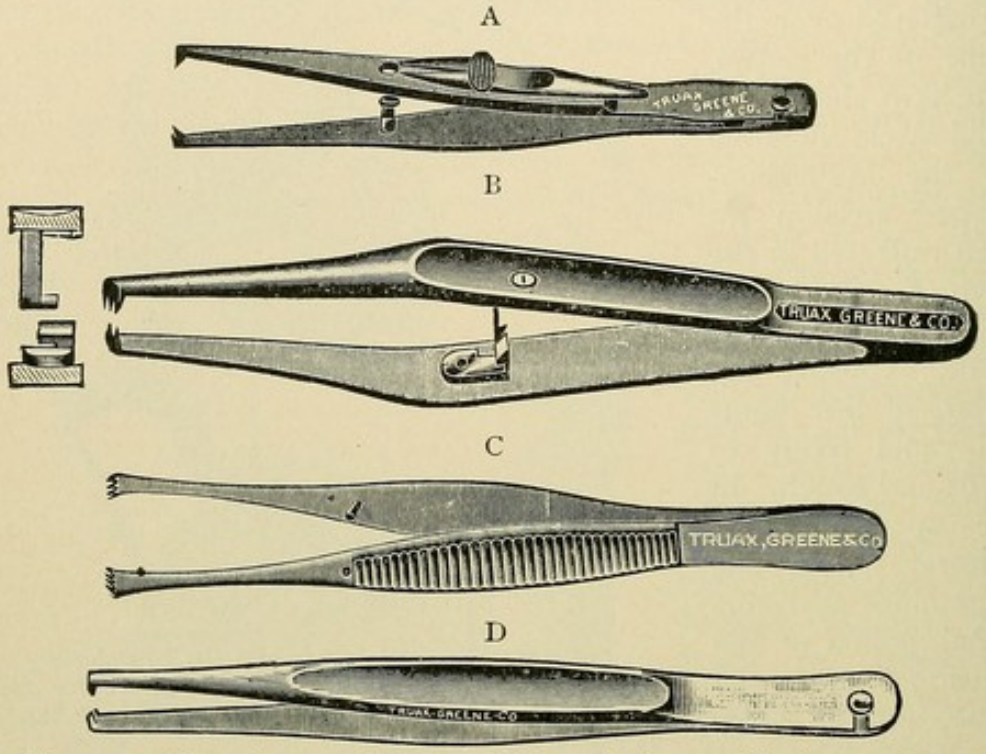

Fig. 537.—Tissue forceps: A, Senn's slide-catch forceps with three or five teeth; B, E. J. Senn's automatic forceps; C, tissue forceps with fine teeth; D, mouse-tooth forceps with three teeth.

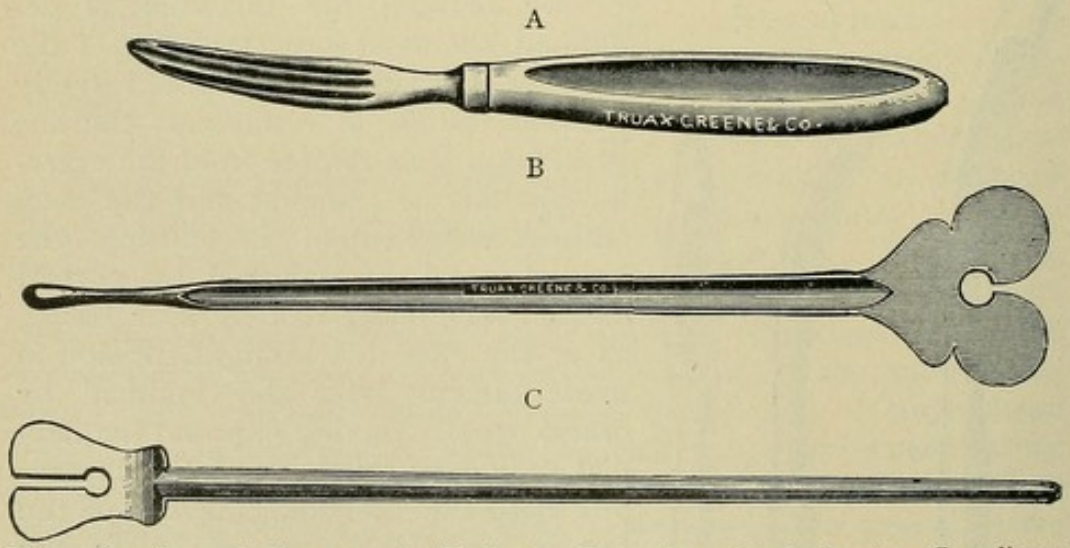

Fig. 538.—Grooved directors: A, Kocher's; B, probe-pointed director; C, ordinary grooved director.

it is incised between two dissecting forceps. The hernial sac should always be laid open, to enable the surgeon to investigate the condition of its contents. Division of the constriction outside of the sac and reduction of the hernial contents without inspection are

procedures that, for obvious reasons, have become obsolete with the adoption of aseptic precautions in general practice.

The next step in the operation consists in relieving the constriction by cutting or stretching the resisting structures. After locating the seat of constriction, an attempt is made to insert the tip of the index-finger between the constricting ring and the hernial contents, and if this can be done, the opening can usually be enlarged to the requisite extent by tearing and dilatation. The speedy and safe removal of the constriction requires, as a preliminary step, the laying open of the hernial sac in its entire length. If the constriction is tight, a grooved or Kocher's director is carefully inserted between the constricting band and the hernial contents, and, by gradual dilatation, sufficient room can usually be secured for the insertion of the tip of the left index-finger, which is then utilized as a guide for the probe-pointed knife, with which the incision or incisions are made to relieve the constriction. The palmar surface of the finger is directed toward that part of the constricting ring where the knife is to be used. Adhesions between the sac and its contents underneath the constricting ring are separated before inserting the hernia knife. If the adhesions are too firm for separation by blunt force, necessitating the use of the knife, it is advisable to leave a thin layer of the sac attached to the intestine to guard against accidental visceral injuries. The hernia knife is inserted with the flat surface resting against the palmar surface of the finger or the director, if the finger can not be used, and when the cutting-edge has passed beyond the constricting ring, the blade is turned so that the edge is directed toward that part of the ring where the incision is to be made. *The cutting should be done rather by pressure than by saw motion, in order to protect the blood-vessels in the neighborhood against injury.* By making pressure against the back of the knife with the finger-tip or director the ring is incised, while the blood-vessels, becoming displaced, escape the cutting-edge of the knife. An ordinary straight or curved probe-pointed bistoury will answer the purpose of a herniotome of special construction very well. The part of the blade not needed for the cutting can be rendered harmless by wrapping a strip of gauze tightly around it. Instead of making one incision, the constricting ring can be nicked in several places. The place of incision must vary according to the location of the hernia. In external inguinal hernia the cut is made in an outward direction; in internal inguinal hernia it is made in an inward direction, to avoid wounding the epigastric artery, and in case doubt remains as to the exact nature of the hernia, the cut is made in an upward direction.

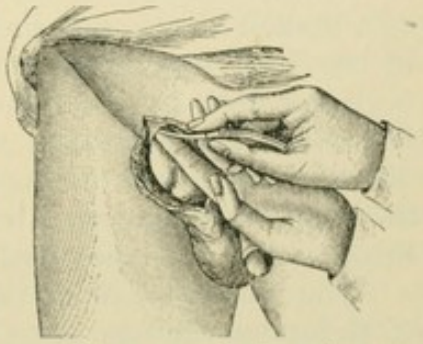

Fig. 539.—Cutting the constricting ring in inguinal hernia (von Esmarch and Kowalzig).

In femoral hernia Gimbernat's ligament is incised, and as the obturator artery may have an anomalous origin from the deep epigastric, it is necessary to make the cut exclusively by making pressure against the back of the knife, so that the movable artery can retreat from the edge of the knife. Incision in an outward direction would endanger the femoral vessels—in an upward direction, the epigastric and spermatic cord or ligamentum rotundum, and in a downward direction, the saphenous vein.

After relieving the stricture the contents of the hernia are subjected to a careful examination to determine what course to pursue. The most important part to examine is the strangulated bowel, as the omentum, if present, is usually removed if the condition of the bowel warrants reduction and if herniotomy is followed by an operation for the radical cure of the hernia, as is now usually done under such circumstances. The positive evidences of gangrene of the bowel are perforations, gas or feces in the sac, and an ashy green color of the strangulated loop. The strangulated loop must be drawn down sufficiently to expose freely the line of constriction, as a limited linear necrosis may be found here, while the remainder of the loop may be in a condition to justify its return after the necrosed area has been buried by a row of seromuscular sutures. If much doubt remain in the mind of the operator as to the condition of the bowel, it becomes necessary to make a systematic and thorough examination. If the bowel present a gray-greenish or brown color, the color itself would be a proof of gangrene.

The vitality of the bowel is tested by the presence or absence of peristalsis and the state of the circulation. If peristalsis follow pinching of the intestinal wall, it is a valuable diagnostic sign, tending to prove the absence of gangrene. More reliable information, however, is to be derived from a careful investigation of the state of the circulation. If any doubt remain as to the vitality of the bowel after the constriction has been relieved, the exposed parts should be douched with hot saline solution. Under this very simple treatment the intense capillary and venous engorgement is often relieved in a very few minutes, as indicated by the change in color of the bowel. A deep red is soon transformed into a bright red, and almost black into red. Such a rapid restoration of the circulation leaves no question as to the advisability of resorting to reduction. If no change is observed in the circulation, superficial needle punctures will demonstrate whether or not the circulation has been completely arrested. If the vascular stasis is complete, little or no blood will escape from the punctures ; if partial, free venous hemorrhage will follow the procedure. The presence of thrombosed mesenteric veins always contraindicates reduction. If the surgeon can not justify himself that it is safe to reduce the hernia, and yet there are no positive evidences of gangrene, it is advisable, after emptying the loop of its contents, to secure it in position by one suture embracing the mesentery and one margin of the wound, to

apply a compress wrung out of hot Thiersch's solution or physiologic solution of salt, and examine the loop every few hours for evidences of a return of the circulation, and in such an event, resort to secondary reduction of the hernia. If the circulation fail to return in from four to six hours, it is safe to assume that gangrene has occurred, when the case is treated accordingly. If there is no local linear gangrene from decubitus and the state of the circulation of the strangulated loop is satisfactory, immediate reduction of the hernia is indicated. If only a small portion of omentum is in the sac and is free from adhesions, it is returned first. If the omentum is adherent to any extent, and more particularly if the omental mass is large, it is excised. The omentum is tied in small sections with fine silk ligatures before the amputation is made. The stump should be lightly iodoformized, after which it is anchored with a catgut suture to the abdominal wall above the hernial aperture, as otherwise the stump retracts, and, by forming adhesions with intestinal coils, may subsequently become a cause of intestinal obstruction. I have seen such cases, and I now invariably resort to this procedure as an important prophylactic precaution. *The intestinal loop must not be returned until it has been emptied of its contents, thus demonstrating its permeability.*

The reduction is made by replacing first that part of the loop that descended last. Before any attempt at reduction is made, it must be determined that the intestine is free; if this is not the case, existing adhesions must be separated. If the patient's general condition justifies prolongation of the operation, the reduction is followed by an operation for the radical cure of hernia by one of the methods now in use. If the strangulated loop is gangrenous, an entirely different course must be pursued. Such patients are usually not in a condition for successful treatment by resection and circular suturing, which otherwise would appeal as the ideal treatment. Primary intestinal resection for this indication has been attended by a fearful mortality. At the present time the surgeon is usually content in performing a life-saving operation, reserving the restoration of the continuity of the intestinal canal for a later operation. If the gangrene is linear and limited, and the vascular condition of the loop is satisfactory, burying the necrosed area with a row of Lembert stitches, with subsequent reduction of the hernia, is the proper course to pursue. Radical operation for the cure of the hernia in such cases is contraindicated. With a mesenteric suture the intestinal loop should be anchored above the hernial opening and gauze drainage established, so that in the event of perforation occurring, the worst that could follow would be a temporary intestinal fistula. If the gangrene involve the entire loop, the following course is to be pursued:

The intestinal loop must be drawn down until healthy bowel can be seen on both sides above the former point of constriction.

In this position the loop is anchored by a mesenteric suture that includes also the ring or some other solid structure. Iodoform gauze is then packed around the bowel, above the seat of the constriction, after which the gangrenous portion is freely incised and the parts thoroughly cleansed. Dry dressings are of no use in such cases. A hot moist antiseptic compress is the proper dressing. Helferich's proposal to perform at the same time a laparotomy and establish an intestinal anastomosis between the afferent and efferent limbs of the loop above the constriction has not met with favor by the profession, for reasons so obvious that it is superfluous to enumerate them. This operation has much to recommend it later, when it becomes desirable to close the artificial anus.

As not infrequently other organs besides the mesentery and intestines find their way into the sac of a hernia, special care is necessary to identify the contents. The bladder has been repeatedly wounded before it was recognized. In women the ovary has been found occasionally in the hernial sac, and if the seat of disease is greatly damaged by the strangulation, it should be removed in the usual way after preliminary ligation of the pedicle, and the stump iodoformized and carefully replaced into the abdominal cavity.

Radical Operation.—In all cases of strangulated hernia treated by operative reduction or the removal of the contents of the hernial sac, a radical operation for the obliteration of the hernial opening should be made if the general condition of the patient justifies prolongation of the anesthesia and operation to this extent. It is advisable to resort to a method of accomplishing this object with the least loss of time, and that, at the same time, promises durable results.

Umbilical Hernia.—In umbilical hernia the attenuated skin is removed with the sac. The structures that furnish the most resisting part of the abdominal wall on each side of the linea alba must be made accessible to direct suturing by buried sutures. The wound surfaces for approximation should be broad, and all the important structures must be brought in contact by separate rows of sutures. The first step in performing the radical operation consists in splitting freely the margins of the wound, securing free exposure of both recti muscles. Ligation of the sac of an umbilical hernia is always contraindicated, even though the hernia be a small one. The entire sac is excised, and, after splitting the margins of the hernial opening, the wound is sutured in the same manner as after any other abdominal operation. During the operation the abdominal contents are protected by a dry compress of sterile gauze held in the jaws of a long hemostatic forceps. The deep sutures of silkworm-gut, two or three to every inch, are first inserted, but not tied. These sutures should be made to include the entire thickness of the abdominal wall minus the peritoneum.

Next, the peritoneum is sutured with fine catgut or silk. The next row of buried sutures of strong catgut includes the sheath of the recti muscles. After tying the deep sutures, the skin is sutured separately with horsehair. If the hernial opening is large and the diastasis of the recti muscles great, a relaxation suture of strong silk in the center of the wound will guard against undue tension on the buried sutures. The patient, on leaving the bed, must be provided with a well-fitting abdominal bandage, and instructed to wear it during the day for at least three months.

Inguinal Hernia.—The simplest and quickest method of obliterating the inguinal canal after extirpation of the sac is by the Nussbaum-Czerny operation. The sac is carefully separated from the spermatic cord and the accompanying vessels, and isolated as far as the internal inguinal ring, or, still better, a little beyond it, after which the sac is twisted and tied with a strong catgut ligature as high up as possible. Below the ligature the sac is transfixed with a needle armed with strong catgut. The ligature is cut in the middle, and each half of the sac is tied separately; half an inch below the ligatures the sac is amputated. The stump, after being iodoformized, is pushed upward, the pillars of the ring are well exposed, and traction upon the cord and vessels is made in the lower angle of the wound, while the pillars are sutured together with at least four strong catgut sutures. Great care is necessary in inserting the deep sutures to locate accurately and to protect the large vessels against injury. I have personal knowledge of two cases of vessel injury in operations for inguinal hernia. In one case the femoral vein was punctured, and in the other one of the sutures was passed through the femoral artery, the patient dying of secondary hemorrhage. In inserting and tying the lowest suture care must be taken to leave sufficient room for the cord and its vessels. The skin-flap is sutured with silkworm-gut and horsehair. The ideal dressing for a wound in this locality, and that requires no drainage, is by sealing it with a few strips of iodoform gauze or a thin layer of aseptic absorbent cotton, held in place with collodion. Over the dry impermeable crust a small aseptic dressing is applied and held in place with a broad strip of adhesive plaster and a spica bandage. The scrotum, placed in an elevated position, should be included in this dressing.

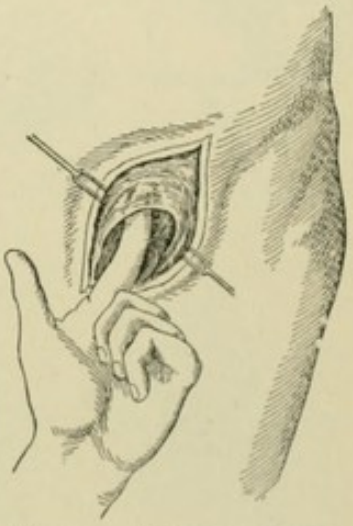

Fig. 540.—Stripping the sac.

Macewen's operation for the radical cure of inguinal hernia has yielded very satisfactory results, and recommends itself as an excellent procedure as a continuation of the operation of herniotomy. The principal feature of this operation is the preservation of the sac,

which is utilized as a cushion over the peritoneal opening of the inguinal canal. The sac is isolated in the usual way, a little beyond the internal inguinal canal, when traction is made on it so as to fold it properly for suturing. With a needle armed with strong catgut, knotted at one end, the base of the sac is transfixed, after which the needle is passed through the sac a number of times in different directions, until the neck of the sac is reached (Fig. 541). By making traction on the catgut thread the sac is drawn into a solid pad, when the free end of the thread is passed with the needle through the abdominal wall on a level with the internal inguinal ring, the skin being drawn to one side. An assistant makes traction on the

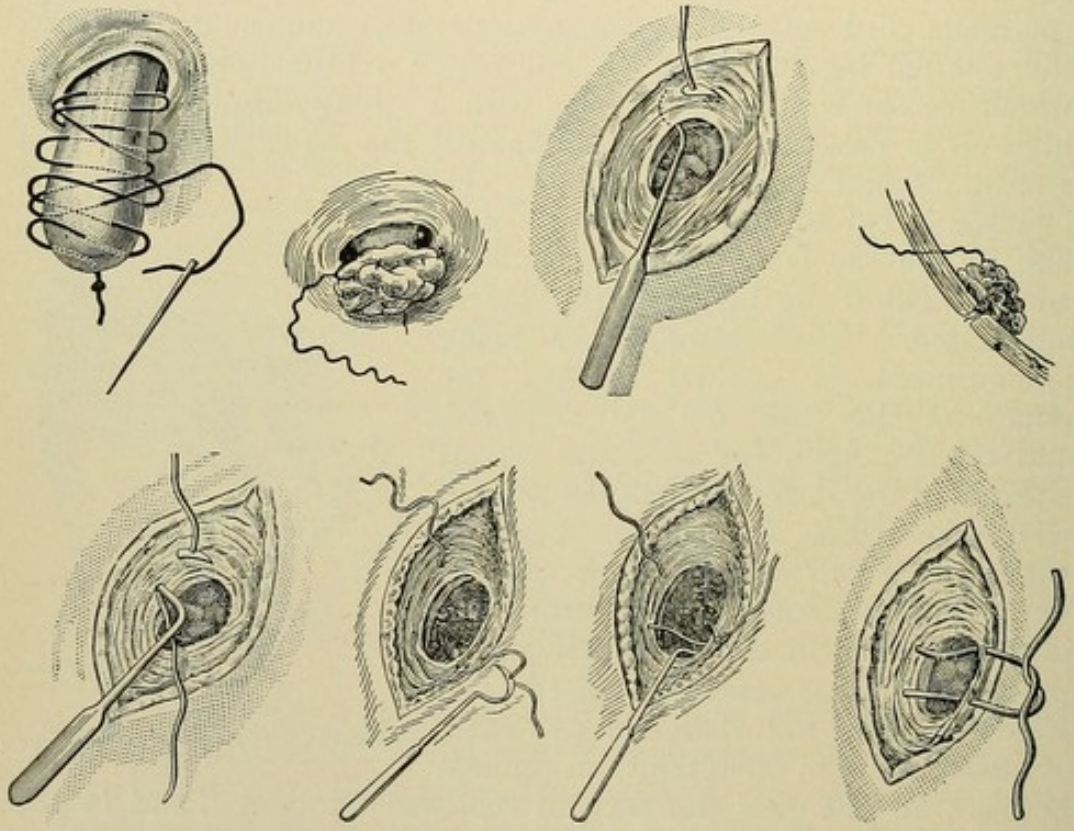

Figs. 541–548.—Macewen's operation for the radical cure of inguinal hernia.
Figs. 541–544.—Suture of the hernial sac.
Figs. 545–548.—Closing the inguinal canal.

thread while the ring is being sutured, and the thread is fastened by passing it several times through the superficial fibers of the external oblique muscle. In closing the inguinal canal, Macewen inserts the sutures with two needles of special construction, but the ordinary round curved needle can be employed for this purpose. As a suture material Macewen uses silver wire, but catgut, silkworm-gut, or silk can be used instead. The left index-finger is introduced into the inguinal canal, and the epigastric artery is located so as not to include it in the suture. Using the index-finger as a guide for the needle, the internal pillar is transfixed at two points, first near the lower border, from without inward, then above, from

within the canal outward. With another needle the lower end of the suture is then passed from within outward, through Poupart's ligament and the conjoined tendon; in the same manner the upper end is passed through the external pillar, when the suture is tied over the external oblique muscle. The suture is tightened gradually over the tip of the index-finger and tied with sufficient firmness to bring the pillars in accurate contact. If the canal is larger, two sutures are used in closing it. The skin is sutured separately with horsehair and silkworm-gut, and the wound dressed in the same manner as already described. If the hernia is a congenital one, enough of the lower part of the sac is left to furnish the testicle with a tunica vaginalis, after which the upper part of the sac is disposed of in the manner previously indicated, and the lower part is sutured with fine catgut over the testicle, close to the cord.

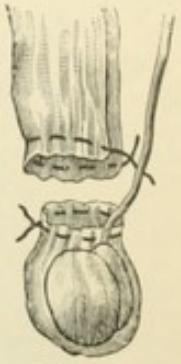

Fig. 549.—Macewen's operation for congenital inguinal hernia.

Bassini's Operation.—The external incision advised by me will expose the inguinal canal to the best advantage for the closure of the inguinal canal by any of the methods heretofore advised. Bassini's operation aims to restore the obliquity of the inguinal canal, and to furnish it with an anterior and a posterior wall that, when brought in contact by pressure, close the canal by a valve-like action. After exposing the inguinal canal, the aponeurosis of the external oblique muscle is incised from the external inguinal ring the entire length of the inguinal canal, and is reflected on both sides in the form of a flap. The sac is next carefully isolated from the cord and vessels as far as the internal inguinal ring, and, after twisting it, is transfixed on a level with the ring with a needle armed with a double silk or catgut ligature. Each section is then tied separately, and the sac amputated at a safe distance below. On elevating the spermatic cord and vessels and retracting the aponeurosis on each side, Poupart's ligament can be seen and felt to the point of entrance of the cord. The external border of the rectus muscle and the conjoined layers of the internal oblique, transversalis, and transversalis fascia are then sutured to the posterior isolated border of Poupart's ligament for a distance of from three to four inches, beginning at the pubes. The spermatic cord and vessels are brought into the upper angle of the wound, and by doing so are displaced about half an inch outward; the internal ring and posterior wall of the inguinal canal are now established. The spermatic cord is then placed carefully over the line of deep sutures, and the aponeurosis sutured over it to the lower angle of the wound, which remains open, constituting the external inguinal ring. The external incision is sutured throughout and sealed with collodion, iodoform gauze, and cotton.

Halsted has modified Bassini's operation by recommending

excision of dilated spermatic veins, and by closing the canal with mattress sutures. Vein excision should be limited to cases in which the veins are distinctly varicose, as excision of normal veins is not

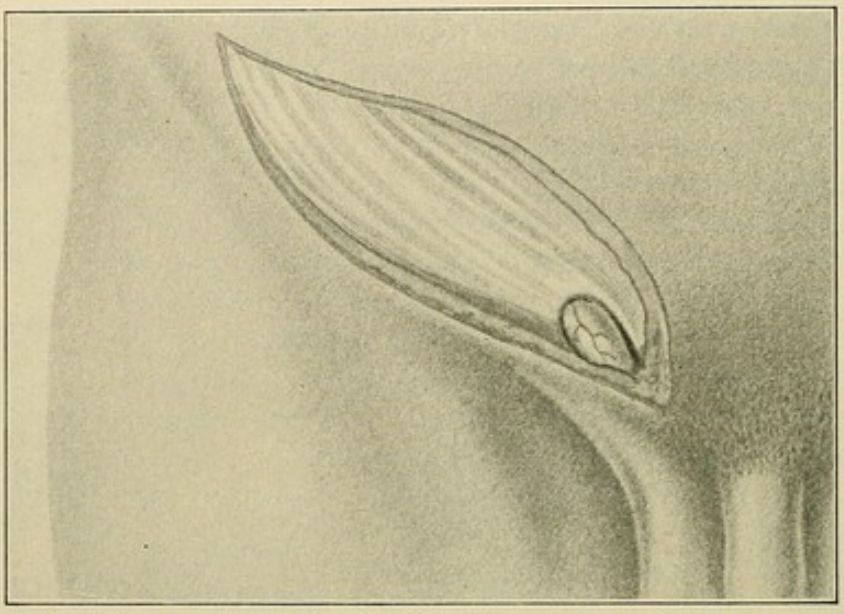

Fig. 550.—Bassini's operation for inguinal hernia: exposure of the aponeurosis of the external oblique muscle and the external inguinal ring.

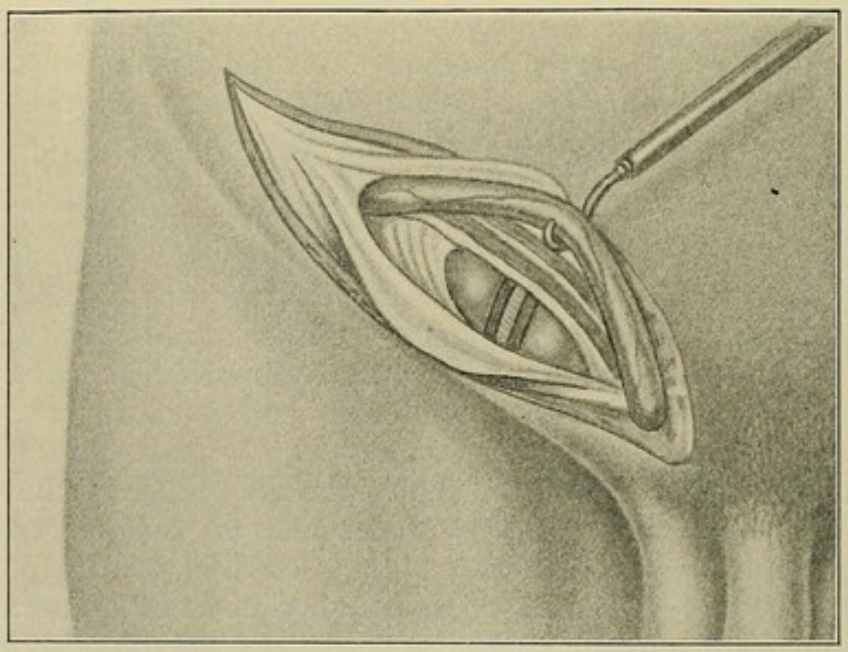

Fig. 551.—The aponeurosis of the external oblique muscle is divided, as well as the internal oblique and transversalis muscles; the spermatic cord is retracted, and at the bottom of the wound, upon the peritoneum, the epigastric vessels can be seen. The layer of tissue with the sharply defined border is the transversalis fascia.

essential to the success of the operation and is liable to be followed by atrophy of the testicle.

Kocher, Bassini, and others permit the patient to leave his bed two weeks after the operation, but I am convinced of the necessity of enforced rest in bed for at least from three to four weeks. I

consider it a necessary precaution in guarding against relapse by yielding of the scar tissue under increased intra-abdominal pressure incident to the change from the recumbent to the erect posture. If the patient is confined to bed for four weeks after the operation, the subsequent wearing of a truss is more harmful than useful.

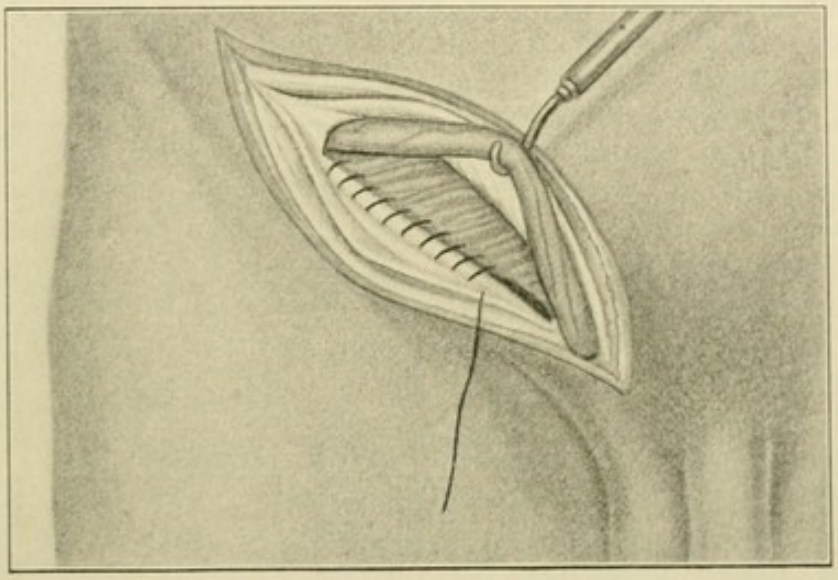

Fig. 552.—Bassini's operation for inguinal hernia: the muscular layer of the internal oblique and the transversalis is attached by suture to the inner border of Poupart's ligament. In this way the internal inguinal ring and the posterior wall of the inguinal canal are formed anew.

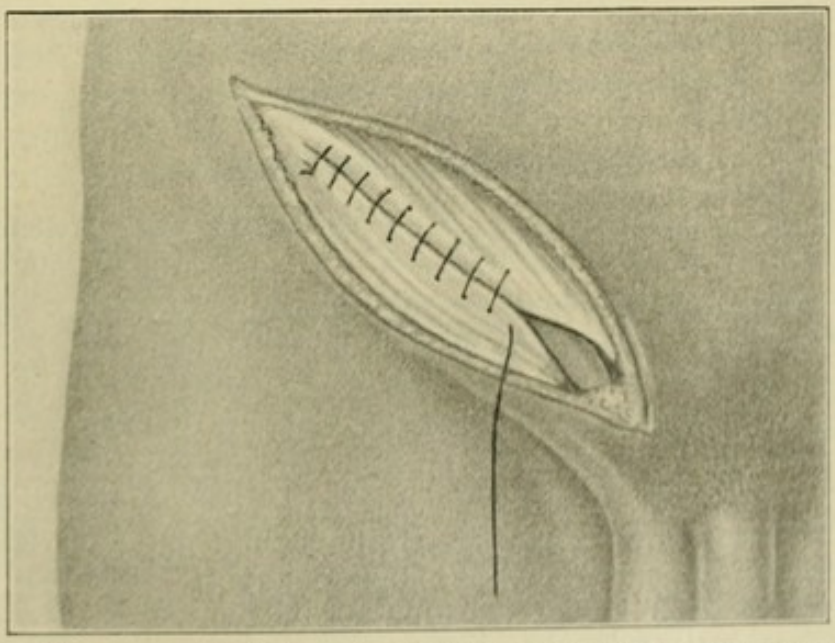

Fig. 553.—The aponeurosis of the external oblique is united over the spermatic cord, except in the situation of the new external inguinal ring.

The absorbable suture is the ideal material for closing the inguinal canal, although many surgeons prefer silk (Kocher) or silver wire (Halsted).

Femoral Hernia.—Exposure of the femoral canal from Poupart's

ligament to the lower margin of the saphenous opening by the curved incision and reflection of the cutaneous flap greatly facilitates the remaining steps of the radical operation (Fig. 535). Isolation of the sac in femoral hernia is a much less difficult task than in inguinal hernia. The femoral vessels are the most important structures to be avoided. As in inguinal hernia, isolation of the sac should be commenced not at the base, but in the hernial canal. The sac is liberated the entire length of the crural canal, where it is twisted, transfixed, tied, and excised in the same manner as in inguinal hernia. Closure of the crural canal by Salzer's method can be relied upon as far as safety and permanency of the result are concerned. For this purpose Salzer employs a flap from the firm fascia of the pectineus muscle. The flap is formed by making a curved incision, with the convexity directed downward from the crista pectinea to Gimbernat's ligament, and is then turned upward and sutured with strong catgut to the lower margin of the inner third of Poupart's ligament. After the flap has been sutured in place, the continuity of the sheath of the pectineus muscle can be restored by a few buried absorbable sutures. Care must be exercised in suturing the flap not to puncture or compress the femoral vessels. I have performed this operation a great many times and have never heard of a relapse.

CHAPTER XXVII.

INTESTINAL FISTULA.

THE term intestinal fistula is used to signify the existence of a communication between the lumen of any part of the intestinal tract and the surface of the body, or with any of the hollow abdominal or pelvic viscera. A practical division must be made as regards the size and character of such abnormal communication into (1) fistula and (2) artificial anus. The difference is one of degree and not of kind. Speaking from a purely surgical standpoint, a fistula of the bowel is an opening through which gas or a part of the liquid and solid intestinal contents escapes, while an artificial anus implies a complete interruption of the fecal circulation at the abnormal outlet. The latter condition is determined either by the size of the defect in the intestinal wall or by the existence of mechanical conditions that divert the intestinal contents in the direction of the abnormal outlet and away from the distal side of the bowel. The mechanical conditions that thus divert the fecal current are either a flexion or the presence of a spur or septum at a point opposite to the abnormal outlet, caused by projection of the intact part of the intestinal wall in the direction of the fistulous opening. The surgeon aims to pro-

duce such an obstruction to the fecal circulation, when he desires to procure rest for the distal part of the intestinal tract, by the formation of an intentional artificial anus. The amount of intestinal contents that escapes from the intestinal canal through such an abnormal outlet depends less on the size of the opening than on the existence of one or both of the above-mentioned mechanical conditions. If the intestinal tube is straight or only slightly curved, even a large opening may resemble a simple intestinal fistula, while, on the other hand, a small opening, associated with a flexion or a well-developed spur, appears clinically as an artificial anus and must be treated as such. Internal fistulæ communicate most frequently with another part of the intestinal tract (bimucous fistula of Dreschfeld), the bladder, vagina, or uterus.

Etiology.—Intestinal fistulæ are divided into (1) intentional and (2) accidental. The surgeon occasionally resorts to the formation of an intestinal fistula or artificial anus in the treatment of inoperable mechanical obstruction, by resorting to a colostomy or an enterostomy, according to the location of the mechanical obstacle that has necessitated the operation. If, in such cases, the intestinal opening is to serve only a temporary purpose, it is closed by operative measures in the same manner as will be advised in the discussion of the operative treatment of accidental fistula, after the distal part of the intestinal canal has been rendered permeable spontaneously or by subsequent operative interference.

Accidental fistulæ are produced, according to the immediate cause: (1) By gunshot and stab wounds of the abdomen; (2) by submural injury of the bowel; (3) by ulceration of the bowel; (4) by strangulation of the bowel; (5) by foreign bodies in the intestinal canal; (6) by malignant tumors; (7) by intestinal actinomycosis; (8) by pelvic and other abdominal abscesses; (9) by appendicitis; (10) by unintentional injury to the bowel during abdominal and pelvic operations; (11) by ligatures; (12) by sutures; (13) by drainage-tubes.

Gunshot and Stab Wounds.—These injuries usually result in fatal septic peritonitis if the intestinal wound or wounds are large enough to permit escape of fecal material into the free peritoneal cavity, and if they are not subjected in time to direct operative treatment. A fecal fistula, external or internal, may result if the wound is small or if only a part of the intestinal wall has been injured, in which event the injured part becomes adherent to the parietal peritoneum or to an adjacent hollow organ. A resulting circumscribed abscess may later, under such circumstances, perforate the abdominal wall or discharge its contents into the adherent organ and thus establish either an external or an internal fistula. According to the experience of surgeons during the Civil War, such an occurrence is more likely to follow injury of the colon than wounds of the small intestine.

Submural Injury.—Partial laceration of the intestinal wall

without a penetrating wound of the abdomen occasionally results in circumscribed peritonitis, caused by the migration of pathogenic microbes from the intestinal canal through the damaged wall to the surface of the bowel, where, if present in sufficient number and virulence, they may produce an abscess that not only completes the intestinal perforation, but may result at the same time in the formation of an external or an internal fistula. Such fistulæ are usually small and close spontaneously in the course of time. In suspected submural injury of the bowel without evidences of complete rupture and fecal extravasation it is of the greatest importance to enforce efficient treatment, with a special view to preventing this remote complication.

Ulceration.—Ulceration of the bowel is frequently followed by the formation of an intestinal fistula if the free peritoneal cavity is shut off by adhesions before perforation takes place and if the ulcer manifests no tendency to repair. In the upper part of the intestinal canal the round, perforating ulcer of the duodenum may produce such a result. I have observed two cases of perforating typhoid ulcer in which a diffuse abscess was formed, which was freely incised and drained. In one case the abscess cavity contained at least a quart of fecal material that had evidently been accumulating for more than a week. The patient's general condition was such as to contraindicate search for and suturing of the perforation. In both cases life was prolonged for from one to two weeks, but the patients finally succumbed to sepsis. It is not difficult to conceive that under more favorable circumstances such patients might recover, under similar treatment, with an intestinal fistula that would in all probability heal spontaneously, or could be closed later by operation with a good prospect of success. From my own personal observation I am satisfied that the ulcers that terminate most frequently in the formation of an intestinal fistula are of a tubercular character. I have observed a number of such instances. The clinical course in such cases is almost typical. The localized peri-intestinal process is usually preceded by symptoms that point to a chronic catarrhal or ulcerative enteritis. A painless, cold abscess appears at the point where the perforated bowel has become attached to the abdominal wall. The abscess develops insidiously and progresses very slowly. If the abscess opens spontaneously or is incised, it contains, as a rule, no fecal material. The fistula forms later, or is produced at once if the granulations lining the abscess wall are scraped away with a sharp spoon. The communicating opening between the lumen of the bowel and the abscess cavity is temporarily blocked with granulations, which, when removed or when destroyed by suppuration and degeneration, permit the establishment of the fistula, through which gas and fecal contents escape. In one case such an abscess was found in the umbilical region, and in another in the right linea semilunaris. In both cases a fecal fistula was established, and the patients eventually

died from the effects of the primary intestinal affection. Such fistulæ hasten the fatal termination and are seldom amenable to successful surgical treatment. Tubercular abscesses in communication with a perforated intestinal tubercular ulcer should not be incised. The proper treatment for such cases is tapping of the abscess, followed by injection of iodoform emulsion—a form of treatment that will postpone, if not prevent, the formation of an intestinal fistula. König is of the opinion that in many cases of tubercular intestinal fistula the primary disease starts in the peritoneum, resulting in perforation of the intestine from without inward. In such cases multiple fistulæ are often established in rapid succession.

Strangulation.—The functional disturbance of the intestine following strangulated hernia, terminating in gangrene, without treatment or under conservative measures, will depend upon the extent of loss of mural tissue, and will vary from a small fistula only large enough to permit the escape of gas, to a perfect artificial anus. Occasionally such an accident follows the reposition by taxis of a damaged intestinal loop. The Littré, femoral, and properitoneal herniæ are most likely to be overlooked by the surgeon, and consequently most frequently give rise to this complication.

Foreign Bodies.—Perforation of the intestinal wall by a foreign body, preceded by a circumscribed plastic peritonitis, frequently results in the formation of an abscess that, when it reaches the surface or an adjacent hollow organ, is followed by an intestinal fistula. Small, slender foreign bodies, such as needles, pins, and fish-bones, often perforate the intestinal wall and find their way to the surface or into neighboring organs without giving rise to an intestinal fistula. In one case I removed four fish-bones from a small abscess in the median line below the umbilicus, after which the abscess healed promptly and permanently. The foreign bodies that are most frequently found in abscesses preceding intestinal fistula are sharp fragments of bone, gall-stones, and enteroliths.

Malignant Tumors.—Malignant tumors may cause intestinal fistula either by producing obstruction, followed by distention and ulceration on the proximal side, or by directly implicating the intestinal wall. The latter mode of origin is the most common. The malignant tumor in such instances invades by contiguity the part or organ that becomes the seat of the intestinal fistula, and at the same time perforates the intestinal wall, so that the fistula is surrounded everywhere by malignant tissue. Carcinoma more frequently pursues such a course than sarcoma. Pyogenic infection of the malignant tumor frequently plays an important rôle in such cases. The suppurative infection often overshadows the malignant disease so completely that the surgeon is misled in his diagnosis and institutes treatment appropriate for abscess when the operation reveals a malignant tumor as the foundation of the difficulty. Carcinoma of the cecum complicated by suppuration has been repeatedly mistaken

for appendicitis. Carcinoma of the sigmoid flexure and cecum occasionally results in a pathologic anastomosis between the affected part of the bowel and an adjacent loop of the small intestine. Carcinoma of the upper part of the rectum only too often invades the bladder and results in the formation of a rectovesical fistula. Carcinoma of the stomach and transverse colon has resulted in pathologic gastrocolostomy.

Actinomycosis.—A number of cases of intestinal actinomycosis have been recorded in which the disease in its course perforated the intestinal wall and gave rise to diffuse abscesses and intestinal fistula. The ileocecal region is the favorite locality for such processes. In the only case of this kind that came under my own observation the disease originated evidently in the ileocecal region, but the abscess reached the cavity of Retzius and was opened in the median line, above the pubes.

Pelvic and Abdominal Abscesses.—By far the most frequent causes of intestinal fistula are pelvic and abdominal abscesses. Such abscesses sometimes are caused by migration of pyogenic microbes through a damaged or inflamed intestinal wall, perforate later the intestine, and finally open or are incised on the surface, when the fistula is completed. The fistulous tract is often long and tortuous. More commonly a pyosalpinx or acute phlegmonous abscess of the parauterine connective tissue pursues such a course. Such abscesses open most frequently into the rectum, bladder, and intestinal coils upon the floor of the pelvis, but they may open into the cecum and sigmoid flexure. Externally they point most generally in the groin, but they may also reach the surface through the sacrosciatic notch, and occasionally extend to the lumbar region. The external fistulous opening may be found in any of these localities. Not infrequent causes of intestinal fistula are tubercular abscesses resulting from tubercular spondylitis and tuberculosis of the pelvic bones. In some cases the abscess is discharged first into the cecum or rectum; not so often into other parts of the large and the small intestine, and later reaches the surface; or the fistula forms in the course of suppurating tubercular tracts. Rectal insufflation is an exceedingly valuable diagnostic test, not only for the purpose of ascertaining whether or not the fistulous tract communicates with the intestine, but also in demonstrating the exact location of the intestinal perforation.

Appendicitis.—Appendicitis is the most frequent cause of intestinal fistula in the ileocecal region. The fistula is produced in one of two ways: (1) By sloughing or perforation of the appendix; (2) by rupture of an abscess of appendicular origin into the cecum or adjoining intestinal loops, with the subsequent formation of an external opening. If, in gangrenous appendicitis, the entire appendix is cast off as a slough with the contents of the abscess, the fistulous opening involves the cecum and occupies that part of the bowel to which the appendix was attached. Clinically such a fistula re-

sembles a cecal fistula produced by other causes. In partial gangrene of the appendix and perforation of the organ treated upon the expectant plan, by incision and drainage, without removal of the appendix, if a fistula persists, the remaining lumen of the appendix communicates with the cecum on one side and the external fistulous tract on the other. The fistulous opening into the bowel under these circumstances is so small that seldom anything but gas escapes. Such fistulæ occasionally heal spontaneously in the course of a few weeks; but after it has become well established, closure of the fistula without operation is not to be expected. A paratyphlitic abscess rupturing into the cecum often terminates in a permanent cure, but sometimes it results in extensive destruction of the cecal wall, followed by the formation of a correspondingly large fistulous opening. The location of the cecal opening will vary according to the situation of the abscess. The cases of cecal fistula that have come under my own observation involved either the anterior or the posterior wall; but it may affect any part of the cecum, and occasionally the abscess ascends in the direction of the ascending colon, which it may perforate, causing a fistula of this part of the large intestine. I have seen three cases of fistula of the cecum following appendicitis in which the opening in the abdominal wall and cecum was large enough to insert three fingers. In all these cases the fecal current was arrested at the opening by the presence of an effective spur, formed by the projection of the opposite wall toward the opening in the cecum. It is in cases of this kind, if the abscess has been opened by the surgeon, that he is charged by the patients and friends with having cut the bowel, when in reality the intestinal opening either was present at the time the operation was made or occurred later by sloughing of the inflamed cecal wall.

Injury of Bowel During Abdominal and Pelvic Operations.—Under this head it is not intended to discuss those gross lesions of the intestines occurring during abdominal and pelvic operations that the surgeon recognizes and treats at once. Reference will be made more particularly to overlooked and incomplete wounds of the bowel as causes of intestinal fistula. Modern gynecology encourages heroic attempts in the removal of abdominal and pelvic tumors that only a few years ago would have been regarded by the boldest surgeons as inoperable. The removal of adherent tumors and pustubes brings the operator often in very close contact with the intestines. The inflammatory processes that have produced the firm adhesions have often resulted in great damage to the adherent part of the intestine. The intestinal wall, from pressure, cicatricial contraction, and impaired nutrition, is often found not much thicker than ordinary writing-paper, hence exceedingly liable to be torn during the separation of firm adhesions. The intestine attached to a tumor or pelvic abscess by firm and old adhesions has lost its outer or peritoneal coat over an area corresponding with the extent of the adhesions. Unless the surgeon observes the necessary pre-

caution of making the detachment at the expense of the tumor or tube, if he does not tear an opening into the bowel he will, at least, seriously damage the intestinal wall. There can be but little doubt that in numerous instances of this kind surgeons have overlooked minute perforations in the bowel that, if they did not result in fatal septic peritonitis, became the direct source later of an intestinal fistula. It must also be remembered that a greatly damaged intestinal wall is permeable to pyogenic microbes, and consequently becomes not infrequently the sole cause of a late infection after laparotomy, and, if the patient survives, of abscess and intestinal fistula. Every experienced surgeon will recall such mishaps when he could assure himself that in other respects the operation was faultlessly performed. The examination of detached intestinal loops for perforations or other serious damage should not be postponed until completion of the operation, as it may be impossible to find them again at that time. The inspection should be made at once, and all defects remedied before additional adhesions are separated. *By pursuing such a course, and by detaching the adhesions at the expense of the part to be removed, we shall hear less in the future of septic peritonitis, abscess, and intestinal fistula arising from this cause after laparotomy.*

Ligatures.—In small wounds and limited gangrene of the bowel Astley Cooper made a small cone, the apex of which corresponded with the injury or disease, and applied a ligature of fine silk around the base. The ligature cuts its way into the lumen of the bowel during the time the resulting defect becomes sealed by plastic lymph. It can readily be conceived under what circumstances such a procedure would prove safe and efficient. If the parts included in the ligature and the ligature itself are aseptic, the formation of a fistula is prevented by the production of new tissue around the ligature and included mass before the ligature reaches the lumen of the bowel. If, on the other hand, the asepsis is not perfect and suppuration occurs in the track of the ligature, an intestinal perforation is very likely to ensue. After separation of adherent intestine bleeding points are often tied with silk. Isolation of the bleeding vessel is usually out of the question, and more or less of bowel tissue is included in the ligature. It must not be forgotten that under such conditions the bowel has been deprived of its peritoneal investment, and consequently the facilities for encapsulation of the ligature are diminished. If to this is added an extremely attenuated bowel-wall, it is not difficult to understand in what way a ligature may sometimes give rise to a late perforation, peritonitis, abscess, and intestinal fistula.

Sutures.—Careless suturing of the abdominal incision is responsible for many accidents to the intestines. Undue haste in completing this part of the operation is often severely punished. Unless the operator resorts to proper precautions, the needle may transfix a part of the circumference of the small intestine;

on tying the suture, the loop is anchored against the external incision, the ligature later cuts its way through the included part of the bowel, and, if a fatal peritonitis does not result, an intestinal fistula is sure to follow. I have seen two cases, occurring in the practice of distinguished surgeons, where there was good reason to believe that the intestinal fistula had such an origin. But this is not the only way in which sutures have produced this complication. Unless the peritoneum is sutured separately, in tying the deep sutures a loop of the underlying intestines may be caught between the sutures and the abdominal wall, and, on tightening the sutures, strangulation results, followed by intestinal obstruction, gangrene of the strangulated part of the bowel or coil, abscess, and fistula. Again, an intestinal coil may escape between the sutures and become strangulated between the margins of the wound, with similar consequences. It is time that surgeons should recognize the suture as a cause of such complications and resort to efficient prophylactic measures. I am strongly convinced of the value of a separate row of buried absorbable peritoneal sutures in closing the abdominal incision, both for the purpose of guarding against accidents to the intestines and as a prophylactic measure against ventral hernia. Whenever it is possible, the omentum should be drawn downward far enough to cover the entire length of the incision. The use of the aseptic compress as an aid in suturing the external wound is so well known that it is necessary only to mention it in connection with this subject.

Drainage-tubes.—The last, but by no means the least, important subject that will be discussed in connection with the etiology of intestinal fistula is the drainage-tube. Prolonged tubular drainage with glass or rubber tubes is a well-known factor in the production of intestinal fistula. The opening in the bowel is produced by pressure atrophy. I am inclined to believe that the elastic pressure caused by rubber drains is more injurious than that exerted by glass tubes. Long-continued tubular drainage for suppurative lesions is more dangerous in this respect than similar methods of drainage for parenchymatous oozing or other aseptic pathologic conditions. In the former case the suppurative inflammation along the drainage canal adds to the destructive effect of pressure. It will be difficult, if not impossible, to eliminate entirely this etiologic element by any amount of care in cases requiring long-continued tubular drainage. In recent cases necessitating drainage for a few days it is advisable to surround the glass or rubber drain with a few layers of iodoform gauze, for the purpose of diminishing the harmful effects of localized pressure. In drainage for suppurative affections it is well, for the same reason, to reduce gradually the size of the tube, and, whenever practicable, interpose between the intestine and the tube a few layers of iodoform gauze.

Treatment.—The treatment of an intestinal fistula must have for its aim closure of the abnormal opening, with as little interference

as possible with the lumen of the bowel. The statement has been made, and is borne out by clinical experience, that many intestinal fistulæ close spontaneously. This favorable termination may be expected in cases in which the opening in the bowel is small, the immediate cause of a benign and temporary character, the general health of the patient not much impaired, and the fistulous opening in the bowel so located that it can readily become attached to the parietal peritoneum or the serous investment of an adjacent organ. The spontaneous healing of an intestinal perforation is always followed by permanent parietal or visceral adhesions. In fistulæ resulting from tuberculosis, malignant disease, and actinomycosis, spontaneous healing, from the very nature of the primary cause, is out of the question, and, in the majority of these cases, operative treatment with a view of closing the fistula is contraindicated. The operative treatment in such cases deserves consideration only in the event that the primary cause can be completely eliminated before an attempt is made to restore the continuity of the bowel. In fistula caused by malignant disease, in which the extent of the primary cause has rendered a radical operation inapplicable, it may be advisable to secure rest for the diseased part of the intestine by establishing an artificial anus on the proximal side. In the treatment of tubercular and actinomycotic fistulæ the primary disease must receive proper attention, and, in case it is amenable to successful treatment, the fistula will heal spontaneously or is subjected later to appropriate surgical treatment.

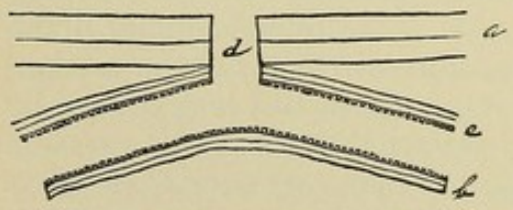

Fig. 554.—Intestinal fistula without lining of mucous membrane: *a*, Abdominal wall; *b*, intestinal wall; *c*, mucous membrane; *d*, fistula.

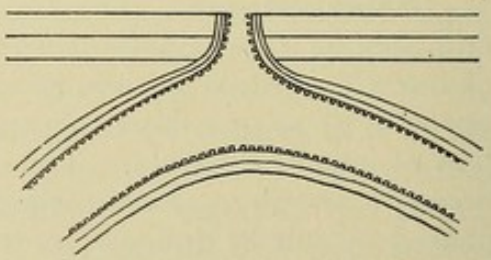

Fig. 555.—Intestinal fistula lined by the mucous membrane of the bowel.

Pathologic Anatomy of Intestinal Fistula.—For the sake of simplicity the different forms of intestinal fistula will be described as they are observed on the surface of the body, although the same remarks will apply to the internal fistulæ, where similar conditions are developed.

Intestinal Fistula.—Intestinal fistula, as defined in the introductory remarks, presents itself in one of two forms: (1) A fistulous tract leads from the surface to the opening in the intestine. (2) The mucous membrane of the intestine lines the fistulous tract and is continuous with the skin on one side and the mucous lining of the intestine on the other. In the first variety the opening in the bowel is more or less distant from the surface, and the tract is lined by gran-

ulations. In the second variety the intestinal wall reaches the surface, and the margins of the opening in the bowel form the border of the external opening, the entire fistulous tract being lined by mucous membrane. In both instances the opening in the bowel is lateral, the intestinal tube either straight or slightly curved, presenting no mechanical impediments to the fecal current.

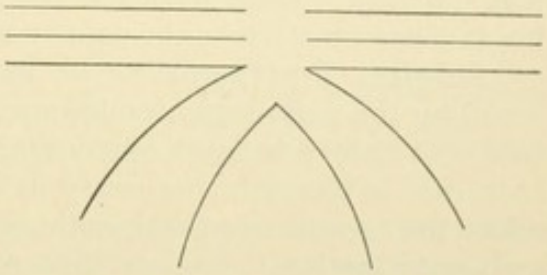

Fig. 556.—Intestinal fistula with flexion.

Artificial Anus.—The interruption, partial or complete, of the fecal current at or in the immediate vicinity of the fistula is usually due to one of three causes: (1) Intestinal obstruction below the fistula; (2) flexion of the bowel at a point corresponding with the location of the fistula; (3) the presence of a spur opposite the opening in the bowel. If perforation of the bowel takes place in consequence of an intestinal obstruction, the cause or causes that have given rise to this accident maintain the obstruction, and all the intestinal contents escape through the fistula, which then serves the purpose of an artificial anus. If the perforated part of the bowel becomes flexed by adhesions or otherwise, the flexion narrows the lumen of the bowel and directs the fecal current toward the abnormal outlet. Under such circumstances a considerable part of the intestinal contents necessarily escapes through the fistulous opening. If the flexion becomes more acute, the intestinal wall opposite the opening forms a spur,—promontorium (Scarpa), éperon (Dupuytren),—which, when fully developed, completely intercepts the fecal current and transforms the fistulous opening into an artificial anus.

From these remarks and the accompanying drawings it will readily be seen that spontaneous healing can be expected only in cases in which the fistulous tract is not lined by mucous membrane and in which the fecal current meets with no impediment by flexion or spur formation. As the fistulous opening in the bowel is often beyond the reach of an examination to determine the actual conditions, time plays an important part in enabling the surgeon to determine whether or not surgical interference is necessary. In the absence of an *indicatio vitalis*, an operation should be postponed until the clinical course has demonstated that nature's resources are inadequate to accomplish the desired object. An early operation is demanded if the fistula involve the upper part of the small intestine and the escape of chyle endangers life from

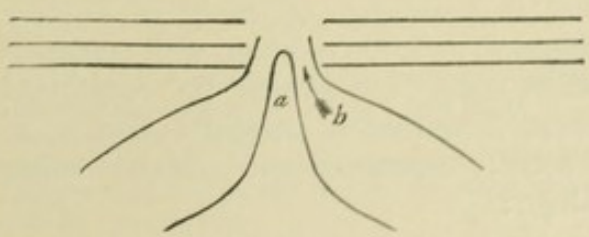

Fig. 557.—Artificial anus: *a*, Spur; *b*, direction of fecal current.

inanition. In the absence of such an indication, and in the absence of positive proof that spontaneous healing is impossible, conservative treatment should be continued until the indications for a radical operation are established. A carefully selected diet, attention to the condition of the bowels, rest, compression over the fistulous tract, and antiseptic treatment of the suppurating tract comprise the leading indications of the expectant treatment.

Surgical Treatment.—The surgical treatment must be governed by the pathologic conditions that characterize each individual case. A careful inquiry concerning the etiology and pathology in each case is therefore necessary in order to enable the surgeon to select the appropriate therapeutic resources.

Cauterization.—Cauterization of the fistulous tract is useful not only in expediting spontaneous healing in cases in which such a result is to be anticipated, but also for the purpose of removing anatomic conditions incompatible with such a termination. Nitrate of silver is most efficient in stimulating the process of repair in cases in which the tract is lined by flabby, infected granulations. Benefit from this agent can be expected only if it can be applied the whole length of the canal. Its application is worse than useless if the entire tract is not accessible, on account of either its length or its tortuous direction. If the fistulous tract is lined by mucous membrane, is short and readily accessible in its whole length, the needle-point of the Paquelin cautery can be resorted to with advantage. The cauterization must be made deep enough to destroy the entire thickness of the mucous membrane. On separation of the tubular eschar the fistulous opening is enlarged, and for a time more of the intestinal contents escape through it; but in a short time the canal becomes blocked by granulations, which eventually result in its closure. Before using the cautery the length of the tract must be carefully determined, in order to protect the bowel against injury from the point of the instrument. The same instrument is of value in the treatment of larger fistulæ, lined by mucous membrane, not complicated by mechanical impediments to the fecal circulation. I have resorted to this procedure in a number of cases of surface fistulæ lined by mucous membrane, and have been well satisfied with the results. Cauterization may sometimes be employed advantageously in the treatment of internal intestinal fistula, as shown by the following case, recently examined and treated before the class at Rush Medical College:

The patient was a housewife twenty-five years of age, with a good family history. The present trouble dates back to childbirth, five and one-half years ago. Soon after confinement she suffered from suppurative mastitis. Five years ago she had an attack of what was called inflammation of the bowels, followed by diarrhea, and was confined to bed two weeks. Later the diarrhea alternated with constipation. Two and one-half years ago an abscess formed in the left ischiorectal fossa, rupturing two inches from the anus within two or three months. Stools later contained blood but no pus. Second opening appeared six months after in left inguinal region, from which gas and fecal matter escaped from the first, then intestinal contents from the first opening. Rectal examination revealed an indurated area about four inches above the anus, in the center of which

a small opening could be felt. The patient was brought to the clinic with the expectation that a laparotomy would be made for the treatment of the intestinal fistula. Injection of peroxid of hydrogen through the inguinal fistula was followed by the escape of white foam from the opening in the rectum, which could be plainly seen through a rectal speculum. The same was observed following a similar injection into the perineal fistula, showing that both abscess cavities communicated with the same intestinal fistula. It was decided to close the rectal opening first. The patient was placed under the influence of an anesthetic, and, while in the Trendelenburg position, the rectal opening was freely exposed by using two Sims specula. A probe was passed from the rectum into the abscess cavity, serving as a guide to the needle-point of the Paquelin cautery, with which the fistulous tract was thoroughly cauterized. For a few days more fecal matter escaped through the fistula, but in the course of a week the cauterized tract was found blocked by granulations that prevented even the escape of gas. The patient continued to improve, and in a few weeks the abscess cavity was healed and the rectal fistula permanently closed.

Drainage of Abscess Cavity.—An abscess cavity interposed between the intestinal opening and the fistulous tract on the surface or in one of the pelvic organs often constitutes an insurmountable obstacle to spontaneous healing. In many cases the abscess cavity is imperfectly drained and is being continually contaminated by fecal material. If the abscess is so located that it can be safely and more efficiently drained, this procedure will often accomplish all that is desired. This method of treatment is particularly indicated in pelvic abscesses complicated by intestinal fistula. It must, however, not be forgotten that under such circumstances the organs in the vicinity of the abscess are often displaced by inflammatory adhesions and exposed to injury in efforts to secure better drainage. The following case will serve as an instructive illustration :

A woman thirty-five years of age applied for treatment of an intestinal fistula in the left groin. The fistula followed a pelvic abscess that was opened above Poupart's ligament. Several weeks later gas and fecal matter escaped through the fistula. This condition had existed for two years. Periodic discharge of increased quantity of pus indicated that the original abscess cavity had not obliterated, owing to imperfect drainage. As no swelling could be felt in the left parametrium, it was decided to drain the abscess into the vagina. Under anesthesia the external opening was enlarged sufficiently to enable the surgeon to follow the tortuous canal into the pelvis to the left side of the uterus. With the left index-finger in the vagina the point of a large pair of hemostatic forceps could be felt when the instrument was pushed through the tissues and the mucous membrane incised over its point. The canal was dilated, and a rubber drain, half an inch in diameter, drawn through, thus establishing through drainage. The abscess cavity was thoroughly irrigated. When the patient was seen the next day, no urine had been passed through the urethra since the operation. The bed was found saturated with urine. Suspecting what had happened, warm boric acid solution was injected into the bladder, which at once escaped through the vaginal portion of the drain. It was evident that in making the tunnel the forceps had transfixed the displaced bladder. The drain was removed, and a Sims catheter inserted into the bladder. The drainage of the abscess cavity from the surface was continued. The wounds in the bladder healed under this simple treatment in the course of a week, and a few weeks later the fistulous opening closed permanently.

Mechanical Repression of Spur.—The spur has been recognized as a cause of the persistence of intestinal fistula for a long time, and different methods of treatment have been devised for its removal. Desault advised the insertion of a roll of charpie into the bowel, with a view to increasing the size of the lumen of the bowel and of repressing the spur. Banks inserted a large rubber tube, which he fastened in the fistula, for the same purpose. As the

formation of the spur takes place in consequence of the flexion of the bowel, we can readily understand why all such mechanical devices have proved of so little value.

Removal of Spur.—The first efforts to remove the spur by

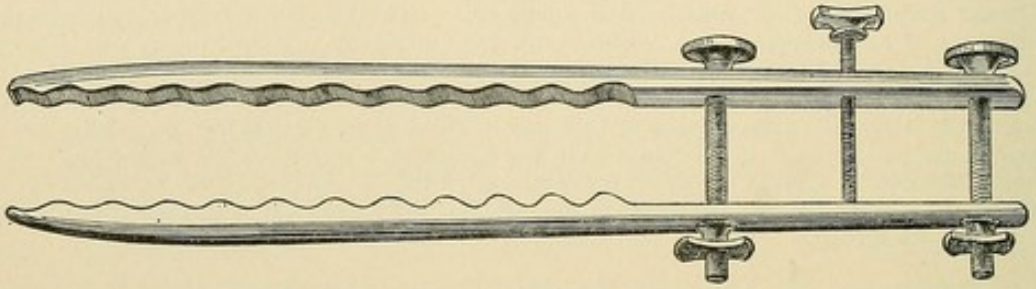

Fig. 558.—Dupuytren's enterotome.

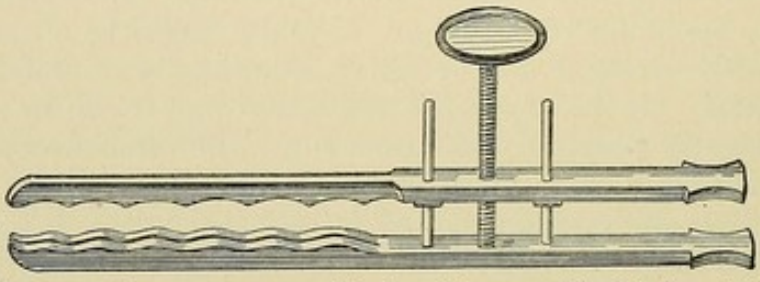

Fig. 559.—Dupuytren's enterotome, modified and improved by Blasius. The instrument is applied to the spur in the manner shown in figure 560.

operative procedure were made by Schmalkalden in 1795. He removed the spur with scissors and knife. The disastrous results that must necessarily have followed this operation led Dupuytren to accomplish the same object by a bloodless method. He devised for this purpose a clamp (enterotome) (Figs. 558–560) which he applied to the spur, and, by tightening the screws connecting the branches, made it cut its way through the tissues by causing linear necrosis of that part of the septum included in its branches. The instrument effects its object in from three to eight days. It is then again applied on the side of the linear section, and the same procedure is repeated until the spur is removed. The results of this operation were quite satisfactory before laparotomy was made a safer procedure.

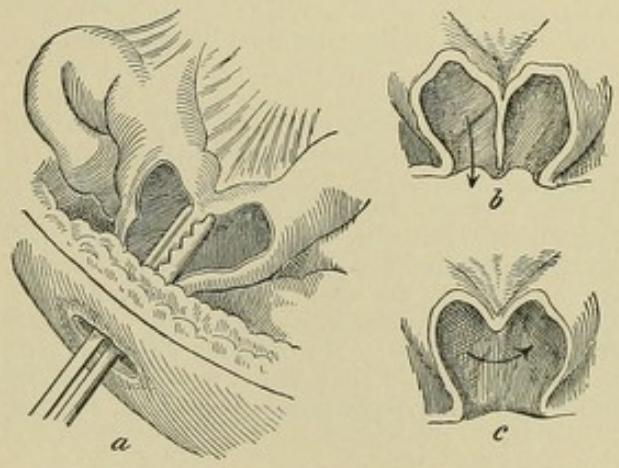

Fig. 560.—Treatment of artificial anus by Dupuytren's clamp: *a*, Enterotome applied; *b*, the spur in section; *c*, bowel after removal of spur (after Esmarch).

In 1824 Dupuytren reported 41 cases, of which number 29 were cured and only 3 died. Later Heinmann collected 83 cases, with a mortality of 4.83 per cent. The most recent statistics collected by Körte comprise 111 cases, with 11 deaths. In many of the cases, however, the fistula remained. After the removal of the spur the margins of the fistula were usually destroyed with the actual cautery. It will be shown later that the spur develops in consequence of flexion, and that if the flexion is arrested in the operative treatment of artificial anus, its removal is superfluous. The recent advances made in intestinal surgery will render Dupuytren's operation obsolete in the near future.

Closure of Fistula by Plastic Operation.—The closure of intestinal fistulæ by plastic operation was introduced by Dieffenbach. It was not his intention, by the operation that he devised, to close the opening in the bowel at once, but to cover it with a bridge of skin, leaving the closure to be accomplished later gradually by granulation. Between two elliptic incisions he excised the margins of the fistulous opening (Fig. 561, *a*) and the skin surrounding it. A bridge of skin was made by making, on one side of the oval defect and the necessary distance from it, a curved incision twice the length of the wound, and, by undermining the skin, mobilizing a part with which to cover the opening. The oval wound was closed by interrupted sutures (Fig. 561, *b*). The operation leaves a crescent-shaped raw surface, produced by sliding the bridge, which was left open to heal by granulation. This operation, as well as plastic closure by pedunculated flaps, had its field of usefulness before abdominal operations were rendered comparatively safe by an improved technic and the general adoption of aseptic precautions, but is seldom, if ever, resorted to at the present time.

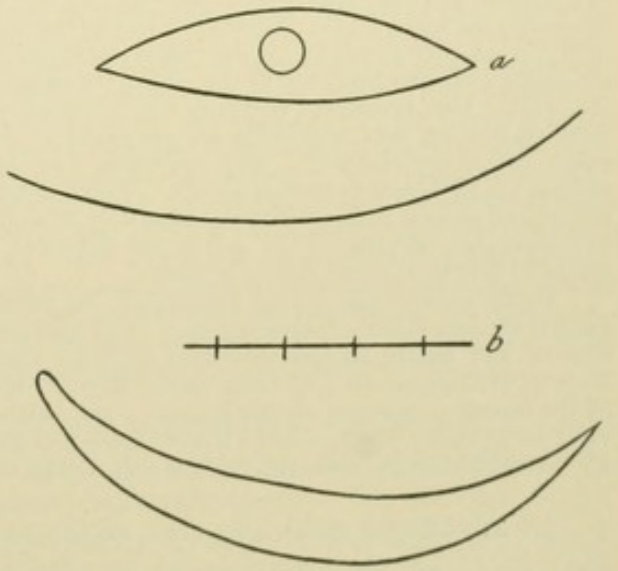

Fig. 561.—Dieffenbach's plastic operation for closure of artificial anus.

Suturing of Fistula without Opening the Peritoneal Cavity.—The closure of an intestinal fistula by vivifying its margins and suturing, without detaching the bowel or opening the peritoneal cavity, has not yielded very satisfactory results. The operation is adapted only for cases in which the intestine is attached to the abdominal wall and the fistulous opening is readily accessible, and where no canalization impediments are present. I have succeeded

in two cases in closing the fistula completely and perfectly by one operation.

The first case was a young man eighteen years of age, who was attacked suddenly by circumscribed suppurative peritonitis in the upper part of the abdominal cavity. An abscess formed, which was opened at the left border of the left rectus muscle, a little below the level of the umbilicus. A few days later nearly all the intestinal contents escaped through the opening. The character of the chyle that escaped indicated that the intestinal perforation was near the stomach. The amount of intestinal discharge gradually diminished in quantity, the patient's general condition improved, but the fistulous opening failed to close. When he came under observation the external opening had contracted so that it would admit only an ordinary grooved director. A long probe could be inserted its entire length. The patient was prepared carefully for the operation by laxatives and careful dieting. The fistulous tract was enlarged in an upward direction, when, upon retraction of the margins of the wound, an opening was found in the intestine large enough to admit the little finger. The intestine was adherent to the abdominal wall. The whole fistulous tract was excised, and with it the margins of the opening in the bowel, without opening the peritoneal cavity. After it was ascertained that no spur or other canalization difficulties were in the way of a normal fecal circulation, the wound was sutured by first bringing in accurate contact the mucous membrane by fine silk sutures, placing them close together. In the next row of buried sutures of catgut the entire thickness of the bowel-wall minus the mucous membrane was included. The next row of buried sutures, of the same material, included the entire thickness of the abdominal muscles, and finally the skin was sutured separately, using for this purpose fine silk. The antiseptic dressing was retained by broad strips of adhesive plaster. Stomach-feeding was prohibited for three days. The entire wound healed by primary union under one dressing. The operation was performed several years ago, and the patient has remained in perfect health. There can be no doubt that in this case the peritonitis and abscess resulted from perforation of a duodenal ulcer. The thickness of the intestinal wall, as well as the size of the lumen of the bowel, indicated that the fistula occupied this part of the intestinal tract.

In the second case, a man aged thirty, the fistulous opening involved the cecum and formed after an attack of appendicitis. The opening was large enough to introduce two fingers, and nearly all the intestinal contents escaped through this abnormal outlet. Four or five operations had been made, with the result that after each operation the size of the intestinal opening was increased. The patient was subjected to preparatory treatment for at least a week, when a similar operation was performed as in the last case, with the same satisfactory immediate and remote results.

In advising a resort to this, so far as life is concerned, absolutely safe operation, it is important to remember the necessity of freely excising the fistulous tract, removing all the scar tissue and a circular strip of the mucous membrane lining the margins of the fistulous opening in the bowel, as well as the importance of bringing in accurate apposition by several tiers of buried sutures the different anatomic structures. A conscientious observance of these precautions will occasionally reward the surgeon by success in closing an intestinal fistula by extraperitoneal suturing.

Intestinal Anastomosis.—The formation of an intestinal anastomosis in the treatment of an intestinal fistula is indicated in cases in which the extraperitoneal methods are not applicable or have proved unavailing, and the usual intraperitoneal operations are contraindicated. Under such circumstances the exclusion from the fecal circulation of the perforated loop, by the formation of an anastomotic communication between the afferent and efferent limbs of the loop, will remove the annoyances incident to an intestinal fistula and place the parts in a more favorable condition for spontaneous healing or more successful surgical intervention. The anastomotic

opening should be made at least two inches in length. The operation can be performed most safely by the use of decalcified perforated bone-plates, the Murphy button, or by Czerny-Lembert sutures. For the purpose of showing the value of this method of procedure in rare cases the following observation, made a few years ago by me, may prove instructive:

A woman thirty years of age suffered for several weeks from pelvic peritonitis, which resulted in the formation of an abscess, which was opened above Poupart's ligament on the left side. A few days after the abscess was incised gas and fecal matter escaped from this opening. Additional abscesses on the same side appeared, which were either opened externally or discharged through the first abscess cavity. The fecal fistula remained. The case came under my observation nearly a year after the first attack. The patient was greatly emaciated; more than one-half of the intestinal contents escaped through the abnormal outlet. The fistulous tract led down into the cavity of the pelvis, to the left of the uterus. Rectal insufflation of hydrogen gas demonstrated that the fistula was above the ileocecal valve. After a few days of preparatory treatment the abdomen was opened, and it was found that the lower part of the ileum was rolled up into a mass by numerous and firm adhesions. A faithful attempt was made to unravel the mass, but had to be abandoned, owing to the extent and firmness of the adhesions. The perforated part of the intestine could not be found. The mass comprised from three to five feet of the lower part of the ileum. Excision of this mass was absolutely out of the question, owing to the patient's general condition and the number and character of the adhesions. The free intestine on the proximal side was finally found, an anastomotic opening between it and the sigmoid flexure established, with the aid of large decalcified perforated bone-plates, and the external incision closed by suturing. Very little fecal material escaped from the fistula after the operation, while the discharges from the bowels became more copious and liquid. It was evident that the fecal current had been diverted away from the numerous adherent coils of the lower part of the ileum into the sigmoid flexure. The patient improved in general health and was relieved from the annoyances incident to an intestinal fistula. A number of times the fistulous opening closed, but reopened; this occurrence was always attended by a limited discharge of pus. The abscess cavity had evidently never healed completely, and undoubtedly maintained the fistula.

It is to be expected that the excluded part of the intestinal canal will continue to undergo progressive atrophy, and that ultimately the fistulous opening will close spontaneously. So far the operation has resulted in restoring the continuity of the intestinal canal by excluding from functional activity the partially impermeable lower part of the ileum. It appears that a similar procedure would often prove of great value in the treatment of vesico-intestinal fistula in which the operative closure of the opening and enterectomy are often found impracticable.

Enterectomy.—The mortality attending enterectomy and circular enterorrhaphy in the treatment of intestinal fistula and artificial anus remains great even in the hands of experienced operators. The statistics of Reichel give a mortality of 37.8 per cent., and those of Hertzberg, 27 per cent. In view of this fact it is apparent that this operation should be reserved for cases not amenable to successful treatment by safer procedures. The indications for this operation can be limited to *exceptional* cases. If the intestine is not attached to the abdominal wall, it is much safer to open the free peritoneal cavity in search of the affected part of the intestine than to follow the fistulous tract as a guide. If possible, the intestine should be tied on each side of the fistula with a strip of gauze or a rubber band before it is detached, in order to guard more efficiently

against fecal extravasation. The operation should be performed with the patient in the Trendelenburg position, and the peritoneal cavity amply protected by aseptic compresses during the resection and suturing. After the resection the continuity of the bowel should be restored by circular enterorrhaphy with the Czerny-Lembert sutures.

Preliminary Transverse Suturing of the Intestinal Opening as a Prophylactic Measure Against Infection During the Operation for Artificial Anus.—There can be little doubt that the operative treatment of intestinal fistula or artificial anus requiring opening of the abdominal cavity has been attended by an alarming mortality, owing to infection caused by the escape of feces through the intestinal opening. Packing the opening with gauze or cotton is a very inefficient way to prevent fecal extravasation. The use of clamps and ligatures on each side of the opening in the bowel is equally unreliable. In 1894 I proposed and practised successfully preliminary transverse suturing of the intestinal opening as a prophylactic measure against infection. This procedure appears to me as an important safeguard against this source of danger, as by preliminary closure of the intestinal opening by suturing, placing the sutures so close together as absolutely to prevent the escape of any of the intestinal contents, a prolific source of infection is excluded. After this has been done the field of operation is once more thoroughly sterilized before the abdomen is opened and the intestine detached. The sutures should include all the tunics of the bowel. With few exceptions this row of sutures will remain as Czerny sutures, to be buried, after the bowel has been detached, by Lembert stitches. The statement has already been made that flexion of the bowel is the most important factor in producing the spur, and that measures that are calculated to correct the flexion will prove useful in removing the spur. In artificial anus, produced accidentally or intentionally, the flexion is caused by the prolapse of the intestinal loop into, and sometimes even beyond, the opening in the abdominal wall. If the intestine is detached, the flexion is diminished or completely corrected, and its recurrence is prevented by transverse suturing of the intestinal opening. The correctness of these statements is apparent, and can be corroborated by the report of two cases of artificial anus which were operated upon in the clinic of Rush Medical College:

The first patient was a man twenty-nine years of age, an Irish-American. About a year before he entered the Presbyterian Hospital he was taken suddenly ill with severe pain in the right iliac fossa. The attending physician made a diagnosis of appendicitis, and four days later opened an abscess at a point about two inches from the inner side of the anterior superior spinous process of the ilium. A few days later feces escaped through the opening. An attempt was made to prevent the escape of fecal matter by applying a compress. Then followed twelve operations, with the intention of closing the fistula, in one of the hospitals in St. Louis. The only result effected by the operations was increased size of the opening. When the case was presented in the clinic of Rush Medical College, the opening in the abdominal wall and the anterior wall of the cecum was large enough to insert three fingers. In the center of the opening was found a well-developed spur that effectually prevented the entrance of any of the intestinal contents into the colon. The border of the opening in the abdominal wall was lined by the ectropic mucous membrane of

the cecum (Fig. 562). The ileocecal valve could be seen and felt below the spur. The patient was prepared for the operation by dieting, laxatives, and a daily warm bath for a week. The operation was commenced by suturing the oblong vertical intestinal opening transversely, using for this purpose fine silk and an ordinary sewing needle (Fig. 563). After the lumen of the intestine with its contents was shut off from the field of operation the surface was once more thoroughly disinfected. The next step in the operation consisted in including in two elliptic incisions the margins of the abdominal opening and

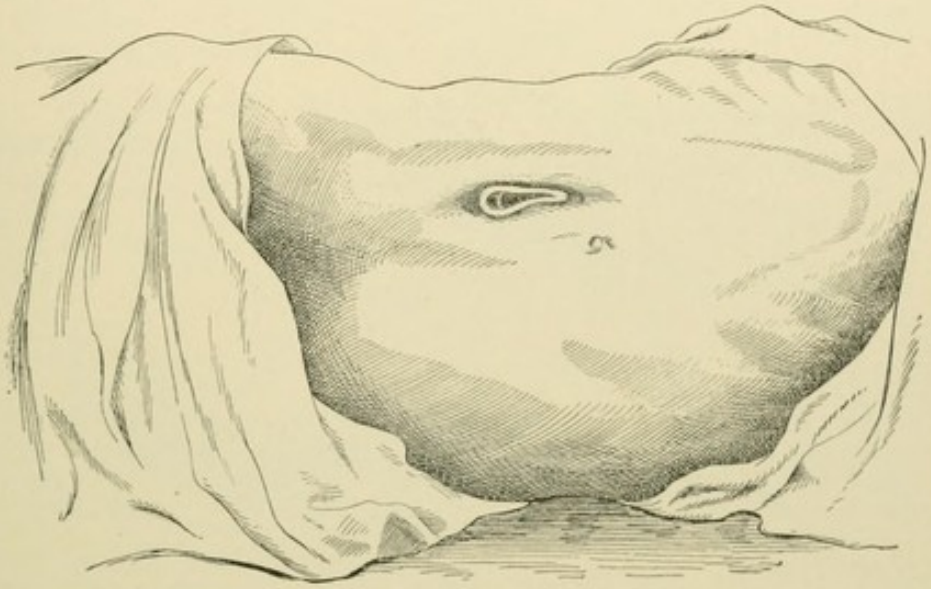

Fig. 562.—Artificial anus following appendicitis. Well-marked ectropion of the mucous membrane.

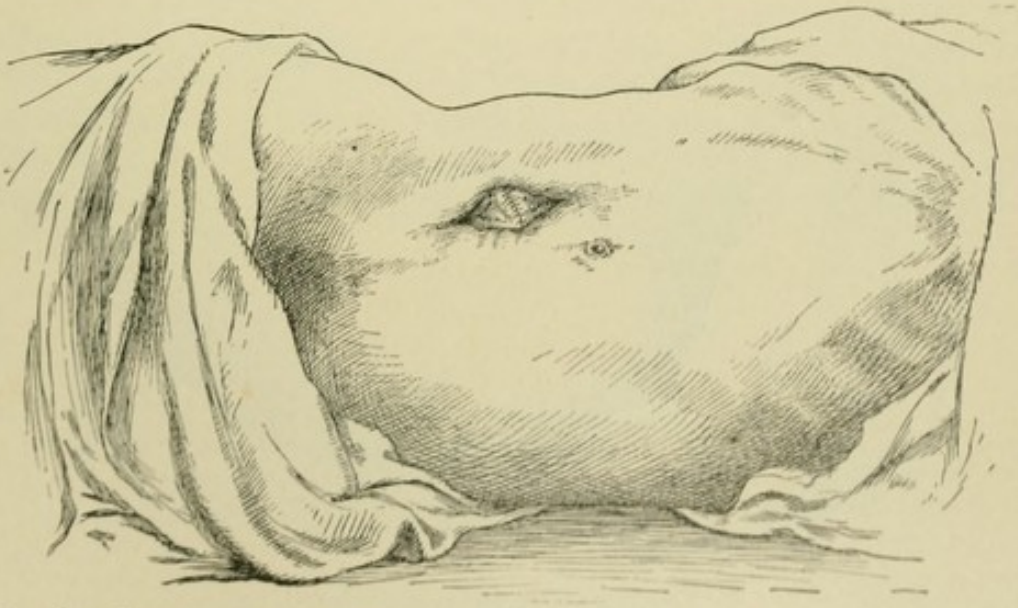

Fig. 563.—Provisional sutures, including all the tunics of the bowel. Transverse suturing of intestinal opening.

the scar tissue in its vicinity. The peritoneal cavity was opened by a straight incision extending downward from the lower angle of the two incisions. The bowel was detached from the abdominal wall and drawn forward into the external incision. The strip of skin and scar tissue were carefully trimmed away from the bowel with scissors, when the provisional sutures were buried by a row of Lembert stitches (Fig. 564).

The prolapsed part of the bowel was cleansed, dried, and replaced in the abdominal cavity, and the external wound closed by four tiers of sutures (Fig. 565). The usual

antiseptic dressing was applied and confined in place by broad strips of adhesive plaster. Not a single untoward symptom followed the operation. The wound healed throughout by primary intention. The bowels responded to a laxative on the third day, and subsequently moved daily without further assistance. The patient left the hospital at the end of four weeks, with instructions to wear a pad for at least six months.

The second case was a girl nine years of age. During October, 1893, she suffered from an acute attack of appendicitis which resulted in the formation of a large abscess. The abdomen was opened and the perforated appendix removed. It was noticed that

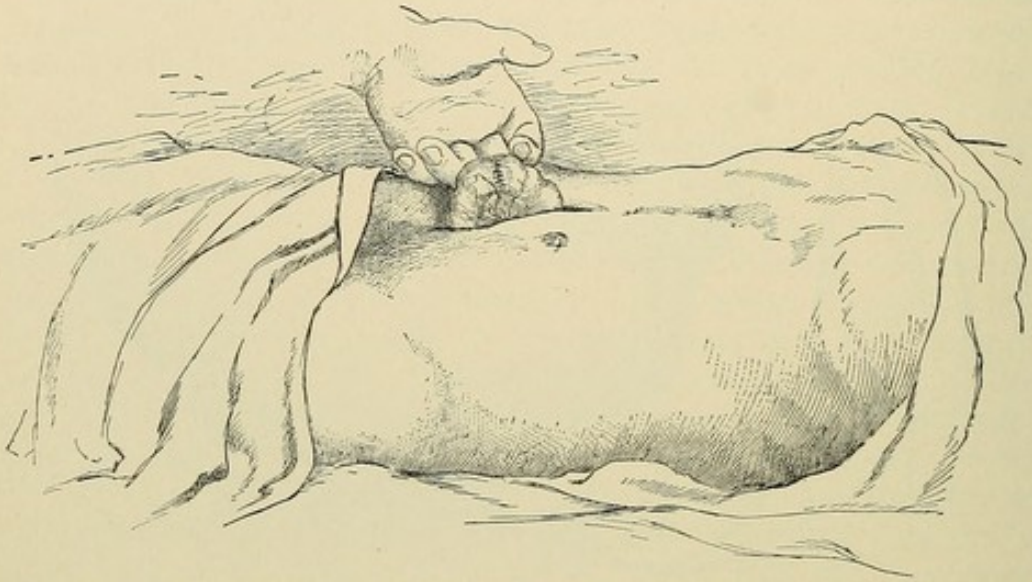

Fig. 564.—Intestine detached and drawn forward into wound. Provisional sutures buried by a row of Lembert stitches.

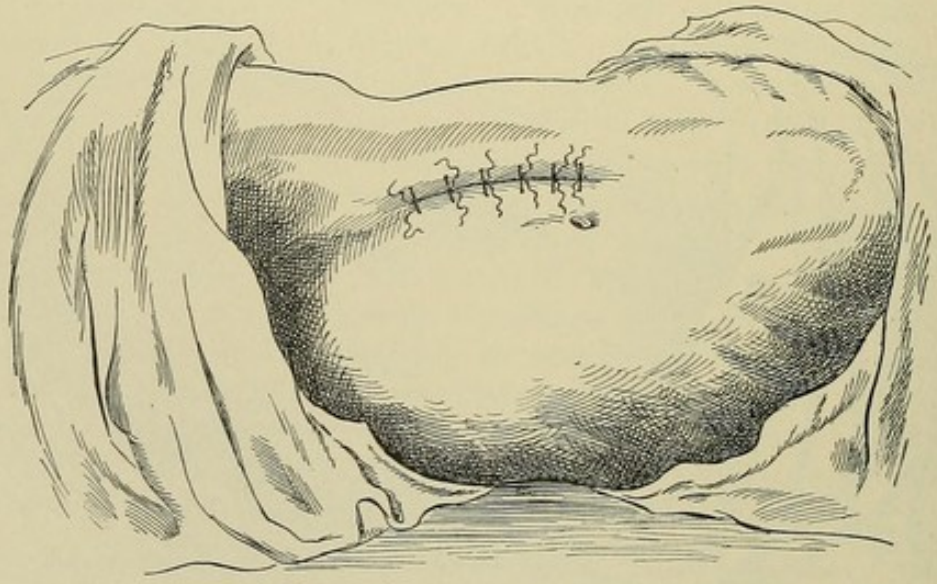

Fig. 565.—Operation completed.

the anterior wall of the cecum presented a large gangrenous patch. It was deemed advisable to anticipate perforation by excluding this area from the free peritoneal cavity by a ring of sutures, uniting the visceral with the parietal peritoneum. The remainder of the incision was closed with the exception of a space for drainage. The patient's general condition improved promptly after the operation. The gangrenous part sloughed away, leaving a large opening in the cecum. Through this opening nearly all the intestinal contents escaped, as an efficient spur formed at the middle of the opening. The contact of feces with the skin produced in this case an intense and diffuse dermatitis. When the patient entered the Presbyterian Hospital in January, 1894, the dermatitis

involved more than one-half of the anterior surface of the abdomen. The treatment of this affection proved very tedious, so that two months later, when the operation was performed before the class of Rush Medical College, a patch of skin the size of the palm of the hand still remained in a state of intense irritation.

The same operation was performed as on the preceding patient, with similar satisfactory immediate and remote results. Instead of constipation, the operation was followed by diarrhea, which continued for several days, provoked probably by bringing the intestinal contents in contact with the colon, which had been almost completely excluded from the fecal circulation for five months. The wound healed by primary intention throughout. The dermatitis disappeared promptly after the removal of the cause. The patient left the hospital in perfect health four weeks after the operation.

A third case was the subject of a large intestinal fistula high up in the intestinal canal.

The patient was a female fifty years of age, who was operated upon for intestinal obstruction a number of months before she came under my care. The symptoms of obstruction abated after the operation, but the fistula remained. An hour after eating nearly all the half-digested food escaped through the fistulous opening that was found to the left of the median line and above the level of the umbilicus. The opening was large enough to admit two fingers. The patient was emaciated to a skeleton. The permeability of the intestinal canal below the fistula was established by rectal insufflation of air. The opening in the bowel was sutured transversely, after which the field of operation was again disinfected, when the abdominal cavity was opened and the adherent intestinal loop detached. The adhesions were found so extensive that the peritoneum was not within reach of the Lembert sutures. After burying the provisional sutures with a row of fine silk sutures that included the entire thickness of the intestinal wall minus the mucosa, the omentum was stitched over the line of suturing, and the omental flap was made to include the whole denuded surface of the intestine. The intestinal loop was returned and the incision completely closed. The wound healed by primary intention throughout, and normal bowel function was restored by the operation. The patient left the hospital four weeks after the operation and has remained in excellent health since.

A study of these cases is well calculated to prove that the provisional closure of the intestinal opening by transverse suturing before using the knife is the most efficient prophylactic measure against infection, and also to show that resection of the intestine for fistula and artificial anus can be avoided in the majority of cases, and that in its place transverse suturing and correction of the flexion will yield better results.

CHAPTER XXVIII.

RESECTION OF JOINTS.

In a treatise on emergency surgery we should not expect to find resection of joints discussed in detail. Primary resection for joint injuries has become the exception, rather than the rule. Before aseptic surgery was known, penetrating wounds of the joints were considered, for good reasons, formidable and dangerous injuries. The fearful mortality that attended gunshot wounds of the large joints during the Civil War led surgeons to resort either to amputation or to typical resection, with the hope of diminishing the immediate risks to life. There can be no question but that these attempts were instrumental in diminishing the mortality, but the results thus achieved were dearly bought. Fortunately, asepsis has introduced a new era in the treatment of open injuries of joints. Compound fractures involving joints and gunshot injuries have lost their terror since ample experience has demonstrated that a timely first-aid dressing, under strictest aseptic precautions, suffices, as a rule, in protecting the patients against wound infection and its manifold complications. In another part of this work it has been shown that these injuries are amenable to successful conservative treatment, provided they are subjected to rational modern surgical treatment before the wound has become infected. It may be stated, as a rule to which there are few, if any, exceptions, that primary resection for recent joint injuries has been relegated to the past, and that the surgeons of the present concentrate all their energies in protecting the wound against infection. In gunshot wounds the first-aid dressing is relied upon, and it must be considered not only unsurgical, but almost criminal, to ascertain by probing or otherwise the extent of the joint injury. Joints that have been penetrated by a bullet, causing extensive comminution of the articular ends, will recover if the wound remains aseptic, and very often the conservative effort is rewarded by a good, if not a perfect, range of motion. In compound fractures with extensive comminution but a small opening in the skin, the same conservative treatment will often yield similar favorable results. If the wound is large, and especially if it has been inflicted by direct force, exploration under the most pedantic aseptic precautions not only is justifiable, but also absolutely necessary. The finger and instruments used in making the intra-articular examination must be made faultlessly aseptic. The surface of the wound and the adjacent skin over a liberal area must be disinfected thoroughly before the examination is made. Fragments of bone completely detached should be re-

moved, and in cases in which one of the articular extremities has been extensively destroyed, an atypical resection may become necessary, not for the purpose of diminishing the risks of infection, but with the intention of leaving the injured joint in the best possible condition for repair and for securing a maximum functional result.

From the foregoing remarks it will be seen that modern surgery does not tolerate typical resection for recent injuries, and that atypical or incomplete resection is reserved for exceptional cases when the extent of destruction of one or both of the articular extremities warrants such a procedure. Acute suppurative inflammation of the large joints, so frequently subjected in the past to amputation and resection as life-saving measures, furnishes no longer an excuse to the surgeon to perform a mutilating operation. Free incision, thorough drainage, immobilization of the joint, antiseptic flushings or continuous irrigation with a mild antiseptic solution, have taken the place of amputation and resection, and the results, so far as both life and limb are concerned, have been vastly improved by the change from mutilating to conservative surgery. A resection may occasionally become necessary after the acute symptoms have subsided in cases in which the articular ends have been extensively destroyed, and in which the suppuration does not yield to the intra-articular antiseptic treatment.

It is not more than ten years since typical resection of joints for tuberculosis appeared to be not only a justifiable, but also an established, surgical procedure. A visitor to any of the large clinics could see one or more resections of the large joints daily. To-day the operation is looked upon with suspicion, as an enormous statistic material has shown that, with some exceptions, the conservative treatment by iodoform injections and rest gives better functional results, and that the operation has very little, if any, more influence in preventing reinfection. In synovial tuberculosis that proves rebellious to the conservative treatment, excision of the diseased capsule meets the pathologic indications, and few, if any, surgeons of to-day would be willing to substitute a complete resection for arthrectomy in such cases. In primary osseous tuberculosis with involvement of the joint typical resection still holds a creditable place in the field of operative surgery. But even in such instances the tendency of the present teaching and practice is to use saw and chisel as sparingly as possible, and limit the operative treatment to the removal of diseased tissue. Arthrectomy and atypical resection have drawn the legitimate indications for complete resection to within very narrow limits, and the restrictions for the operation will become more rigid with the increase of our knowledge pertaining to the nature and intrinsic tendencies of the tubercular affections of joints.

There are three indications of modern date that have opened up new fields for resection—unknown and dangerous ground before aseptic surgery made it possible to deal safely with open wounds of joints. These new indications are:

1. Irreducible dislocations of joints.
2. Angular ankylosis that renders the limb practically useless.
3. Fixation of joints of paralytic limbs (arthrodesis), to render the limb useful by effecting an ankylosis.

These are all operations for aseptic conditions, and should be undertaken only by surgeons well grounded and experienced in aseptic work, and who have at their command all the appliances and facilities for securing perfect asepsis. The operative treatment of such cases is attended by great responsibility on the part of the surgeon, and every precaution must be practised to prevent infection. Ample time and the most pedantic preparations are necessary to render the limb to be operated upon aseptic. Haste and inadequate preparation are inexcusable, as the result of the operation will largely be determined by the thoroughness and care with which the preparations were made.

The operation of excision of the soft tissues of the joint, synovial membrane, and capsule is called *arthrectomy* (Volkmann). Extirpation of the diseased synovial membrane is known as *synovectomy*. The proper designation of the operation of excision of the synovial membrane and the articular ends of the joint is *arthrectomia synovialis et ossis*. Removal of the diseased synovial membrane by scraping with a sharp spoon has been known as *erasion*. *A typical resection* consists in the excision of both articular surfaces of the bones, and by an *atypical resection* is understood the removal of only the diseased portion of the joint, or the excision of a part of the joint for injury or disease, with a view to improving the local conditions for a more satisfactory repair of the injury and a better functional result. In performing a resection of a joint for disease it is necessary to expose the cavity of the joint freely for the purpose of ascertaining the location and extent of the disease and to bring the tissues to be removed within easy reach of the instruments. In resection for tuberculosis, for instance, the diseased soft structures of the joint must be removed with the same thoroughness as in operations for malignant disease; osseous foci must be discovered, and when found, removed by a vigorous use of the sharp spoon, chisel, or saw, according to the extent and location of the disease. In the resection of a joint the external incision must be made with special reference to affording free access to the joint and guarding against accidental injury to any of the important structures around the joint. Vessels, muscles, tendons, and nerves are to be carefully protected, and the periosteum is preserved as far as it is free from disease, as is also the capsule. Muscular and tendinous insertions must be interfered with as little as possible, and bony prominences of the articular extremities, when not the seat of disease, must be carefully preserved. *Temporary resection of bony prominences to which important muscles and tendons are attached has become an important feature of the modern technic of resection, particularly in cases in which it is reasonable to entertain the hope that the patient*

will recover with a useful joint; this is often the case after arthrectomy, and occasionally after an atypical resection.

Filing made a great advance in the technic of resection of joints when he advocated the advisability and utility of temporary resection of the more important bony prominences of the articular extremities, such as the trochanter major, olecranon, and the malleoli. These bony prominences, even in cases of far-advanced joint tuberculosis, are seldom the seat of disease to any extent, and should therefore not be included in the resection. All these prominences serve as points of attachment of important muscles, and if sacrificed, it is difficult, and more often impossible, to furnish the detached muscle or tendon with a new point of anchorage with the same mechanical advantages. Temporary resection of all these prominences secures free access to the respective joints, and after the arthrectomy or resection has been completed, the detached fragment of bone is replaced in its former position and held in place by direct means of fixation. Aseptic bone or ivory nails, silver wire, and catgut are the materials most frequently relied upon in retaining the fragment in position until it has united by bony callus with the shaft of the bone. My experience with temporary resection of the olecranon, trochanter major, malleoli, and the patella has been of the most satisfactory kind, and it is my opinion, based on a large clinical experience, that if the fragment is properly replaced and immobilized by nailing or suturing, *bony union always takes place in the usual time, provided the wound remains aseptic.* After temporary resection of the patella by transverse section I have always resorted to catgut sutures in bringing and holding the fragments in contact, and if the wound remained aseptic, bony union invariably has been observed three or four weeks after the operation. A mattress suture of coarse catgut, aided by two lateral sutures, can be relied upon in keeping the fragments in accurate contact. Temporary resection of the olecranon process is made with the saw or chisel, making the section obliquely from the ulna through the base of the process, so that the ulnar fragment represents a wedge with the base on the side of the olecranon. The trochanter major is removed in a similar manner. In both instances fixation by a bone or ivory nail can be relied upon in holding the fragment in proper position until it has again become a part of the shaft of the bone by bony consolidation. The malleoli are free from any muscular attachments, and, after temporary resection, are securely immobilized by one or two catgut sutures passed through the periosteum and paraperiosteal tissues of the bone on both sides. These processes are detached at their base with the chisel by a straight cut, hence the fracture is a transverse one and is immobilized by the catgut sutures for a sufficient length of time for bony union to take place.

The preservation of muscular attachments by temporary resection of the osseous points of insertion and origin has a promising future, and should be resorted to in all cases in which the muscles,

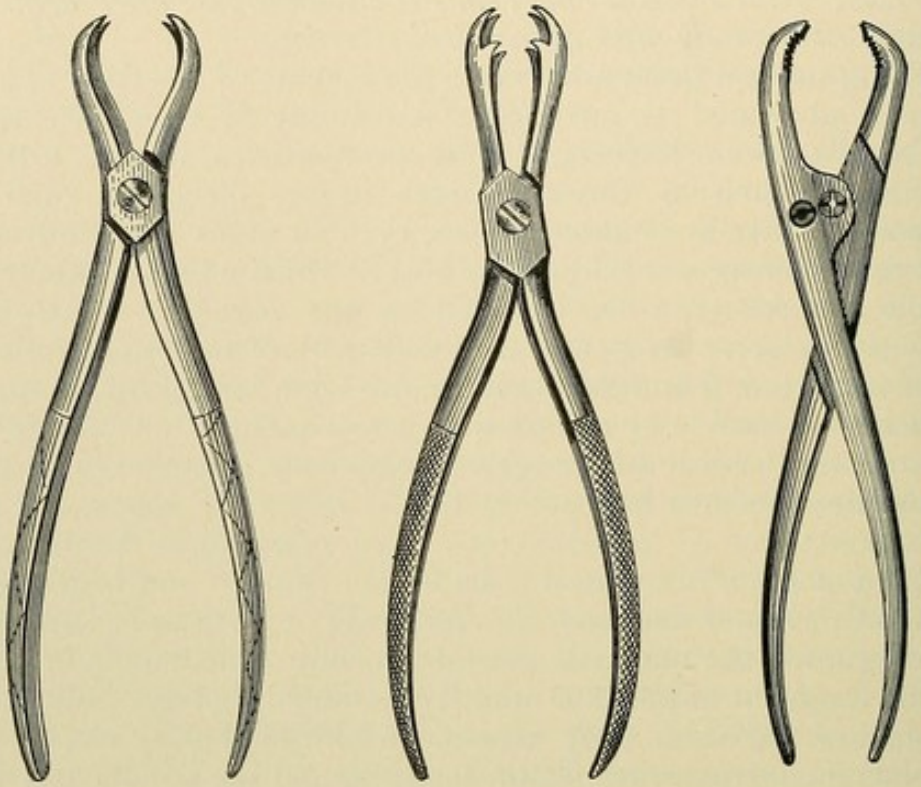

a *b* *c*

Fig. 566.—Bone-holding forceps: *a*, Langenbeck's; *b*, Fergusson's; *c*, Faraboeuf's.

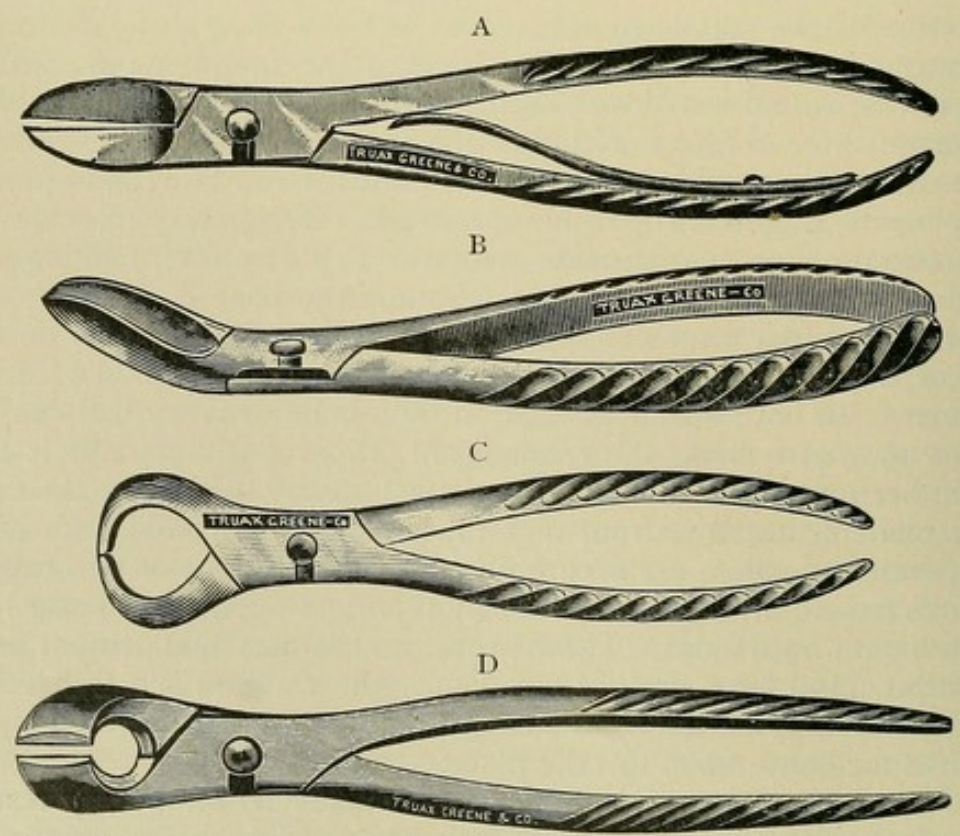

Fig. 567.—Bone-cutting forceps: A, Liston's; B, Liston's curved on the flat; C, Satterlee's cross cutting; D, Velpeau's cross cutting.

Fig. 568.—Langenbeck's narrow saw.



Fig. 569.—Lifting-back metacarpal saw.



Fig. 570.—Macewen's chisel.

Fig. 571.—Von Bruns' chisel.



Fig. 572.—Gouge for use with hand or chisel.

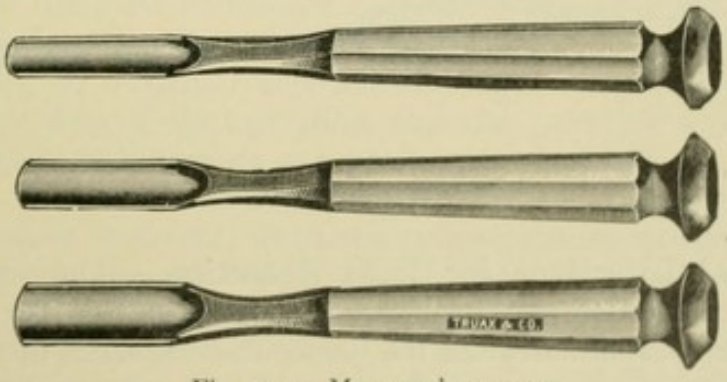

Fig. 573.—Macewen's gouges.

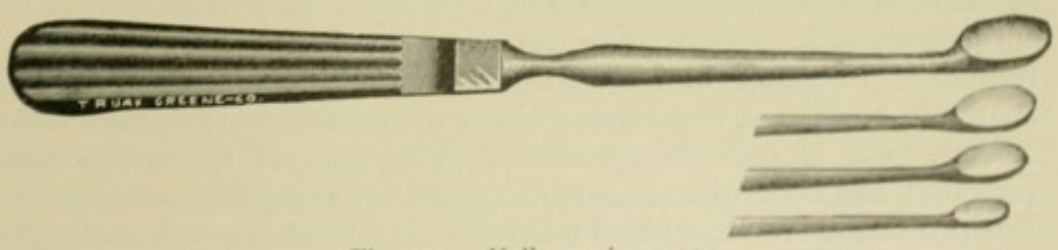

Fig. 574.—Volkmann's spoon.

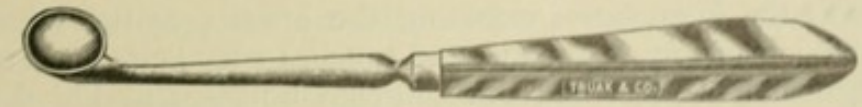

Fig. 575.—Von Bruns' spoon.

tendons, and bone are free from disease, and in which restoration of motion can be expected.

The most important instruments used in making a resection of a large joint are a short stout scalpel, periosteal elevator, Truax's or Butcher's saw, a metacarpal saw, chain saw, bone-cutting forceps, strong grasping forceps, chisel and hammer, Cooper's scissors, dissecting forceps, and broad, sharp-toothed retractors. The necessary fixation material to be used after temporary resection of any portion of the articular ends must be at hand and ready for use, as well as splints or plaster-of-Paris for immobilization of the limb. The chain saw, so frequently in use but a few years ago, is seldom seen in the operating room at the present time, as its place has been largely taken by the chisel in cases in which the ordinary resection saw can not be used.



Fig. 576.—Treves' douche spoon.

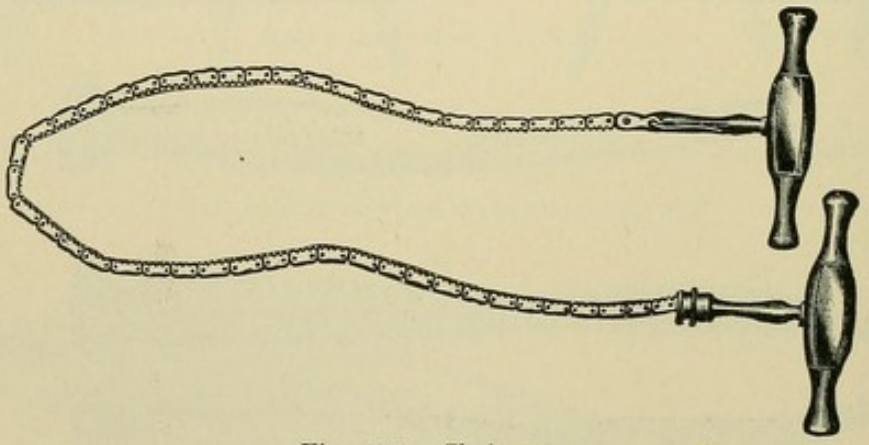

Fig. 577.—Chain saw.

General Directions for Joint Resection.—The incisions for resection of the different joints are made parallel to the important soft structures that surround the joint, and in places in which they are least likely to be exposed to unintentional injury. The principal blood-vessels, nerves, muscles, and tendons must be avoided. The surgeon must be familiar with the anatomy of the joint and its surroundings to enable him to plan the different operations upon an anatomic basis, and to perform them with safety to the important structures at the site of operation. This part of the technic of resection has undergone radical changes for the better during the last two decades. Many new incisions have been devised, with special reference to the anatomy of the tissues at the seat of operation, and with the intention of exposing the interior of the injured or diseased joint freely to the eye and touch, to facilitate the removal of fragments of detached bone, foreign bodies, and the diseased articular structures. The joints of the fingers and the metatarso-

phalangeal joints, the ankle- and the hip-joint, are usually resected through a lateral incision; the arm- and the elbow-joint, through a dorsal incision. The knee-joint is reached most readily and with least risk to important structures through an anterior incision, and the shoulder-joint is most freely exposed by temporary resection of the acromion process and formation of a deltoid flap. As a rule, the incision is made where the joint is nearest the surface of the skin and where the important soft tissues are at a safe distance from the proposed line of incision or where they can be readily displaced during the operation. If a vertical incision does not furnish the required space, it is often pricked by a lateral cut, or the incision is made curved or semilunar, as is done in resection of the hip- and the knee-joint. After the first incision has been made, the knife is used as sparingly as possible, and must largely give place to the periosteal elevator.

In freeing the articular ends, the knife and periosteal elevator must hug the bone closely, for two reasons—first, to avoid injuring unintentionally important para-articular structures; second, to preserve as much as possible of the healthy tissues. Especial care must be exercised in arthrectomy and atypical resection, as it is in such instances that partial restoration of joint motion may be expected, the functional result depending largely on the care exercised in the preservation of the soft structures concerned in joint motion. The importance of subperiosteal resection of joints was emphasized strongly by Ollier, von Langenbeck, and von Volkmann. The capsule of the joint is always opened freely, and if found healthy, it is carefully preserved with the periosteum. Capsule and periosteum must be detached and reflected with the overlying tissues. It is in this step of the operation that the resection knife is indispensable, as the ligaments can not be detached with the periosteal elevator. With short cuts, with the knife directed toward the bone, the capsule is detached, when the periosteum is separated with the raspatory or a narrow straight chisel or gouge. Tearing and contusion of the periosteum are to be carefully avoided. Vogt long ago advocated the advisability of chiseling away the compacta of the bone, with the muscle or tendon insertion, from the articular extremities at points where important muscles and tendons are attached. In a complete resection of a joint the articular extremities are denuded of all soft structures, and turned out of the wound sufficiently to permit their removal with the saw. In children the epiphyseal cartilage must be preserved, if this can be done with the complete elimination of the diseased tissues, as the loss of this important bone-producing center invariably results in great shortening of the limb. A small saw, used by mechanics, does excellent service in excising the articular ends, as with this instrument the section can be made in all possible shapes—straight, curved, or angular. If one or both of the articular ends are loose in the joint in consequence of injury or disease, they are removed with a

sequestrum forceps. Small loose fragments are extracted with dissecting or hemostatic forceps. As restoration of motion of the joint is more likely to occur if only one of the articular surfaces is removed, partial or atypical resection should always take the place of complete resection whenever such a course is compatible with the extent of the injury or disease for which the operation is performed. If the nature of the disease is of such a character that subsequent use of the joint would tend to bring about a relapse, complete resection is made, with the intention of obtaining a bony union between the two resected ends. It is in instances of this kind that the surgeon often imitates the work of the mechanic and resects the articular ends in such a manner that the bone surfaces support each other, a great advantage in the subsequent immobilization of the seat of resection.

Elastic constriction is now invariably employed in resection, as well as amputation, as it not only serves in preventing unnecessary loss of blood during the operation, but is also of the greatest service in rendering the seat of operation bloodless, giving the surgeon a better opportunity to ascertain, by inspection of the bloodless tissues, the extent of the injury or disease. In resection of the hip-joint elastic constriction is inapplicable, and the operator has to rely on the hemostatic forceps in controlling the hemorrhage during the operation. For some time it was customary, after resection of the knee-joint, to complete the operation before removing the elastic constrictor (Neuber). This practice did not survive the test of experience, as the hemorrhage after the removal of the constrictor was often sufficiently copious to require reopening of the wound and ligation of the bleeding vessels; if it were not sufficiently profuse to demand such interference, it always interfered with an ideal speedy healing of the resection wound. *After the resection has been made, the elastic constrictor should be removed and hemorrhage carefully arrested by ligature, tendon, and surface compression, before the wound is sutured;* saline solution should not be used. The bleeding from the bone is often quite profuse, and frequently surface compression has to be continued for some time until it is under control, *but the wound must remain open until it is dry.*

Steel, ivory, and bone nails for fixation of the resected ends, so much relied upon in the past, can always be dispensed with, as immobilization by an external mechanical support can be relied upon in maintaining apposition between the resected ends, if this is what the surgeon desires, and in securing rest for the limb.

Atrophy of the limb in consequence of the disease for which the operation was performed, and as the result of prolonged rest, often reaches a high degree, but the subsequent use of the limb, aided by massage and electricity, will accomplish much in improving the nutrition and function of the muscles. The atrophy not only affects the muscles, but also all the tissues of the limb, and more particularly the bones. Great mistakes have been made in practice by

surgeons who are not sufficiently familiar with the marked atrophy of the bones in long-standing joint disease. The osteoporosis of the articular ends not infrequently reaches such a degree of softening that the bone can be cut with the knife, and yet *the bone is not diseased, but only atrophic to a high degree. In performing a resection a sharp distinction must be made between atrophic, softened, and diseased bone, else the surgeon is liable to carry the resection beyond the required limits, or, perchance, discouraged by the appearance of the softened bone, may deem it necessary to abandon the intended resection and sacrifice the limb by an unnecessary amputation. If, after a complete resection, it is the object of the operation to obtain union between the resected ends by bony ankylosis, the limb must be placed and immobilized in the most useful position and treated as a fracture.*

In resection of the knee-joint the bone sections are made in such a manner that the surfaces of the resected ends come in contact with the leg *slightly flexed*, as the patient walks better and more gracefully with the limb in this than in a straight position. The arm at a right angle is more useful than a straight arm. In cases in which it is probable that joint motion can be restored, efforts in this direction by active and passive motion are made as soon as the operation wound has healed. In mobilizing large joints after incomplete or complete resections, early passive motion may necessitate the administration of an anesthetic at intervals of a week or two, until the pain incident to such movements has been diminished sufficiently for the patient to pass through such ordeals without an anesthetic. Systematic massage and the rational employment of electricity will do much to restore muscle function, nutrition, and joint motion.

Resection of Special Joints.—The general rules that have been laid down to guide the surgeon in his operative work on joints must be variously modified in practice, according to the anatomic structure and environments of the different joints and the nature of the indications that call for the operation. In opening a joint for the purpose of effecting, by direct measures, reduction of an irreducible dislocation, the incision is planned with special reference to secure free access to the bend of the dislocated bone, and with as little injury as possible to vessels, nerves, muscles, and tendons. The modern operations for tuberculosis of joints requiring arthrectomy or resection are characterized by thorough removal of the diseased tissues through incisions that afford free access to the joint, and that do not inflict unnecessary damage to the important soft structures that surround the joint.

The ultimate success of resection depends largely upon the thoroughness with which the operation is performed, the care exercised in the preservation of healthy tissue, and the prevention of injury to important structures involved at the site of operation. The modern incisions that have been devised for resection of the different joints have these objects in view, and the recent improvements in the results of joint surgery are largely due to a more

nearly perfect technic in performing the operation. The success that has attended the open method in the reduction of irreducible dislocations without resection of the head of the dislocated bone has added a new impulse to this department of surgery. Attempts to reduce old dislocations of the shoulder-joint have, in the hands of the most careful and competent surgeons, frequently terminated in disaster, so that the surgeon of to-day has learned caution, and is more inclined to remove the obstacles to reduction by a safe and clean dissection than by brute force. The same can be said of ancient dislocations of the hip-joint. Every surgeon of large experience has had his patience sorely tried in efforts to reduce recent dislocations of the thumb. The cases are by no means rare in which, by the employment of undue force during such attempts at reduction, much damage has been done to the resisting soft structures, which could have been avoided by effecting reduction by the open method, under aseptic precautions.

Resection of Finger-joints.—The joint is exposed by two lateral incisions midway between the extensor tendon and the digital vessels and nerves. By lateral flexion of the finger the articular ends are made accessible, and after they are cleared of soft tissues, are excised with fine cutting forceps or a metacarpal saw. Unless there is sufficient reason to doubt the aseptic nature of the wound, the incisions are sutured throughout, and, after the dressing is applied, the finger is immobilized in a slightly flexed position upon a well-fitting hollow palmar splint. The straight position must be avoided, as in the event of ankylosis taking place the finger would be useless. If joint motion can be restored, efforts in this direction must be made by resorting to active and passive motion as soon as the wound is healed.

Resection of Wrist-joint.—Bourgery resects the wrist-joint through two lateral incisions; von Langenbeck through a straight dorsal incision over the middle of the joint; and Lister through two dorsal incisions, one on the radial, the other on the ulnar, side. If the disease for which the resection is made has resulted in the formation of fistulæ, those are often taken as a guide for the incisions.

Perhaps the best incision so far devised for resection of the wrist-joint is the one described by Kocher. With the hand slightly flexed toward the radial side, an incision four inches in length is made from the middle of the interspace between the fourth and fifth metacarpal bones, over the middle of the joint on the dorsal side, obliquely upward and toward the radial side. After cutting through the fascia and the ligamentum carpi dorsale, the joint is reached between the tendon of the extensor communis and extensor of the little finger, when the capsule of the joint is opened at the base of the fourth metacarpal bone. After detaching the extensor ulnaris tendon from the fifth metacarpal bone and lifting from its groove in the ulna the extensor tendon of the little finger, the soft tissues are retracted and the joint is entered between the pisiform bone and the lunatum,

leaving the tendinous insertion of the flexor carpi ulnaris with the latter bone intact. The tendon of the flexor carpi radialis is not detached from the second metacarpal bone, but the tendon of the supinator longus is severed from the styloid process of the radius. The hand is now dislocated by bending it forcibly in the direction of the radius and the flexor side. The radiocarpal joint now comes into full view, and the diseased carpal bones and articular ends of

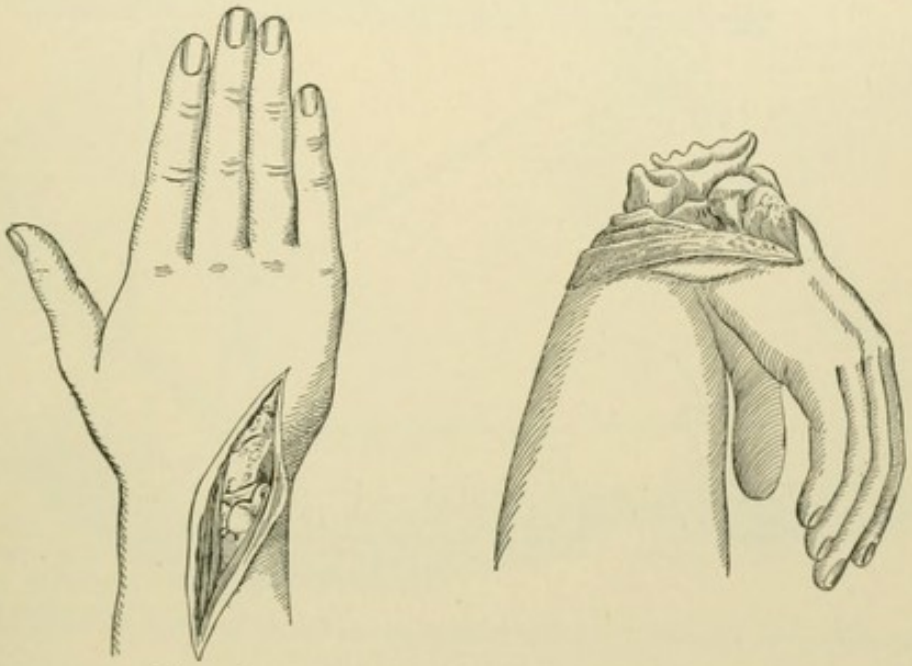

Fig. 578.—Resection of wrist-joint (after Kocher).

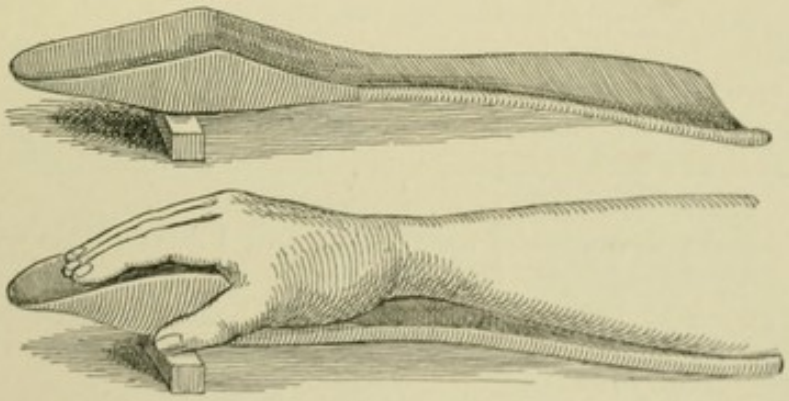

Fig. 579.—Lister's splint for resection of wrist-joint.

the radius, ulna, and metacarpal bones can be removed without any difficulty. After the resection has been completed and hemorrhage arrested, the hand is brought in a straight position and the exposed tendons are covered by suturing the deep fascia over them with fine catgut. The hand must be dressed in the extended position with the fingers flexed, and immobilized upon a well-padded anterior splint. The splint should reach only as far as the base of the fingers, as stiffness of the fingers can be prevented only by early

passive and active motion. The hand must be kept in the extended position for several weeks and sometimes for several months, as the intrinsic tendency after resection of the wrist-joint is to progressive flexion. An anterior plastic splint extending from the bend of the elbow to the base of the fingers, and including the ball of the thumb, is the best means of fixation during the tedious after-treatment.

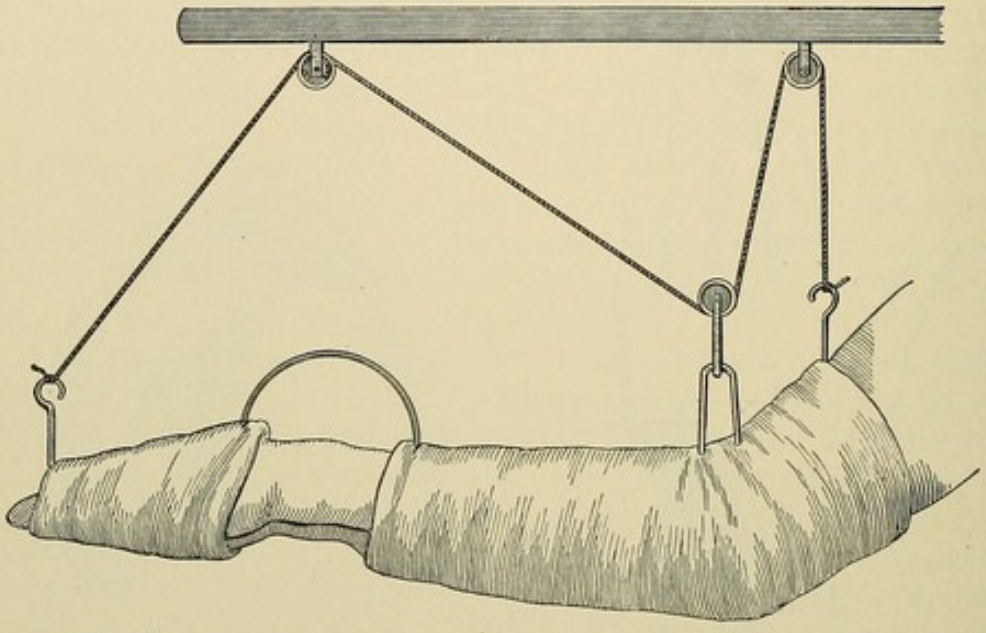

Fig. 580.—Von Esmarch's bracketed suspension splint for resection of wrist-joint.

Resection of the Elbow-joint.—Langenbeck's straight posterior incision is the one usually selected for resection of the elbow-joint with or without temporary resection of the olecranon process. In all cases in which it is not the seat of extensive disease this process should be temporarily detached, carefully preserved, replaced after the resection has been completed, and united with the shaft of the ulna.

In resection of this joint for tuberculosis I have frequently made a temporary resection of the olecranon, and when the articular surface was found diseased, it was removed with a saw, the remaining fragment being saved and utilized, the results being the best. If only the cortex to which the triceps tendon is attached can be saved, this should be done, as it affords, after nailing, the best anchorage for the important triceps muscle. The incision, at least five inches in length, is made equidistant between the epicondyles of the humerus, over the center of the olecranon process, and is continued down to the fascia of the triceps above and the olecranon process and ulnar ridge below the joint. In detaching the soft tissues from the posterior aspect of the joint, special care is necessary in lifting the ulnar nerve out of its groove and in retracting the tissues on that side with a blunt hook or retractor. After the base of the olecranon process has been reached, the arm is flexed,

the margins of the wound carefully retracted, and, with a Butcher's saw or chisel, an oblique incision, terminating on the articular side and base of the olecranon process, is made through the upper end of the ulna. The ligamentous connections of the olecranon are

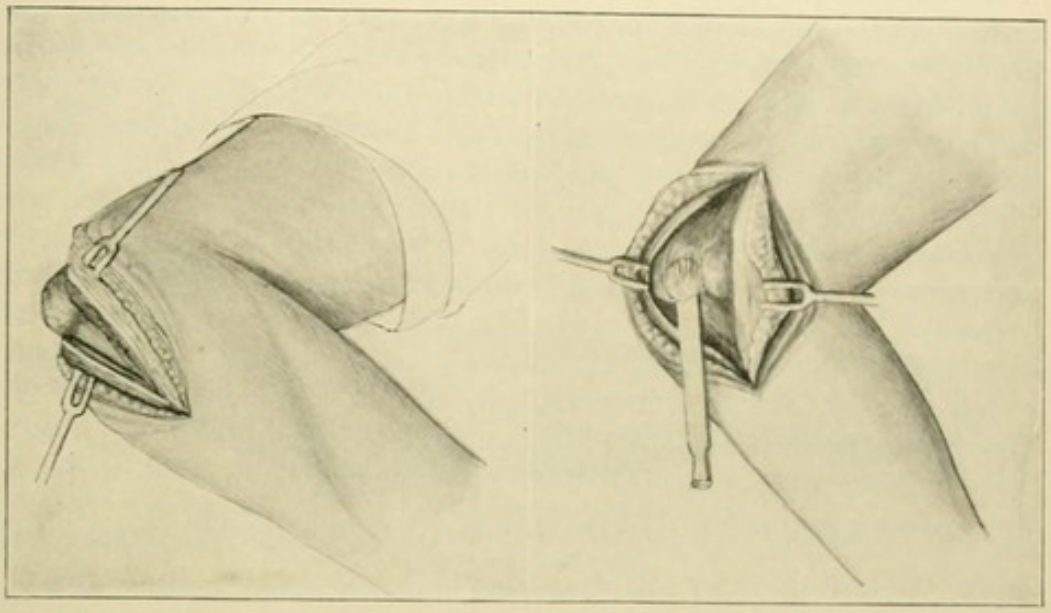

Fig. 581.—Dorsal vertical incision (Langenbeck) for resection of the elbow-joint, exhibiting olecranon and ulnar nerve in its groove.

Fig. 582.—Temporary resection of olecranon with chisel.

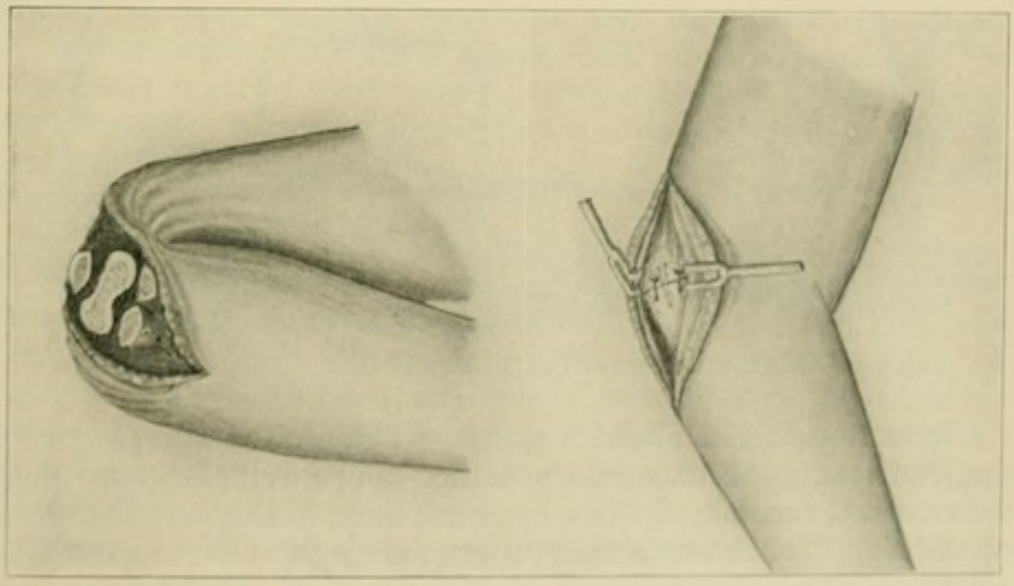

Fig. 583.—Resection completed.

Fig. 584.—Olecranon replaced and held in place by ivory nail and catgut sutures.

severed, after which it is reflected with the tendon of the triceps upward, whereupon the joint is fully exposed. The head of the radius and the articular ends of the ulna and humerus can be resected with saw or chisel without any difficulty by holding the arm in a hyperflexed position. After the resection has been com-

pleted and the hemorrhage arrested, the arm is extended and the olecranon fixed in position with an aseptic ivory nail. The periosteum should be sutured separately with catgut. The arm must be immobilized in a nearly straight position for three or four weeks, until the olecranon has united with the shaft of the ulna by bony callus. Later, flexion is gradually increased day to day until the arm is at a right angle, when active and passive motion is employed systematically and persistently to secure the desired range of joint motion. Electricity and massage will do much in aiding these efforts in the restoration of joint function.

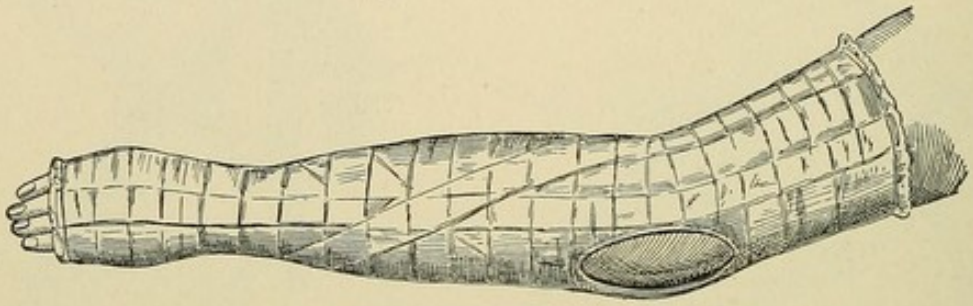

Fig. 585.—Fenestrated plaster-of-Paris suspension splint after resection of the elbow-joint (von Esmarch).

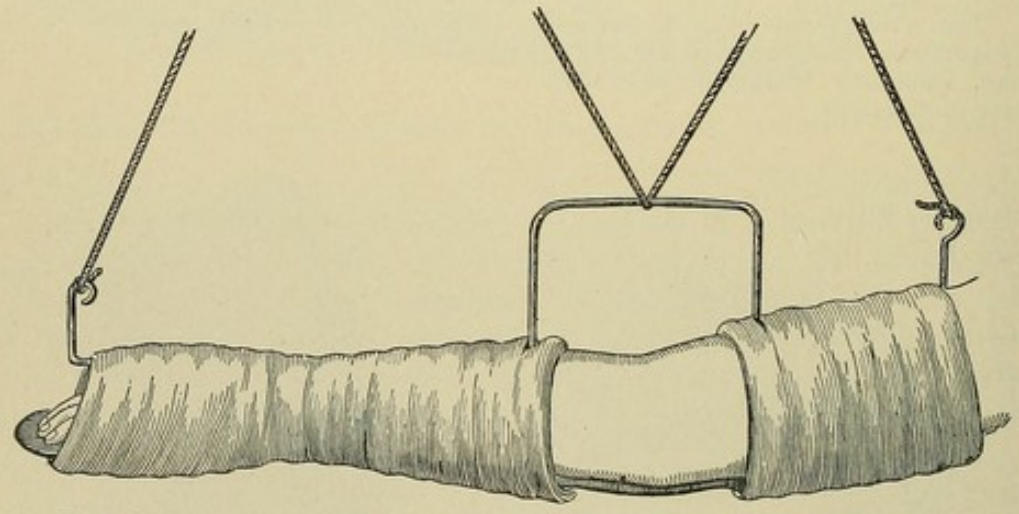

Fig. 586.—Bracketed plaster-of-Paris suspension splint (after von Esmarch).

Resection of the Shoulder-joint.—The progress of surgery of the joints during the nineteenth century can be well shown by giving a condensed account of what has been done in the past in the way of devising different anatomic routes for excision of the shoulder-joint.

Boucher removed parts of the shoulder-joint for gunshot wounds in 1753, and Thomas opened the joint for the extraction of necrosed bone in 1740. The first authenticated case of resection of the shoulder-joint was performed by Ch. White and not by Bent, as stated by Treves in his work on "Operative Surgery," volume 1, page 647. White ("Cases of Surgery," vol. 1) performed the operation in 1768; Bent, of Newcastle, in 1771, three years later.

White's patient was a boy of fourteen, who was the subject of acute suppurative inflammation of the shoulder-joint, terminating in the formation of an extensive abscess, which had discharged itself externally. The description of the operation, given by Mr. White himself, is interesting :

"I began my incision at that orifice which was situated just below the processus acromion, and carried it down to the middle of the humerus, by which all the subjacent bone was brought into view, then took hold of the patient's elbow and easily forced the upper head of the humerus out of its socket, and brought it so entirely out of the wound that I readily grasped the whole head in my left hand, and held it there till I had sawn it off with a common amputation saw, having first applied a pasteboard card betwixt the bone and the skin. I had taken the precaution of placing an assistant, on whom I could depend, with a compress just above the clavicle, to stop the circulation of the artery, if I should have the misfortune to cut or lacerate it ; but no accident of any kind happened, and the patient did not lose more than two ounces of blood ; only a small artery, which partly surrounds the joint, being wounded, which was easily secured."

The patient made a good recovery, and four months later left the infirmary completely cured, the functional result being excellent. Sequestration of the sawed surface of the humerus delayed the healing of the wound. Mr. White's example was followed by Bent in 1771 and by Mr. Orred, of Chester, in 1778. It appears, from the accounts we have of these operations, that the disease for which they were performed was really caries of the shoulder-joint, and that the patients retained limbs which, if not perfect, were at least extremely useful. Notwithstanding this encouragement to extend the practice, it seems to have been afterward treated in England with entire neglect.

In France Moreau the elder performed the operation successfully in 1786, and the army surgeons, particularly Banus, Percy, and Larrey, frequently resorted to it in recent gunshot wounds, instead of removing the limb. In Scotland the operation was revived by Mr. Syme in 1820, and was later performed by Babington, Liston, Baddely, Fergusson, Lawrence, Hunt, Coote, Hutchinson, Erichsen, Birkett, Stubbs, Blackman, and others. In Germany the first resection of the shoulder-joint was made by Lentin in 1771, and he was followed by Wutzer, Fricke, Jäger, Blasius, Textor, Dietz, Heyfelder, Langenbeck, Esmarch, Wilms, and Bartels.

The variety of incisions that have been devised for exposing the shoulder-joint with a view to resecting the head of the humerus is something remarkable. White's original incision was a straight one, extending from the acromion process downward through the center of the deltoid muscle. The same incision was practised by Virgarrus. The incisions of Larrey, Kern, Chassaignac, and Jäger are only slight modifications of White's incision. Baudens commenced

his incision just below the coracoid process of the scapula, and carried the knife along the groove between the pectoralis major and deltoid muscles to the groove for the biceps muscle. If this incision did not afford the necessary room for the removal of the diseased head of the humerus, he enlarged the wound by making two small transverse cuts (but only through the muscles) in a forward direction at each end of the vertical incision. Langenbeck's incision extends from the anterior border of the acromion process near the clavicular junction, in a vertical direction downward through the deltoid muscle, and is the incision that has usually been selected for resection of the shoulder-joint. Baudens' incision was somewhat modified by Malgaigne and Robert. Frank and Reid joined the upper end of the anterior vertical incision by a short transverse cut extending beneath the acromion process. Bouzairies joined two oblique incisions in the shape of the letter V, making a flap including the deltoid muscle, with its base directed upward. Bent made a long incision from the joint downward in the furrow between the pectoralis major and deltoid muscles, and as this did not afford enough room, he made two short transverse cuts, one meeting the upper end of the long cut dividing the clavicular attachment of the deltoid muscle, the other the humeral insertion of the pectoralis major, making thus a quadrangular flap with its base directed toward the body. Bell, Morel, and Guepratte made a semilunar incision with its base directed upward. Wattmann carried the knife from the posterior margin of the acromion process along the border of the deltoid to its insertion, and joined it by another incision extending from the tip of the coracoid process to the same point, making in this way a triangular flap that included the deltoid muscle. Sabatier's flap incisions are the same, except that the space included by the incision is smaller. The elder Moreau made a quadrangular flap with its base directed downward, while a similar flap, with its base in an opposite direction, was advised by Manne, Percy, the younger Moreau, Textor, and Jäger. Syme made a perpendicular incision from the acromion through the middle of the deltoid, nearly to its point of insertion, and then another one upward and backward, from the lower extremity of the former, so as to divide the external part of the muscle.

"The flap thus formed being dissected off, the joint will be brought into view, and the capsular ligament, if still remaining, having been divided, the finger of the surgeon may be passed around the head of the bone, so as to feel the attachments of the spinati and scapular muscles, which can then be readily divided by introducing the scapel first on the one side and then on the other. After this the elbow being pulled across the forepart of the chest, the head of the humerus will be protruded, and may then be easily sawed off, while grasped in the operator's left hand."

Albanese makes a posterior incision in the shape of an inverted L, commencing at the spine of the scapula, at the junction of this with

the acromion process, extending from above downward and forward to the head of the humerus, from where it is directed forward, terminating at the tuberculum majus. The muscles are separated with the periosteum, and through the wound the head of the humerus is removed. It is claimed that this incision has the advantage over other posterior incisions that it does not endanger the circumflex nerve. Ollier's incision extends from the outer border of the coracoid process of the scapula in the direction of the fibers of the deltoid muscle, obliquely outward and downward, a distance of four or five inches, to the shaft of the humerus, and is called the anterior oblique incision. Kocher's posterior curved incision is commenced over the acromioclavicular joint, extends over the shoulder-joint to the middle of the crista scapulæ, and is continued in a curved direction downward to the posterior fold of the axillary space. In Kocher's operation the acromion process is temporarily detached to furnish better access to the joint. Bardenheuer's incision passes directly over the acromion process, which is divided in the same line and temporarily detached.

The incision devised by me has these great advantages over Bardenheuer's, that the scar resulting from the operation is well protected by the prominence formed by the shoulder-joint, and at the same time secures free access to every part of the shoulder-joint and its immediate vicinity. The external incision is made so as to form an oval cutaneous flap, which is turned upward, exposing the upper half of the deltoid muscle (Fig. 587). It is commenced over the coracoid process, and is carried downward and outward in a gentle curve as far as the middle of the deltoid muscle, when it is continued in a similar curve upward and backward as far as the posterior border of the axillary space, on the same level where it was commenced—that is, a point opposite the coracoid. The semilunar flap is next dissected up as far as the base of the acromion process and reflected. The acromion process is detached with a saw and turned downward, with the deltoid muscle attached (Fig. 588). The capsule of the joint is now freely exposed. If the operation is performed for an irreducible dislocation of the shoulder-joint, the head of the humerus can now be located, the cause of resistance to reduction is sought for and removed or corrected, when the reduction can be accomplished by manipulation or by direct measures and manipulation. If the operation has for its object the removal of diseased tissue, the capsule is opened and the interior of the joint subjected to a careful examination, to determine the extent of the operation. If the disease is limited to the soft structures, a complete arthrectomy can be performed without sacrificing any portion of the bony constituents of the joint by dislocating the head of the humerus in different directions for the purpose of rendering the entire capsule accessible to the dissecting forceps, knife, and scissors. If the head of the humerus is sufficiently diseased to indicate a typical resection, it

should be removed as a preliminary step to the subsequent arthrectomy. The glenoid cavity is readily accessible, and should be

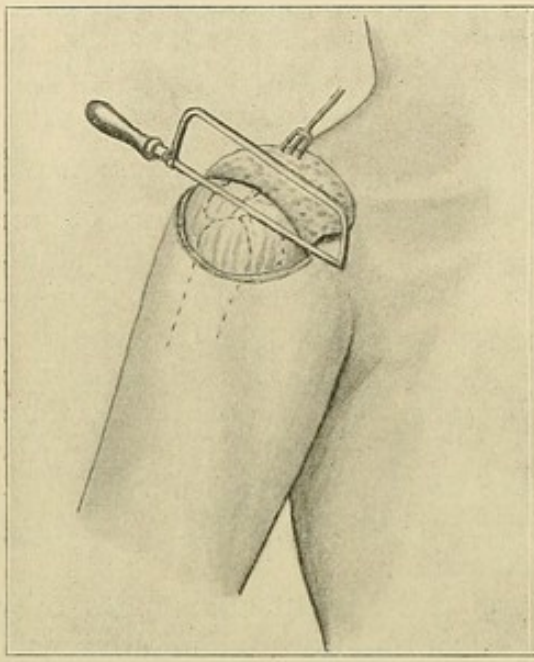

Fig. 587.—Senn's method of resection of the shoulder-joint. External incision, flap reflected, and saw applied over base of acromion.

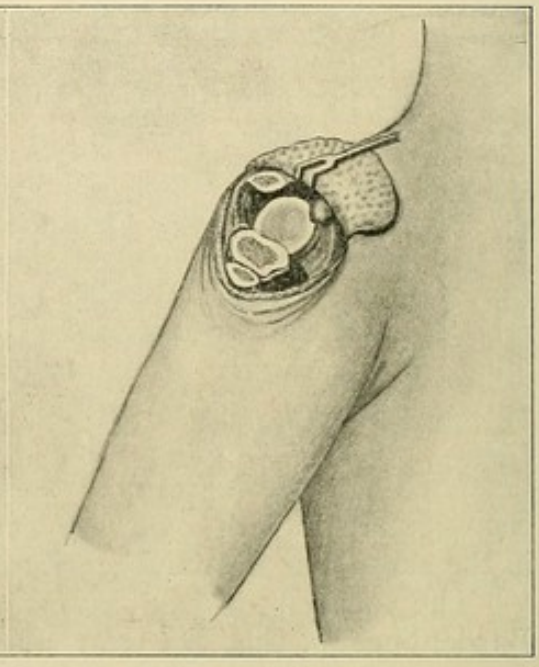

Fig. 588.—Temporary resection of acromion, which is reflected with the deltoid muscle downward. Head of humerus resected.

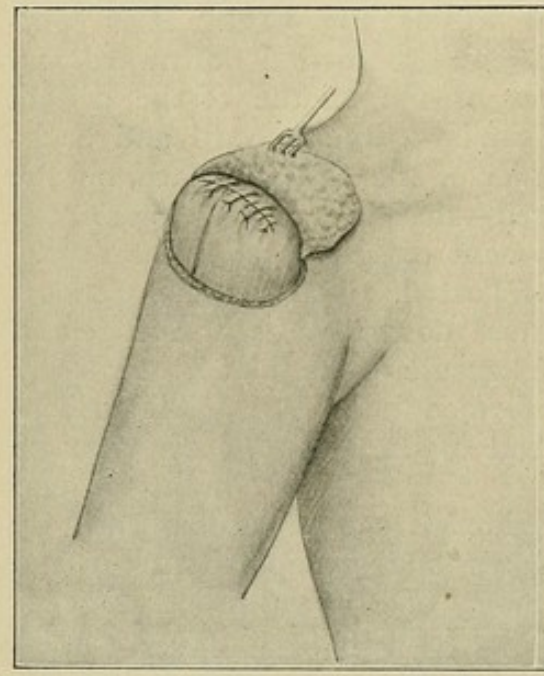

Fig. 589.—Temporarily detached acromion replaced and fastened in position with strong catgut sutures.

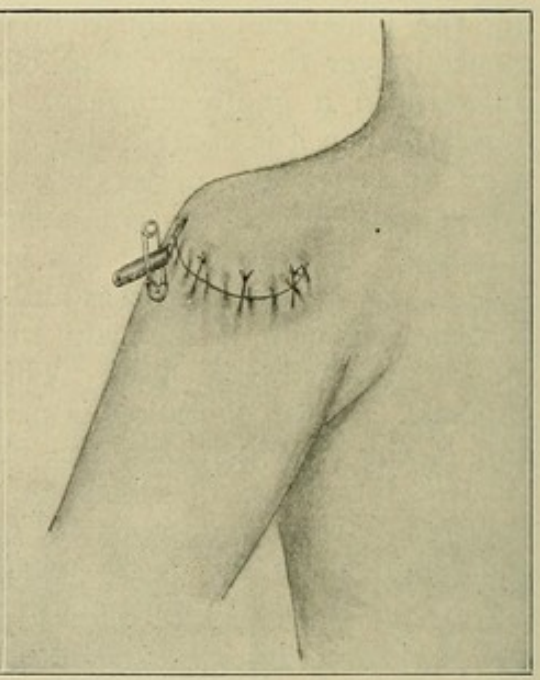

Fig. 590.—Operation completed.

dealt with in accordance with the existing pathologic conditions. After the removal of all diseased tissue and proper preparation of the wound, the acromion process is replaced and held in position

by two or three strong catgut sutures. Silver wire is seldom required in suturing a temporarily detached bony prominence in operations upon the different joints. The catgut sutures hold the fragment long enough in place for bony union to occur. Drilling of the bone ends is unnecessary, as the sutures gain a sufficiently strong hold by including the periosteum and the paraperiosteal structures. In operating upon the shoulder-joint for disease, through tubular or capillary drainage should be established and

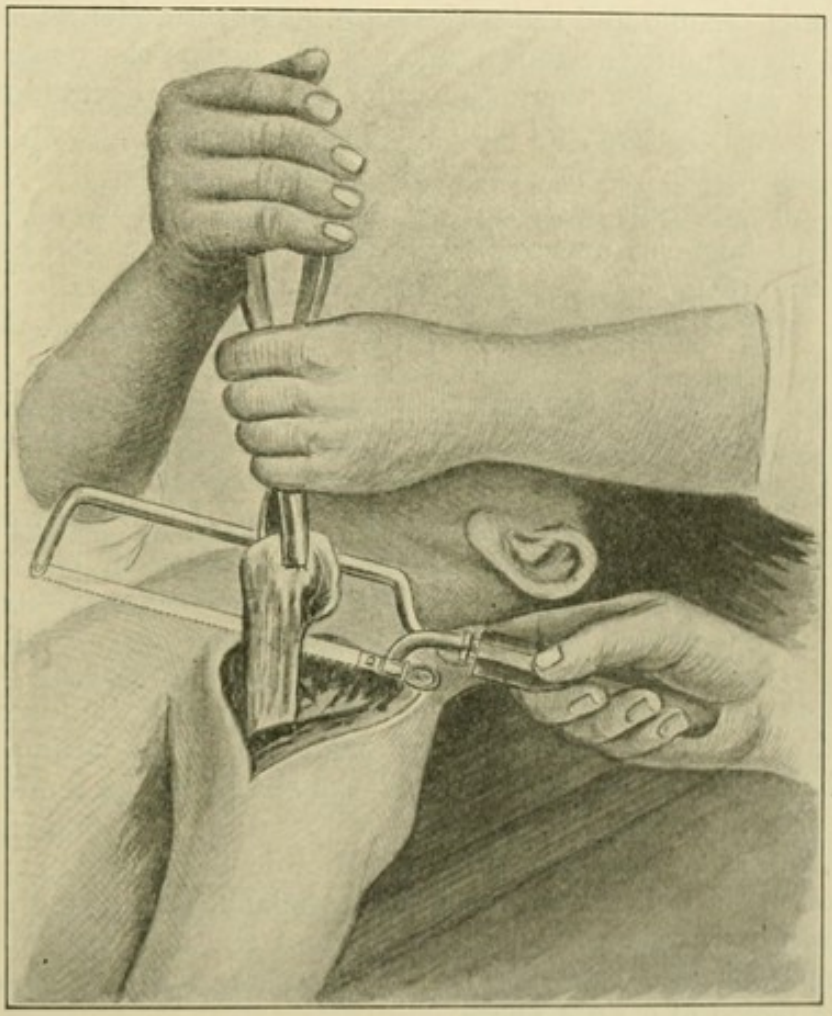

Fig. 591.—Resection of the shoulder through Langenbeck's anterior incision. Division of the humerus with the saw. The head of the bone is fixed by means of Langenbeck's forceps (Zuckerkandl).

continued for two or three days. The divided portion of the deltoid muscle is sutured separately with catgut, when the cutaneous flap is brought down in position and sutured in the usual manner.

In operations for irreducible dislocation drainage is not required and primary healing of the deep and superficial wounds should be aimed at by careful hemostasis and suturing. After applying a copious hygroscopic aseptic dressing, the arm should be immobilized against the side of the chest with a few turns of the plaster-of-Paris bandage. The operation as described, undertaken for the

reduction of an irreducible dislocation, arthrectomy, or resection for disease of the joint, does not involve any of the important tendons, muscles, vessels, or nerves, and for this reason a good functional result may be confidently expected.

The usual method employed for resection of the shoulder-joint is by von Langenbeck's anterior incision. The incision is commenced at the anterior border of the acromion, near its articular junction with the clavicle, and is carried from four to six inches directly downward, extending through the deltoid muscle down to the fibrous capsule and the periosteum. On retraction of the margins of the wound the long tendon of the biceps can be seen in its groove. An incision along the outer border of the tendon opens its sheath, which, together with the capsule of the joint, is then laid open as far as the acromion process. The tendon is lifted out of its groove with a blunt hook and drawn outward. While an assistant rotates the humerus outward, the capsule of the joint and the insertion of the tendon of the subscapular muscle are severed. The arm is then rotated inward, and the tendon of the biceps is displaced inward.

The next step of the operation consists in dividing the tendons of the supraspinatus, infraspinatus, and teres minor muscles close to their insertion into the greater tuberosity of the humerus. The head of the humerus is then dislocated forward into the wound by pressure from behind, and is secured with a grasping forceps, after which, the balance of the capsule being divided, it is removed with a chain or metacarpal saw. If the resection is made for an infected comminuted fracture involving the head of the humerus, all the loose fragments are extracted with sequestrum or hemostatic forceps, and the end of the bone is properly trimmed with bone-cutting forceps. After hemorrhage has been arrested, the sheath of the tendon of the biceps should be sutured separately with catgut. If drainage is required, a tubular drain reaching from the glenoid cavity to the lower angle of the wound should be used, the balance of the wound closed by suturing, a large dressing applied, and the arm well supported and immobilized by bandaging it to the side of the chest with the forearm flexed at a right angle.

Resection of the Metatarsophalangeal Joint of the Big Toe.—Resection of this joint for disease, injury, and hallux valgus is a legitimate operation and yields excellent functional results. The joint is approached through a straight incision half-way between the extensor tendon and the most prominent part of the head of the metatarsal bone. With knife and periosteal elevator all the soft tissues are detached from the head of the metatarsal bone, and the joint freely opened by a transverse incision, when, by bending the toe toward the plantar surface and outer margin of the foot, and with the aid of the periosteal elevator, the head of the metatarsal bone is made accessible for the metacarpal saw. In operations for hallux valgus the entire head of the bone is removed by

making a transverse section through the bone above it. The articular surface of the proximal phalanx is left intact, as by doing so joint motion is preserved. After suturing the wound and applying the usual aseptic dressing, the toe is immobilized by an inside splint, including the inner border of the foot, or by a light plaster-of-Paris splint. In resections of this joint for tuberculosis, the head of the metatarsal bone is excised first, after which the articular end of the proximal phalanx is removed with bone-cutting forceps, the entire capsule of the joint then being made easily accessible for a complete arthrectomy.

Resection of the Ankle-joint.—Tuberculosis, suppurative panarthritis, infected compound fractures, and aggravated cases of equinovarus are the usual indications for resection of the ankle-joint. Typical resection, including the malleoli, the articular surfaces of the fibula and tibia, and the entire astragalus, is seldom performed at the present time. The modern methods of ankle-joint resection have in view the removal of diseased and the preservation of healthy tissue.

The ankle-joint is so constructed that it is somewhat difficult of access without dividing important structures or removing some of its bony constituents, the preservation of which would materially improve the functional result. To overcome the difficulties in the way of gaining free access to this complicated joint Hueter proposed to divide all the tendons, vessels, and nerves by an anterior incision from one malleolus to the other, reuniting the tendons and nerves by suturing after the excision. This incision, as well as a similar posterior incision proposed by another surgeon, has never been employed to any extent, as both inflict too much injury to important structures that should be carefully preserved. A wedge-shaped excision of the tarsus for the correction of bad cases of equinovarus can be made through a lateral incision on the fibular side without sacrificing any important muscular insertions or cutting any of the principal vessels or nerves.

In resections for any other indication the ankle-joint can be made accessible for all practical purposes by making two lateral incisions, one over the internal and the other over the external malleolus. Langenbeck makes the fibular incision in the form of a hook by starting it at the posterior border of the bone, four inches above the tip of the malleolus, following the border of the fibula, and cutting around the margin of the malleolus to its base in front. On the inner side he makes a crescent-shaped incision corresponding with the lower margin of the malleolus. This he joins by a straight incision over the middle of the tibia, giving to the incision the shape of an anchor. Through these incisions the malleolus can be excised, after which the ankle-joint is freely exposed to sight and touch for the remaining steps of the operation. In all resections of the ankle-joint the chisel should take the place of the saw, as its use inflicts less violence on the soft tissues; moreover, the bones,

from the effects of disease and nonuse, have usually become osteoporotic to an extent sufficient to permit their ready cutting with this instrument.

Reverdin and Kocher resect the ankle-joint through a large external lateral incision (Fig. 592). The knife is carried on a level with the ankle-joint, from the outer margin of the extensor muscles in a curve over the external malleolus as far as the tendo Achillis. After dividing the fascia, the extensor tendons and the tendon of the

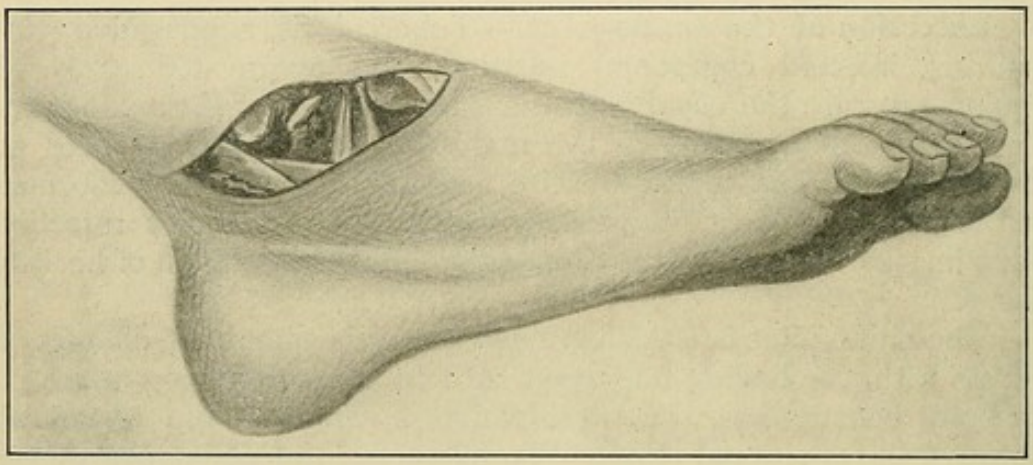

Fig. 592.—Resection of the ankle-joint by the method of Reverdin-Kocher; exposure of the ankle-joint from its outer aspect (Zuckerkandl).

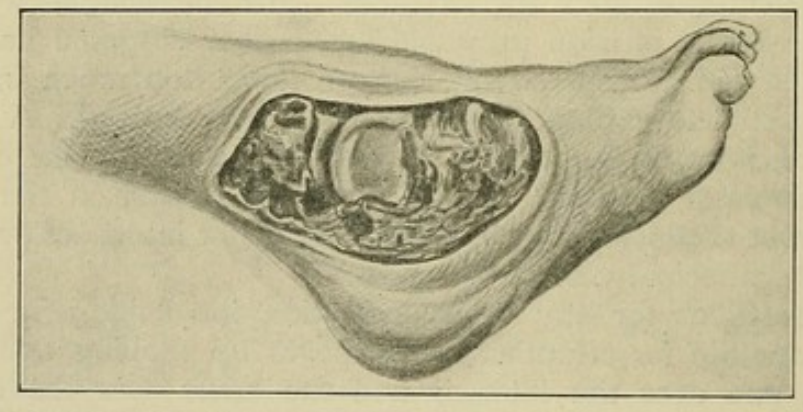

Fig. 593.—First stage of rotation of the foot at the ankle-joint about the inner malleolus (Zuckerkandl).

peroneus tertius are retracted toward the tibial side. The capsule and ligaments are detached from the anterior margin of the tibia and fibula and the margin of the malleolus. The sheath of the peroneal muscles is laid open widely, and the tendons are lifted out of their groove and drawn backward with a blunt hook; if this does not procure enough space, they are divided and, after the excision, united by tendon suture. All the soft structures in front of the joint capsule and sheath of the extensors are next separated as far as the internal malleolus, when the ankle-joint can be readily dislocated by

forcibly bending the foot toward the tibial side. If the ligaments are now carefully detached from the margins of the internal malleolus, the joint is freely exposed to inspection and touch, and the resection can be made to the extent indicated by the revealed conditions.

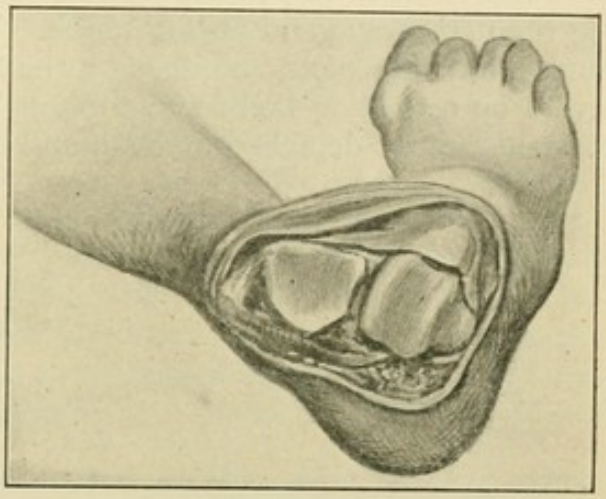

Fig. 594.—Completed rotation; the lower extremities of the tibia and the fibula, as well as the trochlea of the astragalus, are completely exposed (Zuckerkandl).

For several years I have resorted to temporary resection of the malleoli as a preliminary step to resection of the ankle-joint. The malleoli with the overlying soft tissues are temporarily resected in the form of a flap that is reflected downward, the ligaments attached acting like a hinge. The incision is made in the form of a horseshoe, the center of which corresponds with the base of the malleolus, and the bars with the anterior and posterior borders. With a thin chisel the base of the malleolus is cut through on a level with the articular surface of the bone, when the flap is turned down, opening

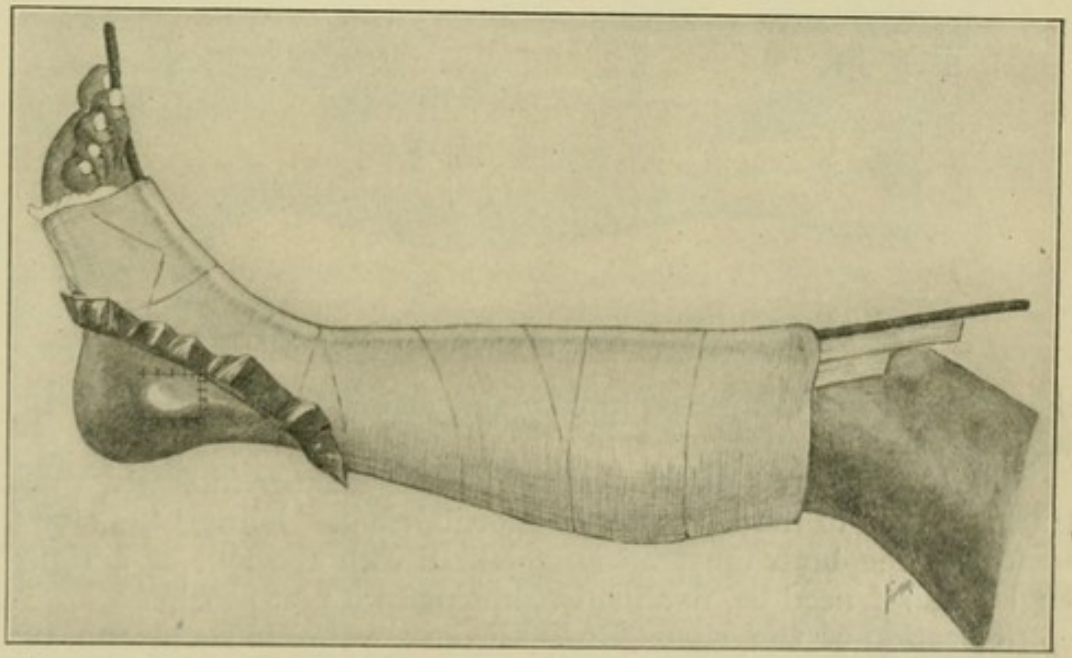

Fig. 595.—Resection of ankle-joint by temporary resection of malleoli. Fixation of joint after resection.

that side of the joint freely. Through such a trap-door incision the astragalus can be removed without any difficulty by fragmenting it

with a chisel. If a complete arthrectomy is necessary, both malleoli are temporarily resected. If the cartilages of the malleoli are affected, they are removed with the sharp spoon or chisel. After the resection or arthrectomy has been completed, the flaps are replaced and the malleoli fixed in position by two or three catgut sutures, including the periosteum and fibrous tissue. The peroneal tendons on the fibular, and the flexor tendons on the tibial, side are carefully protected by retracting them with a blunt hook. Bony union between the temporarily detached malleoli and the articular extremity of the

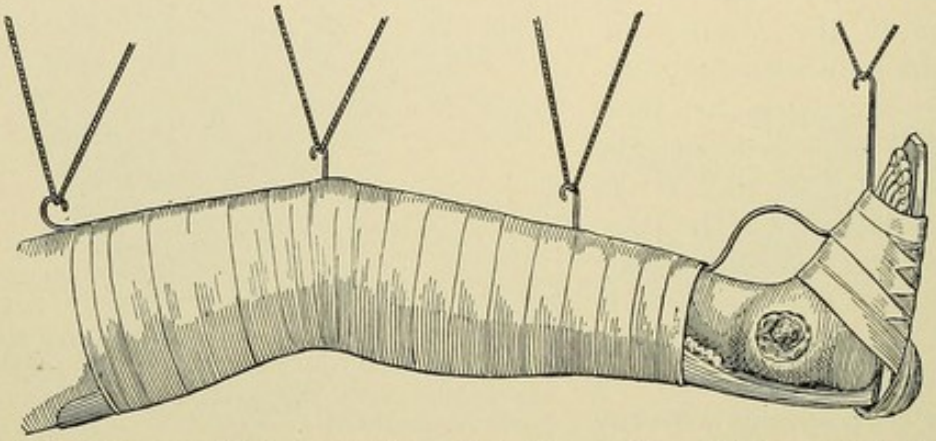

Fig. 596.—Plaster-of-Paris suspension splint for resection of the ankle-joint (after von Esmarch).

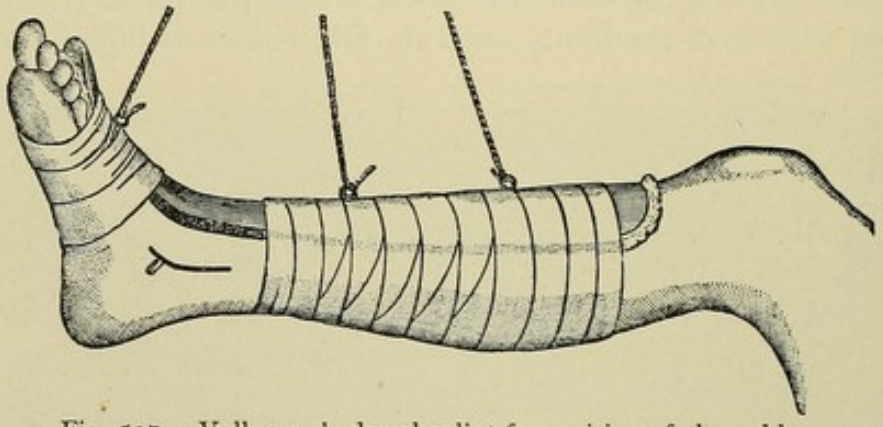

Fig. 597.—Volkmann's dorsal splint for excision of the ankle.

tibia and fibula takes place rapidly and satisfactorily, provided the wound remains aseptic.

The preservation of the malleoli in the manner indicated contributes much to the ultimate functional result. During the after-treatment the limb must be immobilized with the foot at a right angle, and, if need be, fixation is combined with suspension.

Resection of the Knee-joint.—From a technical standpoint, of all the large joints, the knee-joint presents the fewest difficulties to the operator in performing either arthrectomy or resection. Many are the incisions that have been devised to render the knee-joint accessible to direct operative treatment. Textor made an anterior curved incision with the convexity directed downward; Hahn

reversed the direction of the curve, cutting through the tendinous insertion of the quadriceps extensor femoris muscle above the patella. Volkmann made a transverse incision over the center of the patella, dividing the patella on the same plane. Hueter advocated a straight internal lateral incision, while Langenbeck made a curved incision on the same side, with the concavity directed backward. Riedinger aimed to expose the knee-joint by a vertical median anterior incision, with resection of the patella into two equal lateral halves.

I have combined Hahn's superficial incision with Volkmann's method of sawing the patella transversely in the middle, and have come to the conclusion, founded on a somewhat extensive experience, that this method gives the freest access to all parts of the interior of the joint, and, at the same time, yields the best functional results. A curved incision is made from one epicondyle of the femur to the other, reaching as far as the upper border of the patella, and extending on the sides down to the bone and up to the extensor of the

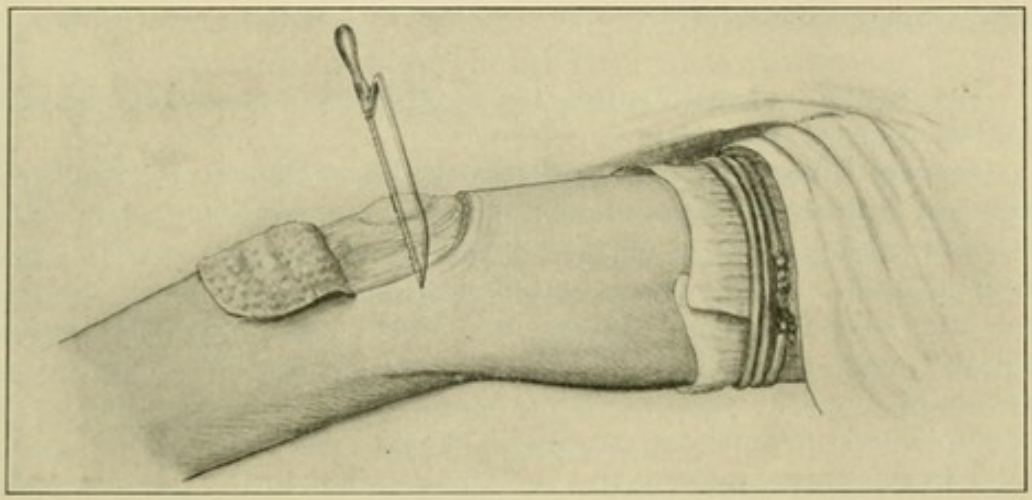

Fig. 598.—Resection of the knee-joint. Exposure of the patella by Hahn's incision. Saw in position for Volkmann's transpatellar incision.

quadriceps. The oval flap is next dissected as far as the patellar tendon and reflected downward. With an amputation saw the patella is then divided transversely in the middle, and the lower fragment, together with the cutaneous flap, turned down as far as the insertion of the tendon of the patella. The upper fragment, with the extensor quadriceps muscle, is turned in an upward direction as far as the upper limits of the synovial recess. If the capsule is much thickened, a vertical incision on each side of the patellar fragment, extended as far as the point of reflection, will facilitate the exposure of the entire recess. The ligaments of the joint on each side are freely divided when the leg is acutely flexed, bringing the synovial sac and all its recesses within the reach of sight and touch.

In operations for tuberculosis the next step of the operation consists in excising the diseased synovial membrane and capsule with dissecting forceps, knife, and scissors. The recesses behind

the head of the tibia and the condyles of the femur require special attention in performing this part of the operation. In atypical resection the osseous foci are sought for and removed with the sharp spoon or gouge and hammer. Before suturing the wound, such cavities must be thoroughly cleansed by mopping with iodoform gauze sponges, iodoformized, and packed with decalcified bone chips.

In 1889 I made numerous experiments concerning the utility of decalcified bone chips in the healing of aseptic bone cavities, and the results obtained were entirely satisfactory. The clinical experience for a period of ten years has more than realized all expectations. A *sine qua non* for success is asepticity of the cavity. The most favorable cases for this procedure are bone tuberculosis without mixed infection, circumscribed osteomyelitis, and small cavities after sequestrotomy.

The same procedure in the form of discs or plates has also proved very successful in the treatment, primary or secondary, of large cranial defects.

The directions for preparing the decalcified bone and for its implantation are as follows:

General Directions for Treatment of Bone Defects by Implantation of Antiseptic Decalcified Bone.—*1. Decalcification and Disinfection of Bone.*—A fresh tibia of an ox is the best material for decalcification. The bone is cut in sections two inches in length, and, after carefully removing the medullary tissue, is kept in dilute muriatic acid, the fluid being changed every few days until the process of decalcification has been completed. After this has been accomplished the bone can readily be cut into pieces about one millimeter in thickness, making the sections parallel to the long axis of the bone. The acid is then removed by washing and by keeping the bone immersed in a weak solution of caustic potash. The bone is then rendered antiseptic by keeping it until needed in a solution of sublimate in alcohol 1 : 500, in a wide-mouthed bottle that is kept hermetically sealed by a glass stopper to prevent evaporation of the solution. When the bone is needed, it is taken from the bottle and placed in a 5 per cent. solution of carbolic acid or a weak solution of sublimate. In making the plates or discs for filling a cranial defect the bone is cut so as to correspond in thickness to the bone removed, and accurately to fit into the opening. A number of small perforations in the disc or plate should always be made, as through these openings the space underneath the bone is kept drained; at the same time the early entrance of granulation tissue into these openings effects fixation of the bone *in situ*, and favors the early removal of the implanted substance by substitution with permanent living tissue. Before implantation both sides of the plate should be dusted with iodoform. For packing bone cavities the decalcified bone should be cut in thin slices or chips, which should be laid upon

a compress of aseptic gauze, so as to remove the surface moisture, when they are dusted with iodoform before they are implanted into the cavity. Aseptic decalcified bone drains, in the absence of more suitable material, can be used in packing bone cavities.

2. *Asepsis at the Seat of Implantation.*—The most essential condition for success in the treatment of bone defects by implantation of decalcified bone is a perfectly aseptic condition of the tissues to be brought in contact with the implanted bone. This condition is easily procured in operations on bones for lesions other than those caused by infection with pus-microbes, such as tumors, parasites, and tuberculous and syphilitic affections uncomplicated by suppuration. In the surgical treatment of these affections, after the removal of the diseased tissue the seat of operation must be aseptic if the ordinary precautions for the prevention of infection from without have been observed. In such cases speedy healing of the external wound and the early partial or complete reproduction of the lost bone are assured.

The next most favorable cases for bone implantation are circumscribed osteomyelitic processes in the epiphyseal extremities of the long bones, as we observe them in cases of primary circumscribed epiphyseal osteomyelitis, or in the form of a recurring attack in the same place, perhaps years after a diffuse osteomyelitis of the entire shaft. Under such circumstances the inflammatory focus can be located externally by the presence of a circumscribed area of tenderness, the tender spot constituting the guide in the search for the abscess. The seat of inflammation is freely exposed with a chisel, and the walls of the abscess cavity are scraped out with a sharp spoon until healthy tissue is reached all around. The precaution should be taken to wash out the cavity with an antiseptic solution before attacking the abscess wall, so as to prevent the contamination of the healthy tissue with the products of the infection by the mechanical diffusion of the pus-microbes. For the final disinfection of such a cavity a strong solution of sublimate is used, and, after thoroughly drying its walls, it is dusted with iodoform. Iodoformization of the cavity and the implantation of antiseptic bone chips are measures well calculated to resist the pathogenic action of pus-microbes that might still remain, and, in the majority of cases, will secure an aseptic healing of the wound.

This method of treating bone cavities is also applicable after operations for necrosis resulting from a previous attack of acute suppurative osteomyelitis. With a view to obtaining an aseptic condition of the cavity it is necessary that the line of demarcation between dead and living tissue should have formed, the involucrum must be well developed, and the soft parts in a healthy condition. The operation that precedes the implantation must accomplish more than the simple extraction of the necrosed bone: it implies the removal of all infected tissue lining the interior of the involucrum and the fistulous tracts in the soft tissues. The involucrum must

be laid open with the chisel sufficiently to expose to sight and direct treatment its entire interior for the purpose of removing with the sharp spoon all the infected granulations; at the same time the fistulous tracts in the soft tissues must be made accessible to the same treatment. After the thorough mechanical removal of all infected tissues the wound surfaces must be irrigated freely with a hot solution of sublimate, and for final disinfection a 12 per cent. solution of chlorid of zinc may be applied with a brush, after which the cavity is flushed again, dried, and iodoformized. In operations for acute diffuse osteomyelitis all known surgical resources are inadequate in rendering the field of operation aseptic, and hence implantation with decalcified bone is contraindicated.

3. Necessity of Performing the Operation by Bloodless Method.—I have previously made the statement that in the implantation of a disc or plate of bone into a defect in the skull the hemorrhage from the brain and its coverings should be carefully arrested before the implantation is made, as otherwise compression of the brain might arise from accumulation of blood underneath the implanted bone. The disc or plate may be relied upon in arresting hemorrhage from the vessels in the bone that other measures have failed to control. In the treatment of bone cavities in regions where it is possible to render the operation bloodless by elastic constriction this should always be employed, as it prevents unnecessary loss of blood during the operation and enables the surgeon to resort to means and measures for procuring an aseptic condition, which otherwise it would be impossible to apply with the same degree of thoroughness and efficiency. Unless special indications present themselves, the elastic constriction is continued until after the dressing has been applied.

4. Implantation.—In the treatment of a bone cavity by implantation with decalcified bone, the chips are poured into the cavity and are packed quite firmly until the surface of the cavity is reached. The bone chips act as an antiseptic tampon, arresting the free oozing from the surface of the bone, which always takes place after the removal of the constrictor. Some blood escapes between the bone chips and coagulates at once, thus forming a desirable and useful cement substance, which permeates the entire packing and temporarily glues, as it were, the chips together and the entire mass to the surrounding tissues.

5. Treatment of External Wound.—The periosteum should be carefully preserved in exposing the bone, and, after the implantation, is sutured over the surface of the bone chips with catgut sutures. If the bone is deeply located, it may become necessary to apply another row of buried sutures in bringing into accurate apposition other soft parts. The skin is finally sutured with silk. It is of great importance to secure accurate apposition of the divided soft parts in order to preserve for the subjacent bone all its natural coverings.

6. Drainage.—In some instances it would be undoubtedly superfluous to secure any form of drainage, as when the cavity is perfectly aseptic and hemorrhage is not in excess of requirements, healing of the entire wound would be accomplished under one dressing. Experience, however, has taught me that tension arising from extravasation of blood often exerts an injurious influence upon the process of healing and should be carefully avoided. As it is desirable to heal as much of the wound as possible without interfering with drainage, I have invariably introduced an absorbable capillary drain in the lower angle of the wound. A string of catgut twisted into a small cord answers an admirable purpose.

7. Dressing of Wound.—The wound is covered with a strip of aseptic silk over which a few layers of iodoform gauze are applied. Over this a cushion of sterile gauze is placed with a thick layer of salicylated cotton along its margins, for the purpose of guarding more securely against the entrance of unfiltered air; the whole of it is retained by a circular bandage of gauze evenly and smoothly applied. For the purpose of securing absolute rest for the limb it is placed upon a posterior splint and kept in a slightly elevated position. If no indications arise, the first dressing is not removed for two weeks, when the entire wound will usually be found healed, except a few granulations at the place where the catgut drain was inserted. A smaller antiseptic compress is applied, and the limb dressed in a similar manner. It is advisable to enforce rest not only until the external wound has healed, but until the whole process of repair has been completed, which embraces a period varying from four weeks to three months, according to the size of the cavity and the age of the patient.

8. Secondary Implantation.—If an operation is followed by suppuration the result of imperfect antisepsis, tubular drainage must be established and the same treatment pursued as in suppurating wounds. If suppuration takes place soon after the operation and is profuse, it is probable that all the bone chips will be lost. If it develops after granulation tissue has had time to form and the purulent discharge is moderate in quantity, the prospects are that the bone will remain and serve its purpose as a nidus for the granulation tissue. In such cases an antiseptic irrigation should be made every three or four days until suppuration has ceased. If the bone chips are lost by suppuration or have to be removed for the purpose of a more thorough disinfection of the cavity, no attempt should be made at reimplantation until suppuration has been arrested, or, in other words, until the cavity has become lined with granulations and is in a comparatively aseptic condition, when the time for secondary implantation has arrived. After the cavity has been irrigated with a strong antiseptic solution, it is dusted with iodoform and the granulations are scarified in a number of places for the purpose of obtaining a sufficient amount of blood to fill the spaces between the bone chips, which are implanted in the same manner as

in the treatment of a recent cavity. Complete closure of the external wound under these circumstances is seldom obtainable, and the surface of the exposed portion of the cavity should be provided with a thin layer of Schede's moist blood-clot. The antiseptic properties of the material used in packing the cavity exert a potent influence in maintaining asepticity after secondary implantation.

If it is the object of the operation to make a typical resection, the articular surfaces are removed on both sides and the sections through the bone made in a slightly oblique direction, so that when the resected ends are brought in contact, the leg will be slightly flexed. Fenwick, of Canada, makes the sections through the bone in such a way that when the surfaces are brought in contact antero-posterior displacement can not take place—that is, the resected surface on the femur side is made convex, and on the tibial side concave. A bow with a scroll saw is the best instrument for making such curved incisions in bone. Kocher and Helferich have described the same method of dealing with the bone-ends, but the credit of utilizing the sawn surfaces as means of fixation belongs to Fenwick. Fixation by the use of silver-plated stout nails driven through the skin and the resected ends, as suggested by Hahn, is superfluous, as adequate fixation can be secured by a well-fitting external support and the use of buried catgut sutures.

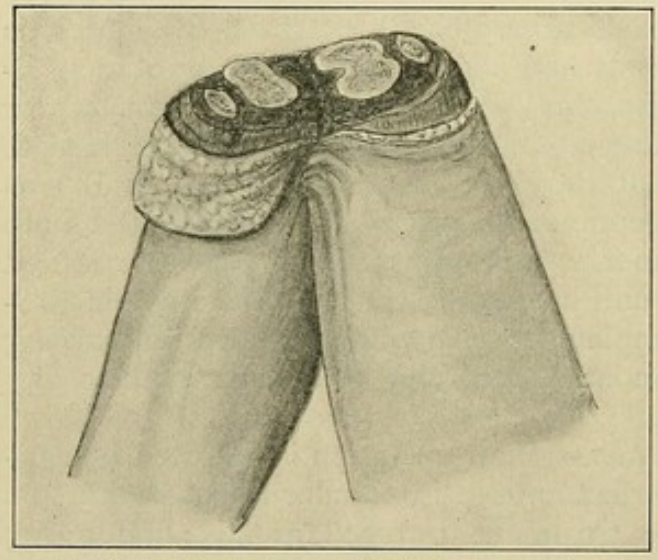

Fig. 599.—Typical resection of the knee-joint.

The most painstaking hemostasis must precede suturing of the wound. Parenchymatous oozing from the cancellated bone, often proving quite troublesome, usually yields promptly to the use of hot water and surface compression. The patella must invariably be preserved if it is not the seat of extensive disease. In operating for joint tuberculosis, in case the disease has disintegrated the cartilage, a thin slice is removed from its lower surface with the saw. Suturing of the patella with catgut suffices to hold the fragments in contact until bony union has taken place. I have never failed in obtaining bony union by suturing with catgut after resection of the knee-joint.

In suturing the patella, a large curved needle and the strongest catgut are used. The first suture is a broad mattress suture, embracing at two points the periosteum and tendinous portion of the quadriceps above, and the periosteum and fibers of the patellar

tendon below. A suture on each side of the patella with catgut of the same size and a few periosteal sutures of fine catgut inside of the mattress suture complete the direct fixation of the patellar fragments. On the sides of the joint the deep tissues are united with buried catgut sutures before the flap is replaced and sutured with silkworm-gut and horsehair. Drainage should be limited to the insertion of

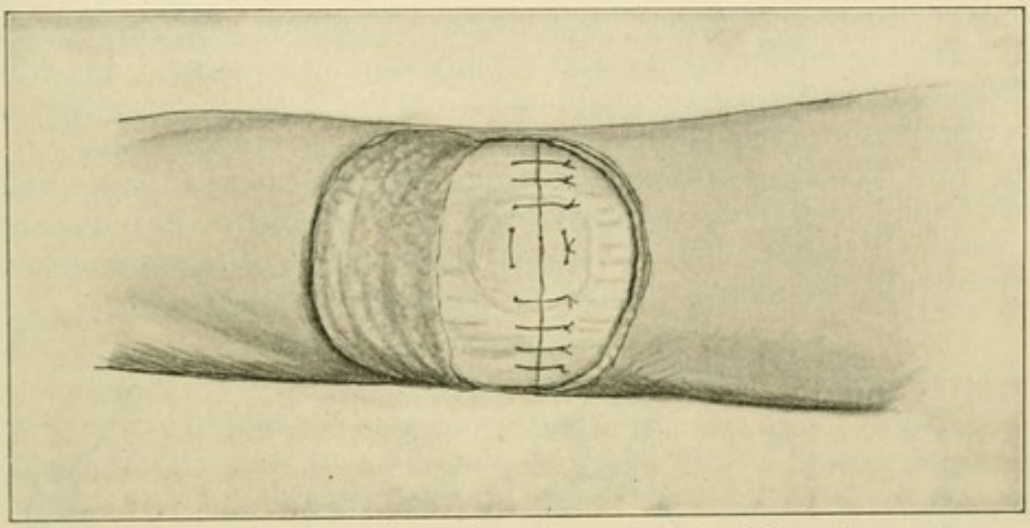

Fig. 600.—Suturing of the patella and capsule of the joint with catgut.

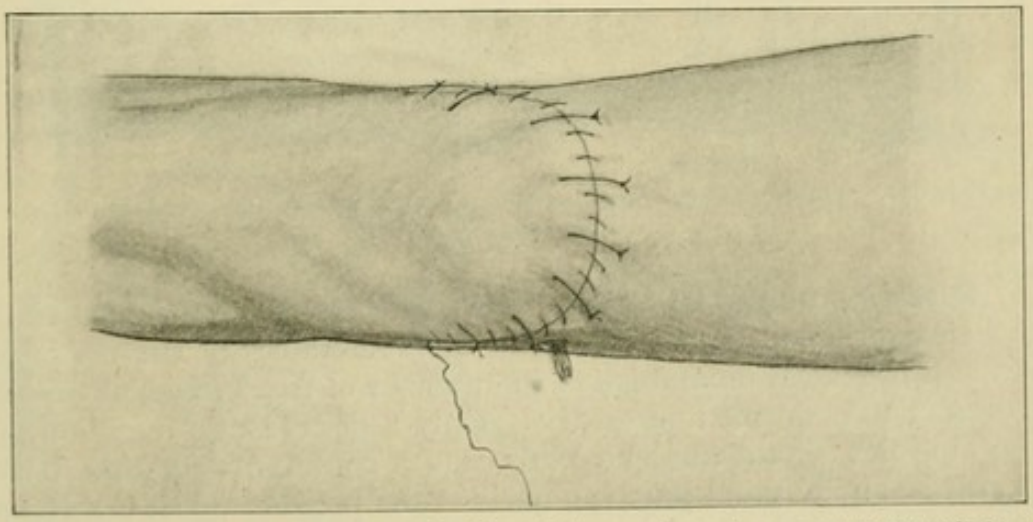

Fig. 601.—Operation completed. Capillary drainage through a separate buttonhole on tibial side, near the line of suturing.

a bundle of catgut into each angle of the wound or into a separate buttonhole.

During the suturing, dressing, and immobilization of the limb a reliable assistant must hold the leg and thigh in proper position. The dressing for the wound must be copious, and include at least one-half of the leg and thigh. A well-fitting hollow posterior splint, reaching from the tuberosity of the ischium to the heel, and supplied with a foot-board at a right angle, should be relied upon for at least a few days in immobilizing the limb. Later, a posterior

plaster splint will answer the purpose until the wound is healed, when a circular plaster-of-Paris splint should be applied and allowed to remain until the bony union is sufficiently firm to abandon any kind of external support.

Restoration of motion after arthrectomy is not only possible, but probable, but no attempts in this direction must be made until the patella has united by bony consolidation, which requires, under the most favorable conditions, from five to six weeks. The first efforts in restoring motion often demand the use of an anesthetic, and what little is gained must be maintained and increased by passive and active motion, systematic massage, and the use of electricity.

In a typical resection in children the epiphyseal cartilages must not be included in the excision, for, even if the operation prove successful, shortening of the limb will take place to an extent incompatible with walking without some kind of mechanical aid.

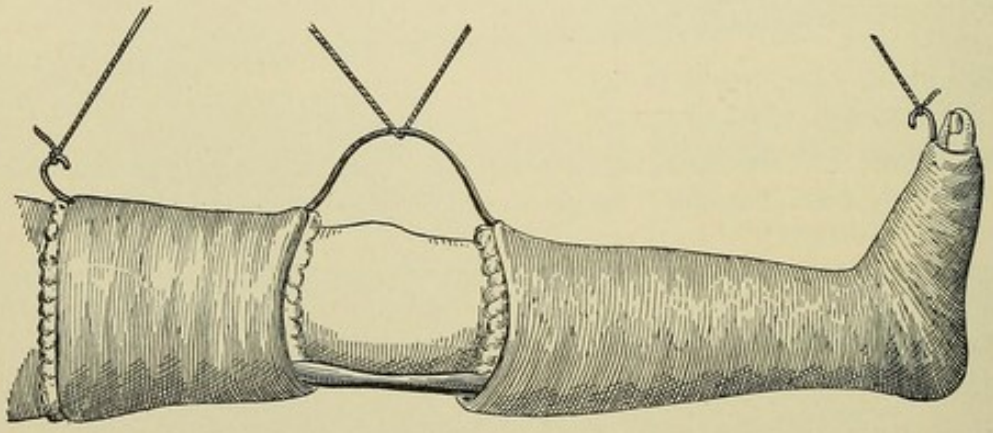

Fig. 602.—Plaster-of-Paris suspension splint for resection of the knee-joint, after Watson (von Esmarch).

Resection of the Hip-joint.—One of the striking indications of the progress made in the treatment of tuberculosis of the hip-joint is the progressive diminution of the number of cases in which resort to resection is deemed necessary. Only a decade ago resection of the hip-joint for tubercular coxitis was a common operation, both in private and hospital practice, while at the present time it is seldom witnessed, even in the large clinics. An immense experience has demonstrated that, on the whole, better results follow the conservative than the operative treatment. Rest in bed or fixation of the joint by an orthopedic appliance, intra-articular injections of iodoform glycerin emulsion, the internal administration of guaiacol, and a nutritious diet conscientiously and persistently carried out have been found so successful in the management of tuberculosis of the hip-joint that typical resection is seldom deemed necessary. Reduction of the irreducible dislocations of the hip-joint under pedantic aseptic precautions has become an established surgical procedure and has yielded the most gratifying results.

Resection is also indicated in acute suppurative synovitis, as a

primary affection or secondary to osteomyelitis of the upper end of the shaft of the femur; if suppuration does not yield to free drainage and antiseptic irrigation, or if the head of the femur has become separated in consequence of the inflammatory disease. Invasion of the hip-joint may also become necessary in ununited fracture of the neck of the femur in youthful patients, and for the removal of fragments in comminuted infected fractures of the joint. Ordinarily the great trochanter, the point of anchorage of most important muscles, is not damaged to any extent by the injury or disease that makes the operation necessary, and on that account should not be included in the resection. In all cases in which the hip-joint is approached by a lateral incision the trochanter major should be resected temporarily if it is not involved sufficiently to demand removal. It is in resections of the hip-joint that the important rule to limit the excision to useless or diseased parts is most frequently ignored. During the last eight years I have never found it necessary to remove the great trochanter in my operative work on the hip-joint, and I have become fully convinced that its preservation has contributed much to the functional result.

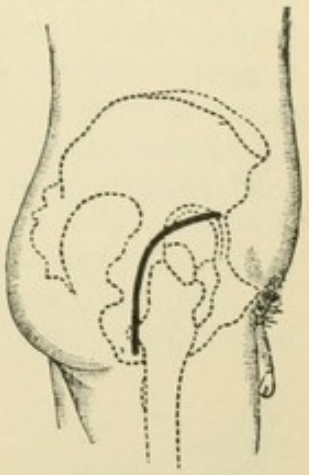

Fig. 603. — Resection of the hip-joint by the curved incision of A. White (Tillmanns).

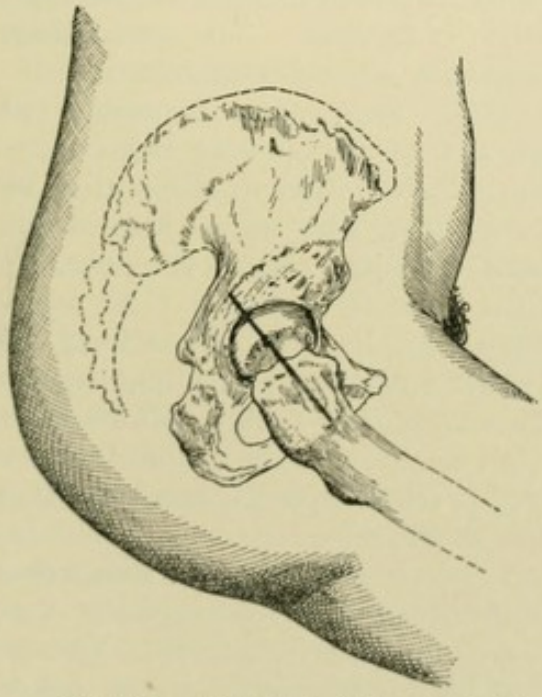

Fig. 604.—Resection of the hip-joint. Vertical incision, after von Langenbeck ("American Text-book of Surgery").

A number of incisions have been recommended for resection of the hip-joint. Anthony White favored a posterior curved incision; von Langenbeck made a straight incision over the center of the great trochanter, and Luecke, Hueter, and Schede recommended the anterior route. For resection of the hip-joint with temporary resection of the trochanter major White's incision deserves the first choice. The incision begins on a line with and half-way between the anterior superior spinous process of the ilium and trochanter major, passes over the most prominent point of the upper border of the trochanter, and follows the posterior border for a distance of three inches. The oval flap, including all the tissues down to the muscles and periosteum, is

reflected forward sufficiently to expose well the base of the trochanter. With a broad, thin, sharp chisel the trochanter is reversed by an oblique cut, including a thin triangular piece of the shaft of the femur. The trochanter, with the muscles attached, is then reflected upward in the form of a deep flap. Retraction of the wound margins in three directions and incision of the capsular ligament now expose the neck of the femur, which is cut through with the chisel at a safe distance from the disease, and the head is extracted with grasping forceps, or enucleated with the periosteal elevator. The removal of the head of the femur and whole or part of its neck exposes the capsule freely for the subsequent arthrectomy.

After the excision and arthrectomy have been completed, the hemorrhage carefully arrested, and the acetabulum thoroughly cleaned with the sharp spoon, the trochanter is replaced and fixed in position with an aseptic bone or ivory nail, aided by sutures of catgut embracing the periosteum and the dense fascia. In a number of cases I have relied on suturing with catgut exclusively in immobilizing the trochanter, and had the satisfaction of observing that the trochanter was perfectly held in place until bony union was sufficiently firm to dispense with direct means of fixation. The acetabulum is drained with a tubular drain and iodoform gauze, which are brought out through a separate opening behind the resection wound. The dressing must be large, embracing the upper half of the thigh and the same side of the pelvis as far as the crest of the ilium. As a primary immobilization dressing a long external splint with foot-board and extension by weight and pulley will be most comfortable and efficient. As soon as the patient is able to leave his bed, a plaster-of-Paris dressing is relied upon in securing fixation and in guarding against undue shortening.

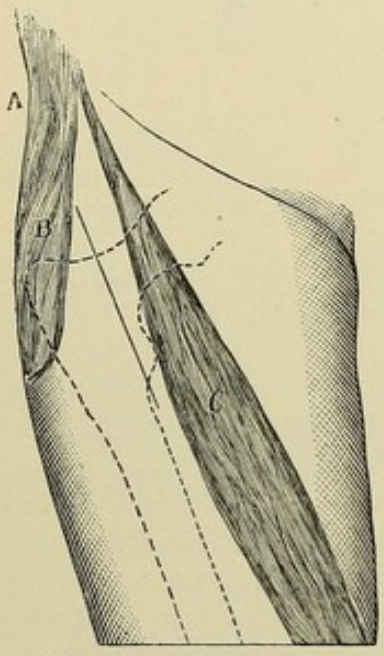

Fig. 605.—Resection of the hip-joint; Luecke's anterior incision: A, Gluteus muscle; B, tensor vaginæ femoris muscle; C, sartorius muscle.

Luecke's anterior incision is an excellent one for the extraction of loose sequestra and resection of the head of the femur, but it does not furnish the required space for a complete arthrectomy. The incision begins immediately below and a fingerbreadth to the inside of the anterior superior spinous process of the ilium, and is extended vertically downward to the level of the trochanter minor. The inner margin of the sartorius and rectus femoris is laid bare and retracted outward. By blunt dissection the outer margin of the iliopsoas muscle is reached and is retracted inward. The capsule of the joint is made accessible by slight flexion, abduction, and out-

ward rotation of the thigh. The capsule is then incised, and the neck of the femur severed with a small saw, or, what is decidedly better, with chisel and hammer. After cutting away the cartilaginous margin of the acetabulum, the head of the femur is extracted with forceps, or lifted out of the acetabulum with the periosteal elevator. Luecke's operation has the decided advantage of not requiring the severance of any muscles or tendons, besides obviating the necessity of sacrificing or temporarily detaching the trochanter major in opening up a comparatively free route into the hip-joint.

CHAPTER XXIX.

AMPUTATIONS AND DISARTICULATIONS.

THE removal of a limb or a part of a limb for injury or disease is called amputation. The same term is used to designate the operative removal of the tongue, penis, breast, and other accessible peripheral organs or parts of organs. Amputation is always a mutilating procedure, and a confession on part of the surgeon that the conditions necessitating its performance were beyond the limits of conservative measures; hence beyond the reach of restorative treatment.

The public always has entertained an exaggerated idea as to the magnitude and importance of this operation, the idea being shared, to a considerable extent, by medical students and the members of the profession the date of whose diplomas extends back to a time when conservative surgery had a very limited field of usefulness. The removal of an entire extremity in a few minutes by a few dexterous strokes of the knife has electrified many medical audiences, and has been the source of self-congratulation and unenviable pride by many operators. Such efforts at display of operative skill were justifiable before anesthetics came into use, but are, fortunately, seldom witnessed at the present time. Aseptic and antiseptic surgery has enlarged the field of conservative surgery, and in the same ratio has reduced the indications for mutilating operations. Surgeons have come to realize that, as far as the safety and best interests of their patients are concerned, technical skill is of minor importance as compared with the practical application of the science of surgery in determining when and where to amputate. All other things being equal, the surgeon who has the smallest amputation statistics is the one who is most useful and successful. A few years ago an amputation reputation carried great import in establishing surgical fame, but at the present time it has ceased to be regarded in so favorable a light. The surgeon who can save a limb is entitled to more credit than he who can remove it by a most brilliant amputation.

The greatest difficulties the emergency surgeon encounters in his practice are not the technical, but the scientific, demands made upon him when in charge of a case in which arises the question of amputation. He feels his own weakness most keenly in deciding upon when and where, and not how, to amputate. It is in determining the legitimate scientific indications for amputation that his conscience and good judgment so often dictate the necessity of a consultation. It is in drawing the line between a conservative course of treatment and a mutilating operation that he is so willing and anxious to avail himself of the advice of one or more of his colleagues. The removal of a limb, except for manifestly clear indications, involves great professional and legal responsibilities. Many unpleasant and costly legal amputations that have figured so conspicuously in the courts in all parts of our country might have been averted by timely and more frequent consultations.

The general practitioner is brought most frequently in contact with the injured in civil life, and upon the course of treatment he pursues will depend the fate of the limb. Under aseptic precautions injuries that upon first sight appeared to warrant a primary amputation often heal, while an apparently insignificant injury, carelessly treated, may give rise to complications endangering the limb and even the life of the patient. Antiseptic surgery frequently succeeds in dealing successfully with complications that heretofore were considered ample to justify a mutilating operation.

Indications for Amputation.—Every conscientious surgeon is anxious to formulate clear indications before resorting to the use of the knife, and this should be more especially the case in deciding upon the propriety of performing an amputation, as this operation must be regarded as one of the most mutilating procedures in surgery. If the indications are not sufficiently clear to warrant amputation, the patient is certainly entitled to the benefit of the doubt. Conservative surgery has advanced sufficiently to demand full recognition, and should take its proper high place in the practice of the general practitioner as well as the professional surgeon.

A careful and systematic study of the indications for amputation implies a comprehensive and an accurate knowledge of the nature and extent of the injury, or the pathologic conditions that have raised the question of amputation. Without such knowledge erroneous conclusions are only too often reached, upon which is based the subsequent faulty treatment. *The indications for amputation have been entirely recast during the last three decades.* The present status of surgery entitles us to the expectation that the limits of conservative surgery will be expanded under further improvements in the treatment of injury and disease, and consequently that the indications for amputation will become still more restricted by a more nearly perfect aseptic technic and improved methods of dealing with infective processes and malignant diseases.

Indications for Primary Amputation.—*1. Extensive crushing of the bones and tearing of large vessels and nerves.* In the section on Compound Fractures it was distinctly stated that in such cases the indications for a primary amputation were furnished rather by the presence of wounds of the large vessels and nerves than by the extent of the bone injury. Severe crushing of a limb with injury of the large vessels and nerves is invariably followed by gangrene, and always warrants a primary amputation as soon as the patient has recovered from shock. *In such injuries conservatism under the strictest aseptic precautions, to determine the point where the amputation should be made by the formation of the line of demarcation, is unwarranted, as it exposes the patient to great risks of infection without furnishing a sufficient compensation in the possible increased length of the stump. Any injury that permanently suspends nutrition at and below the wound justifies a primary amputation.*

2. Extensive tearing and crushing of skin and muscles with slight or no bone injury. Such wounds are most frequently caused by machinery accidents. Conservative surgery can be carried too far in these cases also, as even in the event of a final recovery after a resort to plastic operations or skin-grafting, the limb is worse than useless, and is amputated later on the urgent request of the patient. *The ultimate practical result must be taken into consideration in deciding between primary amputation and a conservative course of treatment.*

Extensive decortication alone may become a sufficient cause for amputation. In a case of this kind I succeeded, by a primary plastic operation, in preserving a useful foot. The patient was a girl ten years of age, who sustained a street-car injury. The toes were crushed, and the skin was torn away as far as Chopart's joint. Amputation through this joint would have resulted in a wound that could not have been covered throughout by skin. For the purpose of saving the foot, a plastic operation was performed, probably the first one of the kind. It was found that by flexing thigh and knee and turning the limb inward, the sole of the foot could be brought in contact with the anterior surface of the abdomen. Under strict aseptic precautions a pocket was made in the skin below the umbilicus, large enough to receive the denuded part of the foot. The edges of the torn skin were carefully trimmed and sutured to the margins of the wound all around. The crushed toes were brought through an incision at the base of the pocket, the same opening being utilized for drainage. The wound was dressed in such a way that the whole foot and anterior surface of the abdominal wall were included in the dressing, the limb and trunk being immobilized by a light plaster-of-Paris dressing. It was expected that this awkward position of the limb would become unbearable to the little patient, but in this we were pleasantly disappointed. The child was restless only for the first two days, and perfectly satisfied and comfortable the remainder of the time. The wound healed rapidly,

and in two weeks the skin, which was firmly attached to the dorsal surface, was detached, including enough on each side to cover the plantar surface. This circular flap furnished an excellent substitute for the skin lost by the accident, and the patient recovered with a very useful foot, minus the crushed toes.

As substitutes for amputation, whole or in part, primary plastic operations of this kind will prove of the greatest value in injuries of the fingers and hands.

Indications for Secondary Amputation.—As much, or perhaps even more, has been achieved by the advancements made by modern surgery to restrict secondary amputations as in limiting the indications for primary amputation. The pride of the surgeon of to-day consists in adopting, in appropriate cases, conservative measures, and in carrying them to the utmost limits, in the place of mutilating operations in the treatment of injuries and disease. Secondary amputations have become less and less frequent, owing to two principal causes, viz.:

1. *Aseptic precautions have succeeded in greatly diminishing the frequency of, if not entirely preventing, wound infection and its complications, which formerly so often made amputation imperative as a life-saving operation.*

2. *Antiseptic surgery deals successfully with a large percentage of suppurative affections that formerly were not within the reach of successful conservative treatment.*

1. *Gangrene* following injury or as a remote result of pathologic conditions that ultimately suspend nutrition always constitutes a well-founded indication for amputation. While there can be no difference of opinion regarding the significance of gangrene as a cause for amputation, the question as to where and when to amputate is often not so easy to decide.

In amputations for traumatic gangrene operative interference must be resorted to promptly when the sepsis attending it endangers the life of the patient, and after the most energetic antiseptic treatment has failed. The amputation must be made through healthy tissue and at a point where the principal blood-vessels are permeable. In gangrene unattended by symptoms indicative of the existence of sepsis sufficient in severity to constitute a source of danger to life, it is wisdom on the part of the surgeon to postpone the amputation until the line of demarcation is well established, as this furnishes the most reliable guide in deciding where to amputate.

2. *Septicopyemia*, so frequent a cause for amputation until recently, is seldom seen at the present time sufficient in severity to justify amputation. Free incisions, efficient drainage, continuous antiseptic irrigation, and the internal administration of heroic doses of alcohol have shown themselves to be such powerful weapons in the hands of the surgeon that amputation as a life-saving operation is reserved for exceptional cases. It is proper to amputate in cases in which the vigorous conservative measures fail in arresting the

septic infection. In cases of well-developed pyemia it is doubtful if an amputation as a life-saving resource will accomplish more than energetic antiseptic treatment of the infected wound.

3. Prolonged exhausting suppuration continues to furnish a certain number of well-selected cases for amputation. Amputation for such an indication becomes necessary most frequently in extensive tuberculosis of bones and joints, complicated by mixed infection with pus-microbes and the formation of large and deep abscesses, more especially in adults and persons advanced in years. But even under such circumstances amputation is becoming less frequently a necessity, as treatment by laying open the abscess cavity from end to end, or, if this can not be done for anatomic reasons, by multiple large incisions followed by curettage, antiseptic irrigation, iodoform gauze tamponade, and partial suturing of the wound, very often succeeds in saving the life and limb of the patient. Amputation certainly should not be entertained until such treatment has proved unsuccessful.

Indications for Amputation by Nontraumatic Pathologic Conditions.—The nontraumatic pathologic conditions that warrant amputation are clinically characterized by their progressive tendencies and their obstinacy to less severe local treatment. They are cases that do not require immediate action, and can be studied at length and in a most thorough manner as to their nature and the necessity for radical treatment by amputation. Moreover, they are cases in which it is easier to decide where and when to perform the operation.

1. Extensive destruction of the skin does not so often warrant amputation since the general use of methods of skin-grafting devised by Reverdin, Thiersch, Wolfe, and Hirschberg. But there are cases of circular ulcer of the leg of long standing, and attended by grave pathologic conditions above and below the seat of ulceration, in which amputation is not only justifiable, but positively indicated. The temporary results of skin-grafting in such instances are often lost very soon after the patient leaves his bed ; besides, there is always considerable danger of such ulcers becoming the starting-point of carcinoma. Amputation, however, becomes a justifiable treatment only after conservative resources, such as rest in bed with the limb in an elevated position, warm aseptic compresses, skin-grafting, and the elastic webbing bandage, have had a fair trial.

2. Gangrene resulting from causes other than trauma and its complications usually necessitates amputation sooner or later. Senile and diabetic gangrene furnish the largest number of cases. Thrombosis and embolism of the principal blood-vessels constitute other prolific causes of gangrene of the lower extremities, especially in the aged, the subjects of advanced arterial *atheroma.* Gangrene from excessive heat and cold, burns, and frost-bites is most frequently met with in the young and vigorous, actively engaged in the pursuits of life.

From a practical standpoint it is important to distinguish between dry and moist gangrene. *In dry or aseptic gangrene life is not endangered by the local cause, and operative interference is never justifiable until the line of demarcation has become well defined, showing the boundary-line between living and dead tissue.* It is in such instances that the surgeon often steps in and completes the task undertaken by the living tissues by limiting the use of his instruments to the removal of dead tissue, permitting the resulting wound to heal by granulation. *In moist gangrene this rule has many exceptions. Amputation for moist gangrene becomes an urgent necessity when the gangrene is progressive and attended by increasing sepsis.* If in such cases the surgeon awaits the appearance of the line of demarcation as a signal for the operation to be performed, he will look for something never to be realized, such patients dying from sepsis. An early operation in the right place is urgently indicated not so much to remove the dead tissues as to get rid of the septic material that they contain, which finds its way into the general circulation, becoming the direct cause of death. In other words, the operation is performed to remove the source of the septic infection.

In selecting the site for the operation the surgeon must satisfy himself of the permeability of the principal arteries at the proposed line of amputation, and if he finds, on performing the operation, that he was mistaken in this respect, he must seek a higher level. For this reason it is advisable to make the first incision in the side of the limb where the large blood-vessels are located, in order to determine their condition before completing the operation. It is in moist gangrene that thrombosis is so liable to proceed rapidly in the direction of the body, and below the common femoral artery it is not always possible to determine beforehand whether or not the principal blood-vessels are permeable. In gangrene following embolism the line of amputation must always cross the affected vessel above the level of the embolus, as thrombosis in a proximal direction often proceeds very rapidly after the impaction of the embolus. In embolism of the popliteal artery at its bifurcation the proximal thrombus often extends several inches above the embolus.

Malignant Tumors.—With the exception of limited malignant disease of the skin, carcinoma and sarcoma of the extremities demand early operative treatment by amputation. *The frequency with which recurrence in the axillary and inguinal regions takes place after amputation for carcinoma has led surgeons to the conclusion that those spaces should be thoroughly cleared out before or after the operation, in the same manner and for the same reasons as the axillary space is cleared out in all operations for carcinoma of the mammary gland, and this regardless of the condition of the lymphatic glands.* This, however, is not done so constantly and so thoroughly as it should be, and a lack of proper precaution in this direction is responsible for many recurrences, early and late, that might have been prevented. Judging from the experience of the past, if a carcinoma of the skin

has extended beyond the subcutaneous connective tissue, the prospects of a local operation are anything but encouraging. In the great majority of such cases amputation is the only treatment that offers any hope of a permanent result.

Sarcoma of the periosteum and bone, when the diagnosis has once been established beyond all doubt, justifies treatment by amputation. A few cases have recently been reported in which it is alleged that in myeloid sarcoma of the epiphyseal extremity of the long bones permanent results have been obtained by exposing the tumor and removing it by the vigorous use of a sharp spoon. While such treatment might appear justifiable in cases in which an early diagnosis is made, the patient should be informed of the uncertainty of the result, and, on the appearance of the first evidences of a recurrence, amputation must be promptly performed. As a rule, to which, however, there are exceptions, the amputation should include the whole affected bone. The exceptions present themselves most frequently in sarcoma of the lower end of the femur, where a high amputation of the thigh is attended by much less risk to life than a disarticulation through the hip-joint.

Atrophic, deformed, paralytic, useless limbs, in a condition not amenable to restoration of function by orthopedic treatment and appliances, often become an incumbrance to the patient and an amputation may be justifiable if the patient makes an urgent request to that effect.

General Technic of Amputation. — Site of Operation. — A modern amputation has in view not only the removal of dead tissue, —sources of infection that threaten life and are beyond the reach of more conservative treatment, malignant tumors of the extremities, limbs that are useless and a burden to the patient,—but also the securing of a painless, useful stump. This last object of the operation often comes in conflict with the pathologic indications that demand the operation. Another, but less important, consideration in deciding upon the method of operating is the cosmetic result, which applies more particularly to amputations of the upper extremity below the wrist-joint.

Aside from the pathologic indications, the functional result demands the first consideration. This can be best illustrated by injury or disease of the ankle-joint and tarsus necessitating amputation. The pathologic indications may be fully met by Syme's amputation through the ankle-joint, but the resulting stump would be far less useful to the patient than if the amputation had been made at the point of selection—that is, at the junction of the middle and lower third of the leg. The old teaching that the amputation should be made as far away from the body as is compatible with the complete removal of diseased tissue has undergone many changes in consequence of improved methods of wound treatment and the additional duty recently imposed upon the surgeon to secure for the patient a painless, useful stump. It was formerly claimed, and perhaps with

good reason, that the danger of an amputation to the life of the patient increases with the approach of the operation toward the trunk. This argument has lost its force since anesthesia, improved hemostasis, and asepsis have come into general use. It still holds good in amputations of the upper part of the thigh, however, as a subtrochanteric amputation of the thigh is attended by much less immediate risk to life than disarticulation at the hip-joint. It is entirely different in amputations through the lower part of the leg, ankle-joint, and tarsus. All things being equal, an amputation at the point of election at the junction of the middle with the lower third of the leg is not attended by more immediate or remote danger to life than an amputation through the ankle-joint. Moreover, it yields an ideal stump for the wearing of an artificial limb, while the reputation of every instrument maker is at stake who provides an artificial limb for a patient who has undergone Syme's amputation.

For the purpose of minimizing the immediate risks to life, amputations at the base of the thigh should be performed below the hip-joint in all cases in which such a course is compatible with the pathologic indications.

On the other hand, in all amputations below the base of the thigh the functional result must be taken into serious consideration in determining upon the site of the operation. Disarticulation at the knee-joint has but few advocates at the present time because the resulting stump is bulbous and ill adapted for the wearing of an artificial limb. In amputations through the upper part of the leg it must not be forgotten that a stump four inches long is the shortest one that enables the patient to wear an artificial limb. It is such a stump, too, that will be most serviceable in wearing a peg-leg, which, among the poorer classes, is largely depended upon for locomotion. *If an amputation has to be done above this level, the next point of selection is through the base of the condyles. For this operation the surgeon should select the Gritti-Stokes' transcondyloid osteoplastic amputation, which yields an ideal conic stump, well fitted for the wearing of an artificial limb.* Whenever admissible, in all amputations of the lower extremity above the ankle-joint, the operation should be made at a point and in such a manner as to secure a conic stump, so keenly appreciated by every manufacturer of artificial limbs, and subsequently by the patient. It must be remembered that when the patient comes to wear an artificial limb, the weight of the body should not fall upon the end of the stump, but upon its sides, something that can be fully and satisfactorily accomplished only if the shape of the stump is conic.

Amputation Neuroma.—Every surgeon is familiar with the fact that the most frequent cause of painful stumps is the so-called amputation neuroma, a bulbous enlargement of the cut end of the principal nerves. This painful remote complication of amputation always develops in the scar tissue of the wound, in which it is invariably found embedded. The most effective prophylactic measure

against the development of such a condition consists in exsection of an inch or two of the principal nerves in the amputation wound, in this manner protecting the nerve-ends against irritation by the scar tissue.

Neuroma as a remote complication of amputation appears in the form of a bulbous enlargement of the end of the principal nerve or nerves in the stump. Such a tumor usually makes its appearance a few weeks or months after the operation, and is the most frequent cause of painful stumps. The usually accepted theory attributes the enlargement of a nerve-end in amputation neuroma to an abundant formation of small myelinic fibers produced from the neuroblasts that have been exposed for a long time to irritation caused by cicatricial tissue. It is well known that an amputation neuroma will develop only in connection with scar tissue and the irritation incident to the condition producing it. Every amputation neuroma will be found embedded in more or less of scar tissue. Witzel has recently shown that in many cases the neuroma is found attached to the end of the bone in the stump. It is more than probable that the cut ends of the nerve-fibers become attached to the scar tissue, which acts the part of a foreign substance and excites the active and abnormal tissue proliferation, upon which depends the formation of the neuroma. The tumor presents itself in the form of a bulbous enlargement of the end of the nerve, which closely resembles a spring onion in outline. Cross-sections of such tumors show the numeric increase of myelinic nerve-fibers. Nicoladoni's assistant has made some very interesting investigations regarding the structure of amputation neuroma, and has come to the conclusion that the numeric increase of nerve-fibers is apparent, and not real. According to his observations, the increase is due to the formation of loops growing out of the elongation of the pre-existing fibers.

Virchow called attention to such a possibility years ago, and emphasized particularly the difficulty in following out and tracing the nerve-fibers. It is very desirable that future research should settle this question definitely. With the poliferation or growth of the nerve-fibers the interstitial connective tissue is increased under the same influence, the resulting tumor constituting histologically a true neurofibroma.

Within a short time the tumor, as a rule, reaches its maximum size, seldom exceeding twice the circumference of the nerve-trunk, when it becomes stationary and manifests little or no tendency to degenerative processes. In the majority of cases the tumor is limited and forms the bulbous extremity of the nerve; in some instances, as in the case reported by Hayem and Gilbert, the nerve is at the same time enlarged for a considerable distance above the tumor, the enlargement being due to an abundant formation of interstitial connective tissue. Every surgeon of large experience knows that an amputation neuroma in some cases is exceedingly prone to

return after excision, and these are undoubtedly the cases in which the nerve is enlarged far beyond the bulbous extremity. I have known instances in which such neuromata were excised four or five times, and an early return of the pain, with recurrence of the tumor, followed each operation. In one case a cure was finally effected by excising four inches of the sciatic nerve, far beyond the apparent limits of the tumor and enlargement of the nerve. Neuroma is more apt to appear in persons the subjects of an inherited or acquired predisposition to the active proliferation of the elements of which a nerve is composed, more especially the presence in the injured nerve of an abnormal abundance of potential neuroblasts.

Virchow, in speaking of the etiology of neuromata, very properly alludes to such a general aptitude, which he terms neuroblasty, or neuromatosis. A surgeon performs two amputations for the same conditions and under the same circumstances, following the same technic and dealing with the same structures : in one the nerve-ends become implicated ; in the other they escape. The one who subsequently suffers from neuroma must necessarily have furnished the essential conditions for the development of this remote complication, which were inadequate or absent in the other. Amputation neuroma has become less frequent since surgeons have become aware of the fact that the exciting cause is always scar tissue formed around the end of the cut nerve. Excising the principal nerves a considerable distance above the level of the wound and primary wound healing under aseptic precautions have succeeded in diminishing the frequency, but not in preventing with certainty the occurrence, of neuroma after amputation. Amputation neuroma will continue to appear in the practice of the most careful and painstaking surgeons. The frequency with which such tumors recur after ordinary excision as generally practised is well known.

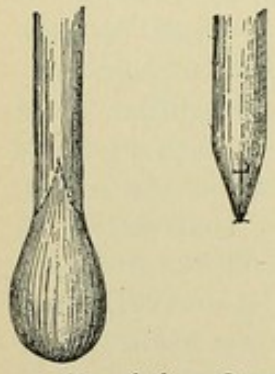

Fig. 606. — Operation for the prevention and cure of amputation neuroma.

I have seen a number of such cases in which excision was performed from four to six times by different operators, all without permanent relief. For nearly three years I have adopted a method of excision that has proved eminently successful in preventing recurrence. This procedure proved permanently satisfactory in several instances in which repeated excision had been followed by speedy recurrences. Recognizing the fact that neuroma after amputation always develops in connection with scar tissue and is undoubtedly the result of irritation of the cut ends of the fibers incorporated in the scar tissue, I was induced to excise the nerve at a safe distance from the tumor in a manner that would prevent such an occurrence. This I accomplished by bringing the cut ends of the nerve-fibers in contact and by interposing between them and the scar tissue the

normal covering of the nerve—the nerve sheath. After dissecting up the scar tissue in connection with the neuroma, the nerve is liberated to the requisite extent and excised at a safe distance from the tumor by making a V-shaped incision, forming a wedge on the part of the nerve removed and two small flaps on the proximal end. These little flaps, according to the size of the nerve, are brought together by from one to three fine catgut sutures, giving the nerve-end a conic shape. In nerves of the size of the median, ulnar, and musculospiral, one suture at the apex of the cone answers the purpose. In operations on the sciatic nerve one terminal and two lateral sutures are necessary. This method of nerve resection furnishes absolute protection to the nerve-fibers against irritation on the part of scar tissue, and interposes between the nerve-fibers and the scar tissue resulting from the operation the normal protection of the nerve—the nerve sheath. Should it become necessary to operate on two nerves in close proximity, the same object is obtained by suturing the nerve-ends together after excision of the neuromata. As an additional precaution the nerve-end can further be protected by covering it with adjacent muscle tissue by a few points of buried absorbable sutures before closing the external wound.

No amputation above the ankle- and the wrist-joint is complete without primary exsection of the principal nerve-trunks in the amputation wound. In amputations of the upper extremity, the highest degree of conservatism must govern the surgeon in planning and executing a mutilating operation. Every inch, and every fraction of an inch, of tissue that can be saved will enhance the functional result. Cosmetic considerations can be entertained only in operating upon persons of wealth; they are out of question in practice among the laboring people. It is seldom necessary to amputate a finger for osteomyelitic affections, as extraction of sequestra and resection of joints will often be rewarded by a useful finger, though shortened and perhaps stiff. The recuperative power of the tissues of the fingers and hands is something marvelous, and will often result in repair of traumatic and pathologic defects that at first appeared almost hopeless. A straight stiff finger is useless and often an incumbrance; hence if such a condition is anticipated, the injured or diseased finger must be placed and held in proper position by an appropriate mechanical support during the whole time required for the completion of the healing process. The finger must be immobilized in a flexed position, which will aid and not interfere with the grasping power of the hand. Limited continuous defects of the finger and hand can be treated by a plastic operation or skin-grafting with a view to securing a maximum functional result, thus limiting amputation to parts hopelessly injured or diseased.

The surgery of the fingers and hands requires, on the part of the surgeon, good judgment and originality in devising operations that will meet the indications of each individual case. Following blindly any text-book is dangerous here, as elsewhere, as

it often leads to unnecessary sacrifice of tissue that could be utilized in maintaining to a greater extent the prehensile power of the hand. As much of the bony framework of the hand should be saved as possible, as a great deal can be accomplished at once or later in restoring soft parts by plastic operation or skin-grafting. In amputations above the wrist-joint the surgeon can take more liberty in the selection of the site of operation, as the functional utility of the stump here is not always proportionate to its length.

Preparations for Operation.—Primary amputations are always emergency operations, and must often be performed hastily and with limited assistance and facilities. Too much haste, however, must

Fig. 607.—Langenbeck's metacarpal saw.

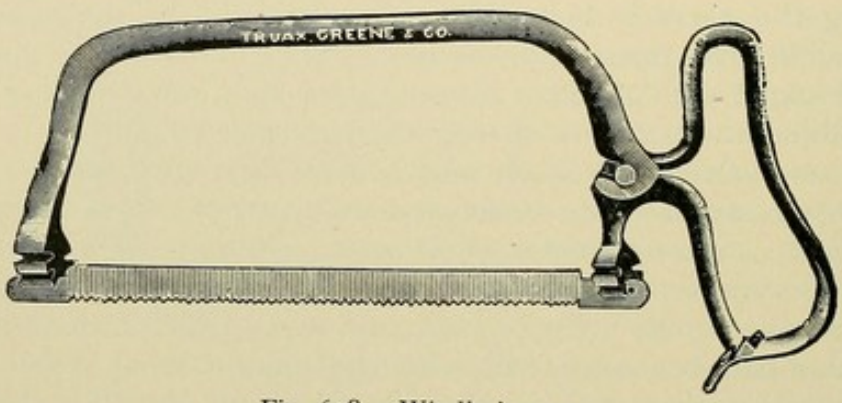

Fig. 608.—Windler's saw.



Fig. 609.—Parker's capital saw.

be scrupulously avoided, and enough time must be devoted in making the necessary preparations. In amputations for disease the usual painstaking preparations for an aseptic operation must always be carried out, as time in such instances does not play so important a rôle as in operations for injury of sufficient gravity to demand an operation. The surgeon frequently finds himself in a position where he must perform the operation without skilled assistance. Under such circumstances he attends to the sterilization of the instruments in person, prepares the antiseptic and salt solutions, and attends to the dressing material. He also administers the anesthetic, instructing the person upon whom he can place the most reliance how to

maintain the anesthesia, and assigning to another the task of holding the limb, and later the stump during the operation. The latter assistant is cautioned never to touch the wound or the field of operation. After the patient is anesthetized, the surgeon disinfects the field of operation in the manner described in detail elsewhere, and during the operation, after the hands have been disinfected

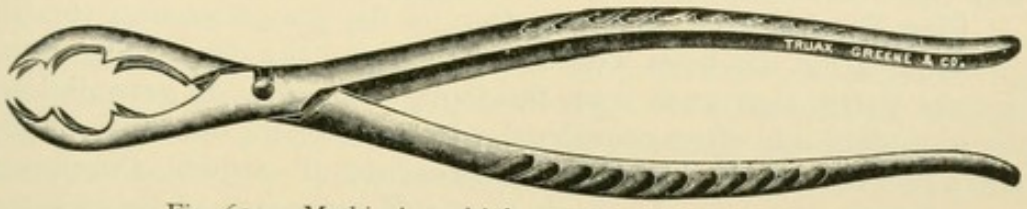

Fig. 610.—Mathieu's multiple point bone-holding forceps.

once more, he takes the instrument from the tray or sterile towel, and attends to the sponging and ligation of vessels himself.

Any amputation can be performed by the aid of a few instruments: all that is required is a scalpel, half a dozen hemostatic forceps, a periosteal elevator, scissors, saw, bone-forceps, needles, suturing and ligature material, and an elastic constrictor. The old-fashioned amputating knives are seldom seen in the operating room since transfixion has been largely abandoned. A stout scalpel of large size is the instrument of choice in dividing the soft tissues in all major amputations, and a smaller one for amputation of the fingers and toes. Kocher's artery forceps is the one best adapted for grasping the blood-vessels, and for seizing and drawing forward the nerve-ends in making primary neurectomy as a prophylactic against the formation of amputation neuroma. Windler's or Butcher's saw is a better instrument than the ordinary more cumbersome amputation saw; the small metacarpal saw is best adapted for dividing the phalanges of the fingers and toes. A medium-sized straight bone-cutting forceps is all that is required for the trimming of the sawn end of the bone. Large

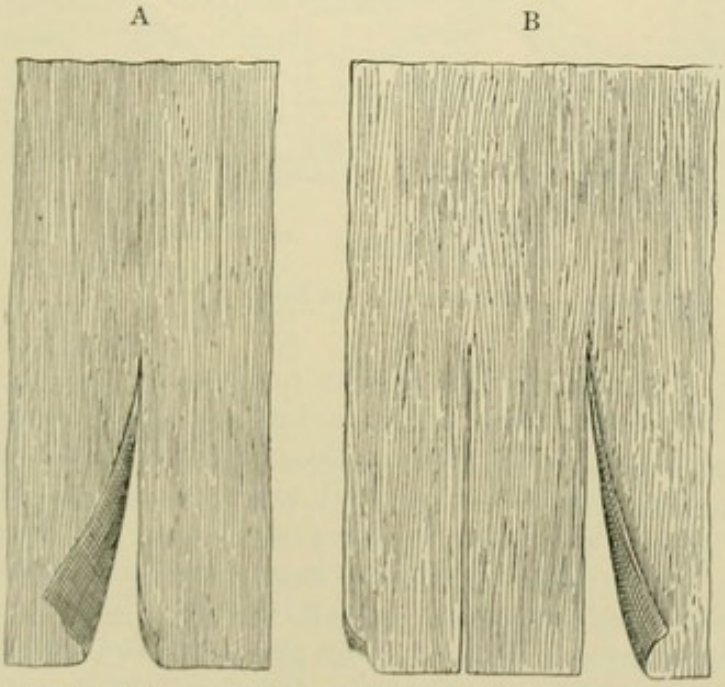

Fig. 611.—Gauze retractors: A, For one bone; B, for two bones.

curved needles are used for the deep sutures, and glover's needles for suturing the flaps. Rubber drains of different sizes are to be kept on hand, and are to be employed as indicated by the condition. The retractors are made of sterile gauze.

During the operation the surgeon takes a position that will afford him the easiest access to the field of operation—usually in such a way that the amputated limb will fall toward his right side.

Flap Formation.—In amputation for dry gangrene after the line of demarcation has been well established and the dead tissues have become partly separated from the living by a wall of granulations, the amputation is often completed with little or no use of the knife. After the bone or bones have been reached all around, the periosteum is separated in the form of a cuff by means of an elevator, while the soft tissues are retracted. The amputation is completed by the use of the saw, dividing the bone sufficiently far above the line of demarcation to permit its face being completely covered by the periosteal cuff.

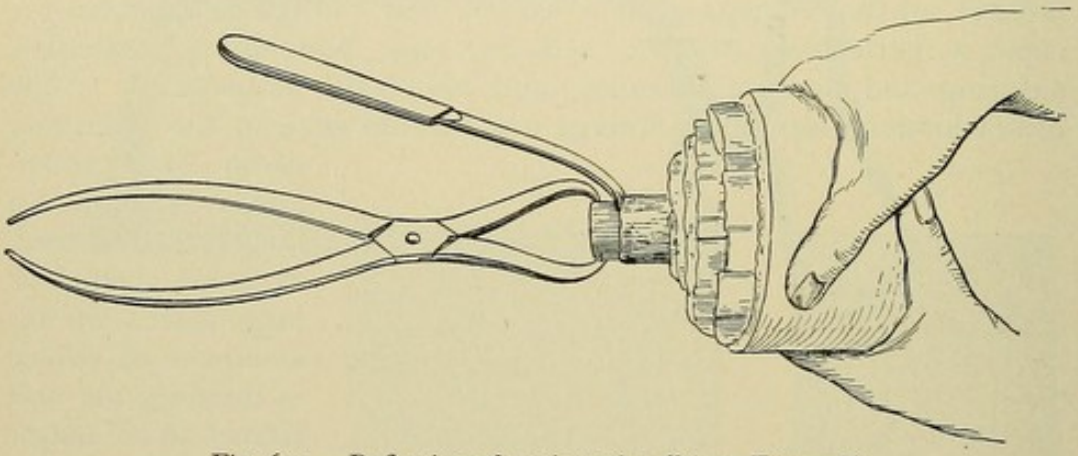

Fig. 612.—Reflection of periosteal cuff (von Esmarch).

An amputation under such conditions does not require prophylactic hemostasis by the elastic constriction, as but very little blood is lost during the operation, which aims to do as little violence as possible to the living soft tissues. Under all other circumstances the elastic constrictor is relied upon in preventing loss of blood during the operation. Some care is necessary in applying the elastic constrictor as a prophylactic hemostatic in amputations. The constrictor must be applied at a safe distance from the proposed line of section through the soft parts, as otherwise the constrictor may slip after completing the section through the muscles, the cut ends of which always retract much further than would be ordinarily expected. The part of the limb to be removed should be wrapped in a compress saturated with an antiseptic solution,—preferably carbolized water,—to guard against contamination of the wound from this source during the operation.

All incisions devised for flap formation are intended to furnish tissue with which to cover the sawn end of the bone and the ampu-

tation wound. The names of many distinguished surgeons are indelibly connected with the different methods of flap formation. To follow any or all of the different methods heretofore devised would not meet the many exigencies with which the surgeon must contend. There are certain well-established rules that should guide the surgeon in making the incisions through the soft tissues, which will enable him to act intelligently in cases in which the local conditions do not admit of the adoption of any of the orthodox methods, which are only too often adhered to too closely, to the detriment of the patient. *In performing an amputation the surgeon must often rely on his own ingenuity in planning the operation best adapted for the case. The operation should be suited to the case, and not the case to the operation.* No inflexible rules can be followed in reference to the location and shape of the incisions in making the flaps. The surgeon will take the tissues from the side of the limb presenting the most favorable conditions for flap formation, and the incisions will be made accordingly. Circular amputation, the oldest method of removing a limb, is seldom performed at the present day, even in its most modern modifications. The old operation and all recent modifications leave a scar directly over the bone in the center of the end of a stump, a location most exposed to irritation. The angular projections at the two corners of the wound, formed by the suturing of the wound, are not only unsightly, but likewise interfere later with the comfortable wearing of an artificial support. Amputation by the transfixion method, so popular at one time, has become nearly obsolete, for very obvious reasons. In the first place, nature does not tolerate muscular tissue over the end of the bone, and if placed there by the surgeon, it is removed in the course of time by atrophy and absorption. In the second place, the large blood-vessels are divided obliquely, and often cut for some distance longitudinally, leaving their ends in a most unfavorable condition for ligation.

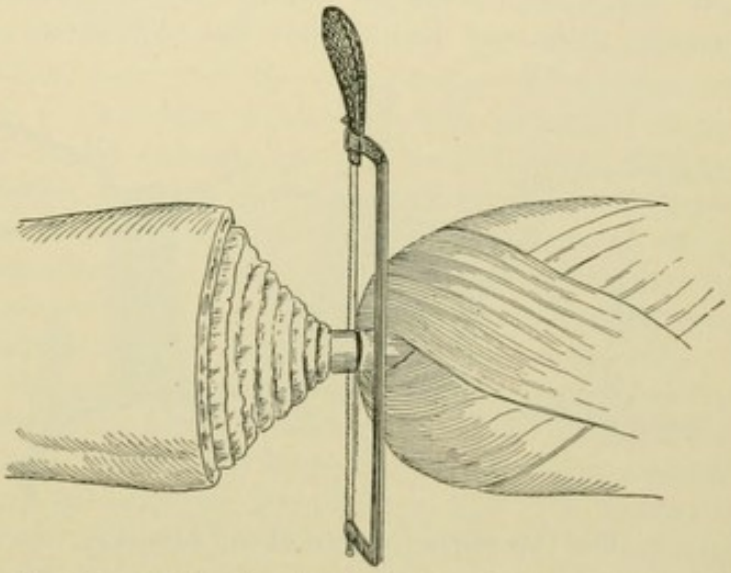

Fig. 613.—Retraction of soft tissues and section of the bone with the saw (von Esmarch).

The ideal method of flap formation consists in making two cutaneous flaps, oval in shape, one longer than the other, including the superficial and deep fasciæ. By making two flaps of unequal length the

line of suturing and the subsequent scar fall away from the end of the bone to a place where the scar tissue does the least harm and finds the best protection against mechanical irritation. *I am strongly impressed with the importance of including in the flap the deep connective tissue*,—something that is not generally advised,—as by doing so an important hold on the cut muscles is secured, a valuable element in preventing retraction ; further, an additional source of blood supply to the flap is preserved. *All amputation flaps should include the deep connective tissue, for the reasons just advanced. Flaps must be made by cutting from without inward, and never from within outward.* In forming the flaps, the surgeon must exercise his mechanical ingenuity in making them of the proper length and shape, so that when they are sutured together, the wound surface will be covered smoothly and evenly without tension or too great redundance of tissue or any considerable pleating of the skin if the wound margins are, as is usually the case, of somewhat unequal length. The student must not forget that his experience in operating on the cadaver must be somewhat modified when he comes to operate on living tissues, as in the latter case the elastic and muscular contractions that always assert themselves as soon as the soft tissues are divided render it necessary to make the flaps of sufficient length to allow for these contractions. The surgeon who has to use the tape-measure, and who outlines the incisions on the surface of the skin by colored dots or lines, is not in possession of the necessary mechanical skill to practise surgery successfully. When such an amputation is completed, the surgeon will often find himself at a loss when he comes to suture the flaps. It is well, in performing a first operation on the living subject, to make ample provision for retraction by making the flaps long, as if they prove to be too long, the mistake can be remedied quickly and with much less detriment to the patient than if they had been made the reverse, the latter mistake requiring an immediate reamputation, with all its immediate and remote consequences.

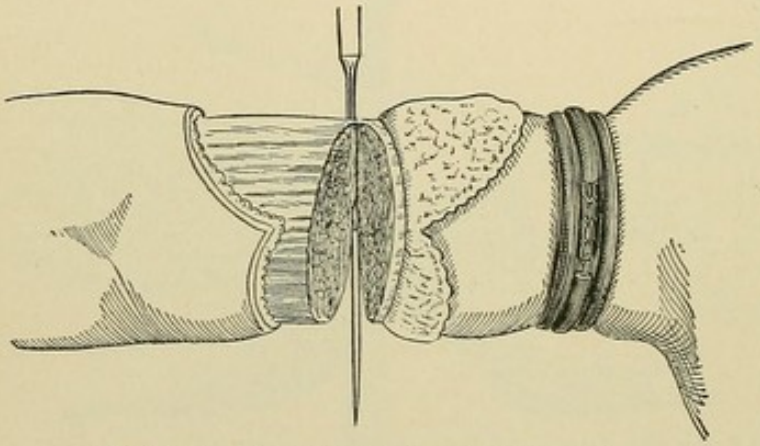

Fig. 614.—Bruns' method of flap formation.

Circular amputation has already been referred to as an operation that does not yield a desirable stump for the comfortable wearing of an artificial limb. The operation, however, has many warm advocates, and recommends itself to those who favor the circular

method only in amputations of the upper extremity. It is the oldest method of amputation, as it was fully described in the oldest text-books treating on operative surgery. The method consists in dividing the soft tissues in either one or two steps. The one-step operation (Celsus) is made by cutting all the soft tissues down to the bone by a single circular sweep of the knife, and sawing off the bone on the same level. In this manner the first amputations were made. It was impossible to suture the wound over the end of the bone, and such wounds had to heal by granulation, resulting in a conic stump, the apex of the cone being the bone covered by scar tissue. Such a stump is, of course, absolutely useless for the wearing of a modern artificial limb. The difficulty in suturing of the wound was overcome later by the subperiosteal removal of a piece of bone half the length of the diameter of the limb (Esmarch). This modification of the original method of circular amputation necessitates two sections of the bone, something that should always be avoided.

Circular amputation in two steps, as devised and recommended by Petit (1718), marked a decided improvement in the technic of the operation, and is the method most generally practised at the present time. After elastic constriction has been applied, the limb to be amputated is firmly grasped above the line of proposed amputation by the operator's left hand, and below by the hand of an assistant. With a small amputating knife the skin and all the tissues down to the muscles are divided by a circular cut, either by one circular sweep, or, better, by two cuts, the first one on the side of the limb, away from the operator, and the second on the side of the limb toward the operator, the latter incision being made by reversing the position of the knife in the first sweep. For the same reasons advanced heretofore I recommend including in the cuff the fascia embracing the muscles. A cuff is then reflected by raising the margins of the skin with fingers or forceps, and separating the cuff with delicate strokes of the scalpel directed toward the base of the stump. *The length of the cuff must correspond with one-half of the diameter of the limb.* No force or tearing is permissible in forming the flap, as it is advisable to disturb the circulation as little as possible, an object best accomplished by making short and clean cuts directed perpendicularly toward the base of the circular flap. *The cut through the muscles should be made obliquely from below upward, and toward the base, and not straight, as is usually advised.* After the limb has been severed, the muscular part of the wound must represent a shallow cup with the end of the bone as its central point. Muscle retraction is most marked the greater the distance from the bone, as the muscles near the bone retain many of their attachments. *By making the incision obliquely and not straight this difference is more than balanced, an object of much importance in closing the wound by suturing.* The second incision should always be made in preference with a strong scalpel, with which the obliquity of the incision can be graded to the requisite degree indicated by the num-

ber, strength, and extent of mobility of the muscles that must be severed. The amputation is completed by making the

Bone Section.—The sawn surface of the bone must be covered by the normal envelop of the bone—the periosteum. *The interposition of periosteum between the bone and the overlying flap is an important technical part of the operation and should never be neglected. Osteophytes*, or any other undesirable consequence, need not be feared if sufficient periosteum is preserved to cover and protect the sawn surface of the bone. If the periosteum and bone are normal at the seat of amputation, the membrane is delicate and firmly attached to the underlying bone surface, and should remain attached to the neighboring soft tissues. According to the size and shape of the bone, the periosteal cover is made in the form either of a flap or of a cuff. A long anterior flap is preferable for the tibia, while a cuff or circular flap will answer an excellent purpose in covering the sawn surface of all the small and round bones. The periosteal flap or cuff is made by cutting separately through the periosteum on a level with the deep incision next the bone, and, with an elevator, lifting up the periosteum in the shape of a flap or cuff, and detaching it far enough so that, after dividing the bone, the periosteal flap or cuff will fall over the end of the bone; in the case of large bones it is fastened by one or two buried catgut sutures. The bone is divided transversely with a fine-toothed amputation saw.

It is during this stage of the operation that the assistant who is holding the limb must exercise special care. The limb must be held in such a way that, when the saw has weakened the bone sufficiently so that it will bend, the blade of the saw is not caught and locked between the surfaces encroaching upon it; on the other hand, fracture of the unsawn portion must be prevented by not bending the bone in the opposite direction. As a rule, the assistant's hands, if they can be relied upon, are the best retractors with which to protect the soft tissues against injury by the saw. If the assistant is not trustworthy, retractors made of aseptic gauze are employed and placed in charge of the assistant. The bone forceps come in use only when a spiculum of bone, the result of fracture, has to be removed; it is useless and even harmful to round off the end of the bone with the forceps, as this is done later with greater nicety under the periosteal flap by resorption of the sharp margins. By interposing a periosteal covering between the end of the bone and the overlying flap the former does not become attached to the latter, as is usually the case if this precaution is neglected. *Free mobility of the flap over the end of the bone is one of the essential conditions of an ideal stump.* The periosteal flap, however, accomplishes more than this. The medullary tissue is a structure exceedingly sensitive to infection, and needs all the protection we can furnish for the prevention of traumatic osteomyelitis. The periosteum is the normal envelop of the bone, and on this account is best adapted as a pro-

tecting cover for the open medullary canal. By closing the medullary canal with a periosteal flap and suturing the same in place we furnish the medullary tissue with a mechanical protection in case the wound should become infected. After the periosteal flap has been sutured in place, the surgeon attends to the

Ligation of Blood-vessels.—Before the elastic constrictor is removed all the principal blood-vessels in the wound are ligated. Very coarse catgut should never be used. Medium-sized catgut can be relied upon in tying any of the large blood-vessels, and fine catgut is used for the small muscular branches. As the blood-vessels, owing to their contractility, retract from the surface of the wound, their anatomic location in the cross-section must be familiar to the surgeon. The intermuscular septa are not only valuable guides to the large vessels, but also to the small muscular branches. Arteries the size of the brachial and popliteal should be isolated sufficiently to secure room for two ligatures one-quarter or one-third of an inch apart, the proximal ligature including the accompanying vein, in the manner described in the section on Ligation of Blood-vessels. Small vessels can be secured more quickly and tied more certainly by substituting the tenaculum for the hemostatic forceps. Before the elastic constrictor is removed the principal nerve-trunks, if the amputation has been made above the wrist- or the ankle-joint, are searched for, drawn forward an inch or two, and cut off squarely with either the knife or the sharp scissors. The intermuscular spaces will aid in searching for nerve-ends retracted from the surface of the wound. The surgeon must satisfy himself, immediately after the amputation is completed, that he has made the flaps properly, as any defects in flap formation must be remedied before any of the blood-vessels are tied. Before the elastic constrictor is removed the stump is elevated, the surface covered with a compress of gauze wrung out of a hot normal salt solution, and the flaps brought over the compress, when firm compression is made with both hands. *It is a mistake to remove the elastic constrictor slowly with the idea that it will diminish the bleeding*, as the result is contrary to the expectations. *The elastic constrictor should be removed as suddenly as it was applied.* Manual compression is maintained for a few minutes, until the first arterial waves have passed by. The escape of any considerable quantity of blood through the compress would indicate that a vessel of large size had been overlooked, in which event the compress is removed quickly and the spurting point caught with hemostatic forceps. If this is not the case, the compress is removed inch by inch, and any bleeding point of the exposed surface is treated in the same manner as described, until the compress is removed, when the ligature takes the place of the forceps. *Careful hemostasis can not be insisted* upon too strongly as the most important preliminary step to suturing of the wound. Troublesome surface oozing is arrested by douching with hot saline

solutions and surface compression. After the wound has been made perfectly dry, the next step of the operation consists in

Suturing of the Wound.—As the periosteal flap is fastened in place before the elastic constrictor is removed, the first row of sutures is inserted. Suturing of the cut muscles with heavy catgut constitutes a very important part of the wound treatment. *The second row of buried sutures includes the ends of the principal muscles, and has for its objects diminution of the wound surface and the securing of a temporary anchorage for the cut muscle. The diminution in the size of the wound by the muscle suturing decreases the amount of primary wound secretion, shortens the time of healing, and improves the functional result. Moreover, the temporary attachment of the muscles secured by the sutures is one of the very best means of guarding against undue retraction and of securing for the muscles a condition of rest best calculated to prevent muscular twitching, one of the greatest sources of discomfort and pain after amputation.*

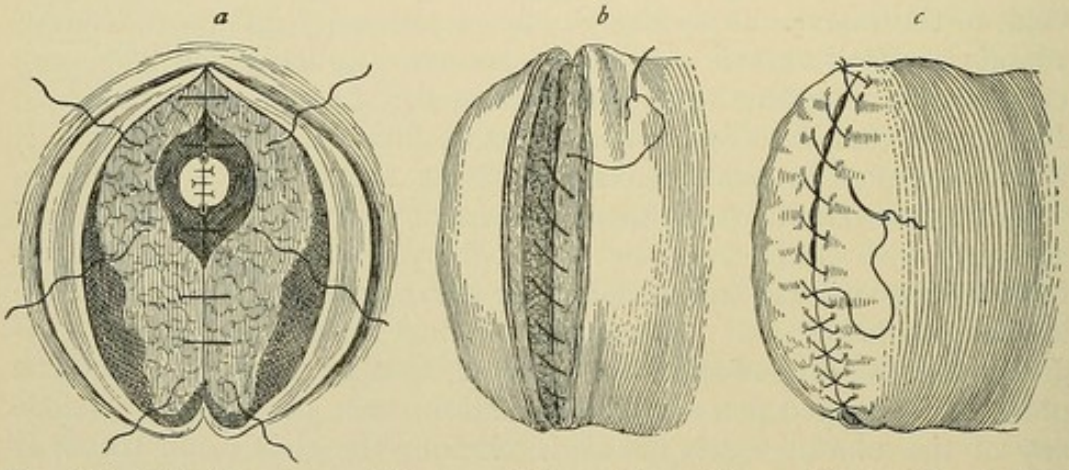

Fig. 615.—Suturing of amputation wound (von Esmarch): *a*, Periosteal and deep muscle sutures; *b*, buried muscle sutures; *c*, skin sutures.

For this suturing the needle should be round, large, and well curved, and the sutures should embrace corresponding extensor and flexor muscles, one or more of which should rest on the end of the bone. These sutures contribute much toward giving the stump the proper cone shape immediately after the operation. The stump is now ready for drainage and suturing of the flaps. *All wounds made by amputations for inflammatory affections must be drained. All large amputation wounds must be drained. Small amputation wounds after the removal of a part of a limb for an aseptic condition can be sutured throughout without making provision for drainage. Drainage of amputation stumps should be established where drainage is most effective, and in such a manner as not to interfere with primary healing of the operation wound.*

The best method of draining an amputation wound consists in making, at the base of the flap, at the most dependent portion of the wound, a buttonhole large enough to insert a tubular drain of

requisite size, which occupies the space between the flap and the sutured muscles, and should not extend beyond the end of the bone. The drain must be well fenestrated and secured with a large safety-pin. Kocher secures the drain by tying to its projecting part a long and strong silk thread, which is brought out through the dressing. When the drain is to be removed it can be done without removing the dressing by making traction on the thread. *The flaps must be sutured as carefully as wounds made for plastic purposes.* Glover's needles, silkworm-gut, and horsehair are used for sewing the external wound. The wound margins must be carefully distributed, which is most effectually done by first fastening together the center of the flaps by a central suture, and then subdividing each half by two lateral sutures. Silkworm-gut of medium size is the best material for the deep interrupted sutures, which must include the entire thickness of the flaps. Usually two or three sutures to the inch will bring the deep tissues of the flap in accurate apposition. The sutures must be tied only with sufficient firmness to bring the margins of the flap in contact, carefully avoiding harmful linear compression.

Dressing of the Stump.—A copious dressing of loose gauze and absorbent aseptic cotton, held in place by a gauze roller, constitutes the best protection against subsequent infection, and at the same time is of much service in securing for the stump, what is so much needed,—uninterrupted equable compression and rest. Before the hygroscopic dressing is applied the sutures are buried by sprinkling over them the borosalicylic powder. A separate ring of cotton is placed around the limb above the gauze, after which a thick cushion of absorbent cotton is placed over the gauze and the cotton ring, the whole being retained in place by a gauze roller carefully applied. *Every stump must be immobilized as constantly and as carefully as a fractured limb.* A well-padded hollow splint, extending from the end of the stump along the surface of the limb, outside of the dressing, to a distance requisite to secure rest of the part of the limb operated upon, and fixed in position by a gauze roller, is the most efficient means of securing muscular rest, and consequently of preventing pain and of procuring for the wound the desirable conditions for a speedy ideal primary healing. The mechanical support should not be dispensed with until the wound is firmly healed throughout. After the operation the limb must be placed at an angle of at least 45 degrees for from six to twenty-four hours, for the purpose of minimizing the amount of primary wound secretion by diminishing the force of the arterial circulation and favoring the return of blood through the veins.

Cutaneous Flaps.—The most skilful and successful method of covering an amputation wound is by cutaneous flaps. As has been described above, the flaps should include the aponeurotic investment of the muscles as an additional source of blood supply, and as an aid in preventing undue retraction of the severed muscles. In

making the flaps the surgeon must imitate his work in plastic surgery, paying due attention to the blood supply, shape, and size of the flaps. Stephen Smith recommended two lateral oval flaps of equal size. The greatest objection to this method of flap formation is the line of suturing and the subsequent location of the scar directly over the center of the stump. The same objection holds good if similar anteroposterior flaps are made. *The one great rule that should govern the surgeon in making the incision is to the effect that the flaps should not be of the same length, in order that the line of suturing and the subsequent scar may not be in the center of the end of the stump.* Another rule of almost equal importance emphasizes the value of rounding off the free margin of the flaps so that they can be sutured together without wrinkling the skin, which always creates dead spaces and leaves the surface of the stump uneven. The square flap of Teale is open to these objections.

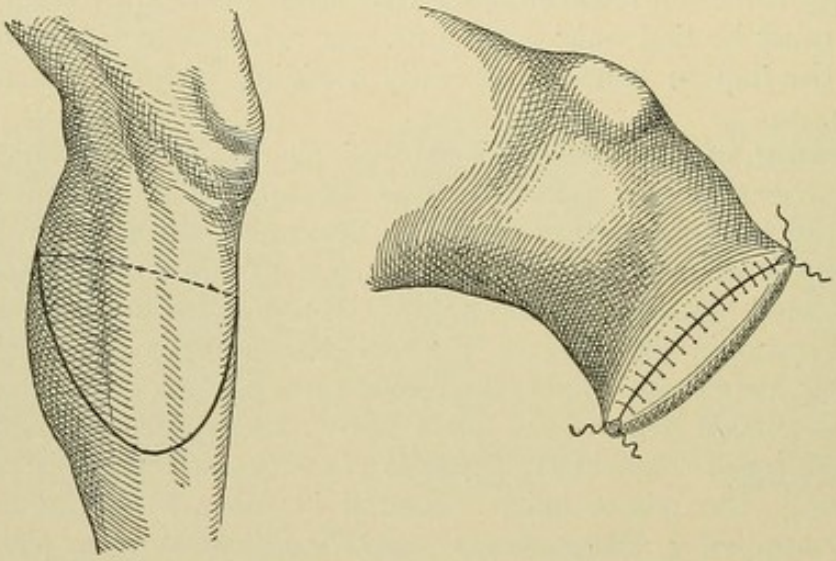

Fig. 616.—Von Langenbeck's long lateral flap.

Liston and Langenbeck covered the operation wound with one long oval flap, which, from a technical point of view, has much to recommend it. The method is likewise well adapted for amputation of the fingers, as it yields a sightly and useful stump. A long oval flap from either the dorsal or the palmar side covers the wound perfectly, and the line of suturing falls away from the surface of the end of the stump. The tissues of the fingers are so well supplied with blood that there is no danger of sloughing of the flap from this source, which is not the case if the amputation is made above the middle of the forearm or above the ankle-joint, where the circulation in the skin is less vigorous and the danger of sloughing consequently increased.

The method of flap formation devised by von Bruns, consisting of a long oval anterior and a short oval posterior flap, recommends itself as the most advantageous, certainly yielding the best immediate and remote results (Fig. 614). This method of amputation

yields the most serviceable stumps for the wearing of artificial limbs, and should therefore constitute the operation of choice in all amputations of the lower extremity above the ankle-joint. If the local conditions indicate it, the operation can be modified by making a long oval posterior and a short oval anterior flap, or by making oval lateral flaps of unequal length. The remaining steps of the operation are identical with circular amputation as described.

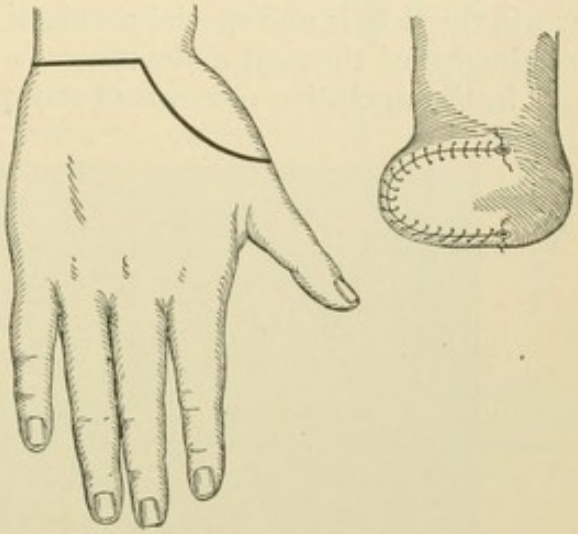

Fig. 617.—Von Walther's lateral radial flap for disarticulation at the wrist-joint.

Musculocutaneous Flaps.—The formation of musculocutaneous flaps by transfixion has been mentioned more for the purpose of recalling a step in the evolution of the history of amputation than with any intention of giving a full description of the operation. Langenbeck improved the operation by making the flap by incision from without inward, instead of by transfixion. He invented and used a small amputation knife in place of old-fashioned transfixion instruments. The musculocutaneous flap is the one especially adapted for disarticulation at the shoulder-joint, when the operation most frequently performed is by a long oval flap that includes the deltoid muscle.

AMPUTATIONS OF THE UPPER EXTREMITY.

No such sharp distinction, from a descriptive, anatomic, and practical standpoint, is made between amputation and exarticulation in this country as on the European Continent. We are in the habit of speaking of amputation, rather than disarticulation, at the shoulder-joint or hip-joint. The old text-books on operative surgery teem with the names of surgeons who have devised new methods of amputation and various modifications, and they contain confusing accounts of the anatomic descriptions upon which some of them are based. The student's memory has been largely taxed by attempts to master the technic of the different operative procedures and in the endeavor to remember the indications for the same. Many an examination for the professional degree has been made memorable by questions relating to the details of complicated methods of amputation, which the candidate never expected to perform, and concerning which the examiner's knowledge was limited to what he learned by glancing over the pages of a superannuated text-book on surgery. We have insisted before that the most successful surgeon is the one who is familiar with anatomy and surgical pathology, and

who is endowed with the requisite amount of common sense and mechanical skill to plan and execute methods and modifications of amputations appropriate for each individual case. Incalculable harm has been done by blindly following the footsteps of others, and this is more especially true of amputations. The surgeon must be familiar with the principles that underlie the manual part of his work, the details and special applications of which principles require originality of thought and action.

In the operative removal of any part of the upper extremity the

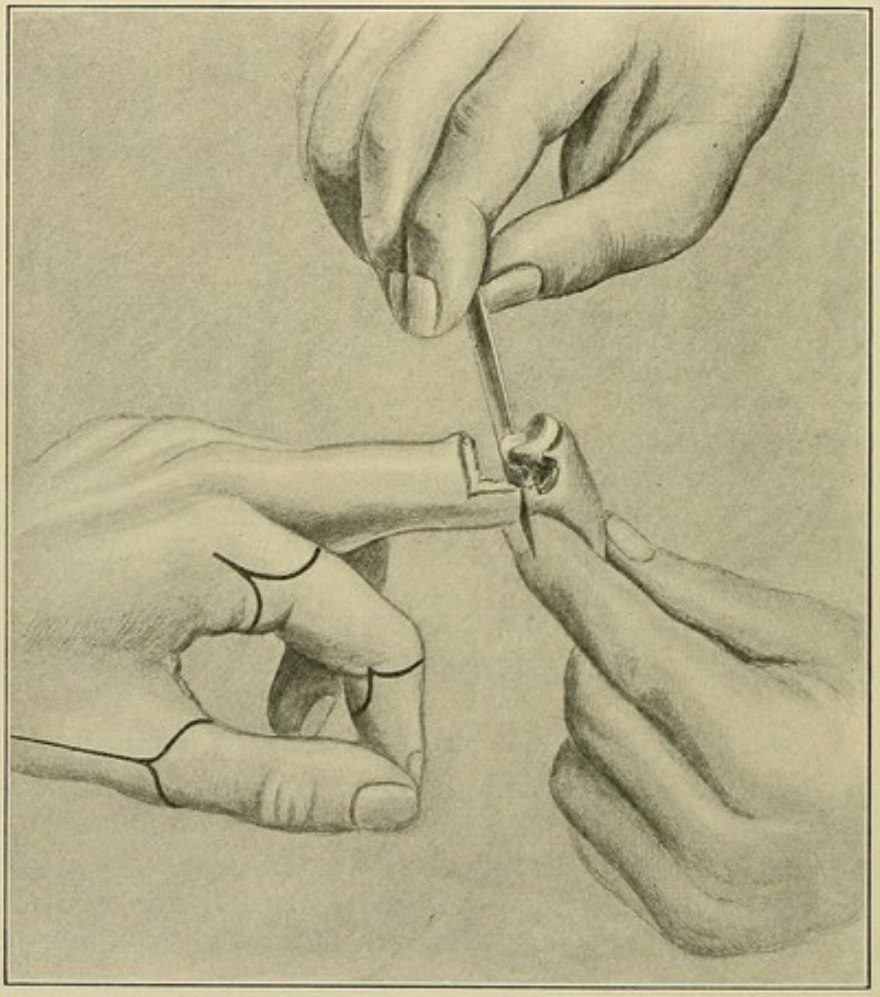

Fig. 618.—Disarticulation of the fingers: disarticulation of the middle finger at the interphalangeal joint; opening of the joint on its dorsal aspect. Formation of a palmar flap by incision from within outward. Upon the thumb: line of incision for removal of the thumb at the carpometacarpal joint by means of an oval incision. Upon the index-finger: flap incisions (Zuckerkandl).

ultimate object of the operation must have in view a maximum functional result. Conservatism to its extreme limits is the rule that must guide the surgeon in performing mutilating operations on the fingers and hands. The prehensile power must be preserved as far as possible in the treatment of injuries and destructive inflammatory affections of the fingers and hands. The hand is the part of the body where atypical operations are most frequently performed.

Every finger and every joint of a finger are necessary for the full grasping power of the hand, but the most important part of the prehensile apparatus is the thumb; for this reason the surgeon is always anxious to save every inch and every fraction of an inch of this the most useful member of the hand.

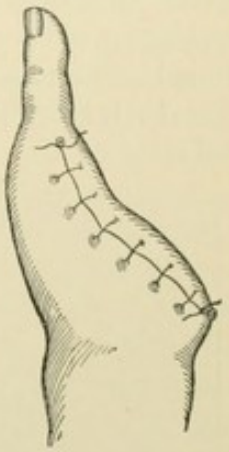

Fig. 619.—Stump after exarticulation of the last four metacarpal bones (von Esmarch).

In the disarticulation or amputation of a finger below the metacarpophalangeal joint the operation of choice is to cover the wound with a long palmar flap, but if the conditions are such that more of the finger can be saved by making a dorsal or a lateral flap, the surgeon should never hesitate to pursue the more conservative course. The skin on the palmar side of the fingers is best adapted as a covering for the amputation wound, and, as it is freely supplied with blood-vessels and possesses a maximum intrinsic recuperative power, there is very little, if any, risk of gangrene in covering the wound with one long oval flap. The flap should always be made by cutting from without inward, never by transfixion. If anything can be gained in preventing harmful shortening of the finger by making a dorsal or lateral flap, the surgeon adapts himself to existing circumstances and pursues the most conservative course. A very important rule to follow in amputating a finger below its base, and one that is too often ignored, is to suture the extensor to the flexor tendon over the articular end or sawn surface of the bone.

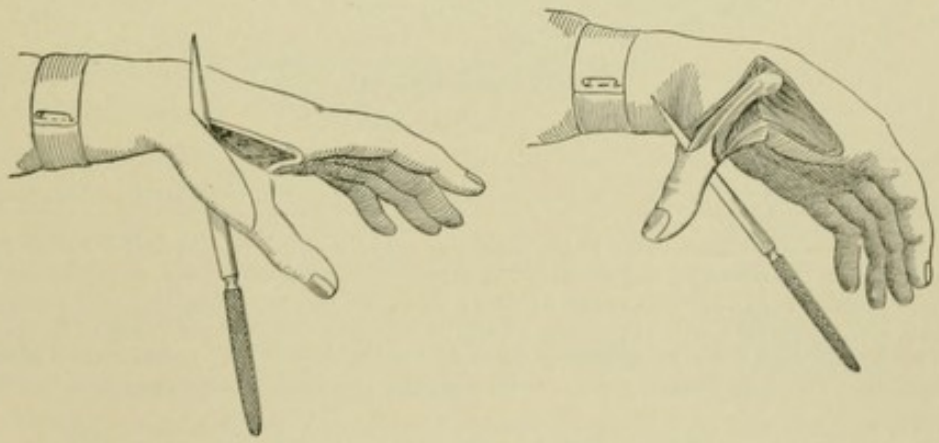

Fig. 620.—Disarticulation of the thumb by radial flap (after von Walther).

Tendon suture under such circumstances becomes a necessity, for the purposes of preventing undue retraction of the flap and of furnishing the cut ends of the tendons with a permanent point of anchorage. Immobilization of the stump is essential in procuring the conditions necessary for an ideal healing of the wound. The fixation dressing should include the hand, and must remain until the wound is firmly healed.

In injuries and diseases of the hand, plastic operations often become necessary for the restoration of the soft tissue and preservation of the bony framework. Atypical operations, in attempts to preserve as much as possible of the prehensile power of the hand, are in vogue here more than elsewhere. The loss of a metacarpal bone has been successfully replaced by an autoplastic operation, consisting in transplanting one half of the adjacent bone. In extensive injuries of the hand the prehensile power is preserved to a wonder-

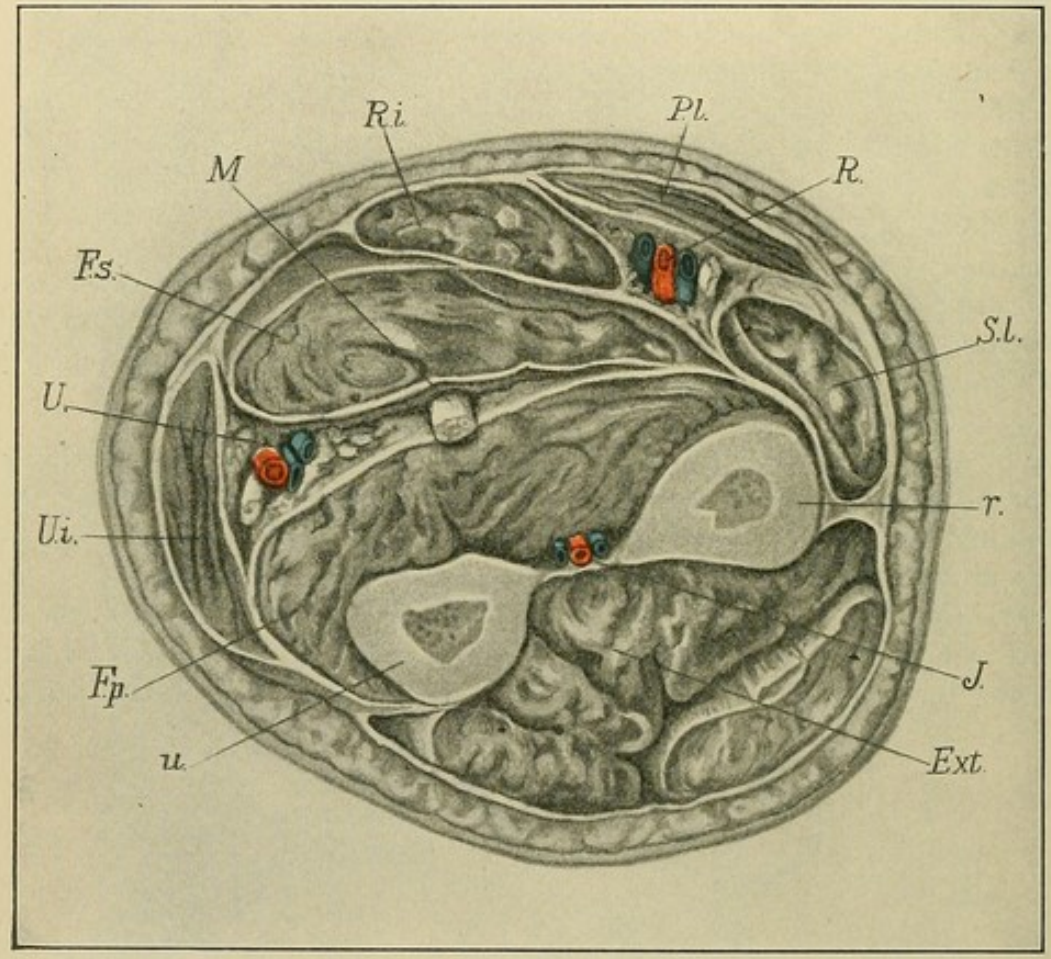

Fig. 621.—Transverse incision through the middle third of the left forearm (after Zuckerkandl) : *r.*, Radius ; *u.*, ulna ; *F.s.*, flexor digitorum sublimis ; *F.p.*, flexor digitorum profundus ; *U.i.*, flexor carpi ulnaris ; *R.i.*, flexor carpi radialis ; *P.l.*, palmaris longus ; *S.l.*, supinator longus ; *Ext.*, group of extensor muscles ; *U.*, ulnar artery in a common sheath with the corresponding veins and ulnar nerve ; *R.*, radial artery with the corresponding veins and nerve ; *M.*, median nerve ; *J.*, interosseous artery.

ful extent by preserving the thumb and little finger, with the corresponding metacarpal bones. In disarticulations at the metacarpophalangeal joints the head of the metacarpal bone should always be preserved in cases in which a good functional result is of greater consequence than the cosmetic effect. Two lateral oval flaps of equal length furnish the best covering for the head of the metacarpal bone. In disarticulation of the little and index-fingers and thumb the flap is taken, in preference, from the palmar surface. Conservatism to the maximum limits is indicated more especially in

operations about the base of the thumb, as the metacarpal bone of this finger constitutes an important part of the grasping power of the hand.

In amputations at and above the wrist-joint conservatism, as far as the length of the stump is concerned, is of minor importance, although the rule holds good here to make the operation as far away from the trunk as is compatible with the indications necessitating the operation.

In amputations of the arm and forearm and disarticulation at the elbow- and wrist-joints, the best immediate and remote results are obtained by making oval anteroposterior flaps of unequal length. It is immaterial on which side the long flap is made. In amputations of the forearm it is often convenient and advisable to cover the wound by one oval lateral flap from either the radial or the ulnar side, as indicated by the location of the injury or the disease that necessitated the operation. For disarticulation of the wrist-joint von Walther recommended such a flap to be taken from the radial side (Fig. 617). Muscle or tendon suture over the end of the bones of the forearm adds materially to the desirable form of the stump

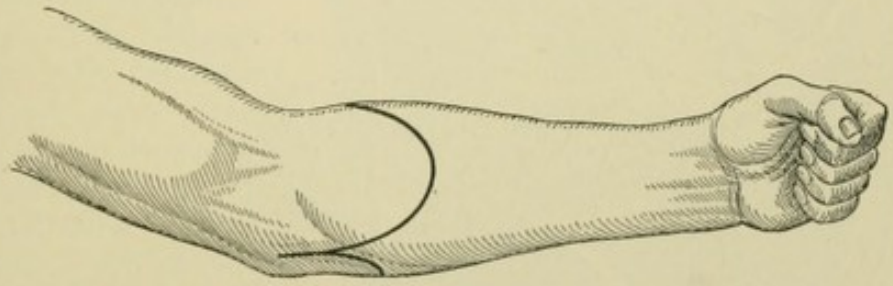

Fig. 622.—Disarticulation at the elbow-joint; flap incision (Zuckerkandl).

and its usefulness. During the suturing and dressing of the wound the stump must be held in a flexed, elevated position, half-way between pronation and supination. In this position it is immobilized either by applying a few turns of the plaster-of-Paris bandage over the dressing or by the use of a well-padded hollow splint. In high amputations of the forearm it must not be forgotten that even a short stump is of great service to the patient, and that on this account, if for no other, a very high amputation is preferable to exarticulation at the elbow-joint.

Disarticulation at the elbow-joint by a long anterior semilunar and a short posterior semilunar flap recommends itself as the best technical procedure when such an operation is in consonance with the conditions it is intended to remove. An oval incision an inch and a half below the condyles outlines the long anterior flap, after which the forearm is forcibly flexed and rotated in such a manner that the posterior surface of the joint is directed forward. A slightly oval incision from one condyle to the other divides the skin, fascia, triceps tendon, and lateral ligaments; and a second incision severs the remaining structures on the anterior surface of

the joint. After the hemostasis and nerve exsection have been completed, the tendon of the biceps is united with the tendon of the triceps with one or two sutures of strong catgut. The stump, properly immobilized, should be bandaged over a cushion of absorbent cotton to the side of the chest, for the purpose of securing the desired rest.

Amputation of the arm between the elbow- and shoulder-joints is one of the easiest of all major operations. Semilunar flaps of unequal length are usually made, although a circular amputation in two steps, as has been described, has a practical application, more especially in cases in which it is desirable to complete the operation in a few minutes. Neuromata are very prone to develop in stumps after amputations of the arm and upper part of the forearm, and for this reason the surgeon must exercise the necessary care for their prevention by primary nerve excision and by securing healing of the wound by primary intention.

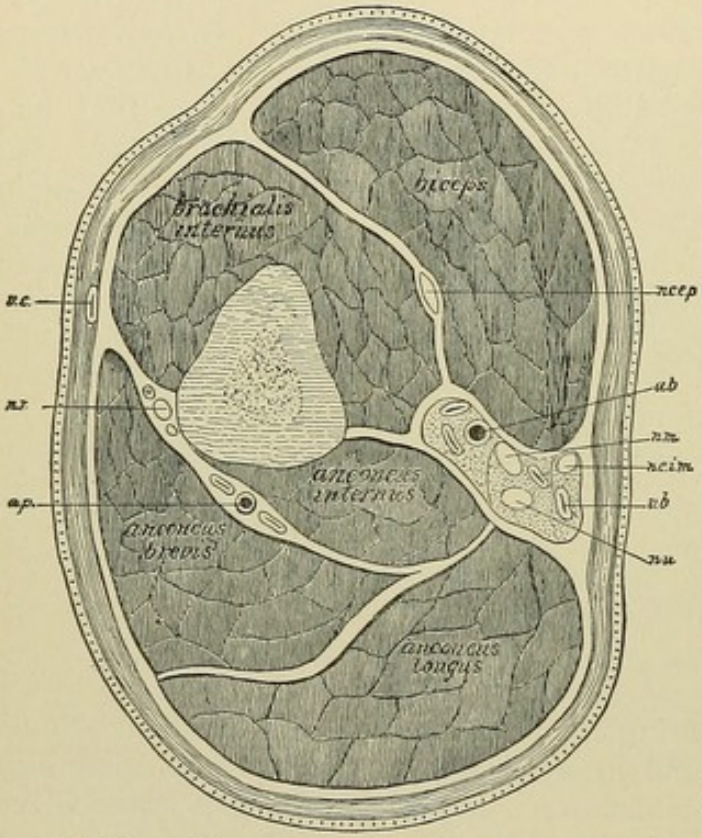

Fig. 623.—Transverse section through the middle third of the right arm (von Esmarch): *v.c.*, Cephalic vein; *n.r.*, musculospiral nerve; *a.p.*, profunda artery; *n.c.e.p.*, external cutaneous nerve; *a.b.*, brachial artery; *n.m.*, median nerve; *n.c.i.m.*, greater internal cutaneous nerve; *v.b.*, basilic vein; *n.u.*, ulnar nerve.

Disarticulation at the shoulder-joint presents no unusual technical difficulties aside from diverting hemorrhage during the operation. It is in this locality that the flap formation should include the muscles, provided this can be done without incurring any risk of incomplete removal of diseased tissue. Prophylactic hemostasis is effected either by elastic constriction or by preliminary ligation of the axillary artery. Elastic constriction above the joint is made by passing a mattress or stout steel needle from before backward, between the neck of the scapula and the axillary vessels, making the constriction between the needle and the chest. The constriction is made with an Esmarch constrictor, rubber tubing, or, if these contrivances are not at hand, with an elastic suspender or a Spanish windlass. *The needle must transfix the tissues at a point sufficiently*

far above the joint to hold the constrictor safely in place after the disarticulation has been made. As an additional safeguard against the slipping of the constrictor it is advisable to transfix the skin with a smaller needle over the shoulder, two and a half to three inches from the margin of the acromion process. Elastic constriction applied in this manner temporarily cuts off all blood supply below the constricting line, and is a favorite method of controlling hemorrhage in disarticulation at the shoulder-joint.

The same object is attained, although to a less nearly perfect degree, by preliminary ligation of the axillary artery. After making the long semilunar flap, including the entire deltoid muscle, and turning it upward, the shoulder-joint is fully exposed, the capsular ligament cut sufficiently to dislocate the head of the humerus, when the free part of the humerus is displaced laterally sufficiently to

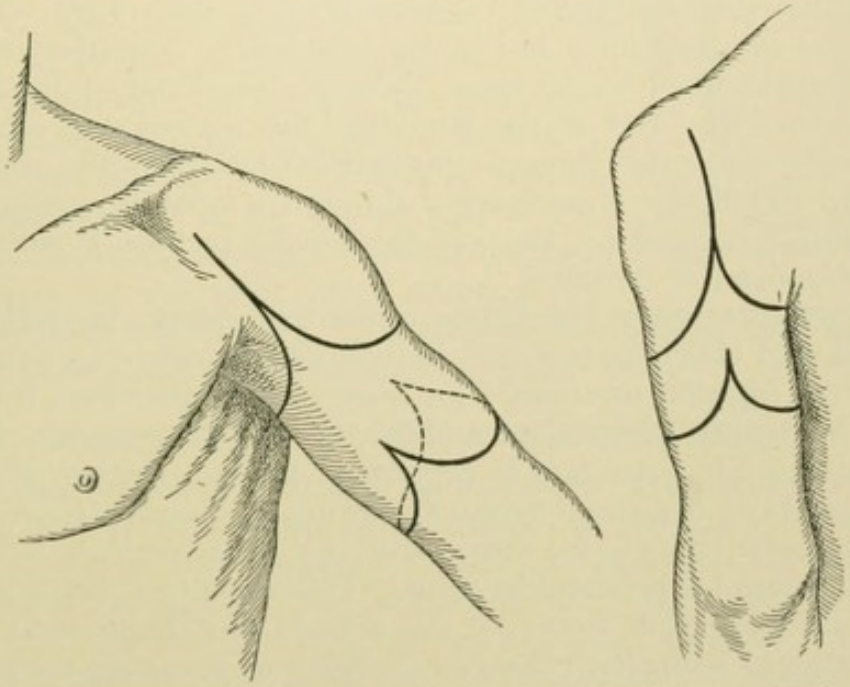

Fig. 624.—Flap incisions for amputation and disarticulation of the arm (Zuckerkandl).

expose the axillary vessels for ligation. The axillary artery is tied above the proposed line of amputation, and a second ligature, about a third of an inch lower down, includes, besides the artery, the corresponding vein. After applying the hemostatic forceps to the artery below the last ligature, the vessel is cut between and the incision made from this point from within outward, in forming the inner short semilunar flap. By proceeding in this manner no blood is lost from the principal vessels, and in making the external flap the spurting points are caught with hemostatic forceps, which are relied upon during the operation to control the hemorrhage from this source.

Elastic constriction merits the preference in cases in which the loss of even a small quantity of blood might prove disastrous to the patient, while preliminary ligation is the method of choice in all

other cases, more especially in disarticulation for malignant disease and infective lesions that have encroached closely upon the shoulder-joint. The deltoid musculocutaneous flap fills in, cushion like, the large lateral defect created by the disarticulation, preserving the rotundity of the shoulder, while a cutaneous flap leaves the acromion process as an unsightly and often inconvenient prominence.

The amputation wound is drained through a buttonhole made in the center and at the base of the short inner flap, leaving the wound free to be sutured throughout. A copious dressing, held in place by broad strips of adhesive plaster and gauze bandage, is relied upon in protecting the wound against infection and in procuring and maintaining rest for the wound. The patient should be placed in the recumbent position, with the chest slightly elevated, and continued so for at least a week. In cases requiring haste in completing the disarticulation the arm is amputated by the circular method, below the shoulder-joint, in the usual manner. A vertical incision is then made down to the bone, through the center of the deltoid muscle, from the end of the stump to the acromion process, the bone being enucleated through this incision with knife and periosteal elevator. Drainage is established through a separate opening, and, after closing the vertical incision, the circular incision is sutured in an anteroposterior direction.

Exarticulation of the entire upper extremity, including the scapula and clavicle, is a very formidable procedure and attended so far by a frightful mortality; for these reasons, therefore, it should never be lightly undertaken and never without adequate reliable assistance. The operation is performed for the removal of malignant tumors of the arm beyond the reach of disarticulation at the shoulder-joint, usually for sarcoma of the humerus with extension of the disease to the shoulder-joint. Occasionally it becomes necessary for malignant disease of the scapula with implication of the soft tissues in a direction that, for its removal, demands the sacrifice of the whole upper extremity. The only prophylactic hemostatic precaution in the removal of the whole shoulder-girdle is the preliminary ligation of the first part of the axillary artery. I have always performed this step of the operation through the amputation wound after making the anterior branch of the oval incision. It is not always necessary to remove the entire clavicle, and, if possible, it should invariably be avoided.

The incision is commenced over the clavicle, at a point where it is the intention to disarticulate or divide the bone, and is carried in front over the bone, until the tendinous expansion of the pectoralis major muscle is reached; from here it is continued downward to the anterior axillary border. After section of the pectoral muscles, the upper part of the axillary artery can easily be reached and tied. The posterior branch of the incision is then made, starting from the straight incision and carrying it over the acromion process in the direction of the posterior axillary border, then in a forward direction

until it meets the anterior branch, in the center of and near the base of the axillary space. The cutaneous borders are reflected backward until the parts to be removed are freely exposed, when the whole clavicle or the part to be excised is lifted carefully from its bed by the cautious use of the knife and the free resort to the periosteal elevator. The scapula is liberated by rapid strokes of a strong scalpel, and the operation finished with all possible speed, for in spite of the diligent and expert use of hemostatic forceps, hemorrhage is quite free and sometimes alarming during this step of the operation. Special care is required during the last part of the exarticulation to divide the vessels and tissues around them at a safe distance *below* the ligature. Two drains should be employed in draining the enormous wound, each at least of the thickness of the middle finger. One of the drains is brought out through a buttonhole in front of the axillary space at the lowest part of the wound; the other, through a similar opening posteriorly on the same level, draining the scapular side of the wound. The dressing and fixation are the same as after disarticulation at the shoulder-joint.

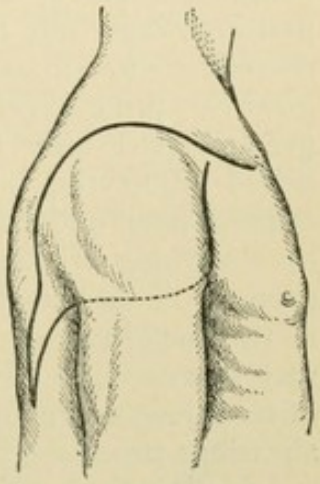

Fig. 625.—Removal of the whole upper extremity (Berger).

AMPUTATIONS OF THE LOWER EXTREMITY.

In man the lower extremities are intended principally for locomotion, and in performing amputations the surgeon's aim should be to interfere as little as possible with this important function. In all amputations between the junction of the middle with the lower third of the leg and through the lower part of the upper third of the thigh, the operation is planned and executed with special reference to securing a painless, useful stump for the wearing of an artificial limb. To meet this indication in a satisfactory manner without coming into conflict with the main purpose of the amputation requires frequently a very keen judgment and no small degree of originality in devising the method of operating appropriate for each individual case. No inflexible rules can be laid down for the guidance of the surgeon. It is in difficult cases requiring exceptional methods of operating that the surgeon can show his skill and moral courage to the best advantage, based on a comprehensive knowledge of the pathologic conditions with which he has to deal, and his ingenuity in devising, often on the spur of the moment, new operative procedures to meet the exigencies of the case.

Amputation of Toes.—In injuries and diseases of the toes requiring amputation the rule to save as much tissue as possible, so forcibly laid down in amputations of the fingers, does not apply.

The functional results are much better after the removal of a whole than of a part of a toe. Resection as a substitute for amputation in inflammatory affections of the joints of the toes, with the exception of the metatarsophalangeal joint of the big toe, can not be advocated, as was done in similar affections of the fingers. The complete removal of any one of the toes, with the exception of the first one, does not impair the usefulness of the foot, and there is, therefore, no excuse for conservatism. Cases of dry gangrene, however, are exceptions to this statement, the removal of the gangrenous part after the line of demarcation has been well established being the best procedure, as a typical operation by any other course, under such circumstances, is not infrequently followed by sloughing of the margins of the flaps and extension of the gangrene. A stump after amputation of any of the toes adds nothing to the usefulness of the foot ; on the contrary, it is usually in the way in wearing a shoe and in walking, and often becomes the seat of troublesome inflammatory affections caused by infection through abrasions produced by mechanical irritation.

In injuries and destructive affections of an isolated toe the operation of choice, with the exceptions previously stated, should always be disarticulation at the metatarsophalangeal joint, followed by resection of the head of the corresponding metatarsal bone. In amputations of the first and fifth toes the principal flap must be taken from the plantar side, as, owing to its structure and prolonged use by supporting the weight of the body in standing and walking, it is much better adapted for a lateral covering of the foot than is the dorsal side. In amputating any of the remaining toes the oval incision is commenced on the dorsal side, over the center of the metatarsal bone, above its head, and is extended on each side of the base of the toe, joining in the middle on the plantar side. With a few strokes of the knife the joint is exposed, and, by a transverse cut on the dorsal side, the extensor tendon and ligaments are cut and the disarticulation completed under extreme flexion of the toe. After cleaning the bone above the head of the metatarsal, the bone section is made by the use of small bone-cutting forceps. After careful hemostasis the heart-shaped wound is sutured throughout in its long axis, unless there are special reasons for establishing drainage.

In amputation of the great toe the metatarsal bone above its head should be divided obliquely with a small saw, as resection by a transverse section of the bone would leave a sharp prominence that, in this locality, must be carefully avoided, for obvious reasons. Disarticulation, on the other hand, without resection of the head of the metatarsal bone would leave an unsightly and troublesome protuberance, the source of a great deal of discomfort and distress in the subsequent wearing of a shoe. The large sesamoid bone, so constantly found in this locality, should be removed, as its presence in the tissues is liable to become a source of irritation when the patient

resumes the use of the foot. If it becomes necessary to remove the corresponding metatarsal bone, whole or on a higher level than is necessary for resection of its head, the dorsal incision is extended to the requisite extent.

Disarticulation of all the toes occasionally becomes necessary for crushing injuries or gangrene following frost-bite. The dorsal incision is made from one side of the foot to the other, directly over the metatarsophalangeal joints. These latter are then opened while the toes are held in a strongly flexed position, and the plantar flap, which is depended upon entirely as a covering for the wound, is made by cutting either from without inward or from the line of disarticulation outward. It is preferable to make the flap by cutting

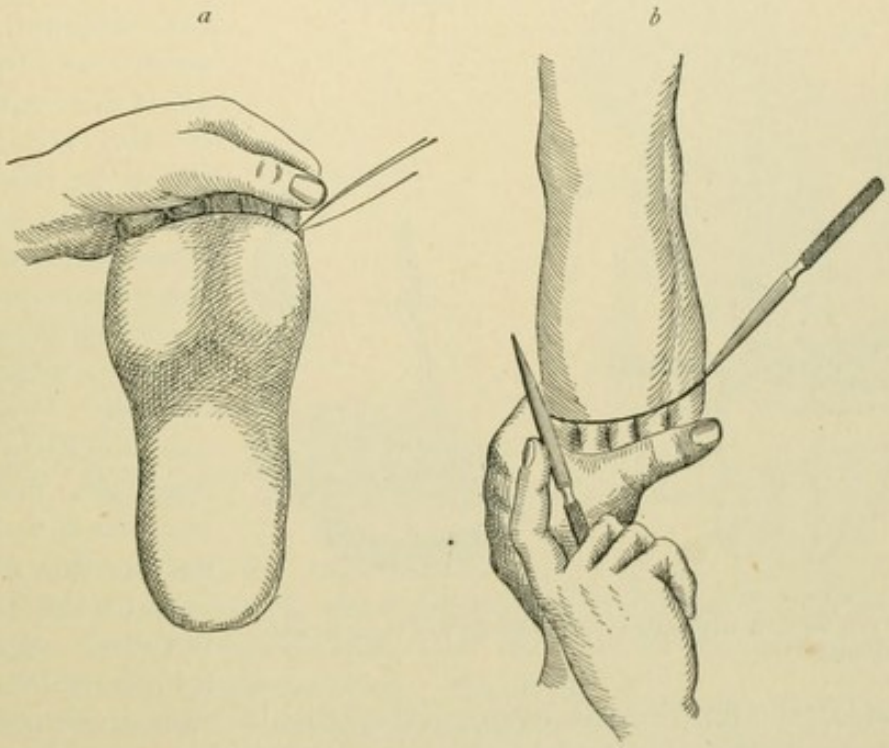

Fig. 626.—Disarticulation of all the toes (von Esmarch): *a*, Plantar incision; *b*, dorsal incision.

from without inward, as in doing so the operator is in a better position to secure proper length and shape of the flap. The plantar flap must be made sufficiently long to permit of its being sutured to the margin of the dorsal incision without producing tension. Making the flap too short is not a rare mistake. In this operation the heads of all the metatarsal bones are preserved, as their excision would seriously impair the plantar arch and, in the same ratio, the functional utility of the foot.

Amputation through the metatarsus at any level is made by the same method of flap formation as in disarticulation at the metatarsophalangeal joints—that is, by covering the wound with an oval plantar flap. After clearing the bones at the proposed line of amputation, the section is made with an ordinary amputation saw. The

obstinate oozings from the medullary canals, as well as the size of the wound, are usually regarded as sufficient reasons for establishing tubular drainage. There is no objection in such cases to through tubular drainage from one angle of the wound to the other, leaving the stitch nearest the angle of the wound untied until after the removal of the tubular drain.

Lisfranc's tarsometatarsal disarticulation has become obsolete. This operation has been the stumbling-block of medical students and the dread of the operator in the clinical amphitheater since it was devised by the illustrious surgeon whose name it bears. When this operation was originated it met with well-deserved favor, as the suppuration that so constantly followed nearly every operation was known to prove less disastrous in disarticulations than in amputations that required bone section and the unavoidable exposure of the medullary tissue to infection, with all its serious immediate and remote consequences —osteomyelitis, sepsis, pyemia, and necrosis. Asepsis has removed this objection, and the surgeon is now free in the use of the saw in the neighborhood of Lisfranc's joint. If, on making the line of section, any of the articular ends are found free, they are removed; if attached, they are permitted to remain. In all amputations between the ankle-joint and the base of the toes the stump must be immobilized at a right angle to the leg, and the fixation dressing, plaster-of-Paris bandage, or a well-padded posterior hollow splint must include the leg as far as the head of the tibia.

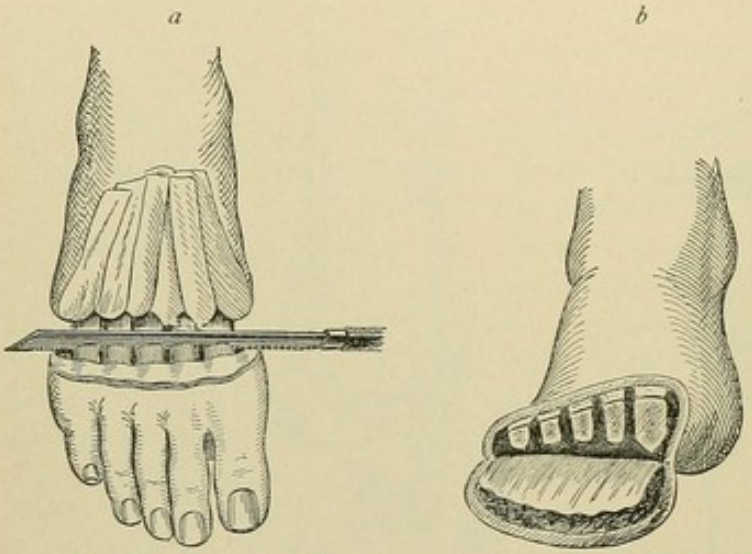

Fig. 627.—Amputation through metatarsus (von Esmarch): *a*, Section with saw; *b*, appearance of wound after amputation.

Mediotarsal Disarticulation.—Mediotarsal disarticulation, an operation devised by Chopart, has recently been severely criticized, and many surgeons have abandoned it, claiming that the stump is less serviceable to the patient than an artificial limb after amputation of the leg at the point of election, and that the immediate risk to life is not increased by substituting amputation of the leg for Chopart's disarticulation. My experience has satisfied me that the functional result following Chopart's operation, when properly performed, is an excellent one—by far superior to anything that could be furnished by the instrument maker after an amputation of the leg. The difficulty heretofore connected with the mediotarsal amputation has been

in preventing retraction of the heel. Subcutaneous section of the tendo Achillis has been practised repeatedly, either at the time the operation was performed or later, after retraction had set in, but the

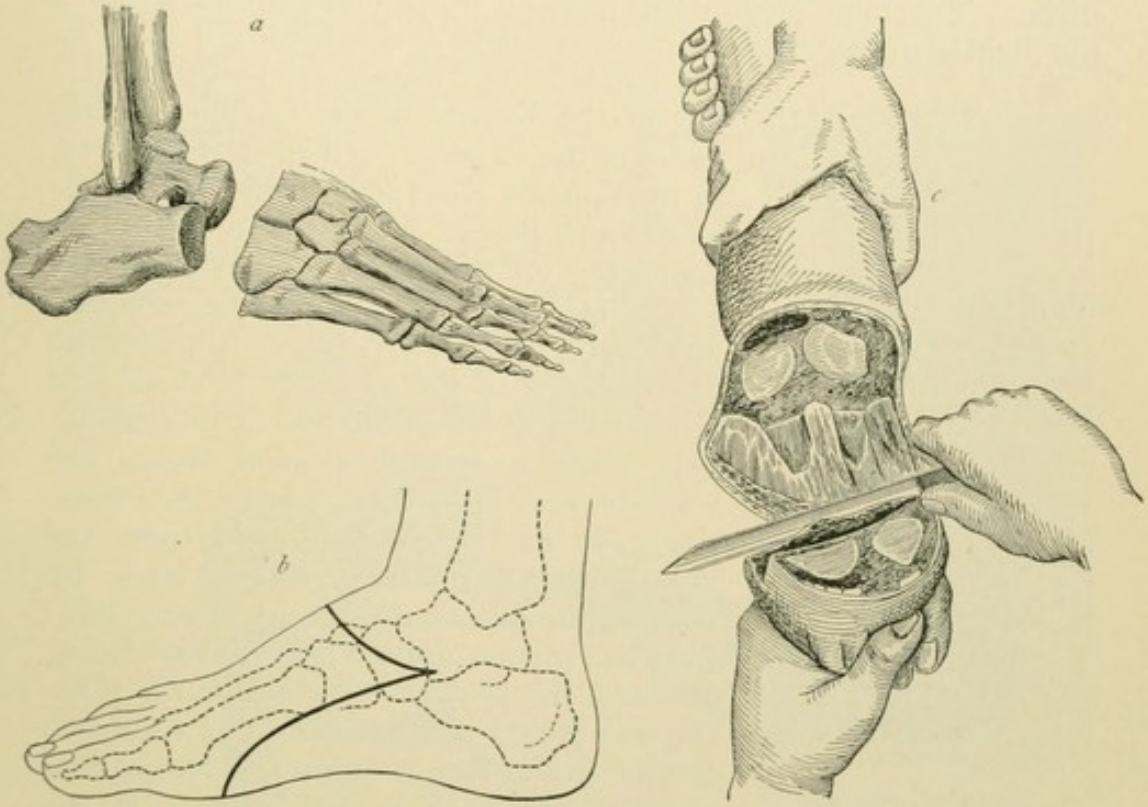

Fig. 628.—Chopart's amputation (von Esmarch): *a*, Mediotarsal joint; *b*, line of incisions; *c*, completion of plantar flap after disarticulation.

results did not fulfil the expectations. During the last four or five years I have succeeded in preventing heel retraction by suturing the cut flexor and extensor tendons over the head of the astragalus with a row of strong catgut sutures. As an aid to the tendon sutures I have supported the heel and posterior surface of the leg by a posterior plastic splint, or applied a circular plaster-of-Paris splint over the dressing, extending from the end of the stump to the knee.

If what remains of the foot after Chopart's disarticulation is held in proper position by these mechanical aids until the tendon ends are firmly united, retraction of the heel will not occur and the patient will recover with a useful limb. Ankle-joint motion is also preserved, adding much to the functional result.

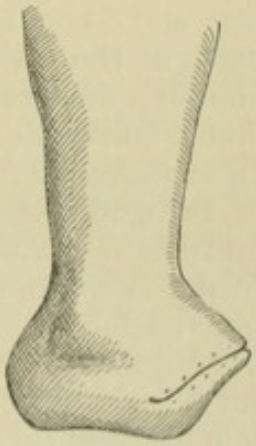

Fig. 629.—Stump after Chopart's disarticulation (von Esmarch).

The line of disarticulation is at the junction of the astragalus and os calcis above with the scaphoid and cuboid bones below. The line of Chopart's joint is found at the outer margin of the foot, about an inch above the tuberosity of the metatarsal bone of the little toe,

at the inner margin, half an inch above the tuberosity of the scaphoid. These two points must be carefully located and marked by indenting the skin with the finger-nail before the first incision is made. The long plantar flap is made by including in the incision the plantar surface between the two points, and extending it as far as the heads of the metatarsal bones, rounding off the free end of the flap by a gentle curve of the incision. All the tissues down to the bones are included in the flap. The foot is now flexed, and the two points are connected on the dorsal side by a slightly curved incision, with the convexity directed downward. This short flap includes all the tissues down to the extensor tendons, and is reflected as far as the line of disarticulation, when a second incision severs the tendons and ligaments. After the disarticulation has been completed from the dorsal side, the plantar flap is made by cutting from above downward, closely hugging the plantar arch. Hemorrhage being arrested, the principal tendons on the plantar and dorsal side are united by from two to four strong catgut sutures. The wound is drained through a small incision in the center and at the base of the plantar flap. Over a copious dressing the fixation splint is applied, as previously indicated. Immobilization of the stump must be continued for at least four weeks, even if the healing of the wound is faultless.

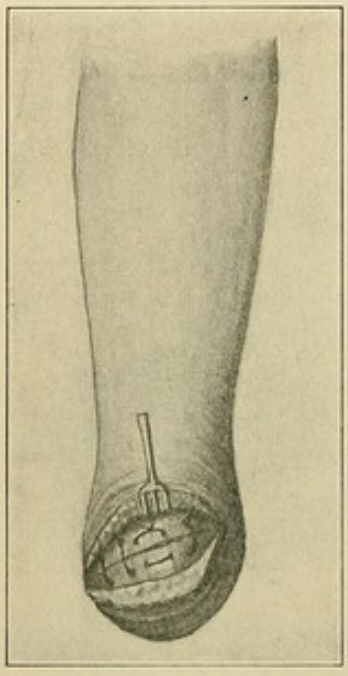

Fig. 630.—Suturing of flexor and extensor tendons after Chopart's mediotarsal disarticulation.

Malgaigne's subastragaloid disarticulation by two lateral flaps and **Syme's amputation through the ankle-joint with excision of the malleoli** are operations no longer entitled to consideration in a modern work on surgery, as amputation of the leg is now almost universally recommended for pathologic conditions and injuries warranting the performance of either of these operations.

Pirogoff's Amputation.—Pirogoff's osteoplastic calcaneotibial amputation has stood the test of time and is deserving of our confidence in appropriate cases. The stump resulting from this operation enables the patient to walk about and follow his occupation without any mechanical support of special construction, a matter of much importance in patients belonging to the working-classes. It is in every sense an osteoplastic procedure, as a part of the os calcis is preserved and becomes later a part of the fibula and tibia, furnishing these bones with a new epiphyseal extremity in every way well adapted to support the weight of the body in standing and walking, as the transplanted part of the os calcis is furnished with a thick elastic cushion of soft tissues admirably fitted for this purpose. I

have performed this operation five or six times, and in every instance the patient was able to walk well, without crutches or cane, in less than a year.

In performing the operation the foot is held at a right angle, and the first incision is made down to the bone, across the plantar surface, from the tip of the external malleolus to that of the internal malleolus. The foot is now flexed toward the plantar side, and the second incision made from the same points transversely over the anterior aspect of the tibiotarsal joint. The next incisions open the ankle-joint in the front and on the sides, when the upper surface of the astragalus is freely exposed.

After the astragalus has been completely dislocated, the foot is depressed sufficiently to bring the posterior surface of the bone into view. Immediately behind the astragalus the os calcis is divided with the saw vertically in a transverse direction. The next step of

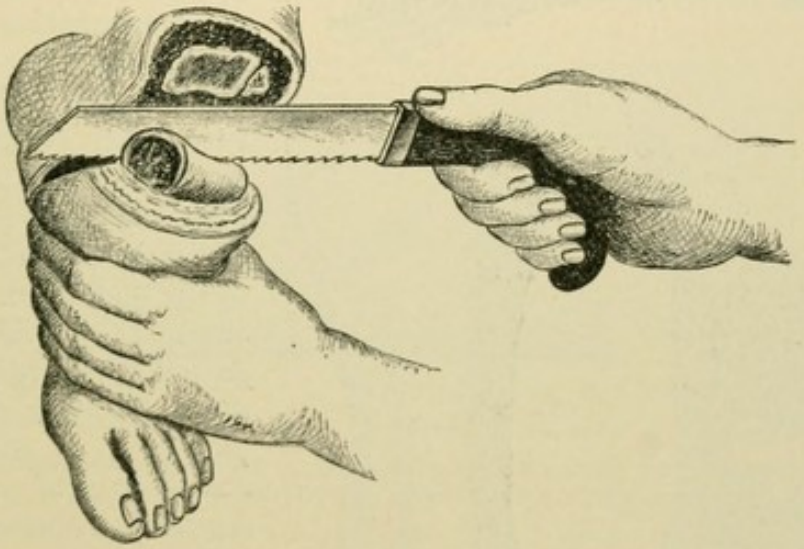

Fig. 631.—Pirogoff's osteoplastic calcaneotibial amputation. Section of os calcis through anterior incision (Wyeth).

the operation consists in clearing the malleoli and resecting them with a thin slice of the tibia. The tendo Achillis is next divided transversely above its insertion, and the skin at the same place is fenestrated for the insertion of a drain. Günther has modified Pirogoff's amputation by dividing the os calcis obliquely from behind forward and downward, and Le Fort and von Bruns remove about one-third of the vertical diameter of the bone by a longitudinal section with the saw. The plantar flap, including a part of the os calcis, must cover the surface of the wound in such a way that there will be absolutely no tension after suturing. The sawn surfaces of the tibia and fibula above, and of the os calcis below, must be brought into accurate contact and immobilized properly. Suturing of the flap can not be relied upon in accomplishing this. The bone surfaces can be held in accurate and uninterrupted contact by resorting to silver-wire suture, bone or ivory nail, or, what I have found reliable in my

practice, by suturing the extensor and flexor tendons with two or three strong catgut sutures.

As extensive bone surfaces always give rise to troublesome oozing, drainage in this operation becomes a necessity. The most efficient drainage is secured by tunneling the base of the plantar flap with hemostatic forceps, and making an opening in the skin large enough to insert a drain the size of the little finger. On the tibial side a smaller drain can be inserted at the angles of the wound. Over the dressing a fixation splint is applied, and special attention paid to make it useful in supporting the plantar flap.

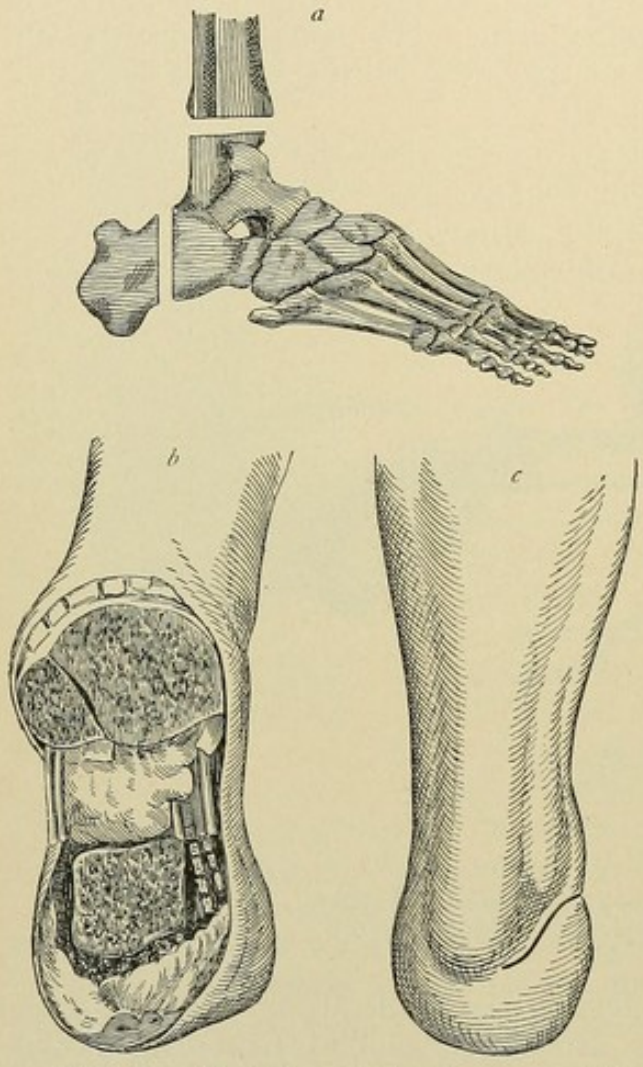

Fig. 632.—Pirogoff's osteoplastic calcaneotibial amputation (von Esmarch): *a*, Line of section through tibia, fibula, and os calcis; *b*, wound surface after amputation; *c*, stump after Pirogoff's amputation.

Amputation of the Leg.—In all amputations of the leg the future utility of the stump must be taken into careful consideration before deciding upon the site of the operation. *A short stump is desirable if the patient, for financial or other reasons, prefers a peg-leg; a stump not less than four inches in length is required to enable the patient to walk with the aid of an artificial limb. The choice of selection of the site of amputation is below the tuberosity of the tibia for the use of a peg-leg, while amputation at the junction of the middle with the lower third yields the best stump for the wearing of an artificial limb. The leg should never be amputated below the junction of the middle with the lower third. Amputation at any point between the two places of election—that is, four inches below the knee-joint and the junction of the middle with the lower third—yields a serviceable stump for the comfortable wearing of an artificial limb.* The technic of the operation is the same whatever anatomic level is selected. Flap formation by transfixion has largely been abandoned in favor of cutaneous flaps. Circular amputation in one or two steps should

never be performed below the knee-joint. The cutaneous flaps, for reasons advanced elsewhere, must be made to include the aponeurotic sheath of the muscles. The cutaneous flaps must be made of unequal length, in order to bring the line of suturing and the external scar resulting from the operation away from the ends of the bone.

The ideal flap formation in amputations of the thigh and leg consists in making a long anterior and a short posterior semilunar flap. However, if the nature of the injury or the location of the disease makes it desirable to reverse the procedure, there is no objection in taking the long flap from the opposite side or in making semilunar lateral flaps of unequal length, as all these deviations from the ideal method accomplish the same object in bringing the line of suturing away from the center of the stump. It is in amputations of the leg and thigh that it is so extremely important to cover the end of the bone with a periosteal flap or cuff, so as to interpose

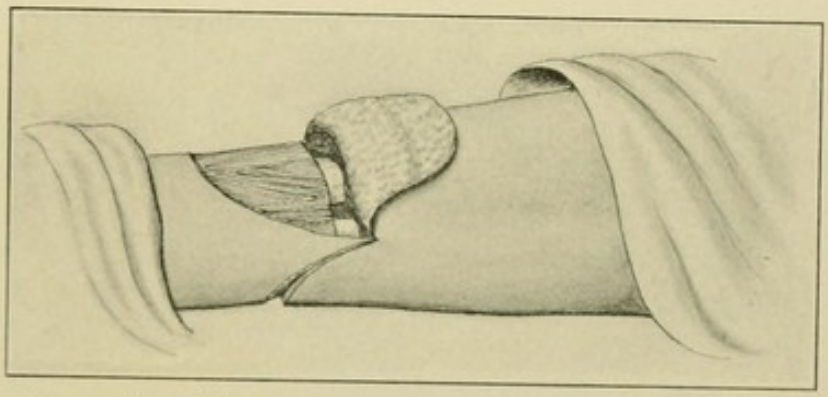

Fig. 633.—Amputation of the leg at the junction of the lower with the middle third. Ideal long oval anterior, and short oval posterior, flaps.

between the flap and the bone the normal envelop of bone—the periosteum.

As the same principles underlie all amputations of the leg, and the technic differs but little in regard to the level where the operation is performed, a description will be given here in detail of an amputation at the junction of the middle with the lower third in illustration of the general remarks on amputation. We will take it for granted that the nature of the injury or the location of the disease is such as to permit flap formation by the ideal method. The limb is held in the extended position, free from the operating table, and on a level suiting the convenience of the surgeon. The base of the long anterior semilunar flap includes one-half of the circumference of the limb, and its length must correspond with two-thirds of the diameter of the limb. At a point corresponding with the proposed level of the amputation the knife is entered at a right angle in the lateral midline of the limb, on the side away from the operator. The incision is carried downward until it is within an inch of the lower limits of the flap, when, in a gentle downward curve, it is

swept across the anterior surface of the limb to the opposite side. Here, in a similar but upward curve, it reaches the midline, and the incision is extended to the same level at which it was commenced. The incision is made deep enough to cut through the fascia of the extensor muscles. The flap must be detached and reflected, without traction, tearing, or violence of any sort, by clean cuts of the knife directed not toward, but away from, the flap. As soon as the dissection has reached a point an inch below the proposed level of amputation, the periosteum of the tibia is incised, raised, and reflected with the cutaneous flap. The posterior flap, about one-third the length of the anterior, is made in a similar manner. The muscles are cut with a strong scalpel obliquely from below upward and in the direction of the bones.

After the bones are freed, a circular incision is made through the periosteum of the fibula, which is then reflected to the distance of an inch in the form of a cuff. The soft parts are then well re-

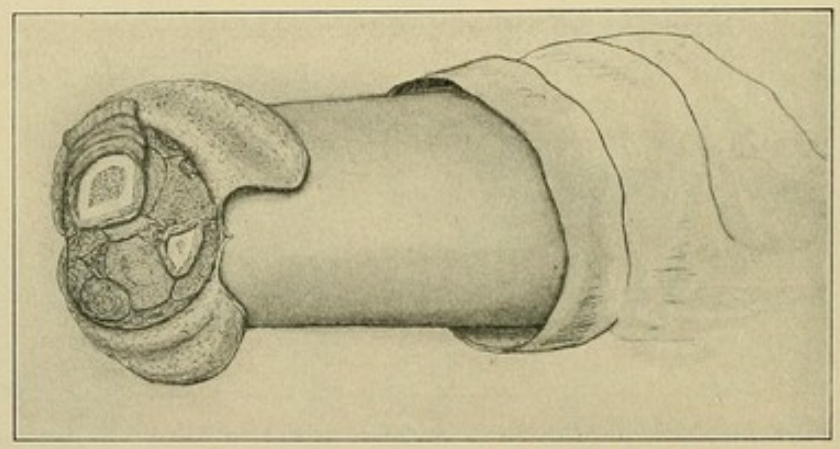

Fig. 634.—Amputation surface, showing section of fibula an inch above the level of that of the tibia; periosteal flap and cuff for sawn surface of tibia and fibula.

tracted by the hands of an assistant or a three-tailed bandage, and *the fibula is divided, first at least an inch above the proposed line of section of the tibia.* This modification of the ordinary method of bone section was first recommended by Gouley, of New York, and Galbraith, of Omaha, and has ever since been followed by me with the most gratifying results, as it materially increases the degree of conicity of the stump.

Section of the tibia must be made in a manner that will minimize the use of the bone-cutting forceps. The spine of the tibia at the end of the bone has always been a source of mischief. It should be removed with the saw and not with forceps, and should be done before the section of the bone is completed. The first section with the saw is made through the spine of the tibia, obliquely from above downward and backward, to the depth of an inch; the transverse section is then made on a line with the lower terminus of the oblique cut, severing first the wedge-shaped piece of the spine. On completing the section the end of the tibia requires

little, if any, trimming with the bone forceps. The principal blood-vessels are now tied, and the nerve-ends are sought for and resected before the Esmarch constrictor is removed. After completion of the hemostasis the wound is drained by a tubular drain passing through a buttonhole in the posterior flap in the middle and at its base. The drain should not reach further than the end of the tibia. The question whether the flaps have been made of proper length must be settled after the amputation has been made, as errors in this connection must be remedied at this time.

The first step in the suturing of the wound consists in bringing the long flap in position, and suturing the periosteal flap over the sawn surface of the tibia with two or three catgut stitches. The periosteal cuff of the fibular end does not require suturing, as it will cover the end of the bone without any mechanical aid. The next row of strong catgut sutures serves as a temporary point of anchorage for the cut muscles. The flexor and extensor muscles are sutured over the ends of the bones, space being left in the flexors for the tubular drain. During the whole time required for suturing and dressing the stump is held in an elevated position by an assistant, who grasps the leg with both hands below the knee, making at the same time downward traction on the skin and muscles.

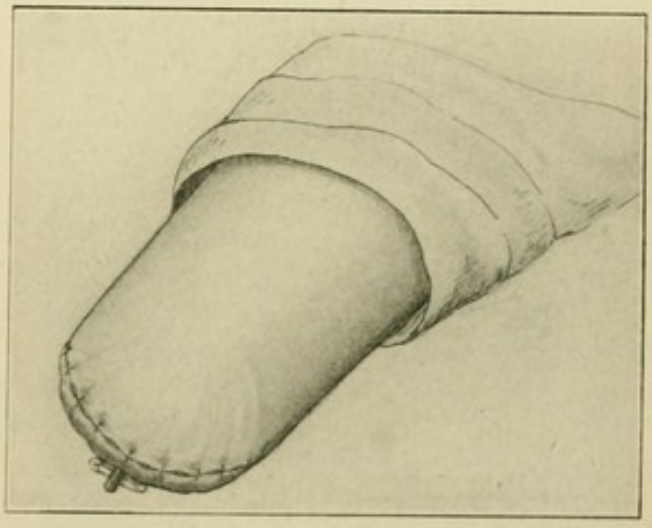

Fig. 635.—Operation completed. Wound drained through a buttonhole at the center and base of the posterior flap.

As a rule, not enough attention is paid to suturing of the flaps. The wound margins must be distributed equally, and carefully united by deep interrupted sutures of silkworm-gut or silk and a continued superficial suture of horsehair. To do this will require time, but unless there are well-grounded objections to painstaking careful suturing, this must be done, as it contributes much to a speedy and ideal healing of the wound. The best needles for this part of the suturing of the amputation wound are the glover's needles.

The interrupted sutures—two or three to every inch—must include all the tissues of the flap, and more especially the aponeurotic sheath of the muscles. The needle punctures must be the same distance from the wound margin on both sides of the flap, in order to insure accurate coaptation and to avoid harmful linear compression. The first suture brings together the center of the two flaps, and the next two equally subdivide each half of the wound again, thus assuring

equal distribution of the wound margins. After all the interrupted sutures are in place, the continued horsehair suture brings together the skin, which is usually found inverted more or less between and underneath the sutures. A mouse-toothed tissue forceps does the most efficient service in picking up the skin preparatory to making the punctures with the needle. *As a rule, the sutures are tied too tightly, which fact often accounts for the marginal necrosis resulting from the interception of the superficial circulation.* The sutures must be tied only with sufficient firmness to bring together and hold in contact the wound margins, carefully avoiding tension. The elasticity of the horsehair suture recommends it very strongly for the suturing of the skin, as it adapts itself to the increased tension caused by the slight swelling of the wound margins, so constantly present even in aseptic wounds.

Fig. 636.—Ideal stump after amputation of the leg.

After the suturing has been completed, the wound is sprinkled with the borosalicylic powder until the sutures are buried, when a copious hygroscopic aseptic dressing is applied, embracing the limb as far as the knee-joint. A gauze roller should always be used in place of the ordinary muslin bandage, as it is more elastic, besides constituting a valuable part of the aseptic dressing. The roller is applied in such a way as to support efficiently the flaps, and also with a view to exercising equable compression, becoming thus an important aid to the sutures and maintaining uninterrupted coaptation of the wound surfaces. The thigh is wrapped in common cotton, and the limb, in the extended position, is immobilized by a hollow, well-padded posterior splint, which should reach from the end of the stump to the base of the thigh. After the amputation the limb is held in an elevated position until the operation is completed, and must be kept at an elevation of at least 45 degrees

for twenty-four hours or longer. The importance of immobilization of the stump by an appropriate external mechanical support should never be ignored, for its influence in preventing pain and undue muscular retraction and its value in aiding the process of repair are in no instance more apparent than after amputation of the leg.

Disarticulation at the knee-joint, a favorite operation during the preaseptic period of operative surgery, has passed into well-deserved desuetude. The bulbous shape of the stump that results from the operation, with and without preservation of the patella, is detested by all manufacturers of artificial limbs. Under aseptic precautions the immediate risks to life are not greater by making a supracondyloid amputation of the thigh than by making a disarticulation at the knee-joint, and the former yields a serviceable, the latter a troublesome or almost useless, stump.

Syme's intracondyloid and Carden's transcondyloid amputations have done something toward diminishing the size of the bulb at the end of the stump, but not sufficiently to adapt it to the wearing of an artificial limb with comfort. The teaching and practice to the effect that, in the operative treatment of injuries and disease that necessitate an amputation at or near the knee-joint, the surgeon should invariably select the supracondyloid level, must appear timely and rational. Fortunately, an operation has been devised in this location by Gritti, and modified by Stokes, that answers all anatomic indications for making an ideal stump for the wearing of an artificial limb.

Gritti-Stokes' Amputation.—Gritti planned and described, from an anatomic and practical standpoint, one of the most nearly perfect of all mutilating operations. He proposed to saw the femur through the base of the condyles and utilize the patella, deprived of its cartilage, as a covering for the end of the bone. Stokes modified the operation by advising section of the bone above the condyles. The operation thus modified is technically called supracondyloid osteoplastic amputation. This operation, of course, is resorted to only in cases in which the patella itself is not diseased. I have, however, had a number of cases of synovial tuberculosis of the knee-joint requiring amputation in which it gave most excellent results. The long anterior oval flap, including the patella, is made by entering the knife about an inch above the epicondyle of the femur, on the side opposite to the operator, after which the flap is outlined in the same manner as in amputation of the leg by the same method of flap formation. The incision is terminated at a point *vis-à-vis* to where it was commenced, an inch above the opposite epicondyle. In reflecting the flap the tendon of the patella is severed above its insertion, and the tendon and patella are reflected with the flap. The short oval posterior flap is next made, and, as usual, the fibrous sheath of the flexor muscles is included. The circular incision through the muscles is made with a stout scalpel, and in such a manner that after the amputation the tissues under-

neath the skin resemble a shallow cup, the deepest portion corresponding to the end of the femur.

As the superficial muscles retract much more than those near the bone, the incision through the muscles must be made very oblique, so as to place the soft tissues of the amputation wound in the best possible condition for suturing, and to give the desired

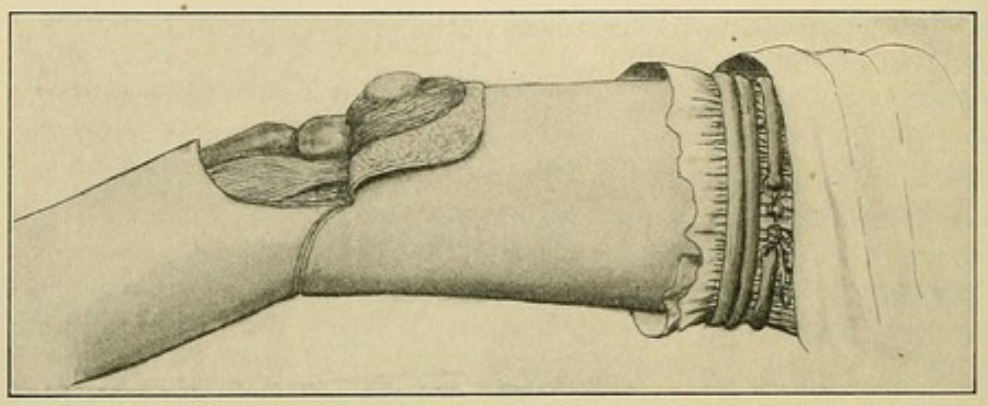

Fig. 637.—Gritti-Stokes' supracondyloid osteoplastic amputation. Flap formation.

shape to the stump. The section through the soft tissues is made on a line with the base of the condyles. As soon as the bone is reached the periosteum is divided by a separate circular cut, and reflected with the periosteal elevator in the form of a cuff, to a distance of at least an inch. The periosteum must remain attached to the adjacent tissues, and no attempt must be made to form a separate periosteal flap or cuff.

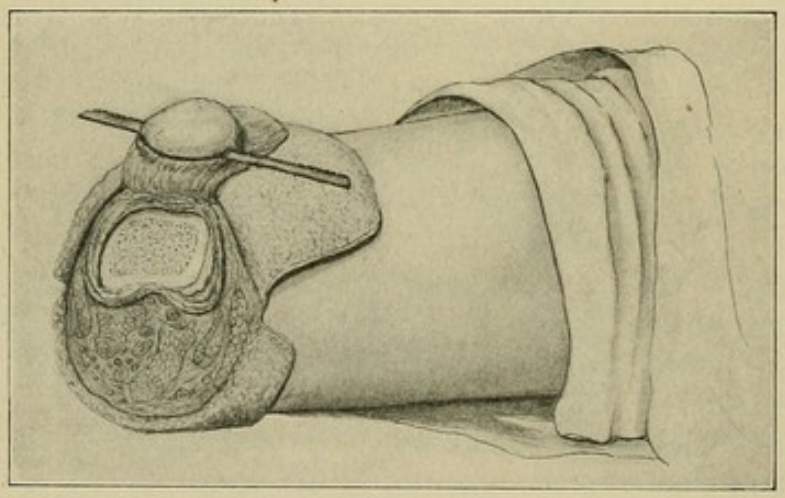

Fig. 638.—Removal of articular surface of patella with saw.

The bone is divided with a saw just above the condyles, transversely to its long axis. During this step of the operation the soft tissues are carefully retracted by the hands of an assistant or by the use of a retractor made of gauze. Unless splintering takes place toward the end of the section, the end of the bone does not require the use of the bone forceps. The line of section through the bone must be above the condyles, but should not open the medullary canal. After the amputation has been made, the long flap is brought into position, and if any defect in flap formation is detected, it must be remedied at this time. If this part of the operation has been found satisfac-

tory, the under surface of the patella is vivified by excising with the saw its under cartilaginous surface.

Perhaps the most difficult part of the operation consists in uniting the vivified patella securely with the end of the femur. *Direct means of fixation are essential in accomplishing this object.* Several means of direct fixation of the patella against the end of the femur suggest themselves. A silver-wire suture embracing the lower margin of the patella and the compacta of the posterior margin of the end of the femur will secure accurate coaptation of the bone surfaces and permanent fixation of the patellar fragment. In the absence of bone or ivory nails this method of fixation has much to recommend it. The ideal method of fixation is by the use of an absorbable aseptic bone or ivory nail. The patella is perforated near its lower margin with a drill, when an ivory or a bone nail, an inch and a half in length, is inserted, and, after the patella is in proper place directly over the end of the femur, is driven its entire length into the spongy tissue of this bone. The projecting portion of the nail on the outer surface of the patella is cut off on a level with the bone with bone forceps, so that this end of the nail is covered by periosteum. As an additional aid the tendon of the patella is sutured with strong catgut to the flexor muscles. I have resorted to this method of fixation of the patella in a number of cases, and have found it absolutely reliable. Further,

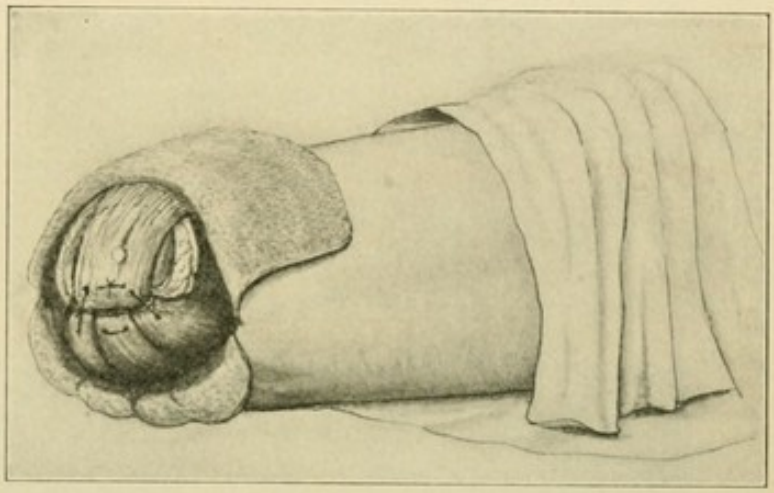

Fig. 639.—Fixation of vivified patella against sawn surface of femur with ivory nail, and suturing of flexor muscles to the patellar tendon.

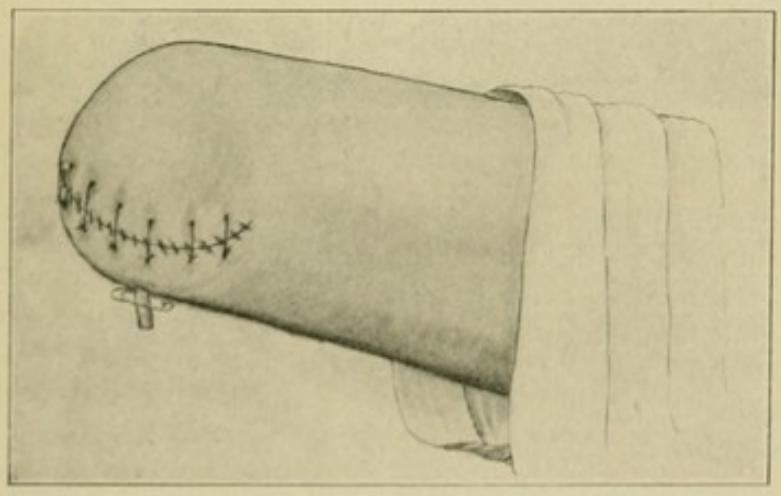

Fig. 640.—Operation completed.

the nails never caused any untoward symptoms and were always removed by absorption. Should suppuration set in after the use of bone or ivory nails, they will become foreign substances, and their removal spontaneously or by operative interference must precede the final healing of the wound.

The third and simplest method of fixation of the patella is by suturing of its tendon to the flexor muscles with at least three strong catgut sutures. I have resorted to this expedient a number of times with entirely satisfactory results, except in the last case. In this instance suppuration of the wound loosened the anchorage by the catgut sutures prematurely, and the patella became displaced and attached to the side instead of the end of the femur. This single failure is perhaps not sufficient ground for abandoning the catgut

Fig. 641.—Stump after Gritti-Stokes' supracondyloid amputation.

suture as a sole means of fixation in such cases, but it has made me more partial to the use of absorbable aseptic nails.

The suturing of the flaps, dressing, and fixation of the stump are the same as after amputation of the leg. The stump after Gritti-Stokes' amputation is conic, the end of the femur rounded by the patellar fragment, which has become a part of the bone. The tissues over the end of the bone are freely movable, and the bursa of the patella does excellent service when the patient begins to wear an artificial limb. *Patients should be warned not to make an attempt to wear an artificial limb for at least a month after the wound has healed. Every stump must be properly prepared for the wearing of an artificial limb.* This preparatory treatment consists in systematic firm bandaging to expedite the physiologic atrophy that always takes place, and in washing the skin with a 50 per cent. solution of alcohol to make it more tolerant to the many sources of

irritation to which it will be exposed in the wearing of an artificial limb.

Amputation of the Thigh.—The same rules that have been laid down for amputation of the leg are applicable and in force in amputating the thigh above the Gritti-Stokes line. Cutaneous semilunar flaps of unequal length are always to be employed as a covering for the amputation wound. The deep incisions must be very oblique, as the powerful superficial muscles of the thigh retract phenomenally in spite of all precautions. The end of the femur must always be furnished with a periosteal covering in the form of a cuff. Muscle suture is of immense importance in minimizing retraction and in guarding against painful muscular twitching by furnishing the cut muscles with a temporary point of anchorage. Muscle suture is made with strong catgut in the form of a transverse row of sutures over the end of the bone, uniting the extensor and flexor muscles. Drainage is always established through a separate opening in the most dependent part of the wound. The flaps are to be sutured with the utmost care, and the stump is dressed and immobilized as in amputation of the leg. Even a short stump enables the patient to walk with the aid of an artificial limb of special construction.

Fig. 642.—Atrophy of phalanx in stump of finger after amputation.

When the question arises as to the advisability of making a disarticulation at the hip-joint or a high amputation of the thigh, the surgeon must not forget that the immediate risks of the operation are really greater in a disarticulation than in a high amputation, and his decision and action must be governed accordingly.

Disarticulation at the hip-joint has been discussed in the chapter on Prophylactic Hemostasis.

INDEX.

Abbé's needle-holder, 211
Abdomen, gunshot wounds of, 273
diagnosis, 277
drainage, 284
hemorrhage from, 280
hydrogen-gas insufflation in, 277
incision for, 280
irrigation after, 283
laparotomy for, 274, 279
after-treatment, 285
preparation of patient, 279
recovery from, without interference, 274
suturing, 283
symptoms, 276
treatment, 278
tapping of, 624
Abdominal abscess, intestinal fistula from, 1008
cavity, drainage of, 687
irrigation of, 283
ligamentous bands in, 873
operation, intestinal fistula from, 1009
section, 770
and iodoformization for intestinal tuberculosis, 945
anesthesia in, 775
antiseptics in, 774
atropin in, 775
corrosive sublimate in, 774
early performance of, 772
examination of intestine, 778
for strangulation, 770
hemorrhage in, 777
in fibrinoplastic peritonitis, 699
incision, 776
intestinal obstruction after, 980
intra-abdominal examination in, 777
mortality, 771
preparations, 774
requirements of surgeon, 773
statistics, 770
sterilization of room, etc., 774
temperature of room, 774
taxis for volvulus, 857
in obstruction of intestine, 755
Abscess, abdominal, intestinal fistula from, 1008
cavity, drainage of, in intestinal fistula, 1015
in cavum Retzii, 676
Abscess, intestinal fistula from, 1006
of brain, traumatic, trephining for, 256
pelvic, intestinal fistula from, 1008
peritoneal, 676
subphrenic, 704
tubercular, intra-articular medication after, 626
Acetate of aluminum as antiseptic, 187
solution, 202
Actinomycosis, intestinal fistula from, 1008
Acupressure, 131
Adhesions in hernia, removal, 995
intestinal, 866, 870
prognosis, 871
Agnew's splint, 373
Air-passages, emergency operations on, 640
Akidopeirasty, 341, 488, 592
Alcohol as antiseptic, 188
as hand disinfectant, 188
for sterilization of catgut, 110
Amputations, 1059. See also *Disarticulations*.
above wrist-joint, 1069
aims of, 1065
at hip-joint, bloodless, 73
Senn's, 77
at wrist-joint, 1085
bone section in, 1076
by transfixion, 1073
Chopart's, 1092
circular, 1073, 1074
in two steps, 1075
covering sawn surface of bone after, 1076
cutaneous flaps in, 1079
drainage after, 1078
emergency, 1070
flap formation, 1072
including deep tissue in, 1074
for atrophy, 1065
for carcinoma, 1064
for crushing of bones, 1061
for gangrene, 1062, 1063. See also *Gangrene*.
for malignant tumors, 1064
for paralysis, 1065
for sarcoma, 1065
for septicopyemia, 1062
for suppuration, 1063
for tearing of muscles, 1061

Amputations for tearing of nerves, 1061
of skin, 1061, 1063
of vessels, 1061
Gritti-Stokes', 1101
Günther's modification of Pirogoff's, 1095
hemostasis after, 1077
in war, 254
indications for, 1060
instruments for, 1071
Langenbeck's oval flap, 1080
Le Fort's modification of Pirogoff's, 1095
ligation of blood-vessels after, 1077
Liston's oval flap, 1080
manual compression in, 1077
musculocutaneous, 1081
neuroma, 1066. See also *Neuroma.*
nontraumatic, indications for, 1063
of appendix, 730
of arm, 1085, 1086
drainage, 1088
of fingers, 1069, 1082, 1083
of forearm, 1085
of great toe, 1090
of hand, 1084
of leg, 1096
suturing wound, 1099
of lower extremity, 1089
of thigh, 1097, 1105
site for, 1066
of toes, 1089
of upper extremity, 1081
oozing after, 1077
osteophytes after, 1076
peritoneal flap in, 1076
Pirogoff's, 1094
plastic operations as substitutes for, 1062
preparations for, 1070
primary, indications for, 1061
removing of constrictor after, 1077
secondary, indications for, 1062
site of operation, 1065
Smith's oval flap, 1080
stump, care of, 1077
dressing of, 1079
immobilization of, 1079
suturing of wound, 1078
Syme's, through ankle-joint, with excision of malleoli, 1094
Teale's square flap, 1080
technic, 1065
through metatarsus, 1091
von Bruns' flap, 1080
modification of Pirogoff's, 1095
Anastomosis button, Murphy's, 789
end-to-end, 819
intestinal, 783. See also *Intestinal anastomosis.*
Anesthesia, accidents during, 50
artificial respiration in, 53
asphyxia in, 51
chloroform, 44
death from, 54
Anesthesia, dilatation of pupils in, 49
ether, 56
food in air-passages in, 51
general, 40
heart depression in, 55
in emergency surgery, 43
in laparotomy, 775
in tracheotomy, 647
infiltration, 59
local, 40, 58
history, 58
preparations for, 45
restoration of respiration in, 51, 52
signs in, 49
stage of excitement, 49
of tolerance, 49
statistics, 41
talking partial, 43
vomiting in, 50
Anesthetic, administration of, 41, 47
chloroform as, 42, 44
ether as, 42, 56
local, cocain, 60
ethyl chlorid, 59
eucain, 61
ice and salt, 58
sulphuric ether spray, 58
mixed, 43
selection of, 42
Aneurysm, traumatic, from modern bullet, 228
Angiotribe, 88
Angiotripsy, 89
Ankle-joint, drainage of, 631
resection of, 1045
incision for, 1045
temporary resection of malleoli in, 1047
Syme's amputation through, with excision of malleoli, 1094
Ankylosis, angular, resection for, 1026
of joints, 394
Anostosis, eccentric, fractures and, 313
Antipyogenic agents, 184
Antipyrin as styptic, 134
Antiseptic irrigation, permanent, 565
pomade, 204
powders, 203
borosalicylic, 204
iodoform-boric, 204
salves, 204
boric acid, 204
borosalicylic, 204
chloral hydrate, 204
unguentum Credé, 205
solutions, 198
acetate of aluminum, 202
aqua binelli, 203
bichlorid of mercury, 201
boric acid, 202
carbolic acid, 201
chlorid of zinc, 203
permanganate of potash, 203

Antiseptic solutions, preparations for use of, 199
saline, 203
Thiersch's, 202
Antiseptics, 186
acetate of aluminum, 187
alcohol, 188
bichlorid of mercury, 191
boric acid, 188
bromin, 188
camphor, 189
carbolic acid, 189
chloral hydrate, 190
chlorid of lime, 190
of sodium, 190
chromic acid, 191
corrosive sublimate, 191
creasote, 192
creolin, 192
formaldehyd, 192
formalin, 192
formic aldehyd, 192
hydrogen peroxid, 194
in laparotomy, 774
iodin, 194
iodoform, 194
juniper, 196
lysol, 196
Peruvian balsam, 196
potassium permanganate, 197
resorcin, 197
salicylic acid, 197
salol, 197
sulphurous acid, 197
thymol, 197
tinctura benzoini composita, 198
turpentine, 198
Antitoxin, hydrophobia, 186
syringe, 615
Anus, artificial, 765, 768. See also *Intestinal fistula.*
Aorta, manual compression of, 82
Appendicitis, 705
abscess formation in, 733
age and, 711
amputation in, 230
bacillus coli communis and, 710
burying of stump, 732
catarrhal, 713
cecitis and, 710
diagnosis, 720
differential, 722
diagnostic symptoms, 722
diet in, 724
drainage, 732
in intermediary operation for, 735
dressing after operation, 733
etiology, 707
fecal concretions and, 711
foreign bodies and, 711
gangrenous, 719
in Spanish-American war, 711
intestinal distention in, 734
fistula from, 1008
laxatives in, 725
Appendicitis, McBurney's muscle-splitting operation for, 726
point in, 721
microbic production of, 709
muscular rigidity in, 721
obliterans, 714
age and, 717
inflammatory origin, 718
morbid anatomy, 718
pathology, 718
symptoms, 717
operations for, early, 726
intermediate, 733
late, 735
opium in, 735
pain in, 720
palpation in, 721
pathology, 712
perforative, 718
peritonitis and, 714, 718
treatment, 702
position in, 733
progressive septic peritonitis with, 733
quieting peristalsis in, 725
relapsing, 719
operation for, 736
subserous enucleation for, 736
when to operate, 736
symptoms, 720
temperature in, 722
tenderness in, 721
treatment, 701, 723
medical, 724
operative, 725
ulcerative, 713
Appendix, abnormalities, 706
amputation of, 230
blood supply, 706, 710
location, 706
obstruction and, 876
size, 706
stump of, burying of, 732
suturing of, 730
Aqua binelli, 203
Arm, amputation of, 1085, 1086
drainage, 1088
suspender constriction of, 68
Arteries, gunshot wounds of, 290
percutaneous temporary ligation of, 87
preliminary ligation of, in continuity, 85
suture of, 123
temporary ligation of, 86
tying of, in continuity, 115
Artery forceps, Halsted's, 112
obliterated, cross-section of, 104
Arthrectomia synovialis et ossis, 1026
Arthrectomy, 1026
Arthrodesis, resection for, 1026
Artificial anus, 765, 768. See also *Intestinal fistula.*
respiration, 53
Ascarides, intestinal obstruction by, 922

Ascending colon and cecum, tuberculosis of, 955
Ascites, tapping for, 624
tubercular, 697
Aseptic catheterization, 632
Aspiration drainage, 654
Ataxia, locomotor, fractures and, 313
Atresia, congenital, anastomosis in, 789
of intestine, congenital, 925
Atrophy after fracture, 396
amputation for, 1065
bone, fractures due to, 312
inactivity, 312, 327
joint resection and, 1032
of phalanx in finger stump, 1105
Autotransfusion, 136
in gunshot hemorrhage, 251
Autotransplantation of bone, 529
Avicenna's reduction of subcoracoid dislocation, 594, 595
Axillary artery, ligation of, 1087
rupture of, in reduction, 586

Bacillus coli communis and appendicitis, 710
intestinal ulceration and, 941
peritonitis and, 671
of tuberculosis in feces, 941
peritonitis and, 671
wound infection with, 164
pyocyaneus, 159
tetani, 159
Bacteria on body, 169
Bacteriology of infection, 157
Bands, ligamentous, in abdominal cavity, 873
location of formation of, 875
obstruction by, 872
fecal extravasation in, 876
operating for, 875
Bardeleben's pelvic supports, 462
Bardenheuer's suprapubic incision of bladder, 299
Barker's resection of intussusceptum, 909
Bassini's operation for inguinal hernia, 1001
Bayer's case of irreducible ileocolic invagination, 906
Bedoin's first-aid package, 233
Beely's plaster-of-Paris hemp splint, 385
Bergmann's method of sterilizing catgut, 110
plaster bandage saw, 552
Bernay's sponge, 179, 180
Bezoars, 920
Bichlorid of mercury, 191, 201
Bircher's fixation method, 536
Bladder, infection of, from catheterization, 633
puncture of, 627
structure of, 634
urinary, gunshot wounds of, 297
Bladder, uninary, perforation of, 297, 298
rupture of, 297–299
suprapubic incision of, 299
wounds of, 297
treatment, 300
Blasius' modified Dupuytren's enterotome, 1016
Bloodless amputation of hip-joint, 73
method of bone implantation, 1052
operations, 65
reduction, 582
suture, 212
Blood-vessel, ligation of, 99
after amputation, 1077
Boeckmann's sterilizer, 175, 176
Bone, autotransplantation of, 529
crushing of, amputation for, 1061
decalcified, 1050. See also *Implantation*.
drainage-tubes, 215
fate of foreign material in, 539
ferrule, fixation by, 540
sterilization, 541
fragments, fate of, 539
hemorrhage from, 134
nails, immobilization by, 468
restoration of, 357
section in amputation, 1076
suture, 531
technic, 533
transplantation of, 361, 408, 409
Bone-cutting forceps, 1028
Bone-plates, preparation, 828
uniting intestine by, 784
Bone-production from periosteum, 353, 355
Bony union after extracapsular fractures, 446–450
after intracapsular fractures, 456
time required for, 417
validity of specimens, 451
Boric acid as antiseptic, 188
ointment, Lister's, 204
solution, 202
Borosalicylic ointment, 204
powder, 204
Bracketed splints, 553
Brain, abscess of, traumatic, 256
Brainard's bone drills, 406
Bridge plaster-of-Paris splint, 548
Bromin as antiseptic, 188
Bruns' chisel, 1029
double metallic nail, 535
flap method, 1074, 1080
modification of Pirogoff's amputation, 1095
spoon, 1029
Brushes, care of, 168
Bryant's test-line, 443, 444
Buchanan's application of plaster-of-Paris splint, 547
Bülau's aspiration drainage, 655
Bullet, leaden, deformities, 221
Mauser, effect on tissues, 218

Bullet, searching for, 222
small-caliber, effect of, 555
on tissues, 218
jacketed, deformities, 221
wounds from, 241

CALCULI, intestinal obstruction from, 914
Callus, definitive, 352, 354
formation, defective, 390, 392
diastasis and, 394
suppuration and, 393
excessive, 390
painful, 400
production, 351
provisional, 352, 354
Camphor as antiseptic, 189
Capillary and tubular drainage of abdominal cavity, 690
drain, 217
drainage of abdominal cavity, 689
Carbolic acid after tapping of joints, 626
as antiseptic, 189
intoxication by, 189
solution, 201
Carcinoma, amputation for, 1064
fractures and, 317
intestinal fistula from, 1007
obstruction from, 970
Catarrhal appendicitis, 713
synovitis, tapping for, 626
Catgut as ligature, 106
sterilization, 107
alcohol, 110
Bergmann's method, 110
formalin method, 108
Hofmeister's method, 108
Senn's modification, 109
Johnston's method, 110
Kocher's method, 110
Cathartics in peritonitis, 679
Catheter case, papier-mâché, 638
Catheterization, aseptic, 632
for intestinal fistula, 1014
in private practice, 639
infection from, 633
technic, 637
Catheters, 633, 635
lubricant for, 638
sterilization, 638
Cautery, actual, 128
Cavum Retzii, abscess in, 676
Cecal tuberculosis, 933
Cecitis, catarrhal, appendicitis and, 710
Cecum and ascending colon, tuberculosis of, 955
resection of, for tuberculosis, 949
tuberculosis of, 951
tumor of, enterectomy for, 798
Chain saw, 1030
Chest, gunshot wounds of, 261
care of patients, 271
cases, 262–267
Chest, gunshot wounds, hemorrhage, 271
treatment, 270
ultimate results, 266
tapping of, 622
Chloral hydrate as antiseptic, 190
ointment, 204
Chlorid of lime as antiseptic, 190
of sodium as antiseptic, 190
of zinc as antiseptic, 190
solution, 203
Chloroform, 44
anesthesia, 42, 44
death from, 54
narcosis in children, 43
Chopart's mediotarsal disarticulation, 1092
Chromic acid as antiseptic, 191
Cicatrix, intravascular, formation of, 104
Cicatrization, 155
Circular amputation, 1073, 1074. See also *Amputation.*
enterorrhaphy, 819. See also *Enterorrhaphy, circular.*
plastic splints, 550, 552
Circulation, embarrassed, in fracture dressing, 551
Circumflex artery, tearing of, in reduction, 586
Circumscribed peritonitis, 673
Clamps, intestinal, 800
ivory, 536
metallic, 535
Clavicle and scapula, exarticulation of, with upper extremity, 1088
fractures of, treatment, 374
Cocain as anesthetic, 60
Cocci, morphology, 158
Cohen's tracheotomy tubes, 647
Cold as hemostatic, 131
Colles' fracture, 475. See also *Fractures.*
Colon, ascending, and cecum, tuberculosis of, 955
distention of, with fluids, in obstruction, 748
objections to, 750
intussusception of, 888
stenosis of, colostomy for, 765
Colorectostomy, 840
Colostomy, 765
after volvulus, 864
closing of artificial anus, 768
drainage in, 768
for intussusception, 900
indications, 768
inguinal, left, Maydl's, 767
Knie's, 769
modern operation, 766
Colotomy, 764
Compression, digital, 84
for hemorrhage on field, 246
elastic, 65
in wound healing, 214
manual, 82

Concretions, fecal, appendicitis and, 711
intestinal, 920
Conic elastic web catheter, 635
Constricting ring, cutting of, 995
Constriction, elastic, applying of, 71
at hip-joint, 73
at shoulder-joint, 81
for hemorrhage on field, 244
in arm amputation, 1086
in emergency surgery, 77
in prophylaxis, 64
of head, 81
of limbs, 66
duration, 68
of skull, 81
paralysis after, 70
removal of, 72
sequelæ of, 70
special localities for, 73
suspender, of arm, 168
Constrictor, elastic, application, 66
Corrosive sublimate as antiseptic, 191
in laparotomy, 774
intoxication, 191
solution, 201
Craniectomy in hemorrhage from middle meningeal artery, 502
in war, 254
Creasote as antiseptic, 192
Creolin as antiseptic, 192
Crepitation, fractures and, 342
Crural canal, Salzer's method of closing, 1004
Cuba, chest injuries in, 269
gunshot wounds in, 229
Cushing's right-angled continuous suture, 815
Cutaneous flaps, 1079
Cylindric elastic web catheter, 635
Cystitis, exciting causes, 636
predisposing causes, 636
Cysts, fractures and, 318
intestinal obstruction by, 967
Czerny suture, 816
in circular enterorrhaphy, 819
Czerny-Lembert suture, 814

Débridement in gunshot fractures, 554
Decalcified bone, 1050. See also *Implantation.*
Decubitus, fractures and, 399
Delayed union, 400
apparatus for, 406, 407
treatment, 403
Delirium traumaticum and fracture, 399
tremens and fracture, 399
De Vilbiss bone-cutting forceps, 500
Diaphragmatic peritonitis, 665
Diarrhea, intestinal obstruction after, 980
Diastasis and callus formation, 394
Dieffenbach's operation for intestinal fistula, 1017
Diffuse septic peritonitis, 667, 672
Disarticulation, 1059. See also *Amputations.*
at elbow-joint, 1085
at hip-joint, 1105
at knee-joint, 1101
at metacarpophalangeal joint, 1084
at metatarsophalangeal joint, 1090
at shoulder-joint, 1086
at wrist-joint, 1085
Lisfranc's tarsometatarsal, 1092
Malgaigne's subastragaloid, 1094
mediotarsal, 1092
of all toes, 1091
of fingers, 1082
of great toe, 1090
of thumb, 1083
Disinfection of field of injury, 173
of operation, 173
of hands, 169
Kümmel's method, 171
turpentine in, 172
of mucous surfaces, 174
Disinvagination, 904
Dislocations, 568
age and, 569
deformity in, 576
deviation of shaft of bone from normal, 577
diagnosis, 578
etiology, 569
exciting causes, 570
fracture and, 575
intracoracoid, 587
mechanism, 569
of both bones of forearm, 600. See also *Forearm.*
of elbow-joint, 599. See also *Elbow-joint.*
of forearm. See *Forearm.*
of hip-joint, 598
of neck of femur, fracture and, 599
of radius, 610. See also *Radius.*
of shoulder-joint, 586. See also *Shoulder-joint.*
of ulna, 609
old, 574
pain in, 578
recent, 574
pathology, 571
reduction of, 580
accidents of, 585
by bloodless method, 582
by manipulation, 582
by open method, 584
fracture during, 585
retroglenoid, 597
rupture of nerves in, 574
of vessels in, 574
shortening in, 578
subacromial, 597
subclavicular, 587
subcoracoid, 587

Dislocations, subglenoid, 597
symptoms, 575
treatment, 578
unreduced, 574
Diverticula attached to fundus of bladder, 883
fecal fistula from perforation, 883
Meckel's, of intestine, 877
mesentery of, 879
obstruction by, 872, 876
operating for, 881
symptoms of, without fecal obstruction, 880
oversized, 882
strangulation by, 802
Diverticulum ilei, 878
Dollinger's bone ligation, 534
Douche spoon, 1030
Downward dislocation of shoulder-joint, 597
Doyen's amputation of appendix, 731
vasotribe, 88
Drainage, 214
after operation for peritonitis, 687
aspiration, 654
capillary, 217
in empyema, 659
of abdominal cavity, 687
of fractures, 566
of suppurating joints, 614, 629
suprapubic, 628
tubular, 215
through, 216
Drainage-tubes, 215
intestinal fistula from, 1011
removal, 216
Dressing material, antiseptic, 180
aseptic, 180
cotton, 182
gauze, 182
hygroscopic capacity of, 181
in emergency work, 183
sterilization, 182
Dry gangrene, 1064
Dugas' test, 592
Dumreicher's distraction method, 603
wedge cushion, 376
Duodenojejunal fossa, hernia of, 884
Duodenum, myoma of, 962
occlusion of, in new-born child, 927
perforating ulcer of, 694
Dupuytren's enterotome, 1016
Dynamic obstruction of intestines, 975

Echinococcus cysts, fractures and, 318
Écraseur, 89
Ectoperitonitis, 663, 672
tissues in, 676
treatment, 676
Edema in strangulated hernia, 984
Elastic catheters, 635
Elastic constriction, 64. See also *Constriction.*
Elbow-joint, disarticulation at, 1085
dislocation of, 599. See also *Forearm, both bones of.*
classification, 600
diagnosis, 600
drainage of, 631
resection of, 1036
for tuberculosis, 1036
Electricity for hemorrhage, 133
in intestinal obstruction, 758
Elevation in prophylaxis, 63
Embolism after fracture, 396
air, 92
fat, after fracture, 398
fractures and, 347
with compound fractures, 515
Emergency operations on air-passages, 640
surgery, 17
anesthesia in, 43
dressing material in, 183
elastic constriction in, 77
importance of, 18
Empyema, 651
after-treatment, 661
bacteriology of, 651
diagnosis, 653
dressing after operation for, 660
etiology, 651
incision of chest-wall for, 656
irrigation in, 659
necessitatis, 654
operation for, 655
puncture in, 623
rib resection in, 656, 657
Schede's thoracoplasty for, 661
surgical treatment, 654
symptoms, 653
tubular drainage in, 659
Enchondroma, fractures and, 318
Endoperitonitis, 664
End-to-end anastomosis, 819
Enterectomy, amount to be resected, 800
clamps in, 800
for fistula, 1019
for gangrene, 799
for obstruction, 797
mortality, 797
for removal of tumor, 798
for sarcomatous intestinal obstruction, 969
for tuberculosis, 947
in infants, 929
in perforation of intestine, 283
in volvulus, 865
Madelung's, 799
marasmus after, 792, 802
partial, on concave side, 802
restoration after, with uncorresponding lumina, 798
rubber tube after, 798
transplantation in, 799
Enteritis, obstruction from, 977

Entero-anastomosis for tuberculosis, 953
Enterolithiasis, 914
high, 916
perforation in, 916
seat of obstruction, 915
ulceration and, 915
Enteroliths, 920
Enteroplasty for tuberculosis, 946
Heineke-Mikulicz method, 946
Péan's, 946
Enterorrhaphy, 808
circular, 808, 809, 819
in obstruction, 786
Maunsell's, 824
Murphy button as substitute for, 826
suturing in, 816
history, 810
inflatable bulb in, 816
insertion of suture, 813
lateral, 808, 818
omental grafting in, 821
serous surfaces in, 810
Enterostomy, 761
anesthesia in, 762
for intussusception, 901
for volvulus, 864
right iliac, 761, 762
inguinal, 763
Enterotomy, 764
Enucleation, subserous, in relapsing appendicitis, 736
Epiphyseolysis and epiphysitis, 314
syphilis and, 319
traumatic, 325
Epiphysitis and epiphyseolysis, 314
Epiploitis, 664
Epityphlitis, 705. See also *Appendicitis.*
Erasion, 1026
Ergot as hemostatic, 135
Esmarch's bracketed wrist-joint splint, 1036
chloroform bottle, 46
inhaler, 46
constrictor, 65, 66, 69
double inclined plane, 377
first-aid package, 234
pelvic supports, 462
splint, 380
suspension splint for ankle-joint resection, 1048
tongue forceps, 52
Ether, administration of, 57
anesthesia, 42, 56
disadvantages of, 56
inhaler, 57
sulphuric, as anesthetic, 58
Etheridge's hemostatic forceps, 112
Ethyl chlorid as anesthetic, 59
Eucain, 61
Evacuation of distended intestines, 780
Eventration, 780
in peritonitis, 683
Exarticulation of upper extremity with scapula and clavicle, 1088
Exclusion, complete, for tuberculosis, 960
partial, for tuberculosis, 953
Exploratory puncture, 614, 617
syringe, 618
Extension and counterextension, 595
Extracapsular fractures. See *Fractures.*

False joint at seat of fracture, 564
Faraboeuf's bone-cutting forceps, 1028
Fascia, deep, suturing of, 208
Fecal concretion, appendicitis and, 711
extravasation in obstruction by bands, 876
fistula, 761
from perforation of diverticulum, 883
obstruction, 924
Feces, examination of, in tuberculosis, 941
Femoral hernia, radical operation for, 1003
Femur, fracture of, crepitus in, 443
inclined plane for, 373
treatment, 373
neck of, fractures of, 421. See also *Fractures, extra- and intracapsular.*
after-treatment, 472
bony union, 357, 413
causes, 432–434
classification, 420
deformity in, 436
diagnosis, 441
dislocation and, 599
eversion in, 437, 442, 444
fascia lata in, 440
fixation, 471
fragments in repair of, 357
greater trochanter in, 444
impacted, 420, 425
treatment, 461, 462
incomplete, 423
incuneated, 425
intracapsular, bony union after, 418
loss of function in, 435
measurements in, 443
motion in, 440
nails in treatment of, 468–470
nonimpacted, 420
treatment, 463
pain in, 434
plaster-of-Paris bandages for, 462
rabbeting in, 431, 466
reduction, 471
Senn's treatment, 471
shortening in, 438, 442
suggillation in, 436

Femur, neck of, fractures of, swelling in, 436
symptoms, 434–441
time required for union, 461
treatment, 412, 461
trochanter major in, 440
shaft of, fractures of, treatment, 544
Fergusson's bone-cutting forceps, 1028
Ferripyrin as styptic, 133
Fetal peritonitis, 667
Fibromata, intestinal obstruction from, 961
Field-hospital, surgeon's work at, 254
Finger-joints, resection of, 1034
Fingers, amputation of, 1069, 1082, 1083
elastic constriction of, 66
First-aid dressing, application of, 239
fixation, 238
immobilization in, 242
package, Bedoin's, 233
behind fighting-line, 233
English, 235
French, 234
German, 234
in military surgery, 231
in Spanish-American war, 235
iodoform gauze in, 234
means of carrying, 236
requirements of, 236
Senn's, 238
splints in, 243
Fissure, 320
Fistula, fecal, 761. See also *Enterostomy*.
intestinal, 1004. See also *Intestinal fistula*.
Fixation dressings, 213, 543
embarrassed circulation in, 551
with bone ferrule, 540
Flap formation for gangrene, 1072
incisions for disarticulation and amputation of arm, 1087
Flexion as hemostatic on field, 246
intestinal, 866
exhibition of symptoms, 867
prophylaxis for recurrence, 869
treatment, 869
Fluhrer's probe, 222
Foramen of Winslow, hernia of, 884
Forceps, anastomosis, Laplace's, 791, 820
Forcipressure, 128
on field, 249
Forearm, amputation of, 1085
both bones of, dislocation of, 600
anterior, 606
diverging, 609
forward, 605
hyperextension for, 604
posterior, 600–603
fracture of both bones of, 374
lateral luxations of, 606
one bone of, dislocation of, 609
Foreign bodies, intestinal fistula from, 1007
Formaldehyd as antiseptic, 192
Formalin as antiseptic, 192
for sterilization of catgut, 108
of sponges, 178
Formic aldehyd as antiseptic, 192
Fracture box, 376
Fractures, 309
akidopeirasty in, 341
ambulatory treatment, 545
ankylosis after, 394
atrophy after, 396
autotransplantation in, 529
bone transplantation for, 408, 409
bony union after, 418
time for, 417
validity of specimens, 451
bracketed splints in, 553
callus formation, defective, 390, 392
excessive, 390
painful, 400
production after, 351
causes, 326
central nervous system in, 399
circular plastic splint for, 550, 552
closed, 322
Colles', 475
diagnosis, 477, 484
impacted, 482
Moore's dressing for, 479, 480
prognosis, 484
reduction, 478, 485
symptoms, 482
treatment, 478
comminuted, 326
comparison in, 341
complicated, 326
compound, 325, 505
after-treatment, 525
amputation for, 519
callus formation in, 561
counteropenings, 524
definition, 506
diagnosis, 513
drainage, 524, 525, 566
dressing of wound, 523, 525
etiology, 511
fat embolism with, 515
ferment intoxication with, 517
fixation, direct, silver wire in, 531
dressing, 543
of fragments, direct, 527
infection of wound in, 515
inflammatory swelling after, 516
irrigation, 527
operative interference, 558, 567
pathology, 514
prognosis, 517
repair, 561
statistics, old, 507
recent, 508
suppuration in, 560
surgeon's duty, 563

Fractures, compound, thrombophlebitis in, 517
treatment, 519
ambulatory, 545
modern, 522
of lacerated wounds, 523
of wounds, 520, 522
compression, of long bone, 330
crepitation and, 342
decubitus and, 399
deformity in, 335
delayed union, 400
delirium traumaticum and, 399
tremens and, 399
dentate, 322, 324
diagnosis, 332
differential, 332
direct, 329
fixation, 388
dislocation and, 575
displacements in, 335
angular, 337
lateral, 337
longitudinal, 339
rotary, 338
dorsal recumbency in, 399
double inclined plane for, 373, 376
drainage in, 566
during reduction, 585
embolism after, 396
fat, 398
emphysema and, 351
examination in, 367
external violence and, 328
extracapsular, bony union after, 446–450
extracervical, 421
false joint at seat of, 564
fat embolism and, 347
urine in, 349
fate of foreign material in, 539
fever after, 344
fibrinous union after, 400
first duties of surgeon, 366
fixation by bone ferrule, 540
by ivory clamps, 536
cylinders, 536
by nails, screws, etc., 535
by Senn's splint, 538
dressing, 543
embarrassed circulation in, 551
fragments in repair of, 351
frequency, 310
from bullets, X-ray in, 225
gangrene after, 397
Graves' treatment, 403
greenstick, 320
gunshot, amputation for, 558
débridement in, 554
in Greece and Turkey, 557
of joints, 556
of leg, 556
resection for, 558
treatment, 554
hemorrhage in, 398
Fractures, hemorrhagic infarcts and, 349
hereditary predisposition to, 319, 327
immobilization, 371
by bone-nails, 468
position, 372
impaction in, 339
inclined plane for, 386
incomplete, 320
indirect, 329
intra-articular, 325
intracapsular and extracapsular, relative number, 421
bony union after, 452, 456
diagnosis, 445
nonunion after, 454
intracervical, 421
ivory pegs for, 407, 417
longitudinal, 323
loss of function with, 333
Malgaigne hooks in, 388
and spear in, 388
mensuration in, 339
multiple, 325
muscular contraction and, 331
new point of motion in, 342
oblique, 323
of femur. See *Femur.*
of limbs on field, immobilization, 253
of patella. See *Patella.*
of skull, 486. See also *Skull.*
osteomyelitis and, 347, 565
overriding in, 339
pain and, 334, 345
paralysis and, 400
pathologic, 311
bone atrophy and, 312
carcinoma and, 317
causes, 312
cysts and, 318
diagnosis, 319
eccentric anostosis and, 313
echinococcus cysts and, 318
enchondroma and, 318
of epiphysis, 314
osteomalacia and, 316
osteomyelitis and, 313–315
osteoporosis and, 312
rachitis and, 315
sarcoma and, 316
scorbutus and, 319
syphilis and, 318
treatment, 320
permanent extension for, 386
plaster-of-Paris splint for, 546
position after reduction, 372
preternatural mobility in, 341
pseudarthrosis and, 400
pseudo-, 310. See also *Fractures, pathologic.*
reduction, 368
remote consequences, 389
repair of, 351, 355
marrow in, 355

Fractures, repair, time for, 404
reposition, 368
restoration of continuity, 357
rupture of nerve-trunks with, 346
shock after, 344
silver-forked, 477
sliding foot-board for, 387
special, 411
splints for, Agnew's, 373
Esmarch's, 380
Gooch's, 380
making of, 380
mantle, 375
pasteboard, 383
plaster-of-Paris, 384
plastic, 384
Raoult-Deslongchamp's, 383
ready-made, 378
straw, 376
suspension, 377
temporary, 381
tin, 383
wire, 383
spontaneous, 311
stiffness after, 394
stimulating repair in, 564
subcutaneous simple, 322
complications, 346
direct fixation for, 388
prognosis, 362
suppuration and, 346
symptoms, 332
following, 344
local, 345
objective, 334
subjective, 333
temporary dressing, 375
tenderness with, 334
thrombophlebitis and, 566
thrombosis after, 396
torsion, 330
transportation of patient, 367
transverse, 322
treatment, 365
T-shaped, 323, 324
ununited, apparatus for, 406, 407
vicious union of, 410
vivifying ends in, 564
X-ray in, 343
Y-shaped, 324
Fragments of bone, fate of, 539
Frank's decalcified bone coupler, 826
intestinal needles, 798
French soft-rubber catheter, 633
Fricke's hemostatic forceps, 112

Galbraith's leg amputation, 1098
Gall-stone, intestinal obstruction from, 914
Galvanocautery, 88
Gangrene after fracture, 397
amputation for, 1062, 1063
flap formation, 1072
circumscribed, of intestine, 799
dry, 1064
Gangrene, dry, toe amputation and, 1090
from gunshot wounds, 559
in strangulated hernia, 985
moist, 1064
of intestine, in hernia, 873, 996
Gangrenous appendicitis, 719
Gastric ulcer, perforating, 693
Gastro-enterostomy, Murphy button in, 789
Gauze drainage of abdominal cavity, 689
retractors, 1071
German plaster bandage shears, 552
Glass drains, 215
Glycerin as vehicle for iodoform, 199
Gonococci in leukocytes, 158
Gonococcus peritonitis, 671
Gonorrheal synovitis, tapping in, 626
Gooch's splint, 380
Gouges, 1029
Gouley's leg amputation, 1098
Grafting, omental, 821. See also *Omental grafting.*
Graves' treatment of fractures, 403
Greco-Turkish war, fractures in, 557
Gritti-Stokes' amputation, 1101
Grooved directors, 994
Gunshot fractures. See *Fractures.*
wounds, 152, 218. See also *Wounds, gunshot.*
Günther's modification of Pirogoff's amputation, 1095

Halsted's mattress suture, 815, 821
modification of Bassini's operation, 1001
straight artery forceps, 112
Hamilton's bone drills with guard, 406
Hand, amputation of, 1084
disinfection, 169
Kümmel's method, 171
turpentine in, 172
Hart's sponge holder, 180
Head, elastic constriction of, 81
Heart, gunshot wounds of, 262
Heineke-Mikulicz enteroplasty, 946
Heister's gag, 51
Hemarthrosis, tapping in, 625
Hematocele, retro-uterine, 668
Hemophilia, hemorrhage with, treatment, 136
Hemorrhage, 90
actual cautery for, 128
acupressure for, 131
air embolism and, 92
angiotripsy for, 89
antipyrin for, 134
arterial, 91
invagination for, 126
aseptic ligature in, 97
autotransfusion after, 136
capillary, 93
classification, 91

Hemorrhage, cold for, 131
diagnosis, 95
digital compression for, 84
écraseur for, 89
elastic constriction for, 64
electricity for, 133
elevation for, 63
ergot for, 135
ferripyrin for, 133
forcipressure for, 128
from bone, 134
from chest wounds in war, 271
from middle meningeal artery, 502
galvanocautery for, 88
hot water for, 129
in abdominal section, 777
in fracture, 398
in gunshot wounds of abdomen, 280
in hemophilic patients, treatment, 136
in hip-joint amputations, elastic constriction for, 73
intra-abdominal obstruction and, 804
ligation for, 85–87
lateral, 122
manual compression in, 82
oil of turpentine for, 133, 135
on field, 244. See also *Wounds, gunshot.*
prevention of, 62
saline infusion in, 138
Spanish windlass for, 89
spontaneous arrest of, 94
steam for, 130
stypticin for, 136
styptics for, 133
suture of vessel for, 124–126
symptoms, 95
tamponade for, 131
thermocautery for, 88
torsion for, 127
transfusion and, 137
treatment, 96
general, 134
venous, 92
vessel suture for, 122
wound suture for, 132
Hemorrhagic peritonitis, 668
Hemostasis after amputation, 1077
in arm amputation, 1086
permanent, on field, 249
prophylactic, 62
elastic constriction in, 64
elevation in, 63
Hemostatic forceps, 111, 112
Hemothorax, puncture for, 622
Hemp plaster-of-Paris splint, 548
Henrotin's gag, 51
Heppe's odor test for chloroform, 44
Hernia, diaphragmatic, 885
femoral, radical operation for, 1003
incarcerated, 983
Hernia, incarcerated, and strangulated, differentiation, 988
inflamed and strangulated, differentiation, 988
inguinal, radical operation for, 999
internal, 883
knives, 993
of duodenojejunal fossa, 884
of foramen of Winslow, 884
strangulated, 983
anesthesia in, 991
cold as aid in reduction, 990
constipation in, 986
diagnosis, 985
differential, 987
edema of loop, 984
etiology, 983
examination of contents, 996
gangrene in, 985, 996
herniotomy for, 992
laparotomy for, 772
other organs in sac, 998
pain in, 986
prognosis, 988
radical operation for, 998
reduction of, after herniotomy, 991
relieving constriction, 995
stricture following, 942
symptoms, 985
taxis in, continuance of, 991
treatment, 989
medical, 989
vitality of bowel in, 996
vomiting in, 986
tuberculosis of, 934
umbilical, radical operation for, 998
Hernial sac, stripping of, 999
suture of, 1000
Herniotomy, 992
circulation after, 996
exposing field for, 992
incisions for, 992
peritoneum in, 994
indications for, 992
obstruction and peritonitis after, 979
opium after, 979
reduction after, 996
removal of adhesions, 995
Hip-joint, amputation of, bloodless, 73
Senn's, 77
dislocations of, 598
drainage of, 631
elastic constriction at, 73
resection of, 1032, 1056
for tuberculosis, 1056
incisions for, 1057
indications, 1056
with temporary resection of trochanter, 1057
Hodgen's suspension splint, 379
Hofmeister's sterilization of catgut, 108
Senn's modification, 109

Hopkins' rongeur forceps as modified by Weir, 500
Horsehair, preparation of, 113
suture for intestine, 813
Houze's tongue forceps, 52
Humerus, fractures of, oblique, treatment, 545
splint for, 382
subcoracoid dislocation of, 590
Husson's sponge holder, 50
Hutchinson's abdominal taxis, 857
Hydrocele, tapping of, 629
Hydrocephalus, puncture in, 621
Hydrogen insufflation in abdominal wounds, 277
in intussusception, 899
in invagination, 889
of bowel, 751
peroxid as antiseptic, 194
Hydrophobia antitoxin, 186
Hydrothorax, circumscribed, puncture in, 623
Hypodermic needles, 614
preparations, sterility of, 616
syringe, 614

Ice and salt anesthesia, 539
Ileocecal abscess, tuberculosis and, 939
opening, congenital stenosis of, 925
valve, competency of, 748, 751
Ileocolostomy, 785, 786, 833
by implantation, 834
by lateral apposition, 835
by perforated discs, 837
Maunsell's, 839
shock after, 837
Ileo-ileostomy by bone-plates, 833
by perforated discs, 831
Ileorectostomy, 839
Ileosigmoidostomy, 789
Ileum, myoma of, 962
tuberculosis of, 951
Ileus, 737. See also *Intestinal obstruction.*
Iliac arteries, transperitoneal ligation of, 86
Immobilization in first aid, 242
of fractured limbs on field, 253
of joints on field, 253
Impaction, 425
by foreign bodies, 912
disintegration of stone, 919
high, 916
treatment, 918
Implantation of bone, 1050
after necrosis, 1051
asepsis at seat of, 1051
by bloodless method, 1052
disinfection, 1050
drainage in, 1053
dressing of wound, 1053
indications for, 1051
method, 1050
secondary, 1053
Implantation of bone, suppuration after, 1053
technic, 1052
treatment of external wound, 1052
Incarcerated hernia, 983
Infarcts, hemorrhagic, in fractures, 349
Infection from puncture, 615
Inflatable bulb, Reder's, 816
Inflated bulbs in circular enterorrhaphy, 820
Infraction, 320
Inguinal canal, closing of, 1000
incision to expose, 992
hernia, radical operation for, 999
Instruments, sterilization of, 174
Insufflation in intussusception, 899
in search for perforations, 282
of hydrogen in invagination, 889
rectal, 751
test for permeability of intestines, 783
Internal hernia, 883
Intestinal anastomosis, 783
by suturing, 790–792
complete physiologic exclusion by, 796
for fistula, 1018
for intussusception, 905
in congenital atresia, 789
in volvulus, 861
indications, 792
lateral implantation and, 826
plates for, 828
Murphy button in, 789
partial physiologic exclusion by, 792
plates for, 784
approximation, 784
bone, 786
suturing in, 790
time required for, 791
clamps, 800
concretions, 920
fistula, 761, 1004. See also *Enterostomy.*
anastomosis for, 1018
cauterization for, 1014
drainage of abscess cavity in, 1023
enterectomy for, 1019
etiology, 1005
forms, 1012
from abdominal abscess, 1008
operation, 1009
from abscess, 1006
from actinomycosis, 1008
from appendicitis, 1008
from carcinoma, 1007
from drainage-tubes, 1011
from foreign bodies, 1007
from gunshot wounds, 1005
from ligatures, 1010
from malignant tumors, 1007
from pelvic abscess, 1008
operation, 1009

Intestinal fistula from stab wounds, 1005
from strangulation, 1007
from submural injury, 1005
from sutures, 1010
from ulceration, 1006
in appendicitis, 734
pathologic anatomy, 1012
plastic operation for, 1017
prophylaxis against infection, 1020
removal of spur in, 1016
repression of spur in, 1015
spontaneous closure, 1012
suturing of, without opening peritoneum, 1017
treatment, 1011
surgical, 1014
loop, anchoring of, in colostomy, 766
needles, 798, 813
obstruction, 737
abdominal section for, 770
taxis for, 857
acute, 739
colicky pains in, 740
constipation in, 739
intestinal coils in, 744
symptoms, 742
tympanites in, 740
vomiting in, 740
after abdominal section, 980
after diarrhea, 980
after herniotomy, 979
after laparotomy, 870
after ovariotomy, 805, 870
after-treatment, 807
alimentation in, 745
anastomosis and lateral implantation in, 826
anastomosis for, 783
anatomicopathologic forms, 847
and peritonitis, differentiation, 741
evacuation in, 781
appendix and, 876
ascites in, 741
bowels after, 807
by adhesion, 802
by band, 802, 872
fecal extravasation in, 876
location of, 875
operating for, 875
by cicatricial stenosis, 868
by circumscribed parietal adhesions, 804
by concretions, 920
by contraction where diverticulum is given off, 881
by diverticula, 802, 872, 876
operating for, 881
by enteroliths, 921
by flexion, 802
by foreign bodies, 912
by margins of opening in mesentery or omentum, 874
Intestinal obstruction by Meckel's diverticulum, 877
by pelvic adhesions, 804
by stenosis, 925
by twisted coils, 792
by visceral adhesions, 804
cathartics and, 748, 807
chronic, 743
diarrhea in, 744
intestinal coils in, 744
symptoms, 743
classification, 847
colorectostomy for, 840
colostomy for, 765
colotomy for, 764
definition, 738
distention in, 740
of colon with fluids in, 748
dynamic, 738, 848, 975
effects of contents above obstruction, 746
electricity in, 758
enterectomy for, 797
enterospasm and, 849
enterotomy for, 761, 764
evacuation in, 780
eventration for, 780
examination for hernia in, 986
fecal, 924
following contusion, 978
frequency, 737
from adhesions, 866, 870
due to peritoneal defects, 805
from atresia, 925
from band constriction, 849
from benign tumors, 961
diagnosis, 968
from blood clot, 804
from calculus, 954
from carcinoma, 970
from compression, 974
from cysts, 967
from enteritis, 977
from fibromata, 961
from flexion, 866
from gall-stones, 914
from healed tubercular ulcers, 938
from internal hernia, symptoms, 849
from ligamentous bands in abdominal cavity, 873
from lipomata, 962
from malignant tumors, 968
mortality, 972
treatment, 972
from myofibroma of the rectum, 964
from myomata, 962
from parasites, 922
from polypi, 962
from sarcoma, 968
enterectomy for, 969
from traumatic paresis, 978
from tumors, 961
from tympanites, 975

Intestinal obstruction from volvulus, 850
hernia and, diagnosis, 987
ileocolostomy for, 833
ileorectostomy for, 839
insufflation in, 750, 751
intra-abdominal hemorrhage and, 804
irrigation of stomach in, 747
jejuno-ileostomy for, 829
laparo-enterotomy for, 797
laparotomy for, 758, 770
lavage of stomach in, 745
Madelung's treatment, 779
manual exploration of rectum in, 754
massage in, 755
mechanical, 738, 848
not due to intussusception, site for incision, 879
paralysis and, 849
peritonitis and, 976
pulse in, 741
puncture of intestine in, 756
rectal injections in, 745
shock after, 807
sigmoidostomy for, 765
stomach-feeding in, 745
stomach-tube in, 746
strangulation, symptoms, 849
support of abdomen in, 748
symptoms, 738
taxis in, 755
temperature in, 741
thirst after, 807
toilet, 806
treatment, medical, 744
operative, 758, 783
mortality, 759
when obstruction can not be found, 784
tubage in, 754
typhlostomy for, 765
occlusion, 912
suture, double, 814
history, 810
suturing, 808. See also *Enterorrhaphy.*
material, 813
wall, resistance of, 752
Intestine, amount safely resected, 800
circumscribed paresis of, 975
contraction of, where diverticulum is given off, 881
distended, evacuation of, 780
Madelung's method of treatment, 779
emptying, in volvulus, 860
examination of, loop by loop, 778
gangrene of, circumscribed, 799
large, typhlostomy for obstruction of, 766
malignant stenosis of, congenital, 925
nonmalignant stenosis of, 925
Intestine, overdistended, in peritonitis, 686
perforation of, enterectomy for, 283
suturing of, 283
permeability of, test for, 783
physiologic exclusion of, complete, 796
partial, 792
in animals, 794
therapeutic value, 794
tissue changes, 794
puncture of, in obstruction, 756
replacing of, 780
resection of, 792
restoring continuity of, 784
search for perforations of, 282
small, submucosa of, 813
stricture of, congenital, 942
following strangulated hernia, 942
following typhoid ulcer, 943
malignant, 944
syphilitic, 943
traumatic, 942
tuberculosis of, 930. See also *Tuberculosis.*
tumor in lumen of, 764
twisted, obstruction by, 792
wounds of concave side, enterorrhaphy for, 808
healing of, 816
Intra-abdominal examination in laparotomy, 777
Intracapsular fractures. See *Fractures.*
Intracoracoid dislocation, 587
Intra-intestinal saline injections in peritonitis, 691
Intralaryngeal tubercular affections, laryngofissure for, 644
Intra-uterine peritonitis, 667
Intubation of larynx, 640
dangers of, 643
diet after, 643
Intussusception, 885
acute, 893
adhesions in, 895
circulation in, 895
gangrene in, 895
irreducibility, 895
pathology, 894
sloughing in, 895
postmortem description, 895
spontaneous cure, 895
adhesions in, 905
age and, 890
air-insufflation in, 899
anastomosis for, 905
ascending, 888
blood in feces in, 894
chronic, 893
adhesions in, 895, 897
hyperplastic changes in, 897
of colon, with carcinoma, 901
pathology, 897
sloughing in, 897

Intussusception, chronic, tumors and, 897
colostomy for, 900
constriction of intussusceptum in, 895
descending, 888
diagnosis, 893
disinvagination, 904
distention of colon in, 888
double, 893
early recognition, 898
enterostomy for, 901
etiology, 889
extra-abdominal treatment of intussusceptum, 907
gangrene and, 808, 907
hydrogen insufflation in, 889, 899
ileocecal, 888, 893
intestinal contractions in, quieting, 898
into walls of rectum, 890
laparotomy for, 901
age and, 903
incision, 904
mortality, 902
lateral implantation in, 908
massage in, 900
mechanism, 890
mortality, 890
of colon, 888
perforation of intussuscipiens in, 888
prognosis, 898
rectal insufflation in, 899
recurrence, 905
reduction, 888, 898
anesthesia in, 889
resection of intussusceptum for, 905, 909
through rectum, 911
rupture in, 900
Senn's taxis for, 904
spontaneous cure, 902
subacute, 893
swelling in, 894
symptoms, 893
taxis for, 904
tenesmus in, 894
total resection for, 907
treatment, 898
tumor and, 891
resection for, 892
ultra acute, 893
Invagination, 885. See also *Intussusception.*
arterial, 126
by rubber ring, 846
suture, 841
material, 845
Nothnagel's test in, 844
symptoms, 849
with intestinal tuberculosis, 959
Iodin as antiseptic, 194
Iodoform, 194
as first aid, 234
gauze, 195
Iodoform glycerin after tapping of joints, 626, 627
as vehicle for, 199
intoxication, 195
from drainage, 689
Irrigation, antiseptic, permanent, 565
in peritonitis, 684, 692
of abdominal cavity, 283
Ivory clamps, 536
cylinders, 536
nails, etc., fate of, 539
use of, 468
pegs for delayed union, 407
for fracture, 417

JEJUNO-ILEOSTOMY, 829
by bone-plates, 833
by perforated discs, 831
by suturing, 830
Jejunum, obstruction of, 764
Jobert's invagination suture, Senn's modification, 841
Johnston's method of sterilizing catgut, 110
Jointed male and female catheter, 636
Joints, ankylosis of, 394
dislocations of, irreducible, resection for, 1026
fixation of, resection for, 1026
gunshot injuries of, 556
wounds of, treatment, 1024
resection of, 1024
atrophy and, 1032
atypical, 1026
detachment of capsule in, 1031
of peritoneum in, 1031
elastic constriction in, 1032
for disease, 1026
general directions, 1030
immobilization after, 1032, 1033
incisions for, 1030
indications, 1025
instruments for, 1029, 1030
limits of, 1025
of special joints, 1033. See also *Finger-joint, Hip-joint, etc.*
preservation of muscular attachments in, 1027
subperitoneal, 1031
success of, 1033
technic, 1026
temporary resection of prominences in, 1026
typical, 1026
stiffness of, 394
suppurating, drainage of, 614, 629
tapping of, 625
technic, 627
Juniper as antiseptic, 196

KAPPELER'S methods of restoring respiration in anesthesia, 52

Karyokinesis, 153
Keen's rongeur forceps, 499
Keith's drain, 217
Kelly's intestinal needles, 798
Kidney, gunshot wounds of, 291
laparotomy for, 295
nephrectomy for, 295, 296
Simon's incision of, 296
treatment, 295
wounds of, 291
Knee, tuberculosis of, resection for, 1049
Knee-joint, disarticulation of, 1101
drainage of, 631
fractures of, temporary plaster-of-Paris splint for, 548
resection of, 1032, 1033, 1048
drainage after, 1055
dressing for, 1055
hemostasis after, 1054
in children, 1056
motion after, 1056
typical, 1054
Knie's colostomy, 769
Kocher's grooved director, 994
hemostatic forceps, 111
method of sterilizing catgut, 110
resection of ankle-joint, 1046
of wrist-joint, 1034
rotation method, 596
sterilization of silk, 106
Koch's hypodermic syringe, 615
Koenig's tracheotomy tube, 648
Kümmel's method of disinfecting hands, 171

Langenbeck's bone drills, 406
bone-cutting forceps, 1028
first aid, 234
incisions for elbow-joint resection, 1036, 1037
narrow saw, 1029
oval flap operation, 1080
resection of ankle-joint, 1045
of shoulder-joint, 1044
Laparo-enterotomy for obstruction, 797
Laparotomy, 770. See also *Abdominal section.*
for intestinal obstruction, 758
for intussusception, 901. See also *Intussusception.*
for perforating typhoid ulcer, 695
for peritonitis, 680
in war, 254
Laplace's anastomosis forceps, 791, 820
Laryngofissure, 643
Larynx, incision of, anterior median, 643
intubation of, 640
dangers of, 643
diet after, 643
stenosis of, intubation for, 640
La stupeur locale, 29
Lateral enterorrhaphy, 818
implantation, intestinal anastomosis and, 826
ligation, 122
Lavage of stomach in intestinal obstruction, 745
Le Fort's modification of Pirogoff's amputation, 1095
Leg, amputation of, 1096
suturing wound of, 1099
fractures, gunshot, 556
of both bones, treatment, 544
Lembert suture, 813
inversion of margins in, 815
tying of, 815
uses of, 815
Lever method of reduction, 595
Lewis' needles and syringe for infiltration anesthesia, 59
Lifting-back metacarpal saw, 1029
Ligation and thrombus, 99
cicatrization after, 101, 103
double, 114
en masse, 121
granulation after, 104
intermediate, 121
lateral, 122
for hemorrhage on field, 250
of arteries in continuity, preliminary, 85
percutaneous temporary, 87
temporary, 86
of axillary artery, 1087
of blood-vessel, advantages, 99
of veins, percutaneous temporary, 87
on field, 249
repair of adventitia after, 603
sloughing and, 115
transperitoneal, of iliac arteries, 86
Ligature, application of, 113
aseptic, 97
carrier, 114
catgut, 106
double catgut, use of, 119
intestinal fistula from, 1010
material, 106
Limbs, elastic constriction of, 66
duration, 68
Lime, chlorinated, 190
Lipomata, intestinal obstruction from, 962
Lisfranc's tarsometatarsal disarticulation, 1092
Lister's boric acid ointment, 204
drainage forceps, 567
splint for resection of wrist-joint, 1035
Liston's bone-cutting forceps, 1028
oval flap amputation, 1080
Little's hemostatic forceps, 111
Lloyd's hip-joint constriction, 75
Lower extremity, amputations of, 1089
Lubricant for catheter, 638
Luecke's resection of hip-joint, 1058

Luer's hemostatic forceps, 112
Lumbar puncture, 621
Lumbricoid worms, intestinal obstruction by, 923
Luxatio humeri erecta, arm in, 588
Lymphadenitis and hernia, differentiation, 988
from tuberculosis, 936
Lysol as antiseptic, 196

Macewen's chisel, 1029
gouges, 1029
manual compression of aorta, 82
operation for inguinal hernia, 999
Madelung's incision in enterectomy, 799
method for distended intestines, 779
Magnesium sulphate injection after evacuation of intestines, 781
Male metal catheter, 635
urethra, 633
Malgaigne hooks and spear in fracture, 388
subastragaloid disarticulation, 1094
Malleoli, excision of, in Syme's amputation of ankle-joint, 1094
temporary resection of, in ankle-joint resection, 1047
Mantle splint, 375
Manual compression after amputation, 1077
exploration of rectum in obstruction, 754
Marasmus following resection of intestine, 792, 802
Marmorek's antistreptococcic serum in peritonitis, 691
Marrow, autotransplantation of, 361
in bone repair, 355
Massage in intussusception, 900
in obstruction, 755
Mathieu's bone-holding forceps, 1071
Mattress suture, Halsted's, 815, 821
Maunsell's circular enterorrhaphy, 824
ileocolostomy, 839
resection of intussusception, 911
Maydl's anchoring of intestinal loop, 766
left inguinal colostomy, 767
Mayo's intestinal needles, 798
McBurney's incision, 683
muscle-splitting operation, 726
point, 721
reduction in shoulder dislocation with fracture, 598
Meatus, disinfection of, before catheterization, 637, 638
Meckel's diverticulum, 877
obstruction by, operating for, 881
strangulation by, 803
Medication, parenchymatous, 614
subcutaneous, 614
Mediotarsal disarticulation, 1092
Meningeal artery, middle, hemorrhage from, 502
Meningitis, puncture for, 621
Mercier's single-elbow prostatic catheter, 635
Mesenteric glands, infection of, from intestinal tuberculosis, 935
suture, Mitchell-Heamner, 816
Mesenteriolum, tying of, 730
Mesenteritis, 664
volvulus from, 851
Mesentery of diverticulum, 879
shortening of, after volvulus, 862
strangulation by margins of opening in, 874
Metacarpal saw, lifting-back, 1029
Metal catheters, 635
Metatarsophalangeal joint of big toe, resection of, 1044
of toe, disarticulation of, 1090
Metatarsus, amputation through, 1091
Meteorismus peritonei, 673
Microbes, air as carrier, 160
Middeldorpf's akidopeirasty, 592
Mikulicz drain, 689
resection of intussusceptum through rectum, 911
tampon, 132
Military spirit of army surgeon, 25
surgeon, courage, 26
duties, 20
education, 23
in war, 27
mental qualifications, 23
military spirit, 25
personal habits, 26
physical condition, 22
punctuality, 25
qualifications, 20
surgery, 17
aseptic, 231
first-aid package in, 231
Milk, intestinal tuberculosis and, 931
Mitchell-Heamner mesenteric suture, 816
Moist gangrene, 1064
Moore's dressing for Colles' fracture, 479, 480
Morris' capillary drainage, 690
Mouse-tooth forceps, 994
Murphy button, 789
as substitute for circular enterorrhaphy, 826
objections to, 790
drain, 217
Muscles, tearing of, amputation for, 1061
Muscular contraction, dislocation from, 589
Musculocutaneous flap, 1081
Myofibroma of rectum, obstruction from, 964

Myomata, intestinal obstruction from, 962

Nails, ivory, fate of, 539
metallic, 535
Narcosis. See *Anesthesia.*
Neck, anatomy of, 645
gunshot wounds of, 259
Necrosis, bone implantation after, 1051
Needle-holders, 211
Needles, 210
intestinal, 798, 813
Nélaton probe, 222
Nerves, gunshot wounds of, 288
suture of, 288
tearing of, amputation for, 1061
Nervous system, central, in fracture, 399
Neuroblasty, 1068
Neuroma after arm amputations, 1086
amputation, 1066
etiology, 1067, 1068
excision of, 1068
growth of, 1067
prophylaxis for, 1066
return of, 1068
structure of, 1067
Neuromatosis, 1068
New-born child, occlusion of duodenum in, 927
Nothnagel's test in invagination suture, 844
Nurse, trained, in operating room, 165
Nussbaum-Czerny operation, 999
Nussbaum's iodoform deodorant, 195

O'Dwyer's extractor, 641
introducer, 641
intubation tubes, 640
Oil of turpentine for hemorrhage, 133, 135
Olecranon process, fractures of, treatment, 373
Olive-tip elastic web catheter, 635
Omental grafting, 821
after hysterectomy, 824
after ovariotomy, 824
in abdominal operations, 823
in peritoneal defects, 824
indications, 823, 824
Omentum, strangulation by margins of opening in, 874
Oncotomy, 698
Oozing, surface, 93
Open method of reduction, 584
Operating room, 164
in private houses, 167
modern, 167
trained nurse in, 165
Opium after herniotomy, 979
Os calcis, posterior process of, fracture of, treatment, 374
Osteomalacia, fractures and, 316
Osteomyelitic processes, bone implantation for, 1051
Osteomyelitis and fractures, 565
fractures and, 313–315
Osteophytes after amputation, 1076
Osteoporosis, fractures and, 312
Ovarian tumor, tuberculosis and, 943
Ovariotomy, adhesions after, 870
intestinal obstruction after, 805

Papier-mâché catheter case, 638
Paracentesis, 614, 620
abdominis, 624
pericardii, 621
Paralysis after elastic constriction, 70
amputation for, 1065
fracture and, 400
of intestines, circumscribed, 975
traumatic, intestinal obstruction from, 978
Parasites, intestinal obstruction from, 922
Parenchymatous injection, 617
medication, 614
Parietal peritonitis, 664
Parker's capital saw, 1070
Pasteboard splints, 383
Patella, Agnew's splint for, 373
fractures of, from muscular contraction, 331
Malgaigne hooks for, 388
treatment, 373
suturing of, after resection, 1054
Péan's enteroplasty, 946
Pelvic operation, intestinal fistula from, 1009
peritonitis, 665, 675
treatment, 702
supports, 462
Pelvis, abscess of, intestinal fistula from, 1008
fractures of, treatment, 374
Penis, elastic constriction of, 66
Perforating gastric ulcer, 693
typhoid ulcer, 695
ulcer of duodenum, 694
Perforation of intestine, search for, 282
suturing of, 283
Perforative appendicitis, 718
Pericardium, puncture of, 621
Perineal section for rupture of urethra, 306
Periosteum, bone-production and, 353, 355
Peritoneal abscess, 676
cavity, drainage of, 687
toilet, 806
flap in amputation, 1076
suture, 813
tuberculosis, 697

Peritoneum, defects of, covering of, 805
effect of scarification, 812
incision of, in herniotomy, 994
irritation of, effect on repair, 811
Peritonitis, 662
acute septic, irrigation in, 685
tubercular, 697
adhesiva seu sicca, 669, 697
after herniotomy, 979
anatomic classification, 663
and intestinal obstruction, evacuation in, 781
appendicitis and, 718
treatment, 702
bacillus coli communis and, 671
bacteriologic classification, 669
chronic, 675
circumscribed, 673, 696
clinical classification, 672
deformans, 669, 698
diaphragmatic, 665
diffuse septic, 667, 672
drainage in, 687
drugs in, 679
etiologic classification, 665
eventration in, 683
exudative, 669
fetal, 667
fibrinoplastic, 669, 674, 698
adhesions in, 699
incisions for, 682
from lesions of female genitalia, 702
from tuberculosis, 936
gonococcus, 671
hematogenous, 674, 700
hemorrhagic, 668
idiopathic, 665, 700
incision of overdistended intestine in, 686
infantum, 667
intestinal obstruction and, 976
differentiation, 741
treatment, 977
intra-intestinal saline injections in, 691
intra-uterine, 667
irrigation in, 684, 692
laparotomy for, 680
metastatic, 666, 674, 700
neonatorum, 667
operation for, 680
drainage after, 687
parietal, 664
pathologic classification, 667
pelvic, 665, 675
treatment, 702
perforation and, 718
perforative, 666, 673
treatment, 692
pneumococcus, 670
puerperal, 666, 675, 703
putrid, 668, 677
septic, general, after-treatment, 691
Peritonitis, septic, general, eventration in, 683
irrigation in, 684, 692
operation for, 680
history, 681
incision, 681
preparations, 680
overdistended intestine in, 686
serum treatment, 691
thirst in, 691
toilet with sponges in, 686
treatment, 677
medical, 679
operative, 680
Marmorek's serum in, 691
treatment, 676
seropurulent, 668, 698
serous, 669
staphylococcus, 670
streptococcus, 670
subdiaphragmatic, 675, 704
suppurative, 668, 697
treatment, 676
symptoms, 662
toilet with sponges in, 686
traumatic, 665
treatment, medical, 679
tubercular infection and, 671
visceral, 664, 674
treatment, 701
with appendicitis, 714
Permanganate of potash as sponge sterilizer, 178
solution, 203
Peruvian balsam as antiseptic, 196
Petit's circular amputation, 1075
fracture box, 377
Peyer's patches in tuberculosis, 935
Phlebitis, thrombosis after fracture and, 396
Physiologic exclusion of intestine, complete, 796
partial, 792
in animals, 795
therapeutic value, 794
tissue changes, 794
Pirogoff's amputation, 1094
Plain trocar, 620
Plaster-of-Paris bandage for fracture of neck of femur, 462
splints, 384, 546
fenestrated, 546
removal, 551
saw for, 552
shears for, 552
strips dressing, 550
Plastic operations as substitutes for amputation, 1062
on hand, 1084
splints, 384
circular, 550, 552
Pleura, puncture of, 622
Pleuritis, secondary, with pneumonia, 652
suppurative, 651

Pleuritis, suppurative, diagnosis, 653
dust in etiology of, 653
nontraumatic primary, 653
surgical treatment, 654
Pneumococcus peritonitis, 670
Pneumonia, croupous, 651
dust as cause of, 653
microbes of, 651
secondary pleuritis with, 652
Polypi, intestinal obstruction from, 962
Porto Rico, gunshot wounds in, 229
Port's first aid, 234
Posterior dislocation of shoulder, 597
plaster splint for leg, 549
Potassium permanganate as antiseptic, 197
Preglenoid dislocation, 587
Primary union, 154
Probe-pointed director, 994
Probes, 221
Probing, 221, 222
Prostatic catheters, 635
Pseudarthrosis, 400
bone transplantation for, 408, 409
silver wire in, 531
treatment, 405
Pseudofracture, 311. See also *Fractures, pathologic.*
Puerperal pelvioperitonitis, adhesions after, 871
peritonitis, 666, 675, 703
sepsis, foudroyant form, 703
peritonitis and, 703
Punctio vesicæ, 627
Puncture, disinfection of skin for, 617
exploratory, 614, 617
for hydrocephalus, 621
in intestinal obstruction, 756
infection and, 615
lumbar, 621
of pleura, 622
Pus-microbes, 157
and suppuration, relation, 160
Putrid peritonitis, 668

Rabbeting, 466
Rachitis and fracture, 315
Radial flap disarticulation of thumb, 1083
Radius, head of, dislocations of, 610
backward, 611
downward, 613
etiology, 610
forward, 612
mechanism, 610
outward, 612
lower end of, fracture of, 475. See also *Fractures, Colles'.*
Raoult-Deslongchamp's splint, 383
Rectal injections in intestinal obstruction, 745
insufflation, 750, 751
Rectum, manual exploration of, 754
myofibroma of, obstruction from, 964
walls of, intussusception into, 890
Reder's inflatable bulb, 816
Reduction, 580
accidents of, 585
bloodless, 582
by manipulation, 582
fracture during, 585
open method, 584
Relapsing appendicitis. See also *Appendicitis.*
Resection as substitute for the amputation, 1090
for gunshot wounds, 255
of bowel, 792, 797. See also *Enterectomy.*
of joints, 1024. See also *Joints.*
of rib in empyema, 656, 657
temporary, of bony prominences, 1026
Resorcin as antiseptic, 197
Respiration, artificial, 53
Retention of urine, puncture for, 627
Retractors, gauze, 1071
Retroglenoid dislocation, 597
Retro-uterine hematocele, 668
Retrovesical hematocele, 668
Reverdin's resection of ankle joint, 1046
Rib resection in empyema, 656, 657
Ribs, fractures of, treatment, 374
Röntgen ray. See *X-ray.*
Roser's dilator, 566
reduction of posterior elbow dislocation, 604
Rotation method of shoulder reduction, 595, 596
Rubber drain, 215
fenestrated, 567
gloves in operations, 172
Rupture of axillary artery in reduction of shoulder, 586
of urethra, 302. See also *Urethra.*
of urinary bladder, 297–299
Rydygier's resection of intussusceptum, 910

Salicylic acid as antiseptic, 197
Saline infusion, 138
for gunshot hemorrhage, 250
intravenous, 140
subcutaneous, 139
injections, intra-intestinal, in peritonitis, 691
solution, normal, 203
Szumann's, 138
Salol as antiseptic, 197
Salpingoperitonitis, 702
Salt and ice anesthesia, 58
Salves, antiseptic, 204. See also *Antiseptic salves.*
in wound dressing, 181

Salzer's method of closing crural canal, 1004
Sarcoma, amputation for, 1065
and fractures, 316
intestinal obstruction from, 968
enterectomy for, 969
Satterlee's bone-cutting forceps, 1028
Sayre's dressing, 375
Scapula and clavicle, exarticulation of, with upper extremity, 1088
Scar, intravenous, histology, 105
Scarification, effect of, on peritoneal healing, 812
of peritoneum, 823, 824
Schede's thoracoplasty, 661
Schimmelbusch-Esmarch inhaler, 47
Schimmelbusch's sterilizing sponges, 178
Schleich's infiltration method, 61
solution, 61
Scorbutus, fractures and, 319
Screws, metallic, 535
Secondary union, 156
Senn's automatic forceps, 994
bloodless amputation at hip-joint, 77
bone suture, 534
chloroform inhaler, 47
decalcified perforated bone-plate, 784
emergency operating case, 174
ether inhaler, 47
excision of amputation neuroma, 1068
first-aid package, 238
hemostatic forceps, 111
hollow perforated splint, 538
injection syringe, 626
lateral pressure apparatus, 463
modification of Hofmeister's catgut sterilization, 109
of Jobert's invagination suture, 841
operation for reduction of shoulder-joint, 1043
probe, 222
resection of ankle-joint, 1047
of elbow-joint for tuberculosis, 1036
of intussusceptum, 909
of knee-joint, 1049
of shoulder-joint, 1041
retractor, 306
sigmoid catheter, 628
slide-catch forceps, 994
taxis for intussusception, 904
tongue forceps, 51
Septicopyemia, amputation for, 1062
Seropurulent peritonitis, 668
Serous suture, 813
Sharp spoon, 567
Shock, definition, 28
delayed, 29
erethic, 35
treatment, 39
from bullet wounds, 33
Shock from gunshot wounds, 252
from operations, 33
local, 29
nature of, 28
protracted, 29
traumatic, 28
diagnosis, 36
etiology, 29–34
nationality and, 30
nervous system and, 30
operation for, 38
pathology, 37
severity of, 32
splanchnic nerve and, 32
symptoms, 34
temperature in, 35
treatment, 38
Shoulder-joint, amputation of, bloodless, 81
disarticulation at, 1086
dislocation of, 586
age and, 587
anterior, 587
complications, 592
examination, 591
Kocher's reduction, 596
lever method of reduction, 595
mechanism of traumatism, 587
pathologic anatomy, 589
reduction in, 594
rotation in, 595, 596
subacromial flatness in, 592
symptoms, 591
treatment, 594
downward, 597
erecta, 588
etiology, 586
forward, 587
from muscular contraction, 589
intracoracoid, 587
posterior, 597
preglenoid, 587
reduction, rupture of axillary artery in, 586
tearing of arteries in, 586
retroglenoid, 597
Senn's operation, 1043
subacromial, 597
subclavicular, 587
subcoracoid, 587
subglenoid, 597
varieties, 587
with fracture, 598
drainage of, 631
elastic constriction at, 81
resection of, 1038
flap incision, 1040
history, 1038
incisions for, 1039
Langenbeck's, 1044
Senn's incision, 1041
Sick in war, transportation, 253
Sigmoidostomy, 765
Silk, sterilization of, 106

Silkworm gut, preparation of, 113
Silver wire in pseudarthrosis, 531
Sims' sponge holder, 180
suture, 126
Skin, cocainization of, 60
disinfection of, for injection, 617
tearing of, amputation for, 1061, 1063
Skull, elastic constriction of, 81
fracture of, 486
at base, 487
comminuted compound, 496
complete, 487
diagnosis, 488
examination, 490
fissure, 487, 488
gunshot, 256, 498
incomplete, 487
prognosis, 490
punctured, 487, 498
symptoms, 488
treatment, 491
trephining in, 492, 493
vault of, 487
with depression, treatment, 493
gunshot wounds of, 255
treatment, 259
Sloughing and ligation, 115
Smith's oval flap amputation, 1080
suspension splints, 378
Soda solution as sterilizer, 176
Sodium chlorid as antiseptic, 190
Soft-rubber catheter, French, 633
South African war, wounds in, 227
Spanish windlass, 89
Spanish-American war, first-aid package in, 235
Spikes, metallic, 535
Spine, fractures of, Verity's suspension splint, 545, 546
gunshot wounds of, 285
Splints in first aid, 243
Sponges, aseptic, 177
Bernay's, 179, 180
gauze, 180
sterilization of, 177
Spoon, sharp, 567
Sputa, intestinal tuberculosis and, 931
Stab wounds, intestinal fistula from, 1005
Staffordshire knot, 534
Staphylococcus peritonitis, 670
Starke's irrigation apparatus, 525
Steam as hemostatic, 130
as sterilizer, 176, 182
Stenosis, cicatricial, intestinal obstruction from, 868
congenital, location of stricture, 939
occlusion of duodeum by, 927
treatment, 927
duodenal and pyloric, differentiation, 940
nonmalignant, of bowel, 925
of colon, colostomy for, 765
Stenosis of intestines, acquired, 929
cicatricial, 929
Sterilization of bone ferrules, 541
of hypodermic needles, 614
preparations, 617
syringes, 614
of room, etc., for laparotomy, 774
Sternum, fractures of, treatment, 374
Stomach feeding in peritonitis, 679
gunshot wounds of, 275
perforating ulcer of, 693
Stools in intestinal tuberculosis, 938
Strangulated hernia, 983. See also *Hernia.*
Strangulation, abdominal section for, 770
by adhesion, 802
by appendix, 804
by band, 802
by diverticulum, 802
by flexion, 802
intestinal fistula from, 1007
Straw splint, 376
Streptococcus infection, 162
peritonitis, 670
pyogenes, 158
Stricture, congenital, of intestine, 942
following strangulated hernia, 942
following typhoid ulcer, 943
malignant, 944
syphilitic, 943
traumatic, of intestine, 942
Stripping hernial sac, 999
Stromeyer's arm cushion, 376
Stump after Chopart's amputation, 1093
after Gritti-Stokes' operation, 1104
care of, 1077
dressing of, 1079
immobilization of, 1079
leg, ideal, 1100
Stypticin as hemostatic, 136
Styptics, 133
for hemorrhage on field, 250
Subacromial dislocation, 597
flatness in dislocations, 592
Subastragaloid disarticulation, Malgaigne's, 1094
Subclavicular dislocation, 587
Subcoracoid dislocation, 587
Subcutaneous medication, 614
Subglenoid dislocation, 597
Sublimate, intestinal adhesions from use of, 870
Submucosa of small intestine, 813
Subphrenic abscess, 704
Subscapular artery, tearing of, in reduction, 586
Sulphate of magnesia injection after evacuation of intestines, 781
Sulphurous acid as antiseptic, 197
Suppurating joints, drainage of, 614, 629
Suppuration, amputation for, 1063

Suppuration and pus-microbes, relation, 160
Suprapubic drainage, 628
Suspension splints, 377
Suture, absorbable buried, 206
bloodless, 212
bone, 531
technic, 533
continued, 212
"etagen," 206
intestinal, 813
fistula from, 1010
nerve, 288
of arteries, 123
of veins, 124
on field, 250
removal of, 210, 212
sinus, 126
tension, 209, 212
vessel, for hemorrhage, 122
wound, 132
Suturing, 206
of external incision after laparotomy, 284
perforations, 283
secondary, 212
tension, 209
transverse, as prophylaxis against infection in fistula, 1020
Sylvester's method of artificial respiration, 54
Syme's amputation through ankle-joint with excision of malleoli, 1094
external urethrotomy staff, 306
Synovectomy, 1026
Synovitis, tapping in, 626
Syphilis, fractures and, 318
Syphilitic stricture of intestine, 943
Syringe, exploratory, 618
hypodermic, 614
Szumann's solution, 138, 251

Tait's drain, 217
hemostatic forceps, 111
Tampon, Mikulicz, 132
Tamponade, aseptic, 131
on field, 246
Tape-measures, 340
Tarsometatarsal disarticulation, Lisfranc's, 1092
Taxis in obstruction, 755
in strangulated hernia, 990
continuance of, 991
Teale's square flap operation, 1080
Tenaculum, minor operating, 114
Tension suture, 209, 212
Test of Dugas, 592
Test-line, Bryant's, 443, 444
Tetanus, bacillus of, 159
infection, 163
Thermocautery, 88
improved, 129
Thiersch's solution, 202
Thigh, amputation of, 1097, 1105
site for, 1066
fractures of, treatment, 545
Thoracentesis, 622
Thoracoplasty, Schede's, 661
Thrombophlebitis and fracture, 566
in compound fractures, 517
Thrombosis after fracture, 396
Thrombus, ligation and, 99, 100
Thumb, disarticulation of, 1083
Thymol as antiseptics, 197
Tibia, sections of, 1098
Tin splints, 383
Tinctura benzoini composita as antiseptic, 198
Tissue forceps, 994
Toe, great, amputation of, 1090
resection of metatarsophalangeal joint of, 1044
Toes, amputations of, 1089
disarticulation of all, 1091
elastic constriction of, 66
Torsion, 127
of testicle and hernia, differentiation, 988
Tracheotomy, 644
after-treatment, 650
anesthesia in, 647
high, 646, 648
instruments for, 647
low, 649
median, 645
rapid, 646
technic, 647
tubeless, 650
tubes, 647, 648
wound dressing after, 650
Transfusion, 137
Transplantation in enterectomy, 799
Transverse suturing before operation for artificial anus, 104
Treves' douche spoon, 1030
Trocars, 614, 620
Trochanter, temporary resection of, in hip-joint resection, 1057
Trousseau's double tracheotomy tube, 647
Truax's needle-holder, 211
Tubage in intestinal obstruction, 754
Tubercular abscess, intra-articular medication after, 626
infection, peritonitis and, 671
peritonitis, acute, 697
Tuberculosis, cecal, 933, 951
and of ascending colon, 955
intestinal, age and, 931
of hernia, 934
of hip, resection for, 1056
of ileum, 951
of intestines, 930
abdominal section and iodoformization for, 945
anatomic location of stricture, 939
cicatrization in, 937
colon bacillus in, 941

Tuberculosis of intestines, complete exclusion for, 960
diagnosis, 940
enterectomy for, 947
entero-anastomosis for, 953
enteroplasty for, 946
etiology, 930
extension of ulcer, 935
feces in, 941
fibrous form, 934
frequency, 930
healing of ulcers, 936, 938
in children, 932
induration in, 939
ileocecal abscess in, 939
infection from blood, 932
lymphadenitis from, 936
ovarian tumor and, 943
partial exclusion for, 953
pathology, 932
peritonitis from, 936
resection of cecum for, 949
seat of infection, 932, 935
stools in, 938
surgical treatment, 944
safety of, 951
swallowing of sputa and, 931
symptoms, 937
ulcerative form, 934
walls in, 936
with intestinal obstruction, 954
with invagination, 959
of knee-joint, resection for, 1049
of urinary organs, 955
peritoneal, 697
abdominal section for, 945
resection of elbow-joint for, 1036
synovial, intra-articular medication after, 626
resection for, 1025
wound infection with, 164
Tubular and capillary drainage of abdominal cavity, 690
drainage of abdominal cavity, 688
Tuffier's angiotribe, 88
Tumors, benign, intestinal obstruction from, 961
diagnosis, 968
in lumen of intestine, 764
intestinal obstruction from, 961
intussusception and, 891
malignant, amputation for, 1064
intestinal fistula from, 1007
obstruction from, 968
mortality, 972
treatment, 972
of abdominal cavity, 619
of cecum, enterectomy for, 798
ovarian, and tuberculosis, 943
Turkey, gunshot fractures in, 557
Turpentine as antiseptic, 198
in hand disinfection, 172
oil of, for hemorrhage, 133, 135
Tympanites, intestinal obstruction from, 975
Typhlostomy, 765
for obstruction of large intestine, 766
Typhoid ulcer, perforating, 695
stricture following, 943

Ulcer, gastric, perforating, 693
multiple catarrhal, of appendix, 713
of duodenum, perforating, 694
typhoid, perforating, 695
Ulceration, intestinal fistula from, 1006
Ulcerative appendicitis, 713
Ulna, dislocation of, 609
Umbilical hernia, radical operation for, 998
Unguentum Credé, 205
Upper extremity, amputations of, 1081
exarticulation of, with scapula and clavicle, 1088
Urethra, male, 633
microbes in, 636
rupture of, 302
catheterization, 305
cause, 302
classification, 302
diagnosis, 303
operations for, 305, 306
perineal section for, 306
recognition of urethra in, 307
retrograde catheterization for, 308
suturing for, 308
treatment, 305
surgical wall of, 305
Urethral canal, anatomy of, 634
curve, schematic representation, 632
Urinary bladder. See *Bladder*.
organs, tuberculosis of, 955
Urine in fat embolism with fracture, 349
retention of, puncture for, 627
Uterus, operations on, steam in, 130

Vaginalitis, suppurative, and strangulated hernia, differentiation, 988
Vaselin, sterilized, as catheter lubricant, 639
Vasotribe, 88
Veins, percutaneous temporary ligation of, 87
suture of, 124
Velpeau's bone-cutting forceps, 1028
Ventrofixation after volvulus removal, 864
Verity's suspension splint, 545, 546
Vertebræ, fractures of, treatment, 374
Vessel suture for hemorrhage, 122
Vessels, tearing of, amputations for, 1061

Vicious union, 410
Visceral peritonitis, 664
Volkmann's dorsal splint for ankle excision, 1048
dropping tube, 527
four-prong retractor, 306
method of uniting fractures, 408
pelvic support, 463
resection of intussusceptum through rectum, 912
sliding foot-board, 387
spoon, 1029
Volvulus, 850
abdominal taxis for, 857
after strangulated hernia, 852
after typhoid ulcer, 853
colostomy after, reduction, 864
diagnosis, 855
emptying bowel in, 860
enterectomy in, 865
enterostomy for, 864
exciting causes, 854
frequency, 850
from elongation, 852
from intestinal adhesions to abdominal wall, 853
incision for, 859
insufflation for, 858
intestinal anastomosis in, 861
laparotomy for, mortality, 858
length of intestinal canal and, 852
of sigmoid flexure, 855
predisposing causes, 850
prognosis, 856
reposition, 859
shortening mesentery after, 862
spontaneous reposition, 854
symptoms, 849, 855
treatment, 856
tympanites in, 855
ventrofixation after removal, 864

Walther's disarticulation at wrist-joint, 1081, 1085
Water, boiling, as sterilizer, 176
hot, for hemorrhage, 129
on field, 250
microbes in, 200
sterilizing of, 201
Watson's suspension splint for knee-joint, 1056
Waxham's mouth-gag, 641
Web catheter, prostatic, 635
Wein's first aid, 234
Wells' hemostatic forceps, 112
Wheelhouse's beaked straight staff, 306
Windlass, Spanish, 89
Windler's saw, 1070
Wire splints, 383
Wound suture, 132
Wounded, transportation of, 253
Wounds, 142
before aseptic surgery, 142
bullet, shock from, 33
Wounds, compression and, 214
contused, 148
drainage of, 214
dressing material for, 180
granulating surfaces of, appearance, 155
gunshot, 218
amputation and, 254
antiseptic dressings, 237
craniectomy for, 254
diagnosis, 220
first-aid treatment, 233, 234
from small-caliber bullet, 241
gangrene from, 559
hemorrhage from, arrest of, 244
autotransfusion in, 251
digital compression for, 246
elastic constriction for, 244
elevation for, 245
flexion for, 246
forcipressure for, 249
hot water for, 250
internal, 247
lateral ligation for, 250
ligation for, 249
saline infusion after, 250
styptics for, 250
tamponade for, 246
vein suture for, 250
immobilization after, 253
in South Africa, 227
infection of, 229
intestinal fistula from, 1005
laparotomy for, 254
of abdomen, 273. See also *Abdomen.*
of arteries, 290
of chest, 261. See also *Chest.*
of heart, 262
of hollow viscera, 220
of joints, treatment, 1024
of kidneys, 291. See also *Kidney.*
of neck, 259
of nerves, 288
of skull, 255
treatment, 259
of spine, 285
of stomach, 275
of urinary bladder, 297
primary dressing of, 252
probing, 221, 222
prognosis, 225
resection for, 255
search for perforation, 282
shock from, 252
treatment, 229
X-ray in, 223
incised, 145
infection of, 157
nonsuppurative, 162
prevention, 164, 185
streptococcic, 162
suppurative, 157
susceptibility to, 161
tetanic, 163

Wounds, infection of, trained nurse and, 65
tuberculous, 164
intestinal, healing of, 816
lacerated, 147
micro-organisms in, 157
of urinary bladder, 297
treatment, 300
poisoned, 152
profusely secreting, dressing of, 184
punctured, 150
repair of, 153
by primary intention, 154
by secondary intention, 156
surgeon's duty, 154
salves in dressing of, 180
splints for, 183
stab, 150
superficial, dressing of, 181
Wounds, suturing, 206
treatment, mechanical, 205
position, 206
Wrist-joint, amputation above, 1069
amputation at, 1085
disarticulation at, 1085
Walther's, 1081
resection of, 1034
Wyeth's bloodless amputation at hip-joint, 75, 76

X-RAYS in fractures, 343
in military surgery, 223

ZINC chlorid as antiseptic, 190
solution, 203
Zoege-Manteuffel's classification of intestinal obstruction, 847

Catalogue of the Medical Publications

OF

W. B. SAUNDERS & COMPANY

PHILADELPHIA — 925 Walnut Street — LONDON, W. C. — 161 Strand

Arranged Alphabetically and Classified under Subjects

See page 18 for a List of Contents classified according to subjects

THE books advertised in this Catalogue as being *sold by subscription* are usually to be obtained from travelling solicitors, but they will be sent direct from the office of publication (charges of shipment prepaid) upon receipt of the prices given. All the other books advertised are commonly for sale by booksellers in all parts of the United States; but books will be sent to any address, carriage prepaid, on receipt of the published price.

Money may be sent at the risk of the publisher in either of the following ways: A postal money order, an express money order, a bank check, and in a registered letter. Money sent in any other way is at the risk of the sender.

SPECIAL OFFER To physicians of approved credit books will be sent, post-paid, on the following terms: $5.00 cash upon delivery of books, and monthly payments of $5.00 thereafter until full amount is paid. Physicians not known to the house will be expected to furnish the names of satisfactory references. Any one or two volumes will be sent on thirty days' time to those who do not care to make a larger purchase.

An American Text-Book *of* Applied Therapeutics.

Edited by JAMES C. WILSON, M. D., Professor of Practice of Medicine and of Clinical Medicine, Jefferson Medical College, Philadelphia. Handsome imperial octavo volume of 1326 pages. Illustrated. Cloth, $7.00 net; Sheep or Half Morocco, $8.00 net. *Sold by Subscription.*

An American Text-Book *of the* Diseases *of* Children.

Second Edition, Revised.

Edited by LOUIS STARR, M. D., Consulting Pediatrist to the Maternity Hospital, etc.; assisted by THOMPSON S. WESTCOTT, M. D., Attending Physician to the Dispensary for Diseases of Children, Hospital of the University of Pennsylvania. Handsome imperial octavo volume of 1244 pages, profusely illustrated. Cloth, $7.00 net; Sheep or Half Morocco, $8.00 net. *Sold by Subscription.*

An American Text-Book *of* Diseases *of the* Eye, Ear, Nose, *and* Throat.

Edited by G. E. DE SCHWEINITZ, M. D., Professor of Ophthalmology, Jefferson Medical College, Philadelphia; and B. ALEXANDER RANDALL, M. D., Professor of Diseases of the Ear, University of Pennsylvania. Imperial octavo, 1251 pages; 766 illustrations, 59 of them in colors. Cloth, $7.00 net; Sheep or Half Morocco, $8.00 net. *Sold by Subscription.*

An American Text-Book *of* Genito-Urinary *and* Skin Diseases.

Edited by L. Bolton Bangs, M. D., Professor of Genito-Urinary Surgery, University and Bellevue Hospital Medical College, New York; and W. A. Hardaway, M. D., Professor of Diseases of the Skin, Missouri Medical College. Imperial octavo volume of 1229 pages, with 300 engravings and 20 full-page colored plates. Cloth, $7.00 net; Sheep or Half Morocco, $8.00 net. *Sold by Subscription.*

An American Text-Book *of* Gynecology, Medical *and* Surgical. **Second Edition, Revised.**

Edited by J. M. Baldy, M. D., Professor of Gynecology, Philadelphia Polyclinic, etc. Handsome imperial octavo volume of 718 pages; 341 illustrations in the text, and 38 colored and half-tone plates. Cloth, $6.00 net; Sheep or Half Morocco, $7.00 net. *Sold by Subscription.*

An American Text-Book *of* Legal Medicine *and* Toxicology.

Edited by Frederick Peterson, M. D., Chief of Clinic, Nervous Department, College of Physicians and Surgeons, New York; and Walter S. Haines, M. D., Professor of Chemistry, Pharmacy, and Toxicology, Rush Medical College, Chicago. *In Preparation.*

An American Text-Book *of* Obstetrics.

Edited by Richard C. Norris, M. D.; Art Editor, Robert L. Dickinson, M. D. Handsome imperial octavo volume of 1014 pages; nearly 900 beautiful colored and half-tone illustrations. Cloth, $7.00 net; Sheep or Half Morocco, $8.00 net. *Sold by Subscription.*

An American Text-Book *of* Pathology.

Edited by Ludwig Hektoen, M. D., Professor of Pathology in Rush Medical College, Chicago; and David Riesman, M. D., Demonstrator of Pathologic Histology in the University of Pennsylvania. *In Press, Ready Shortly.*

An American Text-Book *of* Physiology. **Second Edition, Revised, in Two Volumes.**

Edited by William H. Howell, Ph. D., M. D., Professor of Physiology, Johns Hopkins University, Baltimore, Md. Two royal octavo volumes of about 600 pages each. Fully illustrated. Per volume: Cloth, $3.00 net; Sheep or Half Morocco, $3.75 net.

An American Text-Book *of* Surgery. **Third Edition.**

Edited by William W. Keen, M. D., LL. D., F. R. C. S. (Hon.); and J. William White, M. D., Ph. D. Handsome octavo volume of 1230 pages; 496 wood-cuts and 37 colored and half-tone plates. Thoroughly revised and enlarged, with a section devoted to "The Use of the Röntgen Rays in Surgery." Cloth, $7.00 net; Sheep or Half Morocco, $8.00 net.

THE NEW STANDARD THE NEW STANDARD

The American Illustrated Medical Dictionary.

For Practitioners and Students. A Complete Dictionary of the Terms used in Medicine, Surgery, Dentistry, Pharmacy, Chemistry, and the kindred branches, including much collateral information of an encyclopedic character, together with new and elaborate tables of Arteries, Muscles, Nerves, Veins, etc.; of Bacilli, Bacteria, Micrococci, Streptococci; Eponymic Tables of Diseases, Operations, Signs and Symptoms, Stains, Tests, Methods of Treatment, etc., etc. By W. A. NEWMAN DORLAND, A. M., M. D., Editor of the "American Pocket Medical Dictionary." Handsome large octavo, nearly 800 pages, bound in full flexible leather. Price, $4.50 net; with thumb index, $5.00 net.

Gives a Maximum Amount of Matter in a Minimum Space and at the Lowest Possible Cost.

This is an entirely new and unique work, intended to meet the need of practitioners and students for a complete up-to-date dictionary of moderate price. It contains more than twice the material in the ordinary students' dictionary, and yet, by the use of a clear, condensed type and thin paper of the finest quality, it forms an extremely handy volume only 1¾ inches in thickness. It is a beautiful specimen of the bookmaker's art. It is bound in full flexible leather, and is just the kind of book that a man will want to keep on his desk for constant reference. The book makes a special feature of the newer words, and defines hundreds of important terms not to be found in any other dictionary. It is especially full in the matter of tables, containing more than a hundred of great practical value. An important feature of the book is its handsome illustrations and colored plates drawn especially for the work, including new colored plates of Arteries, Nerves, Veins, Bacteria, Blood, etc.—twenty-four in all. This new work has been aptly termed by a competent critic "The New Standard."

The American Pocket Medical Dictionary. Third Edition, Revised.

Edited by W. A. NEWMAN DORLAND, M. D., Assistant Obstetrician to the Hospital of the University of Pennsylvania; Fellow of the American Academy of Medicine. Containing the pronunciation and definition of the principal words used in medicine and kindred sciences, with 64 extensive tables. Handsomely bound in flexible leather, with gold edges. Price $1.00 net; with thumb index, $1.25 net.

The American Year-Book *of* Medicine *and* Surgery.

A Yearly Digest of Scientific Progress and Authoritative Opinion in all branches of Medicine and Surgery, drawn from journals, monographs, and text-books of the leading American and Foreign authors and investigators. Arranged with critical editorial comments, by eminent American specialists, under the editorial charge of GEORGE M. GOULD, M. D. Year-Book of 1901 in two volumes—Vol. I. including *General Medicine;* Vol. II., *General Surgery.* Per volume: Cloth, $3.00 net; Half Morocco, $3.75 net. *Sold by Subscription.*

Abbott on Transmissible Diseases.

The Hygiene of Transmissible Diseases: their Causation, Modes of Dissemination, and Methods of Prevention. By A. C. ABBOTT, M. D., Professor of Hygiene and Bacteriology, University of Pennsylvania. Octavo, 311 pages, with numerous illustrations. Cloth, $2.00 net.

Anders' Practice *of* Medicine. Fourth Revised Edition.

A Text-Book of the Practice of Medicine. By JAMES M. ANDERS, M. D., PH. D., LL. D., Professor of the Practice of Medicine and of Clinical Medicine, Medico-Chirurgical College, Philadelphia. Handsome octavo volume of 1292 pages, fully illustrated. Cloth, $5.50 net; Sheep or Half Morocco, $6.50 net.

Bastin's Botany.

Laboratory Exercises in Botany. By EDSON S. BASTIN, M. A., late Professor of Materia Medica and Botany, Philadelphia College of Pharmacy. Octavo, 536 pages, with 87 plates. Cloth, $2.00 net.

Beck on Fractures.

Fractures. By CARL BECK, M. D., Surgeon to St. Mark's Hospital and the New York German Poliklinik, etc. With an appendix on the Practical Use of the Röntgen Rays. 335 pages, 170 illustrations. Cloth, $3.50 net.

Beck's Surgical Asepsis.

A Manual of Surgical Asepsis. By CARL BECK, M. D., Surgeon to St. Mark's Hospital and the New York German Poliklinik, etc. 306 pages; 65 text-illustrations and 12 full-page plates. Cloth, $1.25 net.

Boisliniere's Obstetric Accidents, Emergencies, *and* Operations.

Obstetric Accidents, Emergencies, and Operations. By L. CH. BOISLINIÈRE, M. D., late Emeritus Professor of Obstetrics, St. Louis Medical College. 381 pages, handsomely illustrated. Cloth, $2.00 net.

Böhm, Davidoff, *and* Huber's Histology.

A Text-Book of Human Histology. Including Microscopic Technic. By DR. A. A. BÖHM and DR. M. VON DAVIDOFF, of Munich, and G. CARL HUBER, M. D., Junior Professor of Anatomy and Director of Histological Laboratory, University of Michigan. Handsome octavo of 503 pages, with 351 beautiful original illustrations. Cloth, $3.50 net.

Butler's Materia Medica, Therapeutics, *and* Pharmacology. Third Edition, Revised.

A Text-Book of Materia Medica, Therapeutics, and Pharmacology. By GEORGE F. BUTLER, PH. G., M. D., Professor of Materia Medica and of Clinical Medicine, College of Physicians and Surgeons, Chicago. Octavo, 874 pages, illustrated. Cloth, $4.00 net; Sheep or Half Morocco, $5.00 net.

Cerna on *the* Newer Remedies. Second Edition, Revised.

Notes on the Newer Remedies, their Therapeutic Applications and Modes of Administration. By DAVID CERNA, M. D., PH. D., Demonstrator of Physiology, Medical Department, University of Texas. Rewritten and greatly enlarged. Post-octavo, 253 pages. Cloth, $1.00 net.

Chapin on Insanity.

A Compendium of Insanity. By JOHN B. CHAPIN, M. D., LL. D., Physician-in-Chief, Pennsylvania Hospital for the Insane; Honorary Member of the Medico-Psychological Society of Great Britain, of the Society of Mental Medicine of Belgium, etc. 12mo, 234 pages, illustrated. Cloth, $1.25 net.

Chapman's Medical Jurisprudence *and* Toxicology.

Second Edition, Revised.

Medical Jurisprudence and Toxicology. By HENRY C. CHAPMAN, M. D., Professor of Institutes of Medicine and Medical Jurisprudence, Jefferson Medical College of Philadelphia. 254 pages, with 55 illustrations and 3 full-page plates in colors. Cloth, $1.50 net.

Church *and* Peterson's Nervous *and* Mental Diseases.

Second Edition.

Nervous and Mental Diseases. By ARCHIBALD CHURCH, M. D., Professor of Nervous and Mental Diseases, and Head of the Neurological Department, Northwestern University Medical School, Chicago; and FREDERICK PETERSON, M. D., Chief of Clinic, Nervous Department, College of Physicians and Surgeons, New York. Handsome octavo volume of 843 pages, profusely illustrated. Cloth, $5.00 net; Sheep or Half Morocco, $6.00 net.

Clarkson's Histology.

A Text-Book of Histology, Descriptive and Practical. By ARTHUR CLARKSON, M. B., C. M. Edin., formerly Demonstrator of Physiology in the Owen's College, Manchester; late Demonstrator of Physiology in Yorkshire College, Leeds. Large octavo, 554 pages; 22 engravings and 174 beautifully colored original illustrations. Cloth, $4.00 net.

Corwin's Physical Diagnosis. **Third Edition, Revised.**

Essentials of Physical Diagnosis of the Thorax. By ARTHUR M. CORWIN, A. M., M. D., Instructor in Physical Diagnosis in Rush Medical College, Chicago. 219 pages, illustrated. Cloth, $1.25 net.

Crookshank's Bacteriology. **Fourth Edition, Revised.**

A Text-Book of Bacteriology. By EDGAR M. CROOKSHANK, M. B., Professor of Comparative Pathology and Bacteriology, King's College, London. Octavo, 700 pages, 273 engravings and 22 original colored plates. Cloth, $6.50 net; Half Morocco, $7.50 net.

DaCosta's Surgery. **Third Edition, Revised.**

Modern Surgery, General and Operative. By JOHN CHALMERS DA COSTA, M. D., Professor of Principles of Surgery and Clinical Surgery, Jefferson Medical College, Philadelphia; Surgeon to the Philadelphia Hospital, etc. Handsome octavo volume of 1117 pages, profusely illustrated. Cloth, $5.00 net; Sheep or Half Morocco, $6.00 net.

Enlarged by over 200 Pages, with more than 100 New Illustrations.

Davis's Obstetric Nursing.

Obstetric and Gynecologic Nursing. By EDWARD P. DAVIS, A. M., M. D., Professor of Obstetrics in Jefferson Medical College and the Philadelphia Polyclinic; Obstetrician and Gynecologist to the Philadelphia Hospital. 12mo volume of 400 pages, fully illustrated. Crushed Buckram, $1.75 net.

DeSchweinitz on Diseases *of the* Eye. Third Edition, Revised.

Diseases of the Eye. A Handbook of Ophthalmic Practice. By G. E. DE SCHWEINITZ, M. D., Professor of Ophthalmology, Jefferson Medical College, Philadelphia, etc. Handsome royal octavo volume of 696 pages; 256 fine illustrations and 2 chromo-lithographic plates. Cloth, $4.00 net; Sheep or Half Morocco, $5.00 net.

Dorland's Dictionaries.

[See *American Illustrated Medical Dictionary* and *American Pocket Medical Dictionary* on page 3.]

Dorland's Obstetrics.

A Manual of Obstetrics. By W. A. NEWMAN DORLAND, M. D., Assistant Demonstrator of Obstetrics, University of Pennsylvania; Associate in Gynecology, Philadelphia Polyclinic. 760 pages; 163 illustrations in the text and 6 full-page plates. Cloth, $2.50 net.

Eichhorst's Practice *of* Medicine.

A Text-Book of the Practice of Medicine. By DR. HERMAN EICHHORST, Professor of Special Pathology and Therapeutics and Director of the Medical Clinic, University of Zurich. Translated and edited by AUGUSTUS A. ESHNER, M. D., Professor of Clinical Medicine, Philadelphia Polyclinic. Two octavo volumes of 600 pages each, over 150 illustrations. Prices per set: Cloth, $6.00 net; Sheep or Half Morocco, $7.50 net.

Friedrich *and* Curtis on *the* Nose, Throat, *and* Ear.

Rhinology, Laryngology, and Otology, and Their Significance in General Medicine. By DR. E. P. FRIEDRICH, of Leipzig. Edited by H. HOLBROOK CURTIS, M. D., Consulting Surgeon to the New York Nose and Throat Hospital. Octavo, 348 pages. Cloth, $2.50 net.

Frothingham's Guide for *the* Bacteriologist.

Laboratory Guide for the Bacteriologist. By LANGDON FROTHINGHAM, M. D. V., Assistant in Bacteriology and Veterinary Science, Sheffield Scientific School, Yale University. Illustrated. Cloth, 75 cts. net.

Garrigues' Diseases *of* Women. Third Edition, Revised.

Diseases of Women. By HENRY J. GARRIGUES, A. M., M. D., Gynecologist to St. Mark's Hospital and to the German Dispensary, New York City. Octavo, 756 pages, with 367 engravings and colored plates. Cloth, $4.50 net; Sheep or Half Morocco, $5.50 net.

Gould and Pyle's Curiosities of Medicine.

Anomalies and Curiosities of Medicine. By GEORGE M. GOULD, M. D., and WALTER L. PYLE, M. D. An encyclopedic collection of rare and extraordinary cases and of the most striking instances of abnormality in all branches of Medicine and Surgery, derived from an exhaustive research of medical literature from its origin to the present day, abstracted, classified, annotated, and indexed. Handsome octavo volume of 968 pages; 295 engravings and 12 full-page plates. Popular Edition. Cloth, $3.00 net; Sheep or Half Morocco, $4.00 net.

Grafstrom's Mechano-Therapy.

A Text-Book of Mechano-Therapy (Massage and Medical Gymnastics). By AXEL V. GRAFSTROM, B. Sc., M. D., late House Physician, City Hospital, Blackwell's Island, New York. 12mo, 139 pages, illustrated. Cloth, $1.00 net.

Griffith on the Baby. Second Edition, Revised.

The Care of the Baby. By J. P. CROZER GRIFFITH, M. D., Clinical Professor of Diseases of Children, University of Pennsylvania; Physician to the Children's Hospital, Philadelphia, etc. 12mo, 404 pages; 67 illustrations and 5 plates. Cloth, $1.50 net.

Griffith's Weight Chart.

Infant's Weight Chart. Designed by J. P. CROZER GRIFFITH, M. D., Clinical Professor of Diseases of Children, University of Pennsylvania. 25 charts in each pad. Per pad, 50 cts. net.

Hart's Diet in Sickness and in Health.

Diet in Sickness and Health. By MRS. ERNEST HART, formerly Student of the Faculty of Medicine of Paris and of the London School of Medicine for Women; with an Introduction by SIR HENRY THOMPSON, F. R. C. S., M. D., London. 220 pages. Cloth, $1.50 net.

Haynes' Anatomy.

A Manual of Anatomy. By IRVING S. HAYNES, M. D., Professor of Practical Anatomy in Cornell University Medical College. 680 pages; 42 diagrams and 134 full-page half-tone illustrations from original photographs of the author's dissections. Cloth, $2.50 net.

Heisler's Embryology.

A Text-Book of Embryology. By JOHN C. HEISLER, M. D., Professor of Anatomy, Medico-Chirurgical College, Philadelphia. Octavo volume of 405 pages, handsomely illustrated. Cloth, $2.50 net.

Hirst's Obstetrics. Second Edition.

A Text-Book of Obstetrics. By BARTON COOKE HIRST, M. D., Professor of Obstetrics, University of Pennsylvania. Handsome octavo volume of 848 pages; 618 illustrations and 7 colored plates. Cloth, $5.00 net; Sheep or Half Morocco, $6.00 net.

Hyde *and* Montgomery on Syphilis *and the* Venereal Diseases. **Second Edition, Revised and Greatly Enlarged.**

Syphilis and the Venereal Diseases. By JAMES NEVINS HYDE, M. D., Professor of Skin and Venereal Diseases, and FRANK H. MONTGOMERY, M. D., Associate Professor of Skin, Genito-Urinary, and Venereal Diseases in Rush Medical College, Chicago, Ill. Octavo, 594 pages, profusely illustrated. Cloth, $4.00 net.

The International Text-Book of Surgery. **In Two Volumes.**

By American and British Authors. Edited by J. COLLINS WARREN, M. D., LL. D., F. R. C. S. (Hon.), Professor of Surgery, Harvard Medical School, Boston; and A. PEARCE GOULD, M. S., F. R. C. S., Lecturer on Practical Surgery and Teacher of Operative Surgery, Middlesex Hospital Medical School, London, Eng. Vol. I. *General Surgery.*—Handsome octavo, 947 pages, with 458 beautiful illustrations and 9 lithographic plates. Vol. II. *Special or Regional Surgery.*—Handsome octavo, 1072 pages, with 471 beautiful illustrations and 8 lithographic plates. *Sold by Subscription.* Prices per volume: Cloth, $5.00 net; Sheep or Half Morocco, $6.00 net.

"It is the most valuable work on the subject that has appeared in some years. The clinician and the pathologist have joined hands in its production, and the result must be a satisfaction to the editors as it is a gratification to the conscientious reader."—*Annals of Surgery.*

"This is a work which comes to us on its own intrinsic merits. Of the latter it has very many. The arrangement of subjects is excellent, and their treatment by the different authors is equally so. What is especially to be recommended is the painstaking endeavor of each writer to make his subject clear and to the point. To this end particularly is the technique of operations lucidly described in all necessary detail. And withal the work is up to date in a very remarkable degree, many of the latest operations in the different regional parts of the body being given in full details. There is not a chapter in the work from which the reader may not learn something new."—*Medical Record*, New York.

Jackson's Diseases *of the* Eye.

A Manual of Diseases of the Eye. By EDWARD JACKSON, A. M., M. D., Emeritus Professor of Diseases of the Eye, Philadelphia Polyclinic and College for Graduates in Medicine. 12mo volume of 535 pages, with 178 illustrations, mostly from drawings by the author. Cloth, $2.50 net.

Keating's Life Insurance.

How to Examine for Life Insurance. By JOHN M. KEATING, M. D., Fellow of the College of Physicians of Philadelphia; Ex-President of the Association of Life Insurance Medical Directors. Royal octavo, 211 pages. With numerous illustrations. Cloth, $2.00 net.

Keen on *the* Surgery *of* Typhoid Fever.

The Surgical Complications and Sequels of Typhoid Fever. By WM. W. KEEN, M. D., LL. D., F. R. C. S. (Hon.), Professor of the Principles of Surgery and of Clinical Surgery, Jefferson Medical College, Philadelphia, etc. Octavo volume of 386 pages, illustrated. Cloth, $3.00 net.

Keen's Operation Blank. **Second Edition, Revised Form.**

An Operation Blank, with Lists of Instruments, etc., Required in Various Operations. Prepared by W. W. KEEN, M. D., LL. D., F. R. C. S. (Hon.), Professor of the Principles of Surgery and of Clinical Surgery, Jefferson Medical College, Philadelphia. Price per pad, blanks for fifty operations, 50 cts. net.

Kyle on *the* Nose and Throat. **Second Edition.**

Diseases of the Nose and Throat. By D. Braden Kyle, M. D., Clinical Professor of Laryngology and Rhinology, Jefferson Medical College, Philadelphia. Octavo, 646 pages; over 150 illustrations and 6 lithographic plates. Cloth, $4.00 net; Sheep or Half Morocco, $5.00 net.

Laine's Temperature Chart.

Temperature Chart. Prepared by D. T. Lainé, M. D. Size 8 x 13½ inches. A conveniently arranged Chart for recording Temperature, with columns for daily amounts of Urinary and Fecal Excretions, Food, Remarks, etc. On the back of each chart is given the Brand treatment of Typhoid Fever. Price, per pad of 25 charts, 50 cts. net.

Levy, Klemperer, *and* Eshner's Clinical Bacteriology.

The Elements of Clinical Bacteriology. By Dr. Ernst Levy, Professor in the University of Strasburg, and Felix Klemperer, Privatdocent in the University of Strasburg. Translated and edited by Augustus A. Eshner, M. D., Professor of Clinical Medicine, Philadelphia Polyclinic. Octavo, 440 pages, fully illustrated. Cloth, $2.50 net.

Lockwood's Practice *of* Medicine.

A Manual of the Practice of Medicine. By George Roe Lockwood, M. D., Professor of Practice in the Woman's Medical College of the New York Infirmary, etc. 935 pages, with 75 illustrations in the text, and 22 full-page plates. Cloth, $2.50 net.

Long's Syllabus *of* Gynecology.

A Syllabus of Gynecology, arranged in Conformity with "An American Text-Book of Gynecology." By J. W. Long, M. D., Professor of Diseases of Women and Children, Medical College of Virginia, etc. Cloth, interleaved, $1.00 net.

Macdonald's Surgical Diagnosis *and* Treatment.

Surgical Diagnosis and Treatment. By J. W. Macdonald, M. D. Edin., F. R. C. S. Edin., Professor of Practice of Surgery and Clinical Surgery, Hamline University. Handsome octavo, 800 pages, fully illustrated. Cloth, $5.00 net; Sheep or Half Morocco, $6.00 net.

Mallory *and* Wright's Pathological Technique.

Pathological Technique. A Practical Manual for Laboratory Work in Pathology, Bacteriology, and Morbid Anatomy, with chapters on Post-Mortem Technique and the Performance of Autopsies. By Frank B. Mallory, A. M., M. D., Assistant Professor of Pathology, Harvard University Medical School, Boston; and James H. Wright, A. M., M. D., Instructor in Pathology, Harvard University Medical School, Boston. Octavo, 396 pages, handsomely illustrated. Cloth, $2.50 net.

McFarland's Pathogenic Bacteria. **Third Edition, increased in size by over 100 Pages.**

Text-Book upon the Pathogenic Bacteria. By Joseph McFarland, M. D., Professor of Pathology and Bacteriology, Medico-Chirurgical College of Philadelphia, etc. Octavo volume of 621 pages, finely illustrated. Cloth, $3.25 net.

Meigs on Feeding in Infancy.

Feeding in Early Infancy. By ARTHUR V. MEIGS, M. D. Bound in limp cloth, flush edges, 25 cts. net.

Moore's Orthopedic Surgery.

A Manual of Orthopedic Surgery. By JAMES E. MOORE, M. D., Professor of Orthopedics and Adjunct Professor of Clinical Surgery, University of Minnesota, College of Medicine and Surgery. Octavo volume of 356 pages, handsomely illustrated. Cloth, $2.50 net.

Morten's Nurses' Dictionary.

Nurses' Dictionary of Medical Terms and Nursing Treatment. Containing Definitions of the Principal Medical and Nursing Terms and Abbreviations; of the Instruments, Drugs, Diseases, Accidents, Treatments, Operations, Foods, Appliances, etc. encountered in the ward or in the sick-room. By HONNOR MORTEN, author of "How to Become a Nurse," etc. 16mo, 140 pages. Cloth, $1.00 net.

Nancrede's Anatomy *and* Dissection. Fourth Edition.

Essentials of Anatomy and Manual of Practical Dissection. By CHARLES B. NANCREDE, M. D., LL. D., Professor of Surgery and of Clinical Surgery, University of Michigan, Ann Arbor. Post-octavo, 500 pages, with full-page lithographic plates in colors and nearly 200 illustrations. Extra Cloth (or Oilcloth for dissection-room), $2.00 net.

Nancrede's Principles *of* Surgery.

Lectures on the Principles of Surgery. By CHAS. B. NANCREDE, M. D., LL. D., Professor of Surgery and of Clinical Surgery, University of Michigan, Ann Arbor. Octavo, 398 pages, illustrated. Cloth, $2.50 net.

Norris's Syllabus *of* Obstetrics. Third Edition, Revised.

Syllabus of Obstetrical Lectures in the Medical Department of the University of Pennsylvania. By RICHARD C. NORRIS, A. M., M. D., Instructor in Obstetrics and Lecturer on Clinical and Operative Obstetrics, University of Pennsylvania. Crown octavo, 222 pages. Cloth, interleaved for notes, $2.00 net.

Ogden on *the* Urine.

Clinical Examination of the Urine and Urinary Diagnosis. A Clinical Guide for the Use of Practitioners and Students of Medicine and Surgery. By J. BERGEN OGDEN, M. D., Instructor in Chemistry, Harvard Medical School. Handsome octavo, 416 pages, with 54 illustrations and a number of colored plates. Cloth, $3.00 net.

Penrose's Diseases *of* Women. Third Edition, Revised.

A Text-Book of Diseases of Women. By CHARLES B. PENROSE, M. D., PH. D., formerly Professor of Gynecology in the University of Pennsylvania. Octavo volume of 531 pages, handsomely illustrated. Cloth, $3.75 net.

Pryor—Pelvic Inflammations.

The Treatment of Pelvic Inflammations through the Vagina. By W. R. PRYOR, M. D., Professor of Gynecology, New York Polyclinic. 12mo, 248 pages, handsomely illustrated. Cloth, $2.00 net.

Pye's Bandaging.

Elementary Bandaging and Surgical Dressing. With Directions concerning the Immediate Treatment of Cases of Emergency. By WALTER PYE, F. R. C. S., late Surgeon to St. Mary's Hospital, London. Small 12mo, over 80 illustrations. Cloth, flexible covers, 75 cts. net.

Pyle's Personal Hygiene.

A Manual of Personal Hygiene. Proper Living upon a Physiologic Basis. Edited by WALTER L. PYLE, M. D., Assistant Surgeon to the Wills Eye Hospital, Philadelphia. Octavo volume of 344 pages, fully illustrated. Cloth, $1.50 net.

Raymond's Physiology.

A Manual of Physiology. By JOSEPH H. RAYMOND, A. M., M. D., Professor of Physiology and Hygiene and Lecturer on Gynecology in the Long Island College Hospital. 382 pages, 102 illustrations, and 4 full-page colored plates. Cloth, $1.25 net.

Salinger *and* Kalteyer's Modern Medicine.

Modern Medicine. By JULIUS L. SALINGER, M. D., Demonstrator of Clinical Medicine, Jefferson Medical College; and F. J. KALTEYER, M. D., Assistant Demonstrator of Clinical Medicine, Jefferson Medical College. Handsome octavo, 801 pages, illustrated. Cloth, $4.00 net.

Saundby's Renal *and* Urinary Diseases.

Lectures on Renal and Urinary Diseases. By ROBERT SAUNDBY, M. D. Edin., Fellow of the Royal College of Physicians, London, and of the Royal Medico-Chirurgical Society; Professor of Medicine in Mason College, Birmingham, etc. Octavo, 434 pages, with numerous illustrations and 4 colored plates. Cloth, $2.50 net.

Saunders' Medical Hand-Atlases.

See pages 16 and 17.

Saunders' Pocket Medical Formulary. Sixth Edition, Revised.

By WILLIAM M. POWELL, M. D., author of "Essentials of Diseases of Children"; Member of Philadelphia Pathological Society. Containing 1844 formulæ from the best-known authorities. With an Appendix containing Posological Table, Formulæ and Doses for Hypodermic Medication, Poisons and their Antidotes, Diameters of the Female Pelvis and Fetal Head, Obstetrical Table, Diet List for Various Diseases, Materials and Drugs used in Antiseptic Surgery, Treatment of Asphyxia from Drowning, Surgical Remembrancer, Tables of Incompatibles, Eruptive Fevers, etc., etc. Handsomely bound in flexible morocco, with side index, wallet, and flap. $2.00 net.

Saunders' Question-Compends.

See page 15.

Scudder's Fractures. Second Edition, Revised.

The Treatment of Fractures. By CHAS. L. SCUDDER, M. D., Assistant in Clinical and Operative Surgery, Harvard University Medical School. Octavo, 460 pages, with nearly 600 original illustrations. Polished Buckram, $4.50 net; Half Morocco, $5.50 net.

Senn's Genito-Urinary Tuberculosis.

Tuberculosis of the Genito-Urinary Organs, Male and Female. By NICHOLAS SENN, M. D., PH. D., LL. D., Professor of the Practice of Surgery and of Clinical Surgery, Rush Medical College, Chicago. Handsome octavo volume of 320 pages, illustrated. Cloth, $3.00 net.

Senn's Practical Surgery.

Practical Surgery. By NICHOLAS SENN, M. D., PH. D., LL. D., Professor of the Practice of Surgery and of Clinical Surgery, Rush Medical College, Chicago. Handsome octavo volume of over 1000 pages, profusely illustrated. *In Press.*

Senn's Syllabus *of* Surgery.

A Syllabus of Lectures on the Practice of Surgery, arranged in conformity with "An American Text-Book of Surgery." By NICHOLAS SENN, M. D., PH. D., LL. D., Professor of the Practice of Surgery and of Clinical Surgery, Rush Medical College, Chicago. Cloth, $1.50 net.

Senn's Tumors. Second Edition, Revised.

Pathology and Surgical Treatment of Tumors. By NICHOLAS SENN, M. D., PH. D., LL. D., Professor of the Practice of Surgery and of Clinical Surgery, Rush Medical College, Chicago. Octavo volume of 718 pages, with 478 illustrations, including 12 full-page plates in colors. Cloth, $5.00 net; Sheep or Half Morocco, $6.00 net.

Starr's Diets for Infants *and* Children.

Diets for Infants and Children in Health and in Disease. By LOUIS STARR, M. D., Editor of "An American Text-Book of the Diseases of Children." 230 blanks (pocket-book size), perforated and neatly bound in flexible morocco. $1.25 net.

Stengel's Pathology. Third Edition, Thoroughly Revised.

A Text-Book of Pathology. By ALFRED STENGEL, M. D., Professor of Clinical Medicine, University of Pennsylvania; Visiting Physician to the Pennsylvania Hospital. Handsome octavo, 873 pages, nearly 400 illustrations, many of them in colors. Cloth, $5.00 net; Sheep or Half Morocco, $6.00 net.

Stengel *and* White on *the* Blood.

The Blood in its Clinical and Pathological Relations. By ALFRED STENGEL, M. D., Professor of Clinical Medicine, University of Pennsylvania; and C. Y. WHITE, JR., M. D., Instructor in Clinical Medicine, University of Pennsylvania. *In Press.*

Stevens' Materia Medica and Therapeutics. Second Edition, Revised.

A Manual of Materia Medica and Therapeutics. By A. A. STEVENS, A. M., M. D., Lecturer on Physical Diagnosis in the University of Pennsylvania. Post-octavo, 445 pages. Flexible Leather, $2.00 net.

Stevens' Practice of Medicine. Fifth Edition, Revised.

A Manual of the Practice of Medicine. By A. A. STEVENS, A. M., M. D., Lecturer on Physical Diagnosis in the University of Pennsylvania. Specially intended for students preparing for graduation and hospital examinations. Post-octavo, 519 pages; illustrated. Flexible Leather, $2.00 net.

Stewart's Physiology. Fourth Edition, Revised.

A Manual of Physiology, with Practical Exercises. For Students and Practitioners. By G. N. STEWART, M. A., M. D., D. Sc., Professor of Physiology in the Western Reserve University, Cleveland, Ohio. Octavo volume of 894 pages; 336 illustrations and 5 colored plates. Cloth, $3.75 net.

Stoney's Materia Medica for Nurses.

Materia Medica for Nurses. By EMILY A. M. STONEY, late Superintendent of the Training-School for Nurses, Carney Hospital, South Boston, Mass. Handsome octavo volume of 306 pages. Cloth, $1.50 net.

Stoney's Nursing. Second Edition, Revised.

Practical Points in Nursing. For Nurses in Private Practice. By EMILY A. M. STONEY, late Superintendent of the Training-School for Nurses, Carney Hospital, South Boston, Mass. 456 pages, with 73 engravings and 8 colored and half-tone plates. Cloth, $1.75 net.

Stoney's Surgical Technic for Nurses.

Bacteriology and Surgical Technic for Nurses. By EMILY A. M. STONEY, late Superintendent of the Training-School for Nurses, Carney Hospital, South Boston, Mass. 12mo volume, fully illustrated. Cloth, $1.25 net.

Thomas's Diet Lists. Second Edition, Revised.

Diet Lists and Sick-Room Dietary. By JEROME B. THOMAS, M. D., Visiting Physician to the Home for Friendless Women and Children and to the Newsboys' Home; Assistant Visiting Physician to the Kings County Hospital. Cloth, $1.25 net. Send for sample sheet.

Thornton's Dose-Book and Prescription-Writing.

Dose-Book and Manual of Prescription-Writing. By E. Q. THORNTON, M. D., Demonstrator of Therapeutics, Jefferson Medical College, Philadelphia. 334 pages, illustrated. Cloth, $1.25 net.

Van Valzah and Nisbet's Diseases of the Stomach.

Diseases of the Stomach. By WILLIAM W. VAN VALZAH, M. D., Professor of General Medicine and Diseases of the Digestive System and the Blood, New York Polyclinic; and J. DOUGLAS NISBET, M. D., Adjunct Professor of General Medicine and Diseases of the Digestive System and the Blood, New York Polyclinic. Octavo volume of 674 pages, illustrated. Cloth, $3.50 net.

Vecki's Sexual Impotence.

The Pathology and Treatment of Sexual Impotence. By VICTOR G. VECKI, M. D. From the second German edition, revised and enlarged. Demi-octavo, 291 pages. Cloth, $2.00 net.

Vierordt's Medical Diagnosis. Fourth Edition, Revised.

Medical Diagnosis. By DR. OSWALD VIERORDT, Professor of Medicine, University of Heidelberg. Translated, with additions, from the fifth enlarged German edition, with the author's permission, by FRANCIS H. STUART, A. M., M. D. Handsome octavo volume, 603 pages; 194 wood-cuts, many of them in colors. Cloth, $4.00 net; Sheep or Half Morocco, $5.00 net.

Watson's Handbook for Nurses.

A Handbook for Nurses. By J. K. WATSON, M. D. Edin. American Edition, under supervision of A. A. STEVENS, A. M., M. D., Lecturer on Physical Diagnosis, University of Pennsylvania. 12mo, 413 pages, 73 illustrations. Cloth, $1.50 net.

Warren's Surgical Pathology. Second Edition.

Surgical Pathology and Therapeutics. By JOHN COLLINS WARREN, M. D., LL. D., F. R. C. S. (Hon.), Professor of Surgery, Harvard Medical School. Handsome octavo, 873 pages; 136 relief and lithographic illustrations, 33 in colors. With an Appendix on Scientific Aids to Surgical Diagnosis, and a series of articles on Regional Bacteriology. Cloth, $5.00 net; Sheep or Half Morocco, $6.00 net.

SAUNDERS'

QUESTION-COMPENDS.

ARRANGED IN QUESTION AND ANSWER FORM.

The Most Complete and Best Illustrated Series of Compends Ever Issued.

NOW THE STANDARD AUTHORITIES IN MEDICAL LITERATURE

WITH

Students and Practitioners in every City of the United States and Canada.

Since the issue of the first volume of the Saunders Question-Compends,

OVER 175,000 COPIES

of these unrivalled publications have been sold. This enormous sale is indisputable evidence of the value of these self-helps to students and physicians.

SEE NEXT PAGE FOR LIST.

SAUNDERS' QUESTION-COMPEND SERIES.

Price, Cloth, $1.00 net per copy, except when otherwise noted.

"Where the work of preparing students' manuals is to end we cannot say, but the Saunders Series, in our opinion, bears off the palm at present."—*New York Medical Record.*

1. **Essentials of Physiology.** A new work in preparation.
2. **Essentials of Surgery.** By EDWARD MARTIN, M. D. Seventh edition, revised, with an Appendix and a chapter on Appendicitis.
3. **Essentials of Anatomy.** By CHARLES B. NANCREDE, M. D. Sixth edition, thoroughly revised and enlarged.
4. **Essentials of Medical Chemistry, Organic and Inorganic.** By LAWRENCE WOLFF, M. D. Fifth edition, revised.
5. **Essentials of Obstetrics.** By W. EASTERLY ASHTON, M. D. Fourth edition, revised and enlarged.
6. **Essentials of Pathology and Morbid Anatomy.** By F. J. KALTEYER, M. D. *In preparation.*
7. **Essentials of Materia Medica, Therapeutics, and Prescription-Writing.** By HENRY MORRIS, M. D. Fifth edition, revised.
8. 9. **Essentials of Practice of Medicine.** By HENRY MORRIS, M. D. An Appendix on URINE EXAMINATION. By LAWRENCE WOLFF, M. D. Third edition, enlarged by some 300 Essential Formulæ, selected from eminent authorities, by WM. M. POWELL, M. D. (Double number, $1.50 net.)
10. **Essentials of Gynecology.** By EDWIN B. CRAGIN, M. D. Fourth edition, revised.
11. **Essentials of Diseases of the Skin.** By HENRY W. STELWAGON, M. D. Fourth edition, revised and enlarged.
12. **Essentials of Minor Surgery, Bandaging, and Venereal Diseases.** By EDWARD MARTIN, M. D. Second edition, revised and enlarged.
13. **Essentials of Legal Medicine, Toxicology, and Hygiene.** This volume is at present out of print.
14. **Essentials of Diseases of the Eye, Nose, and Throat.** By EDWARD JACKSON, M. D., and E. B. GLEASON, M. D. Second edition, revised.
15. **Essentials of Diseases of Children.** By WILLIAM M. POWELL, M. D. Second edition.
16. **Essentials of Examination of Urine.** By LAWRENCE WOLFF, M. D. Colored "VOGEL SCALE." (75 cents net.)
17. **Essentials of Diagnosis.** By S. SOLIS-COHEN, M. D., and A. A. ESHNER, M. D. Second edition, thoroughly revised.
18. **Essentials of Practice of Pharmacy.** By LUCIUS E. SAYRE. Second edition, revised and enlarged.
20. **Essentials of Bacteriology.** By M. V. BALL, M. D. Fourth edition, revised.
21. **Essentials of Nervous Diseases and Insanity.** By JOHN C. SHAW, M. D. Third edition, revised.
22. **Essentials of Medical Physics.** By FRED J. BROCKWAY, M. D. Second edition, revised.
23. **Essentials of Medical Electricity.** By DAVID D. STEWART, M. D., and EDWARD S. LAWRANCE, M. D.
24. **Essentials of Diseases of the Ear.** By E. B. GLEASON, M. D. Second edition, revised and greatly enlarged.

A New Volume.

25. **Essentials of Histology.** By LOUIS LEROY, M. D. With 73 original illustrations.

Pamphlet containing specimen pages, etc., sent free upon application.

Saunders' Medical Hand-Atlases.

VOLUMES NOW READY.

Atlas and Epitome of Internal Medicine and Clinical Diagnosis.

By Dr. Chr. Jakob, of Erlangen. Edited by Augustus A. Eshner, M. D., Professor of Clinical Medicine, Philadelphia Polyclinic. With 179 colored figures on 68 plates, 64 text-illustrations, 259 pages of text. Cloth, $3.00 net.

Atlas of Legal Medicine.

By Dr. E. R. von Hofmann, of Vienna. Edited by Frederick Peterson, M. D., Chief of Clinic, Nervous Department, College of Physicians and Surgeons, New York. With 120 colored figures on 56 plates and 193 beautiful half-tone illustrations. Cloth, $3.50 net.

Atlas and Epitome of Diseases of the Larynx.

By Dr. L. Grunwald, of Munich. Edited by Charles P. Grayson, M. D., Physician-in-Charge, Throat and Nose Department, Hospital of the University of Pennsylvania. With 107 colored figures on 44 plates, 25 text-illustrations, and 103 pages of text. Cloth, $2.50 net.

Atlas and Epitome of Operative Surgery.

By Dr. O. Zuckerkandl, of Vienna. Edited by J. Chalmers DaCosta, M. D., Professor of Principles of Surgery and Clinical Surgery, Jefferson Medical College, Philadelphia. With 24 colored plates, 217 text-illustrations, and 395 pages of text. Cloth, $3.00 net.

Atlas and Epitome of Syphilis and the Venereal Diseases.

By Prof. Dr. Franz Mracek, of Vienna. Edited by L. Bolton Bangs, M. D., Professor of Genito-Urinary Surgery, University and Bellevue Hospital Medical College, New York. With 71 colored plates, 16 illustrations, and 122 pages of text. Cloth, $3.50 net.

Atlas and Epitome of External Diseases of the Eye.

By Dr. O. Haab, of Zurich. Edited by G. E. de Schweinitz, M. D., Professor of Ophthalmology, Jefferson Medical College, Philadelphia. With 76 colored illustrations on 40 plates and 228 pages of text. Cloth, $3.00 net.

Atlas and Epitome of Skin Diseases.

By Prof. Dr. Franz Mracek, of Vienna. Edited by Henry W. Stelwagon, M. D., Clinical Professor of Dermatology, Jefferson Medical College, Philadelphia. With 63 colored plates, 39 half-tone illustrations, and 200 pages of text. Cloth, $3.50 net.

Atlas and Epitome of Special Pathological Histology.

By Dr. H. Durck, of Munich. Edited by Ludwig Hektoen M. D., Professor of Pathology, Rush Medical College, Chicago. In Two Parts. Part I. *Ready*, including Circulatory, Respiratory, and Gastro-intestinal Tract, 120 colored figures on 62 plates, 158 pages of text. Part II. *Ready Shortly*. Price of Part I., $3.00 net.

Saunders' Medical Hand-Atlases.

VOLUMES JUST ISSUED.

Atlas and Epitome of Diseases Caused by Accidents.

By Dr. Ed. Golebiewski, of Berlin. Translated and edited with additions by Pearce Bailey, M. D., Attending Physician to the Department of Corrections and to the Almshouse and Incurable Hospitals, New York. With 40 colored plates, 143 text-illustrations, and 600 pages of text. Cloth, $4.00 net.

Atlas and Epitome of Gynecology.

By Dr. O. Shaeffer, of Heidelberg. *From the Second Revised German Edition.* Edited by Richard C. Norris, A. M., M. D., Gynecologist to the Methodist Episcopal and the Philadelphia Hospitals; Surgeon-in-Charge of Preston Retreat, Philadelphia. With 90 colored plates, 65 text-illustrations, and 308 pages of text. Cloth, $3.50 net.

Atlas and Epitome of the Nervous System and its Diseases.

By Professor Dr. Chr. Jakob, of Erlangen. *From the Second Revised German Edition.* Edited by Edward D. Fisher, M. D., Professor of Diseases of the Nervous System, University and Bellevue Hospital Medical College, New York. With 83 plates and a copious text. Cloth, $3.50 net.

Atlas and Epitome of Labor and Operative Obstetrics.

By Dr. O. Shaeffer, of Heidelberg. *From the Fifth Revised German Edition.* Edited by J. Clifton Edgar, M. D., Professor of Obstetrics and Clinical Midwifery, Cornell University Medical School. With 14 lithographic plates in colors and 139 other illustrations. Cloth, $2.00 net.

Atlas and Epitome of Obstetrical Diagnosis and Treatment.

By Dr. O. Shaeffer, of Heidelberg. *From the Second Revised German Edition.* Edited by J. Clifton Edgar, M. D., Professor of Obstetrics and Clinical Midwifery, Cornell University Medical School. With 122 colored figures on 56 plates, 38 other illustrations, and 317 pages of text. Cloth, $3.00 net.

IN PRESS FOR EARLY PUBLICATION.

Atlas and Epitome of Ophthalmoscopy and Ophthalmoscopic Diagnosis.

By Dr. O. Haab, of Zürich. *From the Third Revised and Enlarged German Edition.* Edited by G. E. de Schweinitz, M. D., Professor of Ophthalmology, Jefferson Medical College, Philadelphia. With 149 colored figures and 82 pages of text.

ADDITIONAL VOLUMES IN PREPARATION.

CLASSIFIED LIST

OF THE

MEDICAL PUBLICATIONS

OF

W. B. SAUNDERS & COMPANY

ANATOMY, EMBRYOLOGY, HISTOLOGY.

Böhm, Davidoff, and Huber—A Text-Book of Histology, ... 4
Clarkson—A Text-Book of Histology, . . 5
Haynes—A Manual of Anatomy, ... 7
Heisler—A Text-Book of Embryology, . . 7
Leroy—Essentials of Histology, ... 15
Nancrede—Essentials of Anatomy, ... 15
Nancrede—Essentials of Anatomy and Manual of Practical Dissection, ... 10

BACTERIOLOGY.

Ball—Essentials of Bacteriology, ... 15
Crookshank—A Text-Book of Bacteriology, ... 5
Frothingham—Laboratory Guide, ... 6
Levy and Klemperer's Clinical Bacteriology, ... 9
Mallory and Wright—Pathological Technique, ... 9
McFarland—Pathogenic Bacteria, ... 9

CHARTS, DIET-LISTS, ETC.

Griffith—Infant's Weight Chart, ... 7
Hart—Diet in Sickness and in Health, . . 7
Keen—Operation Blank, ... 8
Laine—Temperature Chart, ... 9
Meigs—Feeding in Early Infancy, ... 10
Starr—Diets for Infants and Children, . . 12
Thomas—Diet-Lists, ... 13

CHEMISTRY AND PHYSICS.

Brockway—Essentials of Medical Physics, 15
Wolff—Essentials of Medical Chemistry, . 15

CHILDREN.

An American Text-Book of Diseases of Children, ... 1
Griffith—Care of the Baby, ... 7
Griffith—Infant's Weight Chart, ... 7
Meigs—Feeding in Early Infancy, ... 10
Powell—Essentials of Diseases of Children, 15
Starr—Diets for Infants and Children, . . 12

DIAGNOSIS.

Cohen and Eshner—Essentials of Diagnosis, ... 15
Corwin—Physical Diagnosis, ... 5
Macdonald—Surgical Diagnosis and Treatment, ... 9
Vierordt—Medical Diagnosis, ... 14

DICTIONARIES.

The American Illustrated Medical Dictionary, ... 3
The American Pocket Medical Dictionary, 3
Morten—Nurses' Dictionary, ... 10

EYE, EAR, NOSE, AND THROAT.

An American Text-Book of Diseases of the Eye, Ear, Nose, and Throat, ... 1
De Schweinitz—Diseases of the Eye, . . 6
Friedrich and Curtis—Rhinology, Laryngology, and Otology, and their Significance in General Medicine, ... 6
Gleason—Essentials of Diseases of the Ear, 15
Grünwald and Grayson—Atlas of Diseases of the Larynx, ... 16
Haab and De Schweinitz—Atlas of External Diseases of the Eye, ... 16
Jackson—Manual of Diseases of the Eye, 8
Jackson and Gleason—Essentials of Diseases of the Eye, Nose, and Throat, . . 15
Kyle—Diseases of the Nose and Throat, . 9

GENITO-URINARY.

An American Text-Book of Genito-Urinary and Skin Diseases, ... 2
Hyde and Montgomery—Syphilis and the Venereal Diseases, ... 8
Martin—Essentials of Minor Surgery, Bandaging, and Venereal Diseases, . . . 15
Mracek and Bangs—Atlas of Syphilis and the Venereal Diseases, ... 16
Saundby—Renal and Urinary Diseases, . . 11
Senn—Genito-Urinary Tuberculosis, . . . 12
Vecki—Sexual Impotence, ... 14

GYNECOLOGY.

American Text-Book of Gynecology, . . 2
Cragin—Essentials of Gynecology, ... 15
Garrigues—Diseases of Women, ... 6
Long—Syllabus of Gynecology, ... 9
Penrose—Diseases of Women, ... 10
Pryor—Pelvic Inflammations, ... 11
Schaeffer and Norris—Atlas of Gynecology, ... 17

MATERIA MEDICA, PHARMACOLOGY, AND THERAPEUTICS.

An American Text-Book of Applied Therapeutics, ... 1
Butler—Text-Book of Materia Medica, Therapeutics, and Pharmacology, . . . 4
Cerna—Notes on the Newer Remedies, . . 4
Morris—Essentials of Materia Medica and Therapeutics, ... 15
Saunders' Pocket Medical Formulary, . . 11
Sayre—Essentials of Pharmacy, ... 15
Stevens—Manual of Therapeutics, ... 13
Stoney—Materia Medica for Nurses, . . . 13
Thornton—Dose-Book and Manual of Prescription-Writing, ... 13

MEDICAL JURISPRUDENCE AND TOXICOLOGY.

Chapman—Medical Jurisprudence and Toxicology, ... 5
Golebiewski and Bailey—Atlas of Diseases Caused by Accidents, ... 17
Hofmann and Peterson—Atlas of Legal Medicine, ... 16

NERVOUS AND MENTAL DISEASES, ETC.

Chapin—Compendium of Insanity, . . . 5
Church and Peterson—Nervous and Mental Diseases, ... 5
Shaw—Essentials of Nervous Diseases and Insanity, ... 15

NURSING.

Davis—Obstetric and Gynecologic Nursing, 6
Griffith—The Care of the Baby, ... 7
Hart—Diet in Sickness and in Health, . . 7
Meigs—Feeding in Early Infancy, ... 10
Morten—Nurses' Dictionary, ... 10
Stoney—Materia Medica for Nurses, . . 13
Stoney—Practical Points in Nursing, . . . 13
Stoney—Surgical Technic for Nurses, . . 13
Watson—Handbook for Nurses, ... 14

OBSTETRICS.

An American Text-Book of Obstetrics, . 2
Ashton—Essentials of Obstetrics, ... 15
Boisliniere—Obstetric Accidents, ... 4
Dorland—Manual of Obstetrics, ... 6
Hirst—Text-Book of Obstetrics, ... 7
Norris—Syllabus of Obstetrics, ... 10
Schaeffer and Edgar—Atlas of Obstetrical Diagnosis and Treatment, ... 17

PATHOLOGY.

An American Text-Book of Pathology, . 2
Dürck and Hektoen—Atlas of Pathologic Histology, ... 16
Kalteyer—Essentials of Pathology, . . . 15
Mallory and Wright—Pathological Technique, ... 9
Senn—Pathology and Surgical Treatment of Tumors, ... 12
Stengel—Text-Book of Pathology, . . . 12
Warren—Surgical Pathology and Therapeutics, ... 14

PHYSIOLOGY.

An American Text-Book of Physiology, 2
—Essentials of Physiology, ... 15
Raymond—Manual of Physiology, . . . 11
Stewart—Manual of Physiology, ... 13

PRACTICE OF MEDICINE.

An American Year-Book of Medicine and Surgery, ... 3
Anders—Text-Book of the Practice of Medicine, ... 4
Eichhorst—Practice of Medicine, ... 6
Lockwood—Manual of the Practice of Medicine, ... 9
Morris—Essentials of Practice of Medicine, ... 15
Salinger and Kalteyer—Modern Medicine, ... 11
Stevens—Manual of Practice of Medicine, 13

SKIN AND VENEREAL.

An American Text-Book of Genito-Urinary and Skin Diseases, ... 2
Hyde and Montgomery—Syphilis and the Venereal Diseases, ... 8
Martin—Essentials of Minor Surgery, Bandaging, and Venereal Diseases, . . 15
Mracek and Stelwagon—Atlas of Diseases of the Skin, ... 16
Stelwagon—Essentials of Diseases of the Skin, ... 15

SURGERY.

An American Text-Book of Surgery, . . 2
An American Year-Book of Medicine and Surgery, ... 3
Beck—Fractures, ... 4
Beck—Manual of Surgical Asepsis, . . . 4
Da Costa—Manual of Surgery, ... 5
International Text-Book of Surgery, . . 8
Keen—Operation Blank, ... 8
Keen—The Surgical Complications and Sequels of Typhoid Fever, ... 8
Macdonald—Surgical Diagnosis and Treatment, ... 9
Martin—Essentials of Minor Surgery, Bandaging, and Venereal Diseases, . . 15
Martin—Essentials of Surgery, ... 15
Moore—Orthopedic Surgery, ... 10
Nancrede—Principles of Surgery, ... 10
Pye—Bandaging and Surgical Dressing, . 11
Scudder—Treatment of Fractures, . . . 12
Senn—Genito-Urinary Tuberculosis, . . . 12
Senn—Practical Surgery, ... 12
Senn—Syllabus of Surgery, ... 12
Senn—Pathology and Surgical Treatment of Tumors, ... 12
Warren—Surgical Pathology and Therapeutics, ... 14
Zuckerkandl and Da Costa—Atlas of Operative Surgery, ... 16

URINE AND URINARY DISEASES.

Ogden—Clinical Examination of the Urine, 10
Saundby—Renal and Urinary Diseases, . 11
Wolff—Essentials of Examination of Urine, 15

MISCELLANEOUS.

Abbott—Hygiene of Transmissible Diseases, ... 3
Bastin—Laboratory Exercises in Botany, . 4
Golebiewski and Bailey—Atlas of Diseases Caused by Accidents, ... 17
Gould and Pyle—Anomalies and Curiosities of Medicine, ... 7
Grafstrom—Massage, ... 7
Keating—How to Examine for Life Insurance, ... 8
Pyle—A Manual of Personal Hygiene, . 11
Saunders' Medical Hand-Atlases, . . 16,17
Saunders' Pocket Medical Formulary, . . 11
Saunders' Question-Compends, . . . 14,15
Stewart and Lawrence—Essentials of Medical Electricity, ... 15
Thornton—Dose-Book and Manual of Prescription-Writing, ... 13
Van Valzah and Nisbet—Diseases of the Stomach, ... 13

NOTHNAGEL'S ENCYCLOPEDIA

OF

SPECIAL PATHOLOGY AND THERAPEUTICS

IT is universally acknowledged that the Germans lead the world in Internal Medicine; and of all the German works on this subject, Nothnagel's "Encyclopedia of Special Pathology and Therapeutics" is conceded by scholars to be without question the **best System of Medicine in existence.** So necessary is this book in the study of Internal Medicine that it comes largely to this country in the original German. In view of these facts, Messrs. W. B. Saunders & Company have arranged with the publishers to issue at once **an authorized edition** of this great encyclopedia of medicine in English.

For the present a set of some ten or twelve volumes, representing the most practical part of this encyclopedia, and selected by a competent editor with especial thought of the **needs of the practical physician,** will be published. These volumes will contain the real essence of the entire work, and the purchaser will therefore obtain at less than half the cost the cream of the original. Later the special and more strictly scientific volumes will be offered from time to time.

The work will be translated by men possessing thorough knowledge of both English and German, and **each volume** will be **edited by a prominent specialist** on the subject to which it is devoted. It will thus be brought thoroughly up to date, and the American edition will be more than a mere translation of the German; for, in addition to the matter contained in the original, it will represent the **very latest views of the leading American specialists** in the various departments of Internal Medicine. The whole System will be under the editorial supervision of a **clinician of recognized authority,** who will select the subjects for the American edition, and will choose the editors of the different volumes.

Unlike most encyclopedias, the publication of this work **will not be extended over a number of years,** but five or six volumes will be issued during the coming year, and the remainder of the series at the same rate. Moreover, each volume will be revised to the date of its publicatfon by the American editor. This will obviate the objection that has heretofore existed to systems published in a number of volumes, since the subscriber will receive the completed work while the earlier volumes are still fresh.

The usual method of publishers, when issuing a work of this kind, has been to compel physicians to take the entire System. This seems to us in many cases to be undesirable. Therefore, in purchasing this encyclopedia, physicians will be given the opportunity of subscribing for the entire System at one time; but any single volume or any number of volumes may be obtained by those who do not desire the complete series. This latter method, while not so profitable to the publisher, **offers to the purchaser many advantages** which will be appreciated by those who do not care to subscribe for the entire work at one time.

This American edition of Nothnagel's Encyclopedia will, without question, form **the greatest System of Medicine ever produced,** and the publishers feel confident that it will meet with general favor in the medical profession.

T. S. A. Spilman, M. D.
Ottumwa, Ia.

COLUMBIA UNIVERSITY LIBRARIES

This book is due on the date indicated below, or at the expiration of a definite period after the date of borrowing, as provided by the rules of the Library or by special arrangement with the Librarian in charge.

DATE BORROWED	DATE DUE	DATE BORROWED	DATE DUE

(140)M100

S. A. Spilman, M. D.

RD31 Se52
Senn

COLUMBIA UNIVERSITY LIBRARIES (hsl,stx)
RD 31 Se52 1901 C.1
Practical surgery for the general practi