

# **A manual of operative surgery / By Lewis A. Stimson ... and John Rogers.**

## **Contributors**

Stimson, Lewis Atterbury, 1844-1917.  
Rogers, John, 1866-  
Augustus Long Health Sciences Library

## **Publication/Creation**

Philadelphia : Lea brothers & co., 1900.

## **Persistent URL**

<https://wellcomecollection.org/works/enzczawz>

## **License and attribution**

This material has been provided by This material has been provided by the Augustus C. Long Health Sciences Library at Columbia University and Columbia University Libraries/Information Services, through the Medical Heritage Library. The original may be consulted at the the Augustus C. Long Health Sciences Library at Columbia University and Columbia University. where the originals may be consulted.

This work has been identified as being free of known restrictions under copyright law, including all related and neighbouring rights and is being made available under the Creative Commons, Public Domain Mark.

You can copy, modify, distribute and perform the work, even for commercial purposes, without asking permission.



Wellcome Collection  
183 Euston Road  
London NW1 2BE UK  
T +44 (0)20 7611 8722  
E [library@wellcomecollection.org](mailto:library@wellcomecollection.org)  
<https://wellcomecollection.org>



COLUMBIA LIBRARIES OFFSITE  
HEALTH SCIENCES STANDARD



HX00034029





RD 31

S+5

Columbia University 1900  
in the City of New York

COLLEGE OF PHYSICIANS  
AND SURGEONS



Reference Library


Given by


Dr. William Darrach.


William Darrach  
305 w. 80th.

Oct. 1900











A MANUAL  
OF  
OPERATIVE SURGERY.

BY

LEWIS A. STIMSON, B.A., M.D.,

SURGEON TO THE NEW YORK AND HUDSON STREET HOSPITALS; CONSULTING SUR-  
GEON TO BELLEVUE, ST. JOHN'S, AND CHRIST'S HOSPITALS; PROFESSOR OF  
SURGERY IN CORNELL UNIVERSITY; CORRESPONDING MEMBER  
OF THE SOCIÉTÉ DE CHIRURGIE, PARIS.


AND

JOHN ROGERS, JR., B.A., M.D.,

SURGEON OF GOUVERNEUR HOSPITAL, NEW YORK; INSTRUCTOR OF SURGERY  
IN CORNELL UNIVERSITY.

FOURTH AND REVISED EDITION.

*WITH TWO HUNDRED AND NINETY-THREE ILLUSTRATIONS.*



PHILADELPHIA:  
LEA BROTHERS & CO.

---

Entered according to the Act of Congress, in the year 1900, by  
LEA BROTHERS & CO.,  
In the Office of the Librarian of Congress. All rights reserved.

---




## PREFACE TO FOURTH EDITION.

---

IN this fourth edition the principles which guided the preparation of the third have again been followed, and the part given to conclusions drawn from personal experience has again been somewhat increased.

The size of the book has been reduced by omission of portions of the text and of about forty cuts which seemed to have outlived their usefulness.

LEWIS A. STIMSON.



# CONTENTS.

## PART I.

### THE ACCESSORIES OF AN OPERATION.

	PAGE		PAGE
Anæsthesia,	17	Sutures, twisted,	25
Local,	17	Preparation of materials used in an	
General,	18	operation,	26
Administration of the anæ-		Catgut,	26
thetic,	19	chromicized,	26
Rectal,	20	Silk,	26
Arrest of hemorrhage,	20	Silkworm-gut,	26
Ligature,	20	Sponges,	26
Torsion,	20	Absorbent gauze,	27
Pressure,	20	Bichloride gauze,	27
Cold or heat,	22	Iodoform gauze,	27
Position,	22	Drainage-tubes,	28
Artificial ischæmia,	23	Absorbent cotton,	28
Sutures,	25	Rubber tissue,	28
Interrupted,	25	Sterilization,	28
Continuous,	25	The wound and its treatment,	29

## PART II.

### LIGATURE OF ARTERIES.

General directions,	33	Ligature of the common carotid,	50
Anatomy of the supra-clavicular		At the place of election,	50
region,	35	Ligature of the external carotid,	51
Ligature of the innominate artery,	37	Anatomy,	51
Anatomy,	37	Operation,	53
Operation,	37	Ligature of the internal carotid,	53
Ligature of the subclavian artery,	39	Ligature of the lingual artery,	54
1st portion, left subclavian,	39	Anatomy,	54
1st portion, right subclavian,	40	Operation,	54
2d portion,	40	Ligature of the facial artery,	55
3d portion,	40	Ligature of the occipital artery,	56
Ligature of the superior thyroid,	41	Ligature of the temporal artery,	56
Ligature of the inferior thyroid,	42	Ligature of the abdominal aorta,	56
Ligature of the vertebral artery,	43	Ligature of the common iliac,	57
Ligature of the axillary artery,	43	Anatomy of the common, inter-	
Under the clavicle,	44	nal and external iliac arteries,	57
In the axilla,	44	Extra-peritoneal,	58
Ligature of the brachial artery,	45	Intra-peritoneal,	59
Anatomy,	45	Ligature of the internal iliac,	59
Operation,	47	Ligature of the external iliac,	60
Ligature of the radial artery,	47	Ligature of the gluteal, sciatic and	
Anatomy,	47	internal pudic arteries,	61
Operation, upper third,	48	Ligature of the femoral artery,	62
Operation, lower third,	48	Anatomy,	62
Ligature of the ulnar artery,	49	Operation,	63
Anatomy,	49	At the apex of Scarpa's tri-	
Operation at the junction of the		angle,	63
upper and middle thirds,	49	In the middle of the thigh,	64
Operation in the lower third,	49	In Hunter's canal,	64



	PAGE		PAGE
Ligature of the popliteal artery,	65	Ligature of the posterior tibial,	67
Ligature of the anterior tibial,	65	Guthrie's method,	67
Anatomy,	65	Lateral method,	67
Operation,	66	In the lower third and behind	
Ligature of the dorsalis pedis,	67	the ankle,	69

## PART III.

## AMPUTATIONS.

Circular method,	71	Sub-astragaloid amputation,	96
1st step,	71	Tripier's modification,	97
2d step,	71	Amputation at the ankle-joint	
(b) Cutaneous sleeve,	72	(Syme),	97
3d step,	72	Modifications,	100
Oval method,	73	A. Internal lateral flap	
Flap method,	73	(Roux),	100
Skin flaps and circular division,	74	B. Pirogoff's amputation,	101
Long anterior flap,	74	Comparison of the different methods	
Teale's method,	74	of partial and total amputation	
Amputation of the fingers,	75	of the foot,	104
Phalanges,	75	Amputation of the leg,	105
Through the metacarpo-phalan-		A. Lower third,	105
geal articulation,	76	1. Circular method,	105
Amputation of the metacarpal		Brun's	105
bones,	77	2. Modified circular,	106
Amputation at the wrist,	78	3. Long anterior flap (Bell),	107
Circular method,	78	4. Elliptic posterior flap	
Antero-posterior flaps,	79	(Guyon),	107
External lateral flap,	79	B. Middle third,	108
Amputation of the forearm,	79	1. Long anterior curved flap,	108
Amputation at the elbow-joint,	80	2. Single posterior flap,	108
Anterior flap,	81	3. Skin flaps and circular	
(a) The joint opened from		division,	108
behind,	81	C. Upper third,	109
(d) The joint opened from		1. Long anterior rectangular	
in front,	81	flap (Teale),	109
Lateral flap,	82	2. Long posterior rectangu-	
Circular,	82	lar flap (Lee),	110
Amputation of the arm,	83	3. Modified flap (Bell),	110
Amputation at the shoulder-joint,	83	Comparison of the different methods,	110
General considerations,	83	Amputation at the knee,	111
Oval method (Baron Larrey),	85	A. Disarticulation,	111
Double flap method (Lisfranc),	86	Lateral flaps,	112
Spence's method,	87	B. Amputation through the	
Amputation of the arm, scapula, and		condyles, oval,	112
clavicle,	88	Anterior flap (Carden),	112
Amputation of the toes,	90	Gritti's modification,	113
Distal phalanx of the great toe,	90	Amputation of the thigh,	115
Disarticulation of the great toe,	90	Teale and Carden,	116
Two adjoining toes,	91	Modified flap, in lower third	
Amputation of a metatarsal bone,	91	(Syme),	116
Disarticulation of the 1st or 5th		Long anterior flap,	116
metatarsal,	92	Circular,	117
Disarticulation of all the metatar-		Amputation at the hip-joint,	118
sals bones (Lisfranc's amputa-		Anterior racket or oval,	120
tion),	93	External racket or modified oval,	121
Modifications,	94	Anterior flap,	122
Medio-tarsal amputations (Chopart),	94	Senn's method,	123



## PART IV.

## EXCISION OF JOINTS AND BONES.

	PAGE		PAGE
General considerations,	125	Partial resection of the upper por-	
Major articulations,	128	tion (von Langenbeck),	170
Excision of the shoulder-joint,	128	Other methods of gaining access to	
Ollier's method,	129	the pharynx through the nose,	171
Von Langenbeck's method,	130	Boeckel,	171
By a transverse incision,	131	Ollier,	173
Excision of the elbow-joint,	131	Excision of the inferior maxilla,	173
Central longitudinal incision		General considerations,	173
(v. Langenbeck),	132	Resection of the anterior portion	
Ollier's method,	133	of the body,	176
Nélaton's method,	134	Resection of the lateral portion	
Long radical incision (Hueter),	135	of the body,	176
Osteoplastic method,	136	Resection of the ramus and half	
Bilateral incisions (Vogt),	137	the body,	177
Partial excision,	137	Excision of the entire bone,	178
Excision of ankylosed elbow,	137	Subperiosteal method,	178
Ollier's method,	138	Partial excisions,	178
P. Heron Watson's method,	138	Anchylolysis of the jaw,	178
Operative reduction of old disloca-		Excision of the condyle,	179
tion,	139	Resection of the sternum,	180
Excision of the wrist,	140	Resection of the ribs,	180
Bilateral incisions (Lister),	141	Estlander's operation for empy-	
Radial incision (Ollier),	144	ema,	180
Dorso-radial incision (von Lan-		Excision of the clavicle,	181
genbeck),	145	Excision of the scapula,	182
Excision of the hip-joint,	146	Subperiosteal method (Ollier),	183
Sayre's method,	146	Opening of the joint,	185
Ollier's method,	148	Partial excisions of the scapula,	185
Langenbeck,	148	Resection of the humerus,	185
Anterior incision,	149	Upper portion,	185
Arthrectomy,	150	Middle portion,	186
Anchylolysis of the hip-joint, treated		Lower portion,	186
by subcutaneous division of		Total excision,	186
the neck of the femur (Adams),	150	Excision of the ulna,	186
Division below the trochanter,	152	Excision of the radius,	186
Excision,	152	Partial excisions of the ulna and	
Excision of the knee-joint,	153	radius,	187
Semilunar incision,	153	Excision of the metacarpal bones	
Transverse incision,	154	and phalanges,	187
Arthrectomy,	154	Resection of a phalanx,	187
Excision of the ankle-joint,	155	Resection of the bones of the pel-	
Vogt's method by removal of the		vis,	188
astragalus,	157	Excision of the coccyx,	188
Osteoplastic excision of foot		Resection of the shaft of the fe-	
(Mikulicz),	158	mur,	189
Operative reduction of old Pott's		Resection of the shaft of the tibia,	189
fracture,	160	Resection of the fibula,	190
Excision of the bones and smaller		Of its upper extremity,	191
articulations,	161	Of the lower portion,	191
Excision of the superior maxilla,	161	Excision of the entire fibula,	192
Operation by a median incision,	163	Excision of the bones of the foot,	192
Subperiosteal excision (Ollier),	165	Calcaneum,	192
Excision of lower portion,	166	Subperiosteal method (Ol-	
Excision of upper portion,	167	lier),	192
Simultaneous excision of both su-		Farabeuf,	193
perior maxillæ,	168	Astragalus,	194
Partial and temporary excisions of		Ollier's method,	194
the superior maxilla to facili-		When dislocated,	195
tate the removal of naso-		When shattered,	195
pharyngeal polyps,	168	Metatarsal bones and phalanges,	195
Osteoplastic resection of an-		Operations upon the cranium,	195
terior portion of hard palate		Trephining,	195
(Chalot),	169	Trephine,	195



	PAGE		PAGE
Trephining—		Trephining—	
Chisel,	196	For cerebral abscess due to mid-	
Gigli saw,	197	dle-ear disease,	208
Temporary, by omega flap,	199	Of cerebellum,	210
Craniectomy,	200	Puncture of lateral ventricles,	210
In fracture,	200	For middle meningeal hemor-	
Relation of brain to overlying		rhages,	211
parts (Reid),	200	Resection of fifth nerve within	
Relation of brain to overlying		the skull,	213
parts (Kocher),	204	Of the frontal sinus,	213
Position of lateral sinus,	207	Of the antrum,	213
To open lateral sinus,	207		

## PART V.

## NEUROTOMY, TENOTOMY, OSTEOTOMY, AND MISCELLANEOUS OPERATIONS.

Division and resection of nerves,	215	Spinal accessory,	226
Supra-orbital nerve,	215	First, second, and third nerves for	
Subcutaneous division,	216	wry-neck,	227
Excision of a portion,	216	Median nerve,	228
A. Above the eyebrow,	216	Ulnar nerve,	228
B. Below the eyebrow,	217	Musculo-spiral nerve,	229
Supra-trochlear nerve,	217	Great sciatic nerve,	229
Superior maxillary nerve,	217	Internal popliteal nerve,	229
A. Division of the nerve on the		External popliteal nerve,	229
face,	218	Anterior crural nerve,	229
1. Subcutaneously,	218	Neurorrhaphy,	230
2. Through the mouth,	218	Tenotomy,	230
3. By external excision,	218	General considerations,	230
B. Resection of the infra-orbital		Tendo-Achillis,	231
portion,	218	Tibialis posticus,	231
Tillaux's method,	218	A. Above the malleolus,	231
Lücke's method,	219	B. On the side of the foot,	232
Inferior dental nerve,	220	Tibialis anticus,	232
A. At the mental foramen,	220	Peronei,	232
B. Within the canal,	220	Flexor tendons at the knee,	232
C. Before its entry into the		Sterno-cleido-mastoid,	232
canal,	221	Tenorrhaphy,	232
1. From within the mouth,	221	Osteotomy,	235
2. Through the cheek,	221	Shaft,	235
At the foramen ovale,	222	Femur,	235
Buccal nerve,	223	Supra-condyloid,	236
Lingual nerve,	224	For hallux valgus,	236
Moore's method,	224	Cuneiform, for talipes,	237
Facial nerve,	225	Operations for ununited fracture,	240
Brachial plexus,	225	Suture of patella,	241
Posterior roots,	226	Olecranon,	242
Cervical plexus,	226	Laminectomy,	242

## MISCELLANEOUS OPERATIONS.

Thiersch's skin grafting,	243	Dupuytren's contraction,	247
Separation of web-fingers,	245	Ingrown toenail,	247
Cicatricial flexion of phalanges,	246	Removal of cervical glands,	248

PART VI.

PLASTIC OPERATIONS ON THE FACE.

	PAGE		PAGE
The different methods and their history,	251	Rhinoplasty—	
General principles,	252	B. Ollier's osteoplastic method,	279
Cheiloplasty,	253	C. Alquié's method,	281
A. Lower lip,	253	D. Italian method,	281
1. V-incision,	253	Operations upon the eyelids,	282
2. Oval horizontal incision,	253	Blepharorrhaphy,	282
3. Method of Celsus or Serres,	254	Canthoplasty,	283
4. Dieffenbach,	255	Blepharoplasty,	284
5. Syme-Buchanan,	255	1. In ectropion,	284
6. Buck's method,	257	Wharton Jones,	284
7. Square lateral flaps, Malgaigne,	258	Alphonse Guérin,	284
8. Square vertical flaps,	259	Von Graefe,	285
B. Angle of the mouth (stomatoplasty),	260	Dieffenbach, Adams, and Ammon,	285
Buck,	260	Richet,	286
C. Upper lip,	262	Knapp,	287
1. Vertical flaps,	262	Burow,	287
2. Infero-lateral flap,	262	Dieffenbach,	288
Harelip,	263	Indian method,	288
Single harelip, simple,	263	Richet,	289
1. Double flaps,	264	Hasner d'Artha,	289
2. Nélaton's method,	265	Denonvillier,	290
3. Single flap,	265	Ectropion due to excess of conjunctiva,	291
4. Giraldes's method,	265	2. Entropion,	291
Double harelip, simple,	266	Canthoplasty,	291
Complicated harelip,	267	Ligature,	291
Rhinoplasty,	268	Excision or cauterization of a fold of the skin,	291
1. Superficial defect, not involving the bones or septum,	269	Spasmodic entropion,	292
Lateral, oblique, and vertical flaps,	269	Von Graefe,	292
Denonvillier's method,	270	Division of tarsal cartilage,	293
Von Langenbeck's method,	270	Vertical division,	293
Michon's method,	271	Longitudinal division (Ammon),	293
Restoration of columna,	271	Excision of part of tarsal cartilage,	293
2. Loss of the septum and nasal bones, the skin remaining entire,	272	3. Symblepharon,	294
Dieffenbach's case,	272	Ligature,	294
Ollier's osteoplastic method,	273	Arlt's method,	294
Double layer, or superposed flaps,	274	Teale's method,	295
Pancoast's subcutaneous method,	275	Ledentu's method,	295
3. Loss of more or less of the surface and the septum,	276	4. Pterygion,	296
A. Indian method,	276	Excision,	296
Modifications,	277	Ligature,	296
		5. Trichiasis,	297
		Von Graefe,	297
		Anagnostakis,	297



## PART VII.

## SPECIAL OPERATIONS.

## CHAPTER I.

## OPERATIONS UPON THE EYE AND ITS APPENDAGES.

	PAGE		PAGE
The cornea,	299	Operations undertaken for the relief	
Removal of a foreign body,	299	of cataract—	
Puncture of the cornea,	301	Gayett and Knapp,	320
Evisceration for staphyloma,	301	Linear extraction,	320
The iris,	302	Scoop extraction,	321
Iridotomy,	302	Removal by suction,	322
Simple incision (Cheselden,		Removal of the lens in its	
Bowman),	302	capsule,	323
Simple iridotomy, Wecker,	303	Pagenstecher's method,	324
Double iridotomy, Wecker,	303	Secondary cataract,	324
Iridectomy,	303	Operations for the relief of strabis-	
Antiphlogistic iridectomy,	304	mus,	325
Iridesis,	307	Internal rectus,	326
Corelysis,	308	Subconjunctival method,	327
Operations undertaken for the relief		Secondary strabismus,	328
of cataract,	309	Enucleation of the eyeball,	328
Depression or couching,	310	Extirpation of the contents of	
Scleronyxis,	310	the orbit,	329
Keratomyxis,	311	Operations upon the lachrymal ap-	
Division, Discission, or Solution,	311	paratus,	329
Division through the cornea,	312	Extirpation of the lachrymal	
Division through the sclero-		gland,	329
rotic (Hays),	312	Lachrymal sac, duct, and canal-	
Extraction,	313	iculi,	330
Flap extraction,	313	Slitting up the canaliculus,	331
Von Graefe's method,	317	Puncture of the sac,	332

## CHAPTER II.

## OPERATIONS UPON THE EAR AND ITS APPENDAGES.

Occlusion of the external auditory		Catheterization of the Eustachian	
canal,	334	tube,	335
Introduction of speculum,	334	Opening of mastoid antrum,	336
Paracentesis of the drum-head,	334		

## CHAPTER III.

## OPERATIONS UPON THE MOUTH AND PHARYNX.

Excision of the tonsils,	337	Excision of the tongue—	
Staphylorrhaphy,	338	Sédillot's method,	353
Uranoplasty,	345	Division of the frænum,	355
Fergusson's osteoplastic method,	348	Ranula,	355
Davies-Colley's method,	348	Salivary fistula,	355
Excision of the tongue,	349	Deguisse's method,	356
Through the mouth,	350	Van Buren's method,	356
Kocher,	352		

## CHAPTER IV.

## OPERATIONS PERFORMED UPON THE NECK.

Bronchotomy,	357	Laryngectomy,	364
Subhyoid laryngotomy,	357	Complete,	364
Thyroid laryngotomy,	358	Partial,	365
Crico-thyroid laryngotomy,	359	Pharyngotomy,	366
Laryngo-tracheotomy,	360	Von Langenbeck,	366
De Saint Germain's method,	361	Mikulicz,	367
Tracheotomy,	361	Cheever,	368
By galvano- or thermo-cau-		Esophagotomy,	368
tery,	363	Internal,	369



	PAGE		PAGE
Esophagotomy—		Operation upon thyroid gland—	
External,	370	Enucleation of a portion,	374
Operations upon thyroid gland,	371	Removal of a portion,	374
Ligation of arteries,	373	Removal of isthmus,	375

# CHAPTER V.

## OPERATIONS PERFORMED UPON THE THORAX.

Amputation of the breast,	376	Paracentesis of the thorax,	377
Halsted,	376	Paracentesis of the pericardium,	378

# CHAPTER VI.

## OPERATIONS PERFORMED UPON THE ABDOMINAL WALL, STOMACH, AND INTESTINES.

Paracentesis of the abdomen,	379	Herniotomy, kelotomy—	
Laparotomy,	380	Strangulated inguinal hernia,	426
Operations on the intestines,	383	Femoral hernia,	428
Anatomy,	383	Umbilical hernia,	430
Continuous suture,	385	Obturator hernia,	432
Right-angled continuous,	386	Radical cure of inguinal hernia,	432
Interrupted (Lembert),	386	Czerny,	432
Czerny,	388	Bassini,	434
Halsted's quilt suture,	388	Halsted,	439
Circular enterorrhaphy,	388	McBurney,	439
Intestinal anastomosis,	390	Radical cure of umbilical hernia,	440
Senn's plates,	393	Radical cure of femoral hernia,	440
Murphy's button,	393	Operations upon the rectum,	441
By intussusception,	394	Imperforate anus or rectum,	442
Enterostomy,	395	Prolapse,	444
Right inguinal,	395	Rectopexy,	446
Colostomy,	397	Ablation,	446
Right inguinal,	398	Torsion,	447
Lumbar,	399	Rectotomy,	447
Closure of an artificial anus or		Fistula,	447
fecal fistula,	401	Hemorrhoids,	448
Removal of vermiform appendix,	402	Ligation,	448
McBurney,	404	Whitehead,	448
During period of suppura-		Excision of anus and part of rec-	
tion,	404	tum,	449
Stomach,	405	A. Removal from below,	449
Gastrostomy,	407	B. Removal from below,	
Kader,	409	leaving sphincter,	451
Gastrotomy,	411	C. Hueter's method,	452
For stenosis of pyloric or		D. Removal from behind,	
cardiac orifice,	412	Kraske,	453
Gastrorrhaphy,	414	Liver,	456
Gastroplication,	415	Abscess,	457
Pylorectomy,	416	Hydatids,	459
Gastroenterostomy,	418	Cholecystostomy,	460
Jejunostomy,	421	Operations on bile ducts,	461
Herniotomy, kelotomy,	421	Cholecystenterostomy,	462
General directions,	422	Cholecystectomy,	464
A. Recognition of the sac and		Spleen,	464
bowel,	422	Splenectomy,	465
B. Opening of the sac,	423	Kidney,	465
C. Division of the stricture,	424	Exposure of,	466
D. Examination and return		Lumbar methods,	466
of the bowel,	425	Nephrotomy,	469
E. Treatment of the omen-		Nephrolithotomy,	469
tum,	426	Lumbar nephrectomy,	471

	PAGE		PAGE
Kidney—		Ureter,	474
Abdominal nephrectomy,	472	Operations on,	475
Nephropexy,	474	Wounds of,	477

## CHAPTER VII.

## OPERATIONS UPON THE GENITO-URINARY ORGANS OF THE MALE.

Castration,	480	Urethral fistula—	
Hydrocele,	481	Delpech and Alliot,	500
Puncture of the sac,	481	Sir Astley Cooper,	500
Radical cure,	482	Arlaud,	500
Varicocele,	482	Sédillot,	501
Excision of the scrotum,	482	Rigaud,	501
Subcutaneous ligature,	483	Théophile Anger,	501
Open ligation,	483	Scymanowski,	501
Amputation of the penis,	484	McBurney,	501
Operations for phimosis,	485	Internal urethrotomy,	502
Dorsal incision,	485	External perineal urethrotomy,	503
Circumcision,	485	A. With a guide,	503
Paraphimosis,	487	B. Without a guide,	505
Division of the frænum,	487	Exstrophy of the bladder,	507
Epispadias,	487	Catheterization,	509
Nélaton's method,	488	Puncture of the bladder,	511
Thiersch's method,	490	Litholapaxy,	511
Hypospadias,	492	Lithotomy,	516
Urethroplasty,	493	Lateral lithotomy,	517
Théophile Anger's method,	494	Median lithotomy,	521
Duplay's method,	496	Supra-pubic lithotomy,	523
Urethral fistula,	497	Prostatectomy, supra-pubic,	526
General considerations,	497	Perineal,	527
Urethrorrhaphy,	498	Combined supra-pubic and peri-	
Urethroplasty,	499	neal,	527
Nélaton's method,	499	Tumors of bladder,	527
Reybard, Dieffenbach, and		Removal of seminal vesicles,	530
Delore,	506		

## CHAPTER VIII.

## OPERATIONS UPON THE GENITO-URINARY ORGANS OF THE FEMALE.

Catheterization,	533	Posterior section of the cervix,	561
External urethrotomy,	533	Operations on the uterus and ad-	
Lithotomy,	535	nexa,	562
Urethral lithotomy,	535	Anatomy,	562
Vesico-vaginal lithotomy,	535	Ovariectomy,	564
Occlusion, or atresia vaginae,	536	Oöphorectomy,	566
Perineorrhaphy,	537	Salpingo-oöphorectomy,	567
Prolapse of the posterior wall of the		Tumors beneath broad ligament,	569
vagina,	538	For ectopic gestation,	570
1st variety,	538	Hysteropexy,	571
2d variety,	540	Intra-abdominal shortening of	
Hegar's method,	541	broad ligaments,	572
Laceration of the perineum and		Shortening round ligaments	
sphincter ani,	543	(Alexander),	572
Vesico-vaginal fistula,	549	Laparohysterotomy,	573
Creation of a vesico-vaginal fistula,	554	Symphysiotomy,	574
Obliteration of the vagina; kolpok-		Myomectomy,	575
leisis,	556	Abdominal hysterectomy,	576
Narrowing of the vagina; elytror-		Amputation of gravid uterus,	579
rhaphy,	557	Vaginal hysterectomy,	579
Posterior elytrorrhaphy or colp-		Amputation of cervix,	580
rhaphy (Hegar),	558	Supra-vaginal,	581
Martin,	559	Removal of mucosa of cervix,	582
Lacerated cervix,	559		



# OPERATIVE SURGERY.

---

## PART I.

### THE ACCESSORIES OF AN OPERATION.

---

#### ANÆSTHESIA.

**Local Anæsthesia** may be obtained by the action of cold, or by the application of an agent which exerts locally a benumbing effect upon the nerves.

**Cold.**—The skin can be chilled by the application of ice or by a spray of any substance that evaporates rapidly. *Ice* acts most efficiently when finely broken and mixed with salt; it is conveniently applied in a muslin bag, and the application should be maintained until the skin has become white or until testing shows it to be insensitive.

For chilling by rapid evaporation ethyl chloride is in most common use. It is supplied under the name of "ethylene," in small glass tubes from which it is allowed to escape in a fine jet which can be accurately directed upon the part to be chilled. Ether thrown upon the skin from an atomizer is moderately effective.

**Carbolic Acid** is a fairly efficient and convenient means of producing local anæsthesia. A cloth thoroughly wet with a 3 per cent. solution of the acid is kept upon the skin for fifteen minutes, and then the undiluted acid applied with a brush along the line of the proposed incision.

**Cocaine.**—This is used in the form of a one to four per cent. solution injected into or beneath the skin or into or



about the trunk of a nerve. As it is dangerously toxic only small quantities should be used. When the skin is uninflamed the best method is to insert a hypodermic needle very obliquely into the skin and force a few drops of the solution through it; the needle can then be advanced painlessly along the welt raised by the injection, and additional drops injected until the needle has been introduced to its full length. It is then withdrawn and inserted afresh at the furthest point reached by the injections until the entire distance to be occupied by the incision has been rendered insensitive. The action of the drug is hastened and prolonged, and the chance of poisoning diminished, by temporarily cutting off the blood-supply from the part; in the case of a limb this is most conveniently done by circular elastic constriction.

Injection into inflamed parts is very painful because of the increased tension, and it is, therefore, better in such cases to seek to benumb the nerves supplying the part by injection *beneath* the skin on the proximal side of the proposed incision.

**General Anæsthesia.**—The agents in common use for producing general anæsthesia are ether, chloroform, and nitrous oxide.

The great advantage of ether is in its safety. Chloroform is more rapid in its action and more easily taken, but it is distinctly more liable to cause death during its administration. On the other hand, ether acts unfavorably upon kidneys that are already diseased, and it is not well borne by the elderly with chronic pulmonary complications. Its vapor is inflammable; that of chloroform is not.

Either agent may cause death by suffocation, through obstruction of the air passages by the relaxed and dependent tongue or by the lodgment of vomited matter; but chloroform may also kill by specific action upon the respiratory and circulatory centers.

The indication when suffocation threatens and the face is blue and swollen is to clear the air passages, usually by drawing the tongue forward or by pressing the lower jaw



forward with the fingers placed below and behind its angles. If vomited matter or other foreign body has lodged over or within the larynx the patient should be so placed that his head and shoulders are dependent and should then be forcibly shaken.

Death by the toxic action of chloroform comes in the form of syncope with a pale face, and sometimes after only a small quantity has been given, one or two drachms. This sudden early poisoning is best guarded against by intermitting the administration whenever the patient struggles and not renewing it until after he has taken at least one full breath. The condition is to be met by suspending the patient head downward and practicing artificial respiration.

**Administration of the Anæsthetic.**—Chloroform is best given by letting it fall drop by drop upon a single layer of muslin stretched upon a small wire frame and held close over the mouth and nostrils. This is thought to be somewhat safer than pouring a drachm or two upon a handkerchief and renewing it as it evaporates.

Ether is commonly given from a "cone" made by wrapping a towel about several thicknesses of paper folded in a strip about eight inches wide and one and a-half or two feet long, and then folding it again into a roll which will fit snugly over the chin and nose. The upper end of the roll should be closed by pinning its edges together, and a handkerchief or bunch of absorbent cotton should be pressed into it that it may retain a larger amount of the ether.

Special apparatuses composed of a rubber bag and a mouthpiece and receptacle which permits the admixture of air with the ether vapor in any desired proportion are in quite common use in hospitals and have many advantages.

The method recently introduced by Dr. Thos. L. Bennett of first producing insensibility by nitrous oxide and then continuing with ether has removed the discomforts and inconveniences which made the preliminary stage of etherization so disagreeable for both the patient and the surgeon.



**Rectal Etherization.**—It was shown by Mollière, in 1884, that general anæsthesia could be readily obtained by the administration of ether by the rectum. The method was at once widely tried, but has been abandoned, except in special cases, for it was found to be more dangerous than the method by inhalation. The dangers are that the anæsthetization may unwittingly be made too profound and prolonged, and that the contact of the ether with the intestinal mucous membrane may cause a bloody diarrhœa.

The ether is placed in a bottle provided with a tightly-fitting cork through which passes a rubber tube. The free end of the tube is inserted in the rectum, and the bottle placed in warm water.

The precautions to be observed are that the water should not be warmer than 100° Fahr., and that as soon as anæsthesia is obtained the tube should be withdrawn from the rectum, to be reapplied if necessary. The tube should be large, and should extend downward from the anus to the bottle without loops or coils in which the ether might condense.

### ARREST OF HEMORRHAGE.

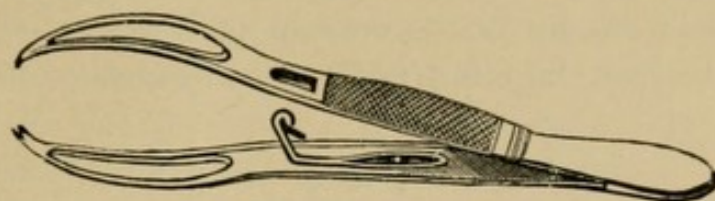
Hemorrhage is arrested : by ligature ; by torsion ; by pressure ; by cold or heat ; by position.

**Ligature.**—The vessel or bleeding point is seized by forceps (Figs. 1, 2 and 3) with as little of the surrounding tissue as possible. It is encircled by silk or catgut, which is tied in a square knot (Fig. 4). Or, if the vessel cannot be seized or held, the ligature is passed under it on a curved needle.

**Torsion.**—The vessel is isolated, grasped by the forceps, drawn out and twisted till it parts. It is not in general use except for small vessels.

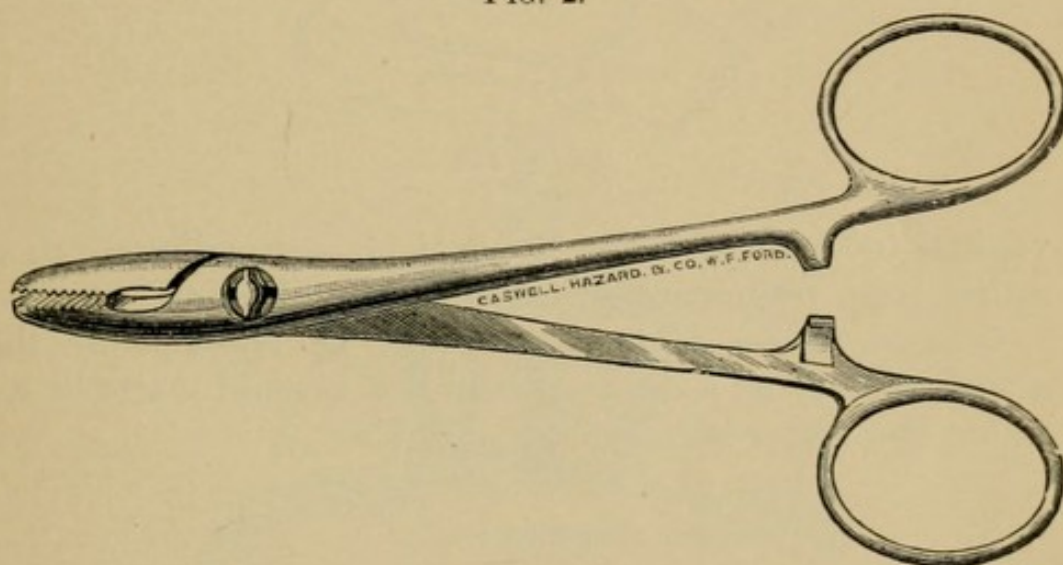
**Pressure** made by sponges, gauze pads, or clamps left in place for a few minutes will frequently be found sufficient to arrest oozing, venous hemorrhage, or the bleeding from small arteries.

FIG. 1.



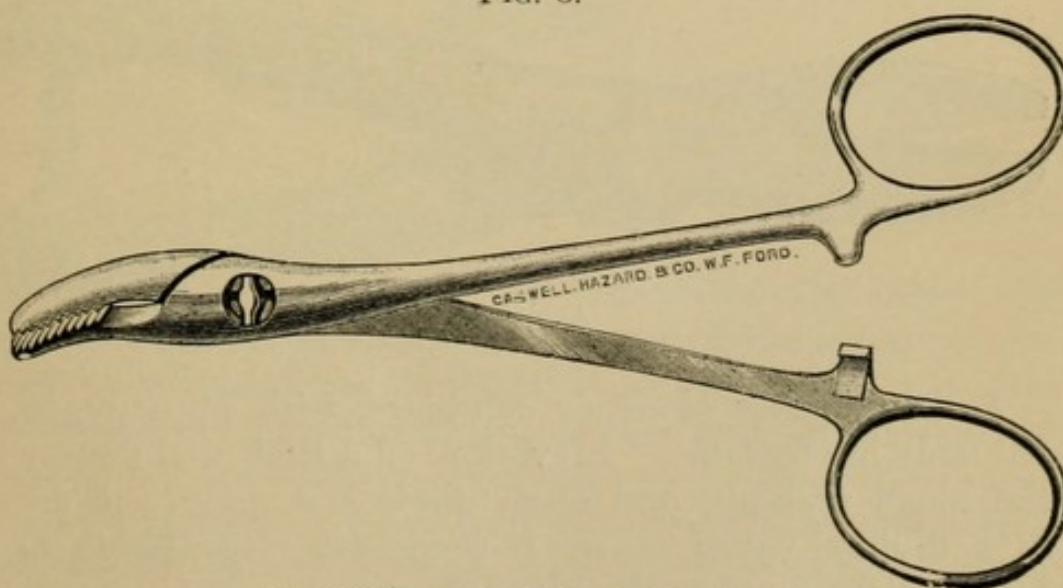
Artery forceps.

FIG. 2.



Self-holding hæmostatic forceps.

FIG. 3.

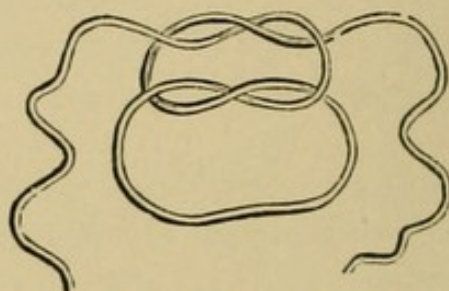


Self-holding hæmostatic forceps; curved.



Very great, crushing pressure by a specially constructed instrument (Fig. 5) has been successfully used and of late even to secure vessels as large as the femoral artery. It has thus far been used almost exclusively in

FIG. 4.

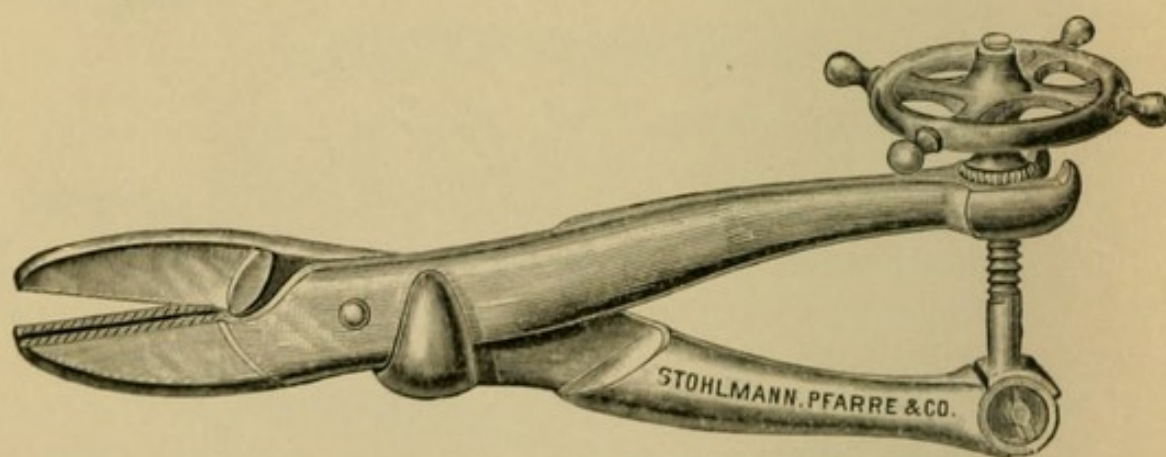


Square knot.

vaginal hysterectomy and its use has been followed in a rather large proportion of cases by late bleeding.

**Cold or Heat.**—Hemorrhage may be checked by the actual cautery at a dull-red heat, by ice-cold water or by water at a temperature of  $110^{\circ}$  to  $120^{\circ}$  F.

FIG. 5.



Angiotribe.

**Position,** either alone or combined with pressure, is a valuable hæmostatic. Elevation of a limb will diminish the blood pressure and often allow a coagulum to form in a divided vessel, where it would otherwise be washed away by the force of the blood flow.

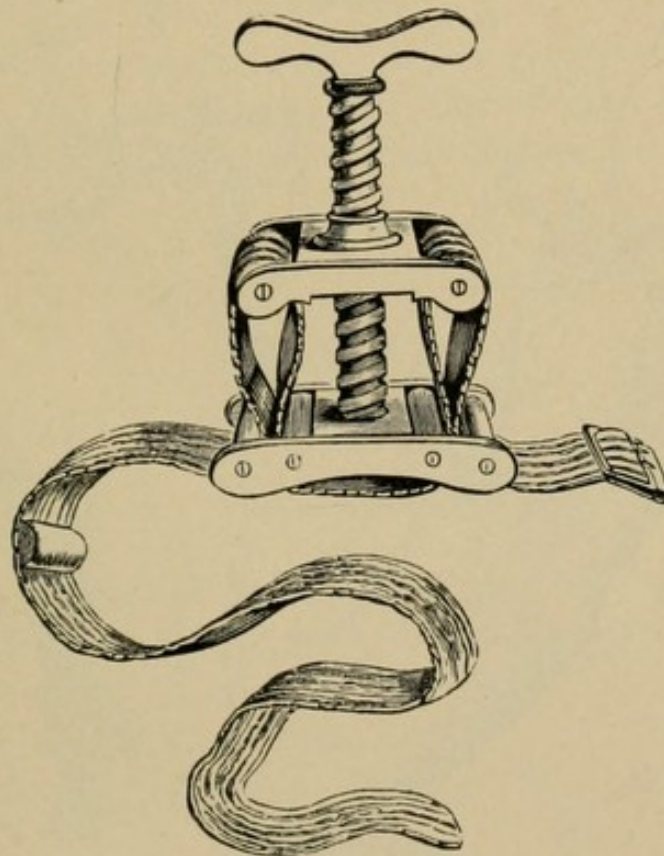


**ARTIFICIAL ISCHÆMIA.**

Loss of blood during an operation upon a limb may be prevented by pressure upon the main artery on the proximal side of the incision. This pressure may be made with the finger, tourniquet, or elastic cord.

The tourniquet (Fig. 6) is composed of a pad, band, and screw; by turning the screw the band may be tightened at will. The principle of its application is the com-

FIG. 6.



Petit's tourniquet.

pression of the artery against the underlying bone. A point should be selected in the course of the artery where such compression can be made; a roller bandage, an inch in diameter, placed over the vessel and parallel to its course, the tourniquet then applied as shown in Figs. 7 and 8 and the screw tightened. Some surgeons prefer to place the pad of the tourniquet upon the roller bandage itself and not on one side as shown in the figure. The

buckle on the band should always be much further from the roller than is represented in the figures.

The *elastic* tourniquet is applied after holding the limb for a short time in an elevated position to diminish the amount of blood in it. Then, without changing the position, a soft but stout rubber cord or band is wrapped several times about the limb sufficiently tight to occlude all the vessels and fastened in position by a single knot.

FIG. 7.

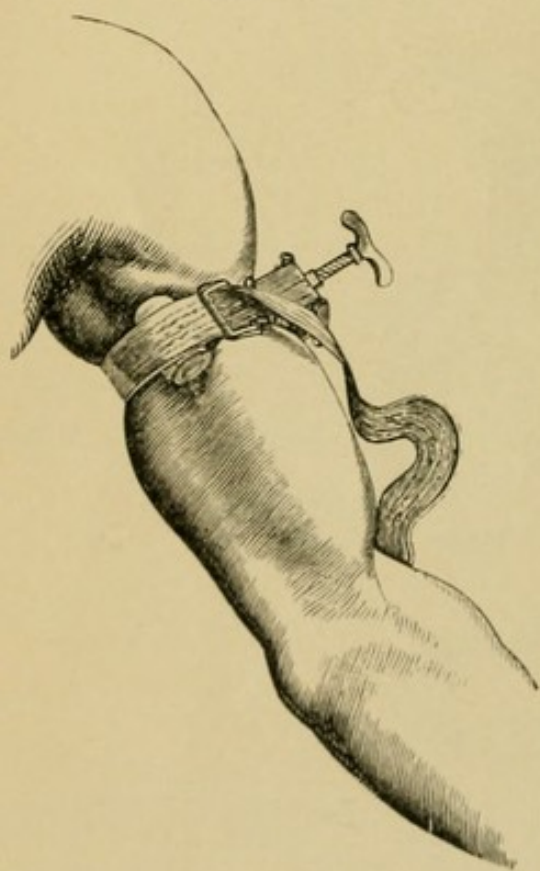
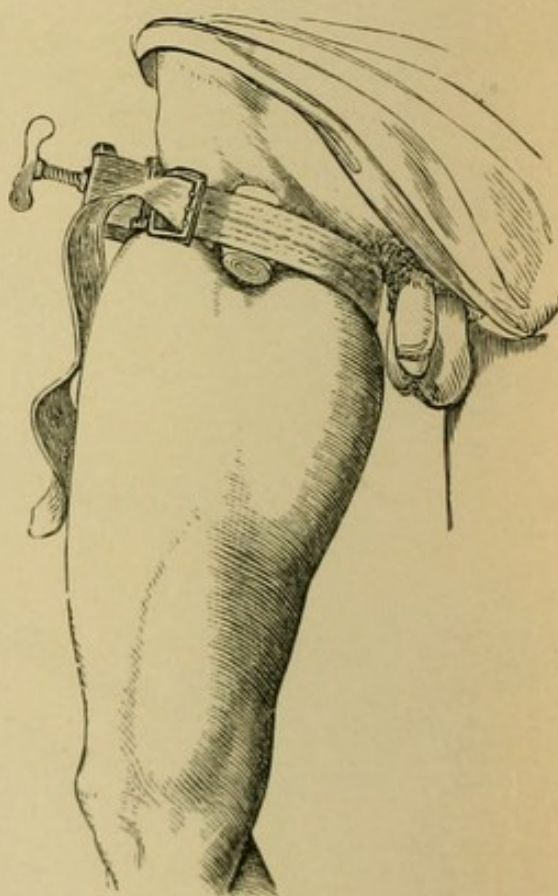


FIG. 8.



Mode of application of tourniquet.

It should be applied at a convenient point, well above the seat of operation. Or the Esmarch rubber bandage, usually two or more inches broad, is applied from the fingers or toes of an extremity spirally upward, each upper turn overlapping the one below from a quarter to half an inch. It is wound tightly enough completely to empty all the vessels of blood as it advances and is carried to the point where the rubber tourniquet can be best ap-



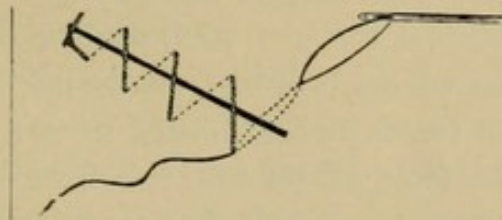
plied, which is then done as already described. The spiral bandage is then removed.

The objections to the rubber bandage and tourniquet are the possibility of pressure paralysis and the certainty of temporary vasomotor paralysis, with its consequent troublesome oozing. The advantages are that an operation can be performed upon the living body with as much ease and accuracy as upon the cadaver. It is very useful whenever careful dissection is necessary.

### SUTURES.

The continuous suture (Fig. 9) is passed in the same manner as the interrupted, but the stitches are not cut apart and tied. It is conveniently fastened at the last by

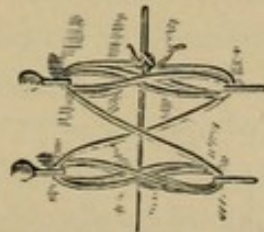
FIG. 9.



Continuous suture.

drawing it double through the last puncture and using the free end to make a knot with the double part attached to the needle.

FIG. 10.



Twisted suture.

The twisted or figure-of-8 suture (Fig. 12) is made by transfixing the lips of the incision with a pin, about the two ends of which a thread is then twisted (Fig. 10).

**Tension or relaxation suture** is the name given to one



employed to relieve strain on the sutures approximating the edges of the wound. The points of entry and emergence should be at a considerable distance from the incision. The thread is passed double, and in order to lessen the tension at any one point its extremities are tied over buttons or plates of lead or pads of gauze.

### PREPARATION OF MATERIALS USED IN AN OPERATION.

**Catgut** ranges from the smallest size, No. 1, up to No. 6. It is first soaked in ether for twenty-four hours to free it from fat, then wound on glass spools which have been recently boiled. The hands which do the winding must be thoroughly scrubbed and disinfected, and during the winding the catgut must touch nothing which is not surgically clean. The catgut is then boiled in alcohol for one hour, and stored for use in boiled absolute alcohol in a sterilized glass vessel. The spools of catgut are sometimes soaked for twenty-four hours in a 1 : 1000 aqueous solution of bichloride of mercury before boiling.

**Chromicized catgut** is made by soaking for twenty-four to forty-eight hours 200 parts of catgut by weight in a mixture of carbolic acid, 200 parts, boiled water 2000 parts and chromic acid 1 part. It is then boiled in alcohol and stored in boiled absolute alcohol.

**Silk** is used in sizes from the smallest, No. 1, to No. 18, the sizes most convenient for average use ranging from 7 to 10. It is wound on sterilized spools, boiled in water for half an hour, and stored in boiled absolute alcohol in a sterilized glass vessel.

**Silkworm-gut** is simply boiled in alcohol for one hour, and stored in boiled absolute alcohol in a sterilized glass vessel.

**Sponges.**—Ordinary sponges are prepared as follows : Decalcify in a solution of one volume of commercial hydrochloric acid and three volumes of water. Examine each sponge separately for pieces of stone or coral, which must be cut or torn out. Then wash in running water to



remove every particle of sand. Place them in a solution of permanganate of potassium of a strength of about 1 to 16 of water till they are stained a chestnut brown. Wash again in running water to remove the excess of permanganate. Place them in a solution of hyposulphide of soda and oxalic acid—about 5j of each to a pint of water, and stir the sponges till they are bleached. Then wash in running water to free from acid and precipitated sulphur. Rinse out in a solution of sodium bicarbonate—about 1 part to 25 of water. This neutralizes any acid and renders the sponge texture more absorbent. Wash again in sterilized water and store in a 1 : 20 carbolic solution or in a two per cent. solution of formaldehyde.

Simple pads of sterilized absorbent gauze, with the margins loosely hemmed, make excellent and cheap sponges; they should be sterilized by steam for half an hour immediately before use.

**Absorbent gauze** is best purchased from the manufacturers. It should be cut into convenient lengths and sterilized by steam for half an hour immediately before use.

**Bichloride gauze** is conveniently made by wringing out the sterilized absorbent gauze in a solution of bichloride of mercury 1 part, common salt 1 part, and water 1000 parts. The salt prevents the bichloride from changing to calomel. It can then be sterilized by steam and kept in a sterilized tight-vessel.

**Iodoform gauze.**—Where the exact proportion of iodoform is unimportant it can be made as follows: Sterilize a strip of absorbent gauze and the hands of the maker. Dissolve about 5ij of castile soap in 3j of a 1 : 20 aqueous carbolic solution. Strain this through a piece of sterilized gauze to render the suds clear, and boil the filtrate. Mix this filtrate with nearly an equal part of iodoform in a sterilized basin. Again sterilize the hands and wring out the strip of sterilized gauze in this mixture. Store in a sterilized tightly-covered vessel in the dark.

The iodoform mixture cannot be boiled without decomposing the iodoform. The soapsuds cause the iodoform to



adhere to the gauze. The basin in which the mixing of the gauze, soapsuds, and iodoform is carried out must be previously cleaned and sterilized.

Some prefer to sterilize the prepared gauze by steam ; but this sometimes decomposes part of the iodoform, and the iodine thus liberated is very irritating to the skin.

**Drainage tubes** are most conveniently made of ordinary rubber tubing—the red is the best—or of glass. These should be boiled and stored in boiled alcohol or a bichloride or formaldehyde solution, and immediately before use boiled again.

Absorbable bone drainage tubes are sometimes used. They can be obtained from the instrument makers.

**Absorbent cotton** is best purchased of the manufacturers. This and plain cotton can be sterilized by dry heat in an oven at 300° F. maintained for half an hour.

**Rubber tissue** is prepared by washing thoroughly in a 1:20 aqueous carbolic solution and soap. It is then washed in alcohol and stored in 1:1000 bichloride of mercury solution.

### STERILIZATION.

The Arnold steam sterilizer is most efficient for general sterilization. It is so constructed that the steam is condensed after it is used and the water needs only infrequent renewal. Gowns, dressings, etc., should be exposed to the steam for from half an hour to three hours, according to the compactness of the bundle. A very serviceable sterilizer can be made from an ordinary asparagus cooker—a covered tin vessel about twice as long as it is wide and deep—furnished with a removable tray.

Instruments, which rust badly when exposed to steam, should be sterilized by boiling in water to which about one per cent. of sodium carbonate has been added (to diminish rusting) and should be used from trays of sterile water or a weak carbolic solution. Cutting instruments, which lose their edge under boiling, may be sterilized by dry heat or by passing through a flame or by a brief exposure to a one or two per cent. formaldehyde solution.



## THE WOUND MADE BY THE SURGEON AND ITS TREATMENT.

The secret of success in operative surgery lies in absolute cleanliness of the operator and his assistants, the wound and its surrounding parts, and of all instruments, dressings, and accessories which come directly or indirectly into contact with the wound.

On the morning of the day before the operation the skin should be washed and scrubbed with green soap, shaved if necessary, and sponged off with a 1 : 1000 solution of bichloride of mercury. It is then spread with a layer of green soap, and covered with compresses saturated in the same material. Over this is placed a piece of rubber tissue to prevent drying, and the "soap poultice" is left in place till the evening before the operation, or for about twelve hours. It is then removed, and the area washed carefully with a 1 : 1000 bichloride solution, and a wet 1 : 5000 bichloride dressing applied and not removed till the patient is on the table—at least twelve hours later. The surface is then washed with ether, and again with the 1 : 1000 bichloride solution. The surgeon, his assistants, and any attendants in the operating room should have their arms bare to the elbow, and wear sterilized gowns reaching to the feet. All these persons must thoroughly scrub with a sterilized brush, green soap, and hot water their arms, hands, and finger-nails. Then clean the finger-nails with a clean instrument, and wash again with chloride of lime and sodium carbonate (washing powder). Then soak hands and arms in 1 : 1000 bichloride of mercury. It is still better to use rubber gloves, sterilized by boiling or by washing in 1 : 1000 bichloride of mercury.

The incision should be clean and smooth, and large enough to give plenty of room and permit easy recognition of all the parts as they are reached. If the operator attempts to work through too small an opening his manipulations and efforts at retraction and clamping are liable to cause bruising of the margins of the wound. In order



to minimize the amount of foreign material the ligatures should be as few and small as possible. Much of the hemorrhage can be stopped by simple pressure, as by clamps left in place for a few moments, or by temporary packing with sponges or pads of gauze. Strong antiseptics and rough handling in a perfectly clean wound are to be avoided. After all bleeding has been checked, every portion of the wound surface should be brought into contact with some other, and held there immovably for from five to ten days. A well-applied dressing, aided by a few sutures, will generally be found sufficient for this purpose. Buried sutures should be used with caution. They unfavorably modify the nutrition of the parts, and thereby conduce to the development of such septic germs as may be present.


The question of drainage depends upon a number of considerations. A large effusion of blood or serum may be expected to follow some operations, and, by separating the apposed surfaces of the wound, prevent primary union. A well-applied dressing and sutures sufficiently far apart—half an inch to an inch—to allow the effusion to escape between them will generally suffice. This may be supplemented by a flat strip of sterilized rubber tissue introduced into the depths of the wound and brought out between the sutures.

If it is thought necessary to use a drainage tube in an aseptic wound the tube should be removed with every antiseptic precaution at the end of twenty-four to thirty-six hours. Pre-existing suppuration in the wound or its vicinity always calls for drainage. If suppuration occurs in a previously aseptic wound, every facility must be given for the escape of pus at the earliest moment. The whole wound may need to be laid wide open and lightly packed with gauze.

An aseptic wound is closed by any suitable one of the different kinds of suture and covered with a strip of sterilized rubber tissue, over which is placed a layer of iodoform gauze, or the rubber tissue may be omitted. Apply next to the iodoform gauze compresses of sterilized ab-



sorbent gauze, cover these with sterilized absorbent cotton, which acts as a filter against germs coming from without and also absorbs leakage from the wound. Bandage tightly enough to cause an even pressure and immobilization, and yet not interfere with circulation.



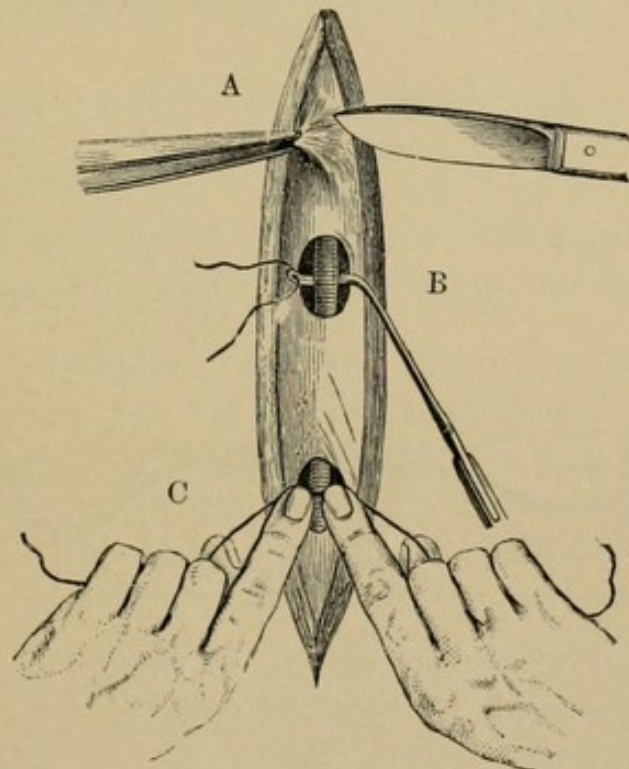
## PART II.

### LIGATURE OF THE ARTERIES.

#### GENERAL DIRECTIONS.

A POINT for the application of the ligature should be chosen, if possible, not nearer than half an inch to any named branch above or below it. The operator should

FIG. 11.



This diagram represents three distinct operations. A. Opening the sheath. B. Drawing ligature round the artery. C. Tying artery.

make himself thoroughly familiar with the anatomical relations of the parts and the landmarks of the operation; he should proceed methodically, in accordance with a



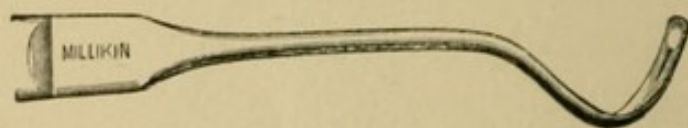
definite plan, and seek for and recognize each layer, each landmark in its order.

The incision should be free, and, so far as possible, its center should correspond with the point at which the ligature is to be applied. It should go fairly through the skin and be carried down to, and then through, the enveloping fascia by repeated applications of the knife.

The knife may then be laid aside and the artery sought for by separating the tissues with the fingers or a director. The sheath is recognized by the communicated pulsation and by the absence of the pinkish-white color and smooth shining surface which characterize the artery. When found, it is pinched up with the forceps, the flat of the knife laid upon it and a hole one-quarter of an inch long carefully made in it. A distinct sheath is found only about the main trunks and is replaced in the others by a layer of cellular tissue, which is more readily separated by tearing with the point of a director or with two forceps.

When the pinkish-white coat of the vessel has been fairly exposed, each edge of the hole in the sheath is grasped in turn with forceps and the sides of the vessel gently separated from the sheath by tearing through the slight attachments with the point of a director.

FIG. 12.



Aneurism needle.

A threaded aneurism needle is then entered on that side where the parts lie that are most to be avoided and passed behind the artery, care being taken not to raise the latter from its bed, until its eye appears upon the other side; the thread is then picked up with forceps and drawn through while the needle is withdrawn. The precaution should never be omitted of trying if compression of the vessel between the finger and the ligature ar-



rests pulsation in its distal branches, for the best surgeons have mistaken a nerve or strip of fascia for the artery. The main trunks can be readily distinguished from the veins by their appearance—the veins being bluish, while the arteries are white and feel like a cord or band under the finger—and by their known anatomical relations; but it is often very difficult to recognize the smaller arteries, since they closely resemble the veins. The operator has to depend upon three indications: (1) the fact that when there are two satellite veins the artery is placed between them; (2) pulsation; (3) alternate compression of the vascular bundle at the two ends of the incision. Pressure at the proximal end causes the artery to shrink and the veins to swell; pressure at the distal end has the contrary effect.

The ligature is then tied with a square knot (Fig. 4), tightly enough to cut the inner coats of the vessel, both ends cut short and the wound closed.

#### ANATOMY OF THE SUPRA-CLAVICULAR REGION.

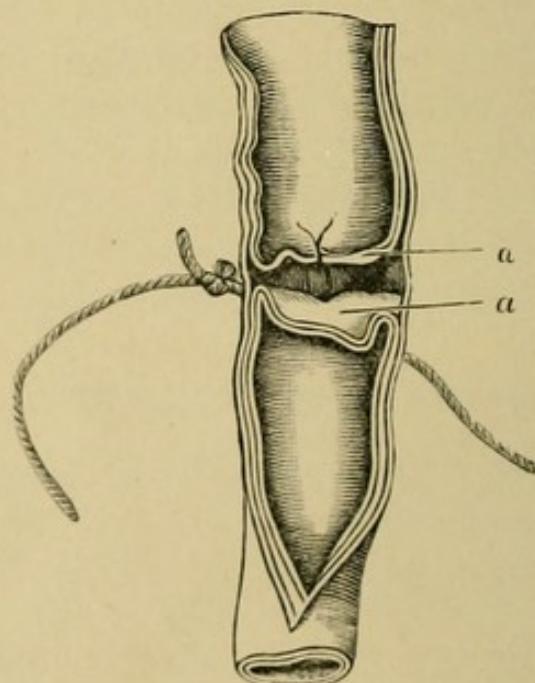
The superficial fascia underlies the platysma, and incloses the sterno-cleido-mastoid in a reduplication of itself. The middle, or sterno-clavicular, fascia has a common origin with the superficial fascia in the linea alba between the two sterno-thyroid muscles, divides into three layers to form sheaths for the sterno-thyroid and sterno-hyoid, unites and again divides to form a sheath for the omohyoid, unites again and finally joins the superficial fascia between the trapezius and sterno-cleido-mastoid. This middle fascia is strong and resisting, and incloses all the vessels of the region except the external jugular vein, which is subcutaneous throughout its course until it turns inward to join the subclavian above the clavicle. These two fasciæ are separated from each other and from the skin by loose cellular tissue, in which a large amount of fat may be deposited, and it is of prime importance that they should be recognized in the search for the vessels.

The vessels which are approached through this region



are the innominate, the subclavian, and the common carotid. The bifurcation of the innominate corresponds with the sterno-clavicular articulation, and in old people, as well as in exceptional cases, rises from five to ten millimeters above it. It lies in front and on the right side of the trachea, and is crossed anteriorly by the left innominate vein. At the bifurcation the subclavian lies behind and to the outer side of the carotid, and is crossed by the pneumogastric and phrenic nerves close to its origin, the

FIG. 13.



*a, a.* Inner coat of an artery ruptured by a ligature.

former giving off the recurrent laryngeal, which turns under the artery and rises again behind it. The carotid, which at first lies behind the sterno-cleido-mastoid, soon reaches its anterior edge, and at the same time increases its distance from the trachea. While the internal jugular lies wholly within the middle cervical fascia, the subclavian vein is enveloped by a reduplication of it and held closely against the clavicle thereby. It is therefore more superficial, and on a lower plane than the curved portion of the subclavian artery, and need not be uncovered in the search for the latter. The branches of the subclavian, seven in

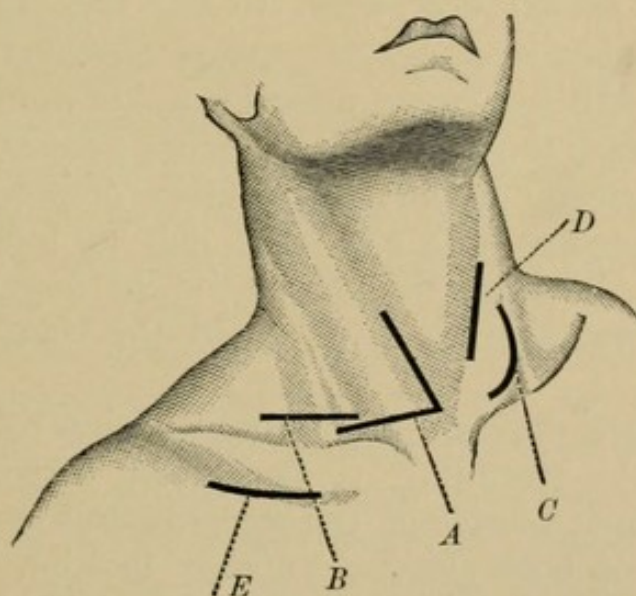


number, arise (with one exception, the transversalis colli) from its first portion, that comprised between its origin and the inner border of the scalenus anticus. The transversalis colli may arise from the first part, or the second (between the scaleni), or even the third (beyond the scaleni). The supra-scapular crosses in front of the scalenus anticus and runs downward and outward to the clavicle, lying below the line of the incision made in tying the subclavian in its third portion.

### LIGATURE OF THE INNOMINATE ARTERY.

**Anatomy.**—The artery is in relation in front with the innominate veins and the pneumogastric nerve; on the

FIG. 14.



Ligature of Arteries. *A.* Innominate. *B.* Second or third portion of subclavian. *C.* Second or third portion of subclavian (SKEY). *D.* Vertebral or inferior thyroid. *E.* Axillary below the clavicle.

inner side with the trachea; on the outer side and behind with the pleura. It lies immediately behind the sternoclavicular articulation.

**Operation.**—(Mott.) An incision  $3\frac{1}{2}$  inches in length is carried along the anterior edge of the right sterno-cleido-mastoid, ending half an inch above the sternum (Fig. 14, *A*). Another, of the same length, is carried outward from the lower end of the first, half an inch above and



parallel to the right clavicle. These incisions are carried down to the superficial fascia, and the triangular flap between them dissected up. If the anterior jugular is encountered it must be drawn downward. The sternal and part of the clavicular attachments of the sterno-cleido-mastoid are now divided half an inch above the bone on a director or with forceps and knife, and the muscle drawn upward and outward, uncovering the sterno-thyroid and sterno-hyoid and the middle cervical fascia, which here is very dense and covered by the inferior thyroid veins. The outer fibers of the sterno-hyoid and sterno-thyroid are now divided, the thyroid veins drawn aside, and the underlying or middle fascia torn through with the director, or opened very carefully with the knife. The common carotid is now seen at the bottom of the wound and traced downward to the innominate. The internal jugular is carefully pressed outward with a retractor; the left forefinger, passed into the wound between the artery and the innominate veins, presses the latter against the sternum, and the operator proceeds carefully to clean the artery with a director half an inch below its bifurcation. The needle, guided by the finger, is passed from the outer side so as to avoid the vein, nerve and pleura.

**Bardenheuer**<sup>1</sup> exposes the innominate by resection of a portion of the sternum. A transverse incision is made along the upper border of the sternum and inner third of the clavicle on both sides. Another incision is made in the median line at right angles to this from the larynx, well down upon the sternum. In the transverse incision the sterno-mastoid, sterno-hyoid, and sterno-thyroid muscles, and the deep fascia are cut through. The inner inch of the left clavicle and first rib are resected subperiosteally. By working inward through this gap the periosteum is freed from the posterior surface of the manubrium, and this bone is chiseled through transversely an inch below its upper border, and removed by cutting the right clavicle and first and second right ribs close to the sternal border.

<sup>1</sup> Deut. med. Woch., Vol. II., No. 40, p. 688.



The periosteum is cut in the median line, the left innominate vein is pushed down and the right drawn to the right side, and the aneurism needle passed from right to left to avoid the pleura.

The innominate has been tied only for aneurism of itself, of the subclavian, or of the primitive carotid; but as the treatment of aneurism by distal ligature yields satisfactory results, this operation is seldom justifiable.

### LIGATURE OF THE SUBCLAVIAN ARTERY.

The anatomical difference between the right and left subclavian is confined to the first portion of the artery, which in the left is much longer, more vertical in its direction, and situated more posteriorly even than the innominate; a separate description therefore is required only for the first portion.

**Operation.**—1ST PORTION. LEFT SUBCLAVIAN.—A V-shaped incision similar to that described for ligature of the innominata (Fig. 14) is made upon the left side and carried through the sterno-cleido-mastoid and outer fibers of the sterno-thyroid and sterno-hyoid muscles and the middle cervical fascia as before described. The carotid is then recognized and, together with the internal jugular, drawn outward with a blunt hook. The muscles are now relaxed by bending the head and neck forward and the cellular tissue torn through with forceps and director. The knife should no longer be used, on account of the risk of injury to the thoracic duct, which is imbedded in the loose tissue between the vessels and the vertebræ and is rendered very difficult of recognition by its small size and thin walls. It runs directly across the route to the artery while passing from the bodies of the vertebræ to the anterior border of the scalenus anticus and can best be avoided by making the search below and to the outer side of it in the lower angle of the wound.

The finger, passed downward and backward behind the carotid, soon feels the artery by pressing it against



the side of the spinal column, the loose cellular tissue surrounding it is easily separated with the director, the vessel cleaned and the needle passed from the inner side. The needle should have a short curve and its point should be kept close against the vessel, so as to avoid injuring the pleura.

1ST PORTION. RIGHT SUBCLAVIAN.—It is exposed in the same manner as the innominate artery, and the ligature passed from the outer side, the pneumogastric and phrenic nerves being pressed inward toward the carotid. The great danger of this operation lies in the proximity of collateral branches.

2D PORTION.—This operation, first proposed and performed by Dupuytren, is rendered dangerous by the fact that one and sometimes several large branches are given off from this part of the artery. The preliminary steps are the same as those employed in ligature of the 3d portion; after the middle cervical fascia has been divided, the tubercle of the first rib and the external border of the scalenus anticus are sought, the muscles bared and divided upon a director, the phrenic nerve which lies upon its anterior aspect being carefully avoided. As soon as the muscular fibers are cut they retract and leave the artery in full view.

3D PORTION. ANATOMY.—The 3d portion of the subclavian lies between the outer border of the scalenus anticus and the tubercle of the first rib in front and the brachial plexus behind, and below the posterior belly of the omohyoid; it is crossed on a much more superficial plane by the external jugular, which enters the subclavian near the middle of the clavicle. In muscular subjects the clavicular insertions of the trapezius and sterno-cleido-mastoid muscles lie near to, or may even join, one another; in others they are from two to three inches apart. Ordinarily the vessel lies at a depth of one or one and a-half inches below the surface, but in very fat persons, or when the clavicle has been pushed upward by an axillary aneurism, this distance may be increased to three inches.



**Operation.**—Beginning an inch outside of the sterno-clavicular articulation, make an incision three or four inches long parallel to and half an inch above the clavicle (Fig. 14, *B*). Divide the skin and the platysma; when the external jugular is exposed draw it aside or divide it between two ligatures. Divide the superficial fascia, and the clavicular portion of the mastoid muscle if necessary, and seek the posterior belly of the omohyoid. Draw this muscle outward and upward, and feel for the tubercle of the first rib, following down the outer border of the scalenus anticus. Depress the shoulder as much as possible, denude the artery with the point of a director, and pass the needle from below, taking care not to include the lowest bundle of the brachial plexus in the ligature. In order to avoid mistaking this bundle for the artery, the tubercle of the first rib should always be found; the artery lies against it, between it and the nerve.

Skey prefers, in difficult cases, a curved incision "commenced about two and a-half or three inches above the clavicle, upon, or immediately on the outer edge of, the mastoid muscle. This incision is carried slightly outward and downward, toward the acromion, and then curved inward along the clavicular origin of the mastoid muscle." (Fig. 14, *C*.) Ordinarily the external jugular is left to the outer side of the incision.

### LIGATURE OF THE SUPERIOR THYROID ARTERY.

It arises close to the bifurcation of the common carotid at the upper border of the thyroid cartilage, and is in relation with the superior laryngeal nerve on its inner side.

**Operation.**—A two-inch incision is made along the anterior border of the sterno-mastoid muscle, with its center opposite the upper border of the thyroid cartilage. The skin, fascia, and platysma are divided, the sterno-mastoid drawn out, and the carotids recognized.

The superior thyroid artery will be found springing from the anterior surface of the external carotid close to the bifurcation of the common carotid artery. Pass the



needle from above down, avoiding the superior laryngeal nerve.

### LIGATURE OF THE INFERIOR THYROID.

**Anatomy.**—After passing vertically upward, the artery curves inward to reach the under surface of the thyroid gland. The highest point of its curve is half an inch below the prominence on the transverse process of the sixth cervical vertebra, named by Chassaignac the *carotid tubercle*. In old people it is somewhat higher. It lies behind the common carotid and internal jugular, and is separated from them by more or less dense cellular tissue. The guides to the vessel are the carotid and Chassaignac's tubercle.

**Operation.**—Make an incision three and a-half or four inches in length along the anterior border of the sterno-cleido-mastoid, ending an inch above the clavicle (Fig. 14, *D*). Lay bare the border of the muscle, and draw it outward, tear through or divide the middle fascia, and draw the carotid and internal jugular outward, with a retractor. Flex the head slightly to relax the parts, feel with the finger for the carotid tubercle, and seek the artery below it, separating the cellular tissue with a director. Pass the needle between the artery and vein.

Drobeck<sup>1</sup> makes an incision along the outer border of the sterno-mastoid muscle from the clavicle to the thyroid cartilage. The omohyoid muscle and, just below and parallel to it, the transversalis colli artery cross the wound transversely beneath the sterno-mastoid, and overlie the phrenic nerve as it passes vertically down on the scalenus anticus. At the inner border of the latter is the ascending cervical artery. The sterno-mastoid and great vessels are drawn toward the median line, and either the ascending cervical or transversalis colli artery is followed back to the thyroid axis. The inferior thyroid artery will be found at the inner side of the ascending cervical close to the inner border of the scalenus anticus just below the carotid tubercle. The recurrent laryngeal nerve lies still

<sup>1</sup> Centralbl. für Chirurgie, 1887, p. 592.



nearer the median line; the ligature should be passed from within outward.

### LIGATURE OF THE VERTEBRAL ARTERY.

**Anatomy.**—The vertebral artery passes from the first portion of the subclavian upward and backward to the transverse process of the sixth cervical vertebra. It is accompanied by a vein which lies in front, and is covered by the deep cervical fascia. The guide to it is the carotid tubercle.

**Operation.**—The incision is the same as for ligature of the inferior thyroid (Fig. 14, *D*). The anterior edge of the sterno-cleido-mastoid is exposed and drawn outward. The middle fascia is divided, and the carotid and jugular drawn inward. The gap between the longus colli and the scalenus anticus is then felt for about half an inch below the carotid tubercle, the deep fascia covering it torn through, the muscles separated, the vertebral vein pushed aside, and the artery exposed.

Chassaignac prefers an incision along the posterior border of the mastoid muscle, and reaches the carotid tubercle by drawing the muscle and vessels inward. If the muscle is very broad some of its clavicular fibers must be divided.

### LIGATURE OF THE AXILLARY ARTERY.

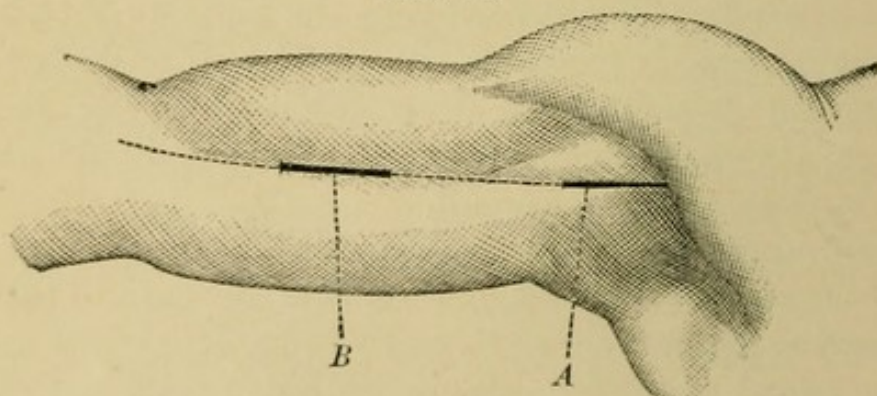
**Anatomy.**—The axillary extends from the middle of the clavicle to the lower edge of the tendon of the teres major. The axillary vein lies on the inner side and in front of it and the brachial nerves invest its lower portion closely. It can be tied below the clavicle in the clavi-pectoral triangle formed by the clavicle, inner border of the pectoralis minor and the thorax or in the axilla. The strong fascia which unites the coracoid process and clavicle and forms the suspensory ligament of the axilla, the costo-coracoid fascia, sends a prolongation about the upper portion of the axillary vein which keeps its walls from sinking in; the cephalic vein ascending in the groove between the deltoid and pectoralis



major perforates this fascia and joins the axillary vein at the inner border of the tendon of the pectoralis minor, close by the origin of the acromial thoracic artery.

**A. Ligature Under the Clavicle.** (Fig. 14, *E*.)—Make an incision extending from the summit of the coracoid process four or four and a-half inches along the lower border of the clavicle. Divide successively the skin, subcutaneous tissue, superficial fascia and pectoralis major, and then tear carefully through the costo-coracoid fascia, avoiding injury to the cephalic vein at the outer part of the wound. The pectoralis minor is now exposed, and after separating the cellular tissue with the point of a director the axillary vein is seen crossing from

FIG. 15.



*A.* Ligature of the axillary artery. *B.* Ligature of the brachial artery.

the upper edge of the muscle to the clavicle. The artery is completely hidden by it, lying on the outer side and a little behind. The vein must now be drawn inward, the needle entered between it and the artery and the ligature applied as near as possible to the clavicle on account of the proximity of the acromial thoracic branch.

**B. Ligature in the Axilla.** **Anatomy.**—The tissues and organs on the outer side of the axilla are arranged in the following order: (1) the skin; (2) the subcutaneous cellular tissue; (3) the fascia; (4) the axillary vein; (5) the internal cutaneous and ulnar nerves; (6) the axillary artery; (7) the median nerve; (8) the coraco-brachialis; (9) the humerus and articular capsule. The old rule for exposing the artery here was to make a longitudinal in-



cision at the junction of the anterior and middle thirds of the axilla, find the vein, count two nerves and look for the artery just beyond the last one. This is a difficult and dangerous method and a much simpler one has been substituted by Malgaigne, who was the first to point out that the coraco-brachialis muscle is the real guide to the artery.

**Operation.**—The arm is abducted completely, the incision commenced at the inner border of the coraco-brachialis over the head of the humerus and carried two and a-half or three inches down the arm parallel to the course of the artery. It should involve the skin only, so as to avoid injury to the basilic vein. If the edge of the coraco-brachialis cannot be distinguished, the incision should be made according to the old rule, at the junction of the anterior and middle thirds of the axilla. The aponeurosis is now divided upon a director over the coraco-brachialis, and the fibers of the inner border of this muscle exposed. The parts are then relaxed by bringing the arm nearer the trunk, and the posterior side of the wound, including the vein, ulnar and internal cutaneous nerves, is drawn back with a retractor; and the artery, overlain by the median nerve, usually appears at the bottom, covered, perhaps, by the posterior part of the sheath of the coraco-brachialis.

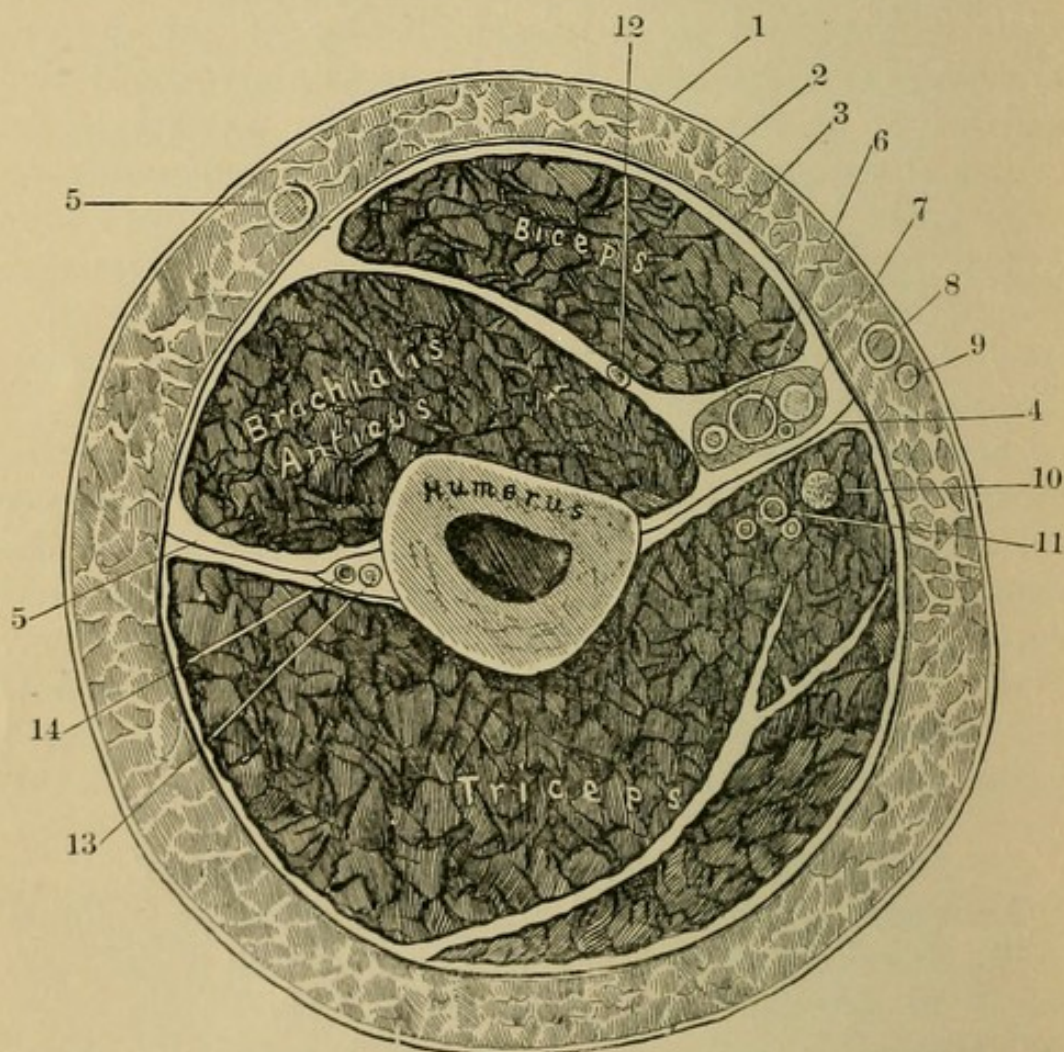
#### LIGATURE OF THE BRACHIAL ARTERY.

**Anatomy.**—The brachial artery runs from the junction of the anterior and middle thirds of the axilla to the middle of the anterior aspect of the elbow. It occupies, when the forearm is supinated, the groove between the biceps and triceps, being partly covered by the former in muscular subjects, and separated from the bone by the inner edge of the coraco-brachialis, and of the brachialis anticus. It lies in the anterior loge of the arm, which is bounded posteriorly on this side by a prolongation of the enveloping aponeurosis, extending down to the bone between the biceps in front and the triceps behind. It lies, consequently, within the sheath of the biceps, and the inner edge of this muscle is the sure guide to it. It lies



between two satellite veins, which anastomose frequently, and has the median nerve in immediate relation with it on the side next the skin. The basilic vein directly overlies it between the skin and the aponeurosis. The artery presents frequent anomalies. The most common is

FIG. 16.



Transverse section of the arm at its middle (TILLAUX). 1. Skin. 2. Subcutaneous tissue. 3. Enveloping aponeurosis. 4. Aponeurosis separating the anterior and posterior loges on the inner side. 5. Division on the outer side. 6. Brachial artery and veins. 7. Median nerve. 8. Basilic vein. 9. Internal cutaneous nerve. 10. Ulnar nerve. 11. Its artery and veins. 12. Muscular cutaneous nerve. 13. Muscular spinal nerve. 14. Superior profunda artery. 15. Cephalic vein.

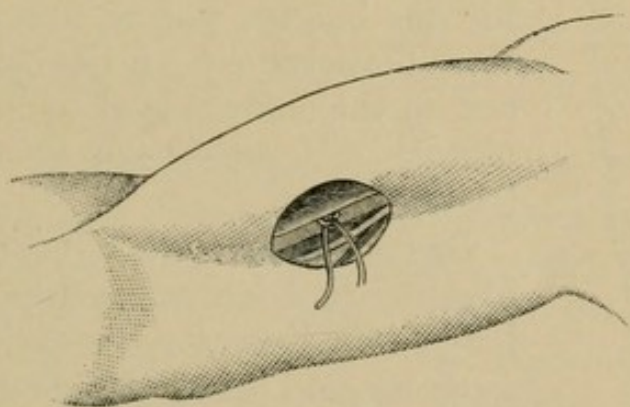
its premature bifurcation into the radial and ulnar, which may take place as high as in the axilla, in which case one of the branches is superficial, perhaps even subcutaneous, while the other follows the usual course. The median nerve occupies the same sheath with the artery, lying first



on the outer side and then crossing, in front or behind, very obliquely to the inner. The ulnar nerve, accompanied by an artery and two veins, lies in the substance of the triceps immediately behind the brachial artery and median nerve, separated from them only by the above mentioned prolongation of the enveloping aponeurosis, and as they form a group differing from the other only in size, the artery may be mistaken for the brachial if met with (Fig. 16). This error will not be made if the fibers of the biceps alone are exposed and the incision confined to the anterior loge.

**Operation.**—Arm abducted, forearm supinated. Make an incision three inches long in the middle third of the

FIG. 17.



Ligature of the brachial artery.

arm, along the inner border of the biceps through the skin and subcutaneous cellular tissue, taking care not to injure the basilic vein, which should be kept posterior to the incision. Divide the aponeurosis and expose the fibers of the biceps. If the muscle is large draw it forward, and the sheath inclosing the artery, nerve, and veins will be disclosed. This is opened carefully, the median nerve separated and pushed aside, the artery separated from its veins, and the ligature passed from the side of the nerve.

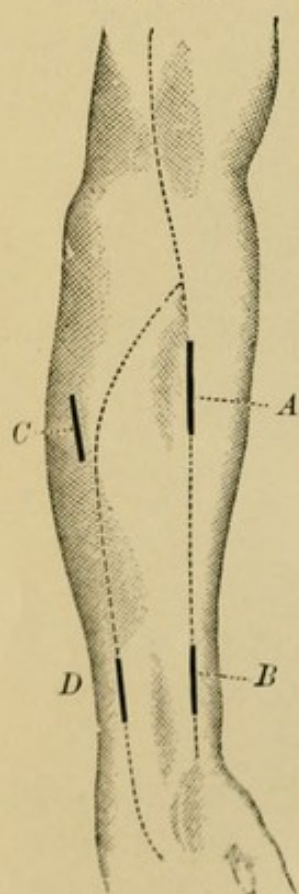
#### LIGATURE OF THE RADIAL ARTERY.

**Anatomy.**—The radial artery extends in a straight line from a point half an inch below the center of the fold of



the elbow to the ulnar side of the styloid process of the radius; it occupies the groove bounded on one side by the supinator longus, on the other by the pronator radii teres and flexor carpi radialis. It is covered only by the skin, cellular tissue, and aponeurosis; but in muscular subjects the muscular interstice in which it lies may be very deep. It is accompanied by two veins and by no nerve. It occupies in its upper third the sheath of the pronator, and consequently the fibers of the supinator longus should not be exposed in the search for the artery, although the edge of the muscle may be taken as a guide to it. The radial nerve lies within the sheath of the supinator longus, and at first comes quite close to the artery; it then passes behind and to the outer side of the tendon of the muscle. It should not be seen during the operation.

FIG. 18.



Ligature of the radial and ulnar arteries.

It occupies in its upper third the sheath of the pronator, and consequently the fibers of the supinator longus should not be exposed in the search for the artery, although the edge of the muscle may be taken as a guide to it. The radial nerve lies within the sheath of the supinator longus, and at first comes quite close to the artery; it then passes behind and to the outer side of the tendon of the muscle. It should not be seen during the operation.

**Operation.** IN THE UPPER THIRD.—Make an incision two and one-half inches long in the line above mentioned, beginning one and one-half inches below the fold of the elbow. Avoiding the superficial veins, carry the incision to the fascia. Recognize the edge of the supinator longus, and divide the fascia along the ulnar side of it, exposing the fibers of the pronator. Press apart the two muscles if necessary, separate the artery from its veins, and pass the ligature.

IN THE LOWER THIRD (Fig. 18).—Make an incision in the above-mentioned line, if the position of the artery cannot be made out by its pulsations, two inches long, ending an inch above the wrist. Divide the fascia in the same line, separate the artery from the two veins and pass the ligature.



**LIGATURE OF THE ULNAR ARTERY.**

**Anatomy.**—In its first third the ulnar artery passes obliquely underneath the superficial layer of muscles, including the superficial flexor of the fingers, to the inner side of the arm, where it becomes superficial and lies between the flexor carpi ulnaris on the inside and the flexor sublimis digitorum on the outside. It then descends to the wrist in the direction of a line uniting the internal condyle of the humerus with the outer border of the pisiform bone. It is accompanied by two veins and is joined by the ulnar nerve just before it becomes superficial, the nerve lying upon the inner or ulnar side of the artery. It may be tied at any point in the middle and lower thirds. As the deep and superficial flexors of the fingers are separated by a fascia, and as the artery lies below this fascia, it is covered in the lower part of its course by two distinct fasciæ, the enveloping fascia of the limb and this second one.

**Operation.** AT THE JUNCTION OF THE UPPER AND MIDDLE THIRDS.—Beginning four finger-breadths below the internal condyle of the humerus make an incision three and one-half or four inches long in the line above mentioned (Fig. 18). Expose the enveloping fascia clearly, and, drawing back the posterior lip of the wound, seek the first muscular interstice in front of the ulna. It is that between the flexor carpi ulnaris and the flexor sublimis digitorum, and can be recognized by the finger as a slight depression, or by the eye as a white line under the fascia. Divide the fascia, beginning at the lower angle where the space between the muscles is broadest, and then, instead of following the interstice directly backward, raise the flexor sublimis and advance transversely across the arm in the search for the artery which lies upon the deep flexor. Isolate the artery and pass the needle from the side of the nerve.

IN THE LOWER THIRD (Fig. 18).—Make an incision slightly to the radial side of the tendon of the flexor carpi ulnaris, or in the line before mentioned, two inches long, and ending an inch above the end of the ulna. Divide



the enveloping fascia upon a director, and tear through the second over the vessel, which can be seen and felt through it. Isolate the artery, and pass the needle from within outward so as to avoid the nerve.

### LIGATURE OF THE COMMON CAROTID.

The place of election for ligature of the common carotid is just above the omohyoid muscle, but the lesion which renders the ligature necessary may require it to be applied at a much lower point. The vessel has been tied successfully at a point one-eighth of an inch from its origin at the bifurcation of the innominata.

The steps necessary to place a ligature upon the common carotid in the first part of its course are the same as for ligature of the first portion of the subclavian or of the innominata (*q. v.*). After the vessel has been exposed, the internal jugular is pressed to the other side, the artery denuded, and the needle passed from the side of the vein.

AT THE PLACE OF ELECTION.—The bifurcation of the common carotid is on a line with the upper border of the thyroid cartilage. The place of election for tying it is about three-quarters of an inch below its bifurcation. The guide to the artery is the anterior border of the sternocleido-mastoid muscle, and the danger is of wounding the jugular vein, which, when full, entirely covers the artery on the outer side.

**Operation.**—Make along the anterior border of the sternocleido-mastoid an incision three inches in length, the center of which corresponds with the crico-thyroid space (Fig. 19). Divide the skin, platysma, cellular tissue, and aponeurosis, and seek for the interstice between the sternocleido-mastoid and the sub-hyoid muscles. When found, the latter must be pressed inward, and the artery will appear at the edge of the sternocleido-mastoid, the vein, which is external to it, remaining covered. The needle is passed from without inward.

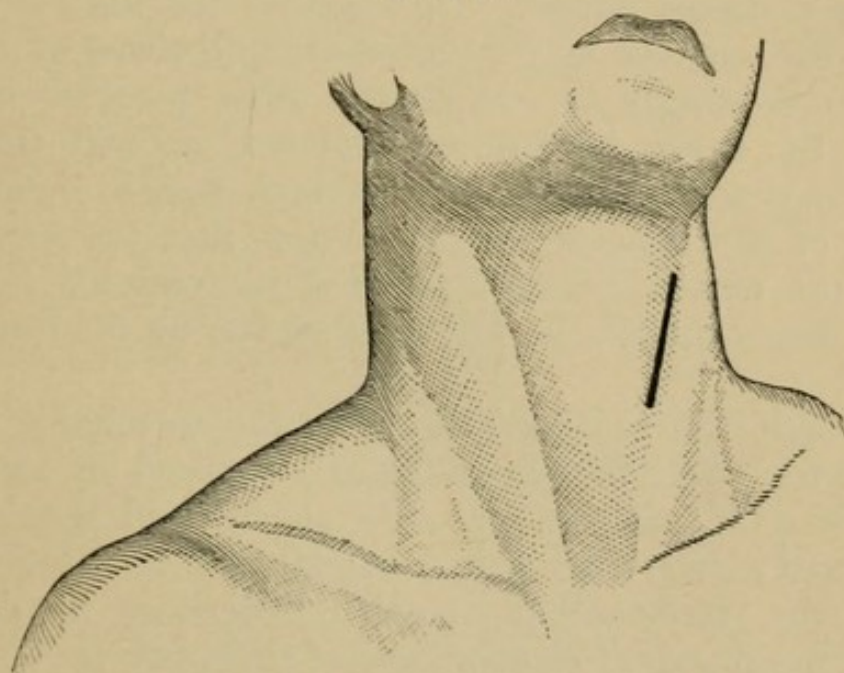
If, instead of pressing the trachea and its muscles inward, the sterno-mastoid is drawn outward, the vein is encountered, almost completely overlying the artery.



**LIGATURE OF THE EXTERNAL CAROTID.**

The free anastomoses which exist within the cranium between the two internal carotids render ligature of the common carotid insufficient certainly to arrest hemorrhage from the external carotid; the ligature must be applied to the vessel itself, despite the number of its branches and the difficulty of recognizing them at the bottom of the incision. The operation is a difficult one, for there are

FIG. 19.



Ligature of the common carotid at the place of election.

many important organs to be avoided, and there is no direct guide to the vessel.

**Anatomy.**—The common carotid divides opposite the upper border of the thyroid cartilage (a little lower in females) into the external and internal carotids, which occupy nearly the same antero-posterior plane, the former being in front. At about three-quarters of an inch above the bifurcation the arteries cross, the external becoming posterior, the internal anterior. The internal carotid gives off no branches outside the cranium, while the external gives off eight. Of these the superior thyroid arises at or very near the bifurcation, the lingual, facial, ascending pharyngeal, and occipital near the point where



the artery passes under the digastric, about an inch above the bifurcation, the others at a considerable distance above. The hypoglossal nerve looping around the occipital artery at its origin crosses the external carotid sending a branch, the *descendens noni*, down the outside of the artery.

There are thus three means of distinguishing the external carotid: (1) its branches; (2) its position with reference to the internal carotid; (3) its immediate relations with the hypoglossal nerve, the internal carotid occupying a deeper plane. In a search for the external carotid the operator may be satisfied with either of these guides, accordingly as one or the other presents itself. Should the nerve be first encountered, he will tie the vessel upon which it lies; should both vessels lie at the bottom of the incision, he will know that the anterior one is the external carotid; and if the vessel which he isolates has a branch, he knows it cannot be the internal carotid.

Although the risks arising from the proximity of a ligature to a large branch are greatly reduced by asepsis, yet it is still desirable that a certain interval should be maintained; and from this point of view the first half-inch of the artery and the portion underlying the digastric are the places of election, and of these two the former alone is practicable. The connective tissue surrounding the two arteries at their origin is, however, unusually compact, rendering their denudation so difficult that any search for branches would be dangerous to the nutrition of the vessel's wall.

M. Guyon<sup>1</sup> has shown that, while the lingual and superior thyroid arteries vary greatly in their points of origin, the average distance between them is from 12 to 18 millimeters, or over half an inch; he calls the portion of the vessel between them the "trunk of the external carotid," and suggests that the ligature should be applied 6 mm. below the point at which the hypoglossal nerve crosses the artery, this nerve being, in the great majority

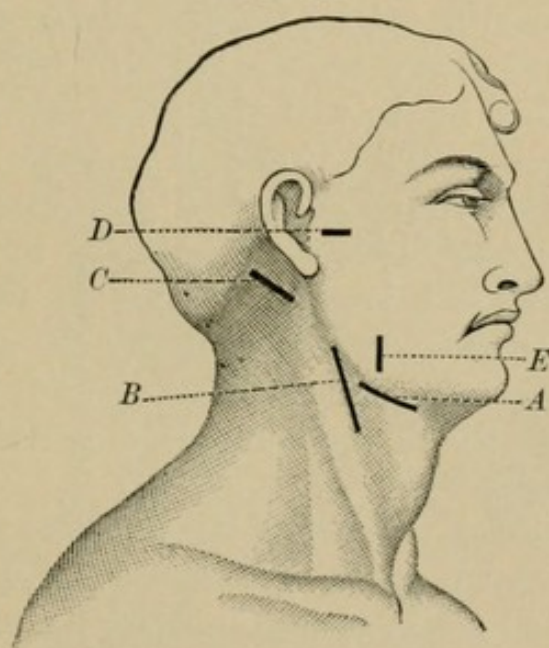
<sup>1</sup> Mémoires de la Soc. de Chirurgie, 1864, p. 555.



of cases, in immediate relation with the origin of the lingual artery.

**Operation.**—When the head is extended and the face turned to the opposite side, an incision carried from the angle of the jaw to the anterior border of the sternocleido-mastoid opposite the top of the thyroid cartilage will cross the artery obliquely (Fig. 20, *B*). It must be carried through the skin, platysma, and subcutaneous cellular tissue, the external jugular being drawn aside when

FIG. 20.



Ligature of—*A*. Lingual artery. *B*. External carotid. *C*. Occipital. *D*. Temporal. *E*. Facial.

encountered. The fascia is then divided in the line of the incision, care being taken not to deviate to the right or left, and when the artery has been thus exposed and cleaned, the needle is passed from behind forward.

The lymphatic glands of the region are numerous and often large, and may be mistaken for the artery. There is no objection to removing any that may interfere with the search for the vessel.

### LIGATURE OF THE INTERNAL CAROTID.

This is to be done according to the method described for the external carotid.



## LIGATURE OF THE LINGUAL ARTERY.

**Anatomy.**—The lingual artery arises from the external carotid, on a level with the great horn of the hyoid bone, and passes between the middle constrictor of the pharynx and the hyoglossus upward and forward. It is occasionally accompanied by a small vein, but the lingual vein is separated from it by the thickness of the hyoglossus muscle. Its one important branch, the sublingual, sometimes has its origin at or near the point where the lingual is usually tied, and may be mistaken for it. The artery may be tied near its origin, between the great horn of the hyoid bone and the posterior belly of the digastric, but its depth at this point, and the presence of large veins, make the operation difficult and dangerous. The place of election is in the triangle bounded posteriorly by the posterior belly of the digastric, anteriorly by the posterior border of the mylo-hyoid, and above by the hypoglossal nerve. It is covered at this point by the skin, platysma, cervical aponeurosis, submaxillary gland, and the hyoglossus muscle, the fibers of which form the floor of the triangle just described.

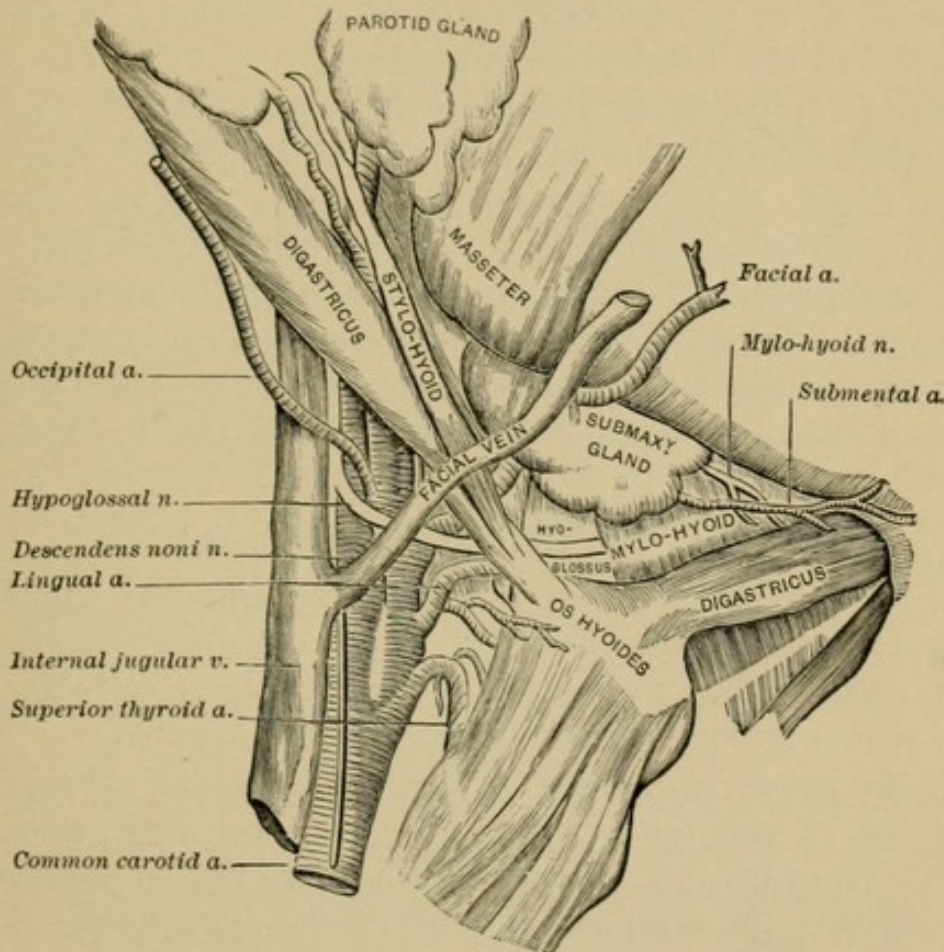
*Dissection*  
**Operation.**—Make a curved incision two inches long, its concavity directed upward, its center one-quarter of an inch above the hyoid bone at a point midway between the median line and the extremity of the great horn (Fig. 20, A). Divide the skin and platysma and then the cervical aponeurosis, which may be very thin. Raise the submaxillary gland, find the posterior belly of the digastric, its attachment to the hyoid bone, the posterior border of the mylo-hyoid, and the hypoglossal nerve accompanied by the lingual vein. Draw the hyoid bone slightly downward with a blunt hook fixed in the lower angle of the triangle bounded by these organs, and then, pinching up the fibers of the hyoglossus with a pair of forceps, divide them carefully along a line parallel to the nerve, and midway between it and the bone. As the cut fibers retract, the artery is disclosed beneath them; separate it from its vein, if there be one, and pass the ligature.



## LIGATURE OF THE FACIAL ARTERY.

The facial artery crosses the inferior maxilla just in front of the anterior edge of the masseter, from which it is separated by the facial vein (Fig. 21). The artery can be exposed by a vertical incision along its course, or by a horizontal one along the lower border of the maxilla.

FIG. 21.



Anatomical relations of the lingual and facial arteries.

**Operation.** (Fig. 20, *E*.)—Beginning at the lower edge of the maxilla, make an incision one inch in length along the course of the artery; divide the skin, subcutaneous tissue and fascia; separate the artery from the vein and pass the needle between them.

If the horizontal incision is used, it should extend three-quarters of an inch on each side of the artery, the anterior edge of the masseter should be recognized and the vessel sought for immediately in front of it.



**LIGATURE OF THE OCCIPITAL ARTERY.**

AT THE MASTOID PROCESS.—The guides to the vessel are the apex and posterior border of the mastoid process, the digastric groove on its inner surface and the digastric muscle.

**Operation.** (Fig. 20, *C*.)—Starting from a point half an inch below and in front of the apex of the mastoid process, carry the incision two inches obliquely backward parallel to the border of this process. Divide the skin and enveloping fascia, and then the sterno-mastoid and its insertion throughout the entire length of the incision. Then divide the splenius and its shining aponeurosis and feel for the digastric groove. Pinch up and carefully divide a thin fascia which covers the anterior face of the splenius. Starting from the belly of the digastric, separate the cellular tissue in the anterior angle of the wound with a director, denude the artery and tie. (*Chauvel.*)

**LIGATURE OF THE TEMPORAL ARTERY.**

(Fig. 20, *D*.) Make a transverse incision one inch long, extending from the tragus of the ear forward over the zygomatic arch. Separate the subcutaneous cellular tissue, which is very dense and fibrous, with a director, and seek the artery imbedded in it about a quarter of an inch in front of the ear. Press the vein backward, pass the needle from behind forward, taking care not to include in the ligature the temporal branch of the auriculo-temporal nerve, which is sometimes in close relations with the artery.

**LIGATURE OF THE ABDOMINAL AORTA.**

This operation has been performed about a dozen times, with a fatal result in every case. The patients survived for periods varying from a few hours to ten days. The artery may be reached through the abdominal cavity by an incision in the median line, or, without dividing the peritoneum, by an incision in the flank similar to König's for extirpation of the kidney (*q. v.*). The application of a ligature, even under the most favorable circumstances,



after the artery has been exposed by the latter method, requires the utmost dexterity, the chance of exciting peritonitis is great, and the presence of the aneurism and the displacements and adhesions it has caused may render it impossible to reach the vessel.

**Operation.** THROUGH THE PERITONEAL CAVITY.—An incision in the linea alba, from a point three inches above the umbilicus to one three inches below it; press the intestines aside with flat sponges, carefully incise the peritoneum covering the aorta, separate the nerves from its anterior surface, and pass the ligature from the outer side.

### LIGATURE OF THE COMMON ILIAC.

**Anatomy of the Common, Internal, and External Iliac Arteries.**—The aorta bifurcates usually on the left side of the fourth lumbar vertebra, and the direction of the common and external iliacs is represented by a line drawn from a point an inch above the umbilicus to another one-half an inch external to the center of Poupart's ligament. The common iliac is usually two inches long, and bifurcates at the sacro-iliac synchondrosis, but this bifurcation may take place at any point between one and a-half and three or even four inches from the origin of the artery. The common iliac gives off no branches.

The external iliac runs downward and outward along the brim of the pelvis from the bifurcation to a point under Poupart's ligament midway between the anterior superior spine of the ilium and the symphysis pubis. Its two branches, the epigastric and circumflex ilii, are given off nearly opposite each other, a short distance above Poupart's ligament, sometimes much higher.

The internal iliac runs downward and backward into the pelvis for one and a-half inches, dividing at the upper border of the great sacro-sciatic foramen into two large trunks. The ureter crosses the vessels at or just below the bifurcation of the common iliac, the vas deferens two and a-half or three inches lower. Both are more closely adherent to the peritoneum than to the arteries. The iliac veins lie upon the inner side and posterior to the arteries ;

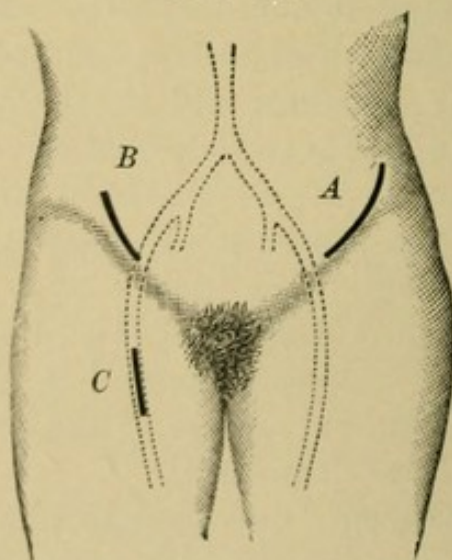


both pass behind the right common iliac, the right vein at its bifurcation, the left vein much higher up. The spermatic vessels and genito-crural nerve lie in front of the external iliac at the lower part of its course, and the circumflex iliac vein crosses it at the same place.

The abdominal wall at the points where the incisions are made is composed of the following layers in the order named: skin, subcutaneous cellular tissue, fascia, external oblique or its aponeurosis, internal oblique, transversalis, and transversalis fascia.

**Extra-peritoneal Operation.**—Beginning at a point a finger's breadth above Poupart's ligament and just outside

FIG. 22.



Ligature of—A. Common iliac. B. External iliac. C. Femoral in Scarpa's space.

of the external iliac artery, make an incision four, five, or six inches in length, according to the thickness of the abdominal wall, parallel at first to Poupart's ligament, and curving upward after passing the anterior superior spine of the ilium (Fig. 22). Divide the skin, subcutaneous tissue, and fascia, exposing the aponeurosis of the external oblique, divide the latter throughout the whole extent of the incision, and then divide the fibers of the internal oblique and transversalis by pinching them up with the forceps and cutting carefully with repeated touches of the knife, until the fascia transversalis, which varies much in density,



is exposed. Raise the fascia at the lower angle of the wound, where it is most dense, with forceps, and make a hole in it large enough to admit the finger. Pass the forefinger through this hole, press back the peritoneum with it, and enlarge the hole upward in the line and to the full extent of the incision, the finger being kept between the peritoneum and the knife.

The peritoneum is now raised from the psoas and iliacus muscles and drawn upward and inward by an assistant, while the operator seeks for the external iliac and passes the forefinger of his left hand along it to the common iliac, the thighs being flexed to relax the abdominal walls. As it is seldom that a good view of the artery can be obtained, the finger must be kept upon it and the loose cellular tissue in which it is imbedded very gently separated with the point of a director. When the artery has been properly cleaned, pass the needle from within outward.

**Intra-peritoneal Operation.**—Open the abdomen in the median line by an incision extending from the symphysis pubis to or a little above the umbilicus and, after pushing aside the intestines with flat sponges or pads, aided by the Trendelenburg position, cut through the peritoneum overlying the artery and pass the ligature from within outward.

Care must be taken not to include the ureter, which usually crosses the vessel at its point of bifurcation. In the extra-peritoneal operation there is less danger of this accident, as the ureter is adherent to the peritoneum and is lifted out of the way as this membrane is stripped up.

### LIGATURE OF THE INTERNAL ILIAC.

Its accompanying vein lies behind and on the inner side.

**Extra-peritoneal Operation.**—Same as for ligature of the common iliac. After the peritoneum has been lifted up, the finger is passed along the external iliac to the bifurcation and then downward for half an inch along the internal iliac. The vein being carefully protected, the artery is bared and the ligature passed from within outward.



The **intra-peritoneal operation** does not differ enough from that for tying the common iliac to require a separate description.

Ligature of the internal iliac has been seldom employed except for traumatic gluteal aneurism, and in these cases, as Van Buren<sup>1</sup> pointed out, the treatment should be to cut down upon the sac, and tie both ends of the artery, hemorrhage being controlled by digital pressure made upon the internal iliac from within the rectum.

### LIGATURE OF THE EXTERNAL ILIAC.

Various cutaneous incisions have been recommended for this operation. Sir Astley Cooper's extended from the external abdominal ring to within a short distance of the superior spine of the ilium; the objections to it are that it involves the division of the superficial epigastric, and, perhaps, of the internal epigastric also, and that the ligature can be applied only to the lower part of the artery. Abernethy's extended outward from the internal inguinal ring parallel to Poupart's ligament; by it the vessel is reached at a greater depth, but it has the great advantage of allowing extension, so that if it should prove necessary the ligature may be applied even to the common iliac. By curving the outer portion of the incision upward away from the superior spine of the ilium, the main branches of the circumflex ilii may be avoided.

**Operation.**—Beginning over the outer side of the artery a finger's breadth above Poupart's ligament, make an incision three or four inches in length, at first parallel with Poupart's ligament, and then curving upward (Fig. 22). Carry this incision through the abdominal wall, and raise the peritoneum from the surface of the iliacus and psoas muscles in the same manner as for ligature of the common iliac. Flex the thighs so as to relax the abdominal muscles, and, while an assistant draws the peritoneum and the contained intestines upward and inward, seek the artery upon the inner border of the psoas. Clean it with

<sup>1</sup> Report on "Aneurism," Proceedings of the International Medical Congress, 1876.



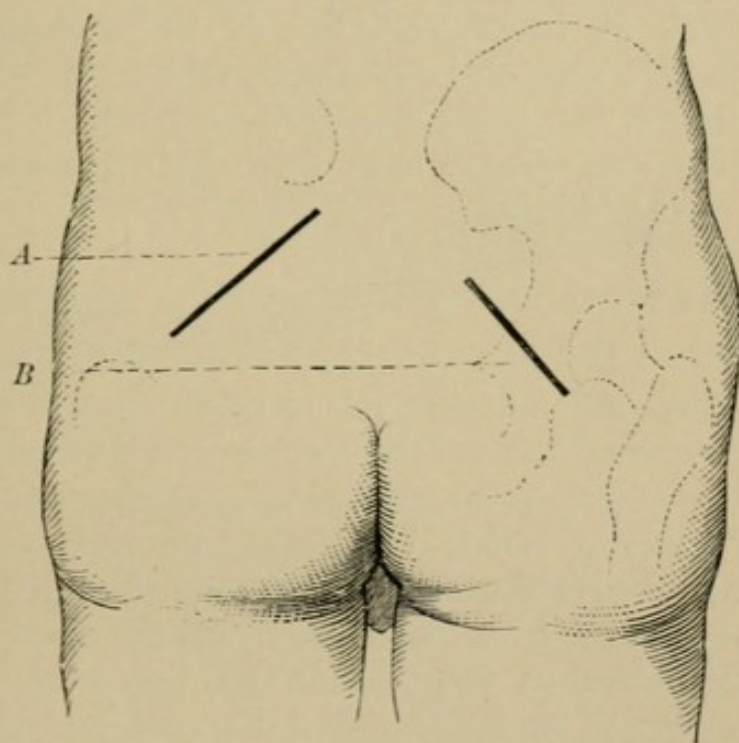
a director or pair of forceps, and pass the needle from within outward.

For the intra-peritoneal operation an incision along the lower part of the linea semilunaris would generally be better than one in the median line, and possibly McBurney's inter-muscular method of reaching the appendix (*q. v.*) would give sufficient room.

### LIGATURE OF THE GLUTEAL, SCIATIC, AND INTERNAL PUDIC ARTERIES.

The proper treatment of injury to either of these arteries is to enlarge the wound and tie both ends of the divided vessel, but it may happen that this would be impossible,

FIG. 23.



Ligature of—A. Gluteal artery. B. Sciatic and internal pudic.

and that ligature in continuity is required. The necessary incisions are those shown in Fig. 23. The place at which the gluteal artery emerges from the great sciatic notch may be roughly stated as opposite a point at the junction of the upper and middle thirds of a line joining the posterior superior spine of the ilium with the great trochanter.



The sciatic, where it crosses the spine of the ischium, lies opposite the junction of the middle and lower thirds of a line joining the tuberosity with the posterior superior spine of the ilium.

After division of the skin and fascia, the fibers of the gluteus maximus are separated and held apart with long retractors, the deep fascia torn through, and the artery sought for.

The *gluteal artery* is to be sought for above the pyriformis muscle at the upper border of the great sacro-sciatic notch, where it can be felt near a small bony tubercle. It is covered by many large veins, which require very careful handling. The ligature should be applied as close to the notch as possible.

The *sciatic* and *internal pudic* arteries leave the great sciatic notch at the lower edge of the pyriformis; the former divides almost immediately, the latter reënters the pelvis through the lesser sacro-sciatic notch, lying on the inner side of the sciatic artery during its passage over the spine of the ischium.

#### LIGATURE OF THE FEMORAL ARTERY.

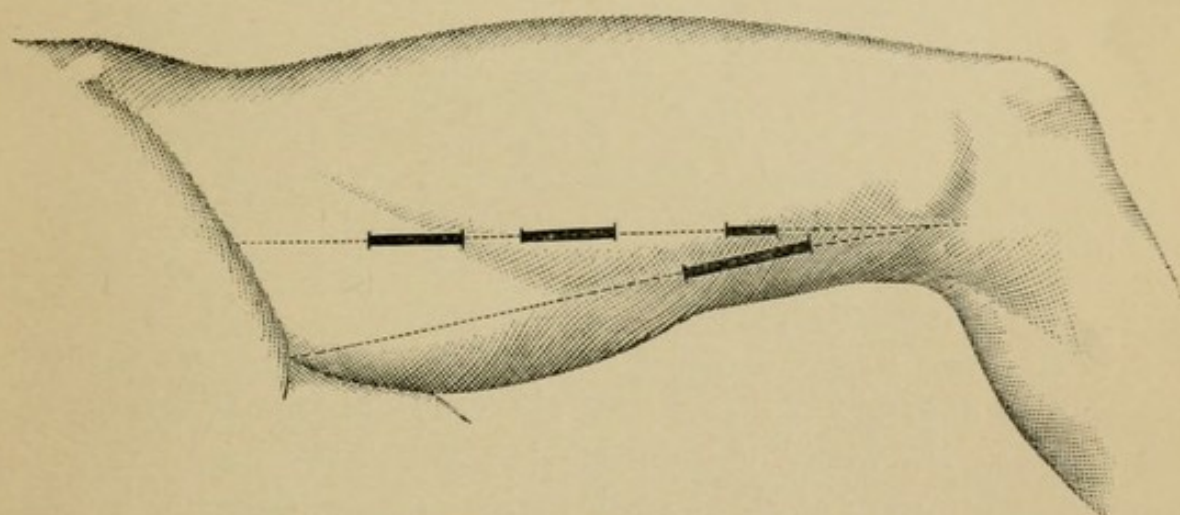
**Anatomy.**—The femoral artery is the continuation of the external iliac, and extends in a straight line from a point midway between the anterior superior spine of the ilium and the symphysis pubis to the ring in the tendon of the adductor magnus about four finger-breadths above the tubercle of insertion of that muscle on the upper portion of the inner condyle of the femur. In the first one or two inches of its course it gives off the superficial external pudic, epigastric, and circumflex ilii, and the much larger and more important profunda arteries. The *anastomotica magna* arises near its lower end. The artery is accompanied throughout by the femoral vein, which, at first, lies upon the inner side, and then becomes posterior. They are separated at first by a distinct septum, which disappears in the lower third. The anterior crural nerve emerges from below Poupart's ligament, about half an inch external to the artery; it divides up rapidly, and one of



its branches, the internal or long saphenous, enters the sheath of the vessels three or four inches below the groin, and leaves it again after the artery has entered Hunter's canal; this name being given to the condensed sheath for a short distance above and below the point where it passes through the tendon of the adductor magnus. The artery passes under the sartorius at about the junction of its upper and middle thirds.

Ligature of the femoral above the origin of the profunda has proved unsatisfactory and has been generally abandoned for that of the external iliac. The artery may be tied at any part of its course, but the point generally

FIG. 24.



Ligature of the femoral artery.

chosen is at the apex of Scarpa's triangle, next that in the middle of the thigh and, lastly, in Hunter's canal.

**Operation.** A. AT THE APEX OF SCARPA'S TRIANGLE (Figs. 22 and 24).—Make an incision three or four inches long, the center of which shall be a little above the point where the inner border of the sartorius crosses a line drawn from the middle of Poupart's ligament to the inner tuberosity of the femur. The internal saphenous vein should be out of danger on the inner side of the incision. Divide the skin, subcutaneous tissue and the fascia lata, exposing the fibers of the sartorius, which may be recognized by their direction downward and in-



ward, those of the adductors, on the contrary, being downward and outward. The limb should now be slightly flexed, the vessels recognized by the touch at the inner border of the sartorius, this muscle drawn outward and the sheath of the vessels pinched up with forceps on the outer side (the vein lying on the inner) and opened. The needle is then passed from within outward.

B. IN THE MIDDLE OF THE THIGH.—Here the vessel lies underneath the sartorius which overlaps it on both sides. The incision is made in the line above mentioned, its center being a little above the middle of the thigh; the sartorius is exposed and drawn outward after the leg has been further flexed. The vessel is then sought for, exposed and tied as before.

C. IN HUNTER'S CANAL.—Abduct and flex the thigh, and rotate it outward so as to make the adductors tense; feel for the tendon of the adductor magnus and make an incision three or four inches long, the center of which is at the junction of the lower and middle thirds of the thigh, in the direction of the tendon, which is that of a line drawn from the spine of the pubis to the tubercle on the inner condyle of the femur. Divide the skin and subcutaneous tissue carefully so as not to wound the internal saphenous vein, and then the fascia upon a director. Recognize the fibers of the sartorius and of the vastus internus which are at right angles with one another, and by pressing the former inward or the latter outward the tendon of the adductor and the curved glistening fibers arching from it to the vastus internus are exposed. If the saphenous nerve is now encountered it should be traced upward, a director passed into the orifice through which it emerges, and the aponeurosis divided upward; if the nerve is not seen it should not be sought for, but the aponeurosis should be pinched up and divided close to the tendon of the adductor. The sheath of the vessels is now opened, and the artery is separated from the closely adherent vein. The needle should be passed from within outward.



**LIGATURE OF THE POPLITEAL ARTERY.**

The artery lies very deep between the condyles of the femur, imbedded in fat, and directly covered by the vein, the walls of which are thick and stiff like those of an artery. The short saphenous vein perforates the fascia near the center of the popliteal space, and empties into the main trunk.

**Operation.**—Make an incision three or four inches long in the vertical diameter of the popliteal space, the center of which shall correspond to the point at which the ligature is to be placed. Divide the skin and cellular tissue, taking care not to injure the saphenous vein, and then the fascia to the full extent of the cutaneous incision. Flex the leg, have the sides of the wound drawn widely apart, and work down through the fat and lymphatic glands to the artery, leaving first the nerve and then the vein upon the outer side. Protecting the vein with one finger, denude the artery and pass the needle from without inward.

If for any reason it is not convenient to place the patient face downward, the upper portion of the artery can be readily reached through an incision on the inner aspect of the thigh passing between the tendon of the adductor magnus on one side, and the sartorius, semi-membranosus, and semi-tendinosus on the other. The artery is found lying close to the femur.

**LIGATURE OF THE ANTERIOR TIBIAL ARTERY.**

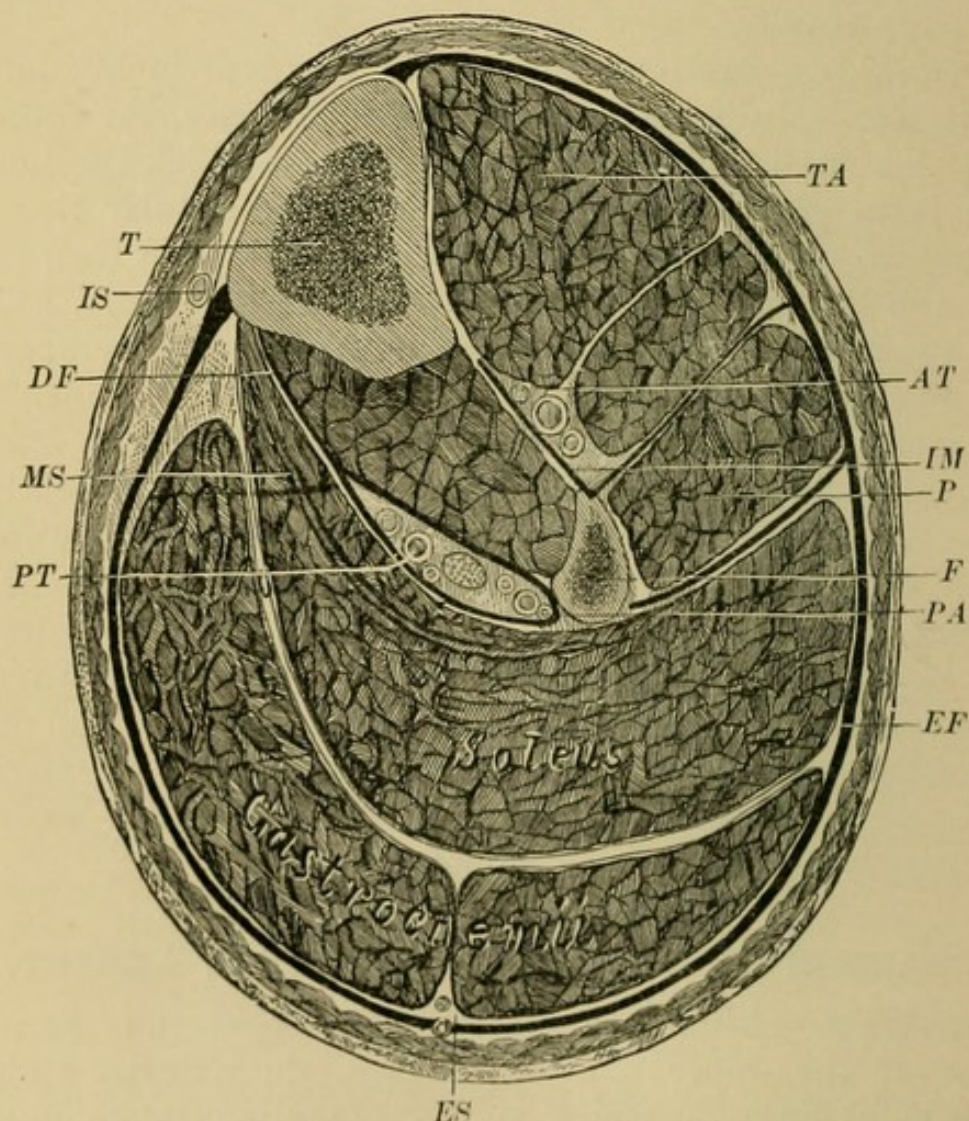
**Anatomy.**—After perforating the interosseous membrane at the upper part of the leg, the anterior tibial runs in a direction which is that of a line drawn upon the anterior aspect of the leg from the upper tibio-fibular articulation to a point midway between the malleoli. It lies at first between the belly of the tibialis anticus and that of the extensor communis digitorum upon the interosseous membrane, afterward between the tibialis anticus and the extensor proprius pollicis or their tendons upon the tibia. It is accompanied by two veins and the anterior tibial nerve, which latter lies first upon the outer



side and then ~~crosses in front to the inner side~~. It may be tied at any point in its course.

**Operation.**—Make in the above-mentioned line an incision the length of which will vary according to the depth

FIG. 25.



Transverse section of the leg, upper third. (TILLAUX.) *T.* Tibia. *F.* Fibula. *EF.* Enveloping fascia. *DF.* Deep fascia dividing to inclose *PT.* Posterior tibial artery and nerve, and *PA.* Peroneal artery. *TA.* Tibialis anticus muscle. *AT.* Anterior artery and nerve. *IM.* Interosseous membrane. *P.* Peroneus longus muscle. *IS.* Internal saphenous vein. *ES.* External saphenous vein and nerve.

at which the artery is placed. Divide the skin and cellular tissue, lay bare the fascia, and divide it along the first muscular interstice, which shows as a white line under it; make also a transverse incision through the fascia from the middle of the longitudinal one to the crest of the



tibia, so as to give more room. Flex the foot upon the leg, separate the muscles from below upward with the finger, draw them apart with retractors, isolate the artery without raising it, and pass the needle from the side of the nerve.

#### LIGATURE OF THE DORSALIS PEDIS.

This artery is the continuation of the anterior tibial, and passes through the posterior end of the first metatarsal space to the plantar aspect of the foot. It lies on the outer side of the tendon of the extensor proprius pollicis, *halluci* and is crossed in its lower portion by the inner tendon of the extensor brevis. It is covered by the skin, superficial fascia, the edge of the extensor brevis, or its tendon, and a deep fascia. Its direction is that of a line drawn from a point midway between the malleoli to the posterior end of the first metatarsal space. The incision should be in this line, and the tendon of the extensor proprius pollicis *halluci* should be left on the inner side.


#### LIGATURE OF THE POSTERIOR TIBIAL.

The posterior tibial artery in its upper and middle portions lies upon the tibialis posticus and the flexor communis digitorum, and is covered by the soleus, from which it is separated by the deep fascia. Near the ankle it is covered only by the integument and fascia. In its upper portion it can be reached by two routes: (1) the one employed by Guthrie, and approved of by Spence and Holmes, through the middle of the calf; (2) the one in more common use, from the inner side of the calf.

**Operation (GUTHRIE).**—Beginning at the lower angle of the popliteal space, make an incision six inches in length directly downward, avoiding as far as possible the superficial veins, carry this incision through the soleus, divide the deep fascia, separate the artery from the vein and nerve, which are superficial to it, and pass the needle from their side.

**LATERAL METHOD.**—Beginning in the middle of the upper third of the leg, make an incision downward from







# Indications for Amputation

## Amputations

### 1 Comp. Fr. or disloc.

1 any " with extensive comminution

ii) " laceration of terminal art.

iii) " " " major Ns

iv) " " " of soft parts - bad runf  
to interfere w. circ. as to  
result in gangrene or sloughing

v) Opening into large joint for danger of  
infection

vi) Infection threatening life

### 2. Indurably non union

i) Extensive necrosis of bone - runf to  
result in loss of function

iii) Sloughing of soft parts down to bone

iv) Where reparative proc. demands  
more than pat. can supply, so  
that the drain on genl syst is too great

v) Persistent uncontrollable deform.  
which renders limb useless

### 3. Injuries w. out Comp Fr.

i) Severe runf to prevent healing

ii) " " " to " " useful. when healed

iii) Hdd by gangrene or infect. serious to life

## Deformities

### Poly or macrodactylitis

Cicatric constr. rendering pt useless or

circumferential interfering w. bl. supply &  
wh. can be remedied by plastic oper.

Contractures after Pylpes rendering pt useless & the  
Arthrozois in some cases.



## Joint Diffic

Comp. Disloc - as above

Septic condit where after resection or other  
pat. is lying ground  
or where resection is unwise

II as <sup>1</sup> or in childr. where chief epiph.  
involved

Ankylosis rendering part useless

## Septic Conditions

Cellulitis advancing uncontrol. where pat  
life is in danger.

Osteomyelitis as <sup>1</sup>

Malignant Pustule

Aneurism - resisting other treatm.

## Malignant Growth

After former Amput. Affected by

Strangling of Flap

Necrosis of Bone

Conical Stump



## Steps in Oper.

Prep. of Part.  
Anesthesia

Means to prevent Haem.

Esmarch

Tourniquet

with this pins

Elevation of part.

Prelim. ligation of main art.

Digital compression of " "

## Regulate Flap

aggregat. " shd =  $1\frac{1}{2}$  diam. of part at  
line of amput. Distributed in 2 ways

Have cicatrix away from stump -

arrange according to strongest set  
of muscles

If of un- length have main vessels  
N. in short flap - (away fr. stump)

Muscle included where flap is low  
to aid circulation

## CIRCULAR METHOD.

### Cutting Bone

when 2 bones  
draw saw  
avoid splinters

Tie Art.

Cut Ns high

Remove Tourniquet etc

make part dry

Sew up -

Drain fr. most dependant part -

Bandage elevate part.



# Sequelae

## Immediate

a. fr. shock  
" " hem.

Sepsis

spasm

pain in amput. part.

## Indirect

Indirect hem

Sloughing of flaps. (esp. in diabetes)

Necrosis of bone

Neuralgia

Critical Stump



## PART III.

### AMPUTATIONS.

---

AMPUTATIONS may be *in continuity* (through the bone), or *in contiguity* (through a joint); to the latter the term *disarticulation* is usually applied. The methods of operation are classified as *circular*, *oval* and *flap*, and the choice of a method is determined by the disposition of the soft parts about the bone, the facility with which the joint can be opened in a disarticulation, the form of the resulting stump and the position of the cicatrix. The comparative merits of these methods and their various modifications will be discussed in connection with the different operations. They may be essentially modified by accidental circumstances and by the necessity which sometimes arises of fashioning the flap from such tissues as are available.

#### CIRCULAR METHOD.

**1st Step.**—The cutaneous incision should be made at a distance below the point where the bone is to be divided equal to two-thirds of the diameter of the limb at that point. While an assistant draws the skin firmly and evenly upward, the operator passes his hand beneath and beyond the limb and places the heel of the knife upon its upper surface, its point directed toward his own shoulder. He then sweeps the knife entirely around the limb, dividing the skin and subcutaneous cellular tissue, down to the enveloping fascia and terminating the incision at the point where it began.

**2d Step.**—*a.* The skin and cellular tissue are retracted and the muscles divided in succession, the deeper ones at



higher levels, so that the surface of section forms a cone, the apex of which is directed upward. The muscles whose origins are most distant must be cut long to allow for their greater retraction.

*or* **b. (CUTANEOUS SLEEVE.)**—The skin and cellular tissue are separated cleanly from the deep fascia and turned back over the limb, the raw surface outward. The sleeve thus formed is lengthened by drawing it up and dividing its attachments to the fascia, care being taken to include all the subcutaneous cellular tissue in it, until the dissection has nearly reached the height at which the bone is to be divided. The fascia and muscles are then cut through to the bone transversely with a single sweep of the knife, held as for making the cutaneous incision.

**3d Step. DIVISION OF THE BONE.**—The soft parts being drawn up and protected by a muslin band four inches wide and two feet long, split for half its length so as to pass on each side of the bone (called the *retractor*), and the periosteum having been divided circularly with the knife along or a little below the line to be traversed by the saw,<sup>1</sup> the operator places the heel of the saw upon the bone, steadies its edge with the thumb-nail of his left hand, and draws it slowly toward himself, cutting a deep groove in the bone; he then completes the division with rapid strokes of the instrument, while the limb is firmly held by two assistants so as to prevent binding of the saw or splintering of the bone.

If there are two bones the retractor should be split into three instead of two parts, and the central one passed between the bones. The saw should be first applied to the larger bone, and, after cutting a deep groove in it, should be inclined backward or forward, so as entirely to divide the second before completing the division of the first.

Gigli's roughened wire, which is so convenient a sub-

<sup>1</sup>The plan sometimes employed of stripping up a sleeve of periosteum and dividing the bone at its base is without value in the adult, and is highly objectionable in the young, because it is likely to lead to the production, within the periosteal sleeve, of a spike of bone. This is the common cause of "conical stump," not the disproportionate growth of the bone at the epiphysis, as has been alleged.



stitute for the chain saw, may be used for the division of even the largest bones of the limbs, and is sometimes more convenient than a saw because of difficulty in keeping the soft parts out of the way of the latter. In using the wire it should be held taut and in a widely-opened angle about the bone. The slight charring of the flesh as the wire becomes heated does no harm ; it can be prevented by pouring water upon the wire.

#### OVAL METHOD.

A scalpel is used instead of the amputating knife ; the incision is commenced at the level at which the bone is to be divided, is carried downward on one side, across the back of the limb, and upward on the opposite side to the point at which it began. The details will be given in connection with certain disarticulations to which this method is especially applicable.

#### FLAP METHOD.

The flaps may be single or double, antero-posterior, bilateral, long rectangular (Teale), or skin flaps with circular division of the muscles (modified flap operation). They may be made by transfixion or from without inward. In making a flap by transfixion it is well first to mark its outline by an incision through the skin and cellular tissue with a scalpel, as otherwise there is danger of making its point too narrow or its edges jagged. The point of the amputating knife is then entered at the nearest angle of the incision and passed through to the other, hugging the bone on its way, and the cut made steadily downward to the apex, with sawing movements of the knife. It is then reëntered and brought out at the same points, but passing on the opposite side of the bone, and the second flap cut in the same manner as the first. The fibers on each side of the bone which have escaped are then divided, the retractor applied, and the bone sawed through as above.

In cutting a flap from without inward the scalpel must be entered at one of the angles of the base of the proposed



flap, carried along a curved line down to the apex of the flap, and thence up to the other angle of the base. The presence of a tumor, or injury to, or disease of, the soft parts may render it necessary to modify the shape of the flap or vary the obliquity of the incision, so as not to include any unfit tissue in the former.

**Skin Flaps and Circular Division of the Muscles.**—In this operation the flaps include only the skin and subcutaneous cellular tissue dissected off from the deep fascia; the latter and the muscles are divided transversely by a sweep of the knife at the base of the flap, the retractor applied, and the bone cleaned and divided a little higher up.

**Long Anterior Flap.**—An anterior flap, its length somewhat greater than the antero-posterior diameter of the limb at its base, is cut by transfixion, or from without inward; the posterior muscles and segment of skin are cut straight across a little below the point of division of the bone, and the anterior flap brought down to cover their cut surface. This method furnishes a good covering for the bone, and a well-placed cicatrix.

In every amputation it is well to dissect out the main nerve trunks, and cut them off high up between the muscles, so that their ends may not become imbedded in the cicatrix.

The choice of one or another method will often be determined by the anatomical and pathological circumstances of the case. When any one may be used, the preference is usually given now to the skin flap with circular division of the muscles.

**Teale's Method.**—In the method to which Mr. Teale's name has been given a very long rectangular anterior flap, comprising half the circumference of the limb and all the tissues down to the bone, is made and doubled back upon itself, thus furnishing a thick pad for the bone and a posterior cicatrix. The method of operating is as follows: (Fig. 41, B) A rectangular anterior flap (posterior in the forearm), equal in length and breadth to half the circumference of the limb at the base of the flap, is marked out by one transverse and two parallel longitudinal incisions,



the latter involving only the skin, the former being carried down to the bone. The longitudinal incisions should be so placed that the principal vessels and nerves will not be included in this flap, but in the posterior one, which is also bounded by a transverse incision carried down to the bone, and is only one-fourth as long as the anterior one. The two flaps are now in turn dissected up close to the bone, and the saw applied at their base. After the vessels have been secured the long flap is doubled back upon itself, and its square end fastened to that of the other with sutures; two or three points of suture are also required to keep the sides of the short flap and of the reversed portion of the long flap in contact with the rest of the latter.

It is found that by retraction of the short posterior flap the cicatrix is drawn up behind and out of the way of the bone, and that a soft mass without any large vessels or nerves is the result of the partial atrophy of the long flap and forms an excellent, non-sensitive stump. The principal objection to this method, one which greatly restricts its applicability, is the great length of the anterior flap, which can be obtained in many cases only by dividing the bone at a much higher point than would otherwise be necessary.

### AMPUTATION OF THE FINGERS.

**Phalanges.**—When the injury or disease is limited to one or two fingers and is of such a nature that the member will be useless, if preserved, the affected phalanx or finger should be removed without hesitation; but usually it is desirable to save as much as possible of the parts and, therefore, whenever a choice can be made amputation in continuity is to be preferred to disarticulation higher up. The incisions should be so arranged that the cicatrix will not lie upon the palmar surface, and for this, as well as for anatomical reasons, the principal flap should be taken from the flexor aspect. No special directions are required for amputation or disarticulation of the middle and distal phalanges. For amputation through the shaft the incision may be circular with a longitudinal ad-



dition one-third of an inch long on each side, or the single anterior flap by transfixion may be used. In disarticulation it is best to enter the joint from the dorsal side with a narrow-bladed knife and cut the anterior flap by carrying the knife through the joint and then forward, hugging the bone.

It must be remembered that the folds on the palmar surface of a finger do not correspond exactly to the joints; the first being half an inch beyond, the middle one a line above, and the distal one a quarter of an inch above the articular surfaces, and also that the prominence of a knuckle when the finger is flexed is formed entirely by the head of the proximal and not by the base of the distal phalanx. When the tissues have not become thickened and infiltrated the articular depressions can be felt upon the sides.

**Amputation Through the Metacarpo-phalangeal Articulation.**—The articular depression can be found very easily by passing the thumb and forefinger along the sides of the finger, especially if the latter be at the same time drawn forcibly away from its metacarpal bone.

The incision should be commenced over the dorsum of the metacarpal bone a quarter of an inch above the articulation, carried through the interdigital web, and then back on the palmar face to a point a quarter of an inch above the flexor fold (Fig. 28, *C*); a similar incision, beginning and ending at the same points, is made on the other side of the finger, the flaps dissected back, the lateral ligaments divided while the finger is drawn first to one side and then to the other so as to facilitate access to them and at the same time make them tense, and then the tendons and the remainder of the capsule divided as the finger is withdrawn.

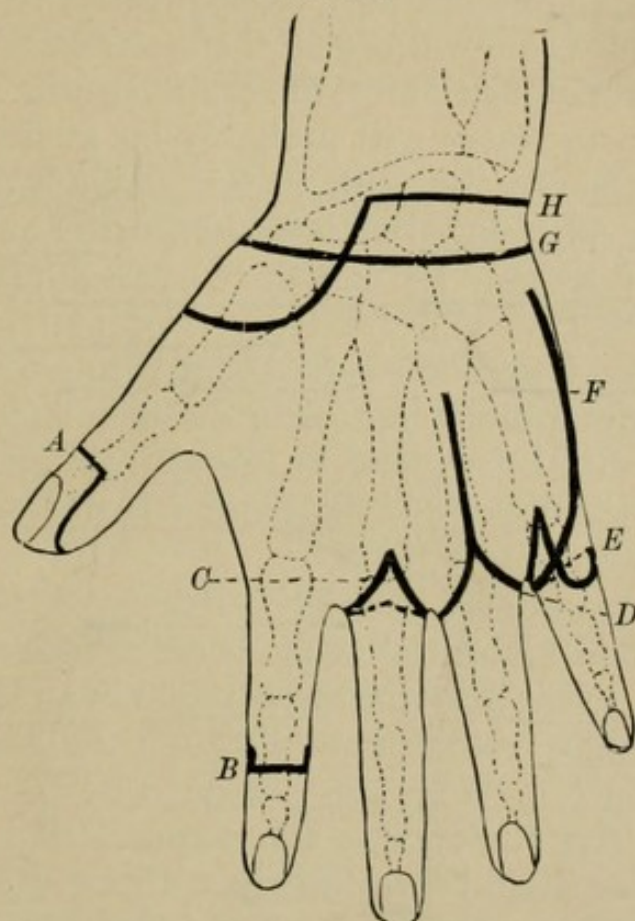
Or an incision may be made only on the side corresponding to the right hand of the operator, the flap dissected back to the joint, the lateral ligament divided, the knife carried transversely through the joint, dividing the tendons and the other lateral ligament, and the other flap cut from within outward, care being taken to make it sufficiently broad.



The head of the metacarpal bone should be removed only in cases where it is more desirable to diminish the deformity than to preserve the strength of the hand.

The incisions may be advantageously modified for the index and little fingers by making a full lateral flap on the free side and carrying the incision transversely across

FIG. 28.



*A.* Disarticulation of the phalanx, anterior flap. *B.* Amputation in continuity, circular. *C.* Metacarpo-phalangeal disarticulation. *D.* Amputation of a metacarpal bone in continuity. *E.* Disarticulation of little finger. *F.* Disarticulation of fifth metatarsal. *G.* Amputation of wrist, circular. *H.* Amputation of wrist. (DUBRUEIL.)

the palmar surface to the angle of the web, and thence obliquely back to the knuckle (Fig. 28, *E*).

### AMPUTATION OF THE METACARPAL BONES.

As the articulations of the first and fifth metacarpal bones with the carpus do not communicate with the other and larger synovial sacs, these bones may be entirely re-



moved without much danger of setting up inflammation within the wrist-joint, but in the case of the other three amputation in continuity is preferable to disarticulation in unclean cases. The relations of the synovial sheaths of the flexor tendons are also of importance in the operation. There is no communication between the main sheath in the palm of the hand and the sheaths of the index, middle, and ring fingers, and consequently, if those tendons are divided as low down as the metacarpo-phalangeal articulation, inflammation of the main sheath with all its disastrous consequences will probably be avoided.

The incisions are the same as for amputation through the metacarpo-phalangeal articulation, with a prolongation upward as far as may be necessary over the back of the bone (Fig. 28, *D*). After its posterior and lateral surfaces have been bared, the bone is cut through with pliers at the point determined on (or is disarticulated from the carpus), the distal fragment is raised from its bed, and, beginning at the upper end, its palmar surface is carefully separated from the soft parts.

In disarticulation of the fifth metacarpal, the incision should be made along the inner border of the hand, and carried down to the bone between the skin and the abductor minimi digiti rather than through the fibers of the latter (Fig. 28, *F*). This gives easier access to the palmar ligaments uniting the bone to the carpus. The lower end of the incision should form a loop with its center in the interdigital web, and its point on the line of the knuckle.

### AMPUTATION AT THE WRIST.

#### (RADIO-CARPAL DISARTICULATION.)

**Circular Method** (Fig. 28, *G*).—While an assistant retracts the skin upon the forearm, the operator sweeps his knife transversely around the wrist, half an inch below the point of the styloid process of the radius. The skin and as much cellular tissue as possible are divided and dissected back as far as the joint, which is then opened by entering the point of the knife just below the styloid



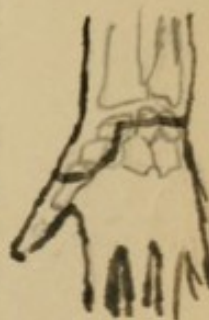process of the radius, and the disarticulation completed while the hand is drawn firmly away from the arm.

**Antero-posterior Flaps.**—The absence of muscular fibers at the wrist deprives this method of most of the advantages which it offers at other points, and the projection on the palmar surface of the trapezium and pisiform bones renders its execution difficult and makes it practically identical with the circular method supplemented by lateral incisions. It should be reserved for cases in which the skin is so infiltrated that it cannot be readily dissected back.

An incision curved downward is carried across the back of the wrist from one styloid process to the other, the flap dissected up, the hand flexed forcibly, the extensor tendons divided, the joint opened beneath them and the palmar flap, which should extend as far down as the base of the metacarpal bones, cut from within outward.

Or the palmar flap may be made from without inward, or by transfixion, before the joint has been opened.

**External Lateral Flap.**—Dubrueil<sup>1</sup> (Fig. 28, *H*). The hand is pronated and the operator makes a curved incision, which, beginning on the dorsal aspect a quarter of an inch below the radio-carpal articular line, at the junction of the outer and middle thirds, passes downward, crosses the outer side of the first metacarpal bone at its center and returns to a point on the palmar surface opposite that at which it began. Its two ends are then joined by a transverse incision passing around the inner side below the end of the ulna. The external flap is dissected up, the joint opened at the radial side and the disarticulation completed.



## AMPUTATION OF THE FOREARM.

The forearm may be divided, with reference to surgical considerations, into upper, middle, and lower thirds. Its shape is cylindrical near the elbow and gradually flattens and narrows toward the wrist. The lower half of the radius and the whole length of the ulna are subcu-

<sup>1</sup> Médecine Opératoire, p. 171.



taneous. The coverings of the lower third are composed almost exclusively of skin and tendons, while thick muscular masses cover the upper two-thirds, especially on the anterior aspect. The absence of suitable coverings in the lower third and the presence there of so many synovial sheaths, the inflammation of which might give rise to dangerous complications, led older surgeons to advise strongly against amputating at this part. But these objections have been greatly diminished by modern methods of treatment which favor rapid uneventful healing and so, unhampered by any other considerations than those established by the extent of the injury or disease that necessitates the operation, we are free to save as much as possible of the limb. Every additional inch adds to the usefulness of the stump.

For the reasons stated, the only method applicable to the lower third is the circular one, and if the conicity of the limb or the infiltration of the parts should otherwise render it impossible to carry the dissection of the cutaneous sleeve to a sufficient height, the circular incision must be supplemented by a short longitudinal one in front. The division of the tendons should be on the same level with that of the bone, and is best accomplished by passing the knife under them, and cutting directly outward.

In the middle third the difficulty of dissecting a cutaneous sleeve is likely to be still greater, and has led to general rejection of the circular method. As lateral flaps are impossible, and the bones have a tendency to project at the angles if antero-posterior flaps are made, it is best to use short lateral skin flaps with short muscular flaps by transfixion (Tillaux), or circular division of the muscles at successively higher levels, and still higher division of the bones.

High up in the upper third, where the position of the bones is more central, and thick muscular masses lie upon the sides, the short flaps should be lateral.

#### AMPUTATION AT THE ELBOW-JOINT.

The guides to the articulation are the epitrochlea on the inner, the epicondyle and the head of the radius on the



outer side. The smooth rounded prominence formed by the latter can be readily felt about half an inch below the epicondyle; and the interarticular line starting from it *(hind of head)* passes at first transversely and then downward and inward toward a point an inch below the epitrochlea, and forms an angle, opening inward, with the transverse diameter of the lower end of the humerus. It is therefore unnecessary to expose the epicondyle and epitrochlea in disarticulating; and these relative positions should be constantly kept in mind during the operation. The skin is freely movable in front, but is adherent to the ulna behind.

The methods in common use are the anterior flap, lateral flap, and circular.

**Anterior Flap.**—The joint may be opened (*a*) from behind, or (*b*) from in front.

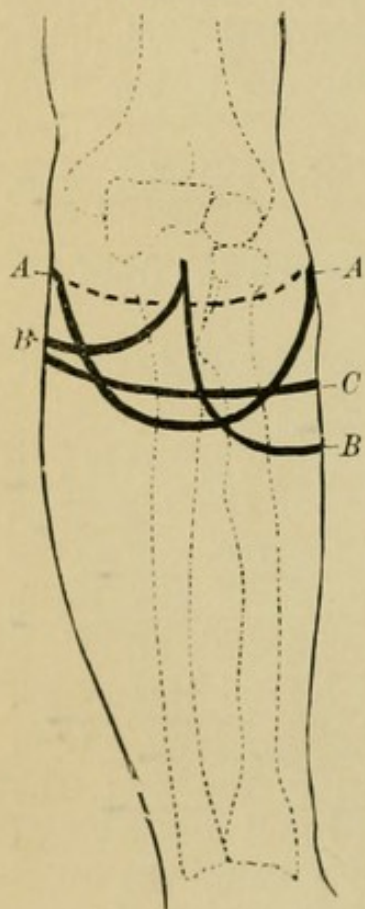
*a. FROM BEHIND.* (*Sédillot.*)—The forearm is flexed, and an incision, slightly convex downward and interesting only the posterior third of the circumference, is made one and a-half inches below the tuberosities of the humerus. The skin is dissected up to the tip of the olecranon, the tendon of the triceps divided, the point of the knife passed into the joint and carried first to one side and then to the other, cutting the posterior and lateral ligaments. A longitudinal incision two and a-half inches long is then carried downward from the outer end of the first, the forearm, still flexed, is pressed backward and inward, and the disarticulation readily completed by passing the knife through the joint, and cutting down and out on the anterior aspect while the skin is forcibly retracted.

*b. FROM IN FRONT.* (*Fig. 29, A.*)—The flap may be made by transfixion, or from without inward; in either case it should be at least three inches long, and its base should be parallel to and three-quarters of an inch below a line drawn through the epicondyle and the epitrochlea. The posterior incision should be slightly convex downward, and should begin and end at the same points as the anterior one; it is made from without inward, not by transfixion.



The head of the radius is then sought for, and the joint opened by entering the knife between it and the humerus and completely dividing the external lateral ligament. The capsule is divided in front by passing the point of the knife along the edge of the ulna over the coronoid process to the internal lateral ligament, which should be cut as high as possible. The olecranon is disengaged

FIG. 29.



Amputation at the elbow-joint. A. Anterior flap. B. External flap. C. Circular method.

from the humerus by drawing it down forcibly, the attachment of the triceps divided, the knife passed behind the bone, and the remaining tissues divided from within outward.

**Lateral Flap.** (Fig. 29, B.)—An external flap four inches long is made by transfixion from a point in the median line in front, a finger's breadth below the bend of the elbow; or from without inward by an incision beginning at the same point and ending half an inch higher on the posterior face of the ulna. A second incision is made transversely across the inner side of the arm about an inch below the upper end of the first. The radio-humeral joint is opened and the disarticulation completed as before.

Instead of a single external flap, two lateral flaps may be made, but the external should be half an inch longer than the internal one.

**Circular.** (Fig. 29, C.)—An incision, transverse or a little lower on the outer than on the inner side, is made about the limb three and a-half inches below the epitrochlea and carried down to the enveloping fascia; the cutaneous sleeve is dissected up for about an inch and the muscles divided transversely at its base. They are then retracted forcibly by an assistant so as to form a cone with its apex directed downward and the deep mus-



cles of the anterior aspect are again divided transversely on a level with the radio-humeral articulation, the external lateral ligament being included in the incision and the joint thereby opened. The disarticulation is completed as before described.

### AMPUTATION OF THE ARM.

This may be performed at any point below the attachments of the muscles of the axilla. Disarticulation at the shoulder is preferable to amputation in continuity above these attachments. As the bone is centrally placed and well covered on all sides, any one of the usual methods of amputation may be employed. As a general rule the biceps should be divided at a lower level than the other muscles because it is not adherent to the humerus and, therefore, retracts more than the others. The circular incision should be half an inch lower on the inner than on the outer side. In muscular subjects flaps should be cut rather thin and, when possible, it is better that the main artery should be in the posterior flap. 12. an an

### AMPUTATION AT THE SHOULDER-JOINT.

GENERAL CONSIDERATIONS.—The exposed position and great accessibility of the head of the humerus have led to the suggestion of many operative methods, most of which can be performed with much ease and regularity upon the cadaver and yield good results in actual practice. But as the operation is usually rendered necessary by malignant disease or compound fracture of the humerus, under circumstances which make it very difficult, if not impossible, to follow regular methods, it is more important to be familiar with the anatomy of the parts and the general principles governing all the methods than with the details of the different ones.

The size of the axillary artery and the difficulty of efficiently compressing the subclavian make the management of the artery an element of prime importance in this operation. The joint should be approached from the outer side,



and the artery divided from within outward after disarticulation, an assistant passing his thumb into the wound above the knife and compressing the vessel before it has been cut. Or the artery may be exposed during the operation and tied before it is cut.

Pressure upon the subclavian may be made by the thumb of an assistant standing behind the patient, or by a rubber cord tightly encircling the axilla, scapula, and clavicle. To prevent slipping of the cord a long mattress-needle is sometimes introduced near the tip of the coracoid process, carried through the capsule of the joint, grazing the head of the humerus, and made to emerge posteriorly near the axillary border of the scapula. The cord is then applied circularly on the proximal side of this skewer.

Wyeth<sup>1</sup> uses two pins, one passing through the anterior axillary fold and piercing the tendon of the pectoralis major from above downward, the other from before backward just below the acromion process through the fibers of the deltoid.

The subsequent retraction of the pectoralis major and latissimus dorsi tends to gaping of the wound and the formation of a broad, unsightly, triangular cicatrix. This must be met by retaining all the skin for the first two or three inches in the flaps, not allowing the incisions to diverge from one another until the end of the flap is nearly reached. This precaution also insures ample covering for the projecting acromion. The outer flap should comprise the entire thickness of the deltoid so that the gap left by the head of the humerus may be properly filled, and it should be dissected up close to the bone so as to avoid injury to the trunk of the posterior circumflex artery.

Instead of attempting to separate the capsule at its attachment to the upper edge of the glenoid cavity by passing the point of the knife under the acromion, it is better to divide it near its center by drawing the edge of the knife across the upper surface of the head of the humerus; and in all incisions beginning between the acromion and coracoid process the point of the knife should be passed

<sup>1</sup> Jour. Am. Med. Assoc., February 7, 1891.



directly down to the humerus so as to divide the strong fibrous arch connecting the two processes.

**Oval Method** (Baron Larrey). (Fig. 30, A). — A longitudinal incision involving all the tissues down to the bone is made on the outer aspect of the shoulder from the edge of the acromion to a point one inch below the neck of the humerus, and an oval one interesting the skin only is then carried from its lower end around the arm, crossing its inner side about an inch below the border of the axilla. The flaps thus marked out are dissected up, the anterior one carefully, until the tendon of the pectoralis major is exposed and divided close to its insertion, the posterior one more boldly, but close to the bone, so as to avoid injury to the trunk of the circumflex artery. The capsule is freely divided across the head of the humerus, the arm rotated inward and then outward, so as to facilitate division of the tendons of the articular muscles, which is best accomplished by cutting directly upon the tuberosities, the humerus thus liberated is thrown outward by adducting the elbow, the knife is passed behind it and carried down and out through the cutaneous incision on the inner side, while an assistant compresses the artery in the wound.

After cutting through the tendon of the pectoralis major, Verneuil isolates the biceps and coraco-brachialis with his fingers, divides them, seeks for the artery, and ties it rather high up before continuing the operation.

It is sometimes not easy to reach and divide the broad tendon of the subscapularis; and when the humerus is broken it is, of course, impossible to use it as a lever to force the head of the bone out of the socket, and this part of the operation may thereby be rendered somewhat difficult. This and the hemorrhage from the branches of the posterior circumflex are the principal objections to this method, which has, nevertheless, yielded excellent results.

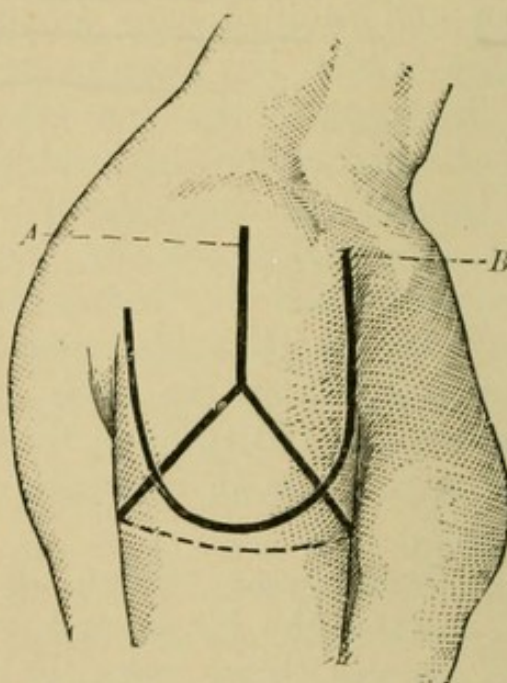
The articulation is uncovered more freely by any of the double flap methods in which an external flap is fashioned out of the deltoid muscle. Of these the Lisfranc method



may be taken as the type, premising only that while the opening of the articulation by transfixion is very easy of execution upon the cadaver, it is sometimes impossible upon the living subject, and inapplicable to cases of malignant disease of the humerus. Under such circumstances the flaps must be made by dissection from without inward.

**Double Flap Method (Lisfranc).** (Fig. 30, *B.*)—Right shoulder. While the arm is abducted the surgeon enters

FIG. 30.



Disarticulation at the shoulder. *A.* Oval method. *B.* Method by double flaps

the point of a two-edged amputating knife at the outer side of the coracoid process, carries it across the outer aspect of the head of the humerus, and brings it out a little below the posterior border of the acromion. He then raises the fibers of the deltoid with his left hand, works the knife downward around the head of the bone, and cuts a broad flap about five inches long. In this manœuvre the joint should be opened at its upper part, the tendons of the supra-spinatus and long head of the biceps entirely divided, and those of the subscapularis and infra-spinatus partly divided. The arm is then adducted, the knife passed



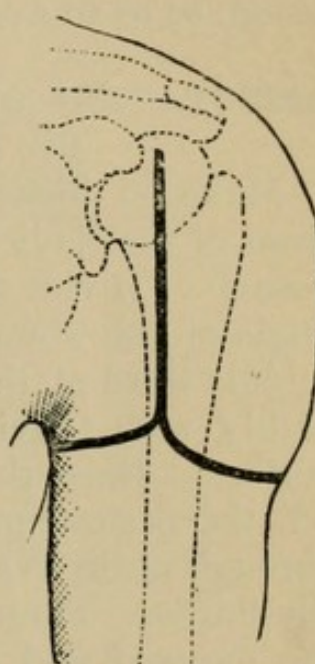
through the joint to the inner side, and a long inner flap cut from within outward.

**Left shoulder.** The knife is passed in the opposite direction, that is, from below the acromion behind to the coracoid process in front, and the operation completed as on the right side.

**Spence's Method.**—Prof. Spence introduced a method, for which he claims the following advantages: 1st. The better form of the stump. 2d. The division of the posterior circumflex artery only in its terminal branches in front. 3d. The great ease with which disarticulation can be accomplished. Another advantage is that an operation for excision of the head of the humerus can be easily transformed into a disarticulation by its means, should that be found necessary.

He describes the operation as follows (Fig. 31):<sup>1</sup> “The arm being slightly abducted, and the humerus rotated outward, I cut down upon the head of the humerus immediately external to the coracoid process, and carry the incision down through the clavicular fibers of the deltoid and pectoralis major muscles, till I reach the humeral attachment of the latter muscle, which I divide. I then, with a gentle curve, carry my incision across and fairly through the lower fibers of the deltoid toward, but through, the posterior border of the axilla. Unless the textures be much torn, I next mark out the line of the lower part of the inner section by carrying an incision through the skin and fat only, from the point where my straight incision terminated, across the inside of the arm to meet the incision at the outer part. If the fibers of the deltoid have been thoroughly divided, the flap, together with the posterior cir-

FIG. 31.



Disarticulation at the shoulder. Spence's method.

<sup>1</sup> Lectures on Surgery, 2d ed., Vol. II., p. 662. Edin., 1876.



cumflex artery, can be easily separated by the point of the finger from the bone and joint, and drawn upward and backward so as to expose the head and tuberosities without further use of the knife. The tendinous insertions of the capsular muscles, the long head of the biceps, and the capsule are next divided by cutting directly on the bone. Disarticulation is then accomplished, and the limb removed by dividing the remaining soft parts on the axillary aspect.

“In cases where the limb is very muscular I dissect the skin and fat from the deltoid at the lower part and then divide the muscular fibers higher up by a second incision, so as to avoid redundancy of muscular tissue.”

#### **AMPUTATION OF THE ARM, SCAPULA, AND PART OR ALL OF THE CLAVICLE.**

Make an incision along the outer two-thirds of the front of the clavicle ; carry the incision through the periosteum. Divide the periosteum transversely at the inner angle of the wound, strip it as far as possible from the middle third of the bone and saw through the bone, preferably with Gigli wire, at the inner end of this denuded surface. Raise the sawn end of the outer fragment, strip off the periosteum from its deeper surface and saw it through again at about the junction of the outer and middle thirds. Through the gap thus made the great vessels are exposed and divided between separate double ligatures for each, close to the first rib.

A second incision is made from the center of the first downward and outward, along the groove between the pectoral and deltoid muscles, to the junction of the anterior axillary fold with the arm ; thence across the inner surface of the arm to the junction of the posterior axillary fold with the arm and thence downward and inward between the teres major and latissimus dorsi to the inferior angle of the scapula.

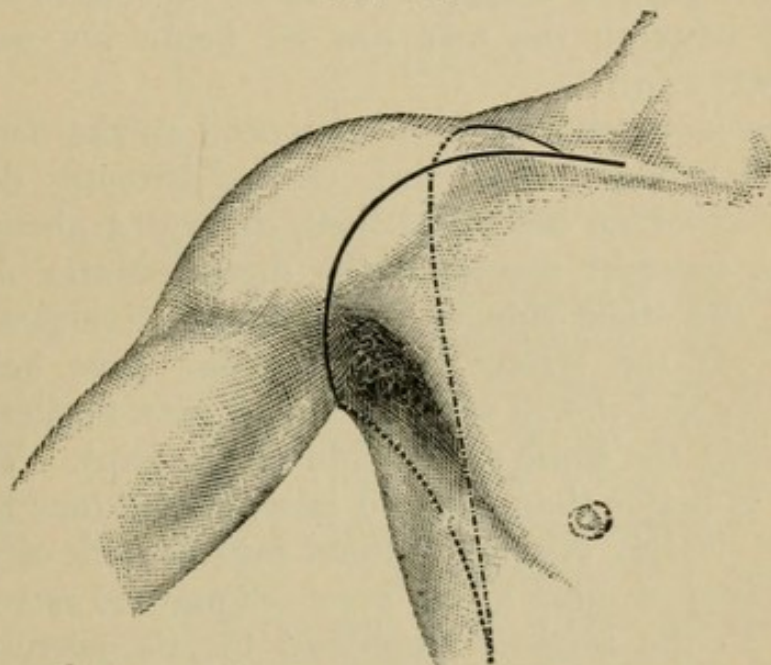
The skin and subcutaneous tissue over the anterior fold of the axilla is raised and the pectoralis major cut where it begins to become tendinous.

The pectoralis minor is severed close to the coracoid



process and after division of the cords of the brachial plexus at the level where the great vessels were cut, only the muscles attached to the trunk and scapula retain the limb. The patient is then turned toward the opposite side. Another incision, through the skin and subcutaneous tissue, is carried from the outer end of the first clavicular incision at the acromio-clavicular joint, across the spine of the scapula to terminate in the second incision at the inferior angle of the scapula. The skin and subcutaneous tissue on the inner side of the incision are raised

FIG. 32.



Amputation of the arm, scapula and part or all of the clavicle. (The dotted lines represent the part of the incision which lies on the posterior aspect of the body.) (TREVES.)

sufficiently to permit division of the clavicular and scapular attachments of the trapezius.

Then, starting at the outer end of the superior border of the scapula, the omohyoid, levator anguli scapulæ, rhomboideus minor and major, and the serratus magnus are divided in this order close to the bone, and the limb detached.

The early ligation of the subclavian vessels prevents any great loss of blood. The sutured wound forms an oblique line running from above downward, outward, and backward.



**AMPUTATION OF THE TOES.**

The different phalanges of the toes may be removed by the same methods, and at the same points, as those of the fingers, but experience has shown that, except for the great toe, it is better to disarticulate at the metatarso-pharyngeal joint, the preservation of a portion of a toe being a source of discomfort rather than an advantage. In the case of the great toe it is desirable to save as much as possible, and amputation in continuity is to be preferred to disarticulation. In all operations upon the foot the incisions should be so arranged that the cicatrices will not occupy the plantar surface. It must be remembered that the web between the toes lies far below the metatarso-phalangeal joint.

The incision should be commenced on the dorsal surface a little above the joint, carried directly down the bone for about an inch, and then, diverging abruptly into the web, straight across in the digito-plantar fold, and back on the other side to the point of divergence (Fig. 33, A). If the strong flexor tendons have been completely divided it will then be found easy to disarticulate by entering the knife at the side of the joint. This oval incision is better than the two lateral semilunar flaps, because its cicatrix does not extend into the sole of the foot.

*The distal phalanx of the great toe* may be removed according to the methods described for the corresponding part of the thumb and fingers (p. 75).

*Disarticulation of the great toe* at the metatarso-phalangeal joint may be done according to the method just described for the other toes, or with a large internal flap. In the latter case an incision (Fig. 34, A) is begun on the outer side of the extensor tendon just below the joint, and carried straight down to the head of the first phalanx. From its lower end a transverse incision is carried around the inner side of the toe to the outer edge of the flexor tendon, and, the toe being then forcibly extended, a plantar excision is carried from the end of the transverse incision (Fig. 34, B), along the outer side of the flexor tendon to the digito-plantar fold, and thence trans-

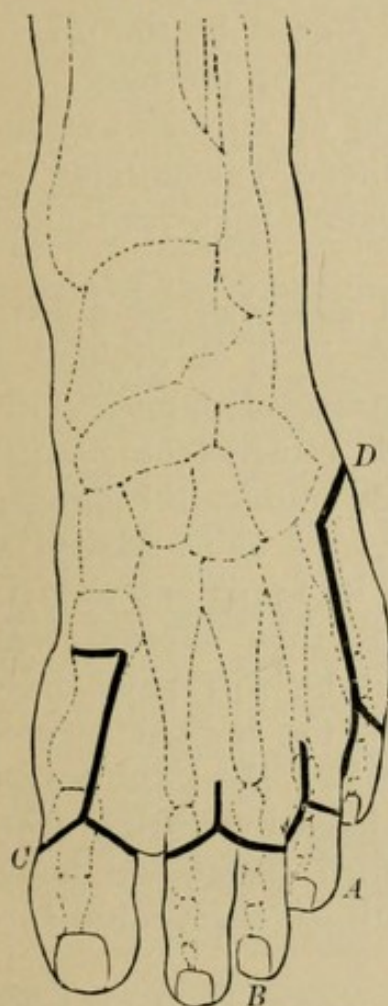


versely around the outer side of the toe to rejoin the first incision near its center.

The internal flap is then dissected from below upward, the extensor tendon divided high up, the lateral ligaments divided, the knife passed through the joint, and the remaining soft parts cut from within outward.

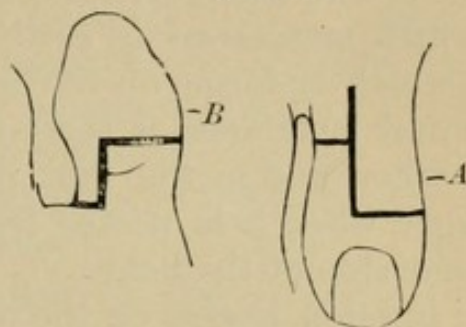
The same incisions made somewhat lower down may be

FIG. 33.



Amputation of the toes and metatarsal bones.

FIG. 34.



Amputation of the great toe.

used for amputation in continuity, but usually the shape and position of the flaps will be determined by the nature and extent of the injury which makes the operation necessary.

*Amputation of the Two Adjoining Toes.*—The dorsal incision should begin in the intermetatarsal space just above the level of the joint (Fig. 33, B), extend down to the beginning of the web, diverge obliquely to the adjoining web, cross the plantar surface in the digito-plantar fold of both toes, and return through the other

adjoining web to the point of divergence. Each toe is then removed separately after division of its tendons and lateral ligaments.

#### AMPUTATION OF A METATARSAL BONE.

Amputation in continuity is much to be preferred to disarticulation on account of the extent of some of the



synovial sacs, the attachments of certain muscles, and the importance of some of the bones in preserving the relations of the others. The synovial sac which forms part of the articulation between the first cuneiform and first metatarsal bones is isolated from the others, but the attachment of the peroneus longus to the base of the latter bone renders its preservation especially important. There is also a separate synovial sac for the articulation between the cuboid and the fourth and fifth metatarsals. The base of the fifth metatarsal is easily recognized by the prominence which it forms on the outer side of the foot; that of the first metatarsal is three-fourths of an inch anterior to the other, and is the first prominence encountered by the finger when it is passed from before backward along the inner side of the bone.

The incision begins on the dorsal aspect at, or a little below, the point at which the bone is to be divided, is carried down well below the metatarso-phalangeal joint (Fig. 33, *C*), diverges into the web, crosses the plantar surface in the digito-plantar fold, and returns through the other web to the point of divergence. A short transverse incision is made through the skin at its upper end to facilitate division of the bone, which is then effected with cutting pliers or a Gigli wire after the soft parts have been separated on both sides. The toe is then pressed backward, the cut end of the bone raised, the knife passed behind it, and the operation completed by cutting from within outward. The first and fifth metatarsal bones should be cut obliquely so as to diminish the prominence of the stump.

For *disarticulation of the first or fifth metatarsal bones* the only modification needed is to begin the incision at a correspondingly higher point—at or a little below the tarso-metatarsal joint (Fig. 33, *D*). After the flaps have been dissected up, the joint is opened by dividing the dorsal and interosseous ligaments, and the bone raised and separated from the remaining soft parts.



**DISARTICULATION OF ALL THE METATARSAL  
BONES. (TARSO-METATARSAL DISAR-  
TICULATION; LISFRANC'S OR  
HEY'S AMPUTATION.)**

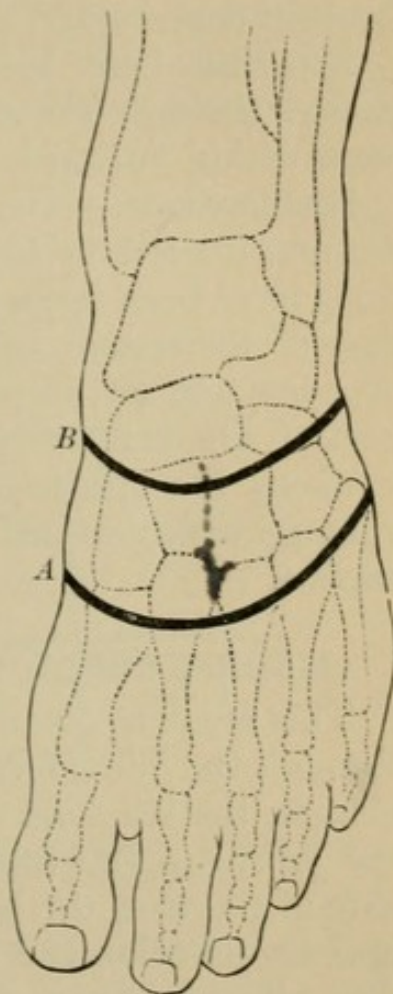
The position and general direction of the tarso-metatarsal articulations, as well as the peculiarity presented by the base of the second metatarsal bone, are sufficiently well shown in Fig. 35 to render a detailed description unnecessary. The guides to the articulation are the projecting bases of the first and fifth metatarsal bones.

The skin being retracted by an assistant, the surgeon makes with a scalpel a curved incision across the dorsum of the foot from the base of the fifth to the base of the first metatarsal bone. (For the left foot the direction of this incision should be reversed.) The incision should involve the skin only; its center should lie half an inch or more below the center of the line of the articulations, and it should begin and end upon the sides of the foot at their junction with the sole. (Fig. 35.)

A plantar flap should then be marked out by a curved incision beginning and ending at the same points as the first and crossing the sole near the origin of the toes.

The dorsal skin flap is then dissected back to the line of the articulation, the tendons and muscular fibers of the short extensor divided, the joints between the fifth, fourth, and third metatarsals, and the corresponding bones of the tarsus opened successively from the outer side, and that between the first metatarsal and first cuneiform from the inner side. With the point of the knife

FIG. 35.



A. Lisfranc's amputation. B. Chopart's amputation.



directed transversely across the dorsal aspect of the base of the second metatarsal, the joint between that bone and the second cuneiform is sought from below upward, and after it has been found and opened the interosseous ligaments uniting the second to the first and third metatarsals are divided by thrusting the point of the knife well down between them, the flat of its blade being held parallel to the long axis of the foot, and the toes being forcibly depressed.

After the bone has been thus disengaged, the knife is passed through the articulation, and the plantar flap cut from within outward.

**Modifications.**—The plantar flap may be cut (1) from without inward, or (2) by transfixion, before the articulations have been opened. Instead of disarticulating it, the base of the second metatarsal may be cut off with pliers or a saw and left in place. Hey sawed off the projecting part of the first cuneiform after disarticulating, but this weakens the attachment of the tibialis anticus, a disadvantage which is not offset by the improvement in the outline.

#### **MEDIO-TARSAL OR CHOPART'S AMPUTATION.**

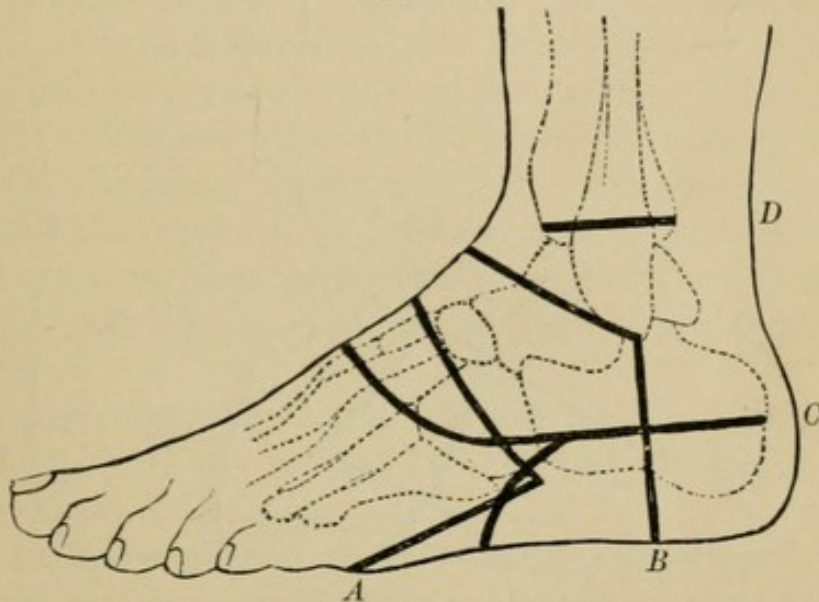
This name is given to the operation of disarticulation through the joints formed by the astragalus and calcaneum behind, the scaphoid and cuboid in front. The guides to the joint are the tubercle of the scaphoid on the inner side of the foot, the head of the astragalus on the dorsum and the anterior end of the calcaneum on the outer border. The first named is one-eighth of an inch in front of the articulation and is the first bony prominence found on drawing the finger from the inner malleolus forward along the side of the foot; the sharp edge of the second can be readily felt when the anterior portion of the foot is forcibly depressed; the latter can usually be made out by adducting the toes and inverting the sole, nearly midway between the tip of the external malleolus and the base of the fifth metatarsal bone, or nearer the latter. When the foot is at right angles with the leg, the ante-



rior articular surfaces of the astragalus and calcaneum are in the same plane, one crossing the foot transversely at the points indicated.

**Operation.** (Figs. 35, 36, 37.)—The surgeon places the thumb and forefinger of his left hand upon the tubercle of the scaphoid and the lower and outer border of the cuboid, with the palm against the sole and makes a curved incision from one to the other, passing an inch anterior to the head of the astragalus and terminating on each side just below the level of the joint. The plantar flap is next marked out by an incision beginning

FIG. 36.



Outer side. A. Chopart's amputation. B. Syme's amputation. C. Subastragaloid amputation. D. Line of section of the bones in Syme's amputation.

and ending at the same points as the first and crossing the sole of the foot four or five finger-breadths nearer the toes. The dorsal flap is next dissected up, the joint entered at either of the points mentioned as guides (preferably between the astragalus and scaphoid on the inner side, after dividing the tendons of the tibiales), opened widely by dividing the dorsal and interosseous ligaments and depressing the toes and the plantar flap cut from within outward.

Syme preferred to make the plantar flap by transfixion before disarticulating.

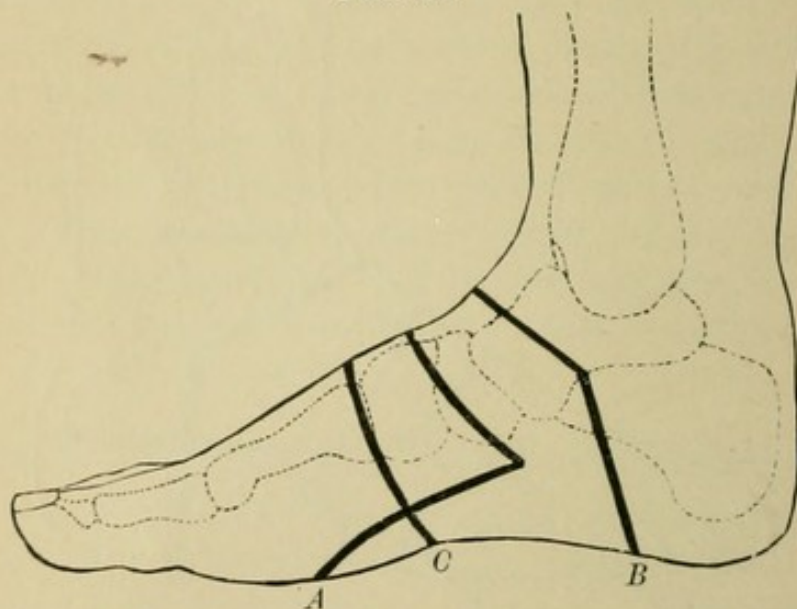


The anterior tendons should be stitched to the deep tissues and the dressing should keep the foot in extreme dorsal flexion at the ankle in order that these tendons may so unite with the stump that their muscles will prevent the heel from being raised by the unopposed action of the muscles of the calf.

### SUB-ASTRAGALOID AMPUTATION.

(Figs. 36, *C*, and 37, *C*.) The guides to this operation are the tip of the external malleolus and the head of the

FIG. 37.



Inner side. *A*. Chopart's amputation. *B*. Syme's amputation. *C*. Subastragaloid amputation.

astragalus. The joint must be entered from in front on the fibular side, and the strong interosseous ligament which forms the key to the articulation must be divided step by step from before backward and inward. The posterior tibial vessels lie behind the inner malleolus, and must be carefully avoided.

Beginning at the outer side of the heel, nearly an inch below the tip of the external malleolus, an incision, extending through to the bone, is carried straight forward to the base of the fifth metatarsal bone; thence, curving forward across the dorsum of the foot to the base of the first meta-



tarsal ; thence obliquely backward and outward across the sole of the foot and around its outer border, rejoining the first and horizontal part of the incision at the calcaneo-cuboid articulation. The soft parts must be separated from the outer surface of the calcaneum and cuboid with division of the peroneal tendons, the dorsal flap dissected back to the head of the astragalus and, on the inner side, beyond the tubercle of the scaphoid, thus dividing the tendon of the *tibialis anticus* and the anterior portion of the internal lateral ligament. The interosseous ligament can then be easily reached by depressing the toes, passing the knife between the astragalus and scaphoid, and cutting backward and inward along the under surface of the former. The soft parts on the inner side are then separated from the calcaneum, injury to the vessels being avoided by keeping close to the bone, between it and the tendon of the *flexor communis*, the foot depressed, and the *tendo Achillis* divided. This last is a very difficult part of the operation, and great care must be taken to keep the edge of the knife close to the bone, so as not to cut through the skin.

The posterior tibial nerve should be dissected out and cut off as high up as possible, so that it shall not be pressed upon the stump.

*Tripier* has modified this by leaving the upper portion of the calcaneum ; the incision is the same ; then after disarticulating at the medio-tarsal joint and freeing the lower surface and sides of the calcaneum, he saws through the latter horizontally, the cut passing from the postero-superior to the antero-inferior angle.

### AMPUTATION AT THE ANKLE-JOINT.

**Syme's Amputation, Tibio-tarsal Amputation.** (Figs. 36, 37, *B.*)—Amputation through the ankle-joint by the circular method, lateral flaps, or a long anterior flap taken from the dorsum of the foot, as proposed by *Baudens*, did not meet with favor, because the delicacy of the coverings or the vicious position of the cicatrix rendered the stump



practically useless; and, although occasional successes were reported, the choice still lay between Chopart's operation and amputation of the leg, until Prof. Syme, in 1843,<sup>1</sup> showed how the excellent plantar flap could be obtained. About the same time Jules Roux, of Toulon, met the same indication by means of a large internal lateral flap carried across the plantar aspect of the heel.

By greatly restricting the necessity for amputation of the leg this operation has become one of the most important and frequently performed of all amputations. The objections urged against it, and the unfavorable results that have sometimes followed its use, seem to have had their origin in a failure to understand or carry out all the details of its execution, or in the introduction of improper modifications. It has seemed desirable, therefore, to reproduce here Prof. Syme's directions for performing it, as published in 1848,<sup>2</sup> six years after he had first put it into practice.

"Succeeding experience taught me that a much smaller extent of flap than had originally been considered necessary was sufficient for the purpose, and that hence the operation could not only be simplified in performance, but increased in safety from bad effects.

"The foot being placed at a right angle to the leg, a line drawn from the center of one malleolus to that of the other, directly across the sole of the foot, will show the proper extent of the posterior flap. The knife should be entered close up to the fibular malleolus,<sup>3</sup> and carried to a point on the same level of the opposite side, which will be a little below the tibial malleolus. The anterior incision should join the two points just mentioned at an angle of 45° to the sole of the foot, and long axis of the leg. In dissecting the posterior flap, the operator should place the fingers of his left hand upon the heel, while the thumb rests upon the edge of the integuments, and then

<sup>1</sup> Lond. and Edin. Monthly Journ. of Med. Science, Feb., 1843.

<sup>2</sup> Contributions to the Path. and Practice of Surgery. Edinburgh, 1848.

<sup>3</sup> "The tip of the external malleolus, or a little posterior to it; rather nearer the posterior than the anterior margin of the bone."  
—Syme, in *Lancet*, 1855.



cut between the nail of the thumb and tuberosity of the os calcis, so as to avoid lacerating the soft parts, which he at the same time gently, but steadily, presses back until he exposes and divides the tendo Achillis.<sup>1</sup> The foot should be disarticulated before the malleolar projections are removed, which it is always proper to do, and which may be most easily effected by passing a knife round the exposed extremities of the bones and then sawing off a thin slice of the tibia connecting the two processes."

Disarticulation is accomplished by opening the joint in front and dividing the lateral ligaments by entering the point of the knife between the sides of the astragalus and the malleoli.

The essentials of the method, as pointed out by the more recent Scotch writers (Lister, Spence, and Bell), are that the plantar incision should run from the tip of the external malleolus directly across the heel, should on no account incline forward, and should terminate at least half an inch below the tip of the internal malleolus (behind and below, according to Lister). In case the heel is unusually long the incision may even incline backward. It is not only unnecessary, but actually dangerous, to make the flap longer than this, for it then becomes impossible to dissect out the calcaneum without scoring the subcutaneous tissue in all directions, and increasing the chances of sloughing. If the incision is made further back and carried any higher on the inner side, the posterior tibial will be cut before its division into the two plantar arteries.

Erichsen and Lister both claim that the integrity of the posterior tibial is not of great importance, the vitality of the flap depending mainly upon anastomosing branches of high origin which lie quite near the bone. Erichsen<sup>2</sup> calls attention to the existence of a "branch of considerable size which arises from the posterior tibial artery, about one and a-half to two inches above the ankle-joint, and

<sup>1</sup>It is now generally considered better to divide the tendon from above downward, after disarticulating, keeping the edge of the knife close to the upper and posterior aspect of the bone.

<sup>2</sup>Science and Art of Surgery, Vol. I., p. 77. Lea, Phila., 1873.



passes down to the inner side of the os calcis," communicating freely above, below, and behind this bone with the peroneal artery on the other side. As these anastomosing loops lie much nearer the bone than the skin, great numbers of them will be divided, and the vitality of the flap endangered, unless the edge of the knife is kept close against the bone during the dissection. Lister goes so far as to say that sloughing of the flap is always the fault of the surgeon, and Bell intimates the same thing.

Roux<sup>1</sup> has shown that this close dissection is not without its dangers from the other side. In two of his cases osteophytes developed within the stump from portions of the periosteum left adherent to the flap. The autopsy in one of these cases showed that six osteophytes had formed and become carious within a year after the operation.

A short longitudinal incision through the deep parts along the middle of the plantar aspect of the calcaneum will sometimes render this step of the operation easier and be less disadvantageous than the employment of great force.

**Modifications.** A. INTERNAL LATERAL FLAP.—When the outer side of the foot has been so altered by injury or disease that the heel flap cannot be obtained, a very good substitute may be had in the large internal flap suggested by Jules Roux and adopted with slight changes by Sédillot, Mackenzie, and others. Spence says this stump can hardly be distinguished from Syme's.

An incision (Fig. 38) is commenced at the outer side of the tendo Achillis, a little above its insertion, carried straight forward under the outer malleolus, then in a curved line across the instep half an inch in front of the anterior articular edge of the tibia and backward to a point just in front of the inner malleolus; thence directly downward to the sole, across it obliquely backward to its outer border and then backward and upward around the heel to the point at which it began. The edges of the flaps are next dissected up for a short distance, the joint entered at the outer side and the internal flap completed from within outward after disarticulation.

<sup>1</sup> Bull. de la Soc. de Chirurgie, Tom. III., p. 491, 1853.

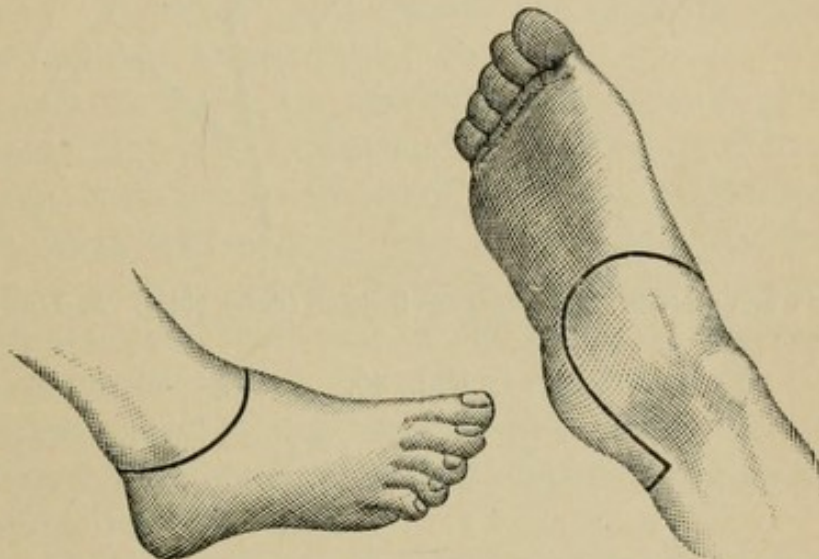


Sédillot's modification of this consists in making the flap more quadrilateral than triangular, by a semicircular incision across the dorsum three finger-breadths in front of the malleoli and by carrying the posterior end of the external horizontal incision across the tendo Achillis to its inner border.

Mackenzie's method differs only in beginning the incision at the inner border of the tendon and a little higher up.

It is probable that a serviceable *external* flap could be

FIG. 38.



Amputation through the ankle-joint by large internal lateral flap. (ROUX.)

made in the same way, although its vascular supply would be scantier.

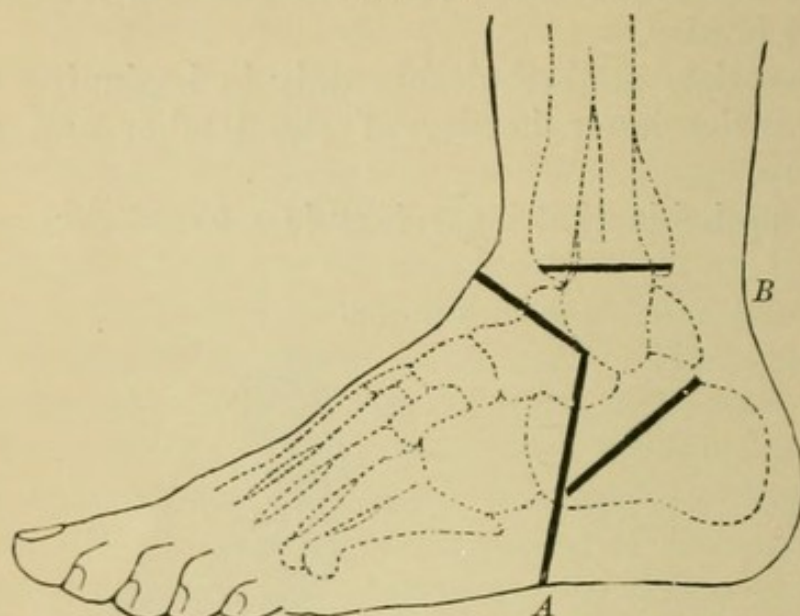
**B. PIROGOFF'S AMPUTATION.**—This is a much more important modification, since it involves not merely the method of performing the operation, but also the retention of the posterior portion of the calcaneum, and its ultimate union with the tibia. The only additional anatomical point that needs mention in connection with it is that the long axis of the calcaneum is directed upward as well as forward.

An incision (Figs. 39 and 40, *A*) is made from the tip of the inner malleolus to a point a little above and in front of the tip of the outer malleolus, crossing the instep



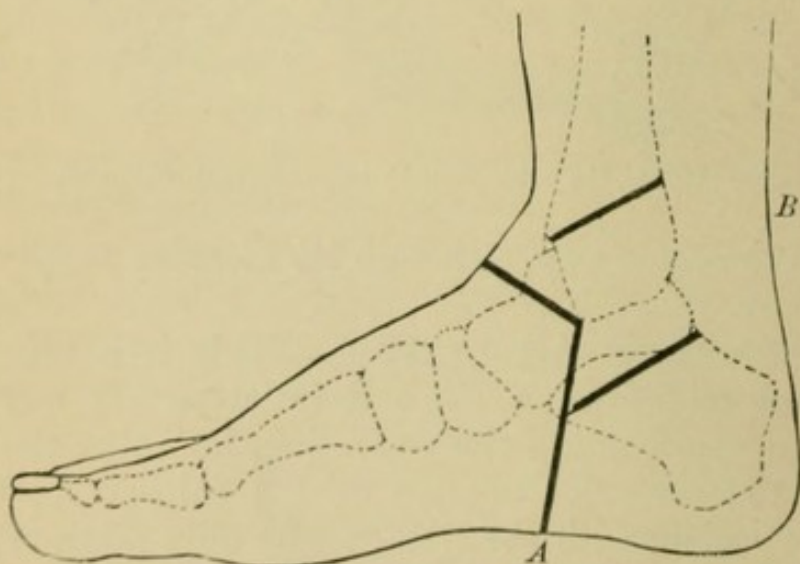
half an inch in front of the anterior edge of the tibia. A second incision crossing the sole at the level of the calcaneo-cuboid articulation unites the extremities of the first,

FIG. 39.



Pirogoff's amputation. *A.* Cutaneous incision (outer side). *B.* Line of section of the bones.

FIG. 40.



Pirogoff's amputation. *A.* Cutaneous incision (inner side). *B.* Parallel section of the bones (Sédillot's modification).

and should be carried boldly down to the bone. The plantar flap is then dissected back for a quarter of an inch, and the dorsal flap to the edge of the joint, the malleoli



well exposed, and the joint opened widely by dividing the lateral ligaments. By drawing the foot forward and depressing it a narrow saw or Gigli wire can be passed through the joint, and applied to the calcaneum behind the posterior lip of the astragalus, and the bone sawn through downward and forward in such a direction that the section will terminate half an inch behind the lower edge of the calcaneo-cuboid articulation. The malleoli and a slice of the tibia are then removed as in Syme's operation, and enough of the anterior angle of the calcaneum removed to make the length of its surface of section correspond with that of the tibia. Some surgeons prefer to reverse this order, and remove the malleoli before sawing through the calcaneum.<sup>1</sup>

The cut surface of the calcaneum must then be brought up against that of the tibia, and if the section of the former has been sufficiently oblique, and has commenced far enough back, this can be done without making excessive tension upon the tendo Achillis, otherwise another slice must be removed from one of the bones or the tendon divided subcutaneously. Suturing together of the bones has been occasionally tried, as has also fastening them together by a long steel pin driven through the sole and the calcaneum into the tibia.

Several modifications of this operation have been suggested, but they can hardly be considered as improvements. Vertical division of the calcaneum, as originally proposed by Pirogoff and Ure,<sup>2</sup> deprives the stump of the advantages of the heel pad by swinging the latter too far forward, and bringing the weight of the body upon the thinner skin covering the insertion of the tendo Achillis. It also causes undue tension of the tendon when the bones are brought together. Sédillot suggested an oblique section of the tibia upward and backward, parallel to that of

<sup>1</sup> Pirogoff's incisions were nearly identical with Syme's. He also divided the calcaneum vertically, and retained the articular surface of the tibia unless it was diseased.

<sup>2</sup> Ure's conception of the operation seems to have been original with him. His case was published in the *Lancet* about the time of the appearance of Pirogoff's book at Leipzig, 1854.



the calcaneum (Fig. 40, *B*). This avoids any stretching of the tendon, and insures a well-placed pad under the heel, but it shortens the limb somewhat, and places the point of support behind the axis of the leg. Pasquier saws both tibia and calcaneum horizontally; this is difficult of execution, endangers the flap, and also leaves the point of the heel too far back. The suggestion which is occasionally made to retain the malleoli is unsurgical and unprofitable—unsurgical, because union between two cut surfaces of cancellous bone is speedier, stronger, and not exposed to greater risks than when one surface is covered with articular cartilage; unprofitable, because nothing is gained in accuracy of adjustment or length of limb.

COMPARISON OF THE DIFFERENT METHODS OF PARTIAL AND TOTAL AMPUTATION OF THE FOOT.—As an offset to the advantage of their less extensive mutilation, Lisfranc's and Chopart's amputations are open to the objection that the unopposed action of the muscles of the calf may raise the heel permanently and bring the weight of the body upon the end of the stump and the cicatrix, and, furthermore, when these amputations have been performed for disease of the bones, those bones which were left behind, even if apparently healthy at the time of the operation, have ultimately become affected.

Syme's amputation gives an excellent stump and the shortening of the limb is no more than is necessary to permit the adaptation of an artificial foot and a spring under the heel, but it is comparatively difficult of execution and the flap is liable to pouch and favor infection. Pirogoff's method is easier of execution and gives a longer limb, but an artificial foot cannot be fitted to it so advantageously; it brings the heel pad a little too far forward and requires a longer time for recovery from the operation. The subastragaloid disarticulation gives a longer limb and a good stump, which shares with Chopart's the advantages accruing from preservation of the ankle joint.

(See also Mikulicz's osteoplastic excision of the heel.)



**AMPUTATION OF THE LEG.**

**A. Lower Third.**—This may be done by the pure or modified circular, or with a long anterior flap made to overhang the square-cut posterior segment of the limb, or with a long elliptic posterior flap, including the whole of the tendo Achillis. The former results in a central adherent cicatrix; in all the coverings are liable to be thin and tender and the artificial limb must be so adjusted that the weight will be received by the sides of the leg and not upon the face of the stump. The compensatory advantages are that the control of the limb is more perfect than with a shorter stump.

**1. CIRCULAR METHOD.**—A circular incision is made through the skin, and a cutaneous sleeve one inch long behind, two inches in front, is dissected up; the soft parts are cut straight through to the bone at the base, and then retracted with a two or three-tailed band, according to the breadth of the interosseous membrane, and the bones sawn through, beginning and ending with the tibia.

**BRUNS'S METHOD.**<sup>1</sup>—While the skin is strongly drawn up, a circular incision is made down to the bone at a distance below the future saw-line equal to two-thirds of the diameter of the leg at the saw-line. Liberating incisions about two inches long are carried upward from the circular incision, dividing all the soft parts over the inner border of the tibia and the outer aspect of the fibula. Without disturbing the attachments of the overlying soft parts, the periosteum is carefully raised from the tibia and fibula as high as the lateral liberating incisions extend, and first the fibula and then the tibia are sawn through, the latter obliquely to prevent projection of the crest. The vessels are then ligated, the extremities of the tendons excised, and buried sutures passed, uniting the muscles and periosteum, and, after rounding off the corners, the wound is closed with a drain in the upper angle of the lateral incisions.

In the upper half of the leg the circular incision is made first through the skin, and then the muscles are divided a finger's breadth higher up. This preservation of the peri-

<sup>1</sup> *Beitrage zur klin. Chir.*, 1893, p. 492.



osteum is to be deprecated in the young for the reasons given in the footnote on page 72.

2. MODIFIED CIRCULAR. (Fig. 41, A.)—Circular incision through the skin, met by a liberating longitudinal one on the antero-external aspect. The soft parts of the

FIG. 41.

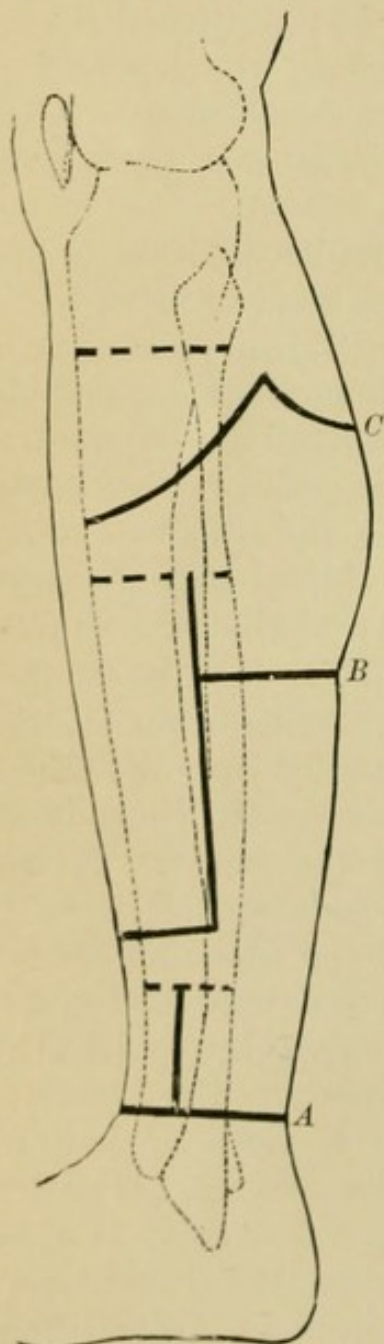


FIG. 42.

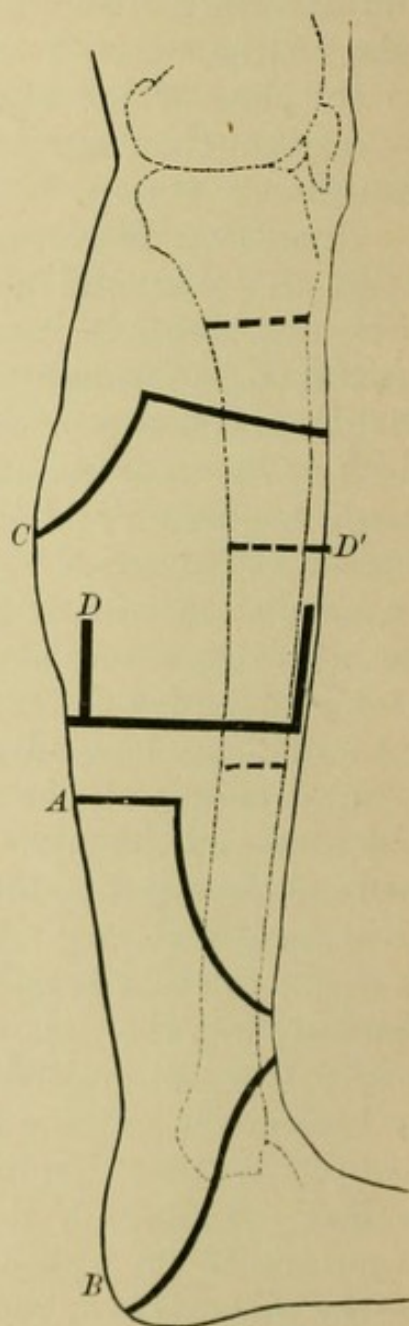


Fig. 41.—Amputation of leg. A. Modified circular. B. Rectangular flaps (TEALE). C. Antero-posterior flaps, upper third (BELL).

Fig. 42.—Amputation of leg. A. Long anterior flap. B. Supra-malleolar amputation by long posterior flap (GUYON). C. At the upper third (SÉDILLOT). D. Skin flaps and circular division of the muscles.



posterior portion are divided rather lower than those of the anterior portion, and all are dissected back to the line at which the bones are to be divided.

Instead of a single liberating incision two may be made, one on each side ; and then by rounding off the corners we may have double skin flaps with circular division of the muscles, the "modified flap" operation.

3. LONG ANTERIOR FLAP (Bell). (Fig. 42, A.)—An anterior flap, equal in length to the diameter of the leg at its base, is marked out by a curved incision through the skin, beginning at the posterior edge of the tibia on the inner side, a little below the point at which the bones are to be divided, and ending at a point directly opposite over the fibula. The anterior muscles are divided transversely half an inch above the lower end of the flap, and carefully dissected off the bones and interosseous membrane as high as the base of the flap. The separation from the interosseous membrane should be made with the finger or handle of the knife, in order that the anterior tibial artery which lies immediately upon the membrane may not be injured. The posterior flap is then made by transfixion and cutting transversely outward, and, the soft parts being retracted, the bones are sawn across a little higher up.

The resulting cicatrix is posterior and not adherent to the end of the bone. Bell<sup>1</sup> reports five cases, in all of which there was complete and rapid recovery, with a useful stump.

4. ELLIPTIC POSTERIOR FLAP (Guyon<sup>2</sup>). (Figs. 42 and 43, B.)—The incision is made in the form of an ellipse, whose lower end crosses the heel below the insertion of the tendo Achillis, and whose upper end is about an inch above the anterior articular edge of the tibia. Beginning at the lower end and dividing the tendo Achillis at its insertion, and hugging the bone all the way, the flap is dissected up posteriorly as high as the upper end of the ellipse. The anterior muscles are then divided by transfixion, the bones sawn through, and the posterior tibial nerve resected.

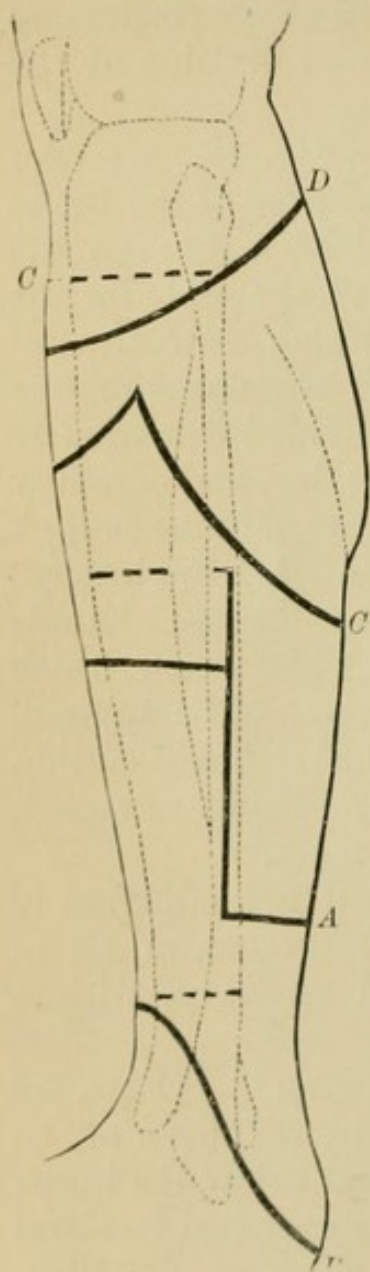
<sup>1</sup> Manual of Surg. Operations, 3d ed., p. 85. Edinburgh, 1874.

<sup>2</sup> Bulletin de la Société de Chirurgie, 1868, p. 337.



In this operation the sheath of the tendo Achillis is not opened, and the tendon itself serves afterward as a covering for the end of the bone.

FIG. 43.



Amputation of the leg and at the knee. *A.* Long posterior rectangular flap (LEE). *B.* Supra-malleolar (GUYON). *C.* At the upper third (SÉDILLOT). *D.* Disarticulation at the knee, oval incision.

**B. Middle Third.**—1. Long anterior curved flap. 2. Simple posterior flap. 3. Skin flap and circular division of the muscles.

1. **THE LONG ANTERIOR CURVED FLAP** is made according to the method described for its use in the lower third. The principal points to be borne in mind are to separate the anterior muscles from the interosseous membrane with the finger or handle of the knife, to make the flap long enough to fall over and cover the broad posterior surface of section without tension, and to saw off obliquely the prominent angle made by the crest of the tibia.

2. **SINGLE POSTERIOR FLAP.**—When the muscles have become atrophied a single posterior flap may be safely made. A transverse incision is made across the front of the leg from the posterior edge of one bone to that of the other, and a long posterior flap cut from within outward, by transfixion. Its length should be equal to the diameter of the leg at its base.

3. **SKIN FLAPS AND CIRCULAR DIVISION OF THE MUSCLES.** (Fig. 42, *D.*)—Longitudinal incisions are made on the anterior and posterior aspects of the leg, midway between the tibia and fibula. They should

extend downward from a point about an inch below the future saw-line to a point at a distance from the saw-line



equal to two-thirds of the diameter of the leg where the bone is to be divided. These are joined by transverse incisions with the corners slightly rounded. The incisions are carried through the skin and subcutaneous tissue, and the flaps thus formed are turned back, drawn up, and dissected from the fascia, with care to include all the subcutaneous cellular tissue, till the point of bone division is nearly reached.

The muscles are then cut transversely to and between the bones, the interosseous membrane divided, a three-tailed retractor applied, and, after circular division of the periosteum, the bones are sawn, finishing with the fibula first. The cicatrix will lie between the tibia and fibula. This is generally the best method for amputation of the leg.

**C. Upper Third.** (*"Place of Election."*)—The bones should never be divided above the attachment of the ligamentum patellæ to the tuberosity of the tibia, and it is better to divide two inches below it, when possible, so as not to open the sheaths of the flexor muscles of the thigh. The circular and the various flap methods may be employed.

4. **LONG ANTERIOR RECTANGULAR FLAP (Teale).**<sup>1</sup> (Fig. 41, *B.*)—This and the following method have been practically abandoned on account of the great sacrifice of sound parts which they entail. From each end of the transverse diameter of the leg at the point at which the bones are to be divided an incision, equal in length to half the circumference of the leg at that point, is made downward and slightly backward, so that the two shall be as far apart as they are at their upper ends, measuring across the front of the leg. Their lower extremities are then united by a transverse anterior incision carried through to the bones and interosseous membrane. The flap thus marked out is dissected up to its base, the separation from the interosseous membrane being made with the finger or handle of the knife so as not to injure the anterior tibial artery.

A posterior flap, one-fourth the length of the anterior

<sup>1</sup> See also page 74.



one, is next cut by a transverse incision straight down to the bones, and dissected back to the same point, the interosseous membrane divided, the bones cleaned and sawn through.

The long flap is then doubled back upon itself, its lower end sewed to that of the posterior flap, and the edges of the lateral incisions fastened together.

5. LONG POSTERIOR RECTANGULAR FLAP (Lee). (Fig. 43, A.)—The incisions are similar to those used in Teale's method, but they involve only the skin, and the short flap is anterior, the long one posterior. The posterior flap contains only the gastrocnemius and soleus, while the deeper layer of muscles, together with the large vessels and nerves, is cut transversely as high as the lateral incisions permit.

1. MODIFIED FLAP (Bell). (Fig. 41, C.)—Two equal semi-lunar flaps of skin three inches long, one antero-external, the other postero-internal, their extremities meeting at opposite points about two inches below the tuberosity of the tibia. These must be reflected up, and with them another inch of skin, embracing the whole circumference of the limb, must be dissected up. The anterior muscles must be cut as high as exposed, and the posterior ones about the middle of their exposed surface. The bones must then be sawn as high as exposed, the fibula being finished first, and the sharp prominence of the edge of the tibia removed.

#### COMPARISON OF THE DIFFERENT METHODS.

Amputation in the lower third gives better command of the limb, but the coverings of the stump are liable to be too thin and tender. The circular and double flap methods formerly gave central cicatrices and stumps that would bear no weight upon their face, and were sometimes so sensitive that even the pressure of a stocking could hardly be borne. Guyon's long posterior flap taken from the heel promises well; in the first case reported the cicatrix, six weeks after the operation, was two inches above the end of



the stump, upon which forcible pressure could be made without causing any pain.<sup>1</sup>

The long anterior flap also yields a cicatrix which is placed posteriorly and out of the way of pressure, and in short it may be said that the reasons which made the upper third the place of election have lost their force since amputation by a long single flap has been shown to be practicable at any point, and since asepsis during healing has improved the character of cicatrices.

After amputation in the upper third the weight of the body may be borne upon the tough skin below the patella, the patient kneeling upon his artificial leg; or the stump may fit into the hollow end of an artificial limb, the upper edge of which will receive the weight from the lower edge of the patella and the broader bony surfaces near the joint. In either case motion at the joint is preserved, and there is no pressure upon the cicatrix.

In children methods of amputating which retain in the flap a considerable strip of the periosteum of the removed bone should be avoided, because of the probability of an objectionable formation of bone by it, giving the stump a shape which, because of an erroneous theory of its production, has been termed "physiological conicity."

### AMPUTATION AT THE KNEE.

Under this head are ranged pure disarticulations and amputations through the condyles of the femur. In disarticulating, the lateral and crucial ligaments should be divided near their attachments to the femur, and the semilunar cartilages removed.

**A. Disarticulation. LONG ANTERIOR FLAP.** (Fig. 44, A.)—A tongue-shaped flap is marked out by an incision beginning half an inch below the line of the articulation nearly as far back as the posterior border of the condyle on one side, and ending at the corresponding point on the

<sup>1</sup>In a letter to me, dated June, 1877, Prof. Guyon states that he has amputated four times by this method, and has every reason to be satisfied with the result. The patients bore their weight upon the stump as freely as upon the other foot. Two cases are reported in the *Bull. de la Soc. de Chirurgie*, 1877, p. 321.—L. A. S.



other, after crossing the leg five inches below the patella. A transverse posterior incision unites the sides of the first an inch below its ends. The flap is dissected up and the disarticulation completed as before.

**LATERAL FLAPS (Smith).**—"Commence an incision about an inch below the tubercle of the tibia and cut to the bone; carry it downward and forward beyond the curve of the sides of the leg, thence inward and backward to the middle of the leg, thence upward to the middle of the popliteal space; repeat this incision upon the opposite side; raise the flap consisting of all the tissues down to the bone until the articulation is reached, divide the lateral ligaments, enter the joint and sever its connections internally and externally."

**B. Amputation Through the Condyles. OVAL METHOD.**—An oval incision crossing the front of the leg three finger-breadths below the end of the patella and the back three finger-breadths higher than in front is made through the skin, which is reflected, and the joint opened above instead of below the patella, which is not included in the flap. The line of incision is similar to that in Fig. 43, *D*, but higher. After disarticulation has been effected, the posterior soft parts divided and the artery tied, the condyles are sawn through above the edge of the articular cartilage. Or the saw may be applied without having previously disarticulated.

**ANTERIOR FLAP (Carden).<sup>1</sup>** (Fig. 44, *B*).—"The operation consists in reflecting a rounded or semi-oval flap of skin and fat from the front of the joint; dividing everything else straight down to the bone and sawing the bone slightly above the plane of the muscles, thus forming a flat-faced stump with a bonnet of integument to fall over it.

"The operation is simple and is performed easily in two ways.

"The operator, standing on the right side of the limb, seizes it between his left forefinger and thumb at the spots selected for the base of the flap and enters the point

<sup>1</sup> British Med. Journal, April 16, 1864.



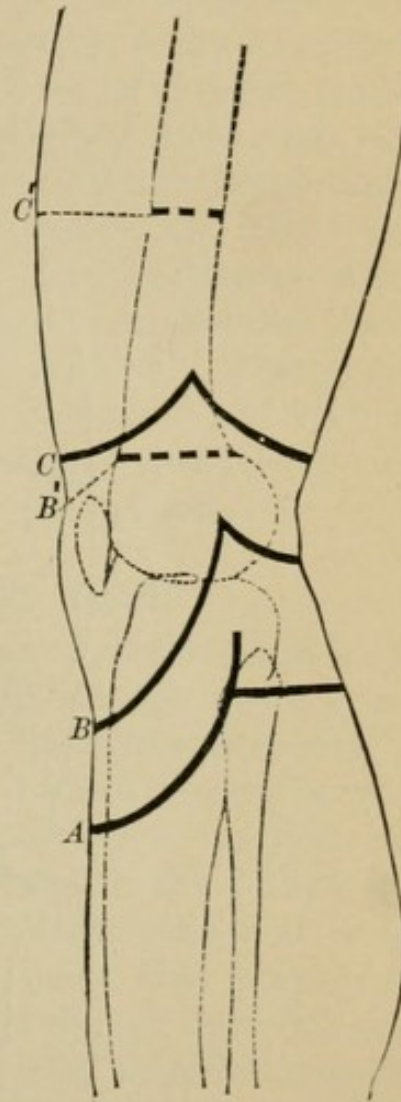
of his knife close to his finger, bringing it round through skin and fat below the patella to the spot pressed by his thumb; then turning the edge downward at a right angle with the line of the limb, he passes it through to the spot where it first entered, cutting outward through everything behind the bone. The flap is then reflected and the remainder of the soft parts divided straight down to the bone;<sup>1</sup> the muscles are then slightly cleared upward and the saw is applied. \*

“Or the flap may be reflected first and the knee examined, particularly if the operator be undecided between resection and amputation. In amputating through the condyles, the patella is drawn down by flexing the knee to a right angle before dividing the soft parts in front of the bone; or if that be inconvenient the patella may be reflected downward. \* \*

“The flap falls easily over the end of the bone, and, when united to the posterior integuments by a few pins and sutures, is drawn strongly upward and backward by the greatly retracted flexors, and has a somewhat puckered and redundant appearance at first. \* ”

**GRITTI'S MODIFICATION.** — This is the analogue of Pirogoff's modification of Syme's amputation at the ankle. The articular surface of the patella is removed and the cut surface of the bone applied against that of the femur. The natural mobility of the skin over the patella is preserved, and the usefulness of the stump in-

FIG. 44.



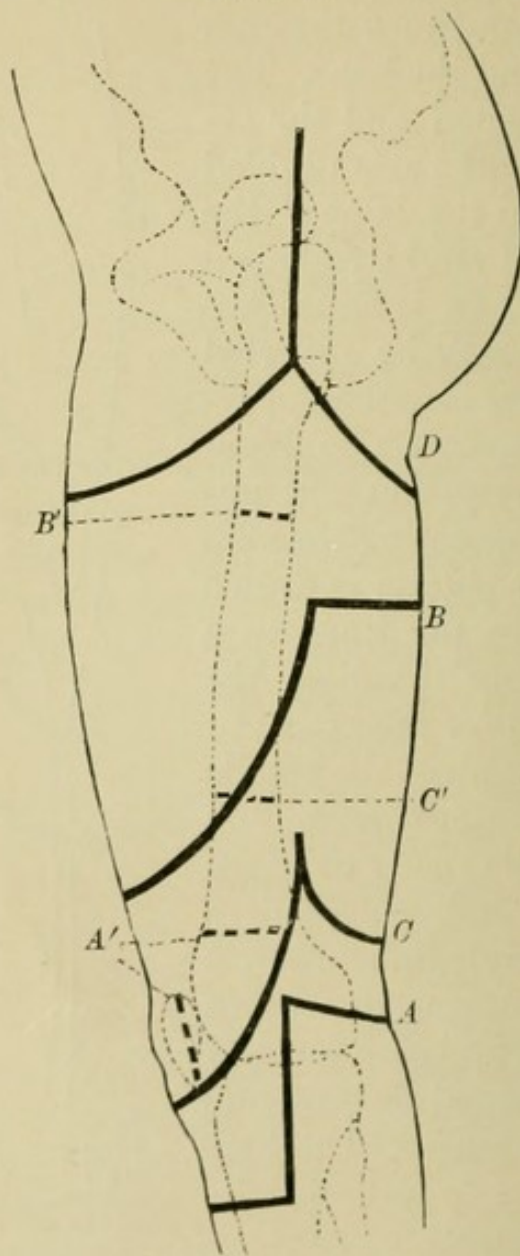
Amputation at the knee and lower third of thigh. A. Disarticulation, long anterior flap. B. Amputation through the condyles (CARDEN). C. Modified flap amputation at the lower third of the thigh.

<sup>1</sup> Lister and Bell recommend a posterior skin flap one inch long.



creased thereby; but it not unfrequently happens that the patella is drawn upward by the quadriceps femoris, and union does not take place between the two bones. Gritti

FIG. 45.



A. Gritti's amputation at the knee; A'. Lines of division of the bone. B. Long anterior flap (SÉDILLOT). B'. Division of bone. C. Amputation at lower third (SPENCE). C'. Division of the bone. D. Disarticulation at the hip.

sawed through the femur at the upper edge of the articular surface, but I have always found it advisable to go nearly an inch higher in order to prevent tilting of the patella. Von Linhart<sup>1</sup> claims that the stump is better than that



obtained by amputation in the lower third of the femur, but not better than that obtained by disarticulation.

A rectangular anterior flap (Fig. 45, *A*) extending from the center of the condyles to the tuberosity of the tibia is marked out, and dissected up after division of the ligamentum patellæ as near as possible to its insertion; the skin covering the back of the knee is divided transversely, or by an incision curved slightly downward, the anterior flap turned back, the synovial membrane separated from its attachment to the femur, and the bone sawn through well above the edge of the articular cartilage. The remaining soft parts are then divided from within outward, and the vessels secured. The articular surface of the patella is then sawn off and its cut surface laid against that of the femur and secured by two or three sutures passed through the periosteum.

#### AMPUTATION OF THE THIGH.

The central position of the femur, and the abundance of the soft parts, have made it possible to employ a great variety of methods of amputation, but the superiority of the flap operation is now generally admitted, with certain modifications depending upon the portion of the limb selected for amputation. Thus, in the lower third when the skin over the patella is uninjured, Carden's method is to be preferred; when, on the other hand, that portion of skin is unavailable, the long anterior flap or Syme's modified flap operation should be used; and in order to compensate for the greater retraction of the posterior muscles they should be cut obliquely instead of transversely in the former operation, and on a lower level than the anterior muscles in the latter. In the middle third the long anterior flap is to be preferred. Lateral flaps should be avoided on account of the tendency of the bone to project at the anterior angle.

The muscles are more abundant on the inner and posterior aspects, and this disproportion increases toward the hip. The femoral artery will be found in the posterior

<sup>1</sup> Compend. v. Operationslehre, 1867, p. 401.



flap below the middle of the thigh, in the anterior flap above; care must be taken not to include the internal saphenous nerve in the ligature placed upon it. The profunda artery lies close behind the bone, but divides early into its branches. The sciatic nerve lies between the short head of the biceps and the adductor magnus; it should be drawn gently downward and divided again high up.

Sometimes the band of the tourniquet prevents the muscles from retracting sufficiently to allow the bone to be cleared to the proper height. Under such circumstances the bone should be divided wherever it is most convenient, and the excess sawn off after the vessels have been tied.

CARDEN'S METHOD has been sufficiently described. (See p. 112.)

MODIFIED FLAP OPERATION IN THE LOWER THIRD (Syme). (Fig. 44, C.)—Two equal semilunar flaps of skin and fat, one anterior, the other posterior, are made, raised from the fascia, and retracted two inches further; "the muscles should then be divided right down to the bone, on a level as high as they are exposed in front, as low as they are exposed behind." The bone is then cleared and sawn through two inches above the level of division of the anterior muscles.

LONG ANTERIOR FLAP.—Sédillot,<sup>1</sup> writing in 1854, says he has used this method exclusively for the preceding seven years. Spence<sup>2</sup> describes a method as first practised by himself in 1858, and claims that his "flap is formed on a principle essentially different from that which regulates the construction" of Sédillot's, a difference which is not recognizable in the descriptions, the length of the flap in each case being equal to the diameter of the limb, the breadth of its base "almost two-thirds of the circumference" according to Sédillot, "fully equal to one-half the circumference" according to Spence, and the muscle contained in it cut obliquely by both, so that it shall not be too thick. Sédillot divides the posterior segment of the limb transversely. Spence divides it obliquely from with-

<sup>1</sup> Médecine Opératoire, 2d edition, Vol. I., p. 455.

<sup>2</sup> Lectures on Surgery, 2d edition, Vol. I., p. 621, Edinb., 1876.



out inward beginning two inches below the base of the anterior flap, and sometimes takes an additional inch of skin, a difference which approximates his method to Teale's. Benjamin Bell also describes a method which is nearly identical, and O'Halloran used a similar one in 1765, but his flap was too short to accomplish its purpose.

Sédillot's description is as follows (Fig. 45, *B*):

The flesh of the anterior aspect of the limb is grasped in the left hand and an incision made through the skin, marking out a flap whose length is equal to one-third and its base to almost two-thirds of the circumference of the limb. The muscles are then divided obliquely upward and backward so that the flap shall not be too thick, the posterior segment of the limb divided transversely, the bone cleared an inch or two higher and sawn through. He also removes the anterior edge of the bone obliquely, as was recommended for the tibia.

Spence recommends the long anterior flap as especially applicable to amputation in the lower third, and he makes it as low as possible, so that its lower margin is on a level with or below the patella. After dissecting up the skin to the upper end of the patella, he cuts obliquely upward through the anterior muscles to the bone immediately above the condyles (Fig. 45, *C*). While the soft parts are retracted and after the bone has been cleared circularly, he elevates the femur so as to project it fully and divides it two inches above the base of the flap.

**MODIFIED CIRCULAR AMPUTATION IN THE LOWER THIRD.**—The incision, involving only the skin, is begun at the outer part of the anterior surface of the thigh, at a distance below the proposed saw-line equal to one-third of the diameter of the limb at the level where the bone is to be divided. It is carried obliquely downward across the front of the thigh and then transversely across the inner and posterior aspects at a distance below the proposed saw-line equal to two-thirds of the diameter already taken and finally upward on the outer aspect to the point at which it began. The skin is next retracted and freed all around for about two inches.



The superficial muscles on the inner and posterior aspects of the thigh are divided at the level of the retracted skin and then the outer and deeper muscles are severed down to the bone at the highest possible level.

In cutting the muscles the obliquity of the original incision is to be maintained. Retractors are now applied and the bone sawed, taking care not to leave a projecting spike at the *linea aspera*.

### AMPUTATION AT THE HIP-JOINT.

The affections which render this most serious operation necessary are often of such a nature that the surgeon's choice of a method of performing it is greatly restricted; he must take his flaps where he can get them, and must regulate his incisions by existing lesions. Moreover, the problem is not to obtain a flap that will bear pressure, but to remove the limb in the manner that involves the least risk to life. This risk, which has proved very great, is due not only to the gravity of the lesions which render surgical interference necessary, but also to three causes which originate in the operation itself. These are loss of blood, shock, and septicæmia. The first two are the principal dangers, as modern methods have minimized the chances of infection, although formerly they were considerable.

The opinion, held by many, that the amount of shock varied directly with the length of time employed in removing the limb, led to the introduction of operative methods characterized by extreme rapidity of execution, not more than thirty seconds being allowed for the removal of the limb from the body; the type of these is the method by a long anterior flap made from within outward by transfixion.

To prevent hemorrhage many expedients have been employed: the same rapidity of execution; compression of the femoral artery upon the pubis, or within the flap by an assistant, who passes his fingers into the wound behind the knife; compression of the aorta; preliminary ligature of the femoral artery; ligature of each



vessel when encountered in the wound; laparotomy and digital compression or ligation (*q. v.*) of the common iliac; compression by an elastic tourniquet applied above steel pins thrust through the thigh. The hemorrhage most to be feared is that from the numerous vessels of the posterior segment of the thigh, for, while the femoral artery can usually be controlled without much difficulty, there is no way of preventing the flow of blood from the others except by compression of the aorta or common iliac through the walls of the abdomen, or of the internal iliac through the rectum, or by previously securing the common iliac either extra- or intra-peritoneally. The latter device, first suggested as a means of hemostasis during operation for gluteal aneurism, has been employed in one or two amputations with success; compression of the aorta, although effectual and entirely harmless in some cases, has proved dangerous or impracticable in others<sup>1</sup> by exciting peritonitis or interfering with respiration.

A simple, efficient, and probably safe method is one recently devised and successfully employed by Dr. McBurney: direct compression of the common iliac artery by the finger introduced through an incision in the anterior abdominal wall.

Dr. Wyeth<sup>2</sup> uses two steel mattress-needles which are thrust through the thigh to prevent the slipping of an elastic tourniquet fastened above them. The first needle is entered one and a-half inches below and just to the inner side of the anterior superior spine of the ilium. It passes externally to the neck of the femur, and comes out just behind the great trochanter about half-way between it and the posterior superior iliac spine. The second needle is entered an inch below the level of the groin internal to the saphenous opening, and, passing through the adductors, emerges about one and a-half inches in front of the tuber ischii. A stout rubber tube is then wound

<sup>1</sup>See Erskine Mason, "Two Successful Cases of Amputation at the Hip-joint," *N. Y. Med. Journ.*, Dec., 1876.

<sup>2</sup>*Journal Am. Med. Assoc.*, Feb. 7, 1891.



tightly enough around the thigh above these pins to occlude the vessels.

Dr. McBurney has also used in two cases, and apparently with great advantage, intra-venous injection of a large quantity of normal salt solution during the operation.

The position of the joint may be determined by that of the anterior inferior spine of the ilium, which is three-quarters of an inch above its upper margin.

Nearly all of the numerous methods for performing amputation at the hip-joint may be considered as variations to a greater or less extent from the operation by flaps, which may be either external and internal or anterior and posterior, and by the anterior and the external oval—sometimes called racket—incision. Disarticulation by external and internal flaps is not to be commended except for cases in which sound tissue cannot be obtained elsewhere. The knife is entered about a hand's breadth vertically below the anterior superior spine of the ilium and made to transfix the thigh from before backward just below the great trochanter; it is then carried down and out, cutting a flap four or five inches long. The muscles are then separated from the great trochanter, and after disarticulation the inner flap is cut of a similar length. Hemorrhage is controlled by the pressure of an assistant's fingers entered in the track of the knife and by ligation of each vessel as soon as possible after it is divided.

When the nature of the disease or injury permits, the operation by the external racket incision is generally given the preference. In this the bone is approached through the least vascular area, and the incision can also be used for exploration before proceeding to amputation.

I. ANTERIOR RACKET OR OVAL METHOD.—The patient having been anæsthetized and placed upon the table, an Esmarch's elastic band is applied from the toes as far upward as is allowed by the nature of the lesion and the line of the proposed incision.

1. An incision, beginning a finger's breadth below Poupart's ligament, is carried down along the course of the femoral artery for about four inches; thence outward and



downward, a little below the base of the great trochanter to the gluteal fold; thence transversely along this fold to the inner side of the thigh, and thence obliquely upward five full finger-breadths below the genito-crural fold to the point where it diverged from the line of the artery. The incision should involve only the skin and the cellular tissue; any vessels that are divided should be immediately tied.

2. The sheath of the vessels is opened, the artery isolated and denuded, and its point of bifurcation determined. A ligature is then applied methodically to the vessel above the origin of the profunda, and a second lower down, including both branches *en masse*, and the artery divided between them. The femoral vein is also carefully denuded and divided between two ligatures at about the same level.

3. The incision is carried down through the muscles, beginning on either the outer or inner side, as is most convenient; on the inner side, after having cut through the adductors at the junction of their fleshy and tendinous portions, seek and tie the obturator vessels, divide the pectineus and psoas on a line with the neck of the femur, and secure all the bleeding points. On the outer side, divide the sartorius and the fascia lata, and then invert the thigh so as to throw the great trochanter forward and facilitate the division of the muscles attached to it.

4. Open the articulation in front and divide the posterior portion of the capsule as close as possible to the femur, together with the remaining tendons that are inserted in the great trochanter.

5. Division of the posterior segment of the limb. Depress the thigh beyond the border of the table, so as to make the wound gape widely, and divide the remainder of the adductors and the muscles attached to the ischium with gentle strokes of the knife, tying each vessel when it is recognized or divided. It is well also to resect the extremity of the sciatic nerve.

II. EXTERNAL RACKET INCISION OR MODIFIED OVAL METHOD. (Fig. 45, *D*.)—The patient is laid upon his side,



his hips at the foot of the table. A straight incision four inches long is begun one inch above the summit of the great trochanter, and carried along its posterior border, and a circular incision is then carried from the lower end of the first around the thigh, passing three inches below the tuberosity of the ischium. These incisions should interest the skin only, their borders should be dissected up for about an inch, and the muscles of the outer aspect divided obliquely upward toward the joint. In front this division should not be carried beyond the outer edge of the rectus muscle, but posteriorly it should be as extensive as possible and close to the bone.

The thigh being flexed and adducted, the capsule is opened, first longitudinally on the finger as a guide, then forward and backward along the edge of the cotyloid cavity, the head of the femur dislocated backward and outward, the knife passed around it and brought down along the inner side of the bone nearly to the level of the circular incision, and then made to cut its way rapidly out on the inner side.

*Esmarch's* method differs slightly from this last. Hemorrhage is controlled by digital pressure on the femoral in the groin. Five inches below the top of the great trochanter divide everything circularly down to the bone, which is at once sawn across. The vessels are then secured. Next the stump of the femur is steadied and the knife entered about two inches above the tip of the trochanter and carried down along its outer surface till it reaches the first circular incision. The bone is freed from soft parts by an elevator entered beneath the periosteum, aided by the knife, the muscular insertions on the trochanters divided, the capsule opened, and the bone removed.

III. ANTERIOR FLAP.—The position of the patient being the same, and the thigh slightly flexed and abducted, the point of a long amputating-knife is entered midway between the anterior superior spine of the ilium and the top of the great trochanter and passed inward and backward to a point one inch below and in front of the tuber-



osity of the ischium, grazing the anterior surface of the neck of the femur, and certainly opening the capsule of the joint if its edge is kept turned obliquely toward it. (The direction may be reversed for the right thigh, the knife being entered on the inner side.)

A well-rounded flap ending at the junction of the upper and middle thirds of the thigh is then cut with rapid sawing movements of the knife, and reflected upward. The limb is forcibly depressed, and if the capsule has been well divided this movement will throw the head of the femur forward out of the socket; and if not, a single cut with the knife across the head of the bone will free it. The leg is then rotated inward so as to bring the trochanter forward, the surgeon passes the knife behind the head of the bone and cuts a short posterior flap from within outward.

**SENN'S BLOODLESS METHOD.**<sup>1</sup>—Start an incision on the outer surface of the thigh about three inches above the trochanter, and carry it vertically downward for about eight inches, exposing the outer surface of the trochanter and femur.

Keeping close to the bone, separate the muscular attachments to the great trochanter, and, while the thigh is flexed, adducted, and rotated inward, open the capsule transversely at its upper posterior aspect. Sever the rest of the ligaments by backward dislocation of the head of the femur, which is then pushed out of the wound and the lesser trochanter and shaft freed as low as desired.

A sinus-forceps carrying a long stout doubled piece of rubber tubing is pushed through the wound behind the femur at the normal level of the lesser trochanter, emerging through a small counter opening on the inner surface of the thigh, where the tube is cut in two; one-half is tied tightly about the anterior segment of the limb, the other is crossed about the posterior segment and its ends brought around and tied in front above the anterior piece of tubing. Starting from the points of emergence of the tourniquet a long anterior and a short posterior flap are raised, consisting of all the tissues down to the muscles,

<sup>1</sup> Chic. Clin. Rev., Feb., 1893, p. 343.



which are then cut circularly in the form of a cone with its apex at the lower limit of denudation of the femur. The thigh is thus removed, and after ligating all visible vessels with catgut and excising about an inch of the exposed sciatic nerve the tourniquet is loosened from the posterior flap first and then from the anterior.



## PART IV.

### EXCISION OF JOINTS AND BONES.

---

EXCISION of a joint may be (1) *complete* or (2) *partial*. In the former case the articular ends of all the bones composing it are removed ; in the latter, one or more are retained. Again, partial excision may consist of (1) partial or (2) total resection of the articular end of one of the members of the joint. The former is often unadvisable ; the latter, to which Ollier<sup>1</sup> has given the name of *semi-articular resection*, has given good results in traumatic cases, and of late also, under antiseptic treatment, in tuberculous affections when the disease is still restricted to a portion of the bone and capsule.

Excision of a bone may be *total* or *partial*, and, in the case of the long bones, with or without either or both epiphyses.

The term *resection* is often employed as a synonym of excision. In the narrower sense it refers to the removal of a portion of a bone, including, however, its entire thickness ; thus, a joint is excised by the resection of the bones composing it.

Joints are excised on account of injury, disease, or ankylosis in a faulty position ; and with the object of obtaining a movable joint, as in the upper extremity, or ankylosis, as at the knee and ankle. The operative procedures may vary with these causes and these objects. Thus, when ankylosis is sought for, the division of the muscles and tendons about the joint is of no special moment ; but if the joint is to be reëstablished, the muscles which con-

<sup>1</sup> Congrès Médical de France, 4th session, 1872, p. 224, and Bull. de la Soc. de Chirurgie, 1873.



trol its movements must not be disabled. In any case the main blood vessels and nerves must be respected; the incisions, whenever practicable, should be parallel to the long axis of the limb; and when it is necessary to divide a tendon or muscle, the line of section should be oblique rather than transverse, so as to favor reunion.

The incisions should be sufficiently free to allow the bone to be thoroughly inspected with a view to the removal of all the diseased portion. It is better to make a clean division with the saw than to remove the bone piecemeal, but the use of the gouge is proper for the removal of small circumscribed areas of disease found upon the surfaces of section, and even very extensively in the young, as a substitute for a formal excision in order not to diminish the subsequent growth of the limb by the destruction or removal of the epiphyseal cartilage.

The synovial membrane in traumatic and non-tuberculous suppurative cases does not require special attention; in tuberculous cases and when much thickened it should be cut or scraped away so as to remove such foci of infection as may exist within its walls or in the fungous granulations on its surface. When ankylosis is sought for, as at the knee, it is prudent to dissect out the sac entirely. If any portion is necessarily left, the destruction of the foci should be sought by thorough scraping, washing with a solution of chloride of zinc, 1 to 30 or 40, or of corrosive sublimate, 1 to 1,000, or by the actual cautery.

The propriety of retaining the periosteum is still a subject of discussion, and one in which the decision will probably vary with the articulation and the circumstances of the case. Certain facts have, however, been already established. Its retention is a safeguard against injury to neighboring tissues during the operation; after excision of a bone it gives firmness to the cicatrix, diminishes the shortening of the limb, and insures the proper attachment of the muscles; and in the case of an articulation, if its relations with the capsule are maintained (*periosteocapsular excision*), it favors the reproduction of the joint with articular cartilages and ligamentary support. On the



other hand, the reproduction of bone is not always desirable, and may be excessive or irregular, unduly limiting the motions of the joint, or even causing ankylosis ; and, finally, the bruising received by the periosteum during the operation may cause it to slough, or the reproduction of bone may fail entirely.

Von Langenbeck<sup>1</sup> has shown that in excision of the shoulder-joint it is of the utmost importance to preserve the relations of the periosteum, the capsule, and the tendons of the capsular muscles, but in all other joints, except perhaps the hip, the importance is not so great or, at least, so well established. Complete restoration of the shoulder-joint and reëstablishment of the control of the muscles over it have never been accomplished except by the subperiosteal method. The periosteum can be removed without difficulty except when it is actively inflamed ; its connection with the bone is very slight in cases of chronic osteitis and synovitis. The tendons, on the other hand, are so firmly attached to the bone that the elevator, or rugine, is sometimes insufficient to remove them properly and the knife must then be used, its edge being kept as close as possible to the bone. Von Langenbeck goes so far as to say that the success of a periosteal-capsular excision depends in great part upon the proper alternation in the use of the knife and elevator.

Vogt and Koenig strongly recommend that, instead of separating the tendons and ligaments from the bone, the latter should be cut through with a chisel so as to leave a shell attached to the soft parts. In children, where the epiphyses are still cartilaginous, this section can be made with the knife.

Excision of single bones may be required on account of injury or disease. The latter is by far the most common cause, and its most common examples are tuberculosis of the small spongy bones and necrosis of the long ones, due to acute osteomyelitis. The incisions should be made from the side where the coverings of the bone are fewest and of least importance ; the periosteum

<sup>1</sup> Archiv für klinische Chirurgie, Vol. XVI.



should be left behind and all the diseased bone should be removed. When the entire shaft of the bone has become necrotic, it must be divided with the chain-saw or cutting-pliers and each piece pulled or cut away from its epiphysis.

## MAJOR ARTICULATIONS.

### EXCISION OF THE SHOULDER-JOINT.

As formerly performed, excision of the shoulder-joint was an operation the results of which, to quote Holmes,<sup>1</sup> were "probably inferior—certainly not superior—to those of natural ankylosis." If ankylosis did not follow, the joint was loose, under slight control, and, at the best, could not be raised above the horizontal line. Ollier<sup>2</sup> and Von Langenbeck,<sup>3</sup> however, have shown that the periosteocapsular method furnishes a much larger measure of success. In a case operated upon by the former, where four inches of the humerus were removed, the ultimate shortening was only half an inch, and the motions were quite full; and the latter reports several cases in which the arm could be raised to the vertical line, and the control of the limb was perfect. In all of Von Langenbeck's cases the operation was undertaken on account of gunshot-injury.

As the capsular muscles are attached to the greater and lesser tuberosities, the capsule and periosteum must be divided between these two bony prominences—that is, in the direction of and near to the tendon of the long head of the biceps. An anterior incision beginning at the acromioclavoid triangle is the best one for this purpose, and has, moreover, the advantage of sparing the posterior circumflex artery and the nerve. The cephalic vein lies in the groove between the deltoid and pectoral muscles, and is avoided by making the incision incline outward. When the soft parts are much thickened and consolidated, this incision needs to be supplemented by a short transverse

<sup>1</sup> Surgery, its Principles and Practice, p. 929. Lea, Phila., 1876.

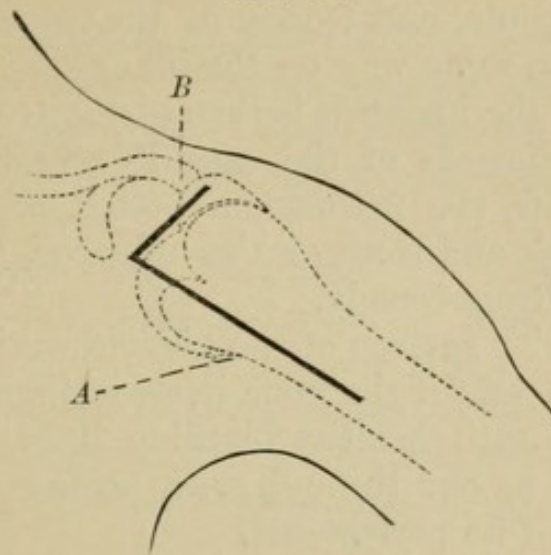
<sup>2</sup> *Traité de la Régénération des Os, and des Résections des Grandes Articulations*, 1867.

<sup>3</sup> *Archiv für klinische Chirurgie*, 1874, Vol. XVI.



one (Fig. 46, *B*) running outward from its upper end parallel to and just below the edge of the acromion, dividing the fibers of the deltoid transversely in its course; sometimes the condition of the parts is such, and the

FIG. 46.



Excision of the shoulder. (OLLIER.) *A*. Regular incision. *B*. Supplementary.

sinuses so placed, that a large external flap, with its base directed upward, has to be made by a triangular or curved incision, and raised up so as freely to expose the outer aspect of the head of the humerus. In any case the trunk of the posterior circumflex artery should be spared.

**Operation (Ollier).** (Fig. 46.)—The arm is adducted and rotated inward. The point of the knife is entered at the beak of the coracoid process, and carried four inches downward and outward in the general direction of the fibers of the deltoid, or as much further as may be necessary. The incision thus made will be external to the inner border of the deltoid, and should comprise all the tissues down to the bone.

The edges of the wound are held apart with retractors, and the capsule and periosteum are divided along the outer edge of the tendon of the long head of the biceps and the bicipital groove to the full extent of the external incision. The outer edge of the incision is raised, and the periosteum, together with the capsule and tendons of the



muscles inserted upon the greater tuberosity, is carefully detached with the elevator and knife, while an assistant rotates the arm inward to increase the extent of and facilitate the dissection.

The tendon of the biceps is then raised from its groove and held out of the way, the arm rotated outward, and the periosteum, capsule, and tendon of the subscapularis dissected off in the same way on the inner side.

The head of the humerus is then dislocated forward, the posterior attachments of the capsule separated with the elevator or knife, the periosteum peeled off the posterior face of the neck and shaft of the humerus, and the bone sawn through transversely.

If the articular surface of the glenoid cavity is affected, it must be scraped; if the bone itself is diseased, it should be gouged out until healthy bleeding bone is reached, or the neck may be cut through with strong cutting-pliers after removal of its periosteum.

VON LANGENBECK'S METHOD differs slightly from the above. He begins his incision at the anterior border of the acromion just outside of the acromio-clavicular junction, and carries it directly downward, the arm being so held as to bring the outer condyle of the humerus in front. This sacrifices the inner fibers of the deltoid by severing their nerves. He carries the incision through the muscle down to the capsule and bone, then raises with toothed forceps the sheath of the tendon of the biceps, which presents in the line of the incision, and opens it carefully from without inward. As soon as the shining tendon is seen he slits the sheath throughout the entire length of the incision, opening the capsule quite up to the acromion, and exposing the articular end of the humerus with the tendon lying upon it.

He then raises the periosteum on the inner side until the lesser tuberosity is reached, lays aside the elevator, and peels off the tendon of the subscapularis with knife and toothed forceps, taking the greatest pains to maintain its relations with the capsule and periosteum. After this dissection has been carried as far as possible on the inner



side, he lifts the tendon of the biceps from its sheath, carries it inward, drops it into the joint, and denudes the bone on the outer side with the same precautions, using the knife instead of the elevator to detach the capsule, tendons, and ligaments. The rest of the operation as above.

If only the articular head of the bone is to be resected, near the upper end of the tuberosities, there is no periosteum to be removed. The ligamentous and muscular attachments are approached from within the joint, and the bone divided with the wire or keyhole saw, without raising it from its place.

BY A TRANSVERSE INCISION. (Nélaton, Perrin.)—A transverse incision three and a-half or four inches long is made parallel to and half an inch below the edge of the acromion, beginning in front between it and the coracoid process. The fibers of the deltoid are divided close to the acromion, and by their retraction expose the capsule largely.

The capsule is divided along the outer edge of the tendon of the biceps, and then transversely in the direction of the external wound; the bone is approached and denuded through this opening, and the operation completed as before.

The vessels and nerves are well protected by this method, but it is difficult of execution.

### EXCISION OF THE ELBOW-JOINT.

Partial excision of the elbow-joint for disease, even when the portions left behind are entirely healthy, gives as a rule less satisfactory results than complete excision. The humerus should be sawn through at or just above the epicondyles, the ulna at the base of the coronoid process and the radius through its neck. The extent of the disease may make it necessary to surpass these limits, but the result will then be less perfect and in any case every effort should be made to preserve the continuity between the periosteum and the tendons of the brachialis anticus and biceps so as to provide for future flexion of the forearm. An exception to the rule of total excision may be



found in the preservation under some circumstances of all the olecranon except its articular surface ; the joint thus obtained is firmer and active extension more powerful.

Reproduction of bone takes place less completely at the elbow-joint than at any other of the major articulations, and consequently the greater the amount removed the greater the danger of the formation of an imperfect, loose and inefficient joint, even when the subperiosteal method has been thoroughly carried out. Ordinarily ankylosis is to be preferred to a very loose joint.

In cases of gunshot-injury Von Langenbeck and Ollier remove as little as possible, making a partial (semi-articular) excision when either the humerus or the bones of the forearm alone are injured. The English authors think the danger in cases of excision for disease is rather of removing too little than too much and recommend that the humerus be sawn through above the condyles.

As the joint is covered anteriorly with soft parts, among which lie nearly all the principal arteries and nerves, and is almost subcutaneous posteriorly, it must be approached from the latter side and the incisions must be made with especial reference to the safety of the ulnar nerve, where it runs between the olecranon and the epitrochlea. The original method, and the one used almost exclusively for many years, was the H-incision, composed of two longitudinal incisions connected midway by a transverse one crossing the tip of the olecranon. It is inferior in its results to later methods and does not need to be described.

The later methods have been devised with the view of sparing the ulnar nerve, preserving the attachment of the triceps and the continuity of the lateral ligaments with the periosteum, and facilitating the operation. Although the central longitudinal incision has been extensively used the preference seems now to be due to methods of approach from the radial side, such as Ollier's, Nélaton's, and Hueter's.

CENTRAL LONGITUDINAL INCISION. (Fig. 47, A.) (Von Langenbeck.)—The forearm being slightly flexed, a



longitudinal incision  $3\frac{1}{2}$  inches long is made a little to the inner side of the median line of the triceps and ulna, and carried down to the bone. The inner edge of the divided periosteum is raised from the ulna, the corresponding half of the tendon of the triceps detached with it, and the dissection continued toward the internal condyle, the knife being kept constantly against the bone, and the flexion of the arm increased as the dissection advances. As the epitrochlea is approached the greatest care is needed to preserve the connection between the periosteum, the muscular attachments, and the internal lateral ligament, and it may be necessary to prolong the first incision upward so as to get more room.

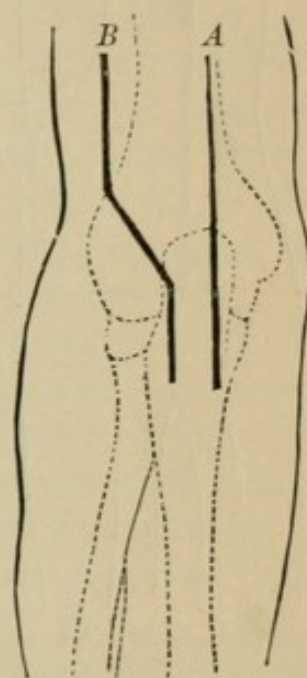
After the inner half of the joint has thus been laid open and the epitrochlea bared, the soft parts are replaced and a similar dissection made upon the outer side with the same precautions.

The humerus is then dislocated backward through the wound and sawn through at, or as near as possible to, the epicondyles, according to the lesion. If the condition of the soft parts does not allow of this projection of the humerus, the wire or keyhole saw must be used.

The ulna is then cleaned circularly as far as necessary and sawn through, and the head of the radius removed with the saw or cutting-pliers.

**OLLIER'S METHOD.**<sup>1</sup> (Fig. 47, *B*.)—The forearm is slightly flexed, and an incision is commenced two inches above the tip of the olecranon on the outer side of the arm at the interstice between the triceps and supinator longus. This incision, involving the skin only, is carried downward to the epicondyle, thence downward and inward in the line of the upper border of the anconæus to the ole-

FIG. 47.



Excision of the elbow-joint. *A.* Von Langenbeck. *B.* Ollier.

<sup>1</sup> *Traité de la Régénération des Os*, p. 340.



cranon, and thence, the point of the knife touching the bone, directly downward along the inner side of the posterior aspect of the ulna for one or two inches.

The fascia is then divided in the line of the incision, and the interstice between the triceps on one side and the supinator longus, radial extensor, and anconæus on the

other, followed down to the capsule and bone. The capsule is opened, and the humerus denuded on its anterior and posterior faces as far inward as possible, care being taken to maintain the relations of the muscular and ligamentary attachments.

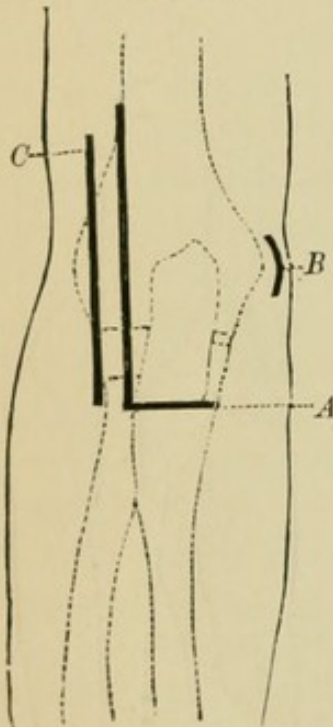
The tendon of the triceps and the periosteum of the ulna are next detached, and in separating the former it is better to begin inside the joint at the free edge of the olecranon.

The denudation of the external condyle and tuberosity of the humerus is then completed, and the external lateral ligament entirely detached, the forearm flexed on its inner side, and the end of the humerus dislocated outward into the wound, thus rendering the difficult dissection of the pro-

jecting epitrochlea easier. When this latter has been completed, the periosteum of the humerus is raised circularly to the proper height, and the bone sawn through. The head of the radius is then removed, the denudation of the ulna completed, and the bone sawn through perpendicularly to its axis.

**NÉLATON'S METHOD.** (Fig. 48, A.)—A longitudinal incision is begun on the outer border of the humerus between the triceps and supinator longus, one and a-half inches above the end of the olecranon, and carried downward for a distance of three inches. A transverse incision cutting through to the bone is next made from the lower end of the first, across the ulna to its inner border.

FIG. 48.



Excision of the elbow-joint. N. Nélaton. B, C. Hueter.



The triangular flap thus formed, including the periosteum of the ulna, is dissected up, the external lateral and orbicular ligaments divided, and the head of the radius removed. The tendon of the triceps is detached and the denudation of the ulna completed.

The ulna is projected through the incision by bending the forearm toward its inner side, and is sawn off.

The humerus is then easily turned out through the incision, denuded from below upward with the usual precautions, and sawn off at the desired height.

LONG RADIAL INCISION (Hueter).<sup>1</sup> (Fig. 48, *B* and *C*).—A preliminary longitudinal incision, half an inch long, is first made directly down upon the tip of the epitrochlea, or rather on its anterior side, so as more surely to avoid the ulnar nerve which lies close behind it, and the muscular attachments and the internal lateral ligament are separated by cutting around this prominence.

The main incision is then made by entering the knife above the point of the external epicondyle and carrying it straight down over it, thus opening the joint and exposing the head of the radius by dividing the external lateral ligament longitudinally and the orbicular ligament transversely. The head of the radius is then removed after sawing through its neck.

The operator then passes his left forefinger through the wound, first to the anterior surface of the humerus to make the capsule tense, and guide the detachment of it and the periosteum, and then along the posterior surface under the tendon of the triceps with the same object.

It is not necessary to carry this dissection very far toward the inner side, because by dislocating the ulna forcibly inward the end of the humerus can be made to project through the radial incision, and then its denudation can be easily and safely completed, and the bone sawn through.

The end of the olecranon is then brought into the center of the incision, and the separation of the triceps begun at the upper free edge of the process with vigorous short

<sup>1</sup> Deutsche Zeitschrift für Chirurgie, 2d vol., p. 68.

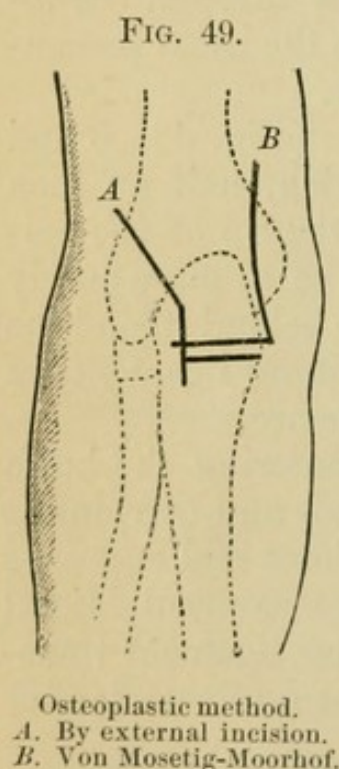


cuts into the substance of the bone, so that it is, as it were, peeled out of its tendinous envelope. When the proper point is reached the bone is sawn through.

**OSTEOPLASTIC METHOD.** (Fig. 49.)—This operation, characterized by primary division of the olecranon and its reunion at the close of the operation, was proposed by Von Bruns, and was at first deemed applicable to old, ir-

reducible, and to fresh compound dislocations. Its use has been extended to operations for foreign bodies in the joint, for ankylosis, and finally to those for fungous arthritis.

The procedure recommended by Von Mosetig-Moorhof begins by a transverse incision running from the lowest point of the external condyle across the olecranon to its inner side, thence upward alongside the olecranon to a point one inch above its tip. The ulnar nerve is then dissected out and drawn aside and the olecranon divided with saw and chisel in the line of the first part of the incision. The flap is then drawn aside, the humerus cleared and sawn off below the epicondyles, the



head of the radius removed and the olecranon scraped and reunited with a silver suture.

I think this exposure of the ulnar nerve is unnecessary and objectionable and have modified the operation by using the lower two-thirds of Ollier's incision and making a second transverse one from the lower end of the first across the base of the olecranon and sawing the latter through in this line, but somewhat obliquely from below upward, into the joint. The joint was then further opened through the lateral incision, the external condyle denuded and the flap, including the upper part of the olecranon, turned upward and inward. This exposed the joint freely and the humerus was then readily denuded and sawn off through the epicondyles. The radius was



then protruded and sawn through at the neck, the olecranon thoroughly scraped, removing most of the coronoid process, and the capsule dissected out. As the scraping of the olecranon had left its sigmoid cavity much too large, I removed a slice one centimeter thick along the line of its original section to shorten it and then sutured the pieces together. The result was very good and active extension more powerful than in any other case I have seen.

**BILATERAL INCISIONS.**—Vogt<sup>1</sup> speaks highly of a method by which he accomplishes the same result without division of the olecranon. His incision begins above the external condyle and is carried well below the head of the radius, dividing the orbicular ligament; then he removes the periosteum from the radius and divides it with saw or chisel just above its tuberosity, draws aside the edges of the wound and explores the joint. If it is extensively diseased, he makes a second incision on the inner side, beginning above and a little behind the epitrochlea and extending about three inches downward, then with a chisel cuts away the attachments of the extensor and flexor muscles from the condyles, leaving a shell of bone attached to them, draws aside the soft parts, divides the capsule, raises the periosteum from the humerus and saws off the end of the latter. Then, if necessary, he scrapes away the surface of the olecranon.

**PARTIAL EXCISION.**—Ollier's and Hueter's methods are especially applicable to that form of semiarticular excision in which only the lower end of the humerus is resected. Nélaton's or Von Langenbeck's, or the lower part of Ollier's can be used for the removal of the ends of the ulna and radius.

### EXCISION OF ANCHYLOSED ELBOW.

When there is ankylosis of the joint, Von Langenbeck's incision can be used, and the ulna divided with a chain-saw or chisel after it has been denuded. The detachment of the capsule and periosteum is then proceeded

<sup>1</sup> Centralblatt für Chirurgie, 1882, p. 555.



with upward, and the lower end of the humerus, with the attached ends of the bones of the forearm, projected through the wound and sawn off.

Or the osteoplastic or either of the two following methods may be employed :

EXCISION OF ANCHYLOSED ELBOW (Ollier).—An incision two and a-half inches long is first made on the outer and posterior side of the limb and carried through to the bone, its center being on a level with the tip of the olecranon. A second incision one and a-half inches long, involving the skin only, is made on the inner side of the ulnar nerve at the level of the internal border of the humerus. The nerve is found on dividing the fascia, is drawn aside together with the posterior lip of the wound with a blunt hook, and is then entirely out of the way of injury.

The lips of the two wounds are separated, the periosteum detached, a narrow saw passed under the triceps, and the humerus sawn nearly through from behind forward, leaving a thin shell of bone in front, which is then broken. The conditions are now those of a movable joint, and more or less of the lower fragment or of each fragment is removed according to the condition of the bone. The triceps should be detached before the olecranon is divided.

EXCISION OF ANCHYLOSED ELBOW (P. Heron Watson<sup>1</sup>).—This method is intended only for the removal of the articular end of the humerus, in cases of more or less complete ankylosis following injury. The advantages claimed for it are that it leaves the attachments of the triceps and brachialis anticus undisturbed, and limits the area of the operation almost exclusively to within the capsular ligament, and thereby seems to secure a more speedy healing of the wound. Watson has used it in six cases, in all of which the results were satisfactory.

1. A linear incision is made over the ulnar nerve at the inner side of the olecranon. 2. The nerve is carefully turned over the inner condyle. 3. A probe-pointed bistoury is introduced into the elbow-joint in front of the humerus

<sup>1</sup> Edinburgh Med. Journ., May, 1873, p. 986.



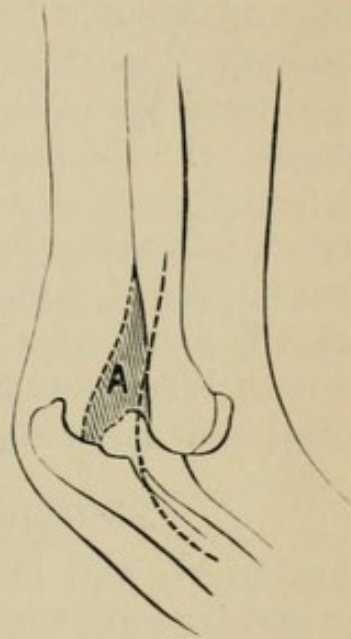
and then behind that bone, and carried upward so as to divide the upper capsular attachments in front and behind.

4. A pair of bone-forceps are next employed to cut off the entire inner condyle and trochlea of the humerus [from above downward], and then introduced in the opposite direction [from below upward and outward], so as to detach the external condyle and capitellum of the humerus from the shaft. 5. The angular end of the humerus is turned out through the incision and sawn off square. 6. The external condyle and capitellum are removed partly by twisting, partly by dissection, without any division of the skin on the outer side of the arm.

If there is dense osseous union that cannot be overcome by flexion and extension under chloroform, the humerus must be divided through the condyle with bone-pliers, and the operation completed as above.

**OPERATIVE REDUCTION OF OLD UNREDUCED BACKWARD DISLOCATION OF THE ELBOW.**<sup>1</sup>—The first incision is made on the outer side (Fig. 50), beginning well up on the supinator ridge and passing downward to and across the head of the radius, and then for one or two inches posteriorly in the interval between the radius and ulna. Through this the newly formed bone (Fig. 50, A) on the back of the humerus is exposed and chiseled away, and the outer aspect of the external condyle freed by dividing its fibrous attachments to the radius and ulna until the capitellum is freely exposed. The sides of the upper portion of the wound are then retracted, the olecranon exposed, and the sigmoid cavity cleared of the mass of fibrous tissue which, more or less, fills it and binds it to the back of the humerus.

FIG. 50.



Incision for the operative treatment of old unreduced dislocation of the elbow. A. Periosteal bridge and new tissue occupying the posterior surface of the lower extremity of the humerus.

<sup>1</sup> L. A. Stimson: N. Y. Med. Journ., Oct. 24, 1891.



A second incision is now made on the inner side. It is about four inches long and slightly curved, with its concavity forward, and it passes close behind the internal epicondyle or its site if it has been broken off and displaced. The ulnar nerve is found on dividing the fascia, and is carefully drawn forward over the internal condyle. The fibrous bands between the condyle and olecranon are divided. If the epicondyle has been torn from its position and is attached to the humerus higher up, it must be freed and brought back with its attached internal lateral ligament. The division of the soft parts must be continued until the trochlear surface of the humerus is freely exposed. If the injury is of long standing, and thereby the flexor muscles permanently shortened, they must be separated from the internal condyle before reduction can be accomplished. Occasionally a mass of bone of new formation is found also at the back of the internal condyle and must be cut away. After the wound is closed the arm is dressed at right angles in an immobilization apparatus.

### EXCISION OF THE WRIST.

Posteriorly and laterally the wrist is covered only by skin and tendons, with no arteries or nerves of importance except the radial artery, which winds around the outer side to pass again through the first metacarpal space to the palmar aspect of the hand and form the deep palmar arch just below the bases of the metacarpal bones. Between the extensor tendons of the thumb and of the forefinger exists a triangular interval, shown in Fig. 51, the apex of which is directed upward and lies near the middle of the dorsal aspect of the epiphysis of the radius. Within this space are found only the tendons of the long and short extensores carpi radiales, with their insertions into the second and third metacarpals, and as experience has shown that these tendons can be detached or divided without prejudice to the subsequent usefulness of the hand, the articulation can be safely approached through this space.

The extensor tendons are lodged in deep grooves upon



the surface of the radius, from which they cannot be raised without opening their sheaths and, therefore, if it is necessary to take more than a thin slice from the bevelled end of the bone, it should be done with a gouge and as a late step in the operation. In this way it is possible to leave the tendons unhurt and even unseen.

On the inner side the tendon of the extensor carpi ulnaris covers the ulna, in front of it passes the flexor carpi ulnaris on its way to its insertion into the pisiform bone and the base of the fifth metacarpal. The anterior aspect is occupied by the numerous and important flexor tendons, the median and ulnar nerves and several arteries or arterial branches of considerable size. Toward the outer side the tendon of the flexor carpi radialis passes through a groove on the surface of the trapezium, to be attached beyond the base of the second metacarpal. An ulnar incision should pass between the flexor and extensor carpi ulnaris at the anterior border of the ulna.

**BILATERAL INCISIONS** (Lister<sup>1</sup>). (Figs. 51 and 52, A, B.)—All adhesions are first broken down by freely moving all the articulations of the hand. The radial incision is made in the situation indicated by the line *L L* in Fig. 51, or Fig. 52, A. It commences above at the middle of the dorsal aspect of the radius on a level with the styloid process. Thence it is at first directed toward the inner side of the metacarpo-phalangeal articulation of the thumb, running parallel to the tendon of the extensor secundi internodii; on reaching the radial border of the second metacarpal bone it is carried downward longitudinally for half the length of the bone.

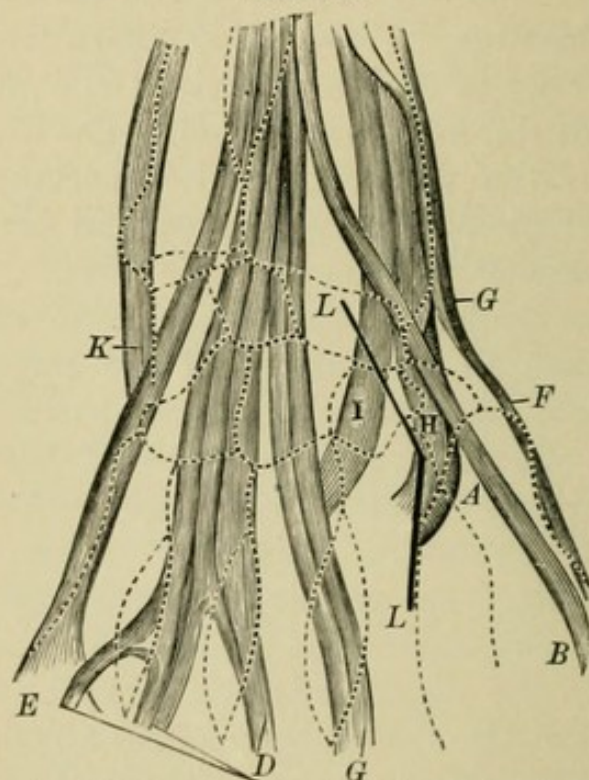
The soft parts on the radial side of the incision are next detached from the bones with the knife guarded by the thumb-nail, so as to divide the tendon of the extensor carpi radialis longior at its insertion into the base of the second metacarpal, and raise it along with that of the extensor breviar, previously cut across, and the extensor secundi internodii, while the radial artery is thrust somewhat outward. The trapezium is then separated from the

<sup>1</sup> Lancet, 1865, p. 335, slightly abridged.



rest of the carpus by means of cutting-forceps applied in line with the longitudinal part of the incision. The removal of the trapezium is reserved till the rest of the carpus has been taken away. The soft parts on the ulnar side of the incision are now dissected up as far as is convenient,

FIG. 51.



Excision of the wrist, Lister. *A.* The radial artery. *B.* Extensor secundi inter-nodii pollicis. *D.* Ext. comm. digitorum. *E.* Ext. min. dig. *F.* Ext. prim. int. pol. *G.* Ext. oss. met. poll. *H, I.* Ext. carp. rad. long. and brev. *K.* Ext. carp. uln. *L, L.* Line of radial incision.

the extensor tendons being relaxed by bending back the hand.

The knife is next entered on the inner side of the arm, two inches above the end of the ulna, immediately anterior to the bone, and is carried downward between it and the flexor carpi ulnaris, and on in a straight line as far as to the middle of the fifth metacarpal bone at its palmar aspect (Fig. 52, *B*). The dorsal lip of the incision is raised, and the tendon of the extensor carpi ulnaris cut at its insertion into the fifth metacarpal, and dissected up from its groove in the ulna, care being taken to avoid isolating it from the integuments, and thus endangering its



vitality. The extensors of the fingers are then readily separated from the carpus, and the dorsal and internal ligaments divided, but the connections of the tendons with the radius are purposely left undisturbed.

The anterior surface of the ulna is then cleared by cutting toward the bone, so as to avoid the artery and nerve; the articulation of the pisiform is opened, if that has not been already done in making the incision, and the flexor tendons are separated from the carpus. While this is being done the knife is arrested by the process of the unciform bone, which is clipped through at its base with pliers. The knife must not be carried further down the hand than the bases of the metacarpal bones, so as not to injure the deep palmar arch. The anterior ligament of the wrist-joint is divided, after which the junction between the carpus and metacarpus is severed with cutting-pliers, and the carpus extracted through the ulnar incision by seizing it with strong forceps and touching with the knife any ligamentous connections that may remain undivided.

The hand being now forcibly everted the articular ends of the radius and ulna will protrude at the ulnar incision. If they appear sound or only superficially affected, the articular surfaces only are removed. The ulna is divided obliquely with a small saw, so as to take away the cartilage-covered rounded part over which the radius sweeps, while the base of the styloid process is retained. The end of the radius is then cleared sufficiently to allow a thin slice to be sawn off parallel to the general direction of the inferior articular surface and the articular facet on the ulnar side of the bone is clipped away with bone-forceps. If, on the other hand, the bones prove to be deeply carious, the pliers or gouge must be used with the greatest freedom.

The metacarpal bones are next dealt with on the same principle. If sound, only the articular surfaces are clipped off.

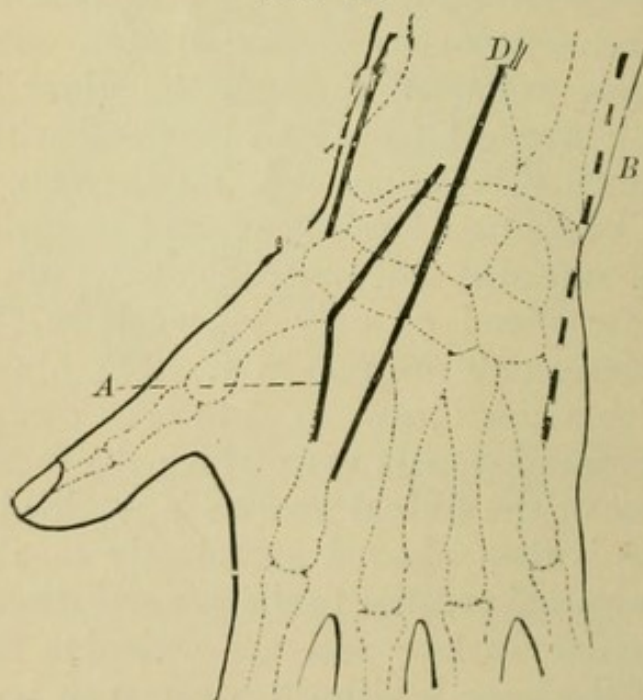
The trapezium is next seized with forceps and dissected out, so as to avoid cutting the tendon of the flexor carpi radialis, which is firmly bound into the groove on its



palmar aspect, the knife being also kept close to the bone elsewhere to preserve the radial artery. The articular end of the first metacarpal is then removed. Lastly, the articular surface of the pisiform is clipped off, the rest of the bone being left if sound. The process of the unciform is also left if sound. The radial wound may be closed with sutures, but the ulnar one must be kept open for drainage, and the limb must be bound upon a splint in such a manner that while the wrist is firmly fixed passive motion can be given regularly to the fingers.

**RADIAL INCISION (Ollier).** (Fig. 52, C).—An incision involving only the skin is begun on the outer side of the wrist, an inch below the styloid process of the radius, and

FIG. 52.



Excision of the wrist. *A.* Lister's radial incision. *B.* Lister's ulnar incision. *C.* Ollier. *D.* Von Langenbeck.

carried upward along the outer border of the bone for a greater or less distance, according to the amount to be removed. A cutaneous branch of the radial nerve is exposed and drawn aside, the fascia divided, and the extensor tendons of the thumb recognized. These tendons are a guide which is easily found. They are superficial, and contained in a separate groove. On opening the sheath



and drawing them aside, the insertion of the supinator longus is exposed, on the outer side of which, and parallel to the tendon, the periosteum of the radius must then be divided.

Using a straight, sharp elevator, the surgeon next detaches the tendon of the supinator, preserving its relations with the periosteum, and then denudes the lower end of the radius inward, removing periosteum and capsule. Then, bending the hand forcibly toward its inner side, he separates the remaining fibrous attachments and dislocates the lower end of the radius outward. The ulna can be protruded through the same wound and denuded from below upward, but it is better to make a longitudinal incision on the inner side for this purpose.

The ends of the radius and ulna are then sawn off, and through the gap thus left the carpal bones are successively removed with gouge and forceps.

**DORSO-RADIAL INCISION** (Von Langenbeck). (Fig. 52, *D*.)—The hand is bent toward the inner side, and an incision is begun at the ulnar border of the second metacarpal bone near its middle and carried upward four inches, crossing the ulnar edge of the tendon of the extensor carpi radialis brevis where it is inserted into the base of the third metacarpal bone, and splitting the dorsal ligament of the wrist exactly between the tendons of the extensor secundi internodii and extensor of the forefinger. This incision should be carried down to the bone, and the soft parts detached on the radial side with an elevator; the tendons, where they lie in the grooves, are raised bodily with the periosteum, and their sheaths are not opened.

The hand is flexed so as to make the first row of carpal bones present in the wound; the scaphoid is separated from the trapezium and taken out, and followed in turn by the semilunar and cuneiform, the interosseous ligament being cut and the bones pried out with a small elevator. The trapezium and pisiform are left if possible.

To take out the second row, the operator steadies the round articular end of the os magnum with the fingers of



his left hand, and, while an assistant abducts the thumb, he divides with a knife the connection between the trapezium and trapezoid, passes the knife into the carpo-metacarpal joint, and cuts the ligaments on the dorsal side of the ends of the metacarpal bones while an aid flexes them. In this way the trapezoid, magnum, and unciform can be brought out together.

The lateral ligaments are then carefully separated from the radius and ulna, the bones protruded and sawn through.

### EXCISION OF THE HIP-JOINT.

In this joint, as in the shoulder, the disease is often confined to the head of the bone, and under such circumstances partial excision should be performed. When the acetabulum is diseased the loose pieces must be picked out and the gouge applied to the roughened surface. The line of section of the femur should pass below the great trochanter, however limited the disease may be, for if this process is left it is liable to protrude through the wound and obstruct the escape of the secretions. If the disease extends beyond this point, additional slices must be removed, or the gouge used until healthy bone is reached.

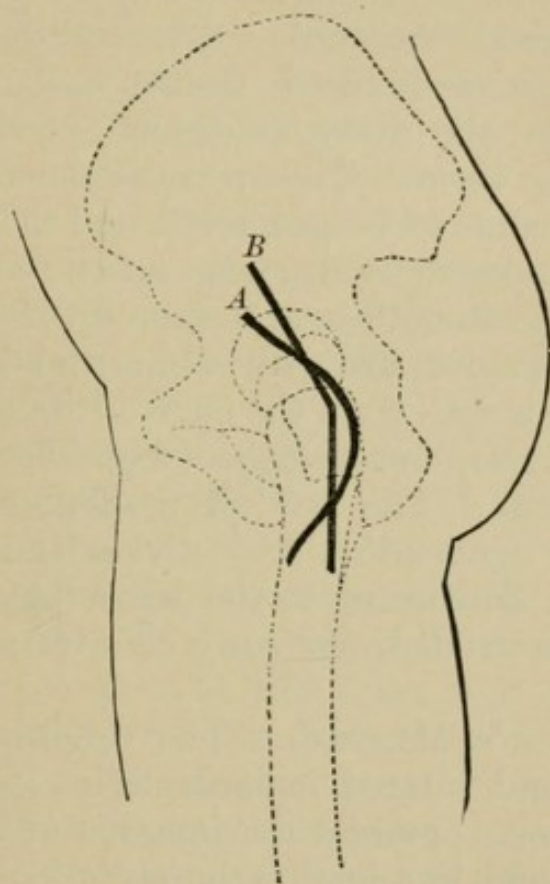
The anatomical disposition of the parts is such that the joint is best approached from the outer and posterior aspect, the incision passing over the top of the great trochanter. Different surgeons have inclined the upper part of the incision forward and backward at various angles, or have dissected up a triangular flap, its apex directed sometimes upward, sometimes downward.

**SAYRE'S METHOD.** (Fig. 53, A.)—Enter the point of the knife midway between the anterior superior spine of the ilium and the top of the great trochanter and drive it down to the bone; then, keeping it firmly in contact with the bone, draw it in a curved line to the top of the trochanter, midway between its center and posterior border, thence forward and inward, making the whole length of the incision from four to eight inches, according to the size of the thigh. Make sure that the periosteum is divided throughout.



Then, drawing aside the soft parts, divide the periosteum transversely just opposite to, or a little above, the lesser trochanter, carrying the division as far as possible around the bone. Beginning at the angle formed by the two incisions, raise the periosteum on each side, together with its membranous attachment, as far as the digital fossa. Then, substituting a knife for the periosteal ele-

FIG. 53.



Excision of the hip. A. Sayre. B. Ollier.

vator, divide the insertions of the muscles at this point, keeping close to the bone, and afterward separate the remaining periosteum as far as can be done without tearing it. Then adduct the leg slightly and raise the head of the femur gently out of the acetabulum; this will detach the last of the periosteum and allow the finger to be passed around the bone as a guide for the saw, which should be applied just above the lesser trochanter.

If the bone cannot be readily dislocated, saw it through first and then remove the head with the forceps or elevator.



If the acetabulum is perforated, the edges must be chipped off very carefully down to the point at which the periosteum on the pelvic side is still adherent.

**OLLIER'S METHOD.** (Fig. 53, *B.*)—Ollier makes a somewhat similar incision. It begins four finger-breadths below the crest of the ilium, and the same distance behind the anterior superior spine, runs downward to the most prominent part of the great trochanter, and thence directly down the shaft of the femur. Its upper part should involve the skin and fascia only. The posterior lip, including the glutæus maximus, is drawn back, exposing the glutæus medius, the fibers of which are then separated without cutting them. This permits the attachments of the glutæus medius to be preserved, and the glutæus minimus can be exposed by drawing apart the edges of the opening made in the other, and then divided in the same manner or drawn forward with a blunt hook.

The capsule is split from the edge of the cotyloid cavity to the digital fossa, and detached together with the tendinous insertions. The head of the femur is dislocated backward, the ligamentum teres divided, and the denudation continued downward to the lesser trochanter. The bone is then protruded and sawn off with a wire or common saw.

**LANGENBECK'S METHOD.**—The thigh is flexed at an angle of  $45^{\circ}$  and rotated inward. The knife is entered just below a point opposite the junction of the upper and middle thirds of a line joining the posterior superior spine of the ilium and great trochanter; in other words, just below the most anterior portion of the great sciatic notch. Thence following the long axis of the flexed femur it is carried in a straight line over the outer surface of the great trochanter, making an incision which penetrates to the bone throughout and is about four or five inches long. The glutæi are thus divided in the direction of their fibers, the margins of the wound retracted, and the capsule opened by a longitudinal aided by a transverse incision close to the edge of the acetabulum. After severing the attachments of the muscles to the great trochanter the head of



the bone is dislocated backward and brought out of the wound and sawed off.

**ANTERIOR INCISION.**—Roser recommends, in order to preserve the trochanter, an anterior incision in the line of the neck of the femur, beginning just outside the crural nerve, and dividing the iliacus, rectus, sartorius, and tensor vaginae femoris. The capsule is divided in the same line, the head turned forward into the wound by rotating the thigh outward, and sawn off.

Lücke and Schede have modified this by making the incision vertical instead of transverse, beginning outside the crural nerve a little below and to the inner side of the anterior superior spine of the ilium, and running directly downward. The inner borders of the sartorius and rectus are exposed and drawn outward, and then the outer border of the psoas-iliacus exposed and drawn inward. Then the thigh is flexed, abducted, and rotated outward, and the capsule divided.

A similar incision and approach to the joint may be used in the operative reduction of old thyroid or dorsal dislocation.

Barker<sup>1</sup> employs the following method: The incision begins on the front of the thigh half an inch below the anterior superior spine of the ilium, and extends about three inches downward and a little inward. The muscles are recognized as the successive layers of tissue are divided. The tensor vaginae femoris and glutæi are drawn to the outer side, the sartorius and rectus to the inner, and the neck of the femur exposed. The external cutaneous nerve will be encountered in the upper angle of the incision; lower down and deeper are the external circumflex vessels. The deeper part of the incision need not be made as long as the more superficial. Any abscess which may be opened should be thoroughly washed out before proceeding further.

The neck of the femur is divided with a narrow saw in the direction of the external wound, and the diseased head removed with sequestrum-forceps. The acetabulum

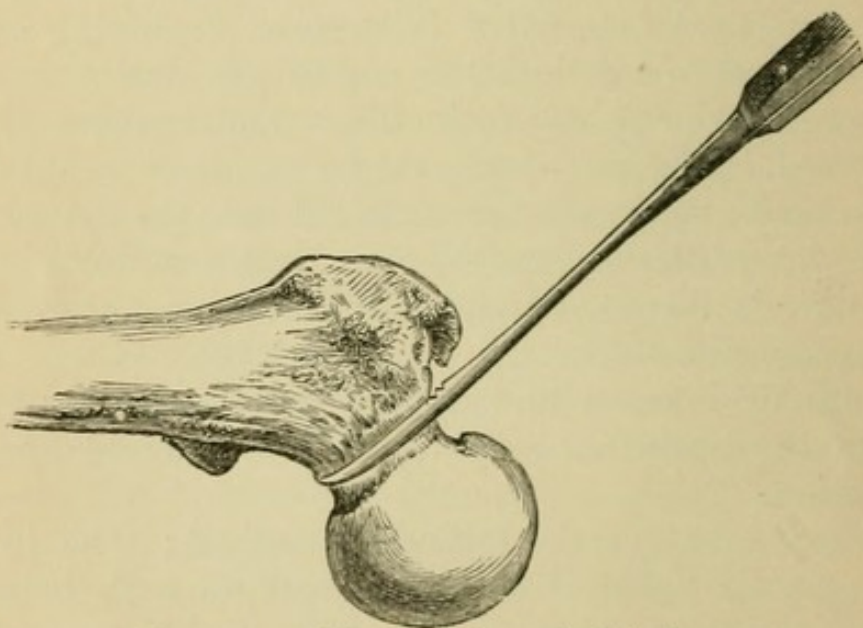
<sup>1</sup> Brit. Med. Journ., 19, 1889.



and all other parts of the joint-cavity are explored by the forefinger, and any diseased tissue cut or scraped away. Mr. Barker fills the wound with iodoform emulsion and generally closes it up tight. The patient is placed upon a double Thomas splint for several weeks.

**ARTHRECTOMY OF THE HIP-JOINT BY CHISELING THROUGH THE GREAT TROCHANTER (Tiling).—**An incision three or four inches long is made along the anterior

FIG. 54.



Subcutaneous division of the neck of the femur.

border of the great trochanter, which is chiseled off and laid back. The capsule of the joint is divided longitudinally, the periosteum elevated from the neck of the femur, and the head of the femur dislocated. Then the lesser trochanter is also chiseled off and the acetabulum cavity is freely accessible.

### **ANCHYLOSIS OF THE HIP-JOINT.<sup>1</sup>**

When the ankylosis is not associated with the loss of a great part of the head and neck of the femur—that is, when it follows inflammation of the joint due to rheuma-

<sup>1</sup> This subject, which properly belongs under osteotomy, is placed here on account of its intimate relations with excision of the joint.




tism, pyæmia, traumatism, or chronic disease that has been arrested at an early stage—Mr. Adams's operation of subcutaneous division of the neck of the femur may be applicable, but usually division below one or both of the trochanters, or excision of the head and neck is to be preferred.

Division below the lesser trochanter is only undertaken to remedy a faulty position of the limb, for there can be no question of establishing a new joint below the insertion of the psoas and iliacus. It is doubtful also if a permanently movable joint can be obtained by division at a higher point; it certainly cannot unless a portion of the bone is removed, and probably not even then, for the tendency of the cut ends to unite after a time is very great.

**SUBCUTANEOUS DIVISION OF THE NECK OF THE FEMUR (Adams<sup>1</sup>).**—The only special instrument needed is a saw somewhat resembling a tenotomy knife, the cutting part being one and a-half inches long and three-eighths of an inch wide, and the shank about two and a-half inches long. (Fig. 55.)

A tenotomy knife is entered a little above the top of the great trochanter and pushed straight in to the neck of

FIG. 55.



Adams's saw for subcutaneous division of the neck of the femur.

the femur, dividing the muscles and opening the capsule freely. The soft parts being fixed by the thumb and fingers of the left hand, the knife is withdrawn and the saw passed promptly down to the bone through the track made by it.

The bone is then sawn through from before backward, so that the line of section shall be at right angles to the

<sup>1</sup> An operation for bony anchylosis of the hip-joint with malposition of the limb, by subcutaneous division of the neck of the thigh bone, by William Adams. London, 1871. Reprinted from the British Medical Journal of December 24, 1870.



long axis of the neck, care being taken to avoid cutting obliquely through the neck, or in a direction parallel with the shaft of the bone.

**SUBTROCHANTERIC OSTEOTOMY.**<sup>1</sup>—An incision is made from one to two inches long on the outer aspect of the thigh an inch to an inch and a-half below the great trochanter, according to the size of the patient. It should expose the external surface of the femur just below the site of the lesser trochanter. The blade of the osteotome is introduced through this incision, and the bone divided just below the trochanter minor. After each stroke of the mallet the chisel is loosened and its direction slightly changed to cut forward or backward. The bone should not be cut entirely through, but when it seems evident that only a thin shell is left it should be carefully fractured. The after-treatment consists in simple extension.

These two operations are the ones most generally employed for the correction of deformity following ankylosis at the hip in a faulty position. Adams's method is, of course, only applicable to those cases in which the femur still possesses a neck, and inasmuch as the disease which most frequently calls for this kind of interference—namely tuberculosis—generally causes more or less destruction of the head and neck of the femur, the second, subtrochanteric osteotomy, has a wider use.

**Excision.**—Posterior incision as above described, with such modifications as may be made necessary by dislocation; division of the neck with the saw, if possible; otherwise with the chisel; then removal of the head, or what remains of it, by chiseling.

The upper end of the bone is then lodged in the acetabulum, after subcutaneous division of such muscles and soft parts as interfere and removal of the upper part of the trochanter, if necessary. Traction by weight and pulley must be kept up for a long time.

<sup>1</sup> Gant's "Science and Practice of Surgery," 1886.



**EXCISION OF THE KNEE-JOINT.**

This should always be complete to this extent, that a slice should be taken from each bone, but it is not always necessary to remove the entire articular surface of the femur. In children the amount removed should be as small as is consistent with the removal of all that is diseased. The patella may be dissected out and removed entire, or the diseased portions extirpated with the gouge or rongeur, or it may be sawn through parallel with its articular surface. As a general thing the latter method is preferable, unless the bone is so extensively affected that the preservation of even its anterior surface is incompatible with a thorough removal of all the disease.

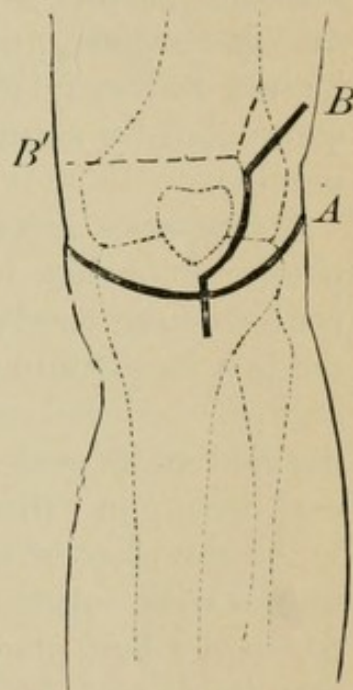
As ankylosis should always be aimed at, the incision may cross the front of the joint and divide the ligamentum patellæ or the patella.

**Semilunar Incision.** (Fig. 56, *A*.)—The knife is entered on one side of the limb at the posterior part of the condyle and carried across midway between the patella and the tuberosity of the tibia to a corresponding point upon the other side. This incision should extend down to the bone throughout, dividing the ligamentum

patellæ. The flap is reflected, the crucial ligaments divided close to their attachment to the tibia, the lateral ligaments divided, the end of the femur cleared as far as may be necessary, with especial care for the safety of the popliteal vessels, protruded through the wound and sawn off. The line of section must be parallel to the line of the articulation, not at a right angle to the axis of the shaft, for that is directed inward and downward. If necessary, additional slices of the bone are removed, or the gouge is used. All the articular cartilages should be removed.

The end of the tibia is next projected, cleaned, and sawn

FIG. 56.



Excision of the knee-joint.  
*A*. Semilunar incision. *B*.  
 Ollier's incision.



off about half an inch below its upper surface. In the young every effort must be made to save each conjugal cartilage and the adjoining portion of the epiphysis in order that the growth of the limb may not be checked.

In sawing the bones it is best not to make a complete section with the saw, but to stop a little short of the posterior surface and complete the separation by fracturing what is left.

Finally, the patella is taken out, and diseased portions of the synovial membrane scraped or clipped off, or the articular surface of the patella may be removed with the saw or rongeur, and the anterior bony shell which is attached to the quadriceps tendon left. The operation is completed by suturing in position the divided ligamentum patellæ.

**Transverse Incision.**—The incision should cross the patella at or just below its center and extend beyond the center of the condyle on each side; at each end should be made a longitudinal incision extending two inches above and one inch below the transverse one; the patella is then divided at its center transversely, the fragments turned up and down, and the joint thus opened and cleaned.

At the close of the operation the patella is replaced and united with sutures; the patella may be entirely removed; or, in the first place, after exposing the bone, the patella may be dissected out, and at the close of the operation the quadriceps tendon reunited.

**ARTHRECTOMY, OR EXTIRPATION OF THE KNEE-JOINT.**—This term has been given to the systematic removal of the synovial membrane and any small portions of the rest of the articulation which may on inspection be found to be diseased. The above-described semilunar incision is employed, and the anterior flap containing the patella reflected. After removing all pulpy and degenerated tissue in the subcrural pouch, the lateral and crucial ligaments, if necessary, are cut, although the latter should be spared whenever possible. The joint is thus thoroughly exposed, and all the diseased parts in its interior excised, together with the semilunar cartilages. Foci of



inflammation in the bone must be removed with the sharp spoon. The field of operation is then flushed out with some antiseptic solution, the ligamentum patellæ sutured in position, and the cutaneous wound loosely united. Whenever it is deemed desirable drainage-tubes may be inserted in the posterior angles of the incision. Immobilization of the leg in extension must be maintained for several weeks.

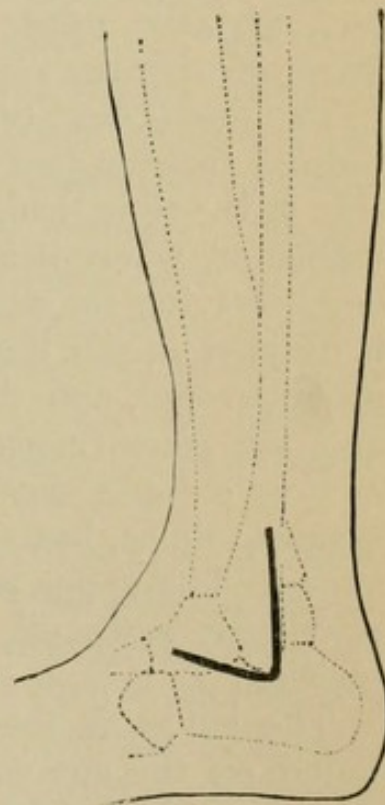
### EXCISION OF THE ANKLE-JOINT.

The results of excision of the ankle-joint have been, on the whole, unfavorable. When the operation has been undertaken on account of caries, the disease has usually returned in the tarsal bones, and rendered secondary amputation necessary. When, on the other hand, it has been performed on account of injury, secondary amputation has been frequently required, and the position of the foot in the cases that recovered has usually been faulty.

As ankylosis is to be expected, the rule in excision is to remove the smallest possible amount of bone, and to make partial instead of complete excision when the disease does not extend to the whole joint. The retention of one or the other malleolus is a great help in preventing shortening, and in the use of a plaster splint. The interosseous membrane between the tibia and fibula must be preserved carefully. It not only has a great tendency to ossify, but also seems to favor the reproduction of bone.

**Operation (TOTAL EXCISION).**—An incision involving only the skin is begun two inches above the external malleolus and a little behind the middle of the fibula, carried

FIG. 57.



Excision of ankle.



directly down to the end of the bone, and thence forward and slightly upward toward the instep for an inch (Fig. 57). The periosteum covering the fibula is divided throughout and dissected up from the bone with the attachment of the lateral ligaments, especial care being taken not to open the sheath of the peroneal muscles at the posterior border of the malleolus, and to remove all the thick periosteum and the interosseous membrane on the inner side. If necessary, a transverse liberating incision may be made through the periosteum at the upper end of the cut. The bone is then divided with a keyhole saw or chisel, the upper end of the lower fragment drawn out of the wound to expose and facilitate the separation of the remaining attachments, and the piece removed.

The soft parts are then held out of the way with retractors, and the upper articular surface of the astragalus sawn off with the keyhole saw, but not removed.

The foot is next turned upon its outer side, and a longitudinal incision two or three inches long made along the side of the tibia, ending half an inch below the tip of the malleolus, where it is then crossed by a short horizontal one involving the skin only. The periosteum of the tibia is divided in the line of the incision and transversely at its upper end, and dissected off, the bone sawn through, and the piece removed. Langenbeck makes the line of section oblique downward and outward, because it is easier to do so, but most surgeons prefer to have it transverse. The upper part of the astragalus, which has been previously sawn off, is then removed through the same incision.

The gouge is used to scrape away any diseased parts found on the cut surface of the astragalus, or the bone may be seized with strong forceps and dissected out entirely.

If the injury has affected the astragalus only (as in some gunshot wounds), its splinters are best removed through a longitudinal incision upon the dorsum of the foot between the extensor tendons of the first and second toes.



**VOGT'S METHOD, BY REMOVAL OF THE ASTRAGALUS.** (Fig. 69.)—A serious objection to the use of the preceding operation in cases of tuberculous disease lies in its insufficient exposure of the interior of the joint to view, and it has been proposed by Hueter to return to the old method of an anterior transverse incision with division of all the extensor tendons, and by Busch to open the joint by cutting across the sole and sawing through the calcaneum. Vogt,<sup>1</sup> however, has proposed and employed another method, which avoids the extensive division of the soft part and which enables the surgeon to explore the joints thoroughly, and, if necessary, to excise the synovial membrane. It consists in primary methodical extirpation of the astragalus without resection of the malleolus.

**Operation.**—A longitudinal incision on the outer side of the extensor tendons, three or four inches long, beginning above between the tibia and fibula, and ending below at the line of the calcaneo-cuboid joint; after division of the fascia the tendons are raised in their sheaths, carefully separated from the underlying parts, and strongly retracted to the inner side. The extensor brevis is then cut, the outer side of the incision retracted, the capsule split longitudinally to its full extent and separated on both sides from the bone with knife and elevator, the head and neck of the astragalus cleared, and the astragalo-scaphoid ligament divided.

A second incision is made from a point somewhat below the center of the first backward below the external malleolus, dividing everything down to the astragalus, but sparing the peroneal tendons. The foot is then supinated, the anterior ligaments cut away from the external malleolus, and the strong interosseous ligament divided by thrusting a small strong knife into the groove between the astragalus and calcaneum. The head of the astragalus is then drawn forcibly outward with a stout hook, while the foot is supinated, the deep portion of the internal lateral ligament cut by passing a knife between the malleolus and the astragalus, the latter drawn forward into the incision, and its posterior attachments cut.

<sup>1</sup> Centralblatt für Chirurgie, 1883, p. 289.



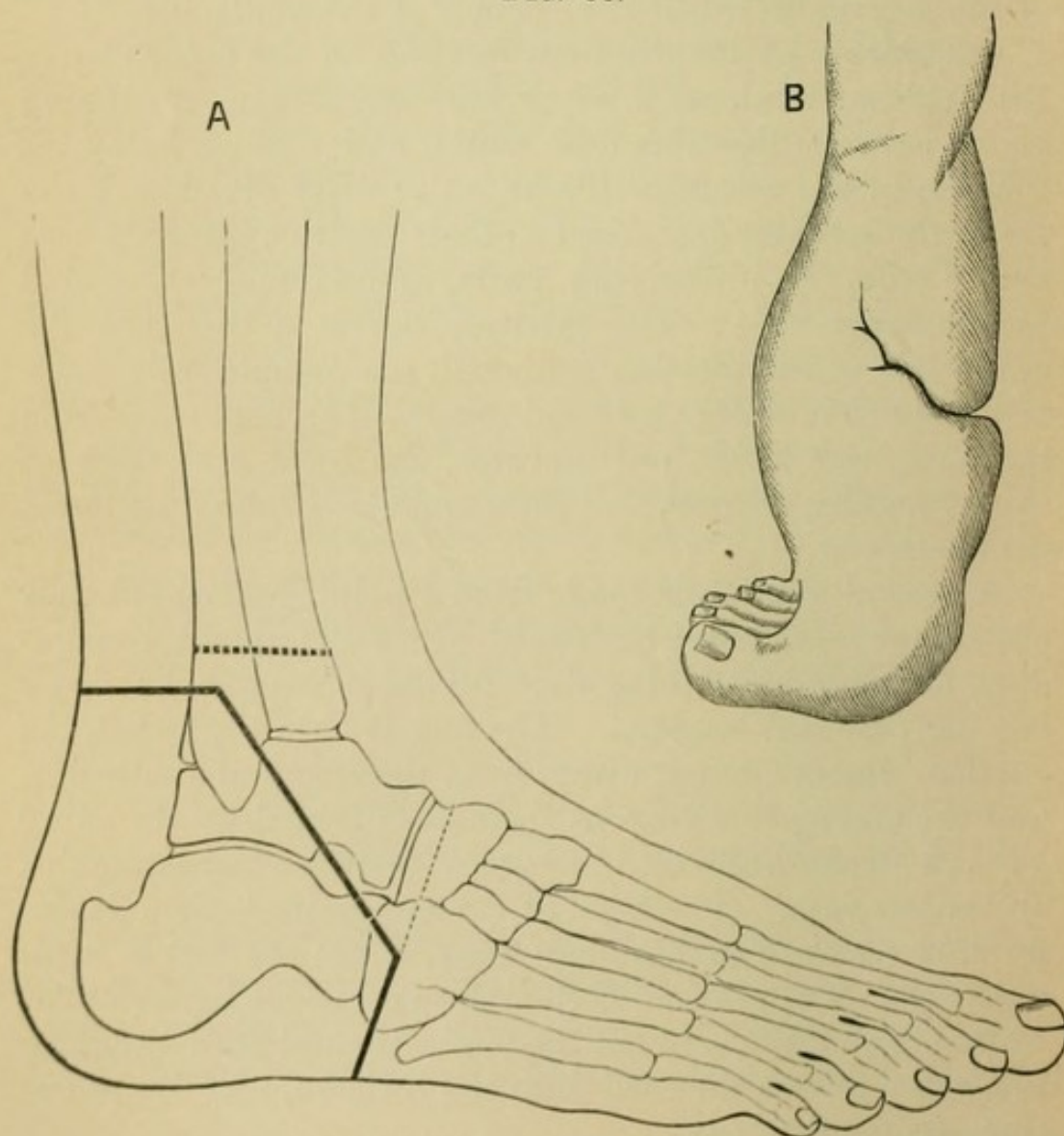
The remainder of the operation will vary with the extent and character of the disease. All the adjoining bones are freely exposed to inspection, and can be scraped, gouged out, or sawn off.

I have found the execution of this operation easy, even when the capsule was much thickened by disease, and its exposure of the interior of the joint is very satisfactory.

#### **OSTEOPLASTIC EXCISION OF THE FOOT (HEEL AND ANKLE) (MIKULICZ).**

This ingenious operation, the results of which have proved very satisfactory, was introduced by Mikulicz in

FIG. 58.



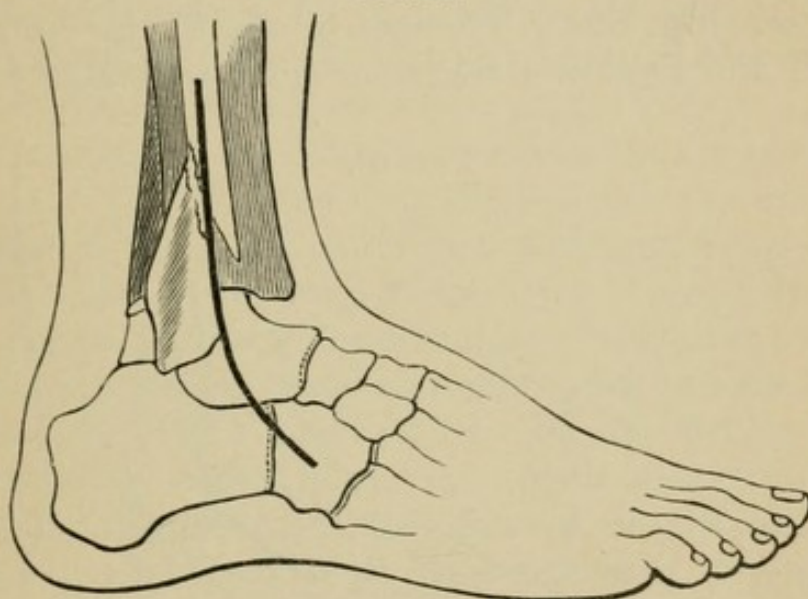
Osteoplastic excision of the foot. (MIKULICZ.)



1881.<sup>1</sup> It is specially applicable to cases in which the integument about the heel has been extensively destroyed.

**Operation.** (Fig. 58.)—Abdominal decubitus. An incision beginning a little in front of the tubercle of the scaphoid is carried directly across the sole of the foot to a point just behind the base of the fifth metatarsal bone. From each end of this one another incision is carried backward and upward to the base of the corresponding malleolus, and the upper ends of the last two incisions are then

FIG. 59.



External incision for the operative treatment of old unreduced Pott's fracture. The astragalus is displaced backward. Its articular surface is partially in contact with the new bone developed under the periosteal bridge at the lower end of the posterior surface of the tibia.

united by a fourth which passes horizontally across and divides the tendo Achillis. In all the incisions the knife is made to touch the bone throughout.

The lateral ligaments of the ankle are next divided, the joint opened from behind, and the calcaneum and astragalus carefully dissected from the tissues in front of the incisions and removed by disarticulating at the mediotarsal joint.

Finally, the malleoli and lower articular surface of the tibia and the posterior portion of the cuboid and scaphoid

<sup>1</sup> Archiv für klinische Chirurgie, Vol. XXVI., p. 191.

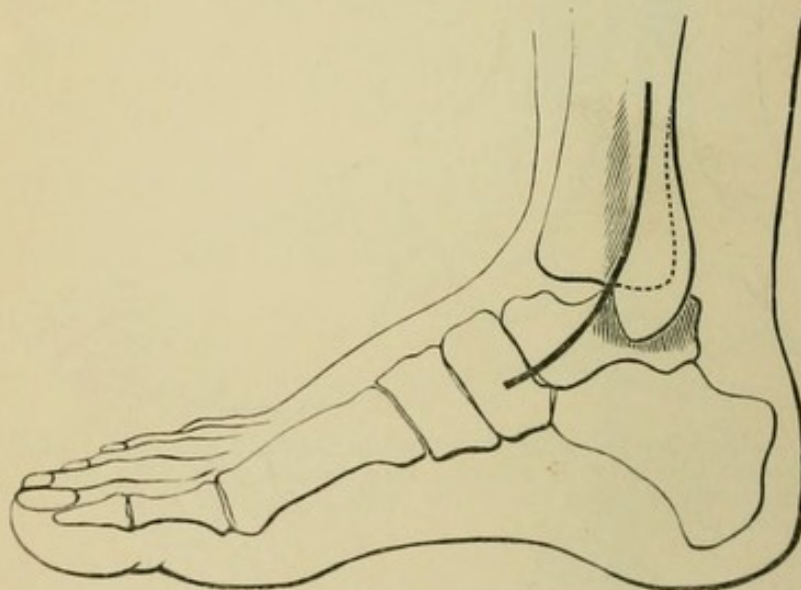


are sawn off, as shown by the dotted lines in the figure, the cut being made from behind forward.

The cut surfaces of bone are then brought into apposition and fastened together with nails or sutures, and the wound closed. Fig. 58, *B*, represents the result.

**OPERATIVE TREATMENT OF OLD UNREDUCED POTT'S FRACTURE.**<sup>1</sup>—The Esmarch rubber bandage or tourniquet is applied and tied below the knee. An incision is begun on the outer side three inches above the ankle, and carried down along the front of the fibula to the malleolus, and thence in a curve forward toward the fifth metatarsal (Fig. 59). The seat of the fibular fracture is exposed, and the lower fragment again separated with the chisel.

FIG. 60.



Internal incision for the operative treatment of old unreduced Pott's fracture. The astragalus is represented as displaced backward.

A second longitudinal incision about five inches long is made over the inner side, extending past the malleolus to the tubercle of the scaphoid (Fig. 60). Through it the mass of new tissue that has formed between the astragalus and the internal malleolus is removed or the broken and displaced malleolus is mobilized.

By now working through both incisions the back of the lower end of the tibia can be freed of such cicatricial tissue

<sup>1</sup> Stimson: N. Y. Medical Journal, June 25, 1892.



or new bone as has formed there, and the foot so mobilized that it can be brought back to its proper place. The periosteum and ligaments are sutured in position with catgut, the wound loosely closed without drainage, and after applying a bulky dressing the tourniquet is removed.

## EXCISION OF THE BONES AND SMALLER ARTICULATIONS.

### EXCISION OF THE SUPERIOR MAXILLA.

This operation may be required on account of malignant tumors of the bone or antrum, or to give access to the base of implantation of a naso-pharyngeal polyp.

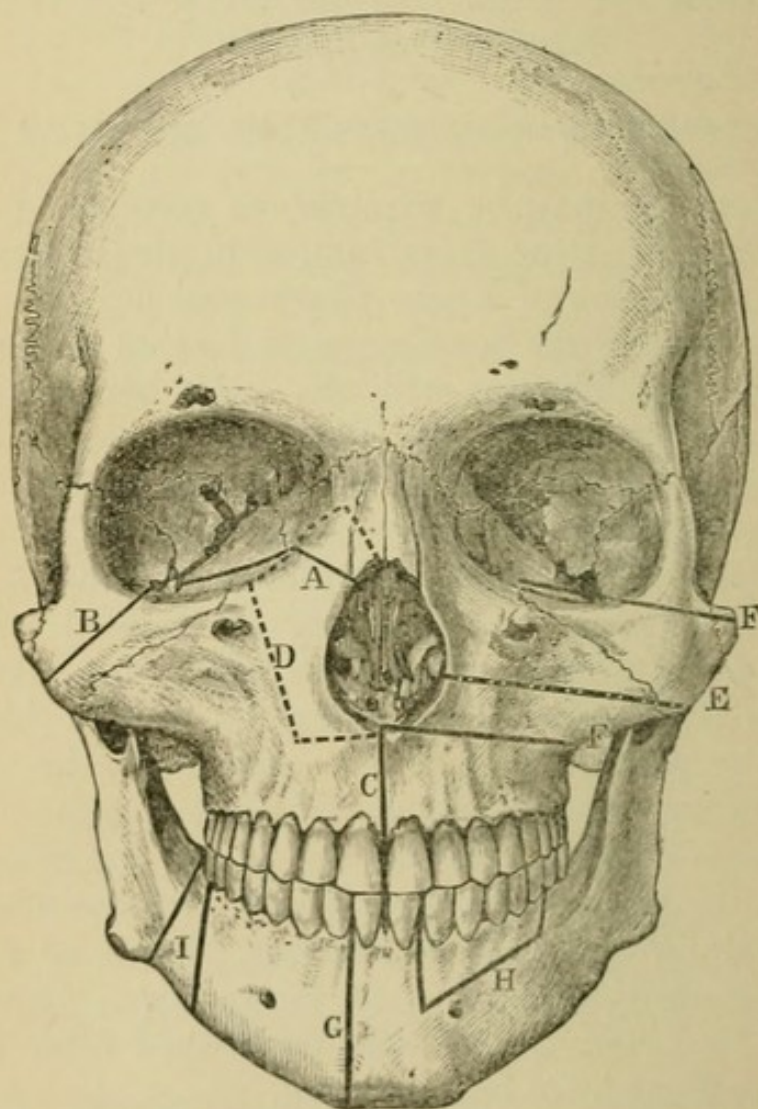
In total excision the bony connections that require to be divided are: (1) The one with the malar bone below the outer angle of the orbit. (2) That with the opposite bone along the center of the hard palate. (3) Those formed by the nasal process near the inner angle of the orbit; and (4) that with the palate bone and pterygoid process of the sphenoid (Fig. 61). The first may be divided by nicking the anterior surface of the bone with a saw, and completing the division with cutting forceps, or with chisel and mallet, or by passing a Gigli wire around it, through the speno-maxillary fissure in the orbit and zygomatic fossa. The second is divided, after having drawn one or both incisor teeth, by means of a saw passed into the nostril, or with cutting forceps with long narrow blades, or a chisel. The third is easily divided with forceps or a chisel, and the fourth by twisting the bone downward after all the other connections have been severed.

The periosteum, covering the floor of the orbit, is thick and easily detached; that on the hard palate is thick and difficult of removal, on account of the irregularities of the surface. There is but little danger of injury to the internal maxillary artery, and it is seldom necessary to apply more than one or two ligatures to its divided branches. Oozing is arrested by packing with aseptic or iodoform gauze.



In partial excision the orbital plate is left, the line of division of the bone passing through the anterior wall of the antrum from the nostril to the lower corner of the union with the malar bone. The remaining attachments are then broken as before. There are also other varieties

FIG. 61.



Lines of bony division in the different operations on the superior and inferior maxillæ. A, B, C. Total excision of the superior maxilla. D. Boeckel's operation. E, C. Guérin's operation. F, F. Langenbeck's operation for naso-pharyngeal polypus. G. Excision of inferior maxilla. H. Removal of a portion of the alveolus (*e. g.*, for epulis). I. Esmarch's operation for anchylosis of inferior maxilla.

of partial excision for the removal of naso-pharyngeal polypi; removal of the nasal process with the nasal bone; removal of part of the hard palate (Nélaton); and temporary removal of different portions, preserving the connec-



tion with the soft parts, and replacing them after the polyp has been removed.

The incisions that have been proposed may be classed as (1) external and (2) median; the former extending from the angle of the mouth upward and outward to the malar bone; the latter passing from or near the middle of the lip up toward the inner angle of the eye. The former are open to the objections that they divide the branches of the facial nerve, endanger Steno's duct and leave a conspicuous scar. The preference is now generally accorded to the median incisions. These follow the outline of the side of the nose more or less closely and some of them are supplemented by a transverse incision, passing a quarter of an inch below the lower margin of the orbit. For partial excision Guérin recommends an incision passing from the side of the wing of the nose along the naso-labial fold to the angle of the mouth (Figs. 61, 63).

In order to avoid the swallowing of blood, it is well not to carry the incision through the lip or divide the gingivo-labial fold until after the anterior face of the bone has been denuded as far as possible.

It is possible to remove the superior maxilla through the mouth without making any cutaneous incisions, but it is a very difficult and painful operation and the hemorrhage is most embarrassing. Larghi has removed both bones through the mouth, upon the cadaver, and says it is easier to remove both together than one alone in this way.

In simultaneous excision of both superior maxillæ, the same incisions may be made on both sides as for the removal of only one, or Dieffenbach's median incision may be made along the ridge of the nose and the middle of the upper lip.

**Operation by a Median Incision.** (Fig. 62, *B*.)—The usual method of operation is as follows: The incision is begun half an inch below the inner canthus of the eye. It is carried down the line of the junction of the nose with the face and along the groove which limits the ala

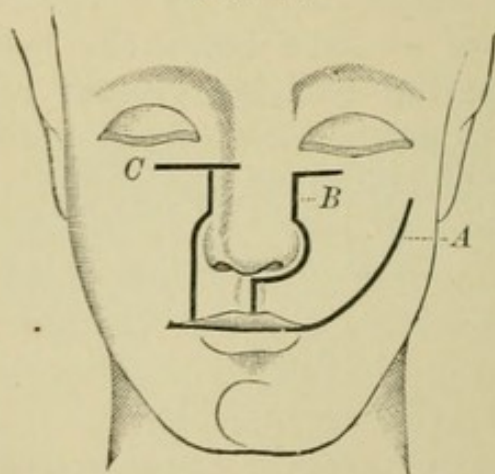


nasi, thence transversely to the septum and so down to the free border of the lip in the median line.

This incision may be supplemented, if necessary, by one joining it at the inner canthus and following the edge of the orbit outward.

The cartilage of the nose is separated from the bone and reflected inward with the small internal flap, the edge of the orbit cleared and the external flap dissected outward as far as to the malar bone above and the tuberosity of the maxilla below, if possible, the infra-orbital nerve being divided at its point of emergence from the foramen.

FIG. 62.



Excision of superior maxilla. A. External incision. B. Nélaton's incision. C. Boeckel's incision.

The periosteum of the floor of the orbit is then detached with the handle of the knife, as far as the speno-maxillary fissure, the malar process or bone cut through with the saw or forceps, and the thin plate of bone forming the floor of the orbit divided with the knife obliquely inward and forward from the anterior end of the speno-maxillary fissure. The superior maxillary nerve, which can be readily distinguished through the bone, should also be divided as far back as possible. Finally, the nasal process is divided.

The incision is then carried through the lip, and the detachment of the external soft parts completed.

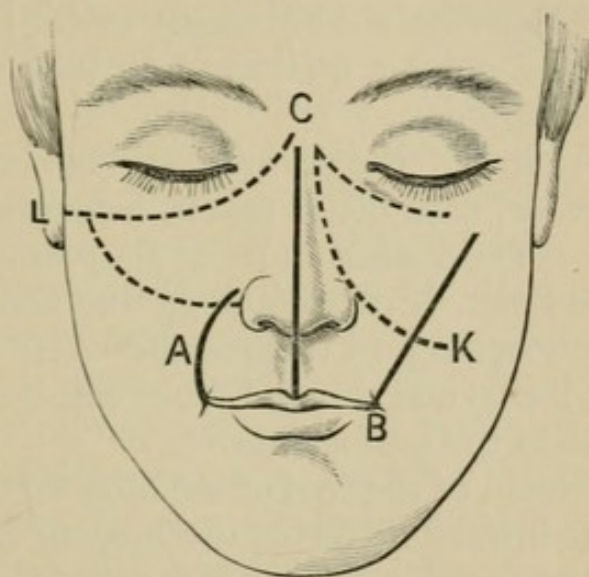
The mucous membrane of the roof of the mouth is divided transversely on a line with the last molar tooth,



and longitudinally in the median line. An incisor tooth is then drawn, and the hard palate divided with saw or forceps close to the septum.

If the mucous membrane of the roof of the mouth is not diseased it may be retained. Instead of the incisions through it just mentioned, one is made along the inner border of the alveolar process, its edge raised, and the membranes detached inward and backward to the median line. After the removal of the bone it unites with the

FIG. 63.



A. Guérin's incision for partial removal of superior maxilla. B. Ollier's incision for subperiosteal excision of superior maxilla. C. Dieffenbach's median incision for removal of both bones. L. Langenbeck's incision for naso-pharyngeal polypus. K. Boeckel's incision for naso-pharyngeal polypus.

cheek, closes in the mouth as before, and may become strengthened by a deposit of bone.

Finally, the bone is grasped with strong forceps, twisted downward to break its posterior connections, and removed, generally bringing with it part of the palate bone, the hamular process of the pterygoid, and some attached muscular fibers.

**Subperiosteal Excision (Ollier).**—This method can be employed with the median incision above mentioned, but Ollier prefers an external one (Fig. 63, B).

An incision is made from the middle of the malar bone to a point on the upper lip one-third of an inch from the



angle of the mouth. If necessary, a second incision must be made at the middle of the lip and carried up around the nostril.

An incision in the mucosa is begun on the outer surface at the interval between the second incisor and the canine tooth (he does not remove the intermaxillary bone, that which supports the incisor teeth) close to the edge of the gum, carried back around the last molar, then forward on the inside to a point corresponding to that at which it was begun, and thence obliquely backward to the median line. A short incision through the periosteum is next made from the anterior external extremity of the former upward and inward to a point a quarter of an inch external to the anterior nasal spine.

The periosteum of the anterior surface is then detached with an elevator, care being taken, however, to divide the infra-orbital nerve with a knife at its point of emergence, and the denudation is carried along the floor of the orbit. Unless it is necessary to remove the nasal process of the maxilla, the lachrymal sac and duct can be left uninjured and adherent to the periosteum.

The periosteum of the roof of the mouth is then separated from without inward as far as the median line.

The nasal and malar processes are divided with forceps, chisel, or chain-saw, as before described, the canine tooth drawn, the edge of the chisel inserted in the gap left by it, and pressed gently backward and inward to the median line, thence directly backward along the suture.

The bone is then twisted out, the palatal sutured to the external periosteum, and the wound closed.

**Excision of the Portion of the Superior Maxilla Lying Below the Infra-orbital Foramen (Guérin's Operation).** (Figs. 61, E C, 63, A).—An incision, slightly convex externally, is made from the ala of the nose to the angle of the mouth, following the crease usually present in the features at this situation. The alveolar mucous membrane is divided at the point of reflection on to the cheek from the level of the last molar tooth to the middle line anteriorly. The soft parts are dissected up and the nostril opened in front.



A narrow saw is passed through the nares and the maxilla sawn horizontally outward. The saw cut passes below the infra-orbital canal well above the teeth and through the malar process and maxillary tuberosity ; or the bone may be chiseled through on this line. The soft palate is detached from the hard by a transverse incision at the last molar tooth. A middle incisor tooth is next removed and the hard palate divided in the median line with a saw, chisel, or forceps introduced through the nostril. The detached piece of bone is loosened with a periosteal elevator and wrenched out.

This operation may be performed subperiosteally (usually for naso-pharyngeal polypus), either by the above-described or by a median incision. The muco-periosteum is divided along the free margin of the inner and outer faces of the alveolar process on the affected side, from the anterior nasal spine around behind the last molar tooth, and detached to the middle line of the hard palate and to its posterior border and upward to near the infra-orbital foramen on the outer surface of the superior maxilla. The lower half of the latter is next removed as indicated above, and at the close of the operation the mucous membrane is united as far as possible by sutures, thus shutting off the nasal from the oral cavity.

This operation affords an excellent view of the nasopharynx.

**Removal of the Superior Maxilla Above the Alveolar Process (Bérard's Operation).**—The median incision is used from below the inner canthus of the eye, following the junction of the nose and face through the center of the upper lip (Fig. 62, *B*). The soft parts on the affected side are raised as for total extirpation of the maxilla and the periosteum of the floor of the orbit is detached as far as the speno-maxillary fissure. The malar process is divided and then the orbital plate inward and forward from the anterior end of the speno-maxillary fissure. The superior maxillary nerve is cut as far back as possible and, finally, the nasal process.

A horizontal saw-cut is then made outward from the



nose above the alveolar process. Any adherent structures between the outer extremity of this cut and that through the malar process are freed with the knife or periosteal elevator and the piece of bone thus mapped out is pried or wrenched away. The sound alveolar process is left *in situ*.

### **SIMULTANEOUS EXCISION OF BOTH SUPERIOR MAXILLÆ.**

An incision may be made from each angle of the mouth to the malar bone and the broad flap reflected toward the forehead, or Dieffenbach's incision made along the ridge of the nose (Fig. 63, C), with or without a transverse one passing across it and below the margin of each orbit.

The bones are removed together, not separately. The malar processes or bones are divided in the usual manner, the nasal processes divided with a chain-saw passed from one orbit to the other through the lachrymal bones, and the vomer separated with cutting forceps. The periosteum of the hard palate is separated from the gums by a semi-circular incision and dissected back, the posterior connections broken, and the bone removed by twisting it downward and forward.

### **PARTIAL AND TEMPORARY EXCISION OF THE SUPERIOR MAXILLA TO FACILITATE THE REMOVAL OF NASO-PHARYNGEAL POLYPS.**

**Resection of Posterior Portion of Hard Palate (Nélaton).**—The soft palate is first divided from before backward along the median line, and the incision prolonged forward through the periosteum of the hard palate as far as may be judged necessary. A transverse incision is next made on one side from the anterior extremity of the first toward the teeth, and the flap, including half the soft palate, dissected off the bone from the median line outward. The mucous membrane on the floor of the corresponding nostril is then divided close to the septum, the bone perforated at the anterior corners of the denuded surface, and the

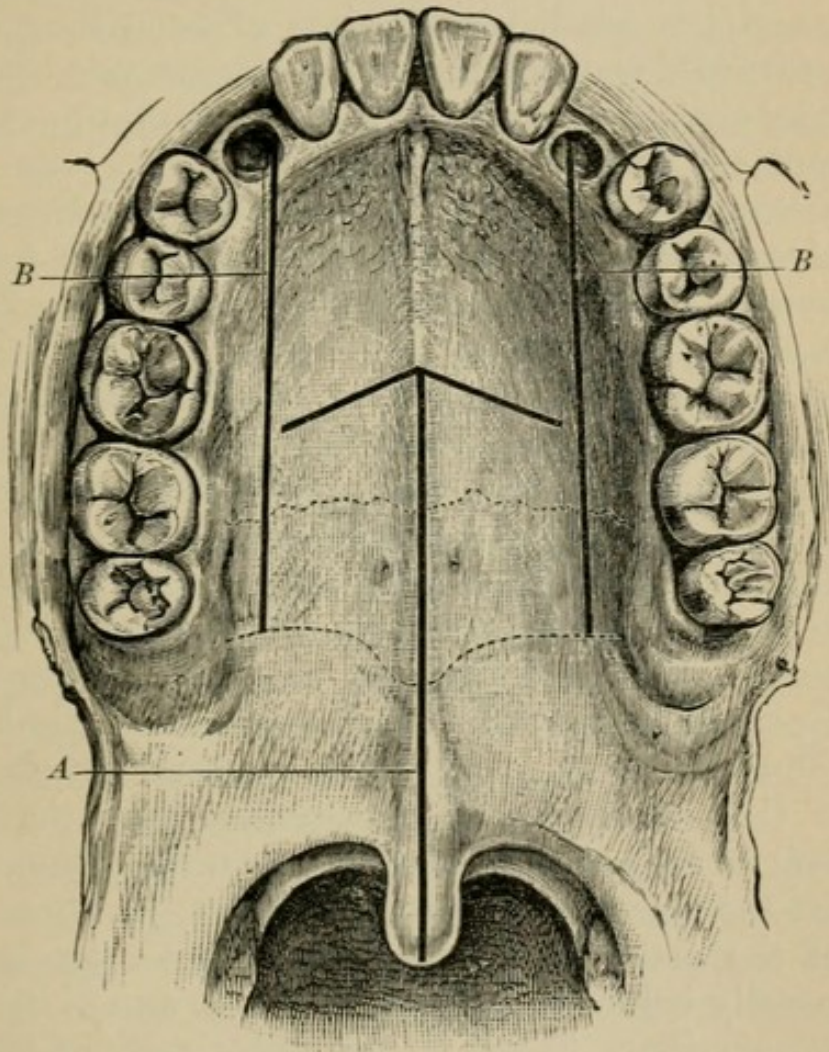


separation of the quadrilateral piece accomplished with cutting forceps.

After removal of the polyp the soft parts are replaced and stitched together. The bone is sometimes reproduced.

A little larger opening may be obtained by making the transverse incision extend from one side of the hard palate

FIG. 64.



Resection of hard palate to expose nasal fossæ. *A.* Nélaton's operation. *B.* Chalot's operation.

to the other, and then chiseling away the included bone—in other words, nearly the whole of the bony floor of the nasal cavity (Fig. 64, *A*). At the close of the operation staphylorrhaphy is performed.

**Osteoplastic Resection of the Anterior Portion of the Palate** (Chalot, Fig. 64, *B*). The upper lip is everted



and the mucous membrane cut in the line of its reflection from the bicuspid teeth of one side to a corresponding point on the other—the nasal fossa is thus entered, the canine teeth are extracted, and the alveolus and hard palate divided on each side by the chisel and knife. The line of section runs through the canine sockets and passes back through the hard palate close to its lateral margins as far as its posterior border. The vomer is then separated, and the quadrilateral piece of bone thus marked out is turned down, the unsevered attachments of the soft palate serving as a hinge. At the close of the operation it is replaced and sutured in position.

**Resection of the Upper Portion, Leaving the Hard Palate and Alveolar Process (Von Langenbeck).**—The following is somewhat abridged from the description in the *Deutsche Klinik*, 1861, page 283 :

An incision convex downward from the ala of the nose to the malar bone, and along the zygoma backward. A second incision from the nasal process of the frontal along the lower border of the orbit, meeting the first at the middle of the malar bone (Fig. 63, L).

The knife penetrates to the bone throughout. The periosteum and overlying soft parts are only separated sufficiently to permit the use of a saw or chisel along the lines thus indicated. But the periosteum on the upper side of the second incision is detached from the floor of the orbit as far back as the speno-maxillary fissure.

Next the masseter is separated from the exposed portion of the malar bone, and a pointed elevator is passed horizontally below the zygomatic arch and through the pterygo-maxillary fissure to the outer wall of the nasal cavity. It is recognized here by a finger introduced through the mouth. A fine saw is passed in this line and made to cut through the zygoma and malar bone upward into the speno-maxillary fissure ; it then follows the floor of the orbit and ends just short of the lachrymal bone ; or the cut may be made with a chisel from before backward.

The saw is then reëntered into the pterygo-maxillary



fissure at the outer extremity of the line of bony division at the lower border of the malar bone, and, passing through the walls of the antrum very nearly in the line of the lower cutaneous incision, enters the anterior nares close to the nasal floor. An elevator is now passed a second time into the pterygo-maxillary fissure, and the portion of the superior maxilla which has been separated is forced up till the free portion of the malar bone is brought into the middle line of the face. The attachments of this fragment consist of the nasal bone and the nasal process of the superior maxilla, with the hitherto undisturbed periosteum and soft parts at the base of the original tongue-shaped incision.

A less satisfactory view of the naso-pharyngeal region is obtained if the floor of the orbit is preserved. The periosteum on the upper side of the orbital incision is not disturbed. The zygoma is cut through as before into the spheno-maxillary fissure. A chisel is driven from before backward in the line of the upper cutaneous incision through the anterior and outer walls of the antrum just below the orbital plate, then through these openings the inner wall of the antrum is divided. The chisel penetrates to the spheno-maxillary fossa. The lower line of bony division is the same as in the last method described, and the fragment is turned over in the same manner.

After the completion of the operation it is replaced and maintained in position by sutures or pressure.

Von Langenbeck's operation is difficult; it destroys the orbicular branches of the facial nerve, often damages the lachrymal duct, and gives very little better view of the nasal cavity than Guérin's partial extirpation of the superior maxilla.

#### OTHER METHODS OF GAINING ACCESS TO THE PHARYNX THROUGH THE NOSE.

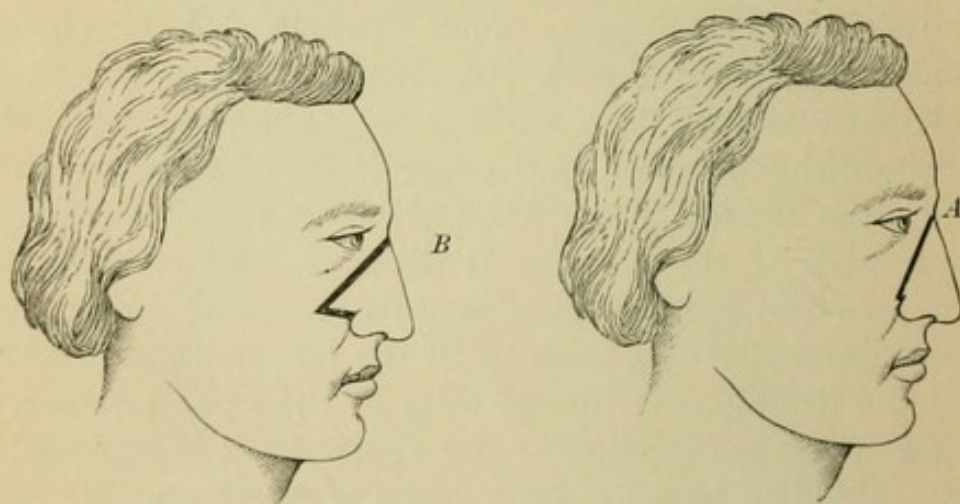
These may here be described, although properly speaking they are not resections of the superior maxilla.

**Boeckel's Operation.** (Fig. 61, *D*, and Fig. 63, *K*).—The incision begins near the root of the nose slightly to one side of the median line. It passes in a curved direction



down to the lower free border of the nasal bone; from here to the junction of the ala and cheek and a short distance outward on the cheek. The second incision passes from the origin of the first at the root of the nose along the edge of the orbit to the infra-orbital foramen. It must clear the lachrymal sac. This tongue-shaped flap is raised with the periosteum and exposes a triangular surface of bone. After retracting the soft parts a chisel is driven through the superior maxilla so as to divide it vertically just inside the infra-orbital foramen between the margin of the orbit and the upper surface of the hard palate. The chisel should be obliquely directed and enter the nasal cavity near the vertical plate of the palate bone.

FIG. 65.



Ollier's operation for removal of a naso-pharyngeal polyp. *B*. Modification for a very large polyp.

The nasal process of the superior maxilla and the nasal bone are cut very nearly in the line of the upper cutaneous incision. The lachrymal sac must be spared. The bony division is carried down to the lower free border of the nasal bone. Finally the chisel is driven into the nasal cavity through the anterior and inner walls of the antrum on a line reaching from the lower termination of the first bony incision to the floor of the nose.

The inferior and middle turbinated bones are removed with the mass thus marked out, which is more or less pyramidal in shape with the apex toward the posterior nares.



At the close of the operation the periosteum and skin are replaced and sutured in position.

*Ollier* turns the whole nose downward. He begins his incision at the edge of the bone close behind the ala of the nose, carries it upward along its side to the highest part of the depression between the eyes, then across and down to the corresponding point on the other side (Fig. 65, *A*). The bone is sawn through in the line of the incision, the necessary liberating incisions made in the septum or the sides, and the nose turned down.

The septum is pressed aside, the polyp extracted, its base of implantation scraped and the nose replaced.

A *modification* which is sometimes desirable on account of the size of the polyp or the distance of its implantation is indicated in Fig. 65, *B*. The incision runs more obliquely backward and a transverse one is made from each end of the ala of the nose. The bone is divided in the direction of the cutaneous incisions, in the vertical one as before described, in the horizontal one by passing a fine saw across the nostrils through holes made between the bone and cartilages and sawing backward. This line of section must be high enough to avoid the roots of the teeth.

In some cases it is sufficient to mobilize the *lower end of the nose* by an incision under the lip in the gingivolabial fold and then by carrying it and the lip upward very free access to the nasal fossæ is obtained.

*Annandale*,<sup>1</sup> after turning the lip and nose upward in this fashion, saws through the alveolus and hard palate in the middle line close to one side of the vomer. The soft palate may also be split if more space is required. The saw cut can then be made half an inch or more wide by prying apart the maxillæ. This affords a somewhat limited means of access to the naso-pharyngeal region.

#### EXCISION OF THE INFERIOR MAXILLA.

This may be total or partial, and partial excision may involve the removal of any part of the body of the bone

<sup>1</sup> Lancet, Jan. 5, 1889.



or of the ascending ramus. Partial excision of the body may sometimes be accomplished through the mouth without the aid of a cutaneous incision, or by an incision along the lower border of the bone with or without another at right angles to it extending toward or even through the lip, or by two vertical incisions downward from the angles of the mouth when only the upper part of the body of the bone is to be removed.

When the ascending ramus also is to be resected the incision should pass along the lower border of the bone to the angle of the jaw, and then upward along the posterior border of the ramus to the level of the lobule of the ear. If the incision is carried higher the facial nerve is necessarily divided with consequent paralysis of the muscles supplied by it, a complication which should be avoided. The horizontal portion of the incision should be a little below the border of the bone in order that the cicatrix may be less conspicuous. Syme removed the entire ramus with the condyle, without opening into the cavity of the mouth, by an incision slightly convex backward extending from the zygoma to, and a little beyond, the angle of the jaw.

The principal danger is of injury to the internal maxillary artery, which lies almost in contact with the inner side of the neck of the condyle. The lingual nerve also is in close relation with the inner side of the ramus, lying between it and the internal pterygoid muscle. Maisonneuve introduced a modification of the method of operating which has rendered it almost easy and has diminished the above-mentioned danger. It consists in separating the attachments of the condyle by twisting and tearing out the bone after all the connections have been divided. If this modification, which sounds, perhaps, rougher and less surgical than it really is, is not adopted, the joint must be approached from in front so as to avoid the external carotid, which lies close behind the bone in the substance of the parotid. It is sometimes allowable to divide the neck of the condyle, or even the ramus below the sigmoid notch, with cutting-pliers, and leave the upper fragment in place.



Another danger is in the division of the attachments of the genio-hyo-glossus muscles to the bone. The tongue, deprived of its support, falls back upon and closes the glottis. As a preliminary, therefore, to any operation in which these attachments are divided, a stout ligature should be passed through the tip of the tongue and held by an assistant. After the operation it should be fastened to a harelip pin in the external incision, or to the skin of the face by a strip of adhesive plaster, and retained for a couple of days, at the end of which time the muscles will usually have formed new attachments.

The bone should be sawn through with a wire or common saw, according to circumstances, or merely nicked with the saw, and its division completed with cutting-pliers. The tooth occupying the proposed line of section should first be drawn.

Ligature of one or both carotids has been performed as a preliminary operation to prevent excessive hemorrhage, but it has proved to be not only unnecessary, but ineffectual. In Mott's case the main operation had to be adjourned to allow the patient to recover from the shock of the preliminary one. In another case in which both carotids had been tied, the main operation had to be abandoned on account of hemorrhage.<sup>1</sup> Syme says the preliminary ligation is unnecessary, because the only arteries that need to be divided are the facial and the transverse branches of the temporal, bleeding from which can be easily controlled, and, furthermore, all the advantages offered by ligation of the carotids can be obtained by their temporary compression during the operation.

The attempt should be made, when possible, to get primary union of the intra-buccal wound and to drain through the external one. This makes it easier to keep the wound clean, and avoids the risks incident to the swallowing of the decomposing discharges.

The results of the operation are usually very good, and the deformity less than might be expected. Subperiosteal

<sup>1</sup> Mentioned by Syme in *Contributions to the Pathology and Practice of Surgery*, Edinb., 1848, p. 19.



excision has been followed by reproduction of the entire bone with condyles and (it is claimed) diarthrodial cartilages, and even when the periosteum is not preserved the cicatrix becomes very firm and fibrous, and able to support a plate with artificial teeth.

**Resection of the Anterior Portion of the Body.**—This may be done by means of a vertical incision in the median line, or of a horizontal one below the free border of the bone, or from within the mouth without any cutaneous incision.

If one of the incisions is made, the external and internal surfaces of the bone are cleared through it, a tooth drawn at each of the proposed points of section, and the bone sawn through.

If no external incision is made, the external surface of the bone is cleared, beginning at the edge of the gum or in the gingivo-labial fold, according as the periosteum is or is not to be preserved, and the lip drawn down under the chin so that the bone protrudes through the mouth. It can then be easily sawn through and freed from its attachments on the inner side.

**Resection of the Lateral Portion of the Body.**—The incision extends along the lower border of the jaw from its angle nearly to the symphysis, and then is carried vertically upward to the base of, but not through, the lip. The flap is dissected up, the elevator being used, of course, if the periosteum is to be preserved, the inner surface of the bone cleared near the symphysis for the passage of a wire-saw, and the section made if possible at a short distance from the median line, so as not to disturb the insertion of the genio-hyo-glossus. This section may be made with a narrow saw from before backward if preferred.

The bone is then drawn downward and outward, its inner surface cleared, and the saw applied behind the last molar tooth or at any suitable point.

Dr. McBurney<sup>1</sup> has devised a remarkably efficient means of maintaining the proper relations of the remaining portions to each other until repair has taken place,

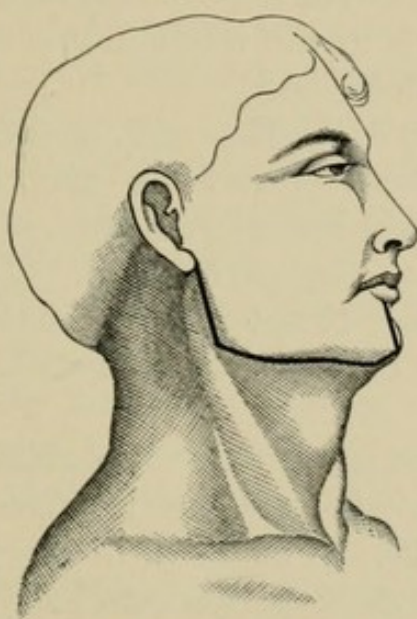
<sup>1</sup> *Annals of Surgery*, 1894.



and of thereby avoiding the great interference with function which formerly ensued.

**Resection of the Ramus and Half of the Body.** (Fig. 66.)—An incision is begun close to the posterior border of the ramus on a level with the lobule of the ear, carried down to the angle of the jaw, and thence along its lower border to the symphysis, where it is met, if necessary, by a vertical one, beginning below the free border of the lip a little to that side of the median line on which the bone

FIG. 66.



Excision of inferior maxilla.

is to be removed. The flap thus marked out is dissected up from the bone as far as can be done without opening into the buccal cavity, and the divided facial artery is tied. The inner surface of the bone is then cleared in the same manner, an incisor tooth drawn, and the bone sawn through.

The jaw is then drawn downward and forward, the denudation of its inner surface completed by dividing the attachment of the mucous membrane and of the internal pterygoid, and the inferior dental nerve cut squarely across at the point where it enters the bone.

The insertion of the temporal muscle upon the coronoid process is divided with curved scissors while the jaw



is forcibly depressed, or the process itself is cut through if it is so long that its extremity cannot be reached.

The remaining soft parts are carefully detached upward toward the condyle, the knife, or better, the elevator or the handle of the scalpel, being kept close to the bone and the separation completed by twisting the jaw out.

**Excision of the Whole of the Inferior Maxilla.**—The incision is made from the lobule of one ear down to the angle of the jaw, along the lower border of the bone to the other angle and then up to the lobule of the other ear. The outer and inner surfaces of the jaw are denuded, the bone sawn through in the median line and each half removed as before described.

In the *subperiosteal method* the incisions are the same, except that the vertical incision may be in the median line, since the genio-hyo-glossus and genio-hyoid muscles remain attached to the periosteum. The attachment of the temporal muscle is not cut, but is freed with the elevator, as is also that of the external pterygoid to the condyle.

**Partial Excisions of the Inferior Maxilla.**—Removal of a portion of the alveolar process is often necessary in the operation for epulis. The teeth in the involved segment are drawn. The muco-periosteum at a sufficient distance from the growth is cut through and the bony segment thus marked out removed through the mouth with a chisel or rongeur.

If a portion of the body of the jaw is to be removed it should be approached by an incision along the lower border of the maxilla. Whenever possible the removal should be so limited as not wholly to destroy the continuity of the bone.

The part represented in Fig. 61 is the ordinary amount removed for epulis; this can be accomplished through the mouth.

### ANCHYLOSIS OF THE JAW.

The most common cause of ankylosis of the jaw is found in cicatricial retraction or adhesions left behind by



intra-buccal ulceration. Rizzoli (1858) was the first to point out that the proper aim of an operation intended to relieve this infirmity should be the establishment of a pseudarthrosis in front of the adhesions or cicatricial bands when the cause itself could not be removed. His operation consisted in the division of the inferior maxilla behind the last molar tooth by means of a specially constructed osteotome introduced through the mouth. Bony union of the fracture was then to be prevented by motion. Esmarch (1859) proposed the removal of a wedge-shaped piece of the bone. By some surgeons the base of the wedge is taken from the alveolar process, by others from the lower border of the jaw. Dieffenbach proposed to divide the ascending ramus horizontally from before backward by means of a chisel passed through the mouth to the anterior border of the ramus.

**Operation** (removal of wedge-shaped piece).—An incision is begun at the angle of the jaw and carried two inches forward along the lower border. A narrow strip of bone is then cleared on both sides up to the edge of the gum, just anterior to the masseter and in front of the contracted tissues, a tooth drawn if necessary, and the bone sawed through. The anterior fragment is then depressed and protruded through the wound, and a wedge-shaped piece from one-third to one-half of an inch in width at its widest part cut off with cutting forceps. (Fig. 61, *I*.)

**Excision of the Condyle.**—This may be required for the relief of ankylosis due to bony or fibrous union between the condyle and the temporal bone. The incision is begun at the lower margin of the zygoma close in front of the temporal artery where it adjoins the ear and carried forward along the zygoma about one and a-quarter inches, the tissues being divided layer by layer until the bone is reached. A second incision, involving only the skin, is then carried from the center of the first directly downward for about an inch. The soft parts are next carefully separated with knife and elevator from the margin of the zygoma and the outer surface of the joint and drawn downward with a hook, thus preserving the



parotid, nerves and vessels from injury. The neck of the condyle is then freed by working around in front and behind with a small elevator, keeping close to the bone, so as to avoid injury to the internal maxillary artery and finally divided with the chisel and rongeur. If there is bony union between the condyle and temporal bone the chisel must be again used to separate them, its edge being kept directed somewhat downward, so as not to break through into the cavity of the cranium. The condyle is then grasped with forceps and twisted out. The knife or scissors may be used to sever any remaining connections, but must be kept close to the bone.

### RESECTION OF THE STERNUM.

It is occasionally necessary to remove a central or lateral portion of the sternum in order to evacuate pus that has formed behind. The bone is exposed by a longitudinal incision, the periosteum detached and a trephine applied, or if the bone is soft the opening can be made with a gouge.

### RESECTION OF THE RIBS.

This is best performed in those regions where the muscular layer covering the bone is thin. In the middle third of the rib the intercostal artery lies in a groove on the inner side of the lower border.

The incision should correspond in length and direction with the portion of bone to be removed, and may be crossed at each end by a short transverse one. The flaps are then dissected up, the periosteum separated as far as possible, a wire-saw passed at the limits of the diseased portion, and the piece removed. Instead of the saw, cutting-pliers may be used.

In *Estlander's operation for empyema* (thoraco-plastik), in which portions of several adjoining ribs are resected to allow the chest wall to sink inward and unite with the visceral pleura, the position of the incision is usually determined by that of the fistula. The incision is made along the intercostal space occupied by the fistula, and the ad-



joining ribs dissected as above described. The limits of the cavity are then determined, and other ribs resected, if necessary, through a vertical incision made from the center of the first. If the costal pleura is so thick as to prevent the attainment of the desired object, it must be cut away from a sufficient part of the area of resection. From three to six ribs have been thus resected, in lengths varying from one to three inches. The operation has been restricted to the ribs between the third and eighth, but in one case a small portion of the clavicle also was removed. Sometimes the thickened visceral pleura has also been dissected off.

### EXCISION OF THE CLAVICLE.

On account of the proximity of the large vessels of the neck this has been considered the most dangerous of all the excisions. The danger, however, varies greatly with the nature and extent of the disease which renders the operation necessary. Thus, when there is osteitis with thickening and loosening of the periosteum, the operator can easily keep close to the bone, and the danger of injury to the vessels, as well as of exciting diffuse inflammation below the deep fascia, is reduced to the minimum. On the other hand, when caries has existed for a long time, the soft parts have become infiltrated and bound down, and the bone thickened and roughened, the difficulties are immensely increased; and when the bone is the seat of a malignant tumor, extending in all directions, its removal may tax the powers of the most skilful. Valentine Mott spoke of his case as the most difficult and tedious operation he had ever witnessed or performed; it lasted four hours, and more than forty ligatures were applied, including two upon the internal jugular vein.

As only the inner half of the bone is in close relation with the vessels, and the danger is especially great at the sterno-clavicular joint, it is advisable first to raise the outer end of the bone from its place by opening its articulation with the acromion or by dividing it a little to the inner side of that joint, and then, after clearing the posterior surface from without inward, to divide the attach-



ments of the inner end while twisting the bone upward about its long axis, and keeping the edge of the knife against it. When this is impracticable the periosteum must be carefully separated near the middle, and the bone sawn through with the usual precautions against injury to the underlying parts. Each half is then raised in turn and dissected out.

For the removal of a tumor no fixed rules can be given. In other cases the directions are as follows :

**Operation.**—The subperiosteal method must be employed throughout. The incision is made along the anterior surface of the bone, and corresponds in length with the portion to be removed. A short transverse incision is then made at each end of the first, the flaps dissected up, and the denudation carried as far as possible around the bone above and below.

The bone is then freed at its acromial end, or divided in the middle, and the separation completed as above described.

#### EXCISION OF THE SCAPULA.

It is impossible to lay down fixed rules for making the incision when the operation is rendered necessary by a tumor of the bone. They will be determined by the circumstances of the case, and especially by the extent of the disease, for while in some cases the acromial end of the clavicle must also be removed, in others the acromion and neck of the scapula may be left behind.

Mr. Holmes<sup>1</sup> says : “The surgeon turns down appropriate skin flaps. \* \* \* When the whole tumor is thus exposed, the muscles inserted into the vertebral border of the bone should be rapidly divided, as also those which are attached to the spine of the scapula. The tumor should be lifted well up and freed from its other attachments, commencing from its lower angle. The subscapular artery is divided near the end of the operation, and can be held till the tumor is removed, or can be at once tied. The ligaments of the shoulder are then easily divided and the mass removed.”

<sup>1</sup> A System of Surgery, Vol. V., p. 669.



Gross<sup>1</sup> made a vertical incision sixteen inches long downward from the superior angle of the scapula, and circumscribed an oval portion by a second curved incision, beginning five inches below the upper end of the first and ending about the same distance above its lower end, and removed the bone after sawing through the acromion and neck of the scapula.

Velpeau<sup>2</sup> recommends three incisions: one along the spine of the scapula, the others starting from the anterior extremity of the first and running, one toward the root of the neck, the other toward the axilla behind.

Syme made two incisions crossing each other near the center of the tumor. Other surgeons have made triangular or semilunar flaps.

In January, 1878, Dr. George A. Peters removed, at the New York Hospital, the entire scapula for malignant disease, leaving the arm. He made an incision along the spine of the scapula, divided the fibers of the deltoid and trapezius, and exposed the tumor, which involved only the acromion and adjoining portion of the spine. He then made a vertical incision across the center of the first, beginning two inches above it and extending to the inferior angle of the scapula, reflected the flaps, dissected out the under surface of the bone from behind forward, separated the acromion from the clavicle and humerus, and then, raising the lower angle of the scapula toward the head, approached the coracoid process from below, and found no difficulty in separating it from its attachments. Only two vessels required ligation, the supra-scapular and a large branch of the subscapular. The result was very good; six weeks afterwards the wound had closed, and the patient possessed a certain degree of control over the humerus.

**Subperiosteal Excision of the Scapula (Ollier). (Fig. 67.)**

1. **INCISION OF THE SKIN AND MUSCULAR INTERSTICES.**—An incision is made along the whole length of the spine of the scapula, and from its posterior extremity two others

<sup>1</sup> Gross's System of Surgery, Vol. II., p. 1078.

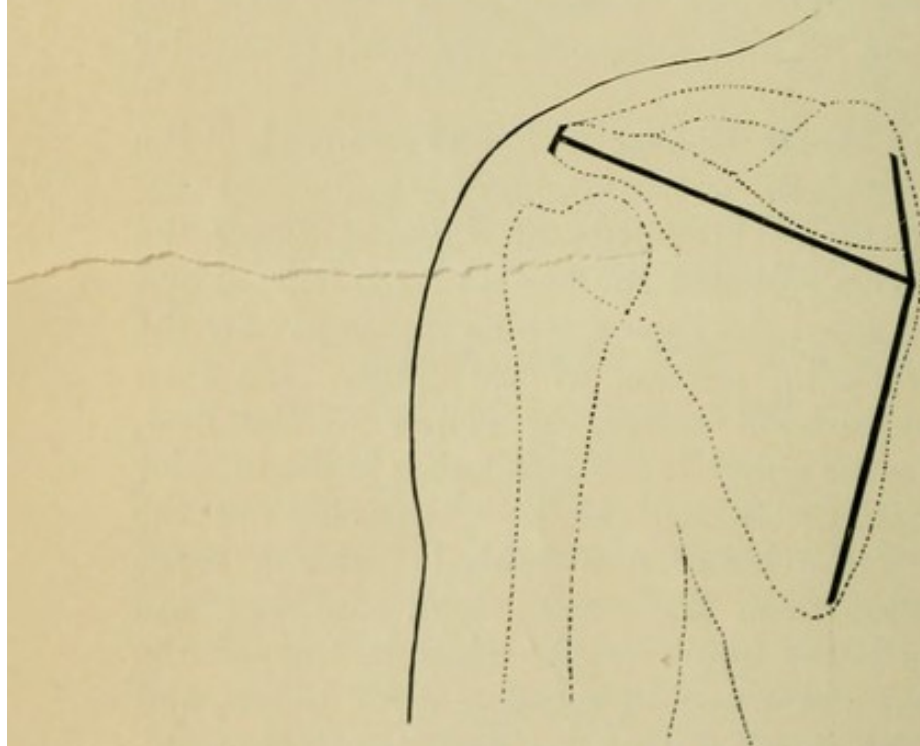
<sup>2</sup> Médecine Opératoire, Vol. II., p. 659.



are made, one following the posterior border down to the inferior angle, the other running obliquely forward and upward for about an inch. A short transverse incision may also be needed at the anterior end of the first.

2. **DENUATION OF THE BONE.**—The attachments of the deltoid and trapezius to the acromion and spine are separated, the periosteum of the posterior border of the scapula divided in the interstice between the rhomboideus and infra-spinatus, and the infra-spinous fossa carefully

FIG. 67.



Excision of the scapula.

denuded. The periosteum is very thin in its lower third. The lower angle is freed by detaching the teres major and serratus magnus, the bone raised, and the subscapularis detached from below upward. If the marginal cartilage is not completely ossified and united with the bone, it should be separated and left adherent to the periosteum.

The supra-spinous fossa is then cleared, care being taken not to injure the supra-scapular nerve in the supra-scapular notch, but to raise it up with the periosteum and its fibrous sheath. The posterior part of the bone is then



carried upward and forward and the denudation of its under surface and anterior border completed.

If the extent of the disease permits, the denudation should stop at the neck of the scapula, which is then divided with a chain-saw or cutting forceps.

3. OPENING OF THE SCAPULO-HUMERAL JOINT. DETACHMENT OF THE ARTICULAR CAPSULE AND DENUDATION OF THE CORACOID PROCESS.—The acromion is next separated from the clavicle, the scapula turned upward, the joint opened from below, and as the bone is pressed steadily upward everything that holds is detached with an elevator. After the coracoid process has been thus separated from most of its muscular and ligamentary attachments, the few that remain can be broken by twisting the bone away. In suitable cases the coracoid process may be divided at its base and left in place, and thus the most difficult and laborious part of the operation done away with.

*The partial excisions of the scapula* do not require detailed description. The acromion, spine and posterior border are reached by straight or slightly curved incisions along the portion to be removed. A crucial or H incision is required at the angles.

### RESECTION OF THE HUMERUS.

The position of the musculo-spiral nerve is the most important element in this operation. In its passage around the posterior aspect of the humerus the nerve lies close to the bone within the sheath of the triceps muscle, and leaves the latter on the outer side of the arm to enter that of the supinator longus at its origin. In approaching the bone, therefore, on the outer side near the junction of the middle and lower thirds, the operator should lay bare the outer border of the brachialis anticus and follow down within its sheath to the bone.

**Upper Portion.**—Same incision as in Ollier's method of excision of the shoulder carried further down along the outer edge of the biceps. The cephalic vein must be sought for and drawn aside. Periosteum and capsule di-



vided, bone denuded and removed as in excision of the shoulder-joint (*q. v.*).

**Middle Portion.**—Incision along the posterior border of the deltoid and outer edge of the biceps. Outer border of the brachialis anticus laid bare and followed down to the bone. Division of the periosteum and denudation of the bone, with especial care for the safety of the musculo-spiral nerve.

Ollier prefers to seek the nerve and draw it aside. He also recommends that whenever it is possible to leave a portion of the shaft connecting the extremities it should be done, as a precaution against shortening and the formation of a pseudarthrosis. If this is not possible the chain-saw is passed at two points, and the intermediate piece removed.

**Lower Portion.**—Incision on outer side of the posterior aspect of the arm, between the triceps and supinator longus, as in Ollier's excision of the elbow (*q. v.*).

**Total Excision.**—Combination of incisions for upper and lower portions. After the ends have been denuded of periosteum the middle portion can be cleared by pushing one end out through its incision and peeling the periosteum back like the finger of a glove until the middle is reached. The bone is then sawn off, and the other half removed in a similar manner through the other incision.

### EXCISION OF THE ULNA.

Longitudinal incision along the posterior aspect of the bone, joined at its upper end by a short one running obliquely upward and outward between the triceps and anconeus. The triceps is drawn to the inner side, and the olecranon freed. After separation of the periosteum the bone is sawn through in the middle, and each piece is dissected out in turn.

### EXCISION OF THE RADIUS (OLLIER).

An incision involving the skin only is made from the styloid process of the radius along the outer border of the forearm to the radio-humeral articulation. The fascia is



divided and the posterior border of the supinator longus found. By following it toward the wrist the knife can be kept between it and the extensor tendons of the thumb, which can then be drawn backward and saved from injury. By following it upward the interstice between it and the extensores carpi radiales is found, through which the operator penetrates to the radius now covered only by the supinator brevis. The latter muscle is then divided longitudinally and the periosteal sheath opened.

The periosteum is detached laterally, the bone sawn through at its middle, and each fragment removed separately.

**Partial Excisions of the Ulna and Radius.**—The incisions and methods are the same as those above described.

### EXCISION OF THE METACARPAL BONES AND PHALANGES.

The metacarpal bones should be exposed by a longitudinal incision along the dorsum. As the extensor tendons cross the bones obliquely this incision should involve only the skin at first, the tendon is then drawn aside and the incision carried down to and through the periosteum, which must be retained when possible. It is advisable that the joints, especially the metacarpo-phalangeal, should not be opened.

The bone is then divided in the middle with cutting forceps and each end dissected out, or the gouge alone may be used.

The after-treatment is important. Extension must be made upon the corresponding finger for a long time to keep it from being drawn up into the hand. In the case of the metacarpal bone of the thumb lateral pressure must also be made.

For *resection of a phalanx* the incision should be made on the side of the finger near the dorsum. For the terminal phalanx the incision should be U-shaped, the arms passing along the sides of the phalanx, the curve around its end.

Resection of the different portions of the thumb, even



if not subperiosteal, is to be preferred to amputation, but the contrary is true of the phalanges of the other fingers.

Lateral pressure, by means of splints or an India-rubber glove finger, and extension by weight must be made to insure the necessary length and proper shape of the member.

### RESECTION OF THE BONES OF THE PELVIS.

Ollier<sup>1</sup> reports a case in which he removed the ascending ramus of the ischium and most of the pubis for suppurative osteo-arthritis of these bones and the pubic synchondrosis. The incision was about four inches long and extended from a fistula in the genito-crural fold up toward the pubis. The periosteum was detached, the ascending ramus of the ischium removed and then the ascending ramus, body and part of the horizontal ramus of the pubis. The bone that was removed was eroded and rarefied, but not necrotic.

### EXCISION OF THE COCCYX (OLLIER).

This may be required on account of disease of the coccyx, of coccygodynia, or as a preliminary to operations upon the rectum.

The limits of the bone are determined by the finger in the rectum, and a longitudinal incision made through the skin and fibrous covering of the bone, from a quarter of an inch above its upper to the same distance below its lower end, and a transverse incision made at the upper end of the first. The posterior surface of the bone is then denuded.

The sacro-coccygeal articulation having been opened by this denudation, its fibro-cartilage is divided, and the cornua cleared. An elevator is then passed through the joint and used as a lever to force out the coccyx, peeling off at the same time the fibrous covering of its anterior surface.

If the sacrum is also diseased, and the gouge is used upon it, it must be remembered that the sacral canal ex-

<sup>1</sup> De la Régénération des Os, Vol. II., p. 180.



tends to its very end, and is there formed posteriorly not of bone, but of fibrous tissue.

### **RESECTION OF THE SHAFT OF THE FEMUR.**

A longitudinal incision is made on the outer side in the groove between the vastus externus and biceps, with a transverse liberating incision at each end. Denudation is carried as far around as possible, the wire-saw passed at each end of the diseased portion, and the denudation completed as the piece is raised from its bed.

In the case of a child traction should be made, and the limb kept at the same length as the other; in the case of an adult the fragments should be brought nearer together, for the patient is older and his power of regeneration less; and, in many cases, it is better to bring the fragments into contact. Shortening is less of an infirmity than pseudarthrosis.

### **RESECTION OF THE SHAFT OF THE TIBIA.**

If the entire diaphysis of the tibia becomes necrotic it may be removed subperiosteally and a fairly useful limb obtained, especially in children. The incision is made parallel to and just in front of the internal border. At the upper end it lies behind the tendons of the sartorius, gracilis, and semitendinosus; further down the internal saphenous nerve is recognized and drawn to one side.

The periosteum is incised on this line, and raised with an elevator which should be well curved to get around the sharp angles of the bone. When the denudation has been completed, if the bone is not already detached, the elevator is used to press back and protect the soft parts behind, while the bone is chiseled or sawn through as close to the dead area as possible. A transverse incision through the periosteum at this point will save undesirable denudation of adjoining healthy bone.

The operation is most frequently required to remove the necrosed fragments which may result from osteomyelitis.

If there is an involucrum, it must be chiseled away



very freely, so as practically to abolish the center cavity, and the sound bone at each end must be freely cut away, so as to leave a surface sloping easily down to the bottom (posterior wall) of the cavity. The object of this free removal of bone is to permit the soft parts to come everywhere into contact with the bone when they are brought back and sutured together over it. No anxiety as to subsequent weakness of the bone need be felt, for the new formation of bone will be ample.

If it is necessary to reach the tibia on its external surface the skin incision should lie a little to the outer side of the crest. The periosteum is cut into close to the anterior border of the bone, and elevated with the attached tibialis anticus muscle. When the gap after a compound fracture involves the entire thickness of a portion of the shaft, a corresponding length must be removed from the shaft of the fibula to secure good apposition of the parts. The fibula is best approached at some distance above or below the site of the tibial injury, as thus there will be less danger of infecting this fresh wound, and subsequent immobility can be more readily secured.

The posterior surface of the tibia is best approached around its internal border. At the upper extremity the incision is made as already described behind the sartorius, gracilis, and semitendinosus, and the periosteum elevated with the attached popliteus muscle.

### RESECTION OF THE FIBULA.

The lower portion of the fibula is subcutaneous, its upper portion is covered by the peroneal muscles. The biceps is attached to its head, and the external popliteal or peroneal nerve, after following the posterior border of the tendon of that muscle, winds around the outer side of the neck of the fibula, and divides into the anterior tibial and musculocutaneous, the latter of which soon becomes superficial. Sometimes this division and even the subsequent ones, takes place as high up as the head of the fibula, and then there is danger of dividing some of the branches during resection of the upper extremity of the bone, unless the method



indicated by Ollier is strictly carried out. The earlier authors considered the division of this nerve unavoidable.

As the upper tibio-fibular articulation communicates in a large proportion of cases with that of the knee, it should not be opened, except when it shares in the disease. The head of the fibula should be divided or gouged out in such a way as to leave this articulation covered by a thin but complete plate of bone.

**Resection of the Upper Extremity of the Fibula (Ollier).<sup>1</sup>**

—A longitudinal incision is begun an inch above the head of the fibula at the posterior border of the tendon of the biceps, and carried down a little behind the bone along the interstice between the soleus and the peroneal muscles. The incision should involve only the skin and fascia.

The nerve is then sought for where it passes around the neck of the fibula, and protected by two blunt hooks placed about an inch apart. While thus protected, it is freed from the cellular tissue, which binds it to the bone, and then drawn forward so as to permit the division of the periosteum. This division is made on the posterior border of the bone, and carried downward as far as is necessary in the interstice between the soleus and peroneal muscles.

The periosteum is then detached and the bone removed, either by dividing it at two points with a wire-saw or chisel and removing the intermediate portion, or by dividing it at the lower limit of the disease, and twisting out the upper fragment, or by modifying the latter method to the extent of dividing the head of the bone with a sharp chisel in such a manner as to leave the tibio-fibular joint unopened.

**Resection of the Lower Portion of the Fibula.**—Longitudinal incision along the antero-external aspect of the bone. Denudation and removal of the bone in the usual manner. For other details, see excision of the ankle-joint.

<sup>1</sup> *Traité de la Régénération des Os*, p. 267.



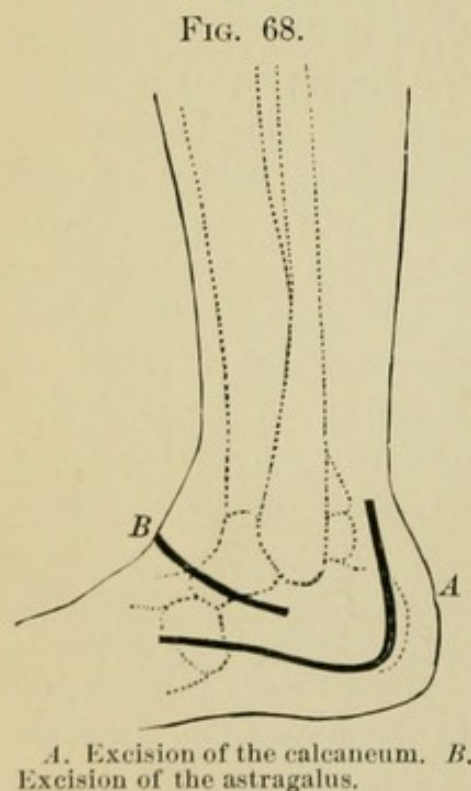
## EXCISION OF THE WHOLE FIBULA.

As the incisions for the resection of the upper and lower portions lie on opposite sides of the peroneal muscles, they cannot be made continuous with each other. Each half of the bone must be removed separately.

## EXCISION OF THE BONES OF THE FOOT.

**Calcaneum.**—Disease in the calcaneum is usually central, leaving a sequestrum inclosed in a shell of rarefied vascular bone, or a cavity is formed within a similar shell

by ulceration and discharge through one or more fistulæ. The removal of the entire thickness of the bone has heretofore given better results than simple gouging out of the diseased portions, *évidement de l'os*, but the anterior portion should if possible be left.



A. Excision of the calcaneum. B. Excision of the astragalus.

**SUBPERIOSTEAL METHOD (Ollier).** (Fig. 68, A.)—An incision involving only the skin is begun at the outer border of the tendo Achillis about an inch higher than the tip of the external malleolus, carried down below the outer tuberosity of the calcaneum and then forward and slightly upward to the upper part

of the base of the fifth metatarsal. The edge of the tendo Achillis and the upper border of the plantar muscles being recognized, the incision is carried down to the bone, care being taken not to cut the peroneal tendons.

The posterior half of the bone is then denuded with an elevator, and the tendo Achillis detached and pressed to the inner side. The under surface and posterior third of the inner surface are next cleared, the peroneal tendons drawn aside with blunt hooks, the external lateral liga-

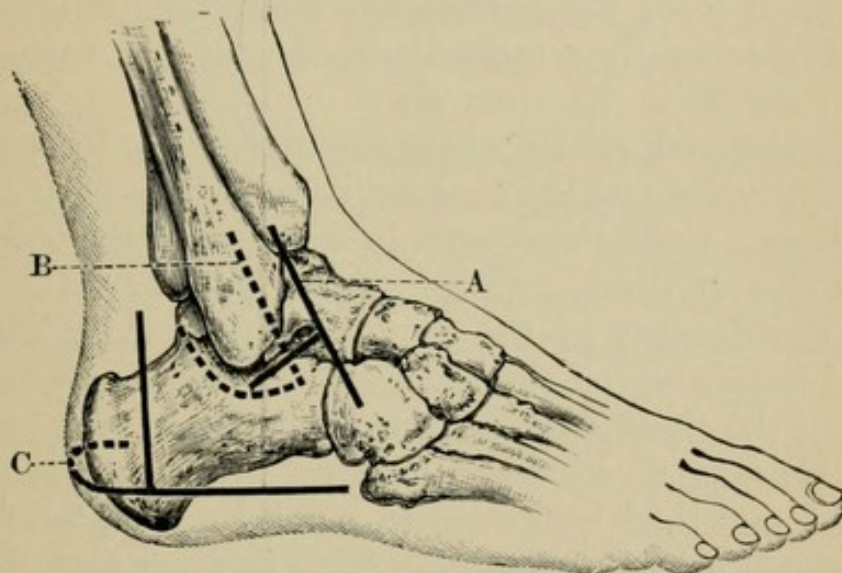


ment detached, the anterior portion of the outer surface denuded, and the calcaneo-cuboid joint opened.

The interosseous ligament is divided with a narrow bistoury, the bone grasped with lion-forceps and turned downward so as to open the calcaneo-astragaloid joints and give access to the calcaneo-scaphoid and internal lateral ligaments and to the inner surface of the bone.

Resection of the posterior portion alone can be accomplished much more expeditiously. The portion to be removed is denuded and then sawn off, either directly or by perforating the bone and sawing it from above downward with a chain-saw.

FIG. 69.



A. Excision of astragalus. (VOGT.) B. Excision of ankle. C. Excision of calcis. (FARABEUF.)

**Farabeuf's Modification.** (Fig. 69, C.)—The incision begins opposite the base of the fifth metatarsal bone externally, and is carried horizontally backward just above the margin of the sole. It passes on the same level around the back of the heel and is prolonged forward about an inch on its internal aspect. A second incision extends from this about two inches vertically upward beside the external border of the tendo Achillis. These incisions involve the skin only. The vertical cut is now deepened and the periosteum divided in this line, taking care not to damage the peroneal tendons which lie just anteriorly.



The periosteum with the associated ligaments is elevated first on the outer surface, aided by deepening the horizontal incision in this part down to the bone. The attachment of the tendo Achillis is cut and the posterior aspect cleared as far as possible.

The periosteum of the anterior end is next separated together with its attached ligaments, and afterward the plantar area is denuded. The anterior extremity is grasped with forceps and twisted outward, while the remaining attachments are severed with the knife, which must be kept close to the bone. The superior surface is reached through the outer incision and the interosseous ligament cut. By careful work with the elevator the internal surface is freed from the periosteum and attached ligaments and the bone finally removed without damage to the vessels and nerves on its inner side.

**Astragalus.**—Excision of the astragalus may be rendered necessary by dislocation, fracture, or tuberculosis, or it may be made as a preliminary step in excision of the ankle.

**Operation** (Ollier). (Fig. 68, *B.*)—Curved incision across the dorsum of the foot, with convexity directed forward beginning on the inner side at the point where the tendon of the tibialis anticus crosses the tibio-tarsal articulation, running forward and outward to the middle of the scaphoid, and then backward to a point a little below the tip of the external malleolus. This incision must expose but not involve the tendons.

The extensor tendons are lifted out of their sheaths and drawn aside, the extensor brevis cut across or detached at its origin, and the neck and outer non-articular surface of the astragalus cleared. The capsular and ligamentary attachments of the bone to the scaphoid and tibia are separated, the interosseous ligament divided, and the foot being turned inward the insertion of the strong internal tibio-astragaloid ligament is detached. The remaining connections are then ruptured by grasping the bone with strong forceps and twisting it out.

The operation is made easier by cutting through the neck of the bone and first removing the head.



See also Vogt's excision of the ankle, p. 157.

When *dislocated* the astragalus may be easily removed by a straight, curved, or crucial incision made over the most prominent part, and avoiding vessels, nerves, and tendons.

When *badly shattered*, as in gunshot injury, the fragments may be removed through a longitudinal incision between the extensor tendons of the first and second toes.

For simultaneous removal of the calcaneum and astragalus see *Osteoplastic excision of the foot*, p. 158.

**Metatarsal Bones and Phalanges.**—A metatarsal bone should be exposed by an incision along the dorsum involving only the skin; the tendon is then drawn aside, the periosteum divided, the bone denuded, sawn through, and removed. Whenever possible, the upper extremity of the bone should be left.

For the first and fifth metatarsals it is better to make the incision more upon the side than upon the dorsum.

If the corresponding toe is to be preserved, extension must be made upon it for a long time, in the manner and for the reasons mentioned under excision of the metacarpal bones.

The phalanges and their articulations are best excised by lateral incisions.

## OPERATIONS UPON THE CRANIUM—TREPHINING.

Although the term trephining, in its narrower sense, implies the use of the trephine, yet it is also employed to indicate the making of an opening in the skull by the use of other instruments, such as the saw and chisel. As such openings are made in different ways and with different purposes, it will facilitate reference and avoid repetition first to describe the methods of using the instruments to make the opening.

As a rule, rarely to be disregarded, the scalp should be widely shaved about the area of operation, and in all the more extensive operations it should be shaved throughout in order the better to maintain asepsis.

**Trephine.**—The incision may be straight, curved, or U-



shaped. It sometimes becomes desirable to make a straight incision crucial, but this form is generally to be avoided because of probable retraction and consequent delay in healing. As the scalp is very vascular it is only when a well-rounded flap is made that it is necessary to take account of the position and direction of the arterial trunks with a view to avoid sloughing.

The incision should be made freely, the knife passing nearly or quite to the bone at the first stroke, in order that the vessels may be the more readily secured. After the hemorrhage has been arrested the pericranium is detached from the portion of bone to be removed, and the center-pin of the trephine (protruding  $\frac{1}{16}$  inch and firmly clamped) is forced by to-and-fro rotatory movements into the bone at the place selected, and these movements continued until the circular edge of the trephine has cut a groove sufficiently deep to insure its steadiness without the aid of the pin, which must then be withdrawn, so as to avoid injury by it to the dura mater. The rotatory movements are continued very cautiously, and all parts of the groove frequently examined with a probe, as its depth increases, so as to have timely notice of complete perforation.

The teeth of the trephine should be freed from dust from time to time by dipping the instrument into water. If, as is usually the case, perforation takes place upon one side of the groove before it does upon the other, the trephine must be slightly inclined so as to act only upon the unsawn portion; and when it is thought that the perforation is complete throughout the greater part of the circle the remainder may be broken by sharply inclining the trephine or with a thin-bladed elevator.

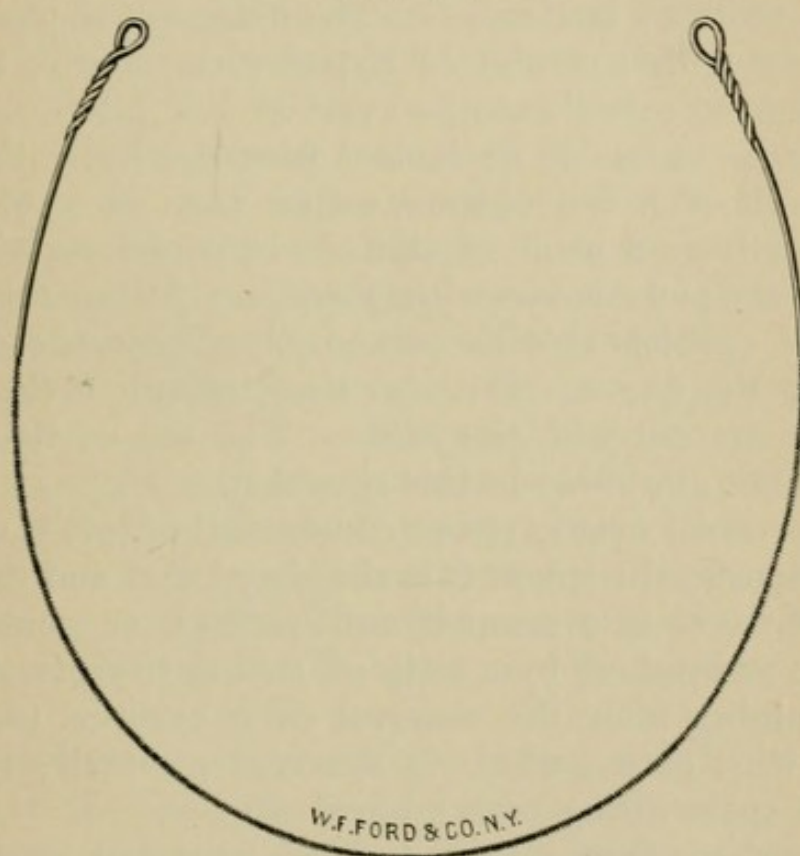
**Chisel.**—The chisel is employed only in cutting bone-flaps of large size, to be temporarily turned back and then replaced, and in craniectomy, and in widening fissures of a compound fracture for their better cleansing. There is some reason to think that jarring of the brain by the strokes of the mallet may be prejudicial, and therefore the chisel should be held very obliquely in order to diminish this effect of the blows. Shallow and triangular gouges are con-



venient, and it is well to use a narrower one to deepen and complete the groove, and after the bone has been wholly cut through at one point to pass a thin periosteum elevator between the bone and the dura beneath the adjoining portion of the groove as it is deepened in order to protect the dura from accidental injury.

**Gigli Wire-saw.**—This is employed for long, straight incisions, or to circumscribe large bone-flaps that are to be

FIG. 70.



Gigli wire-saw.

replaced. The instrument (Fig. 70), is a slender roughened steel wire, and is used like a chain saw. Openings in the bone are made with a small trephine or drill at points in the line of the proposed incision, from one to two inches apart, the dura mater between them detached with a narrow, sharply curved elevator, the wire passed from one to the other, and the bone sawn from within outward by to-and-fro movements of the wire.

Hemorrhage from the diploë is checked by simple



sponge pressure or by plugging the larger vessels with decalcified bone or catgut. If the purpose of the operation requires the brain to be exposed, the dura mater is cut about one-quarter of an inch within the margin of the opening and turned back as a flap; vessels of noteworthy size can be secured by passing a small curved needle under them.

Hemorrhage from the pia or brain is checked by sponge or gauze pressure. If this fails the vessels are clamped and tied with fine catgut ligatures. The Paquelin cautery may be used as a last resort. The brain can be punctured cautiously with a probe or hypodermic needle, but all lateral movements should be avoided.

If the brain has to be incised pass the knife through the summit of a convolution, rather than in a sulcus, as the hemorrhage is less. A clot can be wiped out with fine sponges or picked out with forceps. An encapsulated tumor is enucleated with curved blunt-pointed scissors, aided by the finger. But one that infiltrates the brain must be cut out with the knife. The use of the sharp spoon is not allowable in this situation.

A superficial cyst is either enucleated, or, after cutting off its superficial surface, it is simply packed and drained. A deeper cyst is evacuated and packed, or continuous drainage maintained by a strip of rubber tissue. A cavity remaining after the removal of a cyst or tumor is packed with gauze, which is removed gradually to prevent the space filling with a blood clot.

Hemorrhage from a sinus or large vein can usually be checked by gauze pressure; if this fail, artery clamps can be applied and left in the dressings for a day or two. At the close of the operation a folded strip of rubber tissue is passed as a drain beneath the dura, which is stitched with catgut except at this point and brought out of the lower angle of the skin wound. Often the drain is unnecessary and the wounds in the dura and skin may be closed up tight, the former with catgut, the latter with silk and dressed aseptically.

If the attempt is to be made to replace the button of



bone removed by the trephine, it must be kept in warm salt-solution and then replaced between the dura and pericranium. Thin plates of various metals or celluloid have been used instead of bone and have given good results. The benefit seems to come mainly from increased production of fibrous tissue in the opening. It is claimed that the lining membrane of an egg gives a similar result.

**Temporary Resection of the Skull by Omega Flap.**—(For exploration, removal of tumor, or excision of Gasserian ganglion.) The incision takes the form of a Greek  $\Omega$ , with base downward to secure the best nutrition to the flap. Everything is divided down to the pericranium. The horizontal feet of the loop are each about half an inch long and separated from each other across the base by at least an inch of sound skin. The width of this pedicle should be about half that of the flap. The horizontal cuts serve as liberating incisions to facilitate the turning back of the flap with its attached bone. The dimensions of the loop vary to suit the requirements of each case, but, as used by Wagner,<sup>1</sup> they are as follows: Vertical length, 6.5 cm.; greatest breadth, 5 cm.; with a pedicle of undivided sound tissue, 3 cm. wide.

After the soft parts have retracted the periosteum is cut close up and parallel to the inner edge of the flap and its horizontal continuations below, and the bone cut through along the entire curved portion. When this cut is made with the wire saw it should be so inclined that the outer surface of the bone flap is larger than the inner, in order that the flap when replaced shall not sink below its former level. A periosteal elevator is cautiously pushed in as a lever at the top of the curve and the bone flap snapped at its base by a sudden quick application of force and laid back without disturbing the attached parts. It may be necessary to aid this breaking by chiseling the outer table from either or both angles part way across the bone. The skin flap overlaps the line of bony division about one-quarter to one-half an inch, and is united by interrupted silk sutures, with or without drainage in the lower angle of the wound.

<sup>1</sup> Centralblatt f. Chir., 1889, p. 833.



The horizontal "feet" of the  $\Omega$  may generally be dispensed with. Their only use is as liberating skin incisions to facilitate the turning down of the flap. If needed they can be made after the section of the bone.

**Craniectomy** (Lannelongue). — An incision parallel to and a finger-breadth to one side of the longitudinal sinus is made from the lambdoid to the coronal suture, and the bone cut along the corresponding line with chisel, rongeur, or wire-saw. This has sometimes been extended to reach from the frontal eminence nearly to the transverse sinus.

A similar cut has occasionally been made at the same time on the opposite side of the head, and Lannelongue has performed the operation in the transverse diameter of the skull, the incision corresponding nearly to the coronal suture. A flap, concavity downward, is sometimes fashioned, so as to prevent the lines of skin and bone division from coinciding.

**Trephining in Fracture of the Skull.**—The purpose of the operation is to raise depressed portions of bone and to disinfect the wound when the fracture is compound. After picking out the loose pieces, depressed but still attached pieces can be forced back into place by an elevator passed beneath them; if there are no loose pieces the corner of a chisel should be worked into one of the cracks at the edge of the depression and the piece gently loosened or removed piecemeal until a sufficient opening is made for the introduction of an elevator. This is better than applying a trephine beside the depressed area for it involves less loss of bone.

**The Relation of the Brain to the Overlying Parts. REID'S METHOD.**<sup>1</sup>—The "base line" is drawn through the lowest part of the infra-orbital margin and the center of the external auditory meatus.

*The great longitudinal fissure* is marked by a line running in the middle line of the skull from the glabella to the external occipital protuberance.

*The transverse fissure*, or the fissure of Bichat, by one

<sup>1</sup> Lancet, September 27, 1884.

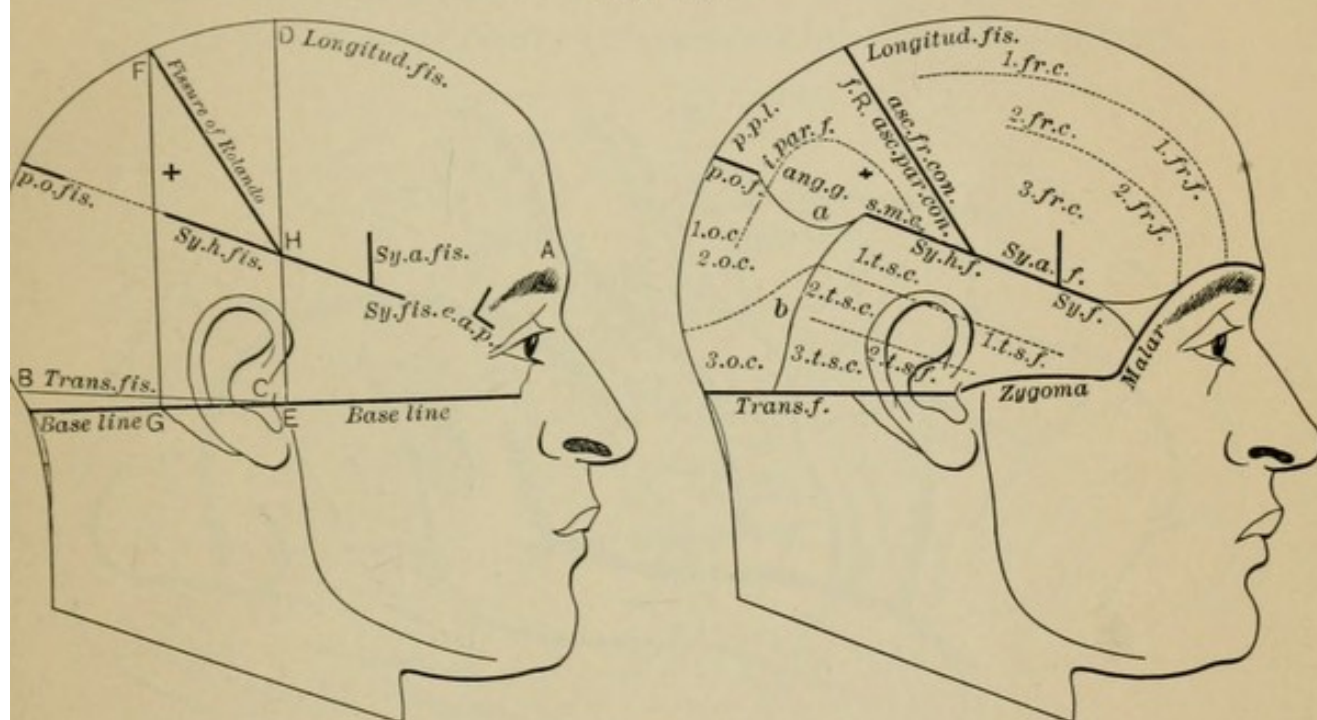


from the external occipital protuberance through the auditory meati.

The *Sylvian fissure* starts one and one-quarter inches horizontally behind the external angular process of the frontal bone, and extends to a point three-quarters of an inch below the most prominent part of the parietal eminence.

The *ascending line* of this fissure starts at a point in this

FIG. 71.



B. Fissure of Bichat. *e. a. p.* External angular process of frontal bone. *Sy. a. fis.* Ascending limb of Sylvian fissure. +. Parietal eminence. F, G, D, H, E. Perpendiculars to base line locating the fissure of Rolando (F. H.). *p. o. fis.* Parieto-occipital fissure. 1. *fr. f.* First frontal fissure. 2. *fr. f.* Second frontal fissure. *asc. fr. con.* Ascending frontal convolution. *i. par. f.* Intra-parietal fissure. *s. m. c.* Supra-marginal convolution. *ang. g.* Angular gyrus. 1. *t. s. c.* First temporo-sphenoidal convolution. 2. *t. s. c.* Second temporo-sphenoidal convolution. 3. *t. s. c.* Third temporo-sphenoidal convolution. 1. *t. s. f.* First temporo-sphenoidal fissure. 2. *t. s. f.* Second temporo-sphenoidal fissure. (STARR.)

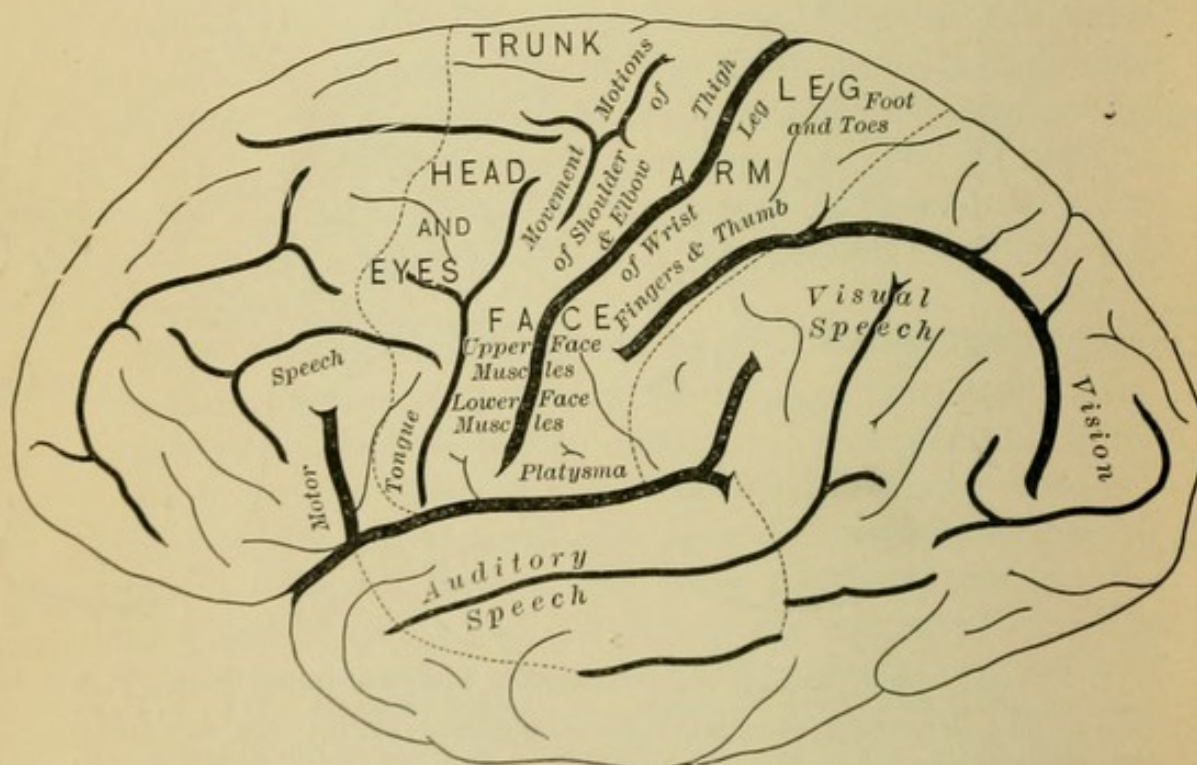
line two inches behind the external angular process, and ascends vertically about one inch.

**Fissure of Rolando.**—Draw a perpendicular to the base line starting in the depression in front of the external auditory meatus, and another perpendicular to the base line starting from the posterior border of the mastoid process at its root. The fissure of Rolando is indicated by a line drawn from the intersection of this second line with



the line marking the great longitudinal fissure, to the point of intersection of the anterior perpendicular with the horizontal limb of the fissure of Sylvius already laid out. A simpler way of indicating the Rolandic fissure is to draw a line three and three-eighths inches long at an angle of  $67^\circ$  with the sagittal meridian of the head, from a point which lies back of the glabella in this meridian 55.7 per cent. of the distance from the glabella to the inion. Cheyne's method of measuring this angle is to halve a

FIG. 72.



Showing the location of the centers on the cortex of the brain. (STARR.)

right angle by doubling a square piece of paper into a triangle, and then halve the  $45^\circ$  thus obtained by folding one of the triangles. By unfolding the crease first made, leaving the last unchanged, there results the sum of  $45^\circ$  and  $22\frac{1}{2}^\circ$ , or  $67\frac{1}{2}^\circ$ , which is near enough for all practical purposes. The line three and three-eighths inches long is then laid off at this angle by means of the folded bit of paper from a spot half an inch behind the mid-point between the glabella and the external occipital protuberances.

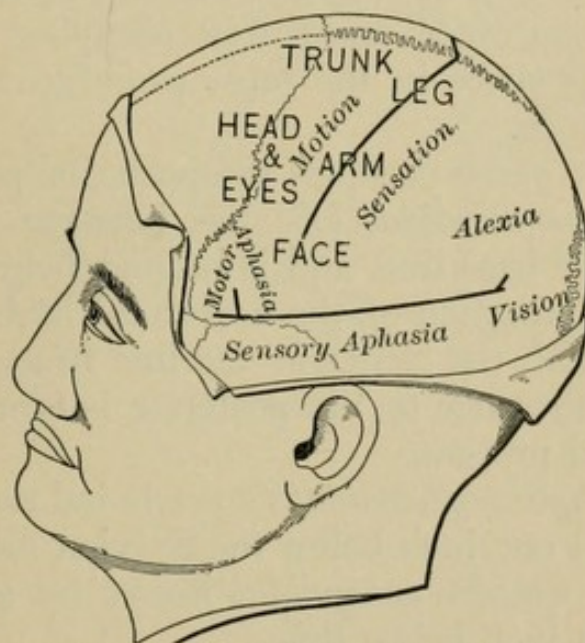


*The parieto-occipital fissure.*—The horizontal limb of the fissure of Sylvius is prolonged to meet the longitudinal fissure. A trephine opening over the *inner inch* of this line will reveal a whole or part of the parieto-occipital fissure. It varies slightly up or down in its location.

*The frontal lobe* lies between the lines indicating the fissures of Rolando and Sylvius and the longitudinal fissure and a line drawn from the glabella close to and parallel to the supra-orbital arch to meet the prolongation of the Sylvian fissure.

*The first frontal fissure* is indicated by a line drawn from

FIG. 73.



Showing the position of the cortical centers with reference to the Sylvian and Rolandic fissures marked on the surface of the skull. (STARR.)

the supra-orbital notch parallel to the longitudinal fissure and ending three-quarters of an inch in front of the fissure of Rolando.

*The second frontal fissure* is indicated by the frontal part of the temporal ridge.

*The ascending frontal convolution* occupies a space three-quarters of an inch broad in front of the fissure of Rolando.

*The parietal lobe* lies between the fissure of Rolando, the horizontal limb of the fissure of Sylvius, the longitudinal and parieto-occipital fissures.



*The intra-parietal fissure* begins on the horizontal limb of the Sylvian fissure—more correctly a little above it—one inch behind its junction with the fissure of Rolando, and passes upward three-quarters of an inch behind the latter for the first third of its length. Then it arches backward and downward and passes half an inch to the outer side of the outer extremity of the line indicating the parieto-occipital fissure.

*The ascending parietal convolution* lies between the fissure of Rolando and this first third of the intra-parietal fissure.

*The inferior parietal lobule* lies between the horizontal limb of the Sylvian fissure and the intra-parietal fissure.

*The supra-marginal convolution* occupies the anterior portion of this space in the most prominent part of the parietal eminence.

*The angular gyrus* occupies the posterior portion.

*The temporo-sphenoidal lobe* lies between the Sylvian fissure and the base line, and is limited behind by a line joining the termination of the horizontal limb of the Sylvian fissure, with the center of the line from the external occipital protuberance to the posterior border of the root of the mastoid process.

*The first temporo-sphenoidal fissure* is indicated by a line parallel to and one inch below the Sylvian fissure.

*The second temporo-sphenoidal fissure* by a line three-quarters of an inch below this.

KOCHER'S METHOD.—Kocher uses a specially constructed instrument of pliable steel bands to mark out the position on the shaved scalp of the different parts of the brain which lie beneath. By reference to the figure the nature of this instrument can be readily understood. An ordinary metal tape measure can be made to answer the purpose. The band A D C E B extends from the glabella along the median line to the lowest point of the external occipital protuberance.

The horizontal band A J Q V B is placed at right angles to this around the side of the head between the same two points. For convenience the lines thus marked

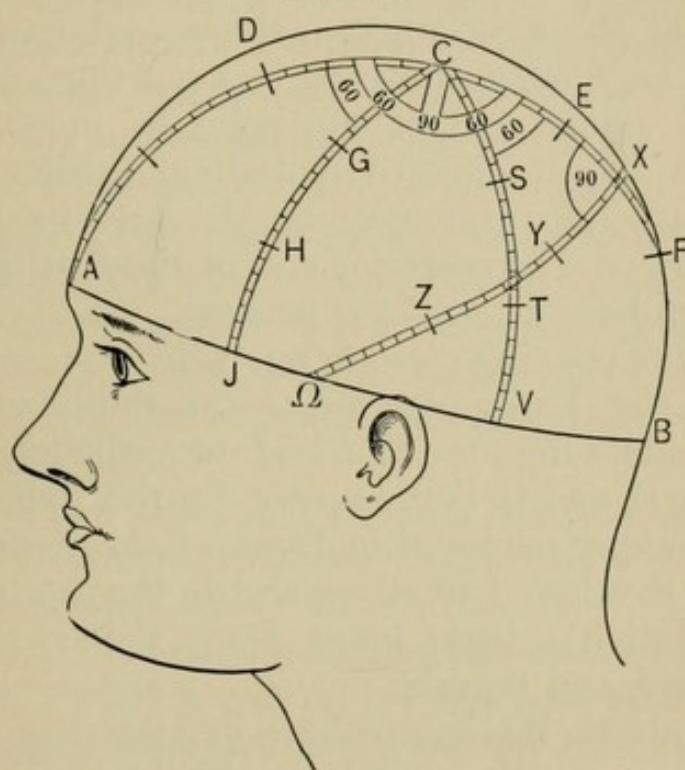


out are called the sagittal and horizontal meridians of the head.

From the center, C, of the sagittal meridian two bands each at the same angle of  $60^\circ$  to the sagittal meridian pass downward to meet the horizontal meridian at the points J and V.

The sagittal meridian is now divided into thirds, the last of which begins at E; and next into fourths, the last of which begins at F. At a point midway between E

FIG. 74.



Kocher's cranial topography. (All the points on the sagittal meridian, D, C, E, X, lie further back than indicated in this figure.)

and F the band X Y Z  $\Omega$  passes at right angles to the sagittal meridian to join the horizontal at  $\Omega$ , which is usually about half an inch behind J. This oblique band X  $\Omega$  is divided into thirds at Y and Z. C J and C V are also divided into thirds at G, H, S, and T. The horizontal meridian marks the lower border of the cerebrum. The point J lies about at the pterion or junction of the frontal parietal and sphenoidal bones, and marks the anterior end of the Sylvian fissure at the spot



where the ascending joins the horizontal limb. It also indicates the point of contact of the frontal and temporal lobes. V lies over the boundary between the temporal and occipital lobes, and is one centimeter below the edge separating the outer and under surfaces of the brain.

C indicates the uppermost point of the anterior central convolution and is in front of the fissure of Rolando. At G the anterior central convolution meets the first and second frontal convolutions, and at H the second and third. S lies over the intra-parietal fissure just above the supra-marginal gyrus. T indicates the posterior extremity of the first temporo-sphenoidal fissure and is below the angular gyrus. X is over the apex of the lambdoidal suture and at the point of meeting of the parieto-occipital and great longitudinal fissures. Q indicates the anterior extremity of the first temporo-sphenoidal fissure. The posterior end of the first third of the sagittal meridian, D, is at the bregma.

A trephine opening close to one side of C reaches the center for the lower extremity—the thigh and leg are near the middle line, the foot and toes slightly posterior.

Between H and G is the center for the upper extremity, in the upper part and in front of the fissure of Rolando the shoulder and elbow and in the ascending parietal convolution a little lower down the center for the wrist, fingers, and thumb.

A little above H the trephine exposes the center for the upper face muscles, just below H the lower face muscles. A finger-breadth directly above Q lies the center governing the movements of the larynx and pharynx.

In front of the middle of the line H J is the center, injury to which produces motor aphasia.

The auditory center lies under the posterior half of the line Z Q.

The center for visual aphasia is below the point T, and just above the line B V is the center for psychical vision or psychical blindness.

C. Winkler<sup>1</sup> has elaborated another system of cerebral

<sup>1</sup> *Nederlandsch. Tijdschrift voor Geneeskunde*, 1892, p. 158.



topography, and Langdon<sup>1</sup> still another. D'Antona's<sup>2</sup> method is simple and easily applied, but as Reid's original scheme and its modifications are most generally known and used, it has not seemed worth while to do more than call attention to these few of the numerous others which have recently been devised.

### THE POSITION OF THE LATERAL SINUS.

According to Birmingham<sup>3</sup> the limit of the up-and-down variation of the position of the lateral sinus is determined thus : At a point one and a-half inches behind the center of the external auditory meatus it begins to arch downward. Measure this distance along the base line. Then, at a point one and a-quarter inches above the base line at this spot, draw a line slightly convex upward to a point half an inch *above* the external occipital protuberance. Take another point half an inch *below* the external occipital protuberance and connect it with the point on the base line one and a-half inches behind the center of the meatus. Outside of these limits there is no danger of opening the lateral sinus.

In its average location it extends from the external occipital protuberance, gradually rising to a point three-quarters of an inch above Reid's base line. The highest point is reached one and a-half inches *behind* the center of the external auditory meatus. From here with a gradual or sharp turn it runs downward and forward on the inner surface of the mastoid portion of the temporal bone immediately in front of a ridge, which on the outer surface of the skull sometimes prolongs the posterior margin of the mastoid process upward and backward and in front of the posterior margin of the process itself. Here it lies about half an inch behind the meatus. At the level of one-quarter or one-sixth inch below the floor of the meatus it turns into the base of the skull.

**To Open the Lateral Sinus.**—Incision about two inches

<sup>1</sup> Cincin. Med. Journ., Aug. 16, 1894.

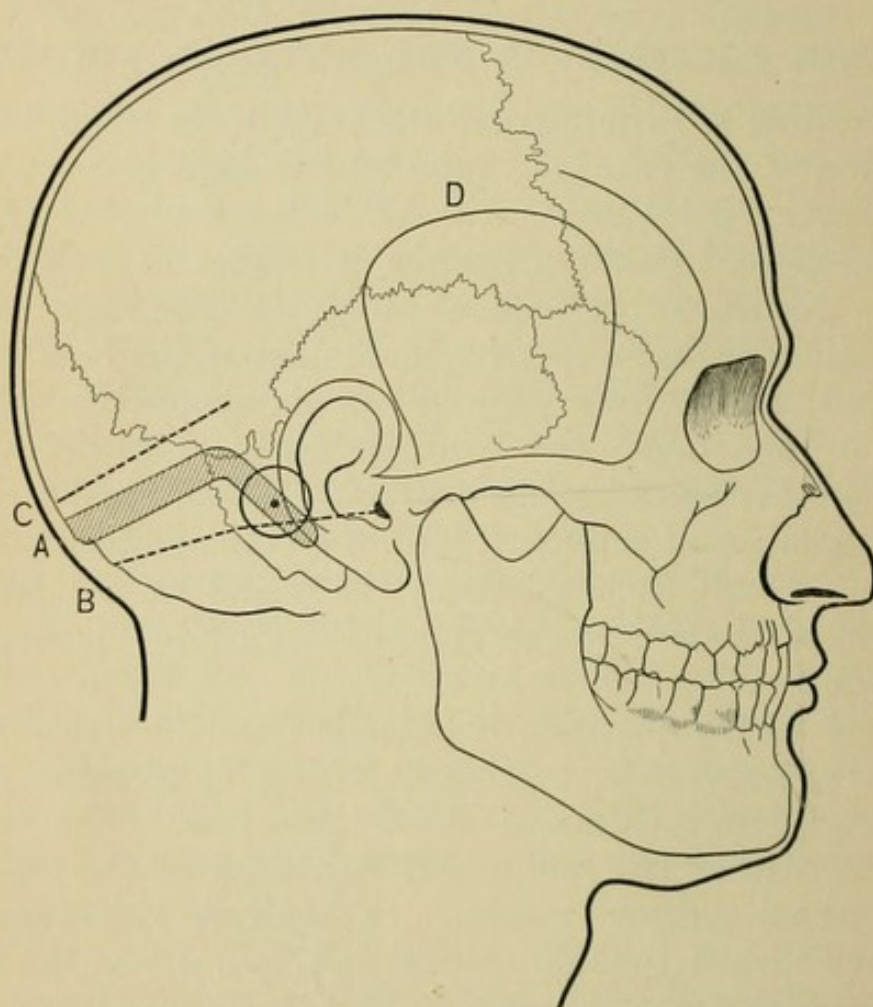
<sup>2</sup> Annals Surg., Dec., 1892.

<sup>3</sup> Dub. Journ. Med. Science, 1891, p. 116.



in length, starting near the lower end of the mastoid process, and passing upward along the ridge on its posterior margin. The periosteum is divided and elevated. The pin of a three-quarter-inch trephine is placed at a point one and one-quarter inches behind the center of the ex-

FIG. 75.



A. External occipital protuberance and lateral sinus. B, C. Limit of up-and-down variation in position of the lateral sinus. D. Incision for exposure of the Gasserian ganglion.

ternal auditory meatus on a level with its upper border. According to Birmingham this will always open up the sinus. The opening in the bone may be enlarged as circumstances require.

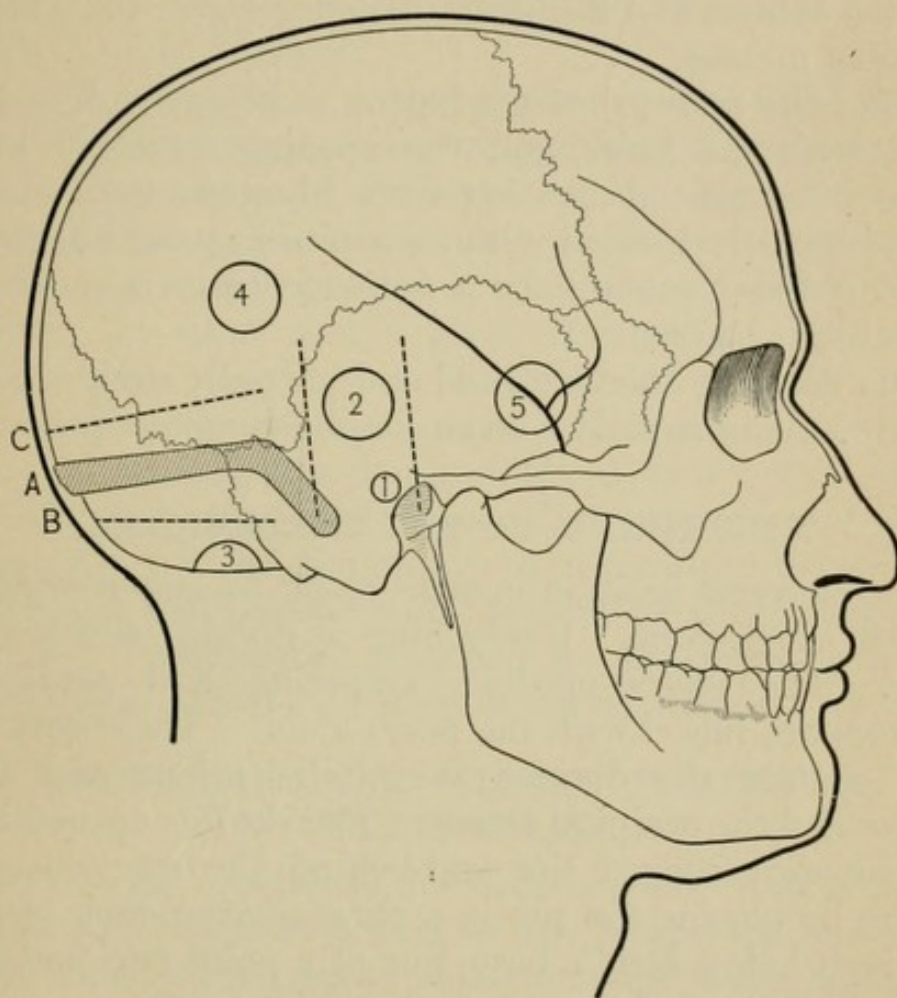
#### **TREPHINING FOR CEREBRAL ABSCESS DUE TO SUPPURATIVE DISEASE OF THE MIDDLE EAR.**

The pus in these cases is most frequently found in the temporo-sphenoidal lobe—next in order of frequency in



the cerebellum. According to Barker<sup>1</sup> the abscess generally occupies a space between two lines drawn perpendicular to Reid's base line. The first passes through the center of the meatus, the second one and one-quarter inches behind this (Fig. 76, 2).

FIG. 76.



1. Trephine opening to enter the mastoid antrum. 2. Trephine opening for abscess following otitis media. 3. Trephine opening to expose the cerebellum. 4-5. Trephine opening for middle meningeal hemorrhage. A. Lateral sinus. B-C. Limit of its up-and-down variation.

A semilunar incision, convexity downward, is made just above and behind the pinna. The periosteum is divided and elevated sufficiently for the use of a three-quarter-inch trephine. The pin of this is placed one and one-quarter inches above the base line in the center of the space enclosed by the perpendiculars. Birmingham<sup>2</sup> shows that

<sup>1</sup> British Medical Journal, 1887, Vol. I., p. 407.

<sup>2</sup> Dublin Jour. Med. Science, 1891, p. 119.



in a certain proportion of cases a trephine thus applied will come down on the bend of the lateral sinus, and proposes as a safer location to place the point of the trephine at least one and three-quarter inches above the base line, or, better still, two inches.

Keen places the pin of the trephine an inch and a-quarter behind and the same distance above the external auditory meatus.

After the removal of the button of bone the dura is incised with the knife, and the opening enlarged in the shape of a crucial incision with blunt-pointed scissors. The abscess is located with an aspirating needle, and an opening large enough for a drainage tube is made with some blunt instrument.

The flaps are then adjusted and partially sutured in position, leaving sufficient room for the escape of pus.

#### **TREPHINING OF THE CEREBELLUM.**

A transverse incision is made along the superior curved line of the occiput. Everything is divided down to the bone. The sterno-mastoid, trapezius, and underlying muscles are raised with the periosteum. These soft parts will contain the divided occipitalis minor and major nerves and the occipital artery. The skull is opened below the superior curved line and behind the masto-occipital suture by placing the pin in a three-quarter-inch trephine one inch below Reid's base line at a point two inches behind the center of the external auditory meatus measured along the base line (Fig. 76, 3).

Barker advises one and one-half inches behind the center of the meatus and one inch below the base line, but Birmingham says a three-quarter-inch trephine would wound the occipital artery in many cases in this situation.

#### **PUNCTURE OF THE LATERAL VENTRICLES (KOCHER).**

An inverted U-shaped incision is made to expose the skull at T (Fig. 74). The enclosed flap should be about



one and one-half inches long by an inch wide. After turning down the skin and securing the vessels the periosteum is incised and elevated, and the point of the trephine entered just below and in front of T. The skull is thin in this region. This exposes the posterior end of the first temporo-sphenoidal fissure. The posterior horn of the lateral ventricle lies about 1 cm. distant from the bottom of the sulcus directly inward.

Another method of locating the opening to be made in the skull (Keen) is to measure one and one-quarter inches back of the external auditory meatus along Reid's base line and then one and one-quarter inches vertically upward. At this point apply the pin of a half-inch trephine. After incising the dura push a grooved director or trocar in a straight line toward a spot about two and one-half or three inches above the opposite meatus. The ventricle will normally be reached at a depth of about two inches—if distended it lies somewhat nearer the surface—and can be recognized by the diminution of resistance offered to the instrument and the escape of fluid along the groove of the director. Drainage is provided for by inserting a small rubber tube or a folded strip of rubber tissue.

#### **TREPHINING FOR MIDDLE MENINGEAL HEMORRHAGE.**

An inverted U-shaped incision is made from the upper part of the posterior border of the frontal process of the malar bone upward nearly to the temporal ridge, and thence backward and downward in a gentle curve, to terminate at the superior border of the posterior extremity of the zygoma. This flap, including a part of the temporal muscle, is turned down and the bone sufficiently bared of periosteum to admit the use of the trephine at the spot presently to be indicated.

Kocher makes an incision from the external angular process of the frontal bone to the eminentia articularis, thence upward and backward for about an inch in front of the ear.

After the soft parts have been raised the skull is opened



over the anterior division of the artery by placing the pin of a three-quarter-inch trephine a thumb's breadth behind the external angular process of the frontal bone and two finger-breadths above the zygoma. Both divisions can be exposed simultaneously by applying the trephine immediately above the middle of the zygoma (Kocher).

Krönlein determines the location of the branches by drawing a line through the upper border of the orbit backward parallel to Reid's base line. The anterior division of the artery lies on the upper line 3 to 4 cm. behind the external angular process of the frontal bone, and the posterior at the intersection of the upper line with another drawn perpendicular to the base line from a point 3 to 4 cm. behind the external auditory meatus—roughly, from about the posterior border of the mastoid process.

The following may be taken as accurate enough for all practical purposes: To expose the anterior division of the artery apply the pin of a three-quarter-inch trephine one inch above the middle of the zygoma and then enlarge the opening downward with the rongeur if it is found necessary to secure the trunk of the vessel. If for the latter purpose the method by osteoplastic resection of the skull is employed, the bone should be chiseled through in the lines of the lower extremities of the inverted U incision, down to the level of the zygoma or nearly to the pterygoid ridge on the greater wing of the sphenoid.

To expose the posterior division of the artery apply the trephine just below the most prominent portion of the parietal eminence.

The common indication, however, is rather to remove a clot than to arrest hemorrhage by securing the trunk of the artery, and the guide to the site of this clot is usually to be found in the relations of the motor centers to the observed paralysis or to a line of fracture. Ordinarily a trephine opening at the lower end of the motor area will expose the clot directly or permit it to be reached by gently separating the dura from the bone about the opening.

I have seen no case in which it became necessary to secure the artery because of hemorrhage persisting after evacuation of the clot.



**RESECTION OF THE SECOND AND THIRD DIVISIONS OF THE FIFTH NERVE WITHIN THE SKULL.<sup>1</sup>**

The omega-shaped incision is used with its base on the zygoma and the top of the curved part at the temporal ridge. It starts at the external angular process of the frontal bone, and passes horizontally along the upper border of the zygoma for about half an inch. Thence in the curved portion upward to the temporal ridge and down to the zygoma and again horizontally about half an inch to the tragus of the ear. The periosteum is divided and the bone chiseled through and turned down with its attached soft parts, as already described.

The middle meningeal artery is secured by passing a sharply curved needle and ligature beneath it, and the dura is carefully separated from the bone below so as to expose the middle fossa of the skull. Any hemorrhage is checked by pressure.

With broad retractors the dura and brain are lifted, taking great care to avoid injury to the other cranial nerves in the immediate vicinity. The first, second, and third divisions of the fifth nerve, as well as the carotid artery and cavernous sinus are well exposed. The dura is stripped back from the second and third divisions to beyond the Gasserian ganglion, and the parts lying between it and the foramen ovale and rotundum are excised. The flap is then replaced and united with interrupted silk sutures.

**OPENING OF THE FRONTAL SINUS.**

The eyebrow is shaved. The incision starts at the center of the supra-orbital ridge and follows the curve of the upper border of the eyebrow to the median line above the root of the nose. Everything is divided down to the bone—the periosteum is raised on each side and the trephine or chisel entered at the inner end of the superciliary ridge.

**Antrum of Highmore.**—A very small trephine should be used, and, in order to avoid a scar, it should be applied through the mouth after dividing the gingivo-

<sup>1</sup> Hartley: N. Y. Med. Journ., 1893, Vol. 55, p. 317.



labial fold, and dissecting up the soft parts as far as to the infra-orbital foramen, just below and to the outer side of which the opening into the antrum should be made.

The antrum may also be opened by drawing the first or second molar tooth, and enlarging its socket with a drill.

No additional directions are needed for trephining the *flat bones* or the *epiphyses of the long ones*.



## PART V.

### NEUROTOMY, TENOTOMY, OSTEOTOMY AND MISCELLANEOUS OPERATIONS.

#### DIVISION AND RESECTION OF NERVES.<sup>1</sup>

DIVISION of a nerve of sensation, or even of a mixed nerve in extreme cases, may be required for the relief of neuralgic pain. It is seldom that a simple division is more than temporarily sufficient. At least half an inch of the trunk of the nerve should be excised, and, as additional security against reunion, the end of the distal segment may be bent back upon itself. Professor Weir Mitchell<sup>2</sup> has seen severe constant pain follow the bending back of the end of the proximal segment.

#### SUPRA-ORBITAL NERVE.

The *frontal* nerve, main branch of the first division of the trigeminus, divides just behind the upper margin of the orbit into the *supra-orbital* and *supra-trochlear* nerves; both branches are distributed to the forehead, the former emerging from the orbit through the supra-orbital notch or foramen, the latter a little nearer the nose. The former is much the larger and more important of the two, the latter supplying only a narrow strip of integument near the median line. The supra-orbital notch or foramen is found at the junction of the inner and middle thirds of the supra-orbital arch, or a little to the inner side of the junction. When it is a notch it can be readily

<sup>1</sup> A description of all known operations on cranial nerves, with the bibliography, can be found in *Chir. Opérat. du Syst. Nerveux*, by Chipault. Paris: Rueff & Co., 1894.

<sup>2</sup> Oral communication.

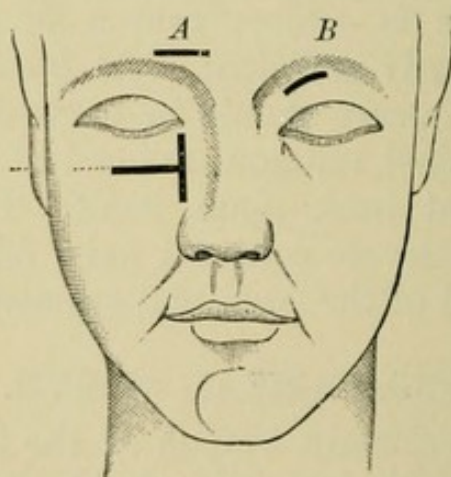


felt through the skin, and is then an important guide in the operation.

The nerve may be divided subcutaneously after its emergence from the notch, or it may be exposed by a transverse incision above or below the eyebrow.

**Subcutaneous Division.**—A tenotomy knife is entered between the eyebrows midway between the nerve and the median line, and passed horizontally beneath the skin until its point has passed beyond the nerve. Its edge is then turned backward and pressed against the bone, and the nerve, lying between it and the bone, divided by withdrawing the knife. Or the knife may be entered at the

FIG. 77.



A, B. Resection of supra-orbital nerve. C. Resection of superior maxillary nerve.

same point, but passed close to the bone instead of just under the skin, its edge turned downward toward the margin of the orbit, and the nerve divided by sweeping the knife downward across the mouth of the supra-orbital foramen.

**Excision of a Portion of the Nerve.** A. ABOVE THE EYEBROW. (Fig. 77, A.)—An incision one to one and a-half inches long is made just above and parallel to the eyebrow, its center corresponding to the position of the nerve. This incision is carried down to the bone, the distal end of the nerve recognized, seized with forceps, dissected out, and cut off.



B. BELOW THE EYEBROW. (Fig. 77, B.)—The eyebrow being drawn up and the eyelid down, the surgeon makes an incision one to one and a-half inches in length along the edge of the supra-orbital arch, dividing successively the skin, orbicular muscle, and tarsal ligament. He then seeks the nerve in the notch, traces it back as far as necessary, while depressing the eye and levator palpebræ with a retractor, and cuts out a portion with curved scissors.

SUPRA-TROCHLEAR NERVE.—König resected this nerve by making a curved incision under the eyebrow at the upper inner edge of the orbit, and seeking the trochlea and the superior oblique muscle. On making the latter tense with a hook the two fine nerves became visible, were seized with forceps, and resected.

### SUPERIOR MAXILLARY NERVE.

After leaving the cavity of the cranium by the foramen rotundum, the superior maxillary nerve crosses the sphenomaxillary fossa, traverses the infra-orbital canal, and appears upon the face at the infra-orbital foramen, where it at once divides up into numerous branches distributed over the cheek, nose, lip, and lower eyelid. Within the infra-orbital canal it gives off the anterior dental branch, and posterior to this canal it gives off the posterior dental, and, through branches to the sphenopalatine ganglion, the palatine nerves distributed to the palate and nasal fossa. The point at which the nerve should be divided will vary according to the region affected; but in this, as in other cases, simple division has usually proved insufficient, and it has been found necessary to excise all that portion of the trunk which lies in the canal. Sometimes the nerve has been cut above the branches going to the ganglion, and the latter torn out forcibly.

The roof of the infra-orbital canal is composed in its posterior half of fibrous tissue, in its anterior half of thin bone, which becomes thicker as it approaches the margin of the orbit. The infra-orbital foramen lies directly above the second bicuspid tooth and from one-quarter to one-half



an inch below the margin of the orbit. The nerve is accompanied on its passage through the canal by the infra-orbital artery.

A. DIVISION OF THE NERVE ON THE FACE.—This may be done: (1) *subcutaneously*; (2) *through the mouth*; (3) *by an external incision*.

1. *Subcutaneously*.—A tenotomy knife is entered about an inch to the outer side of the foramen, carried below it into the canine fossa, hugging the bone, and then swept upward along the surface of the bone so as to divide the nerve close to the foramen, the lip being drawn downward and forward to make the tissues tense.

2. *Through the Mouth*.—An incision is made in the gingivo-labial fold, and the soft parts dissected away from the bone until the nerve is reached and divided.

3. *By External Incision*.—The incision may be transverse, oblique, or curved; it is only necessary that its center should correspond to the foramen. The tissues are divided successively until the bone is reached and the nerve found either by following up one of its branches or by seeking it at its point of emergence.

B. RESECTION OF THE INFRA-ORBITAL PORTION. (Tillaux<sup>1</sup>.) (Fig. 77, C).—A vertical incision is made along the side of the nose from the lachrymal tubercle or the bony ridge of the nasal process of the superior maxilla, which is continuous with the lower edge of the orbit, down to the ala of the nose. A second horizontal one is then begun at the upper portion of the first and carried outward along the lower margin of the orbit beyond its center. These incisions should involve all the soft parts down to the bone. The lower flap is dissected up, the nerve found, and a silk ligature thrown around it close to the foramen.

The upper flap is then raised, together with the lower eyelid and eyeball, exposing the floor of the orbit as far back as possible, upon which the infra-orbital canal can be recognized as a grayish line running obliquely backward and inward.

<sup>1</sup>Traité d'Anat. Topographique, p. 310, and Bull. de la Société de Chirurgie, 1878, p. 413.



The canal is opened with a knife or chisel, the nerve isolated from the artery, raised from its bed with a small hook, and dissected out as far back as may be considered necessary. It is then divided with curved scissors, and the distal portion drawn out by means of the ligature applied to it in the beginning. The length of the portion removed by Tillaux was six centimeters.

Dolbeau<sup>1</sup> divided the nerve with curved scissors on the central side of the branches going to the spheno-palatine ganglion, and tore out the ganglion by drawing upon the nerve.

*Lücke's Method.*<sup>2</sup>—An incision, beginning one centimeter above the outer angle of the eye and close behind the margin of the orbit, is carried downward and slightly forward across the malar bone, dividing its periosteum; from its lower end a second incision is carried backward and upward, terminating over the outer surface of the zygomatic process of the temporal, about a quarter of an inch behind its junction with the malar bone. The latter bone is next divided in the line of the first incision by means of a saw or chisel, after preliminary division of the soft parts and periosteum on its under and inner surface with a small knife, and the zygoma then cut through at its posterior extremity. The attachments of the masseter to the intermediate piece are then separated, and the flap of bone and soft parts raised with a sharp hook.

If necessary, some of the anterior fibers of the temporal muscle should now be divided in order to expose the spheno-maxillary fossa thoroughly, the fat occupying the fossa pressed backward with a retractor, and the spheno-maxillary fissure recognized with a probe. The nerve and artery can be distinguished by the difference in their course, the former running downward, outward, and forward, the latter upward, inward, and forward. The nerve is seized with forceps and divided with a tenotome well forward in the fissure, and then again with scissors as near as possible to the foramen rotundum. The flap is

<sup>1</sup> Oral communication.

<sup>2</sup> Deutsche Zeitschrift für Chirurgie, Vol. 4, p. 322.



then put back, and the wound drained at its lower angle.

An objection to this method is that, in consequence of its interference with the masseter and temporal muscles, the mouth subsequently cannot be freely opened. Lossen and Braun<sup>1</sup> avoid this difficulty by leaving the attachments of the masseter untouched and turning the flap downward instead of upward, after making the second incision from the upper end of the first instead of from its lower end and separating the temporal fascia from the malar bone. Czerny<sup>2</sup> has employed this modification five times with good results.

If wounded vessels cannot be seized and tied, the hemorrhage must be arrested by plugging with antiseptic gauze.

#### INFERIOR DENTAL NERVE.

This nerve may be divided (A) after its exit from the dental canal, (B) in the canal, (C) before its entrance into the canal. The nerve enters the canal by the inferior dental foramen on the inner side of the ascending ramus of the lower jaw at the level of the crowns of the lower teeth; the canal runs obliquely downward and forward just below the alveoli and the nerve emerges through the mental foramen which lies midway between the alveolar process and the lower margin of the jaw below the second bicuspid tooth.

A. AT THE MENTAL FORAMEN.—An incision is made in the gingivo-labial fold above the foramen and the soft parts dissected off until the nerve is reached, usually about one-third of an inch below the bottom of the fold.

B. WITHIN THE CANAL.—An incision is made through the skin down to the bone along the course of the nerve in front of the masseter, the periosteum raised, and the canal opened with a chisel or small trephine. After removal of the outer table of the bone the nerve is easily found in the canal and divided.

Or the canal may be opened at two points and the intermediate portion of the nerve excised.

<sup>1</sup> *Centralblatt für Chirurgie*, 1878, pp. 65 and 148.

<sup>2</sup> *Ibid.*, 1882, p. 249.



Another method is to make a curved incision behind and below the angle of the jaw, and elevate the periosteum and masseter on its outer surface as far as the alveolar margin. Then chisel into the middle of the exposed bone. The oral cavity should not be opened.

C. BEFORE ITS ENTRY INTO THE CANAL. 1. *From within the mouth.*—The mouth being held widely open and the commissure of the lips drawn backward and outward, an incision extending from the last upper to the last lower molar tooth is made one-third of an inch on the inner side of the sharp anterior border of the coronoid process, and carried through the mucous membrane to the tendon of the temporal muscle.

The surgeon passes his finger into the incision and along the inner surface of the bone, between it and the internal pterygoid muscle, until he touches the bony point which marks the orifice of the canal. Passing a blunt hook along the finger, he raises the nerve upon it, isolating it if possible from the accompanying artery, and divides it with blunt-pointed scissors or knife. Or, without introducing the finger, the hook may be passed back beyond the nerve, its point constantly in contact with the bone, then rotated inward so as to carry its point across and behind the nerve, and then withdrawn.

2. *Through the cheek.*—A curved incision is made around the angle of the jaw or around the lower anterior insertion of the masseter and carried through to the bone along its lower portion; then with the elevator and knife the muscle is detached from below upward, and the flap raised with a hook until the level of the inferior dental foramen is reached. The bone is then cut away with a chisel or small trephine and the nerve exposed and excised.

With the same curved incision around the angle of the jaw the inner surface of the latter may be freed from the periosteum and internal pterygoid muscle upward till the lingula is felt; then, with or without dividing this process the nerve can be isolated and divided. Or a vertical incision may be made through the skin and fascia, the fibers of the masseter separated, and the bone thus exposed.



**At the Foramen Ovale.**—Braun's modification of Lücke's method for exposing the superior maxillary nerve can be employed with slight changes for this purpose. The temporal muscle must be retracted or partially divided near its insertion, or the coronoid process cut through at its base.

Krönlein<sup>1</sup> suggests the following method: An incision is made from half an inch behind the angle of the mouth to terminate a similar distance in front of the lobule of the ear. Only the skin and subcutaneous fat are divided, the buccinator and oral mucous membrane being spared. The masseter is cut back to the anterior border of the parotid gland, thus sparing the latter and Steno's duct, which lies well above the line of incision. The coronoid process is bared at its base with a periosteal elevator, divided from the semilunar notch downward and forward, and drawn upward, together with the attached temporal muscle. The branches of the inferior maxillary nerve are then exposed by a blunt dissection on the outer surface of the internal pterygoid muscle. The external pterygoid is drawn upward and the nerves traced back to the base of the skull. At the close of the operation the coronoid process and divided masseter muscle are sutured.

He exposes the superior and inferior maxillary nerves simultaneously at their exit from the skull in the following manner<sup>2</sup>: A curved incision, concavity upward, is made, starting from the most prominent portion of the malar bone, passing down to the level of the lobule of the ear, thence backward and upward in a gentle curve, to terminate over the posterior extremity of the zygoma. The flap of skin and subcutaneous fascia is turned up, the temporal fascia divided along the upper border of the zygoma, and the latter sawn through at its anterior and posterior extremities, as in Lücke's operation. The coronoid process is exposed and cut through at its base downward and forward, and drawn upward with the attached temporal muscle. The internal maxillary artery is secured

<sup>1</sup> Archiv. f. klin. Chir., Bd. XLIII., p. 13.

<sup>2</sup> Deutsch. Zeitsch. f. Chir., 1884, Vol. XX., p. 484.



and the attachment of the external pterygoid muscle separated from the under surface of sphenoid bone. This exposes the inferior maxillary nerve at the foramen ovale, and by working along the spheno-maxillary fissure the superior maxillary nerve is found and followed back to the foramen rotundum. At the close of the operation the parts are replaced and sutured in their proper position.

*Salger*<sup>1</sup> recommends a curved incision, convexity upward, extending from one extremity of the zygoma to the other. Everything is divided down to the skull, the zygoma sawn through at each extremity, and the flap of skin, fascia, temporal muscle, and zygoma turned down. The coronoid process is depressed by opening the mouth, and the nerve found below the external and on the outer surface of the internal pterygoid muscle, and divided as high up as desired.

### BUCCAL NERVE.

The buccal nerve, a branch of the inferior maxillary, may be the seat of painful and persistent neuralgia. It is best approached through the mouth by the following method :

The surgeon places his finger-nail upon the outer lip of the anterior border of the ascending ramus of the lower jaw at its center, and divides in front of this border the mucous membrane and the fibers of the buccinator vertically. He then seeks for the nerve, separating the tissues with a director, and divides it.

*Zuckerkindl* exposes the nerve from the outside of the cheek. A horizontal incision a finger's breadth below the zygoma is made from the anterior border of the masseter muscle nearly to the canine eminence. The fascia overlying Steno's duct is divided, and the latter exposed and drawn downward with its accompanying nerves. The fat on the posterior part of the buccinator muscle is torn through, and the nerve found to the inner side of the insertion of the temporal muscle on the front of the coronoid process. It lies about an inch back of the anterior border of the masseter muscle.

<sup>1</sup> Wien. med. Wochenschr., 1887, Vol. XXXVII., p. 461.



## LINGUAL NERVE.

Division of this nerve may be required for the relief of pain in cases of carcinoma of the tongue.

When the mouth is opened widely the pterygo-maxillary ligament can be readily seen and felt as a prominent fold behind the last lower molar, and the lingual nerve can be felt just below the attachment of the ligament on the inner side of the lower jaw, close to the bone below the last molar tooth.

The tongue should be drawn aside by an assistant, the mucous membrane divided for about an inch parallel to the margin of the alveolar process, beginning at the last molar tooth over the position of the nerve, or, according to Chauvel,<sup>1</sup> one-fifth of an inch from the attachment of the mucous membrane to the side of the tongue. The nerve is then readily found in the submucous tissue, raised upon a hook and divided, or a portion excised.

**Moore's Method.**—Mr. Moore has employed the following method successfully in five cases: He cuts the nerve about half an inch from the last molar tooth, at a point where it crosses an imaginary line drawn from that tooth to the angle of the jaw. He enters the point of the knife nearly three-quarters of an inch behind and below the tooth, presses it down to the bone and cuts toward the tooth. This necessarily divides the nerve. This projection of the alveolar ridge might protect the nerve from a straight bistoury, and therefore a curved one should be used.

The lingual nerve may also be reached from outside the mouth by any one of the methods for resecting the inferior maxillary, or by an incision along the lower border of the jaw just in front of the masseter muscle. In the latter case (Löbker) the upper margin of the wound is drawn up and a portion of the inferior maxilla, where the alveolar process adjoins the ramus, is excised and the nerve exposed on the outer surface of the internal pterygoid. Or the dissection can be carried up under the inner

<sup>1</sup> *Précis d'Opérations de Chirurgie*, p. 435.



surface of the jaw (Luschka). The submaxillary gland is displaced downward and forward, the posterior border of the mylo-hyoid muscle divided and the nerve found under the posterior end of the sublingual gland. Thence it can be followed backward and upward and divided as high as desired.

### FACIAL NERVE.

This nerve has occasionally been stretched and crushed for the relief of clonic spasms of the corresponding muscles. A semilunar incision is made around the lower attachment of the ear with a short liberating incision downward from its center; the flaps are dissected back, and the nerve exposed by drawing the parotid forward and outward.

The nerve is more easily exposed at the posterior border of the ramus. For this an incision is made from just in front of the tragus of the ear to the angle of the jaw. After dividing the parotid fascia the cervico-facial branch will probably be exposed first, and can then be followed back to its junction with the temporo-facial.

### BRACHIAL PLEXUS.

This plexus consists of the four lower cervical nerves and the greater part of the first dorsal. It crosses the floor of the subclavian triangle of the neck, and lies between the anterior and middle scaleni muscles. Its shape is triangular, with the base at the spine and the apex to the outer side of the subclavian artery below the clavicle.

**Operation.**—The head and neck are extended, and the face turned to the opposite side. An incision, starting half an inch above the clavicle in the interval between the sterno-cleido-mastoid and trapezius, is carried forward, for about three inches, parallel to the anterior border of the latter. The skin and platysma are divided and the external jugular vein either cut between two ligatures or drawn to one side. The deep cervical fascia is divided in the line of the external incision, avoiding the supra-



clavicular branches of the cervical plexus, and the outer border of the anterior scalenus muscle recognized. The plexus is felt with the finger just outside the latter and isolated by a little careful dissection. Any particular cord can be identified by tracing it to its point of emergence from the spine through the interval between the *scaleni* muscles.

**Resection of the Posterior Roots of the Brachial Plexus.**—This operation has been performed several times for severe neuralgia of the peripheral branches. An incision about six inches long, with its center just above the spine of the seventh cervical vertebra, is made parallel and close to the *ligamentum nuchæ* and deepened alongside of the spines till the *laminæ* of the fifth, sixth, and seventh vertebræ are reached. These *laminæ* are then bared of soft parts on the affected side out to the bases of the articular processes, and removed with the chisel, *rongeur*, or bone forceps, thus exposing the posterior roots of the nerves previous to their exit from the intervertebral foramina.

### CERVICAL PLEXUS.

An incision about two inches in length is made parallel to and over the posterior border of the sterno-mastoid muscle. Its center should correspond to the center of the muscle. The skin, superficial fascia, and *platysma* are divided and the superficial branches of the cervical plexus are exposed at the middle of the posterior border of the sterno-mastoid muscle and can be traced back toward the spine.

### SPINAL ACCESSORY NERVE.

After passing outward beneath the digastric and stylohyoid muscles and occipital artery, the nerve about half an inch below the apex of the mastoid process enters the under surface of the sterno-mastoid muscle in its upper part, leaves it at about the center of its posterior border, and passes beneath the trapezius at about the junction of the middle and lower thirds of its anterior border. In the substance of the sterno-mastoid muscle it communi-



cates with the second cervical nerve, in the occipital triangle with the second and third, and beneath the trapezius with the third and fourth cervical nerves.

**Operation.**—An incision about three inches long is made downward from the tip of the mastoid process along the anterior border of the sterno-mastoid muscle, the cervical fascia divided and the muscle strongly retracted to put the nerve on the stretch. The nerve is then sought for external to the jugular vein about an inch and a-half below the tip of the mastoid process on the fascia covering the rectus capitis anticus major.

**Section of the Posterior Divisions of the First, Second and Third Cervical Nerves for Spasmodic Wry Neck.**—The chief posterior cervical rotators of the head and their nerve supply are as follows: The rectus capitis posticus major is supplied by the suboccipital or posterior division of the first cervical nerve. The inferior oblique is supplied by the posterior divisions of the first and second cervical nerves and the splenius capitis by the posterior divisions of the second and third cervical nerves.

**Operation.** (Modified from Keen.)<sup>1</sup>—A transverse incision about three inches long is made extending horizontally outward from the middle line of the neck, or slightly overlapping it, an inch and a-half below the external occipital protuberance. It is carried through the trapezius and posterior border of the splenius capitis muscles until the complexus is recognized, the trapezius is dissected up from the complexus and the occipitalis major nerve found at the upper part of the complexus. Divide the complexus transversely and follow the nerve back to its origin from the posterior division of the second cervical nerve and divide the latter as near the vertebra as possible.

Recognize the suboccipital triangle, which is bounded by the superior and inferior oblique and the rectus capitis posticus major muscles. Within this lies the suboccipital nerve close to the occiput and vertebral artery; it must be traced and severed close to the spine. The posterior

<sup>1</sup> Annals Surg., Jan., 1891.



division of the third cervical nerve is found beneath the complexus about an inch lower down than the occipitalis major, and must be cut close to the bifurcation of the main trunk.

Smith<sup>1</sup> made a longitudinal incision about three inches long from the occiput downward about an inch and a-half to one side of the middle line. It passed through the trapezius to the edge of the splenius, then through the complexus, and eventually exposed the posterior divisions of the cervical nerves. The great occipital nerve was recognized, separated, and drawn aside; a part of the external branch of the posterior division of the second nerve was excised; the splenius and complexus separated from the parts beneath, and the entering nerve filaments divided.

The suboccipital nerve was not divided. The result of this operation seems to have been perfect.

**Median Nerve.**—In the arm it is exposed by the method given for ligation of the brachial artery. At the wrist it is reached by an incision about an inch and a-half long, parallel to and just to the ulnar side of the tendon of the palmaris longus.

**Ulnar Nerve.**—Except in the extreme upper part of its course the nerve closely accompanies the triceps and is completely separated from the median nerve and brachial artery by the fascial septum that passes down to the bone between the biceps and triceps. Except near the elbow, it should be sought through an incision parallel to and a little posterior to the brachial artery, and after exposure of the triceps.

At the elbow it can be easily found through an incision an inch and a-half long, curving upward between the internal epicondyle and the olecranon.

In the forearm its course is indicated by a line drawn from the space between the internal epicondyle and the olecranon to the radial side of the pisiform bone. At first, it lies over the flexor profundus beneath the flexor carpi ulnaris. At the wrist it is superficial, and lies on the annular ligament with the ulnar artery on its radial

<sup>1</sup> Brit. Med. Journ., 1891, Vol. I., p. 752.



side. It is easily reached at the wrist by an incision about two inches long extending upward through the skin and fascia from the pisiform bone. The incision is parallel to and close to the radial side of the flexor carpi ulnaris tendon.

### MUSCULO-SPIRAL NERVE.

It winds around the humerus in the musculo-spiral groove between the internal and external heads of the triceps, and reaches the outer side of the arm at about the junction of the middle and lower thirds, and is accompanied by the superior profunda artery. It then pierces the external intermuscular septum and descends in the groove between the brachialis anticus and supinator longus to the front of the external condyle. At this point it is most easily found.

**Operation.**—An incision about three inches long is made at the upper part of the supinator groove, the fascia divided, and the nerve sought in the bottom of the groove; it is then followed upward or downward, according to the circumstances of the case.

**Great Sciatic Nerve.**—An incision three or four inches long is made downward from the gluteal fold, midway between the tuberosity of the ischium and the great trochanter. After division of the skin and fascia the lower border of the gluteus maximus is observed and the hamstring muscles recognized.

The nerve lies on the external rotators of the thigh just in front of and to the outer side of the hamstring muscles.

**Internal Popliteal Nerve.**—It is reached by the incision for ligation of the popliteal artery. It is superficial to the vein and artery and slightly external.

**External Popliteal Nerve.**—This nerve lies close behind and to the inner side of the tendon of the biceps, and is exposed by an incision two or three inches long parallel to and close to the inner side of that tendon.

**Anterior Crural Nerve.**—A longitudinal incision about two inches in length is made downward from Poupart's ligament, about an inch to the outer side of the femoral



artery. The superficial circumflex iliac vessels will be divided; the nerve will be found close beneath the fascia.

### NEURORRHAPHY.

**I. Primary Suture.**—An incision is made in the course of the nerve, exposing it at the point of division. The ends are brought together by a couple of fine sutures of silk or catgut passed directly through the substance of the nerve or through the nerve sheath. They must be so placed and tied as not to strangle the fibers.

**II. Secondary Suture.**—A long incision will probably be necessary; it should be made in the normal course of the nerve and extend well above and below the point of division. The trunk of the nerve should be sought for both above and below the cicatricial tissue of the original wound, and traced downward and upward respectively to the divided and separated ends. Such part of each end as is bulbous or imbedded in cicatricial tissue should be cut away and the divided surfaces brought into apposition and sutured. Tension should be relieved by freeing the nerve above and below and by flexing adjoining joints.

It is not absolutely necessary to success that the divided ends should be brought close together; reunion has taken place across gaps of considerable length, one or two centimeters; it has been thought to be favored under such circumstances by the presence of a suture connecting the two ends.

When there has been a considerable loss of nerve substance, rendering it impossible to bring the divided ends near together, flaps have been cut from the proximal and distal stumps and unfolded, and their extremities united as in tenorrhaphy (Fig. 82); or the distal stump may be freshened and then sutured between the fibers of a neighboring uninjured nerve of similar, or at least partly similar, character.

### TENOTOMY.

The blade of a tenotomy knife should be one inch long, its shank one and three-quarters, its handle strong and marked in such a way that the surgeon can see at a glance



in which direction the edge of the blade is turned. The blade may be straight or curved, it should be thick at the heel, very narrow, and the point should be somewhat rounded and sharpened from side to side like a wedge or chisel. (Sayre.)

A fold of skin should be pinched up at the side of the tendon, and the knife entered at its base, so that a continuous track will not be left on its withdrawal. A preliminary puncture may be made with a sharp-pointed knife or lancet to facilitate the entry of the tenotome.

The knife must be entered "on the flat" and passed either under the tendon or between it and the skin; its edge is then turned toward the tendon and the division effected with gentle sawing movements, the thumb being pressed firmly against the tendon if the knife has been passed under it.

During the entry of the knife and the division of the tendon the latter must be kept firmly upon the stretch, and as soon as the division is complete the knife must be turned upon its side and withdrawn, while the surgeon follows its point with his thumb or finger so as to force out any blood that may be in its track and to prevent the entrance of air.

Seal the wound with plaster or collodion, and *then* bring the member into the desired position.

**Tendo Achillis.**—The knife should be entered on the inner side of the tendon near its border, about one inch above the upper surface of the calcaneum. In this way the posterior tibial artery, which lies between the tendon and the inner malleolus and below the deep fascia, is secured from injury. The heel must be depressed as much as possible, so as to make the tendon more prominent and give additional security to the artery.

**Tibialis Posticus.**—The tendon of this muscle may be divided (A) above the malleolus, or (B) on the side of the foot just behind its insertion into the scaphoid.

A. ABOVE THE MALLEOLUS.—The muscle is made tense by everting the foot; the knife is entered at the inner side of the tendon and passed behind it.



**B. ON THE SIDE OF THE FOOT.**—Same position given to the foot. The knife should be directed from above downward and passed under the upper border of the tendon at a point half an inch below and in front of the tip of the malleolus. Bell<sup>1</sup> prefers to cut toward the bone.

**Tibialis Anticus.**—Can be easily made prominent and isolated.

**Peronei.**—May be divided at the posterior face of the lower end of the fibula, or on the side of the foot below and in front of the tip of the outer malleolus.

**Flexor Tendons at the Knees.**—It must be remembered that the external popliteal nerve accompanies the tendon of the biceps closely, lying upon its inner side.

**Sterno-cleido-mastoid.**—The danger to be avoided in this operation is that of injury to the external jugular vein at the outer border of the muscle, or to the anterior jugular vein at its inner border. The first can usually be seen under the skin and avoided, the other leaves the muscle about three-quarters of an inch above the sternum and passes backward. The muscle should be divided about half an inch above the top of the sternum, and most authorities agree in preferring to divide from before backward. The knife should be entered at the outer border of the muscle. The open operation is now generally preferred as less dangerous and more likely to give a good result.

### TENORRHAPHY.

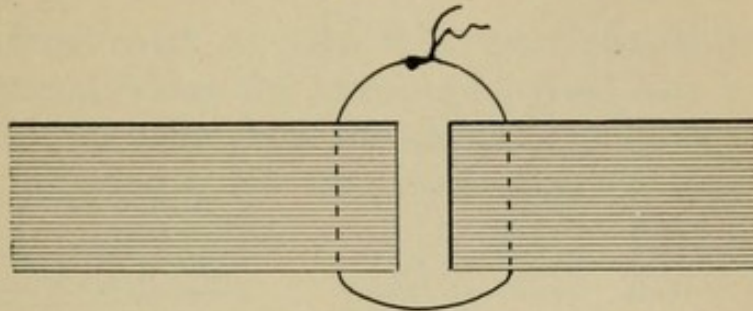
**Primary.**—Performed immediately after the injury. The wound, which is usually transverse, should be enlarged by an incision crossing it in the line of the tendon and carried through skin and fascia. The distal portion of the tendon can be made to appear in the wound by moving its distal joints in the direction taken when its muscle contracts (*e. g.*, flexing the fingers when the flexor tendons have been divided), but to find the proximal end it is often necessary to seek well above the line of division, and it is therefore well to expose the region

<sup>1</sup> Manual of Surgical Operations, 3d edition, p. 288.



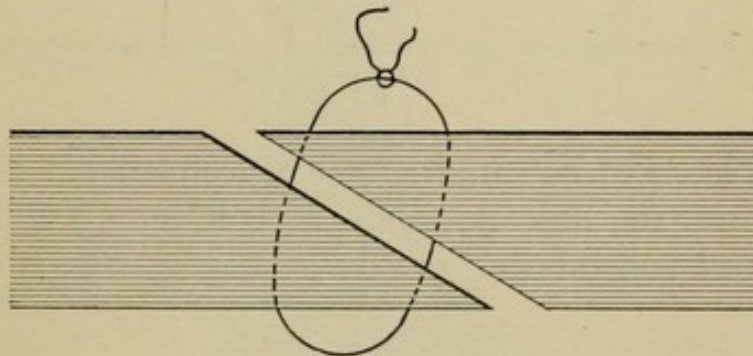
freely. The divided tendon ends are drawn into apposition and stitched together with fine silk, silkworm-gut, or catgut. The common forms of suture are represented in Figs. 78-81.

FIG. 78.



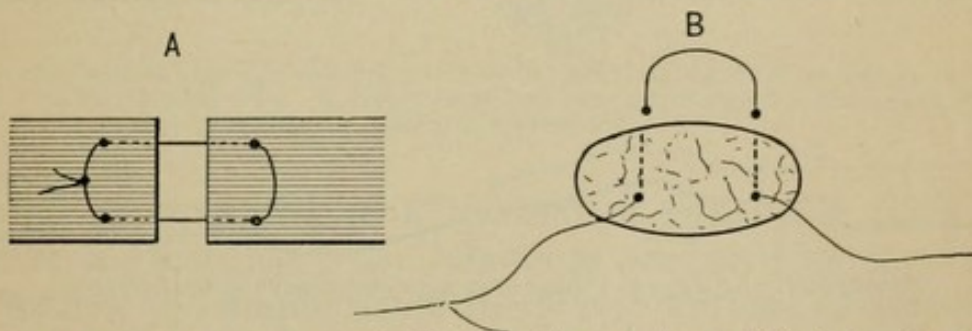
Tenorrhaphy by a suture passed through the substance of each segment.

FIG. 79.



Tenorrhaphy. The tendon ends cut obliquely to increase the surfaces in contact.

FIG. 80.



Tenorrhaphy. Showing the method of inserting a suture which does not readily pull out.

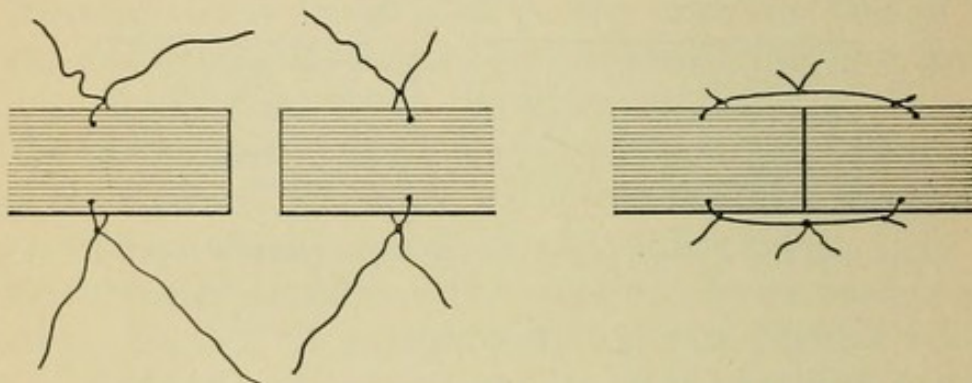
Ingrafting of portions of tendon taken from another region or even another animal has been performed, and it is said successfully. (*Bulletin de la Soc. de Chir.*, 1886, p. 357.)



It is important to immobilize the limb during healing in the position of greatest relaxation of the sutured tendon.

**Secondary.**—Performed after a considerable interval of time has elapsed since the injury. The divided tendon

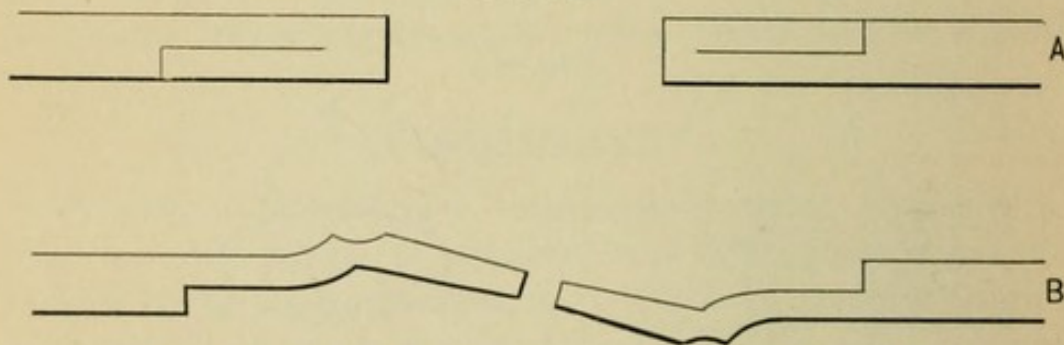
FIG. 81.



Tenorrhaphy by four ligatures inserted and tied (*A*) in each stump, and their free ends then united (*B*).

ends will have to be sought for amid cicatricial tissue and brought into the best possible apposition. The ends can be split and lengthened, as shown in Fig. 82; if this will

FIG. 82.



Tenorrhaphy by flaps to bridge over a gap between the tendon ends.

not do, or if the proximal end of the tendon cannot be found the distal end may be sutured to a neighboring tendon having the same general anatomical course.

The surface from which union is expected should be freshened by scraping.



## OSTEOTOMY.

**Osteotomy of the Femur—**

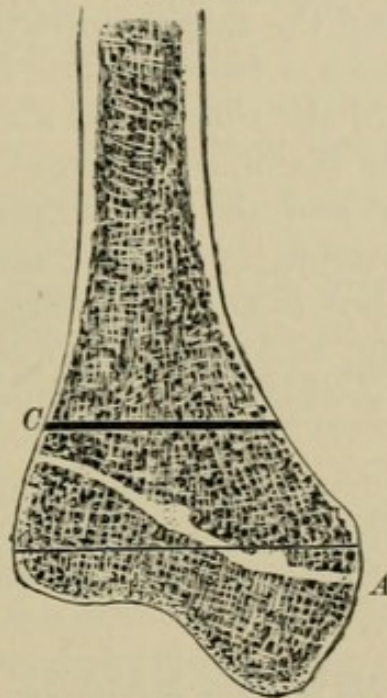
I. THROUGH THE NECK (Adams's operation), described on page 151.

II. BELOW THE GREAT TROCHANTER, described on page 152.

## III. OSTEOTOMY OF THE SHAFT OF THE FEMUR.

In a normal femur the lower epiphyseal line is about on a level with the tubercle of the adductor magnus and transverse in direction. But in cases of genu valgum it is

FIG. 83.



Frontal section through the lower end of the femur in a case of severe genu valgum. *A*. Epiphyseal line. *B*. Transverse line drawn through the adductor tubercle. *C*. Line of bone section in Macewen's operation.

oblique and parallel with the articular surface. This is due to the fact that genu valgum is produced by an overgrowth of the diaphysis of the femur and not of the epiphysis (Fig. 83).

**Osteotomy of the Shaft of the Femur from the Outer Side.**—The knee is partially flexed and supported on a sand-bag beneath its inner surface. A longitudinal incision down to the bone is made on the outer aspect of the thigh about two inches above the top of the external condyle



and well in front of the tendon of the biceps. The periosteum is divided transversely, and stripped back sufficiently to expose the base of the wedge of bone that is to be removed, and then with a chisel this wedge is cut away piecemeal, care being taken throughout to remove the corresponding part of the anterior and posterior shell of the bone. The chisel may be used until the division is complete, or the last part may be broken by forcibly adducting the fully extended leg. At the conclusion of the operation the wound is closed and dressed antiseptically, and the limb is immobilized in the corrected—straight—position.

**Supra-condyloid Osteotomy of the Femur.**—The hip and knee are flexed, and the thigh supported on its outer side. A longitudinal incision two or three inches long is made on the inner side of the thigh close above the condyle and carried through the fascia, the fibers of the vastus internus are drawn forward and the bone exposed at their attachment. The periosteum is divided and a wedge of bone removed as described in the preceding section. After arrest of the bleeding, which may be quite free at the lower angle, the wound is closed and the limb immobilized with plaster of Paris.

Some prefer, in both these operations, simply to divide the bone by driving the chisel straight across, without removing a wedge of bone. (MacEwen.)

#### OSTEOTOMY FOR HALLUX VALGUS.

A longitudinal incision about two inches long is carried down to the periosteum on the mesial surface of the lower part of the first metatarsal bone opening the joint. The bone is divided and a wedge of tissue removed from it sufficient to allow the toe to be brought into line. Usually the head of the metatarsal bone is deformed by overgrowth on its mesial side, in which case it should be freely cut away. No troublesome limitation of motion is to be feared if infection of the wound is avoided.



**CUNEIFORM OSTEOTOMY FOR TALIPES EQUINOVARUS.**

A horizontal incision is made along the outer side of the foot from about the center of the anterior portion of the outer surface of the os calcis across the cuboid to the base of the fifth metatarsal bone. If necessary this is joined at its center by a liberating incision passing perpendicularly to the horizontal incision across the outer surface and dorsum of the foot to or over the scaphoid.

The base of the wedge of bone to be removed will consist mainly of the cuboid with portions of the os calcis, the astragalus, and perhaps a part of the external cuneiform and base of the fifth metatarsal. The apex will correspond to a point on the inner surface of the scaphoid. The amount of bone which may need removal will of course depend upon the extent of the deformity, but in extreme cases it may include portions of all the tarsal and some of the metatarsal bones. In every case the cuboid will form a large proportion of the wedge.

With a blunt periosteal elevator all the soft parts are detached from the bone that is to be removed; the peronæi tendons are retracted or protected; a thin blunt elevator may be pushed close under the plantar surface of the bones to protect the soft parts of the sole. The chisel is then driven in for the first bone cut, generally at the anterior end of the outer surface of the cuboid. It is directed toward the lower part of the scaphoid tubercle. The second line of bony division will usually need to pass just behind the anterior articular surface of the os calcis and through the neck of the astragalus to meet the first incision at the scaphoid tubercle. This wedge of bone is then pried or wrenched out entire, while any remaining attachments beneath are severed with blunt-pointed scissors or a knife kept close to the bone. If then it is found that the foot cannot be made to assume the proper position without tension another slice of bone is chiseled off, especially toward the apex of the wedge. This may be supplemented by tenotomy of any resisting tendons. The



thickened epidermis and the bursa usually found over the site of the cuboid may be excised if there is found to be a redundancy of skin after straightening the foot.

No wiring of the bones is necessary. The soft parts are sutured and the wound dressed antiseptically. Any oozing which may subsequently occur will dry and make of a simple antiseptic dressing a very efficient splint.

Of the great number of other operative procedures which may be used singly or in combination with each other or with cuneiform osteotomy for correcting pes varus or equino-varus mention should be made of tenotomy of resisting tendons (*q. v.*), extirpation of the astragalus (*q. v.*), extirpation of the cuboid or of several tarsal bones simultaneously, linear osteotomy of the tibia and fibula just above ankle-joint (*q. v.*), and Phelps's<sup>1</sup> operation. The latter, although not an osteotomy, will be described here.<sup>2</sup>

It is extensively used for remedying talipes equino-varus, and consists in a simple division of all structures which resist correction of the deformity. The tendo Achillis is first divided subcutaneously; then, while the foot is flexed dorsally, abducted and everted, an incision through the skin is made from just in front of the internal malleolus vertically downward across the inner third of the sole of the foot. After making the parts tense the tibialis anticus and posticus, the deltoid ligament, part of the abductor pollicis, the plantar fascia, and the flexor brevis and longus digitorum are severed as encountered in the wound. The plantar vessels and nerves are spared if possible, although their internal branches have been cut without bad effect.

As each structure is divided an attempt is made forcibly to place the foot in its proper position. Phelps employs a powerful system of levers, and ruptures any resisting ligamentary or fibrous bands. When all opposition has been properly overcome the anterior segment of the foot

<sup>1</sup> New England Medical Monthly, 1891.

<sup>2</sup> This operation is discussed and the results detailed in Transactions Am. Orthopædic Asso., Vol. VII., p. 43.



can be bent backward in overcorrection, thus probably opening the astragalo-scaphoid and calcaneo-cuboid joints. Only in about 10 per cent. of all cases, according to the originator of this operation, will osteotomy be required. When necessary to correct the deformity after all the resisting soft parts have been cut, the neck of the astragalus should be divided from the inside; then, if this is insufficient, a wedge may be removed from the anterior portion of the os calcis; the base of the wedge lies externally, the apex where the neck of the astragalus has been divided. The open wound on the inner side of the foot is either lightly packed with iodoform gauze or allowed to heal under a moist blood clot; over this an antiseptic dressing is applied and encased in plaster of Paris, the foot being maintained in a slightly overcorrected position.

#### CUNEIFORM OSTEOTOMY FOR TALIPES EQUINUS.

Two incisions are employed.

The inner incision passes along the mesial surface of the neck of the astragalus and across the scaphoid to terminate at the internal cuneiform bone. The external incision extends from the middle of the anterior portion of the outer surface of the os calcis across the cuboid to terminate at the base of the fifth metatarsal bone. The soft parts are raised from the dorsum of the foot, and a flat periosteal elevator can be passed close beneath the plantar surface of the bones to protect the soft parts of the sole. A wedge is then cut from the tarsal bones with the base on the dorsum of the foot. Its extent will depend on the degree of the deformity, but the apex must reach to the plantar surface of the bones. A metacarpal saw or chisel can be used.

The wedge, which may be extracted in one piece, will consist chiefly of the scaphoid and cuboid bones, with perhaps portions of the anterior extremities of the astragalus and os calcis. At the close of the operation the soft parts which have been divided are sutured and the foot immobilized with the bones in apposition.



### **CUNEIFORM OSTEOTOMY FOR TALIPES VALGUS OR PES PLANUS.**

An incision is begun just below the apex of the internal malleolus and carried forward two inches. The soft parts are carefully raised from the inner and under surface of the astragalus and a suitable wedge removed from it. The base of the wedge should lie below and include either the neck alone of the astragalus or the articular surfaces of the astragalus and scaphoid.

### **OPERATIONS FOR UNUNITED FRACTURE.**

The aim of the operative treatment for old ununited fracture is to place the freshened ends of the bone in contact and to keep them immobilized in this position.

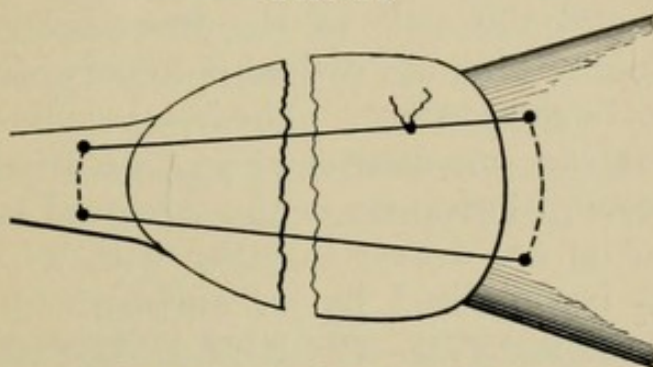
A free incision is necessary. In general it should be in the long axis of the limb, and so placed as to reach the point of fracture by the shortest route with the least possible damage to nerves and vessels. Any tissue which may be found intervening between the ends of the bone is dissected out and removed. It will often be found advantageous to protrude the ends of the bone through the wound. The extremity of each fragment is then pared off with the rongeur or chisel till fresh cancellous tissue is exposed over the whole section of the shaft and the two surfaces can be opposed throughout. If the fragments override, enough bone is removed to allow the ends to be brought into apposition without tension. Wiring is to be condemned as superfluous. It will seldom be found necessary to do more than freshen the ends of bone and maintain them in quiet apposition with a suitable splint. If there is any doubt about their remaining in this position while the splint is applied and subsequently, it is better to drill a small hole about half an inch from the fracture line on each side and tie the ends together with a piece of kangaroo-tendon or stout chromicized catgut or silk. If the limb is handled carefully this will keep the bones in contact and prevent the interposition of soft parts till the limb has been immobilized. In addition to this the peri-



osteum is as far as possible preserved, and any divided soft parts in the neighborhood should be placed in proper position and reunited. This will serve as a sling for the bones to rest in. The wound is then closed layer by layer and dressed antiseptically, with provision for temporary drainage. If pegs or nails have been used they should reach to the skin surface and be included in the dressings, and should be removed in about a week.

### SUTURE OF THE PATELLA.

FIG. 84.



Mediate suture for fracture of the patella.

**Mediate Silk Suture.** (Fig. 84.)—A longitudinal median incision is made extending well above and below the fracture. Clots are washed from the joint with salt solution, and the fibro-periosteal fringe lifted up if one has formed. Then, with a full-curved needle, a stout silk ligature is passed transversely through the ligamentum patellæ close to the apex of the patella, then transversely in the opposite direction through the tendon of the quadriceps close to its insertion, and then drawn tight and tied while the fragments are held together. One or two catgut sutures may be placed in the torn capsule on each side. The incision is then closed without drainage.

Many other more or less complicated methods of holding the fragments together have been devised ; this one is as simple as any, and has proved to be efficient and safe in about one hundred personal cases. In a number of cases catgut sutures passed through the fibro-periosteum near the edge of the fracture have given good results. A transverse



or curved incision permits more exact suturing of the torn capsule but divides several large veins and is more likely to become adherent along the line of fracture. Wire sutures are, in my judgment, to be condemned as unnecessary and as unduly complicating the operation and the repair.

#### OPERATION FOR NON-UNION AFTER FRACTURE OF THE OLECRANON PROCESS.

A median longitudinal incision is made over the posterior surface of the olecranon and ulna, exposing the bone at the point of fracture. The interposed fibrous tissue is cleared away and the ends of the fragments freshened. The olecranon and ulna are drilled obliquely without perforating the articular surface. The holes start on the posterior surface about one-quarter of an inch from the edge of the fracture and terminate *in* the fractured surface.

The fragments are drawn together with a silk suture and the limb immobilized by an antiseptic dressing in complete extension.

Mediate suture, with silk passed through the tendon of the triceps and a hole drilled transversely through the shaft of the ulna half an inch or more below the fracture or even through the periosteum, has given me good results and is probably to be preferred to direct suturing.

#### LAMINECTOMY.<sup>1</sup>

An incision five or six inches long is made in the median line over the summit of the spinous processes in question, and quickly deepened close to one side of them till the laminae are exposed, from which the periosteum with the attached muscles is raised with an elevator out to the articular and transverse processes. The bases of the spinous processes are next cut through with a chisel or bone forceps, and the opposite laminae freed in the same way of periosteum and muscle, without disturbing the muscular attachments of the spinous processes.

<sup>1</sup>Thorburn: Surg. of Spin. Cord. Lloyd: Amer. Journ. Med. Sciences, 1891, Vol. 102, p. 25.



Some operators prefer to make two parallel incisions on each side of the spinous processes, which are then excised, and Horsley, to better expose the laminæ, divides the lumbar aponeurosis and muscles at right angles to the middle of the longitudinal incisions. The sides of the wound are well retracted and the laminæ are divided close to the transverse processes with a rongeur, bone forceps, or chisel, and the posterior arch thus removed.

If the trouble is not then apparent, before opening the dura a probe should be passed up and down to make sure that the cord has been exposed in the proper locality. If then it is considered necessary, the dura is pinched up and opened longitudinally in the median line behind.

Subsequently the wound in the dura is closed with fine catgut or silk sutures and the overlying parts brought together by buried and superficial sutures over a drainage-tube placed in the deepest portion of the wound.

## MISCELLANEOUS OPERATIONS.

### THIERSCH'S SKIN GRAFTING.

*The wound* to which the graft is to be applied must be fresh, clean, dry and perfectly aseptic. If it is already a granulating surface all pus must be carefully scrubbed away and the granulations freely shaved away with a knife. It is then thoroughly washed with a sterilized salt solution (about 3j of common salt to Oj of water). Bleeding is checked by the pressure of a sterilized compress maintained until the grafts are ready to be applied, in order to preserve the asepsis and to prevent the formation of clots of blood which would separate the graft from contact with the raw surface.

*The graft* is commonly taken from the front or outer surface of the thigh, as this presents a conveniently broad surface of skin of the requisite thickness. It must be previously shaved and scrubbed, then rinsed off with alcohol and finally with sterilized water. The skin of the thigh is drawn tense and flat by one hand grasping the



thigh just above the knee and pulling down. With the other hand a broad-bladed razor, ground flat on the surface held next the thigh, is drawn downward toward the knee by quick sawing motions through the skin parallel to and just beneath its surface. The cutting must be done with accuracy and the razor's edge must lie always in the papillary layer of the skin. Practically it must pass just deep enough to leave the cut surface studded with minute specks of blood which do not coalesce for an appreciable length of time. If the knife exposes any particle of the subcutaneous fat the corresponding part of the intended graft must be rejected. The sterilized salt solution is allowed to trickle on the skin immediately in front of the advancing razor-edge and serves to float the graft up into the concavity on the anterior surface of the razor and with a little practice facilitates the cutting. A strip six or eight inches long and one and a-half or two inches wide can be cut and retained on a broad blade. The attached end of the graft is severed with scissors. The graft is then immediately unfolded on the prepared wound surface by retaining the whole width of the free end against one margin of the area to be covered and gently withdrawing the razor while its edge is kept constantly in contact with the wound surface.

If any portions of the graft get turned over so as to oppose the epidermic layer to the wound surface, they must be carefully unfolded. In addition all air bubbles must be pressed out toward the edges; and, in short, every part of the freshly cut surface of the graft must be brought into accurate contact with the underlying raw surface which is to be covered.

Successive grafts are cut and applied until the entire surface is covered.

The grafts are then covered completely with strips of sterilized rubber tissue about an inch wide (after rinsing them in the sterilized salt solution), placed side by side with the edges slightly overlapping.

This arrangement permits drainage and allows the graft to be kept damp with the next applied sterilized com-



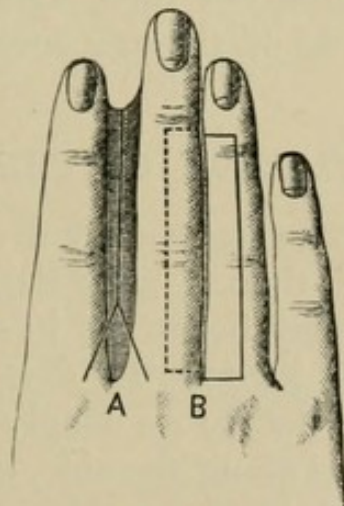
presses, wrung out in either the sterilized salt solution or a sterilized saturated solution of boric acid.

The compresses are covered with a sheet of sterilized rubber tissue to prevent drying. This dressing must be very carefully bandaged in place with even pressure and without disturbing the grafts. From time to time, till it is removed at the end of five days, it must be moistened with the sterilized salt or boric solution.

### SEPARATION OF WEB-FINGERS.

Experience has shown that simple division of the membrane uniting the two fingers is insufficient, because, reunion, beginning at the angle, is certain to extend over the whole length of the incision. A simple way of overcoming this difficulty is to pass a leaden or silver wire through a puncture made at the interdigital angle, keep it there until cicatrization has taken place around it, as around an ear-ring, and then divide the membrane. The angle being already cicatrized, the lateral wounds heal separately.

FIG. 85.



Web fingers.

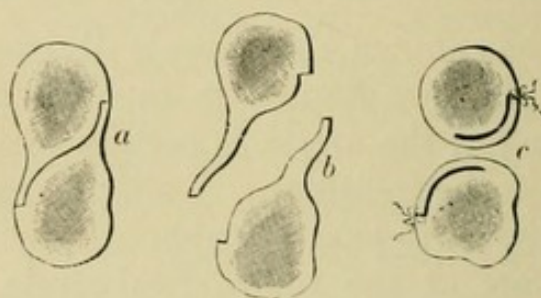
Another plan is to mark out a palmar and a dorsal triangular flap at the interdigital angle, its apex turned toward the ends of the fingers (Fig. 85, A), then to split the remainder of the membrane longitudinally, pare off the ends of the triangular flaps, and unite them in the



interdigital angle. By this means a bridge of integument is formed which prevents reunion of the sides.

These two methods answer very well when there is a distinct interdigital membrane, but some other is required when the fingers are closely approximated. The one which yields the best results is represented in Fig. 85, B, and Fig. 86. A rectangular flap is dissected up from the

FIG. 86.



Formation and adjustment of flaps in operation for web-fingers.

dorsum of one finger, and a similar flap from the palmar surface of the other finger, each being left adherent by its long side. The fingers are then separated and each flap turned in to cover one of the raw surfaces.

#### CICATRICIAL FLEXION OF THE PHALANGES.

The cicatrix must be thoroughly divided to allow complete extension, and then if skin flaps can be obtained from the sides they may be turned in to cover the palmar surface opposite the joints. In dissecting up the flaps care must be taken not to go deeply enough to involve the artery which runs along the side, otherwise the end of the finger may slough.

Instead of small lateral flaps for the flexures of the joints the skin covering the sides of the finger may be mobilized by lateral or dorsal longitudinal incisions and brought together in the median line of the palmar surface, the gaps created on the sides by their removal being left to heal by granulation.



### DUPUYTREN'S CONTRACTION OF THE FINGERS.

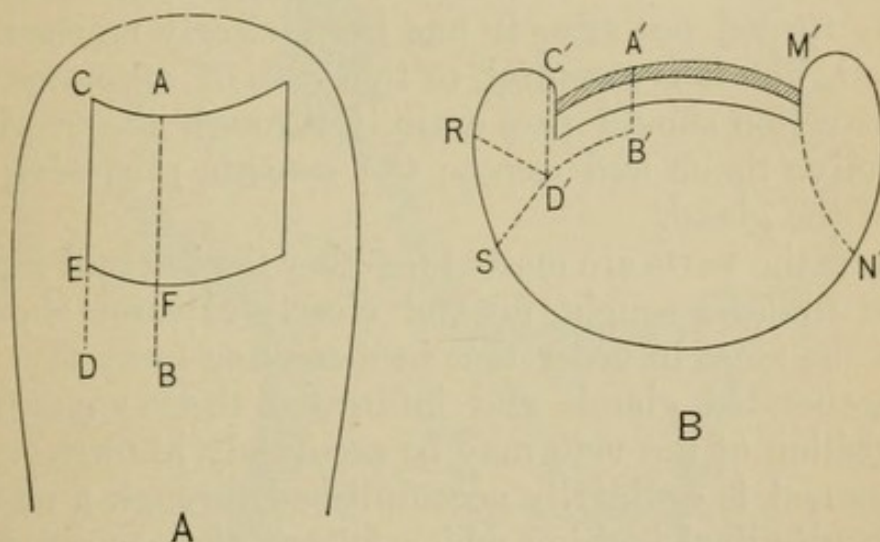
**Open Method.**—A longitudinal incision is made through the skin along the entire length of the constricting band, and crossed at each end by a transverse incision. The flaps thus marked out are dissected up from the aponeurosis, which is then divided transversely or excised.

Resultant gaps in the skin should be closed by flaps or skin grafts.

### INGROWN TOENAIL.

The base of the toe is constricted with a rubber tourniquet and a few minims of a 2 per cent. solution of cocaine injected on the sides and dorsum. The nail is then torn out (in all cases) with forceps, one blade of which is pushed up under it to free it from the matrix.

FIG. 87.



Ingrown toenail. A. A, B, D, C, flap operations (parts removed shown in B. A', B', C', D'). B. R, D', S, wedge operation—M', N', showing part removed by Cotting's operation.

I. A rectangular flap, D, E, F, B (Fig. 87, A), about one-quarter of an inch square, is made and reflected. The strip of matrix underlying it (Fig. 87, A, B, D, C) and the corresponding part of the nail in front, is then thoroughly dissected off, care being taken to carry the dissection entirely beyond the base and side. The flap is next replaced and secured and a light dry dressing applied.



II. The exuberant tissue and adjoining skin is pared off close up to the margin of the nail and matrix (M', N'). The resulting wound is left to close by granulation. (Cotting.) (Fig. 87, B, M', N'.)

III. In certain slight cases a wedge-shaped piece can be excised from the side of the toe, and by closing this gap with sutures the irritated part is drawn away from the nail. (R, S, D', Fig. 87, B.)

### THE OPERATIVE TREATMENT OF DISEASED CERVICAL GLANDS.

The operations required in the treatment of diseased cervical glands comprise opening abscesses, scraping and slitting up sinuses, and partial or complete removal of the enlarged lymph nodes. When the latter have not become matted together into an indistinct mass by inflammatory processes—in other words, when the glands can be felt as rounded, more or less movable tumors, each can be readily turned out after it has been clearly reached and exposed, but it is essential to this ease of execution that the dissection should pass entirely through the overlying connective tissue and expose the smooth, glistening surface of the gland.

When the parts are matted together the internal jugular should first be sought for and clearly exposed above or below the mass in order that in dissecting away the mass of degenerated glands and infiltrated tissue about them the position of the vein may be accurately known.

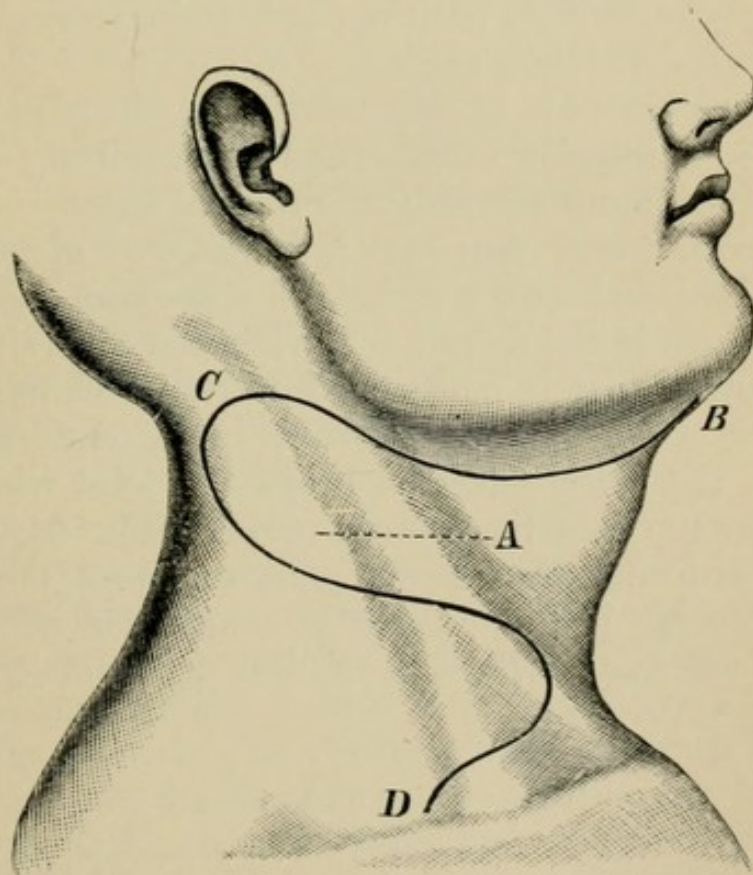
Removal is ordinarily accomplished through a more or less longitudinal incision which follows the general direction of the underlying structures, and is placed over the most prominent part of the tumefaction. This is generally along the anterior or posterior border of the sternomastoid muscle; occasionally it may be necessary to make it along nearly the whole length of both borders to obtain sufficiently free access to all the glands. The incision must be long enough to give a clear view of each structure as it is encountered, and to permit of ready control of the hemorrhage.



The difficulties attending a thorough removal of all diseased parts by even a double longitudinal incision are so great that Dr. Hartley, of New York, has devised an operation in which cutaneous flaps are raised from the surface of the tumor. At first sight it appears unnecessarily severe, but the results hitherto have been excellent, and the scarring is not so noticeable as to offset the great advantages gained by a complete exposure of all the important parts which are in close relationship with the enlarged glands.

The incision is S-shaped (Fig. 88), and involves only the skin, subcutaneous tissue, and fascia; starting below the chin it passes in a curve downward and backward to

FIG. 88.



*B, C, D.* Hartley's incision for the removal of enlarged cervical glands. *A.* Point where the sterno-mastoid is divided.

the hyoid bone, then up behind the angle of the jaw to near the lobule of the ear, whence it sweeps down along



the anterior border of the trapezius, forward over the sterno-mastoid, and downward and backward again to terminate above the middle of the clavicle. The flaps thus formed are dissected up, exposing nearly the whole length of the sterno-mastoid, and the latter is cut transversely near its center and the ends reflected, care being taken not to injure the spinal accessory nerve above. The point where the muscle is divided must not be in the line of the cutaneous incision, but under the middle of one of the flaps, preferably the upper. The great vessels are thus exposed from the mastoid process to the clavicle, and the operator can excise the adherent and diseased glands and avoid injury to the adjacent important structures.

At the close of the operation the divided ends of the sterno-mastoid are united with catgut, the flaps replaced and loosely sutured in position, and drainage provided for in the most dependent angles.

This large incision is only used when the glands in the superior and inferior carotid and submaxillary triangles are involved simultaneously. For less extensive disease the upper or lower flap may be employed alone, or one may be fashioned with a pedicle in a position the reverse of that shown in the figure. The incision for a single flap should approximately correspond to the circumference of the tumor, which is then exposed in its entirety by division of the sterno-mastoid below the joint where it is entered by the spinal accessory nerve. The flap consists of skin, subcutaneous tissue, platysma, and fascia, and after reflecting it the muscle is always cut beneath the center of the flap, and not in the line of the cutaneous incision.



## PART VI.

### PLASTIC OPERATIONS ON THE FACE.

---

PLASTIC operations are required for the relief of congenital defects or for the restoration of parts lost by disease or injury. The methods most commonly employed are of two kinds :

1. BY APPROXIMATION OF THE EDGES.—This is applicable to cases in which the loss of tissue is not great and the adjoining parts are supple. The edges of the gap are simply pared and brought together. It is sometimes necessary to make “liberating incisions” on one or both sides for the relief of tension.

2. BY TRANSFER OF A FLAP.—A flap of suitable shape and size is dissected up and transferred, by turning it about its base, to the place where it is needed, its vitality being insured by the preservation of its base or pedicle. This method admits of a great variety of modifications in its details, from a simple sliding of a skin flap, which differs but slightly from the method by approximation, to the transfer of skin, muscle and bone, or the taking of the flap from another limb or individual.

The names *Indian*, *Italian*, *French* and *German methods* have been given to the different varieties, but Verneuil<sup>1</sup> has pointed out the impropriety of continuing to employ them, especially since at least two of them, the *French* and *German*, have their origin in an oversensitive patriotism not mindful enough of the actual facts. The *Indian* and *Italian methods* were first employed for the restoration of the nose ; in the former a flap was taken from the

<sup>1</sup> Mémoires de Chirurgie, Vol. I. Chirurgie Réparatrice, p. 401.



forehead and brought down by twisting the pedicle which occupied the space between the eyebrows. The term is now applied to any operation in which the flap is made with a long pedicle situated at some distance from the space which the flap is to cover and in which also the flap is brought into place by rotation over a greater or less arc described about the base of the pedicle as a center (see Fig. 115).

In the *Italian method* the flap is taken from a distant part of the body, as in restoration of the nose by a flap taken from the arm (Fig. 117). Tagliacozzi, of Bologna, the originator of this method, allowed the flap to suppurate for a few days, so as to increase its thickness, before fastening it in its new situation. Graefe sought for primary union, and gave, rather pompously, the name *German method* to this modification, ignorant of the fact that it had been suggested more than a century before by Reneaulme de la Garanne, and unmindful of the other fact that it contained no new principle, and must have been entertained by Tagliacozzi, and only rejected for the sake of another advantage incompatible with it.

In the so-called *French method*, the principles of which are found in Celsus, the flap has a broad base, and is brought into place, not by rotation, but by traction in the direction of its axis (Figs. 99 and 110). The variations and combinations of these methods are now so numerous that the names no longer have much descriptive value.

**General Principles.**—The edges of the flaps must be brought together without tension, and united very accurately by means of fine silk, catgut, or silver sutures.

All hemorrhage must cease before the flaps are brought into place. The presence of a clot of blood under a transferred flap may cause failure.

Flaps must be taken from healthy non-cicatricial skin, and whenever the skin is thin and not very vascular the subcutaneous layer should be taken with it to insure its vitality.

The base of the flap should occupy the quarter from which the main supply of blood is received, and the direc-



tion and shape of the flap should be such that it can be brought into place with the least amount of twisting of the base.

The flap should be made considerably larger than the space it is to fill, and, to insure accuracy, it is well to cut it according to a pattern previously made of paper or oil silk. It is well also to mark the angles by fine pins planted erect in the skin.

The raw surface left by the dissection of a flap may be partly covered by drawing its edges together with sutures; the remainder must be left to granulate or may be covered by Thiersch grafting.

If strict asepsis is maintained greater tension can be made with the sutures than would otherwise be safe, and the chances of failure and of cicatricial contraction are less.

### CHEILOPLASTY.

**A. Lower Lip.**—Restoration of the lower lip is usually undertaken to make good the loss of substance occasioned by the removal of an epithelial tumor. The choice of a method depends upon the extent of the disease.

1. **V-INCISION.** (Fig. 89.)—When the tumor is small, involving not more than one-quarter or one-third of the lip, it may be removed by a V-incision, and the sides of the gap brought together with one or two points of interrupted or twisted suture. The mucous membrane on the inside of the lip should be excised to the same extent as the skin, although it is not usually involved in the disease, for otherwise it forms a disagreeable fold or pucker in the lip.

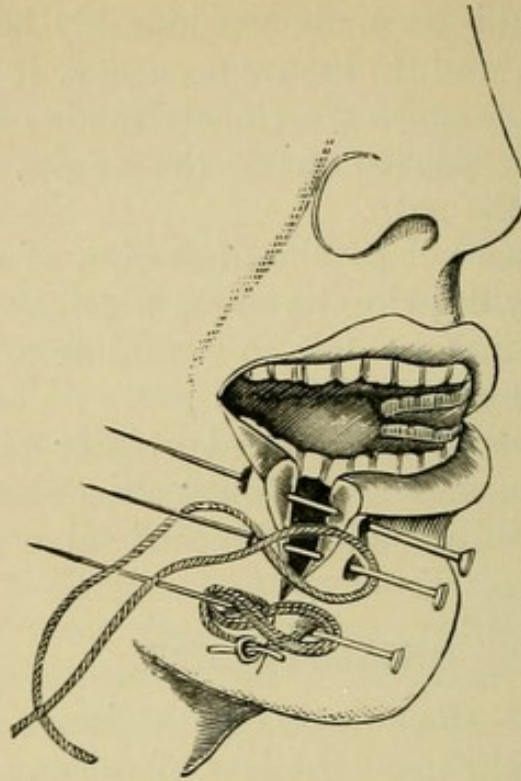
The harelip pins or sutures must be deeply placed, passing close to the mucous membrane on the inside, for this insures confrontation of the raw surfaces throughout their entire breadth and prevents hemorrhage.

2. **OVAL HORIZONTAL INCISION.**—When the tumor covers a considerable extent of surface, but does not penetrate deeply, it may be safely excised by cutting under it with curved scissors. The mucous membrane and skin



may then be stitched together, or the wound allowed to heal by granulation.

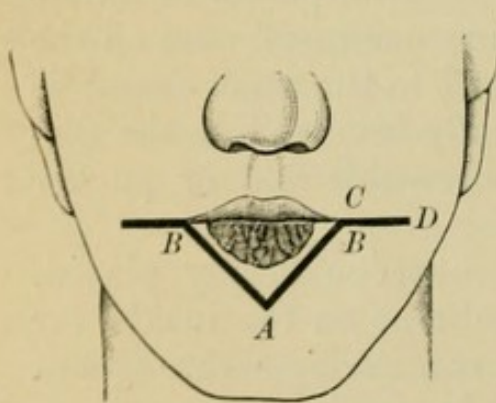
FIG. 89.



Cheiloplasty, V-incision.

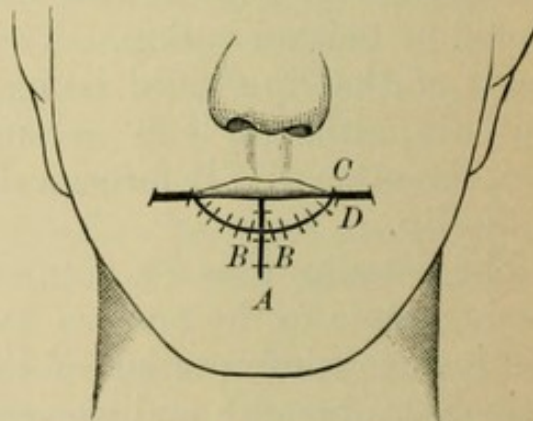
3. METHOD OF CELSUS OR SERRES. (Figs. 90 and 91.)  
—The V-incision is supplemented by a horizontal one on

FIG. 90.



Cheiloplasty. Celsus's incisions.

FIG. 91.



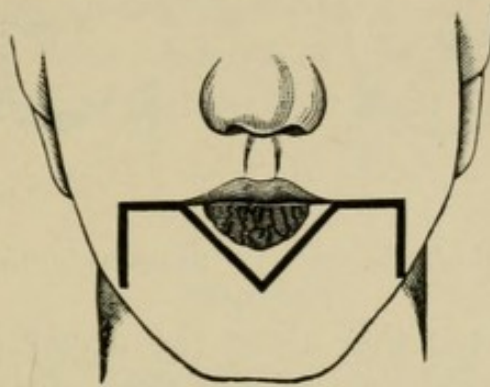
Cheiloplasty. Celsus's flaps in place.

each side carried outward from the angle of the mouth for about two inches, and comprising the whole thickness of



the cheek for the first two-thirds of its length, but dividing the mucous membrane at a somewhat higher level than the skin. The lower gingivo-labial fold is divided close to the gum on both sides, and the dissection carried downward close to the periosteum, and backward toward the angle of the jaw until the edges of the gap in the lip can

FIG. 92.



Cheiloplasty. Dieffenbach's method.

be brought together without tension. The sides of the V are then brought together, and the lip formed from the lower parts of the horizontal incisions (Fig. 91). The mucous membrane and skin are stitched together along the edge of the new lip, and the remaining portion of the lower flap on each side (that which remains external to the new angle of the mouth) is reunited to the upper flap. The mucous membrane at the outer end of the horizontal incision is stitched to the skin and covers the angle.

4. DIEFFENBACH (Fig. 92) adds a vertical incision at the end of each horizontal one, thus marking out two quadrilateral flaps which are brought together in the median line. The gaps left in the cheek by the transfer are allowed to close by granulation.

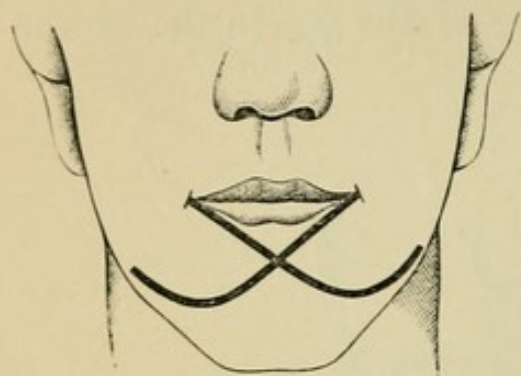
5. SYME-BUCHANAN. (Figs. 93 and 94.)—The method by latero-inferior flaps is ascribed by some to Syme, by others to Buchanan, of Glasgow.

After the tumor has been removed by the usual V-incision, the incisions are prolonged downward and outward for nearly an inch and then curved upward and outward.



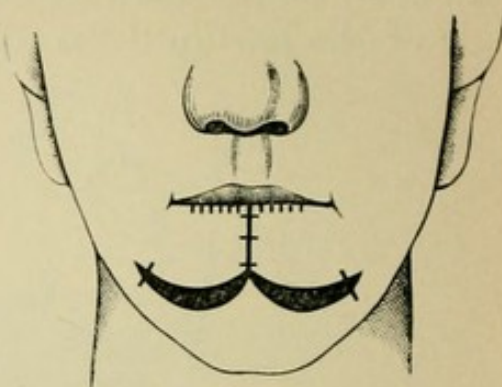
These flaps are dissected off the bone and brought together in the median line. The mucous membrane and

FIG. 93.



Syme-Buchanan incisions.

FIG. 94.



Syme-Buchanan flaps in place.

skin are stitched together along the upper edge, the gaps left below by the shifting of the flaps drawn together as much as possible and the remainder left to heal by granulation.

RANKE and TRÉLAT (Figs. 95 and 96) make the flap on one side longer and lift it over the other to form the

FIG. 95.

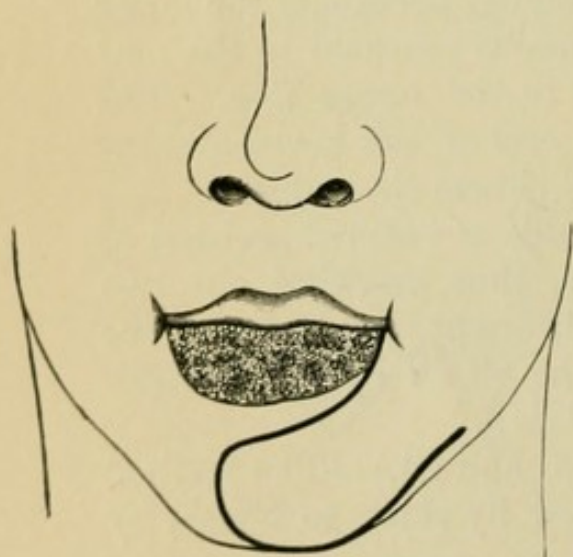
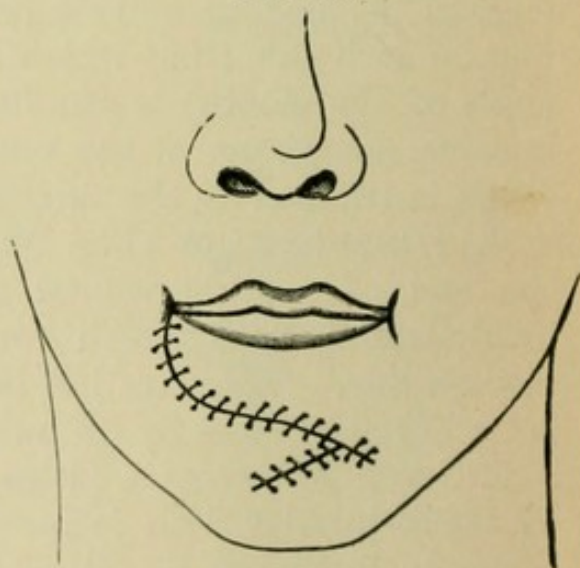


FIG. 96.



Ranke Trélat Method.

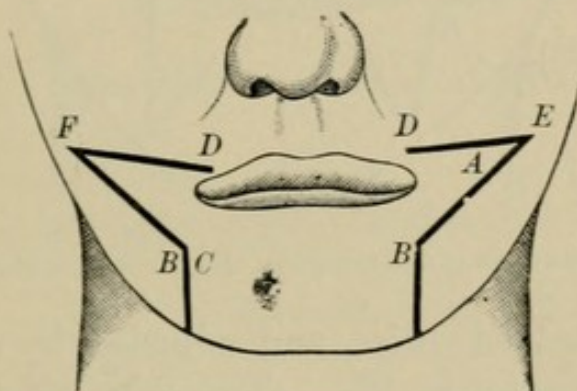
new lip, the shorter flap being used as a support for the former.



6. BUCK'S METHOD. (Figs. 97 and 98.)—Buck preferred to make two operations. He first removed the tumor by the V-incision, brought the sides of the gap together and allowed them to unite. After the union had become complete he restored the angle of the mouth and lengthened the lower lip with material taken from the upper one by the following method.<sup>1</sup>

In Fig. 97, *B B* represent two pins inserted a finger's breadth below the under lip border, one on either side of the chin, a little to the outside of the angle of the mouth, and equidistant from the median line; *D D* are also two

FIG. 97.



Restoration of lower lip. Buck's incisions.

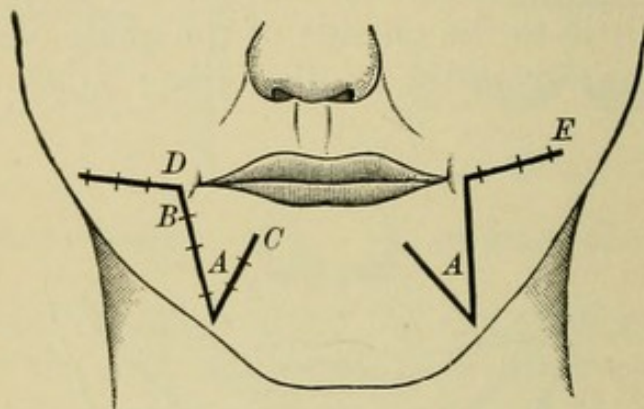
pins inserted, one on either side, into the upper lip at the margin of the vermilion border, equidistant from the median line, and at such distance apart as to include between them sufficient length of lip border for a new upper lip. The steps of the operation are then the following: With the forefinger of the left hand placed on the inside of the mouth, the left cheek is to be kept moderately on the stretch while it is transfixed with a sharp knife at the point *B*. An incision is then carried through the entire thickness of the cheek, upward and a little outward, a distance of one inch and a-half to a point, *E*, near the middle of the cheek. The corresponding side of the upper lip should next be transfixed at the point *D*, and the incision carried through the lip and cheek outward and a little upward to join the first incision at *E*.

<sup>1</sup> Reporative Surgery, 1876, p. 22 et seq.



The next step is to transfer the triangular patch, thus marked out, from the cheek to the side of the chin. For this purpose an incision should be made on the side of the chin from *B* vertically downward to the edge of the jaw and to the depth of the periosteum. The edges of this incision, retracting wide apart, afford a V-shaped space for the lodgment of the triangular patch, which is now

FIG. 98.



Restoration of the lower lip. Buck's flaps in place.

brought around edgewise, and adjusted by sutures in its new position (see Fig. 98). The gap left in the cheek is closed by bringing its edges together and securing them in contact by sutures. By this adjustment a new and naturally shaped angle is formed for the mouth at the point *D*. The incisions should be made with the utmost precision, and special care should be taken that the lining mucous membrane is divided exactly to the same extent as the skin.

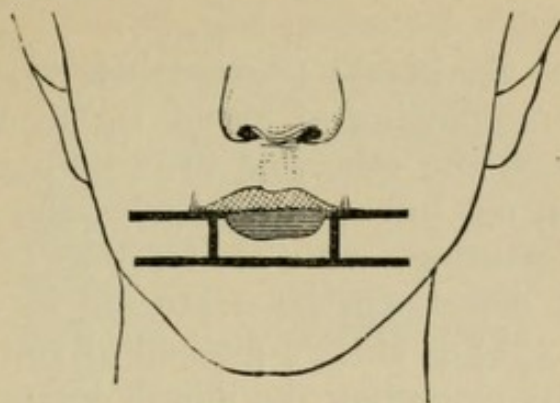
The same procedure may be applied to the other side of the mouth, and executed at the same operation.

7. SQUARE LATERAL FLAPS. (Malgaigne.) (Fig. 99.)—The tumor is circumscribed by two vertical incisions carried downward from the edge of the lip, and a third horizontal one uniting the lower ends of the first two. To fill the square gap thus created, two horizontal incisions are made on each side—one from the angle of the mouth, the other from the lower corner of the gap. The flaps circumscribed by these incisions are brought forward



and united in the median line and the mucous membrane stitched to the skin along the edge of the lip and at the

FIG. 99.

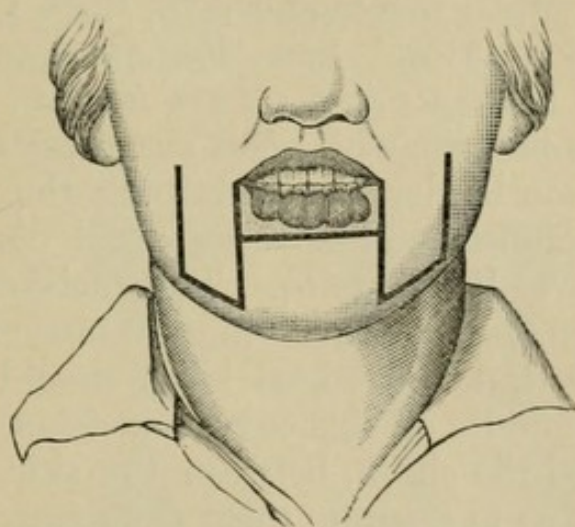


Cheiloplasty. (MALGAIGNE.)

commissures. (See also 3. *Method of Celsus*, p. 254, and *Stomatoplasty*, v. inf.)

8. SQUARE VERTICAL FLAPS. (Fig. 100.)—Sédillot made the flap at right angles to the line of the mouth.

FIG. 100.



Cheiloplasty. (SÉDILLOT.)

The incisions are shown in Fig. 100. Each flap is swung around to meet the other in the median line, its inner vertical border becoming the edge of the lip.

In any of these operations in which a large portion of the lip is made by bringing in a flap from the cheek, the



raw surface of the flap adjoining the angle of the mouth may be covered in by a second flap turned down (or up) from the other side of the angle so as to create a new vermilion surface and border. The effect is much the same as in Buck's operation, Fig. 98.

**B. Angle of the Mouth (Stomatoplasty).**—An attempt to restore a large portion of either lip by means of material taken from the other, or to close a gap by simple approximation, not infrequently leaves the mouth small, rounded and pouting, with obliteration of one or both angles. This defect can be overcome by the operation described (p. 257) as Buck's method of restoration of the lower lip, or by extending the mouth laterally by a horizontal incision involving both skin and mucous membrane and then preventing reunion by stitching the skin and mucous membrane together on both sides and at the angle of the incision. Sédillot considers it indispensable to excise a portion of the skin so as to have a comparative excess of mucous membrane, which when stitched to the skin will roll outward and form a vermilion border. This simple method was modified by Buck as follows :

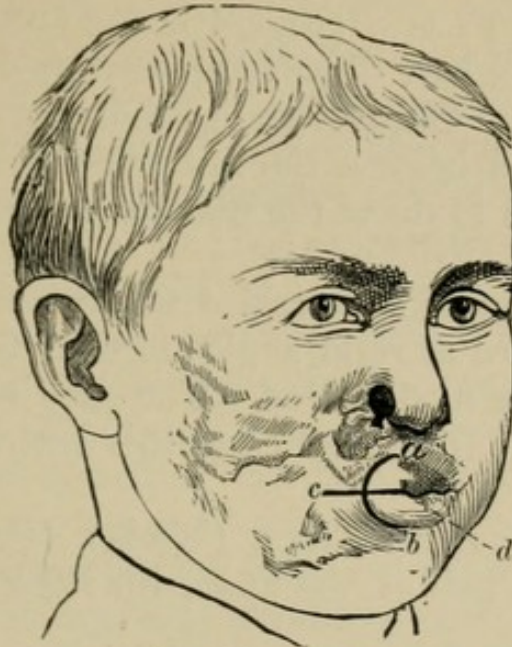**BUCK'S OPERATION<sup>1</sup> FOR ENLARGEMENT OF THE MOUTH AND RESTORATION OF ITS ANGLE.** (Fig. 101.)—An incision is made with great exactness along the line of the vermilion border circumscribing the circular half of the mouth and extending to an equal distance on the upper and lower lips (*a* to *b*). This incision should only divide the skin, without involving the mucous membrane. A sharp-pointed, double-edged knife should then be inserted at the middle of this curved incision and directed flatwise toward the cheek, between the skin and mucous membrane, so as to separate them from each other as far as the new angle of the mouth requires to be extended. The skin alone is next divided from the commissure of the mouth outward toward the cheek. The underlying mucous membrane is then divided in the same line, but not so far outward. The angles at the outer ends of the two incisions are then accurately united by a single

<sup>1</sup> Reporative Surgery, p. 28 et seq.



thread suture. The fresh-cut edges of skin and mucous membrane above and below, that are to form the new lip

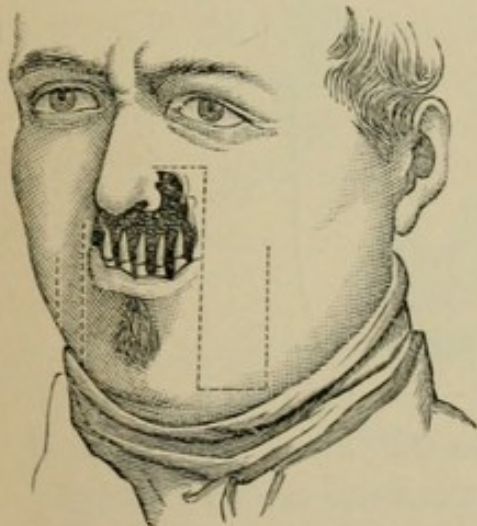
FIG. 101.



Lengthening of the mouth. (BUCK.)

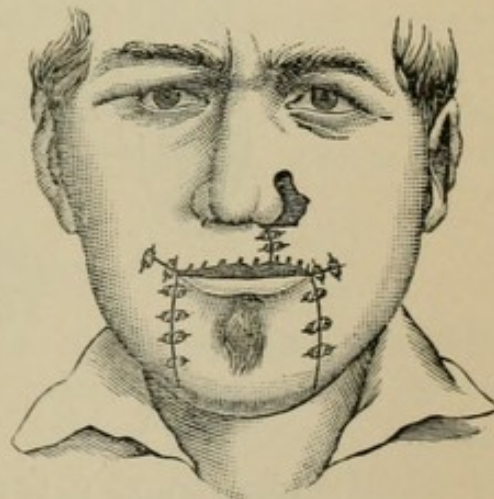
borders, are shaped by paring first the skin and then the mucous membrane in such a manner that the latter shall

FIG. 102.



Cheiloplasty of upper lip. (SÉDILLOT.)

FIG. 103.



Sédillot. Flaps in place.

overlap the former, after they have been secured together by fine thread sutures inserted at short intervals.



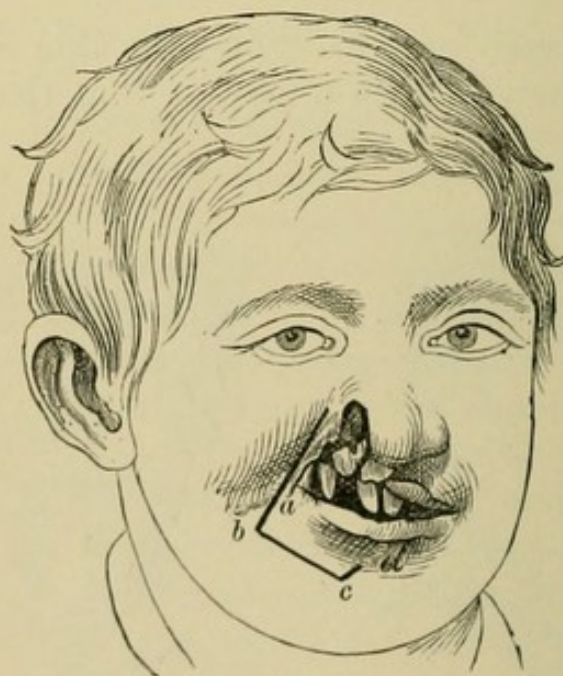**C. Upper Lip.**—The V-incision and the oval horizontal incision (p. 253) may be used when the loss of tissue will be small. Also the square lateral flaps (p. 258) when the gap to be filled is in the center of the lip and rather large.

1. **VERTICAL FLAPS.** (Figs. 102 and 103.)—These may be made with the base directed upward (Sédillot) or downward (Chauvel). Chauvel claims that the latter method is to be preferred because the retraction of the cicatrix in the former tends to draw the new lip upward and expose the teeth.

The flaps comprise the entire thickness of the cheek, are turned inward at right angles to their former position and united in the median line. The gaps left in the cheek by their removal are brought together with sutures or left to granulate.

2. **INFERO-LATERAL FLAP.** (Buck.) (Fig. 104.)—For loss of the right half of the upper lip Buck employed the

FIG. 104.



Repair of upper lip by infero-lateral flap. (BUCK.)

following method, enlarging the mouth afterward and re-establishing the angle by the method described above (p. 260).



The extremity of the under lip, where it joined the right cheek, was divided through its entire thickness at right angles to its border, and the division carried to the extent of one inch from the border (*a* to *b*, Fig. 104). A second incision was made from the terminus of the first parallel to the lip border for a distance of one inch and a-half toward the chin, *b* to *c*. The quadrilateral flap thus formed from the under lip was folded edgewise upon itself, and made to meet the remaining half of the upper lip, and be adjusted to it by its free extremity. In order, however, to make this fold, the under lip had first to be divided obliquely half across its base, *c* to *d*.

The left half of the upper lip was prepared for the new adjustment by dividing the buccal mucous membrane close to the jaw and detaching the parts above toward the orbit from the underlying periosteum, and secondly by paring a strip of vermilion border from the extremity of the half-lip of sufficient length to permit the end of the half-lip to be matched to the free extremity of the under-lip flap. The parts concerned having been thus prepared, the under-lip flap was doubled edgewise upon itself, and its free extremity adjusted to the half of the upper lip, and the two secured to each other in a vertical line below the columna nasi by sutures. The space between the newly adjusted half of the mouth and the neighboring cheek was closed by approximating the opposite parts and securing them to each other by sutures after their edges had been carefully matched. (Fig. 101 shows the result of this operation.)

### HARELIP.

If the patient is a young child its arms should be securely bound to its sides with a towel, and its head firmly held by an assistant. After anæsthesia has been obtained it can be easily kept up by applying to the nostrils from time to time sponges saturated with ether.

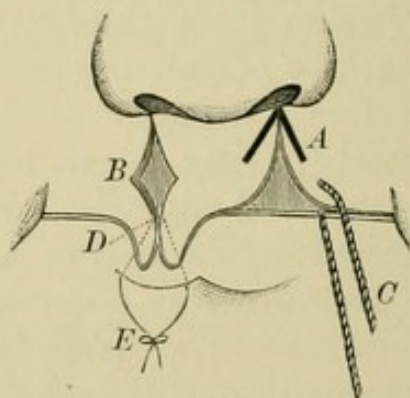
**Single Harelip, Simple.**—The simplest method of operating is to pare the sides of the cleft and bring the raw surfaces together by a few sutures. The objection to the



method is that the retraction of the scar produces a more or less considerable depression in the free border of the lip. It has therefore been generally abandoned for one of the following :

1. **DOUBLE FLAPS.** (Fig. 105.)—In order to hold the parts upon the stretch and insure precision in making the cuts, a stout ligature should be passed through the lip at each angle of the cleft, or each angle should be seized with a tenaculum. The lip being drawn forward and downward by means of the ligature or tenaculum, the mucous membrane is divided close to the gum and the dissection carried upward and backward as far as may be necessary to allow the sides of the cleft to be brought together without tension.

FIG. 105.



Simple single harelip, double flaps. *A.* Incisions. *B.* Flaps turned down. *C.* Ligature for holding lip tense. *D.* Incision to shorten and adjust flaps. *E.* Thread passed through the ends of the flaps.

Then making one side of the cleft tense, by drawing upon its ligature, the lip is transfixed near the angle and the incision carried upward along the border of the cleft to its top, or, if necessary, into the nostril, thus cutting out a narrow flap which remains attached at its lower extremity to the lip (Fig. 105, *A*). A similar flap is then made upon the other side, the two are turned down, so that their raw surfaces face each other, and a thread passed through their free ends (Fig. 105, *E*).

The freshened edges of the cleft are then confronted, a harelip pin placed near the vermilion border and another

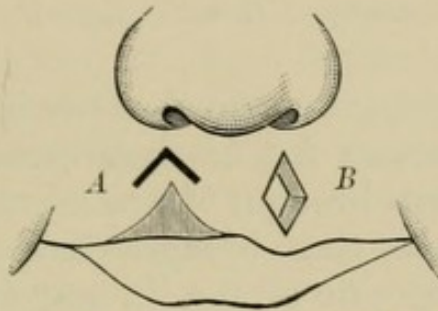


near the nostril, and two or three fine silk or silver sutures inserted between them. The ends of the dependent flaps are then cut off obliquely, enough being left to form a distinct projection on the lip after they have been united with fine sutures. By this means the formation of a notch by the retraction of the cicatrix is avoided.

2. When the cleft was shallow, Nélaton left the flaps attached to each other at the apex, turned them down, and brought the raw surfaces together as above described (Fig. 106).

3. SINGLE FLAP. (Fig. 107.)—A flap is made upon one side only, usually the shorter portion of the lip. The

FIG. 106.



Harelip. Nélaton's method. A. Incision. B. Flap turned down.

opposite side of the cleft, and a portion of the free border of the lip adjoining it are freshened by the removal of a strip of skin and mucous membrane. The sides of the

FIG. 107.



Harelip. Single flap.

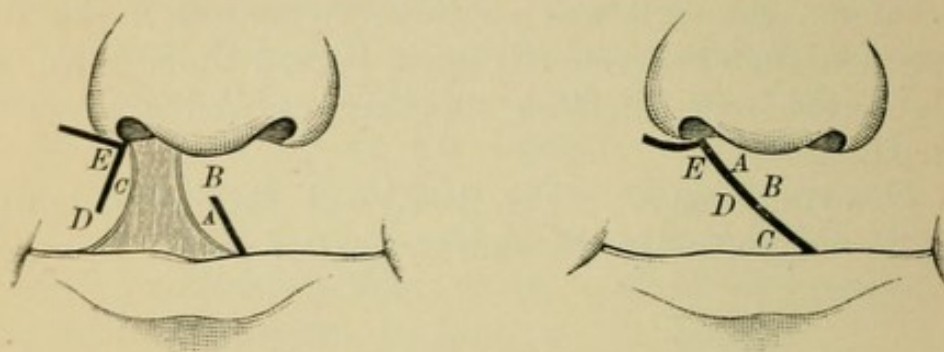
cleft are approximated, and the flap applied to the free border of the lip.

4. GIRALDES'S METHOD. (Fig. 108.)—This is applicable only when the cleft extends into the nostril. The



flap on the short side is made, as before described, with its base below; that on the long side is reversed, being left attached at its upper end. A third, horizontal incision is carried outward from the edge of the nostril, at the

FIG. 108.

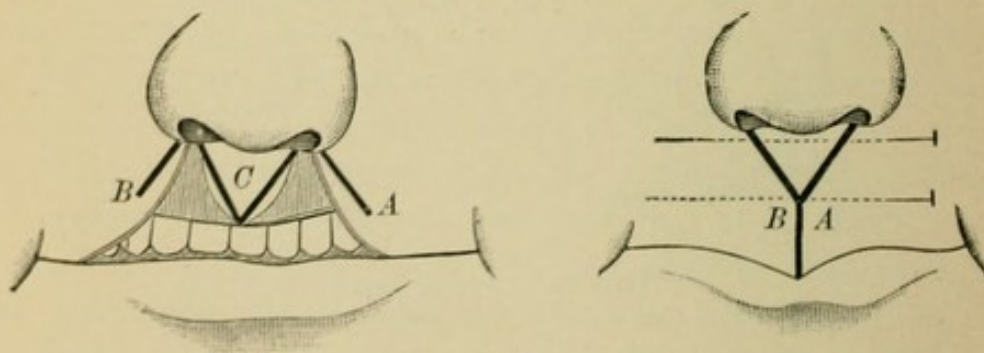


Harelip. Giralde's method.

point of the first flap, to make that portion of the lip more movable. The second flap is then turned upward across the nostril, the first brought down to take its place, and the two raw surfaces thus brought into contact united by sutures. The long side of the lip may also be mobilized, if desirable, by a horizontal incision running from the gap close below the columna and the corresponding nostril.

**Double Harelip, Simple.** (Fig. 109.)—Flaps are made upon the lateral portions, *A* and *B*, as before described

FIG. 109.



Double harelip.

(p. 265, 3), and the sides of the central portion, *C*, are pared. The flaps are then brought together, as shown in



the figure, after mobilizing the lip by free division of the gingivo-labial fold and carrying the dissection well upward and outward, pins passed to include the sides and the central portion at the base and apex of the latter, the flaps trimmed and united with fine sutures.

If the parts are too scanty to permit the use of this method, liberating incisions must be made around the *alæ nasi*, or flaps obtained from the cheek. (See *Upper Lip*, p. 262 *et seq.*)

**Complicated Harelip.**—Harelip may be complicated by fissure of the palate and alveolar process. When the *fissure is single* the bone on the long side of the lip projects beyond its proper line. In very young children, it may sometimes be forced back into place by making pressure upon it with the thumb, but it is easier to fracture it first with Butcher's pliers, the bent blade of this instrument being applied upon the anterior surface near the further nostril. The two portions of the alveolar arch soon unite after they have been brought into contact, especially if the opposing surfaces have been pared. Sutures are not needed.

When there is *double fissure*, the intermediate portion of bone containing the incisor teeth projects so far that it seems to be an appendage of the nose rather than of the mouth. In order to restore it to its place, it is necessary to divide the vomer with strong scissors, or, better, to cut a triangular piece out of the septum of the nose. It is not necessary to fasten the bones together with sutures. The portion of skin covering the projecting bone must be dissected off and used to lengthen the *columna nasi* or fill out the lip.

In extreme cases it may be proper to cut away the projection entirely; but whenever it can be saved and brought into line, it renders valuable service by giving the upper jaw its proper length and furnishing a space into which artificial teeth can be fitted. The three or four teeth which are found in this piece are always so defective and irregularly placed that they have to be drawn.

For uranoplasty, etc., see Operations upon the Mouth.



### RHINOPLASTY.

The different kinds of rhinoplastic operations may be classified according to the nature and extent of the loss which they are designed to repair: 1st. A superficial loss not involving the bones or septum. 2d. Loss of the septum and nasal bones, the skin remaining entire. 3d. Loss of more or less of the surface and septum.

As the loss of tissue is always the result of injury or disease, it presents so many variations in form and extent, that it is difficult in practice to determine the exact boundaries between the classes, and this classification is chosen for convenience of description, and not with the intention of limiting the choice of an operation in any given case to those described in the class to which the lesion might belong. For the same reason, a description of an operation as actually performed will sometimes be more serviceable than any general rules that might be laid down.

As may be readily understood, the existence or non-existence of the septum and nasal bones affects materially, not only the method of operating, but also the result. If unsupported centrally, the new member tends constantly to shrink and flatten, and the surgeon has the mortification of seeing that he has merely substituted one deformity for another. Ollier tried to meet this want by including the periosteum in the flap taken from the forehead by the Indian method. There was, however, no new formation of bone, and the operation in that respect was a failure. On another occasion he took a strip of healthy periosteum from one of the limbs, and tried to graft it under the skin of the forehead, hoping thereby to procure a lamella of bone, which could be used to give solidity to the new nose. Thinking the graft had failed, he withdrew the strip of periosteum after a few days, and then discovered that it had united nicely at one point. There is reason, therefore, to think that a more patient repetition of the experiment might be successful. On a third occasion, he included the periosteum of the fore-

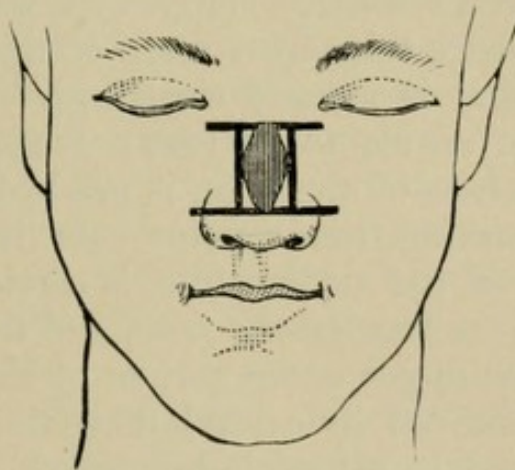


head in a flap transferred by a modification of the French method, and by folding it together longitudinally along the center he got reproduction of bone where the two layers faced each other.

**1. Superficial Defect not Involving the Bones or Septum.**—If the loss of tissue is confined to the integument, that is if the cartilage is spared, as it usually is in cases of epithelioma, no plastic operation should be undertaken. The tumor must be carefully dissected off and the wound grafted or left to granulate. The slight mobility of the integument of the region prevents deformity by cicatricial retraction and the wound heals over, leaving a scar which does not contrast offensively with the neighboring skin.

If, on the other hand, there is a gap to be filled, one that is small and does not involve the free border of the ala, square lateral flaps may be made by horizontal incisions (Fig. 110), and drawn together after they have been rendered freely movable by dissection from the underlying parts.

FIG. 110.



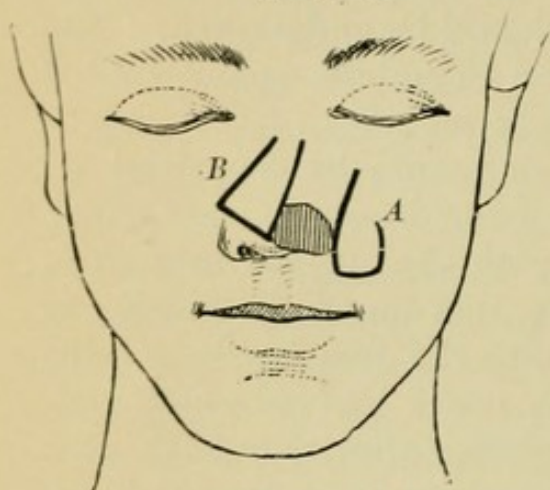
Rhinoplasty. Lateral flaps.

If the gap is larger, or if one of the alæ is lost, suitable oblique or vertical flaps may be taken from the nose or cheek and transferred by rotation. Three of the many variations of this method are shown in Figs. 111 and 112. Fig. 111, *A*, represents a vertical flap taken from the cheek beside and below the nose and left adherent at



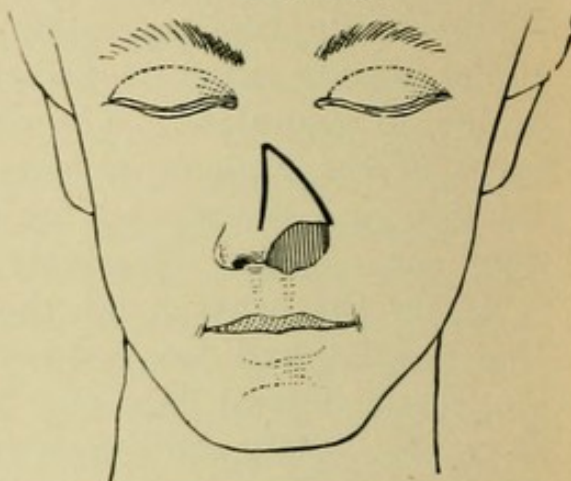
its upper end. The flap should be cut long enough to allow a natural appearance to be given to the free border of the ala by turning it in upon itself. The device will also prevent excessive cicatricial contraction of the border and consequent narrowing of the nostril.

FIG. 111.



Rhinoplasty. A. Single lateral flap.  
B. Langenbeck's method.

FIG. 112.



Rhinoplasty. Denonvillier's method.

DENONVILLIER'S METHOD (Fig. 112) sometimes makes it possible to secure this object more certainly by supplying a border that is already cicatrized. Supposing the lower portion of an ala to be lost, a triangular flap, left adherent to the lobe of the nose, is marked out by an incision which, starting from a point near the lobe on the unaffected side of the median line, is carried directly upward nearly to the root of the nose, and thence obliquely downward to the upper outer corner of the affected ala. The flap is mobilized by careful dissection of the bone and cartilage and transferred downward. The gap left by the transfer heals by granulation or can be closed by a Thiersch graft. For the sake of giving more stiffness to the border, Denonvillier sometimes included a strip of cartilage in it.

VON LANGENBECK<sup>1</sup> restored an ala by taking a triangular flap from the opposite side of the nose (Fig. 111,

<sup>1</sup> *Essais de Chirurgie Plastique d'après les Préceptes du Prof. B. von Langenbeck*, Bruxelles, 1856, quoted by Verneuil.



*B).* The flap was left adherent at the apex of the triangle, which lay near the inner angle of the eye of the affected side, while its base occupied the opposite ala. It was dissected up carefully so as not to include the cartilage, transferred to the other side and fastened to the freshened edges of the gap. The wound left by the removal of the flap healed by granulation and so perfectly that it was difficult to recognize there had been any loss of tissue at that point.

MICHON restored the ala by taking a triangular flap from the septum. The base of the flap was placed anteriorly, parallel to the ridge of the nose, and the apex lay near the junction of the septum with the floor of the nasal fossa. The flap was dissected up and attached to the margin of the loss of substance, its mucous surface directed outward, its apex made fast to the cheek.

THE COLUMNA, with or without the tip of the nose, can be restored from the upper lip. Dupuytren and Dieffenbach cut a vertical cutaneous flap, adherent at its upper end, immediately below the columna, turned it upward, twisting it upon its pedicle so that its cutaneous surface remained external, and secured it in place. As the twisting of the pedicle created considerable deformity, Sédillot and Blandin made the flap of the entire thickness and length of the lip, pared off its cutaneous surface, and turned it directly upward without twisting the pedicle, the mucous membrane thus forming the outer surface. The gap left in the lip was then closed with sutures. In Blandin's case the result was excellent, and the mucous membrane gradually assumed the characteristics of ordinary skin; but in Sédillot's case, in which the tip of the nose had also to be restored, the membrane remained red and covered with thick epidermic scales, and the end of the nose looked much like a cherry.<sup>1</sup> In all his rhinoplastic operations Liston made the columna separately by this method, and found that the mucous membrane soon took on the appearance of ordinary integument.

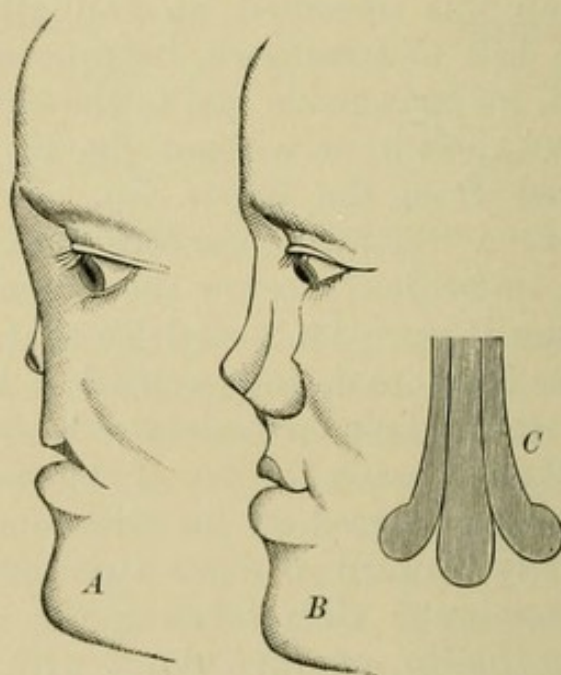
<sup>1</sup> Sédillot : *Médecine Opératoire*, 2d ed., Vol. II., p. 233.



2. **Loss of the Septum and Nasal Bones, the Skin Remaining Entire.**—Baron Larrey, about 1820, operated upon a soldier the bridge of whose nose had been shattered and depressed by the explosion of a gun. He removed the deformity by dissecting up the adherent portions of skin and replacing them in their original position. The details of the operation are lacking.

Dieffenbach published in 1829 the description of an operation by which he overcame the great deformity resulting from the loss of the septum and bones of the nose by scrofulous disease. As the case is a classical one, quoted,

FIG. 113.



Dieffenbach's operation. B. The result. C. The flaps.

and often very incorrectly, in the text-books, and is an indication of what may sometimes be accomplished in extreme cases, the following description of it is given:<sup>1</sup>

The patient was a girl twelve years of age. She had lost the *ossa nasi*, nasal process of the ethmoid, vomer,

<sup>1</sup> As the original work could not be obtained, this description is made up from an English translation of the book, published in 1833, a French translation of the case, in the *Gazette Médicale*, Vol. I., p. 65, 1830, and a brief description with plates, in a collection of Dieffenbach's Plastic Operations, published by two of his pupils in 1846.



and cartilages, and instead of a prominent nose there was a deep pit with a ridge at the bottom. The plan of operation was to divide the remains of the old sunken member into portions, raise them up, and secure them in the proper position. Dieffenbach passed a narrow-bladed knife first into one nostril and then into the other, and cut out, making two incisions, one on each side of the sunken ridge. (Fig. 113, C.) The strip of skin between these incisions was three times as broad at its lower end, where it was connected with the upper lip by the shortened columna, as at its upper part where it joined the forehead. The cheeks were next cut through down to the bones on each side by inserting the knife a few lines below the upper end of the first incision and carrying it obliquely downward, parallel and a little external to the side of the nose, and then around into the nostril, thus separating the lateral attachments of the *alæ nasi*. The columna, being too short, was then elongated by two slight incisions in the upper lip, and the cheeks rendered more movable by dividing their attachments to the bone through the lateral incisions. The flaps were then raised, the sides of the incisions pared obliquely in a manner to which Dieffenbach attaches an importance that seems undeserved, reunited, and fixed with harelip pins and sutures, and the whole retained in place by drawing the cheeks toward the median line and fastening them there with two long pins passed under the nose and through the detached edges of the cheeks. This compression was aided by two splints of leather through which the pins passed. A quill covered with oiled lint was introduced into each nostril.

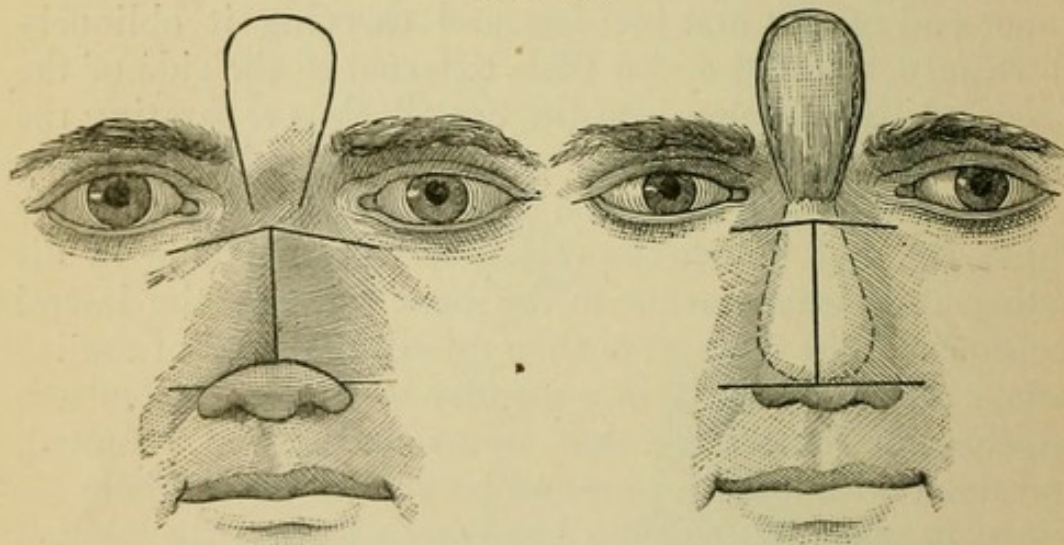
**Osteoplastic Method.**—Ollier successfully treated a somewhat similar case by making a triangular flap, its base constituted by the lower portion of the nose and the adjoining cheeks, its apex situated one and a-half inches above the eyebrows. The frontal portion of the flap included the underlying periosteum. The left nasal bone and vomer having been destroyed by the disease, central support could be obtained for the new nose only by aid of the right nasal bone, which was accordingly loosened with



a chisel and forced downward. The flap was then transferred downward, pinched in laterally to increase its height at the bridge, and supported there by drawing the cheeks, previously loosened from their underlying attachments, toward the nose and fastening them there with long pins.<sup>1</sup>

*Double Layer, or Superficial Flaps.* (Fig. 114.)—Verneuil<sup>2</sup> employed successfully a method suggested to him by Ollier, in which permanent elevation of the bridge of the nose was secured by superposing two flaps and thereby doubling the thickness. The patient had discharged a

FIG. 114.



Rhinoplasty, sunken nose. Double layer, or superposed flaps. (VERNEUIL.)

pistol into his mouth, causing the destruction of a portion of the hard palate and septum, the nasal bones, part of the nasal processes of the superior maxillary, the spine of the frontal, and the anterior wall of the frontal sinuses. The alæ and lobe were uninjured but much flattened; above them was a broad deep groove extending to the middle third of the forehead. The two principal indica-

<sup>1</sup> For further details of this operation the reader is referred to the original account in the *Bulletin de la Société de Chirurgie*, 1862, p. 62; or to its reproduction in Verneuil's *Chirurgie Réparatrice*, p. 428, and in the *Gazette Hebdomadaire*, 1862, p. 98, and also to a similar operation described more fully on p. 279 of this manual.

<sup>2</sup> *Chirurgie Réparatrice*, p. 428, and *Bull. de la Soc. de Chirurgie*; 1862, p. 70.



tions were to bring the lateral portions nearer the median line and to reconstitute the bridge of the nose. The latter could be permanently accomplished only by filling in the great cavity which would be left by raising the sunken parts.

Verneuil made an incision along the median line of the depression and a transverse one at each end of the first, and dissected up the two lateral flaps thus marked out. He then raised an oblong flap from the middle of the forehead, its base remaining adherent between the eyebrows, and turned it directly downward so that its raw surface was directed outward, its tegumentary surface toward the nasal fossæ. The two lateral flaps were then placed upon it and united in the median line. The raw surfaces united with each other, and the result was a nose elevated one-third of an inch above the adjoining surface.

**Subcutaneous Method.**—Prof. Pancoast<sup>1</sup> operated upon a similar case in the winter of 1842–43 by subcutaneous division of the adhesions. The ossa nasi and septum had been entirely destroyed by disease, and the nose was sunken far below the level of the face. “A narrow long-bladed tenotomy knife was introduced on either side by puncture through the skin over the edge of the nasal process of the upper maxillary bone. The knife was pushed up under the skin to the top of the nasal cavity, and then brought down, shaving the inside of the bony wall, so as to detach the adherent and inverted nose upon either side. The point of the nose could now be drawn out. \* \* \* The nose still remained adherent to the top of the nasal chasm. The knife was a third time introduced under the skin in a direction corresponding nearly with the long diameter of the orbits of the eyes and the adhesions separated from the nasal spine and internal angular processes of the os frontis.” The soft parts on the cheek were loosened by sweeping the knife outward along the surface of the bone so far as to divide the infra-orbital nerve and artery on each side, drawn toward the median line, and held together with quilled sutures passed through the cavity of the nose.

<sup>1</sup> Operative Surgery, Phila., 1852, p. 858.



In two weeks the root of the new nose had sunk to the level of the face, but the patient was well satisfied, and refused any further operation, beyond the removal of an elliptical piece of skin to raise this portion again. The ultimate result is not known.

Dubruel<sup>1</sup> quotes a similar operation by Malgaigne, but without giving the date. As it is not mentioned in the latter's *Médecine Opératoire*, edition of 1837, it is probable that Prof. Pancoast's operation antedates it.

About 1893 I successfully met the indication in a case of depression of the bridge due to fracture of the nasal bones by introducing a piece of guttapercha through a small incision on the side of the nose. See Fractures and Dislocations, 1898, p. 156.

3. *Loss of more or less of the Surface and the Septum.*

A. INDIAN METHOD.—This method was introduced into Europe in 1814, by Carpue, an English surgeon, and the stimulus given by it to this class of operations was so great during the succeeding twenty-five or thirty years that this period has been called that of the *renaissance* of rhinoplastic surgery. The ultimate results, however, were not very favorable, and the method has fallen into comparative neglect. It was found that the noses, although sufficiently full, or even excessive at the time of operation, underwent gradual atrophy, and, when central support was lacking, sank to the level of the cheeks. The nostrils, too, closed sometimes to such an extent that they would hardly admit a probe; and, finally, the whole flap had a tendency to slide downward, and collect in a lump at the end of the nose after division or excision of the pedicle. The scar left upon the forehead was a serious disfigurement, and the attempt to diminish it by drawing the sides of the gap together gave rise to complications which endangered the patient's life. The operation itself was not without danger. Dieffenbach lost two out of six patients upon whom he operated in Paris.

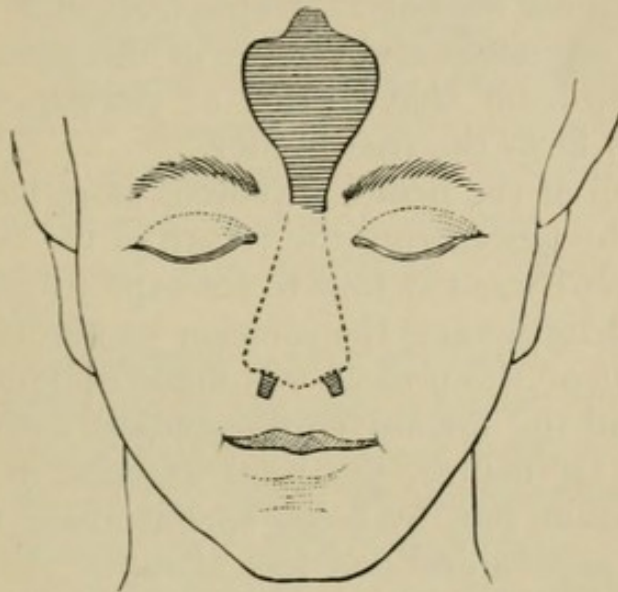
*The operation* was originally performed as follows (Fig. 115): A flap, the size and shape of which were determined

<sup>1</sup> *Médecine Opératoire*, p. 451.



by a pattern previously made of paper or card, was marked out upon the forehead immediately above the nose. Care was taken to make it at least a quarter of an inch broader and half an inch longer than the space it was to fill. Its base was situated between the eyebrows and was half an inch broad. At the upper end of the flap was a project-

FIG. 115.



Rhinoplasty. Indian method unmodified.

ing tab intended to form the columna. The flap, including all the tissues down to, but not through, the periosteum, was then dissected up, brought down by twisting the pedicle, placed in its new position with its raw surface inward and attached by sutures to the freshened edges of the gap it was to fill. Prominence was given to the ridge by stuffing the nostrils with plugs of oiled lint, or drawing the cheeks toward the median line by means of long pins passed transversely through the edges and under the nose. The gap in the forehead was left to heal by granulation. After the flap had united, the pedicle was divided and returned to its original position.

**Modifications.**<sup>1</sup>—Larrey (1820) pointed out the desira-

<sup>1</sup>The dates of these modifications and the award of credit for their suggestion are mainly taken from Verneuil's *Chirurgie Réparatrice*, to which the reader is referred for further details and documentary proof.



bility of saving even the smallest fragments of the original nose, especially if they belonged to the free border of the ala. Professor Bouisson<sup>1</sup> formulated this principle and extended it to the other methods, as follows: 1st. Save as much as possible of the septum. 2d. Give lateral support to the flaps by means of the healthy portion of the cartilage of the alæ. 3d. Insure the regularity of the outline of the nostril by giving the lower border of the flap cartilaginous support. Dupuytren and Dieffenbach opposed the retraction and closure of the nostrils by folding back upon itself that portion of the edge of the flap which was to form the free border.

The torsion of the pedicle involves more or less danger of gangrene by obstructing the return of the venous blood. Lisfranc (1826) was the first to attempt to diminish this defect. By lengthening the incision on one side, the base or attachment of the pedicle was made oblique instead of transverse and the torsion correspondingly diminished at that point. Of course, the total amount of torsion remained the same, but, by being spread along the pedicle, it was made more spiral and less abrupt. Von Langenbeck (before 1856) went a step further and put the base upon the side of the nose close to the eye, the upper incision ending at the eyebrow, the lower just below the tendo oculi. Labbat did about the same thing in 1827.

Auvert, a Russian surgeon (date unknown, but long before 1850), made the flap oblique instead of vertical, still keeping the base between the eyebrows. Alquié, of Montpellier (1850), proposed to make the flap horizontal, the lower incision being hidden by the eyebrow; and Landreau even curved it somewhat upward at the end, so that the base of the pedicle was hardly twisted at all in bringing down the flap. Ward (1854) made a flap which was directed obliquely upward, and Follin (1856) made a transverse one; in each case the base of the pedicle was upon or near the median line of the forehead, a little above the eyebrows. Both cases did well. The objection to a transverse flap is that the retraction of the cica-

<sup>1</sup> Rhinoplastie latérale.



trix upon the forehead draws the corresponding eyebrow upward. The advantages are that the torsion is less, and the scar somewhat disguised by the natural lines.

Various means have been employed to prevent the descent of the flap. Dieffenbach made a longitudinal incision on the side of the nose, and engaged the pedicle in it, paring off its prominences afterward. Blandin excised the portion of skin intermediate between the base of the pedicle and the loss of substance, and thus obtained a raw surface to which the whole length of the pedicle was then united. Instead of excising this intermediate piece of skin, Buck left it attached by its upper end, and used it to cover part of the gap left upon the forehead. Velpeau divided the pedicle close to its base, trimmed it to a point, and engaged it in a vertical incision made in the underlying skin.

B. OLLIER'S OSTEOPLASTIC METHOD.<sup>1</sup> (Fig. 116).—A lupus had destroyed the alæ, columna, lobe, cartilages, and part of the septum. The nasal bones were uninjured, but had suffered an arrest of development, and were bounded inferiorly by a strip of cartilage. The nose was not more than an inch long. The skin of the cheeks and lips had also been involved by the lupus, and, therefore, could not be used for the restoration.

Starting from a point in the median line of the forehead two inches above the eyebrows, Ollier made two incisions diverging downward, each of which ended a quarter of an inch to the outer side of the lower border of the nasal orifice.

In dissecting up the long triangular flap thus marked out, he included the periosteum from above downward as far as to the upper end of the nasal bones; he then continued the dissection along the right nasal bone, leaving the periosteum adherent to it, and on reaching the lower end of the bone he separated from it the cartilaginous strip above mentioned, leaving it adherent to the flap.

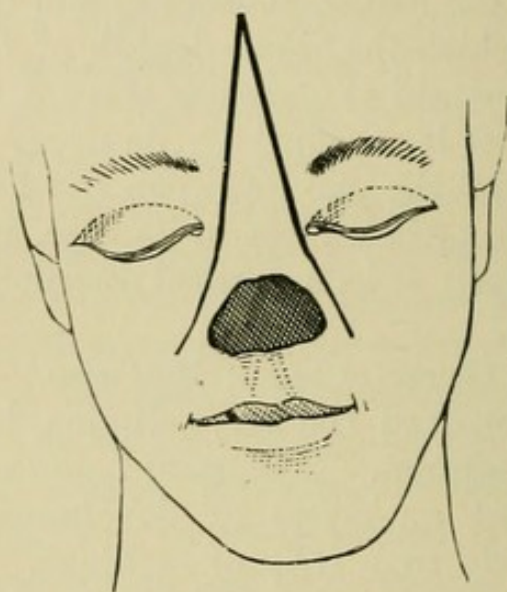
On the left side he divided, with a chisel, the bony connections of the left nasal bone, leaving the bone attached

<sup>1</sup>Traité de la Régénération des Os, Vol. II., p. 469.



to the flap by its anterior surface; this was accomplished by introducing the chisel, first between the two nasal bones, then between the left nasal bone and the frontal, and finally between the left nasal bone and the nasal process of the superior maxillary. Drawing the flap downward, he then divided the cartilaginous septum from before

FIG. 116.



Rhinoplasty. Ollier's osteoplastic method.

backward and downward with scissors, so as to have an antero-posterior flap of cartilage attached by its base to the cutaneous one, and able to furnish central support for the new nose by resting its free border upon the floor of the nasal fossa, or rather upon the remains of the lower portion of the original septum.

He next drew the whole flap downward until the upper border of the left nasal bone came into line with the lower border of the right nasal bone and then fastened the two bones together with a metallic suture. The sides of the flap were then united to the cheeks and those of the frontal incisions drawn together above the apex of the flap.

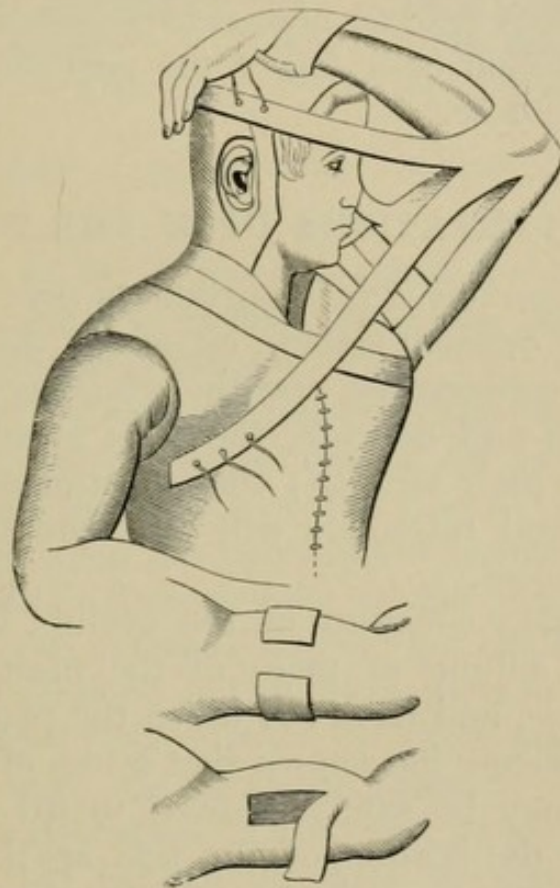
The parts united, the space left by the removal of the left nasal bone was filled with bone produced by the periosteum brought down from the forehead and the result was satisfactory.



C. Alquié used a flap of similar shape in a case in which the alæ and septum were lost, but the columna remained. The apex of the triangle was placed in the space between the eyebrows and the incisions diverged downward and outward. With a narrow tenotome passed along the incisions he separated the skin entirely from the nasal bones and was then able to depress it far enough to attach it to the freshened end of the columna.

D. ITALIAN METHOD. (Fig. 117.)—Tagliacozzi made two nearly parallel incisions along the anterior surface of

FIG. 117.



Rhinoplasty. Italian method.

the arm, their length and the distance between them varying according to the size of the gap the flap was to fill. The apex of the flap was directed toward the shoulder. The intermediate strip of skin was dissected up, but left adherent at both ends and a piece of oiled lint passed under it and kept there until suppuration was established.



The strip was then cut free at its upper end and dressed carefully for about a fortnight, or until its under surface was nearly cicatrized. It was then considered fit to be applied, having undergone the necessary shrinking and thickening. Its edges and those of the nasal aperture were pared and fastened together with sutures and the arm bound fast to the head. When union had taken place between the two, the lower end of the flap was cut loose from the arm and its edges trimmed to the proper shape.

Graefe did not let the flap suppurate, but tried to get primary union.

Dr. Thomas T. Sabine, about 1880, successfully filled by the implantation of a finger the gap left by the destruction of the nose.

#### PLASTIC OPERATIONS UPON THE EYELIDS.

In these operations it is important to save as much as possible of the original tissues, especially the free border of the lid, the conjunctiva, and the orbicular muscle. As the skin is thin and delicate, the flaps must have broad bases to insure their vitality; they must also be so placed that their natural retraction will not tend to reestablish the previous defect.

**Blepharorrhaphy.**—Suture of the eyelids has proved a very valuable adjunct of many of the plastic operations upon the eyelids, and has even taken the place of some of them, for experience has shown that a loss of substance in either eyelid may be safely allowed to fill and heal by granulation if the borders of the lids are kept fastened together. The eye must be kept closed in this way for six months or a year, after which time the scar, in most cases, shows no tendency to retract. When the time comes to separate the lids, this should, at first, be done for only half an inch in the center, and the opening subsequently enlarged at long intervals of time, any indication of cicatricial retraction being meanwhile watched for.

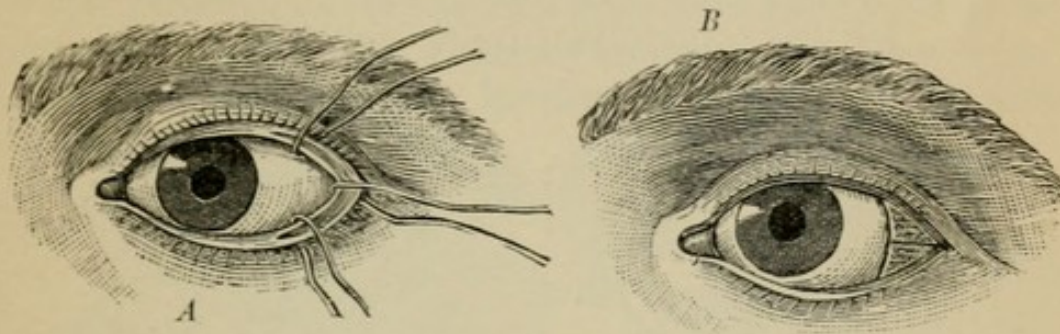
The prolonged occlusion does no harm to the eye; on



the contrary, it may be sufficient in itself to cure a commencing keratitis occasioned by ectropion.

**Operation.**—A narrow strip of conjunctiva is excised from the border of each lid on the conjunctival side of the lashes, beginning and ending a short distance from the

FIG. 118.



Canthoplasty. A. Straight incision. B. Richet's modification.

commissures, so as to leave a space for the flow of the tears. The two raw surfaces are then brought together accurately with silver sutures.

To separate the lids afterward a director should be entered at the opening left at one of the angles, its point pressed against the center of the line of union, and cut down upon between the two rows of lashes.

**Canthoplasty.**—Enlargement of the palpebral opening (Fig. 118). The external angle of the eye is divided horizontally with scissors, and the skin and conjunctiva united along the sides of the incision by three points of sutures, one of them being placed at the angle.

**Richet's modification.**<sup>1</sup> (Fig. 118, B.)—Richet marked out a small flap by two incisions through the skin, beginning at opposite points on the upper and lower lids near the outer angle and meeting at a point external to that angle. The flap, including everything except the conjunctiva, was then excised, the conjunctiva split horizontally, and its two portions trimmed and fastened to the edge of the cutaneous incisions.

<sup>1</sup> Anatomie Médico-Chirurgicale, 4th edition, p. 88.

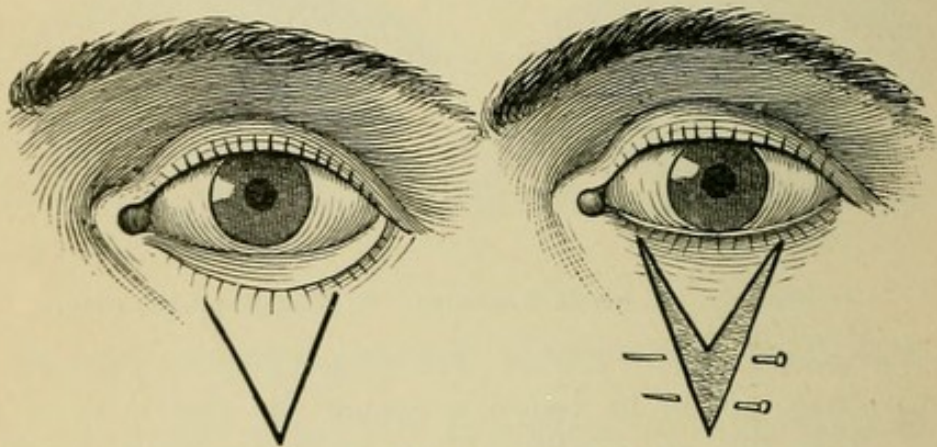


**Blepharoplasty**, to prevent or remedy—

1. **ECTROPION**.—The descriptions will be given for the lower lid only, that being the more frequent seat of the deformity.

**WHARTON JONES**. (Fig. 119.)—Wharton Jones included the contracted cicatrix in a triangular flap one inch high, its base occupying nearly the whole length of the

FIG. 119.

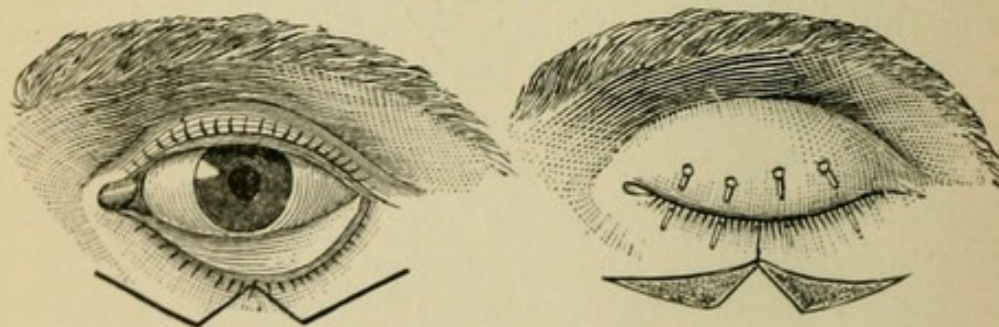


Ectropion. (WHARTON JONES.)

lid border. By dividing the bands of cellular tissue, but without dissecting up the flap, he restored the lid to its normal position and held it there by uniting the edges of the incision below, thus giving it the form of a Y.

**ALPHONSE GUÉRIN**<sup>1</sup> (Fig. 120) made two incisions

FIG. 120.



Ectropion. (ALPHONSE GUÉRIN.)

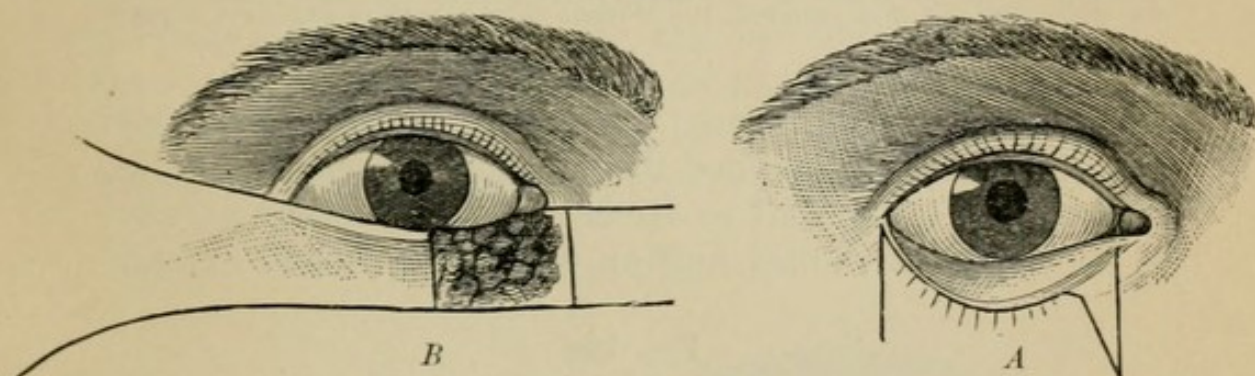
forming an inverted V, the point of which lies just below the center of the free border of the lid. From the lower

<sup>1</sup> *Chirurgie Opératoire*, 4th edition, p. 318.



extremities of these incisions he made a third and fourth parallel to the border of the lid. The two triangular flaps bounded by the 1st and 3d, and the 2d and 4th incisions were then dissected up, the lid raised to its normal position and held there by uniting the adjoining sides of these two flaps in such a manner that their apices and that of the inverted V met at a common point. The gaps left by the removal of the two flaps were allowed to granulate, or covered with Thiersch grafts. For greater security he also united the borders of the lids (blepharorrhaphy).

FIG. 121.



Ectropion. A. Von Graefe's method. B. Knapp's method.

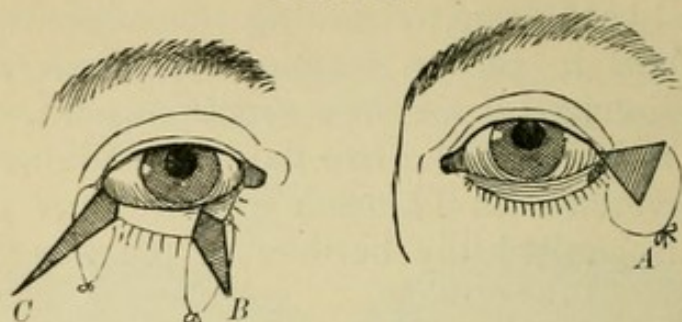
**VON GRAEFE.** (Fig. 121, A.)—Make an incision along the border of the lid just outside of the lashes from the lachrymal point to the external commissure. From each extremity of this make a vertical incision downward from one-half to three-quarters of an inch in length. These incisions should involve only the skin. Cut off the upper inner corner of this flap, not by a straight incision, but by one forming an angle, as shown in the figure, and fasten this angle by a suture to that formed by the border of the lid and the inner vertical incision. Reunite the edges of the transverse incision, cutting the ends of the sutures long enough to reach to the forehead and then fastening them there with adhesive plaster. The excision of the inner angle of the flap raises the eyelids by shortening its border.

**DIEFFENBACH, ADAMS, and AMMON** have proposed other methods of shortening the lid. They are indicated



in Fig. 122, where the shaded spaces represent the portions of skin to be removed, and the threads the manner

FIG. 122.

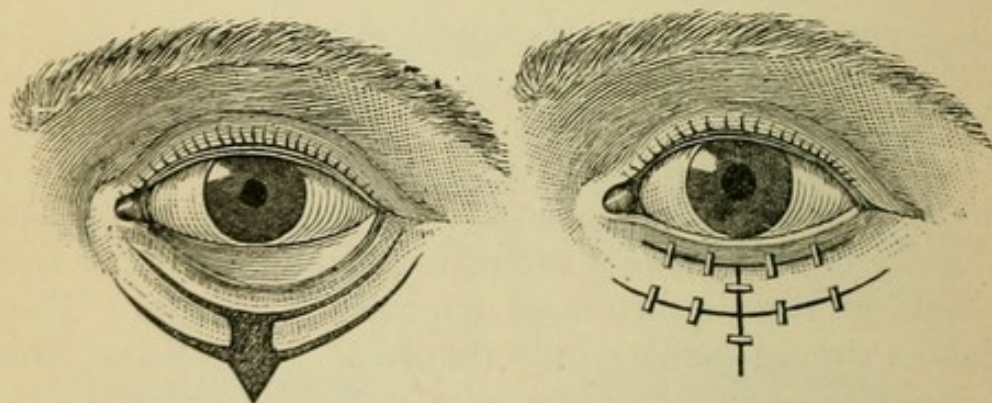


Ectropion. *A.* Dieffenbach. *B.* Adams. *C.* Ammon. The shaded spaces indicate the portions of skin removed; the threads show how their edges are brought together.

in which the edges are afterward brought together. Adams's excision included the whole thickness of the lid.

**RICHET.** (Fig. 123.)—Richet made an incision parallel to the border of the lid, half an inch below it, and extend-

FIG. 123.



Ectropion. (RICHET.)

ing nearly from one angle of the eye to the other. The lid, having been freed by this incision, was then united to the other (blepharorrhaphy).

He next made a second incision parallel to the first and one-third of an inch below it, divided the intermediate strip of skin vertically in the middle and dissected up its two halves. Immediately below the lower end of this vertical incision he removed from the lower border of the second incision a V-shaped flap of skin, its point directed

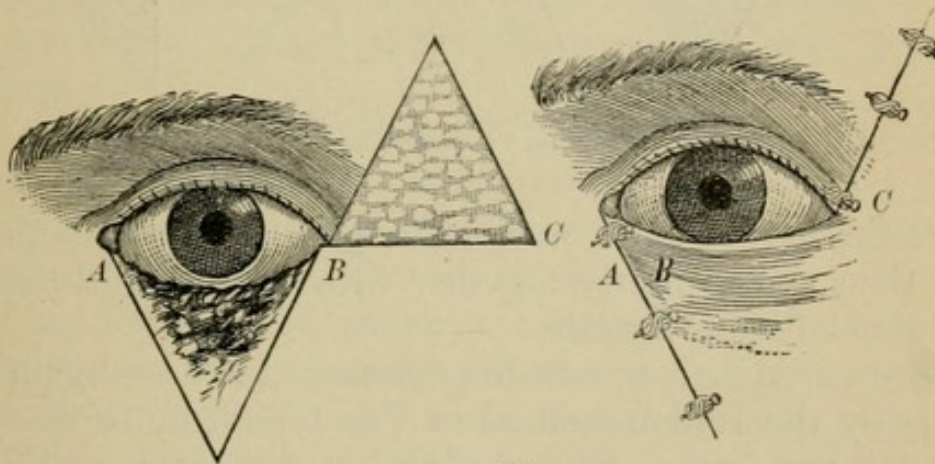


downward. He then raised the two halves of the middle flap, brought them again into contact with the border of the lid, excised their superfluous length, and united them. The sides of the V are then brought together and the edges of the incisions reunited.

KNAPP. (Fig. 121, *B*.)—Knapp employed the following method to remove an epithelioma occupying the inner portion of the lower eyelid, the free border of which was involved. He circumscribed the tumor by two vertical and two horizontal excisions and excised it. The horizontal incisions were then prolonged on both sides, the lower external one being inclined downward so as to make the base of the flap broader, the two flaps dissected up, drawn together and united by their vertical edges.

BUROW. (Fig. 124.)—The loss of substance is made triangular in shape, the apex directed downward; the base

FIG. 124.



Ectropion. (BUROW.)

is then prolonged horizontally outward, and an equal and similar triangle marked out upon the upper side of the prolongation. The skin contained within the second triangle is then excised, and the irregular flap bounded by the outer sides of the two triangles and the prolongation of the horizontal incision dissected outward and downward, and then moved toward the median line until it covers both the open spaces.

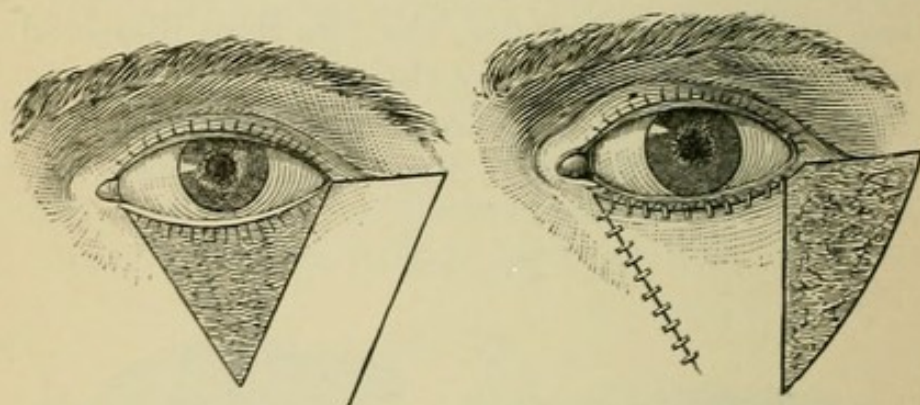
It is not necessary that the two triangular spaces should



touch at one corner ; they may be an inch, or even more, apart, but they must of course be connected by the horizontal incision.

DIEFFENBACH. (Fig. 125.)—When the cicatrix or tumor was large Dieffenbach gave the loss of substance a triangular shape, the apex directed downward. He prolonged outward the horizontal incision forming the base of the triangle, and carried another incision downward and inward from its outer extremity. The quadrilateral flap thus marked out was dissected up and carried inward to

FIG. 125.



Ectropion. (DIEFFENBACH.)

cover the loss of substance. The gap left by its removal was then drawn partly together with sutures, and the remainder left to granulate.

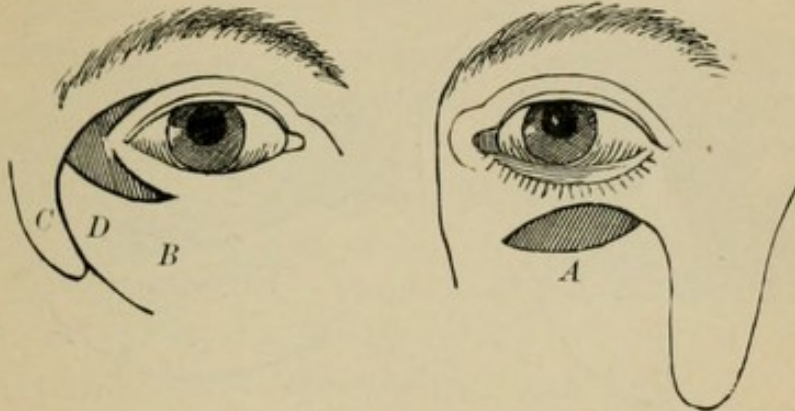
INDIAN METHOD.—Sédillot refers the first blepharoplasty by the Indian method to Von Graefe in 1809. As this was previous to the introduction of rhinoplasty by the same method, the idea was probably entirely original with Von Graefe. The case is mentioned in his *Rhinoplastik*, 1818, but without details. The flap can be taken from the forehead or cheek ; it should be very large and should include the subcutaneous cellular tissue. Fricke, of Hamburg, took a vertical flap from the temporal region to restore the upper eyelid.

One of the modifications of this method, intended to obviate the necessity of dividing the pedicle, is shown in Fig. 126, A.



**RICHET.** (Fig. 126, *B*.)—The lids are freed by two incisions inclosing all the cicatricial tissue, and then united (blepharorrhaphy), the sutures being cut long and their ends fastened upon the forehead. Two flaps are then

FIG. 126.

Ectropion. *A*. Modified Indian method. *B*. Richet.

marked out as shown in the figure, the external one, *C*, raised and used to cover the original loss of substance, and the inner one, *D*, used to fill the gap occasioned by the removal of *C*.

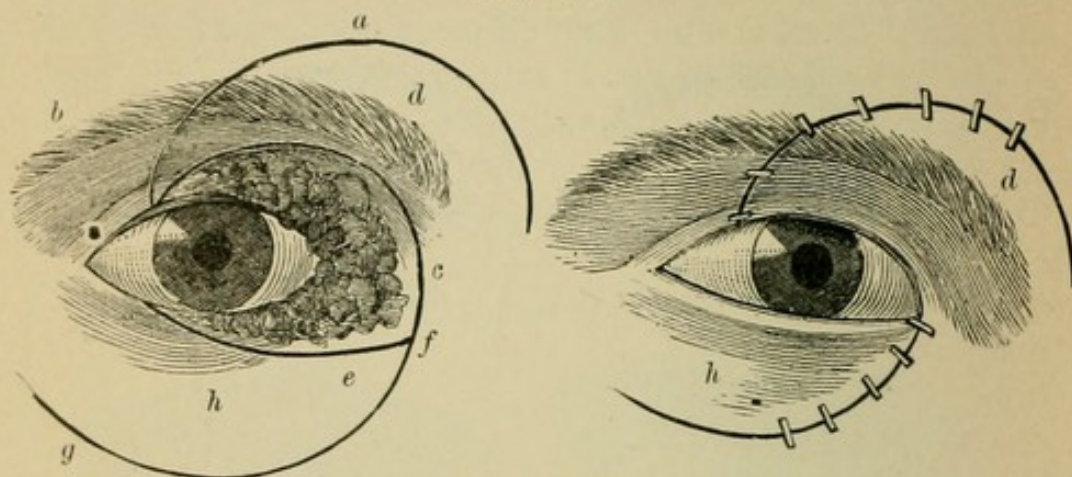
**HASNER D'ARTHA** (Fig. 127) employed the following method in a case where a tumor occupied the commissure and inner portion of each eyelid. He made a curved incision, *a*, beginning at the border of the upper eyelid beyond the limit of the tumor, crossing the eyebrow to the forehead, and then crossing downward to terminate near the root of the nose. A second curved incision, *c*, began at the same point as the first and was carried along the upper and inner edge of the tumor to the point marked *f*. A third curved incision, *e*, began on the border of the lower lid beyond the limit of the tumor and was carried along the lower margin of the latter to the point *f*. A fourth curved incision, *g*, parallel to the border of the lower lid, was carried from the point outward to the cheek.

The tumor and the portion of the lids circumscribed by the incisions *c* and *e* were then removed, and each of the flaps *d* and *h* dissected up to its base. The former was lowered, the latter raised, and the excess of each cut off.



The upper border of the flap *h* formed the free border of the lower lid, and the lower border of the flap *d* formed the free border of the upper lid and the commissure corre-

FIG. 127.

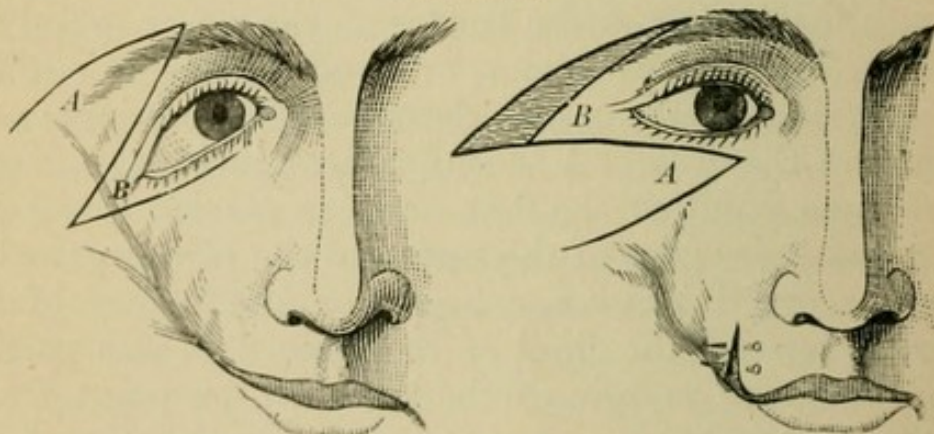


Ectropion. Hasner d'Artha's method.

sponded to the apex of the flap *h*. The skin of the forehead and cheeks was mobilized and reunited to the flaps (Dubrueil).

*Denonvillier's* method "by exchange." (Fig. 128.) In a case of ectropion of the lower lid, with deviation

FIG. 128.



Ectropion. Denonvillier's method "by exchange."

of the outer angle of the eye downward, Denonvillier used the following method: By making three incisions to meet in the form of Z, he marked out two adjoining triangular flaps; one of them included the outer angle of the



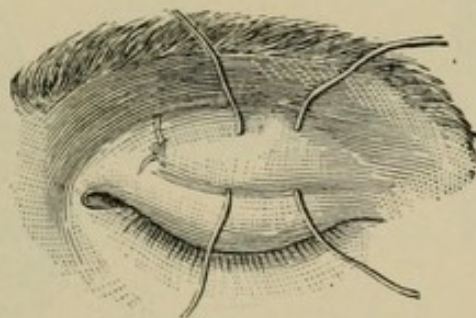
eye, the apex of the other was situated upon the forehead just above the eyebrow. He then dissected up the flaps, restored the angle of the eye to its proper position, brought the upper flap down into the gap made by the lower incision, and the lower flap up into that made by the upper incision.

*Ectropion due to excess of the conjunctiva* may be treated by cauterization of the conjunctiva, or by excision of a portion. The latter operation is simple; a fold is pinched up with forceps and excised with knife or scissors. The edges of the gap may then be brought together by sutures or left to granulate.

2. ENTROPION.—CANTHOPLASTY (*q. v.*) may be employed to remedy moderate entropion, especially if it be due to spasm of the orbicularis.

LIGATURE (Fig. 147), proposed by Gaillard to remedy trichiasis, is equally applicable to the cure of entropion.

FIG. 129.



Entropion ; ligature.

A transverse fold is pinched up, and a needle carrying a stout ligature passed through its base, shaving the anterior surface of the cartilage. The ligature is tied and allowed to cut through the skin. The resulting linear cicatrix maintains the lid in the position given it by the ligature.

Rau has modified this by placing several ligatures instead of only one.

*Excision or cauterization of a fold of the skin* is applicable to cases of entropion due to laxity of the skin of the eyelid. A transverse or a vertical fold is pinched up



quite near to the margin of the lid and excised; the borders of the wound are united by sutures. Instead of excision, cauterization of the strip is sometimes used.

Von Graefe (Fig. 130) treated a case of spasmodic entropion by removal of a triangular piece of skin. He made a cutaneous incision parallel to the free border of the lid and about a line from it, and excised a triangular cutaneous flap, the base of which occupied the median portion of the first incision. The sides of the wound left by the excision of the triangular piece were then drawn together with sutures.

Division of the external canthus will sometimes relieve the condition.

For spasmodic entropion of the upper lid, with retraction of the tarsal cartilage, Von Graefe modified the op-

FIG. 130.

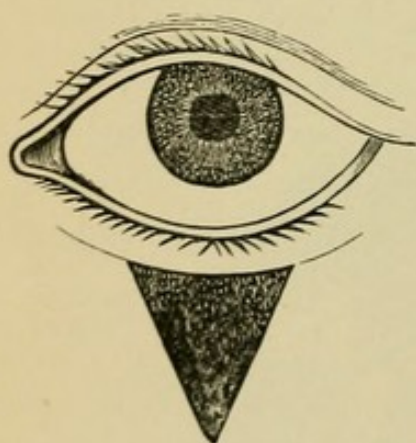
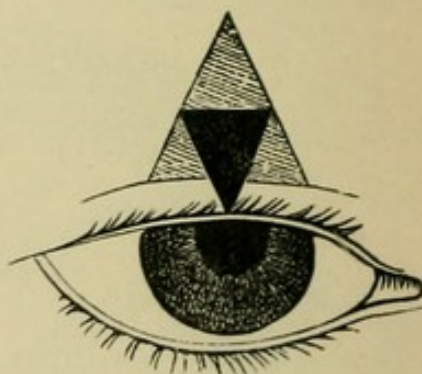


FIG. 131.



Entropion—lower lid. (VON GRAEFE.)      Entropion—upper lid. (VON GRAEFE.)

eration as follows (Fig. 131): After excision of the triangular cutaneous flap, he drew the sides of the wound apart, divided the orbicular muscle horizontally near the edge of the lid and drew it upward, exposing the cartilage. He then excised a triangular piece of the cartilage, the apex being at its lower border, taking care not to include the conjunctiva in the dissection. The sides of the cutaneous wound were then drawn together with three sutures, the middle one of which included also the sides of the gap left in the cartilage.



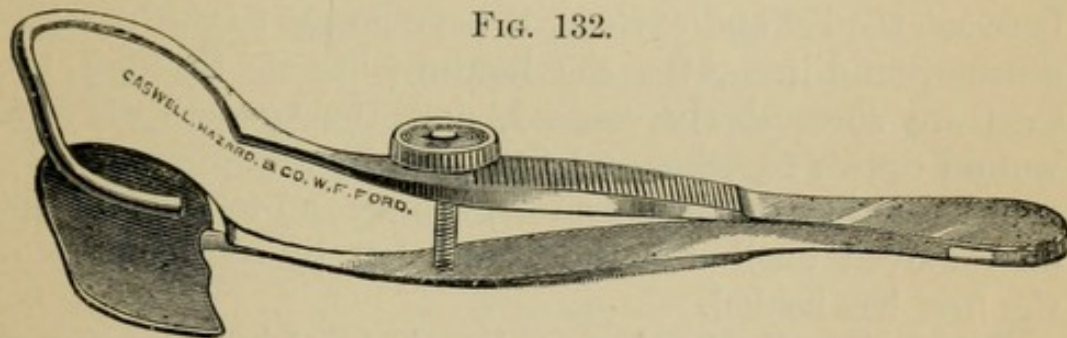
*Division or Resection of the Tarsal Cartilage.*—When the entropion is caused or maintained by shortening or incurvation of the tarsal cartilage, the operation must be directed to the removal of this cause.

*Vertical division* at one or two points of the entire thickness of the lid has been employed. After having been divided, the border of the lid is held in its proper position by ligatures passed through it and fastened to the forehead (upper lid) or cheek (lower lid), while the wound fills and heals by granulation.

A horizontal incision through the conjunctiva from one vertical incision to the other makes it easier to turn the lid out and hold it in place.

*Longitudinal Tarsotomy.* (Ammon.)—The eyelid having been turned out, a knife is passed through it from the

FIG. 132.



Knapp's modification of Desmarres's forceps.

conjunctival side, a quarter of an inch from the border and on a line with the lachrymal point, and an incision made parallel with the border nearly to the outer angle. A longitudinal strip of skin is then excised and the edges of the gap left by the excision are drawn together. By this means the free border of the lid is drawn away from the surface of the eye, turning upon the longitudinal incision as upon a hinge.

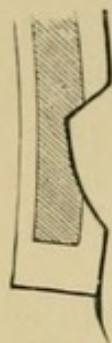
*Excision of Part of the Cartilage.* (Streatfeild.) (Fig. 133.)

The eyelid is fixed with Desmarres's forceps (Fig. 132), the flat blade against the conjunctiva, and an incision made parallel to the border of the lid at the distance of one line from it, and carried to a depth sufficient to expose the



bulbs of the eyelashes. The surgeon, raising the edge of the skin, passes around the bulbs to the tarsal cartilage,

FIG. 133.



Entropion.  
Streetfeild's  
method.

and then makes a second incision at a greater distance from the border of the lid than the first one was, meeting the first at its two extremities and inclosing with it an oval strip of skin. These two incisions are carried into the cartilage, circumscribing a longitudinal wedge-shaped strip, the apex of which reaches nearly to the conjunctival side of the cartilage. The wound is left to heal by granulation, with the expectation that the contraction of the cicatrix will overcome the entropion.

3. SYMBLEPHARON.—When the adhesion between the two layers of the conjunctiva is incomplete, that is, when it does not extend to the bottom of the sulcus between the lid and eyeball, it is sufficient to throw a ligature around it. After the ligature has cut through, the tabs are successively excised, and the borders of each wound drawn together or left to heal by granulation. To avoid reunion of the surfaces, the second tab should not be removed until after the wound left by the removal of the first has healed.

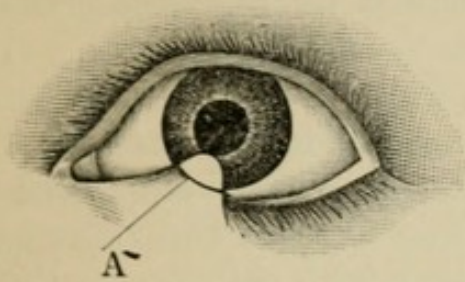
When the adhesion is complete, but not broad, a thread or silver wire may be passed through its base and tied loosely around it. After the hole made by the wire has cicatrized the adhesion is divided. The narrow line of cicatrix left at the bottom of the fold by the wire favors the separate healing of the two sides of the incision.

*Arlt's Method.*—A thread is passed through the fold close to the cornea, and the symblepharon dissected away from the eyeball. Each end of the thread is then attached to a needle and passed through the lid from within outward at the bottom of the wound. By drawing upon the thread and tying it outside the lid the symblepharon is folded upon itself and its point fixed at the bottom of the sulcus. The edges of the wound on the eyeball are then drawn together with sutures, the conjunctiva being loosened by dissection, if necessary.



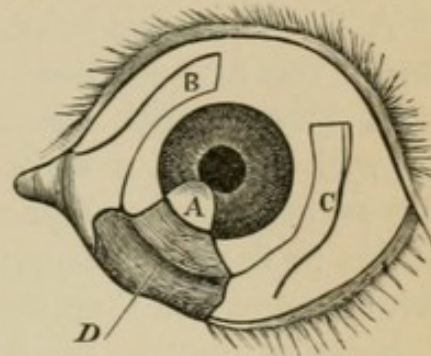
*Teale's Method.* (Figs. 134, 135, 136.)—This symblepharon is separated from the ball of the eye by an incision along the line of its union with the cornea, and dissected down to the bottom of the fold as in Arlt's operation, its

FIG. 134.



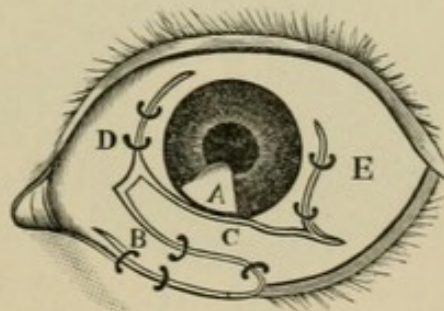
Symblepharon.

FIG. 135.

*B, C.* The flaps.

apex, however, being left upon the cornea. Two long, narrow conjunctival flaps, *B* and *C*, are then dissected up on opposite sides of the eyeball, their bases directed toward the symblepharon, their borders parallel to that of the cornea. These flaps should not include the subconjunctival tissue. The inner flap *B* is brought down and fast-

FIG. 136.



Flaps in place.

ened to the denuded surface of the eyelid, the outer flap *C* covers that of the eyeball. They are fastened in place by means of fine sutures, and the edges of the gaps left by their removal brought together in the same manner.

*Ledentu's Operation.*—Where one lid was adherent throughout its entire length, Ledentu divided the adhesion



to a depth equal to that of the normal fold, dissected a long conjunctival flap from the other half of the eye, leaving it adherent at both ends, brought it down across the cornea, and applied it to the raw surface left on the eyeball by the division of the adhesion. This flap should be at least one-third of an inch broad.

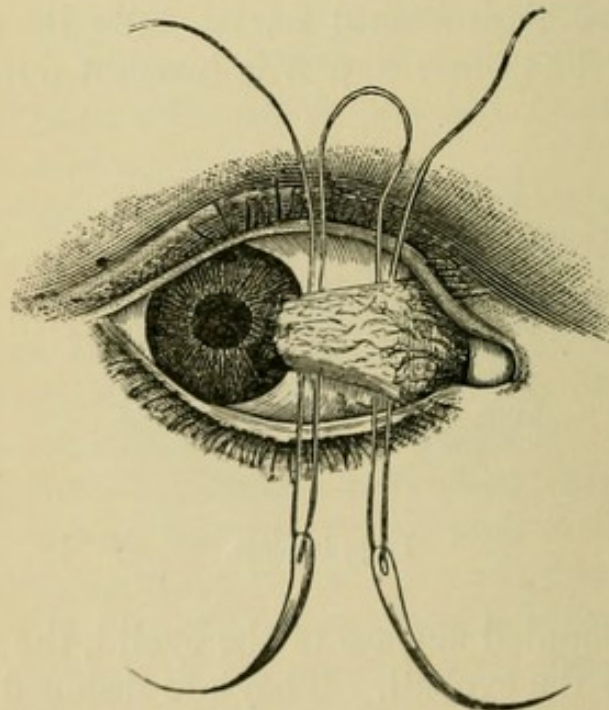
A few successes have been obtained by Thiersch-grafting of the raw surface.

4. PTERYGION. EXCISION.—The pterygion is pinched up with forceps, a knife passed flatwise under it close to the cornea, and the portion of the growth which corresponds to the latter shaved off. The edges of the conjunctival wound are then drawn together with sutures.

Scissors may be used instead of the knife ; in that case the incision must begin at the point of the growth.

*Ligature, Szokalski.*—A thread is passed under the pterygion by means of two small curved needles, as shown

FIG. 137.



Pterygion ; ligature.

in Fig. 137. The thread is cut close to the needles, and thus made to furnish three ligatures, one at each end, en-




circling the growth at right angles to its long axis, and one in the middle, encircling its implantation upon the sclerotic. The ligatures are tied tightly, and the inclosed portion falls in a few days.

5. TRICHLIASIS.—Temporary removal of the deviated lashes is seldom effectual. Permanent removal by destruction of their bulbs, or excision of the border of the lid, is now considered unjustifiable. The direction of the lashes may be changed by operation upon the lid. The retraction following excision of an oval strip of skin, or the use of ligatures as in entropion, is sometimes sufficient, but it may be necessary to act more directly upon the lashes. Simple splitting of the external canthus may be sufficient.

*Von Graefe's Method.*—An incision is made along the free border of the lid on the conjunctival side of the deviated lashes. From each end of this a vertical incision is next made through the free border and the skin. The flap thus circumscribed and containing the lashes is dissected up a short distance. It is then easy to fasten it with sutures in such a position that the lashes can no longer touch the eyeball.

*Anagnostakis* made a cutaneous incision parallel to the border of the upper lid and one-eighth of an inch from it, exposed the orbicular muscle by drawing the skin up, and excised that portion of it which corresponded to the upper part of the tarsal cartilage. The lower edge of the cutaneous incision was then drawn up and fixed to the fibro-cellular layer covering the cartilage by means of three or four sutures, which were then allowed to cut themselves out.







## PART VII.

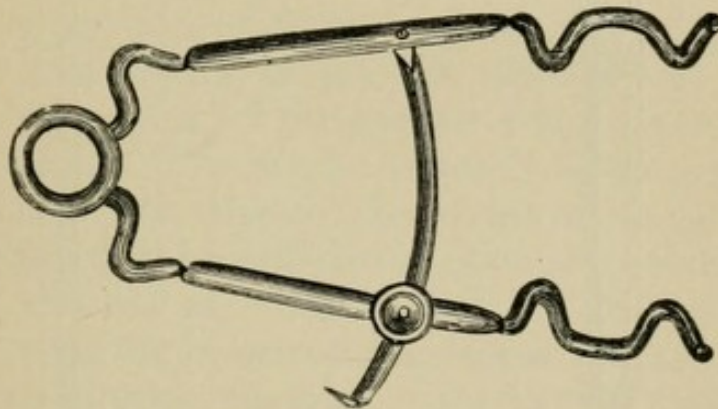
### SPECIAL OPERATIONS.

#### CHAPTER I.

##### OPERATIONS UPON THE EYE AND ITS APPENDAGES.

IN most operations upon the eye the lids should be held open by an eye-speculum (Fig. 138), and the eye-

FIG. 138.



Eye-speculum.

ball fixed by pinching up a fold of the conjunctiva with toothed forceps.


The instillation of a few drops of a 4 per cent. solution of the hydrochlorate of cocaine under the lids will make most operations painless, but the sensitiveness of the iris is not thereby abolished.

##### THE CORNEA.

**Removal of a Foreign Body.**—When the foreign body has penetrated to only a slight depth, it may be easily re-




FIG. 139.



Stop needle and probe for  
puncturing the cornea.

FIG. 140.



Beer's knife.



moved with the point of a knife or fine forceps ; but, if it lies so near the posterior surface of the cornea that there is danger of forcing it through into the anterior chamber by the efforts made for its extraction, a lance-shaped knife must be entered very obliquely and passed behind it, between the layers of the cornea if there is sufficient space, otherwise within the anterior chamber.

If the foreign body falls into the anterior chamber, notwithstanding these efforts to prevent it, the surgeon must wait until the aqueous humor has reaccumulated, and then make an incision three or four millimeters in length at the lower portion of the periphery of the cornea, in the hope that the foreign body will be washed out during the flow of the liquid.

**Puncture of the Cornea.**—This may be made with a broad needle or a well-worn Beer's knife. It is advisable to employ anæsthesia, and to steady the eyeball with fixation forceps. The surgeon stands behind the patient, raises the upper lid, and fixes it against the margin of the orbit with two fingers of his left hand, which also rest against the inner side of the eyeball and prevent it from rotating inward. The needle or knife is then entered a little in front of the edge of the cornea at the outer side. Its direction must be sufficiently oblique to avoid injury to the iris, and not so much so that the instrument will remain between the layers of the cornea and fail to penetrate to the anterior chamber. By partly withdrawing the instrument and twisting it slightly, the incision is made to gape and allow the escape of the liquid ; or a fine blunt probe may be passed into the incision after entire withdrawal of the needle. Subsequent tapplings are effected by reopening the original wound with the probe. Figure 157 represents a combined needle and probe. The needle is provided with a shoulder to prevent its introduction to too great a depth.

**Evisceration of the Globe for Staphyloma.**—The sclerotic is incised with a Beer's knife just in front of the insertion of the external rectus ; into the opening is passed one blade of a pair of small blunt-pointed scissors, and the



anterior portion of the globe is cut away, with the lens and all the vitreous humor. The wound is then closed with catgut sutures passed through the conjunctiva alone.

### THE IRIS.

**Iridotomy.**—Incision of the iris may be performed for the purpose of establishing an artificial pupil. As its success depends upon the retraction of the divided fibers, it should be undertaken only when their contractility is not interfered with by too extensive adhesions or has not been destroyed by disease. The more common lesions to which the operation is applicable are central opacity of the cornea, occlusion of the pupil, and excessive prolapse of the iris after removal of a cataract; but the danger of injury to the lens is so great that the operation is practically restricted to the class of cases last mentioned.

The best place for an artificial pupil is in the lower inner quarter of the iris, the second best in the lower outer quarter. As the portion of the cornea traversed by the knife or needle is likely to become more or less opaque in consequence, the incision in it should be made as far as possible from the point where the pupil is to be created.

*Simple Incision.*—Cheselden, who was the first to perform this operation, entered a narrow-bladed knife through the sclerotic just anterior to the insertion of the external rectus, the point directed toward the center of the globe of the eye. After the point had penetrated to the depth of one-eighth of an inch it was directed forward, passed through the iris to the anterior chamber and transversely across the latter, its edge looking backward. By pressing the edge against the iris and withdrawing it a horizontal incision was made in that membrane.

Bowman punctured the cornea midway between its center and external border, passed a narrow blunt-pointed knife through the puncture into the anterior chamber, and thence through the pupil to the posterior surface of the inner half of the iris, which he then divided by cutting forward. The danger of injury to the cornea during the last step of the operation is very great.



Bell<sup>1</sup> uses a double-edged needle which is "introduced through the cornea near its margin; on arriving at the place where the pupil ought to be, one edge is drawn against the iris and divides it transversely, if possible, without injuring the lens."

Wecker proposes *simple iridotomy* and *double iridotomy*; the former in cases of central opacity of the cornea or lens, the latter when the pupil has become obliterated after removal of a cataract. He uses a small lance-shaped knife with a shoulder, straight or bent upon the flat, and a pair of forceps-scissors.

*Simple Iridotomy.* (Wecker.)—The knife is entered midway between the center and border of the cornea on the side opposite to that on which the pupil is to be made. As soon as the cornea has been perforated the knife is withdrawn and the forceps-scissors passed through the wound to the further border of the pupil, where they are opened and one of the blades passed behind, the other in front of, the iris. By closing them sharply the circular fibers are divided from the margin of the pupil toward the periphery of the iris. The scissors are then withdrawn, the iris replaced if it engages in the wound, a few drops of a solution of atropine placed between the eyelids, and a compress applied.

**DOUBLE IRIDOTOMY.** (Wecker.)—The knife is passed perpendicularly through the cornea and iris one millimeter from the edge of the conjunctiva, on the side toward which the obliterated pupil has been retracted; its point is then made to pass along the posterior surface of the iris until arrested by its shoulder, when it is withdrawn slowly. The forceps-scissors are next introduced through the incision, and one blade passed behind and the other in front of the iris for a distance of one-quarter of an inch or a little less. Two successive sections of the iris are then made, inclosing a triangular flap, the apex of which is directed toward the incision in the cornea. The pupil is formed by the retraction of this flap.

**Iridectomy.**—Excision of a portion of the iris may be

<sup>1</sup> Manual of Surgical Operations, 3d edition, p. 162.

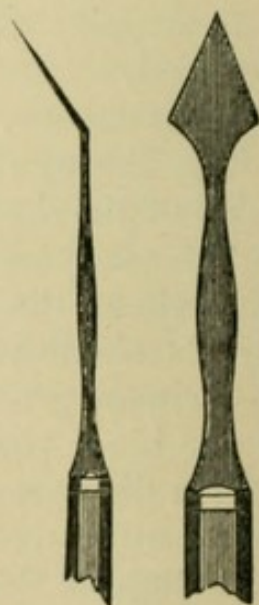


employed for the purpose of creating an artificial pupil (optical iridectomy), or for the relief of tension in glaucoma or irido-choroiditis (antiphlogistic iridectomy), or as a preliminary to the removal of a cataract. The size of the portion excised is determined by the length and position of the line of the incision on the posterior surface of the cornea; the nearer this is to the margin of the cornea the larger will be the portion of the iris removed. In antiphlogistic iridectomy, therefore, when the entire breadth of the iris from the pupil to its outer margin should be removed, the knife must be entered one millimeter outside of the clear portion of the cornea; in optical iridectomy, on the other hand, the excised portion should be small and the knife should be entered within the margin of the cornea. In antiphlogistic iridectomy at least one-fourth of the iris should be removed, the piece being taken from the upper segment in order that the loss may be hidden by the upper eyelid. In optical iridectomy the pupil should be made on the inner side of the lower segment unless corneal opacities are in the way.

FIG. 141.



FIG. 142.



Iridectomy knives.

**Operation for Antiphlogistic Iridectomy.**—The instruments required are a lance-shaped knife, straight (Fig.



141) or bent (Fig. 142), iridectomy forceps (Figs. 143 and 144), and scissors curved upon the flat (Fig. 145).

FIG. 143.

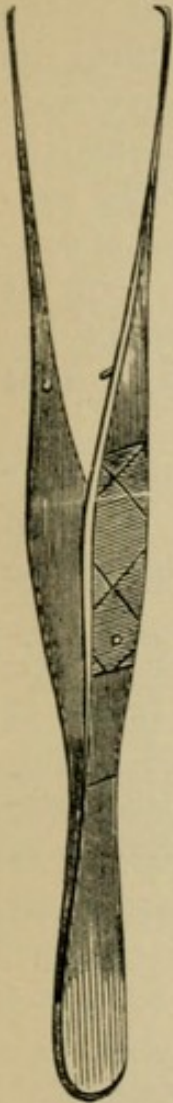
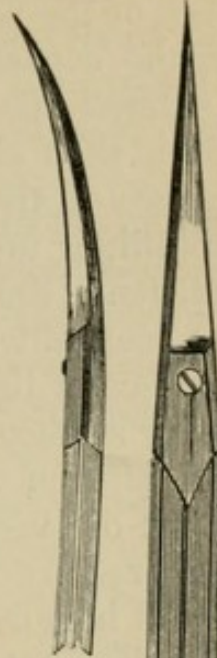


FIG. 144.

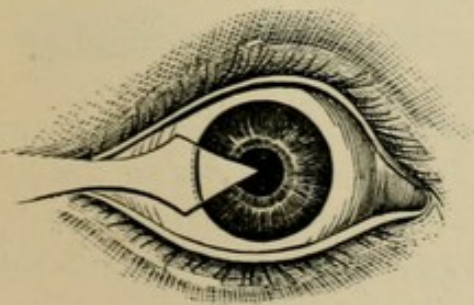


FIG. 145.

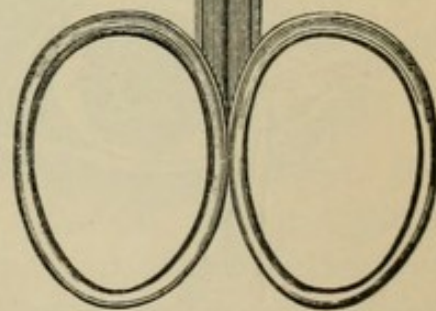


Iridectomy forceps and scissors.

FIG. 146.



Iridectomy. Incision of cornea.



The patient having been anæsthetized and placed in a recumbent posture, the surgeon takes such a position in

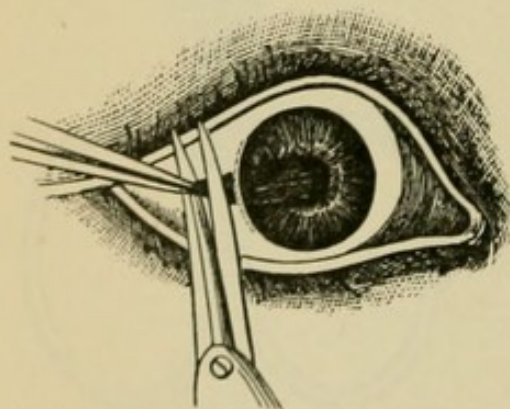


front of or behind him as will facilitate the making of the first incision. The eye-speculum and fixation forceps having been applied, the latter immediately opposite the point of puncture, the knife is introduced perpendicularly to the surface of the sclerotic one millimeter outside of the margin of the cornea and passed steadily in until its point has entered the anterior chamber at its very rim; its direction is then changed and it is carried along the anterior surface of the iris until its point reaches the center of the pupil, or until the length of the incision is considered sufficient (Fig. 146). By inclining the point of the knife to each side, the length of the incision in the posterior surface of the cornea may be made equal to that of the anterior surface.

The knife is then withdrawn and the aqueous humor allowed to run off very slowly in order that the relief of intra-ocular pressure may not be so sudden as to lead to congestion and hemorrhage.


If the iris does not now present in the wound the iridectomy forceps must be introduced closed as far as to the margin of the pupil, which is then seized and drawn out gently through the incision. An assistant then cuts off with the curved scissors all the protruding portion of

FIG. 147.



Iridectomy. Excision of the iris.

FIG. 148.



Tyrrell's hook.

the iris close to the lips of the wound (Fig. 147). Or the fixation forceps may be confided to the assistant before the introduction of the iridectomy forceps, and the sur-



geon left free to use the scissors himself. Instead of the iridectomy forceps, Tyrrell's hook (Fig. 148) may be used to draw the iris out through the incision. It must be introduced upon its side, hooked around the margin of the pupil, and then its point must be turned toward the cornea and away from the center of the eyeball so that it will not catch upon the posterior edge of the incision during its withdrawal.

If any hemorrhage takes place into the anterior chamber the escape of blood before coagulation should be favored by separating the lips of the incision with a curette, and making gentle pressure upon the eyeball. The edges of the iris must be carefully replaced with a spatula and not left included in the corneal wound.

**Iridesis**, or displacement of the pupil by ligature. Critchett,<sup>1</sup> the inventor of this operation, claims that by it the size, form, and direction of the pupil can be regulated to a nicety, and its mobility preserved. It is applicable to numerous groups of cases in which the natural pupil, or even a part thereof, is movable, and has a free edge; but the simplest class is that of central opacity of the cornea, in which it is only required that the natural pupil should be moved slightly to one side, so as to bring it opposite the transparent part of the cornea. It has also been used in cases of conical cornea, to change the shape of the pupil to that of a slit; and in a case where the pupil had been rendered very small and narrow by broad synechiæ, Critchett made it large and almost circular by drawing its sides apart at nearly opposite points.

The *operation* is performed as follows:

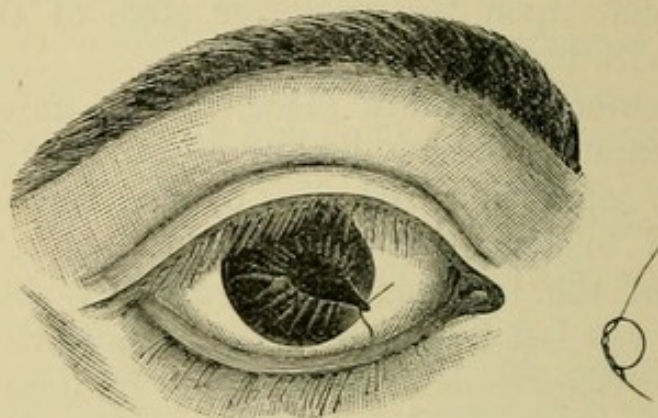
An opening is made with a broad needle through the margin of the cornea close to the sclerotic, and just large enough to admit the canula forceps. A small portion of the iris near but not close to its ciliary attachment is seized and drawn out to the extent considered sufficient for the proposed enlargement of the pupil; a piece of fine floss silk, previously tied in a small loop round the canula forceps, is slipped down, and carefully tightened around the

<sup>1</sup> Ophthalmic Hospital Reports, Vol. I., p. 220.



portion of iris made to prolapse, so as to include and strangulate it (Fig. 149). This manœuvre is best accomplished by holding each end of the silk with a pair of small broad-bladed forceps, bringing them exactly to the

FIG. 149.



Iridesis.

spot where the knot is to be tied, and then drawing it moderately tight. The small portion of the iris included in the ligature speedily shrinks, leaving the little loop of silk, which may be removed on the second day.

If it is desired to make the pupil extend to the periphery of the iris, the margin of the pupil must be seized with the forceps and drawn out through the incision. In this case Soelberg Wells prefers a blunt hook to the canula forceps.

**Corelysis**, or rupture of adhesions uniting the margin of the pupil and the lens. The operation was first performed by Streatfeild, as follows:<sup>1</sup> He punctured the cornea with a broad needle on the outer side near its margin,

FIG. 150.



Streatfeild's spatula hook.

passed his spatula (Fig. 150) along the anterior surface of the iris to the pupil, engaged the adhesions in the notch

<sup>1</sup> Ophthalmic Hospital Reports, Vol. I., p. 6.



on the edge of the spatula, and tore them. When the entire margin of the pupil was adherent, he passed the needle along the surface of the iris, across the pupil to its opposite margin, and cut the adhesions at that point. Then withdrawing the knife, he passed the spatula through the hole thus made, and easily broke up the remaining adhesions. When the adhesions were too strong to be broken with the spatula, he used the canula scissors. A few drops of a solution of atropine should be applied to the eye, both before and after the operation.

### OPERATIONS UNDERTAKEN FOR THE RELIEF OF CATARACT.

A cataract is an opacity of the crystalline lens, or of its capsule, or of both: the former being the much more common variety. It may be hard, soft, or semiliquid, and its condition, in this respect, has an important bearing upon the choice of a method of operation. The lens is composed of a solid nucleus and a soft cortex; the whole lying free within the capsule which is itself attached to the vitreous humor. In consequence of the absence of adhesions between the lens and the capsule, moderate pressure is sufficient to force out the former after the latter has been divided.

In operating upon a cataract, the patient should be recumbent: cocaine anæsthesia is sufficient except with young children or unruly patients, when ether may be necessary. The other eye should be covered with a bandage, unless its sight is entirely lost; and an eye-speculum may be used to keep the lids apart, if the services of a trained assistant cannot be had. The objection to a speculum is that it is somewhat in the way of the knife, cannot be removed promptly enough, and is apt to make dangerous pressure upon the eye. If used, the screw of the instrument should be loosened as soon as the incision has been made. A few drops of a solution of atropine should be placed under the lids a short time before the operation.



The methods of operation may be classified as :

Depression or couching ;

Division, discission, or solution ;

Extraction ;

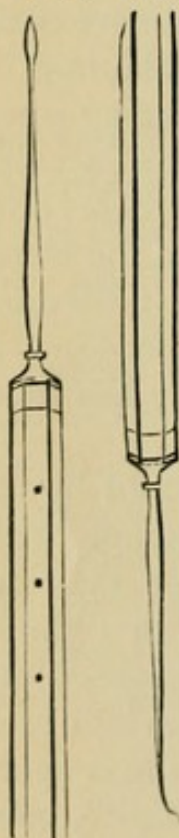
Operation for secondary cataract.

*Depression or couching*, which was the original and, for many years, the only method of removing cataract, is now universally abandoned, on account of the danger that the displaced lens may set up inflammation of the eye by contact with the other parts, especially the iris and ciliary processes, and thus cause total loss of sight. Soelberg Wells states that about fifty per cent. of the eyes thus operated upon have been lost by chronic irido-choroiditis.

The operation will be described, however, for the sake of reference. If the puncture is made in the sclerotic, the operation is called *scleronyxis*; if in the cornea, *keratonyxis*.

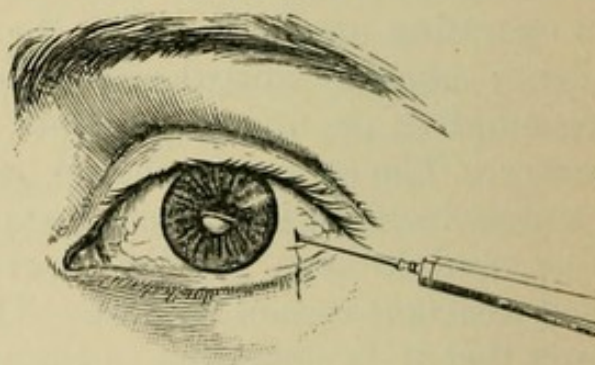
**Scleronyxis.**—A curved couching needle (Fig. 151), its convexity turned upward, is passed through the sclerotic on the temporal side about four milli-

FIG. 151.



Couching needle.

FIG. 152.



Depressing cataract.

meters from the margin of the cornea, and three millimeters below the horizontal diameter of the eye. Its convexity is then turned forward, and the needle carried behind and parallel to the iris, across to the upper and inner



margin of the pupil (Fig. 152), when the handle is lightly tilted upward, and the lens slowly depressed by the concave surface of the needle. After holding it in place for a moment, the needle is slightly rotated to disentangle its point, and withdrawn.

Some authors recommend that the anterior capsule should be formally divided horizontally or vertically before the lens is depressed.

**Keratonyxis.**—The needle is passed through the cornea a little below its horizontal diameter, and midway between its center and margin, and carried backward and inward, through the pupil to the lens, which is then depressed as before.

In the variety of depression called *reclination*, the upper edge of the lens is rotated backward about its transverse axis at the same time that it is depressed, so that its anterior becomes its superior surface.

**Division, Discission or Solution.**—The object of this operation is to tear open the anterior capsule with a fine needle, and by thus bringing the aqueous humor into contact with the lens to promote the gradual softening and absorption of the latter. The selection of the term discission was made in consequence of an erroneous impression, that the more completely the lens was broken up at first the more rapidly would the work of absorption go on, and surgeons, therefore, tried to cut the whole lens into fragments. Experience has since shown that in most cases the absorption must be gradual and the operation frequently repeated, only a small amount of the substance of the lens being allowed to come into contact with the aqueous humor on each occasion. If the lens is all broken up at once, the numerous fragments swell and act as foreign bodies in the aqueous humor and set up inflammation in the iris and cornea, with immediate arrest of the process of absorption. This operation is more especially indicated in the cortical cataract of children and of young persons up to the age of twenty or twenty-five years, also in those forms of lamellar cataract in which the opacity is too extensive to allow of much benefit being



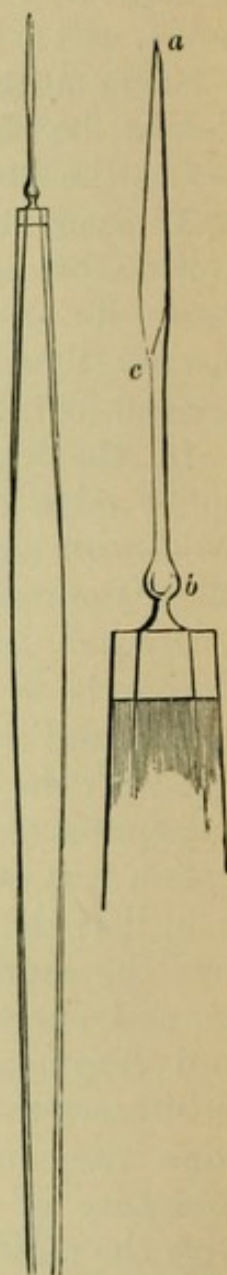
derived from an artificial pupil. After the age of thirty-five or forty absorption is much slower and the iris much more irritable.

There are two methods of performing the operation; in one the needle is passed through the cornea, in the other through the sclerotic.

**Division Through the Cornea.**—The pupil is widely dilated with atropine, the eyelids drawn apart by an assistant, or fixed with the eye-speculum, and a fold of conjunctiva on the inner side of the eye seized with the fixation forceps. A fine spear-shaped needle with a shoulder (Fig. 153) is passed through the outer lower quadrant of the cornea, almost perpendicularly to its surface at a point well within the dilated pupil, so that the iris shall not be touched by the needle. One or more incisions, according to the effect desired, are then made in the anterior capsule of the lens, the needle withdrawn, and a compressive bandage applied. The operation may be repeated as soon as all redness and irritability of the eye have disappeared.

**Division Through the Sclerotic.** (Hays.<sup>1</sup>)—The patient having been prepared as before, the knife-needle (Fig. 154), with its cutting edge upward, is passed through the sclerotic at a point on its transverse diameter three or four millimeters from the temporal margin of the cornea, and perpendicularly to the surface of the eyeball. Its direction is then changed and its point carried between the iris and lens to the opposite

FIG. 154.



Hays's knife-needle.

FIG. 153.



Bowman's fine stop needle.

<sup>1</sup> American Journal of Medical Sciences, July, 1855, p. 81.



margin of the pupil. If it encounters and penetrates the lens on the way, it will probably dislocate it, in which case extraction should be at once performed : if the needle is pushed into the lens without dislocating it, the instrument should be withdrawn until its point is free, and then pushed on again in a better direction.

This being accomplished, the edge of the knife is turned back against the center of the lens, and a free incision made by withdrawing it a short distance, while pressing its edge firmly against the cataract.

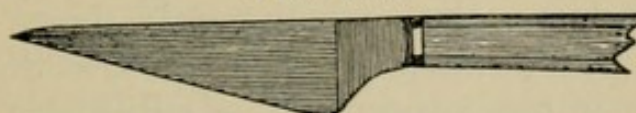
In order to expedite the cure, Wells thinks it is a good plan to combine division with extraction, and remove the whole cataract by a linear incision after it has been softened by contact with the aqueous humor. In children this may be done within a week after the division. The same proceeding may be employed in cases of partial cataract, the transparent portion of the lens being made opaque and softened by the introduction of the needle.

**Extraction.**—The methods of extraction may be classified as—

- The flap ;
- Von Graefe's ;
- The linear ;
- The scoop ;
- Extraction by suction, and
- Removal of the lens in its capsule.

**FLAP EXTRACTION.**—The common flap operation is certainly the best when it is successful. It is nearly

FIG. 155.



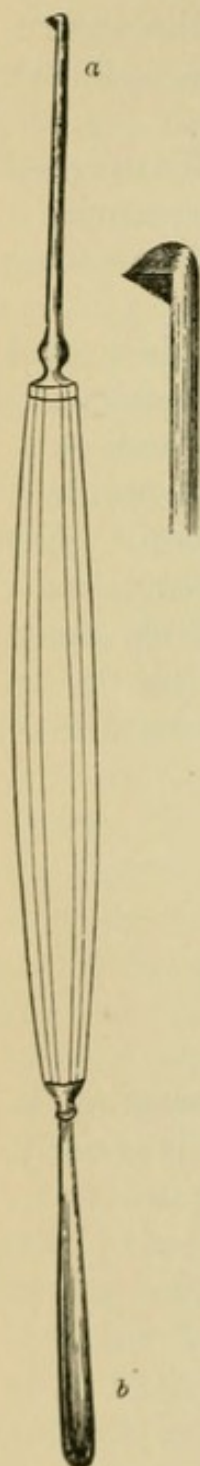
Siehel's knife.

painless, does not affect the appearance of the eye and leaves a natural movable pupil. These advantages, however, are offset by serious disadvantages ; the great size of the flap involves the risk of partial or diffuse suppura-



tion of the cornea, accompanied possibly by suppurative iritis or iridochoroiditis. Prolapse of the iris is a not infrequent complication and the after-treatment requires much more care and attention. But at present this operation is performed about as often as von Graefe's and with the latter's knife instead of Beer's.

FIG. 156.



Von Graefe's  
cystotome and  
curette.

The instruments required are a Beer's (Fig. 140) or Sichel's (Fig. 155) or von Graefe's (Fig. 159) knife, fixation forceps, Graefe's cystotome and curette (Fig. 156) and a small blunt-pointed knife or pair of scissors for enlarging the wound, if necessary.

The section may be made in the upper or lower half of the cornea; the former is rather the more advantageous, the latter the easier of execution.

**Operation.** (Right eye, upper section.)

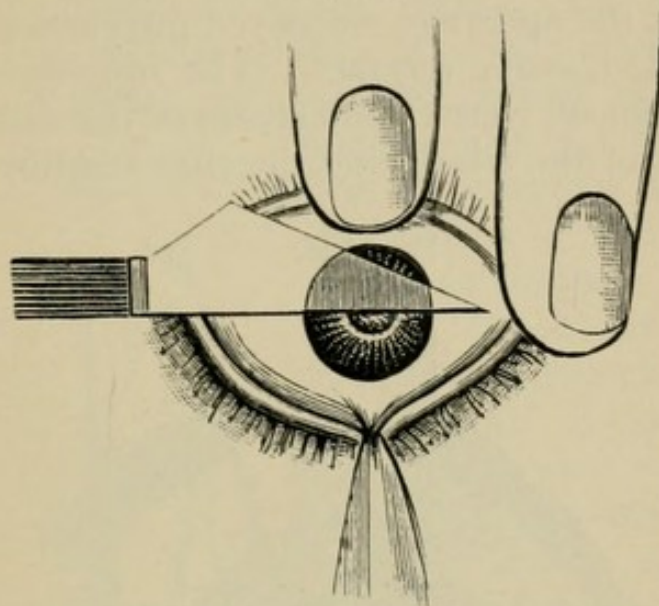
**FIRST STAGE.**—Patient recumbent, the operator seated behind him. The eyelids are separated by an assistant standing at the patient's left side, and drawing the lids gently apart with the forefinger of each hand, without making any pressure upon the eye. The surgeon steadies the eyeball by pinching up a fold of conjunctiva, with fixation forceps, either just below the cornea, as in Fig. 157, or better, perhaps, just below its prolonged horizontal diameter on the inner side, and draws the eyeball gently down. He then enters the point of the knife at the outer side of the cornea half a millimeter within its margin, and just on its transverse diameter, and carries it steadily across the anterior chamber, taking care to keep the side of the blade parallel to the iris, and to press slightly

downward with its back so that it may always fill the incision completely and prevent the escape of the aqueous



humor. The counterpuncture is made by the steady advance of the knife at a point immediately opposite that of entry, the fixation forceps removed, and the knife pushed on in the same direction until the section is all but finished ; when only a small bridge of cornea remains undivided at

FIG. 157.



Flap extraction of cataract. Mode of fixing the eye and making the incision.

its upper border, the edge of the knife is inclined slightly forward, and the section completed by withdrawing the knife. Close the eyelids for a moment before beginning the second stage.

**SECOND STAGE.**—The anterior capsule is next divided by introducing the cystotome through the incision while the patient looks downward, and drawing its point gently across that membrane. Care must be taken not to displace the lens by pressing the point too forcibly against it. Close the eyelids again for a moment.

**THIRD STAGE.**—The patient is again directed to look downward, and steady gentle pressure is made upon the eye with the forefinger or curette placed upon the lower lid (Fig. 158). This pressure should first be directed backward so as to tip the upper edge of the lens forward, and then upward and backward so as to force the lens through the dilated pupil into the anterior chamber and

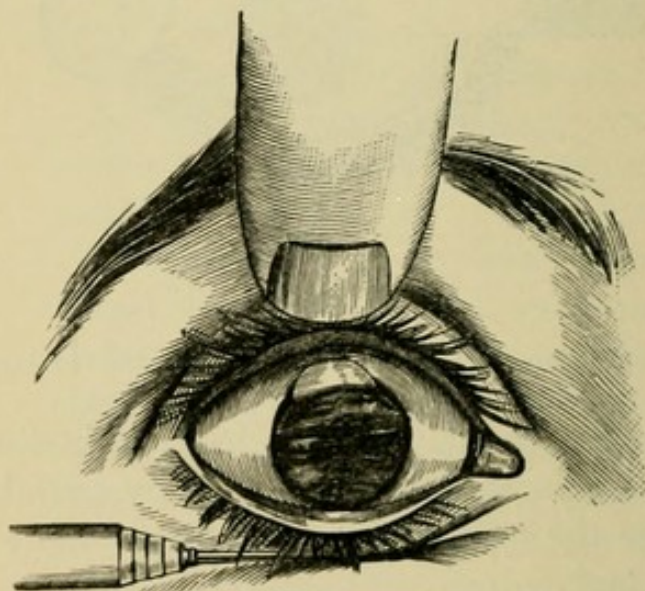


out through the incision. It should be gentle and very steady so as to avoid rupture of the posterior capsule and escape of the vitreous humor.

Any portions of the cortical substance of the lens which may have been left behind in the capsule, or stripped off during the passage of the lens through the pupil and the incision, must then be removed, and the eye closed.

Such was the operation employed for extraction of the ordinary, hard, senile cataract. The objections to it, as before mentioned, were the great size of the flap, the possible prolapse of the iris during the after-treatment, and the

FIG. 158.



Flap extraction of cataract. Removal of the lens by pressure.

risk of iritis excited by the bruising of the iris during the passage of the lens through the pupil. Von Graefe was the first to suggest that this last risk would be diminished by the excision of a portion of the iris, iridectomy, and on putting the suggestion into practice he found that it also enabled him to remove the cataract safely through a much smaller incision. According to Mr. Carter,<sup>1</sup> Von Graefe worked very sedulously during several years to exclude, one by one, the chief sources of the dangers by which extraction was beset, and he arrived at last at the

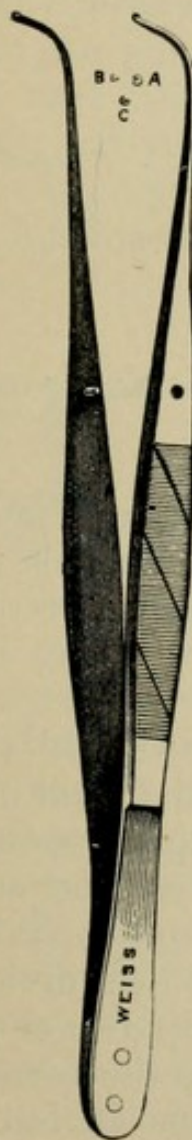<sup>1</sup> Holmes's Surgery, its Principles and Practice, p. 724.



FIG. 159.

Von Graefe's  
cataract knife.

FIG. 160.

Iridectomy  
forceps.

point of losing only four eyes out of one hundred operations. A few improvements in detail have been added since his death, but so far as principles and broad outlines are concerned he had covered the ground. In view of the shortness of the incision, which occupies not more than one-quarter of the periphery of the cornea, the operation is generally spoken of as a "modified linear extraction"; but the curved outline of the incision, and the fact that the lens is removed entire, certainly bring it within the class of flap extractions.

**VON GRAEFE'S METHOD. MODIFIED LINEAR, OR MODIFIED FLAP EXTRACTION.**—The instruments required, besides the eye-speculum and fixation forceps, are a long, thin, narrow knife (Fig. 159), the blade of which is thirty millimeters long and two millimeters wide, iridectomy forceps (Fig. 160), scissors, a cystotome (Fig. 156), and a small hard-rubber or tortoise-shell curette.

The patient is etherized and recumbent; the surgeon stands or sits behind him, holding the knife in his right hand for the right eye, in the left hand for the left eye. The eyeball is secured with the fixation forceps, and the point of the knife is entered in the sclerotic with its edge upward, one millimeter from the upper and outer mar-



gin of the cornea, and two millimeters below a tangent to its circle drawn at the upper end of its vertical diameter (Fig. 161, *A*). The point of the knife is at first directed toward the center of the eyeball, but as soon as it has penetrated to the anterior chamber it is turned so as to pass parallel to and along the anterior surface of the iris downward and inward about seven millimeters to a point corresponding to *B* in Fig. 161. The handle is then depressed, turning on the back of the blade in the incision, until the point is raised to the horizontal line of the puncture, when the handle must be inclined somewhat backward, and the point pushed sharply through the sclerotic

FIG. 161.

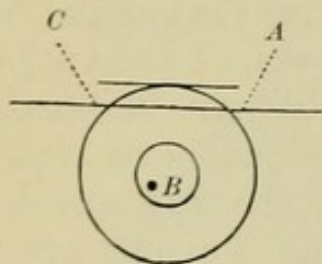
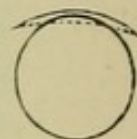


Diagram to illustrate the method of making Von Graefe's incision.

FIG. 162.



Line of Von Graefe's incision.

and conjunctiva at *C*, Fig. 161. Great care must be taken not to make the counter-puncture too far back in the sclerotic, a mistake which may easily happen if the blade is carried too far downward and inward before it is turned up to make the counter-puncture.

The edge is then directed forward, and the incision completed by steady advance and withdrawal of the knife. The incision is represented by the upper, undotted line in Fig. 162; its center should lie at the juncture of the cornea and sclerotic. The little bridge of conjunctiva which remains at the center of the incision is then divided in such manner as to leave a conjunctival flap two or three millimeters long adherent by its base to the cornea. If the cataract is large and hard, it may be advisable to use a broader knife, and make the points of puncture and counter-puncture one millimeter lower, so that it will not



be necessary to use a scoop or make much pressure on the eye to effect the removal of the lens.

Many surgeons prefer to make the incision wholly in the cornea and close to its edge, on the ground that the wound will heal more promptly and kindly, and be accompanied by less risk of loss of the vitreous or of prolapse of the iris.

The object of the *iridectomy*, which is the next step in the operation, is the neutralization of the circular fibers rather than the removal of a large portion of the iris, although some surgeons counsel the latter on account of the greater security it gives against subsequent inflammation. The iridectomy forceps are introduced closed and opened slightly when the point reaches the margin of the pupil. The margin rises between the branches, is seized, withdrawn gently, and cut off with scissors close to the forceps. If this is properly done the angles formed by the edges of the incision and the margin of the pupil will ap-

FIG. 163.




Diagram of the correct and faulty sections of the iris.

pear in the anterior chamber as at *A* and *B* in Fig. 163. The portion of iris removed should extend quite to its ciliary insertion so that there may be none to engage in the external incision and prevent its primary union.

The capsule is next freely divided by two successive lacerations made with the cystotome. Each should begin at the lower edge of the pupil and extend upward, one along the inner, the other along the outer side, to the upper border of the lens, where it has been exposed by the iridectomy. This upper border should also be torn to an extent corresponding to the external incision. This manœuvre must be executed with great delicacy and light-



ness of touch, in order that the lens may not be displaced into the vitreous humor.

The *escape of the lens* is aided by pressure upon the cornea with the curette. The fixation forceps are applied at the inner or outer side, and the curette placed upon the lower edge of the cornea and pressed slightly backward and upward so as to cause the upper edge of the lens to present in the section; the pressure must then be made directly backward, in order that the lens may be rotated around its transverse axis and tilted well forward into the incision. The curette is then pushed slowly upward over the surface of the cornea so as to follow step by step the delivery of the lens. Any fragments scraped off during the passage may be removed by passing the curette again over the surface of the cornea.

If the vitreous humor happens to be liquid it may escape as soon as the first incision is made. In such a case it is best to excise a portion of the iris and remove the lens in its capsule by passing a scoop behind it into the vitreous humor and lifting it out.

**Gayet and Knapp's Modification.**—Instead of lacerating the capsule as above described these surgeons incise it with a knife-needle along the line of the corneal incision. This is followed in the great majority of cases by an unusually uneventful healing free from iritis and other complications, but leaves the pupillary area occupied by the capsule of the lens. In order to clear the pupil the capsule is subsequently (in the third week after the extraction, or later) split with the knife-needle, which permanently frees the pupil from both the anterior and posterior capsules.

**LINEAR EXTRACTION.**—Mr. Dixon suggests<sup>1</sup> *rectilinear extraction* as a more suitable name, because the incision in the cornea is a straight one, in contradistinction to that of a flap extraction which also forms a line, but a curved one. This operation is a modification of one invented by Gibson in 1811, which had fallen into entire disuse before its reintroduction by Von Graefe in 1855.

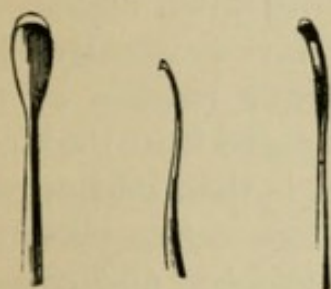
<sup>1</sup> Holmes's System of Surgery, Vol. III., p. 199.



It is designed for the removal of soft cataracts through a small corneal incision, especially the cortical cataract of individuals between ten and thirty years of age. It is also often employed with advantage as supplementary to the needle operation. It is performed as follows :

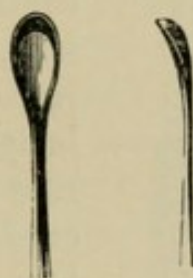
A straight, vertical incision, from four to six millimeters long, is made on the outer side of the cornea, about two millimeters within its margin, with a straight lance-shaped iridectomy knife, which is passed into the anterior chamber parallel to the surface of the iris. The capsule is then freely lacerated with the cystotome, and the escape of the soft lens facilitated by the introduction of a curette into the wound, and by making gentle pressure on the inner side of the eye with the finger. If por-

FIG. 164.



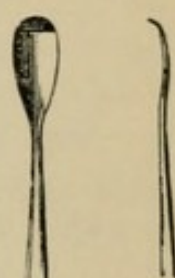Crichtett's scoops.

FIG. 165.



Bowman's scoops.

FIG. 166.



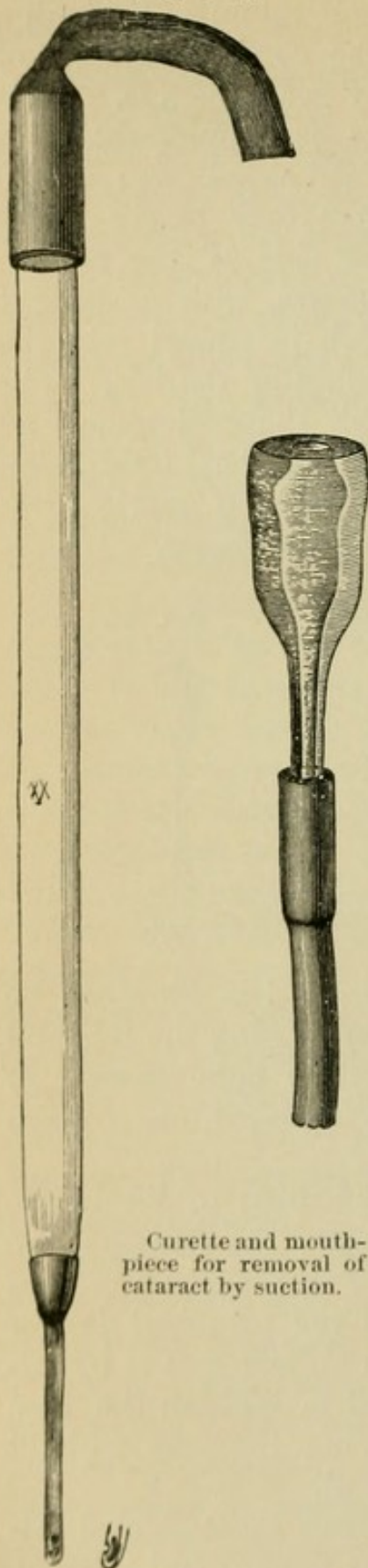
tions of the cortex remain behind the iris they can be brought into the anterior chamber by closing the lids and making gentle pressure in circular lines upon them. If the iris protrudes, it must be gently replaced, or, if much bruised, excised.

**Scoop Extraction.**—This is a modification of linear extraction, devised by Waldau to obviate the dangers and difficulties occasioned by the presence in the lens of a hard nucleus of greater or less size. As the principal danger lies in the bruising of the iris, Von Graefe met it by iridectomy, which afterward suggested to Waldau the idea of introducing a scoop and removing the lens without making any pressure upon the eyeball.

The instruments required are a bent lance-shaped iridectomy knife (Fig. 142), iridectomy forceps and scissors,



FIG. 167.



Curette and mouth-piece for removal of cataract by suction.

and a thin, flat, slightly concave scoop. Waldau's scoop resembled a small spoon. Three different kinds are shown in Figs. 164, 165, 166.

The eye-speculum and fixation forceps having been applied, an incision, eight or nine millimeters long, is made at the upper border of the cornea where it joins the sclerotic. The corresponding portion of the iris is removed, and the capsule freely torn with the cystotome, as before described.

The scoop, with its convexity backward, is then introduced and carried carefully down behind the lens, until its extremity has passed the lower margin of the latter, and engaged it in its hook-like end. It is then withdrawn, care being taken not to press the lens against the iris and cornea. If a little of the vitreous humor escapes at the same time it must be snipped off and a compress applied. It is better to remove any fragments of the lens that may be left behind by gently rubbing the eyeball, rather than reintroducing the scoop.

**Removal by Suction.**—Laugier suggested, in 1847, the removal of soft cataracts by aspiration through a hollow needle. Blanchot modified the method by substituting a small canula for the needle, and introducing it through an incision in the cornea, but the



operation was not favorably received until after it had been again modified by T. Pridgin Teale, Jr., in 1863, who recommended it as a substitute for pressure in the removal of the harder portions of the cataract by linear extraction, and as supplementary to discission. The instruments required are a broad needle and a suction curette. The latter (Fig. 167) is described by Mr. Teale<sup>1</sup> as consisting of three parts, a curette, handle, and suction tube. "The curette is of the size of the ordinary curette, but differs from it in being roofed in to within one line of its extremity, thus forming a tube flattened on its upper surface, and terminating, as it were, in a small cup.

The anterior capsule is first ruptured with a fine needle passed through the cornea, and then an opening is made with a broad needle in the cornea through which the curette is passed to the center of the pupil. The soft matter is then withdrawn by suction.

Soelberg Wells<sup>2</sup> says this operation has been employed at the Royal London Ophthalmic Hospital with great success, and that it is especially indicated in cases of soft cortical cataract. If the cataract is somewhat harder, it is well to break it up with the needle a few days before attempting to remove it.

**Removal of the Lens in its Capsule.**—This operation is indicated when the capsule is opaque, and whenever the eye is exceptionally irritable, or has been chronically inflamed, so that the accidental retention of any fragments of the lens would be a source of serious danger. When successful, this method gives very fine results, but its risks and dangers are so great that it is seldom employed. Originally introduced by Richter and Beer, it was revived by Sperino, Pagenstecher, and Wecker. The former employed the ordinary flap operation without laceration of the capsule. Pagenstecher made a large flap in the sclerotic together with iridectomy. Wecker's method was nearly identical, the incision being made at the sclero-corneal junction.

<sup>1</sup> Ophthalmic Hospital Reports, Vol. IV., part 2, p. 197.

<sup>2</sup> On the Diseases of the Eye, p. 280. Philadelphia: H. C. Lea.



**Pagenstecher's Method.**—The patient having been thoroughly anæsthetized, a large flap is made, usually downward, with a Beer's knife, a small bridge of conjunctiva being left temporarily at its apex. Iridectomy is then performed in the outer lower quadrant, and the conjunctival bridge divided with blunt-pointed scissors. Any posterior synechiæ that may exist are torn through with a fine silver hook, and then the lens removed in its capsule by slight pressure upon the eyeball. If the hyaloid membrane should be ruptured and the vitreous escape, the lens must be removed with the aid of a small scoop passed in behind its lower edge.

**Secondary Cataract.**—Secondary cataracts vary much in thickness and opacity. They may be produced by portions of the lens left behind and becoming entangled in the capsule, by the deposit of lymph upon the latter, or by the proliferation of the intracapsular cells. No operation for secondary cataract should be performed, until, at least, three or four months after the removal of the primary cataract; and if the pupil has become contracted, or if very extensive posterior synechiæ have formed, a preliminary iridectomy should be made. Formerly the plan was to remove the opaque and thickened membrane entirely from the eye, but it has proved very much safer and equally efficacious to make a small opening in the membrane with a needle.

Cocaine anæsthesia is necessary. The eye-speculum and fixation forceps having been applied, Bowman's fine needle (Fig. 153) is passed through the cornea near its margin, and an effort made to tear a hole with it in the center of the membrane or at the part which is thinnest and least opaque.

If the membrane yields before the needle, or if it is too tough to be torn, Mr. Bowman's device of a second needle must be employed. This is to be passed through the cornea on the side opposite to that occupied by the first needle, and then the operator, transfixing and steadying the membrane with one needle, tears it with the other. If any portion of the iris should happen to be bruised or torn, it must be excised through a linear excision.



Dr. Agnew passed a needle through the center of the membrane, thus steadying both it and the eye. He then made a linear incision on the temporal side of the cornea through which he passed a small sharp-pointed hook, the point of which is passed into the same opening in the membrane as the needle. He next tore the membrane, rolled it up about the hook, and either drew it out altogether, or, if this could not be done, tore it widely open.

#### OPERATION TO CORRECT STRABISMUS—STRABOTOMY.

The tendon of the internal rectus is attached to the sclerotic at a distance of five millimeters from the border of the cornea, that of the external rectus at a distance of seven millimeters. Each tendon is seven or eight millimeters broad and is contained in a firm sheath resembling a glove finger, a prolongation or depression of the capsule of Tenon at the point where it is traversed by the tendon about midway between the anterior margin of the orbit and the posterior pole of the eyeball. The capsule of Tenon is a reflection of the periosteum of the orbit from the anterior margin of the latter to the transverse meridian of the eyeball and thence backward to and along the optic nerve thus constituting the diaphragm which divides the orbit into an anterior and a posterior loge, the former of which contains the eyeball (received into a cup-like depression of the diaphragm), the latter the muscles and optic nerve. The capsule sends a prolongation, not only anteriorly along the tendons, but also posteriorly along the muscles, and the union between the muscle and sheath is so firm that even after division of the tendon the muscle can move the eyeball by acting through the attachments of the capsule. If the body of the muscle itself is divided in the posterior loge, its influence upon the movements of the eyeball is entirely lost. This is the chief point to be borne in mind in performing strabotomy, the tendon must be divided, not the muscle, and the amount of deviation of the eye to be overcome is the measure of the extent to which the adjoining tissues must be divided.



*The Operation for Division of the Internal Rectus* will alone be described, that being the one commonly required. The special instruments required are : fine-toothed forceps (Fig. 168), blunt hook (Fig. 169), and blunt-pointed scissors, straight or curved on the flat.

A small but deep fold of conjunctiva and subconjunctival tissue is seized with the toothed forceps just above the lower extremity of the line of insertion of the tendon of the

FIG. 168.


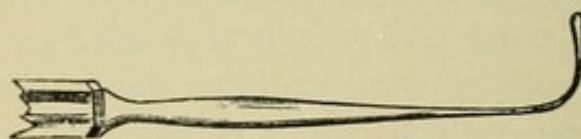


FIG. 169.



Strabotomy hook.

internal rectus, that is, two millimeters below a point on the equator of the eyeball five millimeters beyond the inner margin of the cornea, and divided with the scissors just below the forceps ; additional snips are made with scissors within this opening until the tendon or the sclerotic is exposed. The surgeon then passes the point of the strabotomy hook, which should be somewhat bulbous, through the opening to the lower border of the tendon, and, keeping the point and side of the hook constantly upon the sclerotic, sweeps it at first backward, and then upward and forward around the insertion. When this manœuvre is properly executed, the point of the hook can be seen under the conjunctiva above the upper border of the tendon, while its course is hidden by the latter and prevented from being drawn forward to the margin of the cornea. If the whole of the hook can be seen under the conjunctiva, it is not under the tendon, and the sweep must be repeated. When the tendon has been secured, the conjunctiva may

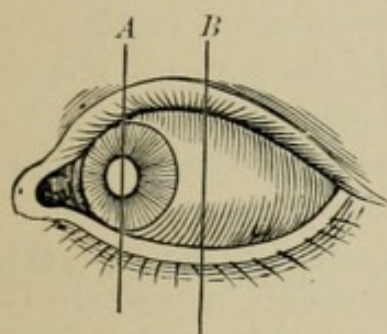


be pressed back over its point, and the tendon divided with scissors close to its insertion, beginning at its upper border; or, the conjunctiva being left in place, the scissors may be passed along the hook as a guide, one blade below the tendon, the other between it and the conjunctiva, and the tendon divided with repeated snips.

After the tendon has been completely cut through, the hook should be swept upward and downward to ascertain if the lateral expansions of the tendon have been divided, for the persistence of even a few of them might be sufficient to prevent the success of the operation.

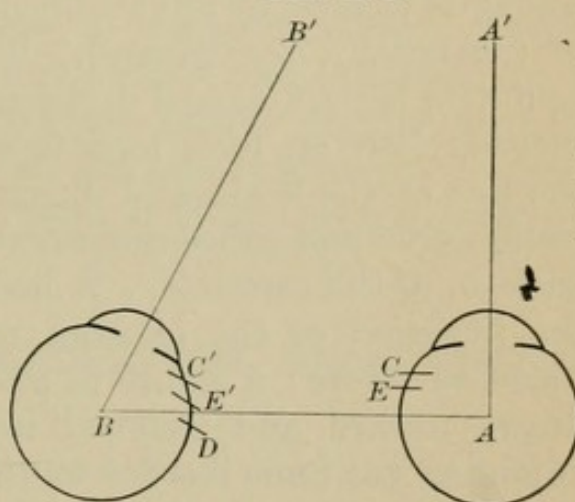
If it is feared that too great an effect has been produced, a deep suture may be passed through the tendon and the

FIG. 170.



Method of estimating the degree of squint.

FIG. 171.



Double operation for strabismus.

conjunctiva on the side toward the cornea so as to limit the amount of retraction. The accommodative movements of the eye should be tested immediately after the operation, and if there is the slightest tendency to divergence when the object is six or eight inches distant from the eye a suture should be inserted.

In the *subconjunctival method* the incision in the conjunctiva is made below the insertion of the tendon on a line with the lower border of the cornea, and the conjunctiva is not pressed away from the anterior surface of the tendon after the hook has been passed under the latter.



If the squint exceeds five or six millimeters, as estimated by the method shown in Fig. 170, both eyes should be operated upon, but at separate times, the insertion of the internal rectus being set back in each case. Thus, if the degree of squint represented in Fig. 171 were corrected by setting back the tendon of the internal rectus from *C'* to *D*, the muscle could only work at a great disadvantage as compared with the internal rectus of the other side, and the result would be the appearance of divergent squint whenever the attempt was made to look at an object near the eye, because the muscles could not turn the eye far enough inward. The condition must therefore be divided between the two eyes, the internal rectus on one side being set back to *E*, on the other side to *E'*.

*Secondary Strabismus following Tenotomy of the opponent* is treated by advancing the insertion of the tendon of the latter (*Prorrhaphy*). Thus, supposing divergent squint to have followed division of the internal rectus, an incision half an inch long is made in the conjunctiva in the line of the horizontal diameter of the cornea, and the conjunctiva and subconjunctival tissue dissected up as far back as to the caruncle. A hook is then passed around the insertion of the internal rectus, and the tendon divided as before; a suture is passed through it, and it is drawn toward, and fastened to, the strip of conjunctiva adjoining the inner border of the cornea. The tendon of the external rectus must then be divided according to the rules laid down for division of the internal rectus, remembering that its attachment to the sclerotic is distant seven millimeters from the edge of the cornea.

### ENUCLEATION OF THE EYEBALL.

As the globe of the eye lies somewhat nearer the inner than the outer side of the orbit, it will be found easier to approach it from the latter quarter. Tillaux<sup>1</sup> divides the conjunctiva and subconjunctival fascia with curved scissors along the attachment of the external rectus, divides

<sup>1</sup> Anatomie Topographique, p. 190.



the tendon of that muscle, carries the scissors backward through the incision, their concavity turned toward the globe, and cuts the optic nerve close to the eyeball. He then seizes the posterior pole of the globe with pronged forceps, draws it out through the conjunctival incision, and divides the remaining conjunctival attachments and tendons close to the sclerotic.

Other surgeons prefer to seek and divide each tendon in turn before cutting the optic nerve.

**EXTIRPATION OF THE ENTIRE CONTENTS OF THE ORBIT.**—In order to gain additional room, it is well first to divide the external commissure of the lids. A bistoury is then entered at the inner angle, carried well back toward the apex of the orbit, and swept along the floor to the outer angle, then reintroduced at the inner angle, and carried along the roof of the orbit to the outer angle. The muscles and optic nerve, which still remain attached to the eye and apex of the orbit, are finally divided with curved scissors introduced from the outer side.

Hemorrhage should be arrested by packing the cavity with antiseptic gauze.

## OPERATIONS UPON THE LACHRYMAL APPARATUS.

*Extirpation of the Lachrymal Gland* (Fig. 172).—The principal portion of the lachrymal gland lies just behind the junction of the upper and outer margins of the orbit, enveloped in a fibrous capsule formed by a reflection of the periosteum or capsule of Tenon. The "accessory" portion, together with the ducts, occupies the adjoining eyelid, and is composed of isolated granulations of granular tissue, which, if left behind after removal of the main portion, may continue to secrete tears and discharge them into the wound, thus causing abscesses and fistulæ.

Tillaux<sup>1</sup> has pointed out that the existence of the fibrous capsule renders it possible to enucleate the gland without opening the posterior loge of the orbit, a defect in the older methods which included division of the external commis-

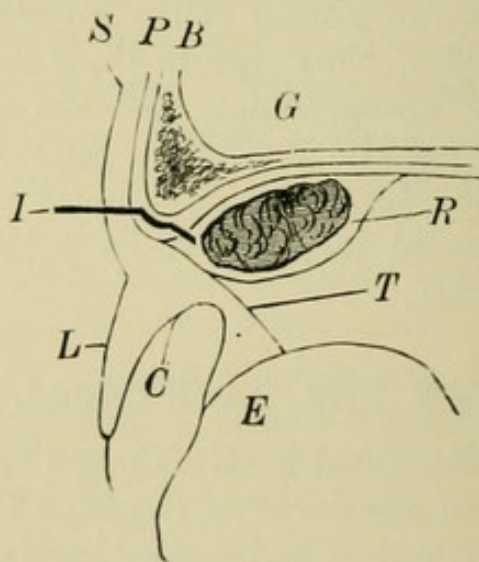
<sup>1</sup> Anatomie Topographique, p. 237.



sure. Make an incision one inch in length along the upper and outer portion of the bony margin of the orbit. Carry this incision through all the soft parts, including the periosteum, down to the bone; separate the periosteum from the bone at the under side of the incision, and depress it. The gland can then be distinctly seen through the thin layer of periosteum which separates it from the roof of the orbit, and can be removed with great ease after the latter has been torn through.

**Lachrymal Sac, Duct, and Canaliculi.**—The lower canaliculus passes downward from the punctum for two millimeters, then turns at a right angle, and passes horizon-

FIG. 172.



Extirpation of the lachrymal gland. *S.* Skin. *P.* Periosteum. *B.* Frontal bone. *G.* Lachrymal gland. *T.* Capsule of Tenon. *R.* Reflected periosteum forming the capsule of the gland. *E.* Eyeball. *C.* Conjunctiva. *L.* Eyelid. *I.* Incision.

tally inward to the lachrymal sac, a distance of about five millimeters; the upper canaliculus passes at first upward for two millimeters, and then downward and inward to the sac. This sharp turn in the course of the canaliculus, which is an obstacle to catheterization, can be temporarily removed by drawing the border of the lid outward. The lachrymal sac lies just behind the tendo oculi, and receives the canaliculi by a common duct two or three millimeters below its upper extremity, their relations thus resembling those of the ileum and cæcum, a resemblance




which is increased by the presence of a valve at the opening of the duct into the sac. This valve, described by Huschka, is thought to prevent the reflux of the contents of the sac into the canaliculi. The direction of the sac is downward and backward at an angle of  $45^{\circ}$ ; it occupies the lachrymal groove, which is bounded anteriorly by a ridge on the nasal process of the superior maxillary bone at the inner angle of the orbit, and is crossed by the tendo oculi just at the junction of its upper and middle thirds. The nasal duct is the direct continuation of the sac and passes downward, backward, and outward; the combined length of the duct and sac is about one inch.

It may become necessary to *slit up the canaliculus* in order to correct a malposition of the punctum, or to facilitate catheterization of the sac and nasal duct. This little operation is best performed as follows (right eye, lower lid): The surgeon stands behind the patient, who is recumbent, and introduces a fine grooved director (Fig. 173) vertically through the punctum for a distance of two millimeters. Then drawing the border of the lid outward and somewhat downward with the forefinger of his left hand, he passes the director horizontally, with its groove upward, along the canaliculus to the inner

FIG. 174.



FIG. 173.



Sharp-pointed  
canaliculus di-  
rector.

Bowman's probe-  
pointed canaliculus  
knife.



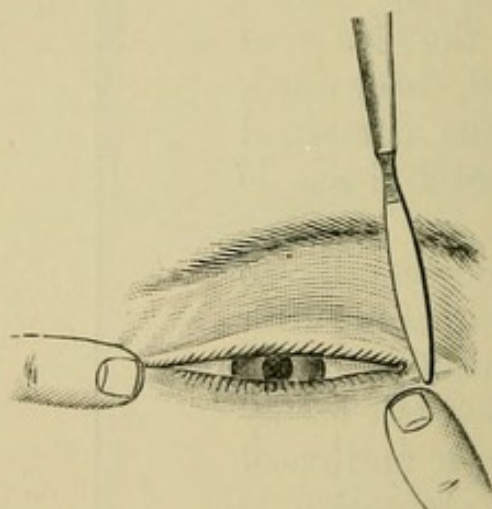
side of the sac. Then, shifting the director to the left hand, he engages a sharp-pointed knife in the groove, and slits up the canaliculus throughout its entire length.

Bowman's probe-pointed canaliculus knife (Fig. 174) may be substituted for the director and knife. It should be very narrow, and its probe point very small.

When one punctum has been entirely obliterated, a plan suggested by Mr. Streatfeild may be employed. He divides the other canaliculus, passes a fine director, suitably bent, through the wound into the obliterated canaliculus and cuts down upon it.

If the divided lower canaliculus remains everted, Mr.

FIG. 175.



Puncture of the lachrymal sac.

Critchett advises that the posterior lip of the incision be cut off with scissors, "effecting the treble object of drawing the canal further inward, of forming a reservoir into which the tears may run, and of preventing reunion of the parts."

**Puncture of the Sac.** (Fig. 175.)—The three guides are the tendo oculi, the anterior margin of the lachrymal groove, and the direction of the sac. While an assistant draws the external commissure outward, so as to make the tendo oculi tense and plainly visible, the surgeon places his left forefinger upon the inner and lower margin of the orbit, so as to have the bony edge between the nail and the pulp



of the finger, and holding the knife in the direction of the canal, that is, nearly parallel to the median plane, and at an angle of  $45^{\circ}$  with the horizon, he passes it along his finger-nail into the sac just below the tendon. It is important to mark the position of the anterior margin of the canal so as to avoid the not infrequent mistake of passing the knife entirely outside of the orbit between the soft parts of the face and the bone.



## CHAPTER II.

### OPERATIONS UPON THE EAR AND ITS APPENDAGES.

#### **OCCLUSION OF EXTERNAL AUDITORY CANAL.**

CONGENITAL occlusion of the external meatus is usually associated with the absence of defective development of the other portions of the auditory apparatus. Before operating upon such an occlusion, therefore, the hearing power should be tested, and the permeability or impermeability of the bony portion of the canal determined by puncture with a needle.

If the occlusion consists of a simple membranous diaphragm it should be divided crucially, and the flaps excised. For deeper and more extensive obstructions cauterization with nitrate of silver is to be preferred.

#### **INTRODUCTION OF SPECULUM.**

The upper portion of the auricle is grasped between the ring and middle fingers of the left hand and drawn gently upward and backward. Into the canal thus straightened the speculum is introduced with the right hand, and then held in place with the thumb and forefinger of the left, the hand being steadied by resting its ulnar border against the patient's head. Complete control of the speculum is thus obtained, and it can be easily moved about so as to bring every part of the tympanum and canal into view. Light should be thrown into it from a concave mirror perforated in the center and having a focal distance of six inches.

#### **PARACENTESIS OF THE MEMBRANA TYMPANI.**

This should be performed while the head of the patient is well supported and a good light is thrown upon the



membrane by a mirror attached to a forehead band. A cataract needle is the instrument usually employed, and the opening should be made in the posterior inferior quadrant of the membrane.

Tillaux<sup>1</sup> calls attention to the fact that all the important elements of the membrane occupy its upper half, and that an incision or rupture near the handle of the hammer may give rise to troublesome and even dangerous hemorrhage. The lower half is less vascular and less sensitive.

If it is desired to maintain the opening for several days, a crucial incision may be made, or a triangular flap excised, but, as a rule, even these incisions heal very quickly.

### CATHETERIZATION OF THE EUSTACHIAN TUBE.

The Eustachian tube is from one and a-half to two inches long, its course is from the pharynx upward, backward, and outward. Its pharyngeal orifice is oval and well-marked except on the lower border, and is situated just above the base of the soft palate. Behind the orifice, between it and the posterior wall of the pharynx, is a depression (Rosenmüller's fossette) in which the beak of the catheter, if carried too far back, may lodge and give the same sensation to the surgeon's hand as if it were engaged in the tube. Of the two mistakes most frequently made in performing catheterization, one is to pass the beak of the instrument between the middle and inferior turbinated bones instead of along the floor of the nasal fossa, and the other is to mistake Rosenmüller's fossette for the orifice. According to Roosa, the first mistake is best avoided by drawing down the patient's upper lip with the left hand, and entering the catheter while it is held in an almost vertical position, its concavity directed toward the median line. After the beak has fairly entered the meatus the stem of the catheter is gradually raised to the horizontal position and passed backward, its beak resting on the floor of the meatus close to the septum, its convexity upward.

Tillaux<sup>2</sup> gives the following directions for finding the

<sup>1</sup> Anatomie Topographique, p. 111.

<sup>2</sup> Ibid., p. 140.



orifice: 1st. Carry the catheter directly backward, its concavity downward, until it touches the posterior wall of the pharynx. 2d. Withdraw it until the beak rests again upon the hard palate. 3d. Carry the catheter again very gently backward, and feel with its beak for the posterior border of the palatine aponeurosis, the firm fibrous continuation of the palatal bone. This aponeurosis feels as hard as bone, and its posterior border can be easily recognized by the softness of the adjoining tissues. 4th. Rotate the beak of the catheter outward and upward, and it will enter the Eustachian tube.

#### OPENING OF THE MASTOID ANTRUM.<sup>1</sup>

The incision begins just above the apex of the mastoid process and is carried upward one and one-half inches parallel to the attachment of the ear, and about one-half an inch behind it. Everything is divided down to the bone, the periosteum elevated, and the posterior margin of the meatus recognized. A one-quarter-inch drill is driven *straight inward* at such a point that the hole it makes shall lie as near as possible to the back of the bony meatus and its upper border be not more than one-twelfth of an inch above the level of the upper margin of the meatus. It must not penetrate deeper than three-quarters of an inch or the external semicircular canal will be damaged. Deep perforations back of a line one-quarter of an inch behind the posterior margin of the meatus are liable to wound the lateral sinus. The antrum, which is about the size of a pea, is usually reached at a depth of three-fifths of an inch.

Or, preferably, the gouge is used and the antrum sought at the point above indicated by freely cutting away the bone behind the meatus including the posterior wall of the latter as far as to the middle ear.

<sup>1</sup> Birmingham. Dub. Jour. Med. Sci., 1891, p. 116.



## CHAPTER III.

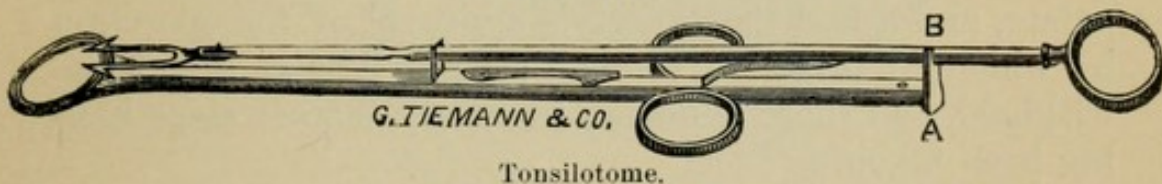
### OPERATIONS UPON THE MOUTH AND PHARYNX.

#### EXCISION OF THE TONSILS (AMYGDALOTOMY).

THE tonsils may be excised with a knife and volsella, or with a specially contrived instrument, the tonsilotome or guillotine.

Anæsthesia is not required. If the patient is young or nervous it is well to put a large piece of cork between the jaws on each side to prevent the mouth from being closed. The tonsilotome (Fig. 176) is composed of two rings and a fork mounted upon stems so arranged that they can be

FIG. 176.



worked with the thumb and fingers of one hand. The two rings slide flatwise upon each other, and the inner edge of one is sharp, so that when drawn across the other it divides anything lying within it. The fork is thrust forward across the ring and drawn away vertically from it by the same movement which draws one ring across the other. The rings having been placed over the tonsil, the hook is driven into the latter by a quick movement of the thumb and finger and draws it further into the ring, holding it tense as the other blade cuts across its base. The pain is very slight.

If the tonsilotome cannot be used the tonsil must be seized with pronged forceps, and excised between them



and the pillars with a probe-pointed knife, the posterior portion of the blade being guarded with diachylon plaster so as to avoid injury to the tongue.

### STAPHYLORRHAPHY.

At the conclusion of his historical account of this operation Verneuil<sup>1</sup> states that it has been invented four different times. The earliest record of the operation is found in a French book published in 1766,<sup>2</sup> in which it is said that a dentist, named Lemonnier, closed a fissure of both hard and soft palates by freshening its edges with a knife and bringing them together with sutures. He also closed perforations of the hard palate by exciting suppuration of their borders.

In 1799 Eustache, a physician of Beziers, proposed to reunite by sutures the edges of an incision which he had made the day before in the soft palate of a patient for the purpose of removing a pharyngeal polyp. The patient refused the operation. Four years later, in 1803, Eustache sent to the Académie Royale de Chirurgie at Paris a remarkable paper upon congenital fissures in the soft palate, and asked the Society's approval of the operation by which he proposed to close them. The approval was withheld, and there is no record of any further steps having been taken.

In December, 1816, Von Graefe said, before the Medico-Chirurgical Society of Berlin, that, after many unsuccessful attempts to close fissures of the soft palate, he had at last succeeded by drawing the edges together with sutures after freshening them by applying muriatic acid and the tincture of cantharides. This remark was reported in the proceedings of the Society in *Hufeland's Journal*, January, 1817. Between 1816 and 1820 Von Graefe repeated the operation three times, each time without success.

In 1819, Roux, apparently in entire ignorance of Von Graefe's attempt, closed a fissure by paring the edges and

<sup>1</sup>Chirurgie Réparatrice, 1877. Art. Staphylorrhapie.

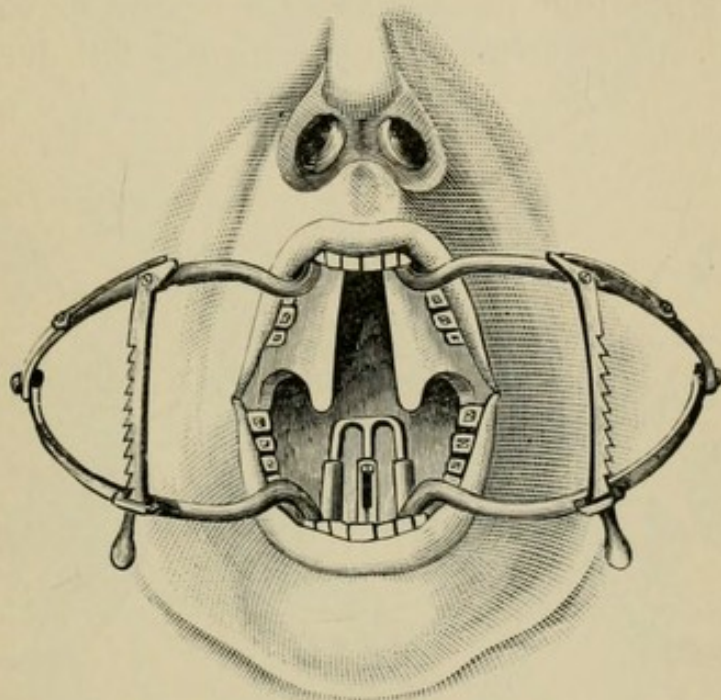
<sup>2</sup>Traité des Principaux objets de Médecine, par Robert.



applying sutures. The case at once became very widely known, and had much influence in popularizing the operation.

When the extent of the lesion which staphylorrhaphy is designed to repair is considered, the operation seems to be very simple. It is only necessary to freshen the edges of the gap and draw them together with sutures. Practically, however, the operation is a difficult one; the parts lie at a considerable distance from the surface, the

FIG. 177.



Whitehead's modification of Smith's gag.

manipulations are constantly interfered with by involuntary movements of deglutition, the flow of blood increases the obscurity, and the practical difficulties in the way of placing the sutures are great. Finally, unless some of the muscles of the palate are divided, the tension exerted by them upon the sutures is sufficient to prevent union.

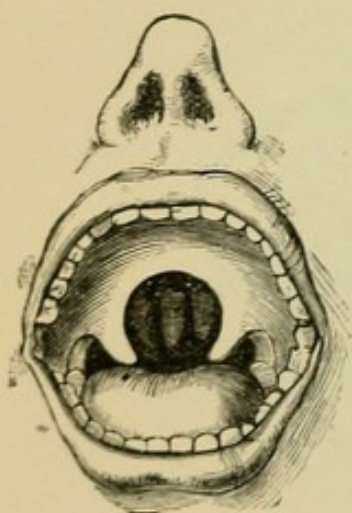
A great variety of methods have been suggested to overcome these difficulties. Mr. T. Smith diminished the first by the invention of a gag (Fig. 177), designed to hold the jaws apart during the operation. Van Buren avoided



the passage of blood into the trachea during the employment of anæsthesia by placing the patient so that the head should hang down over the end of the table, and the blood escape through the nose. The same device was afterward employed by Trélat.

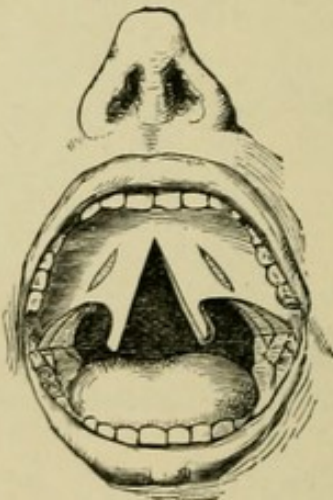
Sir William Fergusson relieved the tension by dividing the levator palati on each side. He did this by passing a knife, bent at a right angle, through the cleft and dividing the muscle from behind forward, without touching the mucous membrane on the anterior face of the palate. The incision should be perpendicular to the center of a line joining the hamular process and the orifice of the Eustachian tube. The former can be readily felt just behind

FIG. 178.



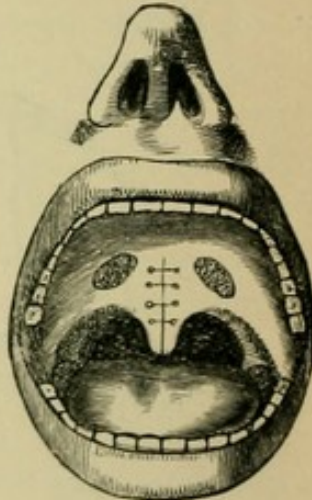
Cleft.

FIG. 179.



Incisions.

FIG. 180.



Sutures.

the last upper molar tooth, the latter can usually be seen through the cleft in the palate. He also recommended division of the palato-pharyngeus muscle.

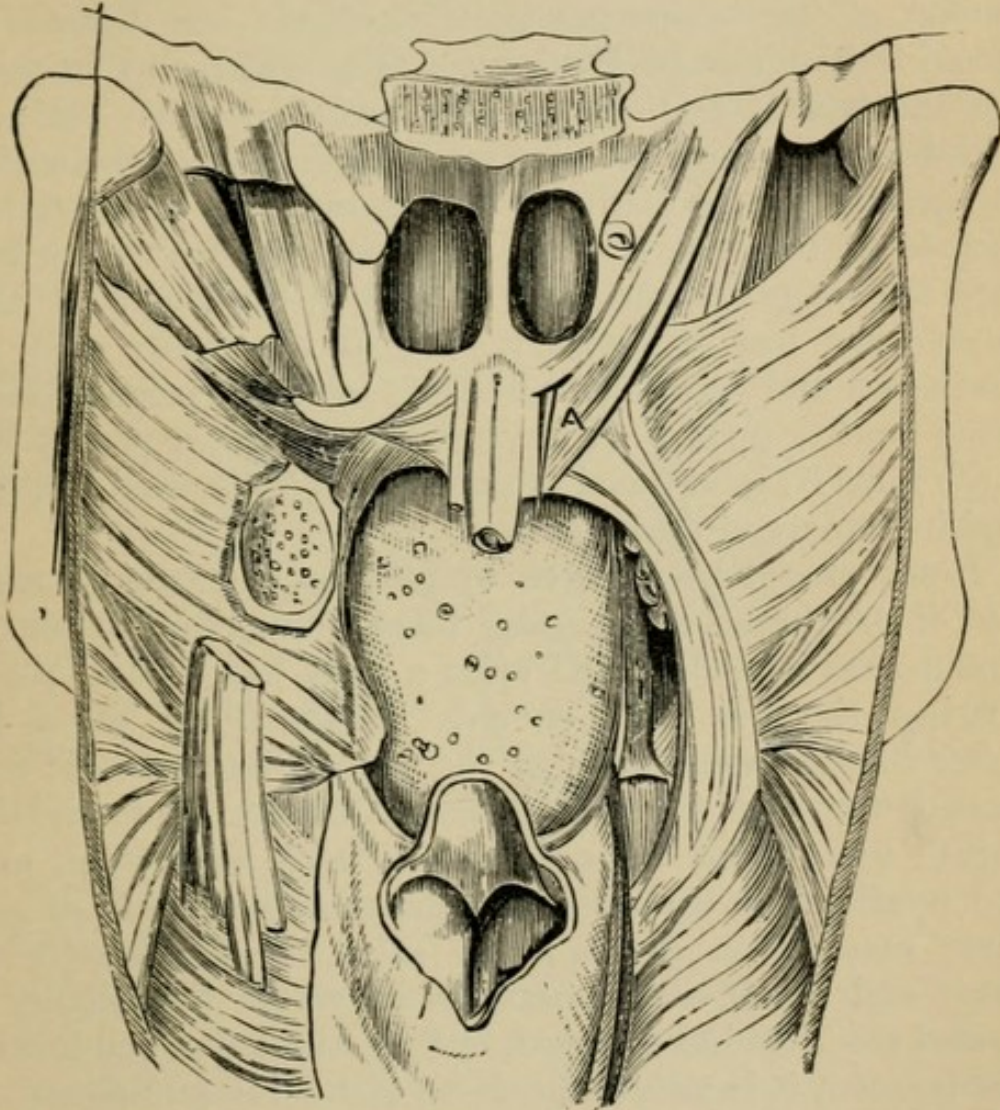
Sédillot<sup>1</sup> divided the muscle from before backward. He drew the velum downward and inward with pronged forceps, and made an incision downward and outward about one centimeter above and on the outer side of the base of the uvula, and just behind and on the inner side of the last upper molar, crossing the levator palati at right angles (Fig. 179). A length of one centimeter is usually

<sup>1</sup> Médecine Opératoire, Vol. II., p. 65.



sufficient, but it must be increased if the muscular contractions persist. The relaxation of the parts produced by these incisions is shown by a comparison of Figs. 178 and 180. Unless the incisions are exceptionally large their sides remain in contact; in any case they promptly

FIG. 181.



Division of muscles of soft palate.

reunite. He then divided the anterior and posterior pillars, seizing each in turn near its center with pronged forceps, and cutting it with scissors.

Mr. George Pollock<sup>1</sup> has modified this slightly by making the incision on the anterior surface of the palate

<sup>1</sup> Holmes's System of Surgery, Vol. IV., p. 426.



smaller. One of the halves of the palate is drawn toward the median line by means of a ligature passed through it near the base of the uvula, and a thin narrow knife is entered close to the hamular process, a little in front of it and on its inner side, and its point carried upward, backward, and somewhat inward, until it can be seen through the cleft, having divided on its way part, if not all, of the tendon of the tensor palati. The blade now lies above most of the fibers of the levator (Fig. 181), and by raising the handle and cutting downward, as the knife is withdrawn, an incision of considerable length, including the greater portion of the levator, is made on the posterior surface of the palate, while that on the anterior surface need not be greater than the breadth of the knife. If the muscle has been effectually divided the palate will be pendulous and flaccid, and will not contract spasmodically when pulled upon. If any resistance should persist the knife must be introduced again through the wound and the incision enlarged downward.

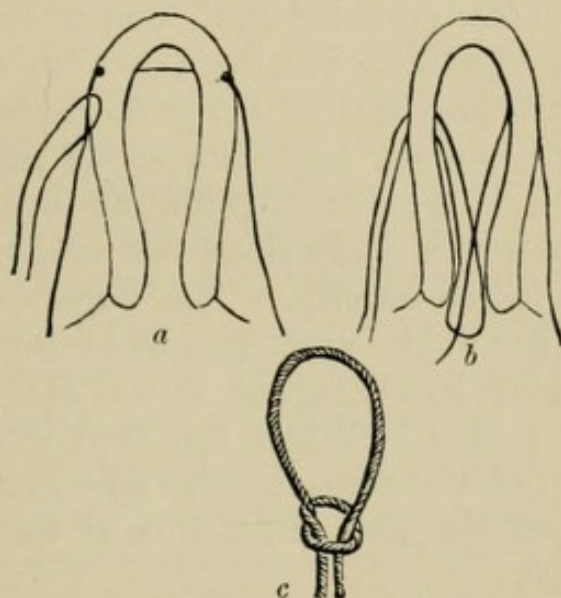
Roux placed his sutures by putting a needle at each end of the thread, and passing them from behind forward. Trélat used a needle fixed upon a long handle, the point bearing the eye and curved in the form of a U. After having been threaded the point of the needle was passed through the palate from behind forward, the thread was drawn through with a hook or forceps, and the needle, still threaded, withdrawn and passed in the same manner on the opposite side. The objection to these and to all other methods in which the needle is passed from behind forward, is that, since the point cannot be seen, it is very difficult to make the punctures on one side correspond properly with those on the other. If silk sutures are used each end may be passed from before backward, the two tied together loosely, and the knot pulled back through one of the punctures, thus bringing the loop behind the palate.

The method now usually employed is the one introduced by Bérard. A curved needle fixed on a long handle is threaded with a ligature three feet long, and its



point passed through the palate from before backward; the thread is caught with hook or forceps on the posterior side, and its end drawn out through the mouth, the needle is then withdrawn and slipped off the thread. It is next threaded with a second ligature and passed in the same manner through the opposite half of the palate, the loop seized as before, drawn through a short distance, and held while the needle is withdrawn, leaving the thread double in the puncture—the loop behind the palate, the two ends in front. The posterior end of the first ligature is then passed through the loop of the second one (Fig.

FIG. 182.



Staphylorrhaphy ; passing the sutures.

182, *b*), and, by the withdrawal of the latter, drawn through the second puncture (Fig. 182, *a*). Instead of using the same needle to pass both ligatures, it is more convenient to have two curved spirally in the opposite directions, one for each side.

If silver sutures are used, thread loops should be passed from before backward on each side, one end of the wire engaged in each and drawn through.

After a suture has been passed, the ends should be brought out through the mouth, and tied together for safety. When all have been passed, the anterior one is



drawn upon to bring the edges of the cleft together, and the knot tied. The knot may be an ordinary square one, an assistant holding the first twist with dressing forceps until the second is made, or it may be a noose, as shown in Fig. 182, *c*, secured by a second knot. If silver wire is used, it may be fastened by twisting it, or by clamping a small lead button upon it. Verneuil first passes the ends of the wire through the eyes of a shirt button, and then ties or twists. He thinks this favors more accurate adjustment of the edges, and facilitates removal of the wire.

The edges of the cleft are pared by seizing the tip of the uvula with toothed forceps, making it tense, entering the point of a narrow-bladed knife one or two millimeters back from the edge, and cutting down to the tip; then turning the knife and cutting up to the anterior angle of the cleft. Care should be taken to do this thoroughly. When the cleft is very short (bifid uvula), Nélaton employed the method already described under his name for single uncomplicated harelip. The flaps were left adherent to each other at the apex (angle of the cleft) and to the uvula at their bases, turned down, and the raw surfaces drawn together. When the cleft was too long for this he separated the flaps at the apex, shortened them by trimming off the free ends, turned them down, and united as before.

There is no settled rule of practice establishing the order in which the different steps of the operation shall be executed, except that most surgeons are agreed upon the advisability of paring the edges of the cleft before passing the sutures. Mr. Callender recommended that the muscles should be divided a day or two before the attempt to close the cleft, on the ground that the second operation is much simplified by the freedom from the bleeding occasioned by division of the muscles. Mr. Smith, on the other hand, stretched the palate by drawing upon all the sutures, divided the palato-pharyngeus and levator palati, and then, if the edges of the cleft did not come easily together, made two lateral oblique cuts, one on either side, above the



higher suture, separating, to a limited extent, the soft from the margin of the hard palate.

Bonfils, according to Dubrueil, closed an opening left at the upper part of the palate by the partial failure of an operation for staphylorrhaphy, by taking a flap from the hard palate, according to the Indian method of autoplasty (*q. v.*).

### URANOPLASTY.

Verneuil<sup>1</sup> attributes the success of modern uranoplastic operations to the use of the method by double flaps, adherent at both ends and brought together laterally (*lambeaux en pont*), and to the retention of the periosteum in the flaps. He ascribes the first use of double flaps to Dieffenbach, and thinks the retention of the periosteum was brought about by Ollier's most valuable experimental and clinical researches upon the properties of this tissue. To Von Langenbeck, by whose name the method is usually known, he gives only the credit of being the first to adopt Ollier's suggestion, and to make it a rule of practice.

This estimate of the facts does not seem to be entirely correct. It is true that Dieffenbach used double lateral flaps, but a large part of the success of the modern method is due to the greater breadth now given to the flaps. Tillaux has shown that the branches of the posterior palatine artery are given off like the plumes of a feather, and that to avoid division of these branches, and insure the nutrition of the flap, the incision must be made close to the alveolar process. This necessity is as absolute in the case of a small perforation as in that of a larger one. As for the retention of the periosteum, Von Langenbeck was certainly the first to point out its importance as a means of preventing gangrene of the flap. Ollier's investigations turned upon its value in favoring reproduction of the bone.

Fissure of the hard and soft palate endangers an infant's life by interfering with the ingestion of food. The exact measure of this danger has not yet been established

<sup>1</sup> Chirurgie Réparatrice, Art. Uranoplastie.



by statistics, but it is certainly considerable.<sup>1</sup> On the other hand, all recorded operations for cleft palate upon children less than one month old have terminated fatally, and those undertaken during the first five or six months of the child's life, although not so fatal, show but few successes. Billroth and Simon think the operation should be performed about the eighth month, but most surgeons are agreed upon the propriety of postponing it until the third or fourth year. If a child has lived six months without operation, it has certainly learned to overcome the mechanical difficulties in the way of its nourishment, and there is, consequently, no reason to interfere surgically until the second indication arises. That is found in the defective articulation and phonation occasioned by the lesion, and, as children with cleft palate do not begin to speak before the third or fourth year, the operation may be safely postponed until that time.

The special instruments required are a speculum oris, or two blunt hooks to be placed at the angles of the mouth and fastened together by a rubber band passing behind the head, pronged forceps with long handles, curved needles of the pattern selected, a periosteum elevator bent at a right angle on the flat, a small knife similarly bent, and sponges on long handles.

The edges of the perforation or fissure are first freshened by the removal of a strip one or two millimeters thick. An incision is then made on each side close to the gum, extending from the last molar tooth forward as far as may be necessary, and exposing the bone throughout. The elevator is introduced into this incision and the periosteum separated from without inward, care being taken not to injure the palatine arteries at the anterior and posterior palatine foramina.

If the cleft involves the soft palate its sides will be found to round off toward the hamular processes, and the velum to be tightly adherent to the posterior portion. The flaps cannot be brought together until the attachments of the two halves of the velum at these points are entirely

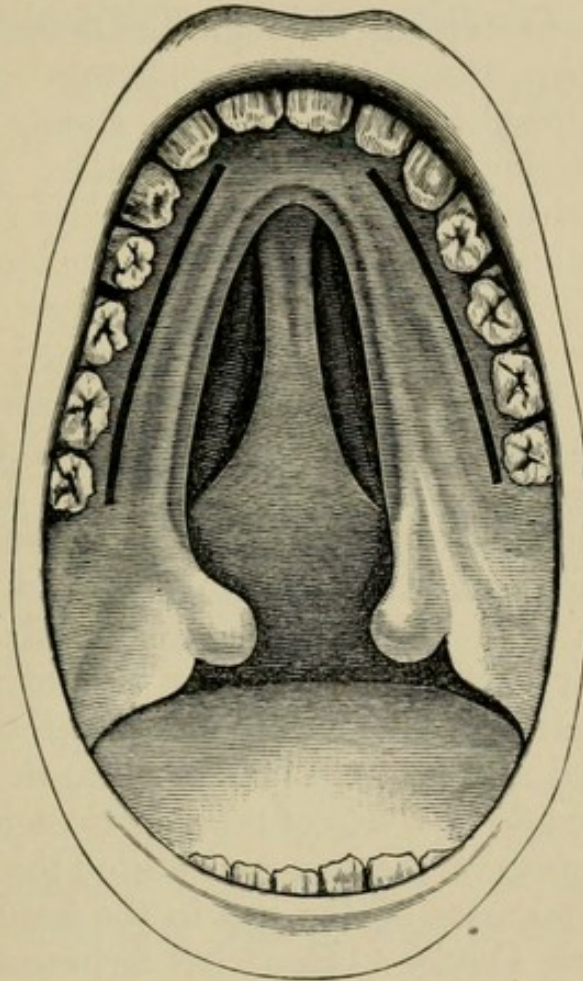
<sup>1</sup> Lannelongue : *Mém. de la Soc. de Chirurgie*, 1877, p. 470.



separated, a step which may be accomplished by means of a small, curved, sharp elevator introduced through the lateral incisions, or by the bent knife introduced through the fissure.

The bleeding during this stage of the operation is very free, but, as Ehrmann<sup>1</sup> has remarked, usually ceases as soon

FIG. 183.



Incisions in uranoplasty.

as the flaps are completely liberated. If it continues pressure should be made for a few moments with the finger, or ice applied. Trélat carries his incisions farther back, stopping from one-fourth to one-half an inch behind the posterior border of the hard palate, and entirely disregarding the posterior palatine artery.

The flaps are brought together in the median line and

<sup>1</sup> Mémoires de l'Acad. de Médecine, Vol. XXXI.



the sutures applied, beginning at the anterior extremity of the cleft. The sutures should be left in at least four days and then removed, not all at once, but by installments.

If the fissure is unilateral, the vomer remaining attached on the other side, Von Langenbeck recommends that the lateral incision along the gum should be made only upon the side occupied by the fissure. The flap on the other side should be dissected up from the median line outward.

If the fissure extends through the dental arch and is wide at the point, Rouge<sup>1</sup> recommends that one of the flaps should be detached in front also and swung in sideways upon the posterior attachment as a center.

This method of operating has practically superseded all others for closing congenital defects in the hard palate. A great number have been proposed and more or less extensively used, but are now so seldom resorted to that only a few need be briefly mentioned for purposes of reference.

Sir Wm. Fergusson's<sup>2</sup> osteoplastic method consisted in cutting through the alveolar margin of the hard palate on each side, fracturing the anterior extremity of the strips of bone covered with their muco-periosteum and uniting them in the median line. Schönborn<sup>3</sup> made a flap base down from the upper part of the posterior wall of the pharynx. It comprised all the soft parts in front of the vertebræ; this was turned and brought forward into the cleft. Lannelongue turned down a flap of muco-periosteum from each side of the septum of the nose and united the free edges to the freshened margins of the gap in the hard palate.

More recently Davies-Colley<sup>4</sup> has fashioned muco-periosteal flaps of nearly equal size from the whole of the under surface of the rudimentary palatine processes of the superior maxilla and palate bones. The pedicle of flap No. 1 occupies the whole length of one side of the cleft. The pedicle of No. 2 corresponds to the posterior border of as much hard palate as exists on that side. No. 1 is turned over into the gap, thus placing its raw surface in-

<sup>1</sup> *L'Uranoplastie et les Divisions Congénit. du Palais*, 1871, p. 108.

<sup>2</sup> *British Med. Jour.*, April 4, 1874.

<sup>3</sup> *Langenbeck's Archiv*, 1876, Vol. XIX., p. 527.

<sup>4</sup> *British Med. Jour.*, October 25, 1890, and April 28, 1894.



feriorly ; No. 2 is then slid over this raw surface as far as possible without tension, and sutured. The denuded lateral areas are left to heal by granulation.

Acquired losses of substance in the hard palate, if of any magnitude, are best treated by an "obturator" or vulcanized rubber plate, which a dentist can fit into the roof of the mouth.

### EXCISION OF THE TONGUE.

Excision of the tongue, partial or complete, may be rendered necessary by hypertrophy of the organ or by the presence of a tumor. The hemorrhage is controlled by ligation of the vessels as they are divided or by preliminary ligation of one or both lingual arteries. Langenbuch<sup>1</sup> devised a method of so placing two temporary ligatures upon the tongue that bleeding is entirely prevented during the removal by the knife of any portion of the anterior half or even two-thirds of the member. He enters the point of a well-curved needle carrying a stout ligature a little to the left of the median line of the tongue behind the part which is to be removed, passes it deeply down through the substance of the tongue, and brings it out on the right side through the floor of the mouth so as to include the branches of the lingual artery in its loop. To prevent slipping, the needle is then passed through the edge of the tongue ; another is passed in the same manner on the opposite side, and each tied tightly. The ends may then be used to draw the tongue forward.

It has also been suggested that, when it is necessary to operate very far back upon the tongue, its base can be brought forward by dislocating the lower jaw downward and forward on both sides.

The tongue is drawn well forward, the tumor or portion to be removed seized with double-pronged forceps and rapidly excised by a V-shaped incision made with a blunt-pointed bistoury so as to avoid injury to the vessels in the

<sup>1</sup> Archiv für klinische Chirurgie, Vol. XXII., Part I., 1878, p. 72.



floor of the mouth ; all bleeding points are then secured and the sides of the wound brought together with sutures.

If a larger portion, say a lateral half, of the tongue is to be removed, the operation may be done as follows : Two stout ligatures are passed through the tip, one on each side of the median line, to be used to draw the organ forward ; the tip then raised, the frænum cut with scissors, and the scissors then pushed along under the tongue and mucous membrane to free them as far back as necessary. Then the tongue is split along the median line, from before backward, completely freed from the underlying parts by tearing with the finger, the mucous membrane of the floor divided with the scissors, and the posterior section made with knife or scissors.

COMPLETE THROUGH THE MOUTH.—This operation has been extensively employed by Whitehead,<sup>1</sup> and bears his name. He does not practise a preliminary ligation of the lingual arteries, but secures them as they are divided.

The mouth is made as aseptic as possible and the face and neck shaved and cleaned. The lingual artery on each side is ligated ; and through these incisions, which may be extended if necessary, any enlarged or suspicious glands, including one or both submaxillaries, are removed. The wounds are then closed and dressed antiseptically.

After this the patient's head is placed in a more or less erect position with a slight inclination forward, to allow the blood to escape from the mouth. The jaws are held well apart with a suitable mouth-gag and a ligature passed through the tongue in the median line about an inch from the tip. With this the tongue is drawn out and up, while first the frænum and then the anterior pillar of the fauces are divided by blunt-pointed scissors. With short snips of the scissors all the muscles with the overlying mucous membrane on the under surface of the tongue are cut on a plane with the lower border of the inferior maxilla and as far back as the safety of the epiglottis permits. It may be necessary to draw the lower incisor teeth and thus gain more room for manipulating

<sup>1</sup> *Lancet*, 1881, Vol. I., p. 698.



the scissors. The tongue is then drawn upward by the ligature passed through its substance and the posterior section completed with knife or scissors. The *dorsalis linguæ* vessels can be readily secured in the stump.

**REGNOLI'S METHOD.**—Regnoli, of Pisa, published in 1838 the description of a method by which he successfully removed the anterior portion of the tongue. He made a semicircular incision through the skin along the lower border of the jaw, beginning and ending at the angles, and added a second one to it in the median line, extending to the hyoid bone. The tegumentary flaps were dissected back, and the muscles divided at their attachments to the inferior maxilla. The tongue was then drawn down through the large opening thus made, its anterior portion readily excised, and the wound closed. Billroth has revived and modified Regnoli's operation and employed it in several cases. It has the advantage of furnishing free drainage, allowing the wound to be treated antiseptically, and facilitating the removal of implicated lymphatic glands.

**BILLROTH'S METHOD.**—A semicircular incision is made along the lower border of the inferior maxilla from one angle to the other. The flap, containing the skin, fascia, and platysma, is dissected back and the lingual arteries tied beneath the hyoglossus muscle, as described on page 54.

Enlarged or suspicious glands, including the submaxillary and sublinguals, are dissected out. After transfixing the tip of the tongue with a ligature to prevent its falling back and closing the opening of the larynx, a knife is thrust up through the floor of the mouth close behind the symphysis and swept backward on both sides as far as the anterior pillars of the fauces. It should divide the mucous membrane and muscles attached to the jaw near enough to the bone to clear all disease and yet leave sufficient tissue to permit the divided muscles to be at least partially sutured in position again.

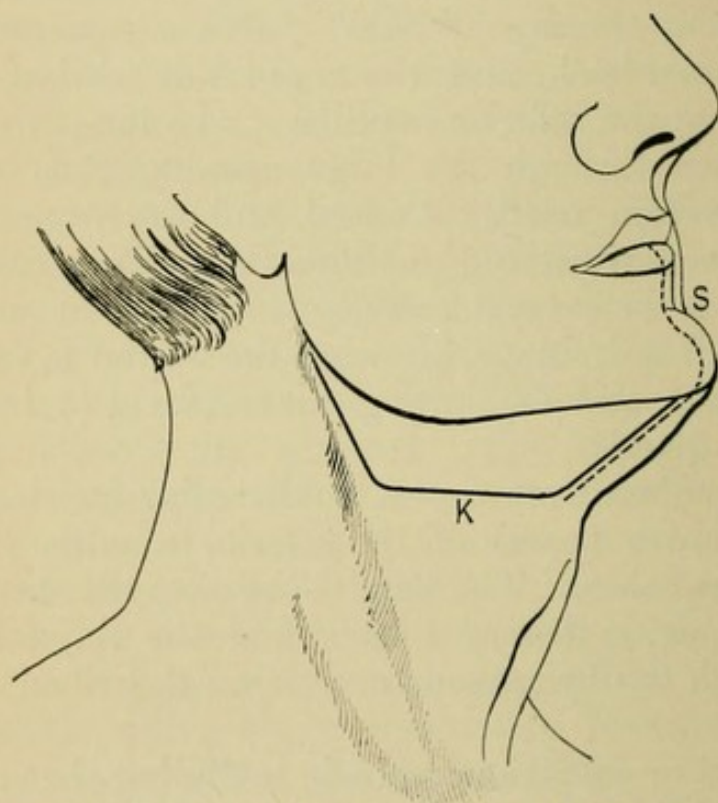
After the attachments of the geniohyoid, geniohyoglossus, and digastric muscles have been severed, together



with the anterior part of the hyoglossus, the tongue is drawn out through this gap and excised. A drain is introduced, the muscles sutured in position, and the wound closed.

**LATERAL SUPRA-HYOID METHOD.** (Kocher.<sup>1</sup>) (Fig. 184.)—This method has for its object the very thorough removal of all diseased tissues of the tongue and pharynx and all infected glands in the neck. Preliminary laryngo-

FIG. 184.



Removal of the tongue. K. Kocher's incision. S. Sédillot's incision.

tracheotomy is advantageous to facilitate the operation and permit antiseptic treatment of the wound.

The incision is made from the under border of the lower jaw near the symphysis, in the direction of the anterior belly of the digastric, to the hyoid bone, thence along its greater cornu, and then upward to the angle of the jaw; after division of the platysma and fascia the triangular flap is turned up.

The submaxillary fossa is then emptied by removal of

<sup>1</sup> *Deutsche Zeitschrift für Chir.*, 1880, 134.



the submaxillary and diseased lymphatic glands, the facial and lingual arteries and veins having been divided between double ligatures.

The larynx and œsophagus are then covered with a sponge forced in behind the tongue, and an incision made into the floor of the mouth by cutting through the mylohyoid muscle close to the jaw, and carried along the bone as far as may be necessary.

The tongue is now freely accessible through the wound, and can be drawn out through it and split, and cut off as near its base as is desirable, or it can be entirely removed in the same manner, the opposite lingual artery being readily secured when divided. The side, and even the posterior part of the pharynx, are also accessible.

The tracheotomy tube should be retained, the wound packed with antiseptic gauze, and the patient fed through an œsophageal tube.

**SÉDILLOT'S METHOD.** (Fig. 184.)—Sédillot, commenting upon Regnoli's case, expresses the opinion that the excision could have been accomplished quite as readily through the mouth, and, as he also found by experiments upon the cadaver that the tongue cannot be brought far enough forward through such an opening to facilitate excision at or near its base, he suggested and employed division of the inferior maxilla in the median line as a preliminary operation.

One of the median incisor teeth on the lower jaw having been drawn, an incision is made in the median line from the free border of the lower lip to the hyoid bone, and the jaw sawn through in the line of the incision, or, better, by two oblique lines forming a  $>$ , the apex directed to one side. The attachment of the genio-hyo-glossus muscles to the bone are next divided, the two halves of the jaw drawn apart, the tongue pulled forward and to one side, and its attachments to the hyoid bone divided on the other side, in doing which the lingual artery is divided and must be tied at once. The tissues on the other side are then divided in a similar manner, and the other lingual



artery having been tied the remaining attachments are severed and the tongue removed.

The divided maxilla is fastened together again with silver sutures passed through holes pierced in it with a drill, the sides of the incision in the lip accurately adjusted to each other, and the lower angle of the wound left open for drainage.

The bone has sometimes been divided on the side instead of in the median line.

Von Langenbeck makes an incision from the angle of the mouth vertically down to the thyroid cartilage. Through this the submaxillary and lymphatics are extirpated, the digastric and hyoglossus muscles cut through, the lingual artery tied, and the jaw sawn obliquely in front of the masseter from above downward and backward. After drawing apart the segments the mucous membrane is severed from the inner surface of the posterior one as far back as the anterior pillar of the fauces. Through this gap not only the tongue but also the tonsil and soft palate can be removed if necessary. The operation is concluded like Sédillot's.

Billroth's modification of this consists in dividing the jaw and overlying soft parts on both sides, and turning down the intermediate chin segment.

Crespi and Bastianelli<sup>1</sup> have still further modified Langenbeck's operation as follows: An incision is carried vertically down through the middle of the lower lip and chin to the lower border of the jaw, along the latter horizontally to near the angle, and thence vertically down for about an inch to the anterior border of the sterno-mastoid muscle. The soft parts are separated from the outer surface of the jaw to within an inch of the insertion of the masseter, the facial and lingual arteries ligated, the salivary and lymphatic glands removed, and the jaw divided obliquely from behind forward in front of the second molar tooth. This affords access to the retrobuccal and pharyngeal region, and permits of removal of the tonsil and adjoining parts.

<sup>1</sup> *Centralb. f. Chir.*, 1890, p. 556.



**DIVISION OF THE FRÆNUM.**

The tip of the tongue is raised upon the handle of a director, in the slit of which the frænum is engaged, and divided with curved scissors close to the director. Only the semi-transparent edge of the constricting band should be cut, and then the rest torn by pressing the tongue up toward the roof of the mouth. If the ranine vessels should chance to be divided the bleeding can be controlled by torsion or ligation or by touching the points with nitrate of silver, or, if necessary, with the actual cautery. J. L. Petit reported a case of suffocation caused by the tongue falling back upon the glottis after division of the frænum, and Guérin mentions another.

**RANULA.**

The anterior wall of the cyst should be caught up with toothed forceps and excised. A director should be passed at intervals between the sides of the incision to prevent reunion, and the filling up of the sac may be hastened by painting its interior with nitric acid or tincture of iodine. In some cases it is sufficient to pass a thread or wire seton through the cyst.

**SALIVARY FISTULA.**

Salivary fistula communicating directly with portions of the parotid gland can usually be closed by cauterization and compression, but when the fistula communicates with Steno's duct the cure is much more difficult. If the distal portion of the duct is still permeable a leaden wire may be passed through it from the mouth into the proximal portion of the duct. The saliva will follow the wire, and if the fistula does not close spontaneously its edges should be pared and brought together with sutures. The orifice of the duct is readily found opposite the second upper molar tooth.

When the distal portion of the duct is obliterated several methods may be employed. One is that of Deguise, and consists in the formation of a new channel in the



cheek for the saliva; another is that of Van Buren, and consists in the bodily transfer of the fistulous orifice from the outer to the inner surface of the cheek.

**DEGUISE'S METHOD.**—Deguise made a puncture through the fistulous opening obliquely backward to the inner surface of the cheek and passed one end of a leaden wire through it; he next made through the same opening a second puncture directed obliquely forward, brought the other end of the wire through it and tied the two ends together. The loop of the wire being thus drawn into the fistula the saliva followed its two branches into the mouth, and the fistula healed at once. Some surgeons use a silk ligature and tie it tightly so as to cut through the tissues included in the loop. Agnew's method of doing this is by the passage of a curved needle around the duct from within the mouth.

**VAN BUREN**<sup>1</sup> cured a salivary fistula, the result of a gunshot wound, by passing two fine silver wires through the skin at opposite points on its edge, then isolating the duct and fistulous opening for half an inch by dissection backward from the latter, making an incision through the wound to the inner side of the cheek, drawing the fistulous opening through it, and fastening it there by means of the wires. The gap left on the cheek was then closed with fine silver sutures.

The duct was so short, the fistula being an inch behind the anterior margin of the masseter, that it could not be brought quite to the inner surface of the cheek. The wires, however, which were left in place until the fifth week, kept open a track, which became permanent, for the passage of the saliva from the end of the duct to the mouth.

<sup>1</sup> New York Medical Journal, Vol. I., p. 53, and Contributions to Practical Surgery, 1865, p. 205.



## CHAPTER IV.

### OPERATIONS PERFORMED UPON THE NECK.

#### BRONCHOTOMY.

THIS is a general term covering operations undertaken to open the larynx or cervical portion of the trachea. These operations are: *Laryngotomy*, *tracheotomy*, and *laryngo-tracheotomy*. Laryngotomy is further subdivided into *sub-hyoid pharyngotomy* or *laryngotomy* (called *supra-laryngeal bronchotomy* by Sédillot, and *indirect laryngotomy* by Planchon), *thyroid laryngotomy* or *thyrotomy*, *crico-thyroid laryngotomy*, and *tracheotomy*, which is further subdivided into high and low, depending upon whether the trachea is opened above or below the isthmus of the thyroid gland. The names indicate the points at which the opening is made into the air-passages.

**Sub-hyoid Pharyngotomy or Laryngotomy.**—This operation, originally performed upon animals by Bichat for the purpose of studying the movements of the vocal cords, was afterward proposed by Vidal to give access to an abscess situated in the glotto-epiglottidean folds, and by Malgaigne to allow the removal of a foreign body lodged in the upper part of the larynx. It is also applicable to the removal of polyps situated at the same point and not accessible through the mouth. Follin thus removed ten from the anterior surface of the arytenoid cartilages.

The shoulders are raised and the head extended. A transverse incision two inches long, its center in the median line, is made through the skin immediately below the hyoid bone, and the platysma, sterno-hyoid, and thyro-hyoid muscles, and thyro-hyoid membrane divided. The mucous membrane lying between the epiglottis and the base of the tongue then presents in the incision, is drawn



downward with forceps, and opened with the knife or scissors. The epiglottis is then seized with a hook or pronged forceps and drawn out through the wound, freely exposing the larynx to view.

Velpeau made the first incision in the median line, divided the thyro-hyoid membrane transversely, and then plunged the knife backward and downward, making a vertical incision in the base of the epiglottis through which he passed the blades of a pair of forceps and withdrew the foreign body.

*Aplavin*<sup>1</sup> has modified this operation as follows : With the head well extended the trachea is opened and plugged by a tampon-canula—a tracheotomy tube surrounded by a rubber bag, which is inflated after its introduction till it fills the lumen of the trachea. The pharynx is incised transversely as above described and the hyoid bone cut through with scissors on each side from one-half to three-quarters of an inch in front of its extremities. If there is fear of wounding the lingual vessels a part of the hyoglossus muscle is cut close above the hyoid bone and the vessels recognized and drawn up. By raising this segment of bone and depressing the thyroid cartilage, pretty free access can be obtained to the parts close around the opening of the larynx.

At the conclusion of the operation the mucous membrane is sutured first ; then external to it a silk suture is passed on each side through the skin and upper border of the thyroid cartilage behind and over the hyoid bone about one-half an inch in front of its points of division. After uniting the thyro-hyoid membrane and overlying soft parts the two silk ligatures are knotted externally and thus prevent undue tension on the other sutures.

**Thyroid Laryngotomy or Thyrotomy.**—In this operation the thyroid cartilage is divided vertically in the median line, between the anterior attachments of the vocal cords. It is suitable for the removal of foreign bodies or polyps from the interior of the larynx and for fractures, stenosis, or disease of this organ.

<sup>1</sup> Archiv f. klin. Chir., Vol. XLI., p. 324.



The head is well extended, or allowed to hang from the edge of the table. A preliminary tracheotomy and plugging of the trachea may be necessary.

Steadying the larynx with the thumb and forefinger of his left hand, the surgeon makes an incision along the projecting angle of the thyroid cartilage in the median line, from its upper border to the cricoid cartilage. As soon as the crico-thyroid membrane is exposed, he makes a small opening in it near its upper border and passes one blade of a strong blunt-pointed pair of scissors through it to the upper border of the larynx, keeping exactly in the median line, and thus divides the thyroid cartilage throughout its entire length. Or a grooved director may be passed through the opening made in the crico-thyroid membrane, and the cartilage divided upon it with a curved bistoury. Or, again, the division may be made with the knife, layer by layer, from before backward; but whenever possible the upper border of the larynx should be left uncut to preserve the relation of the vocal cords.

The conoid and thyro-hyoid ligaments and thyro-hyoid membrane must often be separated to a greater or less extent from the upper and lower border of the thyroid cartilage to permit its lateral halves to be retracted sufficiently to expose thoroughly the cavity of the larynx.

At the conclusion of the operation the wound may either be closed immediately with silk or silver-wire sutures, or left open and packed for a couple of days.

**Crico-thyroid Laryngotomy.**—In this operation the opening is made in the crico-thyroid membrane. The French writers, Sédillot, Dubrueil, Chauvel speak of this method as having been entirely abandoned because the opening cannot be made sufficiently large. Holmes, on the other hand, considers it suitable in all cases in which only the vocal cords or the tissues above them are involved, and says it is practiced in spasm of the glottis from any cause, in erysipelatous affections spreading down the throat, and in cases of foreign body lodged in or above the glottis. If the opening proves to be too small it can be enlarged



downward through the cricoid cartilage (laryngo-tracheotomy). The operation may be required in cases of urgency when no tube is at hand. A pair of forceps or scissors, a hair-pin, or pieces of bent wire will suffice to keep the wound open, and the incision can be made with a penknife.

**Operation.**—Dorsal decubitus, shoulders raised upon a cushion or narrow pillow so that the head may fall back and keep the throat tense. The surgeon, standing at the patient's right side, fixes the larynx with his left thumb and middle finger placed on either side, and the index upon its upper border, and makes a cutaneous incision in the median line corresponding to the crico-thyroid membrane. He draws the sterno-thyroid muscles apart, lays bare the membrane, and divides it transversely or vertically; in the latter case the incision should begin a short distance below the inferior border of the thyroid cartilage, so as to avoid a small artery which crosses at that point, and extend to the cricoid cartilage. (For the method of inserting the canula, see *Tracheotomy*.)

**Laryngo-tracheotomy.**—The opening occupies part of the crico-thyroid membrane, the cricoid cartilage, and the first two or three rings of the trachea. The upper border of the isthmus of the thyroid usually corresponds to the second ring of the trachea; it should not be divided. In children under six years it commonly rises to the lower border of the cricoid cartilage.

Dorsal decubitus, with shoulders raised, head thrown back, and neck slightly stretched. The larynx is fixed as for crico-thyroid laryngotomy, and an incision made through the skin exactly in the median line from the middle of the thyroid cartilage to about one inch below the cricoid. The muscles are carefully drawn apart, the isthmus of the thyroid depressed if necessary, after nicking and tearing with blunt hooks the suspensory fascia at its upper border, the trachea steadied and drawn upward with a sharp hook thrust into the upper part of the crico-thyroid membrane, and the point of the bistoury entered close below the hook and made to cut downward through



the cricoid cartilage and one or two of the rings of the trachea. The edges of the incision are then held apart and the canula introduced, or the forceps if the operation has been undertaken with a view to the removal of a foreign body or a polyp.

**De Saint Germain's Method.**—Dorsal decubitus, shoulders raised, neck extended. The surgeon feels for the cricoid and thyroid cartilages, and the depression between them. Then, standing upon the patient's right side, he places his left thumb and middle finger on either side of the larynx, and by pressing them in between it and the vertebral column, pushes the larynx forward, makes tense the skin covering it, and at the same time marks the situation of the lower border of the thyroid cartilage with the nail of his left forefinger.

The knife, a straight, sharp-pointed bistoury, is held like a pen, its back directed upward, and the middle finger so placed upon its side as to limit to half an inch the depth to which the point can penetrate. It is then entered with a quick sharp stab in the median line close against the nail of the left forefinger and made to cut downward with a sawing motion through the cricoid cartilage and one or two tracheal rings, care being taken to make the incision in the skin fully as long as that in the trachea. The wound is held open with a "dilator," and the canula introduced between its branches; the pressure of the latter is usually sufficient to arrest hemorrhage, but ligatures can be easily applied if necessary. In only one case out of ninety-seven did Saint Germain injure the posterior wall of the trachea, and in only three did hemorrhage occur.<sup>1</sup>

**Tracheotomy.**—The trachea may be opened at any point between the cricoid cartilage and the upper border of the sternum, a distance averaging in the adult from two and one-half to three inches, in the child under ten years of age from one and one-half to two and one-half inches. Its course is obliquely backward as well as downward, so that while its upper end is almost subcutaneous it be-

<sup>1</sup> Bull. de la Société de Chirurgie, 1877, pp. 271 and 327.



comes deeply placed before it passes behind the sternum. It is crossed at its upper end by the isthmus of the thyroid gland, the breadth, thickness, and vascularity of which vary within very wide limits, although its upper border usually corresponds to the second ring of the trachea. A communicating branch uniting the two inferior thyroid arteries crosses just below the lower border of the isthmus. The lower portion is covered anteriorly by the thyroid veins, always greatly distended when the respiration is obstructed, and by the thymus gland in children under two years of age, and occasionally in unhealthy older ones.

To the dangers depending upon the normal arrangement of the parts are added those of not infrequent anomalies in the origin and course of the arteries and veins. Thus, the left brachio-cephalic vein may cross the trachea well above the sternum, the left carotid may arise from the innominate, and sometimes a thyroidea ima artery is given off from the transverse portion of the arch of the aorta, and ascends along the anterior surface of the trachea in the median line. Finally, an aneurism of the innominate, or of the arch of the aorta, may rise in front of this portion of the trachea.

**Operation.**—The patient is placed upon his back with shoulders raised and head thrown back. A trustworthy assistant, standing behind the head, holds it firmly in a straight line with the body; others control the patient's limbs if he has not been anæsthetized. The surgeon, standing at the patient's right side, recognizes with his finger the hyoid bone and thyroid and cricoid cartilages, and, marking with his left forefinger the upper border of the cricoid cartilage, makes an incision downward from it in the median line from one and one-half to two inches in length, according to the size of the patient. He carries the incision through the skin and fascia, separates the sterno-hyoid and sterno-thyroid muscles with the handle of his knife, and lays bare the isthmus of the thyroid. If any large veins are encountered, they must be carefully drawn aside or divided between two ligatures, but bleed-



ing from smaller ones may be safely disregarded, for, as Trousseau pointed out, it will cease as soon as the trachea is opened, and the venous congestion relieved by the admission of air to the lungs.

It is well to have one or two assistants hold the sides of the incision apart during the dissection, if they can be depended upon to do so without disturbing the relations of the parts by drawing too forcibly toward one side or the other.

The isthmus of the thyroid is next drawn upward with a blunt hook, and three or four rings of the trachea exposed below it, and divided from below upward. If for any reason it is desirable to make the incision higher up, or if the isthmus is unusually broad, it may be divided between two ligatures, in which case the incision of the trachea should be made from the lower border of the cricoid cartilage downward.

The incision in the trachea should always be free enough to admit the canula readily, and should be made by a quick thrust with a sharp-pointed knife, which must be prevented from penetrating too deeply at first, by holding it close to its point. After the puncture has been thus made, it is enlarged by gentle sawing movements of the knife, or with scissors.

The knife is retained in the trachea as a guide, until the dilator has been introduced. The best dilator is the three-bladed one; it is introduced closed, its blades then expanded, and the permanent canula passed in between them. The canula should be curved, double to facilitate cleaning, and provided with an opening on its convexity through which the expired air can pass to the larynx.

Some surgeons steady the trachea by drawing it toward the chin with a tenaculum introduced at the lower edge of the cricoid cartilage. Gurdon Buck used for this purpose a rather narrow lance-shaped knife, bent at a right angle on the flat, and also grooved on the back for use as a director.

**Galvano- or Thermo-cautery.**—The danger of hemorrhage, especially in the adult, has led many surgeons to



use the galvano- or thermo-cautery. Its hemostatic advantages, however, are offset by a large eschar which it causes, and the possible necrosis of the tracheal cartilages.<sup>1</sup> The cautery should be used only to divide the soft parts, the trachea should be opened with the knife.

### LARYNGECTOMY.<sup>2</sup>

**Complete.**—A preliminary tracheotomy is necessary. A pad is placed under the shoulders and the head thrown well back. The incision is in the median line, and extends from the thyro-hyoid space to the second or third tracheal ring. A transverse incision joins this at the upper end and passes outward parallel to the hyoid bone as far as each sterno-mastoid muscle. The skin, fascia, and platysma are drawn aside and the superior thyroid arteries secured at the posterior margin of the thyro-hyoid muscle beneath the sterno-hyoid close to the upper border of the thyroid cartilage. Next the inferior thyroid arteries are ligated below, beneath the posterior edge of the sterno-thyroid muscles.

By means of a periosteal elevator or blunt-pointed scissors entered beneath the fascia in the middle line the crico-thyroid, sterno-thyroid, and thyro-hyoid muscles on each side are detached and retracted with the other soft parts. The thyroid cartilage is drawn first to one side and then to the other, and the inferior constrictor muscle separated. All cutting should be done with the blunt-pointed scissors kept close to the cartilages. The superior laryngeal nerves and the thyro-hyoid membranes and ligaments are divided, the epiglottis drawn out and its extra-laryngeal attachments cut. The larynx is next pulled forward and separated from any remaining connection with the pharynx or œsophagus to a point just below the cricoid cartilage. Great care is necessary to avoid opening the œsophagus. The trachea is secured from slipping down by a temporary suture on each side and is cut across below the

<sup>1</sup> See the discussion in the *Société de Chirurgie*, May 9 to June 13, 1877.

<sup>2</sup> Hahn, *Volkmann's Sammlung*, 1885, No. 260.



cricoid cartilage. The divided end is secured at the surface in the wound with interrupted silk sutures and the mucous membrane sutured to the margins of the skin incision.

When there is doubt about the extent of the laryngeal disease, the thyroid cartilage should be split in the middle line as soon as it has been exposed. This is done by steadying the larynx and cutting from before backward with the knife or from below upward with blunt-pointed scissors entered through the crico-thyroid membrane. If then on inspection it is found that the whole larynx must be sacrificed the operation is proceeded with as already described. It is usually recommended to remove the cricoid cartilage in all cases of total extirpation, as it is of no functional value and its retention interferes with the act of swallowing.

**Partial.**—An incision is made in the median line as in total laryngectomy, and from its upper end a second is made parallel to and just below the hyoid bone on the affected side as far as the sterno-mastoid muscle. This involves the skin, fascia, and platysma. The thyroid cartilage is then divided vertically exactly in the median line with the knife or scissors.

After separation of the alæ Mr. Butlin<sup>1</sup> advises, if the disease is of limited extent, that it be cut away, with a wide margin of healthy tissue, meaning that it be scooped out of the concavity of the ala with the surrounding mucous membrane. The ala of the thyroid is then restored to its place. Mr. Butlin claims that cancer does not infiltrate the cartilage, and therefore it is only necessary to scrape and cauterize the part adjacent to the disease.

If one-half of the thyroid cartilage must be removed, the sterno-thyroid muscle is cut at its upper end and laid back. The thyro-hyoid, sterno-thyroid, and crico-thyroid muscles are carefully detached with the elevator or blunt-pointed scissors. The thyroid and crico-thyroid membranes and superior laryngeal nerve are cut close to the cartilage, and vessels are secured as they are divided.

<sup>1</sup>Op. Surg. Malig. Disease.



The superior cornu of the thyroid cartilage is cut through at its base. The whole or part of the epiglottis is left and the aryteno-epiglottic fold of mucous membrane spared as much as possible. The pharyngeal wall must be freed with great care. The inferior cornu is divided, any remaining attachments severed with short snips of the scissors and the ala removed.

The parts are then sutured in their proper positions as nearly as possible after placing over the denuded surface all the mucous membrane obtainable.

### PHARYNGOTOMY.

This is an operation required for the removal of foreign bodies or diseased tissue from the pharynx or immediately adjoining parts which are not accessible through the mouth. Langenbeck's (page 354), or the Crespi-Bastianelli methods (page 354), for reaching the base of the tongue are also useful for exposing the tonsil and posterior pharyngeal wall. Aplavin's sub-hyoid pharyngotomy (page 358) gives a somewhat limited view of the parts around the entrance to the larynx.

Gaps left after excision of portions of the wall of the pharynx must be left to granulate; if the epiglottis has been disturbed its attachments must as far as possible be replaced and sutured in their proper position.

VON LANGENBECK'S METHOD.<sup>1</sup>—After a preliminary tracheotomy the head is extended and chin turned to the side opposite to the one to be operated upon. The incision extends from the middle of the lower border of the body of the inferior maxilla downward across the greater cornu of the hyoid bone along the posterior border of the thyro-hyoid muscle to the cricoid cartilage or a little further. After division of the superficial fascia, platysma, and omohyoid, the lingual, and superior thyroid arteries and facial vein are cut and secured. Both branches of the superior laryngeal nerve are divided. After freeing the attachments of the digastric and stylo-hyoid from the hyoid bone the pharynx is laid open through the whole

<sup>1</sup> Archiv f. klin. Chir., 1879, Bd. 24, p. 825.



length of the wound. The thyroid cartilage can be turned on its long axis so that its posterior surface is visible in the wound and the pharynx is accessible as high as the soft palate.

Another method of the same surgeon's is as follows: A U-shaped flap of skin and subcutaneous tissue is made, the base of which is above and corresponds in width to the length of the zygoma. Its sides and bottom follow the anterior border of the masseter muscle, the posterior border of the ramus, and the intervening portion of the lower border of the jaw, respectively. The inferior maxilla is sawn through in front of the insertion of the masseter, and the ramus dislocated by turning it outward and upward.

Butlin<sup>1</sup> describes an operation by Czerny, which is virtually the same as Von Langenbeck's for excision of the tongue. The incision extends from the angle of the mouth to the extremity of the hyoid bone, and the jaw is sawn through obliquely from above and without downward and inward between the second and third molar teeth.

MIKULICZ'S METHOD.<sup>2</sup>—After a preliminary tracheotomy and plugging of the fauces or larynx an incision is made from the tip of the mastoid process to the level of the greater cornu of the hyoid bone. The periosteum and overlying parts are raised from the outer and inner surface of the ascending ramus of the inferior maxilla, special care being taken to avoid injury if possible to the facial nerve, parotid gland, and external carotid artery. The ascending ramus is then divided horizontally just above the angle, and partially or entirely excised after severing the tendon of the temporal muscle.

After drawing aside the body of the jaw, together with the masseter, internal pterygoid, digastric, and stylo-hyoid muscles, the region of the tonsil is exposed. The lateral wall of the pharynx is then incised and access thus obtained to the palate, base of the tongue, and posterior

<sup>1</sup> Operat. Surg. Malig. Disease.

<sup>2</sup> Deut. med. Wochens., 1886, Vol. XII., p. 157.



pharyngeal wall as far up as the naso-pharynx. If the digastric muscle and hypoglossal nerve are divided the entrance of the larynx can be reached. The disease is removed with the knife or scissors, the mucous membrane drawn together, and the wound closed and drained.

**CHEEVER'S METHOD.**—An oblique incision is made from the lobule of the ear downward along the anterior border of the sterno-mastoid muscle to the hyoid bone or below it. A second is carried forward from this along the lower border of the body of the inferior maxilla. The tissues are divided layer by layer, and the vessels secured. Enlarged lymphatic glands are removed as they are encountered. The branches of the facial nerve are recognized and drawn to one side. The hypoglossal nerve lies behind and in the lower end of the incision, and is drawn outward and backward with the great vessels. The glossopharyngeal nerve lies anteriorly.

The fascia investing the posterior part of the submaxillary gland is slit up, and the facial artery tied. The digastric and stylo-hyoid muscles are divided, the submaxillary gland drawn forward and the parotid up, and the wall of the pharynx thus exposed.

The tonsil and the surrounding mucous membrane are then removed. Bird<sup>1</sup> dispensed with the incision along the lower border of the jaw, but slit the cheek from the angle of the mouth to the angle of the jaw and removed the tonsil, using one finger in the mouth for a guide.

### **ŒSOPHAGOTOMY.**

The œsophagus begins in front of the sixth cervical vertebra in the median line, or just behind the cricoid cartilage; at first it inclines slightly toward the left, then returns to the median line as it passes behind the sternum, inclines to the right at the arch of the aorta, and again to the left as it approaches the diaphragm. The left recurrent laryngeal nerve lies between its cervical portion and the trachea, the right recurrent nerve lies upon its outer side. It is covered anteriorly by the trachea and left

<sup>1</sup> Clin. Soc. Trans., Vol. XVI., p. 9.



lobe of the thyroid gland, and crossed by the left inferior thyroid artery and vein. The guide to it is the trachea.

**Internal Œsophagotomy.**—Dr. Sands employed an instrument constructed on the principle of the Otis urethrotome. It consisted of a long shank carrying a bulb with a sheathed knife which could be made to project not more than an eighth of an inch from the surface of the enveloping bulb by turning a screw in the handle. Other surgeons have used similar instruments, but on account of the danger of perforating the œsophagus operations performed by the knife from the interior of the organ have been practically abandoned in favor of Abbe's "string saw" method,<sup>1</sup> which is one of combined dilatation and division.

It is used for cicatricial strictures which are undilatable and generally impermeable to any instrument passed from above, but which reason and experience have shown may be passed from below, where the tube is contracted and funnel-shaped, while above it is dilated and pouched.

Gastrostomy is first performed, the opening into the stomach being made large enough to admit two fingers with the exploring instrument to the cardiac orifice of the stomach. Into the latter a bougie carrying a long silk cord is passed and brought out at the mouth; the other end of the cord remains in the abdominal wound. Then the stricture is made tense by engaging a conical bougie in it, and the string, held well back at either end in the pharynx and stomach, is drawn tight and sawed up and down a few times. After this bougies are passed up to the largest size or till firm resistance is encountered. In Abbe's first case external œsophagotomy was performed, and after division and dilatation of the stricture as above described a rubber tube was drawn up from the stomach and wedged into the contraction for twenty-four hours, thus maintaining the dilatation.

When there is no further trouble in the passage of bougies from above, the gastrostomy wound is closed, but instruments must subsequently be introduced through the

<sup>1</sup> New York Medical Record, February 25, 1893.



stricture at regular intervals till the danger of recontraction is over.<sup>1</sup>

**External Œsophagotomy.**—The operation of external œsophagotomy may be required for the relief of stricture, or the removal of a foreign body. In the former case, it may be performed above or at the level of the stricture for the purpose of dividing or dilating it, or below the stricture so as to allow the introduction of food into the stomach. The left side of the œsophagus is more accessible in the neck than the right, and the incision may be made in the median line or parallel to the inner border of the sterno-cleido-mastoid muscle. As the walls of the œsophagus are flaccid, a guide should be used if it is possible to introduce one. A sufficiently convenient one is a pair of long curved forceps, or even a urethral sound, introduced through the mouth; the point can be made to press the wall toward the approaching knife.

**Lateral Incision.**—Dorsal decubitus, head extended, face turned slightly to the right. The surgeon, standing at the patient's left, makes an incision through the skin, subcutaneous cellular tissue, and the platysma a little on the inner side of the inner border of the sterno-cleido-mastoid from a point one inch above the sternum to the level of the upper border of the thyroid cartilage. If the external or anterior jugular is encountered, it must be drawn aside or divided between two ligatures. The fascia is then divided, the omo-hyoid muscle drawn aside, and then the side of the thyroid gland followed downward. The sterno-cleido-mastoid and the great vessels are drawn outward with a blunt hook, the trachea and thyroid gland to the right, and then the surgeon, working with blunt instruments, separates the tissues at the bottom of the wound and exposes the œsophagus, which can be recognized by its flattened appearance and thick wall. If more room is needed, the sternal head of the sterno-cleido-mastoid must be divided. Then a guide is introduced through

<sup>1</sup> A résumé of this operation with a report of cases and description of the various expedients which may be necessary will be found in the *Annals of Surgery*, March, 1895, p. 253. Dr. Woolsey.



the mouth, and the wall of the œsophagus pressed up at the bottom of the wound. The surgeon, having satisfied himself that the recurrent laryngeal nerve and inferior thyroid artery are out of the way, punctures the œsophagus by picking it up with two hooks or toothed forceps and cutting between them, and enlarges the opening with scissors or a blunt-pointed bistoury.

At the close of the operation the wound in the œsophagus is closed with catgut, that in the overlying parts being left open and packed; the patient is fed by the rectum or with the stomach tube for several days; or a tube, through which the patient should be fed for several days, is passed through the wound well into the œsophagus and carefully packed about. The capital point is to insure drainage of the wound which will certainly be infected from the œsophagus during the operation or shortly thereafter.

If a permanent fistula is desired (below a malignant contraction, for instance) the margins of the cutaneous and œsophageal wounds are united with sutures.

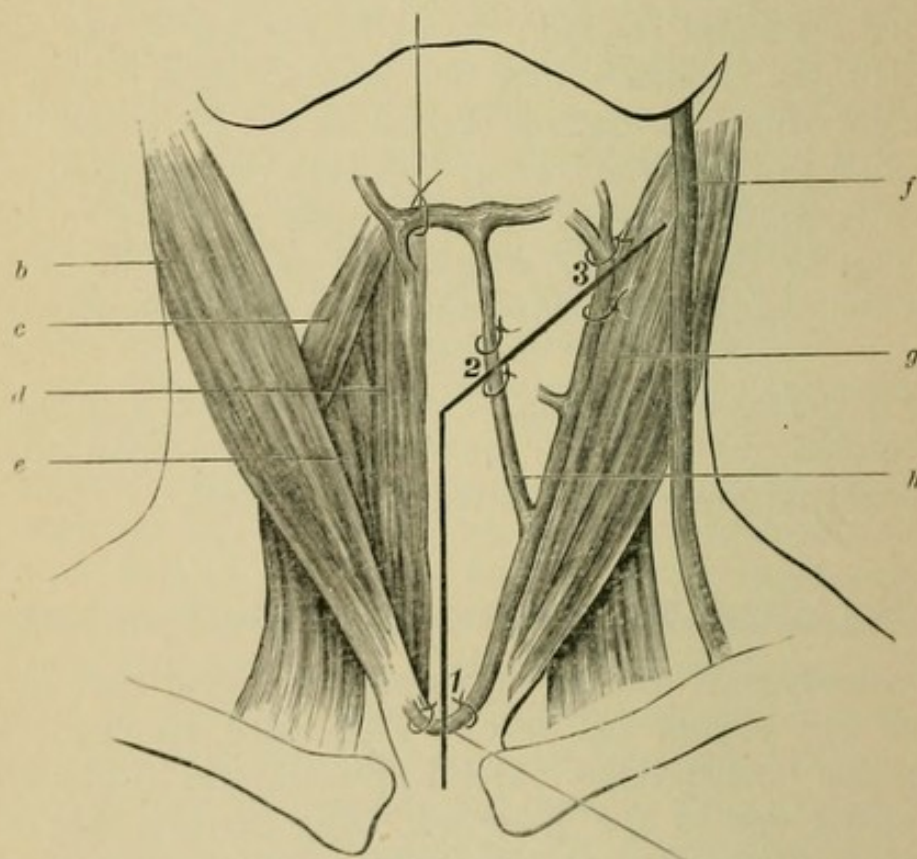
### THE OPERATIONS ON THE THYROID GLAND.

**Anatomy.**—Normally the isthmus is about half an inch broad and covers the second and third tracheal rings, while the lateral lobes extend upward and backward to the lower end of the pharynx, lying on each side of the larynx, and downward, in contact with the upper end of the œsophagus. The thyroid is enveloped by the fascia of the neck and possesses a capsule enclosing the gland tissue proper. When enlarged the organ is covered with a plexus of veins; the most constant and important of these are represented diagrammatically in Figs. 185 and 186 and need no further explanation. The gland is overlapped by the sterno-mastoid and has resting on its surface the sterno-hyoid, omo-hyoid, and sterno-thyroid muscles in this order from before backward. One or more accessory thyroids may be found above or below the lateral lobes, and it should be noted that the latter may, when



enlarged, extend downward behind the sternum. The lateral lobes overlap the great vessels of the neck with their accompanying nerves, and are in contact at their lower posterior portions with the inferior thyroid artery, the recurrent laryngeal nerve, and middle cervical ganglion of the sympathetic. The artery passes horizontally inward from the inner border of the scalenus anticus

FIG. 185.



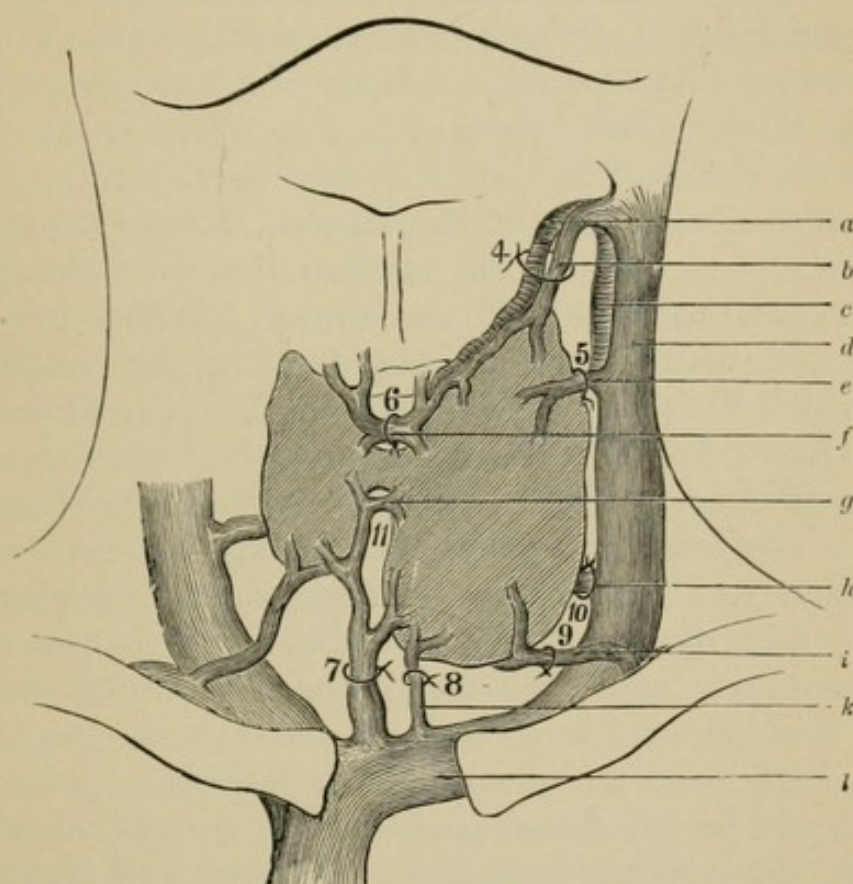
*a.* Chin. *b.* Sterno-mastoid. *c.* Omo-hyoid. *d.* Sterno-hyoid. *e.* Sterno-thyroid. *f.* Vena jugularis ext. *g.* Vena jugularis obliqua. *h.* Vena jugularis ant. *i.* Vena jugularis inf. communicans. *j.* Vena jugularis sup. communicans. 1, 2, 3. Double ligatures applied to the above-mentioned veins in the line of the incision. (KOCHER.)

muscle about half an inch below the carotid tubercle, then forward on the œsophagus and trachea, and divides into an ascending and descending branch. At its point of bifurcation it is crossed (in front or behind) by the recurrent laryngeal nerve, and at the inner border of the scalenus anticus the middle cervical ganglion lies directly upon it. Great care is necessary in securing the artery in order to avoid injury to these structures; paralysis of



one recurrent nerve produces paralysis of the corresponding vocal cord, of both nerves, severe dyspnœa, which may end fatally if not relieved by tracheotomy; injury to the sympathetic at this point destroys the three cardiac branches which are given off here or just below. The operations which are considered justifiable are removal of a *portion* of the gland, enucleation of the same, and liga-

FIG. 186.



a. Sup. thyroid artery. b. Sup. thyroid vein. c. Carotid artery. d. Internal jugular vein. e. Accessory sup. thyroid vein. f. Sup. communicating thyroid vein. g. Inf. communicating thyroid vein. h. Accessory inferior thyroid vein. i. Inferior thyroid vein. k. Thyroidea ima veins. l. Left innominate vein. The numerals indicate the points where the above-mentioned veins are ligated.

tion of the afferent arteries, the latter being applicable to rapidly growing, vascular (not fibrous or cystic) goitres in young subjects.

**Ligation of the Arteries.**—On account of the danger of a general atrophy only the vessels in immediate connection with the enlarged part should be secured, the superior and inferior thyroid arteries of one side, for example. Then



if this fail the others, starting with the nearest, may be successfully tied. The superior arteries are exposed and ligated as described on page 41, and the inferior preferably by Drobeck's method (p. 42), especially if the gland is much hypertrophied.

**Enucleation of a Portion of the Gland.**—Some cases of sharply defined tumor of the thyroid, such as cystic goitre, need only a longitudinal incision over the most prominent part of the growth with division of the tissues layer by layer, and ligation of the vessels encountered till the gland is reached. The capsule and layer of gland tissue (sometimes no thicker than a sheet of paper) overlying the tumor is then divided and the latter shelled out.

**Removal of a Portion of the Thyroid Gland (Kocher).**—The incision extends in the median line from the sternal notch to the upper limit of the tumor. From this point it runs obliquely toward the angle of the jaw on the side from which the affected half of the gland is to be removed (Fig. 185). If the entire gland is to be removed, a procedure which must be seldom justifiable, the oblique incision is made on both sides, thus giving the skin-cut the form of a Y. The integument, fascia, and platysma are divided and the flaps turned back. The sterno-hyoid, sterno-thyroid, and omo-hyoid muscles, which may be much thinned and stretched out over the surface of the tumor, will have to be cut. If adherent to its surface they should be lifted and pushed aside with blunt-pointed scissors or a periosteal elevator. A plexus of large thin-walled veins, which tear very easily, will be found lying close over the surface of the enlarged gland, and should be divided separately between double ligatures. The anterior surface of the growth is thus cleared and the lateral aspect approached. The sterno-mastoid muscle is retracted and the common carotid artery and internal jugular vein are carefully freed with a blunt instrument. The superior thyroid artery is secured at the upper extremity of the tumor and, together with the accompanying veins, divided between a double ligature. It is generally recommended to cut the branches of the inferior thyroid artery close to



the tumor and secure each as it is divided, as in this way there is less danger of injuring the recurrent laryngeal nerve which is in close relationship with it on each side. Furthermore, on the left side the main portion of the artery lies in contact with the œsophagus ; and the thoracic duct, which is at first posterior to the artery, arches over it to reach the left subclavian vein. Or the trunk of the inferior thyroid artery may be tied, preferably by Drobeck's method, as described on page 42.

The dissection is continued close to the capsule, which must nowhere be opened ; every vessel, as it is encountered, is tied and cut separately after careful inspection, and the lateral surface of the tumor cleared. Its margin is lifted up, starting at one side above and working downward and inward ; the trachea and œsophagus are separated with special regard for the recurrent laryngeal nerve which lies in the groove between these structures. Thus the dissection is carried from the side as far as the middle line posteriorly. The gland is then drawn forward and upward. The vessels entering it from below are secured and divided and the gland removed.

**Removal of the Isthmus.**<sup>1</sup>—A median longitudinal incision is employed. It extends from the upper to the lower border of the enlarged isthmus and involves the integument and superficial fascia. The anterior jugular vein, if encountered, is secured and cut between a double ligature. The interval between the sterno-hyoid and sterno-thyroid muscles is opened up and the muscles drawn aside. The isthmus is exposed after ligating separately each one of the enlarged veins which may be encountered in front of it. It is then freed on its upper and lower border and posteriorly with a blunt instrument. The capsule itself must not be opened and every vessel should be tied as it is encountered.

An aneurism-needle threaded with a double ligature is then made to perforate the isthmus on each side from behind forward at its junction with the lateral lobes, the ligatures are tied, and the intermediate segment of the isthmus removed.

<sup>1</sup> Jones : *Lancet*, 1875, Vol. I., p. 120.



## CHAPTER V.

### OPERATIONS UPON THE THORAX.

#### AMPUTATION OF THE BREAST.

THE patient is placed upon her back, inclined somewhat toward the opposite side, and the arm abducted so as to make the skin and pectoral muscle tense. Two curved incisions are made, enclosing an elliptical strip of skin of greater or less breadth according to the extent of its implication in the disease, the long axis of which is directed toward the axilla; that is, upward and backward. The upper and lower skin flaps are then dissected off the anterior surface of the gland, its upper border turned, exposing the pectoral muscle, and the loose cellular tissue between it and the muscle rapidly divided with a few strokes of the knife, beginning at the upper border of the inner angle, while the gland is drawn away from the chest wall, and the removal completed along the lower incision, or at the axillary angle of the wound.

Bleeding during the operation must be controlled by clamps upon the bleeding points, and the vessels secured afterward with ligatures or by torsion. The incision is then prolonged just posterior to the anterior fold of the axilla, up to the arm. The axillary vein is exposed at the outer end of the incision, where it is most superficial and is kept constantly in sight as the dissection progresses. The axillary glands whether perceptibly enlarged or not, together with the surrounding fat and connective tissue, are removed *en masse*.

HALSTED'S OPERATION.<sup>1</sup>—Halsted's method, in which the greater part of the pectoralis major is systematically

<sup>1</sup> Annals of Surgery, 1894.



removed in all cases of carcinoma, is now generally employed, with or without modifications of the skin incision. The main incision broadly encircles the nipple and involved skin and is prolonged to the arm along the front of the anterior fold of the axilla; a second incision passes from the outer part of the first toward the middle of the clavicle. The skin flaps are dissected back, and all the narrower part of the pectoralis, except, perhaps, the fibers coming from the clavicle, is divided close to the humerus. The muscle, with the overlying gland, is then cut away from the chest, the pectoralis minor divided if necessary, and then a very clean dissection made of the axilla, removing all the fat and lymphatic glands and the bundle of tissue connecting them with the mamma and pectoralis major.

#### PARACENTESIS OF THE THORAX.

Each of the lower posterior intercostal arteries enters its corresponding intercostal space near the spinal column, and passes obliquely from below upward across the space to shelter itself in a groove on the inner side of the lower border of the upper rib. It occupies this groove until it reaches the anterior third of the space, when it leaves it to anastomose with the branches of the anterior intercostal artery coming from the internal mammary. At this point, however, it is so small that its division is not of much consequence. The only part of its course where its injury is to be feared is in the posterior third of the intercostal space before it has passed behind the lip of the rib. Consequently, if an opening is to be made into the pleural cavity, either with a knife or trocar, a point in the middle third of one of the intercostal spaces should be selected, preferably the seventh, certainly not higher than the sixth, nor lower than the eighth on the right side, the ninth on the left.

After determining the position of the intercostal space, often a matter of considerable difficulty in consequence of the infiltration of the parts, make an incision parallel to it, one or one and one-half inches in length. Divide the



tissues layer by layer, until the rib can be distinctly felt with the finger introduced into the wound. Place the end of the finger upon the upper border of the lower rib, and, keeping the knife close to the border, divide the muscles and pleura.

If a trocar or the aspirator is used, it must be thrust in with a sharp push so as certainly to penetrate the pleura, which is often thick and tough. The outer end of the canula is then connected with a Dieulafoy or Potain aspirator by means of a rubber tube and the effusion drawn off. A better method is to make use of the principle of the siphon. After filling the canula and tube, previously rendered aseptic and filled with sterilized water, the end of the tube is occluded and the canula thrust into the pleural cavity. The tube is then conducted beneath the surface of a 1:50 solution of carbolic acid below the level of the patient's bed, and released, thus siphoning off the liquid in the chest.

#### PARACENTESIS OF THE PERICARDIUM.

Normally the pericardium is in contact with the chest wall only in the median line under the sternum; but when its sac is distended with liquid the area of contact becomes much larger, especially by extension downward and to the left. The heart is at the same time pressed upward and backward. The limits of the pericardium can be ascertained with great accuracy by percussion and auscultation, and this should always be done before puncturing. At the point selected for puncture the pulsations of the heart should be imperceptible, or at least very faint, and it should be absolutely flat on percussion. It should also be remembered that the internal mammary artery runs parallel to the side of the sternum, and a finger's breadth from it.

If the knife is used the tissues must be divided layer by layer, and the finger should always be introduced into the wound before the pericardium itself is incised, to make sure that the heart is not in contact with it.



## CHAPTER VI.

### OPERATIONS UPON THE ABDOMINAL WALL, STOMACH, AND INTESTINES.

#### PARACENTESIS OF THE ABDOMEN.

IN order to avoid injury to the different viscera, and especially to the internal epigastric artery, which runs from the middle of Poupart's ligament toward the umbilicus, the puncture should be made either in the median line midway between the umbilicus and the symphysis pubis, or midway between the umbilicus and the anterior superior spine of the ilium. The instrument used is a trocar and canula or the needle of an aspirator. The depth to which it shall be allowed to penetrate is regulated by the finger placed upon its side, and it should be plunged in sharply, without a preliminary incision, at the selected point, which should be absolutely flat upon percussion. As there is a possibility of syncope occurring during the operation, in consequence of the withdrawal of pressure, it is prudent first to pass a broad, many-tailed flannel bandage about the abdomen, crossing its ends behind, so that an assistant standing at each side can draw upon them and tighten the bandage as the liquid escapes. It is usually sufficient, however, to have an assistant make steady pressure with one hand on each side of the abdomen. During the operation the patient should be seated or inclined toward one side.

Should hemorrhage ensue, the attempt must first be made to control it by the pressure of the canula. This failing, the entire thickness of the abdominal wall must be pinched up and compressed, or, in extreme cases, the wound must be enlarged and the vessel tied.



When it is necessary to practice paracentesis upon a pregnant woman, Ollivier recommends the selection of the neighborhood of the umbilicus for the puncture; Scarpa preferred the left hypochondrium, Velpeau the left flank.

### **LAPAROTOMY.**

If time permits, preparatory treatment with baths and laxatives is continued for several days, and in a female pelvic case the vagina is rendered as aseptic as possible by numerous 1 : 2000 bichloride douches. An aperient is given the evening before and an enema in the morning of the operation; the patient passes water or is catheterized immediately before being placed on the table. The preparation of the skin surface, the surgeon, the attendants, instruments, and accessories has been already given. Sterilized sponges, round and flat, and a few on clamps or handles, and pads of gauze should be at hand, and two sterilized basins of warm boiled water, one to contain the clean sponges, and the other, which will need frequent changing, to rinse the soiled sponges.

All parts of the patient, except the abdominal surface, all the tables for instruments, sponges, and dressings, and everything not previously sterilized, which may be touched by any person or thing concerned in the wound, are covered with sterilized towels, dry or wet in a 1 : 1000 bichloride of mercury solution. The numbers of clamps, sponges, and pads are written down immediately before the operation and verified at the close.

The incision may be made in almost any part of the abdominal wall, but is most often median and should divide the tissues layer by layer. The linea alba is indistinct below the umbilicus, and if the incision is median one or other rectus sheath will generally be opened. It will then be found convenient immediately to unite by a catgut suture the anterior and posterior layers of the opened sheath, and the linea alba can thus be more quickly reformed at the close of the operation. The properitoneal fat is recognized and all bleeding stopped. The peritoneum is then nicked and the opening enlarged with blunt-



pointed scissors to the length of the abdominal wound, which must be made large enough to permit easy recognition of everything as it is encountered.

The position of the bladder must be remembered. The field of operation is then fenced in like a well with sterilized gauze pads or flat sponges, and the viscera outside of the spot in question entirely hidden in the rest of the unopened abdominal cavity.

Pelvic operations are much facilitated by the Trendelenburg position—the hips elevated above the shoulders, thus causing the viscera to gravitate out of the way. Each vessel is secured separately, if possible, before division; there must be no cutting in the dark and no ligation of large masses of tissue *en masse*. In general catgut is preferable to silk for almost all pedicles or vessels.

At the close of an aseptic laparotomy the perfectly dry and clean wound is inspected for a few moments to be sure that there is no more bleeding; the clamps, sponges, and pads are removed and counted, and the viscera are then allowed to resume their normal positions. A flat sponge or pad is placed over the viscera in the abdominal wound to protect them and to absorb such blood as may flow from the needle punctures, and over this the wound is closed by various methods.

Silk, silver wire, or silkworm-gut can be passed through the whole thickness of the abdominal wall and peritoneum, from half an inch to an inch from the margin of the wound, and about the same distance apart; the amount of tension necessary in tying them will vary with the thickness of the abdominal wall, its laxity, or distention. Before the last one or two are tied the protecting sponge is withdrawn. Or the peritoneum may be first sutured over the sponge by the continuous or interrupted catgut suture and the sponge withdrawn before it is entirely closed, then sutures of silk, silver wire, or silkworm-gut are passed as before, but only through the parts in front of the peritoneum; or after closing the peritoneum and removing the sponge the overlying parts can be sutured with catgut, layer by layer. Schede<sup>1</sup> recommends buried

<sup>1</sup> Centralblatt für Chirurgie, 1893.



sutures of silver wire for all the layers except the peritoneum and skin. In a continuously aseptic wound the sutures should not be removed for at least seven days, and then with every antiseptic precaution, especially if they include the peritoneum.

The sutured wound may be covered with a strip of sterilized rubber tissue. Iodoform gauze is next applied, and over this layers of plain, sterilized, or bichloride gauze.

This is held in place with a couple of transverse strips of adhesive plaster and covered with a layer of sterilized absorbent gauze, and the dressing completed by a broad abdominal binder or a broad roller bandage applied circularly around the body and each thigh in the form of a spica to prevent slipping.

The sponges contaminated in the course of a laparotomy, where any form of sepsis or noxious element is present, should be kept apart from the others as far as possible, and only used in the contaminated area, which latter must be kept separated by sterilized sponges or pads, with the utmost care, from the rest of the abdominal cavity. The towels in the neighborhood of the wound are changed or covered with clean ones as fast as they become soiled, and the wall of pads or sponges surrounding the operation area must be replaced by fresh ones when they become saturated with the noxious materials, and without disturbing the position of the protected viscera.

The wound at the finish is made as clean and dry as possible. Wherever peritoneum has been divided or stripped up it should be replaced and secured with fine catgut sutures. There may remain a large denuded area liable to infection or studded with fine bleeding points, as, for instance, after dissection of an adherent tumor. This can be conveniently treated with a large square of iodoform or sterilized gauze, the center of which is tucked down into contact with this area, and the edges brought out of the abdominal wound. Other strips of sterilized gauze are packed into this as into a bag. If pus has been



present one or more sterilized drainage tubes of rubber or glass with lateral perforations must be run down from the surface to the bottom of the infected region. Sometimes a strip of gauze is packed inside of the tubes to aid the escape of fluid on the principle of capillarity. And this strip is frequently changed with every antiseptic precaution.

In female pelvic cases it may be desirable to pass a tube through a counter-opening in the vault of the vagina. Hence the necessity of the preliminary cleansing of the vagina in every case where there is even a possibility of pelvic complications. The vagina is afterward packed with sterilized or iodoform gauze, the vulva covered with an antiseptic dressing, and the patient catheterized for several days subsequently. After inserting the tubes, and with as little displacement of the protected viscera as possible, the sponges or pads are removed and counted and their places supplied by a light packing of strips of iodoform or simple sterilized gauze, the ends of which protrude through the incision. Before packing the wound it may be advisable to flush out the infected region with warm boiled water or sterilized salt solution, and sometimes a large part of or the whole peritoneal cavity is thus treated and counter-openings for drainage, with packing, are made.

At the close of the operation the peritoneum is first sutured over a sponge or pad down to the point of exit of the tubes and packing, and the sponge then removed. The overlying parts are drawn together to a corresponding extent with silk, silkworm-gut, or silver wire passed through everything in front of the peritoneum, and a dressing which covers the ends of any tubes is then applied, as in an aseptic case.

### OPERATIONS ON THE INTESTINES.

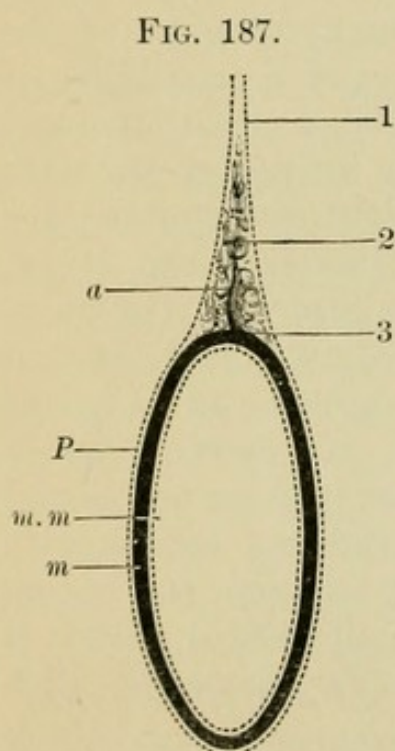
**Anatomy.** (Fig. 187.)—The parts of the intestines which have a mesentery are completely covered by peritoneum except along a narrow interval where the laminae of the mesentery diverge to encircle the bowel



(Fig. 187, 2). Thus the outer wall of the gut, along the line where the mesentery meets it, is formed by a strip of the muscular coat about five-sixteenths of an inch wide (Fig. 187, 3), and this is apt to be the weak point in a row of sutures involving this portion of the circumference of the bowel. The arteries in the mesentery form freely anastomosing loops from which, close to the intestine, arise straight vessels with little or no intercommunication,

and having a circular and fairly well-defined distribution, so that, while a portion of the mesentery at a distance from the intestine may be destroyed with comparative impunity, an injury to the smallest part in immediate proximity to the gut involves a probability of sloughing of a corresponding extent of intestine.

An anatomical knowledge of the mesentery is of value in a search for the upper or lower end of the small intestine. The parietal attachment of the mesentery extends from the left side of the second lumbar vertebra downward to the right iliac fossa, and, if the finger trace the left layer of the mesentery of a loop of intestine back toward the spine, it passes off toward the left side of the abdomen, and the right layer will lead



Section of small intestine and mesentery. 1. Mesentery. 2. Triangular space between diverging layers of the mesentery. 3. Its base resting on *m*, the muscular coat of the gut. *P*. Peritoneum. *m, m*. Mucous membrane.

to the right side of the abdomen. This will show which end is the upper or lower in any particular loop. Also the upper part of the small intestine has a greater diameter, is thicker walled (*valvulae conniventes*), and more vascular than the lower part. The coats of the intestine from without inward are: (1) the peritoneal, (2) the longitudinal, (3) circular muscular, (4) the submucosa, a tough fibrous membrane, (5) the *muscularis mucosae*, and



(6) the mucosa, the latter making up about two-thirds of the thickness of the wall.

Unless the suture includes a shred of the submucosa it is very apt to tear out. This coat is recognizable by the increased resistance which it offers to the passage of the needle after the peritoneal and muscular layers have been transversed.<sup>1</sup> The colon and sigmoid flexure are recognizable by their corrugations, their more or less fixed positions, the appendices epiploicæ, which are most numerous in the transverse colon, and by the longitudinal bands of muscular fibers. The anterior band is the largest and most prominent, and lies in front of the cæcum, colon, and sigmoid flexure. In the transverse colon it corresponds to the attachment of the great omentum, and in the ascending colon and cæcum it is the unfailing guide to the appendix vermiformis, from the attachment of which to the cæcum the anterior, inner, and posterior longitudinal bands all start. The appendix lies about opposite a point indicated on the abdomen by the center of the line passing from the right anterior superior spine of the ilium to the umbilicus. It may or may not have a mesentery and commonly lies behind the lower end of the ileum, and often in close relation with the iliac vessels and ureter, and is not infrequently found in the pelvis.

To be successful the closure of an intestinal wound must be water-tight, and no stitch may perforate all the coats; there must be no subsequent giving way of any part of the wound, either from slipping of a suture or ulceration or sloughing at the site of its insertion, and the lumen of the bowel must not be unduly narrowed. A round sewing needle and black silk are generally used.

*The continuous suture* is applied like the ordinary continuous suture already described, and is carried a short distance beyond the extremities of a longitudinal wound. The needle penetrates the peritoneal and muscular coats of the intestine, catching up a few fibers of the submucosa, but nowhere perforating the mucosa. The stitches are placed at intervals of about a quarter of an inch close to

<sup>1</sup> Halsted : American Journal Medical Sciences, 1887, p. 436.

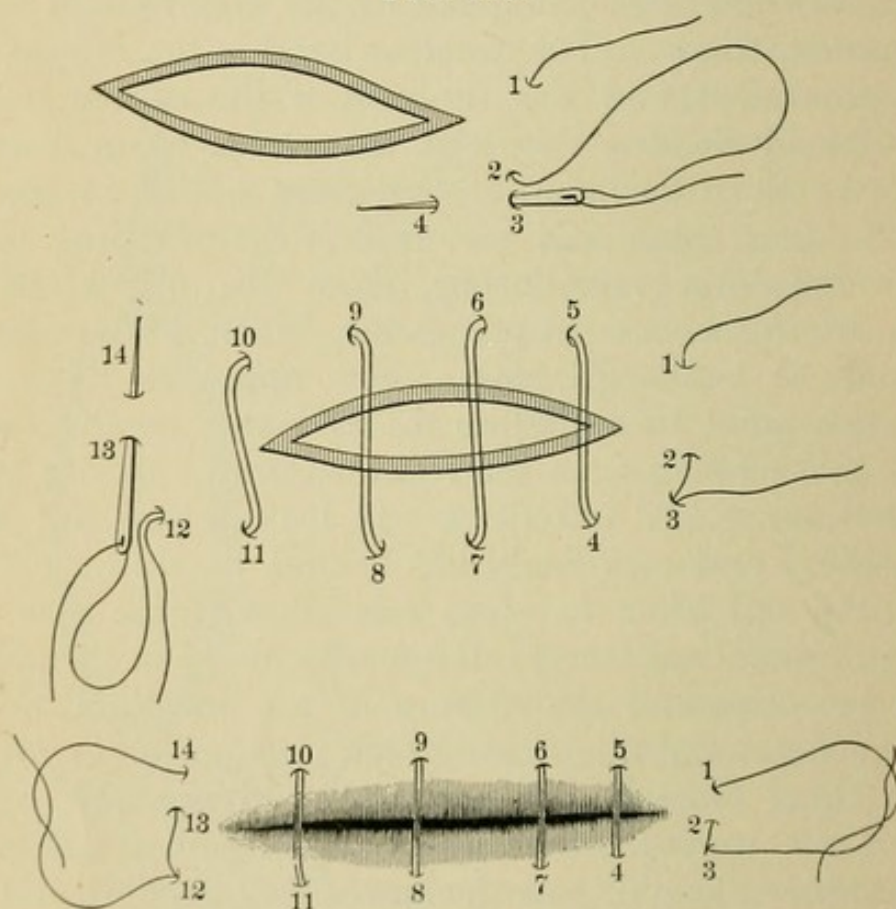


the margins of the wound, which are turned in to bring the peritoneal surfaces in apposition.

The *right-angled continuous suture* (Fig. 188) differs from this last only in having the buried portions parallel to the line of the wound and the exposed portions at right angles to it.

The continuous suture can be rapidly applied, and is useful for reinforcing weak points in an interrupted suture

FIG. 188.



Right-angled continuous intestinal suture. (GREIG SMITH.)

line, but it is inapplicable for closing a complete transverse division of the bowel. All parts of the continuous suture may not be drawn equally tight, and the contraction of the gut tends to loosen it and allow the wound to gape.

The *interrupted suture of Lembert* is the most approved and generally used intestinal suture. The needle penetrates a fold of the peritoneal, muscular, and a few shreds



of the submucous coat of the gut on opposite sides of the wound, the margins of which are inverted and the peritoneum brought together. The sutures should be placed about on eighth of an inch from the margin of the wound

FIG. 189.

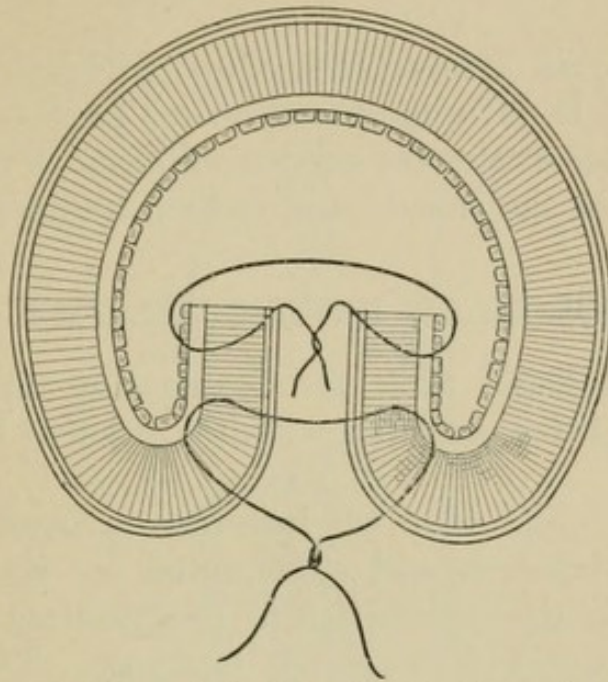
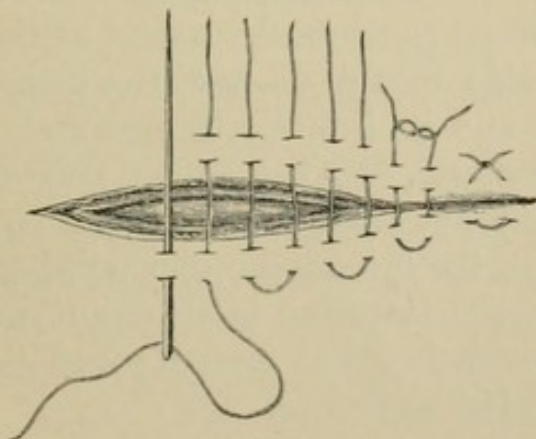


Diagram representing the method of inserting the Czerny-Lembert suture. The Lembert suture is below, the Czerny at the cut edge.

and about the same distance apart, and each should grasp a fold of the intestine about one-tenth or one-twelfth of an inch wide. None must touch the mucosa.

FIG. 190.



Halsted quilt suture for the intestines.



*Czerny's method* consisted of an interrupted line of sutures passing through *all* coats of the intestine and tied inside. A second row of Lembert sutures is then added to bring the peritoneal surfaces on each side of the wound in contact over the first row of sutures. Czerny's suture is now generally passed through all coats *except* the outer one.

*Halsted's quilt suture*<sup>1</sup> (Fig. 190) will bear a considerable strain. It is a modification of Lembert's method. The needle penetrates the superficial coats of the gut twice on each side of the wound and is then knotted.

### CIRCULAR ENTERORRHAPHY.

This is the usual term for designating an end-to-end suture of the intestine from which a segment has been removed.

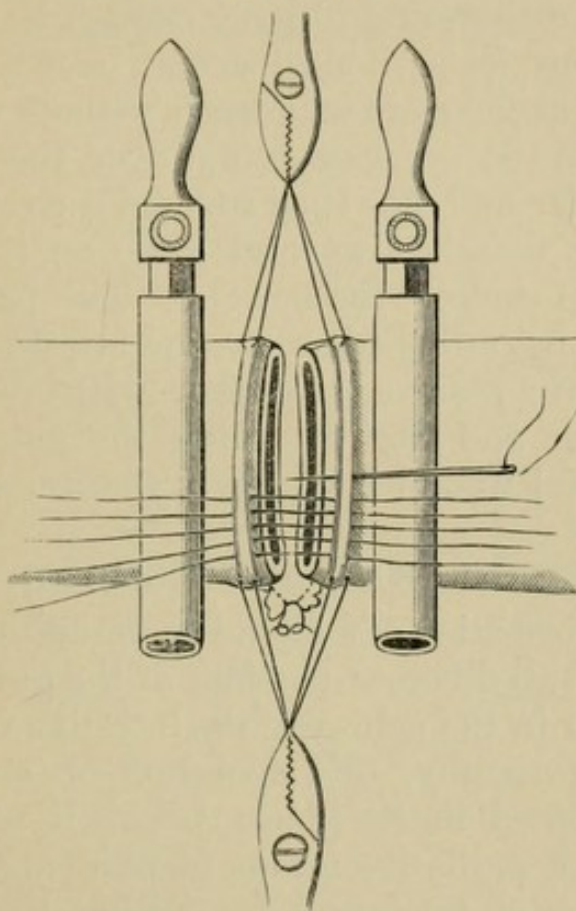
**Operation.**—The loop of intestine is carefully drawn out of the abdomen and surrounded by warm pads or sponges while the opening into the peritoneal cavity is protected by a gauze or sponge packing. The feces are squeezed out of the loop, and about an inch above and below the limits of the segment of gut to be removed the intestine is constricted tightly enough to close its lumen, either by the fingers of an assistant or by one of the specially designed clamps, or by a strip of iodoform gauze, which is passed through a small hole made in the mesentery by a blunt instrument at a little distance from the gut and tied snugly about it. After thoroughly protecting the exposed peritoneal surface, at the spot selected on the lower side of the disease, the intestine is divided squarely across and its interior immediately irrigated with warm boiled water. With a clean pair of scissors, the mesentery of the diseased part is cut as close to the gut as possible up to the intended upper point of the intestinal division, where the intestine is then cut squarely across, and the interior below the constricting gauze band immediately irrigated as before.

<sup>1</sup> American Journal Medical Sciences, October, 1887.



The divided mesentery, if broad, may be partly resected triangularly and its sides sutured together. Bleeding is checked by separate ligation with fine catgut of each vessel. Meanwhile every portion of peritoneum is scrupulously protected from infectious matter, and before the next step instruments which have touched infectious

FIG. 191.



Circular enterorrhaphy.

matter or the interior of the intestine are discarded and the hands carefully washed.

The ends of the gut are then brought into apposition and the mucous membrane united evenly all around by a continuous catgut or silk suture. The mesenteric border of the gut is drawn together by a Lembert silk suture, and then the opposite free border. By gentle traction on the ends of these sutures (Fig. 191) the gut is flattened out and on the line thus indicated the necessary number of



Lembert sutures are added, but not tied till the last is in place. The peritoneal surfaces must be very carefully brought into contact at the mesenteric attachment of the bowel to avoid leakage into the areolar tissue between the diverging layers of the mesentery; but weak points must not be so reinforced by continuous or interrupted sutures that the lumen of the intestine becomes unduly narrowed. The fold of detached mesentery is drawn together at its cut edge with catgut, and if long enough it is sometimes advised to suture its peritoneal surface over the line of intestinal union as far as it will reach without tension.

Senn sutures the great omentum over the outer row of Lembert sutures and has thus covered a circular enterorrhaphy with a detached omental graft an inch wide and long enough to encircle the bowel.<sup>1</sup> The parts are again irrigated with warm boiled water, the intestinal clamps or gauze bands are removed together with the protective sponge packing, and after returning the gut to the abdomen the parietal wound is closed in the usual way.

### INTESTINAL ANASTOMOSIS.

This is the formation of a lateral communication between the lumina of two different portions of the gut. Owing to the contraction in the calibre of the intestine which follows circular enterorrhaphy, this operation of anastomosis is frequently adopted in its place; though it was originally introduced as a palliative means of relieving an irremovable obstruction of the bowel by uniting the parts above and below the obstruction.

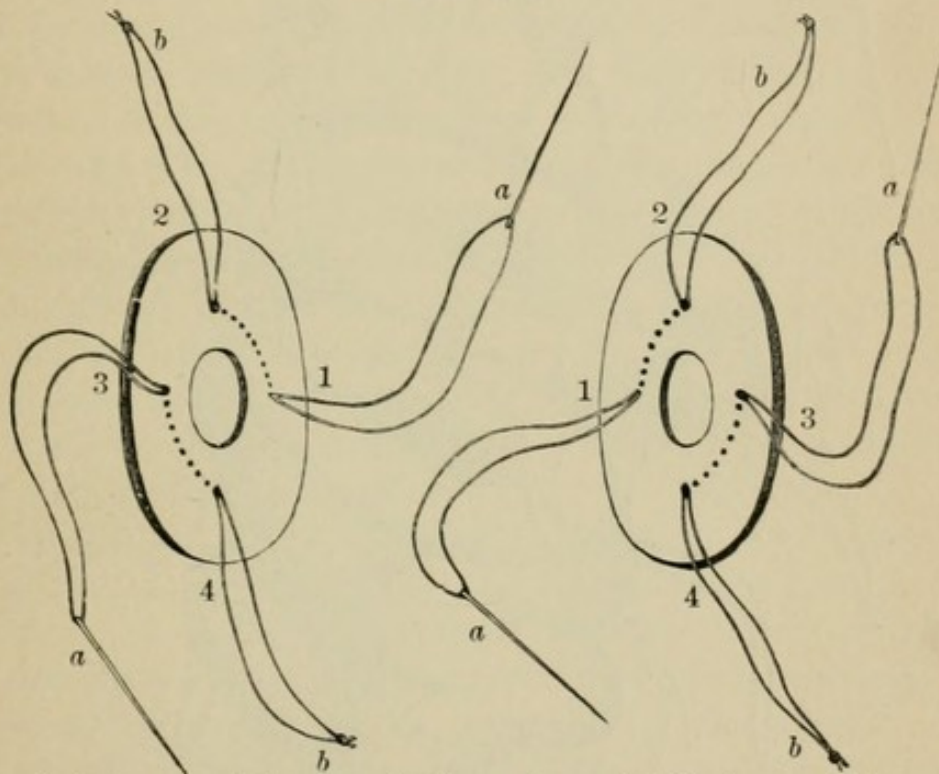
**Operation.**—Above and below the obstructions healthy portions of the gut are selected which can be brought into apposition without tension, along several inches of surface. The rest of the peritoneal cavity is walled off with sponges, and if possible the selected loops of intestine are drawn out of the abdomen and surrounded by warm cloths. About one-quarter of an inch to the under side of the center of the convex free border as the intestine lies ex-

<sup>1</sup>Trans. Int. Med. Cong., 9th session, Washington, 1887, Vol. I., p. 435.



posed, the apposing loops are united for about five inches by a continuous silk suture through the peritoneal coats alone. About an inch above and below this suture line, on each loop, an iodoform-gauze band is passed through the mesentery, at a little distance from the intestine, and tied around the gut just tightly enough to prevent the entrance of fecal matter. Each loop is then opened along its convex free border for nearly the same distance (about four inches) parallel to and immediately in front of the

FIG. 192.



Senn's plates. *a, a*. Lateral or fixation suture. *b, b*. End or apposition suture. Thread passed through 2 is brought out through 1, and that through 4 out through 3. (TREVES.)

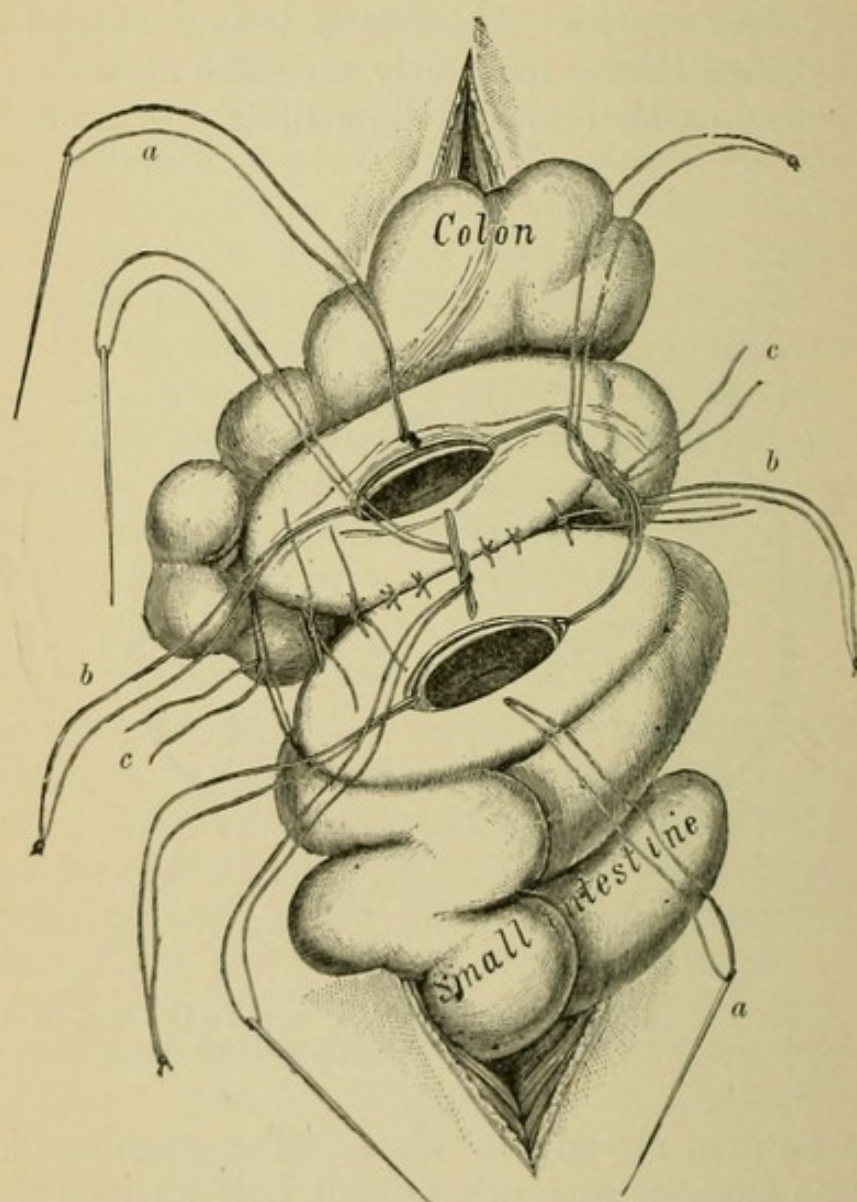
row of sutures already in place. The openings should terminate opposite each other about half an inch short of the end of the suture line. The interior of each isolated loop is immediately irrigated clean with warm boiled water while the exposed peritoneal surface is protected as far as possible.

Soiled towels or protecting sponges are then replaced by clean ones, anything which has touched the interior of the intestine or its contents is discarded and the hands



carefully washed. After this the edges of the two openings are united to each other all around by a continuous catgut or silk suture. The exposed parts are again irrigated and the protectives and instruments changed.

FIG. 193.



Intestinal anastomosis, with Senn's plates. *a, a*. Lateral or fixation sutures. *b, b*. End or apposition sutures. *c, c*. Posterior sutures. (SENN.)

Finally, a continuous silk suture, beginning and ending with the one already placed, is applied along the skin-side of the opening.

In cases of enterectomy the segment of gut to be removed is excised as described in circular enterorrhaphy.



The open ends of the intestine are then turned in to bring peritoneal surfaces into contact, and closed by a continuous silk suture carried back and forth once or twice and in no spot entering the mucosa. The constricting gauze bands are removed from the intestine and the anastomosis proceeded with.

Senn<sup>1</sup> reinvented and greatly improved the forgotten method of uniting different portions of the gut laterally by means of perforated absorbable plates which bring into contact broad areas of peritoneum around a central opening.

Two contiguous loops of intestine are opened to the same extent longitudinally, on the side opposite the attachment of the mesentery, and sufficiently to admit the plates edgewise. After introduction the plates are rotated enough to make their perforations correspond to the openings made in the intestine. About a quarter of an inch from the margins of the openings on each side, the wall of the intestine is perforated by the two lateral sutures which are armed with needles. The other two sutures are tied across the extremities of the openings without perforating the intestinal wall.

The sutures serve the double purpose of holding the parts in apposition and keeping the openings patent.

After the parts are brought together union is further secured by a continuous or interrupted suture through the peritoneal coat around the margins of the plates. The plates, which Senn made of decalcified bone, are supposed to become absorbed or disintegrated between the third and tenth days.

This method has been largely abandoned in this country on account of the later contraction of the fistula.

The Murphy "button" has attained great and growing popularity as a means of uniting different portions of the intestine. A description of the device and its application will be found in the paragraphs on cholecystenterostomy. Quite recently a satisfactory substitute has been found in

<sup>1</sup>Trans. Int. Med. Cong., 9th session, Washington, 1887, Vol. I., p. 435.

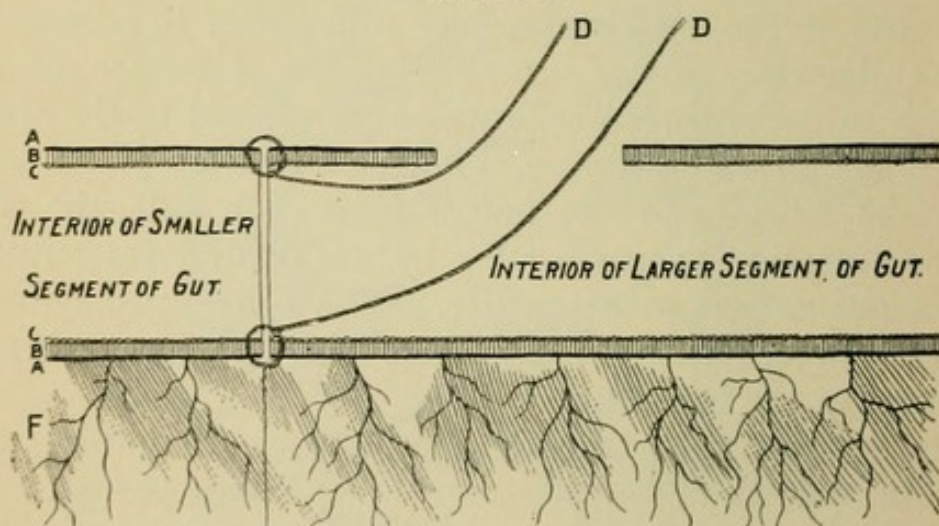


a piece of raw potato perforated and fashioned into similar shape.

Various methods have been devised for uniting portions of gut of unequal diameter, but they have now been generally superseded by closing the transversely divided ends and performing lateral anastomosis.

*Union of Divided Intestine by Intussusception.* (Maunsell.)<sup>1</sup>—The disease is excised by transverse division of the gut as described in circular enterorrhaphy. The cut ends of the intestine are united by one suture through the entire wall at the point of the mesenteric attachment and

FIG. 194.



Maunsell's method; first two sutures brought out through the incision in the lower segment.

by another at the point directly opposite. The portion of intestine which lies on the lower or rectal side of the line of division, starting about an inch from this line, is opened longitudinally on its convex free border for about two inches. Through this incision the long ends of the two sutures are passed and the gut invaginated and its partly united cut ends drawn out through the opening. (Figs. 194 and 195.) The union of these cut ends is then completed by interrupted sutures of fine silk including the entire thickness of the wall close to the cut edge. The intestine is then withdrawn from the opening and the longitudinal slit closed by Lembert sutures.

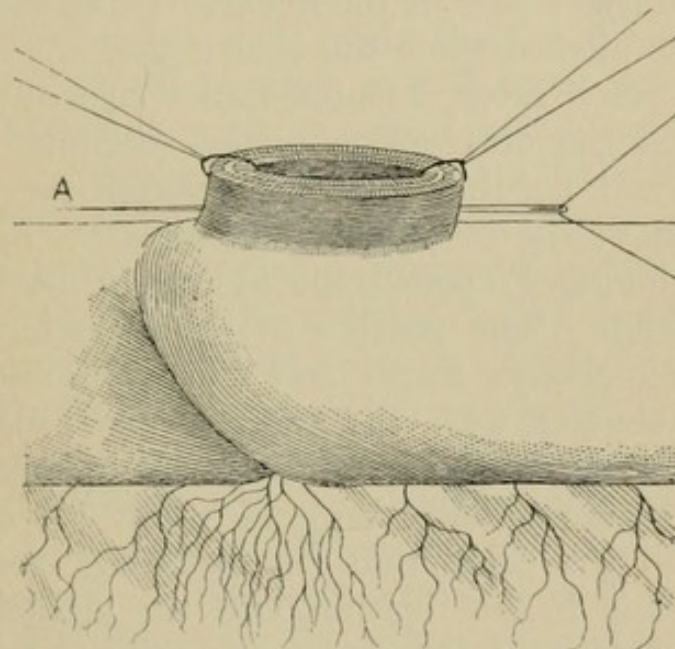
<sup>1</sup> Amer. Journ. Med. Sci., 1892, Vol. 103, p. 245.



**ENTEROSTOMY.**

Instead of excision of a portion of the gut with immediate restoration of its continuity by circular enterorrhaphy or lateral anastomosis, circumstances such as an uncertain amount of gangrene, the bad condition of the patient, etc., may require that the bowel be simply freed from its constriction and the damaged part left outside the abdomen till the slough separates. It is fastened to the margins of the abdominal wound by a couple of sutures. In course of time it is treated by the method described for the closure of an artificial anus.

FIG. 195.



Maunsell's method ; protruding ends ready for suture.

**RIGHT INGUINAL ENTEROSTOMY (NÉLATON'S OPERATION).**

As long ago as 1819, it was proposed to establish an artificial anus in the ileum in case the intestinal obstruction could not be found or removed by laparotomy ; but Nélaton was the first (1840) to substitute this for the other operation, giving up the search after the obstruction entirely. His theory was that many obstructions would relieve themselves in time, if a temporary outlet should be furnished to the accumulation above ; in some cases, on the other hand, where the obstruction is permanent, an



artificial anus in the ileum meets the "vital indication" perfectly—for example, when the obstruction is in the lower portion of the small intestine; while in others, again, where the occlusion occurs below the ileo-cæcal valve, and the relief afforded would, consequently, be imperfect, the obstruction is usually due to malignant disease, which in itself would soon destroy life and against which neither laparotomy nor any other operation would avail.

It is also essential to the proper nourishment of the patient that the greater part of the small intestine should remain serviceable; that is, that the opening should be made in the lower part of the ileum. Of course, this cannot be accomplished when the obstruction is situated high up, but, in other cases, Nélaton found that the intestinal loops nearest the obstruction always occupied the right iliac fossa, and he, therefore, cut through the abdominal wall just above the outer half of Poupart's ligament on the right side, and opened the first loop that presented in the incision. The portion of the intestine below an obstruction is always empty and shrunk, and does not come into contact with the anterior abdominal wall, so that there is no danger of making the opening in it by mistake. It occasionally happens when the obstruction is situated in the colon that the distended cæcum fortunately presents in the incision, and the artificial anus is established below the ileo-cæcal valve.

**Operation.**—Make an incision parallel to and about an inch above Poupart's ligament, beginning at the anterior superior spine of the ilium and ending opposite the internal abdominal ring.

Divide the tissues layer by layer, pick up and nick the peritoneum and open it for about one and a-half inches. The first distended intestinal loop which presents is drawn out till its free border is on a level with the skin, and retained by two silk sutures, which, at the same time, draw together the extremities of the abdominal wound. Each suture passes through all the parietal tissues and the peritoneal and muscular coats of the intestine. The skin and



bowel are closely united all around by interrupted sutures, none of which must enter the lumen of the gut.

The suture line is covered by a strand of iodoform gauze pasted down with flexible collodion, and the center of the protruding intestinal wall opened in its long axis for about half an inch.

The parietal peritoneum can be drawn out and stitched to the skin before the bowel is sutured in place, thus bringing into contact a larger surface of parietal and visceral peritoneum.

### COLOSTOMY.

**Left Inguinal Colostomy.**—Make an incision between two and three inches long, according to the thickness of the abdominal wall, parallel to and about an inch above Poupart's ligament, with its center at the level of the anterior superior spine of the ilium, or a little lower. The tissues are divided layer by layer, the peritoneum opened, and the skin and parietal peritoneum united by a few sutures, not including the muscles. The sigmoid flexure, which is recognized by its anterior longitudinal band, its convoluted surface, or appendices epiploicæ, is drawn into the opening and retained by a couple of silk or silkworm-gut sutures passed about two inches apart through both lips of the wound at its extremities and the longitudinal band of the colon. The gut is then closely united to the margins of the wound by fine silk sutures passing through the already joined skin and peritoneum and the outer coats of the intestine. No suture should penetrate to its interior. The amount of the circumference of the gut to lie external to the sutures is about half an inch when the operation is for the temporary relief of obstruction. For a permanent artificial anus two-thirds of the circumference of the bowel should lie anterior to the suture line. The center of the exposed intestinal wall is then opened longitudinally with a knife or thermo-cautery for about half an inch and drainage tubes inserted.

Before opening the bowel the suture line can be covered with a strip of iodoform gauze pasted over with flexi-



ble collodion. If there is no urgency the opening can be deferred for five or six days till adhesions have shut off the general peritoneal cavity.

Some surgeons prefer not to unite the skin and parietal peritoneum, but to suture the outer coats of the intestine to the skin alone. The gut adhering to all parts between the skin and parietal peritoneum is thought less liable to retract than if adherent only to the intervening parietal peritoneum with its movable subserous areolar tissue.

Maydl<sup>1</sup> hangs the intestine on a sterilized rod passed through the mesentery close to the bowel and laid on the skin transversely to the wound. The apposing walls of this loop are united by a few interrupted sutures through the peritoneal coats and the rest of the walls left to adhere to the abdominal wound; but if immediate opening is intended, the sutures are passed through the skin and peritoneum around the margins of the incision, and through the serous and muscular coats of the gut, completely shutting off the peritoneal cavity. The exposed wall of the intestine is opened transversely for one-third of its circumference, and drainage tubes placed within it. Two or three weeks later the bowel is entirely divided on this line and the cut edges sutured to the skin for a permanent artificial anus.

If the operation is merely temporary the intestine is opened longitudinally, and when adhesions have formed the rod is withdrawn, and the bowel retracts and the fistula sometimes closes spontaneously.

**Right inguinal colostomy** only differs from the last operation in that the abdominal incision is placed on the right side and the cæcum is opened instead of the sigmoid flexure.

In either right or left inguinal colostomy the opening in the abdominal wall may be made by the "inter-muscular" method devised by Dr. McBurney for operations upon the appendix (q. v.). It seems probable that a certain amount of sphincteric control of the opening may be thus obtained.

<sup>1</sup> *Centralb. f. Chir.*, 1888, No. 24.



**Lumbar Colostomy.**—This operation was first suggested by Callisen,<sup>1</sup> in 1797, as a substitute for Littre's or inguinal colostomy with a view to avoiding the dangers incidental to an incision through the peritoneum. He proposed to open the descending colon in the posterior third of its periphery, where it is not covered by peritoneum. So far as known, Amussat was the first to perform the operation in 1839, and although he opened the ascending colon, and by a transverse instead of a vertical incision, the operation was essentially the same as that proposed by Callisen. All that portion of the descending colon which lies above the crest of the ilium is usually uncovered by peritoneum on its posterior aspect, and although the actual breadth of the uncovered portion varies with the degree of distention of the bowel, it usually amounts to one-third of the entire circumference, and is bounded on each side by one of the three longitudinal bundles of unstriated muscle characteristic of the colon. In position it corresponds nearly to the outer border of the quadratus lumborum, and very exactly to a vertical line drawn a full half inch behind the center of a transverse one, uniting the anterior and posterior superior spines of the ilium (Mason). On the right side (ascending colon) the uncovered portion is more often smaller, and the existence of an actual meso-colon, although rare, is yet more frequent than upon the left side.

Callisen proposed a vertical incision a little external to the outer border of the erector spinæ; Amussat made a transverse one midway between the last rib and the crest of the ilium, while Baudens used an oblique one passing downward and outward at an angle of  $45^{\circ}$ . The latter is to be preferred, because, while giving sufficient room, it inflicts less injury upon the vessels and nerves of the parts, the general direction of which is the same as that of the incision.

*The operation* is performed as follows: The patient is etherized, and placed in a position midway between the

<sup>1</sup> Erskine Mason: Six Cases of Lumbar Colotomy, Amer. Journ. of Med. Sciences, Oct., 1873.



prone and right lateral, a hard cushion being placed transversely under the right loin to keep the spine straight or slightly curved toward the left. Mason says the operation has been performed with the patient seated and leaning forward over the back of another chair, local anæsthesia being obtained by means of the ether spray. The anterior and posterior superior spines of the left ilium are then recognized, and a vertical line drawn upward from a point one-half to three-quarters of an inch behind the center of a transverse line drawn from one to the other. This vertical line should be marked with iodine or nitrate of silver, in order to serve as a guide during the operation.

If the occlusion of the intestine has not been complete, and there is reason to suppose that the colon will be found empty, it may now be distended by injecting air through the rectum.

A transverse or an oblique incision four or five inches long is then made, its center lying in the vertical line above mentioned midway between the last rib and the ilium. The underlying tissues are recognized and divided layer by layer, until the fascia transversalis and quadratus lumborum are reached. The former is next carefully divided, and, if the adipose tissue covering the colon does not then appear in the wound, the latter should be enlarged on the inner side by dividing the outer fibers of the quadratus. The intestine must always be sought for in the angle of the wound nearest the spine, and whenever it is desired to increase its exposed area this must be done in the same direction.

The colon can usually be recognized by its distention and shape, and possibly by one of its longitudinal bands.

Two stout ligatures are next passed by means of curved needles through the presenting portion of intestine and used to draw it up into the wound, and fasten it to the skin at the sides of the incision. The wound is then filled with sponges or gauze, and the bowel opened by a longitudinal or crucial incision. As soon as the discharge has ceased, the sponges or gauze are withdrawn, the parts cleaned, the extremities of the tegumentary wound closed



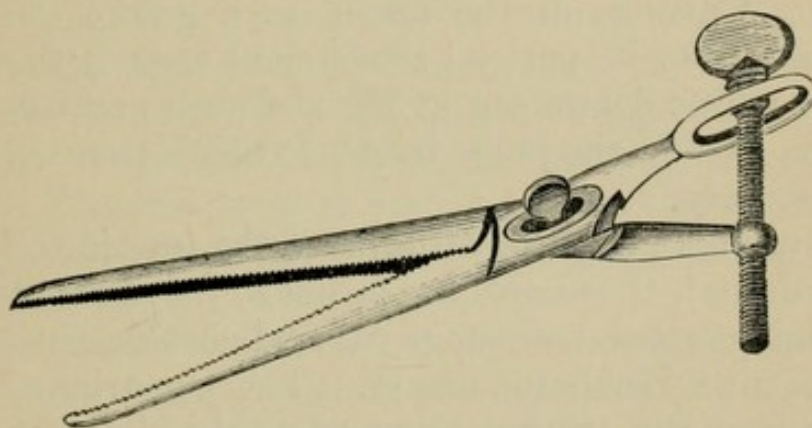
with sutures, and the edges of the opening in the intestine made fast to the skin with a few sutures of fine silk.

### CLOSURE OF AN ARTIFICIAL ANUS OR FECAL FISTULA.

If the opening in the gut is large, the remaining part of the intestinal wall is pressed forward into it and forms a sort of valve or spur, which prevents more or less completely the descending current of feces from entering the lower segment of the bowel.

If this spur were absent the fistula might close spontaneously, and to accomplish its removal Dupuytren's enterotome was formerly introduced through the opening and

FIG. 196.



Dupuytren's enterotome.

clamped upon the spur, which was thus cut through by four or five days of continued pressure.

Immediately before undertaking any operation the lumen of the gut above and below the fistula is plugged by a sponge tied to a string which serves to withdraw the sponge when all is ready to close the intestinal opening. The interior of the gut is then irrigated clean and the skin surrounding the fistula thoroughly scrubbed and washed with bichloride solution.

In most cases the fistulous tract between the intestine and skin is lined with mucous membrane, and if the spur is slight or absent, an attempt to close the fistula should



first be made by separating the mucous membrane at its junction with the skin, and after removing the sponge plugs, inverting it, and uniting the freshened surfaces with fine catgut. Over this the pared edges of the abdominal opening are sutured with fine silk, aided, if necessary at the sides, by liberating incisions through the skin and fascia.

If this fails or a more elaborate operation seems necessary, an incision two or three inches long is carried across the fistula in any suitable direction, and layer by layer down to the peritoneum. This is opened at one extremity of the incision and a finger inserted into the abdomen to determine the limit of the adhesions; and as soon as possible the peritoneal cavity is walled off by sponges packed in around the open intestine, which has been previously plugged above and below as already described. Cutting on the finger as a guide, the gut is separated from its parietal attachment around the fistula, and if possible drawn out of the abdomen and constricted above and below the plugs by gauze bands passed through the mesentery.

The sponge plugs are withdrawn, the interior of the gut irrigated, and, if the opening is small, its edges are freshened and inverted, and the peritoneal coat drawn together over it with Lembert sutures. The constricting bands are removed and the gut returned to the abdomen, which is closed in the usual way. If the opening is extensive, the damaged segment of the gut is excised and circular enterorrhaphy or lateral anastomosis done.

The fistulous tract is then dissected out of the abdominal wall and the wound closed.

#### **THE OPERATION FOR THE REMOVAL OF THE VERMIFORM APPENDIX.**

In a case of appendicitis operated on in the period of quiescence, an incision three or four inches long is made at the outer border of the right rectus muscle, with its center about on the line joining the umbilicus and the anterior superior spine of the right ilium. The lower ex-



tremity of the incision should not reach the deep epigastric artery, the course of which is indicated by a line drawn from the femoral ring to the umbilicus.

The tissues are divided layer by layer, all bleeding stopped, and the peritoneum pinched up and opened. Adhesions are separated by the finger-nail or blunt-pointed scissors, and if necessary divided between a double ligature. The anterior longitudinal band of the colon is traced to its origin at the root of the appendix. After walling off the surrounding peritoneum with a sponge packing, the appendix is isolated and a double ligature of stout catgut passed by an aneurism needle through its mesentery close to the root of the appendix. The needle is withdrawn, the loop of the ligature cut, and on one side the mesentery, which usually contains a single artery, is tied off, and on the other side the appendix is ligated as close to the cæcum as possible. The mesentery and appendix are then excised close to the distal side of the ligatures. The cæcal stump of the appendix is held isolated and in view till thoroughly cauterized with the Paquelin or pure carbolic acid, but in using the latter care must be taken to prevent its spreading to the neighboring surface of the cæcum.

The sponge protectives are then removed, the parts allowed to assume their normal position, and one end of a strand of iodoform gauze is placed in contact with the cauterized stump and the other end brought out of the abdominal wound.

The peritoneum and overlying parts are closed in the usual way except where the gauze drain emerges. Here a suture of silk is passed through the entire thickness of the abdominal wall, including the peritoneum, and left untied till the drain is removed forty-eight hours later. This must be done with every antiseptic precaution, and only done if no inflammatory symptoms exist. The dressings then applied are left undisturbed about ten days.

Instead of ligating the appendix as described it may be inserted into the colon as follows: A fine silk suture is passed circularly a little beyond the base of the appendix,



in and out through the serous and muscular layers of the colon, like a purse-string. The appendix is cut off about half an inch from its base, and a silk suture tied across the cut end at its center. Against this suture is engaged the notched end of a probe or a match, and by pressure with the probe the stump can be easily inverted; the probe is withdrawn as the circular suture is drawn tight and tied.

**Dr. McBurney**<sup>1</sup> has given us a method which, while more difficult of execution, obviates the risk of hernia: An incision, oblique downward and inward, is made about an inch and a-half to the inner side of the anterior superior spine of the ilium. The aponeurosis of the external oblique is split in the direction of its fibers, the sheath of the internal oblique divided transversely, and its fibers and those of the transversalis carefully separated without cutting from the ileum to the rectus. The fascia and peritoneum are divided, the sides of the opening held apart with broad retractors, and the appendix removed as above described.

**Operation during the Period of Inflammation.**—If a distinct tumefaction is perceptible, with a probability of the presence of pus, the incision is made about four inches long parallel to the outer border of the right rectus over the most prominent part of the tumor, or, if there is no tumefaction, over the most tender spot, and the appendix removed as already described. If the peritoneum is reached without a previous escape of pus it is opened at an angle of the incision, preferably the upper, and a finger inserted to determine the position of the mass and the limit of the adhesions. Through this exploratory opening a sponge packing is inserted as soon as possible, and the inflamed area walled off from the rest of the abdominal cavity.

The peritoneal opening is then enlarged and the dissection carried into the densest part of the tumefaction. Fresh adhesions are best separated by tearing with the finger-nail, but the possibility of lacerating the bowel must not be forgotten, and, if necessary, the blunt-pointed scis-

<sup>1</sup> *Annals of Surgery*, 1894.



sors and double catgut ligature are used for the strongest adhesions, especially those involving omentum. The moment pus appears the manipulations are suspended, while it is encouraged to flow out or else sponged rapidly away without disturbing the relations of the surrounding parts.

The opening in the abscess cavity is cautiously enlarged without getting beyond the adhesions which protect the rest of the peritoneal cavity. If such an accident does occur a clean sponge is immediately packed into the rent and the dissection continued until the appendix is found. It is excised and the stump cauterized and tied as above described.

An abscess cavity in the pelvis may sometimes need to be drained by a tube passed through a counter-opening in the rectum and a cavity in the loin by a tube passed through the back just above the iliac crest.

After every trace of pus has been sponged or washed away one or more tubes should extend from the abdominal wound into every recess of the suppurating region and each surrounded with an iodoform-gauze packing. The sponge protectives are then removed and their places supplied by strips of iodoform gauze, the upper and lower angles of the wound are sutured in the usual way, and a strip of iodoform gauze placed over the intestines beneath them. The ends of all the strips of gauze are brought out at the center of the wound and counted.

After the first twelve to twenty-four hours the dressings will probably be saturated with the blood-stained serous discharge and need changing, which then and afterward must be done with every antiseptic precaution. The gauze directly beneath the suture line can probably be removed in twenty-four to forty-eight hours, but it will require a vigorous pull.

### STOMACH.

**Anatomy.**—The cardiac orifice lies about one inch to the left of the sternum beneath the seventh left costal cartilage. The pyloric orifice in the empty stomach lies in the median



line or close to the right of it and two or three inches below the end of the gladiolus, and is in relation with the neck of the gall-bladder, the portal vein, the gastroduodenalis, and right gastro-epiploica arteries, the pancreas, and the splenic vein. The lesser curvature is connected with the transverse fissure of the liver by the lesser omentum, which contains from left to right the gastric, pyloric, and hepatic arteries, the portal vein, and common bile duct. The great omentum passes downward from the greater curvature, on which lie the right and left gastro-epiploica arteries, across the colon, to which the anterior layer is generally adherent, the posterior always. The transverse mesocolon is near the posterior surface of the stomach. The left lobe of the liver descends in front of the stomach a variable distance, generally not below the ninth left costal cartilage. When the stomach is distended, it is in contact with the anterior abdominal wall over quite a large area below the left lobe of the liver; when it is empty, this area of contact becomes very small, and lies between the left lobe of the liver and a transverse line drawn at the level of the anterior end of the ninth rib. The guide to this line, as Tillaux has shown, is the anterior end of the tenth rib, which can be readily felt projecting beyond the border of the cartilages of the false ribs, and can be made to yield a sort of friction sound by rubbing it against the ninth. Sédillot claimed that when the stomach was empty, it was nowhere in contact with the anterior abdominal wall, being separated from it by the liver and transverse colon, and recommended that it should be approached by a crucial incision through the left rectus muscle two or three inches below the xiphoid appendix of the sternum. He passed his finger along the border of the left lobe of the liver to the diaphragm, encountered the stomach there, seized it with pronged forceps introduced along the finger, and drew it up to the incision while pressing the colon downward. Although, as stated, more recent investigations have shown that the normal stomach when empty is still in contact with the anterior abdominal wall, these directions for finding the stomach



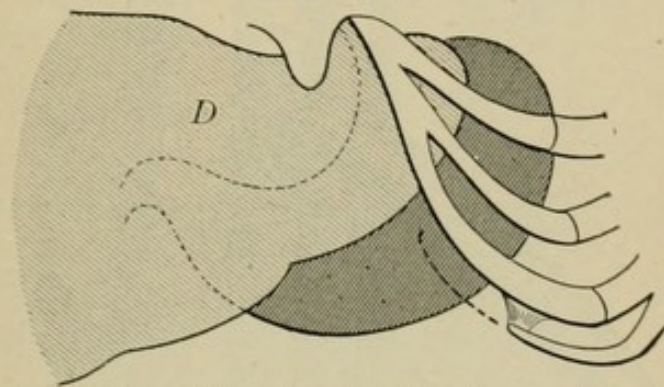
may be useful in cases where it has been drawn back and bound down to the posterior wall by inflammatory adhesions or neoplasms.

### GASTROSTOMY.

It consists in the establishment of a fistula through the walls of the stomach and abdomen.

**Operation.**—An incision one and a-half or two inches long is made parallel to and a finger-breadth from the free border of the left costal cartilage, ending below opposite the end of the tenth rib. The tissues are divided layer by layer, the peritoneum pinched up and opened. When

FIG. 197.



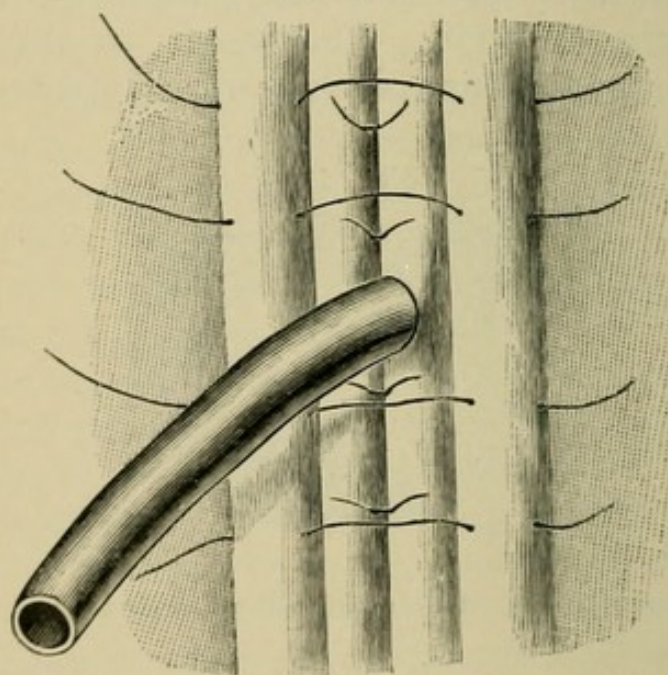
Anatomical relations of the stomach with reference to gastrostomy.

the stricture is close the stomach and intestines are usually empty and the abdomen deeply sunken by atmospheric pressure. In such cases, when each successive layer is divided it rises from the underlying mass, and when the peritoneum is opened the air rushes in and the abdominal wall rises away from the stomach and becomes level with the sternum and ribs. The stomach is recognized just below the left lobe of the liver by its white color, smooth surface, and the arrangement of its arteries. If it does not present in the wound the transverse colon and omentum are pressed down, the fingers passed up under the left lobe of the liver and to the left close to the diaphragm and vertebral column, and the lesser curvature sought for. When found a fold of the stomach is picked up by the



fingers and a spot fixed upon which avoids too much traction and is suitable for a fistula. The method now in favor in gastrostomy is to stitch the parietal peritoneum to the skin all around the incision, and then to fasten the unopened stomach in the wound by several sutures which traverse its muscular coat but do not enter its cavity, and whose deeper ends then transfix the abdominal wall. This gives a broad surface of contact between the peritoneum of the stomach and that of the abdominal wall, and favors

FIG. 198.



Kader's method of gastrostomy. First and second rows of sutures.

their prompt union. The protruding portion of the stomach may also be transfixed with two long pins which rest upon the skin and prevent strain on the sutures. The opening of the stomach is delayed as long as possible, from one to eight days. If necessary, food can be introduced by puncturing with an aspirating needle.

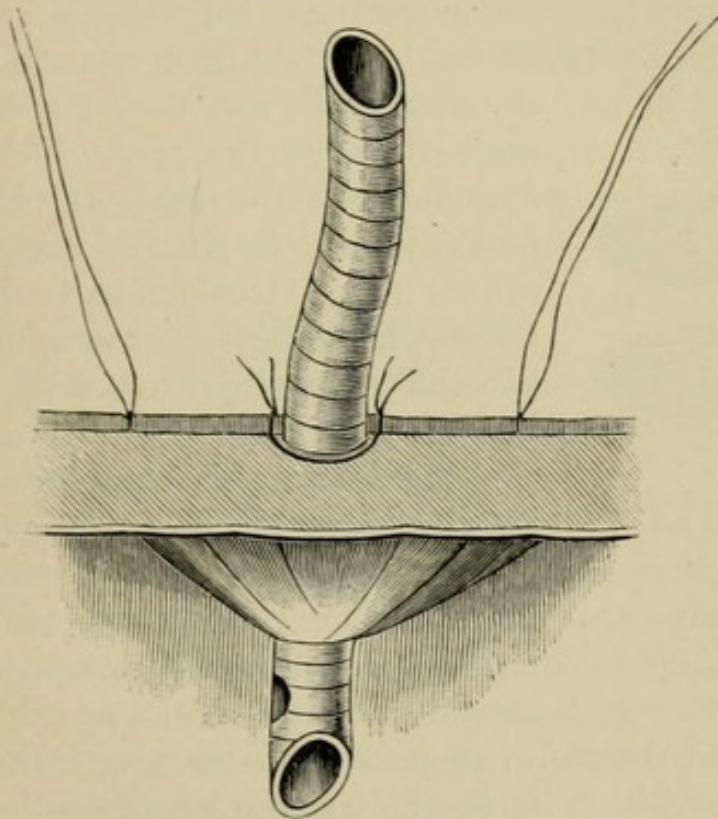
Witzel<sup>1</sup> divides the skin parallel to the ribs and a finger's breadth distant, then the rectus muscle longitudinally, and the transversalis horizontally. Next the anterior wall of the stomach is drawn into the abdominal

<sup>1</sup> *Centralb. f. Chir.*, 1891, p. 601.



wound sufficiently to permit of its being folded lengthwise and sutured over a rubber tube, which at one extremity enters the viscus and at the other is brought out of the opening in the skin. The stomach is then fastened in the wound in the ordinary way by a row of sutures around the folds enclosing the tube, and over the latter the skin is united, leaving only a small hole for the exit of the tube. This is intended to make the fistula

FIG. 199.



Kader's method. Final condition.

communicate less directly with the surface of the body, and thus insure better retention of the gastric contents. It is important that the tube should fill and even distend the orifice by which it enters the stomach.

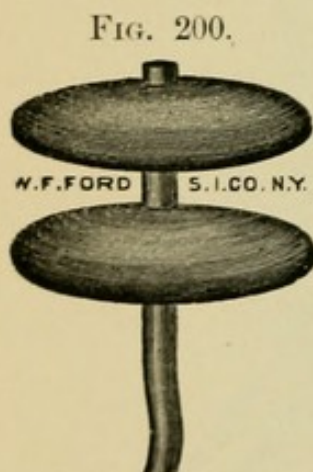**Kader's Method.**<sup>1</sup> (Figs. 198, 199.)—This is claimed to be more generally applicable than Witzel's, and certainly it gives most satisfactory control against leakage. Incision as in Witzel's. The sides of the opening are held

<sup>1</sup> Kader, *Centralblatt für Chir.*, 1896, p. 665.



apart, and a small fold of the stomach drawn out through it and fixed with hooks or two stout silk sutures. A small opening is made in it, and through this a rubber tube as large as a lead pencil is introduced for about two inches and fixed by a catgut suture at the opening. On each side of the tube at half-inch intervals are placed two silk Lembert sutures in such manner that they appose serous surfaces one centimeter wide and create a ridge on the inner surface of the stomach. This ridge is then heightened and the apposed serous surface increased by a second, parallel, row of sutures. (Fig. 198.)

Fixation sutures, to hold the stomach against the abdominal wall, are then passed at the ends through the muscularis of the stomach and the parietal peritoneum and adjoining fascia, and supported by others along the sides so as to narrow the opening rather closely about the tube. The resultant condition is shown in Fig. 199.



Plug of two hollow rubber disks for closing a gastrostomy fistula.

After healing is complete the tube is withdrawn and is reinserted only for the introduction of food. Meanwhile the lateral pressure of the contents of the stomach upon the projecting fold prevents leakage. E. J. Senn

reports good results in respect of absence of leakage from a method by which he creates a mamelon upon the surface of the stomach by Lembert sutures at its base. At the apex of this mamelon he makes the opening and then inverts it about half an inch, securing the inversion by a few sutures.

Leakage from a straight fistula of this organ can be controlled to a certain extent by a mechanical device consisting of two hollow rubber disks closely joined at their centers by a hollow rubber cylinder communicating with each. (Fig. 200.) The lower disk is passed through the fistula into the stomach, and both disks are then distended with air or water and thus made to block the opening.



In cases where the stomach need not be opened for some days it is sufficient, after uniting the skin and parietal peritoneum, to pass a couple of harelip pins through its outer coats, enclosing a portion of the stomach wall about three-quarters of an inch square. The pins are simply laid upon the skin transversely to the abdominal wound, and the opening made in the center of the square they enclose after adhesions have formed.

A crucial abdominal incision below the ensiform process was used by Sédillot. Others have employed a vertical incision in the linea alba, in the substance of the outer part of the left rectus, or in the left linea semilunaris.

Hahn opened and fixed the stomach in the eighth intercostal space after first entering the abdomen by an incision parallel with the lowest rib.<sup>1</sup>

### GASTROTOMY.

This is the operation in which the surgeon opens the stomach and then closes the opening at the conclusion of the operation.

**Operation.**—If it is performed for the removal of a foreign body which can be felt through the anterior abdominal wall, the incision, at least two inches long, is made over the tumefaction and in the direction which inflicts the least damage on the intervening tissues. Otherwise the incision is made in the median line just below the ensiform process or parallel to the left costal cartilages, as in gastrostomy. The tissues are divided layer by layer, the peritoneum opened, and one finger introduced to locate the foreign body.

After protecting the surrounding peritoneal surface by gauze pads or sponges, the part of the stomach wall to be opened is carefully drawn into the abdominal wound and held there by a couple of temporary retention sutures passed through the peritoneal and muscular coats on each side of the intended opening, which is then made parallel to the course of the blood vessels, that is, transversely to

<sup>1</sup> *Centralb. f. Chir.*, 1890, p. 193.



the long axis of the stomach. The foreign body is removed gently, with due regard for its sharp points, or the ulceration or sloughing which may exist, and if necessary the stomach is washed out. There must be as little sponging or irritation of its interior as possible.

The incision in the stomach is closed by a continuous silk suture of the mucous membrane, then by a row of Lembert sutures, which are reinforced by a continuous silk suture through the peritoneal coat. After the region of the wound has been made dry and clean, the temporary retention sutures are withdrawn, the protecting sponges are removed from the abdominal cavity and the parietal wound closed and dressed as described for an aseptic laparotomy.

Greig Smith does not suture the mucous membrane of the stomach, but closes the wound by a row of Lembert sutures reinforced by a continuous or interrupted suture of the peritoneal coat. The continuous suture prevents gaping of the wound during expansion of the stomach.

By gastrotomy Bull<sup>1</sup> and Richardson successfully removed foreign bodies impacted in the œsophagus near the cardiac orifice of the stomach. Richardson demonstrated that the lower three inches of the œsophagus are thus accessible by an incision parallel to the left costal cartilages, through which he introduced his whole hand into the stomach and extracted a set of false teeth from the lower end of the gullet.<sup>2</sup>

**Gastrotomy for Benign Stenosis of the Pyloric or Cardiac Orifices.** (Sometimes called Loretta's operation.)—Before the operation the stomach is washed out repeatedly with an alkaline solution. The pylorus is reached by an incision four or five inches long, usually in the linea alba between the xiphoid appendix and the umbilicus; or else approximately parallel to and about an inch from the right costal cartilages, starting an inch below and an inch and a-half to the left of the xiphoid appendix and terminating near the level of the cartilage of the ninth rib.

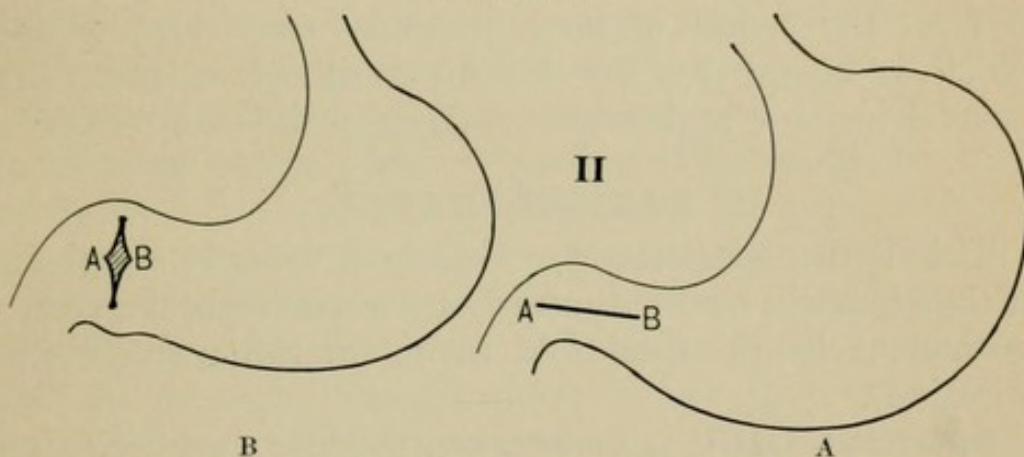
<sup>1</sup> New York Medical Journal, October 29, 1887.

<sup>2</sup> Lancet, October 8, 1887.



The tissues are divided layer by layer, and the peritoneum opened. The surrounding peritoneal surface is protected and held out of the way in the usual manner, while the pylorus is sought for, and such adhesions as may exist are divided between double catgut ligatures. The anterior wall of the stomach is drawn into the abdominal wound, and after again carefully protecting the surrounding peritoneal surface is incised transversely for from one to three inches between its two curvatures near the pylorus, but outside of the inflammatory zone adjoining it. Guided by two fingers grasping the pylorus externally, the forefinger of the right hand is passed through the stomach into the pyloric orifice. This may

FIG. 201.



Pyloroplasty. A. The incision, A, B, along the contracted pylorus. B. Closure of this wound transversely. The point A united to B.

require considerable force, or the orifice may have become so contracted that preliminary dilatation with some small instrument is necessary. McBurney used a small bivalve anal speculum. Dilatation is continued till it is felt that any further stretching would threaten a rupture of the viscus. The wound in the stomach is then sutured as described in gastrotomy for a foreign body, and, after cleansing and drying the field of operation and removing the protective pads or sponges, the parietal wound is closed as usual.

To reach the cardiac orifice, the abdominal incision is made obliquely from a point just below the ensiform proc-



ess parallel to and about one inch from the left costal cartilages. The anterior wall of the stomach is opened by a longitudinal incision made between the two curvatures and as near the cardiac end as possible.

**Pyloroplasty.**—Instead of performing gastrotomy and divulsion of the pylorus, the stricture can be relieved by longitudinal division followed by transverse reunion. (Fig. 201.) The median or right oblique abdominal incision is employed, any adhesions about the pylorus are separated, and after carefully walling off the surrounding peritoneum with sponges an incision opening the lumen of the viscera about an inch and a-half long is carried across the pyloric ring, through the neighboring anterior wall of the stomach and first part of the duodenum. The opposite extremities of this incision are then united to each other to form the center of an apparently transverse wound, which is closed by the Czerny-Lembert suture. The parietal incision is then closed tight in the usual way.

#### **GASTRORRHAPHY.**

This is the operation for closing a wound or opening in the stomach, or to diminish its capacity by creating a permanent longitudinal fold in its anterior wall (Gastroplication).

**Operation.**—If it is undertaken to close a gastric fistula, the interior of the stomach, the fistulous tract, and surrounding skin are made as clean as possible. A sponge tied to a string is pushed through the fistula and held by an assistant against its interior orifice. An incision is then made not less than two inches long in any convenient direction across the fistula and through the abdominal wall, layer by layer, until the peritoneum is reached. This is opened at one extremity of the wound and a finger inserted to determine the limit of the adhesions. On this finger as a director, the peritoneal incision is enlarged around the fistula, which is then surrounded by sponges packed into the abdominal cavity. The liberated stomach is drawn into the abdominal wound, and the margins of the opening in the stomach freshened and closed as



described in gastrotomy, after withdrawing the sponge from the interior of the stomach.

The fistulous tract is excised from the abdominal wall, and, after the operation area has been thoroughly cleansed and dried, the wound is closed in the usual way with or without a gauze packing.

If the operation is undertaken for a perforating wound or ulcer of the stomach, immediately after opening the peritoneal cavity by an ample incision, either median, just below the ensiform process, or parallel to the left costal cartilages, all extravasated material must be sponged away or irrigated out of the peritoneal cavity with boiled water, and the opening in the stomach closed as described in gastrotomy. The operation area is walled around by sponges or pads and a sponge is then passed into the lesser peritoneal sac through a small opening made in the great omentum, between the stomach and transverse colon. If the lesser sac is found infected, or there is even a suspicion of an opening on the posterior surface of the stomach, this opening must be sought for and closed. If it cannot be reached and sutured through the great omentum (between the stomach and transverse colon), rather than leave it unclosed, Greig Smith advises an incision in the anterior wall of the stomach, through which the opening in the posterior wall may be closed from within. After everything has been made as clean as possible, and all sponges removed from the abdominal cavity, tubes surrounded by a plentiful gauze packing should extend into all the infected regions in the greater and lesser peritoneal sacs and connect them with the skin surface.

The parietal wound is then partially closed and dressed antiseptically.

**Gastroplication.**—To diminish the capacity of the stomach, it is exposed by one of the incisions above described and its anterior wall drawn well out through the wound. Two points, several inches apart according to the size to be given to the tuck, are caught up and, the intermediate portion being depressed in a longitudinal fold, are fastened together by a broad Lembert silk suture. Similar



sutures are placed on each side at half-inch intervals to lengthen and maintain the fold. The stomach is then dropped back and the parietal opening closed.

#### **PYLORECTOMY.**

The stomach should be repeatedly washed previously and should be empty at the time of operation. The abdominal incision is made in the linea alba between the ensiform process and umbilicus, or over the most prominent part of the tumor, and more or less transversely, from just to the left of the median line in the direction of the free border of the right costal cartilages and not less than an inch from them. Other forms of incision that have been employed are longitudinal at the outer border of the right rectus, transverse over the tumor, or crucial. At first the incision is only made large enough for exploration; if then the operation is deemed feasible, it is enlarged till it is from three to five inches long.

Sponges are packed into the abdomen around the tumor, which is drawn as much as possible into the abdominal wound. The great and small omenta are cut close to the greater and less curvatures of the stomach, after first securing the vessels between double ligatures, till the point toward the left is reached where the stomach wall is to be divided. Great care must be taken not to wound the portal vein, hepatic artery, or common bile duct which lie behind the pylorus, and no damage must be done to the transverse mesocolon. If the disease involves this structure the operation should be abandoned.

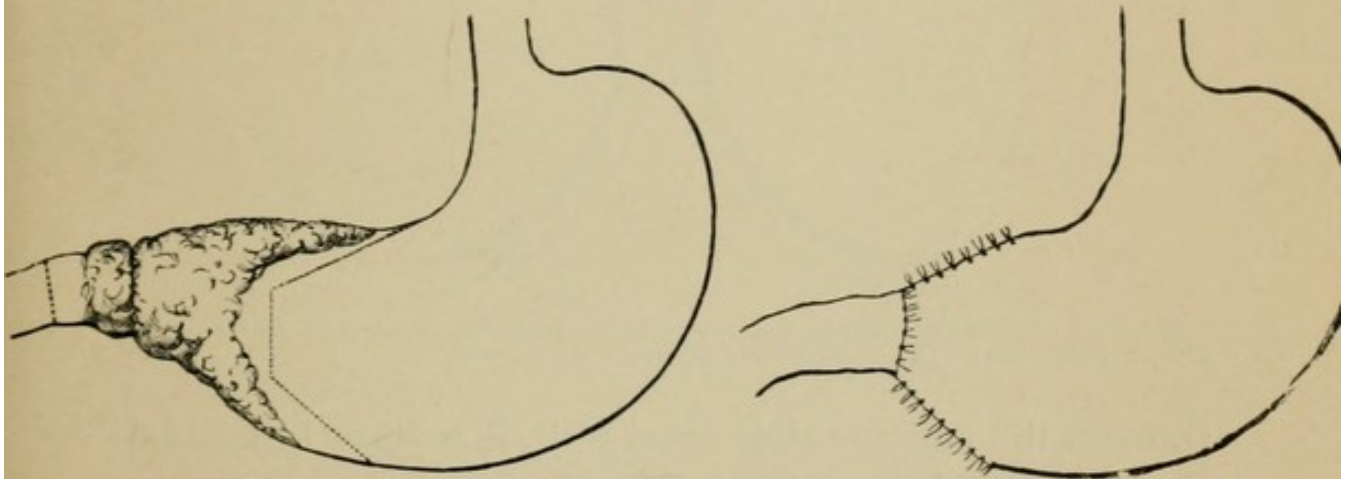
Fresh sponges are now packed around the liberated pyloric end of the stomach, and the growth, with a margin of healthy tissue, is excised with scissors. All vessels are secured as they are divided, the lumen of the duodenum is immediately plugged by a sponge, and after removing all extravasated matter and renewing the sponge packing around the field of operation, the large opening in the stomach is narrowed on the side of the less curvature by Czerny-Lembert sutures till the opening which remains next the greater curvature approximates the size of the



duodenum. If circumstances require the implantation of the duodenum near the less curvature, the opening in the stomach is narrowed below or on both sides in the same way (Fig. 202), the posterior walls of the stomach and duodenum at their respective points of division are then approximated and the margins of the wounds behind are inverted to bring the posterior peritoneal surfaces in contact.

The redundant mucous membrane is raised at its cut edge and sutures of fine silk are passed beneath it from the inside, at intervals of an eighth of an inch, through the muscular and peritoneal coats of the stomach and

FIG. 202.



Pylorectomy. Showing method of narrowing the opening in the stomach.

duodenum. When knotted the sutures lie beneath the mucous membrane, which can be closed over them by a continuous or interrupted suture (Fig. 203). Only about the posterior half of the stomach and duodenum can be united in this way.

The sponge is then withdrawn from the duodenum and the remainder of the wound is closed by the Czerny-Lembert suture. After testing the suture line by filling the stomach with water, the operation area is made clean and dry, the protective sponge packing is removed, and the abdominal wound is closed in the usual way.

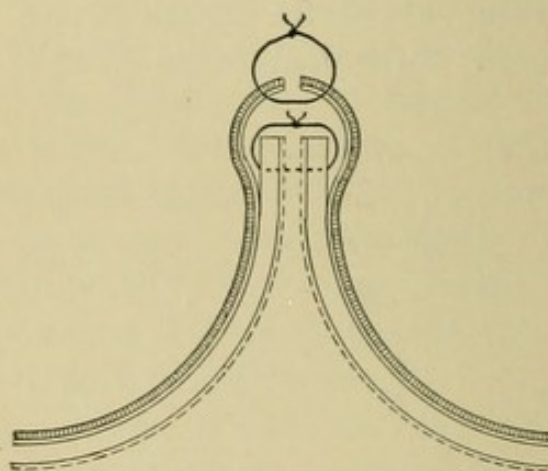
Senn's omental graft to surround the suture line in the viscera might be useful.



In extensive resections of the pylorus, Billroth and others have closed the resulting wounds in the stomach and duodenum by Lembert sutures and then restored the continuity of the alimentary canal by performing a gastro-enterostomy.

On account of the high mortality of pylorectomy for malignant disease, this operation is now rarely done; in general it may be stated that when the tumor can be felt

FIG. 203.



Wölfler's methods of uniting the wound in the posterior portion of the stomach after pylorectomy. The shaded lines represent the mucosa.

through the anterior abdominal wall, it is scarcely justifiable to attempt its removal.

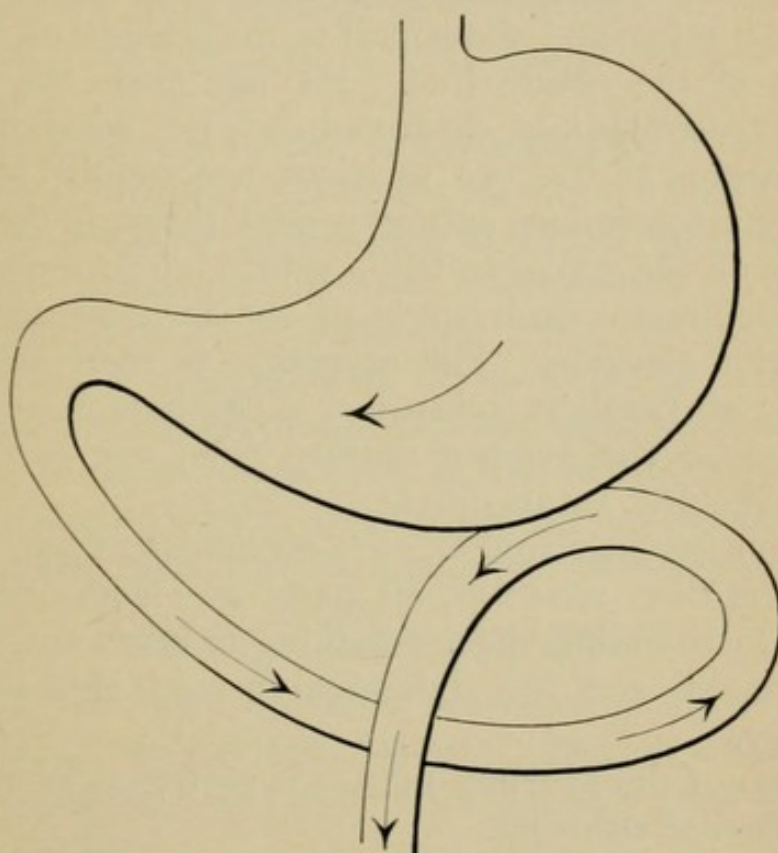
### GASTRO-ENTEROSTOMY.

The preliminary washing of the stomach and the abdominal incision are the same as for pylorectomy, but the abdomen is more commonly opened in the median line between the ensiform process and the umbilicus. The first loop of intestine which presents is grasped and traced upward to the duodenum. It should be noted that this part of the gut is thicker, of greater diameter, and more vascular than that nearer the colon. Czerny advises that the origin of the jejunum be sought for at once by drawing up the stomach, great omentum, and transverse colon, and following back the transverse mesocolon to the spine; immediately to the left of this lies the



end of the duodenum. A portion is then selected as near to the latter as will permit easy coaptation with the stomach, the great omentum is pushed to the left and the intestine drawn to the right and upward over the colon. The anterior wall of the stomach near the greater curvature and the selected portion of intestine are drawn as far as possible into the abdominal wound, and the loop of intestine should be so twisted or placed that at the

FIG. 204.



*Gastroenterostomy*; diagram to show the method of union to secure similarity in direction of the peristalsis of the stomach and intestine.

conclusion of the operation the direction of its peristaltic wave shall not be opposite to that of the stomach. (Fig. 204.)

The rest of the abdominal contents are walled off by a protective sponge-packing, and the selected loop of intestine, squeezed empty by the fingers, is prevented from filling by a rubber or gauze band passed through the mesentery and constricting each extremity of the selected loop.



A continuous silk suture through the peritoneal and muscular coats is then made to unite the anterior surface of the stomach near its greater curvature to the posterior surface of the intestine a little to the mesenteric side of its free border, for about four inches.

In addition, a row of Lembert sutures may be placed anterior to the continuous suture, although this is not absolutely necessary. The stomach and intestine are opened parallel and close to this suture line, and the interior of each irrigated clean—the incisions should terminate opposite each other and about half an inch short of the extremities of the suture line. Having made the wounds and their surroundings clean and dry, the adjoining posterior margins of the two incisions are rapidly sewn together by a continuous suture passed through the entire thickness of the walls, and this suture is continued as far as possible around each angle of the incision and along the anterior margins. The operation is then completed by a row of Lembert sutures or a continuous suture extending along the anterior surface from one end to the other of the first suture line.

The constricting band at each extremity of the loop of intestine is then removed, all parts are made clean and dry, the surrounding sponge-packing is taken out, the viscera replaced, and the abdominal wound closed in the usual way.

The use of the Murphy button is preferred by many to any method of suturing.

In order to prevent passage of the bile into the stomach through the opening Braun made an anastomosis between the two sides of the loop of jejunum, and Jaboulay made one between the duodenum and jejunum. With the same object Kocher made the opening into the intestine transverse and semilunar in shape so as to form a valve. See Tillmann's *Surgery*, Vol. III., p. 98, Am. Ed.

In *posterior gastroenterostomy* the opening is made in the posterior wall of the stomach after having exposed it by tearing through the transverse meso-colon with as lit-



the injury as possible to its vessels. This modification has many advantages.

*Jejunostomy* for inoperable cancer of the pylorus has been performed a few times. A longitudinal incision is made to the left of the umbilicus, the omentum and transverse colon pressed upward, and a loop of the upper portion of the jejunum brought into the wound and secured there by sutures as in gastrostomy. The opening made in the intestine should be only large enough to admit the tube through which food is to be introduced.

Maydl<sup>1</sup> has proposed a more complicated method, as follows :

The abdomen is opened transversely about four finger-breadths below the ensiform process, a loop of jejunum some ten or twelve inches long extracted, and, with every antiseptic precaution, divided transversely. The proximal segment is then connected with the distal a few inches below the point of division by an anastomosis operation to preserve the biliary and pancreatic secretions, and the distal segment fixed in the abdominal wound as in gastrostomy, or the distal segment may be attached to the stomach, thus making a gastroenterostomy.

### HERNIOTOMY, KELOTOMY.

Under this head are to be described the operations for the relief of strangulated *inguinal*, *femoral*, *umbilical*, and *obturator hernias*, and those for the radical cure of the first three varieties.

It has been well said that there is no operation in which the unforeseen has a larger share than in herniotomy, none in which the surgeon is called upon to show more skill, sagacity, and decision. The causes of this are to be found in the absence of absolute guides to the hernial sac, the changes in the sac and overlying tissues brought about by inflammation or time, the character of the hernia—whether composed of omentum, intestine, cæcum, or bladder, and, lastly, the difficulty of determining not only the extent of the injury done to the strangulated

<sup>1</sup> Maydl : Wien. med. Wochensch., 1892, p. 697.



tissues, but even, in some cases, the route taken by the hernia in its descent. It is desirable, therefore, that the account of the different operations should be preceded by some general considerations upon these subjects.

**General Directions.** A. RECOGNITION OF THE SAC AND BOWEL.—The first difficulty encountered in the course of the operation is that of recognizing the sac. The thickness of the connective tissue covering it varies greatly in different cases; each layer must be pinched up with forceps, opened with the knife lying upon its side, as in opening the sheath of an artery, then raised upon the finger or a director, and divided to the full extent of the cutaneous incision, after having been carefully scrutinized. Occasionally a cyst containing liquid is found in front of the hernia, and may at first be mistaken for it, for usually the sac contains a certain amount of serum. Careful examination of the tissues before division is absolutely necessary, because in those rare cases where there is no sac (hernia of the cæcum or of the bladder), and in others where it is quite undistinguishable, it is only by recognizing the muscular coat when he reaches it, that the surgeon avoids opening the intestine or bladder by mistake. As the sac is approached, each layer should be pinched up in a narrow fold and moved gently across the underlying parts; if a smooth globular tumor is felt below, the surgeon makes an opening in the fold, confident that the wall of the intestine is not included in it; but if he is unable to pinch up the fold, or if, instead of the sensation of a smooth globular mass, he gets only that of an empty space, he examines the surface again, divides any fibrous bands he may find at the neck of the hernia, and tries to introduce his finger through it into the abdominal cavity. If he succeeds, he knows the sac has been opened; if he does not succeed, he renews the examination and continues the dissection.

Maisonneuve said the surgeon may know he has not reached the intestine so long as he is not certain of having done so; but this is not true of all cases; the intestine is not always smooth and shining; it may be dark, dull,



congested, and thickened, and in hernia of the cæcum or sigmoid flexure it may have no peritoneal coat.

When the hernia is small and recent the sac is bluish, and can be pinched up between the thumb and finger, so that its smooth opposing surfaces can be felt to glide upon one another. When it is large and of long standing, the sac may be exceedingly thin and unrecognizable, or very thick and adherent. If small, it should be thoroughly isolated, and its boundaries everywhere defined; if large and adherent, its neck alone should be cleared.

B. OPENING OF THE SAC.—The propriety of opening the sac used to be a subject of dispute. The only objection to it, but that a serious one, was the danger of thereby setting up peritonitis. On the other side there was the danger of returning the hernia into the abdomen in a gangrenous condition, or unreduced when the stricture was formed by the sac itself. Now, however, the rule is always to open the sac with every antiseptic precaution and relieve any constriction which may be found by cutting down upon it layer by layer from without. Then either immediately or after an interval a radical cure is performed.

The liquid which is usually contained in the sac may not only serve to call attention to its accidental opening, but may also be taken advantage of to open it safely when it has been recognized. It, of course, collects at the most dependent point, and there intervenes between the sac and the bowel, so that the former can be pinched up and opened without injury to the latter. When this is not the case, the surgeon must pinch up a very small fold of the sac wherever he can do so, or do as Mr. Liston did in a case where, as he says, "there was no possibility of pinching up the sac, either with the finger or forceps; it contained no fluid, and was impacted most firmly with bowel; very luckily the membrane was there; and, observing a pelleton of fat underneath, I scratched very cautiously with the point of the knife in the unsupported hand, until a trifling puncture was made, sufficient to admit the blunt point of a narrow bistoury."<sup>1</sup> The opening should be en-

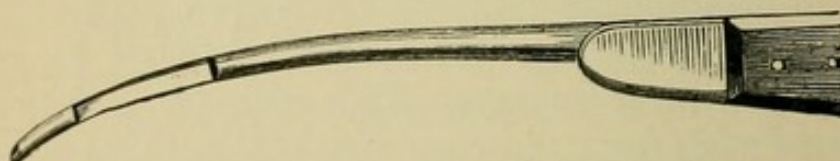
<sup>1</sup> *Op. Surgery*, p. 462, quoted by Jos. Bell, *Manual of Surgical Operations*, p. 231.



larged until the finger can be introduced, and then the sac slit up on it as a guide. If the omentum is then found filling the sac, it must be cautiously unfolded or incised, for it is probable, especially in umbilical hernia, that a strangulated loop of intestine will be found in its center.

C. DIVISION OF THE STRICTURE.—The left forefinger is passed up into the neck of the sac by which the stricture is usually constituted, the pulp upward, the nail pressing against the intestines; if the stricture lies or can be drawn outside the opening in the abdominal wall through which the hernia made its escape, it may be divided freely without risk, but if it lies within the opening the division must be made with reference to the anatomy of the region. If the division cannot be made at the desired point, but only at some other where an incision of the necessary ex-

FIG. 205.



Hernia knife.

tent would be dangerous, the stricture must be slightly nicked at that point, and advantage then taken of the partial liberation to make a second cut in the proper place.

The end of the finger, or its nail, is gently engaged in the stricture, its pulp against the selected point of division, and the knife, a probe-pointed, slightly curved bistoury, passed on the flat along its palmar surface until the point has passed through the stricture. The surgeon then turns its edge upward and presses it against the stricture with the end of the finger on which it rests. A slight crackling announces the division, which must be extended or repeated at different points until the finger can be passed freely through into the abdomen.

Instead of an ordinary probe-pointed bistoury, a specially constructed hernia knife (Fig. 205) is often used. It is probe-pointed and its cutting edge not more than an



inch long. The knife may also be guided upon a director instead of the finger. The "hernia director" is broader than the ordinary one, and sometimes has a broad flange on each side to keep the bowel from rolling over against the edge of the knife. It is, however, more surgical to cut down upon the constriction layer by layer and then divide it from without, the gut being protected by the finger or a director.

D. EXAMINATION AND RETURN OF THE BOWEL.—The bowel should be gently drawn out about an inch in order that the constricted part itself may be examined, for it is very likely to be badly damaged. If the entire loop is in suitable condition it must be carefully cleaned of all blood and gradually returned into the cavity of the abdomen. It is not always easy to decide, however, whether or not its condition is suitable for return, and some surgeons have recommended that in cases of doubt it should be covered with warm, wet cloths and kept under observation for some time, the stricture, of course, having been previously divided.

A very great change in the color of the loop is far from proving the existence of gangrene. A deep red vinous color does not preclude recovery, especially if the surface has not lost its lustre; but if it is black, or deep brown, or grayish-yellow, or if it is dull, flaccid, or wrinkled, it is certainly gangrenous. Of course, when the characteristic gangrenous odor, or the fecal odor consequent on perforation, exists, there can be no doubt.

Occasionally, when in doubt as to the vitality of a small part of the intestine, I have covered it in by a few Lembert sutures as if it were a cut in the wall.

It is not always easy to return the intestines even after the stricture has been divided. The surgeon should try to reduce one end at a time, by squeezing its contents back into the abdomen and pushing the gut in afterward. If rupture occurs, and the bowel is otherwise in good condition, it must be closed with Lembert sutures and returned into the abdomen.

If the intestine is gangrenous, an artificial anus must



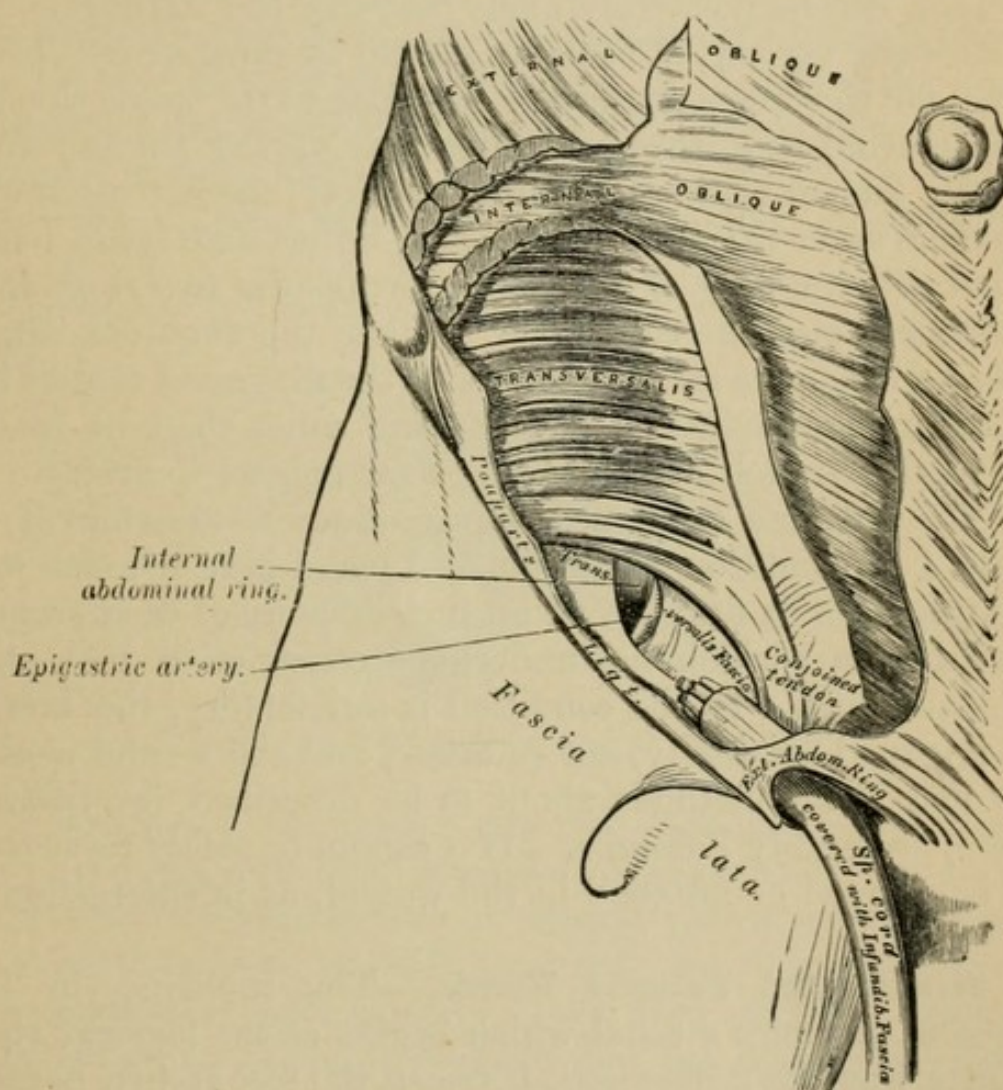




206), and also emerges at the external abdominal ring. The former is by far the more common variety.

**Operation.**—The parts having been well shaved and disinfected, the patient is anæsthetized and placed upon his back, with his shoulders slightly raised. An incision is

FIG. 207.



Inguinal hernia, showing the transversalis muscle, the transversalis fascia, and the internal abdominal ring.

then made from a point a little above and external to the external ring along the summit of the swelling to its lower end, and carefully deepened until the sac is reached. This is then opened by pinching it up and incising as above described. The best point for opening it is at its extreme lower end, because a little serum is usually collected there,



separating it from the bowel, but if no such point is found the neighborhood of the neck should be tried, because that part is usually free from adhesions. The constriction, which is usually in the neck of the sac if the hernia is old, is then sought for, and, if found above the external ring, must be nicked or divided directly upward, or cut down upon from without.

If it can be positively made out that the hernia is of the *oblique* variety, the cutting should be done on the outer side, for the epigastric artery lies close to the inner side of the internal ring, through which this variety passes; and if it is known to be of the *direct* variety, the cutting must be done upon the inner side. But, unfortunately, in most cases the dragging of the hernia brings the two rings immediately opposite each other, so that the inguinal canal can no longer be said to exist, and the diagnosis cannot be made with certainty. The incision must then be made upward, parallel to the course of the epigastric artery.

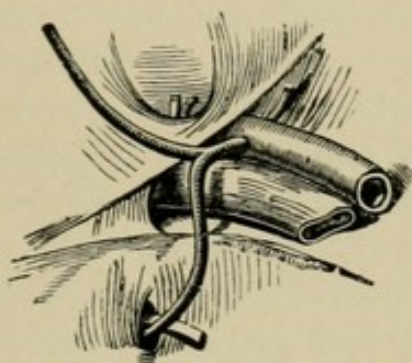
The intestine must next be examined to ascertain if it is in a fit condition to be returned; and here it must not be forgotten to draw down an inch or more of each end so that the part which has undergone constriction may also be examined. If the condition is satisfactory, the bowel is returned gradually, not *en masse*, and the wound closed by one of the methods about to be described for radical cure, preferably Bassini's. If it cannot be safely returned, it is resected or fastened in the wound, as in enterostomy.

**Strangulated Femoral Hernia.**—The intestine in its descent occupies a canal which begins at the femoral ring under Poupart's ligament, between the free arched border of Gimbernat's ligament and the femoral vessels (Fig. 206), and ends at the saphenous opening in the fascia lata of the thigh. After passing through the opening it turns upward over the groin. The normal length of the canal is about an inch, but in hernias of long standing it is much shortened by the approximation of its two ends. The seat of stricture is now thought to lie in most cases at the saphenous opening, or just above it, and not at the



base of Gimbernat's ligament, as was formerly supposed; free division is possible at the former point on the upper and inner side without the risk of injury to any organ, except possibly the spermatic cord, and that is at such a distance as to be practically out of harm's way. Under ordinary circumstances, Gimbernat's ligament can also be safely divided on the inner side, but in about one and one-half per cent. of cases the obturator artery pursues the anomalous course shown in Fig. 208, and then lies directly in the way of the knife. The neck of the sac under such circumstances is entirely surrounded; on its outer side are femoral vessels, above is the common trunk of the epigastric and obturator arteries, on its inner side the obturator

FIG. 208.



Variations in origin and course of obturator artery.

artery, below it the bone. The only safe plan of relieving the stricture, therefore, is to nick it slightly, to the depth of one or two millimeters, at several points on its upper and inner borders, or fully to expose the ring and divide its upper inner part layer by layer from without inward. The coverings of the hernia are thin and composed of the skin, subcutaneous tissue, cribriform fascia sometimes, septum crurale, and peritoneum.

The incision may be straight or curved, the convexity directed downward and outward, or T-shaped, the horizontal branch being made along Poupart's ligament, the other passing directly downward over the saphenous opening, and should be made from without inward. The single straight incision just to the inner side of the



femoral vessels is the one usually employed. The underlying tissues must be divided, and the sac exposed or opened in the manner described under *General Directions*, and the seat of stricture sought for and divided according to the rules above laid down.

The gut is then pulled down and examined, and if its condition is satisfactory it is returned and a radical cure performed. If not, it is resected or fastened in the wound.

**Strangulated Umbilical Hernia.**—It is generally claimed that true umbilical hernia, that is, hernia through the umbilical ring, is almost always congenital, and that the hernias which occur during adult life emerge, not through the ring, but through an accidental opening in the linea alba near it, and therefore deserve the name of *peri-umbilical* given them by Gosselin. While this condition, that is, of escape through a chance opening in the linea alba, may exist in some cases, Richet<sup>1</sup> has sought to prove by anatomical considerations and by the results of the examination of three cases of hernia, that true umbilical hernia, on the contrary, is the rule, and the other is the exception. He shows that the weak point of the ring is its upper portion, and that when the cicatrix is pressed downward and given a semicircular form by the hernia, a complete ring, which seems to be situated above that corresponding to the vein and arteries, is constituted by the cicatrix below and the upper part of the opening above, and exactly resembles a distended accidental perforation.

The coverings of the hernia are the skin, cellular tissue, and peritoneum; its contents are the small intestine, sometimes the transverse colon, and in the adult the omentum.

On account of the pathological changes which take place in the sac and its contents, it is best to undertake a formal laparotomy if the hernia is strangulated or irreducible. An incision is made gently curving outward around one side of the base of the hernial tumor, and prolonged a couple of inches above and below it in the me-

<sup>1</sup> Anatomie Médico-Chirurgicale, Part II., p. 378.



dian line. The incision is deepened layer by layer and the peritoneum opened in the median line above and below the neck of the hernial sac, and in the intermediate space divided on the finger as a guide, in the line of the cutaneous incision close outside the neck of the sac, sparing the margin of the rectus muscle as much as possible. A sponge protective packing is placed on the surrounding viscera, and an incision is made through the neck and body of the sac, including the overlying skin, at right angles to the center of the curved incision around the base of the hernial tumor, exposing the hernial contents without damaging them.

The constriction is thus relieved, and the dissection is continued till the hernial contents are freed from adhesions to each other and the sac. If they consist of omentum alone, the excess is excised on the proximal side of the strangulation and the abdominal wound treated as described below. If of intestine, the gut is surrounded by warm cloths or placed in the abdomen on sponge protectives. Then the hernial sac, together with the overlying skin and the umbilicus, is excised with division of the peritoneum close around the neck of the sac.

The intestine is next inspected, and if gangrene is present the gut is resected or left outside the partially closed abdominal wound for the slough to separate. A couple of Lembert sutures, or a stout silk loop through the mesentery, serve to retain the healthy part above and below the damaged area in the margins of the wound.

If the gut is healthy, after excision of the excess of omentum and of the sac with its overlying skin and umbilicus, the sponge protective packing is removed, the edges of the sheaths of the recti muscles are freshened, and the abdominal wound closed in the usual way with close approximation of the recti. The wound is then dressed in the ordinary manner.

If the hernia is very large it is better that the first incision should be made in the median line and prolonged upward an inch or two above the hernial orifice. The sac should be freely but very carefully opened in the line of



the incision, for extensive adhesions are often present ; or the abdominal cavity may be opened just above the hernial orifice, and the wall of the latter divided at its upper part. After reduction of the hernia the entire circuit of the orifice is excised, and the wound closed as after laparotomy.

**Strangulated Obturator Hernia.**—A long incision is made parallel to the femoral vessels and about an inch from them on the inner side. The pectineus muscle is exposed and divided, as are also any fibers of the obturator externus whose division may be necessary to give access to the seat of the stricture. The relations of the artery and nerve to the neck of the sac must be determined, and the division made in such a direction that they will not be injured.

If the gut can be returned into the abdomen a radical cure can then be attempted. This consists simply in isolation of the sac, its ligation as high as possible after reduction of the hernia, excision of the distal portion, closure of the orifice with silkworm-gut, and suture of the wound in the overlying soft parts.

The same may be said of hernia occurring in such unusual localities as Petit's triangle, the great sacrosciatic foramen, etc.

If the gut is gangrenous it must be fastened in the wound as in enterostomy, or resected if the condition of the patient permits.

### **RADICAL CURE OF INGUINAL HERNIA.**

**Czerny's Operation.**<sup>1</sup>—An incision is made three or four inches long over the inguinal canal and upper end of the hernial sac, with its center opposite the external abdominal ring. The aponeurosis of the external oblique muscle and the sac are exposed, and the neck of the latter dissected free from the surrounding parts. This is most easily done after the body of the sac has been opened and the hernial contents freed from adhesions and reduced, and one finger passed through the interior of the neck of the sac to make it tense and serve as a guide in the dissection.

The neck of the sack is drawn down and tied off as

<sup>1</sup> *Wien. med. Woch.*, 1877, No. 21.



high up as possible or at the internal abdominal ring, with a stout catgut ligature, which is drawn tight over the tip of the finger placed inside the neck to prevent prolapse of the hernia and its inclusion in the ligature. Czerny drew the serous surface together by a continuous (purse-string) silk suture passed from the inside. The sac distal to the ligature is excised, though any part or the whole of it can be left undisturbed if it seem advisable.

The sides of the opening in the abdominal wall are drawn together with catgut or silkworm-gut sutures passed through all the layers between the skin and peritoneum, and closed over the cord, which is left to emerge through as small an opening as possible at the lower angle of the suture line. The skin wound is closed with interrupted fine silk sutures, and if it seem necessary a strip of rubber tissue is placed in the lower angle of the wound for drainage.

Ball<sup>1</sup> applied torsion to the sac and its neck before ligating and excising the distal portion. Barker<sup>2</sup> dissects out and divides the neck of the sac, transfixes and ties it off with a silk ligature, and then uses the long ends of the latter as a suture to close the internal ring and overlying wound. He does not remove the body of the sac. The rest of the wound is closed by both as in Czerny's operation. Macewen<sup>3</sup> dissects out the sac, its neck, and the immediately adjoining peritoneum. He then inverts and reinverts the apex of the sac into its neck, transfixes and ties together with a firm catgut or silk ligature the mass thus formed and fastens it on the inner surface of the internal abdominal ring. The latter is closed by suturing the conjoined tendon to the inner surface of Poupart's ligament. The external ring is narrowed as much as possible by silkworm-gut stitches and the cutaneous wound united over it.

The main feature of the last three operations is the attempt to obliterate the funnel-shaped depression leading

<sup>1</sup> Brit. Med. Jour., 1887, II., p. 1272.

<sup>2</sup> Ibid., p. 1203.

<sup>3</sup> Ibid., p. 1263.



into the neck of the hernial sac and to substitute at this point an elevation.

Kocher's <sup>1</sup> method has yielded excellent results, and is as follows: An incision three or four inches long is made in the long axis of the hernial tumor; its center is over the external ring; only the skin and subcutaneous tissue are divided; none of the external oblique muscle is cut. After dissecting out the body and neck of the sac up to the internal abdominal ring and reducing the hernia, a finger is passed up the inguinal canal and on its tip as a director an artery clamp is forced through the external and internal oblique and transversalis muscles at a point about half an inch to the outer side of the internal ring. Without removing it from the puncture the clamp is passed on down the inguinal canal and made to seize the apex of the sac, which is then drawn up and pulled through the puncture and twisted into a round cord. The latter is laid upon the outer surface of the external oblique and lower down *in* the inguinal canal and secured there by five or six sutures passed through all the structures (except the skin, subcutaneous tissue, and peritoneum) on each side of the inguinal canal. The last one or two sutures through the extremity of the twisted sac and the pillars of the external ring draw the latter together. The cutaneous wound is then closed and dressed antiseptically.

**Bassini's Operation.**<sup>2</sup>—An incision three or four inches long is made from the level of the upper part of the internal abdominal ring obliquely downward over the long axis of the hernial tumor. The aponeurosis of the external oblique muscle is exposed and divided from the upper border of the internal abdominal ring over the whole length of the inguinal canal, and the neck of the hernial sac isolated from the cord and surrounding parts. (Fig. 209.) The body of the sac is nicked and opened sufficiently to free its contents from possible adhesions, and to permit reduction of the hernia by a finger passed through the interior of the neck of the sac to its abdominal

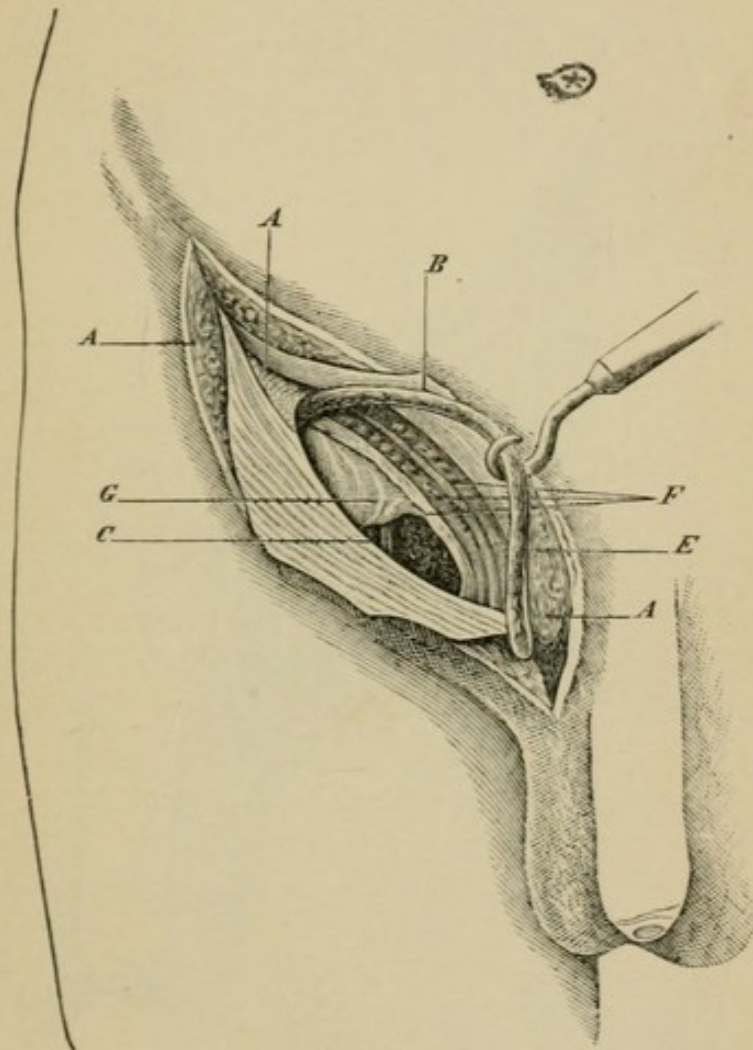
<sup>1</sup> *Annals Surg.*, 1892, Vol. 16, p. 505.

<sup>2</sup> *Centralb. f. Chir.*, 1890, Vol. 40, p. 429.



orifice. The neck is then drawn down, dissected free, and encircled or transfixed as high up as possible by a stout catgut ligature, which is drawn tight over the tip of the finger still kept inside the neck of the sac to prevent the prolapse of any viscus and its inclusion in the ligature.

FIG. 209.



*A, A, A.* Subcutaneous cellular tissue. *E.* Spermatic cord. *B, C.* Aponeurosis of external oblique divided and turned back. *G.* Epigastric vessels. *F.* Internal oblique and transversalis muscles and vertical fascia of Cooper.

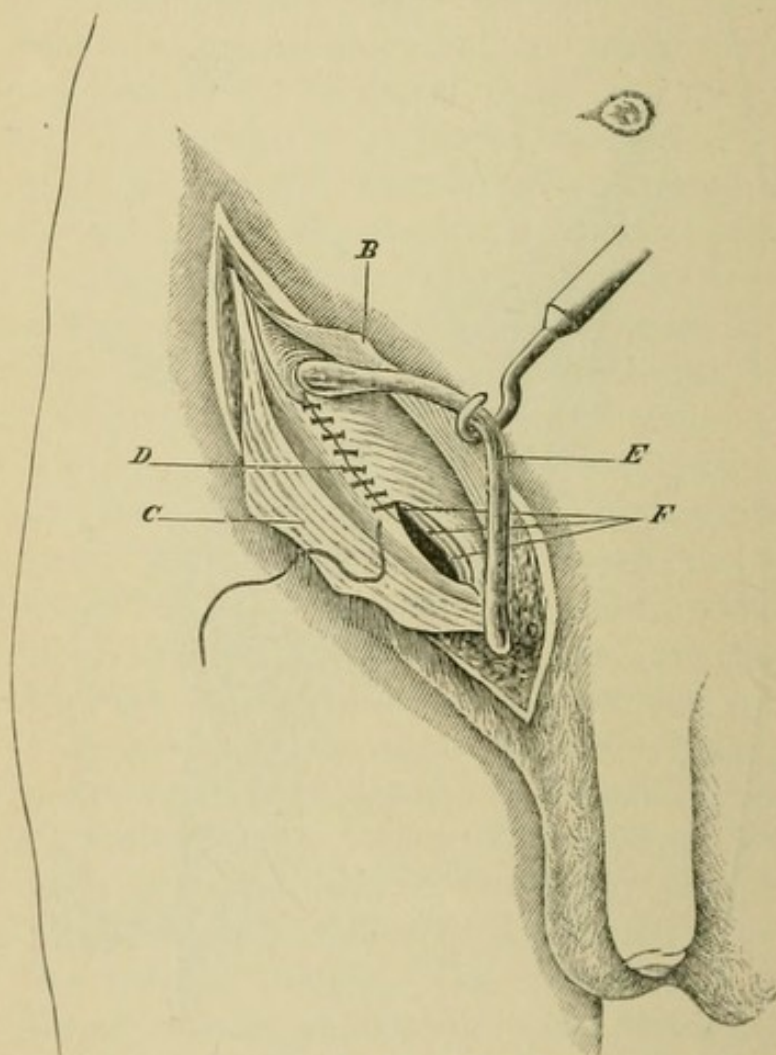
The lower portion of the sac is then dissected out and excised.

The margins of the wound, including the divided aponeurosis of the external oblique muscle, are well retracted, and on the outer side of the internal abdominal ring and inguinal canal, the upper border of Poupart's ligament is



exposed, and on the inner side the conjoined edge of the internal oblique and transversalis muscles and the transversalis fascia. After raising the cord these structures on the inner side of the internal abdominal ring and inguinal canal are united beneath the cord to Poupart's ligament

FIG. 210.



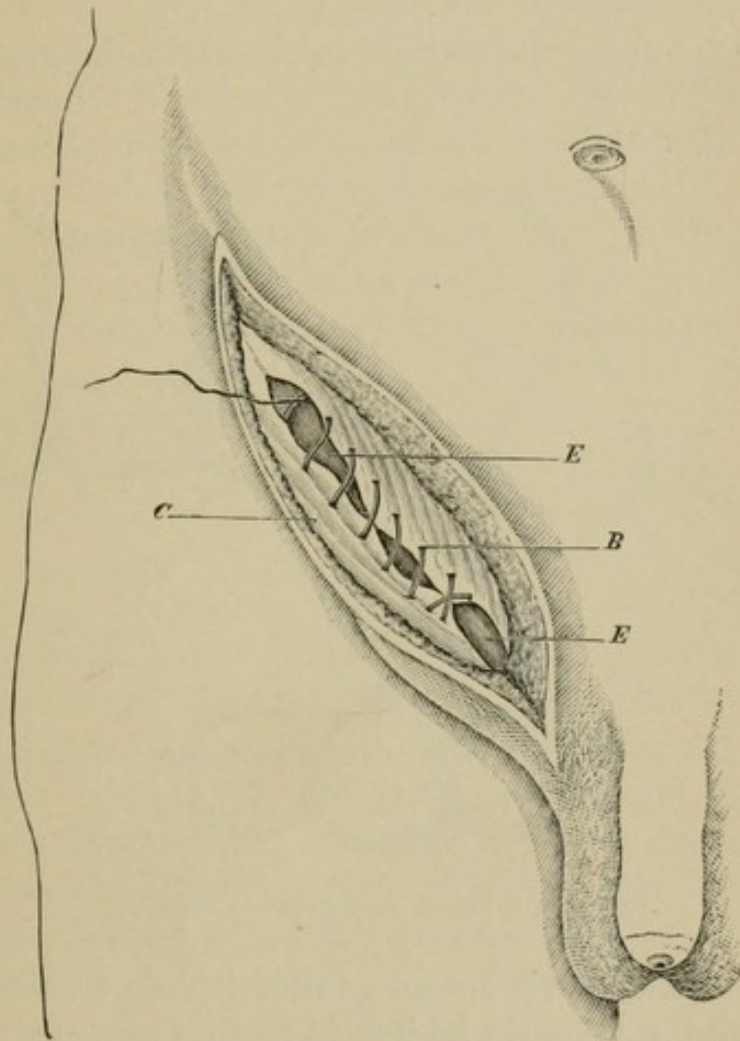
Suture of the conjoined tendon and transversalis fascia (*F*) to the posterior border of Poupart's ligament (*D*). *E*. The cord. *B, C*. Aponeurosis of the external oblique.

by interrupted silkworm-gut or catgut sutures extending upward from the crest of the pubes till only enough space in the upper and outer part of the internal abdominal ring is left for the cord to pass without undue compression. The lower two sutures should include the outer border of the rectus muscle. (Fig. 210.)



The cord is then placed on this new posterior wall of the inguinal canal and the divided aponeurosis of the external oblique muscle united over it by catgut sutures, leaving as small an aperture as possible at the lower angle for the cord to emerge. (Fig. 211.) The skin wound is sutured with interrupted silk and dressed antiseptically

FIG. 211.



Suture of the divided aponeurosis of the external oblique (*B, C*) over the spermatic cord (*E*).

without drainage, and in children it is wise to add a plaster-of-Paris spica.

Bassini uses silk for the buried sutures and forms the new internal abdominal ring about half an inch to the inner side of the anterior superior spine of the ilium; that is, he divides the internal oblique and transversalis



muscles above and to the outer side of the internal abdominal ring, transplants the cord to the outer extremity of this incision, fastens the internal oblique and transversalis under it and the external oblique over it. If the hernia is complicated by undescended testicle Bassini unfolds the vas deferens by a careful dissection and brings the testicle down from the inguinal canal and sutures it to the bottom of the scrotum. If this is impossible castration is performed.

Lauenstein places the testicle in the abdomen along with

FIG. 212.

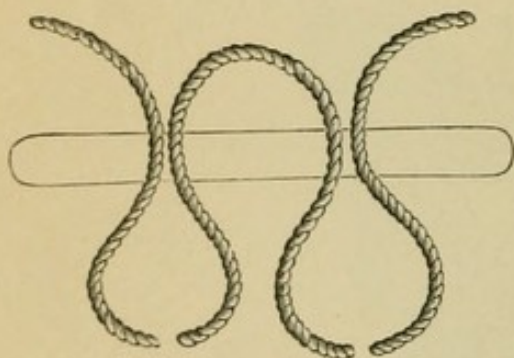


FIG. 213.

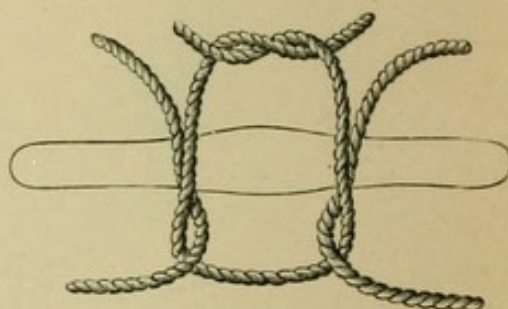
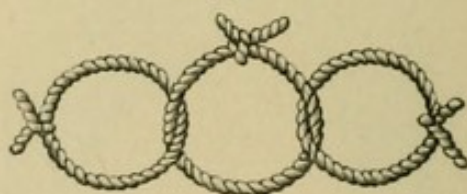


FIG. 214.



Method of tying off omentum in sections.

the stump of the sac. In congenital hernia enough of the fundus of the sac should be left to form a tunica vaginalis.

In direct inguinal hernia the orifice of the hernia is formed by the external abdominal ring, the neck of the sac is short and passes over the cord and lies to the inner side of the deep epigastric artery. After tying off the neck of the sac of a direct inguinal hernia, the parts on the inner side of the abdominal orifice, between the peritoneum and external oblique tendon, are sutured, as in the indirect variety, to Poupart's ligament.



If the hernia is an epiplocele the excess of omentum is tied off with stout catgut close to the neck of the sac and excised. If it is very large, the pedicle should be spread out and tied in sections, as illustrated in Figs. 212, 213, 214.

*Halsted's operation*<sup>1</sup> is as follows: The aponeurosis of the external oblique and the external abdominal ring are exposed by an incision starting some 5 centimeters above and external to the internal ring and extending to the spine of the pubes. In this line the aponeurosis of the external oblique and the fibers of the internal oblique and transversalis muscles and the transversalis fascia are cut from the external ring to a point about 2 centimeters above and external to the internal ring. The peritoneum and neck of sac are thus exposed, the latter opened, the hernia reduced, and the neck of the sac ligated or sutured and the distal portion excised. The cord is then isolated, and, after removing all but one or two of its veins, it is transplanted to the outer angle of the incision. Beneath it mattress sutures are passed: on the inner side through the aponeurosis of the external oblique, the internal oblique and transversalis muscles, and transversalis fascia; on the outer side through the aponeurosis of the external oblique, Poupart's ligament, and the transversalis fascia. This obliterates the canal and places the cord on the outer surface of the external oblique aponeurosis, where it is covered by skin and subcutaneous tissue only. The cutaneous wound is then closed by superficial sutures and dressed antiseptically without drainage.

**M'Burney's Operation.**<sup>2</sup>—The incision, division of the aponeurosis of the external oblique muscle, and the treatment of the sac are the same as in Bassini's operation.

Sutures are then passed through the skin, the aponeurosis of the external oblique (including the inner pillar of the external ring), and the conjoined tendon firmly binding these structures together with deep inversion of the skin and usually covering in the cord. On the oppo-

<sup>1</sup> Annals of Surgery, 1893, Vol. 17, p. 542.

<sup>2</sup> New York Medical Record, 1889, Vol. 35, p. 312.



site side of the wound the skin is inverted and sutured to Poupart's ligament, including at the lower part the outer pillar of the external ring ; the lower angle of the wound is sutured with silk and drawn together above with two or more tension sutures passed through the skin and superficial fascia and tied over pledgets of iodoform gauze. The space of about one-fifth of an inch left between the lips of the wound is packed snugly with iodoform gauze down to the peritoneum to insure healing by granulation and the obliteration of the inguinal canal by dense cicatricial tissue. This operation was at first extensively used, but of late has largely yielded place to Bassini's ; it is, however, a safer and surer operation for the less experienced, and for strangulated and infected cases in which the wound cannot safely be closed. It is also worthy of remembrance in the history of the evolution of radical cure that this was the first method in which the aponeurosis of the external oblique was divided and the internal ring freely exposed in the effort to ensure complete removal of the sac.

**Radical Cure of Umbilical Hernia.**—If the hernia is irreducible, the treatment is the same as that described for strangulated umbilical hernia.

If reducible, an incision is made which encircles the base of the hernial tumor, extending an inch or two above and below it in the median line, and deepened layer by layer till the abdominal cavity is opened at one extremity of the incision. A flat sponge is inserted, and on the finger as a guide the peritoneum is divided in the line of the cutaneous incision around the neck of the sac, and the latter excised together with the body of the sac, the overlying skin, and the umbilicus. The peritoneum is then sutured with catgut, the edges of the sheaths of the separated recti muscles are freshened throughout the whole length of the wound, and the recti closely approximated with interrupted catgut or silkworm-gut sutures. Over this the superficial fascia and skin are united with silk after excision of any redundant portions.

**Radical Cure of Femoral Hernia.**—Starting from Pou-



part's ligament a vertical incision some three or four inches long is made just to the inner side of the femoral vessels. It must be deepened carefully, as the coverings of the hernia may be very thin and consist only of skin and superficial fascia if the hernia has passed through the cribriform fascia. After exposing and opening the sac and returning the bowel or possibly excising the omentum, the neck of the sac is isolated and tied off high up with silk or stout catgut.

Various procedures have been adopted for the succeeding steps in the operation. Billroth removed the portion of the sac distal to the ligature and sutured the middle third of Poupart's ligament to the fascia covering the abductor muscles, or to that on the inner aspect of the femoral vessels. Berger united Poupart's ligament to the pubic portion of the fascia lata covering the pectineus muscle. A flap cut from the latter muscle has been turned up and fastened in the femoral ring.

Macewen employs the same principle as for the cure of inguinal hernia (*q. v.*); *i. e.*, the sac is folded into a pad and secured on the inner surface of the femoral ring, which is then drawn together with silk or silkworm-gut passed through the available soft parts adjoining its boundaries. Kocher exposes the sac and saphenous opening by a vertical incision, but does not divide the fascia lata overlying the canal; the sac is then drawn through a puncture in Poupart's ligament just over the canal and twisted, and its extremity is brought down over the ligament into the canal again, and secured there by two or three silk sutures passed through it and Poupart's ligament and the pectineal fascia.

After obliterating the track of the hernia by whatever method is adopted, the external wound is closed.

## RECTUM.

**Anatomy.**—The rectum is from six to eight inches long, and for about its first three inches is supplied with a mesorectum. In front the peritoneum descends to within about three inches, and behind about five inches



from the anus. The second portion of the rectum is in relation in front, in the male, with the trigonum of the bladder, the vesiculæ seminales, and the vasa deferentia and the prostate, the posterior margin of which can normally be reached by the finger. In the female this portion of the rectum is attached to the posterior vaginal wall.

Below the prostate the levatores ani join the rectum from one and a-half to two inches from the anus, at a point just above the internal sphincter. The superior hemorrhoidal artery lies on the outer surface of the rectum behind, a little to the left of the middle line, till within about four inches of the anus. It then divides into its terminal branches, which have a longitudinal distribution between the mucous and muscular coats and communicate freely about the anus.

The veins have a similar distribution, and communicate through the superior hemorrhoidal with the portal system, and through the middle and inferior hemorrhoidal with the internal iliac veins. The sphincter is supplied by the fourth sacral nerve.

#### **IMPERFORATE ANUS OR RECTUM.**

In order to understand their different congenital deformities, it is essential to bear in mind the manner in which the rectum and anus are developed. The rectum, like the rest of the intestine, is formed by the third blastodermic layer of the ovule, and originally communicates with the pedicle of the allantoid vesicle, that which afterward becomes the bladder and the posterior portion of the urethra. The anus, on the other hand, is formed by a dimple in the outer blastodermic layer, the one which forms the epidermis. In the ordinary course of events the communication between the rectum and the bladder or urethra closes, and another forms between the rectum and anus by absorption of the layer of tissue between them. The malformations are the result of arrest of development of the colon, rectum, or anus, or of the persistence of the septum, and present several varieties.



The first, and slightest, is not a true arrest of development, but a simple closure of the orifice of the anus by a tegumentary layer or by adhesion of its sides, the deep communication between it and the rectum being complete. This requires only separation of the adherent edges with a director, or division of the layer with a knife.

2. The rectum and anus may be fully developed, but the thin membranous diaphragm between them may persist, like the hymen in the vagina. The treatment of this also is simple: crucial incision or large puncture of the membrane.

3. The anus may be entirely absent, while the rectum is normally developed; the distance between the lower end of the latter and the surface being from half an inch to an inch.

4. The anal cul-de-sac being properly developed, the rectum or colon may terminate at any distance above it, or may even not exist at all, being represented by a fibrous cord extending from the ileo-cæcal valve to the anus.

5. The arrest of development may involve both the anus and the rectum.

6. The rectum may open into the bladder, urethra, or vagina.

It is often exceedingly difficult to determine the character of the malformation during life, and yet it is very important that this should be done, for if the imperviousness begins at a point too high up to be reached through the perineum, the only possibility of relief is in the establishment of an artificial anus in the lumbar or inguinal region. Depaul<sup>1</sup> says that when the obstruction begins at the ileo-cæcal valve the transverse distention of the abdomen is much less than in rectal obstruction.

If the surgeon decides to go in search of the blind end of the rectum and create an anus in the perineum, he must make an incision in the median line from the scrotum to the tip of the coccyx, after having previously introduced a sound into the bladder if the patient is a boy, or

<sup>1</sup> Bull. de la Société de Chirurgie, 1877, p. 536.



into the vagina if a girl. He then divides the tissues layer by layer in the line of the incision, feeling at each step for the distended rectum, which can sometimes be seen and felt to bulge downward when the child strains or cries. Or an exploratory puncture may be made, and the needle or trocar used as a guide if the bowel is reached by it.

The search for the bowel should be made in the direction of the axis of the anal cul-de-sac, if the latter is sufficiently developed, and advantage taken of the fact pointed out by M. Forget,<sup>1</sup> that a fibrous cord, representing a rudimentary portion of the rectum, occupies more or less of the distance separating the two. If, on the contrary, the anus is lacking, the search must be made toward the concavity of the sacrum. Verneuil proposed to excise the coccyx, so as to diminish the danger incurred during the search, but as this may be followed by prolapse of the rectum it should be practised only when a simple incision has proved insufficient.

When the end of the bowel is reached it must be seized with pronged forceps, or two stout ligatures must be passed through it, and it must be partly separated from the adjoining tissues, drawn down, opened, and made fast to the integument or the margin of the anus. The anterior and posterior portions of the cutaneous incision must finally be closed by sutures. It would be perfectly proper when in doubt as to the presence or position of the rectum to open the abdomen in the median line, and then, after ascertaining the conditions, if necessary perform a colostomy.

When the rectum opens into the vagina it may be reached through a median or crucial incision in the perineum, separated from the vaginal wall with a knife or curved scissors, and drawn down and fastened as before. The former opening will then close spontaneously.

#### **PROLAPSE OF THE RECTUM.**

The mucous membrane of the rectum is very loosely attached to the muscular coat, and when the sphincter is

<sup>1</sup> Bull. de la Société de Chirurgie, 1863 and 1877.



relaxed or disabled prolapse may occur to a degree that requires operative interference. This interference may involve the mucous membrane alone, or it may also include the anus or the entire rectum. In the first case the indication is to promote adhesions between the mucous and muscular coats, or to remove portions that may be in excess ; in the second to narrow the anal orifice, or fasten the posterior portion of the bowel to the firm tissues near the sacrum by sutures. The former is accomplished by making deep longitudinal incisions through the mucous membrane, or by pinching up folds at three or four different points and tying a strong ligature about each. The incisions are likely to give rise to severe hemorrhage, and consequently the method has fallen into disuse ; the actual cautery, however, applied at points or in lines, has been used as a substitute as follows :

In a slight or partial prolapse the bowels are emptied in advance and the parts reduced and put on the stretch with the bivalve speculum. The point of a Paquelin cautery is drawn the whole length of the prolapse in four longitudinal lines about a quarter of an inch wide and equally distant from each other, without destroying the entire thickness of the mucous membrane. To avoid penetrating too deeply Cripps advises that the cautery be used at a black heat only. If the skin about the anus is not touched the afterpain is slight. A tube reaching above the sphincter is inserted to give exit to flatus, while the bowels are kept confined for several days. For several weeks thereafter the patient must defecate in the recumbent position and avoid straining efforts, while the adhesions caused by the cauterization become firm between the mucous and muscular coats.

There are two methods of narrowing the anal orifice. Dupuytren pinched up with forceps several of the radiating folds of integument and cut them off with curved scissors, trusting to cicatricial retraction for the narrowing he desired.

Robert made two incisions, extending from the extremities of the transverse diameter of the anus to the tip of



the coccyx, removed the skin, subcutaneous tissue, and portion of the sphincter contained within the V thus marked out, and brought the sides of the gap together with sutures.

**Rectopexy.**—In cases of extensive prolapse the rectum has been secured in the concavity of the sacrum behind or to the abdominal wall in front or in the left inguinal region.

For the first procedure an incision is made in the median line from just behind the anus to the tip of the coccyx, and deepened backward and upward till the concavity of the sacrum is reached. A catgut suture is then passed through the fibrous tissue in front of this bone, and through the back of the rectum without entering its lumen, and the wound either closed immediately or after two or three days, during which it is lightly packed.

To secure the rectum to the anterior abdominal wall, the peritoneal cavity is opened in the median line just above the pubes, and the gut secured at the peritoneal edge of the wound, as in hysteropexy, by a silk suture passed through the whole thickness of the abdominal wall, and the anterior longitudinal band of muscular fibers in the rectum. The lumen of the latter, of course, must not be entered.

In the left inguinal region the abdomen is opened as for colostomy, and the upper end of the rectum fastened to the wall near the wound in a similar manner, or by a suture passed through the whole thickness of the mesorectum and parietal peritoneum.<sup>1</sup>

**Ablation.**—For pronounced cases with gangrene present or threatening Treves<sup>2</sup> divides the rectum circularly layer by layer at the muco-cutaneous junction, taking care to avoid injury to any small intestine which may have become herniated into the pouch formed by the prolapse. The cut edges of the skin and intestinal mucous membrane are then united with catgut. If the peritoneum is opened the wound must be immediately closed.

<sup>1</sup> Berg. *Annals Surg.*, 1893, Vol. XVII., p. 373.

<sup>2</sup> *Lancet*, 1890, Vol. I., p. 376.



**Torsion.**—When the sphincter has been destroyed or removed Gerster<sup>1</sup> supplies a substitute by twisting the rectum on its long axis till its walls form a rather close spiral. After isolating from two to five inches of its lower end the gut is turned through half a circle or more, and its free extremity sutured to the margin of the skin.

**Rectotomy.**—There is occasionally found, especially in women, a form of stricture occupying the lumen of the rectum like a thin perforated diaphragm, which is probably the result of a partial persistence of the foetal membrane between the anal portion which is developed from below upward by the dimpling of the skin, and the rectal portion which comes down from above to meet it. For the treatment of this, after emptying the bowels, the sphincter is first very thoroughly dilated and then a blunt director is forced through the base of the stricture in the posterior median line and brought back into the rectum in the same line above it. By hooking the finger or a loop of stout wire over the point of the director the stricture can be drawn down within reach from the anus and divided layer by layer, and all bleeding points secured with ligatures. A drainage tube and light packing are passed through the anus to the point of division.

Strictures more extensive than these, yet not suitable for excision, are divided with the knife or cautery in the median line posteriorly carrying the division through the rectal wall below the stricture, and the sphincter toward the coccyx, to secure the most perfect drainage possible. A tube and packing are placed in the incision.

### FISTULA.

After having thoroughly dilated the sphincter a blunt director is passed from without till its point is felt within the rectum, or if no aperture exists it is thrust through the mucous membrane where the least tissue intervenes.

The point is then pulled down out of the rectum, or, if this is impossible, the anus is held open with a speculum,

<sup>1</sup> *Annals Surg.*, 1894, Vol. XIX., p. 612.



and the parts on the director divided at right angles to the anal margin. If there is no external orifice, the director is bent to a sharp angle and passed with the assistance of the speculum from the internal opening, the skin incised on its point and the parts on the director cut as before. Sinuses in all directions must be slit up and granulations scraped away. Multiple fistulæ should be opened into each other if possible, and if more than a single complete division of the sphincter is necessary one division should be allowed to heal before the next is made. In women the sphincter decussates in front with the sphincter vaginae and cannot be completely divided at this point without considerable loss of power.

### HEMORRHOIDS.

*Ligation.*—Concerning the treatment of hemorrhoids by ligation there are a few points which deserve mention. The sphincter should be temporarily paralyzed by forcible dilatation. Every pile that is more than half an inch in diameter must be transfixed by a needle carrying a double ligature, and then strangulated by tying it at its base; the smaller piles do not need to be transfixed, it is sufficient to throw a single ligature about each. When the tegumentary margin would be included in the ligature it should be cut through it with scissors. The ends of the ligatures should not be cut off as soon as they are tied, but after three or four have been placed at opposite points of the circumference, it will be found easy to get an excellent view of the interior by drawing them outward and apart.

*Whitehead's Operation.*<sup>1</sup>—The sphincter is well dilated, and the mucous membrane, starting posteriorly, is divided at its junction with the skin by blunt-pointed scissors around the entire circumference of the bowel. It is dissected up with the dilated veins to the internal sphincter, or till all the pile-bearing mucous membrane is drawn outside of the anus. The mucous membrane is then divided transversely by short snips of the scissors close to its still attached upper border, and each part as it is cut is sutured

<sup>1</sup> British Medical Journal, 1887, Vol. I., p. 449.



to the edge of the skin. The vessels are secured as they are divided.

### EXCISION OF THE ANUS AND PART OF THE RECTUM.

This operation may be rendered necessary by disease otherwise incurable. The resulting condition is seldom satisfactory, owing to the loss of the sphincter if the anus is excised, and its almost certain paralysis from injury to the nerves during the manipulation, if the anus is left. It must be remembered that the peritoneum descends upon the anterior surface of the rectum to within about an inch of the prostate, but not quite so far upon the sides or behind; its average distance from the anus is from two to two and one-half inches in front and five inches behind. If the upper limit of the tumor on the posterior side cannot be reached by the end of the finger introduced through the anus, its removal should not be attempted from below. The nature and extent of its connections with the important organs on the anterior surface must also, of course, be carefully determined.

**A. Removal from below of the Anus and Part of the Rectum.**—Two curved incisions, meeting in front and behind in the median line, are made through the skin, one on each side of the anus, and at a distance of about one inch from it. They are carried down to the rectum, remaining of course, external to the neoplasm if it has broken through the rectal wall, and the rectum is then dissected upward as far as necessary, using the fingers instead of the knife for this purpose whenever possible. A sound should be introduced into the bladder as a guide if the patient is a man, and a finger into the vagina if the patient is a woman. When the upper limit of the tumor is reached, the rectum is drawn well down, its posterior wall divided longitudinally, and the diseased portion removed.

If the disease extends upward more than one and a-half inches, it is advisable to prolong the incision backward to the tip of the coccyx, and perhaps even along the side of this bone.



Velpeau took the precaution to pass a number of threads through the intestine above the proposed line of excision, bringing them out through the skin beyond the external limits of the disease. After the removal of the tumor, he had only to tighten and tie these threads to bring the edges of the incisions through the intestine and the skin together.

Richard Volkmann<sup>1</sup> has modified this operation somewhat and claims that by thorough drainage and the strictest attention to disinfection of the wound during and after the operation, excision of the rectum can be carried to a very considerable height, and even the peritoneal cavity opened, without danger to the patient. He empties the bowel thoroughly, makes a circular incision about the anus, a straight one in the median line back from the circular one to the coccyx, and, if necessary, another in the median line of the perineum; the bowel itself must not be cut into. He then draws the rectum down, dissects it out circularly to the necessary height, passes ligatures through the healthy portion after Velpeau's plan, and cuts off the lower portion containing the tumor. Bleeding points are temporarily secured by self-retaining forceps, and afterward with catgut.

If the peritoneal cavity is opened, a sponge sterile or wet with an antiseptic solution is kept pressed against the opening, until the excision is completed; then if the opening is small its edges are drawn out with artery forceps, and a ligature thrown around it as if it was a vessel; if it is large, it is closed with catgut sutures.

The upper end of the gut is then drawn down and fastened to the skin very accurately with alternate deep and superficial sutures, two or three drainage tubes are inserted, cut off close to the surface, and stitched fast.

During the operation, the bleeding surface is constantly protected against infection by irrigation with an antiseptic solution, and for the first three or four days constant antiseptic irrigation is kept up through a tube passed well

<sup>1</sup> Ueber den Mastdarmkrebs und die Exstirpation recti in Klinischer Vorträge, No. 131 (Chirurgie, No. 42), p. 1113, 13th March, 1878.



into the wound near one of the drainage tubes; daily antiseptic injections are afterward made through the drainage tubes until the wound has healed.

Volkman claims that these precautions strictly carried out insure the patient against the chief danger of the operation, that of exciting diffuse pelvic cellular inflammation, which spreads rapidly upward behind the peritoneum, and causes death by sepsis. Although the bleeding during the operation is very severe, he has never known it to have fatal consequences.

He thinks, also, that cancer is much less likely to return locally after excision of the anus than it is when the sphincters are preserved, and, therefore, he prefers total excision of the anus and of the rectum to the upper limit of the disease, even when the anus itself is not involved.

**B. Resection of the Rectum from below, leaving the Sphincter.**—After thoroughly emptying the bowels in advance the patient is placed in the lithotomy position, or on the side with the hips and knees flexed. An incision is made in the median line posteriorly through the anus and rectal wall below the disease, and carried to the coccyx. With a sound in the urethra or finger in the vagina, another incision in the median line in front is carried through the anus and lower healthy rectal wall into the perineum. The buttocks are separated and the lips of these incisions drawn apart with blunt retractors.

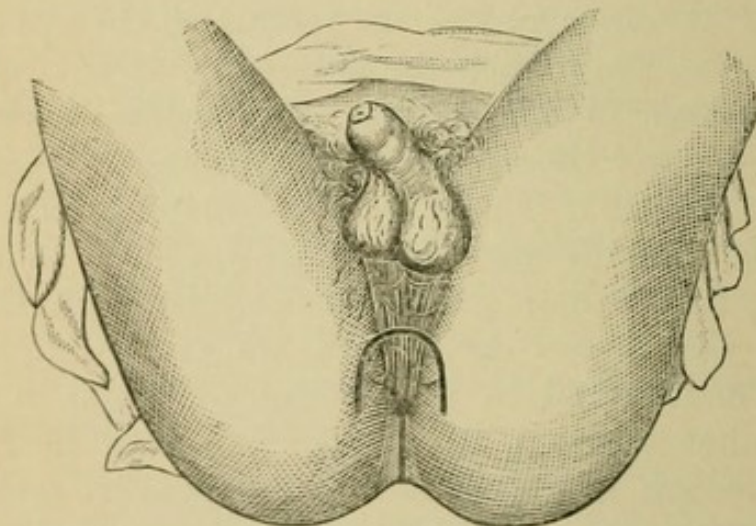
The sound rectum is then divided transversely below the disease and above the sphincter by lateral incisions joining the upper extremities of the incisions through its anterior and posterior walls. By working with the fingers and blunt-pointed scissors from within outward through the transverse incisions in the rectal wall, the diseased rectum above is separated all around on its outer surface from the surrounding tissues and drawn down. The vessels are tied as they are cut, but if the dissection is made mostly by tearing with the fingers the greater part of the hemorrhage can be arrested by pressure. A temporary suture with the ends left long is then passed through the anterior and posterior walls of the rectum above to pre-



vent its retraction, while the diseased part is excised by a transverse division of the bowel in the healthy tissue below the retention sutures.

The cut ends of the rectum are united all around by interrupted sutures passed with a sharply curved needle, and then the incisions in its anterior and posterior walls. A large drainage tube surrounded by light packing and reaching above the point of division is placed in the rectum, the wounds in the perineum and behind, including the sphincter, are closed with deep sutures and a drainage tube placed in the lower angle of each.

FIG. 215.



Resection of the rectum, showing Hueter's curved incision. The straight incision is that for posterior rectotomy.

**C. Hueter's Operation by a Perineal Flap.** (Fig. 215.)—The patient occupies the lithotomy position and a sound is introduced into the urethra. A flap, including the anus and adjoining part of the perineum, is marked out of an inverted U-shape, having the anus a little in front of the center of the base, which is posterior. To form this an incision is made through the skin and subcutaneous tissue, starting at the level of the posterior end of the tuber ischii outside of the outer border of the sphincter ani, passing forward and crossing the perineum close to the posterior insertion of the scrotum, then backward to terminate on the other side of the anus outside the



sphincter opposite the starting point. The incision is deepened, and anteriorly, in the bend of the U, the junction of the accelerator urinæ with the compressor urethræ muscles cut through, and the flap including the sphincter ani turned down.

Working in from in front the rectum is isolated on all sides and the diseased portion excised by transverse division of the bowel through healthy tissue above and below the disease. The bleeding in this large wound is stopped by ligation or pressure.

The cut ends of the rectum are brought together all around with sutures, and the flap replaced, with a drain and light packing in each lower angle. A tube and packing reaching above the line of division is then inserted through the anus. The mucous membrane might first be united by a separate row of sutures not entering the muscular coat, which is afterward brought together by sutures of catgut penetrating the muscular coat alone, so as to bring the suture line in the mucosa below that in the muscularis and thus make communication less easy for the feces from the interior of the bowel to the perirectal tissue. Zuckerkandl's method for reaching the seminal vesicles (*q. v.*) is very similar to this operation.

**D. Resection of the Rectum from behind (Kraske's Operation) with Removal of the Coccyx and part of the Sacrum.**<sup>1</sup>—The patient is placed on the right side and an incision is made in the median line from the middle of the sacrum to the anus and carried down to the bone. The fibers of the gluteus are detached from the lower part of the left half of the sacrum and from the coccyx, and the latter bone removed. The left side of the incision is then drawn forcibly aside and the greater and lesser sacrosciatic ligaments successively divided close to their attachment to the sacrum. This gives access to a large portion of the rectum, but if more room is desired it can be obtained by chiseling away the lower left part of the sacrum below

<sup>1</sup> Arch. f. klin. Chir., 1886, Vol. XXXIII., p. 566. For a review of this operation and its modifications, see Frank: Wien. klin. Woch., 1891, Vol. IV., p. 800.



the third sacral foramen and including the fourth without opening the sacral canal. The anterior branches of the fourth and fifth sacral nerves are necessarily divided in this procedure.

The posterior branches and the fifth nerve are of no importance, but the nerve-supply of the levator ani, coccygeus, and sphincter ani on the left side is of course cut off.

Hochenegg's modification of the bone removal is represented in Fig. 216.

Bardenheuer still further modified it by the removal of all the sacrum below the third sacral foramen, which destroys the possibility of subsequent restoration of the function of the sphincter.

The rectum is now freed by division of the connective tissue binding it to the sacrum, and drawn downward so far as may be necessary to bring the subsequently cut ends of the gut into apposition without undue tension on the sutures. To give more room and greater protection to the important male organs lying close in front of the rectum, the sphincter and rectal wall from the anus up to the tumor can be cut posteriorly in the median line; but it is not always necessary.

The growth is then freed by the finger and blunt-pointed scissors from its lateral and anterior connections and excised with a margin of healthy tissue, by transverse division of the rectum above and below.

If the relations of the tumor make it necessary, the peritoneal cavity must be opened and involved portions of the peritoneum, together with any glands which can be felt, removed with the tumor. The peritoneum is then drawn together with fine catgut sutures and secured against infection by an iodoform-gauze packing. The anterior half of the divided bowel is united by silk sutures through its mucous and muscular coats, while the posterior half is left open and, if possible, sutured to the skin at the margins of the wound; it can afterward be closed by a secondary operation.

If the anus and adjacent rectal wall have been split posteriorly, the rectal part of the wound is closed by in-







above. Afterward the patient will have to be kept on a water-bed.

A colotomy performed a week or two before this operation is of great assistance in keeping the wound aseptic and avoiding the very frequent and early dressings otherwise necessary.

Heineke recommends an L-shaped incision from the anus to the coccyx, then along the left border of the sacrum up to the fourth sacral foramen, and then transversely to the right border of the sacrum. The bone is chiseled through in this line and the flap turned down and to the right. Rydygier dispenses with the transverse incision in the skin.

Levy divides the sacrum transversely a finger's breadth above its lower extremity, and from each end of the transverse incision carries one downward toward the ischial tuberosities, the soft parts attached to the side of the sacrum below its point of transverse division are cut, and the bone-and-skin flap turned down.

Hegar employs a V-shaped incision starting at the posterior inferior spines of the ilia and following the sides of the sacrum to the tip of the coccyx. The periosteum is separated from the anterior surface of these bones; the sacrum sawed transversely and turned up.

Almost any of these methods of operation gives access to the female pelvic organs.

### LIVER.

**Anatomy.**—The level of the upper surface of the liver is indicated by a line drawn through the fifth chondrosternal articulation on the right side and through the sixth on the left. It is uncovered by the ribs where it crosses the subcostal angle, from the ninth right to the eighth left costal cartilage. The left lobe extends one and a-half to two inches beyond the left margin of the sternum. The lung descends over the upper surface of the diaphragm and liver on the right side to the lower border of the sixth rib in the mammary line, in the mid-axillary line to the upper border of the eighth rib, and in



the scapular line to the upper border of the tenth rib. The pleura descends about half an inch lower, following the costo-chondral junction, or the bony extremities of the ribs, and the lower border of the eleventh rib. As the twelfth rib is sometimes very short, it may be overlooked. Therefore the ribs should be counted, and the lower edge of the pleura will be found passing horizontally from the lower border of the twelfth dorsal vertebra to the lower border of the eleventh rib.

The gall-bladder is about four inches long and an inch wide, and normally holds about an ounce. Its fundus touches the abdominal wall immediately below the ninth costal cartilage near the outer border of the right rectus muscle. The cystic duct is about an inch long, and the common duct three inches long. The latter descends in the right border of the lesser omentum behind the first portion of the duodenum, in front of the portal vein and to the right of the hepatic artery; it then passes between the pancreas and duodenum, behind the pancreaticoduodenal artery, to empty into the middle of the inner side of the second portion of the duodenum.

**Abscess of the Liver.**—An incision, preferably longitudinal, three or four inches long is made over the most prominent part of the tumor below the ribs. The incision is deepened to the peritoneum, and if the liver is found adherent beneath this incision the abscess is simply incised for about an inch and drained with a large tube, and packing if necessary, bearing in mind the very friable character of the abscess-walls. If the liver is not adherent where the abdomen has been opened, but is found to be so at some other spot below the ribs, another incision is made through the parietes over this spot, and the abscess reached through the safely adherent area. The first incision, having served as a guide, is closed in the usual way and well protected from infection before the abscess is opened.

If the abscess must be opened immediately, and there are no adhesions to the parietal peritoneum, a sponge packing is inserted to protect the rest of the abdominal



cavity, and the point of an exploring-needle buried in the liver. The piston is immediately withdrawn and the needle slowly pushed on in a straight line. By withdrawing the piston as soon as possible pus will flow into the cylinder when it is first reached, and by pushing the needle always in a straight line unnecessary and easily-inflicted damage to the gland is avoided. If the first exploration fail, the needle must be taken out and reinserted in different straight directions till pus is found.

With the needle as a guide, a knife is then passed through the liver-substance into the abscess-cavity, while the liver is kept in as close contact with the abdominal wall as possible, rolling the patient on one side if necessary. The index-finger is quickly passed along the track of the knife and the opening enlarged to an inch or more and hooked up without force into the abdominal wound. Hemorrhage is controlled by packing. After the pus has been evacuated, the interior or the abscess-cavity is irrigated with warm boiled water; its opening is then plugged with a sponge, and the parietal peritoneum and the skin around the margins of the abdominal wound are united with catgut. After removal of the protective packing from the abdomen the liver is fastened in the wound by interrupted catgut or fine silk sutures passed through its substance at a little distance outside of the abscess-opening, to shut off its communication with the general peritoneum.

If the stitches show a tendency to tear out, sterilized gauze must be packed around the opening in the liver and the ends brought out of the abdominal wound.

The sponge plug is then removed and a large drainage tube inserted. Immediately before incising the liver an attempt can be made to unite the parietal and visceral peritoneum with catgut sutures around the proposed area of the incision. But the stitches may tear out or puncture and cause leakage from the abscess into the general peritoneal cavity. As the liver ascends and descends with respiration it cannot be fastened to the abdominal wall at a less distance than half an inch from the free border of the ribs and costal cartilages.



Whenever there is time it is always best to secure firm adhesions of the liver to the parietes in the selected region before evacuating the pus. A longitudinal incision two or three inches long is carried down layer by layer and the peritoneum opened and the liver exposed. After carefully protecting the surrounding viscera with sponge, the presence of pus is verified with a fine aspirating needle, and the point of puncture is then covered with an iodoform-gauze packing large enough to hold the margins of the abdominal wound apart and in contact with the liver. In addition, the parietal peritoneum and skin can be united with catgut around the margins of the incision. A fairly tight antiseptic dressing is applied, and in the course of two or three days adhesions will have shut off the abdominal cavity and the abscess can be safely opened without an anæsthetic.

It is generally unwise to approach an abscess of the liver through the thoracic cavity; but if unavoidable, the selected intercostal space should be enlarged by resection of a rib, and the layers of the parietal and diaphragmatic pleura carefully united with catgut sutures around the proposed line of drainage. The surface of the liver is then exposed by an incision through the diaphragm and the future drainage track packed with iodoform gauze till adhesions have formed.

If the liver and diaphragm are already adherent, the abscess can be opened immediately, provided the pleural cavity is secured from infection.

It is unsafe to aspirate a possible abscess of the liver through the unopened abdominal or thoracic wall.

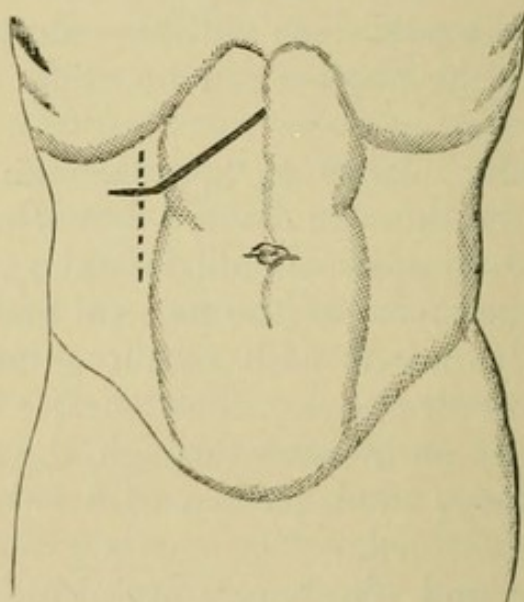
### **HYDATID CYST OF THE LIVER.**

The operative treatment of hydatid cyst of the liver is almost identical with that of abscess. After partial evacuation of its contents by a trocar and canula or aspirating needle the cyst wall can be more readily drawn into the abdominal wound and sutured there, and thus the rest of the abdominal cavity is more effectually protected than in the case of an abscess, and a cyst can be more safely opened immediately.



**Cholecystostomy.** (Fig. 217.)—An incision three or four inches long is made vertically downward from the lower border of the liver opposite the tip of the cartilage of the tenth rib, and deepened layer by layer and the peritoneum opened. If an extensive dissection or an operation on the cystic or common duct is anticipated more room will be needed, and it is better to use an incision about four inches long, starting from the median line an inch below the ensiform process, extending obliquely downward and outward, and terminating horizontally. If the liver is enlarged the oblique incision

FIG. 217.



Incisions for exposing the gall-bladder.

should follow a line parallel to and just above its free border.

Bevan<sup>1</sup> recommends a F-shaped incision, the central portion of which lies beside the rectus, while the upper end curves partly across the rectus about three-quarters of an inch from the costal border, and lower portion curves outward at about the level of the umbilicus. He claims that while this gives ample exposure it largely spares the nerve-supply of the rectus.

When a distended gall-bladder is encountered it is carefully surrounded with a protective sponge packing and

<sup>1</sup> *Annals of Surg.*, July, 1899.



enough fluid drawn off with an aspirator to allow the walls thus relaxed to be pinched up on each side of the needle by the fingers or padded forceps and drawn into the abdominal wound. Sponges are wedged around it to prevent leakage into the peritoneum, and the fluid is evacuated by a trocar and canula, or a knife plunged into the bladder wall at the point of puncture made by the needle. In selecting this point of puncture allowance must be made for retraction of a distended bladder. If the bladder is not distended, a finger is passed along its inner surface following the cystic and common duct, to explore for the trouble as far as the intestine. A careful dissection with the finger nail and blunt-pointed scissors may be necessary to separate adhesions to surrounding viscera and even to find the gall-bladder.

After protecting the rest of the abdominal cavity with a sponge packing the fundus of the bladder is drawn as far as possible into the abdominal wound and opened enough to admit one finger. All stones are then gently scooped or irrigated out, the abdominal wound partly closed in the usual way, and the protective sponges removed. The gall-bladder is fastened in the wound by a continuous silk suture passed through the skin, peritoneum, and the whole thickness of the bladder wall around the margin of the opening in it. The suture line must be far enough away from the free border of the ribs to allow for the respiratory movements of the liver.

A large rubber drainage tube is passed into the fistulous opening and an abundant absorbent dressing applied which will need frequent renewal. It is not advisable to close a wound of the gall-bladder by the Czerny-Lembert method of suture and leave no communication with the parietal incision.

**Operations Involving the Cystic or Common Bile Duct.** (Fig. 217.)—The oblique incision is used, or the vertical changed later if necessary into a crucial or J-shaped incision. After locating the stone by the exploring finger and protecting the rest of the abdomen by a sponge-packing, an attempt is made to manipulate the calculus back



into the bladder or forward into the intestine, but bearing in mind that the ducts are easily lacerated and very slightly distensible.

If it seem feasible to reach the stone from the interior of the gall-bladder, this viscus is opened in the manner already described, and one of the specially devised cholelithotomy forceps used to clip or nibble the stone into fragments, guided by the other hand in the abdomen. The operation is completed as described for cholecystostomy. On the same principle an impacted calculus has been crushed by padded forceps applied to the exterior of the duct, and has been broken by the point of an aspirating needle puncturing the duct. Dr. McBurney extracted one after splitting the distal portion of the duct through an opening made in the duodenum for the purpose. For a stone otherwise irremovable from the cystic duct cholecystectomy is preferable to needling or crushing externally with padded forceps. But there must be no doubt about the patency of the common duct.

For a calculus impacted below the cystic duct, the oblique abdominal incision is used and the surrounding viscera are well protected and retracted by a sponge packing. The duct is opened in its long axis over the stone sufficiently to extract the latter, and the opening then closed by interrupted Czerny-Lembert sutures, which because of the generally increased thickness of the duct wall from the irritation caused by the presence of the calculus is not very difficult. A drainage tube and iodoform gauze packing is carried from the abdominal wound down to the neighborhood of the suture line and the abdominal wound partly closed in the usual way.

If an opened gall-bladder must be sutured in the abdominal wound at the same time, its opening must be separated as far as possible from the drainage tube by intermediate suturing.

### **CHOLECYSTENTEROSTOMY.**

This term is used to designate the establishment of a permanent fistulous communication between the gall-blad-



der and the intestine. The operation is designed to create a route by which the bile can pass into the intestine when the common duct is permanently obstructed, and when both the cystic and hepatic ducts are patent and communicate, and for some cases of persistent biliary fistula. The abdomen is opened, preferably by the vertical incision, and a convenient loop of intestine as near the duodenum as possible is isolated by iodoform-gauze bands tied around the gut above and below, and to this isolated loop the gall-bladder is sutured and the communication established in the same manner as described for intestinal anastomosis.

The bladder is first emptied by an aspirating needle entered as near as possible to the site of the future fistula. A continuous fine silk suture is passed uniting the serous coats of the bladder and the intestine at the convex free border of the latter for a distance of about an inch and a-half, and in front of this, as the parts lie exposed, a row of Lembert sutures is inserted. After carefully protecting the surrounding parts by a fresh sponge packing, the opposing surfaces of the gall-bladder and intestine are opened longitudinally for about an inch close in front of the Lembert sutures, and the interior of each irrigated clean. The mucous membranes are united by a continuous fine silk or catgut suture, and a row of Lembert sutures continuous with those already in place completes the serous apposition all around. The gauze constricting bands and sponges are removed and an iodoform-gauze packing placed around the suture line and the ends brought out of the abdominal wound, which is partly closed in the usual way.

Murphy's "button" has proved peculiarly valuable in cholecystenterostomy. The button can be made small enough to be easily passed off by the intestine, and at the same time leave a communication with the gall-bladder large enough to be useful in spite of any probable subsequent cicatricial contraction.

The abdomen is opened by the vertical incision, the bladder is aspirated, and a selected loop of intestine iso-



lated as usual, and a protective sponge packing placed in the abdomen. A "purse-string" suture of fine silk is passed through the serous coat of the bladder and intestine enclosing an area on each large enough to contain a slit the length of the diameter of the buttons. The buttons are inserted in the longitudinal slits then made in the bladder and gut, and the wounds are drawn tight around the central cylinder by tying the sutures. The buttons are simply pressed together, and the wounds, with the suture in each, are shut within the concavity bounded by the margins of the buttons holding the serous surfaces in apposition.

The calculi are not disturbed, but left to be defecated with the button, and the abdominal wound is closed without drainage after removing the sponges.

### **CHOLECYSTECTOMY.**

The abdomen is opened by the oblique incision and the gall-bladder surrounded with sponges. Starting at the fundus, an incision is made on each side of the bladder through the peritoneum at a little distance from the liver, and the bladder dissected out with blunt-pointed scissors as far as the cystic duct. The latter is divided between a double ligature of silk, and the peritoneal flaps closed over the liver by a continuous catgut suture. The abdominal wound is partly closed around a tube, and light iodoform-gauze packing carried down to the former site of the gall-bladder.

### **SPLEEN.**

**Anatomy.**—The pedicle of the spleen will be formed by the gastro-splenic omentum passing from the hilum to the stomach and, continuous with this above, the suspensory ligament passing to the diaphragm. The splenic artery lies above the vein behind the upper border of the pancreas. The gastro-splenic omentum contains its terminal five or six branches which arise at a variable distance from the spleen and may enter its hilum over a considerable area. Most of the vasa brevia arise from these and



turn backward to the stomach, and near the termination of the main splenic artery the gastro-epiploica sinistra is given off. The venous branches correspond to the arterial.

### SPLENECTOMY.

A vertical incision three or four inches long is made along the outer border of the left rectus muscle above the umbilicus, and the peritoneum opened. If the spleen has prolapsed into an already existing wound, the latter is simply enlarged as much as necessary. Adhesions are separated or divided between double catgut ligatures, and the tumor, which must be very gently handled, is fully exposed. After surrounding it with a sponge packing it is turned out of the abdominal wound, generally the lower end first. The abdominal opening should be made large enough to allow the tumor to pass without force, and the margins of the wound should be held back to avoid all traction on the pedicle. Starting at its lower edge, successive pairs of artery clamps are applied to the pedicle in advance of the line of division which is then made between them.

The spleen is then removed and the vessels in the grasp of each clamp are ligated separately with silk. As each clamp is removed bleeding points are sought for and secured; after this Greig Smith advises that the whole pedicle be surrounded by a ligature drawn moderately tight to lessen the arterial pressure distal to it on the ligatures of each vessel. The abdominal wound is then closed tight in the usual way.

### KIDNEY.

**Anatomy.**—The kidney lies imbedded in fatty tissue which is more abundant behind than in front, and from which it can be easily enucleated. Posteriorly the upper half rests against the diaphragm and the lower half upon the transversalis aponeurosis, and is crossed posteriorly by the last dorsal, the ilio-hypogastric, and ilio-inguinal nerves. In front, from above downward, the liver, du-



odenum, and hepatic flexure of the colon are in contact with the right kidney; the stomach with the spleen externally, the pancreas and descending colon are in relation with the anterior surface of the left kidney.

Thus the colon generally lies vertically in front of a renal growth on the right side, and on the left side crosses it obliquely from above downward and outward. The peritoneum over such a tumor can be divided on the outer side of the colon, but not on the inner, without interfering with the blood-supply of the bowel.

The renal artery, which may divide into one or more branches before entering the hilum, subdivides into terminal branches, which are said commonly to lie in front of the veins. The renal vein subdivides earlier than the artery, and the left vein receives the left spermatic and left inferior phrenic veins which are within reach of injury during treatment of the renal pedicle. The vessels lie in front of the ureter, which terminates near the lower border of the kidney in its pelvis. The latter subdivides in the hilum into two or three short trunks (infundibula), which in turn subdivide into the calices opening over the papillæ; so that a finger cannot pass from the pelvis into the first subdivision and much less into the second or calices.

As the twelfth rib may be rudimentary or absent the ribs should always be counted before a lumbar operation, in order to avoid the pleura, which is generally found to pass horizontally from the lower border of the twelfth dorsal vertebra to the lower border of the eleventh rib.

### EXPOSURE OF THE KIDNEY.

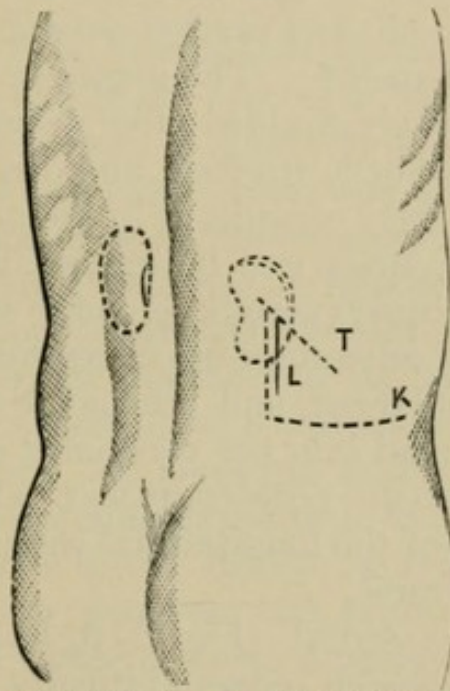
**Lumbar Methods.**—The patient lies upon the sound side with a sand-bag under the loin to widen the opposite exposed costo-iliac space.

A. THE LONGITUDINAL INCISION is made along the outer border of the muscular mass formed by the erector spinæ and sacro-lumbalis, which is about two and a-half to three inches from the vertebral spines, and it should extend through the skin from the eleventh rib to the iliac



crest. (Fig. 218.) It is deepened through the middle layer of the lumbar fascia or the aponeurosis of the transversalis, and the posterior surface of the quadratus lumborum is exposed. The outer border of the muscle is cleared and drawn toward the spine, and after retraction of the sides of the wound, the peri-renal fat can usually be seen through the thin anterior layer of the lumbar fascia, moving synchronously with respiration. Space can be advantageously gained by dividing the outer portion of the quadratus close to its attachment to the ilium.

FIG. 218.



Incision for exposing the kidney. L. Longitudinal or vertical incision. T. Transverse or oblique incision. K. König's incision.

On division of the thin intervening fascia the fatty capsule of the kidney is reached, and by tearing through it and stripping it toward the sides the posterior surface of the middle and lower portions of the kidney and its pelvis are exposed to sight and touch. At the outer border of the quadratus muscle the last dorsal, the iliohypogastric, and ilio-inguinal nerves will be encountered, and one or all may be divided if they cannot be sufficiently retracted.

Some additional space can be gained by drawing the last



rib forcibly upward with a blunt hook, which is safer than resection of a portion of the twelfth and even the eleventh rib, as has been done in a few cases. If the pleural or peritoneal cavity is accidentally opened, the rent should be immediately closed with fine catgut sutures and protected by an iodoform-gauze packing.

Except in persons who are very fat, this incision gives ample room for exploration, nephropexy, nephrotomy, and even for nephrectomy when the kidney is not very much enlarged.

B. THE TRANSVERSE INCISION (Fig. 218, T) is begun just within the outer margin of the sacro-lumbalis, a little below the twelfth rib, and carried outward parallel to the rib for about four inches. The muscular and aponeurotic layers are successively divided after recognition, until the retro-peritoneal layer is reached, and the kidney exposed by division of its fatty capsule, as in the preceding description. Additional space can be gained by a short longitudinal cut at the inner (vertebral) end of the main incision.

This incision is advantageous in nephrectomy when the kidney is much enlarged, and whenever it may be necessary to insert a hand into the peritoneal cavity.

C. THE COMBINED LONGITUDINAL AND TRANSVERSE INCISION consists of the longitudinal incision joined at any part by the transverse.

D. KÖNIG'S INCISION.<sup>1</sup> (Fig. 218, K.)—Starting from the last rib, the incision passes vertically downward along the outer border of the sacro-lumbalis and erector spinæ, curves forward just above the highest part of the iliac crest, and passes horizontally toward the umbilicus to end at the outer border of the right rectus. The vertical part of the incision is deepened first and carried down layer by layer until the peritoneum is reached in front of the anterior layer of the lumbar fascia. After the fingers are placed in the lower angle of this wound to protect the peritoneum beneath the horizontal part, the latter is deepened through the successive muscular layers until the peritoneum is exposed. It may often be advisable to make the vertical

<sup>1</sup>Centralb. f. Chir., 1886, No. 35, p. 593.



part of the incision run obliquely into the horizontal in the form of a flattened curve. This incision affords very free access to the kidney and a good part of the ureter, and the size of the wound does not materially add to the risks, but rather lessens them by the increased facility afforded for dealing with the pedicle or any complications.

At the close of the operation the divided muscles in the horizontal and curved parts of the incision are united by deep sutures and heal readily, while the vertical part can be packed and drained if necessary. In any ordinary case the horizontal part of this incision need not be extended beyond the vertical prolongation of the anterior axillary line.

**Nephrotomy.**—The kidney is exposed by the longitudinal lumbar incision, and if the abscess or cyst which has made the operation necessary is perfectly apparent it only remains to cut into the most prominent part of the diseased tissue with the knife or thermo-cautery. But if there is any doubt about the presence or location of the disease it must be sought by an aspirating needle passed through the convex border of the kidney and its track followed by a knife. A finger then plugs and enlarges this incision while, if necessary, an assistant makes counter-pressure through the anterior abdominal wall to lift the kidney into the incision; then if the cavity is very irregular, or if there are separate pouches, the septa should be freely broken down to secure efficient drainage, and the interior of the cavity thoroughly scraped with a sharp spoon if its condition requires it.

Occasionally it will be possible and desirable to draw the edges of the sac into the parietal wound and stitch them to the skin or deeper tissues. Rubber tubes packed around with iodoform gauze are passed into all parts of the abscess cavity for drainage, and into any spaces in the cellular tissue about the kidney which may have been opened up and infected.

The extremities of the external wound are drawn together with silk, and a large absorbent dressing applied,

**Nephrolithotomy.**—After the kidney has been exposed.



preferably by König's incision, which also gives access to the upper part of the ureter, the surgeon proceeds to seek for signs of the presence and location of a calculus; the horizontal part of this incision should not be made at first of the full length, but later it is prolonged if found necessary.

The posterior surface of the gland is freed and the kidney palpated between the thumb and finger and any click or spot of especial density noted.

A fine needle is then passed systematically through the cortex or wall of the pelvis at intervals of half an inch, and not deeper than two and a-half inches in a normal adult kidney, in order to avoid possible injury to the main vessels. Should this fail to detect the stone, the finger may be introduced through an incision in the cortex and thus a thorough digital examination be made of the interior of the pelvis and calices.

If no stone is found the wound is closed with catgut sutures passed through the substance of the kidney, and the external wound is brought together around a drainage tube placed in contact with the renal wound.

When a stone is felt by the needle, an incision is made with the knife or thermo-cautery through the cortex longitudinally. Unless it is very manifestly better to open the pelvis directly, an incision through the cortex is preferable to one through the walls of the pelvis on account of the less danger of a urinary fistula and troublesome hemorrhage. Bleeding from the parenchyma is readily controlled at the last by deep sutures closing the wound in the kidney.

Through the opening thus made the stone is picked or scooped out. If it is large or branched it may have to be crushed with a lithotrite or strong sequesterum forceps; septa should be divided with blunt-pointed scissors; occasionally stones have been encountered so large, or so numerous and difficult of removal, that nephrectomy has been considered wiser than nephrolithotomy. After removal of the stone the orifice of the ureter is sought and that canal explored to determine whether it is free or



whether plugged by a stone or mass of fibrin. If such an obstruction is found it may be pushed back into the kidney, or washed out by a stream of water directed into the distended ureter through the renal wound, or perhaps pushed downward into the bladder.

The stone or stones having been extracted from the kidney, the wound in its substance or in the pelvic wall is closed with catgut sutures unless there is so much suppuration present that every facility must be given for the escape of pus. Sometimes the gland will have become a mere abscess cavity containing the stone. Rubber tubes and iodoform-gauze packing are placed in contact with the kidney wound or in its interior, as its condition may require, and in the space possibly opened up behind it. A strip of gauze is carried down to the peritoneum beneath the curved part of the external wound, if König's incision has been used, and the wound closed with silk sutures up to the space where the drainage emerges.

**Lumbar Nephrectomy.**—The kidney is exposed by König's incision, but, if there is any doubt about its removal, it should first be explored by the longitudinal incision, and afterward a transverse incision of the necessary length can be added at any convenient part of the longitudinal. The length of the transverse or horizontal part of König's incision is regulated by the size of the tumor. If inflammation has not materially changed the tissues immediately surrounding the kidney, it is comparatively easy, after reaching its posterior surface, and tearing through the perirenal fat, to work the fingers in close contact with the capsule around the convex border and the two extremities and enucleate the kidney from its bed by separating all the attachments except the pedicle constituted by the renal vessels and the ureter.

In cases of long-continued suppuration where everything has become matted together, as, for instance, after nephrotomy for abscess, it may be easier to open the capsule and separate the kidney from its interior. The manipulations must be gentle and without undue traction on the pedicle, and if abnormal vessels are encountered



at the extremities of the gland they should be divided between double catgut ligatures. After isolation of the pedicle it may be tied off in sections by silk ligatures passed on a large full curved aneurism pedicle needle; occasionally the main artery can be recognized by sight or touch, and it is desirable that it, as well as the ureter, should receive a separate ligature whenever possible. If the pedicle cannot be isolated and brought into view or reached on account of the condition or situation of the adhesions, the entire pedicle can be tied *en masse*, preferably by the elastic ligature, which is drawn tight by the fingers in the depths of the wound and retained by a knot or clamp.

The part of the kidney substance distal to the ligature is then cut away, leaving enough margin to prevent slipping of the ligature, and the large stump which sometimes remains when the adhesions to the anterior surface have been very extensive is scraped as much as is safe and the elastic ligature is left to slough out. Occasionally the pedicle may be secured by a long, strong clamp till the kidney is excised and then the pedicle is tied by one or more ligatures on the proximal side of the clamp. If the ureter has been separately divided it is well to close it with a ligature, and if necessary to disinfect the stump or fix it in the external wound. The pedicle is finally again inspected to avoid any chance of hemorrhage, and then after the insertion of rubber drainage tubes and iodoform-gauze packing the external wound is partially closed.

During the course of a nephrectomy it may be necessary to enter the abdominal cavity; this can be done through the anterior extremity of König's or of the transverse incision; the surrounding peritoneal cavity is protected by the usual sponge-packing, and after removal of the latter at the close of the operation an iodoform-gauze packing is inserted unless there is a certainty of asepsis, in which case the peritoneum can be again closed tight.

**Abdominal Nephrectomy.**—The place of selection for the parietal incision is at the outer border of the rectus muscle, where it is sometimes called Langenbuch's incision. It



should not be less than four inches long, and should have its center as nearly as possible opposite the center of the tumor. The incision is sometimes made parallel to this, but further outward with the idea of making the operation wholly extra-peritoneal, and then it is only a modification of lumbar nephrectomy by the longitudinal incision. Sometimes the abdomen is opened in the median line. After division of the tissues in successive layers, including the peritoneum, the viscera are pushed aside and protected by flat sponges or brought out of the abdomen and wrapped in warm cloths.

The peritoneum over nearly the whole length of the enlarged kidney is then incised longitudinally on the outer side of the colon in order not to interfere with the blood-supply of the latter. This must always be done in this way unless the size of the tumor and the position of the colon make it impracticable. Occasionally it is possible, as shown by Halsted, to attach the edges of the divided peritoneum covering the kidney to those of the divided anterior parietal peritoneum, and thus entirely to shut off the general peritoneal cavity from the field of operation. By working with the fingers or blunt-pointed scissors the peritoneum is stripped from the anterior surface of the gland and the structures at the hilum exposed. All vessels, as they are encountered, are secured in advance whenever possible and divided between double ligatures. It may even be advantageous to go directly to the artery through a special incision in the peritoneum and tie it as the first step in the operation. The ureter is then isolated between two ligatures, and if extensively diseased it is brought out of the abdomen behind and fastened to the skin through the wound made in the loin for drainage ; or if healthy the stump is simply disinfected and left.

During the removal of the kidney every effort must be made to avoid infection of the peritoneal cavity by its contents or those of the ureter. After this the gap in the posterior parietal peritoneum may be rapidly closed with a continuous catgut suture, and lumbar drainage provided for the space formerly occupied by the kidney by the insertion of a rubber tube and gauze, if necessary, through



a small incision made in the loin. The abdominal wound is closed in the usual way, with or without drainage, according to the necessities of the case.

The presence and condition of the other, presumably sound, kidney should always be ascertained as soon as the peritoneal cavity is opened in abdominal nephrectomy.

In cases of floating kidney in which the gland is fully pedunculated and invested by peritoneum, its removal will be conducted as in the case of any other pedunculated abdominal tumor, without stripping off the peritoneum.

**Nephrorrhaphy or Nephropexy.**—This is the operation by which an abnormally movable kidney is permanently fixed in its proper position by suturing it to the abdominal wall.

The kidney is exposed by the longitudinal lumbar incision at the outer border of the sacro-lumbalis, and the fatty capsule divided longitudinally and stripped back from the surface of the kidney. Three or four stout catgut or silkworm-gut sutures are then passed with a curved needle from the anterior to the posterior surface, well within the convex border, at intervals of about half an inch, and then through the cut edge of the lumbar fascia in the inner lip of the wound, so that when tied they hold the kidney snugly up against the abdominal wall. The wound may then be closed for primary union, or packed with iodoform gauze to heal by granulation. Guyon sought to strengthen the cicatricial connection by removing a long strip of the fibrous capsule; and Sulzer<sup>1</sup> recommends that the capsule be split and reflected so as to form a flap which can be stitched in the parietal wound. Others have sought to avoid sutures and increase the extent and strength of the adhesion by holding the kidney up against the sides of the wound by means of a gauze loop passed around its lower portion and left in place for a week or more.

### URETER.

**Anatomy.**<sup>2</sup>—The ureter lies behind the peritoneum on the psoas muscle and genito-crural nerve in the upper part

<sup>1</sup> Deut. Zeit. f. Chir., Vol. XXXI.

<sup>2</sup> Cabot: American Journal of the Medical Sciences, 1892, Vol. CIII., p. 43.



of its course, and is crossed from within outward by the spermatic or ovarian vessels. As the ureters approach the pelvis they lie close to the spine between the psoas and the body of the vertebra, the right ureter being a little further outward than the left, owing to the interposition of the inferior vena cava, with which it is in close relationship.

When the peritoneum in this region is stripped up from the parts beneath the ureter will always be found adhering to its under surface and on the left side, about half an inch to an inch outside of the point where the peritoneum becomes attached to the spine ; on the right side the distance is slightly greater. The ureters cross the common or external iliac vessels to enter the pelvis, where they lie pretty closely over the lateral edges of the sacrum. They then run in the recto-vesical fold of peritoneum to enter the base of the bladder at a distance of two inches from each other and pass for a half to three-quarters of an inch between the mucous and muscular coats of the viscus before terminating. The vas deferens is between the ureter and the bladder. The narrowest part of the canal is close to the bladder, and this region, which is the most difficult of access, is also the one where a calculus is most likely to lodge. In the female the ureter for the last two, and in some cases three, inches of its course, lies in the broad ligament in close relationship with the cervix and vault of the vagina, and it can be reached by an incision in the vault extending outward and backward within the layers of the broad ligament.

**Operations on the Ureter.**<sup>1</sup>—Almost the only indications for operations upon the ureter are found in wounds of it or in the necessity for the removal of an impacted calculus. The ureter should always be opened extra-peritoneally for the removal of a stone, inasmuch as the wound cannot be satisfactorily closed with sutures, and it has been proven that at least a longitudinal wound will in time, if there is proper drainage, spontaneously close and allow the urine to pass in its natural channel.

<sup>1</sup> A summary of this subject with the bibliography will be found in the *Annals of Surgery*, 1894, p. 257.



The ureter should generally first be explored through a median abdominal opening made below the umbilicus, and always thus explored if there is doubt about the location of the stone. In some instances it has thus been possible to manipulate the calculus up into the pelvis of the kidney or down into the bladder, and even when it was soft to break the stone into fragments with the fingers and then get them into the bladder.

If the ureter must be opened, an incision is made three or four inches long wherever necessary in a line drawn from a point on the anterior edge of the sacro-lumbalis a finger's breadth below the twelfth rib, parallel to the rib as far as its tip, thence downward toward the middle of Poupart's ligament till about opposite the anterior superior spine of the ilium. From this point the line again turns inward to end at the outer border of the rectus muscle.

The tissues are divided layer by layer till the peritoneum is reached, and then the latter membrane is gently raised by the fingers from the parts beneath till the ureter is exposed adhering to its under surface. In the middle third of the course of the ureter it will be found about half an inch to an inch from the spinal attachment of the peritoneum. The ureter is incised longitudinally over the stone sufficiently to extract the latter. In several instances this wound has then been closed by a continuous suture of fine silk through the outer wall of the ureter, but not penetrating its lumen, and with one end of the suture left within reach from the parietal opening to remove it in case of suppuration. This may at any rate narrow the opening and so hasten its repair, though Cabot<sup>1</sup> considers suturing a wound of the ureter unnecessary.

A rubber tube and iodoform-gauze packing is placed in contact with the ureteral wound for drainage of escaping urine, and the ends brought out of the external incision which is partially closed around them.

In some cases where the stone can be felt through the vault of the vagina, and it is between the layers of the broad ligament not more than an inch or an inch and a-

<sup>1</sup> Loc. cit.



half from the bladder, an incision can be made in the vault outward and backward and the finger pushed up separating the intervening tissues in the broad ligament till the stone is reached. The ureter is then opened longitudinally on its under side and the stone picked out. Such a wound has been successfully closed with sutures, but it will generally be found sufficient to place a drainage tube and packing in contact with it and bring the ends out through the vagina.<sup>1</sup>

In other cases if the stone has reached the bladder cavity and lies between the mucous and muscular coats, it should be attacked through the interior of the bladder, probably by a suprapubic cystotomy; but, if it is further off and the bladder wall must be opened to expose the stone, there is great danger of urinary infiltration in the surrounding parts, and Cabot's method, described below, should be used.

With these exceptions the lower third of the ureter must generally be approached from behind. An incision is made three or four inches long, starting just below the tip of the coccyx and following the lateral border of that bone and the sacrum on the side of the affected ureter. The sacro-sciatic ligaments are divided close to the sacrum and the coccyx excised, and if necessary the lower lateral border of the sacrum also, as in Kraske's operation.

With a large sound in the rectum to map it out and push it aside, the ureter is sought for close to the edge of the sacrum and opened longitudinally on its under side opposite the calculus sufficiently to extract the latter. The resulting wound is simply packed and drained.

*Wounds of the Ureter.*—Extraperitoneal wounds of the ureter involving a part of its circumference should be treated as already described, *i. e.*, by a counter-opening and drainage through the abdominal wall in a direction as nearly as possible directly backward. When the wound has been intraperitoneal or has involved the entire circumference of the ureter, the divided ends have been ligated with catgut and the stumps disinfected and covered

<sup>1</sup> Cabot : Loc. cit.



with an iodoform-gauze packing, which was brought out of the abdomen, and the corresponding kidney has then been extirpated.

Or, after ligating and disinfecting the divided lower end of the ureter, the upper end has been brought out in the loin through a counter-opening made above the crest of the ilium behind, and a urinary fistula established, for the cure of which nephrectomy has been subsequently performed.

Some recent experiments on dogs<sup>1</sup> seem to prove that one ureter can be implanted in the rectum, or colon, without especial danger or subsequent inconvenience, and this fact might be of great service in case of an accidental division of one ureter during a pelvic operation.

There is also reason to believe that it may be possible to obtain reunion of the divided ureter and reestablishment of the flow of urine to the bladder by partial suturing of the divided ends after trimming them obliquely or into corresponding salient and reëntrant V's. If union can be thus obtained over a part of the wall, the remaining fistula may heal as after longitudinal or oblique wounds. A few cases have been reported in which invagination of the upper into the lower end has been successful.<sup>2</sup>

In several reported instances, when it has been divided near its lower end, the ureter has been implanted in the bladder above the point where it normally enters this viscus. The cut end of the ureter is slit up longitudinally for half an inch and its margins sutured with catgut to the edges of an opening in the bladder. Drainage must be provided for.

Kelly<sup>3</sup> has successfully employed on the human subject a method used by Van Hook in experiments on dogs, and has called the operation *uretero-ureterostomy*. Other similar cases are being reported. The divided extremity of the distal segment is tied off by ligature and just below

<sup>1</sup> Annals Surgery, 1892, Vol. XVI., p. 193.

<sup>2</sup> Markoe and Wood, Annals of Surgery, June, 1899.

<sup>3</sup> Annals Surgery, 1894, p. 70.



the latter the lumen of the distal segment is opened longitudinally sufficiently to permit the upper segment to be inserted into the lower. A couple of sutures in the cut edge of the proximal stump are threaded on needles and passed through the slit into the lumen of the lower stump and out through its walls just below the longitudinal opening and used to draw the upper into the lower portion of the tube. The ends of these sutures are tied, and one or two others inserted at the point where the stumps are in contact. Gauze is then packed around the suture line and brought out of the abdominal wound for drainage.



## CHAPTER VII.

### OPERATIONS UPON THE GENITO-URINARY ORGANS OF THE MALE.

#### CASTRATION.

THE usual preparations for an antiseptic operation are made, and a sterilized towel wet in a 1:1000 solution of bichloride of mercury is wrapped around the penis and pinned to the loose skin at its root. The scrotum on the affected side is grasped by the thumb and fingers of the left hand and drawn tight in such a way as to make the diseased testis and its cord prominent and tense. An incision is then made from the external abdominal ring along the entire length of the anterior portion of the scrotum; but if the skin is involved this incision should be made elliptical in the direction required to include the diseased area.

After division of the skin and dartos the testicle is slipped out of the wound, and the cord is dissected out until a healthy portion is reached; it may be necessary to follow it into the inguinal canal, splitting the aponeurosis of the external oblique for the purpose. It is then divided by repeated cuts of the knife and the vessels are caught and tied with catgut as they bleed. Hemorrhage from the scrotal wound must be completely checked by ligation or by torsion and pressure.

Drainage is unnecessary unless the wound has been exposed to infection, in which case a small rubber tube with lateral perforations is placed in its depths and brought out at the most dependent angle, while the surface is partly drawn together around an iodoform-gauze packing. Sometimes a healthy part of the cord cannot be reached and it must be tied through diseased tissue. It is then



especially necessary to ligate each vessel separately, and an iodoform-gauze packing is placed in contact with the stump.

A dry dressing is applied with a hernia bandage, over which is placed a sheet of rubber tissue, perforated for the penis, to prevent soiling by urine, and the whole retained by a flannel spica bandage.

### HYDROCELE.

The operations for the relief of hydrocele are *palliative* or *radical*. The object of the former is simply to remove the liquid from the sac; that of the latter to prevent its reaccumulation by excising the sac, or by obliterating its cavity by exciting adhesive inflammation of its walls. Injection of the tincture of iodine is the means most commonly employed for the latter purpose. The position of the testicle within the sac should always be ascertained, in order that it may not be injured by the trocar. This is best accomplished in most cases by examining the sac by transmitted light, the testicle appearing as an opaque spot in the general translucency; its usual position is at the lower posterior portion of the sac.

**Puncture of the Sac.**—The tumor is grasped at its upper portion in such a manner as thoroughly to stretch the skin covering it, and a sterilized trocar is plunged into the center of its anterior surface, supposing the testicle to occupy its usual position below and behind. The depth to which the trocar enters is regulated by the finger placed along its side, and the surgeon satisfies himself that the point is well within the sac by moving it freely in all directions. The canula should fit the trocar snugly in order that its anterior end may not push the tissues before it instead of penetrating them. If the intention is only to remove the liquid, the canula is withdrawn as soon as the flow has ceased, and the puncture closed with adhesive plaster or collodion; but if a radical cure is to be attempted, the tincture of iodine must first be thrown in.

Care must be taken that the injection is not thrown into the subcutaneous connective tissue, an accident that



is very likely to be followed by sloughing of the scrotum; the surest way of avoiding this accident is to throw in the injection before the liquid has entirely ceased to flow out. If the accident does occur, free incisions must be made at once into the scrotum at the seat of the infiltration.

**Radical Cure by Excision.** (Volkmann.)—With every antiseptic precaution the sac is freely laid open by a longitudinal anterior incision and the cut edges of the skin and tunica vaginalis stitched together all around. The cavity is then lightly packed and allowed to heal by granulation, a process which requires a couple of weeks. If the surgeon is sure of the asepsis the packing may be withdrawn at the end of three days, and then by applying firm pressure, the wound can be caused to heal much sooner.

### VARICOCELE.

The treatment of varicocele may be palliative or radical. By the former, support is given to the testicle and the over-distended veins; by the latter, it is sought to obliterate the lumen of the veins at one or more points. There are several risks involved in the radical treatment, which, when taken in connection with the usual harmlessness of the affection and the efficacy of palliative measures, should make the surgeon slow to employ it. The risks are: Possible sepsis, possible atrophy of the testicle, in consequence of the obliteration of all the veins or the inclusion of the artery in the ligature; and, finally, the return of the affection if all the veins are not obliterated. The palliative treatment consists in wearing a suspensory bandage, or in excising a large portion of the scrotum, with the expectation that what is left will act as a natural suspensory.

**Excision of the Scrotum.**—A long clamp is required, between the blades of which a large fold of the scrotum is pinched up parallel to and including the raphé. This fold is then cut off about one-eighth of an inch from the outer side of the blades, and numerous interrupted sutures applied before the clamp is removed. If bleeding is feared,



these sutures should be cut about a foot long, and not tied until after the clamp has been taken off and all bleeding points secured.

The radical treatment consists in obliterating the lumen of the veins by dividing them, excising a portion, compressing and strangulating them by means of ligatures or clamps, or simply exposing them to the air. Of these excision is the only method to be commended.

**Subcutaneous Ligature.**—A needle carrying a catgut or aseptic silk ligature is passed through between the veins and the cord, reëntered at the point of emergence, passed around the other side of the veins close under the skin and brought out and tightly tied at the first point of entry. If this is very exactly done, so as not to include the deeper part of the skin at either puncture in the loop, and is treated antiseptically, it will usually heal without suppuration. Its execution is facilitated by making the punctures with a knife.

**Open Method of Ligation.**—A fold of the scrotum over the enlarged veins above the globus major is pinched up and divided with scissors, making a longitudinal incision about an inch long. The thumb and forefinger of the left hand grasp the vas deferens, pushing it backward, while the veins at the same time are forced forward into the cutaneous wound. The veins are isolated by a slight dissection with the knife or blunt-pointed scissors and a ligature of catgut or fine silk is passed under them by an aneurism needle. After another inspection to make certain the vas is not included, the ligature is tied tightly and the ends cut short. The small incision is then closed without drainage and closed antiseptically.

Some surgeons pass the ligature double, tying off a segment of the vein, which is then excised and the divided ends brought into apposition by the long ends of the ligature, which are then cut short.

Others thoroughly expose a single vein, divide it, and then dissect out and excise an inch or two of it; this is repeated with one or several others according to circumstances.



**AMPUTATION OF THE PENIS.**

**Partial.**—The root of the penis is constricted by a piece of rubber tubing and the skin is slightly drawn back toward the pubes and divided by a circular sweep of the knife. With a sound in the urethra the corpora cavernosa are cut transversely at the level of the retracted skin down to the corpus spongiosum, which is then dissected out by a few strokes of the knife, and, after withdrawal of the sound, is cut transversely, including the urethra, about half an inch longer than the corpora cavernosa to allow for retraction of the urethra. The cut ends of the vessels in sight, including the two dorsal arteries and the arteries of the corpora cavernosa, which lie in the center of these bodies, are tied with fine catgut, the tourniquet removed, and, after checking the hemorrhage by ligation or torsion, the cut edges of the urethra and skin are united with fine silk.

To prevent cicatricial contraction of the mouth of the urethra, the latter should be split longitudinally for about half an inch on its under surface before stitching it to the skin.

**Complete.**—The patient is placed in the lithotomy position, a sound introduced into the bladder, and the scrotum is split from before backward along its raphé. The corpus spongiosum is dissected out as far as the triangular ligament, and divided about an inch in front of the latter after withdrawal of the sound.

A circular incision continuous with the anterior extremity of the scrotal incision is next made through the skin around the root of the penis; the suspensory ligament is divided, and by dragging on the penis and retracting the sides of the scrotal wound, the corpora cavernosa and their posterior prolongations, the crura, are removed from the rami of the pubes and ischium by the knife or periosteal elevator. All the attachments of the penis having thus been severed and the bleeding points tied, as they are encountered, with fine catgut, the urethra is split for half an inch on its floor and sutured to the edges of the wound well forward in the perineum, and the



remainder of the wound is united between the testicles so as to form a separate scrotum for each of them.

When this extensive operation is undertaken for cancer of the penis the inguinal glands on both sides should be removed at the same time, whether perceptibly enlarged or not.

### OPERATIONS FOR PHIMOSIS.

**Dorsal Incision.**—A director is passed through the preputial orifice along the dorsum of the glans to the corona, a curved sharp-pointed bistoury guided along it, the skin transfixed at the point of the director and divided straight down to the preputial orifice. Nothing more is absolutely required, for the wound left to itself will heal promptly; but it is well to round off the corners and to unite the edges of the mucous membrane and skin by fine sutures. This is a very satisfactory operation when the prepuce is not redundant, but if there is much excess of tissue the foreskin will present an awkward, lop-eared appearance for many years, and in such cases, therefore, circumcision is to be preferred.

This operation is often required in cases of sub-preputial chancroid, and care should then be taken to prevent or correct infection of the wound by the chancroidal virus.

**Circumcision.**—A number of instruments have been invented and a great variety of methods proposed, which do not need to be repeated here, for the object they had in view, that of insuring division of the skin and mucous membrane of the prepuce at the same level, is not a matter of much importance, since any excess of the latter can be readily removed afterward. There is, however, one modification introduced by Dr. Keyes<sup>1</sup> which is of importance, for it insures the removal of the constriction and protects the wound from being harmed by erections while healing. This modification consists in an additional longitudinal division of the skin for about half an inch along the dorsum of the penis (Fig. 219, *AC*). The

<sup>1</sup> Van Buren and Keyes: *Genito-Urinary Diseases, with Syphilis*, New York, 1874, p. 11.



corners left by this incision are rounded off, and the effect is to increase the circumference by twice the length of the incision.

**Operation.**—A probe is first introduced and swept over the surface of the glans to break up any adhesions that may exist, and the edge of the preputial orifice is then caught at opposite points with the thumb and forefinger of each hand and drawn forward, care being taken to make the tension upon the less elastic mucous membrane, and not only upon the skin. While the prepuce is thus drawn forward, an assistant clasps a pair of long narrow-

bladed forceps vertically upon it just in front of the apex of the glans, directing the blades forward as well as downward (the penis being horizontal) parallel to the general direction of the corona, and the glans should then be moved freely behind them to make sure that it is not caught between the blades. The portion of prepuce in front of the forceps is then cut away with scissors or a knife and the forceps taken off.

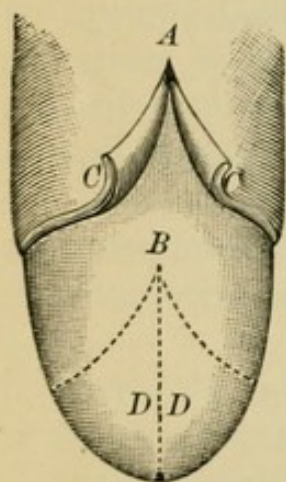
It will then be seen that the glans is still covered by a more or less tightly fitting sheath of mucous membrane, while the looser and more elastic skin retracts to or beyond the corona, leaving a belt of

raw surface below (Fig. 219).

The mucous membrane is next divided with scissors along the dorsum back to the corona (Fig. 219, *BD*), and the skin divided in the same direction along the dorsum for a distance of half an inch from its cut edge (Fig. 219, *AC*). The corners are rounded off, and the edges of the mucous membrane and skin fastened together with numerous fine sutures, the first being placed exactly in the median line in front, the second at the frænum. If fine silk is used, and the sutures placed close to the edge, they may be left to cut their way out and come away in the dressings.

If broad adhesions exist between the glans and prepuce,

FIG. 219.



Circumcision. Raw surface left by retraction after first incision.



and it is feared that the raw surfaces left by their division will reunite, all the mucous membrane may be removed, except a ring about one-eighth of an inch wide adjoining the corona; the skin is then drawn forward, and united to the narrow ring of mucous membrane. The raw surface on the glans, having nothing to adhere to, cicatrizes naturally.

### PARAPHIMOSIS.

A description of the methods of reduction by taxis or by compression of the engorged prepuce and gland does not lie within the proposed scope of this work, and the operation of division of the constricting band hardly needs to be described, for it consists simply in dividing the band from without inward at one or more points, until the constriction is sufficiently relieved to allow the prepuce to be drawn forward. It is well to make the first incision in the median dorsal line so as to profit by it afterward, if an operation for phimosis is considered necessary.

### DIVISION OF THE FRÆNUM.

Verneuil<sup>1</sup> employs the following method: He makes the frænum tense, transfixes it close to its attachment to the glans with a narrow bistoury or tenotome held with its side parallel to the surface of the penis, and cuts out backward, making a triangular flap nearly half an inch long, with its apex directed backward. The liberated glans is drawn forward, the flap disappears, and the edges of the wound, which assumes the shape of a lozenge, are united by sutures.

### EPISPADIAS.

The deformity known as epispadias is characterized by fissure of the roof of the urethra. In its complete form it is associated with separation of the symphysis pubis, and often with exstrophy of the bladder, in which case its treatment is subordinate to that of the more important defect (*q. v.*). In its slightest degree it is confined to a fissure occupying the dorsal portion of the glans penis,

<sup>1</sup>Chirurgie Réparatrice, 1887, p. 730.



and extending from the meatus to the corona (epispadias balanique). The existence of this form has been denied, but Verneuil<sup>1</sup> reports two cases, in neither of which did the malformation cause any disturbance of function. In the more important varieties the urethra lies above the corpora cavernosa instead of below them, and is open on the roof from its anterior extremity nearly to the bladder; the glans is fairly developed, and may be grooved more or less deeply along its dorsum, while the rest of the corpus spongiosum is represented by a thin layer of erectile tissue under the urethra. There is sometimes partial or complete incontinence of urine, and the operative indication is to supply a channel through which the urine can be conducted without dribbling to a urinal.

**Nélaton's Method.**—The prepuce is drawn downward and forward by means of a ligature passed through it, and held in this position during the operation. An incision is then made along each side of the urethral gutter at the junction of the skin and mucous membrane, beginning at the prepuce and ending at the abdominal wall. The external lip of each incision is dissected up for about one-sixth of an inch, forming a flap on each side continuous with the skin; the inner lip of each incision is also slightly loosened. The flaps must be made as thick as possible.

A third flap is then marked out upon the abdominal wall, immediately above the urethral orifice leading to the bladder, by two vertical incisions united at their upper ends by a transverse one; it should be as broad as, and a little longer than, the penis, dissected from above downward to its base, which corresponds to the interpubic ligament, and then reversed, its cutaneous surface inward, and its sides made fast by sutures to the inner lips of the incision on the penis, care being taken to make the contact as broad as possible. Demarquay<sup>2</sup> and Dolbeau<sup>3</sup> preferred to make the flap by prolonging the first two incisions up

<sup>1</sup> Loc. cit., p. 718.

<sup>2</sup> *Maladies Chirurgicales du Penis*, 1877, p. 623.

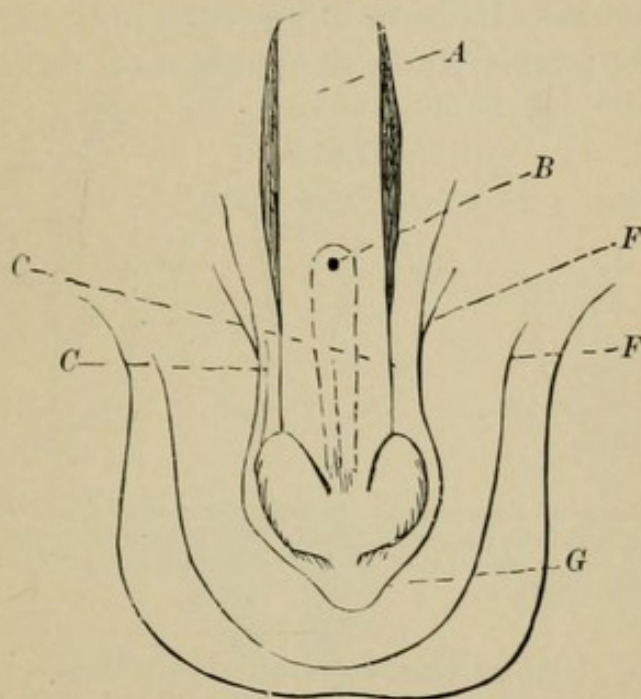
<sup>3</sup> *De l'Epispadias*, Paris, 1861. Planche IV., Fig. I.



the abdomen, thinking that the continuity of the incisions upon the abdomen and penis would increase the chances of success (Fig. 220, *C, C*).

In order to give the abdominal flap greater thickness, and prevent its retraction during the process of cicatrization, Nélaton reinforced it by another taken from the scrotum. This scrotal flap is limited by concentric curved incisions (Fig. 220, *F, F*), the upper one circumscribing the under half of the root of the penis in the peno-scrotal

FIG. 220.



Epispadias. Nélaton's operation. *A*. Abdominal flap. *B*. Urethral infundibulum. *C, C*. Lateral incisions at junction of skin and mucous membrane. *F, F*. Scrotal incisions circumscribing *G*, the scrotal flap.

angle, the other at a distance below the first equal to the length of the penis, and is left adherent at both ends. After the flap has been dissected up, the penis is passed under it, bringing the raw surface of the reversed abdominal flap into contact with that of the scrotal flap, and the great circumference of the latter is fastened by three sutures to the outer lips of the two incisions made along the sides of the urethral gutter.

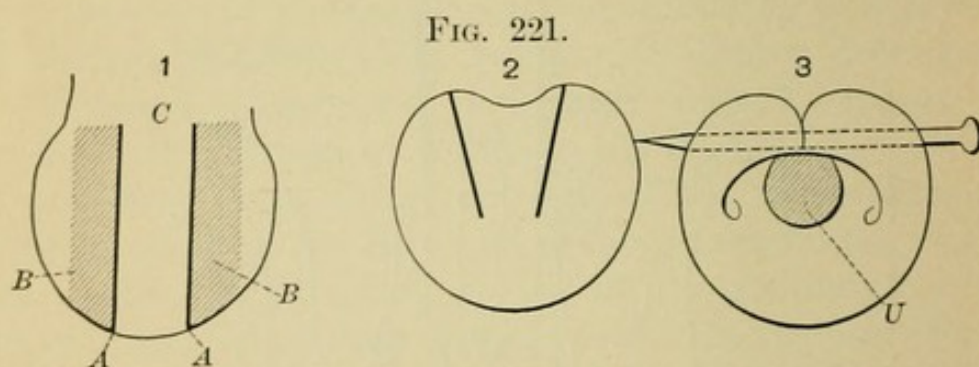
The canal thus formed is very large, and both Nélaton and Dolbeau found it necessary to diminish its size by ap-



plying the actual cautery to its interior. The operation devised by Thiersch is generally deemed superior.

**Thiersch's Method.**<sup>1</sup>—This operation requires several months for its completion, since it is composed of four distinct operations performed at different times. In order to prevent the urine from coming into contact with the raw surfaces of the flaps Thiersch makes an opening into the urethra through the perineum and maintains it during the entire period of treatment.

**FIRST STEP.** (Fig. 221.)—Creation of the meatus and the portion of the canal occupying the glans. The surgeon makes a deep incision along each side of the urethral groove in the glans, pares the surface of the outer lip of



Epispadias. Thiersch's operation. 1. The glans seen from above. *A, A.* The incision on each side of the gutter *C.* *B, B.* The freshened surface. 2. Transverse section of glans showing the incisions. 3. The freshened surfaces brought together and closing in the urethra *U.*

each incision, brings the freshened surfaces into contact, and fixes them with two or three points of twisted suture.

**SECOND STEP.** (Figs. 222, 223.)—Creation of the urethra along the body of the penis. The surgeon makes an incision through the skin and subcutaneous tissue at the edge of the urethral gutter on the right side, makes a short transverse cut outward from each end, and dissects up the rectangular flap thus marked out. On the left side he makes a longitudinal incision one centimeter external to the edge of the gutter, and a transverse incision from each end. This flap is dissected up, making it as thick as possible, and turned over so as to form a roof for

<sup>1</sup> Archiv für Heilkunde, 1869. pp. 20-36, and Langenbeck's Archiv, Vol. XV., Part II., p. 379.

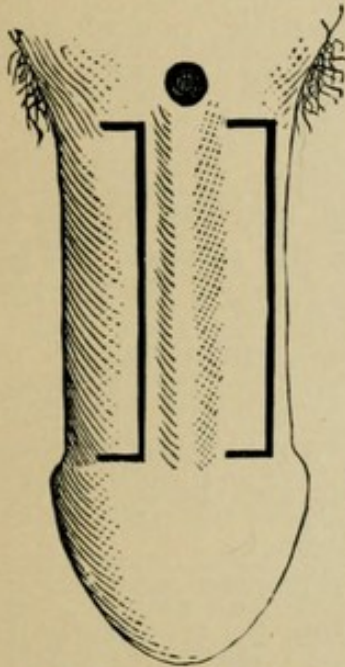


the urethral gutter, its cutaneous surface directed downward, its raw surface upward. Several ligatures are passed through it near its free border and then through the base of the right-hand flap, and the latter drawn across the former so that their raw surfaces are brought into contact throughout. The free edge of the right flap is then fastened to the skin forming the outer edge of the incision on the left side.

**THIRD STEP.**—To close the gap remaining between these two new portions of the urethra. A transverse incision is made in the prepuce, the glans passed through it, the borders of the gap pared and fastened to the edges of the incision in the prepuce.

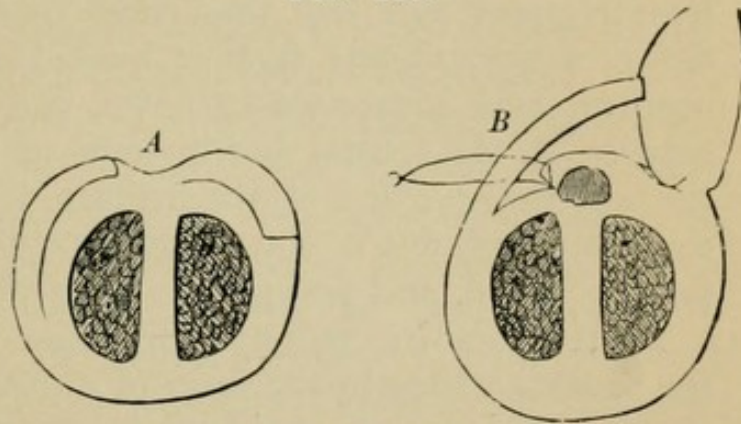
**FOURTH STEP.**—To close the posterior portion of the canal or infun-

FIG. 222.



Epispadias. (THIERSCH.)  
Second step. Incisions limiting the two lateral flaps.

FIG. 223.



Epispadias. (THIERSCH.) Transverse section of penis, showing flaps.

dibulum. The method employed is similar to that used in the second step of the operation, the flaps being taken from the groins. The left flap has the form of an isosceles triangle, and its base occupies the left half of the upper semi-circumference of the opening; it is turned over so that its cutaneous surface is directed downward, and its free border is united to the freshened posterior edge of the roof of the new urethra. The other flap is quadrilateral, its base corresponds to the right inguinal ring, and it is



drawn over the first one so that their raw surfaces are brought into contact and fastened together with sutures.

Finally, the fistula established in the perineum is closed.

### **HYPOSPADIAS.**

The deformity known as hypospadias is characterized by a congenital abnormal opening of the urethra upon the under surface of the penis. Sometimes the urethra ends at the abnormal opening, sometimes it is continued more or less imperfectly beyond it either in the form of a tube, which is usually imperforate at one or two points, or in that of a gutter. The varieties of hypospadias are usually classified in three groups, the balanitic, penile, and scrotal, according as the abnormal opening is found at a point in the urethra corresponding to the glans, the pendulous portion of the penis or the scrotum. The balanitic is the most frequent and least important, and the penile is less frequent and less important than the scrotal. The defect never extends further back than the bulb of the urethra, and consequently never causes incontinence of urine. In the scrotal and in some of the penile varieties the anterior portion of the urethra forms a tense fibrous cord binding down the glans, curving the body of the penis upward, and preventing its erection.

In the balanitic variety, when the anterior portion of the urethra exists in the form of a gutter, no treatment is required unless the opening is too small. The slight deficiency in length involves no loss of function, and attempts to reconstitute the defective portion of the canal by some plastic operation usually fail. In fact, if the canal exists between the meatus and the abnormal opening, it may be better to slit it up than to try to close the latter.

The scrotal variety is considered irremediable, and has never been the subject of surgical interference. In it the scrotum is bifid, the penis usually very small, and the urethral orifice at the bottom of an infundibulum resembling a vulva. Individuals thus deformed have often been mistaken for hermaphrodites and sometimes for females.

In the penile variety, when the anterior portion of the



urethra is normal, the opening may be closed by freshening the surface about its edge and covering it with a flap taken from the adjoining skin. When the anterior portion exists only in the form of a more or less shallow groove, it may be transformed into a complete canal by one of the methods of urethroplasty hereinafter described. The two other modes of operating, urethrorrhaphy and perforation, have now been discarded; in the former the edges of the groove were pared and brought together with sutures, in the latter a trocar was passed along through the tissues of the under side of the penis from the extremity of the glans to the abnormal opening of the urethra, and the route thus created kept open by the frequent passage of sounds.

If the penis is incurvated it must be straightened as a preliminary to any operation. To accomplish this it is not sufficient to divide only the fibrous band on its under surface, for the retraction is partly maintained by the shortness of the inferior portion of the sheaths of the corpora cavernosa and the septum between them. If the skin on the under surface is flexible enough to allow the penis to be straightened after the internal bands have been divided, this division may be made subcutaneously, following the example of Bouisson, by introducing a tenotome and pressing its edge against the sheath of the corpora cavernosa and the septum while the glans is drawn steadily away from the scrotum. Ordinarily, however, this is not possible, and one or two transverse incisions one centimeter long must be made through the skin and deeper parts. By the straightening of the penis these transverse incisions are transformed into longitudinal ones, and their sides are then drawn together by sutures. Several months must then be allowed to elapse before the subsequent plastic operation is undertaken, in order that the cicatrix may become perfectly soft and attain its full vitality.

In the earlier operations of *urethroplasty* the floor of the urethra was formed by a long narrow vertical flap taken from the scrotum, its base adjoining the orifice of the



urethra, and its borders fastened to the edges of two longitudinal incisions on the under side of the penis. In short, the method resembled that already described as employed by Nélaton for the relief of epispadias, even to the reinforcement of the flap by a transverse one taken from the skin above the root of the penis. The results of these attempts were so unsatisfactory that when Nélaton was consulted in 1872, concerning a patient affected with hypospadias, he advised that nothing should be done, saying that he had made many canals through which the urine was carried to the end of the penis, but they interfered with erection, and did not facilitate fecundation.<sup>1</sup> The surgeon who received this advice, Théophile Anger, thereupon devised another method, ignorant that a similar one had been employed shortly before by Thiersch in epispadias and by Scymanowski for urethral fistula, and, having put it into execution, obtained an excellent result.

*Théophile Anger's Method.*—In this case the urethral opening was at the peno-scrotal angle, the anterior portion of the canal was entirely lacking, and the penis was so curved that the extremity of the glans was not more than half an inch from the opening. The penis was first straightened by two short transverse incisions carried to such a depth that the corpora cavernosa were exposed at the bottom of the wound; the bleeding was slight, and the wound healed promptly. The plastic operation was performed nearly four months afterward, and was only partially successful, the posterior portion of the flap disappearing by absorption. A second operation six months later, was entirely successful, and the condition of the parts, when the patient was shown to the Société de Chirurgie five months afterward, was entirely satisfactory; the tissues were supple, there was no stricture in the canal, and erection was perfect, except for a very slight incurvation downward.

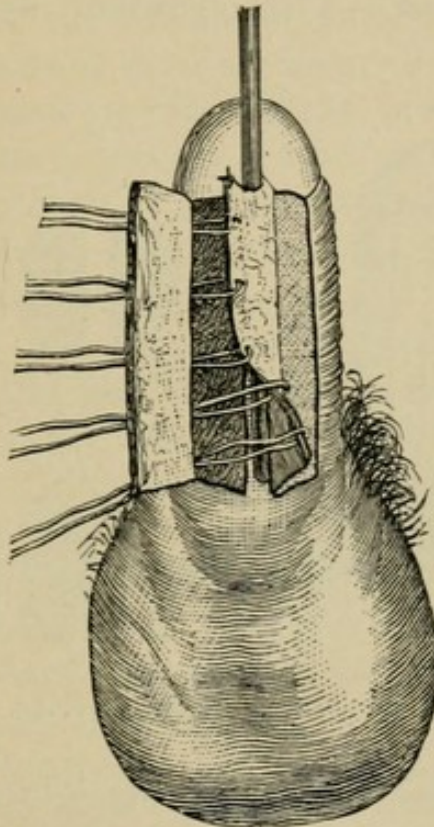
The first plastic operation was as follows: An incision, extending from the glans to the scrotum, was made

<sup>1</sup>Théophile Anger in Bull. de la Soc. de Chirurgie, séance du 21 Janvier, 1874.



through the skin on the left side parallel to the median line and one and a-half centimeters from it, and from each extremity of this an oblique incision was carried to the median line, the posterior one ending on the scrotum just behind the urethral opening (Fig. 224). The cutaneous flap circumscribed by these three incisions was dissected up so that it could be turned back with its epidermic surface directed inward, and thus constitute the floor of the

FIG. 224.



Hypospadias. Théophile Anger's method.

new canal. A second longitudinal incision was then made a little to the right of the median line, parallel to and as long as the first, a transverse incision one and a-half to two centimeters long carried outward from each end of it, and the flap thus circumscribed dissected up.

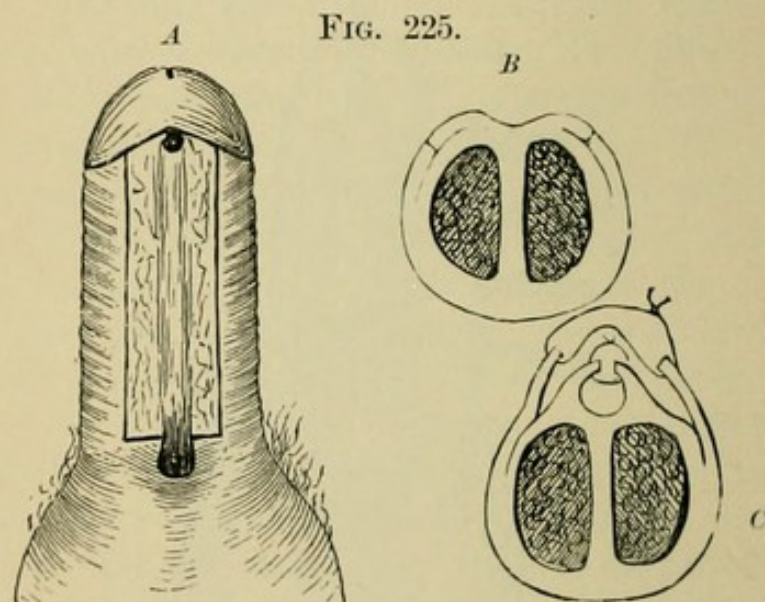
A sound was then introduced into the urethra, the first flap drawn back over it, and six sutures placed close to its free longitudinal border; the two ends of each suture were then attached to a needle and carried through the base of



the second flap from within outward, as shown in the figure, drawn tight, and fixed by pinching a tube of lead upon them. Finally, the second flap was drawn over the first, and its edge made fast to the outer lip of the first incision, thus covering in all the raw surface.

Anger tied in the catheter and left it for several days, but admits that this was a mistake. When he repeated the operation he left the catheter in for only twenty-four hours, and then reintroduced it only when the urine had to be drawn off.

**Duplay's Method.**—The operation has three steps or



Hypospadias. Duplay's method.

stages. In the first, the penis is straightened and a meatus made; in the second, the portion of the urethra which is lacking is restored; and, in the third, this new portion is united to that which previously existed.

**FIRST STEP.**—The penis is straightened by transverse or subcutaneous incisions as before described, and the meatus made by paring a strip of the surface of the glans on each side of the groove representing the urethra, and bringing them together with one or two points of twisted suture over a piece of gum catheter placed in the groove. If necessary, the groove may be deepened by one or two longitudinal incisions on its floor (roof of the urethra).



SECOND STEP.—Two longitudinal incisions, extending from the glans nearly to the abnormal urethral opening, are made, one on each side of the median line, at a distance from each other equal to the circumference to be given to the new urethra; and from each end of these a short transverse incision is made toward, but not quite to, the median line (Fig. 225, *A*). The rectangular flaps thus circumscribed are dissected up toward the median line, turned back over a gum catheter, and their free borders fastened together with sutures (Fig. 225, *B* and *C*). The outer lips of the two incisions are then loosened sufficiently by dissection to allow them to be drawn over the others and fastened together in the median line with interrupted or twisted sutures. Care must be taken to attach the anterior ends of all four flaps to the pared surface of the glans, so that the new urethra may be continuous with the piece previously made.

THIRD STEP.—To close the gap between the termination of the old and the beginning of the new portions of the urethra, Duplay freshened the edges and brought them together with double rows of sutures.

### URETHRAL FISTULA.

Urethral fistulæ, as a rule, are more difficult to close the further they are from the bladder. Those occupying the perineum and scrotum are long, pass through thick tissues, and will usually heal spontaneously if the full caliber of the urethra in front of them is maintained. Occasionally it becomes necessary to freshen their sides with a knife, caustics, or cautery.

Fistulæ occupying the pendulous portion of the penis have but little tendency to close spontaneously, unless they are recent and small; the distance between the mucous and cutaneous surfaces is so short that the walls of the fistula cicatrize promptly without uniting, and that renders a spontaneous cure practically impossible. Operations undertaken for the purpose of closing them, exclusive of simple cauterization, are divided into two classes, *urethrorrhaphy* and *urethroplasty*. In the former, the sides



of the fistula are pared and brought together in the median line; in the latter, the loss of substance is made good by the transfer of cutaneous flaps.

It has always been held that the principal obstacle to the closure of a fistula is the frequent passage of urine through it, and although this has been occasionally questioned, especially with reference to normal urine, it is still considered one of the principal indications to prevent this passage. The choice lies between three methods: 1st, Introducing a catheter and drawing off the urine as often as it becomes necessary to empty the bladder; 2d, tying in a catheter; 3d, establishing a free passage for the urine at some point on the proximal side of the fistula. The first two methods are open to serious objections; the frequent passage of the catheter is calculated to disturb the adjustment of the flaps, stretch the sutures, and irritate the urethra; and, moreover, a small quantity of urine is sure to escape through the canal beside or behind it. A catheter retained in the urethra for several days is even worse; as Ducamp<sup>1</sup> pointed out more than fifty years ago, it violates the two conditions necessary to the cicatrization of every wound, moderate degree of inflammation and of humidity, by irritating the canal and provoking an excessive flow of mucus. After two or three days at the latest it not only fails to remove the urine as fast as it collects in the bladder, but actually favors its escape alongside and through the wound. It excites cystitis of the vesical neck, and sooner or later gives rise to the complex of symptoms known as urinary fever. In short, it is not only inefficient after the first day or two, but is positively harmful. The objection to the third method, unless a perineal fistula exists and can be sufficiently enlarged, is that as usually practised it involves an additional and considerable wound in the perineum.

**Urethrorrhaphy.**—This term is applied to the simple approximation of the sides of a fistula after they have been pared. Verneuil<sup>2</sup> considers the method applicable to all

<sup>1</sup>Traité des Rétentions d'Urine, 1825, p. 237; quoted by Verneuil.

<sup>2</sup>Chirurgie Réparatrice, p. 696.



circular fistulæ not more than one-fifth of an inch in diameter if the surrounding tissues are thick, and also to oblong fistulæ of much greater size when their long axis is in the median line and their sides can be easily brought together. He thinks the numerous failures which have followed the use of the operation have been caused by a lack of attention to details, and he suggests that the paring of the edges should be oblique so as to give the fistula the form of a funnel with its apex at the opening into the urethra, the mucous membrane of which should not be included in the paring. Fine metallic sutures should be used, applied at short intervals, not penetrating to the canal of the urethra, and tied over a leaden plate on the surface. The line of reunion should be longitudinal, not transverse, and if primary union is not obtained the sutures should be retained to favor secondary union. During the operation a sound should be kept in the urethra in order that the canal may have its full size.

**Urethroplasty.**—The methods that have been suggested and employed have been very numerous, but most of them count more failures than successes. This is especially true of those by which longitudinal or transverse flaps have been dissected up on opposite sides of the fistula, and brought together by their edges across its center, for the tissues are usually too thin to afford a sufficiently broad surface of coaptation, and the urine finds its way at once through the wound. It has been proposed to overcome the latter obstacle to union by passing a piece of thin India-rubber under the flaps, but it is doubtful if the presence of the foreign body would not have a more unfavorable effect upon the thin, delicate flaps than the urine which it is designed to keep away.

*Nélaton's Method.*—Nélaton pared the edges of the fistula and dissected up the skin subcutaneously for about an inch around it by entering the knife through a short transverse incision below it. The skin thus liberated was pinched up in a longitudinal fold along the median line, and fixed in this position by twisted or quilted sutures.

*Reybard* made the dissection through the fistula, thus



avoiding the transverse incision of the skin. *Dieffenbach* and *Delore* employed a similar method, but instead of dissecting up the skin subcutaneously they raised two longitudinal or transverse flaps and fastened them together by their raw and under surfaces (not edges) in the center, the former passing his sutures through a leather splint on each side, the latter applying them in three rows, one above the other.

*Delpech* and *Alliot* dissected up a single flap, drew it entirely across the fistula, and fastened it to a raw surface prepared upon the opposite side.

*Sir Astley Cooper* cut away the skin in such a manner as to leave a raw surface of quadrilateral form with the fistula in its center, and then covered it with a flap of the same shape, taken from the scrotum by the Indian method of autoplasty.

*Arlaud*<sup>1</sup> obtained a complete success in a remarkable case, where the urethra had been completely divided just in front of the peno-scrotal angle, and its two cut ends were nearly an inch apart, by adapting a method previously employed by *Roux* to close a fistula in the trachea. The principle is the same as in *Delpech's* method, the difference in detail being that two flaps are used instead of only one; the second one, that which has its cutaneous surface pared, being drawn under the first.

Two transverse flaps, one in front of the fistula, the other behind it, were marked out by longitudinal incisions four centimeters apart; the anterior one was dissected up for a distance of two centimeters toward the glans, and the posterior one dissected back over the scrotum, until it could be easily drawn forward far enough to cover the fistula entirely. The anterior portion of the cutaneous surface of the second (scrotal) flap was then thoroughly pared, the flap drawn forward so as to cover the fistula, and the anterior flap drawn back over the other and fastened there by four points of twisted suture.

<sup>1</sup> Bull. de la Société de Chirurgie, 1857, p. 550, and *Verneuil's Chirurgie Réparatrice*, p. 654.



*Sédillot* dissected up a small flap on each side, its base adjoining the edge of the fistula, its free border directed outward, reversed and united them by their free borders in the median line (their epithelial surfaces directed inward), and brought the sutures out through the meatus. The raw surface of the flaps was then covered by a third flap transferred by the Indian method, or by sliding.

*Rigaud* closed a large fistula at the peno-scrotal angle by the method already described as *Nélaton's* method of treating epispadias. He took a quadrilateral median flap from the scrotum, its base adjoining the fistula, turned it forward over the fistula, and covered its raw surface with two flaps taken from the sides and drawn together to meet in the median line.

*Théophile Anger* has likewise proposed to close urethral fistulæ by the method he employed so successfully in a case of hypospadias; and

*Scymanowski*<sup>1</sup> reports a success obtained by a method which differed but slightly from *Anger's*. He made the flaps much longer than the fistula, and freshened the cutaneous surface of the reversed flap by blistering it, so that it could unite with the raw surface upon which it was laid.

*Dr. McBurney*, by the use of methods similar to the last named, has obtained a number of brilliant successes in urethral fistula and hypospadias; several of the cases are reported in the proceedings of the New York Surgical Society between 1881 and 1884. In cases in which previous operations had failed and had left cicatricial tissue about the opening he sought to close, he first removed the cicatricial tissue and supplied its place with flaps taken from the adjoining skin. To close the openings he used flaps similar to *Anger's* (Fig. 224), leaving the epidermis upon the surface of the one first turned in over an area corresponding exactly to the opening, and freshening with the knife all the remaining portion of its surface. He also dissected up for a line or two the anterior edge of the central unfreshened portion and tucked it under the freshened anterior margin of the opening.

<sup>1</sup> Handbuch der Operativen Chirurgie, 1870.



## INTERNAL URETHROTOMY.

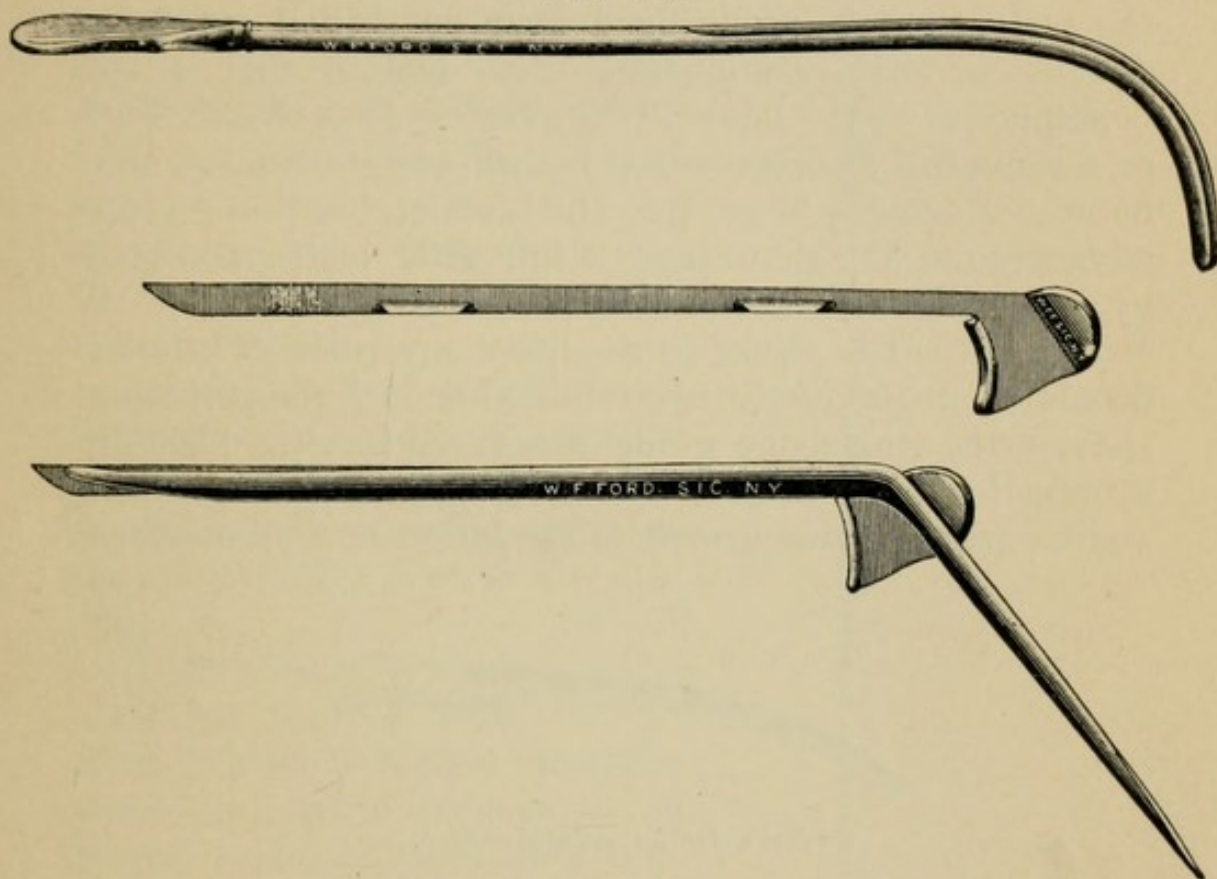
Every antiseptic precaution is necessary. A stricture in the penile urethra is conveniently divided under cocaine by the Otis urethratome up to any desired size; the bladder may then be washed with a sterilized saturated solution of boric acid, about four ounces of which are left in. The passage of full-sized sounds must be kept up subsequently.

For anterior strictures too tight to admit this urethratome, and for deep strictures, with the observance of certain precautions, the instrument of Maisonneuve is very useful. The flexible filiform bougie is passed through the stricture and secured to the staff, which then follows the bougie into the bladder, and the stricture is divided by slipping the knife along the whole length of the groove while the penis is drawn out on the staff to straighten and render tense the urethra, care being taken to make the section exactly in the median line of the roof. The knife is blunted on its summit and is supposed to divide only the narrowed portions of the canal. After a stricture beyond four and a-half inches from the meatus has been cut in this way, the patient is placed in a lithotomy position, the perineal region thoroughly disinfected and shaved, and a broadly-grooved staff, about the size of a No. 28-30 F. sound, is passed to the bladder. It is so held in the median line by an assistant as to make the curved part of the staff prominent in the perineum. McBurney's gorget (Fig. 226), with the knife protruded, is then plunged into the center of the perineum, opening the membranous urethra and striking the groove in the staff, into which the gorget is pushed, sheathing the knife which is then withdrawn, while at the same time, by slightly tilting the staff and advancing the gorget, the latter slips into the bladder as evidenced by the gush of urine. A soft-rubber catheter is inserted into the bladder on the gorget through the perineal puncture and retained by a silk suture through the skin, and the gorget is withdrawn. The bladder and urethra are thoroughly irrigated with a saturated solution of boric acid, and the catheter connected with a tube termin-



ating beneath the surface of a 1:60 solution of carbolic acid in a bottle under the bed. A slight dressing retained by a split T-bandage around the catheter is sufficient, and at the end of five days a sound is passed through the whole length of the urethra entering the bladder alongside of the

FIG. 226.



McBurney's gorget and grooved sound.

catheter, which if all goes well, is removed twenty-four hours later, and a single antiseptic pad placed on the punctured wound in the perineum.

When the bladder and urine are not extensively diseased and there are no other complications, such as multiple fistulæ, this method of treating deep strictures is generally preferred to the usual external urethrotomy.

#### EXTERNAL PERINEAL URETHROTOMY.

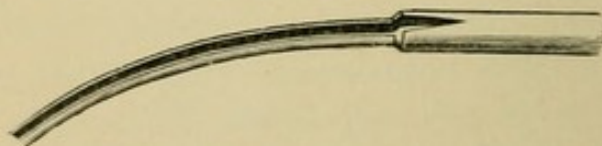
A. WITH A GUIDE.—Prof. Syme, who introduced this operation, employed as a guide a staff, the straight



portion of which was of full size, and its curved portion much smaller and grooved on the convexity. The change from the full to the small size was abrupt, not gradual (Fig. 227). This instrument has been superseded, in the United States at least, by the tunnelled instruments introduced by Van Buren,<sup>1</sup> which are passed into the bladder over a fine whalebone bougie as a guide, the beak of the instrument being bridged over or drilled out for a distance of about one-quarter of an inch, so that it can be slipped over the bougie (Fig. 228). If a Syme's staff or a tunnelled catheter cannot be had, any instrument may be used which can be got into the bladder, but it is a great advantage to be able to pass a full-sized instrument step by step as the stricture is divided.

The patient is placed in the lithotomy position (dorsal decubitus, thighs flexed upon the abdomen),<sup>2</sup> the perineum shaved, the whalebone guide introduced into the bladder, a tunnelled silver catheter of full size, grooved on the convexity, passed down over it to the stricture and confided

FIG. 227.



Syme's staff for perineal section.

to an assistant, who also draws the scrotum forward out of the way. An incision, varying in length according to the position of the stricture, is made in the median line, and the end of the catheter exposed. If the stricture is deeply placed the sides of the incision must now be held apart, while the guide is carefully followed from before backward with short, cautious strokes of the knife in the median line, and the catheter pushed along as the route

<sup>1</sup> Van Buren and Keyes, *Genito-Urinary Diseases*, p. 127.

<sup>2</sup> A convenient method of keeping the thighs fixed is to pass a stout cane under the knee and fasten it with a cord or roller bandage passed from one end around the patient's neck to the other end. An instrument has been specially constructed for the purpose (Fig. 229), but a stout stick does very well.



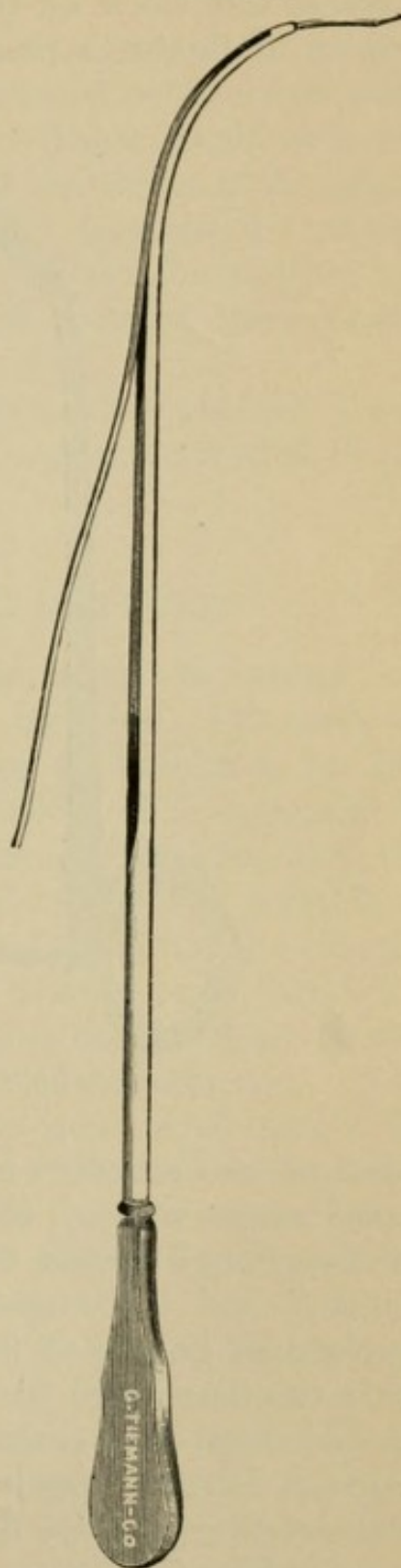
is opened, until the posterior limit of the stricture having been passed, it slips into the bladder. Care must be taken not to divide the whalebone guide by a careless stroke of the knife.

If Syme's staff is used, the incision is carried down until the groove in the curve of the staff can be felt by the finger; the handle of the staff is then grasped with the left hand, the point of a narrow bistoury passed into the groove behind the stricture, and the latter divided by cutting from behind forward.

Any bands that are found on the roof of the urethra must be divided, and a full-sized steel sound passed to make sure that the stricture has been thoroughly relieved.

**B. WITHOUT A GUIDE.**—The cases are rare in which a fili-form whalebone bougie cannot be passed through a stricture which allows urine to pass, and consequently external urethrotomy without a guide is not often required. The patient is placed in the lithotomy position, the perineum shaved, and a full-sized sound, preferably grooved, passed down to the stricture and confided to an assistant, who also draws the scrotum forward, keeping its raphé exactly in the median line. An incision, two and a-half to three inches long, is made in the median line, and the end of the

FIG. 228.

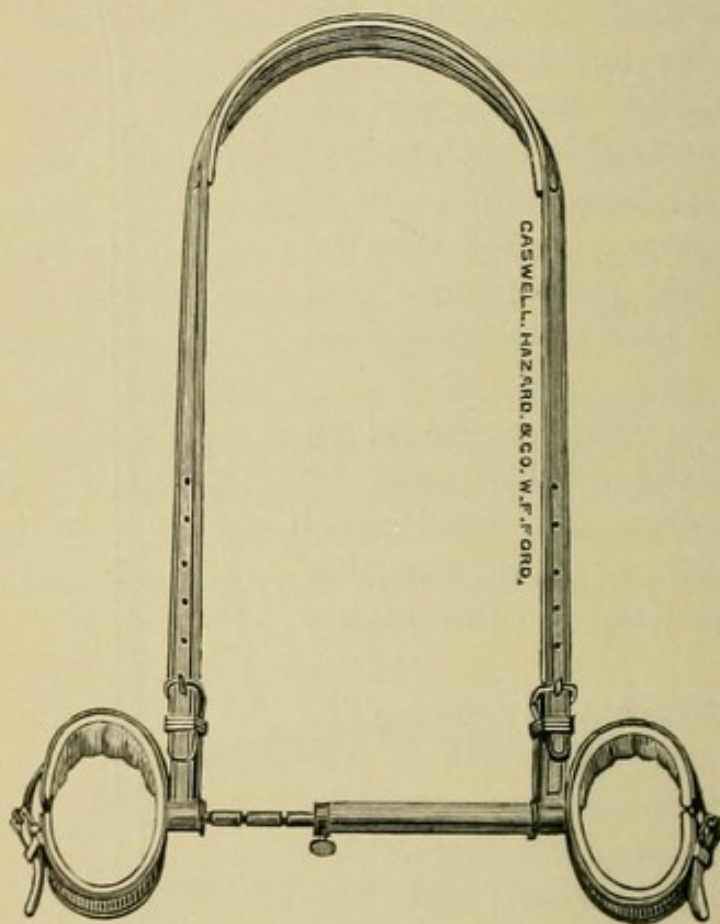


Tunnelled instrument and whalebone guide.



sound exposed by opening the urethra half an inch in front of the stricture. The sound is then partly withdrawn, the sides of the wound held widely apart by means of ligatures passed through the cut edges of the

FIG. 229.



Clover's crutch, for operations upon the perineum.

urethra, and an effort made to pass a fine probe or whale-bone bougie through the stricture from before backward; if the effort succeeds, the operation becomes one "with a guide," and is completed as before described. If the probe can be passed for only a short distance, a line or two, the tissues are divided upon it, and the attempt renewed until the canal behind the stricture is reached. Success depends largely upon full exposure of the end of the stricture in order that the search for the opening may be aided by the eye.

If these efforts fail entirely, the urethra must be sought



for behind the stricture—a most difficult task unless a perineal fistula exists through which a guide can be passed into the bladder, or unless this portion of the urethra is distended with urine and can be punctured in the median line. The bottom of the wound should be freely exposed by retraction of the sides, the index-finger passed well into the rectum and pressed up toward the center of the pubic arch as a guide, and the wound then deepened by successive cuts directly in the center. After the urethra has been thus opened it must be slit forward through the stricture.

Occasionally surgeons have opened the bladder above the pubes and passed a sound from within outward to the stricture as a guide.

### EXSTROPHY OF THE BLADDER.

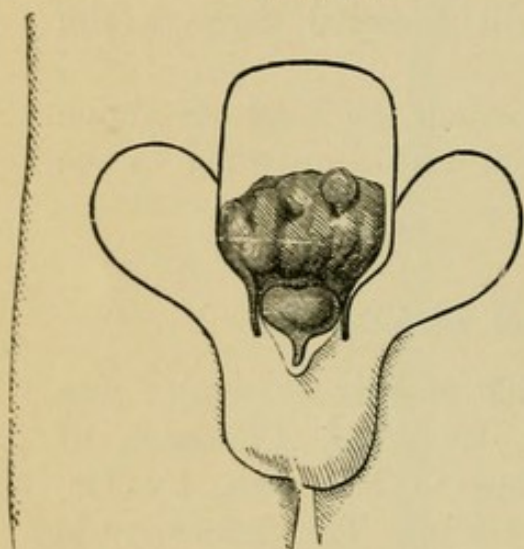
The first operation for the relief of this deformity was performed, according to Gross, by Prof. Pancoast, of Philadelphia, in 1858; according to Erichsen, by Dr. Daniel Ayres, of Brooklyn, in 1859. The deformity is much more frequent in males than in females, and the operative indication is to cover in as much as possible of the exposed mucous membrane and facilitate the adaptation of a urinal by making the urine escape through a comparatively small opening; for, as the sphincter cannot be restored, there will always be incontinence. The method at first employed was the same as Nélaton's for epispadias: a tegumentary flap was raised from the abdomen above the bladder, reversed so as to cover the latter, and then covered itself in turn by lateral flaps, one from each side.

The first flap (Fig. 230) should be square, its base adjoining and slightly broader than the upper margin of the opening, its length should be sufficient to cover in the bladder completely when turned down over it. A pyri-form flap is dissected up on each side, its breadth equal to the length of the first flap, and its base directed downward and inward, as shown in Fig. 230, or downward and out-



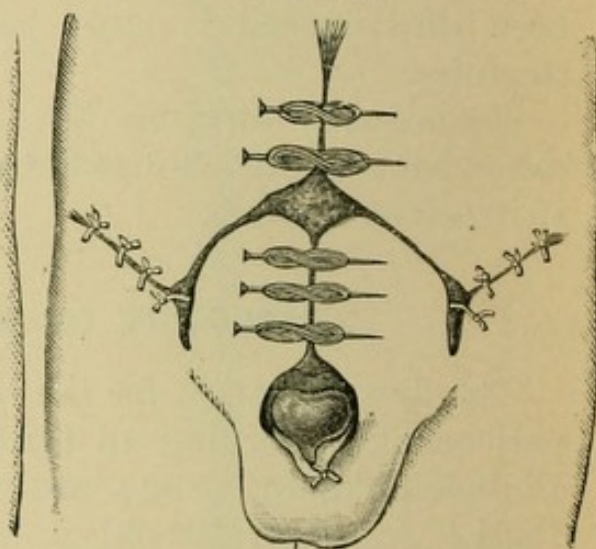
ward so as to require less twisting and include more of the cutaneous branches coming from the femoral artery. These two flaps are then drawn across the reversed umbilical flap, meeting in the median line, and are fastened to each other with twisted sutures, the pins including a portion of the thickness of the umbilical flap also, so as to keep the raw surfaces in contact (Fig. 231).

FIG. 230.



Wood's operation for exstrophy of the bladder. Incisions.

FIG. 231.



Flaps in place.

The edges of the gaps left by the removal of the flaps are drawn together as well as possible with twisted and wire sutures, broad strips of adhesive plaster applied to give support and relieve tension, and the patient kept in bed in a sitting posture with the knees drawn up. The sutures may be removed at the end of a week. Healing may be hastened by using Thiersch skin grafts on granulating surfaces. Of late years many other devices have been tried, some of them with gratifying success.

When the symphysis is absent Trendelenburg first performs an operation to remedy the epispadias. Later he divides the sacro-iliac synchondrosis on each side from behind forward, sufficiently to mobilize the iliac bones and allow the gap in front to be closed by pressing together the sides of the pelvis. Subsequently the margins of the



defect in the soft parts are freshened and brought together with sutures. This may need to be supplemented by a flap operation and Thiersch skin grafts.

Czerny, starting at the edges of the defect, frees the wall of the bladder from the underlying parts and sutures its margins together to form a closed sac. Then this is covered in by two lateral flaps, base down, as in the first operation described. Afterward the neck of the bladder and the freshened edges of the prostatic portion of the urethra are brought together, and then the epispadias is attended to.

Rutkowski and Mikulicz<sup>1</sup> have successfully used a portion of the intestine to enlarge the bladder, and in a few cases the ureters have been transplanted into the rectum or colon.

#### CATHETERIZATION (WITH CURVED METAL CATHETER).

The obstacles to the passage of a catheter, exclusive of stricture and of false passage, are found either at the triangular ligament, in the membranous, or in the prostatic portion of the urethra. As the fixed portion of the canal begins anteriorly at the opening in the subpubic or triangular ligament, the flaccid pendulous portion in front of this point may be carried aside if the catheter is held improperly, and doubled upon itself in front of the beak of the instrument. This difficulty is overcome by drawing the penis gently up the shaft of the instrument so as to straighten out the portion of the canal yet to be traversed, and by keeping the beak in the median line and making it follow the roof rather than the floor of the urethra, so as to avoid especially the normal pouch-like dilatation found on the under side just in front of the opening in the ligament.

The obstacle in the membranous portion is caused by the spasmodic contraction of the muscles which envelop this part of the canal. The nature of the obstruction is

<sup>1</sup> Centralblatt für Chir., 1899, Nos. 16 and 22.



recognized by the tight grasp of the instrument by the muscles and the quivering of the fibers transmitted through it to the hand of the surgeon. The

FIG. 232. difficulty is overcome by making gentle pressure with the beak of the catheter in the proper direction, so as to tire out the muscles.



Mercier's  
elbow catheter.

The most serious obstacle is found in the prostatic portion, and is due either to inflammatory swelling of the mucous membrane or of the gland (abscess of the prostate), or, much more commonly, to senile change in the shape and size of this organ. A description of the nature of these changes and lesions does not come within the scope of this work, and the reader is referred for them to special treatises upon the subject. It is sufficient here to say that in the former case the inflammation must be reduced or the abscess evacuated *secundum artem*, or, failing this, the bladder must be punctured above the pubes, or through the rectum. In the other case, catheters of different curves should be tried, such as Mott's long catheter of large curve, or Mercier's soft, single or double-elbowed catheter. It is also well to pass the forefinger of the left hand into the rectum to make sure that the catheter has entered at the apex of the prostate, and that it has not passed out of the canal into a false passage, and to try to lift its beak over the obstacle by making direct pressure upon the curve in front of the prostate, while the handle is simultaneously depressed.

If these means fail, and soft instruments of gum or vulcanized rubber cannot be introduced, the bladder must be punctured.

**Passage of the Catheter.**—The patient having been brought to the side of the bed or placed upon a lounge, the surgeon, standing on one side, separates the lips of the meatus with the thumb and forefinger of the left hand, introduces the beak of the catheter, previously well warmed



and oiled, and passes it down to the penoscrotal angle, holding the shaft of the instrument parallel to the groin. He then sweeps the handle around to the median line of the abdomen, keeping it close to the surface, draws the penis gently up the shaft, and presses the instrument bodily downward toward the feet; as soon as the beak reaches the lower border of the symphysis he draws the scrotum up and presses the catheter gently onward, still holding it parallel to the body, and then when the beak has closely approached or engaged in the opening in the triangular ligament he gradually raises the handle, brings it forward in the median line, and depresses it between the thighs. Failure to enter the opening in the triangular ligament is indicated by the bulging of the curve of the instrument in front of the symphysis, its rebound when the slight pressure on the handle is removed, and the mobility of the beak when the handle is gently rotated about its longitudinal axis.

As the shaft passes the vertical line the root of the penis and the integument covering the symphysis should be pressed down with the palm of the hand laid broadly upon it, so as to stretch the suspensory ligament.

#### PUNCTURE OF THE BLADDER.

*Above the Pubes.*—The only instrument required is a straight, or, better, a curved trocar and canula, or aspirator needle. The surgeon satisfies himself by percussion that the distended bladder rises well above the pubes, and then making the skin tense with the thumb and fingers of his left hand, he plunges in the trocar close above the symphysis pubis in the median line, the concavity of the instrument turned toward the bone.

Some surgeons prefer to make a preliminary incision in the median line, and others even continue the use of the knife until the bladder can be felt at the bottom of the wound.

#### LITHOLAPAXY.

It is the operation of introducing a lithotrite into the bladder through the urethra and with it crushing a stone



into fragments, which are then removed by the wash bottle and evacuators represented in Fig. 236.

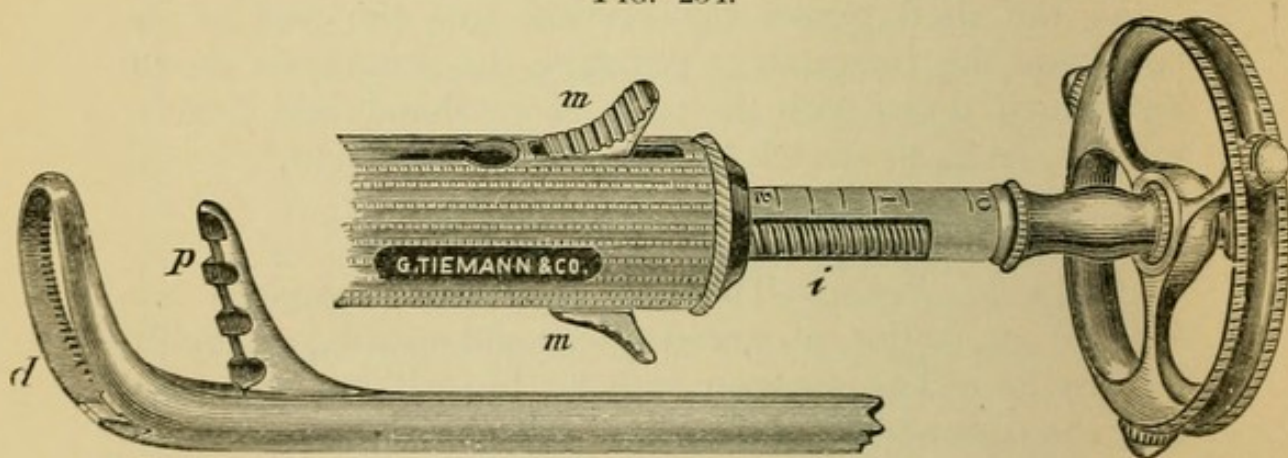
The modern lithotrite is a steel instrument consisting of a straight shaft eleven inches in length, having at one end a "beak" about an inch long inclined at an angle of from  $110^{\circ}$  to  $130^{\circ}$ , and at the other a cylindrical roughened handle containing a screw. It is composed throughout of two parts, one fitting accurately in a deep groove in the other, and having at the handle a male screw which can be thrown into and out of gear by means of a button upon

FIG. 233.



Sir Henry Thompson's lithotrite.

FIG. 234.



Keyes's fenestrated lithotrite.

the other part. While trying to catch a stone the screw should be out of gear, in order that the male blade may be advanced and withdrawn more rapidly, but when the stone has been fairly caught the button must be pressed back and the screw-power used to crush it.

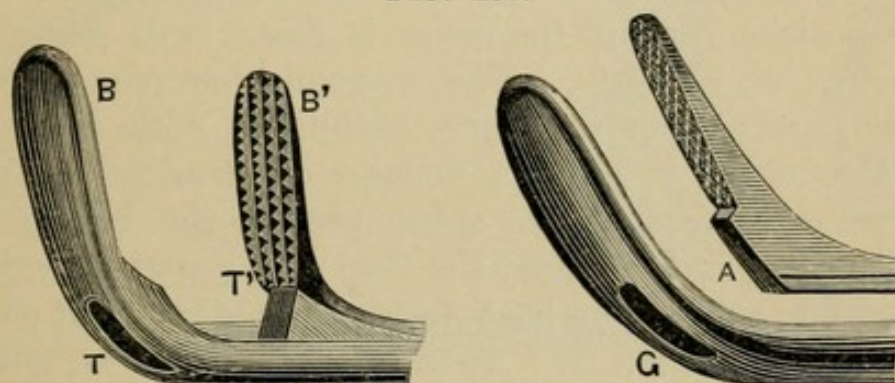
Many different patterns have been proposed for the beak or jaws with the view either of securing the thorough pulverization of the fragments, or of preventing the clogging of the instrument by the impaction of the mor-



tar-like detritus between the jaws. The latter difficulty can be overcome by leaving the jaw of the female blade entirely open, that is, with a large fenestra extending from side to side and from the extremity of the beak to its angle, and by making the male shaft long enough to allow its jaw to be passed through the female one. In its simplest terms, then, the jaws should consist of two parallel bars, one-fourth of an inch apart, between which a third one fitting loosely in the gap, can be forced.

A small fenestra at the angle of the beak will not prevent clogging, although it may diminish it if there is a corresponding projection at the heel of the male jaw, as in

FIG. 235.



"Scoop" lithotrite.

Fig. 235; and it is open to the objection that it may lodge a sharp angular fragment, which, projecting beyond its edges, will lacerate the neck of the bladder and the floor of the urethra during the withdrawal of the instrument.

For catching and crushing small fragments the "scoop" lithotrite is commonly used; the jaw of its female blade is broad and shallow, with no fenestra or with only a small one at its angle. The edges of both jaws should be bevelled, and the male considerably narrower than the female, so that they may be brought together with the least possible danger of including a fold of mucous membrane between them.

**Operation.**—The patient is anæsthetized and placed upon his back, with his hips raised upon a firm pillow or cushion in order that the stone may gravitate away



from the neck of the bladder. If the urine is turbid, and especially if it is ammoniacal, it should be drawn off before the operation and the bladder thoroughly washed with a borax solution (one or two drachms to the pint), of which from two to four ounces should be left in the bladder to facilitate the crushing. The surgeon, standing at the patient's right side, introduces a freshly boiled lithotrite after greasing the instrument with vaseline. Care must be taken not to depress the handle too soon, a mistake which is likely to be made on account of the apparently great depth to which the instrument has to penetrate before the bladder is reached.

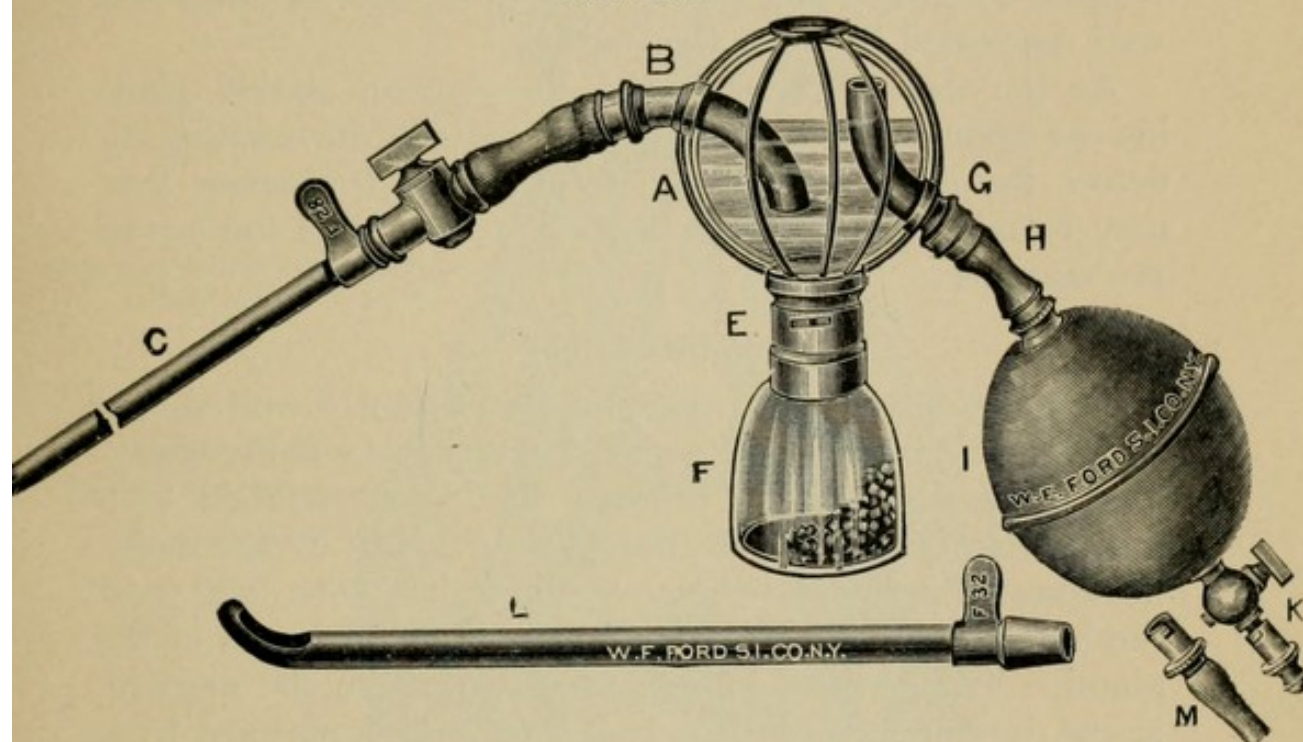
As soon as the instrument has entered the bladder, it is allowed to glide across it, its shaft being held steadily in one position, and if the stone is free it will generally be touched on the way. The surgeon then gently turns the beak away from the stone, withdraws with his right hand the male blade for a distance determined by previous measurement of the stone, presses the jaw of the female blade gently against the floor and posterior wall of the bladder, rotates the beak toward the stone, and closes the male blade upon it. As soon as the stone is felt to be firmly caught, the beak is rotated back to the vertical position, and the screw thrown into gear by pressing back the button on the handle with the thumb of either hand. The lithotrite with the stone in its grasp is then drawn away from the posterior wall and rotated to either side to make sure that the mucous membrane is not caught between its jaws, and then, grasping the cylindrical handle firmly with his left hand, the surgeon crushes the stone by turning the screw with his right, and continues this action until the register upon the handle shows that the male blade has been driven well home. The screw is then thrown out of gear, the male blade drawn back, the beak turned again toward the spot where the stone was caught, and the instrument closed whether the fragments are felt or not, for it may be confidently expected that they will be found there.

After crushing the stone in this manner several times



the smaller fragments are washed out by the evacuating tube and washing-bottle (Fig. 236) and the lithotrite re-introduced ; and this alternation in the use of the instruments is continued until the bladder is emptied. This frequent washing is important because by the removal of

FIG. 236.



Evacuating-tube and washing-bottle.

the smaller fragments it is made easier to seize and crush the larger ones.

The washing is done as follows : The washing-bottle is filled with tepid water, then the tube is introduced, and as soon as the urine begins to flow through it the bottle is coupled to it. Or the coupling may be done just before the tube has entered the bladder, and the air in the tube allowed to rise to the top of the bottle, by turning the stopcock, before the introduction is completed and the washing is begun.

By quick compression and relaxation of the rubber bulb the water is rapidly forced into the bladder and drawn back again, bringing the fragments with it ; these fragments sink to the bottom of the bottle and are not returned with the



returning stream. The amount of water driven back and forth at each movement will vary with the sensitiveness and distensibility of the bladder; two or three ounces are sufficient to wash effectively. If the curved tube is used, its eye should be in turn directed to different quarters of the bladder; if the straight tube with a square end is used, it must be passed just through the neck, and its outer end well depressed between the thighs.

At the close of the operation the surgeon should place his ear upon the hypogastrium and listen while washing, to detect the click against the tube of any fragments that may remain. This is a more delicate test than the use of the searcher.

### LITHOTOMY.

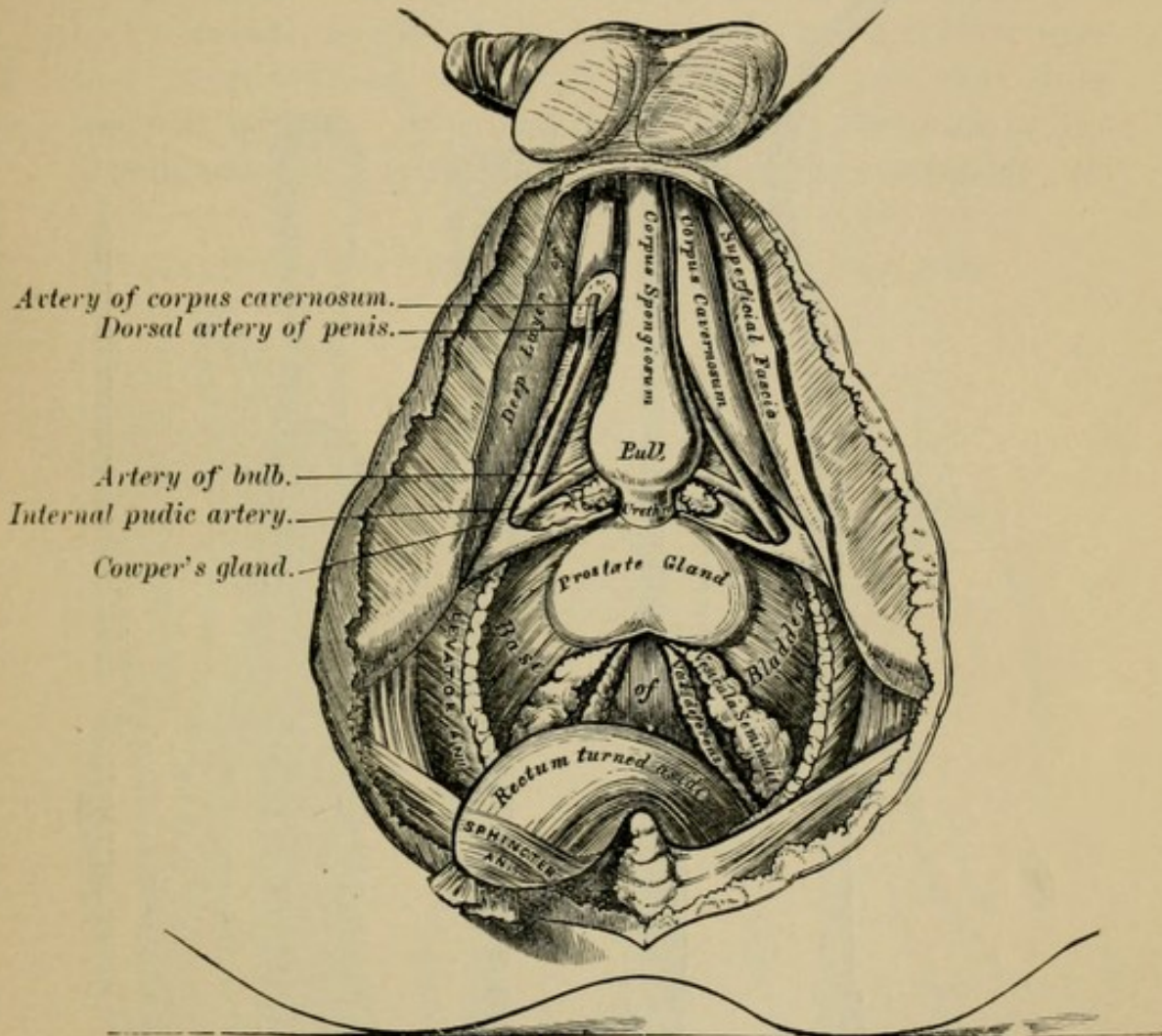
The anatomy of the perineum is sufficiently well shown in Fig. 237 to render a detailed description unnecessary. The dimensions of the prostate have been studied with much attention, and were the basis of many of the modifications of perineal lithotomy, for it has been held that the incision should not be carried beyond the limits of the gland. The greatest radius, measuring from the urethra, is one inclined about  $30^{\circ}$  backward and downward from the transverse diameter, and in the normal adult prostate this measures about three-quarters of an inch at the largest part of the gland, that which adjoins the neck of the bladder. But, as the diameter of the prostate diminishes as the distance from the bladder increases, an incision which remains within its limits at one point may extend far beyond them at another; and this fact, taken in connection with the great variations in the size of the gland, indicates the futility of attempts to regulate the incision with mathematical precision. Fortunately, the depth of the incision is not a measure of the size of the stone which can be safely removed through it, for the neck of the bladder and the prostatic portion of the urethra are normally dilatable to a diameter of nearly an inch.

If the stone is large and the traction made with too much force, the neck of the bladder may be torn off, but



more commonly the incision is lengthened by tearing at its outer end, an accident which is less dangerous than extending the incision with the knife would be, for it spares the rich plexus of veins about the prostate.

FIG. 237.



A view of the position of the viscera at the outlet of the pelvis.

*Lateral Lithotomy.*—The instruments required are a staff with a long curve, deeply grooved on its convexity (Fig. 238), a stout scalpel with a cutting edge of one and one-half inches (Fig. 239), a Blizard's knife (Fig. 240), a blunt gorget (Fig. 241), if the patient is fat, a scoop (Fig. 242), forceps of different patterns (Figs. 243, 244, 245), a syringe and tube for washing out fragments, and a shirted canula (Fig. 246) to control hemorrhage. The



latter can be readily made by passing the beak of a female silver catheter through the center of a piece of iodoform

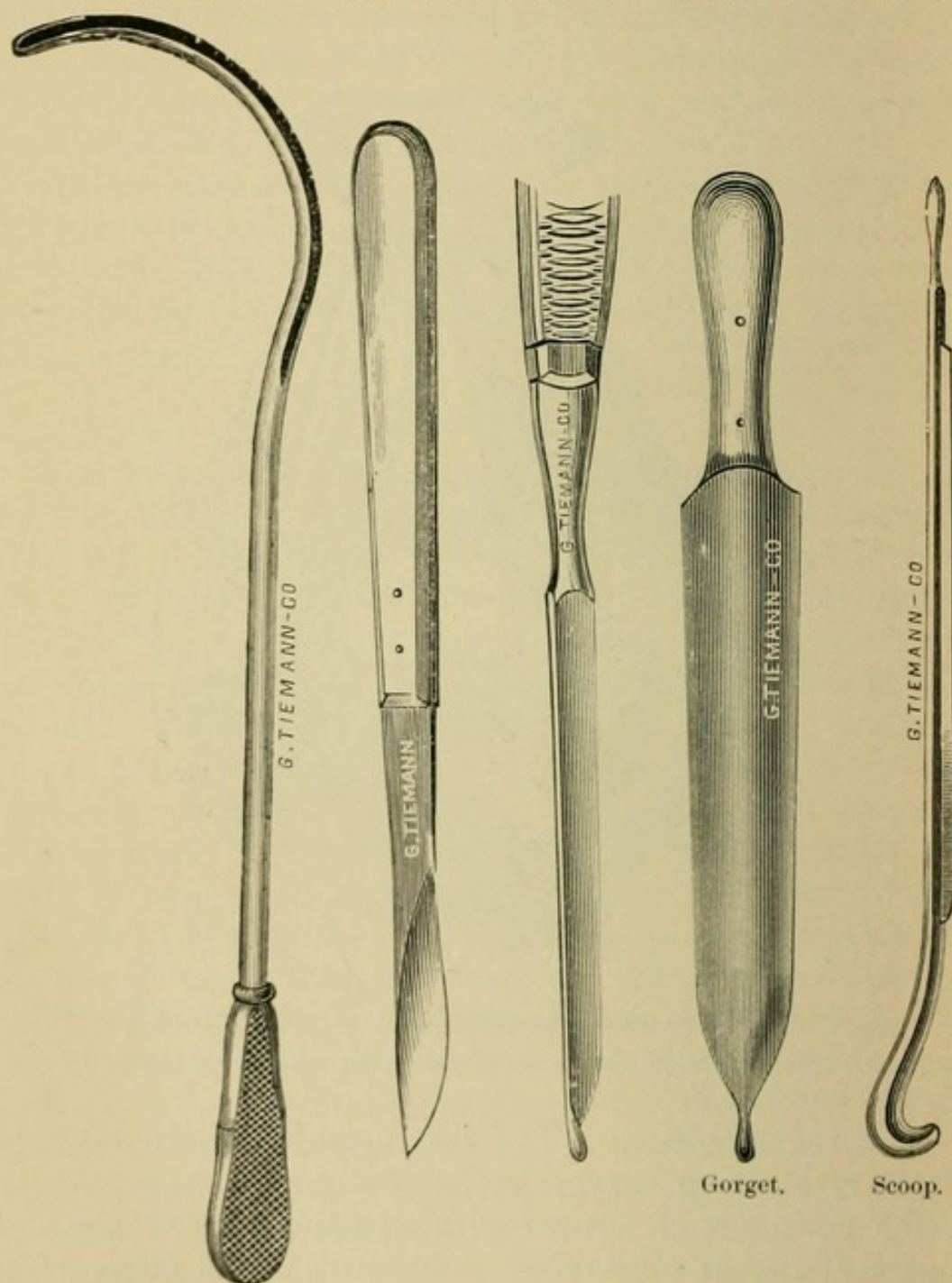
FIG. 238.

FIG. 239.

FIG. 240.

FIG. 241.

FIG. 242.



Gorget.

Scoop.

Lithotomy staff.

gauze eight inches square, and tying the two firmly together, as shown in the figure. It is then introduced



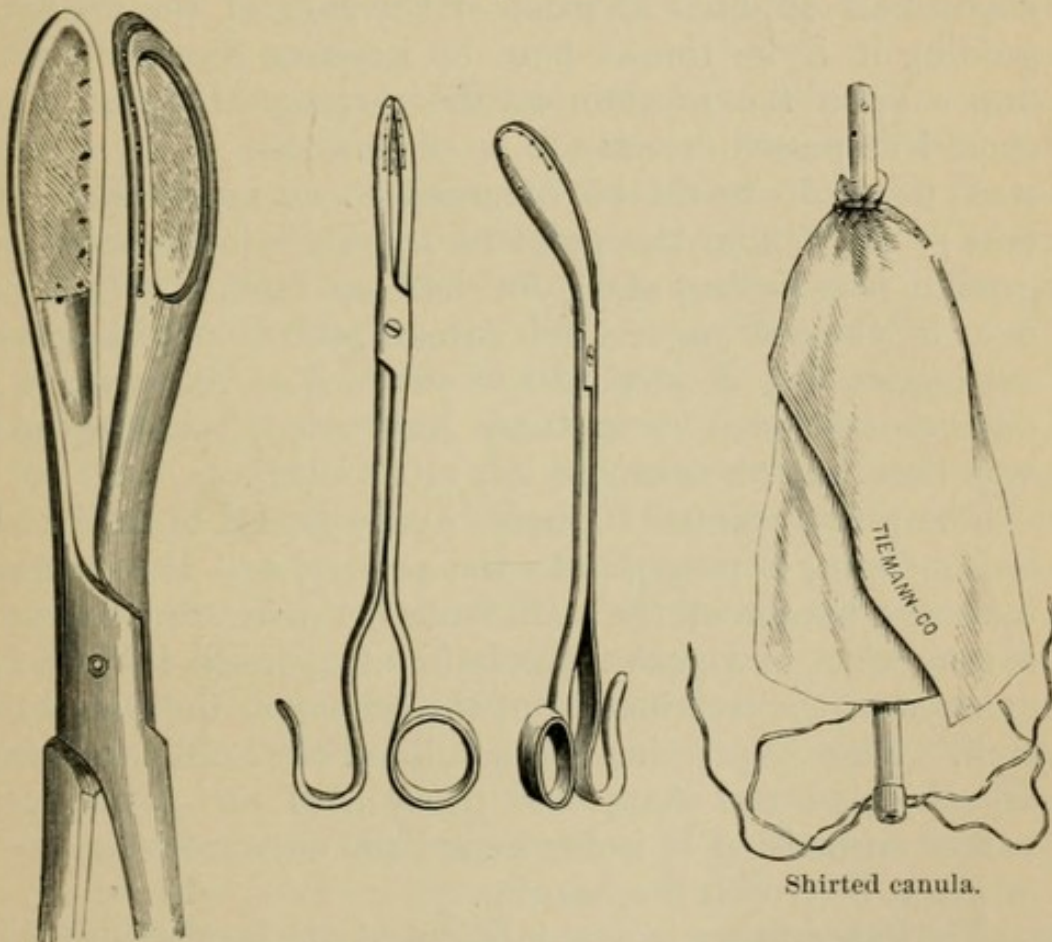
into the wound, the beak of the catheter in the bladder, the pouch tightly packed afterward with pledgets of gauze, and the whole kept in place by a T-bandage. Three assistants, at least, are required: one to administer the anæsthetic, the others to hold the knees and the staff.

**Operation.**—The patient, having had his bowels emptied by an enema, is placed upon his back, his ankles bound fast to his wrists, the staff introduced, and the stone touched with it. It is not necessary that the beak of the staff should rest upon the stone during the operation; on

FIG. 243.

FIGS. 244, 245.

FIG. 246.



Shirted canula.

the contrary, it is better to hook the staff up under the symphysis so as to keep it steady, with its curve bellied out in the median line of the perineum, and the integument stretched over it by drawing the scrotum up around the staff.



The operator passes his index-finger into the rectum, and satisfies himself that the staff enters at the apex of the prostate and passes centrally through it, and that the rectum is empty. Then withdrawing his finger he feels along the raphé of the perineum for the groove in the staff, aiding himself, if necessary, by depressing and raising the handle several times.

Having found the groove he confides the staff to his chief assistant, enters the scalpel a little to the patient's left of the raphé, from one and one-quarter to one and one-half inches in front of the anus, and passes it in almost parallel to the rectum so as to enter the groove about half an inch in front of the apex of the prostate, guiding it, if he thinks best, by keeping his left index-finger upon the prostate in the rectum. (If the knife should be passed directly in to the nearest point on the staff, the bulb would be involved to an unnecessary extent.) As soon as the point of the knife has entered the groove, it is pushed along for half an inch, dividing the floor of the urethra to that extent, and then withdrawn, cutting steadily downward and outward so as to make a cutaneous incision about three inches long, passing midway between the anus and left tuber ischii.

The probe-pointed Blizard's knife, guided upon the left index-finger, is passed into the groove, and the surgeon takes the handle of the staff from the assistant, depresses it somewhat, and pushes the knife along until its point is arrested at the termination of the groove at the end of the staff. Then depressing the handle of the knife, and bearing in mind the shape and position of the prostate, he makes an incision in it downward and outward at an angle of about  $30^{\circ}$  with the horizon.

The index-finger is next introduced, the staff withdrawn, and the neck of the bladder gently dilated with the finger, or, if the perineum is deep and fat, with the blunt gorget carried in along the groove in the staff. If the stone is more than one inch in diameter, the knife must be reintroduced and the prostate cut upon its right side also.

The forceps are then introduced as the finger is with-



drawn, and the stone sought for by opening and closing the blades at different points on the floor of the bladder; or the small end of the scoop may be introduced, placed in contact with the stone, and the forceps guided along it. If the stone is seized in a faulty direction, it must be dropped and caught again, or straightened with the fingers while still held between the blades. Extraction should be made slowly downward and outward in the line of the external incision, and aided by lateral movements of the handles. If it is found that the stone is too large to be removed without employing too much force, it must be crushed and the fragments removed separately. Small stones and fragments are best removed with the scoop and by thorough washing.

In operating upon children certain modifications are required. If the incision in the urethra and at the neck of the bladder is not sufficiently free, it may happen that, in the attempt to introduce the finger, the urethra will be torn entirely across and the bladder pushed up before it. Again, the bladder is placed higher in the child than it is in the adult, and therefore the point of the knife must be more raised in making the deep incision, and care must be taken not to let it slip in between the rectum and bladder. Mr. Erichsen<sup>1</sup> says he has known this to occur in several instances, and the forceps to be passed into this space under the impression that it was the bladder.

It has also happened to some surgeons to force the beak of the staff through the roof of the urethra into the space between the bladder and posterior face of the pubes, and to be so deceived by its freedom of motion in the loose cellular tissue of that region that they thought it was in the bladder, and cut upon it accordingly.

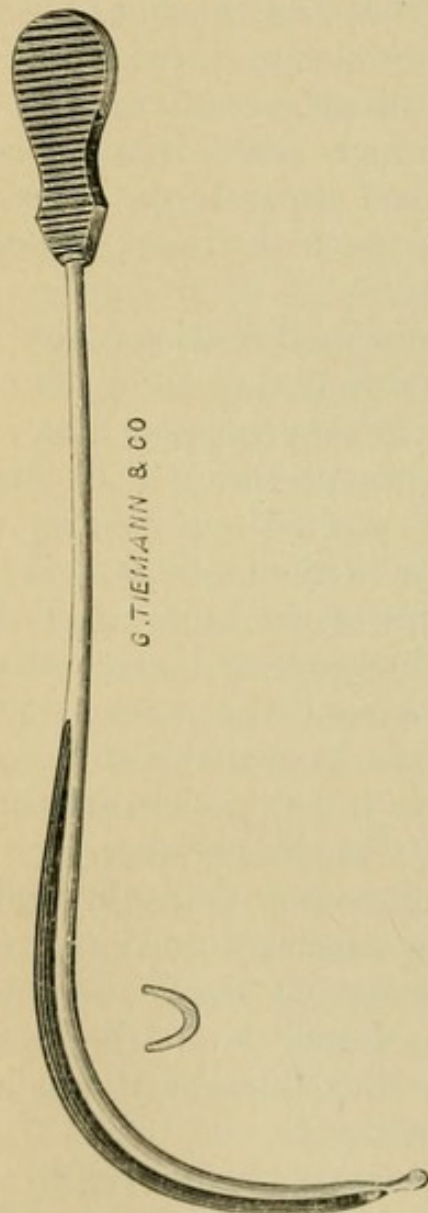
**Median Lithotomy.**—The only instruments required other than those used in the lateral operation are a staff, director, and knife. The staff has a central, broad, deep groove on its convexity (Fig. 247), the director has a ball-point (Fig. 248), and the knife is straight, stout, and sharp-pointed, with a cutting edge upon the back also for a short distance from the point (Fig. 249).

<sup>1</sup> Science and Art of Surgery, Vol. II., p. 682, Phila., 1873.




The patient having been bound in the lithotomy position and the staff introduced, the surgeon places his left index-finger in the rectum against the apex of the prostate, and plunges the knife with its edge upward into the raphé of the perineum half an inch in front of the anus in such

FIG. 247.




Staff for median lithotomy.

FIG. 248.



Ball-pointed director.

FIG. 249.



Double-edged scalpel.

a direction that its point will enter the groove of the staff just at the apex of the prostate. The knife is pushed very slightly back along the groove so as certainly to open the urethra and nick the end of the prostate, then brought for-



ward, dividing the membranous portion of the urethra, and swept around the bulb by raising the handle, making an external incision upward along the raphé for about one and a quarter inches. The director is next passed along the staff into the bladder, the two separated angularly to make partial dilatation of the neck, the staff withdrawn, and the dilatation completed with the finger. The forceps are then introduced and the stone removed as in lateral lithotomy.

### **SUPRAPUBIC CYSTOTOMY FOR VESICAL CALCULUS.**

The patient and the skin surface are prepared in the usual way for an aseptic operation, and after etherization the bladder is irrigated clean with a warm saturated solution of boric acid. The viscus is then distended with as much of this solution as can be ejected from an irrigator vessel elevated not more than two feet; such a pressure is harmless, while the injection of a fixed amount of fluid or the use of a hand syringe may not be, owing to the uncertainty as to the capacity of the bladder and the condition of its walls.

The catheter is then withdrawn from the urethra and a thin-walled soft-rubber bag (*colpeurynter*), is placed in the rectum above the sphincter and cautiously distended by a Davidson syringe, using not more than eight or ten ounces of water. This simply presses the bladder forward and brings its floor more within reach, but it does not materially alter the relation of the peritoneum to its anterior wall, and hence this use of the *colpeurynter* can generally be dispensed with.

An incision two or three inches long is then made from just below the upper border of the symphysis pubis upward in the median line and deepened layer by layer as nearly as possible between the recti, and the underlying fascia is divided.

If more space is required the recti and fascia can be cut transversely to a greater or less extent close to the pubes. The peritoneum does not descend on the anterior



wall of the bladder below the urachus, which can sometimes be felt as a cord attached to a knot on the fundus, and by carrying the dissection directly inward through the prevesical fat with blunt-pointed scissors, aided by the finger, and avoiding unnecessary laceration of the tissues, the bladder is exposed; after pushing upward the fatty and cellular tissue which carries the peritoneum with it, a tenaculum is inserted in the highest-exposed part of the bladder wall and a knife is plunged into it just below the tenaculum, opening the bladder mesially downward for about an inch. Each side of the incision is grasped by catch forceps which serve to hold the opening in the abdominal wound.

The peritoneum may descend as a fold unusually low in front, and this must be recognized in the dissection, which in such cases should be first downward and inward behind the pubes and then up over the anterior surface of the bladder, pushing the unopened peritoneum out of the way; the numerous veins which are encountered are drawn aside or ligated as they are divided, but it is unnecessary to waste time searching for bleeding points, as the hemorrhage generally ceases spontaneously on opening the bladder.

The interior of the latter is then explored by sight and touch, and any loose stones are picked up with instruments, preceded, if necessary, by crushing; the mouth of a diverticulum containing a stone may have to be gently dilated, but never cut, and the stone scooped or irrigated out, or first nibbled into fragments by forceps; projecting portions of the prostate preventing the free escape of urine are excised as described under prostatectomy, and finally the interior of the bladder is washed free from all clots and *débris* with warm boric solution.

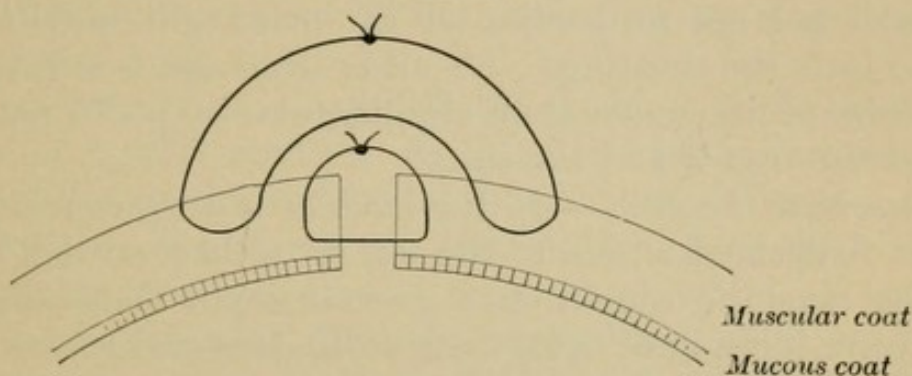
As a general rule, a wound in a comparatively normal bladder wall should be closed with sutures, but if there is much pus or inflammatory change present it is better to leave the wound open.

To insert the sutures a blunt tenaculum is placed in each extremity of the incision in the bladder, lifting up and steadying it. Interrupted sutures of chromicized cat-



gut are then inserted by a fine, curved needle at intervals of a quarter of an inch close to the edges of the wound and passing through the cut surface without entering the thin mucous membrane; over and between these is placed a row of chromicized catgut Lembert sutures extending a short distance beyond the extremities of the incision, and after all the sutures have been tied the bladder is filled with boric solution to test their efficacy.

FIG. 250.



Method of suturing a wound of the bladder.

Weak points are then reinforced by additional Lembert sutures. An iodoform-gauze packing is placed in contact with this suture line, and if considered necessary one or more rubber drainage tubes can be added; the abdominal wound is then partially closed with silk sutures, a couple of which are left untied till the drainage is removed several days later if all goes well, when the wound can be closed tight.

An antiseptic dressing is applied and a catheter for continuous drainage is fastened in the bladder through a perineal puncture as described under external urethrotomy by McBurney's gorget. Some surgeons prefer to leave the urine to escape by its natural path, or tie a catheter in the urethra for a day or two.

In about half of the properly selected cases primary union of the bladder may be expected.

If the bladder wound must be left open its lips may be temporarily fastened in the margins of the abdominal incision, and the latter is partially closed above and below,



while a light iodoform-gauze packing is placed in any pockets which may have become infected around the opening in the bladder. A rubber drainage tube with lateral perforations near its lower extremity is then inserted into the deepest part of the bladder, and the other extremity passing out of the wound is connected with a tube which terminates below the surface of a 1:60 carbolic solution contained in a bottle under the bed.

To favor the action of the tube, it is surrounded at its exit from the bladder by a tight iodoform-gauze packing, but still a large proportion of the urine will inevitably escape into the dressings; no other drainage is required. The tube is prevented from slipping out by a silk suture passed through it and the skin.

*Transverse Incision.*—If the bladder is very contracted and it is deemed unsafe to use the rectal bag, so that the bladder must be sought at a greater depth than usual, a transverse incision dividing both recti gives easier access to it. This incision, slightly convex downward, is made close along the upper margin of the symphysis and extended about two inches to either side of the median line. After it has been carried through the recti and fascia into the prevesical space the subsequent operations are as above described.

Langenbuch divides the suspensory ligament of the penis and exposes the lower part of the bladder below the pubes by an inverted  $\Lambda$ -incision. The vertical limb lies over the symphysis and the oblique ones follow the edges of the descending rami of the pubes.

### PROSTATECTOMY.

*Suprapubic.*—The rectal bag is inserted and filled, and the bladder is opened and washed out, as already described, and if the enlargement is pedunculated it is simply surrounded with or without transfixion by a silk ligature, the ends of which are left long and brought out of the abdominal wound, while the mass is left to slough away or is immediately excised with scissors,



When the projection cannot be ligated it may be removed with the *écraseur* or galvano-cautery. The uniform "collar" projection of the prostate is excised by dividing its margins transversely above and below, and shelling out each semi-circular half with the fingers after incising the mucous membrane on the summit of the ridge.

Keyes strongly recommends the use of the *rongeur* forceps to cut away the hypertrophied posterior lip of the orifice. In no case should any portion of the projecting valve be left behind, and finally the patency of the urethral canal is ascertained by the passage of the finger as far as the first joint.

Hemorrhage is controlled by packing with iodoform gauze or by the cautery. At the close of the operation the extremities of the abdominal wound are drawn together around the opening in the bladder, which, if possible, is sutured to the margins of the wound, while all spaces which are liable to infection are packed with iodoform gauze, and a siphon drain is placed in the bladder.

**Perineal Prostatectomy.**—The urethra is opened in the membranous portion for about an inch or an inch and a-half by an external urethrotomy, and after inserting a gorget the finger is passed to the bladder by gradual dilatation of the urethra and the projection located and explored. The finger must then be withdrawn to make room for the *écraseur*, galvano-cautery, or one of Thompson's forceps by which the growth is snared or torn from its attachments.

Hemorrhage is checked by irrigation with very hot or very cold water, or by packing, and the subsequent treatment is the same as for external urethrotomy. This method is seldom used because of its limited applicability and the difficulty of manipulation.

For hypertrophy of the lateral lobes of the prostate Dittel<sup>1</sup> proposes an incision from the coccyx to the median line of the perineum, passing around one side of the sphincter. The dissection is carried down to the prostate in front and at the sides of the rectum, which is rendered

<sup>1</sup>Wien. med. Woch., 1890, Nos. 18-19.



prominent by packing, and a cuneiform section is removed from the enlarged portions of the gland like a tumor, without opening the urethra. The resulting wound is then drawn together with catgut and a strand of iodoform gauze inserted for drainage. Or a curved incision circumscribing the anterior half of the anus may be made; the flap is turned down, and the prostate reached by working along the front of the rectum.

*Combined Suprapubic and Perineal Method.*—Belfield<sup>1</sup> and Alexander<sup>2</sup> first open the bladder above the pubes and then reach the prostate by a median incision in the perineum opening the membranous urethra. The capsule of the prostate is opened at its apex and stripped off back to the base, and one lobe separated from above downward and removed, while the prostate is pressed into the perineal wound by the finger of an assistant within the bladder. Nicoll<sup>3</sup> carries the perineal incision backward past one or both sides of the anus.

**Enlarged Prostate Treated by Castration.**—Cases of hypertrophied prostate complicated by retention and cystitis have been successfully treated by castration. The prostate atrophies within a year or less and the obstruction to the escape of urine thus disappears. The operation is simple and less dangerous than prostatectomy, and the results have been satisfactory in the soft forms.

### TUMORS OF THE BLADDER.

The bladder is rendered as aseptic as possible by washing and is then explored by a suprapubic cystotomy. When malignant disease is found lying near the fundus (which is its rarest location), and of limited extent, a sponge is placed in the interior of the bladder to soak up all the urine, and if the peritoneal cavity must be opened to effect a thorough removal of the disease, it is protected by a sponge packing and the bladder wall divided with scissors,

<sup>1</sup> Am. Journ. Med. Sci., Nov., 1890.

<sup>2</sup> N. Y. Med. Record, Dec. 12, 1896.

<sup>3</sup> Lancet, April 14, 1894.



including the peritoneum, if necessary, well outside the limits of the growth.

The peritoneal part of the wound in the bladder is then closed by Lembert silk sutures, which must not enter the mucous membrane, the protective packing removed, after thorough cleansing of the abdominal cavity, and the peritoneum above the bladder drawn together with catgut. The rest of the bladder wound is treated as in simple suprapubic cystotomy.

If the cancer occupies the sides or base of the bladder most surgeons, in this country at any rate, advise against an attempt at radical removal and are content with curetting to ameliorate symptoms.

A few successful cases are reported in which the disease has been removed with the surrounding mucous membrane, but leaving the muscular coat from which the growth is sometimes found separated by a layer of fat.

Helferich<sup>1</sup> resects the pubes through a transverse incision above the symphysis and so gains access to the anterior surface of the bladder.

Niehans<sup>2</sup> performs a very similar operation which he calls an osteoplastic resection of the pubes.

Zuckerkindl<sup>3</sup> exposes the base and adjacent posterior surface of the bladder by a curved transverse incision through the perineum in front of the anus and rectum, which are turned down and drawn back. (See removal of seminal vesicles.)

Bramann<sup>4</sup> chisels out a small piece of the symphysis, including the portion connected with the recti, by a T-shaped incision, the horizontal limb lying above the pubes between the cords and the vertical over the symphysis; at the conclusion of the operation the bone is sutured back in position and the patient fixed in a half-sitting position with the legs flexed.

For total extirpation of bladder or its mucous membrane, see *American Journal of the Medical Sciences*, Jan-

<sup>1</sup> Archiv f. klin. Chir., 1888, p. 625.

<sup>2</sup> Centralb. f. Chir., 1888, p. 521.

<sup>3</sup> Wien. med. Presse, 1889, Nos. 21-22.

<sup>4</sup> Centralb. f. Chir., 1893, No. 17.



uary, 1891, p. 101, and *Wien. med. Presse*, 1889, Nos. 27-28.

Benign growths which are more or less pedunculated are treated in the manner described for suprapubic prostatectomy and their bases scraped or cauterized or touched with a ten per cent. solution of chloride of zinc.

If the tumor has a small enough pedicle, the latter can be grasped by a pair of forceps close to the bladder wall, and the tumor twisted off on the distal side of the forceps, which are held immovable; but unless all portions of the growth are removed it is liable to recur. Benign tumors can occasionally be torn from their attachments by forceps introduced through an external urethrotomy wound, but care must be taken not to force the bladder wall into the grasp of the instrument by pressure on the hypogastrium. There is less danger of rupturing the bladder than might be supposed, owing to the usual hypertrophy of the muscular coat underlying the tumor.

### REMOVAL OF THE SEMINAL VESICLES.<sup>1</sup>

ZUCKERKANDL'S INCISION.<sup>2</sup>—The patient is placed in the lithotomy position with a sound in the urethra to mark its position and the bladder partially filled with a saturated solution of boric acid. A slightly curved incision with its concavity towards the anus is made transversely across the perineum, having its center about one inch and a-half in front of the anus. From each extremity of this a straight diverging incision about an inch and a-half long passes back on either side of the anus to end near the tuber ischii. After division of the skin and subcutaneous tissue a finger is placed in the rectum and the perineal septum cut through, avoiding the anterior rectal wall.

The dissection is deepened till above the sphincter ani, which is then turned down with the rectum while the bulb of the urethra is pushed forward, and the pubic portion of the levator ani is divided on each side of the prostate.

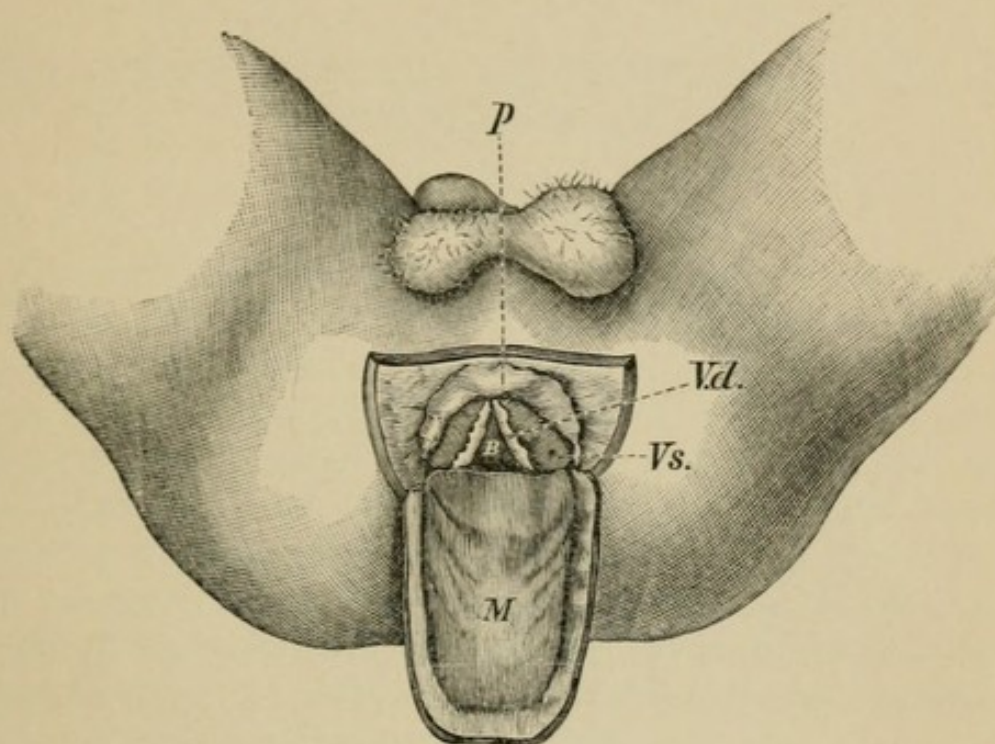
<sup>1</sup> See also Ullmann: *Centralb. f. Chir.*, Feb. 22, 1890.

<sup>2</sup> *Wien. med. Presse*, 1889, p. 856.



Free hemorrhage may be expected from the hemorrhoidal and prostatic plexus of veins, but it is easily controlled by pressure or clamps. Then, by tearing through the loose connective tissue, the rectum is easily separated a little more fully from the bladder, the base of which can be

FIG. 251.



Zuckerkandl's incision for removal of the seminal vesicles. *P.* Prostate. *Vd.* Vas deferens. *Vs.* Vesicula seminalis. *M.* Rectum.

made more prominent by manipulating the sound, and the prostate, vasa deferentia, and seminal vesicles are brought into clear view.

It only remains to dissect off one or both vesicles and to ligate the corresponding vas deferens with catgut.

The wound is closed and dressed antiseptically with a rubber drainage tube and light iodoform-gauze packing in its most dependent angles. The seminal vesicles can also be reached by an incision beside the sacrum and coccyx as in Kraske's operation for cancer of the rectum (Bolton).

The vas deferens, cord, and testicle can be extirpated at the same time by an incision starting over the internal abdominal ring and passing down through the inguinal



canal into the scrotum. This incision is deepened layer by layer above the pubes, the peritoneum recognized and pushed up, and then by working with the fingers from above and below (through Zuckerkindl's incision) the vas can be separated from the bladder and pulled out through the opening in the abdominal wall.



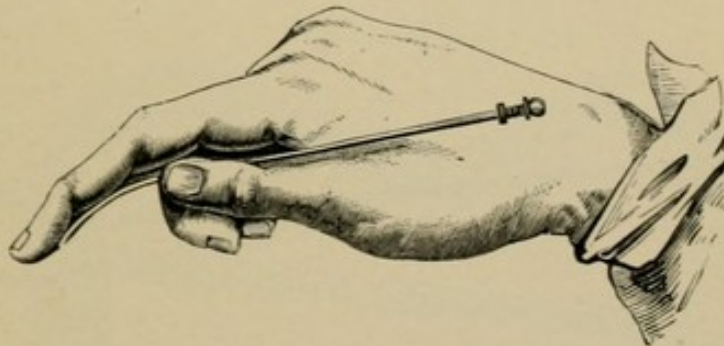
## CHAPTER VIII.

### OPERATIONS UPON THE GENITO-URINARY ORGANS OF THE FEMALE.

#### CATHETERIZATION.

THE surgeon, standing on the right side of the patient and holding the catheter in his right hand, with its convexity lying on the palmar surface of the index-finger and its beak not quite reaching to the end of the distal phalanx (Fig. 252), separates the nymphæ with the thumb and middle finger of his left hand, introduces his right index-finger at the fourchette and brings it forward, recognizing the entrance to the vagina and its anterior border, and stopping when he feels the pouting orifice of the urethra. Then keeping the pulp of the finger below and in contact with the orifice he passes the catheter in.

FIG. 252.



Mode of holding the catheter.

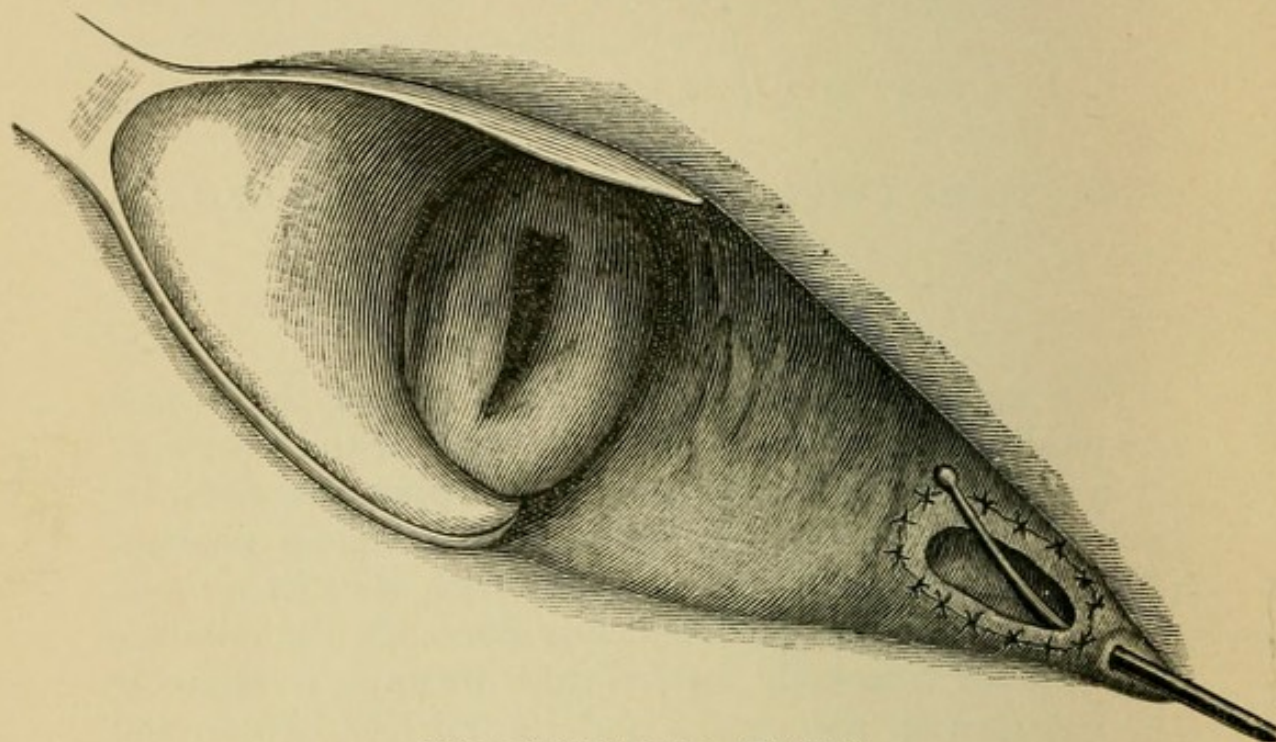
#### EXTERNAL URETHROTOMY.

*The Buttonhole Operation* (Emmet) (Fig. 253).—The patient is anæsthetized and placed on the left side, and the fourchette retracted with a small Sims's speculum. A full-sized metal sound is introduced into the urethra, then the



tissues in the vaginal surface are caught up with a tenaculum and divided longitudinally midway between the meatus

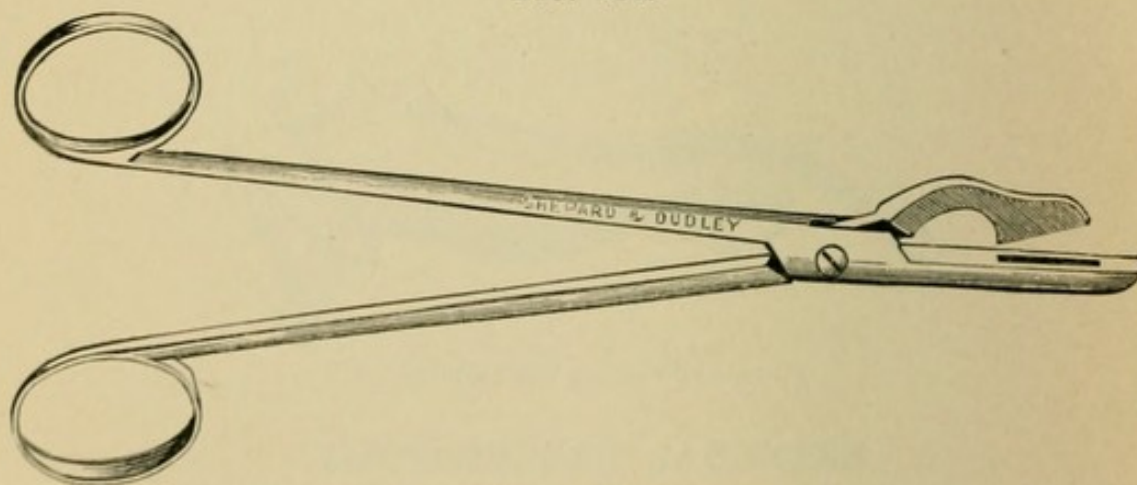
FIG. 253.



External urethrotomy. (EMMET.)

and the neck of the bladder. The incision may then be extended with scissors. Neither the neck of the bladder

FIG. 254.



Emmet's buttonhole scissors.

nor the meatus should be divided. If the incision is to be kept open, the urethral mucous membrane must be drawn



out through it and stitched with catgut to the edge of the divided vaginal surface. The incision may be conveniently made with Emmet's buttonhole scissors (Fig. 254).

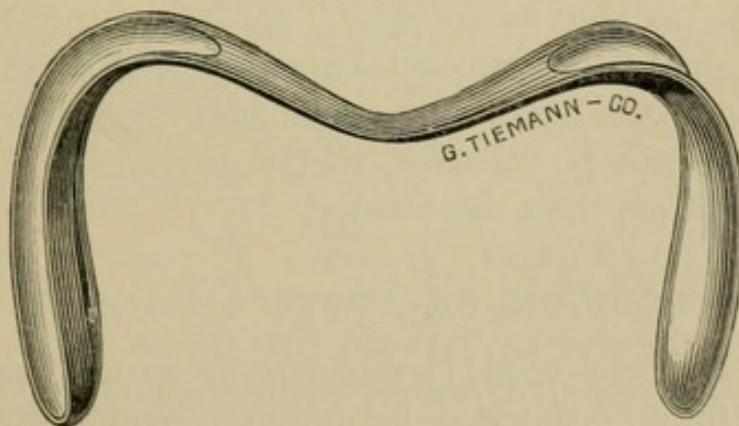
### LITHOTOMY.

Besides the *suprapubic*, which is performed in the manner already described, there are the *urethral* and *vesico-vaginal* operations. In the former the stone is removed through the urethra after the calibre of this canal has been increased by an incision along its anterior (upper) wall, or on one or both sides, incisions which do not extend into the vagina. In the latter the stone is removed through an incision made in the vesico-vaginal septum.

**Urethral Lithotomy.**—The only instruments actually required are a director, a probe-pointed knife, and forceps, but some surgeons prefer to make the incision with a single or double lithotome introduced alone or upon a director. Lateral incisions should incline upward rather than downward; consequently, if the double lithotome is used, its concavity should be turned toward the symphysis. The extraction of the stone requires no additional description.

**Vesico-vaginal Lithotomy.**—The patient may be placed in the usual lithotomy position, or upon the side, or upon

FIG. 255.



Sims's speculum.

the face. A Sims's speculum (Fig. 255) is pressed against the posterior wall of the vagina, and a grooved catheter



introduced into the bladder and confided to an assistant, who keeps it pressed well against the vesico-vaginal septum.

Guiding his knife upon the groove the surgeon makes an antero-posterior incision in the median line of the anterior wall of the vagina, about one inch in length, and not involving the neck of the bladder, passes in his index-finger, and then the forceps upon the finger as a guide.

Emmet places no sutures, but allows the wound to close spontaneously, keeping the bladder clean by frequent washings. Guyon closes the incision immediately with sutures.

In a discussion in the *Société de Chirurgie*<sup>1</sup> the fact was brought out that lithotomy and lithotrity upon the female are more dangerous operations than they are usually said to be. The fatal complications are of two kinds: peritonitis in patients who have previously been affected by it; and pyæmia, originating in inflammation of the spongio-vascular tissue constituting part of the vesico-vaginal septum. Speaking generally, it may be said that lithotrity<sup>2</sup> is more dangerous in the female than lithotomy, that the supra-pubic operation should be used for large calculi, dilatation of the urethra for small ones, and, with crushing, for large friable ones when the inflammation is not high and there has been no previous peritonitis; urethral or vesico-vaginal lithotomy in other cases. As to the comparative merits of urethral and vesico-vaginal lithotomy opinions are divided; the former is followed occasionally by permanent incontinence; the latter by fistula; probably, too, the latter is somewhat more dangerous than the former.

#### OCCLUSION, OR ATRESIA VAGINÆ.

When the occlusion is due simply to an imperforate hymen it may be relieved by successive punctures with a

<sup>1</sup> Bull. de la Société de Chirurgie, 1877, pp. 182 and 400.

<sup>2</sup> In this remark reference is made to the old operation of lithotrity. The few cases of litholapaxy in the female of which I have knowledge have been successful.



small trocar or aspirator, and when all the accumulated menstrual blood has been thus removed, and the cavity well washed out with a two per cent. solution of carbolic acid, the hymen may be excised, or a large puncture made, and kept open by frequently passing a sound. It must be remembered that very serious complications, such as peritonitis and septic poisoning, may follow this simple operation when there has been a large accumulation of menstrual blood above the obstruction.

When, on the other hand, this occlusion is due to incomplete development of the vagina, a more systematic operation is required. The surgeon first assures himself by digital examination through the rectum of the existence of the uterus, then places the patient upon her back with her thighs flexed and abducted, and introduces a sound into the bladder and confides it to an assistant. He next passes his left index-finger into the rectum, and makes a transverse incision across the center of the obliteration, and carries it in the direction of the uterus by successive short cuts with the knife or by tearing with a director or his fingers, guiding his course by the sound in the bladder and the finger in the rectum. As soon as fluctuation can be felt in front of the uterus he punctures with a trocar and enlarges the puncture with a probe-pointed bistoury.

### PERINEORRHAPHY.

Dr. Emmet<sup>1</sup> has shown that the lesion previously known as "partial rupture of the perineum," and supposed to be a laceration along the posterior median line of the tissues at the lower part of the vagina and perineum, is actually a transverse rent at or within the ostium vaginæ, which, by the dropping and eversion of the lower lip of the wound, is made to present the appearance of a longitudinal one. He also recognized and described a variety of this lesion in which the laceration is submucous, in which the muscular and fascial diaphragm, constituted in part by the sphincters and closing the outlet of the pelvis, is

<sup>1</sup> Principles and Practice of Gynecology, 1884, p. 364.



torn away from the supporting fasciæ and muscles which run upward to attach its center to the inner side of the bony pelvis, and, having thus lost its support, allows the posterior part of the vulva to be everted, with production of a rectocele by protrusion of the rectum through the (subcutaneous) gap. To this latter condition he gives the name *prolapse of the posterior wall of the vagina*. The two conditions, the subcutaneous and the complete rents, are essentially the same, and require for their relief nearly the same denudation of the surface. The aim of the operator in either case is to lift up the depressed everted lower lip, unite its edge to that of the mucous membrane of the vagina at the crest of the rectocele, and thus cover in the latter and renew its anterior support.

Laceration of the vulvar orifice in the posterior median line may occur without coexistence of the above-described lesion, beginning at the fourchette and extending backward, but such laceration is unimportant because it involves only parts that lie outside the real support of the viscera.

A third form is the important one in which laceration of the sphincter ani in the median line takes place. In non-instrumental delivery this begins as a longitudinal slit in the recto-vaginal septum and extends from within outward and forward. When caused by the forceps it begins at the fourchette and extends backward. To this form Dr. Emmet limits the term *rupture of the perineum*.

Accepting this classification, I shall describe the operation for, 1st, prolapse of the posterior wall of the vagina—two varieties, with and without laceration of the mucous membrane of the vagina; and, 2d, rupture of the perineum (and the sphincter ani).

*Prolapse of the Posterior Wall of the Vagina.* (1st variety, without surface laceration.) *Operation.*—Thighs flexed on abdomen and supported under the arm of an assistant on each side, who also draw aside the labia and hold the tenacula during the act of denudation. The operator seizes with a tenaculum the mucous membrane of the vagina at the crest of the rectocele in the median



line at a point which can be drawn down to the urethral orifice by gentle traction, and having thus drawn it down, has it held in place by the assistant. Then, with two other tenacula, he hooks up the lowest caruncle or vestige of the hymen, on each side, and draws them upward and outward to the first tenaculum. This movement creates an inverted, crescentic, transverse fold within the vagina just below the first tenaculum, its horns shading gradually into the sulcus on each side, and a shallow longitudinal fold in the median line between the last two tenacula. The opposed surfaces of these folds constitute the area to be denuded.

Dropping one lateral tenaculum, he gives the other to an assistant who draws it gently outward to define by this traction the limits of the denudation on that side, and then the surgeon denudes by catching up the mucous membrane with a hook or pronged forceps and removing it with scissors in successive strips. The process is then repeated on the opposite side. Care must be taken not to denude too high on the posterior wall.

Sutures are then passed to unite the parts in the positions given them by the first approximation of the three

FIG. 256.

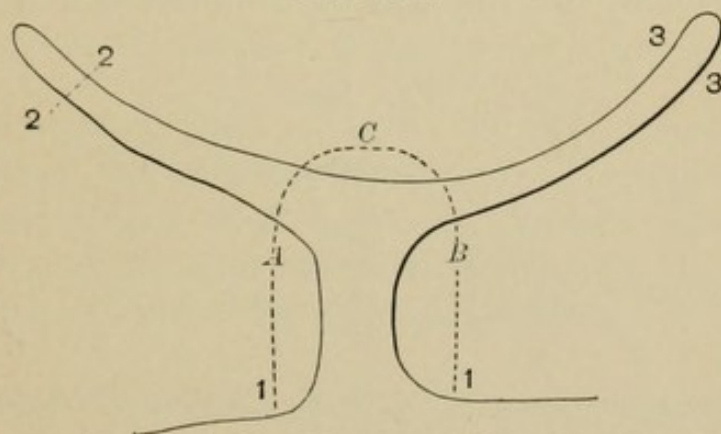


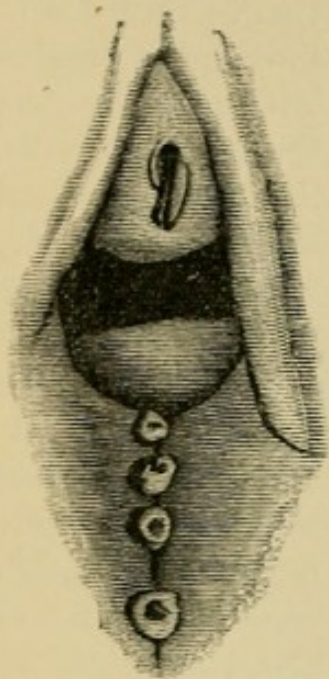
Diagram showing the line of union and direction of the sutures.

tenacula, producing the line of union indicated in Fig. 256. The sutures of the crescentic part should be of silver wire; those of the central line may be of silver, silk, or catgut. A final silver suture should be passed through



the labium near the caruncle on one side, across to the posterior wall of the vagina, under its mucous membrane for nearly an inch just above the edge of the denudation, and then through the other labium at a point opposite to that at which it began.

FIG. 257.



Appearance at completion of operation.

In passing the sutures a thick, straight sewing-needle armed with silk should be used, and the tissues to be traversed by it should be pressed forward by the finger in the rectum. The sutures should not be buried throughout their course, but should cross the fold midway between its free edge and its bottom. The silver wire is drawn through in the loop of the silk. The appearance, when the operation is completed, is shown in Fig. 257, the crescentic part being hidden within the vagina.

**2D VARIETY. PROLAPSE WITH SURFACE LACERATION.**—The position of the patient is the same as in the preceding form, and the area of denudation is determined

FIG. 258.

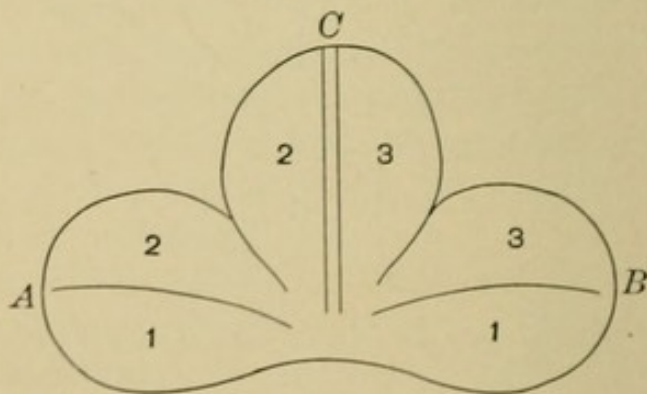


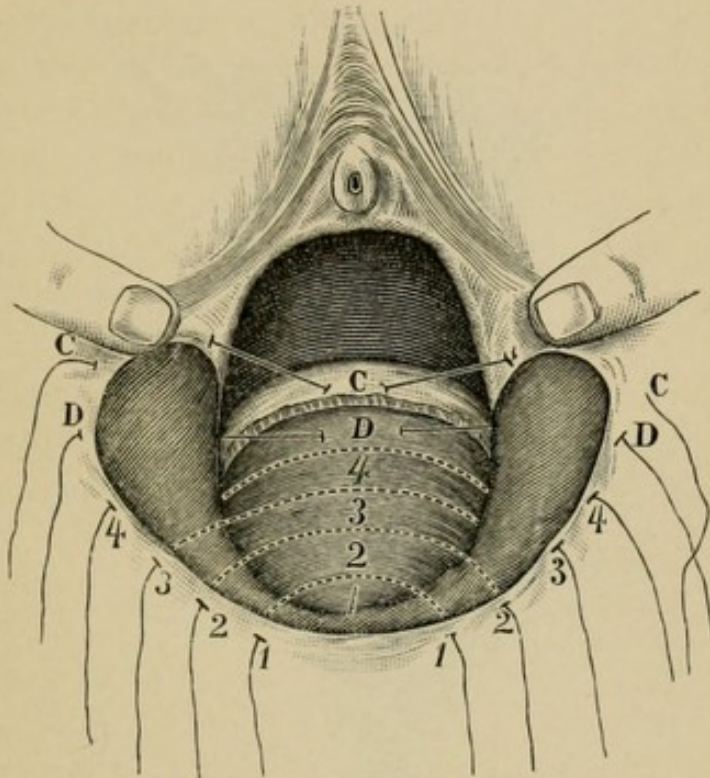
Diagram showing area of denudation. The parts bearing corresponding figures are brought into apposition by the sutures.

in like manner ; speaking generally, it must extend downward to the line of junction between the skin and the cica-



tricial mucous membrane. Its shape, when spread out, is that of a trefoil (Fig. 258). The sutures are passed in order from below upward, and none tightened till all are in place. The lower ones are buried throughout their course; the upper ones are partly exposed on each side, as shown in Fig. 259. The suture marked *D* includes about an

FIG. 259.



Emmet's operation for diminishing the vaginal outlet by external sutures.

inch of the recto-vaginal septum; the uppermost suture *C* passes through the mucous membrane of the septum above the denudation, and when tightened draws it down like a hood to protect the approximated edges, and also sustains all the traction while the opposed denuded surfaces are uniting.

Dr. Emmet leaves the sutures in place for about three weeks.

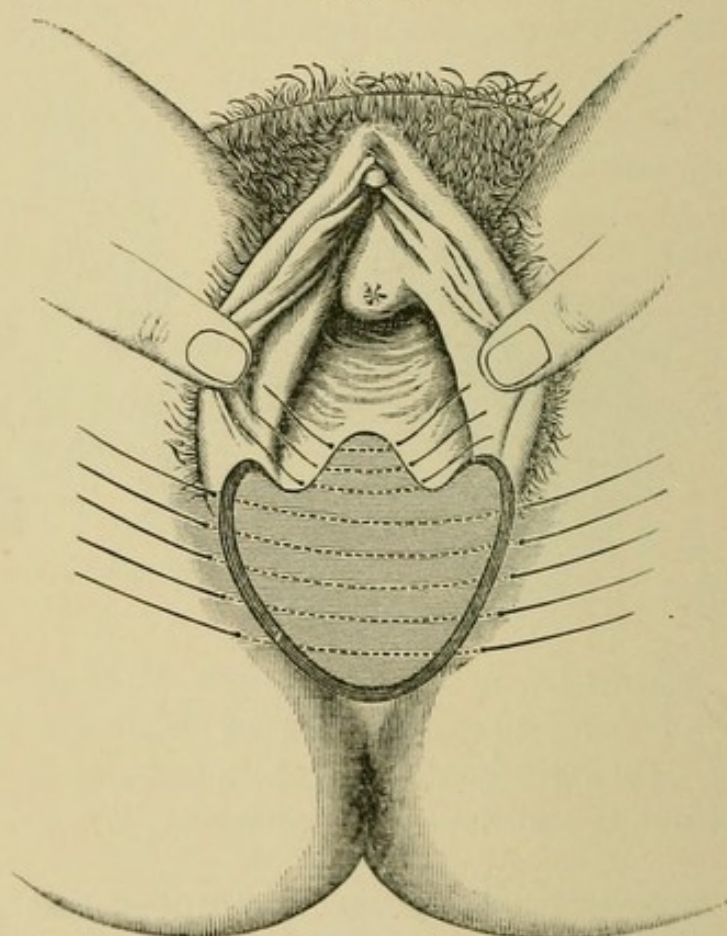
### PERINEORRHAPHY.

**Method of Hegar or Simon-Hegar. INCOMPLETE RUPTURE.**—This is based on the principle that the rent



when spread out has the form of a triangle with its apex in the posterior vaginal wall. (Fig. 260.) After every antiseptic precaution, bullet forceps are hooked in the three following points : in the crest of the rectocele in the posterior vaginal wall, and in the opposite lowest caruncles, which lie on the inner surface of each labium majus.

FIG. 260.



Incomplete rupture of the perineum. Perineorrhaphy by Simon's method. (POZZI.)

The labia are held apart and traction is made on the forceps, thus putting the tissues between them on the stretch, while a narrow strip of mucous membrane is removed on the lines made straight by traction, which join the crest of the rectocele with the two caruncles in the grasp of the forceps. The space between these limits is rapidly denuded, and the denudation is continued on the posterior vaginal wall and adjacent skin as far as the cicatricial tissue extends, so that the raw surface when flattened out has



the form of a triangle with its apex in the rectocele, and its base, which is slightly convex toward the anus, between the two lower forceps on the inner surfaces of the labia majora.

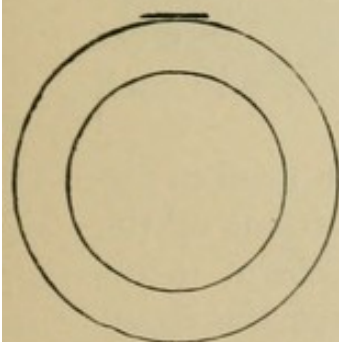
Starting at the apex (Fig. 260), at intervals of about three-eighths of an inch, sutures of silver wire or silk-worm-gut are passed on a well-curved needle, so as to be just buried under the denuded surface, emerging about a quarter of an inch from its edge.

At least two of these sutures should pass deeply enough in the upper lateral portions of the raw area to grasp some of the fibers of the levator ani muscle.

Martin's continuous circular suture applied in tiers is considered better by many surgeons than the interrupted suture. Catgut is used, threaded on a sharply curved needle.

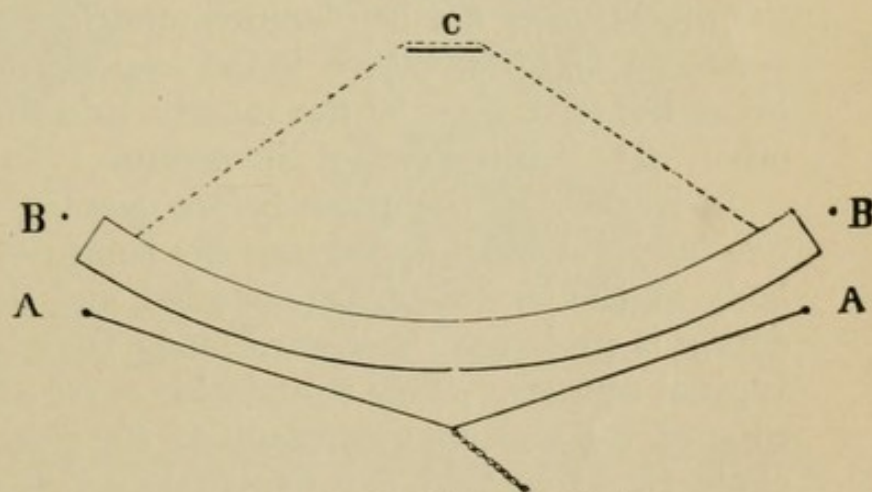
**Laceration of the Perineum, including the Sphincter Ani.**—If the anterior wall of the rectum is ruptured for more than one or one and a-half inches above the upper margin

FIG. 261.



Sphincter.

FIG. 262.



Ruptured sphincter, and suture.

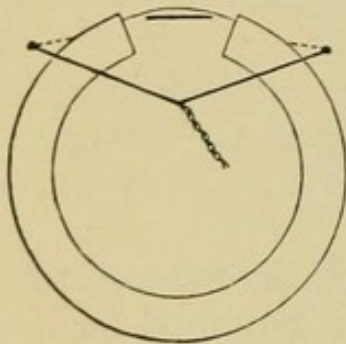
of the sphincter, it may be better to close it by a preliminary operation, leaving the restoration of the perineum for a subsequent one. Dr. T. Addis Emmet was the first to show why it is not sufficient simply to close the gap between the vagina and rectum, and to demonstrate the need of bringing the ends of the severed sphincter into close



contact with each other, and with the end of the recto-vaginal septum.

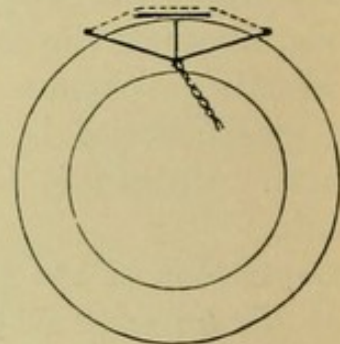
Let Fig. 261 represent the perfect sphincter, and Fig. 262 the sphincter ruptured and spread out with the points of entrance and exit of needle *AA*, the dotted line showing the course of the suture, including the end of the recto-vaginal wall *C*. As the suture is twisted, the three points are brought nearer together, as in Fig. 263, until they finally unite, as in Fig. 264. If the first needle is

FIG. 263.



Suture partly drawn.

FIG. 264.



Suture fully drawn.

passed in and out at *BB*, complete union of the ends of the muscle will not be obtained, and loss of function will persist. The first suture is the important one, and must bring the torn ends of the muscle into contact with each other and with the end of the septum.

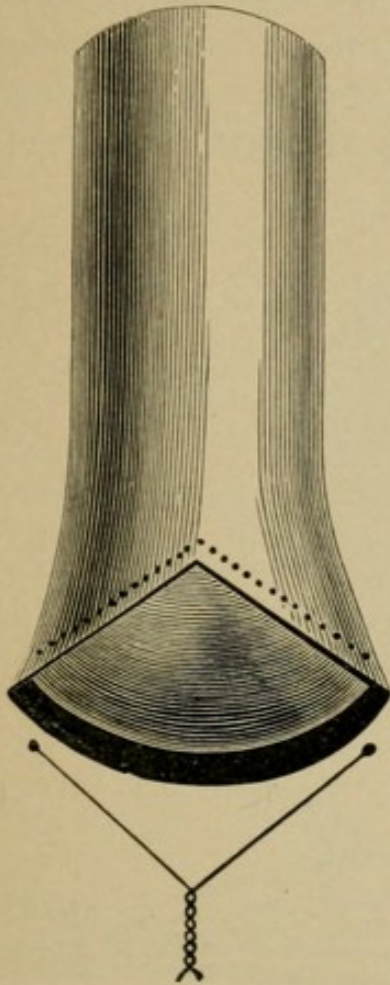
In freshening the parts before passing the needles the two lateral triangles, forming the ruptured surface of the body of the perineum, are denuded, and the line of denudation is prolonged backward along the edge of the recto-vaginal septum. This denudation must extend along the edge of the mucous membrane of the rectum, but not include it. Fig. 265 is a schematic representation of the end of the ruptured bowel, the points of entrance and emergence of the needle, and the course of the first suture.

The rule for passing the first suture, then, is to enter the needle as low down as the lower edge of the anus, pass it thence upward through the recto-vaginal septum, completely encircling the rent, and bring it out alongside the lower edge of the anus on the other side. Its action, then,



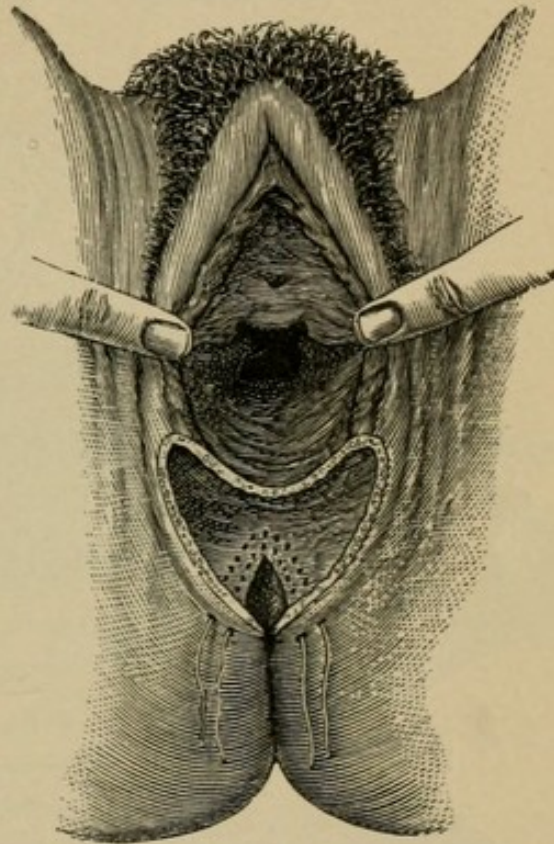
is like that of a purse string, it puckers up the open parts, controls the action of the sphincter, and guards against the two principal sources of failure, recto-vaginal fistula and non-union of the sphincter (Fig. 266).

FIG. 265.



Ruptured sphincter. First suture.

FIG. 266.



Complete perineal rupture. First and second sutures in place.

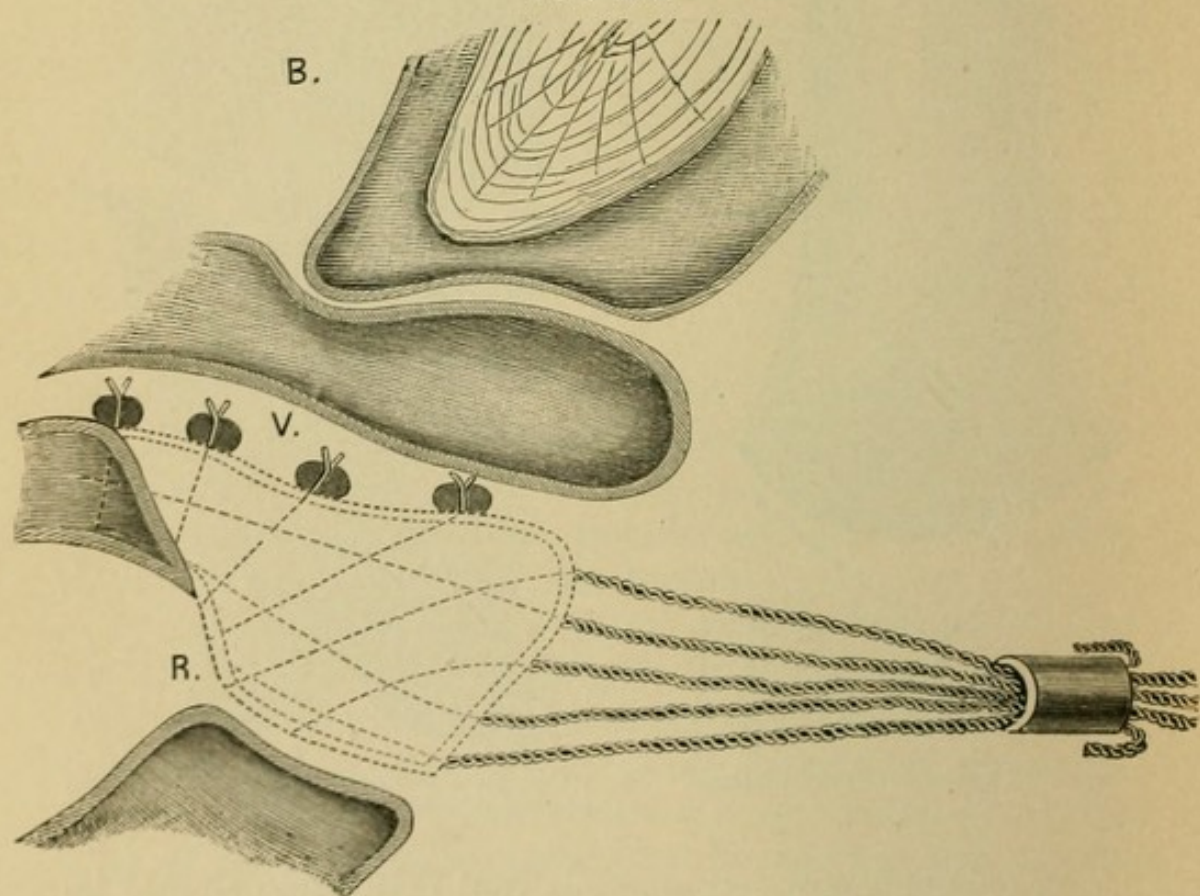
Dr. Emmet now recommends that this injury should be treated as if it were "a recto-vaginal fistula in the median line, with the sides easily approximated."

The denudation is done with scissors, beginning at the outlet and near the rectal surface, and continuing from below upward, so as to avoid the flow of blood over the surface yet to be freshened. Since the sides of the tear, after retraction, are not sufficiently broad to give a good surface for union, a portion of the adjoining vaginal mu-



cous membrane must be removed, and the angle must also be extended on the vaginal surface for half an inch or more beyond the rectal edge. Then, beginning at the angle, several transverse, interrupted silver sutures are passed from the vaginal edge on one side, under the denuded surface across the gap, and under the opposite denuded surface to the opposite vaginal edge, and two or three additional sutures are passed by the old method, that is, beginning in the skin near the lower edge of the anus, continuing up through the tissues alongside the rent,

FIG. 267.



Half-section through the pubes.

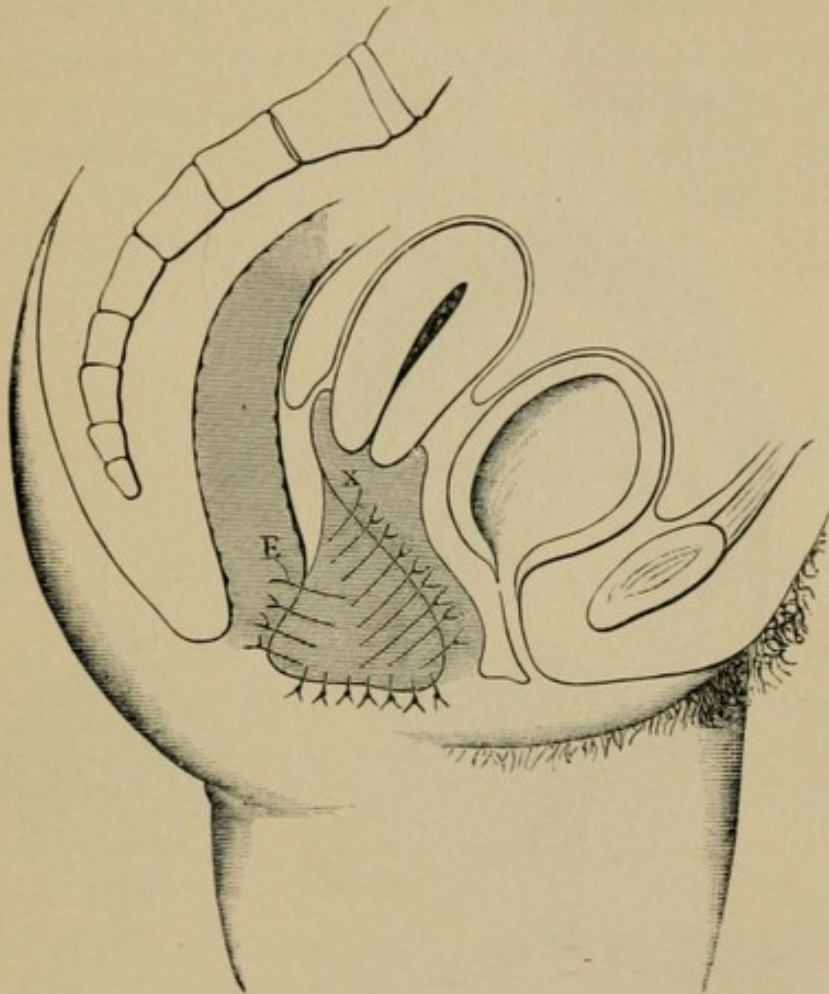
through the septum, and down on the other side, so as completely to include the rent. Fig. 267 shows these different sutures. The last two mentioned are the 2d and 4th in the figure, counting from below upward.

*Complete Laceration with Rupture of the Sphincter Ani.*—A slight modification of Hegar's method is used in the



gynecological service of Roosevelt Hospital, and it gives most excellent results. Before denuding the perineum the rectum is first sutured. The edges of the rent in the rectum are freshened and the raw surface is made a little broader below than above to thoroughly expose the ex-

FIG. 268.



Complete laceration of the perineum. Perineorrhaphy—Simon-Hegar method; general disposition of the sutures. (POZZI.)

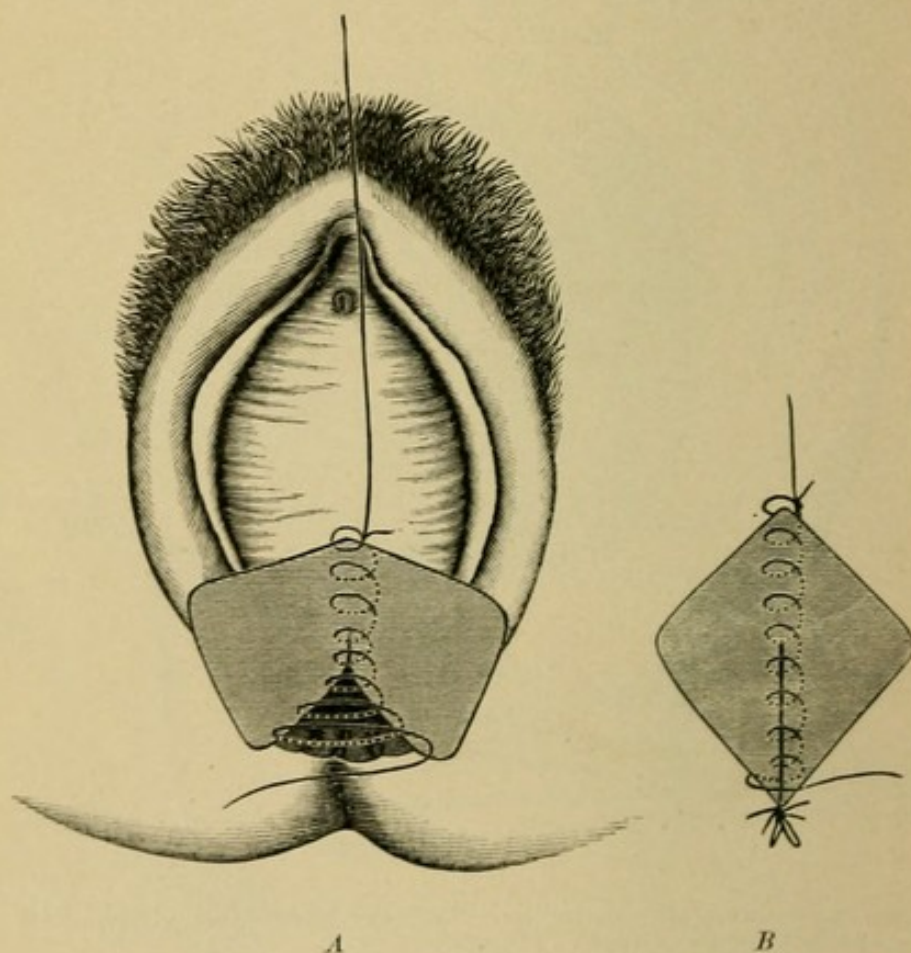
tremities of the sphincter muscle. The denuded areas of muscular and mucous tissue are then brought into apposition by interrupted sutures of chromicized catgut or silk-worm-gut passed just within the limits of denudation at intervals of about a quarter of an inch and knotted in the rectum from above downward (Fig. 268). The ends are left long and protruding from the anus, and at the expiration of a couple of weeks those sutures which can be reached



are removed and the ends of the others are cut short and the sutures are left to cut their way out.

The rest of the operation is then finished by Hegar's method for incomplete rupture with Martin's continuous sutures of catgut placed in tiers from the bottom of the rent just external to the rectal wall up to the original level of the vaginal mucous membrane (Fig. 269). A

FIG. 269.



Complete laceration of the perineum. Perineorrhaphy—Martin's method. *A*. Deep plan of continuous suture. *B*. Passage from the deep to the superficial. (POZZI.)

tension suture of silk should be passed through the skin of the perineum, without entering the rectum, a little beyond the extremities of the freshly united sphincter and the ends of the suture fastened over lead buttons or balls, which will permit it to be loosened if there is much subsequent swelling or œdema,




## VESICO-VAGINAL FISTULA.

The patient is prepared for the operation by measures directed to the improvement of her general condition, by regularly syringing the vagina with warm water, and by dividing any cicatricial bands that may have formed in it.

*Position.*—The patient is placed upon the left side, with the thighs flexed, the right rather more so than the left, the left arm is drawn behind her back, and her chest brought flat down upon the table. Some prefer the knee-elbow position, and Simon placed the patient flat upon her back, raised the hips, and flexed the thighs as far as possible upon the abdomen.

FIG. 270.



*a.* Vesical surface. *b.* Vaginal surface. *cc.* Line of paring.

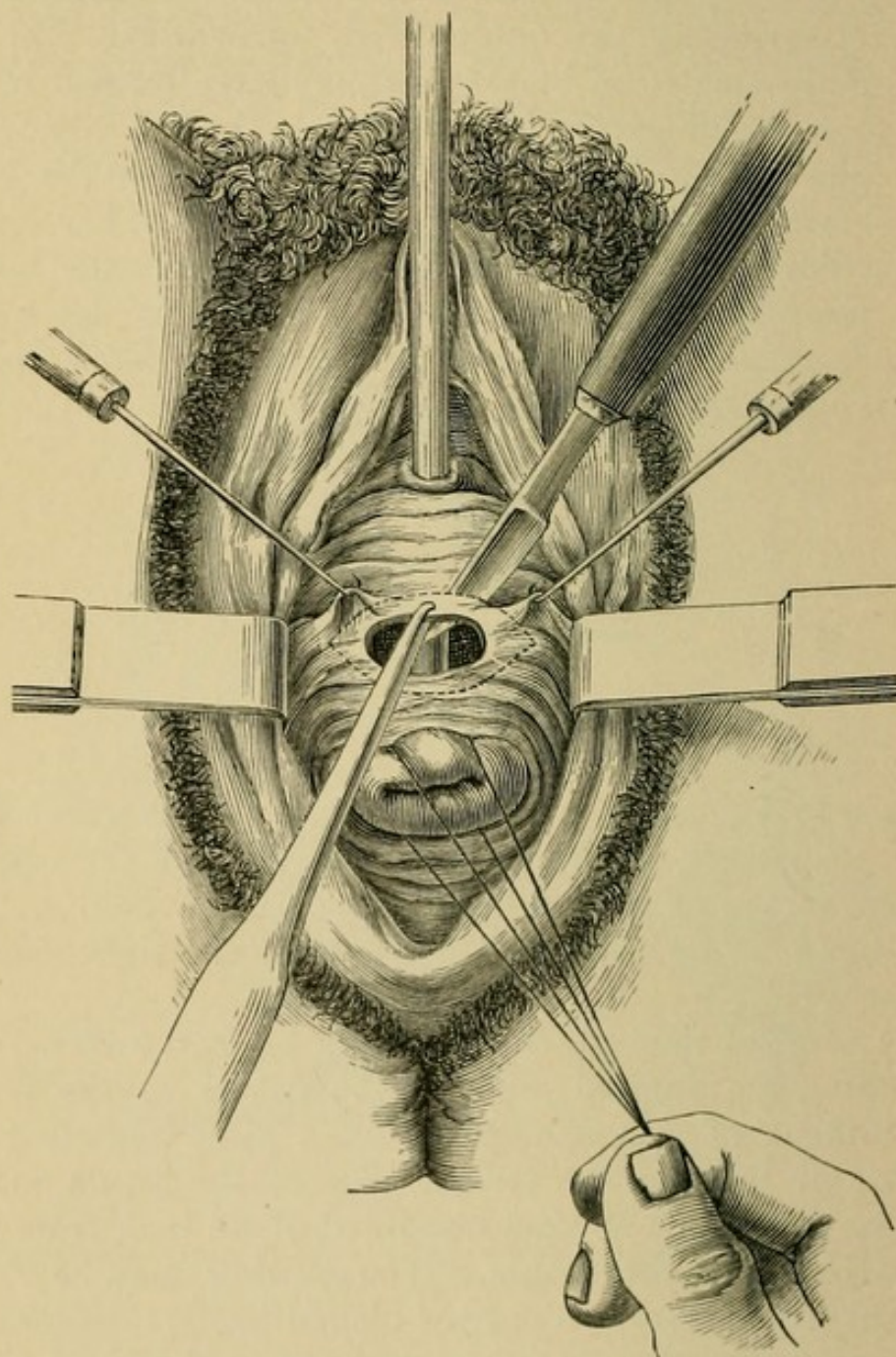
If the first position is employed, an assistant stands behind the patient, draws the posterior wall of the vagina back by means of a broad Sims's speculum held in his right hand, while with his left he raises the right side of the nates.

The surgeon then pinches up, with toothed forceps or a tenaculum, the vaginal edge of the fistula at the point most difficult of access, and cuts off a piece including in breadth all between the vesical edge of the fistula and a point in the vagina at least one-third of an inch from the vaginal edge of the fistula. The cutting may be done with curved scissors or a narrow bladed knife. Successive portions of the edge are raised and removed in like manner, until the denudation is complete, the resulting raw surface being funnel-shaped, with its narrowest part at the edge of the vesical mucous membrane, the membrane itself not being included in it (Fig. 270). Or the point of the knife may be entered into the mucous membrane



of the vagina one-third of an inch from the edge of the fistula, brought out at the vesical border, and then carried

FIG. 271.



Drawing down the uterus to facilitate the paring.

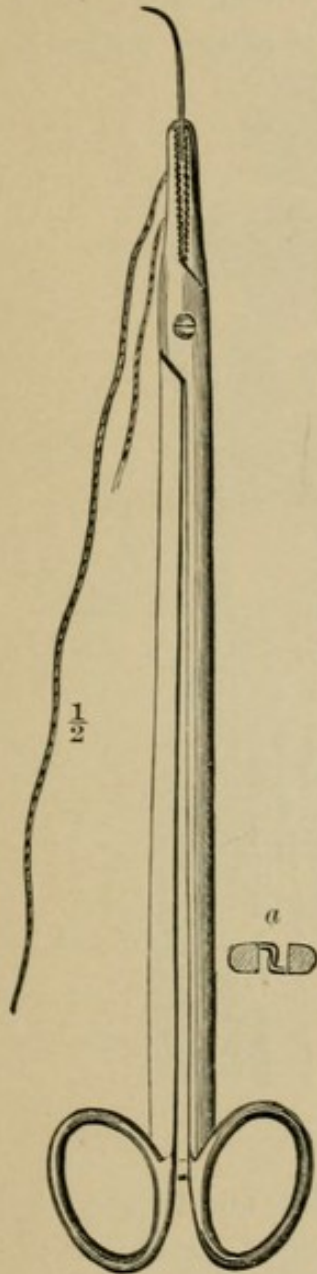
right and left around the opening so as to cut off a complete ring of tissue.

If the anterior wall of the vagina is freely movable, Simon brings the fistula into plain view by passing a



stout ligature through the cervix of the uterus and drawing it down toward the vulva (Fig. 271). He also pares the edges of the fistula very freely, and does not hesitate

FIG. 272.



Needle-holder.

FIG. 273.

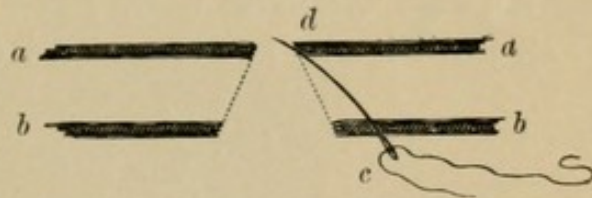
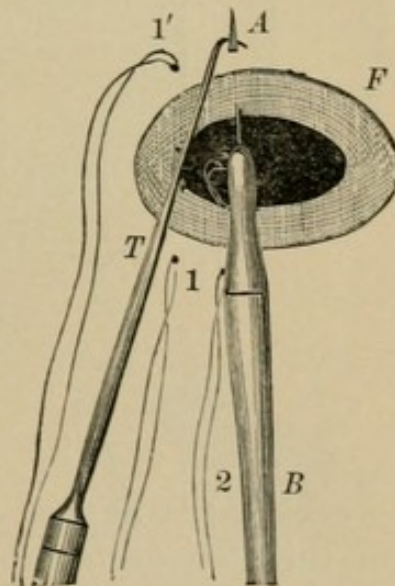
*a.* Vesical surface. *b.* Vaginal surface. *c.* Needle.

FIG. 274.



Passing the needle.

to include the mucous membrane of the bladder in the incision.

As soon as the hemorrhage has ceased, the sutures may be passed. The needle, three-quarters of an inch long, round,



slightly curved, and armed with a fine double silk suture, is fixed in a needle-holder, and entered at the angle of the wound which is most difficult of access, half an inch from the edge of the raw surface, and its point brought out at the edge of the vesical mucous membrane, but not including it (Fig. 273) and there fixed with a blunt hook (Fig. 277), until it can be seized and drawn through with the

FIGS. 275, 276, 277.

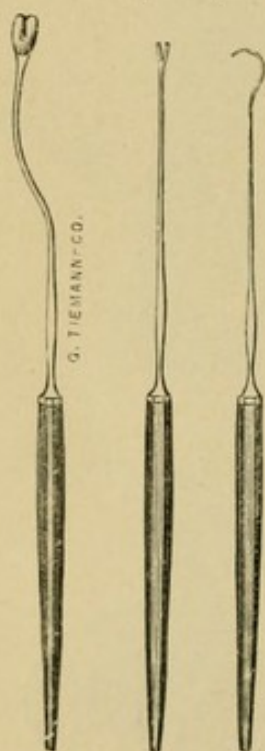
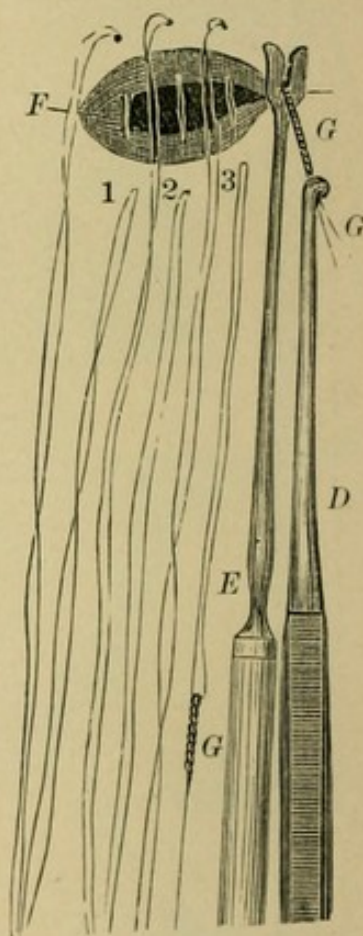


FIG. 278.

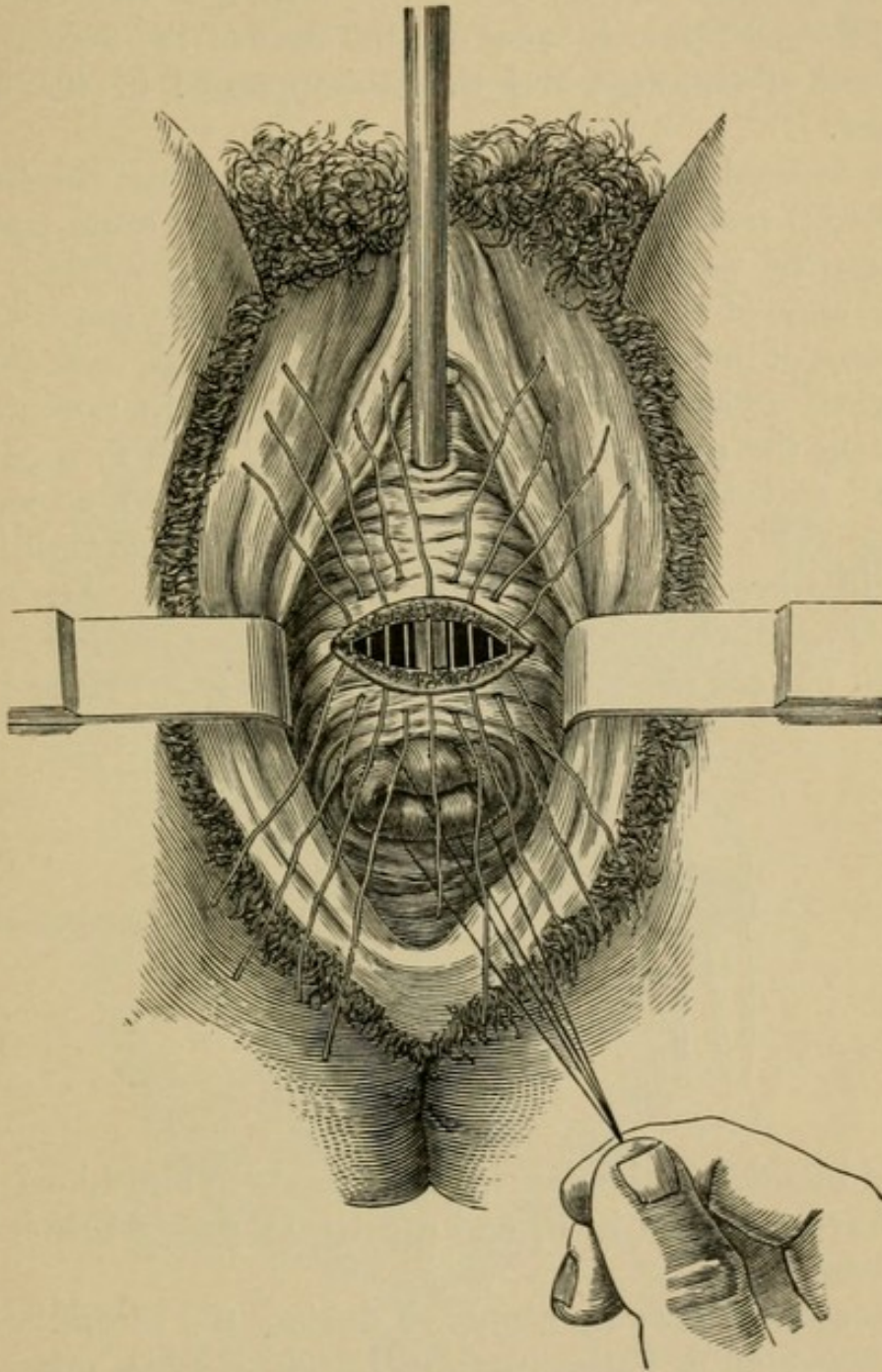


needle forceps. It is then entered at the corresponding point on the opposite side, and brought out on the vaginal surface half an inch from the edge of the opening (Fig. 274). The ends of the ligature are given into the charge of the assistant who holds the speculum, and another needle is passed in the same manner at the distance of one-sixth of an inch from the first; and so on, until a sufficient number have been passed. During the



passing of the needles the sides of the fistula are fixed by the tenaculum.

FIG. 279.



Simon's method of placing the sutures.

When the needle is seized with forceps and pulled through, counter-pressure must be made upon the tissues, and this is best done by means of the split rod or fork, represented in Fig. 276, its prongs passing on either side of the needle.




After all the ligatures have been passed, a silver wire, about twelve inches long, is fastened to the loop of the first ligature (Fig. 278, *C*), and drawn through with the help of the fork. The silk is cut off, the ends of the wire drawn aside out of the way, and the others passed in the same manner.

Simon used fine silk sutures (two rows when the fistula was large) tied in the ordinary manner, and often passing through the vesical mucous membrane (Fig. 279).

The ends of the silver sutures being drawn together, and the edges of the wound carefully approximated, each thread is slightly twisted so as to keep the parts in apposition, and then the ends of the first are seized with forceps and twisted with the help of the shield (Fig. 275), as shown in Fig. 278; care being taken not to twist so tightly as to strangulate the tissues engaged in the loop. The other sutures are then twisted in the same manner, and the ends of each cut off about half an inch from the surface (Fig. 280).

FIG. 280.



The bladder is then syringed to remove any blood that may have collected in it, and a catheter passed into it and left there.

The sutures may be removed during the second week.

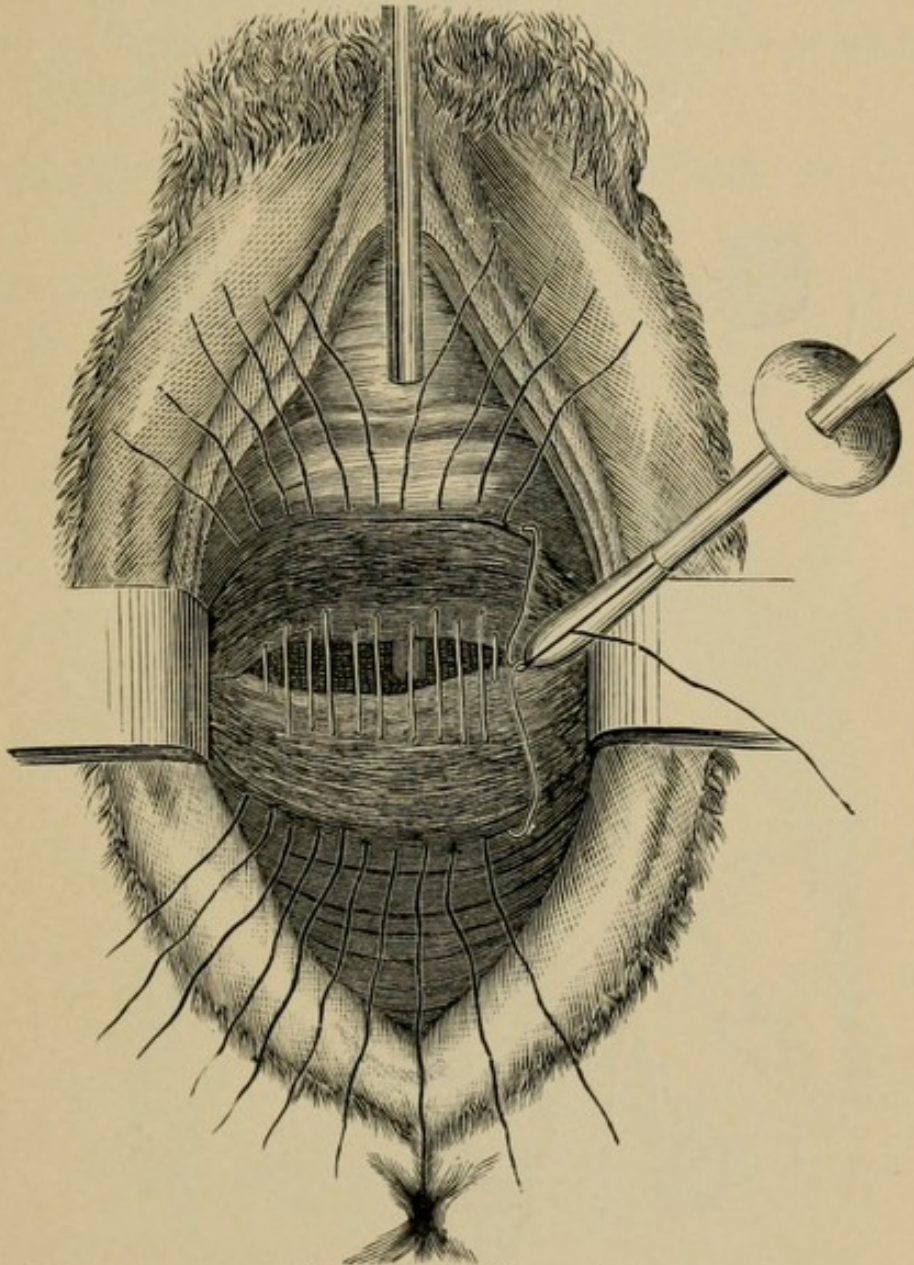
*Creation of a Vesico-vaginal Fistula.*—This operation is sometimes required in the treatment of chronic cystitis. Dr. Emmet<sup>1</sup> performs it as follows: Anæsthesia; Sims's position. A Sims's speculum is introduced into the vagina and a director, abruptly curved an inch and a-

<sup>1</sup>Chronic Cystitis in the Female, American Practitioner, February, 1872, and Vesico-vaginal Fistula, p. 43.



half from its extremity, introduced through the urethra. While the director is held by an assistant with its point firmly pressing in the median line against the base of the bladder a little behind the neck, the surgeon seizes the projecting tissue on the vaginal surface with a tenaculum,

FIG. 281.



Obliteration of the vagina.

and exposes the beak of the director by cutting upon it with a pair of scissors. One of the blades of the scissors is then passed through the opening and a cut made backward in the median line.

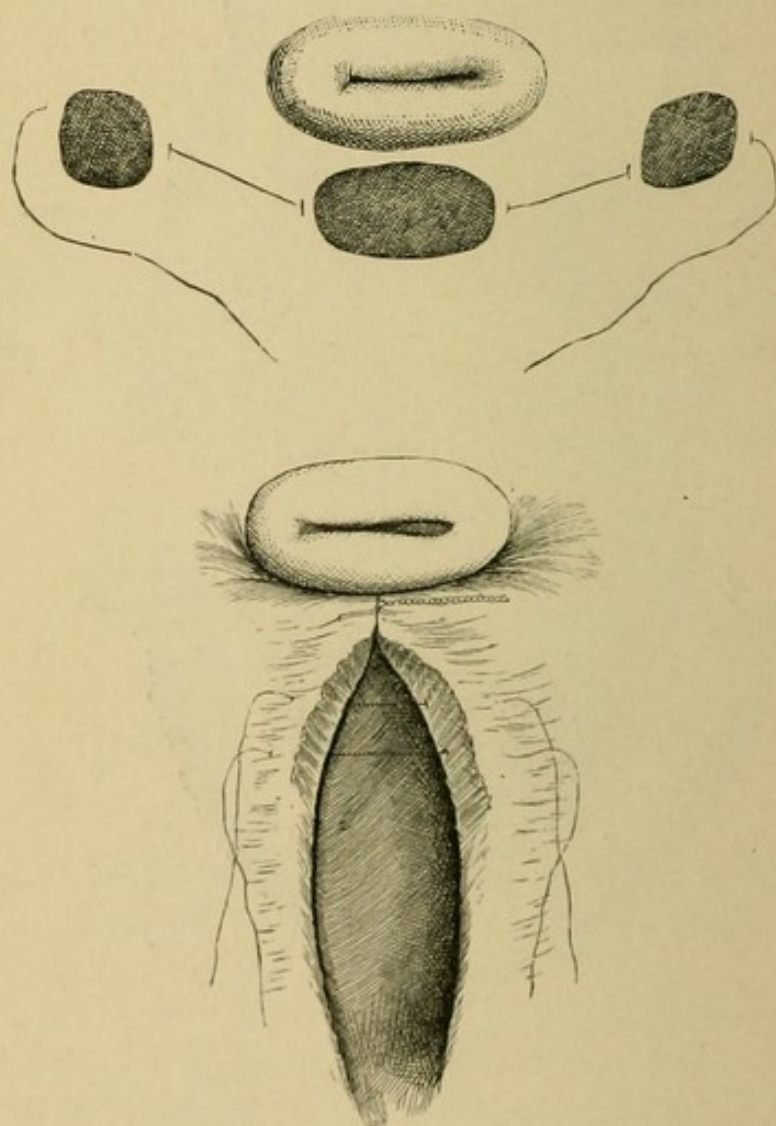


If the opening tends to close spontaneously too soon, a hollow glass stud made of half-inch tubing should be buttoned into it. The vesical rim of this stud need not be more than a slight flare, the vaginal rim should be larger.

#### OBLITERATION OF THE VAGINA; KOLPOKLEISIS.

(Fig. 281.) When a vesico-vaginal fistula cannot be closed by the means above described, the escape of urine

FIG. 282.



Emmet's operation for procidentia.

may be prevented by closing the vagina. Vidal de Cassis first performed this in 1833 by effecting union between the labia majora, but it has been found that complete



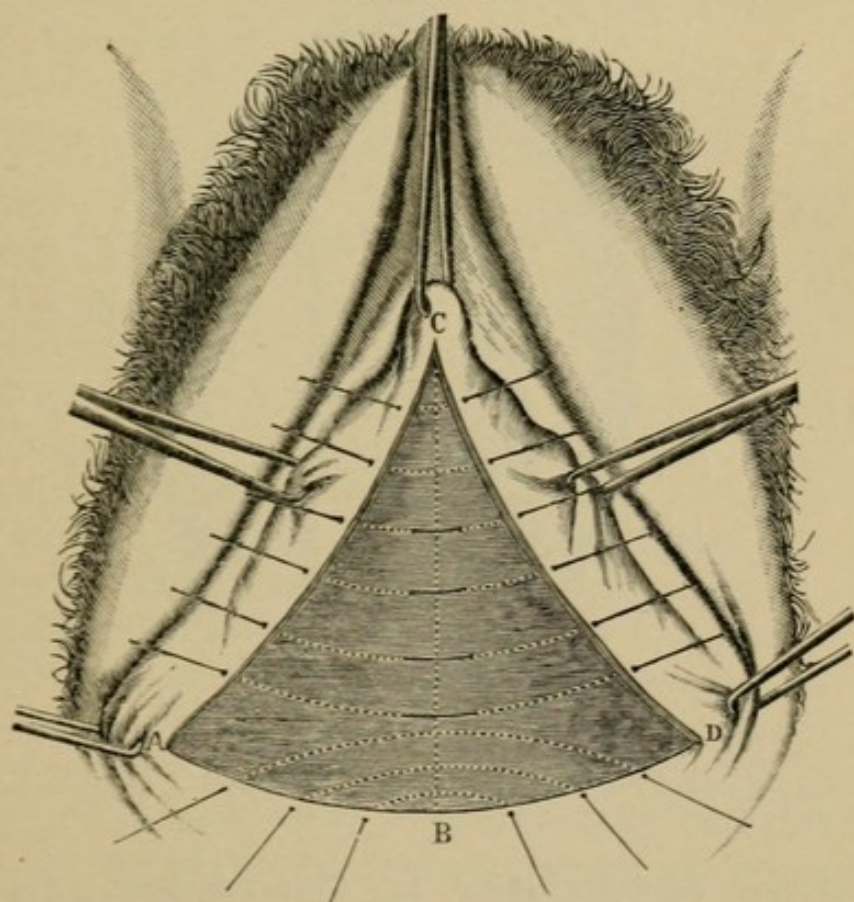
closure cannot be thus obtained, a small opening remaining at the lower angle. Simon's method of uniting the anterior and posterior walls of the vagina instead of the labia is much more trustworthy. It was first performed in 1855.

A strip of mucous membrane encircling the vagina just below the fistula is removed, the opposing raw surfaces brought together by sutures, and the bladder kept empty by a catheter until union has taken place.

### ELYTRORRHAPHY, OR NARROWING OF THE VAGINA.

This is an operation intended to prevent prolapse of the uterus. The method, introduced by Sims, of removing a

FIG. 283.



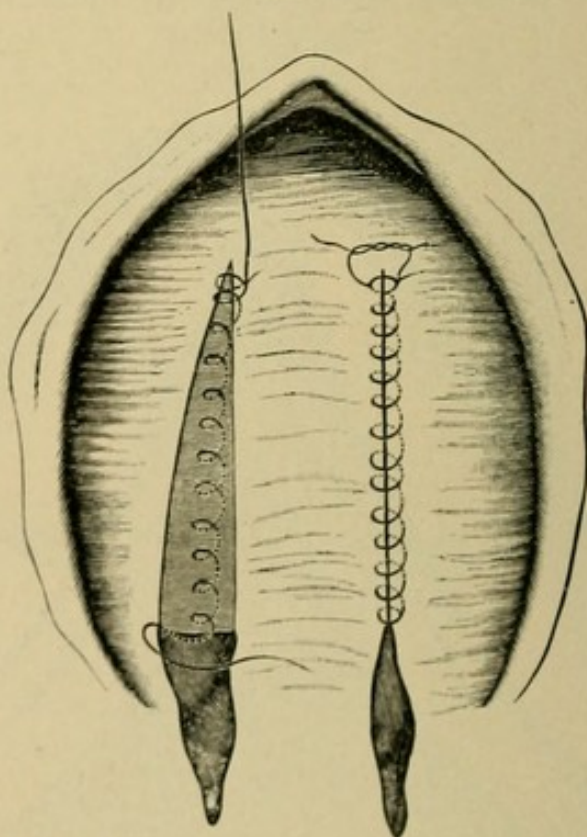
Colpo-perineorrhaphy by Hegar's method. (POZZI.)

longitudinal strip of mucous membrane from each side of the vagina, and bringing the raw surfaces together, has



proved not only inefficient, but often actually harmful by supplying a pouch in which the cervix became engaged, thus causing extreme retroversion. Dr. Emmet avoided this defect by closing the pouch at its upper end, but the mechanical difficulties in the way of performing the operation are so great that he has substituted for it another in which he catches up on a tenaculum three folds of the vaginal mucous membrane, one on each side, and the third in front of the cervix (Fig. 282), denudes them over a space half an inch square, and draws them together with a suture. The three folds radiating from these points are then pared, and united stitch by stitch along the anterior wall of the vagina.

FIG. 284.



Colpo-perineorrhaphy by Martin's method. Bilateral denudation of posterior vaginal wall; continuous sutures in layers. (POZZI.)

**Posterior Elytrorrhaphy or Colporrhaphy.** (HEGAR'S METHOD.)—The entire thickness of a portion of the mucous membrane is removed from the posterior vaginal wall in the form of an isosceles triangle (Fig. 283), with its



base about two inches broad at the fourchette, and its apex in the median line two inches above the fourchette. For very marked prolapse these measurements may be extended a quarter or half an inch. The denuded area is folded together by the interrupted, or better by Martin's suture as described for perineorrhaphy.

**MARTIN'S METHOD.** (Fig. 284.)—Two narrow strips of mucous membrane are removed from the posterior vaginal wall on each side of the median line from just below the cul-de-sac to a finger's breadth above the fourchette.

The operation is completed by perineorrhaphy with Martin's suture throughout.

**ANTERIOR.**—A portion of the entire thickness of the mucous membrane on the anterior vaginal wall is excised in the form of a circle, oval or diamond, measuring generally about an inch or an inch and a-half in its longitudinal diameter, and situated about the same distance from the meatus.

The denuded surface is folded together by the interrupted or purse string or Martin's suture.

### LACERATED CERVIX.

Dr. Thomas Addis Emmet<sup>1</sup> was the first to point out that after laceration of the cervix the lips rolled out, their mucous membrane became eroded by contact with the floor of the pelvis, and that the proper method of treatment was to freshen the torn surfaces and bring them together with sutures, so as to restore to the cervix its normal size and form. In cases which have long remained unrecognized or untreated, the lips become centrally enlarged by the inflammatory process, so that they cannot be properly brought together until after the removal of a thick piece on each side of the inside of each lip (Figs. 285 and 286). In like manner, when the eversion is increased and the coaptation of the lips prevented by cystic degeneration of the mucous follicles lining the cervical canal, free punctures must be made with

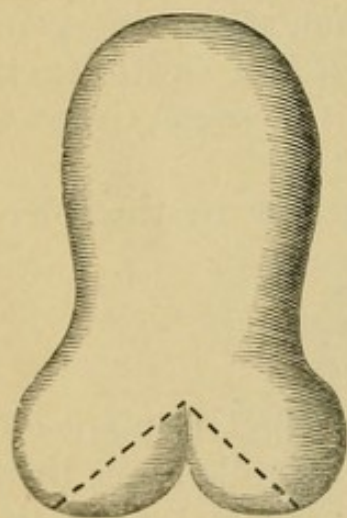
<sup>1</sup> American Journal of Obstetrics, November, 1874.



the point of a knife to let out the blood and the contents of the cysts. It is well to do this several days or weeks before the operation, apply tincture of iodine to the cervix, and bring the lips together temporarily by putting a plug of cotton into the posterior cul-de-sac and leaving it there for several hours at a time. The puncturing and application of iodine must be frequently repeated until the cysts shall have all disappeared and the erosions become nearly or entirely healed.

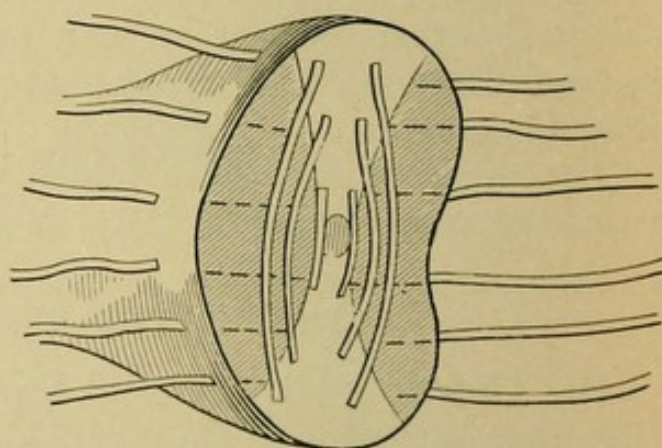
The patient is placed on her left side, a Sims's speculum introduced, and a loop of wire placed around the cervix above the vaginal reflection and tightened by drawing its

FIG. 285.



Lacerated cervix. Side view.

FIG. 286.



Lacerated cervix. Showing denuded surface (the shaded part) and sutures.

ends down through a canula so as to prevent bleeding ; or an injection of hot water just before the operation will answer the same purpose. The lips are then separated and the lacerated surfaces thoroughly freshened with curved or angular scissors or a knife, leaving a broad undenuded strip in the center to form the lining of the restored canal. This strip should be shaped somewhat like an hour-glass in order to allow for the shrinking of the cervix which follows the operation (Fig. 286). The freshening should be done from below upward, so that the blood may not interfere, and must be carried deeply enough to remove all diseased glands and follicles.



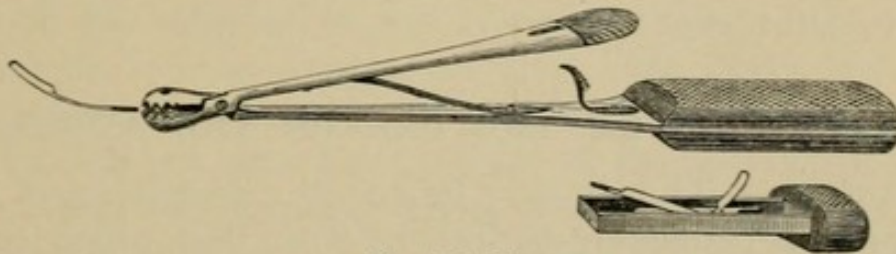
A tenaculum is then engaged in each lip, and the two drawn together; if proper coaptation is prevented by the central enlargement of the cervix above mentioned, simple freshening of the surface is not sufficient, but a greater thickness of tissue must be removed. The freshening at the angles of the fissure should be superficial, so as not to involve the circular artery which often lies just at that point.

The sutures should be of silver wire, and passed with a short, round needle if the tissues are soft, or with a lance-shaped one if they are dense and indurated. From three to five will be needed on each side if the laceration is extensive and double. The first one on each side should be entered just beyond the angle of the fissure so as to include the branches of the circular artery if necessary. The needle is entered on the outside of the lip and brought out at the edge of the undenuded strip which is to form the canal, and then passed in the opposite direction (from within outward) at corresponding points through the other lip. Care must be taken to obtain accurate approximation along the vaginal edge, but the inner edges of the denuded surfaces do not require attention.

### POSTERIOR SECTION OF THE CERVIX.

This operation may be rendered necessary by irreducible flexion of the uterus. The patient being placed in position

FIG. 287.



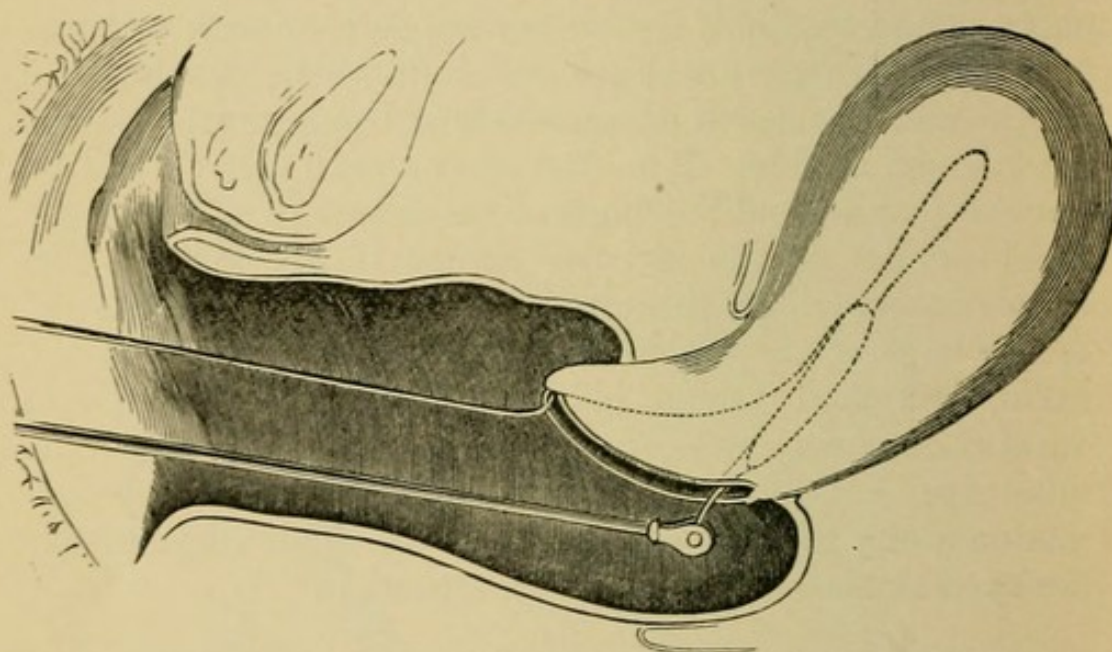
Sims's knife.

and a Sims's speculum introduced, the cervix is fixed by a tenaculum and its posterior lip divided with scissors as high as to the vaginal junction. The blade of a Sims's knife (Fig. 287) is then introduced through the os inter-



num, and the tissues cut so as to lay open the posterior wall of the cervix (Fig. 288). The blade is then turned toward the anterior wall, and the little shoulder which, as Dr. Emmet has pointed out, usually exists there at the point of flexion is cut through. Instead of making this second incision Dr. Wylie practises and recommends divulsion with a strong steel dilator.

FIG. 288.



Posterior section of the cervix.

A roll of cotton saturated with a solution of persulphate of iron, one part to two of water, is placed so as to occupy the whole cervix, and retained by a plug of wet cotton in the vagina.

#### OPERATIONS ON THE UTERUS AND ADNEXA.

*Anatomy.*—The broad ligaments, consisting of two layers of peritoneum, continuous with that which covers the uterus, are attached to its sides from the cornua to the level of the internal os; externally they are attached to the sides of the pelvis in a vertical but broader line, about midway between the obturator foramen and the great sciatic notch. The Fallopian tube passes outward



from the angle of the uterus in the highest part of the broad ligament, while in front and a little lower down the round ligament diverges to the internal abdominal ring, and contains a branch of the epigastric artery passing to the uterus. Behind the Fallopian tubes are the ovaries which are subject to great variation in position—normally each occupies the apex of a ligamentous triangle directed backward, the base of which is in the broad ligament, and through which the branches of the ovarian artery and the pampiniform plexus of veins enter the gland. The inner angle of the ligamentous triangle passing to the fundus of the uterus is a rounded fold of peritoneum containing muscular fiber, and called the utero-ovarian ligament. The outer angle blends with the upper border of the broad ligament, and is called the infundibulo-pelvic ligament.

The ovarian arteries arise from the abdominal aorta, and at the brim of the pelvis cross the bifurcation of the common iliac vessels and the ureter, and run in a tortuous course in the upper border of the broad ligament, or more exactly in the infundibulo-pelvic ligament, to the cornua of the uterus, where they anastomose with the uterine arteries along the respective sides.

Each ureter crosses the common iliac artery near its bifurcation, and runs from behind downward, forward, and inward in front of the internal iliac artery and its anterior division, lying in the base of the broad ligament, which is limited by the levator ani muscle. Near the level of the external os the ureter is crossed on its inner side by the uterine artery, and then runs along the side of the vagina about half an inch from the cervix, entering the bladder just above the middle of the anterior vaginal wall. The uterine artery arises from the anterior trunk of the internal iliac near the synchondrosis, and passes downward and forward to a point just above the spine of the ischium, where it leaves the pelvic wall, but still descends almost to the tuberosity of the ischium; it then turns up toward the vagina, reaching the uterus at the utero-vaginal junction. Opposite the external os it gives



off the circular artery of the cervix and continues along the side of the uterus between the layers of the broad ligament, and at the superior cornu it anastomoses with the ovarian artery.

The peritoneum is firmly adherent to the fundus of the uterus, but gradually becomes more loosely attached until it can be readily stripped up with the finger in the vesico-uterine depression. Posteriorly it descends about three-quarters of an inch on the vaginal wall, and is likewise easily peeled off to the same level as in front. With a normal uterus and an empty bladder, the latter lies upon the cervix for about half an inch.

### OVARIOTOMY.

The patient is prepared in the usual way for a laparotomy, and immediately before the operation she is catheterized, the sponges, pads, and clamps are counted and the number of each written down. An incision three or four inches long is made in the median line between the umbilicus and the pubes, which, if necessary, is later extended upward with a slight semicircular deviation, including the umbilicus and passing to the left of it to avoid the falciform ligament. The incision is deepened layer by layer and the peritoneum first opened above by pinching up a fold with the fingers or forceps and nicking it, and then enlarging it downward by cutting on the fingers inside as a director, care being taken to avoid the bladder, which may be recognizable from within as a thickened fold lying near the pubes.

When the peritoneum is adherent to the tumor it may be simpler to prolong the incision above the latter to make certain that the abdominal cavity has been opened and that the peritoneum is not simply stripped from the parietes. Sometimes, also, the bladder is drawn far up above its usual position, but it can be recognized by its vascularity or by a sound passed in through the urethra. A sponge protective packing is wedged around the exposed cyst, which is then punctured with a large trocar and canula,



the latter being provided with a tube to conduct the fluid to one side, and as soon as possible the walls are grasped by the fingers or by forceps and drawn into the wound, while, at the same time, pressure is made on the parietes, or the patient is rolled on one side to favor the escape of the contents. If the latter are too thick to flow readily, the puncture may have to be enlarged sufficiently to permit them to be scooped out by hand, and through this opening other loculi are entered by the finger, knife, or trocar, and enough liquid evacuated to permit of an attempt to turn the cyst out of the abdomen.

The adhesions are cautiously separated by the fingernail and blunt-pointed scissors or divided between double catgut ligatures.

The peritoneal cavity must be constantly protected by the addition of fresh sponges as the dissection progresses, though usually no harm follows from the escape into it of some of the cyst-contents. When the pedicle has been fully exposed, often by bringing the cyst out of the belly, if broad it is secured in sections by the interlocking silk ligature passed on a blunt-pointed aneurism needle, and the tumor or what remains of it is excised; or the pedicle may be divided with scissors and the vessels secured as they are encountered by clamps, and after removal of the tumor ligated separately.

A comparatively small pedicle can be ligated *en masse* with stout silk, but it is well also to secure by separate ligatures the vessels that appear on the cut surface.

If there have been few or no adhesions and the cyst has been removed practically without opening it, the abdominal wound can be closed entirely in the usual way, after taking out and counting the sponges and clamps. But drainage by rubber tubes and iodoform-gauze packing is imperative whenever there is even a possibility of infection, and especially if a portion of the cyst wall has been necessarily left behind owing to its too firm adhesion to important structures. If there has been much peritoneal laceration accompanied by oozing from minute blood-vessels, drainage and hemostasis are conveniently pro-



vided for by a large sheet of iodoform gauze placed in contact with the lacerated surface and having all its edges brought out of the abdominal wound.

This pouch is then stuffed with strips of gauze which are subsequently removed one by one, to gradually reduce its bulk. The parietal opening is partially closed and dressed antiseptically in the usual way.

### OÖPHORECTOMY.

This term is used to designate the removal of macroscopically normal ovaries and Fallopian tubes for hemostatic or analgesic purposes.

After the usual preliminaries, including catheterization, the patient is placed in Trendelenburg's position, which greatly facilitates all intra-abdominal operations on the pelvic organs.

An incision about three inches long is made in the median line above the pubes, and deepened layer by layer till the peritoneal cavity is opened. Two fingers are passed through the incision to the fundus of the uterus and thence outward, following one Fallopian tube to its extremity, which is drawn up into the abdominal wound together with the ovary. Flat sponges are placed around them, and a ligature is placed about the ovarian artery and veins at the edge of the broad ligament. Others are placed upon the tube and the utero-ovarian ligament close to the uterus. The tissues distal to these ligatures are then cut, and the intermediate portion of the broad ligament tied in one or two ligatures. The ovary and tube are then excised, and after a final inspection of the pedicle for hemorrhage it is dropped back into the abdomen.

The same proceeding is repeated upon the other side, the flat sponges are removed, and finally the abdominal incision is closed tight in the usual way and dressed without drainage.



**SALPINGO-OÖPHORECTOMY, OR THE REMOVAL OF A TUBE DISTENDED WITH PUS, AND ITS OVARY.**

After the usual preliminaries, including antiseptic vaginal douches, the patient is catheterized and placed in Trendelenburg's position, as described for oöphorectomy. An incision not less than four inches long is made in the median line above the pubes, afterward extended, if necessary, around the umbilicus to afford plenty of room for manipulation. The incision is deepened layer by layer, the bleeding stopped, and the peritoneum nicked in the upper angle of the wound and opened downward on the finger as a guide, stopping short of the bladder, which can be recognized on the inside as a thickened fold near the pubes ; or, if there is any doubt, by a sound passed through the urethra. The omentum and intestines are pushed back, separating adhesions with the finger-nail or blunt-pointed scissors, till there is a full exposure of the uterus and its appendages, which are then surrounded with flat sponges or pads, completely shutting off the rest of the peritoneal cavity.

The fingers are passed outward from the fundus of the uterus, following every crevice around first one tube and then the other, till some spot is found where, by slight pressure or tearing, the tip of the index-finger can be worked under or around the mass and the tube freed, generally in company with its ovary. If pus should be discovered escaping, the dissection is stopped till it has been entirely sponged away, enlarging, if necessary, the hole from which it comes. The somewhat free oozing is controlled by sponge packing, and when a more or less distinct pedicle has been formed, or the finger recognizes a dangerous amount of resistance to its progress, the stripping up and gently tearing process is stopped.

With a blunt-pointed aneurism needle a stout catgut ligature is then passed under the infundibulo-pelvic ligament, or the outer attachment of the freed mass consisting of the ovary and diseased tube, tying off this ligament close to the mass and including the ovarian artery, the



position of which can be ascertained in advance by palpating the broad ligament and noting the pulsation.

Another catgut ligature is passed through the broad ligament in the angle formed by the junction of the uterus and Fallopian tube, and the latter is secured with the termination of the artery close to the uterus.

Beginning on the uterine side of the outer ligature, the tissues attached to the under side of the tube are cut with blunt-pointed scissors, clamping each vessel or bleeding point as it is encountered, and in this way, when the tube alone is diseased, it is generally easy to leave the ovary undisturbed, and this is always done by some surgeons; but in such an instance there should be no preliminary ligature of the infundibulo-pelvic ligament with the ovarian artery, and the scissors must be kept close to the tube, while bleeding is controlled by individual ligature of each vessel as it is cut.

The diseased mass is then excised on the distal side of the ligature next to the uterus and the stump disinfected. Before its division the tube is secured by a clamp to prevent the escape of pus if it has not already occurred.

Ligature *en masse* of the pedicle, which is almost always bulky, is only mentioned to be condemned. After changing the sponges and securing any vessels which still bleed, the cut edges of peritoneum forming the broad ligament are united with fine catgut sutures over the denuded area which lies under the Fallopian tube, and when it has been possible to perform the operation without the escape of a drop of pus, and without leaving a large oozing surface, the protective sponges are removed and the abdominal wound closed tight in the usual way.

Otherwise the peritoneal cavity is made as clean and dry as possible and rubber tubes with lateral perforations are placed in the suspected regions, with one always in Douglas's pouch, and surrounded by strips of iodoform gauze, around the ends of which the abdominal wound is partially closed.

Sometimes the Fallopian tube will be found changed into an abscess sac, with very firm adhesions, which only



permit the sac to be opened, or not more than partially removed; very rarely it can be only partially exposed, but the pus can always be reached somewhere by a careful dissection, aided possibly by a guiding puncture with an aspirating needle. The surrounding parts are then carefully protected by a sponge packing and the abscess cavity thoroughly evacuated and washed out with boiled water, and drained with rubber tubes and iodoform gauze. Communication between the abdominal wound and the opening in the sac, which may be at a distance from the surface, is maintained by packing, which should also extend into and protect all possibly infected regions around the abscess. Aided by an exploring finger in the vagina it will sometimes be possible and very advisable to force a blunt-pointed forceps from the bottom of the abscess cavity into the posterior fornix, and thus pass a tube to afford drainage in the most dependent regions as well as from the surface of the abdomen. The vagina is packed around the tube and a dressing is placed on the vulva, while every precaution is taken to prevent infection from the urine and feces.

If the vermiform appendix is found involved or adherent to a diseased tube, as often happens, it should be excised at the same time. Whenever in a case in which the abdominal wound has been closed tight symptoms of secondary hemorrhage appear, the diagnosis should be at once verified by untying a stitch in the lower angle of the wound and passing a small sponge on a holder into Douglas's pouch. If done with every antiseptic precaution this exploration is free from danger, even if no hemorrhage is found.

#### **TUMORS LYING BENEATH THE BROAD LIGAMENT.**

An opening is made in the overlying peritoneum generally in front of the Fallopian tube, and through this the dissection, guided by the sense of touch, is carried out by the tip of the finger tearing through the loose connective tissue surrounding the capsule of the tumor, and



the latter enucleated. The few vessels are clamped as they are encountered and tied later, and drainage is provided for as after salpingo-oöphorectomy.

### OPERATIONS FOR ECTOPIC GESTATION.

In the early stages of this condition before the placenta has formed, the operation is conducted, according to the situation of the mass, in the same way as in ovariectomy or salpingo-oöphorectomy, or for a tumor lying below the broad ligament.

Later, after the formation of the placenta, the general rule is to open the abdomen in the median line below the umbilicus, and, after protecting the peritoneal cavity by a sponge packing, the sac is entered in front like an ovarian cyst, avoiding if possible the site of the placenta, which can usually be recognized by the surrounding vascularity. But sometimes the placenta may have to be perforated, and then the hemorrhage from it is controlled by clamps or deep sutures.

The fœtus and amniotic liquid are extracted while the surrounding parts are well guarded, and when it seems perfectly feasible the sac may be dissected out with the placenta, separating adhesions with the tip of the finger or blunt-pointed scissors and arresting the bleeding as it occurs; but more often the complete removal is impossible, and the opening in the sac is either stitched to the margins of the abdominal wound or kept in communication with it by packing and drainage applied on the principles already enunciated, while the placenta is left to slough away with the attached umbilical cord.

If the operation is performed for hemorrhage following rupture of an extra-uterine gestation, the abdomen is opened in the same way and one hand passed to the fundus of the uterus and thence outward to the boggy mass, which, if it can be raised to the surface, is easily secured and treated. But if this is impossible, an attempt, guided by the hand inside the belly, is made to seize one or both extremities of the broad ligament with its contained vessels, by long-bladed clamps.



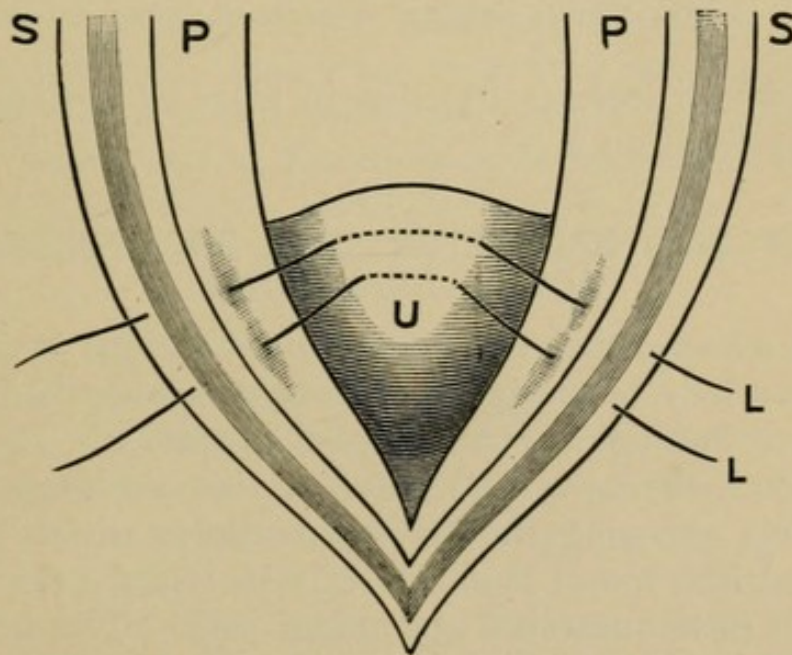
The blood and *débris* are then rapidly scooped out of the peritoneal cavity and a search is made for bleeding points, which are immediately caught and tied, and then a decision can be made as to extirpation of the sac, which does not differ from an inherent tube or an ovarian cyst, except that the placenta in the great majority of cases should not be disturbed.

The treatment of a case in which suppuration has occurred does not differ from that of an intra-abdominal or pelvic abscess.

### HYSTEROPEXY.

The peritoneal cavity is opened by a median incision of about three inches just above the pubes, and the fundus of the uterus is brought up to the abdominal wall, to which it is fixed by three silk or silkworm-gut sutures passed transversely across the fundus and front of the

FIG. 289.



uterus, within the substance of which they are buried for about an inch, and then through the parietal peritoneum and muscles and tied in the wound (Fig. 289). The uterine peritoneum covering the sutures should be scraped slightly to provoke adhesions. Some carry the sutures

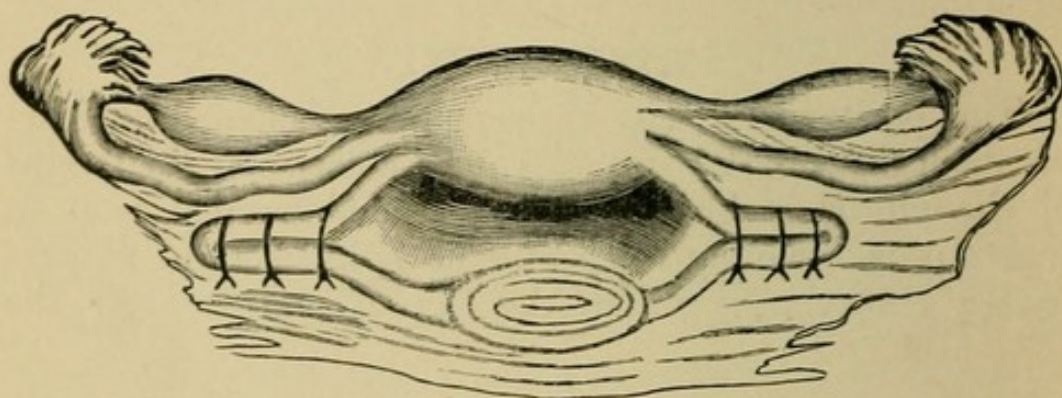


entirely through the abdominal wall, tie them outside and remove them after a fortnight.

### INTRA-ABDOMINAL SHORTENING OF THE ROUND LIGAMENTS.

Wylie opens the abdomen in the median line and shortens the round ligaments as shown in Fig. 290. Polk

FIG. 290.



Hysteropexy. Wylie's method of shortening the round ligaments.

ties the two ligaments together in front of the uterus, so that they form an X.

### ALEXANDER'S OPERATION<sup>1</sup> FOR SHORTENING THE ROUND LIGAMENTS.

With every antiseptic precaution an oblique incision an inch and a-half or two inches long is made over the inguinal canal terminating near the spine of the pubis. The external abdominal ring is cleared and the inter-columnar fascia is divided, exposing the fine yellow fat in which the reddish cord-like round ligament will be found near the upper limit of the external abdominal ring. The other side is treated in the same manner.

A slight dissection may be necessary to isolate the round ligament, and, aided by a sound in the cavity of the uterus, enough traction is made on the cords to raise the uterus to the desired position. Often four or five inches

<sup>1</sup> Liverpool Med.-Chir. Journ., January, 1883, p. 113.



of the round ligament can thus be easily drawn out through the ring.

The ligaments on each side are held in their new position by a couple of sutures of catgut or silkworm-gut passed through them and the external and internal pillars of each ring. The wound in the intercolumnar fascia is closed with fine catgut and the external wound is sutured and dressed antiseptically without drainage.

Tampons or pessaries must be worn for a month.

### LAPARO-HYSTEROTOMY.

By this term is meant the making of an opening into the cavity of the uterus for any purpose, commonly the extraction of a fœtus. In the latter instance the time of election, according to Senn,<sup>1</sup> is during the first stage of labor.

The patient is catheterized, and with every antiseptic precaution, including preliminary antiseptic douches for the vagina, an incision about six inches long is made in the median line above the pubes, and, bearing in mind that the abdominal wall is apt to be very thin and that the enlarged uterus is in contact with it without the interposition of other viscera, the incision is cautiously deepened layer by layer till the peritoneal cavity is opened in the whole extent of the wound and the surface of the uterus exposed.

Sponges are packed around the latter and a longitudinal incision about an inch long is made in its anterior wall at a point midway between the junction of the Fallopian tubes with the uterus. To lessen the hemorrhage this incision is enlarged downward by tearing sufficiently to extract the child, head first, which must be done as rapidly as possible after rupturing the membranes. As the bleeding is most free from the cervical region, the rent must not approach this too closely.

The uterus is immediately turned out of the abdomen and protected by a warm towel, and its neck below the opening constricted by an elastic ligature tightly enough

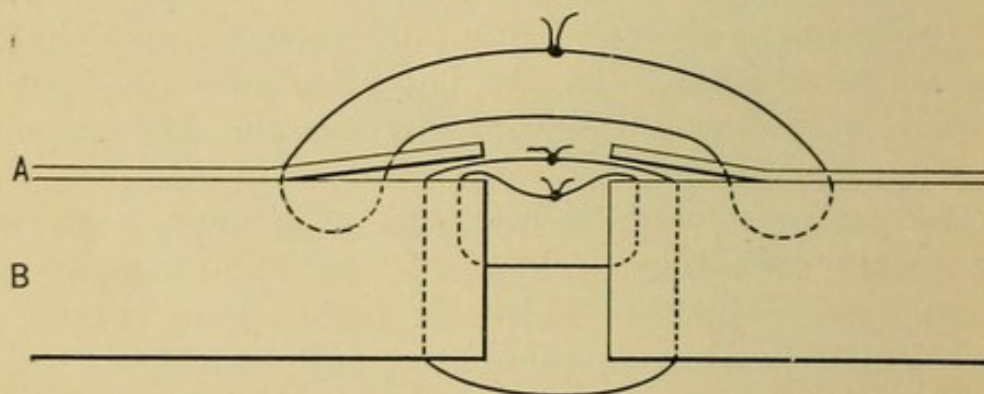
<sup>1</sup> Amer. Journ. Med. Sci., Sept., 1893.



to arrest the bleeding. The placenta is next peeled off with its attached membranes, and after cleansing the interior of the uterus the rent is closed by a row of interrupted stout catgut sutures passed at intervals of half an inch through the entire thickness of the uterine wall, exclusive of the peritoneum, and about half an inch from the torn edge.

Another row of sutures is placed between these in the same way, but including only half the muscular thickness and these are covered in by a row of catgut Lembert

FIG. 291.



Closure of the uterine wound after Cesarean section. A. Peritoneum. B. Muscular wall of the uterus.

sutures which should pass through enough of the muscular tissue to secure good peritoneal apposition over the line of suture. (Fig. 291.)

The abdominal cavity is cleansed and the elastic ligature removed from the uterus, but the latter is not replaced in the belly until after contraction has occurred or been induced by pressure, rubbing, or the subcutaneous injection of ergot. The abdominal wound is then closed tight in the usual way and dressed without drainage, and an iodoform-gauze packing is placed in the interior of the uterus from the vagina.

### SYMPHYSIOTOMY.<sup>1</sup>

The patient is catheterized, and, after thorough disinfection of the abdominal wall and the external genitals, a

<sup>1</sup> Morisani : *Ann. de Gynec. et d'Obst.*, April, 1892, p. 241. Charpentier : *Bull. de l'Acad. de Méd.*, March, 1892, p. 352.



longitudinal incision two or three inches long is made over the symphysis and carried down to the bone.

The origin of one pyramidalis muscle is divided sufficiently to admit the index-finger, which is inserted behind the pubes, separating and pushing back from the bone the prevesical tissues and on this finger as a guide the symphysis, which usually is not exactly in the middle line, is divided by a probe-pointed cartilage knife from above and behind downward and forward, sparing if possible the ligamentum arcuatum or triangular ligament. A sound is sometimes first placed in the urethra and bladder to draw them to one side.

After extraction of the child, *per vias naturales*, the pubic bones can be reunited by buried silk sutures, or the wound may be closed by silk sutures passed through the skin and the anterior portion of the symphysis. But it will generally be found sufficient to insert simple superficial sutures and, after dressing the wound antiseptically, to immobilize the pelvis by a stout binder or bandage.

#### **MYOMECTOMY, OR THE REMOVAL OF A SUBPERITONEAL FIBROID TUMOR OF THE UTERUS.**

The abdomen is opened as usual in the median line below the umbilicus sufficiently to admit the hand, and after exploration the incision is enlarged if necessary, and adhesions carefully separated or divided between double catgut ligatures. The rest of the peritoneal cavity is shut off by a sponge protective packing, and when the growth has a distinct pedicle the latter is simply surrounded by a silk ligature which may in addition first transfix the pedicle if it is large, and the growth is excised; or, when there is no pedicle and the tumor is sharply defined, two semilunar flaps are cut from the peritoneum on its base, and through the gap thus made the tumor enucleated by the tip of the finger or blunt-pointed scissors.

The vessels, which are principally superficial, are clamped and tied as they are encountered, and if there is bleeding from vessels buried in the base it can be controlled by a deep catgut suture passed on a curved needle.



The peritoneal flaps are closed over the denuded surface with fine catgut, and if it seems advisable after removal of the sponge protectives an iodoform-gauze packing is placed in contact with any region where hemorrhage or infection is possible, and the abdominal wound is partially closed around the ends of the gauze. When all goes well this packing is removed after twenty-four or forty-eight hours, and the gap is then closed by a stitch inserted for this purpose at the time of the operation.

### **ABDOMINAL HYSTERECTOMY.<sup>1</sup>**

After rendering the vagina aseptic, the patient is catheterized and placed in Trendelenburg's position and a median incision about eight inches long is made above the pubes and deepened layer by layer till the abdomen is opened. The intestines are covered and pushed back from the pelvis by flat sponges or pads, and the ovarian artery and vessels tied on each side at the free border of the broad ligament. The uterine arteries are next isolated and tied low down near the cervix after recognizing their position by palpation of the broad ligament with the thumb and finger close to the uterus; an opening is made in the posterior (sometimes the anterior) layer of the broad ligament, and an aneurism needle passed about the artery. After the four arteries have been thus secured, the broad ligaments are cut across, and the peritoneal portions of the incisions carried across the front and back of the uterus, in front just above the vesical reflection, and behind at about the level of the internal os. Then by dissecting down with knife or scissors between the uterus and bladder, aided by the finger of an assistant in the vagina, the vagina is reached and opened in the anterior fornix. The peritoneum on the back of the cervix is next dissected down for some distance, and then, with the finger as a guide in the opening in the anterior fornix, the incision is carried around the cervix, and the uterus and appendages thus removed.

<sup>1</sup>Stimson. *Medical News*, July 27, 1889.



Instead of tying the uterine arteries as above described, a long clamp may be placed in the broad ligament below and parallel to the tube after the ovarian artery has been tied (to prevent venous bleeding), the broad ligament cut across below it, and the artery sought for and tied deep between its cut edges. The operation is then continued as above.

(If it is desired to preserve one or both tubes and ovaries, the first ligatures should be placed not about the ovarian arteries but about the tubes close to the uterus, and the broad ligament divided downward beside the uterus.)

After removal of the uterus, the cut edge of the vagina in front and behind is sutured to the corresponding cut edge of the peritoneum, and the sides of the broad ligaments sewed together with a continuous suture; a drain of iodoform gauze is placed in the vagina, part of it extending into the peritoneal cavity and part under the broad ligament, and the anterior abdominal wound is closed.

If the uterus has become greatly altered by the growth of a tumor, no description can be given which is applicable to all cases. The abdomen is opened by a median incision which may have to be prolonged from the symphysis to the ensiform process, and the limits of the bladder, which is apt to be drawn above its usual position, are ascertained by a sound in the urethra if necessary. Adhesions, which may exist between the tumor and any abdominal viscus, are carefully separated or divided between double catgut ligatures, and the mass is gradually lifted out of the belly by a hand placed beneath it, ascertaining its connections and the position of the ovaries, tubes, and the broad ligaments, and the cavity is immediately protected by a sponge packing or warm towels.

It may be possible to follow the formal method of removal already given, but otherwise the enlarged uterus is transfixed below by a couple of pins made for the purpose with guarded points, and under these, which prevent it slipping, an elastic tourniquet or *écraseur* is applied, in-



cluding both broad ligaments, with due regard for the position of the bladder ; frequently a smaller pedicle can be found or must be manufactured, generally by dividing the broad ligaments in sections between double catgut ligatures. The mass distal to the tourniquet is then excised and the cervical canal disinfected by a drop of pure carbolic acid.

If the stump is to be treated extra-peritoneally, it is left in the lower angle of the wound with the tourniquet in place and the pins resting on the surface of the abdomen ; the protective packing with blood clots, etc., is removed ; and the wound is closed in the usual way around the stump, with care to secure peritoneal apposition, if necessary, by sutures below the ligatures.

Sometimes the pins may have to be withdrawn from the stump and the latter fixed at the level of the parietal peritoneum, where it can be retained by a couple of silk sutures through the abdominal wall on each side of the wound, which is then closed above and below around a packing placed in contact with the stump and its edges.

If the pedicle is to be treated by the intra-peritoneal method, the base of the growth is cut in the form of a cone or triangle with its apex in the cervical canal at the level of the rubber tourniquet, and, after disinfecting the canal and securing the open mouths of any vessels in sight, the peritoneal margins of the stump are united with catgut, the tourniquet removed, and deep catgut sutures placed to arrest whatever bleeding follows. The stump is then dropped back into the abdomen, and the latter cleansed, drawing the peritoneum as far as possible over any exposed raw surfaces, and the parietal wound is closed around drainage carried down to the stump, or it is closed tight without drainage.

It is always advisable, when practicable, to place independent catgut ligatures upon the ovarian arteries. Ligatures *en masse* are so apt to slip, and dangerous hemorrhage is so frequent an accident after their use, that if the condition of the patient permit the attempt should always be made to secure vessels on the cut surface of the pedicle and then remove the ligature *en masse*,



**Amputation of the Gravid Uterus.** (PORRO'S OPERATION.)—In a true Porro's operation the foetus is viable and is extracted before the uterus is excised. The abdomen is opened and the foetus removed as described for laparo-hysterotomy, except that the longitudinal direction of the uterine incision is of less consequence. In Müller's modification the parietal incision is made sufficiently long to permit the uterus to be turned out of the abdomen before the child is removed.

After tying the cord the uterus is immediately lifted out of the belly and an elastic ligature or *écraseur* is thrown around the cervix and broad ligaments. The uterus with the ovaries and tubes is then amputated transversely about three-quarters of an inch above the constriction, and the stump is fastened in the lower angle of the wound by a couple of pins transfixing it distal to the ligature and resting on the skin with the points protected. The abdominal cavity is cleansed and the protective sponges are removed and the wound is closed in the usual way around the stump, stitching the edges of the peritoneum with catgut to the uterine peritoneum below the constricting band, though this is not always necessary.

In this, as in similar operations, it is advisable to place two dressings on the wound, the upper to remain undisturbed, while the lower, covering the sloughing pedicle, is changed as often as required.

**Vaginal Hysterectomy.**—The patient is catheterized and placed in the lithotomy position and the external genitals are thoroughly disinfected. The vagina is held open by broad retractors and the uterus is pulled down by volsella forceps grasping the cervix, while the adjoining mucous membrane is cut well clear of the disease by blunt-pointed scissors. Keeping close to the uterus the dissection is continued on its anterior and posterior surface by the tip of the finger and short snips of the scissors, but at the sides, after division of the mucous membrane, the cellular tissue is simply pushed up as high as possible, or till the pulsations of the uterine artery are felt. The finger is finally thrust through the utero-vesical fold of peri-



toneum, and after cleansing the vagina of clots and *débris* flat sponges are poked in around the uterus.

Douglas's pouch is entered in the same manner, controlling the hemorrhage from the vaginal wound by a few catgut sutures through its cut edges, and then the finger is hooked over the fundus, pulling it down into the posterior opening and thus bringing within reach the upper border of the broad ligaments, which are seized by long-bladed clamps and divided on the uterine side. Guided by the finger, other clamps are placed on the remaining tissues close to the uterus, which is then excised.

Injury to the ureters is avoided by thorough separation of the lower lateral cellular tissue early in the operation, the ureters being pressed forward with the anterior layer of the broad ligament. Richelot<sup>1</sup> leaves the clamps in place for twenty-four to forty-eight hours, but whenever possible it is better to secure with a silk ligature, at a proper distance from the clamps, the tissues in the grasp of each before they are severed from the uterus. Then if the adnexa can be separated and drawn down the pedicle of each may be secured with one or more clamps, which can be either left in place or the tissues in their grasp can be ligated with silk and the ovaries and tubes thus excised.

A rubber drainage tube surrounded by iodoform-gauze packing is placed in the vaginal wound and covered by an antiseptic dressing on the vulva.

### AMPUTATION OF CERVIX UTERI.

**Infra-vaginal.**—The cervix may be removed with the bistoury or scissors, the *écraseur*, or the galvano-cautery; flaps may be made and united as shown in Fig. 292. In the latter the cervix is split transversely from below up. The patient is placed in Sims's position, the speculum introduced, the cervix slit transversely, and each lip seized in turn with forceps, and cut off as near the vaginal junction as is considered proper. The mucous membrane of

<sup>1</sup> Annals of Surgery, September, 1893, p. 33.

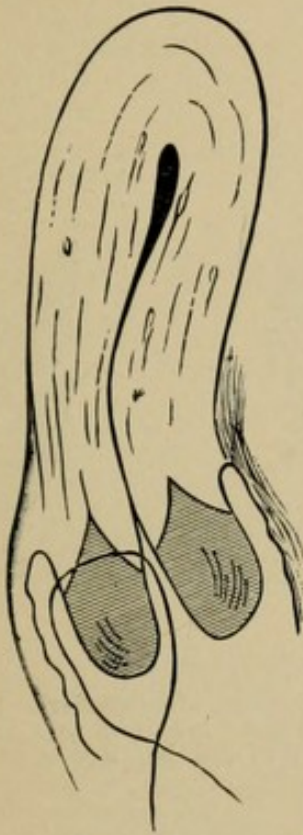

the interior is then drawn down and made fast with silver sutures to the outer edge of the cervix so as to cover in the raw surface. The hemorrhage is often very severe.

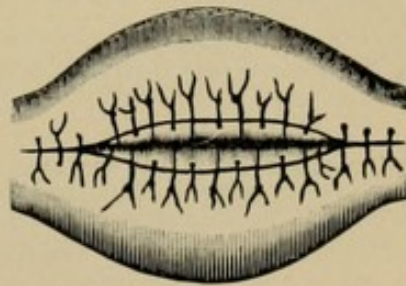
**Supra-vaginal.**—After thorough disinfection of the external and internal genitals the patient is placed in the lithotomy position and the cervix is grasped by a volsella forceps. The mucous membrane around the cervix well

clear of the disease is divided by scissors curved on the flat, and, keeping close to the uterus, the mucous membrane is dissected or peeled off with the left forefinger and the scissors in front and behind, but at the sides, after the first incision of the mucous membrane, the cellular tissue between the broad ligaments is simply pushed aside.

FIG. 292.



A



B

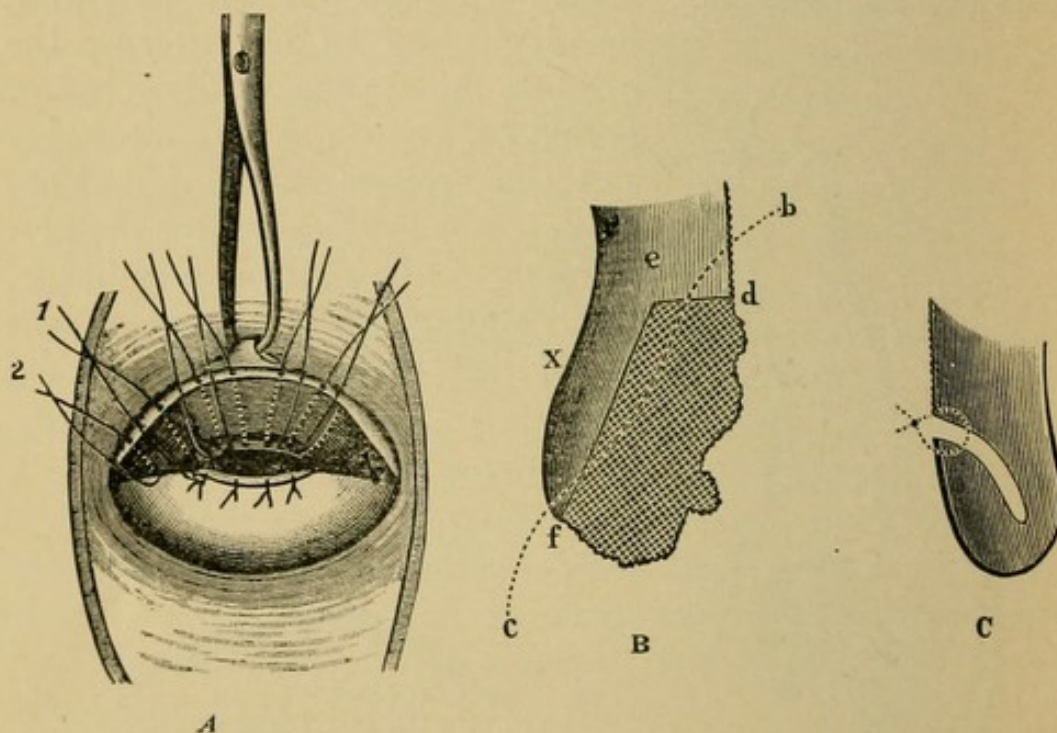
Amputation of the cervix with double flaps. (SIMON.) A. Sectional view showing lines of incision for formation of flaps and method of suture. B. Front view of cervix, operation complete. (POZZI.)

When a point is thus reached in front and behind where the peritoneum ceases to strip up readily, the structures within the broad ligaments are seized by long-bladed clamps close to the uterus and divided on the uterine side. The uterus can then probably be dragged lower, and, with a sound in the canal, the uterine tissue is cut obliquely upward from the exterior to the sound,



while the finger protects the surrounding parts, and in this way the cervix and a considerable portion of the body of the uterus is removed. A packing of iodoform gauze is placed in the vagina in contact with the cut surface, and the clamps are left in place for twenty-four to forty-eight hours, when they can be removed without disturbing the packing.

FIG. 293.



Amputation of cervix by one flap or excision of the mucosa. (Schroeder's operation.) A. Showing method of placing the sutures. (1 and 2 are those uniting the commissures.) B. Section showing shape of incisions (e f) and (b c) line of suture. C. Shows position of flaps after suturing.

**Schroeder's Flap Operation for the Removal of Diseased Cervical Mucous Membrane.**—The cervix is split transversely from below up to the vault of the vagina and the front and back halves thus formed retracted. The mucous membrane and underlying tissue are then removed from the lower part of the cervical canal, as shown in Fig. 293, B, f, e, d. After this the remaining external part of the cervix (Fig. 293, B, X) is folded in and sutured over the raw surface, as illustrated in Fig. 293, A and C. The operation is concluded by uniting the lateral commissures (Fig. 293, A, 1 and 2).



# INDEX.

**A**BDOMEN, operations on, 379  
 paracentesis of, 379  
 Alexander's operation, 572  
 Amputations, 71  
   circular method, 71  
   flap methods, 73  
     Teale, 74, 109  
   oval method, 73  
 Anæsthesia, general, 18  
   local, 17  
   rectal, 20  
 Anastomosis, intestinal, 390  
 Ankle, amputation at, 97  
   excision, 155  
     osteoplastic, 158  
 Antrum, trephining, 213  
 Anus, closure of artificial, 401  
   excision of, 449  
   fistula, 447  
   imperforate, 442  
 Aorta, ligature of abdominal, 56  
 Appendix, removal of vermiform, 402  
 Arm, amputation, 83  
   with scapula, 88  
 Arteries, ligature of, 33  
 Arthrectomy of hip-joint, 150  
 Astragalus, excision, 157, 194  
 Atresia vaginæ, 536  
 Axillary artery, ligature, 43

**B**ASSINI, inguinal hernia, 434  
 Bladder catheterization, 509  
   exstrophy, 507  
   puncture, 511  
   tumors, 528  
 Blepharoplasty, 284  
 Blepharorrhaphy, 283  
 Brachial artery, ligature, 45  
   plexus, 225  
 Brain, topography, 200  
   abscess, 208  
   ventricles, 210  
 Breast, amputation of, 376  
 Broad ligament, tumors of, 569  
 Bronchotomy, 357  
 Buccal nerve, 223

**C**ALCANEUM, excision, 192  
 Canthoplasty, 283  
 Carotid, ligature of common, 50  
   of external, 51  
   of internal, 53  
 Castration, 480  
 Cataract, depression or couching, 310  
   division or solution, 311  
   extraction, 313  
   operations for, 309

Catheterization, female bladder, 533  
   male bladder, 509  
 Cervical glands, 248  
   plexus, 226  
 Cervix, amputation of, 591  
   lacerated, 559  
   posterior section, 561  
 Cheiloplasty, 253  
 Cholecystectomy, 464  
 Cholecystenterostomy, 462  
 Cholecystostomy, 460  
 Chopart's amputation, 94  
 Circumcision, 485  
 Clavicle, excision, 181  
 Cleft palate, 338  
 Coccyx, excision, 188  
 Colostomy, 397  
   left inguinal, 397  
   lumbar, 399  
 Colporrhaphy, 558  
 Corelysis, 308  
 Cornea, operations on, 299  
 Craniectomy, 200  
 Cranium, operations upon, 195  
 Crural nerve, anterior, 229  
 Cystotomy, supra-pubic, 523

**D**ORSALIS pedis, ligature, 67  
 Dressings, preparation of, 26  
 Dupuytren's contraction, 247

**E**AR, operations on, 334  
 Ectopic gestation, 570  
 Ectropion, 284  
 Elbow, amputation at, 80  
   excision, 131  
   of ankylosed, 137  
   reduction of dislocated, 139  
 Elytrorrhaphy, 557  
   posterior, 558  
 Enterorrhaphy, circular, 388  
 Enterostomy, 395  
 Entropion, 291  
 Epispadias, 487  
 Estlander, resection of ribs, 180  
 Eustachian tube, 335  
 Excision of joints and bones, 125  
 Exstrophy of bladder, 507  
 Eye, operations on, 299  
 Eyeball, enucleation, 328  
 Eyelids, plastic operations, 282

**F**ACE, plastic operations, 251  
 Facial artery, ligature, 55  
   nerve, 225  
 Femoral artery, ligature, 62



- Femur, creation of false joint, 150  
 excision of head, 146  
   of shaft, 189  
 division of neck, 151  
 osteotomy, 152, 235  
 Fibula, resection, 190  
 Fifth nerve, extra-cranial resection, 216  
   intra-cranial resection, 213  
 Fingers, amputation, 75  
   Dupuytren's contraction, 247  
   web, 245  
 Fistula in ano, 447  
   salivary, 355  
   urethral, 497  
   vesico-vaginal, 549  
 Foot, amputations, 93, 104  
   excision of bones, 192  
 Forearm, amputation, 79  
 Fracture, operation for ununited, 240  
 Frænum of tongue, 355  
   of penis, 487  
 Frontal sinus, 213
- G**ALL-BLADDER, operations on, 460  
 Gasserian ganglion, 213  
 Gastro-enterostomy, 418  
 Gastroplication, 415  
 Gastrorrhaphy, 414  
 Gastrostomy, 407  
 Gastrotomy, 411  
 Genito-urinary operations in female, 533  
   in male, 480  
 Gigli wire saw, 197  
 Glands, cervical, 248  
 Gluteal artery, ligature, 61  
 Goitre, operations for, 371  
 Gritti, amputation at knee, 113  
 Guyon, amputation of leg, 107
- H**ALLUX valgus, 236  
 Halsted, inguinal hernia, 439  
 Harelip, 263  
   complicated, 267  
   double, 266  
 Hemorrhage, arrest, 20  
 Hemorrhoids, 448  
 Hernia, radical cure of femoral, 440  
   inguinal, 432  
   umbilical, 440  
   strangulated femoral, 428  
   inguinal, 426  
   obturator, 432  
   umbilical, 430  
 Herniotomy, 421  
 Hip, amputation at, 118  
 Hip-joint, excision, 146  
   ankylosis, 150  
 Humerus, resection, 185  
 Hydrocele, 481  
 Hypospadias, 492  
 Hysterectomy, abdominal, 576  
   vaginal, 579  
 Hysteropexy, 571
- I**LIIAC artery, ligature of common, 57  
   of external, 60  
   of internal, 59  
 Innominate artery, ligature, 37
- Inferior dental nerve, 220  
 Inferior thyroid artery, ligature, 42  
 Intestines, anastomosis, 390  
   operations on, 383  
   suture of, 385  
 Iridectomy, 303  
 Iridesis, 307  
 Iridotomy, 303  
 Iris, operations on, 302  
 Ischæmia, artificial, 23
- J**AW, ankylosis of, 178  
 Jejunostomy, 421
- K**ELOTOMY, 421  
 Kidney, methods of exposure, 465  
   operations on, 464  
 Knee, amputation at, 111  
   through the condyles, 112  
   Carden, 112  
   Gritti, 113  
   disarticulation, 111  
   excision, 153  
 Kolpoplexis, 556  
 Kraske, excision of rectum, 453
- L**ACHRYMAL apparatus, 329  
 gland, removal, 329  
 sac and duct, 330  
 Laminectomy, 242  
 Laparo-hysterotomy, 573  
 Laparotomy, 380  
 Laryngectomy, 364  
 Laryngotomy, 357  
   cricothyroid, 359  
   thyroid, 358  
 Laryngotracheotomy, 360  
 Leg, amputation, 105-110  
 Ligature of arteries, 33  
 Lingual artery, ligature, 54  
   nerve, 224  
 Lips, plastic operations, 253-267  
 Lisfranc's amputation, 93  
 Litholapaxy, 511  
 Lithotomy, 516  
   lateral, 517  
   median, 521  
   supra-pubic, 523  
   in female, 535  
 Liver, operations on, 456  
   abscess of, 457  
   hydatids of, 459
- M**ASTOID cells, 336  
 Maxilla, inferior, ankylosis, 178  
   excision, 173  
   superior, excision, 161  
   partial, 166, 167, 168  
   temporary, 168  
 McBurney, appendix, 404  
   inguinal hernia, 439  
 Median nerve, 228  
 Medio-tarsal amputation, 94  
 Metacarpal bone, amputation, 77  
   excision, 187  
 Metatarsal bone, amputation, 91  
   excision, 195



Mikulicz, excision of heel, 158  
Mouth, operation on, 337  
Musculospiral nerve, 229  
Myomectomy, 575

**N**ASO-PHARYNGEAL polyp, 168, 172  
Neck, operations on, 357  
Nephrectomy, abdominal, 472  
lumbar, 471  
Nephrolithotomy, 469  
Nephropexy, 474  
Nephrotomy, 469  
Neurorrhaphy, 230  
Neurotomy, 215  
Nose, plastic operations, 268

**O**CCIPITAL artery, ligature, 56  
Oesophagotomy, 368  
Olecranon, suture, 242  
Oöphorectomy, 566  
Operation, preparation for, 26  
Orbit, extirpation of, 329  
Osteotomy, 235  
cuneiform, for talipes, 237  
for hallux valgus, 236  
Ovariectomy, 564

**P**ALATE, cleft, 338  
Patella, suture of, 241  
Paracentesis, abdomen, 379  
thorax, 377  
pericardium, 378  
Paraphymosis, 487  
Pelvis, resection of bones, 188  
Penis, amputation of, 484  
Pericardium, paracentesis, 378  
Perineorrhaphy, 537  
Hegar, 541  
Perineum, laceration, 543, 546  
Phalanges, contraction of, 246  
excision, 187, 195  
Pharynx, access to, 168-173  
Phimosis, 485  
Pharyngotomy, 366  
subhyoid, 357  
Pirogoff, amputation at ankle, 101  
Plastic operations, 251  
eyelids, 282  
face, 251  
lip, 253  
nose, 268  
Popliteal artery, ligature, 65  
nerve, 229  
Pott's fracture, reduction of old, 160  
Preparation for operation, 26, 29  
Prostatectomy, 526  
Pterygion, 296  
Pudic artery, ligature, 61  
Pylorotomy, 416  
Pyloroplasty, 414  
Pylorus, stricture of, 412

**R**ADIAL artery, ligature, 47  
Radius, excision, 186  
Ranula, 355  
Rectopexy, 446  
Rectum, excision, 449

Rectum, operations on, 441  
prolapse, 444  
Rhinoplasty, 268  
Ribs, resection, 180  
Round ligaments, shortening, 572  
Roux, amputation at ankle, 100

**S**ALPINGECTOMY, 567  
Salpingo-oöphorectomy, 567  
Scapula, excision, 182  
Seminal vesicles, removal, 530  
Sciatic artery, ligature, 61  
nerve, 229  
Senn, amputation at hip, 123  
Shoulder, amputation at, 83  
excision of, 128  
Sinus, frontal, 213  
lateral, 207  
Skin-grafting, 243  
Spinal accessory nerve, 226  
Splenectomy, 465  
Sponges, preparation of, 26  
Staphylorrhaphy, 338  
Sterilization, 28  
Sterno-cleido-mastoid, 232  
Sternum, resection of, 180  
Stomach, operations on, 405  
Strabismus, operation for, 325  
Subastragaloid amputation, 96  
Subclavian artery, ligature, 39  
Superior thyroid artery, ligature, 41  
maxillary nerve, 217  
Supraclavicular region, 35  
Supraorbital nerve, 215  
Suprapubic cystotomy, 523  
Sutures, 25  
Symblepharon, 294  
Syme, amputation at ankle, 97  
Symphysiotomy, 574

**T**ALIPES, osteotomy, 237  
Tarso-metatarsal amputation, 93  
Temporal artery, ligature of, 56  
Tendo Achillis, 231  
Tenorrhaphy, 232  
Tenotomy, 230  
Thiersch, skin-grafting, 243  
Thigh, amputation, 115  
Thorax, operations on, 376  
paracentesis, 377  
Thyroid artery, ligature of inferior, 42  
superior, 41  
gland, operations, 371  
Tibia, resection, 189  
Tibial artery, ligature of anterior, 65  
posterior, 67  
Tibialis anticus, 232  
posticus, 231  
Toenail, ingrown, 247  
Toes, amputation, 90  
Tongue, excision, 349  
Kocher, 352  
Tonsils, amputation, 337  
Torticollis, 227  
Tracheotomy, 361  
Trephining, cranium, 195  
omega flap, 199  
for abscess, 208  
for hemorrhage, 211



Trephining to reach cerebellum, 210  
Trichiasis, 297  
Tympanum, paracentesis, 334


**U** LNA, excision, 186  
Ulnar artery, ligature, 49  
    nerve, 228  
Uranoplasty, 345  
Ureter, operations on, 474  
    wounds of, 477  
Uretero-ureterostomy, 478  
Urethral fistula, 497  
Urethroplasty, 499  
Urethrorrhaphy, 498  
Urethrotomy, external, 503, 533  
    internal, 502  
Uterus, amputation of gravid, 579  
    of cervix, 580  
    laceration of cervix, 559  
    prolapse of, 557, 571  
    removal of, 576, 579

Uterus, removal of mucosa, 582  
    tumors of, 575


**V** AGINA, atresia of, 536  
    narrowing of, 557  
    obliteration of, 556  
    prolapse of posterior wall, 538  
Varicocele, 482  
Ventricles, puncture of, 210  
Vermiform appendix, 402  
Vertebral artery, ligature, 43  
Vesico-vaginal fistula, 549  
    creation, 554  
Vesicles, removal of seminal, 530

**W** EB-FINGERS, 245  
    Wrist, amputation at, 78  
    excision of, 140  
Wound, its treatment, 29  
Wry-neck, 227











# CATALOGUE OF PUBLICATIONS OF LEA BROTHERS & COMPANY,

706, 708 & 710 Sansom St., Philadelphia.  
111 Fifth Ave. (Cor. 18th St.), New York.

The books in the annexed list will be sent by mail, post-paid, to any Post-Office in the United States, on receipt of the printed prices.

## INDEX.

- ANATOMY.** Gray, p. 11 ; Treves, 30 ; Gerrish, 11 ; Brockway, 4.  
**DICTIONARIES.** Dunglison, p. 8 ; Duane, 8 ; National, 4.  
**PHYSICS.** Draper, p. 8 ; Robertson, 24 ; Martin & Rockwell, 20.  
**PHYSIOLOGY.** Foster, p. 10 ; Chapman, 5 ; Schofield, 25 ; Collins & Rockwell, 6. [Luff, 19 ; Remsen, 24.  
**CHEMISTRY.** Simon, p. 26 ; Attfield, 3 ; Martin & Rockwell, 20 ;  
**PHARMACY.** Caspari, p. 5. [Bruce, 4 ; Schleif, 25.  
**MATERIA MEDICA.** Culbreth, p. 6 ; Maisch, 19 ; Farquharson, 9 ;  
**DISPENSATORY.** National, p. 21.  
**THERAPEUTICS.** Hare, p. 13 ; Fothergill, 10 ; Whitla, 31 ; Hayem & Hare, 14 ; Bruce, 4 ; Schleif, 25 ; Cushny, 6.  
**PRACTICE.** Flint, p. 9 ; Loomis & Thompson, 19 ; Malsbary, 20.  
**DIAGNOSIS.** Musser, p. 21 ; Hare, 12 ; Simon, 25 ; Herrick, 15 ; Hutchison & Rainey, 16 ; Collins, 6.  
**CLIMATOLOGY.** Solly, p. 26 ; Hayem & Hare, 14.  
**NERVOUS DISEASES.** Dercum, p. 7 ; Gray, 11 ; Potts, 23.  
**MENTAL DISEASES.** Clouston, p. 5 ; Savage, 24 ; Folsom, 10.  
**BACTERIOLOGY.** Abbott, p. 2 ; Vaughan & Novy, 30 ; Senn's (Surgical), 25. Park, 22 ; Coates, 6. [Vale, 21.  
**HISTOLOGY.** Klein, p. 17 ; Schafer's, 25 ; Dunham, 8 ; Nichols &  
**PATHOLOGY.** Green, p. 12 ; Gibbes, 10 ; Coats, 6 ; Nichols & Vale, 21.  
**SURGERY.** Park, p. 22 ; Dennis, 7 ; Roberts, 24 ; Ashhurst, 3 ; Treves, 29 ; Cheyne & Burghard, 5 ; Gallaudet, 10.  
**SURGERY—OPERATIVE.** Stimson, p. 27 ; Smith, 26 ; Treves, 29.  
**SURGERY—ORTHOPEDIC.** Young, p. 31 ; Gibney, 10.  
**SURGERY—MINOR.** Wharton, p. 30. [Ballenger &  
**FRACTURES and DISLOCATIONS.** Stimson, p. 27. [Wippert, 3.  
**OPHTHALMOLOGY.** Norris & Oliver, p. 21 ; Nettleship, 21 ; Juler, 17 ;  
**OTOLOGY.** Politzer, p. 23 ; Burnett, 5 ; Field, 9 ; Bacon, 4.  
**LARYNGOLOGY and RHINOLOGY.** Coakley, p. 6 ;  
**DENTISTRY.** Essig (Prosthetic), p. 9 ; Kirk (Operative), 17 ; American System, 2 ; Coleman, 6 ; Burchard, 4.  
**URINARY DISEASES.** Roberts, p. 24 ; Black, 4.  
**VENEREAL DISEASES.** Taylor, p. 28 ; Hayden, 14 ; Cornil, 6 ;  
**SEXUAL DISORDERS.** Fuller, p. 10 ; Taylor, 29. [Likes, 19.  
**DERMATOLOGY.** Hyde, p. 16 ; Jackson, 16 ; Pye-Smith, 24 ; Morris, 20 ; Jamieson, 16 ; Hardaway, 12 ; Grindon, 12.  
**GYNECOLOGY.** American System, p. 3 ; Thomas & Mundé, 29 Emmet, 9 ; Davenport, 7 ; May, 20 ; Dudley, 8 ; Crockett, 6.  
**OBSTETRICS.** American System, p. 3 ; Davis, 7 ; Parvin, 22 ; Playfair, 23 ; King, 17 ; Jewett, 17 ; Evans, 9.  
**PEDIATRICS.** Smith, p. 26 ; Thomson, 29 ; Williams, 31 ; Tuttle, 30.  
**HYGIENE.** Egbert, p. 9 ; Richardson, 24 ; Coates, 6.  
**MEDICAL JURISPRUDENCE.** Taylor, p. 28.  
**QUIZ SERIES, POCKET TEXT-BOOKS and MANUALS.**  
 Pp. 18, 25 and 27.



**ABBOTT (A. C.). PRINCIPLES OF BACTERIOLOGY:** a Practical Manual for Students and Physicians. New (5th) edition thoroughly revised and greatly enlarged. In one handsome 12mo. vol. of 585 pages, with 109 engrav., of which 26 are colored. *Just ready.* Cloth, \$2.75, *net.*

One of its most attractive characteristics is that the directions are so clearly given that anyone with a moderate amount of laboratory training can, with a little care as to detail, make his experiments suc-

cessfully. To those who require a condensed yet nevertheless complete work upon Bacteriology we most cordially recommend it.—*The Therapeutic Gazette.*

**AMERICAN SYSTEM OF PRACTICAL MEDICINE.** A SYSTEM OF PRACTICAL MEDICINE. In contributions by Various American Authors. Edited by ALFRED L. LOOMIS, M.D., LL.D., and W. GILMAN THOMPSON, M.D. In four very handsome octavo volumes of about 900 pages each, fully illustrated. *Complete work now ready.* Per volume, cloth, \$5; leather, \$6; half Morocco, \$7. *For sale by subscription only.* Prospectus free on application.

Every chapter is a masterpiece of completeness, and is particularly excellent in regard to treatment, many original prescriptions, formulæ, charts and tables being given for the guidance of the practitioner.

"The American System of Medi-

cine" is a work of which every American physician may reasonably feel proud, and in which every practitioner will find a safe and trustworthy counsellor in the daily responsibilities of practice.—*The Ohio Medical Journal.*

**AMERICAN SYSTEM OF DENTISTRY.** In treatises by various authors. Edited by WILBUR F. LITCH, M.D., D.D.S. In three very handsome super-royal octavo volumes, containing about 3200 pages, with 1873 illustrations and many full-page plates. Per vol., cloth, \$6; leather, \$7; half Morocco, \$8. *For sale by subscription only.* Prospectus free on application to the Publishers.

**AMERICAN TEXT-BOOKS OF DENTISTRY.** In Contributions by Eminent American Authorities. In two very handsome octavo volumes, richly illustrated:

**PROSTHETIC DENTISTRY.** Edited by CHARLES J. ESSIG, M.D., D.D.S., Professor of Mechanical Dentistry and Metallurgy, Department of Dentistry, University of Pennsylvania, Philadelphia. 760 pages, 983 engravings. Cloth, \$6; leather, \$7. *Net.*

No more thorough production will be found either in this country or in any country where dentistry is understood as a part of civilization.—*The International Dental Journal.*

It is up to date in every particular. It is a practical course on prosthetics which any student can take up during or after college.—*Dominion Dental Journal.*

**OPERATIVE DENTISTRY.** Edited by EDWARD C. KIRK, D.D.S., Professor of Clinical Dentistry, Department of Dentistry, University of Pennsylvania. 699 pages, 751 engravings. Cloth, \$5.50; leather, \$6.50. *Net. Just ready.*

Written by a number of practitioners as well known at the chair as in journalistic literature, many of them teachers of eminence in our colleges. It should be included in the list of text-books set down as most useful to the college student.—*The Dental News.*

It is replete in every particular and treats the subject in a progressive manner. It is a book that every progressive dentist should possess, and we can heartily recommend it to the profession.—*The Ohio Dental Journal.*



**AMERICAN SYSTEMS OF GYNECOLOGY AND OBSTETRICS.**

In treatises by the most eminent American specialists. Gynecology edited by MATTHEW D. MANN, A. M., M. D., and Obstetrics edited by BARTON C. HIRST, M. D. In four large octavo volumes comprising 3612 pages, with 1092 engravings, and 8 colored plates. Per volume, cloth, \$5; leather, \$6; half Russia, \$7. *For sale by subscription only.* Prospectus free on application to the Publishers.

**AMERICAN TEXT-BOOK OF ANATOMY.** See *Gerrish*, page 11.

**ALLEN (HARRISON).** A SYSTEM OF HUMAN ANATOMY; WITH AN INTRODUCTORY SECTION ON HISTOLOGY, by E. O. SHAKESPEARE, M. D. Comprising 813 double-columned quarto pages, with 380 engravings on stone, 109 plates, and 241 wood cuts in the text. In six sections, each in a portfolio. Price per section, \$3.50. Also, bound in one volume, cloth, \$23. *Sold by subscription only.*

**A PRACTICE OF OBSTETRICS BY AMERICAN AUTHORS.** See *Jewett*, page 17.

**A TREATISE ON SURGERY BY AMERICAN AUTHORS.** FOR STUDENTS AND PRACTITIONERS OF SURGERY AND MEDICINE. Edited by ROSWELL PARK, M. D. See page 22.

**ASHHURST (JOHN, JR.).** THE PRINCIPLES AND PRACTICE OF SURGERY. For the use of Students and Practitioners. Sixth and revised edition. In one large and handsome octavo volume of 1161 pages, with 656 engravings. Cloth, \$6; leather, \$7.

As a masterly epitome of what has been said and done in surgery, as a succinct and logical statement of the principles of the subject, as a model text-book, we do not know its equal. It is the best single text-book of surgery that we have yet seen in this country.—*New York Post-Graduate.*

**A SYSTEM OF PRACTICAL MEDICINE BY AMERICAN AUTHORS.** Edited by WILLIAM PEPPER, M. D., LL. D. In five large octavo volumes, containing 5573 pages and 198 illustrations. Price per volume, cloth, \$5; leather \$6; half Russia, \$7. *Sold by subscription only.* Prospectus free on application to the Publishers.

**ATTFIELD (JOHN).** CHEMISTRY; GENERAL, MEDICAL AND PHARMACEUTICAL. New (16th) edition, specially revised by the Author for America. In one handsome 12mo. volume of 784 pages, with 88 illustrations. Cloth, \$2.50, *net*.

It is replete with the latest information, and considers the chemistry of every substance recognized officially or in general practice. The modern scientific chemical nomenclature has been adopted, bringing the work into close touch with the latest *United States Pharmacopœia*, of which it is a worthy companion.—*The Pittsburg Medical Review.*

**BALLENGER (W. L.) AND WIPPERN (A. G.).** *Shortly.* A POCKET TEXT-BOOK OF DISEASES OF THE EYE, EAR, NOSE AND THROAT. In one handsome 12mo. volume of about 400 pages, with many illustrations. *Lea's Series of Pocket Text-books*, edited by BERN B. GALLAUDET, M. D. See p. 18.

**BARNES (ROBERT AND FANCOURT).** A SYSTEM OF OBSTETRIC MEDICINE AND SURGERY. Octavo, 372 pages, with 231 illus. Cloth, \$5; leather, \$6.



**BACON (GORHAM).** ON THE EAR. One 12mo. volume, 400 pages, 109 engravings and a colored plate. Cloth, *net*, \$2.00. *Just ready.*

It is *the best* manual upon otology. | dents of medicine.—*Cleveland Jour-*  
An intensely practical book for stu- | *nal of Medicine.*

**BARTHOLOW (ROBERTS).** CHOLERA; ITS CAUSATION, PREVENTION AND TREATMENT. In one 12mo. volume of 127 pages, with 9 illustrations. Cloth, \$1.25.

**BARTHOLOW (ROBERTS).** MEDICAL ELECTRICITY. A PRACTICAL TREATISE ON THE APPLICATIONS OF ELECTRICITY TO MEDICINE AND SURGERY. Third edition. In one octavo volume of 308 pages, with 110 illustrations.

**BILLINGS (JOHN S.).** THE NATIONAL MEDICAL DICTIONARY. Including in one alphabet English, French, German, Italian and Latin Technical Terms used in Medicine and the Collateral Sciences. In two very handsome imperial octavo volumes containing 1574 pages and two colored plates. Per volume, cloth, \$6; leather, \$7; half Morocco, \$8.50. *For sale by subscription only.* Specimen pages on application to the publishers.

**BLACK (D. CAMPBELL).** THE URINE IN HEALTH AND DISEASE, AND URINARY ANALYSIS, PHYSIOLOGICALLY AND PATHOLOGICALLY CONSIDERED. In one 12mo. volume of 256 pages, with 73 engravings. Cloth, \$2.75.

A concise, yet complete manual, | Concise, practical, clinical, well  
treating of the subject from a prac- | illustrated and well printed.—*Mary-*  
tical and clinical standpoint.—*The* | *land Medical Journal.*  
*Ohio Medical Journal.*

**BLOXAM (C. L.).** CHEMISTRY, INORGANIC AND ORGANIC. With Experiments. New American from the fifth London edition. In one handsome octavo volume of 727 pages, with 292 illustrations. Cloth, \$2; leather, \$3.

**BROCKWAY (F. J.).** A POCKET TEXT-BOOK OF ANATOMY. In one handsome 12mo. volume of about 400 pages, with many illustrations. *Shortly.* *Lea's Series of Pocket Text-books*, edited by BERN B. GALLAUDET, M. D. See page 18.

**BRUCE (J. MITCHELL).** MATERIA MEDICA AND THERAPEUTICS. New (6th) edition. In one 12mo. volume of 600 pages. *Just ready.* Cloth, \$1.50, *net.* See *Student's Series of Manuals*, page, 27.

— PRINCIPLES OF TREATMENT. In one octavo volume. *Preparing.*

**BRYANT (THOMAS).** THE PRACTICE OF SURGERY. Fourth American from the fourth English edition. In one imperial octavo vol. of 1040 pages, with 727 illustrations. Cloth, \$6.50; leather, \$7.50.

**BURCHARD (HENRY H.).** DENTAL PATHOLOGY AND THERAPEUTICS. Handsome octavo, 575 pages, with 400 illustrations. Cloth, *net*, \$5.00; leather, *net*, \$6.00.



**BURNETT (CHARLES H.).** THE EAR: ITS ANATOMY, PHYSIOLOGY AND DISEASES. A Practical Treatise for the Use of Students and Practitioners. Second edition. In one 8vo. volume of 580 pages, with 107 illustrations. Cloth, \$4; leather, \$5.

**CARTER (R. BRUDENELL) AND FROST (W. ADAMS).** OPHTHALMIC SURGERY. In one pocket-size 12mo. volume of 559 pages, with 91 engravings and one plate. Cloth, \$2.25. See *Series of Clinical Manuals*, page 25.

**CASPARI (CHARLES JR.).** A TREATISE ON PHARMACY. For Students and Pharmacists. In one handsome octavo volume of 680 pages, with 288 illustrations. Cloth, \$4.50.

The author's duties as Professor of Theory and Practice of Pharmacy in the Maryland College of Pharmacy, and his contact with students made him aware of their exact wants in the matter of a manual. His work is admirable, and the student who cannot understand must be dull indeed. The book is full of new, clean, sharp illustrations, which tell the story frequently at a glance. The index is full and accurate.—*National Druggist*.

**CHAPMAN (HENRY C.).** A TREATISE ON HUMAN PHYSIOLOGY. New (2d) edition. In one octavo volume of 921 pages, with 595 illustrations. *Just ready*. Cloth, \$4.25; leather, \$5.25, *net*.

In every respect the work fulfils its promise, whether as a complete treatise for the student or as an admirable work of reference for the physician.—*North Carolina Medical Journal*.

**CHARLES (T. CRANSTOUN).** THE ELEMENTS OF PHYSIOLOGICAL AND PATHOLOGICAL CHEMISTRY. Octavo, 451 pages, with 38 engravings and 1 colored plate. Cloth, \$3.50.

**CHEYNE (W. WATSON).** THE TREATMENT OF WOUNDS, ULCERS AND ABSCESES. In one 12mo. volume of 207 pages. Cloth, \$1.25.

One will be surprised at the amount of practical and useful information it contains; information that the practitioner is likely to need at any moment. The sections devoted to ulcers and abscesses are indispensable to any physician.—*The Charlotte Medical Journal*.

**CHEYNE (W. W.) AND BURGHARD (F. F.).** SURGICAL TREATMENT. In six octavo volumes, illustrated. *Now ready*. Volume 1, 299 pages and 66 engravings. Cloth, \$3.00 *net*. Volume 2, 382 pages, 141 engravings. Cloth, \$4.00 *net*.

**CLARKE (W. B.) AND LOCKWOOD (C. B.).** THE DISSECTOR'S MANUAL. In one 12mo. volume of 396 pages, with 49 engravings. Cloth, \$1.50. See *Students' Series of Manuals*, page 27.

**CLELAND (JOHN).** A DIRECTORY FOR THE DISSECTION OF THE HUMAN BODY. In one 12mo. vol. of 178 pages. Cloth, \$1.25.

**CLINICAL MANUALS.** See *Series of Clinical Manuals*, page 25.

**CLOUSTON (THOMAS S.).** CLINICAL LECTURES ON MENTAL DISEASES. New (5th) edition. In one octavo volume of 750 pages, with 19 colored plates. Cloth, \$4.25, *net*. *Just ready*.

*Dr. FOLSOM'S Abstract of Laws of U. S. on Custody of Insane*, octavo, \$1.50, is sold in conjunction with *Clouston on Mental Diseases* for \$5.00, *net*, for the two works.



- CLOWES (FRANK).** AN ELEMENTARY TREATISE ON PRACTICAL CHEMISTRY AND QUALITATIVE INORGANIC ANALYSIS. From the fourth English edition. In one handsome 12mo. volume of 387 pages, with 55 engravings. Cloth, \$2.50.
- COAKLEY (CORNELIUS G.).** THE DIAGNOSIS AND TREATMENT OF DISEASES OF THE NOSE, THROAT, NASOPHARYNX AND TRACHEA. In one 12mo. volume of 526 pages with 92 engravings and 2 colored plates. *Just ready.* Cloth, \$2.75. *net.*
- COATES (W. E., JR.).** A POCKET TEXT-BOOK OF BACTERIOLOGY AND HYGIENE. In one handsome 12mo. volume of about 350 pages, with many illustrations. *Shortly.* *Lea's Series of Pocket Text-books*, edited by BERN B. GALLAUDET, M. D. See page 18.
- COATS (JOSEPH).** A TREATISE ON PATHOLOGY. In one vol. of 829 pages, with 339 engravings. Cloth, \$5.50; leather, \$6.50.
- COLEMAN (ALFRED).** A MANUAL OF DENTAL SURGERY AND PATHOLOGY. With Notes and Additions to adapt it to American Practice. By THOS. C. STELLWAGEN, M.A., M.D., D.D.S. In one handsome octavo vol. of 412 pages, with 331 engravings. Cloth, \$3.25.
- COLLINS (C. P.).** A POCKET TEXT-BOOK OF MEDICAL DIAGNOSIS. In one handsome 12mo. volume of about 350 pages, with many illustrations. *Shortly.* *Lea's Series of Pocket Text-books*, edited by BERN B. GALLAUDET, M. D. See page 18.
- COLLINS (H. D.) AND ROCKWELL (W. H.).** A POCKET TEXT-BOOK OF PHYSIOLOGY. 12mo. of 316 pages, with 153 illustrations. *Just ready.* Cloth, \$1.50; flexible red leather, \$2.00, *net.* *Lea's Series of Pocket Text-books*, edited by BERN B. GALLAUDET, M. D. See page 18.
- CONDIE (D. FRANCIS).** A PRACTICAL TREATISE ON THE DISEASES OF CHILDREN. Sixth edition, revised and enlarged. In one large 8vo. volume of 719 pages. Cloth, \$5.25; leather, \$6.25.
- CORNIL (V.).** SYPHILIS: ITS MORBID ANATOMY, DIAGNOSIS AND TREATMENT. Translated, with Notes and Additions, by J. HENRY C. SIMES, M.D. and J. WILLIAM WHITE, M.D. In one 8vo. volume of 461 pages, with 84 illustrations. Cloth, \$3.75.
- CROCKETT (M. A.).** A POCKET TEXT-BOOK OF DISEASES OF WOMEN. In one handsome 12mo. volume of about 350 pages, with many illustrations. *Shortly.* *Lea's Series of Pocket Text-books*, edited by BERN B. GALLAUDET, M. D. See page 18.
- CROOK (JAMES K.)** ON MINERAL WATERS OF THE UNITED STATES. Octavo, 575 pages. *Just ready.* Cloth, \$3.50, *net.*
- CULBRETH (DAVID M. R.).** MATERIA MEDICA AND PHARMACOLOGY. In one handsome octavo volume of 812 pages, with 445 illustrations. Cloth, \$4.75.
- CUSHNY (ARTHUR R.).** TEXT-BOOK OF PHARMACOLOGY. Handsome 8vo., 728 pages, with 47 illus. *Just ready.* Cloth, \$3.75, *net.*



**DALTON (JOHN C.).** A TREATISE ON HUMAN PHYSIOLOGY. Seventh edition. Octavo, 722 pages, with 252 engravings. Cloth, \$5; leather, \$6.

— DOCTRINES OF THE CIRCULATION OF THE BLOOD. In one handsome 12mo. volume of 293 pages. Cloth, \$2.

**DAVENPORT (F. H.).** DISEASES OF WOMEN. A Manual of Gynecology. For the use of Students and Practitioners. New (3d) edition. In one handsome 12mo. volume of 387 pages, with 150 illustrations. Cloth, \$1.75, *net*. *Just ready*.

**DAVIS (EDWARD P.).** A TREATISE ON OBSTETRICS. FOR STUDENTS AND PRACTITIONERS. In one very handsome octavo volume of 546 pages, with 217 engravings and 30 full-page plates in colors and monochrome. Cloth, \$5; leather, \$6.

From a practical standpoint the work is all that could be desired. A thoroughly scientific and brilliant treatise on obstetrics.—*Med. News*.

**DAVIS (F. H.).** LECTURES ON CLINICAL MEDICINE. Second edition. In one 12mo. volume of 287 pages. Cloth, \$1.75.

**DE LA BECHE'S** GEOLOGICAL OBSERVER. In one large octavo volume of 700 pages, with 300 engravings. Cloth, \$4.

**DENNIS (FREDERIC S.) AND BILLINGS (JOHN S.).** A SYSTEM OF SURGERY. In contributions by American Authors. Complete work in four very handsome octavo volumes, containing 3652 pages, with 1585 engravings and 45 full-page plates in colors and monochrome. Per volume, cloth, \$6.00; leather, \$7.00; half Morocco, gilt back and top, \$8.50. *For sale by subscription only*. Full prospectus free on application to the publishers.

It is worthy of the position which surgery has attained in the great Republic whence it comes.—*The London Lancet*.

It may be fairly said to represent the most advanced condition of American surgery and is thoroughly practical.—*Annals of Surgery*.

No work in English can be considered as the rival of this.—*The American Journal of the Medical Sciences*.

**DERCUM (FRANCIS X., EDITOR).** A TEXT-BOOK ON NERVOUS DISEASES. By American Authors. In one handsome octavo volume of 1054 pages, with 341 engravings and 7 colored plates. Cloth, \$6.00; leather, \$7.00. *Net*.

Representing the actual status of our knowledge of its subjects, and the latest and most fully up-to-date of any of its class.—*Jour. of American Med. Association*.

The most thoroughly up-to-date treatise that we have on this subject.—*American Journal of Insanity*.

The work is representative of the best methods of teaching, as developed in the leading medical colleges of this country.—*Alienist and Neurologist*.

The best text-book in any language.—*The Medical Fortnightly*.

**DE SCHWEINITZ (GEORGE E.).** THE TOXIC AMBLYOPIAS. Their Classification, History, Symptoms, Pathology and Treatment. Very handsome octavo, 240 pages, 46 engravings, and 9 full-page plates in colors. Limited edition, de luxe binding, \$4. *Net*.



**DRAPER (JOHN C.).** MEDICAL PHYSICS. A Text-book for Students and Practitioners of Medicine. In one handsome octavo volume of 734 pages, with 376 engravings. Cloth, \$4.

**DRUITT (ROBERT).** THE PRINCIPLES AND PRACTICE OF MODERN SURGERY. A new American, from the twelfth London edition, edited by STANLEY BOYD, F.R.C.S. In one large octavo volume of 965 pages, with 373 engravings. Cloth, \$4; leather, \$5.

**DUANE (ALEXANDER).** THE STUDENT'S DICTIONARY OF MEDICINE AND THE ALLIED SCIENCES. New edition. Comprising the Pronunciation, Derivation and Full Explanation of Medical Terms, with much Collateral Descriptive Matter, Numerous Tables, etc. Square octavo of 658 pages. Cloth, \$3.00; half leather, \$3.25; full sheep, \$3.75. Thumb-letter Index, 50 cents extra.

**DUDLEY (E. C.).** THE PRINCIPLES AND PRACTICE OF GYNECOLOGY. New (2d) edition. Handsome octavo of 717 pages, with 453 illustrations in black and colors, and 8 colored plates. Cloth, \$5.00, *net*; leather, \$6.00, *net*. *Just ready.*

The book can be safely recommended as a complete and reliable exposition of the principles and practice of modern gynecology.—*International Medical Magazine.*

**DUNCAN (J. MATTHEWS).** CLINICAL LECTURES ON THE DISEASES OF WOMEN. Delivered in St. Bartholomew's Hospital. In one octavo volume of 175 pages. Cloth, \$1.50.

**DUNGLISON (ROBLEY).** A DICTIONARY OF MEDICAL SCIENCE. Containing a full explanation of the various subjects and terms of Anatomy, Physiology, Medical Chemistry, Pharmacy, Pharmacology, Therapeutics, Medicine, Hygiene, Dietetics, Pathology, Surgery, Ophthalmology, Otology, Laryngology, Dermatology, Gynecology, Obstetrics, Pediatrics, Medical Jurisprudence, Dentistry, etc., etc. By ROBLEY DUNGLISON, M. D., LL. D., late Professor of Institutes of Medicine in the Jefferson Medical College of Philadelphia. Edited by RICHARD J. DUNGLISON, A. M., M. D. Twenty-first edition, thoroughly revised and greatly enlarged and improved, with the Pronunciation, Accentuation and Derivation of the Terms. With Appendix. In one magnificent imperial octavo volume of 1225 pages. Cloth, \$7; leather, \$8. Thumb-letter Index for quick use, 75 cents extra.

The most satisfactory and authoritative guide to the derivation, definition and pronunciation of medical terms.—*The Charlotte Med. Journal.*

Covering the entire field of medicine, surgery and the collateral sciences, its range of usefulness can

scarcely be measured.—*Med. Record.*

Pronunciation is indicated by the phonetic system. The definitions are unusually clear and concise. The book is wholly satisfactory.—*University Medical Magazine.*

**DUNHAM (EDWARD K.).** MORBID AND NORMAL HISTOLOGY. Octavo, 450 pages, with 363 illustrations. Cloth, \$3.25, *net*.

The best one-volume text or reference book on histology that we know of published in America.—*Virginia Medical Semi-Monthly.*

**EDES (ROBERT T.).** TEXT-BOOK OF THERAPEUTICS AND MATERIA MEDICA. In one 8vo. volume of 544 pages. Cloth, \$3.50; leather, \$4.50.

**EDIS (ARTHUR W.).** DISEASES OF WOMEN. A Manual for Students and Practitioners. In one handsome 8vo. volume of 576 pages, with 148 engravings. Cloth, \$3; leather, \$4.



**EGBERT (SENECA).** A MANUAL OF HYGIENE AND SANITATION. In one 12mo. volume of 359 pages, with 63 illustrations. *Just ready.* Cloth, *Net*, \$2.25.

It is written in plain language, and, while primarily designed for physicians, it can be studied with profit by any one of ordinary intelligence. The writer has adapted it to American conditions, and his suggestions are, above all, practical. —*The New York Medical Journal.*

**ELLIS (GEORGE VINER).** DEMONSTRATIONS IN ANATOMY. Eighth edition. Octavo, 716 pages, with 249 engravings. Cloth, \$4.25; leather, \$5.25.

**EMMET (THOMAS ADDIS).** THE PRINCIPLES AND PRACTICE OF GYNÆCOLOGY. Third edition. Octavo, 880 pages, with 150 original engravings. Cloth, \$5; leather, \$6.

**ERICHSEN (JOHN E.).** THE SCIENCE AND ART OF SURGERY. Eighth edition. In two large octavo volumes containing 2316 pages, with 984 engravings. Cloth, \$9; leather, \$11.

**ESSIG (CHARLES J.).** PROSTHETIC DENTISTRY. See *American Text-Books of Dentistry*, page 2.

**EVANS (DAVID J.).** A POCKET TEXT-BOOK OF OBSTETRICS. In one handsome 12mo. volume of about 300 pages, with many illustrations. *Shortly.* *Lea's Series of Pocket Text-books*, edited by BERN B. GALLAUDET, M. D. See page 18.

**FARQUHARSON (ROBERT).** A GUIDE TO THERAPEUTICS. Fourth American from fourth English edition, revised by FRANK WOODBURY, M. D. In one 12mo. volume of 581 pages. Cloth, \$2.50.

**FIELD (GEORGE P.).** A MANUAL OF DISEASES OF THE EAR. Fourth edition. In one octavo volume of 391 pages, with 73 engravings and 21 colored plates. Cloth, \$3.75.

**FLINT (AUSTIN).** A TREATISE ON THE PRINCIPLES AND PRACTICE OF MEDICINE. Seventh edition, thoroughly revised by FREDERICK P. HENRY, M. D. In one large 8vo. volume of 1143 pages, with engravings. Cloth, \$5.00; leather, \$6.00.

The work has well earned its leading place in medical literature. — *Medical Record.* The best of American text-books on Practice. — *Amer. Medico-Surgical Bulletin.*

— A MANUAL OF AUSCULTATION AND PERCUSSION; or the Physical Diagnosis of Diseases of the Lungs and Heart, and of Thoracic Aneurism. Fifth edition, revised by JAMES C. WILSON, M. D. In one handsome 12mo. volume of 274 pages, with 12 engravings.

— A PRACTICAL TREATISE ON THE DIAGNOSIS AND TREATMENT OF DISEASES OF THE HEART. Second edition enlarged. In one octavo volume of 550 pages. Cloth, \$4.

— A PRACTICAL TREATISE ON THE PHYSICAL EXPLORATION OF THE CHEST, AND THE DIAGNOSIS OF DISEASES AFFECTING THE RESPIRATORY ORGANS. Second and revised edition. In one octavo volume of 591 pages. Cloth, \$4.50.

— MEDICAL ESSAYS. In one 12mo. vol. of 210 pages. Cloth, \$1.38.

— ON PHTHISIS: ITS MORBID ANATOMY, ETIOLOGY, ETC. A Series of Clinical Lectures. In one 8vo. volume of 442 pages. Cloth, \$3.50.



**FOLSOM (C. F.).** AN ABSTRACT OF STATUTES OF U. S. ON CUSTODY OF THE INSANE. In one 8vo. vol. of 108 pages. Cloth, \$1.50. With *Clouston on Mental Diseases* (new edition, see page 6) \$5.00, *net*, for the two works.

**FORMULARY, POCKET**, see page 32.

**FOSTER (MICHAEL).** A TEXT-BOOK OF PHYSIOLOGY. New (6th) and revised American from the sixth English edition. In one large octavo volume of 923 pages, with 257 illustrations. Cloth, \$4.50; leather, \$5.50.

Unquestionably the best book that can be placed in the student's hands, and as a work of reference for the busy physician it can scarcely be excelled.—*The Phila. Polyclinic*.

This single volume contains all that will be necessary in a college course, and all that the physician will need as well.—*Dominion Med. Monthly*.

**FOTHERGILL (J. MILNER).** THE PRACTITIONER'S HANDBOOK OF TREATMENT. Third edition. In one handsome octavo volume of 664 pages. Cloth, \$3.75; leather, \$4.75.

**FOWNES (GEORGE).** A MANUAL OF ELEMENTARY CHEMISTRY (INORGANIC AND ORGANIC). Twelfth edition. Embodying WATTS' *Physical and Inorganic Chemistry*. In one royal 12mo. volume of 1061 pages, with 168 engravings, and 1 colored plate. Cloth, \$2.75; leather, \$3.25.

**FRANKLAND (E.) AND JAPP (F.R.).** INORGANIC CHEMISTRY. In one handsome octavo volume of 677 pages, with 51 engravings and 2 plates. Cloth, \$3.75; leather, \$4.75.

**FULLER (EUGENE).** DISORDERS OF THE SEXUAL ORGANS IN THE MALE. In one very handsome octavo volume of 238 pages, with 25 engravings and 8 full-page plates. Cloth, \$2.

It is an interesting work, and one which, in view of the large and profitable amount of work done in this field of late years, is timely and well needed.—*Medical Fortnightly*.

The book is valuable and instructive and brings views of sound pathology and rational treatment to many cases of sexual disturbance whose treatment has been too often fruitless for good. — *Annals of Surgery*.

**FULLER (HENRY).** ON DISEASES OF THE LUNGS AND AIR PASSAGES. Their Pathology, Physical Diagnosis, Symptoms and Treatment. From second English edition. In one 8vo. volume of 475 pages. Cloth, \$3.50.

**GALLAUDET (BERN B.).** A POCKET TEXT-BOOK ON SURGERY. In one handsome 12mo. volume of about 400 pages, with many illustrations. *Shortly*. *Lea's Series of Pocket Text-books*, edited by BERN B. GALLAUDET, M. D. See page 18.

**GANT (FREDERICK JAMES).** THE STUDENT'S SURGERY. A *Multum in Parvo*. In one square octavo volume of 845 pages, with 159 engravings. Cloth, \$3.75.

**GIBBES (HENEAGE).** PRACTICAL PATHOLOGY AND MORBID HISTOLOGY. Octavo, 314 pages, with 60 illustrations. Cloth, \$2.75.

**GIBNEY (V. P.).** ORTHOPEDIC SURGERY. For the use of Practitioners and Students. In one 8vo. vol. profusely illus. *Preparing*.



**GERRISH (FREDERIC H.). A TEXT-BOOK OF ANATOMY.**

By American Authors. Edited by Frederic H. Gerrish, M. D. In one imp. octavo volume of 915 pages, with 950 illustrations in black and colors. *Just ready.* Cloth, \$6.50; flexible waterproof, \$7; leath., \$7.50, *net*.

In this, the first representative treatise on Anatomy produced in America, no effort or expense has been spared to unite an authoritative text with the most successful anatomical pictures which have yet appeared in the world.

The editor has secured the co-operation of the professors of anatomy in leading medical colleges, and with them has prepared a text conspicuous for its simplicity, unity and judicious selection of such anatomical facts as bear on physiology, surgery and internal medicine in the most comprehensive sense of those terms. The authors have endeavored to make a book which shall stand in the place of a living teacher to the student, and which shall be of actual service to the practitioner in his clinical work, emphasizing the most important subjects, clarifying obscurities, helping most in the parts most difficult to learn, and illustrating everything by all available methods.

**GOULD (A. PEARCE). SURGICAL DIAGNOSIS.** In one 12mo. vol. of 589 pages. Cloth, \$2. See *Student's Series of Manuals*, p. 27.

**GRAY (HENRY). ANATOMY, DESCRIPTIVE AND SURGICAL.**

New and thoroughly revised American edition, much enlarged in text, and in engravings in black and colors. In one imperial octavo volume of 1239 pages, with 772 large and elaborate engravings on wood. Price of edition with illustrations in colors: cloth, \$7; leather, \$8. Price of edition with illustrations in black: cloth, \$6; leather, \$7.

This is the best single volume upon Anatomy in the English language.—*University Medical Magazine*.

*Gray's Anatomy* affords the student more satisfaction than any other treatise with which we are familiar.—*Buffalo Med. Journal*.

The most largely used anatomical text-book published in the English language.—*Annals of Surgery*.

Particular stress is laid upon the practical side of anatomical teach-

ing, and especially the Surgical Anatomy.—*Chicago Med. Recorder*.

Holds first place in the esteem of both teachers and students.—*The Brooklyn Medical Journal*.

The foremost of all medical text-books.—*Medical Fortnightly*.

*Gray's Anatomy* should be the first work which a medical student should purchase, nor should he be without a copy throughout his professional career.—*Pittsburg Medical Review*.

**GRAY (LANDON CARTER). A TREATISE ON NERVOUS AND MENTAL DISEASES.** For Students and Practitioners of Medicine.

New (2d) edition. In one handsome octavo volume of 728 pages, with 172 engravings and 3 colored plates. Cloth, \$4.75; leather, \$5.75.

An up-to-date text-book upon nervous and mental diseases combined. A well-written, terse, explicit, and authoritative volume treating of both subjects is a step in the direction of popular demand.—*The Chicago Clinical Review*.

The descriptions of the various

diseases are accurate and the symptoms and differential diagnosis are set before the student in such a way as to be readily comprehended. The author's long experience renders his views on therapeutics of great value.—*The Journal of Nervous and Mental Disease*.



**GREEN (T. HENRY).** AN INTRODUCTION TO PATHOLOGY AND MORBID ANATOMY. New (8th) American from the eighth London edition. In one handsome octavo volume of 582 pages, with 216 engravings and a colored plate. Cloth, \$2.50, *net*. *Just ready*.

A work that is the text-book of probably four-fifths of all the students of pathology in the United States and Great Britain.—*The American Practitioner and News*.

It is fully up-to-date in the record of fact, and so profusely illustrated as to give to each detail of text sufficient explanation. The work is an essential to the practitioner—whether as surgeon or physician. It is the best of up-to-date text-books.—*Virginia Med. Monthly*.

**GREENE (WILLIAM H.).** A MANUAL OF MEDICAL CHEMISTRY. For the Use of Students. Based upon BOWMAN'S *Medical Chemistry*. In one 12mo. vol. of 310 pages, with 74 illus. Cloth, \$1.75.

**GROSS (SAMUEL D.).** A PRACTICAL TREATISE ON THE DISEASES, INJURIES AND MALFORMATIONS OF THE URINARY BLADDER, THE PROSTATE GLAND AND THE URETHRA. Third edition. Octavo, 574 pages, with 170 illustrations. Cloth, \$4.50.

**GRINDON (JOSEPH).** A POCKET TEXT-BOOK OF SKIN DISEASES. In one handsome 12mo. volume of 350 pages, with many illustrations. *Shortly*. *Lea's Series of Pocket Text-books*, edited by BERN B. GALLAUDET, M. D. See page 18.

**HABERSHON (S. O.).** ON THE DISEASES OF THE ABDOMEN. Second American from the third English edition. In one octavo volume of 554 pages, with 11 engravings. Cloth, \$3.50.

**HALL (WINFIELD S.).** TEXT-BOOK OF PHYSIOLOGY. Octavo of 672 pages, with 343 engravings, and 6 full page colored plates. *Just ready*. Cloth, \$4.00; leather, \$5.00, *net*.

**HAMILTON (ALLAN MCLANE).** NERVOUS DISEASES, THEIR DESCRIPTION AND TREATMENT. Second and revised edition. In one octavo volume of 598 pages, with 72 engravings. Cloth, \$4.

**HARDAWAY (W. A.).** MANUAL OF SKIN DISEASES. New (2d) edition. In one 12mo. volume of 560 pages, with 40 illustrations and 2 plates. Cloth, \$2.25, *net*. *Just ready*.

The best of all the small books to recommend to students and practitioners. Probably no one of our dermatologists has had a wider everyday clinical experience. His great strength is in diagnosis, descriptions of lesions and especially in treatment.—*Indiana Medical Journal*.

**HARE (HOBART AMORY).** PRACTICAL DIAGNOSIS. THE USE OF SYMPTOMS IN THE DIAGNOSIS OF DISEASE. New (4th) edition. In one octavo volume of 623 pages, with 205 engravings and 14 full-page colored plates. Cloth, \$5.00, *net*. *Just ready*.

It is unique in many respects, and the author has introduced radical changes which will be welcomed by all. Anyone who reads this book will become a more acute observer, will pay more attention to the simple yet indicative signs of disease, and he will become a better diagnostician. This is a companion to *Practical Therapeutics*, by the same author, and it is difficult to conceive of any two works of greater practical utility.—*Medical Review*.



**HARE (HOBART AMORY).** A TEXT-BOOK OF PRACTICAL THERAPEUTICS, with Special Reference to the Application of Remedial Measures to Disease and their Employment upon a Rational Basis. With articles on various subjects by well-known specialists. New (7th) and revised edition. In one octavo volume of 776 pages. Cloth, \$3.75, *net*; leather, \$4.50, *net*.

Its classifications are inimitable, and the readiness with which anything can be found is the most wonderful achievement of the art of indexing. This edition takes in all the latest discovered remedies.—*The St. Louis Clinique*.

The great value of the work lies in the fact that precise indications for administration are given. A complete index of diseases and remedies makes it an easy reference work. It has been arranged so that

it can be readily used in connection with Hare's *Practical Diagnosis*. For the needs of the student and general practitioner it has no equal.—*Medical Sentinel*.

The best planned therapeutic work of the century.—*American Practitioner and News*.

It is a book precisely adapted to the needs of the busy practitioner, who can rely upon finding exactly what he needs.—*The National Medical Review*.

**HARE (HOBART AMORY)** ON THE MEDICAL COMPLICATIONS AND SEQUELÆ OF TYPHOID FEVER. Octavo, 276 pages, 21 engravings and two full-page plates. *Just ready*. Cloth, \$2.40, *net*.

A very valuable production. One of the very best products of Dr. Hare and one that every man can

read with great profit.—*Cleveland Journal of Medicine*.

**HARE (HOBART AMORY, EDITOR).** A SYSTEM OF PRACTICAL THERAPEUTICS. In a series of contributions by eminent practitioners. In four large octavo volumes comprising about 4500 pages, with about 550 engravings. Vol. IV., *just ready*. *For sale by subscription only*. Full prospectus free on application to the Publishers. Regular price, Vol. IV., cloth, \$6; leather, \$7; half Russia, \$8. Price Vol. IV. to former or new subscribers to complete work, cloth, \$5; leather, \$6; half Russia, \$7. Complete work, cloth, \$20; leather, \$24; half Russia, \$28.

The great value of Hare's *System of Practical Therapeutics* has led to a widespread demand for a new volume to represent advances in treatment made since the publication of the first three. More than fulfilling this request the Editor has secured contributions from practically a new corps of equally eminent authors, so that entirely fresh and original matter is ensured. The plan of the work, which proved so successful, has been followed in this new volume, which will be found to present the latest developments and applications of this most practical branch of the medical art. The entire *System* is an unrivalled encyclopædia on the practical parts of medicine, and merits the great success it has won for that reason.



**HARTSHORNE (HENRY).** ESSENTIALS OF THE PRINCIPLES AND PRACTICE OF MEDICINE. Fifth edition. In one 12mo. volume, 669 pages, with 144 engravings. Cloth, \$2.75.

— A HANDBOOK OF ANATOMY AND PHYSIOLOGY. In one 12mo. volume of 310 pages, with 220 engravings. Cloth, \$1.75.

— A CONSPECTUS OF THE MEDICAL SCIENCES. Comprising Manuals of Anatomy, Physiology, Chemistry, Materia Medica, Practice of Medicine, Surgery and Obstetrics. Second edition. In one royal 12mo. vol. of 1028 pages, with 477 illus. Cloth, \$4.25; leather, \$5.

**HAYDEN (JAMES R.).** A MANUAL OF VENEREAL DISEASES. New (2d) edition. In one 12mo. volume of 304 pages, with 54 engravings. Cloth, \$1.50, *net*.

It is practical, concise, definite and of sufficient fulness to be satisfactory.—*Chicago Clinical Review*.

This work gives all of the practically essential information about the three venereal diseases, gonorrhœa, the chancroid and syphilis. In diagnosis and treatment it is par-

ticularly thorough, and may be relied upon as a guide in the management of this class of diseases.—*Northwestern Lancet*.

It is well written, up to date, and will be found very useful.—*International Medical Magazine*.

**HAYEM (GEORGES) AND HARE (H. A.).** PHYSICAL AND NATURAL THERAPEUTICS. The Remedial Use of Heat, Electricity, Modifications of Atmospheric Pressure, Climates and Mineral Waters. Edited by Prof. H. A. HARE, M. D. In one octavo volume of 414 pages, with 113 engravings. Cloth, \$3.

This well-timed up-to-date volume is particularly adapted to the requirements of the general practitioner. The section on mineral waters is most scientific and practical. Some 200 pages are given up to electricity and evidently embody the latest scientific information on the subject. Altogether this work is the clearest and most practical aid to the study of nature's therapeutics that has yet come under our observation.—*The Medical Fortnightly*.

For many diseases the most potent remedies lie outside of the materia medica, a fact yearly receiving wider

recognition. Within this large range of applicability, physical agencies when compared with drugs are more direct and simple in their results. Medical literature has long been rich in treatises upon medical agents, but an authoritative work upon the other great branch of therapeutics has until now been a desideratum. The section on climate, rewritten by Prof. Hare, will, for the first time, place the abundant resources of our country at the intelligent command of American practitioners.—*The Kansas City Medical Index*.

**HERMAN (G. ERNEST).** FIRST LINES IN MIDWIFERY. In one 12mo. vol. of 198 pages, with 80 engravings. Cloth, \$1.25. See *Student's Series of Manuals*, page 27.

**HERMANN (L.).** EXPERIMENTAL PHARMACOLOGY. A Handbook of the Methods for Determining the Physiological Actions of Drugs. Translated by ROBERT MEADE SMITH, M. D. In one 12mo. volume of 199 pages, with 32 engravings. Cloth, \$1.50.



**HERRICK (JAMES B.).** A HANDBOOK OF DIAGNOSIS. In one handsome 12mo. volume of 429 pages, with 80 engravings and 2 colored plates. Cloth, \$2.50.

Excellentlly arranged, practical, concise, up-to-date, and eminently well fitted for the use of the practitioner as well as of the student.—*Chicago Med. Recorder.*

This volume accomplishes its objects more thoroughly and completely than any similar work yet published. Each section devoted to diseases of special systems is preceded with an exposition of the methods of physical, chemical and

microscopical examination to be employed in each class. The technique of blood examination, including color analysis, is very clearly stated. Uranalysis receives adequate space and care.—*New York Med. Journal.*

We commend the book not only to the undergraduate, but also to the physician who desires a ready means of refreshing his knowledge of diagnosis in the exigencies of professional life.—*Memphis Medical Monthly.*

**HILL (BERKELEY).** SYPHILIS AND LOCAL CONTAGIOUS DISORDERS. In one 8vo. volume of 479 pages. Cloth, \$3.25.

**HILLIER (THOMAS).** A HANDBOOK OF SKIN DISEASES. Second edition. In one royal 12mo. volume of 353 pages, with two plates. Cloth, \$2.25.

**HIRST (BARTON C.) AND PIERSOL (GEORGE A.).** HUMAN MONSTROSITIES. Magnificent folio, containing 220 pages of text and illustrated with 123 engravings and 39 large photographic plates from nature. In four parts, price each, \$5. *Limited edition. For sale by subscription only.*

**HOBLYN (RICHARD D.).** A DICTIONARY OF THE TERMS USED IN MEDICINE AND THE COLLATERAL SCIENCES. In one 12mo. volume of 520 double-columned pages. Cloth, \$1.50; leather, \$2.

**HODGE (HUGH L.).** ON DISEASES PECULIAR TO WOMEN, INCLUDING DISPLACEMENTS OF THE UTERUS. Second and revised edition. In one 8vo. vol. of 519 pp., with illus. Cloth, \$4.50

**HOFFMANN (FREDERICK) AND POWER (FREDERICK B.).** A MANUAL OF CHEMICAL ANALYSIS, as Applied to the Examination of Medicinal Chemicals and their Preparations. Third edition, entirely rewritten and much enlarged. In one handsome octavo volume of 621 pages, with 179 engravings. Cloth, \$4.25.

**HOLMES (TIMOTHY).** A TREATISE ON SURGERY. Its Principles and Practice. A new American from the fifth English edition. Edited by T. PICKERING PICK, F.R.C.S. In one handsome octavo volume of 1008 pages, with 428 engravings. Cloth, \$6; leather, \$7.

— A SYSTEM OF SURGERY. With notes and additions by various American authors. Edited by JOHN H. PACKARD, M.D. In three very handsome 8vo. volumes containing 3137 double-columned pages, with 979 engravings and 13 lithographic plates. Per volume, cloth, \$6; leather, \$7; half Russia, \$7.50. *For sale by subscription only.*



**HORNER (WILLIAM E.).** SPECIAL ANATOMY AND HISTOLOGY. Eighth edition, revised and modified. In two large 8vo. volumes of 1007 pages, containing 320 engravings. Cloth, \$6.

**HUDSON (A.).** LECTURES ON THE STUDY OF FEVER. In one octavo volume of 308 pages. Cloth, \$2.50.

**HUTCHISON (ROBERT) AND RAINY (HARRY).** CLINICAL METHODS. A GUIDE TO THE PRACTICAL STUDY OF MEDICINE. In one 12mo. volume of 562 pages, with 137 engravings and 8 colored plates. Cloth, \$3.00.

A comprehensive, clear and remarkably up-to-date guide to clinical diagnosis. The illustrations are plentiful and excellent. As examples of the more recent additions to medical knowledge which receive recognition, we mention Widal's test for typhoid and the Neuron theory of the nervous system.—*Montreal Medical Journal*.

**HUTCHINSON (JONATHAN).** SYPHILIS. In one pocket-size 12mo. volume of 542 pages, with 8 chromo-lithographic plates. Cloth, \$2.25. See *Series of Clinical Manuals*, p. 25.

**HYDE (JAMES NEVINS).** A PRACTICAL TREATISE ON DISEASES OF THE SKIN. New (4th) edition, thoroughly revised. In one octavo volume of 815 pages, with 110 engravings and 12 full-page plates, 4 of which are colored. Cloth, \$5.25; leather, \$6.25.

This edition has been carefully revised, and every real advance has been recognized. The work answers the needs of the general practitioner, the specialist, and the student.—*The Ohio Med. Jour.*

A treatise of exceptional merit characterized by conscientious care and scientific accuracy.—*Buffalo Med. Journal*.

A complete exposition of our knowledge of cutaneous medicine as it exists to-day. The teaching inculcated throughout is sound as well

as practical.—*The American Journal of the Medical Sciences*.

It is the best one-volume work that we know. The student who gets this book will find it a useful investment, as it will well serve him when he goes into practice.—*Virginia Medical Semi-Monthly*.

A full and thoroughly modern text-book on dermatology.—*The Pittsburg Medical Review*.

It is the most practical handbook on dermatology with which we are acquainted.—*The Chicago Medical Recorder*.

**JACKSON (GEORGE THOMAS).** THE READY-REFERENCE HANDBOOK OF DISEASES OF THE SKIN. New (3d) edition. In one 12mo. volume of 637 pages, with 75 illustrations and a colored plate. *Just ready*. Cloth, \$2.50, *net*.

As a student's manual, it may be considered beyond criticism. The book is singularly full.—*St. Louis Medical and Surgical Journal*.

Without doubt forms one of the best guides for the beginner in dermatology that is to be found in the English language.—*Medicine*.

**JAMIESON (W. ALLAN).** DISEASES OF THE SKIN. Third edition. In one octavo volume of 656 pages, with 1 engraving and 9 double-page chromo-lithographic plates. Cloth, \$6.



**JEWETT (CHARLES).** ESSENTIALS OF OBSTETRICS. In one 12mo. volume of 356 pages, with 80 engravings and 3 colored plates. Cloth, \$2.25. *Just ready.*

An exceedingly useful manual for student and practitioner. The author has succeeded unusually well in condensing the text and in arranging it in attractive and easily tangible form. The book is well illustrated throughout.—*Nashville Jour. of Medicine and Surgery.*

— **THE PRACTICE OF OBSTETRICS.** By American Authors. One large octavo volume of 763 pages, with 441 engravings in black and colors, and 22 full-page colored plates. *Just ready.* Cloth, \$5.00, *net*; leather, \$6.00, *net.*

A clear and practical treatise upon obstetrics by well-known teachers of the subject. A special feature of this work would seem to be the excellent illustrations with which the book abounds. The work is sure to be popular with medical students, as well as being of extreme value to the practitioner.—*The Medical Age.*

**JONES (C. HANDFIELD).** CLINICAL OBSERVATIONS ON FUNCTIONAL NERVOUS DISORDERS. Second American edition. In one octavo volume of 340 pages. Cloth, \$3.25.

**JULER (HENRY).** A HANDBOOK OF OPHTHALMIC SCIENCE AND PRACTICE. Second edition. In one octavo volume of 549 pages, with 201 engravings, 17 chromo-lithographic plates, test-types of Jaeger and Snellen, and Holmgren's Color-Blindness Test. Cloth, \$5.50; leather, \$6.50.

The volume is particularly rich in matter of practical value, such as directions for diagnosing, use of instruments, testing for glasses, for color blindness, etc. The sections devoted to treatment are singularly full and concise.—*Medical Age.*

**KING (A. F. A.).** A MANUAL OF OBSTETRICS. Seventh edition. In one 12mo. volume of 573 pages, with 223 illustrations. Cloth, \$2.50.

From first to finish it is thoroughly practical, concise in expression, well illustrated, and includes a statement of nearly every fact of importance discussed in obstetric treatises or cyclopedias. The well-arranged index renders the book useful to the practitioner who is in haste to refresh his memory.—*Virginia Medical Semi-Monthly.*

**KIRK (EDWARD C.).** OPERATIVE DENTISTRY. Handsome octavo of 700 pages, with 751 illustrations. *Just ready.* See *American Text-Books of Dentistry*, page 2.

We have only the highest praise for this valuable work. It is replete in every particular, and surpasses anything of the kind heretofore attempted. We can heartily recommend it to the profession.—*The Ohio Dental Journal.*

**KLEIN (E.).** ELEMENTS OF HISTOLOGY. New (5th) edition. In one 12mo. volume of 506 pages, with 296 engravings. *Just ready.* Cloth, \$2.00, *net.* See *Student's Series of Manuals*, page 27.

It is the most complete and concise work of the kind that has yet emanated from the press.—*The Medical Age.* This work deservedly occupies a first place as a text-book on histology.—*Canadian Practitioner.*



**LANDIS (HENRY G.). THE MANAGEMENT OF LABOR.** In one handsome 12mo. volume of 329 pages, with 28 illus. Cloth, \$1.75.

**LA ROCHE (R.). YELLOW FEVER.** In two 8vo. volumes of 1468 pages. Cloth, \$7.

**LAURENCE (J. Z.) AND MOON (ROBERT C.). A HANDY-BOOK OF OPHTHALMIC SURGERY.** Second edition. In one octavo volume of 227 pages, with 66 engravings. Cloth, \$2.75.

**LEA'S SERIES OF POCKET TEXT-BOOKS,** edited by BERN B. GALLAUDET, M. D. Covering the entire field of Medicine in a series of 16 very handsome 12mo. volumes of 350-450 pages each, profusely illustrated. Compendious, clear, trustworthy and modern. The following volumes constitute the series.

COATES' Bacteriology and Hygiene. BROCKWAY'S Anatomy. COLLINS and ROCKWELL'S Physiology. MARTIN and ROCKWELL'S Chemistry and Physics. NICHOLS and VALE'S Histology and Pathology. SCHLEIF'S Materia Medica, Therapeutics, Medical Latin, etc. MALS-BARY'S Practice of Medicine. COLLINS' Diagnosis. POTTS' Nervous and Mental Diseases. GALLAUDET'S Surgery. LIKES' Genito-Urinary and Venereal Diseases. GRINDON'S Dermatology. BALLENGER and WIPPERN'S Diseases of the Eye, Ear, Throat and Nose. EVANS' Obstetrics. CROCKETT'S Gynecology. TUTTLE'S Diseases of Children.

For separate notices see under various authors' names.

**LEA (HENRY C.). A HISTORY OF AURICULAR CONFESSION AND INDULGENCES IN THE LATIN CHURCH.** In three octavo volumes of about 500 pages each. Per volume, cloth, \$3.00.

— **CHAPTERS FROM THE RELIGIOUS HISTORY OF SPAIN; CENSORSHIP OF THE PRESS; MYSTICS AND ILLUMINATI—THE ENDEMONIADAS; EL SANTO NIÑO DE LA GUARDIA; BRIANDA DE BARDAXI.** 12mo., 522 pages. Cloth, \$2.50.

— **FORMULARY OF THE PAPAL PENITENTIARY.** In one octavo volume of 221 pages, with frontispiece. Cloth, \$2.50.

— **SUPERSTITION AND FORCE; ESSAYS ON THE WAGER OF LAW, THE WAGER OF BATTLE, THE ORDEAL AND TORTURE.** Fourth edition, thoroughly revised. In one handsome royal 12mo. volume of 629 pages. Cloth, \$2.75.

— **STUDIES IN CHURCH HISTORY.** The Rise of the Temporal Power—Benefit of Clergy—Excommunication. New edition. In one handsome 12mo. volume of 605 pages. Cloth, \$2.50.

— **AN HISTORICAL SKETCH OF SACERDOTAL CELIBACY IN THE CHRISTIAN CHURCH.** Second edition. In one handsome octavo volume of 685 pages. Cloth, \$4.50.

**LEHMANN (C. G.). A MANUAL OF CHEMICAL PHYSIOLOGY.** In one 8vo. volume of 327 pages, with 41 engravings. Cloth, \$2.25.



**LIKES (SYLVAN H.).** A POCKET TEXT-BOOK OF GENITO-URINARY AND VENEREAL DISEASES. In one handsome 12mo. volume of about 350 pages, with many illustrations. *Shortly.* *Lea's Series of Pocket Text-books*, edited by BERN B. GALLAUDET, M. D. See page 18.

**LOOMIS (ALFRED L.) AND THOMPSON (W. GILMAN, EDITORS).** A SYSTEM OF PRACTICAL MEDICINE. In Contributions by Various American Authors. In four very handsome octavo volumes of about 900 pages each, fully illustrated in in black and colors. *Complete work now ready.* Per volume, cloth, \$5; leather, \$6; half Morocco, \$7. *For sale by subscription only.* Full prospectus free on application to the Publishers. See *American System of Practical Medicine*, page 2.

**LUFF (ARTHUR P.).** MANUAL OF CHEMISTRY, for the use of Students of Medicine. In one 12mo. volume of 522 pages, with 36 engravings. Cloth, \$2. See *Student's Series of Manuals*, page 27.

**LYMAN (HENRY M.).** THE PRACTICE OF MEDICINE. In one very handsome octavo volume of 925 pages, with 170 engravings. Cloth, \$4.75; leather, \$5.75.

Complete, concise, fully abreast of the times and needed by all students and practitioners.—*Univ. Med. Mag.* An exceedingly valuable text-book. Practical, systematic, complete and well balanced.—*Chicago Med. Recorder.*

**LYONS (ROBERT D.).** A TREATISE ON FEVER. In one octavo volume of 362 pages. Cloth, \$2.25.

**MACKENZIE (JOHN NOLAND).** ON THE NOSE AND THROAT. Handsome octavo, about 600 pages, richly illustrated. *Preparing.*

**MAISCH (JOHN M.).** A MANUAL OF ORGANIC MATERIA MEDICA. New (7th) edition, thoroughly revised by H. C. C. MAISCH, Ph. G., Ph. D. In one very handsome 12mo. volume of 512 pages, with 285 engravings. *Just ready.* Cloth, \$2.50, *net.*

Used as text-book in every college of pharmacy in the United States and recommended in medical colleges.—*American Therapist.* The best handbook upon pharmacognosy of any published in this country.—*Boston Med. & Sur. Jour.* in America. The work has no equal.—*Dominion Med. Monthly.*

Noted on both sides of the Atlantic and esteemed as much in Germany as



**MALSBARY (GEORGE E.).** A POCKET TEXT-BOOK OF THEORY AND PRACTICE OF MEDICINE. In one handsome 12mo. volume of 405 pages, with 45 illustrations. *Just ready.* Cloth, \$1.75, *net*; flexible red leather, \$2.25, *net*. *Lea's Series of Pocket Text-books*, edited by BERN B. GALLAUDET, M. D. See page 18.

**MANUALS.** See *Student's Quiz Series*, page 27, *Student's Series of Manuals*, page 27, and *Series of Clinical Manuals*, page 25.

**MARSH (HOWARD).** DISEASES OF THE JOINTS. In one 12mo. volume of 468 pages, with 64 engravings and a colored plate. Cloth, \$2. See *Series of Clinical Manuals*, page 25.

**MARTIN (EDWARD).** A MANUAL OF SURGICAL DIAGNOSIS. In one 12mo. volume of about 400 pp., fully illustrated. *Preparing.*

**MARTIN (WALTON) AND ROCKWELL (WM. H.).** A POCKET TEXT-BOOK OF CHEMISTRY AND PHYSICS. In one handsome 12mo. volume of about 350 pages, with many illustrations. *Shortly.* *Lea's Series of Pocket Text-books*, edited by BERN B. GALLAUDET, M. D. See page 18.

**MAY (C. H.).** MANUAL OF THE DISEASES OF WOMEN. For the use of Students and Practitioners. Second edition, revised by L. S. RAU, M. D. In one 12mo. volume of 360 pages, with 31 engravings. Cloth, \$1.75.

**MEDICAL NEWS POCKET FORMULARY**, see page 32.

**MITCHELL (S. WEIR).** CLINICAL LESSONS ON NERVOUS DISEASES. In one 12mo. volume of 299 pages, with 19 engravings and 2 colored plates. Cloth, \$2.50. Of the hundred numbered copies with the Author's signed title page a few remain; these are offered in green cloth, gilt top, at \$3.50, *net*.

The book treats of hysteria, recurrent melancholia, disorders of sleep, choreic movements, false sensations of cold, ataxia, hemiplegic pain, treatment of sciatica, erythromelalgia, reflex ocularneurosis, hysteric contractions, rotary movements in the feeble minded, etc. Few can speak with more authority than the author.—*The Journal of the American Medical Association.*

**MITCHELL (JOHN K.).** REMOTE CONSEQUENCES OF INJURIES OF NERVES AND THEIR TREATMENT. In one handsome 12mo. volume of 239 pages, with 12 illustrations. Cloth, \$1.75.

Injuries of the nerves are of frequent occurrence in private practice, and often the cause of intractable and painful conditions, consequently this volume is of especial interest. Doctor Mitchell has had access to hospital records for the last thirty years, as well as to the government documents, and has skilfully utilized his opportunities.—*The Med. Age.*

**MORRIS (MALCOLM).** DISEASES OF THE SKIN. New (2d) edition. In one 12mo. volume of 601 pages, with 10 chromo-lithographic plates and 26 engravings. Cloth, \$3.25, *net*. *Just ready.*

**MÜLLER (J.).** PRINCIPLES OF PHYSICS AND METEOROLOGY. In one large 8vo. vol. of 623 pages, with 538 cuts. Cloth, \$4.50.



**MUSSER (JOHN H.). A PRACTICAL TREATISE ON MEDICAL DIAGNOSIS,** for Students and Physicians. New (3d) edition, thoroughly revised. In one octavo volume of 1082 pages, with 253 engravings and 48 full-page colored plates. *Just ready.* Cloth, \$6.00, *net*; leather, \$7.00, *net*.

Notices of previous edition are appended.

We have no work of equal value in English. — *University Medical Magazine*.

His descriptions of the diagnostic manifestations of diseases are accurate. This work will meet all the requirements of student and physician. — *The Medical News*.

From its pages may be made the diagnosis of every malady that afflicts the human body, including those which in general are dealt with only by the specialist. — *North-western Lancet*.

It so thoroughly meets the precise demands incident to modern research that it has been adopted as a leading text-book by the medical colleges of this country. — *North American Practitioner*.

Occupies the foremost place as a thorough, systematic treatise. — *Ohio Medical Journal*.

The best of its kind, invaluable to the student, general practitioner and teacher. — *Montreal Medical Journal*.

**NATIONAL DISPENSATORY.** See *Stillé, Maisch & Caspari*, p. 27.

**NATIONAL FORMULARY.** See *Stillé, Maisch & Caspari's National Dispensatory*, page 27.

**NATIONAL MEDICAL DICTIONARY.** See *Billings*, page 4.

**NETTLESHIP (E.). DISEASES OF THE EYE.** New (5th) American from sixth English edition, thoroughly revised. In one 12mo. volume of 521 pages, with 161 engravings, and 2 colored plates, test-types, formulæ and color-blindness test. Cloth, \$2.25. *Just ready.*

By far the best student's text-book on the subject of ophthalmology and is conveniently and concisely arranged. — *The Clinical Review*.

It has been conceded by ophthalmologists generally that this work for compactness, practicality and clearness has no superior in the English language. — *Journal of Medicine and Science*.

The present edition is the result of revision both in England and America, and therefore contains the latest and best ophthalmological ideas of both continents. — *The Physician and Surgeon*.

**NICHOLS (JOHN B.) AND VALE (F. P.). A POCKET TEXT-BOOK OF HISTOLOGY AND PATHOLOGY.** In one handsome 12mo. volume of 452 pages, with 213 illustrations. *Just ready.* Cloth, \$1.75, *net*; flexible red leather, \$2.25, *net*.  
*Lea's Series of Pocket Text-books*, edited by BERN B. GALLAUDET, M. D. See page 18.

**NORRIS (WM. F.) AND OLIVER (CHAS. A.). TEXT-BOOK OF OPHTHALMOLOGY.** In one octavo volume of 641 pages, with 357 engravings and 5 colored plates. Cloth, \$5; leather, \$6.

A safe and admirable guide, well qualified to furnish a working knowledge of ophthalmology. — *Johns Hopkins Hospital Bulletin*.

It is practical in its teachings. We unreservedly endorse it as the

best, the safest and the most comprehensive volume upon the subject that has ever been offered to the American medical public. — *Annals of Ophthalmology and Otology*.



**OWEN (EDMUND). SURGICAL DISEASES OF CHILDREN.**

In one 12mo. volume of 525 pages, with 85 engravings and 4 colored plates. Cloth, \$2. See *Series of Clinical Manuals*, page 25.

**PARK (ROSWELL). A TREATISE ON SURGERY BY AMERICAN AUTHORS.** New and condensed edition. *Just ready.*

In one royal octavo volume of 1261 pages, with 625 engravings and 37 full-page plates. Cloth, \$6.00, *net*; leather, \$7.00, *net*.

*This work is also published in a larger edition, comprising two volumes. Volume I., General Surgery, 799 pages, with 356 engravings and 21 full-page plates, in colors and monochrome. Volume II., Special Surgery, 800 pages, with 430 engravings and 17 full-page plates, in colors and monochrome. Per volume, cloth, \$4.50; leather, \$5.50, net.*

The work is fresh, clear and practical, covering the ground thoroughly yet briefly, and well arranged for rapid reference, so that it will be of special value to the student and busy practitioner. The pathology is broad, clear and scientific, while the suggestions upon treatment are clear-cut, thoroughly modern and admirably resourceful.—*Johns Hopkins Hospital Bulletin.*

The latest and best work written upon the science and art of surgery. *Columbus Medical Journal.*

The illustrations are almost entirely new and executed in such a

way that they add great force to the text.—*The Chicago Medical Recorder.*

The various writers have embodied the teachings accepted at the present hour.—*The North American Practitioner.*

Both for the student and practitioner it is most valuable. It is thoroughly practical and yet thoroughly scientific.—*Medical News.*

A truly modern surgery, not only in pathology, but also in sound surgical therapeutics.—*New Orleans Med. and Surgical Journal.*

**PARK (WILLIAM H.). BACTERIOLOGY IN MEDICINE AND**

**SURGERY.** 12mo., 688 pages, with 87 illustrations in black and colors, and 2 plates. *Just ready.* Cloth, \$3.00 *net*.

**PARRY (JOHN S.). EXTRA-UTERINE PREGNANCY, ITS CLINICAL HISTORY, DIAGNOSIS, PROGNOSIS AND TREAT-**

**MENT.** In one octavo volume of 272 pages. Cloth, \$2.50.

**PARVIN (THEOPHILUS). THE SCIENCE AND ART OF OB-**

**STETRICS.** Third edition. In one handsome octavo volume of 677 pages, with 267 engravings and 2 colored plates. Cloth, \$4.25; leather, \$5.25.

In the foremost rank among the most practical and scientific medical works of the day.—*Medical News.*

The book is complete in every department, and contains all the necessary detail required by the modern

practising obstetrician.—*International Medical Magazine.*

Parvin's work is practical, concise and comprehensive. We commend it as first of its class in the English language.—*Medical Fortnightly.*



**PEPPER'S SYSTEM OF MEDICINE.** See page 3.

**PEPPER (A. J.).** FORENSIC MEDICINE. *In press.* See *Student's Series of Manuals*, page 27.

— SURGICAL PATHOLOGY. In one 12mo. volume of 511 pages, with 81 engravings. Cloth, \$2. See *Student's Series of Manuals*, p. 27.

**PICK (T. PICKERING).** FRACTURES AND DISLOCATIONS. In one 12mo. volume of 530 pages, with 93 engravings. Cloth, \$2. See *Series of Clinical Manuals*, page 25.

**PLAYFAIR (W. S.).** A TREATISE ON THE SCIENCE AND PRACTICE OF MIDWIFERY. Seventh American from the ninth English edition. In one octavo volume of 700 pages, with 207 engravings and 7 plates. Cloth, \$3.75 *net*; leather, \$4.75, *net*. *Just ready.*

In the numerous editions which have appeared it has been kept constantly in the foremost rank. It is a work which can be conscientiously recommended to the profession.—*The Albany Medical Annals.*

This work must occupy a foremost place in obstetric medicine as a safe guide to both student and

obstetrician. It holds a place among the ablest English-speaking authorities on the obstetric art.—*Buffalo Medical and Surgical Journal.*

An epitome of the science and practice of midwifery, which embodies all recent advances.—*The Medical Fortnightly.*

— THE SYSTEMATIC TREATMENT OF NERVE PROSTRATION AND HYSTERIA. In one 12mo. volume of 97 pages. Cloth, \$1.

**POCKET FORMULARY.** see page 32.

**POCKET TEXT-BOOKS,** see page 18.

**POLITZER (ADAM).** A TEXT-BOOK OF THE DISEASES OF THE EAR AND ADJACENT ORGANS. Second American from the third German edition. Translated by OSCAR DODD, M. D., and edited by SIR WILLIAM DALBY, F. R. C. S. In one octavo volume of 748 pages, with 330 original engravings. Cloth, \$5.50.

The anatomy and physiology of each part of the organ of hearing are carefully considered, and then follows an enumeration of the diseases to which that special part of the auditory apparatus is especially liable. The indications for treat-

ment are clear and reliable. We can confidently recommend it, for it contains all that is known upon the subject.—*London Lancet.*

A safe and elaborate guide into every part of otology.—*American Journal of the Medical Sciences.*

**POTTS (CHARLES S.).** A POCKET TEXT-BOOK OF NERVOUS AND MENTAL DISEASES. In one handsome 12mo. volume of about 450 pages. *Shortly.* *Lea's Series of Pocket Text-books*, edited by BERN B. GALLAUDET, M. D. See page 18.

**PROGRESSIVE MEDICINE,** see page 32.

**PURDY (CHARLES W.).** BRIGHT'S DISEASE AND ALLIED AFFECTIONS OF THE KIDNEY. In one octavo volume of 288 pages, with 18 engravings. Cloth, \$2.



**PYE-SMITH (PHILIP H.).** DISEASES OF THE SKIN. In one 12mo. vol. of 407 pp., with 28 illus., 18 of which are colored. Cloth, \$2.

**QUIZ SERIES.** See *Student's Quiz Series*, page 27.

**RALFE (CHARLES H.).** CLINICAL CHEMISTRY. In one 12mo. volume of 314 pages, with 16 engravings. Cloth, \$1.50. See *Student's Series of Manuals*, page 27.

**RAMSBOTHAM (FRANCIS H.).** THE PRINCIPLES AND PRACTICE OF OBSTETRIC MEDICINE AND SURGERY. In one imperial octavo volume of 640 pages, with 64 plates and numerous engravings in the text. Strongly bound in leather, \$7.

**REICHERT (EDWARD T.).** A TEXT-BOOK ON PHYSIOLOGY. In one handsome octavo volume of about 800 pages, richly illustrated. *Preparing.*

**REMSSEN (IRA).** THE PRINCIPLES OF THEORETICAL CHEMISTRY. New (5th) edition, thoroughly revised. In one 12mo. volume of 326 pages. Cloth, \$2.

A clear and concise explanation of a difficult subject. We cordially recommend it.—*The London Lancet.*

The book is equally adapted to the student of chemistry or the practitioner who desires to broaden his theoretical knowledge of chemistry.—*New Orleans Med. and Surg. Jour.*

The appearance of a fifth edition of this treatise is in itself a guarantee

that the work has met with general favor. This is further established by the fact that it has been translated into German and Italian. The treatise is especially adapted to the laboratory student. It ranks unusually high among the works of this class. This edition has been brought fully up to the times.—*American Medico-Surgical Bulletin.*

**RICHARDSON (BENJAMIN WARD).** PREVENTIVE MEDICINE. In one octavo volume of 729 pages. Cloth, \$4; leather, \$5.

**ROBERTS (JOHN B.).** THE PRINCIPLES AND PRACTICE OF MODERN SURGERY. New (2d) edition. In one octavo volume of 838 pages with 473 engravings and 8 plates. *Just ready.* Cloth, \$4.25, *net*; leather, \$5.25, *net.*

— THE COMPEND OF ANATOMY. For use in the Dissecting Room and in preparing for Examinations. In one 16mo. volume of 196 pages. Limp cloth, 75 cents.

**ROBERTS (SIR WILLIAM).** A PRACTICAL TREATISE ON URINARY AND RENAL DISEASES, INCLUDING URINARY DEPOSITS. Fourth American from the fourth London edition. In one very handsome 8vo. vol. of 609 pp., with 81 illus. Cloth, \$3.50.

**ROBERTSON (J. MCGREGOR).** PHYSIOLOGICAL PHYSICS. In one 12mo. volume of 537 pages, with 219 engravings. Cloth, \$2. See *Student's Series of Manuals*, page 27.

**ROSS (JAMES).** A HANDBOOK OF THE DISEASES OF THE NERVOUS SYSTEM. In one handsome octavo volume of 726 pages, with 184 engravings. Cloth, \$4.50; leather, \$5.50.

**SAVAGE (GEORGE H.).** INSANITY AND ALLIED NEUROSES, PRACTICAL AND CLINICAL. In one 12mo. volume of 551 pages, with 18 typical engravings. Cloth, \$2. See *Series of Clinical Manuals*, page 25.



**SCHAFER (EDWARD A.). THE ESSENTIALS OF HISTOLOGY, DESCRIPTIVE AND PRACTICAL.** For the use of Students. New (5th) edition. In one handsome octavo volume of 359 pages, with 392 illustrations. Cloth, \$3.00, *net*. *Just ready.*

Nowhere else will the same very moderate outlay secure as thoroughly useful and interesting an atlas of structural anatomy.—*The American Journal of the Medical Sciences.*

The most satisfactory elementary text-book of histology in the English language.—*The Boston Med. and Sur. Jour.*

— **A COURSE OF PRACTICAL HISTOLOGY.** New (2d) edition. In one 12mo. volume of 307 pages, with 59 engravings. Cloth, \$2.25.

**SCHLEIF (WILLIAM). MATERIA MEDICA, THERAPEUTICS, PRESCRIPTION WRITING, MEDICAL LATIN, ETC.** 12mo., 352 pages. Cloth, \$1.50, *net*; flexible red leather, \$2.00, *net*. *Just ready.* *Lea's Series of Pocket Text-books.* Edited by BERN B. GALLAUDET, M. D. See page 18.

**SCHMITZ AND ZUMPT'S CLASSICAL SERIES.** Advanced Latin Exercises. Cloth, 60 cts. Schmidt's Elementary Latin Exercises. Cloth, 50 cents. Sallust. Cloth, 60 cents. Nepos. Cloth, 60 cents. Virgil. Cloth, 85 cents. Curtius. Cloth, 80 cents.

**SCHOFIELD (ALFRED T.). ELEMENTARY PHYSIOLOGY FOR STUDENTS.** In one 12mo. volume of 380 pages, with 227 engravings and 2 colored plates. Cloth, \$2.

**SCHREIBER (JOSEPH). A MANUAL OF TREATMENT BY MASSAGE AND METHODICAL MUSCLE EXERCISE.** Octavo volume of 274 pages, with 117 engravings.

**SENN (NICHOLAS). SURGICAL BACTERIOLOGY.** Second edition. In one octavo volume of 268 pages, with 13 plates, 10 of which are colored, and 9 engravings. Cloth, \$2.

**SERIES OF CLINICAL MANUALS.** A Series of Authoritative Monographs on Important Clinical Subjects, in 12mo. volumes of about 550 pages, well illustrated. The following volumes are now ready: YEO on Food in Health and Disease, new (2d) edition, \$2.50; CARTER and FROST's Ophthalmic Surgery, \$2.25; HUTCHINSON on Syphilis, \$2.25; MARSH on Diseases of the Joints, \$2; OWEN on Surgical Diseases of Children, \$2; PICK on Fractures and Dislocations, \$2; SAVAGE on Insanity and Allied Neuroses, \$2.

For separate notices, see under various authors' names.

**SERIES OF STUDENT'S MANUALS.** See page 27.

**SIMON (CHARLES E.). CLINICAL DIAGNOSIS, BY MICROSCOPICAL AND CHEMICAL METHODS.** New (2d) edition. In one very handsome octavo volume of 530 pages, with 135 engravings and 14 full-page colored plates. Cloth, \$3.50. *Just ready.*

This book thoroughly deserves its success. It is a very complete, authentic and useful manual of the microscopical and chemical methods which are employed in diagnosis. Very excellent colored plates illustrate this work.—*New York Medical Journal.*

In all respects entirely up to date.—*Medical Record.*

The chapter on examination of the urine is the most complete and advanced that we know of in the English language.—*Canadian Practitioner.*



**SIMON (W.).** MANUAL OF CHEMISTRY. A Guide to Lectures and Laboratory Work for Beginners in Chemistry. A Text-book specially adapted for Students of Pharmacy and Medicine. New (6th) edition. In one 8vo. volume of 536 pages, with 46 engravings and 8 plates showing colors of 64 tests. Cloth, \$3.00, *net.* Just ready.

It is difficult to see how a better book could be constructed. No man who devotes himself to the practice of medicine need know more about chemistry than is contained between

the covers of this book.—*The North-western Lancet.*

Its statements are all clear and its teachings are practical.—*Virginia Med. Monthly.*

**SLADE (D. D.).** DIPHTHERIA; ITS NATURE AND TREATMENT. Second edition. In one royal 12mo. vol., 158 pp. Cloth, \$1.25.

**SMITH (EDWARD).** CONSUMPTION; ITS EARLY AND REMEDIABLE STAGES. In one 8vo. volume of 253 pp. Cloth, \$2.25.

**SMITH (J. LEWIS).** A TREATISE ON THE DISEASES OF INFANCY AND CHILDHOOD. Eighth edition, thoroughly revised and rewritten and much enlarged. In one large 8vo. volume of 983 pages, with 273 engravings and 4 full-page plates. Cloth, \$4.50; leather, \$5.50.

A safe guide for students and physicians.—*The Am. Jour. of Obstetrics.*

For years the leading text-book on children's diseases in America.—*Chicago Medical Recorder.*

The most complete and satisfactory text-book with which we are acquainted.—*American Gynecological and Obstetrical Journal.*

**SMITH (STEPHEN).** OPERATIVE SURGERY. Second and thoroughly revised edition. In one octavo volume of 892 pages, with 1005 engravings. Cloth, \$4; leather, \$5.

One of the most satisfactory works on modern operative surgery yet published. The book is a compen-

dium for the modern surgeon.—*Boston Medical and Surgical Journal.*

**SOLLY (S. EDWIN).** A HANDBOOK OF MEDICAL CLIMATOLOGY. In one handsome octavo volume of 462 pages, with engravings and 11 full-page plates, 5 of which are in colors. Cloth, \$4.00. Just ready.

A clear and lucid summary of what is known of climate in relation to its influence upon human beings.—*The Therapeutic Gazette.*

The book is admirably planned, clearly written, and the author speaks from an experience of thirty years as

an accurate observer and practical therapist.—*Maryland Med. Jour.*

Every practitioner of medicine should possess himself of a copy and study it, and we are sure he will never regret it.—*St. Louis Medical and Surgical Journal.*

**STILLÉ (ALFRED).** CHOLERA; ITS ORIGIN, HISTORY, CAUSATION, SYMPTOMS, LESIONS, PREVENTION AND TREATMENT. In one 12mo. volume of 163 pages, with a chart showing routes of previous epidemics. Cloth, \$1.25.

— **THERAPEUTICS AND MATERIA MEDICA.** Fourth and revised edition. In two octavo volumes, containing 1936 pages. Cloth, \$10; leather, \$12.



**STILLÉ (ALFRED), MAISCH (JOHN M.) AND CASPARI (CHAS. JR.). THE NATIONAL DISPENSATORY:** Containing the Natural History, Chemistry, Pharmacy, Actions and Uses of Medicines, including those recognized in the latest Pharmacopœias of the United States, Great Britain and Germany, with numerous references to the French Codex. Fifth edition, revised and enlarged, including the new U. S. Pharmacopœia, Seventh Decennial Revision. With Supplement containing the new edition of the National Formulary. In one magnificent imperial octavo volume of about 2025 pages, with 320 engravings. Cloth, \$7.25; leather, \$8. With ready reference Thumb-letter Index. Cloth, \$7.75; leather, \$8.50.

**STIMSON (LEWIS A.). A MANUAL OF OPERATIVE SURGERY.** New (3d) edition. In one royal 12mo. volume of 614 pages, with 306 engravings. Cloth, \$3.75.

A useful and practical guide for all students and practitioners.—*Am. Journal of the Medical Sciences.*

The book is worth the price for the illustrations alone.—*Ohio Medical Journal.*

**STIMSON (LEWIS A.). A TREATISE ON FRACTURES AND DISLOCATIONS.** In one handsome octavo volume of 831 pages, with 326 engravings and 20 plates. Cloth, \$5.00, *net*; leather, \$6.00, *net*.

Præeminently the authoritative text-book upon the subject. The vast experience of the author gives to his conclusions an unimpeachable value. The work is profusely illustrated. It will be found indispensable to the student and the practitioner alike.—*The Medical Age.*

Taken as a whole, the work is the best one in English to-day.—*St. Louis Medical and Surgical Journal.*

Pointed, practical, comprehensive, exhaustive, authoritative, well written and well arranged.—*Denver Medical Times.*

**STUDENT'S QUIZ SERIES.** Thirteen volumes, convenient, authoritative, well illustrated, handsomely bound in cloth. 1. Anatomy (double number); 2. Physiology; 3. Chemistry and Physics; 4. Histology, Pathology, and Bacteriology; 5. Materia Medica and Therapeutics; 6. Practice of Medicine; 7. Surgery (double number); 8. Genito-Urinary and Venereal Diseases; 9. Diseases of the Skin; 10. Diseases of the Eye, Ear, Throat and Nose; 11. Obstetrics; 12. Gynecology; 13. Diseases of Children. Price, \$1 each, except Nos. 1 and 7, *Anatomy and Surgery*, which being double numbers are priced at \$1.75 each. Full specimen circular on application to publishers.

**STUDENT'S SERIES OF MANUALS.** 12mos. of from 300–540 pages, profusely illustrated, and bound in red limp cloth. HERMAN'S First Lines in Midwifery, \$1.25; LUFF'S Manual of Chemistry, \$2; BRUCE'S Materia Medica and Therapeutics (sixth edition), \$1.50, *net*. BELL'S Comparative Anatomy and Physiology, \$2; ROBERTSON'S Physiological Physics, \$2; GOULD'S Surgical Diagnosis, \$2; KLEIN'S Elements of Histology (5th edition), \$2.00, *net*; PEPPER'S Surgical Pathology, \$2; TREVES' Surgical Applied Anatomy, \$2; RALFE'S Clinical Chemistry, \$1.50; and CLARKE and LOCKWOOD'S Dissector's Manual, \$1.50. The following is in press: PEPPER'S Forensic Medicine.

For separate notices, see under various author's names.



**STURGES (OCTAVIUS).** AN INTRODUCTION TO THE STUDY OF CLINICAL MEDICINE. In one 12mo. volume. Cloth, \$1.25.

**SUTTON (JOHN BLAND).** SURGICAL DISEASES OF THE OVARIES AND FALLOPIAN TUBES. Including Abdominal Pregnancy. In one 12mo. volume of 513 pages, with 119 engravings and 5 colored plates. Cloth, \$3.

**TAIT (LAWSON).** DISEASES OF WOMEN AND ABDOMINAL SURGERY. Vol. I. contains 546 pages and 3 plates. Cloth, \$3.

**TANNER (THOMAS HAWKES)** ON THE SIGNS AND DISEASES OF PREGNANCY. From the second English edition. In one octavo volume of 490 pages, with 4 colored plates and 16 engravings. Cloth, \$4.25.

**TAYLOR (ALFRED S.).** MEDICAL JURISPRUDENCE. New American from the twelfth English edition, specially revised by CLARK BELL, Esq., of the N. Y. Bar. In one 8vo. vol. of 831 pages, with 54 engravings and 8 full-page plates. Cloth, \$4.50; leather, \$5.50 *Just ready.*

To the student, as to the physician, we would say, get *Taylor* first, and then add as means and inclination enable you.—*American Practitioner and News.*

It is the authority accepted as final by the courts of all English-speaking countries. This is the important consideration for medical men, since in the event of their being summoned as experts or wit-

nesses, it strongly behooves them to be prepared according to the principles and practice everywhere accepted. The work will be found to be thorough, authoritative and modern.—*Albany Law Journal.*

Probably the best work on the subject written in the English language. The work has been thoroughly revised and is up to date.—*Pacific Medical Journal.*

— ON POISONS IN RELATION TO MEDICINE AND MEDICAL JURISPRUDENCE. Third American from the third London edition. In one octavo volume of 788 pages, with 104 illustrations. Cloth, \$5.50; leather, \$6.50.

**TAYLOR (ROBERT W.).** THE PATHOLOGY AND TREATMENT OF VENEREAL DISEASES. In one very handsome octavo volume of 1002 pages, with 230 engravings and 8 colored plates. Cloth, \$5.00, *net*; leather, \$6.00, *net*.

By long odds the best work on venereal diseases.—*Louisville Medical Monthly.*

In the observation and treatment of venereal diseases his experience has been greater probably than that of any other practitioner of this continent.—*New York Medical Journal.*

The clearest, most unbiased and ably presented treatise as yet published on this vast subject.—*The Medical News.*

Decidedly the most important and authoritative treatise on venereal

diseases that has in recent years appeared in English.—*American Journal of the Medical Sciences.*

It is a veritable storehouse of our knowledge of the venereal diseases. It is commended as a conservative, practical, full exposition of the greatest value.—*Chicago Clinical Review.*

The best work on venereal diseases in the English language. It is certainly above everything of the kind.—*The St. Louis Medical and Surgical Journal.*



**TAYLOR (ROBERT W.). A PRACTICAL TREATISE ON SEXUAL DISORDERS IN THE MALE AND FEMALE.** In one 8vo. vol. of 448 pp., with 73 engravings and 8 colored plates.

The author has presented to the profession the ablest and most scientific work as yet published on sexual disorders, and one which, if carefully followed, will be of unlimited value to both physician and patient.—*Medical News.*

—**A CLINICAL ATLAS OF VENEREAL AND SKIN DISEASES.** Including Diagnosis, Prognosis and Treatment. In eight large folio parts, measuring 14 x 18 inches, and comprising 213 beautiful figures on 58 full-page chromo-lithographic plates, 85 fine engravings and 425 pages of text. Complete work now ready. Price per part, sewed in heavy embossed paper, \$2.50. Bound in one volume, half Russia, \$27; half Turkey Morocco, \$28. *For sale by subscription only.* Address the publishers. Specimen plates by mail on receipt of ten cents.

**TAYLOR (SEYMOUR). INDEX OF MEDICINE.** A Manual for the use of Senior Students and others. In one large 12mo. volume of 802 pages. Cloth, \$3.75.

**THOMAS (T. GAILLARD) AND MUNDE (PAUL F.). A PRACTICAL TREATISE ON THE DISEASES OF WOMEN.** Sixth edition, thoroughly revised by PAUL F. MUNDE, M. D. In one large and handsome octavo volume of 824 pages, with 347 engravings. Cloth, \$5; leather, \$6.

The best practical treatise on the subject in the English language. It will be of especial value to the general practitioner as well as to the specialist. The illustrations are very satisfactory. Many of them are new and are particularly clear and attractive.—*Boston Med. and Sur. Jour.*

This work, which has already gone through five large editions, and has been translated into French, German, Spanish and Italian, is the most practical and at the same time the most complete treatise upon the subject.—*The Archives of Gynecology, Obstetrics and Pediatrics.*

**THOMPSON (SIR HENRY). CLINICAL LECTURES ON DISEASES OF THE URINARY ORGANS.** Second and revised edition. In one octavo vol. of 203 pp., with 25 engravings. Cloth, \$2.25.

—**THE PATHOLOGY AND TREATMENT OF STRICTURE OF THE URETHRA AND URINARY FISTULÆ.** From the third English edition. In one octavo volume of 359 pages, with 47 engravings and 3 lithographic plates. Cloth, \$3.50.

**THOMSON (JOHN). DISEASES OF CHILDREN.** In one crown octavo volume of 350 pages, with 52 illus. Cloth, \$1.75, *net.* Just ready.

**TODD (ROBERT BENTLEY). CLINICAL LECTURES ON CERTAIN ACUTE DISEASES.** In one 8vo. vol. of 320 pp., cloth, \$2.50.

**TREVES (FREDERICK). OPERATIVE SURGERY.** In two 8vo. vols. containing 1550 pp., with 422 illus. Cloth, \$9; leath., \$11.

—**A SYSTEM OF SURGERY.** In Contributions by Twenty-five English Surgeons. In two large octavo volumes. Vol. I., 1178 pages, with 463 engravings and 2 colored plates. Vol. II., 1120 pages, with 487 engravings and 2 colored plates. Complete work, cloth, \$16.00.



**TREVES (FREDERICK).** SURGICAL APPLIED ANATOMY. In one 12mo. volume of 540 pages, with 61 engravings. Cloth, \$2. See *Student's Series of Manuals*, page 27.

**TUTTLE (GEORGE M.).** A POCKET TEXT-BOOK OF DISEASES OF CHILDREN. In one handsome 12mo. volume of 374 pages, with 5 plates. *Just ready.* Cloth, \$1.50, *net*; flexible red leather, \$2.00, *net.* *Lea's Series of Pocket Text-books*, edited by BERN B. GALLAUDET, M. D. See p. 18.

**VAUGHAN (VICTOR C.) AND NOVY (FREDERICK G.).** PTOMAINS, LEUCOMAINS, TOXINS AND ANTITOXINS, or the Chemical Factors in the Causation of Disease. New (3d) edition. In one 12mo. volume of 603 pages. Cloth, \$3.

The work has been brought down to date, and will be found entirely satisfactory.—*Journal of the American Medical Association.*

The most exhaustive and most recent presentation of the subject.—*American Jour. of the Med. Sciences.*

The present edition has been not only thoroughly revised throughout but also greatly enlarged, ample consideration being given to the new subjects of toxins and antitoxins.—*Tri-State Medical Journal.*

**VISITING LIST.** THE MEDICAL NEWS VISITING LIST for 1900. Four styles: Weekly (dated for 30 patients); Monthly (undated for 120 patients per month); Perpetual (undated for 30 patients each week); and Perpetual (undated for 60 patients each week). The 60-patient book consists of 256 pages of assorted blanks. The first three styles contain 32 pages of important data, thoroughly revised, and 160 pages of assorted blanks. Each in one volume, price, \$1.25. With thumb-letter index for quick use, 25 cents extra. Special rates to advance-paying subscribers to THE MEDICAL NEWS or THE AMERICAN JOURNAL OF THE MEDICAL SCIENCES, or both. See p. 32.

**WATSON (THOMAS).** LECTURES ON THE PRINCIPLES AND PRACTICE OF PHYSIC. A new American from the fifth and enlarged English edition, with additions by H. HARTSHORNE, M. D. In two large 8vo. vols. of 1840 pp., with 190 cuts. Cloth, \$9; leather, \$11.

**WEST (CHARLES).** LECTURES ON THE DISEASES PECULIAR TO WOMEN. Third American from the third English edition. In one octavo volume of 543 pages. Cloth, \$3.75; leather, \$4.75.

— ON SOME DISORDERS OF THE NERVOUS SYSTEM IN CHILDHOOD. In one small 12mo. volume of 127 pages. Cloth, \$1.

**WHARTON (HENRY R.).** MINOR SURGERY AND BANDAGING. New (4th) edition. In one 12mo. volume of 594 pages, with 502 engravings, many of which are photographic. *Just ready.* \$3.00, *net.*

We know of no book which more thoroughly or more satisfactorily covers the ground of Minor Surgery and Bandaging.—*Brooklyn Medical Journal.*

Well written, conveniently arranged and amply illustrated. It covers the field so fully as to render it a valuable text-book, as well as a

work of ready reference for surgeons.—*North Amer. Practitioner.*

The part devoted to bandaging is perhaps the best exposition of the subject in the English language. It can be highly commended to the student, the practitioner and the specialist.—*The Chicago Medical Recorder.*



**WHITLA (WILLIAM).** DICTIONARY OF TREATMENT, OR THERAPEUTIC INDEX. Including Medical and Surgical Therapeutics. In one square octavo volume of 917 pages. Cloth, \$4.

**WILLIAMS (DAWSON).** THE MEDICAL DISEASES OF CHILDREN. In one 12mo. volume of 629 pages, with 18 illustrations. *Just ready.* Cloth, \$2.50, *net.*

The descriptions of symptoms are full, and the treatment recommended will meet general approval. Under each disease are given the symptoms, diagnoses, prognosis, complications, and treatment. The work is up to date in every sense.—*The Charlotte Medical Journal.*

**WILSON (ERASMUS).** A SYSTEM OF HUMAN ANATOMY. A new and revised American from the last English edition. Illustrated with 397 engravings. In one octavo volume of 616 pages. Cloth, \$4; leather, \$5.

— THE STUDENT'S BOOK OF CUTANEOUS MEDICINE. In one 12mo. volume. Cloth, \$3.50.

**WINCKEL** ON PATHOLOGY AND TREATMENT OF CHILD BED. Translated by JAMES R. CHADWICK, A. M., M. D. With additions by the Author. In one octavo volume of 484 pages. Cloth, \$4.

**WÖHLER'S** OUTLINES OF ORGANIC CHEMISTRY. Translated from the eighth German edition, by IRA REMSEN, M. D. In one 12mo. volume of 550 pages. Cloth, \$3.

**YEAR-BOOK OF TREATMENT** FOR 1892, 1893, 1896, 1897 and 1898. Critical Reviews for Practitioners of Medicine and Surgery. In contributions by 25 well-known medical writers. 12mos., about 500 pages each. Cloth, \$1.50. In combination with THE MEDICAL NEWS and THE AMERICAN JOURNAL OF THE MEDICAL SCIENCES, 75 cents.

**YEO (I. BURNEY).** FOOD IN HEALTH AND DISEASE. New (2d) edition. In one 12mo. volume of 592 pages, with 4 engravings. Cloth, \$2.50. See *Series of Clinical Manuals*, page 26.

We doubt whether any book on dietetics has been of greater or more widespread usefulness than has this much-quoted and much-consulted work of Dr. Yeo's. The value of the work is not to be overestimated.—*New York Medical Journal.*

— A MANUAL OF MEDICAL TREATMENT, OR CLINICAL THERAPEUTICS. Two volumes containing 1275 pages. Cloth, \$5.50.

**YOUNG (JAMES K.).** ORTHOPEDIC SURGERY. In one 8vo. volume of 475 pages, with 286 illustrations. Cloth, \$4; leather, \$5.

In studying the different chapters, one is impressed with the thoroughness of the work. The illustrations are numerous—the book thoroughly practical.—*Medical News.*

It is a thorough, a very comprehensive work upon this legitimate surgical specialty and every page abounds with evidences of practicality. It is the clearest and most modern work upon this growing department of surgery.—*The Chicago Clinical Review.*



# PERIODICALS.

## PROGRESSIVE MEDICINE.

A Quarterly Digest of New Methods, Discoveries, and Improvements in the Medical and Surgical Sciences by Eminent Authorities. Edited by Dr. Hobart Amory Hare. In four abundantly illustrated, cloth bound, octavo volumes, of 400-500 pages each, issued quarterly, commencing March 1st, 1899. Per annum (4 volumes), \$10.00 delivered.

## THE MEDICAL NEWS.

Weekly, \$4.00 per Annum.

Each number contains 32 quarto pages, abundantly illustrated. A crisp, fresh weekly professional newspaper.

## THE AMERICAN JOURNAL OF THE MEDICAL SCIENCES.

Monthly, \$4.00 Per Annum.

Each issue contains 128 octavo pages, fully illustrated. The most advanced and enterprising American exponent of scientific medicine.

## THE MEDICAL NEWS VISITING LIST.

Four styles, Weekly (dated for 30 patients); Monthly (undated, for 120 patients per month); Perpetual (undated, for 30 patients weekly per year); and Perpetual (undated, for 60 patients per year). Each style in one wallet-shaped book, leather bound, with pocket, pencil and rubber. Price, each, \$1.25. Thumb-letter index, 25 cents extra.

## THE MEDICAL NEWS POCKET FORMULARY.

Containing 1600 prescriptions representing the latest and most approved methods of administering remedial agents. Strongly bound in leather; with pocket and pencil. Price, \$1.50, net.

## COMBINATION RATES:

PER ANNUM.	American Journal of the	Alone.	In Combination.	
	Medical Sciences, . . . . .	\$ 4.00	\$7.50	\$15.00
	Medical News . . . . .	4.00		
	Progressive Medicine . . . . .	10.00		
	Medical News Visiting List . . . . .	1.25		
	Medical News Formulary . . . . .	1.50 net,		

In all \$20.75 for \$16.00

First four above publications in combination . . . \$15.75

All above publications in combination . . . 16.00

Other Combinations will be quoted on request.


Full Circulars and Specimens free.

**LEA BROTHERS & CO., Publishers,**


706, 708 & 710 Sansom St., Philadelphia.

111 Fifth Avenue, New York.











RD 31

S+5

Stringer

Annex

1900

Operative Surgery

Res. E Kaplan - Dept. Anatomy

ON PERSONAL RESERVE SHELF

11-10-56

MAR 23 1965

Hibbs Libr'y

COLUMBIA UNIVERSITY LIBRARIES (hsl, stx)

RD 31 S15 1900 C.1

A manual of operative surgery.



2002109263



