

**Brain and spinal cord : a manual for the study of the morphology and fibre-tracts of the central nervous system / by Emil Villiger ... tr. by George A. Piersol.**

**Contributors**

Villiger, Emil, 1870-1931.

Piersol, George A.

Augustus Long Health Sciences Library

**Publication/Creation**

Philadelphia & London : Lippincott, [1912], [©1912]

**Persistent URL**

<https://wellcomecollection.org/works/p9bjsvd4>

**License and attribution**

This material has been provided by This material has been provided by the Augustus C. Long Health Sciences Library at Columbia University and Columbia University Libraries/Information Services, through the Medical Heritage Library. The original may be consulted at the the Augustus C. Long Health Sciences Library at Columbia University and Columbia University. where the originals may be consulted.

This work has been identified as being free of known restrictions under copyright law, including all related and neighbouring rights and is being made available under the Creative Commons, Public Domain Mark.

You can copy, modify, distribute and perform the work, even for commercial purposes, without asking permission.

**wellcome  
collection**

Wellcome Collection  
183 Euston Road  
London NW1 2BE UK  
T +44 (0)20 7611 8722  
E [library@wellcomecollection.org](mailto:library@wellcomecollection.org)  
<https://wellcomecollection.org>

COLUMBIA LIBRARIES OFFSITE  
HEALTH SCIENCES STANDARD



HX64085635

QM451 .V71

Brain and spinal cor

EMIL VILLIGER  
BRAIN AND SPINAL CORD  
PIERSOL

**RECAP**



Q.M451

V71


cop. 2

**Columbia University**  
**in the City of New York**


COLLEGE OF  
PHYSICIANS AND SURGEONS  
LIBRARY




DR. C. G. DYKE







Digitized by the Internet Archive  
in 2010 with funding from  
Columbia University Libraries



# BRAIN AND SPINAL CORD

A MANUAL FOR THE STUDY OF THE MORPHOLOGY AND  
FIBRE-TRACTS OF THE CENTRAL NERVOUS SYSTEM

BY

DR. MED. EMIL VILLIGER

PRIVATDOZENT IN NEUROLOGY AND NEUROPATHOLOGY IN THE UNIVERSITY OF BASEL

TRANSLATED BY

GEORGE A. PIERSOL, M.D., Sc.D.

PROFESSOR OF ANATOMY IN THE UNIVERSITY OF PENNSYLVANIA

*FROM THE THIRD GERMAN EDITION*

*WITH 232 ILLUSTRATIONS*



PHILADELPHIA & LONDON  
J. B. LIPPINCOTT COMPANY



REPLACE  
AND REPAIR

Replace

QM451

V71

cop. 2

Copyright, 1912, by J. B. LIPPINCOTT CO.

## TRANSLATOR'S NOTE

---

THE increasing attention given to the study of the Central Nervous System has emphasized the need of a suitable guide for laboratory exercises. The usefulness of Dr. Villiger's excellent manual has been greatly increased by the addition of Part III, illustrating the architecture of the brain-stem by series of consecutive sections, which first appeared in the second edition. While of much assistance to the student in identifying details under the microscope, the series so well represents the actual preparations, that close study of the illustrations alone will amply repay where satisfactory specimens are inaccessible.

The translator has respected the author's desire to retain the brevity and clearness which characterize the book; he has refrained, therefore, from amplifying the text, which appears, with slight changes, as in the original. Through the courtesy of the firm of Wilhelm Engelmann, of Leipzig, in supplying advance proofs, it has been possible to include the new figures, which have been added to the third German edition. The selected bibliography, appended by the translator, will be of service, it is hoped, to those desirous of consulting the original papers or the more comprehensive works pertaining to the Central Nervous System.

PHILADELPHIA,

September, 1912.



0




## PREFACE TO THE THIRD EDITION

---

THE cordial reception accorded the second edition has rendered necessary, within a short time, issuing a new edition. Radical changes or amplifications, notably the desired additions to the series of microscopical representations of brain sections, could not be undertaken. Notwithstanding the first intention to print the edition without alterations, the hearty coöperation of the publishers has made it possible to introduce, particularly in Part II, some new figures, to which I wish to direct especial attention.

E. VILLIGER.

BASEL,  
April, 1912.





## AUTHOR'S PREFACE

---


THE second edition presents substantial changes. While some sections, pertaining to morphology as well as to fibre-tracts, have been simplified and made clearer, others have been treated with greater completeness. Certain figures have been replaced by better ones, and many new ones, relating to the paths of conduction, have been added. The chief change, however, lies in the addition of Part III, in which I have attempted to meet the often expressed wish, that the conduction-paths be represented not only by diagrams, but also by microscopical pictures. I am well aware that this third part presents considerable gaps. Unfortunately at the time only vertical sections through the brain-stem were at my disposal; further, the drawing of the new and especially the microscopical illustrations made such claims upon me, that it was impossible to satisfy all desires. Nevertheless, I indulge the hope that the study of the fibre-tracts will be facilitated by the microscopical representations now given and by the newly added schematic figures.

Moreover, I wish particularly to emphasize, that this second edition remains a manual and as such is designed primarily to assist the student, with all possible conciseness and clearness, in the study of the anatomy of the central nervous system.

It is my privilege to take this opportunity of expressing my sincerest thanks to Professors J. Kollmann and N. K. Corning for their kindness in placing at my disposal numerous microscopical preparations. My especial acknowledgment is due the firm of Wilhelm Engelmann, of Leipzig, whose cordial coöperation enabled me to carry out the radical changes made necessary by the introduction of larger figures, particularly the microscopical illustrations.

E. VILLIGER.





# CONTENTS

## PART I.—MORPHOLOGY.

	PAGE		PAGE
Subdivision of the Central Nervous System...	3	Mesencephalon—Mid-Brain .....	66
Development of the Brain.....	4	Lamina quadrigemina.....	66
Development of the Spinal Cord.....	8	Pedunculi cerebri .....	66
Form, Size and Weight of the Brain.....	9	Aquaeductus cerebri (Sylvii).....	68
General Consideration of the Brain.....	11	Gray Masses of the Mid-Brain.....	68
Telencephalon—End-Brain .....	17	Summary.....	69
Pallium—Cerebral Mantle.....	18	Isthmus rhombencephali.....	70
Rhencephalon—Olfactory Brain .....	25	Metencephalon.....	71
1. Lobus olfactorius.....	26	Pons Varolii.....	71
A. Lobus olfactorius anterior....	27	Cerebellum.....	72
B. Lobus olfactorius posterior....	29	A. Lobus superior .....	72
2. Gyrus fornicatus.....	30	B. Lobus posterior.....	73
3. Hippocampus .....	32	C. Lobus inferior.....	74
4. Gyrus dentatus.....	32	Myelencephalon—Medulla oblongata.....	77
5. Uncus—Gyrus uncinatus. Gyrus intralimbicus. Gyrus fascio- laris .....	35	Ventriculus quartus .....	79
6. Gyri Andreae Retzii.....	36	Fossa rhomboidea.....	81
Pars optica hypothalami.....	37	Gray Masses of the Rhombencephalon.....	82
Internal Configuration.....	38	Summary of the Rhombencephalon.....	85
Gray Masses and Nuclei.....	46	Brain-Membranes—Meninges .....	86
Summary of Telencephalon.....	50	Dura Mater.....	87
Diencephalon—Inter-Brain.....	52	Arachnoidea.....	88
Thalamus opticus.....	54	Pia Mater .....	88
Pars mamillaris hypothalami.....	56	Spinal Cord—Medulla spinalis .....	89
Ventriculus tertius.....	57	External Configuration .....	89
The Nuclei of the Diencephalon.....	58	Internal Configuration.....	90
Summary.....	63	Membranes of the Spinal Cord.....	93
		Dura mater spinalis.....	93
		Arachnoidea spinalis .....	93
		Pia mater spinalis.....	93

## PART II.—FIBRE-TRACTS.

Methods of Investigating the Fibre-Tracts ....	97	II. Rhencephalon .....	118
Histogenesis of the Nervous System.....	102	Bulbus olfactorius.....	118
Development of the Ependyma and Neu- rogia Cells.....	103	Gyrus fornicatus.....	119
Development of the Nerve-Cells.....	105	Hippocampus and Gyrus dentatus....	120
Development of the Cells of the Cerebro- Spinal Ganglia and of the Sympathetic Ganglia .....	105	Hippocampus .....	121
The Formed Elements of the Nervous System .....	106	Gyrus dentatus .....	122
A. The Support-Cells .....	106	Cerebral Localization.....	123
B. The Nerve-Cells.....	107	The Motor Centre.....	124
Microscopical Structure of the Cerebral Cortex.....	114	The Sensory Centres—Sense-Centres ...	126
I. Cortex of the Pallium.....	114	The Speech Centres.....	128
		General Division of the Paths of Conduction...	131
		Conduction Paths of the Telencephalon.....	134
		1. Association Fibres .....	134
		2. Commissural Fibres.....	135
		3. Projection Fibres.....	135




	PAGE		PAGE
A. Short Paths.....	135	1. Paths of the Anterior Column ....	161
B. Long Paths.....	137	2. Paths of the Lateral Column.....	161
Radiatio corporis striati.....	144	3. Paths of the Posterior Column ....	163
Connections of the Corpus Striatum.....	144	Medulla Oblongata.....	166
Fibre-Tracts of the Rhinencephalon.....	144	Origin of the Cerebral Nerves.....	172
1. Peripheral Tract.....	144	Nervus olfactorius.....	172
2. Central Tract.....	145	Nervus opticus.....	172
A. Connection of the bulbus olfactorius with the primary centres.....	145	Nervus oculomotorius.....	175
B. Connection of the primary centres with the secondary or cortical centres.....	145	Nervus trochlearis.....	176
3. Connection of the two primary centres.....	149	Nervus abducens.....	176
4. Further connections of the primary centres.....	149	Nervus trigeminus.....	176
5. Connection of the two cortical centres.....	149	Nervus facialis and Nervus intermedius Wrisbergi.....	178
6. Further connections of the cortical centres.....	149	Nervus acusticus.....	179
Conduction Paths of the Diencephalon.....	150	1. Nervus cochleae.....	179
Conduction Paths of the Mesencephalon.....	151	2. Nervus vestibuli.....	181
Conduction Paths of the Metencephalon.....	154	Nervus glossopharyngeus and vagus.....	184
Microscopical structure of the Cerebellar Cortex and Fibre-Tracts.....	154	Nervus accessorius.....	185
Spinal Cord.....	159	Nervus hypoglossus.....	186
The Gray Matter.....	159	General Survey of the Principal Paths.....	186
The White Matter.....	160	A. Projection Paths.....	186
		I. Centripetal Paths.....	186
		1. Ascending sensory spinal paths.....	186
		2. Sensory paths of the cerebral nerves.....	188
		II. Centrifugal Paths.....	191
		B. Reflex Paths.....	192
		C. Association Paths.....	197

PART III.—SERIAL SECTIONS OF THE BRAIN-STEM.

A. From the anterior end of the corpus callosum to the quadrigeminal region.....	205	B. From the caudal part of the medulla oblongata to the quadrigeminal region.....	235
--	-----	---	-----



PART I.  
MORPHOLOGY.





# BRAIN AND SPINAL CORD

## MORPHOLOGY

The brain and the spinal cord together constitute the central nervous system (*systema nervorum centrale*).

The **brain** (*encephalon*) is that part of the central nervous system lodged within the cranial case; the **spinal cord** (*medulla spinalis*) is that part within the vertebral canal. The boundary between the two is neither macroscopically nor microscopically sharply defined. The lowest segment of the brain corresponds perfectly in form and structure with the uppermost one of the spinal cord and is called, therefore, *medulla oblongata*—the lengthened marrow. An approximate coarse boundary line is supplied by the lowest bundle of the so-called pyramidal decussation, or by the highest root-bundle of the first cervical nerve.

A further separation of the brain into different segments is best accomplished by embryology. The nervous system develops from a broad axial stripe of the outer germ-layer, the ectoderm, that immediately overlies the chorda dorsalis or noto cord. Within this stripe, the cells of the outer germ-layer grow into elongated cylindrical or spindle-form elements, while those within the adjoining ectoderm become flattened. In this manner the outer germ-layer differentiates into two zones: (1) the thinned out *cuticle plate* and (2) the thicker axially placed neural or *medullary plate*.

The two zones soon become more sharply defined from each other; the medullary plate curves ventrally and at its margins rises above the surface of the germ. In this manner arise the *medullary ridges*, which include between them the broad, and at first shallow, *medullary groove*. The ridges are simple folds of the outer germ-layer, along the juncture of the medullary and cuticle plates.

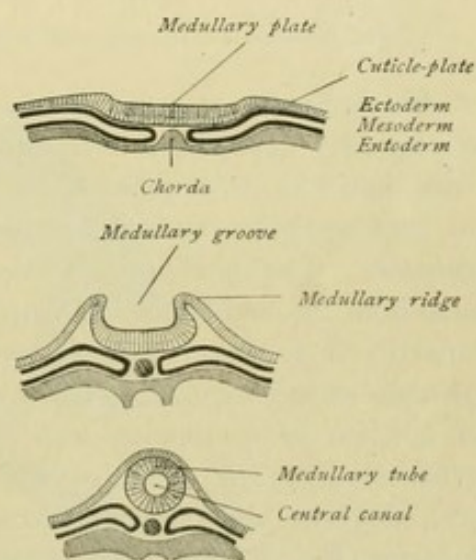


FIG. 1.—Schematic representation of the formation of the medullary tube from the outer germ-layer.



The medullary plates are converted into the *medullary tube* very early. This tube is formed by a typical folding process. The medullary ridges progressively rise above the dorsal surface of the embryo, bend medially and grow towards each other until their summits meet and later fuse. As the medullary ridges rise above the surface of the embryonic area, they draw along the cuticle-plate; the latter, however, does not come into relation with the nervous system, but becomes the epithelial covering of the body. In the medullary tube, which encloses a cleft-like space, the central canal (*canalis centralis*), filled with primary lymph, we distinguish the *brain-tube* and the *spinal tube*; from the former develops the brain and from the latter the spinal cord.

### DEVELOPMENT OF THE BRAIN.

The fundamental form is the simple brain-tube. In consequence of increased growth in certain parts and diminished growth in others, the brain-tube early exhibits a segmentation. At first it consists of three dilatations, the **primary brain-vesicles**,

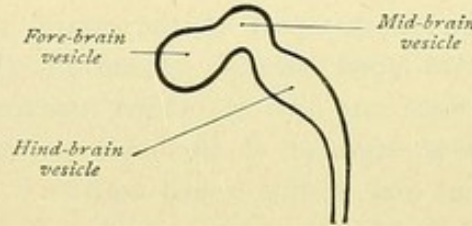
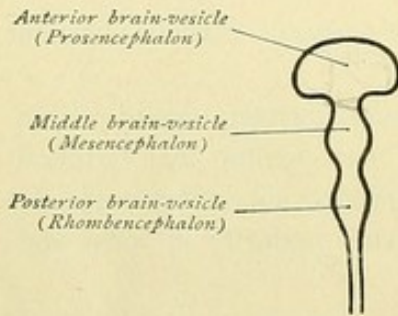


FIG. 2.—Schematic representation of the three primary brain-vesicles.

separated by two annular constrictions, the vesicles being designated as *anterior*, *middle* and *posterior*. From these three brain-vesicles later arise the three chief divisions: the *Fore-brain* or *Prosencephalon*, the *Mid-brain* or *Mesencephalon* and the *Hind-brain* or *Rhombencephalon*. The three primary vesicles subsequently give rise to five **secondary brain-vesicles**, since the fore-brain differentiates into the *telencephalon* and the *diencephalon*, while the hind-brain divides into the *metencephalon* and the *myelencephalon*. The hind-brain is separated from the mid-brain by a narrow constricted segment, the *isthmus* (*isthmus rhombencephali*). The myelencephalon is continuous with the spinal cord. The primitive brain-tube, therefore, differentiates into six divisions (Fig. 3): the telencephalon, the diencephalon, the mesencephalon, the isthmus, the metencephalon and the myelencephalon.

In the later stages, the development of the nervous substance is especially vigorous in the two lateral walls of the neural tube, while the median areas of its floor and roof (the *floor-* and *roof-plates*) for the most part remain thin and epithelioid. The different divisions of the brain-tube participate in the further development in very

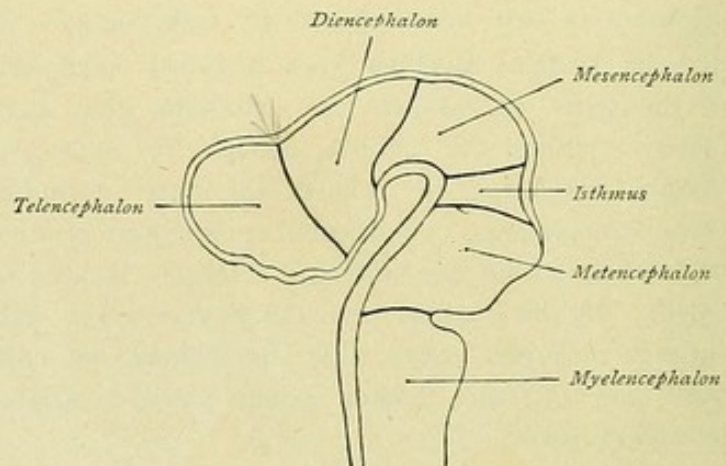


FIG. 3.—The five secondary brain-vesicles. (His.)



unlike degree. Certain segments remain far behind, while others far outstrip their surroundings in consequence of their vigorous growth. Along with the displacement of

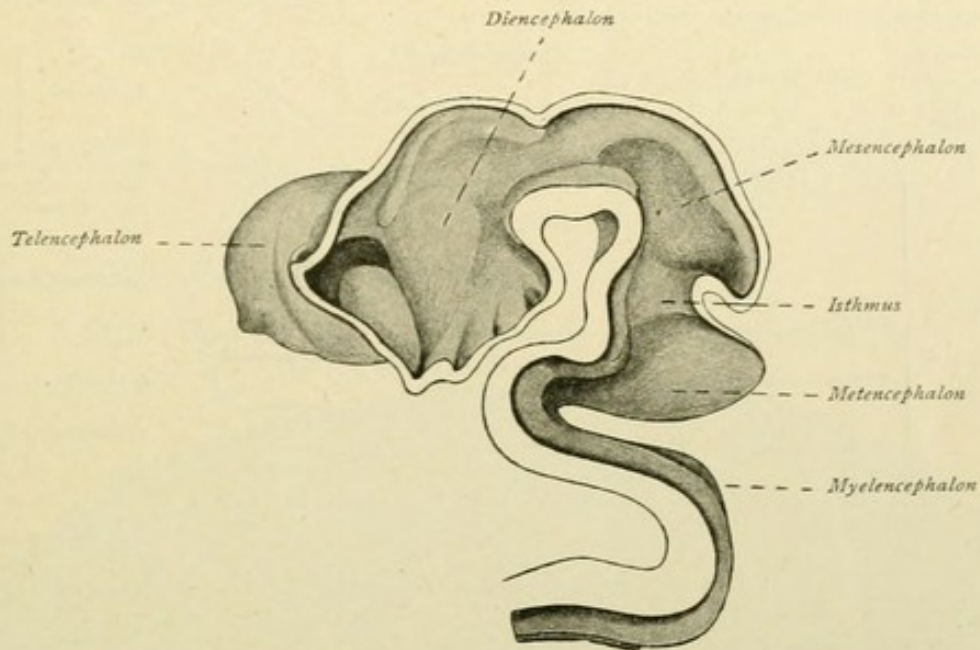


FIG. 4.—Brain of human embryo of five weeks. After a model by His.

certain brain-segments induced by unequal growth, other processes contribute to the effacement of the original fundamental plan of the whole. Among such factors belong partic-

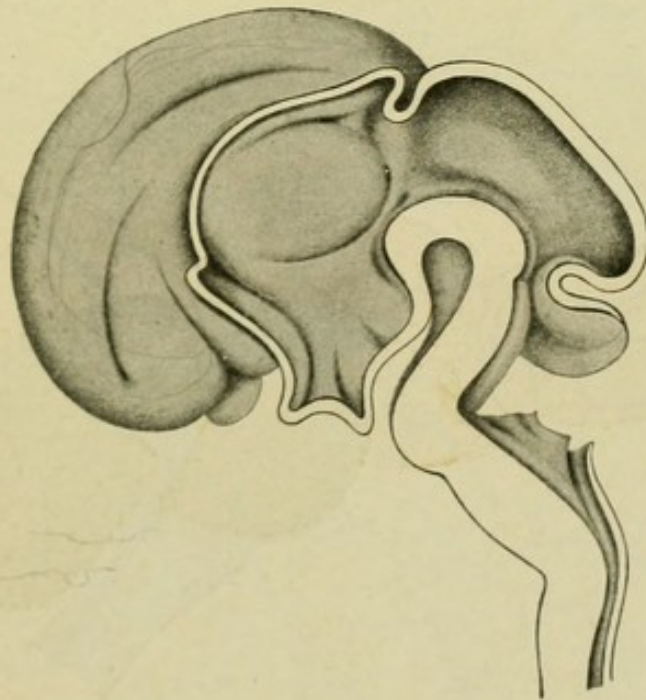


FIG. 5.—Brain of human embryo of the third month. After a model by His.

ularly the appearance of robust cross-fibres (corpus callosum, pons). Consequently it is impossible to mark off superficially the individual segments on the brain of the adult.



The developmental relations of the parts of the brain to the individual brain-vesicles is best explained by the accompanying table after His. It will serve as guide in the consideration of the morphology. (Compare also Figs. 5, 6, 7, 8, 9.)

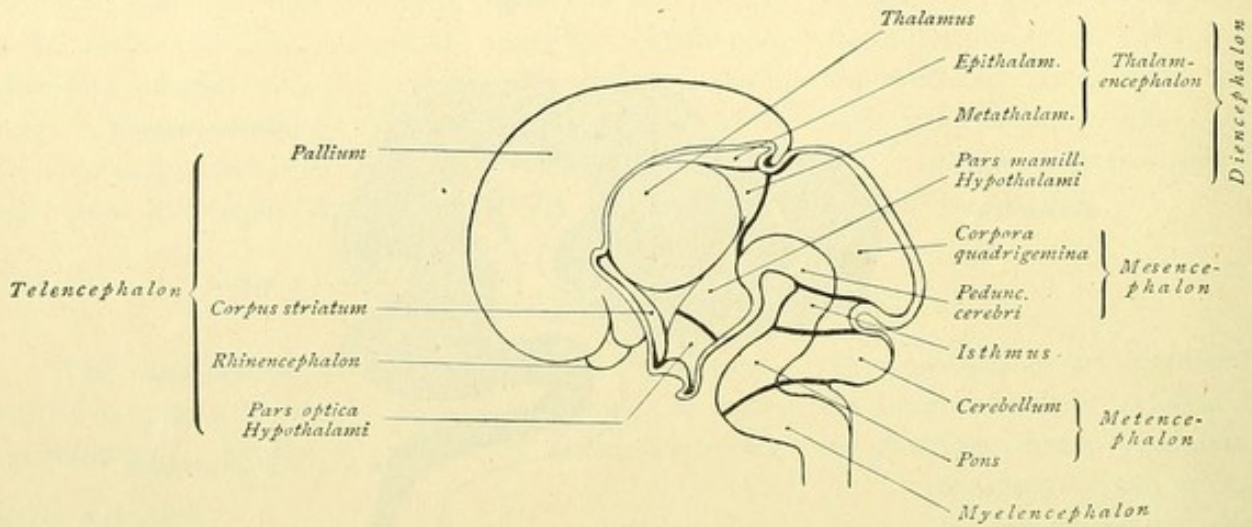


FIG. 6.—Diagram showing the further development of the five secondary brain-vesicles. (His.)

The prosencephalon and the mesencephalon together are also designated the *cerebrum* or great brain. The *brain-stem* (*truncus cerebri*) embraces the so-called the *brain-*

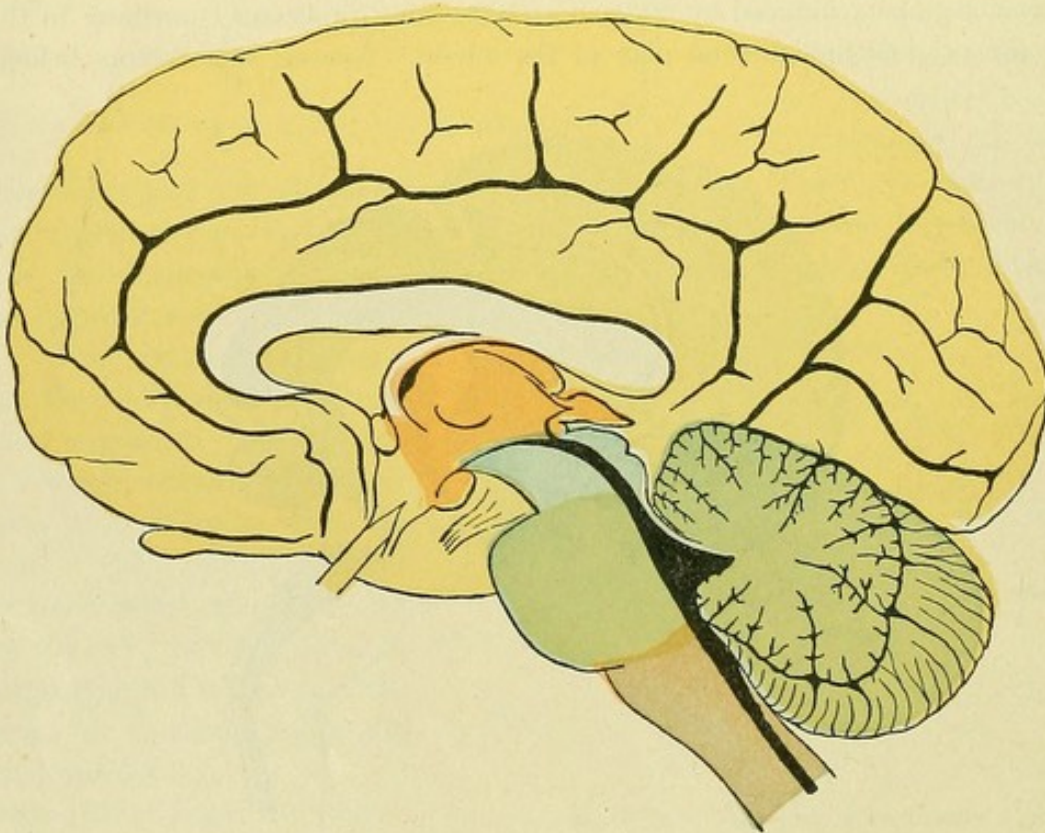


FIG. 7.—Median sagittal section through the adult brain. Telencephalon is yellow; diencephalon red; mesencephalon blue; metencephalon green; myelencephalon violet.

*ganglia*; it consists of the stem of the end-brain, the inter-brain, the mid-brain, the isthmus, the pons and the medulla oblongata.



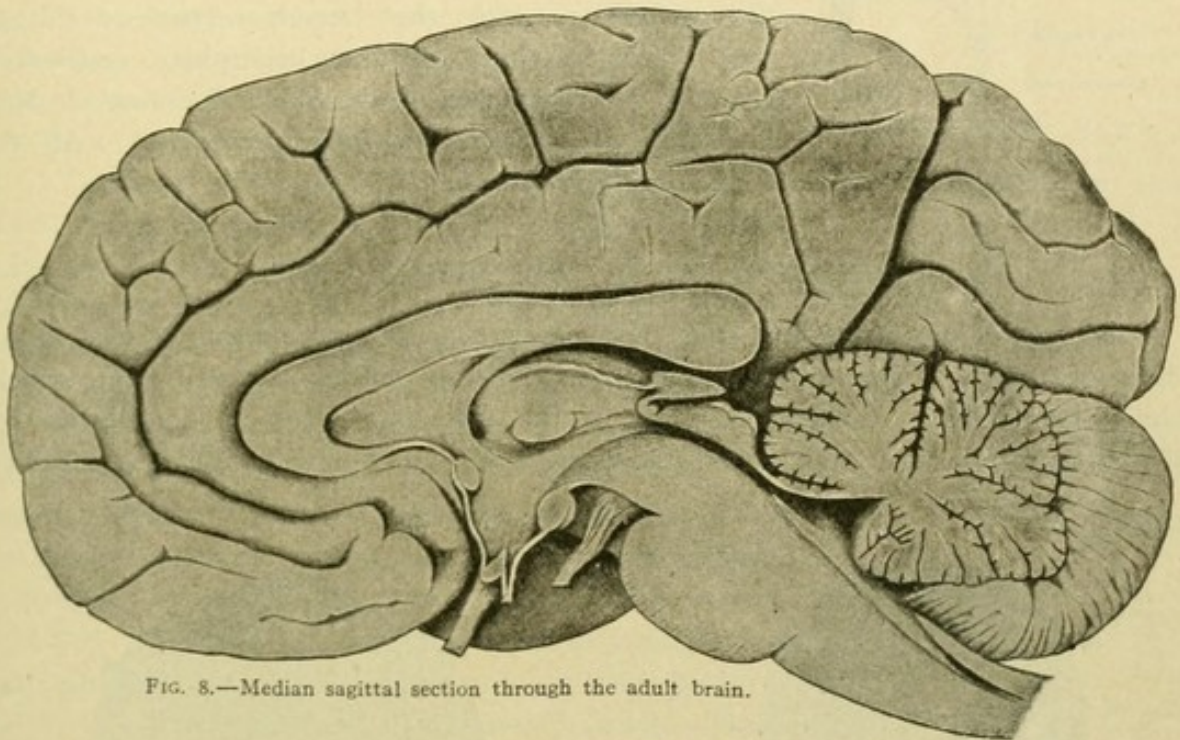
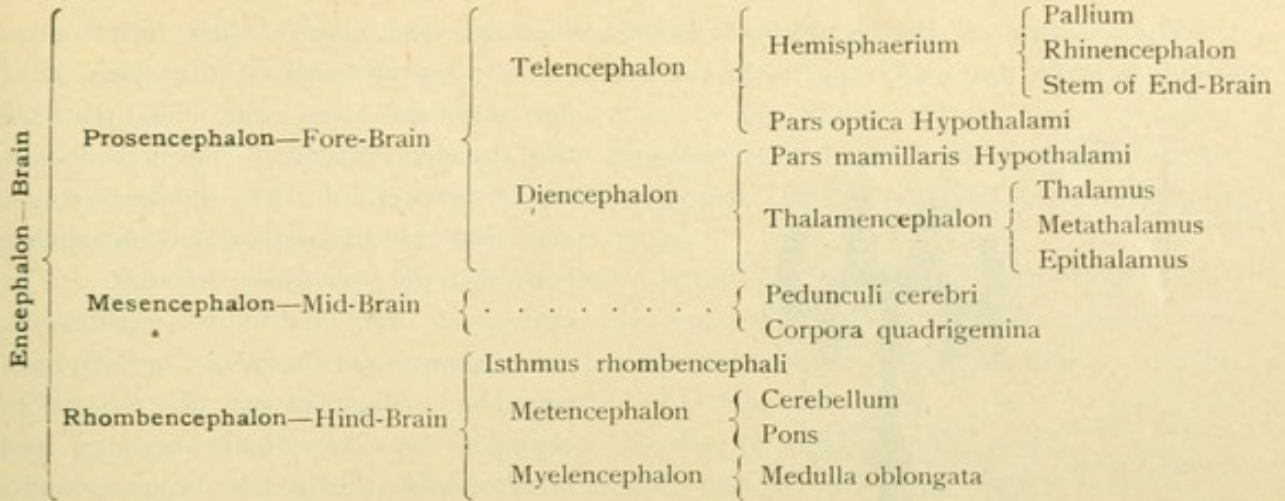


FIG. 8.—Median sagittal section through the adult brain.

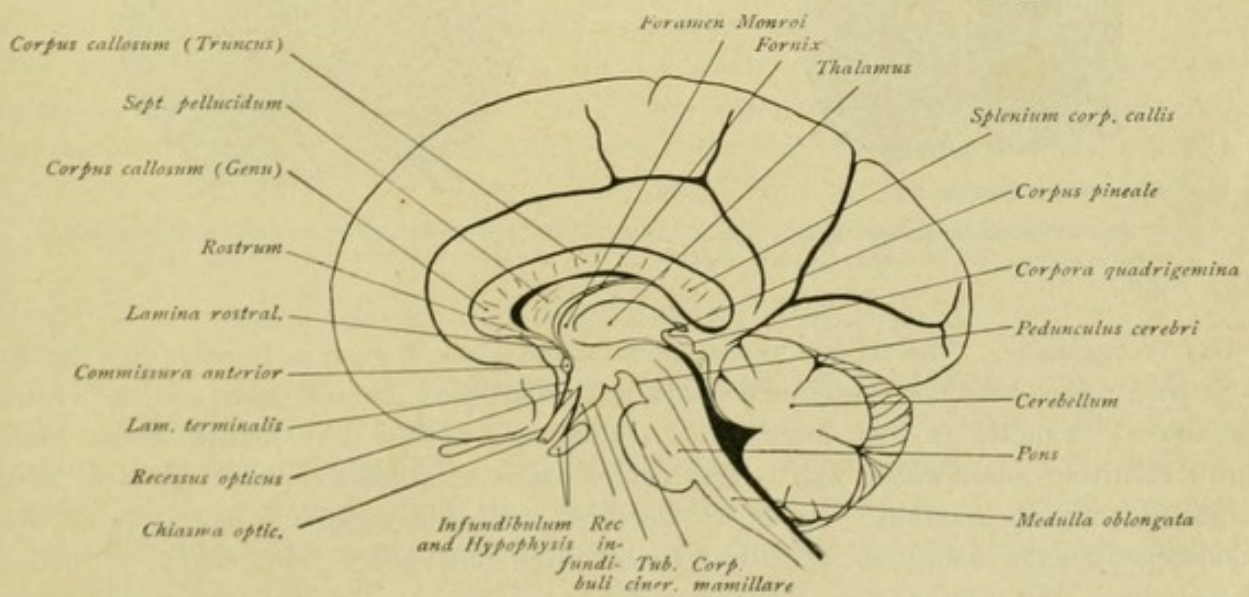


FIG. 9.—Median sagittal section through the brain.



The cavities of the embryonal brain-vesicles likewise change their form under the influence of the various growth-processes. The central canal of the spinal cord

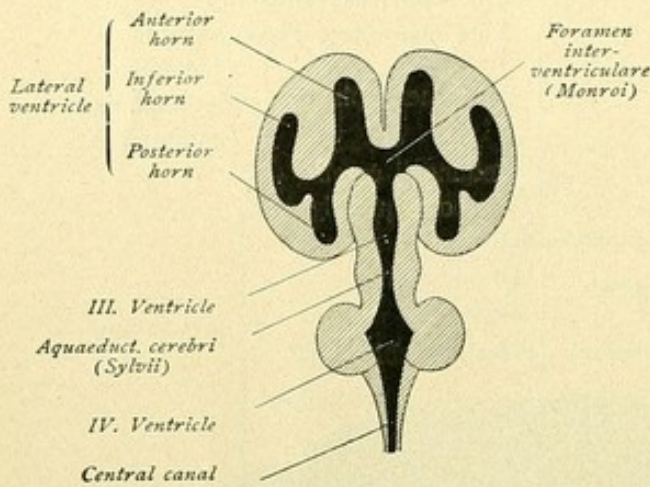


FIG. 10.—Diagram showing the brain-ventricles.

is continued into the hind-part of the myelencephalon. The cavity of the fore-part of the myelencephalon and that of the entire metencephalon become the *fourth ventricle*. The cavity of the mid-brain remains as the *aquaeductus cerebri* or Sylvian aqueduct. The cavity of the dien-cephalon or inter-brain becomes the *third ventricle*, which communicates with the lateral ventricles—the cavities of the hemisphere-vesicles—by means of the Y-like foramen of Monro (*foramen interventriculare*). All these

spaces are filled with a fluid, the *liquor cerebro-spinalis*.

#### DEVELOPMENT OF THE SPINAL CORD.

The part of the neural tube that becomes the spinal cord appears of oval form on transverse section. The central canal forms a dorso-ventrally directed cleft, which is bounded laterally by the thickened walls of the medullary tube, but dorsally and ventrally by thinner parts of the same; therefore, a separation into a right and left half is

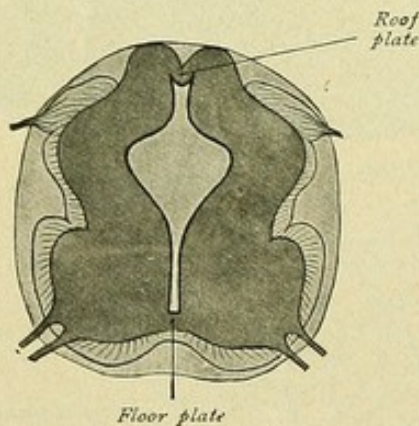


FIG. 11.—Cross-section of spinal cord of a human embryo of four and one-half weeks. (His.)

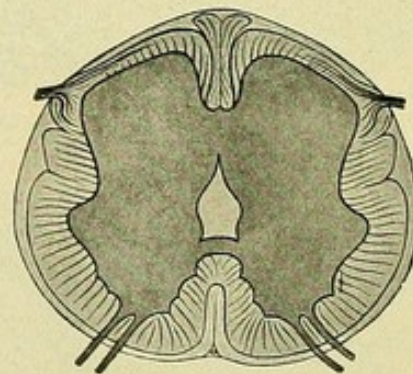


FIG. 12.—Cross-section of spinal cord of a human embryo of three months. (His.)

easily recognizable. The thinner dorsal and ventral walls appear as commissures behind and before, the dorsal or posterior commissure being called the *roof-plate* and the ventral or anterior commissure the *floor-plate*. During the further development, these plates grow relatively little, while both lateral halves continue to thicken, their growth being especially marked ventrally. In this locality on each side appears a ventral projection. Consequently, the floor-plate is pushed farther from the surface and, finally, a median longitudinal cleft, the *fissura mediana anterior*, is formed in front. A similar change



occurs in the dorsal region, the roof-plate being likewise pushed in and disappearing at the bottom of the *sulcus medianus posterior*. The spinal cord now consists of two robust lateral halves, separated from each other by an anterior fissure and a posterior sulcus. During this further development also the central canal has changed its form, since the dorsal part of the original dorso-ventrally directed cleft becomes closed in consequence of the apposition of the lateral walls.

At first the spinal cord extends the entire length of the vertebral canal with a fairly constant volume. The lower end of the cord becomes rudimentary and defined from the preceding part, assumes a conical form and becomes the *conus medullaris*. A further alteration in the extension of the spinal cord is brought about by the inequality between its growth and that of the surrounding vertebral canal. The latter constantly increases in length, the lower segment of the spine developing with especial vigor. Since the growth of the cord fails to keep pace with that of the spine, the cord apparently shortens and no longer extends the entire length of the vertebral canal. The *conus medullaris* is drawn up from the sacral canal and enters the lumbar region, until, finally, it is found opposite the first or second lumbar vertebra. During this *ascensus medullae spinalis* the end of the *conus medullaris* is drawn out into a thin thread, which extends as far as the coccygeal region and is known as the *filum terminale*. A further consequence of this ascensus is a change in the course of the nerves emerging from the spinal cord. In the cervical region the course of the nerves is still horizontal; in the thoracic region it is more and more oblique; while in the lumbar region, and, still more in the sacral, the nerves are directed downward. The nerve-trunks emerging from the last part of the cord lie, therefore, for a long distance within the vertebral canal before they leave the latter. They surround the *conus medullaris* and the *filum terminale* and in this manner lead to the formation of the so-called horse-tail or *cauda equina*. In completion, the spinal cord undergoes some further changes in its form. Gradually two segments acquire greater development, the one in the cervical portion and the other in the upper part of the lumbar region. They are known as the cervical enlargement (*intumescentia cervicalis*) and the lumbar enlargement (*intumescentia lumbalis*) respectively.

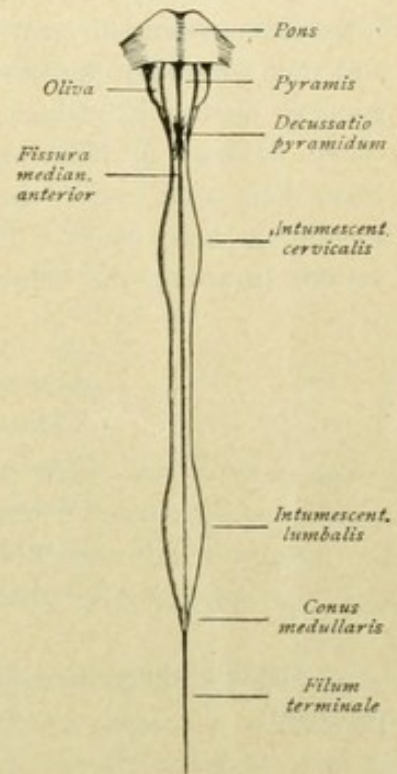


FIG. 13.—Anterior aspect of spinal cord. Schematic.

#### FORM, SIZE AND WEIGHT OF THE BRAIN.

The brain possesses in a general way the form of the cranial cavity. It is applied so closely to the inner wall of the skull, that a cast of the cranial cavity repeats to a considerable degree the form of the brain. Corresponding to the numerous variations in the configuration of the skull, sometimes the brain is more spherical and at other times more ellipsoidal in form. Its dorsal surface is arched, its ventral one flattened.



The length of the brain is, on an average, between 160-170 mm. and its greatest transverse diameter 140 mm. The female brain is usually somewhat shorter than the male. The weight of the brain has long been the subject of numerous investigations. The average brain-weight of the adult man has been found to be 1375 grams, that of the adult woman 1245 grams. The minimal weight of the male brain has been placed at 960 grams, that of the female brain at 800 grams. As maximal weights, 2000 grams and over, 1900 grams, 1861 grams and 1807 grams have been specified.

The difficulty of determining the average brain-weight lies in the fact that various factors exert a substantial influence. In this connection age plays a prominent rôle. Observations show that the mean brain-weight in both sexes reaches its maximum towards the twentieth year, remains stationary between the twentieth and fiftieth years, and then gradually decreases. Further influences are body-weight and body-length. In general, heavier individuals possess a heavier brain and with increase in height is associated increase in brain-weight; small individuals, however, possess a relatively heavier brain than large ones. In relation to the form of the skull, a higher average brain-weight has been found in the broad-headed type than in the long-headed. Many observations regarding the influence of race exist, with the following results:

	Grams.
Caucasian race: average brain-weight,	1335
Chinese: average brain-weight,	1332
Sandwich Islander: average brain-weight,	1303
Malay and Indian: average brain-weight,	1266
Negro: average brain-weight,	1244
Australian: average brain-weight,	1185

Definite differences in the brain-weight among the European nations have been recorded:

	Grams.
German: average brain-weight,	1425
English: average brain-weight,	1346
French: average brain-weight,	1280

Among all peoples, the female sex shows a smaller average brain-weight.

Further, the influence of culture is to be noted. According to the measurements of P. Broca, among the cultured nations the brain-mass probably gains somewhat in the course of time. Based on the measurements of Egyptian skulls, E. Schmidt found that nations, which have regressed from a higher culture, exhibit a smaller cranial capacity than that possessed by them during the period of their cultural bloom.

Finally, pathological conditions must also be considered, since sometimes they induce an increase and at other times a decrease of the brain-weight.

Of great interest has always been the question, to what extent do the absolute and relative proportions of the brain indicate the favored position which man enjoys in comparison with other animals. It has long been known, that man does not possess absolutely the heaviest brain. The brain-weight of the elephant reaches 4000 grams and more, while that of certain cetaceans may be 3000 grams. It is, however, clear that,



in proportion to body-weight, these animals possess relatively a smaller brain-mass than does man. On the other hand, several investigators have shown that man does not possess relatively the heaviest brain, since in this respect he is surpassed by certain song-birds, apes and mice. If, however, one compares, as did Ranke, the weight of the spinal cord with that of the brain, man is found to possess the heaviest brain. While this proportion in the adult human subject is approximately 2 per cent., in the anthropoid apes this ratio increases to about 6 per cent., and among the other mammals it rises to from 23 to 47 per cent.

It is particularly difficult to establish a definite relation between brain-weight and intelligence. The comparison of many brains shows, that it is not permissible to estimate the intellectual capacity of an individual merely according to his brain-weight. The following data exist regarding the weights of the brains of distinguished men:

	Grams.		Grams.
Turgenjeff:	2012	Broca:	1484
Cuvier:	1861	Dupuytren:	1437
Byron:	1807	Dante:	1420
Kant:	1600	Liebig:	1352
Schiller:	1580	Tiedemann:	1254
Gauss:	1492	Döllinger:	1207

This comparison shows, that while the majority of these brains exceeded the average weight of 1375 grams, there are also men of eminent intellect who possess a relatively low brain-weight. Moreover, there are records of notable brain-weights (2028 and 1900 grams) among individuals of insignificant mentality. Remarkably low brain-weights (300 grams and less) occur among idiots.

According to the present investigations, the conclusion is justified, that psychic functions can proceed normally only where the brain-weight has passed a certain minimum. According to Obersteiner, the lowest level to which the brain-weight may sink without noticeable impairment of the intellectual faculties is for the male brain 1000 grams and for the female 900.

It is to be noted, that weighing the entire brain supplies only an uncertain index of the psychic capability, for the reason that the individual parts of the brain, so varying in structure and function, do not undergo uniform increase or diminution in size and weight. An accurate knowledge of the weights of the individual parts of the brain would be of great importance, especially an exact determination of the weight of the gray substance of the end-brain, the cerebral cortex, with which particularly the higher psychic functions are associated. Even then we would fail to reach a positive result, since, in addition to the weight, other relations must be considered, especially the finer structure.

#### GENERAL INSPECTION OF THE BRAIN.

Let us first examine the dorsal surface of the brain. This is strongly arched in the sagittal as well as in the frontal direction—*facies convexa cerebri* (Fig. 14). A deep median vertical cleft (*fissura longitudinalis cerebri*) divides the whole into two



symmetrical halves, the *hemispheres* of the end-brain. On probing to the bottom of the fissure, one learns that the separation is not complete, since in the middle of the cleft the two halves are united by a broad horizontal commissure, the *corpus callosum*. In front of the latter, the fissure passes to the ventral surface of the brain; behind the commissure, the fissure likewise penetrates deeply and ends in a large transverse cleft (*fissura transversa cerebri*), which separates the hemispheres from the subjacent cerebellum. The surface of the hemispheres exhibits clefts and furrows of varying depths and the intervening convolutions.

The ventral surface of the brain, known as the *basis cerebri*, is much more complexly modelled. In the first place, we perceive to what extent the hemispheres occupy also the base of the brain. In the anterior part, the *fissura longitudinalis cerebri* runs in the mid-line, as far backward as an X-shaped structure, the *chiasma opticum*. On

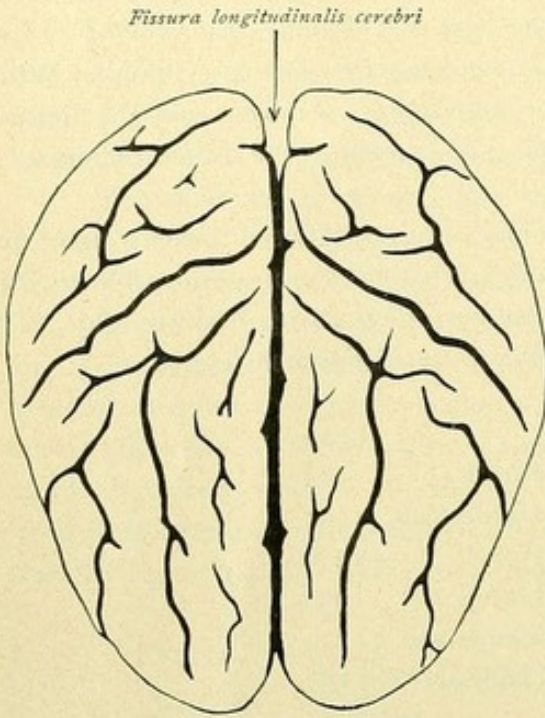


FIG. 14.—Brain viewed from above; frontal pole below.

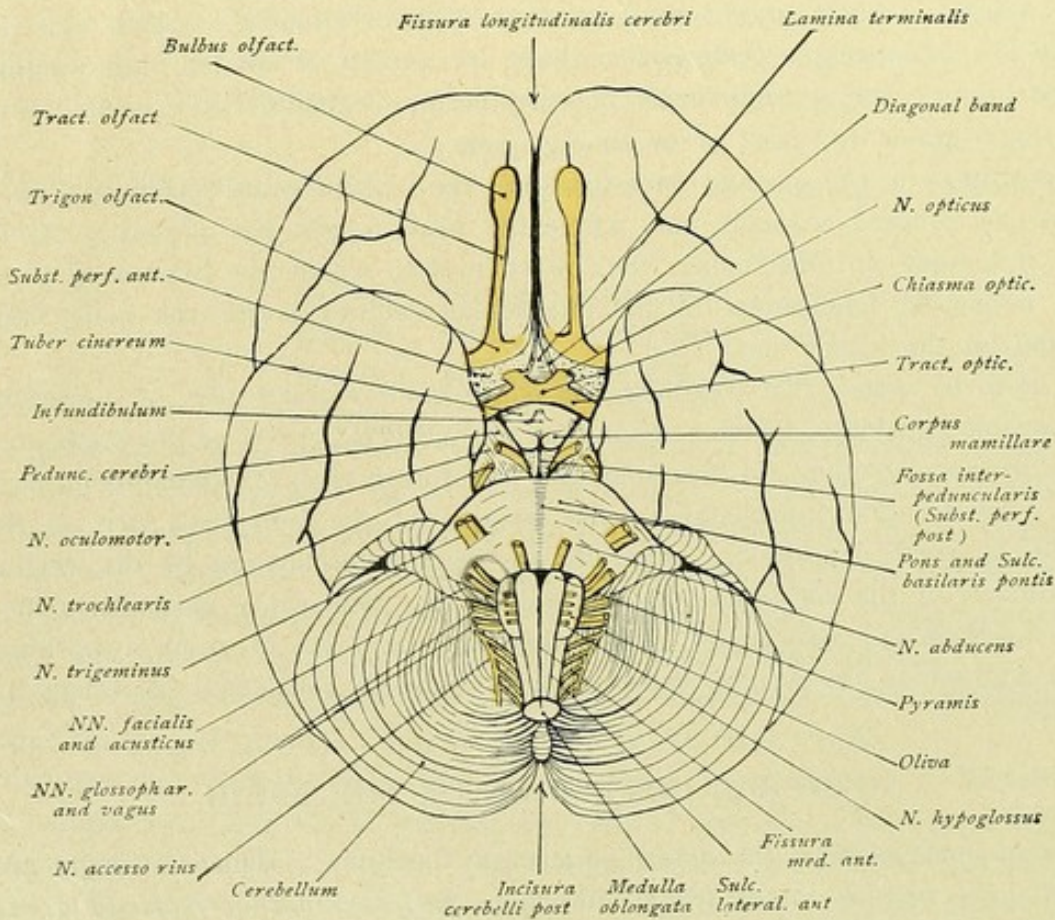


FIG. 15.—Basal aspect of the brain.



folding the chiasma slightly backward, one sees a thin gray and easily torn lamella stretching from the front border of the chiasma into the depth of the *fissura longitudinalis cerebri*; this is the *lamina terminalis*. Forwards from the chiasma lead the nerves of sight (*nervi optici*), while posteriorly and laterally, on each side, extends the visual path, the *tractus optici*. Lateral from the chiasma and the optic tract lies a gray field, penetrated by larger and smaller openings, the *substantia perforata anterior*. The anterior boundary of this field presents a triangular area, the *trigonum olfactorium*, from whose front point a narrow white-stripe, the *tractus olfactorius*, leads forward to end in the broadened terminal *bulbus olfactorius*. The olfactory nerve-fibres (*fila olfactoria*) extend from the ventral surface of the bulb as delicate white thread-like strands, that have been torn in removing the brain. *Bulbus olfactorius*, *tractus olfactorius*, *trigonum olfactorium*, *substantia perforata anterior* are all parts of the *rhinencephalon*. These will be more closely considered in connection with the rhinencephalon.

Behind the chiasma opticum rises a gray hump, the *tuber cinereum*, that tapers to the *infundibulum* bearing a bean-shaped gray body, the *hypophysis* or *pituitary body*. The hypophysis lies in the sella turcica of the body of the sphenoid and may readily become separated in consequence of the tearing of the thin infundibulum, when the brain is taken out, so that only the conical pointed part of the infundibulum presents, while the hypophysis remains within the sella turcica. Laterally, the tuber cinereum is bounded by the *tractus optici*, whose further course is over the forward and outwardly coursing cerebral stalks, the *pedunculi cerebri*, and then to pass deeply. Behind the tuber cinereum, rise two white pyriform structures, the *corpora mammillaria* or *candicantia*. Behind these and between the *pedunculi cerebri* lies the *fossa interpeduncularis*, which is prolonged backward into the *recessus posterior* and forward into the *recessus anterior*. The floor of this depression is formed by the *substantia perforata posterior*, a gray surface modelled by numerous apertures and divided into halves by a median furrow. Towards the cerebral peduncle it is bounded by a groove, the *sulcus nervi oculomotorii*, from which emerge the fibres of the oculomotor nerve.

Behind these deeply sunken structures, appears a white, broad, transverse bridge, the *pons Varolii*, which in front and behind is sharply bounded, in the middle is impressed by a broad median furrow, the *sulcus basilaris*, and at the sides narrows and then extends laterally and backward to sink into the cerebellum. Behind the pons lies the tapering bulb, the *medulla oblongata*, which is prolonged into the spinal cord. It presents the median longitudinal furrow, the *fissura mediana anterior*, that is bounded on each side by a white strand, the pyramid or *pyramis*. Beyond the pyramidal tract, the *sulcus lateralis anterior* extends as a shallow groove, beyond which, in turn, lies an elongated egg-shaped elevation, the *oliva* or olivary eminence. The medulla covers the median part of the cerebellum, occupying a broad furrow, known as the *vallecula cerebelli*, behind which appears the strongly arched ventral surface of the cerebellum. A deep median cleft, the *incisura cerebelli posterior*, separates the two halves of the little brain, the *hemisphaeria cerebelli*, which exhibit numerous, more or less parallel narrow tracts, the *folia*. On slightly raising the cerebellum, the *fissura transversa cerebri* appears as a deep cross cleft, separating the cerebellum from the cerebrum and opening into the *fissura longitudinalis cerebri*.



Closer examination of the base of the brain leads further to the location of the exits of the individual cerebral nerves from the brain, concerning which the following table may afford explanation. The exits of these nerves from the skull are also noted.

Nerve	Exit from the Brain	Exit from Skull
I. <i>Fila olfactoria</i>	Bulbus olfactorius	Lamina cribrosa
II. <i>N. opticus</i>	Chiasma opticum	Foramen opticum
III. <i>N. oculomotoris</i>	Sulcus nervi oculomotorii, close in front of pons, on medial edge of cerebral peduncle	Fissura orbitalis superior
IV. <i>N. trochlearis</i>	Dorsal, behind the corp. quadrigemina, lateral to frenulum veli medullaris anterioris. Course around the cerebral peduncle	Fissura orbitalis superior
V. <i>N. trigeminus</i>	Front border of pons, lateral, near the entrance of middle cerebellar peduncle into the cerebellum	R. ophthalmicus: Fis. orbit. sup. R. maxillaris: Foram. rotundum R. mandibularis: Foram. ovale
VI. <i>N. abducens</i>	Hind border of pons, in the groove between the latter and the medulla (pyramid)	Fissura orbitalis superior
VII. <i>N. facialis</i>	Lateral to <i>N. abducens</i> , on hind border of pons, in front of and lateral to olive	Porus acusticus internus— Meatus acusticus internus— Canalis facialis Foramen stylo-mastoideum
VIII. <i>N. acusticus</i>	Lateral to <i>N. facialis</i> , on hind border of pons, lateral to olive	Porus acusticus
IX. <i>N. glosso-pharyngeus</i>	Behind the <i>N. facialis</i> and <i>N. acusticus</i> , in upper part of furrow behind olive	Foramen jugulare
X. <i>N. vagus</i>	Behind the <i>N. glossopharyngeus</i> , in the furrow behind the olive	Foramen jugulare
XI. <i>N. accessorius</i>	Upper root-fibres (cerebral portion): behind <i>N. vagus</i> , in the furrow behind the olive  Lower root-fibres (spinal portion): between the front and hind roots of the cervical nerves, as far as 5th or 6th.	Foramen jugulare
XII. <i>N. hypoglossus</i>	Sulcus lateralis anterior, between pyramid and olive	Canalis hypoglossi

*N.* I, II and VIII are sensory nerves,  
*N.* V, VII, IX and X are mixed nerves,  
*N.* III, IV, VI, XI and XII are motor nerves.

Let us now examine a median sagittal section through the brain. In the first place, we recognize the brain-mass belonging to the hemisphere, with its fissures and convolutions, and, further, the corpus callosum, the large commissure connecting the



two cerebral hemispheres. The middle part of the bridge is the body (*truncus corporis callosi*); behind, the commissure thickens to form the *splenium*; while in front, it bends sharply downward and forms the knee, *genu corporis callosi*, that tapers into the beak-like *rostrum corporis callosi*. The latter is prolonged as a short thin white lamella, the

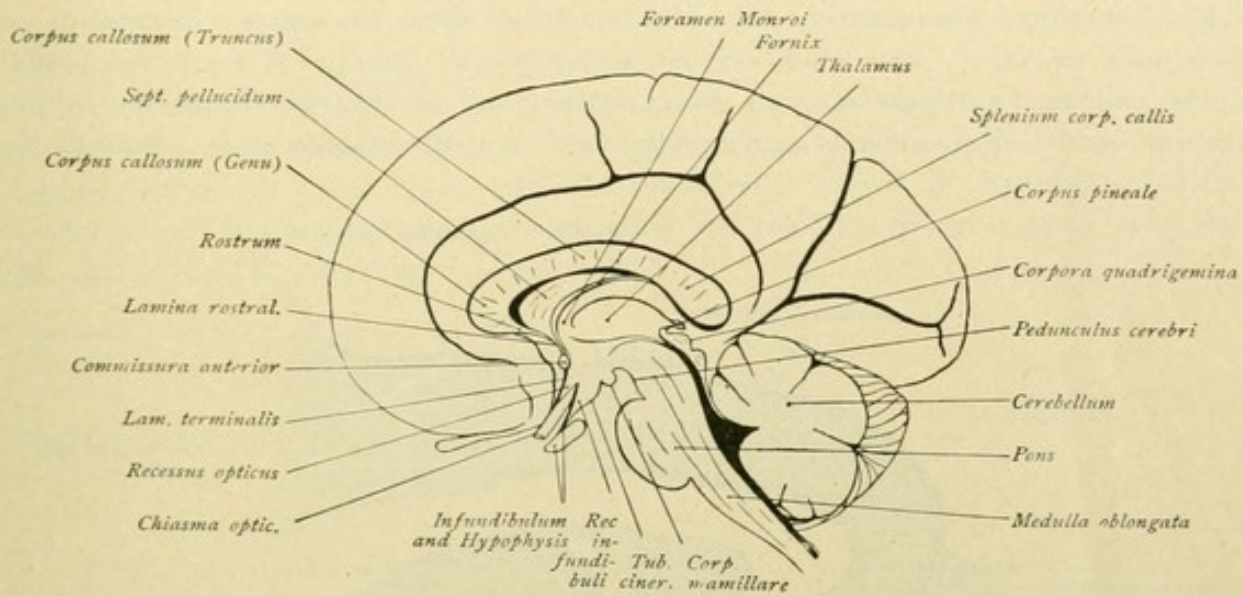


FIG. 16.—Median sagittal section through the brain.

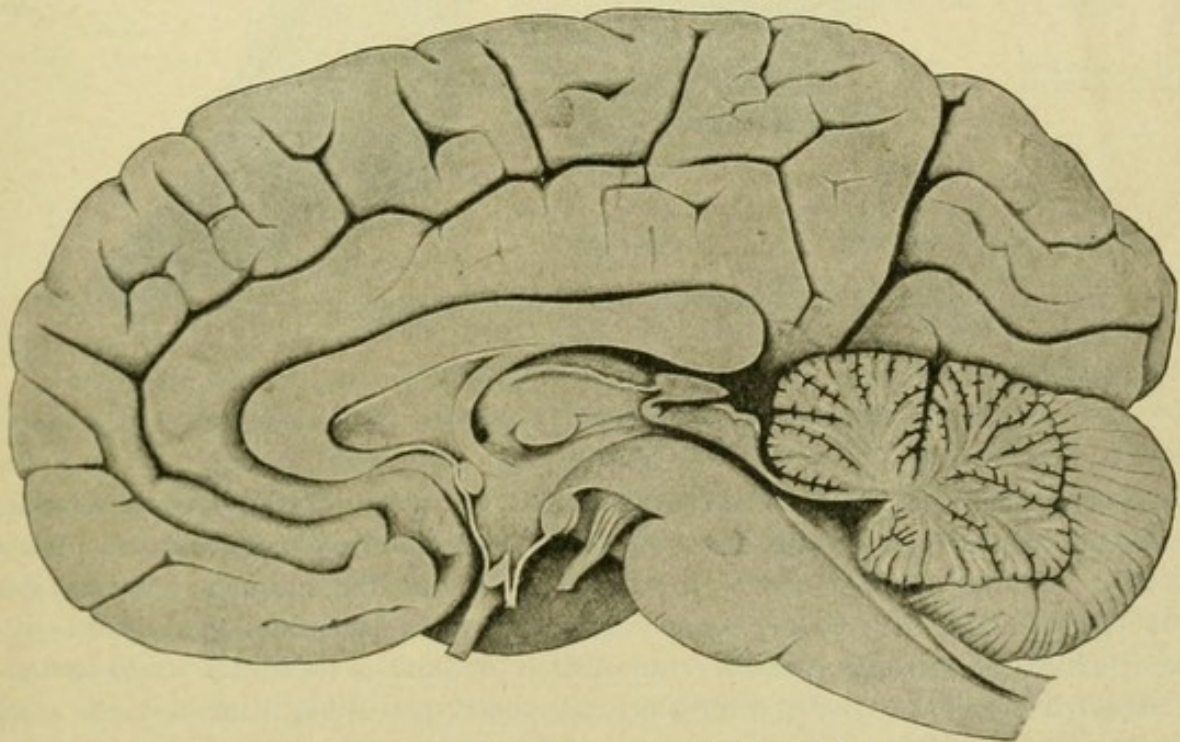


FIG. 17.—Median sagittal section through the adult brain.

*lamina rostralis*, which is continuous with the attenuated lamina terminalis that extends to the front surface of the chiasma opticum. Behind the corpus callosum, covered by the hinder part of the hemisphere, lies the cerebellum; the deep fissura transversa cerebri is plainly seen separating the hemisphere and cerebellum.



Let us examine the parts of the brain lying beneath the corpus callosum. Closely attached to the under surface of the latter, a lamella of white matter extends forward from the place where the splenium joins the body or trunk of the corpus callosum. The structure gradually leaves the corpus callosum, arches downward with forwardly directed curve until close behind the lamina rostralis, and then sinks deeply into the brain-substance, just behind a transversely cut white bundle of fibres, the anterior commissure or *commissura anterior*. This white lamella belongs to the *fornix*. Between the fornix, on the one hand, and the truncus, genu, rostrum and lamina rostralis of the corpus callosum, on the other, extends a thin white sheet, the *septum pellucidum*. Beneath the

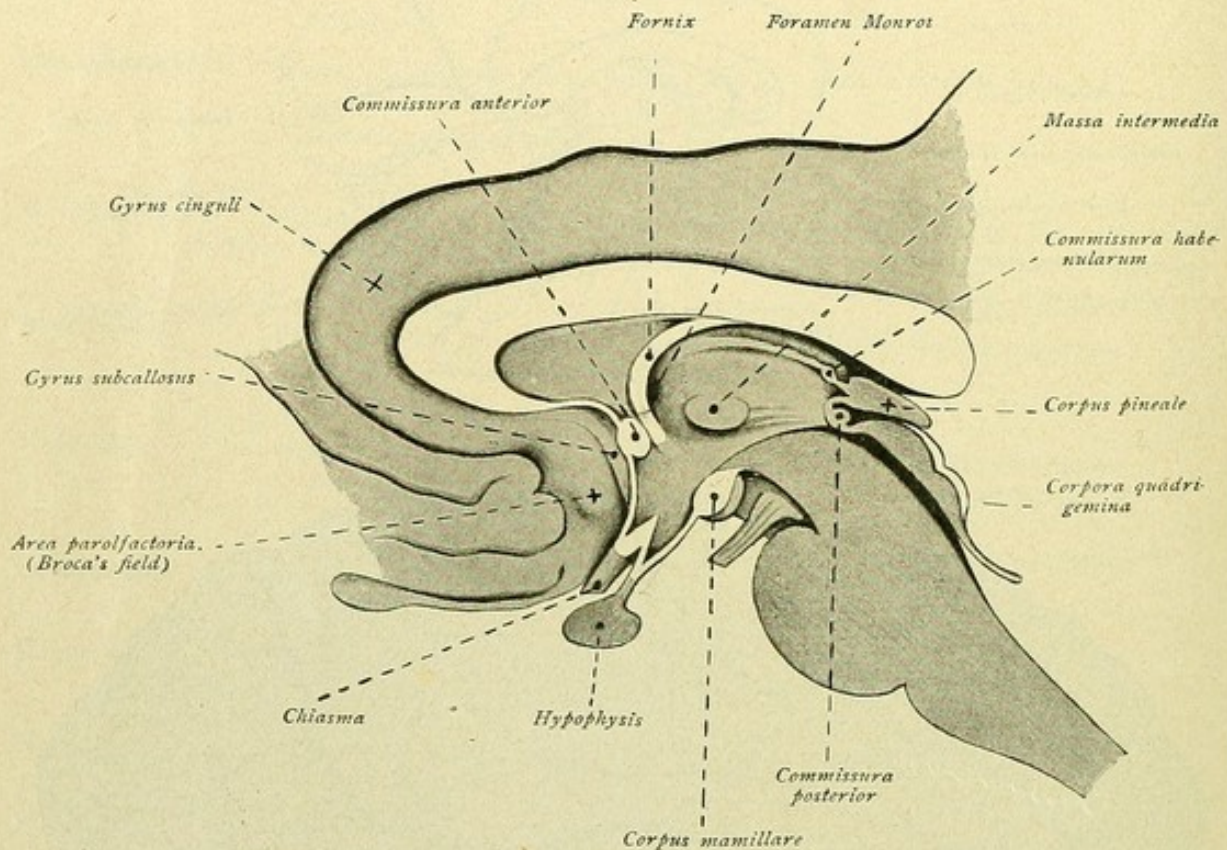


FIG. 18.—Median sagittal section through the adult brain; subcallosal region.

fornix and the hind part of the corpus callosum is situated the *thalamus*, between whose fore-end and the descending fornix lies an opening, the *foramen interventriculare* or *foramen of Monro*. At the posterior end of the thalamus, beneath the splenium corporis callosi, lies the pineal body, the *corpus pineale*. The cleft, which penetrates the pineal body in front, is called the *recessus pinealis*. Immediately beneath is found the cross-section of the *commissura posterior cerebri*, with which are joined, proceeding backward, the *lamina quadrigemina*, the *velum medullare anterius* and the *cerebellum*. On the median surface of the thalamus, behind the foramen interventriculare, lies the cross-section of the middle commissure or *massa intermedia*, by means of which the opposed surfaces of the two thalami are connected.

The *sulcus hypothalamicus (Monroi)* is a furrow that extends backward from the foramen interventriculare, beneath the massa intermedia, towards the commissura posterior



and separates the region of the thalamus from the more dependent *hypothalamus*. On examining this region more closely, we note again parts that have been mentioned in connection with the base of the brain: in front the *lamina terminalis* that joins the anterior surface of the *chiasma opticum*, the *recessus opticus* between the lamina and the chiasma and behind the latter, the *recessus infundibuli*, the *infundibulum* with the *hypophysis*, the *tuber cinereum*, the *corpus mamillare*, and the *substantia perforata posterior*, forming the floor of the *fossa interpeduncularis* (*Tarini*).

Continuing backward, the cerebral peduncle, the pons and the medulla oblongata are seen in cross-section. The sulcus hypothalamicus, running backward from the foramen interventriculare, opens into the *aquaeductus cerebri*, or *aqueduct of Sylvius*, which extends beneath the quadrigeminal plate and joins the fourth ventricle that underlies the cerebellum (Figs. 16, 17, and 18).

## TELENCEPHALON.

The **telencephalon** or end-brain includes:

- The hemisphaerium,
- The pars optica hypothalami.

To the **hemisphaerium** belong:

- The pallium or cerebral mantle,
- The rhinencephalon,
- The stem of the telencephalon—the gray nuclei of the end-brain.

To the **pars optica hypothalami** belong:

- The lamina terminalis,
- The chiasma opticum,
- The tuber cinereum,
- The infundibulum,
- The hypophysis.

The hemisphaerium contributes the chief mass of the end-brain.

In order to study the morphology of the telencephalon to the best advantage, one proceeds in the following manner: the brain is placed on the dorsal surface, with the base upward; the pons, cerebellum and medulla oblongata, all connected, are completely separated from the brain by a transverse cut passing through the front border of the pons. A second cut, sagittal and in the mid-line, divides the two hemispheres from each other.

In the first place, let us examine a hemisphere in general. Each **hemisphere** presents three surfaces: a convexly arched *dorso-lateral surface*, a flat *median surface*, and a *basal surface*, which is subdivided by a deep incision into a smaller anterior and a larger posterior part. We distinguish further an anterior frontal pole (*polus frontalis*), a posterior pole (*polus occipitalis*) and a temporal pole (*polus temporalis*), the latter representing the fore-end of the posterior division of the basal surface. A *dorsal border* marks the transition of the lateral to the median surface; its medial continuation forms the base to the *basal border*. The lateral border corresponds to the transition of the lateral at the basal surface.







anterior horizontal limb backward and somewhat obliquely upward and at its end usually divides in a Y-like manner into a *ramus ascendens* and a *ramus descendens*. Approximately from the middle of the dorsal border of the hemisphere, the *sulcus centralis* or *fissure of Roland*, runs obliquely downward and forward toward the posterior ramus of the *fissura cerebri lateralis*. As a rule, this furrow exhibits two knee-like bends, one at the junction of the upper and middle thirds, the other at the transition of the second and lower thirds; the fissure, moreover, usually crosses the upper border of the hemisphere.

**Lobus frontalis.** The frontal lobe lies above the *fissura cerebri lateralis* and in front of the central fissure, and presents the following fissures and convolutions. The *sulcus praecentralis superior* begins somewhat below the upper border of the hemisphere and runs more or less parallel with the *sulcus centralis*. Somewhat lower, the *sulcus praecentralis inferior* continues in the same direction and below penetrates between the *ramus anterior ascendens fissurae cerebri lateralis* and the lower end of the *sulcus centralis*. The upper end of the inferior precentral sulcus almost constantly lies in advance of the lower end of the superior fissure. As variations, the precentral fissures may connect with the central fissure and the lower precentral may join the *fissura cerebri lateralis*.

The *sulcus frontalis superior* extends forward from the superior precentral sulcus, approaching the upper border of the hemisphere in front. At times the fissure cuts through the *sulcus praecentralis superior* towards the central fissure, thereby producing the cruciform type of precentral furrow. In many cases the superior frontal sulcus is interrupted by two or three annectant convolutions. The fissure may also be doubled.

The *sulcus frontalis inferior* likewise extends forward, from the inferior precentral fissure, but more arched and downward. The fissure is usually clearly marked, but it may present very variable forms and be interrupted by deep or superficial annectant convolutions. Ordinarily a short furrow, the *sulcus radiatus*, extends downward from the inferior frontal between the anterior horizontal and ascending rami of the *fissura cerebri lateralis*.

The small *sulcus frontalis medius* is generally to be seen between the superior and inferior frontal fissures. This sulcus is often readily identified, but it may exhibit the most diverse forms, since it may be displaced or effaced by annectant convolutions. At times the fissure is clearly recognizable as a continuous and deep furrow.

The foregoing fissures bound the following convolutions. The *gyrus centralis anterior* lies between the superior and inferior precentral fissures in front and the central fissure behind. The *gyrus frontalis superior* is bounded by the superior frontal fissure below and the superior prefrontal fissure behind. Between the superior and inferior frontal fissures extends the *gyrus frontalis medius*, which is subdivided by the median frontal sulcus into a *pars superior* and a *pars inferior*. The *gyrus frontalis inferior* lies below the inferior frontal fissure. This convolution, also known as *Broca's convolution* on the left side, includes three subdivisions:—

The *pars opercularis*, between the lower end of the inferior precentral fissure and the anterior ascending ramus of the *fissura cerebri lateralis*;

The *pars triangularis*, between the anterior ascending and horizontal rami of the lateral fissure; and

The *pars orbitalis*, between the anterior horizontal ramus and the trunk of the lateral fissure.



Behind the sulcus centralis, or fissure of Rolando, and above the ramus posterior of the fissure of Sylvius, stretches the *parietal lobe*, while below the last named fissure lies the *temporal lobe*. Posteriorly, both lobes pass into the *occipital lobe* without a definite boundary. As a conventional boundary, we may adopt a line that unites the dorsal end of the parieto-occipital fissure, which incises the upper border of the hemisphere, with the incisura praeoccipitalis. The *fissura parieto-occipitalis* is a deep cleft on the hind part of the median surface of the hemisphere (Fig. 22), which incises the upper border of the hemisphere and extends a short distance on its dorso-lateral aspect. It is readily identified as a deep incision on the upper border of the hemisphere about midway between the central fissure and the occipital pole, rather nearer the latter. The *incisura praeoccipitalis* appears as a slight notch on the lateral border of the hemisphere, approximately at the junction of the middle and posterior thirds (Fig. 19).

**Lobus parietalis.** The *sulcus postcentralis* extends behind and more or less parallel with the central fissure. This furrow is sometimes continuous, and sometimes

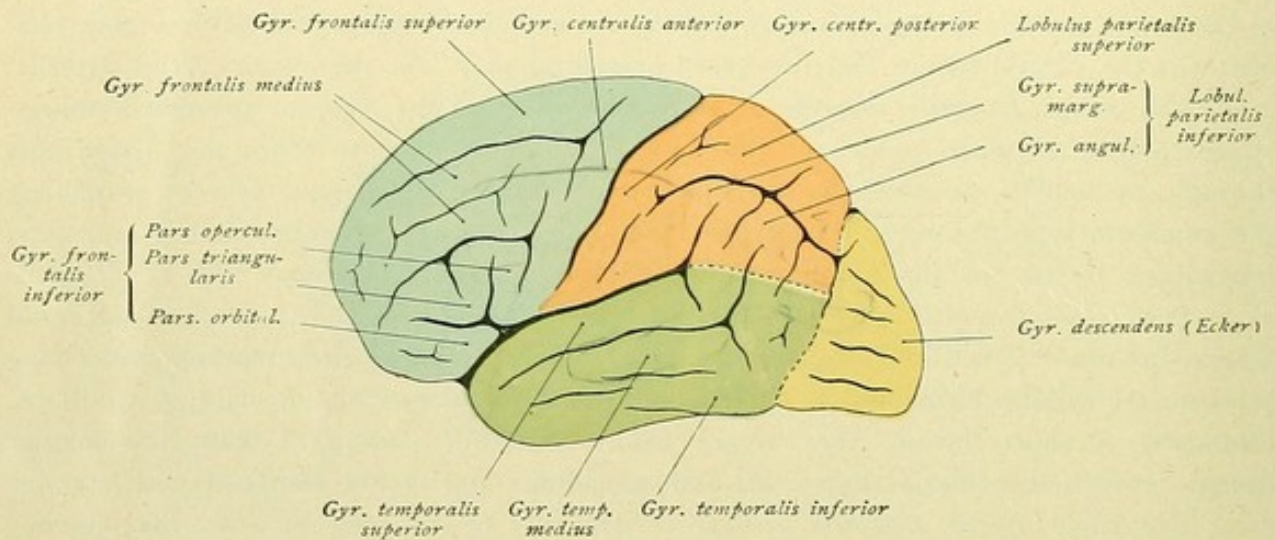


FIG. 20.—Dorso-lateral cerebral surface. Fissures and convolutions.

subdivided into two parts, the *sulcus postcentralis superior* and *inferior*. Each subdivision may retain its individuality, or at the same time join the *sulcus interparietalis*. When the superior postcentral fissure is independent, it usually exhibits variations in form and size, sometimes being unbranched and paralleling the central fissure, but often forming a three- or four-limbed furrow. As does the precentral, so the postcentral fissure at times anastomoses with the central fissure; the inferior postcentral fissure, moreover, may connect with the Sylvian fissure.

The *sulcus interparietalis* begins, mostly with a bifurcation, behind the upper end of the inferior postparietal fissure. By the junction of this sulcus with one or other of the postcentral fissures, a veritable vortex of furrows, a fissure-star, is formed. The sulcus interparietalis pursues an arched course backward, beneath the dorso-lateral end of the parieto-occipital fissure, and usually opens out into the *sulcus occipitalis transversus*. Occasionally the interparietal fissure passes across the transverse occipital furrow and continues backward as the *sulcus occipitalis superior*. The interparietal fissure is often made up of several parts; during its course isolated fissures are given off upward as



well as downward. A short furrow, known as the *sulcus parietalis transversus* (Brisaud), extends upward, towards the border of the hemisphere, from in front of the dorsal end of the parieto-occipital fissure. Often two furrows pass downward. One sulcus runs behind the ascending end-branch of the ramus posterior of the Sylvian fissure and is called the *sulcus intermedius primus* (Jensen). It often extends as a continuation of the upper transverse parietal fissure, but may be strongly developed and, indeed, may establish a connection between the interparietal fissure and the ascending end of the superior temporal fissure. The other sulcus is given off farther backward, runs behind the ascending end of the superior temporal fissure and is known as the *sulcus intermedius secundus* (Eberstaller). Both of these sulci intermedii may also exist as independent fissures.

By means of the foregoing fissures the following convolutions are defined: the *gyrus centralis posterior* lies behind the sulcus centralis, bounded below by the fissura cerebri lateralis and behind by the fissura postcentralis. Above the sulcus interparietalis lies the *lobulus parietalis superior*, while beneath this fissure extends the *lobulus parietalis inferior*. This lower parietal lobule presents two special convolutions, the *gyrus supramarginalis* and the *gyrus angularis*. The *gyrus supramarginalis* encloses the ascending terminal stem of the ramus posterior of the Sylvian fissure and is bounded by the sulcus intermedius primus behind. The *gyrus angularis* surrounds the ascending end of the superior temporal fissure, and is bounded in front by the sulcus intermedius primus and behind by the sulcus intermedius secundus.

**Lobus temporalis.** One of the most constant fissures is the *sulcus temporalis superior*. It begins in front at the temporal pole, extends backward and upward parallel to the fissura cerebri lateralis and ends, as a rule, in the *gyrus angularis* by running upward behind the ascending terminal branch of the fissura cerebri lateralis. At times one finds a forking into an ascending and a descending branch. The *sulcus temporalis medius* runs below the superior temporal fissure. The fissure is seldom continuous, usually being made up of several parts. Below the middle temporal fissure, and on the basal surface, extends the *sulcus temporalis inferior*. The three temporal convolutions are defined by these fissures. The *gyrus temporalis superior* extends below the sulcus cerebri lateralis and above the superior temporal fissure; the *gyrus temporalis medius* lies between the superior and middle temporal sulci; and the *gyrus temporalis inferior* is located below the inferior temporal fissure. The surface of the upper temporal convolution facing the Sylvian fissure presents the *gyri temporales transversi*, also known as the convolutions of Heschl, which are weakly developed in the front half and more strongly behind.

**Lobus occipitalis.** The anterior boundary of the lobus occipitalis is formed in part by the *sulcus occipitalis transversus*, a sulcus liable to many variations respecting its position, length and direction. In addition, there are the *sulci occipitales superiores* and the *sulci occipitales laterales*. By means of these fissures the *gyri occipitales superiores* and the *gyri occipitales laterales* are defined. Towards the occipital pole, the convolutions join a vertical gyrus, known as the *gyrus descendens* (Ecker).

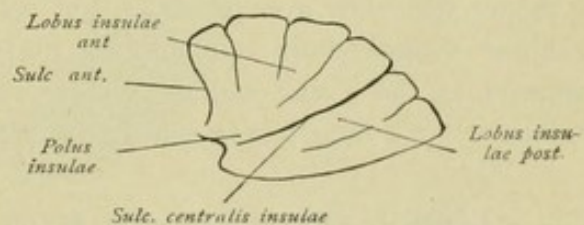


FIG. 21.—Fissures and convolutions of the insula.



**Insula.** On penetrating the depth of the *fissura cerebri lateralis*, by drawing apart the edges of the bounding lobes, one comes to a deep depression, the *fossa cerebri lateralis* (*Sylvii*), at the bottom of which lies the insula, also known as the *basal lobe* (*Stammlappen*). Those parts of the lobes bounding the Sylvian fissure, which cover the island, together constitute the *operculum*. Since the frontal, parietal and temporal lobes participate in its production, we distinguish a *pars frontalis*, a *pars parietalis* and a *pars temporalis* of the operculum. The surface of the temporal lobe directed towards the insula presents the *sulci* and *gyri temporales transversi*. Similar fissures and convolutions exist also upon the surfaces of the parietal and frontal opercula facing the island. The insula appears in the form of an irregular conical projection, a three-sided pyramid whose apex—the *island-pole*—is directed forward and outward. The island is

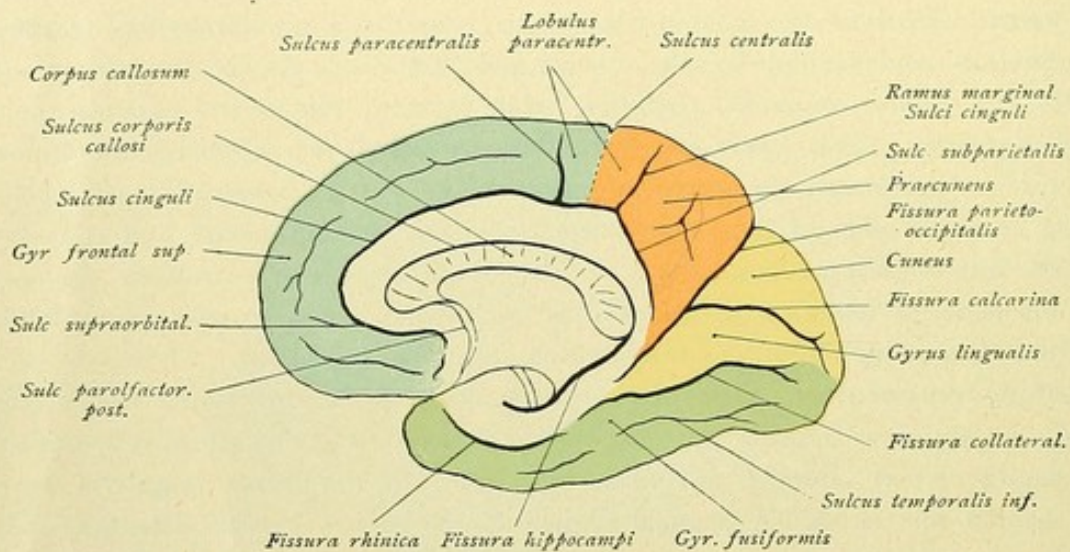


FIG. 22.—Medial cerebral surface. Fissures and convolutions.

encircled by a deep fissure, the *sulcus circularis* (*Reili*). Since this furrow, strictly considered, is not circular but rather triangular, a *sulcus anterior*, a *sulcus superior* and a *sulcus inferior* may be distinguished. The sulcus anterior separates the island from the orbital part of the frontal operculum, the sulcus superior from the fronto-parietal operculum, and the sulcus inferior from the temporal operculum. The island is divided into a *lobus insulae anterior* and a *lobus insulae posterior* by the *sulcus centralis insulae*, a fissure that runs from in front and below backward and upward. The anterior lobule exhibits several short convolutions, the *gyri breves insulae*, while the posterior lobule appears as the *gyrus longus insulae*, which now and then is subdivided into two convolutions by a long furrow which parallels the *sulcus centralis insulae*.

#### LOBES AND GYRI OF THE MEDIAL AND BASAL SURFACES.

All four cerebral lobes, with which we have now become somewhat intimately acquainted on the dorso-lateral aspect of the hemisphere, are continued onto the medial and partly also onto the basal surface. They do not extend, however, over the entire medial surface, but bound a large annular tract that belongs to the rhinencephalon. Let us first examine the defining fissures and sulci.



The *sulcus cinguli*, or *calloso-marginal fissure*, begins beneath the rostrum of the corpus callosum. It runs forward, around the knee, and then backward, more or less parallel with the corpus callosum, as far as the splenium. Here it bends at a blunt

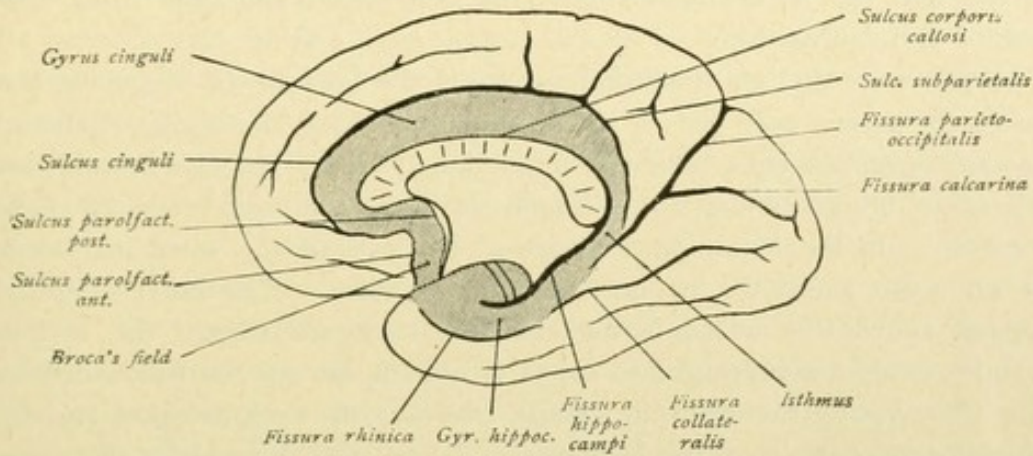


FIG. 23.—Medial cerebral surface. Gyrus fornicatus is shaded.

angle upward towards the superior margin of the hemisphere as the *ramus marginalis*. During its entire course, several and sometimes deep incisions branch off, upward as well as downward. In front of the obtuse bend, approximately over the middle of the

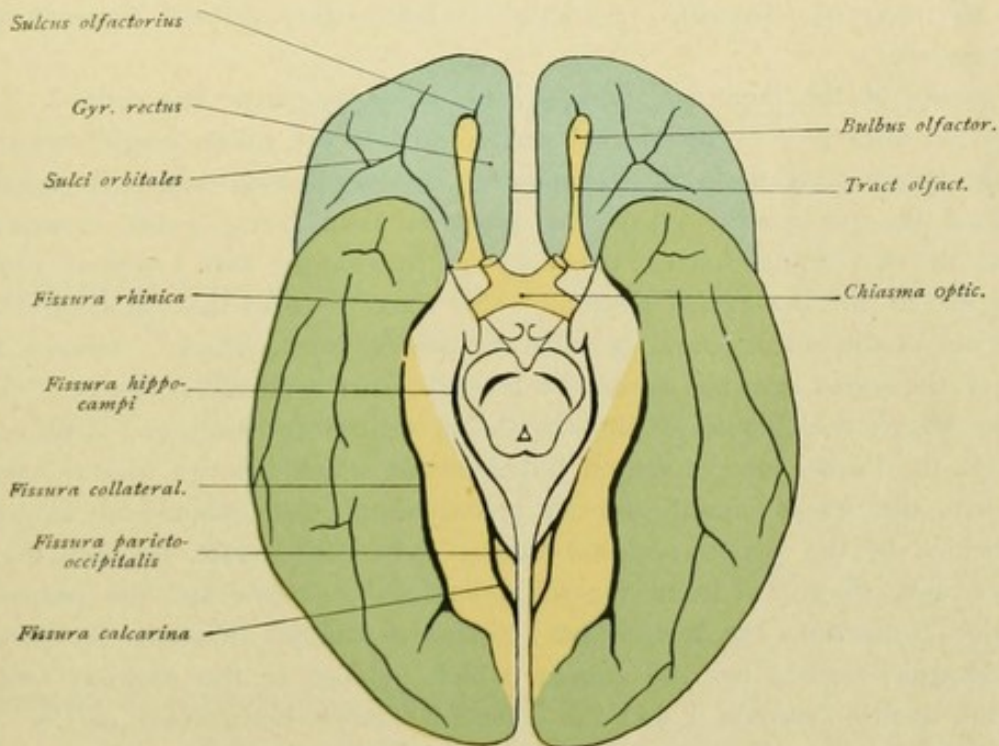


FIG. 24.—Basal surface of the brain. Fissures and convolutions.

corpus callosum, the fissure usually sends a side branch, the *sulcus paracentralis*, upward. Another branch, the *sulcus supraorbitalis* (Broca), is given off at the level of the genu. Finally, a third fissure, the *sulcus subparietalis*, which represents a continuation of the chief furrow, runs backward and around the splenium corporis callosi. Immediately beneath the knee and the rostrum of the callosum, the *sulcus corporis callosi* begins, at



first as only a shallow fissure. It often appears there as the prolongation of the sulcus parolfactorius posterior (see Rhinencephalon, page 26), then continues around the genu, closely follows the convex surface of the corpus callosum, runs around the splenium and continues into the *fissura hippocampi*, the deep cleft that runs from behind and above forward and downward.

In the posterior part of the medial surface of the hemisphere, beginning about midway between the turned-over end of the central fissure and the occipital pole, the deep *fissura parieto-occipitalis* runs obliquely forward and downward, behind the lower end of the subparietal branch of the sulcus cinguli, as far as the region beneath the splenium corporis callosi. In the lower part, at about the level of the splenium, the furrow is joined at an acute angle by the deep *fissura calcarina*. The latter, slightly arched and somewhat above the medial border, extends backward toward the occipital pole, where it may end as a simple groove, or, as is usually the case, in two widely divergent branches. Occasionally the calcarine fissure overruns the occipital pole and terminates on the dorso-lateral surface of the hemisphere. The stem formed by the union of the parieto-occipital and calcarine fissures extends downward and close behind the hippocampal fissure, without, however, joining the latter. The *fissura collateralis* begins at the level of the occipital pole, below the calcarine fissure, and passes forward below the common stem of the parieto-occipital and calcarine fissures. Its continuation into the anterior part of the temporal lobe constitutes the *fissura rhinica*, whose front end is known as the *incisura temporalis* (Schwalbe). Below the collateral fissure is the *sulcus temporalis inferior*.

By means of the foregoing fissures, the following parts are defined. The tract occupying the front part of the medial surface outside the sulcus cinguli belongs to the *frontal lobe*, more particularly to the superior frontal convolution. It extends backward beyond the paracentral sulcus, its posterior limit being a line drawn from the medial end of the central sulcus, between the paracentral and marginal rami of the sulcus cinguli, to the last-named fissure. The tract between the paracentral and marginal branches of the sulcus cinguli is called the *lobulus paracentralis*. Here is found the transition of the gyrus centralis anterior into the gyrus centralis posterior. The larger part of the paracentral lobule belongs to the precentral convolution. Behind the tract belonging to the frontal lobe, a region broadens out which belongs to the *parietal lobe*. It lies above the sulcus cinguli and its prolongation, the subparietal fissure, and is bounded behind by the parieto-occipital fissure. The entire tract, between the marginal arm of the sulcus cinguli in front, the subparietal fissure below and the parieto-occipital fissure behind, constitutes the *praecuneus* or *quadrate lobule*. Between the parieto-occipital and calcarine fissures lies the *cuneus*, which belongs to the *occipital lobe*. Below the calcarine fissure, between it and the collateral fissure, lies another part of the occipital lobe known as the *gyrus lingualis*. On the basal aspect of the hemisphere, below the collateral fissure, the *gyrus fusiformis* extends as a part of the temporal lobe. It is also called the *gyrus occipito-temporalis*.

A large annular tract belonging to the *rhinencephalon* is enclosed by the foregoing convolutions and lobes. Externally it is bounded by the sulcus cinguli, the common stem of the parieto-occipital and calcarine fissures, the front end of the collateral fissure and the *fissura rhinica*. The inner boundary is contributed by the sulcus corporis callosi



and the fissura hippocampi. In its entirety, this tract constitutes the *gyrus fornicatus* or the *limbic lobe*. It is subdivided into the *gyrus cinguli*, which arches around the corpus callosum, and the *gyrus hippocampi*, which is included between the hippocampal fissure on the one side and the collateral and rhinal fissures on the other and hooks around the anterior end of the hippocampal fissure to form the *uncus*. The gyrus cinguli and the gyrus hippocampi are continuous, behind and below the splenium, by means of the *isthmus gyri fornicati*.

Turning once more to the basal surface, in the posterior and larger division, we note the sulci and gyri already mentioned:—the fissura hippocampi, the fissura parieto-occipitalis and calcarina, joining to form a common stem, the fissura collateralis, the fissura rhinica, the sulcus temporalis inferior and the convolutions extending between these furrows. The anterior and smaller division of the basal aspect belongs to the lobus frontalis, being known as its *orbital surface*. Near the medial border of the latter, the straight *sulcus olfactorius* runs forwards and somewhat medially and lodges the olfactory bulb and tract. The sulcus is deep and almost always extends farther forwards than the anterior end of the bulbus olfactorius. Behind, it divides into a *ramus medialis* and *lateralis*, which embrace the tuberculum olfactorium. Lateral to the olfactory fissure lie some furrows of uncertain number and arrangement, the *sulci orbitales*. By their union the most varying patterns are produced, including H - , X - , L - , T - , K - and Z - like forms. Medial from the sulcus olfactorius extends the *gyrus rectus*. The *gyri orbitales* are bounded by the orbital fissures.

## RHINENCEPHALON.

The rhinencephalon embraces: (a) the peripheral division and (b) the central or cortical division.

The **peripheral division** includes the *lobus olfactorius*, to which belong:

- The bulbus olfactorius,
- The tractus olfactorius,
- The tuberculum olfactorium, with the gyri olfactorii medialis and lateralis,
- The area parolfactoria (*Broca*),
- The substantia perforata anterior,
- The gyrus diagonalis rhinencephali,
- The gyrus subcallosus (*Zuckerkindl*).

The **central or cortical division** includes:

- The gyrus fornicatus (*Arnold*),
- The hippocampus,
- The gyrus dentatus,
- The gyrus uncinatus,
- The gyrus intralimbicus,
- The gyrus fasciolaris,
- The gyri Andreae Retzii or callosal gyri.



## I. LOBUS OLFactorIUS.

The olfactory lobe falls under two subdivisions, one in front, the *lobus olfactorius anterior*, and one behind, the *lobus olfactorius posterior* (Figs. 25 and 26). These are separated from each other by a fissure, the *sulcus parolfactorius posterior* (the embryonic *fissura prima* of His), which runs behind the trigonum olfactorium, between the latter and the substantia perforata anterior, and continues toward the medial surface of the hemisphere.

To the *lobus olfactorius anterior* belong :

The bulbus olfactorius,

The tractus olfactorius,

The tuberculum olfactorium and the diverging gyri olfactorii medialis and lateralis,

The area parolfactoria.

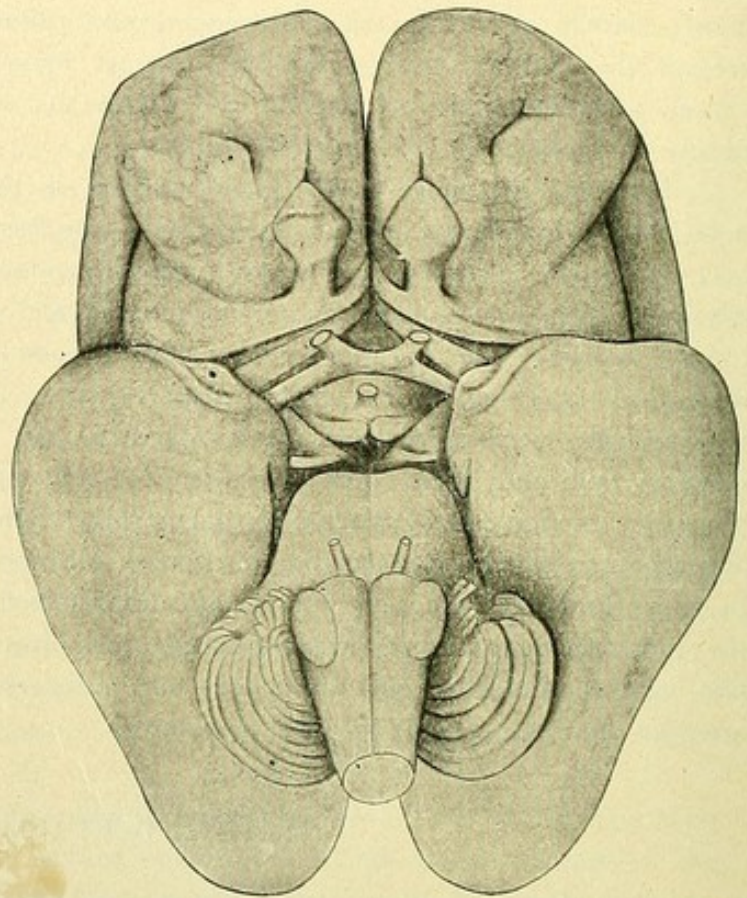


FIG. 25.—Brain of human foetus of between five and six months. Basal aspect.

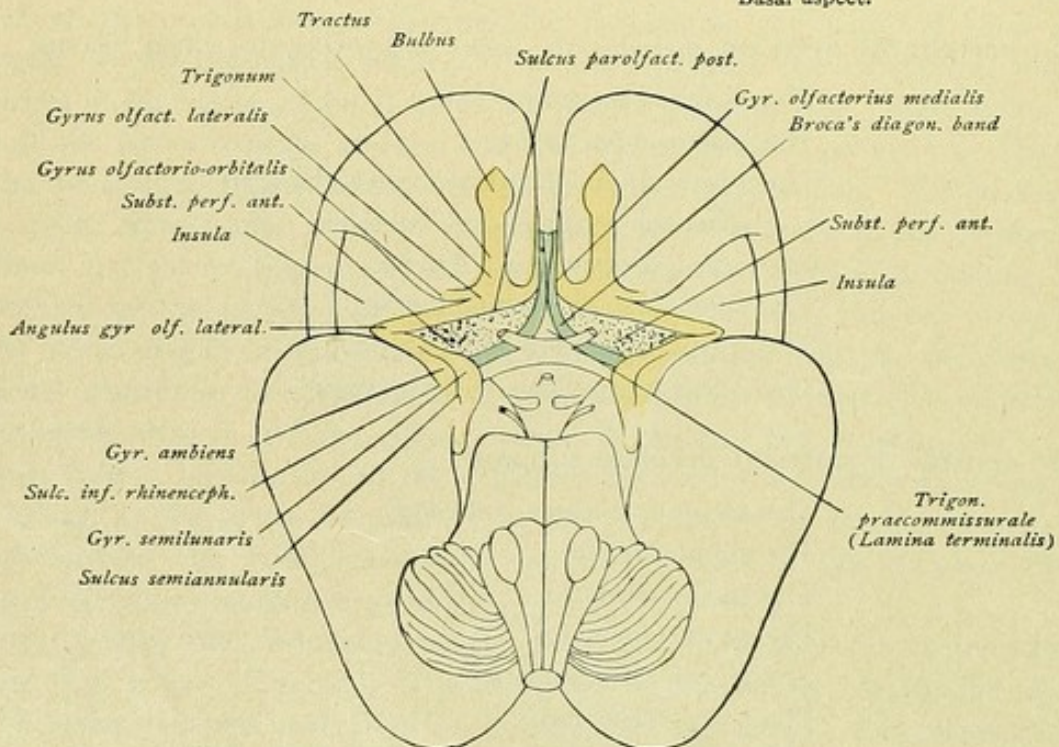


FIG. 26.—Schematic representation of the lobus olfactorius.



To the **lobus olfactorius posterior** belong :

- The substantia perforata anterior or gyrus perforatus rhinencephali,
- The diagonal band of Broca, or gyrus diagonalis rhinencephali,
- The gyrus subcallosus.

#### A. LOBUS OLFactorIUS ANTERIOR.

The **bulbus olfactorius** presents usually an oval form—an ellipse or a vertically flattened band—and constitutes an enlargement of the tractus olfactorius in front. On the under surface, delicate threads, the *fila olfactoria*, pass out and descend into the nasal fossa through the apertures of the lamina cribrosa. They are disposed in two series and may be designated as the *fila olfactoria medialis* and *lateralis*. They are so delicate that they are always broken off when the brain is removed.

The **tractus olfactorius** lies as a white strand in the olfactory sulcus and, on cross-section, reveals the form of a triangle with base below and apex above buried in the sulcus. The hind part of the tract, toward the tuberculum olfactorium, is narrow and somewhat compressed.

The **tuberculum olfactorium**, into which the tractus is prolonged behind, appears in its true form only after the bulb and tract have been raised from the olfactory sulcus and the latter itself rendered more gaping by pulling apart the bounding convolutions. Then the tuberculum appears as a pyramidal elevation, whose apex penetrates the sulcus and whose base forms an irregular triangular field, the *trigonum olfactorium*.

From the tuberculum proceed the medial and lateral olfactory convolutions whose courses are as follows :—

The **gyrus olfactorius medialis** runs as a narrow convolution medially. In front, it is bounded by the medial posterior branch of the sulcus olfactorius; medially and behind, by the sulcus parolfactorius posterior (the fissura prima of His). A white fasciculus of fibres, the *stria olfactoria medialis*, the continuation of the medial strand of the olfactory tract, streams into the gyrus olfactorius medialis, soon to become lost in the gray substance of the convolution.

On following the medial gyrus farther, it is found to radiate within a small field on the medial surface of the hemisphere, that lies immediately below the rostrum of the corpus callosum and is bounded both in front and behind by a small fissure. The furrow in front is the *sulcus parolfactorius anterior*, while the one behind is the continuation of the *sulcus parolfactorius posterior*, already mentioned. The small field is called the *area parolfactoria*, or field of Broca. It joins the gyrus olfactorius medialis with the gyrus fornicatus, particularly with the gyrus cinguli (Figs. 18 and 23), and thus establishes the connection of the lobus olfactorius anterior with the central region of the rhinencephalon.

The **gyrus olfactorius lateralis** runs laterally. In the fetal brain of from four to five months, one readily recognizes that the gyrus passes outward towards the Sylvian fossa, its so-called front limb proceeding from the trigonum almost at right angles; then, at the medial margin of the fossa and after an acute bend, the hind limb runs backward and medially to the anterior border of the gyrus hippocampi. Here the gyrus ends, to a certain extent, in two claws, the medial one of which is known as the *gyrus semilunaris rhinencephali*, and the lateral as the *gyrus ambiens rhinencephali*. The



fissure separating the claws is the *sulcus semiannularis* (Figs. 25 and 26). In consequence of the subsequent strong development of the frontal and temporal lobes, which approach each other more and more, the angle formed by the two limbs of the gyrus olfactorius

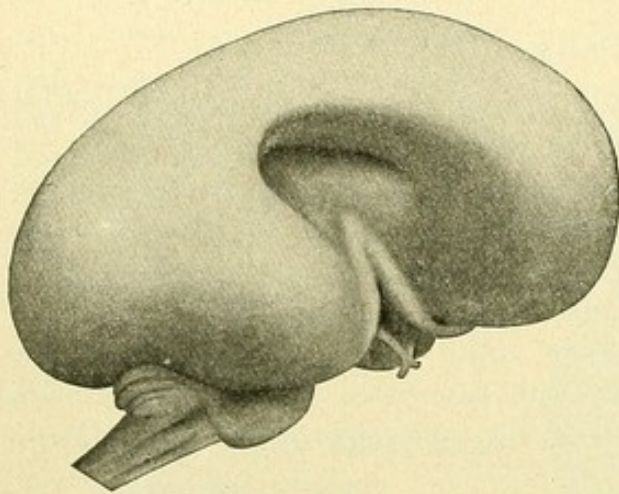
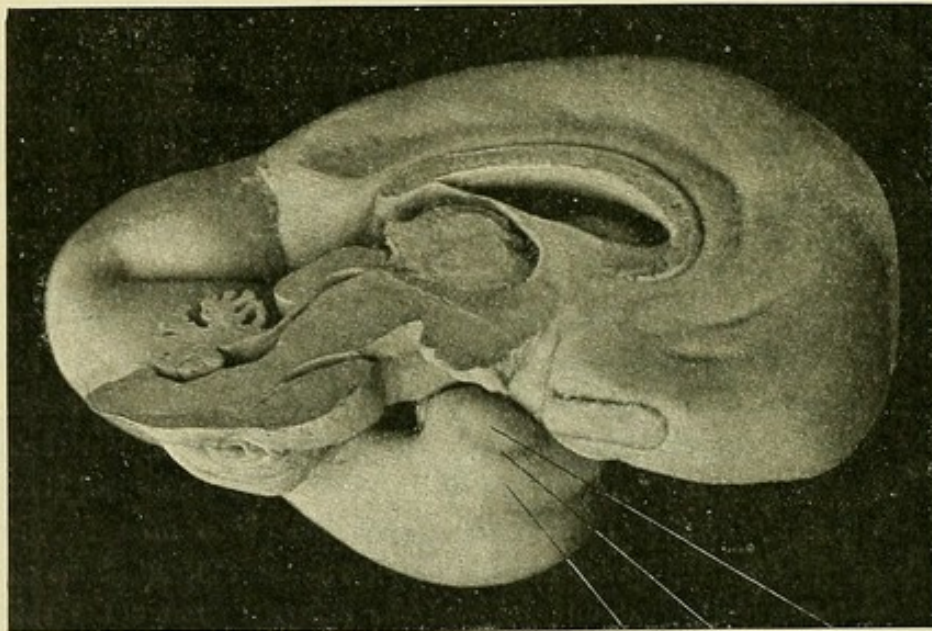


FIG. 27.—Schematic representation of the gyrus olfactorius lateralis in the foetal brain.

lateralis becomes progressively more acute, although the demarcation of the gyrus from the insula is still distinct. In the later stages, the limbs become more closely approximated and the apical part of the convolution is incised by the *sulcus centralis insulae*, which meanwhile has been formed. The result is, that the previous connection of the two limbs, as well as the demarcation of the convolution towards the insula, vanishes, the convolution now appearing to expand within the substance of the insula.

Since these relations persist in the adult, it was assumed that the lateral olfactory convolution, which bounds the insula medially, belonged to the island; hence it was designated the *limen insulae*. The latter, however, belongs to the rhinencephalon and represents the gyrus olfactorius lateralis, which is subdivided into a



Gyrus Sulcus Gyrus  
ambiens semiannularis semilunaris

FIG. 28.—Oblique mesial aspect of the brain of a human foetus of four months. Photograph.

front and hind limb—pars anterior and posterior. The area enclosed by the limbs was named by Retzius, the *angulus gyri olfactorii lateralis*.

The pars anterior usually appears as a fairly broad convolution, which extends from the tuberculum olfactorium outward and somewhat obliquely backward and is sep-



arated from the substantia perforata anterior by a fissure, the *sulcus arcuatus rhinencephali*, that follows the gyrus olfactorius lateralis medially as far as the gyrus hippocampi.

Laterally and in front, the pars anterior joins the orbital convolution to form the *gyrus olfactorio-orbitalis* of Retzius, which medially is bounded by the postero-lateral branch of the sulcus olfactorius. The gyrus is commonly simple, but may be divided into two parts by a short fissure; likewise, it may be subdivided by a longitudinal fissure into two subsidiary convolutions, an anterior and a posterior.

The *stria olfactoria lateralis* passes as a white fibre-bundle outward along the pars anterior toward the angulus gyri olfactorii lateralis, here lying quite near the substantia perforata anterior. It then bends backward in the angle and later disappears. Occasionally the lateral olfactory root consists of two bundles, of which the medial follows the border of the substantia perforata, until it is finally lost within the substance. It is to be further noted, that a third or middle root may be found between the lateral and medial ones. It soon vanishes, however, within the substantia perforata.

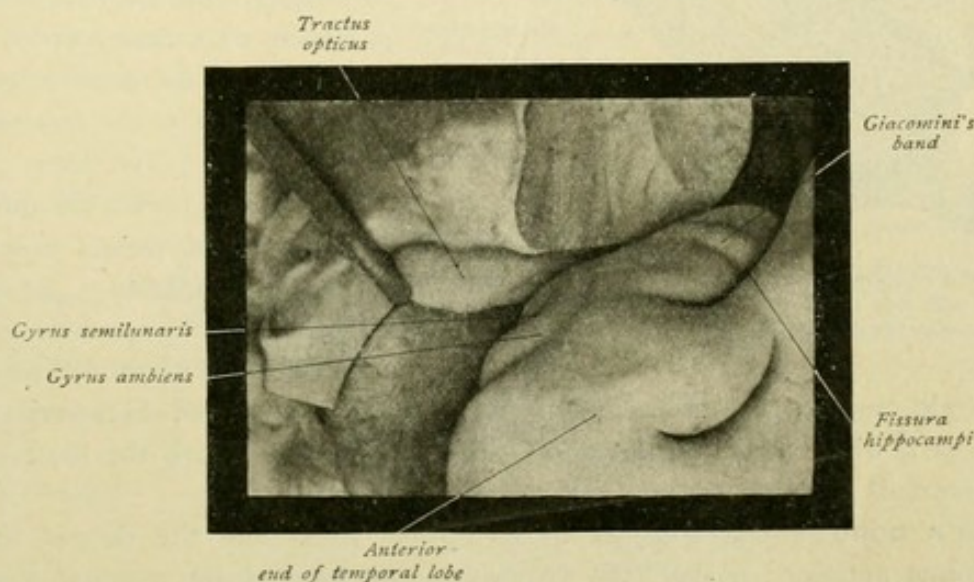


FIG. 29.—Region around the tip of the temporal lobe of the adult brain. Photograph.

After recurving in the angle, the lateral olfactory convolution, as the hind limb or pars posterior, continues inward and backward toward the front end of the gyrus hippocampi.

On examining more closely the antero-median surface of the gyrus hippocampi in the adult brain, one sees the convolutions in which the posterior limb fades away—the gyrus semilunaris medially and the gyrus ambiens laterally. The gyrus ambiens arches around the gyrus semilunaris and then is lost within the uncus.

#### B. LOBUS OLFACTORIUS POSTERIOR.

The *substantia perforata anterior* is an oblique quadrangular field lying behind the trigonum olfactorium, between the latter and the tractus opticus. It exhibits numerous small openings for the passage of blood vessels, especially in its anterior part in the vicinity of the trigonum. This front part constitutes the substantia perforata anterior proper, the *gyrus perforatus rhinencephali*.



The posterior part, bordering the tractus opticus, differs from the anterior chiefly in its lighter color and smoother surface. This part is known as the *diagonal band of Broca*, or the *gyrus diagonalis rhinencephali*.

Gyrus perforatus and gyrus diagonalis form the essential features of the lobus olfactorius posterior. To the latter belongs an additional small field on the medial surface of the hemisphere, the *gyrus subcallosus* of Zuckerkandl. This field is easily located, since it is continuous with the diagonal band of Broca, lying behind the area parolfactoria, separated from the latter by the sulcus parolfactorius posterior, and in front of the commissura anterior and the lamina rostralis (Fig. 18).

The **gyri subcallosi** (the stalks of the callosum of Broca) descend close together

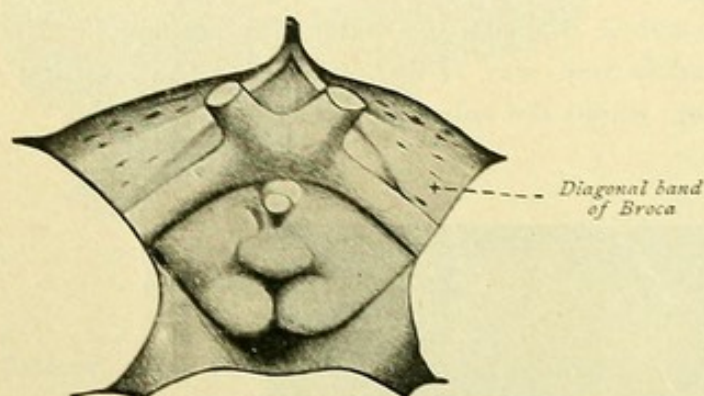


FIG. 30.—Middle region of the brain-base of a human foetus, 34.5 cm. long. At each side of the chiasma is seen the substantia perforata anterior, with the diagonal band of Broca. (His.)

from the rostrum of the corpus callosum. They are separated from each other by a medial furrow, the *sulcus subcallosus medianus* of Retzius, and form the narrow *trigonum praecommissurale*, which lies in front of the anterior commissure and belongs to the *lamina praecommissuralis*. The latter is a thin lamella that covers the anterior commissure and passes over into the lamina terminalis. At the lower border of the precommissural trigone, the two gyri subcallosi diverge

at almost right angles and proceed, on each side, outward and backward along the optic tract as a white band, the *diagonal band of Broca*, to reach the front end of the gyrus hippocampi.

**Broca's band** is distinguished by its lighter color from the deeper tinted substantia perforata anterior; further, the disposition and form of the vascular foramina are characteristic. These are oval or elliptical, their longer diameters paralleling the axis of Broca's band. Although the band is always present, it is not always plainly visible, in some cases it being superficial only in certain places, while in others it is buried beneath a layer of gray substance that must be removed before the band is seen.

## 2. GYRUS FORNICATUS.

To the peripheral region of the rhinencephalon, the lobus olfactorius, is attached the central district. Here the gyrus fornicatus first claims closer attention. It is an annular tract on the medial surface of the hemisphere, encircled by the cerebral mantle and composed of two chief convolutions, the *gyrus cinguli* and the *gyrus hippocampi*, connected with each other by means of the *isthmus*.

The **gyrus cinguli** forms the arching convolution, paralleling the convex upper surface of the corpus callosum, between the sulcus cinguli and the sulcus corporis callosi. It presents numerous variations in consequence of the inconstant relations of the sulcus cinguli. The latter, in fact, does not represent a simple fissure, but consists



of several parts, known as the pars anterior, pars intermedia and pars posterior. As a result, numerous annectant or bridging convolutions arise, which unite the gyrus cinguli with the neighboring convolutions of the pallium. When the composite parts join to form a simple sulcus, the course already described (page 22) as typical is observed. In its entire path, several incisions, some deep, branch toward the frontal lobe, while those passing into the gyrus cinguli are few and mostly short. The surface of the gyrus cinguli exhibits likewise some shallow furrows. Owing to these peculiarities, as well as to its smooth surface, the gyrus is more or less clearly defined from the adjacent convolutions. Accordingly, the gyrus cinguli takes the following course. It begins narrow beneath the knee of the corpus callosum, as the direct continuation of Broca's field. In its further course, around the genu and over the truncus corporis callosi, the convolution is broader. Farther behind, at the bend around the splenium, it again distinctly narrows and, where it is deeply incised by the fissura parieto-occipitalis, passes over into the isthmus gyri fornicati.

When the sulcus cinguli does not form a simple furrow, the convolution assumes an entirely different character. Doubling and splitting of the convolution may exist, as well as separation into two, three or four parts. Concerning the annectant convolutions,

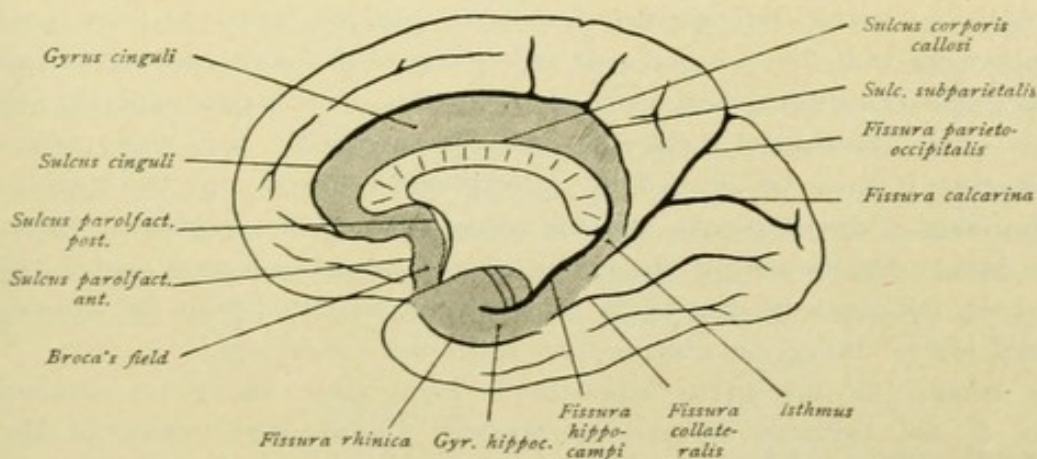


FIG. 31.—Medial cerebral surface. Gyrus fornicatus is shaded.

it may be noted that of these one is fairly constant in the fore part of the gyrus cinguli and establishes a connection between the latter and the gyrus frontalis superior. A second annectant convolution is found in the middle portion, the connection between the gyrus and the lobulus paracentralis, while a third appears in the posterior division, providing continuity with the praeuncus. The last connection is often double in consequence of the sulcus subparietalis existing as a separate furrow and not as the hind part of the chief fissure. In such cases the gyrus cinguli appears to radiate into the praeuncus.

The chief variations of the gyrus cinguli are found mostly in its front part. Here the convolution may be doubled by an inner or outer parallel fissure. If an outer secondary fissure be present, the gyrus cinguli proper appears markedly narrowed at the knee of the callosum; in such case, the convolution lying between the secondary fissure and the sulcus cinguli proper must be reckoned as part of the gyrus cinguli.



The delimitation of the gyrus becomes more difficult when it consists of several pieces. Then each portion behind appears as a wedge beneath the part in front, and the entire convolution is markedly narrowed, particularly towards the genu corporis callosi. The convolution appears notched in its upper part. For this reason Rolando compared it to a cock's comb and called it the "ridged convolution"; hence also the designation of the sulcus cinguli as the "festooned fissure" (*Pozzi*).

In consequence of the deep incision into the gyrus fornicatus by the common limb of the parieto-occipital and calcarine fissures behind the splenium, the isthmus is produced; this marks the transition of the gyrus cinguli into the gyrus hippocampi.

The **gyrus hippocampi** proceeds forward, becomes broader and, at the level of the substantia perforata anterior, bends around the front end of the *fissura hippocampi* to form the *uncus*. On its outer side, the gyrus hippocampi is bounded by the common stem of the parieto-occipital and calcarine fissures, the anterior part of the collateral fissure and the fissura rhinica.

As the gyrus cinguli, so also the gyrus hippocampi exhibits connections with the convolutions lying to its outer side. In this relation the great variability of the fissura collateralis comes into consideration. When the fissura rhinica is connected with the fissura collateralis, two annectant convolutions are found, an anterior and a posterior. The former, the *gyrus rhinencephalo-temporalis anterior*, joins the front part of the gyrus hippocampi with the temporal pole and is one of the most constant bridges. The other, the *gyrus rhinencephalo-lingualis*, connects the gyrus hippocampi with the gyrus lingualis. The last-named bridge is mostly superficial, but may present manifold variations. It may be divided by a longitudinal furrow into two parts, of which one or the other is deeply placed and the remaining one is superficial. Quite rarely, the entire bridge may be deeply situated, in which case the collateral fissure ends in the calcarine. In the event of the fissura rhinica being separated from the fissura collateralis, a third bridge, the *gyrus rhinencephalo-fusiformis*, is present.

The surface of the gyrus hippocampi, from where the gyrus approaches the hind end of the callosum forward, particularly toward the bottom of the fissura hippocampi, exhibits a lighter color. This tract is known as the *substantia reticularis alba* (Arnold). Moreover, mention must be made of the peculiar character of the surface of that part of the gyrus which lies between the fissura rhinica and the fissura hippocampi. Here the surface is covered with numerous small nodules or wartlike elevations, designated as *verrucae gyri hippocampi*.

### 3. HIPPOCAMPUS.

The hippocampus or cornu Ammonis also belongs to the central region of the rhinencephalon. Since this structure is seen only after the lateral ventricle has been opened, its further consideration will be postponed (page 43).

### 4. GYRUS DENTATUS.

When, in order to determine the depth of the hippocampal fissure, the gyrus hippocampi is pulled downward, one sees a gray notched or corrugated band, the *fascia dentata* (Tarini) or the *gyrus dentatus* of Huxley. Farther inward and over the



gyrus dentatus, is seen a white band, which passes from the uncus gyri hippocampi backward; this is the *fimbria hippocampi*. In its further course the fimbria is continuous with the fornix.

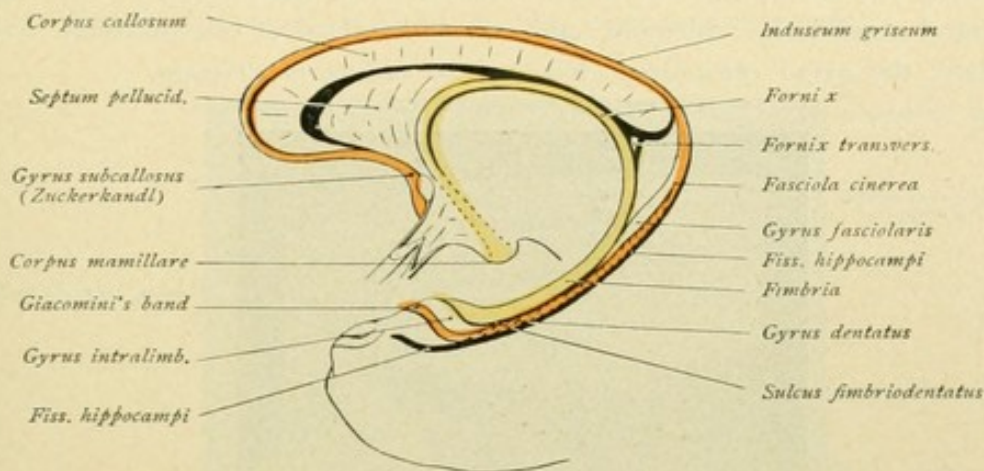


FIG. 32.—Relations of the dentate gyrus. Gyrus dentatus is red; fimbria and fornix are yellow.

The gyrus dentatus is separated from the gyrus hippocampi by the *fissura hippocampi*, and from the fimbria by the *sulcus fimbrio-dentatus*. Following the dentate gyrus farther backward, it is seen to run at first parallel with the fimbria to the splenium corporis callosi. Here the gyrus leaves the fimbria, loses its incisions and knobs, becomes smooth and, as the *fasciola cinerea*, passes around the callosum to spread out over the latter as a thin lamella of gray substance, the *induseum griseum*. In the middle, the induseum exhibits the *striae longitudinales mediales* or *striae Lancisii*, while on each side, in the sulcus corporis callosi, lies the *stria longitudinalis lateralis* or

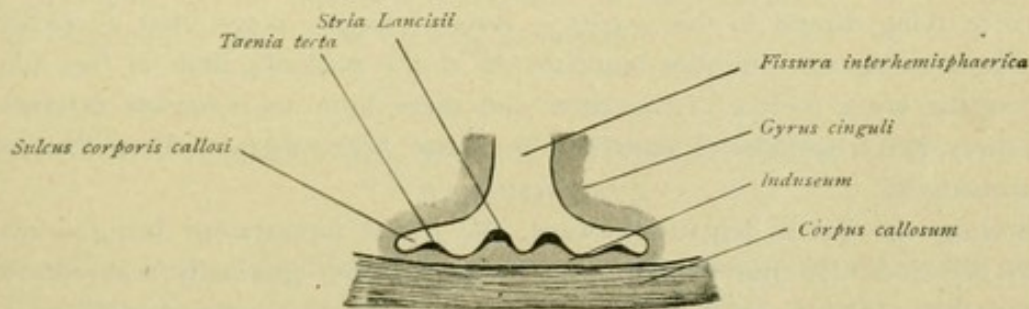


FIG. 33.—Induseum and striae longitudinales on the upper surface of the corpus callosum.

*taenia tecta* (Fig. 33). Induseum and striae longitudinales run forward around the knee of the callosum and in their farther course pass into the gyrus subcallosus, with which, in turn, Broca's band (page 30) joins.

According to most authors, the fasciola cinerea constitutes the direct continuation of the gyrus dentatus. As shown by Retzius, however, the gyrus dentatus is not prolonged directly into the fasciola cinerea (Fig. 34). On examining the area beneath the splenium where the gyrus dentatus leaves the fimbria, a thin strand is seen next the fascia dentata, which likewise sinks into the depth of the sulcus fimbrio-dentatus



between the fascia dentata and the fimbria. This small cylindrical strand was called by Retzius the *gyrus fasciolaris*. It is separated from the gyrus dentatus by a small furrow, the *sulcus dentato-fasciolaris*, and forms, by union with the pointed end of the gyrus dentatus, the fasciola cinerea of the authors. The fasciola extends as a gray semi-cylinder strand around the splenium and, on the surface of the callosum, continues as a broad plate, the *gyrus epicallosus* (Retzius) or *induseum griseum*.

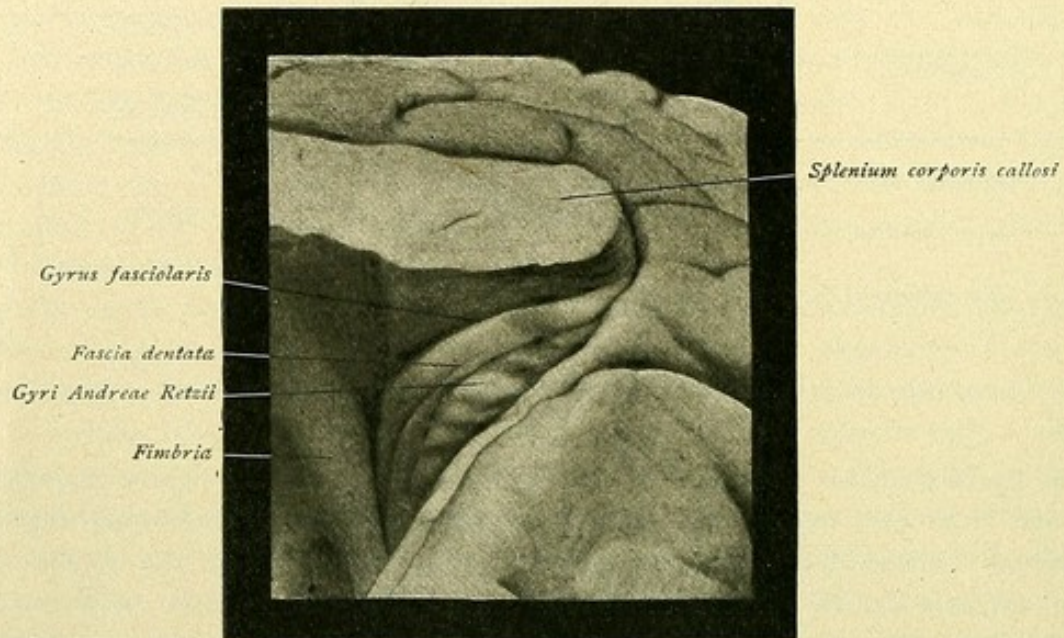


FIG. 34.—Gyrus fasciolaris and gyri Andreae Retzii.

Retzius agrees with Zuckerkandl, that the striae longitudinales mediales and laterales correspond to local elevations of the induseum. In front, they pass into the gyrus subcallosus and also in part, at least so far as the taenia tecta is concerned, into the substance lying lateral to this gyrus. Retzius further notes, that a portion of the gray lamella covering the callosum branches off at the posterior limit of the splenium to continue on the lower surface of the latter and there form an *induseum inferius*. Since this structure often resembles a convolution, it has been designated by Retzius as the *gyrus subsplentialis*.

Following the gyrus dentatus forward, the gyrus hippocampi being drawn downward, one perceives that the dentate gyrus here likewise gradually separates from the fimbria and then, after a bend at right angles—the *angulus gyri*—passes as a smooth slightly convex band onto the uncus. This *band of Giacomini*, as it is termed, passes over the under surface of the uncus, from the outer side onward and somewhat backward, and thence continues onto its upper surface. The band courses from the inner side forward and outward, as far as a thin sheet of medullary substance, the *velum terminale* (Abbey), adhering to the uncus. This entire course is plainly exposed after removal of the gyrus hippocampi.

Retzius recognizes two divisions of the gyrus dentatus, a longitudinal and a transverse. The former, proceeding from the *angulus gyri dentati*, extends backward within the *fissura hippocampi*. The transverse division, on the contrary, proceeding from the *angulus*, represents the front end of the convolution. The transverse part—



the *limbus Giacomini*—is further subdivided into a *pars occulta*, which lies buried in the hippocampal fissure, and a *pars aperta*, which is visible on the upper surface of the uncus. In front, the *pars occulta* is limited by a furrow that corresponds morphologically to the end of the *fissura hippocampi*. Behind, the limitation is usually less definite, at times the *limbus Giacomini* appearing to pass over into this part.

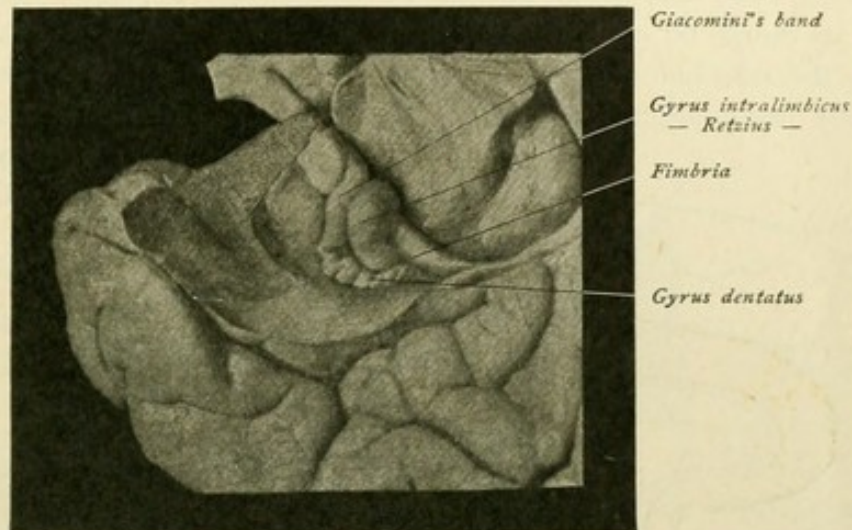


FIG. 35.—Giacomini's band. The under surface of the uncus is exposed by removing part of the gyrus hippocampi.

On the portion of the under surface of the uncus lying in front of Giacomini's band, one distinguishes two, often only one, or occasionally three, sulci and included convolutions, which pass from the anterior limiting fissure. These are designated as the *sulci* and *gyri digitati externi*. Small tip-like extensions of the Giacomini band radiate forward for a short distance within the *sulci digitati*; consequently, this part of the *limbus* appears more or less festooned. The anterior termination of Giacomini's band is as yet undetermined.

##### 5. GYRUS UNCINATUS, GYRUS INTRALIMBICUS AND GYRUS FASCIOLARIS.

According to most authors, the uncus gyri hippocampi or the gyrus uncinatus, is the continuation of the gyrus hippocampi, bent around the anterior end of the hippocampal fissure, which extends as far as the beginning of the fimbria and is divided into an anterior and posterior part by the Giacomini band. According to Retzius, however, the front division of the uncus must differ morphologically from the posterior. He regards, therefore, the anterior part as belonging to the gyrus hippocampi and designates this part alone as the *gyrus uncinatus*; the region lying behind the Giacomini band constitutes the *gyrus intralimbicus* of Retzius. This intralimbic gyrus appears sometimes as a small slightly arched surface, sometimes as one or several knobs, and occasionally is sharply defined by a fissure from the fimbria and the gyrus dentatus. The convolution continues for a short distance backward within the *sulcus fimbrio-dentatus*. Farther behind in the same sulcus, a gray strand again



appears. This gradually thickens, lies attached to the gyrus dentatus, or separated from the latter by the sulcus dentato-fasciolaris, and, as the *gyrus fasciolaris* of Retzius, passes around the splenium corporis callosi.

#### 6. GYRI ANDREAE RETZII.

These, also known as the *callosal convolutions*, represent rudimentary gyri, which appear as round or oval elevations on the medial surface of the gyrus hippocampi, beneath the splenium and in the angle formed by the dentate and hippocampal gyri. They are not constant and may be little more than mere suggestions, or, when

strongly developed, may resemble a spirally wound cord. Zuckerkandl designates them as *callosal convolutions*, and Giacomini reckons them, in view of their structure, as belonging to the hippocampus. G. Retzius named the convolutions in honor of their discoverer, Anders Retzius, his father, the *gyri Andreae Retzii* (Fig. 34).

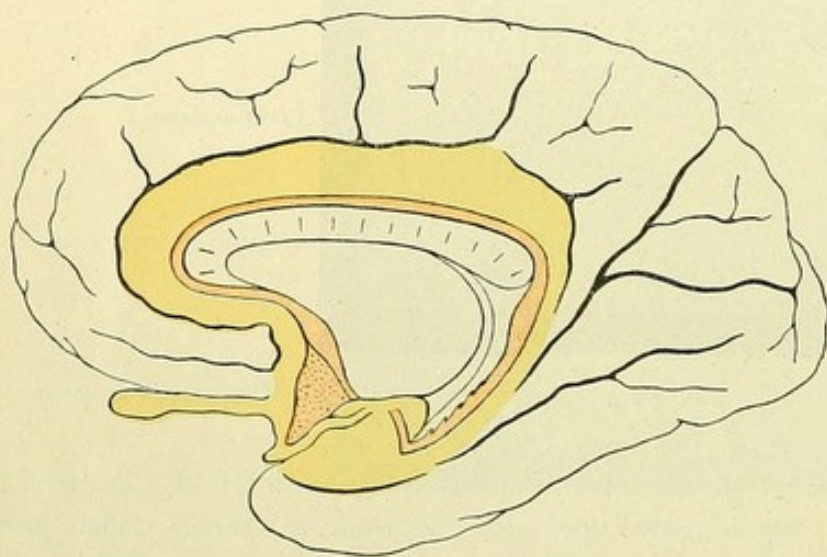


FIG. 36.—Schematic representation of the regions of the rhinencephalon: Yellow—lobus olfactorius anterior and gyrus fornicaus; red—lobus olfactorius posterior and gyrus dentatus.

**Summary.** Taking a general survey of the entire rhinencephalon (Fig. 36), we distinguish a peripheral and a central region.

The peripheral region includes a front and a hind part, the lobus olfactorius anterior and the lobus olfactorius posterior. The central region embraces a large annular tract on the medial surface of the hemisphere, and includes the gyrus fornicaus and the gyrus dentatus.

Peripheral and central regions are closely united with each other, the lobus olfactorius anterior being connected with the gyrus fornicaus and the lobus olfactorius posterior with the gyrus dentatus. Moreover, the lobus olfactorius anterior is connected, on the one hand, with the gyrus cinguli by means of the gyrus olfactorius medialis and, further along, the area parolfactoria; on the other hand, it is joined with the front end of the gyrus hippocampi by means of the gyrus olfactorius lateralis. The lobus olfactorius posterior is connected with the gyrus dentatus by means of Broca's diagonal band, the gyrus subcallosus and the induseum covering the corpus callosum. As will appear later, the olfactory centre is supposed to lie chiefly in the cortex of the gyrus hippocampi. Therefore, the impulses transmitted from the nasal mucous membrane by the fila olfactoria must be carried from the bulbus olfactorius and transferred to the central region of the rhinencephalon. The course of this olfactory tract will best explain the connections of the individual parts of the rhinencephalon (page 144).



## PARS OPTICA HYPOTHALAMI.

This division of the telencephalon includes :

- The lamina terminalis,
- The chiasma opticum, with the tractus optici,
- The tuber cinereum,
- The infundibulum,
- The hypophysis.

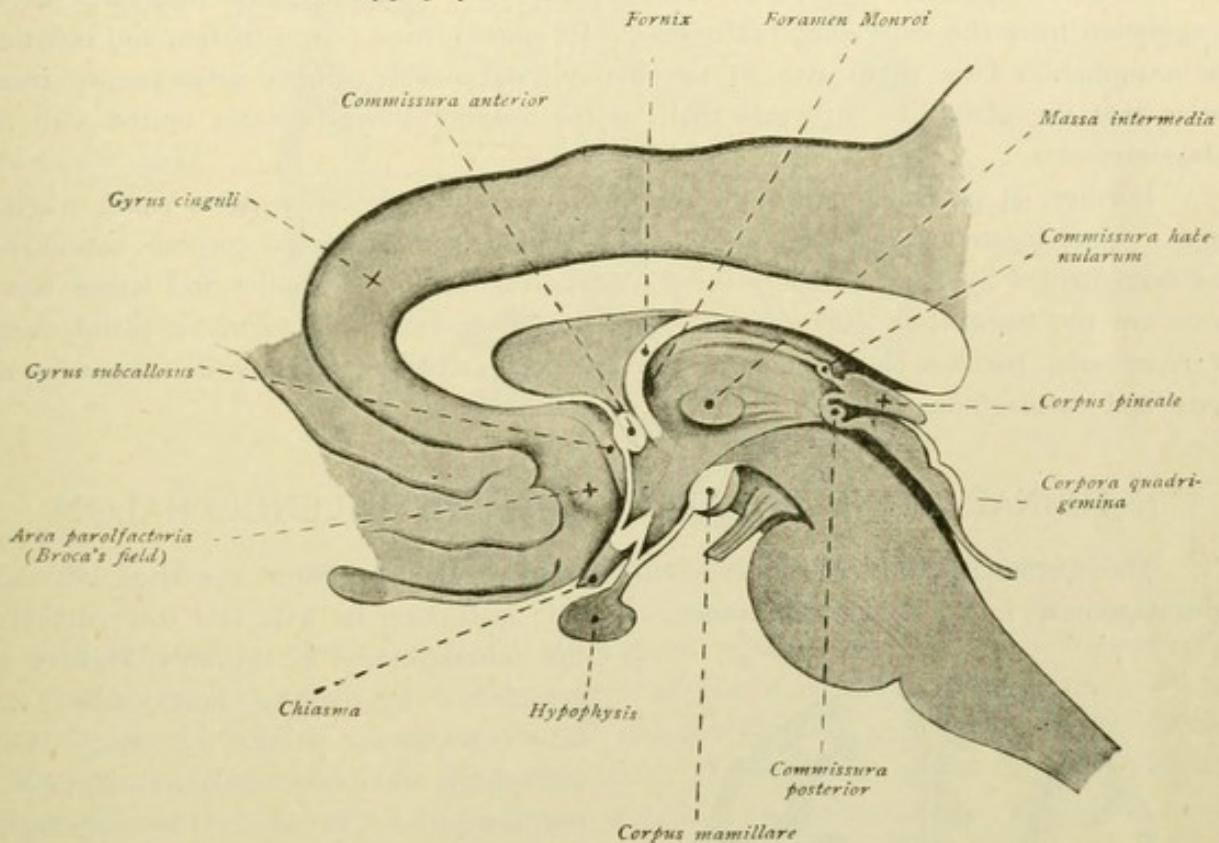


FIG. 37.—Median sagittal section through the lower part of the brain.

The **lamina terminalis**, or *end-plate*, rises as a thin sheet in front of the chiasma opticum and continues in front of the commissura anterior and the columnae fornicis. Between it and the chiasma lies the *recessus opticus*. The thin lamella originally formed the middle part of the front wall of the fore-brain; later it is displaced, lies more deeply, and then forms the anterior wall of the third ventricle, in whose roof-plate it is continued.

The **chiasma opticum** forms a white quadrangular plate, from the anterior corners of which proceed the *nervi optici* and from the posterior corners the *tractus optici*. The latter run as flattened cords outward and backward along the hind border of the substantia perforata anterior; after passing around the pedunculi cerebri and, farther along, above and somewhat lateral to the uncus gyri hippocampi, they lead into the region of the metathalamus.

The **tuber cinereum** lies behind the chiasma, bounded laterally by the optic tracts and the cerebral peduncles and behind by the corpora mamillaria. This gray elevation is a thin lamina and assists in forming the floor of the third ventricle. Traced



forward, it passes into the lamina terminalis, and in this anterior position is pushed into the ventricle by the chiasma. Below, the tuber cinereum is continuous with a hollow funnel-shaped structure, the *infundibulum*, whose cavity is known as the *recessus infundibuli*. To the end of the infundibulum is attached the *hypophysis cerebri* or *pituitary body*, a gray mushroom-shaped structure, about the size of a bean, whose longest diameter is placed transversely.

The **hypophysis**, on being sectioned, is seen to be composed of a larger *anterior* and a smaller *posterior lobe*. Genetically, only the posterior lobe belongs to the brain, as a ventral evagination from the diencephalon. The lobus anterior originates as an evagination from the embryonal oral recess. In consequence of constriction and isolation, the evagination later gives rise to the hypophysial vesicle, which subsequently transforms into the gland-like structure that, as the anterior lobe, becomes united with the lobus posterior.

Further, at particular points of the tuber cinereum, one often notes small evaginations. One, located mostly medial and immediately in front of the corpora mamillaria, has been named by Retzius the *eminentia saccularis*, while the smaller and lateral elevations are the *eminentiae laterales*. In Fig. 30 the eminentia saccularis is plainly seen. It represents, perhaps, a rudiment of the saccus vasculosus strongly developed in the bony and cartilaginous fishes.

## INTERNAL CONFIGURATION OF THE TELEENCEPHALON.

The examination of the inner configuration of the end-brain is carried out most advantageously in the following manner. A brain is laid on its base and the removal of

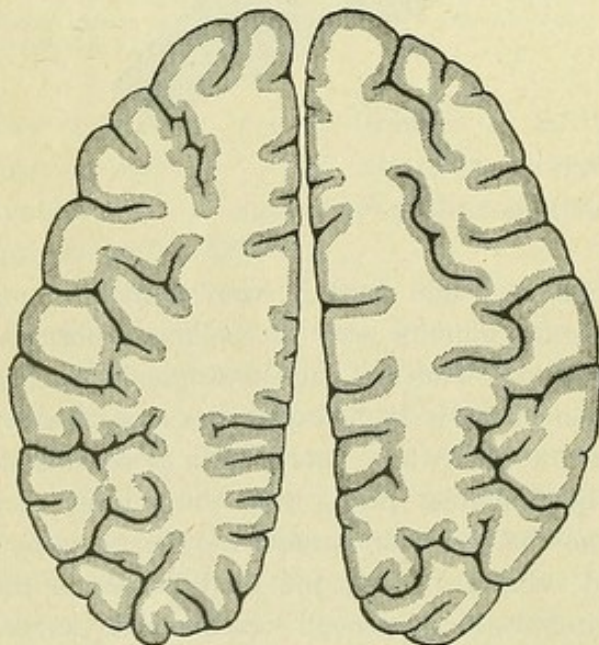


FIG. 38.—Horizontal section through the cerebral hemispheres, showing white and gray substance.

the hemispheres is begun. This is accomplished by passing horizontally, with slow continuous stroke, a long brain-knife from the convex lateral surface of the hemisphere as far as the longitudinal cerebral fissure. In this manner first the right and then the left hemisphere are removed, from above downward, in disk-like pieces about one centimeter thick. The last horizontal section should fall about 5 mm. above the dorsal surface of the corpus callosum.

Each section distinctly exhibits two different substances—the *white substance*, light in color and situated in the interior, and the *gray substance*, which everywhere encloses the former and continues as a band at the periphery (Fig. 38). In the first pieces, the white substance is less voluminous than the gray. The deeper one cuts, however, the greater the amount of white substance revealed, and in the last section, passing imme-



diately above the callosum (Fig. 39), in each hemisphere is seen a large white medullary field, the *centrum semiovale* (Vieussens), which peripherally is bounded by the gray band representing the cerebral cortex, the *substantia corticalis*.

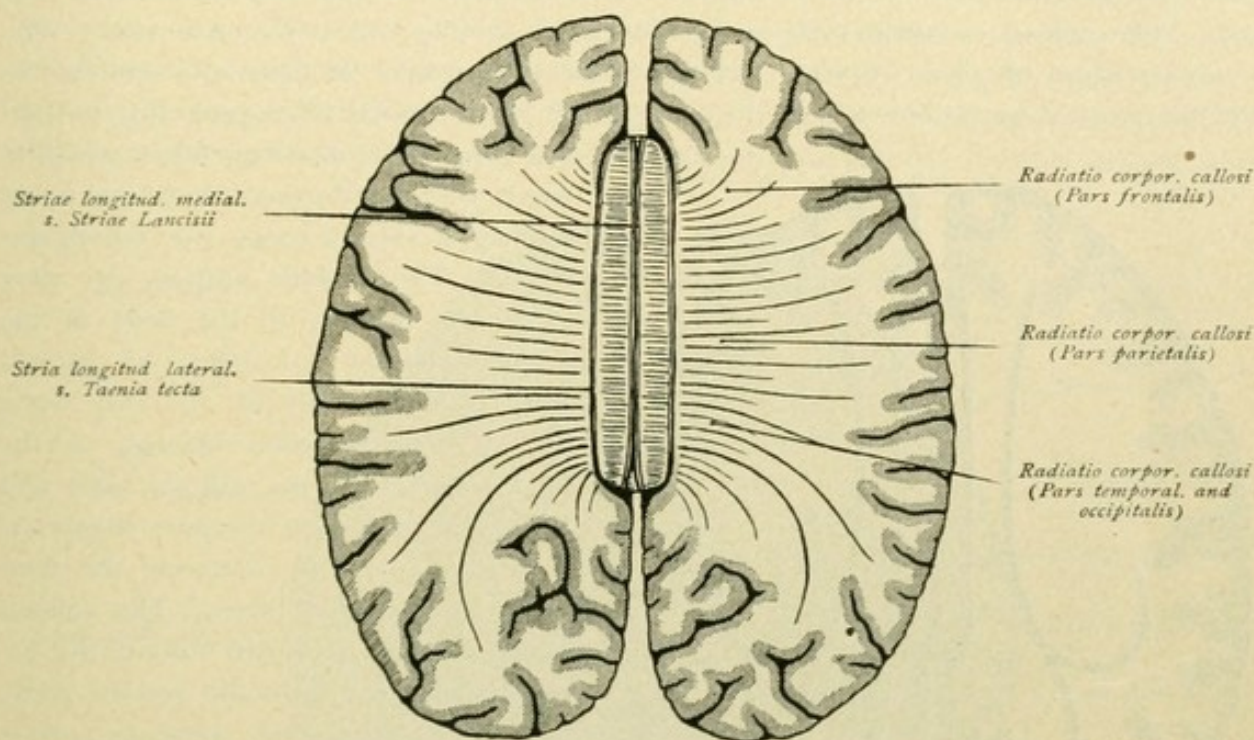


FIG. 39.—Horizontal section at the level of the corpus callosum, showing radiation of callosal fibres.

The *substantia corticalis* is not everywhere equally developed as to thickness, in this respect varying according to the region of the brain. In general, the cerebral cortex is more developed on the summit of the convolutions and less so at the bottom of the fissures, being thicker on the outer convex surfaces than on the medial and basal aspects of the hemispheres. The cortex reaches its maximum development in the upper part of the central convolutions and in the lobus paracentralis, and its minimum in the occipital pole. When closely examined, even with the unaided eye, one recognizes that the cerebral cortex is not homogeneous, but is composed of alternating gray and white strata arranged parallel with the surface. The white bands are known as *Baillarger's stripes*. The cortex of the occipital lobe, particularly around the calcarine fissure, exhibits this stratification quite distinctly. Here three layers are found, an outer and an inner gray stratum and, between them, a thin light band, the *stripe of Vicq d'Azyr* (Fig. 40), or, since Gennari first described it, the *stripe of Gennari*. The explanation of this lamellation will be given later by the microscopical examination of the cerebral cortex (page 114).

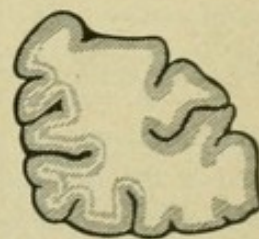


FIG. 40.—Vertical section through occipital lobe. The narrow light band is the stripe of Gennari.

In consequence of the removal of the upper part of the hemispheres, as already suggested, the corpus callosum comes plainly in view. The dorsal surface of this bridge lies before us, while on each side it is separated from the overlying medial surface of the hemisphere by the sulcus corporis callosi.



The **corpus callosum**, or *commissura cerebri magna*, forms a white medullary mass that connects the hemispheres. Strands of transversely coursing fibres, the *striae transversae*, are seen on the surface of the *truncus* or body of the corpus callosum. They penetrate the wall of the hemispheres and form the *radiatio corporis callosi* (Fig. 39). The callosal radiation includes an anterior, a middle and a posterior part. The anterior portion, the *pars frontalis*, belongs to the callosal knee or *genu* and connects the anterior parts of the frontal lobes. In consequence of the frontal lobes projecting beyond

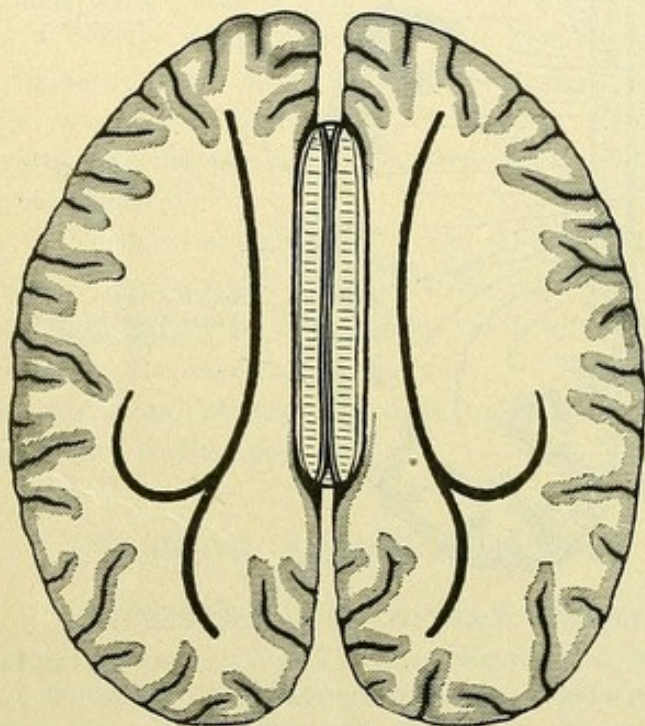


FIG. 41.—Horizontal section at the level of the corpus callosum. The heavy lines within the centrum semiovale indicate the incisions made in opening the lateral ventricles.

the *genu*, the connecting fibres sweep in curves far forward toward the frontal poles, forming a sort of tongs, the *forceps anterior*. The middle portion, the *pars parietalis*, belongs to the body of the corpus callosum and unites the parietal and temporal lobes of the two sides. The posterior portion belongs to the hind segment of the callosal body and the splenium and, as the *pars temporalis* and *pars occipitalis*, connects the temporal and occipital lobes. The callosal fibres arch far backward toward the occipital poles and form the *forceps posterior*. The *induseum griseum* covers the upper surface of the corpus callosum as a thin investment, that presents two medial linear thickenings, and, on each side, a lateral one. The medial longitudinal stripes, the *striae longitudinales mediales* or *striae of Lancisii*, are separated by a longitudinal furrow, the *raphe corporis callosi*. The lateral stripes, situated within the corresponding sulcus corporis callosi, are the *striae longitudinales laterales* or the *teniae tectae*.

Now follows the opening of the lateral ventricles. Such parts of the hemispheres which still overlie the corpus callosum are removed as far as the level of the dorsal surface of the callosum. On separating these parts with the fingers, in properly hardened brains, it is possible to demonstrate the *radiatio corporis callosi*, especially the *forceps anterior* and *posterior*. A pointed knife is now passed through the roof of the lateral ventricle, at the side of the body of the callosum and from 1–2 cm. behind the *genu*. The incision is lengthened straight forward as far as the level of the *genu* of the callosum and backward, in a slightly outwardly convex curve, to a point behind the splenium. By gradually widening the opening medially and laterally the ventricle is exposed.

#### THE LATERAL VENTRICLE.

In each lateral ventricle we distinguish three outpouchings or horns, the *cornu anterius*, the *cornu posterius* and the *cornu inferius*, invading the frontal, occipital and temporal lobes respectively, and the middle chief part or body, the *pars centralis*, uniting the three horns.



The front horn, the **cornu anterius**, is bounded in front, partly below and above by the fibres of the corpus callosum. The radiation of the callosal knee closes the anterior horn in front and in addition forms a part of the floor. The medial wall and, at the same time, the partition between the two anterior cornua are contributed by the *septum pellucidum*. The latter consists of two thin plates, the *laminae septi pellucidi*, between which lies the completely closed *cavum septi pellucidi*. A part of the floor and the lateral wall of the anterior horn are formed by a gray protuberance, the *corpus striatum*. The thickened front part of the latter, which projects into the anterior horn, is known as the

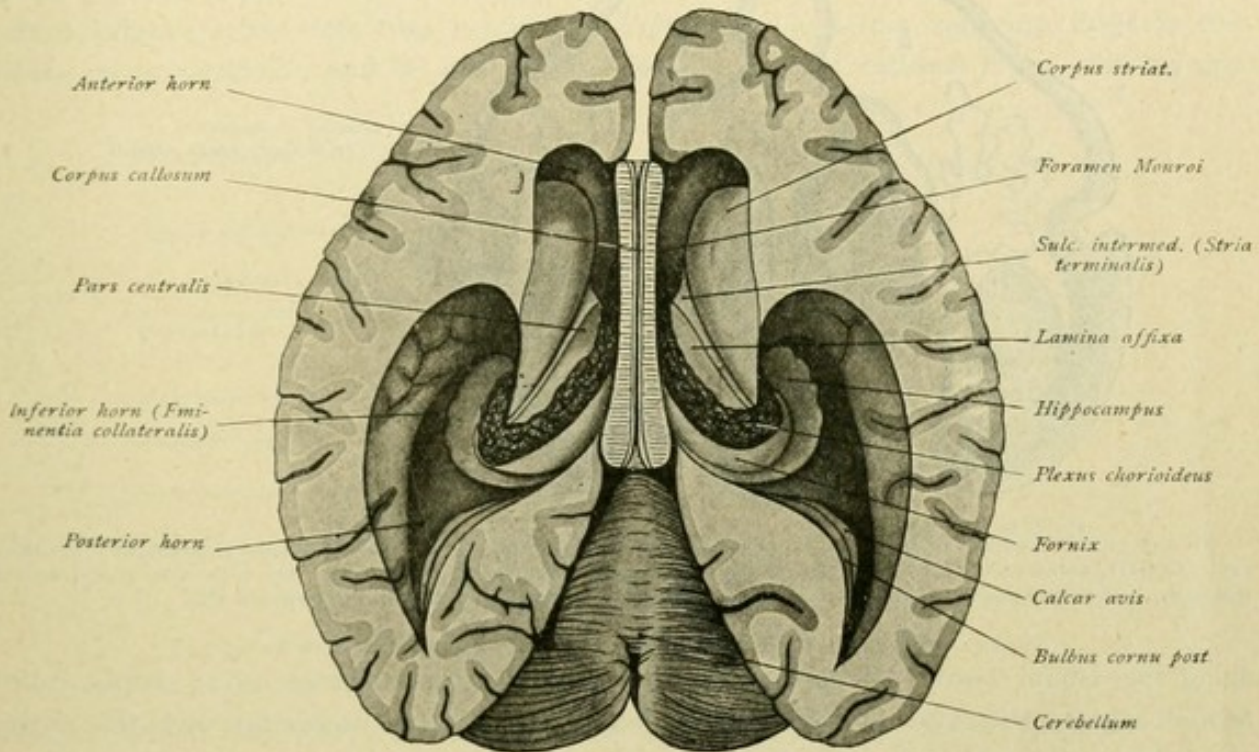


FIG. 42.—The lateral ventricles, viewed from above.

head, or *caput*; passing backward, the striatum markedly narrows and, as a narrow tail-like band, the *cauda corporis callosi*, continues through the pars centralis into the cornu inferius, of which horn it contributes a portion of the roof.

The **pars centralis** is a thin horizontal cleft, roofed in by the radiation of the callosum. On the floor, laterally, is the corpus striatum; next follows the *stria terminalis* or *stria cornea*. This structure forms the floor of a groove, the *sulcus intermedius*, situated between the corpus striatum and the adjoining thalamus. The stripe is called stria cornea on account of its bluish coloration, produced by the underlying vena terminalis. Medial to the stria terminalis comes a thin lamella, the *lamina affixa*, that covers the lateral part of the thalamus, to which it is attached. Farther medially, follow the *plexus chorioideus ventriculi lateralis* and the dorsal surface of the part of the *fornix* which is free and unattached to the callosum.

Regarding the **plexus chorioideus**, it must be especially emphasized that this structure, composed of pial tissue, really only seemingly lies within the lateral ventricle. As in all other parts, so also here the ventricle is lined with ependyma which invests the choroid plexus with a thin epithelial layer, the *lamina chorioidea epithelialis*; the plexus



lies, therefore, extraventricular. Laterally the lamina chorioidea begins at the lamina affixa; medially it is continuous with the epithelium covering the fornix (Fig. 63). On removing the plexus chorioideus, the lamina chorioidea epithelialis is taken away with it, the epithelial layer tearing through the medial border of the lamina affixa and

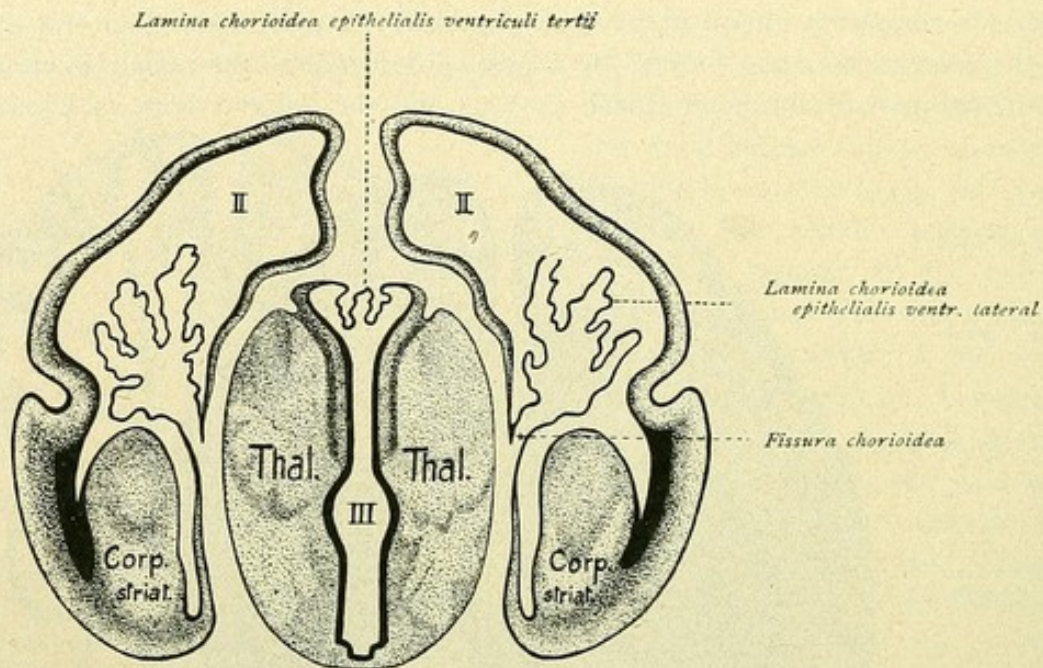


FIG. 43.—Frontal section of the brain of a human embryo of 50 mm. In the middle are the thalami, with the third ventricle (III), whose roof is formed by the lamina chorioidea epithelialis ventriculi tertii. On each side, lateral to the thalamus, is the hemisphere-vesicle with the lamina chorioidea epithelialis of the lateral ventricle (II).

along the lateral border of the fornix. In these locations delicate white stripes, called *taeniae*, mark the lines of separation; hence, the *taenia chorioidea* and the *taenia fornicis* are distinguished.

These *taeniae*, evidently, as such do not exist in the normal and undamaged brain; they are, therefore, artefacts as are also the *taenia fimbriae*, *taenia thalami* and *taenia ventriculi quarti*, to be described later. Their true relations are to be understood only by reference to embryology. While the original wall of the embryonic brain-tube for the most part thickens during development and becomes nervous substance, in certain places, namely in the roof of the third and of the fourth ventricle and along a band-like area on the medial wall of the hemisphere, such conversion into nervous tissue never occurs, the brain-wall there being represented by only a thin epithelial plate, the lamina chorioidea epithelialis. Where the latter joins the typical wall, the nervous substance is thinned out to a slender wedge.

The lamina chorioidea, moreover, at certain places undergoes a complicated invagination toward the cavity of the ventricles, accompanied by the superimposed pial tissue, the process leading to the formation of the plexus chorioidea. When later the brain-membranes are removed, as when, for example, the plexus of the lateral ventricle is taken off, the epithelial lamina is also removed and there remain only delicate linear borders, known as the *taeniae*, that mark the torn edges along those lines at which the brain-substance joins the epithelial plate.



The plexus chorioideus ventriculi lateralis passes forward, becoming more deeply placed, toward the anterior cornu. Here is found the Y-shaped foramen interventriculare Monroi, which connects the two lateral ventricles with each other and with the third ventricle. Behind, the choroid plexus continues outward and downward into the inferior cornu.

The hind horn, the **cornu posterius**, forms a narrowing cleft of variable length, with convex lateral and concave medial arched walls. The lateral superior wall is formed by the fibre-radiation of the corpus callosum; the remaining boundaries are contributed by the medullary portion of the occipital lobe. On the medial wall, usually two longitudinal ridges project into the ventricle. The upper and less constant ridge is the *bulbus cornu posterius*, and is due to the laterally arching callosal fibres—the forceps

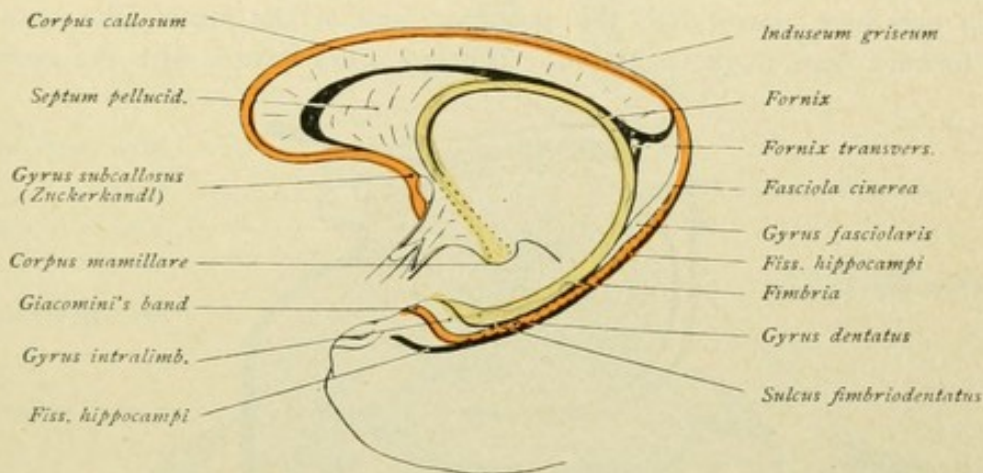


FIG. 44.—Relations of the gyrus dentatus (red), the fimbria and the fornix (yellow).

posterior, which here curve around the deeply incising fissura parieto-occipitalis. The lower and constant ridge is the *calcar avis* and owes its existence to the deep penetration of the fissura calcarina.

The lower horn, the **cornu inferius**, curves downward and far forward in the temporal lobe, to end blindly before reaching the tip. The roof is formed laterally by the callosal radiation known as the *tapetum*, medially by the cauda corporis striati and the stria terminalis. The floor exhibits the *eminentia collateralis*, a longitudinal ridge produced by the deep invagination of the fissura collateralis. Behind, toward the posterior horn, the eminence continues into a triangular, slightly convex field, the *trigonum collaterale*. The medial wall of the inferior horn is occupied by a remarkable semilunar curved protuberance, the *hippocampus* or *cornu Ammonis*, for whose production the deep fissura hippocampi is responsible. It begins behind the pars centralis or body of the lateral ventricle, in advance of the front end of the calcar avis, and extends in a laterally convex curve downward and forward. Towards the anterior extremity of the inferior horn, the hippocampus broadens and then ends in several claw-like elevations, the *digitationes hippocampi*, which vary in development, in some cases being merely suggested, while in others they may number four or five or even seven. The indentations lying between the digitations are called the *sulci interdigitales*. The marginal portion of the fornix, unattached to the corpus callosum, the dorsal surface of which has been mentioned in



relation with the pars centralis of the lateral ventricle, continues backward and outwards; it accompanies the hippocampus medially into the inferior horn. The plexus chorioideus ventriculi lateralis, which is directly prolonged from the pars centralis into the inferior horn, where it forms part of the medial boundary, is especially well developed—*glomus chorioideum*—at the juncture of the pars centralis and the inferior cornu. If the plexus be separated from the fimbria, a thin lamina, the *taenia fimbriae*, remains. At its front end, the wall of the inferior horn constitutes a delicate occluding lamella, which is clothed with the ependyma and termed the *velum terminale* of Aeby. The fornix and the hippocampus now merit closer examination (Figs. 44, 45 and 46).

The **fornix** represents a paired structure, that extends in a bold curve from the uncus gyri hippocampi as far as the corpora mamillaria. From the inferior horn of the lateral ventricle on each side, the *fimbria*, at first narrow, extends backward toward the splenium and here passes into the posterior limit of the fornix, the *crus fornicis*, which runs forward beneath the callosum. The two crura fornicis with the under surface

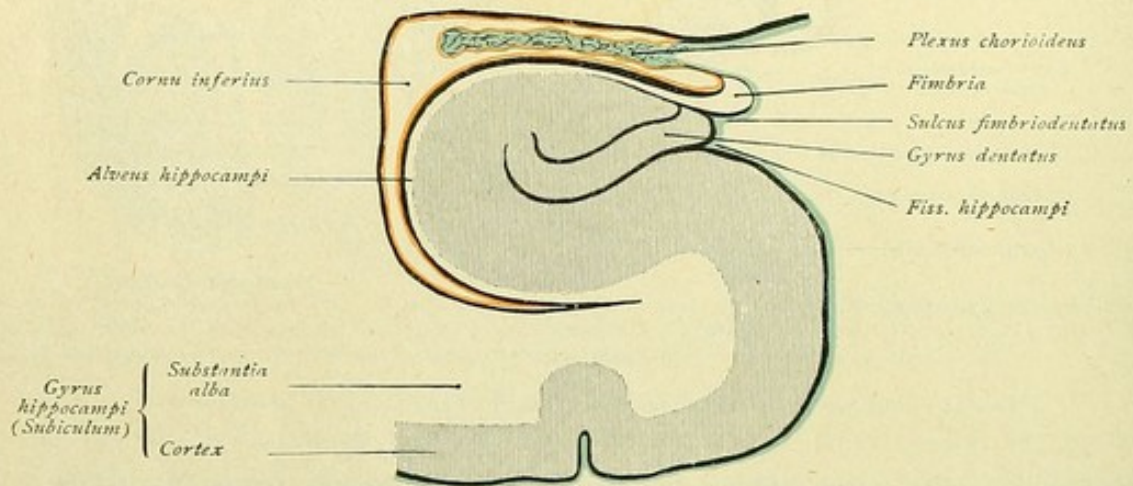


FIG. 45.—Frontal section through the inferior horn of the lateral ventricle; free-surface of the gyrus hippocampi is on the right. Ependyma is red; pia mater and plexus chorioideus blue.

of the corpus callosum form an equilateral triangle, whose apex is directed forward. The two limbs of this triangle are connected by strands of fibres running crosswise and constituting the *fornix transversus* or *commissura hippocampi*. The entire triangular fibre-plate, also designated as the *psalterium* or *lyra Davidis*, is often separated from the under surface of the callosum by a small cleft, the *cavum psalterii*, sometimes misleadingly called Verga's ventricle.

The crura of the fornix, which curve around the posterior parts of the thalami and pass toward the under surface of the callosum, by their union form the *corpus fornicis*. In its posterior part, the body is attached to the corpus callosum, while it extends as far forward as the vicinity of the foramen interventriculare. The under surface of the fornix exhibits a median groove, the *sulcus medianus fornicis*. In front, the corpus fornicis divides into two anterior columns, the *columnae fornicis*, which, as white cylindrical cords, sweep downward in forwardly directed curves, in advance of the thalami and behind the commissura anterior, and on each side disappear in the hypothalamic region. They contribute the anterior boundary of the foramen interventriculare and eventually end in the corpora mamillaria.



The **hippocampus** or **cornu Ammonis** is, as already mentioned, produced by the deeply invaginating fissura hippocampi. These relations are best understood by examining a frontal section passing immediately behind the uncus gyri hippocampi (Figs. 45 and 46). It will be seen, that the entire cortical formation is pushed in toward the ventricle by the penetration of the hippocampal fissure, thereby producing, in a sense, an almost completely closed hollow cylinder, in which lies the gyrus dentatus as a gray cord. The upper end of the scrolled plate bends sharply outward and terminates as a thin lamella. This invaginated cortex, protruding into the ventricle, is the hippocampus. Since the latter at the same time overlies the gyrus hippocampi, this convolution is also called the *subiculum cornu Ammonis*. The white fibre-layer covering the

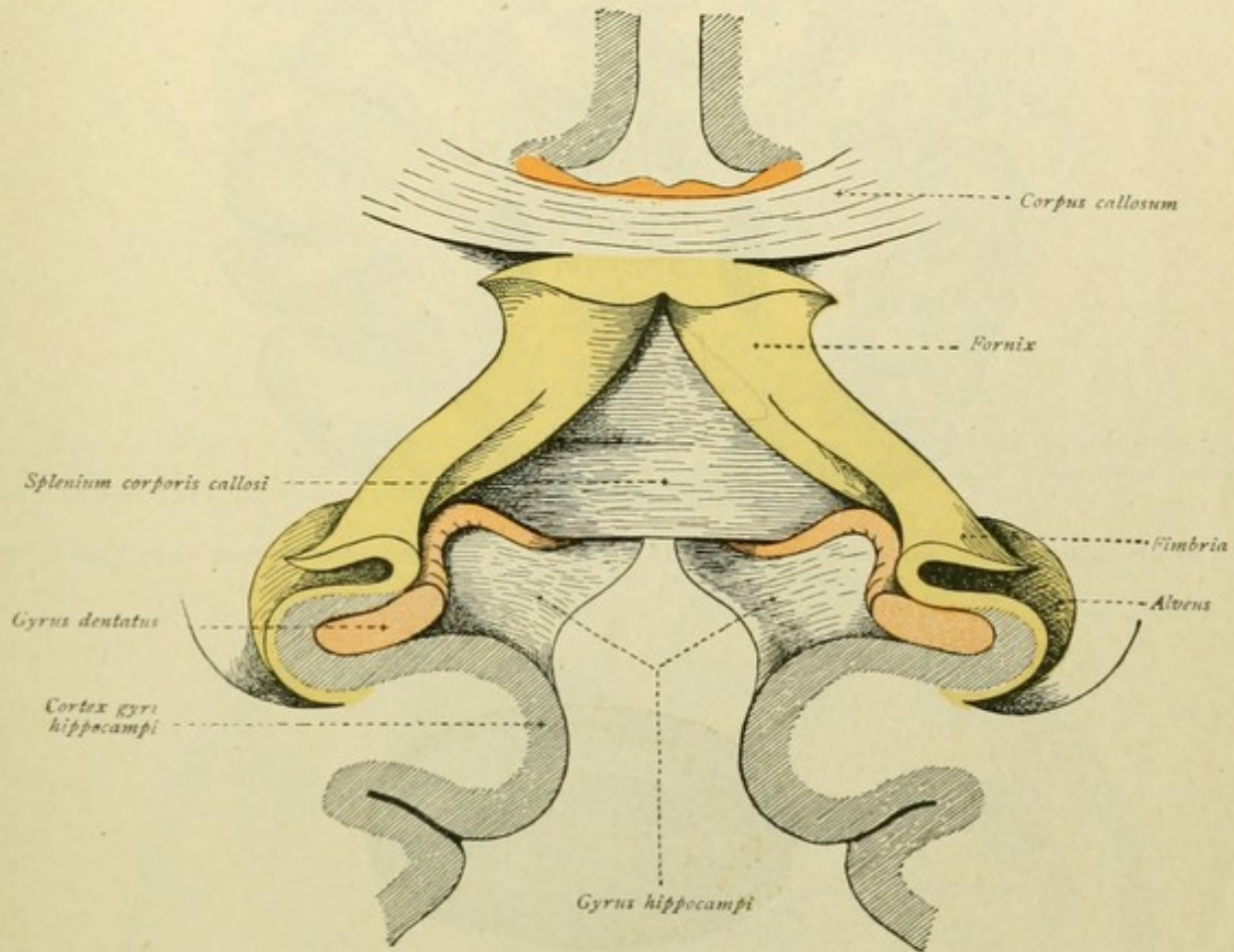


FIG. 46.—Section across the hippocampal region; the posterior end of the corpus callosum is viewed from in front and below. Transition of the alveus and the fimbria (yellow) into the fornix. The course of the gyrus dentatus (red) is seen behind the splenium and, as the induseum, over the corpus callosum.

ventricular surface of the invaginated cortex is the *alveus*. At the sharp outward bend of the cortical plate, the alveus becomes continuous with the fimbria.

On following the entire structure backward toward the splenium (best accomplished by making several consecutive vertical sections behind the uncus), it will be seen that the cortical formation of the gyrus hippocampi passes over into the cortex of the isthmus gyri fornicati and, farther along, into that of the gyrus cinguli. The gyrus dentatus separates from the fimbria and, as the *fasciola cinerea*, passes around the splenium to continue over the corpus callosum as the *induseum*. Alveus and fimbria are prolonged into the fornix, the alveus going into the medial and the fimbria into the lateral part of the fornix.



## GRAY MASSES AND NUCLEI.

In addition to the gray cortex, the *substantia corticalis*, other definite gray masses, known as the *nuclei* or *ganglia of the end-brain*, are found within the interior of the hemispheres. They are the *nucleus caudatus*, the *nucleus lentiformis*, the *claustrum* and the *nucleus amygdalae*, and are constituent parts of the stem of the telencephalon.

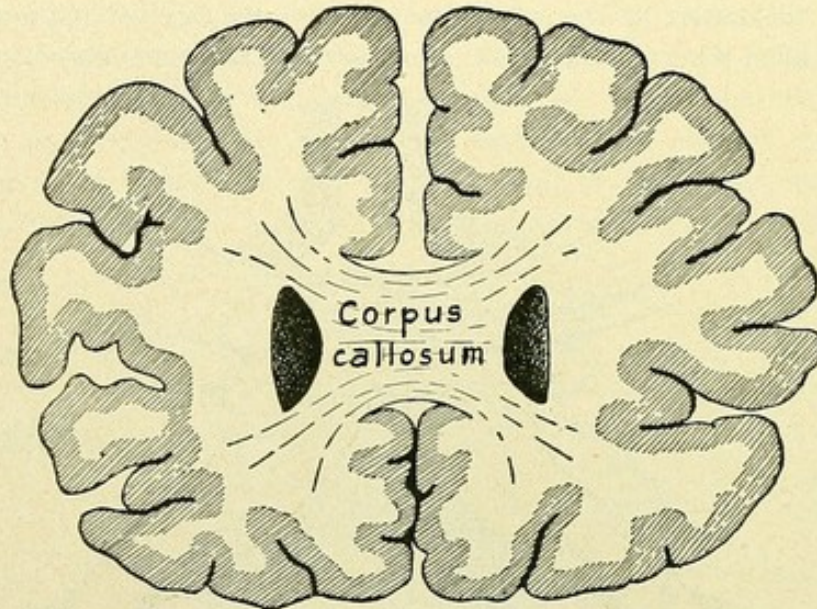


FIG. 47.—Frontal or vertical section of the brain, passing through the knee of the corpus callosum; on each side of the latter is the anterior horn of the lateral ventricle.

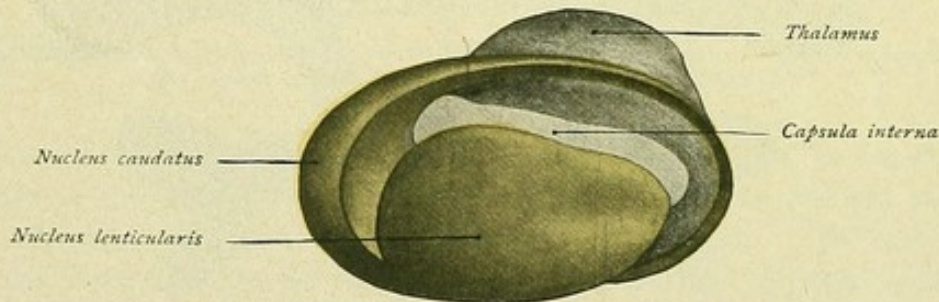


FIG. 48.—Model of the corpus striatum and the thalamus. Nucleus caudatus and lentiformis are yellow; in front and below they are continuous, elsewhere, separated by the capsula interna.

The **nucleus caudatus** forms the part of the corpus striatum that has been mentioned in connection with the lateral ventricle. The corpus striatum is divided by a traversing fibre-mass into two portions, a dorsal and medial one, the nucleus caudatus, and a lateral one, the nucleus lentiformis. The separating fibre-mass is the *capsula interna*. The thickened front end of the corpus striatum, that projects into the anterior horn of the lateral ventricle, and the narrow band, that extends backward through the pars centralis and into the inferior horn, belong to the nucleus caudatus. These are, therefore, more appropriately called respectively the *caput* and the *cauda nuclei caudati*, than the head and tail of the corpus striatum. The lateral edge of



the dorsal surface of the caudate nucleus reaches the lateral margin of the lateral ventricle, its medial edge touches the stria terminalis, and its lateral surface lies against the internal capsule (Figs. 49 to 52).

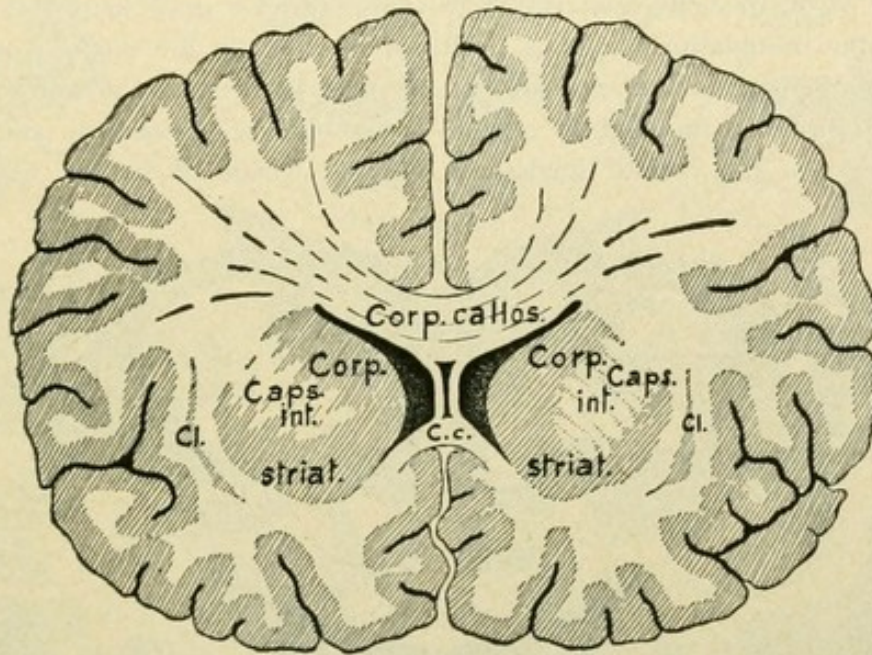


FIG. 49.—Frontal section of the brain, through the septum pellucidum, which extends between the body (*Corp. callos.*) and the rostrum (*C. c.*) of the corpus callosum and forms the medial wall of the anterior horns of the lateral ventricles. The corpus striatum is partially divided by the capsula interna. *Cl.*, claustrum.

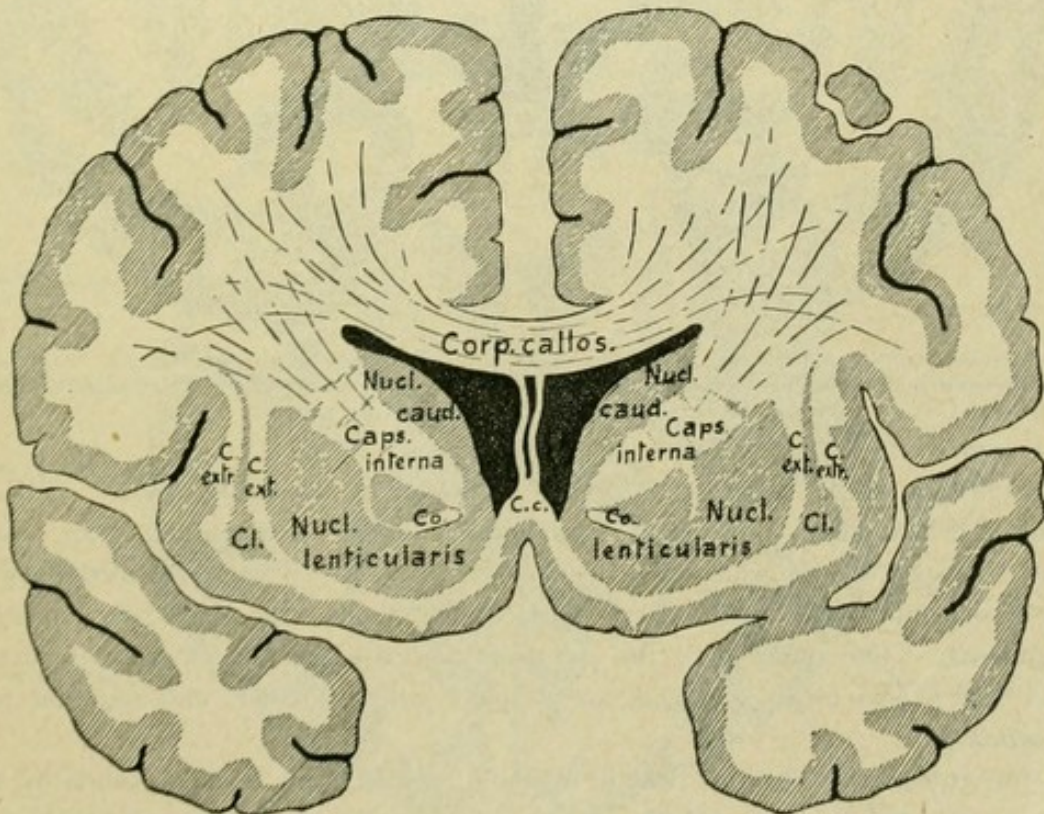


FIG. 50.—Frontal section of the brain, through the tips of the temporal lobes. *Cc.*, corpus callosum, lamina rostralis; *Co.*, commissura anterior; *C. ext.*, capsula externa; *Cl.*, claustrum; *C. extr.*, capsula extrema.



The **nucleus lentiformis**, or *nucleus lenticularis*, constitutes a wedge-shaped mass, whose base is directed outward and the apex inward. It lies lateral and, at the same time, ventral to the nucleus caudatus and thalamus, separated from the latter by the internal capsule. In front and ventrally, the lenticular nucleus is directly continuous with the head of the nucleus caudatus. Dorsally, delicate gray stripes connect the two nuclei; hence the designation "corpus striatum" applied to the nuclei conjointly. The nucleus lentiformis bounds the internal capsule laterally with its downward and inward sloping medial surface. Its slightly convex lateral surface is vertical and borders the *capsula externa*, a thin white medullary lamella which is limited externally by a

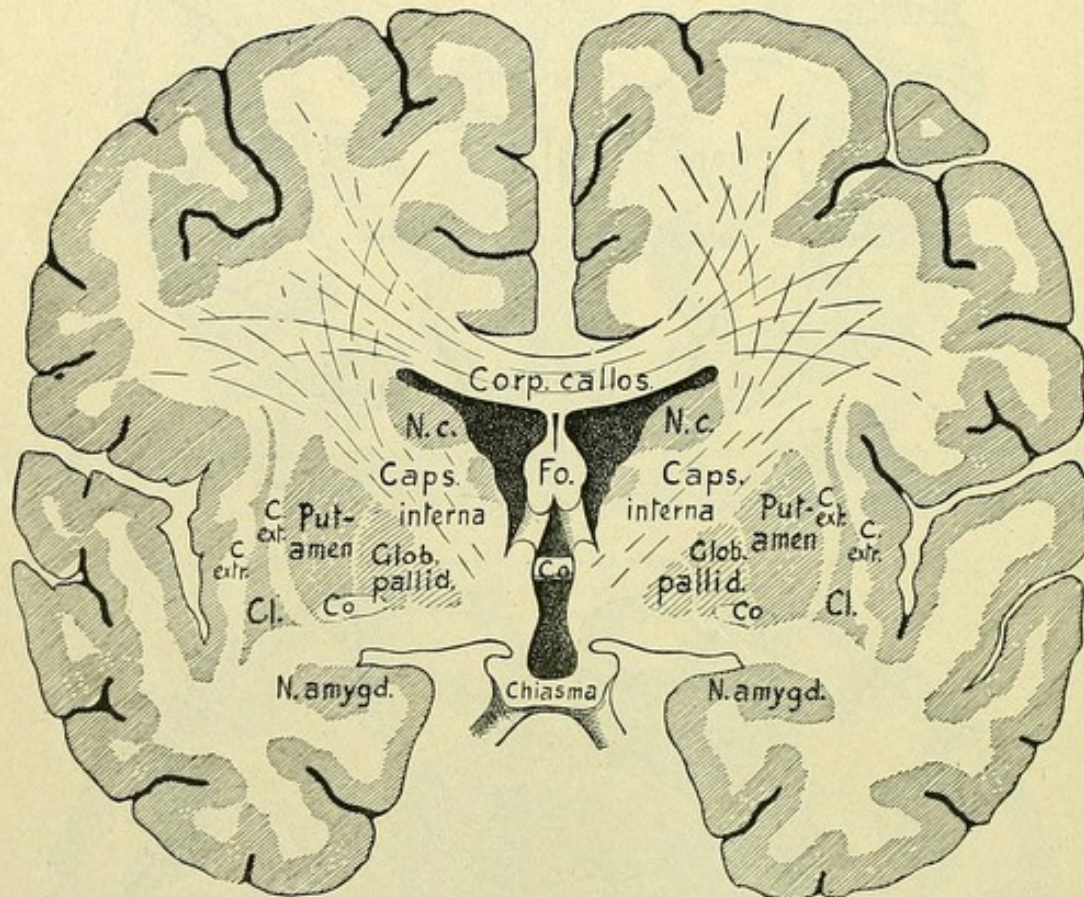


FIG. 51.—Frontal section of the brain, passing through the foramen interventriculare Monroi. *Fo.*, pillars of the fornix, between which and the corpus callosum is seen a part of the septum pellucidum; *N. c.*, nucleus caudatus; *Co.*, commissura anterior; *C. ext.*, capsula externa; *Cl.*, claustrum; *C. extr.*, capsula extrema.

narrow scroll-like sheet of gray substance known as the *claustrum*. The ventral surface of the lenticular nucleus is horizontal and, in the middle part, continuous with the cortex of the substantia perforata anterior. Two thin medullary sheets, more or less parallel with the lateral surface, subdivide the lenticular nucleus into three segments. The outer one, the *putamen*, exceeds the others both in intensity of color and size. The inner segments are of paler color, smaller, and together form the *globus pallidus*.

In the **internal capsule**, which extends between the nucleus caudatus and the thalamus on the medial side and the nucleus lentiformis on the lateral (Fig. 53), two limbs are distinguished, an anterior *pars frontalis capsulae internae*, between the caudate



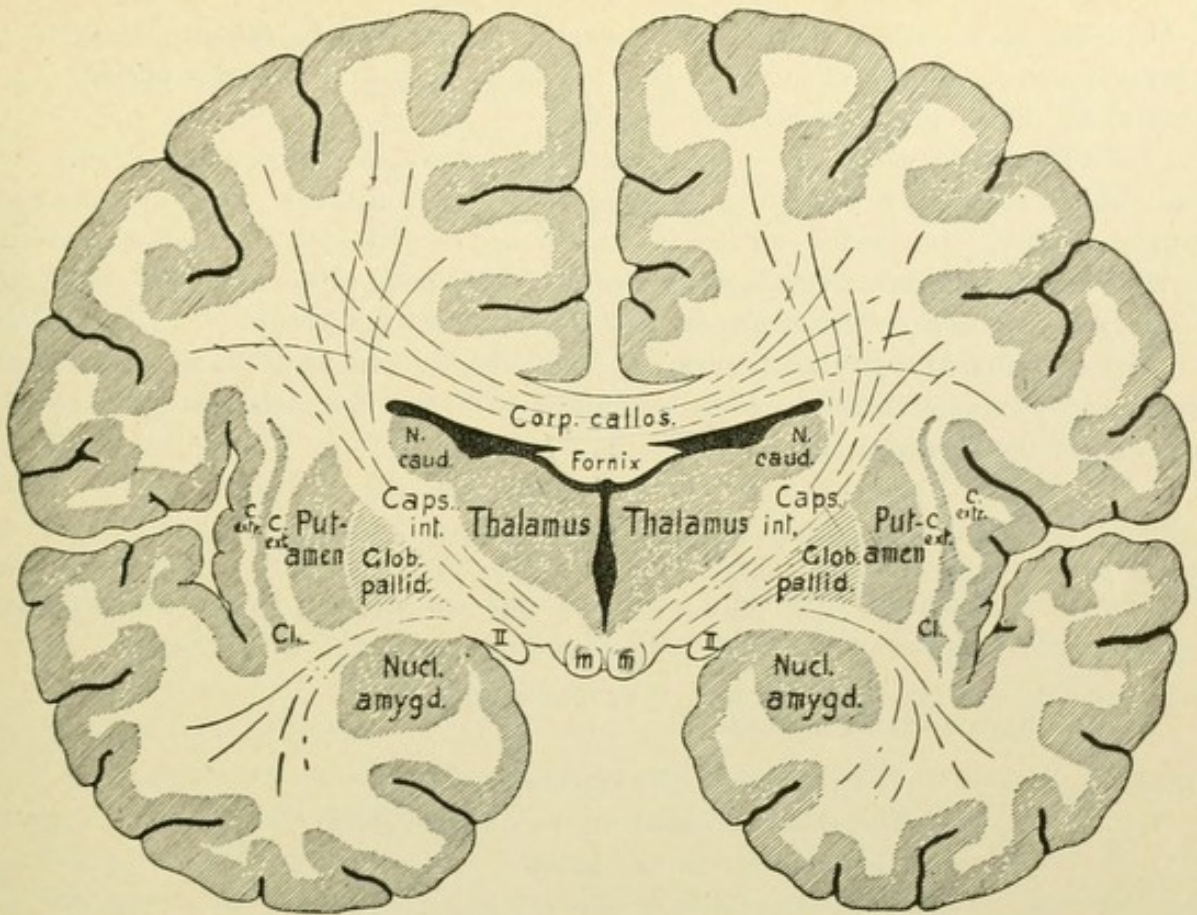


FIG. 52.—Frontal section of the brain, passing through the thalamus and the third ventricle. *C. ext.*, capsula externa; *Cl.*, claustrum; *C. extr.*, capsula extrema; *II*, tractus opticus; *m*, corpus mamillare.

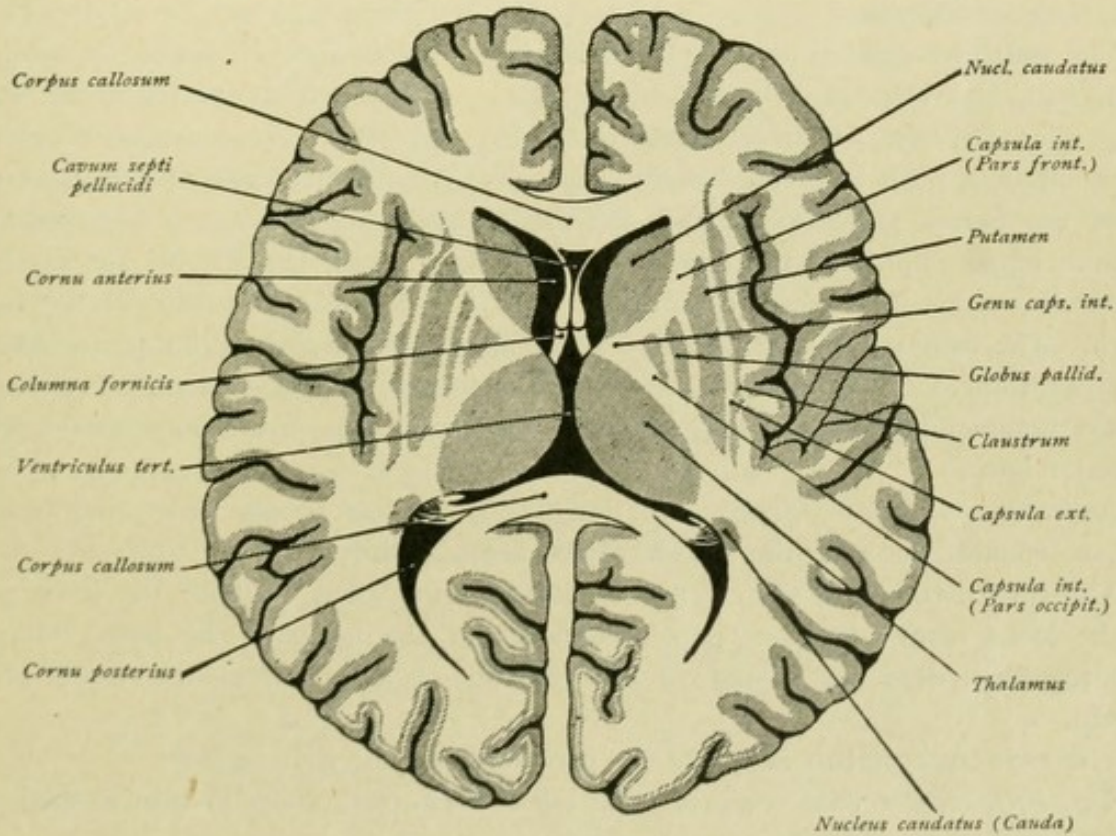


FIG. 53.—Horizontal section of the brain.



and lenticular nuclei, and a posterior limb, *pars occipitalis capsulae internae*, between the lenticular nucleus and the thalamus. The two limbs meet in a laterally opening angle known as the knee, the *genu capsulae internae*.

The **claustrum** constitutes a broad flattened nucleus, a narrow plate of gray substance, which ventrally is somewhat thickened and, more medially, joins the *substantia perforata anterior*. Its medial surface is smooth and bounds the thin *capsula externa*. The lateral surface presents small projections and borders a white medullary sheet, the *capsula extrema*, between the claustrum and the cortex of the island.

The **nucleus amygdalae** lies beneath the lenticular nucleus in the extreme anterior segment of the temporal lobe. It is continuous with the cortex of the *gyrus hippocampi* and of the *substantia perforata anterior*.

### SUMMARY OF THE TELEENCEPHALON.

The telencephalon, or end-brain, forms the most anterior and largest division of the encephalon and comprises the *hemisphaerium*, and the *pars optica hypothalami*.

#### A. The **hemisphaerium** includes :

The pallium or the cerebral-mantle,  
The rhinencephalon or the olfactory brain,  
The stem of the end-brain.

The two hemispheres, separated from each other by the *fissura longitudinalis cerebri*, are connected by the *lamina terminalis*, the *corpus callosum*, the *commissura anterior* and the *fornix transversus*.

The **pallium** exhibits the cerebral lobes and convolutions, separated by the intervening clefts and furrows. As *fissures* or *total furrows* are designated those deeply incising chief furrows, which are early developed and which, in consequence of their deep penetration, push in the wall of the ventricle. To these belong : the *fissura cerebri lateralis*, the *fissura parieto-occipitalis*, the *fissura calcarina*, the *fissura collateralis* and the *fissura hippocampi*. At the bottom of the *fissura cerebri lateralis* lies the *fossa cerebri lateralis*, which in a measure corresponds to a ventricular protrusion of the *corpus striatum*. The *fissura parieto-occipitalis* corresponds to the *bulbus cornu posterioris*, the *fissura calcarina* to the *calcar avis*, the *fissura collateralis* to the *eminentia collateralis*, while the *fissura hippocampi* is responsible for the production of the hippocampus within the inferior horn.

As *sulci* or *cortical furrows* are designated the less deeply penetrating grooves which are confined more to the surface of the hemisphere.

The chief divisions of the cerebral mantle are : the *lobus frontalis*, the *lobus parietalis*, the *lobus temporalis*, the *lobus occipitalis* and the *insula*. The latter, however, strictly regarded, does not belong to the cerebral mantle, but to the trunk of the end-brain.

The **rhinencephalon** falls into the peripheral and cortical regions.

The *peripheral region* comprises the *lobus olfactorius*, which in turn is subdivided into the *lobus olfactorius anterior* and *posterior*.



The *lobus olfactorius anterior* includes :—

- The bulbus olfactorius,
- The tractus olfactorius,
- The tuberculum olfactorium,
- The area parolfactoria of Broca.

From the tuberculum olfactorium the gyrus olfactorius lateralis extends laterally toward the fossa Sylvii, here forms the angulus gyri olfactorii lateralis, then runs backward and ends as the gyrus semilunaris and gyrus ambiens at the front border of the gyrus hippocampi. The gyrus olfactorius medialis extends medially from the tuberculum, its continuation forming on the medial surface of the hemisphere the area parolfactoria of Broca, which, in turn, is prolonged upward into the gyrus cinguli.

The *lobus olfactorius posterior* claims the substantia perforata anterior and the diagonal band of Broca, which latter passes into the gyrus subcallosus, situated on the medial aspect of the hemisphere behind the area parolfactoria.

The *cortical region* has as its chief components :—

The gyrus fornicatus, made up of the gyrus cinguli and the gyrus hippocampi with the connecting isthmus.

The hippocampus or cornu Ammonis, pushed into the inferior horn of the lateral ventricle by the hippocampal fissure.

The gyrus dentatus.

The gyrus uncinatus, the gyrus intralimbicus, the gyrus fasciolaris and the rudimentary callosal convolutions or gyri Andreae Retzii. Concerning the connections of the peripheral and central regions consult pages 145-149.

The **stem of the end-brain** has as its most important part the corpus striatum, which is separated by the capsula interna into the medially situated nucleus caudatus and the laterally placed nucleus lentiformis. The latter is subdivided by the medullary laminæ into the putamen and the globus pallidus. To the stem of the end-brain belong, further, the claustrum, separated from the nucleus lentiformis by the capsula externa, and the nucleus amygdalæ, located in the extreme front part of the temporal lobe. All these nuclei are connected with the cortex of the substantia perforata anterior.

Within each hemisphere, the lateral ventricle expands into its three horns, the anterior, posterior and inferior, and the uniting body or pars centralis. The two lateral ventricles communicate with each other and with the third ventricle through the foramen interventriculare or foramen of Monro.

**B. The pars optica hypothalami** includes :—

- The lamina terminalis,
- The chiasma opticum, with the tractus optici,
- The tuber cinereum,
- The infundibulum,
- The hypophysis.



## DIENCEPHALON.

To the diencephalon, sometimes called the *inter-brain*, on account of its position between the end- and the mid-brain, belong :

The thalamencephalon and the pars mamillaris hypothalami.

The diencephalon surrounds the third ventricle. The immediate roof of the latter is formed by the *lamina chorioidea epithelialis* and the *tela chorioidea ventriculi tertii*, which lies above and fused with the epithelial sheet. As secondary coverings, over the tela, follow the fornix and the corpus callosum.

The dissection of the brain proceeds in the following manner, the display of the fornix being next undertaken. To this end, the callosum is cut through transversely, from 1 to 2 cm. in advance of the posterior border of the splenium. This is best accomplished by passing the knife, from the side and horizontally, above the crus fornicis and then cutting through the corpus callosum from below upward and somewhat obliquely backward. The callosum is now pulled up, its attachment to the psalterium severed, and separated from the body of the fornix and, farther forward, from the upper border of the septum pellucidum.

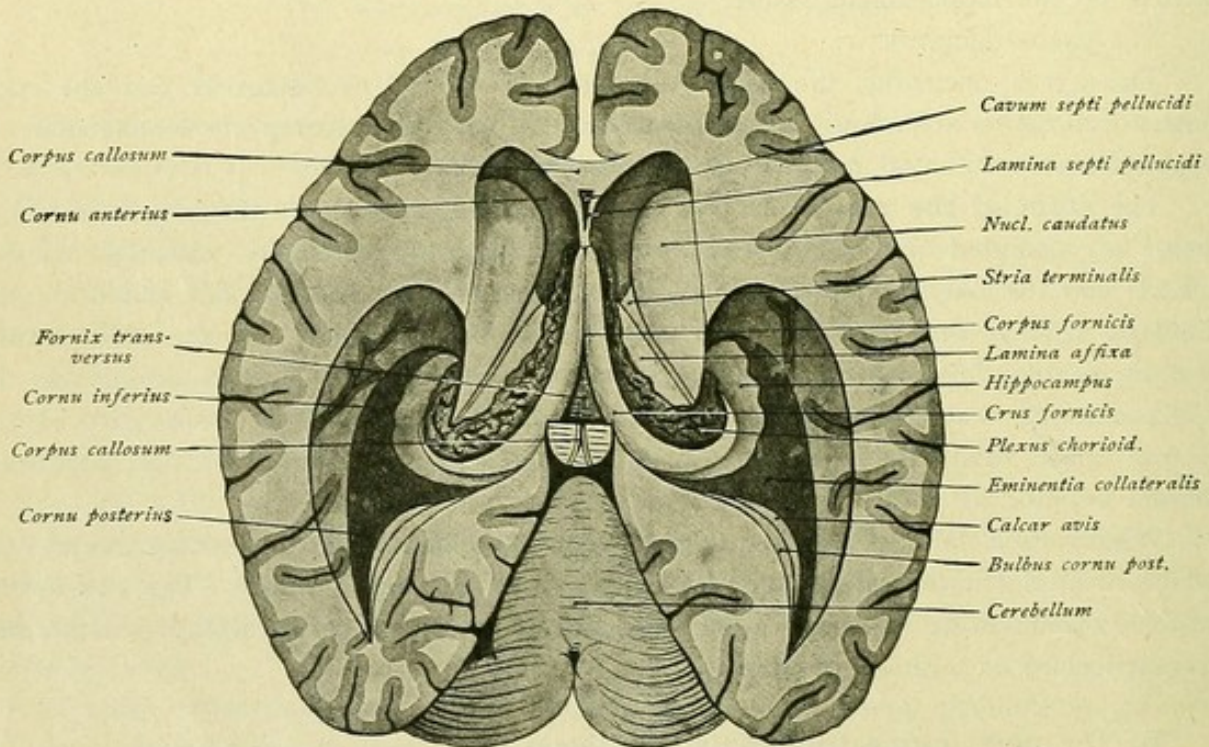


FIG. 54.—Lateral ventricles exposed by removal of the corpus callosum.

After removal of the corpus callosum it is to be noted, how on each side the fimbria ascends from the inferior horn and passes into the crus fornicis, how the crura fornicis approach each other and meet to form the corpus fornicis, and how the columnae fornicis bend downward in front of the foramen interventriculare (Fig. 54). Further to be observed are the partition separating the lateral ventricles, the septum pellucidum,



with the cavum septi between its laminae, and the course of the plexus chorioideus ventriculi lateralis from the inferior horn through the pars centralis as far as the foramen interventriculare. By means of a probe or bristle may be readily demonstrated the manner in which the two lateral ventricles are connected by the foramen of Monro. The latter marks the position at which the plexus chorioideus ventriculi lateralis is continuous with the choroid plexus of the third ventricle. It must not be forgotten, however, that the plexus really lies extraventricular. On removing the choroid plexus, the taenia chorioidea and the taenia fornicis are recognizable, and, likewise, the anterior part of the thalamus.

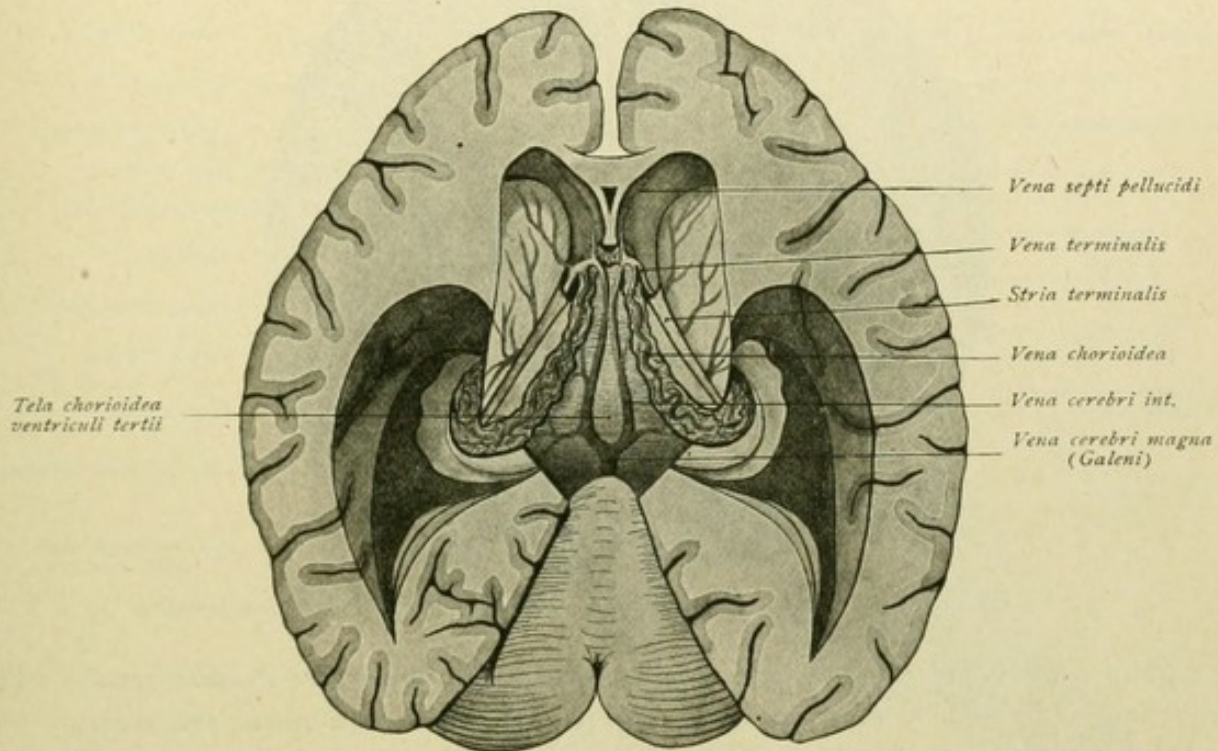


FIG. 55.—Lateral ventricles, after removal of the fornix. Tela chorioidea ventriculi tertii is exposed.

Beneath the fornix lies the tela chorioidea ventriculi tertii (Fig. 55). In order to exhibit the latter, we proceed in the following manner: one peduncle of the fornix is lifted and sectioned with a sharp knife medialward and, at the same time, obliquely backward, the section being continued through the hind end of the corpus callosum, thus cutting across the pars occipito-temporalis of the radiatiō corporis callosi. A similar section is executed on the other side. The posterior end of the callosum is now raised and turned forward, with the fornix. The latter is cut off at the posterior margin of the septum pellucidum, where the corpus fornicis passes into columnae fornicis. After removal of the fornix, the tela chorioidea lies free, beneath which the lamina chorioidea epithelialis alone remains as the roof of the third ventricle. The removal of the tela chorioidea is carried out from in front; it is raised behind the columnae fornicis and carefully reflected backward. Compare Figs. 62 and 63 for orientation. We now pass to the consideration of the thalamencephalon.



## THALAMENCEPHALON.

The **thalamus opticus** (Figs. 56 and 57) presents an ovoid mass of gray substance, with the thicker end behind. Its dorsal and medial surfaces are free, while its lateral and ventral ones are fused with the neighboring structures. The dorsal surface

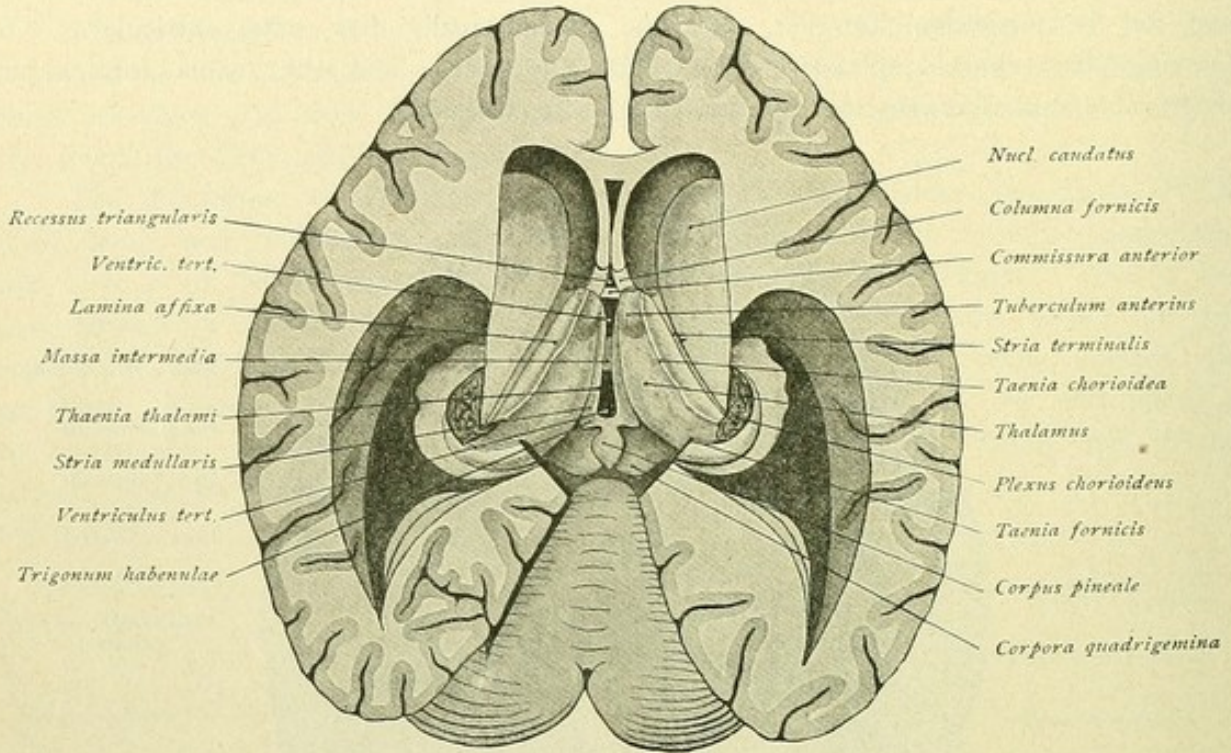


FIG. 56.—Lateral and third ventricles exposed; the tela chorioidea has been removed.

is slightly convex and covered by a thin layer of white fibres, the *stratum zonale*. The outer limit is formed by the *stria terminalis*, lodged within the *sulcus intermedius*; the medial boundary is a white stripe, the *stria medullaris*, which indicates the boundary

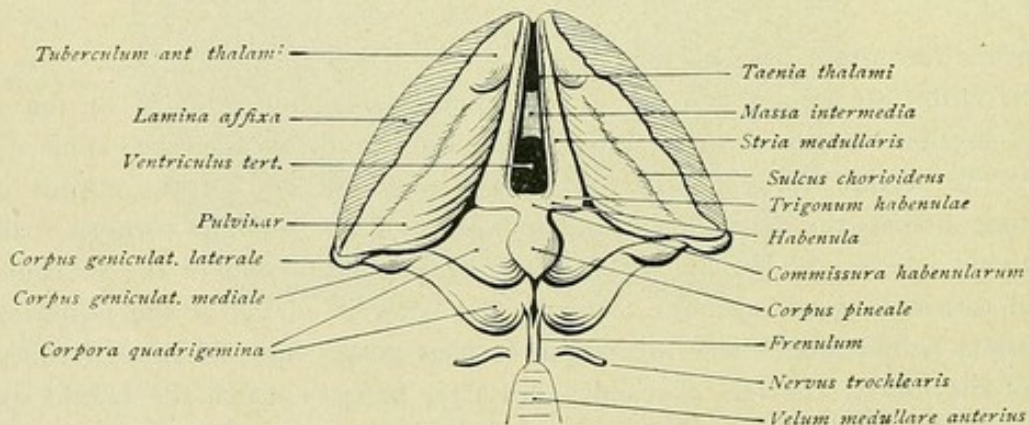


FIG. 57.—Thalamus, epithalamus and metathalamus, viewed from above.

between the dorsal and medial thalamic surfaces. A furrow, the *sulcus chorioideus*, runs from before backward and outward and lodges the *plexus chorioideus* of the lateral ventricle (Fig. 57). At its front end, the dorsal surface exhibits a small round elevation,



the *tuberculum anterius thalami*; behind is a similar projection, the *pulvinar*. The stria medullaris, the medial boundary, widens behind into a triangular field, the *trigonum habenulae*. From the latter proceeds medially a white fibre-strand, the *habenula*, which in front joins with the habenula of the opposite side to form the *commissura habenularum*, while behind it passes into a flattened structure, the *corpus pineale*. Medially the stria medullaris is continuous with the lamina chorioidea epithelialis, over which spreads out the tela chorioidea. On removal of the latter, the epithelial layer is separated from the stria medullaris. There remains, however, along the line of transition a delicate border, the *taenia thalami*, which behind adheres to the dorsal surface of the habenula and the pineal body and is continuous with the taenia of the opposite side.

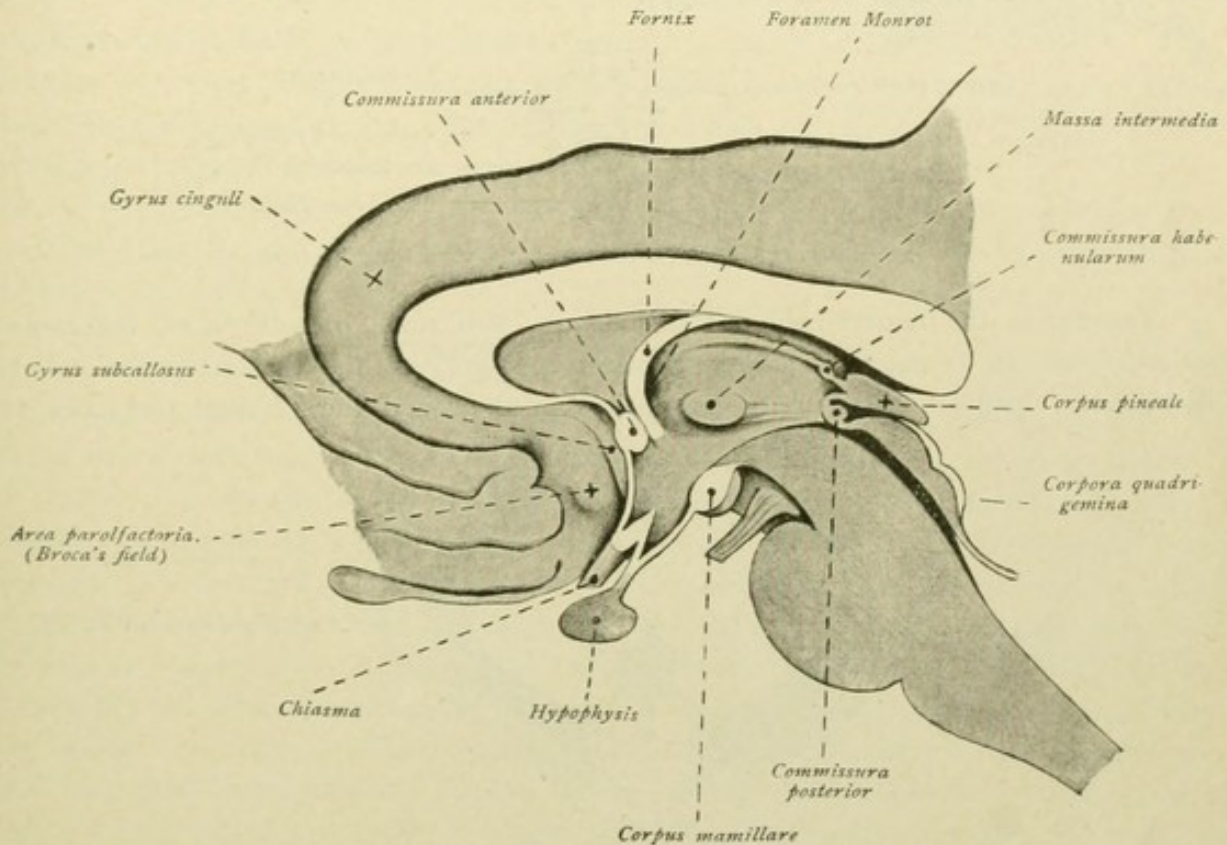


FIG. 58.—Median sagittal section of the lower part of the brain.

The medial surface of the thalamus is vertical and contributes the lateral wall of the third ventricle. Its lower limit is indicated by the *sulcus hypothalamicus* or *sulcus Monroi*, that leads from the foramen interventriculare to the entrance of the aquaeductus cerebri. The median surfaces of the two thalami are united, about the middle, by the *massa intermedia*, often called the *middle commissure*. The ventral surface of the thalamus borders on the hypothalamus, the lateral surface on the capsula interna (Fig. 58).

Behind the commissura habenularum lies the *corpus pineale*, so called on account of its resemblance to a pine-cone. It extends from an outpouching of the dorsal brain-wall, the most posterior part of the roof of the third ventricle, and is a small unpaired body, whose base is directed forward and the apex backward. In its anterior part, at the base and between the upper and lower lamellæ, lies the small evagination from the third ventricle, termed the *recessus pinealis*. The upper lamella is continuous on each side



with the habenula, the commissura habenularum forming the dorsal wall of the recess. The lower lamella is prolonged into the posterior commissure and the quadrigeminal plate. Since the lamina chorioidea epithelialis is attached to the dorsal surface of the pineal body, a considerable pocket is left between this surface and the lamina chorioidea of the third ventricle; this is the *recessus suprapinealis*. Sand-like granules, the brain-sand or *acervulus*, are usually present within the interior of the pineal body.

The posterior commissure, *commissura cerebri posterior*, is a bundle of transversely coursing fibres which projects into the ventricle and ventrally bounds the entrance of the recessus pinealis. Its ventral surface defines the *aditus ad aquaeductum cerebri*. The commissure is best seen when the posterior wall of the third ventricle is viewed from in front (Fig. 59).

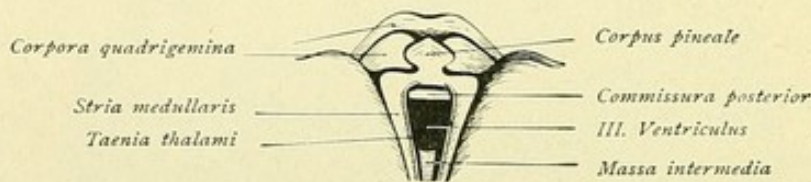


FIG. 59.—Posterior wall of the third ventricle, viewed from in front.

Turning to the region behind the thalamus, two small protuberances, the *corpora geniculata*, are to be noted as additional parts belonging to the thalamencephalon. On following the tractus opticus in its course backward around the cerebral peduncle, two

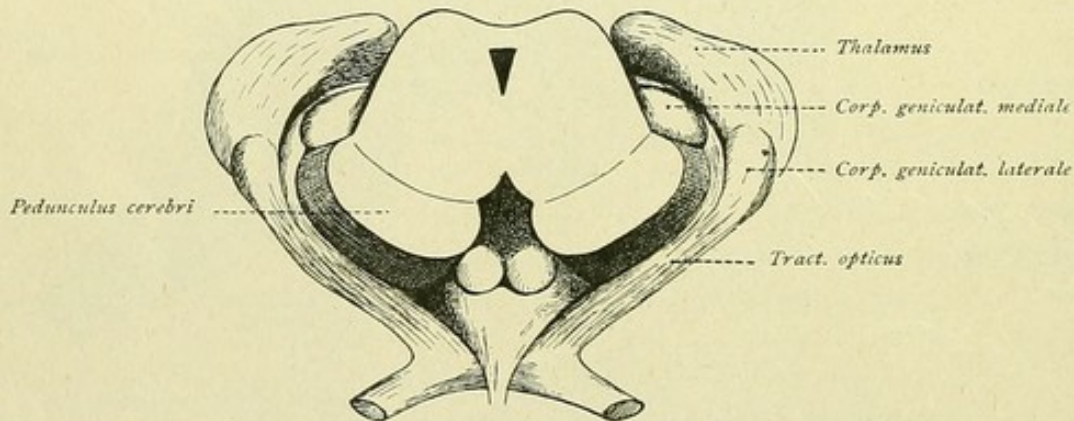


FIG. 60.—Course of the tractus opticus around the cerebral peduncles toward the corpora geniculata.

protuberances are encountered—the elongated oval *corpus geniculatum mediale* and the *corpus geniculatum laterale*. The latter is a small elongated elevation at the hind and lower end of the thalamus, lateral to the pulvinar. The medial body is separated from the lateral body and the pulvinar by a deep furrow.

### PARS MAMILLARIS HYPOTHALAMI.

The pars mamillaris hypothalami comprises the *corpora mamillaria*. These, also known as the *corpora candicantia*, are two round or oval relatively prominent projections on the basal surface of the brain, between the tuber cinereum and the substantia perforata posterior. While separated from each other by a deep median cleft, their opposed surfaces are closely pressed together (Fig. 15). Although the boundaries of the mamillary bodies



are sharp medially, in front and behind, antero-laterally each knob is continued into a narrow stalk directed toward the substantia perforata anterior. This stalk, the *brachium corporis mamillaris*, is always present, although variably developed, sometimes being broad and at other times narrow. Occasionally an additional small lateral projection, the *tuberculum mamillare laterale*, is present, showing with especial distinctness when it is bounded by a small furrow medially as well as laterally.

Further, to be mentioned is the *stria alba tuberis* of Lenhossék. This is a delicate white band, scarcely one millimeter in width, that springs with fine converging fibres at the hind slope of the mamillary body, runs forward, traverses the tuber cinereum obliquely forward and outward, and, finally, disappears beneath the optic tract. According to Lenhossék, the *stria alba tuberis* is nothing more than a separated bundle of fornix fibres, which here pass superficial to the mamillary body (Fig. 61). In several cases Retzius found the *stria* distinct only on one side, while in other cases it was present on both sides.

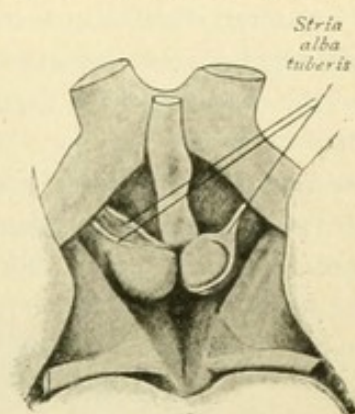


FIG. 61.—Part of the basal surface of the brain, showing the striae albae tuberis. (Retzius.)

### VENTRICULUS TERTIUS.

The third ventricle is a median inpaired cleft-like cavity, that communicates in front with the lateral ventricles by means of the *foramen interventriculare* or *foramen of Monro*, and behind with the fourth ventricle by means of the *aquaeductus cerebri* or *Sylvian aqueduct*. The front wall is formed, in the lower part by the *lamina terminalis*, in the upper part by the *commissura anterior* and the *columnae fornicis*, while the back wall is formed by the *commissura habenularum* and the *commissura posterior* (Fig. 58). The side walls are contributed by the medial surfaces of the thalami and of the hypothalami, separated by the *sulci hypothalamici*. The floor of the third ventricle, in the hind part, is formed by the cerebral peduncles and the intervening posterior perforated substance; in the front part it includes the *corpora mamillaria*, the *tuber cinereum*, with the *infundibulum* and *hypophysis*, and the *chiasma opticum*. The immediate roof of the ventricle consists of the lamina chorioidea epithelialis, which is fused with the overlying tela chorioidea ventriculi tertii, behind is attached to the dorsal surface of the habenula and of the corpus pineale, and laterally passes into the stria medullaris.

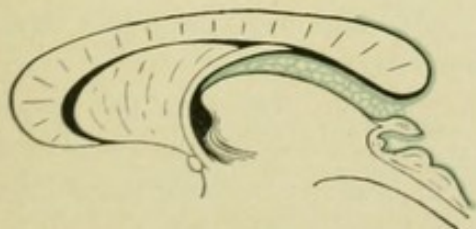


FIG. 62.—Tela chorioidea ventriculi tertii is blue.

The **tela chorioidea ventriculi tertii**, or **velum interpositum**, represents an expansion of the pia cerebri between the ventral surface of the corpus callosum and the fornix, on the one hand, and the dorsal surface of the diencephalon, on the other. The tela in form resembles an equilateral triangle, whose apex lies in front, behind the columnae fornicis, and whose base is behind, beneath the splenium corporis callosi (Figs. 55, 62 and 63). It consists of two laterally continuous sheets, of which the dorsal one is attached to the under surface of the callosum and the fornix, while the ventral one in the middle overlies the lamina chorioidea epithelialis of the third ventricle and at the



sides covers the larger part of the dorsal surface of the thalamus. Laterally, where the two sheets are continuous, richly vascular villi-like tufts of the dorsal sheet project into the lateral ventricle to constitute the plexus chorioideus. Similarly, villi from the ventral sheet project into the third ventricle, where they appear as two narrow stripes close to the mid-line and together constitute the *plexus chorioidea ventriculi tertii*. The choroid plexus of the lateral ventricle is inserted laterally in the lamina affixa—*taenia chorioidea*—and medially at the free edge of the fornix—*taenia fornicis*. The two stripes of the plexus chorioidea ventriculi tertii are attached laterally to the stria medullaris—*taenia thalami*. The choroid plexus of the lateral ventricles and the band-like plexus of the third ventricle come together at the foramen interventriculare. Between the dorsal and ventral sheets of the tela chorioidea lies arachnoidal connective tissue. In this run,

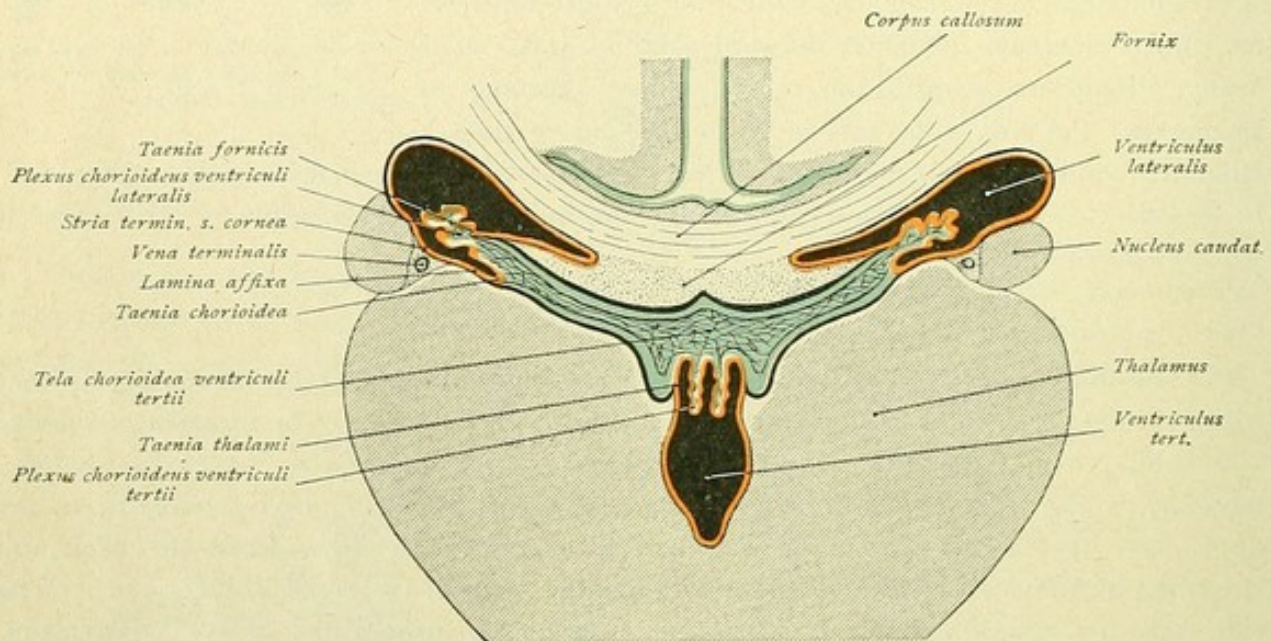


FIG. 63.—Diagram showing the relations of the corpus callosum, fornix and the tela chorioidea ventriculi tertii. Pia, blue; ependyma, red.

in the mid-line and close together, two veins, the *venae cerebri internae*, into which empty in front the *vena septi pellucidi*, from the septum pellucidum, the *vena terminalis*, from beneath the stria terminalis, and the *vena chorioidea*, from the choroid plexus of the lateral ventricles. Behind, at the hind end of the tela chorioidea, the *venae cerebri internae* unite to form the *vena cerebri magna* of Galen (Fig. 55).

Certain outpouchings of the third ventricle claim mention. Of these the recessus suprapinealis, the recessus pinealis, the aditus ad aquaeductum cerebri, the recessus infundibuli and the recessus opticus have been noted. In front, is the *recessus triangularis*, between the *columnae fornicis* and the *commissura anterior* (Fig. 56).

### THE NUCLEI OF THE DIENCEPHALON.

**The Thalamus.** The thalamus consists of three chief nuclei, the *nucleus anterior*, the *nucleus medialis* and the *nucleus lateralis*, which are imperfectly separated from one another by white medullary stripes, the *laminae medullares*.



The **nucleus anterior** includes the front and dorsal portion of the thalamus; it is, therefore, also known as the *dorsal nucleus*. It penetrates wedge-like between the medial and lateral nuclei, is covered dorsally by the *stratum zonale*, and rests ventrally upon a bifurcation of the *lamina medullaris interna*. The thickened front end produces the protuberance on the dorsal surface of the thalamus known as the *tuberculum anterius* or *corpus album subrotundum*.

The **nucleus medialis** is bounded laterally by the lamina medullaris interna and medially by the central gray substance, a sheet of gray matter which invests the floor

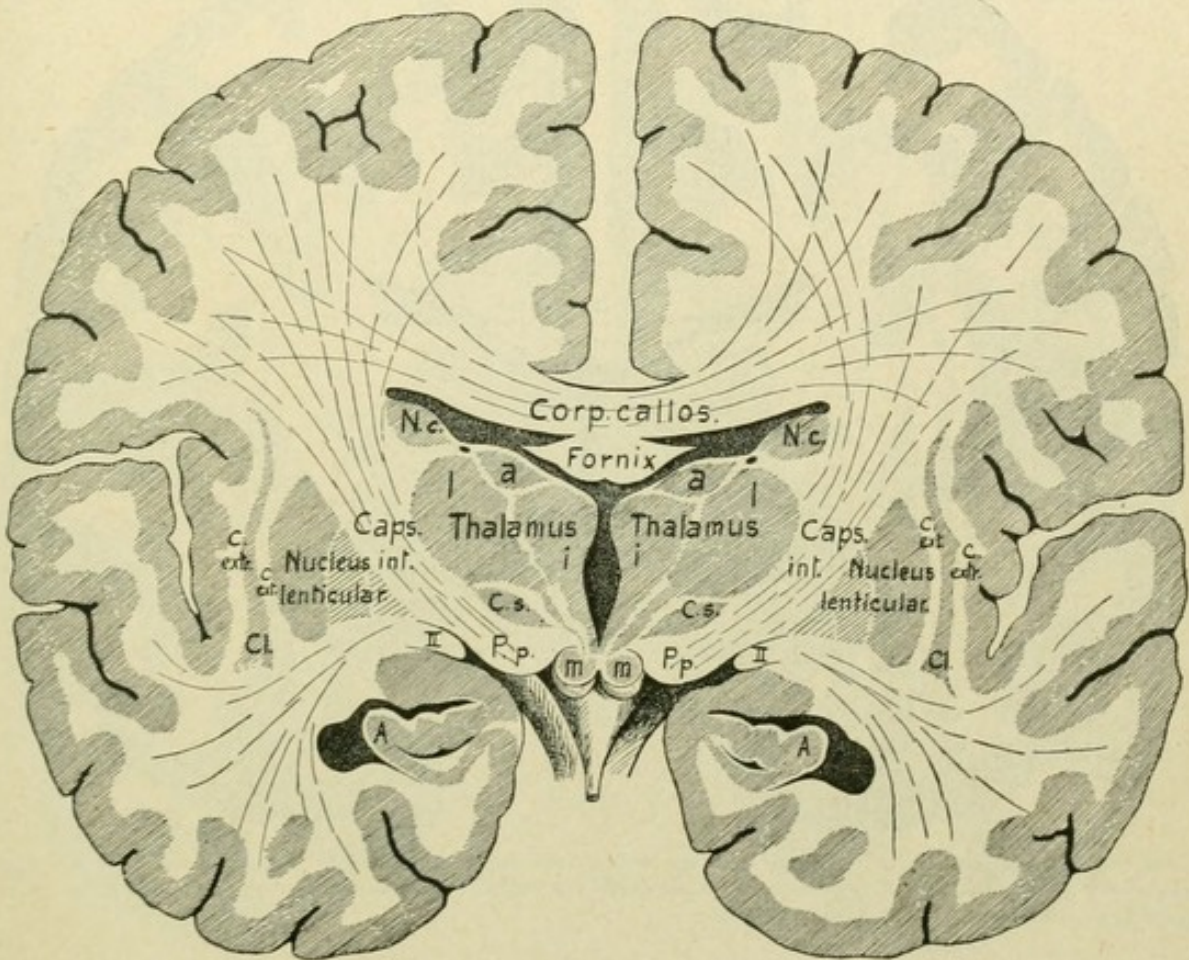


FIG. 64.—Frontal section of the brain, passing through the third ventricle. *Thalamus a, i, l.*, nucleus anterior, internus and lateralis thalami; *Nc.*, nucleus caudatus; *C. s.*, corpus subthalamicum; *II*, tractus opticus; *P. p.*, pes pedunculi; *m*, corpus mamillare; *A*, hippocampus or cornu Ammonis; *C. ext.*, capsula externa; *Cl*, claustrum; *C. ext.*, capsula extrema.

of the third ventricle and the medial surface of the hypothalamus and also forms the *massa intermedia* or middle commissure. Anteriorly the medial nucleus is closely connected with the nucleus anterior, although it does not reach the front end of the thalamus; hence, in a series of vertical sections carried through the brain, from before backward, the medial nucleus first appears after the anterior nucleus begins to diminish. Behind, the medial nucleus passes into the pulvinar.

The **nucleus lateralis**, the largest of the thalamic nuclei, includes the upper and lateral portion of the thalamus and surrounds, in large part, the anterior and medial nuclei. Its medial boundary is formed by the lamina medullaris interna; laterally it is bounded by the posterior limit of the internal capsule, from which it is separated by the



*lamina medullaris externa* and the *stratum reticulare*. The dorsal surface of the nucleus is covered by the stratum zonale and assists in forming the dorsal surface of the thalamus. The lateral part of this last-named surface is clothed by the ependyma of the lateral ventricle and contributes that portion of the floor of the ventricle known as the lamina affixa; the medial part of the same surface belongs to the external surface of the diencephalon and is covered by the ventral sheet of the tela chorioidea. The

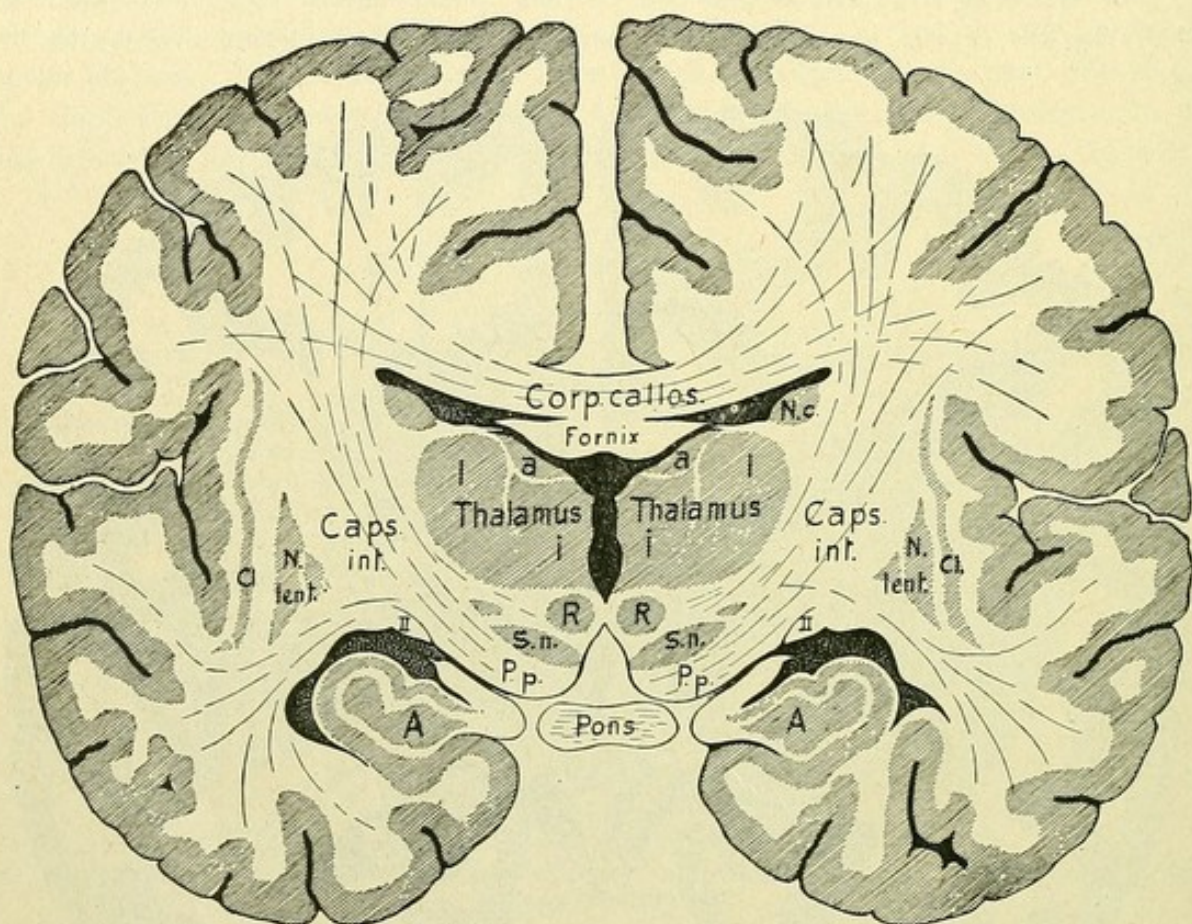


FIG. 65.—Frontal section of the brain, passing through the subthalamic region. *Thalamus a, i, l.*, nucleus anterior, internus and lateralis thalami; *R*, nucleus ruber; *S. n.*, substantia nigra; *P. p.*, pes pedunculi; *II*, tractus opticus; *A*, cornu Ammonis; *Cl*, claustrum; *N. c.*, nucleus caudatus.

ventral surface of the nucleus lateralis rests upon the regio hypothalamica. In front, the lateral nucleus aids the anterior one in defining the foramen interventriculare; behind it passes into the pulvinar.

The **lamina medullaris externa** covers the entire outer surface of the lateral nucleus and in the region of the pulvinar broadens into a triangular medullary area, known as *Wernicke's field* (Fig. 207).

The **stratum reticulare**, or the *lattice layer*, forms the real outer limit of the thalamus and constitutes a thin lamella of gray substance that invests the entire outer surface of the lateral nucleus and of the pulvinar, separating the latter from the internal capsule.

As special nuclei of the thalamus are to be noted the centrum medianum and the nucleus semilunaris, the latter being also known as the *corpus patellare*.

The **centrum medianum** (Luys) belongs to the nucleus medialis and presents a rounded mass of gray substance that is lodged between the medial and lateral nuclei



and the pulvinar. Laterally it is bounded by the lamina medullaris interna, medially it blends with the nucleus medialis (Fig. 207).

The **nucleus semilunaris** (Flechsig) belongs to the nucleus lateralis, in whose ventral part it lies, and leans against the centrum medianum in the form of a crescent.

Additional **special nuclei** of the diencephalon are: the *nucleus habenulae* or *ganglion habenulae*, within the trigonum habenulae, and the *nucleus corporis geniculati medialis* and *lateralis*, within the corresponding geniculate bodies.

Ventral to the thalamus, the *regio subthalamica* or the *hypothalamus* spreads out between the internal capsule and the central gray substance of the third ventricle.

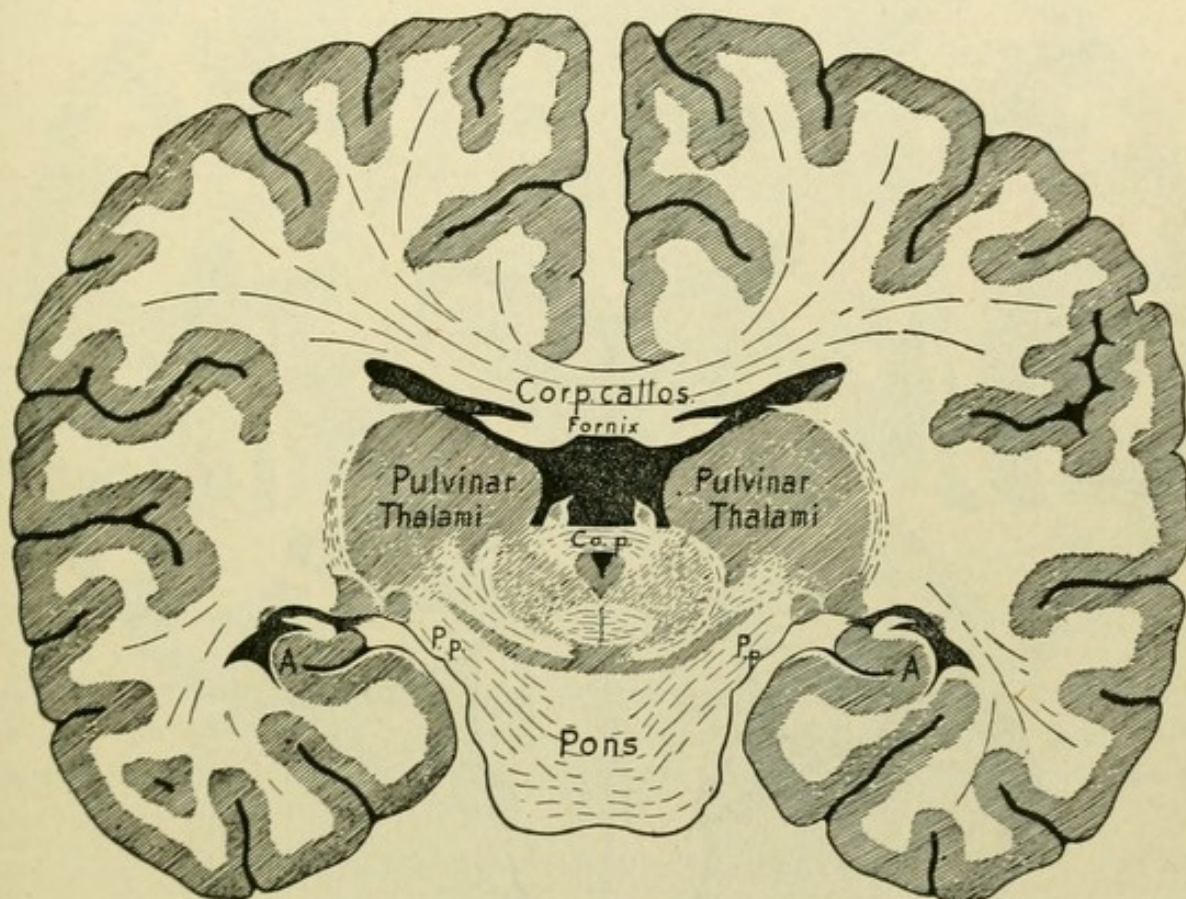


FIG. 66.—Frontal section of the brain, passing through the pulvinar and the upper end of the Sylvian aquaeduct. *Co. p.*, commissura posterior; *P. p.*, pes pedunculi; *A*, cornu Ammonis or hippocampus.

Within each **corpus mamillare** lie two nuclei, a larger round *nucleus medialis* and a smaller *nucleus lateralis*, which arches around the medial nucleus and includes the front and outer part of the mammillary body (Fig. 201). Close to these two nuclei, at the lateral and ventral side of the nucleus lateralis, is found a small *nucleus accessorius*.

The **nucleus hypothalamicus**, or **corpus subthalamicum** (Luys), lies within the hind part of the hypothalamus. This lentiform nucleus lies beneath the nucleus lateralis thalami and medially to the globus pallidus of the lenticular nucleus (Fig. 64).

**The Capsula Interna.** Let us turn once more to the internal capsule. It lies between the nucleus lenticularis, on the one side, and the nucleus caudatus and the thalamus on the other. In frontal sections, it appears as a lamella of white substance that runs obliquely from above downward and inward, bounded externally by the lenticular



nucleus and medially by the caudate nucleus, the thalamus and the subthalamic region (Fig. 67). An *upper* and a *lower region* may be distinguished in the internal capsule. The upper region, between the lenticular nucleus on the one side and the caudate nucleus and thalamus on the other, is known as the *regio thalamica capsulae internae*. The lower region lies between the nucleus lenticularis and the hypothalamus and is the *regio subthalamica capsulae internae*.

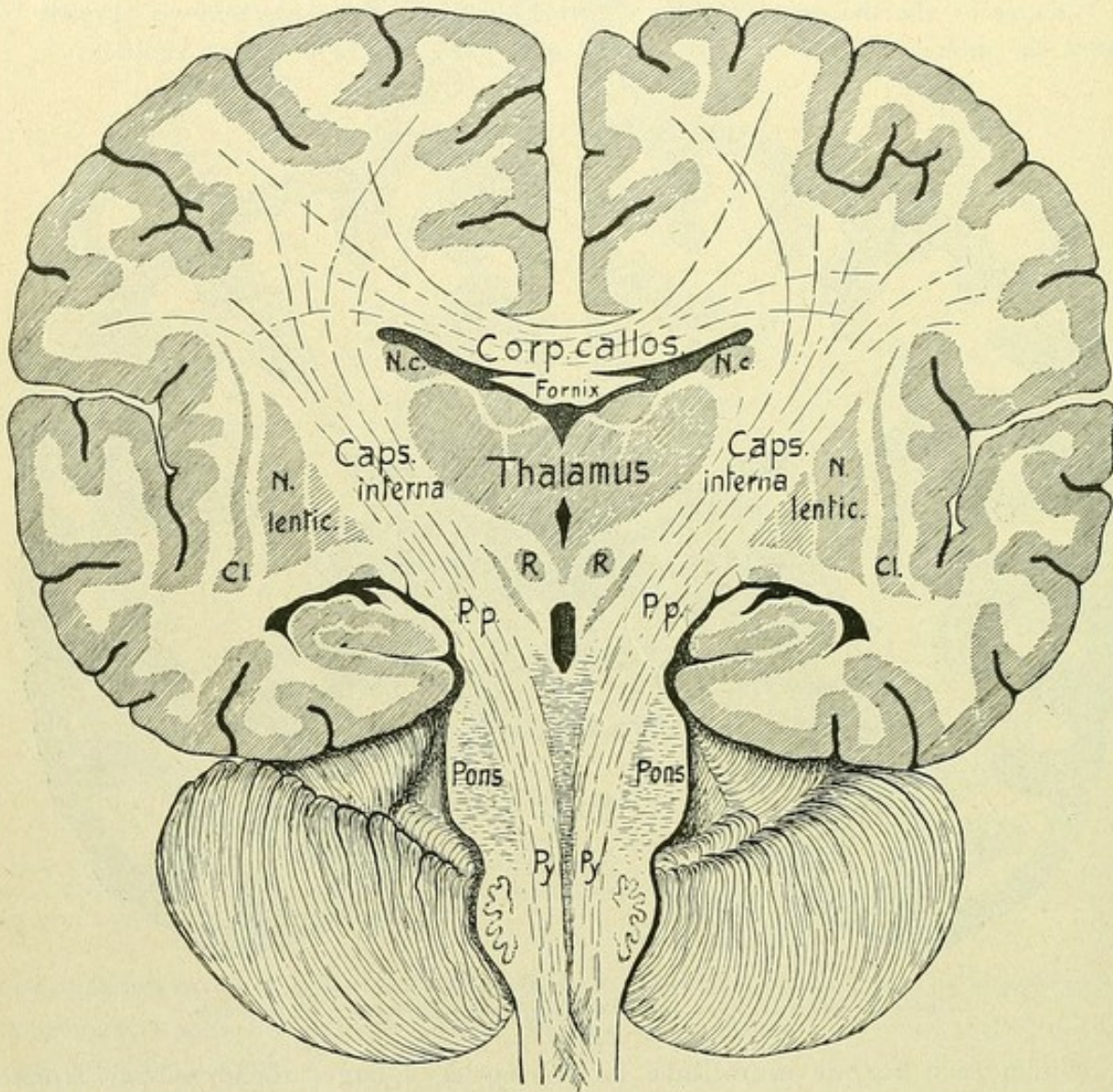


FIG. 67.—Frontal section through the brain, showing the continuation of the internal capsule into the pes pedunculi (*P.p.*); *N. c.*, nucleus caudatus; *Cl.*, claustrum; *R.*, nucleus ruber; *Py.*, pyramidal tract.

In horizontal sections (Fig. 68), the internal capsule forms, in the region of thalamus, an outwardly opening angle with a shorter anterior limb, *pars frontalis*, lodged between the lenticular and caudate nuclei, and a longer posterior limb, *pars occipitalis*, between the lenticular nucleus and the thalamus. The two limbs come together at the knee, *genu capsulae internae*. The anterior limb of the capsule is also called the *pars lenticulo-caudata*, the posterior one the *pars lenticulo-thalamica*. The hind limb extends some millimeters beyond the nucleus lenticularis, this part constituting the *pars retrolenticularis*.



The relations are different in horizontal sections passing through the subthalamic region. Here, the posterior limb and the pars retrolenticularis of the internal capsule alone are seen, the anterior limb having disappeared. These relations are readily under-

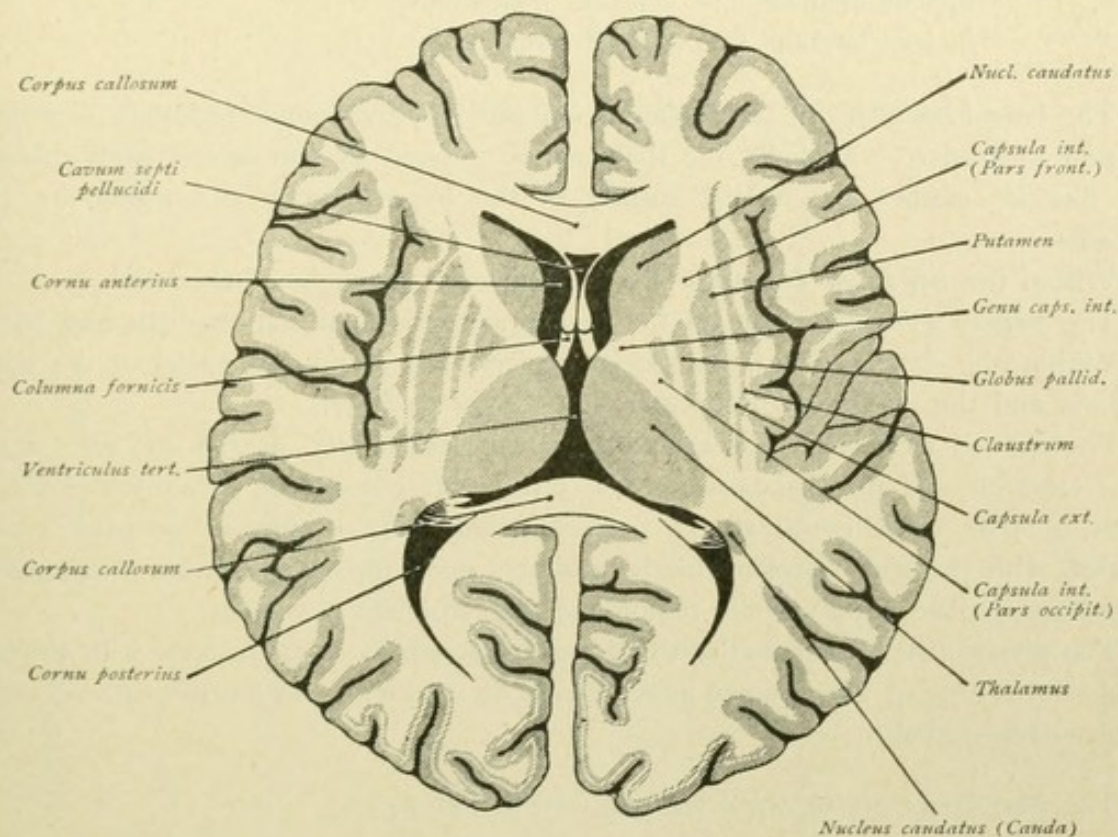


FIG. 68.—Horizontal section of the brain. The internal capsule is seen to include two limbs and a knee.

stood, when we recall that in the front part of this region the nucleus lenticularis is continuous with the head of the nucleus caudatus, from which it follows, that in the subthalamic region the anterior limb must disappear between the lenticular and caudate nuclei (Fig. 48).

#### SUMMARY OF THE DIENCEPHALON.

The diencephalon or inter-brain is subdivided into the *thalamencephalon* and the *pars mamillaris hypothalami*.

##### A. The *thalamencephalon* includes:

- The thalamus,
- The epithalamus,
- The metathalamus.

##### To the *epithalamus* belong:

- The corpus pineale,
- The regio habenulae—trigonum habenulae, commissura habenularum.
- The commissura posterior.

##### To the *metathalamus* belong:

- The corpora geniculata.



B. The **pars mamillaris hypothalami** includes the corpora mamillaria.

The **thalamus** consists of three chief nuclei:

- Nucleus anterior or dorsalis,
- Nucleus medialis (+ centrum medianum),
- Nucleus lateralis (+ nucleus semilunaris).

The lateral boundary of the thalamus is formed by the lamina medullaris externa and the stratum reticulare. Medially the thalamus is covered by the central gray substance, which likewise clothes the medial surface of the hypothalamus and forms the massa intermedia.

Within the *trigonum habenulae* lies the nucleus or ganglion habenulae.

The *corpora geniculata* contain the nucleus corporis geniculati medialis and lateralis.

Within the *hypothalamus*, as special centres, are found the nuclei of the corpora mamillaria and the nucleus hypothalamicus, or body of Luys.

The *capsula interna* lies between the nucleus lenticularis, on the one side, and the nucleus caudatus and the thalamus, on the other. It consists of an anterior limb, pars frontalis or pars lenticulo-caudata, a posterior limb, pars occipitalis or pars lenticulo-thalamica, with the pars retrolenticularis, and the genu capsulae internae. In horizontal sections through the hypothalamic region the pars frontalis is wanting.

The diencephalon encloses the **third ventricle** which communicates with the lateral ventricles by means of the foramen interventriculare, and with the fourth ventricle through the aquaeductus cerebri.

The *boundaries of the third ventricle* are as follows:—

*Anterior wall:* Lamina terminalis,  
Commissura anterior,  
Columnae fornicis.

*Posterior wall:* Commissura habenularum,  
Corpus pineale,  
Commissura cerebri posterior.

*Lateral walls:* Medial surfaces of the thalami and the hypothalami.

*Floor:* Cerebral peduncles,  
Substantia perforata posterior,  
Corpora mamillaria,  
Tuber cinereum, with infundibulum and hypophysis,  
Chiasma opticum.

*Roof:* Lamina chorioidea epithelialis;  
secondarily, tela chorioidea ventriculi tertii,  
fornix and corpus callosum.

The diencephalon, together with the telencephalon, constitutes the prosencephalon or the fore-brain. The pars optica hypothalami and the pars mamillaris hypothalami together form the hypothalamus.

The foregoing relations are presented in recapitulation in the following table:







## MESENCEPHALON.

The mesencephalon, or mid-brain, forms the smallest of the brain-segments. Dorsally, it extends from the root of the pineal body to the posterior edge of the quadrigeminal plate; ventrally, from the mammillary bodies to the front border of the pons. It is traversed longitudinally by the *aquaeductus cerebri* or *Sylvian aqueduct*. The dorsal part of the mid-brain includes the quadrigeminal plate, *lamina quadrigemina*; the ventral part the cerebral peduncles, *pedunculi cerebri* and the *substantia perforata posterior*; and the lateral part the *brachia quadrigemina*.

### LAMINA QUADRIGEMINA.

The quadrigeminal plate stretches from the root of the pineal body to the front end of the velum medullare anterius. By means of a shallow median longitudinal furrow and one running transversely, the plate is subdivided into four parts, each of which appears as a white hemispherical elevation. The two front and larger elevations are the anterior quadrigeminal bodies, the *colliculi superiores*, the two hind and smaller ones are the posterior quadrigeminal bodies, the *colliculi inferiores*. The front part of the longitudinal furrow, between the superior colliculi, is broad and forms the *trigonum subpineale*, on which the pineal body rests; it sometimes presents a slight elevation, the *colliculus subpinealis*. In its hind part, the furrow is bounded by two strands of white fibres, which extend to the velum medullare anterius and are known as the *frenula veli medullaris anterioris*. Lateral from the root of the frenulum, on each side emerges the trochlear nerve (Fig. 69).

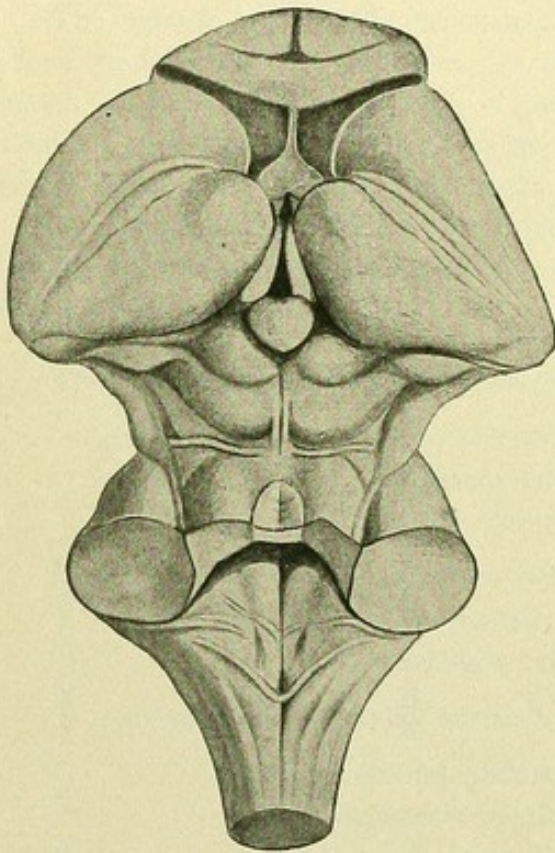


FIG. 69.—The mesencephalon and the myelencephalon; dorsal aspect; IV ventricle partially exposed.

Each colliculus continues laterally into an arm or brachium. From the colliculus superior passes the *brachium quadrigeminum superius*, which runs as a distinct white cord between the thalamus and the medial geniculate body and disappears in the vicinity of the lateral geniculate body. The colliculus superior, *brachium quadrigeminum superius*, *corpus geniculatum laterale* and *pulvinar* stand in relation with the *tractus opticus*. From the colliculus inferior proceeds the *brachium quadrigeminum inferius*, which is broader, flatter and shorter than the upper, and disappears beneath the medial geniculate body.

### PEDUNCULI CEREBRI.

The cerebral peduncles, with the *substantia perforata posterior*, form the ventral portion of the mid-brain and are bounded by the optic tract in front and by the pons and its peduncles behind (Figs. 15 and 75). Cross-sections of the mid-brain show a



subdivision of the cerebral peduncle into a ventral segment, the *basis pedunculi*, and a dorsal area, the *tegmentum*. Between these subdivisions lies a grayish black substance

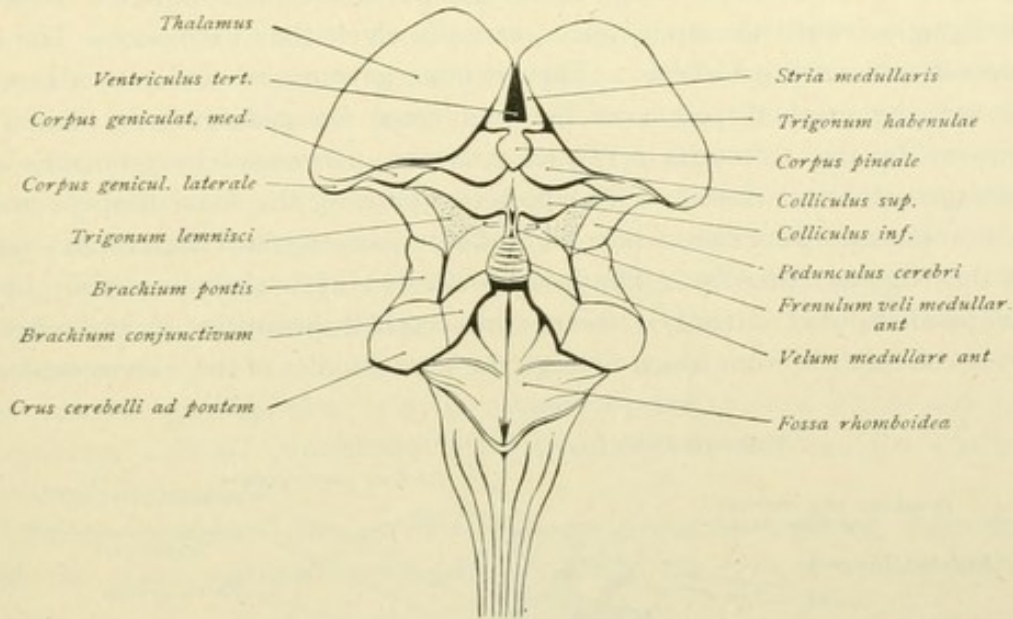


FIG. 70.—Dorsal view of mesencephalon and myelencephalon. Schematic.

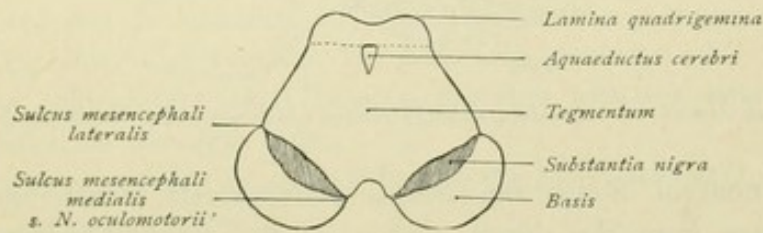


FIG. 71.—Section through the mesencephalon.

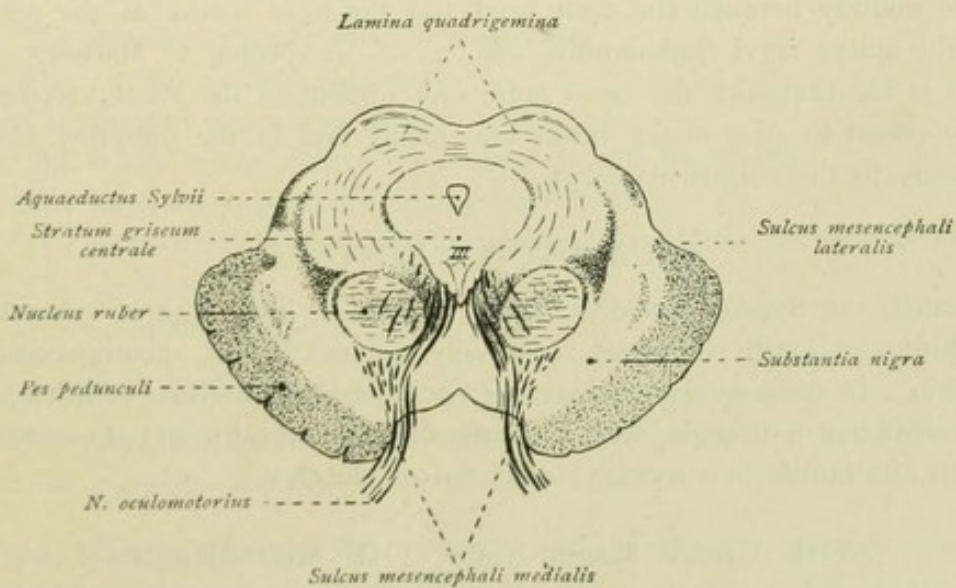


FIG. 72.—Section through the mesencephalon, at the level of the oculomotor nucleus (III).

in the form of a crescent, the *substantia nigra* of Sömmering. Superficially the basis and the tegmentum are separated by two furrows, medially by the *sulcus nervi oculomotorii*



or *sulcus mesencephali medialis* and laterally by the *sulcus mesencephali lateralis*. Dorsally the tegmentum is overlaid by the quadrigeminal plate.

The cerebral peduncles emerge from the pons as robust striated columns and extend divergently toward the optic tracts, beneath which they disappear. The course of the fibre-bundles is worthy of note. They exhibit an outward and forward twist (Fig. 75). Between the cerebral peduncles lies the *fossa interpeduncularis* (Tarini), whose floor is formed by the *substantia perforata posterior*, penetrated by numerous apertures for the passage of blood-vessels. The posterior part of the fossa deepens toward the pons into the *recessus posterior*, while the anterior part, toward the corpora mamillaria, sinks into the *recessus anterior*. The fossa is divided by a shallow median furrow into two symmetrical halves; laterally, toward the cerebral peduncle, it is limited by the *sulcus nervi oculomotorii*, from which emerge the fibre-bundles of the *nervus oculomotorius*.

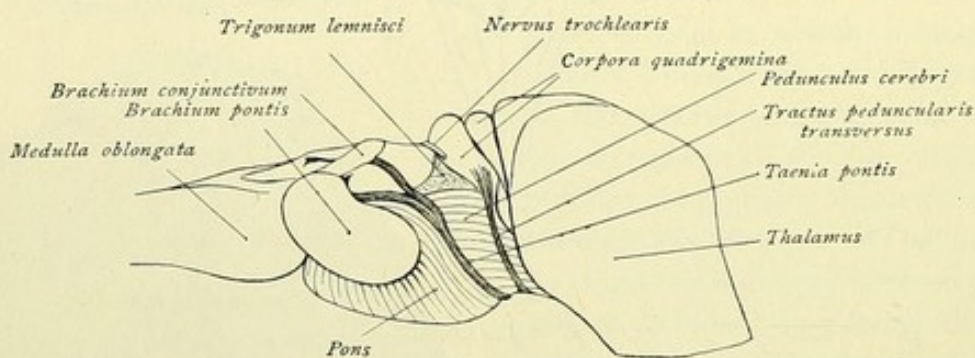


FIG. 73.—Lateral view of the brain-stem, showing tractus peduncularis and taenia pontis. Schematic.

A special strand of fibres, the *tractus peduncularis transversus*, remains to be noted. This springs from the dorsal surface of the cerebral peduncle, between the brachium quadrigeminum posterius and the corpus geniculatum mediale, winds around the peduncle midway between the optic tract and the front border of the pons and disappears in the *sulcus nervi oculomotorii* (Fig. 75). According to Marburg, the tractus peduncularis is identical with the basal optic root present in the lower vertebrates. The fibres are supposed to arise in the retina and finally end in the *ganglion ektomamillare* located laterally to the corpus mamillare.

#### AQUAEDUCTUS CEREBRI.

This canal, the Sylvian aqueduct, forms a passage, lined with ependyma, that connects the third and fourth ventricles. Dorsally lies the lamina quadrigemina, ventrally the tegmentum. In cross-sections, where the canal passes into either ventricle, it presents an outline resembling a triangle, with the base directed dorsally and the apex ventrally; in the middle, its outline is varyingly cordiform or elliptical.

#### THE GRAY MASSES OF THE MID-BRAIN.

Surrounding the aquaeductus cerebri is the central gray substance, *stratum griseum centrale*. At the bottom of this stratum, at the level of the superior colliculi, lies the *oculomotor nucleus*, which joins the upward prolongation of the small *nucleus nervi trochlearis* (Figs. 88 and 89). Lateral, at the edge of the central gray substance, lies



the small *nucleus radialis decedentis nervi trigemini*. The *nucleus of the posterior commissure and posterior longitudinal bundle* is located in advance of that of the oculomotor nerve. Ventral and lateral to the central gray substance, the *formatio reticularis* spreads out. Between the basis pedunculi and the tegmentum lies the *substantia nigra*, which extends upwards as far as the hypothalamus, while between the *substantia nigra* and the central gray substance is located the red nucleus, the *nucleus ruber* or *nucleus tegmenti*, which appears round in cross-sections (Fig. 207).

As small nuclei of the tegmentum, the *ganglion dorsale tegmenti* and the *ganglion profundum mesencephali laterale et mediale* are to be noted. The *ganglion dorsale* is a small round nucleus lying behind the trochlear nucleus, while the *ganglion profundum* is lodged within the *formatio reticularis*, ventro-lateral to the nuclei of the oculomotor and trochlear nerves.

The anterior quadrigeminal body is covered by the stratum zonale and contains the *stratum griseum colliculi superioris*; the posterior body encloses the centrally placed *nucleus colliculi inferioris*.

Within the posterior part of the *substantia perforata posterior*, towards the front border of the pons, scattered nerve-cells constitute the *ganglion interpedunculare* of Gudden.

#### SUMMARY OF THE MESENCEPHALON.

The mesencephalon or mid-brain includes dorsally the *corpora quadrigemina*, with the *brachia quadrigemina* and ventrally the *pedunculi cerebri*.

The superior colliculi and their brachia, together with the lateral *corpora geniculata*, stand in relation to the optic tracts.

The **pedunculus cerebri** is subdivided into the *basis pedunculi* and the *tegmentum*, separated by the *substantia nigra*.

The **chief gray masses** are:—

- The stratum griseum colliculi superioris,
- The nucleus colliculi inferioris,
- The stratum griseum centrale,
- The nuclei of the nervus oculomotorius and trochlearis,
- The small nucleus of the nervus trigeminus,
- The nucleus of the posterior commissure and posterior longitudinal bundle,
- The nucleus ruber,
- The substantia nigra.

The **smaller nuclei** are:—

- The ganglion dorsale et profundum tegmenti,
- The ganglion interpedunculare.

The mid-brain is traversed by the *aqueductus cerebri* or *Sylvian aqueduct*. This narrow canal establishes communication between the third and fourth ventricles.

The mesencephalon and the prosencephalon together constitute the cerebrum.



## ISTHMUS RHOMBENCEPHALI.

The isthmus rhombencephali forms the transition from the mid-brain to rhombencephalon, which latter is subdivided into the metencephalon and the myelencephalon.

To the isthmus belong the *brachia conjunctiva*, the *velum medullare anterius* and the *trigonum lemnisci*, which structures collectively constitute the dorsal part of the isthmus. Ventral are the cerebral peduncles. The isthmus surrounds the upper end of the fourth ventricle.

The **brachia conjunctiva cerebelli**, *crura cerebelli ad cerebrum*, or *superior cerebellar peduncles*, form two flattened cylindrical columns that emerge from the cerebellum. They embrace the anterior medullary velum, converge forward and come together behind the quadrigeminal plate. At the sides, the brachia conjunctiva border on the pontile peduncles, separated from the latter by the *sulcus lateralis mesencephali*, which runs at first toward the corpus geniculatum lateralis and then laterally.

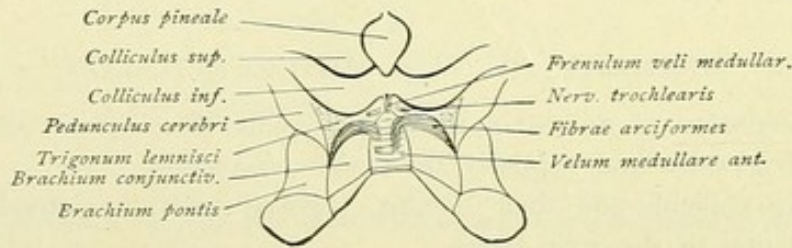


FIG. 74.—Dorsal view of the isthmus rhombencephalon.

The **velum medullare anterius** is a thin medullary sheet that stretches between the brachia conjunctiva or the superior cerebellar peduncles. Dorsally it is covered by and fused with the lingula of the cerebellum and assists in roofing in the anterior part of the fourth ventricle (Fig. 79). From the narrow front end of the velum arises the *frenulum veli medullaris anterioris* that extends toward the inferior colliculi.

In advance of the front end of the brachium conjunctivum, lies a triangular field, the *trigonum lemnisci*. It is usually distinguishable from the whiter brachium by its gray color. Laterally, the trigonum borders on the cerebral peduncle, separated by the *sulcus lateralis mesencephali*, in front it is bounded by the brachium quadrigeminum inferius and the inferior colliculi. The area contains the fibre-tracts of the fillet or lemniscus and, deeply placed, the *nucleus lemnisci lateralis*. Occasionally one notes delicate white fibre-strands that pass from the sulcus mesencephali lateralis over the brachium, particularly in the vicinity of the quadrigeminal bodies. Some of the strands bend medially at right angles and pass backward through the anterior medullary velum. These *fibrae arciformes* belong to a bundle that ascends from the spinal cord to the cerebellum, the tractus spino-cerebellaris ventralis or Gowers' tract (page 161).



## METENCEPHALON.

To the metencephalon belong the pons and the cerebellum.

## PONS VAROLII.

We distinguish a *pars dorsalis* and a *pars basalis* pontis. The *pars dorsalis* corresponds to the *pars intermedia* of the floor of the fourth ventricle. The *pars basalis* forms a broad white bolster, that expands transversely and is bounded in front by the cerebral peduncles and behind by the medulla oblongata. The lateral boundary is indicated by a line connecting the points of emergence of the roots of the trigeminal and facial nerves. Lateral to this line, the pons narrows and passes on each side into the *brachium pontis*, or *middle cerebellar peduncle*, which extends backward and enters the cerebellum. The ventral surface of the

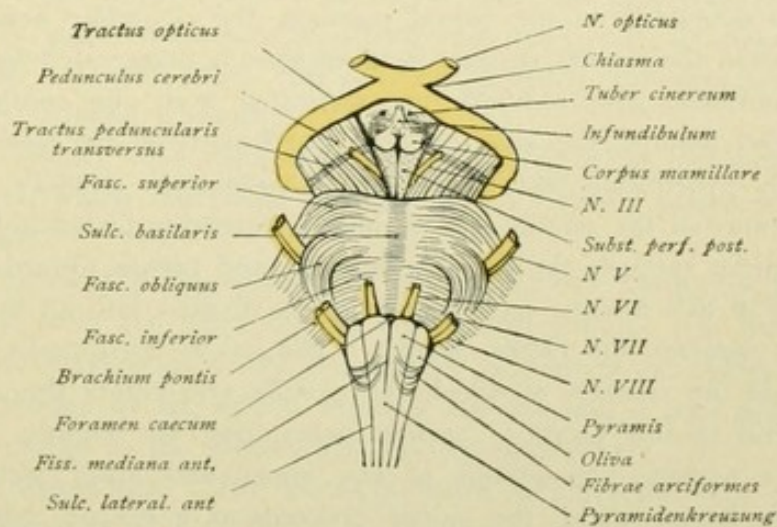


FIG. 75.—Ventral view of the brain-stem.

pons is arched in the sagittal and transverse directions and exhibits a distinct transverse striation. These transverse fibres are grouped in three more or less well-defined bundles.

The *fasciculus superior pontis*, which courses in advance of the attachment of the trigeminal nerve.

The *fasciculus inferior pontis*, in the lower third of the pons.

The *fasciculus medius pontis*, between the foregoing bundles, which crosses the fasciculus inferior in convex curves and runs towards the places of attachment of the facial and acoustic nerves. On account of this course, the bundle is also called the *fasciculus obliquus pontis* or *fasciculus arcuatus* (Foville).

The ventral pontile surface is modelled in the mid-line by a broad furrow, the *sulcus basilaris*, in which the basilar artery usually lies. This furrow, however, is not caused by the basilar artery, but by the two adjacent longitudinal ridges, the *eminentia pyramidales*, which contain the pyramidal tracts. The sulcus basilaris is present even when the basilar artery pursues an irregular course; it disappears, however, in degeneration of the pyramidal tracts.

The *taenia pontis* or *fibra pontis* is a special band of fibres that arises in or medial to the sulcus mesencephali lateralis, runs along the front border of the pons and disappears in the sulcus nervi oculomotorii; these fibres are also called the *fila lateralia pontis* (Fig. 73).



## THE CEREBELLUM.

The cerebellum, or little brain, is a medially situated structure of kidney-like form. It underlies the occipital lobes of the cerebrum, from which it is separated by the large transverse fissure, and lies behind the pons and the corpora quadrigemina and above the medulla oblongata. We distinguish an *upper* and a *lower surface* and an *anterior* and a *posterior border*. Both surfaces are arched; the under and more strongly convex surface exhibits in the middle a broad sagittal depression, the *vallecula cerebelli*, in which lies the medulla oblongata. The anterior border is indented in the mid-line by the *incisura cerebelli anterior*; likewise, the posterior border by the *incisura cerebelli posterior*. At the borders of the incisura are the *anguli anteriores* and *posteriores*. Front and hind borders meet in the *anguli laterales*. The median part of the cerebellum, lying between the incisura anterior and posterior, is known as the worm, the *vermis cerebelli*. The *vermis superior* is defined from the lateral portions, the *cerebellar hemispheres*, by two shallow furrows, while the *vermis inferior* is more sharply demarcated by deeper grooves. The narrow convolutions, *gyri cerebelli*, are separated from one another by numerous more or less parallel fissures, the *sulci cerebelli*, particularly in the worm and the hemispheres. A deeply penetrating fissure, the *sulcus horizontalis cerebelli*, extends on each side from the entrance of the pontile arm or middle cerebellar peduncle in the cerebellum along the front border towards the *angulus lateralis* and thence toward the *angulus posterior*. By means of this fissure, each hemisphere is divided into an upper and a lower surface, the *facies superior* and *facies inferior*. The *sulcus horizontalis* is readily located when we pass from the position at which the pontile arm enters the cerebellum. The *sulcus* begins lateral to this location, at first penetrating but slightly, and is here distinguished by the narrow convolutions of the upper and lower surfaces entering its depth. From the lateral angle, the *sulcus* proceeds as a deeper cleft along the hind border, more on the lower than the upper surface, toward the *incisura cerebelli posterior*.

The worm and hemisphere regions of the cerebellum are subdivided into definite *lobes* by certain more or less deeply cutting fissures. In each hemisphere three lobes are distinguished: *lobus superior*, *lobus posterior* and *lobus inferior*, the individual lobes of the hemisphere always corresponding to definite segments of the worm-region.

**A. Lobus Superior.** The *lobus superior* is bounded in front by the *incisura cerebelli anterior*, at the side by the *sulcus horizontalis cerebelli* and behind by the *sulcus*

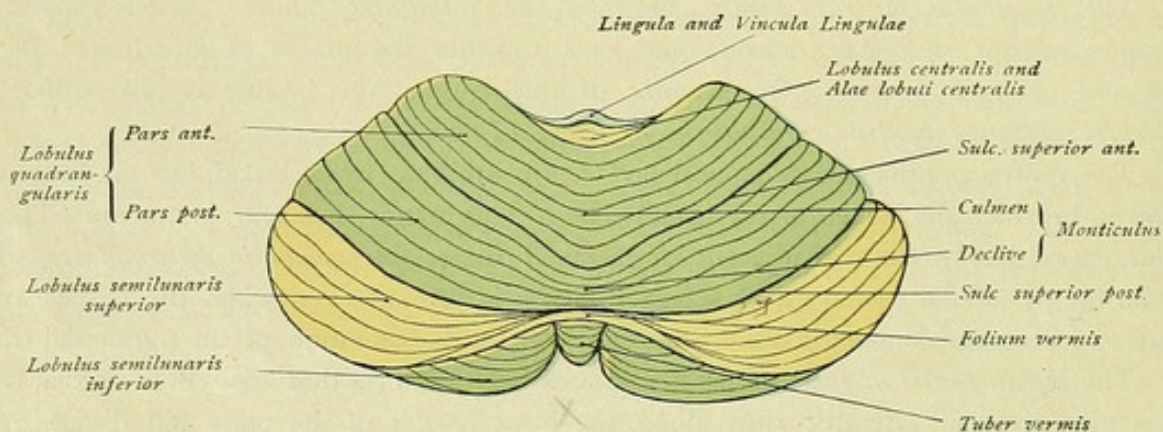


FIG. 76.—Upper surface of the cerebellum.



superior posterior. The *sulcus superior posterior* starts in the sulcus horizontalis somewhat in advance of the lateral angle and passes as a deep curved fissure, directed posteriorly with its convexity toward the hind end of the vermis superior. The sulcus is readily recognized by the different relations of the bounding lamellæ, since those of the superior lobe run obliquely outward and forward, while the lamellæ of the posterior lobe run parallel.

Passing from before backward, the worm and the hemisphere present the following parts of the lobus superior :

WORM	HEMISPHERE
Lingula . . . . .	Vinculum lingulae
Lobulus centralis . . . . .	Ala lobuli centralis
Monticulus { Culmen } . . . . .	Lobus quadrangularis { Pars anterior
{ Declive } . . . . .	{ Pars posterior

The **lingula** lies deeply placed in the incisura cerebelli anterior and consists of from four to six or eight small lamellæ, which rest upon and are fused with the velum medullare anterius. Lateral from the posterior lamellæ, the *vincula lingulae* extend toward the middle cerebral peduncle.

Behind the lingula, and separated from it by the sulcus praecentralis, follows the **lobulus centralis**, which overhangs the lingula and laterally sends out its lamellæ, the *alae lobuli centralis*.

The **monticulus**, the largest segment of the superior worm, lies behind the lobulus centralis, separated from the latter by the sulcus postcentralis. It includes the *culmen* and the *declive* and corresponds to the hemisphere-segment of the *lobulus quadrangularis*. The latter is subdivided by the sulcus superior anterior into a *pars anterior* and a *pars posterior*, corresponding to the culmen and declive respectively.

**B. Lobus Posterior.** The lobus posterior includes the hind part of the upper surface and the posterior half of the under surface of the cerebellum. It is separated

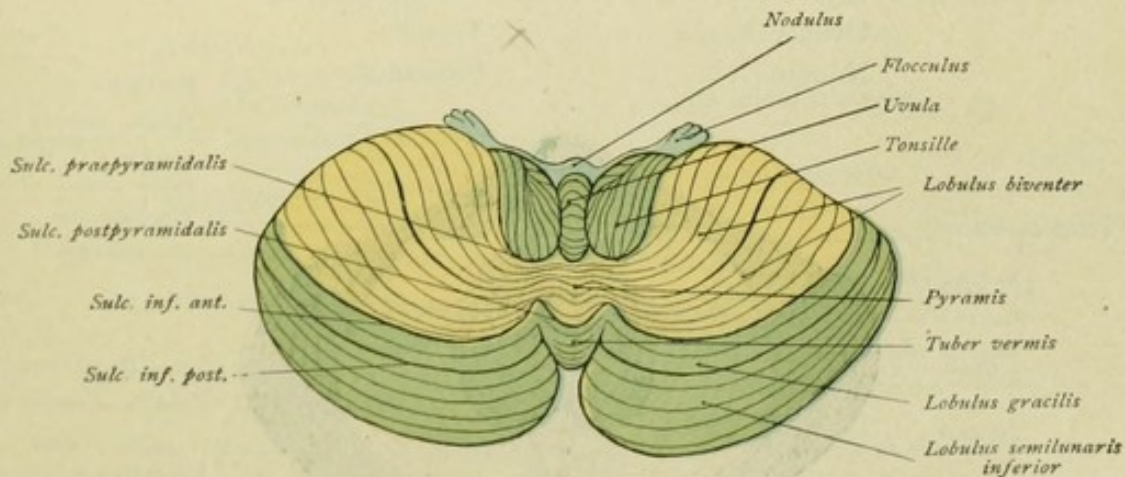


FIG. 77.—Lower surface of the cerebellum.

from the lobus superior by the sulcus superior posterior, and from the lobus inferior by the sulcus postpyramidalis in the worm and by the sulcus inferior anterior in the hemisphere. The *sulcus inferior anterior* may be readily identified if the course of the sulcus superior posterior be followed. It begins at the side, on the front border of the hemi-



sphere, in the sulcus horizontalis cerebelli at the place where the sulcus superior posterior opens, thence runs in a curve toward the worm, where it ends in the deeply penetrating *sulcus postpyramidalis*.

By means of the sulcus horizontalis and the sulcus inferior posterior, the posterior lobe of the hemisphere is subdivided into three parts, which correspond with two segments of the worm.

WORM	HEMISPHERE
Folium vermis.....	Lobulus semilunaris superior
Tuber vermis.....	{ Lobulus semilunaris inferior
	{ Lobulus gracilis

The **folium vermis** lies in the incisura cerebelli posterior, forms a single stout lamella and connects the two upper crescentic lobules, the *lobuli semilunares superiores*.

The **tuber vermis** or *tuber valvulae* corresponds to the lobulus semilunaris inferior and the lobulus gracilis. The *lobulus semilunaris inferior* is broad medially and narrow laterally, and often separated into two parts, an anterior and a posterior, by a lateral fissure that runs into the sulcus horizontalis. The anterior and smaller part maintains approximately the same width throughout and at the side is applied to the lateral end of the lobulus gracilis. The posterior and larger part exhibits usually two or three small lobules, often two crescentic segments, of which one begins medially at the worm with the thicker end and ends laterally in a point, and the other begins broad at the side and becomes pointed toward the worm. The *lobulus gracilis* lies in front of the lobulus semilunaris inferior, maintains a more or less constant thickness throughout, and is separated from the lobulus semilunaris inferior by the sulcus inferior posterior and from the lobus inferior by the sulcus inferior anterior.

**C. Lobus Inferior.** This lobe includes the following parts :

WORM	HEMISPHERE
Pyramis.....	Lobulus biventer
Uvula.....	Tonsilla
Nodus.....	Flocculus

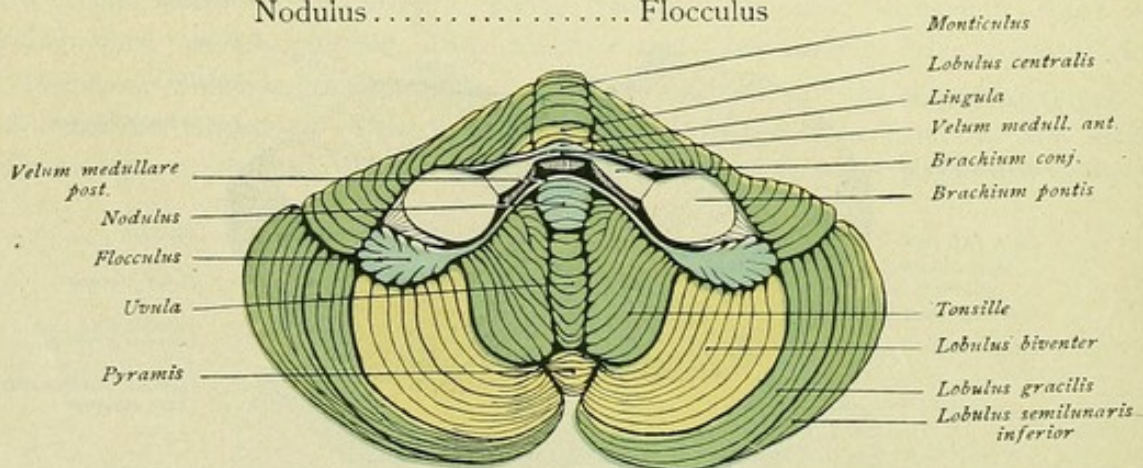


FIG. 78.—Cerebellum viewed from below and in front.

The **pyramid**, separated from the tuber vermis by the *sulcus postpyramidalis*, connects the biventral lobule of the one side with that of the other. A fissure splits each *lobulus biventer* into two portions, an anterior medial and a posterior lateral.



The **tonsilla** is embraced by a medially concave curve described by the *sulcus praepyramidalis*, which separates the pyramis from the uvula.

In advance of the **uvula** lies a small conical structure, the **nodulus**. Immediately in front of the latter is a thin white sheet, the *velum medullare posterius*, that continues laterally on each side as the *pedunculi flocculi* to join the *flocculus*. Lateral to the latter, between the lobulus quadrangularis of the superior lobes and the lobulus biventer is seen the accessory flocculus, *flocculus secundarius*.

On removing the tonsil, a broad lamella, the *ala uvulae*, or the *furrowed band*, is seen passing outward from the uvula. The posterior margin of this band is free, its anterior one is continuous with the posterior medullary velum. The deep recess, whose floor is formed by the *ala uvulae* and the *velum medullare posterius*, lodges the tonsil and is called the *nidus avis*. Its lateral wall is contributed by the lobulus

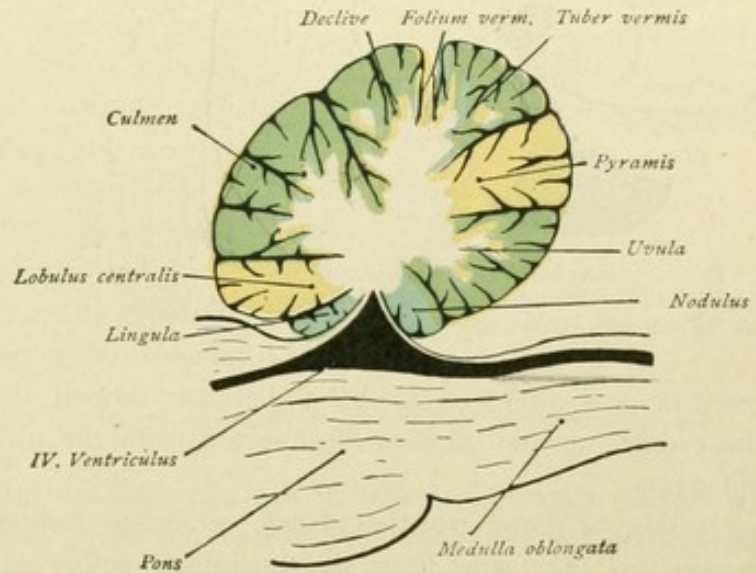


FIG. 79.—Median sagittal section through the worm of the cerebellum.

biventer and the pedunculus flocculi, while it is bounded medially by the uvula and behind by the pyramid. The lobulus biventer forms the lateral, the tonsil the medial and the flocculus the anterior part of the lobus inferior.

The foregoing relations are recapitulated in the following table:

	VERMIS	HEMISPHAERIUM
Lobus superior	Lingula .....	Vinculum lingulae
	— <i>Sulcus praecentralis</i>	
	Lobulus centralis .....	Ala lobuli centralis
	— <i>Sulcus postcentralis</i>	
	Monticulus { Culmen } .....	Lobulus quadrangularis { Pars anterior — <i>Sulc. sup. ant.</i> — Pars posterior
	{ Declive }	
	— <i>Sulcus superior posterior</i> —	
Lobus posterior	Folium verm. ....	Lobulus semilunaris superior
	— <i>Sulcus praecentralis</i>	— <i>Sulcus horizontalis cerebelli</i> —
	Tuber verm. ....	Lobulus semilunaris inferior
	— <i>Sulcus postpyramidalis</i> —	— <i>Sulcus inferior posterior</i> —
	Pyramis .....	Lobulus gracilis
	— <i>Sulcus praepyramidalis</i>	— <i>Sulcus inferior anterior</i> —
Lobus inferior	Uvula .....	Lobulus biventer
	Nodulus .....	Tonsilla
		Flocculus ( <i>Flocculus secundarius</i> )

On sectioning the cerebellum, we recognize the internally situated white medullary substance, the *corpus medullare*, and the *substantia corticalis*, which invests the periphery as a thin continuous band of gray matter. The medullary substance of the cerebellum



is composed of that of the hemispheres and of the worm, which are continuous medially. Stout tracts of medullary substance, the *laminae medullares*, pass outward from the medullary centre and send off, mostly at acute angles, *secondary medullary laminae*.

The latter, in turn, give off still smaller sheets, which finally are enclosed by gray substance and represent the cerebellar convolutions or folia, the *gyri cerebelli*. This structure, when viewed in sagittal sections, is known as the *arbor medullaris*, on account of the tree-like branching. In sagittal sections through the worm, where this delicate figure is particularly well seen, it is called the *arbor vitae vermis*.

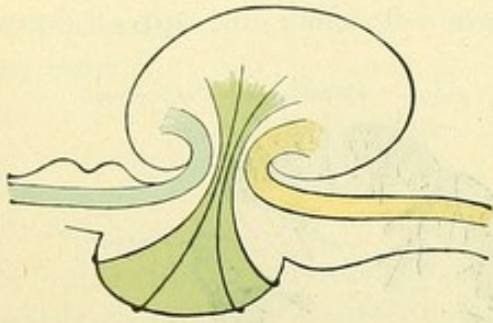


FIG. 80.—Schematic representation of the crura cerebelli. Blue, superior peduncle; green, middle peduncle; yellow, inferior peduncle.

The **medulla** of the hemispheres is connected with neighboring parts of the brain by masses of nerve fibres. These masses constitute more or less robust columns, which are termed the *peduncles*, *crura* or *brachia* of the cerebellum and serve to connect it with the pons, the mid-brain and the medulla oblongata.

The **brachia pontis**, *middle cerebellar peduncles*, or *crura cerebelli ad pontem*, emerge on each side from the horizontal sulcus at the anterior border, between the

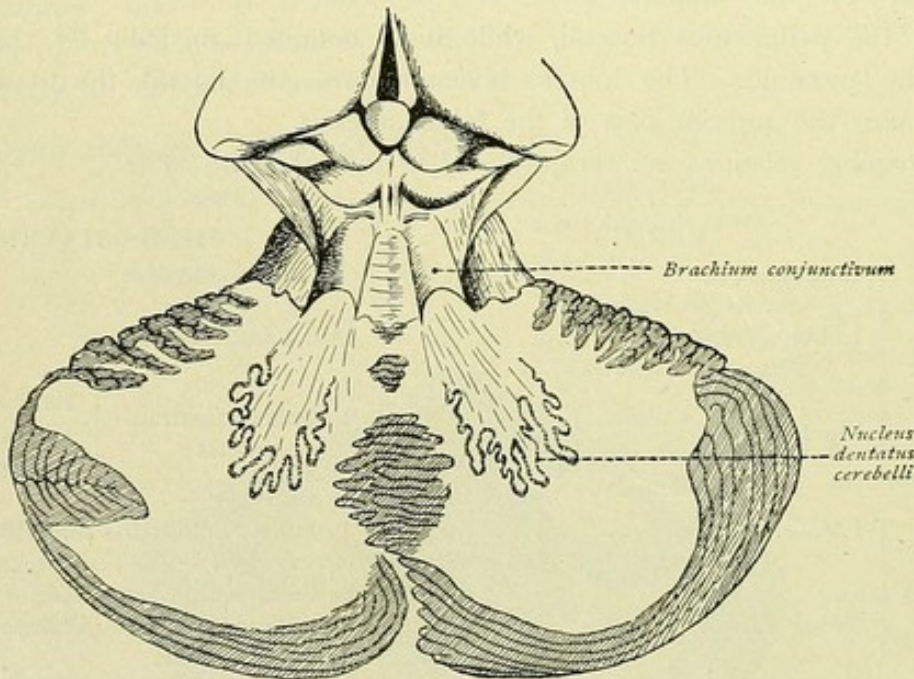


FIG. 81.—Superior cerebellar peduncles, also termed crura cerebelli ad corpora quadrigemina and brachia conjunctiva. Portion of the cerebellum has been removed to expose the dentate nuclei.

lobulus quadrangularis, tonsilla and flocculus, and pass convergingly forward, to blend with the pons.

The **crura cerebelli ad cerebrum** or *superior cerebellar peduncles*, also known as the *crura cerebelli ad corpora quadrigemina* and the *brachia conjunctiva cerebelli*, lie



in front of the pontile crura, pass as flattened cylindrical columns convergingly forward and disappear beneath the quadrigeminal bodies. The velum medullare anterius stretches out between them.

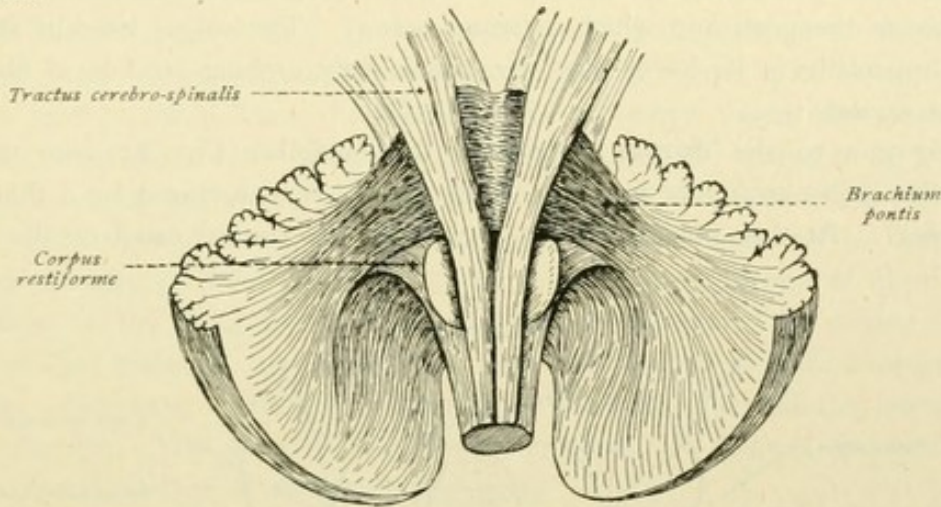


FIG. 82.—Brachia pontis or middle cerebellar peduncles and corpora restiforme or inferior cerebellar peduncles.

The **crura cerebelli ad medullam oblongatam** or *inferior cerebellar peduncles*, also often called the *corpora restiformia*, pass out between the foregoing cerebellar arms and turn sharply backward and downward into the medulla oblongata.

## MYELENCEPHALON.

### MEDULLA OBLONGATA.

The upper boundary of the medulla oblongata is marked ventrally by the inferior edge of the pons and dorsally by the striae acusticae in the floor of the fourth ventricle; the lower boundary is indicated by the attachment of the upper root-bundles of the first cervical nerves, or, ventrally, by the lower limit of the pyramidal decussation.

Let us first examine the **ventral surface** of the medulla (Fig. 75). In the mid-line runs the *fissura mediana anterior*, which is prolonged into the fissure of the spinal cord bearing the same name, but separated from it by the crossing fibre-bundles of the pyramidal decussation, *decussatio pyramidum*. Toward the lower edge of the pons, the fissure widens into a small depression, the *foramen caecum*. On both sides the median fissure is bordered by the *pyramid*, a slightly convex tapering column, broad above and narrow toward the spinal cord, which appears to pass into the anterior column of the cord. Only a small part of the pyramidal fibres, however, actually maintains a course along the anterior median fissure in the anterior column of the spinal cord, since the greater part crosses the mid-line in the *decussatio pyramidum* and continues within the lateral column of the cord of the opposite side. The part which continues within the anterior column is known as the *anterior pyramidal tract*, that within the opposite lateral column as the *lateral pyramidal tract*. These will receive more detailed attention in the consideration of the fibre-paths (page 161).



The **pyramid** is bounded on the outer side by the *sulcus lateralis anterior*, from which emerge the root-bundles of the hypoglossal nerve. Lateral to the sulcus lateralis and adjoining the pyramid is seen the *oliva*, an ovoid eminence whose thicker end reaches as far as the pons and which narrows below. The sulcus lateralis anterior may be marked, especially in its lower part, by transversely arching strands of fibres, known as the *fibrae arcuatae*.

Turning now to the **dorsal aspect** of the medulla (Fig. 83), we note, in the lower part, the *sulcus medianus posterior*, which above is soon closed by a thin medullary sheet, the *obex*. At this point, beneath the obex, the central canal of the cord opens

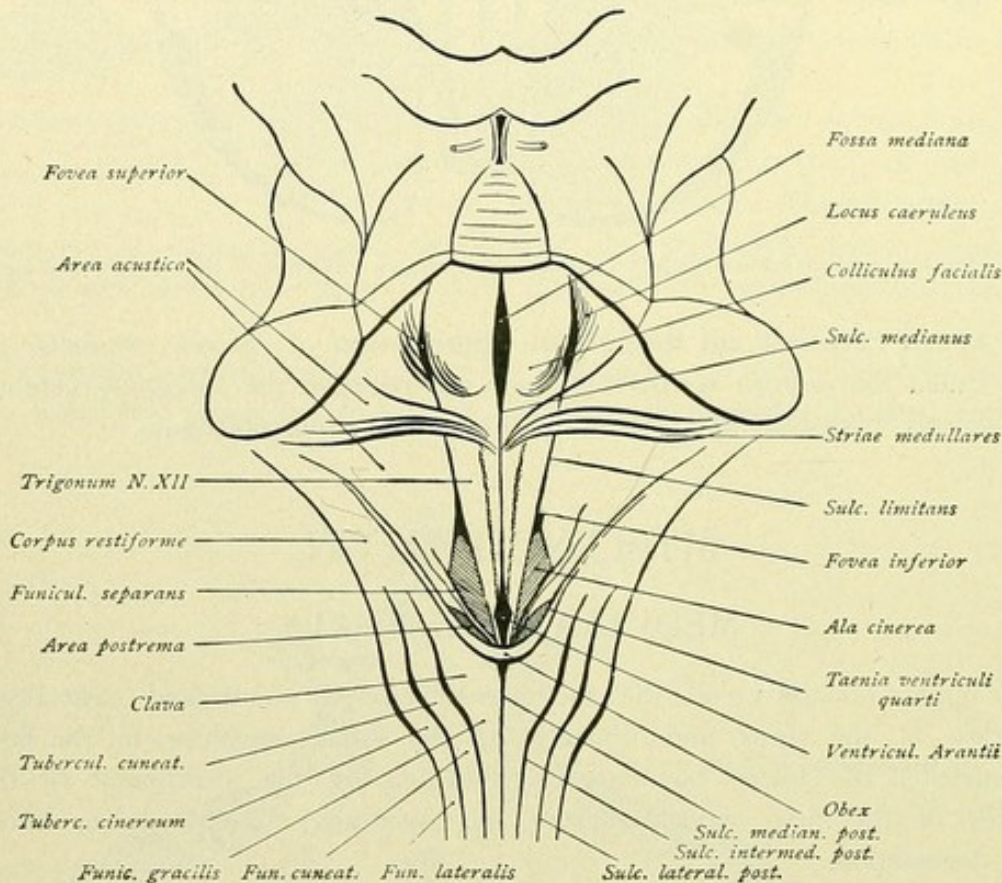


FIG. 83.—Fossa rhomboidea, showing details of the floor of the fourth ventricle.

into the fourth ventricle. Lateral to the sulcus medianus, next comes the *sulcus intermedius posterior*, which in the upper part of the medulla runs laterally and then disappears. Farther outward is the less distinct *sulcus lateralis posterior*, which likewise turns outward and may be followed to about the level of the middle of the olive. Between the median and lateral posterior sulci, the posterior column, *funiculus posterior*, represents the upward prolongation of the corresponding column of the spinal cord. By means of the sulcus intermedius posterior the funiculus is subdivided into two special tracts. On each side of the posterior median fissure, between the latter and the posterior intermediate fissure, lies the *fasciculus gracilis*, or *Goll's column*, continued upward from the cord. In the upper part it broadens into the *clava* and then, again narrowing, proceeds laterally and upward. Between the lateral and intermediate posterior sulci runs the *fasciculus cuneatus*, the upward prolongation of *Burdach's column*, which at the level of



the clava expands into the *tuberculum cuneatum* and higher up also bends outward. Lateral to the sulcus lateralis posterior, between it and the sulcus lateralis anterior, the lateral column, *funiculus lateralis*, ascends from the spinal cord. After reaching the lower end of the olive, the column passes laterally and dorsally, close to the olive, almost as far as the pons. It is separated into a dorsal and a ventral part by a slight furrow, along which emerge the delicate root-fibres of the accessory, vagus and glossopharyngeal nerves. The dorsal part of the funiculus lateralis broadens above and, in the region behind the tuberculum cuneatum, swells into the *tuberculum cinereum*. Farther above, it passes laterally in company with the upper ends of the column of Goll and of Burdach. These upward and laterally directed portions of the column of Goll and of Burdach and the dorsal segment of the funiculus lateralis collectively constitute the *corpus restiforme* or *inferior cerebellar peduncle*, also called the *crus cerebelli ad medullam oblongatam*, that passes to the cerebellum. Medially, the corpus restiforme borders the lateral margin of the fourth ventricle. The *fossa rhomboidea*, which forms the floor of the fourth ventricle, overlies the dorsal surface of the preceding parts.

#### VENTRICULUS QUARTUS.

Isthmus, metencephalon and myelencephalon together surround the fourth ventricle, a cavity filled with a small amount of cerebro-spinal fluid, which below passes into the central canal of the spinal cord and above is continuous with the Sylvian aqueduct.

Three **segments** are distinguished, the pars inferior, the pars intermedia and the pars superior ventriculi quarti.

The *pars inferior* belongs to the medulla oblongata and is embraced by the corpora restiformia.

The *pars intermedia* forms the middle and broadest portion and continues above into the region between the pontile crura.

The *pars superior* belongs to the isthmus rhombencephali, its dorsal boundary being formed by the brachia conjunctiva cerebelli and the velum medullare anterius.

The **floor** of the fourth ventricle is formed by the *fossa rhomboidea* and its **roof** by the *anterior medullary velum*, the *superior cerebellar peduncles* or brachia conjunctiva, the *posterior medullary velum* and the *tela chorioidea*. The posterior medullary velum and the tela chorioidea together constitute the *tegmen fossae rhomboideae*, the roof in the limited sense. The edge along which the anterior and posterior medullary vela meet is known as the *fastigium*; at this place the fourth ventricle projects into the medullary substance of the cerebellum, forming the tent-like *recessus tecti*. The pars intermedia extends laterally on each side into the *recessus lateralis ventriculi quarti*. Originally the fourth ventricle is a closed cavity, except above where it communicates with the third ventricle by means of the aquaeductus cerebri and below where it is continuous with the central canal of the spinal cord. Its floor and roof are clothed with epithelium, the *ependyma*. On the roof this epithelium lines the anterior and posterior medullary vela and then continues as the thin *lamina chorioidea epithelialis*, which is attached to the tela chorioidea ventriculi quarti and thence is prolonged onto the borders of the abutting parts of the brain. If the ventricle be forcibly opened behind from above, as when the tela chorioidea is removed, the thin epithelial lamina is likewise torn. The separation takes place where the lamina passed onto the more robust surrounding parts of the brain, only



a thin white edge, the *taenia ventriculi quarti*, remaining along the borders of the tear. The taenia of the fourth ventricle begins at the obex, thence passes onto the corpus restiforme, there forms the posterior border of the recessus lateralis and continues along the peduncle of the flocculus and the posterior medullary velum. The tela chorioidea of the fourth ventricle represents that part of the pia mater cerebri that projects between the ventral surface of the cerebellum, more particularly the uvula and the tonsilla, and the dorsal surface of the medulla oblongata (Fig. 84). The two pial sheets are united by subarachnoidal tissue. The tela chorioidea has the form of an equilateral triangle, whose anteriorly directed base is attached in the middle to the nodulus and at the sides along the posterior medullary velum and the flocculus, and whose apex is directed posteriorly toward the hind end of the fourth ventricle. It pushes into the ventricle villiform processes that constitute the *plexus chorioideus ventriculi quarti*, subdivided into medial and

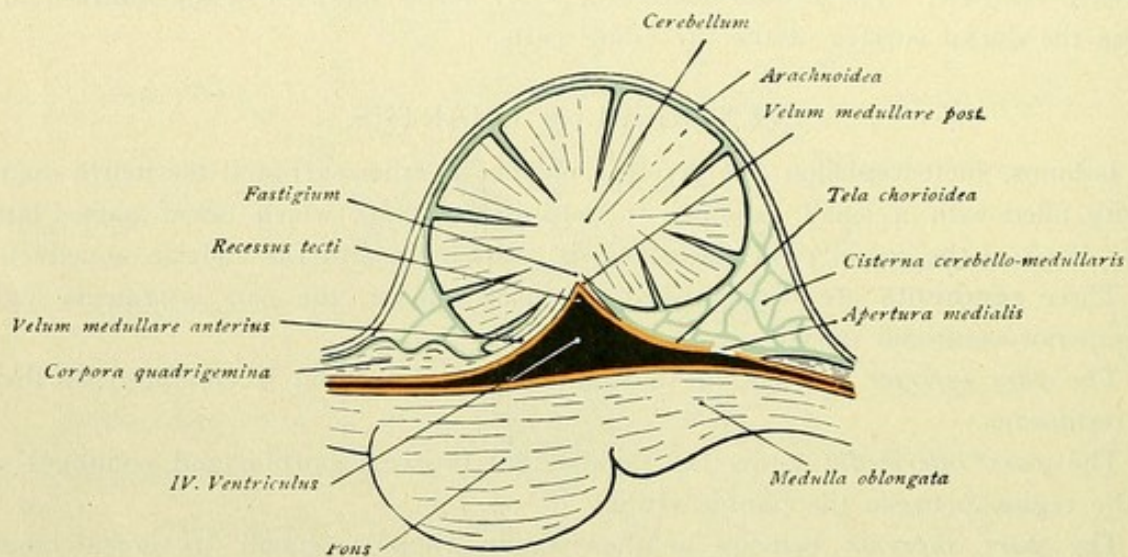


FIG. 84.—Sagittal section through fourth ventricle, showing relations of the tela chorioidea. Ependyma, red; pia mater, blue.

lateral portions. The *medial plexus* consists of two thin stripes that pass in the mid-line, close together, from behind forward to the nodulus. From the latter, the *lateral plexus* continues, on each side, outward into the recessus lateralis ventriculi quarti. In the early condition, the tela chorioidea, with the lamina chorioidea epithelialis, completely closes the posterior part of the fourth ventricle. Later, however, openings are formed at those places, at which the tela chorioidea and the lamina epithelialis are broken through. Such an opening is the *apertura medialis ventriculi quarti* or the *foramen of Magendi*, situated in the posterior part of the tela chorioidea immediately in front of the obex. At the sides, in each lateral recess, is found the *apertura lateralis ventriculi quarti* (Key-Retzii) or the *foramen of Luschka*. Through these three openings the ends of the medial and lateral parts of the choroid plexus of the fourth ventricle pass and project into the subarachnoid space, communication between the ventricle and the subarachnoid space being in this manner established. The villi which protrude through the apertura lateralis are readily found, since they lie medial to the flocculus, between the latter, the lobulus biventer and the tonsilla.



**Fossa Rhomboidea.**—The floor of the fourth ventricle, the fossa rhomboidea, is, as indicated by its name, rhomboidal in outline. Its posterior part, bordered by the corpora restiformia, belongs to the myelencephalon; its middle part lies in the metencephalon; and its anterior part belongs to the isthmus. By means of a longitudinal furrow, *sulcus medianus fossae rhomboideae*, it is divided into symmetrical halves. Transversely coursing white bands, the *striae medullares* or *striae acusticae*, which run from the lateral recesses toward the mid-line, separate the pars superior from the pars inferior fossae rhomboideae. The part of the fossa included between the medullary striae constitutes the pars intermedia.

The **striae medullares** present many variations in their course and development. They may be wanting or many, but are seldom identical in development

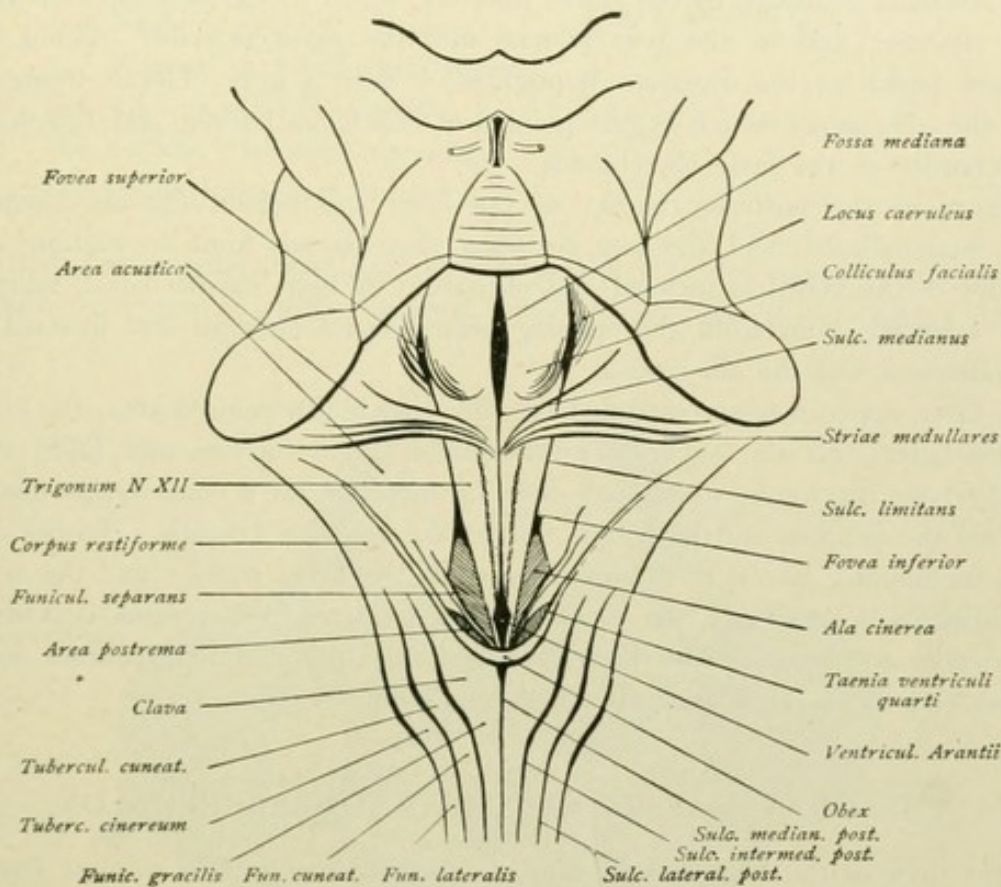


FIG. 85.—Dorsal surface of the medulla oblongata. Fossa rhomboidea.

and course on the two sides. Often they run obliquely outward and upward from the sulcus medianus.

The **pars inferior** of the ventricle deepens in its lower portion, presents several fields defined by furrows and, on account of its peculiar shape, is called the *calamus scriptorius*. At the lower border of the pars inferior lies the *obex*, a thin white medullary sheet from which the taeniae ventriculi quarti pass laterally. Immediately in front of the obex, where the sulcus medianus sinks into the central canal of the spinal cord, is a small depression, the *ventriculus Arantii*. In the pars superior, the median sulcus widens into the *fossa mediana*. On each side of the median furrow, a flat ridge, the *eminentia medialis*, extends the entire length of the ventricular floor. This ridge is narrow in its lower part and forms



a triangular field, the *trigonum nervi hypoglossi*, whose base is above at the striae medullares and apex below, directed toward the ventriculus Arantii.

On careful inspection, two special divisions of this field are recognized, an outer broader part, the *area plumiformis* (Retzius), and an inner narrower one, the *area medialis trigoni nervi hypoglossi* (Retzius). At the border between those two fields are to be seen mostly short, obliquely coursing delicate furrows and folds, and likewise a thin feathery band. Such markings are often visible also at the lateral border of the trigonum hypoglossi. Retzius, therefore, named this lateral and broader field, "area plumiformis."

In the upper part of the ventricular floor, the eminentia medialis is broader and projects more into the ventricle. The elevation is termed the *colliculus facialis*. Laterally, the eminentia medialis is defined by the *sulcus limitans*, which in the pars superior widens into the *fovea superior*, and in the pars inferior into the *fovea inferior*. Below the fovea inferior, and lateral to the trigonum hypoglossi, is seen a gray oblique triangular field, known as the *ala cinerea*, which begins pointed at the fovea inferior and broadens toward the lower border of the fossa rhomboidea.

In front of the posterior border of the fossa and behind the ala cinerea, lies a small gray mammillated field, the *area postrema*, that extends from the mid-line along the lower border of the ventricle forward and outward. A light narrow band, known as the *funiculus separans*, runs from the opening central canal outward and forward, between the area postrema and the ala cinerea.

The fovea superior is accompanied laterally by a bluish colored area, the *locus caeruleus*. The latter and the superior fovea exhibit small furrows and folds, *rugae loci caerulei et foveae superioris*, which may often be followed, for a considerable distance, forward toward the isthmus and backward toward the recessus lateralis. To the outer side of the sulcus limitans, lateral to the fovea superior, the fovea inferior and the ala cinerea, the *area acustica* is seen as a flat elevation, which toward the recessus lateralis presents the *tuberculum acusticum*. The funiculus separans, above noted, courses toward the lower inner end of the area acustica and there disappears.

#### THE GRAY MASSES OF THE RHOMBENCEPHALON.

In the floor of the *trigonum lemnisci*, in the isthmus, lies the *nucleus lemnisci*.

The pons includes a larger ventral portion, the *pars basilaris pontis*, and a smaller dorsal one, the *pars dorsalis pontis*. These two divisions are readily seen in a cross-section. The basal part exhibits numerous transversely coursing white fibre-strands that continue laterally into the pontile crura or middle cerebellar peduncles. In the lower part of the basilar division, between the thin white fibre-bundles, grayish lamellæ represent the cross-sections of the tracts of fibres, which descend from the cerebral peduncles, pass through the entire pons and continue to the medulla oblongata and the spinal cord. These are the pyramidal tracts, the *fasciculi longitudinales pyramidales*. The *fibrae pontis superficiales* are seen as transversely coursing fibres that pass ventral to the pyramidal tracts, while the *fibrae pontis profundae* run dorsal to or partly through the pyramidal strands. The pontile nuclei, *nuclei pontis*, are small masses of gray substance lying scattered between the bundles of fibres.



The *pars dorsalis pontis*, also termed the *tegmentum pontis*, appears gray in transverse sections. It contains the following nuclei:—

- The nucleus nervi abducentis, within the colliculus facialis,
- The nucleus nervi facialis,
- The nucleus motorius et sensibilis nervi trigemini,
- The nucleus tractus spinalis nervi trigemini,
- The nuclei nervi acustici, within the area acustica, embracing:—
  - Nucleus medialis } nervi cochleae,
  - Nucleus dorsalis }
  - Nucleus medialis } nervi vestibuli,
  - Nucleus lateralis (Deiters) }
  - Nucleus superior (Bechterew) }
  - Nucleus n. vestibularis spinalis }
- The nucleus olivaris superior,
- The nucleus corporis trapezoidei,
- The nuclei reticulares tegmenti.

Within the cerebellum (Fig. 87), in addition to the cortex or substantia corticalis covering the entire surface, special gray masses are found within the corpus

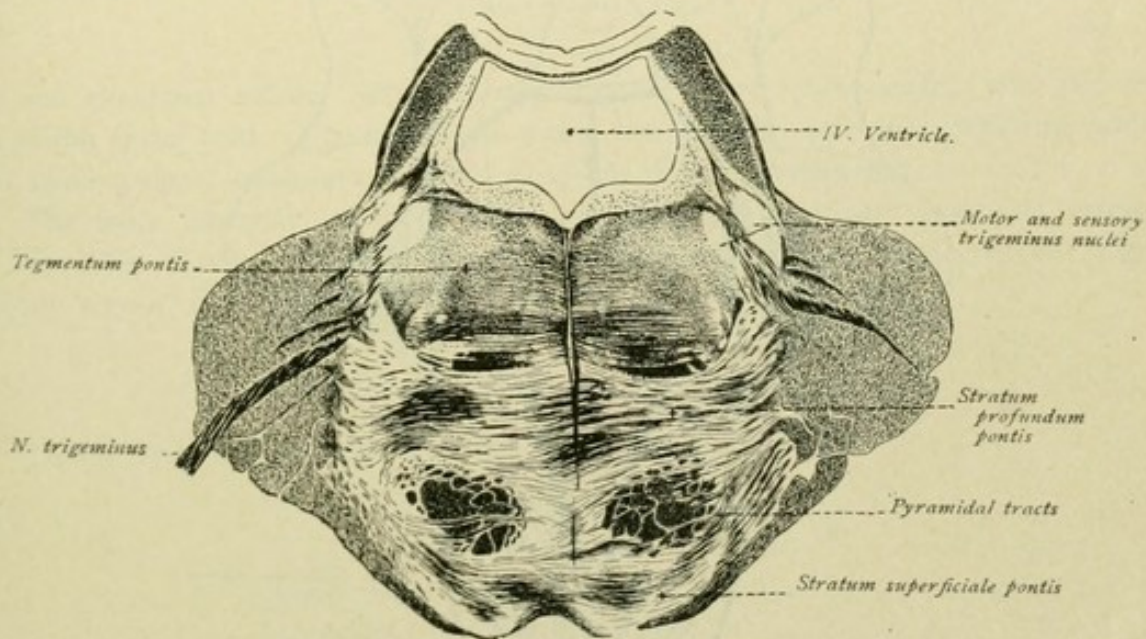


FIG. 86.—Cross-section of brain-stem in region of pons.

medullare. In the medial part of the hemisphere lies the *nucleus dentatus*, which appears as a much plicated lamella of gray substance with a medially directed opening, the *hilus nuclei dentati*. Within the worm, the *roof-nucleus*, *nucleus fastigii* or *nucleus tecti*, lies on each side of the mid-line. Between the nucleus fastigii and the nucleus dentatus, two additional centres are found, the *nuclei globosi*, small gray masses lateral to the roof-nucleus, and the *nucleus emboliformis*, medial to the dentate nucleus.



Within the medulla oblongata, in the fasciculus gracilis within the clava, lies the *nucleus fasciculi gracilis*, while in the fasciculus cuneatus, in its position corresponding

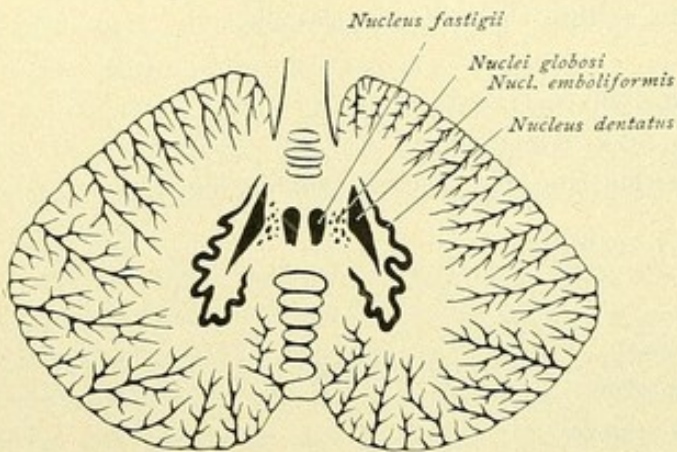


FIG. 87.—Horizontal section of the cerebellum, exposing the internal nuclei.

to the tuberculum cuneatum, lies the *nucleus fasciculi cuneati*. The tuberculum cinereum corresponds to the *nucleus tractus spinalis nervi trigemini*. Within the olive are found the *nucleus olivaris inferior*, with the nuclei of the two accessory olives, the *nucleus olivaris accessorius ventralis* and *dorsalis*. The *nuclei arcuati* lie ventral to the pyramidal tracts, while within the lateral columns are the *nuclei laterales*.

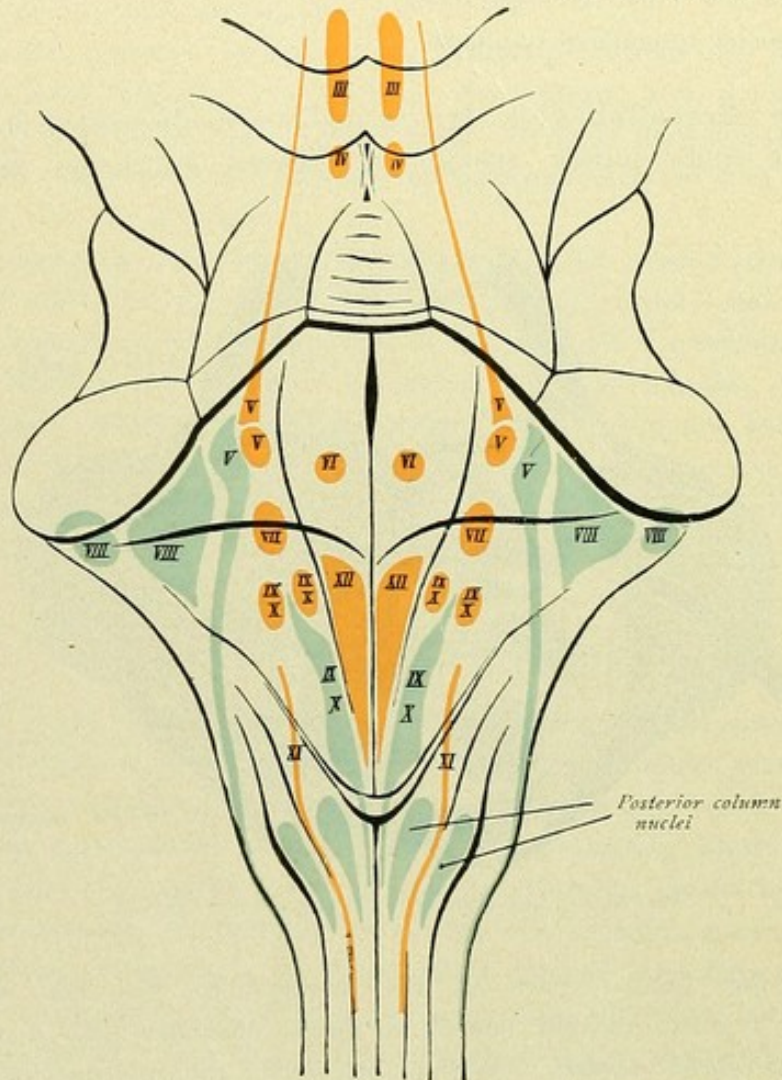


FIG. 88.—Diagram of the brain-stem, dorsal aspect, showing the location of the nuclei of the cerebral nerves. Motor nuclei are red, sensory nuclei are blue.

The floor of the trigonum hypoglossi contains the *nucleus nervi hypoglossi*. Close to the latter but within the floor of the ala cinerea, is the *sensory nucleus of the vagus*



nerve, which anteriorly is continuous with the like nucleus of the glossopharyngeal nerve. In this region, medial to the ala cinerea, the *motor nucleus dorsalis of the glossopharyngeal and vagus nerves* appears as a small group of cells. The *nucleus tractus solitarii* occupies the elongation of the sensory nucleus of the glossopharyngeal and vagus nerves. Somewhat lateral, but more deeply placed, lies the *nucleus ventralis* or *nucleus ambiguus* of the ninth and tenth nerves. The caudal prolongation of the nucleus ambiguus con-

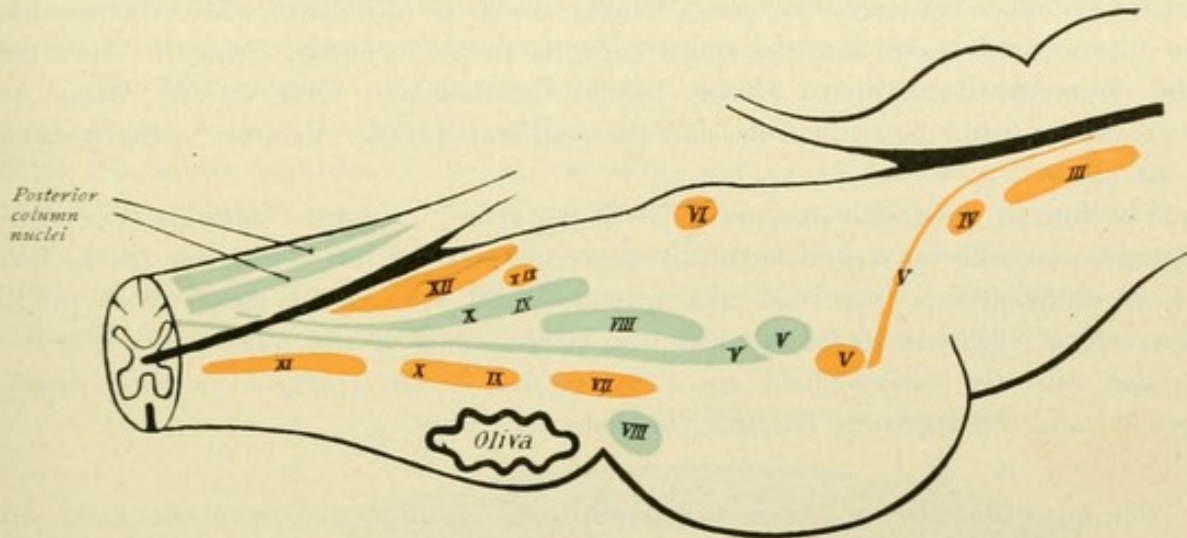


FIG. 89.—Diagram of brain-stem, lateral aspect, showing location of nuclei of cerebral nerves. Motor nuclei are red, sensory nuclei are blue.

tains the elongated *nucleus nervi accessorii*, whose spinal part reaches into the ventral horn of the spinal cord. The nerve-cells within the *formatio reticularis*, occurring scattered or in small groups, constitute the *nucleus of the formatio reticularis*.

The more important of these nuclei are discussed at greater length in connection with the Fibre-Tracts. The positions of the nuclei of the cerebral nerves are diagrammatically shown in Figs. 88 and 89.

#### SUMMARY OF THE RHOMBENCEPHALON.

To the **rhombencephalon** or hind-brain belong :

The isthmus rhombencephali,  
The metencephalon,  
The myelencephalon.

It encloses the fourth ventricle.

To the **isthmus rhombencephali** belong :

Dorsal—The brachia conjunctiva cerebelli,  
The velum medullare anterius,  
The trigonum lemnisci ;  
Ventral—The crura cerebri.

To the **metencephalon** belong :

The pons and the cerebellum.



The **cerebellum** is subdivided into the *worm* and the *hemispheres*. More or less deeply penetrating fissures separate the *lobes* of the hemispheres from one another. The chief segments are the lobus superior, the lobus posterior and the lobus inferior, each of which is made up of lobules. The individual lobes and lobules of the hemispheres correspond to definite divisions of the worm.

The **myelencephalon**, or the **medulla oblongata**, has as its upper boundary, ventrally the lower border of the pons, dorsally the striae medullares fossae rhomboideae. Below, the medulla passes into the spinal cord, its ventral boundary being the lower end of the pyramidal decussation. Dorsal, behind the rhomboid fossa, are the dorsal and lateral columns, with their tubercula, and the restiform bodies. Ventral, lie the pyramids and the olives.

The **fourth ventricle** has as its roof the velum medullare anterius, the brachia conjunctiva cerebelli, the velum medullare posterius and the tela chorioidea; as its floor, the fossa rhomboidea. It is connected with the third ventricle by means of the aqueductus cerebri, below is continuous with the central canal of the spinal cord, and communicates with the subarachnoid space by means of the apertura mediana (foramen Magendii) and the aperturæ laterales (foramina Luschkae).

The most important **masses of gray substance** within the rhombencephalon are :

The nucleus lemnisci,	
The nucleus pontis,	
The substantia corticalis cerebelli,	
The nucleus dentatus	} cerebelli,
The nucleus fastigii	
The nucleus globosi	
The nucleus emboliformis	
The nucleus gracilis,	
The nucleus cuneatus,	
The nucleus lateralis,	
The nucleus arcuatus,	
The nucleus olivaris inferioris,	
The nuclei nervorum, within the floor of the fourth ventricle.	

## THE MENINGES.

The membranes investing the brain are three: the *dura mater*, the *arachnoid* and the *pia mater*.

The *dura mater* forms the outermost covering of the brain. Beneath it lies the *arachnoid*, a delicate transparent membrane that is separated from the *dura* by the subdural space. The innermost covering is the *pia mater*, separated from the *arachnoid* by the subarachnoidal space. The *arachnoid* and the *pia* have been also regarded as the outer and inner layers of the soft-brain membrane, the *leptomeninges*, in contrast to the hard brain-membrane, the *pachymeninges*, represented by the *dura*.



## DURA MATER.

The dura mater consists of two lamellæ. The *outer lamella*, which lies against the bone and serves as the inner periosteum of the cranial case, consists of soft, loose vascular connective tissue. The *inner lamella* is denser, made up of fibrous connective tissue, and contains few blood-vessels. While the outer layer appears as periosteum and is prolonged on the cerebral nerves as robust sheaths, the inner layer comes into closer relation with the brain, since it sends processes between the larger divisions of the brain. Such processes are :

1. The **falx cerebri**, or *falx cerebri major*, which, penetrating between the hemispheres, begins in front at the crista galli, attached by its convex upper border to the sides of the sulcus sagittalis of the cranial vault, and extends backward as far as the protuberantia occipitalis interna. Between the outer and inner lamellæ, along the upper convex border of the falx, is a blood-space, which is triangular in cross-section and known as the *sinus sagittalis superior*. The lower concave border of the sickle-like falx is free and encloses the smaller *sinus sagittalis inferior*. From the internal occipital protuberance

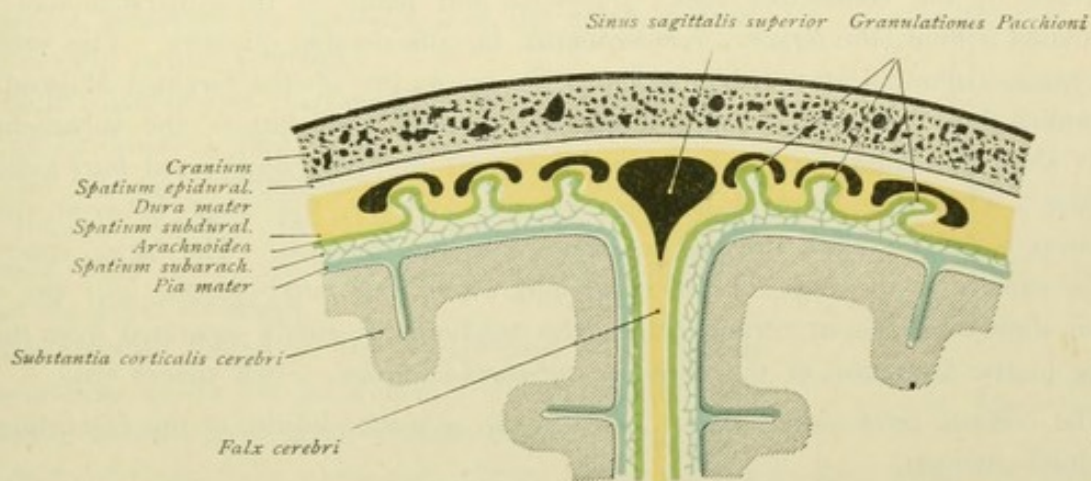


FIG. 90.—Schematic section through the skull and the meninges.

forward, the falx is attached to the tent-like *tentorium cerebelli*, the line of junction being the tent-edge, while the border attached to the crista galli is the crest-edge. In front, the falx only incompletely separates the two frontal lobes, but behind its height is so increased, that it penetrates almost, but not quite, to the upper surface of the corpus callosum.

2. The **falx cerebelli**, or *falx cerebri minor*, which forms a small sagittal prolongation of the large falx, penetrates between the cerebellar hemispheres and descends from the internal occipital protuberance to the foramen magnum. The convex border encloses the *sinus occipitalis* and is attached along the crista occipitalis. Corresponding to the terminal limits of the crest, the cerebellar falx divides into two diverging arms, which enclose the continuations of the sinus occipitalis.

3. The **tentorium cerebelli**, which forms a dorsally arched transverse partition between the basal surface of the occipital lobes of the cerebrum and the dorsal surface of the cerebellum. The outer convex margin is attached, on each side, along the lineae transversae of the occipital and parietal bones, where it encloses the *sinus transversus*, and along the dorsal edge of the petrous portion of the temporal bone, where it conveys the *sinus petrosus superior*. Thence the attachment of the tentorium passes to the pro-



cessus clinoides anterior. In front, the free inner margin of the tentorium meets the outer one and then extends backward and slightly upward to unite with the lower edge of the falx cerebri. Along this line of union lies the *sinus rectus*, which in front receives the *vena cerebri magna Galeni* (Fig. 55) and behind opens into the *confluens sinuum* or the *torcular Herophili*.

4. The **diaphragma sellae turcicae**, which forms a bridge of dural tissue over this depression in the sphenoid bone. Between the basal and dorsal lamellæ of the diaphragma sellae turcicae lies the hypophysis or pituitary body. An opening in the middle of the membrane, the *foramen diaphragmatis*, affords passage to the infundibulum.

#### ARACHNOIDEA.

This delicate transparent membrane consists of connective tissue and is devoid of blood-vessels. It is separated from the dura by the *subdural space* and connected with the pia by strands of connective tissue. These strands form the *subarachnoidal tissue*, and the cleft between the arachnoid and the pia is the *subarachnoidal space*. The latter is traversed by the connective tissue trabeculæ and plates of the subarachnoidal tissue and contains a fluid, the *liquor cerebro-spinalis*, in considerable quantity. The subarachnoidal space communicates with the ventricles by means of the foramen Magendii and the foramina Luschkae (page 80). Over the cerebral convolutions the subarachnoidal tissue is scanty, in these localities the arachnoid and the pia being fused into a common membrane. Over the cerebral fissures, on the contrary, the space between the two membranes is larger, since the pia penetrates into the fissures. The large spaces are found principally at the base of the brain and where the latter passes into the spinal cord; in these locations, at certain places, the arachnoid is widely separated from the pia, resulting in the formation of the *cisternae subarachnoideales*. Such spaces are:

The *cisterna cerebello-medullaris*, between the posterior border of the cerebellum and the medulla oblongata;

The *cisterna fossae Sylvii*, over the Sylvian fossa;

The *cisterna chiasmatis*, surrounding the optic chiasm;

The *cisterna interpeduncularis*, between the cerebral crura;

The *cisterna ambiens*, ascending laterally from the cerebral peduncles to the corpora quadrigemina;

The *cisterna corporis callosi*, along the convex dorsal surface of the callosum.

In certain places, as on both sides of the sinus sagittalis superior or along the sinus transversus, villous projections from the outer surface of the arachnoid push before them the thin dura mater and encroach on the venous sinuses. Such elevations are called the *arachnoidal villi* or *Pacchonian granulations* (Fig. 90). According to the investigations of Key and Retzius, these structures facilitate the passage of serous fluid into the venous spaces.

#### PIA MATER.

The innermost brain-membrane consists of delicate bundles of connective tissue, contains numerous blood-vessels, and directly invests the surface of the brain, penetrating to the bottom of all the fissures. By means of the subarachnoidal tissue, the pia is attached to the arachnoid. Between the pia and the surface of the brain, there exists only a very narrow cleft, the *subpial* or *epicerebral space*.



## THE SPINAL CORD.

The spinal cord or *medulla spinalis* presents a compressed cylindrical column, somewhat more flattened in front than behind, that is enclosed within its protecting membranes and only incompletely fills the vertebral canal. Above, it passes into the medulla oblongata, the upper limit corresponding to the lower end of the pyramidal decussation. Below, the spinal cord reaches to the level of the first or second lumbar vertebra. It is not everywhere of equal thickness, but in two places exhibits spindle-shaped enlargements (Fig. 91):

a. In the cervical region of the spine the cervical enlargement, *intumescentia cervicalis*, from the third cervical to the second thoracic vertebra;

b. In the lower part of the thoracic spine the lumbar enlargement, *intumescentia lumbalis*, from the ninth thoracic to the second lumbar vertebra.

Both enlargements correspond to the regions in which the large limb-nerves arise.

The lumbar enlargement below passes over into a short conical segment, the *conus medullaris* or *conus terminalis*, from which proceeds a long delicate thread-like process, the *filum terminale*.

The average length of the spinal cord is 45 cm. in men, and from 41-42 cm. in women. In accordance with the pairs of spinal nerves given off from the cord, we recognize a *pars cervicalis*, from which the cervical nerves emerge; a *pars thoracalis*, from which the thoracic nerves arise, and a *pars lumbalis*, from which the lumbar and the sacral nerves are derived.

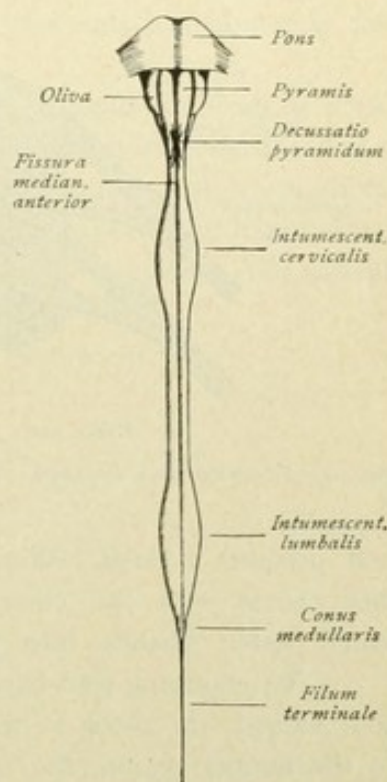


FIG. 91.—Front view of the spinal cord. Schematic.

### EXTERNAL CONFIGURATION.

The anterior or ventral surface of the spinal cord is cleft in the mid-line by a deep longitudinal furrow, the *fissura mediana anterior*; the posterior or dorsal surface is modelled

by a superficial longitudinal groove, the *sulcus medianus posterior*. By means of these two furrows the spinal cord is divided into symmetrical halves. Lateral to the posterior median sulcus, in each half runs the *sulcus lateralis posterior*, along which the posterior root-bundles enter.

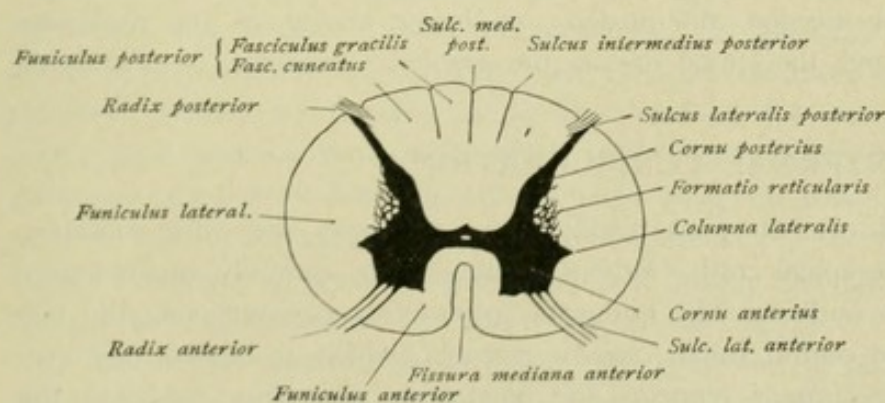


FIG. 92.—Transverse section of the spinal cord.



Lateral to the anterior median fissure, on each side extends the *sulcus lateralis anterior*, which is not a continuous furrow, unless the emerging anterior root-fibres are torn away. In the upper thoracic and the cervical region, an additional delicate longitudinal groove, the *sulcus intermedius posterior*, is distinguishable between the median and lateral posterior sulci. The anterior root-fibres that emerge along the anterior lateral

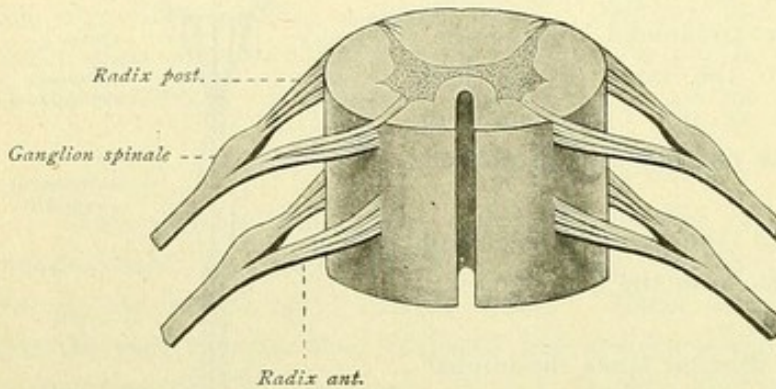


FIG. 93.—Schematic representation of the formation of the spinal nerves.

sulcus form individual bundles, the *radices anteriores*, separated from one another by intervals. The posterior root-fibres, which enter along the posterior lateral sulcus in an unbroken row, likewise form outwardly converging bundles, the *radices posteriores*. Each pair of anterior and posterior root-bundles passes to a definite foramen intervertebrale (Fig. 93). Here, the posterior

root presents a small fusiform swelling, the *ganglion spinale*, and then unites in its further course with the corresponding anterior root, thereby forming the spinal nerve, which latter divides into an anterior and posterior division.

The emerging root-bundles run not only outward, but at the same time caudalward, and, indeed, the more so the nearer to the caudal end of the spinal cord they emerge. In the lumbar region, the course of the nerve-roots within the vertebral canal is nearly parallel with the long axis of the cord, so that the conus medullaris and the filum terminale lie in the midst of a generous bundle of nerve-roots, which, on account of the supposed resemblance to a horse's tail, is designated the *cauda equina*.

By means of the longitudinal furrows, the spinal cord is subdivided into the following columns :

The *funiculus anterior*, between the anterior median fissure and the anterior lateral sulcus ;

The *funiculus lateralis*, between the anterior and posterior lateral sulci ;

The *funiculus posterior*, between the posterior median fissure and the posterior lateral sulcus. The posterior column is separated by the *sulcus intermedius posterior* into a medial and a lateral division, the medial one being known as the *fasciculus gracilis*, or *Goll's column*, and the lateral one as the *fasciculus cuneatus*, or *Burdach's column*.

#### INTERNAL CONFIGURATION.

Even with the unaided eye, one can readily distinguish gray and white substance in a transverse section of the spinal cord. When cut across, the centrally situated gray substance appears H-form in outline. The bridge of gray substance connecting the two limbs of the H, encloses the central canal, *canalis centralis*, which is immediately surrounded by the *substantia gelatinosa centralis* and lined with ependyma. Above, the central canal widens at the transition of the spinal cord into the medulla oblongata and



passes over into the fourth ventricle. Below, at the lower end of the conus terminalis, it expands into the *ventriculus terminalis* (Krause), becomes again narrow at the transition into the filum terminale and, finally, ends blindly.

The part of the gray bridge that passes behind the central canal is known as the *commissura posterior*, that which lies in front is the *commissura grisea anterior*. In front of the latter, between it and the bottom of the anterior median fissure, is the *commissura alba anterior*.

The **gray substance**, in each half of the spinal cord, presents in front a thick swelling, the *anterior horn* or *cornu anterius*, and behind a more slender part, the *posterior horn* or *cornu posterius*. Since the gray substance extends continuously throughout the entire length of the cord, the anterior and posterior horns appear in longitudinal sections as columns; they are called also, therefore, the *columnae griseae*. The lateral

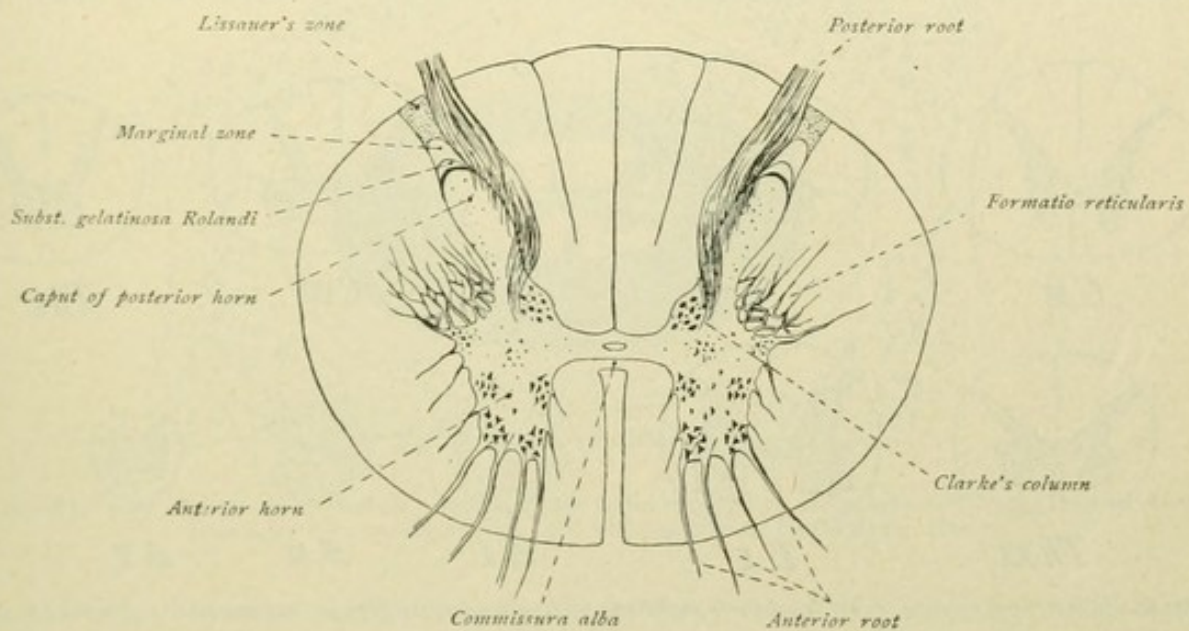


FIG. 94.—Transverse section of the spinal cord.

part of the gray substance, in the lower cervical and the upper thoracic regions of the cord, becomes more independent and there forms the *lateral horn* or *columna lateralis*. In the entire cervical and upper thoracic cord, the gray substance extends into the white matter as a network of gray trabeculae and strands, which occupy the angle between the lateral and posterior horns and constitute the *formatio reticularis*. The posterior cornu begins ventrally as the *base*, then becomes narrower and forms the neck, *cervix columnae posterioris*; dorsally follow the head of the horn, *caput columnae*, and the point, *apex columnae posterioris*, which latter embraces a crescentic field, the *substantia gelatinosa Rolandi*, and the dorsally situated *marginal zone*. Medial to the neck of the posterior cornu and close to the posterior commissure, one finds the *nucleus dorsalis* or *Clarke's column* as a small group of cells within the gray substance of the upper lumbar, the entire thoracic and the lower cervical regions.

The **white substance** surrounds the gray and is subdivided, as already noted, into three tracts—the *anterior column*, between the anterior median fissure and the anterior roots, the *posterior column*, between the posterior median fissure and the posterior roots,



and the *lateral column*, between the anterior and posterior roots. The posterior column is further divided by the sulcus intermedius posterior into the medially situated fasciculus gracilis or Goll's column, and the laterally placed fasciculus cuneatus or Burdach's column.

In the essentials, the make-up of the spinal cord is the same in its various segments, the central gray substance in the characteristic **H** being everywhere enclosed by the white matter. The size and form of the cord in cross-sections, as well as the proportions of the gray and white substance, however, vary in the individual regions. In regard to size, the stronger development in the cervical and lumbar enlargements is at once noticeable. So far as the form is concerned, transverse sections are so characteristic in the different regions that, within certain limits, the region from which a section has been taken can be determined from such data alone. Thus, cross-sections of the cord in the cervical region, particularly at the level of the IV-VIII nerve, and in part

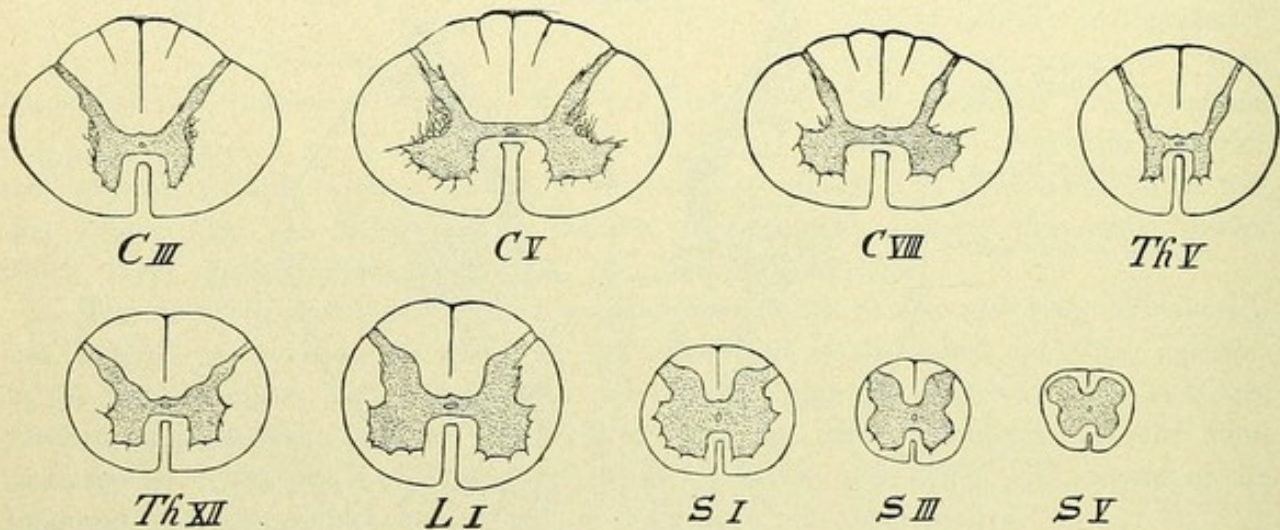


FIG. 95.—Transverse sections of the spinal cord at different nerve-levels. *C*, cervical; *Th*, thoracic; *L*, lumbar; *S*, sacral.

also in the highest thoracic segments are transversely oval; in the thoracic region the cross-section is almost circular; while in the lumbar region it is more quadrate, with more marked ventral flattening. The quadrate form is especially evident in the sacral and likewise in the coccygeal cord, where, however, in contrast to the lumbar region, the strongest flattening is dorsal with coincident ventral narrowing.

Regarding the proportion of the gray and the white substance, it is readily seen that the gray substance is most abundant in those segments from which the large limb-nerves arise, that is in the cervical and lumbar enlargements. In these segments the great development of the anterior horns is particularly evident. The gray substance in the dorsal cord, on the contrary, is poorly developed, the **H**-form being here seen to best advantage. The white substance exhibits a robust development in the cervical, as well as the thoracic region. Towards the lumbar cord it progressively decreases in amount and, in the sacral region and toward the conus medullaris, the white matter forms only a thin peripheral zone surrounding the gray matter, which at these levels considerably exceeds in amount the white.



## THE MEMBRANES OF THE SPINAL CORD.

As is the brain, so also the spinal cord is surrounded by three envelopes—the dura mater, the arachnoid and the pia mater.

**Dura mater spinalis.** This membrane forms a strong fibrous investment consisting of two layers, the outer, which fuses with the periosteum of the vertebræ, and an inner, which is the spinal dura proper. The space between these two layers is filled with loose connective tissue, contains the large venous plexus and is traversed by lymph-spaces; it is the *cavum interdurale* or *cavum epidurale*. The dura extends as a long

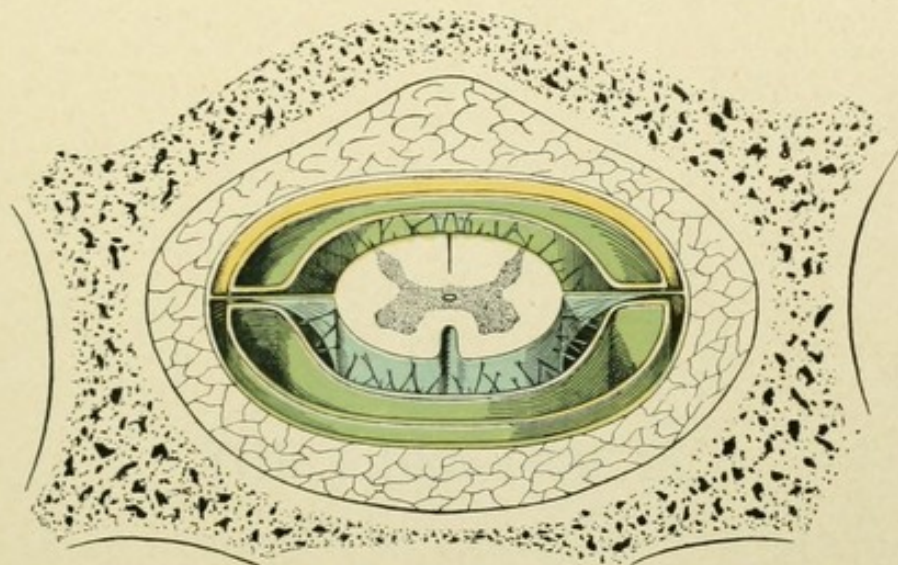


FIG. 96.—Schematic representation showing relations of the spinal meninges to one another and to the vertebral canal. Dura is yellow; arachnoid, green; pia, with ligamentum denticulatum, blue.

wide sac over the conus medullaris, narrows at the level of the second or third sacral vertebræ, thence, as the *filum duræ matris spinalis*, clothes the filum terminale and finally passes into the periosteum of the coccyx.

**Arachnoidea spinalis.** This is a delicate vascularless membrane, separated from the dura mater by the *cavum subdurale* and from the pia mater by the *cavum subarachnoideale*. It is connected with the subarachnoidal fibres, which are particularly robust and numerous toward the sulcus medianus posterior; in the lower cervical and in the thoracic region, they form a special partition, the *septum subarachnoideale* or *septum cervicale intermedium*. Within the subarachnoidal space the liquor cerebro-spinalis circulates.

**Pia mater spinalis.** This membrane encloses the spinal cord as a delicate vascular envelope and forms, by penetrating within the anterior median fissure, the *septum anterius*. The pia is connected with the dura mater by means of the *ligamentum denticulatum*. The latter consists of from 19–23 small triangular processes, with their bases attached to the pia, which extend outward from the lateral surface of the cord between the anterior and posterior roots of the spinal nerves, to be attached by their points to the dura mater. The ligamentum denticulatum serves as a suspensory band that holds the spinal cord in position.







PART II.  
THE FIBRE-TRACTS.



THE UNIVERSITY OF CHICAGO  
LIBRARY



# THE FIBRE-TRACTS.

## METHODS OF STUDYING THE FIBRE-TRACTS.

The older anatomists contented themselves with the task of describing the brain simply from the exterior and, in a sense, without further leading conceptions. In this period originated the terminology that owes its existence to merely purely superficial and accidental resemblances. As examples, one recalls the designation of the corpora quadrigemina as the "nates" and "testes," the suggested resemblance of the corpora mamillaria to the female breasts, of the calcar avis to the cock's spur, of the lyra Davidis to a harp, or of the fornix to an arch.

In order to render more exact investigation possible, the pioneer observers first sought to overcome the softness of the central nervous substance, and to that end employed various chemical agents, as alcohol, corrosive sublimate and salt solutions. Cold was also used to give the brain greater consistence, and, indeed, Gennari and Reil made their observations on frozen brains. In this manner, in a purely morphological way, began the foundation of the study of the internal connection of the individual brain-segments and, until the middle of the nineteenth century, the method of direct mechanical dissociation of the alcohol-hardened brain was employed to demonstrate the chief fibre-tracts (Gall and Spurzheim, Burdach, Reil, Arnold, Foville).

A distinct advance in brain-anatomy was made when the structure of the central nervous system began to be studied from the standpoint of development. In this Tiedemann and Reichert were pioneers. In the introduction to his "Anatomie und Bildungsgeschichte des Gehirns," Tiedemann observes that the origin and development of the brain were an almost totally neglected part of anatomy and physiology. He mentioned the law formulated by Harvey, that the embryo of man and of the animals does not appear in a completed and only diminished form, but that it begins with a simpler form, successively passes through lower formative stages and finally reaches a higher stage of development. Why, says Tiedemann, should not a similar progression from a simpler to a more complex structure also occur in the construction of the brain of the embryo and of the foetus; and, further, should not this process supply explanations concerning the form and structure of the brain, so intricate in its completed condition? Tiedemann busied himself for several years with the construction of the embryonal and foetal brain. The pure morphology of the brain, however, reached high-water mark with the embryological method of examination followed by C. B. Reichert. Through the work of Schmidt, Mihalkovics, Kölliker, His and others, this method has led to a strict scientific division of the brain and to the establishing of a comprehensive morphological basis.



By these "embryological" methods much was gained, but by no means all. Embryology taught us to understand the development of the form, but told us nothing concerning the intimate connection of the parts, a clear insight into which alone leads to a comprehension of the function of the central nervous system. The question of the intimate connection of the parts, however, is nothing but the question of the fibre-tracts and therewith we enter a new phase of brain-investigation. We may designate this phase as the physiological in contrast to the pure morphological, since the extraordinarily difficult and laborious endeavors of the later investigators to unravel the intricate fibre-complex of the central nervous system are all undertaken from the physiological standpoint and with a physiological aim.

After Helmholtz had shown for the invertebrates and Remak for the vertebrates, that the nerve-fibres proceed from the nerve-cells, it became evident that the simple method of dissociation no longer sufficed. What neurology had then to attempt was not merely the accurate description of the external form, but, before all else, the establishing and the tracing of the intricate paths which the nerve-fibres pursue, and the definite establishment of all the numerous connections joining centre with centre within the interior of the central nervous system and bringing the latter into relation with the periphery. Although tracing these fibre-paths even within the peripheral nerves is by no means easy because of the peculiar plexus-formation and anastomoses of certain nerves, such task is especially difficult within the brain and spinal cord, since here often within a small space the most diverse paths run side by side and, further, decussations and interfeltings of the nerve-fibres make the direct tracing of the nerve-tracts impossible.

A method of fundamental importance for following the nerve-paths through longer stretches was now introduced, namely, the method by series of consecutive sections, introduced by Benedikt Stilling. The necessity of cutting the brain and spinal cord into thin segments for the accurate investigation of their finer structure, even the older investigators recognized and suggested means by which to accomplish this end. As early as 1824, Rolando made thin cross-sections of hardened spinal cord with a razor and examined them with a hand-lens. But the segments cut by Rolando were not sufficiently thin to be used with higher amplification; moreover, they were made without system. In 1836 Valentin examined microscopically the spinal cord of freshly-killed sheep and pigeons, by cutting the cord, under water, with a pointed two-bladed knife, into the thinnest possible lamellæ and then carefully compressing the sections while being observed. In this manner Valentin studied the spinal cord layer by layer, from without inward, in longitudinal sections, and expressed the opinion, that for the correct understanding of the structure of the spinal cord examination by strata is the only proper way. Four years later, Hannover advanced along this line even farther than Valentin. He employed a brain and spinal cord hardened in chromic acid, which he cut into thin sections with a sharp knife, and examined the relations of these lamellæ piece by piece.

Shortly after the appearance of Hannover's paper, the great doctor of Cassel, Benedikt Stilling, began in 1841 his investigations concerning the structure of the spinal cord. Stilling was the first to cut a spinal cord into many consecutive sections, as thin and transparent as possible, and then to study in each section the distribution of the white and gray substance. He traced progressively from section to section the changes in the picture, and finally, by reproducing the individual pictures, gained, at least to a



certain degree, a clear conception of the internal structure of the cord. This method by series of consecutive sections, which Stilling designated as "investigation layer by layer," is even to-day the one most employed in the examination of the central nervous system. During the continual use of so productive a method, it was inevitable that the original technique of Stilling should undergo many alterations and improvements. The employment of the method was facilitated by better hardening of the organs. Already in 1832, Ludwig Jacobson recommended potassium chromate as a preservative for anatomical preparations. Hannover first put Jacobson's discovery to use for histological investigation. Later chromic acid was displaced from the technique by one of its salts. At any rate, no one has rendered greater service than Heinrich Müller by the introduction of potassium bichromate, now so universally serviceable. From him came also the classic Müller's fluid, which, indeed, even to-day is much used in its original composition. Later followed many new hardening reagents. One of these, formalin or formol, must be especially mentioned, since in recent years its many advantages have brought it into universal use. Formol was introduced in histological technique by Blum in 1893.

The *method of consecutive sections* was further facilitated by the introduction of the microtome, by which exact cutting and large regular sections are made possible, so that an entire brain may be laid into a series of thin sections without losing one. We may mark the sections in their proper sequence, determine in each the topography of the gray substance and of the fibre-tracts, and, by means of the series, from these isolated data construct a composite picture of the principles of construction of the part of the brain under discussion.

The application of Stilling's mode of investigation was materially facilitated by the *methods of staining*. For a long time Gerlach's carmine staining was dominant. An important advance was gained by Weigert's admirable hematoxylin-method. At present we have at our disposal a quite considerable number of different dyes, which may be used with advantage in investigating fibre-paths. But neither the Weigert stain, nor any other of the procedures so far recommended and used, is capable of solving the question, the answer to which has always been most sought for the correct understanding of the structure of the nervous system. Continually was asked: In what manner are the nerve-fibres related to the nerve-cells? In what manner are the nerve-cells related to one another? How do the nerve-fibres in the brain and spinal cord arise and how do they end?

In this connection, two methods were epoch-making—Ehrlich's *methylene blue method* and Golgi's *silver-method*. Ehrlich's procedure, which was introduced in 1886 and depends on the coloring of the living nerves by means of methylene blue, was subsequently improved by Retzius, Apathy, Bethe and others. Golgi's method is older. A number of years before, the Italian investigator had obtained preparations, in which the nerve-cells and their processes stood out with great sharpness as dark figures, by treating the brain-substance with the chromic acid salts and with silver nitrate. Golgi described his method as early as 1873, but at first his observations were little known. Not until the publication of an elaborate paper in 1886, did Golgi excite widespread attention and his results and methods become the starting point of an energetic examination of the central nervous system. For example, the Spanish savant, Ramón y Cajal, was able, by the use of the Golgi method on embryos and young animals, to arrive at results that partly solved many of the dominant questions, or placed them in a new light. At first



through the labors of this investigator, soon also through those of others, especially of Kölliker, Lenhossék, van Gehuchten and Retzius, a clear picture took the place of the previous schemata. The most important findings of these researches are, that the nerve-fibres are nothing more than extraordinarily long processes of the nerve-cells, that every nerve-fibre, from beginning to end, is to be regarded as a part of a single nerve-cell, and that every nerve-cell, with the nerve-fibres proceeding from it, represents an histological individuality or nervous unit. Waldeyer christened such anatomical unit, neurone, and therewith founded the neurone-theory.

The method of Stilling enables us to trace a nerve-tract through a long stretch. The identity, however, is possible and certain only so long as the fibre-bundles composing the tract do not suffer interruption, or so long as they are not deflected from the plane of the section, or do not separate into widely diverging fibres. The accurate identification and tracing of the fibre-tracts, even when they branch in the most diverse directions or resolve, have necessitated the search for new methods.

One of these additional methods is the *pathologico-anatomical* one, based on the investigation of secondary degenerations. Rokitansky announced in the first edition of his *Pathological Anatomy* (1847), that atrophy of the brain following apoplexy and inflammation leads to atrophy of different fibre-paths, when extensive, indeed, to the disappearance of an entire hemisphere and the related fundamental tracts. This communication for a time remained unnoticed. In 1850 Ludwig Türck described more closely such secondary degenerations and inferred from his findings, that in those cases of cross-section of the spinal cord, in which the direction of physiological conductivity and that of the degeneration were identical in the secondarily degenerating cord-paths, the degeneration itself was caused by the disturbance of functions. Notwithstanding these exceedingly important results, at first only few investigators followed Türck along this line of investigation. In later years, however, this method has been universally employed and to it we are indebted for the many papers by which our knowledge of the fibre-paths of the central nervous system has been materially extended. The method depends upon the principle, that every nerve-fibre in its function is dependent upon the related nerve-cell. Destruction of the latter, or separation of the nerve-fibre from its cell, results in degeneration of the related fibre. Let us assume that a descending tract of the spinal cord has been destroyed in some part of its course. What happens? The portions of the nerve-fibres below the injury are separated from their trophic centre; they therefore die. This destruction or secondary degeneration within the spinal cord proceeds downward. On examining a cross-section of the cord passing below the seat of injury and comparing it with a corresponding section of a normal spinal cord, the seat of the degeneration is readily located and the involved tracts may be accurately followed by means of serial sections.

This method of investigation by secondary degeneration is closely related to the physiological method or the method of vivisection. Certain nerve-centres or nerve-fibres of an animal may be directly stimulated or destroyed, and from the resulting symptoms conclusions drawn as to the relations of the nerve-centres or nerve-tracts to the peripheral parts; thereby a functional differentiation of the nerve-fibres is also possible.

The *pathological method* is based on a principle similar to that of the vivisection procedures. Here also the destruction of parts of the central nervous system is concerned, but these mutilations are not experimental but caused by the establishing of



diseased processes. In this relation, the study of the pathological changes in certain affections of the spinal cord is of primary importance.

By means of the *experimental method*, which has been used on animals with such great success, we are able to follow and to study the course of the fibre-bundles by degenerations. This method, employed only under certain conditions, was introduced by Gudden and his pupils and is the atrophy-method, or the method of developmental arrest. Gudden's method is distinguished from other experimental procedures in that it is directed against the young animal. The chief difference consists therein, that, following an experimental impression on the new-born animal, the entire process proceeds much more rapidly and completely than in the adult. The absorption of the disintegration products from the elementary parts destroyed goes on much more rapidly and completely in the new-born, so that scarcely a trace of the fibres and only few remains of the cells are left. In addition, the technique is relatively easy, while a further distinct advantage, as Gudden himself pointed out, is the almost incredibly rapid and admirable healing of the injury without disturbing secondary processes.

In 1852 Waller showed, that the peripheral stump of a cross-sectioned peripheral nerve undergoes degeneration. For a long time it was believed, that the peripheral segment alone degenerated, and that the central one remained unaffected by such changes. Since the study of Ranvier on degeneration and regeneration of sectioned nerves, however, we know that also the central segment suffers important modifications. Ranvier showed, that in the central segment of the axis-cylinder new fibrillæ were formed, which became new nerves, using the sheath of the degenerating peripheral segment as a support to reach the periphery. The nerve reassumes its function—it is regenerated. If, however, from any cause the developing nerve fails to secure such support, its further development is arrested and a nervous tumor, a neuroma, is formed, as seen in amputation-stumps. But in these cases, especially when of long standing, a certain grade of atrophy of the nerves, as well as a diminution in the number of the corresponding nerve-cells, may be observed. These changes are exceptionally rapid and marked so soon as the interference occurs in young individuals, particularly in the new-born. If in a new-born animal a motor nerve is removed, a certain region of the cerebral cortex destroyed, or the spinal cord partially cut through, not only is always a degeneration of the fibres in the separated peripheral stump to be observed, but also atrophy and indeed complete disappearance of the cells of origin. Gudden believed at first, that this difference from the Wallerian degeneration was attributable to the lesion being in the new-born animal. Later, he recognized that it was not the age, but the position that exercised the influence. Then, too, Forel proved, that the death of the cell after destruction of the related fibre occurred in the adult, as well as in the new-born animal. Death of the cell depends alone on the place where the fibre is sectioned. Section of a motor nerve at the periphery is followed by only a slow impairment and diminution in the size of the cells and fibres of the central stump. Section of the same nerve at its point of emergence from the brain, results in the death of the central root, as well as of all the cells of origin within the nucleus of the nerve. The method of Gudden has been rich in results. In 1872-74 Gudden proved, by extirpation of the cortical motor zone in dogs, that the pyramidal tracts run direct from the cerebral cortex to the spinal cord. Other important results are the establishing of the nuclei of origin of almost all the



motor cerebral nerves, the course of the medial fillet and the termination of the optic tract. Closely connected with the method of Gudden are the pathological cases of early lesion and consequent atrophy of certain parts of the central nervous system, as well as the cases of congenital malformation involving the cerebro-spinal axis.

Our knowledge concerning the fibre-tracts, moreover, has been especially advanced by the *embryological method* introduced by Flechsig, based on the study of the development of the nerve-fibres. This method rests on the fact, that the different fibre-systems within the central nervous system acquire the medullary substance at a definite time, which, however, varies for the individual systems. On examining the infantile brain, it is found that certain fibres are already medullated, while others have not yet acquired this sheath. This difference between the medullated and non-medullated fibres is readily appreciable microscopically and, therefore, the examination of the nervous system in its various developmental stages affords the possibility of delimiting and tracing certain fibre-systems.

An additional means, which has contributed much not only to the morphology but also especially to the accurate investigation of the fibre-tracts, is the *comparative anatomical method*. Since in the different classes of animals this or that part of the brain is varyingly developed, in correspondence with different functional development, the investigations in the domain of comparative anatomy have supplied numerous explanations concerning the many-sided connections of individual parts of the central nervous system.

Finally, a combination of these various methods has been attempted. Eninger united the comparative anatomical method and that of Flechsig. Bechterew combined vivisection with the study of development and created the *embryologico-physiological method*. Admirable results were also achieved by Bechterew with his *pathologico-physiological method*, which consisted in studying secondary degenerations with simultaneous stimulation of the degenerated parts by means of the electrical current.

## HISTOGENESIS OF THE NERVOUS SYSTEM.

The elements of the nervous system are developed from the outer germ-layer or the ectoderm. As we have already seen, the brain and the spinal cord arise from a broad medial strip of ectoderm. Here the *medullary plate* is formed, which is bounded externally by the cuticle-plate. The medullary plate sinks and, at the same time, projects with

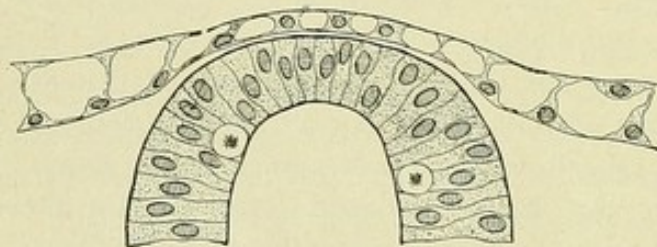


FIG. 97.—Dorsal half of neural tube, overlaid by the ectoderm; epithelial and two dividing (so-called germ-) cells. (His.)

its edges above the level of the embryonic area; in this way is formed the *medullary groove*, bounded by the *medullary ridges*. The medullary groove closes and becomes the medullary or neural tube.

The **medullary tube**, the direct successor of the medullary plate, consists at first of closely pressed epithelial cells, each of which extends the entire thickness of the layer. The wall of the entire tube, therefore, originally exhibits the character of a single-layered columnar epithelium, whose cells are bounded by the *membrana limitans externa* on the one side, and by the *membrana limitans interna* on the other (Fig. 97). Each epithelial cell encloses a large nucleus. In the inner zone, other large cells are irregu-



larly scattered between the epithelial elements, from which they are clearly distinguished by their round form and transparent homogeneous protoplasm. His designated these as the *germ-cells*.

The epithelial cells multiply rapidly and, consequently, become laterally compressed and elongated. Their nuclei lie at different heights and give rise to the appearance of a three- to six-celled layer. In reality, however, the cells completely retain the character of a single-layered columnar epithelium.

Some of the epithelial cells are early transformed. They grow into the *spongio-blasts* of His, from which are developed the supporting elements, the *ependyma* and *neuroglia cells*.

Others of the epithelial cells change to pear-shaped elements and become the *neuro-blasts*, which are transformed into the nerve-cells.

Both kinds of cells, the spongioblasts and the neuroblasts, therefore, are derivatives from the original ectodermic elements of the medullary plate. The above mentioned "germ-cells" of His are nothing more than cells of the primary medullary area undergoing mitosis and represent elements, whose division supplies the material for the increase of the indifferent ectodermal cells, on the one hand, and of their derivatives, the spongioblasts and the neuroblasts, on the other.

#### DEVELOPMENT OF THE EPENDYMA AND THE NEUROGLIA CELLS.

The **ependyma cells** maintain in the foetal stage the character of an epithelium and the relations to the *membrana limitans externa* and *interna*. In the brain, as in the spinal cord, the ependyma cells extend from the inner to the outer surface of the neural wall, the length of the cells keeping pace with the increase in the tube. The inner portion of the cell, nearer the central canal, retains more the character of a cell-body—*ependyma cell*, while the outer portion gradually diminishes to a delicate fibre, which as an *ependyma fibre* radially traverses the neural wall. The entire arrangement constitutes the ependyma system or the *ependymium*.

On examining this ependymal framework more closely, a distinctive disposition of the ependyma cells is seen in the spinal cord. In a cross-section of the medullary tube of a 3-4 day chick embryo (Fig. 98), we recognize how the ependyma fibres traverse the wall of the tube, at the sides passing almost parallel from the central canal and ventrally and dorsally diverging radially. In consequence of the coming together of the nucleus-bearing portions of the cells, there appears within the medullary tube, in the vicinity of the central canal, a broad, richly nucleated zone, the *inner layer* of His or the *ependymal nuclei-zone* of Lenhossék. In a general way, this zone corresponds to the later epithelium of the central canal. The ependyma fibres of the later anterior commissure present a rough appearance, being heavy and beset with spines; they also emphasize the already slight meridional disposition of the more laterally situated ependyma fibres. In a somewhat later stage, the ependyma fibres exhibit varicosities, particularly in their inner portions; in addition, in their outer portions they undergo a subdivision into several branches, all of which extend to the periphery, where they end in small triangular expansions.

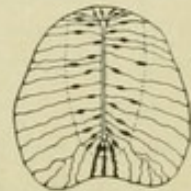


FIG. 98.—Transverse section of neural tube of a four-day chick embryo. (Lenhossék.)



Subsequent stunting of the lateral parts of the ependyma framework is most marked in the spinal cord of the higher forms. In the other parts of the central nervous system, the ependyma cells and fibres retain their embryonal form, even after completed growth. The ependyma cells are, therefore, phylogenetically as well ontogenetically, the oldest cells of the supporting framework, arising directly from the

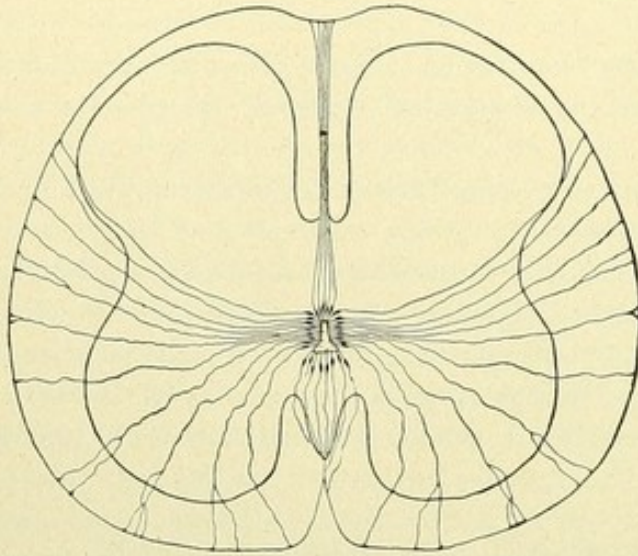


FIG. 99.—Transverse section of the spinal cord of a human embryo, 14 cm. long, showing ependymal framework. (*Lenkossék.*)

ectoderm cells, or, indeed, being in a modified way these themselves. During later stages, the elements, particularly the ependyma fibres, are curtailed in varying degrees; a part of the ependyma cells later migrate and become the neuroglia cells.

The **neuroglia cells** arise only after the formation of the ependyma framework. On examining the spinal cord of a ten-day chick, one finds a number of elements which closely resemble the ependyma cells, their fibres likewise extending to the periphery and there ending in conical thickenings. They differ from the ependyma cells proper, however, in that their cell-

bodies no longer lie at the central canal, but farther outward. At first such cells are encountered only in the vicinity of the central canal and in meagre number; later, however, they are more numerous and occur also in the peripheral zone. This is explained by the manner in which the neuroglia cells arise. Originally these cells lie, as do the ependyma cells, at the central canal; then the cell-bodies migrate

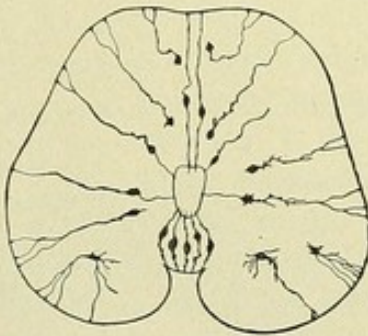


FIG. 100.—Development of the neuroglia cells. Spinal cord of a ten-day chick. (*Lenkossék.*)

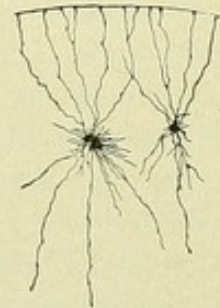


FIG. 101.—Neuroglia cells from the white substance of the spinal cord of an embryo of 30 cm. in length. (*Lenkossék.*)

from the region of the epithelium, part of the cell-body becoming a thin fibrilla, that later disappears. Small spines and branches appear on the former smooth cell-bodies, as well as similar thorny outgrowths for a short distance along the process stretching from the cell-bodies to the periphery. At first such migrated cells are present only in sparing number; later, however, their number materially increases and the cells are distributed more or less uniformly throughout the entire cross-section of the spinal cord.



This radiating sustentacular apparatus constitutes in man and the higher mammals an embryonal feature. Subsequently, the picture changes. The radial type disappears and the shape of the cells alters. The minute spicules and branches develop very markedly, while the peripherally directed processes atrophy. The cells become the true *spider* or *neuroglia cells*. The latter, therefore, pass through various developmental stages; at first they are ependyma cells, then radial sustentacular cells, from which arise the neuroglia cells.

## DEVELOPMENT OF THE NERVE-CELLS.

The **neuroblasts**, from which the nerve-cells arise, are developed in the innermost layer of the medullary tube, bordering the central canal. Thence they migrate outward through the inner layer and localize within a dorso-ventrally expanding region, that is bounded medially by the *inner layer* and laterally by the *marginal zone*. On examining a cross-section of the

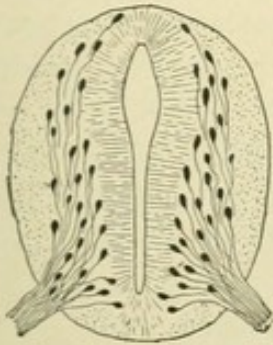


FIG. 102.—Transverse section of the spinal cord of a four-weeks human embryo. Differentiation into the inner layer, next the lumen of the canal, the middle or mantle layer, containing the neuroblasts, and the outer peripheral layer. (His.)

medullary tube of a four-weeks human embryo (Fig. 102), the cleft-like central canal is seen in the middle, bordered by the inner plate, outside of which lies the stratum of neuroblasts, broad ventrally and thinner dorsally. Following His, we call this stratum the *mantle layer*. Peripheralward, the latter joins the *marginal zone*—the Randschleier of His.

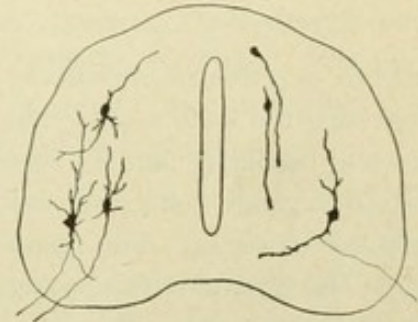


FIG. 103.—Further development of the neuroblasts. On the right, two neuroblasts exhibit processes bearing growth-wedges.

The neuroblasts are pear-shaped cells, with oval nuclei, which send out a peripherally directed process that bears at its end a characteristic thickening, the *growth-wedge* of Cajal. This process is nothing less than the

later nerve-fibre. While the rapidly growing fibres endeavor to

reach their objective point, the cells change their form. On the surface appear small humps and jagged protuberances. These projections later elongate and become compact branches beset with small knobs. By the further development of the knobs and the manifold division of the outgrowths, the later *protoplasmic processes* or *dendrites* of the cells arise. In this manner the nerve-cell, or rather the *neurone*, is formed as an independent individual. It includes the cell-body and the outgrowing protoplasmic processes or dendrites and sends out the delicate *nerve-process* or *neurite*, which in its later development becomes the nerve-fibre.

## DEVELOPMENT OF THE CELLS OF THE CEREBRO-SPINAL GANGLIA AND THE SYMPATHETIC GANGLIA.

The **spinal ganglia** are developed from a band of ectodermic cells located where the medullary plate passes into the cuticle-layer. In the stage of the medullary groove,

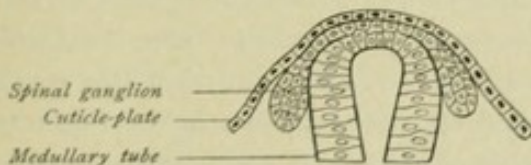


FIG. 104.—Development of the ganglion-strand. Schematic.

this *ganglion-strand* occupies, on each side, the prominent ridge of the medullary plate and, as the medullary tube separates from the overlying ectoderm, unites temporarily with the strand of the other side to form a common medial cord. In consequence of the formation of the medul-



lary tube, the elements of the ganglion-strand, the *ganglioblasts*, are displaced laterally and form, on each side of the medullary tube, segmentally arranged cell-groups. The latter are the anlagen of the future spinal ganglia. During their migration along the medullary tube, the ganglioblasts become spindle-shaped. This form becomes subsequently still more pronounced, each of the two pointed ends gradually growing out into a nerve-fibre, the centrally directed one growing into the dorsal portion of the

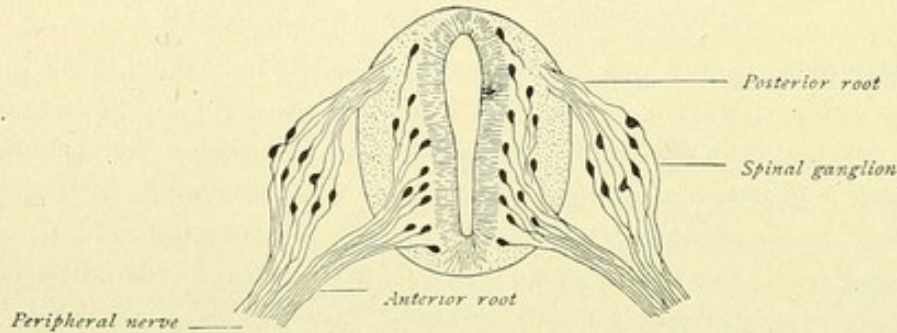


FIG. 105.—Neuroblasts and ganglioblasts.

cord as a posterior root-fibre, and the other, as the peripherally directed sensory fibre, traversing the body to its termination. The bipolarity of the ganglion-cells later disappears, the cells becoming unipolar elements. This unipolarity is manifested not only by the cells of the spinal ganglia, since the cells of the corresponding ganglia of the cerebral nerves are also unipolar elements. The ganglion acustici alone contains permanently bipolar cells.

The **sympathetic ganglia** originate from the cerebro-spinal ganglia. According to the younger His, this development is accomplished by an actual migration of cellular elements from the spinal ganglia.

## THE FORMED ELEMENTS OF THE NERVOUS SYSTEM.

The formed elements of the nervous system are the support-cells and the nerve-cells.

### A. THE SUPPORT-CELLS.

These include the *ependyma cells* and the *neuroglia cells*. The former constitute the epithelial lining, the *ependyma*, of the central canal and its prolongations—the fourth ventricle, the aquaeductus cerebri, the third ventricle and the lateral ventricles.

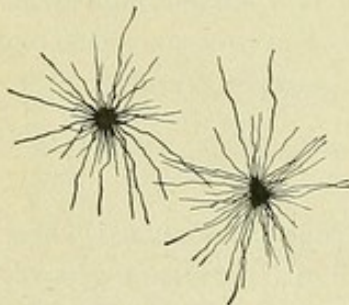


FIG. 106.—Neuroglia cells from the human cerebral cortex.

The **neuroglia cells**, the *spider cells* or *astrocytes*, are present in all parts of the gray and white substance and form, by means of their numerous processes, the framework proper, the *astropilemma* or *spongipilemma*. As chief forms, we distinguish the short-rayed and the long-rayed neuroglia cells. They all possess numerous processes, which, however, are seldom uniformly distributed around the circumference of the cell-body, but usually emerge in separate close tufts, like bundles of rays. The processes are delicate, mostly of the same thickness, from beginning to end of uniform width and end free. While in the majority of cells they proceed in all directions, there are also astrocytes in which the processes exhibit a one-sided development, or arise from the two poles of the cell.



For a long time the supporting tissue proper of the nervous system, or the neuroglia, as distinguished from connective tissue, blood-vessels and lymphatics, was regarded as a sort of ground-substance in which the nerve-cells and nerve-fibres were embedded. The chief rôle therein was played by a kind of cement-substance, the *glia*, to which belonged special cells and fibrous elements, the glia cells and glia fibres. In 1811 Keuffel first succeeded in demonstrating a definite meshwork in cross-sections of the spinal cord, by brushing out the nervous substance, and believed that this reticulum represented nothing more than the prolongations of the pia mater. Arnold and Virchow termed the neuroglia a granular ground-substance, but, as early as 1853, Virchow demonstrated round or fusiform cells within this ground-mass and regarded the tissue as of nervous character, believing that the nerve-cells were developed from the neuroglia. Bidder went somewhat further and spoke of fibrillæ and stellate cells with processes. In 1863 Kölliker pointed out that the supporting tissue of the nervous system consisted of nothing else than a complex of anastomosing stellate cells, which by their union formed a reticulum for the nervous elements. He still assumed, however, an anastomosis between the processes of the cells. It remained for Deiters, by means of isolation, to represent the neuroglia cells in their correct form. The greatest service, however, was rendered by Golgi. Through his investigations, it became clear that the neuroglia is not a special issue, but that it is represented by certain elements—the neuroglia cells, spider cells or astrocytes.

#### B. THE NERVE-CELLS.

The first accurate description of the nerve-cell was given by Remak in 1838. Thirteen years later, R. Wagner discovered in the nerve-cells of the electrical lobes in the brain of torpedo, that of the processes passing out from the cells only a single one is connected with a nerve-fibre. In 1854 Remak communicated similar results in his studies on the nerve-cells of the gray ventral columns of the spinal cord of the ox. These observations of Wagner and of Remak were confirmed, in 1865, by Deiters' investigations on the human brain and spinal cord. Deiters found that among the many processes passing from a nerve-cell always one ran unbranched, while the others underwent repeated division. The unbranched process he named the *nerve-process* or *axis-cylinder process*, and the branched ones the *protoplasmic processes*. In his investigations Deiters employed the method of isolation, this teasing method being subsequently long used to demonstrate the nerve-cells. It is evident, however, that with such technique, by which the cells were torn from all their relations, other investigators could achieve little more than Deiters had already done, and that the most diverse statements concerning the conception of the relations of adjacent elements to each other were inevitable. Thus, a direct union of neighboring cells with each other was accepted by many investigators as an undoubted fact. Sometimes it concerned broad connecting bridges or anastomoses, sometimes the passage of delicate end-fibres into each other. According to other investigators, all nerve-cells possessed more than a single typical nerve-process. Gerlach's work merits the greatest consideration. Gerlach succeeded in demonstrating an exceptionally rich felt-work of the most delicate nerve-fibres in all parts of the gray substance. He extended the observations of Deiters, who had seen the protoplasmic processes repeatedly branch and also the most delicate of these ramifications still further subdivide, in that he held, that the finest ramifications of the protoplasmic processes



eventually formed a delicate "nerve-fibre reticulum." This Gerlach regarded as the most important constituent of the gray substance. According to Gerlach, the divisions of the delicate protoplasmic processes observed by Deiters were only the beginning of the nervous reticulum. Gerlach, however, went still further. He assumed that from this network of nerve-fibres, by the gradual confluence of the minute branches, broader nerve-fibres were again formed, which emerged from the gray substance. Accordingly, the nerve-fibres had a two-fold origin, on the one hand, directly from the cells as nerve-processes or axis-cylinder processes, and, on the other, indirectly from the cells through the medium of the reticulum of nerve-fibres resulting from the branching of the protoplasmic processes. Gerlach supposed, therefore, that the end-twigs of the sensory fibres entered the delicate network, which, on the other side, received the branched protoplasmic processes of the motor nerve-cells. Gerlach's fibre-reticulum can be best pictured by comparing it with the capillary network of the blood-vessels; the sensory fibre is the artery, which is resolved into the capillary network; the protoplasmic processes of the cells form the beginnings of the venous reticulum, from which proceeds the nerve-process representing the vein.

This nerve-fibre reticulum of Gerlach enjoyed for a long time general acceptance. With the improvements in the methods of investigation, however, a powerful revulsion took place. In this, the chief rôle was played by the silver-method of Golgi. This investigator made the important discovery, that the nerve-processes of the cells, regarded as unbranched, may give off delicate collateral branches. Moreover, that there are many cells in the brain and spinal cord whose nerve-processes are not continued as medullated nerve-fibres, as in the case of the other cells and in conformity with the general law announced by Deiters, but resolve into their ultimate end-twigs immediately after emerging from the cells or after a short course.

Golgi divided, therefore, the nerve-cells of the brain and the spinal-cord into two classes: Type I, cells with long nerve-processes, which latter are directly prolonged into nerve-fibres; Type II, cells with short nerve-processes, which after a short course, almost immediately after exit from the cells, break up into their terminal branches.

Later, the two varieties were described as the types of Deiters and of Golgi. Also functionally these two cell-types differ. Golgi regarded the Deiters cells as motor and the others as sensory elements. He interpreted the protoplasmic processes as merely the nutritive organ of the nerve-cell and questioned their nervous significance. Of most importance, however, is the hypothesis advanced by Golgi and his pupils concerning the internal connection of the central nervous apparatus. Golgi denied anastomoses of the protoplasmic processes with one another and, consequently, a connection between the cells in the sense of Gerlach, although suggesting a view somewhat similar. He championed the existence of a "general nervous network," which, on the one hand, arises from the delicate collateral branches of the long nerve-processes and from the terminal subdivisions of the nerve-processes of cells assumed by him to be sensory elements, and, on the other hand, receives additional constituents, such as the end-twigs of the nerve-fibres which enter the gray substance. This network he believes to exist throughout the entire gray substance of the spinal cord and of the brain.

Opposed to this "nervous network" are the important considerations of His and of Forel. As early as 1883, based upon embryological investigations, His had shown



the independence of the nerve-cells from one another; while in 1887, chiefly upon pathological experiences with Gudden's atrophy-method, Forel opposed the acceptance of a general network. What he, for the first time, especially emphasized, was the principle of contact instead of continuous reticular connection. There was still wanting, however, the histological proof, and this proof was supplied by the Spanish savant, Ramón y Cajal. By means of his investigations, it was established that every nerve-cell, with its emerging nerve-fibres, represented an histological as well as a neurological entity—a *neurone*,—and that the entire nervous system is built up of such nervous units.

Closer examination of such a nervous unit or neurone (Fig. 107), shows that two kinds of processes leave the cell-body: (a) the branching *protoplasmic processes* or the *dendrites* and (b) the *axis-cylinder process*, also called the *nerve-process*, *axone* or *neurite*. The nerve-process is distinguished by its uniform diameter and smooth, regular structure. During its course it gives off many secondary twigs, the *collaterals* or *paraxones*, and ends by forming a *terminal arborization* or *telodendrion*. All these parts—the cell with its dendrites and the axone with its telodendrion—constitute collectively a nervous unit or a *neurone*.

Concerning the function of the individual parts of the neurone, the cell-body with its dendrites forms the perceptive and impulse-giving element, while the nerve-process with its collaterals and the end-arborization, is the organ of transmission, carrying the impulse from the nerve-cell to other elements. The protoplasmic processes or dendrites, therefore, conduct *cellulipetally*, receiving the impulse and carrying the same to their own cell-body; the nerve-process or neurite conduct *cellulifugally*, receiving the nervous stream from its own cell-body and conducting it to other cells.

The manner in which the transference from one neurone to the other occurs is not definitely known. According to certain investigators, the chaining together of the nervous units is effected by the nerve-process of one cell, split into the delicate fibres of its end-arborization, being closely applied to or overlying the dendrites and cell-body of another cell, whereby the transference of the impulse is accomplished. The opponents of the theory of mere contact hold that there exists not only a simple application, but also a continuous connection between the nervous substance of the nerve-processes and of the protoplasmic parts in the form of an extremely delicate nervous network. Even if definite proof were supplied as to the connection of the individual neurones with one another by means of such a network, it remains none the less certain, that the nerve-cells with their processes are the essential elements for the entire nervous activity and that they must be regarded as the elements of the nervous system, which anatomically, trophically and as regards specific function, enjoy a certain degree of independence. We are, therefore, justified in designating them as nervous units or neurones.

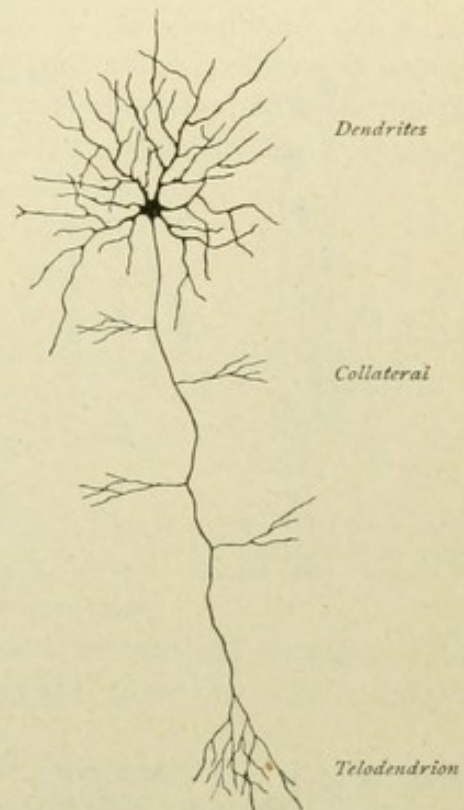


FIG. 107.—Schematic representation of a neurone.



The nerve-cells are found chiefly in the central nervous system; further, in the ganglia, the sense-organs and in the course of the cerebro-spinal and the sympathetic nerves. They are of variable size (4 to 135  $\mu$ ) and of manifold shape. The chief characteristic of every nerve-cell consists in its always possessing processes. Nerve-cells without processes, the so-called apolar cells, are never found in the nervous system of the adult. Such cells are either immature forms and found only during the earliest period of embryonic development, as the germ-cells of His, or they are artificial products, arising from the tearing off of the processes during isolation.

According to the number of the processes, unipolar, bipolar and multipolar cells are distinguished.

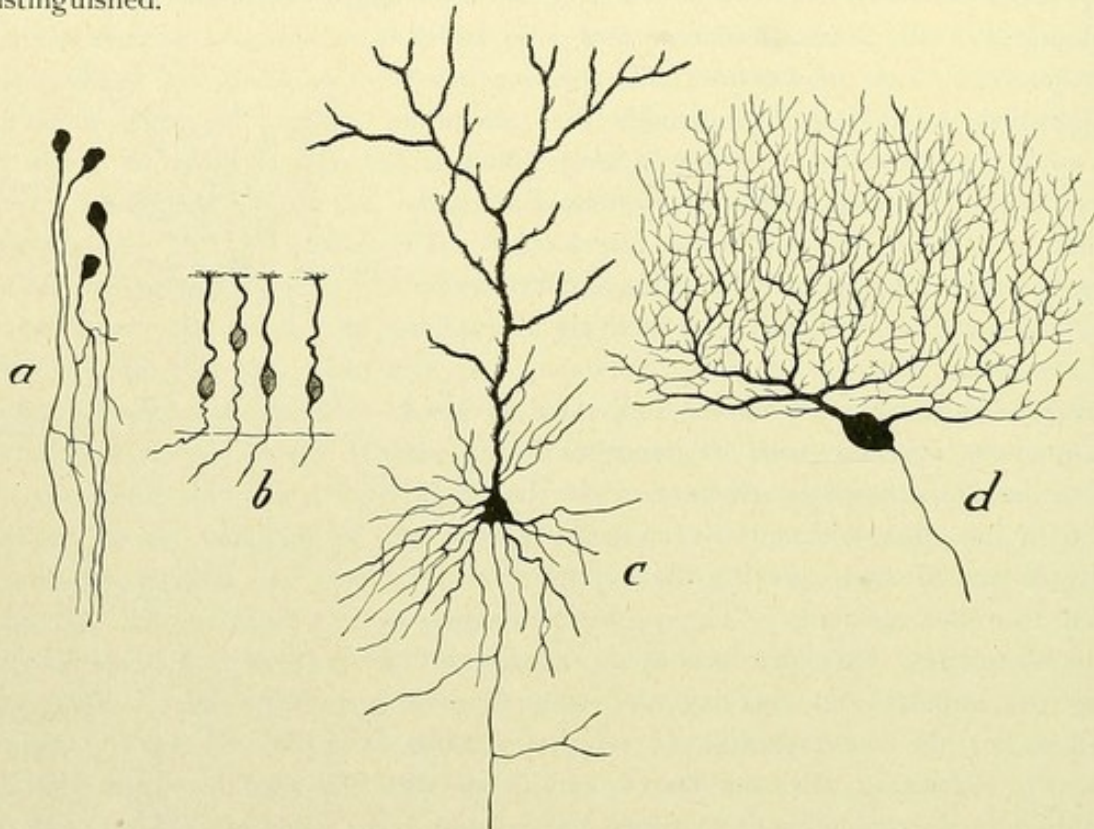


FIG. 108.—Nerve-cells of different types. *a*, unipolar cells; *b*, bipolar cells; *c*, pyramidal cell; *d*, Purkinje cell.

**Unipolar Cells.** These are numerous during embryonic development, as the neuroblasts; much less frequently they are encountered in the nervous system of the adult, as in the retina and in the mesencephalon on each side of the aquaeductus cerebri as the cells of origin of the upper motor root of the nervus trigeminus. The nerve-cells of the cerebro-spinal ganglia are apparently unipolar, with the exception of the cells of the ganglion spirale and of the ganglion Scarpae; in their embryonic condition, however, these elements are bipolar, only later becoming unipolar, when their nerve-processes divide, at a certain distance from the cell-bodies, into a central and a peripheral branch.

**Bipolar Cells.** These elements are found almost exclusively in the peripheral sensory nervous system, as in the epithelium of the olfactory mucous membrane, in the retina and in the spinal and vestibular ganglia.

**Multipolar Cells.** These are the most numerous and the most important elements of the nervous centres. Connected with these are two kinds of processes—the nerve-process, axis-cylinder or neurite, and the protoplasmic processes or dendrites.



The *nerve-process* or *neurite* is usually single, although cells with several nerve-processes occur within the central cortex, as the cells of Cajal. To this category belong also the multipolar cells of the sympathetic described by different authors. The neurite leaves the cell by means of a small conical elevation, the *implantation cone*; the origin may be either from the cell, or, as is very often the case, from one of the protoplasmic processes, near or at some distance from the cell-body. Its smooth regular quality and uniform diameter throughout its entire course are characteristic of the nerve-process.

The *protoplasmic processes* or the *dendrites* are broad and dense at their origin from the cell-body, become gradually thinner and repeatedly undergo antler-like division to form often an arborization of extraordinary richness, the finest twigs of which end free.

Their irregular course and knobbed condition are characteristic of the dendrites, which are often beset with numerous knots, thorns or spines.

According to the **behavior of their nerve-processes**, nerve-cells are grouped into two classes.

1. *Cells with long nerve-processes*, Deiters' cell-type (Fig. 109), in which the neurite is extremely long and becomes the axis-cylinder of a central or peripheral nerve-fibre.

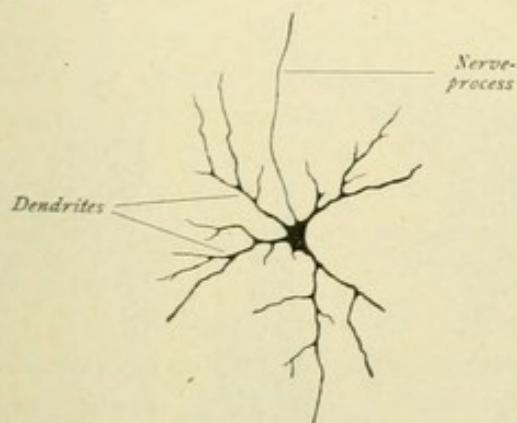


FIG. 109.—Nerve-cell from spinal cord of a newborn cat.

2. *Cells with short nerve-processes*, Golgi's cell-type (Fig. 110), in which the short neurite does not become a nerve-fibre, but, close to the cell, undergoes repeated division and resolves into its end-arborization. These elements are conveniently designated as *Golgi cells*, or cells of Golgi's *Type II*, as distinguished from the cells of Golgi's *Type I*, or the cells with long neurites.

According to the **behavior of the protoplasmic processes**, are distinguished:

a. *Stellate cells*, the dendrites of which arise separately from the entire circumference of the cell-body and extend in all directions, as the motor anterior horn-cells and the tract-cells of the spinal cord.

b. *Cells with a chief dendrite*, in which a robust protoplasmic process arises, along with other dendrites, gives off lateral branches and ends arborized, as the pyramidal cells of the cerebral cortex and the mitral cells of the bulbus olfactorius.

c. *Cells with polar dendrites*, in which the cell-body is mostly fusiform and gives off from opposite sides a basal and an apical dendrite. The basal dendrite forms a tuft resembling the roots of a tree, while the apical dendrite springs from a chief protoplasmic process, which eventually likewise resolves into numerous branches. The nerve-process springs from a basal dendrite, as in the pyramidal cells of the hippocampus.

d. *Cells with monopolar dendrites*, in which usually several chief dendrites arise from one pole of the cell-body and soon break-up, after repeated division, into a wide arborization. The nerve-process arises from the other pole, as in the Purkinje cells of the cerebellum, or in the granule cells in the gyrus dentatus.

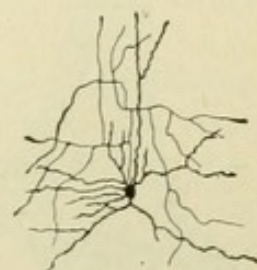


FIG. 110.—Nerve-cell with short axone or nerve-process; cerebral cortex.



With regard to their intimate **structure**, the nerve-cells may be divided into two chief groups, in accordance with the behavior of their protoplasm towards the basic anilin dyes. Following Nissl, we distinguish *somatochromic* and *karyochromic cells*; in the former both nucleus and protoplasm stain, in the latter only the nucleus. After staining with basic anilin colors, such as methylene blue or thionin, the protoplasm of the somatochromic cells exhibits a part taking the dye, the *chromophilic substance*, and a part remaining uncolored, the *chromophobic substance*. The stainable part appears as a multitude of deeply colored bodies having the form of spherical granules, threads, flakes, spindles or jagged particles, which also extend into the dendrites, but do not invade the axis-cylinder process. These are known as *Nissl bodies* or *granules*. On

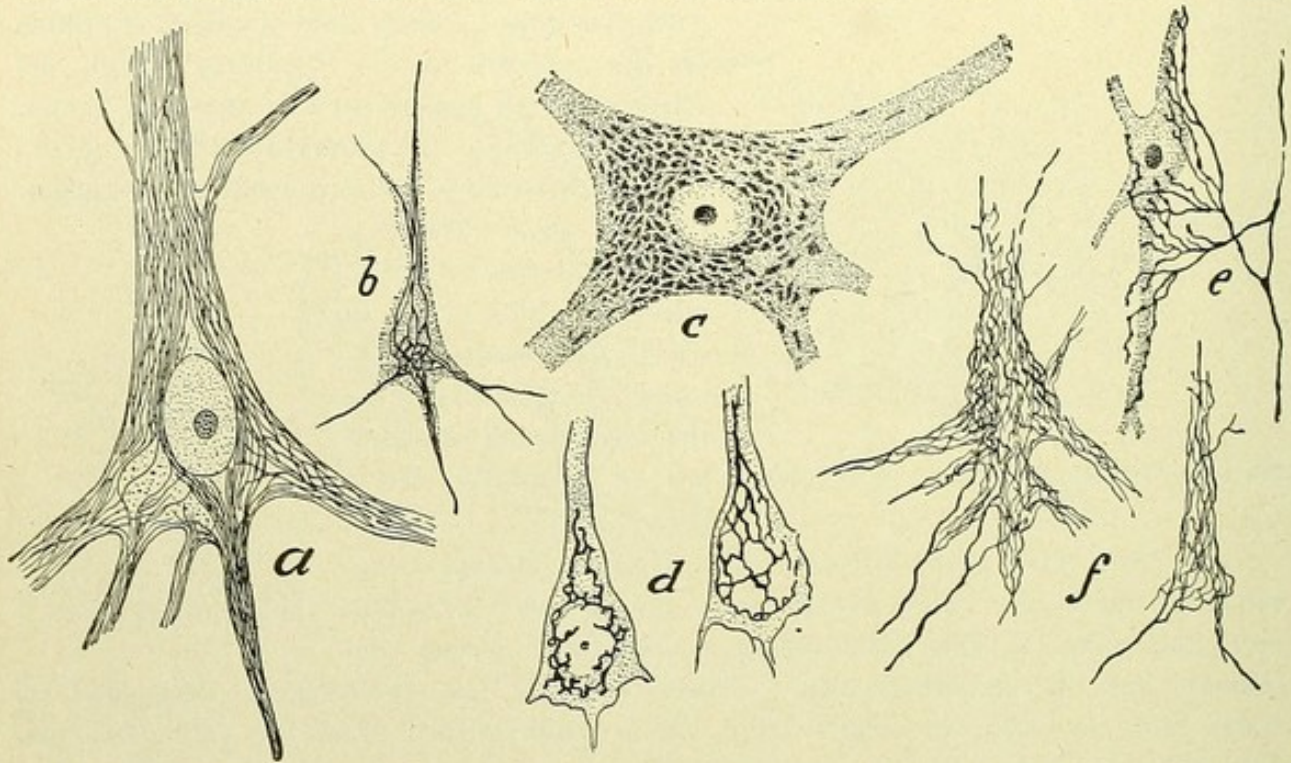


FIG. 111.—Structural details of nerve-cells. *a*, pyramidal cell from adult human motor cortex, showing neurofibrillar network; *b*, pyramidal cell from adult human visual cortex; *c*, anterior horn-cell from human spinal cord showing Nissl bodies; *d*, Golgi-Holmgren canals in pyramidal cell of rabbit; *e*, ending of nerve-fibres on nerve-cells; *f*, pericellular or Golgi network. (*a*, *b*, *d*, *e*, and *f* after Cajal; *c*, after Schmaus.)

account of the mottled appearance of the cell-body conferred by the staining substance, von Lenhossék calls the latter *tigroid*. The arrangement of the chromophilic substance is variable, the granules sometimes being irregularly scattered, at other times disposed in concentric layers, or, as in the case of fusiform cells, grouped as a sort of cap at each pole of the cell-nucleus. A conical mass of the chromophilic substance is usually found at the points of division of the dendrite-stems. Concerning the chromophilic part of the protoplasm, the *nerve-fibrillae* or *neurofibrillae* deserve first notice. These occur within the cell-body, as well as within the processes, and constitute a more or less extensive reticulum, the *fibrillar network*. In Fig. 111, *a* and *b*, such intracellular networks are represented. The figures *e* and *f* show, further, how nerve-fibres, after resolving into delicate arborizations, end at the cells and how the finest fibres form a delicate network over the surface of the cell-body and the dendrites, this constituting the *external network* of Golgi.



The chromophilic and the chromophobic substance differ also in their functional relations. The chromophilic substance is wanting in the protoplasm of a large number of nerve-cells and, therefore, does not represent a vital element of the nerve-cell. It accumulates during the resting condition, is sometimes notably reduced during the period of activity and disappears in lesions of the neurone, to reappear in generous quantity, however, after temporary injury and recovery of the cell. These characteristics seem to prove, that the chromophilic substance exercises a nutritive rather than a nervous function. The chromophobic substance seems to represent the element possessing the function of conducting the nervous stream, the fibrillae and the perifibrillar substance probably sharing in this conduction.

In addition to the Nissl bodies, the protoplasm of many cells contains *pigment granules*, which are usually disposed in groups of variable size. The pigment is commonly not uniformly distributed within the cell, but arranged at the base of one of the dendrites. It is wanting during early life and increases with age. Marinesco regards the pigment granules as regression- and age-products of the nerve-cells. Claiming mention are, further, the fine channels, the *canals of Holmgren*, which lie within the interior of the cell and communicate with the lymph-canals situated outside the nerve-cell.

The **nucleus** of the nerve-cells appears as a clear spherical vesicle, possesses a distinct nuclear membrane and lies most frequently in the middle of the cell. Within the nucleus are found one or several deeply staining *nucleoli*, which often contain still smaller bodies, the *nucleololi*. The remaining interior of the nucleus is traversed by a meagre supporting substance, the *linin framework*, on which rests the chromatin, as well as against the nuclear membrane.

Concerning the relations of the cells to the surrounding tissue, it should be noted, that the cells are enclosed within cavities, the *pericellular spaces*, which communicate with the perivascular lymph-channels of the central nervous system.

The **envelopes** of the nerve-cells are, according to Cajal, of two kinds. (*a*) The cell-membrane proper, the *membrana fundamental*, which invests every cell of the gray substance as an extremely delicate, homogeneous, elastic cuticle, and (*b*) a *connective tissue envelope*, a delicate nucleated membrane, which surrounds all the peripheral cells—ganglion cells and the cells of the sympathetic—with the exception of the cells of the retina and of the olfactory mucous membrane.

The *ependyma* and the *neuroglia cells* are sustentacular elements and together form the supporting framework of the nervous system.

The nerve-cells are usually closely placed in larger or smaller groups and constitute the essential components of the gray masses of the nervous system; exceptionally they occur singly, scattered within the white substance.

The **nerve-fibres** are the axis-cylinder processes or nerve-processes of the nerve-cells, and, while everywhere encountered within the gray masses, constitute the chief components of the white substance of the nervous system. They serve to establish relations of the nerve-cells with one another, whether the relations be between neighboring or widely separated cells of one and the same region of gray substance, as between the various regions of the cerebral cortex; whether the relations be between the cells of a certain region and those of one far remote, as between the central cortex and the



deeper placed gray masses (thalamus, pons, medulla oblongata and spinal cord); or whether the relations be between the central and the peripheral nervous system.

The nerve-cells are, therefore, the specific function-bearing elements. They are the force-sources or the transposition-apparatus of the various forms of nervous activity and, at the same time, also the nutritive organs, the trophic or nutritive centres, of the nerve-fibres which pass from the cells. A nerve-fibre separated from its nutritive centre loses its function and no longer conducts. A nerve-cell with its protoplasmic processes, or dendrites, and its nerve-process, or neurite, constitutes a nervous unit, or a neurone. The protoplasmic process conducts cellulipetally; the nerve-process conducts cellulifugally and through it, by means of its end-arborization, as well as of its collaterals, occurs the transference of the impulse from one neurone to the other.

Cells of the same function usually lie together, closely packed, and constitute a *region*, a *centre*, a *ganglion* or a *nucleus*. In like manner fibres of the same function usually lie together, closely placed, and form a path of conduction or a *fibre-system*.

## MICROSCOPIC STRUCTURE OF THE CEREBRAL CORTEX.

### I. CORTEX OF THE PALLIUM.

Based on the arrangement of the nerve-cells, the following six strata or layers are distinguished.

1. **The molecular layer.** This constitutes the most superficial stratum and is a dense feltwork, composed principally of fibres running mostly parallel to the surface; hence,

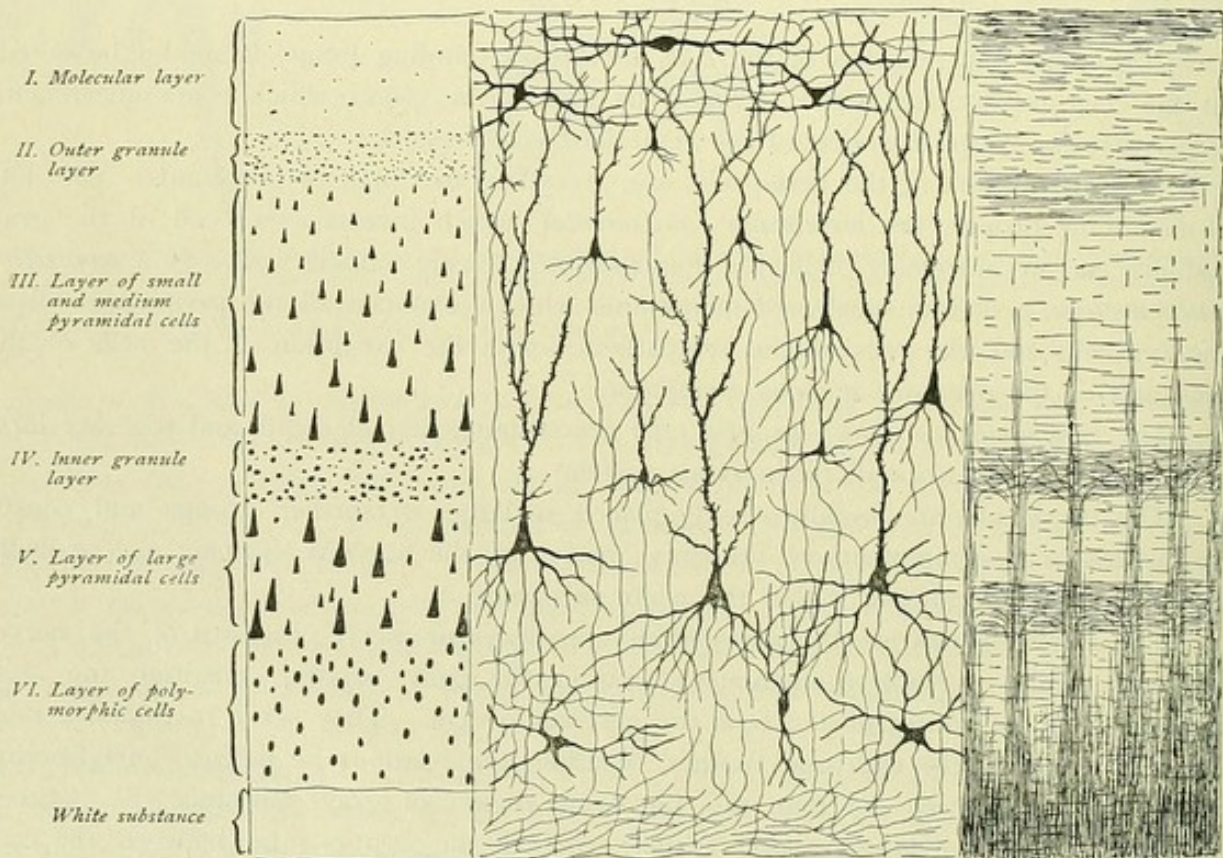


FIG. 112.—Schematic representation of the structure of the cerebral cortex.



it is also designated as the layer of tangential fibres or the *tangential fibre-layer*. In addition to numerous neuroglia cells, this layer contains the terminal ramifications of the dendrites of the more deeply lying pyramidal cells and the end-arborizations of the nerve-fibres coming from the white substance and ending in the cortex. Further, it contains certain cells, including medium sized polygonal elements, with from four to six dendrites and a nerve-process arborizing within the molecular layer, and fusiform or triangular cells, with few more or less horizontally coursing dendrites and two or several nerve-processes, that also run horizontally and end within the molecular layer. The elements with several neurites encountered within the tangential fibre-layer, are known as *Cajal cells*.

2. **The outer granule layer**, a stratum of small pyramidal cells.

3. **The layer of small and medium sized pyramidal cells.**

4. **The inner granule layer**, a stratum of small pyramidal cells.

5. **The layer of large pyramidal cells.** The cell-body of the pyramidal cells is pyramidal in form, the base presenting towards the white substance and the apex directed towards the molecular layer. The apex is prolonged into a robust protoplasmic process, the *primordial branch*, which gives off lateral twigs at right angles, runs toward the molecular layer and there ends after repeated division. The *basal dendrites* pass off from the base of the cell-body, radiating laterally, or towards the white matter. The *nerve-process* springs from the base of the cell, or from a basal dendrite close to the cell-body, and runs towards the white substance; during its course through the gray substance, the nerve-process gives off fine collaterals, that run horizontally or obliquely and end after a number of branchings.

6. **The layer of polymorphic cells.** Here are found cells, ovoid, fusiform, triangular or polygonal in form, which often exhibit a robust protoplasmic process, directed towards the molecular layer. Each cell sends off a nerve-process that passes to the white substance, after giving off a number of collaterals. Additional cells, with short nerve-processes or of Golgi's II type, are encountered, not only in this layer, but also within the strata of small and large pyramidal cells. Finally, the so-called *cells of Martinotti* occur as fusiform or triangular elements, whose distinguishing characteristic consists therein, that the nerve-process traverses the layer of the pyramidal cells to reach the molecular stratum, where it ends.

Regarding the **disposition of the nerve-fibres**, thicker or thinner parallel bundles of fibres enter the cortex from the white substance, proceed towards the periphery, and, gradually diminishing in thickness, towards the layer of the small pyramidal cells resolve into their component fibres. These bundles are known as the *medullary rays* or *radii* and consist of the nerve-processes of the pyramidal and of the polymorphic cells, which are passing from the cortex, and of the nerve-fibres, which enter from the white substance and end within the cortex; these last are also called the *terminal fibres*. Between the individual medullary rays are narrow interspaces containing delicate horizontally coursing fibres, which form the *interradial feltwork*. The latter are somewhat denser where the medullary radii break up into their individual fibres and thereby produce the *stripe of Baillarger*. The fibres of the interradial feltwork are the collaterals of the nerve-processes of the pyramidal cells. Towards the periphery, beyond the interradian feltwork where the radii resolve into their component fibres, lies the *supraradial*



*feltwork*, which marks the ending of the terminal fibres and, farther outward, joins the layer of tangential fibres.

The cerebral cortex does not, however, present the same structure in all regions. Local variations occur, in relation to the arrangement of the several cell-layers, as well as in regard to the behavior of the fibre-layers. There exists a *cyto-* and a *myelo-*

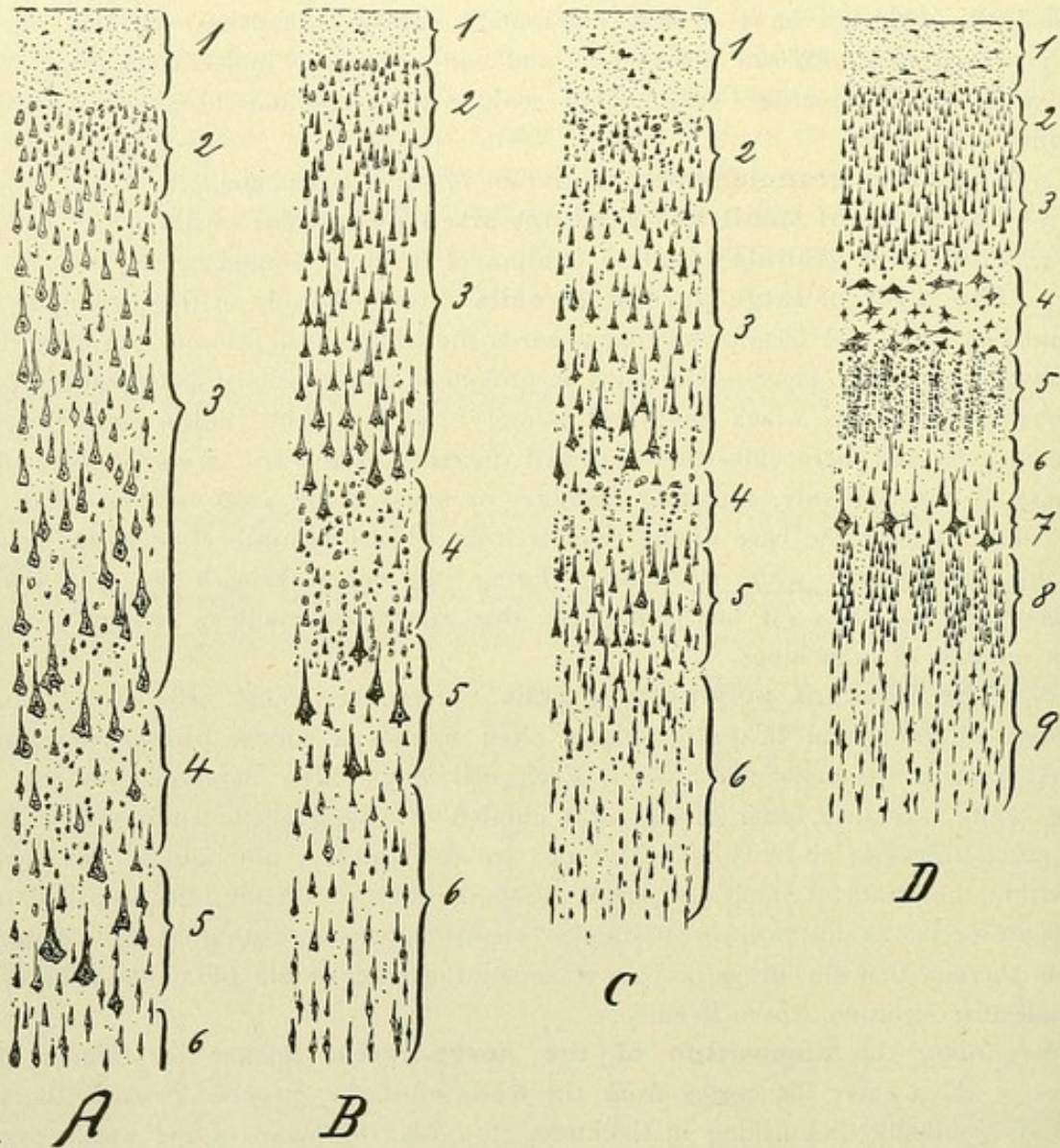


FIG. 113.—Structure of the cerebral cortex in different regions. A, cortex of precentral convolution; B, postcentral convolution; C, superior temporal convolution (auditory cortex); D, surrounding the calcarine fissure (visual cortex). (Cajal.)

*architectonic differentiation*, the recent investigations of Brodmann and of Vogt having shown that the entire cerebral cortex may be subdivided into numerous histologically different cortical fields. While it is impracticable here to discuss in detail the differences, Fig. 113 presents these relations, so far as the make-up of the cell-layers is concerned, in the precentral and postcentral convolutions and in the auditory and visual cortical areas, according to the earlier studies of Ramón y Cajal. The preponderance of



the large and giant pyramidal cells in the precentral convolution is to be noted in contrast to the peculiar structure of the visual cortex, in which the original six-layered type is

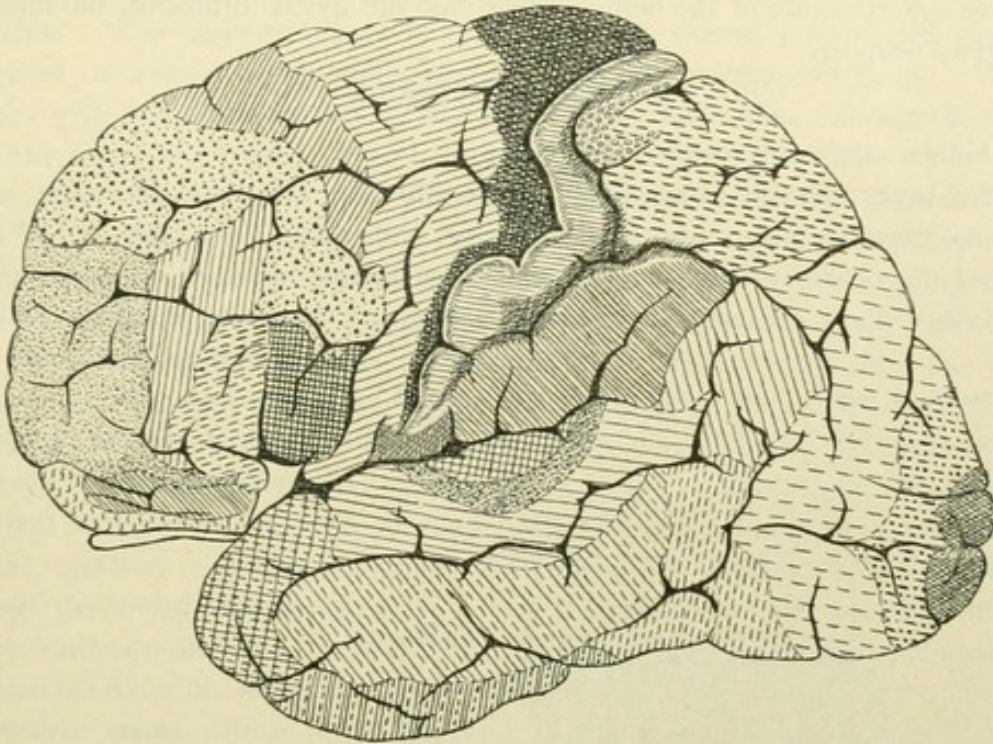


FIG. 114.—Lateral surface of hemisphere, with cytoarchitectonic cortical areas. (*Brodmann.*)

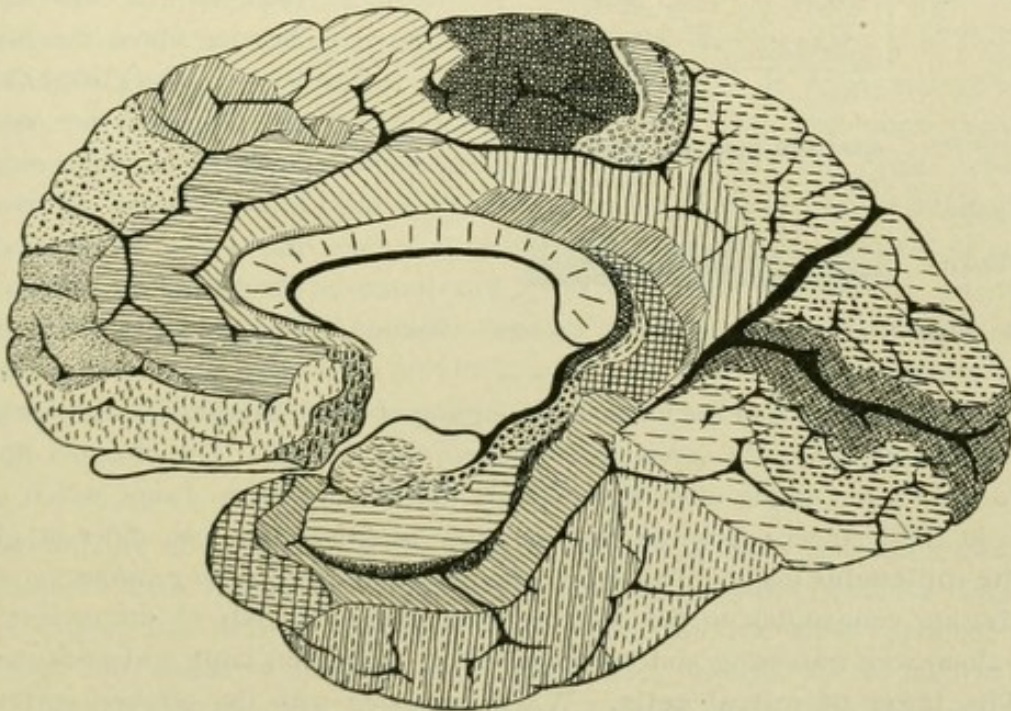


FIG. 115.—Mesial surface of hemisphere, with cytoarchitectonic cortical areas. (*Brodmann.*)

transformed into one of nine layers, by the introduction of special layers of stellate cells (Fig. 113, D 4 and 5).



## II. RHINENCEPHALON.

Microscopic structure of the bulbus olfactorius, the gyrus fornicatus, the hippocampus and the gyrus dentatus.

## BULBUS OLFACTORIUS.

The bulbus olfactorius exhibits the following layers :

1. **The layer of the superficial nerve-fibres.** This, the *fibre-layer*, is formed by the nerve-fibres coming from the olfactory epithelium (Fig. 116). Within the epithelium of the olfactory mucous membrane, the bipolar nerve-cells lie among the sustentacular cells. They are elongated narrow fusiform or irregular elements, with a thick peripherally directed process, that ends within the epithelium, and a delicate centrally directed process, beset with varicosities, that traverses the tunica propria undivided. United into small bundles, the *fila olfactoria*, the central fibres pass through the apertures of the lamina cribrosa, enter the bulbus olfactorius and there form a close feltwork of crossing fibres, the *fibre-layer*.

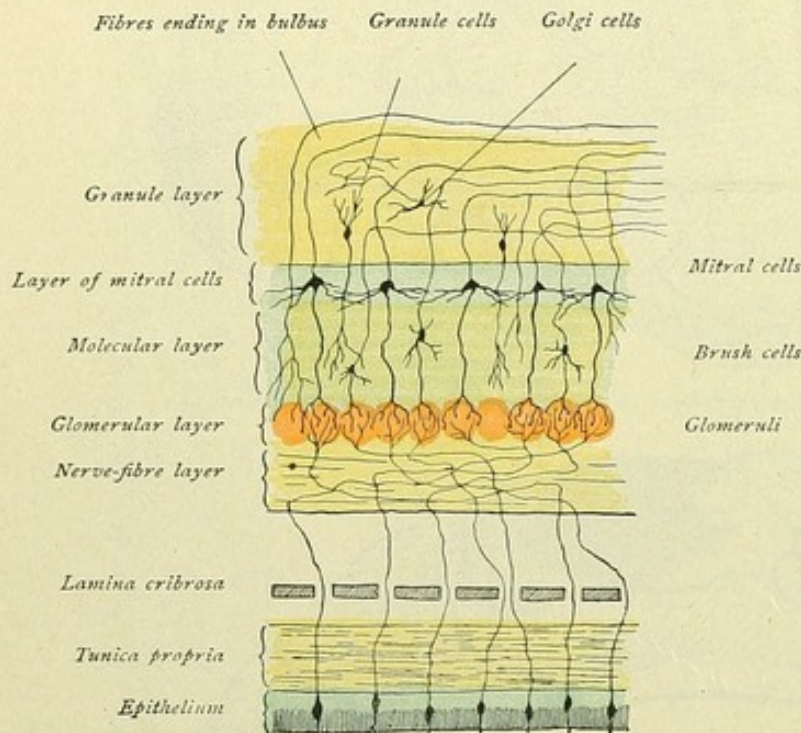


FIG. 116.—Olfactory mucous membrane and bulbus olfactorius. Schematic.

United into small bundles, the *fila olfactoria*, the central fibres pass through the apertures of the lamina cribrosa, enter the bulbus olfactorius and there form a close feltwork of crossing fibres, the *fibre-layer*.

2. **The glomerular layer.** Joining the stratum of nerve-fibres, the layer of glomeruli olfactorii follows. Here the end-arborizations of the fibres from the fibre-layer meet those of the dendrites of certain cells, namely, the brush and mitral cells. In consequence of the close intermingling of these delicate terminal twigs, small round or ovoid structures, the *glomeruli olfactorii*, are formed. The olfactory fibres composing the fibre-layer divide often into two, or indeed into three, twigs, which enter the glomeruli; in this manner, such ramifications may penetrate into two different glomeruli.

3. **The molecular layer.** This layer, also known as the *stratum gelatinosum* of Clarke, forms a stratum comparable to the layer of small pyramidal cells of the cerebral cortex. Within it, along with traversing and branching fibres, are found large and small *brush-cells*.

4. **The layer of mitral cells.** When compared with the cerebral cortex, it represents the layer of the large pyramidal cells. The component *mitral cells* are of quite characteristic form. The cell-body is large, exhibits the form of a triangle or a mitre, and resembles that of the Purkinje cells of the cerebellar cortex. The protoplasmic processes are of two kinds, the ordinary dendritic stems and the so-called olfactory brushes, the *penicilli olfactorii*. The former pass obliquely from the cells, then run more



horizontally, branch once, and end, usually after a long course, free, forming a feltwork within the deepest part of the molecular layer. The olfactory brushes traverse the molecular layer and assist in forming the glomeruli with their elaborate varicose end-arborizations. The nerve-processes of the mitral cells extend towards the granule-layer, bend sagittally at various levels and continue within the tractus olfactorius. During their course they give off collaterals, which end in free branches within the superficial and deep strata of the molecular layer.

The *brush-cells* are often spindle-form in shape and horizontally placed. The larger cells are found within the molecular layer, external to the mitral cells, which latter they in general resemble in giving off the two kinds of dendrites and in sending their nerve-processes to the granule-layer. The small brush-cells, also known as the *peripheral brush-cells*, lie close beneath and between the glomeruli. They likewise send one dendrite to the glomerulus, the nerve-processes behaving like those of the large brush-cells.

5. **The granule-layer.** Within this stratum are found the *granule cells* or *granula*, peculiar small elements with long processes. These granula also penetrate between the mitral cells and, beyond these, into the molecular layer as far as the glomeruli. The granule cells are triangular, resembling the pyramidal cells, or fusiform or pear-shaped, all being placed vertically. An outwardly directed process, mostly single but rarely double, divides repeatedly after a longer or shorter course, usually close beneath the mitral cells, to form a brush-like terminal arborization, that ends within the most superficial region of the molecular layer at the glomeruli in delicate filaments. In the opposite direction, that is inward, the granules exhibit several processes, which are usually smooth and slightly branched and end free after a short course. As yet, a nerve-process has not been discovered. In addition to the granules, this layer contains cells of Golgi's II type—multipolar elements with fusiform or polygonal cell-body and a nerve-process that breaks up within the granule-layer. The nerve-fibres running within the granule-layer are partly the nerve-processes of the mitral and brush cells; further, fibres enter the bulb to end some within the granule-layer, and some within the molecular layer in the vicinity of the glomeruli, after having penetrated the layer of mitral cells.

The nerve-processes of the mitral and brush cells, that pass to the tractus olfactorius, end within the cortex of the tractus and of the tuberculum olfactorium and within the olfactory area of the substantia perforata anterior and the adjoining parts of the septum pellucidum. These end-stations exhibit the structure of a modified cerebral cortex.

#### GYRUS FORNICATUS.

The structure of the cortex of the gyrus fornicatus deviates from the typical make-up of the cerebral cortex chiefly in relation to the layer of the large pyramidal cells. Within the gyrus cinguli, this stratum contains, in the outer half, few small pyramid cells and, in the inner half, those of medium size. The latter, almost all of uniform diameter, lie deeply placed and together, in consequence of which disposition the middle portion of the layer appears poor in cells and, on account of the ascending primordial branches of the pyramidal cells, is called the *stratum radiatum*. Towards the corpus callosum, all layers suffer diminution in thickness and in the size of the cells. The cortex of the gyrus hippocampi bears, in many respects, a close resemblance to that of the gyrus cinguli. That part of the gyrus hippocampi which borders the fissura collateralis and rhinica,



however, exhibits slight deviation from the common type. Towards the fissura hippocampi, the molecular layer is broader. Within the layer of small pyramidal cells, the cells are irregularly arranged in chains of hillocks, while within the third layer are found larger pyramidal cells with very long primordial branches; moreover, of these cells the largest are very deeply placed, whereby the conspicuous radial striation, the stratum radiatum, is produced. The layer of polymorphic cells contains almost exclusively small irregular cells, that are embedded within a close network of nerve-fibres.

#### HIPPOCAMPUS AND GYRUS DENTATUS.

The hippocampus, or *cornu Ammonis*, and the gyrus dentatus represent two special convolutions. On following the gyrus hippocampi dorsally, one reaches the *subiculum*, that constitutes that part of the hippocampal convolution in which gradually begins a change in the structure of the cerebral cortex, leading finally to the typical structure of the hippocampus. The white substance splits into two layers: the one passes to the free surface of the hippocampus and constitutes the *alveus*, the other passes to the lateral wall and roof of the inferior horn of the lateral ventricle. The alveus is

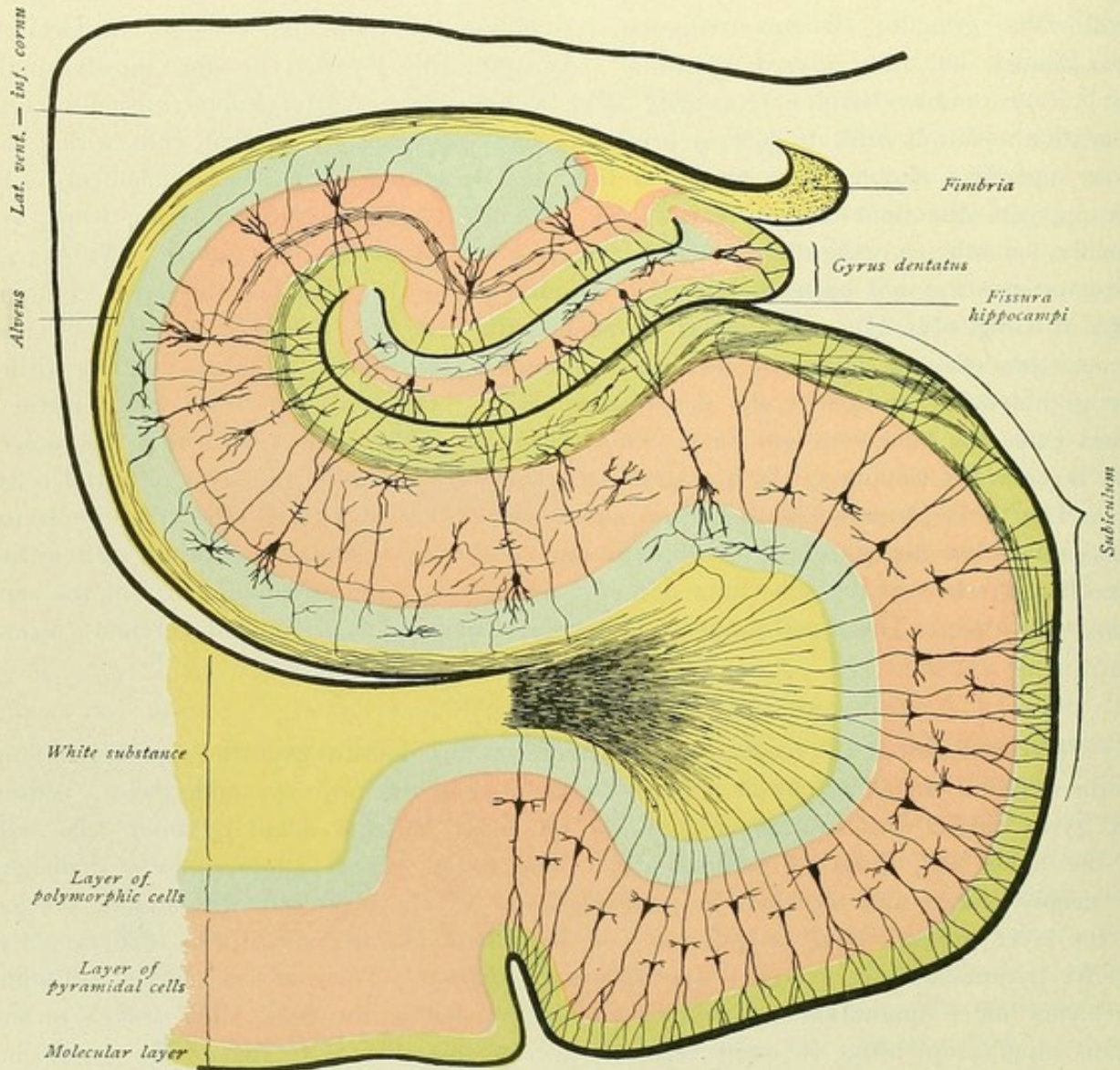


FIG. 117.—Hippocampus or cornu Ammonis and gyrus dentatus in transverse section. Schematic.



continuous with the fimbria. The uppermost layer of the gray substance, the *substantia reticularis alba*, corresponding to the molecular layer of the typical cortex, divides into a superficial and a deep stratum. The superficial layer adjoins the molecular layer of the gyrus dentatus and forms the *lamina medullaris circumvoluta*. The deep layer forms the *stratum lacunosum*, that arches around and embraces the lamina medullaris and ends in a recurved hook at the medial side of the cell-layer of the gyrus dentatus. Between the lamina medullaris circumvoluta and the stratum lacunosum, lies the *stratum moleculare*. The pyramidal cells of the subiculum gradually collect into a single layer of cells as they approach the hippocampus. At first the arrangement of the cells is still irregular, towards the gyrus dentatus the cells form a single thick layer, but within the terminal sheet of the hippocampus they once more are irregularly disposed. In this way two special zones are produced, a deep layer of pyramidal cells, the *stratum lucidum*, and, between the latter and the stratum lacunosum, the *stratum radiatum*, so called on account of the traversing long primordial stems of the pyramidal cells. The layer of polymorphic cells is known as the *stratum oriens*. The **gyrus dentatus** exhibits three strata: the *molecular layer*, the *granule-layer* or the *stratum granulosum*, and the layer of *polymorphic cells*. The relations between the strata of the modified cortex of the special convolutions and those of the typical cerebral cortex are shown in the following table and Fig. 117:

Cerebral Cortex	Hippocampus	Gyrus dentatus
Molecular layer	{ <i>Lamina medullaris circumvoluta</i> <i>Stratum moleculare</i> <i>Stratum lacunosum</i>	} Molecular layer
Layer of pyramidal cells	{ <i>Stratum radiatum</i> <i>Stratum lucidum</i>	} Granule-layer or stratum granulosum
Layer of polymorphic cells.	{ <i>Stratum oriens</i>	} Layer of polymorphic cells or stratum oriens
White substance	{ <i>Alveus</i>	

## HIPPOCAMPUS.

The individual layers exhibit the following cells:

1. *Lamina medullaris* and *stratum moleculare*:
  - a. Small cells of Golgi II type.
  - b. Fusiform cells, with nerve-processes that break up in stratum moleculare.
2. *Stratum lacunosum*:
 

Small triangular or stellate cells, with ascending and descending dendrites and nerve-processes that split up in the stratum lacunosum.
3. *Stratum radiatum*:
  - a. Cells of the same character as those of the stratum lacunosum—aberrant cells of the stratum lacunosum.
  - b. Pyramidal cells—aberrant cells of the stratum lucidum.
  - c. Cells of Golgi II type.
  - d. Triangular or fusiform cells, descending nerve-processes ending around the pyramidal cells.



4. *Stratum lucidum*:

Pyramidal cells, with long primordial stems ascending within the stratum radiatum and nerve-processes running to the alveus. Within the portion of the hippocampus bordering the gyrus dentatus, giant pyramidal cells are found. Each of the nerve-processes of these elements gives off, soon after its origin from the cell, a collateral, which traverses the stratum radiatum and passes to the stratum lacunosum.

5. *Stratum oriens*:

- a. Aberrant pyramidal cells.
- b. Cells with ascending nerve-processes, that end around the pyramidal cells.
- c. Martinotti cells.

Along with the fibres passing from the cortex to the alveus, are found also those which come from the alveus and end within the cortex.

## GYRUS DENTATUS.

The gyrus dentatus constitutes a small modified cerebral cortex, which adjoins the lamina medullaris circumvoluta of the hippocampus and receives within its hilus the end of the hippocampus. The white substance of the gyrus dentatus is not directly applied to the layer of polymorphic cells, but is separated from the latter by the cortical formation, which corresponds to the region of the hippocampus bordering the gyrus dentatus. It follows, that the fibres coming from the gyrus dentatus break through the end of the hippocampus lying within the hilus, the alveus, therefore, representing the cortical white substance of both the hippocampus and the gyrus dentatus.

Passing from the fissura hippocampi towards the ventricle, the following strata are encountered:

- |   |   |
|---|---|
| <ul style="list-style-type: none"> <li>a. <i>Molecular layer</i>, bordering the lamina medullaris of the hippocampus,</li> <li>b. <i>Stratum granulosum</i>,</li> <li>c. <i>Layer of polymorphic cells</i>,</li> <li>d. <i>Molecular layer</i>,</li> <li>e. <i>Layer of giant pyramidal cells</i>,</li> <li>f. <i>Layer of polymorphic cells</i>,</li> <li>g. <i>Alveus</i>.</li> </ul> | } Gyrus dentatus.<br><br><br><br><br>} Hippocampus. |
|---|---|

The cells exhibited by the individual strata of the gyrus dentatus are the following:

1. *Molecular layer*:

- a. Cells of Golgi II type,
- b. Aberrant granule-cells.

2. *Stratum granulosum*.

This layer is formed of the granule-cells, closely placed and disposed in several rows. The cells are modified pyramidal cells, distinguished by the absence of the basal dendrites and a primordial stem. The ascending dendrites end within the molecular layer, while the nerve-process passes through the layer of polymorphic cells, then through the molecular layer and the stratum of pyramidal cells of the hippocampus, and exhibits during its further course peculiar local thickenings, with small protruding out-



growths. The nerve-processes unite into a bundle and then end, after forming a reticular plexus, around the cell-bodies of the large pyramidal cells and their dendrites. They establish relations, therefore, between the granule-cells and the giant pyramidal cells of the hippocampus, from which, in turn, the impulse may be conveyed to other pyramidal cells by the collaterals that pass to the stratum lacunosum.

3. *Layer of polymorphic cells:*

- a. Cells with ascending nerve-processes, ending within the granule-layer,
- b. Cells with ascending nerve-processes, passing to the alveus,
- c. Cells of Golgi II type.

As in the hippocampus, so here, among the fibres passing from the gyrus dentatus are those coming from the alveus and ending within the gyrus dentatus.

In its further course, the gyrus dentatus continues, as the induseum griseum, over the corpus callosum. The medial and lateral thickenings, the stria Lancisii and the taenia tecta, likewise display the character of cortex; within the stria Lancisii a molecular layer with tangential fibres, a middle layer with fusiform cells and a deep layer are distinguishable.

## CEREBRAL LOCALIZATION.

The various subdivisions of the brain are broadly divided, with regard to their functions, into two chief groups, the higher and the lower. The higher subdivisions are the cerebral hemispheres, and in these the cerebral cortex, which through the great development of the cerebral mantle and the formation of the convolutions attains such extraordinary expansion, plays the principal rôle and represents the material substratum of intellectual activity. The lower subdivisions are interposed between the cerebral hemispheres and the spinal cord and include the medulla oblongata, the pons, the cerebellum, the region of the corpora quadrigemina, and the cerebral ganglia—that region, therefore, also designated as brain-stem. These lower parts possess no direct import for intellectual activity, but have rather the task of regulating, independently of consciousness or volition, the many functions necessary for the maintenance of the body. "The lower brain segments supply an apparatus, by which the general condition of the body may be reflected from within. For the moulding of the intellectual processes, the mechanism of the cerebrum proper is authoritative."—(Flechsig.)

It is unquestionably the service of the anatomist, Franz Joseph Gall, first to have recognized the significance of the cerebral cortex for intellectual activity. Since Gall, anatomists have ceased to seek a definite point in the brain, to which all motor and sensory nerves converge and which might be identified anatomically as the seat of the centralized soul. As well known, René Descartes interpreted the pineal body as the organ of the soul; Sömmering located the sensorium commune in the fluid of the ventricles; according to Varolius, the soul had its seat in the soft brain-substance; Thomas Willis regarded the central ganglia as perception-centres, and the corpus callosum as the seat of the imagination, while he placed thought within the cerebral convolutions. Gall, moreover, established the principle, that the individual convolutions are not all intellectually equivalent and in this fundamental view already approached the modern theory of localization. In setting up his own localization theory he went too far, in that he subdivided the entire cerebral surface into twenty-seven separate areas, which areas were the



carriers of definite intellectual faculties and, further, that along with the greater development of such a definite brain-area, a corresponding stronger projection appeared on the skull. Following the theory, the possibility was assumed, that, by careful examination of the skull, a person's endowment or character might be determined. In the scientific world, Gall's phrenology did not long endure. Although the present theory of localization differs entirely in its essentials from phrenology, we must nevertheless admit that localization was advanced more by Gall than by the labors and views of the physiologist, Flourens, who defended the theory of the equivalence of the parts of the cerebrum. Gall and his pupil, Bouillaud (1825), had already learned that circumscribed injury of the cerebrum in the frontal region may lead to disturbances of speech.

According to Gall and Bouillaud, in 1836 the French physician, Marc Dax, furnished the proof, that motor aphasia appeared only after disease of the left cerebral hemisphere, and in 1861 Broca announced the theorem, that particularly the left third frontal convolution was the seat of speech; hence this region is even to-day commonly called Broca's convolution.

This discovery of the motor speech-centre by Broca was the foundation of the theory of localization. Although the proof of the functional variation of the cerebral cortex shattered Flourens' teaching of functional equivalence, this theory was finally entirely overthrown, not only by further pathological experience, but especially by experimental physiology, since in 1870 Fritsch and Witzig discovered the electrical irritability of the cerebral cortex. These investigators succeeded in inducing movements of certain parts of the body by stimulation of definite cortical regions by means of the galvanic current, and, further, reached the conclusion, that while stimulation of certain cortical regions produced movements, no such result followed stimulation of other regions. These investigations were confirmed and supplemented in 1873 by those of Ferrier, who employed the faradic current instead of the galvanic. In consequence of these observations, it was possible to establish a definite cortical region as the centre for movement. Other investigators, particularly Nothnagel, Carville and Duret, Goltz and Munk, subsequently succeeded, reversing the order, in producing paralysis of certain muscles and impairment of certain sensory activities by removal or destruction of definite cortical regions. These labors, along with the numerous investigations of other workers, have established with increasing stability the localization of the functions of the cerebral cortex.

It is admitted, therefore, that the individual regions of the cerebral surface are not equivalent, but of entirely different significance. Each cortical field presiding over a definite function is designated as a centre, and of such cerebral cortical centres, although as yet not accurately delimited, we recognize the following.

#### THE MOTOR CENTRE.

According to the newer investigations, the motor centre embraces especially the anterior central or precentral convolution, and, further, the posterior part of the frontal lobe and the lobulus paracentralis. It includes the following regions.

**a. Upper region:** lobulus paracentralis and the upper quarter of the precentral convolution—the centre for the movements of the lower extremity. A further separation into particular centres for certain groups of muscles is often made; the data, however, are so far from accord, that a subdivision into definite subcentres may be here omitted.



The largest part of the superior frontal convolution, especially the region bordering the paracentral lobule and the upper fourth of the precentral convolution, constitutes the centre for the muscles of the trunk.

**b. Middle region:** the middle two-fourths of the precentral convolution—the centre for the movements of the upper extremity. The further delimitation within this centre of subcentres for movements of the fingers, the hand, the arms and the shoulder, is so ordered, that the centre for the fingers occupies the lowest position, and that for the shoulder the highest.

**c. Lower region:** the lower fourth of the precentral convolution—the centre for the musculature of the face, the tongue, mastication, the larynx and the pharynx. Small special centres for the upper and lower facial nerve are assumed to exist.

Within the posterior part of the middle frontal convolution lies the centre for the movements of the eyes and of the head, particularly for the direction of the head and the eyes towards the opposite side (conjugate deviation). According to other investigators, a second projection centre for the winking movements of both eyes has its seat in the gyrus angularis.

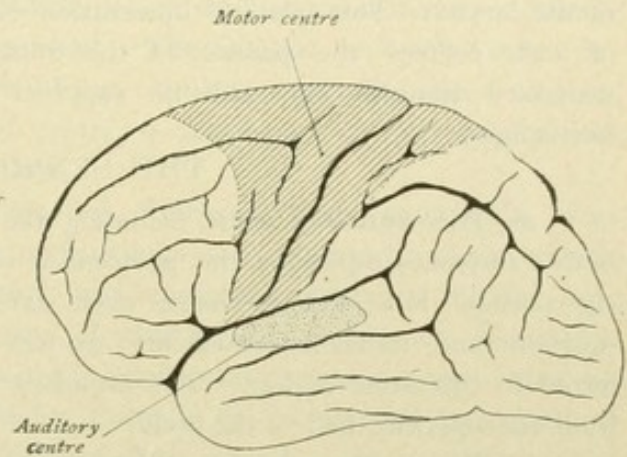


FIG. 118.—Cerebral localization. Motor and auditory centres.

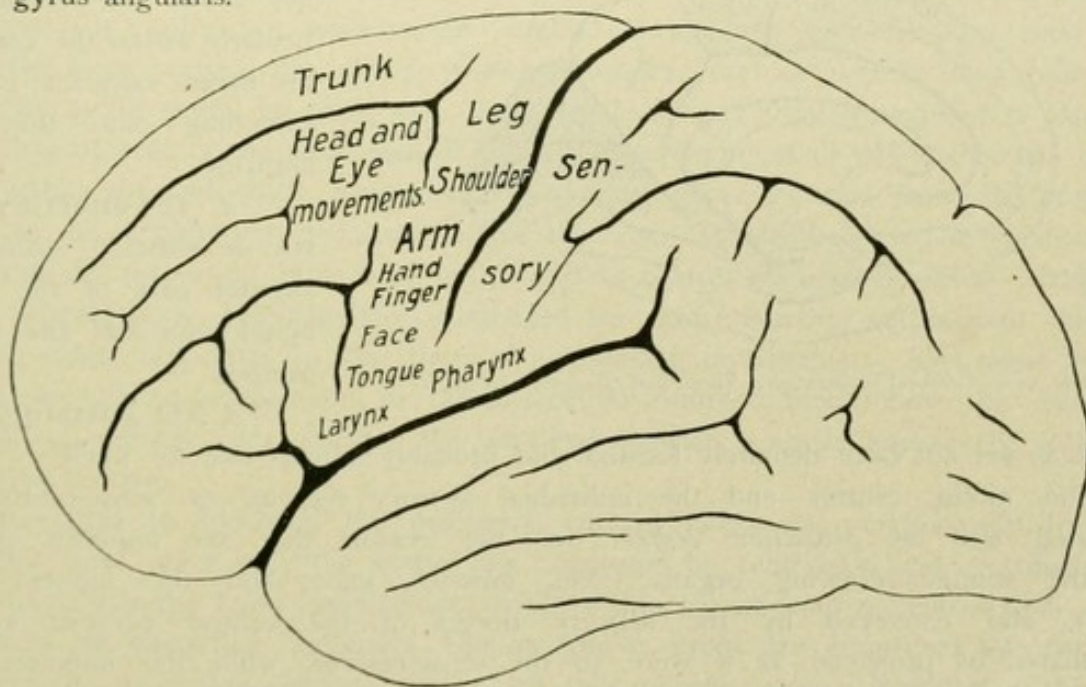


FIG. 119.—Cerebral localization. The chief regions of the motor centre.

In regard to the motor centres it is particularly to be noted, that stimulation within the centre calls forth contraction and movements of the corresponding muscle-area of the opposite half of the body, and that in like manner injuries lead to paralysis in the opposite side of the body. This will be further discussed in connection with the motor conducting paths (page 139).



This rule is not, however, without exception. From certain centres, not only the corresponding muscles of the opposite side are controlled, but also those of the same side; that is, there exists for certain muscles a bilateral innervation. This is true for those muscles whose action, as a rule, is not unilateral but symmetrically bilateral, as, for example, in the case of the frontalis, orbicularis oculi and corrugator supercilii muscles supplied by the upper facial branch, or the muscles of mastication, of the pharynx and of the larynx. This bilateral innervation explains the fact, that after unilateral destruction of such centres the paresis of the muscles concerned is not pronounced, since the necessary stimulus may still be supplied from the unaffected centres of the opposite hemisphere.

### THE SENSORY CENTRES.

*a.* The **sensory area**, including the centres for touch, pain and temperate sensibility, embraces especially the postcentral convolution and the adjoining anterior part of the parietal lobe and, perhaps, even extends onto the precentral convolution. The position- and movement-sensibility, as well as space- and orientation-sense, are transferred to this same region. The impulses, passing to the sensory area, come essentially from the opposite half of the body.

*b.* The **auditory centre** is located in the middle part of the gyrus temporalis superior and includes additionally the gyri transversi of the upper temporal convolution, that lie buried within the fissure cerebri lateralis.

*c.* The **visual centre** lies within the cuneus, particularly within the cortex of the fissura calcarina, perhaps extending onto the gyrus lingualis.

*d.* The **olfactory centre** is situated within the anterior part of the gyrus hippocampi and the hippocampus.

*e.* The **gustatory centre** has as yet not been definitely located, but probably adjoins that for smell.

The motor centres and the individual sensory regions or sense-centres are designated also as *projection centres*, for the reason that the impulses passing from the stimulus-receiving organs (skin, muscles, joints and the higher sense-organs), and conveyed by the sensory nerves of the central nervous system, are radiated or projected, as it were, to the sense-centres, while the impulses from the motor centres are similarly projected towards the periphery and conveyed by the motor nerves especially to the muscles. Stimulation within the sense-centres induces sensation (touch, sight, hearing, smell, etc.); stimulation within the motor zone leads to movements. These incoming and outgoing conductions follow quite definite paths, which are termed afferent or centripetal and efferent or centrifugal projection-tracts respectively.

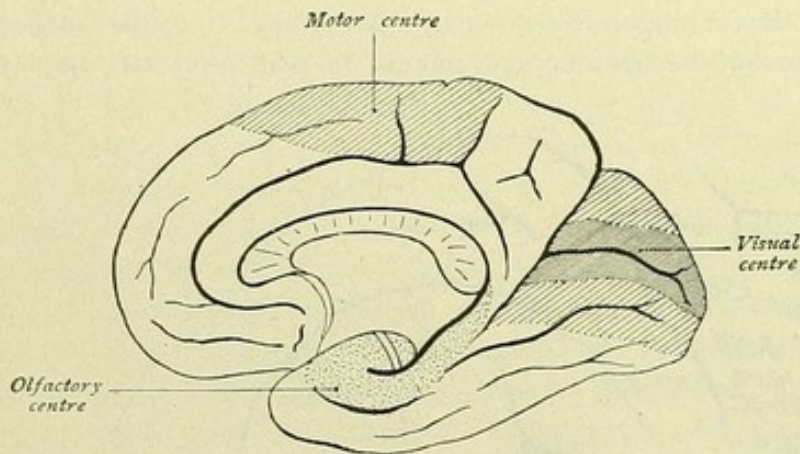


FIG. 120.—Cerebral localization. Visual and olfactory centres.



Viewing the surface of the cerebral hemispheres and imagining the individual projection centres outlined, it will be evident that the latter occupy only a certain part, perhaps a third, of the entire cerebral cortex. In addition to these motor and sensory fields, there remains a large area that embraces certain parts of the frontal, parietal, occipital and temporal lobes, together with the deeply situated central lobe or the insula—a tract of still slightly known function. According to Flechsig, this entire large area is designated the *association centres*, of which, following him, an anterior, a middle and a posterior association centre are distinguished. The anterior or frontal centre includes the fore-part of the frontal lobe; the middle or insular centre, the island of Reil; and the posterior or parieto-occipito-temporal centre, a large part of the occipital and temporal lobes and almost the entire parietal lobe.

According to the theory advanced first by Flechsig, these association areas constitute the substratum for the higher psychic functions—an apparatus which collects the activities of the sense-centres to higher unity, and comprises centres of all the more complex associations. They are the chief bearers of what we call experience, knowledge and cognizance and, in part, of speech, in short the intellectual centres proper. Flechsig was led to the advancement of this theory chiefly through his histological investigations based on the method of the development of the medullary sheath. He proved that the myelin-ripening of the individual nerve-tracts proceeds from below upward, that is from the spinal cord and the lower brain-segments towards the cortex of the end-brain. Already at birth, according to Flechsig, the individual tracts have reached, in large part, their development within the lower divisions of the brain, while within the cerebrum only few paths of conduction have developed. At first, one sense-conductor after the other gradually pushes out towards the cerebral cortex. In the new-born child, only two of the sense-centres, the olfactory and gustatory, are developed; then follow the centres for tactile sense, for sight and, lastly, for hearing. Only subsequent to the completed development of the sense-centres, does the development of the intellectual centres begin within the individual territories. Medullary fibres proceed from the projection centres to the neighboring association areas, the latter likewise become functionally active and eventually numerous tracts bind both kinds of centres with each other. Based on further investigations, Flechsig later subdivided the entire cerebral cortex into thirty-six different areas, according to the time of completed myelination. The areas first becoming medullated correspond to the projection centres; then follow the embryonic intermediate centres and, finally, the terminal districts, which exclusively form the association centres.

According to Flechsig, the projection centres differ also anatomically from the association ones, since only the former are connected by centripetal and centrifugal projection tracts with the lower brain-centres, while within the association centres such projection tracts are altogether wanting. The association areas are connected by fibre-tracts only with the projection centres, from which they receive sensory stimuli; on the other hand, they may influence the sensory areas by reflex stimuli or inhibition. The association and projection centres also vary in their histological make-up, since the association centres exhibit a specific although uniform texture, while the projection centres present a structure which not only differs from that of the association centres, but varies within the individual fields.



This important theory of Flechsig, however, can no longer be accepted in its entirety. Further investigations have not substantiated the assumption, that only a portion of the cortex is connected with the lower lying brain-centres by means of projection tracts, since such paths have been proven also for the association fields mapped out by Flechsig. Furthermore, it has been determined, that not only the projection centres possess a special and for each region specific texture, but that there also exists within the association tract a large number of areas of different structure. As has been shown by the investigations of Vogt and Brodmann, the entire cerebral cortex may be mapped out in numerous fields, which differ from one another in regard to cellular stratification, as well as in regard to fibre-relation, there existing a cyto- and a myelo-architectonic differentiation of the cerebral cortex (Figs. 114 and 115).

Concerning the relations of each individual anatomically definable field to function, however, we still know very little, and it remains for future physiological and clinicopathological investigations to advance our understanding concerning this problem. With Brodmann we may assume, "that each specific cytological difference must be the expression of a definite physiological dignity and that, therefore, all the variously structured cortical fields also preside over different functions. Not, of course, in the sense that one assigns complex intellectual processes or attributes to specially delimited territories, but in the only warranted sense of Wernicke, who associates only the most elementary functions with definite localities of the cerebral cortex." A question, for which the answer has long been sought, is the existence of definite recollection or memory centres. Many facts point to the actual existence of such memory centres beside the projection centres. Thus, clinical cases are known, in which loss of a perception region was attended with cessation of the corresponding perception, but not of the related memory-pictures; on the contrary, certain cases with cortical lesions in the immediate vicinity of the perception centres, for example, of the convolutions adjoining the visual and auditory centres, exhibited neither blindness nor deafness, but failure of memory and disturbances of the function of recognition. Thus lesions of both occipital lobes lead to so-called visual agnosia or perception blindness. The patient may still be able to give information regarding the form and color of an object, but the object itself is unknown, he being no longer able to recognize the object or, usually, its spatial relations. Further, lesions of the left temporal lobe cause the so-called auditory agnosia or perception deafness, in which condition not only the spoken words, but also auditory stimuli of all kinds are no longer understood. Likewise, lesions situated in the middle third of the postcentral convolution, or farther backward in the parietal lobe, may lead to so-called tactile agnosia, in which, for example, the form of any object no longer is recognized, notwithstanding the integrity of the individual impressions necessary for touch-, space- and muscle-sense.

### THE SPEECH CENTRES.

The speech centre in its entirety includes certain cortical areas of the lateral surface of the hemisphere and, in right-handed individuals, is located on the left side.

*a.* The **motor speech centre**, Broca's centre presiding over the ability to speak, lies within Broca's convolution embracing the base of the gyrus frontalis inferior. It extends, perhaps, also to the adjacent part of the lowest region of the precentral convolution and to the anterior part of the insula. Upon the integrity of this centre depends



the ability to carry out the co-ordinated movements necessary in speaking. Damage of the centre leads, therefore, to abolition of the execution of motor speech. Voluntary speech, repeating words or reading aloud are no longer possible. This centre, therefore, is also termed the centre of motor aphasia.

*b.* The **sensory speech centre**, the tone-picture or auditory centre, lies within the posterior third of the gyrus temporalis superior and the adjoining part of the gyrus supramarginalis. It is also known as *Wernicke's centre* and represents the cortical region where the memory-pictures of the heard and spoken words are retained. If the centre be injured, the patient, while still hearing the spoken word, can no longer comprehend what he hears. He has lost speech-understanding. The centre is also designated as the centre for word-deafness or sensory aphasia.

*c.* The **visual centre**, where the memory-pictures of written characters are stored, lies within the gyrus angularis. Injury of

the centre is followed by inability to recognize the printed or written letters, or to form words from them. The centre is also termed the centre for word-blindness or alexia.

*d.* A special *writing centre* is still often assumed to lie within the base of the gyrus frontalis medius. Its existence, however, is scarcely longer to be accepted, since the centre for writing is blended with the motor centre for the hand within the middle region of the precentral convolution.

These speech centres are, therefore, centres of memory, namely, for the movement-conceptions of articulation, the acoustic pictures of speech and the visual pictures of written speech. Individuals, who, in consequence of lesions of these centres, have lost the memory of the motor, auditory and visual conceptions of speech, are neither paralyzed, deaf, nor blind, but only wanting in speech-understanding. We are, therefore, warranted in assuming the existence of memory centres beside the projection centres; further, it must be noted, that the projection centres serve not only sensation and innervation, but also memory, and, on the other hand, that the regions adjoining the projection centres are not to be regarded as exclusive commemorative centres, since the existence of projection tracts to them has been proven.

Concerning the association function of the cerebrum, we must assume that the binding together of conceptions or recollections of the same kind occurs in the cortex within the individual-cortical fields, but that all the higher association processes are connected with the collective activity of many, perhaps of all, the cortical regions.

Finally, it must be especially emphasized, that the two cerebral hemispheres are functionally by no means identical. In connection with localization of the speech centre, it has been pointed out, that in right-handed individuals the left hemisphere is concerned. Not only for speech does the left hemisphere outweigh the right, but also for manipu-

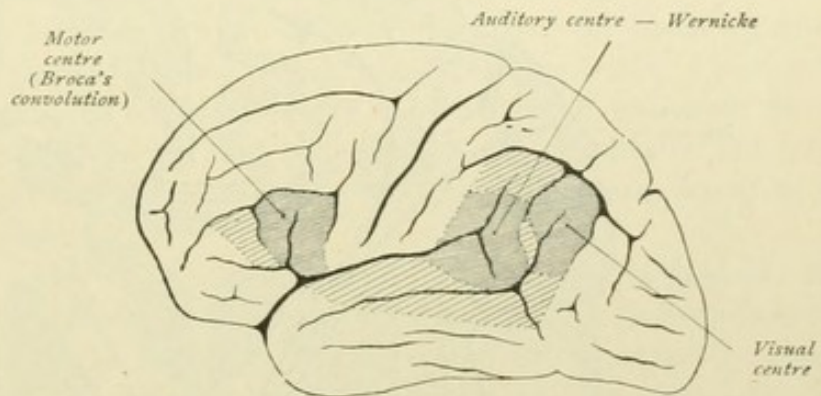


FIG. 121.—Cerebral localization. Speech centre.



lation. For proof of this we are indebted especially to the investigations of Liepmann, who has made us acquainted with the clinical picture of apraxia. By apraxia is understood the inability to execute the appropriate movements during continued motion; that is, the apraxic patient is still able to carry out certain simple movements, as flexing, lowering, raising or extending the arm, but has lost the ability to perform combinations of consecutive movements, such as made in greeting, beckoning, or threatening. Such expressive movements are executed in an entirely abnormal manner, likewise the imitation

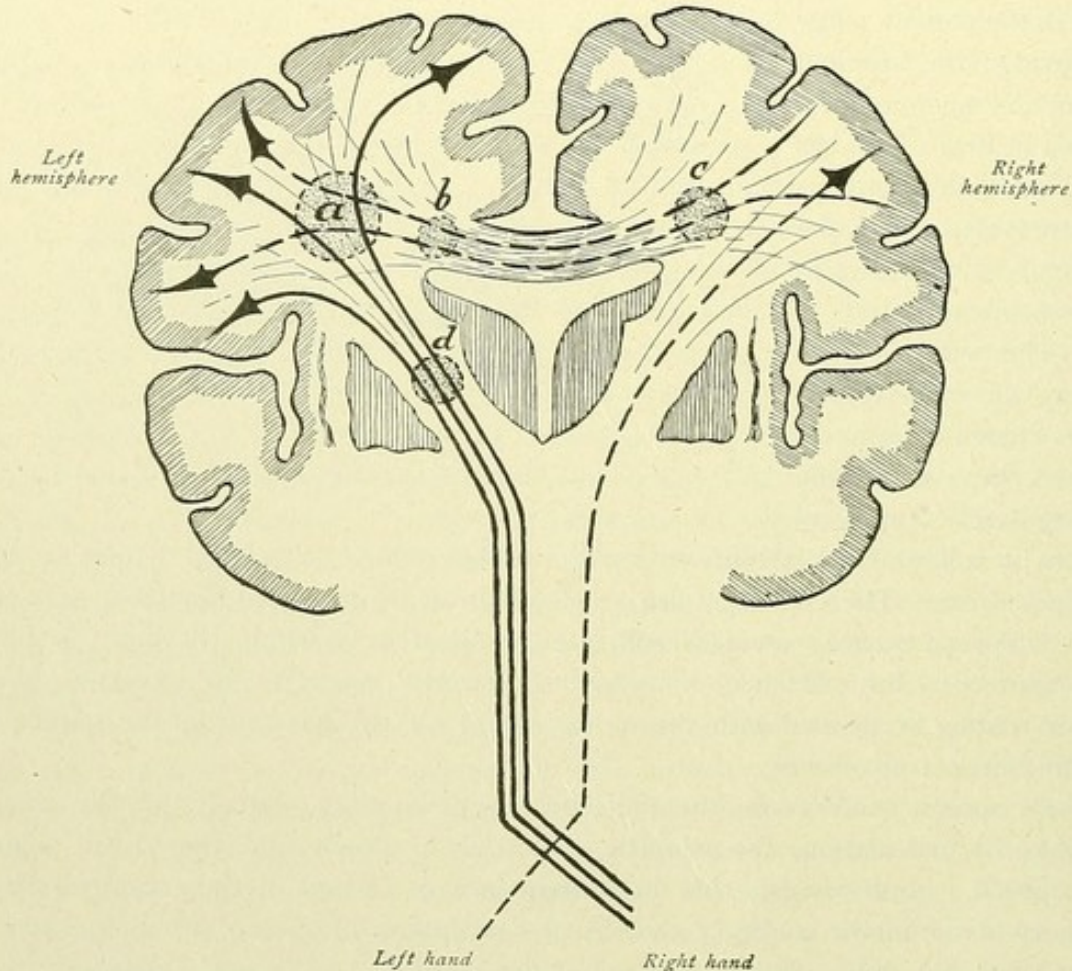


FIG. 122.—A lesion in *a* causes paralysis on the right side and dyspraxia, or impaired combination-movement, on the left; lesions in *b* and *c* cause dyspraxia on the left side; lesion in *d* causes paralysis on the right side.

of definite movements, and objects are no longer properly used or handled. In many lesions of the left hemisphere, followed by paralysis and apraxia of the right hand, a similar affection of the left hand may be recognized. Moreover, in numerous cases of extensive lesion of the corpus callosum, dyspraxia of the left hand is present. According to Liepmann, one is, therefore, warranted in assuming that the recollection of certain acquired dexterities and also the supervision of the execution of the same are in predominating degree concerns of the left hemisphere, which are conveyed to the right hemisphere by means of the corpus callosum.



## GENERAL DIVISION OF THE CONDUCTION PATHS.

The entire nervous system is built up of nervous units or neurones. With regard to their physiological tasks, the neurones may be divided into two chief groups, those which conduct impulses centrifugally and those which conduct centripetally.

The *centrifugal paths* serve to convey impulses from the central nervous system to peripheral organs, especially to the organs of movements or the muscles. These may, in a general way, also be called *motor paths*. The *centripetal paths*, on the contrary, convey impulses coming from the periphery to the central nervous system. By means of them we receive information of what goes on in nature outside of our bodies (higher sense-nerves); they bring us, however, also information of the processes, which are taking place within all the organs of our own bodies, information of which we are in part conscious and in part unconscious, the latter impulses being continually active in regulating the most diverse functions of our bodies. The centripetal paths are also, in a general way, designated as *sensory paths*.

It is particularly to be noted, that, as a rule, more than a single neurone is concerned in the constitution of the afferent and efferent paths, and that these are made up of two, three or several neurones in sequence. In this way, for example, the great cortico-muscular paths, by means of which voluntary movements of the musculature of the extremities are called forth, consist of two neurones. The first neurone extends from the motor cortical centre through the brain-stem to the spinal cord, where it ends within the gray substance of the anterior horn. The second neurone extends from the anterior horn of the cord to the muscle. In like manner, the sensory path is composed of several neurones, which conduct impulses from the periphery, as for example the integument of the leg, through the peripheral nerves, the spinal cord and the brain-stem to the sensory region. The first neurone conducts the impulse from the periphery to the spinal cord or to the posterior column nuclei, the second from the cord or the nuclei of the posterior column to the thalamus, and the third neurone arises in the thalamus and ends in the cerebral cortex. Owing to the insertion of further neurones, the entire make-up may become still more complicated, in this manner longer or indirect paths being formed in addition to the shorter direct ones. Since the motor and sensory paths conduct impulses from the centre to the periphery and, conversely, from the periphery to the centre, that is similarly "project," these paths are also called *projection tracts*.

Two additional important connecting links, the *association conduction* and the *reflex conduction*, exist between the motor and sensory paths. They are established by means of intercentral tracts. Through the **reflex conduction**, a reflex movement, the reflex, is liberated without the accompaniment of psychic processes. This conduction is effected by the so-called *reflex collaterals*, although individual neurones, intercalated between the centripetal and centrifugal tracts, may also participate. Let us take as an example of a simple reflex, the patellar or the corneal reflex. The patellar reflex is manifested by a contraction of the quadriceps muscle and extension of the leg, in response to stimulation of the sensory nerves in the quadriceps tendon, as when, for example, the tendon is struck with the percussion hammer below the patella, while the leg is relaxed and dependent. This entire phenomenon is carried out by the following paths: the impulse is carried from the tendon of the muscle to the spinal cord, by way of the



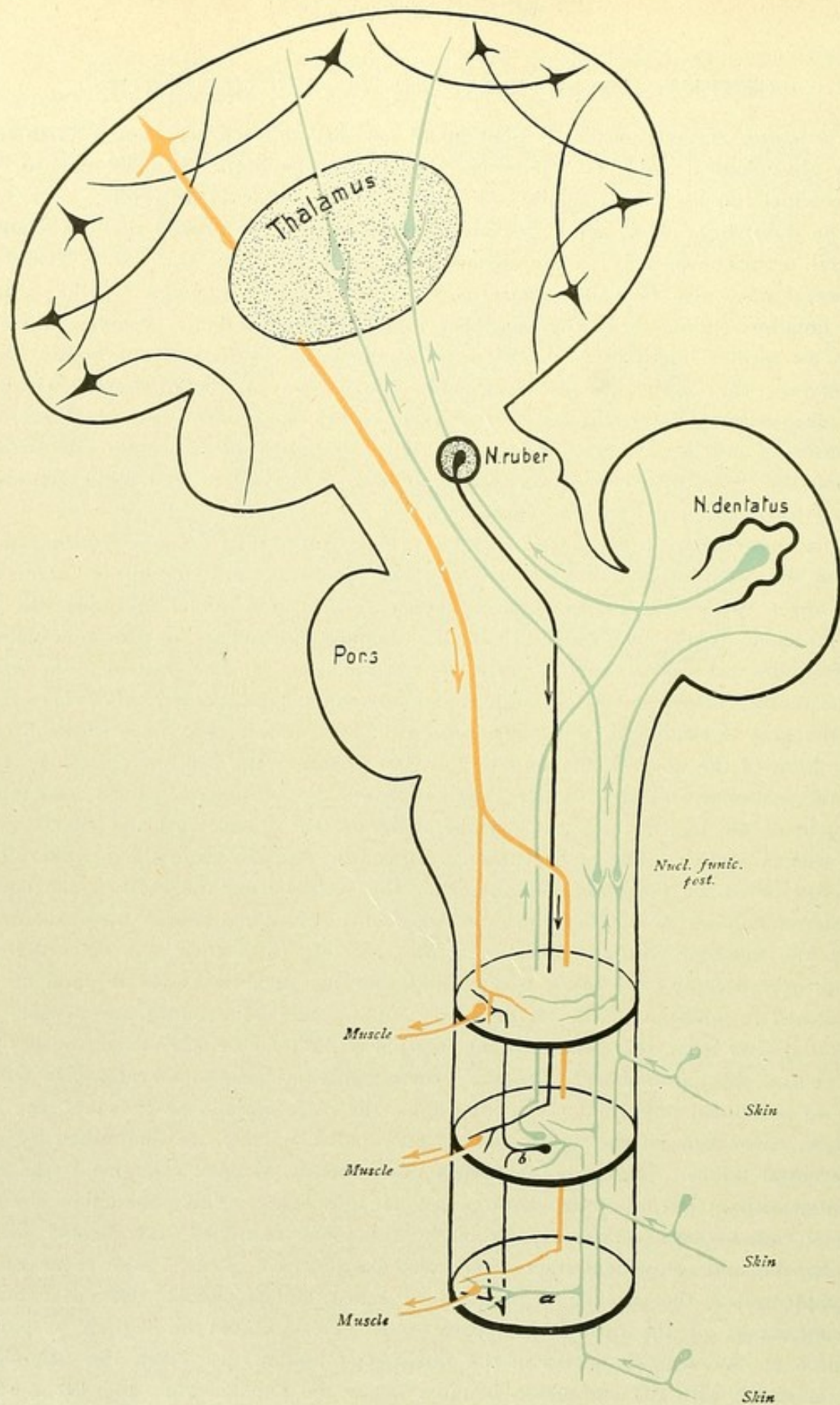


FIG. 123.—Schematic representation of the physiologically different conductions. Red, centrifugal tracts; blue, centripetal tracts; black, intercentral tracts.



spinal ganglion, by the sensory or afferent nerves. On entering the spinal cord, the sensory fibre divides into an ascending and a descending branch, which branches subsequently end within the gray substance of the cord, or, as in the case of the ascending branch, first within the nuclei of the posterior column. Before dividing into these branches, however, the entering sensory fibre gives off a delicate collateral branch, a reflex collateral, which runs to the anterior horn and there ends. Similar reflex collaterals, moreover, are also given off from the ascending primary branch, as shown in Fig. 123, *a*. By means of these reflex collaterals, the impulse may be directly transferred to motor anterior horn-cells and thence conveyed by motor fibres to the muscle. In a similar manner the corneal reflex or tactile lid-reflex occurs. This reflex consists in contraction of the *M. orbicularis oculi* on touching the integument of the eyelid, the conjunctiva or the cornea. The afferent path is here the ophthalmic branch of the *N. trigeminus*. From the sensory trigeminal fibres entering the pons, collateral branches are given off, which pass as reflex collaterals to the nucleus of the *N. facialis*. The efferent path lies within the ocular facial.

In place of the reflex collaterals, however, individual neurones may transfer the impulse from the sensory to the motor tracts. For example, a sensory fibre on entering the spinal cord may transfer the impulse first to cells, whose axis-cylinders do not leave the cord, as do those of the motor anterior horn-cells passing to the periphery, but enter the white substance and divide into ascending and descending branches. These division-branches, after a longer or shorter course, end within the gray substance of cord-segments of higher or lower levels (Fig. 123, *b*). First within these segments occurs the transference to true motor cells. In this manner, not only the motor cells of the same level are impressed, but the stimulus is carried to higher and lower lying cord-segments and, consequently, transferred to a larger number of motor neurones.

The further possibility exists, that the impulse may be conducted from the spinal cord by the ascending tracts to the higher lying subcortical centres and that first here the transference to the motor paths occurs. The resulting movements are mostly more complicated than the simple reflexes, although, as in the case of the latter, they are unconsciously executed. As shown in Fig. 123, the impulse may be conducted through certain paths from the spinal cord to the cerebellum, thence to the nucleus ruber, and from the latter be carried downward to the cord and, finally, to the muscle.

The second intercentral connection between the sensory and motor parts is furnished by **association conduction**. By means of the latter, a conscious voluntary action is rendered possible, by means of the system of *association fibres* within the cerebral hemispheres. An impulse is carried through the sensory path as far as the cerebral cortex and here transferred to cells within a certain sense-centre; in these cells, it may be assumed, the material stimulus is released, which corresponds to psychic sensation. One may simply imagine, that from this locality the impulse is transferred by an additional neurone directly to the cells in the motor cortical region and thence farther carried by the motor tract. The cortical connection is, however, far more complex, since only after traversing numerous intermediate neurones does the impulse finally reach the motor centre and from there pass to the motor path, since coöperation of the various cortical centres must be assumed in explanation of the complex psychic processes.



## CONDUCTION PATHS OF THE TELEENCEPHALON.

We distinguish two chief kinds of fibre-tracts, association fibres and projection fibres.

The **association fibres** serve, firstly, to bind together neighboring or remote regions of one hemisphere and, as such, may be designated as the association fibres proper, or *association fibres* in the strict sense. Secondly, they serve to connect the regions of both hemispheres and, in this capacity, are termed *commissural fibres*.

The **projection fibres** unite the cortex of the hemispheres with the lower lying parts of the brain and with the spinal cord—*centrifugal* or *corticofugal tracts*; the projection fibres also include those passing in the opposite direction from the lower parts and ending within the cortex—*centripetal* or *corticopetal tracts*.

## I. ASSOCIATION FIBRES.

These are distinguished as short and long fibres. The short fibres unite adjoining convolutions and are also called intralobular or U-fibres, or *fibrae propriae* or *arcuatae*. The long fibres connect the regions of one hemisphere which are more or less separated and are also termed *interlobar bundles*. The most important of these are:

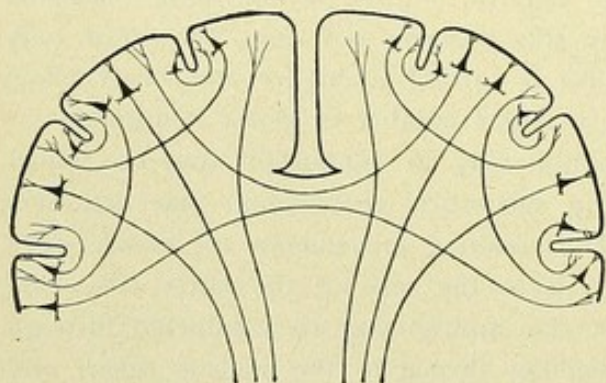


FIG. 124.—Association fibres, commissural fibres and projection fibres.

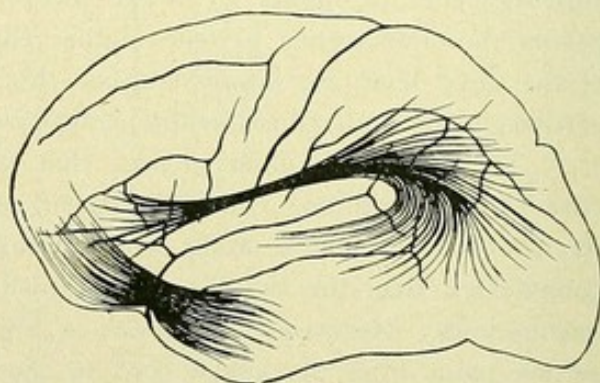


FIG. 125.—Association fibres. Fasciculus uncinatus and fasciculus longitudinalis superior.

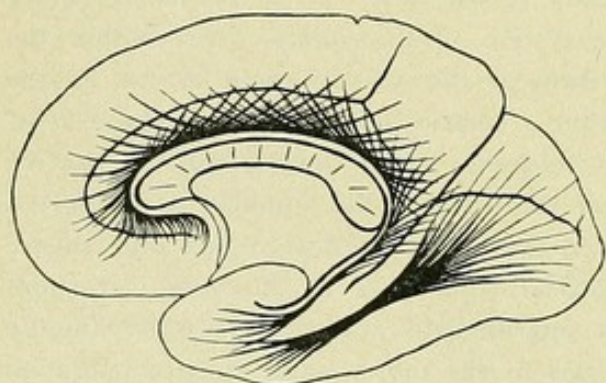


FIG. 126.—Association fibres. Cingulum and fasciculus longitudinalis inferior.

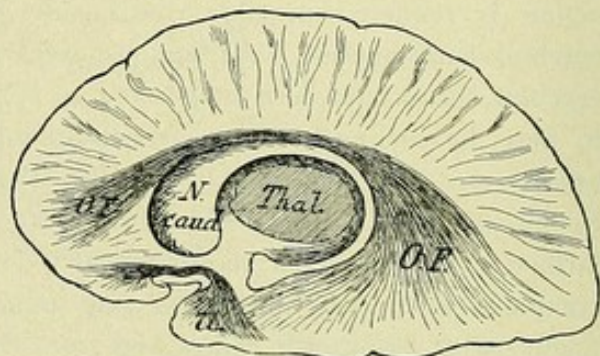


FIG. 127.—Association fibres. O.F., fasciculus occipitalis; U., fasciculus uncinatus.



a. The *fasciculus uncinatus*, connecting the orbital surface of the frontal lobe with the temporal pole and the anterior part of the gyri temporales.

b. The *fasciculus longitudinalis superior* or *arcuatus*, connecting the operculum frontale and parietale with the lobulus parietalis inferior, the occipital lobe and the posterior part of the upper and middle temporal convolutions.

c. The *fasciculus longitudinalis inferior*, connecting the occipital pole, the cuneus, the gyrus lingualis and fusiformis with the temporal pole.

d. The *cingulum*, also called the *fornix periphericus*, running within the gyrus fornicatus, as association bundles of the rhinencephalon.

e. The *fasciculus fronto-occipitalis* (Forel-Onufrowicz), running immediately beneath the corpus callosum, over the nucleus caudatus and within the corona radiata, and connecting the frontal with the occipital lobe. According to recent investigations, this bundle is to be regarded rather as a projection fibre-system.

f. The *association bundles*, which pass through the capsula externa and extrema.

## II. COMMISSURAL FIBRES.

These unite both hemispheres and include :—

a. The *corpus callosum*, connecting the cortical districts of the pallium.

b. The *commissura anterior*, connecting the districts belonging to the rhinencephalon.

c. The *commissura hippocampi*, connecting the same districts as the preceding.

The fibres constituting the corpus callosum connect the cortical districts of one hemisphere with those of the other hemisphere and form the *radiatio corporis callosi*, which is subdivided into a pars frontalis, pars parietalis, pars temporalis and pars occipitalis (page 40). The commissura anterior includes a *pars anterior* or *olfactoria* and a *pars posterior* or *interhemisphaerica*. The pars olfactoria connects the lobus olfactorius of one side with that of the opposite side. The pars interhemisphaerica connects the two gyri hippocampi with each other. The commissura hippocampi, also termed the *fornix transversus*, or *lyra Davidis*, connects the two hippocampi with each other.

## III. PROJECTION FIBRES.

These unite the cortex of the telencephalon with the lower lying parts of the brain, as the corpus striatum, thalamus, regio subthalamica, corpora quadrigemina, pons and medulla oblongata, and with the spinal cord. They arise from the crest of the convolutions and form collectively the *corona radiata*. To them also belong, as already noted, fibres which ascend to the cortex from lower parts of the brain. Short and long tracts are distinguished.

### A. SHORT TRACTS.

1. *Fibres passing from all parts of the cortex to the thalamus and, vice versa, from the thalamus to the cortex—tractus cortico-thalamici and thalamo-corticales* or the *peduncles of the thalamus*. Such connections include :

a. The cortex of the frontal lobe with the anterior end of the thalamus ;



b. The cortex of the central convolutions and of the anterior part of the parietal lobe with the outer and inner thalamic nuclei;

c. The cortex of the posterior part of the parietal and of the occipital lobes with the pulvinar;

d. The occipito-temporal lobe with the ventral and medial parts of the thalamus.

An important ascending tract from the thalamus to the cortex is the *tegmental tract*, or *tegmental radiation*. The fibres pass from the ventral region of the thalamus, partly through the internal capsule direct to the cortex and partly first through the lenticular nucleus, subsequently joining the fibres following the internal capsule. The course of those traversing the lenticular nucleus is shown in Fig. 129; compare also Fig. 154. Fibres pass also in the opposite direction, from the cortex to the ventral part of the thalamus. The tegmental path is also designated as the *tractus cortico-tegmentalis*.

2. *Fibres passing from the cortex of the visual centre to the superior colliculus and to the corpus geniculatum laterale and, in the opposite direction, from the lateral geniculate body to the cortex.* The corpus geniculatum laterale and the pulvinar, together with the superior colliculus, constitute the primary visual centre, the connection of these parts with the cortical visual centre within the occipital lobe forming the *optic radiation* of Gratiolet. In this connection it is to be noted, that the fibres to the cortex pass only

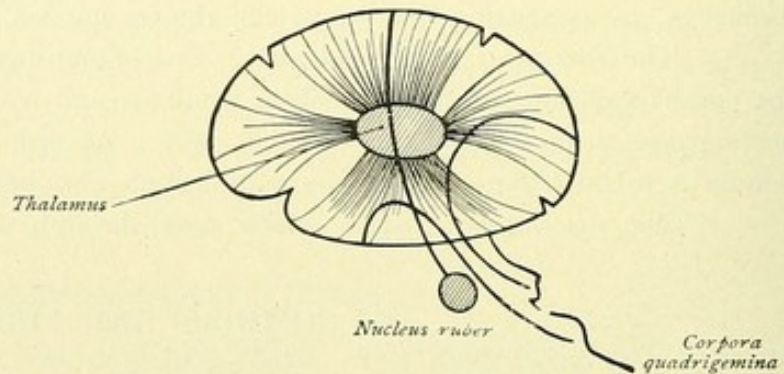


FIG. 128.—Projection tracts. Stalks of the thalamus. Fibres to the anterior and posterior corpora quadrigemina and to the nucleus ruber.

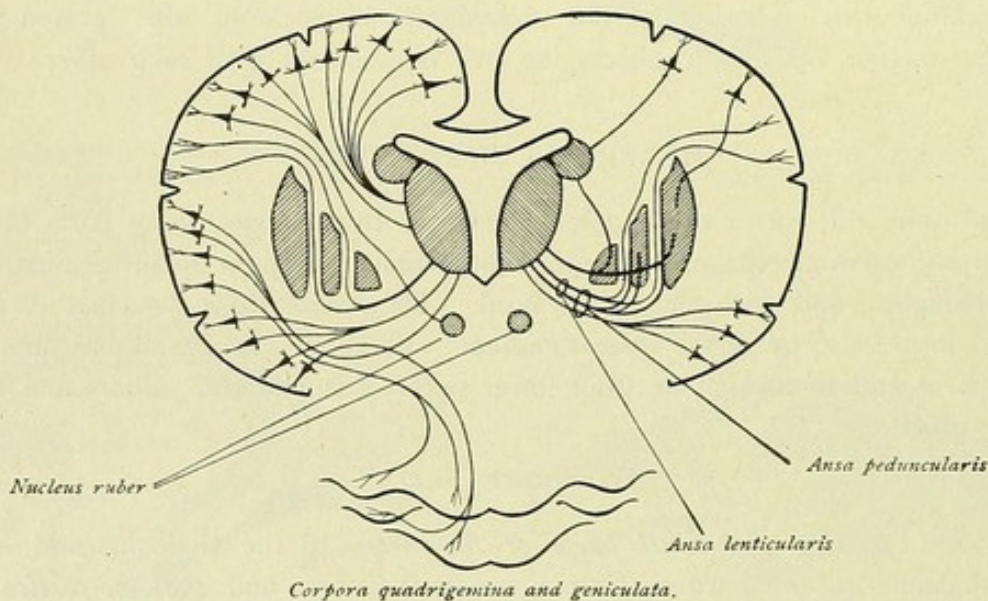


FIG. 129.—Short projection tracts. Fibres to thalamus, to nucleus ruber and to the corpora quadrigemina. Fibres of the tegmental tract, which proceed from the thalamus and traverse the lenticular nucleus. On the right, fibres to the nucleus caudatus and to the putamen of the lenticular nucleus.



from the corpus geniculatum laterale, the chief end-station of the tractus opticus, and from the pulvinar thalami, fibres from the superior colliculus to the cortex not being authenticated.

3. *Fibres passing from the cortex of the auditory centre to the inferior colliculus and to the corpus geniculatum mediale and, reversed, from the latter to cortex.* As in the case of the superior colliculus, so also in that of the inferior, the presence of a quadrigemino-cortical tract is unproven.

4. *Fibres passing from the cortex (frontal lobe, regio opercularis) to the nucleus ruber.*

5. The *fornix* passing, as the equivalent of a bundle of the corona radiata, from the hippocampus to the diencephalon, the fibres ending within the corpus mamillare.

#### B. LONG TRACTS.

The fibres pass from the cortex through the internal capsule to the crista or basis pedunculi cerebri, to end within the pons, the medulla oblongata and the spinal cord. The chief tracts are:—

1. *The frontal pontile tract.* The fibres arise within the cortex of the frontal lobe, traverse the posterior part of the anterior limb of the internal capsule

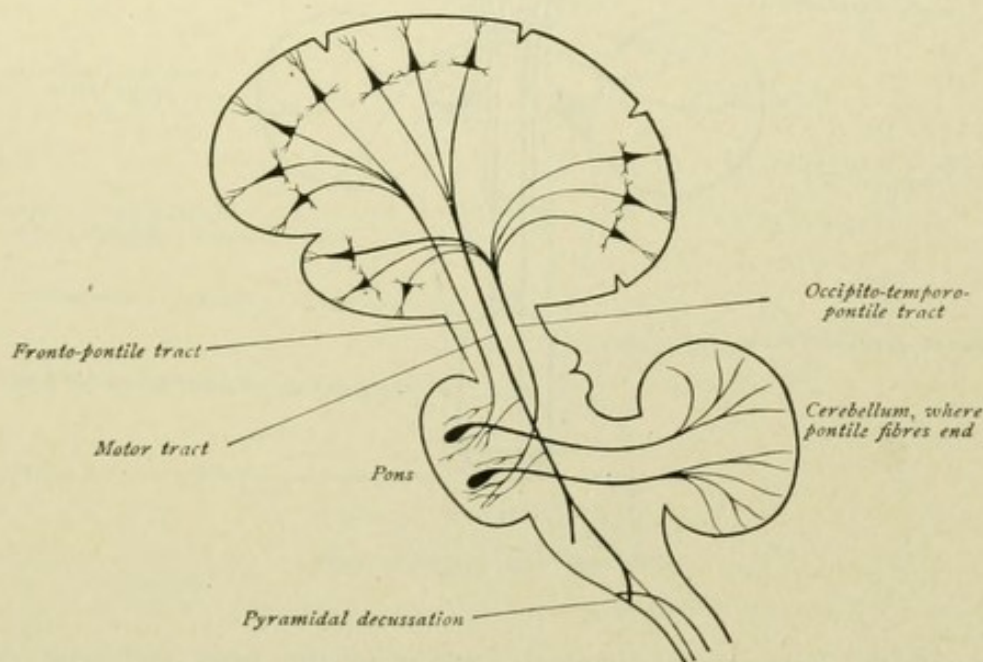


FIG. 130.—The long projection tracts.

form the inner fifth of the basis pedunculi and end within the pons in the pontile nucleus.

2. *The occipito-temporal pontile tract.* The fibres arise within the cortex of the occipital and temporal lobes, traverse the posterior segment of the internal capsule, form the outer fifth of the basis pedunculi and end within the pons in the pontile nucleus. The *tractus corticis ad pontem* further is joined by the *tractus ponto-cerebellares*, connecting the pons with the cerebellum (Figs. 130 and 133).



3. *The motor tract.* The fibres arise within the cortex of the precentral convolution and the paracentral lobule, pass through the knee and anterior two-thirds of the posterior limb of the internal capsule, form the middle three-fifths of the basis pedunculi, and continue to the medulla oblongata and the spinal cord. The entire motor tract comprises the *cortico-bulbar* and *cortico-spinal tracts* (Fig. 132).

a. The *cortico-bulbar tract* or *tract of the motor cerebral nerves.* The origin of the fibres is known for only the facial and hypoglossal nerves, the fibres of which arise within the cortex of the lower part of the precentral convolution. The tract

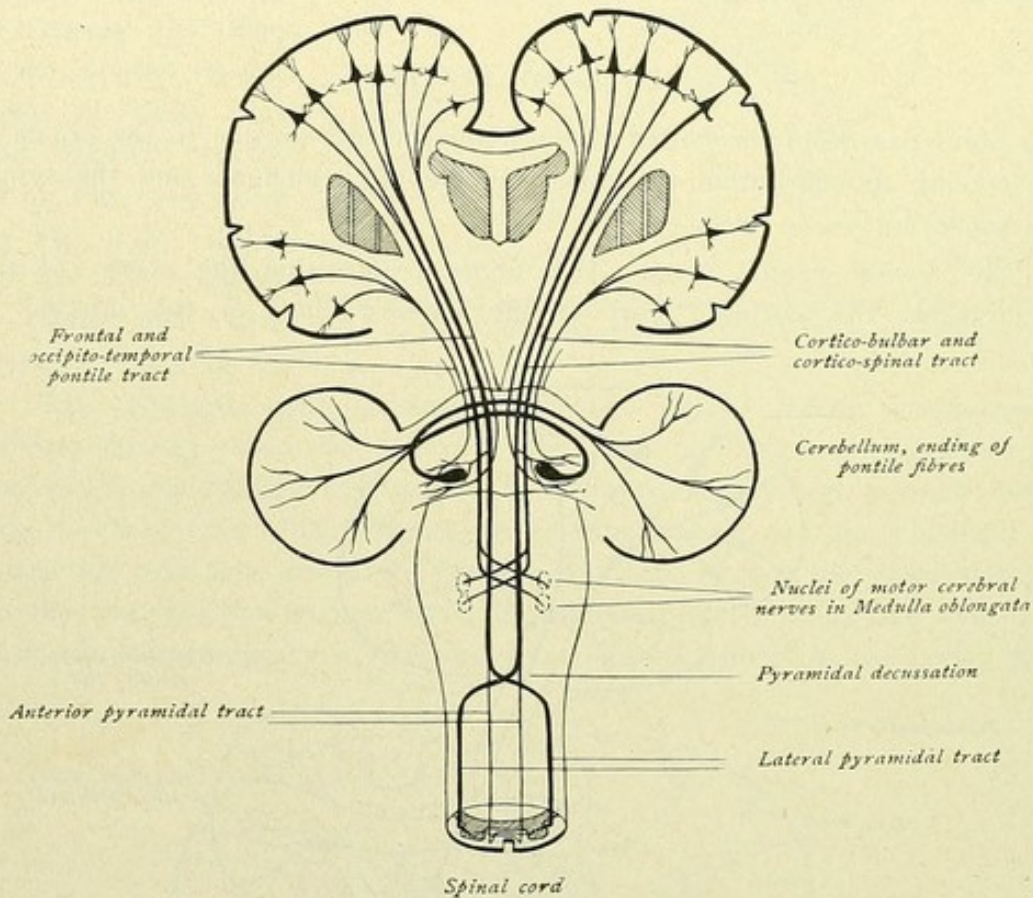


FIG. 131.—Long projection tracts.

passes through the knee of the internal capsule to the basis pedunculi cerebri and ends in the nuclei of the motor nerves of the opposite side.

b. The *cortico-spinal tract* or *tract of the motor spinal nerves.* The fibres of this path, also known as the *tractus cerebro-spinalis* or the *pyramidal tract*, take origin in the cortex of the lobulus paracentralis and of the upper and middle parts of the motor region of the precentral convolution, traverse the anterior two-thirds of the posterior limb of the internal capsule, and continue through the basis pedunculi and the pons to the medulla oblongata. At the transition of the medulla to the spinal cord, the fibres of the pyramidal tract cross to the opposite side, forming the *pyramidal decussation*. The latter, however, is not complete, since a small portion of the fibres continues uncrossed



in the anterior column of the spinal cord as the *fasciculus cerebro-spinalis anterior* or *anterior pyramidal tract*. The termination of these fibres is within the anterior horn of the spinal cord and, moreover, in the anterior cornu of the opposite side, the fibres crossing through the anterior commissure. The larger part of the fibres crosses to the opposite side, and descends in the lateral column of the spinal cord as the *fasciculus cerebro-spinalis lateralis* or *lateral pyramidal tract*, to end in the anterior horn of the same side.

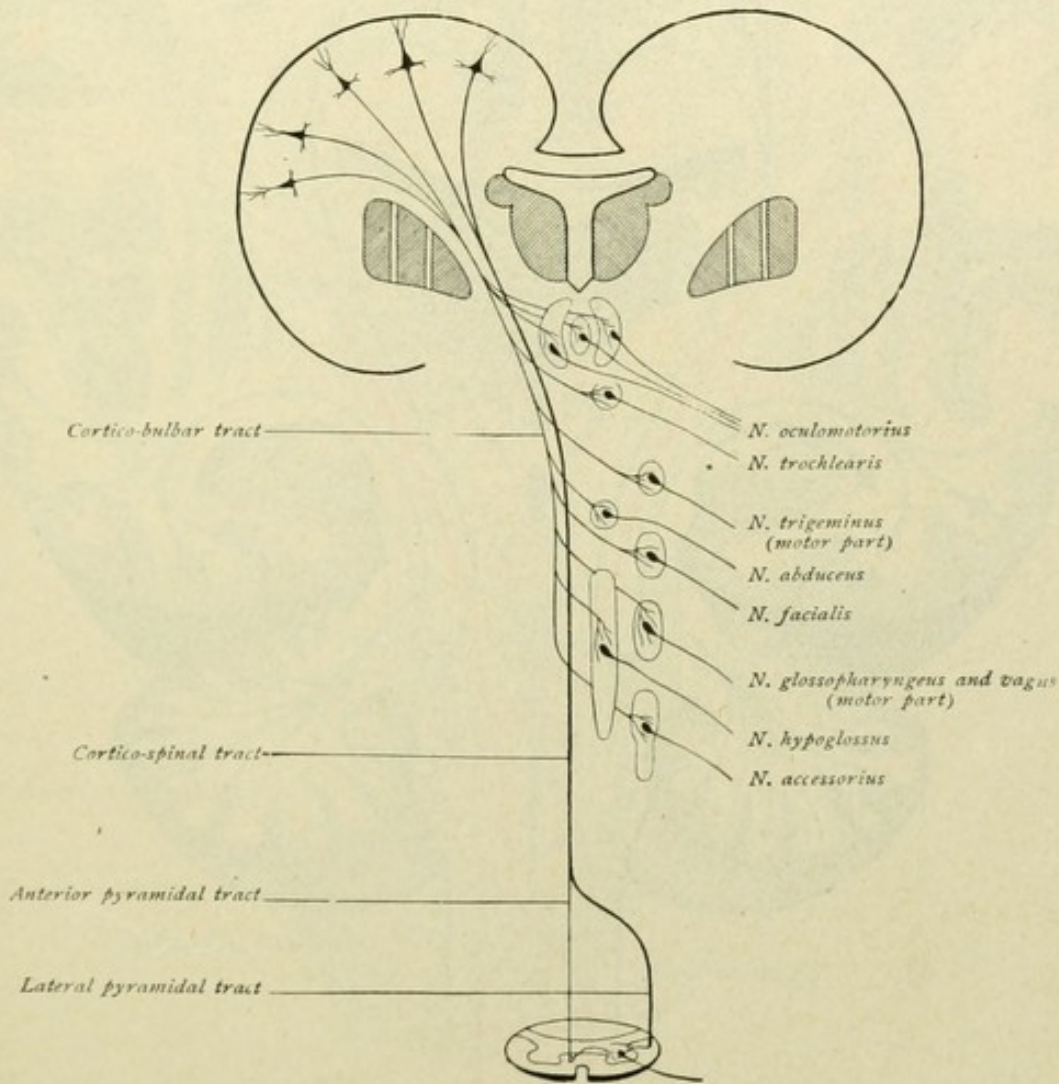


FIG. 132.—Cortico-bulbar and cortico-spinal tracts.

The course of the motor tract explains the fact, that movements induced by stimulation of the motor cortical region occur chiefly in the muscles of the opposite half of the body, or that injury of the central neurones of the motor tract is followed by paralysis of the muscles of the opposite half of the body. Such paralyse of one side (hemiplegia) are usually caused by lesions within the capsula interna, less frequently by lesions within the cerebral peduncle or the pons. Since the speech-tract takes its origin within the left hemisphere, lesions of the motor paths within the left hemisphere, or right-sided hemiplegias, are usually associated with disturbances of speech.



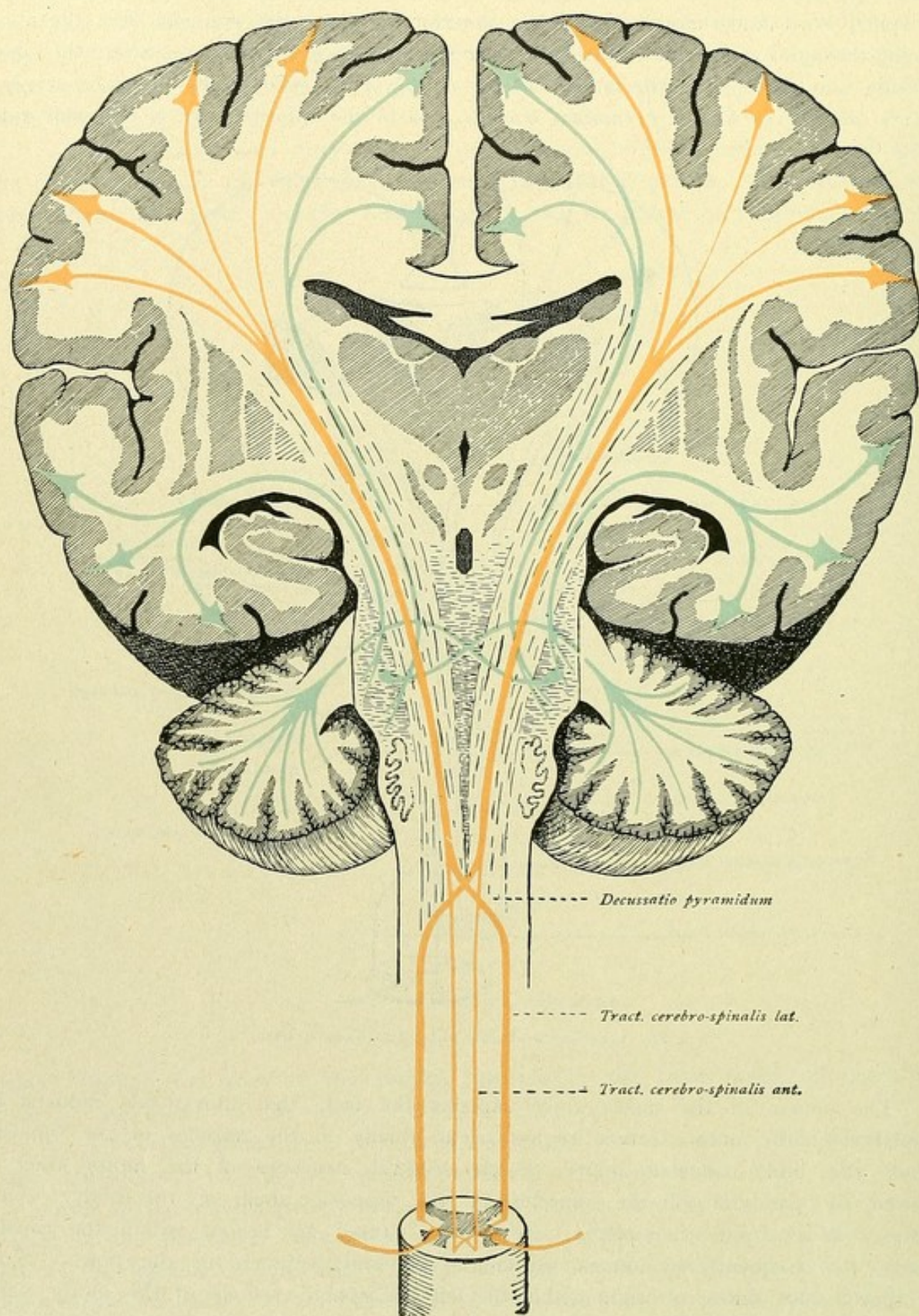


FIG. 133.—Motor tract (red) and the frontal and occipito-temporal pontile tracts (blue); these paths are continued by the ponto-cerebellar tract (also blue).



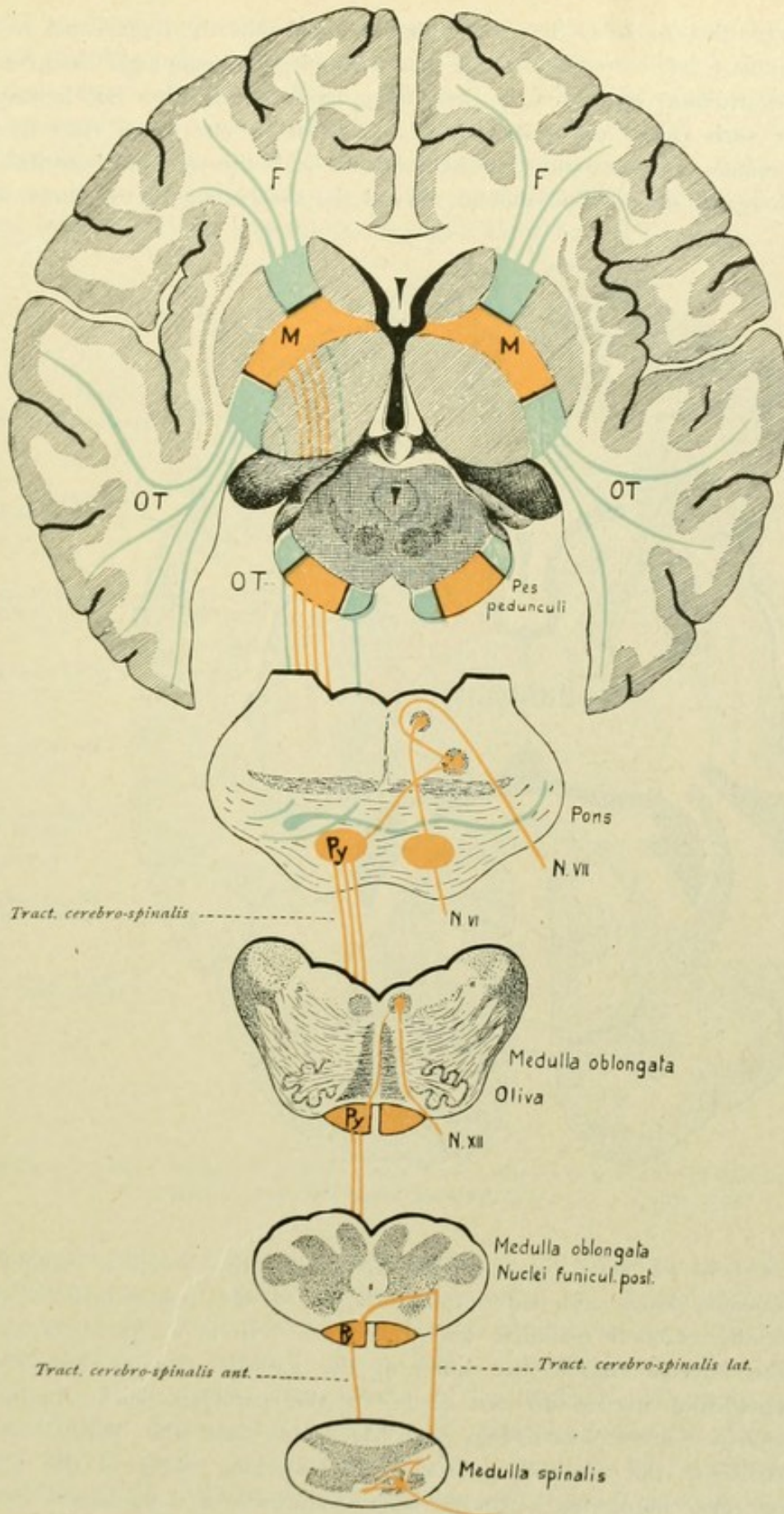


FIG. 134.—Motor tract (red) and the frontal (*F*) and the occipito-temporal (*OT*) pontile tract (blue).



In Fig. 136, the course of the motor tract is schematically represented to explain the most important forms of paralysis. In total hemiplegia, hemiplegia completa (Fig. 136, *a*), the destruction of an entire descending motor tract from one hemisphere is concerned. In such cases, the lesion usually lies within one motor tract somewhere along the brain-stem between the internal capsule and the pyramidal decussation in the medulla oblongata, since within this stretch all the descending motor fibres are com-

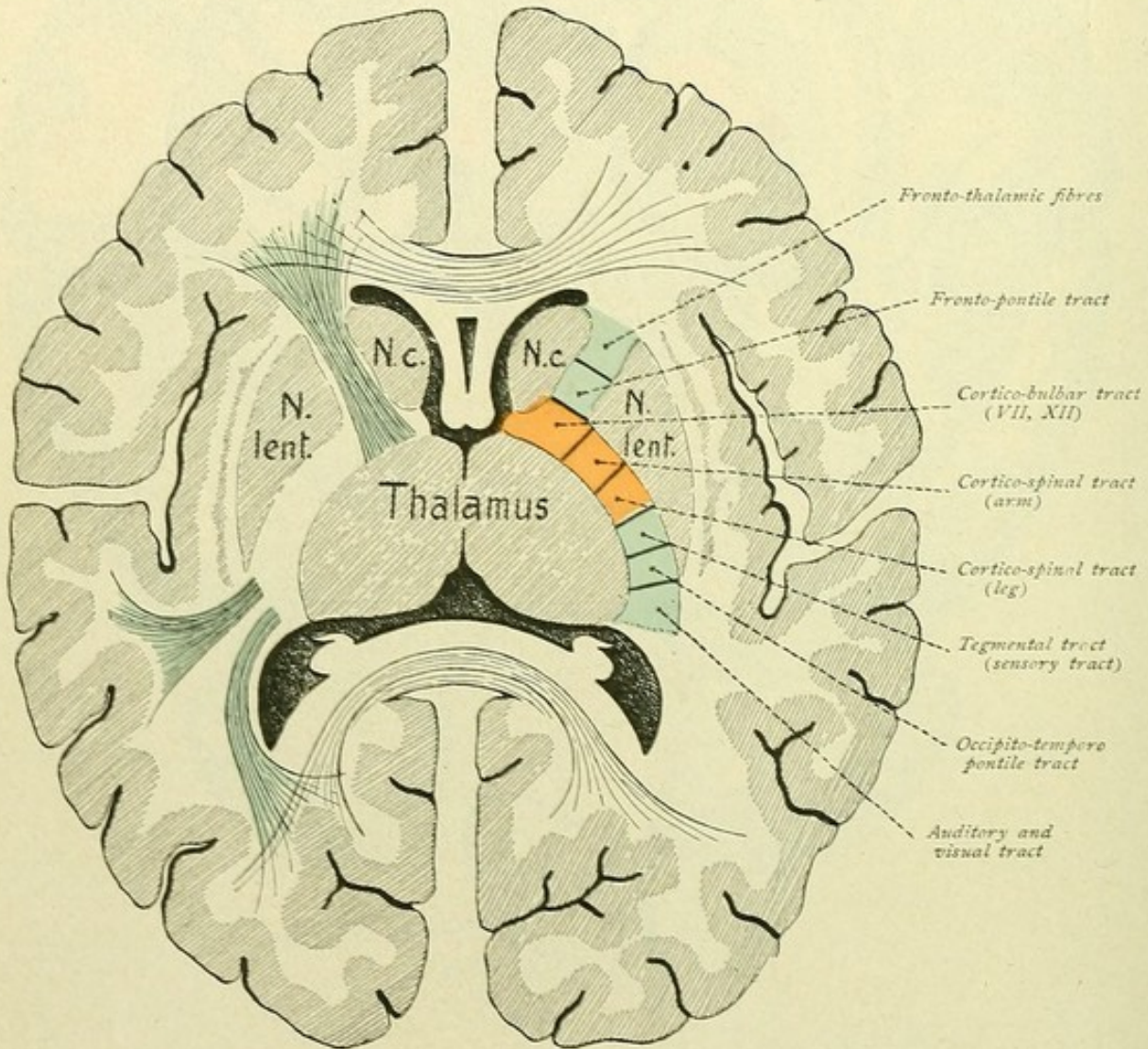


FIG. 135.—Course of the tracts through the internal capsule.

pressed into a field of small area. Most frequently the lesion is situated within the internal capsule (knee and anterior two-thirds of the posterior limb), less frequently within the cerebral peduncle and the pons. If in a lesion of the motor tract within the internal capsule the knee of the capsule remains uninvolved, the facial and hypoglossal nerves do not share in the paralysis, such condition constituting hemiplegia incompleta (Fig. 136, *b*). In case the lesion be located within the region of the cerebral peduncle, the emerging fibres of the oculomotor nerve are often also implicated. Under such conditions a homolateral oculomotor paralysis exists in conjunction with the crossed hemiplegia, the condition being



designated as hemiplegia alternans oculomotoria, or Weber's paralysis (Fig. 136, *c*). Hemiplegia alternans is also encountered in affections of the pons and in lesions within the range of the medulla oblongata. Thus, in pontile lesion, paralysis of the extremities on one side occurs with paralysis of the facial nerve on the other—hemiplegia alternans facialis or Gubler's paralysis (Fig. 136, *d*). Further combinations are: crossed limb-palsy with homolateral paralysis of the abducens, or crossed hemiplegia with homolateral hypoglossal or lingual paralysis.

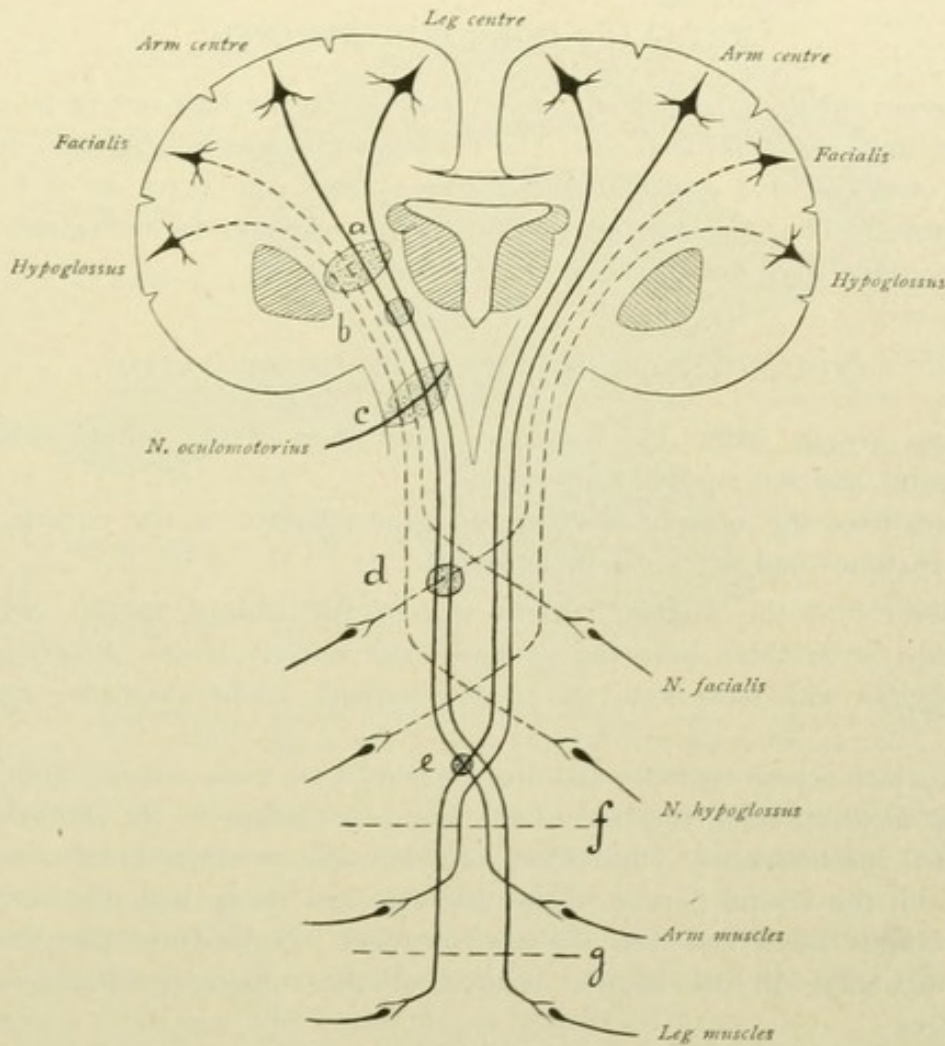


FIG. 136.—Schematic representation of the course of the motor tract, explaining the most important forms of paralysis.

Hemiplegias following complete destruction of the entire motor cortical region of one hemisphere are rare, by reason of the large extent of the motor centre. Cortical diseases are more frequently limited to circumscribed areas and paralyzes resulting from cortical lesion are confined, as a rule, to particular portions of one-half of the body. In such cases one speaks of monoplegia, or, more definitely, as monoplegia cruralis, monoplegia brachialis, or monoplegia facialis, according to the involvement of the motor centre for the leg, arm, or face respectively. Such palsies are frequently associated with sudden seizures of convulsions (cortical or Jacksonian epilepsy).



A lesion of both pyramidal tracts descending in the anterior and lateral columns of the spinal cord leads to paraplegia or paralysis of both upper or lower extremities (Fig. 136, *f, g*)—paraplegia brachialis or superior and paraplegia cruralis or inferior. In very rare cases, the lesion may involve the pyramidal decussation in such manner, that the fibres for one extremity are interrupted above and those for the other below their place of crossing. In such cases hemiplegia cruciata results, that is, paralysis of the arm on one side and of the leg on the other (Fig. 136, *e*).

### RADIATIO CORPORIS STRIATI.

The corpus striatum is divided by the internal capsule into two parts, the *nucleus caudatus* and the *nucleus lenticularis*. The last-named nucleus is subdivided into a lateral portion, the *putamen*, and a medial, the *globus pallidus*, the latter, in turn, exhibiting smaller segments. The separation of the lenticular nucleus into the individual components is effected by white fibre-sheets, the *laminae medullares*.

### CONNECTIONS OF THE CORPUS STRIATUM.

*a.* Fibres arising within the cortex pass, as fibres of the corona radiata, to the nucleus caudatus and the nucleus lenticularis.

*b.* Fibres from the nucleus caudatus and the putamen of the nucleus lenticularis pass to the thalamus and the regio subthalamica.

The fibres from the caudate nucleus traverse the internal capsule and reach the globus pallidus, while those from the putamen pass directly to the globus pallidus and then run, together with those from the caudate nucleus, to the thalamus—*radiatio strio-thalamica*.

Fibres, which course ventrally and are augmented by those coming from the globus pallidus, pass medially along the base of the lenticular nucleus to the subthalamic region—*radiatio strio-subthalamica*. These fibres form the *ansa lenticularis* and come into relation partly with the ventral portion of the thalamus and partly with the corpus subthalamicum or corpus Luysi and with the nucleus ruber. Some fibres pass still lower, as far as the mid-brain, to the inferior colliculi of the corpora quadrigemina and the substantia nigra.

The *ansa lenticularis*, together with the inferior stalk of the thalamus which conveys chiefly fibres from the temporal lobe to the ventral and medial parts of the thalamus, forms the *ansa peduncularis* (Fig. 129).

## FIBRE-PATHS OF THE RHINENCEPHALON.

### I. PERIPHERAL TRACT.

This extends from the olfactory mucous membrane to the bulbus olfactorius. The impulse is conducted by the peripheral processes of the intraepithelial bipolar olfactory cells to the latter, and thence, by their central processes, *fila olfactoria*, to the glomeruli olfactorii.



## 2. CENTRAL TRACT.

**A. Connection of the bulbus olfactorius with the primary centres.** Within the glomeruli, the impulse is transferred to the olfactory brush of the mitral and brush cells; it then reaches the mitral or brush cells and thence, by means of their axones, is conducted centrally to the primary centres (Fig. 137). The bulbus olfactorius is, as it were, an intercalated ganglion, being the end-station of the peripheral tract and the

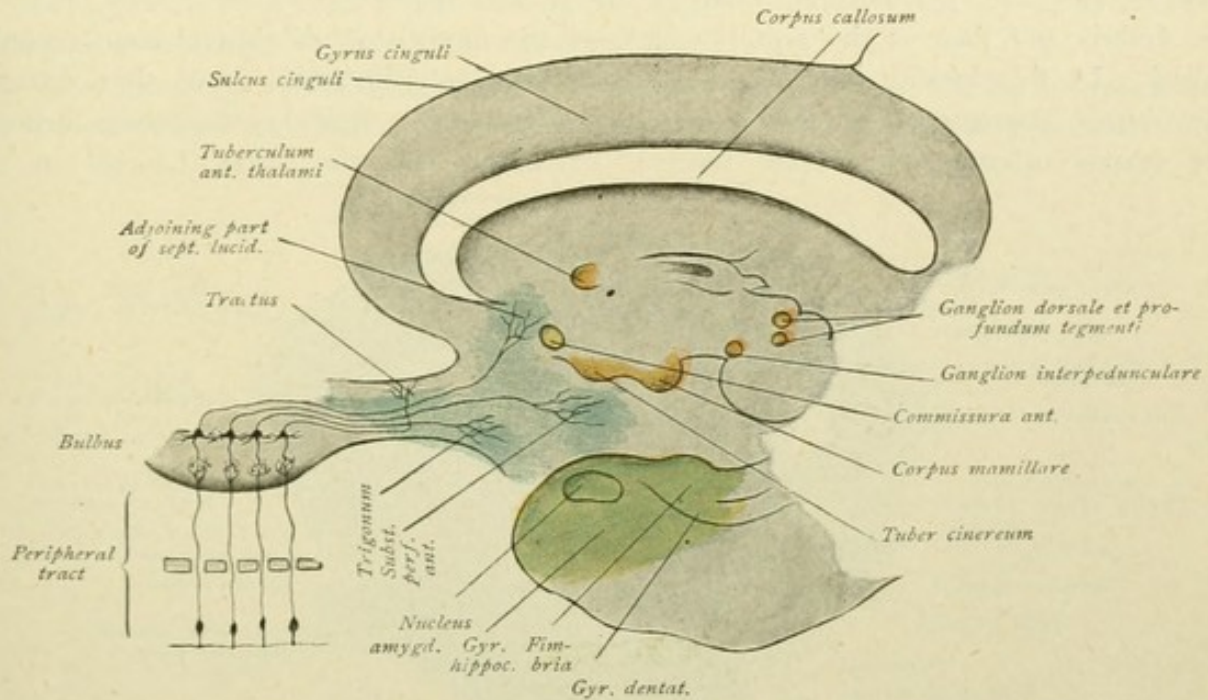


FIG. 137.—Fibre-tracts of the rhinencephalon. Peripheral tract: olfactory mucous membrane to olfactory bulb. Central tract: connection of the olfactory bulb with the primary centres.

starting point of the central tract. The primary centres include the gray substance of the tractus olfactorius and of the trigonum olfactorium, the substantia perforata anterior and the adjoining part of the septum lucidum.

**B. Connection of the primary centres with the secondary or cortical centres.** The secondary or cortical centres are: the gyrus hippocampi, the hippocampus and the gyrus dentatus. The connection is established by:

*a. The stria olfactoria lateralis.* The fibres pass from the trigonum olfactorium through the gyrus olfactorius lateralis to the anterior end of the gyrus hippocampi and terminate within the cortex of the same.

*b. The olfactory bundle of the hippocampus (Zuckerkanal).* The fibres arise within the trigonum olfactorium and the substantia perforata anterior, extend to the septum lucidum, are augmented by fibres from the septum and then pass backward through the fornix as far as the hippocampus.

*c. The stria Lancisii.* The fibres pass from the trigonum olfactorium as the stria olfactoria medialis towards the gyrus subcallosus, thence over the corpus callosum and through the gyrus dentatus to the hippocampus formation.

According to Dejerine, the *nucleus amygdalae* is also a cortical centre. With this nucleus a fibre bundle, the *taenia semicircularis*, stands in close relation. The fibres



arise within the substantia perforata anterior and the septum lucidum, are augmented by fibres coming from the anterior commissure, then extend convergingly toward the sulcus intermedius, where they run backward between the nucleus caudatus and the thalamus and end within the nucleus amygdalae. During the ascending anterior course of the bundle, fibres are given off at right angles and enter the thalamus (Fig. 138).

The **fornix** has already been referred to as the corona radiata bundle of the hippocampal formation. The fornix fibres arise from the pyramidal cells of the hippocampus and the polymorphic cells of the gyrus dentatus. They extend, first as the fimbria and then as the posterior limb of the fornix, toward the splenium corporis callosi. In this locality fibres pass across to the opposite fornix limb, thus forming the *fornix transversus* or the *commissura hippocampi*. During its course beneath the corpus callosum, the fornix receives accessions from the striae Lancisii in the

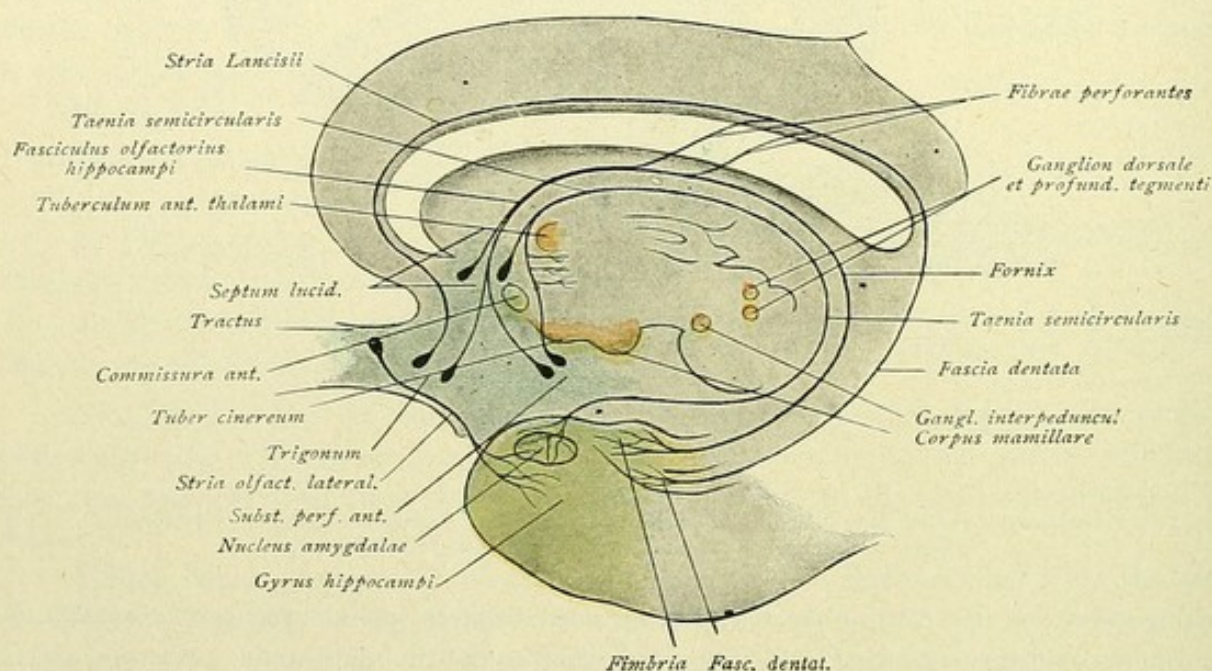


FIG. 138.—Fibre-tracts of the rhinencephalon. Connections of the primary centres with the secondary or cortical centres.

form of fibres which pierce the corpus callosum. These are known as the *fibrae perforantes* and constitute the *fornix longus* of Forel. In addition to those from the striae Lancisii, other *fibrae perforantes* from the gyrus fornicatus penetrate the callosum. The fornix fibres continue downward, as the *columnae fornicis*, behind the anterior commissure. The majority of the fornix fibres terminate within the corpus mamillare—*tractus cortico-mamillaris*; another part of the fibres, however, passes to the stria medullaris thalami and with these to the ganglion habenulae, as the *tractus cortico-habenularis*.

Some fibres of the fornix reach their end-station by another route. Such aberrant fibres branch off either above the foramen Monroi, passing in front of the anterior commissure, or at the level of the tuber cinereum, and course to the corpus mamillare as the *stria alba tuberis* of Lenhossék (page 57).

The paths proceeding from the corpus mamillare, as well as those related to the ganglion habenulae, may here be considered.



The **corpus mamillare** consists of two nuclei or ganglia, a medial and a lateral one. The medial ganglion forms the chief portion, while the lateral ganglion is small and arches around the medial. From the medial ganglion arises the *fasciculus mamillaris princeps*, which extends obliquely upward and outward. The fibres of this bundle divide into two branches, one of which becomes the *fasciculus thalamo-mamillaris* or *tractus mamillo-thalamicus*, the other the *fasciculus tegmento-mamillaris* or the *tractus mamillo-tegmentalis* (Fig. 139).

The *fasciculus mamillo-thalamicus*, or the bundle of Vicq d'Azyr, ends with freely separated fibres within the nucleus anterior thalami.

The *fasciculus mamillo-tegmentalis*, the tegmental bundle of the corpus mamillare of Gudden, passes backward and enters the tegmentum of the cerebral peduncle. The

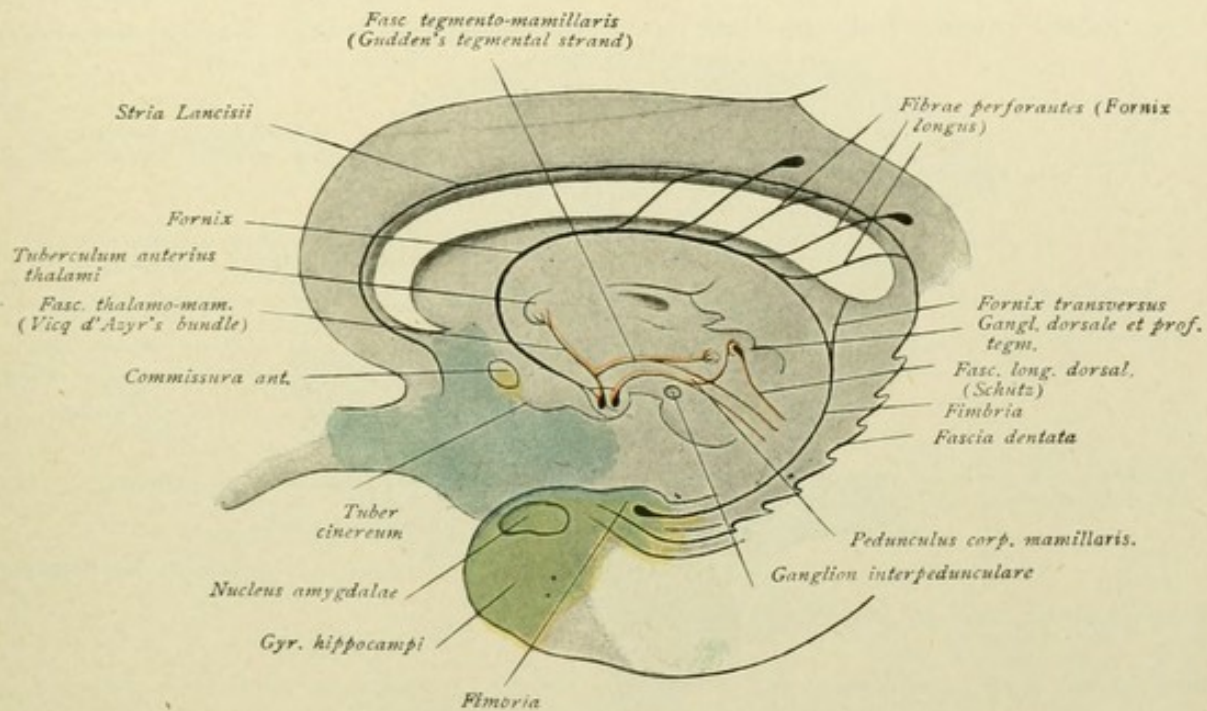


FIG. 139.—Fibre-tracts of the rhinencephalon. Further connections of the cortical centres. The fornix and the system of the corpus mamillare.

major part of the fibres ends in a small ganglion, the *ganglion profundum tegmenti*, and in the neighboring gray substance of the Sylvian aqueduct, some fibres branching off to the posterior longitudinal fasciculus, while others are supposed to extend as far as the *formatio reticularis* of the pons.

The *pedunculus corporis mamillaris* has its origin within the lateral ganglion of the mammillary body. The bundle courses within the tegmentum and ends in the *ganglion dorsale tegmenti* and in the surrounding gray substance. Fibres are also described as reaching the vicinity of the medial fillet. The dorsal longitudinal bundle of Schütz arises within the dorsal tegmental nucleus and the central gray substance (Fig. 139).

Concerning the course and destination of these bundles which pass from the corpus mamillare to the tegmental region, we are by no means sufficiently informed. According to other findings, also ascending bundles run within the pedunculus corporis mamillaris; these are said to arise within the tegmentum from the *ganglion profundum*, as well as from the fillet-layer, and to end within the corpus mamillare.



The *dorsal longitudinal bundle of Schütz* (Kölliker's dorsal gray longitudinal bundle, Bechterew's dorsal longitudinal bundle of the central gray substance) is not to be confused with the strand commonly designated as the posterior longitudinal bundle. The longitudinal bundle of Schütz extends through the gray substance of the entire brain-stem and is connected with the nuclei of all the cerebral nerves and many other ganglia. It is termed the *fasciculus longitudinalis dorsalis*, while the "posterior longitudinal bundle" is designated as the *fasciculus longitudinalis medialis*.

The majority of the fibres of the stria medullaris thalami end within the *ganglion habenulae*. The *stria medullaris thalami* conveys:

- a. Fibres coming from the fornix—*tractus cortico-habenularis*.
- b. Fibres coming from the septum lucidum and from the area olfactoria—*tractus olfacto-habenularis*.
- c. Fibres coming from the interior of the thalamus—*tractus thalamo-habenularis*.

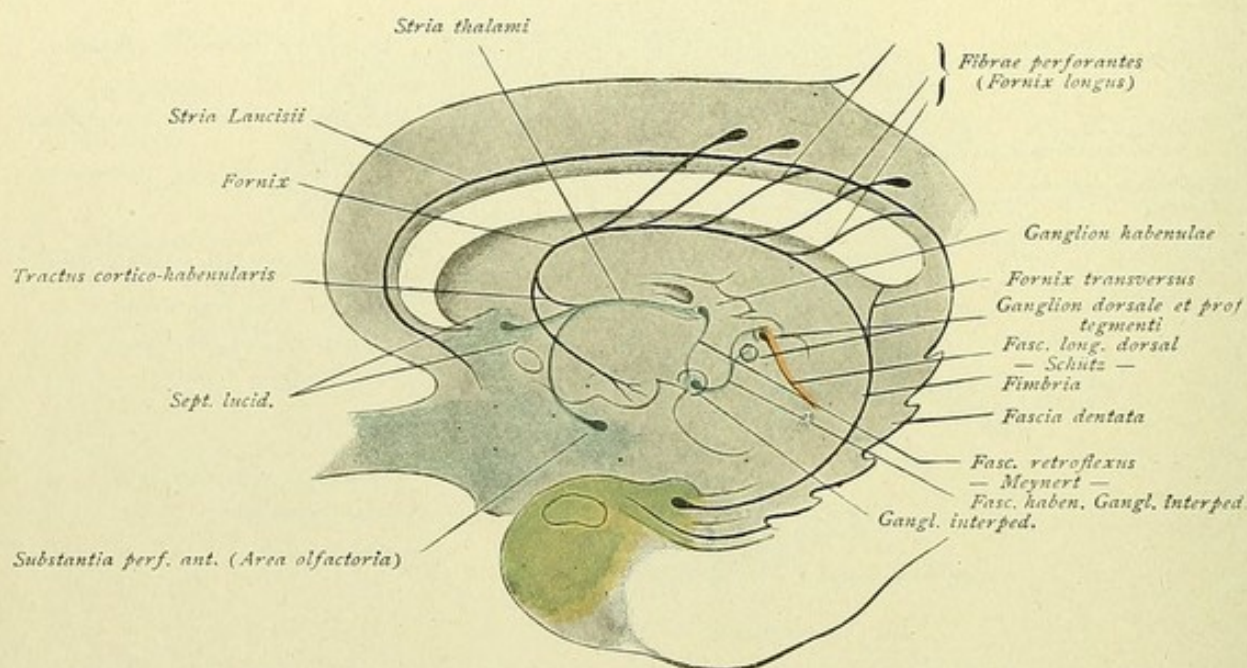


FIG. 140.—Fibre-tracts of the rhinencephalon. Further connections of the cortical centres. The fornix and the system of the ganglion habenulae.

The fibres of the stria thalami which do not end within the ganglion habenulae traverse the latter and enter the commissura interhabenularis—a bundle of transverse fibres lying in front of the glandula pinealis. Some of these fibres end in the ganglion of the opposite side, others pass to the roof of the mid-brain, especially to the superior colliculus, while still others, perhaps, come into relation with the posterior longitudinal bundle.

Within the ganglion habenulae, the *fasciculus retroflexus* of Meynert takes its origin. This bundle ends within the substantia perforata posterior, in the region immediately in front of the pons, in a small nucleus, the *ganglion interpedunculare* of Gudden. The bundle is called, therefore, also the *tractus habenulo-peduncularis*.

Within the ganglion interpedunculare arises the *tegmental tract of the interpeduncular ganglion*. The fibres pass dorsalward as far as the central gray to end partly in the ganglion tegmenti profundum and partly in the ganglion tegmenti dorsale and the surrounding central gray substance. Here joins, in turn, the dorsal longitudinal bundle of Schütz.



3. **Connection of the primary centres of the two sides.**—The fibres arise within the cortex of the tractus olfactorius and pass, forming the *pars olfactoria* of the anterior commissure, to the tractus of the opposite side. Here they end, partly within the granule-layer and within the locality of the olfactory glomeruli of the bulbus.

4. **Further connections of the primary centres.**—Direct fibres pass to the tuber cinereum, to the corpus mamillare, to the lower lying brain-segments and to the spinal cord. They form the olfactory radiation to the diencephalon and to the mid-brain—*tractus olfacto-mesencephalicus*, the basal olfactory bundle of Wallenberg.

The tract of fibres passing to the corpus mamillare is further joined by the fibre-system of the mammillary body, whereby further relations with the thalamus and the mid-brain are established. A similar connection of the primary centres is effected through the fibre-system of the ganglion habenulae.

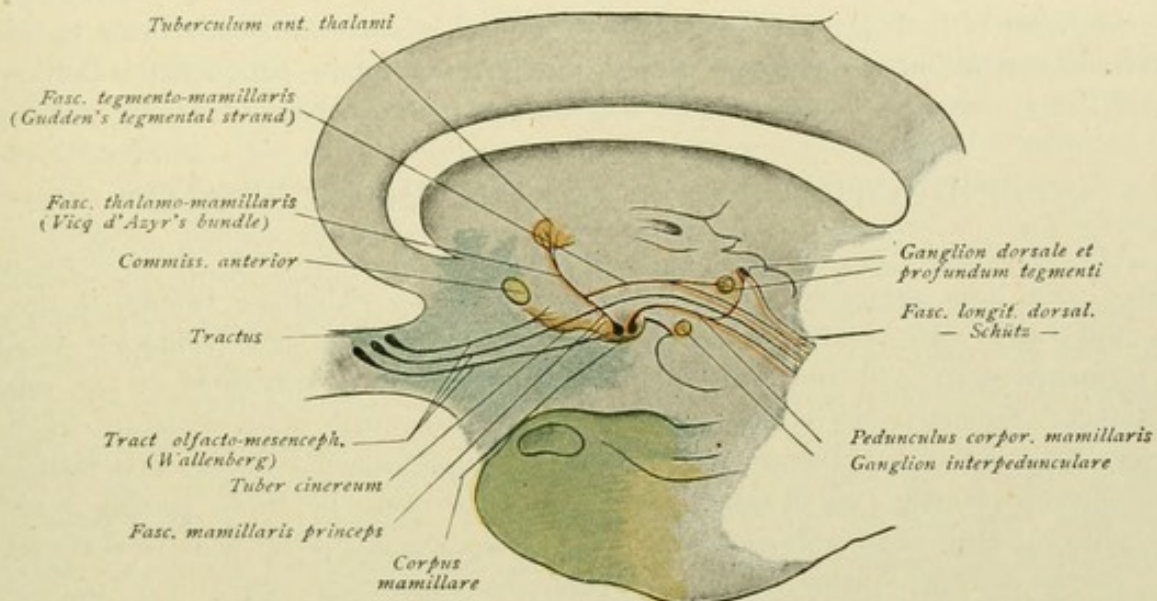


FIG. 141.—Fibre-tracts of the rhinencephalon. Further connections of the primary centres. Basal olfactory bundle of Wallenberg and the system of the corpus mamillare.

Ascending fibres from the lower brain-segments, as strands from the vicinity of the end-nucleus of the trigeminus, are also credited with terminating within the primary olfactory centres. Since terminal arborizations of the trigeminus are found within the regio olfactoria of the nasal mucous membrane and since this nerve, perhaps, also shares in the conduction of olfactory stimuli, it is not impossible that impulses may be carried from the olfactory region to the cortical olfactory centre by means of the ascending central trigeminal tract.

5. **Connection of the cortical centres of the two sides.**—This is accomplished by the fibres of the fornix transversus, and, perhaps, by the pars interhemisphaerica of the anterior commissure.

6. **Further connections of the cortical centres.**—The *fornix periphericus* of Arnold, or the *cingulum*, is to be regarded as an association bundle of the rhinencephalon. It appears as an arcuate bundle, which surrounds the rostrum, knee, body and splenium of the corpus callosum; at the isthmus it becomes narrow and expands toward the front end of the uncus. It consists of fibres which do not extend the entire length of the tract, but form larger or shorter strands, whose crooked ends radiate within the white



substance of the neighboring convolutions. The cingulum appears to be, therefore, not properly an association bundle of the rhinencephalon, but an association strand of the different convolutions of the medial surface of the hemisphere (Fig. 126).

Reviewing the entire fibre-tracts of the rhinencephalon, we recognize, in the first place, that a centripetal projection path conducts the impulse from the regio olfactoria to the primary centres and thence to the cortical centre proper; secondly, that a centrifugal projection path transfers impulses from the cortical olfactory centre to subcortical centres (corpus mamillare, ganglion habenulae), from which latter then, by means of further paths, still other nuclei may be influenced. Thirdly, the tracts that arise within the primary centres and pass directly to the subcortical ganglia, constitute special reflex paths, and by means of these, in consequence of the transference of the impulse to the most diverse nuclei of the brain-stem, as the nuclei of the motor nerves, the most varied reflex movements may be induced. Finally, the peripheral and central districts of the rhinencephalon of both hemispheres are brought into relation with each other by means of certain systems of commissural fibres; through the fornix periphericus, the central district is also connected with the adjoining regions of the pallium.

### CONDUCTION PATHS OF THE DIENCEPHALON.

The connections which unite the diencephalon with other parts of the brain have, in large part, been presented in the preceding section. To these belong, in the first place, the *tractus cortico-thalamici* and *thalamo-corticales*—the thalamic peduncles—of which the tegmental tract and the optic radiation may be again mentioned as of especial importance. Others to be recalled are those fibre-tracts which unite certain parts of the olfactory brain with the thalamencephalon and the hypothalamus—fornix, stria medullaris, basal olfactory bundle, which tracts are joined, moreover, by those passing from the diencephalon to the mid-brain—fasciculus mamillo-tegmentalis, pedunculus corporis mamillaris, tractus habenulo-peduncularis. Further, the connections which join the corpus striatum with the thalamus and with the subthalamic region—the *radiatio strio-thalamica* and *strio-subthalamica*.

Within the pulvinar thalami and the corpus geniculatum laterale, which parts, together with the superior colliculus, constitute the *primary visual centre* (page 172), the fibres of the tractus opticus end. The corpus geniculatum mediale, with the inferior colliculus, constitutes the *primary auditory centre*, since within these parts, particularly within the medial geniculate body, the fibres of the lateral fillet end; the latter, as later to be described (page 179), serves to conduct the impulses from the end-nuclei of the acoustic nerve farther centrally and, hence, represents the *primary auditory tract*. From the corpus geniculatum laterale and the pulvinar thalami, the optic radiation passes to the cortex of the visual centre in the occipital lobe; from the corpus geniculatum mediale, the *secondary auditory tract* passes to the cortex of the auditory centre in the temporal lobe.

Within the thalamus, moreover, end certain fibre-strands which come from the cerebellum, the medulla oblongata and the spinal cord. Bundles of fibres, from the nucleus dentatus and in small part also from the nucleus tecti, pass forward from the cerebellum, constituting collectively the *superior cerebellar peduncle*. The larger part of these fibres, after decussation, reaches the nucleus ruber in the tegmentum of the mid-brain and there ends—*tractus cerebello-tegmentalis*; the smaller part of the fibres passes



directly to the thalamus, joining such as come from the red nucleus—*tractus rubro-thalamicus*. The fibres proceeding from the medulla oblongata and from the spinal cord form the large ascending sensory path, *tractus spino- et bulbo-thalamicus*, the detailed origin and course of which will be later considered. For the present suffice it to note, that this tract, known as the *medial fillet* or *lemniscus medialis*, carries fibres from the spinal cord, the nuclei of the posterior column and the end-nuclei of the sensory cerebral nerves. Its termination is principally within the lateral nucleus and the centrum medianum of the thalamus. Impulses from the spinal cord, the nuclei of the posterior column and the olivary nucleus of the medulla may reach the thalamus also by way of the cerebellum and the superior cerebellar peduncle. These paths are shown in Figs. 142 and 147. The *tractus thalamo-olivaris* is a spinalward coursing path, that connects the thalamus with the olive of the medulla (Fig. 147); it is also termed the *central tegmental tract*. Since the olive sends fibres to the cerebellum, impulses from the thalamus may be conveyed to the cerebellum by this tract.

Probably still other paths proceed from the thalamus downward, to end within the mid-brain, the pons, the medulla and the spinal cord. Such connections, however, are not accurately determined. The descending *tractus thalamo-spinalis* accompanies the tractus rubro-spinalis to the spinal cord, within which it courses in the dorsal part of the lateral column.

Finally, mention must be made of the *system of the ventricular gray*, which gray substance covers the medial surface of the thalamus and hypothalamus and the floor of the third ventricle and is continuous with the gray substance surrounding the aquaeductus Sylvii and investing the floor of the fourth ventricle. The fibres from the cells situated within this gray substance pass to all the thalamic nuclei, while delicate longitudinal strands proceed caudalward through the gray in the medulla oblongata and into the spinal cord. This system of longitudinal fibres, which has been already noticed in connection with the fibre-tracts of the rhinencephalon, is the *fasciculus longitudinalis dorsalis*, or dorsal longitudinal bundle of Schütz, and is closely connected with the nuclei of the cerebral nerves and other ganglia. Concerning the significance of the entire system, we are, at present, insufficiently informed. According to Edinger, it is not unlikely, that all these nuclei and fibres constitute a central apparatus of the sympathetic.

## CONDUCTION PATHS OF THE MESENCEPHALON.

The mesencephalon, which, as the smallest of the brain segments, includes the quadrigeminal region and the cerebral peduncles, is traversed by several main tracts, on the one hand, and is the termination or the origin of many fibre-strands, on the other.

**I. The chief tracts traversing the mid-brain** are those which descend from the cortex of the cerebral hemispheres, already described in connection with the conduction paths of the telencephalon, namely: the *frontal pontile tract*, the *occipito-temporal pontile tract* and the *motor tract*. These three chief paths pass through the basis pedunculi or crusta, the frontal fibres occupying the medial and the occipito-temporal the lateral part, while the motor tract appropriates the middle portion of the crusta between the pontile tracts. An additional traversing path is the *sensory tract* or *medial fillet*, which ascends from the spinal cord, the nuclei of the posterior columns and the end-nuclei of the sensory cerebral nerves and continues to the thalamus, joined by the tegmental tract that unites the thalamus with the sensory region in the cortex of the parietal lobe. This



ascending sensory tract, however, does not pass through the crusta of the cerebral peduncle, but through the tegmental area. Of the additional traversing paths, the *tractus thalamo-olivaris* or the *central tegmental tract* deserves special mention.

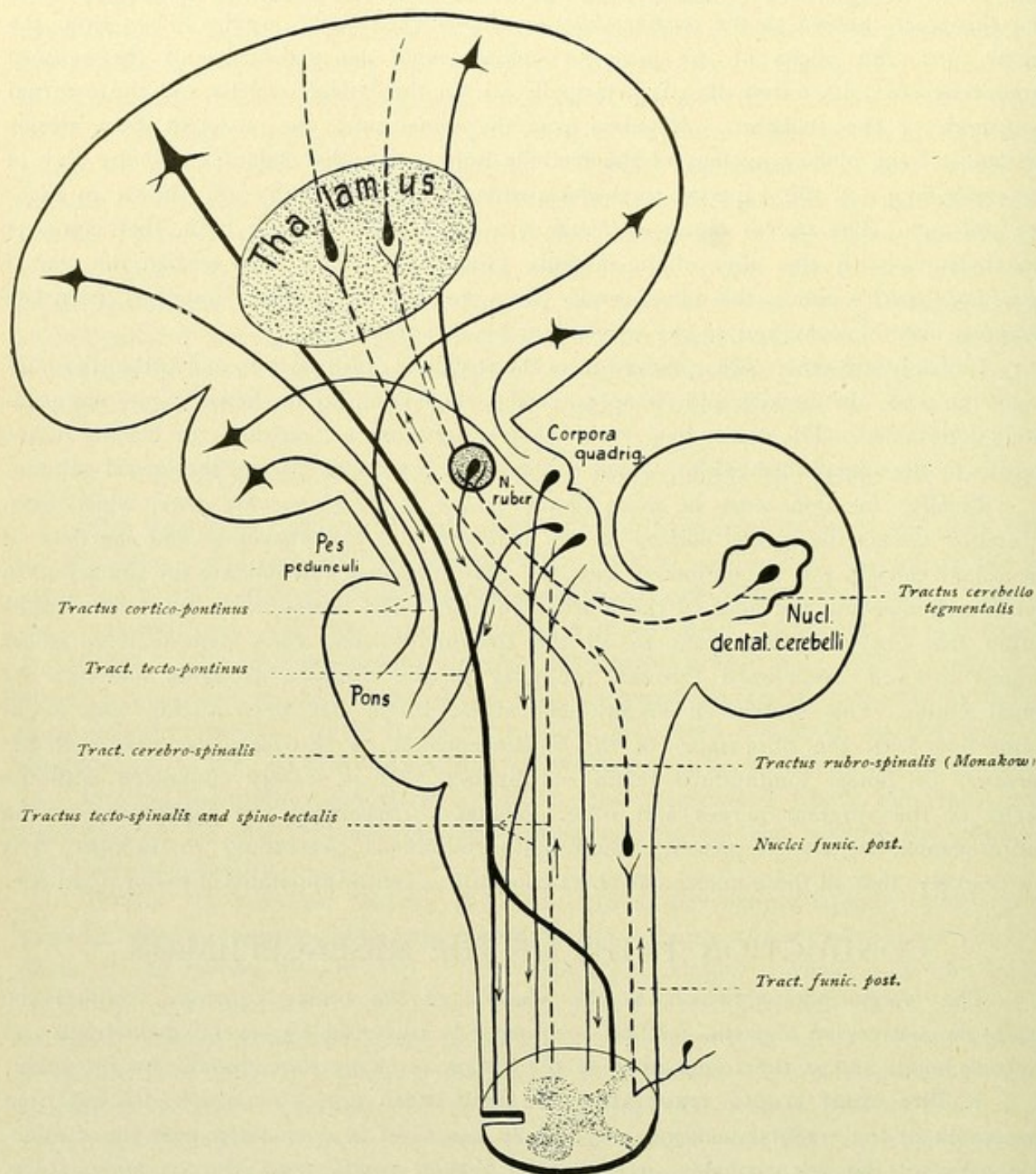


FIG 142.—Schematic representation of the chief connections of the mid-brain and of the tracts passing through the mid-brain.

## II. Tracts ending within the mid-brain:

a. Within the region of the superior colliculus end some fibres of the optic tract; within the inferior colliculus, the fibres or collaterals of the lateral fillet, which latter represents the primary auditory path.



*b. Within the quadrigeminal region* end additional fibres from the cortex, *tractus cortico-tectales*—in the superior colliculus principally fibres from the occipital lobe and in the inferior colliculus those from the temporal lobe; further fibres are those of the *tractus spino-tectales*, which ascend from the lateral column of the spinal cord.

*c. Within the nucleus ruber* end, first, fibres from the cortex (frontal lobe, regio opercularis) and from the corpus striatum; second and most important, fibres from the cerebellum. The last take their origin in the nucleus dentatus, in small part also in the nucleus tecti, and, perhaps, also in the cortex of the cerebellum, and form the brachia conjunctiva or superior cerebellar peduncles. After decussation within the tegmentum of the mid-brain, the fibres end in the nucleus ruber and, in part, also in the thalamus—*tractus cerebello-tegmentalis*.

*d. Small individual fibre-bundles*, which in part end in the mid-brain and in part run still farther caudally—the tegmental bundle of the ganglion interpedunculare, fibre-strands from the corpus mamillare and from the posterior longitudinal bundle.

### III. Tracts arising within the mid-brain:

*a. Tractus tecto-bulbaris et tecto-spinalis*, fibre-strands which arise from the deep medullary substance of the corpora quadrigemina, cross (Meynert's tegmental decussation) and terminate within the nuclei of the medulla oblongata and within the anterior and lateral columns of the spinal cord. Since fibres of the visual tract end within the superior colliculus and those of the auditory tract within the inferior colliculus, the impulses brought to the mid-brain by these paths may be conveyed to the medulla and the cord by the tecto-bulbar and the tecto-spinal tract respectively. These paths, therefore, are also called the *visuo-acoustic reflex tract*. The tract leading to the anterior column is known also as the *fasciculus longitudinalis praedorsalis*, since the bundle lies ventral to the posterior longitudinal bundle in its course through the brain-stem.

*b. Tractus tecto-cerebellares*, from the quadrigeminal plate to the cerebellum.

*c. Tractus tecto-pontinus (Münzer)*, a small fibre-strand that arises within the quadrigeminal region, more especially within the inferior colliculus, and ends in the pontile nuclei in the vicinity of the pyramidal tract.

A small bundle, the *tractus tecto-reticularis* of Pavlov, extends from the quadrigeminal region to the tegmentum of the pons and ends within the nucleus reticularis tegmenti.

*d. Tractus rubro-spinalis*, also known as *Monakow's bundle*, arises in the red nucleus of the tegmentum. The fibres emerging from the nucleus cross and descend through the pontile tegmentum and the medulla oblongata to the lateral column of the spinal cord, to end within the anterior horn.

Moreover, the *tractus rubro-reticularis* includes fibres which pass, crossed and uncrossed, from the red nucleus to the formatio reticularis of the pons and of the medulla oblongata; a further bundle, the *tractus rubro-laquearis*, passes from the red nucleus to the nucleus of the lateral fillet.

*e. Fasciculus longitudinalis medialis*, commonly called the posterior longitudinal bundle, is composed of fibres taking their origin in different places. The principal fibre-strands arise from Deiters' nucleus and from the nucleus of the posterior commissure and of the posterior longitudinal bundle, situated in front of the oculomotor nucleus (p. 182).

*f.* Finally it must be noted, that the oculomotor and the trochlear nerves, as well as a small motor root of the trigeminus, have their origin within the mid-brain.



## CONDUCTION PATHS OF THE METENCEPHALON.

Before considering the individual fibre-tracts connecting the cerebellum and the pons with other parts of the brain and the spinal cord, the structure of the cerebellar cortex must be more closely examined.

## HISTOLOGY OF THE CEREBELLAR CORTEX.

The **cerebellar cortex** presents the following layers :

1. The *molecular layer*—the outermost stratum ;
2. The *layer of Purkinje cells*—the middle stratum ;
3. The *granule layer*—the innermost stratum.

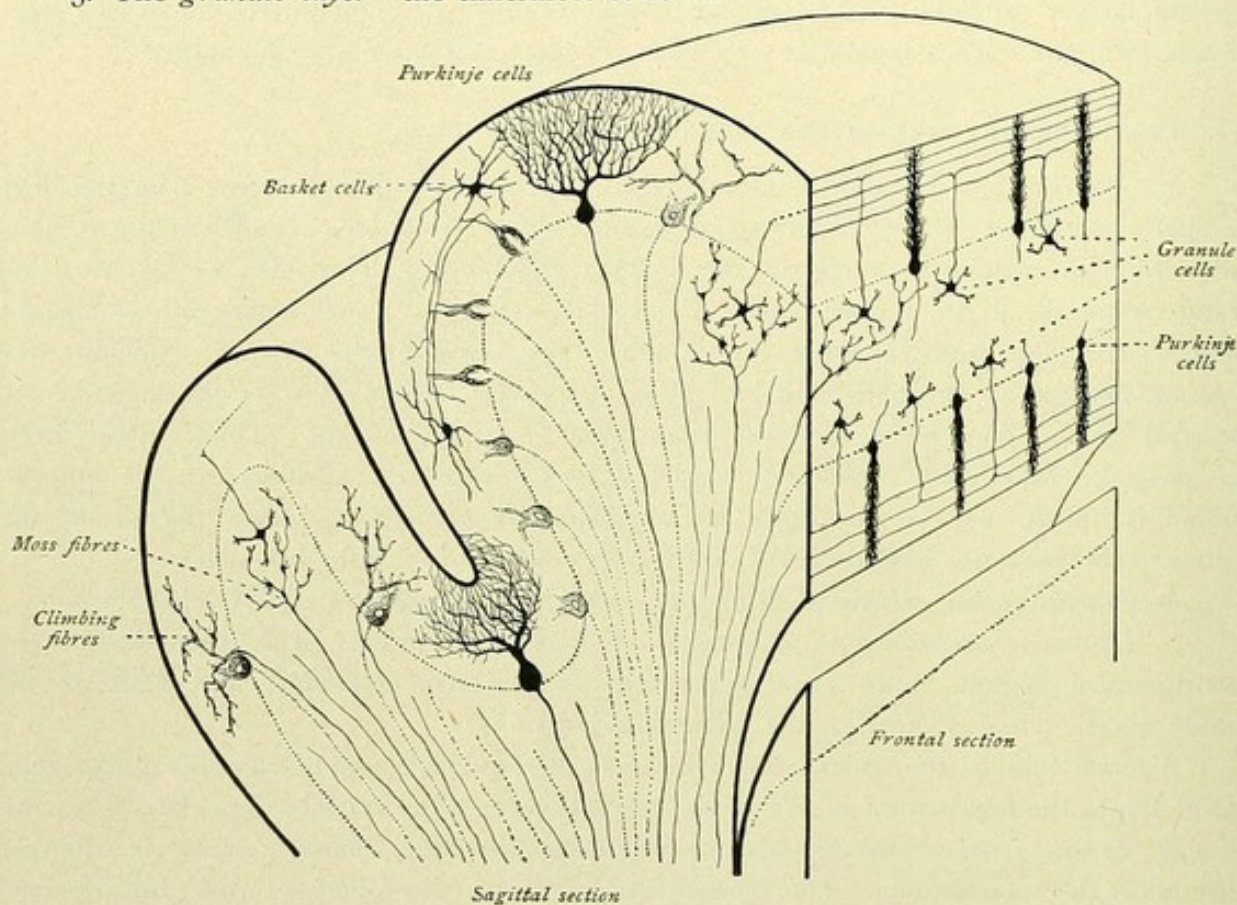


FIG. 143.—Schematic representation of the cerebellar cortex.

The **Purkinje cells** send their richly branched protoplasmic processes or dendrites into the molecular layer, while the axones of the cells pass through the granule layer to the white substance of the cerebellum.

Within the **molecular layer**, in addition to small cortical cells with short axones, are found the *basket-cells*. The latter are distinguished by their axones, which run sagittally and parallel to the surface and give off numerous collaterals that pass inward and surround the cell-bodies of the Purkinje cells with basket-like ramifications (Fig. 143).

Within the **granule layer**, the small *granule-cells* are the chief elements. They are small spherical cells with from three to five short dendrites. Their axones pass into the molec-



ular layer, where they divide into two branches, that run parallel to the surface and in correspondence with the direction of the cerebellar convolutions or *folia*. These axones extend, therefore, in the frontal plane and not, as do those of the basket-cells, in the sagittal plane. During their course, the branches give off collaterals which pass to the Purkinje cells. In addition to the granule-cells, *Golgi II type cells* occur, whose dendrites often extend far into the molecular layer and whose axones resolve into branchings of unusual richness.

**Nerve-fibres** enter the cortex from the subjacent white substance. Of these, the "*climbing fibres*" pass to the molecular layer and there end among the dendrites of the Purkinje-cells, while the "*moss fibres*" terminate chiefly within the granule layer. Impulses, conveyed by these fibres which enter the cerebellum, are transferred to the different varieties of cortical cells. In this connection, it is worthy of special note, that by means of the basket-cells impulses are conveyed in the sagittal direction and by means of the granule-cells in the frontal direction and transferred to numerous Purkinje cells.

### FIBRE-TRACTS OF THE CEREBELLUM.

All cortical regions of the cerebellum are linked together by means of arched fibres, the *fibrae arciformes*. Such association systems unite neighboring folia or lobules of the cerebellum. The cortex, moreover, sends centrifugal fibres to the nuclei—to the nucleus dentatus and the nucleus fastigii, as well as to Deiters' nucleus.

The **chief connections of the cerebellum** are:

1. *Tractus ponto-cerebellares*, composed of fibres which arise in the pontile nuclei and proceed to the cerebellar hemisphere of the opposite side. These tracts form the middle cerebellar peduncle. Since the ponto-cerebellar tract continues the *tractus corticis ad pontem*, connecting the cerebral cortex with the pontile nucleus, impulses are carried from the cerebrum to the cerebellum. Relations between the cerebral cortex and the cerebellum may be further established by way of the thalamus and the inferior olive.

Some fibres pass in the opposite direction, from the cerebellum through the middle cerebellar peduncle to the pons and thence, as the *fibrae rectae pontis*, dorsally within the raphe of the pons to the centro-lateral *nucleus*

*reticularis tegmenti pontis*, thus constituting the *tractus cerebello-tegmentalis pontis*.

2. *Tractus cerebello-tegmentales*, composed of fibres which arise in the nucleus dentatus and partly in the nucleus fastigii or roof-nucleus of the cerebellum, pass for-

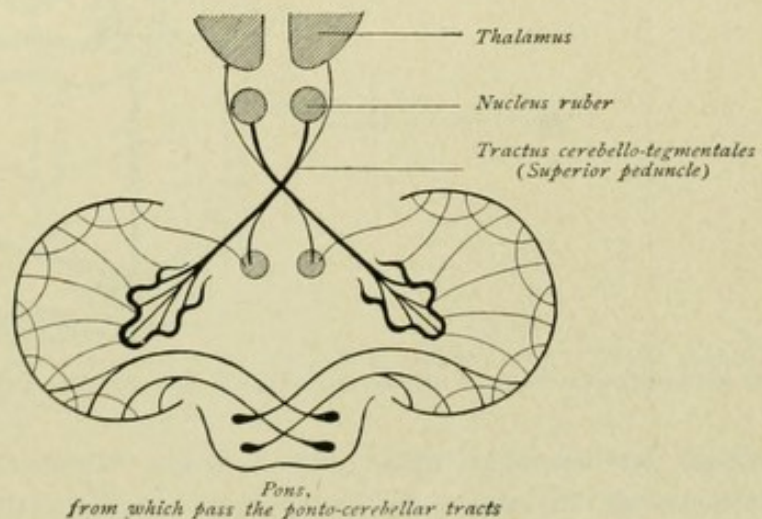


FIG. 144.—Fibre-tracts of the cerebellum.



ward, decussate in the quadrigeminal region and end within the nucleus ruber or the thalamus. They constitute the superior cerebellar peduncle or brachium conjunctiva, the crossing being known as the *decussation of the superior peduncle*. These fibre-bundles, chiefly from the nucleus dentatus cerebelli, give off descending collateral branches, which may be followed as a special bundle as far as the pons and the medulla oblongata, where they probably end in motor nuclei. In addition to this

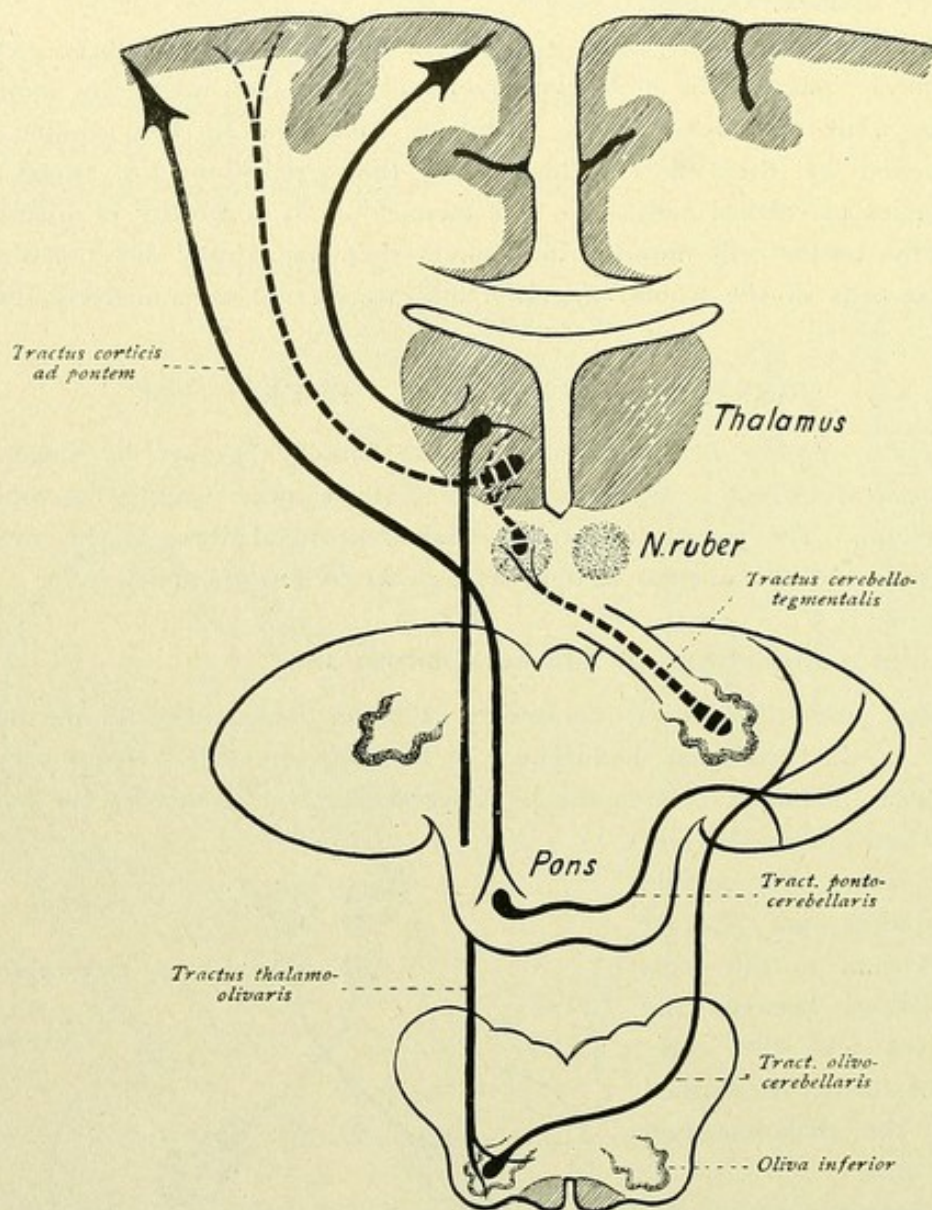


FIG. 145.—Connections of the cerebral cortex with the cerebellum and of the cerebellum with the cerebral cortex.

robust cerebellofugal tract, other efferent bundles pass caudalward from the roof-nucleus, of the same and the opposite side, into the tegmental area of the medulla oblongata, where they end around the cells of the substantia reticularis. These fibres, however, emerge from the cerebellum by way of the inferior cerebellar peduncle or restiform body and are specially designated as the *tractus cerebello-tegmentalis bulbi*, while those in the superior peduncle are called the *tractus cerebello-tegmentalis mesencephali*.



By means of the middle cerebellar peduncles, therefore, especially impulses from the cerebrum are conveyed to the cerebellum. The superior cerebellar peduncle, on the contrary, carries impulses by way of the red nucleus and the thalamus from the cerebellum to the cerebrum. In addition, however, by way of the tractus cerebello-tegmentalis mesencephali (cerebellum to red nucleus), as well as by the tractus cerebello-tegmentalis pontis et bulbi, the possibility exists, that impulses from the cerebellum

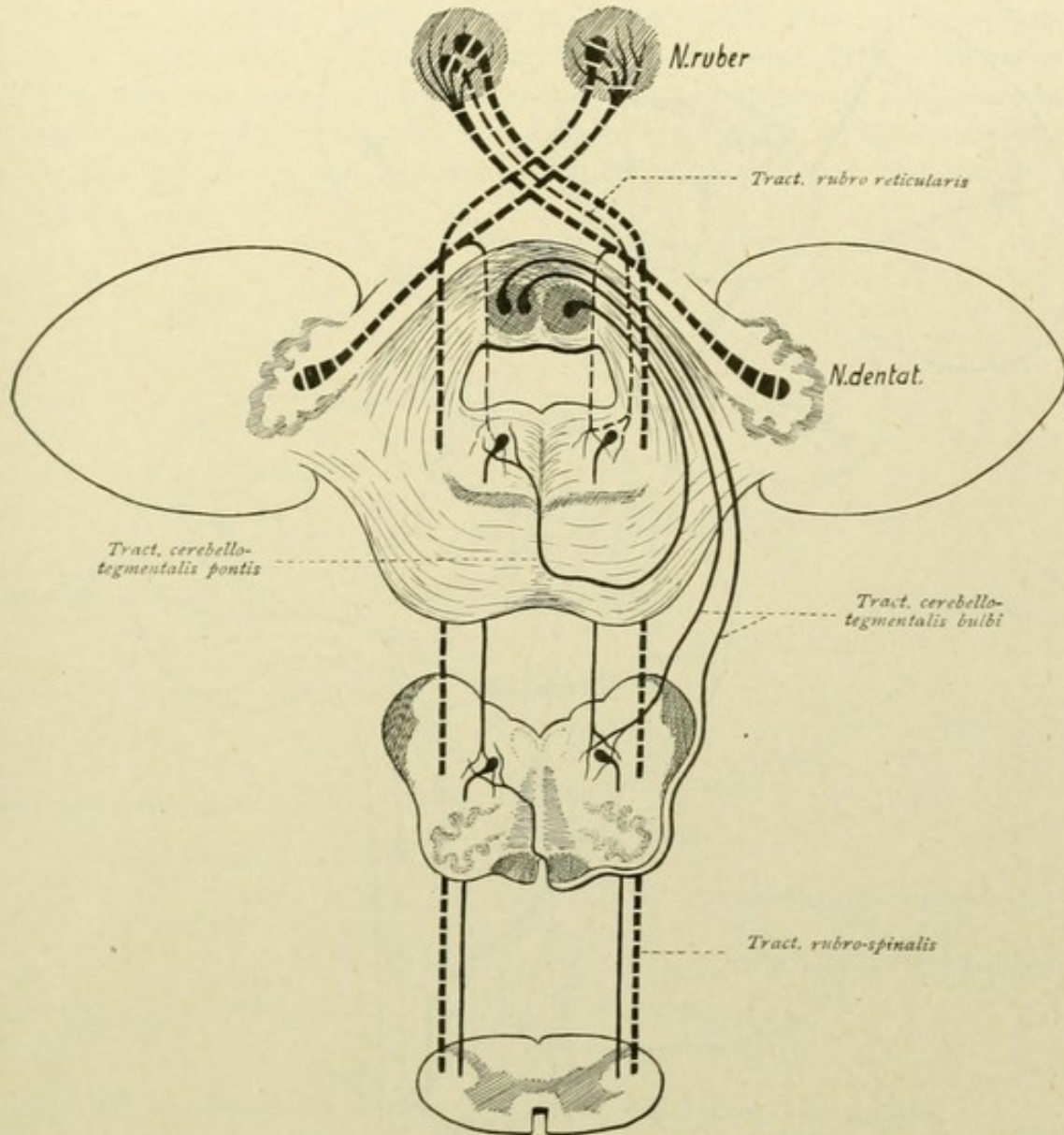


FIG. 146.—Tractus cerebello-tegmentalis mesencephali—nucleus dentatus cerebelli—nucleus ruber. Tractus cerebello-tegmentalis pontis et bulbi. Tractus rubro-reticularis and tractus rubro-spinalis; also the tracts coursing within the formatio reticularis.

may be finally transferred to the motor nuclei of the cerebral nerves and to the gray substance of the spinal cord. Since the tractus rubro-reticularis passes from the red nucleus to the cells of the formatio reticularis of the pons and of the medulla oblongata and the tractus rubro-spinalis passes to the spinal cord, while other fibres spring from the cells of the formatio reticularis, around which also the tractus cerebello-tegmentalis pontis et bulbi end, certain fibre-strands reach far down into the medulla and the spinal cord.



3. *Constituents of the inferior cerebellar peduncle*, fibres which come from the spinal cord and the medulla oblongata and pass to the cerebellum by way of the peduncle or restiform body. The constitution and destination of the latter

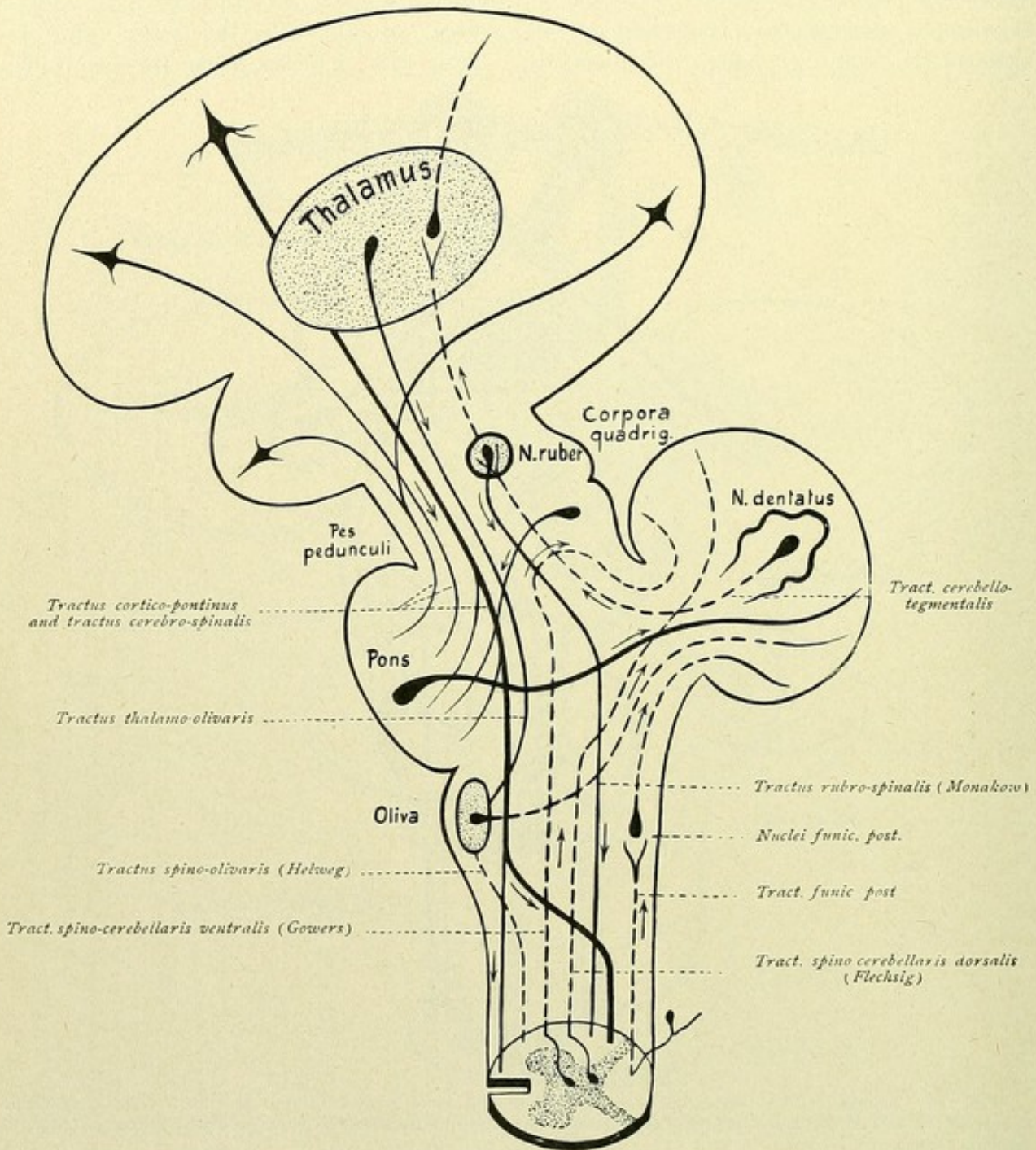


FIG. 147—Schematic representation of the chief connections of the cerebellum.

will be further considered in connection with the fibre-tracts of the medulla oblongata (page 170).

The chief connections of the pons and of the cerebellum are represented in Figs. 144, 145 and 147. It is to be noted, further, that numerous tracts, descending as well as ascending, traverse the pons (Figs. 142 and 147).



## THE SPINAL CORD.

## THE GRAY SUBSTANCE.

Exclusive of the supporting tissue, the gray substance consists principally of nerve-cells with their protoplasmic and nerve-processes and nerve-fibres ending around the nerve-cells. Topographically regarded, four different cell-groups may be distinguished. Thus, in the **anterior horn** in the cervical and lumbar enlargements, a *ventro-medial* and a *ventro-lateral* and a *dorso-medial* and a *dorso-lateral group* are clearly recognized; between these groups lies the *intermediate zone* or *central field* that borders the posterior horn.

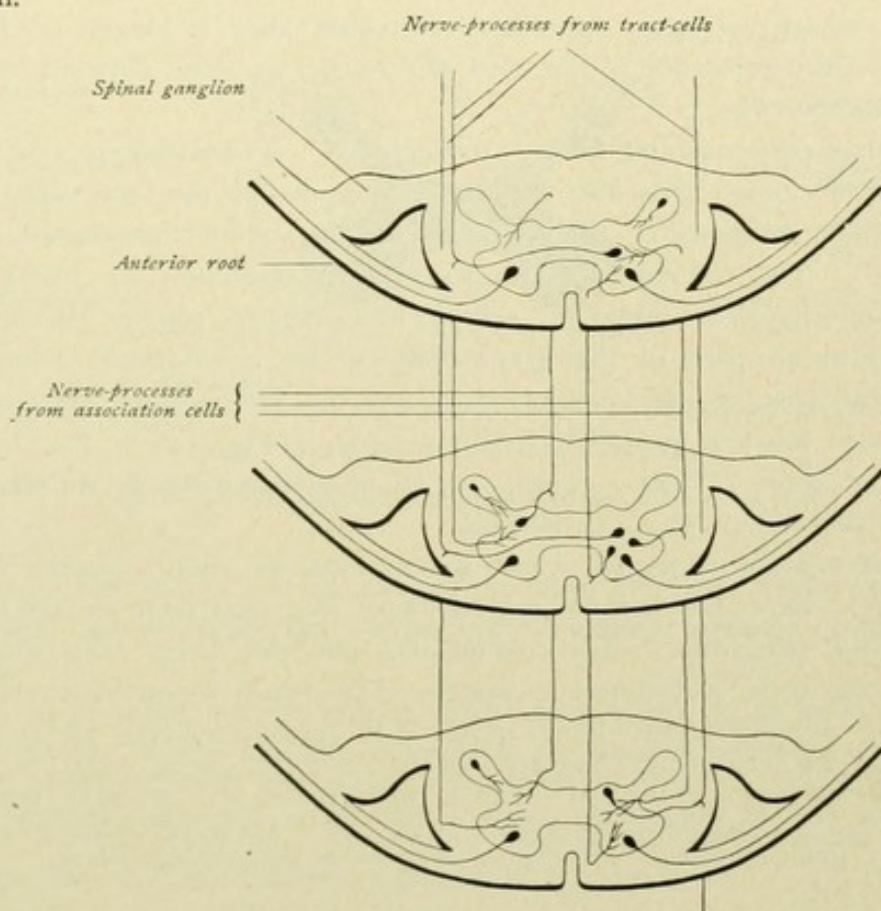


FIG. 148.—Schematic representation of the different classes of cells of the spinal cord.

Dorsal to the dorso-lateral cells, is situated the *cell-group of the lateral horn*, while *Clarke's column* lies somewhat medial to the transition of the intermediate zone into the posterior horn.

Everywhere within the **posterior horn**, mostly small cells are scattered without the definite disposition of the anterior cornu; nevertheless, also here different groups are defined, as the *basal*, the *central* and the *marginal cells* and those of the *substantia Rolandi*.

In contrast to this subdivision of the cord-cells according to position and arrangement within the gray substance, a classification according to the behavior of their nerve-



processes is more appropriate for a presentation of the fibre-tracts. Therefore, we divide the cells of the spinal cord into :

1. *Cells, whose axones pass from the spinal cord.* They lie within the anterior horn and are called the *motor anterior horn-cells*. Their nerve-processes form the anterior roots emerging from the spinal cord.

2. *Cells, whose axones pass into the white substance.* Within the latter, the axone divides into an ascending and a descending branch. The descending branch, after a short course, again enters the gray substance, where it ends; the ascending branch courses upward within the white substance. These cells are termed *column-cells*, of which two varieties are distinguished :

a. Cells, whose axones, that is, ascending branches, pass upward and as special paths connect the spinal cord with the brain; such are *tract-cells*.

b. Cells, whose ascending branches or axones after a longer or shorter course again enter the gray substance of the cord and serve to unite different cord-segments; such are *association-cells*.

The column-cells may be further distinguished as *homolateral* and *contralateral*. The axones of the former pass into the white substance of the same side, those of the latter to the white substance of the opposite side by way of the anterior commissure—*commissure-cells*. The column-cells are designated respectively as anterior, lateral or posterior column-cells according to the column in which they course. While the column-cells are found in all parts of the gray substance, the contralateral column-cells occur chiefly within the base of the posterior horn and the intermediate zone. (Commissure-cells are shown in the first and second cross-sections in Fig. 148.)

3. *Cells of Golgi II type.* These are found predominatingly within the posterior horns and the substantia gelatinosa Rolandi.

The *motor anterior horn-cells*, whose axones form the motor anterior roots, occupy a special position, since they are the only elements that send their axones from the central organ to the periphery. The column-cells and the Golgi cells, with their entire expansions, belong to the central nervous system. The *tract-cells* establish relations between the spinal cord and the higher lying centres; the association-cells serve to transfer an impulse received within the cord to higher and lower lying cell-complexes; while the field of activity of the cells of Golgi's II type is limited to the immediate vicinity. The nerve-processes of the association-cells are also spoken of as *endogenous fibres*.

### THE WHITE SUBSTANCE.

The white substance consists essentially of the longitudinally coursing nerve-fibres. The following chief systems of fibres are distinguished :

a. Fibres, which arise within the cerebral cortex and within certain parts of the brain, descend within the spinal cord and there end.

b. Fibres, which arise within the gray substance of the spinal cord and end in higher lying parts—axones of the tract-cells.

c. Fibres, which unite particular levels of the spinal cord—axones of the association-cells.

d. Fibres, which arise from the spinal ganglia as continuations of the posterior roots, enter the spinal cord and course within the posterior columns.



## 1. TRACTS OF THE ANTERIOR COLUMN.

The *tractus cerebro-spinalis anterior* or the *anterior pyramidal tract* passes medially, along the anterior median fissure. The fibres end, after crossing in the anterior commissure, within the anterior horn of the opposite side.

The field of the anterior pyramidal tract is shared by fibres that descend from the mid-brain. They constitute the *tractus tecto-spinalis*, or *fasciculus sulco-marginalis*. The fibres, in part, cross after their origin in the corpora quadrigemina. A portion of the fibres pass also to the lateral column of the cord—*tractus tecto-spinalis lateralis*.

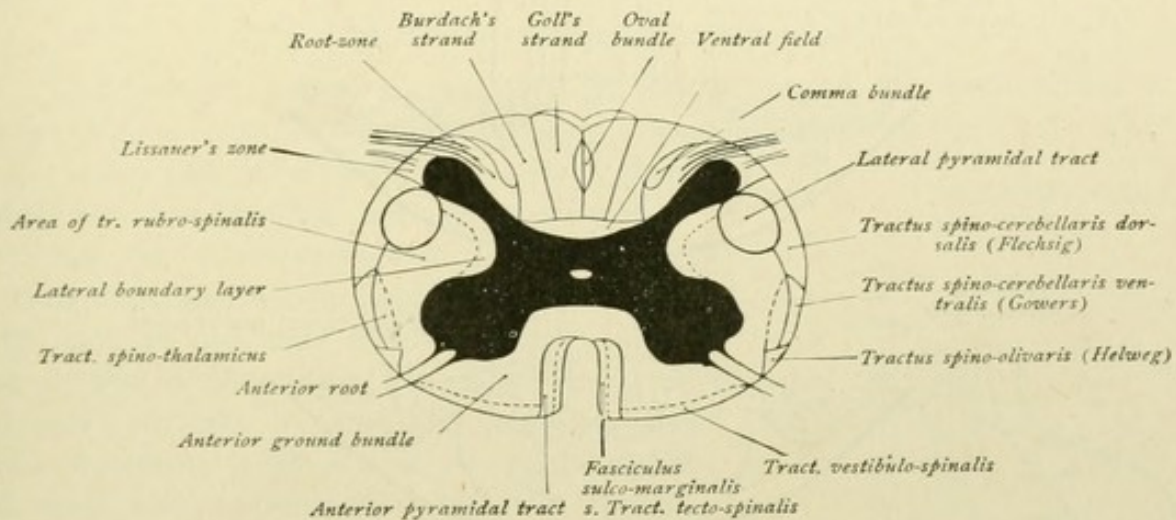


FIG. 149.—Fibre-systems of the white substance of the spinal cord.

At the ventral border of the anterior column, fibres are found which come from Deiters' nucleus and constitute the *tractus vestibulo-spinalis anterior* or the *anterior marginal bundle*.

Lastly, as an additional descending path within the anterior column, the posterior longitudinal bundle, or the *fasciculus longitudinalis medialis*, must be noted.

The remaining part of the anterior column constitutes the *anterior ground bundle* or *fasciculus anterior proprius*. Within this field longitudinally course the endogenous fibres, which serve to unite different segments of the spinal cord.

## 2. TRACTS OF THE LATERAL COLUMN.

The *tractus cerebro-spinalis lateralis* or the *lateral pyramidal tract* extends as a robust bundle in the dorsal part of the lateral column. The termination of the fibres is in the anterior horn of the same side of the cord.

The *tractus spino-cerebellaris dorsalis* or *direct cerebellar tract* lies at the periphery, lateral to the pyramidal tract. The fibres arise from the cells of Clarke's column, extend upward within the lateral column and pass, as a constituent of the restiform body, to the cerebellum, where they end within the anterior superior worm.

The *tractus spino-cerebellaris ventralis* or *Gowers' tract* also lies at the periphery of the lateral column, in front of the direct cerebellar tract, and likewise ends within the



cerebellum. The fibres take their origin from cells, on the same and the opposite side, which lie in the lateral part of the posterior horn and in the central field of the gray substance. They ascend at first with the direct cerebellar tract, do not, however, enter the restiform body, but continue as far as the pons, then enter the superior cerebellar peduncle and pass backward to the cerebellum, where they end within the anterior part of the superior worm (Fig. 74, *fibrae arciformes*).

The *tractus spino-olivaris* or *triangular bundle of Helweg* is an additional small tract, which lies at the periphery of the lateral column, ventral to Gowers' bundle, and establishes relations between the spinal cord and the inferior olivary nucleus in the

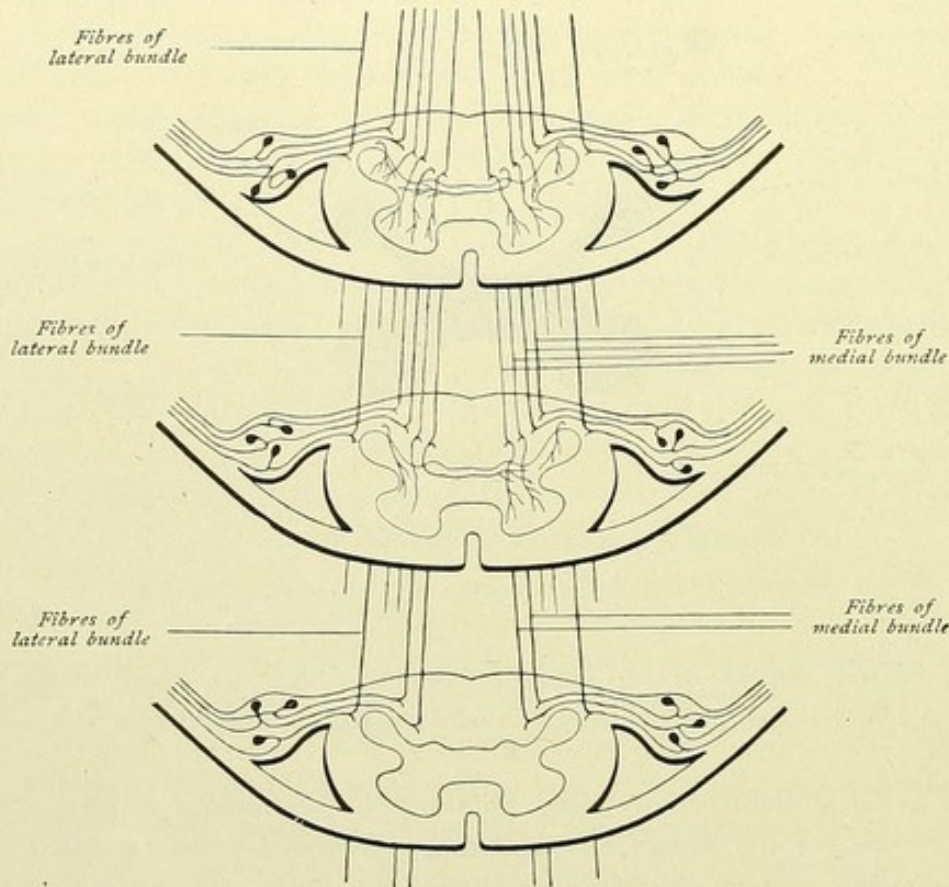


FIG. 150.—Diagram of the tracts of the posterior column.

medulla oblongata. The source of the fibres has not been positively determined. They form, perhaps, an ascending tract, arising within the gray substance of the cord and ending in the olive; according to other views, the bundle conveys both ascending and descending fibres. The entire area of the lateral column included between the foregoing tracts and the gray substance, belongs to the *lateral ground bundle* or *fasciculus lateralis proprius*. Within this again appear numerous endogenous fibres, long and short association fibres, which bind together various higher and lower lying segments of the spinal cord. The short fibres lie close to the gray substance and form the *lateral boundary zone*. In addition, within the lateral ground bundle are found the following sets of fibres: the *tractus rubro-spinalis* or Monakow's bundle, whose fibres descend from the nucleus ruber of the opposite side and lie within the cord medial to the direct cerebellar and ventral to the lateral pyramidal tract, partly within the field of the latter. The *tractus*



*vestibulo-spinalis lateralis*, from Deiters' nucleus, passes somewhat more ventral. Medial to Gowers' bundle lies the *tractus spino-thalamicus*. The fibres of this path are the axones of the commissure-cells of the cord, which pass through the anterior commissure to the opposite lateral column and there turn upward. The termination of the path is in the thalamus. The *tractus spino-tectalis* consists of a fibre-strand, that accompanies the spino-thalamic tract and ends in the region of the corpora quadrigemina. The entire path is, therefore, also called the *tractus spino-tectalis et thalamicus*. Approximately within the same field, the *tractus tecto-spinalis lateralis* descends from the quadrigeminal region; likewise, in the vicinity of the spino-thalamic fibres, the *tractus thalamo-spinalis* descends as a path from the thalamus.

### 3. TRACTS OF THE POSTERIOR COLUMN.

The posterior column is composed, in largest part, of the continuations of the sensory posterior root-fibres, that proceed from the spinal ganglia (Fig. 150). The cells of the latter give off a nerve-process, which soon divides into two branches, one passing peripheralward and the other centralward. The centrally coursing branches enter the spinal cord, as the posterior root, as two more or less distinct bundles. One of these is made up of fine fibres, lies lateral and passes toward the substantia gelatinosa Rolandi; the other consists of coarse fibres, lies medial and passes toward the posterior column. The entrance zone of the lateral bundle, between the apex of the posterior horn and the periphery of the cord, is known as Lissauer's *marginal zone*; that of the medial bundle, to the inner side of the posterior horn, is called the *radicular zone*. Immediately upon entering the spinal cord, the fibres of both bundles undergo a Y-form branching. Both resulting branches assume a longitudinal direction and during their course, respectively up or down, give off numerous collaterals to the gray substance of the cord. The descending branch is the thinner and ends, after a short course, within the gray substance. According to their length, the ascending fibres are short, medium or long. The short fibres pass into the gray substance after a very limited course; those of medium length proceed farther upward, but likewise end within the cord by bending over into the gray substance; while the long fibres ascend to the medulla oblongata, where they end within the posterior column nuclei, the nucleus gracilis and cuneatus.

The fibres entering the cord below are displaced more and more towards the mid-line by the

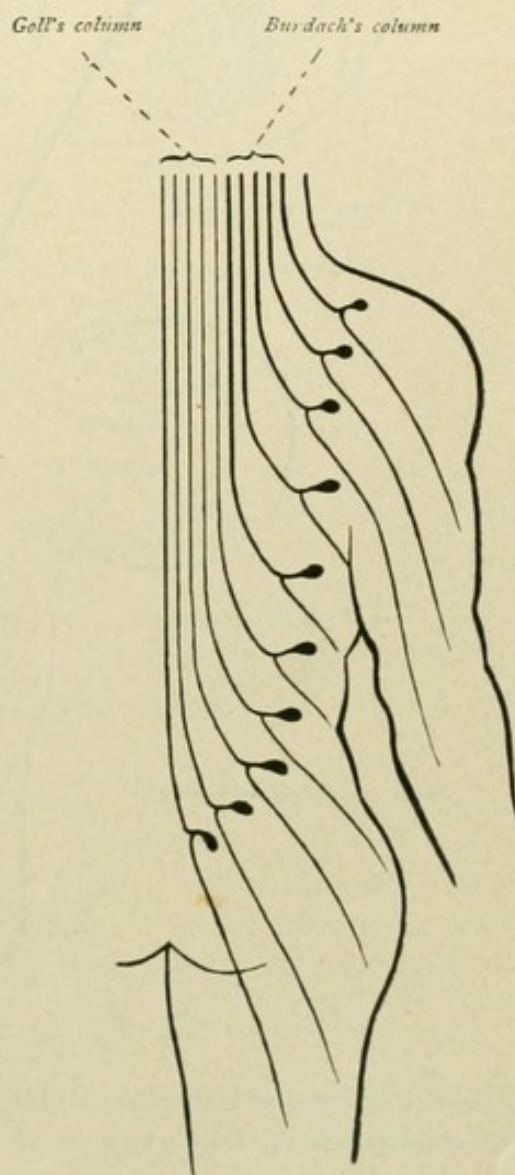


FIG. 151.—Diagram illustrating the gradual medial displacement of the long tracts of the posterior column.



fibres entering at higher levels; those fibres, therefore, that on entering the cord occupy the lateral part of the posterior column, as they ascend soon collectively constitute the middle and, finally, the innermost part of the column. Hence, as already noted, the posterior column exhibits in the cervical region of the cord, a subdivision into the medial *fasciculus gracilis*

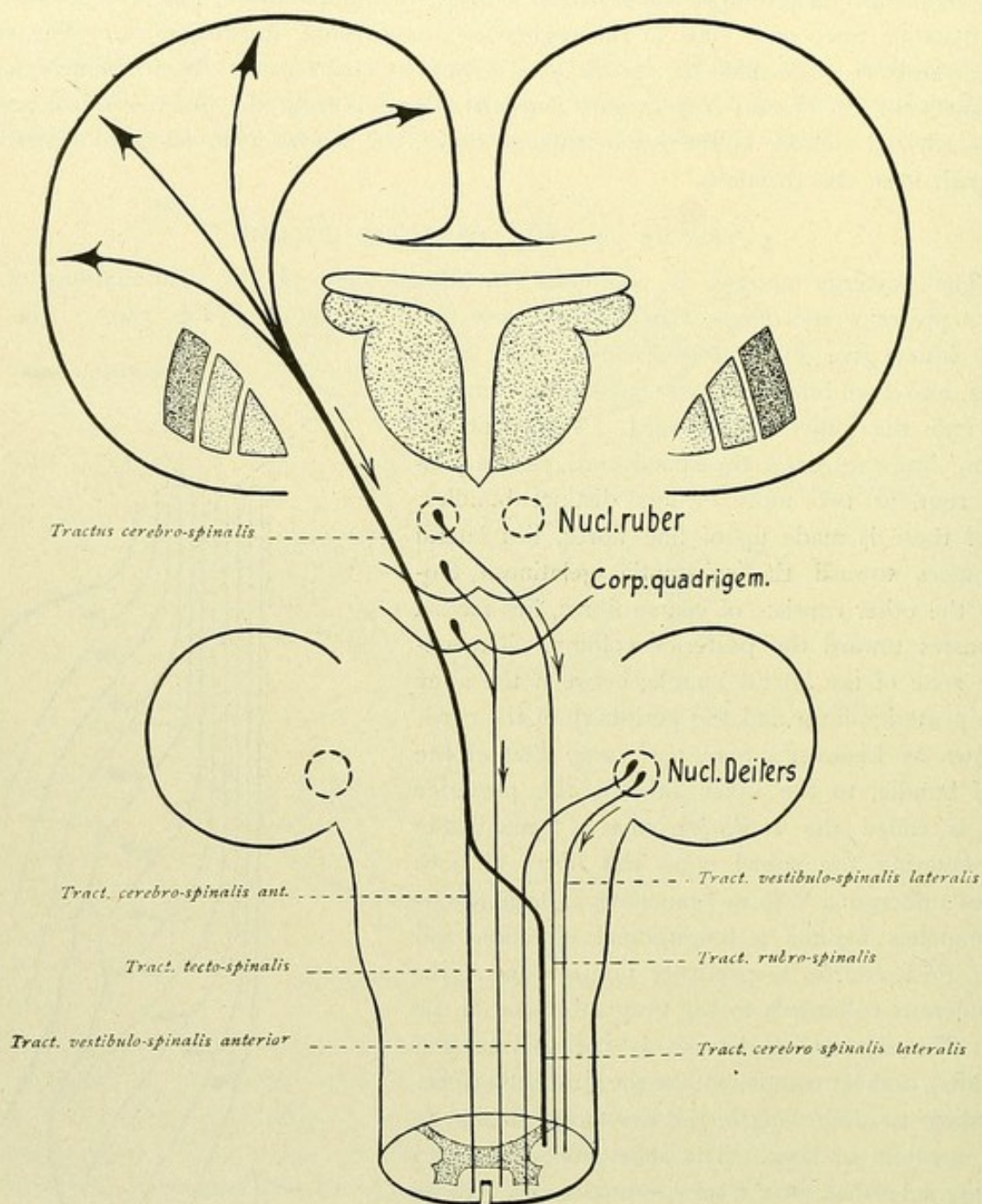


FIG. 152.—The chief tracts descending to the spinal cord.

or *Goll's column* and the lateral *fasciculus cuneatus* or *Burdach's column*—a demarcation not emphasized in the lower part of the cord. *Goll's column* consists essentially of fibres that come from the lower segments of the cord and is nothing more than the continuation of the laterally situated fibres of the lower segments, which during their ascent have been pushed toward the mid-line by the new increments of fibres entering at higher levels. Or, we may



say, in the cervical region of the cord, Goll's column is composed of fibres which ascend from the lower parts of the cord and conveys sensory fibres from the lower extremities and the lower half of the trunk, while Burdach's column carries sensory fibres that enter the spinal cord from the upper half of the trunk and the upper extremities (Fig. 151).

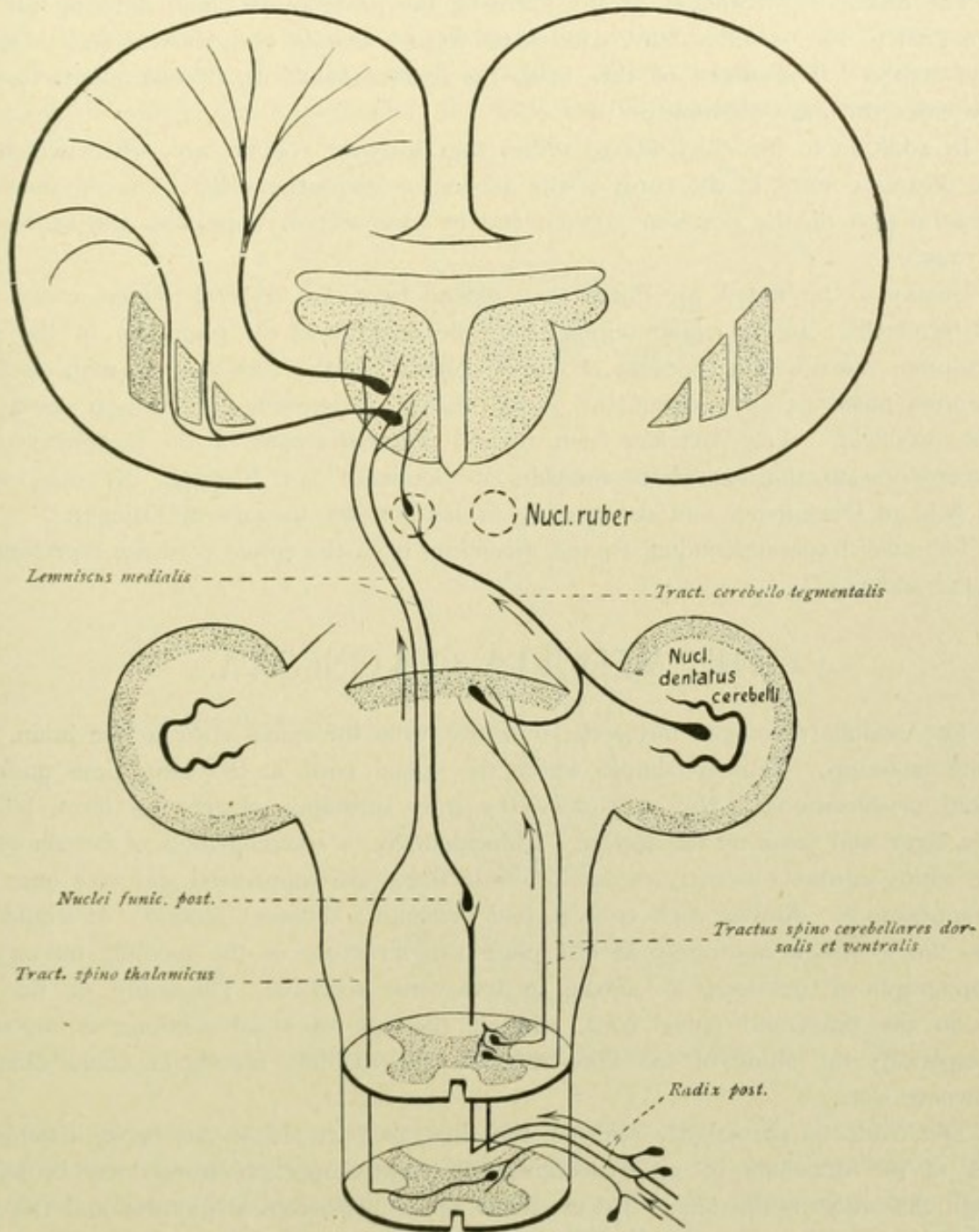


FIG. 153.—The chief tracts ascending from the spinal cord.

The terminal arborization of the ascending fibres and of the collaterals occurs in almost all parts of the gray substance of the same side of the cord; a small part of the fibres passes, by way of the posterior commissure, to the opposite side to end within the posterior horn. The short fibres and the collaterals of the lateral bundle, in particular, end within the homolateral posterior horn and also within the central field; the main fibres



and collaterals of the median bundle, which end within the cord, arborize around the cells of Clarke's column, the cells of the intermediate zone and the anterior horn cells. The collaterals from the posterior column, which break up around the anterior horn cells, constitute the *reflex collaterals*.

The descending branches of the fibres of the posterior column, entering the root-zone medial to the posterior horn, caudalward form a bundle that in cross-section appears comma-shaped. The fibres of this field, the *comma bundle of Schultze*, after a short course enter the gray substance.

In addition to the chief fibres, within the posterior column are others which arise in the posterior horns of the cord, as the axones of association-cells. They course within the ventral part of the posterior column and in cross-section appear as the *ventral field* (Fig. 149).

Finally to be noted are fibres that extend from the cervical region as far as the conus terminalis. In the upper regions, they lie dorsally at the periphery of the posterior column, more within the area of Goll's column; farther below, they migrate toward the septum posterius and, within the sacral region, in cross-section appear as a small medial oval field. This part has been termed the *oval bundle* of the posterior column. It corresponds to the *bandelette médiale* of Gombault and Philippe, the *dorso-medial sacral field* of Obersteiner and the *tractus cervico-lumbalis dorsalis* of Edinger.

The chief tracts descending to and ascending from the spinal cord are represented in Figs. 152 and 153.

## THE MEDULLA OBLONGATA.

The medulla oblongata forms the transition from the spinal cord to the brain. The intimate make-up, relatively simple within the spinal cord, at the same time undergoes manifold modifications. Not only does the gray substance change its form, but new masses, large and small nuclei, appear. Coincidentally, a rearrangement of certain systems of the white substance occurs, certain tracts of fibres are suppressed and new ones make their appearance. Almost each cross-section presents a different picture. It would carry us too far to follow accurately at this place the structure of the medulla oblongata in its topographical relations, as shown in transverse sections. The study of the fibre-tracts in the brain and spinal cord, without the use of serial sections, is impossible; and especially the study of the fibre-tracts in the medulla oblongata offers difficulties as nowhere else.

The reader is particularly referred, therefore, to Part III of this book, in which, by means of the drawings of serial sections, the most important tracts may be followed through the entire brain-stem. By means of these microscopical pictures and the assistance of the following diagrammatic figures, the reader will be able to find his way.

In the consideration of the morphology, the most important gray masses of the medulla oblongata have been mentioned; we may limit ourselves, therefore, to the presentation of the connection of these gray masses with other parts of the central nervous system. Then, as supplementary, the origin of the cerebral nerves will be more closely considered, since, as pointed out in the morphological section, the nuclei of most of the cerebral nerves are situated along the floor of the fourth ventricle.



We proceed most advantageously, if we trace upward the fibre-systems of the white substance of the cord, which were described in the preceding section. At the same time, we will ignore the fibre-systems, which come from the brain and descend in the cord and have been mentioned repeatedly in previous sections.

Let us first follow the *tract of the posterior column*. The fibres of Burdach's and of Goll's column end in the nuclei of the posterior column, that is, within the *nucleus fasciculi cunati* and the *nucleus fasciculi gracilis*. From these nuclei further tracts are developed, of which one in particular, the tract establishing relations between the pos-

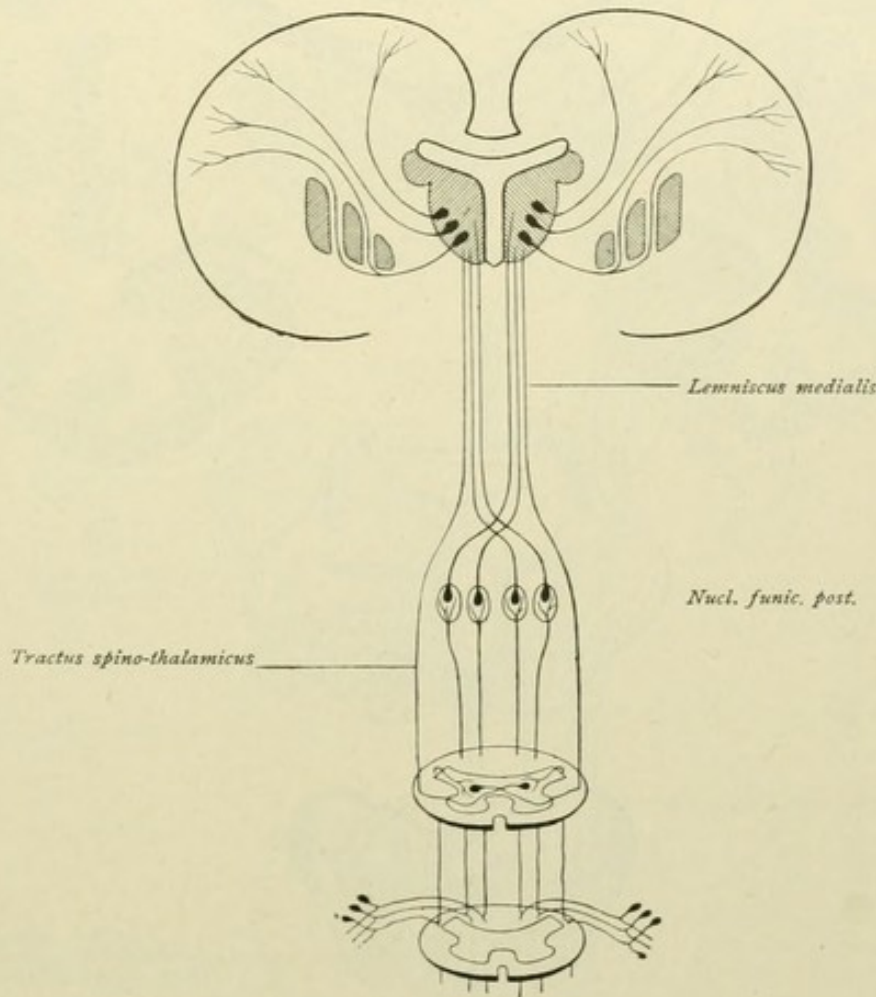


FIG. 154.—Posterior column tract, medial fillet and tegmental tract.

terior column nuclei and the thalamus, now concerns us. The fibres pass, as the axones of the cells within the cuneate and gracile nuclei, in ventrally directed courses, the *fibrae arcuatae internae*, toward the mid-line, where by decussation they form the raphe. After crossing, the fibres assemble close to the mid-line and, turning upward, pass longitudinally to higher levels. The field so formed is known as the *interolivary stratum*, on account of its position between the two inferior olivary nuclei. The fibre-bundles can be traced through the pons and the mid-brain as far as the thalamus, where they end in the nucleus lateralis and in the centrum medianum. This is the path usually called the *medial fillet* or *lemniscus medialis*; it is also known as the *tractus bulbo-thalamicus*.



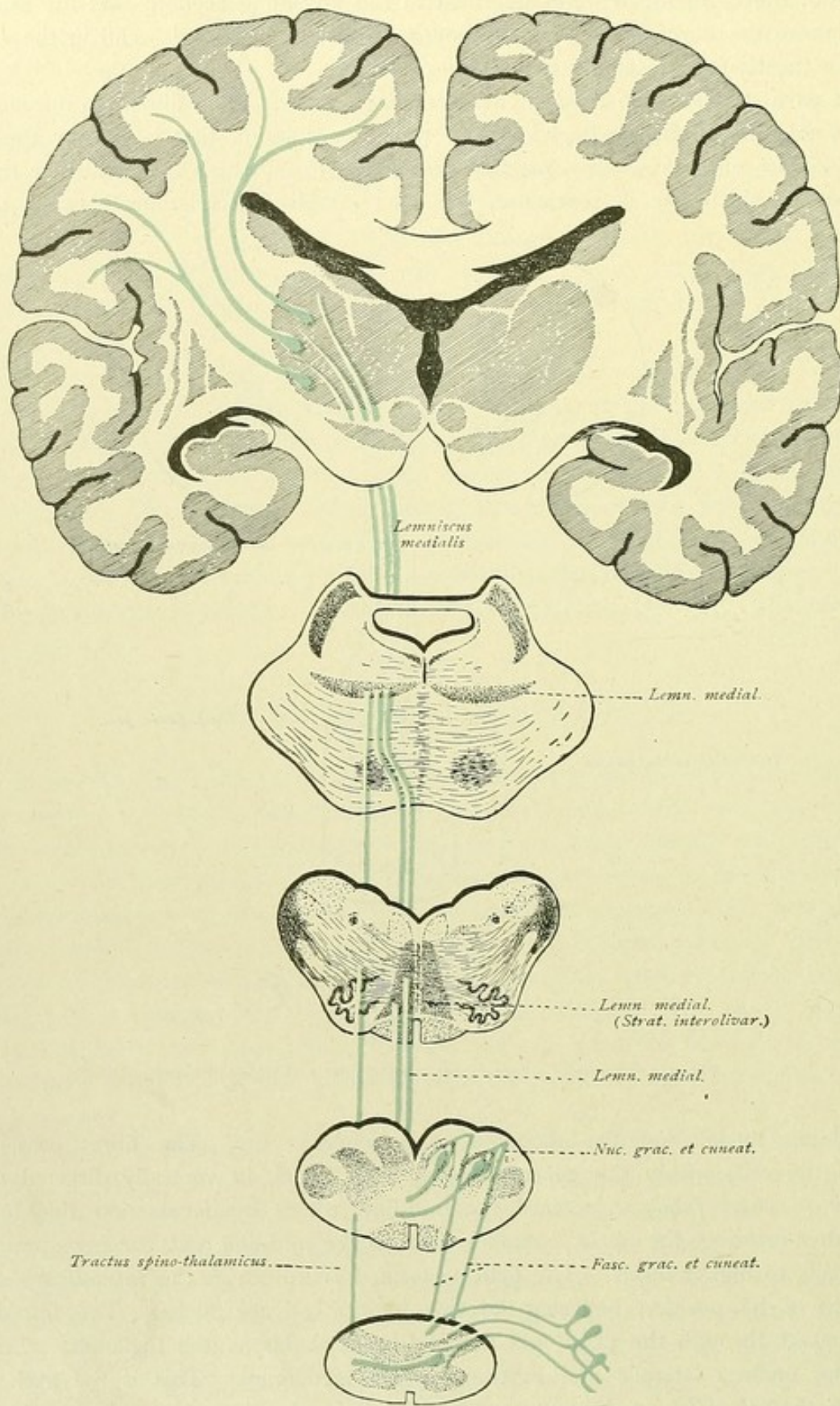


FIG. 155.—Course of the medial fillet.



The medial fillet is not composed exclusively of fibres which come from the nuclei of the posterior columns. During its course through the medulla oblongata, the fillet-tract is augmented by the fibres from the spinal cord, which we have studied as the tractus

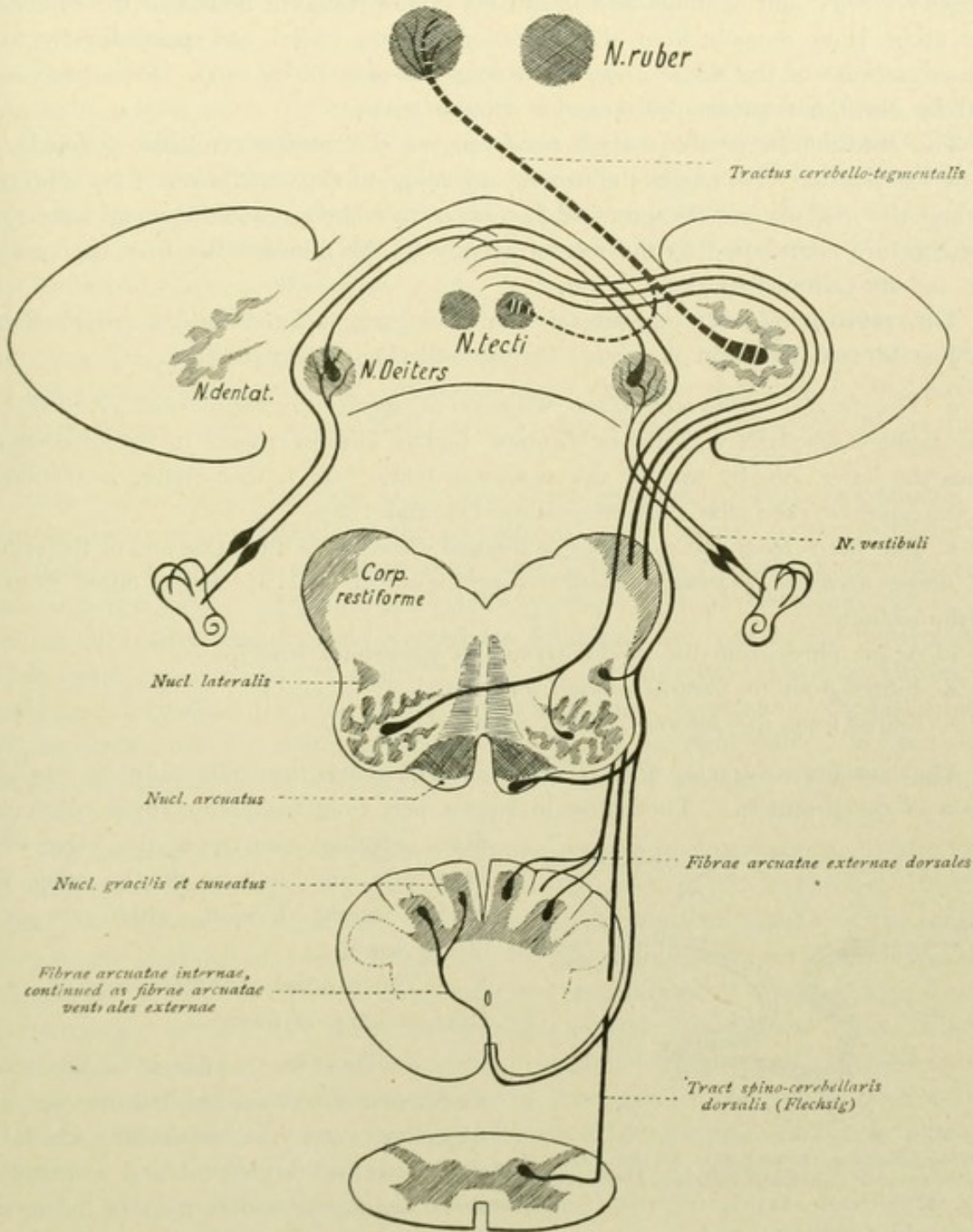


FIG. 156.—Formation of the restiform body.

spino-thalamicus. In addition, as will be pointed out later, fibres come from the terminal nuclei of the cranial nerves. All these contributions collectively constitute the medial fillet, which ends within the thalamus.

Still other tracts arise from the posterior column nuclei and unite the latter with the cerebellum. Some of these fibres pass, as do the above-mentioned fibrae arcuatae



internae, first towards the mid-line and there cross. They course, however, not longitudinally within the interolivary stratum, but pass ventrally along the raphe as far as the anterior medial fissure, then around the pyramids and the olives as the *fibrae arcuatae externae ventrales*, and continue as constituents of the restiform bodies to the cerebellum. Other fibres issue dorsally from the posterior column nuclei and pass directly to the corpus restiforme as the *fibrae arcuatae externae dorsales* (Fig. 156). Perhaps these are joined by direct fibres from the posterior column tracts.

The constitution of the corpus restiforme, or the inferior cerebellar peduncle, may now be considered. Although the tracts ascending to the cerebellum from the spinal cord and the medulla are the principal factors in its make-up, additional paths of especial importance are contributed to the restiform body by the fibre-bundles from the vestibular nerve and its end-nucleus.

The **restiform body** consists of two chief parts, a lateral and a medial division. The **lateral division** is formed by the following fibre-bundles:

*a.* The *tractus spino-cerebellaris dorsalis* or *direct cerebellar tract*. Although the *tractus spino-cerebellaris ventralis* or Gowers' bundle likewise passes to the cerebellum, it reaches the latter, not by way of the restiform body, but, farther above, in conjunction with the superior cerebellar peduncle (Figs. 157 and 178).

*b.* The fibres from the nucleus gracilis and cuneatus of the same and of the opposite side: *fibrae arcuatae externae dorsales et ventrales*, as well as direct fibres from the posterior column.

*c.* A few fibres from the *nuclei arcuati* or *pyramidal nuclei*.

*d.* Fibres from the *lateral column nuclei*.

*e.* Fibres from the *inferior olivary nucleus*.

The last fibres—*tractus olivo-cerebellaris*—contribute the chief bulk of the lateral division of the peduncle. They arise in largest part from the contralateral olive, a few

fibres coming also from the olive of the same side, and end, as do the other fibres of the lateral division, within the cortex of the worm.

The **medial division** consists of two chief varieties of fibres:

*a.* One set of fibres is the sensory root-fibres of certain cerebral nerves, as the trigeminus and the vestibular, which pass direct to the cerebellum and constitute the *direct sensory cerebellar tract* of Edinger.

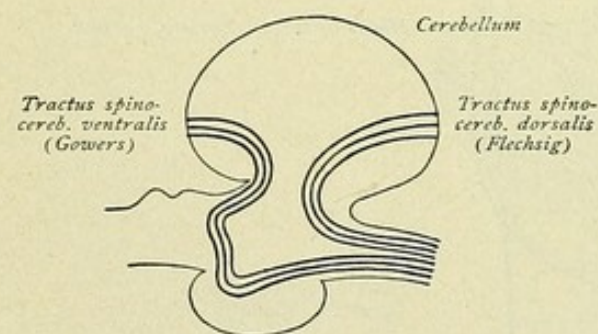


FIG. 157.—Schematic representation of the course of the tractus spino-cerebellaris dorsalis and ventralis.

*b.* The other fibres connect the nuclei of the sensory cerebral nerves with the cerebellum; among these connections, those of the vestibular nucleus with the cerebellum deserve special notice.

The termination of the fibres of both sets is, in largest part, within the nucleus tegmenti of the cerebellum. Fibres pass also in the opposite direction from the nucleus tegmenti or roof nucleus to the end-nuclei of the sensory nerves, Deiters' and Bechterew's



nuclei especially receiving such fibres. These bundles, that bring the nuclei of the sensory cerebral nerves into relation with the cerebellum, constitute the *tractus nucleo-cerebellaris*. The latter forms an *indirect sensory cerebellar tract*, in contrast to the above-mentioned direct one. Fibres from the cerebellum also pass caudally to the medulla oblongata by way of the restiform body.

The *tractus cerebello-bulbaris* or *fastigio-bulbaris* is a descending bundle, which proceeds especially from the nucleus tecti of the opposite side and, perhaps, also from the nucleus dentatus. The bundle is known also as the *tractus uncinatus* (Russel-Thomas). The fibres pass above the superior cerebellar peduncle and, in their farther course, reach the medial division of the restiform body. Their termination is partly within Deiters' nucleus and partly, farther caudalward, within certain nuclei of the medulla oblongata, along with collaterals to the motor nuclei of cerebral nerves—V, VII and X. Attention has been called to these paths, as the *tractus cerebello-tegmentales bulbi*, when considering the chief connections of the cerebellum. Such cerebellofugal tracts proceed from the restiform body, with the *fibrae arcuatae externae ventrales*, to the olive and the pyramid and ascend within the raphe to the *formatio reticularis* of the medulla oblongata.

The inferior olivary nucleus, as we have seen, gives off a robust fibre-bundle, which passes to the corpus restiforme of the opposite side and, thence, to the cerebellum. A small number of fibres, on the other hand, arise within the cerebellar cortex and descend to the opposite olive. The olivary nucleus possesses still further connections. Thus, from the ascending tractus spino-cerebellares collaterals are sent to the inferior olivary nucleus, while other fibres are received from the tractus spino-olivaris or Helweg's triangular tract, as well as from the tractus thalamo-olivaris. By means of the last-mentioned path, impulses from the thalamus, and also from the cerebral cortex by way of the thalamus, are carried to the inferior olive and, by way of the olivo-cerebellar tract, to the cerebellum (Fig. 145).

The **medial fillet** or *interolivary stratum* appears in cross-sections of the medulla as a field, that lies between the two olives at the sides of the raphe (see Part III). Dorsally, as the apex of this field, the *posterior longitudinal bundle* or the *fasciculus longitudinalis medialis* is seen as a small bundle of longitudinally coursing fibres. It will be considered more fully in connection with the vestibular nerve (page 182). Lateral to the interolivary stratum and dorsal to the olive, a field spreads out which, in addition to numerous scattered nerve-cells, contains longitudinally coursing nerve-fibres. This area, the upward continuation of the *formatio reticularis* of the spinal cord, is known as the *association field of the medulla oblongata*. The *formatio reticularis* extends far up into the mid-brain and contains numerous connecting paths, of longer or shorter course, by which manifold relations are established between certain nerve-nuclei. It is probable that within this *formatio reticularis* run those association fibres which unite the nuclei of the vagus, facial and phrenic nerves for coördinated activity during respiration. Repeated mention has been made of tracts, coming from other parts of the brain, which have their ending within this *formatio reticularis*. The reader should refer to the section on the Reflex Tracts (page 192), as well as to the microscopical illustrations in Part III.



## THE CEREBRAL NERVES.

## NERVUS OLFACTORIUS.

The first member of the conventional series of twelve cranial nerves, the nervus olfactorius, is represented by the short peripheral paths, the *filæ olfactoria*, connecting the olfactory mucous membrane with the glomeruli within the bulbus olfactorius. Since the structures formerly described as the first cerebral nerve, the olfactory bulb and tract, are parts of the rhinencephalon, their consideration falls properly with that of the brain. They have been discussed under the Fibre-Paths of the Rhinencephalon (page 144), to which the reader, therefore, is referred.

## NERVUS OPTICUS.

The fibres of the optic nerve arise within the retina and are the axones of the ganglion cells located within the ganglion-cell layer of the nervous tunic of the eye. They extend to the chiasma. Here, one part of the fibres passes to the tractus opticus

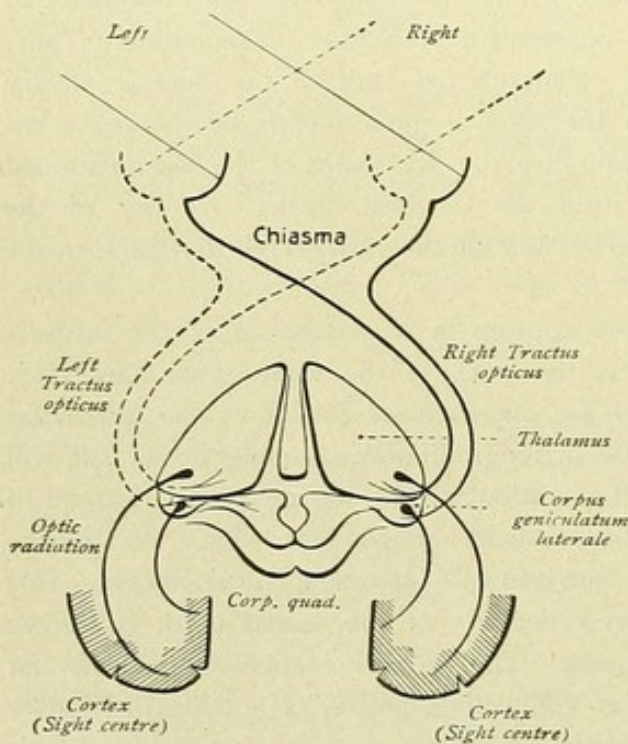


FIG. 158.—The path of visual impulses.

of the opposite side, the other part passes direct to the tract of the same side. The fibres end within the corpus geniculatum laterale, the pulvinar and the superior colliculus; these end-stations constitute *primary visual centres*. From the lateral geniculate body and the pulvinar, fibres pass through the hindmost part of the posterior limb of the capsula interna to the *secondary or cortical visual centres* within the cortex of the cuneus, thereby forming the *optic radiation* of Gratiolet. Fibres also pass in the opposite direction from the cortical visual centre to the primary centres. It must be noted further, that fibres exist, which arise within the primary centres and end within the retina.

The *visual fibres proper* terminate within the corpus geniculatum laterale and the pulvinar thalami and probably do

not invade the superior colliculus of the corpus quadrigeminum, at least in the higher vertebrates. The optic fibres which pass to the superior colliculus are concerned with a special duty. Stimuli carried by these fibres to the superior colliculus are transferred to the deeper lying oculomotor nucleus, resulting in the liberation of the pupillary reflex. These optic fibres ending in the superior colliculus are known, therefore, as *pupillary fibres*.



The pupillary reflex consists in a contraction of the pupil in response to the entrance of light. The reaction is exhibited by both eyes; that is, when the light falls on only one eye, the contraction occurs not only in the stimulated eye (direct reaction), but also in the other eye (consensual reaction).

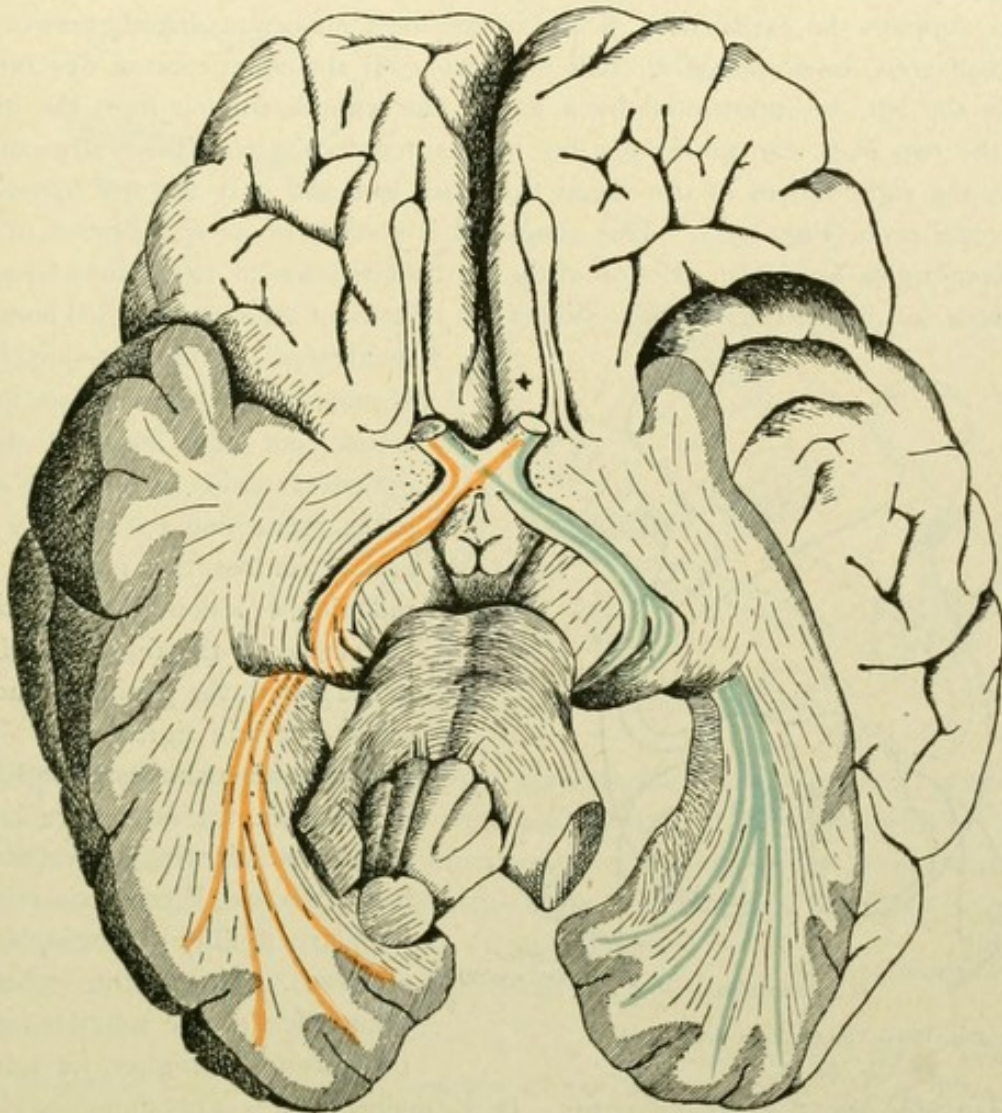


FIG. 159.—The course of the visual path.

The *intercentral paths* of the pupillary reflex are not positively established, although it may be regarded as certain, that the entire reflex-tract is made up of a sequence including several neurones. It may be assumed that the stimulus passes:

- a.* From the retina to the superior colliculus;
- b.* From the superior colliculus to the nucleus of the oculomotor nerve;
- c.* From the oculomotor nucleus to the ciliary ganglion;
- d.* From the ganglion ciliare to the sphincter pupillae muscle.

Since the illumination of one eye causes uniform contraction of both pupils, the reflex being, therefore, homo- and heterolateral, it follows that the impulse from one colliculus must be transferred to both oculomotor nuclei, or one nucleus must be able to stimulate



both the right and left sphincter pupillae muscles. The particular fibre-bundle, by means of which the impulse is transferred from the superior colliculus to the oculomotor nucleus, is not definitely determined. In Fig. 160, the reflex path is schematically represented, with the assumption, that the fibres proceeding from the superior colliculus reach both oculomotor nuclei.

A knowledge of the course of the fibres of the optic nerve, particularly their semi-decussation, supplies the explanation of one of the most important disturbances of vision—*hemioptia* (half seen) or *hemianopsia* (half not seen). If the conduction of one optic tract, for example the left, be interrupted by a lesion, the stimuli coming from the left retinal halves of the two eyes can no longer be transmitted to the cortical centres in the left hemisphere, the right halves of the visual fields are lost and only the left halves of fixed objects are still seen (Fig. 158). This condition is spoken of as *homolateral* or *homonymous hemianopsia* or *hemioptia*. Lesion of the left tractus leads to right-sided homonymous hemianopsia or to left-sided hemioptia; lesion of the right tract leads to left-sided homonymous hemianopsia or to right-sided hemioptia.

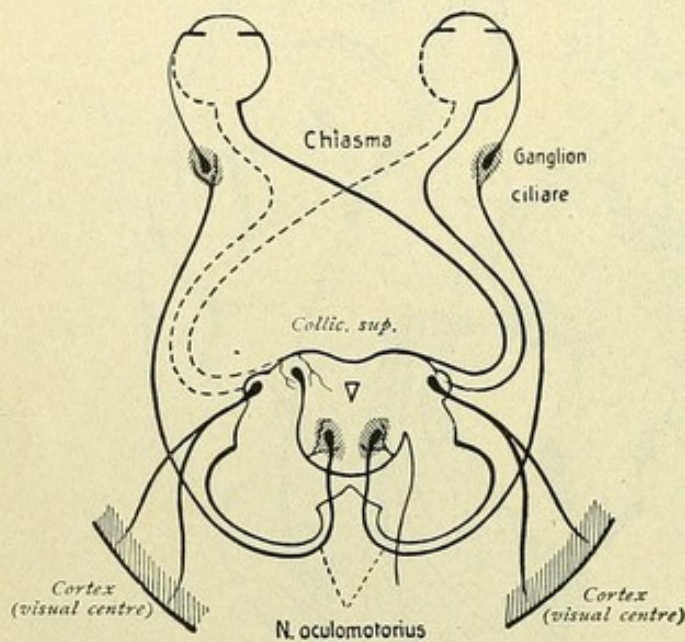


FIG. 160.—The pupillary reflex path.

Homonymous hemianopsia follows, of course, not only lesion of the tractus opticus, but also lesion of the secondary paths connecting the primary and secondary centres, that is within the optic radiation, or lesion of the cortical centre. In relation to the diagnosis of the seat of the lesion, the pupillary reaction possesses a certain significance. If in homonymous hemianopsia the light-reflex is lost when the insensitive half of the retina is illuminated, the seat of the lesion is the tractus (Wernicke's hemianopsic pupillary rigidity or hemioptic pupillary reaction). If, on the contrary, the light-reflex of the pupil is intact, then the lesion lies higher, for example, in the internal capsule or in the cerebral cortex. In the majority of cases of homonymous hemianopsia, we have to do with tumors of the occipital lobe, more rarely with lesions of the tractus opticus. Complications associated with hemianopsia, such as hemiplegia, hemiparesis, contractions and aphasic disturbances (with right-sided hemianopsia), must also be borne in mind.

The same-sided or homonymous hemianopsia is the opposite of the *heteronymous hemianopsia*, which occurs more rarely than the homonymous. When the temporal halves of both visual fields are wanting, such heteronymous hemianopsia is known as *temporal hemianopsia*. In such cases, the lesion is situated within the chiasm, either in the middle or in the anterior or the posterior angle of the chiasm, whereby the decussating fibres are involved. Temporal hemianopsia is observed, for example, in acromegaly, in which the enlargement of the hypophysis cerebri concurrently affects the chiasm. When the nasal halves of both visual fields are wanting, the condition is spoken of as *nasal hemianopsia* and is produced by involvement of the uncrossed fibres, as when the chiasm is subject to pressure on both sides in the lateral angle by enlarged carotids.



## NERVUS OCULOMOTORIUS.

The oculomotor nerve arises in the *nucleus nervi oculomotorii*, which lies in the region of the superior colliculus, ventral to the aquaeductus Sylvii, within the floor of the central gray substance (Figs. 88 and 89). The nucleus consists of a medially placed *medial nucleus* and

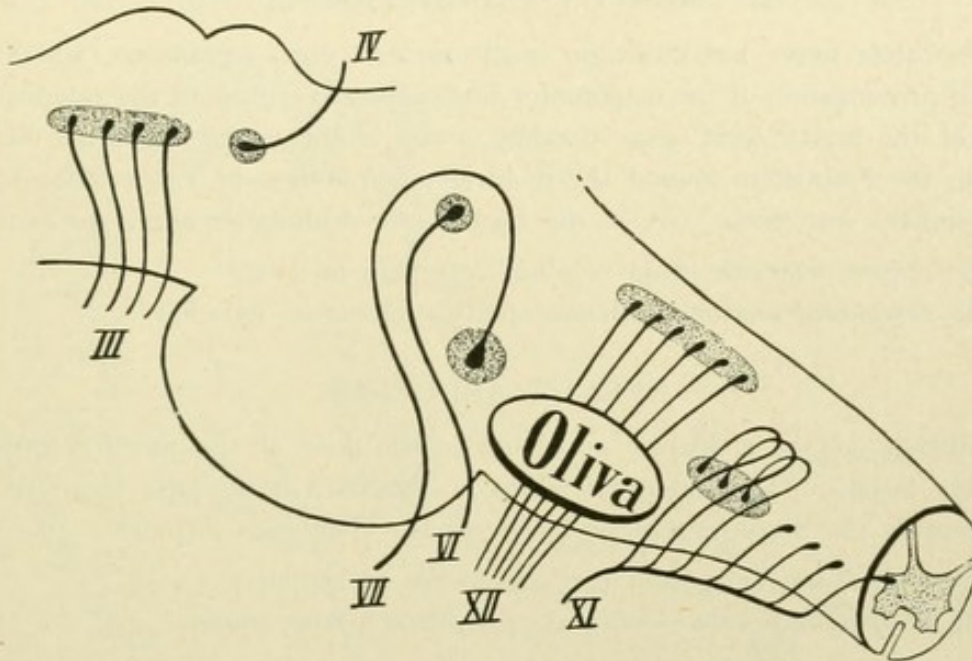


FIG. 161.—The deep origins of the motor cerebral nerves.

a pair of large-celled *lateral nuclei*. The nerve conveys fibres which originate within the medial nucleus and the lateral nucleus of the same and, in part, of the opposite side. The fibres pass ventrally in laterally convex curves and emerge from the brain-stem along the sulcus nervi oculomotorii on the medial surface of the pedunculus cerebri. The voluntary innervation of the nucleus proceeds, as in the case of all the motor cerebral nerves, from the cerebral cortex. The entire path of conduction includes:

- a. The *central neurone*—cerebral cortex to nucleus;
- b. The *peripheral neurone*—nucleus, peripheral nerve, muscle.

It must be pointed out, however, that the course of the central path is not yet known; probably the path is composed of several neurones. Likewise, uncertainty exists regarding the location of the cortical centres, which have been variously assumed as lying within the gyrus angularis, the occipital lobe or the frontal lobe. The centre for voluntary eye-movements, however, is quite generally regarded as including the posterior part of the second or middle frontal convolution. Investigations have shown, that the entire oculomotor nucleus is made up of certain groups of cells, of which a particular group always gives origin to the fibres for a particular muscle. Concerning these special subdivisions of the nucleus, however, we shall not enter more fully, for the reason that these relations, as yet, have been by no means definitely established. Fig. 162

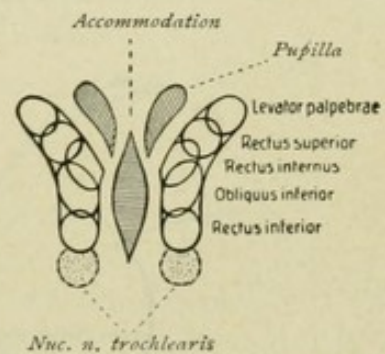


FIG. 162.—Subsidiary nuclei of the oculomotor nucleus. (Bernheimer.)



represents the individual cell-groups, according to the investigations of Bernheimer on monkeys. In the middle is the medial chief nucleus, on either side the lateral chief nucleus with its various subdivisions, and, medial from the latter, the small lateral nucleus, which is also known as the *nucleus of Edinger-Westphal*.

#### NERVUS TROCHLEARIS.

The trochlear nerve has its origin in the *nucleus nervi trochlearis*, which is located in the caudal prolongation of the oculomotor nucleus in the region of the inferior colliculus. The fibres of the fourth nerve pass dorsally, cross in the velum medullare anterius and emerge from the brain-stem behind the quadrigeminal bodies, on either side of the frenulum veli medullaris anterioris. As in the case of the oculomotor nervi, the path includes:

- a. The *central neurone*—from cerebral cortex to nucleus;
- b. The *peripheral neurone*—nucleus, peripheral nerve, muscle.

#### NERVUS ABDUCENS.

The nucleus of the abducens nerve lies in the floor of the fourth ventricle and in the colliculus facialis. The emergent fibres of the sixth nerve pass ventrally and leave the brain-stem at the posterior border of the pons. The path includes:

- a. The *central neurone*—from cerebral cortex to nucleus;
- b. The *peripheral neurone*—nucleus, peripheral nerve, muscle.

#### NERVUS TRIGEMINUS.

Here a motor part and a sensory part are to be distinguished (Figs. 163 and 164).

1. **Motor Portion.** The *central neurone* takes origin in the cerebral cortex of the lower third of the central convolutions, passes with the pyramidal tracts downward and

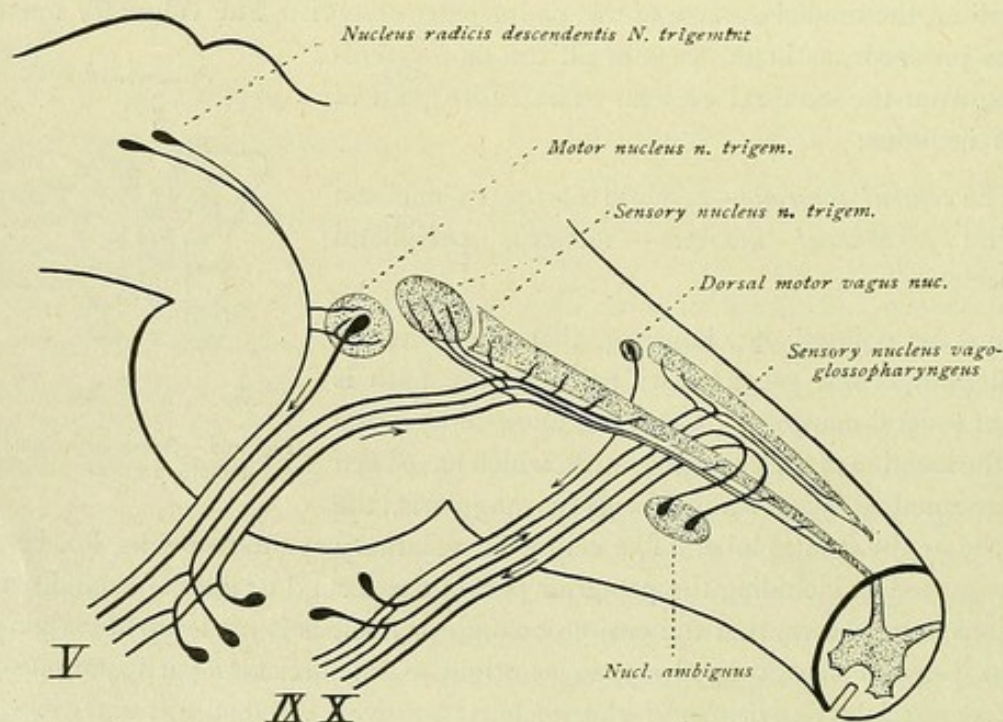


FIG. 163.—Course of the trigeminus, vagus and glossopharyngens within the brain-stem.



ends in the *chief motor nucleus*, within the dorso-lateral part of the tegmentum of the pons. The *peripheral neurone* arises within this motor nucleus, the motor root of the nerve receiving also fibres from the nucleus of the opposite side. The fibres emerge from the pons as the *portio minor nervi trigemini* and pass to the muscles. A small part of the motor root arises from small cells, which lie lateral to the Sylvian aqueduct within the region of the corpora quadrigemina and constitute the *nucleus radialis descendens*

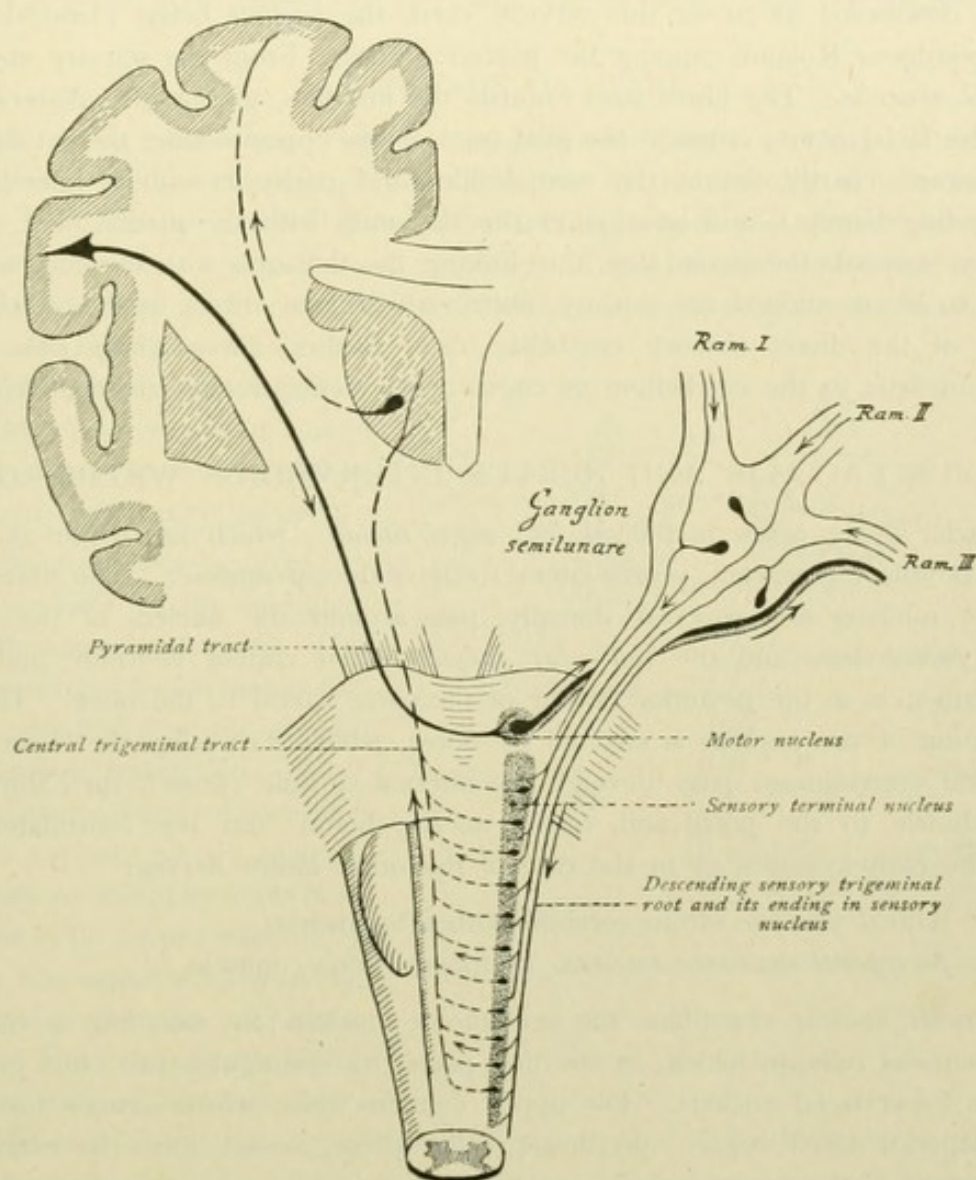


FIG. 164.—Course and relations of the root-fibres of the trigeminal nerve.

*nervi trigemini*. This group of cells joins caudally the cell-area of the locus caeruleus. The fibres arising from these cells, after giving off collaterals to the chief motor nucleus, pass outward with the other peripherally directed processes of the motor neurones.

2. **Sensory Portion.** The origin of the sensory part of the trifacial nerve lies within the *ganglion Gasseri*. The axones of the unipolar ganglion cells of this ganglion divide into two branches. One of these extends peripherally as the peripheral nerve, the other passes centrally, enters the pons as the *portio major nervi trigemini*, and runs to the *sensory end-nucleus* of the trigeminus, close to the motor nucleus. Here each



fibre divides into an ascending and a descending branch. The ascending branch ends within the sensory nucleus within the pontile tegmentum. The descending branch ends, after giving off numerous collaterals, in a nucleus that is nothing more than the caudal prolongation of the sensory nucleus. The descending branches form collectively the *tractus spinalis nervi trigemini*; the gray substance in which this path ends, constitutes the *nucleus tractus nervi trigemini*. The descending tract, as well as the nucleus, can be followed downward as far as the cervical cord, the nucleus being identical with the *substantia gelatinosa Rolandi* capping the posterior horn. From the sensory end-nucleus arises the *II neurone*. The fibres pass towards the mid-line, giving off collaterals to the nucleus of the facial nerve, cross to the fillet-tract of the opposite side, there turn upward and run forward (partly within the medial fillet and partly as a more laterally placed special ascending bundle), and later enter the thalamus with the medial fillet. Finally, a *III neurone* succeeds the second one, thus linking the thalamus with the cortical sensory area. Still to be mentioned are sensory fibres, which pass direct to the cerebellum as constituents of the direct sensory cerebellar tract; further, fibres which pass from the sensory end-nucleus to the cerebellum as constituents of the *tractus nucleo-cerebellaris*.

#### NERVUS FACIALIS AND NERVUS INTERMEDIUS WRISBERGI.

The facial nerve arises in the *nucleus nervi facialis*, which lies within the ventral area of the pontile tegmentum, ventro-lateral to the abducent nucleus. The fibres springing from the nucleus first proceed dorsally, pass around the nucleus of the abducent nerve—the *facial knee* and the *colliculus facialis*—then course ventrally and emerge from the brain-stem at the posterior border of the pons, lateral to the olive. The voluntary innervation of the nucleus is effected by fibres, which start from the lower third of the precentral convolution, pass through the internal capsule (knee), then through the cerebral peduncle to the pons, and, finally, to the homo- and the contralateral facial nucleus. The path includes, as in the case of the other motor nerves:

- a. The *central neurone*—from cerebral cortex to nucleus;
- b. The *peripheral neurone*—nucleus, peripheral nerve, muscle.

The *facial nucleus* resembles the oculomotor nucleus in including a number of different groups of cells, in which, in the first place, we distinguish two chief groups, an upper and a lower facial nucleus. The upper contains cells, whose axones form collectively the superior facial branch; the lower, cells whose axones form the inferior facial branch. Moreover, the superior facial nucleus receives its innervation from the motor centres of both hemispheres, a fact of clinical significance. This bilateral innervation explains why, in central facial paralysis, the muscles supplied by the upper facial division are not involved in the paralysis, since innervation is still provided by the unaffected central neurones of the other hemisphere. In peripheral facial palsy, on the contrary, all the muscles supplied by both the upper and lower facial are paralyzed.

The **nervus intermedius Wrisbergi** (the nerve of Sapolini, by whom it was regarded as the thirteenth cerebral nerve) is a mixed nerve, which accompanies the facial and continues as the chorda tympani. The *motor fibres* take origin in a small cell-group lying dorso-medial to the facial nucleus. The *sensory fibres* arise within the *ganglion geniculi*. The axones arising from the cells of this ganglion divide into two branches.



One of these passes peripherally and forms, after joining the motor fibres, the peripheral nervous intermedius, that continues as the chorda tympani. The other branch passes centrally, enters the brain-stem and ends within the *nucleus tractus solitarii* as part of the gustatory path (page 189).

### NERVUS ACUSTICUS.

The acoustic nerve consists of two parts, the nervus cochleae and the nervus vestibuli.

#### 1. NERVUS COCHLEAE.

This nerve takes origin within the *ganglion spirale cochleae*. The peripherally directed fibres of these bipolar ganglion cells run to the auditory cells within the organ of Corti; the centrally directed fibres enter the brain-stem and end in two nuclei. The latter are the *nucleus ventralis nervi cochleae*, situated ventral and lateral to the corpus restiforme, and the *nucleus dorsalis nervi cochleae*, or *tuberculum acusticum*, which lies dorsally, although connected with the ventral nucleus. The impulses carried by these peripheral neurones are conveyed to the higher levels by the central path including:

*a.* Neurones passing from the nucleus ventralis to the mid-line, forming the *corpus trapezoides*. The path is augmented by fibres from the *superior olive* and from the *nucleus of the corpus trapezoides*. After crossing the mid-line, some fibres end within the superior olivary nucleus, while others are joined by fibres from the nucleus of the corpus trapezoides and from the superior olive of the side on which the path now runs.

The fibres form collectively the *lateral fillet* or *lemniscus lateralis*, which ends within the corpus geniculatum mediale and, chiefly by collaterals, within the inferior colliculus. Some fibres extend as far as the superior colliculus. The lateral fillet receives additional fibres from a group of cells lying in the midst of the tract, known as the *nucleus lemnisci lateralis*.

*b.* Neurones passing from the nucleus dorsalis or tuberculum acusticum over the corpus restiforme and, as the superficial *striae acusticae*, toward the mid-line; thence coursing deeply to cross the raphe and reach the opposite superior olive, they join the lateral fillet and finally end within the corpus geniculatum mediale.

*c.* Neurones arising within the lateral geniculate body and passing to the auditory centre within the cortex of the gyrus temporalis superior. Fibres also run in the opposite direction, from the auditory centre to the medial geniculate body and to the inferior colliculus.

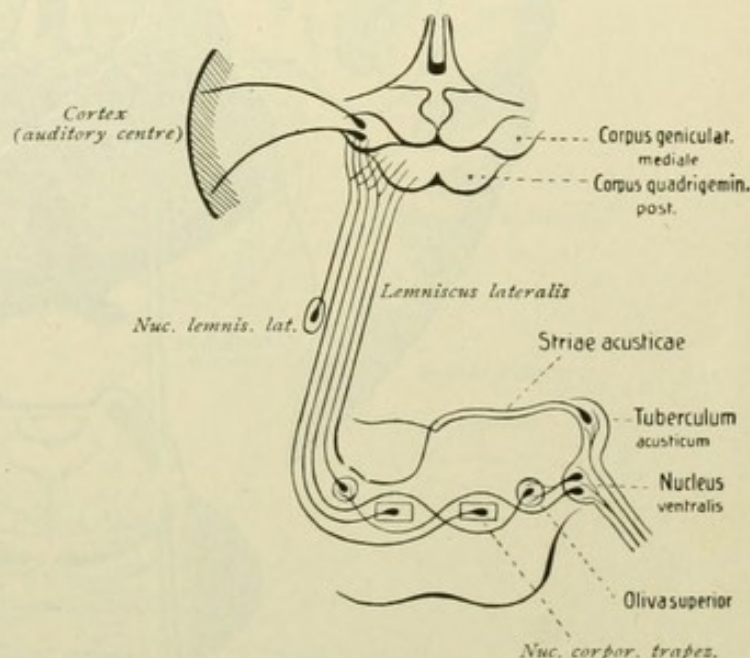


FIG. 165.—The auditory path.



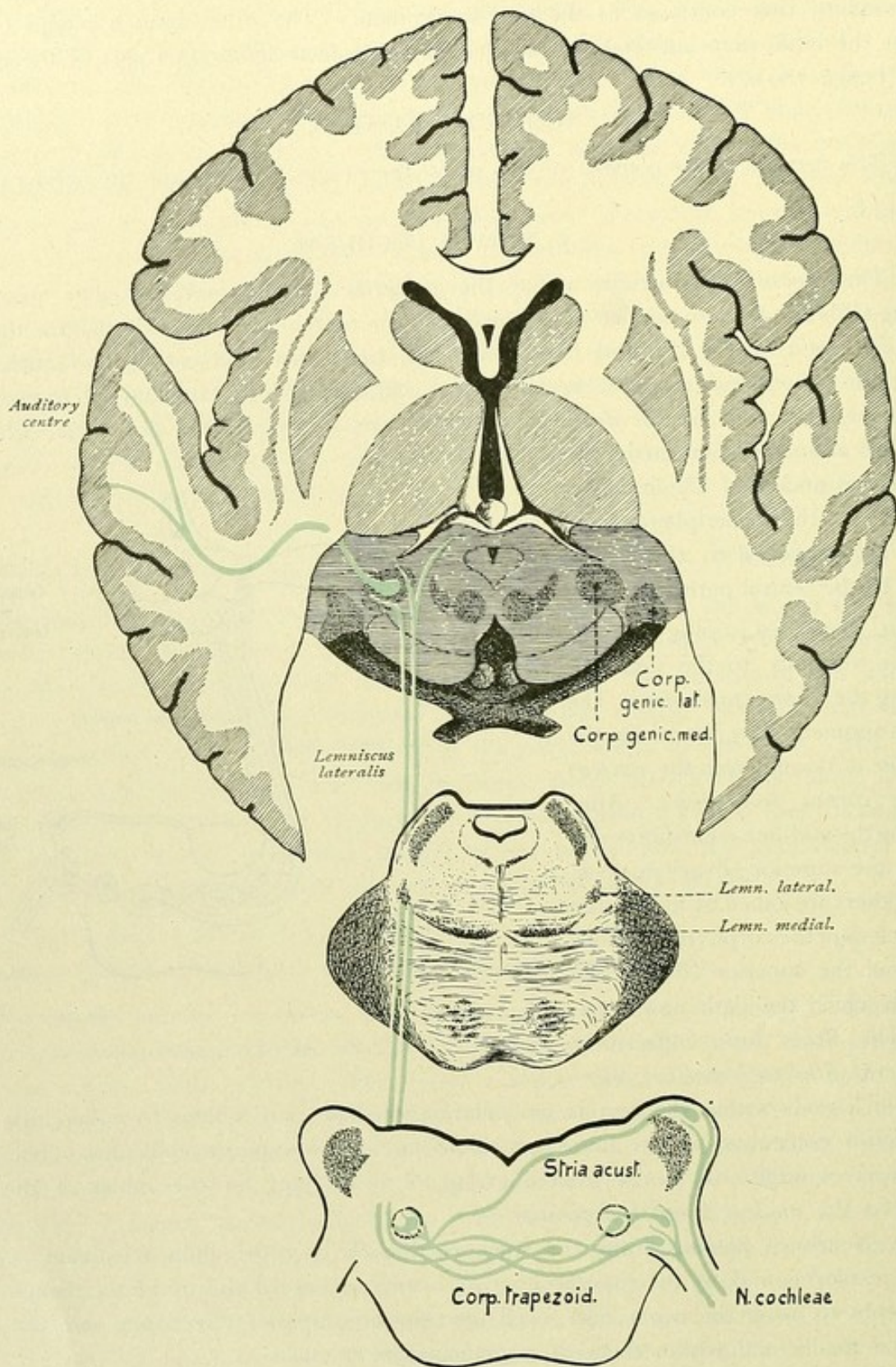


FIG. 166.—Course followed by the auditory impulses.



## 2. NERVUS VESTIBULI.

The vestibular division of the auditory nerve arises within the *ganglion vestibulare* or *Scarpa's ganglion*, located at the bottom of the internal auditory canal. The peripherally directed processes or fibres of these ganglion cells run to the ampullae, the utricle and saccule of the internal ear; the centrally directed fibres enter the brain-stem and divide into ascending and descending branches. The descending branches form a *descending vestibular root* and end within the *nucleus nervi vestibularis spinalis*, which extends as far as the posterior column nuclei. The ascending branches end within the *nucleus medialis*, as well as within the lateral *Deiters' nucleus* and the upper *Bechterew's nucleus*. From these end-nuclei, fibres pass to the cerebellar worm as constituents of the *tractus nucleo-cerebellaris*. A part of the vestibular fibres pass direct to the roof-nucleus

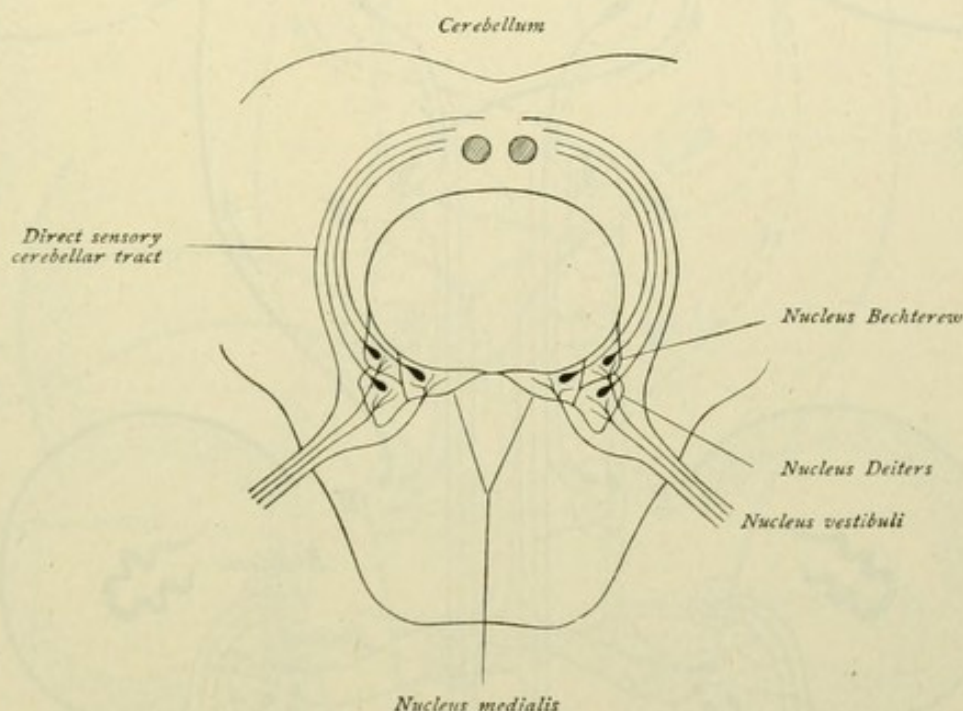


FIG. 167.—Path of the impulses from the vestibular nerve.

of the cerebellum as constituents of the direct sensory cerebellar tract, the fibres giving off collaterals to Deiters' nucleus. The medial nucleus is brought into relation with the superior olive by means of fibres. Perhaps fibres pass also to the *formatio reticularis* and to the thalamus.

In view of its importance, the system of Deiters' nucleus claims closer attention. This nucleus receives, on the one hand, fibres from the roof-nucleus of the cerebellum; on the other hand, as we have seen, Deiters' nucleus gives origin to a fibre-bundle that, as the *tractus vestibulo-spinalis*, passes to the spinal cord.

Within the same nucleus, moreover, also another path, the *posterior longitudinal bundle* or the *fasciculus longitudinalis medialis*, takes its origin. The fibres pass from Deiters' nucleus toward the mid-line, some crossing the latter and then dividing into ascending and descending branches. The ascending branches can be followed upward as far as the oculomotor nucleus; the descending branches pass to the anterior column of the



spinal cord. The posterior longitudinal bundle, however, does not consist exclusively of fibres from Deiters' nucleus. Other fibres take origin in the common *nucleus of the commissura posterior and of the fasciculus longitudinalis medialis* within the forepart of

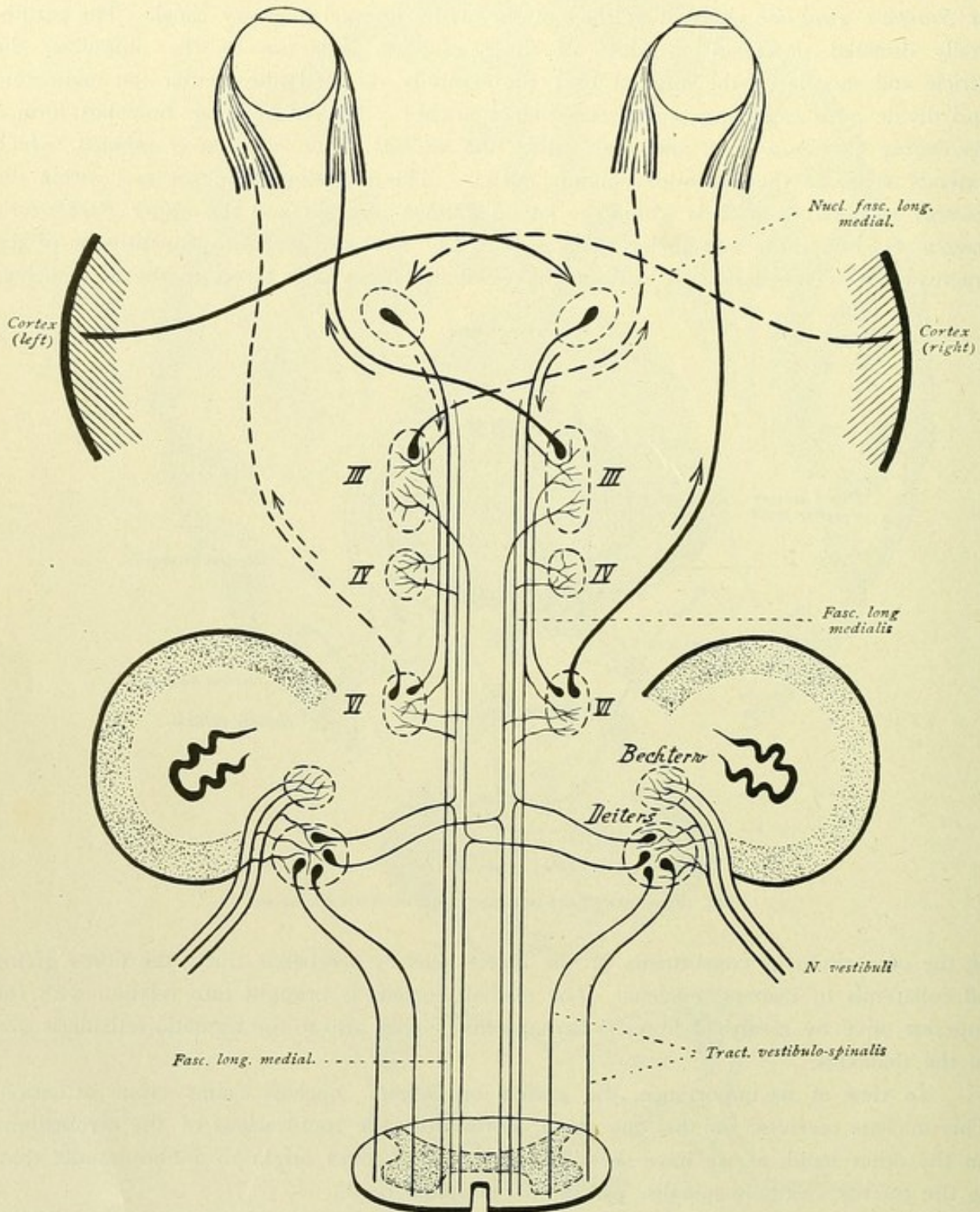


FIG. 168.—Origin and course of the posterior longitudinal bundle.

the mid-brain, in front of the oculomotor nucleus. The posterior longitudinal bundle may be traced from its nucleus through the mid-brain, the pons and the medulla oblongata into the spinal cord, during its course giving off numerous collaterals to the nuclei of the



nerves supplying the ocular muscles. This bundle is of great importance. It establishes relations of the nuclei of the eye-muscles to one another, among which that of the abducens to the oculomotorius nucleus deserves particular attention. Of especial importance is the connection of the abducent nucleus with those cells of the oculomotor nucleus, from which pass the fibres for the rectus internus, since the synergic function of the

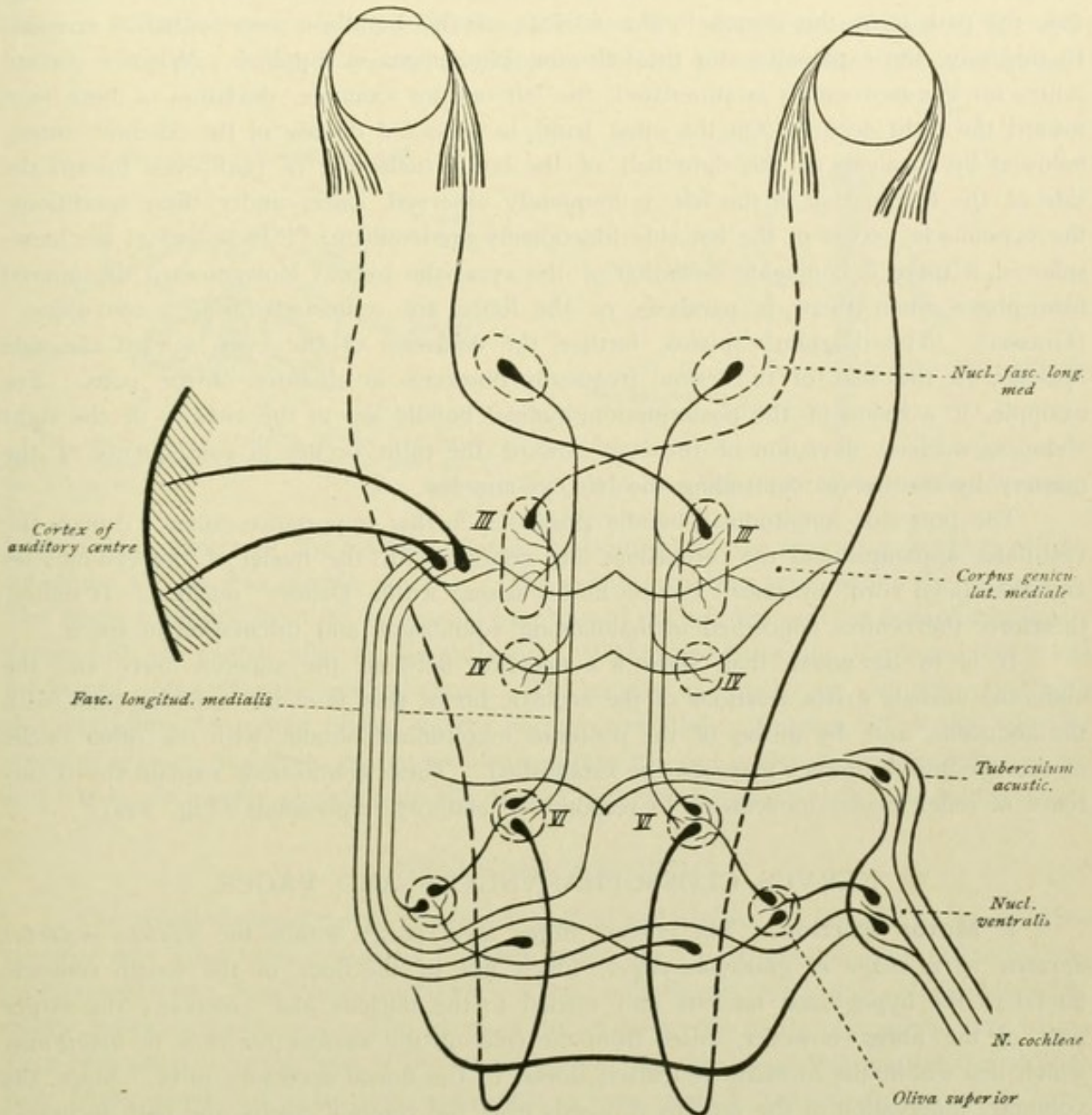


FIG. 169.—Course of the auditory path. Connection of the superior olive with the nucleus of the abducens (VI) and, by means of the posterior longitudinal bundle, with the nuclei of the other nerves (III, IV) to the ocular muscles.

rectus externus and internus, which consists in the conjugate deflection of the eyes toward one side, can be explained only by the existence of a direct or an indirect connection between these nuclei. Fig. 168 represents the manner in which the coördinate action of the two muscles may be explained upon an anatomical basis. Connection of the abducens nucleus with that of the oculomotorius, by means of the posterior longitudinal bundle, is



positively established. Further, that the nerve-fibres for the rectus internus arise, in greater part, from the cells of the oculomotor nucleus of the opposite side. On the other hand, it is still undecided, whether the efferent paths from the cortical centre for synergic eye-movements are first interrupted in a special centre within the quadrigeminal region, or pass directly into the posterior longitudinal bundle. In any event, this tract undergoes a total or partial decussation before it enters the posterior longitudinal bundle. In Fig. 168, the path from the cortex to the nucleus of the bundle is represented as crossed. In this way, the explanation for the following phenomena is supplied. When a cortical centre for eye-movements is stimulated, the left one for example, deviation of both eyes toward the right occurs. On the other hand, in left-sided disease of the cerebral cortex, followed by paralysis of the right half of the body, deflection of both eyes toward the side of the lesion, that is the left, is frequently observed, since, under these conditions, the eye-muscle nerves of the left side functionally predominate. "In lesions of the hemispheres, if there is conjugate deviation of the eyes, the patient looks toward the injured hemisphere when there is paralysis, or the limbs are contorted during a convulsion" (Grasset). The diagram explains, further, the deviation of the eyes, toward the side opposite to the seat of the lesion, frequently observed in diseases of the pons. For example, if a lesion of the posterior longitudinal bundle lies in the vicinity of the right abducens nucleus, deviation of the eyes toward the right occurs in consequence of the mastery by the nerves controlling the left eye-muscles.

The posterior longitudinal bundle possesses further importance, since it brings the vestibular apparatus and the cerebellum into relation with the nuclei of the eye-muscles and the spinal cord, by means of the fibres arising within Deiters' nucleus. It unites, therefore, the centres concerned in maintaining equilibrium and orientation in space.

It is to be noted, that, since a connection between the superior olive and the abducens nucleus exists, relations of the acoustic nerve, that is of the auditory path, with the abducens, and, by means of the posterior longitudinal bundle, with the other nuclei of the eye-muscle nerves may also be established. These connections explain the occurrence of reflex ocular movements in response to auditory impressions (Fig. 169).

#### NERVUS GLOSSOPHARYNGEUS AND VAGUS.

1. **Motor Portion.** The efferent fibres arise partly within the *nucleus motorius dorsalis nervi vagi et glossopharyngei*, which lies in the floor of the fourth ventricle lateral to the hypoglossal nucleus and medial to the nucleus alae cinereae; the larger part of the fibres, however, arises from the cells of the *nucleus ventralis* or *ambiguus*, which lies within the *formatio reticularis* dorsal to the dorsal accessory olive. Since the voluntary innervation of the nucleus proceeds from the cerebral cortex, the path includes:

- a. The *central neurone*—from the cerebral cortex to nucleus;
- b. The *peripheral neurone*—nucleus, peripheral nerve, muscle.

The root-bundles passing out from the dorsal nucleus are the equivalents of motor preganglionic sympathetic fibres destined for the innervation of involuntary muscle; this nucleus, therefore, is also designated as the *sympathetic motor nucleus*. The fibres proceeding from the nucleus ambiguus, on the contrary, are for the voluntary muscle; this nucleus, therefore, is known as the *somatic motor nucleus*. The latter consists of several



groups of nerve-cells, the individual groups representing centres for the particular groups of muscles innervated by the vagus. The positions of these centres within the nucleus, however, are not yet sufficiently determined.

2. **Sensory Portion.** The efferent fibres arise within the *ganglion superius et petrosum nervi glossopharyngei* and *ganglion jugulare et nodosum nervi vagi* respectively. The peripherally directed branches form the peripheral sensory nerves; the centrally directed branches enter the brain-stem as the sensory root-fibres and pass to the end-nuclei. One part of the fibres ends within the *nucleus alae cinereae*, while another part

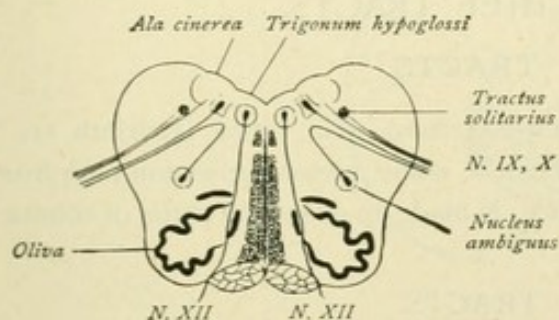


FIG. 170.—Transverse section of the medulla oblongata. Origin of the IX and X (motor part) and of the XII nerve.

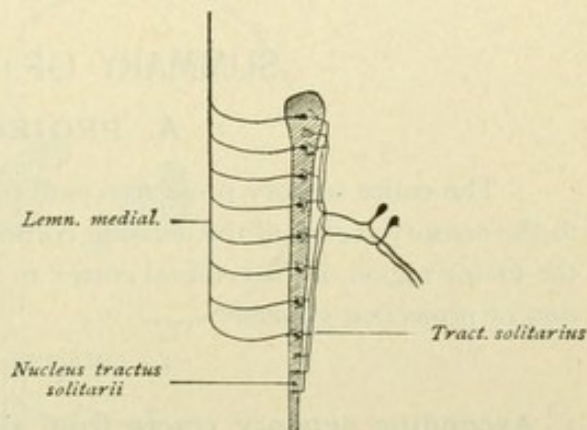


FIG. 171.—Origin of the IX and X nerves, sensory part.

forms a descending root, the *tractus solitarius*, and ends within the accompanying tract of gray substance, the *nucleus tractus solitarii*. The central neurones arise within the end-nuclei. The fibres emerging from the end-nuclei pass toward the mid-line and the interolivary layer, thence with the medial fillet to the thalamus. Within the latter, the third neurone takes origin and ends within the cerebral cortex. The sensory end-nuclei are also connected with the cerebellum, by means of the tractus nucleo-cerebellaris. Further, all of the centrally coursing sensory root-fibres do not terminate within the end-nuclei of the glossopharyngeus and vagus, since some of them join the descending tractus spinalis of the trigemini nerve.

### NERVUS ACCESSORIUS.

The spinal accessory nerve presents a cerebral and a spinal portion. The fibres of the *cerebral part* arise from a nucleus, situated within the caudal prolongation of the nucleus ambiguus; further, from a small dorsal nucleus, which represents the caudal prolongation of the dorsal motor vagus nucleus. The fibres of the *spinal portion* of the accessorius take origin from cells situated in the base of the lateral horn and in the dorsolateral part of the anterior horn of the spinal cord, as far down as the fifth, or even seventh, cervical segment of the cord.

The path includes:

- a. The *central neurone*—from cerebral cortex to the nucleus;
- b. The *peripheral neurone*—nucleus, peripheral nerve, muscle.

As well known, the accessorius supplies the sterno-cleido-mastoideus and trapezius muscles. These fibres include the spinal portion of the nerve and constitute the ramus externus, while the fibres of the cerebral portion, as the ramus internus, pass to the vagus, as a part of which they are to be regarded.



## NERVUS HYPOGLOSSUS.

The nucleus of the hypoglossal nerve lies in the floor of the fourth ventricle, within the *trigonum nervi hypoglossi*. The efferent fibres pass from the nucleus, proceed ventrally and emerge from the brain-stem between the pyramid and the olivary eminence. The path includes:

- a. The *central neurone*—from cerebral cortex (lower third of the precentral convolution), knee of internal capsule, nucleus.
- b. The *peripheral neurone*—nucleus, peripheral nerve, muscle.

## SUMMARY OF THE CHIEF TRACTS.

## A. PROJECTION TRACTS.

The entire sensory projection path from the sense-surfaces (skin, retina, labyrinth, etc.) to the sensory region of the cerebral cortex, as well as the entire motor projection path from the motor region of the cerebral cortex to the muscles, is made up of several paths of conduction or projection systems.

## I. CENTRIPETAL TRACTS.

## 1. Ascending sensory tracts from the spinal cord.

a. The path for the conduction of *impulses of touch, temperature and pain* from the trunk and the extremities.

*Neurone I:* The impulse is conveyed from the periphery to the ganglion-cells within the spinal ganglion and thence to the spinal cord by the posterior roots. The latter enter the spinal cord and end within the gray substance.

*Neurone II:* Origin within the gray substance of the spinal cord. The fibres pass, as the axones of commissure-cells, by way of the anterior gray commissure to the opposite lateral column and form the tractus spino-thalamicus, which higher up joins the medial fillet and with it ends within the thalamus.

*Neurone III:* Origin within the thalamus. Course to the cerebral cortex, in part direct by way of the internal capsule, and in part after traversing the lenticular nucleus. Cortical ending within the area of somatic sensibility.

The conduction of impulses of contact or tactile sensibility is not limited to the spino-thalamic tract, but takes place also through the long tracts of the posterior columns.

b. The path for the conduction of the *muscle-sense* from the trunk and the extremities.

*Neurone I:* The impulse is conveyed, as in the case of those of touch, temperature and pain, first to the spinal cord. The fibres enter as posterior roots, do not, however, end within the gray substance of the spinal cord, but ascend within the posterior column to the medulla oblongata, where they first find their ending within the nucleus gracilis and cuneatus.

*Neurone II:* Origin within the posterior column nuclei; course, after decussation, as medial fillet to thalamus and there end.

*Neurone III:* Origin within the thalamus. Course to cortical somatic sensory area.

The conduction of muscle-sense is not only by way of the posterior column nuclei and the medial fillet, but also shares the tracts passing to the cortex by way of the cerebellum, that is by



the tractus spino-cerebellaris ventralis et dorsalis. From the cerebellum, the conduction passes through the superior cerebellar peduncle to the thalamus and thence to the cerebral cortex. It is to be noted, that tracts lead to the cerebellum also from the posterior column nuclei.

The partly uncrossed (muscle-sense or deep sensibility) and partly crossed (pain and temperature) conduction of sensibility within the spinal cord, explains the peculiar disturbances of sensibility in hemileSIONS of the cord, as manifested in the Brown-Séguard symptom-complex. In hemilateral lesions of the spinal cord, we find, on the same side

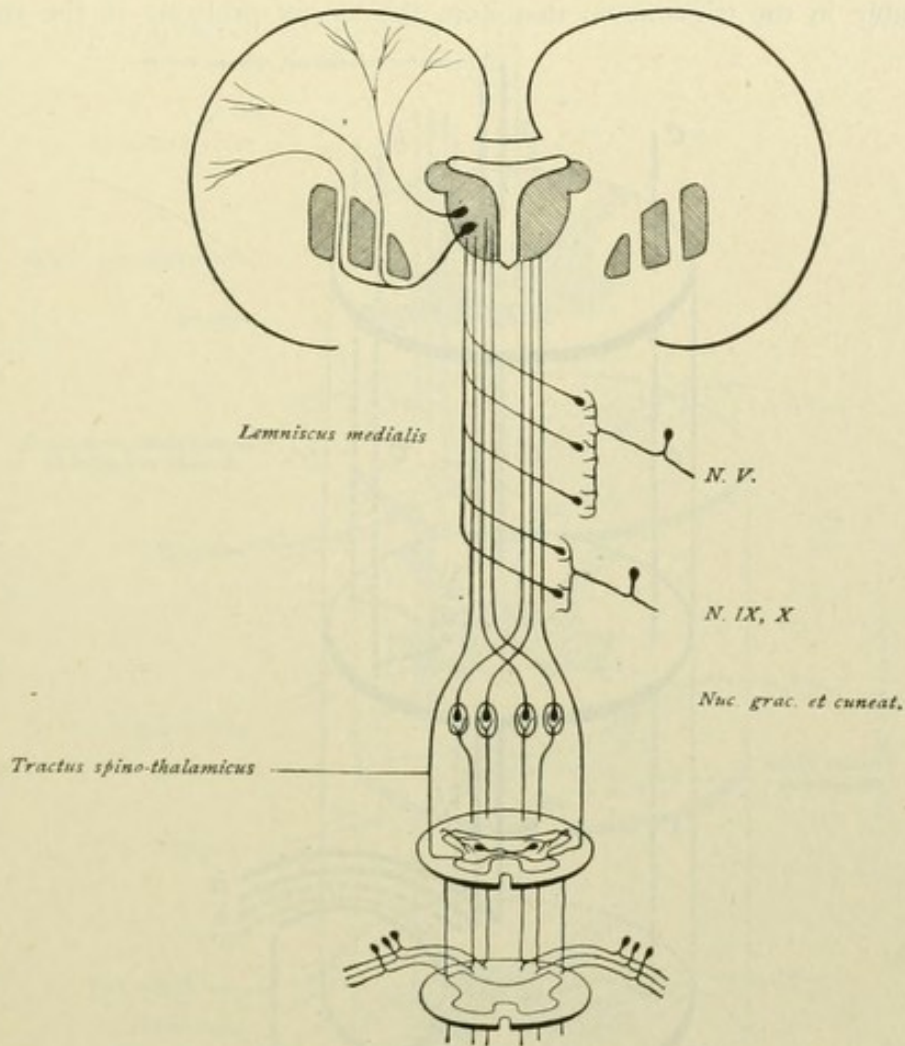


FIG. 172.—The sensory tract.

as the lesion, paralysis in consequence of interruption of the descending motor paths, and disturbances of the deep sensibility or muscle-sense in consequence of the involvement of the ascending paths of the posterior column and of the spino-cerebellar tracts; while, on the side opposite the lesion, are found disturbances of superficial sensibility, pain and temperature impulses in consequence of the crossed path of the tractus spino-thalamicus.

Further, the fact that the conduction of sensibility, especially of muscle-sense, also takes place by way of the cerebellum, supplies the explanation of those pathological disturbances, which we designate as ataxia or errors of coördination, since the impulses proceeding from the muscles and articulations are no longer transmitted to the cerebellum in consequence of the lesion of the posterior column tracts.



## 2. Sensory Tracts of the Cerebral Nerves.

*a.* The path for the *impulses of touch, temperature and pain* from the integument of the head (with the exception of the occipital region and certain areas of the external ear—supplied respectively by the occipital and great auricular nerves), further, from the conjunctiva, the mucous membranes of the nasal fossæ, of the mouth and tongue, of the palate, of the pharynx, etc., lies in the trigeminus, the glossopharyngeus, or the vagus.

*b.* The path for the *impulses of orientation and movement—muscle-sense*—from the face lies probably in the trigeminus; that from the larynx probably in the vagus.

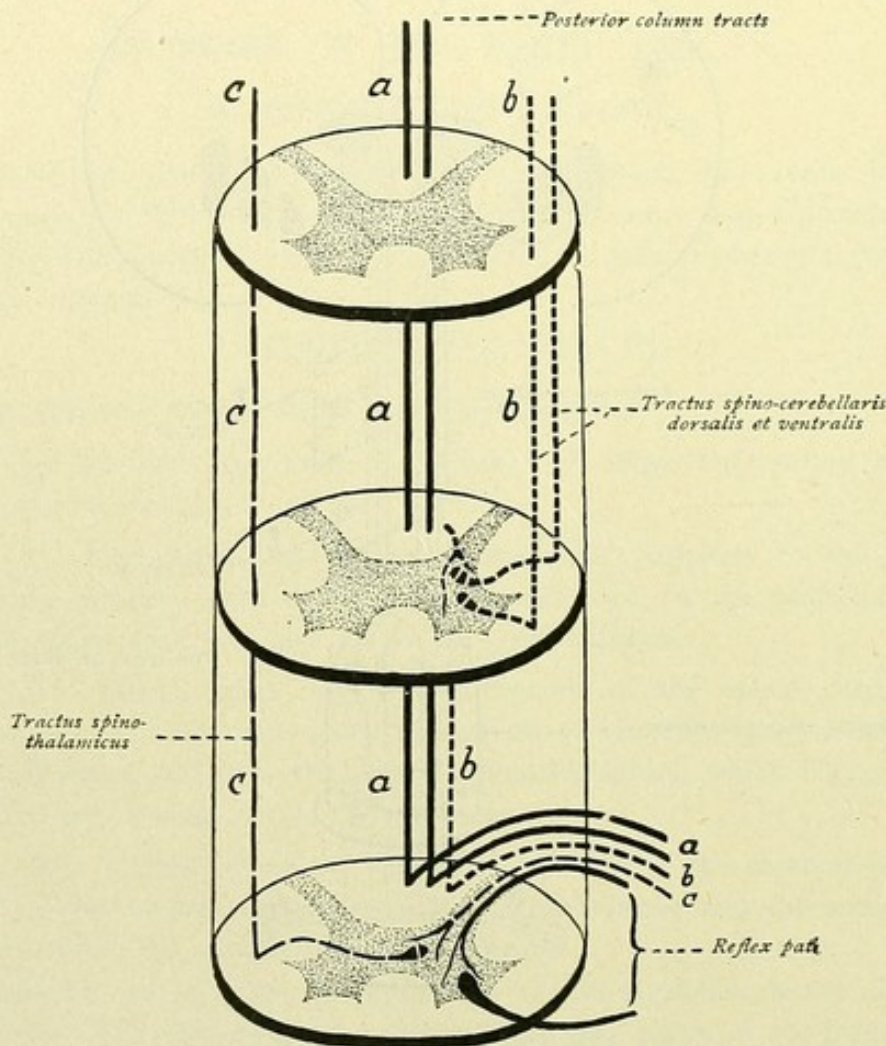


FIG. 173.—Ascending tracts from the spinal cord. *a + b* = conduction of muscle-sense; *c* = conduction of impulses of pain and temperature; *a + c* = conduction of tactile sensibility.

The impulse is carried from the periphery to the ganglion of the corresponding nerve, and thence to the end-nucleus within the brain-stem. To the peripheral neurone I is added the central neurone II. The latter arises within the sensory end-nucleus, its axone, the efferent nerve-fibre, passes upward with the medial fillet and ends within the thalamus. From here the neurone III extends to the cerebral cortex.

*c.* The path for the *visceral impulses*, from the lungs, heart, œsophagus, stomach, etc., lies in the vagus and the sympathetic.

*d.* The path for the *equilibrium impulses* lies in the vestibular nerve, supplemented by spinal fibres. The path leads to the cerebellum, thence by way of the superior cerebellar peduncle to the nucleus ruber and the thalamus, and then to the cerebral cortex.



*e.* The path for the *taste impulses* lies in the glossopharyngeus, the intermedius and the third division of the trigeminus. Neurone I leads from the periphery (the tongue) to the end-nucleus (nucleus of the tractus solitarius); neurone II from the end-nucleus to the thalamus; neurone III from the thalamus to the cortical gustatory centre.

Concerning the paths, which serve to conduct the gustatory impulses, the following may be noted. It is generally accepted, that the taste impulses from the anterior two-

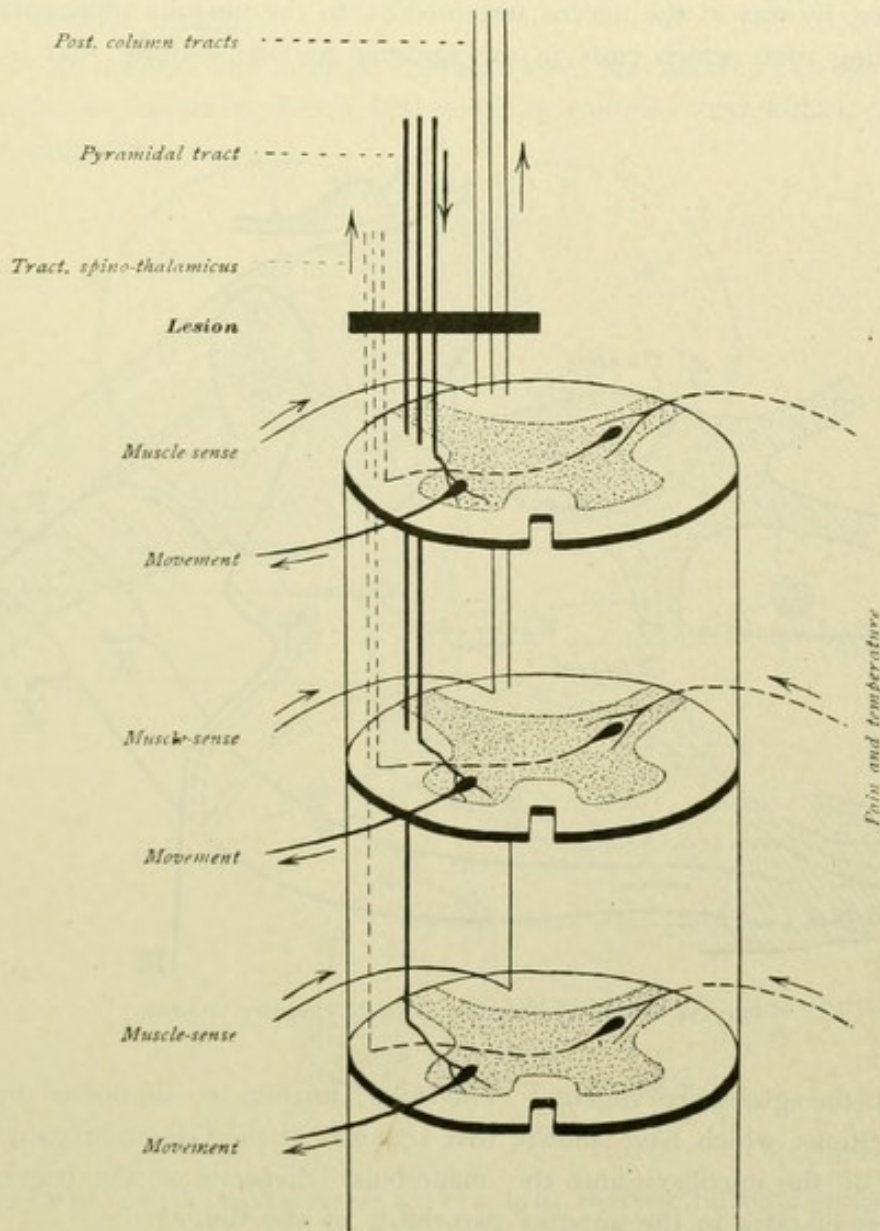


FIG. 174.—Diagram explaining Brown-Séquard's hemilateral lesion.

thirds of the tongue are conveyed centrally by the lingual branch of the trigeminus; from the posterior third of the tongue, by the glossopharyngeus. While the course of the taste-fibres by means of the glossopharyngeal nerve is readily understood, opinions concerning the path followed by the taste-fibres from the anterior two-thirds of the tongue vary. Thus, it is assumed by some, that these fibres run backward in the chorda tympani to the ganglion geniculi and thence proceed, either through the great superficial petrosal nerve to the sphenopalatine ganglion and on centrally by the maxillary division



of the trigeminus, or through the small superficial petrosal nerve to the otic ganglion and centrally by the mandibular nerve. According to others, the chorda fibres reach the glossopharyngeus by way of the small superficial petrosal and the tympanic nerve. It is assumed, further, that not only the chorda fibres, but also the gustatory fibres of the glossopharyngeus, by way of the small superficial petrosal nerve, reach the trigeminus and in it pass centrally. Finally, according to the view which seems, perhaps, the most reasonable, the chorda fibres pass, by way of the chorda tympani, to the geniculate ganglion and thence, by way of the nervus intermedius, to the medulla oblongata, where they form a descending root, which ends in the nucleus tractus solitarii, that is, the sensory

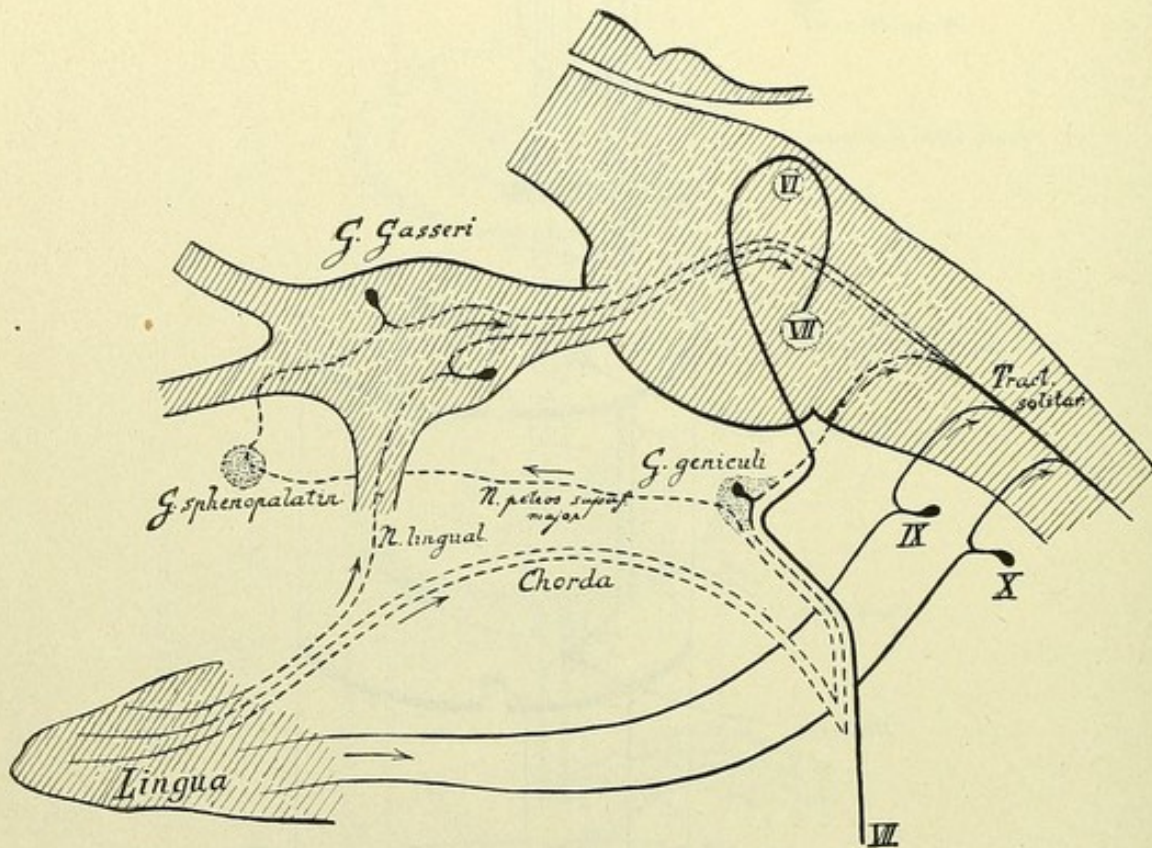


FIG. 175.—Possible conduction paths for gustatory impulses.

end-nucleus of the glossopharyngeus. This view, further, is supported by the experimental investigations, which have shown, that removal of the Gasserian ganglion or intracranial section of the maxillary and the mandibular divisions of the trigeminus are not followed by loss of taste in the anterior two-thirds of the tongue.

f. The path for *olfactory impulses* leads from the olfactory mucous membrane by way of the fila olfactoria to the bulbus olfactorius, thence to the primary centres and from the latter to the secondary or cortical olfactory centre within the gyrus hippocampi.

g. The path for *auditory impulses* lies within the nervus cochleae. Neurone I conveys the stimulus from the hair-cells of Corti's organ to the end-nucleus. Neurone II passes from the end-nucleus to the corpus geniculatum mediale and to the inferior colliculus, the fibres forming the lateral fillet. Neurone III unites the corpus geniculatum mediale with the cortical auditory centre within the gyrus temporalis superior.



*h.* The path of the *visual impulses* lies within the nervus opticus. Neurone I extends from the retina to the corpus geniculatum laterale, to the pulvinar and to the superior colliculus. Neurone II connects the corpus geniculatum laterale and the pulvinar with the secondary or visual centre within the cortex of the cuneus.

## II. CENTRIFUGAL TRACTS.

1. The efferent **cortico-muscular** or **motor tract** takes its origin in the motor region of the cerebral cortex.

*Neurone I:* through the internal capsule (knee and anterior two-thirds of the posterior limb), the basis or crusta of the cerebral peduncle (middle three-fifths), the pons and the medulla oblongata.

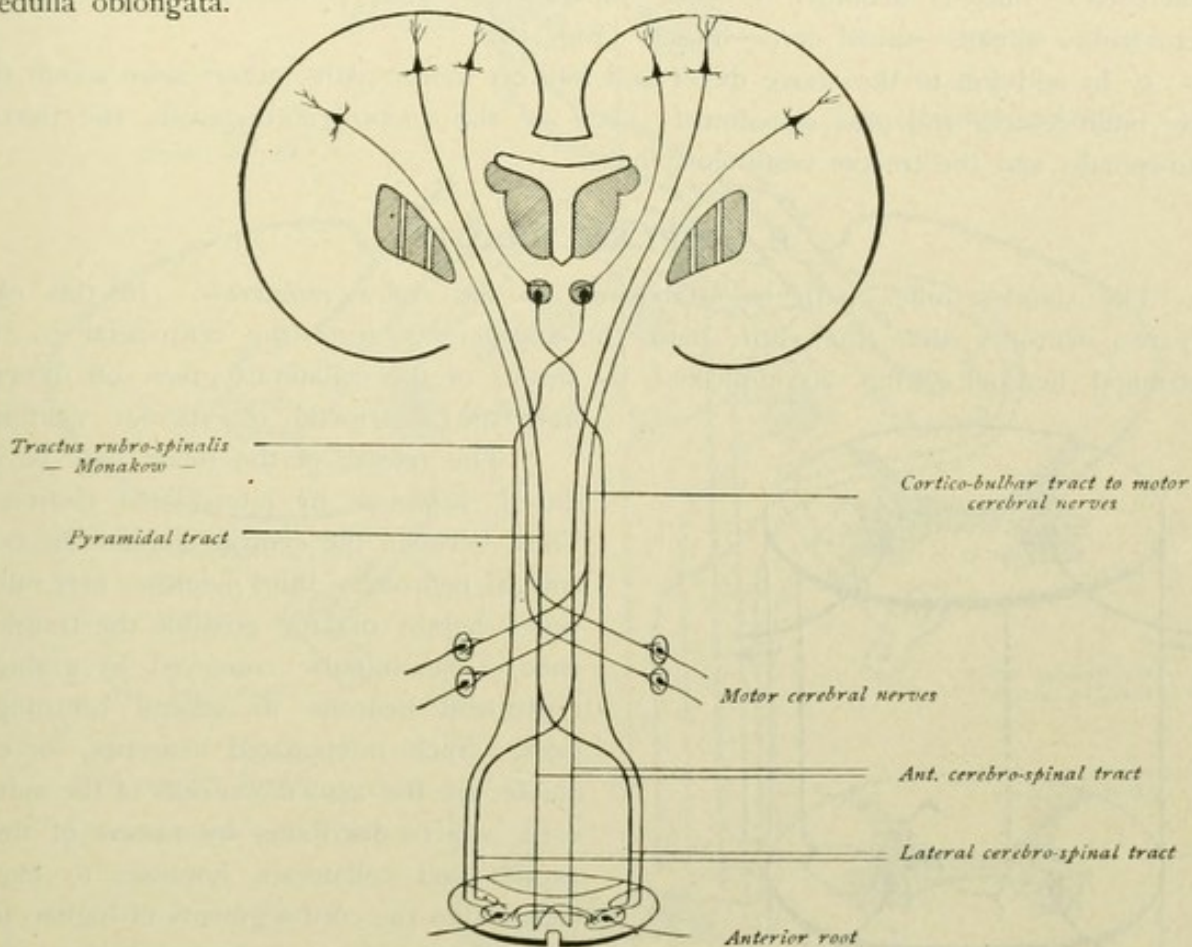


FIG. 176.—Motor paths.

*a.* as the *tract of the motor cerebral nerves*, to the contralateral nuclei of the motor cerebral nerves.

*b.* as the *pyramidal tract proper*, to the spinal cord—crossed as the lateral pyramidal tract, uncrossed (in the medulla oblongata) as the anterior pyramidal tract—to end around the ventral horn-cells.

*Neurone II:* origin within the nuclei of the motor cerebral nerves, peripheral course as the motor cranial nerves to the muscles; or, in like manner, as

*Neurone II:* origin in the cells of anterior horn of the spinal cord, peripheral course through the ventral roots, as the motor spinal nerves to the muscles.



2. A **special motor speech-tract** does not exist. The speech-tract is identical with those paths, which, as part of the cortico-bulbar tract, pass from the cortical centre for the facial and hypoglossal nerves to the nuclei of the nerves necessary for speech.

3. A **cortico-rubral motor path** goes to the spinal cord by way of the nucleus ruber, as follows:

*Neurone I:* from the cerebral cortex to the nucleus ruber;

*Neurone II:* nucleus ruber, tractus rubro-spinalis, spinal cord;

*Neurone III:* spinal cord, anterior root, muscle.

4. An **indirect motor path** passes to the spinal cord by way of the pons and the cerebellum, as follows: frontal and occipito-temporal pontile tract—pontile nucleus—cerebellar cortex—nucleus dentatus cerebelli—superior cerebellar peduncle—nucleus ruber—tractus rubro-spinalis—spinal cord—muscle (Fig. 147).

5. In addition to the above direct and indirect motor paths, others arise within the lower brain-centres and pass spinalward; such are the tractus rubro-spinalis, the tractus tecto-spinalis and the tractus vestibulo-spinalis.

### B. REFLEX TRACTS.

The simplest reflex path is established by the *reflex collaterals*. In this case only two neurones share the entire path, the transference from the centripetal to the centrifugal neurone being accomplished by means of the collaterals given off directly from the centripetal or afferent neurone.

The release of the reflex may be induced, however, by intercalated neurones. Thus, between the centripetal and the centrifugal neurone a third neurone may intervene, thereby making possible the transference of the impulse conveyed by a single centripetal neurone to several centrifugal ones. Such intercalated neurones, for example, are the association-cells of the spinal cord, which distribute, by means of their axones and collaterals, impulses to many cells within the cord-segments of higher and lower levels. To this category belongs, further, the posterior longitudinal bundle. Impulses carried to Deiters' nucleus by the vestibular nerve may be distributed to the nuclei of the eye-muscles and to the motor cells of the cord by means of fibres, which proceed from Deiters' nucleus and run within the posterior longitudinal bundle. In consequence of the introduction of several neurones between the centripetal and the centrifugal conduction, the entire reflex mechanism may become very complex.

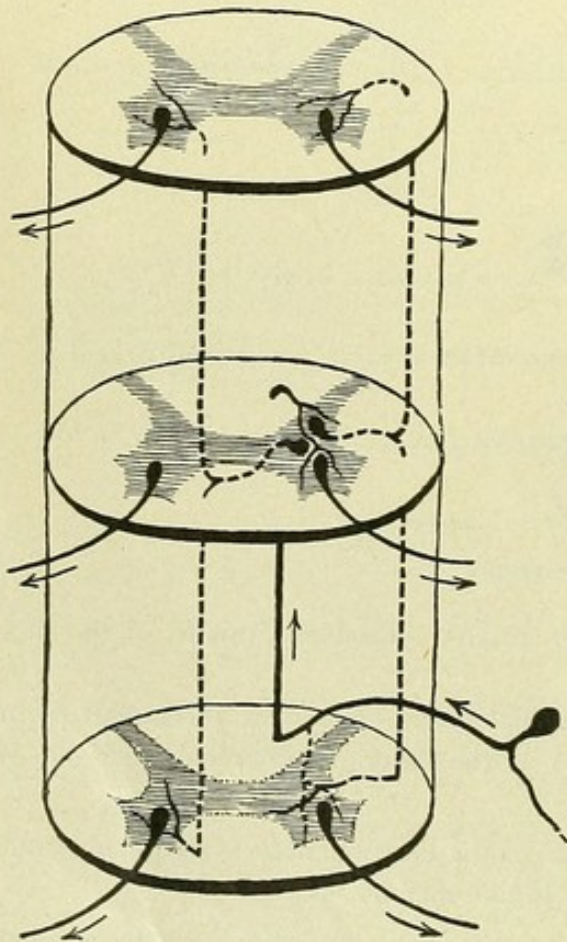


FIG. 177.—Reflex paths in the spinal cord. Broken lines represent neurones distributing impulses to other levels.



The **cerebellum**, with its afferent and efferent paths, calls for special consideration. The cerebellum is the centre for the reflex and unconscious maintenance of equilibrium, during rest as well as during changes in the position of the centre of gravity. The *centripetal paths* lie especially within the nervus vestibuli and within the ascending fibre-systems from the spinal cord and from the medulla oblongata. These ascending paths from the cord are the tractus spino-cerebellaris dorsalis and ventralis; from the medulla

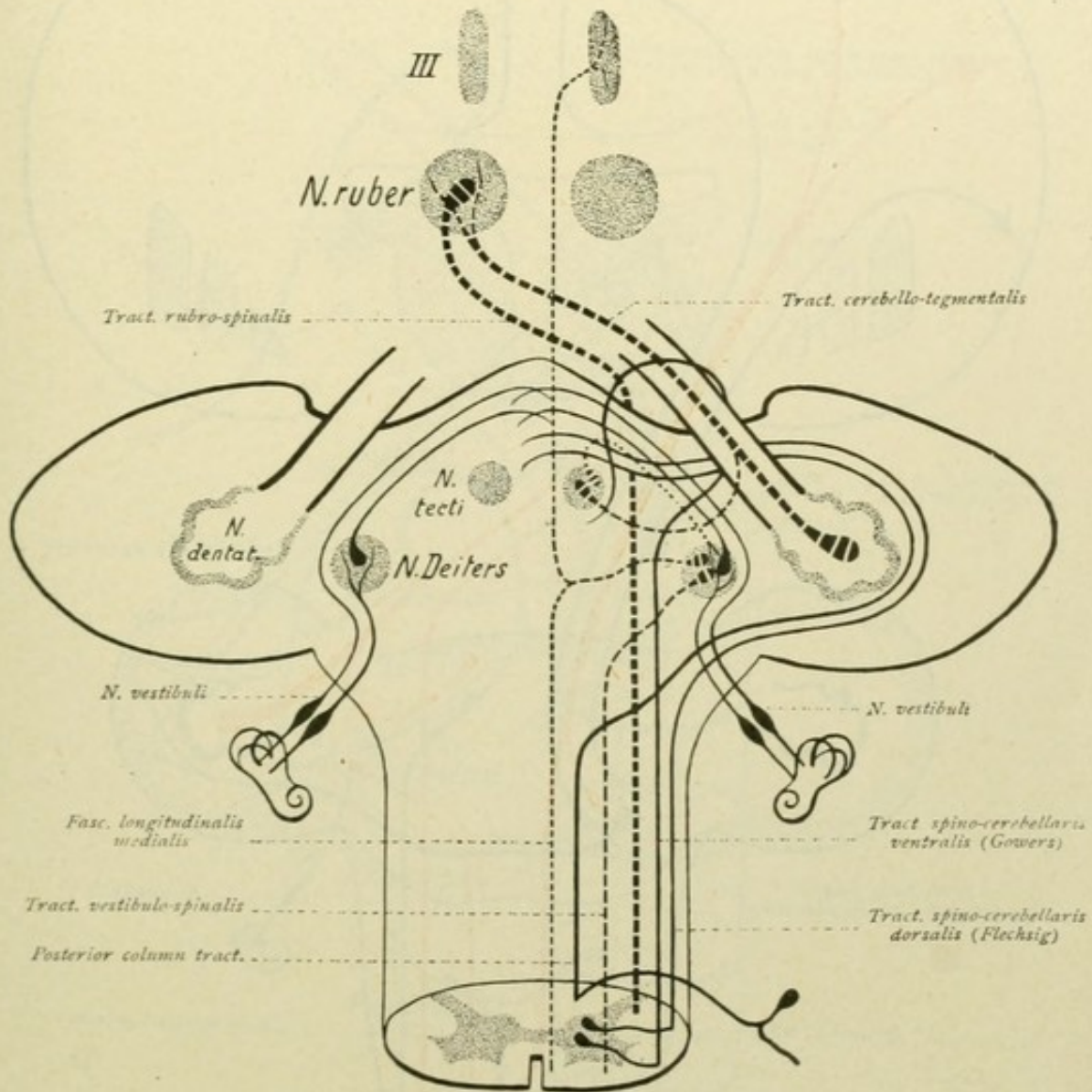


FIG. 178.—Spino-cerebellar and cerebellofugal tracts. Vestibulo-cerebellar tract-system of Deiters' nucleus.

oblongata the fibres arising within the nucleus gracilis and cuneatus. An indirect conduction from the spinal cord is perhaps effected by the tractus spino-olivaris or Helweg's triangular tract, which ends within the inferior olivary nucleus, and thence by the tractus olivo-cerebellaris to the cerebellum, by way of the restiform body. The direct and the indirect sensory cerebellar tract, as well as the tracts from the quadrigeminal region, are also included among the centripetal paths. By means of the *cerebellofugal tracts*, impulses may be carried from the cerebellum to other paths and by means of the latter, in turn, be transferred to motor paths. The chief cerebellofugal tracts proceed from Deiters' nucleus and from the nucleus dentatus. From Deiters' nucleus arise the tractus vestibulo-



spinalis and the posterior longitudinal bundle, the last-named system coming into relation with the spinal cord and with the nuclei of the nerves supplying the ocular muscles—

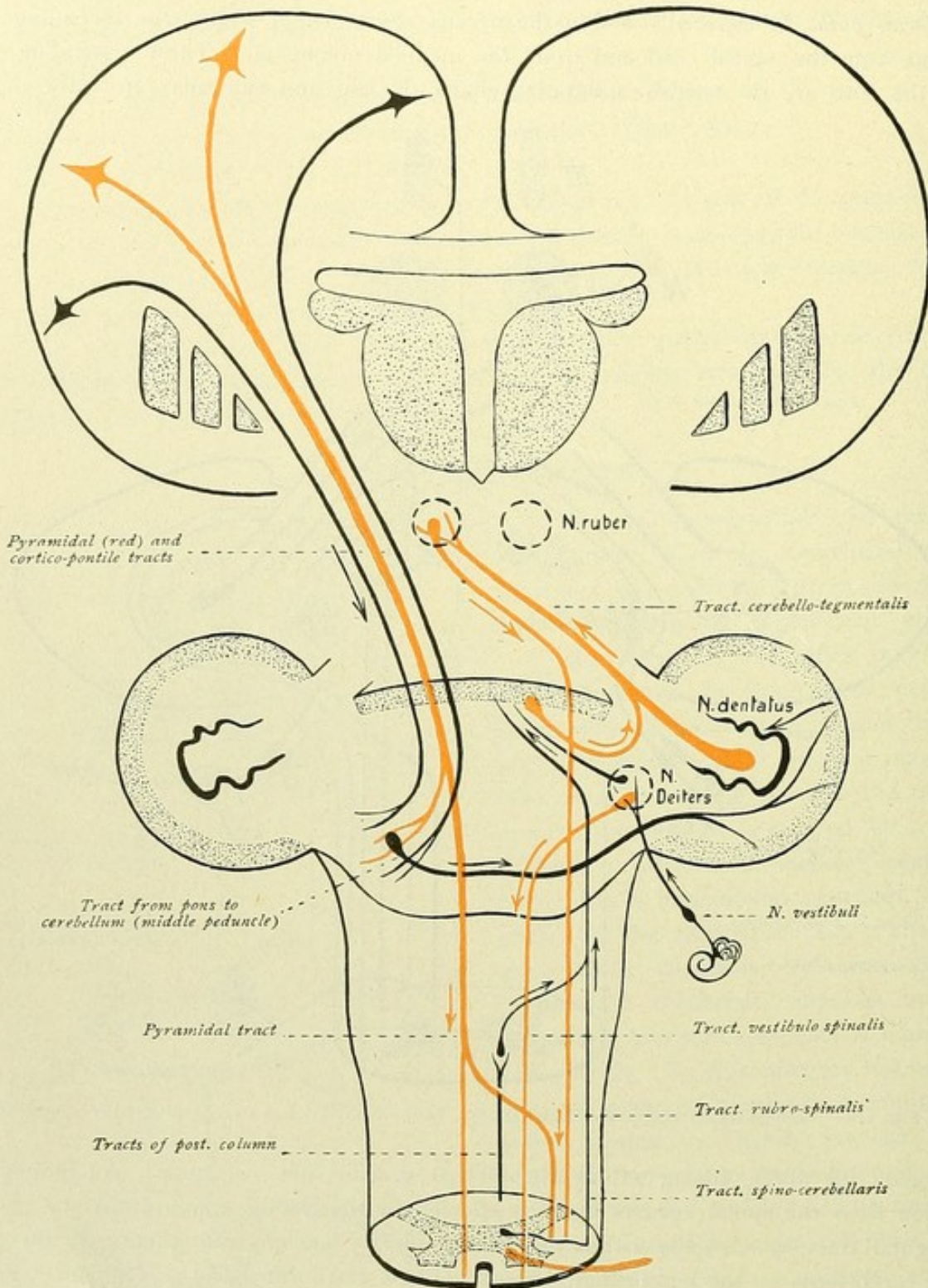


FIG. 179.—Cerebellopetal and cerebellofugal tracts.

that is, binding together the centres concerned in maintaining equilibrium and relations to space. From the nucleus dentatus arises the superior cerebellar peduncle, whose fibres end within the nucleus ruber, whence the tractus rubro-spinalis passes to the spinal cord.



It is to be noted, that the relations of the cerebellar hemispheres with the spinal cord are homolateral or of the same side. Additional cerebellofugal paths are those which, as the tractus tegmentalis pontis et bulbi, run within the tegmental region of the pons and medulla oblongata, whereby transference to motor nuclei may in turn be effected.

If the maintenance of equilibrium be adjusted to a voluntary movement, the cerebellum is also directly stimulated from the cerebral cortex. The paths for such impulses

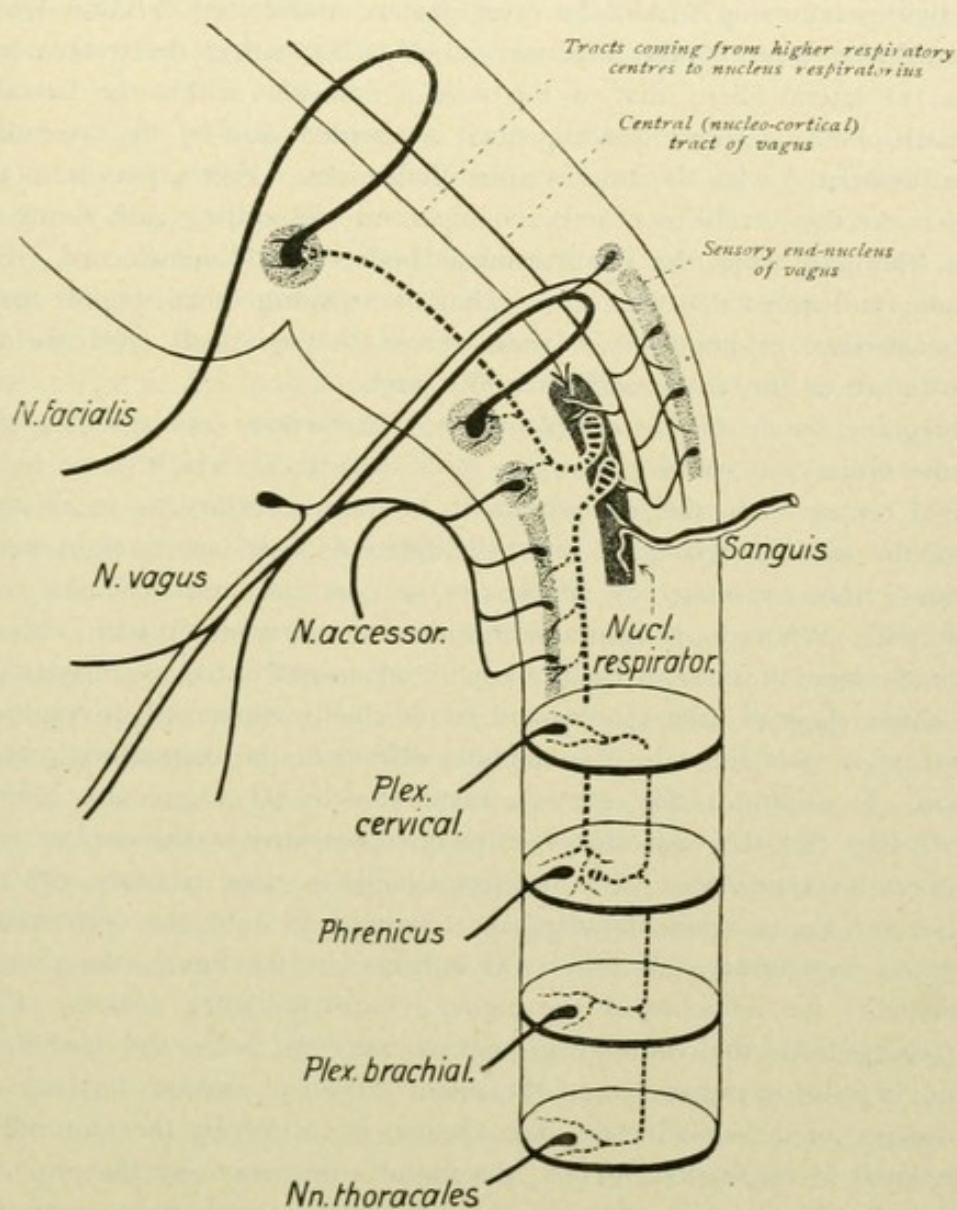


FIG. 180.—Schematic representation of the tracts chiefly concerned in respiration.

are the frontal and the temporo-occipital cortico-pontile tracts, which end in the pontile nuclei, whence the conduction to the cerebellum is by the middle cerebellar peduncle. In addition, the pontile nuclei are under the influence of the pyramidal tract, from which, within the pons, collaterals are given off to the nuclei. By means of the superior cerebellar peduncle (cerebellum-nucleus ruber—thalamus—cortex), the cerebellum sends impulses to the cerebral cortex and thereby influences conscious innervation (Figs. 145 and 147).

Besides the cerebellum, other organs that preside over reflex activity call for mention. Such organs, in the first place, are the thalamus and the corpora quadrigemina.



The centripetal paths of the thalamus are: the ascending tract of the medial fillet, the fibres of the optic tract ending within the pulvinar, the fibres from the olfactory centres and the fibres from the cerebellum by way of the superior peduncle. The thalamofugal paths lie within the tractus thalamo-spinalis, the tractus rubro-spinalis and the central tegmental tract. By means of the connections between the thalamus and the cerebral cortex, impulses coming from the periphery are carried to the cortex and, in reversed direction, activities occurring within the cerebrum are transferred to lower lying centres.

The centripetal path of the superior colliculus lies within the tractus opticus and partly within the lateral fillet; that of the inferior colliculus within the lateral fillet. A centripetal path of the corpora quadrigemina is afforded also by the ascending tractus spino-tectalis, associated with the tractus spino-thalamicus. Fibres pass from the quadrigeminal region to the cerebellum and an important descending path forms the tractus tecto-spinalis, the path from the quadrigeminal bodies to the spinal cord. Since fibres from the optic and acoustic nerves end within the quadrigeminal region and the path effects the transference of impulses of these nerves to the spinal cord, the tecto-spinal tract is also known as the *visuo-auditory reflex path*.

The foregoing by no means completes the enumeration of the reflex paths, since throughout the brain-stem course numerous additional tracts, which serve to unite functionally related centres. In this connection, it is only necessary to recall the complex mechanism of the medulla oblongata, in which different nuclei are brought into the most varied relations, whereby numerous simple, as well as the most complex, reflex processes are effected. While it is impracticable here to consider all such reflex paths, in order to obtain some notion of such complicated mechanisms, we may represent, by means of a simple diagram, the centres and tracts chiefly concerned in respiration.

Respiration is maintained by the stimulus carried to the respiratory centre through the circulation. In addition, the reflexes transmitted by the vagus also come into consideration. In Fig. 180, the respiratory centre is represented by the *nucleus respiratorius* within the *formatio reticularis*. This nucleus stands in close relation with the sensory end-nucleus of the vagus, since impulses are conveyed to it by the collaterals given off from the central vagus-tract. Moreover, as indicated in the figure, the nucleus respiratorius is also under the influence of the higher lying respiratory centres. By means of the paths passing from the respiratory nucleus, as well as by the farther connecting neurones, the impulse is transferred to the motor nuclei of certain cerebral nerves and the gray substance of the spinal cord and, thence, is carried by the motor fibres to the muscles concerned in respiration. Thus, the impulse is carried by the phrenic nerve to the diaphragm; by the thoracic nerves to the intercostales and levatores costarum; by the cervical plexus to the scalene, sterno-hyoid and sterno-thyroid muscles (depression of the larynx); by the brachial plexus to the rhomboidei and pectoralis minor; by the accessorius to the sterno-cleido-mastoid and trapezius; by the vagus to the crico-arytaenoideus posticus and thyero-arytaenoideus (widening of the vocal cleft) and the levatores veli palatini et uvulae (elevation of the soft palate and the uvula); the facial nerve to the facial muscles (widening of the nasal apertures and the oral cavity). The paths passing from the nucleus respiratorius course in the medulla oblongata within the *formatio reticularis*, and, as shown in the accompanying diagram, numerous motor nuclei are brought into common activity by means of these association tracts (Fig. 220).



### C. ASSOCIATION TRACTS.

When discussing cerebral localization, it was pointed out, that the various divisions of the brain were divided in a general way, according to their function, into higher and lower parts. Functionally the highest division is the cerebrum, with the cerebral cortex; the lower divisions intervene between the spinal cord and the cerebrum and include the medulla oblongata, the pons and the cerebellum, the mid-brain and the diencephalon or inter-brain.

All nerve tracts, which convey to the central nervous system the most varied impulses from the individual sense-organs and the various organs within the body, find their immediate ending within the lower brain-centres; within these lower centres arise efferent paths, by means of which the stimuli received are again projected towards the periphery and transferred to the organs of movement. In this manner are brought about all those movements that we designate as simple and complex reflexes, which occur without participation of our consciousness. The impulses conveyed to the central nervous system, however, are not confined to the subcortical centres, but are carried by other paths to the cerebral cortex, where, in the appropriate sensory centres, impulses are called forth which psychically correspond to what we designate as sensation. This impulse within the sensory cortical centres continues, so long as the stimulus continues. With the stimulus, the impulse disappears and therewith the sensation also ceases. We are able, however, to picture an object, even when we no longer perceive it, or to recognize it when it again appears. Therefore, on its first appearance, the stimulus must have called forth a permanent impulse, in addition to the vanishing sensory impulse; the latter is designated the concept impulse. The retention of this impulse makes possible the recognition, the proving, or the representation of the object; that is, there remain persistent traces of previous sensory or motor impulses, the so-called latent dispositions. These latent dispositions or subconscious impressions, when later awakened by new impulses, render possible the conscious memory or conception of sensation and movement. The ability to call into activity and to convert the latent dispositions or impressions into conceptions is what we call thought.

In addition to this *mnemonic function*, the cerebrum possesses the *associative function*. One conception can awaken others by reason of the linking together of the latent dispositions. By union of partial conceptions (visual, gustatory, olfactory, tactile and other sensations), the complete conception is attained; by the blending of the complete conceptions, the general conceptions are formed. In this way are "reproduced" entire complexes of conceptions, which are definitely connected and, as it were, lie prepared; it may be, however, that certain complexes of conception are arranged in other and new sequences, new conceptions being thereby "produced." The associative function consists, therefore, in the reproduction and production of conceptions, and on this possibility of a definite sequence of conceptions depends the exercise of the higher psychic processes, that is, thought.

By means of these associative processes, the individual cortical areas within the same projection and memory fields, as well as the different projection and memory fields, are brought into connection with one another. Such connection between the dispositions



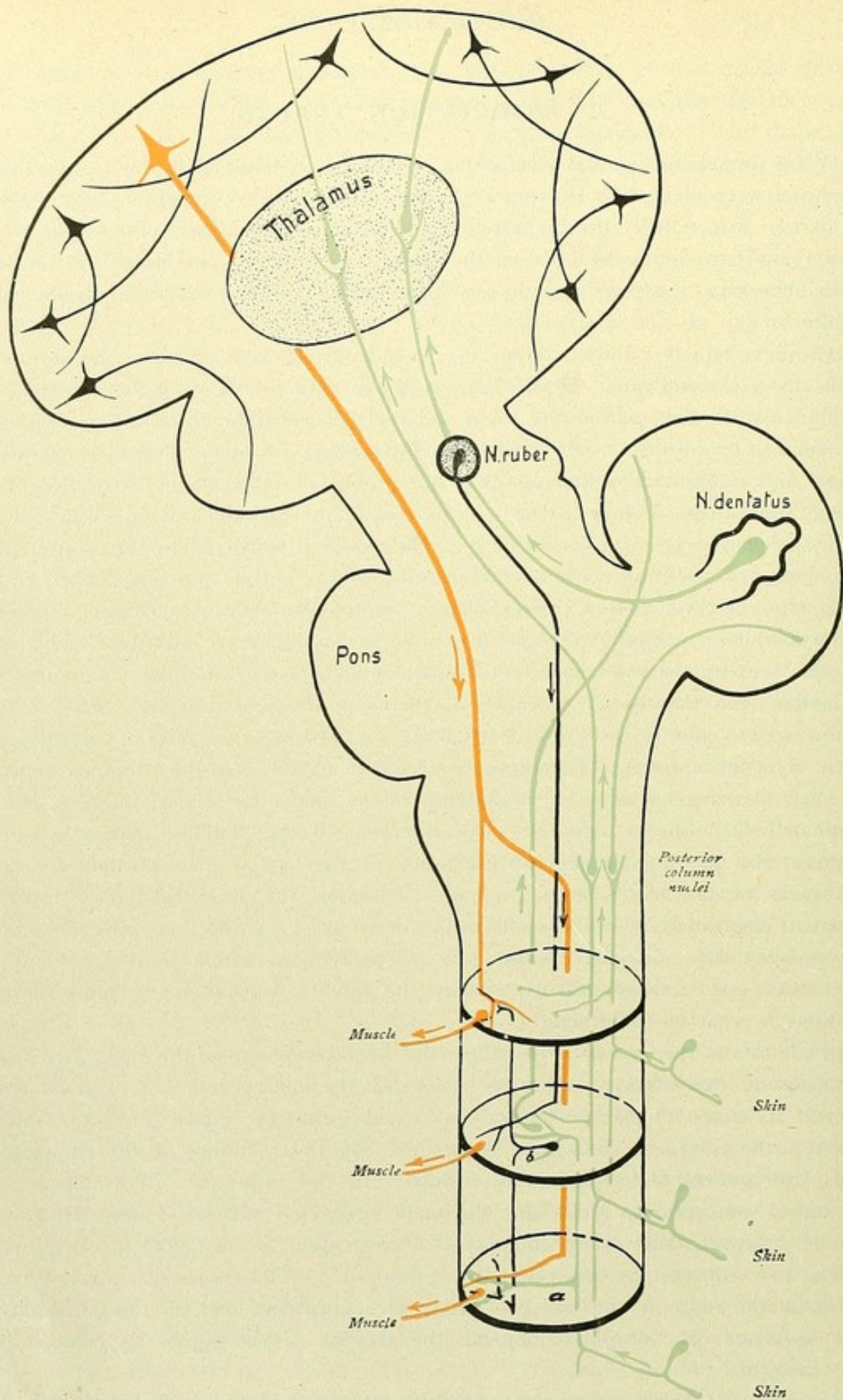


FIG. 181.—Schematic representation of the physiologically different conductions. Red, centrifugal tracts; blue, centripetal tracts; black, intercentral tracts.



or residues of the same kind exists everywhere within the corresponding cortical areas. The association between residues of different kinds, as well as the connection of projection areas with memory centres and of the various projection and memory centres with one another, is established by means of the association fibres, which as short and long fibres unite adjoining convolutions and remote regions respectively.

Since, however, the widely different processes of the outer world and of the body proper give rise to the formation of manifold impressions and to the exercise of the most simple as well as the highest psychic processes, something further always occurs. The influences taken up by the organism react outwardly, since they always find expression in the various movements of the organs. While the purely reflex reactions are carried out unconsciously, through the agency of the lower brain-centres and without the participation of the cerebrum, the voluntary movements, our conduct and voluntary acts are dependent upon the activity of the cerebral cortex, every action, indeed, being determined by conceptions and, in the final analysis, by kinaesthetic or motor concepts. These relations will be best understood, if, in conclusion, we consider more closely those most important movements concerned in speech, by means of which our entire sensations, conceptions and thoughts find expression.

When discussing cerebral localization, it was pointed out, that in right-handed, therefore, in the majority of individuals, the speech-zone, with its different centres, was located within the left hemisphere. The chief centres include (Fig. 182): the *sensory speech-centre* (*A*), within the posterior third of the superior temporal convolution, where the memory-pictures of the heard words are deposited—the centre, therefore, for the memory of word-tones—and the *motor speech-centre* (*M*), within the posterior third of the inferior frontal convolution, in whose cells the memory-pictures of the spoken words lie and on whose integrity depends the ability to carry out the coördinated movements of certain muscles necessary for speech.

These two speech-centres, the sensory and the motor, stand in close relation with each other, the latter dependent upon the former, since speech is acquired by repetition of the word-sounds heard. On observing the development of speech in the child, we find in the connection of these two centres the basis for the possibility of pronouncing by repeating but without understanding. The development of speech teaches, moreover, that speech proper, that is, the intelligent utterance of sounds, in contrast to their mere repeating, is preceded by an understanding of speech without speaking—a stage of “normal deaf-mutism.” The child understands much, but speaks little or nothing of what it understands; it is, for the time, deaf-mute. Therefore, an intimate connection is early established between the memory of the word-sound or the acoustic word (*A*) and the idea (*B*). In Fig. 182, this close connection, as well as that between the sensory and motor speech-centres, is represented by the double line, *A*—*B*. In this relation it should be emphasized, that the idea-centre (*B*) is represented as a definitely bounded cortical area only as a schematic expedient, and that, as a matter of fact, we must conceive the formation of the idea as a complex process involving, more or less, the entire cerebral cortex.

From this speech-comprehension without speaking ( $a^1 - a^2 - a - A - B$ ) and the first mere repeating of spoken words ( $a^1 - a^2 - a - A - M - m - m^1 - m^2$ ), later comes the repeating of words with the understanding of speech; that is, speech proper. The



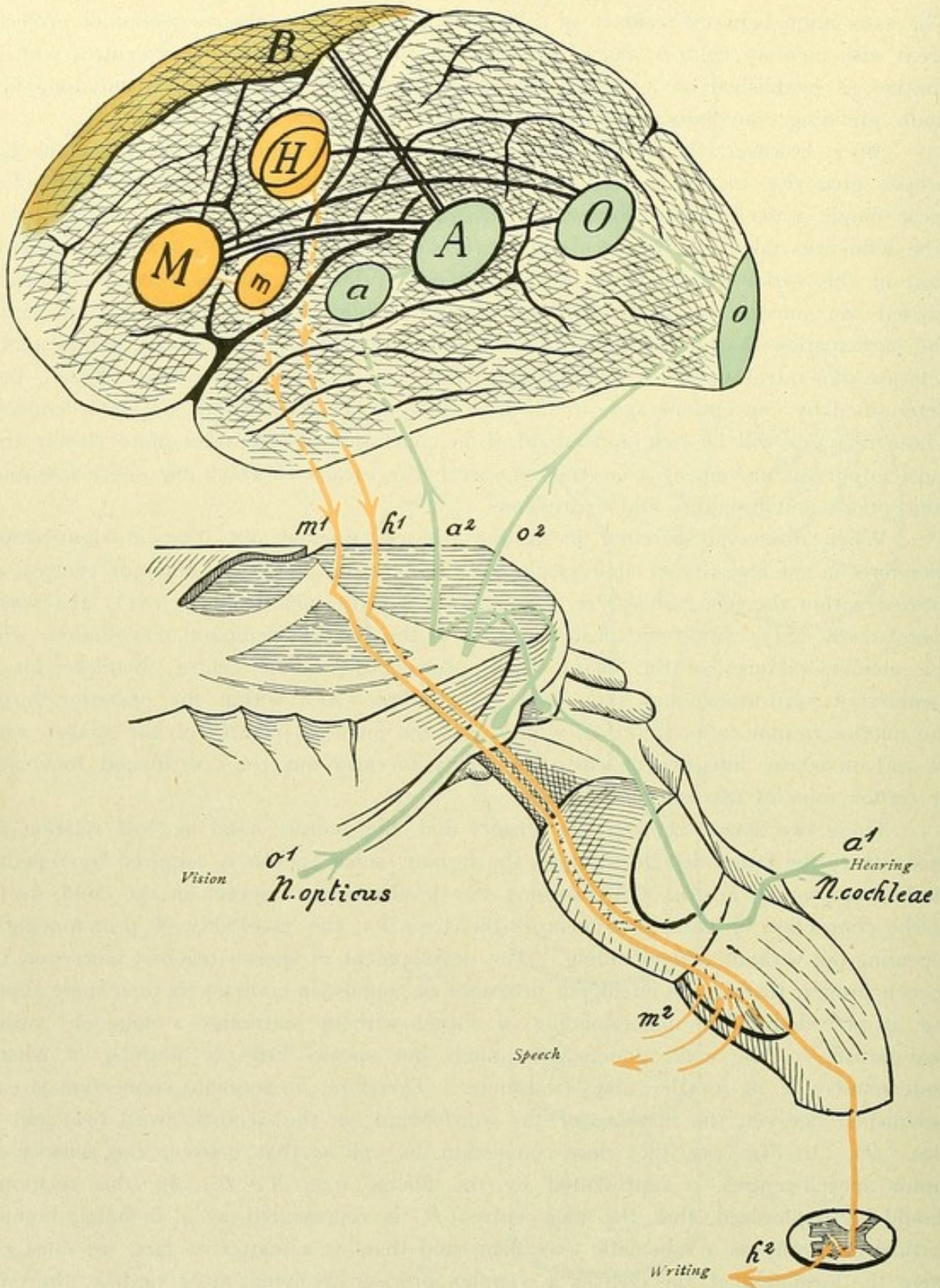


Fig. 182.—Scheme of spoken and written speech. *B*, conception centre; *M*, motor speech-centre (*Broca*); *A*, sensory speech-centre (*Wernicke*); *O*, visual letter-centre; *m*, motor centre (facial, lingual and laryngeal musculature); *a*, auditory centre; *o*, visual centre; *H*, motor centre for hand; *m*<sup>1</sup> *m*<sup>2</sup> *h*<sup>1</sup> *h*<sup>2</sup> — cortico-muscular tracts for speaking and writing; *a*<sup>1</sup> *a*<sup>2</sup> *o*<sup>1</sup> *o*<sup>2</sup> — auditory and visual tracts.



latter first takes the path:  $B - A - M - m - m^1 - m^2$ ; later, in consequence of the connection  $B - M$ , it follows:  $B - M - m - m^1 - m^2$ . The centre,  $m$ , represents the motor centre proper, in the lower third of the precentral convolution (the motor centre for the face, tongue, and larynx). The path,  $m^1$ , is the motor cortico-bulbar tract, which passes through the knee of the internal capsule, the crista or base of the cerebral peduncle to the nuclei of the appropriate motor cerebral nerves. Path  $m^2$  is the periph-

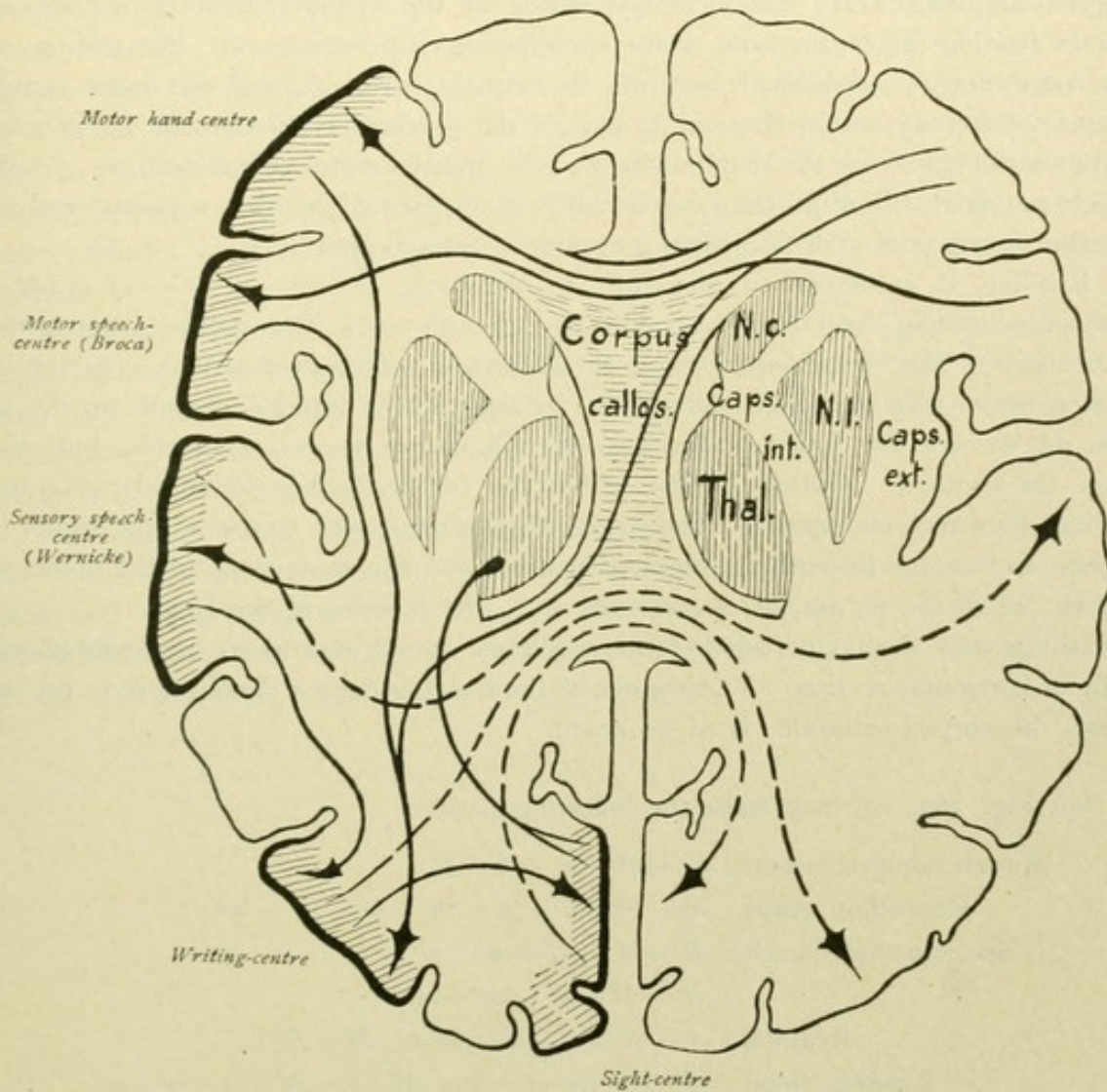


FIG. 183.—Connections of the individual centres of the speech zone, represented on a horizontal section through the brain.

eral motor neurone from the motor nucleus to the muscle. Likewise, close to the sensory speech-centre ( $A$ ), the auditory centre proper is represented ( $a$ ). The path  $a^1$  shows the course of the auditory tract as far as the medial geniculate body; the path  $a^2$  is the last neurone in the auditory tract, which extends, by way of the internal capsule, from the geniculate body to the cortical auditory centre.

The foregoing connections represent speech in the more limited sense; later, as the result of learning written speech—reading and writing—the expansion to speech in its widest sense follows. By written speech is understood the speech of the letters; the latter are to be regarded not as signs for ideas, as hieroglyphics, but as signs for sounds. We



learn to separate the individual words into syllables and letters, each simple sound, vocals and consonants, being associated with a visual letter-picture; by copying the optical picture of the letter we learn to write. The sensory speech-centre or the acoustic word now comes, therefore, into closer relation with the visual apparatus. Not only the acoustic word, but also the motor word, or the centre for the motor memory-pictures of the words, becomes connected with the visual letter-centre, or visual centre,  $O$ , within the gyrus angularis; here the memory-pictures of the written characters are deposited, since for reading the sensory and motor speech-centres are necessary. For writing, moreover, connection is established between the visual centre,  $O$ , and the motor centre for the upper extremity within the middle part of the precentral convolution, the centre,  $N$ , for the musculature of the hand, wherein the grapho-motor memories are developed through practice. In Fig. 182, this locality is represented by two superimposed ovals, since the existence of a distinct writing-centre is not accepted.

Reading is accomplished, therefore, by the path:  $o^1 - o^2 - o - O - A$  or  $M - B$ ; spontaneous writing by:  $B - A$  or  $M - O - H - h^1 - h^2$ . The path  $o^1$  represents the first neurone of the visual path leading to the lateral geniculate body; the path  $o^2$  is the second neurone from the geniculate body, by way of the internal capsule, to the visual centre proper,  $o$ . The latter is shown in the diagram in the occipital pole, but, as well known, the centre is localized chiefly within the cortex of the cuneus, particularly surrounding the calcarine fissure. The path,  $h^1$ , represents the course of the motor tract from the arm centre through the internal capsule and the brain-stem to the spinal cord; the path,  $h^2$ , is the peripheral motor neurone to the muscles of the hand.

In Fig. 183, the connections of the individual speech-centres are represented schematically in horizontal section. The course of the tracts from one hemisphere to the other, through the corpus callosum, is to be noted.

On Fig. 182, we may trace the following paths:

- Speech comprehension:  $a^1 - a^2 - a - A - B$ ;  
 Repeating words:  $a^1 - a^2 - a - A - M - m - m^1 - m^2$ ;  
 Spontaneous speech:  $B - A - M - m - m^1 - m^2$   
                                    $B - M - m - m^1 - m^2$   
 Reading:  $o^1 - o^2 - o - O - A$  or  $M - B$ ;  
 Reading aloud:  $o^1 - o^2 - o - O - A$  or  $M - B - M - m - m^1 - m^2$ ;  
 Spontaneous writing:  $B - A$  or  $M - O - H - h^1 - h^2$ ;  
 Copying:  $o^1 - o^2 - o - O - H - h^1 - h^2$ ;  
 Dictated writing:  $a^1 - a^2 - a - A$  or  $M - O - H - h^1 - h^2$ .

At the same time, the diagram explains the different types of the disturbances of speech or aphasia.

A lesion of the speech-centre,  $M$ , leads to cortical motor aphasia. The patient can neither speak spontaneously, nor repeat; moreover, since reading and writing depend upon the integrity of the sensory as well as of the motor speech-centre, reading, spontaneous writing and dictated writing are also impaired. On the other hand, the patient understands what is spoken, since  $A$  is intact, and can copy writing.



A lesion of the sensory speech-centre, *A*, leads to cortical sensory aphasia. In the first place, comprehension of speech is lost; further, repetition, reading and dictation writing are suspended, while spontaneous writing and copying, as well as speech, are retained. In speaking, however, the patient manifests the symptoms of paraphasia, that is, the interpolation of incorrect words and exchange and mutilation of words.


Destruction of both chief centres, the motor and the sensory, leads to total aphasia.

When the efferent path from the motor speech-centre, *M*, is interrupted by a subcortical effusion, the clinical picture of subcortical motor aphasia or word-dumbness appears; when the lesion involves the path to the sensory speech-centre, subcortical sensory aphasia follows. These subcortical aphasias leave inward speech intact, and the ability to read and write are retained. On the other hand, in subcortical motor aphasia, voluntary speech, repeating and reading aloud, are suspended or involved; in subcortical sensory aphasia, speech-comprehension, repeating and dictation writing are wanting or impaired.

If the path from the idea-centre to the motor speech-centre (*BM*) be interrupted, the patient is said to be affected with transcortical motor aphasia, with loss of voluntary speech and writing; if the path from the sensory centre to the idea-centre be broken, the resulting condition is termed transcortical sensory aphasia, with loss of the comprehension of speech and of writing.

An interruption of the path uniting the sensory and motor speech-centres (*AM*) leads to the so-called conduction aphasia. The ability of repeating words is impaired; speech and comprehension of writing and the ability to copy are retained, as well as spontaneous speech and writing; the performance of these functions, however, is attended with the manifestations of paraphasia and paragrammia.







PART III.

SERIAL SECTIONS THROUGH THE BRAIN-STEM  
OF A FOUR-YEAR-OLD CHILD

A

FROM THE ANTERIOR END OF THE CORPUS CALLOSUM TO THE  
QUADRIGEMINAL REGION



PART III

FEDERAL BUREAU OF INVESTIGATION  
UNITED STATES DEPARTMENT OF JUSTICE

REPORT OF THE DIRECTOR OF THE FEDERAL BUREAU OF INVESTIGATION  
ON THE MATTER OF THE



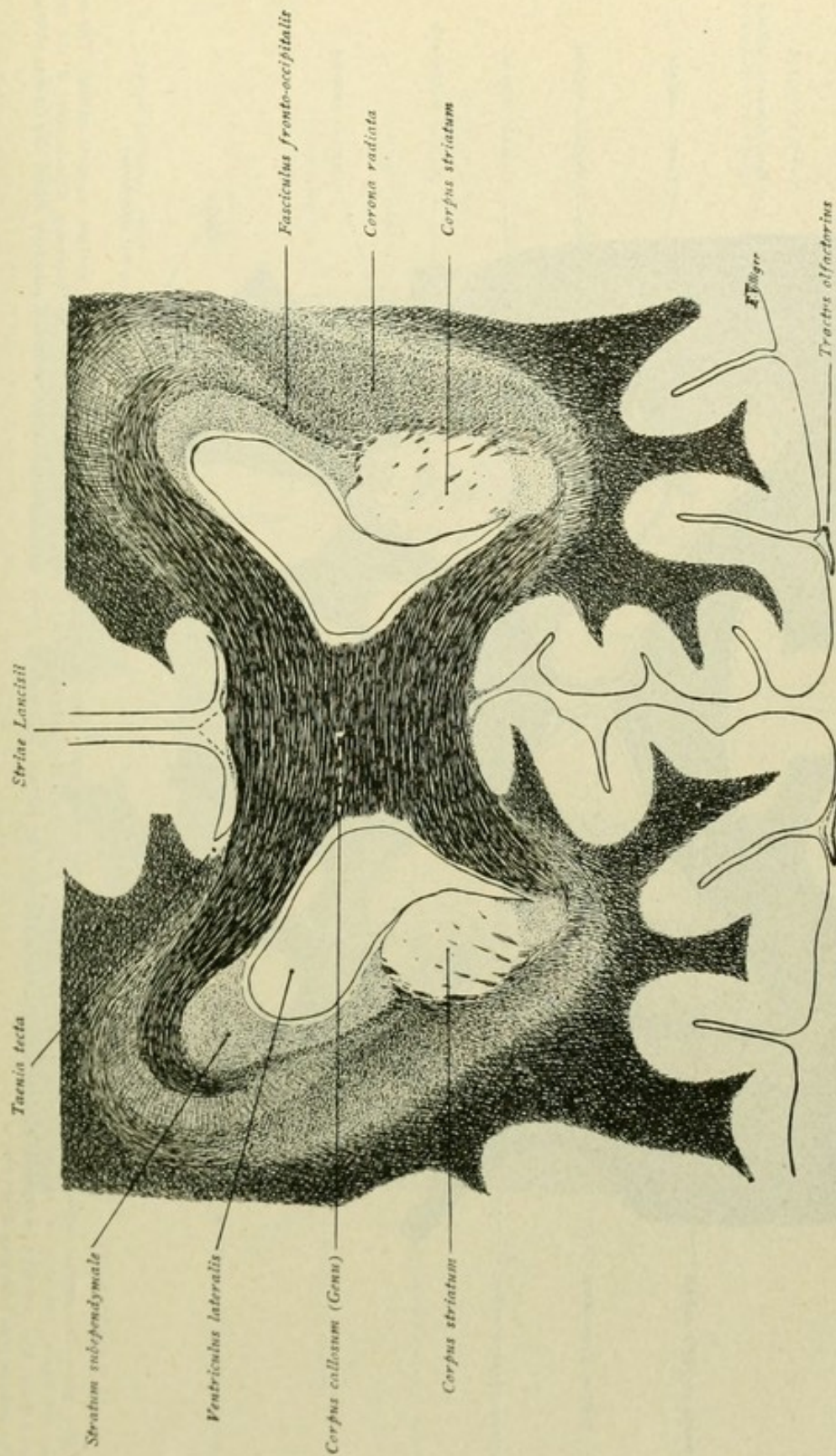


FIG. 184.—Frontal section at the level of the genu corporis callosi. On each side of the corpus callosum lies the anterior horn of the lateral ventricle, bounded laterally by the stratum subependymale and the corpus striatum. Converging toward the latter are seen the fibre-strands of the corona radiata, while medial to the corona and above the corpus striatum lies the fasciculus fronto-occipitalis. On the upper surface of the callosum, near the mid-line, are the striae longitudinales Lancisii and lateral, within the sulcus corporis callosi, is the tertia tecta; delicate fibre-bundles beneath the callosum represent prolongations of the striae. Tractus olfactorius lies in olfactory sulcus.



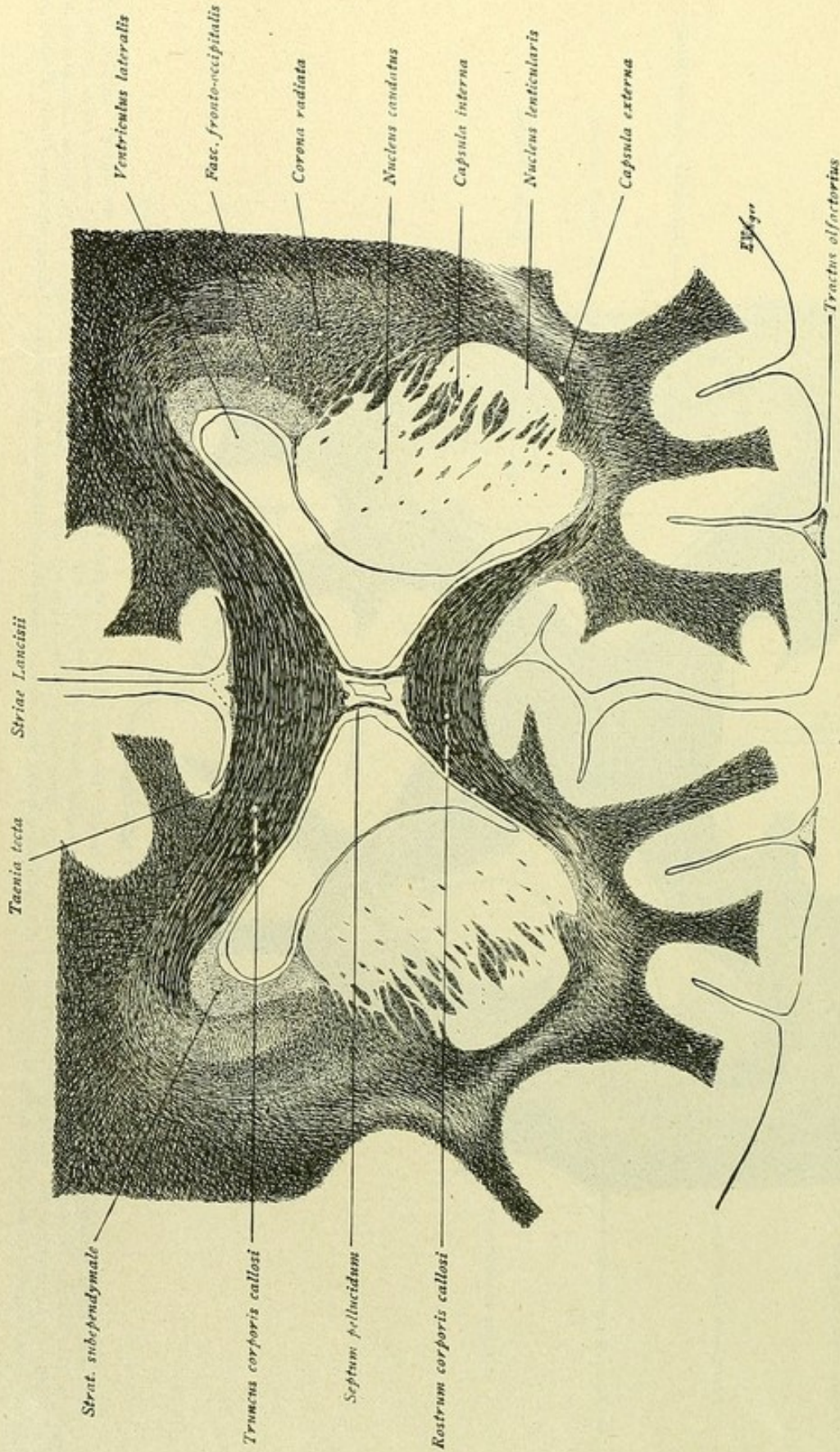


FIG. 185.—The septum pellucidum, with the two laminae and the cavum septi pellucidi, extends between the truncus and the rostrum corporis callosi. The corpus striatum, the lateral boundary of the anterior horn of the ventricle, is divided into nucleus caudatus and nucleus lenticularis by the traversing fibre-bundles of the capsula interna. Lateral from nucleus lenticularis lies the capsula externa; upon the corpus callosum the striae Lancisii and taeniae tectae; in olfactory sulcus the tractus olfactorius, gradually passing into trigonum olfactorium.



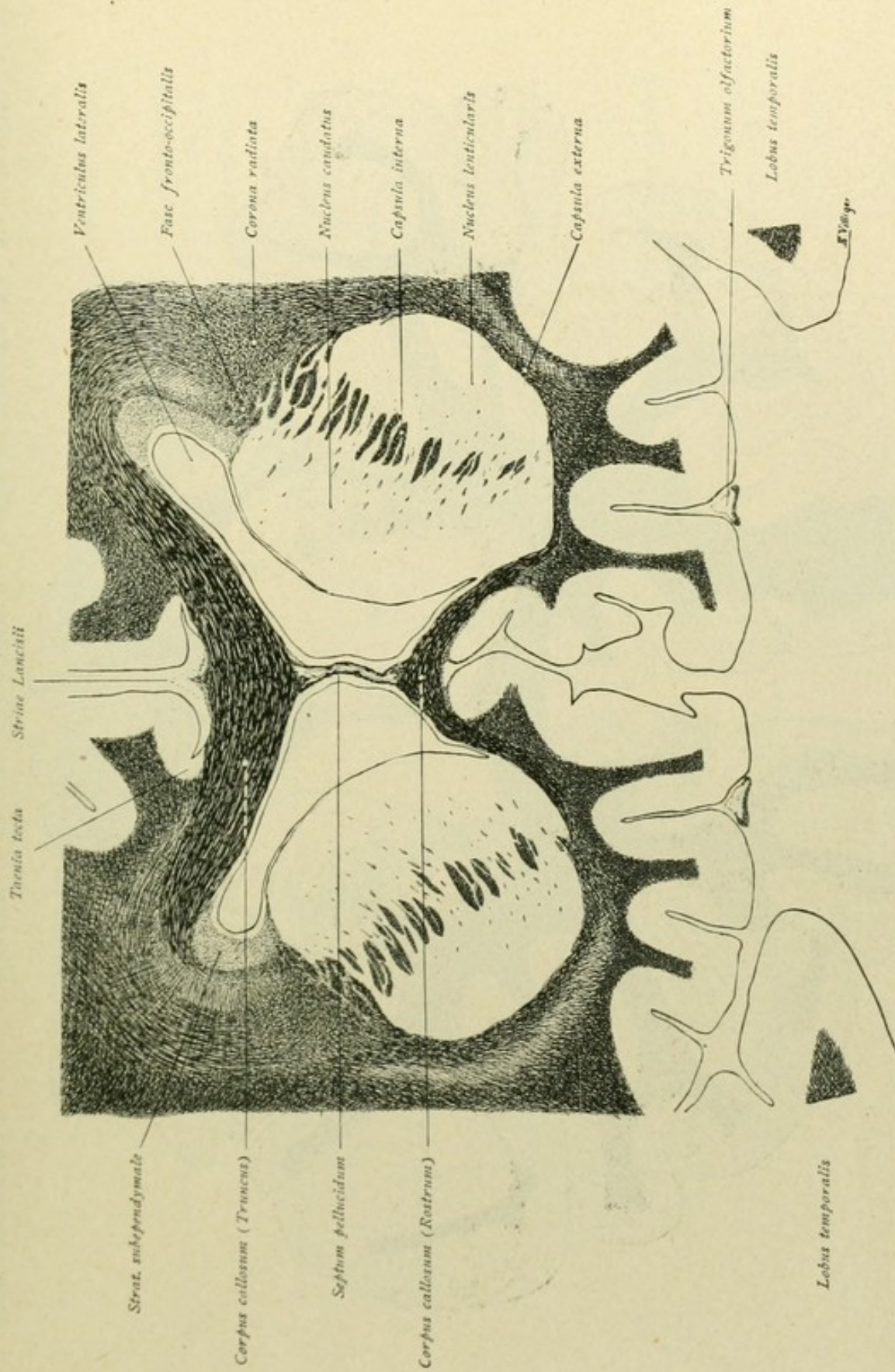


FIG. 186.—The rostrum corporis callosi is sectioned lower, hence the septum pellucidum is longer. Owing to increase in the nucleus lenticularis, the area of the corpus striatum is larger. Tuberculum olfactorium now lodged in olfactory sulcus; ventro-lateral is the cut anterior end of the temporal lobe.



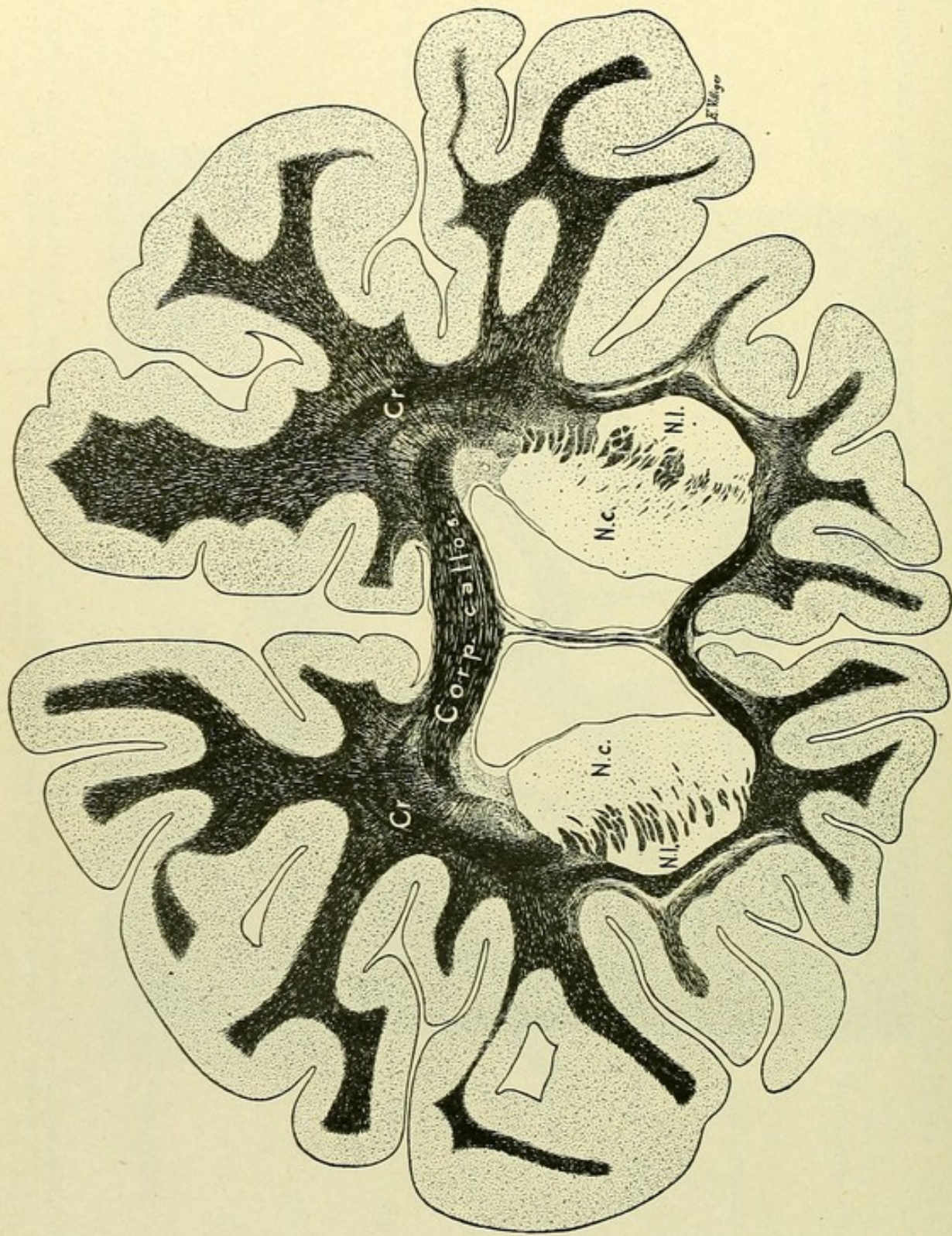


FIG. 187.—Frontal section through the cerebrum in the region of the anterior part of the corpus striatum, supplementary to preceding figure. *Cr.*, corona radiata; *N.c.*, nucleus caudatus; *N.l.*, nucleus lenticularis.



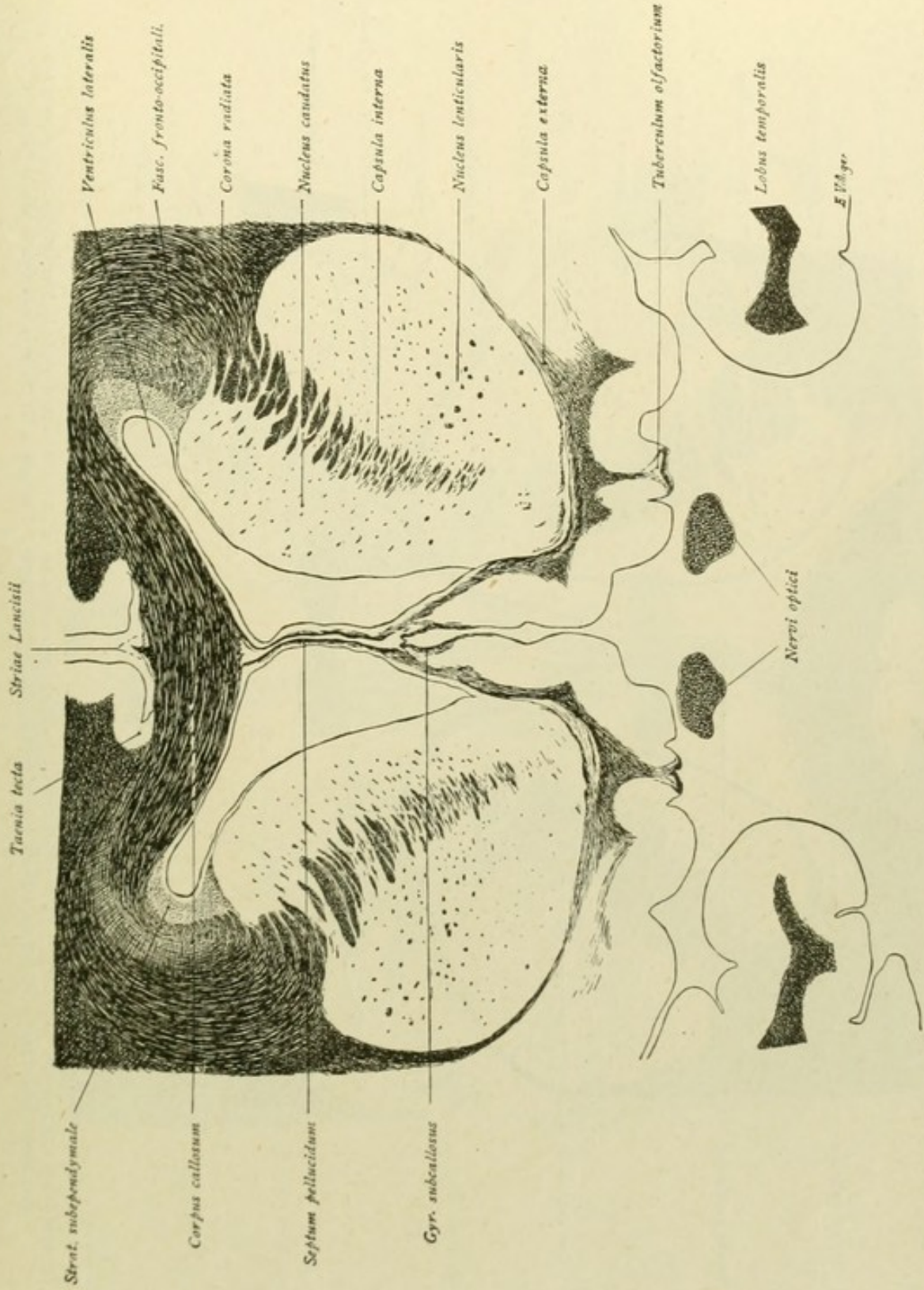


FIG. 188.—The nucleus lenticularis is increasing, while the nucleus caudatus is already becoming smaller. Strands of fibres pass dorsally from the tuberculum olfactorium towards the septum pellucidum and the external capsule. The fibres of the striae longitudinales, which in Fig. 186 lie close beneath the rostrum, here pass ventrally, marking the transition of the striae into the gyri subcallosi.



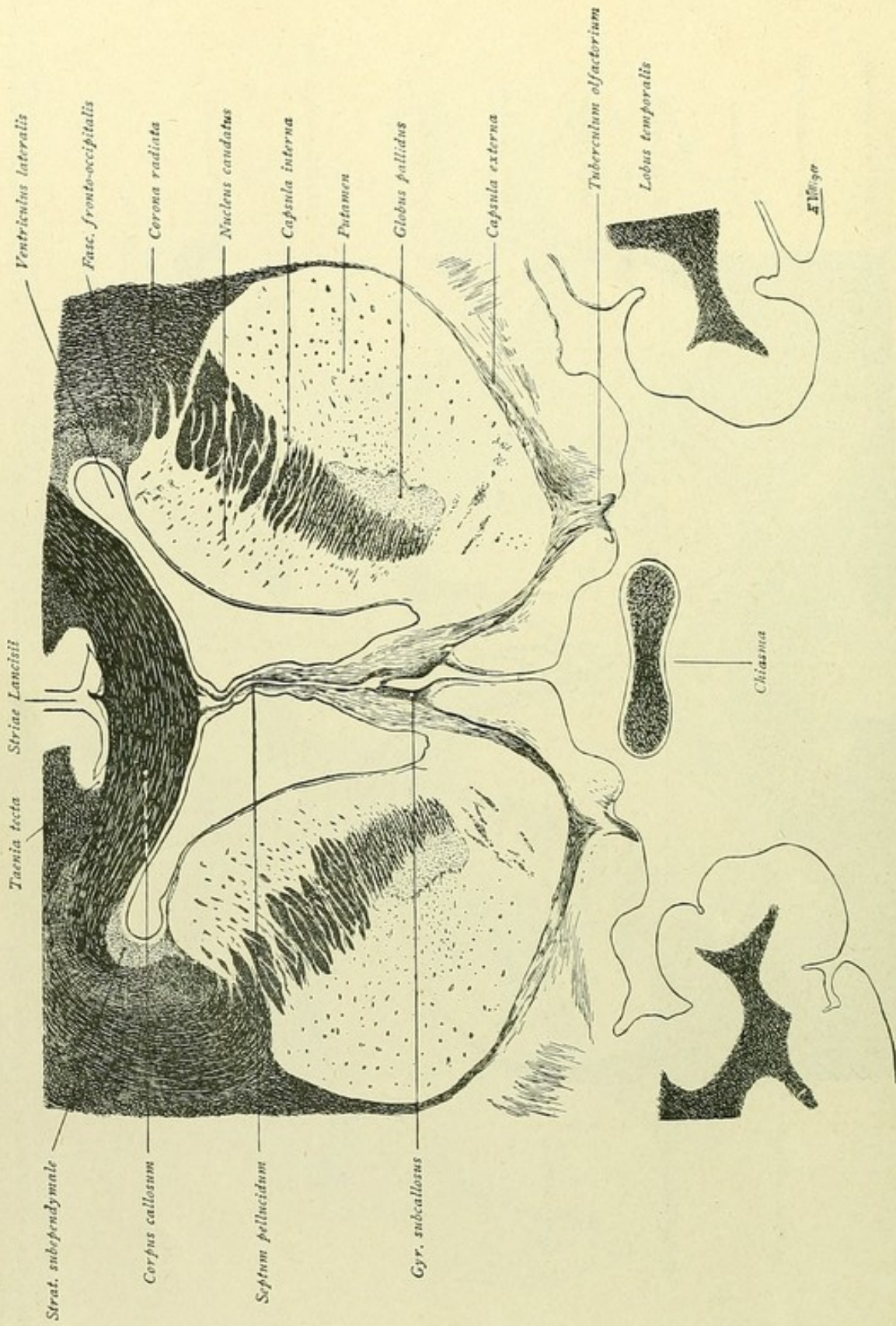


FIG. 189.—The capsula interna is larger. The nucleus lenticularis exhibits a subdivision into globus pallidus and putamen. As in Fig. 188, the fibre-strands from the tuberculum olfactorium pass dorsally toward the septum pellucidum and the capsula externa. The descent of the gyri subcallosi is also to be noted.



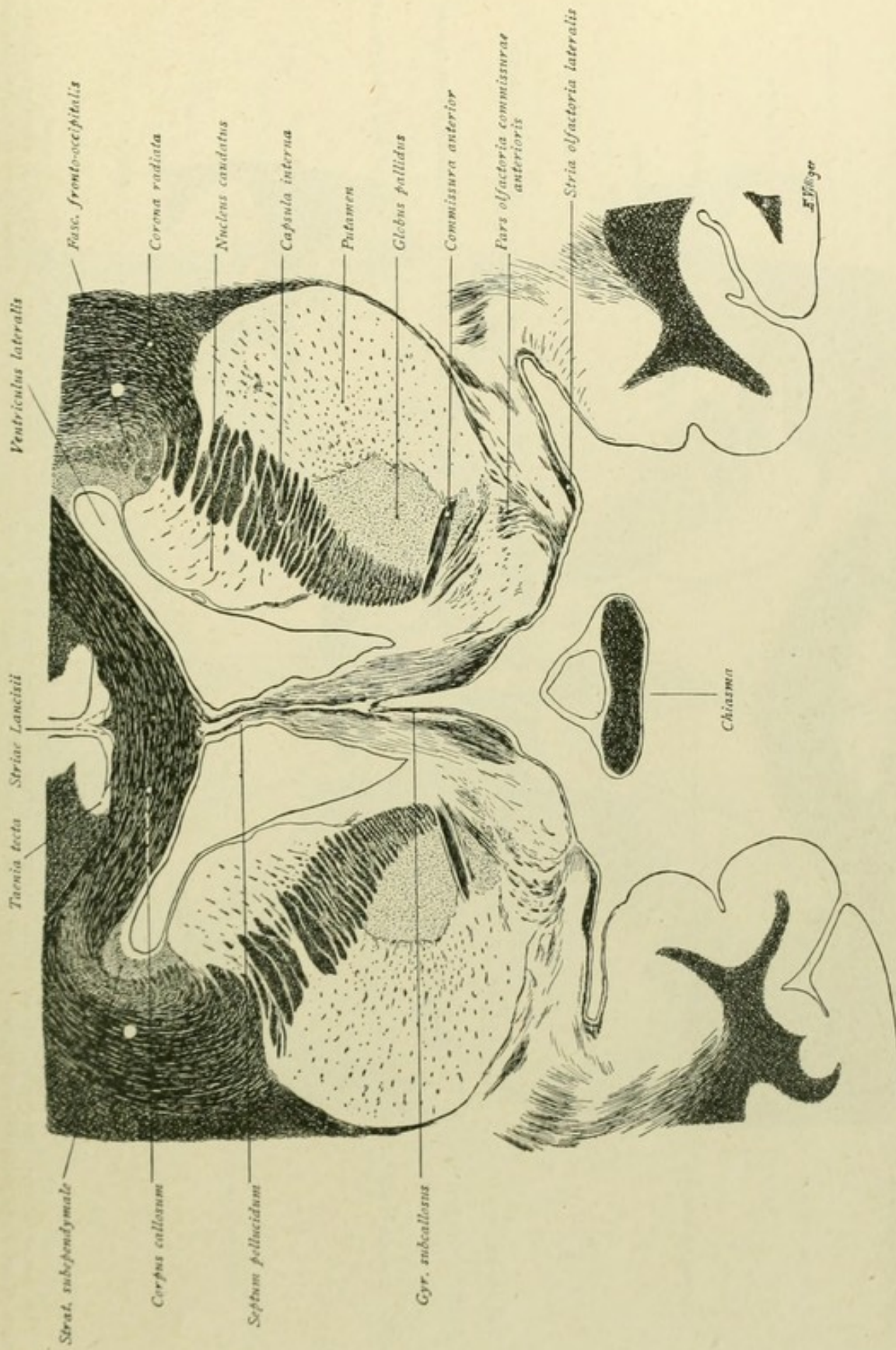


FIG. 190.—The nucleus caudatus is progressively smaller, while the putamen and globus pallidus of the nucleus lenticularis are larger. The fibres of the commissura anterior are seen crossing the ventral part of the globus pallidus. From the place occupied by the tuberculum olfactorium in Fig. 189, fibre-strands pass upward toward the septum pellucidum, in laterally convex curves toward the anterior commissure (pars olfactoria commissurae anterioris) and laterally toward the capsula externa. The course of the stria olfactoria lateralis toward the anterior end of the temporal lobe is clearly shown.



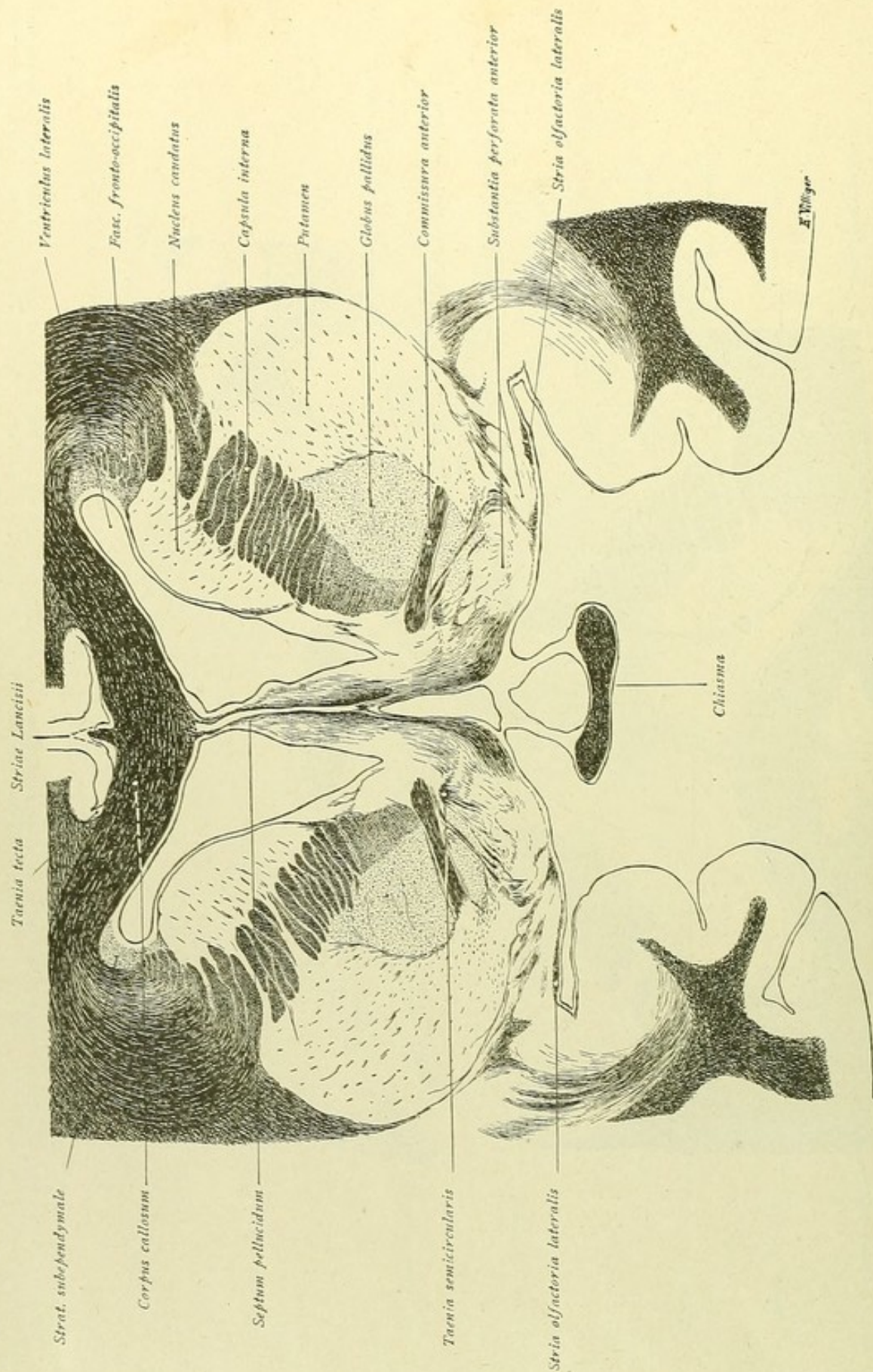


FIG. 191.—Ventral to the corpus striatum lies the substantia perforata anterior, from which fibres ascend toward the septum pellucidum, the anterior commissure (pars olfactoria commissurae anterioris) and the capsula externa. The gyri subcallosi lie lower and radiate toward the substantia perforata. Special fibre-strands from the substantia perforata and from the septum pellucidum collect, ventral to the anterior commissure, to become the taenia semicircularis. The stria olfactoria lateralis passes toward the temporal lobe.



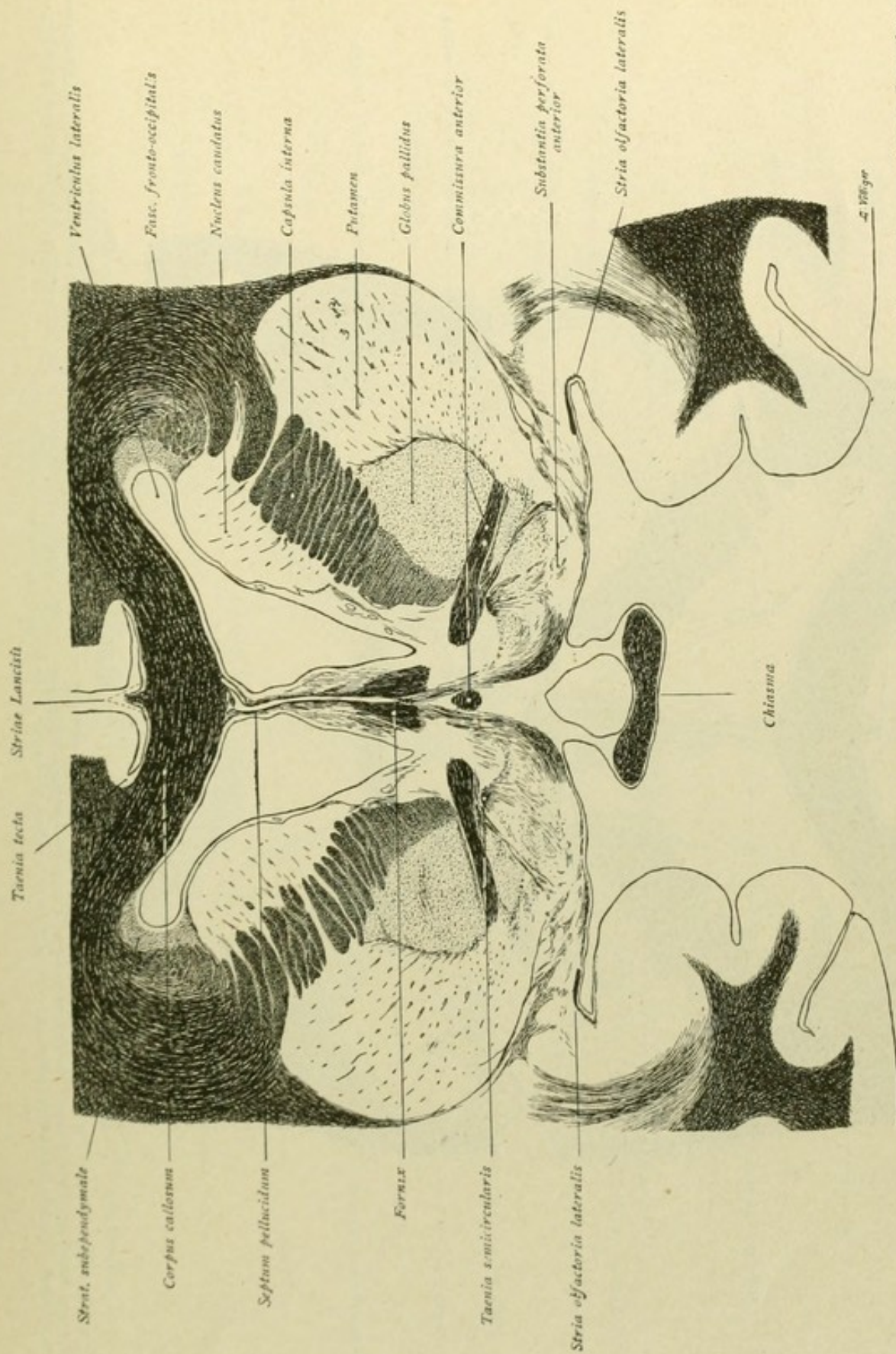


FIG. 192.—Ventral to the septum pellucidum, appear the fibre-bundles of the fornix and, still lower, those of the middle part of the anterior commissure. From the substantia perforata anterior, the fibres shown in the preceding figure pass in various directions; moreover, fibres pass from the same source to the fornix (olfactory bundle of the hippocampus—tractus olfacto-ammonicus).



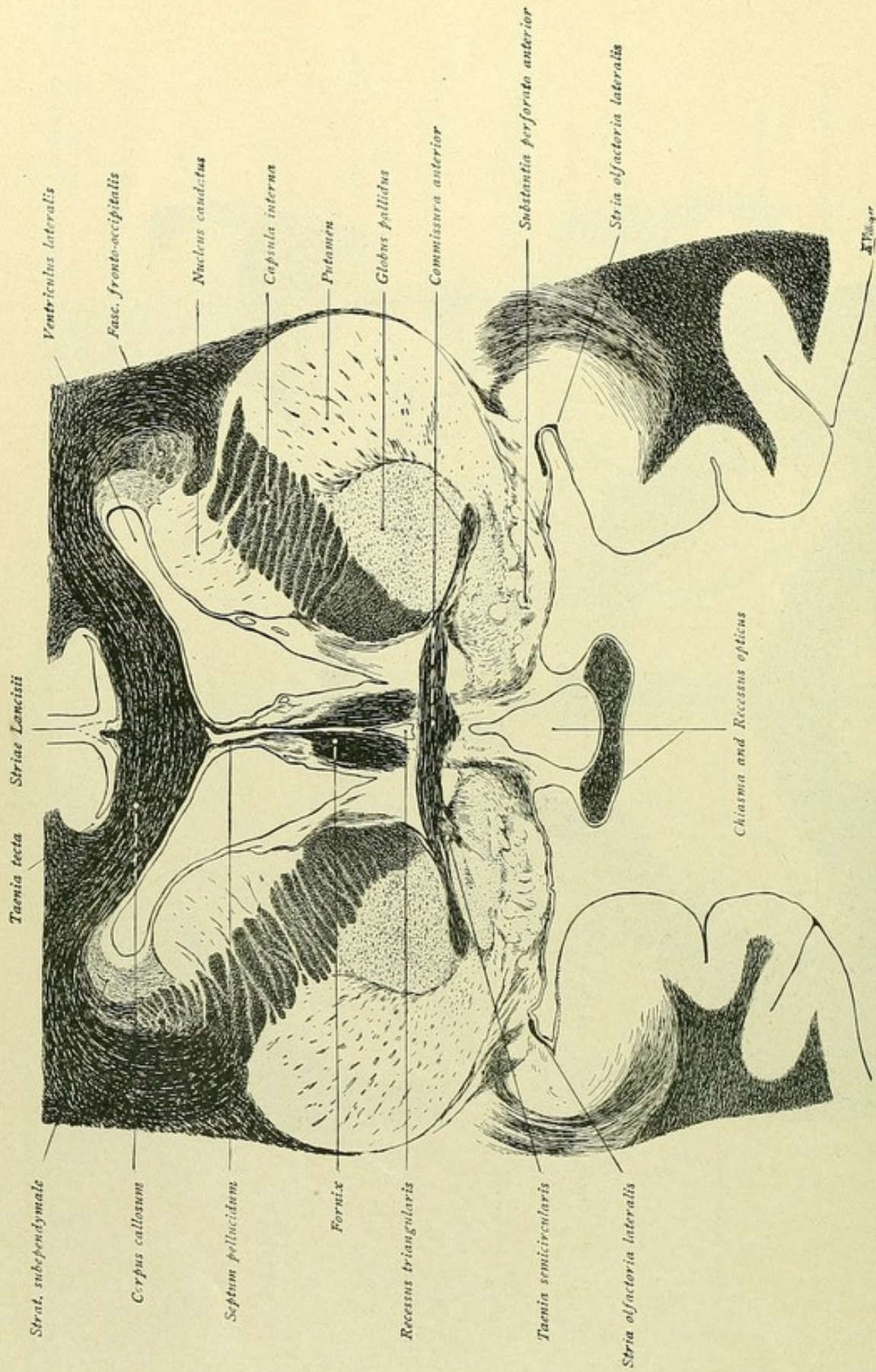


FIG. 193.—The fibre-bundles of the fornix are more robust. The triangular space between the columns of the fornix and above the transversely coursing anterior commissure is the recessus triangularis; that beneath the commissure and above the chiasma is the recessus opticus. Again note the course of the fibres passing from the substantia perforata. The stria olfactoria lateralis lies farther lateral and the taenia semicircularis is augmented by fibres from the commissura anterior.



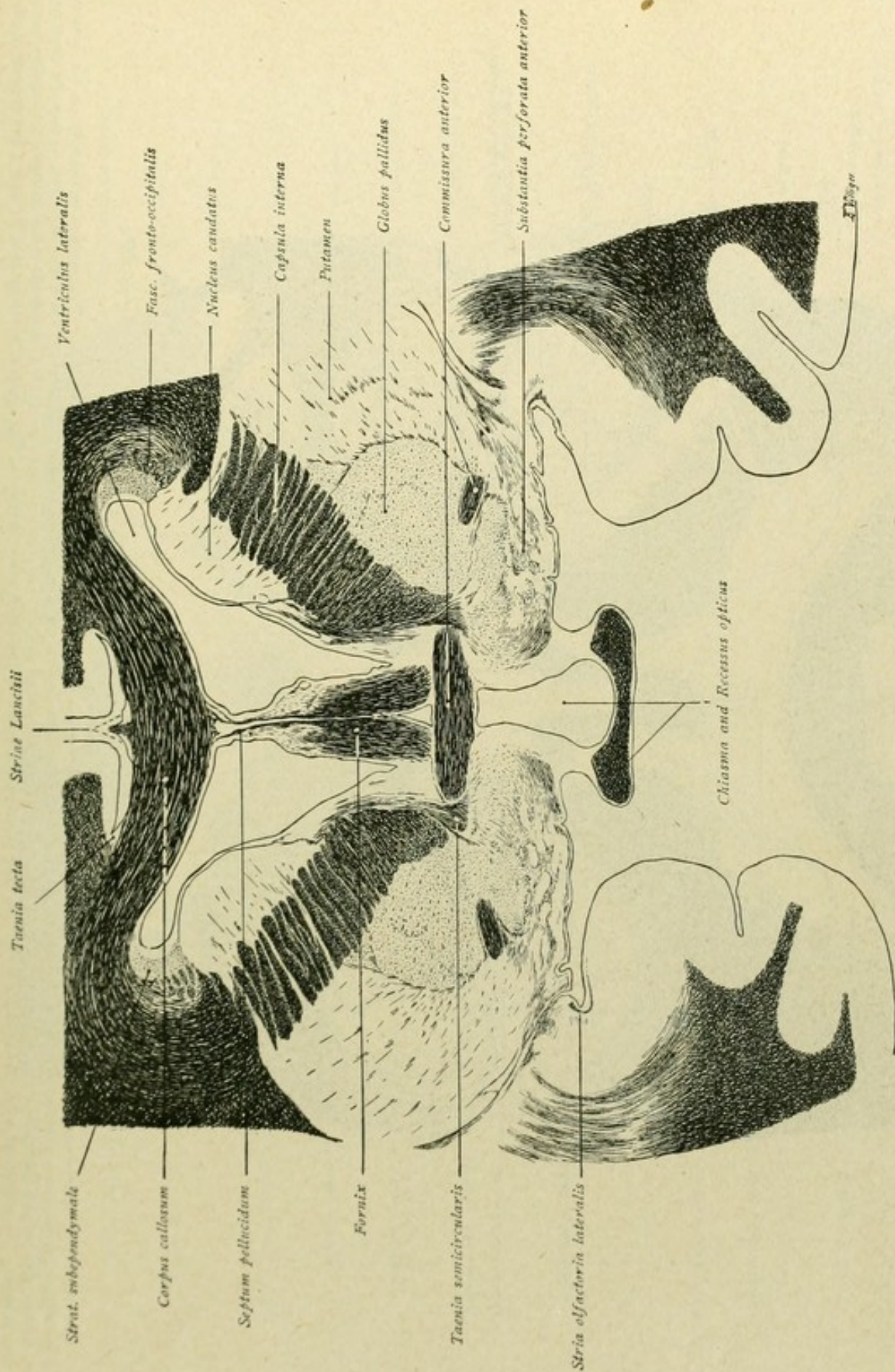


FIG. 194.—The commissura anterior is represented by its median and lateral parts. The taenia semicircularis is ascending toward the nucleus caudatus. The tractus optici are beginning to separate from the chiasma.



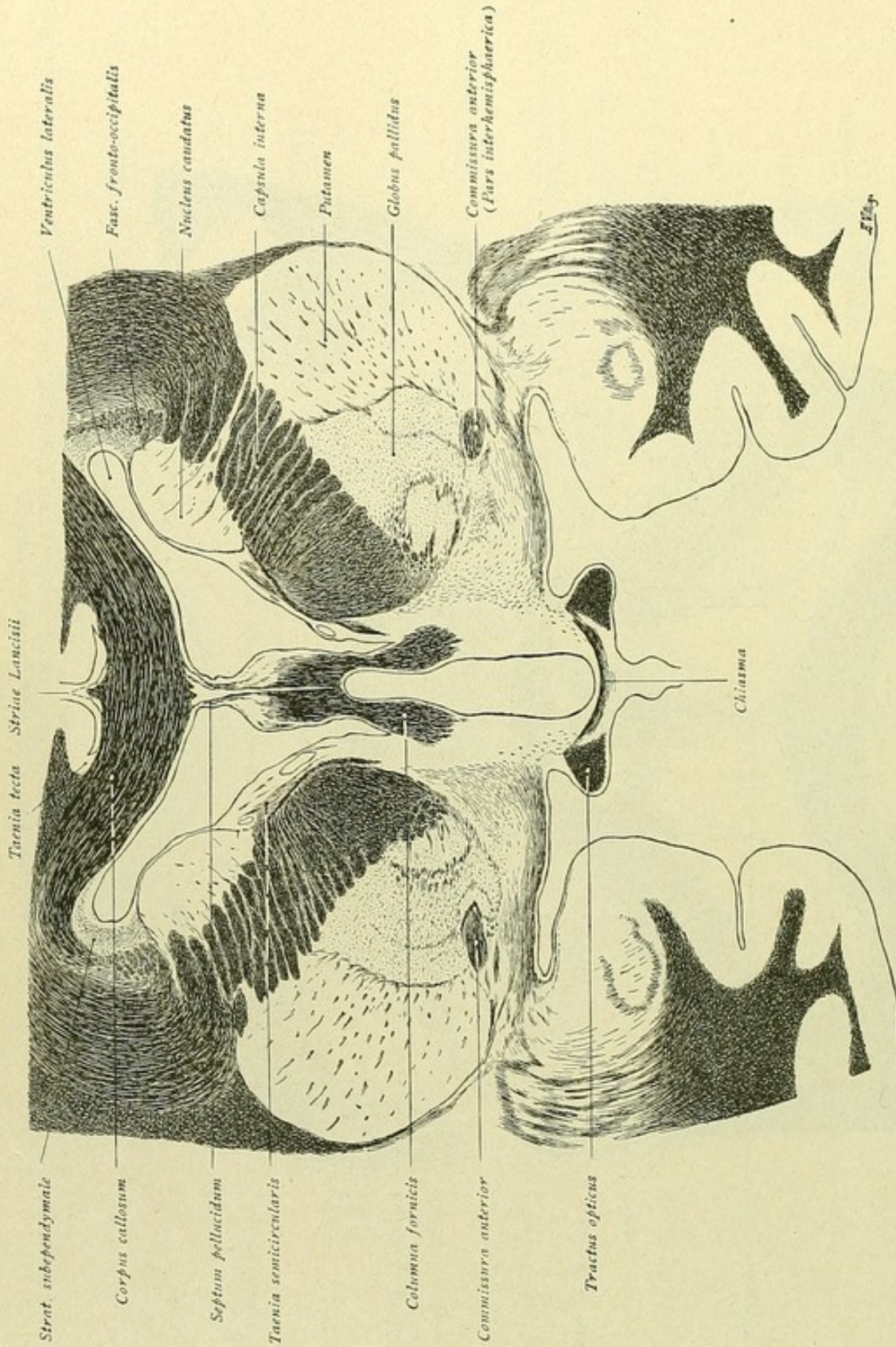


FIG. 195.—The nucleus caudatus becomes progressively smaller and in the succeeding figures gradually passes into the tail. The nucleus lenticularis, on the contrary, increases, the globus pallidus exhibiting further differentiation into its segments. The capsula interna, which separates the caudate and lenticular nuclei, is strongly developed. The columnae fornicis pass ventrally from the fornix. The taenia semicircularis has almost reached the nucleus caudatus; farther backward, it lies between the caudate nucleus and the thalamus. Vento-lateral to globus pallidus is seen the pars interhemisphaerica of the commissura anterior. The chiasma is represented by only a few strands of fibres between the tractus optici.







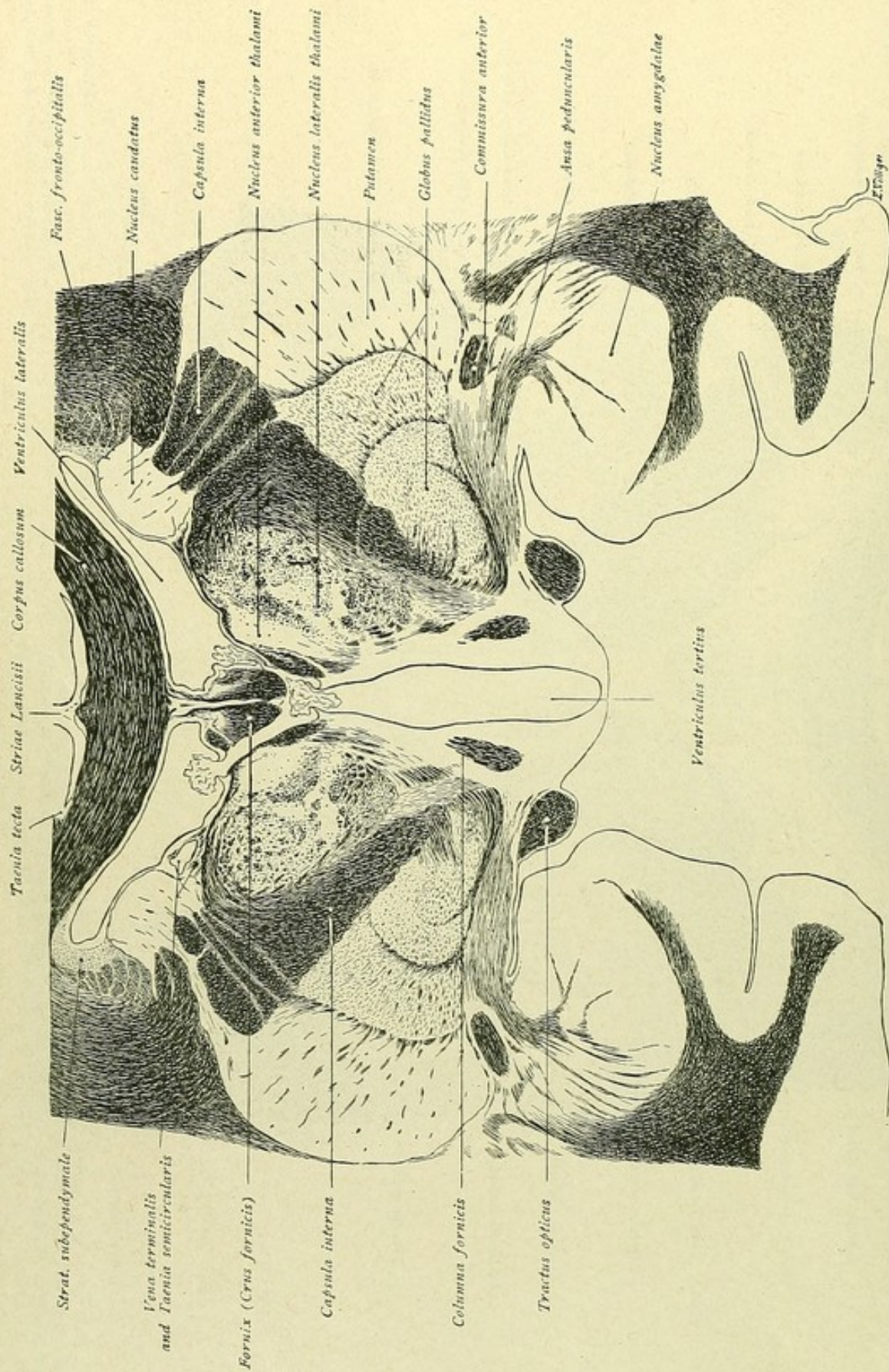


FIG. 197.—The thalamus exhibits differentiation into nucleus anterior and nucleus lateralis. As in the preceding figure, the ansa lenticularis and peduncularis are recognized as fibre-strands passing upward from the nucleus lenticularis and the temporal lobe toward the thalamus. The columnae fornicis are more ventrally located and the tractus optici course more laterally. The nucleus amygdalae, within the temporal lobe, is considerably larger.



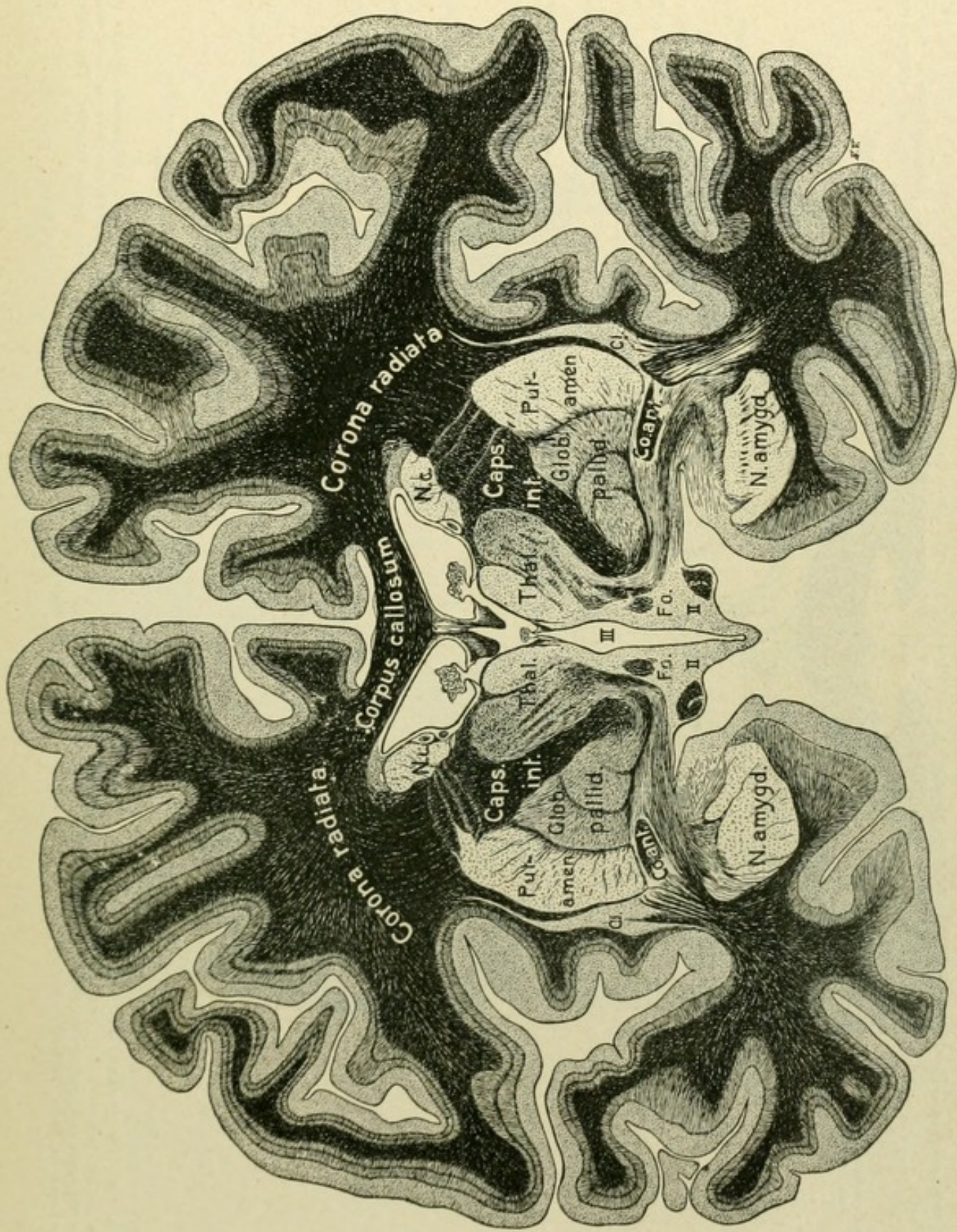


FIG. 198.—Frontal section through the cerebrum, supplementing Fig. 197. N.c., nucleus caudatus; III, third ventricle; F.o., columnna fornicis; II, tractus opticus; Co. ant., commissura anterior; Cl., claustrum.



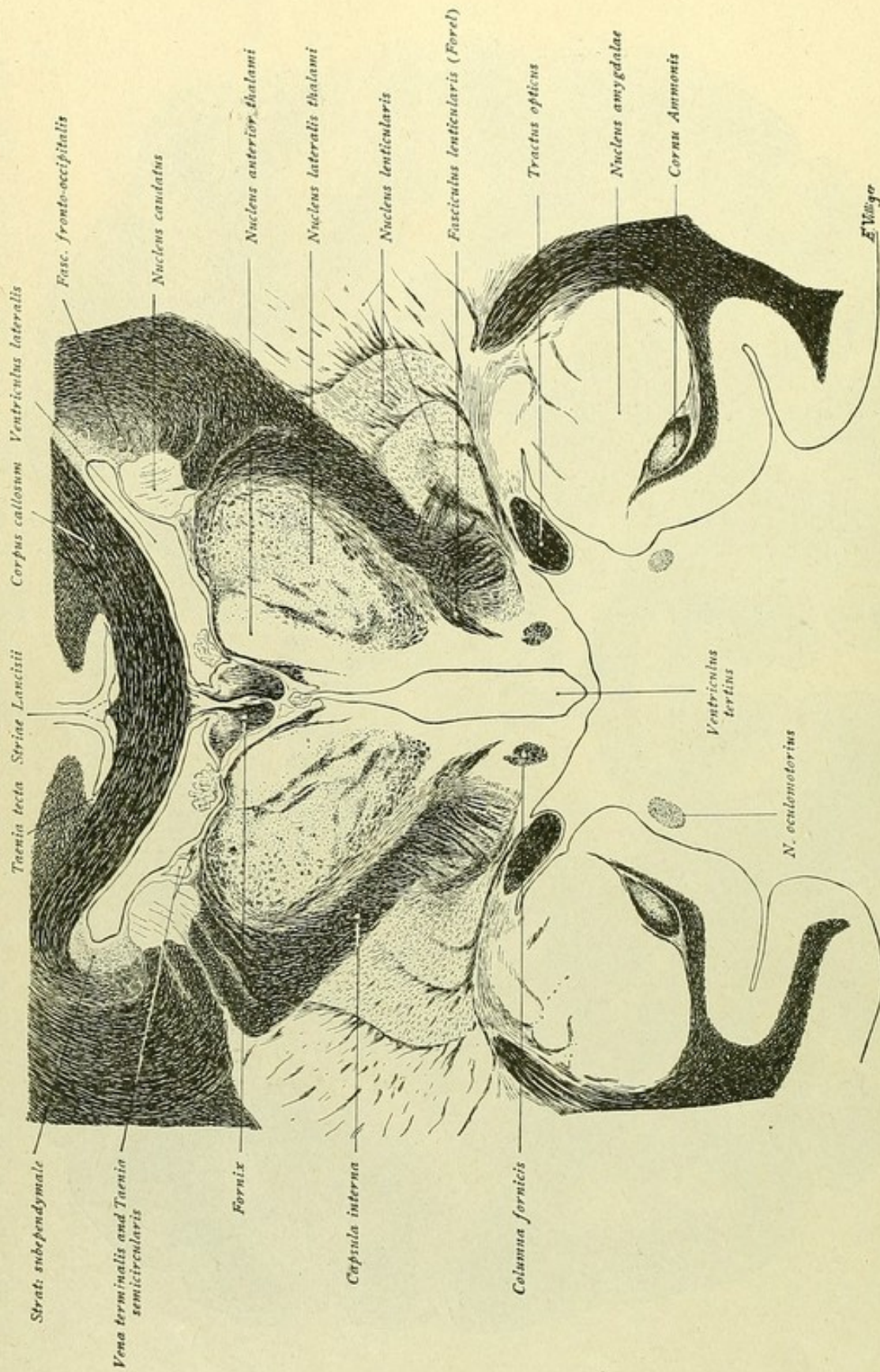


FIG. 199.—The thalamus has increased in size and the differentiation into nucleus anterior and nucleus lateralis is more distinct. The capsula interna, which now penetrates farther baseward, is traversed ventrally by fibre-strands from the nucleus lenticularis. The fibres assemble into a distinct bundle, the fasciculus lenticularis (Forel), which, for the most part, enters into relations with the thalamus. The columnae fornicis lie still deeper and the tractus optici extend farther laterally. The anterior end of the hippocampus or cornu Ammonis appears within the temporal lobe ventral to the large nucleus amygdalae.



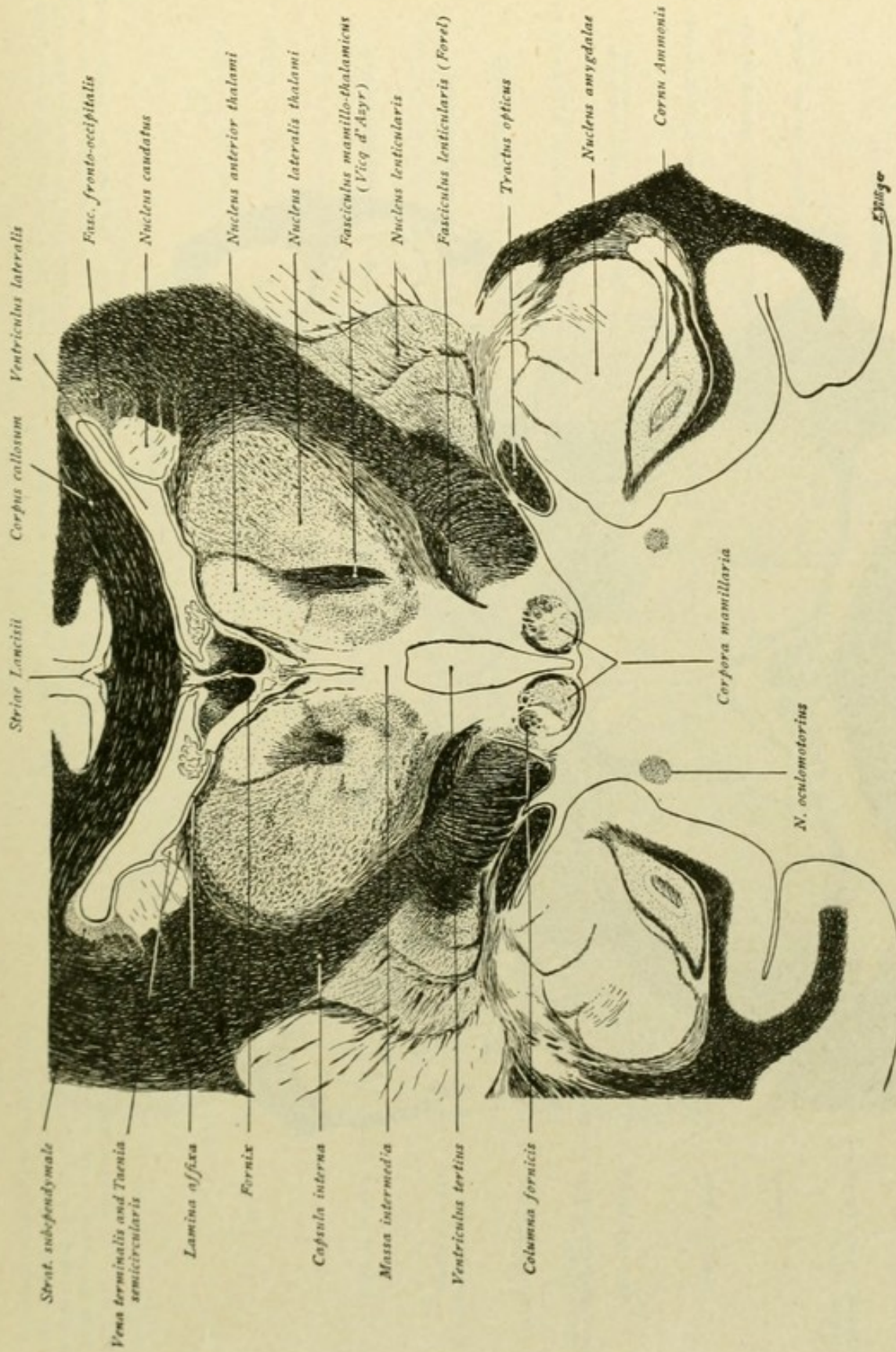


FIG. 200.—The section ventrally cuts the corpora mamillaria, in whose lateral nuclei the columnae fornicis end. From the medial nucleus, the fasciculus mamillo-thalamicus passes upward to end in the nucleus anterior thalami. The two thalami are connected with each other by the massa intermedia. Within the temporal lobe appears the descending horn of the lateral ventricle, with the hippocampus or cornu Ammonis. Note, further, the extension of the ependyma in the lateral ventricle, comparing Fig. 63.



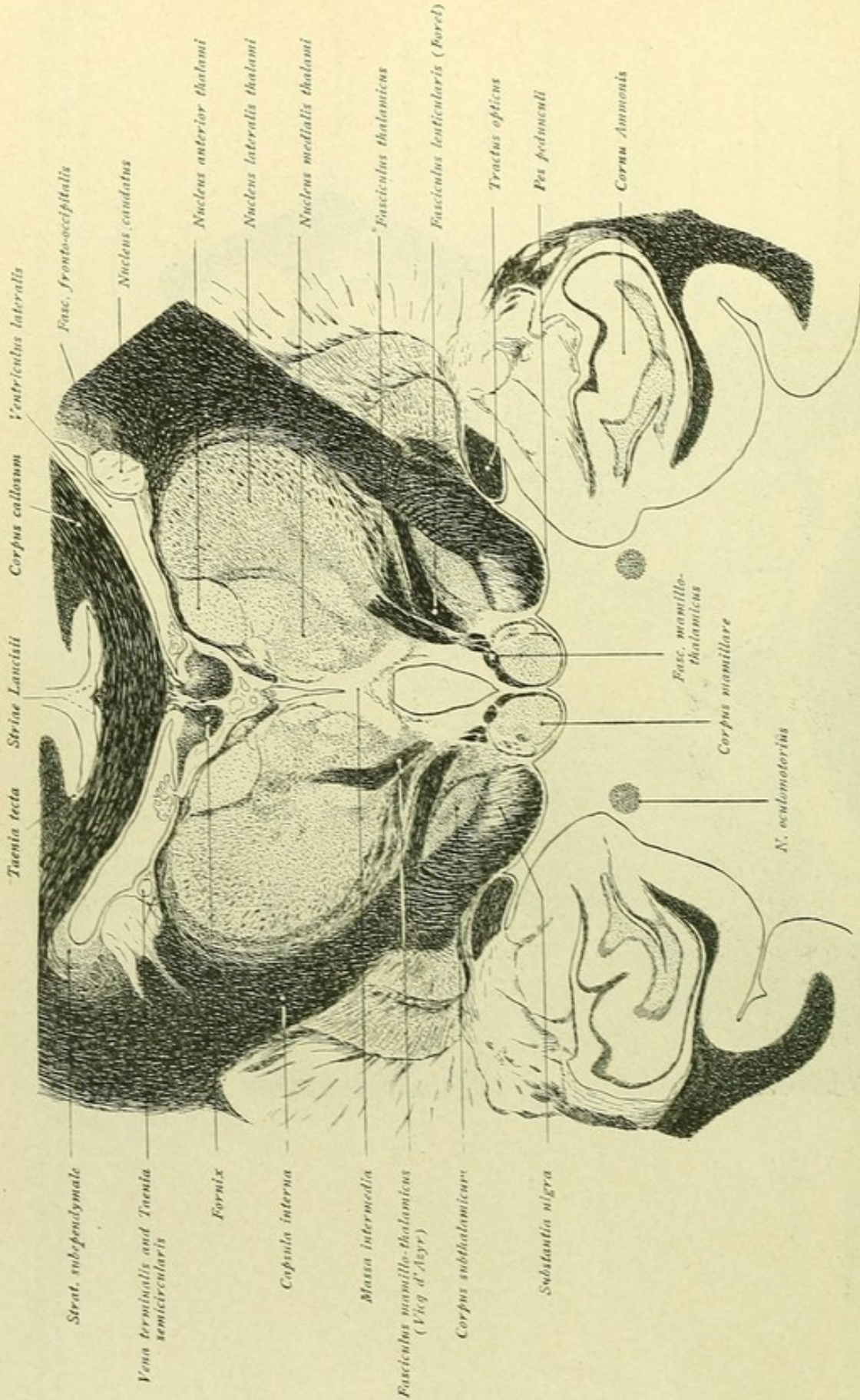


FIG. 201.—The thalamus now shows differentiation into its three chief subdivisions—the nucleus anterior, medialis and lateralis. The fasciculus mamillo-thalamicus ascends from the medial nucleus of the corpus mamillare toward the nucleus anterior thalami. The fasciculus thalamicus appears as a new fibre-bundle above the fasciculus lenticularis, separated from the latter by the zona incerta. The capsula interna continues into the pes pedunculi, the corpus subthalamicum and the substantia nigra appearing as new gray masses, lateral to the corpus mamillare. Within the temporal lobe a trace of the nucleus amygdalae is still to be seen; the cornu Ammonis in the descending horn of the lateral ventricle has become larger.



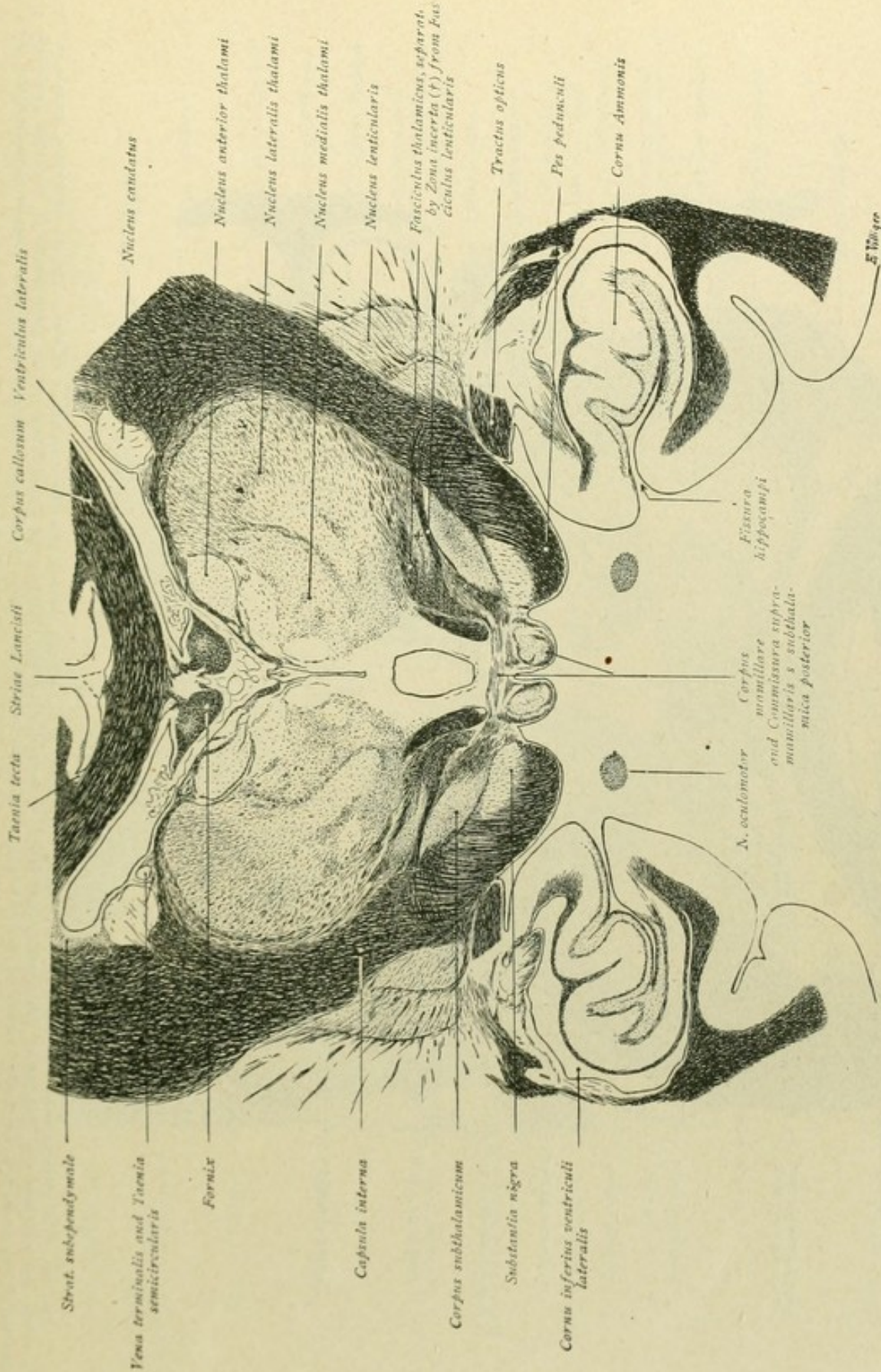


FIG. 202.—Of the thalamic nuclei, the nucleus anterior has become smaller, while the medial and lateral nuclei have increased. Within the regio subthalamica, the corpus subthalamicum is more strongly developed. Fibre-bundles, which pass above the corpora mamillaria from one subthalamie body to the other, form constituents of the commissura supramamillaris. Lateral to the corpus mamillare, lies the pes pedunculi, separated from the corpus subthalamieum by the substantia nigra. The manner is clearly shown, in which the cortex of the gyrus hippocampi, is pushed into the descending horn of the lateral ventricle by the deeply penetrating fissura hippocampi, to form the cornu Ammonis or hippocampus.



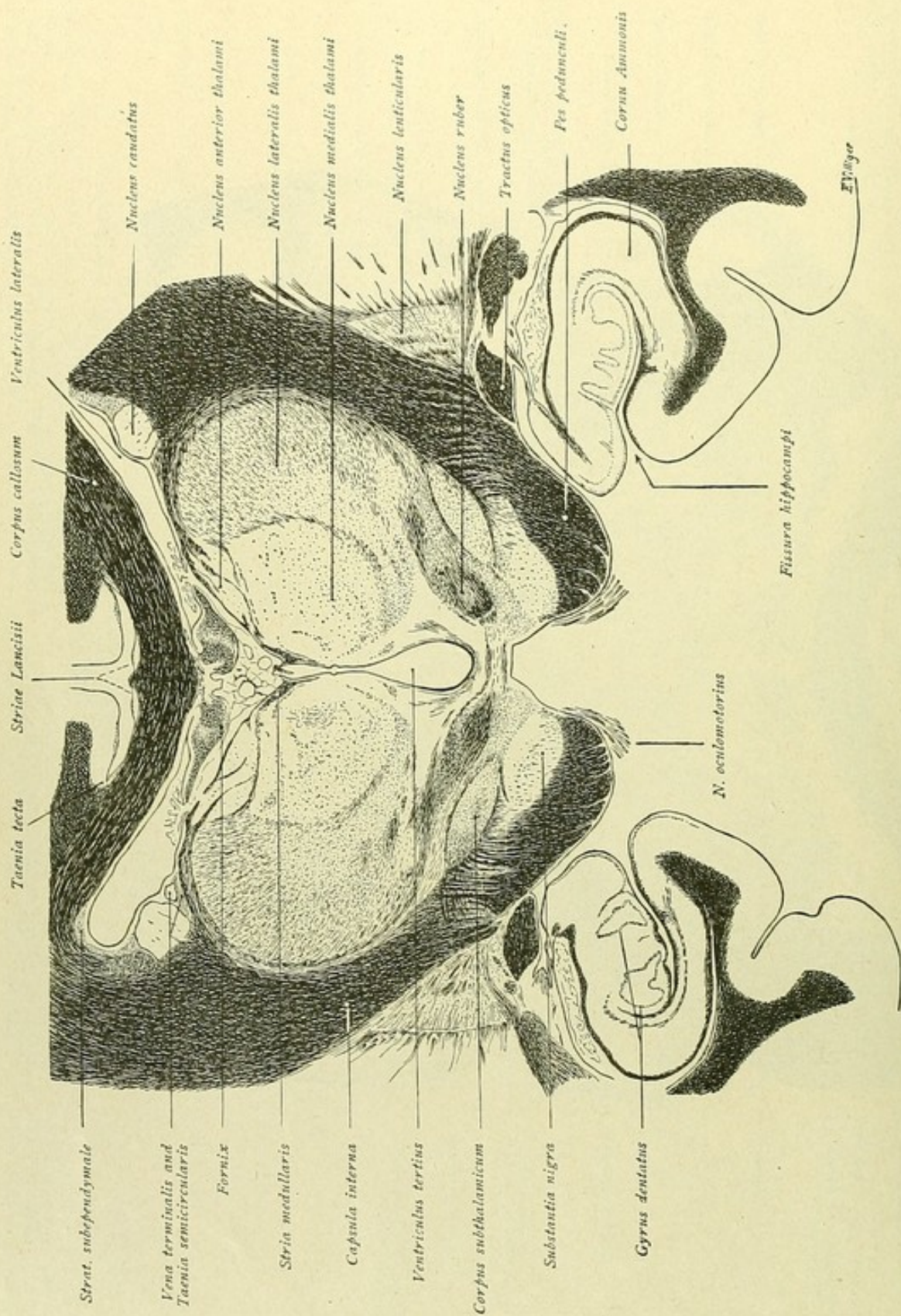


FIG. 203.—The subdivision of the thalamus into its three chief nuclei is in this and the following figure especially evident. The tela chorioidea spreads out beneath the fornix and one sees the invaginated plexus within the lateral and third ventricles; further, the consolidation of the fibre-strands of the stria medullaris at the transition of the dorsal into the medial surface of the thalamus. Within the subthalamic region, on the right side and medial to the corpus subthalamicum, the nucleus ruber is exposed; within the hippocampal formation, the granule layer of the gyrus dentatus is recognized.



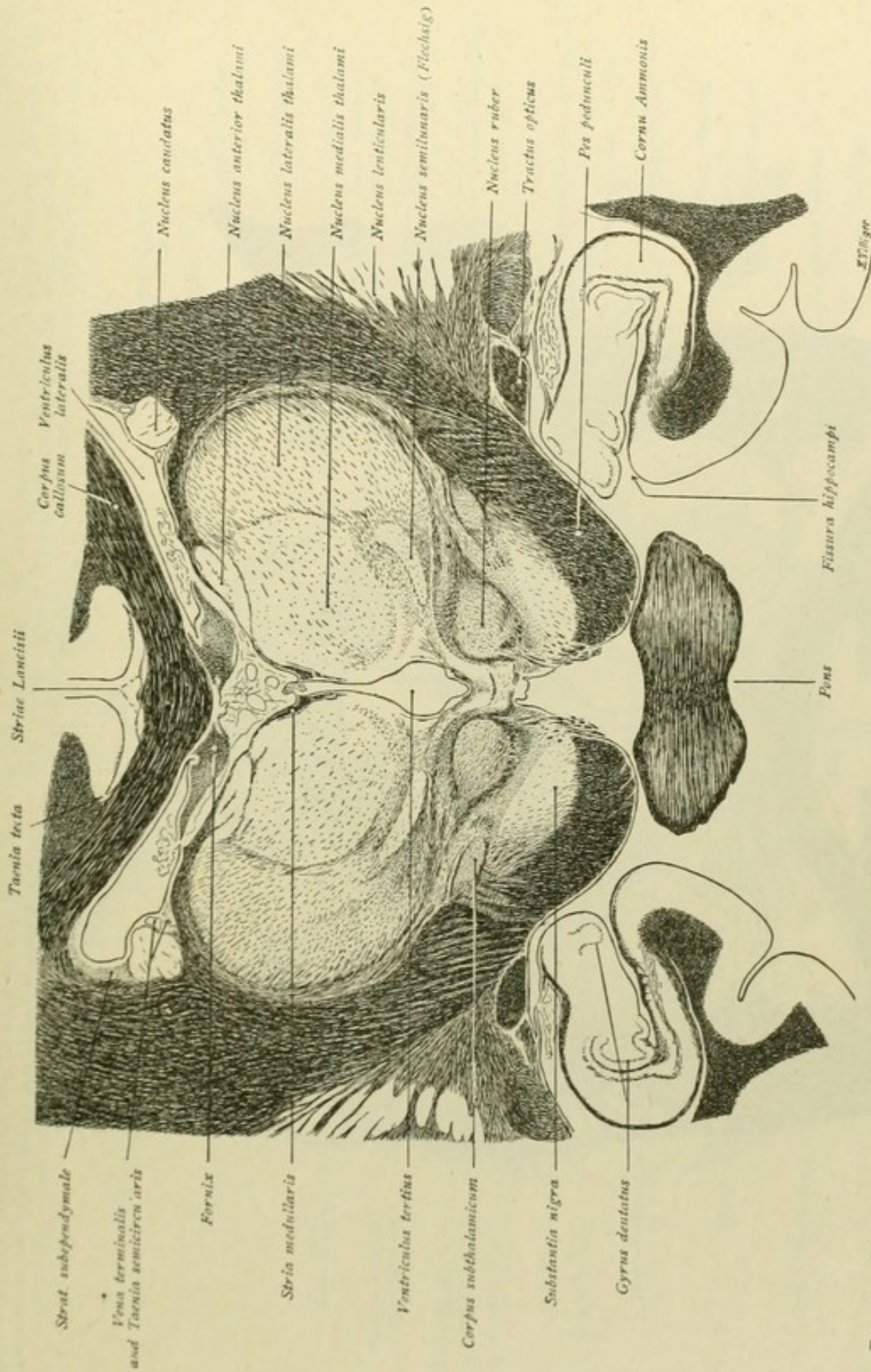


FIG. 204.—The nucleus semilunaris appears as a new nucleus within the ventral thalamic area, while within the subthalamic region, medial to the corpus subthalamicum is seen the nucleus ruber. Ventral to the latter, the substantia nigra expands above the pes pedunculi; below the peduncle the most anterior part of the pons is encountered. The thalamus is subdivided into its three chief nuclei by the laminae medullares; the lateral nucleus is covered laterally by the lamina medullaris externa, which, as the outer boundary of the thalamus, rests against the stratum reticulare or lattice-layer.



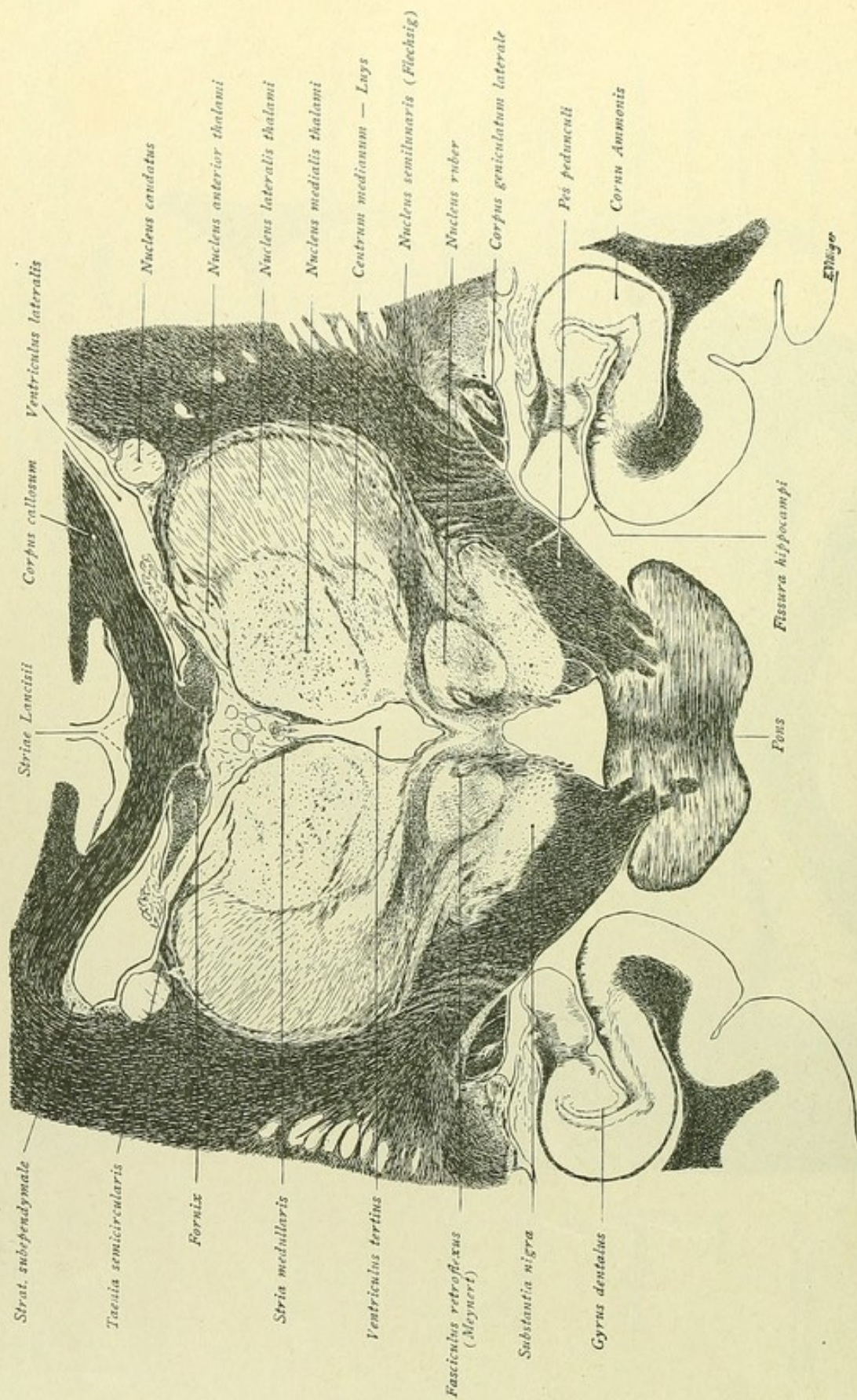


FIG. 205.—The centrum medianum appears within the ventral part of the thalamus, above the nucleus semilunaris; the medial part of the now larger nucleus ruber is traversed by the fasciculus retroflexus. Only a small portion of the corpus subthalamicum is still recognizable; the substantia nigra, on the contrary, is well developed. Fibre-bundles now penetrate the pons from the pes pedunculi, and, on the right side, is seen the corpus geniculatum laterale, in which a part of the fibres of the tractus opticus ends.



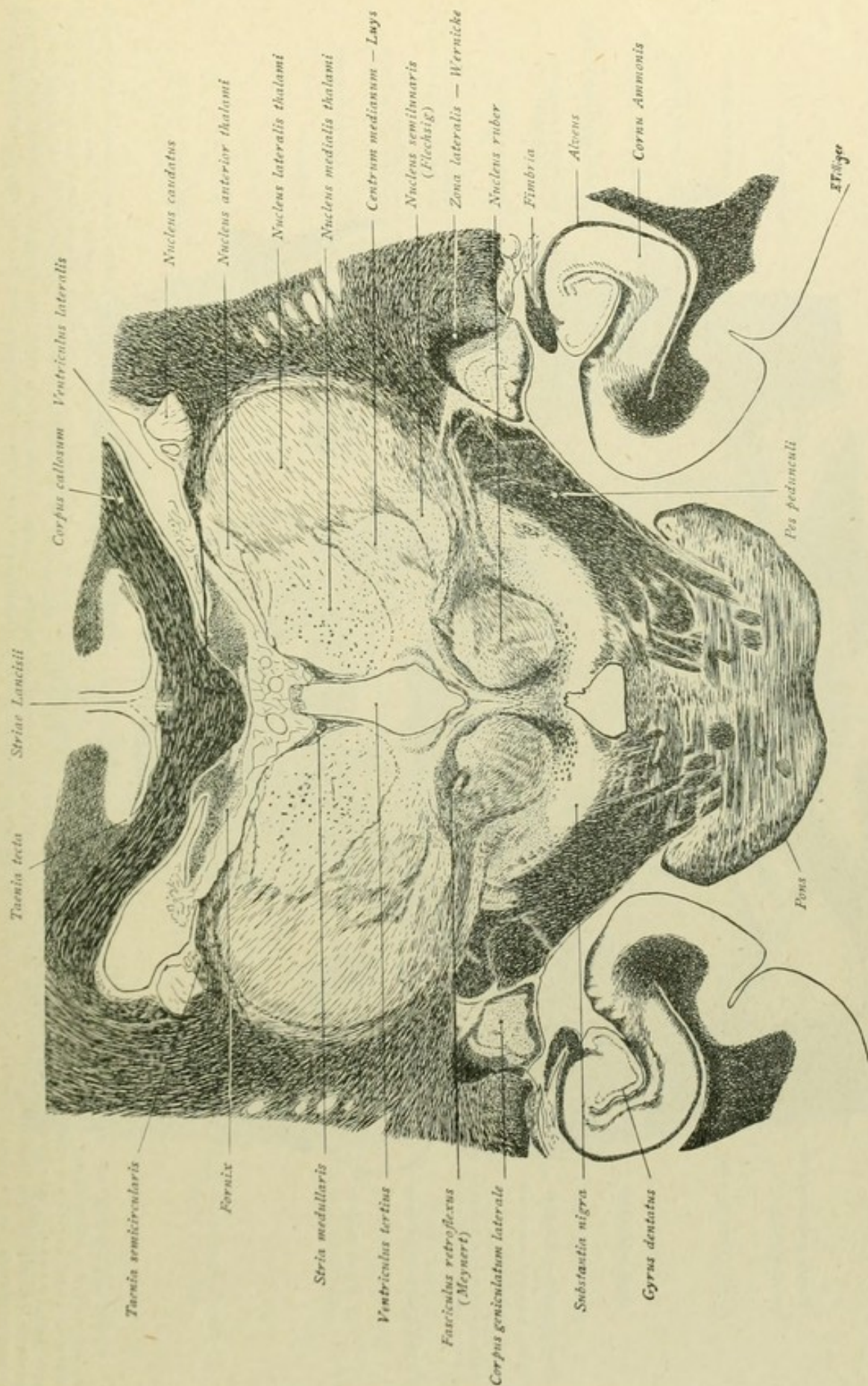


FIG. 206.—The subdivision of the thalamus into the chief nuclei is still more evident. Within the subthalamic region, the nucleus ruber has become larger; likewise the substantia nigra is strongly developed and the fibre-bundles of the pes pedunculi penetrate deeply into the pons. The fasciculus retroflexus is more dorsally placed, and in the position occupied by the tractus opticus, the corpus geniculatum laterale appears of large size and invested dorsally by the fibres of Wernicke's field. The hippocampal region should be compared with that represented in Fig. 45.



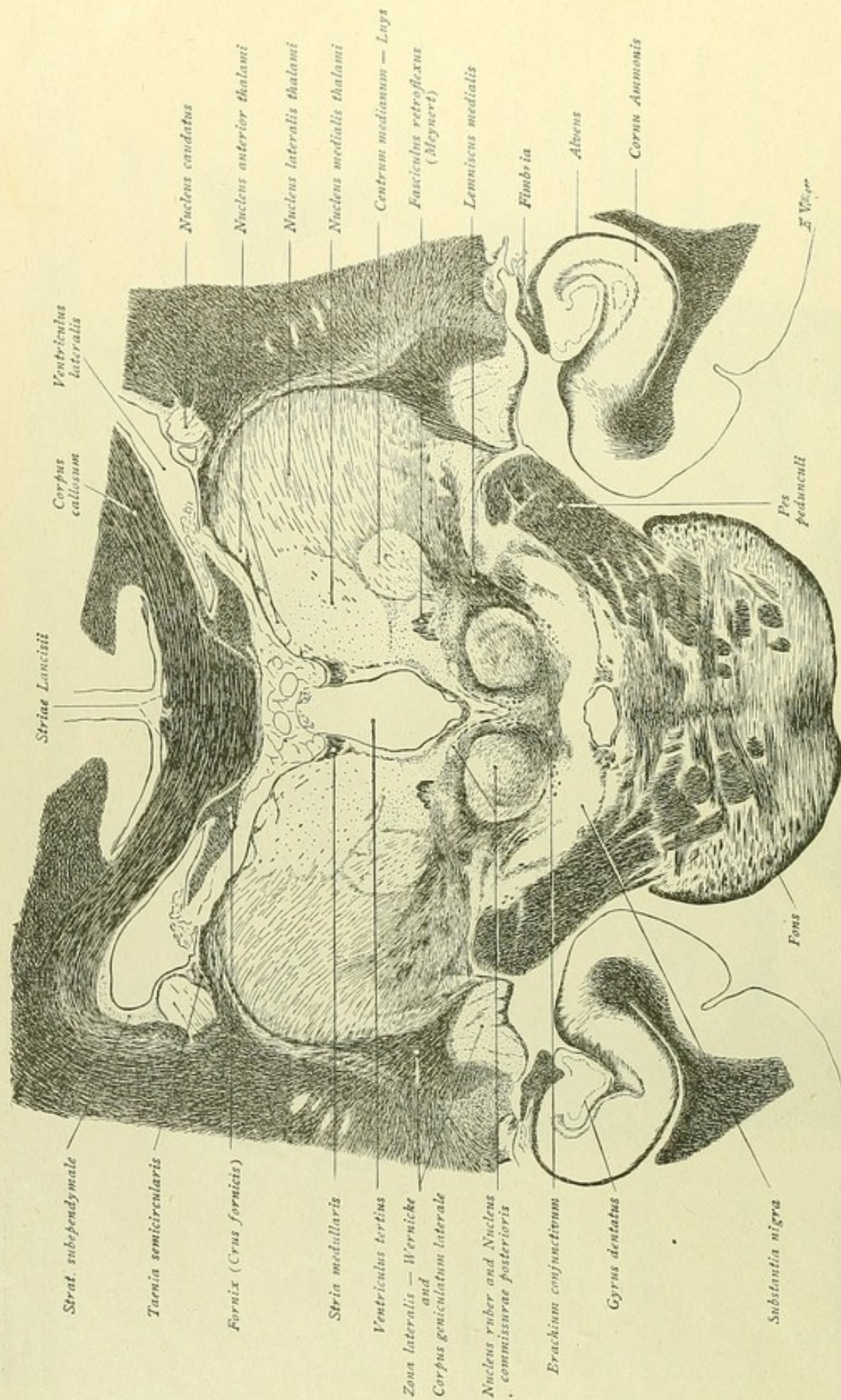


FIG. 297.—Within the thalamic area, the anterior and medial nuclei, in contrast to the lateral nucleus and the centrum medianum, have decreased; likewise the nucleus caudatus, which is now represented by the tail alone. The fasciculus retroflexus passes medially to the centrum medianum. The nucleus ruber has become smaller; somewhat dorsal to it lies a small gray mass, the nucleus of the posterior commissure and of the posterior longitudinal bundle, from which delicate fibre-strands pass medially and ventrally between the two red nuclei, bounding a small triangular field of gray substance, the nucleus of the oculomotor nerve. Fibres from the decussating superior cerebellar peduncle or brachium conjunctivum enter the red nucleus along its ventro-medial border. Lateral to the nucleus ruber, the fibres of the medial fillet are seen streaming towards the thalamus. Wernicke's field, surmounting the corpus geniculatum laterale, prolongs its apex upward and passes over into the lamina medullaris externa and the stratum zonale of the thalamus.



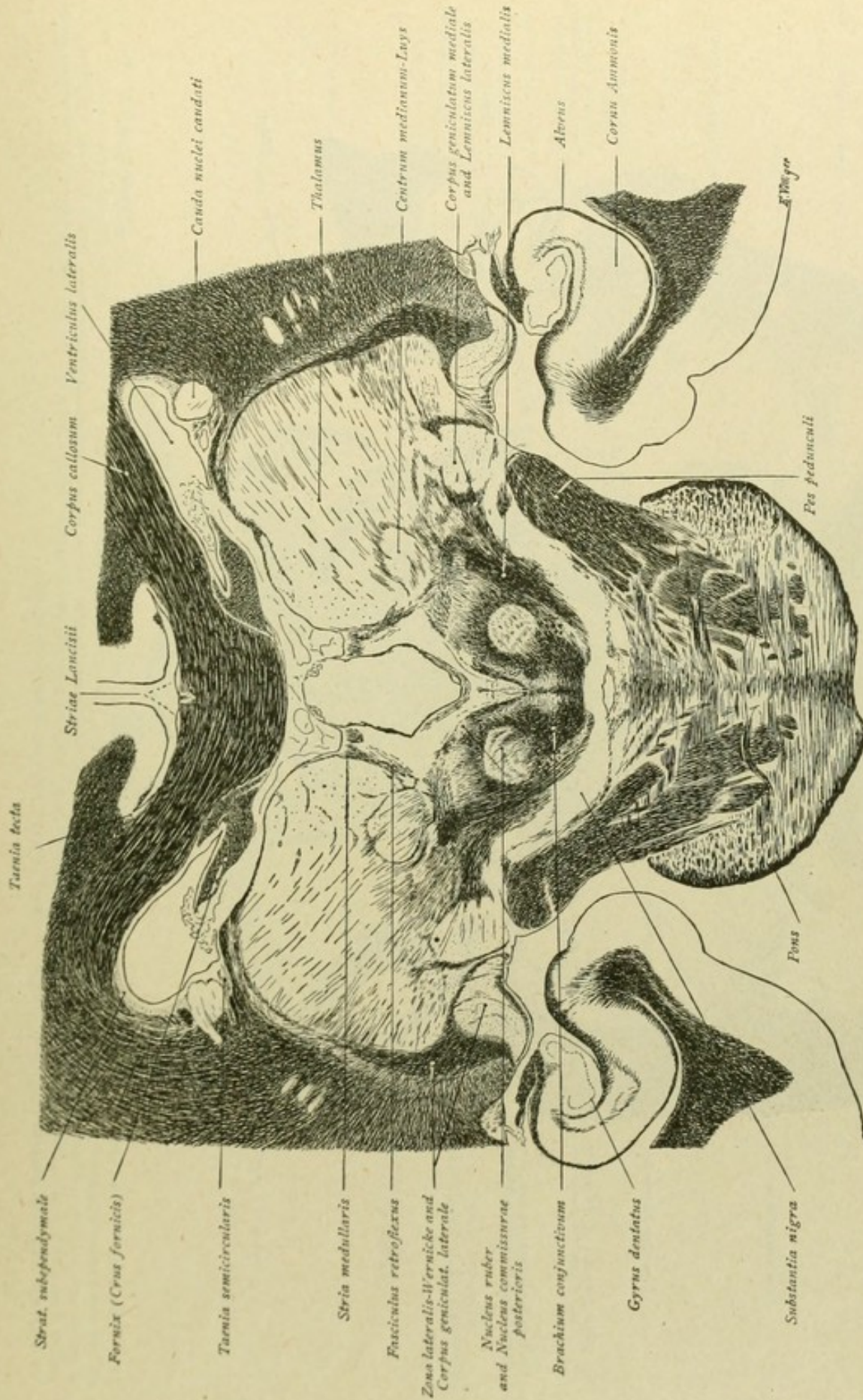


FIG. 208.—Within the thalamic area, the centrum medianum is still plainly defined. The stria medullaris is broad and passes over into the trigonum habenulae; the fibre-strands passing thence ventrally along to the fasciculus retroflexus. The fibres of the superior cerebellar peduncle (brachium conjunctivum) are seen entering the red nucleus; lateral to the last-named nucleus, those of the lemniscus medialis directed toward the thalamus, while still further lateral are those of the lateral fillet or lemniscus lateralis ending in the corpus geniculatum mediale. Above the nucleus ruber lies the small nucleus of the posterior commissure and of the posterior longitudinal bundle, and, enclosed by this bundle on each side, is medially located the triangular field of the oculomotor nuclei. The substantia nigra has become narrower and the fibre-bundles of the pes pedunculi have penetrated lower within the pons.



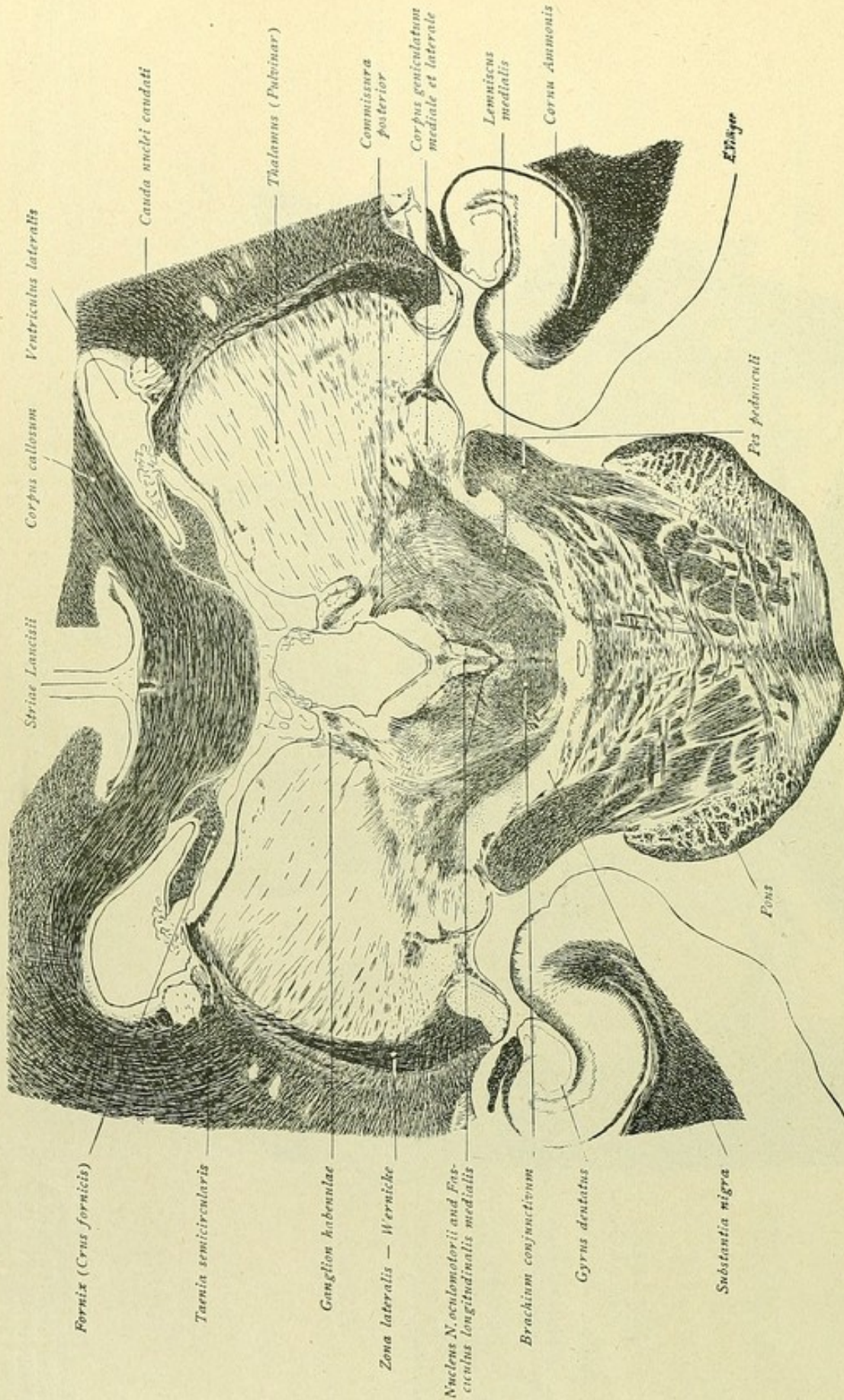


FIG. 209.—The thalamus is now represented by the pulvinar. Where in the preceding figure lay the stria medullaris, now appears the ganglion habenulae. The fibres of the commissura posterior arch dorsally from the nucleus of the commissure. The corpora geniculata are smaller and over the lateral one the zona lateralis or field of Wernicke still expands. Ventral to the oculomotor nucleus and the posterior longitudinal bundle, course the superior cerebellar peduncles, lateral to which the fibres of the medial fillet pass dorsally. The substantia nigra has become still narrower and the pes pedunculi penetrate deeply the pons. In this and already in the preceding section, the corpus callosum has thickened into the splenium, to which laterally are applied the crura fornicis.



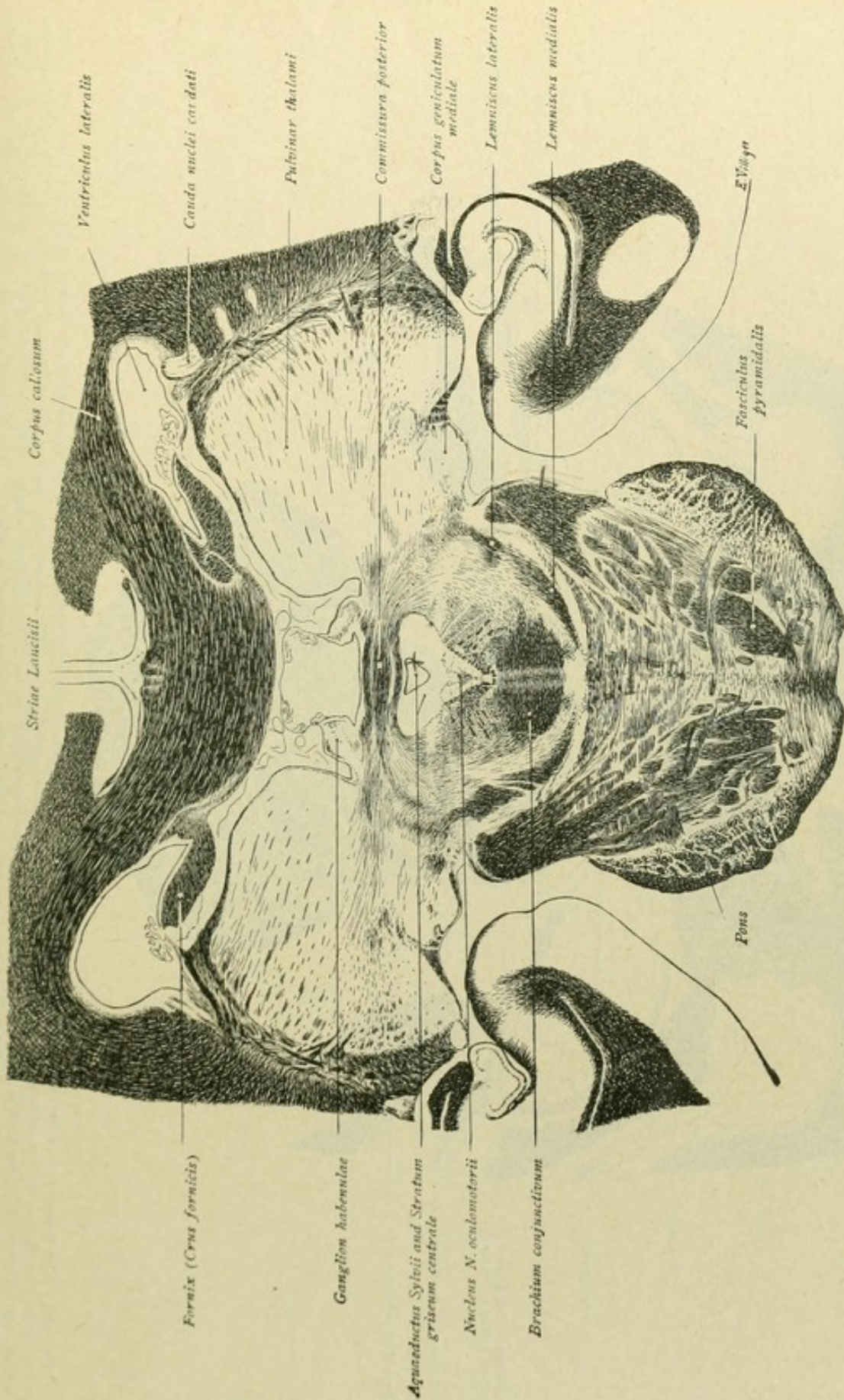


FIG. 210.—The section passes through the commissura posterior, beneath which lies the aqueductus Sylvii, surrounded by the stratum griseum centrale. Ventrally within the latter and bounded at the sides by the posterior longitudinal bandic, is the oculomotor nucleus. Farther ventrally, follows the decussation of the superior cerebellar peduncles and, ventro-lateral from this, the lemniscus medialis or medial fillet, which dorso-laterally joins the lateral fillet. Of the peduncular fibres entering the pons, the cortico-ponsile tracts end in the pontile-nuclei, while those belonging to the pyramidal tracts occupy a more ventral position.



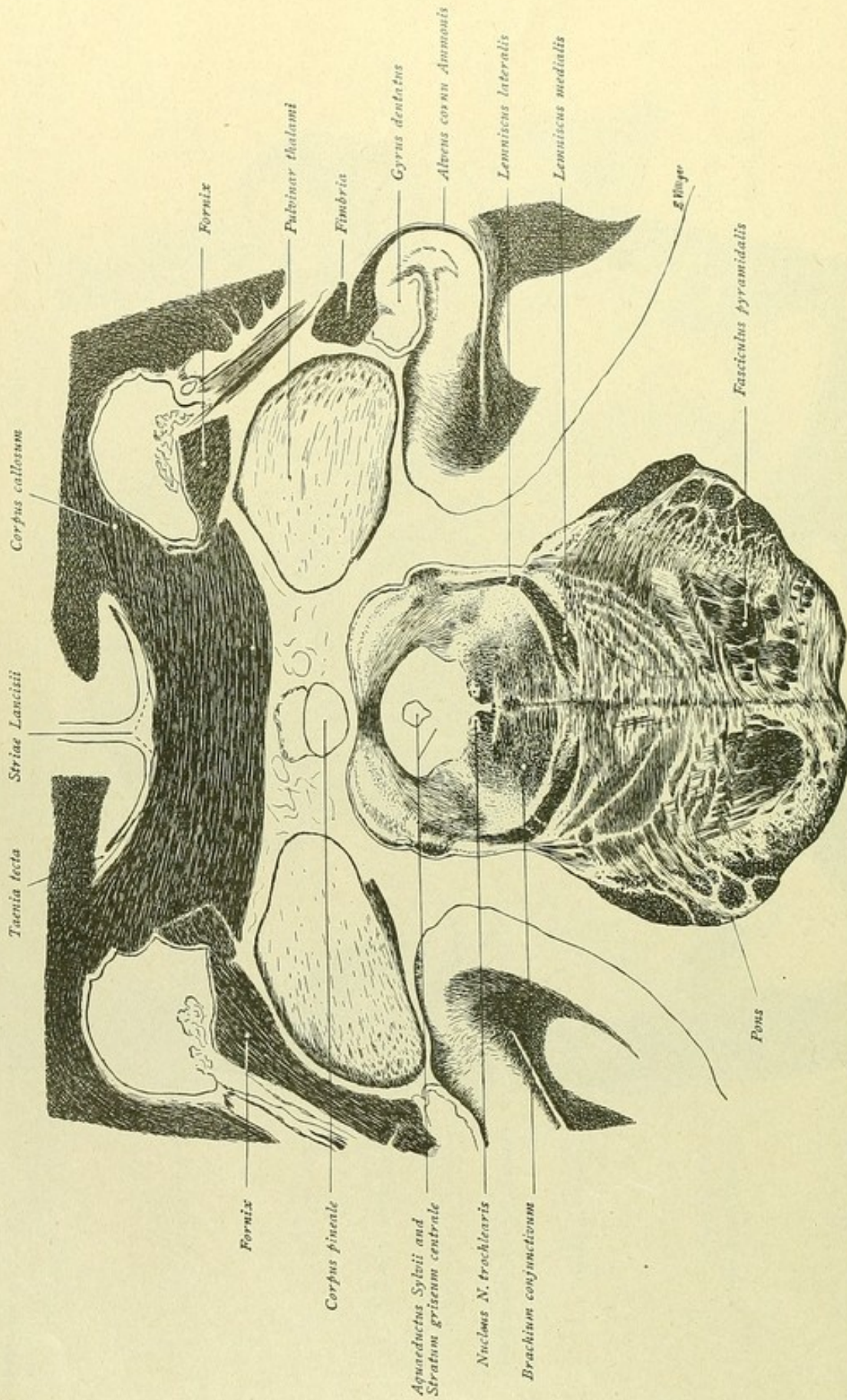


FIG. 211.—The thalamus is now represented by only the posterior part of the pulvinar. Medially, beneath the splenium of the corpus callosum, is the corpus pineale. Below the latter, the section of the brain-stem includes the quadrigeminal region and the pons. The aquaeductus Sylvii is surrounded by the stratum griseum centrale, within the ventral part of which lies the nucleus of the trochlear nerve, embedded within the posterior longitudinal bundle. More ventrally, follow the decussation of the superior peduncles and, still lower, the lemniscus medialis or medial fillet, which above is joined by the ascending fibres of the lemniscus lateralis. Within the pons, the ventrally located pyramidal tracts have assembled into compact bundles.



B

FROM THE CAUDAL END OF THE MEDULLA OBLONGATA  
TO THE QUADRIGEMINAL REGION



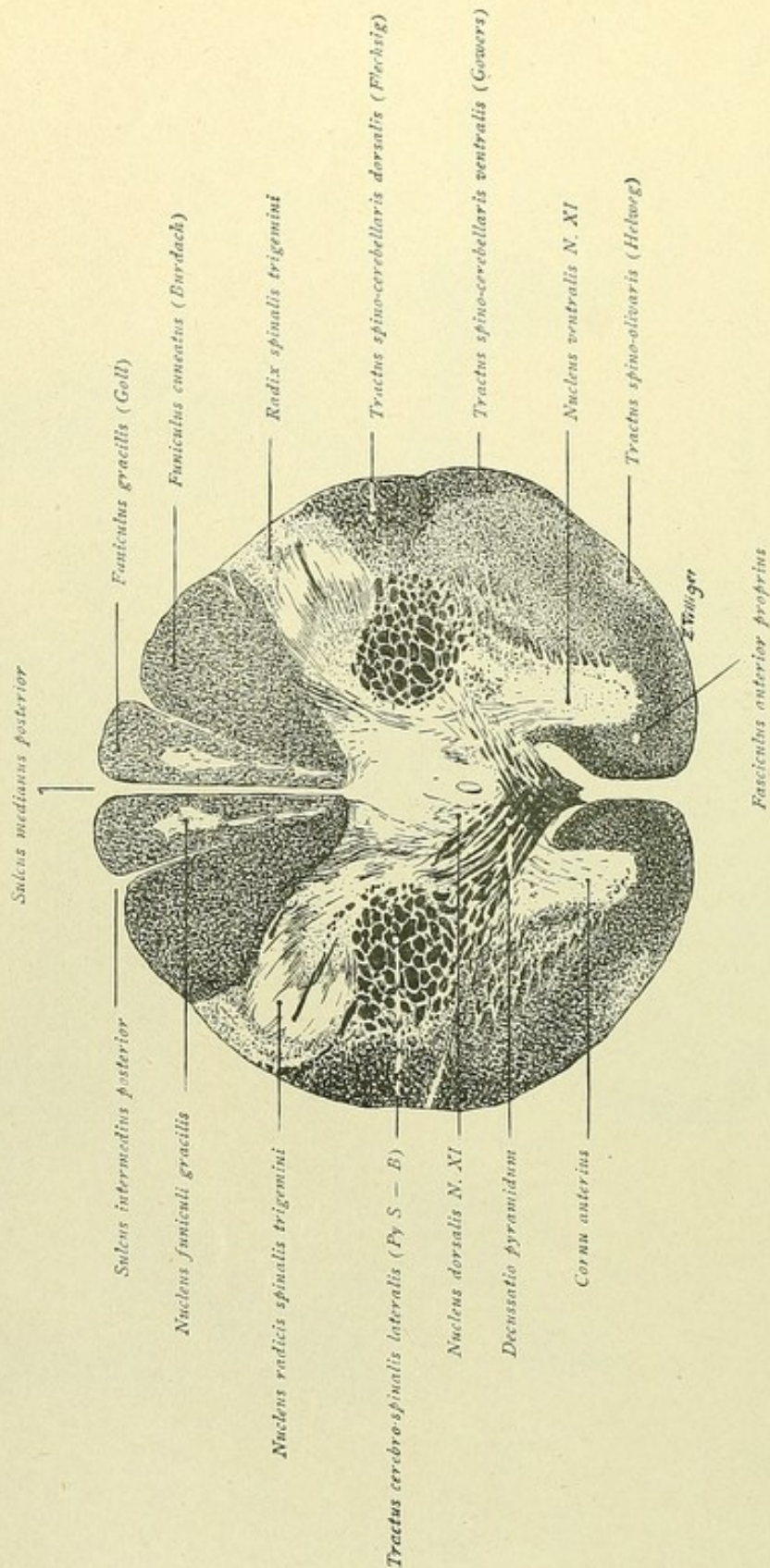


FIG. 212.



FIG. 212.—The section passes through the caudal end of the medulla oblongata. The gray substance exhibits ventrally the anterior cornu, which toward the lateral columns are less sharply defined and dorso-laterally pass into the lateral horns and the processus reticulares. Behind are seen the latero-ventrally displaced posterior cornua, which are connected with the central gray substance by means of the thinner neck. Within the white substance certain tracts are plainly defined. Thus, the posterior column clearly exhibits a subdivision into the lateral fasciculus gracilis or column of Goll, with its nucleus just appearing. Delicate fibres are seen entering the lateral fasciculus cuneatus or column of Burdach and the medial fasciculus gracilis or column of Goll, with its nucleus just appearing. Delicate descending or spinal root of the trigeminus. These fibres and their collaterals end within the substantia gelatinosa Rolandi, the crescentic area of transversely cut fibres represents the nucleus radialis spinalis tegmenti. Within the lateral column, ventral to the neck of the posterior horn, the tractus cerebro-spinalis or the lateral pyramidal tract (*Py S—B*) appears as an almost round bundle. The fibre-strands, which pass from this bundle ventro-medially towards the anterior median fissure, belong to the pyramidal tract. The section corresponds, therefore, to the level of the last crossing fibres of the pyramidal tract (*decussatio pyramidum*). At the periphery, to the side of the lateral pyramidal tract, the spino-cerebellar tracts are plainly seen; also at the periphery, but placed more ventrally, is a clear field through which the triangular tract of Helweg passes. The remaining area of the lateral column, between the peripheral tracts and the gray substance, does not permit of subdivision into definitely defined fibre-systems; within this area, however, course the tractus spino-thalamicus, spino-tectalis and tecto-spinalis and vestibulo-spinalis. Likewise, the anterior column exhibits no clear subdivision into definite bundles. The anterior pyramidal tract, indicated in the figure by a somewhat darker tint, lies along the anterior median fissure; between this tract and the anterior horn extends the fasciculus anterior proprius or anterior ground bundle. Within the central part of the anterior horn, a somewhat more definite group of cells represents the ventral nucleus of the spinal accessory nerve; the dorsal nucleus is seen as a small cell-group in the central gray substance, lateral to the central canal.



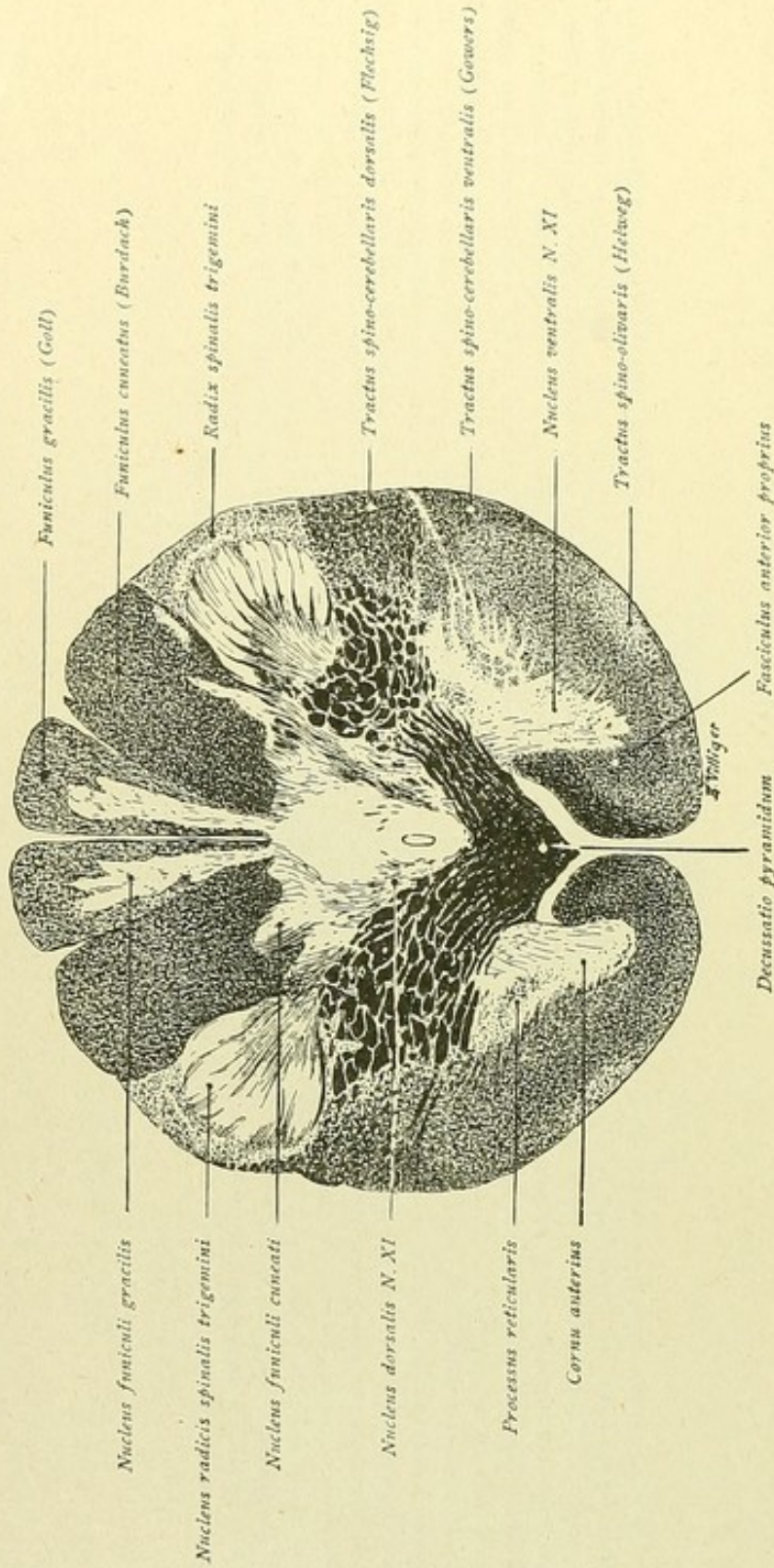


FIG. 213.



FIG. 213.—The anterior horns, with the ventral nucleus of the accessorius, are completely separated from the central gray substance by the decussating and dorso-laterally coursing pyramidal bundles. In the middle, dorsal to the pyramidal decussation, lies the central canal; lateral to the canal, the dorsal accessory nucleus. Farther behind the central gray substance is prolonged into gray masses projecting into the posterior columns. Goll's column is invaded by the wedge-like nucleus funiculi gracilis and Burdach's column by the nucleus funiculi cuneati, here still slightly developed. The substantia gelatinosa Rolandi, or nucleus radialis spinalis trigemini, is enclosed peripherally by the descending trigeminal root. Within the lateral column, the spino-cerebellar tracts and Helweg's bundle are distinctly defined. Medial to the spino-cerebellar tracts, runs the tractus rubro-spinalis (Monakow) and more ventrally placed are the tractus spino-thalamici, tecto-spinalis, spino-tectalis and vestibulo-spinalis, whose exact positions and boundaries, however, cannot be established. Within the anterior column, the ground bundle bordering the anterior horn is clearly seen, while the fibres of the pyramidal tract lie along the anterior median fissure. The fibrae arcuatae internae are already recognizable as delicate fibres that sweep in curves from the posterior column nuclei through the gray substance to a position ventral to the central canal.



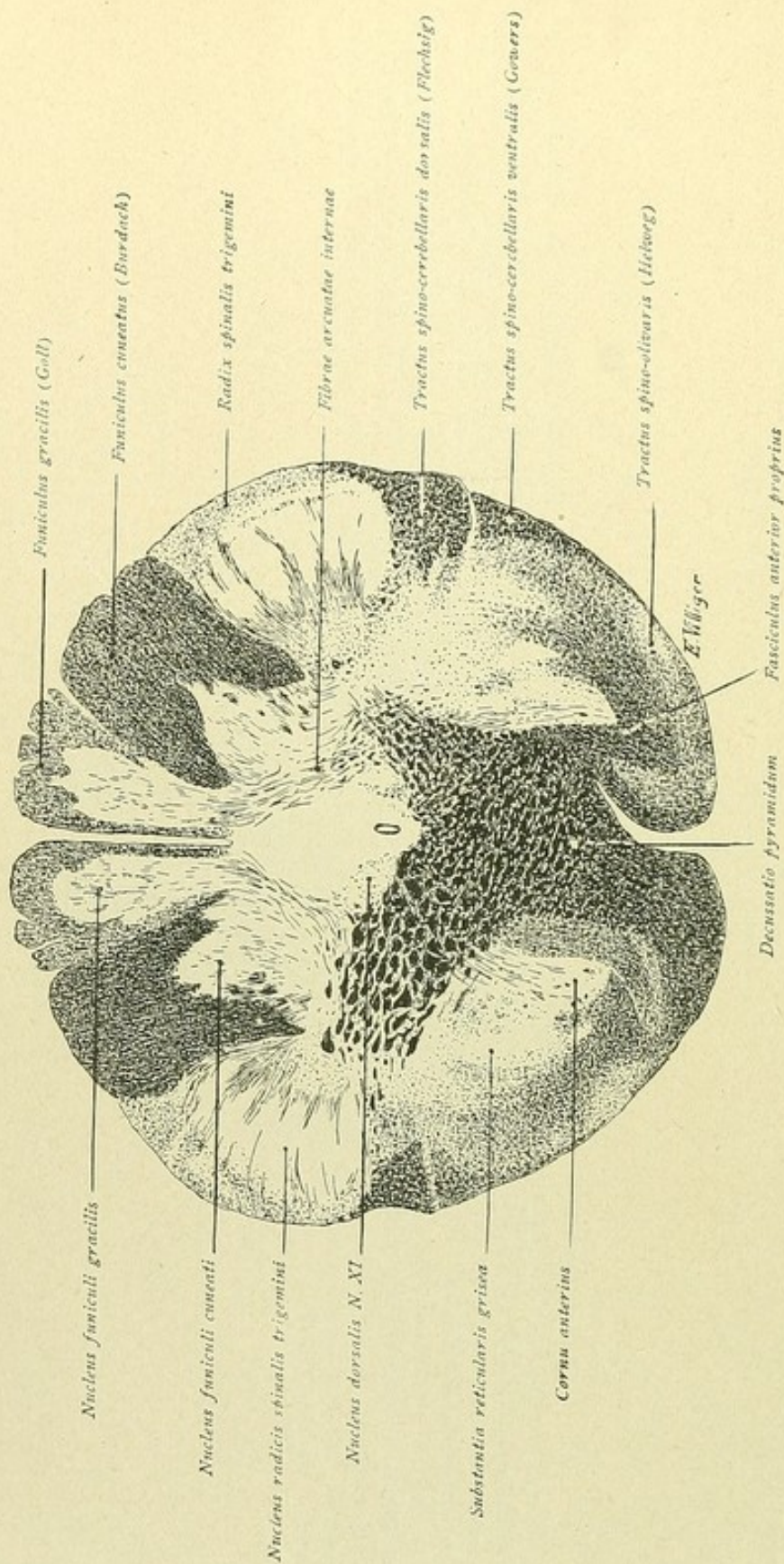


FIG. 214.



FIG. 214.—The gray substance is more voluminous, the posterior column nuclei and the large nuclei tractus spinalis trigemini being more conspicuous. Only a trace of the anterior horn is still recognizable and in the location, previously occupied by the lateral horn and the processus reticularis, the substantia reticularis now expands. Ventral to the central canal and the dorsal nucleus of the accessorius, lies the area of the decussating pyramidal tracts, while between this decussation and the remains of the anterior horn, the anterior ground bundle is migrating dorsally. The course of the fibrae arcuatae internae, which emerge from the posterior column nuclei, is more evident. The fibres of the posterior columns are progressively diminishing, since they are gradually ending around the cells of the corresponding nuclei; the boundaries of the columns of Goll and of Burdach, however, are still maintained. The descending root of the trigeminus is larger and the spino-cerebellar tracts and Helweg's bundle are as evident as in the preceding figure, while a definite apportionment of the antero-lateral ground bundle to the already mentioned fibre-systems is as impracticable here as it was before, or will be at higher levels.



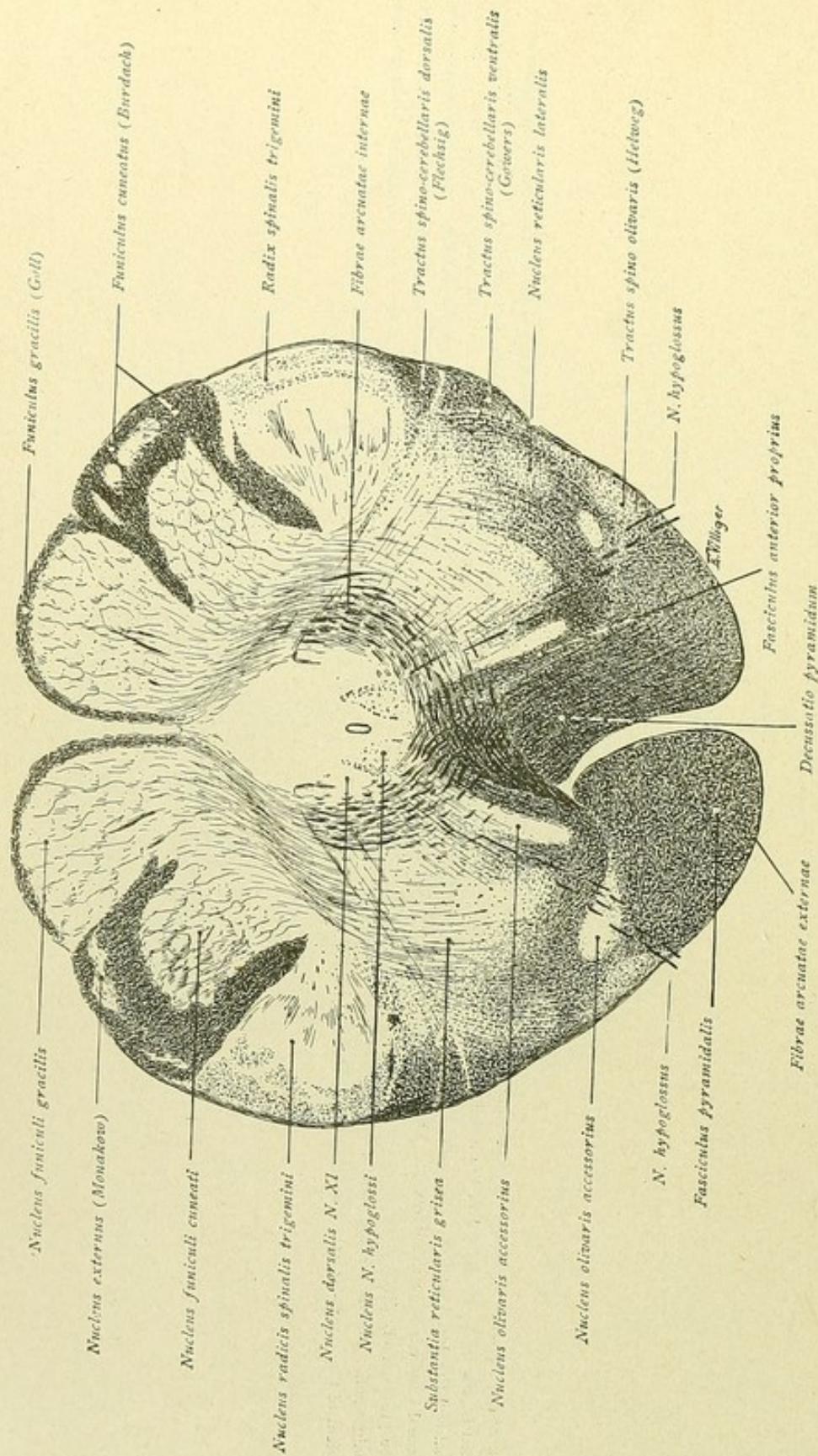


FIG. 215.



FIG. 215.—The greater development of the posterior column nuclei is accompanied by greater diminution of the posterior columns. Within the remains of Burdach's column, a special nucleus, the nucleus externus or Monakow's nucleus, appears. The nucleus radialis spinalis trigemini lies medial to the spinal root of the nerve. The fibrae arcuatae internae pass ventrally from the posterior column nuclei in bold curves, in part traverse the greatly developed substantia reticularis grisea and cross below the central canal, thus forming the decussation of the fillet. Ventral to the latter are seen the decussating pyramidal tracts, one bundle of which has already assumed its ventral position. At the periphery, ventral to the spinal trigeminal root, course the spino-cerebellar and the spino-olivary tracts, the latter of which is somewhat more medially situated, while the anterior ground bundle is displaced farther backward. The delicate fibrae arcuatae externae course ventrally along the anterior fissure, follow the margin of the medulla oblongata to become a constituent of the corpus restiforme in their path to the cerebellum. The accessory olives and the nucleus reticularis lateralis appear as new nuclei; further, on each side of the central canal, ventro-medial to the dorsal accessorius nucleus, is the hypoglossal nucleus, from which the root-bundles of the nerve may be followed ventrally to where they emerge lateral to the pyramidal bundles. Delicate fibres pass laterally from the vicinity of the dorsal accessorius nucleus, traversing the substantia reticularis grisea, as root-bundles of the XI nerve.



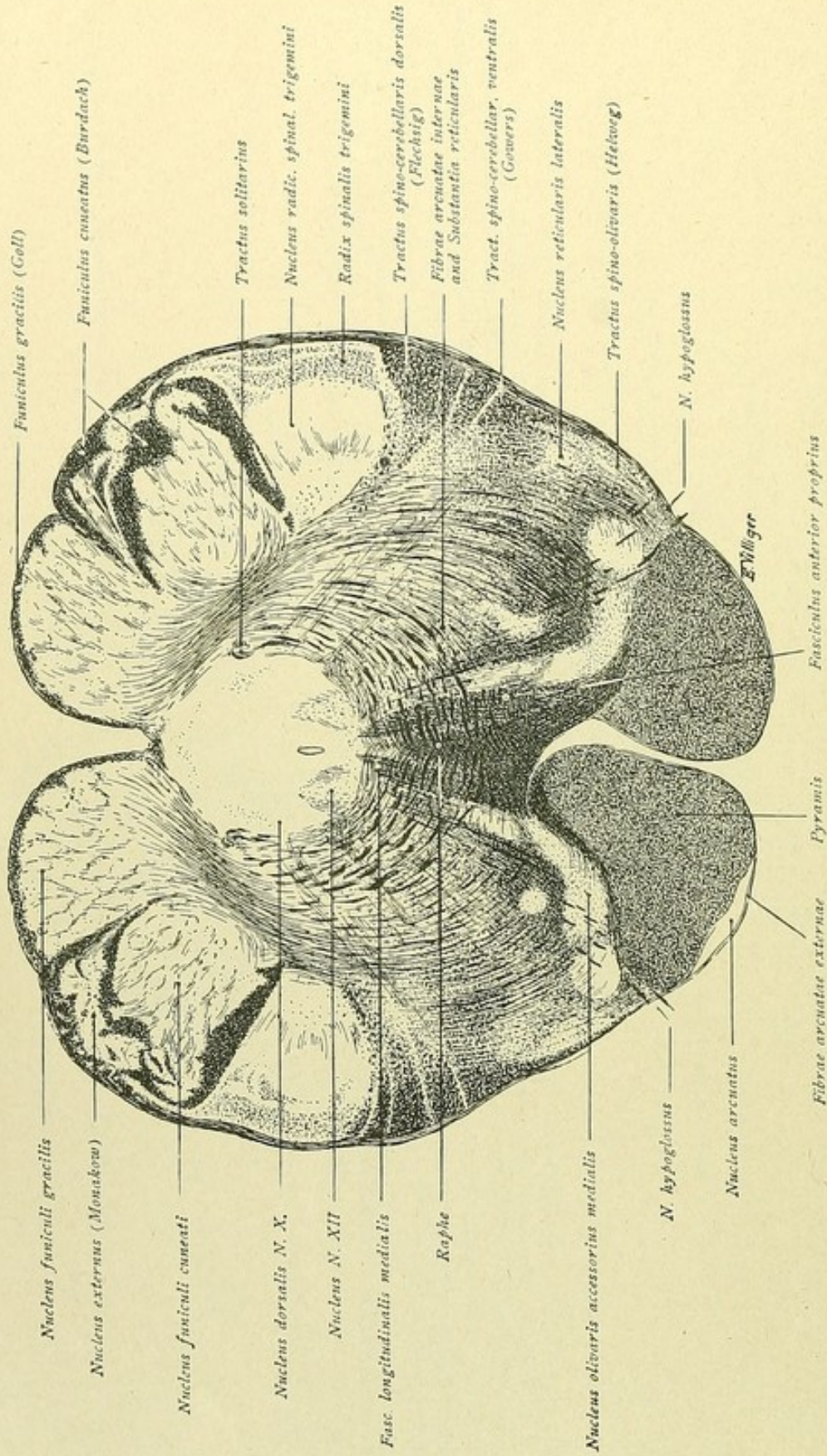


FIG. 216.



FIG. 216.—The dorsal half of the section is in larger part occupied by gray substance contributed by the posterior column nuclei, the central gray substance and the nuclei of the spinal root of the trigeminus. At the periphery course the posterior column tracts, now reduced to a minimum, and the laterally situated spinal roots of the trigeminus. At each side of the central canal lies the hypoglossal nucleus; somewhat dorso-lateral, the dorsal vagus nucleus and the distal part of the tractus solitarius with the small associated end-nucleus. The fibrae arcuatae internae pass ventrally from the posterior column nuclei in bold curves through the substantia reticularis and from the raphe by their crossing in the mid-line ventral to the central canal. A large part of the fibres, after decussating, is located close to the raphe. These fibres then bend brainward and, as constituents of the medial fillet, traverse the brain-stem to the thalamus. Another part of the crossed arcuate fibres proceeds farther ventrally and, as the fibrae arcuatae externae, skirts the pyramid and follows the periphery dorsally to the vicinity of the nucleus cuneatus, where, the higher we ascend in the brain-stem, the fibre-bundles of the restiform body gradually collect. In consequence of the establishment of the fillet-layer on each side of the raphe, immediately over the pyramidal tracts, the anterior ground bundle is still further displaced dorsally, its upper point now being defined as the posterior longitudinal bundle or the fasciculus longitudinalis medialis. Lateral to the anterior ground bundle, and resting on the pyramid, lies the medial accessory olive, while between the latter and the spinal or descending root of the trigeminus spreads out the extensive substantia reticularis grisea, ventro-laterally in which the nucleus reticularis lateralis is found. As in the preceding figures, the spino-cerebellar tracts and Helweg's bundle occupy the periphery, ventral to the spinal trigeminal root. These tracts are crossed superficially by the ascending strands of the fibrae arcuatae externae, which, as the figure shows, are being joined by fibres from the tractus spino-cerebellaris dorsalis in their ascending course. The root-fibres of the hypoglossus pass from the nucleus ventrally through the accessory olive, to emerge at the periphery lateral to the pyramid; the root-fibres from the dorsal vagus nucleus are seen passing laterally through the substantia reticularis.



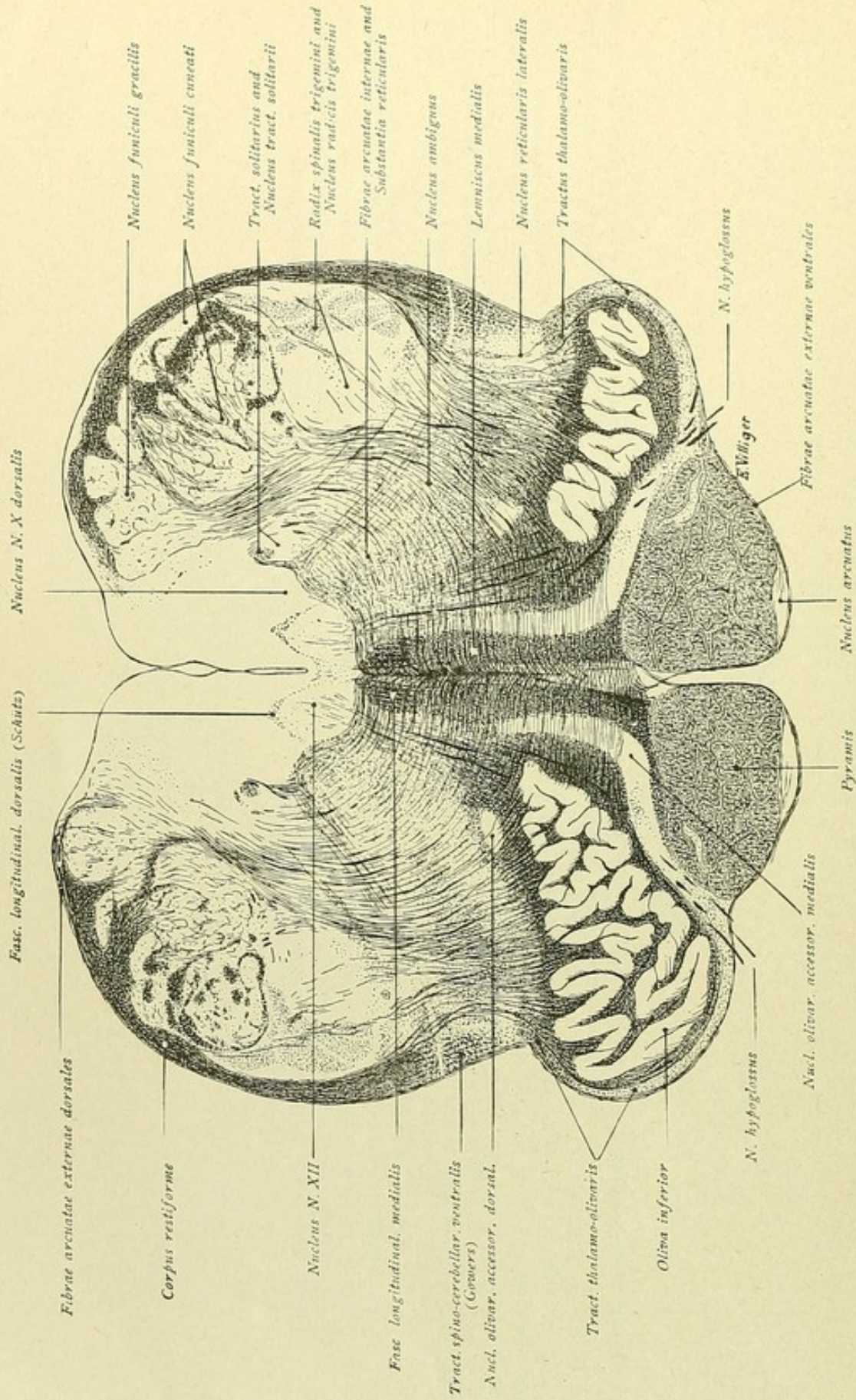


FIG. 217.



FIG. 217.—The oliva inferior appears as a new nucleus. The central canal lies higher and is about to open out into the IV ventricle. On each side of the canal is seen the large nucleus of the hypoglossal nerve, from which the root-bundles course ventrally to emerge between the pyramid and the olive. The dorsal longitudinal bundle of Schütz appears as a group of delicate transversely cut fibres overlying the hypoglossal nucleus. Dorso-lateral to the latter lies the dorsal nucleus of the vagus, as well as the tractus solitarius with the associated nucleus tractus solitarii. Within the dorso-lateral region of the section, the remains of the posterior column nuclei are evident; ventro-lateral lies the end-nucleus of the trigeminus and its spinal root. The fibres at the periphery, lateral to the posterior column nuclei, belong for the most part to the corpus restiforme. Towards this region the fibrae arcuatae externae are seen ascending from the bottom of the anterior median fissure. They are augmented by fibres, which come from the pyramidal and lateral column nuclei, as well as by the ascending bundles of the tractus spino-cerebellaris dorsalis. Behind, the fibrae arcuatae externae dorsales pass from the posterior column nuclei toward the same region, as do also the fibrae olivo-cerebellares from the olivary nucleus. All these fibres directed towards this locality join to form the corpus restiforme, which, as we ascend, becomes a robust bundle and passes to the cerebellum. In the middle of the section, the raphe is now clearly seen, and on each side of the raphe the medial fillet, which expands as a sharply-defined field of transversely cut fibres, between the medial accessory olives and above the pyramids. Dorsally, the fillet-layer is capped by the posterior longitudinal bundle. On account of its position between the olives, the fillet-layer is also designated the interolivary stratum, or, in contrast to the more laterally placed gray reticular formation, the substantia reticularis alba. The oliva inferior is encased by a close felting of fibres, while behind the nucleus lies the dorsal and, ventro-medial, the medial accessory olivary nucleus. At the lateral border of the olive are encountered delicate fibres, which belong to the tractus thalamo-olivaris. The nucleus lateralis and, dorso-medial from this, the motor nucleus of the vagus, the nucleus ambiguus, are additional centres within the substantia reticularis lateralis. From the nucleus ambiguus fibres ascend toward the dorsal vagus nucleus, where one part passes medially toward the hypoglossal nucleus, as far as the mid-line, and another part turns dorsally.



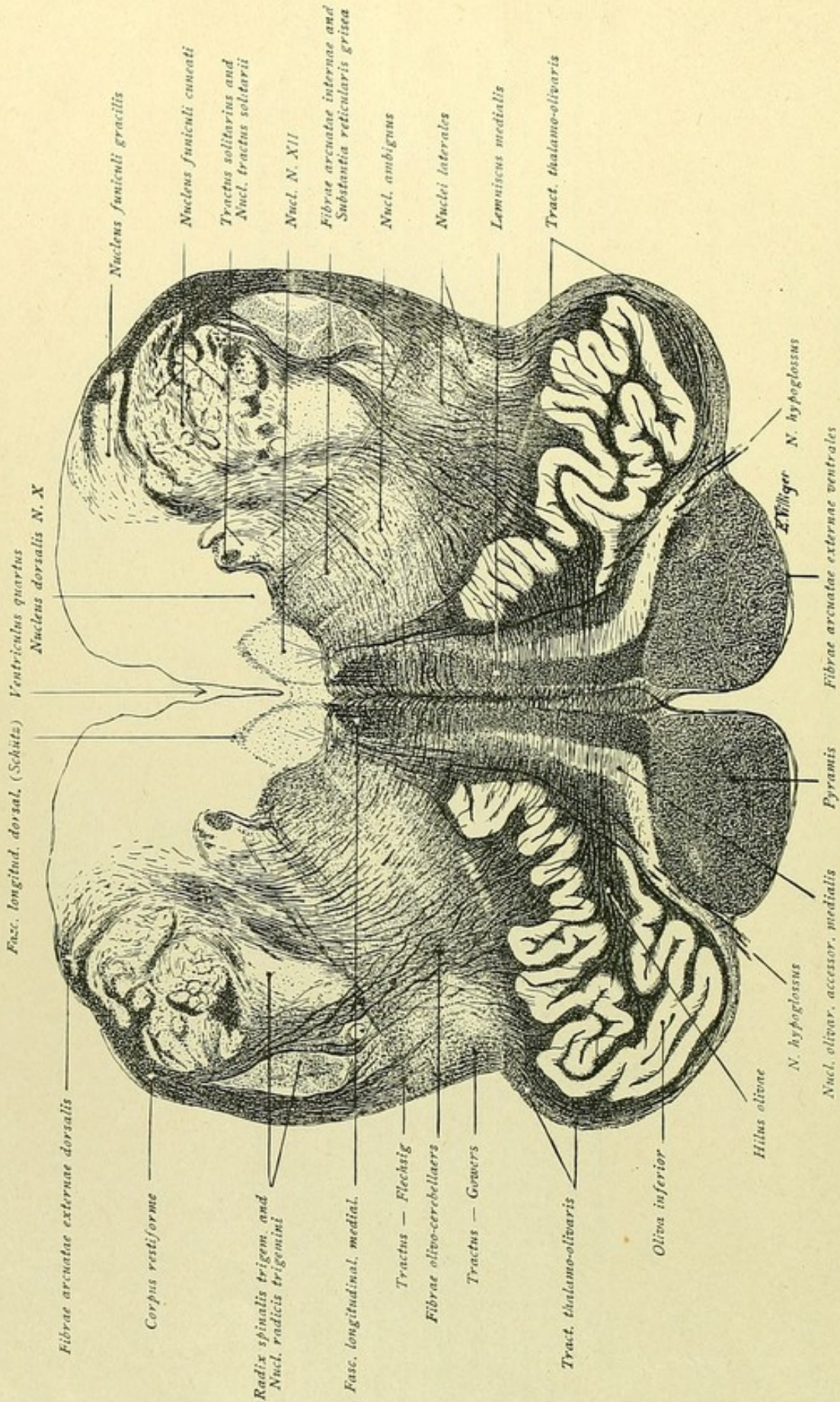


FIG. 218.



Fig. 218.—When compared with the preceding figure, this one presents no important differences. The central canal now opens into the fourth ventricle. Certain masses of gray substance, as the remains of the posterior column nuclei, are smaller, while others, as the hypoglossal and vagal nuclei, are larger; this is particularly true of the olivary inferior. Also the interolivary stratum or fillet-layer, from which the posterior longitudinal bundle is differentiated by its deeper color, is larger and rests upon the pyramid as a column. More evident are also the fibres olivo-cerebellares, which pass from the olive of the same and of the opposite side and ascend to the corpus restiforme. It is to be noted, that, on emerging from the hilus, the fibres run first medially and only after crossing the mid-line obliquely upward toward the restiforme body, passing between the spinal trigeminal root and its end-nucleus.

In order to gain a proper conception of the course of the pyramidal tract, it is recommended that the student begins with figures representing higher levels. The pyramidal tract passes from the motor cortical area through the internal capsule, the cerebral peduncles and the pons to the lower part of the medulla oblongata. Here occurs the partial decussation. A part remains ventral as the uncrossed anterior pyramidal tract, while the larger part undergoes decussation. The crossing bundles proceed dorso-laterally and take up their position in the spinal cord in front of the posterior horn, in which location they then continue caudward as the lateral pyramidal tract. This course becomes clear, if one begins with say Fig. 221 and follows the pyramidal bundles, in reverse order, through the levels represented by Figs. 220 to 212. On the other hand, in tracing the formation of the medial fillet and its development from the posterior column nuclei, and, likewise, the formation of the corpus restiforme by the various fibre-systems, one examines in sequence Figs. 214 to 220. Compare also Figs. 133, 134, 155 and 156.



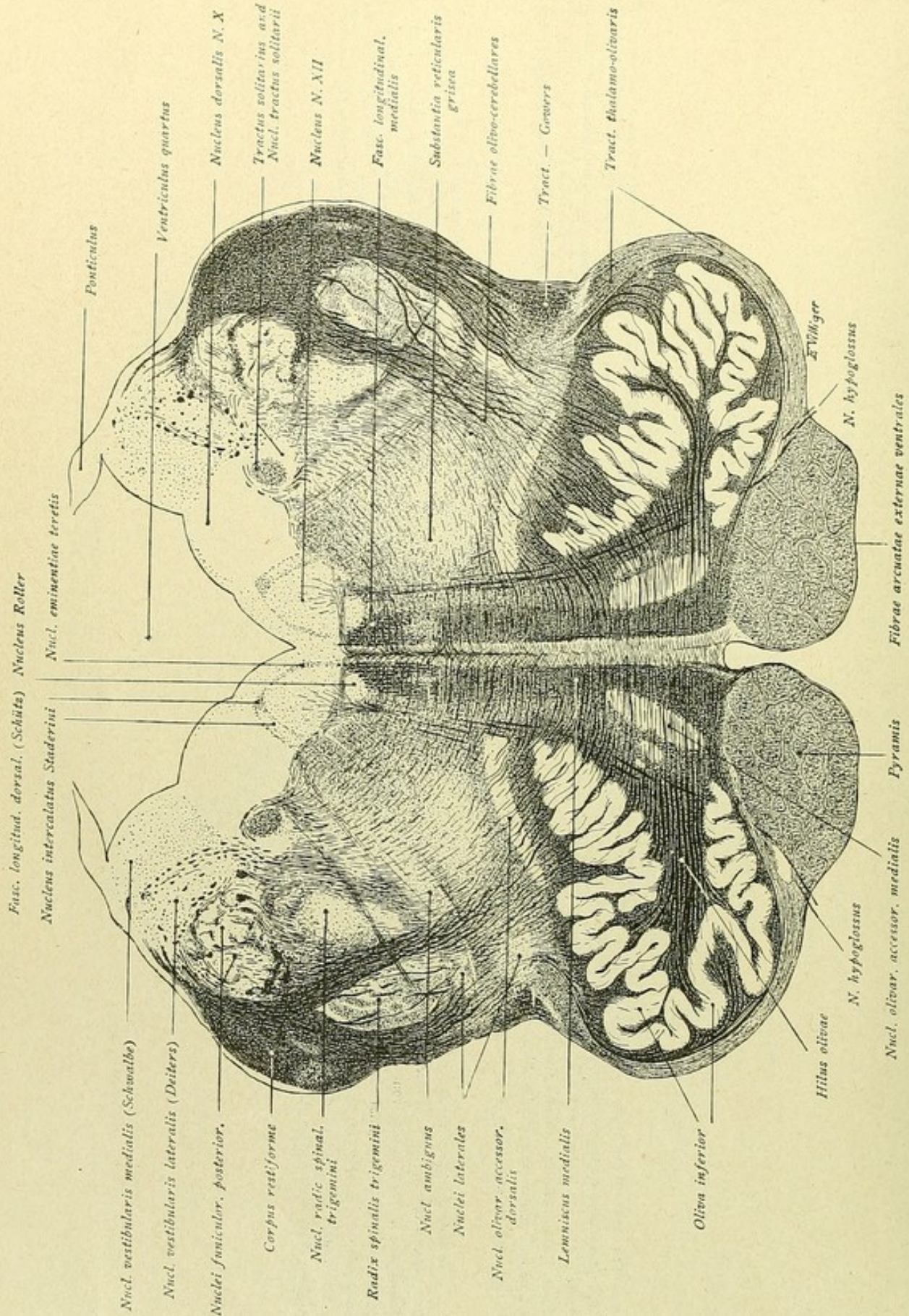


FIG. 210.



FIG. 219.—The section passes through the middle of the olivary inferior. Medial to the latter lies the medial accessory olive, dorsal the dorsal one. Behind, the IV ventricle broadens out, laterally still covered by the ponticulus, which medially passes into the taenia ventriculi quarti. Within the floor of the ventricle appear the sharply-defined gray masses, which are responsible for the corresponding superficial elevations. The hypoglossal nucleus lies medially, in the floor of the trigonum nervi hypoglossi, surmounted by the fasciculus longitudinalis dorsalis of Schütz. Lateral to the hypoglossal nucleus is the small nucleus intercalatus of Staderini, medial to it the nucleus eminentiae teretis, and ventral Roller's nucleus, bordering the fasciculus longitudinalis medialis, commonly known as the posterior longitudinal bundle. The root-fibres of the hypoglossus pass ventrally from the nucleus hypoglossi and emerge between the pyramid and the olive. Lateral to the trigonum hypoglossi follows the swell of the ala cinerea, in whose depth lies the nucleus alae cinereae or the dorsal vagus nucleus, ventro-lateral to which is seen the tractus solitarius with its end-nucleus. Farther dorso-lateral to the dorsal vagus nucleus, the section is occupied by the area acustica, with its two centres, the nucleus vestibularis medialis and the nucleus vestibularis lateralis or Deiters' nucleus. Ventral to the latter, the remains of the posterior column nuclei are still recognizable. The corpus restiforme, now a robust stalk with which the fasciculus spino-cerebellaris dorsalis or direct cerebellar tract has completely merged, receives its chief increment of fibres from the olive. Within the lateral part of the substantia reticularis grisea, the nucleus ambiguus and, farther ventro-lateral, the nuclei laterales appear as special cell-groups. Among the peripherally situated paths, the tractus spino-cerebellaris ventralis (Gowers) and the tractus thalamo-spinalis are distinctly marked off. The long but dispersed fibre-systems, such as the tractus spino-thalamicus and spino-tectalis, lie medial to the nuclei laterales. Ventrally are the pyramidal tracts, encircled by the fibrae arcuatae ventrales; above the pyramids, on either side of the raphe, extends the medial fillet, which dorsally is overlaid by the posterior longitudinal bundle. The root-bundles of the vagus pass from the periphery, ventral to the trigeminus root and nucleus, toward the tractus solitarius and the dorsal vagal nucleus. The efferent fibres from the nucleus ambiguus also pass obliquely dorsally. One part of these ascending fibres bends dorso-laterally and joins the vagus roots of the same side; another part runs medially, ventral to the hypoglossal nucleus, and crosses the mid-line to join the vagus roots of the other side.



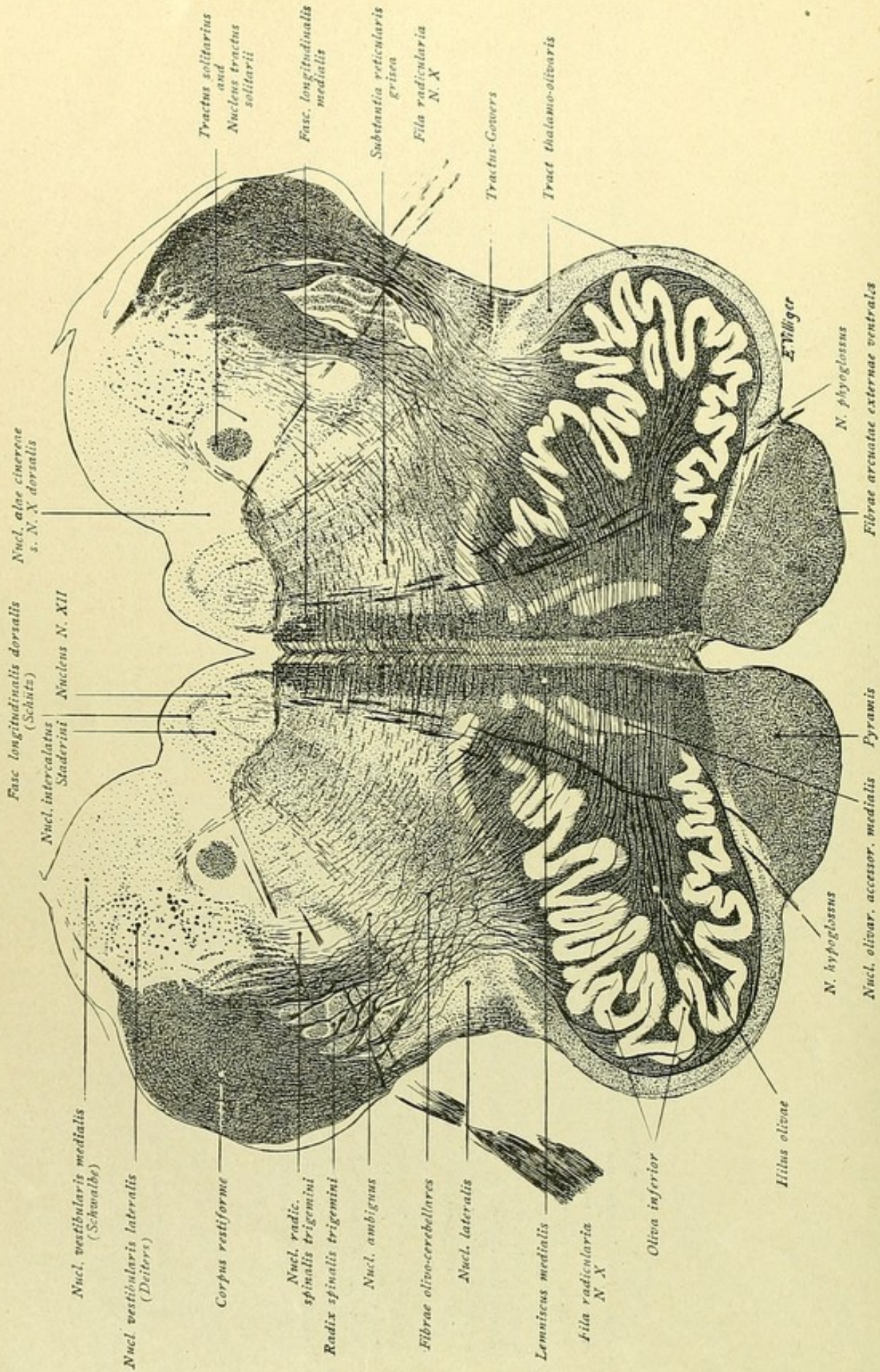


FIG. 220



FIG. 220.—Compared with the preceding figure, there are no important changes. Within the dorsal region, the nucleus alae cinereae has become smaller; the tractus solitarius and the accompanying end-nucleus, on the contrary, have increased. Also larger is the lateral acoustic field, with the medial and lateral vestibular nuclei, the last one (Deiters' nucleus), now embracing a large part of the region previously identified with the posterior column nuclei. The descending or spinal root of the trigeminus is largely traversed by the ascending fibrae olivo-cerebellares, the trigeminal end-nucleus being medially displaced. The olivary nucleus exhibits considerable expansion; the two accessory olives, of which the medial is double, approach each other and together constitute a lid for the hilus. Above the pyramid, on either side of the raphe, extends the medial fillet, dorsally capped by the posterior longitudinal bundle. The hypoglossal nucleus and root-fibres, as well as the vagus fibres and nuclei, are essentially as in the preceding figure. Within the substantia reticularis, dorsal to the olive and lateral to the fillet, numerous longitudinally coursing fibres are seen; these may be considered as association fibres, that serve to unite different segments of the medulla oblongata with one another, with higher lying parts of the brain and with the spinal cord. Following Edinger, these fibres may be termed the tractus associativae and the region in which they course, the association field of the medulla oblongata. Edinger has pointed out, that probably within this formatio reticularis run those connecting fibres, which associate the facial, vagal and phrenic nuclei to coordinated activity in respiration.



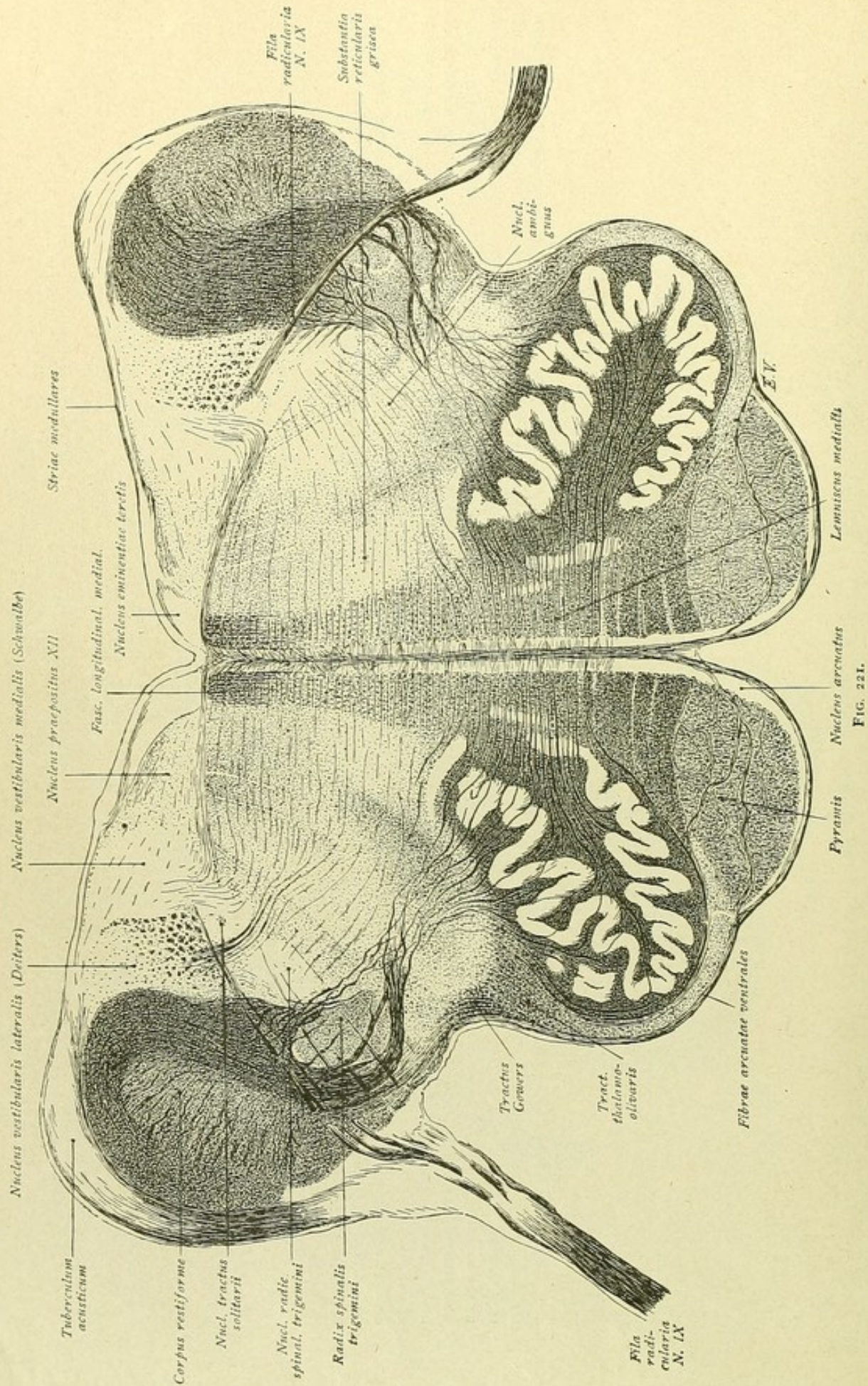


FIG. 221.



FIG. 221.—Within the dorsal region, the nucleus of the hypoglossus and the nucleus alae cinereae has disappeared. In place of the former, we encounter a nucleus, known as the nucleus praepositus XII, which overlies the fine fibres of the fasciculus longitudinalis dorsalis (Schütz) and medially adjoins the nucleus eminentiae terebris. In place of the nucleus alae cinereae, now lies the nucleus vestibularis medialis (Schwalbe), with which the nucleus intercalatus has united. Farther laterally, Deiters' nucleus follows, with the cross-sectioned bundles of the descending vestibular root. From the vestibular nuclei fibres pass medially, in part towards the posterior longitudinal bundle, and in part, as the fibrae arcuatae internae, more ventrally towards the raphe. The medial vestibular nucleus may be followed caudward; owing to the encroachment of the nucleus alae cinereae at lower levels, the medial nucleus is divided. One of the resulting gray columns remains lateral as the nucleus medialis, the other as the nucleus intercalatus. The lateral part of the section includes the now robust corpus restiforme, to which the fibrae olivo-cerebellares still ascend. It rests like a hood upon the spinal root of the trigeminus, which is broken up by the olivo-cerebellar fibres, while the trigeminal end-nucleus is pushed dorso-medially. The nucleus of the tractus solitarius still borders dorso-medially the trigeminal nucleus; on the right side, however, only a few bundles of the tract remain. Toward this locality, the entering root-fibres of the glossopharyngeal nerve run. Dorso-lateral, the corpus restiforme is covered by the tuberculum acusticum, from which pass medially the superficially coursing strands of the striae medullares or striae acusticae, which embrace the nucleus eminentiae terebris and then disappear within the raphe. The olive has decreased and its hilus is still occluded by the accessory olives. The medial fillet is somewhat ventrally displaced and the region between it and the posterior longitudinal bundle appears broken; here lie the fibrae praedorsales, which, as the tractus tecto-spinalis, descend from the quadrigeminal region through the brain-stem into the anterior column of the spinal cord. The raphe is particularly conspicuous between the fillet-layers and the fibrae arcuatae externae are marked in their path around the pyramid and the olive. In the angle between the olive and the lower edge of the restiform body, still is seen the tractus spino-cerebellaris ventralis or Gowers' tract, which, therefore, has not entered the restiform body, as has the tractus spino-cerebellaris dorsalis or direct cerebellar tract. Medial to Gowers' tract lie the nuclei laterales and approximately in the same locality, somewhat more medial, course the uncertainly defined spino-thalamic, spino-tectal and vestibulo-spinal tracts.







FIG. 222.—Ventrally, a part of the pons is sectioned; in the middle, the pyramidal tracts appears surrounded by the gray substance of the pontile nucleus, while ventrally they produce the superficial eminentiae pyramidales, between which is the sulcus basilaris. Dorsally are almost the same relations as shown in Fig. 221, the nucleus praepositus hypoglossi and the nucleus eminentiae terebris, however, being smaller. Dorsolateral to the corpus restiforme lies the tuberculum acusticum, from which the delicate striae acusticae course medially along the dorsal border. The nucleus ventralis cochlearis, below the restiform body, is connected with the tuberculum acusticum. The entering nervus cochleae (N. VIII) divides the cochlear nucleus into two parts, a lateral and a medial half, from the last of which delicate fibres pass ventro-medially to become constituents of the corpus trapezoides and the lateral fillet. Dorsally these fibres are accompanied by isolated bundles of the olivo-cerebellar fibres that are still ascending to the restiform body and, on the right side, traverse the spinal root of the trigeminus. The end-nucleus of the latter is bounded dorsally by delicate fibres arcuatae internae, that emerge from Deiters' nucleus. Somewhat farther dorso-medially are to be seen some glossopharyngeal strands; perhaps, these root-bundles belong to the nervus intermedius Wrisbergi. Quite behind, the fibrae arcuatae internae are proceeding from the vestibular region and coursing medially towards the posterior longitudinal bundle and the raphe. The latter is very strongly developed and bounded on each side, above by the posterior longitudinal bundle, lower by the fibrae praedorsales and in the vicinity of the olive by the medial fillet, which now lies deeper and expands ventro-lateral to the olive. The gray substance on either side of the raphe and ventral to the posterior longitudinal bundle constitutes the nucleus centralis inferior, while laterally, within the substantia reticularis grisea, is seen the nucleus reticularis lateralis. Within this nucleus, the efferent fibres for the parotid and sublingual glands are supposed to arise. It is also possible that delicate fibres from this position ascend dorsally and then bend laterally and medially, finally to pass out with the glossopharyngeal fibres of the same and of the opposite side. The nucleus reticularis lateralis has been called, therefore, the nucleus salivatorius (Kohnstamm). Farther laterally, in the position at lower levels occupied by the nucleus ambiguus, appears a more or less well-defined group of cells, the nucleus of the facial nerve. The completely closed upper end of the inferior olivary nucleus appears as a plicated ring of gray matter. Lateral to it lies the tractus thalamo-olivaris and, farther peripherally, the tractus spinocerebellaris ventralis, or Gowers' tract. Between these paths are found the fibre-systems of the rubro-spinal, spino-tectal and spino-thalamic paths. On the left side, lateral to the pyramidal bundle, several root-strands of the abducens nerve are visible.



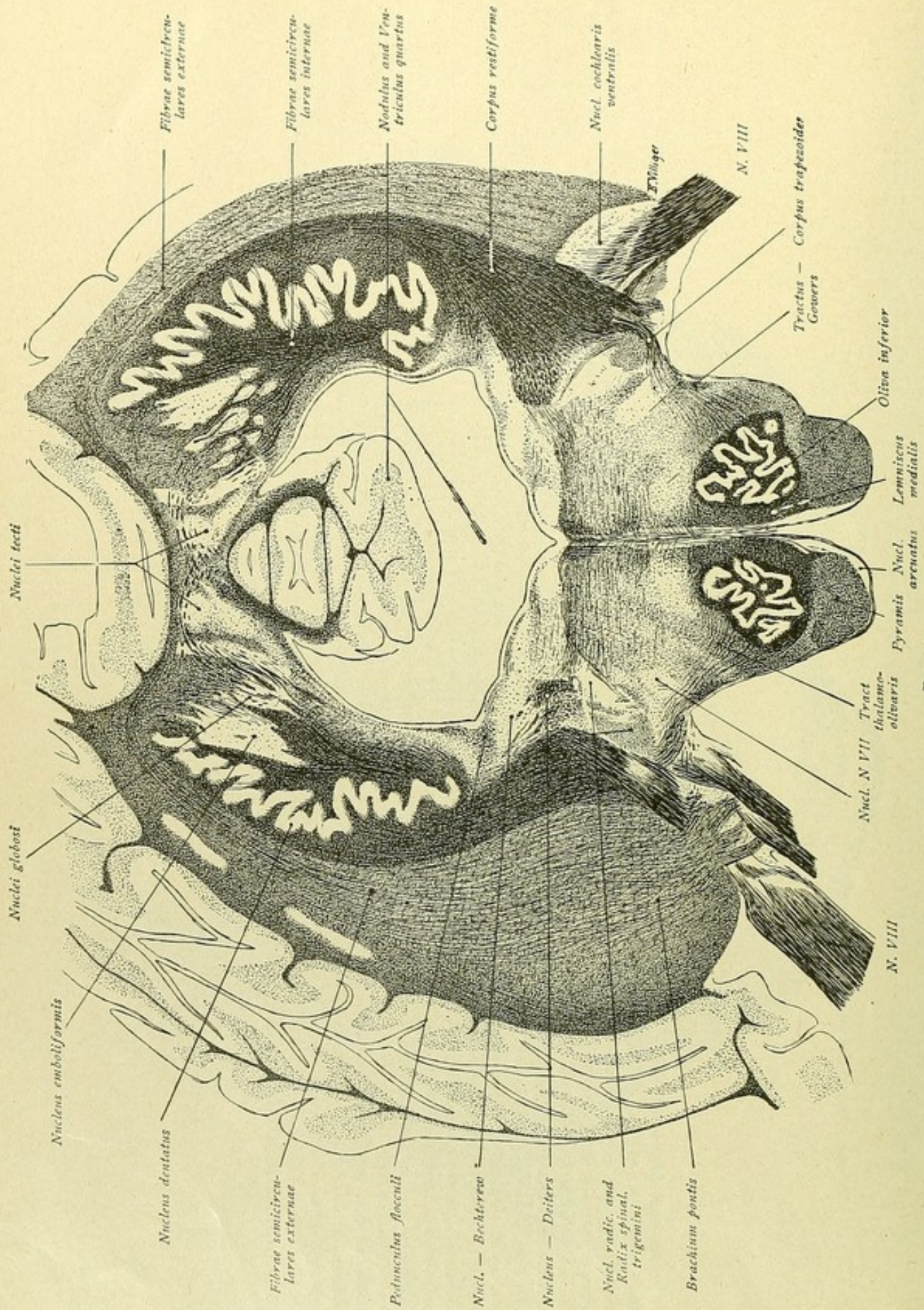


FIG. 223.



FIG. 223.—This section shows the medulla oblongata continuous with the cerebellum. In the middle, the nodulus projects into the IV ventricle; moreover, lateral within the medullary substance, is seen the nucleus dentatus, within the hilus of which lies the nucleus emboliformis. Medial to the latter is a small island of gray substance, the nucleus globosus, while still more medially is seen the nucleus fastigi, nucleus tecti, or roof-nucleus. The section of the medulla oblongata exhibits the relations already noted. The level corresponds to the entrance of the acoustic fibres. On the left, the root-bundles of the vestibular nerve penetrate as far as Deiters' nucleus; on the right, a part of the nervus cochleae, with the ventral acoustic nucleus, is seen. Dorsal to Deiters' nucleus and traversed by the fibres of the pedunculus flocculi, lies Bechterew's nucleus, also known as the nucleus angularis, which is connected with the triangular nucleus of Schwalbe. The corpus restiforme is seen ascending to the cerebellum. The ascending fibres may be followed dorsally, as the fibrae semicirculares externae, towards the region of the worm, where they course medially over the nucleus dentatus and dorsal to the roof-nucleus to decussate with the fibres from the opposite side. The fibrae semicirculares externae, that ascend lateral to the restiform body and dorsally take the same medial course, belong to the middle cerebellar peduncle. Here the fibrae ponto-cerebellares, from the pontile nuclei, pass to the cerebellum by way of the brachia pontis. Additional ascending fibres proceeding from the vicinity of Deiters' nucleus constitute the medial division of the corpus restiforme, the so-called indirect sensory cerebellar tract of Edinger, or the tractus nucleo-cerebellaris. These fibres serve to connect the nuclei of certain cerebral nerves, particularly the nervus vestibuli, with the roof-nuclei. Certain root-strands of the vestibular nerve pass direct, without interruption in the vestibular nucleus, to the cerebellum. Also from within the nucleus dentatus, ascending bundles, the fibrae semicirculares internae, traverse the nucleus emboliformis and globosus and arch to the roof-nucleus, where they form the decussation. A part of the constituents of the latter pursue a descending course. These fibres descend from the contralateral roof-nucleus, pass above the brachium conjunctivum and thence, medial to corpus restiforme, continue ventrally and caudally to the medulla oblongata. This bundle is identical with the tractus uncinatus of Cajal and the faisceau en crochet of Russel-Thomas and has been called also tractus fastigio-bulbaris by Marburg. The exact termination of this bundle is not definitely determined, although it is regarded as establishing relations of the roof-nucleus with Deiters' nucleus and also with the substantia reticularis. Perhaps the strands designated as fibrae arcuatae internae in Fig. 222, right side, are to be regarded as belonging to this bundle.



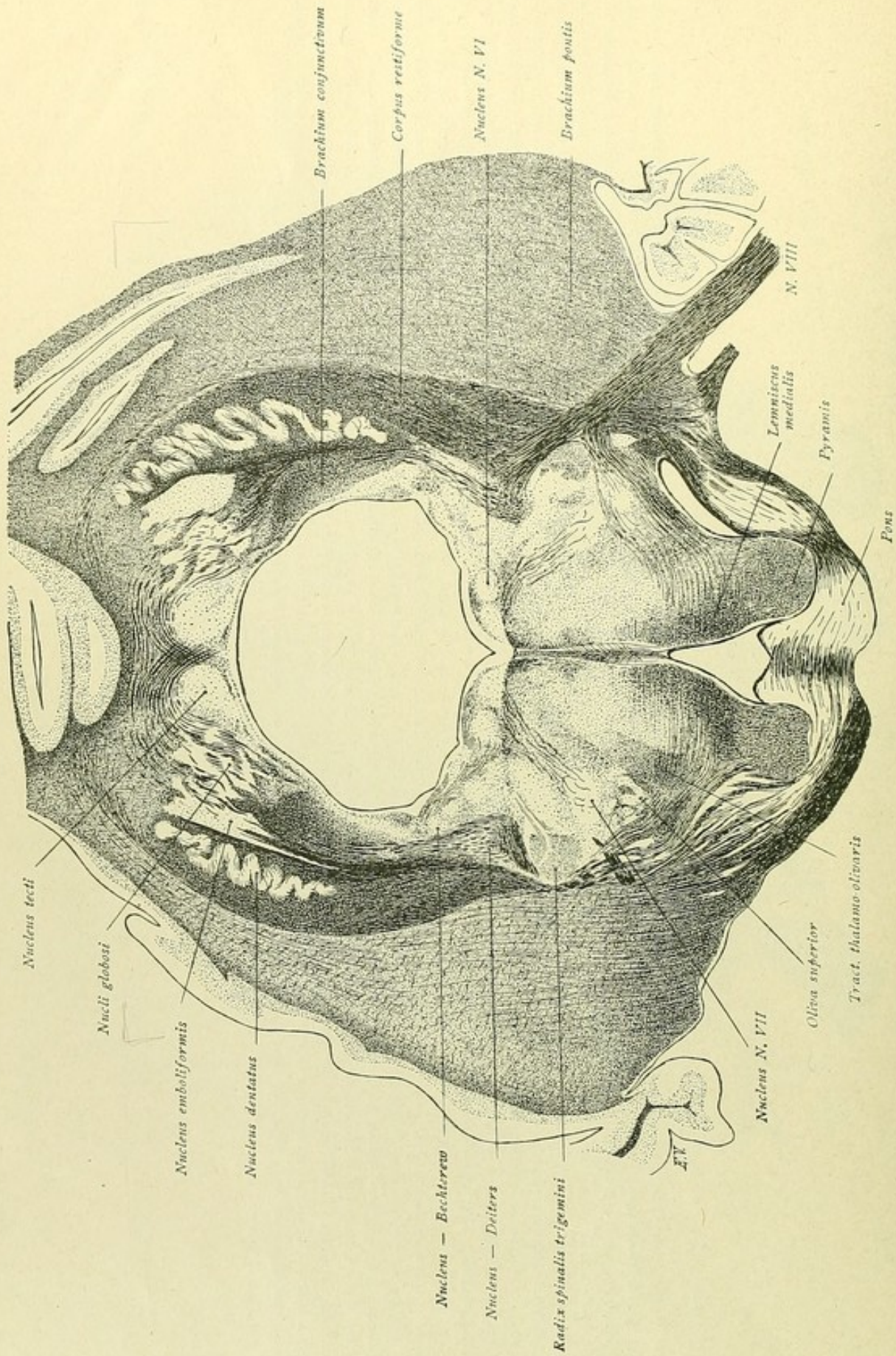


FIG. 224.



FIG. 224.—As in the preceding figure, the medulla oblongata is continuous with the cerebellum; ventrally, however, the pontile fibres are encountered, which here surround the pyramidal tracts. The course of the cerebellar peduncles again claims particular attention. Laterally the brachium pontis ascends and more medially courses the corpus restiforme, from which isolated fibre-strands run dorsally, medial to the nucleus dentatus and between the latter and the nucleus emboliformis. The course of the tractus nucleo-cerebellaris or the indirect sensory cerebellar tract is evident, from the vicinity of the nucleus of Deiters and of Bechterew upward through the nucleus emboliformis and globosus to the nucleus tecti, where the decussation occurs. With these strands run also those of the tractus fastigio-bulbaris, consisting of fibres which descend from the roof-nucleus to the medulla oblongata. The fibres of the sensory cerebellar tract pass medial to the nucleus dentatus and rest laterally upon the superior cerebellar peduncle, whose fibres are derived from the nucleus tecti and tecti and, in the next figure, may be followed to the nucleus ruber. Within the ventral part of the figure are still encountered familiar relations. Above the pyramidal tract lies the medial fillet and, farther backward, the praedorsal and the posterior longitudinal bundle run close to the raphe. From the facial nucleus, the root-bundles pass dorso-medially to the vicinity of the nucleus of the abducens. Lateral and dorsal to the facial nucleus lie the descending root of the trigeminus and its accompanying nucleus. The oliva inferior has disappeared and a new gray mass, the oliva superior, has come into view ventro-medial to the facial nucleus. The superior olive is surrounded ventrally and, on the right, also dorsally by the fibres of the corpus trapezoides. Medial to the superior olive is located the tractus thalamo-olivaris, while ventral to the olive is Gowers' tract, traversed by the ventral trapezoidal fibres.



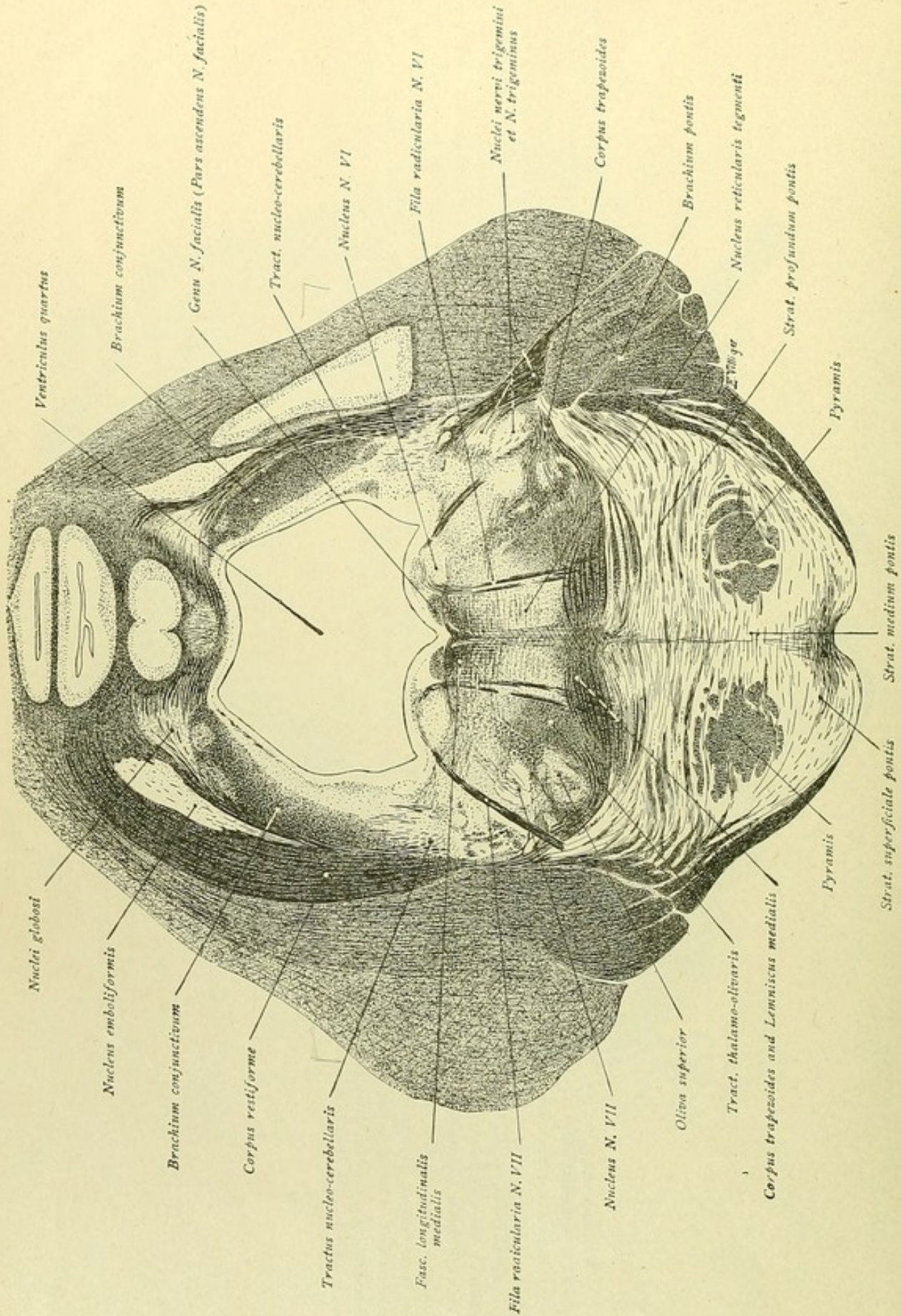


FIG. 225.



FIG. 225.—The pontile region is separated into two subdivisions: ventral, the pars basalis and dorsal, the pars dorsalis or the tegmentum. The boundary between the two is the medial fillet, traversed by the fibres of the corpus trapezoides. Within the basal part, the gray substance exhibits a strong development, the nuclei pontis. In the middle, course the two pyramidal tracts. The transverse fibres passing ventral to the pyramids form the stratum superficiale; those passing dorsal to the pyramidal tracts form the stratum profundum pontis, while those which pass through the pyramidal tracts constitute the stratum medium or stratum complexum pontis. All these transversely directed pontile fibres pass laterally into the middle cerebellar peduncle and on to the cerebellum. The nucleus of the abducens lies dorsally within the tegmentum. The fibres proceeding from the dorso-medial surface of this nucleus and leading to the vicinity of the medial fillet are root-bundles of the abducens nerve. In their farther course, they traverse the basal part of the pons and emerge on the surface at the lower border of the pons not far from the mid-line. The bundle of transversely cut fibres, medial to the abducens nucleus and overlying the posterior longitudinal bundle, is the ascending root of the facial nerve, while the fibres, which appear to spring from the dorso-lateral border of the abducens nucleus and course ventro-laterally to the lateral side of the facial nucleus, are the emerging root-fibres of the facialis. The course of this nerve from its nucleus is so ordered, that the bundles pass first dorso-medially to the inner side of the abducens nucleus, then follow for a distance a longitudinal direction, then bend laterally around the nucleus of the abducens and proceed obliquely outward and downward towards the surface. During this course, they pass between the facial and trigeminal nuclei. As they encircle the abducens nucleus, the facial fibres produce an elevation on the floor of the IV ventricle, the colliculus facialis. Somewhat medial to the abducens nucleus is found the nucleus eminentiae teretis, while over the nucleus lies the posterior longitudinal bundle of Schütz. In the angle, where the floor and side of the fourth ventricle come together, a trace of the vestibular nucleus is still seen and, likewise, the tractus nucleo-cerebellaris, or indirect sensory tract, that ascends to the worm-region of the cerebellum; on the left side, the ascending bundles of the corpus restiforme are evident. The superior cerebellar peduncle, or brachium conjunctivum, appears as a large compact fibre-mass in the side-wall of the ventricle. At the ventral border of the dorsal or tegmental part of the pons, the trapezoidal fibres are seen surrounding the oliva superior; also ascending fibres passing from the olive to the abducens nucleus. Medial to the superior olive courses the tractus thalamo-olivaris, while dorsal to the latter, and lateral to the root-fibres of the abducens, is located the nucleus reticularis lateralis pontinus or nucleus salivatorius of Kohnstamm. About on the same level, but between the abducens root-fibres and the raphe, lies the nucleus reticularis tegmenti. Within the most lateral part of the tegmentum, the trigeminal nucleus and a portion of the descending root are encountered. On the left side, the root is already broken up by gray substance; on the right side, it and its nucleus lie against the entering trigeminal root, which is seen penetrating the brachium pontis.



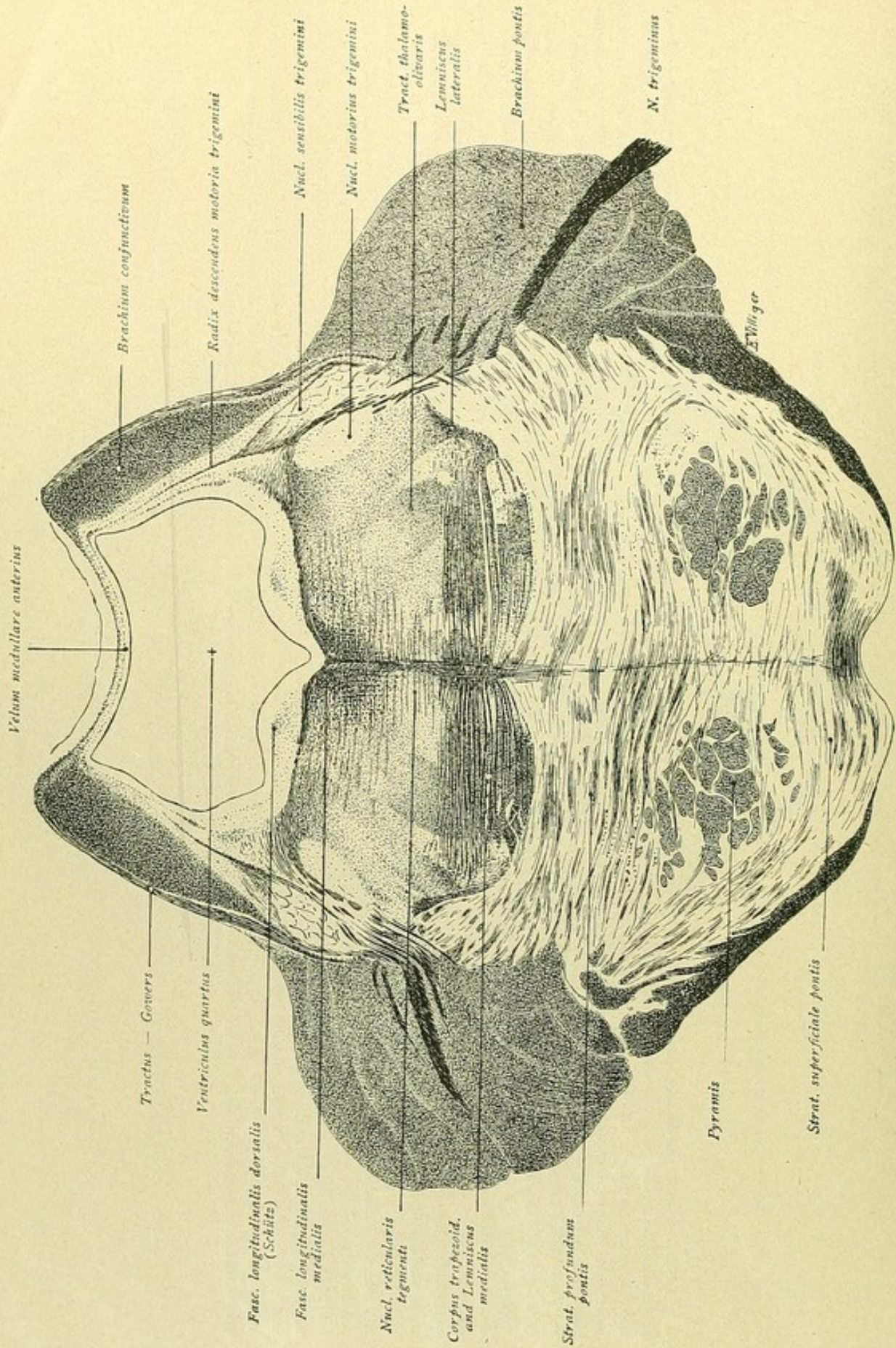


FIG 226.



FIG. 226.—The section passes through the origin of the trigeminus. The root-bundles of the nerve can be followed through the brachium pontis to the corresponding nuclei within the dorso-lateral part of the pontile tegmentum. Lateral lies the motor nucleus, medial the sensory one; further, the cerebral, mesencephalic, or descending motor root of the trigeminus is seen descending from the lateral wall of the ventricle to the nuclei. The fibres, which pass medially from the sensory nucleus, constitute the secondary sensory trigeminus tract. Over the posterior longitudinal bundle are still recognized isolated fibres belonging to the facial root; above these is the nucleus funiculi teretis, which overlies the delicate fibres of the fasciculus longitudinalis dorsalis of Schütz. In the lateral angle of the fourth ventricle are situated the small cell-groups of the locus caeruleus belonging to the trigeminus nucleus. Laterally, the ventricle is bounded by the brachia conjunctiva, between which the velum medullare anterius stretches across as the roof of the ventricular cavity. Within the ventral part of the pontile tegmentum are seen the transversely coursing fibres of the corpus trapezoides and between them the bundles of the medial fillet. On the right side, a trace of the superior olive is still recognizable; farther laterally, the fibres of the lateral fillet, into which the corpus trapezoides is prolonged, have collected into a small bundle. Above the medial fillet and lateral within the substantia reticularis, runs the central tegmental path or tractus thalamo-olivaris; farther medial, the nucleus reticularis tegmenti lies at the side of the raphe. The nucleus centralis superior dorsally joins the preceding nucleus; then follow the fibrae praeforsales, or tractus tecto-spinalis anterior, and quite behind lies the posterior longitudinal bundle, already somewhat laterally expanded. The nucleus at the side of the posterior longitudinal bundle is known as the nucleus reticularis tegmenti dorsalis, while gray substance lying dorso-lateral to the central tegmental tract represents the nucleus reticularis lateralis or nucleus salivatorius. In the vicinity of the lateral fillet course the spino-thalamic, the spino-tectal and the rubro-spinal fibre-systems. Gowers' bundle, on the other hand, has now assumed an upward direction and passes over the brachium conjunctivum to the velum medullare anterius; thence the bundle turns backward to the worm of the cerebellum. Within the pars basalis of the pons, the relations are as in the preceding figure—the pyramidal tracts, the superficial, middle and deep strata of the pontile fibres and the brachia pontis being well defined. Additionally to be seen are the fibrae perpendiculares pontis, which ascend from the stratum superficiale through the middle to the raphe and thence to the nucleus centralis superior; also the fibrae cortico-bulbares motoriae, which pass dorsally from the pyramidal tracts into the tegmental region to the motor nuclei of the cerebral nerves. They appear in the figure as small obliquely cut strands, lying above the pyramidal tracts between the transversely coursing pontile fibres.



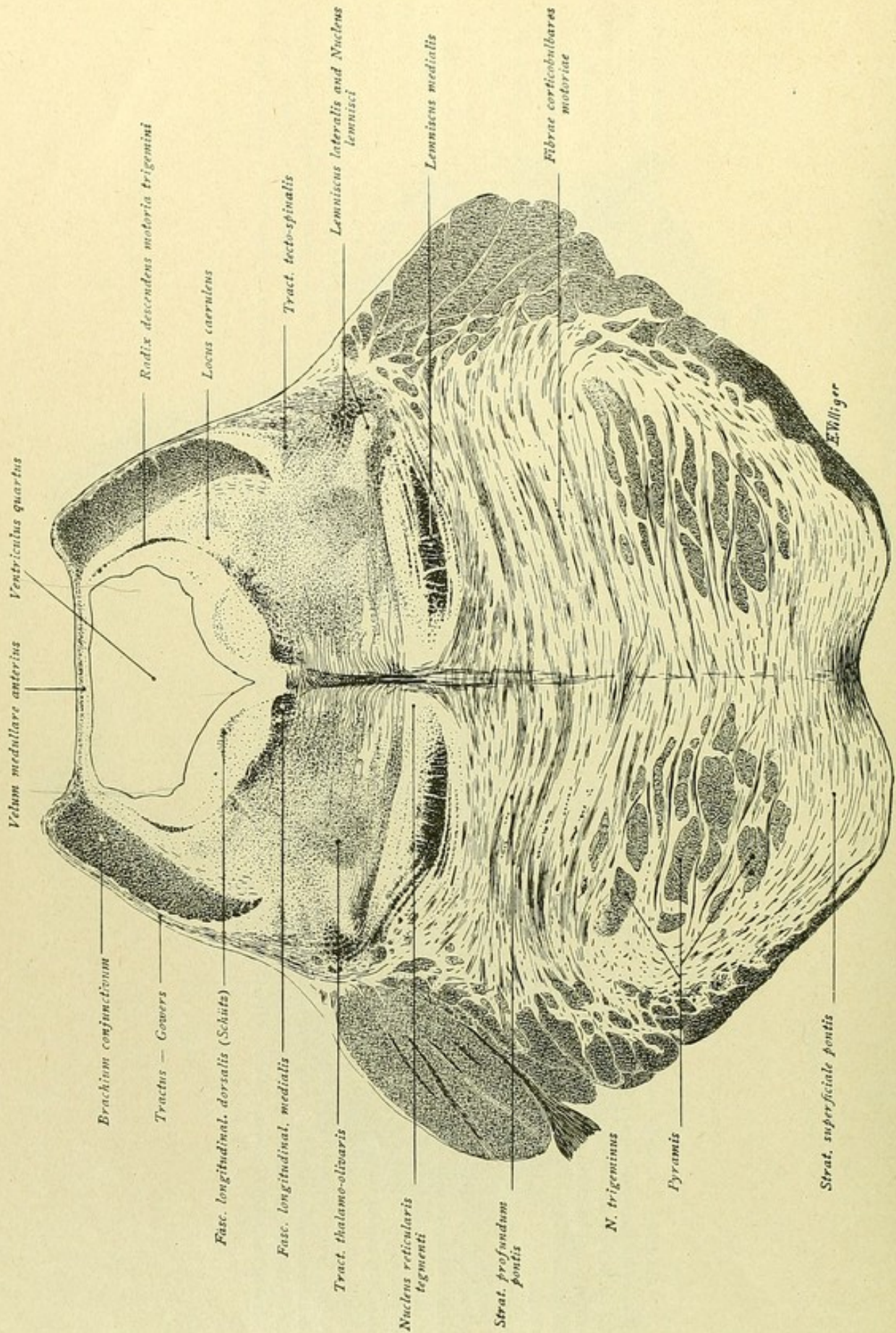
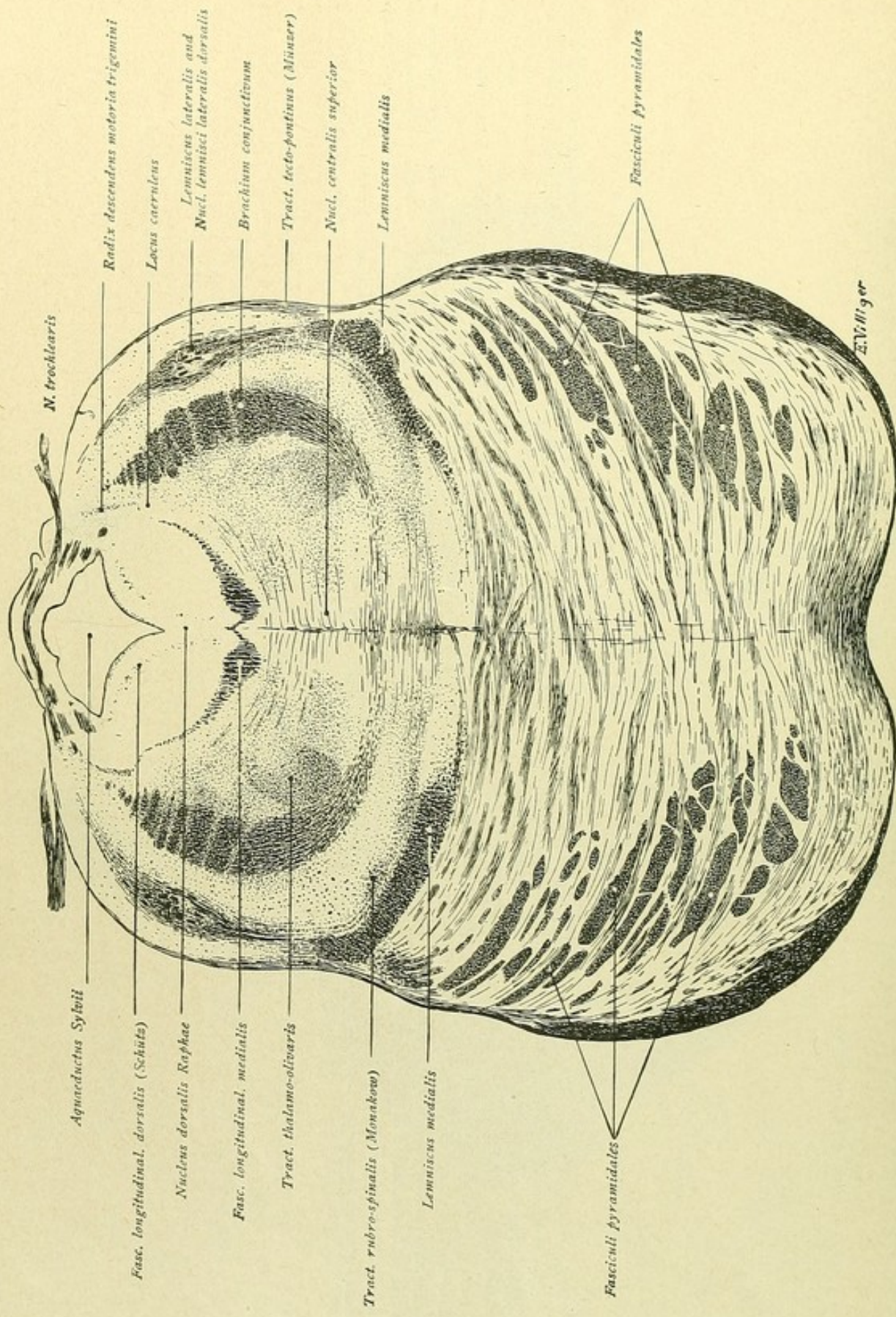


FIG. 227.



FIG. 227.—The most important difference between this and the preceding figure is the disappearance of the nuclei of the trigeminus and of the trapezoidal fibres. The tegmental region is defined from the pars basalis by the transversely expanded medial fillet; laterally, this tract is joined by the lateral fillet, bounded by the nucleus lemnisci. Of the fibre-systems, which in the preceding figure occupied this vicinity, the spino-thalamic strands have joined the medial fillet, Gowers' bundle is passing dorsally over the brachium conjunctivum to gain the anterior medullary velum, while the tractus rubro-spinalis and spino-tectalis have been pushed somewhat dorsal to the lateral fillet. Within the lateral part, runs the tractus thalamo-olivaris to the substantia reticularis; at the side of the raphe lie the gray masses of the nuclei already mentioned—ventrally the nucleus reticularis tegmenti, in the middle the nucleus centralis superior, and, towards the posterior longitudinal bundle, the nucleus reticularis tegmenti dorsalis. Above the posterior longitudinal bundle is found the nucleus funiculi teretis, which is overlaid by the fasciculus longitudinalis dorsalis of Schütz. The small descending motor root of the trigeminus is seen within the lateral wall of the fourth ventricle, medial to the brachium conjunctivum, extending ventrally as far as the nuclei of the locus caeruleus. Within the pars basalis, the pyramidal tracts are more broken up by the traversing fibres of the stratum medium; dorsally course the bundles of the stratum profundum and ventrally those of the stratum superficiale, from which latter the fibrae perpendiculares ascend to the raphe and the fibrae cortico-bulbares motoriae pass to the motor nuclei of the cerebral nerves.





*N. trochlearis*

*Aqueductus Sylvii*

*Radix descendens motoria trigemini*

*Fasc. longitudinal. dorsalis (Schütz)*

*Locus caeruleus*

*Nucleus dorsalis Raphae*

*Lemniscus lateralis and Nucl. lemnisci lateralis dorsalis*

*Fasc. longitudinal. medialis*

*Brachium conjunctivum*

*Tract. thalamo-olivaris*

*Tract. tecto-pontinus (Münzer)*

*Tract. rubro-spinalis (Monakow)*

*Nucl. centralis superior*

*Lemniscus medialis*

*Lemniscus medialis*

*Lemniscus medialis*

*Fasciculi pyramidales*

*Fasciculi pyramidales*

*E.V. Meyer*

FIG. 228.



FIG. 228.—The fourth ventricle is now passing into the aqueductus Sylvii. On either side of the ventricular roof, formed by the anterior medullary velum, the trochlear nerve emerges. The sectioned bundles within the velum form the decussation of the trochlear fibres, while those more ventral and lateral to the aqueduct belong to the roots ascending from the nucleus of the trochleari. Ventral to the aqueduct lies medially a gray mass, known as the nucleus dorsalis raphae, which extends as far as the posterior longitudinal bundle. The latter expands dorso-laterally, and medially is connected with the bundle of the opposite side by means of a small bridge of fibres. Ventral to the posterior longitudinal bundle, close to the raphe, lies the nucleus centralis superior, bounded laterally by the fibrae praedorsales. The tractus thalamo-olivaris lies farther lateral. The brachia conjunctiva extend farther ventrally, their lowest fibres already passing medially to cross ventral to the nucleus centrales superior in the vicinity of the nucleus reticularis tegmenti. The medial fillet is displaced farther to the side and the lateral fillet courses upward and dorsally, broken up by the gray substance of the nucleus lemnisci lateralis dorsalis. The spino-tectal fibres pass backward in company with the lateral fillet, from which, however, they cannot be distinguished. The rubro-spinal tract lies dorsal to the medial fillet, shifting more and more laterally as it ascends. The delicate fibre-bundle, at the periphery and lateral to the lateral fillet, which continues ventrally to the pons, is the tractus tectopontinus of Münzer. Within the ventral pontile area, the pyramidal bundles possess a more dorso-lateral position, although the fibrae perpendiculares are still seen ascending from the stratum pontis superficiale to the raphe.



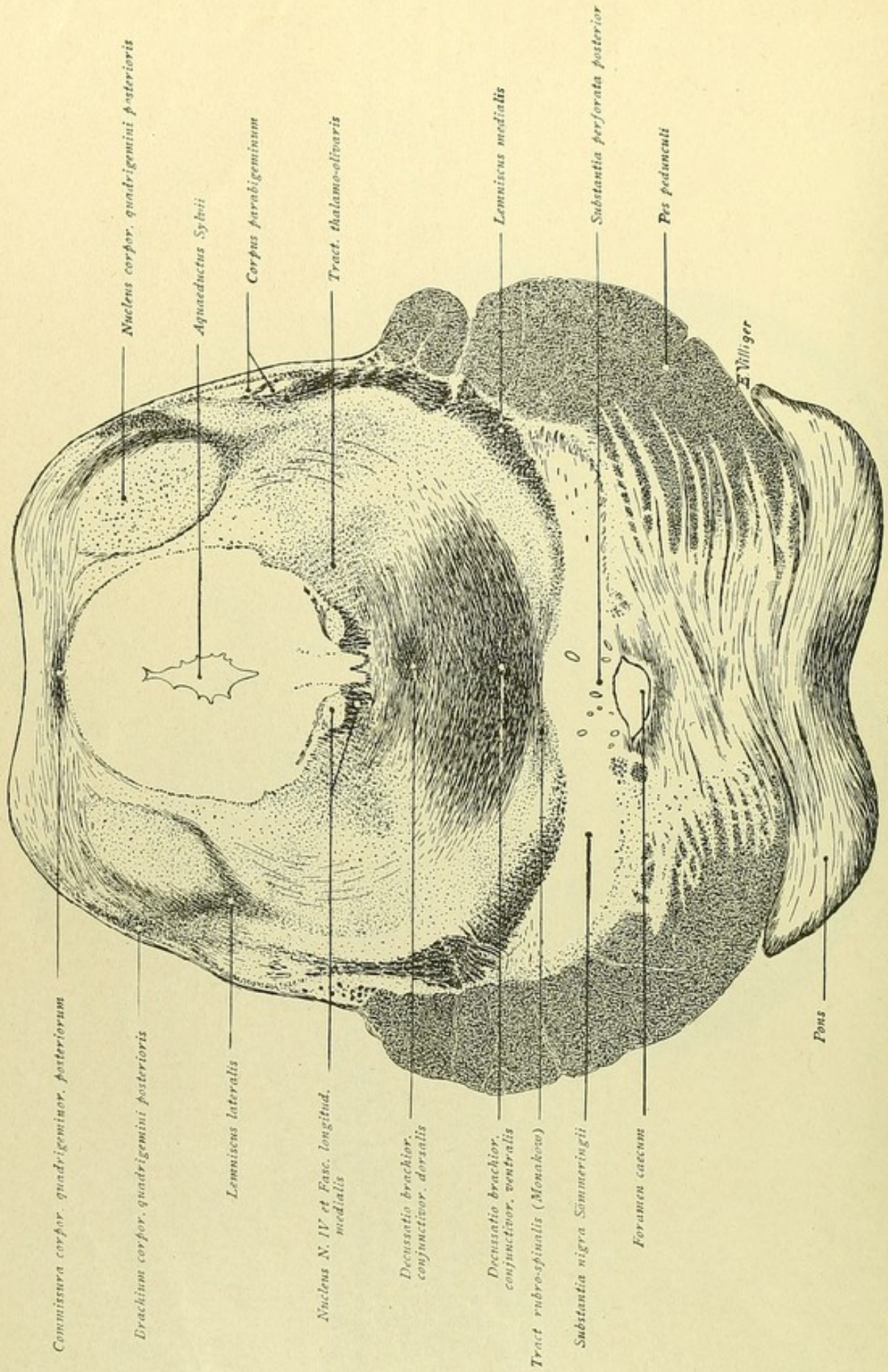
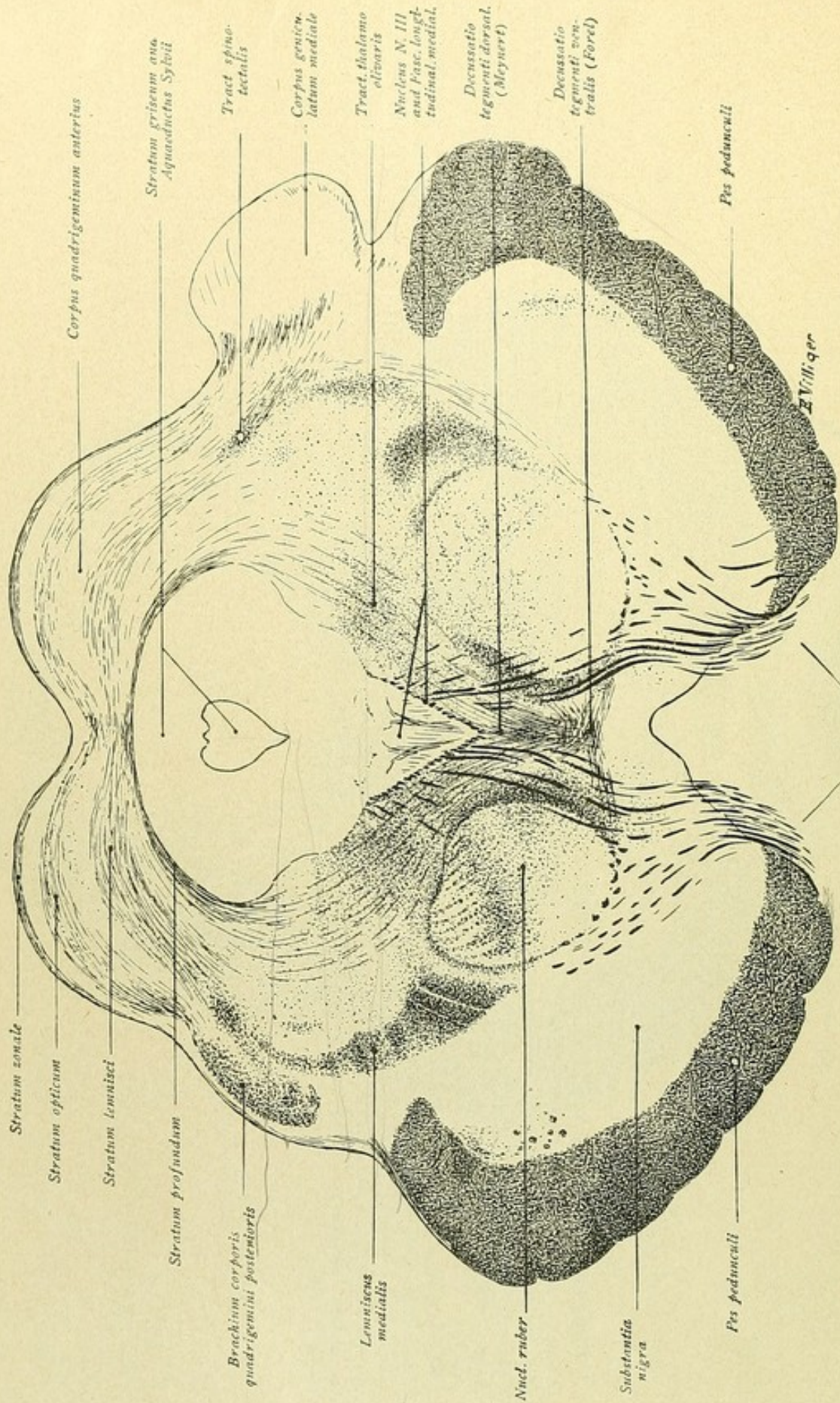


FIG. 229.



FIG. 279.—Dorsal are the nuclei of the inferior quadrigeminal bodies, which ventrally are embraced by the fibres of the lateral fillet; with these fibres are blended those of the spino-tectal system. The fibres running medially from the dorsal border of the colliculus constitute the *commissura corporum quadrigeminorum posteriorum*. Other fibres proceed ventro-laterally from the dorso-lateral border of the nucleus towards the periphery and form the *brachium corporis quadrigemini posterioris*. The medial fillet has attained a higher position and its most dorsal fibres traverse an area of gray substance, the *corpus parabigeminum*, situated at the periphery ventro-lateral to the nucleus of the inferior colliculus. The *aquaeductus Sylvii* is surrounded by the central gray substance; on each side, embedded within the posterior longitudinal bundle, is the round nucleus of the trochlear nerve, from which the root-bundles ascend dorso-laterally. Somewhat lateral to the posterior longitudinal bundle lies the thalamo-olivary tract, while directly ventral to the bundle are the *fibrae praedorsales*. Farther ventral is seen the decussation of the superior cerebellar peduncle or *brachium conjunctivum*, also known as *Wernick's commissure*, in which a dorsal and a ventral division are recognized. Fibres from the nuclei tecti, emboliformis and globosi take part in the dorsal decussation, while those from the nucleus dentatus enter the lower one. Ventral to the decussation of the cerebellar peduncle is the *rubro-spinal* or *Monakow's tract*. The lower part of the section still exhibits a portion of the pons, lateral the *pes pedunculi* and, between the latter and the medial fillet, the *substantia nigra*. In the middle, ventral to the decussation of the cerebellar peduncle, is seen the *substantia perforata posterior* and, beneath this, the *foramen caecum*. In this region, somewhat dorso-lateral to the *substantia perforata*, is located the ganglion *interpedunculare* of Gudden.





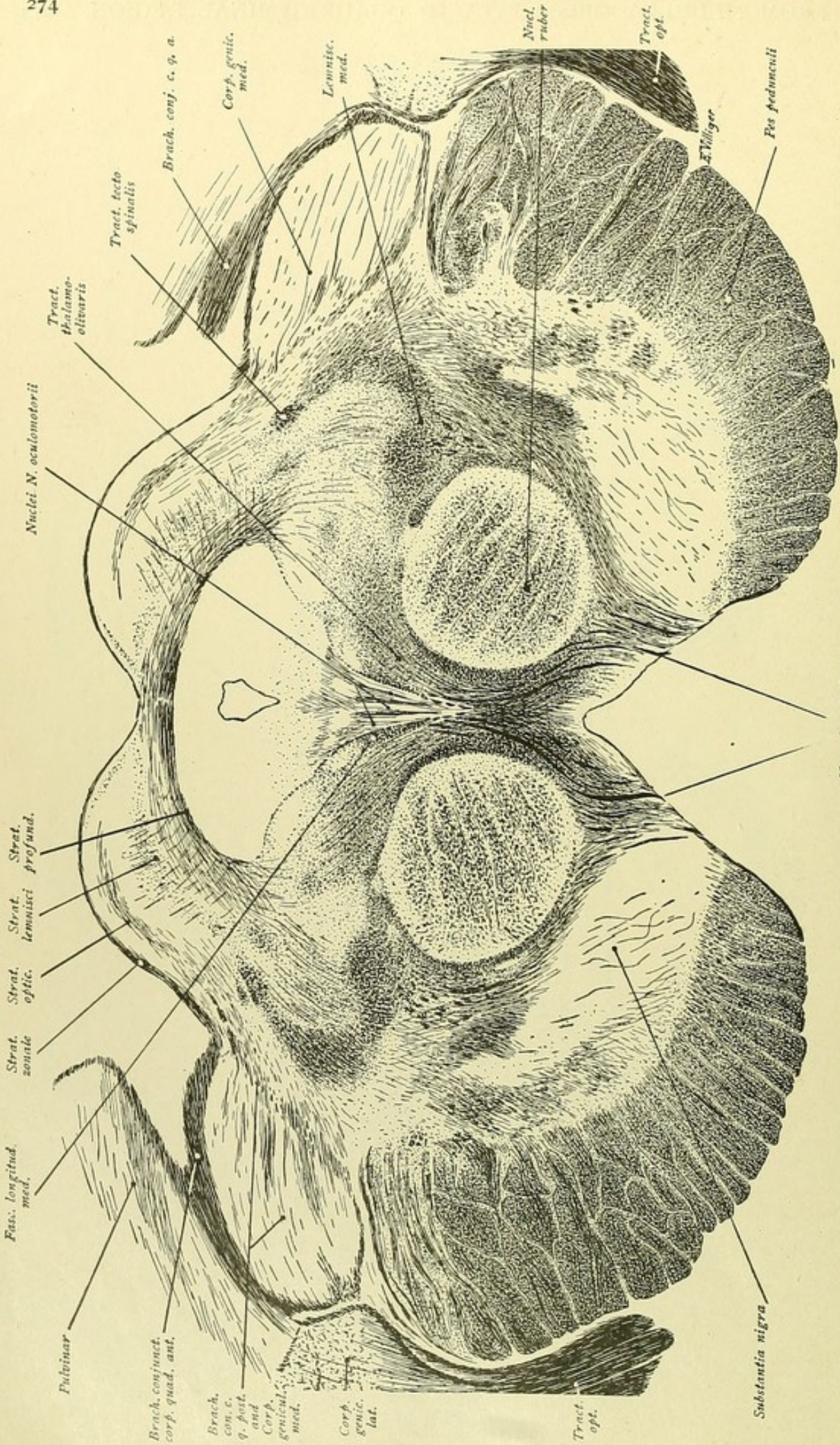
*N. oculomotorius*

FIG. 230.



FIG. 230.—Dorsally, the section passes through the anterior quadrigeminal bodies or superior colliculi, and ventrally through the cerebral peduncles. The portion above the aqueductus Sylvii includes the quadrigeminal plate, the entire middle region, as far as the substantia nigra, is the tegmentum, while the area ventral to the substantia nigra belongs to the pes pedunculi. Within the quadrigeminal region a stratification is evident. The delicate fibres along the surface form the stratum zonale; next comes a band of gray substance overlying the stratum opticum; then follows another band of gray substance and the stratum lemnisci, which latter lies in the continuation of the ascending medial fillet and the tractus spino-tectalis. A final inner gray stripe separates the stratum lemnisci from the delicate arched fibres, which constitute the deep medullary substance and bound externally the central gray or stratum griseum surrounding the aqueductus Sylvii. In the middle, ventral to the aqueduct, lies the oculomotor nucleus, consisting of a medial and the lateral chief nuclei. The posterior longitudinal bundles, which bound the oculomotor nucleus, are arranged as a V, with the apex of the angle directed ventrally. The deeply colored fibres, seen taking a sinuous course towards the medial surfaces of the peduncles, are root-bundles of the oculomotor nerve. They pass, in part, through the large round red nucleus, in which the fibres of the superior cerebellar peduncle have now entered. Laterally, the medial fillet appears as a crescent and dorsally is joined by the fibres of the spino-thalamic tract. Lateral to the dorsal part of the medial fillet and the spino-tectal tract, on the left side, the fibres of the brachium of the inferior colliculus are encountered; on the right side, they are passing to the adjacent corpus geniculatum mediale. The region ventral to the posterior longitudinal bundles and between the red nuclei deserves especial attention. The fibres, which descend in curves from the stratum profundum of the superior colliculus, pass between the posterior longitudinal bundle and the red nucleus and, ventral to the oculomotor nucleus, cross the mid-line, thus forming the decussatio tegmenti dorsalis or Meynert's fountain decussation. After crossing, these fibres run ventro-lateral to the posterior longitudinal bundle as the praedorsal bundle, already repeatedly mentioned. Somewhat lower than Meynert's decussation is seen the decussatio tegmenti ventralis or Forel's decussation. At this place the rubro-spinal fibres cross after emerging from the red nuclei.





N. oculomotorius  
FIG. 231.



FIG. 231.—On comparing this figure with the preceding one, it is seen that parts of the corpora geniculata medialis, as well as of the corpora geniculata lateralia, of the pulvinar thalami and of the tractus opticus are shown. On following the fibres of the optic tract, they may be traced to the lateral geniculate body, the pulvinar and, by way of the brachium corporis quadrigemini anterioris, to the superior colliculus. The subdivision of the quadrigeminal region into different layers is also evident; additionally, one recognizes radial fibres passing from the upper layer into the medullary substance and thence, as the delicate tecto-spinal fibres, between the posterior longitudinal bundle and the red nucleus, through the tractus thalamo-olivaris to a position ventral to the oculomotor nucleus, where the fibres enter the tegmental decussation of Meynert. The differentiation of the oculomotor nucleus into its medial and two lateral subdivisions is also pronounced, as is also the course of the root-bundles from the nucleus to the surface of the cerebral peduncles. The medial fillet rests upon the lateral surface of the red nucleus and dorsally joins the tractus tecto-spinalis. Lateral to the last-named path, the fibres of the brachium corporis quadrigemini posterioris enter the corpus geniculatum mediale. In the ventral part, the substantia nigra, traversed by delicate fibres, serves to separate the tegmental region from the fibre-bundles of the basal part of the cerebral peduncle. A subdivision of the latter into its chief component tracts is not recognizable, but it may be noted, that within the middle part of the pes pedunculi run the motor cortico-bulbar and the cortico-spinal tracts, while the frontal cortico-pontile tracts occupy the medial and the occipito-temporal cortico-pontile include the lateral fifth.



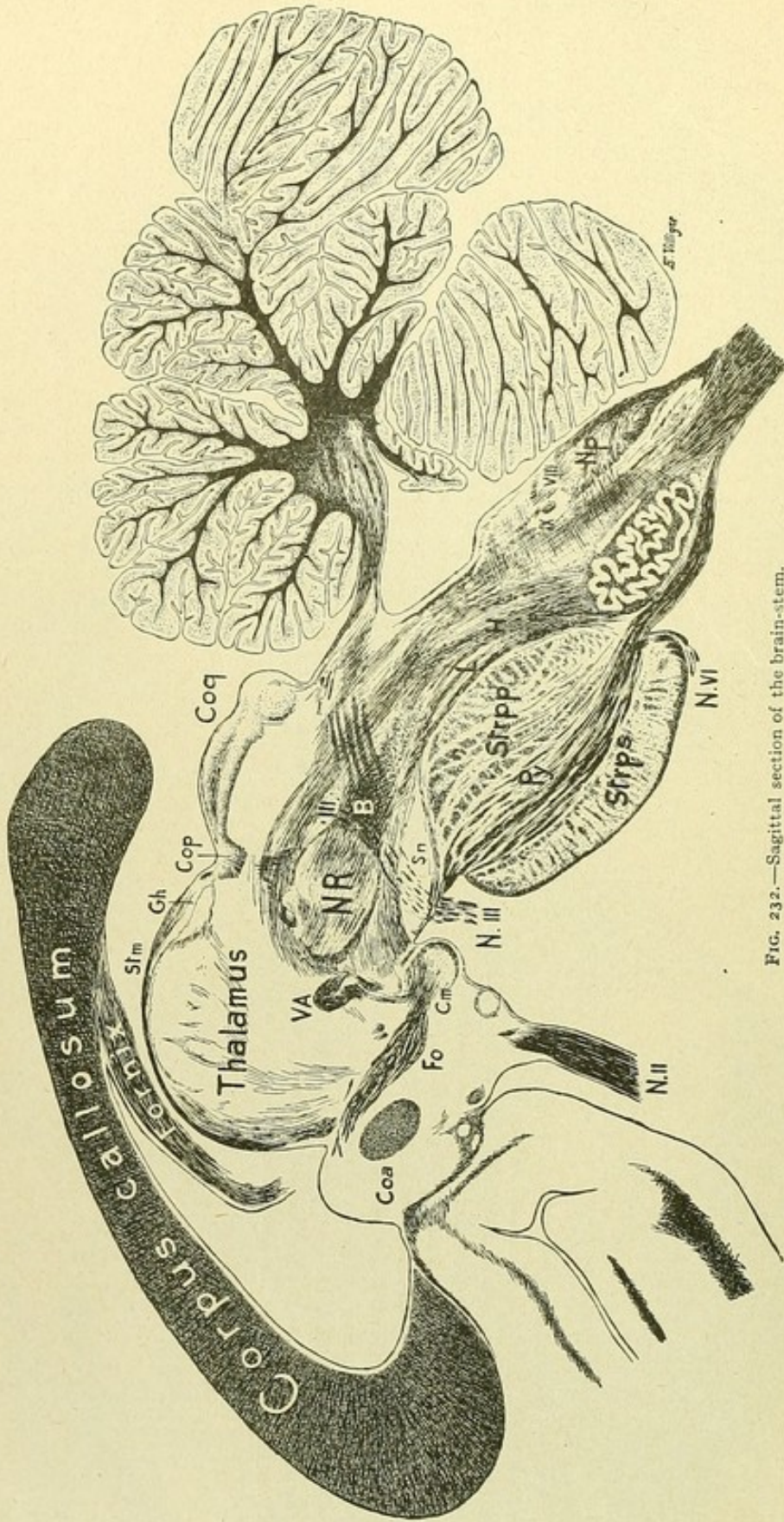



FIG. 232.—Sagittal section of the brain-stem.



Fig. 232.—The great brain-commissure or the corpus callosum overlies, with its posterior end or splenium, the diencephalon and, in part, also the mid-brain. From the under surface of the callosum, the fornix passes forward over the thalamus, the descending columna fornicis (*Fo*) being traceable behind the commissura anterior (*Coe*) to the corpus mamillare (*Cm*). A portion of the thalamus with its chief nuclei is not seen; the stria medullaris (*Stm*), however, can be followed over the surface of the thalamus to the ganglion habenulae (*Gh*), with which the fibres of the commissura posterior join. In the subthalamic region the optic nerve is cut; behind this, follow the tuber cinereum and the corpus mamillare. From the latter, the fasciculus mamillaris princeps ascends dorsally and divides into its two bundles, one of which, the fasciculus mamillo-thalamicus or bundle of Vicq d'Azyr (*V.A.*), passes to the nucleus anterior thalami, and the other, the fasciculus mamillo-tegmentalis or Gudden's tegmental bundle, passes caudally over the nucleus ruber (*NR*). The fibres which pass ventral to the red nucleus and above the substantia nigra (*Sr*) belong to the pedunculus corporis mamillaris. The nuclear column of the oculomotor nerve lies dorso-spinal to the red nucleus; the root-bundles of the oculomotor (*N. III*) are seen traversing the substantia nigra to gain the surface of the cerebral peduncle. The fibres from the cerebellum to the red nucleus, by way of the brachium conjunctivum, are also seen (*B*). Behind the posterior commissure (*Cop*) lies the quadrigeminal region (*Cog*); the superior colliculus exhibits subdivision into different layers and within the inferior colliculus its nucleus is clearly defined. The hind-brain, with the cerebellum and the pons, is attached to the mid-brain. The pons shows the subdivision into the pars dorsalis or tegmentum and the pars basalis. Within the latter, ventrally, lies the stratum pontis superficiale (*Strps*), dorsally the stratum profundum (*Strpp*), and, between these two layers, the stratum medium, traversed by the spinalward directed fibres of the pyramidal tracts (*Py*). The medial fillet (*L*) rests upon the stratum profundum and constitutes the boundary of the tegmental region; somewhat more dorsal from the fillet, courses the tractus thalamo-olivaris (*H*), whose connection with the inferior olive is evident. Within the medulla oblongata, the pyramidal tract descends ventral to the olive; within the dorsal part, the nuclei of the area acusticae (*VIII*), the nucleus tractus solitarii (*IX*) and the posterior column nuclei are recognizable as small gray masses. These latter nuclei (*NP*), nuclei funicularum posteriorum, behind adjoin the posterior tracts of Goll and of Burdach and ventrally border the substantia gelatinosa. The fibrae arcuatae internae are seen passing ventrally to the olive from the posterior column nuclei.







## SELECTED REFERENCES.

The following list includes important books and monographs relating to the anatomy of the Central Nervous System, which the student may consult with advantage. Extended bibliographies will be found in Obersteiner and in the year-books of Anatomy and Neurology.

- BARKER, L. F. The Nervous System and its Constituent Neurones. 1899.
- BECHTEREW, W. Die Leitungsbahnen im Gehirn und Rückenmark. 1899.
- BRODMANN, K. Die Cortexgliederung des Menschen. Jour. f. Psychol. u. Neurol., Bd. X., 1907.
- BRODMANN, K. Die feinere Anatomie des Grosshirns. Lewandowsky's Handbuch der Neurologie, 1910.
- CAJAL, S. RAMÓN Y. El sistema nervioso del Hombre e de los Vertebrados. 1902.
- CHARPY, A. Systeme Nerveux. In Poirier's *Traité d'Anatomie Humaine*, Tome III., 1899.
- CUNNINGHAM, D. J. Surface Anatomy of the Cerebral Hemispheres. 1892.
- DALTON, J. C. Topographical Anatomy of the Brain. Atlas. 1885.
- DEJERINE, J. Anatomie des Centres Nerveux. 1901.
- DOGIEL, A. S. Der Bau der Spinalganglien des Menschen und der Säugethiere. 1908.
- DONALDSON AND DAVIS. Areas of Cross-Sections of the Spinal Cord at the Level of each Spinal Nerve. *Journal of Comparative Neurology*, Vol. XIII., 1903.
- EDINGER, L. Vorlesungen ueber den Bau der nervösen Zentralorgane. 1908.
- FLECHSIG, P. Die Leitungsbahnen im Gehirn und Rückenmark. 1876.
- GEHUCHTEN, VAN A. Anatomie du Systeme Nerveux de l'Homme. 1906.
- HÄBERLIN, C. Zur Topographie der Hirnventrikel. *Arch. f. Anat. u. Entwickl.* 1909.
- HELD, H. Die Entstehung des Nervengewebes. 1909.
- HIS, W. Die Formentwicklung des menschlichen Vorderhirns. 1889.
- HIS, W. Die Entwicklung des menschlichen Gehirns. 1904.
- HORSLEY, V. The Cerebellum: Its Relation to Spacial Orientation and to Locomotion. Boyle Lecture. 1905.
- JACOBSOHN, L. Ueber die Kerne des menschlichen Hirnstamms. Akademie der Wissenschaften, Berlin. 1911.
- JAKOB, C. Vom Tierhirn zum Menschenhirn. Atlas. 1911.
- JOHNSTON, J. B. The Nervous System of Vertebrates. 1906.
- JOHNSTON, J. B. The Morphology of the Fore-Brain Vesicle in Vertebrates. *Journal of Comparative Neurology and Psychology*. Vol. XIX., 1909.



- KAES, T. Die Grosshirnrinde des Menschen in ihren Massen u. in ihrem Fasergehalt. 1907.
- KOELLIKER, A. Handbuch der Gewebelehre. Band II., 1896.
- KUPFFER, K. Die Morphologie des Centralnervensystems. In Hertwig's Handbuch der Entwicklungslehre. Bd. II., Th. 3, 1906.
- LENHOSSEK, M. Der feinere Bau des Nervensystems. 1895.
- LEWANDOWSKY, M. Handbuch der Neurologie. I. Allgemeine Neurologie. 1910.
- MALONE, E. Ueber die Kerne des menschlichen Diencephalon. Akademie der Wissenschaften, Berlin. 1910.
- MARBURG, O. Mikroskopisch-topographischer Atlas des menschlichen Zentralnervensystems. 1910.
- MONAKOW, C. Der rothe Kern, die Haube u. die Regio subthalamica bei einige Säugthieren u. bei Menschen. Arbeiten a. d. Hirnanatomischen Institut in Zürich. Bd. III., 1909.
- NEBELTHAU, E. Schnitte durch das menschliche Gehirn. 1898.
- NEUMAYER, L. Histo- und Morphogenese des peripheren Nervensystems, der Spinalganglien und des Nervus sympathicus. In Hertwig's Handbuch der Entwicklungslehre. Bd. II., Th. 3, 1906.
- OBERSTEINER, H. Anleitung beim Studium des Baues der nervösen Centralorgane. 1912.
- PARKER, G. H. The Phylogenetic Origin of the Nervous System. Anatom. Record, Vol. IV., 1910.
- RETZIUS, G. Das Menschenhirn. 1896. Atlas of special regions.
- SACHS, E. On the Structure and Functional Relations of the Optic Thalamus. Brain, Vol. CXXVI., 1909.
- SABIN, F. R. Atlas of the Medulla and Midbrain. 1901.
- SCHÄFER AND SYMINGTON. Neurology. In Quain's Anatomy, Vol. III., 1908.
- SMITH, E. A new Topographical Survey of the Human Cerebral Cortex. Jour. of Anatomy and Physiology, Vol. XLI., 1907.
- STREETER, G. L. Die Entwicklung des Nervensystems. In Keibel and Mall's Handbuch d. Entwicklungsgeschichte d. Menschen. Bd. II., 1911.
- TILNEY, F. Contribution to the Study of the Hypophysis Cerebri, with Especial Reference to Its Comparative Histology. 1911.
- VOGT, C. La myeloarchitecture du thalamus du cercopitheque. Jour. f. Psychol. u. Neurol., Bd. XII., 1909.
- WERNICKE, C. Atlas des Gehirns. 1897.
- ZIEHEN, T. Die Morphologie des Centralnervensystems der Säugetiere. In Hertwig's Handbuch der Entwicklungslehre. Bd. II., Th. 3, 1906.
- ZIEHEN, T. Die Histogenese von Hirn- und Rückenmark. In Hertwig's Handbuch der Entwicklungslehre. Bd. II., Th. 3, 1906.
- ZIEHEN, T. Nervensystem. In Bardeleben's Handbuch der Anatomie. 1899.



# INDEX

- Abducens, 176  
Accessorius, 185  
Acervulus, 56  
Acusticus, 179  
Ala cinerea, 82  
    lobuli centralis, 73  
    uvulae, 75  
Alveus, 45, 120  
Angulus gyri olfact. lat., 28  
Ansa lenticularis, 144, 219  
    peduncularis, 144, 219  
Anterior column, 90  
    tracts, 161  
    commissure, 135  
    ground bundle, 161  
Apertura medialis ventric. quarti (Magendii), 80  
    lateralis ventric. quarti (Luschkae), 80  
Aphasia, 202  
Apraxia, 130  
Aquaeduct. cerebri Sylvii, 68  
Arachnoidea cerebri, 88  
    spinalis, 93  
Arachnoidal villi (Pacchioni), 88  
Arbor medullaris, 76  
    vermis vitae, 76  
Arcuate fibres, 167, 170  
    nucleus, 84, 170  
Area acustica, 82  
    medial. trigoni N. XII., 82  
    parolfactoria (Broca), 27  
    plumiformis, 82  
    postrema, 82  
Ascensus medullae spinalis, 9  
Association cells, 160  
    area, 171  
    centres (Flechsig), 127  
    conduction, 133  
    fibres, 134  
    tracts, 197  
Astrocytes, 106  
Astropilemma, 106  
Auditory centre, 126  
    path, 190  
Axis-cylinder, 111  
    process, 109  
Axone, 109  
Baillarger's stripe, 39, 115  
Band of Giacomini, 34  
Bandelette médiale (Gombault-Philippe), 166  
Basal ganglia, 46  
Basket cells, 154  
Basis cerebri, 12  
    pedunculi, 67  
Bechterew's nucleus, 181  
Bipolar cells, 109  
Brachia cerebelli, 76, 156  
    ad cerebrum, 76  
    ad corp. quadrig., 76  
    ad medullam, 76  
    ad pontem, 76, 155  
    conjunctiva, 70, 76, 156  
    corp. mamillar., 57  
    pontis, 76, 155  
    quadrigemina, 66  
Brain development, 4  
    form, 9  
    membranes, 86  
    morphology, 3  
    size, 10  
    weight, 10  
Brain-sand, 56  
Brain-stem, 6  
Brain-vesicles, 4  
Broca's callosal stalks, 30  
    centre, 128  
    convolution, 20  
    diagonal band, 30  
    field, 27  
Bulbus cornu post., 43  
    olfactorius, 27, 118  
Burdach's column, 78, 164  
Cajal's cells, 111, 115  
Calamus scriptorius, 81  
Calcar avis, 43  
Callosal convolutions, 36  
    radiations, 40  
Calloso-marginal fissure, 23  
Capsula externa, 48, 135  
    extrema, 50, 136  
    interna, 48, 61, 142  
Cauda equina, 9  
Cavum epidurale, 93  
    interdurale, 93  
    psalterii, 44  
    septi pellucidi, 41  
    subdurale, 93



- Central tegmental tract, 151  
 Centrifugal tracts, 131, 191  
 Centripetal tracts, 131, 186  
 Centrum medianum (Luys), 60, 228  
   semiovale (Vieussens), 39  
 Cerebellar cortex, 154  
   falx, 87  
   peduncles, inferior, 76, 170  
     middle, 76, 157  
     superior, 76, 156  
   tent, 76  
   tracts, 155  
 Cerebellum, 72, 152  
 Cerebral cortex, 39  
   crura, 66  
   ganglia, 46  
   mantle, 18  
   nerves, 172  
   nerves, table, 14  
   peduncles, 66  
 Cerebro-spinal fluid, 88  
 Cerebrum, 11  
 Chiasma opticum, 37, 174  
 Cingulum, 135, 149  
 Cisterna ambiens, 88  
   cerebello-medullaris, 88  
   chiasmatis, 88  
   corporis callosi, 88  
   fossae Sylvii, 88  
   interpeduncularis, 88  
 Clarke's column, 90, 159  
 Claustrum, 50  
 Clava, 78  
 Climbing fibres, 155  
 Cochlearis, 179  
 Colliculus facialis, 82, 178  
   subpinealis, 66  
 Column-cells, 160  
 Columna fornicis, 44  
 Columnae griseae, 91  
 Comma bundle of Schultze, 166  
 Commissura anterior, 16, 135  
   alba, 91  
   grisea, 91  
   cerebri magna, 40  
   habenularum, 55  
   hippocampi, 44, 135, 146  
   posterior cerebri, 56  
     medullae, 90  
   supramamillaris, 225  
 Commissure-cells, 160  
   fibres, 135  
 Confluens sinuum, 88  
 Conus medullaris, 9, 89  
   terminalis, 89  
 Convolutions, see Gyri  
 Cornu Ammonis, 45, 120  
 Cornua ventriculi lat., 40, 41, 42  
 Corona radiata, 135  
 Corpora candicantia, 56, 147  
   geniculata, 56  
   mamillaria, 56, 147  
   restiformia, 77, 170  
 Corpus album subrotund., 59  
   callosum, 14, 40  
   fornicis, 44  
   geniculatum, 56  
   Luys, 61  
   mamillare, 56, 147  
   medullare cerebelli, 75  
   parabigeminum, 271  
   patellare (Tschish), 60  
   pineale, 55  
   restiforme, 77, 170  
   striatum, 41, 48, 144  
   subthalamicum, 61, 224  
   trapezoides, 179  
 Cortical cells, 39  
 Cortico-bulbar tract, 138  
 Cortico-spinal tract, 138  
 Crura cerebelli, 76, 155  
   ad cerebrum, 76  
   ad corp. quadrig., 76  
   cerebelli ad medullam, 77  
   ad pontem, 76  
   fornicis, 44  
 Crus fornicis, 44  
 Culmen cerebelli, 73  
 Cuneus, 24  
 Cuticle-plate, 3  
  
 Declive cerebelli, 73  
 Decussation, cerebellar peduncles, 156  
   fillet, 167  
   Forel's, 274  
   Meynert's, 274  
   motor, 77, 138  
   pyramidal, 77, 138  
   sensory, 167  
 Deiters' cells, 111  
   nucleus, 181  
 Dendrites, 111  
 Development, brain, 4  
   ependyma cells, 103  
   nerve-cells, 105  
   neuralgia, 104  
   spinal cord, 8  
   spinal ganglia, 105  
 Diagonal band of Broca, 30  
 Diaphragma sellae turcicae, 88  
 Diencephalon, 52, 150  
   summary, 63  
 Digitationes hippocampi, 43  
 Direct cerebellar tract, 161  
 Direct sensory cerebellar tract, 170



- Dura mater cerebri, 87  
     spinalis, 93
- Edinger-Westphal nucleus, 176
- Embolus, 83
- Eminentia collaterale, 43  
     medialis, 81  
     pyramidalis, 71  
     saccularis, 38
- Encephalon, 3
- End-brain, 4, 17, 134
- Endogenous fibres, 160
- End-plate, 37
- Ependyma cells, 103  
     nuclear zone, 103
- Ependymium, 103
- Epicerebral space, 88
- Eyes, movements of, 184
- Facialis, 178
- Facial knee, 178  
     nucleus, 178
- Falx cerebelli, 87  
     cerebri, 87  
         major, 87  
         minor, 87
- Fascia dentata (Tarini), 32
- Fasciculus ant. propr., 161  
     arcuatus, 135  
         (Foville), 71  
     cerebro-spinalis ant., 139  
         lateralis, 139  
     cuneatus, 77, 90, 164  
     fronto-occipitalis, 135, 207  
     gracilis, 77, 90, 164  
     lateral. propr., 162  
     lenticularis (Forel), 222  
     longitudinal. dorsal. (Schütz), 148, 151  
         inferior, 135  
         medialis, 148, 153, 182  
         superior, 135  
         praedorsalis, 153  
     mamillaris princeps, 147  
     mamillo-tegmentalis, 147  
     mamillo-thalamicus, 147  
     obliquus pontis, 71  
     pyramidalis, 82, 138  
     retroflexus (Meynert), 148  
     solitarius, 185  
     sulco-marginalis, 161  
     tegmento-mamillaris, 147  
     thalamicus, 224  
     thalamo-mamillaris, 147  
     uncinatus, 135  
     Vicq d'Azyr, 147
- Fasciola cinerea, 33
- Fastigium, 79
- Fibra pontis, 71
- Fibrae arciformes, 70, 155  
     arcuatae, 78, 167  
         ext. dorsales, 170, 247  
         ext. ventrales, 170, 247  
         internae, 167, 242  
     pontis profundae, 82  
         superficiales, 82  
     propriae, 134  
     terminales, 115
- Fibrillar network, 112
- Fila lateralia pontis, 71  
     olfactoria, 27, 118, 144
- Fillet, lateral, 179  
     mesial, 167
- Filum terminale, 9, 89
- Fimbria, 33, 44
- Fissura calcarina, 24  
     cerebri lat., 18  
         longitud., 11  
         transversa, 12  
     chorioidea, 42  
     collateralis, 24  
     hippocampi, 24  
     longitudinalis cerebri, 11  
     mediana ant., 77, 89  
     parieto-occipital., 20, 24  
     prima (His), 26  
     rhinica, 24  
     Rolandi, 19  
     transversa cerebri, 12
- Flechsig's association centre, 127  
     direct cerebellar tract, 161, 170
- Feltwork, interradian, 115  
     supraradial, 115
- Flocculus, 75  
     accessory, 75  
     peduncle of, 75
- Folium vermis, 74
- Foramen caecum, 77  
     diaphragmatis, 88  
     interventriculare, 8, 43  
     Luschkae, 80  
     Magendii, 80  
     Monroi, 8, 43
- Forceps, 40
- Fore-brain, derivatives, 65
- Forel's tegmental decussation, 274
- Formatio reticularis, 85
- Fornix, 44, 137, 146  
     longus (Forel), 146  
     periphericus (Arnold), 135, 149  
     pillars of, 44  
     transversus, 44, 146
- Fossa cerebri lateralis (Sylvii), 18  
     interpeduncularis (Tarini) 68  
     mediana, 81  
     rhomboidea, 81
- Fountain decussation, 273



- Frenulum veli medullaris, 70  
 Frontal pontile tract, 137  
   lobe, 19  
 Funiculus anterior, 90, 161  
   lateralis, 90, 161  
   posterior, 90, 163  
   separans, 82  
 Fourth ventricle, 79  
  
 Ganglioblasts, 106  
 Ganglion-strand, 105  
 Ganglion ectomamillare, 68  
   habenulae, 61, 148  
   interpedunculare (Gudden), 69, 148  
   profund. mesencephali, 69  
   tegmenti dorsale, 69, 147  
 Gennari's stripe, 39  
 Germ-cells, 103  
 Giacomini's band, 34  
 Globus pallidus, 48  
 Glomeruli olfactorii, 118  
 Glomus chorioideum, 44  
 Glossopharyngeus, 184  
 Golgi-Holmgren canals, 113  
 Golgi's network, 112  
   cells, 111  
 Goll's column, 90, 164  
 Gowers' tract, 161, 170  
 Granule layer, cerebellum, 154  
   olf. bulb, 119  
 Gratiolet's optic radiation, 136, 172  
 Gubler's paralysis, 143  
 Gudden's tegmental bundle, 147  
 Gustatory centre, 126  
   paths, 190  
 Gyrus, or Gyri, ambiens, 27  
   Andreae Retzii, 36  
   angularis, 21  
   centralis ant., 19  
     post., 21  
   cerebelli, 76  
   cinguli, 30  
   dentatus, 32, 121, 122  
   descendens (Ecker), 21  
   diagonalis, 30  
   digitati externi, 35  
   epicallosus, 34  
   fasciolaris, 34, 35  
   fornicatus, 25, 30, 119  
   frontalis, 20  
   fusiformis, 24  
   hippocampi, 32  
   insulae, 22  
   intralimbicus, 35  
   lingualis, 24  
   occipitales, 21  
   olfactorio-orbitalis, 29  
   Gyrus olfact. lateral., 27  
     medial., 27  
   orbitales, 25  
   perforatus, 29  
   profundi, 18  
   rectus, 25  
   rhinenceph.-fusiform., 32  
   rhinenceph.-lingual., 32  
   rhinenceph.-temporales, 32  
   semilunaris, 27  
   subcallosus (Zuckerkandl), 30  
   subsplenialis, 34  
   supramarginalis, 21  
   temporales, 21  
     transversi, 21  
   transitivi, 18  
   uncinatus, 35  
  
 Habenula, 55  
 Hearing, cortical centre, 126  
 Helweg's triangular tract, 162, 171  
 Hemianopsia, 174  
 Hemiopia, 174  
 Hemiplegia alternans oculomot., 143  
   facial., 143  
   completa, 142  
   cruciata, 144  
   incompleta, 142  
 Hemisphaerium, 17  
 Heschl's convolutions, 21  
 Hind-brain, 85  
 Hippocampus (cornu Ammonis), 45, 120  
 Hypoglossus, 185  
 Hypophysis, 38  
 Hypothalamus, 64  
  
 Incisura praeoccipitalis, 20  
   temporalis (Schwalbe), 24  
 Indirect sensory cerebellar tract, 171  
 Induseum griseum, 33, 123  
   inferius, 34  
 Infundibulum, 37  
 Insula, 22  
 Intermedius Wrisbergi, 178  
 Inter-brain, 52  
 Internal capsule, 48  
 Interolivary stratum, 117  
 Interradial feltwork, 115  
 Intumescencia cervicalis, 89  
   lumbalis, 89  
 Island of Reil, 22  
 Isthmus gyri fornicati, 30, 31  
   rhombencephali, 4, 70  
  
 Lamina affixa, 41  
   chorioidea ventric. lat., 41  
   ventric. quarti, 79  
   ventric. tertii, 57



- Lamina medullaris circumvoluta, 121  
     praecommissuralis, 30  
     quadrigemina, 66  
     rostralis, 15  
     septi pelucidi, 41  
     terminalis, 15, 37  
 Laminae medullares cerebelli, 76  
     thalami, 60  
 Lancisi's striæ, 33  
 Lateral column, 90, 161  
     ground bundle, 162  
     nuclei, 85, 170  
     pyramidal tract, 161  
     tracts, 90, 161  
     ventricle, 40  
 Lattice layer of thalamus, 59, 227  
 Lemniscus lateralis, 179, 190  
     medialis, 167, 187  
 Leptomeninx, 86  
 Ligamentum denticulatum, 94  
 Limbic lobe, 25  
 Limbus Giacomini, 34  
 Limen insulae, 28  
 Lingula cerebelli, 73  
 Liquor cerebro-spinalis, 8  
 Lissauer's marginal zone, 163  
 Lobi cerebelli, 72, 73, 74  
     insulae, 22  
 Lobuli cerebelli, 72, 73  
 Lobulus paracentralis, 24  
 Lobus frontalis, 19  
     occipitalis, 21  
     olfactorius, 26  
     olfact. ant., 27  
     post., 29  
     parietalis, 20  
     temporalis, 21  
 Locus caeruleus, 82, 177  
 Luys' body, 60, 228  
 Lyra Davidis, 44, 135  
  
 Mammillary bodies, 61  
 Mantle layer, 105  
 Marginal zone, 91  
 Martinotti cells, 115  
 Massa intermedia, 55  
 Medial fillet, 149, 167, 187  
 Medulla oblongata, 77, 166  
     spinalis, 89, 159  
 Medullary groove, 3  
     plate, 3  
     ridge, 3  
     tube, 4  
 Membrana limitans, 102  
 Meninges, 86  
 Mesencephalon, 4, 66  
     summary, 69  
 Metathalamus, 63  
  
 Metencephalon, 4, 77  
 Meynert's fountain decussation, 153, 273  
 Mid-brain, 66  
 Middle commissure, 55  
 Mitral cells, 118  
 Molecular layer, 114, 121, 122, 154  
 Monakow's nucleus, 243  
     bundle, 153, 162  
 Monoplegia, 145  
 Monticulus cerebelli, 73  
 Moss fibres, 155  
 Motor tract, 131, 138, 151, 191  
     centre, 124  
 Multipolar cells, 110  
 Myelencephalon, 4, 77, 166  
  
 Nerve process, 108  
     cells, 106  
 Nervus abducens, 176  
     accessorius, 185  
     acusticus, 179  
     cochleae, 179  
     facialis, 178  
     glossopharyngeus, 184  
     hypoglossus, 186  
     intermedius (Wrisbergi), 178  
     oculomotorius, 175  
     olfactorius, 172  
     opticus, 172  
     Sapolini, 178  
     trigeminus, 176  
     trochlearis, 176  
     vagus, 184  
     vestibuli, 181  
     Wrisbergi, 178  
 Neural or medullary tube, 102  
 Neurite, 109  
 Neurobiasts, 103  
 Neurofibrillæ, 112  
 Neuroglia, 103  
 Neuroglia cells, 103, 106  
 Neurone, 109  
 Nidus avis, 75  
 Nissl's bodies, 112  
 Nodus, 75  
 Nucleus alae cinereae, 85, 185  
     ambiguus, 85, 184  
     amygdalae, 50, 145, 219  
     arcuati, 84, 170  
     caudatus, 47, 144  
     corpor. geniculati, 61  
         mamillaris, 61, 147  
         trapezoides, 83, 179  
     dentatus cerebelli, 83  
     dorsalis (Clarkii), 91, 157  
     emboliformis, 83  
     eminentiae teretis, 263  
     fastigii, 83



- Nucl. funiculi cuneati, 84, 167  
     *gracilis*, 84, 167  
     *globosi*, 84  
     *habenulae*, 61, 148  
     *hypothalamicus*, 61  
     *intercalatus Staderini*, 251  
     *laterales*, 84, 170  
     *lemnisci*, 70, 82, 179  
     *lenticularis*, 48  
     *lentiformis*, 48, 144  
     *nervorum*, see Cerebral Nerves, 172  
     *olivaris accessor.*, 84  
         *inferior*, 84, 170  
         *superior*, 179  
     *pontis*, 82  
     *praepositus XII*, 255  
     *respiratorius*, 196  
     *reticularis lateralis*, 243  
         *tegmenti*, 83, 155  
     Roller, 251  
     *ruber*, 69, 137, 155, 227  
     *salivatorius*, 257  
     *semilunaris (Flechsig)*, 60, 227  
     *tecti*, 83  
     *thalami*, 58, 59
- Obex, 78  
 Occipital lobe, 21  
 Oculomotorius, 175  
 Olfactory bulb, 27, 118  
     *bundle, basal*, 149  
     *centre*, 126, 149  
     *nerve*, 118, 172  
     *path*, 190  
     *tract*, 27, 145  
     *tubercle*, 27  
 Oliva inferior, 84, 170  
     *superior*, 83, 179  
 Operculum, 22  
 Optic radiation, 172  
     *tract*, 172  
 Optico-acoustic reflex tract, 153  
 Opticus, 172  
 Oval bundle, 166
- Pacchionian granulations, 88  
 Pachymeninx, 86  
 Pallium, 18  
 Paraplegia, 143  
 Parietal lobe, 20  
 Pars mamillaris hypothalami, 56  
     *optica hypothalami*, 37  
 Pedunculi cerebri, 66  
 Pedunculus corpor. mamillaris, 147  
     *flocculi*, 75  
 Penicilli olfactorii, 118  
 Pia mater cerebri, 88  
     *spinalis*, 93
- Pineal body, 55  
 Pituitary body, 38  
 Plexus chorioideus ventric. lat., 42  
     *ventric. quarti*, 80  
     *ventric. tertii*, 58  
 Pons Varolii, 71  
 Pontile nuclei, 82  
     *tegmentum*, 83  
     *tracts*, 137  
 Posterior column, 163  
     *comma bundle*, 166  
     *nuclei*, 167  
     *oval bundle*, 166  
     *triangular bundle*, 166  
     *ventral field*, 166  
 Posterior horn cells, 159  
 Post. longitudinal bundle, 148, 153, 182  
     *of Schütz*, 148, 153, 182  
 Praecuneus, 24  
 Projection fibres, 131, 135, 186  
 Prosencephalon, 4  
 Protoplasmic processes, 109  
 Psalterium, 44  
 Pulvinar, 55  
 Pupillary reflex, 173  
 Purkinje cells, 154  
 Putamen, 48  
 Pyramidal nuclei, 170  
     *tracts*, 137, 161, 191  
 Pyramids, decussation, 77  
 Pyramis cerebelli, 74
- Quadrate lobule, 24
- Radiatio corpor. callosi, 40  
     *striati*, 144  
     *strio-subthalamica*, 144  
     *strio-thalamica*, 144  
 Radicular zone of cord, 163  
 Radii, cortical fibres, 116  
 Randschleier, 105  
 Recessus anterior, 68  
     *infundibuli*, 38  
     *lateral. ventric. quarti*, 79  
     *opticus*, 17  
     *pinealis*, 55  
     *posterior*, 68  
     *suprapinealis*, 56  
     *tecti*, 79  
     *triangularis*, 58  
 Reflex collaterals, 131, 166, 192  
 Reflex conduction, 131, 191  
 Regio subthalamica, 61  
 Restiform body, 158, 170  
 Rhinencephalon, 25, 144  
 Rhombencephalon, 4, 70  
 Roof-nucleus, 83  
 Rostrum, 15  
 Rugae loci caerulei, 82



- Saccus vasculosus, 38  
 Sapolini's nerve, 178  
 Schultze's comma bundle, 166  
 Schütz's longitudinal bundle, 148, 153  
 Sensory centres, 126  
   cerebellar tracts, 170  
   speech centre, 199  
   tracts, 186  
 Septum anterius, 93  
   cervicale intermed., 93  
   pellucidum, 16, 41  
   subarachnoideale, 93  
 Sinus occipitalis, 87  
   petros. sup., 87  
   rectus, 88  
   sagittal., 87  
   transversus, 87  
 Smell, cortical centre, 126  
 Speech centres, 199  
   disturbance, 202  
   path, 200  
 Spinal cord, 159  
   cells, 160  
   development, 8  
   membranes, 93  
   tracts, 161  
 Spongioblasts, 103  
 Spongiopilemma, 106  
 Stratum gelatinosum, 118  
   granulosum, 115, 119, 122, 154  
   griseum centrale, 68, 225  
     colliculi sup., 69  
   lacunosum, 121  
   lucidum, 121  
   moleculare, 114, 118, 121, 122, 154  
   oriens, 121  
   radiatum, 121  
   reticulare, 60, 227  
   zonale, 54  
 Stria alba tuberculi (Lenhossék), 57, 146  
   cornea, 41  
   medullaris, 54, 148  
   olfactoria lat., 29, 145  
     med., 27, 145  
   terminalis, 41  
 Striae acusticae, 81, 179  
   Lancisii, 33, 40, 145  
   longitudinales (corp. callosi), 40  
   medullares or acusticae, 81, 179  
 Stripe of Baillarger, 39  
   sennari, 39  
   Vicq d'Azyr, 39  
 Subarachnoidal space, 86, 88  
   tissue, 88  
 Subdural space, 86  
 Subiculum, 45  
 Subpial space, 88  
 Substantia cortical. cerebelli, 83, 154  
   cerebri, 38, 114  
   gelatinosa centralis, 91  
     Rolandi, 91  
   nigra (Sömmering), 67  
   perforata ant., 29, 145  
     post., 68  
   reticularis alba, 247  
     (Arnold), 32, 121  
   grisea, 241, 247  
 Sulcus or sulci arcuat. rhinencephali, 29  
   basilaris (pontis), 71  
   centralis insulae, 22  
     Rolandi, 19  
   cerebelli, 72, 73, 74, 75  
   chorioideus, 54  
   cinguli, 23  
   circularis (Reili), 22  
   corpor. callosi, 23  
   dentato-fasciolaris, 34  
   digitati externi, 35  
   fimbrio-dentat., 33  
   frontales, 19  
   hypothalamicus (Monroi), 16, 55  
   interdigitales, 43  
   intermedius, 41  
     post., 90  
     primus (Jensen), 21  
     secundus (Eberstaller), 21  
   interparietalis, 20  
   lateralis ant., 89  
     post., 89  
   limitans, 82  
   median. fornicis, 44  
     fossae rhomboid., 81  
     post., 89  
   mesencephali lat., 68  
     med., 68  
   Monroi, 16, 55  
   nervi oculomotorii, 67  
   occipitales, 21  
   occipitalis transvers., 20, 21  
   olfactorius, 25  
   orbitales, 25  
   paracentralis, 23  
   parietal. transvers. (Brissaud), 21  
   parolfact. ant., 27  
     post., 26  
   postcentralis, 20  
   praecentralis, 19  
   radiatus, 19  
   semiannularis, 28  
   subcallos. med., 30  
   subparietal., 23  
   supraorbital. (Broca), 23  
   temporales, 21  
 Supraradial feltwork, 116  
 Sylvian aqueduct, 68




- Sylvian fissure, 18  
 fossa, 18  
 valley, 18  
 System of Deiters' nucleus, 181
- Taenia chorioidea, 42  
 fimbriae, 44  
 fornicis, 42  
 pontis, 71  
 semicircularis, 146, 214  
 tecta, 33, 40  
 thalami, 58  
 ventriculi quarti, 80
- Taeniae, 42  
 Tapetum, 43  
 Taste, cortical centre, 126  
 paths, 189  
 Tegmen fossae rhomboid., 79  
 Tegmental decussation, 153, 273  
 tract, central, 151  
 Tegmentum, 67  
 pontis, 83  
 Tela chorioidea ventric. quarti, 79  
 ventric. tertii, 52, 57  
 Telencephalon, 17, 134  
 internal configuration, 38  
 Telodendrion, 109  
 Temporal lobe, 21  
 Tentorium cerebelli, 87  
 Thalamencephalon, 54  
 Thalamus, 54, 58  
 Third ventricle, 57  
 Tigroid, 112  
 Tonsilla, 75  
 Torcular Herophili, 88  
 Tracts, projection, 186  
 Tract. bulbo-thalamicus, 151, 167  
 cerebello-bulbaris, 170  
 cerebello-tegmentalis, 150, 156  
 cerebro-spinalis, 138, 161  
 cervico-lumbalis dorsal., 166  
 corticis ad pontem, 137  
 cortico-habenularis, 146, 148  
 cortico-mamillaris, 146  
 cortico-tectales, 153  
 cortico-tegmentalis, 136  
 cortico-thalamici, 150  
 fastigio-bulbaris, 171, 259  
 habenulo-peduncularis, 148  
 mamillo-tegmentalis, 147  
 mamillo-thalamicus, 147  
 nucleo-cerebellaris, 170, 181  
 olfacto-ammonicus, 215  
 olfacto-habenularis, 148  
 olfacto-mesencephalic., 149  
 olfactorius, 27, 145  
 olivo-cerebellaris, 170
- Tract. opticus, 13, 172  
 peduncularis transvers., 68  
 ponto-cerebellares, 137, 155  
 rubro-reticularis, 153  
 rubro-spinalis (Monakow), 153, 162  
 rubro-thalamicus, 151  
 solitarius, 185  
 spinalis N. V., 178  
 spino-cerebellaris dorsal. (Flechsig), 161, 170  
 ventral. (Gowers), 70, 161, 170  
 spino-olivaris (Helweg), 162, 170  
 spino-tectalis, 153, 163  
 spino-thalamicus, 151, 163, 169, 186  
 tecto-bulbaris, 153  
 tecto-cerebellares, 153  
 tecto-pontinus (Münzer), 153, 269  
 tecto-reticularis (Pavlov), 153  
 tecto-spinalis, 153, 161, 163  
 tegmento-mamillaris, 147  
 thalamo-corticales, 135, 150  
 thalamo-habenularis, 148  
 thalamo-mamillaris, 147  
 thalamo-olivaris, 151, 171  
 thalamo-spinalis, 151, 163  
 uncinatus, 171, 259  
 vestibulo-spinalis, 161, 163, 181
- Trigeminus, 176  
 Trigonum collaterale, 43  
 habenulae, 55  
 lemnisci, 70  
 nervi hypoglossi, 82  
 olfactorium, 27  
 praecommissurale, 30  
 subpineale, 66
- Trochlearis, 176  
 Truncus cerebri, 8  
 Tuber cinereum, 37  
 valvulae, 74  
 vermis, 74
- Tuberculum acusticum, 82, 179  
 cinereum, 79  
 cuneatum, 79  
 mamillare laterale, 57  
 olfactorium, 27  
 thalami ant., 59
- Uncus, 35  
 Unipolar cells, 110  
 Uvula, 75
- Vagus, 184  
 Vallecula cerebelli, 72  
 lateralis, 18  
 Velum interpositum, 57  
 Velum medullare ant., 70  
 post., 75  
 terminale (Abbey), 34, 44




- Vena cerebri interna, 58  
  magna (Galen), 58  
  chorioidea, 58  
  septi pellucidi, 58  
  terminalis, 58  
Ventral field of cord, 166  
Ventriculus Arantii, 81  
  lateralis, 40  
  quartus, 79  
  terminalis (Krause), 91  
  tertius, 57  
Verga's ventricle, 44  
Vermis cerebelli, 72  
Verrucae gyri hippocampi, 32  
Vestibularis, 181  
Vicq d'Azyr's stripe, 40  
  bundle, 147  
Vinculum lingulae, 73  
Visual centre, 127  
  path, 191  
Visuo-auditory path, 196  
Weber's paralysis, 143  
Wernekink's commissure, 271  
Wernicke's centre, 129  
  field, 60, 229  
  pupillary reaction, 174  
Wrisberg's nerve, 178  
Writing centres, 202  
Zona incerta, 224, 225
























QM451

V71

cop. 2

Villiger

Brain and spinal cord.

APR 5 1977. *Reaz Pina* u.s. 12/20

DEC 20 1948 *W. R. Goodrich*  
Per. Res. shelf for until Dec. 30

Res. for *John P. John, Bard*

JAN 6 1949 *John P. John*

AUG 1 1947 *R. L. Merrick*

AUG 18 1948 *Reun*

JAN 20 1951 *Richard Lash*



