

Notes on operative dentistry / by Marshall H. Webb.

Contributors

Webb, Marshall H.
Augustus Long Health Sciences Library

Publication/Creation

Philadelphia : White Dental Manufacturing Co., 1883.

Persistent URL

<https://wellcomecollection.org/works/dfjftfr5>

License and attribution

This material has been provided by This material has been provided by the Augustus C. Long Health Sciences Library at Columbia University and Columbia University Libraries/Information Services, through the Medical Heritage Library. The original may be consulted at the the Augustus C. Long Health Sciences Library at Columbia University and Columbia University. where the originals may be consulted.

This work has been identified as being free of known restrictions under copyright law, including all related and neighbouring rights and is being made available under the Creative Commons, Public Domain Mark.

You can copy, modify, distribute and perform the work, even for commercial purposes, without asking permission.



Wellcome Collection
183 Euston Road
London NW1 2BE UK
T +44 (0)20 7611 8722
E library@wellcomecollection.org
<https://wellcomecollection.org>

DUPLICATE



HX00020346

RK501 W38
Columbia University
in the City of New York
School of Dental and Oral Surgery





Reference Library

DONATED BY Sir Van Horst









PROTOTYPE

K. GUTENKUNT

PHILADELPHIA

Marshall W. Webb.

NOTES

ON

OPERATIVE DENTISTRY

BY

MARSHALL H. WEBB, D.D.S.,

Lecturer on Operative Dentistry and Dental Histology in the Dental Department of the University of Pennsylvania; Member of the American Dental Association; Pennsylvania State Dental Society; New York Odontological Society; Odontological Society of Pennsylvania; Harris Dental Association of Lancaster, Pa.; and Honorary Member of the Dental Society of the State of New York, and of several other Dental Associations.

SECOND EDITION.

PHILADELPHIA:
THE S. S. WHITE DENTAL MANUFACTURING COMPANY.
1883.

RK501
W38
1883

COPYRIGHT.


THE S. S. WHITE DENTAL MFG. CO.

1883.

.....
Press of Patterson & White.
.....

TABLE OF CONTENTS.

	PAGE
Histology	10
The Deciduous Teeth—Prevention of Irregularity and	
Decay	52
Application of the Rubber Dam	60
Preparation of Filling Materials	67
The Mallet	72
Filling Cavities in Masticating Surfaces	89
Filling Cavities within Labial and Buccal Walls	93
Pieces of Porcelain for Filling Cavities of Decay	96
Filling Cavities within Approximal Walls	100
Preparation of Cavities for Restoration of Contour	104
Restoration of Contour, and Prevention of Extension of	
Decay	111
Summary of Principles relating to Filling Teeth	117
Covering and Protecting Frail Walls of Enamel with	
Gold	119
Placing Crowns on Roots of Teeth	124
Attaching Crowns to Teeth where Roots are Missing	134
Irritation and Death of the Pulp	150
Filling Pulp-Chambers	157
Treatment of Abscess	160
Pericementitis	164
Necrosis	168



PREFACE.

THESE Notes on Operative Dentistry are published for the purpose of aiding those engaged in performing operations for the preservation of the natural teeth, and to enable the earnest, careful student, who possesses the necessary ability, to become such a practitioner as every one should desire and aim to be,—the author believing that if the methods described are faithfully followed each such student can make of himself a really fine operator.

In the description of details, the modes of treatment of the teeth and of operating upon them must necessarily be the methods practiced by the author, and he gives those only which have proved to be—not the easiest but—the very best. The methods followed by different practitioners vary so much that it is almost impossible to ascertain and award the credit due to the author of each; but the methods and suggestions of several first-class operators will be given with due credit in those cases in which the special plan of operating is distinctive enough to have become associated with the name of the practitioner.

The results of the recent investigations made in histology by Prof. Carl Heitzmann and Dr. C. F. W. Bödecker, of New York, are quoted or stated in the first

part of this work, partly because that which follows was written in the light of these latest and best discoveries, partly for the reason that the nearer perfect our knowledge of the dental and other tissues and their elements, and of the living matter throughout and connecting them all, the better qualified we are to make fine discriminations in reference to deviations from normal action, and the more fully prepared we become for the prevention and treatment or cure of disease.

The closing part, which is a selection from the writings of Dr. W. H. Atkinson, of New York, on "Reproduction of Bone, with Special Reference to the Variable Portions of the Maxillæ," merits the closest attention of those who desire to understand the subject of which it treats. In this essay, principles are announced which are not only valuable in leading to an understanding of necrosis, but which are really in advance of anything relating to reproduction of bone previously presented.

All that is possible should be done to save the natural teeth and all parts adjacent to them, so that the wearing of artificial dentures may not become necessary. With the teeth made safe by proper treatment and restored to usefulness by operations successfully performed, and with the enamel kept clear of deposits, each smile of the patient brings to view organs which not only serve the purpose of mastication but add to the attractions of the wearer.

Each operation ought to be well performed at every point, and be made fine throughout, regardless of the fee expected, and the gold should always be given a finely-finished surface. By taking the necessary care and time, beautiful and permanent fillings can be made; the success of the operator be assured and his future made bright,

—every satisfactory operation benefiting not alone the patient but not less the faithful practitioner.

The author sincerely hopes that these Notes will serve the purpose of aiding operators to do such work as is referred to, and he would remind all, that in literature, sculpture, painting, and music, and in operations such as dentists ought to perform, it is not the aim of a Dryden, a Michael Angelo, a Raphael, a Beethoven, or a Varney, to write, carve, paint, bring forth in “concord of sweet sounds,” or to produce in gold, that which requires but little time and skill, and is simply cheap and inartistic; it is the endeavor of the *artist*, whatever the sphere of his efforts, to produce the perfect and beautiful.

MARSHALL H. WEBB.

LANCASTER, PA., U. S. A.,

October 28, 1882.

only on the 12th of the month, and the same day.

1. The first of the month, and the same day.

2. The second of the month, and the same day.

3. The third of the month, and the same day.

4. The fourth of the month, and the same day.

5. The fifth of the month, and the same day.

6. The sixth of the month, and the same day.

7. The seventh of the month, and the same day.

8. The eighth of the month, and the same day.

9. The ninth of the month, and the same day.

10. The tenth of the month, and the same day.

11. The eleventh of the month, and the same day.

12. The twelfth of the month, and the same day.

OPERATIVE DENTISTRY.

BY operative dentistry is meant the application of remedial agents for the correction of perverted function and the removal of abnormal growths, so that the elements of the tissues and organs may be normally reproduced and maintained; the observance of dentition throughout its course, that irregularity of the teeth may be averted, modified, or corrected; and the performance of such operations as shall prevent or arrest solution of the lime-salts, or decay.

HISTOLOGY.

SINCE a knowledge of the histology, as well as of the anatomy, of the teeth and their associate parts is necessary, that the operator may discriminate closely between the different phases of perverted action in the tissues, and thus be able to remove obstructions to normal function, a description of the minute structure of the dentine, cementum, enamel, pericementum, and pulp will here be given, preceded by some brief general statements relating to the elements of tissues, development of the teeth, and the structure of bioplasm (protoplasm).

The elements of tissues are called embryonal corpuscles, bioplasm, or medullary bodies. The elements of these bodies are granules; those of granules, molecules; and those of molecules are atoms. Hence, as it has been graphically described, by the aggregation of atoms in compliance with type by the affinity or affinities of each when awakened and engaged, molecules are formed; in obedience to a like law granular aggregation of molecules is brought about; and then the elements of tissues—corpuscles—are constituted. These bodies, formerly so-called cells, are named (and properly) in accordance with the type of tissue which they build. In nerve, bone, and muscle, for instance, they are called respectively nerve-tissue corpuscles (ganglionic corpuscles and axis cylinders), bone-corpuscles or osteoblasts, and medullary corpuscles.

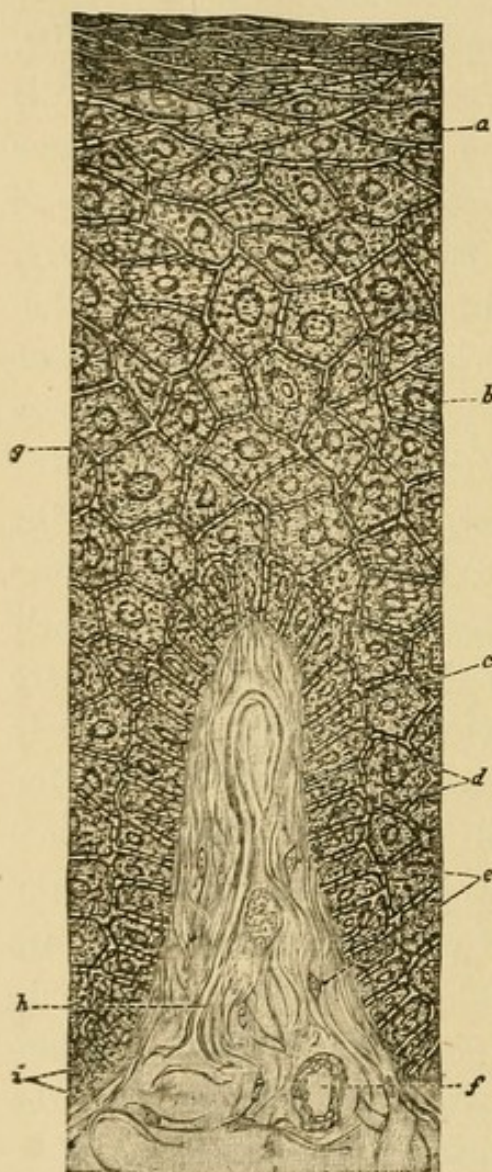
Dentinal and enamel elements are medullary corpuscles or "odontoblasts."

The development of the teeth, succinctly stated by Dr. Atkinson, is as follows: "The first apparent change is called the granular stage, and constitutes, as its name implies, an accumulation of granules, which in process of time becomes the secondary stage, called the papillary, which merges into the third stage, denominated the follicular. When the papules, which constitute the sides of the follicle, have increased sufficiently to unite and close the mouth of the follicle by fusing together, we have the saccular stage, inclosing the germ of the tooth, called the tooth-pulp, consisting of two planes of granular bodies destined to calcification, according to the law of their production, as demanded by the use to which they are assigned. The enamel elements calcify immediately against the first stratum of dentinal elements, towards the periphery of the pulp, until complete. The dentinal bodies calcify towards the center of the pulp until the series of these is exhausted by calcification, and then we say that the tooth is fully developed, leaving now the pulp in the pulp-chamber. The cementum is produced in like manner by characteristic elements, calcifying from the zonal or interglobular layer towards the periphery."

In 1872, Dr. Carl Heitzmann, of New York, discovered a delicate reticulum of living matter pervading the whole mass of bioplasm (protoplasm), and he very soon afterwards found the same minute structure in other tissues of the animal body, mainly epithelium and connective-tissue. Max Schultze described the delicate "thorns" which pierce the cement-substance between epithelial bodies, and connect one such body with another (Fig. 1, *d*), in 1864, and in 1873 Dr. Heitzmann found that these thorns are

fibers of living matter, and that they are continuous with

FIG. 1.*



Part of papilla of the gum near a tooth, magnified 350 diameters; *a*, flat epithelia; *b*, cuboidal epithelium; *c*, columnar epithelium; *d*, Max Schultze's thorns; *e*, connective-tissue corpuscles; *f*, small vein; *g*, reticulum of living matter; *h*, capillary; *i*, connective-tissue bundles.

the reticulum of living matter in the epithelial bodies themselves (*g*, Fig. 1); he also attributes the movement of the cilia of the ciliated epithelium to the constant action of this same living matter throughout the epithelial body. The cement-substance in all epithelial and endothelial formations is pierced by fibers of living matter, as illustrated between the epithelial bodies shown in Fig. 1.

Dr. Heitzmann found that a minute lump of protoplasm, magnified to 1000 diameters, "displays a marvelously complicated structure, which essentially can be designated to be reticulated in nature." When Dr. Heitzmann saw "this reticulum, with its points of intersection, changing its shape, growing in certain conditions," he thought,

"Here is a formation in the protoplasm which is pos-

* The drawings for the cuts to illustrate epithelium and the distribution of living matter in dentine, cementum, enamel, etc., were made by Dr. C. F. W. Bodecker from specimens which he prepared.

sessed of all the properties that are necessary for the condition of living matter, viz., *motion, change of shape, and growth;*" and he concluded that "the solid nucleus, the threads emanating from the nucleus, the granules serving as points of intersection, and the investing layer, are the *real* formations of living matter." He describes the net-like structure of protoplasm thus: "The nucleolus is connected with the wall of the nucleus, and this again with the granules of the protoplasm by very fine threads, which are to be regarded as the living matter of the protoplasm, while the fluid contained within these meshes of living matter does not possess the property of life." This net-like structure is shown, though rather indistinctly, in the protoplasmic body or bone-corpuscle illustrated in Fig. 2, *b*. The main properties of living matter are motion and reproduction. Dr. Heitzmann and his pupils have noticed "contraction and extension, alternately, in every variety of protoplasmic formation; also the increase in size of living matter (swelling of the granules), both in the physiological process of propagation and in the pathological process of inflammation." A half-per-cent. solution of chloride of gold imparts a violet shade to living matter, by which it can be distinctly recognized with high powers of the microscope.

Soon after Dr. Heitzmann discovered the net-like structure of protoplasm, he observed that the living matter, in the form of a reticulum, was present in all the four varieties of connective tissue, viz., myxomatous, fibrous, cartilaginous, and bony.*

Dr. C. F. W. Bödecker, of New York City, after having

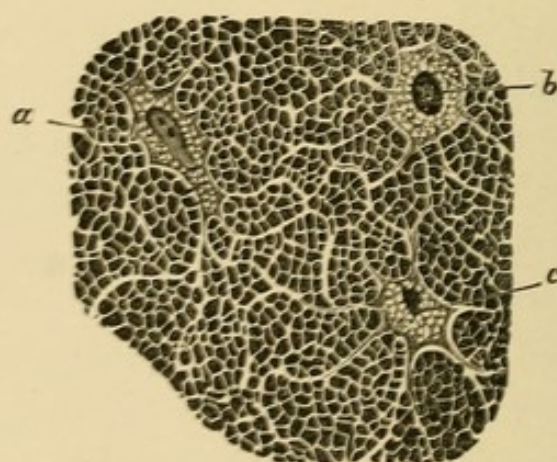
* Dr. Heitzmann very often traces the fibers of living matter for the benefit of his pupils, while instructing them in other elements of tissue, and it was the author's good fortune to have seen them.

pursued the study of various tissues with Dr. Heitzmann (whose pupil he was), extended his researches to the dental tissues; the study of bone had prepared him for the discovery of living matter, which he found distributed throughout the dentine, cementum, and enamel.

In studying bone Dr. Bödecker found a much more delicate net-work of canaliculi than other observers had thought to be present. He found that "the lacunæ of bone-tissue are the spaces in the glue-giving basis-substance, each of these spaces containing a protoplasmic body, with a distinctly visible net-like arrangement, to be regarded as the living matter of the protoplasm. The basis-substance of bone is pierced by canaliculi, which communicate with each other as well as with the lacunæ."

* * * * "The protoplasmic bodies, which do not quite fill the lacunæ, send offshoots of the living matter into the canaliculi."

FIG. 2.



Cross-section from compact bone of the lower jaw of a man about thirty years of age, magnified 1000 diameters; *a*, *b*, and *c*, protoplasmic bodies or bone corpuscles.

In Fig. 2 are shown three protoplasmic bodies or bone-corpuscles; from the offshoots of these, fibers of living matter are distributed through the light reticulum of the basis-substance of the bone. "All three bone-corpuscles

are drawn in the front view, as seen by an immersion-lens, magnifying, with the eye-piece, 1000 times linear. We observe in the center of the protoplasmic bodies *a* and *b*,—a shining, oblong nucleus in *a*, and a round one in *b*, in which the nucleoli are not distinctly visible. Around the nuclei we see a narrow seam, traversed by numerous fine threads, which are cone-shaped. Their bases are directed towards the nucleus, from the periphery of which they arise, while their points are in connection with the nearest granules of the protoplasm. Within the protoplasmic substance there are finer and coarser granules, all of which are connected with one another by very fine threads.”

PREPARATION OF SPECIMENS.*

The method which Dr. Bödecker has found to be the best for the preparation of bone, dentine, and cementum for microscopical purposes is “to immerse only a few teeth in a large vessel with a considerable amount of chromic-acid solution of the strength of a half to one per cent.; to renew the same every third or fourth day, and add, to enforce the action of the fluid, very small quantities of dilute hydrochloric acid. By this treatment the teeth, after a few months, become dark green from the reduction of the chromic acid to the sesquioxide of chromium. This method is doubtless the best for softening teeth, both human and animal, when still in the jaw—wonderful specimens can be obtained in this way by cutting bone and tooth at the same time—and also for preparing specimens from embryos, in order to study the history

*From an essay on “The Distribution of Living Matter in Human Dentine, Cement, and Enamel,” by Dr. C. F. W. Bödecker, read before the American Dental Association, August, 1878.

of development of teeth. This method is highly recommended, although the chromic acid softens the cement and dentine only to a certain depth, so that a tooth kept ever so long in the chromic acid solution never is fit to be cut through in its whole substance at one time.

"The sections so obtained are ready for staining with carmine or hematoxylon after they have been immersed in and washed with distilled water; also for staining with chloride of gold, which latter may be done in the following way: thin sections, after having been washed in distilled water for twenty-four hours and thus freed from the remnants of chromic acid, are to be placed in a solution of chloride of gold of the strength of half of one per cent., by means of glass rods, as metals must be avoided in the treatment with chloride of gold. These sections are to remain in the solution for a half to one hour, and must then be thoroughly washed with distilled water and exposed to daylight for several days, when they are ready for mounting in the ordinary way in glycerin diluted with fifty per cent. of distilled water."

"The only method which enabled me to obtain specimens of teeth provided with all hard tissues is the following: a fresh tooth, or one kept a short time in chromic-acid solution, is sliced under water by a watch-spring saw, and ground as thin as possible upon a corundum-wheel of a lathe, always being kept under water. The lamella thus obtained should be placed in a large quantity of chromic-acid solution of the strength of half of one per cent. for one or two days, with the view of hardening the soft parts of the tooth and dissolving the lime-salts. After this the specimen may be stained with carmine, hematoxylon, chloride of gold, etc., as above described, and mounted in dilute glycerin."

“The best method* of preparing pulp-tissue for examination is, immediately after the removal of the tooth from the mouth, to place it in an aqueous solution of chromic acid of one-half to one per cent. in strength. To this mixture may be added, every third or fourth day, to hasten the process of decalcification, one or two drops of dilute hydrochloric acid. It is important to use a large quantity of the liquid—not less than a quart for one or a few teeth—and renew the same at least every six or eight days. After the teeth have been in the chromic-acid solution a few weeks, the peripheral portion of the dentine will become sufficiently soft to be cut by a razor. When the hard portions of the dentine are reached by the cutting-instrument, the extraction of the lime-salts must again be continued in the manner described above until the pulp-cavity is reached.

“Another method is to split the tooth as soon as possible after its extraction from the mouth with a strong pair of excising-forceps. The teeth best adapted for this method are the incisors, canines, and bicuspid. By an experienced manipulator the pulps of molars can be extricated from their inclosing walls, but with less success than in the teeth before mentioned. In splitting, put the cutting-edges of a sharp pair of excising-forceps in the longitudinal direction near the apex of a single-rooted tooth, then make a sharp and quick pressure, when, as a rule, the tooth will split into halves with the pulp-cavity exposed. Immediately moisten the pulp with a solution of chloride of sodium in water, of the strength of about one-half per cent., and then remove the pulp. The

* Essay read before the New York Odontological Society, March, 1882, by Dr. C. F. W. Bödecker, of New York, on the “Minute Anatomy, Physiology, Pathology, and Therapeutics of the Dental Pulp.”

greatest care must be taken in removing the fragments of the tooth from the pulp-tissue to avoid tearing the organ, which greatly alters the microscopical aspect of nerve-tissue. If the pulp is to be stained with carmine, hematoxylon, fuchsin, hyperosmic acid, picro-indigo, or chloride of gold, etc., it should be placed in the staining-fluid immediately after its removal from the hard parts of the tooth.

“Among the reagents mentioned I have found but one of considerable value, viz., the solution of chloride of gold of the strength of one-half of one per cent. This reagent can be applied to fresh pulps as well as to very thin sections obtained after hardening in chromic acid. These specimens, however, must, as a matter of course, be carefully washed with distilled water before adding the chloride-of-gold solution. This reagent may be allowed to remain in contact with the specimens for from twenty to thirty minutes, when they should again be washed in distilled water and exposed to daylight. In a few days fresh specimens will assume a bright violet color, while sections which have previously been in a chromic-acid solution become brownish-violet. Osmic acid, in solution of one per cent. in strength, renders the contours of the constituent tissues, and especially those of the medullated nerve-fibers, more distinct, as it stains the nerve-fat dark green. Both fresh and chromic-acid specimens may be treated with osmic acid. Thin sections do not require more than an hour's exposure to this reagent, while whole fresh pulps may be left in it for two or three hours. Except the ammoniacal solution of carmine, which is known to be excellent for staining certain parts of the tissue, I would not lay stress upon applying any of the other reagents mentioned.

"If we wish to examine the pulp, together with the inclosing dentine, or a pulp-stone, the specimen, previously softened by chromic acid, must be imbedded in a mixture of paraffin and wax, which is best done in the following manner: place the softened tooth in absolute alcohol for about twenty-four hours; then prepare a box made of rather thick paper, somewhat larger than the specimen; warm the imbedding mixture, which consists of about eight parts of paraffin and one of white wax, until it is barely liquid; pour enough of it into the paper box to about half fill it; then take the specimen out of the alcohol, and as soon as it begins to dry place it in the paper box and pour over it some more of the paraffin and wax, so as to cover it completely. But care must be taken not to have the imbedding mixture too hot, as it may injure the living matter. The specimen then, after the mixture has become sufficiently hard, is ready for cutting, when very thin sections can easily be obtained.

"If a fresh pulp is thin enough it may, immediately after its removal from the split tooth, be transferred to the slide, with the addition of an indifferent fluid, such as the solution of chloride of sodium, etc. But a slight and careful pressure upon the cover is necessary in order to spread fresh specimens. The fresh pulps of lower incisors, being the thinnest, are the best adapted for examining the system of blood-vessels. In a short time, however, these blood-vessels fade away, and the specimen becomes unfit for preservation. Isolated pulps may be placed between two plates of velvet-cork, and thus cut into thin sections with the razor. I would recommend dilute glycerin as the best preserving-fluid for pulp-specimens I have found."

DENTINE.

"We know" (states Dr. Bödecker, in the essay from which we have previously quoted) "that the basis-substance or matrix of the dentine is analogous to that of bone, viz., glue-giving, and at the same time infiltrated with lime-salts. We learn from the researches of E. Neumann that the basis-substance is denser on the walls of the tubuli, and more resistive to the action of strong acids, which cause the appearance of a sheath around each tubule after the solution of the intermediate substance of the matrix between the tubuli. Analogous relations also exist in bone-tissue, in which the basis-substance is decidedly denser on the walls of the lacunæ and Haversian canals.

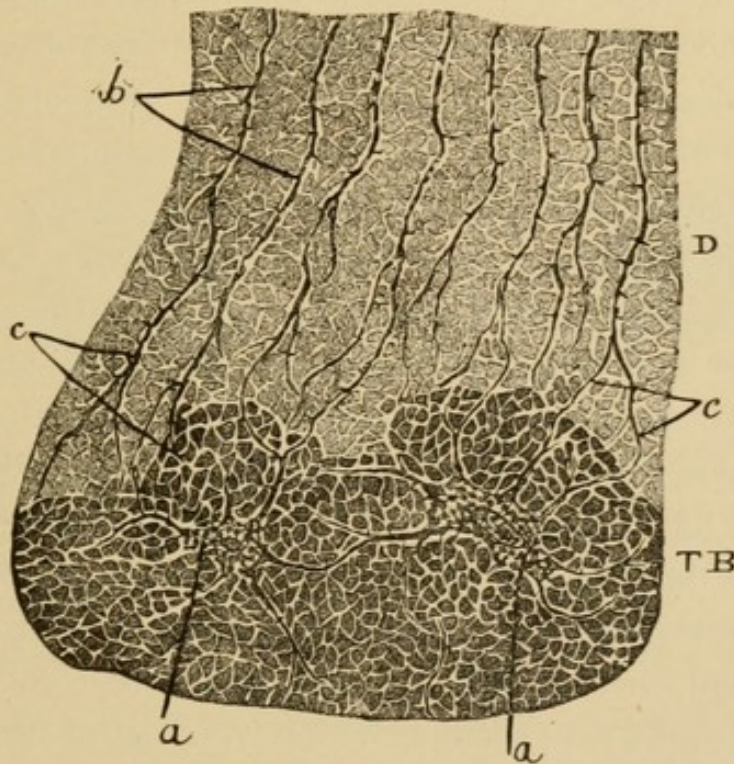
"With low powers we cannot see anything but the tubuli, which I propose to term hereafter 'dental canaliculi.' These canaliculi, as is well known, run in curved sigmoidal lines from the boundary of the pulp-cavity to the periphery of the dentine; they are directed obliquely upward in the crown, and assume a more horizontal direction in the region of the neck, while in the root they remain horizontal or sometimes turn downward to a varying extent. Besides the main sigmoidal curvature, each individual canaliculus exhibits a more or less wavy course in its way through the dentine, and the individual curvatures are, as a rule, very marked on the outer periphery of the dentine."

* * * * "On specimens treated with chloride of gold, the fibers and their delicate offshoots show a distinct violet color, characteristic of living matter within protoplasmic formations, while the space between the fiber and the wall of the canaliculus remains unstained, and the basis-substance between the tubuli only assumes a slight violet tinge."

"Longitudinal sections of dentine, stained with carmine or chloride of gold, if examined with high powers—from 1000 to 1500 diameters (immersion lens)—exhibit the following:

"The canaliculi of the dentine run in a more or less wavy course through the basis-substance, and are, as a rule, bifurcated only on the periphery of the dentine, towards both enamel and cementum. Each canaliculus contains a central, slightly-beaded fiber, which on its

FIG. 3.



Cross-section of root of molar. Stained with half-per-cent. solution of chloride of gold. Magn. 1200 diam. *D*, dentine; *TB*, cement (tooth-bone); *a a*, protoplasmic bodies of the cement, branching and uniting; *b*, dentinal fibers, with their transverse offshoots; *c c*, ramification of dentinal fibers and their union with the offshoots of cement-corpuscles.

Union between dentine, *D*, and cement, *TB*; *a a*, cement-corpuscles with large, branching offshoots connected with one another as well as with the dentine-fibers, *b*, at the bifurcation of the latter, *c c*.

whole periphery sends delicate thorn-like elongations through the light space between the central fiber and the wall of the canaliculus. The thorns are distinctly

conical, their bases being attached to the dentinal fibers, and their points directed towards the basis-substance. The smallest thorns spring in an almost vertical direction from the dentinal fiber, while somewhat larger offshoots may run obliquely through the basis-substance, and directly unite neighboring fibers with one another in the vicinity of the enamel and cementum.

"The basis-substance shows a distinct net-like structure. The light spaces surrounding the dentinal fibers send delicate elongations into the basis-substance, in which, through repeated branching, a light net-work is established, the meshes of which contain the decalcified glue-giving basis-substance. The finest offshoots of the dentinal fibers can be traced only into the mouths of the elongations of the canaliculi; on the periphery of the latter, owing to their great delicacy, the offshoots are lost to sight. Coarser offshoots of the dentinal fibers, at the localities mentioned before, traverse the basis-substance within its light net-work, at the same time uniting dentinal fibers directly, and sending slender, conical offshoots into the light net-work of the basis-substance.

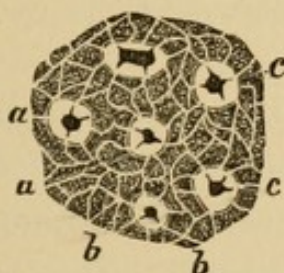
"The dentinal fibers are either in direct connection with coarser offshoots of the protoplasmic bodies of the cementum, or the light net-work of the basis-substance of the dentine is in communication with that of the basis-substance of the cementum. The latter condition prevails on the periphery of the neck of the tooth, where the basis-substance of the dentine is not pierced by the larger offshoots of the dentinal fibers, but only by a delicate net-work, through which the connection between dentine and cementum is indirectly established.

"Where the dentine is in contact with the pulp, the dentinal fibers directly communicate with the odonto-

blasts (John Tomes) in a growing tooth, and with the protoplasmic bodies of the pulp in a fully-developed condition, where no regular odontoblasts can be seen.

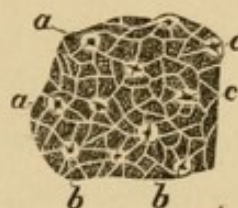"In cross-sections of dentine the dentinal canaliculi are visible in the shape of round or oblong holes; the center of each is occupied by the dentinal fiber, which has the shape of a small, roundish dot. Again, we see that the periphery of the dentinal canaliculus is sharply marked, and repeatedly interrupted by light offshoots leading into the light net-work which pierces the basis-substance between the canaliculi. The central fibers look very distinct and dark violet in specimens stained with chloride

FIG. 4.



Cross-section of dentine of incisor. Stained with half-per-cent. solution of chloride of gold. Main mass of dentine. Magn. 2000 diam. *a a*, dentinal canaliculi with the central dentinal fiber; *c c*, the latter with star-like offshoots, the basis-substance between the canaliculi pierced by a delicate, light net-work, *b b*.

FIG. 5.



Cross-section of dentine of incisor. Stained with half-per-cent. solution of chloride of gold. View from outer periphery of dentine near enamel. Magn. 2000 diam. *a a*, dentinal canaliculi with the central dentinal fibers, *c c*, the latter with star-like offshoots; the basis-substance, *b b*, between the canaliculi, pierced by a delicate, light net-work.

of gold, and send slender, conical, radiated offshoots through the surrounding dentinal canaliculi respectively, towards the mouth of the light interruptions in their walls.

"In directly transverse sections, one, two, or sometimes even three such offshoots can be seen in a star-like arrangement. Each offshoot springs with a broad base from the central dentinal fiber, while its pointed end is always directed towards the perforation in the wall of the canaliculus, where, as a rule, it is lost to sight.

Slightly oblique sections of the canaliculi exhibit both transverse and longitudinal projections of the dentinal fibers. In such an oblique section we may succeed, by cautiously changing the focus, in seeing star-like radiated offshoots up to five in number, all arising from a single dentinal fiber.

“Towards the boundary between dentine and enamel, and dentine and cementum, as is well known, the dentinal canaliculi ramify, and, according to their ramifications also, the dentinal fibers bifurcate, becoming thinner the nearer to the surface of the dentine. Both longitudinal and transverse sections of this part of the dentine show details identical with the main mass, the only difference being that near the periphery the fibers are more delicate and more closely packed together.

“In some teeth I have met on the periphery of the dentine of the crown with the so-called ‘interglobular spaces’ (Czermak), which may be considered as remnants of the embryonic condition of the dentine. They represent lacunæ of greatly varying sizes, bounded by curved lines, the convexities of which are directed towards the central cavity. These spaces sometimes contain protoplasm,—that is to say, embryonal elements which have not been transformed into basis-substance and not calcified. The dentinal fibers enter the protoplasmic bodies, and each fiber is united with the net-work of the protoplasm by means of delicate thorn-like projections. At other times the basis-substance of the dentine is developed within the interglobular spaces, but devoid of lime-salts. In this instance the dentinal fibers, without investment and without changing their course, pierce the basis-substance and send offshoots to this through the surrounding light spaces.”

CEMENTUM.

"It has long been known that there exists a striking analogy between the structures of the cementum and bone.

"Within the basis-substance of the cementum there are numerous branching spaces, in correspondence with the lacunæ of bone. The offshoots of these spaces in the cementum, like the spaces themselves, are very marked in dry specimens, because of their being filled with air. In chromic-acid specimens, on the contrary, the offshoots are much less prominent, and less prominent the more thoroughly the decalcification has been effected. No essential difference is noticeable between the lacunæ and canaliculi of ordinary bone and those of the cementum; in both tissues there exists a great variety as to the general arrangement, the size of the lacunæ, and the number and ramifications of their offshoots.

"The walls of the lacunæ and the coarser offshoots, if viewed with a highly magnifying lens (immersion, 1000 to 1500 diam.), appear interrupted on their peripheries by light spaces, which lead into a light, delicate net-work, piercing the whole basis-substance to such an extent that only the meshes have to be considered as the fields of calcified glue-giving basis-substance.

"Each lacuna contains a protoplasmic body with a central nucleus,—the cement-corpuscle. The nucleus sometimes is relatively large and surrounded only by a narrow seam of protoplasm; while in some small lacunæ a body of the appearance of a nucleus is present without a noticeable amount of surrounding protoplasm. The net-like structure of both the nuclei and the protoplasm is plainly visible in all cement-corpuscles. From the periphery of each corpuscle conical offshoots arise, the coarser of

which penetrate into the larger offshoots of the lacunæ, while the finest offshoots of the protoplasm traverse the light rim between the walls of the lacunæ and the periphery of the protoplasm, being directed towards a light interruption on the boundary of the lacunæ.

“Cement-corpuscles, on the average, are round or spindle-shaped bodies, the long diameter of which corresponds to the direction of the lamellæ. In teeth of juvenile and middle-aged persons we meet with cement-corpuscles surpassing three or four times the size of ordinary ones, in which two or three nuclei are visible. Instead of multinuclear bodies, a number of medullary nucleated elements may fill a large lacuna, all these elements being connected with one another by very delicate threads. The longitudinal diameter of such large lacunæ is sometimes arranged radiately, therefore, perpendicularly to the direction of the lamellæ.

“Numerous cement-corpuscles send broad and branching offshoots through the basis-substance in a perpendicular or oblique direction to the lamellæ, and not infrequently a direct union is established between two or three cement-corpuscles by means of such large offshoots (Fig. 3, *a a*).

“In some teeth broad, spindle-shaped spaces pierce the cementum in a radiated direction, all of which contain protoplasm with delicate offshoots directed towards the net-work in the basis-substance. Nay, sometimes medullary spaces traverse the lamellæ in different directions, which, besides a varying number of medullary elements, contain capillary blood-vessels, evidently in connection with the capillaries of the periosteum. These formations may be considered as remnants of the embryonic condition of the cementum, and are never present in large numbers. All protoplasmic formations within the cemen-

tum, though varying greatly in shape, agree in being connected with one another by the delicate net-work which pierces the basis-substance.

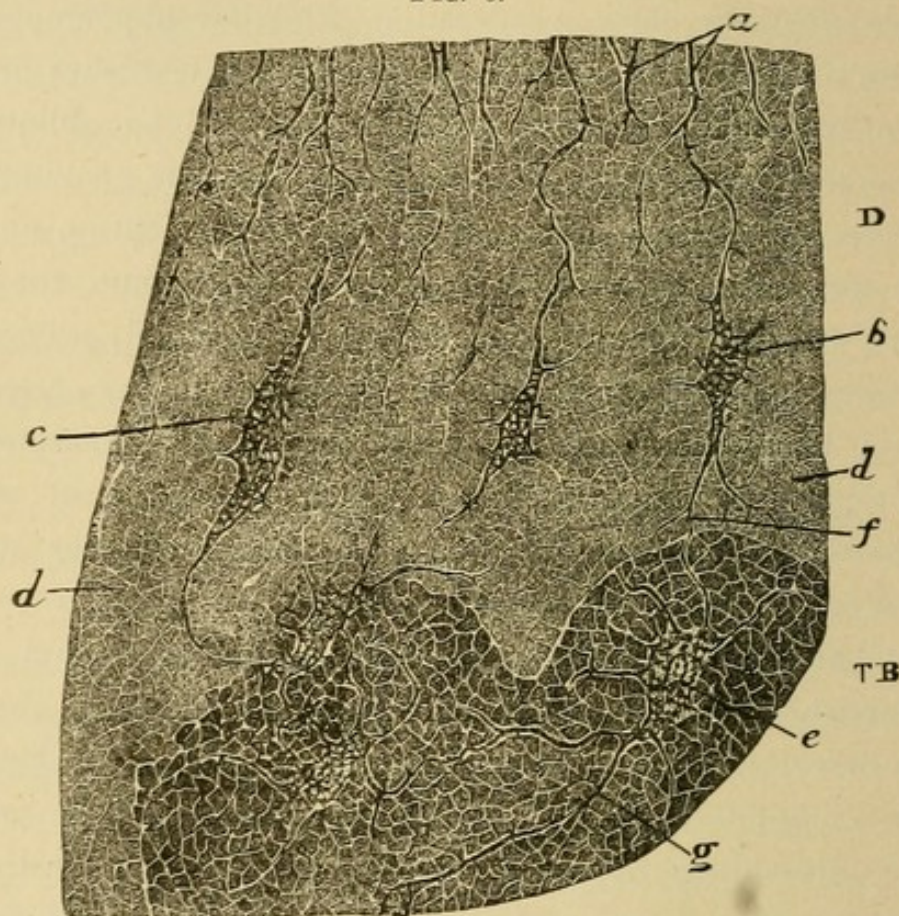
“On the periphery of the cementum, on the line of the connection with the periosteum, the net-work of the protoplasm is usually very broad, and the fields of the basis-substance show a prevailing globular appearance. Also, numerous spindle-shaped protoplasmic bodies are seen in connection with the cementum in an oblique arrangement, forming the transition into the structure of the periosteum. Between the calcified cementum and the striated connective-tissue of the periosteum there often exists a narrow zone, occupied by closely-packed spindle-shaped protoplasmic bodies only. In the periosteum itself there are less numerous, partly nucleated protoplasmic bodies, between which the fields of an apparently homogeneous glue-giving basis-substance are seen.

“The connection between dentine and cementum is established either by a gradual change of one tissue into the other, without a distinct line of demarkation, or there exists a boundary formed by a more or less marked wavy line, presenting irregular, bay-like excavations; lastly, it occurs that between the bay-like excavations and the dentine there is interposed a stratum of the structure of cementum, with a gradual change of the tissue of the former into that of the latter.

“Where a gradual change takes place, the dentinal canaliculi show irregular, mainly spindle-shaped enlargements, which stand in the direction of the dentinal canaliculi themselves, or run obliquely through the basis-substance of the cementum. The distal end of such a spindle is, as a rule, in connection with a regular lacuna

of the cementum, or with an analogous formation of a neighboring dentinal canaliculus. Many of the latter simply pass into the light, delicate net-work characteristic of the basis-substance of cementum. The dentinal fiber is in direct union with the protoplasm which fills the

FIG. 6.



Transition of dentine, *D*, into cement, *TB*, with an intermediate layer of cement-structure. *a*, bifurcating dentine-fibers, in union with elongated cement-corpuscles, *b* and *c*; the latter imbedded in the basis-substance, *d*; between this and the regular cement, with protoplasmic bodies, *e*, the wavy boundary; all cement-corpuscles united with one another by large offshoots, *f* and *g*. Magnified 1200 diameters.

spindle-shaped spaces, or it is lost to sight upon entering the net-work of the basis-substance of the cementum.

“Where a boundary with bay-like excavations is present between dentine and cementum, spindle-shaped enlargements of the dentinal canaliculi may be seen, much smaller than in the former instance. The majority of the dentinal

canaliculi, however, reach the boundary of the cementum after repeated bifurcations, by which both the calibers of the canaliculi and their central fibers are gradually diminished in size.

“A connection of the dentinal fibers with the coarser offshoots of the cement-corpuscles is often observed. The light net-work of the basis-substance of the dentine always passes into that of the cementum. Not very rarely, also, on the bottom of a bay-like excavation, partly nucleated protoplasmic bodies are present, into which the dentinal fibers inosculate. The connection between these and the coarser offshoots of the cement-corpuscles under these circumstances is established by such intervening protoplasmic bodies.

“For the designation of the protoplasmic formations between the dentine and enamel, and dentine and cementum, I choose the term ‘interzonal layer,’ as first proposed by Dr. W. H. Atkinson.”

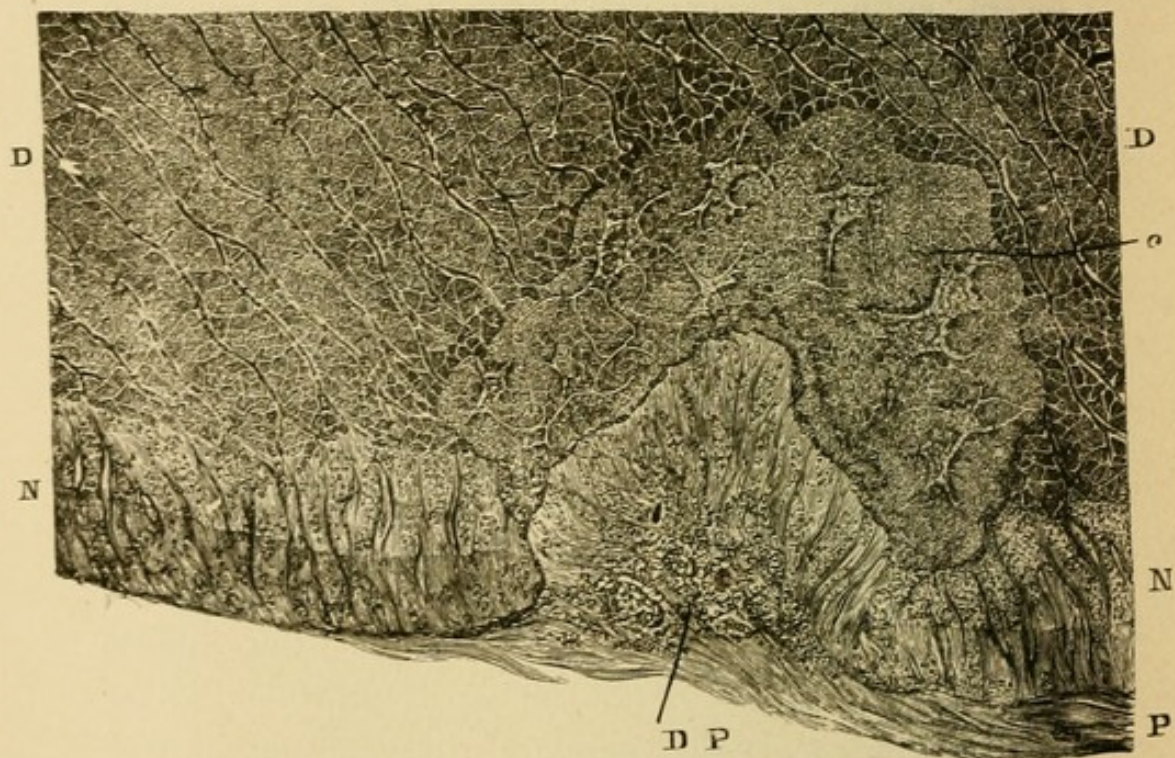
NECK OF TOOTH.

“There are certain peculiarities about the minute anatomy of the neck of the human tooth which, so far as I can judge from the literature within my reach, have not been heretofore mentioned.” * * * *

“The cementum around the neck forms a narrow layer which is cut off obliquely at the place of junction with the enamel. The cementum and enamel in this situation—being of the same width—are separated by a boundary which runs from the outer periphery obliquely downwards to the dentine. This relation I have found in the majority of teeth, and it is only exceptionally that I have met with cementum regularly overlapping the enamel. The cementum on the neck is built up by delicate prisms,

or spindles, arranged vertically to the surface of the dentine. The prisms represent the fields of the basis-substance, and are separated from one another by light rims, holding beaded fibers, or traversed by delicate vertical threads. In transverse sections, when the prisms are cut obliquely, they exhibit irregular, opaque fields separated from each other by light rims.

FIG. 7.



Anomalous formation of cementum on the neck of a human tooth. *D, D*, dentine; *N, N*, cementum on neck of tooth, with spindle-shaped or prismatic fields of basis-substance; *D, P*, depression in the cementum of the neck, filled with elements of periosteum, surrounded upward by a zone of regularly developed cementum. Magnified 1200 diameters.

“These formations closely resemble the protoplasmic bodies of the periosteum next to the cementum alluded to in the former chapter; hence I do not hesitate to consider the bony formation on the neck as being produced by calcification of the osteoblasts of the periosteum. The cementum on the neck of the tooth is devoid of lamellæ and lacunæ, which appear deeper below, together

with all the characteristic features of the fully-developed structure of the cementum. The lamellæ become the more distinct, and the lacunæ, with their contents (the cement-corpuscles), the more numerous, the broader the diameter of the layer of the cementum.

"The outer surface of the cementum is covered on its upper part with epithelial elements, in close resemblance with those of Nasmyth's layer of the enamel. This layer turns over into the epithelial coat of the gum. Further down, the cementum, though still endowed with properties characteristic of the neck of the tooth, is surrounded by the fibrous connective-tissue of the periosteum."

ENAMEL.

"The best specimens of enamel for examination I obtained by grinding fresh teeth, and staining them for one hour with the half-per-cent. solution of chloride of gold, as mentioned in the description of methods for the examination of teeth in general.

"In longitudinal sections we see delicate, beaded fibers, which occupy the central portion of the interstices between the enamel-rods. These fibers I propose hereafter to term the 'enamel-fibers.'

"From such a fiber arise very minute conical fibrillæ, which traverse the rims between the fiber and the neighboring outlines of the rods, and fade away from the moment they enter the latter. The columns of the basis-substance are themselves pierced by delicate canaliculi,

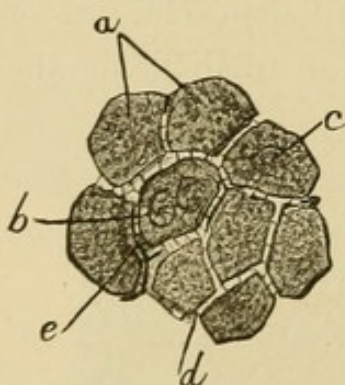
FIG. 8.



Longitudinal section of enamel. *a*, enamel-rods, traversed by prevailing vertical spaces; *b*, enamel-fibers, branching and partly uniting through delicate offshoots. Numerous fine thorns of the fibers directed towards the light interruptions within the rods. Magnified 1200 diameters.

running in an almost vertical direction through the enamel-rods, regularly enough to give the appearance of squares, although these are much smaller than usually represented in the books. In the midst of a minute square light canals are seen, not infrequently running parallel with the outlines of the enamel-rod. The square fields thus produced by the rectangular crossing of light channels look, under the power of 1200 diameters, finely granular. In specimens not fully decalcified it is impossible to decide whether there is a light net-work within the enamel prisms analogous to that in the basis-substance of the dentine and cementum, or whether the granular appearance is merely due to the deposition of lime-salts. In thoroughly decalcified specimens of enamel, however, such as were first made by Dr. Frank Abbott, there is

FIG. 9.



Cross-section through enamel. *a*, rods of enamel, partly exhibiting formations like nuclei; *b*, *c*, *d*, light interstices between the rods, traversed by delicate beaded fibers, *e*, or by vertical thorns. Magnified 2000 diameters.

no difficulty in seeing, with high powers, the reticular structure of protoplasm. I am indebted to the above-named observer for having first drawn my attention to this fact.

“Cross-sections of the enamel which we obtain also in longitudinal sections of the tooth, on account of the different directions of the bundles of the enamel-rods, plainly exhibit the irregular polyhedral fields of the enamel-rods. The light interstices between the polyhedral fields contain in many instances delicate, beaded fibers, surrounding the polyhedral fields of the enamel-rods. The fibers, if cut transversely, have the appearance of dots, and connect with one another directly or by means of intervening delicate threads.

“Extremely fine thorns traverse in a vertical direction the light space between two neighboring enamel-rods, even where a fiber is not visible. These threads are identical with the delicate thorns first described by Max Schultze, in 1864, in the cement-substance of epithelial formations.

“The rods of the enamel on an average are half the diameter of the columns of the basis-substance in dentine; therefore four columns of the former will correspond to two of the latter, and consequently two dentinal fibers will answer to four enamel-fibers. Sometimes in the cross-section of an enamel-rod I met with roundish formations occupying the center of the rod, one or two in number, which, owing to a denser granulation and a surrounding shell, have the appearance of nuclei. The enamel-fibers run a very straight course towards the surface, and are here, on the average, a trifle thicker than near the boundary of the dentine.

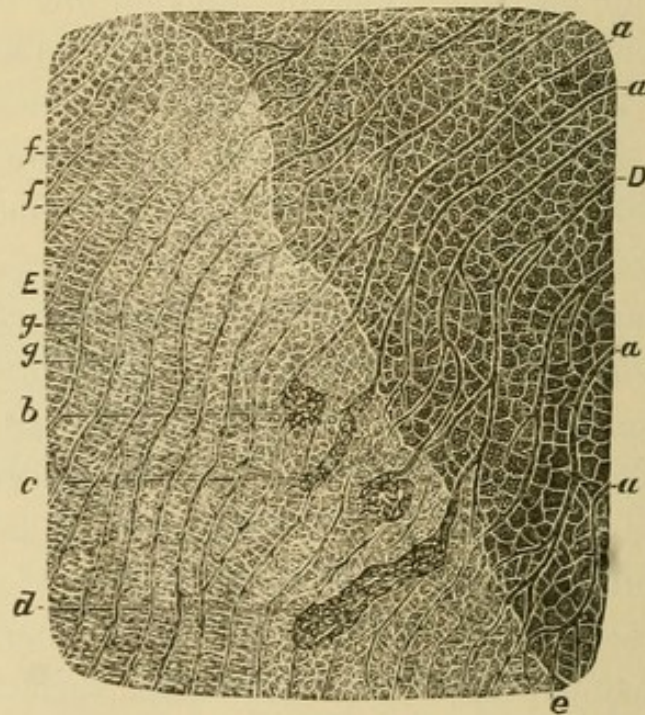
“The outermost surface of the enamel is covered with flat epithelia (Nasmyth's membrane), which in the transverse section have the appearance of shallow spindles; not infrequently there also occurs a stratified epithelium on the surface of the tooth. The enamel-fibers are in connection with these epithelial bodies, which, if detached, show delicate offshoots adhering in regular intervals—the broken enamel-fibers. Sometimes the surface of the enamel is coated with a thin, uniform layer of protoplasm, with regularly scattered nuclei. In such an instance single epithelia are not traceable, though scarcely any doubt can arise about the epithelial nature of this layer.

“At the place of junction of the enamel with the dentine a direct connection is often seen between the enamel- and dentine-fibers. The latter, through repeated bifur-

cations, being closely brought together, continue their course into the enamel-fibers without any interruption. The direction of the fibers of the two tissues, however, is almost never identical, inasmuch as the enamel-rods, and consequently the enamel-fibers, as a rule, owing to their wavy course in this situation, are obliquely intercepted upon the dentine.

"We can very often trace dentinal fibers up into the enamel in a varying distance, without a distinct union between the enamel- and dentine-fibers, as the former do not reach the surface of the dentine, but terminate above

FIG. 10.



Union of dentine with enamel. *D*, dentine; *E*, enamel; *a a*, dentinal fibers, being in union with large protoplasmic bodies, *b c d*, or directly running into enamel-fibers, *e g*. The latter often are lost in the delicate irregular net-work on the bottom of the enamel, *f f*. Magnified 1200 diameters.

its level in different heights, while the zone close above this is occupied by a delicate, irregular net-work, analogous to that of the dentine. Here no rods of enamel are visible, either in longitudinal or transverse sections,

but with low powers of the microscope only a finely-granular layer is presented.

“In many places the dentinal canaliculi upon entering the enamel suddenly become enlarged, and form more or less distinctly spindle-shaped cavities of greatly varying diameters, analogous to the spindle-shaped enlargements on the boundary of the cementum. These enlargements run either in the main direction of the dentinal canaliculi or deviate obliquely. They invariably contain protoplasmic bodies, which plainly show the reticular structure, and sometimes contain one or more compact clusters, to be considered as nuclei. The spindle-shaped protoplasmic bodies, on their proximate ends, are in direct connection with the terminations of the dentinal fibers which have arisen from their repeated bifurcations, while on the distal ends they may show delicate fibers, viz., enamel-fibers, or delicate conical thorns, traversing the light space between the surface of the protoplasmic body and the wall of the cavity. These thorns are lost to sight on passing into the net-work at the bottom of the enamel. In some places, especially on the cusps, the spindle-shaped enlargements of the dentine-fibers are quite numerous, and of an almost uniform size and direction, forming regular rows of spindles within the enamel. In the teeth of younger individuals the spindle-shaped enlargements are comparatively larger and more regular than in the teeth of old people.

“The boundary line between the dentine and enamel is either straight or slightly wavy, and with more or less deep bay-like excavations, analogous to those on the boundary between dentine and cementum. The concavities of the bays are directed towards the dentine. In this interzonal layer at the bottom of the bays we meet with fibers occupying the curved spaces between dentine and

enamel, or we will see in a correspondingly bent direction protoplasmic bodies directly connected with the dentinal fibers downwards, and with the enamel-fibers upwards. In specimens stained with chloride of gold the dentine is always much deeper in color than the enamel, hence the relations described are very plainly marked on such specimens."

PERICEMENTUM.*

"The pericementum * * * is a formation of connective tissue, identical with the periosteum which covers all bones. It consists of a layer interposed between the roots of the teeth and their corresponding bony alveoli, and is common to both. It is continuous with the connective tissue—the so-called sub-mucous layer—of the gum, and with the periosteum of the maxillæ. Its fibers are connected with the cementum of the root as well as with the wall of the alveolus."

"The course taken by the connective-tissue bundles is slightly wavy and oblique, starting from the cementum and running upward towards the alveolus. The bundles of this tissue are very dense, without many decussations. The parallel direction of the bundles begins to change into a diverging one at about the height of the border of the socket, where the bundles became coarser, decussate, and thus produce the elastic connective-tissue cushion termed the gum.

"From the anatomical disposition of the pericementum conclusions may be drawn as to its physiological action. It is obvious that the relatively soft and elastic layer between the two bony formations—cementum and alveolus—

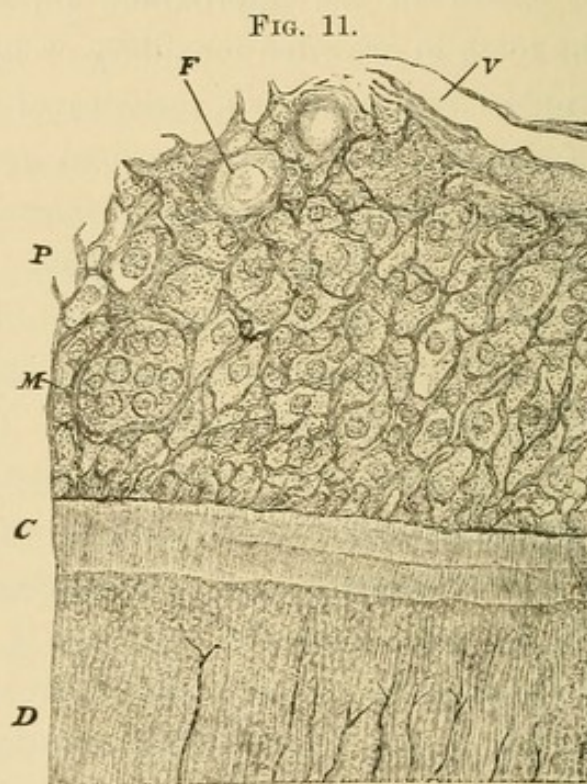
* "On Pericementum and Pericementitis." By C. F. W. Bodecker, M.D., D.D.S., *Dental Cosmos*, 1879.

is designed to lessen the concussion upon the jaw-bones during mastication. The oblique direction of the connective-tissue bundles is the most favorable for the suspension of the tooth within its socket, as the bundles correspond to the funnel shape of the socket, in the center of which is situated the conical root of the tooth. The elasticity of the layer of pericementum admits of a slight degree of motion of the roots; hence we understand the formation of facets on the approximal surfaces of the crowns of the teeth in crowded maxillary arches.

“My specimens represent two varieties of pericementum,—one of a reticular structure, termed myxomatous; the other is altogether fibrous. The myxomatous variety I have met with as a rule in young individuals. It consists of delicate fibers, or bundles of fibers, in a net-like arrangement, which in many instances are supplied with round or oblong nuclei at the points of intersection. The meshes contain either a hyaline, apparently structureless, sometimes finely-granular basis-substance, or they hold protoplasmic bodies provided with a varying number of nuclei. The nearer to the cementum the narrower is the myxomatous reticulum, and the smaller therefore are the inclosed protoplasmic bodies. The latter, in the immediate vicinity of the cementum, stand in more or less regular rows, entirely analogous to the protoplasmic bodies around the developing bony tissue, known, since Gegenbaur, as ‘osteoblasts.’ Some of the meshes of the myxomatous tissue are considerably larger and contain multinuclear protoplasmic bodies, termed ‘myeloplaxes’ by Robin, of Paris; giant cells by R. Virchow, of Berlin, and myeloid cells by English authors. Other meshes hold fat globules, which, in specimens preserved and hardened in a solution of chromic acid, very often contain closed spaces, so-called

vacuoles. The myxomatous reticulum is traversed by numerous blood-vessels, mainly capillaries and veins, some of which can be seen entering the medullary spaces of the compact bone of the wall of the alveolus, and in connection with the capillary system of the cancellous portion of the alveolus. I have met with but few nerve fibers in my specimens.

"Fig. 11 illustrates a portion of the myxomatous variety



Pericementum of myxomatous structure. *D*, dentine; *C*, cementum of neck; *P*, pericementum; *M*, multinuclear protoplasmic body; *V*, capillary blood-vessel; *F*, fat globule with a vacuole. Magnified 500 diameters.

of pericementum as shown with a relatively low power. High amplification of the microscope plainly demonstrates the delicate reticular structure of all protoplasmic bodies; the reticulum being visible not only in the contents of the meshes, but also within the fibers of the myxomatous reticulum. The latter feature is recognizable best on specimens deeply stained with chloride of gold. The

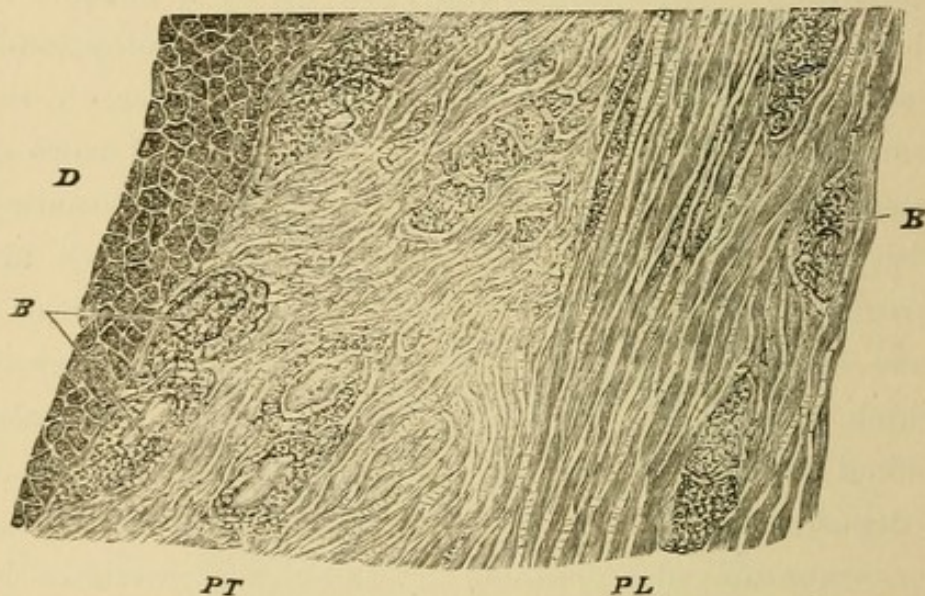
apparently structureless or indistinctly granular myxomatous basis-substance, held in the meshes of the myxomatous reticulum, proves to be a reticular structure just as well as the protoplasm itself.

“The second variety of pericementum is built up by fibrous connective-tissue, which prevails in adults and persons in advanced age. The bundles of the fibrous connective-tissue may be uniform in width throughout the whole pericementum; or there exists a zone of myxomatous or indistinctly fibrous character close around the cementum. The bundles are built up by a number of fibers, which hold a varying number of protoplasmic bodies; as a rule, more numerous the nearer to the cementum. On the latter there may be found rows of osteoblasts or scattered protoplasmic bodies alternating with bundles of a delicate connective-tissue, which are directly attached to the cementum. In a few instances I have seen rows of osteoblasts the refracting power of which was considerably augmented. Such corpuscles looked shining and structureless, evidently on account of a deposition of lime-salts. The fibrous variety of the pericementum also contains fat-globules, sometimes in surprisingly large quantities.

“High magnifying powers of the microscope reveal a structure of the fibrous connective-tissue, as follows: The fibers, a certain number of which combine in the formation of a bundle, are delicate spindles, directly connected with one another at their pointed ends. These spindles are separated from one another by a narrow layer of a light substance, to the presence of which Tomsa, of Kiev, Russia, first drew attention, and for which he proposed the term ‘cement-substance.’ This substance is doubtless kindred to the gluey basis-substance which mainly builds

up the spindles of the connective-tissue. The interstices between the spindles are traversed in a vertical direction by extremely minute threads every way analogous to the thorns in the cement-substance surrounding epithelial elements. These threads in many instances are visible in specimens hardened by the chromic-acid solution; they become very plain when thin sections have been immersed in a half-per-cent. solution of chloride of gold for one or two hours, or until the specimen has assumed a dark

FIG. 12.



Pericementum of fibrous structure. *D*, cementum of root; *PL*, pericementum, the fibers of which are built up by spindles, in longitudinal section; *PT*, pericementum, the elementary spindles of which are finer and cut obliquely; *B*, protoplasmic bodies, either so-called connective-tissue corpuscles or so-called osteoblasts. Magnified 1200 diameters.

violet color. If the stain be complete, we also recognize that the spindles are not homogeneous, as they look in fresh, unstained specimens, but are rather traversed by a delicate, dark violet reticulum, the points of intersection of which are slightly thickened, and thus represent granules. (See Fig. 12).

“Between the spindles of the basis-substance protoplasmic bodies are seen—the formerly so-called connective-

tissue cells. Some of these bodies exhibit shining, compact, oblong nuclei, with a certain amount of surrounding protoplasm, while others are devoid of nuclei, and split into spindle-shaped or polygonal lumps, which in size and shape fully correspond to the elementary formations of the fibrous basis-substance. Where there is a central nucleus, it is invariably bounded by a light rim, which is pierced by radiating thorns. The latter connect the circumference of the nucleus with the granules of the protoplasm next to the nucleus. The protoplasm under all circumstances exhibits the well-known reticular structure. From the periphery of a protoplasmic body, each being surrounded by a light rim, minute threads spring forth and run into the reticulum within the spindles of the basis-substance. The same relations are seen on protoplasmic bodies next to the cementum,—the so-called osteoblasts. The offshoots of these formations run partly to the spindles of the basis-substance and partly into the light reticulum within the cementum. In some instances, between the cementum and the osteoblasts there is interposed a small layer of fibrous basis-substance in the shape of delicate slender spindles. The walls of the capillaries, which consist of a single layer of endothelia, are also connected with the neighboring spindles of the basis-substance by means of delicate threads, which traverse the light rim around the blood-vessels,—the so-called perivascular space. Lastly, such offshoots run also into the light reticulum of the bone-tissue, where the pericementum is attached to the wall of the alveolus.”

* * * * “In its juvenile condition the pericementum represents a myxomatous connective-tissue, the fibrous portion of which is relatively scanty, while the protoplasmic portion prevails. In this instance two varieties of basis-

substance occur, viz., the fibrous, building up the reticulum, and the myxomatous, filling a certain portion of the meshes. This condition arises, first, from the indifferent or embryonal tissue, not only in the pericementum, but in all formations of connective-tissue which, when fully developed, exhibit a fibrous structure. The only way to explain the formation of the myxomatous tissue is, that a part of the protoplasm constituting the embryonal elements remains unchanged, a part is transformed into spindles of the myxomatous reticulum, and a part into myxomatous basis-substance."

* * * * "The myxomatous tissue as such never changes directly into a fibrous one, but must first be reduced into its embryonal or protoplasmic condition, and from this in turn fibrous connective-tissue may arise. The latter process is explained by the splitting and elongation of the protoplasmic bodies into spindles, which become solidified; in other words, the lifeless fluid is transformed into a gluey basis-substance.

"At no time has the reticulum of the living matter been interrupted or torn; the pericementum has never ceased to be a tissue either in its embryonal, myxomatous, or fibrous condition. On the theory here explained, all changes in inflammatory processes of the pericementum may be easily understood."

THE MINUTE STRUCTURE OF NORMAL PULP-TISSUE.

"If we examine a thin longitudinal or transverse section of the pulp with low powers of the microscope (200 diameters), we recognize a large number of blood-vessels and bundles of medullated nerve-fibers. The majority of these blood-vessels are capillaries; the veins are less numerous, and arteries are scarce. In many pulps we find

no arteries at all; in others a limited number, very often in the midst of the medullated nerve-bundles. The medullated nerve-bundles mostly run in a longitudinal direction, but not infrequently we observe smaller bundles, or single medullated nerve-fibers, diverge from the longitudinal direction, running obliquely through the pulp-tissue.

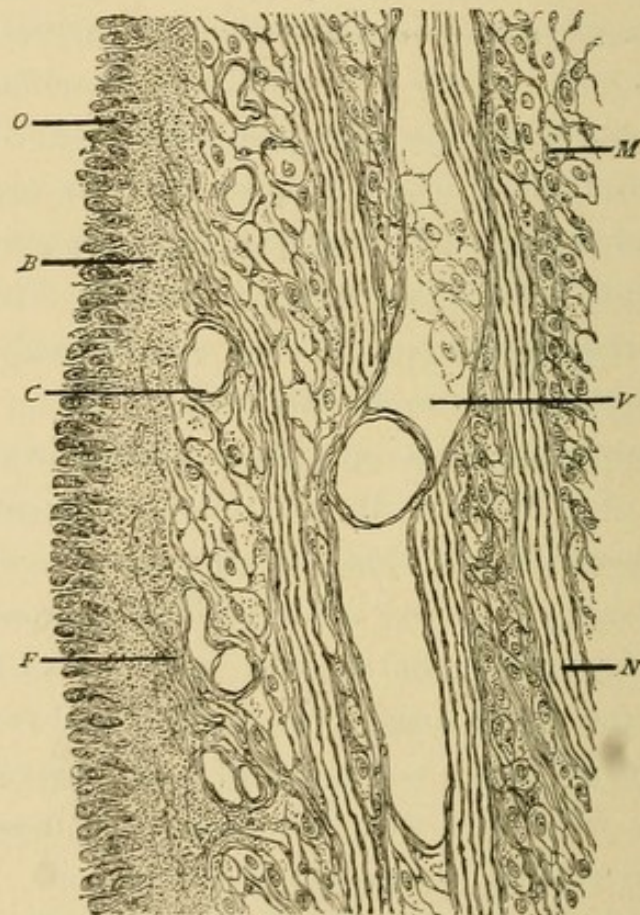
“In transverse sections of the pulp we meet with arteries, veins, and capillaries,—the first cut across, the others distributed in all directions. The bundles of medullated nerve-fibers are seen most distinctly in transverse sections. They often hold in their interstitial tissue capillary vessels and arterioles, which also appear in transverse section. In very thin sections it often happens that the nerve-fibers fall out, and then we see a roundish, empty space, bounded by the sharply-defined external perineurium. The absence of an endothelial coat renders such spaces easily recognizable in distinction from blood-vessels.

“The main mass of the pulp, as seen with low powers, is composed of a delicate fibrous reticulum, containing a large number of bright, shining corpuscles. Longitudinal sections in many instances exhibit delicate fibrous bundles scattered throughout the reticular structure of the pulp, mostly in the neighborhood of large blood-vessels and nerve-bundles. Pulps composed of a fibrous connective-tissue only are rather exceptional, and, as it seems, are without any relation to the age of the person. They are probably the result of morbid processes. Toward the outer surface of the pulp the reticular structure is, as a rule, denser than in the middle portions. This peripheral part is surrounded by a wreath of elongated formations arranged in a radiating manner all around the pulp—the so-called ‘odontoblast layer.’

“Higher powers of the microscope (500 to 600 diameters)

reveal a minute reticular structure, consisting of delicate fibers of anastomosing bioplasson cords, with very small oblong nuclei at their points of intersection. The mesh-spaces inclosed by this reticulum either look pale and finely granular throughout, or there is, besides the pale granular substance, a bright yellowish body, either homogeneous or granular, of the size and aspect of a nucleus. The number of the latter formations varies greatly in

FIG. 13.



Segment of the pulp of a first molar. Longitudinal section. *M*, myxomatous connective tissue; *V*, vein; *C*, capillary blood-vessel; *N*, bundle of medullated nerve-fibers; *F*, terminal non-medullated nerve-fibers; *B*, bioplasson layer, containing the terminations of the nerves; *O*, layer of medullary corpuscles, termed odontoblasts. Magnified 250 diameters.

different pulps. Where bundles of a fibrous tissue traverse the reticulum, there the latter blend with the former. In the fibrous bundles, besides the delicate fibrillæ, we see scanty and small oblong nuclei.

“As mentioned before, the fibrous connective-tissue prevails at the periphery of the larger blood-vessels and nerve-bundles. In transverse sections these nerve-bundles invariably exhibit a distinct fibrous sheath containing oblong nuclei—the so-called external perineurium. The nuclei imbedded in the sheath do not project above the level of the sheath, as is plainly observable on empty ones where the fibres have fallen out, while the endothelia of blood-vessels of any description invariably protrude toward the inclosed space, thus affording an excellent means of distinction between blood-vessels and empty nerve-sheaths.

“The arteries are characterized by the presence of a layer of smooth muscles, outside of which is seen a slight fibrous coat. The layer of smooth muscles necessarily thickens the walls of the blood-vessels, thus rendering them easily recognizable in transverse sections. The veins are marked by their large caliber and a fibrous coat, being at the same time filled with blood-corpuscles. The capillaries are composed of a single endothelial layer, which is separated from the adjacent reticulum by an extremely delicate light rim. They are either found empty or containing a few blood-corpuscles.

“In longitudinal sections the medullated nerve-fibers show the well-known fluted double contour of considerable refraction (the sheath of Schwann). Inside of this is the myelin (nerve-fat), concealing the central axis-cylinder. Schwann's sheath exhibits delicate oblong or spindle-shaped nuclei, and external to this we observe a very delicate layer of fibrous connective tissue—‘the internal perineurium.’ In cross-sections of the nerve-bundles a more or less circular group of medullated nerve-fibers is seen, each of which in its center exhibits the axis-cylinder

in the shape of a roundish, glistening dot, the single nerve-fibers being separated from one another by the delicate internal perineurium. Not infrequently capillary and arterial blood-vessels are met with between the nerve-fibers which, at the periphery of the bundles, blend with the nucleated sheath of the external perineurium.

“As to lymphatics of the pulp, I can say that in some specimens I have seen branches of vessels of the size of veins without an adventitial coat, being composed of large, flat, slightly-protruding endothelia. These vessels I believe to be lymphatics, as they contained a finely-granular coagulated albumen, scanty granular corpuscles, and a very limited number of blood-corpuscles. As to the distribution of lymphatics, I must abstain from positive statements.

“At the periphery of the pulp the delicate reticulum constituting the pulp-tissue is very dense, and its small meshes are supplied with numerous corpuscles looking like nuclei. In this layer we meet with only very narrow capillary blood-vessels. The outer surface of this layer is bounded by radiating rows of shining corpuscles of the size and appearance of nuclei. These rows are separated from one another in a longitudinal direction by light rims, in which delicate fibrillæ can be frequently observed.

“In chromic-acid specimens stained with carmine, or, still better, in those treated with chloride of gold, high powers (1000 to 1200 diameters) reveal an extremely minute reticular structure pervading all formations of the pulp-tissue. It is this structure, that of bioplaxson as well as basis-substance, that C. Heitzmann discovered in 1873. (*‘Untersuchungen über das Protoplasma, Sitzungs-Berichte der Kaiserlichen Academie in Wien.’*) Starting from the center of a mesh-space, we see a body like a

nucleus, either homogeneous and apparently destitute of structure, or with the appearance of a vesicle with a distinct, bright wall. Inside the hollow nucleus we see a varying number of bright granules, interconnected with one another as well as with the inclosing wall by means of delicate filaments. Around the nucleus a minute light rim is seen, which again is traversed by radiating filaments connecting the nucleus with the extremely delicate grayish reticulum pervading the light basis-substance contained in the mesh-spaces of the fibrous net-work. The delicate reticulum in the basis-substance is recognizable, even though the central nucleus be absent. The fibrous or bioplasson net-work which incloses the mesh-spaces also shows a delicate reticulum in connection with the nuclei at the points of intersection. Thus, all coarser reticular structures, as well as the fields of basis-substance, are traversed by an extremely delicate reticulum, which C. Heitzmann claims to be living matter proper. In this view I fully concur, and, so far as my experience goes, I would mention that inflammation in general, as well as that of the dental pulp, cannot be understood unless the presence of living matter throughout all formations of bioplasson as well as basis-substance is admitted. It is this matter which grows and leads to a new formation, so strikingly shown in inflammation. I may add that fibrillæ of living matter are directly connected with the blood-vessels by means of delicate offshoots penetrating the light rim around the blood-vessels called the 'perivascular space.'

"The formations at the periphery of the dental pulp, termed 'odontoblasts' by J. Tomes, and which by some observers have been considered as epithelial-like formations, under high amplifications exhibit the following:

“Longitudinal fields, somewhat resembling epithelia, border the pulp in a radiatory direction. Such a field may appear in the shape of a finely-granular bioplasson or basis-substance, in which there are imbedded oblong nuclei in varying numbers. The nuclei exhibit coarse granules and a dense reticulum of living matter, while the elongated fields inclosing the nuclei exhibit pale granules and a delicate bioplasson reticulum. Between these latter formations a delicate light rim is seen, wherein we observe sometimes broad, sometimes delicate, fibrillæ in connection with the reticulum of neighboring formations, accompanied by delicate conical offshoots, which penetrate the surrounding rims at right angles. In many instances these formations between the odontoblasts can be followed into the dentinal fibers, lodging in the midst of the dentinal canaliculi.

“It is obvious, from what I have seen, that the odontoblasts furnish the matrix for the basis-substance of the dentine, whereas the dentinal fibers, being formations of living matter, originate *between* the odontoblasts. When studying secondary dentine I described and depicted a specimen corroborating this assertion. (*Dental Cosmos*, vol. xxi., p. 412).

“The manner in which the bioplasson of the odontoblasts is transformed can be understood only on the basis provided by the researches of C. Heitzmann (*loc. cit.*), who claims that the liquid held in the meshes of the reticulum of living matter is rendered solid and glue-yielding by a chemical process, while the living reticulum itself remains unchanged, and merely becomes invisible because it has nearly the same refracting power as the basis-substance. Where the refracting power varies enough, the formations of living matter remain distinctly perceptible.

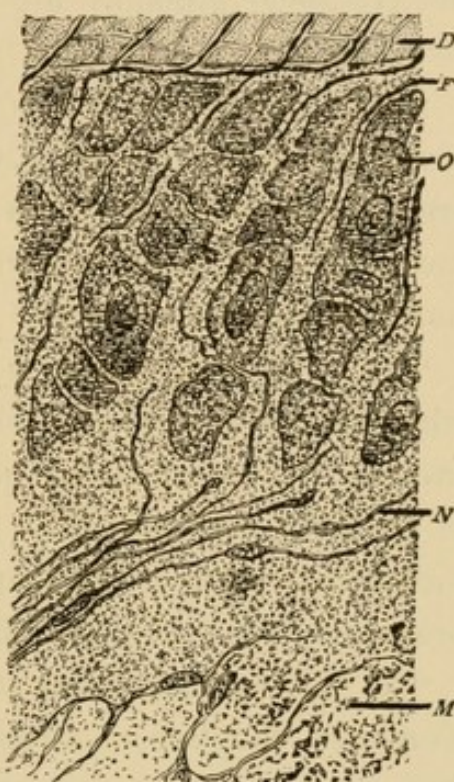
Such is the case with the dentinal fibers and their transverse conical offshoots within the dentinal canaliculi.

"In sufficiently stained chloride-of-gold specimens of a nine-months' fetal pulp I have observed that the medullated nerve-fibers, upon approaching the periphery of the pulp, are destitute of their myeline sheath, and now, being bare, the axis-cylinders split into numerous extremely delicate beaded fibrillæ—the 'axis fibrillæ.' They are marked by a dark violet color, and run in the light rims between the rows of the odontoblasts near the pulp-tissue proper, and are connected with the odontoblasts by means of delicate conical offshoots. In some instances I have observed that these axis fibrillæ terminated in knob-like extremities. But whether the nerve-fibers directly anastomose with the dentinal fibers I am unable to say. That an indirect connection of the two is established by the intervening reticulum of living matter I positively assert.

"The results of my researches of the normal pulp are as follows:

"I. The dental pulp is a variety of connective-tissue termed myxomatous, representing an embryonal form of

FIG. 14.



Segment of the pulp of a temporary tooth, stained with chloride of gold. *M*, myxomatous connective-tissue; *N*, terminal non-medullated nerve-fibers, in a uniformly granular bioplasm layer; *O*, rows of medullary corpuscles, termed odontoblasts; *F*, dentinal fibers between the odontoblasts; *D*, dentine. Magnified 1200 diameters.

it. Pulp-tissue, therefore, is a remnant of embryonal tissue, lasting in some instances throughout life, and kindred to those formations termed 'adenoid tissue.'

"II. The myxomatous tissue of the pulp is intermixed with a delicate fibrous connective-tissue in varying quantities. Pulps entirely or nearly built up by fibrous connective-tissue probably are not to be considered physiological.

"III. The pulp-tissue is traversed by a close system of blood-vessels, viz.: arteries, veins, and capillaries. Arteries are not invariably found in the pulp, but they are by no means of exceptional occurrence. Lymphatics in small numbers are also present.

"IV. The pulp-tissue is richly supplied with nerves, which, in the shape of bundles of medullated nerve-fibers, traverse the myxomatous tissue. Toward the periphery of the pulp they lose their myeline sheaths, become non-medullated, and, in the shape of minute beaded fibrillæ, branch between the odontoblasts.

"V. The odontoblasts at the periphery of the pulp are elongated bioplasm formations with rows of nuclei. They are medullary corpuscles such as we see wherever a new tissue arises from a former one. They build up the basis-substance of the dentine by solidification (transformation into glue, and infiltration with lime-salts). The reticulum of living matter traversing the odontoblasts remains unchanged in the basis-substance of the dentine.

"VI. The dentinal fibers originate between the odontoblasts. Being formations of living matter, they are in direct connection with the reticulum of living matter—first of the odontoblasts and afterwards of the basis-substance of the dentine. The connection between the

ultimate nerve-fibrillæ and dentinal fibers is very probably an indirect one by means of the intervening reticulum of living matter."

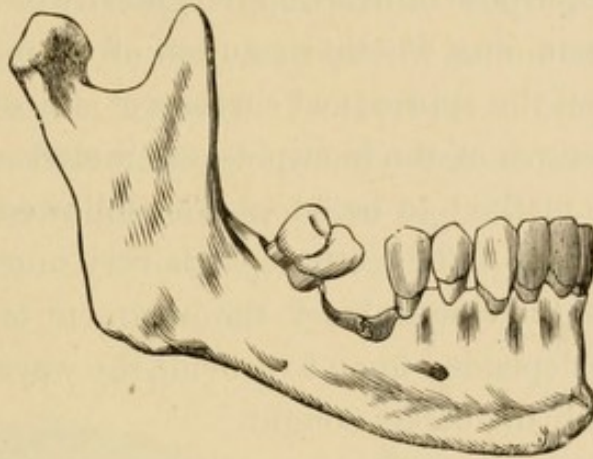
THE DECIDUOUS TEETH—PREVENTION OF IRREGULARITY AND DECAY.

THE deciduous teeth should be kept in place till displaced by the advancing permanent ones, but it is sometimes necessary to remove decay and fill cavities in them that they may be preserved. In most cases, however, they should be extracted when devitalization of the pulp occurs, and particularly when abscess has appeared, for the reason that solution and absorption of the tissues of the roots of these teeth (as the permanent advance and push upon them) does not normally take place after the death of the pulp, and absorption is necessary that malposition of the permanent teeth may be prevented.

The first permanent molar should not be extracted after the second has been fully erupted, except to correct an irregularity; and when the extraction of one of these teeth is decided upon (particularly if one or more of the others are pulpless), it is best, in many cases, to remove them all, as the spaces are then more likely to be closed and their places supplied by the moving forward bodily of the second, aided by the third molars, the development of which is then likely to be perfect, and their eruption complete. If irregularity of the teeth takes place after the twelfth year, the second bicuspid (sometimes the first), rather than the first permanent molar (unless it be a pulpless one), ought to be extracted. Should the first be

extracted after the eruption of the second permanent molars, these teeth (especially the two lower ones) may incline or tip forward (Fig. 15), and the bicuspid may

FIG. 15. .



move backward in many cases, thus causing imperfect occlusion. In cases where calcification is defective, and where solution of the lime-salts of the teeth takes place rapidly, and the first and second molars are still in position with their pulps living, it is advisable to extract the third molars, even though there are no cavities in them, that decay of the posterior approximal surfaces of the second molars may be prevented. It is very rarely ever necessary to resort to extraction, except of the teeth just named, and under the circumstances indicated. The

FIG. 16.*



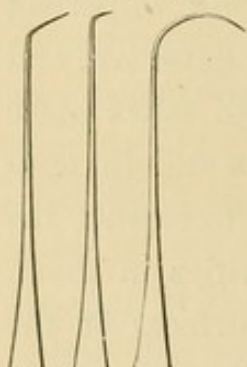
natural teeth should be kept in place till they are lost either by accident or through the absorption (or because of necrosis) of the alveolar process and the gums.

* Fig. 16.—Universal root and deciduous tooth forceps.

About the time of the eruption of the first permanent molars, and while the deciduous are being displaced by the permanent teeth (and for years after the eruption of the latter), examinations should be made frequently, not only for the purpose of averting irregularity of the organs, but for ascertaining whether solution of enamel has commenced upon the approximal surfaces of any of the teeth, or in the fissures of the bicuspid and molars.

Since the method to be adopted or followed in correcting irregularity of the teeth depends very much upon the character of the case in hand, the judgment of the operator must be depended upon to provide the ways and means to accomplish the object sought.

FIG. 17.*



Solution of the lime-salts of the approximal surfaces can be prevented by occasionally polishing the enamel, and having the patient pass floss-silk between the teeth daily. This will not require as much attention on the part of the operator and patient as when the so-called permanent separations have been made.

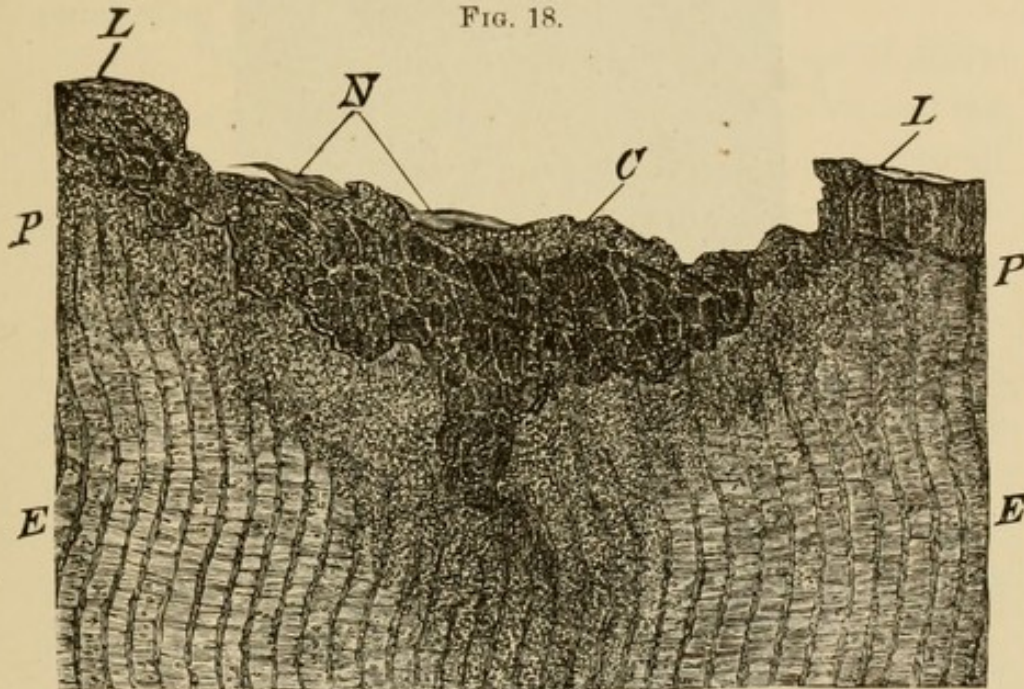
According to the latest and best investigations, decay of the enamel and dentine is the same as the breaking or *taking* down of the elements of any of the other tissues of the body. It is the solution of the lime-salts of the basis-substance of both the enamel and dentine, by an acid holding a greater affinity for some one of the elements of these tissues than they hold for one another, aided, in the dentine, by the inflammation which takes place in the fibers of living matter. It is simply return of the elements of the tissues to their primal condition.

* Fig. 17.—Instruments for making examinations.

Dr. Frank Abbott, of New York, after having examined, microscopically, many decayed teeth from the mouths of over thirty different persons, sums up the results of his researches as follows :

“I. In enamel, caries in its earliest stage is a chemical process. After the lime-salts are dissolved out, and the basis-substance is liquefied, the protoplasm reappears, and breaks apart into small, irregularly-shaped, so-called medullary or embryonal bodies. (See Fig. 18).

FIG. 18.

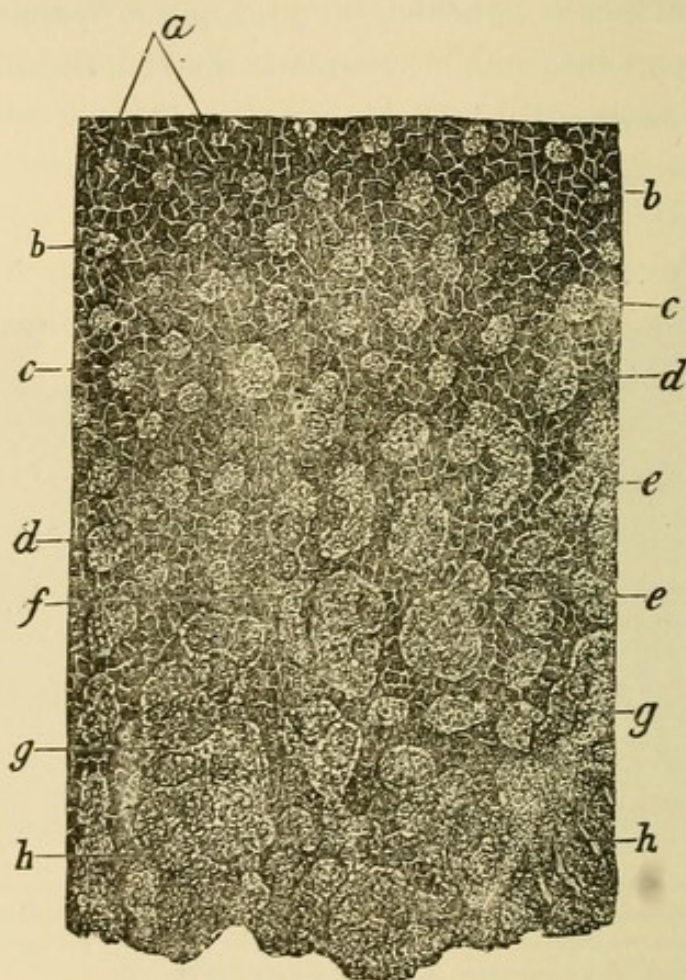


Section of enamel magnified about 1200 diameters; *E, E*, unchanged enamel, partly deprived of its lime-salts; *P, P*, zone of enamel with lime-salts so dissolved out as to be granular; *C*, shallow depression filled with protoplasmic bodies; *N*, flat epithelial bodies, remnants of Nasmyth's membrane; *L, L*, similar flat epithelia.

“II. Caries of dentine consists in a decalcification, and in turn a dissolution of the glue-giving basis-substance, around the canaliculi as well as between them. The living matter contained in the canaliculi is transformed into nucleated protoplasmic bodies, which, together with protoplasmic bodies originating from the living matter in the basis-substance, form the so-called indifferent or inflammatory tissue. (See Fig. 19).

“III. Cement, if attacked by caries, exhibits first all the phenomena known to be present in the early stages of inflammation of bone. The protoplasmic cement-corpuscles, as well as the basis-substance, after its decalcification and liquefaction, produce indifferent or inflammatory elements.

FIG. 19.



Cross-section of dentine magnified 1000 diameters ; *a*, transverse section of the dentinal fiber with delicate radiated offshoots ; *b, b*, canaliculi moderately enlarged ; *c, c*, still further enlarged ; *d, d*, two or more nuclei surrounded by a varying amount of protoplasm ; *e, e*, canaliculi enlarged to ten or fifteen times their original diameter and filled with a partly nucleated protoplasm ; *f*, longitudinal cavities arising from the confluence of several cavities in one main direction ; *g, g*, large spaces between which only scanty traces of unchanged basis-substance are left ; *h, h*, basis-substance entirely disappeared, in the place of which so-called medullary elements remain.

“IV. The indifferent elements originating through the carious process from enamel, dentine, and cement do not proceed in new formation of living matter, but become

disintegrated and transformed into a mass crowded with micrococci and leptothrix.

“V. Caries of a living tooth, therefore, is an inflammatory process, which, beginning as a chemical process, in turn reduces the tissues of the tooth into embryonic or medullary elements, evidently the same as during the development of the tooth have shared in its formation; and its development and intensity are in direct proportion to the amount of living matter which they contain, as compared with other tissues.

“VI. The medullary elements, owing to want of nutrition and to continuous irritation, become necrosed, and the seat of a lively new growth of organisms common to all decomposing organic material.

“VII. Micrococci and leptothrix by no means produce caries; they do not penetrate the cavities in the basis-substance of the tissues of the tooth, but appear only as secondary formations, owing to the decay of the medullary elements.

“VIII. In pulpless teeth ‘caries is a chemical process, assisted only by the decomposition of the glue-giving basis-substance of dentine and cement.’ ”

When solution of the enamel has commenced at or near the part of one tooth that is in contact with another, the teeth should be separated by pressure, so that needless cutting of tissue may be avoided; the rubber-dam should be applied, and the superficial decalcified basis-substance of the enamel removed by the use of fine, sharp files, and narrow strips cut from emery-cloth of the finer grades, such as No. $\frac{1}{2}$ and No. 0. If, after the removal of the decalcified portion from the periphery of the enamel-columns or rods, the whole surface presents the appearance of normal

tissue, this surface should be carefully polished with pulverized pumice, applied upon linen tape or a soft-rubber disk. If there remains a portion of enamel of a lighter or other shade than that which surrounds it, all that part where dissolution had taken place has evidently not been removed, and it may extend to the dentine, thus necessitating the cutting out of all the lime-salts where solution of tissue has occurred, and the thorough preparation and careful filling of the cavity presented.

In those cases especially where the system has been maintained in good condition during childhood and youth, and the tissues are first-class, solution takes place slowly, and does not become very extensive, so that where only the outer layers of the enamel-prisms are dissolved away, this portion can be removed, and, after a finely-finished surface is made, decay will not be likely to commence again.

In no case should a permanent separation be made between the teeth, however, for, even in such cases as those just mentioned, food may so wedge against the gum as to bring about its recession, and the exposure of the necks of the teeth, and finally lead to the formation of a cavity at these parts.

Moreover, separations should not be made, for the reasons that they interfere with mastication, annoy the patient, and, with few exceptions, solution of the lime-salts of the parts that have been cut is not prevented. The teeth separated again come in contact almost invariably, except where they are prevented by antagonizing teeth; food, wedging between them, undergoes fermentation, and solution of the enamel and dentine takes place, and that, too, in a part of the tooth where it is difficult to perform a first-class operation. This may not occur, however, till

long-continued pressure of food paralyzes the nerves in the papillæ of the gum-tissue pressed upon, and breaks the nutrient circuit, or obstructs the movement of the molecules of living matter through that fine reticulated line between the gum and the brain, and the patient is no longer notified of the presence of such obstruction to the neural and vascular circulation. This condition of the gum-tissue as inevitably leads to the return of the elements to their embryonal state, as does interference with the nutrition of any other part of the system.

APPLICATION OF THE RUBBER DAM.

THAT operations may be properly performed, and that gold or any other filling-material may be inserted in cavities as well as possible, it is necessary that the parts be kept dry by the use of the rubber dam. Even the vapor contained in the exhalations from the lungs, as well as the touch of a finger, prevents the cohesion of gold, which cohesion is essential to success in the insertion of all, and particularly in the making of really fine, fillings. It is not only absolutely necessary for the pieces of foil to cohere in all those cases where the gold must be made solid and strength must be gained for the protection and support of enamel (frail walls of which must be incased, as it were, in gold), but when fillings are inserted in the masticating surfaces of the teeth it is also necessary that cohesion of the particles of foil be unimpaired, to prevent the scaling-off of the gold as the cusps wear away and the dentine becomes exposed from attrition.

The rubber dam (for which we are indebted to Dr. S. C. Barnum) ought to be applied in every case, and it can be used in all cases so as to exclude moisture, provided the operator has the ability to apply it successfully.

In addition to having the rubber dam applied, and particularly when operating upon the lower teeth, it is best to take the saliva from the mouth by means of Fisk's saliva ejector, if running water be at hand; if not, then a common saliva ejector may be used. This may be manipu-


lated either by the patient or by an assistant of the operator. The light-medium rubber is the best for general use. It should be cut into pieces about nine inches long and seven and one-half or eight inches wide. Each piece ought to be kept for the patient for whom it was first used; a convenient way of keeping it, and the name of the patient with it, is to have a blank-book made of dense blotting-paper.

The application of the rubber dam and the clamp, as well as the removal of decay and nearly the whole of the preparation of a cavity for filling, gives the patient pain, but the operator ought always to feel that he has living tissue to operate upon, and while performing each operation thoroughly, he can and should be kind and sympathetic, and handle his patient gently. Although pressing away the gum is necessary, in order that the rubber dam may be carried to the neck of the tooth to be operated upon and be tied to each tooth adjoining, yet, when properly applied, with carefully fitted clamps and ligatures of waxed floss-silk, inflammation of the tissue does not take place, except, perhaps, in rare instances, and in these it soon subsides.

Patients usually endure operations just in accordance with the way they are handled by the operator, and he must first gain the confidence of his patient by being conscientious and sincere, and by showing that he knows exactly what he is about, and doing nothing but what he would have done for himself. Very little, if any, more pain need be inflicted during the proper preparation of a cavity for the insertion of one material than for another, and it need not often be necessary to keep a patient in the chair over two hours; yet patients sometimes suffer far more pain and fatigue in one hour having

an ordinary and, perhaps, almost worthless filling inserted by unskilled and careless hands, than during the performance of an extensive, difficult, and fine operation taking

FIG. 20.*



the skilled and careful operator three, four, or even five hours to complete.

* Fig. 20 represents several sets of holes in a piece of rubber dam, showing how each set ought to be located for the teeth as they are to be operated upon, the sets of holes to be cut as needed at different times, and some of them made in different portions of the same (or in other pieces of) rubber dam.

All the holes ought to be made within the upper (or lower) half of the rubber dam (the center being shown by the dotted line) and at the same distance—a full inch—from the upper margin of the rubber as shown

After selecting the proper place in the rubber dam for making the holes for the teeth to which it is to be applied in the case in hand, it should be carefully folded at that part and cut with scissors, or the holes can be made with a punch. The holes should be fully a line in diameter for the molars, or almost a line and one-half in diameter when the rubber is to be stretched over a clamp, and from half a line to the sixteenth of an inch for the other teeth (Fig. 20). The width of the rubber dam between the holes should be about an eighth of an inch, or should correspond to the space at the necks of the teeth to which it is to be applied. With the exception of the holes for the upper incisors (Fig. 20, *a*) and those for the upper cuspids and bicuspid, no hole ought to be cut within about three inches of the edge, for the reason that less margin of rubber than this cannot be nicely folded and held away from the teeth to which it is attached.

RUBBER-DAM CLAMPS.

Various forms and sizes of clamps are made for the rubber dam, the most complete, satisfactory, and useful of

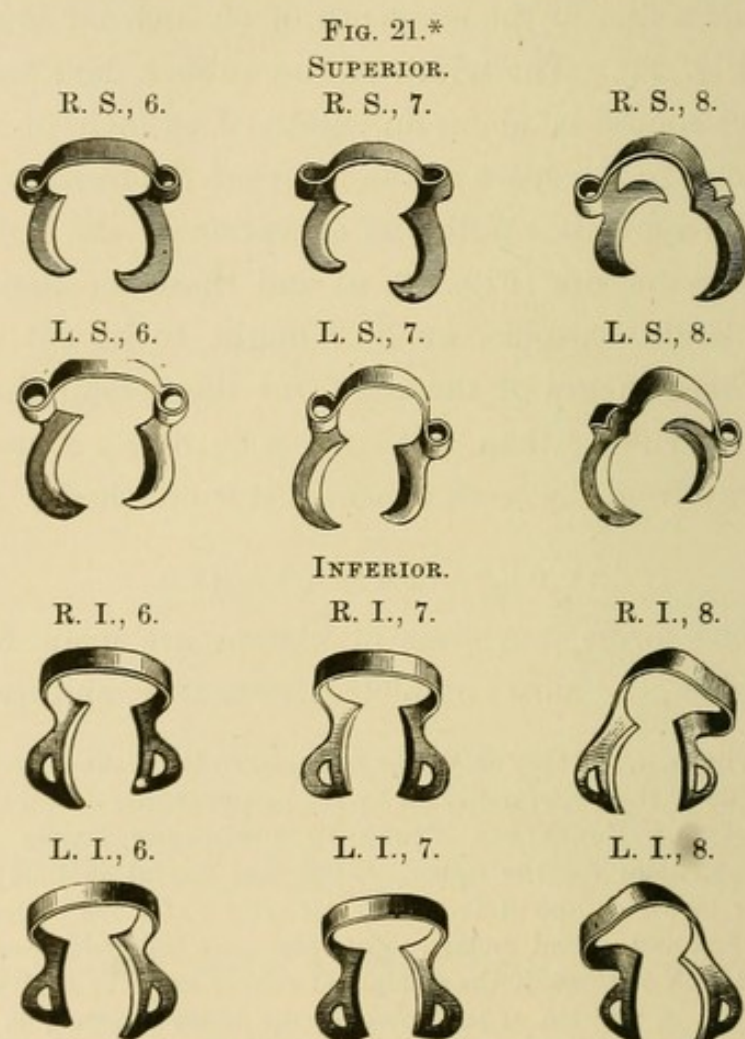
above the holes, *a*, and they should be arranged in the manner illustrated, on each side of the center indicated by the perpendicular dotted line.

LOCATION OF HOLES FOR TEETH IN DIFFERENT PARTS OF THE MOUTH.—*a*, holes for the upper central and lateral incisors; *b*, for the upper bicuspid and first molar, left side; *c*, for the upper bicuspid and first and second molars, right side,—one hole additional to be made just back of these, if the clamp and rubber are to be applied to the third molar; *d*, position of the holes for the lower incisors; *e*, for the lower bicuspid and first molar, right side; *f*, lower left bicuspid and first and second molars;—the + indicates the position for holes for the other teeth.

While the holes in their general arrangement are shown full size, the rubber cannot be illustrated as large as it ought to be. It should be seven and one-half or eight inches wide (counting from the line above the holes, *a*) and nine inches long,—four and one-half inches each way from the perpendicular dotted line. The holes for the second upper bicuspid are too large in the cut.

which, and those causing the patient the least pain, are the set of thirty-two (a special clamp for each separate tooth) devised by Dr. Delos Palmer, of New York. Those intended for the molars are here illustrated (Fig. 21).

The clamps should be put in place with suitable forceps. The one selected for the tooth to be operated upon ought to be placed in position first, in almost every case (especially

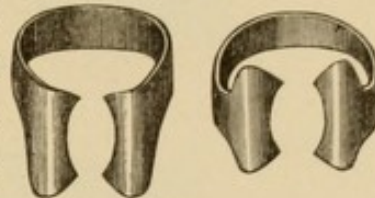


on the molars), and the rubber dam then stretched over the clamp and the tooth to which it is fixed, and at once applied to the one adjoining or to the two teeth anterior

*A special clamp, designed by Dr. Delos Palmer, for each separate molar is here shown (Fig. 21). The letters and numbers signify that R. S., 6, for instance, is intended for the *right superior sixth* tooth (first

to it. The clamp invented by Dr. H. C. Longnecker, of Philadelphia, is a good form for general use (Fig. 22); because of the recurvature of the flanges, it does not bear upon the festoons of the gums so as to injure them. As the rubber is stretched over each crown, the floss-silk must be passed between the teeth to carry down the part that separates the hole for one tooth from the one for the other. In most cases the rubber should be

FIG. 22.*



carefully tied to each tooth to which it is applied. Where there is danger of cutting or tearing the rubber dam and floss-silk, while placing them between the teeth, the sharp, irregular edges of enamel surrounding the cavity within the approximal wall of either tooth ought to be removed with a fine ribbon-saw passed from the masticating surface to the neck of the tooth. Clamps need be applied in but few cases other than to the molars.

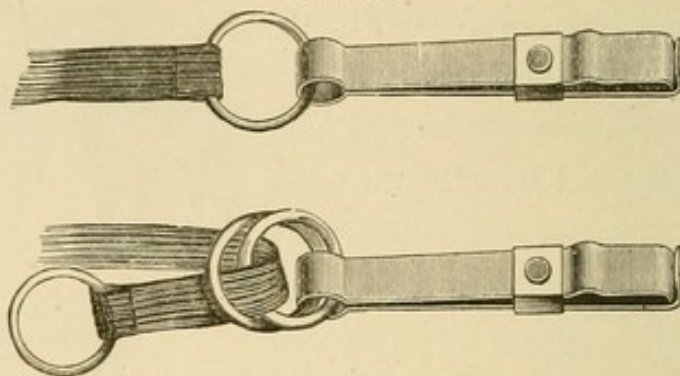
The rubber dam ought to be applied to a sufficient number of teeth to make the tooth to be operated upon accessible, although it is scarcely necessary to apply it to but three or (rarely more than) four teeth, even when cavities within the approximal walls are to be prepared and filled.

molar), counting back from the median line. The universal screw-clamp, devised by Dr. E. Parmly Brown, is an excellent appliance, also, and many more of the clamps and other appliances which have been made should be mentioned, as well as many articles that have been written from time to time relating directly or indirectly to a number of the points in operative dentistry herein considered, but it would be too much of a task to refer to the merit of each and to name the credit due the inventors and writers.

* There are several sizes of these clamps. Those with the straight hoops are often unavailable for the tooth to be operated on, but they serve well when placed on the one back of it to keep the rubber dam out of the way.

The edges of the rubber ought to be carefully folded or nicely placed back upon the side of the face, and held out of the way by a rubber-dam holder (Fig. 23), and for the

FIG. 23.




comfort of the patient, a fine, soft napkin should be put under the rubber next to the lips, chin, and cheeks.

PREPARATION OF FILLING-MATERIALS.

GOLD FOIL.

IN the preparation of gold for the various operations required, a half-leaf of light gold foil for small (or the smallest), a whole leaf for medium, and two leaves for large fillings, should be taken from the book by means of a spatula or the foil-carrier, and placed upon a piece of spunk covered with white kid. The foil should then be smoothly folded with an ivory or nickel-plated spatula (Fig. 24) into a tape-like form of about seven, nine, or

FIG. 24.



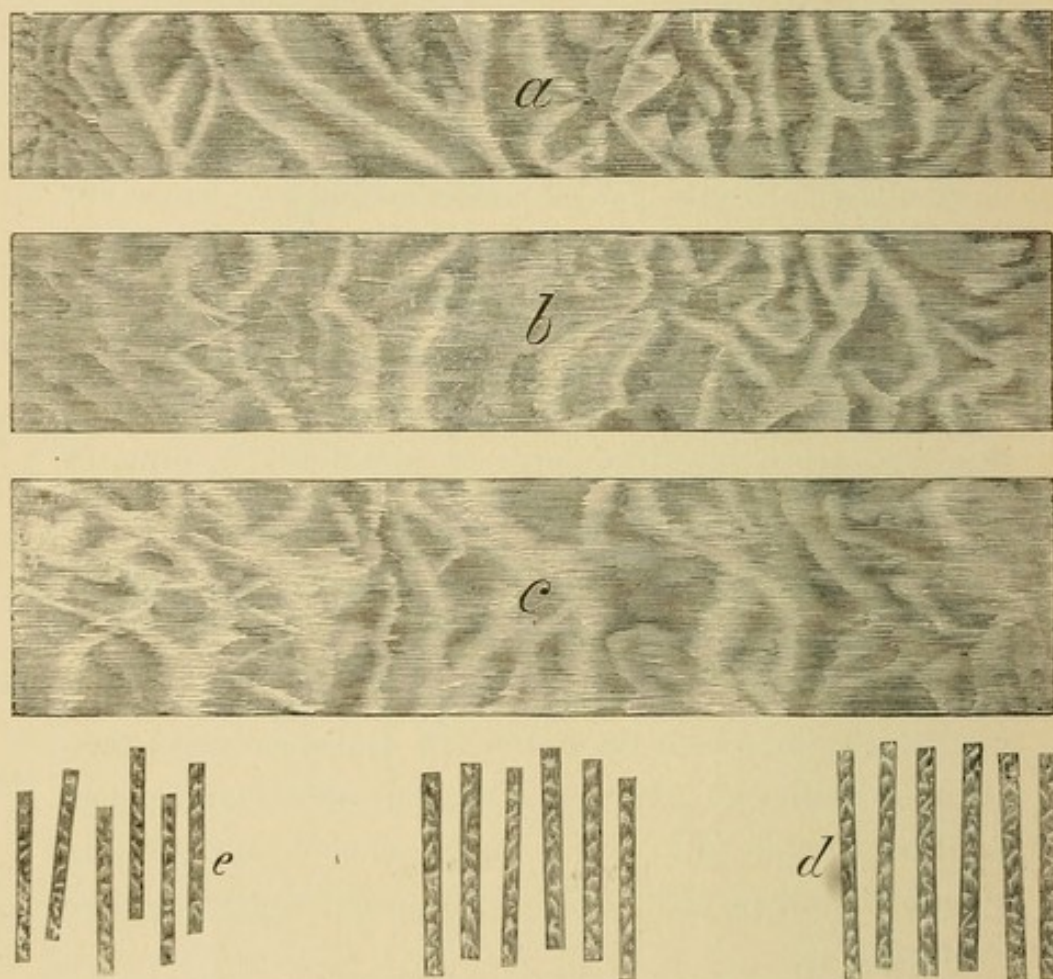
eleven lines in width (Fig. 25, *a*, *b*, and *c*, thus making Nos. 12, 20, and 32—if the foil be No. 4) respectively; then taken up with the foil-carrier and cut across into pieces about a line wide (*d*). For some cases, such as the filling of pulp-chambers, the pieces of foil ought to be less than a line wide (*e*).

As these pieces are cut from the ribbon they should fall upon the kid covering the spunk, or upon very fine linen napkins. Each of the pieces of foil can afterward be readily taken up with light-pointed foil-carriers (Fig. 26), or the packing-instrument, and passed over the flame of alcohol till the piece has a rose-tinted shade or is made cohesive, when it must be put in place at once and solidified.

Heavy foil, such as Nos. 30, 40, and 60, cut into the same

sized pieces as folded foil (Fig. 25, *d*), can be used to advantage in most cases, especially in extensive restoration of contour of missing tissue, although light foil, when prepared as just described, can be more easily inserted in small cavities, fissures, and grooves.

FIG. 25.



When prepared in the manner described, each piece of foil can be readily introduced, folded over and again upon itself, and each fold separately solidified. The operator can be certain of these convenient narrow pieces remaining firmly anchored in the starting-point, and each additional piece readily adheres to and is easily made compact with that already in position, thus making the whole filling uniform in density. Each piece of foil should

remain in the position in which it is placed, and the forms of the pieces, when prepared as described, will be such that they can be inserted in all classes of cavities conveniently and with certainty.


The abuse and not the use of cohesive gold has led to its condemnation, and they alone condemn it who have not prepared and manipulated it properly and successfully.

Foil should always be prepared in the manner stated and be used in the form illustrated, and all gold ought to be cohesive, particularly when a mallet is used, so that the particles or pieces may surely and permanently remain together. There is no other method by which gold can be made so solid and so uniform in density, with such ease, certainty, and rapidity, as with the electro-magnetic mallet, but it ought always to be well adjusted, the battery should be properly attended to, and the apparatus must be operated understandingly.

TIN.


For the filling of narrow fissures and small sulci of the bicuspid and molars, tin is next to gold in value as a filling-material, and when put solidly in place in such cavities attrition does not wear away the material so deeply as to impair the operation. The rubber dam should be applied, the cavity prepared, and the foil folded, cut (with the foil shears, Fig. 27), and made compact with the mallet, as carefully when tin is inserted as if gold were used. More time is usually required, however, to properly fill a cavity

FIG. 26.



with tin foil than with gold, when the electro-magnetic mallet is used, mainly for the reason that in tin there is not that cohesive property to keep each piece in place with certainty while the material is being solidified; therefore, since time rather than material is valuable to all those

FIG. 27.



having a full practice, it is better for both patient and operator to make use of gold rather than tin as a permanent filling-material.

A M A L G A M.

If, in performing an operation which is to be a permanent one, the operator cannot so manipulate gold, in any given case, as to make the filling moisture-tight, and yet decides not to use tin, but to insert amalgam instead; or generally, if an amalgam is to be used at all by those who restore completely the contour of missing tissue and make the margins free from contact, they certainly need "contouring amalgam," which is said to be the best (or the "standard") of such materials. This amalgam is composed of about 58 parts of silver, 37 of tin, and 5 of gold, and it is claimed to be quick-setting, and to have good edge-strength and "good color,"—that is, a better color than most other alloys.

The amalgam mass, when ready for insertion, should be a little plastic—sufficiently so not to crumble, but to pack nicely, piece by piece, with very light malleting. The same care should be taken in filling with amalgam as with any other material. It is best, especially in large cavities and

in filling the deciduous teeth, to first fill the cavity (after applying the rubber dam) so far as to entirely cover the dentine with oxychloride of zinc, and secure anchorage in the cement, or to so use the amalgam that it may come in direct contact with the enamel only; thus, to a great extent, avoiding discoloration of the tissue.

THE MALLET.

BEFORE entering into a description of operations, it seems well to consider the mallet and its uses.

During the year 1860 Dr. W. H. Atkinson introduced the mallet for making each piece of gold compact as it is placed in the cavity, he having received the idea of using a hand-mallet from Dr. E. Merit, of Pittsburgh, Pa., who had used such an instrument for condensing gold (*en masse*) after it all had been put in the cavity.

That an assistant or malleter might be dispensed with, various forms of automatic and "engine" mallets were afterwards invented, manufactured, and used with varied success, but the finest and best instrument now made and in use, when properly understood and skillfully operated, is the electro-magnetic mallet.

That operators may the better understand and operate the electro-magnetic mallet, a full description of the construction, adjustment, and movement of its parts, and management of the battery, is here given.

THE ELECTRO-MAGNETIC MALLET.

Electricity is manifested as atmospheric, statical or frictional, voltaic or galvanic, dynamic, and magnetic. Magnetic electricity consists in the spiral circulation of electricity through a wire around a bar of soft iron, making the metal temporarily magnetic.

Dr. W. G. A. Bonwill first conceived the idea of the

electro-magnetic mallet, February 27, 1867, while his attention was called to the electric telegraph by the more than ordinarily distinct tapping of the "sounder" in a telegraph office at the Continental Hotel, Philadelphia,—within a square of the spot where Franklin succeeded in his experiment of collecting electricity from the clouds.

In the construction of the electro-magnetic mallet Dr. Bonwill gained some ideas from the electric telegraph instrument, the sound of which had indicated to him that some such taps, if given with greater force, might have sufficient impact to solidify gold. There was nothing new in the arrangement of a coil of wire around a bar of soft iron, which bar, upon the passage of a current of electricity through the coil, becomes a magnet and attracts to it one end of an armature moving upon a pivot at its center; for in 1832 Prof. Morse was experimenting in this direction, and the device can now be seen in every telegraph instrument. Dr. Page did not make any claim of originality for a similar device used in 1836 in his experiments in reference to magneto-electrical apparatus for "administering electricity as a remedial agent;" but in order that, when the encoiled bar is demagnetized by the breaking of the current on the wire surrounding it, the armature thus released should not travel beyond reach of the attraction of the bar when the circuit is again closed and the bar again becomes a magnet, he added a small thumb-screw, against which when set free the armature recoiled and stopped. This Dr. Page claimed as a valuable improvement only in connection with an electro-magnet. Dr. Bonwill modified and improved the electro-magnet and the armature, and so arranged two magnets and an armature as to make the electro-magnetic mallet,—inventing and constructing such parts as were necessary to complete it. The

name of Dr. W. G. A. Bonwill will, therefore, be connected with, and be as inseparable from, the electro-magnetic mallet as that of Prof. S. F. B. Morse and the electro-magnetic telegraph. As with the telegraph, so with the electro-magnetic mallet, modifications and improvements have been made by others as well as by its originator, but such of these changes as add value to the fine and wonderful piece of mechanism but increase rather than cancel the debt of gratitude we all owe its inventor.

Although Dr. Bonwill has since invented an instrument which he calls a "mechanical mallet," similar in appearance to the hand-piece of the dental engine, and operated like it with the foot; yet in a letter received from him, he states that he is "not unmindful of the part" the writer has played "in assisting to give the electro-magnetic mallet a glory second to no other invention ever given to dentistry." The real glory of the electro-magnetic mallet consists in the good it has done those who have used it successfully. Of such assistance has it been to the writer since the spring of 1873 that he feels it has already done much towards prolonging his life.*

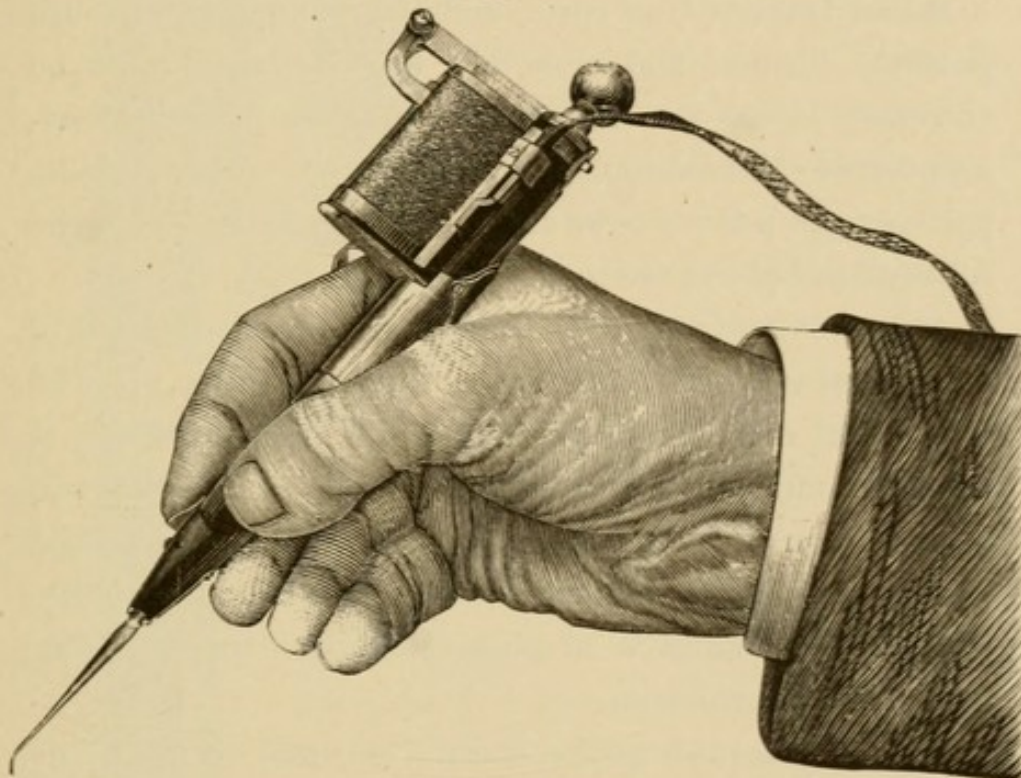
The manner of, or one position of the hand in, holding the electro-magnetic mallet is here illustrated (Fig. 28), the thumb and index finger serving to steady and guide the instrument the same as a pen or pencil, and to close and open the circuit.

The electro-magnetic mallet here shown, and as now made, consists of a pair of magnets; an armature, and a device for regulating the length of the stroke of the same; a hard-rubber hand-piece in which the packing instrument

* That the electro-magnetic mallet be made to work well, aid in making fine fillings, and benefit the operator, has ever been the sincere wish and strong desire of the author.

is placed and operated, the same resting against a hard-rubber piece called a plunger, which is so adjusted by a screw as to have the end of the armature or the mallet-head drive the packing instrument only to a certain extent; then there is a very important part called the interrupter, or automatic circuit-breaker. There are other important parts which will be referred to further on.

FIG. 28.



The cores of the magnets are made of the best soft iron. They are placed side by side, about one-quarter inch apart. At one end they are connected with each other by screws through an end-plate—a piece of soft iron about a half-inch long, and of the same width and thickness as the cores. Each core is made about one and a quarter inches long, three-quarters of an inch wide, and an eighth of an inch thick through the center along its whole length, and the iron is rounded down a little to the edges so as to make both sides slightly convex. The insulated copper

wire can then be more closely placed around the iron, thus insuring more complete "saturation of the core." A small flange should be left at the end of each core over which the armature is to rest, that the rubber end-piece may be held in place while the wire is being (and after it has been) wound around the iron. The soft iron end-plate which is screwed to and which connects the cores keeps the hard-rubber at that end in place.

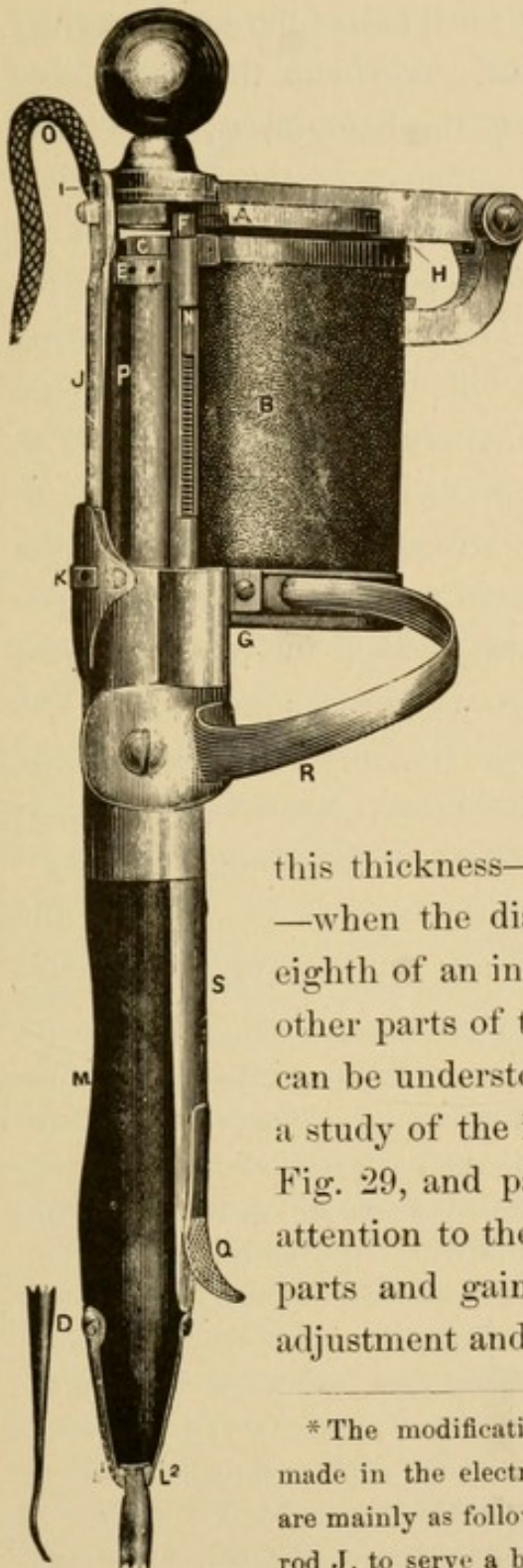
When the soft iron cores, end-plate, and armature are properly formed and smoothly finished, they must be annealed,—heated to redness and placed in hot finely-granulated charcoal to cool gradually. All other metallic parts, except a few screws and the springs at the end of the rubber hand-piece, are made of brass.

After the hard-rubber end-pieces are accurately fitted to and placed upon the cores, the soft iron end-plate must be screwed to each core separately while the copper wire is being wound around the same. When five layers are wound upon one core the end-plate should be detached from it and placed upon the other core to keep the rubber piece at the end of it in place while the wire is being wound around the iron.

Previous to placing the end-pieces upon the core, its sides ought to be entirely covered with the finest silk court-plaster, that the wire may be the better insulated from the iron. Copper wire No. 23 (American gauge), insulated with silk, should be very carefully and closely wrapped around the core, and after one layer is on, this and each succeeding layer had best be covered with one thickness of Japanese bibulous paper, which should be simply saturated with a solution of gum-shellac in alcohol; this makes the insulation more complete. After five layers of wire are thus placed upon each core, the magnets should be put

together, the iron end-plate screwed to both cores, and one

FIG. 29.



end of the wire from one magnet twisted with one from the other. One of the loose ends is thereafter to be connected with the interrupter, and the other end fastened to one of the posts over which one of the tubes of the connecting cord which connects the mallet with the battery is to be placed. It has been said that "the thickness of the helical coil must be equal to the diameter of the core," and five layers of No. 23 wire make up

this thickness—six layers more than do it—when the diameter of the core is one-eighth of an inch. The mechanism of the other parts of the electro-magnetic mallet can be understood by reference to and by a study of the instrument as illustrated in Fig. 29, and particularly by paying close attention to the description of the various parts and gaining a knowledge of their adjustment and movements.*

* The modifications and improvements which I made in the electro-magnetic mallet, briefly stated, are mainly as follows: In 1874 I put on the shaft or rod J, to serve a better purpose than the device previously used to fix the stroke of the armature, and to make its movement

The connection of the mallet with the battery is made by means of small metallic tubes attached to the two sets of wires of the conducting cord, each tube fitting tightly over a projecting wire or post. The index finger is placed through the ring attached to the hand-piece; the end of the finger resting upon the flange of the slide, which, when pressed downward towards the end of the packing instrument, brings the positive and negative poles of the battery in contact under the slide at S. The circuit being thus closed, there instantly follows an influx of the electrical current through the helices, when the armature A, acting as a mallet, is attracted to the electro-magnets B, and, at the same instant, it strikes upon the hard-rubber plunger C, which is so adjusted as to have sufficient movement to impart a blow to the packing instrument D, the end of the handle of which is placed against it. The plunger is adjusted and kept in place by means of the screw E. A spiral spring fits loosely around the plunger, and, after each blow is struck, immediately carries it towards the armature to again receive and impart the blow given by the armature to the packing instrument.

steady, or prevent the oscillation which attended the operation of the instrument when only the rod to which the armature is attached supported it. I attached the conducting cord differently, and made the wires come in closer contact with the mallet through small tubes (on the reverse side of the instrument as here illustrated, but seen in cut No. 28). Principally by lessening the number of layers and the size (using No. 23, instead of No. 22, American gauge) of wire upon the cores of the magnets, I made these and other parts of the mallet much smaller than the Bonwill "Improved" instrument, which I was using when I made these last changes, in 1875. I made the soft iron cores a little convex on *both* sides, so that the insulated copper wire could be the more certainly and perfectly wrapped around them, and thus insure more complete "saturation" of the iron. I made no special change in the armature, except to make it lighter, improve its appearance, and change the manner of hinging it to

The instant the armature is attracted to the magnets, it also strikes upon the hard-rubber point F on the rod of the interrupter, and thus breaks the circuit at the platinum points at G. When the armature is carried away from the magnets by the spring H, and is caught at I, the rod of the interrupter is carried back to its position by the spiral spring surrounding it, and the circuit is again closed. The instrument is thus kept in operation as long as slight pressure is made upon the slide by the index finger.

The ends of the soft iron cores should be a little below the surface of the hard-rubber plates—the rubber extending about the thickness of fine card-board beyond the ends of the cores, so as to prevent actual contact of the armature with them. When the armature does not strike any part of either of the cores (and is not loosely fixed where it is hinged to the upright which supports it), its movement is almost noiseless and less unsteady, and the working of the whole instrument is more satisfactory.

the upright which supports it. I changed the manner of preventing the turning of the rod of the interrupter, and to this rod attached the hard-rubber piece differently, to act as an insulating point; I made the spiral spring of lighter brass wire, and in this way, and with the advantages gained by the rod J, I was enabled to make such adjustments as to have the instrument operate more regularly and evenly, and the armature give a more distinct blow than any similar or other mallet. I fitted a spiral spring around the plunger C, to keep it always towards the armature A. I so fitted the spring L¹ as to more securely keep the packing instrument D against the plunger C. Dr. I. F. Wardwell added the second spring L², and the two, made of steel and properly tempered and fitted, hold the packing instrument nicely in place. Among some other changes which I made in the electro-magnetic mallet (and which can be seen by comparing other instruments with the one here illustrated,) I will simply mention the manner (though perhaps not a method entirely original) of closing the points to make the circuit complete under the slide at S.—MARSHALL H. WEBB.

The device *J* is an attachment by which the stroke of the armature is regulated and the force of the blow to some extent controlled. The armature, ordinarily, ought to have no more play or movement than one-sixteenth of an inch above the plunger, but when a little heavier than the usual blow is required, without recharging two of the four cells of the battery while performing an operation (though this had best be done), the stroke of the armature should be lengthened a little by turning the nut *K* upon the shaft or rod *J*. A lighter blow can be had (so far as changing the length of the stroke of the armature aids in this) by screwing up the nut *K* to a certain extent. The hard-rubber piece *I* is inserted to lessen the sound of the armature when it is thrown back from the magnets.

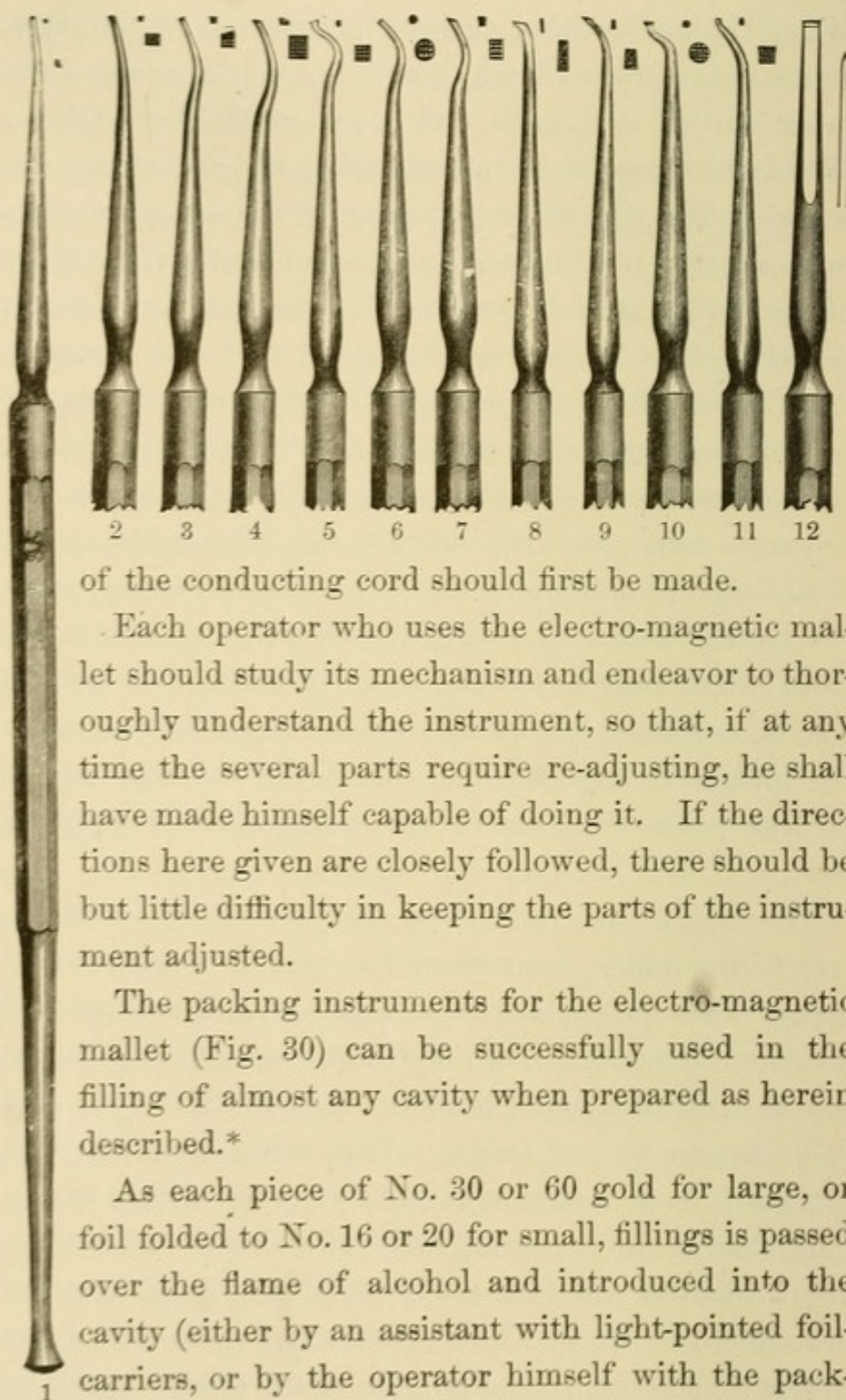
The packing instrument *D* passes up through the hard-rubber hand-piece *P*; it is kept in position and in contact with the plunger *C* by means of the springs L^1 , L^2 , and is steadied, directed, and turned by the thumb through the opening *M*. The hard-rubber plunger or adjuster *C* should be so regulated by means of the screw *E* that when the packing instrument is pressed against it the armature will so strike the same that there shall be but space sufficient through which to pass a piece of note paper between the armature (when this is pressed upon the plunger) and the rubber plates upon which it strikes. The rod of the interrupter should, at the same time, be so adjusted that the hard-rubber point *F* just touches, but is not moved by, the part of the armature or mallet-head which strikes upon it. This is done by raising or lowering the hard-rubber part *F*, or the metallic nut in which it is placed, and which screws on to the rod of the interrupter. When this part is in the proper position the small nut adjoining must be screwed tightly against it, so that the

part may be firm and immovable upon the rod of the interrupter during the operation of the instrument. When the spiral spring surrounding the rod of the interrupter is compressed by the small nut N, it accelerates the movement of the parts and more rapid blows follow. When the pressure upon the spring is lessened by unscrewing the nut which regulates it, the armature plays more slowly; but it should be remembered that the force of the spring must be sufficient to connect the platinum points at G, and thus close the circuit when the armature is thrown back by the spring H, after having driven the rod of the interrupter forward and broken the circuit. Greater strength of the spring H, which throws the armature back from the magnets the instant the circuit is broken or interrupted at G, is more necessary when the battery is freshly charged than when the fluids become mixed and the power is thus lessened. The tension can be regulated accordingly by turning the nut under the spring H; however, it is rarely, if ever, necessary to do this when the force of the spring is once properly fixed.

The cord O, which conducts the current from the battery to the mallet, consists of two sets of a dozen small copper wires each, placed near together, and covered and insulated with silk. Each of the two sets of wires is put into the end of a small brass or German-silver tube, and held therein by soft solder. This being done, the two tubes are fixed nearly together by figure-of-eight wrapping, then another covering and a stitching of silk thread, after which the tubes are ready to be slipped tightly on to posts fitted to them. These posts are on the side of the rubber hand-piece (See Fig. 28). Care should be taken that the small wires do not break, and if the mallet ceases

to operate at any time, a careful examination of this part

FIG. 30.



of the conducting cord should first be made.

Each operator who uses the electro-magnetic mallet should study its mechanism and endeavor to thoroughly understand the instrument, so that, if at any time the several parts require re-adjusting, he shall have made himself capable of doing it. If the directions here given are closely followed, there should be but little difficulty in keeping the parts of the instrument adjusted.

The packing instruments for the electro-magnetic mallet (Fig. 30) can be successfully used in the filling of almost any cavity when prepared as herein described.*

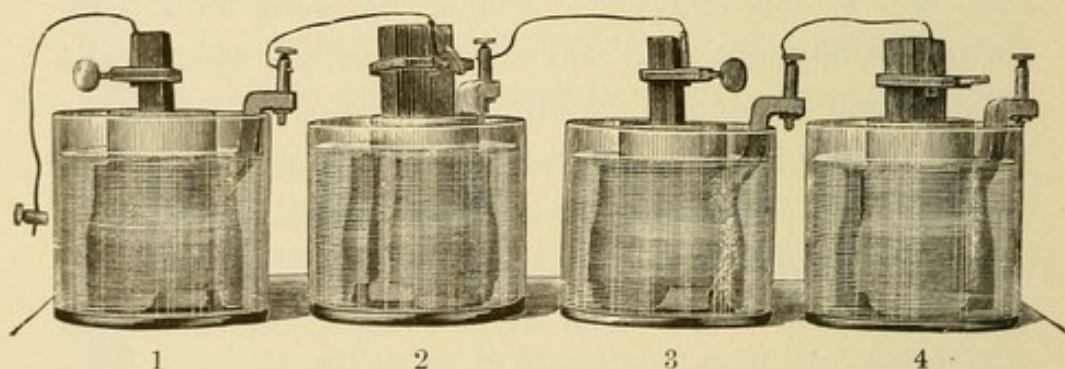
As each piece of No. 30 or 60 gold for large, or foil folded to No. 16 or 20 for small, fillings is passed over the flame of alcohol and introduced into the cavity (either by an assistant with light-pointed foil-carriers, or by the operator himself with the pack-

* Nos. 5 and 11 of this set are points designed by Dr. C. S. Wardwell.

ing instrument) and simply attached to the part (one or two pieces) placed by hand in the starting-point, or that already there, the electro-magnetic mallet should be set in operation, and the finely-serrated point of the packing instrument touched upon or placed (*not pressed*) against the gold in a manner similar to that of making dots on paper with a pencil. Light, medium, or hard blows can be made without changing the adjustments of the instrument, as fine or heavy lines are made on paper with a pen. When the electro-magnetic mallet is operated and guided as here indicated, gold can be carried against and over the margins (even frail edges) of enamel without fracturing them, and without the packing instrument passing off and puncturing the rubber dam and wounding tissue. Almost the same blow is required throughout each and every operation, because the gold should be solid and uniform in density; hence the action of the battery must always be about the same in intensity and constancy, and the pieces of gold for a given operation ought to be of nearly the same size; all foil should be cohesive, as well as be made compact. By a simple touch of the packing instrument each piece of cohesive gold is made to adhere to that placed in the starting-point; a slight movement of the slide Q by the index finger (placed through the ring R) connects the platinum points and thus completes the circuit at S, under the slide, and the armature A is attracted to the magnets B, and imparts a blow to the packing instrument D through the hard-rubber plunger C, and at the same instant touches upon the part F, when the current is temporarily interrupted or cut off at G. The successive and rapid recurrence of these movements, with a full current of electricity in a properly-adjusted electro-magnetic mal-

let, enables an operator, with careful and intelligent guidance of the instrument, to go over the whole surface of the foil much better, and make the gold more solid and uniform in density with greater ease and rapidity than by any other known method. This is true of the work of the electro-magnetic mallet, because to expel the air from between the particles of foil and place them in absolute contact in every given piece or body of gold, or, in other words, to place all the cohesive particles within the "sphere of influence" of one another, a certain number of blows of given force are necessary; and to thus go over the whole of each piece being impacted by any other known method would require the expenditure of

FIG. 31.



more time and greater effort. That gold be made compact it is not so desirable that a heavy blow simply be struck, as it is necessary that rapid, regular, and only moderately heavy blows be skillfully given to each piece of foil. By no other method can this be done so well and so perfectly as with the electro-magnetic mallet.

The operator ought to keep the battery in good condition and charge it himself, unless he has some one who is very careful and faithful, and who appreciates its importance fully enough to attend to it properly for him.

The improved Bunsen cell, with a large carbon, should

be used for the electro-magnetic mallet. Four cells are required, and new zincs must be amalgamated before the battery is charged. To do this, place one of the zincs in a glass jar and fill in the water till it is on a level with the top of the round portion of the zinc; then lift the zinc out of the water and pour into this, little by little, three and a half fluidounces of sulphuric acid. Replace the zinc and keep it in the solution a half-hour, or a little longer,—until the zinc is so acted upon by the acid as to take up the mercury then to be dropped upon the whole surface. Do this with each of the zincs; then pour away the solution used, and charge the four cells; thereafter two of the cells ought to be recharged each week alternately.

The whole battery should be kept clean, and the zincs must be well amalgamated; mercury should be dropped along the top of new zincs each day for the first two or three weeks, and to keep them bright a little mercury ought to be placed upon each zinc almost every time the battery is recharged. When the blocks of carbon become disintegrated and the edges crumble, or the surface can be easily scraped off, new carbons must be substituted.

The *electropoion fluid*—the solution for the porous cups—is made in a large, strong glass or porcelain-lined vessel, by dissolving a half-pound of the bichromate of potash in a half-gallon of boiling water. When this solution is cold, add ten fluidounces of chemically-pure sulphuric acid.

In charging the battery, sufficient of the bichromate solution should be put into each porous cup (after the carbon is placed in it) to fill it within about an inch of the top. Each zinc being placed in one of the jars, and the porous cups containing the carbon and solution being

put in position as illustrated in Fig. 31, pour in enough water to fill each glass jar to within about a sixteenth of an inch of the top of the cylindrical portion of the zinc; then remove the porous cup (with the carbon) and the zinc, and slowly pour one and a half fluidounces of chemically-pure or two ounces of the ordinary commercial sulphuric acid into the water in the jar; after which replace the zinc and porous cup. (In place of this a solution, consisting of nine parts of water to one of sulphuric acid, may be poured into the glass jar to just cover the zinc.) The solutions should be on a level, one with the other. Care must be taken that none of the bichromate solution is poured into the glass jars in charging the porous cup; also, that the acid solution does not get into the porous cups. Now connect the four cells (carbon to zinc). Connect the conducting cord to the mallet, and one of the two sets of wires of the other end of this cord (or additional conducting wires if they are required) to the carbon of the first cell, and the other set to the zinc of the fourth or last. The copper wire connecting the carbon of one to the brass post attached to the zinc of the next cell must not touch anything at any other point. The parts where the zinc of one cell is connected with the carbon of the next, etc., and those where the wires connect with the mallet, should be bright and tight. With all this properly done, the battery is always in readiness.

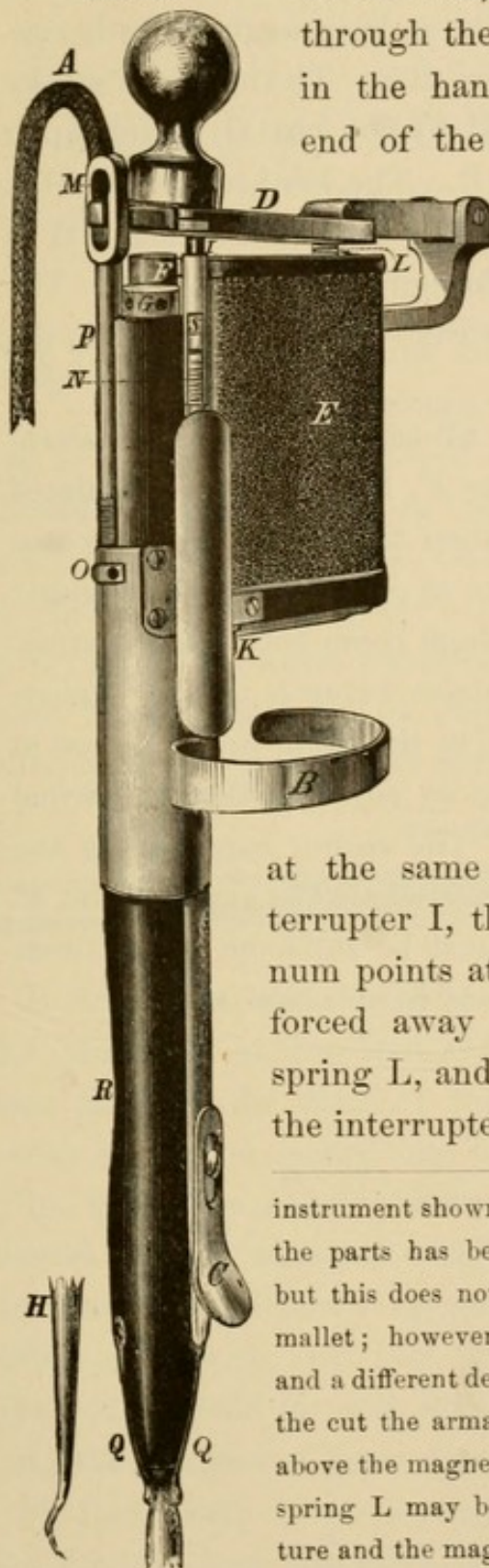
ADDITIONAL DIRECTIONS FOR OPERATING THE ELECTRO-
MAGNETIC Mallet AS IT IS NOW MADE.*

Connect the instrument with the battery by passing the tubes attached to the silk-covered cord A over the two

*The electro-magnetic mallet manufactured by The S. S. White Dental Manufacturing Co., and here illustrated, is made after the pattern of the

pins (on the reverse side of the instrument, but not seen

FIG. 32.



in the cut). Place the index finger through the ring B, resting the mallet in the hand; gentle pressure of the end of the finger upon the flange of

the slide C completes the circuit. The armature D, being thus attracted to the electro-magnets E, strikes upon the end of the hard-rubber plunger F, against which rests the swell end of the packing instrument H. Every time the armature is attracted to the magnets it strikes the plunger F (which is adjusted by the screw-nut G), and,

at the same time, the rod of the interrupter I, thus disconnecting the platinum points at K. The armature is then forced away from the magnets by the spring L, and is caught at M; the rod of the interrupter is carried back to its posi-

instrument shown in Fig. 29. The shape of some of the parts has been modified by the manufacturer, but this does not interfere with the working of the mallet; however, the parts are lettered differently and a different description of them must be given. In the cut the armature D is purposely shown too far above the magnets E, in order that the position of the spring L may be seen, the space between the armature and the magnets being actually not over the sixteenth of an inch at the interrupter I.

tion by the recoil-spring N, which surrounds it, bringing the platinum points in contact again, the instrument being thus kept in operation as long as pressure is continued upon the flange of the slide. The length of stroke of the armature is regulated by the nut O, acting upon and firmly setting the rod P. The hard-rubber cushion at M lessens the sound. The packing instrument H is controlled by the thumb through the opening R. The springs Q, Q keep the instrument in contact with the plunger F.

When the mallet needs adjustment press the instrument H against the plunger F, this being so regulated by the screw-nut G that when the armature is pressed towards the magnets it comes in contact with the plunger sufficiently to leave only enough room between the armature-plate and the rubber plates beneath to pass a piece of thin writing-paper, while, at the same time, the rod of the interrupter I should be so adjusted that the armature-plate shall *just touch it*. The spring surrounding the rod of the interrupter is regulated by the small nut at S. The tension of the spring must be sufficient at all times to bring the platinum points at K into close contact.

FILLING CAVITIES IN MASTICATING SURFACES.

WHEN solution of the lime-salts of the enamel and dentine has advanced along a fissure or in a sulcus or the sulci of a bicuspid or molar, the rubber dam should be neatly applied to the tooth in which the cavity is found, as well as to the one or more adjoining, so that the parts shall be kept dry and be brought more plainly into view. The saliva remaining in a cavity or about the teeth is best taken up on Japanese bibulous paper, applied in the form of pellets with foil-carriers (Fig. 33).

FIG. 33.



If decay has made considerable progress beneath, and the dentine is so dissolved away and discolored as to be seen through the plate of the translucent enamel, the cavity should be opened into by means of enamel chisels (Fig. 34). The softer portions of the decayed dentine should then be removed with sharp excavators (Fig. 35), the fissures sufficiently opened, and anchorage for the filling made with keen burs operated by a dental engine. The walls should be well shaped, with very little undercut; the margins of enamel evenly and smoothly finished with fine, sharp burs; a starting-point made (if one of the fissures does not serve the same purpose), and the

whole cavity so prepared (Fig. 36, *b*) that all the gold

FIG. 34.*

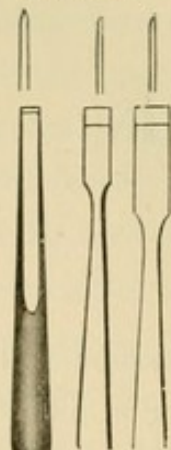


FIG. 35.†

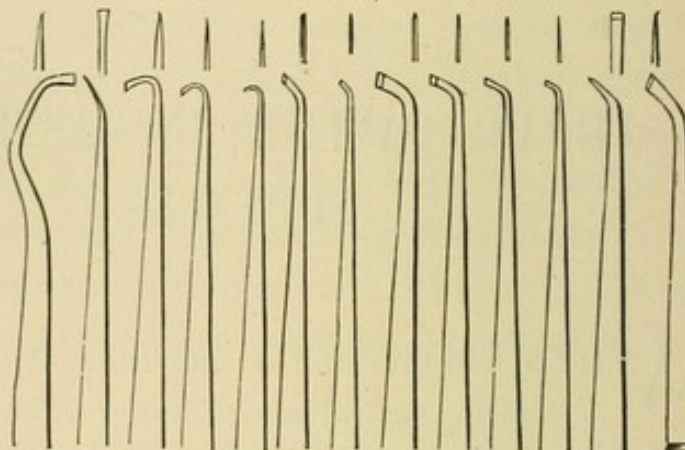
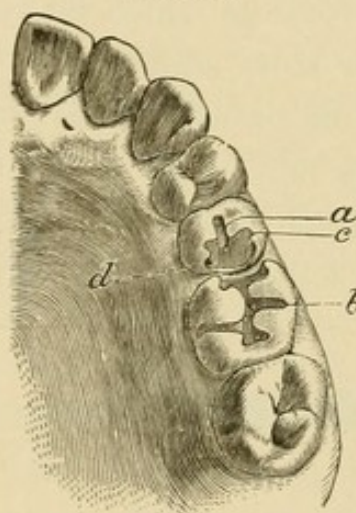


FIG. 36.



may be thoroughly condensed with the mallet.

If, in making gold compact, any part or the whole of it becomes displaced, the mass ought to be removed at once; otherwise the filling would be imperfect. Gold in the form of cylinders and pellets, and when in a non-cohesive

condition, may be used so as to prevent decay in some so-called simple cases; but when really fine or first-class operations are to be performed, foil ought to be so carefully prepared, introduced, and solidified that the operator can be positive that each piece has been firmly anchored in

*The first of these instruments belongs to the set devised by the author for the electro-magnetic mallet, in which chisels can be operated nicely and effectively.

†This illustration shows some of the most useful forms of excavators.



FIG. 37.*—THE S. S. WHITE DENTAL ENGINE.

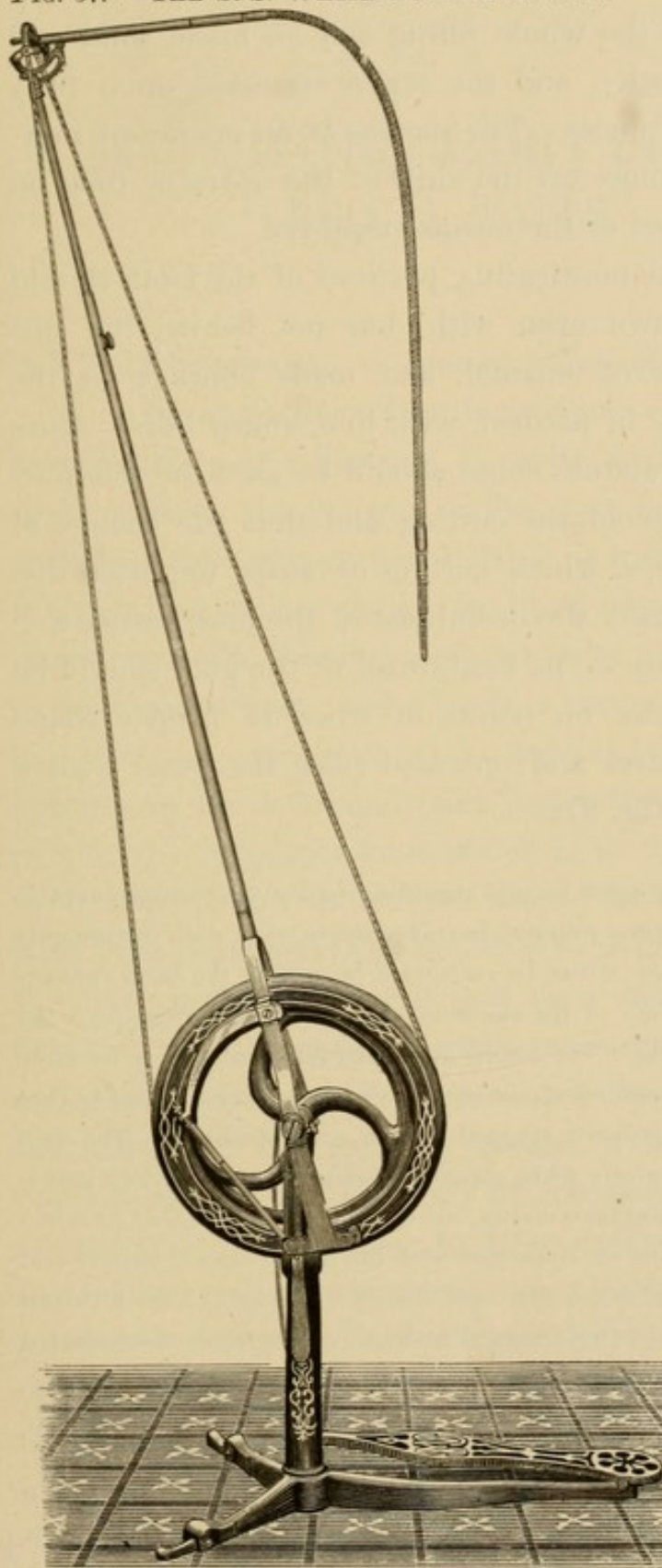



FIG. 38.—CONE-JOURNAL HAND-PIECE.



*The dental engine here illustrated (Fig. 37) is so well and favorably


place, or has adhered to that already in position, and being certain of this the whole filling can be made solid and uniform in density, and the organ operated upon fully restored to usefulness. The success of an operation, however, depends more on the skill of the operator than on the material used or the means employed.

Fillings in the masticating portions of the teeth should be trimmed down even with, but not below, the surrounding edges of enamel, and made concave in the central parts (as in nature), with fine, sharp burs. Burs rather than corundum cones should be used for this purpose, so as to avoid the cutting and thus the change of form of the cusps, which cutting of cusps too often disfigures and impairs the usefulness of the masticating surfaces of the teeth. The final finish of the gold should be done with pumice on points of wood of proper shape held in a mandrel and operated (like the burs) with a dental engine (Fig. 37).

known that nothing need be said regarding it, but the electro-magnetic burring engine, in some respects, has advantages other such instruments do not have. It may either be suspended or held in the hand conveniently, and, by the use of the electric engine, the operator escapes "the tyranny of the treadle." It can be used with satisfaction only by those who understand something of electricity, and who exercise weekly care to keep the battery properly charged and in good condition. The electric engine operates nicely when connected with the same battery that is used for the electro-magnetic mallet, but if more power is needed (as when both engine and mallet are connected with the same four-cell battery and used every day steadily), a fifth cell should be added. This fifth cell can be and ought to be so arranged as to be connected or disconnected with the other four cells almost instantly at the will of the operator. Many improvements have been made in the construction of the electric engine, making it compact and convenient in form; the new Cone-Journal Hand-piece (Fig. 38) can as well be fitted to it as to the S. S. White Dental Engine.

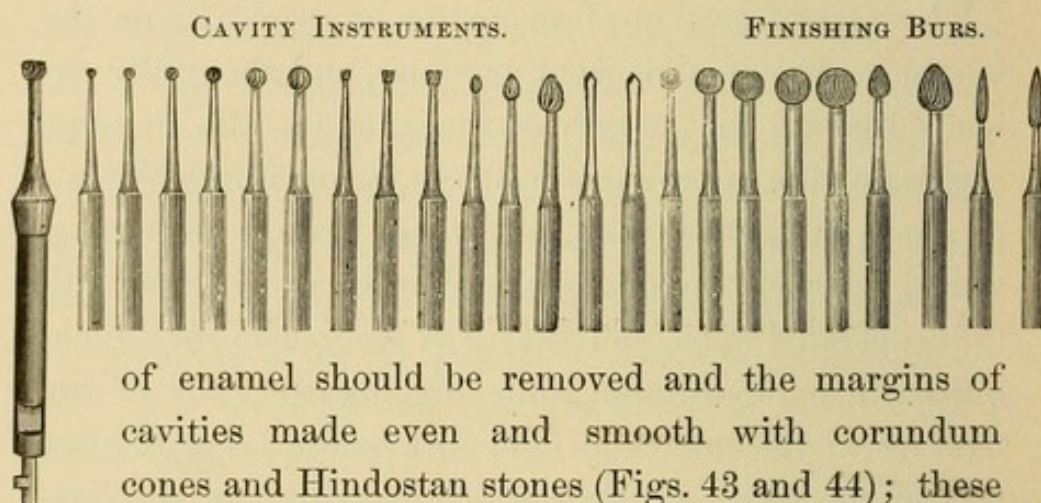
FILLING CAVITIES WITHIN LABIAL AND BUCCAL WALLS.

WHEN solution of enamel takes place within the labial portion of an incisor or cuspid, or on the buccal surface of a bicuspid or molar, and the cavity extends beneath the margin of the gum (as also in some cavities within approximal walls), it is sometimes difficult to apply the rubber dam. In these cases a ligature of waxed floss-silk should be placed twice around the tooth to be operated upon, and after it is secured to the adjoining tooth or teeth, and while holding the ends of the ligature in the left hand (and just before tying the last part of the surgeon's knot which is to tighten the ligature), both it and the rubber should be pressed, *Fig. 39.* with a flat burnisher (*Fig. 39*), above the margin of the cavity so as to bring it into view and secure dryness. In such cases it is often necessary to hold a ligature, together with the rubber dam, above the margin of the gum by means of a broad-pointed excavator. Previous to commencing an operation it is desirable to have everything at hand that may be required. A suitable clamp (preferably from the Delos Palmer set) should be used in many of these cases, but more especially when the rubber dam is to be applied to the upper, and always when applying it to the lower, molars. The clamp should first be adjusted to the tooth, and the rubber then




stretched over it from the posterior to the anterior part, and also applied and fastened with ligatures of waxed floss-silk to the adjoining tooth or teeth. After the removal of the softer portion of the decayed dentine with sharp excavators, the margins of the cavities just referred to should be evenly and smoothly finished, and the enamel undergoing solution should be removed by means of fine, keen burs (Fig. 40). In some cases discoloration

FIG. 40.*



of enamel should be removed and the margins of cavities made even and smooth with corundum cones and Hindostan stones (Figs. 43 and 44); these being kept wet with water from a drop tube (Fig. 41). A magnifying glass should be used to examine the margins

FIG. 41.



of all cavities in order that they may be made as perfect as possible. A slight undercut should be made around the cavity along the boundary-line between the enamel and dentine, and a starting-point drilled in the dentine just inside the enamel in a direction where there is no liability of the drill getting into too close proximity to the pulp. The first, second, and sometimes a third piece of

* These cuts illustrate many of the most useful forms of burs.

foil should be placed in the starting-point by hand with a suitable instrument (Fig. 42), and after that has been inserted all the gold ought to be made compact with the mallet. When the cavity is entirely filled the gold should be trimmed down to conform to and yet be flush with the surrounding surface of enamel, by means of sharp chisels or files, fine burs, small corundum wheels, and Hindostan stones (Figs. 43 and 44). All this should be done previous to the removal of the rubber dam, after which the gold and surrounding enamel ought to be finely finished with pulverized pumice applied on wood, leather, or rubber points or cones.

FIG. 42*

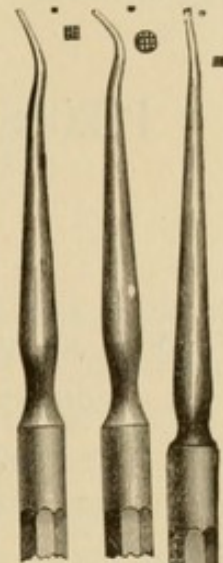


FIG. 43.†

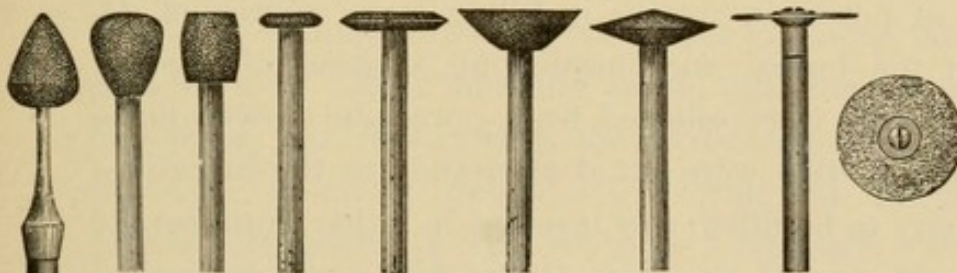
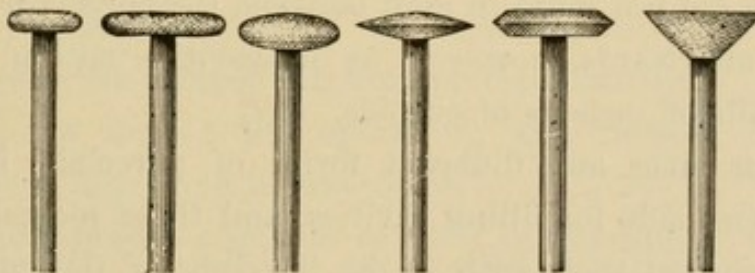


FIG. 44.†



*From the set of instruments devised by the author for the electro-magnetic mallet.

† These cuts, Figs. 43 and 44, show the most useful forms and sizes of corundum wheels and cones and Hindostan stones.

PIECES OF PORCELAIN FOR FILLING CAVITIES OF DECAY.

FOR a number of years a few operators have occasionally inserted a piece of carefully-selected porcelain in a large cavity within the labial walls of incisors or cuspids with oxychloride of zinc, and afterwards filled in foil between the porcelain and the margin of the enamel, thus presenting only a narrow line of gold to view.*

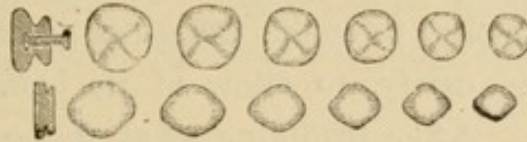
During and after the year 1870, when he was practicing in Reading, Pa., Dr. F. Hickman frequently used pieces of porcelain crowns in filling large cavities of decay in the buccal and masticating surfaces of molars. These pieces were selected from porcelain crowns made for other work; were fitted accurately to the margin of the cavity to be filled, and inserted in either gutta-percha or oxychloride of zinc, the plastic filling the interstices between the porcelain and the margins of the cavity. Dr. Hickman did not build in gold between the porcelain and enamel afterwards, however, as in cavities within the labial walls of incisors or cuspids.

Various sizes and different forms of porcelain have since been made for filling cavities, and these pieces are so well shaped that, with slight beveling of the edges, but little trimming is necessary to prepare them for insertion. Some of these have a platinum pin inserted in

* It has been stated that Dr. B. Wood, in 1862, suggested to Dr. S. S. White the idea of using porcelain for such purposes.

them, but, while these are the best so far devised for filling large crown cavities, they can rarely be used except in pulpless molars.

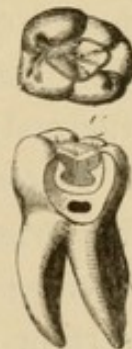FIG. 45.



In inserting pieces of porcelain, the shade and shape of the piece to be used in each case must first be carefully selected, after which the rubber dam ought to be applied, the cavity prepared, and the porcelain fitted and inserted. If the piece is to be placed in a cavity in the masticating surface of a molar the entire cavity ought to be filled with oxychloride or oxyphosphate of zinc, and, while the cement is yet sufficiently plastic, the porcelain must be pressed to place, and the surplus material that escapes should be trimmed away at once, thus exposing the margins to view. After allowing ample time for the cement to harden, the rubber dam should be removed and the porcelain trimmed down with corundum wheels till proper occlusion of the teeth is obtained. FIG. 46.*

Oxychloride and oxyphosphate of zinc, as well as gutta-percha, wear away, but when only a narrow line of the material is left between the enamel and the porcelain, attrition does not impair the operation, and further decay is not likely to take place.

Gutta-percha ought to be used in the filling of cavities within the buccal walls of molars, and especi-



*Section of a molar showing the position of a piece of porcelain in oxychloride of zinc. The thickness of dentine remaining below the cement is shown where a part of the pulp-chamber was exposed in the preparation of the specimen.

ally where the cavity to be filled extends to or under the margin of the gum, because this material is not dissolved and washed away by the fluids of the mouth. After the piece of porcelain has been properly fitted, it should be heated just enough to soften the gutta-percha previously placed in the cavity, to allow of its being pressed at once to place. After trimming away the gutta-percha to the margin of enamel and porcelain, first with a warm, flattened burnisher, and then with chloroform applied on pellets of Japanese bibulous paper, the operation is complete, and the rubber dam should be removed. Even though the surface of the porcelain be on a line with that of the enamel surrounding it, the gloss left from the burning of the piece should then be removed with Hindostan stones, because a less artificial, and therefore a finer, appearance in the mouth is presented.

Previous to filling with gutta-percha, or with any material other than oxychloride or oxyphosphate of zinc, one of these cements ought to be placed in the bottom of all deep cavities as a non-conductor of the currents incited by heat and cold in the dentinal fibers, in order that the pulp so nearly exposed may be better protected than by gutta-percha, or that, after a metallic substance is inserted, thermal changes may not produce shock.

Pieces of porcelain cannot be easily inserted in any but what may be called large-medium or in extensive cavities of decay, and it is scarcely necessary to try inserting them in other than these, because it usually requires comparatively little time to fill well with gold, by the aid of the electro-magnetic mallet, small cavities in the masticating and buccal surfaces of molars and bicuspids.

When cavities are carefully prepared and the pieces of

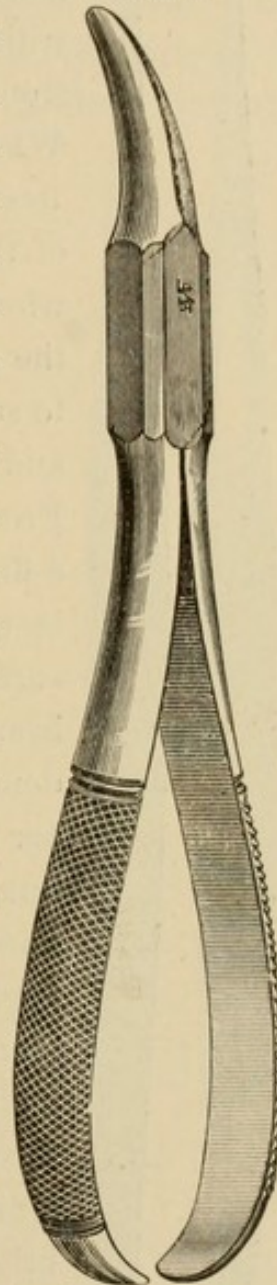
porcelain are properly fitted, inserted, and finished, these operations not only present a finer appearance and protect the margins of enamel better than fillings made of amalgam, but they are really more durable than fillings of any plastic substance or any known material except gold.

FILLING CAVITIES WITHIN APPROXIMAL WALLS.

SOLUTION of the basis-substance of the enamel almost invariably commences at or near the part of the tooth which is in contact with its neighbor on either side, and soon extends along the whole approximal surface, involving the dentine, in which tissue decay progresses rapidly. When this takes place upon the approximal surfaces of the incisors and cuspids they should be separated by wedging with wood, or by having previously pressed linen tape or cotton between them. When the necessary space has been made in this way, particularly between the incisors and cuspids, white gutta-percha should be placed in the cavity or cavities, also in the space gained, and allowed to remain a day or two, until the irritation incited by the wedging has subsided. Rubber ought not to be used for pressing teeth apart, for the reason that it causes far more irritation than other substances. It is oftentimes best to place a wedge of orange or boxwood between the teeth, even after having pressed them apart, not only to gain more space than that obtained from previous wedging, but to arrest their tendency to approach each other, and to steady the organs for the performance of the operation; particularly if the irritation from the slow wedging has not passed away, so as to admit of the insertion, by the aid of the mallet, of all, or nearly all, the gold. When the required space has been gained, the rubber dam should be applied; the quick

wedging should be resorted to, if found necessary, and the operation commenced. The cavity should be carefully prepared and the edges of enamel smoothly and evenly finished; a slight groove or undercut should be made toward the cutting-edge and at the cervical wall, and a starting-point drilled in this wall toward the palatal edge. All the anchorage should be made in the dentine, just inside the line of junction of this tissue with the enamel. In the filling of these cavities, particularly the small ones, more than those in any other location, it is necessary to use what is known as "hand-pressure," and pack some of the gold (mainly into the undercuts) with small curved instruments having fine and sharp serrations (Fig. 48). Cohesive gold can be very successfully used in these cases, as well as in all others, but it should be prepared from a half-leaf of light foil, such as No. 4, so folded as to be equivalent to No. 12 or No. 16, and then cut into strips about a half-line wide. In many cavities of this class, as well as in most others, all the gold can be best impacted by the quick, decided, even blow given by the usual one-sixteenth inch stroke of the electro-magnetic mallet. The whole operation of inserting the gold, as before described, can be so completed that there shall be perfect restoration of contour of missing tissue.


FIG. 47.*



* Fig. 47 shows a good form of wedge-forceps devised by Dr. Corydon Palmer.

After the preparation of cavities such as those just referred to, particularly the larger ones, and previous to

FIG. 48.*



the insertion of the gold, the edges of enamel forming the margin should be made smooth and be evenly finished, but not rounded, with emery-cloth; first a narrow strip cut from No. $\frac{1}{2}$, and then one from No. 0. When the gold has been made compact and its surface has been trimmed down to the edge of the enamel which surrounds it, and the whole has been so shaped as to conform to the contour of the tissue which the gold is to substitute,—upon the approximal surface and labial edge by means of a No. 1 or No. 0 Froid file, and upon the palatal portion with a fine bur,—strips of fine emery-cloth should be so manipulated as to perfectly finish the surface of the gold, and leave the parts beautifully formed. All this can best be done previous to the removal of the rubber dam, after which the filling should be finished by the use of finely pulverized pumice, and then silex, each mounted and applied upon fine linen tape. Rouge may then be applied upon a strip of fine chamois-skin. When the gold is made solid throughout, pumice, silex, and rouge leave a finer finish than the burnisher, but not so bright a luster. The burnisher need not be used, and should not, for the reason

* Small curved instruments, right and left, with fine, sharp serrations.

NOTE.—All the instruments illustrated in this book are similar to those used by the author in his practice.

that, besides the undesirable luster which it leaves, gold that is made compact at every part with the mallet can have but very little, if any, impression made upon it by the burnisher.

All operations ought to be performed artistically and made as nearly perfect as possible, so that if gold is exposed to view its appearance shall be beautiful and rather pleasing than otherwise.

PREPARATION OF CAVITIES FOR RESTORATION OF CONTOUR.

WHEN solution of the enamel of the approximal surface of a bicuspid or molar has taken place, and the dentine has also undergone dissolution, separation by pressure is necessary, as in the case of the incisors. Though sufficient space may be gained between the incisors by quick wedging, yet such wedging of bicuspids and molars can not be done so easily and rapidly as in the case of incisors, especially when the cavity extends almost to the margin of the cementum. In such cases, the gold should be built into and from the starting-point, along the cervical wall and grooves, and to the part where the convexity of the filling must be gradually increased. When so much of the gold has been inserted with the mallet, and smoothly finished with separating or other files (care being taken not to cut the rubber dam), a wedge of hard wood ought to be placed between the gold and the tooth adjoining, and sufficient space thus secured to enable the operator to so complete the filling that there shall be no spaces between the teeth, except at and near the necks. If the operator cannot do this, a wedge of boxwood should be inserted from the neck to a point midway between it and the masticating surface of the tooth, and cut away with burs to the form the filling should have; but such an appliance ought not to be depended upon to retain any portion of the gold. Unless separation by pressure is

made in some such manner as indicated, the gold cannot be so finished as to have the teeth come closely together, and prevent the wedging of food between them. Pressure ought not to be rudely made or too long continued, else circulation in the capillaries and protoplasmic bodies of the pericementum may be so interfered with as to prevent the return of the parts to the normal condition after the wedge has been removed.

After sufficient space has been gained, the rubber dam should be applied to the two teeth separated by pressure, and to the tooth adjoining each, that those pressed apart may not come together during the performance of the operation, or the insertion and finishing of the filling, and that the organs may be the better operated upon.

All cavities, wherever located, ought always to be made accessible. A cavity within the approximal wall of a bicuspid or molar should be opened into from the masticating surface (Fig. 36, *a*, *b*, and *c*), except in rare cases, because, even when there appears to be but little solution of the lime-salts, this surface would be almost reached upon the perfect removal of the tissue where dissolution of the basis-substance had taken place, and the plate of enamel would be liable to fracture, if hard substances were to come in contact with it during the mastication of food. It is far better to cut away the enamel between the cavity and the masticating surface, because a clearer view is thus obtained, and the entire operation can be performed in a satisfactory manner, with certainty of a good result. In addition to this, the adjoining fissure or sulcus is usually imperfect, and it should be prepared (as at *a* and *b*, Fig. 36) and filled in connection with, and at the time of, the performance of the operation within the approximal wall. That operations may be successful, every

cavity must be so prepared that no decalcified or partially decalcified tissue remains, except there be a little discolored dentine near the pulp, and that should be left for its protection. The margins of enamel should be slightly beveled when gold is to be placed over them, and they ought always to be made smooth and even with fine, sharp burs, files, and emery-cloth. A groove, about the sixty-fourth of an inch deep, should be cut along each wall of the cavity (*c*, Fig. 36), and must be made in the dentine within and near the line of both the buccal and palatal or lingual walls of enamel. It ought to extend from the masticating surface to (but not along) the cervical wall, except in some cavities in the incisors, because of there not being such a body of tissue at that part as to make it safe to remove any of it for the purpose named. The greatest pain is felt when the operator reaches the interzonal layer, because it is this part—along the boundary-line of dentine toward the enamel—where there is more living matter than elsewhere in the dentine or in the enamel. The neck of a tooth is also very sensitive, for the reason that this part, too, is supplied with so many fine fibers of living matter. Care ought therefore to be taken that no more cutting than is absolutely necessary be done about this part.

In the preparation of a cavity within the approximal walls of enamel of a bicuspid or molar, enough of the tissue toward the buccal, palatal, or lingual wall must be cut away to free the edges, thus enabling the operator to so restore the contour of the parts, and so finish the filling or fillings as to keep the margins of enamel from contact with the tooth adjoining. This is the only way to keep the margins of enamel permanently separated, and thus prevent extension of decay.

If solution of enamel, or decay, does not extend to or beneath the margin of the gum (and especially if calcification is imperfect), both the enamel and dentine of the approximal, as well as of the buccal, surface of the tooth being operated upon ought to be cut away with fine burs to fully the thirty-second of an inch above the part where the gum closes around the tooth; so that, when the operation is completed, this part may be protected from particles of food. When the necks of the teeth are kept separate as in nature, and the gum is in normal condition, it protects the portion of enamel, and covers the well-inserted and finely-finished gold beneath its margins so perfectly that solution of the basis-substance of the tissue of the part, and even its discoloration, is prevented. This protection of the parts continues, unless in after-years there be diminished circulation in the capillaries and lack of nutrition to the gum, and it commences to return to embryonal corpuscles. Decay may then take place at the necks of the teeth, though, at the age when there is usually loss of molecular tone and recession and loosening of the gum-tissue, there follows deposition of lime-salts under or about the margins of the gums. This deposit may incite pericementitis, and the result may be the breaking of the fine line of living matter between the epithelial and other bodies of the part, and prevention of the rebuilding of the tissue. When the gum is in normal condition, it is so close to the necks of the teeth as to prevent lodgment of foreign matter beneath its margins.

The gum fills the space between the teeth almost entirely, and protects the parts it covers, and this tissue should always be guarded by full restoration of the contour of the missing enamel. The gold ought to be finely finished at all points, that there may be no obstruction to the

tissue again closing around the neck of the tooth operated upon. In this manner the margin of enamel at or near the neck of the tooth against which the gold is placed and smoothly finished is protected by the gum, and, if the whole operation has been properly performed, extension of decay at that point is prevented.

In cases where calcification is imperfect, and solution of the lime-salts of the teeth takes place rapidly, it is well to keep cavities of decay filled with gutta-percha or oxychloride of zinc until there is more complete deposition of lime-salts in the basis-substance of the enamel and dentine. If a permanent operation be performed with gold before perfect calcification takes place, it is necessary to free the edges of enamel and to keep the margins from contact by full and complete restoration of the contour of the missing tissue.

All the better grades of white gutta-percha are composed mainly of the simple so-called red gutta-percha and oxide of zinc. More depends upon the preparation than upon the component parts of the material, so that care must be taken in its manufacture.

Three grades of white gutta-percha are prepared,—the “low heat,” the “medium,” and the “high heat.” The “medium,” which becomes sufficiently plastic at a temperature of about 200° F., is the best grade for general use. The gutta-percha should be softened on a porcelain or metal plate over hot water, and with some preparations of gutta-percha even of proper grade the water must be raised to the boiling-point to make the material soft enough to be worked nicely. The instruments for packing and the flattened burnisher for trimming gutta-percha had best be heated on a metal plate, although careful heating over the flame of alcohol will answer the purpose.

The instruments ought to be warmer than the material that is being used.

Instruments for packing gutta-percha should be of such shape as to reach all parts of cavities, and be medium or rather large-pointed, and finely serrated (Fig. 49). The cavity should be kept dry with the rubber dam, and the gutta-percha ought to be made to adhere to the dentine and enamel. The whole cavity must be filled by carefully adding one small piece to another. In trimming a gutta-percha filling the flat burnisher ought always to be pressed toward the margin of the cavity, thus avoiding the loosening of any of the material from the edges.

FIG. 49.

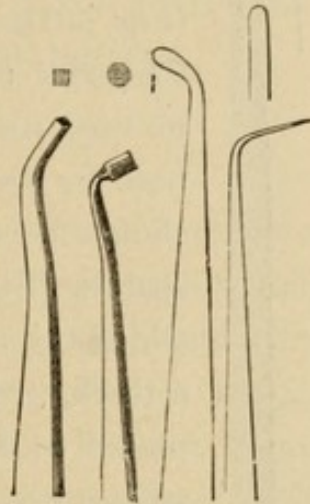




FIG. 50.



of enamel. After this is done the surface of the gutta-percha should be nicely finished with linen tape and small

FIG. 51.



pellets of Japanese bibulous paper saturated with chloroform.

In using oxychloride or oxyphosphate of zinc place a little of the fluid upon a porcelain palette (Fig. 50) or a piece of glass, and put sufficient of the oxide of zinc for the case for which it is to be used near the fluid, and, when all is in readiness for the insertion of the material, the powder should be worked into the liquid with a small spatula (Fig. 51). Sufficient powder should be added to and mixed with the liquid to make a thick, creamy mass, when it must be carefully placed in the cavity at once, and gently pressed against every part of the dentine with small pellets of cotton. Oxyphosphate of zinc usually sets so quickly that it requires more rapid manipulation than the oxychloride.

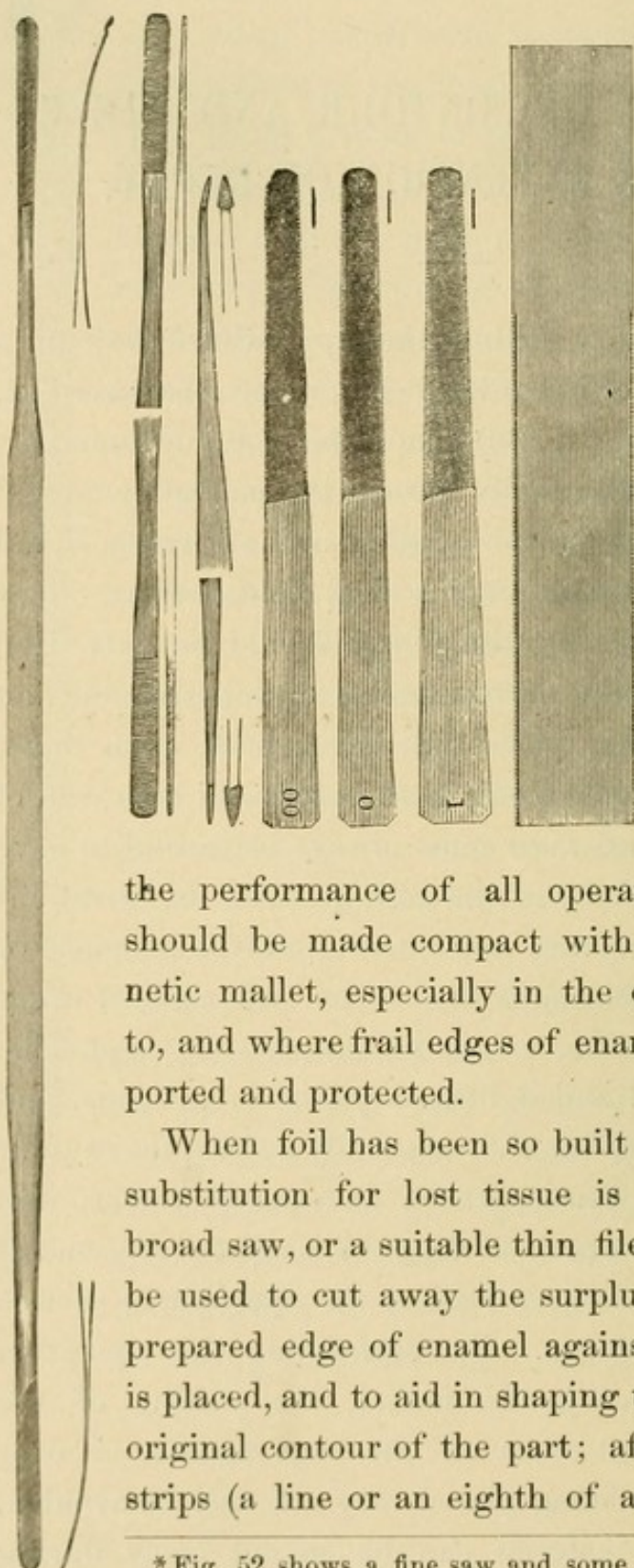
In most cases, after the preparation of cavities, particularly those that are deep, carbolic acid ought to be applied, not only to serve as a disinfectant, but to coagulate the protoplasm of the ends of the fibers in the dentinal canaliculi and partially obtund sensation. In those cases where thermal changes may produce more than the usual shock in healthy tissue after the gold has been inserted or the operation completed, oxychloride of zinc ought to be placed in the bottom of the cavity as a non-conductor of the currents incited by heat and cold in the dentinal fibers.

RESTORATION OF CONTOUR, AND PREVENTION OF EXTENSION OF DECAY.

WHEN a cavity within the approximal wall of a bicuspid or molar has been prepared as described, a starting-point (*a*, Fig. 36) should be made in some part of the cervical wall, usually toward the palatal or lingual surface, and in that portion of the dentine between it and the enamel or cementum which shall be the safest. This point in which to start the filling should be only deep enough to retain the narrow pieces of cohesive foil first inserted while other pieces are being built upon them, and the filling carried along to the groove in each wall of the cavity. The operator must always be careful to have a piece of foil or some of the gold between the serrations or end of the packing-instrument and the enamel or dentine. The gold ought then to be built against every portion of the dentine, and packed as perfectly as possible along the enamel and a little beyond its margins, and carried fully to the line that originally defined the contour of the part. To thus perform an operation it is necessary to build that part of the gold nearest to the buccal and masticating surfaces against the approximal surface of the tooth adjoining. By performing this operation with the electro-magnetic mallet, the passing of the packing instrument from off the edge against or over which the gold is being placed may not only be avoided, but the surplus material can be so cut away during

the performance of the operation that comparatively little

FIG. 52.*



trimming is afterwards necessary. Cohesive gold foil, No. 30, 40, or 60 for large, or foil folded to No. 16 or No. 20 for smaller fillings, and which has not been in contact with the fingers, but prepared and manipulated as hereinbefore described, ought to be used in

the performance of all operations. The gold should be made compact with the electro-magnetic mallet, especially in the case just referred to, and where frail edges of enamel are to be supported and protected.

When foil has been so built in place that the substitution for lost tissue is complete, a fine, broad saw, or a suitable thin file (Fig. 52) should be used to cut away the surplus material to the prepared edge of enamel against which the gold is placed, and to aid in shaping the filling like the original contour of the part; after which narrow strips (a line or an eighth of an inch wide), cut

*Fig. 52 shows a fine saw and some suitable files for trimming and shaping gold fillings.

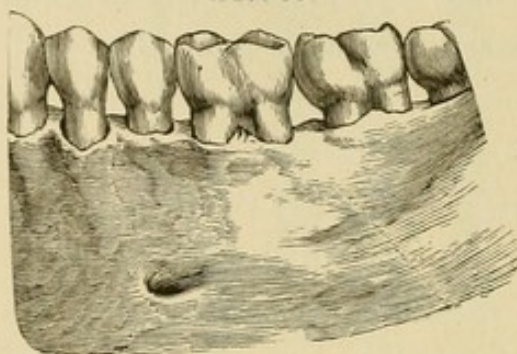
from fine emery-cloth or emery-paper, should be so manipulated as to properly finish the surface of the gold. When this has been done, the rubber dam should be removed, and the finishing completed by the use of fine pumice and silex on linen tape. The gold at the masticating surface should be trimmed down with fine burs, and made concave, or finished to represent the original contour or outline of the part operated upon. The gold should be so placed in the cavity as to be flush with the prepared margins of enamel, and made concave when such concavity is indicated. Fine burs, rather than corundum cones, should be used for trimming and shaping such fillings, as well as those in the palatal surfaces of the incisors and cuspids, because the form of the remaining part or parts of the cusps and prepared edges of enamel against which the gold is placed may be changed or disfigured, and the teeth made less useful if finished with corundum points. The polishing of the gold upon the surfaces referred to should be done with pumice and silex upon suitably-shaped points of wood, rubber, or leather.

Restoration of the contour of a part or parts of the crown of a tooth signifies not only the building-out and finishing of the gold to the line that defined the figure originally, but by it is meant the knuckling-up of the tooth restored to the one adjoining in such manner that the margins of enamel shall be free from contact, and that food cannot be forced between the teeth from the masticating surface.

For full restoration of contour it is necessary to gain space to prepare the cavity, pack the gold, and finish the filling. This must be done either by wedging at the time of performing the operation, or by previously placing or pressing wood, linen tape, or cotton between the teeth as before described.

In every case the gold ought to be built out to the original contour of the part and a little beyond the margins; then finished down to the surface of the enamel, so that the outline of the whole filling shall be the same as the line that defined the contour of the lost tissue:—contour signifying “the line that bounds, defines, or terminates a figure” (Fig.

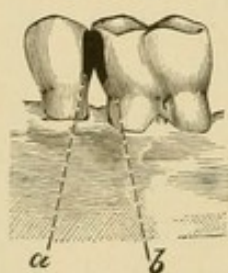
FIG. 53.



minates a figure” (Fig. 53). This line ought always to be fully restored, particularly on the approximal surfaces of bicuspids and molars, and the gold should be carefully trimmed down to and

finely finished flush with the margins of enamel, which margins, in these cases more especially than in others, must be free from the tooth adjoining, to prevent extension

FIG. 54.*



of decay (Fig. 54, *a*, *b*). When operations have been so performed as to entirely prevent fluids from entering between the gold and the tissue against which it is placed, and all discoloration has been removed from the surface of the remaining tissue, the gold tint may be seen through

the light walls or edges of the translucent enamel soon after the removal of the rubber dam and completion of the operation. If there is a dark line or spot at a part where the gold should be against the dentine and enamel, the operation has been imperfectly performed, and, if not re-performed, as it ought to be, there follows extension of decay and failure of the filling. If gold is not placed compactly against and is not flush with the edges of

* Fig. 54 shows restoration of contour and (*a*, *b*,) free edges of enamel.

enamel, the operation is not such as is demanded for the preservation of the remaining tissue. A flat surface of gold should not be made, because the tooth thus operated upon and the one adjoining may move closer together, and solution of enamel will then take place at or near the part or parts in contact. In such cases solution of the lime-salts usually takes place near the buccal, palatal, or lingual wall of enamel that is in contact along the approximal surface against which gold (or other material used) has been placed, while other parts around the same filling may remain free from decay. Decay about fillings is not likely to take place where there is full restoration of the contour of the missing tissue and such close knuckling-up of the teeth as to leave the margins of enamel free from contact and prevent the wedging of food between the approximal surfaces that are restored.

Restoration of contour prevents contact of the margins of enamel, and this prevention is necessary for the preservation of the remaining tissue, especially when the tissues (the enamel and dentine) of the tooth operated upon are not fully calcified. In many of these cases, where about the space of half a bicuspid remains because of the extraction of a tooth, and fillings are required within the approximal walls of the molar or bicuspid adjoining, the contour should be carried beyond the original line far enough to entirely close the space referred to,—thus increasing the surface for and aiding mastication, as well as giving needed support to the teeth remaining in the arch such as they originally had. The contour of missing tissue ought always to be so restored with gold that the enamel of one organ may not be in contact with that of the next in the arch, and that a part of the gold in the one may be against or tightly knuckled-up to the

normal tissue of the tooth adjoining, or to a filling, if one has been inserted in it (Fig. 54). Then comfort in mastication is assured and solution is not likely to take place, because the free margins of enamel against which the gold has been placed will be washed by the fluids taken into the mouth as well as be cleansed by the saliva, which is kept in almost constant motion by the action of the tongue, lips, and cheeks.

Dr. H. C. Longnecker, of Philadelphia, Pa., writing upon this subject, fairly states, in the following paragraph, whatever there is to be considered as objections to the operations just described, viz.: "The labor, skill, expense, and time required for this method of operating will, I think, be admitted by all; but while these may be and doubtless are practical objections, they in no manner impair the correctness of the principle. These operations represent the ideal, the poetry of dentistry; they are useful; they are beautiful. Let us guard the beautiful with reverent care; the useful will take care of itself."

When operations have been performed in the manner herein described, and the fillings are as finely finished as suggested, they are the best for the protection of the enamel against or over which the gold is placed, and for the prevention of the wedging of food against the gums and their consequent recession. They subserve well the purpose of mastication, and present a beautiful appearance, and this is the only way to keep the margins of enamel of the approximal surfaces of the teeth permanently separated,—fully restore the contour of the tissue that is lost.

SUMMARY OF PRINCIPLES RELATING TO FILLING TEETH.

THE following ten articles are given as indicating some of the principles which ought to guide all operators in the filling of teeth :

I. Gold, *properly used*, is the *best* known material for the permanent preservation of the teeth.

II. With restoration of contour so complete as to keep the margins of enamel free from contact with the tooth adjoining, extension of decay is prevented.

III. "Failure in operations is mainly due" to the gold not being packed closely against the dentine and enamel at every part, thus allowing fluids to enter at such parts and further decay to take place. The failure of a filling, therefore, is "mainly due" to the *incompatibility* of the operator with his work.

IV. A cavity that can be "satisfactorily filled with anything is worth filling" with gold. The contour of any tooth can be restored with gold if the operator has the ability to properly apply the rubber-dam and perform the operation.

V. Skillful operators first see that the parts are in healthy condition, and then so perform operations with gold as to prevent further decay, or they fill with oxychloride of zinc to avoid shock from changes of temperature and cover with gold.

VI. A filling-material "may be the *best* that is known

for the tooth, *and yet leak badly*," because of "defective manipulation;" but to save the tooth that best material, gold, must be so inserted as to prevent leakage.

VII. "Gutta-percha, *properly used*," is a *good* filling-material, but it serves a temporary purpose only, except where there is no friction from mastication, from the free use of brush and powder, or from floss-silk, when it may prevent decay for several years.

VIII. "A *good* gutta-percha filling, *in its proper place*, is better than a *poor* gold one," and better than any other material inserted in a careless and imperfect manner.

IX. The *excellence* of "amalgam, *per se*," consists only in enabling an operator to fill a cavity with it where he might otherwise resort to extraction. [Amalgam shrinks, and fluids penetrate between it and the enamel, which becomes fractured little by little; oxidation takes place, and, while slightly retarding decay, the oxide discolors tissue, especially the dentine in the teeth of young persons, and the filling presents an unsightly appearance.]

X. "The use of 'plastic' filling-materials" does not tend to the exercise of that care and the development of that skill which are necessary for the successful practice of "that dentistry which has for its standard of excellence 'ability to make' *good* 'gold fillings.'" An operator with such ability can not only perform operations with gold so as to "*save teeth*," but he can insert any other material better than one who has not the "ability to make gold fillings."

COVERING AND PROTECTING FRAIL WALLS OF ENAMEL WITH GOLD.

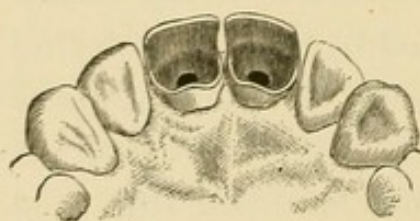
WHERE frail edges of enamel are to be supported and protected, the margins should be slightly beveled, so that the tissue may be the better kept in place by the gold, which should be evenly finished, to present a fine appearance when the operation is completed.

Should a crown present a dark appearance, owing to the discoloring of the protoplasm in the fibers throughout the dentinal canaliculi and the net-work of living matter in the basis-substance, efforts should be made at bleaching with chloride of lime and acetic acid; but the appearance may be improved only temporarily. Previous to the use of such agents, the foramen should be closed with gold and part of the pulp-chamber securely filled, and as much dentine removed as can be afforded without making the crown too frail. The method of packing the cavity full of alum, and saturating this with "Labarraque's solution of chlorinated soda," may be employed. The bleaching is supposed to be produced by the action of free chlorine upon the discolored protoplasm in the fibers of the dentine.

Oxychloride of zinc may serve the purpose of giving nearly the proper shade or tint through the enamel; but this may not add the necessary strength to the tissue, which must be supported and protected when the dentine is removed. To restore the shade of a crown approximately, it may be necessary to remove all the dentine from

the cutting-edge to the neck of the tooth, with the exception of a thin layer about the line of junction of the enamel and cementum. The cutting-edge of the labial wall of enamel must in many cases be cut off and slightly beveled outwardly with a corundum wheel, and evenly and finely finished with fine emery-cloth, so that it will line with the edges of the other teeth, when the remaining tissue is protected by a covering of gold of a full thirty-second or even the sixteenth of an inch in thickness, and the cutting-edges present an even line or edge to the sight. The mesial and distal edges, as well as the cutting-edge of enamel, must be evenly and smoothly finished with strips of emery-cloth, No. $\frac{1}{2}$ and No. 0. (A case prepared as described and ready for the gold is here illustrated, Fig. 55.) The discolored dentine, extending some

FIG. 55.



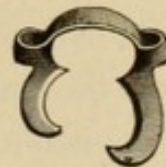distance into the root, must be cut away; all foreign particles should be removed, and the pulp-chamber somewhat enlarged with a Gates drill to the apical foramen, which should then be closed with gold and the operation of restoring the contour of the crown commenced. The gold in that part of the pulp-chamber not directly in sight ought to be inserted by the aid of a hand-mallet, and all the rest made compact with the electro-magnetic mallet. The packing-instrument must be very carefully operated upon the foil placed against the inner portion and the edge of the labial wall of enamel. Cohesive gold, No. 4, folded to No. 16 or 20, ought to be placed against the wall of enamel, and No. 30 gold built into the body of the crown. The whole of such an operation can be performed without fracturing the enamel. When completed properly, these operations

not only support and protect the tissue against and over the edges of which the gold has been placed, but the delicate gold-tint is seen through the translucent enamel, even though there may have been marked discoloration before the operation was commenced.

The following description of a clinic operation performed by the author before the First District Dental Society of New York, February 7, 1882, illustrates both extensive restoration of contour and the binding in and protection of the parts of the tooth remaining:

This operation was performed on the left upper second molar, a pulpless tooth with the whole anterior approximal and a good portion of the masticating surface missing, all the other teeth on that side of the mouth being in position. There had been such treatment as was necessary to allay pericementitis, and all obstruction to return of the surrounding tissues to normal condition was removed. The decomposed pulp-tissue had been taken out of the roots of the molar, and each root had been temporarily filled with cotton, and the cavity of decay with gutta-percha, some months before. The opening in each buccal root had been very carefully followed up and slightly enlarged with a delicate Gates drill. At this clinic, after the rubber-dam had been applied, narrow strips of light gold foil were carefully placed in each root, from the apical foramen to the large or bulbous portion of the pulp-chamber, which was then filled with oxychloride of zinc—Agate cement. A piece of light-medium rubber-dam, about eight inches square, was selected, and five holes were cut in it, two of them a little larger than the others, for the first and second molars. With the Delos Palmer clamp, "L. S., 7" (Fig. 56), applied to the second molar—the "left superior

FIG. 56.



seventh" tooth from the median line—the rubber dam was stretched over clamp and tooth, and brought forward over the first molar, each bicuspid, and the cuspid,—these being the five teeth for which the holes were made. A ligature of waxed floss-silk was then placed in position and tied at the neck of the first molar and that of the cuspid. This having been done (the operator doing all of it alone in less than five minutes), the edges of the rubber were carefully folded and held out of the way with a rubber-dam holder, and the patient made more comfortable by the placing of a fine napkin under the rubber next to the lips, chin, and cheeks. All was now ready for the operation, and the parts were quite accessible as well as dry. While the cement in the bulbous portion of the pulp-chamber was hardening, the preparation of the cavity was completed and sufficient anchorage for the filling made; the margins of the cavity were cut even and smooth; the cusps were taken off almost an eighth of an inch, and the whole of each remaining wall—buccal, palatal, and posterior approximal—was otherwise trimmed, slightly beveled, and prepared for the gold with corundum wheels. When the cavity was thus prepared, and a good medium-sized starting-point had been made in the dentine in line with the palatal root at the edge of the cement, the filling was commenced and the grooves were filled with No. 30 foil. Most of the operation was carried forward with No. 60 gold, each piece of foil used being passed over the flame of an alcohol lamp,—making it as cohesive as possible,—and placed in the cavity by an assistant. The gold was put in place and made compact with the electro-magnetic mallet attached to a freshly-charged four-cell Bunsen battery, after the starting-point and a portion of each groove had been filled, and as the narrow

strips of foil were placed along the cervical wall and put compactly and safely in position over all the margins, the surplus material was trimmed away from the edges wherever trimming was required, without puncturing the rubber-dam. The whole operation was carried steadily forward with but little labor till the contour was fully restored, including the covering of the buccal, palatal, and posterior edges of the crown to the depth of almost an eighth of an inch, and the building down of each cusp with gold in one solid mass. Over two books of one-eighth of an ounce each, or about one hundred and twenty-eight grains of gold, were used in the filling, and the insertion of the same and the restoration of the contour, including the trimming away of the surplus material and the shaping of the crown with the electro-magnetic mallet, as the work was progressing, required about two hours and ten minutes. This operation did not cause pericementitis, though the pressure of the ligature and the clamp induced slight inflammation of the lower part of the pericementum and gum surrounding the neck of the tooth.

PLACING CROWNS ON ROOTS OF TEETH.

SHOULD solution of the lime-salts of the enamel and dentine not be prevented or arrested, little by little the tissues become fractured and their contour broken up; the death of the pulp takes place; the crown is soon gone, and the edges of enamel yet remaining scarcely rise above the surrounding soft tissue. Even when a case presents with here and there a crownless root, treatment such as is herein mentioned should be commenced and continued until the remaining tissues are in normal condition; after which, all operations that may be required ought to be performed as perfectly as possible, and artificial crowns placed upon the roots—especially those of the incisors, cuspids, and first bicuspids.

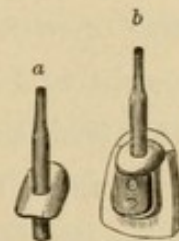
Where fracture of enamel has been extensive, and its contour is almost or entirely broken up, it is not only necessary to carefully prepare the root for the placing of an artificial crown upon it, but, as in all operations upon pulpless teeth or roots, special care must be taken that inflammation of the pericementum is not induced.

Preparatory to mounting a crown in the manner now to be described, the root should be cut beyond the margin of the gum and a plain "pivot-tooth" placed upon it by means of a wood pivot surrounded with white gutta-percha, which, when made plastic by heat and the crown inserted, protrudes and presses the gum away from the margin of the root. After this temporary crown has

been in place a few days (or perhaps only for a day or two) a gold wire, No. 12 or 13, should be accurately fitted in and placed as far up the root as possible. A gold plate, No. 26 (18-k.), should be fitted to the prepared surface of the root, and an opening made in it just large enough for the wire to pass through. The plate and wire should be placed in position and the latter marked with the point of a knife or lancet-blade, so that, when the wire is put into a suitable hole made in charcoal and the plate placed upon it, there shall be no difficulty in deciding just where to solder the parts together. When thus fitted, soldered, and then annealed, the gold wire and plate should again be placed in position and more accurately fitted to the root. There should be no movement of the metal while the edges of the plate are being fitted to the prepared surface of the root by the aid of the mallet. After this is done the wire should be cut off to within about two lines of the outer surface of the plate, and the edge of the latter so trimmed as to be on a line with the circumference of the root, and then, with wire and plate in position, an impression of the parts should be taken in plaster of Paris. An

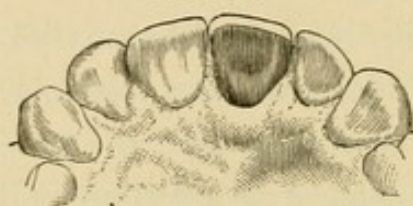
FIG. 57.

illustration of a wire and plate, after having been fitted as described, is here given (Fig. 57, *a*). When this is done and the wire and plate taken from the root and put in place in the impression, a correct model of the teeth and parts adjoining can be made, with the gold in the same relative position as when in the mouth. After the model is made, the gold removed from it, the end of the wire which extended outside the root to aid in marking the position of the wire and plate in the impression cut off and filed down to the surface of the plate, a thick,



narrow gold backing should be fitted and riveted to a suitable crown (plain "plate-tooth" with "straight pins") and a groove cut along each side, and in some cases near the cutting-edge of the porcelain, as illustrated in Figs. 57, *b* and 59, *b*. This is done in order that the parts may then be built out and the porcelain more perfectly secured, and the contour of the palatal portion restored with pure gold, as shown in the cut with crown in place

FIG. 58.



(Fig. 58). After the backing is placed upon the porcelain it should be attached to the plate with wax, and the whole carefully removed from the model,

incased in plaster and sand, gradually heated, and soldered. The porcelain ought then to be examined with a magnifying-glass, so that the operator may thus determine whether any fracture has taken place during the heating and soldering. The parts, prepared as described and illustrated, may be held by screwing the wire in a hand-vise while the gold foil is being built in place. The gold foil should not only be built into the grooves and made compact throughout, but the cutting-edge (or cusps, if the crown be a bicuspid), after being slightly beveled, ought to be covered with solid gold as a protection from the occlusion of the lower teeth. The narrow line of gold need not be made conspicuous, if it be visible at all. This can be nicely done with the electro-magnetic mallet, and the crown made ready for insertion by the time of the next appointment with the patient.

A very good and less difficult method of preparing crowns is to back the whole of the porcelain and restore the contour of the palatal portion with fine gold plate (18- to 22-k.), united with correspondingly fine solder.

The apical foramen should be closed with gold. If gutta-percha or oxychloride of zinc be used for this purpose, some of the material may be pressed through the foramen, but with gold the operation can be made more certain and satisfactory. To avoid any exposure of gold, should recession of the gum take place, the edge of the plate ought to be so cut away that the porcelain may be accurately fitted upon the labial portion of the root.

When all is in readiness for placing the crown upon the root, fine barbs should be made with a knife or lancet along the entire surface of the gold wire, and a thin layer of white gutta-percha (such as requires little heat) placed around the wire and against the plate; the metallic parts should be heated sufficiently to just soften the gutta-percha, and, with the root dried, the whole must be immediately pressed and carefully hand-malleted to place. The surplus stopping should be trimmed off with a lancet a few hours or the day after the crown is placed upon the root, or when the gutta-percha shall be thoroughly cooled. The gum will then have been so pressed away that the boundary-line between the crown and root can be seen, and the edge of the gutta-percha smoothly finished with pellets of Japanese bibulous paper, lint, or cotton, saturated with chloroform.

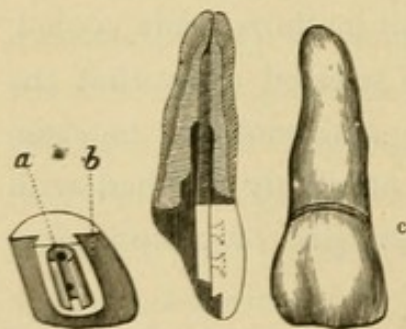
There is a still less difficult and yet good method of placing crowns upon roots of teeth, and one, too, that does not require so much time as that just described; but the root should be prepared and a gold wire fitted in it in the same manner. A suitable plain "pivot" crown, having a hole in it a little larger than the gold wire, should be selected and fitted to the surface of the root as perfectly as possible, and the opening in the porcelain filled with fine, well-seasoned hickory-wood, which must

then be cut off even with the base of the crown, and a hole drilled in the center and entirely through it large enough to insert one end of the wire. The surface of the wire should be roughened or finely barbed along its whole length, and one end placed (not malleted) tightly in the opening made for it in the wood in the crown, the whole being then placed upon the root and finished as above described.

An artificial crown, by whatever method mounted, can be more successfully placed upon a root, and all operations better performed, when the rubber-dam is applied than where it is not used, and it should therefore be secured, if the operator can apply it, to the adjoining teeth and then to the root before the final fitting and mounting of the crown.

Building crowns of gold upon roots of teeth and facing them with porcelain makes the most secure and satisfac-

FIG. 59.



tory operation, though difficult.

After preparing the root, closing the foramen with gold, and cutting away the irregular or projecting edges to within about a half-line of the margin of the gum (which is left to aid in applying the rubber-dam), a

gold wire, No. 13 or 14, with a fine, sharp thread cut upon it, should be accurately fitted in the pulp-chamber to near the apical foramen. To the platinum pins of the porcelain selected for the case a cylinder or tube made of gold plate should be fitted, and, after it is opened (Fig. 59, *a*), riveted, and then closed, it should be placed in plaster and fine sand, and carefully heated and soldered. A thread must then be cut in the cylinder corresponding to that

upon the wire to which it is to be attached. This is done in order that the crown may be more securely attached to the root than by the method described by the writer in the *Dental Cosmos*, June, 1873. The end of the gold tube next to the cutting-edge of the crown may be beveled and a slot made in the wire at that point, so that the cylinder shall be prevented from turning; while still greater strength is added by impacting gold into the open part, thus spreading the slotted end of the wire. A groove should be cut with a corundum disk in each side (*b*), and sometimes along the cutting-edge of the porcelain, into which gold foil is to be placed, to secure greater strength and permanency.

When all is in readiness for the operation, the rubber-dam should be applied to two teeth on each side of the root and to the root itself. The ligature of waxed floss-silk should be placed twice around the root, and tightened and pressed well to place with a burnisher; the ends of the silk wrapped twice, as in tying a surgeon's knot, and the ligature then attached to the ring at the end of an elastic rubber-dam holder and held just below the edge of the slightly upraised lip, so that, when the holder is fixed to a tie put around the patient's neck, there shall be constant tension upon the ligature. After this has been done the root should be trimmed down with corundum wheels or cones to the ligature, although not close enough to displace it. The porcelain should then be so fitted as to leave a half-line of space to be filled with gold (as at *c*) between it and the root after the wire has been placed in the cylinder and screwed into the root. In placing the parts in position a little oxychloride of zinc, of nearly the consistence of cream, should be placed in the root next to the gold that closes the foramen, and the

gold wire at once put in this and screwed securely to place. After the oxychloride of zinc has crystallized, sufficient of it and of the dentine should be cut away with small burs to secure good anchorage for the gold now to be placed as perfectly and solidly as possible around the wire, to and over the margin of the root, along the gold tube, into the grooves made in the porcelain, and between it and the labial margin of the root (*c*). While the gold is being placed around the wire in the root, the porcelain can be turned a little to one side upon the gold wire till the cylinder is reached and restoration of the contour of the parts commenced. All the gold should be cohesive and impacted by the aid of the electro-magnetic mallet, with which the surplus foil can easily be trimmed away from the margin of the root as placed upon it, and the form of the crown so nicely carried forward that but little dressing is afterwards necessary. The gold should be filed even with the margin of the root, and finished with narrow strips of fine emery-cloth at and near the point, while the rubber-dam is yet in place. After this is removed the gold should be so cut away as to allow proper occlusion of the teeth, and a little space should be gained by very careful wedging for trimming and finishing the gold in the manner before described along each approximal surface separately.

In placing crowns upon roots of second bicuspid and molars, it may be well to insert a suitable gold wire, with a fine, sharp thread cut upon it, and to build around over the same, and restore the entire contour of the crown with gold foil; but a better, if not a stronger, operation can be made by filling the pulp-chamber, as well as the entire crown, with cohesive gold, and using the mallet. Such operations are not so difficult as those

where gold crowns are faced with porcelain, nor do they require so much time. In some cases two books of No. 30 or 60 gold (should so much be required) can be carefully impacted and the crown properly formed in about two or two and a half hours, with the aid of the electro-magnetic mallet and an assistant to pass the narrow pieces over the flame of alcohol and to place.

Among the cases presented at the clinic given under the auspices of the First District Dental Society of New York, in April, 1881, was one where it had been said to be impossible to apply the rubber-dam to the remaining part of a molar. The buccal wall alone was standing, and the fracture extended three-sixteenths of an inch

FIG. 60.

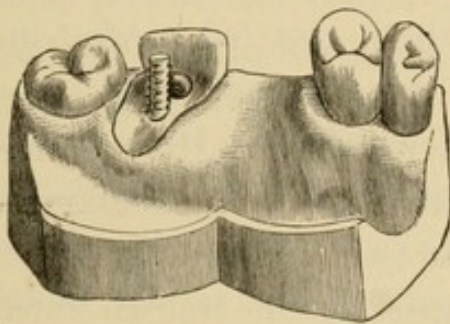
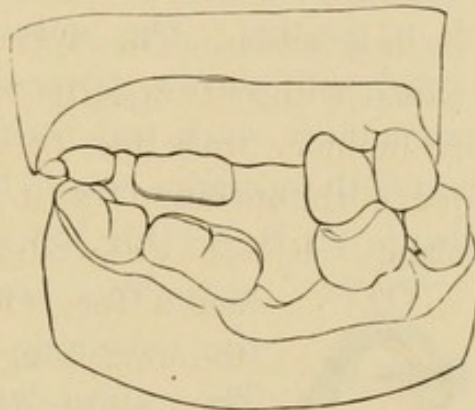



FIG. 61.



above the margin of the gum and alongside the palatal root, and in order to get a clamp and the rubber-dam on this part of the tooth, the gum had to be pressed away some distance with gutta-percha. In operating upon this case at that clinic the author demonstrated what can be done in overcoming difficulties in applying the rubber-dam for the performance of extensive and difficult operations with gold.

FIG. 62.



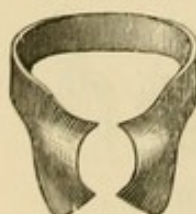The crown, as prepared for the restoration of its contour with gold, is here illustrated (Fig. 60); the buccal

wall having been cut off an eighth of an inch (see Fig. 61), to be covered and bound in with foil. A gold wire was fitted in the palatal root, and another in one of the buccal roots (Fig. 60). These were soldered together, and a hook was made on one part of the wire (Fig. 62), which was carefully fitted to a depression cut to correspond with it in the dentine of the palatal root along one side of the somewhat enlarged pulp-chamber. When the wire was put in place, the hook was pressed toward the depression, so that, in order to come away, it would have to bring with it nearly all the dentine between the depression and the surface of the root. The other wire was barbed, and, though it did not fit very tightly before the barbing, the use of a hand-mallet was necessary to put it in position. The apical foramen of each root was closed with narrow strips of light gold foil. After this preliminary work had been done, and when the larger part of the operation was to be performed, a Delos Palmer clamp, "R. S., 8" (Fig. 63), was placed on the third molar,

FIG. 63.



FIG. 64.



and a Tees "festooned" clamp (Fig. 64) on the remaining part of the second molar. The rubber-dam was then stretched over each clamp separately, and put on the second bicuspid, the rubber bridging over the space left by the loss of the first molar. The clamps and rubber-dam were applied in about three minutes.

After the clamps and rubber-dam had been adjusted and the parts had dried, and the final preparation had been made, oxychloride of zinc was placed in each root, and, while the cement was yet plastic, the two united wires were driven to the place to which they had been fitted (Fig. 60). When the cement had hardened

sufficiently, it was cut away from all parts where foil could be placed advantageously and made to strengthen the operation. The contour of the entire crown was then fully restored with gold. This operation took one hundred and fifty grains, or two and a half books, of gold—cohesive foil, Nos. 30 and (principally) 60. With the assistance of friends, who annealed and placed each piece of foil in the cavity ready for packing, it was all made compact, and the crown and cusps were restored and put in proper shape, with the electro-magnetic mallet, in four hours.

This operation was performed without inciting pericementitis, although the pressure of the clamp, being kept in place so long and held so far up on the tooth, brought about some inflammation of the pericementum and the gum surrounding the neck of the tooth. This, however, soon passed away.

ATTACHING CROWNS TO TEETH WHERE ROOTS ARE MISSING.

WHERE tooth and root are both missing, a porcelain face can be successfully built into one or both of the adjoining teeth, with gold attachments. The insertion of a crown without plate or clasps is a difficult operation, but when well performed, if the crown is attached to teeth that are firm in their sockets, it is both satisfactory and permanent.

The principal beneficial results gained by the building-in of crowns under such circumstances are, the longer preservation of the remaining teeth and the gums and alveolar process in normal condition; the prevention of the absorption of the hard as well as the soft tissues under and because of the pressure of plates,—the loosening and loss of teeth from this cause sometimes occurring years before there would be solution of the lime-salts of the maxillary border and recession of the gums. To secure sufficient anchorage for the insertion of a crown, it may sometimes be necessary to destroy a pulp; but this ought to be the last resort, and should be done only when calcification of the enamel and dentine is complete or apparently so. The end, if well attained, justifies the means, mainly because the normal condition of the remaining teeth, the gums, and the alveolar process is better maintained than when a plate is worn.

The first report given of the attachment of a crown to

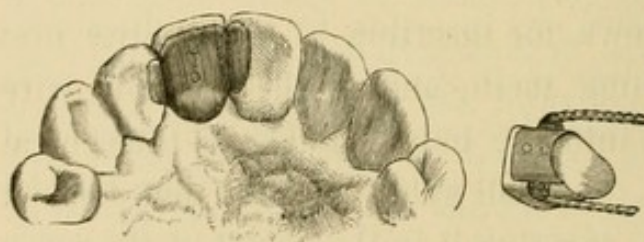
natural teeth, without plate or clasp, appeared in the *Dental Cosmos* for October, 1869. In this article it was stated that Dr. B. J. Bing, of Paris, had inserted several crowns in this manner, some of which had then been in place nearly a year. Dr. Bing backs a porcelain crown with 18-carat gold plate, and to this, for the insertion of crowns of the central and lateral incisors, he usually solders a gold wire, each end of which he builds with gold into a cavity newly made, or into one caused by decay in the palatal portion of the enamel of each of the two teeth adjoining,—in some cases, also, extending and building a small gold plate or wire into a cavity in each approximal surface next to the space to be filled.

The first operation of attaching a crown to adjoining teeth to fill the space of a missing tooth and root by the author was performed February 12, 1873, in the following manner: After suitably forming the cavities in the approximal wall of each tooth next to the space left by the one that had been extracted (unnecessarily) some years before, an impression of the parts was taken in plaster of Paris, and a plain porcelain crown was selected, fitted to place, and backed with 18-carat gold plate. A portion of the backing extended about one and a half lines from each side of the crown for insertion in the cavities prepared in the adjoining teeth, and to these a gold wire was soldered to fit into the pulp-chamber of the central and lateral incisors. A small gold plate was then formed to fit upon the gum, covering it to the extent of the space occupied by the neck of the natural tooth. When the backing was riveted to the pins in the porcelain and placed in position, and while the whole rested on the small plate upon the gum, the backing and plate were so secured by wax that they could be removed intact, and,

after being placed in a matrix, soldered. Each extended side of the backing and the surface of the wire was barbed with an engraver's lossing-tool, so that the gold foil when filled into every part would the better secure the crown.

The porcelain, with the gold attachments, being ready for insertion, a piece of light-medium rubber-dam was put in place on two teeth on each side of the space to be filled, and over the gum upon which the crown was to rest. (The rubber takes up but little space, and this is more than compensated for when the ligature of waxed floss-silk is pressed to or near the neck of each adjoining tooth.) Oxychloride of zinc was then placed in the pulp-chamber of the central and lateral incisors and the crown was at once pressed to place. When the cement had hardened sufficiently to safely admit of further progress in the work, a portion of it was cut away from around the wire so as to make proper anchorage for the gold. Small pieces of light cohesive gold foil were then impacted around part of the wire and that portion of the plate extending into the cavities, and the crown was thus secured. The porcelain and gold attachments as prepared for insertion

FIG. 65.



and the crown in position are here illustrated (Fig. 65).

The cavity in the central incisor was then extended to the cutting-edge of

the tooth, so that access might be had to the wire and both sides of the plate. Foil could not otherwise have been put in place, unless a portion of the labial margin of enamel had been cut away, and this would have been

objectionable because of the exposure of gold. A small part of the labial instead of the cutting-edge of the enamel of the lateral was removed, for the reason that there is not such a body of tissue in a lateral as to safely allow it to be cut away to the same extent as in a central incisor. The margin of enamel was so formed, and the foil so inserted and finished, however, that, though the gold could be seen, it was not conspicuous.

While the operation just described proved successful, —remaining firmly fixed in place till the death of the patient, nine years after the crown was inserted,—there is a possibility in such cases of the porcelain being broken from the platinum pins which hold it to the gold plate.

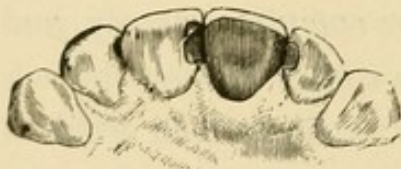The method followed by the author in cases of this character since performing his first operation is quite different from the mode adopted in the case just described, which was executed somewhat according to Dr. Bing's plan, and, though the work is more difficult, yet the improved crown is stronger, and more complete, cleanly, and beautiful than when gold plate is simply riveted and soldered to the porcelain. It was to avoid such an accident as the breaking of the porcelain from the pins that the author modified the method of preparing and inserting crowns. Among the changes introduced were those of cutting a groove (though not too deeply) in each side and along the cutting-edge of the porcelain, and placing gold foil solidly in the grooves and slightly over the cutting-edge, to make the porcelain more secure than when the platinum pins alone hold it, and to protect the edge from the occlusion of the lower teeth; also, to build the attachments of the crown into the approximal surfaces only of the adjoining teeth.

The necessities of the case may require that a groove

shall be cut with a disk across the porcelain between the pins, in which the wire to connect the artificial crown with the natural teeth is to be placed, either under the plate or so that the edges of the latter may be joined to it.

A starting-point should be made, either between the gold backing and the porcelain or between this and the wire, and the latter should be firmly fixed in a hand-vise while the gold foil is being put in place and made compact with the electro-magnetic mallet. The greater part of the preparation of a crown which remains to be made, and the whole of the building of gold foil about it, is done out of the mouth, at whatever time may best suit the operator. The work requires care, and must be skillfully and well done. When the gold is properly and solidly placed in the grooves and over the backing and wire, it not only aids in securing the porcelain, but the contour

FIG. 66.



of the crown can be nicely filled out (Fig. 66) and the operation made durable and beautiful.

The surface of the gold placed along the base of the crown to the edge of the porcelain, which is to rest against the gum, together with the palatal portion, ought to be properly formed and finished before the crown is put in place, in the manner before described. There should be a little space between the wire and the cervical wall in each tooth to which the crown is to be attached, and narrow pieces of light cohesive gold foil should be carefully placed in this space between the wire and the enamel with small suitably-curved instruments, and afterwards solidified with the mallet. The surface of the gold at this part, at least, should be smoothly finished,

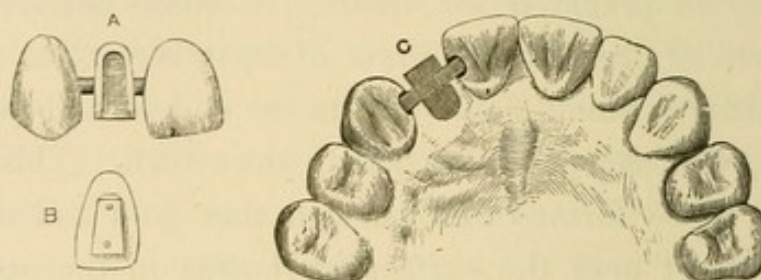
with narrow (one-sixteenth inch) strips of fine emery-cloth, before the rubber-dam is removed.

In cases where the pulp is living in one or both of the teeth to which an artificial crown is to be attached, the heavy gold plate or the wire must be so arranged as to fit as accurately and be made as secure as possible in the cavities prepared for them. In some cases, where the form of the cavity admits of it, it is well to adjust and solder a small gold plate to the end of and at right angles with the wire attached to the crown. This plate should be so formed and beveled that gold foil can be solidly built over the surface of it next to the artificial crown and into the groove made around the cavity in the dentine along the boundary-line between this tissue and the enamel. When all is in readiness for the operation, oxychloride of zinc should be placed in each cavity and the crown immediately put in place, and very carefully held there till the cement has so crystallized as to securely hold the ends of the wire and the plates. About an hour is necessary for such perfect crystallization as to safely admit of the preparation for and the packing of the gold foil. The oxychloride of zinc should be left between the little plate, or end of the wire, and the bottom of the cavity, not only because it fills all parts where gold cannot well be placed, but because the preparation also protects the dentinal fibers from thermal changes.

The crown devised by Dr. I. F. Wardwell, of New York, and as built in by him, affords an excellent plan for the insertion of crowns where the pulp is living in each tooth adjoining, and is the best of the various methods or modifications yet mentioned herein that have been practiced by the few who have attached crowns to teeth without plate or clasp. His plan consists in so

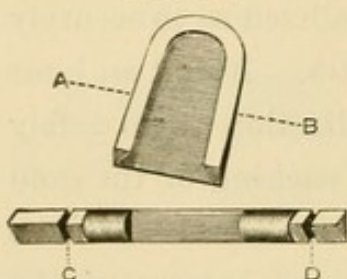
arranging and soldering a thick, narrow gold plate to the platinum pins in the porcelain crown, and so beveling the sides of the plate towards it as to have this plate slide tightly into another gold plate shaped to receive it (Fig. 67, A, B). This second gold plate is soldered to the gold

FIG. 67.



wire (Fig. 68), which is built into cavities (Fig. 67, c) in the adjoining teeth with gold foil, and, by inclosing the beveled sides of the plate on the porcelain, "dove-tails" or holds the crown in position. The crown is then

FIG. 68.



Enlarged view of gold staple and wire, to be soldered together at the line A, B; C, D, grooves cut around the three-sided wire.

pressed into place and made secure by filling in gold foil near the cutting-edge of the tooth, after the wire, with the plate soldered to it, is built into place.

One of the most satisfactory operations the author ever performed was the insertion of a crown where the root of a cuspid had been extracted, on which account the lady had been subjected to the wearing of a gold plate for some time. The crown was prepared and the contour filled out with foil as described and illustrated (Fig. 66), and gold wire, No. 13, was attached to and built in with the porcelain, and fitted in the pulp-chamber of the adjoining lateral incisor. This same wire extended from the anterior to near the posterior approximal surface of the first bicuspid,

the pulp of which was in normal condition. When the crown was ready for insertion, it was placed and held in position with oxychloride of zinc, and cohesive gold foil was then carefully packed around the exposed portion of the wire in the root and made compact with the electromagnetic mallet, as was also that placed in the cavity in the crown of the incisor and in the cavity in each approximal wall of the bicuspid, as well as around and over the wire, joining the two fillings in this tooth through the enlarged fissure. All crowns should be prepared and finished in the manner described, with such change or additional work as is necessary to place them on roots, or to attach them to single or the two adjoining teeth where roots are missing.

Methods have been devised and adopted with the object of lessening the time necessary to perform these (as well as other) operations, and making them simple, easy, and cheap by the use of amalgam or other plastic filling-materials; but, in addition to the excellent judgment and ability required, sufficient time must be taken, and the use of gold is necessary for the doing of really fine, beautiful, and permanent work.

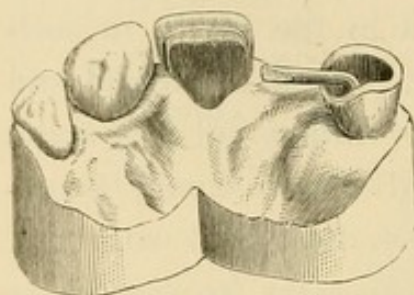
When a crown is to be attached to one tooth alone, the operation is not likely to be successful (except where a bicuspid crown is built into a molar) unless the tooth which is to support the crown is pulpless, and then such an operation can be made both durable and beautiful.

When it is decided to build into one tooth only, a gold wire, no lighter than No. 12, should be used. It ought to be fitted as far up the root as it is safe to enlarge the pulp-chamber for it, but the drilling may properly be done only after every part of the pulp has been removed and the apical foramen has been carefully closed with

small, narrow pieces of light gold foil, which must not be put in place so long as there is any irritation about the end of the root.

In the case here illustrated (Fig. 69) the wire is fitted in the root and bent to receive the crown. The cavity is

FIG. 69.



prepared for the filling-in of gold. The cuspid (as well as the other teeth remaining in the mouth) became so abraded as to expose the dentine, so that the margins of enamel had to be prepared for the

placing of gold over them, and, when the crown was built into place, they were carefully covered with and are thus protected by the solid metal. After the porcelain part of the crown of the lateral incisor had been fitted to the model and soldered to the wire (shown in Fig. 69, —this portion of the wire should be flattened somewhat in some cases), the groove was made around the porcelain, the foil was solidly built in place, and finished in the manner hereinbefore described, and the crown was then inserted and the contour of the cuspid restored with gold. (The root of the left central incisor remains, and the crown which is fitted upon it is prepared for the building on of gold foil.*)

When the lateral incisor crown, in the case illustrated, was ready for insertion, and the gold at the base, which was to rest upon the gum, had been nicely fitted to it, and the whole of the gold was smoothly finished, a good-sized piece of light-medium rubber-dam was applied to the teeth (the cuspid and the central and lateral incisors) on each side of the space to be filled, and so arranged as to cover

*The outline of the groove is not distinctly shown in the cut (Fig. 69).

the gum and the root between these teeth. The crown was made to so rest upon the gum as to press the blood from the capillaries of the part, and thus prevent particles of food from getting under it. While the thickness of the rubber-dam might, to some slight extent, prevent the placing of such a crown against the gum as firmly as it should be pressed, yet this thickness is compensated for by the pressing-up of the gum when the floss-silk ligatures are placed about the neck of each adjoining tooth. After all this had been done, fine barbs were cut around the gold wire with a sharp knife-blade, oxychloride of zinc was placed in the pulp-chamber of the cuspid, and, while the cement was still plastic, the crown was at once pressed to place, and for a few moments held there.

After the oxychloride of zinc had hardened sufficiently to safely admit of it, the cement was cut away from around the wire at such parts as would make proper anchorage for the gold. There was, and in every such case there should be, a little space left between the wire and the cervical wall, to be filled with gold for the protection of the enamel at this part. Narrow pieces of light cohesive foil were first placed in this space with small, suitably-curved instruments, and afterwards solidified with the mallet; after which a little larger and heavier (none over No. 32), though still narrow, pieces of folded foil were used for placing around and about the wire in the root, filling the cavity, restoring the contour, and covering and protecting the prepared margins of enamel. The pieces of gold were made thoroughly cohesive, and were compacted with the electro-magnetic mallet. The surface of the gold placed around the wire, between it and the cervical wall, as well as all that part near the gum, was smoothly

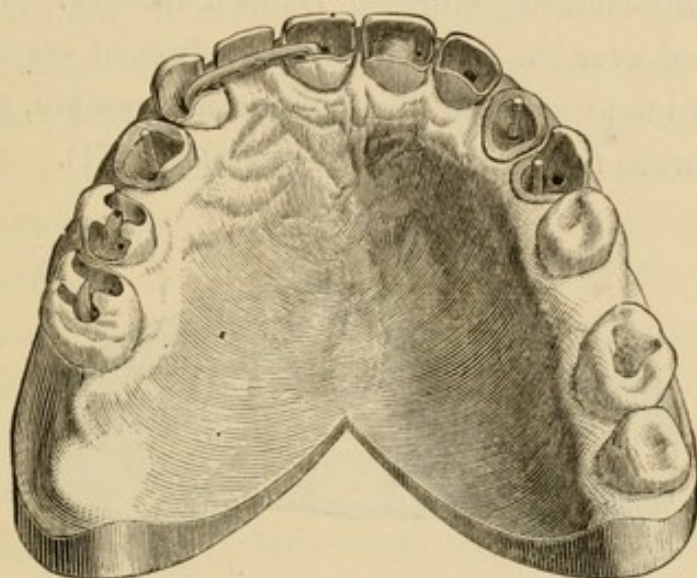
finished with small files and very narrow (one-sixteenth inch wide) strips of emery-cloth before the removal of the rubber-dam; after which the remainder of the gold was made smooth and so trimmed down as to make sure of the proper occlusion of the teeth. The crown attached to the cuspid was made just short enough to be free from the striking of the lower teeth. The operation was finished at another time with Hindostan stones, together with pumice upon fine wood made into suitable shape.

When a crown can be securely attached to one instead of two teeth, the time of building-in the same is lessened about one half. The slight movement which takes place in the socket of the tooth supporting the crown is not interfered with by the gold wire holding the porcelain, as when two teeth are fixed together. If it should afterwards become necessary to perform operations upon the adjoining teeth, the rubber-dam can be applied as readily as before attaching the crown.

The most extensive operation of attaching a crown to the two adjoining teeth by the author was performed before the Pennsylvania State Dental Society, at Delaware Water Gap, in July, 1879. In this case solution of enamel had taken place in many of the teeth, and cavities of decay had been prepared and filled from time to time. The enamel was abraded and the dentine exposed along the entire cutting-edge of each tooth that occluded with another. The right upper lateral incisor had been lost twelve years before. The crown of the left cuspid was missing, and but a small portion of the enamel and dentine of the first bicuspid upon either side remained. These last were pulpless, as were also the right cuspid and central and left lateral incisors, and the pulp-chamber of each of these had been filled. All the operations made necessary

by the abrasion and fracture of the enamel from time to time, and because of imperfections in the fillings previously inserted, were performed before the insertion of the crown in the space left by the loss of the lateral incisor. After this crown had been adjusted, and each cavity and pulp-chamber had been prepared for the gold, the case appeared as here illustrated (Fig. 70).

FIG. 70.



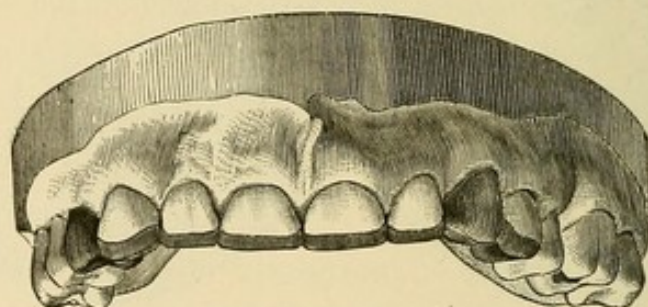
The apical foramen of each pulpless tooth was closed, and the whole of each pulp-chamber in which a wire was not placed was filled with gold. A gold screw was placed in the pulp-chamber and extended into the crown of each bicuspid (Fig. 70).* The pulp-chamber of the left cuspid was so shaped with burs as to make sure and certain anchorage for the cohesive gold foil placed in it, and for the permanent support of the entire gold crown. The crown of this tooth was not faced with porcelain, because the teeth of the gentleman for whom these operations

*The cut (Fig. 70) illustrates the case very well, though there are parts and grooves in which to anchor the gold that are not distinctly shown.

were performed were but slightly exposed to view; and then, too, the gold had to be placed over the cutting-edges of the incisors, the cuspid, and bicuspid, to protect them from the occlusion of the lower teeth and restore them to near their former length.

The contour of each crown was restored with cohesive gold, made compact with a well-adjusted electro-magnetic mallet, guided carefully, and operated with the power of a freshly-charged four-cell Bunsen battery. The foil was placed over the finely prepared edges of enamel, the gold was made as solid throughout as possible, and the margins were not marred in the least (Fig. 71).

FIG. 71.



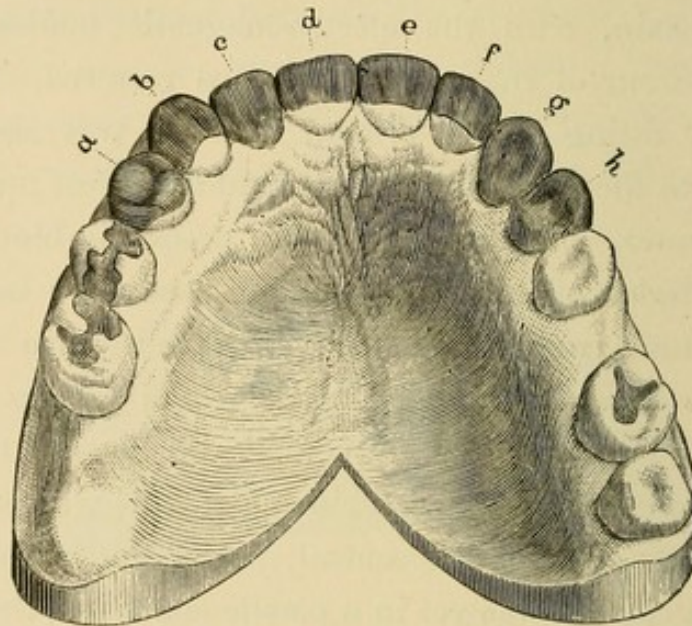
The lower incisor had so elongated after the loss of the upper lateral that it almost closed upon the gum. This was partly owing to the abrasion of the remaining teeth, and in part due to the lower incisor gradually rising in the alveolar process. Because of this mal-occlusion of the teeth a porcelain crown (plain "plate-tooth") with "cross-pins" was used, and fitted and soldered to the gold wire, there being no space for a backing of plate. When the wire was prepared, the porcelain grooved and fitted to it, and ready for the placing-on of the gold foil, the whole crown appeared as illustrated (Fig. 70), the wire extending into each root about four lines, or full three-eighths of an inch. The cutting-edge of the porcelain was removed to

the same extent that the incisors were abraded. This was done in order that the gold near and covering the labial edge of enamel might be on the same line, and that the same appearance might be presented and the same protection given to the cutting-edge of each tooth (Fig. 71). The wire of the crown was held in a hand-vise, while cohesive gold foil was being placed and made compact in the grooves, around the wire, and over the cutting-edge of the porcelain, with the electro-magnetic mallet. The whole contour of the crown was thus restored. During the final fitting of the crown, its base was accurately adjusted to the gum, and so prepared as to rest upon it in such manner, when inserted, as to press the blood from the capillaries of the part. When ready for insertion, light-medium rubber-dam was applied to the two teeth on each side of and across the space which was to receive the crown; small barbs were made all around the wire with a sharp knife, and oxychloride of zinc was placed in the pulp-chamber of the central incisor and cuspid, and, while the cement was yet in a plastic condition, the crown was pressed to place. After it had been in position an hour to allow of complete crystallization of the oxychloride of zinc, portions of the cement and of the dentine were removed with a small bur, so as to obtain still further anchorage for the gold foil then put in place around the wire, into each cavity, and over the prepared margins of enamel. Principally No. 30 gold (one-quarter ounce cohesive foil) was used in this case, and each piece was solidly compacted with the electro-magnetic mallet. A few pieces of light folded foil were placed with small hand-pressure instruments in the space between the wire and the cervical wall, but these pieces were gone over with the mallet after they were put in place. With this

and all the operations completed, the case appeared as illustrated (Fig. 72).

Under favorable circumstances, as many as eight artificial crowns, in place of the incisors and bicuspid, could be permanently attached to the cuspids and first molars; but that the operation may be successful, these teeth

FIG. 72.



Finished case—*a, b, d, f, g, and h*, pulpless teeth; *g*, whole crown restored with gold; *a, f,* and *h*, almost entire gold crowns; the teeth *b* and *d* support the gold crown faced with porcelain, *c*, and fully one-fourth of the crown of each of these is restored with gold, as is also that of *e*, the pulp of which is living.

must be firm in their sockets and very little recession of the gums should have taken place. In the performance of such an extensive and difficult operation, the heavy gold wire (about No. 10, 18-carat) to which to attach the crowns should be well fitted and anchored in the pulp-chamber of each cuspid. The wire can be sufficiently well anchored in the molars without endangering the pulps. In such a case, as in all others, the cavities should first be prepared, the wire then fitted and the crowns attached, proper occlusion with the lower teeth secured, the parts

built out with foil, and the whole of the remaining work entirely finished before the crowns are built in place. Each crown ought to be as separate and distinct from the other (excepting at the part where the wire is fixed) as the crowns of the natural teeth—especially the base of the crown, or that part corresponding with the neck of a tooth. Thus arranged there would not be much of each crown against the gum, and that which is against it should be nicely fitted and be close enough to keep out particles of food. The author would have such a number of crowns inserted rather than wear a plate, but the whole operation would have to be well performed, by a really fine operator, or it should not be done at all.

Any operator of ability, who will endeavor earnestly and conscientiously to perform the various operations herein described, can, if he has entire charge of the mouths of his patients, secure them against the necessity of wearing plates to support artificial crowns, excepting, of course, in cases where the teeth are lost by accident, by disease, such as extensive necrosis of the alveolar border, or from the natural absorption of the gums and alveolar border late in life.

IRRITATION AND DEATH OF THE PULP.

IF operations are not performed to prevent the progress of decay, the enamel and dentine are not alone liable to be remanded back to primary elements, but, through the continuous presence of agents that bring about solution of the lime-salts, especially where calcification of the tissue is imperfect or where function has been interfered with, the pulp is soon reached, when pain or disease is incited by influences operating through the cavity of decay.

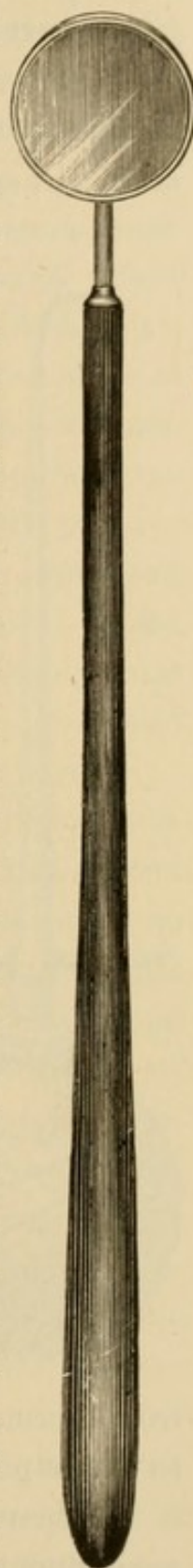
Irritation of the pulp may be brought about not only by the agents that dissolve the lime-salts from the basis-substance of the hard tissues—the enamel and dentine—but also by the impingement of foreign substances or softened dentine upon the exposed or nearly-exposed tissue, when some phase of odontalgia or neuralgia may follow.

If irritation of the pulp be due to the acid which brings about the solution of the lime-salts, it should subside after tepid salt water has been injected and the parts are thus cleansed, the softer portions of dentine removed, and bicarbonate of soda, potash, or ammonia applied. Should the exposed or nearly-exposed pulp be impinged upon by the softened dentine, or a foreign substance which has been forced during mastication upon it, and the nutrient currents be obstructed, thus inducing irritation, it should cease after the removal of the obstruction.

When the pain has ceased, the parts should be dried with Japanese bibulous paper, and an application of carbolic acid should be made to disinfect the dentine which may need it, and to coagulate the protoplasm at the exposed part of the pulp, if there be such exposure. After this has been done a piece of fine card-board should be placed over the nearly or fully-exposed part of the pulp, so that it shall not be pressed upon during the insertion of gutta-percha; all of which is but preparatory treatment.

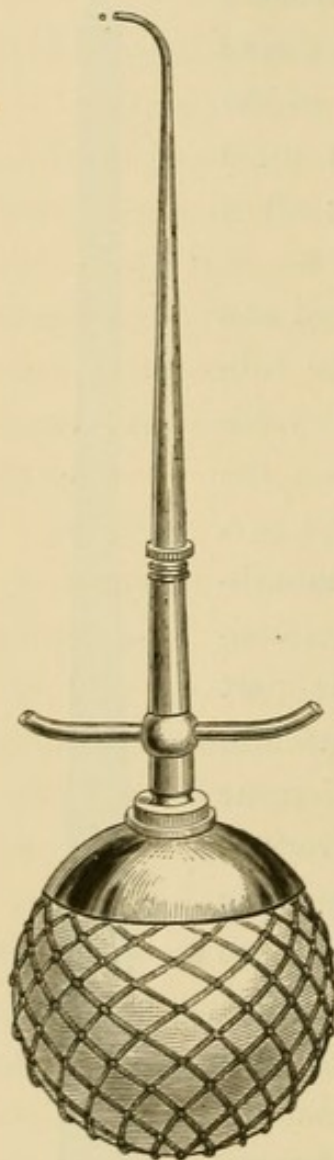
After the pulp has been thus protected and ease secured for about two weeks, the rubber-dam should be applied, the temporary filling removed, and light reflected upon the parts—this should be done during the performance of every operation—by a mouth-mirror (Fig. 73), when all the decayed dentine should be cut away, except the part directly over the pulp, as the protection afforded even by partially decalcified dentine is much better than an artificial covering, because infiltration of lime-salts is very likely to take place throughout the basis-substance of such dentine. When this has been done, and the warm-air syringe (Fig. 74) has been used to drive out the moisture as well as to expel the chippings from the cavity, the dentine remaining over the pulp should be moistened with carbolic acid or a saturated solution of salicylic acid in alcohol. To place a capping or to put artificial protective covering over

FIG. 73.



a nearly or partly-exposed pulp, it is best to flow carbolie acid over the part, and, before evaporation follows, to take some of the oxide of zinc on the end of a small spatula, place it at the entrance to the cavity, and, with a puff of warm air, spread it over and about the exposure, there to

FIG. 74.



be retained by the deliquesced carbolie acid. After this has been done, put in oxychloride or (preferably in many cases) oxyphosphate of zinc, so mixed and placed as to flow down one side of the cavity, over the layer of oxide of zinc and carbolie acid, over the whole of the dentine, and to the outer margin of enamel. The rubber-dam should not be removed for about an hour after the cement has been placed in the cavity, because dryness favors its perfect crystallization. These cases should be kept in this condition for some time (in some instances a year or more) before inserting the permanent filling, although under favorable conditions the operation may be proceeded with immediately or very soon after the oxychloride of zinc has hardened; but, whenever the operation is to be performed, enough of the cement should be retained to protect the pulp

from thermal changes, and yet sufficient must be removed to secure proper anchorage for the gold.

When simple shock in healthy tissue takes place on account of cold, warmth restores the nutrient currents.

For instance, if a large cavity is filled with gold without the dentine having had such protection from thermal currents as oxychloride of zinc affords, cold water shocks the tissue, and the pain which follows usually ceases upon the application of warm fluids.

When anything irritates the pulp, there is an increase in the neural and vascular currents to the parts. Cold drives or keeps back part of the molecules of living matter and the blood-corpuscles, and ease for the time at least is secured. Heat induces acceleration of the currents, thus favoring the swelling of the granules throughout the protoplasmic bodies of the pulp, and those at the point of intersection in the net-work of living matter; the blood (the flow of which is increased by the warmth) in the capillaries so presses upon the fibers of living matter that the pain is intensified, until the vessels are ruptured, and the fibers are torn at the end of the root.

Every effort ought to be made to preserve the pulp in each case presented, and particularly where the enamel and dentine are not fully calcified. It is even better to retain a pulp that is not quite in the normal condition than to have it die before the patient arrives at the age of maturity, because a possible further infiltration of lime-salts throughout the basis-substance of the hard tissues can be hoped for. Dr. Bödecker has demonstrated that the myxomatous condition is the normal physiological condition of the pulp, while the fibrous condition is the result of morbid action and inflammation of the pulp, which destroys the myxomatous tissue and replaces it with fibrous.

If the death of a pulp cannot be prevented, the tissue should be removed from its chamber as soon as vitality is lost to the extent that its removal may cause but little

pain. The ether-spray may be used successfully in many cases, the cold induced through the rapid evaporation of the ether driving or keeping back the neural and vascular currents while the yet partially vital tissue is being removed.

If arsenic is used at all for devitalizing pulps, it ought to be very carefully applied to the tissue, and only in minute quantity, and should be covered with a piece of courtplaster of suitable size. The entire cavity should then be filled with gutta-percha in such manner that it and the arsenic cannot be displaced. The careless and unreliable method of placing pellets of cotton saturated with sandarac varnish in cavities should not be resorted to. Even with the greatest care, arsenic is a dangerous substance to handle, for many have been the cases of necrosis traceable directly to the abuse if not to the use of this material.

In some few cases where the bulbous portion of a pulp has become devitalized without the application of a drug, and has sloughed away from the still living part in the root or roots, the living portion has been carefully capped, and has remained in a tolerable condition, at least, for such length of time as to indicate the performance of this operation under favorable conditions rather than the destruction of the tissue and the substitution of a foreign material.

When pulp-tissue has been carefully removed with small broaches having fine barbs upon them (Fig. 75) before putrescence occurs, and the parts have been cleansed, the apical foramen should be closed entirely with light gold foil, so that infiltration cannot take place, and the pulp-chamber and cavity of decay may be permanently filled at once.

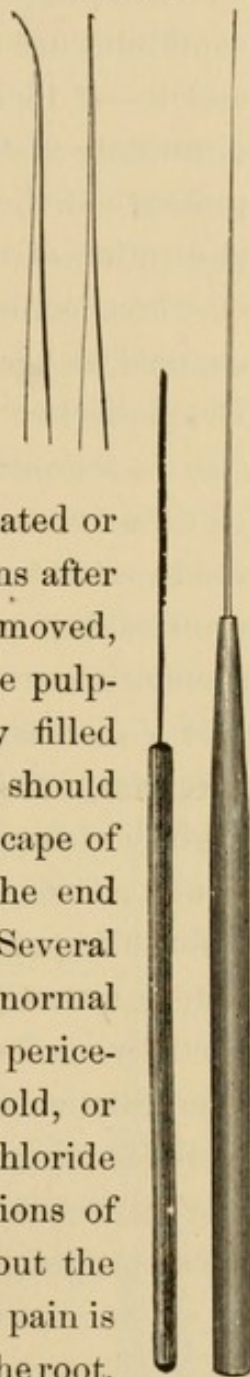
Should pulp-tissue not be removed soon after its de-

vitalization, or before putrescence takes place, sulphureted and phosphureted hydrogen-gas from the disintegrating pulp may escape through the apical foramen (particularly if the cavity of decay be closed), and irritation of the tissues that surround or are adjacent to the end of the root may be thus induced. This irritation may be incited not only by the gas, but also by particles of the pulp or any foreign matter which may be forced through the foramen during the cleansing of the pulp-chamber.

FIG. 75.

The patient should be informed of the symptoms likely to be manifested, and be advised to call at once when pain is indicated or pronounced; and if there be such symptoms after the putrescent matter has been carefully removed, the parts disinfected and cleansed, and the pulp-chamber and cavity of decay temporarily filled with cotton and gutta-percha, this dressing should be removed, a short time given for the escape of the gases or fluid which may be about the end of the root, and the parts again closed. Several such dressings may be required before normal action has been re-established within the pericementum, when a permanent filling of gold, or gold to close the foramen, and then oxychloride of zinc, should be inserted. The indications of pericementitis and alveolar abscess are about the same, with the exception that in abscess the pain is dull and is confined principally to the end of the root.

When gas emanating from putrescing and disintegrating pulp-tissue escapes through the apical foramen, nutrition of the elements of the tissues about the apex of the



root is interfered with. A separation of the elements of a part of the tissues is incited by this gas, which is absorbed by the watery fluids exuding from the adjacent capillaries, and inception of alveolar abscess is thus pronounced. If conditions are such that there cannot be return to normal action,—if there is an accumulation of pus-corpuscles,—distention of the parts takes place, and, because of the presence of the pus-corpuscles, severe pain is induced, and absorption of that part of the alveolar process ensues, all of which continues until the contents of the sac are discharged, either through the apical foramen or the alveolus. Dr. Bödecker has seen, under the microscope, that the “sac is a product of plastic pericementitis,—it is built up of dense fibrous connective-tissue. The inner surface of the sac is not smooth, but largely provided with irregular protrusions, or papillary outgrowths of a myxomatous structure, crowded with inflammatory elements.”

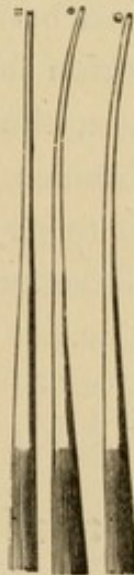If a discharge of pus does not follow the removal of a temporary filling or dressing, the foramen should be slightly enlarged to allow of the escape of the purulent liquid. Even should abscess follow, and though the pain before the pus is discharged through the alveolar process may be severe (unless the patient be kept during this time partially under the influence of morphia), yet no such manifestation will be likely to ensue when normal action of the parts again takes place, if the pulp-chamber is thoroughly cleansed, and the entire chamber and cavity of decay properly and permanently filled.

FILLING PULP-CHAMBERS.

WHERE death of the pulp has just taken place, or in those cases where the tissue has not become putrescent, the apical foramen should be closed with gold as soon as the bleeding has ceased,—exudation of blood usually following the rupture of the vessels by the removal of the pulp from the end of the root. The parts of the vessels that are ruptured at the apical foramen while the pulp is being removed retract; the vessels which convey the nutritive supply to this tissue transport it to other pulps or parts, and when extravasated blood remains about the end of the root or roots, as the result of the rupture of the capillaries, it is absorbed and a tolerable condition again established. Some obstruction of the current in the capillaries within the pericementum is sometimes induced through the death of the pulp; but this is usually evanescent, particularly if the devitalized tissue is at once removed.

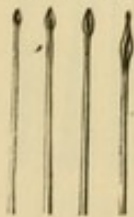
By opening through the crown of a molar or other tooth, each pulp-chamber can be made accessible. Gold ought to be used for closing the foramen, for the reason that narrow strips of light foil can be put in place with the certainty of having the air in the pulp-chamber pass out alongside of the piece of foil as it is carefully moved toward the end of the root,—using such instruments as are here illustrated (Fig. 76).

FIG. 76.



The accurate measurement of the length and diameter of the pulp-chamber, which should always be taken just before introducing the gold, can be more strictly observed in closing the foramen with foil than in the introduction of oxychloride of zinc or gutta-percha. When, also, foil is placed as near to the end of the root as is possible without passing through the foramen, the gold, when carefully and solidly put in place, entirely prevents fluids from entering the pulp-chamber; and this is the most important point about, and almost the entire object in, filling pulp-chambers. If the foramen be not properly closed, the filling of pulpless teeth cannot well be otherwise than unsatisfactory, and the operation an almost useless one. Whenever a small broach can be passed to the end of a root, the foramen can be closed with gold. The pulp-chamber should first be thoroughly cleansed, and the foramen then closed with light gold foil folded once upon itself, or made into three or four thicknesses, and cut into very narrow strips. Cotton is the next best material for the filling of pulp-chambers. The cotton should be moistened with carbolic acid, a few fibers at a time, and then carefully placed in position at the foramen, and so solidly packed as to prevent infiltration of fluids from the end of the root. It can thus be carried to the foramen easier than if saturated with oxychloride of zinc. It is sometimes necessary to take a fine drill (Fig. 77)

FIG. 77.* and carefully enlarge the pulp-chamber, but it is better to fill to the end of the root without the drilling. After the dead pulp has been removed and its chamber properly prepared for filling, the foramen should be closed with gold, and then, and not till then, the pulp-chamber can be safely



* Gates's drills.

filled with oxychloride of zinc, instead of gold, and the operator can be quite certain to get this material to the gold at the end of the root, and get the air out at the same time. The foramen being closed with gold, the oxychloride of zinc cannot pass through to the end of the root any more than fluids can thus enter the pulp-chamber. It is well to use oxychloride of zinc in this manner instead of gold, in some cases (as in those where the pulp has remained dead in its chamber for some time, and where an abscess has been formed), for the reason that the chloride of zinc coagulates the protoplasm, and prevents or arrests the decomposition of the ends of the fibers in the dentinal canaliculi. In closing the foramen each narrow strip of foil should be taken on the end of a suitable packing-instrument and placed near the end of the root, tapping carefully with a light hand-mallet till the feel and the sound of the instrument indicate that the gold is placed solidly in position. There is less liability of getting gold through the foramen against or into the tissues outside the end of the root by tapping the instrument with a mallet than by placing the foil in position by pressure.

TREATMENT OF ABSCESS.

IN the treatment of pulpless teeth, and especially those wherein the pulp has been dead for some time and abscess is in its incipency, or where it has gone on to such an extent as to prevent rebuilding of the tissues surrounding the end of the root, it is sometimes necessary to carry a small drill just through the foramen, so as to make a fresh wound, and secure healing by "first intention," without inflammation or suppurative action; for, so long as putrescent tissue remains in the pulp-chamber, and the mephitic gas arising from it escapes through the apical foramen, so long may the production of pus-corpuscles continue. It may lead to the almost constant throwing off of inflammatory elements or pus-corpuscles from the tissue that is involved. This transformation of the tissue that is destroyed into pus should be changed, and the parts gotten into such condition as to favor return to normal action, else the abscess may become chronic.

Japanese bibulous paper, carefully wound upon a broach of suitable size, should be used for drying out the pulp-chamber and for applying remedial agents. If the bibulous paper when withdrawn can be clearly seen through the liquid which adheres to it, when examined with a magnifying glass, it may be known that the fluid is protoplasm from the elements of the tissues about the end of the root. In such cases a little deliquesced chloride of zinc ought to be carried to, but not beyond, the end of

the root, to coagulate the protoplasm, when the foramen should be at once closed with gold, and the entire operation may then be completed. If the surface of the paper on the broach cannot be so clearly seen through the fluid after withdrawing it from the pulp-chamber, pus may be looked for, when further treatment will be required. The elements of the tissues about the end of the root were originally uninterruptedly connected with one another as the elements of other tissues are, by delicate threads of living matter, and thus represent what is called a tissue. "If the inflammatory elements are torn apart, the inflamed tissue ceases to be a tissue; it is destroyed—transformed into pus. The pus-corpuscles are the inflammatory elements sprung from the involved tissue itself."

In the treatment and cure of abscess where there has been a fistulous opening, it is often necessary, after removing every part of the disintegrated pulp-tissue, to force an escharotic—carbolic acid or creasote—through the apical foramen and into the sac, to prevent the transformation of the inflammatory elements into pus, and also through the fistule to the surface of the gum, after which there will likely be rebuilding and, to some extent, a new formation of tissue; provided there is no further interference with or obstruction to the circulation in the capillaries of the pericementum, and nutrition be such that normal function can take place.

It is sometimes necessary to gradually enlarge this fistulous opening with pellets of cotton, and to cut the alveolar process with a bur to reach the end of the root and remove the saccule, if this newly-formed connective-tissue still be there, and a part of the end of the root, if it be necrosed;—afterwards securing healing by granulations, the rebuilding of the tissues taking place from the root

outwardly,—and the opening at the gum should not be allowed to close till reformation of the tissues of the part is complete.

Chronic abscess interferes with the supply of nutrient material to the cementum through the vessels held within the connective-tissue covering it, and notably lessens the vitality of the parts; and, in consequence of this obstruction to the circulation, the vitality of the pericementum may thus be destroyed. Then, and not till then, all the tissues of the tooth—pulp, dentine, enamel, and cementum—are in a non-vital condition. These tissues alone may not only become devitalized, but, if function within and about those adjacent be so interfered with as to prevent the supply of protoplasm to them, they may become involved; the surrounding alveolar process, and even a portion of the maxilla, may become necrosed, and still further complications arise, because of the continuous action and advancing stages of alveolar abscess.

In cases where the foramen is so large that it cannot without great difficulty be closed with foil, because of the drilling through or absorption of the end of the root, a gold wire should be fitted accurately into it, and carefully put in position and held there with oxychloride of zinc; after which the whole pulp-chamber should be filled with the cement. After closing the foramen in each of the roots of molars and filling the greater part or the whole of the canal in each root with gold, it is best to fill the bulbous portion of the pulp-chamber and a part of the cavity of decay with oxychloride or oxyphosphate of zinc. When this material has hardened, sufficient anchorage ought to be made, and the operation completed with gold. When it is necessary to use the pulp-chamber for anchorage, as in cases where the greater part of or the

entire crown is to be restored with gold, each root, as well as the bulbous portion of the chamber, should be filled entirely with cohesive foil, made solid throughout by the use of the mallet. In most cases the gold in the pulp-chamber can thus be made as strong as wire, and, because of the more perfect adaptability of foil, better anchorage is secured.

PERICEMENTITIS.

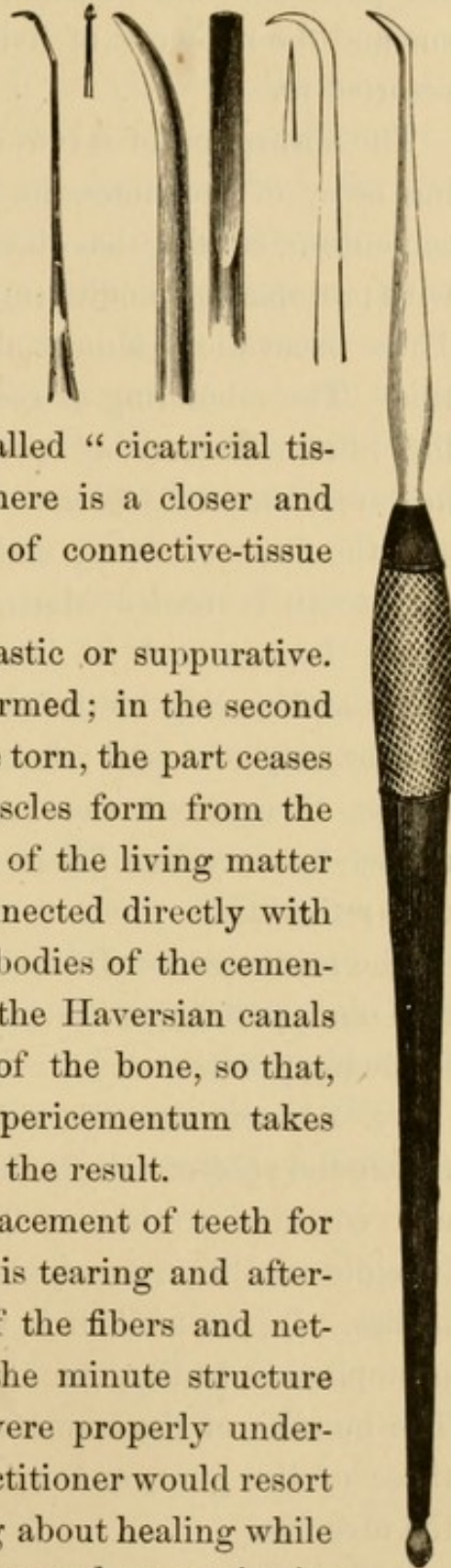
THERE is a difference between alveolar abscess and pericementitis, which takes place about the neck of a tooth. Alveolar abscess is the breaking-down of tissue into pus at the end of a root, while pericementitis about and beyond the neck of a tooth is a suppurative inflammatory process, and necrosis of a portion of the surrounding alveolar border may follow, as in what is called "Riggs's disease." The first step for the cure of alveolar abscess is to get rid of the pus, which is a direct product from the inflamed part or tissue involved about the end of the root. Pericementitis usually subsides after the thorough removal of calcareous deposits from the neck of the tooth with instruments called scalers (Fig. 78), or the cutting or burring away of the necrosed portion, if there is necrosis, of the alveolar border.

There are two varieties of pericementum,—the myxomatous and the fibrous. The former is the connective-tissue covering the cementum of the teeth of young persons, which in the adult changes to the fibrous variety.

In pericementitis there is a return of the fibrous connective-tissue to the myxomatous, and from this to its embryonal condition. If the fibers of living matter connecting the connective-tissue corpuscles, forming the reticulum throughout the pericementum and joining like fibers from the adjacent bone-corpuscles of the alveolus, be not broken, the rebuilding of this or the formation of

new tissue takes place, through the course of embryonal to myxomatous, and thence to fibrous connective-tissue again. If the net-work of living matter be broken, the part torn ceases to be a tissue, and pus is the result. After the healing of pericementitis there is not quite the same arrangement of the elements as at first. A so-called "cicatricial tissue" is formed, in which there is a closer and more irregular distribution of connective-tissue bundles.

FIG. 78.



Pericementitis is either plastic or suppurative. In the first a new tissue is formed; in the second the fibers of living matter are torn, the part ceases to be a tissue, and pus-corpuscles form from the embryonal mass. The fibers of the living matter of the pericementum are connected directly with those from the protoplasmic bodies of the cementum, and also with those of the Haversian canals and those in the canaliculi of the bone, so that, wherever destruction of the pericementum takes place, necrosis of the bone is the result.

In the extraction and replacement of teeth for the "cure" of abscess, there is tearing and afterward imperfect connection of the fibers and network of living matter. If the minute structure of the tissues of the part were properly understood and appreciated, no practitioner would resort to extraction, but would bring about healing while keeping the tooth to be operated upon in its

place. Inflammation results from the breaking-down of the pericementum occasioned by the tearing of the tissue and the net-work of living matter when extraction is resorted to.

The absorption of a root or part of a root is the dissolving away of the lime-salts in the basis-substance of the cementum, causing bay-like excavations which are filled with protoplasmic bodies (myeloid bodies—"giant-cells"). These excavations almost always result from pericementitis. The rebuilding of cementum and the formation of the fibrous variety of pericementum may take place, however, especially when extraction is not resorted to and the fibers of living matter are not torn. Extraction of a tooth or root or destruction of a pulp should very rarely be resorted to, because of the breaking of the fibers and tearing of the net-work of living matter, even if it be only of a part; for, be it remembered that all the tissues throughout the body are uninterruptedly connected by very fine fibers of living matter in the form of a reticulum.

The results of Dr. Bödecker's researches on pericementum and pericementitis are summed up by him in the following points:

"I. Pericementum is a layer of connective-tissue between the root of the tooth and the wall of the alveolus, and common to both. This connective-tissue in the juvenile condition is myxomatous, rich in protoplasmic bodies. In the adult it is fibrous, scantily supplied with protoplasmic bodies, the so-called connective-tissue cells. The bundles of the connective-tissue are continuous with those of the gum, and with those of the periosteum of the alveolus.

"II. Inflammation of the pericementum is either a

plastic (formative) or suppurative (destructive) process. These two kinds differ from each other only in degree and intensity.

"III. Plastic pericementitis is characterized by the formation of nests of inflammatory elements, arising from medullary elements which have appeared from the connective-tissue after dissolution of its basis-substance.

"IV. Plastic pericementitis may terminate in resolution, if the inflammatory elements be not numerous, and the basis-substance be re-established; or it leads to hyperplasia of the connective-tissue, if a large number of inflammatory elements have formed and the inflammatory process has repeatedly recurred.

"V. Pericementitis in its more intense degrees is always accompanied by cementitis of the root of the tooth, and by osteitis of the wall of the alveolus. Plastic pericementitis leads to a new formation of cementum as well as of bone-exostosis.

"VI. Suppurative pericementitis results from the breaking apart of the inflammatory elements which have arisen from the connective-tissue of the pericementum itself. Emigrated colorless blood-corpuscles probably share in the formation of pus-corpuscles; but no proof thereof is possible. The main mass of pus-corpuscles is due to a transformation and destruction of the inflamed tissue."

NECROSIS.

IF this were intended to be a complete work on Oral Surgery, it would be necessary to give in detail all that relates to necrosis of the maxillæ, including various operations, purely surgical, that have not been mentioned herein.

Necrosis resulting from suppurative pericementitis, and the death of the alveolar border or edge of bone surrounding the teeth near their necks, in what is called Riggs's disease, has already been referred to; but, in addition to this, it seems best to give some of the principles (based upon the latest and best discoveries in embryology and histology) relating to the diagnosis, removal, and treatment of larger or more extensive portions of the maxillæ in necrotic condition. Hence it is that the following article by Dr. W. H. Atkinson, of New York, is here presented :

“REPRODUCTION OF BONE, WITH SPECIAL REFERENCE TO THE
VARIABLE PORTIONS OF THE MAXILLÆ.

“Necrosis has been looked upon as a sudden stroke of death to a given territory of bone. This is the exact opposite of the truth in every case that has fallen under my observation, in my own or the practice of others, hospital or private. However sudden the privation of nerve-current and blood-current may be, there must be a period of solution of the lime-salts of the part involved, to constitute either caries or necrosis.

“It is to the understanding of this process that we are indebted for correct diagnosis and treatment. And just here we enter upon the dispute between the old *expectante* and the modern *pragmatic extirpative* methods. The old says, ‘Let alone, and await the setting up of the *line of demarkation* before attempting to operate.’ The new says, ‘Extirpate the carious or necrosed portion, just so soon as it is possible to determine the portion deprived of the nerve- and blood-circulation;’ thus limiting and marvelously lessening the extent of the destruction of tissue. Just how far the solution of lime-salts may extend and the part still be amenable to re-solidification, is not definitely settled; but that vigorous cutting at this time, through the dead and dying portion, well into the healthy adjoining tissues, is to be considered good conservative treatment, is no longer in doubt.

“To comprehend the loss of tissues involves an understanding of their production, nutrition, and maintenance, as displayed in embryological histology, no less than the alternations of generation of the small bodies which are the elements, the changes of which constitute nutrition in the adult. Function is so deeply laid in the basis of molecular metamorphosis, that we must accept dogmatic assertion of primary postulates from which to proceed, rather than claim to be able to demonstrate the mutations of combination and separation of the elements producing the perceptible mass-changes in the organs of the body in health and disease. Hence our knowledge is but comparative rather than absolute in the discriminations of healthy or diseased manifestations, so varied by constitutional and accidental conditions of environment.

“A sort of compromise between nutritional changes in the adult and tissual metamorphoses in the embryo is

present in all reproductions of tissues, continuity of which has been broken by mechanical, chemical, or dynamic interruption of function. All reproduction of tissue (other than that of nutritional maintenance) demands a utricle, or pocket to contain the pabulum, or protoplasm, from which is then to be evolved the elements of the new tissue which is so to be rebuilt according to the demands of the type of the destroyed portions of tissue. This holds good preëminently in bones, nerves, tendons, and blood-vessels. I have not yet seen muscles reproduced in this way.

“The prevailing methods in surgery of treating caries and necrosis by expectante and drainage should no longer be resorted to. The portions already dead, or greatly debilitated, should be thoroughly removed well up to the healthy territory,—securing a pocket to receive the pabulum out of which to attain reproduction by what has been called ‘first intention.’

“All tissues arise from protoplasm. If we regard protoplasm as the first example of tissue, arising out of pabulum,—which is a reduced magma of food-elements,—we shall then regard it as the *one tissue*, modifications of which are presented in the various tissues composing the human body.

“In the light of this view of the subject, we must give the following classification of tissues:—

“I. Protoplasm.

“II. Indifferent or embryonal corpuscles.

“III. Connective-tissue corpuscles, nerve-tissue corpuscles, and muscular-tissue corpuscles.

“IV. Limitary-tissue corpuscles. (This is usually denominated epithelium, and is characteristic of skin, membranes, and some forms of morbid growths).

“Limitary tissue covers the body as a whole and lines all

tracts,—phono-respiratory, alimentary, genito-urinary, optical, auditory, and sudoriparous.

“ To enter into the question of the possibilities respecting reproduction of epithelium from protoplasm, without resorting to the so-called ‘skin-grafting’ method, and discuss the point of a possibility of attaining a new formation not readily detectable as veritable ‘scar-tissue,’ would lead us too far from the immediate object of this paper, viz., the possibility of reproducing the variable portions of the maxillæ where the teeth are kept in situ but deprived of the alveolar plates constituting their sockets. The tooth-bearing parts of the jaw-bones are the portions of these structures liable pre-eminently to caries and necrosis.

“ Examples of well-formed jaw-bones without teeth in man are too rare to afford comparisons as to liability to deteriorate, as set against the list with teeth. No case of necrosis of an edentulous human jaw has come under my observation in history or in practice.

“ Molecular metamorphosis (the commerce of tissues) constitutes the measure of production, maintenance, and destruction of tissues; and hence must be apprehended to enable us to institute beneficent diagnosis and treatment. Normal nutritional changes do not attract attention. But when disease (as aberrant molecular metamorphosis is called) invades the body, the abnormality forces recognition. Disease is one in origin, and one in mode. Debility is its origin, and modifications of tissue its mode, the degrees of which constitute its various manifestations.

“ Mal-nutrition is always asthenic, and induced by starvation through deficiency of food, or bad food, contagion, or mis-applied remedies. The important point is to be able to distinguish between the cases that are sure to result

in destruction of bone territories deprived of pabulum, when left alone, and those in which resolution may be induced before the periostitis becomes osteitis. Bone-structure is so low in nutritional endowment that it is dangerous to trust to any constitutional or local treatment other than prompt extirpation of the seat of inflamed bone, from which caries or necrosis is sure to spread if not promptly and thoroughly removed quite up to or slightly beyond the limit of healthy territory.

“To comprehend the reproduction of any tissue, organ, or system, it is indispensable to be acquainted with its production, maintenance, and loss. To be able to assert that any apprehensions of these processes are new, it is also indispensable that we be familiar with what has been known or assumed by those who have dealt with the propositions involved in the subject.

“A review of the proceedings of those engaged in treating loss of bones and parts of bones from lesion of nutrition or mechanical lesion will fairly indicate the status of their apprehension and comprehension of the subject under consideration. The range and variety of method and management is sufficiently extensive to satisfy the most strenuous advocate for freedom,—all the way from expectante or let-alone treatment to ‘boiling oil,’ ‘lowered heat,’ ‘cauterization;’ and intermediate modes, down to the demoniac ‘imprisonment of the part in plaster bandages,’ and other means of absolute ‘fixity,’ may be instanced as the thorough-base of text-book and journal doctrine.

“He who takes it upon himself to deal with the disabilities and sufferings of his fellows, in morals, medicine, or surgery proper, should be so divine in nature as to be proof against being dazed, hardened, or deterred from

comprehending each case, and then doing with steady purpose whatever is indicated. He who essays to help the injured should be so in love with nature as to feel inclined to remove every obstruction to her methods, in all the kingdoms of her dominion, be it in mineral, vegetable, animal, or human.

“What naturalist has not felt impelled to release the struggling shoot he saw wriggling around a dry leaf, stick, or stone, to attain the light and the air? In like manner the truly divine surgeon is impelled to disregard mere etiquette, and rush to the help of the afflicted with kindly inspirational activity, which is ever auspicious wherever the afflatus is implicitly followed.

“If there is one predominant dead-weight in the path of the surgeon it is the cold assumption to know exactly beforehand all the ins and outs of a complicated operation, and to perform it ‘*secundum artem*.’ Timidity and reverent regard for text-book authority and the prevailing teachings of the medical schools engender hesitation and doubt as to the correctness of the deductions afforded by cases in practice.

“Little by little advancement was made as the light of success added confidence to the interpretations arrived at under the inspirations of necessity in cases pronounced hopeless by those in authority. When several of these patients recovered, with little deformity, some of those who subsequently saw them denied that they had ever been veritable cases of necrosis. But this question was easily settled by the testimony of competent observers who saw them, and by, in some cases, producing the bones themselves that had been removed from the territory now occupied by reproductions; which reproductions were so exactly normal in appearance and usefulness of function

as to defy detection as new bone by any who had not seen them in the course of death of parts, removal, and the procurement of the requisite receptacle or pocket in which the new formations were obtained. This pocket, by the way, is the *sine qua non* to success in these undertakings.

“The heresy of the vaunted textual statement that ‘periosteum is the bone-producer,’ has now happily been set at rest by the discovery that reproduction of tissues follows the same course of metamorphosis as their original production. All the periosteum that is yet attached to the soft tissues surrounding a necrotic territory, and which has the uninterrupted supply of blood-vessels and nerves, is of great importance, and should be sedulously preserved. But where the blood- and nerve-supply are cut off, the dead periosteum should be removed with the necrosed bone, since it is no longer able to perform its functions.

“The principal use of the connective-tissue (constituting periosteum) is as a support to nerves and blood-vessels, by which pabulum may be carried to its inner side, next to the bone, there to be converted into, 1st, ‘protoplasm;’ 2d, ‘embryonal corpuscles;’ 3d, ‘bone-plates of osteoblasts;’ which, 4th, become true bone by deposits of the requisite lime-salts; and, lastly, the periosteum then serves as means of sheathing to bone and tendon at the places of attachment or insertion of the muscle. The ado made by surgeons for the necessity of preserving periosteum where reproduction of bone is desired, will be superseded upon a close study of embryological bone-production.

“Written or spoken directions, however clear they may be, are less instructive than clinical display of diagnosis and treatment of cases of any sort; but especially of the simpler ones of necrosis and caries. Clinical instructions, of necessity, are limited to the few who can come near

enough to clearly take in the essential features of the examination, deliberation, and discernment of the diagnosis upon which the treatment depends.

“A rigid adherence to rules in diagnosis frequently tends to render a true one impossible, as it often occurs that a step in the operation must be taken before diagnosis can be completed. Furthermore, early symptoms are too obscure to be detected by any but the well-trained observer. Just so soon as the ability to detect to a certainty the departures from health that are liable to run into caries and necrosis becomes more general among practitioners, there will no longer be such predominant multiplicity of examples of this justly detested disease!”

