

Anatomy of the brain and spinal cord / by J. Ryland Whitaker.

Contributors

Whitaker, J. Ryland
Augustus Long Health Sciences Library

Publication/Creation

Edinburgh : E. & S. Livingstone, 1899.

Persistent URL

<https://wellcomecollection.org/works/bqrakz6k>

License and attribution

This material has been provided by This material has been provided by the Augustus C. Long Health Sciences Library at Columbia University and Columbia University Libraries/Information Services, through the Medical Heritage Library. The original may be consulted at the the Augustus C. Long Health Sciences Library at Columbia University and Columbia University. where the originals may be consulted.

This work has been identified as being free of known restrictions under copyright law, including all related and neighbouring rights and is being made available under the Creative Commons, Public Domain Mark.

You can copy, modify, distribute and perform the work, even for commercial purposes, without asking permission.



Wellcome Collection
183 Euston Road
London NW1 2BE UK
T +44 (0)20 7611 8722
E library@wellcomecollection.org
<https://wellcomecollection.org>


COLUMBIA LIBRARIES OFFSITE
HEALTH SCIENCES STANDARD




HX64085651

QM451 .W58 1899 Anatomy of the brain


RECAP







Columbia 1910.



ANATOMY
OF THE
BRAIN AND SPINAL CORD.

PRINTED BY
E. & S. LIVINGSTONE
4 MELBOURNE PLACE
EDINBURGH.

ANATOMY
OF THE
BRAIN AND SPINAL CORD

BY

J. RYLAND WHITAKER, B.A., M.B.(Lond.)

FELLOW OF THE ROYAL COLLEGE OF PHYSICIANS, EDINBURGH;
LECTURER ON ANATOMY, SURGEONS' HALL, EDINBURGH, AND LADIES' SCHOOL OF
MEDICINE, MINTO HOUSE, EDINBURGH; EXAMINER IN ANATOMY,
ROYAL COLLEGE OF PHYSICIANS, EDINBURGH.

SIXTH THOUSAND.

EDINBURGH: E. & S. LIVINGSTONE.

1899.

[ALL RIGHTS RESERVED.]

anonymous

1.21.36

QM451

.W58

1899

TO

SIR JAMES ALEXANDER RUSSELL,


LL.D., M.A., M.B., B.Sc., F.R.C.P.E., F.R.S.Ed.,

LATE LORD PROVOST OF EDINBURGH,

This little Manual is respectfully Dedicated

IN TOKEN OF MANY KINDNESSES.

THE AUTHOR.



PREFACE TO THIRD EDITION.

THIS little book, first written whilst a student at the earnest request of students, has now reached a third edition, and has become a favourite, perhaps undeservedly, with those for whom it was originally intended. Although fully conscious of its many defects, I fear that my time, now so much occupied with teaching, leaves me no chance of remodelling the book in a way that more mature years and experience would suggest. It must practically remain in the same garb, however imperfect, in which it first appeared. This the student, at least, will probably not regret.

In this edition my work has been confined to the removal of the more glaring blemishes and errors, and to the rewriting and bringing up to date some of the sections. As the book is now much used by senior students and by practitioners, a general summary, for their special use, has been added at the end.

Though the actual number of pages has been slightly increased, the matter has been shortened, for the individual pages have been made smaller, more margin

having been allowed, so that the book reads more easily and more room has been obtained for extra plates.

To Dr W. F. HARVEY, and to my other demonstrators and students who have so kindly, more than once, read over the proofs, I cannot sufficiently express my gratitude.

Finally, it remains for me to thank Messrs M'Lagan & Cumming for the trouble they have taken in the reproduction of the plates, and the Messrs Livingstone and staff for their uniform courtesy and excellent execution of the work.

SURGEONS' HALL,
EDINBURGH, *1st May 1899.*

TABLE OF CONTENTS.

	PAGE
DEDICATION,	v
PREFACE,	vii
LIST OF PLATES,	xiii

SECTION I.

THE SPINAL CORD, ITS MEMBRANES, AND ITS VESSELS, ...	3
--	---

Chapter I.

MEMBRANES OF THE SPINAL CORD,	3
I. DURA MATER,	4
II. PIA MATER,	6
III. ARACHNOID,	9
CEREBRO-SPINAL FLUID,	10

Chapter II.

SPINAL VESSELS,	11
------------------------	----

Chapter III.

THE SPINAL CORD,	12
I. FISSURES OF THE CORD,	14
II. SPINAL NERVES,	16
III. WHITE AND GREY MATTER OF CORD,	17
1. WHITE MATTER,	18
White Columns,	18
White Commissure,	25
Structure of White Matter,	26
2. GREY MATTER,	27
Cornua,	28
Grey Commissure,	29
Neuroglia,	30
Nervous Constituents,	31
Vesicular Columns,	32
IV. DEEP ORIGINS OF SPINAL NERVES,	37

SECTION II.

	PAGE
THE BRAIN, ITS MEMBRANES, AND ITS VESSELS,	43
DISSECTION TO EXPOSE MEMBRANES,	43
DISSECTION TO REMOVE BRAIN,	44

Chapter I.

MEMBRANES OF BRAIN,	45
I. DURA MATER,	45
Falx Cerebri,	46
Falx Cerebelli,	47
Tentorium Cerebelli,	47
II. PIA MATER,	49
III. ARACHNOID,	50
IV. VENOUS SINUSES,	52

Chapter II.

VESSELS OF THE BRAIN,	57
I. ARTERIES,	57
II. VEINS,	61

Chapter III.

SUB-DIVISIONS OF THE BRAIN,	63
I. MEDULLA OBLONGATA,	65
1. Fissures of Medulla,	66
2. White Matter—Areas of Medulla,	67
3. Grey Matter of Medulla,	77
Recapitulation,	85
II. PONS VAROLII,	87
1. White Matter of the Pons,	89
2. Grey Matter of the Pons,	91
III. CEREBELLUM,	92
1. Lobes of Cerebellum,	95
2. Peduncles of Cerebellum,	97
3. Medullary Vela,	100
4. Grey Matter of Cerebellum,	101
Minute Structure of Grey Matter,	102
5. White Matter of Cerebellum,	105
THE 4th VENTRICLE,	106


TABLE OF CONTENTS.

xi

	PAGE
IV. CEREBRUM,	113
I. EXTERIOR OF CEREBRUM,	114
1. Fissures of Cerebral Hemispheres, ...	114
2. Lobes and Convolutions	116
Structure of Cerebral Cortex,	128
II. BASE OF CEREBRUM,	132
III. INTERIOR OF CEREBRUM,	138
1. VENTRICLES,	141
Lateral Ventricle,	142
The 3rd Ventricle,	146
The 5th Ventricle and Septum Lucidum, ..	147
Velum Interpositum,	148
Choroid Plexus,	149
Veins of Galen,	150
Great Transverse Fissure,	150
2. BASAL GANGLIA,	151
Corpora Striata,	151
Optic Thalami,	153
Corpora Geniculata,	155
PINEAL GLAND,	156
3. WHITE STRANDS,	157
Corpus Callosum,	157
Anterior Middle, and Posterior Com- missures,	160
Fornix,	160
Internal and External Capsules,	163
IV. CRURA CEREBRI, &c.,	165
1. Crura,	165
2. Corpora Quadrigemina,	169
3. Aqueduct of Sylvius,	170
ORIGINS OF CRANIAL NERVES,	170
GENERAL SUMMARY,	180

SECTION III.

OUTLINES OF DEVELOPMENT OF—	190
I. THE SPINAL CORD,	191
II. THE BRAIN,	193
INDEX,	199



LIST OF PLATES.


PLATE	PAGE
I.—Fig. 1, General View of the Brain and Spinal Cord (Hirschfeld and Leveillé). Figs. 2 and 3, Membranes of the Spinal Cord,	4
II.—Figs. 4, 5, and 6, Membranes of the Spinal Cord. Fig. 7, Central Canal of Spinal Cord (Foster). Fig. 8, Sections of Spinal Cord,	8
III.—Sections of Spinal Cord at various levels,	14
IV.—Fig. 13, Tracts of Spinal Cord. Fig. 14, Vesicular Columns and Deep Origins of Spinal Nerves. Fig. 15, Blood-Vessels,	22
V.—Various kinds of Nerve Cells of Spinal Cord,	28
VI.—Figs. 23, 24, 25, and 26, White Tracts of Spinal Cord (Bristowe). Fig. 27, Pia Mater. Fig. 28, White Nerve Matter of the Spinal Cord. Fig. 29, Anterior Horn of the Spinal Cord,	32
VII.—Fig. 30, Different kinds of Cells of the Spinal Cord, Neuroglia, &c. (Van Gehuchten). Figs. 31 and 32, Collaterals (Edinger),	34
VIII.—Fig. 1, Collaterals. Fig. 2, Spinal Ganglion. Fig. 3, Neuroglia Cells (Van Gehuchten). Fig. 4, Nerve Cells,	40
IX.—Fig. 33, Diagrammatic View of Parts of the Brain. Fig. 34, Membranes of the Brain,	41
X.—Fig. 35, Membranes and Vessels of the Brain (H. & L.). Fig. 36, Venous Sinuses (Wilson's Plates),	48
XI.—Figs. 37 and 38, Venous Sinuses (Wilson),	52
XII.—Figs. 39 and 40, Blood-Vessels of the Brain (H. & L.),	58

PLATE	PAGE
XIII.—Blood-Vessels of the Brain,	60
XIV.—Blood-Vessels of the Brain, and Areas of Motion and of Sensation,	62
XV.—Views of the Medulla,	66
XVI.—Fig. 50, Diagram of Course of Fibres in the Spinal Cord,	70
XVII.—Sections of the Medulla,	78
XVIII.—Figs. 57 and 58, Nuclei in the 4th Ventricle (Edinger),	82
XIX.—Figs. 59 and 60, Pons. Fig. 61, Crura Cerebri, ...	90
XX.—Figs. 62 and 63 (H. & L.), Figures of Cerebellum,	94
XXI.—Figs. 64 and 65, Cerebellum. Fig. 66 (Edinger), and Fig. 67, Structure of Cerebellum (Ferrier),	98
XXII.—Structure of Cerebellum (Edinger)	102
XXIIA.—Figs. 68 and 69, Structure of Cerebellum (Van Gehuchten),	104
XXIII.—Convolution of the Brain,	118
XXIV.—Convolution of the Brain,	124
XXV.—Figs. 74 and 75, Relation of Fissures, &c., to Skull and Scalp,	128
XXVI.—Figs. 76, 77, and 78, Structure of Cerebrum (Ramon y Cajal),	130
XXVII.—Fig. 79, Base of the Brain,	134
XXVIII.—Fig. 80, Side View of the Brain,	136
XXIX.—Diagram of Ventricles,	138
XXX.—Diagram of Ventricles,	142
XXXI.—Diagram of Ventricles,	144
XXXII.—Velum Interpositum, &c.,	146
XXXIII.—Diagram of Ventricles,	148
XXXIIIA.—Fig. 1, Velum Interpositum, Fig. 2, Fornix, &c., ...	150
XXXIV.—Capsules,	154

LIST OF PLATES.

XV

PLATE	PAGE
XXXV.—Fig. 87, Nuclei of 3rd and 4th Nerves (Edinger). Fig. 88, Optic Nerves (Hill). Fig. 89, Fornix. Fig. 90, Nucleus Caudatus (Edinger). Fig. 91, Fornix (own specimen, and Hill),	160
XXXVI.—Fig. 92, Blood-Vessels to Capsules. Fig. 93, Ver- tical Section of the Cerebrum. Fig. 94, Diagram of the 3rd Ventricle. Fig. 95, Fascia Dentata, &c.,	164
XXXVII.—Fig. 96, Diagram of Tracts of Fibres (Hill). Fig. 97, Tracts of Medulla (Edinger, Hill, Bruce). Fig. 98, Inter-peduncular Space (Holden). Fig. 99, Resti- form Body (Edinger),	168
XXXVIII.—Nuclei of Origin of Cranial Nerves,	172
XXXIX.—Nuclei of Origin of Cranial Nerves,	176
XL.—Figs. 100 and 101, Tracts of Degeneration in the Brain and Spinal Cord,	182
XLI.—Diagram of Course of Motor Fibres (Van Gehuchten),	184
XLII.—Diagram of Course of Sensory Fibres (Van Gehuchten),	186
XLIII.—Diagrams of Development of the Brain and Spinal Cord (after Quain, Kölliker, Schwalbe, and Edinger),	192
XLIV.—Diagrams of the Vesicles of the Brain and the Parts Developed therefrom (after Van Gehuchten), ...	194

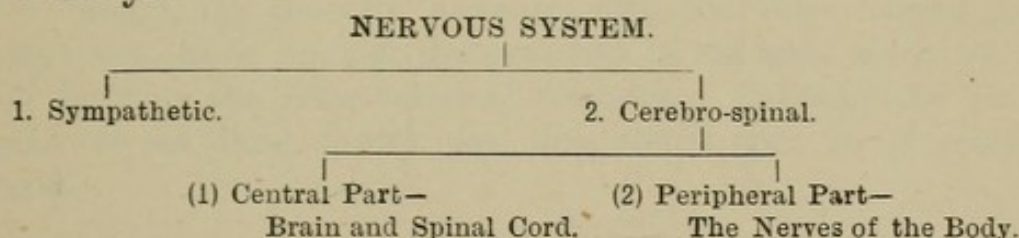


ANATOMY

OF THE

BRAIN AND SPINAL CORD.

THE nervous system of man comprises two portions, the *Sympathetic* and the *Cerebro-spinal*. The latter, the cerebro-spinal, has two parts: a *central*, which consists of the *brain* and *spinal cord*, and a *peripheral*, which consists of the several *nerves* of the body.



The Central Nervous System of man, the only part treated of in this book, is, as we have just seen, made up of the Brain and Spinal Cord. Surrounded by the bony wall of the cranium in the one case, and of the spinal canal in the other, these two parts of the great cerebro-spinal nervous system are continuous with each other through the foramen magnum. They are each enveloped in three distinct membranes, the *Meninges*, which form additional protective sheaths around them, and help to support them in their respective cavities.

The Brain and Spinal Cord are, moreover, each composed of two kinds of nervous substance, known from their colour as the White and Grey Matter respectively; but with this difference in their arrangement, namely, that in the Brain the grey matter is situated chiefly on the outside, forming the cortex; whilst in the Spinal Cord the white substance is external, and the grey matter forms the central core or pith.

We shall describe, firstly, the Spinal Cord, with its Vessels and Membranes; and, secondly, the Brain, with its Vessels and Membranes.

SECTION I.

SPINAL CORD AND MEMBRANES.

DISSECTION.—To see the spinal cord and its membranes it will be necessary to open the vertebral canal. To do this, remove the muscles from the vertebral grooves, and saw through the laminæ of the vertebræ on each side, close to their union with the pedicles, being careful, especially in the dorsal region, to direct the edge of the saw inwards. Carry the incision downwards as far as the lower end of the sacral canal, and upwards as high in the neck as may be convenient. Break through with the chisel any partially sawn arches, cut through the various ligaments, and remove the pieces of bones thus detached. Carefully clear away the connective tissue, veins, and fat covering the outer aspect of the dura mater, snip through the articular processes with the bone forceps, and dissect out one or more of the processes of the dura mater which pass through the inter-vertebral foramina. Examine the outer surface of the dural sheath, and then slit it open in its entire length.

CHAPTER I.

MEMBRANES OF SPINAL CORD.

(Plates I. and II.)

These membranes are identical in many respects with those of the Brain, and are therefore similarly named. They are the Dura Mater, the Pia Mater, and the Arachnoid. The Dura Mater is the most external, the Pia Mater is in close contact with the cord, and the Arachnoid forms a vertical, tubular partition between the others, dividing the

space between them into two—viz., the sub-dural and the sub-arachnoid. Thus we speak of the sub-dural space, meaning that between the dura mater and the arachnoid, and of the sub-arachnoid, or that between the arachnoid and the pia mater. For convenience we shall describe (1) the Dura Mater; (2) the Pia Mater; (3) the Arachnoid.

I.—THE DURA MATER.

(Figs. 2 to 6.)

The Dura Mater, the most external and the strongest covering of the cord, is a firm fibrous membrane, continuous at the foramen magnum with the similar membrane which lines the cranial cavity. Enclosed in the spinal canal, it does not, however, form an endosteum to the bones, and in this respect differs from the cranial dura mater. Its outer surface has a shining, pearly-white appearance, and is separated from the walls of the spinal canal by loose areolar tissue with a little fat, and by a plexus of veins. Slender fibrous bands, especially at its lower end, attach it closely to the posterior common ligament of the vertebræ. In extent the dural sheath reaches from the foramen magnum to the second or third piece of the sacrum, where it ends in a conical *cul-de-sac*. As you will see upon opening it, the cavity which it encloses is much longer and wider than its contents—the spinal cord—for this latter ends at the first or second lumbar vertebra. Below the pointed termination of the spinal marrow—*conus medullaris*—the cavity of

FIG. 1.

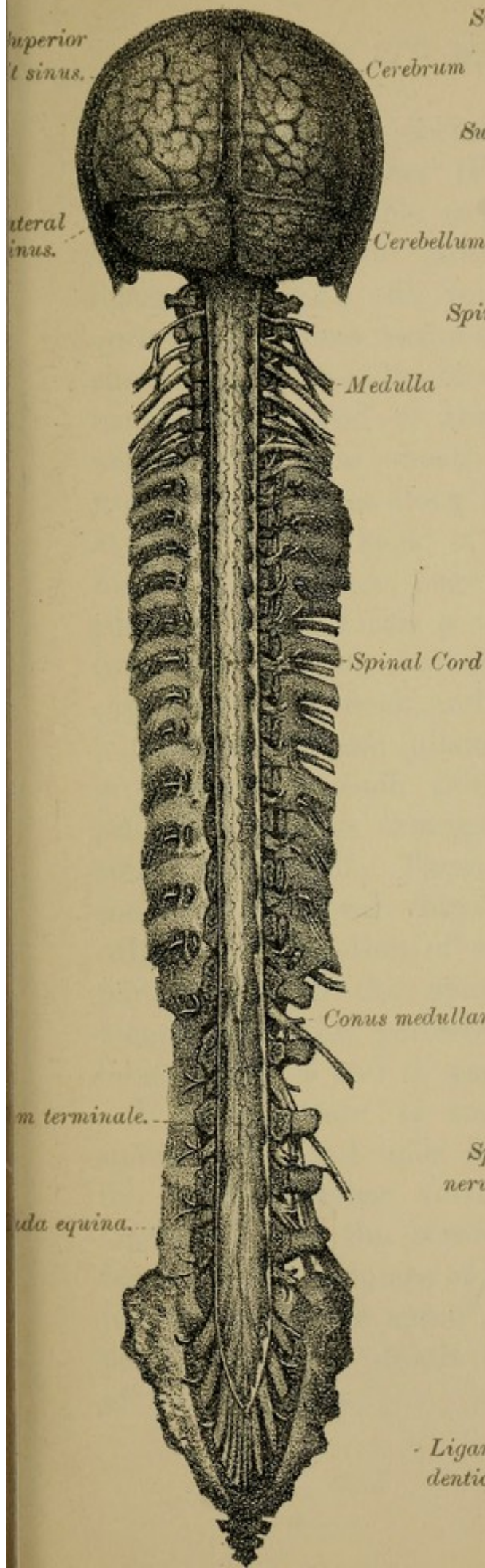


FIG. 2.

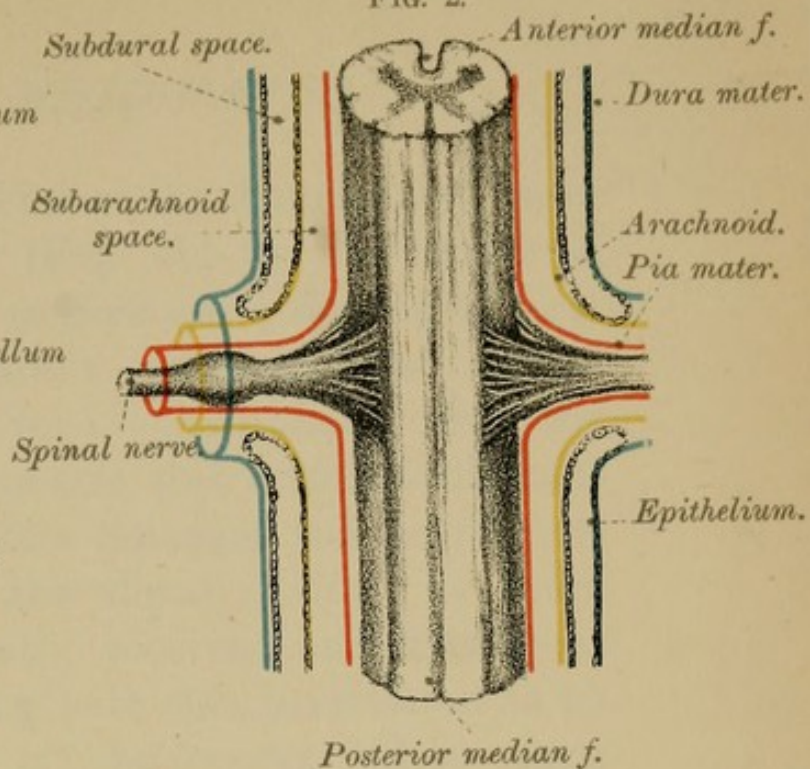
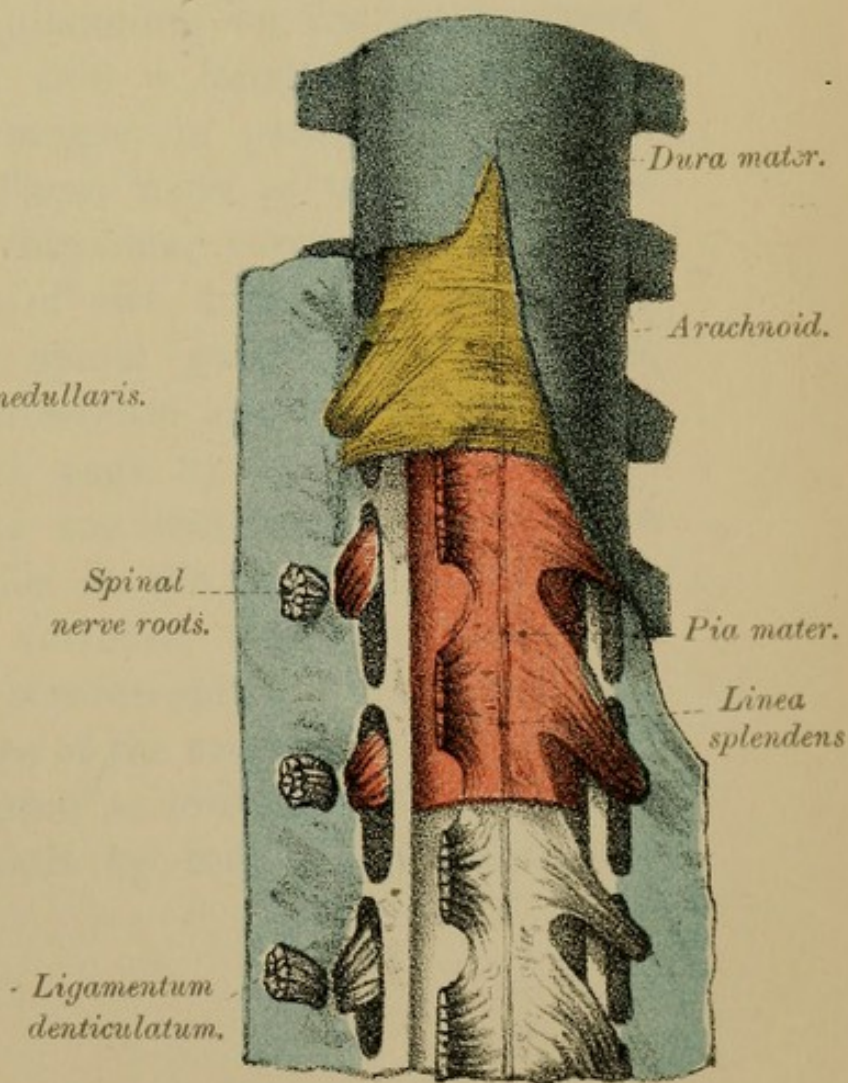



FIG. 3.





the dural sheath is occupied by bundles of nerve roots—*cauda equina* (Fig. 1)—in the midst of which you will be able to pick out a slender, silvery-looking thread, the *filum terminale* or central ligament (Fig. 1, fil. ter.). Continuous with the apex of the *conus medullaris*, this terminal filament runs down the middle line amongst the nerve roots to the lower end of the dural cavity. It there pierces the dural sheath, receives an investment from it, and passes along with this investment to be attached to the back of the coccyx (*filum duræ matris spinalis*, see page 13). Thus, we see that the dura mater forms a very loose covering to the cord, and we find, moreover, that it has a greater capacity in the neck and back than it has in the loins. Smooth and glistening on its inner aspect, it presents on each side a longitudinal series of rounded openings arranged in pairs, one for each spinal nerve root. These roots, as they pass out to the inter-vertebral foramina, carry with them a tubular prolongation of the dura mater which, in part, ensheaths the spinal ganglia, and, in part, blends with the periosteum of the neighbouring bones (Figs. 4 and 6, page 8).

It is important to recollect that, although the spinal cord itself ends at the spot indicated—viz., the second lumbar vertebra, the dura mater, the arachnoid, and the cerebro-spinal fluid, extend as far as the second piece of the sacrum, so that injuries inflicted upon the spine as low down as this latter point may cause death by inducing inflammation of the meninges.

MINUTE STRUCTURE OF THE DURA MATER. — Under the microscope the dura mater will be seen to consist of white fibrous and elastic tissues, arranged in longitudinal bands or lamellæ, with flattened, branched, connective tissue corpuscles, clasping the bundles of fibrils. Both its inner and outer surfaces are smooth and covered by epithelial plates. Many lymphatics and blood-vessels, as well as slender nerve filaments derived from both spinal and sympathetic systems, are furnished to its substance.

II.—THE PIA MATER.

(Figs. 2 to 6.)

DISSECTION.—After slitting open the dura mater, the first membrane you will see is the delicate arachnoid. Pierce it with a sharp-pointed blow-pipe and inflate, as far as you can, the sub-arachnoid space. Next, to expose the pia mater, remove a small piece of the arachnoid from any part of the cord, leaving it intact elsewhere.

The Pia Mater is a delicate, highly-vascular, fibrous membrane, which so closely surrounds the spinal cord that it cannot easily be stripped off. It also furnishes sheaths to the roots of the spinal nerves. A distinct process or fold of it passes into the anterior median fissure of the cord, and other smaller septa penetrate the spinal marrow at various points, carrying with them blood-vessels and lymphatics for the nutrition of both its white and grey matter. The largest of these septa is seen at the posterior median fissure (Fig. 6, Plate II., page 8). It is not, however, a fold of pia mater like that in the anterior fissure, but consists of the

supporting tissue of the cord called neuroglia (see page 30). If you compare the pia mater of the cord with that of the brain, you will find that the former is thicker, less vascular and more adherent to the subjacent nervous tissue.

The outer surface of the pia mater is comparatively rough, and has the three following structures connected with it—the *linea splendens*, the *ligamentum denticulatum*, and the *septum posticum*.

1. The *linea splendens* (Fig. 3, page 4) is a thickened fibrous band along its anterior aspect. It is sometimes difficult to make out.

2. The *ligamentum denticulatum* is a well-defined structure (Figs. 3 and 5, lig. dent.) which runs longitudinally on each side of the cord in the form of a toothed white band, having its serrated edge turned outwards. It helps to support the spinal marrow within its dural sheath. Internally, it is attached to the pia mater, about midway between the lines of origin of the anterior and posterior nerve roots, reaching upwards as high as the medulla oblongata, and ending below on the pointed extremity of the cord, the *conus medullaris*. Externally, its outer margin forms a series of tooth-like processes, about twenty-one in number, which are fixed to the inner surface of the dura mater, in the intervals between the points of exit of successive nerve roots. The highest of these denticulations is attached opposite the margin of the foramen magnum, between the last cranial and first spinal nerve, and the lowest between the twelfth dorsal and first lumbar nerves. The *ligamentum denticulatum*

thus partially divides the sub-arachnoid space into an anterior and a posterior compartment.

3. At the back of the cord is another process or partition—the *septum posticum* (Figs. 4, 6, page 8, sep. post.)—which crosses the sub-arachnoid space and serves to connect the pia mater with the arachnoid.

Below the end of the cord, the pia mater, though at first retaining its tubular form, afterwards becomes suddenly reduced in size, and is finally prolonged as a sheath to the delicate thread-like continuation of the spinal cord, the *filum terminale* or central ligament (Fig. 1); the silvery hue of which will enable you to distinguish it among the surrounding bundles of nerve roots (*cauda equina*).

Lying between the pia mater on the one hand, and the arachnoid on the other, but connected with both, is a quantity of delicate connective tissue arranged in the form of a spongy network, the sub-arachnoid trabeculæ, which are clothed with epithelial plates (Fig. 4, page 8, sub-arach. trab.). The lacunæ or areolæ, thus formed, contain the greater part of the cerebro-spinal fluid.

MINUTE STRUCTURE OF THE PIA MATER (Fig. 27, Plate VI., page 32).—The pia mater consists of a basis of white fibrous connective tissue, which is arranged in interlacing bundles, and supports a plexus of blood-vessels. Both its surfaces are covered by epithelial cells. It possesses a complete network of lymphatics; and its nervous supply is derived from the sympathetic system.

FIG. 5.

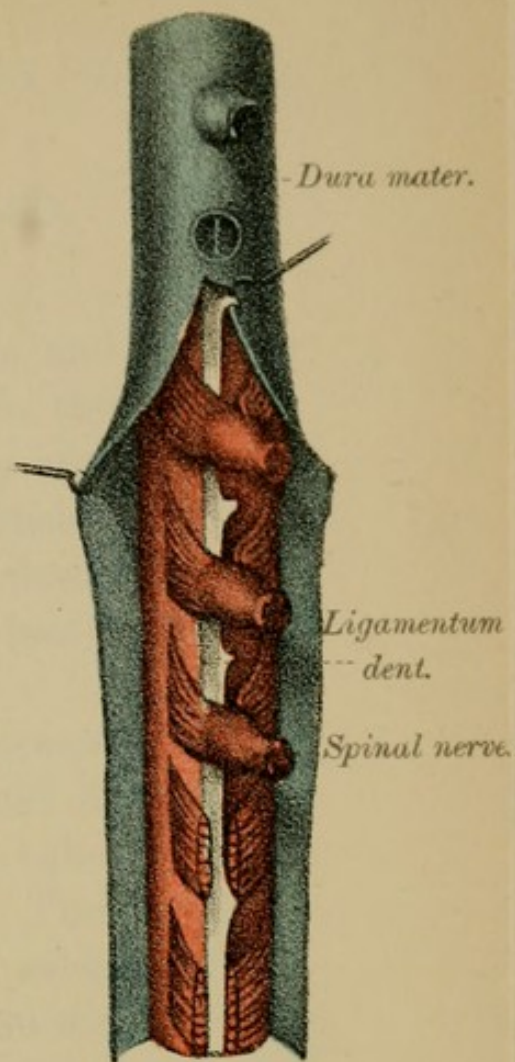


FIG. 4.

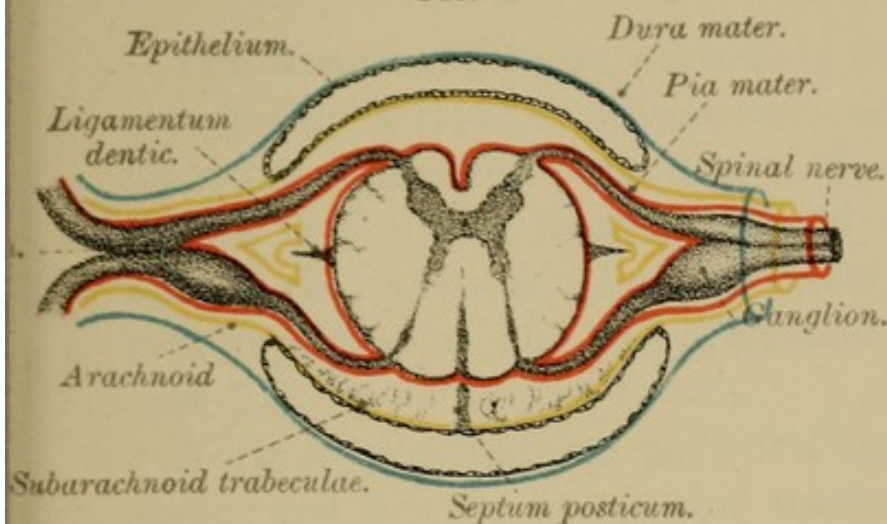


FIG. 6.

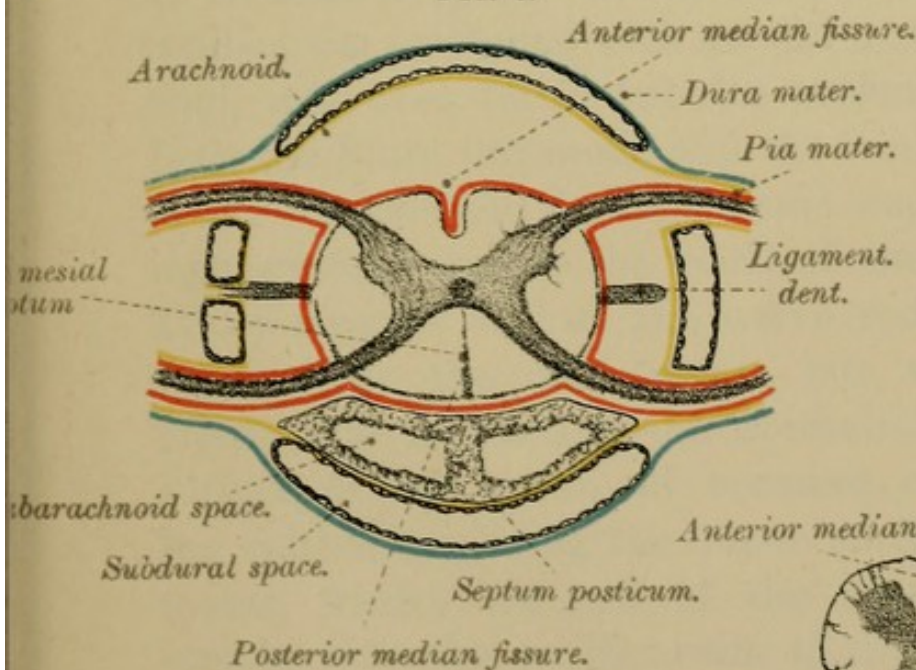
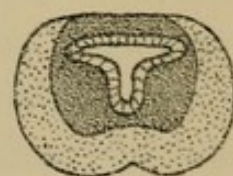
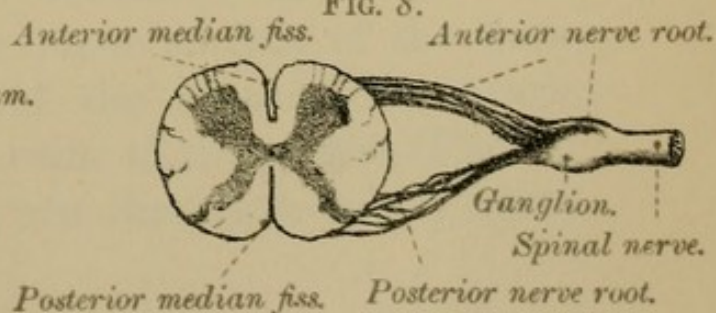



FIG. 7.



Transverse section of lower part of spinal canal.

FIG. 8.





III.—THE ARACHNOID.

(Figs. 2 to 6.)

The Arachnoid is an extremely fine and delicate membrane. It is non-vascular, and thus differs materially from the other two. Many authors deny that it is a special membrane, and consider it to be one of the layers of the pia mater, describing the two together as the pia-arachnoid (see pages 50 and 51).

Forming a cylindrical partition between the dura mater and the pia mater, the arachnoid divides the space between them into two—the sub-dural and sub-arachnoid, previously referred to. The sub-dural space is very narrow, for the outer surface of the arachnoid is in more or less close contact with the dura mater. The sub-arachnoid space is much larger and contains the chief part of the cerebro-spinal fluid. It is crossed by the sub-arachnoid trabeculæ which connect the arachnoid with the pia mater. The arachnoid, moreover, forms tubular prolongations around both the filum terminale and the teeth-like processes of the ligamentum denticulatum; and similar coverings are furnished to the roots of the spinal nerves. These sheaths enclose the nerve roots as they pass outwards to the dura mater, but, when the roots pierce that membrane, the epithelium of the outer surface of the arachnoid becomes continuous with the epithelium lining the inner surface of the dura mater, whilst the rest of the arachnoidal sheath blends with the perineurium of the nerves (Figs. 2 and 4, epith.). Thus we see that each spinal nerve

root receives a covering from all three membranes of the cord. It is stated, too, that the sub-dural and sub-arachnoid spaces, though they do not directly communicate with one another, are both continuous with the lymphatic plexuses which surround the spinal nerves. It may perhaps be well to mention that the sub-dural space was formerly spoken of as "the cavity of the arachnoid"—the arachnoid membrane itself being then looked upon as a serous membrane, enclosing a serous cavity, and the epithelial lining of the deep surface of the dura mater as one of its layers.

MINUTE STRUCTURE OF THE ARACHNOID.—The arachnoid consists of bundles of white fibrous tissue, interlacing with one another, and arranged for the most part longitudinally. Both its surfaces are covered by epithelial cells. The source from which it derives its nerve-supply is still very doubtful; most probably it is the sympathetic system. As we have said, many authors regard the arachnoid as one of the layers of the pia mater.

Cerebro-spinal Fluid.—The cerebro-spinal fluid, about two fluid ounces in quantity, is a clear-looking, alkaline liquid, containing little or no albumen. It chiefly occupies the interstices of the sub-arachnoid trabeculæ. By its means, probably, an equality of pressure is maintained upon the brain and cord; hence we find that any sudden disturbance of the fluid, such as would be caused by pressure on a spina bifida, at once gives rise to serious cerebral symptoms—such as convulsions and loss of consciousness.

CHAPTER II.

SPINAL VESSELS.

(Fig. 15, Plate IV., page 22.)

DISSECTION.—Remove the cord with its sheaths from the spinal canal, by cutting through the spinal nerves at their exit through the inter-vertebral foramina, and snipping the bands of connective tissue which attach it to the posterior common ligaments.

1. **Arteries.**—The arteries on the surface of the spinal cord are the anterior and posterior spinal.

The **ANTERIOR SPINAL ARTERY**, formed above by the union of two branches, arising one from each vertebral artery, runs along the front of the cord underneath the *linea splendens*. As it passes downwards it is reinforced by a series of anastomotic branches from arteries in the neck and back. It gives off branches to the *pia mater*, to the roots of the spinal nerves, to the anterior median fissure (a cleft seen on the front of the cord), and ends below upon the *filum terminale*.

The **POSTERIOR SPINAL ARTERIES**, two in number, run downwards, one on each side, behind the line of origin of the posterior nerve roots. They are derived from the same source as the anterior, and are joined by small branches which enter the inter-vertebral foramina along the roots of the spinal nerves. They anastomose freely and send offsets into the septum at the back of the cord—the posterior median septum.

2. **Veins.**—The veins of the spinal cord lie within the pia mater, have an anterior, a posterior, and right and left lateral trunks, and form a fine plexus over the surface of the cord. They are larger on the back than on the front of the cord. Laterally, after being joined by veins from the bodies of the vertebræ, branches pass out with the spinal nerves through the inter-vertebral foramina, and open into either the vertebral, inter-costal, or lumbar veins, according to the regions in which they occur.

3. **Lymphatics.**—There are no lymphatic vessels, properly so-called, in the nervous system, but there are lymph spaces round the nerve cells—peri-cellular, and round the blood-vessels—peri-vascular.

CHAPTER III.

THE SPINAL CORD.

The Spinal Cord is the elongated cylindrical column of nervous substance contained in the vertebral canal. Composed of two kinds of nervous matter—an outer cortical part, consisting principally of white nerve fibres, and an inner grey core or pith, consisting chiefly of nerve cells and their processes—it is invested by three membranes, the meninges; gives origin to thirty-one pairs of spinal nerves; and is partially divided by anterior and posterior median fissures into two lateral segments, which are united across the middle line by a band of fibres called a commissure. You have

already seen that the spinal marrow is much smaller than the capacity of its bony case, so much so, that, in the adult, it occupies two-thirds only of the length of the spinal canal. About eighteen inches long, it reaches from the foramen magnum to the lower border of the first or second lumbar vertebra. Above, it is continuous with the medulla oblongata; below, it ends in a pointed extremity, the *conus medullaris*, from the apex of which it is prolonged downwards as a delicate thread-like filament, the *filum terminale*. According to the regions of the spine in which they are situated, different portions of the cord have received special names; thus we speak of the *cervical*, *dorsal*, and *lumbar* portions. The spinal cord, moreover, presents two swellings or enlargements—an upper one, the *cervical enlargement*, extending from about the third cervical to the second dorsal vertebra, and a lower or *lumbar enlargement*, which, beginning at the tenth dorsal vertebra, is largest opposite the twelfth, and then gradually tapers away to the pointed extremity of the cord. The connection between the increase of nervous substance in these two parts of the cord and the origin of the large nerve bundles given off to the upper and lower limbs respectively is sufficiently obvious.

Filum terminale.—This filament is the atrophied remnant of the embryonic spinal cord. In its upper part it is composed of nervous matter surrounding a central canal, but in its lower part it becomes solid and consists of cells (the exact nature of which

is not decided), of blood-vessels, and ultimately of mere prolongations of pia mater and of dura mater (see page 5).

We shall now examine (1) the exterior of the cord with its spinal nerves; then (2) the interior.

I.—FISSURES OF THE CORD.

On both the anterior and posterior aspects of the spinal cord there is seen a median longitudinal cleft or depression, which penetrates some distance into the nervous substance, and partially divides it into two lateral halves. These clefts are called the *anterior* and the *posterior median fissures* (Fig. 10, Plate III., page 14). The transverse band which connects the two halves at the bottom of these fissures is called the commissure of the spinal cord.

1. The ANTERIOR MEDIAN FISSURE is the wider of the two, though in depth it extends through only one-third of the thickness of the cord. It contains a distinct fold of the pia mater, which conveys blood-vessels into the interior of the spinal marrow (Fig. 4, Plate II., page 8; Fig. 15, Plate IV., page 22). At the bottom of this fissure lies the transverse band of nerve fibres, the *anterior* or *white* part of the commissural band (Fig. 14, Plate IV., page 22), which unites together the two lateral halves of the cord.

2. The POSTERIOR MEDIAN FISSURE, narrower but deeper than the anterior, is rather a septum than an actual fissure, for it does not contain a fold of the pia mater, but is filled up by blood-vessels

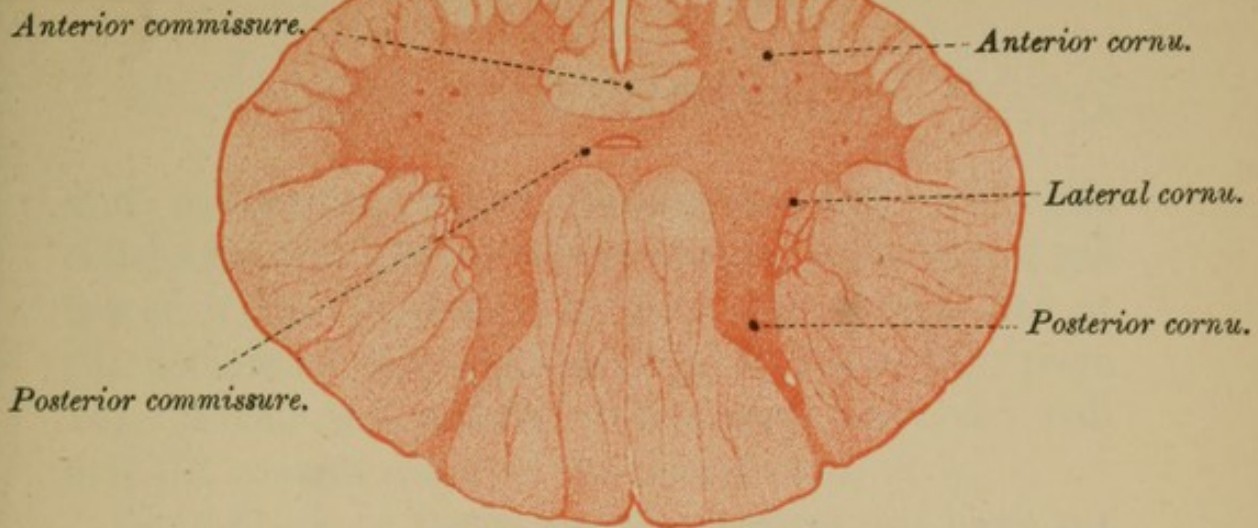


FIG. 10.—DORSAL REGION—

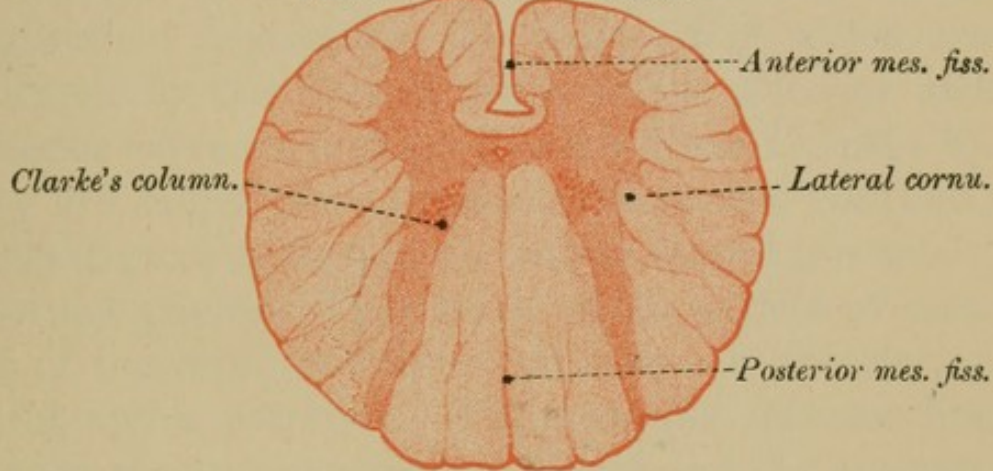


FIG. 11.—LUMBAR REGION

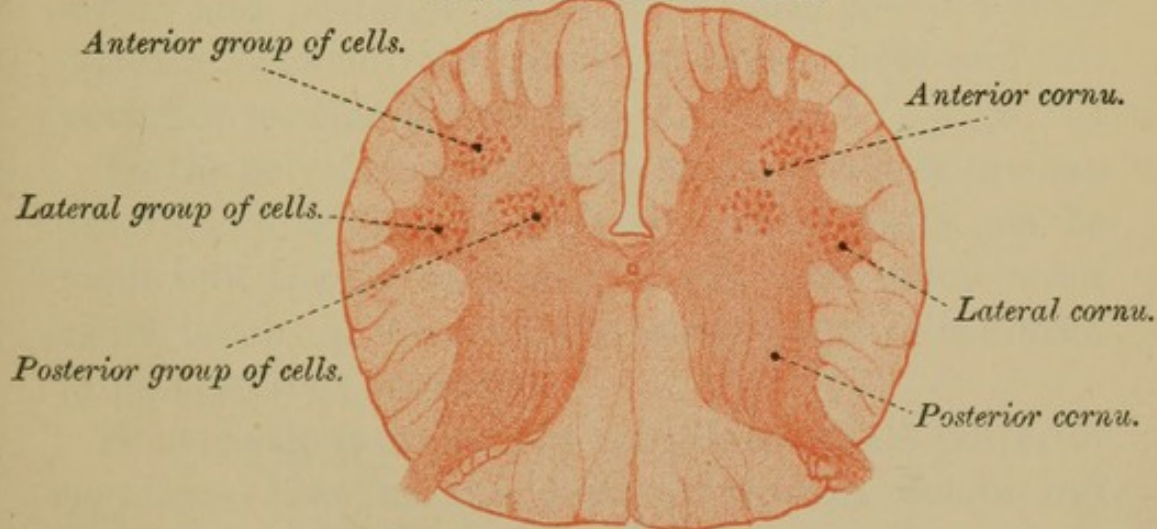
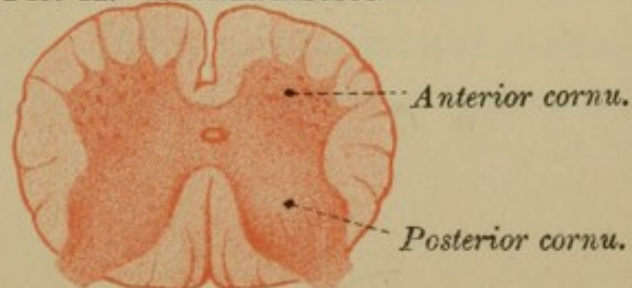



FIG. 12.—SACRAL REGION—





and connective tissue (ependyma and neuroglia cells) attached closely to the deeper layer of the pia mater. The *posterior* or *grey* commissure lies at the bottom of this septum (Fig. 9, Plate III., page 14). About the middle of this grey band you will find the central canal of the spinal cord.

In addition to these median fissures, we have yet to describe, on each side of the cord, two lateral longitudinal depressions, the positions of which are indicated by the lines of origin of the anterior and posterior nerve roots (Figs. 5 and 8, Plate II., page 8). They are called the ANTERO-LATERAL and POSTERO-LATERAL grooves, though the antero-lateral is scarcely a distinct groove. They mark off the surface of each half of the cord into three columns—an anterior, a lateral, and a posterior. The *anterior column* lies between the anterior median fissure and the anterior nerve roots; the *lateral column* between the anterior and posterior nerve roots; and the *posterior column* between the posterior nerve roots and the posterior median fissure (Fig. 15, Plate IV., page 22).

In the cervical region, close to the posterior median fissure, two additional slightly marked clefts can be made out, one on each side, which, with other minor clefts, break up the cord into many tracts or columns, to be described hereafter.

Some authors divide the cord thus—(1) A posterior segment—between the posterior median fissure and the posterior nerve roots. (2) An antero-lateral segment—between the anterior median fissure and the posterior nerve roots. The antero-lateral segment is again divided, by the line along which the anterior

nerve roots take origin, into (*a*) an anterior part, between the anterior median fissure and the anterior nerve roots; and (*b*) a lateral part, between the anterior and posterior nerve roots. From a developmental point of view this sub-division is the more correct.

II.—SPINAL NERVES.

(Figs. 5 and 8, Plate II., page 8; Fig. 15, Plate IV., page 22.)

Along the sides of the spinal cord arise, as we have already seen, the several spinal nerves—thirty-one pairs—eight cervical, twelve dorsal, five lumbar, five sacral, and one coccygeal. Each nerve takes origin, called its superficial origin, by two roots—an anterior and a posterior—springing from the antero-lateral and postero-lateral grooves respectively. The roots are enclosed in sheaths similar to those of the cord itself, and they pierce the dura mater by two separate openings, one for each root (Figs. 3 and 6). Sometimes each root, especially the posterior one, consists of two bundles, perforating the dura mater by two separate openings. Except in the case of the first nerve, the posterior roots are the larger, and their fasciculi more numerous and thicker than those of the anterior roots. They, moreover, become connected with a ganglion, or collection of nerve cells (spinal ganglion, Fig. 8, page 8; Fig. 14, page 22), before they join the anterior roots to form a spinal nerve. The anterior roots are motor, the posterior sensory in function, whereas the spinal nerves themselves are

mixed nerves, carrying both motor and sensory impulses. These nerve roots, with the exception of the first or highest, are not attached to the cord opposite the vertebra below which they leave the vertebral canal, but at a higher level. This difference between the points of origin and exit (a matter of considerable clinical importance),* though slight in the cervical region, increases as we descend the cord, until, at its lower end, the nerve roots form an almost vertical bundle, known as the *cauda equina* (Fig. 1). In the upper part of the cervical region of the cord, a little in front of the posterior roots of the first four nerves, we see a series of nerve filaments which are the twigs of origin of the spinal part of the spinal accessory nerve. They soon unite to form a single trunk, which ascends to the foramen magnum.

III.—WHITE AND GREY MATTER OF THE SPINAL CORD.

A transverse section of the spinal cord, such as that represented in the Figures Plate III., page 14, will demonstrate to you the interior of the cord and its sub-division into two lateral halves. It will show you distinctly (1) the existence of the white cortex; (2) the central grey core; and (3) the commissural band, composed of white matter and grey matter, connecting together its lateral segments.

* See Hilton's "Rest and Pain," 5th Ed., 1892, page 86.

1. THE WHITE MATTER.

Taking up such a section of the spinal cord, and examining it with the naked eye, you will see, as we have just said, that the white matter forms the outer or cortical part of the cord, and surrounds the grey centre. This white matter, arranged in a series of columns, gradually increases in amount from below upwards, being specially augmented in the cervical and lumbar enlargements. Compared with the grey matter, it is more abundant in the neck and back, but less so in the loins (Plate III., page 14).

1. White Columns of the Cord, and their Sub-divisions.—Your attention, you will remember, has already been called to the fact that the exit and entrance of the nerve roots sub-divide each lateral half of the cord into three longitudinal white segments or columns—namely, an ANTERIOR, a LATERAL, and a POSTERIOR; each of which, however, can be again sub-divided into smaller tracts or strands of fibres which have received special names and have special functions (Fig. 13, Plate IV., page 22).

Tracts or Strands.—To determine by actual dissection these various tracts or strands would be impossible; the task has, however, been accomplished by the study of development and by the aid of experimental physiology and pathology; for “we may learn as much of the course of nerve fibres by studying them in their birth as in their death—in their development as in their decay.” The development teaches us that different tracts or

bundles of fibres acquire their white substance—medullary sheath—at different periods of their growth (see page 41), so that, in specially prepared specimens, we are enabled to pick out and trace these tracts or systems through successive sections of the cord. On the other hand, the study of physiology and the selective action exercised by disease (so analogous to that exercised by certain poisons) affords equally valuable information. For to physiology and pathology are we indebted for the knowledge that, when a nerve fibre degenerates in consequence of injury or disease, the proper nerve substance is replaced by connective tissue, which, when treated with staining reagents, behaves differently from the surrounding undegenerated nerves.

By the above means, then, we can define with more or less certainty the following tracts or systems in the several white columns of the spinal cord (see Table, page 25).

(a) **Anterior Column.**—In this column have been mapped out a median and a lateral division.

1. The median division—the **DIRECT PYRAMIDAL TRACT**—*antero-internal tract—fasciculus of Türck*—is a well-marked bundle of fibres, situated close to the anterior median fissure (Fig. 13, page 22). It is a descending or motor tract, and is, as we shall see hereafter, a continuation of that part of the anterior pyramid of the medulla oblongata which does not decussate in the medulla, hence its name, *direct* pyramidal tract. It decreases in size from above downwards, and can be traced as a distinct

fasciculus to the first lumbar nerve, though isolated fibres have been followed as far as the fourth pair of sacral nerves. Its fibres, as they descend in the cord, cross over at lower levels to the opposite side, and thence through the grey matter of the cord become connected with the anterior nerve roots of that side.

2. The lateral part of the anterior column, **ANTERO-EXTERNAL TRACT**, forming by far the larger part of the column, has also been called the *anterior root zone*, *basis bundle*, or *anterior ground tract*. It is mostly made up of short commissural fibres between different segments of the cord.

(b) **Lateral Column.**—This well-defined column marked off on the surface of the cord by the antero-lateral and postero-lateral grooves, and limited internally by the grey matter, is composed of five distinct strands of fibres (Fig. 13, page 22).

1. Thus occupying the posterior part of the column, at a little distance from the surface of the cord, is a bundle of fibres, known as the **CROSSED PYRAMIDAL TRACT** (*crossed pyram.*, Fig. 13). This, as we shall afterwards see, is the continuation downwards of the chief part of the anterior pyramid of the medulla oblongata of the *opposite* side; hence the name, *crossed* pyramidal tract. This crossed pyramidal tract exists in all regions of the cord. It is the principal motor tract, and decreases in sectional area as we descend the cord; for its fibres constantly turn into the grey matter (Fig. 23, &c., Plate VI., page 32, and Plate XLI., page 184).

2. The DIRECT CEREBELLAR TRACT.—The thin lamina of white matter, which separates the crossed pyramidal tract from the surface of the cord, constitutes the *direct lateral cerebellar tract*, so called from its connection with the cerebellum on the same side (Fig. 13, page 22; and Plate VI., Fig. 23, &c., page 32, *lat. cereb.*). It is an ascending tract, and extends from the level of the second lumbar nerve upwards to the restiform body. Its fibres are probably connected through a group of cells called Clarke's column, with the posterior nerve roots on the same side. It most likely carries visceral sensations and sensations from tendons, and is concerned with the maintenance of equilibrium.

3. ASCENDING ANTERO-LATERAL TRACT (Hadden and Gowers).—This area is situated in the anterior part of the lateral column, in front of the direct cerebellar tract (Fig. 13, page 22). It lies on the surface of the cord and extends into the anterior column nearly as far as the anterior median fissure. It is called by Gowers the *antero-lateral ascending tract*—comma-shaped tract—not, however, to be confounded with the ill-defined descending comma tracts described in the posterior columns. Gowers' tracts exist most likely in all regions of the cord, but their lowest limits have not yet been defined. Their fibres can be traced to the cerebellum. They are sensory routes from the spinal cord to the brain.

4. DESCENDING ANTERO-LATERAL TRACT.—Closely associated with Gowers' tract, and occupying about three-fourths of the antero-lateral column (see Fig. 13)

is the *descending antero-lateral tract* (Löwenthal and Marchi). Its fibres mingle with those of Gowers' tract and come from the cerebellum of the same side. Some of them probably pass out by the anterior nerve roots. It may be an indirect motor tract, or may belong to the crossed pyramidal tract.

5. The rest of the lateral column is called the MIXED ZONE or LATERAL GROUND BUNDLE (Fig. 13), though it is often divided into two parts—*anterior* and *posterior mixed strands*—the latter being also called the *limiting layer* (Fig. 13). It consists of fibres with a short course—*commissural fibres*.

Thus we see that the lateral column contains in all five tracts—the crossed pyramidal tract; the three cerebellar tracts (two ascending and one descending); and the mixed zone.

(c) **Posterior Column.**—The arrangement of the strands in this column somewhat resembles that in the anterior (Fig. 13). Thus, especially in the cervical region, we find, close to the posterior median fissure, (1) a narrow band called the POSTERO-INTERNAL TRACT—*posterior median column, fasciculus of Goll*; and (2) an external division named the POSTERO-EXTERNAL TRACT—*cuneate fasciculus, posterior root zone, fasciculus of Burdach*.

The POSTERO-INTERNAL TRACT, *Goll's tract*, increases in size from below upwards. It is best seen in the dorsal region, for at lower levels it is not distinct from the next fasciculus, the fibres of the two being intermingled. It is a direct tract from

Anterior median f.

FIG. 13.

Direct pyramidal tract.

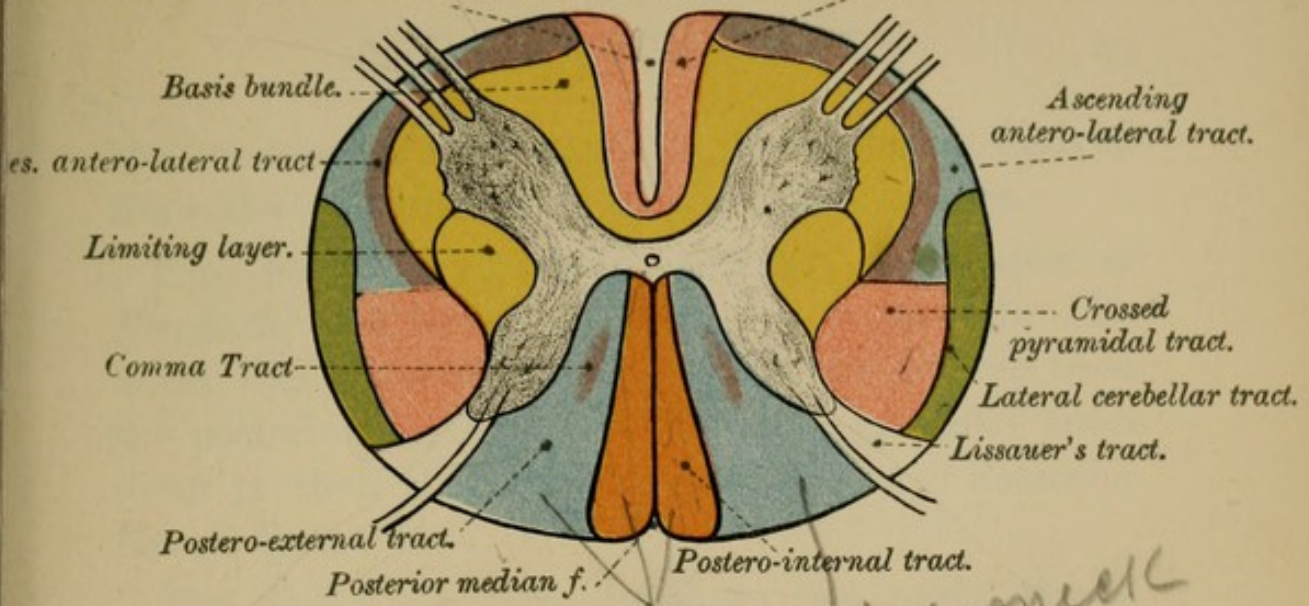


FIG. 14.

Anterior root.

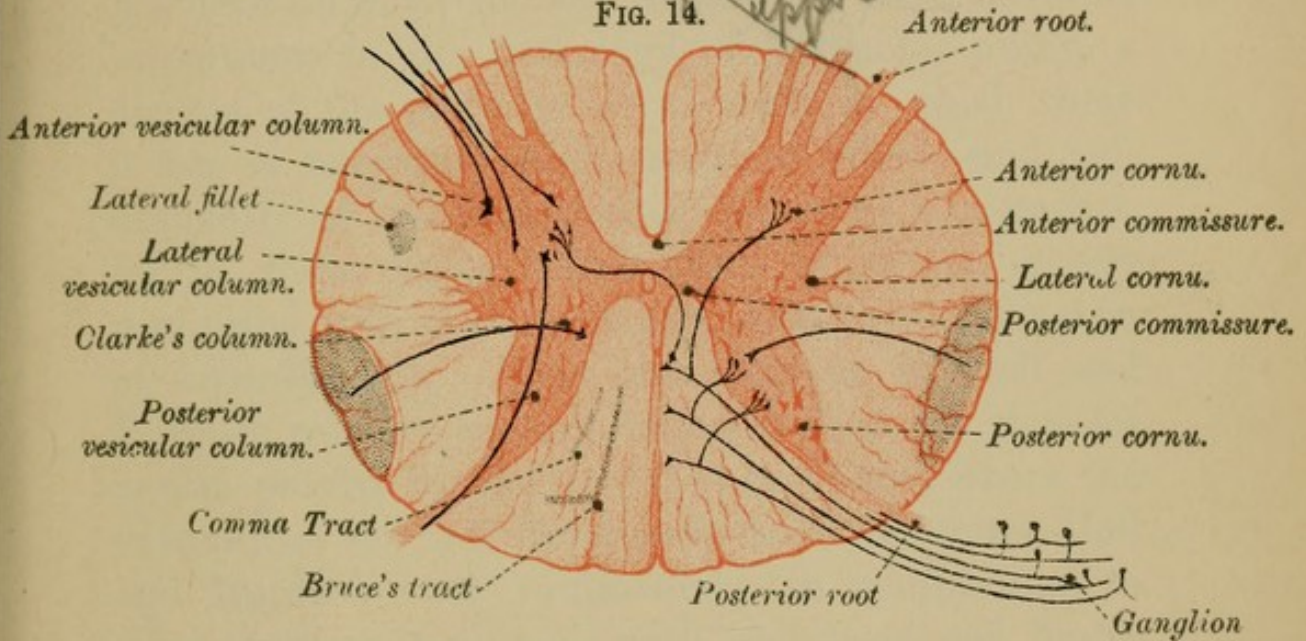


FIG. 15.

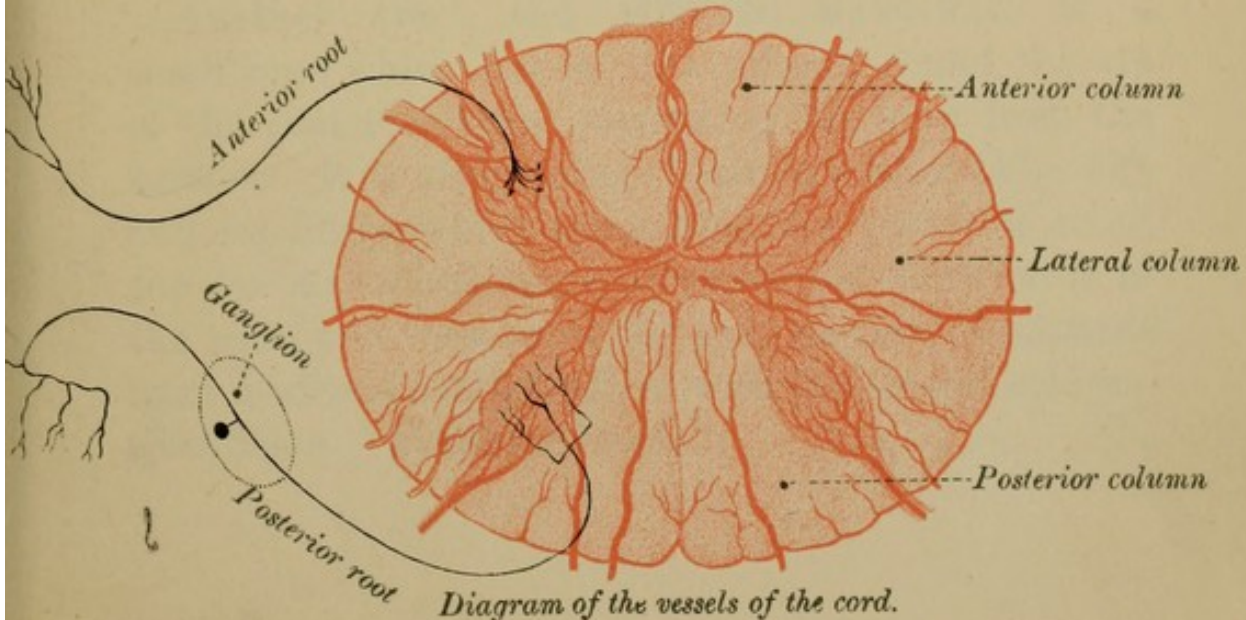


Diagram of the vessels of the cord.



the muscles to the brain, its fibres being derived from the posterior roots of the spinal nerves.

The POSTERO-EXTERNAL STRAND, *fasciculus of Burdach*, also increases in size as it ascends. Its fibres, like those of the last bundle, are derived from the posterior nerve roots. We shall presently trace them to their ultimate destination (see "Posterior Nerve Roots").

The distinction between these two parts of the posterior column (Goll and Burdach) is of considerable importance in the pathology of locomotor ataxy, a disease of the posterior nerve roots, in which there is loss of muscular sense—sense of effort—and consequently of co-ordination of muscular movements, for in these tracts travel fibres which are closely connected with that sense and with the mechanism of co-ordination. That the columns of Goll and Burdach conduct sensory impulses from the muscles is also proved by the fact that in whales, where the extremities are not developed, these columns—Goll and Burdach—are rudimentary in comparison to what they are in animals with well-developed limbs.

Another tract, the POSTERO-MARGINAL, is a small zone which lies in this column round the tip of the posterior horn, separating the horn from the surface. It is often called Lissauer's tract (Fig. 13), and its fibres, which come from the posterior roots, run for a short distance upwards and downwards in the tract, and then enter the grey matter. Lissauer's tract is sometimes described with the lateral column. (See below, "Posterior Roots.")

Several other minor strands have been described in the different columns of the cord, but are not of sufficient importance to detain us here. Some of them—Bruce's tract, the lateral fillet, and the comma tract—are figured in Figs. 13 and 14, Plate IV., page 22. It is well, however, to remember that the several tracts are not so definite as the figures would indicate, for with the ascending fibres we find descending intermingled, and *vice versa*.

To sum up, then, the pyramidal tracts, direct and crossed, and part of the antero-lateral tract, are descending or motor tracts; the posterior column, the lateral cerebellar tract (spino-cerebellar), and Gowers' tract are, on the other hand, ascending or sensory tracts. The rest of the white matter is chiefly commissural.

Of sensory impulses, those of *touch* and of *muscular sense* travel along the posterior columns, though there are reasons for thinking that common sensibility not only ascends along the posterior columns but also along the lateral columns of the same and opposite sides.

Sensations of pain most likely travel along the lateral columns of the opposite side to that at which they enter the cord, though their exact course has not yet been worked out. Some hold that sensations of pain pass through the grey matter.

Sensations of temperature—heat and cold—travel in the antero-lateral column, in the fasciculus of Gowers.

Vaso-motor impulses are conducted by the lateral columns.

TABLE OF WHITE TRACTS OF THE SPINAL CORD.

(Fig. 13, Plate IV., page 22.)

Anterior column.	<ol style="list-style-type: none"> 1. <i>Direct pyramidal tract.</i> Antero-internal—Fasciculus of Türk. Uncrossed pyramidal tract. 2. <i>Antero-external</i>—Basis bundle. Anterior root zone. Anterior ground fibres.
Lateral column.	<ol style="list-style-type: none"> 1. <i>Crossed pyramidal tract.</i> 2. <i>Direct lateral cerebellar tract.</i> 3. <i>Antero-lateral ascending tract</i> or comma tract (Gowers). Sensory zone. 4. <i>Antero-lateral descending tract</i> (Löwenthal and Marchi). 5. <i>Mixed zone</i>—anterior mixed; posterior mixed or limiting layer.
Posterior column.	<ol style="list-style-type: none"> 1. <i>Postero-internal</i>—Fasciculus of Goll. 2. <i>Postero-external</i>—Fasciculus of Burdach. Posterior root zone. Fasciculus cuneatus. Posterior ground fibres. 3. <i>Marginal zone</i>—Lissauer's tract.

2. White Commissure.—The two anterior white columns of opposite sides of the cord are united across the middle line by a band of white fibres, the anterior or white commissure, seen at the bottom of the anterior median fissure (*ant. com.*, Fig. 9, page 14). Its constitution is too complex for an elementary work of this kind. Suffice it to say that it consists (1) of *decussating fibres*—axis-cylinder processes and protoplasmic processes of the nerve cells of the anterior horn (see “Grey Matter”); (2) of *collaterals* from different sources (see below); and (3) of *neuroglia* cells and their prolongations (see “Neuroglia”).

MINUTE STRUCTURE OF THE WHITE MATTER.—Besides blood-vessels and lymphatics, the white matter of these various columns of the spinal cord consists—(1) of a supporting framework of connective tissue called *neuroglia*, which will be fully described under the grey matter (page 30); (2) of *medullated* or *white nerve fibres* running for the most part longitudinally; and (3) of *non-medullated nerve fibres* which run with the white nerve fibres.

The *white nerve fibres* of the spinal cord are the axis-cylinder processes of nerve cells, and have the same structure as peripheral nerves, consisting of a central core or axis-cylinder. In transverse section this core, though made up of a number of fibrillæ, appears as a dark spot, surrounded by a laminated white (medullary) sheath (Fig. 28, page 32). Usually, however, neither neurilemma nor nodes of Ranvier can be detected, though some hold that they are both present. In their course along the spinal cord, the axis-cylinder processes turn in at right angles to their direction, and entering the grey matter, there break up into brushlets of branches which end free.

COLLATERALS.—Moreover, the longitudinal fibres of these columns give off at more or less right angles to their course a series of side branches called *collaterals** which can be traced to different parts of the grey matter, in which they end in *tufts* or *brushlets* of fine varicose fibrillæ. These brushlets

* For full account of Collaterals, see the able translation and interesting summary of Kollikers' and other papers, by William Aldren Turner, M.B. Edin.; M.R.C.P. Lond.—*Journal of Anatomy and Physiology*, Vol. xxv.

ultimately end in little knobs, and do not anastomose with each other, nor with the neighbouring fibrillæ, nor with the processes of nerve cells, but merely form a beautiful plexus around the body of the cells. Some authors hold that they do unite. At the point where the collaterals are given off, the fibres usually have a small triangular-shaped enlargement (Fig. 31, page 34).

2. THE GREY MATTER.

The grey matter occupies the interior of the cord, and is completely surrounded by the white substance. It forms two columns extending through the entire length of the cord, one in each half; and these two columns are united across the middle line by a vertical transverse grey band—the posterior or grey commissure. In transverse section, therefore, the grey matter presents more or less the appearance of the capital letter H, for it is arranged in two irregularly crescent-shaped masses—one in each lateral half of the section (Plate III., page 14). These two grey crescents are united across the middle line by a transverse band of grey matter—the cross-bar of the H—which represents the grey commissure previously mentioned. Each grey crescent is semi-lunar in shape, having its horns or cornua pointing—the one forwards and outwards, the other backwards and outwards—hence they are known as the *anterior* and the *posterior cornua*. The convexity of each grey mass looks inwards towards the middle line, whereas the corresponding concavity is directed outwards.

1. **Cornua.**—The ANTERIOR HORN of each crescent, irregular in outline, is, for the most part, shorter and thicker than the posterior, and arches outwards towards the place from which the anterior nerve roots take their superficial origin. It does not, however, quite reach the surface of the cord, some white matter being interposed. It can be divided into an enlarged anterior part or head, a narrow part or neck, and a hinder part or base.

The POSTERIOR HORN, on the other hand, is longer, more slender and more pointed than the anterior, and almost reaches the surface of the cord at the fissure along which the posterior nerve roots take their superficial origin. Here it tapers to a point called the *apex* cornu posterioris, which contains a stratum of rather clear-looking connective tissue, known from its gelatinous aspect as the *substantia gelatinosa* of Rolando. Near its base the posterior horn, like the anterior, is somewhat constricted, forming the *cervix* or neck, while the slightly enlarged part between the apex and neck forms the *caput* cornu posterioris.

The outer concave side of each crescent, slightly behind its centre, assumes the form of a network, projecting outwards into the white substance. This network, called the *processus reticularis*, is best seen in the cervical region. Immediately in front of this process, and about midway between the anterior and posterior cornua, lies a collection of grey matter—the *intermedio-lateral tract*—*lateral vesicular column*—which may be regarded

FIG. 16.

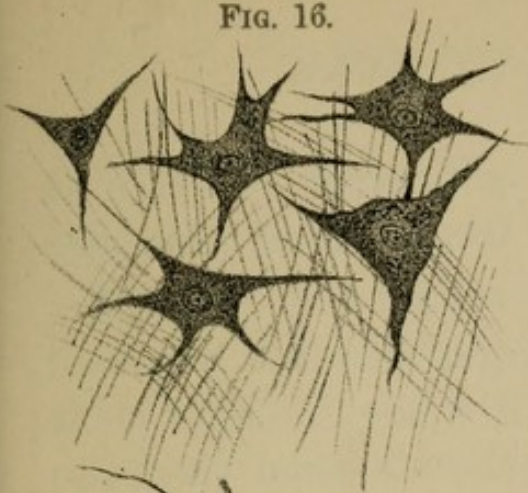
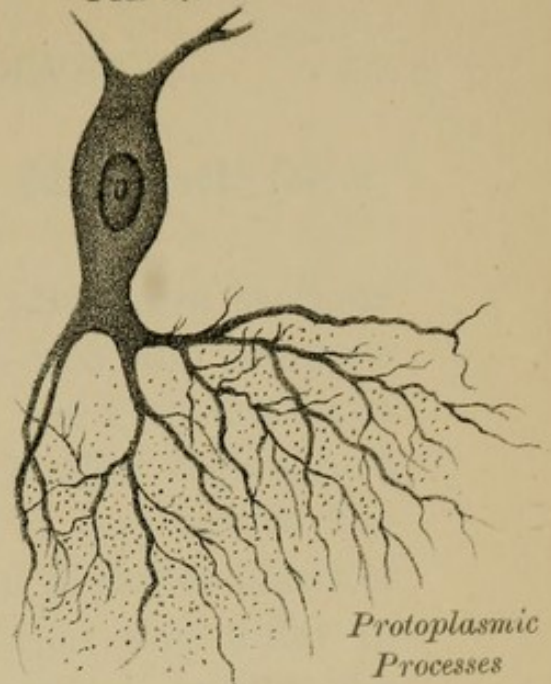
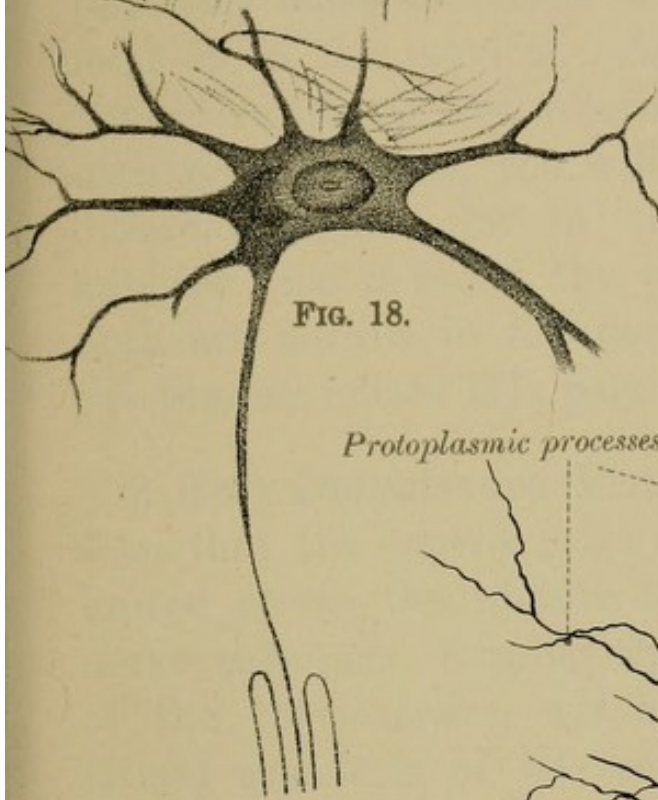


FIG. 17.



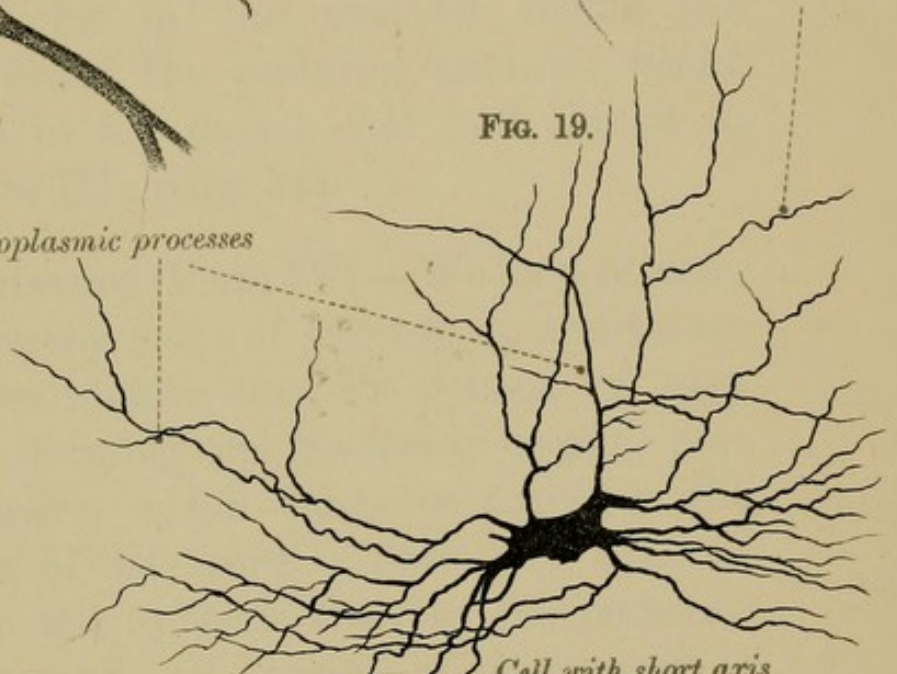
Protoplasmic Processes

FIG. 18.



Protoplasmic processes

FIG. 19.



Cell with short axis cylinder process.

FIG. 20.



FIG. 21.

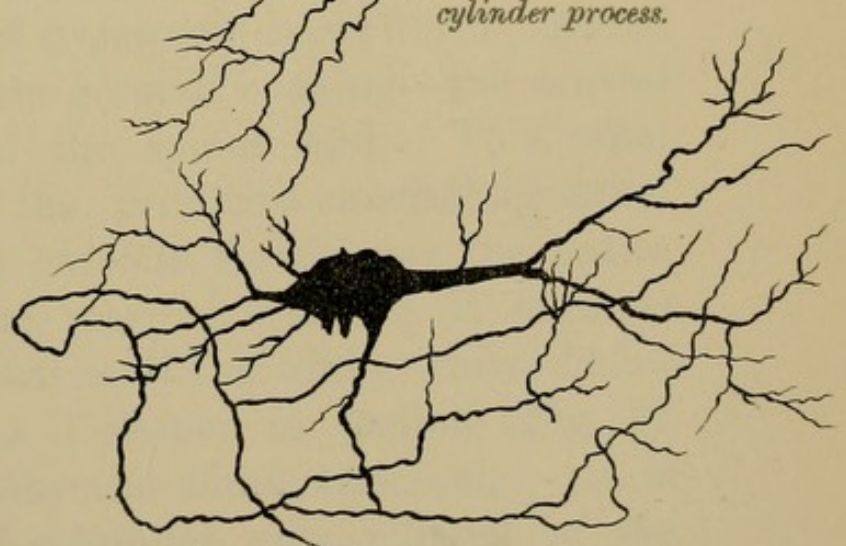
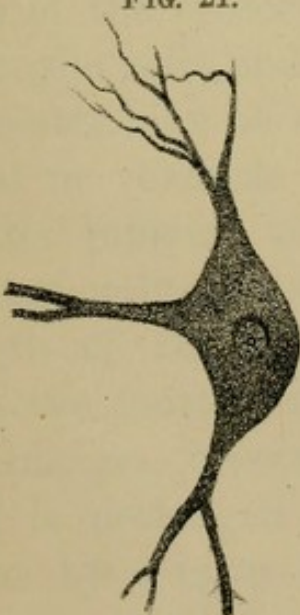



FIG. 22.—Cell with long axis cylinder process.



as a lateral horn (Fig. 14, page 22). Look for it, especially in the dorsal region.

If, now, you take a series of transverse sections from the different regions of the cord, and compare them together, you will find that the grey matter is relatively most abundant in the lumbar region, and least so in the cervical. Again, if you notice the respective sizes of the anterior and posterior horns of each grey crescent, you will see that they differ in different regions, for in the cervical region the anterior horn is broad, the posterior narrow; whilst both are narrow in the dorsal, and both broad in the lumbar (Plate III., page 14).

2. Grey Commissure (Plate IV).—We have already seen that the convex sides of the two crescents are united across the middle line by a band of grey nerve substance, forming the *posterior* or *grey* part of the *commissure*, which connects together the lateral segments of the cord. This grey band is placed nearer to the anterior than to the posterior ends of the crescents, and consists of nerve cells, of neuroglia cells, and of transverse nerve fibres. About its centre may be seen a small opening—the central canal or ventricle of the spinal cord. This canal is the remains of the primitive medullary canal of the embryo, and extends throughout the entire length of the spinal marrow. Above, it expands into the fourth ventricle of the brain, whilst below it enlarges, becomes T shaped in section (Fig. 7), and is prolonged into the filum terminale. It is lined by a layer of columnar cells, ciliated in the

child, though it is doubtful whether such is the case in the adult.

MINUTE STRUCTURE OF THE GREY MATTER. — To examine the minute structure of the grey matter you will require specially prepared microscopic sections. Such specimens will show you that there are two chief constituents of the grey matter, namely— (1) A ground substance or stroma, called **NEUROGLIA** (nerve glue); and (2) **NERVOUS ELEMENTS**—nerve cells and their processes—embedded in this stroma.

1. **Neuroglia** (Plates VII. and VIII., pages 34 and 40), already referred to under the structure of the white matter, is a delicate and peculiar kind of connective tissue which pervades both the grey and white substance of the cord. It consists entirely of cells, which are of two kinds—*ependyma cells* and *neuroglia cells* (Fig. 30, page 34).

(1) **EPENDYMA CELLS** are epithelial cells which line both the central canal of the cord and the various spaces—ventricles—of the brain. In the mid-line of the cord the processes of these cells extend from the central canal to the deep aspect of the pia mater, thus forming a mesial septum, especially well seen on the posterior aspect of the cord (Fig. 30, page 34).

(2) **NEUROGLIA CELLS.**—*Cells of Deiters*—*Spider cells*—*Astrocytes*—vary much in size. They have numberless processes, long or short, which usually do not bifurcate, but which, after extending a variable distance from the cell, end free without anastomosing.

The processes of neighbouring cells cross and recross each other, and form an intricate network throughout both the grey and white matter. As shown by the action of staining reagents, there is a distinct chemical difference between the body of the neuroglia cell and its processes, and as a consequence some have described these processes as separate fibres, and not as processes of the neuroglia cells.

Neuroglia is pretty evenly distributed throughout the grey substance, but upon the surface of the cord beneath the pia mater is a distinct layer, and around the central canal will be found a considerable collection of it, which has been called the central grey nucleus.

The substantia gelatinosa of Rolando, previously referred to, was formerly regarded as a similar accumulation of neuroglia, but is now known to contain many nerve cells.

Neuroglia has for its function to support the delicate nerve tissues and to protect them from injury from without. It is of especial interest, clinically, as being the probable seat of many of the inflammatory processes which affect the central nervous system.

2. The Nervous Constituents of the grey matter are of two kinds—(1) *Multipolar nerve cells*, the cell-bodies of the *neurones*—occurring either singly (Fig. 16, &c., page 28), or collected into groups—called *vesicular columns*. (2) *Non-medullated* and *medullated nerve fibres*, which are either strands

of fibres from various sources, or branched and unbranched processes of nerve cells, which traverse the grey matter in all directions.

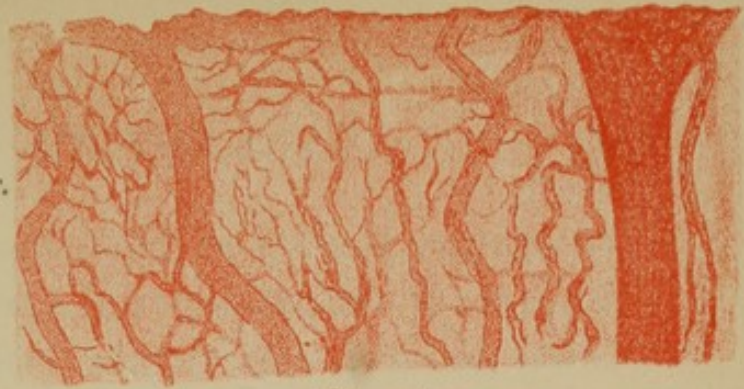Vesicular Columns (Fig. 11, page 14). We shall consider (1) the groups of nerve cells; and (2) their structure. The various groups of nerve cells seen in transverse sections of the spinal cord are, you will readily understand, sections of columns of cells, which extend either through the whole length of the grey matter, or only through certain regions of it; hence they are known as vesicular or ganglionic columns. They are best marked in the cervical and lumbar regions.

(a) **ANTERIOR VESICULAR COLUMN.** The largest of these groups is that situated in the fore part of the anterior cornu. It can be traced throughout the entire length of the cord, and is known as the anterior vesicular column—*motor ganglionic column*—though it can be sub-divided into two groups—the one anterior or inner, the other lateral (Fig. 11, page 14). In the lumbar region an additional posterior group, which lies behind the anterior, makes its appearance.

Since it is from these groups of cells of the anterior cornu that the anterior or motor nerve roots spring, the entire collection has been termed the “motor vesicular column.”

The cells of these columns exercise a trophic influence on motor nerves and on muscles. As we shall afterwards see, there are two strata of cells presiding over the muscles: (a) an upper stratum—the

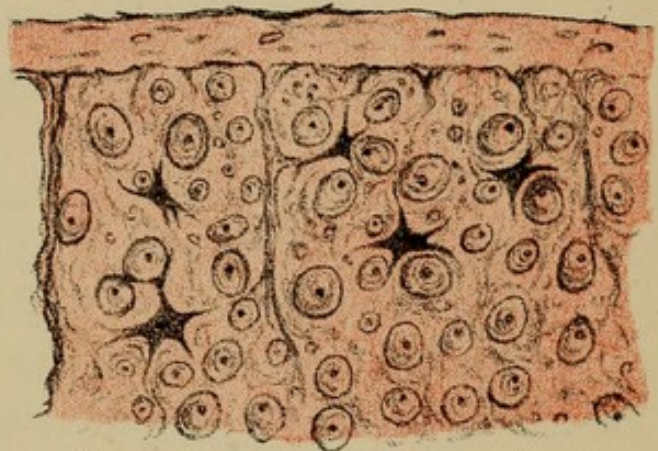
FIG. 27.



Pia mater.

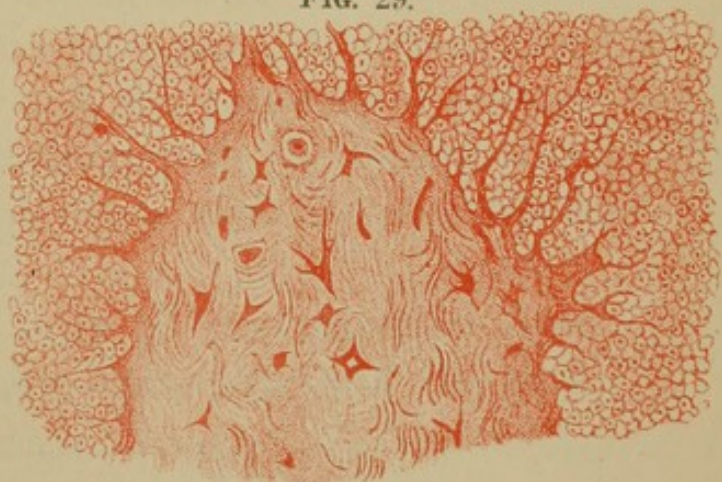FIG. 28.

Neuroglia cells.



Transverse section of white matter of spinal cord.

FIG. 29.



Anterior cornu of spinal cord.

FIG. 23.

Ascending antero-lat.

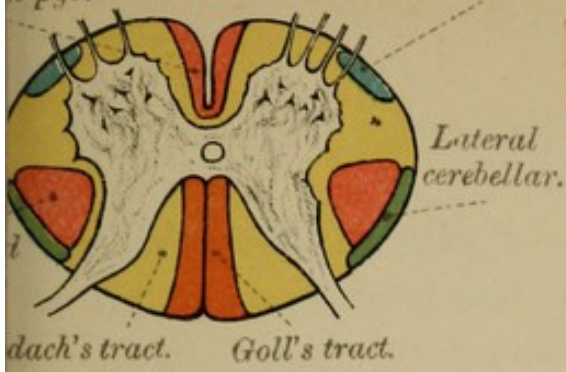


FIG. 24.

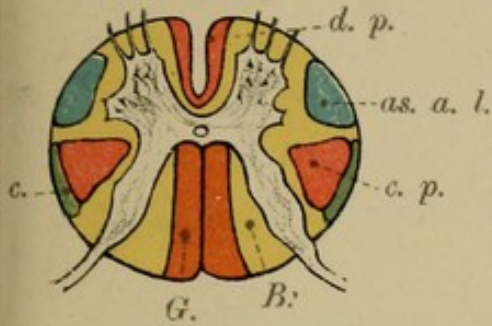


FIG. 25.

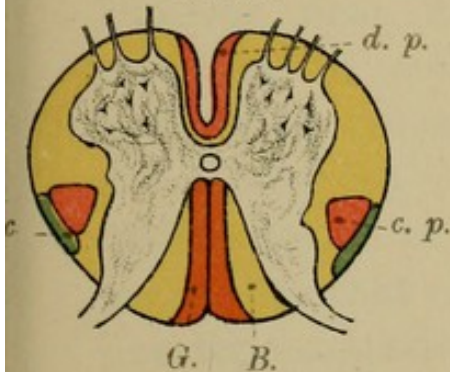
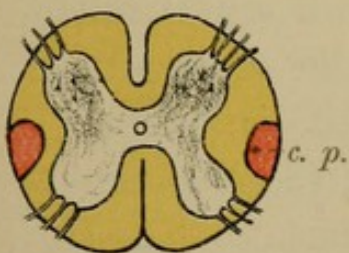



FIG. 26.



Sections of tracts at various levels



*first trophic realm**—situated in certain regions of the brain surface; and (b) a lower stratum—the *second trophic realm*—the nerve cells of the anterior horn. Now, in any injury to the cells of the upper stratum—*first trophic realm*—the muscles are paralysed and rigid, and any atrophy which follows is by no means rapid, being due to disuse; whereas, if the cells of the anterior vesicular column, second stratum—*second trophic realm*—be injured, the paralysed muscles are flaccid and degenerate rapidly.

(b) POSTERIOR VESICULAR COLUMN.—The cells of the posterior horn are for the most part not arranged in distinct groups. At the base of the posterior horn, however, near its inner angle, is a well-marked collection of cells variously known as POSTERIOR VESICULAR COLUMN, *Clarke's column*, *Dorsal nucleus* (Fig. 10). Though it is found along only the middle region of the cord, from the level of the 7th cervical to that of the 2nd lumbar nerve, it probably has representations in all regions of the cord, even as far as the bulb. As we have seen, its cells are, on the one hand, connected with the posterior or sensory nerve roots, and, on the other, with the lateral cerebellar tracts, and through them with the cerebellum of the same side. P, 21

Injury to the other cells of the posterior horn causes sensory and trophic disturbances of the skin.

* These well-chosen terms we owe to John Wyllie, M.D., LL.D., late Lecturer on Medicine, School of Medicine, Edinburgh.

(c) LATERAL VESICULAR COLUMN.—A third group of nerve cells—the *nucleus of the intermedio-lateral tract*, often called *the lateral horn* (Fig. 14)—lies at the base of the posterior cornu on its outer side, within the column of grey matter of the same name, and, like it, can be distinguished in the dorsal region only.

TABLE OF VESICULAR COLUMNS.

(See Figs. 10, 11, Plate III., page 14.)

1. Anterior vesicular column.	{	Antero-internal group. Antero-external group. Posterior group—found in lumbar region.
2. Lateral vesicular column.	{	Lateral horn—found in thoracic and lumbar regions.
3. Posterior vesicular column.	{	Clarke's column; dorsal nucleus—found from the 7th or 8th cervical to the 2nd lumbar nerve.

STRUCTURE OF THE NERVE CELLS.—The nerve cells of the grey matter of the spinal cord vary considerably, in size, in shape, and in structure. Firstly as to shape and size:—Most of the cells are multipolar and stellate in transverse section, and have two sets of processes—protoplasmic and axis-cylinder processes.

The largest cells are found in the anterior vesicular column, especially in its outer group, and similar cells occur in Clarke's column. In the posterior horn most of the cells are small and spindle-shaped, and are called *solitary cells*; others are larger, have long curved processes, and are known as *comet cells*.

FIG. 30.

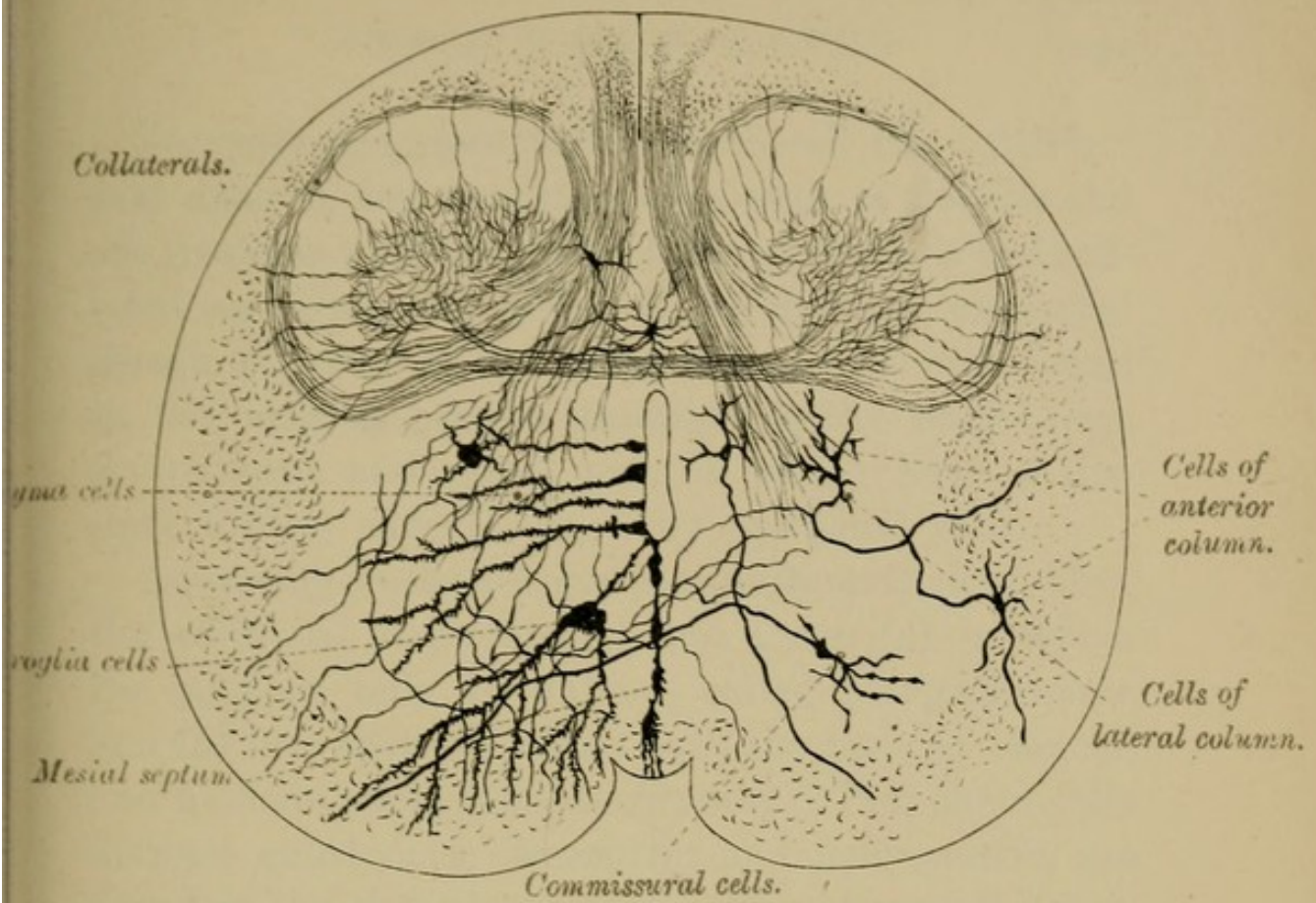


FIG. 31.

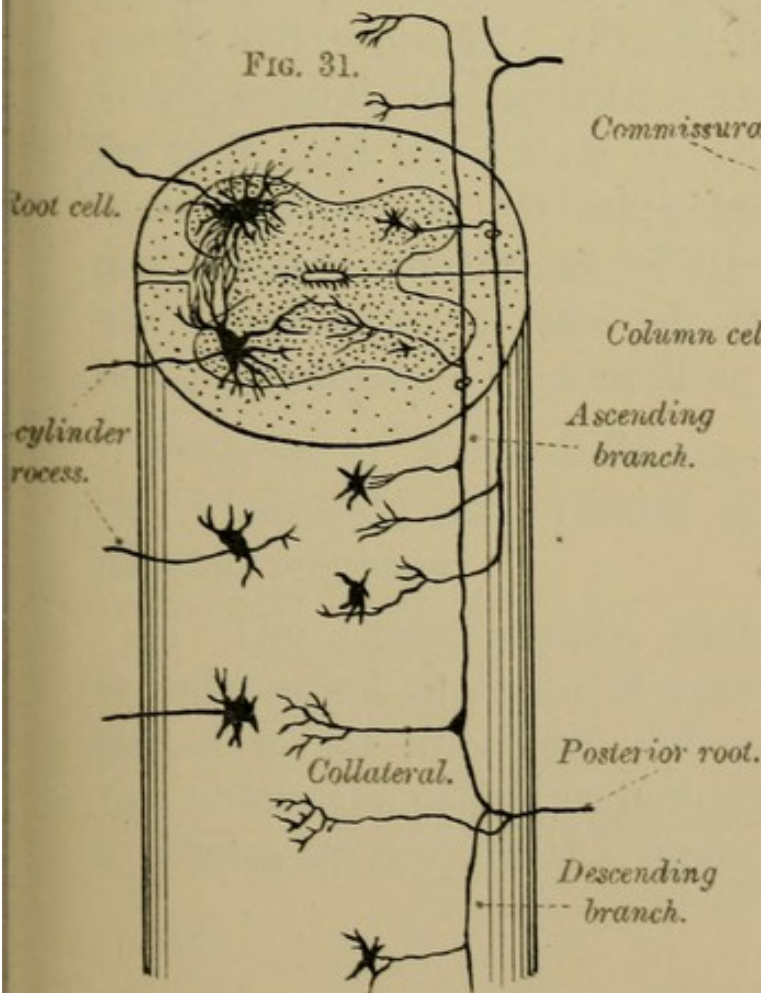
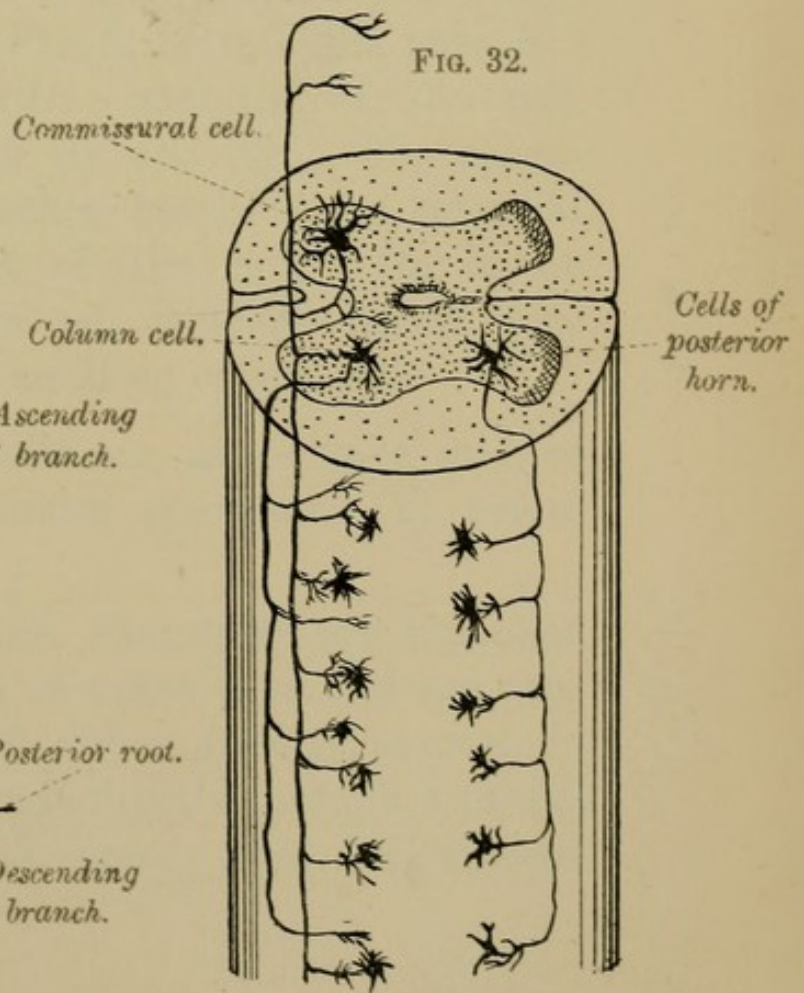



FIG. 32.





Secondly as to structure:—Each cell has a distinct oval nucleus, and contains a network of fibrillæ and one or more nucleoli. The body of the cell is fibrillated and granular, and has no distinct nucleated sheath, differing in this respect from the cells found in the various ganglia throughout the body—*e.g.*, sympathetic and spinal ganglia, which have a distinct fibrous capsule, lined by epithelial cells.

According to their behaviour with methylene blue, the cells are distinguished into those (*a*) in which the nucleus only is stained, called *Caryochromes*, and (*b*) into those in which both the body of the cell and nucleus stain, *Somatochromes*. Two chemically distinct substances, *chromatic* and *achromatic*, are found in the *Somatochromes*. The *chromatic* matter when stained appears as granules, stripes, cones, blocks and networks. (Fig. 4, Plate VIII., page 40.) It is probably the nutritive material of the cell, for it is used up during its activity. The *achromatic* matter, on the other hand, is the essential protoplasmic constituent of the cell. On it the life and activity of the cell depend—the activity being accompanied by a swelling of the cell.

Processes of Nerve Cells are, as we have said, of two kinds—(1) axis-cylinder processes; (2) protoplasmic processes.

(1) The AXIS-CYLINDER PROCESSES are branched or unbranched processes of nerve cells, and are connected to the nerve cell either directly, as seen in the motor type of cell, or indirectly through a plexus of fibres, as seen in the sensory type. Composed

of many primitive fibrillæ they, in many cases, soon acquire a medullary sheath, and become the axis-cylinders of nerve fibres, which, after a longer or shorter course, end in the grey matter in fine brush-lets of branches. They are centrifugal processes, carrying impulses away from the cell.

(2) The PROTOPLASMIC or GREY PROCESSES are a series of delicate ramifying branches which cross and recross each other in all directions (Figs. 17 and 19, Plate V., page 28). They are centripetal processes, carrying impulses to the cell, and may, through their relation to neuroglia and to blood-vessels, subserve the nutrition of the nerve elements.

At the cells the protoplasmic and axis-cylinder processes are in most cases continuous with each other, passing through the cells without interruption: their terminal processes, however, do not anastomose with the processes of other nerve cells, but are merely in contact with the nerve elements. Hence it follows (1) that nerve cells, most likely, do not generate nerve motion, but are nutritive only; and (2) that contact, and not actual continuity, is sufficient for the conduction of motor, sensory, and reflex impulses along the spinal cord.

CLASSIFICATION OF THE NERVE CELLS.

1. *Cells with short axis-cylinder processes.* In these cells the axone soon breaks up into branches which do not become encased in a medullary sheath, but form a fine plexus of fibrillæ. They are the *sensory type* of cell, and are almost entirely confined in their distribution to the posterior horns (Fig. 19, page 28).

2. *Cells with long and distinct axis-cylinder processes* (Fig. 22, page 28), which do not branch, or branch but slightly, and which

ultimately become clothed with a medullary sheath. They are regarded as the *motor type* of cell, and may be sub-divided into two groups—

- (a) *Root Cells* which occur in the anterior horn. Their axis-cylinder process is continued into the anterior nerve roots; and their protoplasmic processes pass in various directions through the grey matter (Fig. 31, Plate VII., page 34).
- (b) *Column Cells* which are met with in all parts of the grey matter. They are so called because their axis-cylinder processes pass into the antero-lateral white columns of the same or of the opposite side (commissural cells) of the cord (Fig. 32, Plate VII., page 34).

IV.—DEEP ORIGINS OF SPINAL NERVES.

(Fig. 14, Plate IV., page 22.)

The several spinal nerves are, as you know, mixed nerves, for they contain both motor and sensory fibres. They each spring from the spinal cord by two roots, an anterior—motor, coming from the antero-lateral grooves, and a posterior—sensory, from the postero-lateral grooves. These attachments to the cord are called the superficial origins of the nerves. The deep origins are the nerve cells in the grey matter, to or from which the nerve roots can be traced.

(1) **The Anterior Nerve Roots** — *motor roots*. Most of the fibres of these roots can be traced from the nerve cells of the anterior horn. The cells from which they spring are called root cells, and the several bundles of white fibres which can be seen passing through the peripheral white substance to the antero-lateral grooves—their superficial origin—are the axis-cylinder processes of these cells. Other fibres of the anterior roots come from cells in the opposite anterior and posterior horns (Fig. 14, page 22).

(2) **The Posterior Nerve Roots**—*sensory roots*—before reaching the spinal cord, pass through the spinal ganglion, in which there are unipolar nerve cells. At a little distance from these cells, the pole, or axis-cylinder process, bifurcates in a T-shaped manner, one limb of the T becoming the distal, the other the central end of a nerve fibre of the posterior root. The central processes enter the cord in two sets—a lateral set which goes to the marginal zone (Lissauer's tract), and a mesial set which enters the postero-external strand. On entering the spinal cord, all the fibres, mesial and lateral, at once divide into ascending and descending branches, which give off collaterals to different parts of the grey matter. (Figs. 31 and 32, Plate VII., page 34.) The descending branches after a short course turn at right angles into the grey matter and end free in little tufts. Of the ascending fibres, those of Lissauer's tract lose themselves in the substantia gelatinosa of Rolando; those of the rest of the column after a long, short, or intermediate course enter the grey matter. At first they occupy the postero-external tract, but as they ascend they become more internal and are found in the fasciculus of Goll, their place in the postero-external strand being taken by fibres of the nerve roots which enter the cord at higher levels: hence it follows—1st, that these two columns of Goll and Burdach are not physiologically distinct; and, 2nd, that the greater part of the column of Goll consists of fibres, which come from the legs, whereas the fibres that constitute the column of Burdach mostly come from the upper limbs and neck.

The columns of Goll and Burdach ultimately end in nuclei (nucleus gracilis and nucleus cuneatus) in the medulla; from which fibres can be traced to the opposite side of the brain, in what is known as the *superior pyramidal or sensory decussation*.

Besides the fibres of the posterior roots which are thus connected with the nerve cells of the ganglia, there are others having no such connection, but which merely pass through the ganglia on their way to nerve cells in the spinal cord. On entering the cord these fibres pass at once into the grey matter, through which they can be followed in various directions, even as far as the cells of the anterior horn (Fig. 14, Plate IV., page 22).

NOTE.—Gaskell suggests that each spinal segment has two sets of nerve roots:—

1. A SOMATIC SET.—The motor and sensory nerves usually described—(a) the former, the MOTOR, being *aganglionic* and connected with the cells of the anterior horn; and (b) the latter the SENSORY, being *ganglionic* and connected with the cells of the posterior horn.

2. The other set of nerve roots—the SPLANCHNIC SET, or visceral set—are distributed to blood-vessels, to the heart, and to other hollow viscera. They consist of two groups—

(a) A *ganglionic set*, connected with the cells of Clarke's column—their ganglia being the lateral ganglia of the sympathetic trunk. They are the *motor group*, and pass to the lateral ganglia of the sympathetic, thence to the walls of blood-vessels and viscera. When stimulated, they cause contraction of blood-vessels and viscera, and give rise to increased activity and to increased waste.

- (b) An *aganglionic set*, connected with the cells of the lateral horn. They are the *inhibitory group*, and do not pass to the ganglia of the sympathetic, but run on as medullated nerve fibres to ganglia situated in the tissues themselves. Stimulation of this set causes dilatation of the vessels and various inhibitory phenomena—such as cardio-inhibition. They diminish activity and tend to promote repair.

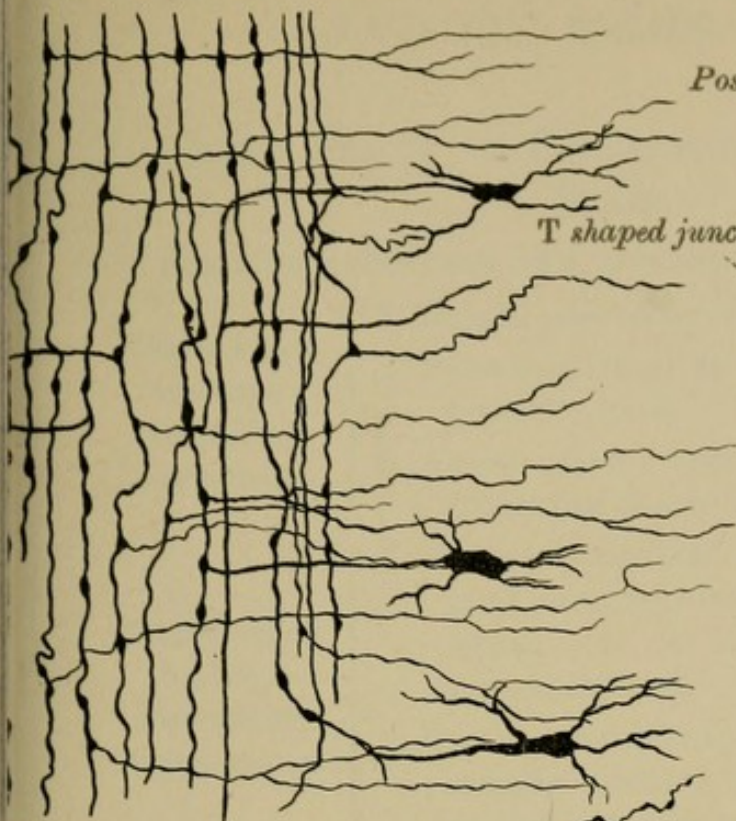
SUMMARY.—To sum up, then, we have the spinal cord presented to us as an elongated mass of nervous substance, consisting of white and grey matter; invested by three membranes; having two distinct enlargements; giving origin to thirty-one pairs of spinal nerves; nourished by spinal vessels, and divided by anterior and posterior fissures into two lateral segments, each with three sub-divisions which can be mapped out into numerous tracts, or systems of varying significance.

We see, moreover, that our ideas in regard to the constitution of the spinal cord must undergo at least this modification, that whereas formerly the spinal cord was regarded as made up of two distinct elements—nerve fibres and nerve cells—we must now consider that there is only one nerve element—the *neurone*—the nerve cell with its protoplasmic and axis-cylinder prolongations. These neurones are arranged in tiers, one above the other, and are connected together by their protoplasmic and by their axis-cylinder processes and collaterals. These facts have important bearings on the physiology of the spinal cord.

The following Tables will be found useful for reference :—

FIG. 1

Nerve fibres with collaterals.



Ganglion of the posterior root
of a spinal nerve.

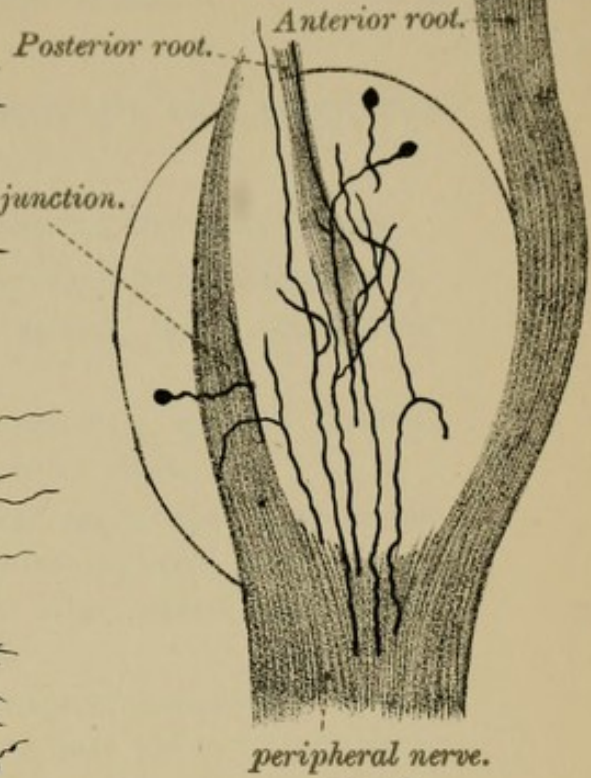
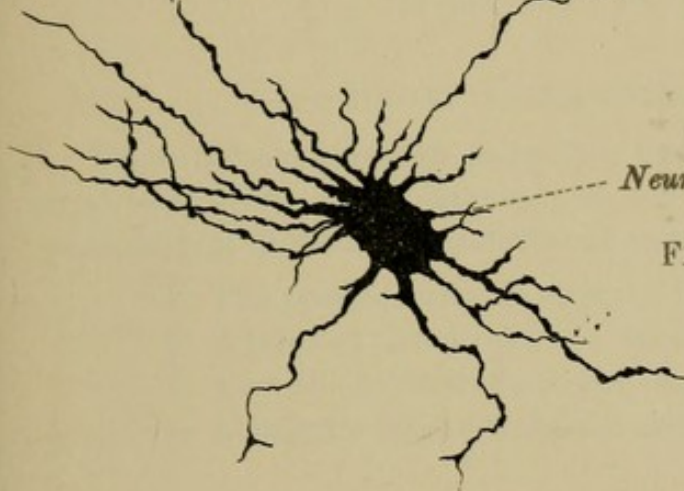


FIG. 2



Neuroglia cells.

FIG. 3

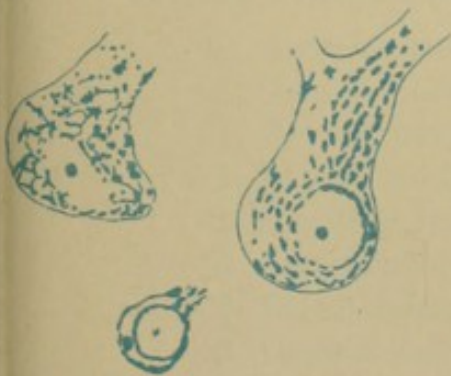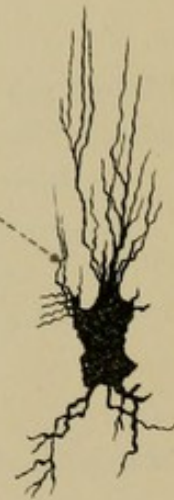
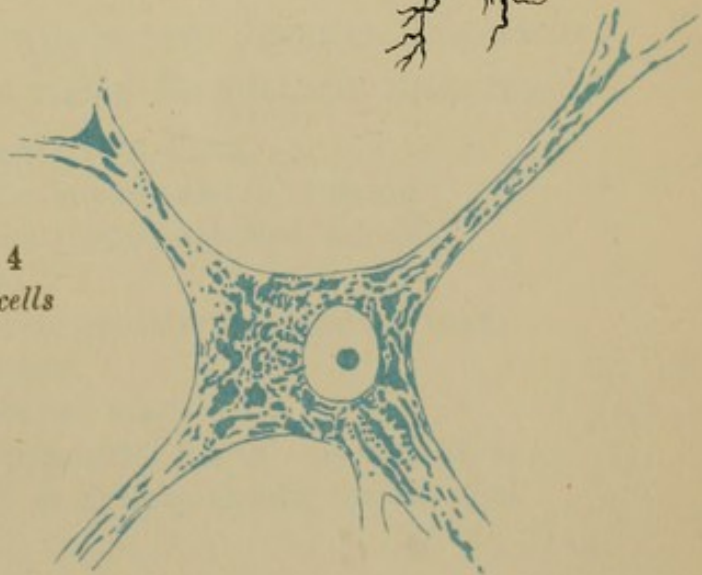


FIG. 4
Nerve cells





I.—LONG TRACTS OF CONDUCTION TO AND FROM THE BRAIN.

TABLE OF ASCENDING AND DESCENDING DEGENERATIONS.

Tracts which undergo Ascending Degeneration.	<ol style="list-style-type: none"> 1. Lateral cerebellar tract, from visceral tract. 2. Postero-internal strand, Goll's tract, from posterior roots. 3. Antero-lateral ascending tract of Gowers, from crossed sensory roots.
Tracts which undergo Descending Degeneration.	<ol style="list-style-type: none"> 1. Crossed pyramidal tract—the chief motor tract—contains 90 per cent. of the motor fibres. It is often called the lateral pyramidal tract. 2. Direct pyramidal tract, fasciculus of Türk, usually contains only about 10 per cent. of the motor fibres.

II.—SHORT COMMISSURAL TRACTS.

These neither undergo ascending nor descending degeneration, or at least for no great distance, and are therefore considered to be commissural fibres between different segments of the cord,

1. The postero-external strand—fasciculus of Burdach.
2. Antero-external column—anterior root zone.
3. Part of the lateral column—lateral limiting layer.
4. Lissauer's tract—marginal zone.

TABLE OF THE ORDER IN WHICH THE SEVERAL TRACTS OF WHITE MATTER RECEIVE THEIR MEDULLARY SHEATHS.

1. Anterior and posterior root fibres.
2. Ground fibres of the antero-external column.
3. Ground fibres of the postero-external column.
4. Lateral mixed zone.
5. Limiting layer and antero-lateral ascending tract.
6. Postero-median column.
7. Direct lateral cerebellar tract.
8. Crossed and direct pyramidal tracts. In man these tracts get their medullary sheath, for the first time, at birth.

GOWERS' TABLE.

SHOWING THE APPROXIMATE RELATION TO THE SPINAL NERVES OF
THE VARIOUS MOTOR, SENSORY, AND REFLEX FUNCTIONS
OF THE SPINAL CORD.

MOTOR.	(Nerves.)	MOTOR.		SENSORY.	REFLEX.
	C				
	1	Small rotators of head	1	Scalp	1
	2	Depressors of hyoid	2		2
St. - mastoid,	3	Lev. ang. scapulæ	3	Neck and upper part	3
Upper neck	4		4	of chest	4
muscles,	5	Diaphragm	5	Shoulder	5
Upper part		Serratus		Arm, outer side	
of		Flex. of elbow			
Trapezius		Supinators			
	6	Ext. wrist and fingers	6	Radial side, fore-	6
Lower neck	7	Ext. elbow	7	arm and hand;	7
muscles,		Flex. wrist and fingers		thumb	
Middle part	8	Pronators	8	Arm, inner side	8
of				ulnar side of	
Trapezius				forearm and	
	D	Muscles of hand	1	hand; tips of	1
	2		2	fingers	2
	3		3		3
	4		4		4
	5		5	Front of thorax	5
Lower part	6	Intercostals	6	Ensiform area	6
of	7		7		7
Trapezius	8		8		8
and dorsal	9		9	Abdomen	9
muscles	10	Abdominal muscles	10	(Umbilicus 10th)	10
	11		11		11
	12		12	Buttock,	12
				upper part	
	L		1	Groin and Scrotum	1
	2	Cremaster	2	(front)	2
	3	Flexors of hip	3	outer side	3
Lumbar	4	Extensors of knee	4	Thigh	4
muscles		Abductors of hip		front	
	5	Ext. and abduct. of hip	5	inner side	5
Peroneus, l.				Leg, inner side	
Flex. of	S	Flexors of knee	1	Buttock, lower part	1
ankle, Ext.	1	Intrinsic muscles of foot	2	Back of thigh	2
of ankle	2		3	Leg } except inner	3
	3	Perineal and anal		& foot } part	
	4	muscles	4	Perinæum and anus	4
	5		5		5
	Co.		co	Skin from coccyx to	co
				anus	

SECTION II.

BRAIN AND ITS MEMBRANES.

The term BRAIN, or ENCEPHALON, includes all that part of the great central nervous system which is enclosed within the cavity of the cranium. Invested by three membranes or meninges, it presents, as you will afterwards see, four distinct sub-divisions:— (1) The CEREBRUM, a large convoluted mass, or big brain; (2) the CEREBELLUM, or little brain; (3) the PONS VAROLII, a white transverse band uniting the two halves of the little brain; and (4) the MEDULLA OBLONGATA, or bulb, the enlarged upper end of the spinal cord (Figs. 33 and 34, page 44).

From a developmental point of view, the brain is divided into six parts: Telencephalon, Diencephalon, Mesencephalon, Isthmus Rhombencephali, Metencephalon, Myelencephalon (see “Development,” page 190).

We shall describe (1) the membranes and vessels of the brain, and (2) the several parts of the brain; but before doing so we shall, for convenience, give *seriatim* the following dissections:—

DISSECTION.—1. *To expose the Membranes of the Brain.*—Make an incision along the middle line through the entire thickness of the scalp, from the root of the nose in front to the external occipital protuberance behind. Turn back the pericranium to the level of the ears, and then saw through the outer table of the skull-cap along a line passing round the skull, about half-an-inch above the

external occipital protuberance behind, and about the same distance above the supra-orbital arch in front. Break through the inner table with the chisel and forcibly raise the detached skull-cap, which you will find more or less adherent to the subjacent membrane, especially along the lines of the cranial sutures. Branches of the meningeal arteries will be seen ramifying on the outer surface of the exposed membrane, between it and the bone.

2. *To Remove the Brain.*—With a sharp pair of scissors cut through the dura mater at the same level at which you have sawn the bones, and reflect it upwards towards the top of the head. Examine as far as you can the strong process, *falx major*, passing down mesially between the cerebral hemispheres. Divide this process in front where it is attached to the crista galli of the ethmoid, and cut through the veins which enter the sinus contained within its upper border. Raising the falx out of the longitudinal fissure, turn it back, but do not cut it behind. Now pass the fingers of the left hand beneath the fore-part of the brain, and gently raise it from the anterior cranial fossæ, taking care to detach the small white rounded bands, OLFACTORY LOBES, 1st pair of nerves, from the cribriform plate of the ethmoid. The OPTIC NERVES, 2nd pair, and the two INTERNAL CAROTIDS will now be seen close to the anterior clinoid processes, and should be divided. Piercing the dura mater, external to the carotid, are the round 3rd nerves, and in the free margin of the tentorium cerebelli, now exposed, are seen the slender 4th nerves. Cut through these, and through the INFUNDIBULUM which passes down towards the sella turcica of the sphenoid. Then with the point of the knife make an incision through the margin of the tentorium on each side, just behind and parallel to the upper margin of the petrous part of the temporal bone, carrying the incision as far back as necessary, but being careful not to injure the parts beneath. You will now see the following nerves, which will require to be divided one after another. Just below the anterior end of the tentorium will be found the large 5th nerves; nearer the middle line, the slender 6th nerves; below and external to the 5th, the 7th or facial, and 8th or auditory nerves, and the auditory artery; immediately below the 8th are the 9th, 10th and 11th nerves. Cut the 9th, the glosso-pharyngeal, and the 10th, the vagus, but leave intact the spinal part of the spinal accessory nerve; lower down near the middle line is the 12th or hypoglossal nerve, consisting of two bundles, which pierce the dura mater by two

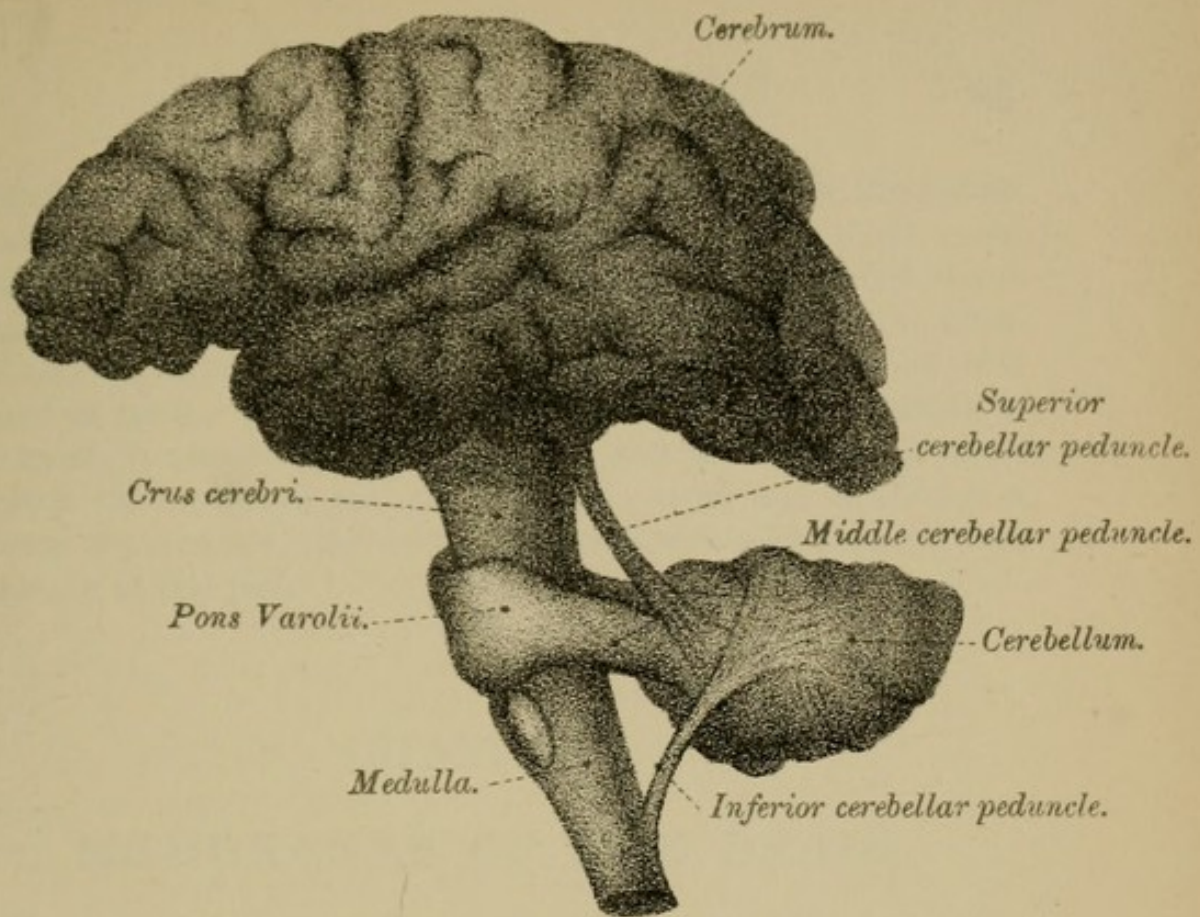
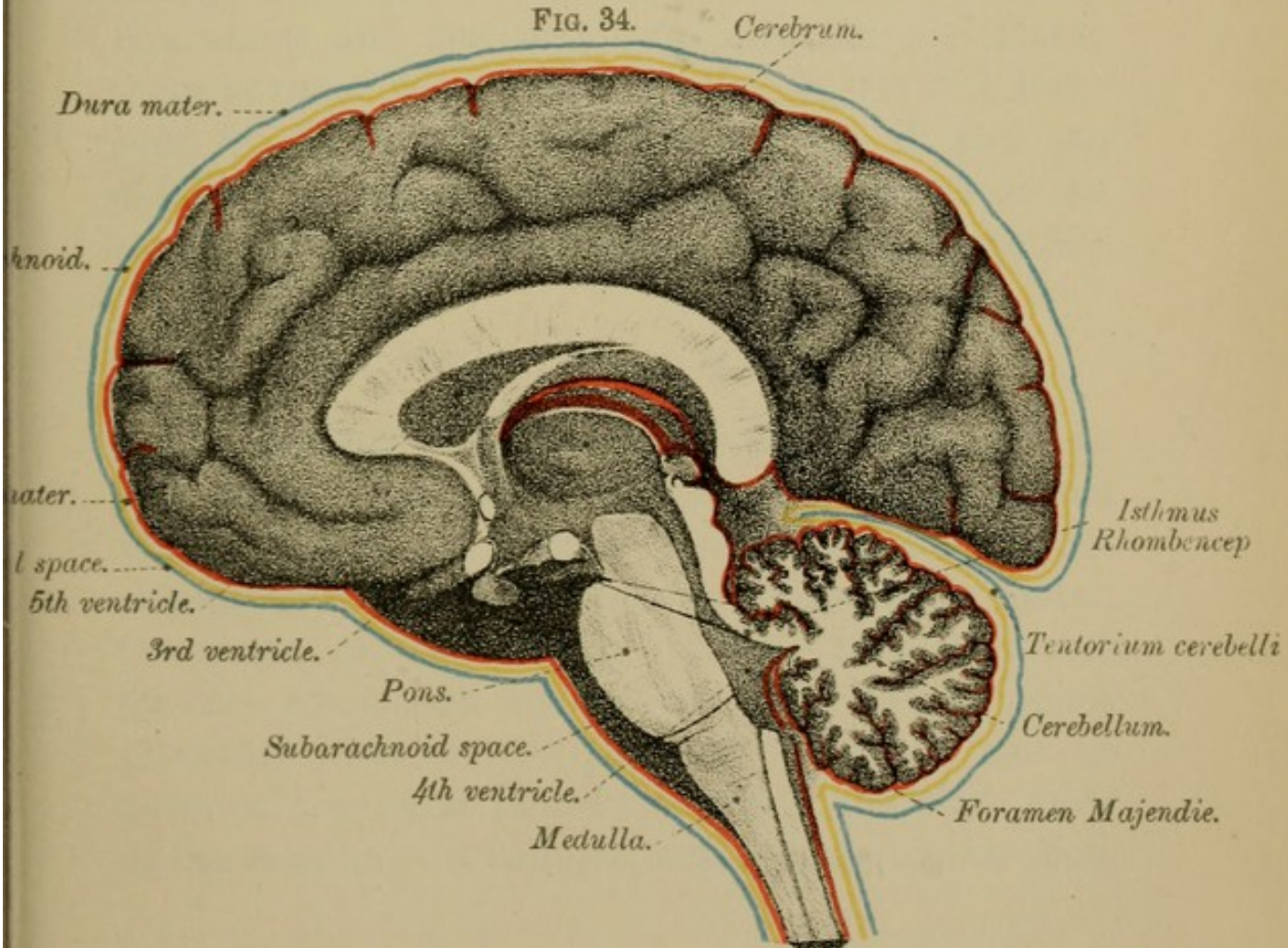



FIG. 34.





separate openings. Next pass the knife as far down the spinal canal as possible, and divide the spinal cord, the nerve roots attached to its sides, and the vertebral arteries as they wind round from the back. Snip through the veins of Galen, and the brain can now be easily removed from its bed, and should be at once placed in spirit. Leave it there for a few days; then examine it and carefully remove the pia mater, except at the back of the brain between the cerebrum and cerebellum, in order not to disturb a process of pia mater—the velum interpositum—which passes into the brain at this point.

CHAPTER I.

MEMBRANES OF THE BRAIN.

To examine the first of these membranes—the cranial dura mater—replace, as far as you can, the falx major and the tentorium cerebelli, and fasten them in their places by a few stitches. It will, however, be far more satisfactory for you if you can obtain a specimen specially prepared to show the arrangement of the dura mater (Plate XI., page 52).

I.—THE DURA MATER.

The Cranial Dura Mater is a dense white fibrous membrane, rough externally, but smooth and polished within. It is lined by a layer of epithelial cells similar to that which lines the spinal dura mater. Composed of two layers (though these are not distinct from each other)—an inner, which sends processes between the parts of the brain, and an outer, which forms the endosteum of the inner table of the cranium—it adheres to the bones of the skull,

in two places especially: (1) along the lines of the cranial sutures, and (2) at the base of the cranium. This latter fact accounts for the rare occurrence of accumulations of pus or blood at the base of the brain between the dura mater and the bone. The dura mater, moreover, sends a tubular process along each of the several cranial nerves as they leave the skull through their various foramina; part of this tubular process forms a sheath to the nerve, part of it becomes attached to the pericranium. The dura mater also passes into the orbital cavities, and there blends with the periosteum. At the lower margin of the foramen magnum the dura mater is closely attached to the bones, and becomes continuous with the spinal dura mater. Along certain lines the two layers, of which the cranial dura mater is composed, separate from each other, leaving variously shaped channels, called **VENOUS SINUSES**, for the passage of the blood from the brain into the venous system.

Of the partitions given off from its inner layer, two—the **FALX CEREBRI** and the **FALX CEREBELLI**—are vertical; the third, the **TENTORIUM CEREBELLI**, is usually said to be horizontal, though it is far more vertical than horizontal, for it slopes downwards and backwards.

1. **The Falx Cerebri**—so called from its sickle-shaped form (Fig. 37, page 52)—is the vertical mesial process of dura mater which is lodged in the great longitudinal fissure, and separates the inner surfaces of the cerebral hemispheres from each other.

In front it is pointed, and is attached to the apex and to the posterior margin of the crista galli. Behind it widens out, and is fixed along the middle line to the upper surface of the tentorium cerebelli. Its upper convex margin contains the superior longitudinal sinus, and adheres to the ridges seen on each side of the median depression, on the inner aspect of the vault of the skull. The lower margin contains the inferior longitudinal sinus. It is concave and free, and in front is in contact with the upper surface of the corpus callosum, though behind it is some distance from that body.

2. The Falx Cerebelli (Fig. 37) is the small median vertical triangular partition attached behind to the internal occipital crest, and above, at its widest part, to the mid-line of the under surface of the tentorium cerebelli. Its free concave margin projects forwards and fits into the notch between the halves of the cerebellum. Its posterior attached margin contains the occipital sinus, which is single above but bifid below.

3. The Tentorium Cerebelli (Fig. 37), supporting the posterior part of the cerebrum, slopes forwards and upwards, somewhat horizontally, as an arched tent-like partition between the big brain and the little brain. The posterior convex margin is attached behind to the transverse ridges on the inner aspects of the occipital, parietal, and temporal bones, and further forwards it is fixed to the upper margin of the petrous part of the temporal bones. It ends in front at the posterior clinoid processes. This margin

contains the lateral sinuses behind and the superior petrosal sinuses in front. The anterior concave margin, free in the greater part of its extent, is attached on each side by a narrow slip to the anterior clinoid processes. Between this margin and the dorsum sellæ of the sphenoid is an oval opening for the passage of the crura cerebri, the superior peduncles of the cerebellum, and the posterior cerebral arteries. Along the middle line of the upper surface of the tentorium runs the straight sinus, which receives the veins of Galen from the interior of the brain (Fig. 37, page 52).

The MINUTE STRUCTURE of the dura mater of the brain is similar to that of the spinal cord. It consists of layers of fibrous tissue. The larger arteries lie near the outer surface of the membrane, whereas the veins are embedded in its midst or lie between its layers where these exist. There are few capillaries in its substance, but on its inner aspect is a rich network of vessels covered by epithelial cells and surrounded by peri-vascular spaces which by means of stomata communicate with the sub-dural space (ROBERTSON).

THE AGREEMENTS AND DIFFERENCES IN THE ARRANGEMENT OF THE CRANIAL AND SPINAL DURA MATER MAY BE ARRANGED AS FOLLOWS :—

(a) Agreements—

1. Both are fibrous membranes.
2. Both invest their respective organs.
3. Both form the outer boundary of the sub-dural space.

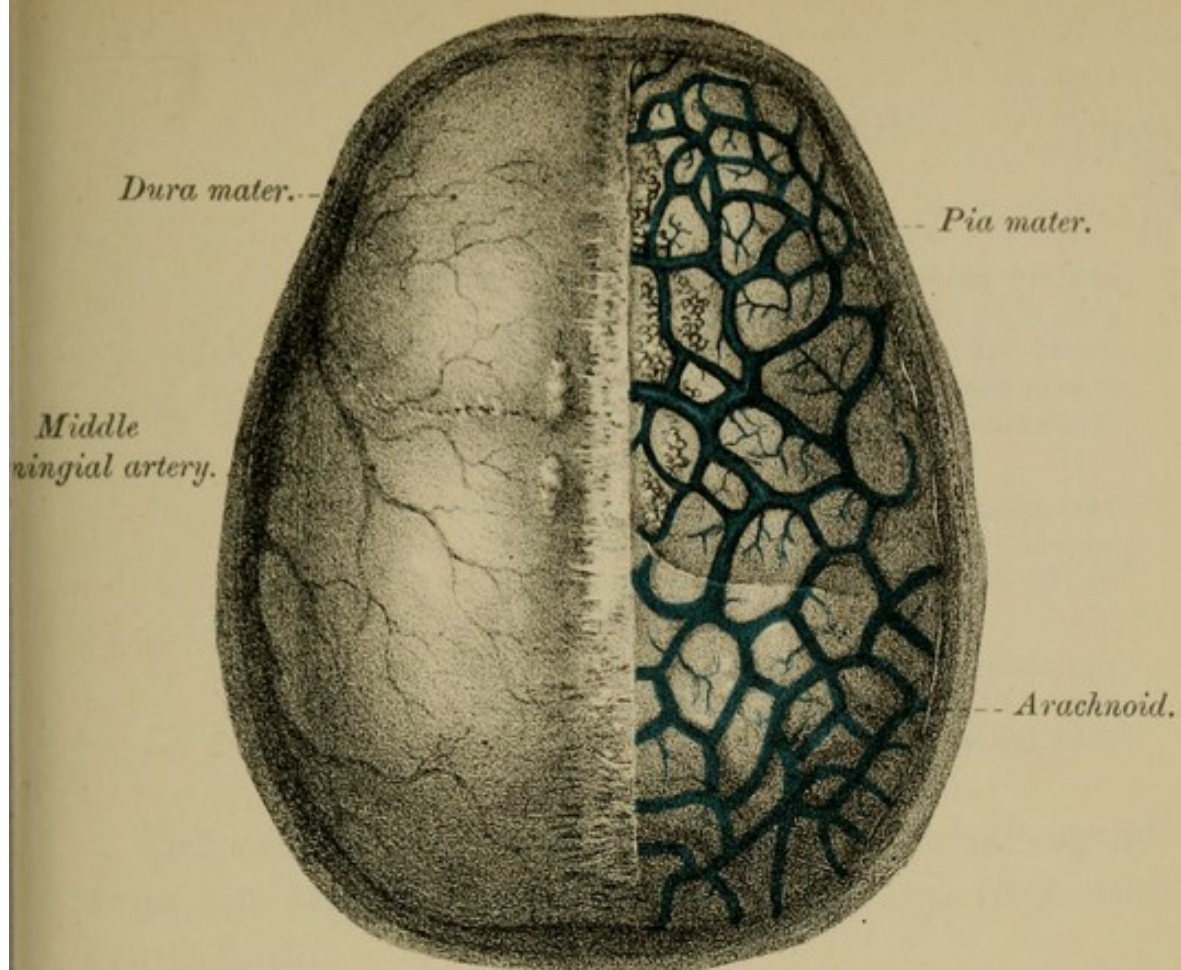
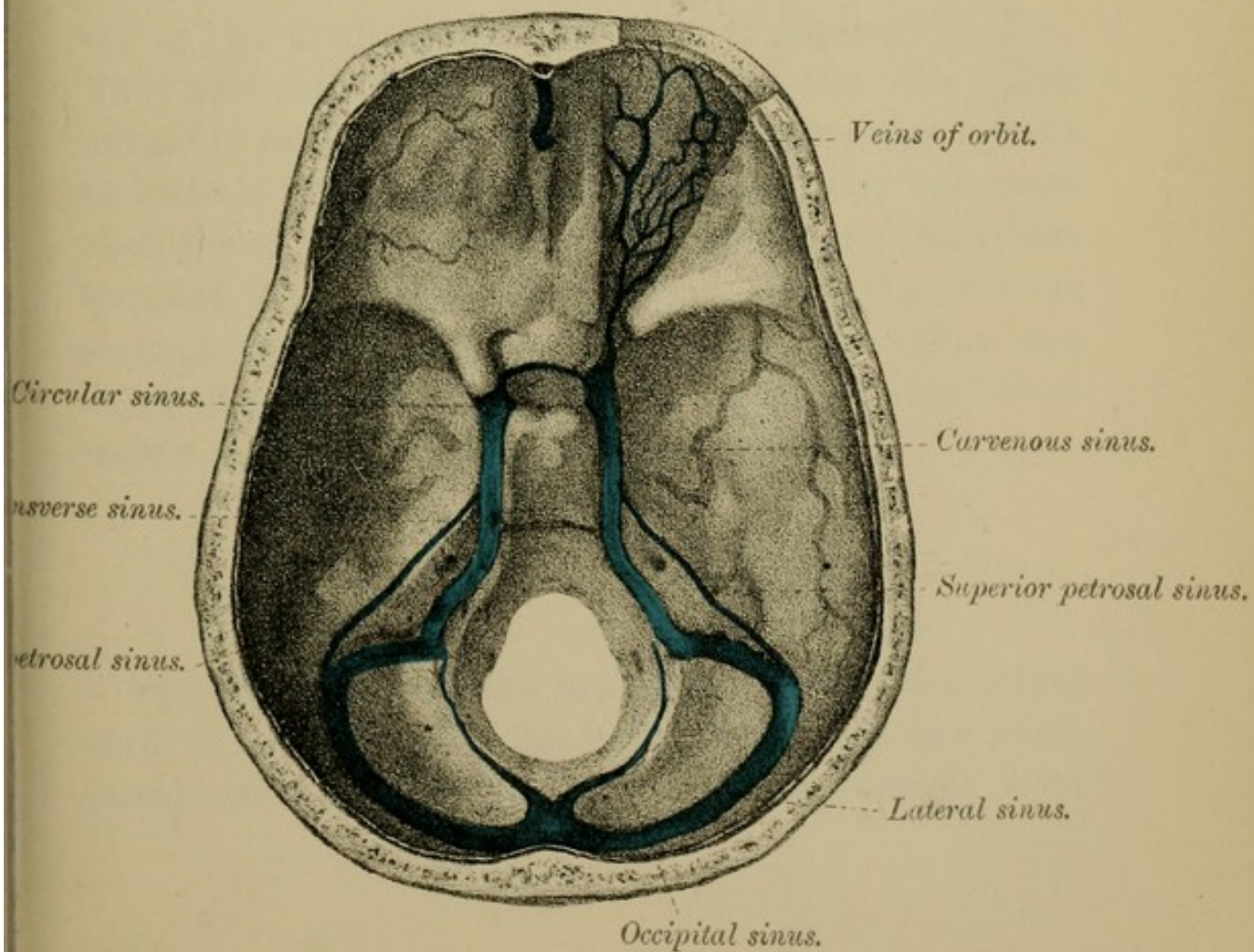



FIG. 36.





b) Differences—

1. The cranial dura mater forms the periosteum of the bones; the spinal does not, though some authors hold that there are two layers in the spinal dura mater—the outer forming the periosteum of the bones.
2. The cranial dura mater sends off processes between the parts of the brain; not so the spinal dura mater—it gives off no such processes.
3. The cranial dura mater, by the separation of its constituent layers, encloses the various venous sinuses; the spinal dura mater does not form sinuses.

The cranial dura mater receives its nerve supply from the 4th and 5th cranial nerves, and from the sympathetic.

Pacchionian Bodies (or Glands) are small white elevations, which indent the inner surface of the vertex of the skull, along each side of the middle line. They are said to be out-growths of the villi which normally exist in the arachnoid. Their exact nature and use is unknown. Some hold that they are mere excretions, others that they are communications between the sub-arachnoid space and the venous sinuses of the dura mater, others that they are ligaments which fix the pia mater to the dura mater and help to suspend the brain.

II.—THE PIA MATER.

(Fig. 34, page 44, and Fig. 35, page 48.)

The Pia Mater of the brain, like that of the spinal cord, is an extremely fine vascular membrane, composed of a plexus of capillary blood-vessels held

together by delicate connective tissue (Fig. 35, page 48). It is practically one layer with the arachnoid (page 51). Covering the surface of the brain, it dips into the various fissures between the convolutions; and from its inner surface numberless blood-vessels emerge for the nourishment of the substance of the brain. Besides the septa between the convolutions, the pia mater also sends into the brain through a large fissure, called the *great transverse fissure*, a special prolongation, the *velum interpositum*, the margins of which are wrinkled and folded, forming a vascular fringe, the *choroid plexus*; and a similar vascular process of pia mater, known as the *tela choroidea inferior*, or choroid plexus of the 4th ventricle, lies in the roof of that cavity (see "Ventricles," page 141).

In STRUCTURE the pia mater of the brain corresponds to the inner of the two layers of the pia-arachnoid described on the following page. It receives its nerve supply from the 3rd, 5th, 6th, 7th, and 8th nerves, as well as from the sympathetic.

III.—THE ARACHNOID.

The Arachnoid is a smooth, glistening, transparent, colourless membrane, situated between the dura mater and the pia mater (Fig. 35). Formed of a single layer, it is, on the one hand, separated from the dura mater by veins, and, on the other, envelops the brain but does not pass into its fissures. It is closely connected to the pia mater beneath by the sub-arachnoid trabeculæ, which are far more numerous than those in the spinal cord. At certain spots,

especially at the base of the brain, the pia mater and the arachnoid are more widely separated from each other, forming the SUB-ARACHNOID SPACE, which contains most of the cerebro-spinal fluid.

MINUTE STRUCTURE.—The arachnoid is not a distinct membrane from the pia mater, and the two are often described together under the name pia-arachnoid. This consists of two layers of epithelium—a superficial and a deep—the latter being in contact with the brain. The two layers are united by numberless trabeculæ covered by epithelial cells. The nerve supply to the arachnoid is probably the 5th, the facial, and the spinal accessory nerves.

Sub-dural and Sub-arachnoid Spaces (Fig. 34).—The space between the dura mater and the arachnoid is called the sub-dural space, and is lined by epithelial cells. The space between the arachnoid and pia mater is the sub-arachnoid space, and is crossed by the sub-arachnoid trabeculæ. It contains cerebro-spinal fluid. Both its inner and outer walls are lined by epithelial cells, which also cover the surfaces of the trabeculæ. The sub-arachnoid space is most distinct in the following situations—(1) at the great longitudinal fissure; (2) at the base of the brain, in the triangular interval, called the inter-peduncular or opto-peduncular space; and (3) posteriorly, between the cerebellum and the medulla oblongata.

Cerebro - spinal Fluid.—Most of this fluid is contained in the meshes of the sub-arachnoid trabeculæ, though a little is found in the sub-dural space.

It communicates with the fluid in the central canal of the spinal cord, and in the ventricles of the brain, through an opening—the *foramen of Majendie*—in the roof of the 4th ventricle (Fig. 34, page 44), and through two similar lateral openings in the ventricular roof between the medulla and cerebellum. Corresponding communications also exist at the inferior horns of the lateral ventricles. The cerebrospinal fluid is not merely intended to fill the subarachnoid space, but helps to protect the nerve centres from sudden shocks; acting, in fact, as a water-bed (HILTON) on which the brain rests. According to Foster it is probable that the cerebrospinal fluid, being of the nature of lymph, also subserves the nutrition of the brain.

IV.—VENOUS SINUSES.

(Figs. 36, 37, Plates X., XI., pages 48 and 52.)

The sinuses of the brain, formed by the separation of the two layers of the dura mater, are lined by epithelial cells continuous with those lining the interior of the veins. These sinuses are fifteen in number—five paired and five single. The single sinuses are the superior and the inferior longitudinal, the straight, the circular, and the transverse. The paired set includes the two lateral, the two superior, and the two inferior petrosals, the two cavernous and the two occipital. Other smaller sinuses are sometimes described.

FIG. 37.

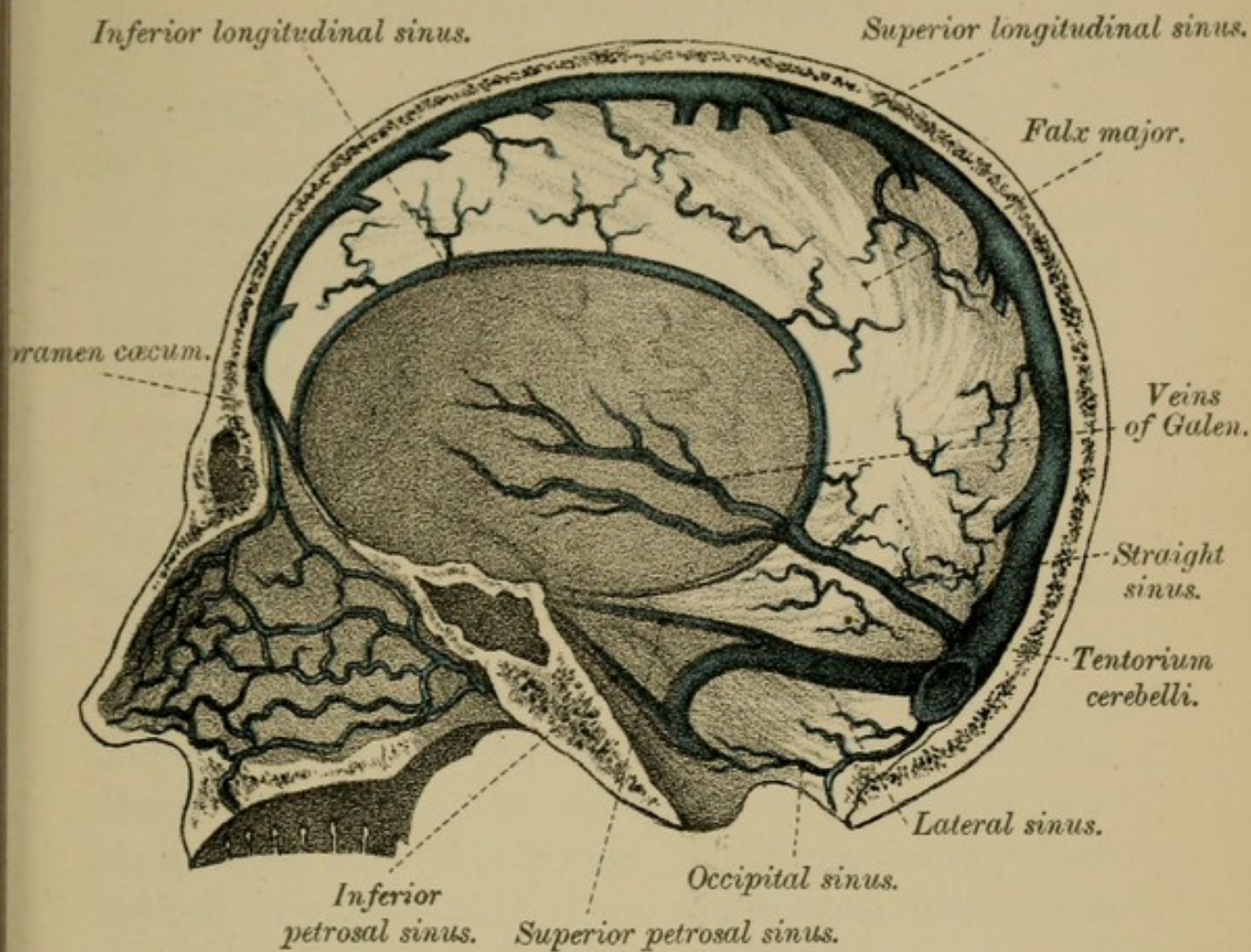
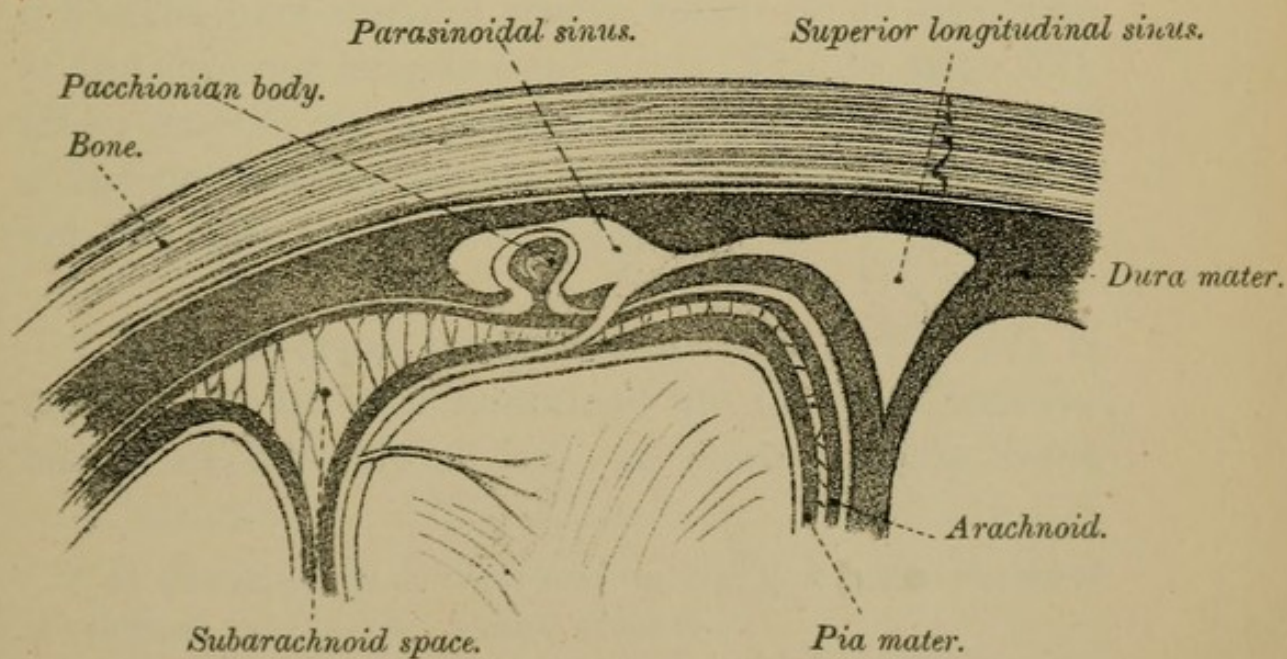



FIG. 38.





1. **The Superior Longitudinal Sinus** (Figs. 37, 38, page 52) begins in front at the foramen cæcum as a small vein, which often communicates with the veins of the nose, and thence arches upwards and backwards in the convex margin of the falx cerebri to reach the internal occipital protuberance, where it is joined by several other sinuses at the triangular dilatation, called the torcular Herophili,* or the meeting of the sinuses. Cut open the sinus in its entire length and you will see that it is wider above than below, being triangular in section, and that it increases in size as it passes backwards, its cavity being crossed by many slender bands—*chordæ Willisii*. Many veins, from the substance of the brain, pour their blood into this sinus. They run mostly from behind forwards—that is, in the reverse direction to the blood current in the sinus. They pierce the wall of the sinus by slit-like openings, which act as valves, and thus prevent regurgitation of the blood. Before entering the sinus they pass through small spaces, called the para-sinoidal spaces, which lie on each side of the superior longitudinal sinus (Fig. 38, page 52). Other smaller veins enter this sinus from the diploë of the surrounding bones, and it receives an emissary vein through the parietal foramen.

2. **The Inferior Longitudinal Sinus** (Fig. 37) is really a small vein contained in the free concave border of the falx major. It commences in front

* As Holden points out, the term torcular is a mistranslation of the original word, *σολήν*—a canal or gutter.

by minute venous radicles within the substance of the falx, and ends behind in the straight sinus.

3. The Lateral Sinuses (Fig. 36).—These are two in number, right and left, the right being usually the larger of the two. Through them most of the venous blood from the brain reaches the internal jugular veins. They commence at the internal occipital protuberance, and running outwards and downwards in the attached margin of the tentorium cerebelli, in the grooves on the inner surface of the occipital, parietal, and temporal bones, finally turn forwards to end in the bulb of the internal jugular vein. Blood enters these sinuses from the superior and inferior petrosal sinuses, from the inferior cerebral and cerebellar veins, from the diploë of the bones, and from the scalp by emissary veins.

4. The Straight Sinus (Fig. 37) lies in the middle line of the upper surface of the tentorium cerebelli, where the falx major is attached. Behind, it ends at the meeting of the sinuses; while in front it receives the inferior longitudinal sinus and the veins of Galen, the latter bringing blood from the third and the lateral ventricles of the brain. Some cerebral and cerebellar veins also open into this sinus.

5. The Cavernous Sinuses (Fig. 36), so called from the spongy appearance of their interior, are placed in the grooves on each side of the body of the sphenoid. They are oval in vertical transverse section, and contain, in their thickened outer wall,

the third, the fourth, and the ophthalmic division of the fifth nerves; while internally, and separated from the blood of the sinus by a thin lining membrane, is the internal carotid artery, with the sixth nerve on its outer side. These sinuses communicate with the circular sinus, and with the superior and inferior petrosal sinuses; and receive small cerebral veins and the veins from the orbit (Fig. 36, page 48).

6. **The Circular Sinus** (Fig. 36) surrounds the pituitary body in the sella turcica. At each side it communicates with the cavernous sinuses.

7. **The Petrosal Sinuses** (Fig. 36) are two on each side—the superior and the inferior. The *Superior Petrosal sinus* lies along the upper border of the petrous part of the temporal bone, and connects the cavernous sinus with the lateral sinus. The *Inferior Petrosal sinus* runs in the groove between the occipital bone and the petrous part of the temporal bone. It unites the cavernous sinus to the lateral sinus after the latter has passed out of the skull to become the internal jugular vein. Cerebral, cerebellar, tympanic, and auditory veins pour their blood into one or other of these sinuses.

8. **The Transverse or Basilar Sinus** (Fig. 36), sometimes double, is placed across the basilar process of the occipital bone, and connects together the inferior petrosal sinuses. It communicates below with the anterior spinal veins.

9. **The Occipital Sinuses** (Fig. 36) commence near the foramen magnum as two small channels which run upwards in the attached margin of the falx cerebelli, and then join above to form a single sinus which opens into the torcular Herophili.

Emissary Veins are small vessels which pass through foramina in the skull, and unite the veins of the scalp with the cranial sinuses. If it were not for these veins injuries to the scalp would lose half their significance (TREVES).

The Meningeal Arteries, which supply the dura mater with blood, ramify in branching grooves on the inner surface of the cranium, between it and the outer surface of the dura mater (Fig. 35, page 48). From the fossæ in which they ramify they are called the anterior, the middle, and the posterior meningeal arteries, and they arise from the ethmoidal, ascending pharyngeal, internal maxillary, occipital, and vertebral arteries. For the description of these vessels see your dissecting manual. We shall now pass on to examine the vessels of the brain.

CHAPTER II.

VESSELS OF THE BRAIN.

(Figs. 39, 40, Plate XII., page 58.)

DISSECTION.—Remove with great care the pia mater, and in doing so, at the under surface of the brain, dissect out the vessels and the cranial nerves.

I.—ARTERIES.

The arteries of the brain are derived from the *two internal carotids* and from the *two vertebrals*.

I. **The Internal Carotid Arteries**, when they reach the anterior clinoid processes, give off the ophthalmic branches, and then divide into anterior, and middle cerebral, and posterior communicating.

1. The **ANTERIOR CEREBRAL ARTERIES** run forwards to the fore part of the great longitudinal fissure, and curving round the anterior end of the corpus callosum, pass backwards on its upper surface, under the name of the arteries of the corpus callosum. At their commencement they are joined by a short transverse branch—the *anterior communicating*; while behind they anastomose by small branches with the posterior cerebral arteries. They supply blood to the frontal and olfactory lobes, to the optic nerves, to the corpus callosum, and to the anterior perforated spots (Figs. 39, 40).

2. The **MIDDLE CEREBRAL or SYLVIAN ARTERIES** are the largest branches of the internal carotid, and

run upwards and outwards in the fissure of Sylvius till they reach the surface of the island of Reil, where they ramify in the pia mater, forming part of the cortical system of arteries. They anastomose with the anterior and posterior cerebral arteries, and are distributed by four branches to part of the frontal, parietal, and temporal lobes (Figs. 42, 43, page 60). Other branches of the Sylvian artery are furnished through the anterior perforated spot to the corpus striatum, and are all terminal arteries, belonging to the "ganglionic system" of branches. They are the lenticular, the lenticulo-striate, the lenticulo-optic; and will be again referred to in describing the nuclei of the ventricles of the hemispheres. The middle cerebral artery is the one chiefly concerned in cerebral hæmorrhage.

3. The ANTERIOR CHOROIDAL ARTERIES, one or two in number, are either branches of the internal carotids or of the middle cerebrals. Entering the fissure between the temporal lobe and the crus cerebri (Fig. 40, page 58), they reach the descending cornu of the lateral ventricle, and there form the vascular fringe called the choroid plexus.

4. The POSTERIOR COMMUNICATING ARTERIES run backwards and join the posterior cerebral arteries (branches of the basilar artery), and thus is established a free anastomosis between the carotids and the vertebrals.

II. **The Vertebral Arteries**—branches of the subclavian—enter the foramen magnum by perforating the posterior occipito-atlantal ligament and the dura

FIG. 39.

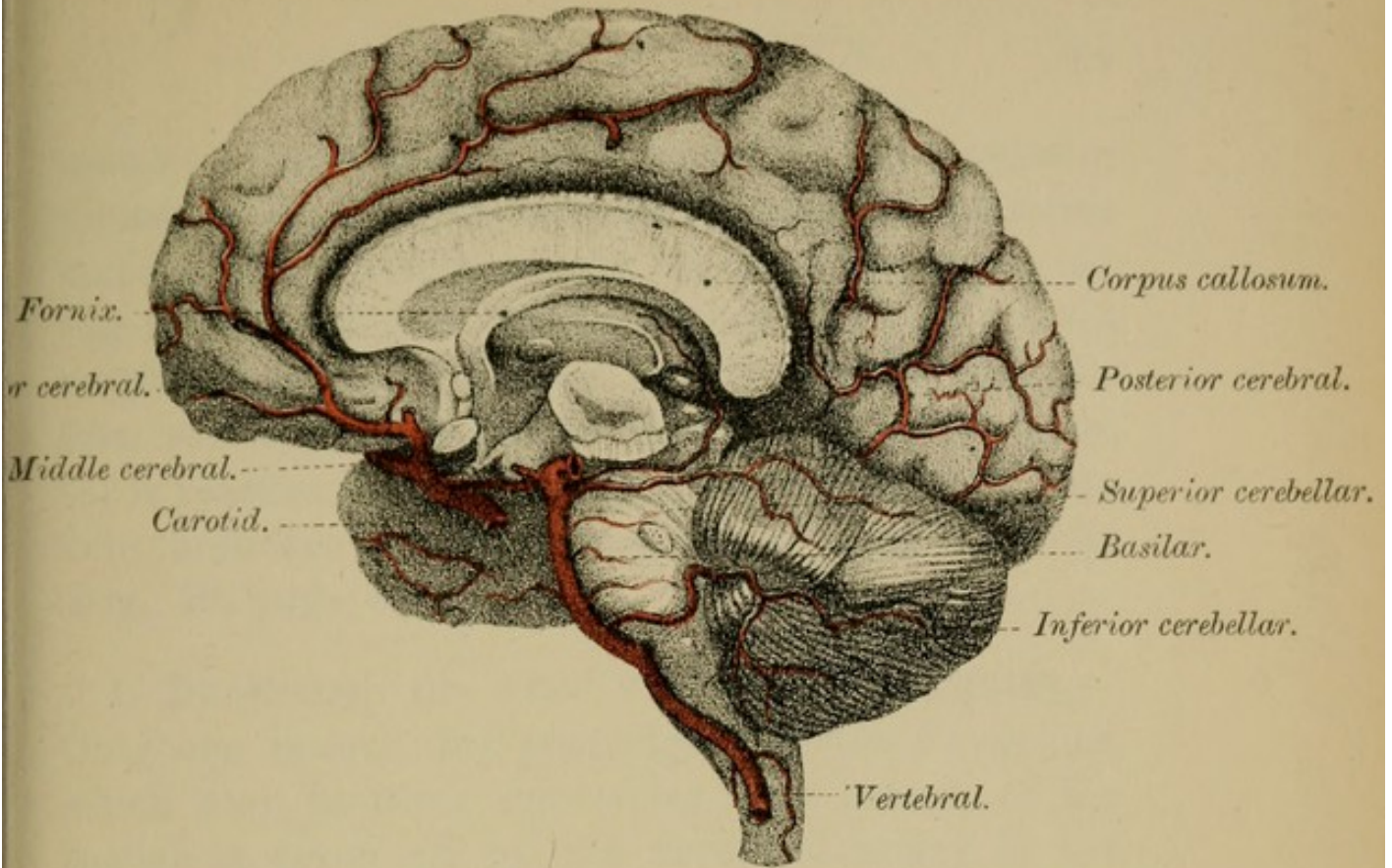
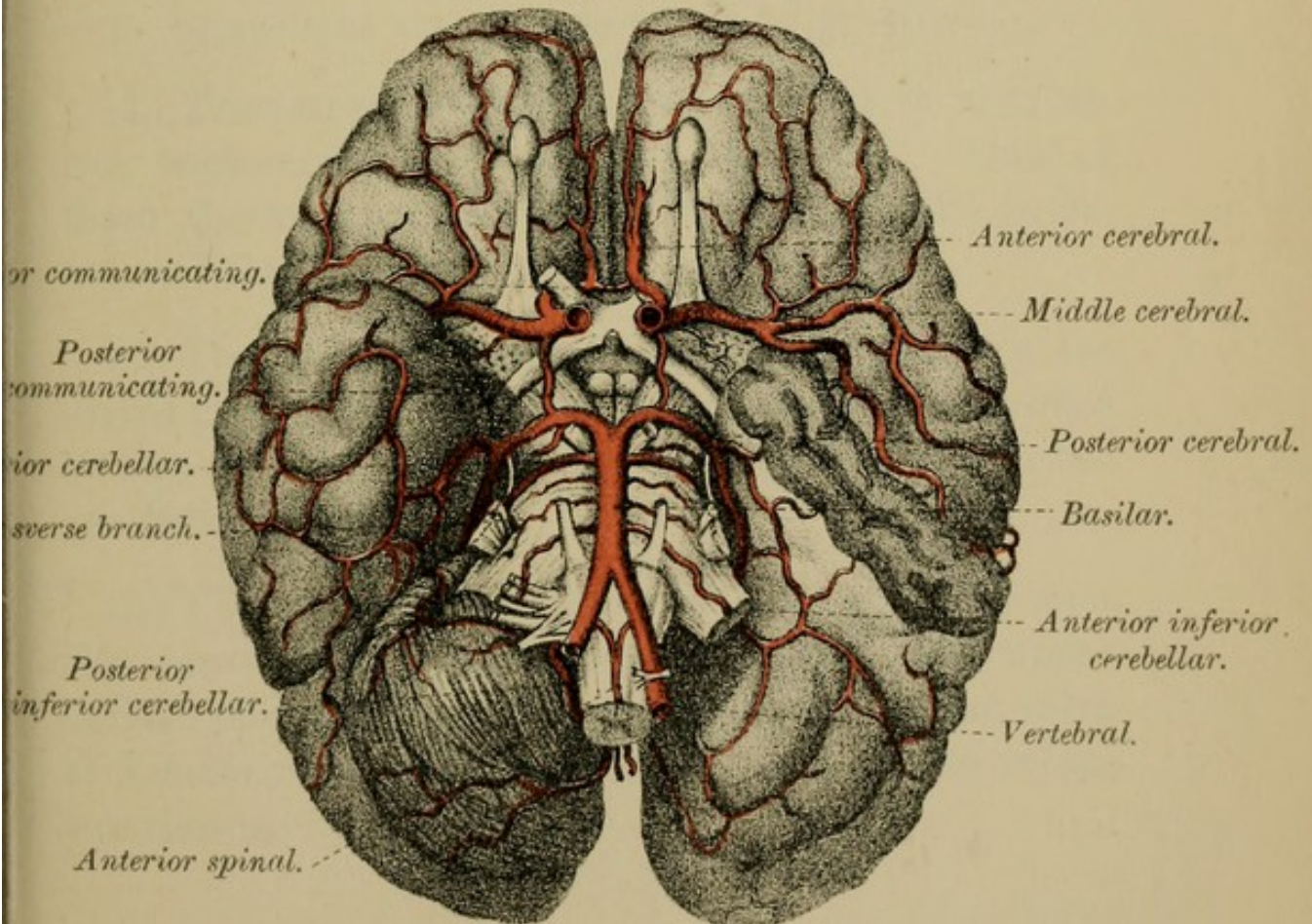



FIG. 40.





mater. They then curve round to the anterior surface of the medulla between the 12th cranial nerve and the anterior roots of the 1st cervical nerve. At the lower border of the pons they unite to form a single trunk—the basilar artery—which may be seen running in the groove on the front of the pons, till it reaches its upper margin, when it divides into two branches—the *posterior cerebral arteries* (Fig. 40, page 58).

1. BRANCHES OF THE VERTEBRAL ARTERIES.—Only one branch, the *posterior inferior cerebellar*, which may, however, sometimes be a branch of the basilar, is given off by the vertebral artery to the brain. It supplies the under surface of the cerebellum.

2. BRANCHES OF THE BASILAR (Fig. 40):—

(1) *Transverse branches*, three or four in number, run transversely outwards on the pons. One of them, the internal auditory branch, enters the internal auditory meatus.

(2) The *anterior inferior cerebellar arteries* are distributed to the anterior part of the lower surface of the cerebellum, and anastomose with the other cerebellar arteries.

(3) The *superior cerebellar arteries*, given off near the termination of the basilar, supply the upper surface of cerebellum, and send branches to the valve of Vieussens, to the pineal gland, and to the velum interpositum.

(4) The *posterior cerebral arteries*—the terminal branches of the basilar—curve outwards and backwards, round the crura cerebri, to the under surface of the posterior cerebral lobes, supplying them and anastomosing with the anterior and the middle cerebral arteries. They send branches to the posterior perforated spot and to the velum interpositum (posterior choroidal), and give three chief cortical branches (Fig. 40).

Circle of Willis (Figs. 39, 40, page 58).—This important arterial inosculation takes place at the base of the brain between the internal carotids and the vertebrals. In front the circle is formed by the anterior communicating artery which joins together the two anterior cerebral arteries; behind by the two posterior cerebral arteries, branches of the basilar; and on each side by the internal carotids, the anterior cerebrals, and the posterior communicating.

CIRCLE OF WILLIS.

In Front :

ANTERIOR COMMUNICATING.

On each Side :

Left.

ANTERIOR CEREBRAL.

INTERNAL CAROTID.

POSTERIOR COMMUNICATING.

Right.

ANTERIOR CEREBRAL.

INTERNAL CAROTID.

POSTERIOR COMMUNICATING.

Behind :

THE TWO POSTERIOR CEREBRALS,

BRANCHES OF THE

BASILAR.

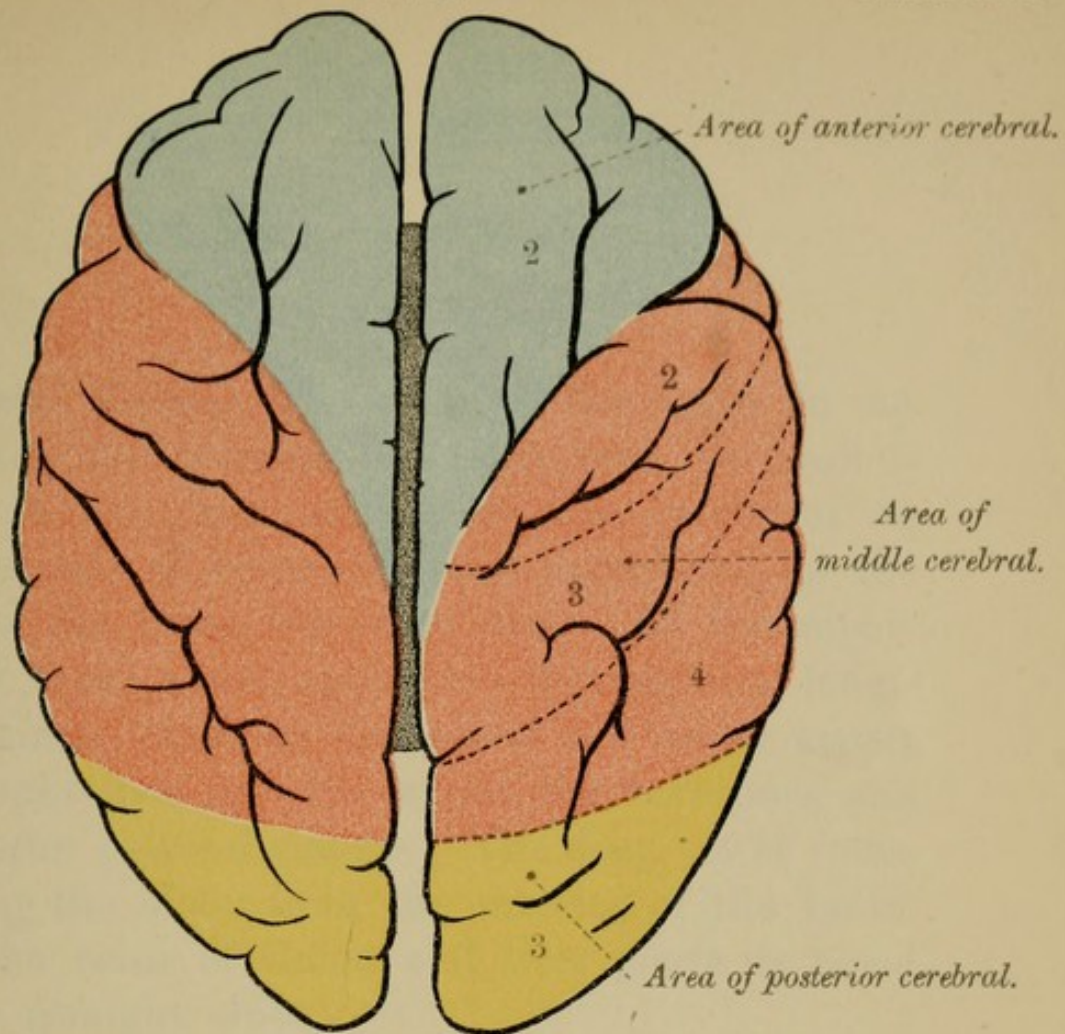
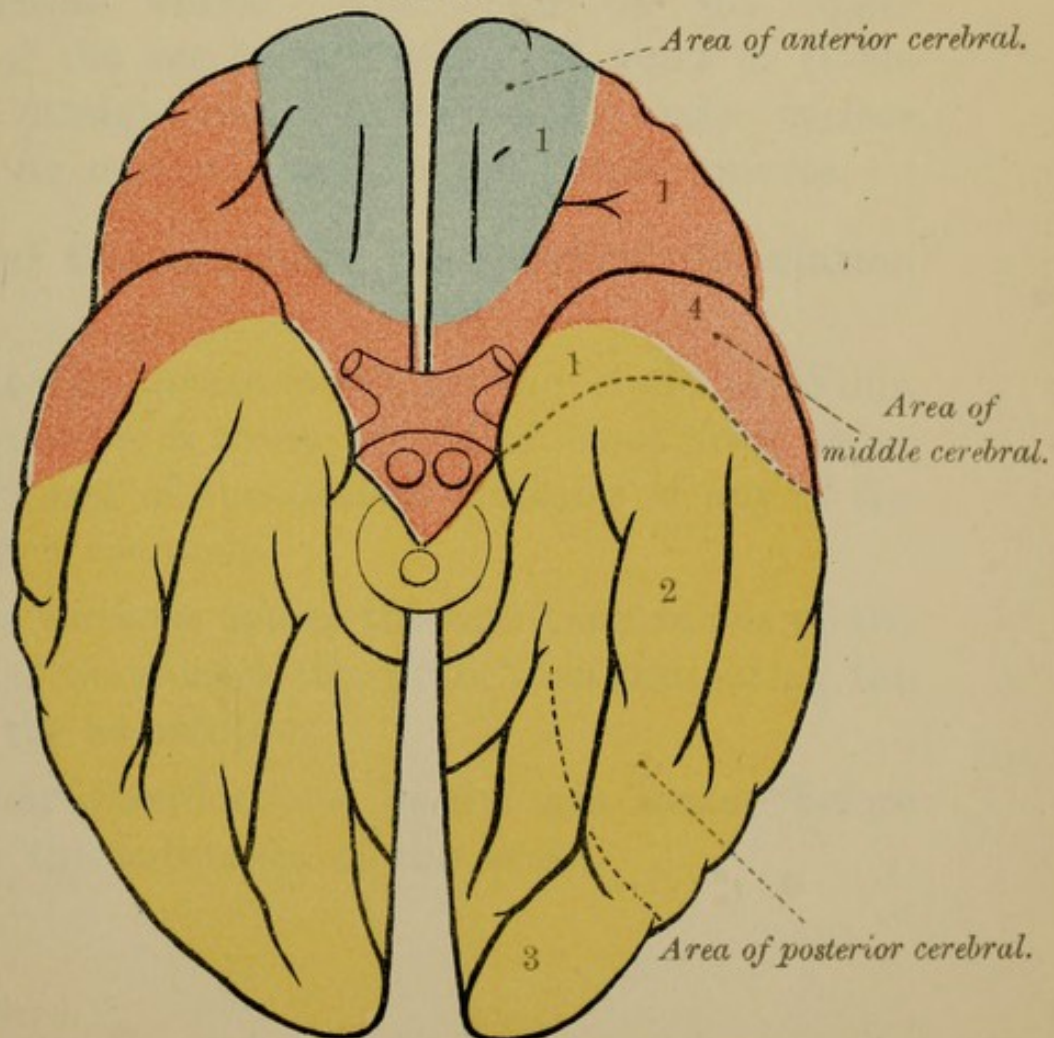




FIG. 43.





II.—VEINS.

Cerebral Veins.—The veins of the brain do not accompany the arteries, but open into the various sinuses in the dura mater. In the cerebrum we have two sets of veins—the one superficial, on the surface of the brain, the other deep. Of the superficial set those above open into the superior longitudinal sinus; those on the lateral and under aspect of the brain open into the lateral, the cavernous and the superior petrosal sinuses. The deep set of veins, gathering the blood from the interior of the brain, enters the veins of Galen, and thus pours its blood into the straight sinus.

Cerebellar Veins.—The veins on the upper surface of the cerebellum enter the veins of Galen and the straight sinus; those on the under surface end in the occipital, and in the lateral sinuses.

Special Characters of the Cerebral Circulation are—

1. The free anastomosis at the circle of Willis, which provides a ready supply of blood from other vessels in case of the sudden blocking of any of the more direct channels.

2. The tortuous course through bony canals of the arteries as they enter the skull, thus mitigating the force of the heart's beat.

3. Their ramifications in the pia mater before entering the substance of the brain.

4. The thinness of the arterial walls, and the smallness of the capillaries.

5. Except at the circle of Willis, and at their terminations by capillary vessels, there is little communication between the branches of the cerebral arteries, so that if any artery be obstructed, the nutrition of the area to which it is supplied becomes impaired.

6. The existence of venous sinuses which are without valves, and which do not run with the arteries—the larger arteries, in fact, having no companion veins.

Plates XIII., page 60, and XIV., page 62, will give you an idea of the distribution of the chief arterial branches to the cerebral cortex. The numbers 1, 2, 3, and 4 indicate the branches and the parts to which they are distributed.

FIG. 44.

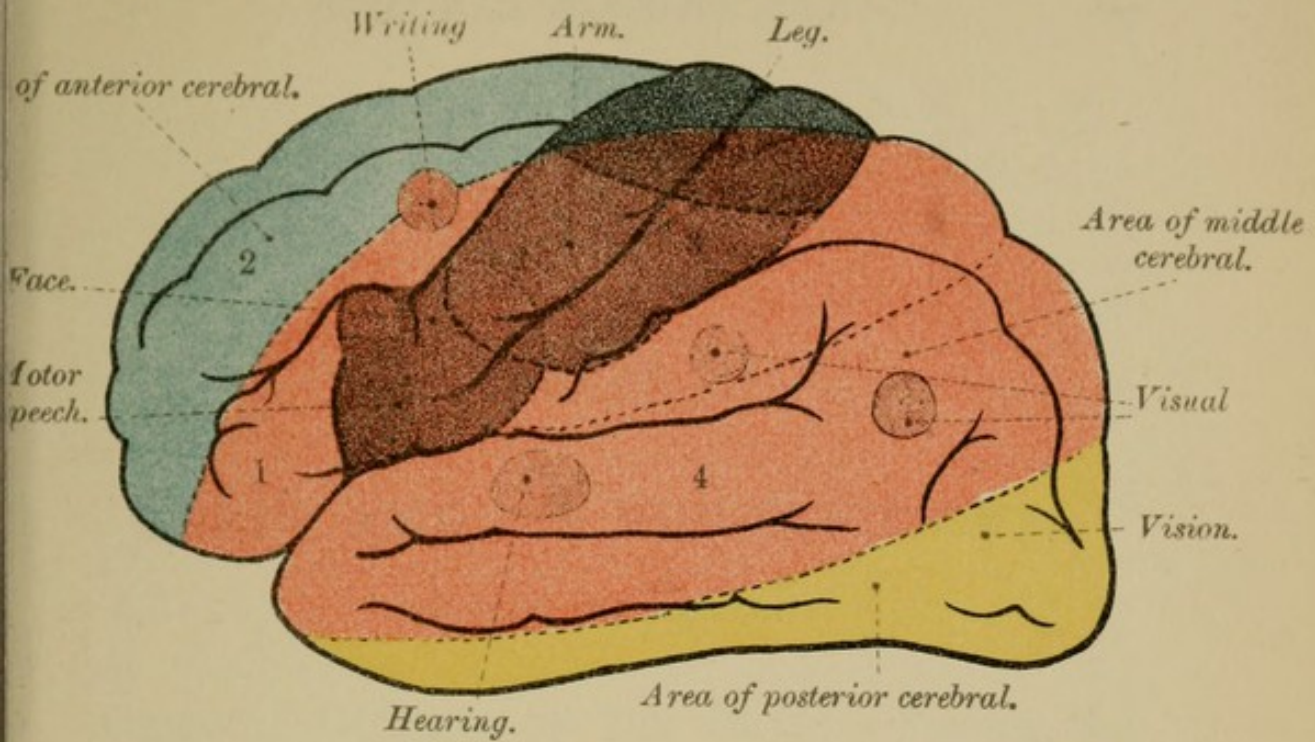


FIG. 45.

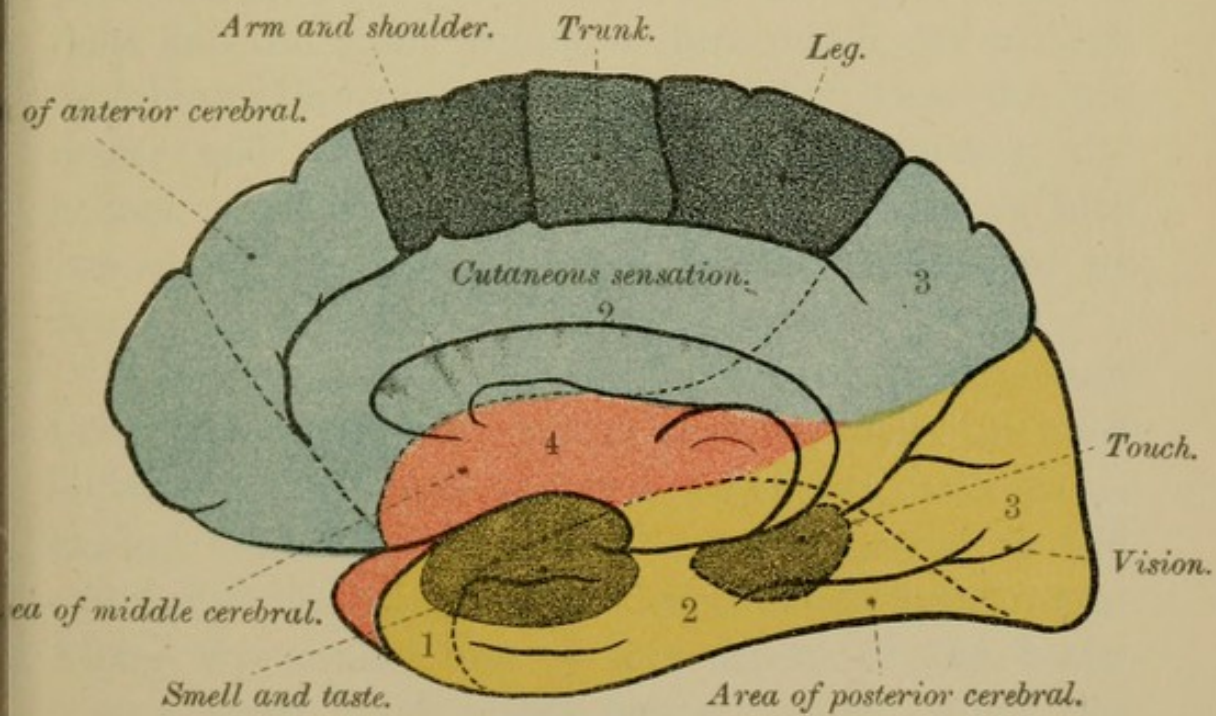



DIAGRAM OF ARTERIES AND CHIEF CENTRES IN BRAIN.



CHAPTER III.

BRAIN AND ITS SUB-DIVISIONS.

(Figs. 33, 34, page 44.)

GENERAL OUTLINE OF THE BRAIN.—Placing the brain before you, you will see that it is an oval-shaped mass of nervous substance, that has not inaptly been likened to the kernel of a walnut; for, says Wilks, “one cannot but be forcibly struck with the resemblance between the human head and a walnut. There is, first, the pericranium and the skin, then the bone and the shell; within a dura mater and a thick membrane lining the shell of the fruit; then the pia mater and the delicate membrane covering the kernel, which is again made up of convolutions into two masses joined together by a commissure or corpus callosum.”

Viewed from above, the surface of the brain is seen to be arched and convex, and presents many tortuous folds or convolutions of nerve substance, with intervening fissures or furrows, the whole giving to the exterior of the organ a most characteristic appearance. Along the middle line of this aspect of the brain runs a deep longitudinal fissure, which, when the brain is *in situ*, lodges the falx cerebri and divides

the mass into two similar halves. These symmetrical halves are called the **CEREBRAL HEMISPHERES**, and they together form the first great division of the **Encephalon**—the **CEREBRUM**—which is united to the rest of the brain and to the spinal cord by two masses of nerve substance known as the **CRURA CEREBRI**. On separating the walls of this median longitudinal fissure you will find that, in front and behind, the cleft extends right through to the base of the cerebrum; but that, in the middle of its extent, it is interrupted below by a transverse band of nerve fibres, the **CORPUS CALLOSUM**, or great commissure of the brain.

The under-surface or base of the brain, convoluted like the upper surface, is very irregular, for it fits into the corresponding fossæ at the base of the skull. On this aspect you will recognise the other sub-divisions of the brain (Fig. 34, page 44), viz.: (1) the **CEREBELLUM** or little brain, lying behind and below the posterior part of the cerebral hemispheres; (2) the **PONS VAROLII** which, when viewed from the front, appears as a broad white band, crossing transversely between the two halves of the cerebellum; (3) the **MEDULLA OBLONGATA** (Fig. 34), or bulb, placed between the pons above and in front, and the cerebellum behind, and serving to connect these several parts of the brain with the spinal marrow below. The sub-divisions of the brain, from a developmental point of view, are given on page 194.

We shall describe (1) the **MEDULLA**; (2) the **PONS**; (3) the **CEREBELLUM**; and (4) the **CEREBRUM**.

I.—MEDULLA OBLONGATA.

(Figs. 46 to 49, Plate XV., page 66).

DISSECTION.—If you have only one brain to work upon it will be best to pass on at once to the study of the cerebrum (page 113) and afterwards return to the medulla. If you have more than one brain, then cut through the crura cerebri, and begin the examination of the medulla.

The Medulla Oblongata—Myelencephalon—the most complicated portion of the central nervous system, is, as you already know, the expanded upper end of the spinal cord, and, like it, is composed of grey and white matter. It has anterior, posterior, and lateral aspects. The anterior surface rests upon the basilar process of the occipital bone; the posterior is hidden by the cerebellum. In general outline it is more or less conical, with its long axis nearly vertical, its base being directed upwards and forwards towards the Pons Varolii, its apex downwards and backwards, and continuous with the spinal marrow at the lower border of the foramen magnum. In length, the medulla measures about one and-a-quarter inches; in breadth, at its widest part, about one inch; in thickness about half-an-inch. On its ventral or anterior aspect it is convex, and is limited above by the lower border of the pons; below, by what is known as the decussation of the pyramids—several bands of fibres passing, at the bottom of the anterior median fissure, from one side of the medulla to the other. Behind, that is on its dorsal aspect, the medulla, in its lower half, is convex, and resembles the spinal cord, but, in its upper half, it expands laterally and becomes flattened from before

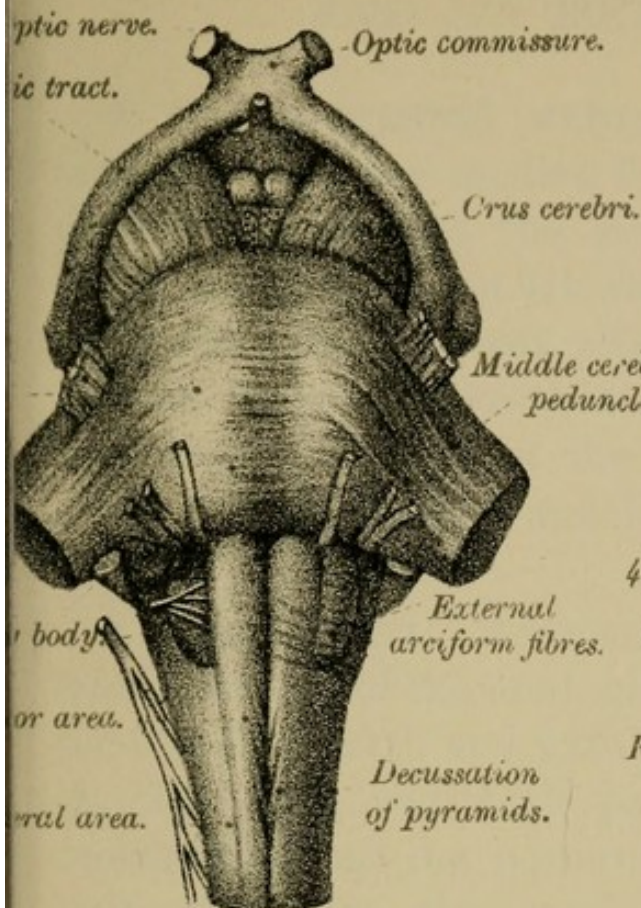
backwards, forming part of the rhomboidal depression called the floor of the 4th ventricle. On this aspect, the upper boundary of the medulla is marked by several transverse lines—the *striae acusticae*—running across the widest part of the ventricular floor (Fig. 47); the lower boundary is purely artificial, corresponding with the lower margin of the foramen magnum. The lateral aspect of the medulla supports an oval eminence, the olivary body, crossing the lower part of which, as well as the surface of the medulla just below it, you will be able to make out several transverse streaks, the external arciform fibres (Figs. 46, 49), the significance of which you will understand hereafter.

1. FISSURES OF THE MEDULLA.

Like the spinal cord the medulla is a symmetrical organ, being divided by superficial median clefts—anterior and posterior—into two similar lateral segments, which are again sub-divided into anterior, posterior, and lateral areas by the continuation upwards, though not in a direct line, of the place of origin of the anterior and posterior spinal nerve roots (Figs. 46 and 48, page 66).

1. The ANTERIOR MEDIAN FISSURE of the medulla, a direct continuation upwards of the anterior median fissure of the spinal cord, ends above, at the lower margin of the pons, in a slight recess, needlessly named the foramen cæcum. At the lower limit of the medulla, this same fissure is interrupted by the bands of fibres known as the decussation of the pyramids (Fig. 46, page 66).

FIG. 46.



Anterior median f.

FIG. 47.

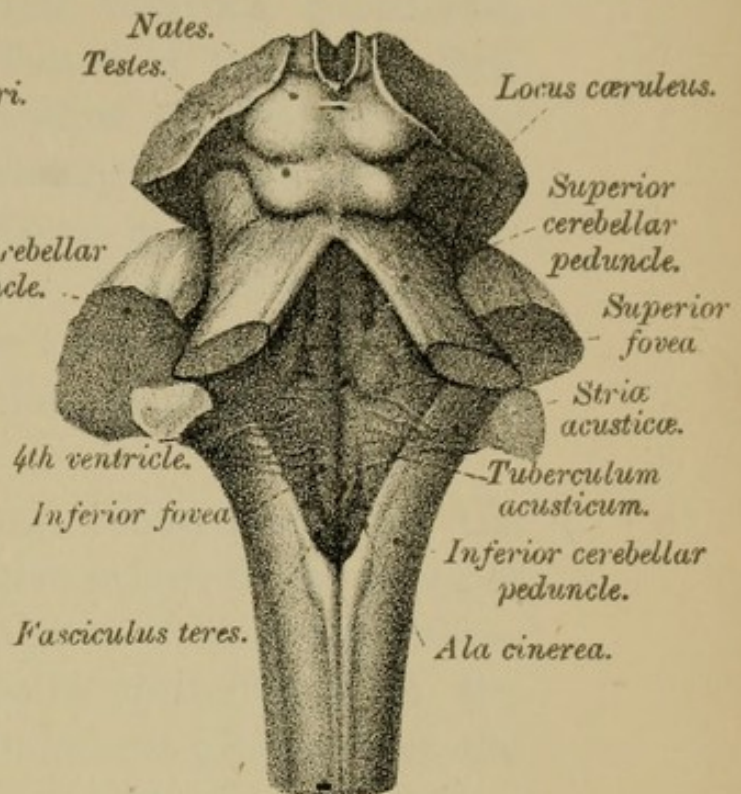


FIG. 48.

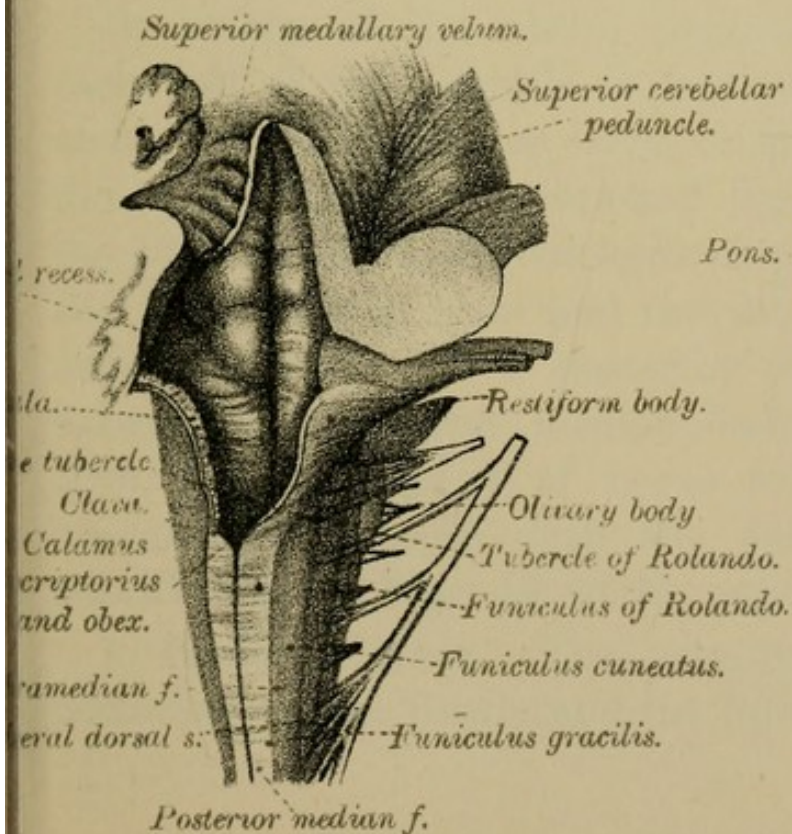
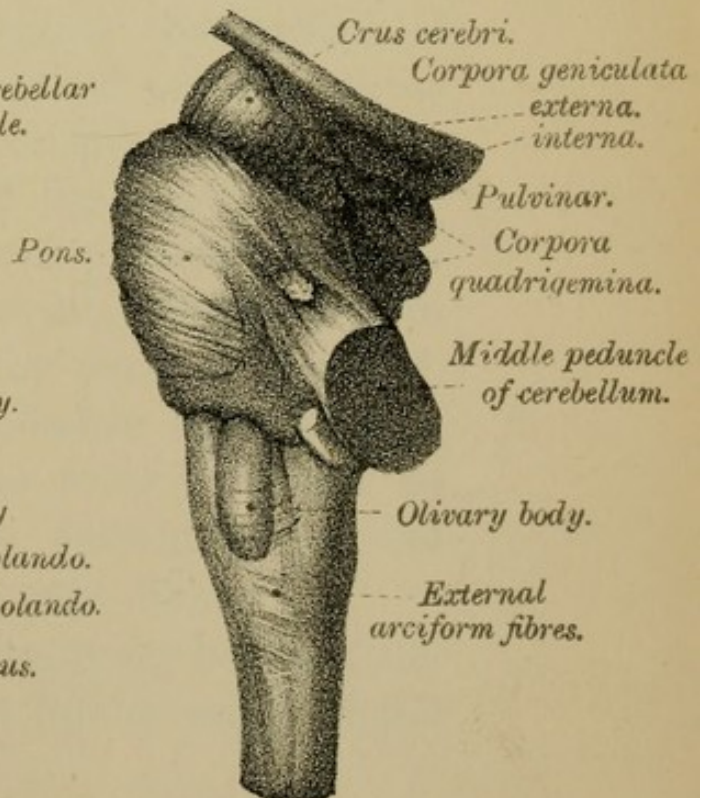



FIG. 49.





2. The POSTERIOR MEDIAN FISSURE, continuous with the posterior median fissure of the spinal cord, expands above into the shallow rhomboidal space called the floor of the 4th ventricle, along the centre of which runs a mesial groove, in a line with the median fissure of the cord. External to the posterior median fissure of the medulla are two minor sulci—the paramedian and lateral dorsal sulci (Figs. 47, 48).

3. The LATERAL FISSURES, continuous with the lateral fissures of the cord, give origin to the roots of the 9th, 10th, 11th and 12th pairs of cranial nerves—the 9th, 10th and 11th pairs springing from the continuation of the postero-lateral groove, and the 12th pair from the continuation of the antero-lateral groove.

2. WHITE MATTER OF THE MEDULLA.

(Areas of the Medulla.)

By means of the above fissures the surface of each half of the medulla is marked out into three areas, viz.: an *anterior area* or pyramid, between the anterior median fissure and the line of origin of the 12th nerve; a *lateral area* or pyramid, between the 12th nerve in front and the 9th, 10th, and 11th nerves behind; and a *posterior area* or pyramid, between the posterior median fissure and the 9th, 10th, and 11th pairs of nerve roots. It will be convenient to begin with the description of the posterior area (Figs. 46 to 49, page 66).

1. **Posterior Area.**—This area, lying between the posterior median fissure and the line of origin of the

9th, 10th, and 11th pairs of nerve roots, may be divided into an upper or anterior part, and a lower or posterior part. The *upper portion* of this area enters into the formation of the floor of the 4th ventricle, a cavity which should naturally be described at this stage, but, owing to the fact that many of its parts are connected with the pons and cerebellum, its description must be deferred until we have treated of that division of the brain.

The *lower portion* of the posterior area, very similar in appearance to the spinal cord, is, for the most part, formed by the upward prolongation of the various white tracts of the posterior column of the cord, the several strands there defined changing, when they reach the medulla, their position, their arrangement, and their names. These changes we shall now describe.

In dealing with the white substance of the posterior column of the cord, you will doubtless remember that we called your attention to the existence, in the cervical region, of a strand of fibres close to the posterior median fissure, called the *postero-internal strand—fasciculus of Goll*. Now, traced into the medulla, this strand, which lies between the posterior median and the paramedian fissures, becomes more prominent, and at the point where the central canal of the cord becomes the cavity of the 4th ventricle, the fasciculus enlarges, and is removed a little to one side. It is called the FASCICULUS or FUNICULUS GRACILIS—slender, and its enlarged upper end is known as the CLAVA—a club (Fig. 48, page 66). When followed

upwards it tapers to a point and becomes gradually lost, though we shall afterwards be able to trace its fibres along with those of the next fasciculus, first to collections of grey matter—nucleus gracilis and nucleus cuneatus—in the medulla, and thence to the cerebrum and cerebellum (see “Sensory Decussation,” page 83).

The outer division of the posterior column of the spinal cord, the *postero-external strand*—*fasciculus of Burdach* or *cuneate fasciculus*—passes into the medulla under this latter name. It lies between the paramedian and lateral dorsal sulci, and expanding above into a tubercle—the CUNEATE TUBERCLE (Figs. 48, 50)—reaches upwards beyond the clava, and forms one of the lateral boundaries of the lower part of the 4th ventricle (Fig. 48, page 66).

Besides the tracts just described there are on this aspect of the medulla two other strands, known respectively as the FUNICULUS of ROLANDO and the RESTIFORM BODY. They are not represented on the surface of the posterior column of the spinal cord; for the former is chiefly grey matter, and the latter belongs mainly to the lateral column.

(a) The FUNICULUS of ROLANDO.—The first of these tracts, the *funiculus of Rolando*, is of a greyish colour, for there is little or no white matter on its surface. It lies outside the funiculus cuneatus, between it and the line of origin of the roots of the 9th, 10th, and 11th pairs of cranial nerves. Like the two tracts previously mentioned, it expands above into a tubercle—the TUBERCLE of ROLANDO (Figs. 48, 50).

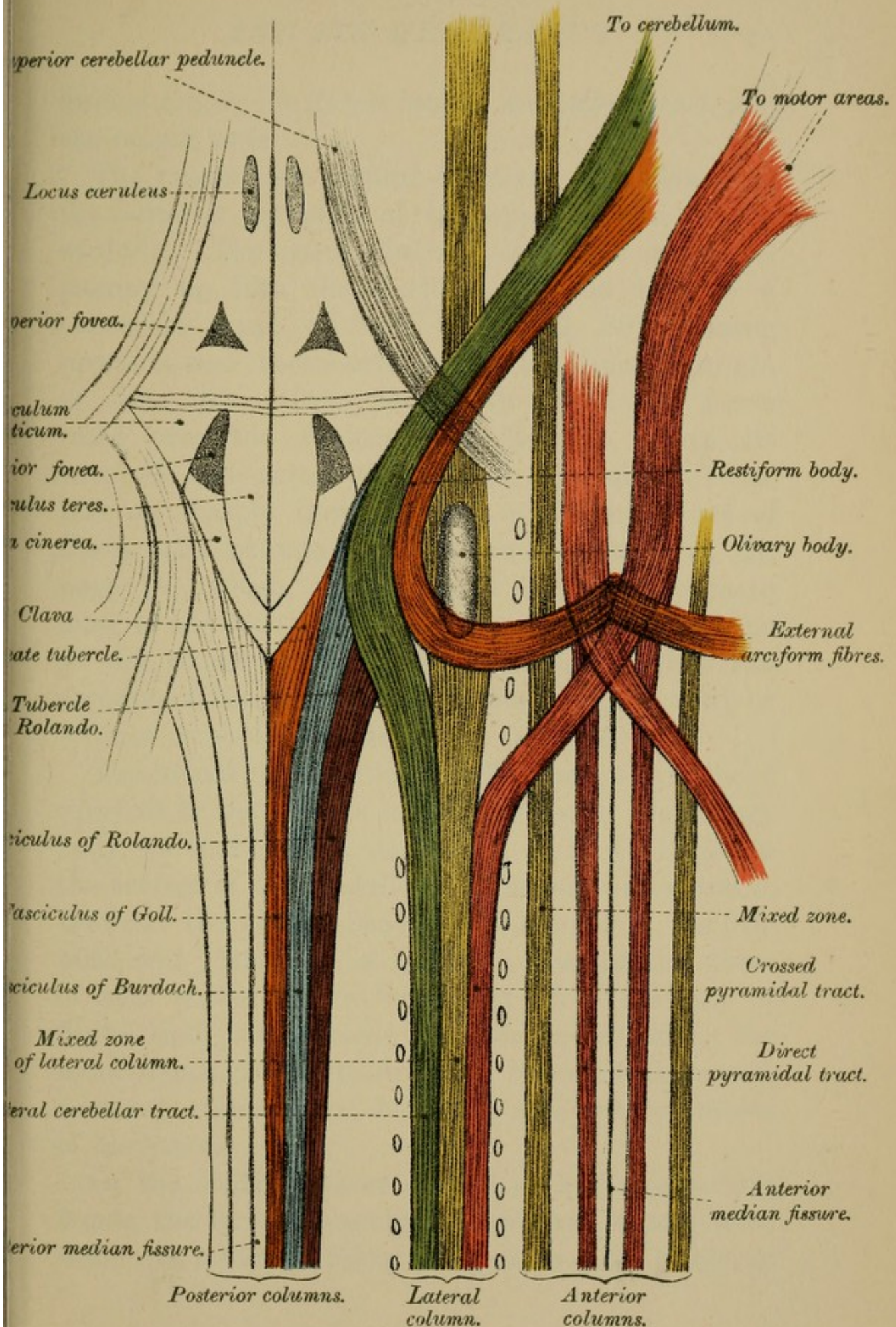
The funiculus of Rolando is often very poorly developed in the adult brain, but in the medulla of children it is always well marked.

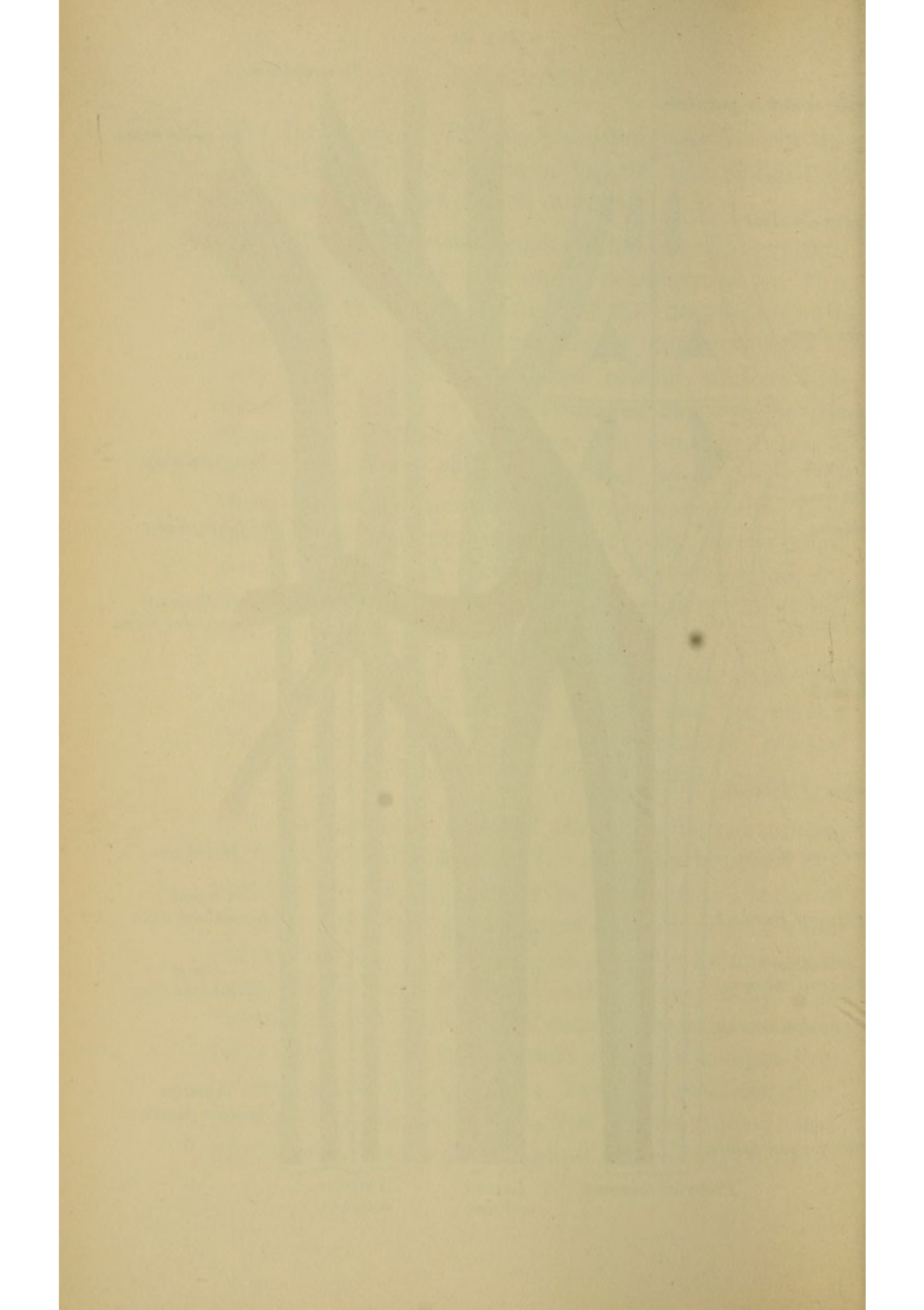
(b) The RESTIFORM BODY.—The remaining prominence, the largest and most conspicuous on this surface of the medulla, is called the INFERIOR CEREBELLAR PEDUNCLE or RESTIFORM BODY—*restis*, a rope (Figs. 47, 48). Placed behind, and to the outer side of the lateral column of the cord, it lies above the level of the clava, the cuneate tubercle and the tubercle of Rolando, and, when looked at from the surface, seems to be incorporated with these fasciculi, though not so in reality; for, as we shall presently see, it is composed of fibres derived, for the most part, from the lateral columns of the spinal cord (Fig. 50, page 70).

On this area of the medulla, then, we note four strands: (a) the funiculus gracilis and its clava; (b) the funiculus cuneatus and its tubercle; (c) the funiculus of Rolando; and (d) the restiform body.

2. The Lateral Area of the medulla, continuous with the lateral column of the cord, lies between the roots of the hypoglossal nerve in front and those of the 9th, 10th, and 11th nerves behind. It is wider below than above, where it is partially hidden from view by the oval eminence—the olivary body. To determine the origin of its various strands we must refer back to the constitution of the corresponding column of the spinal cord. You will recollect that, in that column, we traced five tracts—the *crossed pyramidal*, the (*ascending and descending*) *antero-*

FIG. 50.





lateral tracts, the *direct lateral cerebellar tract*, and the *mixed zone*.

The *crossed pyramidal tract* can be followed to the anterior pyramid of the opposite side of the medulla. The *direct lateral cerebellar tract*, on passing up into the medulla, will be seen as a superficial band of fibres (Figs. 49, 50), running upwards and backwards across the line of origin of the 9th, 10th, and 11th pairs of nerve roots, over the funiculus of Rolando, above its tubercle and across the cuneate funiculus. Then, turning sharply upwards, it is joined by a set of fibres—the EXTERNAL ARCIFORM FIBRES (Fig. 50, page 70), which, together with it, form the main mass of the RESTIFORM BODY or INFERIOR PEDUNCLE of the CEREBELLUM (Figs. 48, 50). (For a full account of the constitution of the restiform body or inferior cerebellar peduncle, see page 99.)

The *mixed zone* of the lateral column, when traced upwards to the bulb, is seen to dip under the olivary body, so that only a small part of it is visible on the surface of the medulla as a narrow white strand, between the olivary body and the roots of the 9th, 10th, and 11th pairs of nerves. Most of the fibres of this strand go to form part of a network of fibres that will become familiar to us under the name FORMATIO RETICULARIS. Some of them are, however, commissural between different segments of the cord.

Of the *antero-lateral ascending* and *descending tracts*, the former is probably a crossed sensory tract from the posterior roots, and passes most likely to

the cerebellum; the latter, the descending tract, starts in the cerebellum, being part of the indirect or secondary motor tract.

Thus, then, the fibres of the lateral column of the spinal cord, on reaching the medulla, are disposed of in three ways (see Fig. 50): (1) Some—crossed pyramidal tract—go to the opposite anterior pyramid; (2) others—direct lateral cerebellar tract—to the restiform body, and thence to the cerebellum of the same side; (3) others—antero-lateral tracts—to or from the cerebellum; (4) others—the mixed zone—pass partly behind, and partly beneath the olive to the *formatio reticularis*. The constitution and ultimate destination of these strands of fibres will be seen hereafter. They are figured on Plates XL., XLI., XLII., pages 182, 184, and 186.

Olivary Body.—The olivary body is an oval prominence, about half-an-inch long, placed at the upper end of the lateral area of the medulla. It is bounded in front by the roots of the 12th nerve, but is separated behind from those of the 9th, 10th and 11th nerves by a narrow white tract, which, as we have already seen, is part of the mixed zone of the lateral column of the cord. Above, the olive almost touches the lower border of the pons; below, it is crossed transversely by delicate fibres—the external arciform fibres—already referred to. If you cut into it you will see that it contains a grey core called the inferior olivary nucleus (see page 81).

3. The Anterior Area, also called the *anterior pyramid* of the medulla (Fig. 46, page 66), lies

between the anterior median fissure and the roots of the hypoglossal nerve, which serve to separate it from the olivary body. It is a pear-shaped prominence, which is broader above than below, though it becomes slightly constricted before disappearing beneath the transverse fibres of the pons. The pyramids of the two sides will afterwards be traced through the pons to the cerebral peduncles, and thence to the cerebral cortex. To their constitution you will require to give your closest attention, for it is somewhat complicated and of the greatest importance (Fig. 50, page 70). Note that although we are tracing these pyramidal tracts upwards, they are in reality *descending* or *motor* strands.

The anterior column of the spinal cord, you will remember, had a median division, *direct pyramidal tract*, and a lateral division, *basis bundle* or *anterior root zone*. Now, the pyramids of the medulla are, to a small extent only, made up of fibres derived from this inner division—direct pyramidal tract—of their own side of the cord; by far their greater part is composed of fibres—crossed pyramidal tract—which come from the *opposite lateral* column of the spinal cord. This crossed tract, after leaving the opposite lateral column, passes upwards and inwards through the anterior commissure, across the bottom of the anterior median fissure, where it decussates in a series of bundles, with a similar set of fibres from the other side, constituting together the *decussation of the pyramids*. Turning upwards this crossed tract then forms the inner and by far the larger part of the opposite anterior pyramid (Fig. 50); the outer

and smaller part of the same pyramid being formed by the continuation upwards of the direct pyramidal tract of the same side. Thus, for example, the LEFT ANTERIOR PYRAMID of the medulla is chiefly made up of the *crossed pyramidal tract* of the RIGHT LATERAL COLUMN, and, to a much smaller extent only, by the *direct pyramidal tract* of its own side. We must note, however, that although the fibres of the direct pyramidal tract do not decussate in the medulla, they do decussate as they pass down the spinal cord, and ultimately, through the nerve cells of the anterior horn, become connected, like the crossed tracts, with the anterior nerve roots of the opposite side to that at which they left the brain. The pyramidal tracts are the chief motor tracts, and their decussation explains the phenomena of certain forms of paralysis, in which when one side of the brain, say the left, is injured, loss of motion ensues, not on that side but on the opposite side of the body. "In cases, then, in which we find total or partial paralysis of the muscles on one side, with increased excitability to mechanical stimuli and a tendency to contracture, we can justly conclude that the opposite pyramidal tracts are affected" (EDINGER).

The outer division of the anterior column of the spinal cord—*antero-external tract*—will afterwards be traced through the upper part of the medulla (see "White Matter," floor of 4th ventricle, page 113) to the following destinations—(1) to the *formatio reticularis*, (2) to the posterior longitudinal bundle, and (3) to the tract of the fillet.

EXTERNAL ARCIFORM FIBRES (Fig. 49, page 66).—These are a set of fibres which, as at present seen, emerge from the anterior median fissure of the medulla, cross over the surface of the anterior pyramids, over the lower part of and below the olives, and finally turn upwards, along with the lateral cerebellar tract, to form, with it, part of the restiform body. They will be again referred to in treating of the grey matter of the medulla.

TABLE OF OBJECTS SEEN ON SURFACE OF MEDULLA.

Fissures.	{ Anterior median, with decussation of the pyramids. Posterior median. Two lateral, with nerve roots—the 12th from antero-lateral ; 9th, 10th, 11th from postero-lateral groove.	
Areas.	{ 1. Anterior area.	{ Anterior pyramids. Decussation of pyramids.
		{ Olive. External arciform fibres. Tract of white matter.
	{ 2. Lateral area.	{ Restiform body. Funiculus of Rolando and its tubercle.
		{ Funiculus cuneatus and its tubercle. Funiculus gracilis and its clava.
	{ 3. Posterior area.	{ Lower part. { Funiculus cuneatus and its tubercle. Funiculus gracilis and its clava.
		{ Upper part. { Lower half of the floor of 4th ventricle.

SUMMARY.—Thus, then, we see that the surface of the medulla oblongata presents four fissures—an anterior, two lateral, and a posterior: three areas—an anterior, with its pyramids and their decussation; a lateral, with its olive; a posterior, with its funiculus

gracilis, funiculus cuneatus, and funiculus of Rolando, and their respective enlargements; and, finally, the restiform body, or inferior cerebellar peduncle.

TABLE OF RELATIONS BETWEEN WHITE TRACTS OF CORD
AND THEIR REPRESENTATIVES IN THE MEDULLA.

	<i>Cord.</i>	<i>Medulla.</i>
Anterior column.	$\left\{ \begin{array}{l} 1. \text{ Direct pyramidal tract} \\ 2. \text{ Mixed zone} \end{array} \right.$	$\left\{ \begin{array}{l} \text{to outer part of the anterior pyramid of the medulla of the same side.} \\ \text{to posterior longitudinal bundle.} \\ \text{to olivary peduncle and fillet.} \\ \text{to formatio reticularis.} \end{array} \right.$
Lateral column.	$\left\{ \begin{array}{l} 1. \text{ Crossed pyramidal tract} \\ 2. \text{ Direct lateral cerebellar tract} \\ 3. \text{ Mixed zone} \\ 4. \text{ Antero-lateral ascending tract} \\ 5. \text{ Antero-lateral descending tract} \end{array} \right.$	$\left\{ \begin{array}{l} \text{to the inner part of the pyramid of opposite side; a few fibres go to the pyramid of the same side.} \\ \text{to restiform body and thence to the cerebellum of same side.} \\ \text{to olivary fillet.} \\ \text{to formatio reticularis.} \\ \text{to the cerebellum—probably crossed sensory tract.} \\ \text{from the cerebellum of same side.} \end{array} \right.$
Posterior column.	$\left\{ \begin{array}{l} 1. \text{ Postero-internal strand (Goll)} \\ 2. \text{ Postero-external strand (Burdach)} \\ 3. \text{ Lissauer's tract} \end{array} \right.$	$\left\{ \begin{array}{l} \text{to funiculus gracilis, and to its nucleus.} \\ \text{to funiculus cuneatus, and to its nucleus.} \\ \text{to formatio reticularis.} \\ \text{to the grey matter of the posterior horn.} \end{array} \right.$

3. GREY MATTER OF THE MEDULLA.

From the white strands of the medulla, which have so far occupied our attention, we next turn to the consideration of the arrangement of its grey substance. This is far more irregular than that of the spinal cord, and for its satisfactory study you will require a special series of preparations, though the accompanying figures will no doubt give you material assistance (Fig. 51, &c., Plate XVII., page 78).

The grey matter of the medulla oblongata may be described under two heads—(1) that represented in the spinal cord, and derived from one or other of its grey crescents; (2) that not so represented, but forming isolated collections or nuclei not obviously connected with the grey matter of the spinal cord.

1. Grey Matter derived from the Grey Crescents.—Transverse sections of the lower part of the medulla will show you that the grey matter of the medulla has an arrangement very similar to that of the grey matter of the spinal cord; but that higher up in the medulla the appearance of the grey crescents becomes much changed. (Compare Figs., Plate XVII., page 78, with Figs., Plate III., page 14.)

(a) The *anterior cornu* of the spinal cord, as we trace it upwards, loses its characteristic shape, for, owing to the fact that the fibres of the crossed pyramidal tract cut their way through the neck of the anterior horn, the head becomes separated from the base, and the *neck* is replaced by a reticulum of fibres, part of the *FORMATIO RETICULARIS*. The *head* of the anterior horn, thus detached, enlarges, and,

PLATE XVII.

Fig. 53.

<i>a. m. f.</i>	Anterior median fissure.
<i>a. n.</i>	Arciform nucleus.
<i>as. gloss.</i>	Ascending root of the glossopharyngeal nerve.
<i>e. a. f.</i>	External arciform fibres.
<i>h. n.</i>	Hypoglossal nerve.
<i>n. c.</i>	Nucleus cuneatus.
<i>n. g.</i>	Nucleus gracilis.
<i>n. l.</i>	Nucleus lateralis.
<i>n. o. b.</i>	Nucleus of olivary body.
<i>p. m. f.</i>	Posterior median fissure.
<i>p. t.</i>	Pyramidal tract.
<i>s. g. R.</i>	Gelatinous substance of Rolando.
<i>5th as.</i>	Ascending root of 5th nerve.

Fig. 52.

<i>a. m. f.</i>	Anterior median fissure.
<i>f. c.</i>	Fasciculus cuneatus.
<i>f. g.</i>	Fasciculus gracilis.
<i>h. n.</i>	Hypoglossal nerve.
<i>n. c.</i>	Nucleus cuneatus.
<i>n. g.</i>	Nucleus gracilis.
<i>p. m. f.</i>	Posterior median fissure.
<i>p. t.</i>	Pyramidal tract.
<i>s. g. R.</i>	Substantia gelatinosa Rolando.
<i>s. p. d.</i>	Superior pyramidal decussation.
<i>5th as.</i>	Ascending root of the 5th nerve.
<i>s. d.</i>	Sensory decussation.

Fig. 51.

<i>a. c.</i>	Anterior cornu.
<i>a. m. f.</i>	Anterior median fissure.
<i>d. p.</i>	Decussation of the pyramids.
<i>d. p. t.</i>	Direct pyramidal tract.
<i>f. B.</i>	Fasciculus of Burdach.
<i>f. G.</i>	Fasciculus of Goll.
<i>m. z.</i>	Mixed zone.
<i>p. c.</i>	Posterior cornu.
<i>p. m. f.</i>	Posterior median fissure.

Fig. 56.

<i>a. m. f.</i>	Anterior median fissure.
<i>a. n.</i>	Arciform nucleus.
<i>a. o.</i>	Accessory olive.
<i>c. r.</i>	Corpus restiforme.
<i>e. a. f.</i>	External arciform fibres.
<i>g. n.</i>	Glossopharyngeal nerve.
<i>l. or f.</i>	Lemniscus or Fillet.
<i>n. a.</i>	Arciform nucleus.
<i>n. am.</i>	Nucleus ambiguus.
<i>n. f. t.</i>	Nucleus of fasciculus teres.
<i>n. o. b.</i>	Nucleus of olivary body.
<i>p. l. b.</i>	Posterior longitudinal bundle.
<i>p. t.</i>	Pyramidal tract.
<i>v.</i>	Vagus.
<i>5th as.</i>	Ascending root of the 5th nerve.

Fig. 55.

<i>a. m. f.</i>	Anterior median fissure.
<i>a. n.</i>	Arciform nucleus.
<i>a. o.</i>	Accessory olive.
<i>e. a. f.</i>	External arciform fibres.
<i>f. r.</i>	Formatio reticularis.
<i>f. s.</i>	Fasciculus solitarius.
<i>h. n.</i>	Hypoglossal nerve.
<i>n. am.</i>	Nucleus ambiguus.
<i>n. c.</i>	Nucleus cuneatus.
<i>n. f. t.</i>	Nucleus of fasciculus teres.
<i>n. g.</i>	Nucleus gracilis.
<i>n. h.</i>	Nucleus of the hypoglossal nerve.
<i>n. o. b.</i>	Nucleus of olivary body.
<i>p. t.</i>	Pyramidal tract.
<i>r.</i>	Raphé.
<i>v.</i>	Vagus nerve.
<i>v. n.</i>	Vagus nucleus.
<i>4th vent.</i>	4th ventricle.
<i>5th as.</i>	Ascending root of the 5th nerve.

Fig. 54.

<i>a. m. f.</i>	Anterior median fissure.
<i>a. n.</i>	Arciform nucleus.
<i>a. o.</i>	Accessory olive.
<i>e. a. f.</i>	External arciform fibres.
<i>f. c.</i>	Fasciculus cuneatus.
<i>f. g.</i>	Fasciculus gracilis.
<i>f. r.</i>	Formatio reticularis.
<i>i. a. f.</i>	Internal arciform fibres.
<i>n. c.</i>	Nucleus cuneatus.
<i>n. g.</i>	Nucleus gracilis.
<i>n. l.</i>	Nucleus lateralis.
<i>n. o. b.</i>	Nucleus of olivary body.
<i>p. m. f.</i>	Posterior median fissure.
<i>p. t.</i>	Pyramidal tract.
<i>s. g. R.</i>	Gelatinous substance of Rolando.
<i>t. R.</i>	Tubercle of Rolando.
<i>5th as.</i>	Ascending root of the 5th nerve.

FIG. 53.

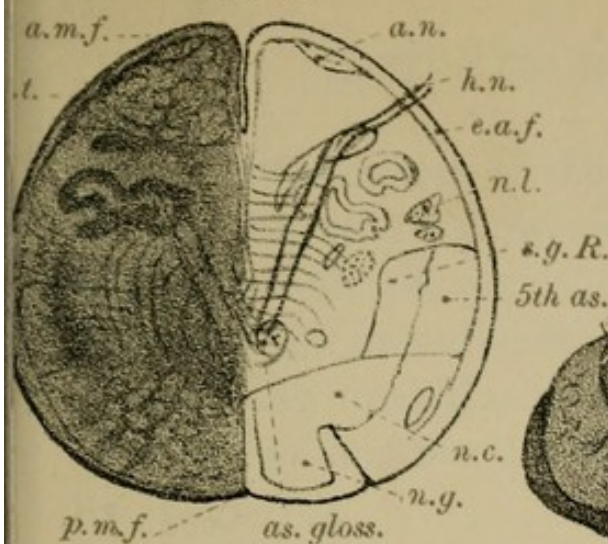


FIG. 56.

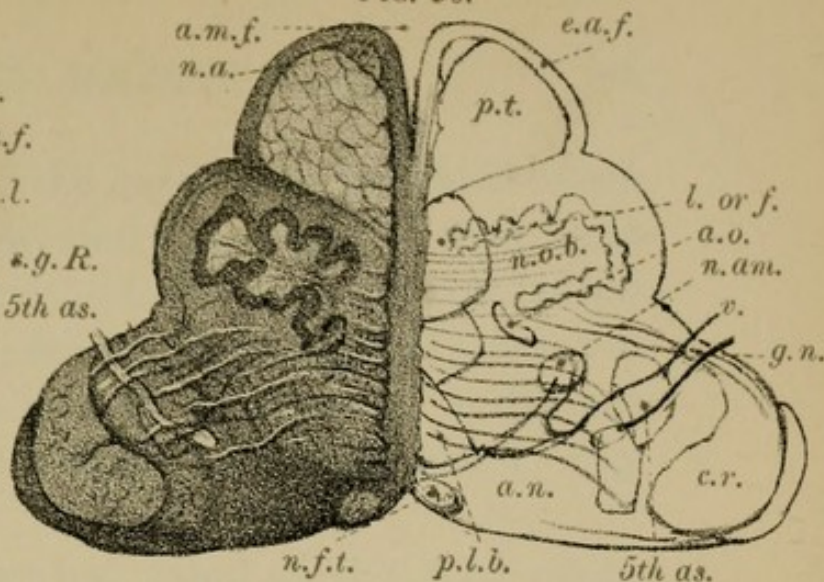


FIG. 52.

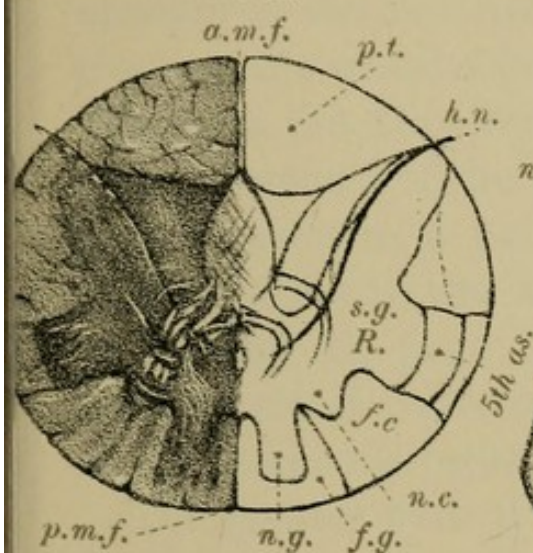


FIG. 55.

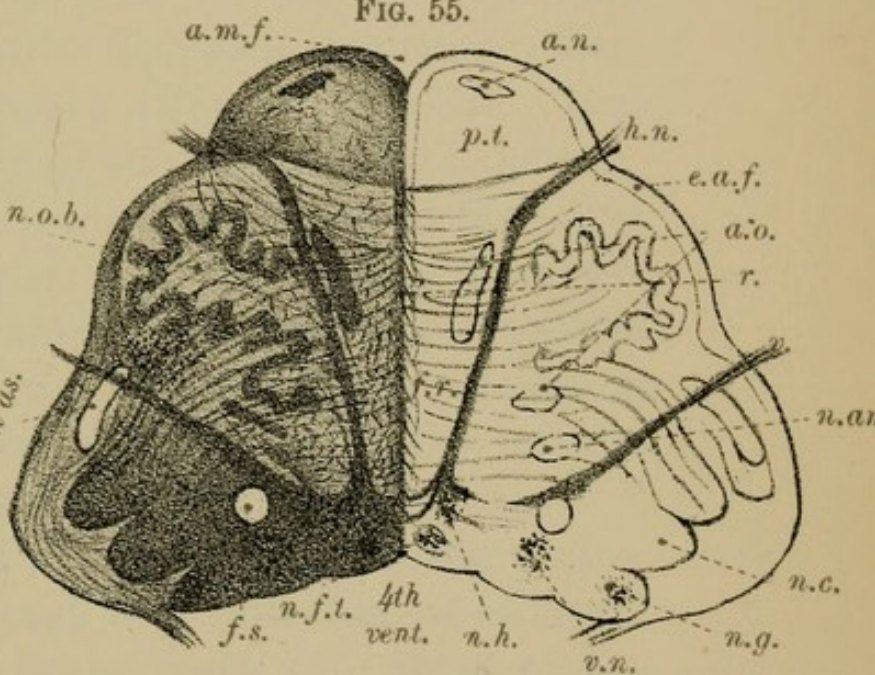


FIG. 51.

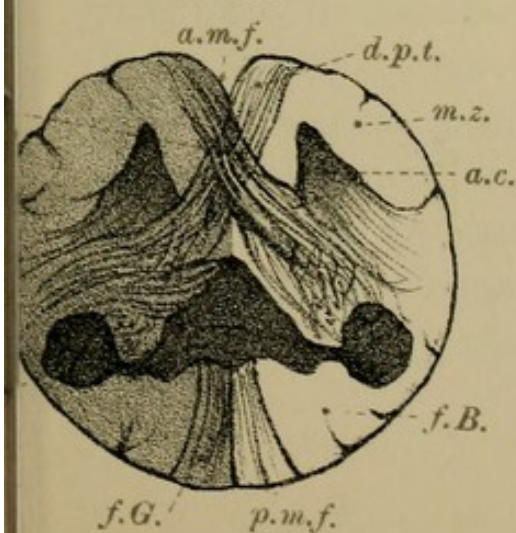
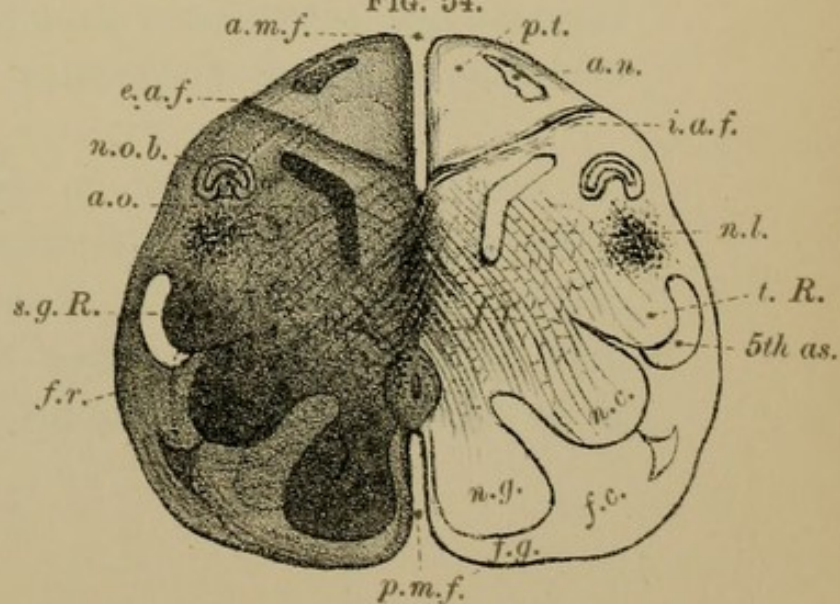



FIG. 54.





by the interposition of the anterior pyramids between it and the anterior median fissure, is pushed from the antero-lateral aspect of the cord to the lateral aspect of the medulla, where, in sections of the lower part of the medulla, it may be seen as a distinct grey collection, the NUCLEUS LATERALIS (*n. l.*, Fig. 54, page 78).

Again, when the central canal of the cord opens out into the floor of the 4th ventricle, the grey matter which surrounds that canal is brought to the surface, and hence the *base* of the anterior horn appears on the ventricular floor as a narrow grey tract close to the median furrow (Fig. 57, page 82). It is known as the NUCLEUS of the HYPOGLOSSAL NERVE; and in sections of the medulla at this level the nerve may be seen as a band of fibres running from the nucleus towards the anterior surface of the medulla (*n. h.*, Fig. 55, page 78). Close to this nucleus is another small collection of nerve cells—the nucleus of the fasciculus teres (*n. f. t.*, Fig. 55, page 78).

The greater part of the anterior horn—the *neck*—is replaced, as above said, by a reticulum of cells and fibres, part of these latter being the fibres of the crossed tract on their way to the opposite side of the medulla. This network constitutes the anterior part of the *formatio reticularis* or grey reticulum (Figs. 54, 55, *f. r.*).

(*b*) The grey matter of the *posterior horn*, on reaching the medulla, also takes up a lateral position and increases in amount. The *head* of the horn, much enlarged, comes nearer to the surface, and appears at about the middle of the medulla as a

well-marked grey nucleus, the TUBERCLE of ROLANDO (*t. R.*, Fig. 54), beneath the surface prominence of the same name. To its outer side will be seen a band of white fibres, the ASCENDING ROOT of the FIFTH CRANIAL NERVE (*5th as.*, Fig. 54).

The grey matter of the *base* of this horn is also much increased in amount, and, between the median line and the grey nucleus of Rolando, grows out as two superficial aggregations—the inner one into the fasciculus gracilis to form the NUCLEUS of the FASCICULUS GRACILIS, the outer into the fasciculus cuneatus to form the NUCLEUS CUNEATUS (Fig. 54). Each nucleus thus lies beneath the corresponding white tract on the surface, and causes the elevations called the clava and the cuneate tubercle. To these nuclei, as we have seen, can be traced most of the fibres of the posterior column of the spinal cord. The nuclei themselves may be followed as far as the pons. From them start a set of fibres (internal arciform fibres) which cross the middle line and go to form the sensory decussation (see page 83).

The *neck* of the posterior cornu, like that of the anterior, is replaced by a network of fibres, the white reticulum, which becomes continuous with the grey reticulum, constituting together the FORMATIO RETICULARIS (Figs. 54 and 55), a network of longitudinal, oblique, and transverse fibres (arciform fibres), with nerve cells and neuroglia cells embedded amongst them. The fibres of this reticulum are chiefly commissural in nature, though there are reasons for thinking that sensory impulses, and impulses which inhibit spinal reflexes, travel through

it to the cerebrum (see "Sensory Decussation," s. d., Fig. 52, page 78). Some of its longitudinal fibres are derived from the mixed zone—anterior root zone—of the anterior column of the spinal cord.

2. Isolated Grey Masses or Nuclei of the Medulla.—The chief of these nuclei are—

- (1) The corpus dentatum or olivary nucleus.
- (2) The accessory olives.
- (3) The arciform nucleus.

(a) The CORPUS DENTATUM or *olivary nucleus* (Fig. 55) is contained in the centre of the olivary body, which must be cut into in order to see it. It is covered superficially by the external arciform fibres (Fig. 55). This ganglion consists of flask-shaped, multipolar nerve cells, and neuroglia cells arranged as a zig-zag lamina or crumpled sheet of grey matter, concave and open on its inner aspect. Through this opening, called the *hilum*, enters the olivary peduncle, a bundle of nerve fibres, which passes into the centre of the olivary nucleus, to be there distributed in different directions.

The corpus dentatum or olivary ganglion is closely connected with a grey mass in the cerebellum—the corpus dentatum of the cerebellum—for any injury to this latter nucleus causes atrophy of the opposite olivary ganglion (Fig. 99, Plate XXXVII., page 168).

(b) Two other isolated nuclei—the ACCESSORY OLIVES (Fig. 55)—will be found, the one on the inner

side of, the other behind, the corpus dentatum. They are linear in shape, and are closely connected with the olivary nucleus.

(c) The third nucleus — ARCIFORM NUCLEUS; nucleus of the external arciform fibres (Fig. 54)—is placed amongst these fibres as they cross over the anterior pyramids of the medulla. The nucleus itself is continuous above with the nucleus pontis (See "Pons").

The remainder of the grey matter—the nuclei of the several cranial nerves—will be studied in relation to the floor of the fourth ventricle (page 111).

TABLE OF GREY MATTER OF THE MEDULLA.

	<i>Cord.</i>	<i>Medulla.</i>
Grey Matter of the Spinal Cord.	Anterior Cornu.	Head—Nucleus lateralis.
		Neck—Anterior part of the formatio reticularis.
	Posterior Cornu.	Base—Nucleus of the hypoglossal nerve.
		Head—Nucleus of Rolando.
		Neck—Posterior part of the formatio reticularis.
Isolated grey nuclei in the Medulla.		Base—{ Nucleus gracilis.
		{ Nucleus cuneatus.
		{ Nuclei on floor of 4th ventricle.
		Nucleus of the olivary body.
		Accessory olivary nuclei.
		Nucleus of the external arciform fibres.

Raphé.—A transverse section of the medulla will show you that above the level of the pyramidal decussation the medulla is partially divided into two lateral segments by a central median raphé or partition, which forms a thin membranous septum of nerve substance, extending from the anterior median fissure to beneath

FIG. 57.

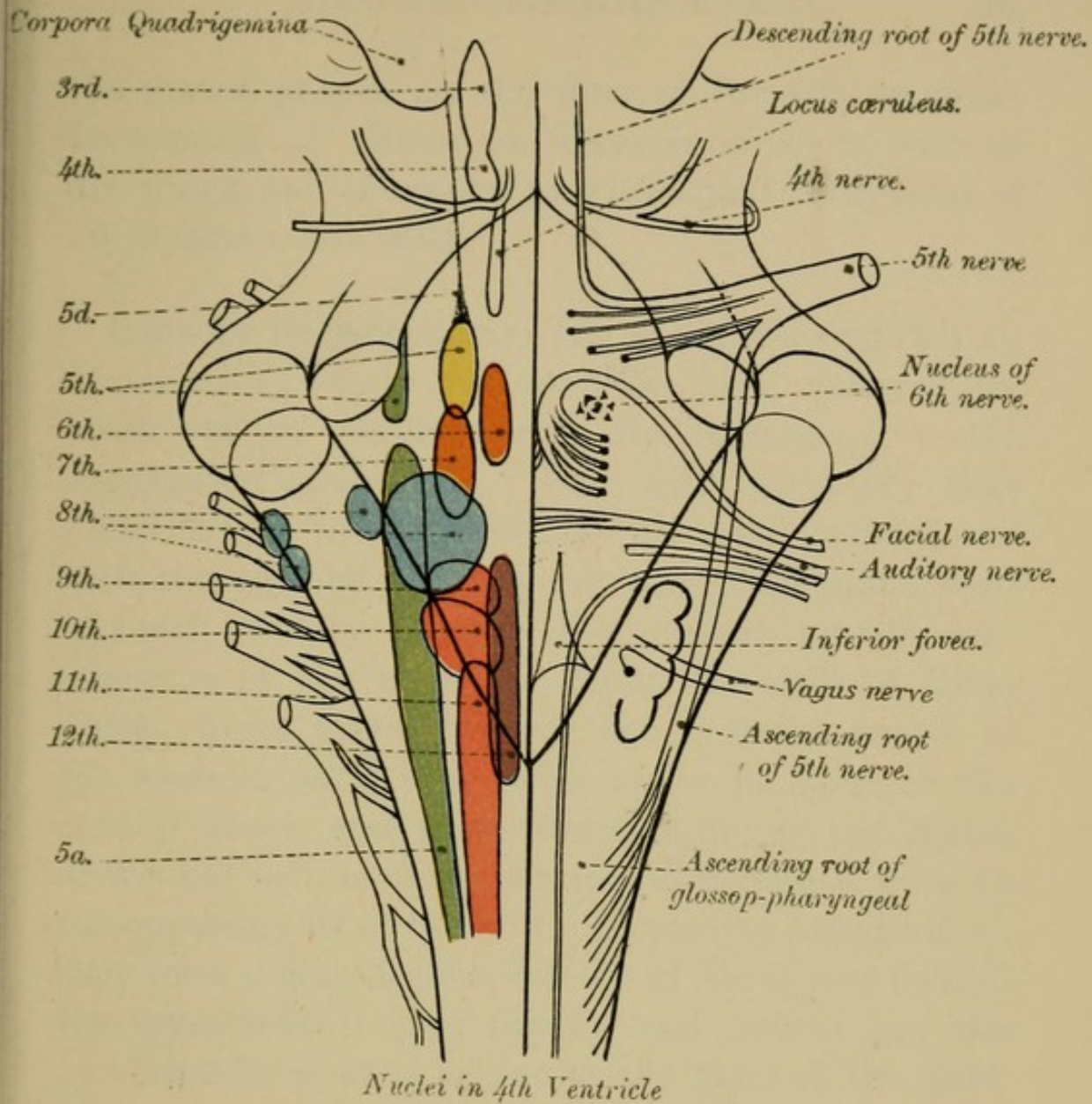
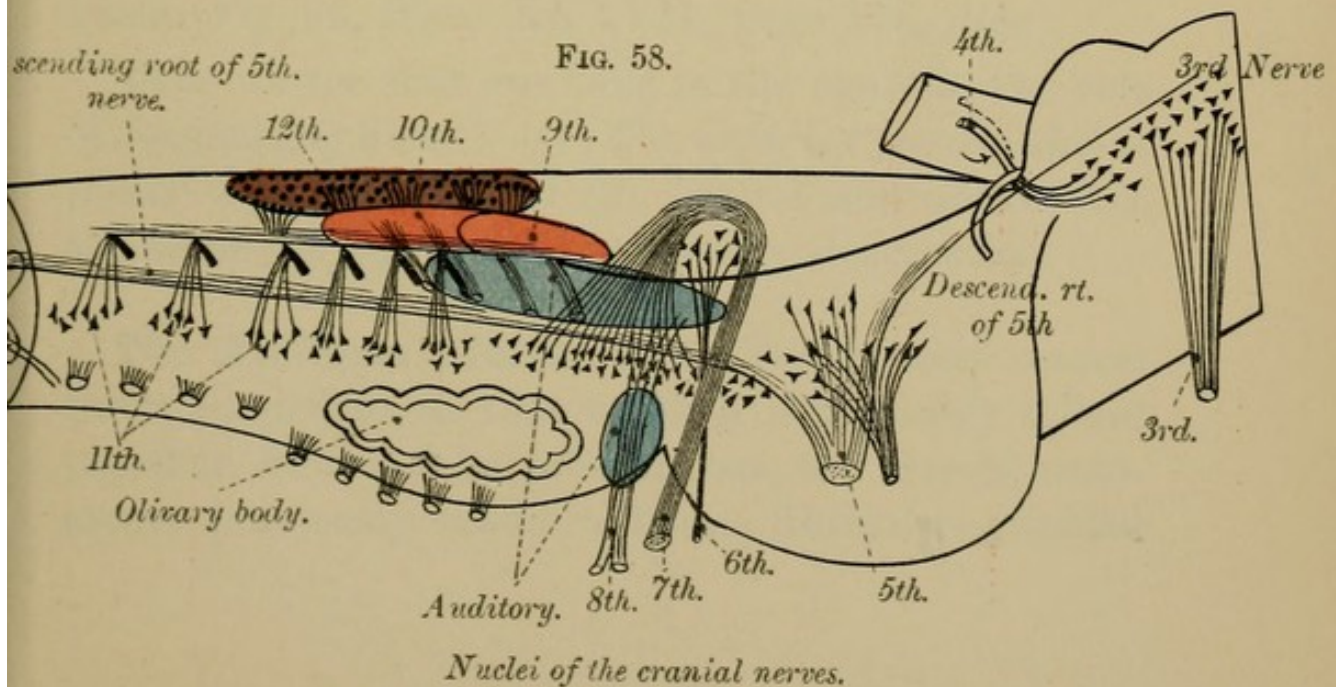



FIG. 58.





the central groove on the floor of the 4th ventricle. It consists of numerous fibres running in various directions, and interspersed with small collections of multipolar nerve cells.

Sensory Decussation.—The SUPERIOR PYRAMIDAL decussation, which has so often been referred to, must not be confused with the inferior or motor decussation (page 73). You will remember that fibres can be traced from the posterior spinal nerve roots through the posterior columns of the spinal cord to their primary stations, the nucleus gracilis and cuneatus of the medulla. From the cells of these nuclei, fibres travel towards the anterior aspect of the medulla until they come to lie in front of the central canal, and there decussating in the raphé, above and behind the pyramidal decussation, cross to the opposite side of the bulb. Becoming longitudinal, they form a considerable bundle of fibres just behind the pyramids (motor fibres), and ascend to the cerebrum in what is known as the tract of the fillet, or lemniscus. They are crossed sensory tracts to the brain (Fig. 96, Plate XXXVII., page 168, *fillet*).

Thus we see that we have in the medulla two sets of decussating fibres :—(1) The *inferior pyramidal* or *motor* decussation; and (2), behind and above this, the *superior pyramidal* or *sensory* decussation.

The Arciform Fibres have already been several times alluded to, so that we shall now merely collect together, for the sake of clearness, the several statements previously made. These fibres are divided

into a superficial or external set, and a deep or internal set.

1. The SUPERFICIAL ARCIFORM FIBRES form two groups:—

(a) The *anterior external arciform fibres*, which spring, you will remember, from the anterior median fissure, through which they can be traced to the central raphé, where they probably cross over to the posterior column of the opposite side of the medulla, to the nucleus gracilis and cuneatus. Emerging from the fissure, they wind round the anterior pyramids below, and over the outer surface of the olives, across the line of origin of the 9th, 10th, and 11th pairs of nerves. Turning upwards, they then blend with the fibres of the direct lateral cerebellar tract, and with them form the chief part of the restiform body (Fig. 50, page 70).

(b) The other group—the *posterior external arciform fibres*—passes from the posterior column of one side to the restiform body of the same side (Fig. 99, Plate XXXVII., page 168).

2. The DEEP ARCIFORM FIBRES are a delicate network of fibres found between the olives and behind the pyramids. The exact course and origin of these fibres are not yet known with certainty. Many of them are derived from the nuclei of the posterior columns before mentioned (superior pyramidal decussation). Others enter the centre of the olivary nucleus through its hilum, and either join the cells of that nucleus or pass through the nucleus to the restiform body directly, or first make for the

surface, and then, along with the external arciform fibres, go to the restiform body.

Recapitulation.—Since the constitution of the medulla is so complicated, it will be well to summarise the above facts in a somewhat different order. Commencing at the anterior median fissure, we meet on each side of that fissure—

1. The ANTERIOR PYRAMIDS OF THE MEDULLA, composed of longitudinal fibres, derived chiefly from the crossed pyramidal tracts of the opposite lateral columns, and to a small extent from the direct pyramidal tracts of the same side. Most of the motor fibres coming from the brain are contained in these pyramids, though others, as we shall afterwards see, first go to the pons, thence to the cerebellum, thence to spinal cord (secondary motor tract).

2. Superficial to the anterior pyramids are a set of fibres, which, having their origin in the nucleus gracilis and nucleus cuneatus of the one side of the medulla, and having decussated in the middle line, emerge from the anterior median fissure, cross over the surface of the anterior pyramids and the olives of the opposite side to that from which they started, and go to join the restiform body. They are the *superficial arciform fibres* (Figs. 55, 56, *e.a.f.*), and amongst them is a mass of grey matter, the ARCIFORM NUCLEUS.

3. In the middle line behind the pyramids, between them and the central canal, are thick white bundles of fibres arranged in concentric curves. They spring from the region of the posterior columns,

nucleus gracilis and cuneatus, and form the SUPERIOR PYRAMIDAL DECUSSATION, or decussation of the fillet. Higher up in the medulla this same region is occupied by fibres which traverse the medulla in all directions—*formatio reticularis*. Neuroglia cells, and a few nerve cells are scattered amongst the fibres, many of which are known as the deep arciform fibres.

4. Outside the *formatio reticularis*, between it and the surface, but behind the pyramids, is the OLIVARY NUCLEUS (*n.o.b.*, Fig. 56) with the OLIVARY PEDUNCLES. This nucleus is covered superficially by the external arciform fibres (Fig. 56). Close to it are the ACCESSORY OLIVES (Figs. 55, 56, *a.o.*, page 78).

5. Behind the olives you will see the NUCLEUS LATERALIS (*n.l.*, Fig. 54), the upward continuation of the anterior cornu of the spinal cord.

6. Posterior to the nucleus lateralis appears the grey TUBERCLE of ROLANDO (Figs. 53, 54, *t.R.*)—the enlarged head of the posterior horn of the spinal cord. On its outer side will be seen the ascending root of the 5th nerve (*5th as.*, Fig. 54). Superficial to the tubercle of Rolando are the fibres of the DIRECT LATERAL CEREBELLAR TRACT, which are on their way, along with the arciform fibres, to the inferior cerebellar peduncles or restiform body.

7. Posterior and internal to the nucleus of Rolando is a mass of grey matter—the NUCLEUS CUNEATUS (*n.c.*, Fig. 54)—lying beneath the cuneate tubercle; and still nearer the middle line is another grey collection, the NUCLEUS of the FUNICULUS GRACILIS (Figs. 54, 55, *n.g.*).

In front of the nucleus cuneatus will be seen a special white rounded fasciculus, known as the *FASCICULUS SOLITARIUS* (*f.s.*, Fig. 55), the ascending root of the glosso-pharyngeal nerve.

Close to the middle line, internal to the nucleus cuneatus, lies the nucleus of the hypoglossal nerve, from which the nerve itself may be seen running forwards to its superficial origin.

The rest of the grey matter, internal to the nucleus of the funiculus gracilis, and on each side of the posterior median groove, belongs to the floor of the 4th ventricle (Fig. 57, page 82), and will be fully described with that cavity.

The next division of the brain to be considered is the metencephalon, comprising the pons and cerebellum.

II.—PONS VAROLII.

GENERAL OUTLINE.—**The Pons Varolii**—part of the metencephalon, the other part being the cerebellum—is a broad white band which crosses transversely between the two halves of the cerebellum above the level of the anterior aspect of the medulla oblongata. It rests on the body of the sphenoid. Composed of grey and white matter, it presents an upper and a lower border—an anterior and a posterior surface (Fig. 46, page 66, and Figs. 59, 60, Plate XIX., page 90).

The **UPPER BORDER** is arched, being higher in the middle than at the sides, and from it spring the *crura cerebri*, or cerebral peduncles. Two cranial nerves, the 3rd and 4th, are seen at this border, the former being near the middle line.

The LOWER BORDER, which marks the upper limit of the medulla in front, is horizontal, and is almost in contact with the upper margin of the pyramids and the olives (Figs. 46, 49, page 66). At this border are seen, from within out, the 6th, 7th, and 8th cranial nerves.

The ANTERIOR SURFACE of the pons is convex, and rests on the dorsum sellæ of the sphenoid bone. Along the middle line it presents a shallow groove, which lodges the basilar artery. On each side of this groove is a longitudinal elevation caused by the continuation upwards of the pyramids of the medulla. At the sides, the pons becomes narrowed, and passes as two rounded bundles, one on each side, into the cerebellum, forming its *middle peduncles*. From the lateral part of this aspect of the pons springs the 5th cranial nerve.

The POSTERIOR SURFACE of the pons has ill-defined limits, being continuous below with the medulla, above with the cerebral peduncles. Flattened from before backwards it forms the upper part of the floor of the 4th ventricle, and will be described with that cavity (page 106).

When we examine transverse sections of the pons, we find that it can be divided into two portions, a ventral portion and a dorsal portion. The latter, called the tegmentum, is a continuation upwards of the constituents of the spinal cord and medulla, with the exception of the pyramidal tracts. The former, the ventral part, contains, besides the proper fibres of the pons, the upward continuation of the pyramids of the medulla.

It is interesting to note that in mammalia the size of the pons bears a direct relation to the size of the lateral lobes of the cerebellum; and that in birds, reptiles, and fishes, where we have no cerebellar hemispheres, the pons also is wanting.

We shall consider the constitution of the Pons according to the following table:—

TABLE OF THE STRUCTURE OF THE PONS VAROLII.

I. WHITE MATTER OF THE PONS.

1. Transverse fibres.
 - (1) Superficial.
 - (2) Deep.
2. Longitudinal fibres.
 - (1) Superficial.
 - Anterior pyramids.
 - (2) Deep.
 - (a) Lemniscus, or fillet.
 - (b) Posterior longitudinal bundle.
 - (c) Fasciculus teres.
3. Fibres of the 5th, 6th, 7th and 8th cranial nerves.
4. *Formatio reticularis*.
5. *Raphé*.

II. GREY MATTER OF THE PONS.

1. Nucleus pontis.
2. Superior olive.
3. Nuclei of origin of 5th, 6th, 7th and 8th cranial nerves.
4. Locus cæruleus.

1. WHITE MATTER OF THE PONS.

DISSECTION.—To see the arrangement of the white fibres of the pons, you will require to dissect down on each side of the middle line, through the superficial transverse fibres, until you reach a longitudinal set passing upwards from the medulla. Reflect the longitudinal fibres, when a still deeper transverse group will come into view.

The white or medullated nerve fibres of the pons are arranged in two sets, a transverse and a longitudinal, each being again divisible into a superficial and a deep group.

1. Transverse fibres.—(1) The SUPERFICIAL TRANSVERSE fibres appear on the surface of the pons, and (2) the DEEP TRANSVERSE fibres lie behind the superficial longitudinal ones (Figs. 59, 60, page 90). At the lower part of the pons, near the medulla, the deep set of transverse fibres forms a special collection, called, from its peculiar arrangement, the *trapezium* (Fig. 59). Traced laterally, all the transverse fibres of the pons pass into the middle peduncle of the cerebellum. Some of these fibres are commissural between the two halves of the cerebellum; others are connected with the nucleus pontis of the same side or of the opposite side.

2. Longitudinal fibres.—(1) The SUPERFICIAL LONGITUDINAL fibres (Figs. 59, 60) are mostly the upward continuation of the *anterior pyramids* of the medulla, and in transverse sections are seen as two rounded bundles behind the superficial transverse fibres, though many of them are intersected by these latter. (2) The DEEP LONGITUDINAL bundles (Figs. 59, 60) are placed near the dorsal aspect of the pons, which is chiefly made up of the *formatio reticularis*, and of a prolongation of the grey matter of the medulla. Three distinct sets of longitudinal fibres can, however, be recognised—viz., (a) the *lemniscus*, or fillet, the continuation of the sensory decussation; (b) the *posterior longitudinal bundle*,

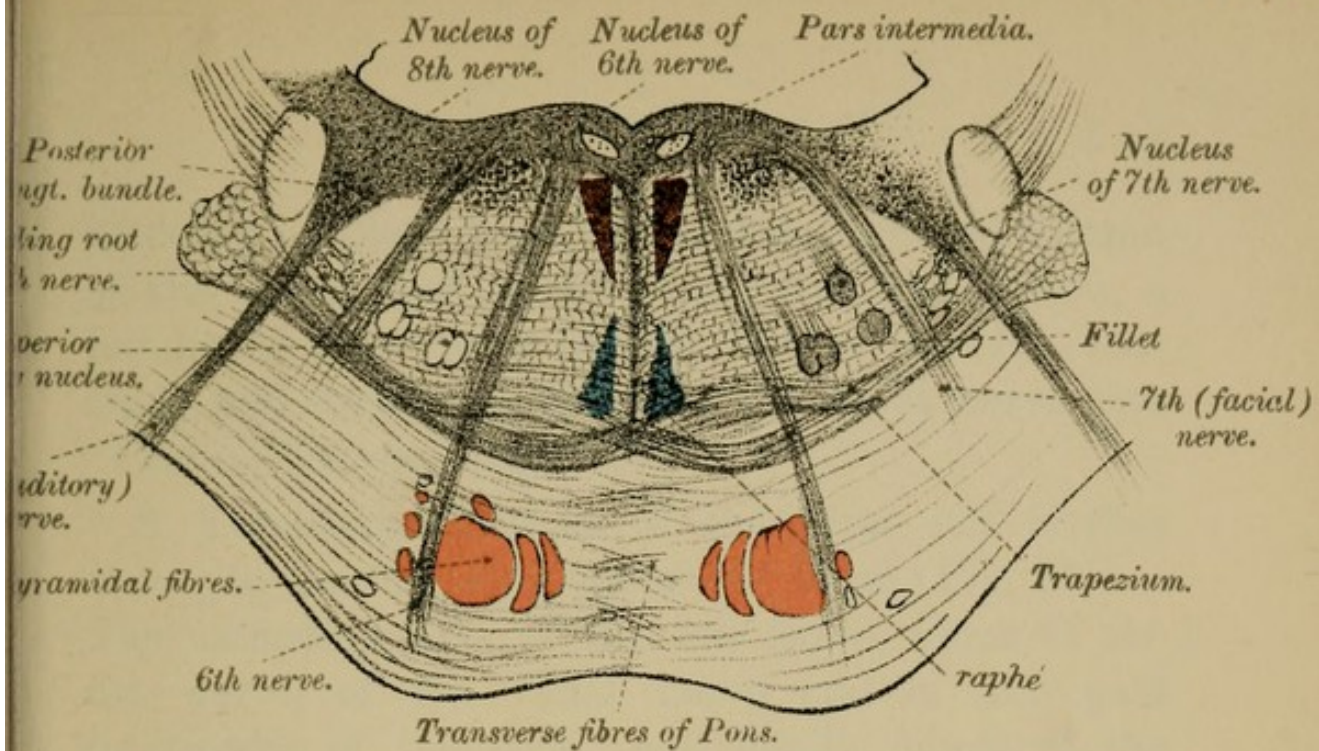


FIG. 60.

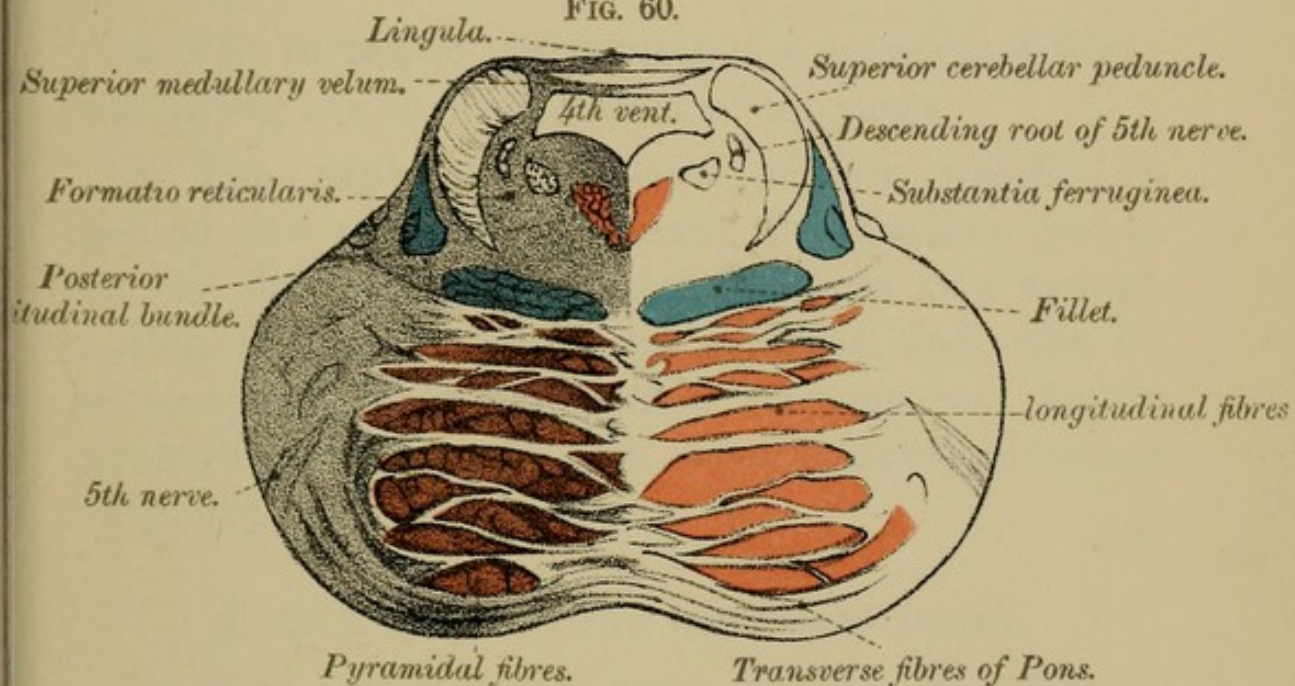
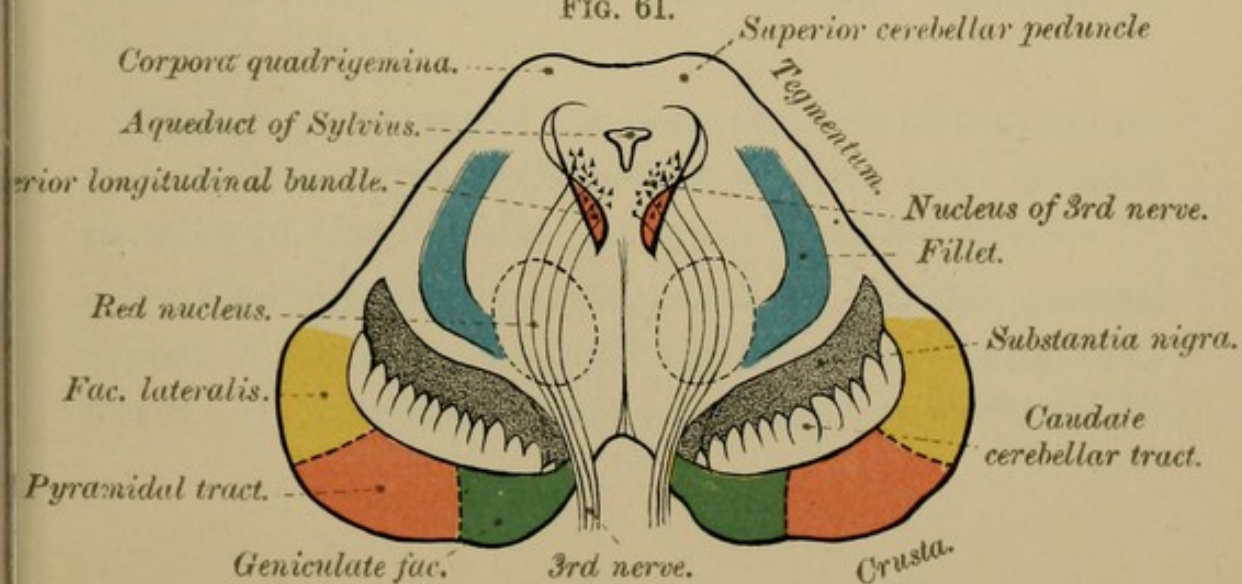



FIG. 61.





made up of fibres traced from antero-lateral column of the spinal cord; and (c) the *fasciculus teres*, a bundle of fibres seen in the floor of the 4th ventricle, and containing fibres of the facial nerve (see "Cranial Nerves," page 170).

3. Transverse sections of the pons will further show you the following additional fibres (Fig. 59):—The ascending root of the 5th nerve, fibres of the 6th nerve, of the facial nerve and of the pars intermedia of the facial, and finally, fibres of the 8th nerve.

4. **The formatio reticularis** is a network of fibres occupying the tegmental part of the pons.

5. **The raphé** is a mesial septum which lies behind the trapezium, beneath the median groove on the floor of the 4th ventricle. It is a continuation of the raphé of the medulla, and, like it, is composed of fibres, partly nervous and partly neuroglia, which cross each other in every direction (Fig. 59).

2. GREY MATTER OF THE PONS.

DISSECTION.—To see the grey matter of the pons you will require a series of transverse sections similar to those represented in Plate XIX., page 90.

The grey matter of the pons consists of multipolar and stellate nerve cells, either scattered or arranged in more or less definite groups. Thus we have—

1. **The nucleus pontis**, situated on the ventral aspect of the pons, amongst the superficial transverse fibres. It consists of many scattered nerve cells, to

which can be traced fibres from the cerebrum—cortico-pontine fibres; and fibres from the cerebellum—ponto-cerebellar fibres.

2. **The superior olivary nucleus** (Fig. 59), placed on the dorsal part of the pons, behind the trapezium, at some little distance from the middle line, in a region which would correspond to the prolongation of the lateral area of the medulla.

3. **The nuclei of origin** of the 5th, 6th, 7th, and 8th cranial nerves.

4. **The locus cæruleus**—a bluish spot, which will be described with the upper part of the floor of the 4th ventricle (page 106).

III.—CEREBELLUM.

(Plates XX., XXI., XXII., XXIIA., page 94, &c.)

The Cerebellum, or Little Brain, the second division of the metencephalon, is placed behind the pons and medulla, and, like the rest of the brain, is composed of grey and white matter. It occupies the two lower fossæ of the occipital bone, lying beneath the level of the tentorium cerebelli, which separates it from the posterior part of the cerebral hemispheres. Ellipsoidal in shape, with its long diameter transverse, it will be seen to consist of a median division, called, from its worm-like appearance, the VERMIFORM PROCESS, of two lateral divisions, the CEREBELLAR HEMISPHERES, and of the three PEDUNCLES—superior, middle, and inferior—by means of which it is brought into relation with the cerebrum, with the

pons, and with the medulla. The median division, the vermiform process, though incorporated with the rest of the cerebellum, is quite a separate division of the little brain. This is shown by the fact that it is the only part of the cerebellum which is developed in birds, in reptiles, and in fishes. Even in many mammals the central lobe is much larger than the lateral lobes.

We shall consider the several parts of the cerebellum in the following order—(1) The lobes; (2) the peduncles; (3) the medullary vela; (4) the grey matter; and (5) the white matter (see Fig. 62, &c., Plate XX., page 94).

CEREBELLAR HEMISPHERES.

(Figs. 62, 63, page 94.)

The Cerebellar Hemispheres present three surfaces—an anterior, a superior, and an inferior—the last two being separated from each other by a definite margin, in which runs a well-marked cleft, the **GREAT HORIZONTAL FISSURE**. The hemispheres are darker in colour than those of the cerebrum, and consist of a central white core and of numerous crescentic laminæ of grey matter with their convexities backwards (Fig. 62, page 94).

1. The **UPPER SURFACES** of the cerebellar hemisphere are concave, and are separated from each other along the middle line by a slightly raised ridge, with a shallow groove on each side. This raised portion is the **SUPERIOR VERMIFORM PROCESS**, and across it the two cerebellar hemispheres are continuous with each

other, there being no definite line of demarcation between them (Fig. 62, page 94).

2. The UNDER SURFACE of each hemisphere is, on the other hand, convex, and is divided from its fellow by a wide median groove or hollow, the VALLECULA, in which you will see a definite division of the cerebellum, the INFERIOR VERMIFORM PROCESS. Posteriorly, the hemispheres are separated by a mesial notch—INCISURA CEREBELLI POSTERIOR—which receives the free anterior margin of the falx cerebelli.

3. The ANTERIOR SURFACE of the cerebellum presents in the middle line a wide notch—the INCISURA CEREBELLI ANTERIOR—which lodges the Pons Varolii and Medulla, and in which, when these are removed, we see from above downwards—

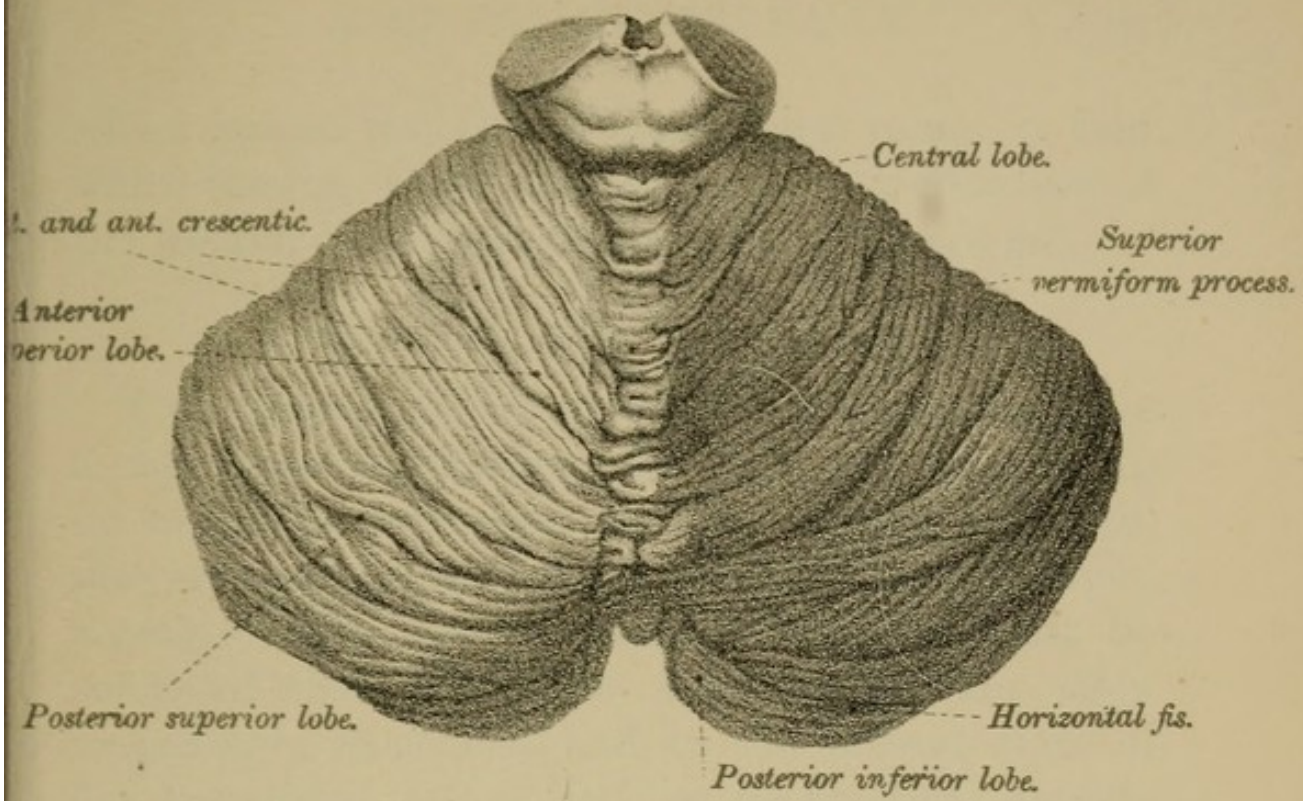
- (a) Anterior end of superior vermiform process.
- (b) Valve of Vieussens, or superior medullary velum.
- (c) Cavity of the 4th ventricle.
- (d) Anterior end of inferior vermiform process, and anterior part of mesial fissure of under surface.

At the sides are the cerebellar hemispheres, with—

(a) The three peduncles—superior, middle, and inferior.

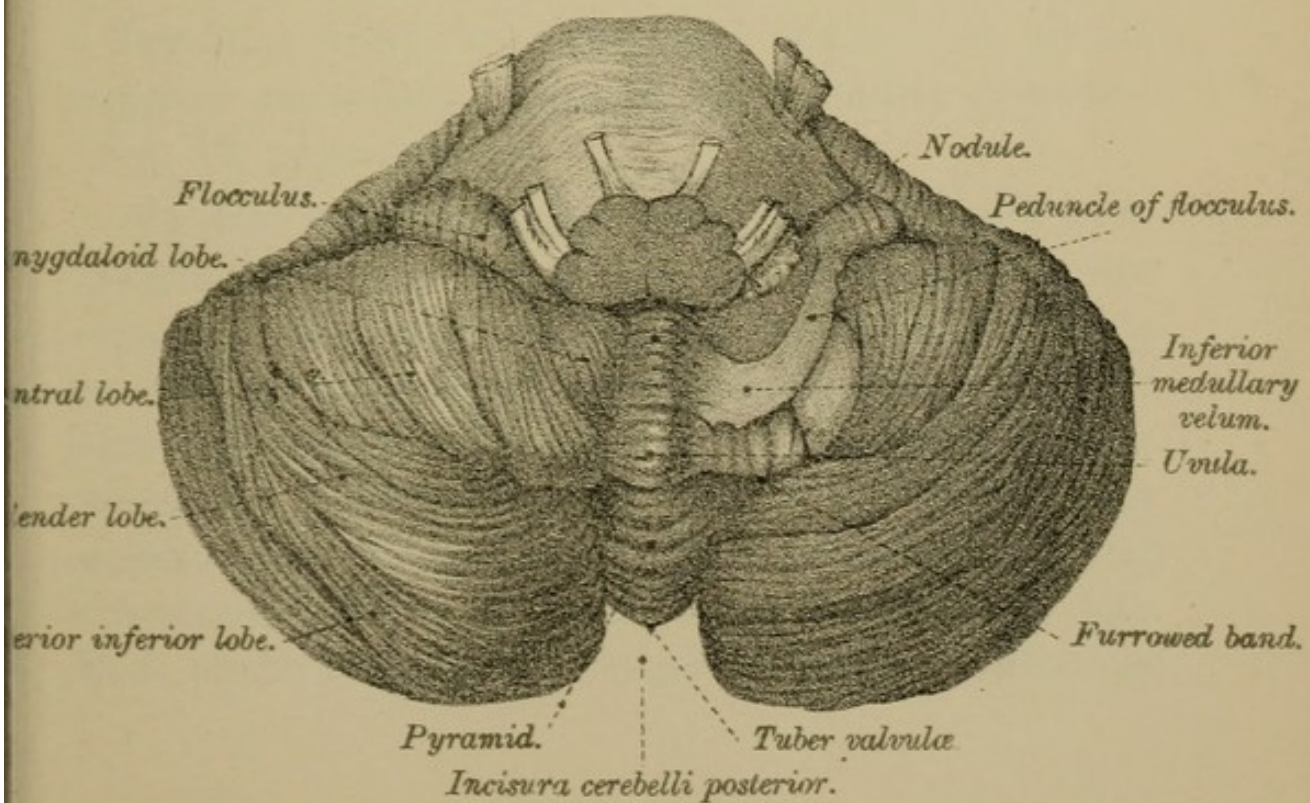
(b) Outside the middle peduncle is the longitudinal sulcus which separates the upper from the lower lobes. In this sulcus, near the middle peduncle, is lodged the flocculus, from the inner end of

FIG. 62.




UPPER ASPECT OF CEREBELLUM.

FIG. 63.



LOWER ASPECT OF THE CEREBELLUM.



which passes the inferior medullary velum, a thin white lamina, which extends to the anterior end of the inferior vermiform process (Fig. 63, page 94).

1. LOBES OF THE CEREBELLUM.

The surfaces of the cerebellar hemispheres have a laminated appearance, for they are broken up by numerous transverse furrows, varying in depth, into crescent-shaped folia, which have been grouped together under special names, though it must be confessed that the lobes thus formed are often exceedingly ill-defined, and, in the present state of our knowledge, are of little or no practical importance. A tabular list of them is given for the purpose of reference.

1. On the *upper surface* of the cerebellar hemispheres the lobes are (Fig. 62, page 94):—

(1) The CENTRAL LOBE (Fig. 62), situated near the centre of the anterior margin, and consisting of a few folia, which are continued upwards on to the superior medullary velum, to be presently described (Fig. 48, page 66).

(2) The ANTERIOR SUPERIOR, and (3) the POSTERIOR SUPERIOR LOBES (Fig. 62). These lobes are separated from each other by a more or less distinct sulcus, which arches transversely across the surface of each hemisphere. The anterior superior lobe is often called the QUADRATE LOBE, and is divided into an anterior portion, named the *anterior crescentic*, and a posterior portion, the *posterior crescentic* (Fig. 62). Each of the lobes on the upper surface is continuous

across the superior vermiciform process with the corresponding one on the opposite side.

2. On the *under surface* of the hemispheres the lobes are better marked, and more easily distinguished from each other than they are on the upper surface (Fig. 63). Enumerated from behind forwards we find—(1) a few folia, the POSTERIOR INFERIOR LOBE; (2) the SLENDER LOBE; (3) the BI-VENTRAL LOBE; (4) an oval mass, the AMYGDALOID LOBE or tonsil; and, finally (5), a fringe-like lobe, the FLOCCULUS.

3. On the *superior vermiciform process* the lobes are—an anterior, the LOBULUS CENTRALIS; a middle, the MONTICULUS CEREBELLI; and a posterior, or COMMISSURA SIMPLEX.

4. On the *inferior vermiciform process* the lobes are:—

(1) The TUBER VALVULÆ (Fig. 63), placed between the posterior inferior and the slender lobes of opposite sides.

(2) The PYRAMID (Fig. 63), between the bi-ventral lobes.

(3) The UVULA (Fig. 63), between the amygdaloid lobes, and connected with them by a grey band, called, from its ridged appearance, the *furrowed band* (Fig. 63).

(4) The NODULE (Fig. 63), or *laminated tubercle*, the pointed anterior end of the inferior vermiciform process. It is placed between the flocculi, projects into the roof of the 4th ventricle, and is continuous with the inferior medullary velum (page 101).

2. PEDUNCLES OF THE CEREBELLUM.

The Peduncles of the Cerebellum are three for each hemisphere — the superior, the middle, and the inferior. They severally connect the cerebellum (1) to the pons—*crura ad pontem*; (2) to the medulla—*crura ad medullam*; and (3) to the cerebrum—*crura ad cerebrum*.

1. **The Superior Peduncles** (part of the *Isthmus Rhombencephali*) are two white bands, right and left (Fig. 47, page 66), hidden beneath the anterior part of the cerebellum, and to see them you will require to divide the cerebellum by a vertical median incision, and to draw the parts asunder. The *crura ad cerebrum*, or superior peduncles, arise in the middle of the white substance of the hemispheres, behind the inferior cerebellar peduncles, and, running upwards and forwards from the anterior aspect of the cerebellum to the under surface of the corpora quadrigemina, pass to the dorsal or tegmental part of the cerebral peduncles. At first the superior peduncles form the lateral walls of the upper part of the 4th ventricle, and leave between them a triangular interval which is bridged over by a lamina of nerve substance, the **SUPERIOR MEDULLARY VELUM** (Fig. 48, page 66). As they ascend the peduncles meet in the middle line, and form part of the roof of the 4th ventricle. The fibres of which they are composed come from the corpus dentatum of the cerebellum and from the cerebellar

PLATE XXI.

(Page 98.)

Fig. 66.—Section through the Cerebellum of a dog, showing arrangement of the different layers.

- A.* Layer of superficial epithelial cells.
- B.* Horizontal bipolar cells.
- C.* Molecular layer.
- D.* Granular layer.
- a.* Epithelial cells.
- b.* Horizontal bipolar cells.
- c.* Triangular cells.
- e.* Vertical bipolar cells.
- f.* " "
- g.* " "
- h.* Purkinjé's cells, on the axis-cylinder of which is a collateral (*i*), which ascends to the molecular layer and breaks up into branches.
- j.n.o.s.* Fibres from the medullary layer, ramifying like trees amongst Purkinjé's cells.
- p.* Moss fibres.
- r.* "

FIG. 64.

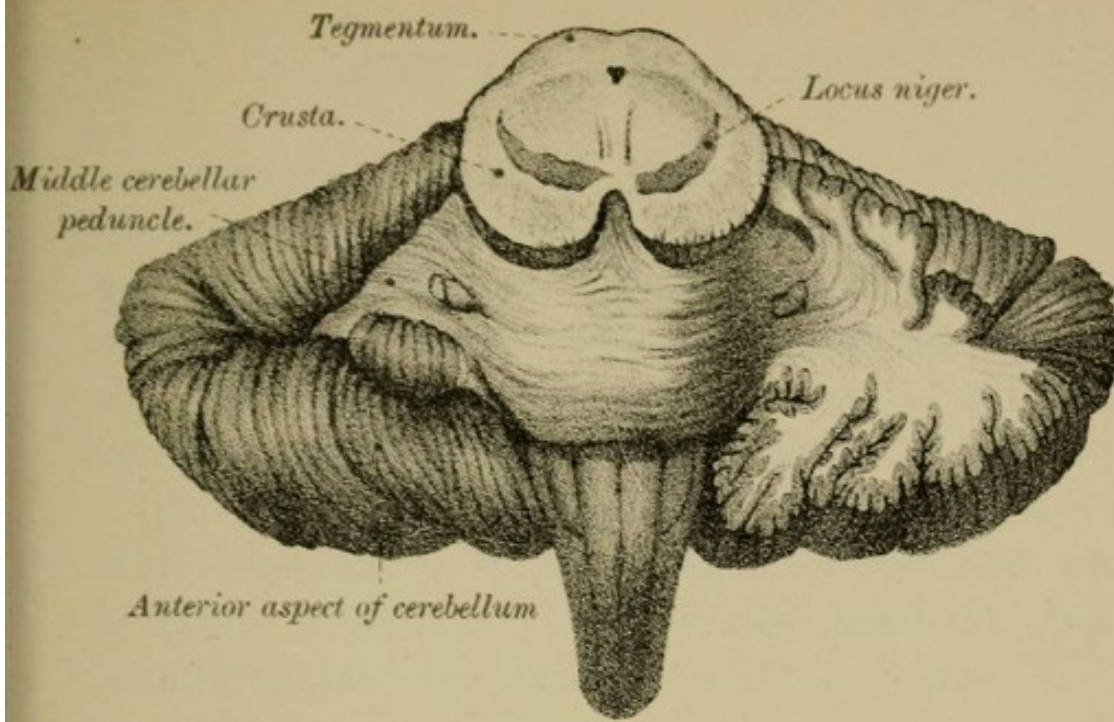
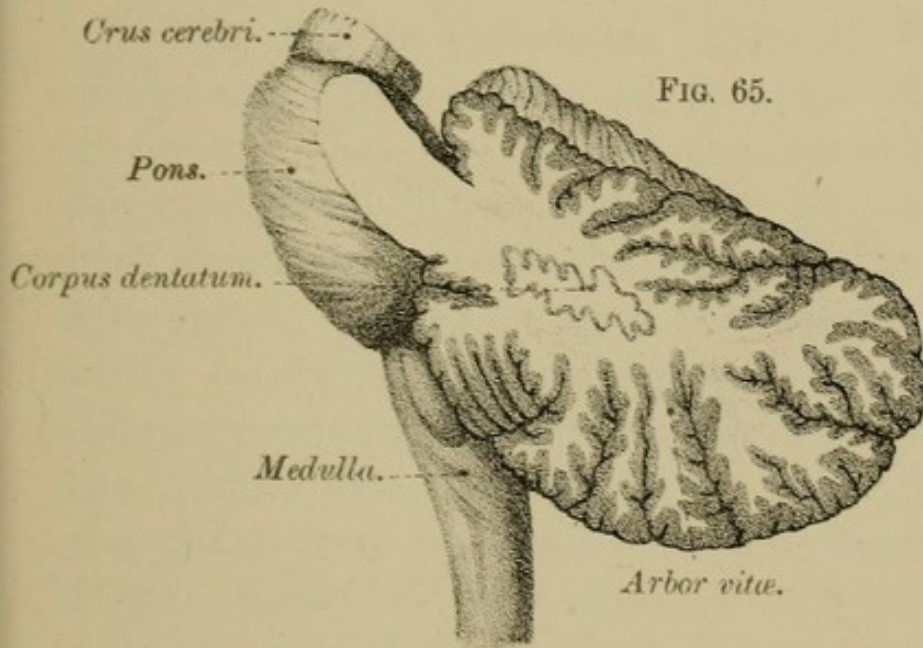


FIG. 65.



a. FIG. 66. b.

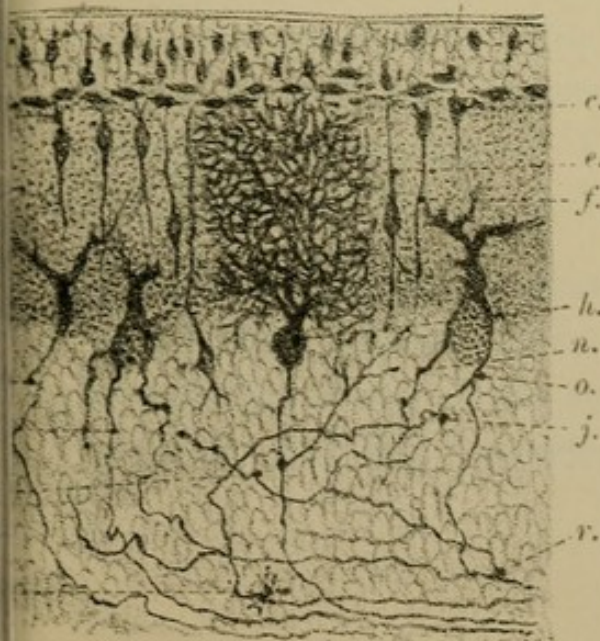
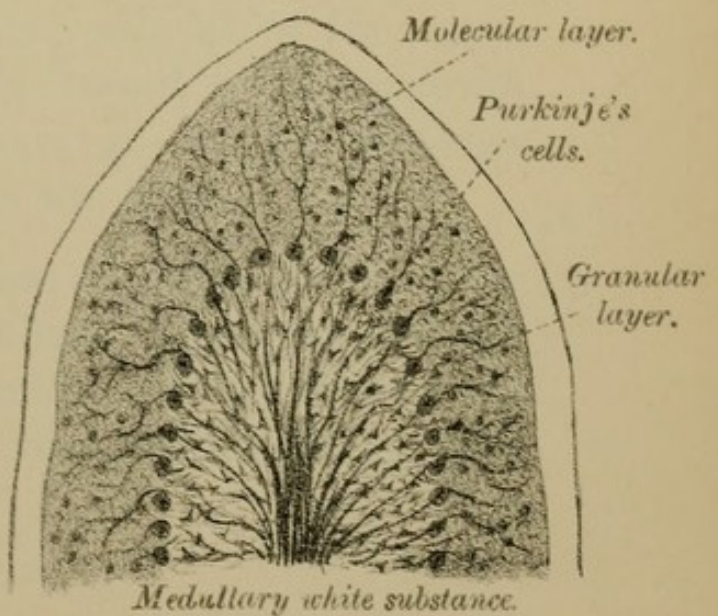



FIG. 67.





convolutions. Most of them decussate with the fibres of the peduncle of the opposite side, and then pass up as a distinct bundle, with those that do not decussate, to the higher parts of the brain—to the red nucleus, to the optic thalamus, and to the cerebral cortex (Fig. 99, page 168).

The superior peduncles are separated from the middle peduncles by an oblique sulcus from which proceeds a delicate lamina—the band of Reil—lemniscus lateralis (see “Auditory Nerve”).

2. The Middle Peduncles (Figs. 47, 49, page 66) of the cerebellum—*crura ad pontem*—are best seen in front. They are merely the continuation into the cerebellum of the lateral part of the pons, that part which lies beyond the superficial origin of the fifth nerve. Emerging from the lateral part of the white centre of the hemispheres, in front of the inferior peduncles, the middle peduncles pass towards the middle line, and, becoming incorporated with the pons, form its superficial and deep transverse fibres. Some of these fibres—inter-cerebellar—go from one half of the cerebellum to the other; others become connected with a nucleus in the pons—*nucleus pontis*—of the same side or of the opposite side, and can thence be traced to the opposite cerebral hemisphere. Others go to the posterior longitudinal bundle and to the fillet.

3. The Inferior Peduncles (Fig. 47, page 66) of the cerebellum—*crura ad medullam*, or *restiform bodies*—constitute one of the lateral boundaries of the lower part of the 4th ventricle, and then pass upwards

between the superior and middle peduncles into the white matter of the cerebellar hemispheres. Their constitution is somewhat complex, for they consist (1) Of a *spinal part*, composed of fibres from (a) the lateral column of the same side—direct lateral cerebellar tract already described; (b) from the posterior column of the same side—the posterior external arciform fibres (Fig. 99, Plate XXXVII, page 168); (c) from the posterior column of the opposite side—the anterior external arciform fibres (Fig. 99). (2) Of an *olivary part*, composed of fibres from the opposite olives—cerebello-olivary fibres (Fig. 99, page 168). (3) Of fibres uniting the roof nuclei of the cerebellum with the nuclei of origin of the 5th, 8th, 9th and 10th cranial nerves.

3. MEDULLARY VELA.

1. **The Superior Medullary Velum**—valve of Vieussens (Figs. 48, 60, pages 66, 90)—is a delicate sheet of nerve substance placed across the triangular interval left between the superior cerebellar peduncles before they meet in the middle line. Triangular in shape, with its apex forwards, it forms part of the roof of the upper division of the 4th ventricle, and consists of a white lamina crossed on its upper surface by several transverse grey ridges, with intervening furrows, called the *LINGULA* (Fig. 60, page 90), not to be confounded with the *ligula* (Fig. 48, page 66), the epithelial thickening along the lower margin of the 4th ventricle. The white and grey matter of the superior medullary velum

are continuous at the sides with the white and grey matter of the cerebellar hemispheres.

2. The Inferior Medullary Vela — valves of Tarini — consist of two thin delicate semilunar folds or laminae of nerve substance, one on each side, hidden beneath the amygdaloid lobes of the cerebellum, which must be removed with great care to see them. By their inferior (or posterior) convex border, each of these semilunar folds blends with the white substance of the inferior vermiform process and with the furrowed band; their anterior concave semilunar edge is free, or rather continuous with the layer of epithelium which lines the under surface of the pia mater roofing over the 4th ventricle. Externally these two semilunar folds are attached by a white band or peduncle to the flocculus; internally, a central part, very thin, continues the lateral portions across the middle line in front of the nodule (Fig. 63, page 94).

4. GREY MATTER OF THE CEREBELLUM.

The Grey Matter of the cerebellum consists of two parts: that on the surface—the *cortex cerebelli*; that in its interior—the *grey nuclei*.

1. The grey matter of the *cortex* of the cerebellum not only covers its surface, but lines the sides and passes across the bottom of its various fissures or sulci, so that in reality it forms a thin lamina folded on itself in a series of leaves or plates. A mesial vertical section will enable you to see this arrangement, and will show you the beautiful tree-like

appearance—ARBOR VITÆ—of the grey and white matter (Fig. 34, page 44; and Fig. 65, page 98).

2. The chief masses of grey matter in the *interior* of the cerebellar hemispheres are the CORPORA DENTATA, placed one in each hemisphere. In structure they are similar to the corpus dentatum of the olivary body, and are, as you will remember, closely connected with it. They each consist of a wavy band of brown coloured nerve substance, enclosing white matter, the whole forming a pouch-like wavy lamina or capsule, open at its upper and inner side (Fig. 65). Through this opening bundles of white nerve fibres pass into the centre of the corpus dentatum, and can be traced from the superior cerebellar peduncles, from the superior medullary velum, and from the restiform body.

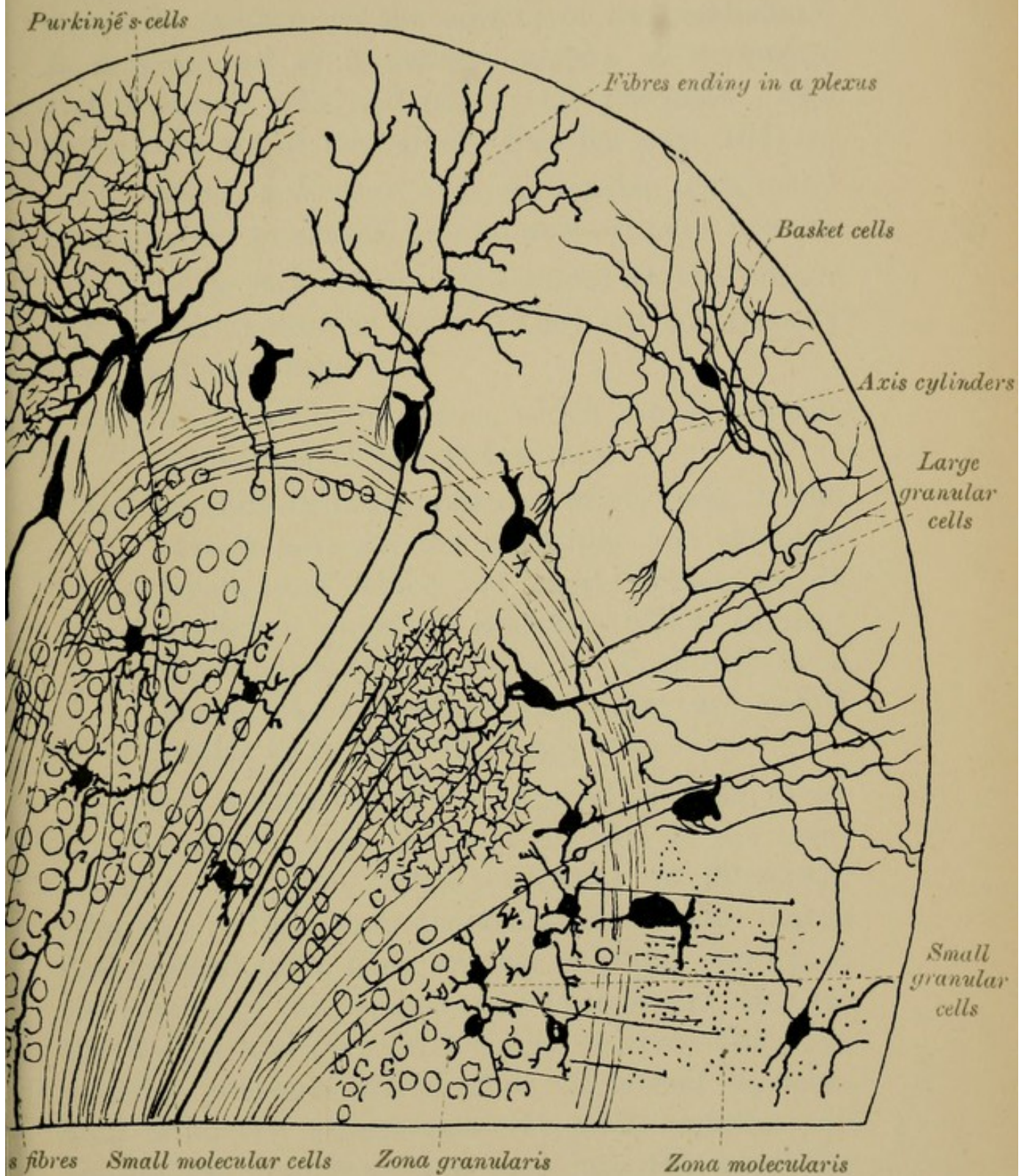
The other nuclei found in the white centre of the cerebellum are the nucleus globosus, the nucleus emboliformis, and the nucleus fastigii. They are situated near the middle line, internal to the corpus dentatum.


MINUTE STRUCTURE OF THE GREY MATTER.

In the Figs., Plate XXIIA., page 104, Van Gehuchten, the various elements are, for clearness sake, separated from each other. The circles represent the free surface.

The grey cortex of the cerebellum consists of three layers (Plate XXII., page 102; Fig. 68, page 104; and Figs. 66, 67, page 98):—

- (1) An *outer*—the molecular layer.
- (2) A *middle*—the layer of Purkinjé's cells.
- (3) An *inner*—the granular layer.





1. The OUTER LAYER—molecular layer—forms a clear grey stratum on the surface of the cerebellum. It is composed of a delicate matrix of neuroglia, and of nerve cells and nerve cell processes. The nerve cells are of two kinds (Fig. 68, page 104):—

(1) *Small molecular cells*, multipolar, with many protoplasmic processes, but no axis-cylinder process.

(2) *Large molecular cells*—placed at the deeper part of the molecular layer. They are transversely elongated, and have—

(a) Protoplasmic processes, which ramify towards the surface of the cortex; and

(b) An axis-cylinder process, which runs transversely between the molecular and granular layers, and which, at right angles to its direction, gives off branches which encircle the bodies of the cells of Purkinjé, in a basket-like network; hence they are called *basket cells* (Fig. 68, page 104).

2. The MIDDLE LAYER is formed of cells which are characteristic of the grey matter of the cerebellum. They are called the CELLS OF PURKINJÉ (Fig. 68), or from their shape ANTLER CELLS. Large flask-shaped cells, they are set at right angles to the surface of the cerebellum. Their larger ends are the deeper, and give off a single process—the axis-cylinder process—which sends off lateral branches and ultimately passes into the white matter. Of the lateral branches some pass into the molecular layer, some spread out in the granular layer. The outer process of the cells is much larger, and

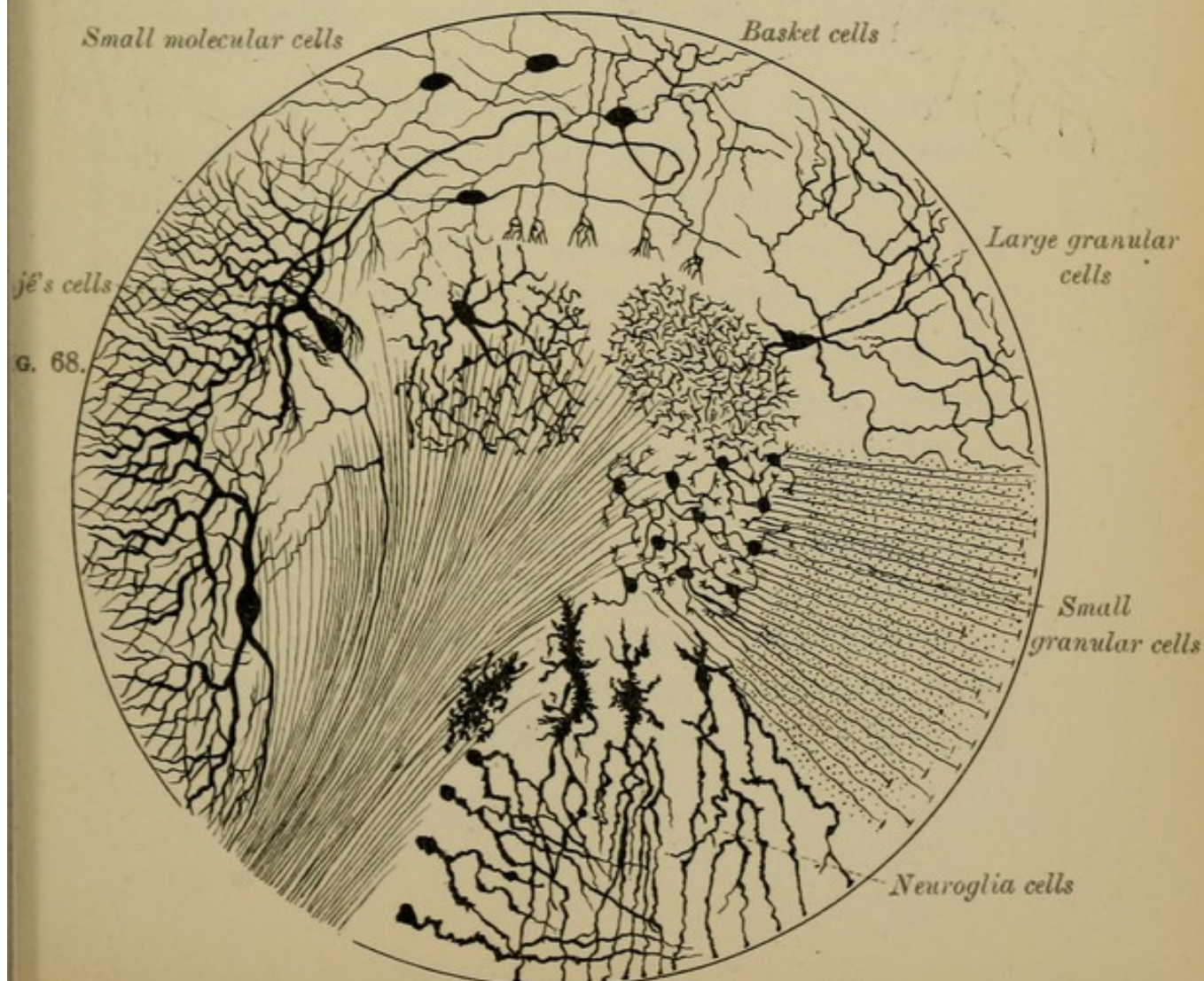
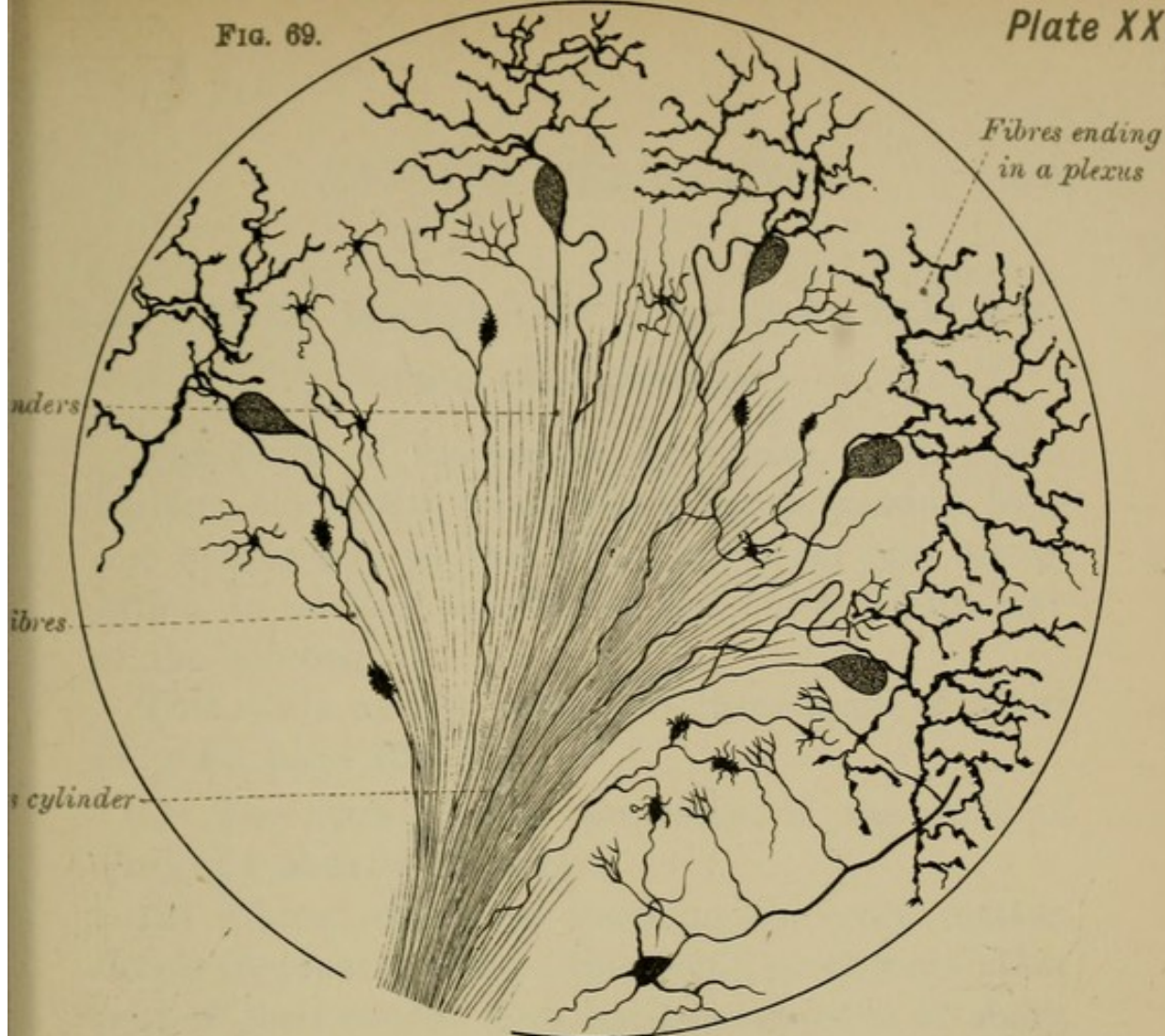
breaks up into leaf-like branches, like the horns of a deer, hence the name antler cells. These branches, called protoplasmic processes, spread out in planes across the laminæ, and form a rich plexus, ramifying towards the surface. Their ramifications end free, and do not anastomose with each other, nor with the processes of neighbouring cells, though some of them are said to be attached to the connective tissue, and to the blood-vessels, at the margin of the molecular layer.


3. The INNER or GRANULAR LAYER—*rust-coloured layer* of Turner—consists of nerve cells and neuroglia cells embedded in a delicate matrix of fine interlacing fibrillæ.

Its nerve cells are of two kinds—small granular and large granular (Plate XXII., page 102).

(1) The *small granular cells* are polyhedral in shape. Their protoplasmic processes end in little tufts of short thick branches (Fig. 68), and their axis-cylinder process is very slender, and arises either from the body of the cell or from one of the protoplasmic processes. Passing with an undulating course towards the molecular layer, the axis-cylinder process ends in two branches which run parallel with the laminæ of the cerebellum.

(2) The second kind of cells—the *large granular cells*—are found throughout the thickness of the granular layer; they have axis-cylinder and protoplasmic processes, the former giving off collaterals (Fig. 68).





5. WHITE MATTER OF THE CEREBELLUM.

(Plates, pages 102 and 104.)

The fibres of the several peduncles of the cerebellum, along with commissural bands, passing from one hemisphere to the other, and from one convolution to another, constitute the entire white core of the cerebellum.

This white matter consists of three kinds of fibres (Fig. 69, page 104):—

(1) The axis-cylinder processes of the cells of Purkinjé already described.

(2) Fibres which, on reaching the grey matter, divide frequently, and at this point, or at some other part of their course, form little mossy tufts of short, thick branches—hence they are called *moss fibres* (Fig. 69).

(3) A set of fibres which end in a plexus in the molecular layer, and appear to be prolongations of Purkinjé's cells, though not so in reality (Fig. 69).

Throughout the white matter, moreover, there are many neuroglia cells with their prolongations.

The FUNCTIONS of the cerebellum are as yet unknown. It probably contains psychical centres like the cerebrum. The classical experiments of Flourens point to the fact that it is a centre for the co-ordination of muscular movements, such as walking. Others hold that it is a centre which presides over equilibrium. Later experiments published in Dr Courmont's thoughtful and interesting work on the *Cerebellum and its Functions* show that the

cerebellum is also an organ connected with the emotions. He produces many facts of comparative anatomy in support of his theory, and adduces a formidable mass of clinical evidence, showing that, in cases of disease (tuberculosis, &c.) of the cerebellum, the emotional side of the patient's character is markedly affected, whereas the intellectual aspect remains intact.

THE 4th VENTRICLE.

ITS POSITION, FLOOR, ROOF, WALLS, AND NUCLEI.

In describing the posterior aspect of the medulla oblongata, on page 68, you will remember we treated of its lower or posterior division only; we now proceed to consider its anterior or upper half, that half which is connected with the 4th ventricle.

The 4th Ventricle is a conical-shaped space placed between the medulla and pons in front and the cerebellum behind. It is lodged in the forepart of the vallecule on the under surface of the cerebellum, and has a quadrilateral floor and a tent-like roof. We shall require to examine (1) its floor, (2) its lateral boundaries, (3) its roof, (4) its lining, (5) the openings into it, (6) its choroid plexus, and (7) the various collections of grey matter or nuclei beneath the floor.

I. The Floor, or Anterior Wall of the 4th Ventricle (Fig. 47, page 66), is a diamond-shaped depression of the figure of an heraldic lozenge, and resembles two triangles placed base to base. It

looks backwards and upwards, and its lower or posterior part occupies the back of the medulla; its upper or anterior part the back of the pons. Its formation is due to the separation from each other of the walls of the posterior median fissure of the spinal cord, and the consequent opening out of the central canal of the cord, thus bringing the grey matter round that canal to the surface. Of its four angles, two are lateral—right and left—and mark the widest transverse diameter of the ventricular floor; of the other two angles, the superior is on a level with the upper border of the pons, the inferior on a level with the lower border of the olivary body. From some supposed likeness to a writing pen, the apex of the lower part of the ventricular floor has been called the *calamus scriptorius*. At the lateral angles the space is prolonged for a short distance between the cerebellum and medulla, the prolongations being called lateral recesses. Running across the widest part of the ventricular floor, opposite the lateral angles, are the STRIÆ ACUSTICÆ (Fig. 47, page 66), which join the auditory nerve, and which, you will remember, mark the upper limit of the medulla on this aspect. They also serve to divide the ventricular floor into two divisions, a lower portion belonging to the medulla, and an upper portion belonging to the pons (Figs. 47, 50, pages 66, 70), both of which are again sub-divided, by the vertical median groove that runs from the superior to the inferior angle, into two lateral segments. Thus we get the entire ventricular floor marked out into four divisions—two above and two below the

striæ acusticæ (Fig. 47). On examining each of the lower divisions you will see, at about their centre, a small triangular depression called the INFERIOR or POSTERIOR FOVEA (Fig. 47), the base of which is directed downwards, the apex upwards, in close contact with the striæ; while its inner and outer margins are prolonged downwards, as two grooves, the inner until it meets the central median furrow near the lower angle of the ventricle, and the outer until it reaches the lateral wall of the cavity. Thus we find that each part of the lower division of the ventricular floor can be mapped out into the following four distinct areas:—

1. The *inferior fovea* (Figs. 47, 50), the space enclosed within the sides of the triangular depression just described.

2. A raised area, which lies between the median furrow and the inner margin of the fovea. It forms the lower part of the *fasciculus* or *eminentia teres*, and is often called the *trigonum hypoglossi* (Fig. 47).

3. The *tuberculum acusticum*, enclosed between the lateral wall and the outer margin of the fovea (Fig. 47). It is a part of a larger area, situated above the striæ acusticæ which cross it superficially.

4. The *ala cinerea* with the *eminentia cinerea*, placed below the base of the inferior fovea (Fig. 47).

In like manner each of the two upper segments of the ventricular floor, which differ from those of the lower half in being covered by a thin layer of white matter, has a similar triangular depression

(Figs. 47, 50), the SUPERIOR or ANTERIOR FOVEA, between which and the central furrow is a prolongation of the fasciculus teres (Fig. 47). Extending from the apex of this fovea to the upper angle of the ventricle is a shallow depression, which, from its dark aspect, is called the *locus cæruleus* (Fig. 47), the colour being due to a mass of pigmented nerve cells (substantia ferruginea) lying beneath.

II. Lateral Walls of the 4th Ventricle.—The lateral boundaries of the lower half of the ventricular cavity are formed from below upwards by (*a*) the FUNICULUS GRACILIS and its CLAVA (Figs. 48, 50, pages 66, 70); (*b*) higher up, by the tapering end of the FUNICULUS CUNEATUS (Figs. 48, 50); and (*c*) highest of all by the RESTIFORM BODY or inferior peduncle of the cerebellum (Figs. 48, 50). The boundary of the upper division of the floor is the SUPERIOR CEREBELLAR PEDUNCLE (Fig. 48) of either side.

III. The Roof of the 4th Ventricle.—The roof of the 4th ventricle is tent-like in shape—its apex projecting backwards towards the cerebellum. The lower half of the roof is formed by pia mater which at this point is reflected from the cerebellum to the back of the medulla. It is, however, deficient in the middle line—a hole, called the *foramen of Majendie*, being left in the roof. Its under surface is lined by a layer of flattened epithelial cells, and a thickening of this epithelium at the lower angle of the ventricle is called the *obex* (Fig. 48, page 66). A similar thickening, with the addition of a little white nervous

matter, skirting the side of the lower half of the floor, is called the *ligula* or *tænia* (Fig. 48). The roof of the upper portion of the ventricle is formed partly by the SUPERIOR CEREBELLAR PEDUNCLES after they meet in the middle line, and partly by the SUPERIOR and INFERIOR MEDULLARY VELA, laminae of grey and white matter already described (page 100).

IV. Ependyma Ventriculorum.—The floor of the 4th ventricle is covered by a layer of grey matter—the *ependyma ventriculorum*—consisting of neuroglia derived from the central grey nucleus round the canal of the spinal cord. Upon this ependyma lies a layer of ciliated epithelial cells continuous with the epithelium lining the central canal of the spinal marrow, and with that which lines the cavities of the third and lateral ventricles of the brain.

V. Openings into the 4th Ventricle.—At the superior angle, the 4th ventricle communicates by a narrow channel, AQUEDUCT of SYLVIVS (*iter a tertio ad quartum ventriculum*), with the THIRD VENTRICLE (Fig. 80, page 136); below, at the inferior angle, the cavity is continuous with the CENTRAL CANAL of the SPINAL CORD; behind, at the lower part of the roof, just above the inferior angle, a small rounded opening, the FORAMEN of MAJENDIE, puts the ventricle in communication with the SUB-ARACHNOID SPACE (Fig. 34, page 44); while at each side, near the lateral angles, are similar openings in the roof, between the cerebellum and

medulla. Through these openings the cerebro-spinal fluid can find its way from the sub-arachnoid space into the cavities of the brain and spinal cord.

VI. Choroid Plexus.—The choroid plexus of the 4th ventricle consists of two longitudinal vascular folds of the pia mater which forms the roof of the 4th ventricle. These vascular fringes run along each side of the middle line of the roof, projecting into the ventricle, though covered everywhere by the epithelium which follows all their windings and folds, and separates them from the cavity of the ventricle. Part of this plexus passes, as a vascular tuft, into each lateral recess.

VII. Grey Matter or Nuclei beneath the Floor of the 4th Ventricle.—Connected with the grey matter of the floor of the 4th ventricle we have the nuclei of origin of most of the cranial nerves. This grey matter is also the site of certain physiological centres—such as the vaso-motor, respiratory, and cardiac.

1. Nuclei beneath the *lower division* of the ventricular floor (Figs. 57, 58, page 82):—

(1) The first of these nerve nuclei lies beneath the lower part of the surface prominence known as the *fasciculus teres*, which skirts the median furrow on the ventricular floor. This prominence, which not only occupies the lower part of this area, but also passes up under the striæ acusticæ, gives origin in its lower part to the 12th or hypoglossal nerve, and is hence called the **HYPOGLOSSAL NUCLEUS**;

and in sections of the medulla at this level the fibres of the nerve may be seen running out from this nucleus towards the periphery (Figs. 55, *h.n.*, 57, pages 78, 82).

(2) The *tuberculum acusticum*, corresponding in position to the tubercle of Rolando, covers the PRINCIPAL AUDITORY NUCLEUS (Figs. 57, 58, page 82). It extends beneath the striæ into the upper division of the ventricular floor (Figs. 57, 58).

(3) The *ala cinerea* and its *eminentia* contain the nuclei of origin of several nerves: thus, in its lower part, we have the nucleus of the SPINAL ACCESSORY NERVE (Fig. 57); in its upper part, and extending into the inferior fovea, are the nucleus of the VAGUS below (Fig. 57), and of the GLOSSO-PHARYNGEAL above (Fig. 57).

2. The nuclei beneath the *upper division* of the ventricular floor are the following:—

Close to the lateral recesses are the SENSORY and MOTOR nuclei of the 5TH NERVE, the motor being internal, the sensory external (Fig. 57). The nucleus of the 6TH NERVE (Figs. 57, 58) lies under the forepart of the fasciculus teres, superficial to, but higher up and nearer the middle line than the nucleus of the 7th; the nucleus of the 7TH or FACIAL NERVE is placed deeper, and internal to the 5th, but external to the nucleus of the 6th nerve (Fig. 57). The outer or accessory nucleus of the AUDITORY or 8TH NERVE lies external to the facial nucleus.

These various nuclei will be again referred to in the section on the "Superficial and Deep Origins of the Cranial Nerves" (page 170).

The White Matter of this part of the medulla consists of the continuation of the pyramids, and, behind these, of the *formatio reticularis*, and of two longitudinal bands—the fillet, and the posterior longitudinal bundle. The former is derived from the posterior column, being in part a continuation of the sensory decussation. The latter is derived from the antero-lateral column of the spinal cord, and can be traced up under the grey matter of the floor of the 4th ventricle to the *crura cerebri*. The posterior longitudinal bundle is connected with the nuclei of origin of the 3rd, 4th, and 6th cranial nerves.

IV.—THE CEREBRUM.

GENERAL OUTLINE.—In man the cerebrum is by far the largest division of the brain, and weighs on an average from 46 to 53 oz. Above, it occupies the vault of the cranium; below, at its base, it is lodged, in front, within the anterior and middle cranial fossæ, but behind, it rests on the upper surface of the *tentorium cerebelli*. An egg-shaped mass of nervous substance, it is larger behind than in front, and is partly separated by the great longitudinal or *inter-hemispherical* fissure into two halves—the **CEREBRAL HEMISPHERES**—which are united across the middle line by a thick band of white matter, called the **CORPUS CALLOSUM**. Each hemisphere is ovoid in shape and is composed of a white stalk or peduncle—the **CRUS CEREBRI**—surmounted by a convoluted grey crust, mapped out by furrows or

SULCI into a series of larger or smaller folds called CONVOLUTIONS.

Internally, the cerebrum consists of strands of white nerve fibres; of masses of grey matter—GANGLIONIC MASSES; of connecting bands—COMMISSURES; and its centre is hollowed out into a large cavity, sub-divided into smaller spaces called VENTRICLES.

We shall describe—(1) the EXTERIOR or cortex of the cerebrum, with its FISSURES, LOBES, and CONVOLUTIONS; (2) the BASE; (3) the INTERIOR, with its VENTRICLES, GANGLIA, and WHITE STRANDS; and (4) the peduncles or CRURA CEREBRI.

I.—EXTERIOR OF THE CEREBRUM.

The Grey Matter of the outer surface of the cerebrum is known as the great hemispherical ganglion, cortex, or bark of the brain. It is divisible into an upper part, called the mantle or pallium; and a basal part, the rhinencephalon (see page 125).

Each hemisphere is a triangular pyramid, and presents three borders and three surfaces—an outer surface, convex; a mesial, plane and vertical; and an irregular under surface or base. Examine—(1) the fissures, and (2) the lobes and convolutions.

1. FISSURES OF CEREBRAL HEMISPHERES.

Of the **Fissures** of the hemispheres the largest and most evident sub-divide the surface of the cerebrum into lobes, and may be called INTERLOBULAR; the smaller fissures—INTRA-LOBULAR—

divide the lobes into convolutions, which, in most cases, have received definite designations.

1. **The Inter-lobular Fissures** are the fissure of SYLVIVS; the fissure of ROLANDO; and the PARIETO-OCCIPITAL fissure (Fig. 70, page 118).

(1) **The Fissure of Sylvius**, unlike the other sulci of the hemispheres, is not a mere indentation of the cerebral cortex, but is formed by the folding upon itself of the entire brain substance. It is a deep cleft which begins on the under surface of the hemisphere, at a point called the anterior perforated spot, and then runs transversely upwards and outwards on the base of the brain to the lateral aspect of the hemisphere, where it divides into two limbs—an anterior, short, *vertical*, ascending limb, and a posterior, which runs horizontally backwards on the surface of the hemisphere—hence called the *horizontal* limb (Fig. 70, page 118). Sometimes there are two short limbs—the one being then called anterior, the other vertical.

(2) **The Fissure of Rolando** (Fig. 70), found only in man and in apes, is one of the first fissures to appear in the development of the brain. It commences above at the median longitudinal cleft, or close to it, and in some cases even appears on the inner surface of the hemisphere. Descending obliquely forwards across the outer surface of the hemisphere, it ends below, near the anterior part of the horizontal limb of the fissure of Sylvius, but in most cases falls short of that fissure. It is not of uniform depth throughout, being deeper below than it is in its upper part (CUNNINGHAM).

(3) **The Parieto-occipital Fissure** appears on both the outer and inner surfaces of the hemisphere. The EXTERNAL PARIETO-OCCIPITAL FISSURE is a short cleft on the outer aspect of the hemisphere near its hinder end (Figs. 70, 71); the INTERNAL PARIETO-OCCIPITAL FISSURE, continuous above with the external, is a very constant fissure, and descends vertically on the mesial aspect of the hemisphere (Fig. 72, page 124). It will be noticed with that surface.

2. **The Intra-lobular Fissures** separate individual convolutions from each other, and will be described with the convolutions which they serve to map out. Those which have received special names are—

- | | |
|------------------------------|--------------------------------|
| 1. Præcentral (Fig. 71), | 6. Callosal (Fig. 72). |
| 2. Intra-parietal (Fig. 70). | 7. Calloso-marginal (Fig. 72). |
| 3. Parallel (Fig. 70). | 8. Calcarine (Fig. 72). |
| 4. Triradiate (Fig. 73). | 9. Dentate (Fig. 72). |
| 5. Collateral (Fig. 72). | |

2. LOBES AND CONVOLUTIONS OF CEREBRAL HEMISPHERES.

The cerebral hemispheres are at first perfectly smooth and without convolutions, and this developmental type is retained in the case of many animals—*e.g.*, the insectivora. In the adult brain each cerebral hemisphere has five principal lobes. Of these, four are bounded by the inter-lobular fissures, and take their names from the bones of the skull in relation to which they lie: they are the *frontal*, the *parietal*, the *occipital*, and the *temporal*. The

fifth lobe—the *central lobe, insula, or Isle of Reil*—is not in contact with the bones of the skull, but is hidden within the fissure of Sylvius, the margins of which must be separated in order to see it. Two other lobes are sometimes described—the *olfactory lobe* (see page 119) and the *limbic lobe* (see page 125).

I. The Frontal Lobe (Figs. 70, 71, page 118) is pyramidal in shape, and is bounded behind by the FISSURE of ROLANDO, which separates it from the parietal lobe; below, by the FISSURE of SYLVIVS, which separates it from the temporal lobe; internally, by the GREAT LONGITUDINAL FISSURE, which separates it from its fellow of the opposite side. It has three surfaces—an *outer*, an *inner* or mesial, and an *inferior* or orbital.

The *outer surface* has four convolutions: one, the ASCENDING FRONTAL CONVOLUTION (Figs. 70, 71), runs parallel to and in front of the fissure of Rolando, and is limited in front by the præcentral sulcus (Figs. 70, 71); behind by the fissure of Rolando. The rest of the surface in front of this gyrus is mapped out by two horizontal parallel sulci into three antero-posterior gyri—the SUPERIOR, the MIDDLE, and the INFERIOR FRONTAL CONVOLUTIONS (Figs. 70, 71), which are sometimes classed together under the term *pre-frontal lobe*. The posterior part of the left inferior frontal convolution is called Broca's convolution, and contains the centre for speech (Fig. 44, page 62). It deserves special notice. It curves round the anterior and vertical limbs of the fissure of Sylvius, by which means it

can be sub-divided into three parts—(1) an anterior part, *pars orbitalis*; (2) a middle part, *pars triangularis*; and (3) a posterior part, *pars opercularis*, or *basilaris* (Fig. 70, Nos. 1, 2, 3, page 118). This last is the part that contains the centre for speech (see Fig. 44, page 62).

The *orbital surface* of the frontal lobe, bounded on the inner side by the longitudinal fissure, and behind by the fissure of Sylvius, passes in the rest of its extent into the outer aspect of the hemisphere. At about its centre it has a three-legged sulcus—the TRIRADIATE or INTRA-ORBITAL FISSURE—which sub-divides the surface into three gyri, an INTERNAL ORBITAL, an ANTERIOR ORBITAL, and a POSTERIOR ORBITAL (Fig. 73, page 124), all of which are mere prolongations, into this surface, though not directly, of the convolutions of the outer surface. Thus the superior frontal convolution becomes continuous with the internal orbital, the middle with the anterior orbital, and the inferior with the external orbital.

On the surface of the internal orbital convolution, lodged in a triangular sulcus—the OLFACTORY GROOVE—is a club-shaped body, the OLFACTORY BULB and its PEDUNCLE, sometimes regarded as a separate lobe. Traced backwards, the olfactory peduncle bifurcates behind into two white bands, the outer passing backwards towards the fissure of Sylvius, where it is lost, the inner running to the side of the great longitudinal fissure (Fig. 79, page 134). The small conical elevation between these two limbs is called the OLFACTORY TUBERCLE, or *trigonum olfactorium*, often regarded as the middle root of the olfactory

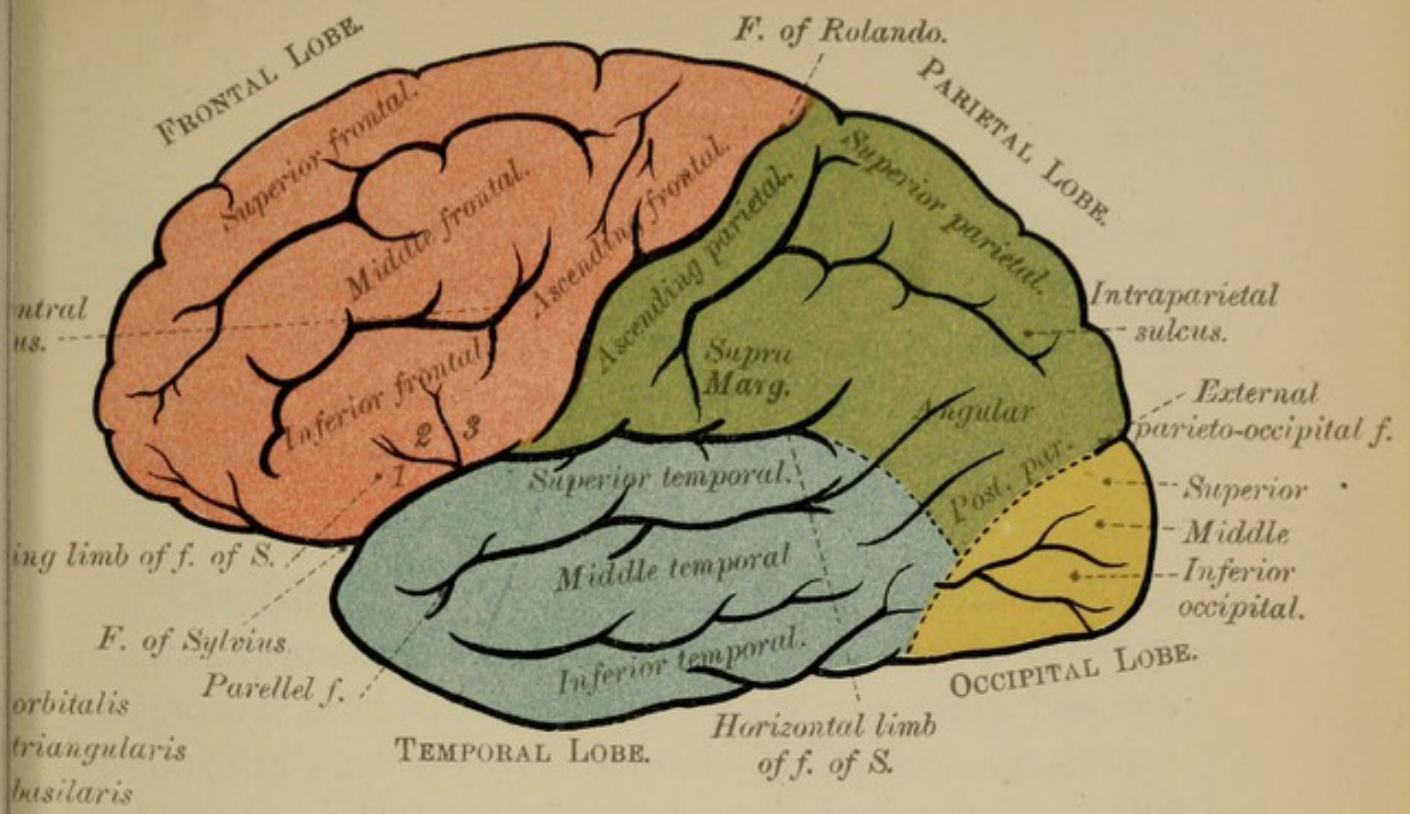
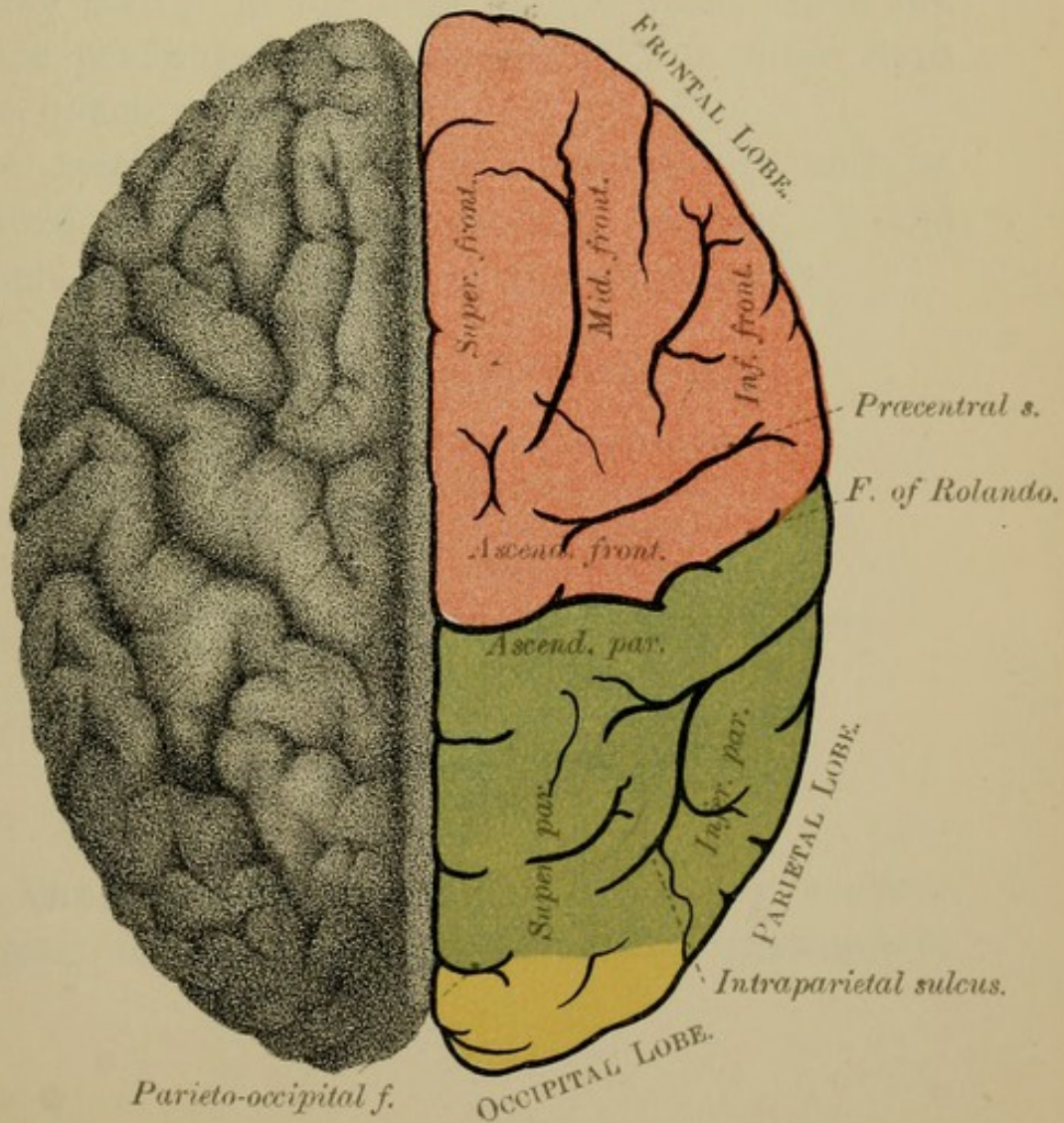



FIG. 71.





peduncle. The area internal to the inner limb is known as the olfactory area of Broca. The portion of the internal orbital convolution internal to the olfactory groove is called the *gyrus rectus*. It is separated behind by a slight fissure from the area of Broca.

The Olfactory Lobe.—The olfactory bulb and the parts connected with it are, as we have said, often regarded as a separate lobe. This lobe comprises the following parts—(1) An *anterior division*, consisting of (a) the olfactory bulb and its peduncle; (b) of the olfactory area of Broca; (c) of the trigonum olfactorium: and (2) a *posterior division*, consisting of the grey matter at the base of the brain, called the anterior perforated spot, crossed by the outer limb of the olfactory peduncle.

The *mesial surface* of the frontal lobe will be described with the corresponding surface of the hemisphere. (See “Table of Convolution.”)

TABLE OF THE FRONTAL CONVOLUTIONS.

Frontal lobe	{	Outer surface	Ascending frontal.
			Superior frontal.
			Middle frontal.
			Inferior frontal.
	{	Inner surface	See mesial surface of hemispheres.
	{	Lower surface	Internal orbital.
			Anterior orbital.
			Posterior orbital.

II. **The Parietal Lobe** has an *inner surface* belonging to the inner aspect of the hemisphere

(see "Mesial Surface"), and an *outer surface*, lateral and convex, which is bounded in front by the FISSURE of ROLANDO, separating it from the frontal lobe; behind by the EXTERNAL PARIETO-OCCIPITAL FISSURE, separating it from the occipital lobe; and below by the HORIZONTAL LIMB of the FISSURE of SYLVIVS, separating it from the temporal lobe.

This surface is furrowed by two sulci—the one is directed downwards parallel to and behind the fissure of Rolando, and forms the posterior limit of the ASCENDING PARIETAL CONVOLUTION (post-central); the other, the INTRA-PARIETAL SULCUS, often continuous with the last-named sulcus (Fig. 71), arches from before backwards through the centre of the surface, and sub-divides it into an upper division—the SUPERIOR PARIETAL LOBULE (Fig. 71, page 118); and a lower division—the INFERIOR PARIETAL LOBULE (Fig. 71, page 118). The inferior parietal lobule is again divisible into three parts—an anterior part arching round the posterior end of the horizontal limb of the fissure of Sylvius, and called the SUPRA-MARGINAL GYRUS or CONVOLUTION of the PARIETAL EMINENCE (TURNER); a middle part, the ANGULAR GYRUS, behind the horizontal limb of the fissure of Sylvius, and continuous round the hinder end of the parallel sulcus with the middle temporal convolution; and a posterior, behind the angular gyrus, and called the POST-PARIETAL CONVOLUTION (Fig. 71, page 118).

The angular gyrus probably contains the centre for sight, though the occipital lobes are the chief centres connected with this function. The ascending

frontal and ascending parietal convolutions contain the motor centres (Fig. 44, page 62).

TABLE OF CONVOLUTIONS OF PARIETAL LOBE.

Parietal lobe	Outer surface	Ascending parietal Superior parietal Inferior parietal.....	{ Supra- marginal. Angular. Post-parietal.
	Inner surface	Sec mesial surface of hemispheres	

III. **The Occipital Lobe.**—This lobe presents a greater number of individual variations in the arrangement of its convolutions than any of the other lobes. Pyramidal in shape, with the apex backwards, it has three surfaces—an *external*, in contact with the parietal and occipital bones; an *internal*, forming part of the mesial surface of the hemisphere; and an *inferior*, continuous with the under surface of the temporal lobe. At present we shall notice the external surface only; the others will be described with the corresponding surfaces of the hemispheres. The *external surface* is bounded in front by the EXTERNAL PARIETO-OCCIPITAL FISSURE, and by a line drawn downwards from this fissure across the surface of the hemisphere to its lower margin (Fig. 70, page 118, dotted line). The other boundaries of the external surface are the margins of the hemisphere. Two longitudinal sulci divide the surface into three antero-posterior convolutions—a SUPERIOR, a MIDDLE, and an INFERIOR OCCIPITAL (Fig. 70)—but these convolutions are by no means constant.

The inner aspect of the occipital lobes contains the centre connected with sight (Fig. 44, page 62).

TABLE OF CONVOLUTIONS OF OCCIPITAL LOBE.

Occipital lobe	{	Outer surface	{ Superior. Middle. Inferior.
		Inner surface	See inner surface.
		Under surface	See next section.

IV. **The Temporal Lobe** (Fig. 70, page 118), occupying the middle fossa at the base of the skull, is conical in shape and has three surfaces—an *upper*, a *lower*, and an *external* or lateral.

The *external surface* is bounded above by the HORIZONTAL LIMB of the FISSURE of SYLVIVUS, which separates it from the parietal lobe; below, by the INFERIOR TEMPORAL SULCUS, which separates it from the under surface. Behind, there is no definite line of demarcation between it and the outer surface of the occipital lobe—the line prolonged downwards from the external parieto-occipital fissure serving as its limit. This surface has three antero-posterior fissures—the SUPERIOR (or PARALLEL), the MIDDLE, and the INFERIOR TEMPORAL—the upper two sulci separate from each other the SUPERIOR, the MIDDLE, and the INFERIOR TEMPORAL CONVOLUTIONS. The inferior fissure is, as we have said, the boundary between the outer and the lower surfaces.

The *upper surface* of this lobe is hidden within the fissure of Sylvius, and is marked out by somewhat inconstant sulci into two or three indefinite gyri.

The *inferior surface* presents a transverse depression caused by the upper margin of the petrous part of the temporal bone, and this may be taken as the limit between the temporal and the occipital lobes—the part in front of the groove being convex, and belonging to the temporal lobe; the part behind the groove being concave, and belonging to the occipital lobe. These two parts are taken together under the term occipito-temporal, and their convolutions are two in number—a SUPERIOR and an INFERIOR OCCIPITO-TEMPORAL CONVOLUTION, separated from each other by the COLLATERAL FISSURE (see Fig. 72, page 124).

TABLE OF CONVOLUTIONS OF TEMPORAL LOBE.

Temporal lobe	External surface	{ Superior temporal. Middle temporal. Inferior temporal.
	Lower surface	{ Superior and inferior occipito-temporal.
	Upper surface	{ Two or three indefinite gyri.

V. **The Central Lobe**—insula, Isle of Reil—the first to be developed, lies deeply within the fissure of Sylvius, and cannot be seen unless you separate the sides of that fissure. Triangular in shape, it consists of five or six convolutions, called GYRI OPERTI (Fig. 73, page 124), which are limited externally by a deep sulcus separating them from the adjacent convolutions collectively known as the OPERCULUM (Fig. 73), and formed by the contiguous ends of the ascending frontal, ascending parietal, and the

inferior frontal convolutions. In front and behind, the Isle of Reil is separated by well-marked sulci from the frontal and temporal lobes respectively.

VI. Fissures and Convolution of the Median Surface of the Hemispheres (Fig. 72, page 124).—Most of the convolutions of this surface are parts of lobes already described, but it will be well to group them together under the above heading. To examine them you will require a mesial vertical section of the hemispheres.

Arching through this aspect of each hemisphere is seen the cut surface of the CORPUS CALLOSUM (Fig. 72, page 124), which we shall take as our guide to the study of the gyri and sulci.

The CALLOSAL FISSURE—ventricle of the corpus callosum (Fig. 72). This fissure commences in front below the anterior end of the corpus callosum. It runs along the upper margin of the corpus callosum, and then turns round its posterior extremity, and, skirting the inner border of the temporal lobe, ends in the notch of the *uncus* (Fig. 72). Between the callosal fissure and the upper margin of the hemisphere lies the CALLOSO-MARGINAL FISSURE (Fig. 72), which, commencing in front beneath the anterior end of the corpus callosum, extends backwards, parallel to the margin of the hemisphere, to a level with the hinder end of the corpus callosum, where it turns upwards to the mesial border of the hemisphere, a little behind the fissure of Rolando (Fig. 72). The original direction of the calloso-marginal fissure is continued by a small sulcus

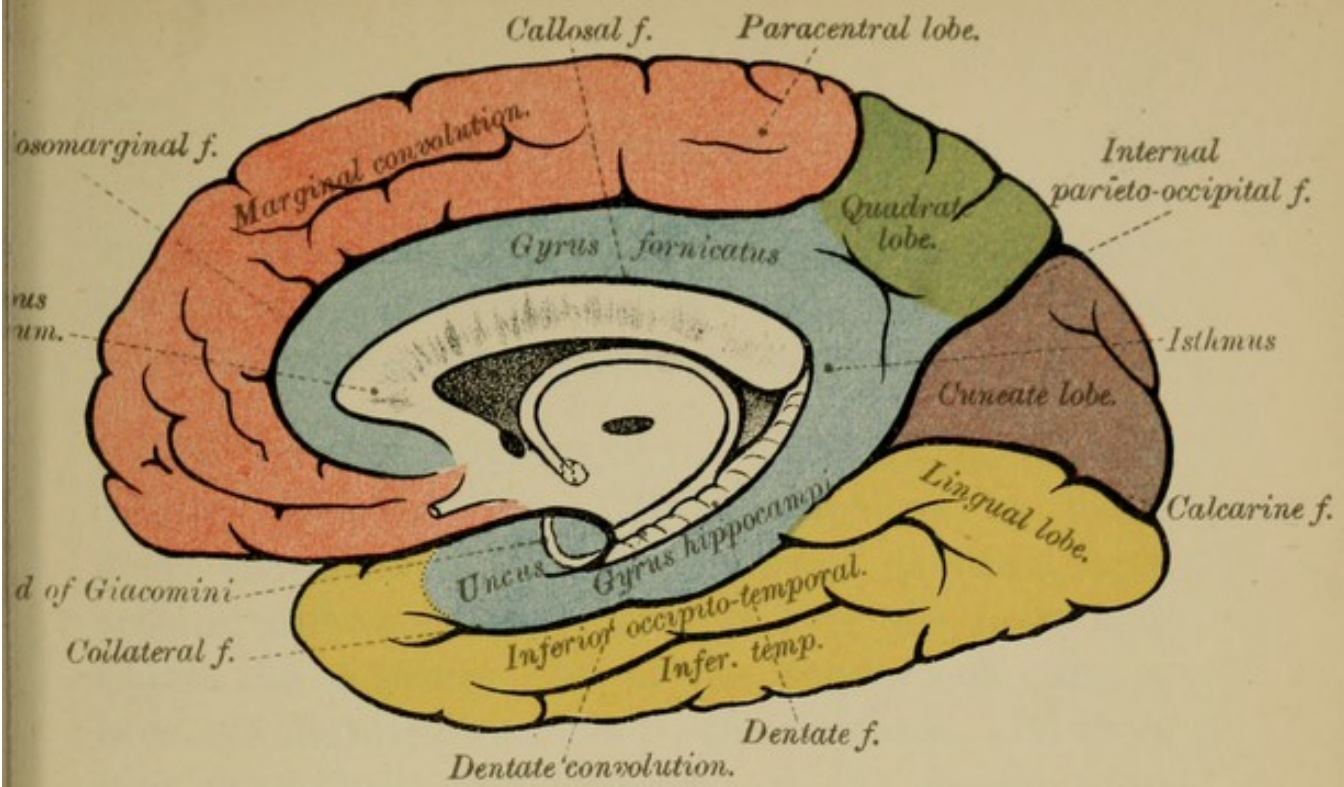
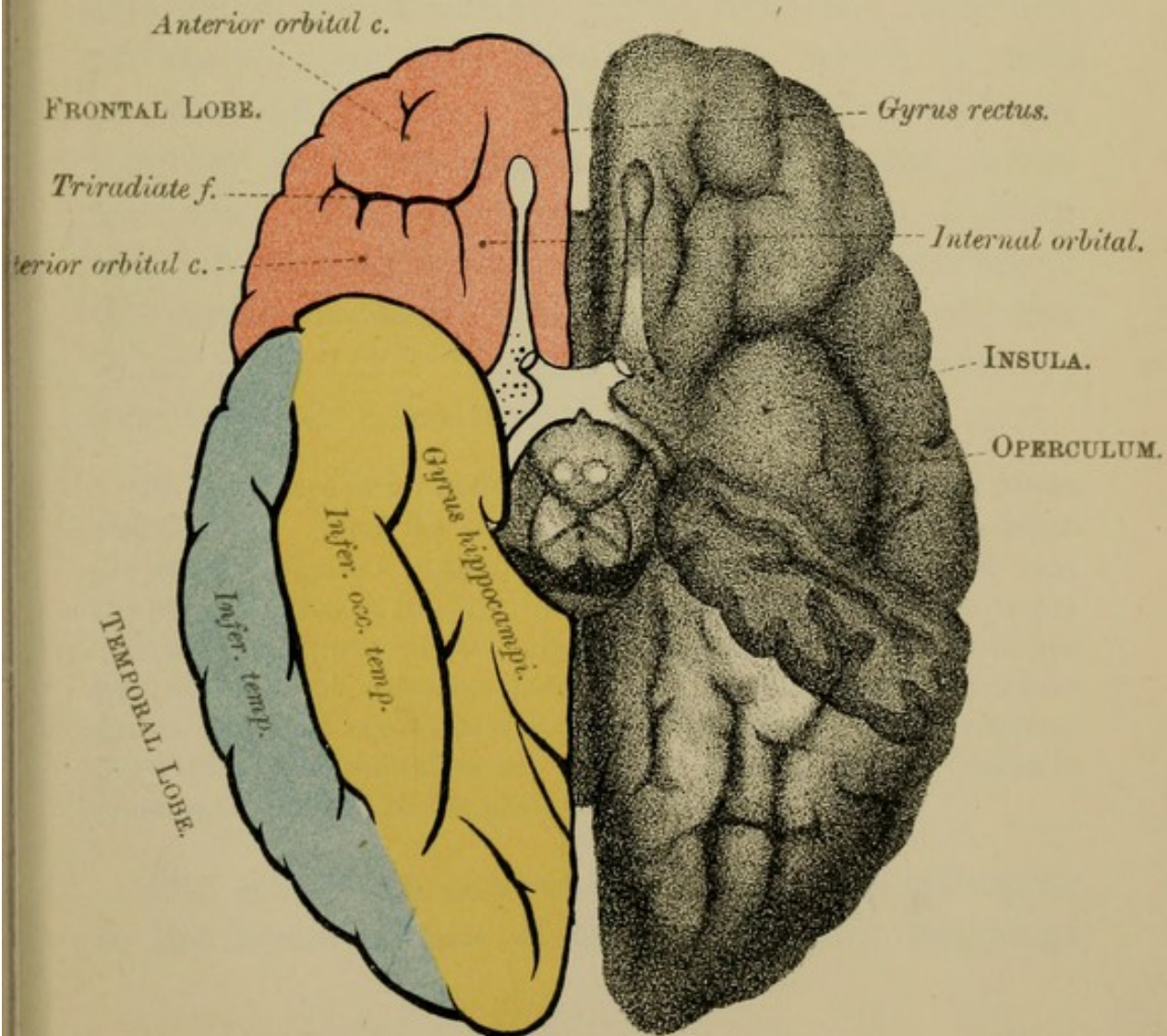
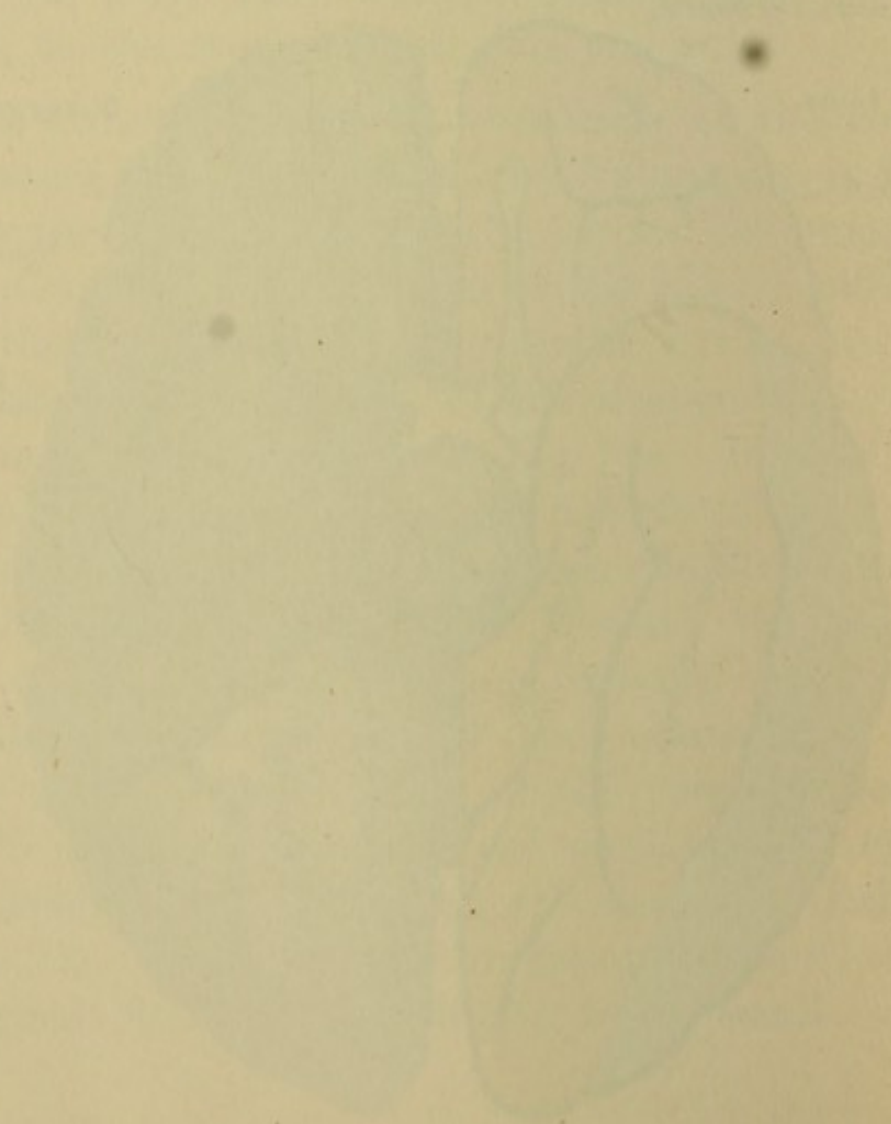


FIG. 73.





which, along with the calloso-marginal, separates the *gyrus fornicatus* below from the *marginal convolution* and the *quadrate lobe* above.

The **GYRUS FORNICATUS**—convolution of the corpus callosum (Fig. 72)—commences in front below the anterior end of the corpus callosum, and arching upwards and backwards over the body and round the posterior end of the corpus callosum, it becomes slightly constricted—the *isthmus*—and then runs downwards and forwards, on the mesial edge of the temporal lobe, as the *superior occipito-temporal convolution*, *gyrus hippocampi*. It is also called the *uncinate gyrus*, from the hook-like process—*uncus gyri fornicati*—in which it ends in front (Fig. 72). This group of convolutions, together with the septum lucidum, fornix, cornu ammonis, fascia dentata, fasciola cinerea, median and lateral longitudinal striæ and the peduncles of the corpus callosum, forms the *limbic lobe* referred to on page 117. The limbic lobe and the olfactory lobe together constitute the Rhinencephalon.

N.B.—There is no little confusion in the naming of the above convolutions. Thus the superior occipito-temporal is often called the *uncinate gyrus*. Again, either the whole convolution, or only the posterior part of it—viz., that near the hinder end of the corpus callosum—is known as the *hippocampal convolution*; while the part beneath the calcarine fissure—or at other times the whole gyrus—is called the *lingual lobe*. The inferior occipito-temporal convolution is often called the *fusiform lobe*, though this name is sometimes confined to the posterior part of that gyrus.

The **MARGINAL CONVOLUTION** (Fig. 72), belonging to the mesial surface of the frontal lobe, begins at

the anterior perforated spot, and, running along the upper edge of the hemisphere above the callosomarginal sulcus, becomes continuous above with the superior frontal convolution. Inferiorly, it passes into the gyrus rectus of the orbital surface, and posteriorly it is limited by the vertical part of the callosomarginal fissure (Fig. 72). The hinder part of the marginal gyrus is called the *paracentral lobule* (Fig. 72); it is the mesial aspect of the ascending frontal convolution.

The INTERNAL PARIETO-OCCIPITAL FISSURE (Fig. 72) lies behind the vertical part of the CALLOSO-MARGINAL FISSURE, the two enclosing between them the mesial surface of the parietal lobe, called the QUADRATE LOBE or PRÆCUNEUS (Fig. 72).

Below the internal parieto-occipital fissure will be seen the CALCARINE SULCUS (Fig. 72), which runs forwards from the posterior border of the hemisphere to join the internal parieto-occipital sulcus. They together enclose the wedge-shaped mesial aspect of the occipital lobe, called the CUNEATE LOBE or cuneus (Fig. 72).

The DENTATE (hippocampal) FISSURE (Fig. 72), continuous behind with the callosal sulcus, ends in front, as we have already seen, in the notch of the uncus. This fissure separates the *hippocampal gyrus* from the *fimbria* or *tænia hippocampi*, which will be seen in the descending horn of the lateral ventricle.

The DENTATE CONVOLUTION or FASCIA DENTATA is a notched gyrus, the free edge of the superficial grey

matter of the hemisphere (Fig. 72). It lies at the bottom of the dentate fissure, and is continuous in front with a small band—band of Giacomini—which crosses the uncus of the gyrus fornicatus, and behind with a thin grey lamina, the fasciola cinerea, and through it with the mesial and lateral longitudinal striæ of the corpus callosum. It is part of an abortive convolution which can be seen on opening up the fissure of the corpus callosum (see “Corp. Call.,” page 157), and its continuation, the dentate fissure.

Passing into the lateral ventricles, above the fimbria, through a fissure called the great transverse fissure (described on page 150), is a vascular inflection of pia mater known as the choroid plexus of the lateral ventricles. These structures will be better seen when we dissect the lateral ventricles (see page 141).

TABLE OF THE CONVOLUTIONS OF THE MESIAL SURFACE.

Convulsions of Mesial surface	{	Gyrus fornicatus.
		Marginal.
		Hippocampal (uncinate).
		Dentate.
		Quadrate (præcuneus).
		Cuneus.
		Paracentral lobule.

It may be well to note that besides the *motor* and *sensorial areas* named above, the cerebral convolutions also contain other areas, *areas of association*—the intellectual areas. These comprise most of the frontal, parietal, temporal, and occipital lobes (see pages 157 and 181).

The figures in Plate XXV., opposite, will show you the relations of the fissures and convolutions to the scalp and to the cranial bones. The various methods for locating these fissures and convolutions will be found in your surgical works.

STRUCTURE OF THE CORTEX OF THE BRAIN.

(Fig. 78, Plate XXVI., page 130.)

The Grey Matter of the cerebral cortex is arranged in several more or less distinct layers, composed of nerve cells and nerve fibres, of neuroglia, blood-vessels, and lymphatics.

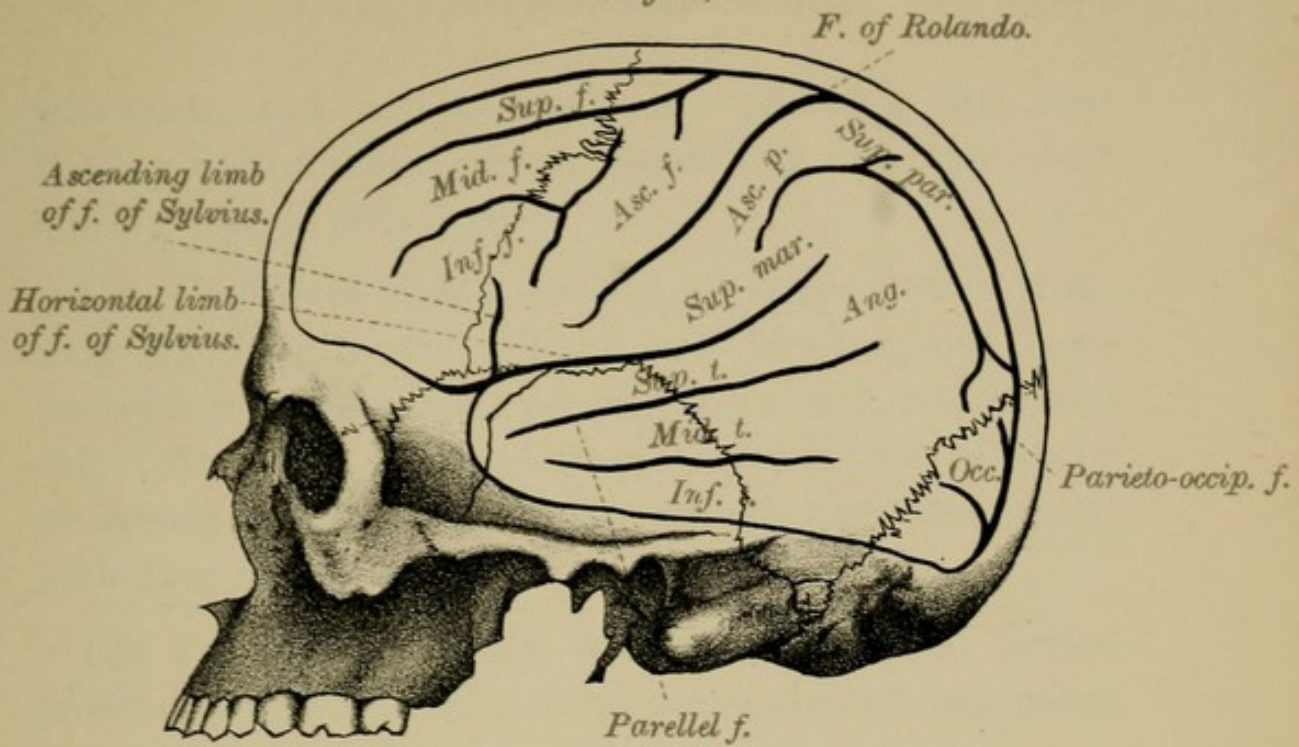
Seen with the naked eye a vertical transverse section of the cerebral cortex shows six strata, alternately white and grey—three white and three grey. The white layers correspond to regions in which there are many nerve fibres gathered into transverse bundles; the grey layers to parts in which there are few or no fibres.

With the microscope, four layers of the cortex are usually described according to the kinds of *nerve cells* met with in the various layers. Enumerated from without inwards they are—(1) the *molecular* or superficial layer; (2) the layer of *small pyramidal cells*; (3) the layer of *large pyramidal cells*; and (4) the layer of *polymorphous cells*.

1. The Molecular Layer.—The nerve cells of this layer are of three kinds:—

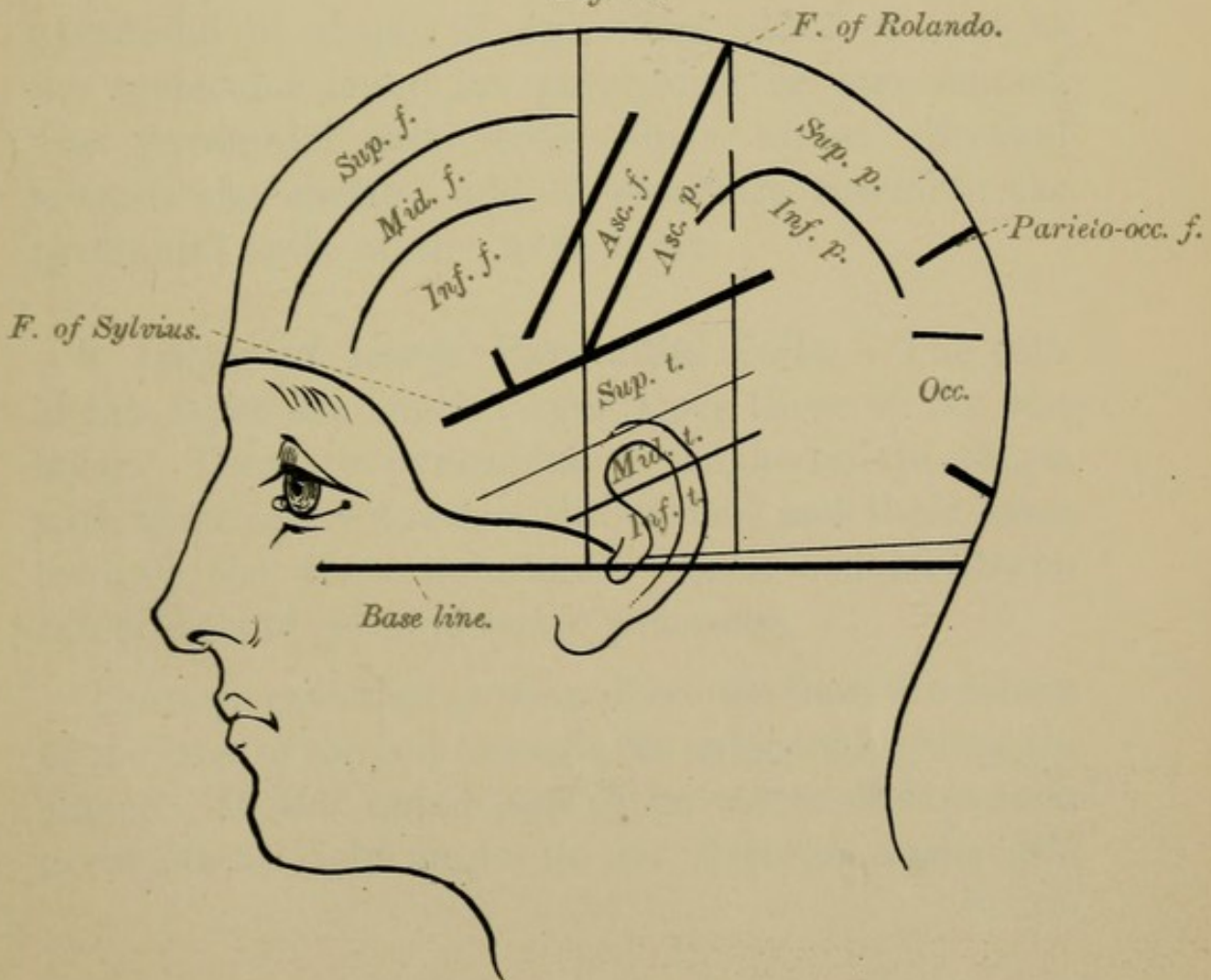
(1) *Polygonal Cells*, which are scattered throughout the layer. They have several protoplasmic

Fig. 74.

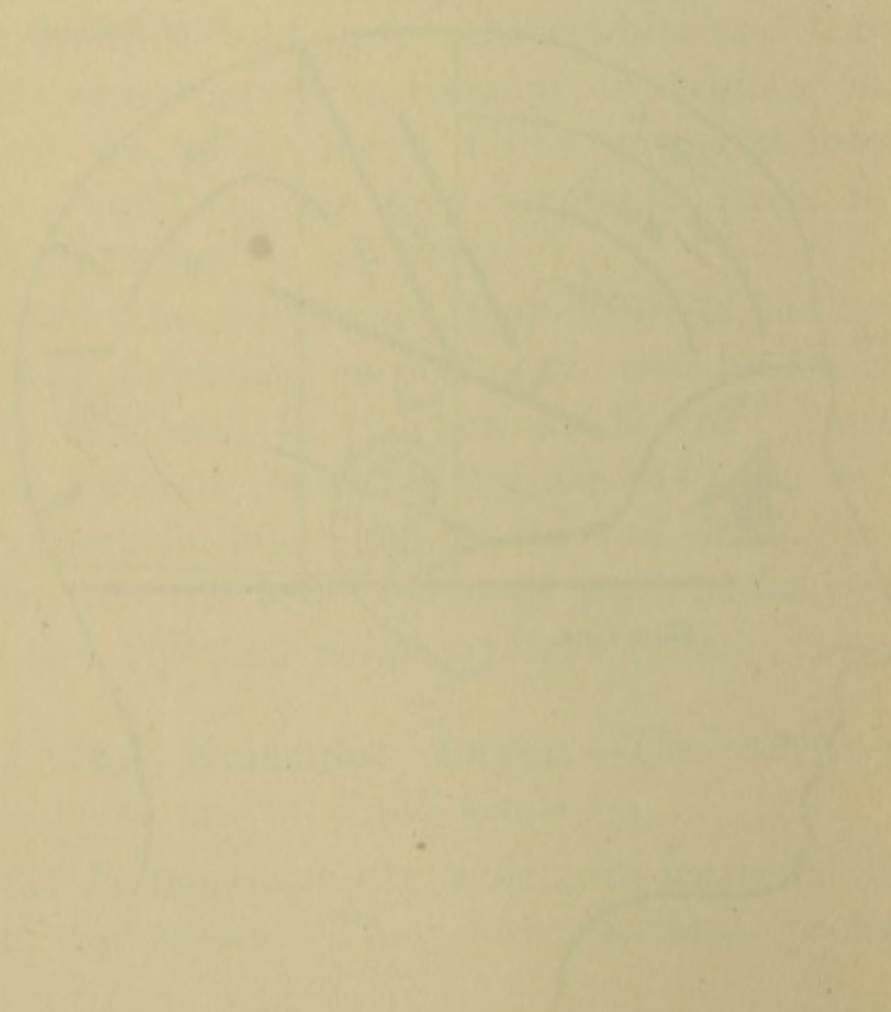



RELATIONS OF FISSURES OF CEREBRUM
TO SKULL.

Fig. 75.



RELATIONS OF FISSURES OF CEREBRUM
TO SCALP.



processes, and an axis-cylinder process; this last having a horizontal or an ascending direction, and ending free in this layer.

(2) *Fusiform Cells*—ovoid in shape, with their long axis horizontal. They are bipolar, and have protoplasmic processes passing from each end of the cell. At some distance from the cell one of these processes gives rise to an axis-cylinder process, which ends free in this layer.

(3) *Triangular Cells*, with usually three protoplasmic processes and several axis-cylinder processes, which ascend and end in the molecular layer.

2. Layer of Small Pyramidal Cells.—The cells of this layer are, as indicated by their names, mostly pyramidal in shape, though those situated next to the molecular layer are polyhedral or star-shaped. The pyramidal cells have their apices directed towards the surface, and in structure resemble the pyramidal cells of the next layer.

3. Layer of Large Pyramidal Cells.—The cells of this layer are much larger than those of the last layer. They are pyramidal or polyhedral in shape, with their apices towards the surface and their bases towards the white substance. Each cell has *axis-cylinder* and *protoplasmic processes*.

The *axis-cylinder process* descends from the centre of the base of the cell towards the subjacent white substance. In the upper part of its course this process gives off at right angles to its direction many side

PLATE XXVI.

(page 130.)

Fig. 78.—*M.L.* Molecular layer.

p. Polygonal cell.

m. Fusiform cell.

n. Triangular cell.

S.P. Layer of small pyramidal cells.

L.P. Layer of large pyramidal cells.

P.C. Layer of polymorphous cells.

W.S. White substance.

a. Bunches of fibres of the pyramidal cells.

b. Small pyramidal cell.

c. Axis-cylinder of small pyramidal cell.

d. Large pyramidal cell.

e. Axis-cylinder of large pyramidal cell.

f. Cell with ascending axis-cylinder process.

g. Sensitive cells of Golgi.

Fig. 77.—Pyramidal cell with axis-cylinder process and collaterals, and their terminal swellings.

Fig. 76.—Terminal branches of the apical process of a pyramidal cell.

Fig. 78.

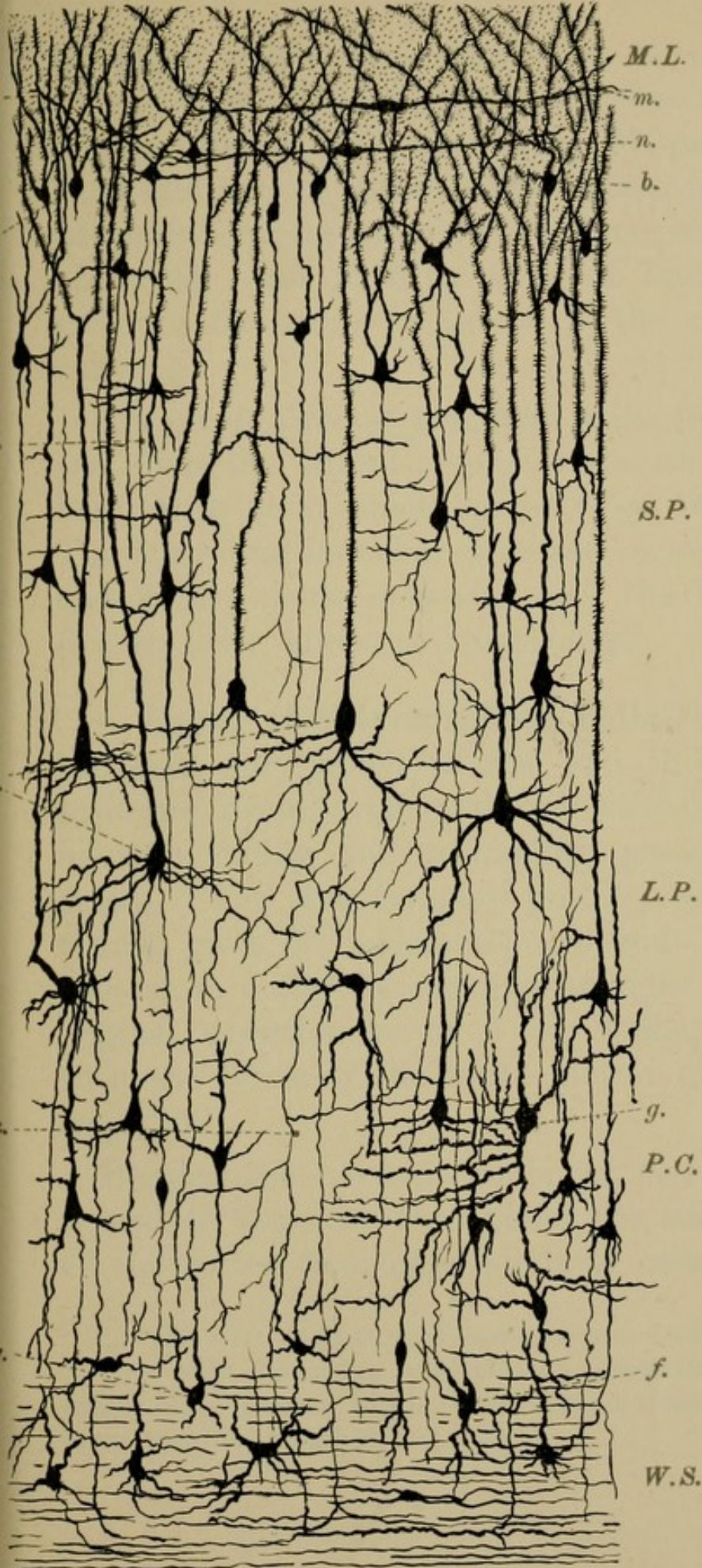
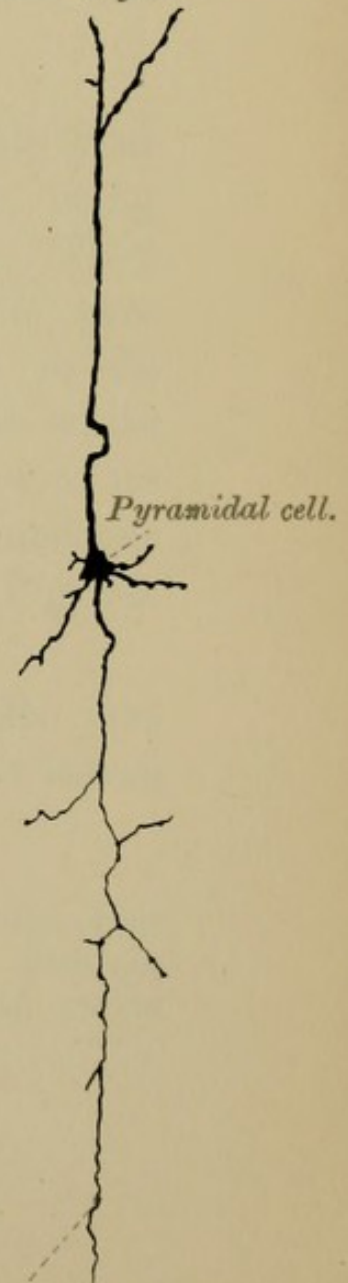



FIG. 76.

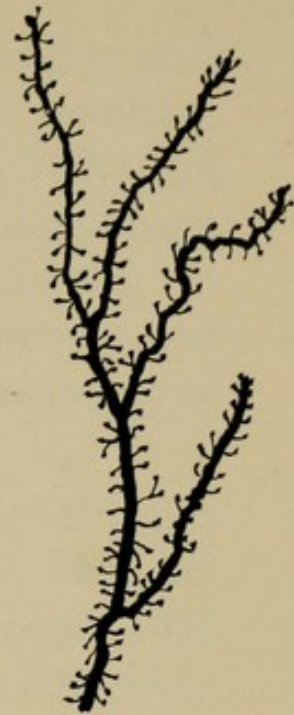

Fig. 77.





branches—collaterals—which run horizontally and branch dichotomously. The branches are granular, and end free in little knobs (Fig. 77, page 130). In the lower part of its course the axis-cylinder process becomes tortuous, and gives off no collaterals. It ultimately ends in little tufts of branches in the grey matter at lower levels of the cerebro-spinal axis.

The *protoplasmic processes* arise from the apex and from the lateral angles of the cells. They are beset with short thick spines (Fig. 76, page 130). The horizontal branches cross and recross each other, and form a dense network. All the branches end free in little knobs or thickenings.

4. Layer of Polymorphous Cells.—In this layer the cells vary much in size and in shape, being fusiform, ovoid, triangular and star-shaped. They have ascending and descending protoplasmic processes. The axis-cylinder process, sinuous in its course, gives off collaterals, and ends in the white substance, either by bending at right angles to its original direction, or by T or Y shaped junctions with the fibres of the white matter (W.S., Fig. 78, page 130).

Besides the several kinds of nerve cells just described, there are throughout the last three layers of the cortex two other kinds of cells:—

1. Cells with short axis-cylinder processes—*cells of Golgi*—star-shaped, with branching protoplasmic processes, and with an axis-cylinder process, which, after a short course, ends free in dense tree-like branches.

2. Cells with ascending axis-cylinder processes.—These cells are fusiform or globular in shape, and are mostly met with in the polymorphous layer. Besides their protoplasmic processes, they have an axis-cylinder process, which ascends from the apex of the cell towards the cortex, giving off collaterals on its way (Fig. 78). Ultimately this process ends in tree-like branches beset with small spines, knobbed at their extremities.

The *white* and *grey nerve fibres* found in the grey cortex are the protoplasmic and axis-cylinder processes of the nerve cells of the cortex, or of those at lower levels of the nervous system. In structure they are like the fibres of the spinal cord.

Neuroglia pervades the entire cortex, passing especially along the line of its vessels. In structure it is similar to the neuroglia of the spinal cord described on page 30. It forms a superficial stratum under the pia mater, being known as the superficial stratum of the molecular layer.

The blood-vessels and lymphatics have already been described (page 57).

The above may be regarded as the typical structure of the chief part of the cerebral cortex, but there are differences in different regions which space will not allow us to describe.

II.—BASE OF THE CEREBRUM.

Though the heading of this section is "Base of the Cerebrum," it will be as well to consider the base of the entire brain, and not confine ourselves merely to the under surface of the cerebrum (Fig. 79, Plate XXVII., page 134).

The Base or under aspect of the brain is, as we have already seen, very irregular in shape. In connection with it we recognise the following structures: (1) the medulla, (2) the cerebellum, (3) the pons Varolii, (4) the crura cerebri, (5) the under aspect of the frontal, temporal, and occipital lobes, (6) part of the great longitudinal fissure and of the fissure of Sylvius, (7) the anastomosing circle of blood-vessels—the circle of Willis—and (8) the superficial origins of the cranial nerves.

If we now examine more particularly that part of the base of the brain which lies between the great longitudinal fissure in front, the under surface of the frontal and temporal lobes on each side, and the crura cerebri behind (Fig. 79), we shall find an irregular shaped interval which consists of grey and white matter stretching across the middle line and uniting the under aspect of the hemispheres. In this space, called the *inter-peduncular*, or *opto-peduncular* space, are the following structures:—

Commencing in front, at the longitudinal fissure, we see (*a*) the ANTERIOR END of the CORPUS CALLOSUM—the ROSTRUM. Hidden within the fissure, and passing backwards and outwards from it, towards the fissure of Sylvius, are two narrow white bands, (*b*) the PEDUNCLES of the CORPUS CALLOSUM, between which lies a thin grey lamina, (*c*) the LAMINA CINEREA—lamina terminalis. Passing across the middle line, behind the median fissure, is a white band of nerve fibres, (*d*) the OPTIC COMMISSURE, which is prolonged forwards at the sides into two

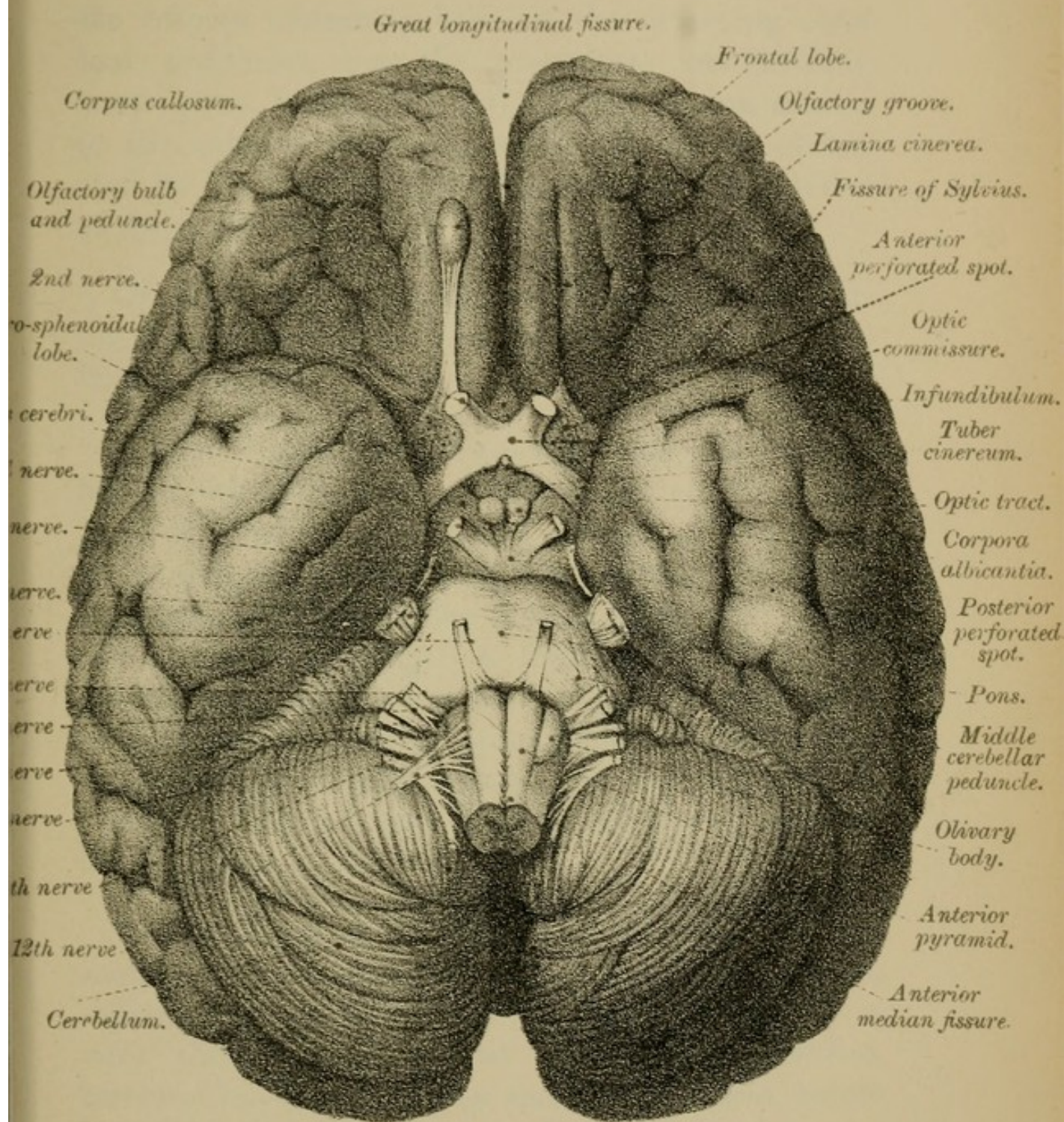
rounded bundles, (*e*) the OPTIC NERVES; and backwards as flattened white strands, (*f*) the OPTIC TRACTS, which curve round the outer sides of the crura cerebri.

External to the optic commissure, at the root of the fissure of Sylvius, and behind the olfactory peduncles, are two triangular shallow depressions, one on each side—the ANTERIOR PERFORATED SPOTS (Fig. 79), greyish laminae, perforated for the passage of blood-vessels into the interior of the brain. These perforated grey laminae are continuous internally with the lamina cinerea; externally, with the hemisphere. Across them run the external roots of the olfactory peduncles, and the peduncles of the corpus callosum. In the middle line, behind the optic commissure, is a small grey elevation—(*g*) the TUBER CINEREUM (Figs. 79, 80)—which is continuous, above the optic commissure, with the lamina cinerea.


Projecting downwards from the tuber cinereum is a funnel-shaped process, (*h*) the INFUNDIBULUM (Figs. 79, 80), to the apex of which is attached (in the entire brain) the posterior of the two lobes of the (*i*) PITUITARY BODY (Fig. 80, page 136).

Behind the tuber cinereum, between it and the crura cerebri, are two small rounded pea-shaped nodules, (*j*) the CORPORA ALBICANTIA (Figs. 79, 80), which we shall afterwards see are closely connected with the anterior pillars of the fornix (Fig. 80). Between the corpora albicantia and the tuber cinereum is a small vascular, trefoil-shaped eminence—the EMINENTIA VASCULARIS—homologous with

FIG. 79.



BASE OF BRAIN



the saccus vasculosus of lower vertebrata. Behind the corpora albicantia, between the diverging cerebral peduncles, lies the POSTERIOR PERFORATED SPOT—pons Tarini (Fig 79)—a grey lamina similar to the anterior perforated spot, and, like it, perforated for the passage of blood-vessels into the interior of the cerebrum.

Of these several structures the only ones requiring further notice are the pituitary body and the lamina cinerea.

1. The *Pituitary body*.—This body is usually left in the sella turcica when removing the brain. It is of a reddish colour, and consists of two lobes, an anterior and a posterior. The anterior lobe, which in structure resembles the thyroid body, was originally a hollow prolongation from the pharynx, but subsequently becomes solid. The posterior lobe is a downward tubular prolongation of the cavity—diencephalon—from which the 3rd ventricle is formed. The pituitary body in some way modifies the nutrition of the body.

2. The *Lamina cinerea* is a triangular-shaped membrane, composed of two lateral grey layers, separated from each other in the mid-line by a very thin portion, almost transparent—*lamina terminalis*—which closes the 3rd ventricle below and in front. Placed between and attached to the peduncles of the corpus callosum in front, the lamina cinerea is continuous behind with the tuber cinereum, and at the sides with the anterior perforated spots.

We may now turn our attention to the superficial origins of the cranial nerves:—

1. On the under aspect of the frontal lobe, lying in the olfactory groove, is the olfactory bulb, often called the 1st nerve. From it arise the olfactory nerves.

2. Springing from the fore and outer part of the optic commissure on each side are the optic nerves.

3. At the upper or anterior border of the pons, internal to the crura cerebri, are the 3rd nerves.

4. At this same border, but external to the crura cerebri, are the 4th nerves.

5. At the side of the pons, where it becomes the middle peduncle of the cerebellum, are the 5th nerves.

6. At the lower border of the pons, near the middle line, are the 6th nerves.

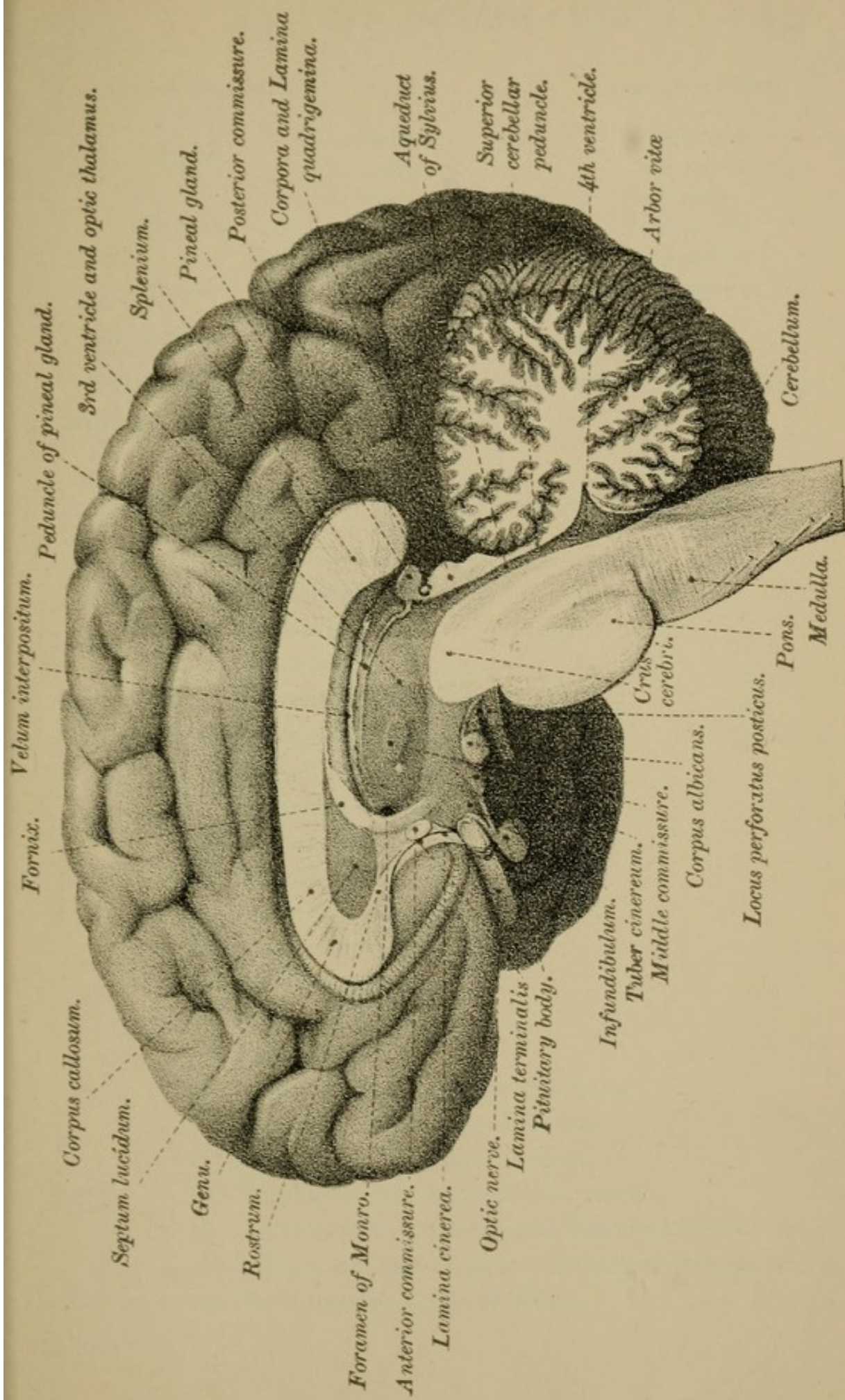
7. At a little distance from the middle line are the 7th and 8th nerves.

8. On the side of the medulla, behind the olivary body, are the 9th, 10th, and 11th nerves in this order from above downwards.


9. In front of the olivary body arises the 12th nerve.

TABLE OF CRANIAL NERVES.

ENGLISH METHOD.	NAMES.	GERMAN METHOD.
1st pair,	Olfactory,	1st nerve.
2nd pair,	Optic,	2nd nerve.
3rd pair,	Oculomotor,	3rd nerve.
4th pair,	Patheticus or Trochlearis,	4th nerve.
5th pair,	Trigeminus or Trifacial,	5th nerve.
6th pair,	Abducens,	6th nerve.



MESIAL SECTION OF BRAIN



ENGLISH METHOD.	NAMES.	GERMAN METHOD.
7th pair,	{ 1. Facial,	7th nerve.
	{ 2. Auditory,	8th nerve.
8th pair,	{ 1. Glosso-pharyngeal,	9th nerve.
	{ 2. Vagus,	10th nerve.
	{ 3. Spinal Accessory,	11th nerve.
9th pair,	Hypoglossal,	12th nerve.

(For the further account of these nerves, see "Superficial and Deep Origins of the Cranial Nerves," page 170.)

TABLE OF OBJECTS SEEN ON THE BASE OF THE BRAIN.

1. The Medulla.
2. The Cerebellum.
3. The Pons.
4. The Crura Cerebri.
5. Inter-peduncular space.
6. Posterior perforated spot.
7. Corpora albicantia.
8. Eminentia vascularis.
9. Pituitary body.
10. Infundibulum.
11. Tuber cinereum.
12. Anterior perforated spots.
13. Optic commissure.
14. Optic tracts.
15. Optic nerves.
16. Lamina cinerea—lamina terminalis.
17. Peduncles of the corpus callosum.
18. Rostrum of the corpus callosum.
19. The Cranial Nerves (see Table, above).
20. Under aspects of Frontal and Temporal Lobes.
21. Sylvian, and part of great longitudinal fissures.
22. Blood-vessels—Circle of Willis.

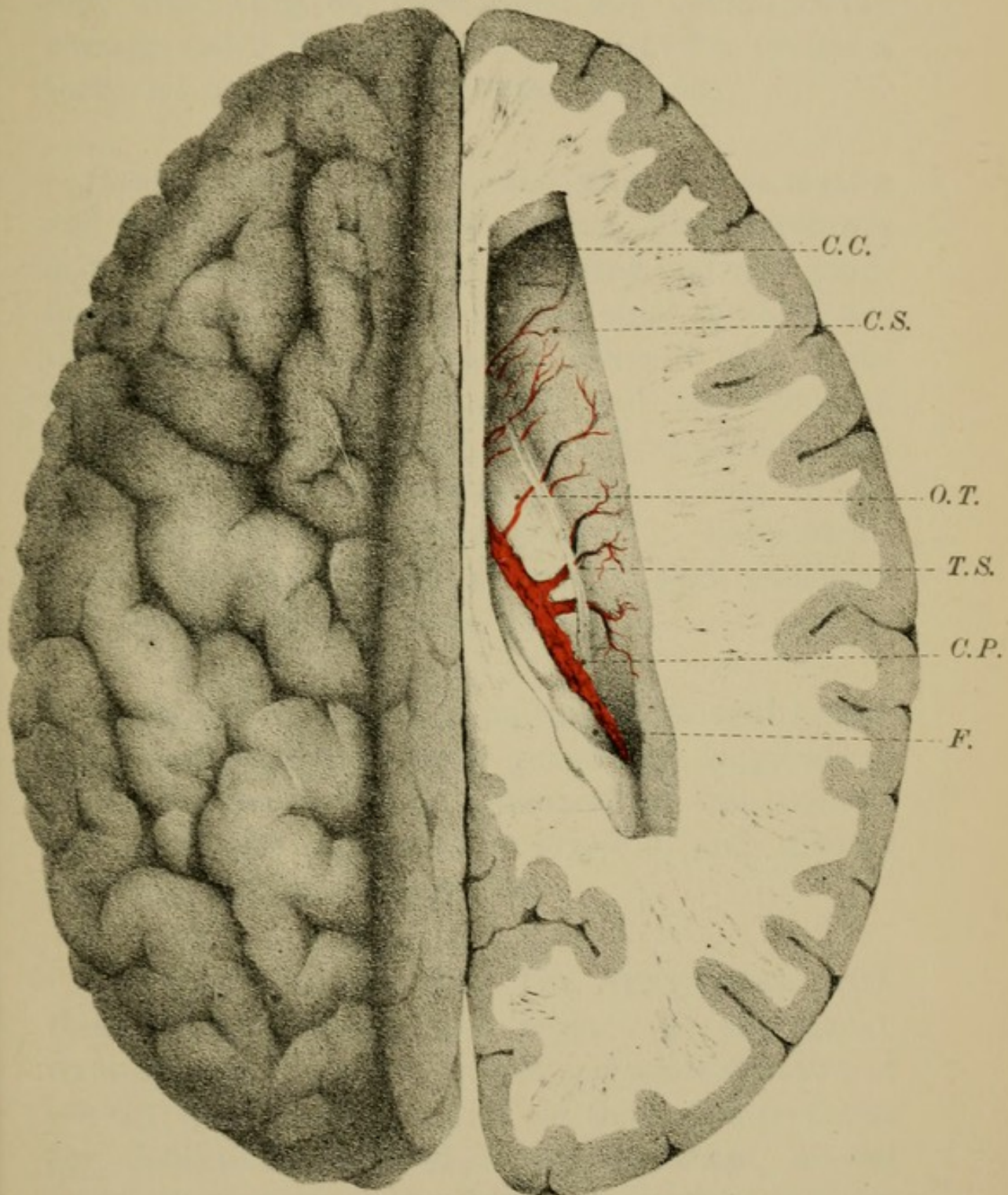
III.—INTERIOR OF THE CEREBRUM.

GENERAL OUTLINE.—We now proceed to examine the interior of the cerebrum. This we do by a series of horizontal and vertical sections (see “Dissection,” page 140).

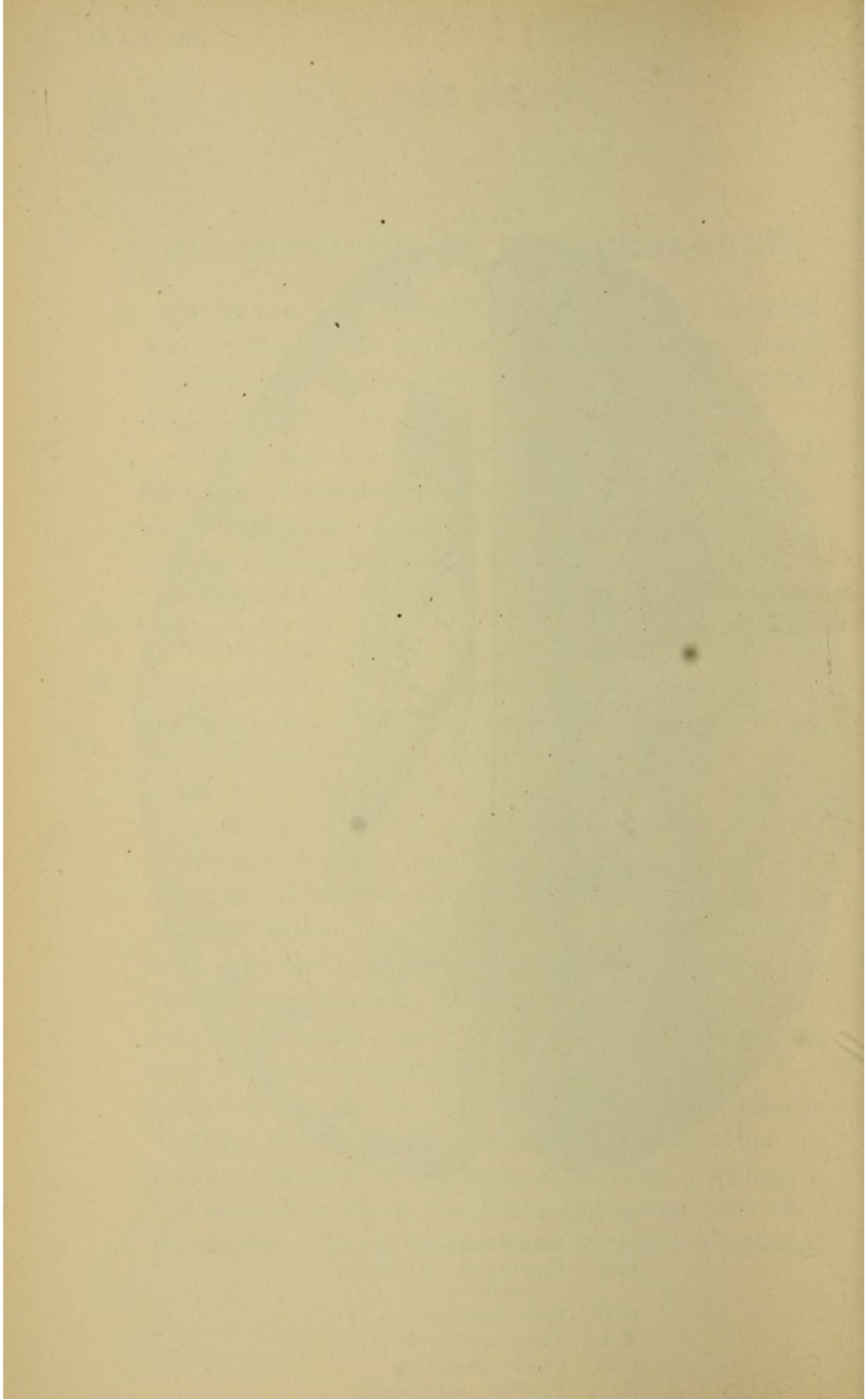
Above the level of the corpus callosum, each hemisphere consists of a solid white central core—*centrum ovale*, composed of strands of fibres, surrounded externally by a wavy edge of grey matter—the *cerebral cortex*.

Ventricles.—Below the level of the corpus callosum, however, the centre of the cerebrum is occupied by an irregular cavity, the remains of the original cerebro-spinal embryonic canal (see “Development”). This cavity, somewhat T-shaped in coronal section (Figs. 93, 94, page 164), is sub-divided by partitions or septa into smaller spaces called VENTRICLES. Thus we have (1) the 3RD VENTRICLE, a vertical mesial longitudinal cleft-like space—represented by the upright part of the T—lying beneath the corpus callosum, and extending below to the base of the brain; and (2) the LATERAL VENTRICLES, two lateral diverticula—the cross stroke of the T—hollowed out in the substance of the hemispheres. Uniting these various ventricles with each other are narrow passages or channels, constricted portions of the tube from which the brain and spinal cord were developed. Thus, in front, as we shall afterwards

FIG. 81.



- C.C. *Corpus callosum.*
- C.S. *Corpus striatum (nucleus caudatus).*
- O.T. *Optic thalamus.*
- T.S. *Tænia semicircularis.*
- C.P. *Choroid plexus*
- F. *Posterior part of fornix.*



see, are the FORAMINA of MONRO, which connect the lateral ventricles with the 3rd ventricle and with each other (Fig. 80, page 136); and behind is the passage called the AQUEDUCT of SYLVIVS, or iter a tertio ad quartum ventriculum (Fig. 80).

Basal ganglia.—Besides the white nerve matter and the central cavity, the interior of the cerebrum is occupied by large masses of grey matter—ganglionic masses—basal ganglia—the chief of which are the CORPORA STRIATA, which belong to the telencephalon; the OPTIC THALAMI and the CORPORA GENICULATA, which belong to the diencephalon; and the CORPORA QUADRIGEMINA, which belong to the mesencephalon (see “Development”). Each hemisphere, therefore, forms a kind of shell enclosing and overlapping the basal ganglia.

Commissures.—Finally, uniting together the cerebral hemispheres and their ganglia are longitudinal and transverse bands or commissures—the CORPUS CALLOSUM, the ANTERIOR, POSTERIOR, and MIDDLE COMMISSURES, and the FORNIX.

We shall describe—(1) The VENTRICLES, with their communications and septa; (2) the BASAL GANGLIA; (3) the COMMISSURES and other STRANDS of FIBRES; but before doing so we shall give *seriatim* the dissections required to expose these several parts, so that the subsequent description of them may be less disconnected and more easily understood.

DISSECTION:—

A. To expose the Corpus Callosum.

Place the brain upon its base with the convex surface uppermost. Take a large sharp knife, moistened in spirit, and cut from the right hemisphere a horizontal slice about half-an-inch in thickness. This will expose an oval-shaped central white mass of nervous substance in the hemisphere—the *centrum ovale minus*, studded here and there with small red spots—*puncta vasculosa*—the cut ends of the blood-vessels. Surrounding the white centre is the wavy grey edge, about one-eighth of an inch thick, the cerebral cortex before referred to.

Remove a series of slices similar to the first, until you reach the level of the upper surface of the corpus callosum, then, with one sweep of the knife, cut off the opposite hemisphere to this same level, when you will see the *centrum ovale majus*, under which term is included the whole area now exposed. The upper surface of the corpus callosum is marked by a mesial groove, the *raphé*, and by median and lateral *longitudinal striæ*. Procure, if possible, a second brain, and make a mesial section of it, to enable you the better to examine the corpus callosum and the parts beneath.

B. To expose the Lateral Ventricles.

1. THE BODY.—Cut through the corpus callosum a little on each side of and parallel to the middle line, and with the back of the knife raise its fibres, being careful not to injure the parts seen in the floor of the cavity beneath. Enumerated from before backwards, these parts are—

- (1) The nucleus caudatus (Fig. 81, page 138).
- (2) The *tænia semi-circularis*, " "
- (3) The optic thalamus, " "
- (4) The choroid plexus, " "
- (5) The edge of the fornix, " "

2. CORNUA.—Next trace the cavity, forwards and outwards, as it winds round the front of the caudate nucleus into the frontal lobe—this is the *anterior horn*; then follow it backwards into the occipital lobes—the *posterior horn*; and downwards and outwards into the temporal lobe—the *descending or lateral horn*.

In the posterior horn you will see the *hippocampus minor* (Fig. 82, &c.); in the descending horn, the *hippocampus major*, the *pes hippocampi* (Fig. 82), the *tænia hippocampi*, and part of the *choroid plexus* of the lateral ventricles (Fig. 82, page 142).

C. To expose the Fornix, the Septum Lucidum,
and the 5th Ventricle (Fig. 84, page 146).

Make a transverse incision through the centre of the corpus callosum, and turn its ends backwards and forwards. Pass a sharp knife along the fore part of the under aspect of the corpus callosum, and sever its attachment to the septum lucidum. Lift up the anterior part of the corpus callosum, when you will expose the SEPTUM LUCIDUM, and the cavity enclosed between its two layers—the 5TH VENTRICLE. Next reflect the posterior half of the corpus callosum, detaching it with the greatest care from the subjacent fornix where they are blended together. This will expose the *body of the fornix*.

D. To expose the Velum Interpositum and the
3rd Ventricle (Figs. 84, 85, pages 146 and 148).

Cut transversely through the middle of the fornix, and turn back the cut ends; the VELUM INTERPOSITUM, a delicate process of pia mater, will thus be brought into view. Examine this velum, and then detach it in front and throw it back, so that it may be again replaced if needed. The 3RD VENTRICLE will be seen beneath it, extending to the base of the brain between the optic thalami. In front are the *anterior commissure*, the *anterior pillars of the fornix*, and the *foramina of Monro*; behind are the *pineal gland* and its *peduncles*; the *posterior commissure*, the *corpora quadrigemina*, and the *aqueduct of Sylvius*; while crossing the space transversely is the *middle commissure*.

I.—VENTRICLES OF THE BRAIN.

The Ventricles of the Brain are five in number—four, viz., the TWO LATERAL (1st and 2nd), the THIRD and the FOURTH ventricles are the remnants of the cerebro-spinal embryonic canal, and are continuous with each other and with the ventricle or central

canal of the spinal cord. The 5TH VENTRICLE, on the other hand, belongs to a different category from the rest, and the term ventricle as applied to it is somewhat misleading, for it has none of the characters of the other ventricles, being neither a part of the original medullary canal, nor lined by the same epithelium as the rest, nor in any way connected with them in the adult. It will be noticed along with the septum lucidum. The 4TH VENTRICLE has already been described (page 106).

THE LATERAL VENTRICLES

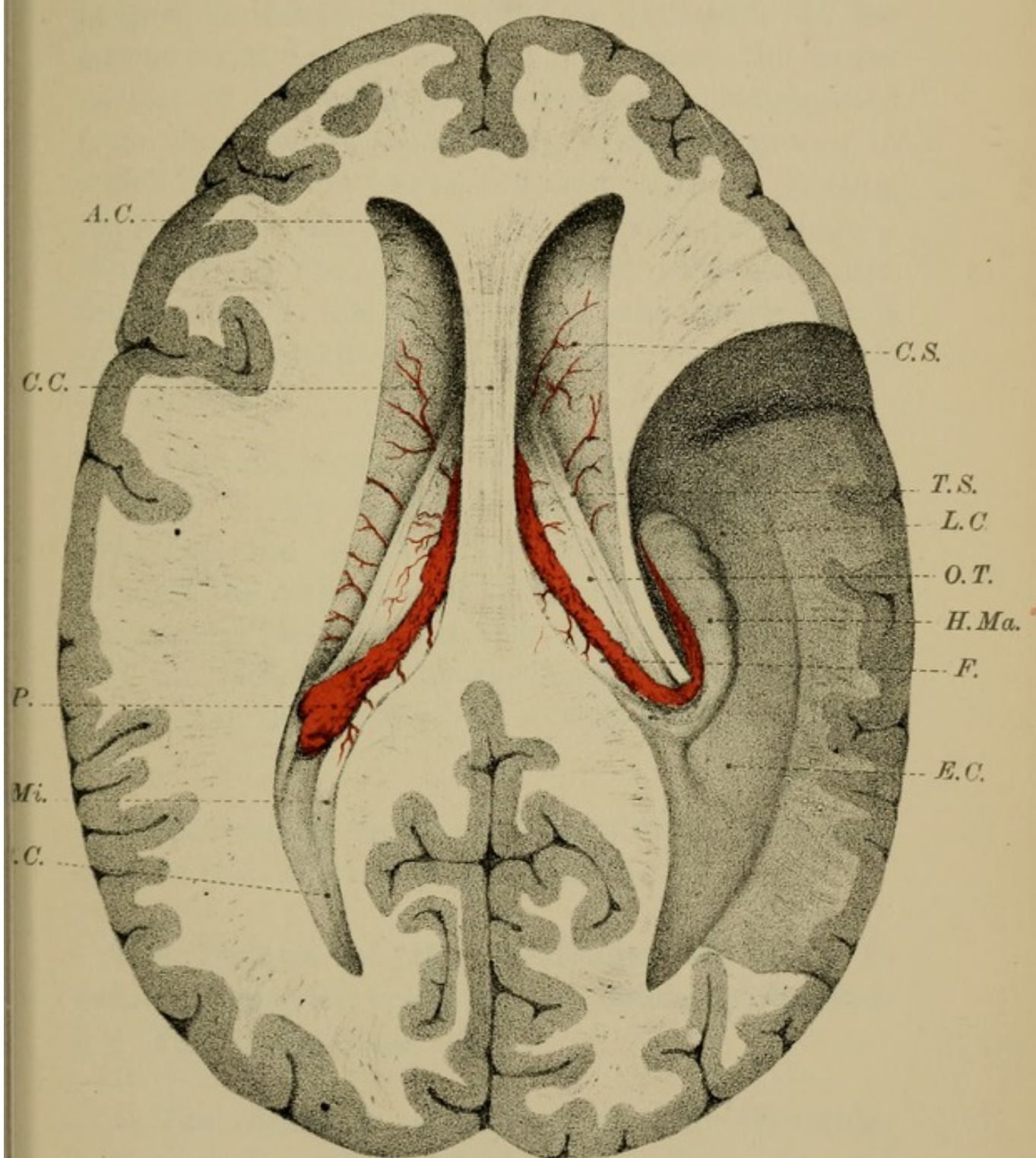
(1st and 2nd).

The LATERAL VENTRICLES, or ventricles of the hemispheres (right and left), are two irregular crescent-shaped cavities hollowed out in the substance of the cerebral hemispheres (Figs. 81, 82). Placed back to back, each ventricle consists of a central part or BODY, and of three prolongations or recesses—the ANTERIOR, the POSTERIOR, and the descending or LATERAL HORNS (Fig. 82, page 142).

The Body of the Ventricle is the highest and largest portion, and, whether looked at from above or in coronal section, is triangular in shape. It is deeper in front than behind, and deeper near the middle line than at the sides, where the roof and sloping floor meet and blend with the substance of the hemispheres.

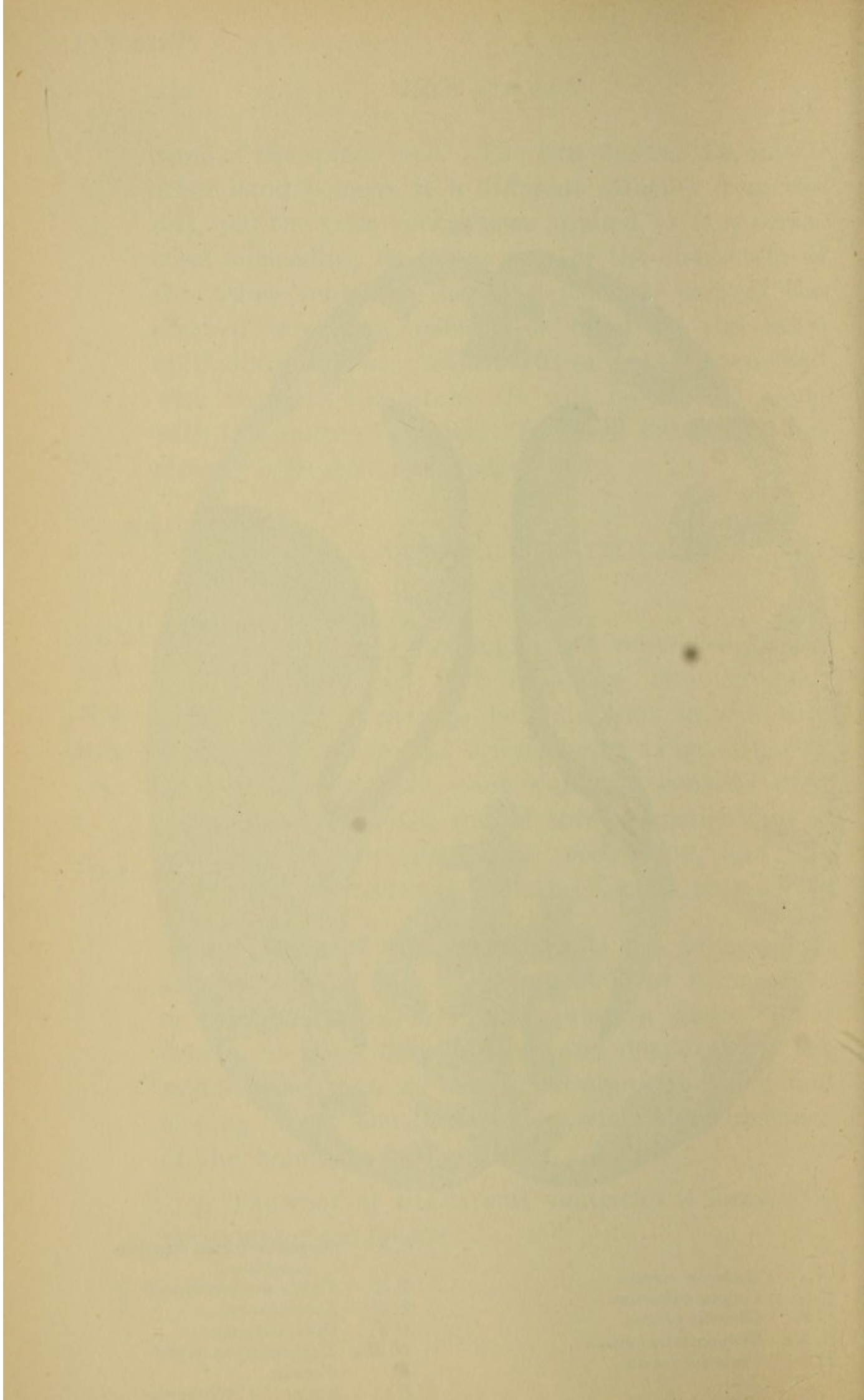
1. The *roof* of the lateral ventricles is formed by the CORPUS CALLOSUM.

FIG. 82.



A.C. Anterior cornu.
 C.C. Corpus callosum.
 C.P. Choroid plexus.
 H.Mi. Hippocampus minor.
 P.C. Posterior cornu.

C.S. Corpus striatum (nucleus caudatus).
 T.S. Tænia semicircularis.
 L.C. Lateral cornu.
 O.T. Optic thalamus.
 H.Ma. Hippocampus major.
 F. Fornix.
 E.C. Eminentia collateralis.



2. The *floor* presents from before backwards—(a) a small part of the CORPUS CALLOSUM where it turns down in the longitudinal fissure; (b) a club-shaped eminence—the NUCLEUS CAUDATUS of the corpus striatum; (c) an oval grey mass—the upper surface of the OPTIC THALAMUS, which is separated from the nucleus caudatus by a shallow groove in which lies (d) the TÆNIA SEMI-CIRCULARIS. Resting on the optic thalamus is (e) the vascular fringe—the CHOROID PLEXUS of the lateral ventricles; and, finally, close to this fringe, nearer the middle line, is (f) the thin sickle-shaped free edge of the BODY of the FORNIX.

3. The *inner wall* of the ventricle is formed in front by a thin double vertical triangular mesial partition—the SEPTUM LUCIDUM—which extends between the corpus callosum and the fornix. Behind the septum lucidum, the floor, formed by the fornix, and the roof, formed by the corpus callosum, blend together in the middle line, so that there is no inner wall.

4. *Externally*, the floor and roof meet, as we have seen, in the mass of the hemispheres.

The Cornua of the Ventricles are three in number—anterior, posterior, and lateral or descending (Fig. 82, &c., page 142).

1. **The Anterior Cornu** is a short triangular horn-shaped cavity, which turns forwards and outwards from the fore part of the body of the

ventricle round the anterior end of the nucleus caudatus into the substance of the frontal lobe.

Its *roof* and *anterior wall* are formed by the CORPUS CALLOSUM; its *floor* by the substance of the FRONTAL LOBE; its *inner wall* by the SEPTUM LUCIDUM; while, both *behind* and *below*, is the NUCLEUS CAUDATUS.

2. **The Posterior Horn** is a similar recess, passing outwards, backwards, then inwards into the substance of the occipital lobe.

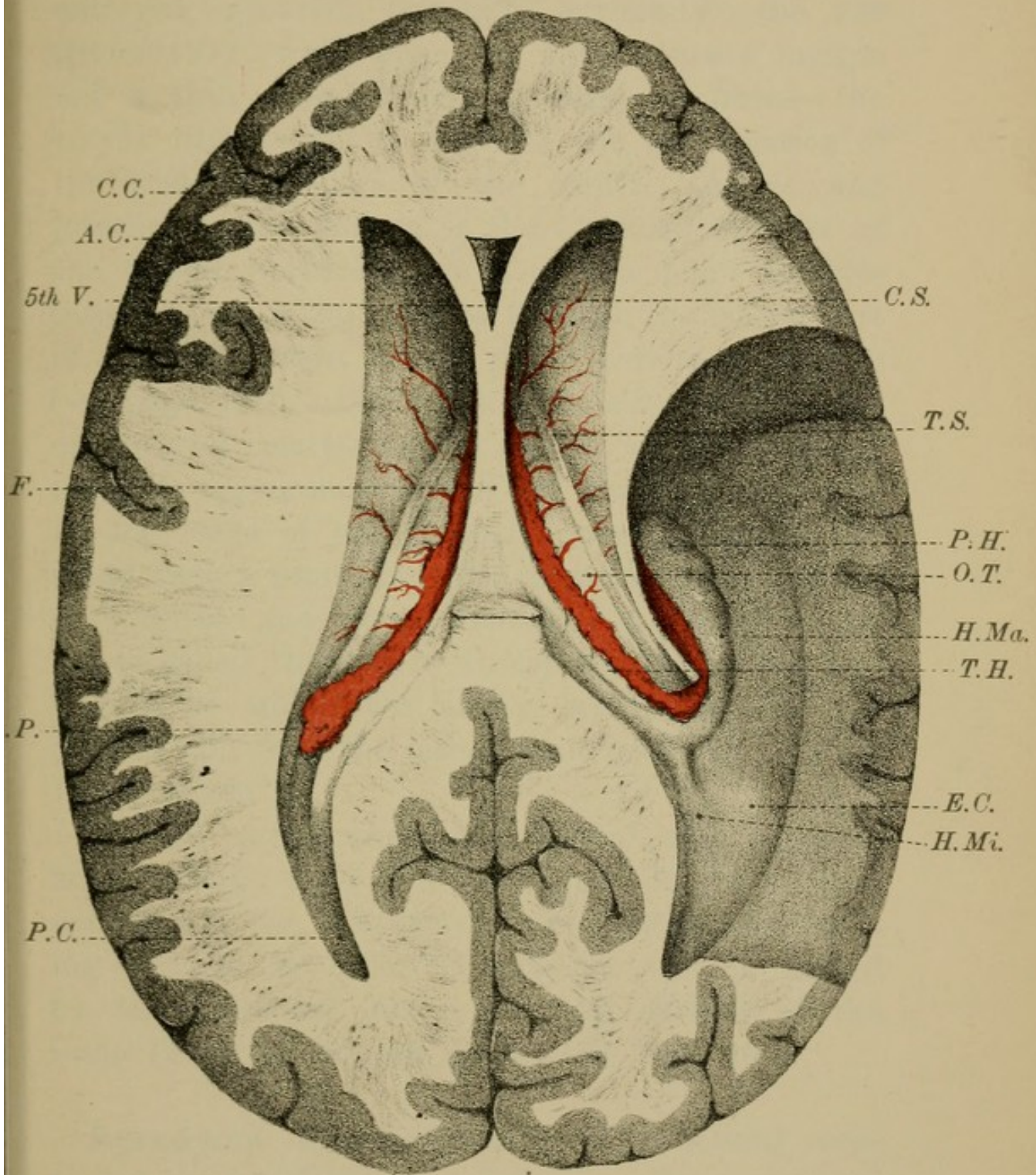
Its *roof* is formed by the CORPUS CALLOSUM; its *floor* by an oval prominence—the HIPPOCAMPUS MINOR (Fig. 86, page 154), caused by the calcarine sulcus seen on the mesial surface of the hemisphere.

3. **The Lateral Horn**—descending horn—curves round the posterior end of the optic thalamus as a bent finger-like passage with its convexity outwards. It runs first backwards and outwards, then downwards, forwards, and finally inwards (B.O.D.F.I.) in the substance of the temporal lobe (Fig. 82, &c., page 142).

In its *roof* are—the CORPUS CALLOSUM; the posterior extremity of the OPTIC THALAMUS; the TÆNIA SEMI-CIRCULARIS; and, finally, the tapering end of the NUCLEUS CAUDATUS, which, at the anterior part of the horn, swells out and passes into the nucleus amygdalæ.


In the *floor* of the passage lies a curved elongated projection following the bend of the horn, and called the HIPPOCAMPUS MAJOR (cornu ammonis). This prominence is caused by the hippocampal (dentate)

FIG. 83.



C.C. Corpus callosum.
 A.C. Anterior cornu.
 5th V. 5th ventricle.
 F. Fornix.
 C.P. Choroid plexus.
 P.C. Posterior cornu.

C.S. Corpus striatum (nucleus caudatus).
 T.S. Taenia semicircularis.
 P.H. Pes hippocampi.
 O.T. Opticus thalamus.
 H.Ma. Hippocampus major.
 T.H. Taenia hippocampi.
 E.C. Eminentia collateralis.
 H.Mi. Hippocampus minor.



fissure on the surface of the brain. Below, at the apex of the horn, the HIPPOCAMPUS ends in an enlarged, grooved, paw-like, extremity—the PES HIPPOCAMPI; while along its inner concave margin lies a thin, white, tapering band of fibres—the TÆNIA HIPPOCAMPI or FIMBRIA, the prolongation of the posterior pillars of the fornix. Above and internal to the fimbria is the CHOROID PLEXUS of the lateral ventricles, which at this point projects into the ventricular cavities through the lateral part of what is known as the *great transverse fissure* (see page 150). Below the fimbria is the free edge of the grey matter of the cortex, which, from the notched appearance caused by the entrance over its free edge of the choroidal artery, receives the name FASCIA DENTATA. The choroidal artery carries with it into the lateral ventricles a process of pia mater called the *velum interpositum*, in the free margin of which the artery breaks up into the choroid plexus of the lateral ventricles (see “Velum Interpositum”).

At the point where the lateral and posterior horns diverge from each other you will see a slight eminence—the EMINENTIA COLLATERALIS—varying in size in different subjects. It is caused by the collateral fissure on the surface of the brain (Figs. 82, 83, 86, pages 142, 144, 154).

Ependyma Ventriculorum.—The lateral ventricles are lined by a layer of neuroglia covered on the surface by columnar ciliated epithelium, continuous with the epithelium of the other ventricles.

Communications.—Between the anterior pillars of the fornix and the optic thalami are two slit-like openings, one on each side—the FORAMINA of MONRO (Fig. 80, page 136). By means of these openings the two lateral ventricles communicate directly with the 3rd ventricle and indirectly with each other. Through these same foramina, as we shall afterwards see, the choroid plexuses of the lateral ventricles are continuous with those of the 3rd ventricle.

THE 3rd VENTRICLE.

The 3RD VENTRICLE (Fig. 85, page 148; Fig. 93, page 164) is the narrow, vertical, cleft-like space, situated in the middle line between the optic thalami. It lies beneath the body of the fornix, and extends down to the base of the brain, being deeper in front than behind.

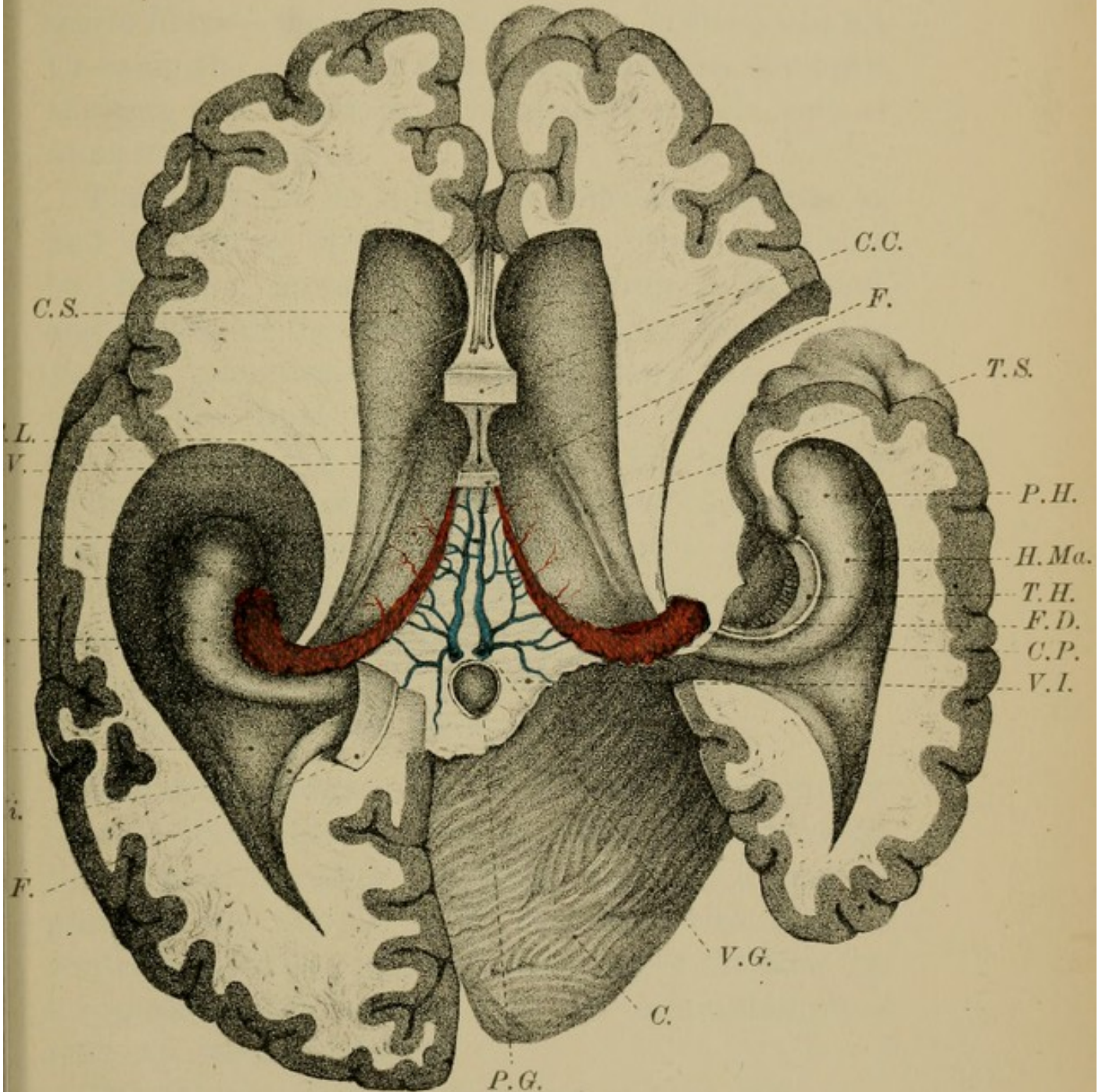
Boundaries.—The *roof* is formed by a layer of flattened epithelial cells, which covers the under surface of the VELUM INTERPOSITUM.

In its *floor* are the structures contained within the inter-peduncular space at the base of the brain (Fig. 98, page 168)—viz., the LOCUS PERFORATUS POSTICUS, the CORPORA ALBICANTIA, EMINENTIA VASCULARIS, the TUBER CINEREUM, the INFUNDIBULUM, the OPTIC COMMISSURE, the LAMINA CINEREA and LAMINA TERMINALIS.

In *front*, the ventricle is limited by the ANTERIOR PILLARS of the FORNIX, the ANTERIOR COMMISSURE, and by the LAMINA CINEREA and TERMINALIS; *behind*, by the AQUEDUCT of SYLVIVS, and the POSTERIOR


VELUM INTERPOSITUM

FIG. 84.



C.S. Corpus striatum (nucleus caudatus).
 S.L. Septum lucidum.
 5th V. 5th ventricle.
 O.T. Optic thalamus.
 P.H. Pes hippocampi.
 H.Ma. Hippocampus major.
 E.C. Eminentia collateralis.
 H.Mi. Hippocampus minor.
 F. Fornix cut.
 P.G. Pineal gland.

C.C. Corpus callosum.
 F. Fornix (anterior pillars) cut.
 T.S. Tænia semicircularis.
 P.H. Pes hippocampi.
 H.Ma. Hippocampus major.
 T.H. Tænia hippocampi.
 F.D. Fascia dentata.
 C.P. Choroid plexus.
 V.I. Velum interpositum.
 V.G. Veins of Galen.
 C. Cerebellum.



COMMISSURE, above which is the base of the PINEAL GLAND. At the *sides* the walls of the cavity are formed by the inner or vertical faces of the OPTIC THALAMI, along each of which runs a bundle of white fibres—the PEDUNCLES of the PINEAL GLAND. Crossing the centre of this space, between the optic thalami, is a broad, grey band—the middle, soft, or GREY COMMISSURE.

The 3rd ventricle is lined by epithelium similar to, and continuous with that of the other ventricles. On the roof, however, the epithelium is flattened, and follows all the folds of the vascular fringes—the *choroid plexuses*—which hang down along the middle line from the under surface of the velum interpositum (Fig. 94, page 164). The lateral walls of the ventricle are covered by a layer of ependyma, and the floor consists of grey matter continuous with the grey matter of the aqueduct of Sylvius. This grey matter comes to the surface of the brain, at the posterior perforated spot, at the tuber cinereum and at the lamina cinerea.

Communications.—The 3rd ventricle communicates in front, through the FORAMINA of MONRO, with the lateral ventricles; behind, through a narrow passage—the AQUEDUCT of SYLVIUS—with the 4th ventricle; and below, at the fore part of the floor, by a conical-shaped passage with the infundibulum—ITER AD INFUNDIBULUM.

The 4th ventricle was described at page 106.

The 5th Ventricle and the **Septum Lucidum** (Dissection, page 141).—The *Septum Lucidum* is

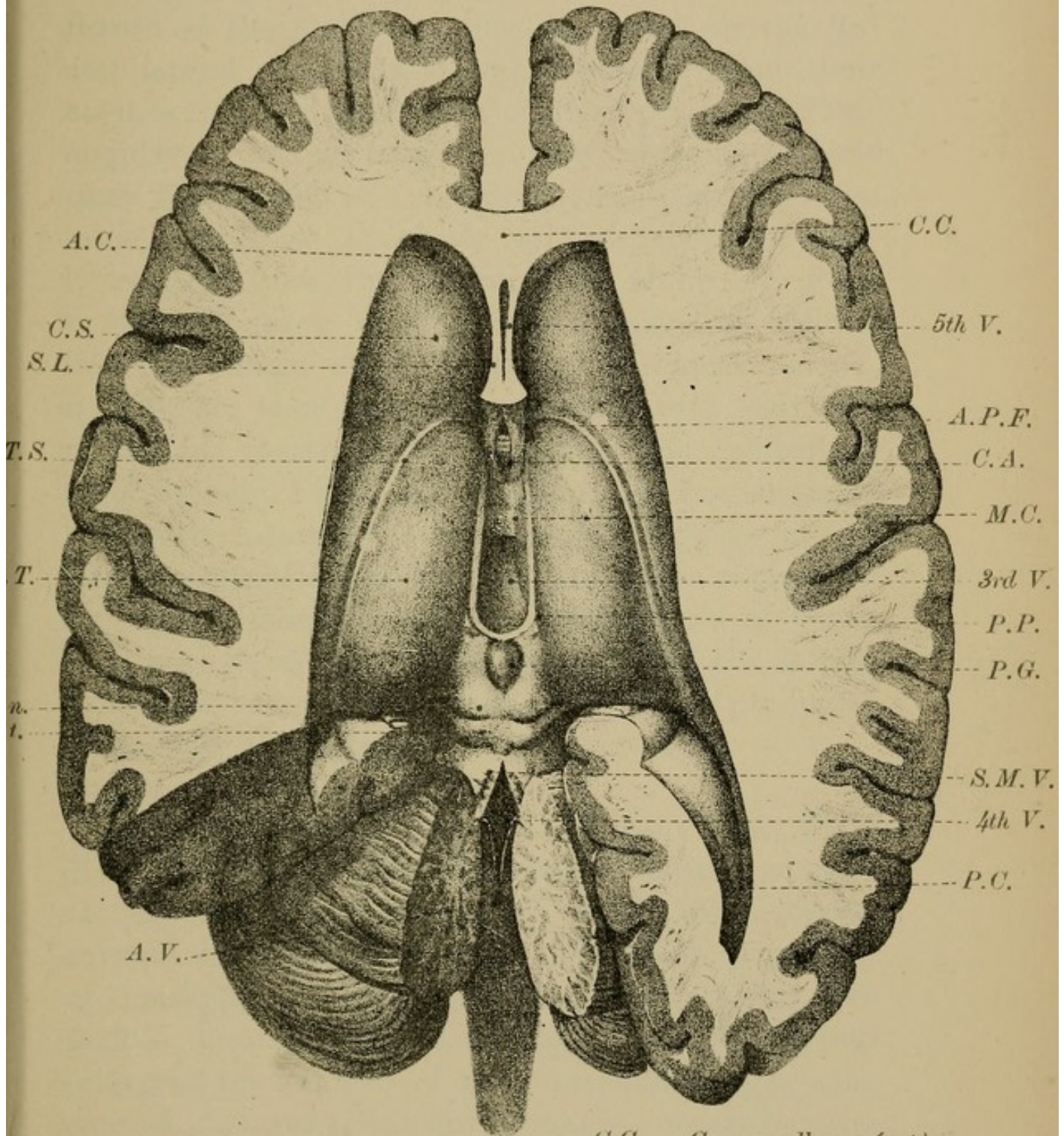
the thin, double, vertical, mesial partition which separates the lateral ventricles from each other in front (Fig. 85; Fig. 80, page 136; Fig. 93, page 164). Triangular in shape, it fills up the interval between the concavity of the knee-shaped bend of the corpus callosum and the anterior pillars of the fornix. Broader in front than behind, it gradually tapers to a point where the corpus callosum and fornix come in contact with each other. Between the two layers of which it is composed it encloses a narrow slit-like cavity, the 5TH VENTRICLE, or ventricle of the septum. Internally, next the cavity of the 5th ventricle, each lamina of the septum is composed of a thin layer of grey matter, derived originally from the grey matter of the cortex. Externally, next the cavity of the lateral ventricles, each lamina of the septum consists of white matter representing the medullary or white matter of the hemispheres, and, like the rest of the lateral ventricles, is covered by a layer of ependyma and epithelium. The cavity of the 5th ventricle itself is not lined by epithelium like the other ventricles, nor, does it in any way communicate with them.

As we shall see in the section on "Development," the septum lucidum was originally part of the wall of the hemispherical vesicle which became cut off from the general surface by the development of the corpus callosum and fornix.

The Velum Interpositum (Dissection, page 141) is a thin horizontal partition, which you have already seen in the roof of the 3rd ventricle, and in the

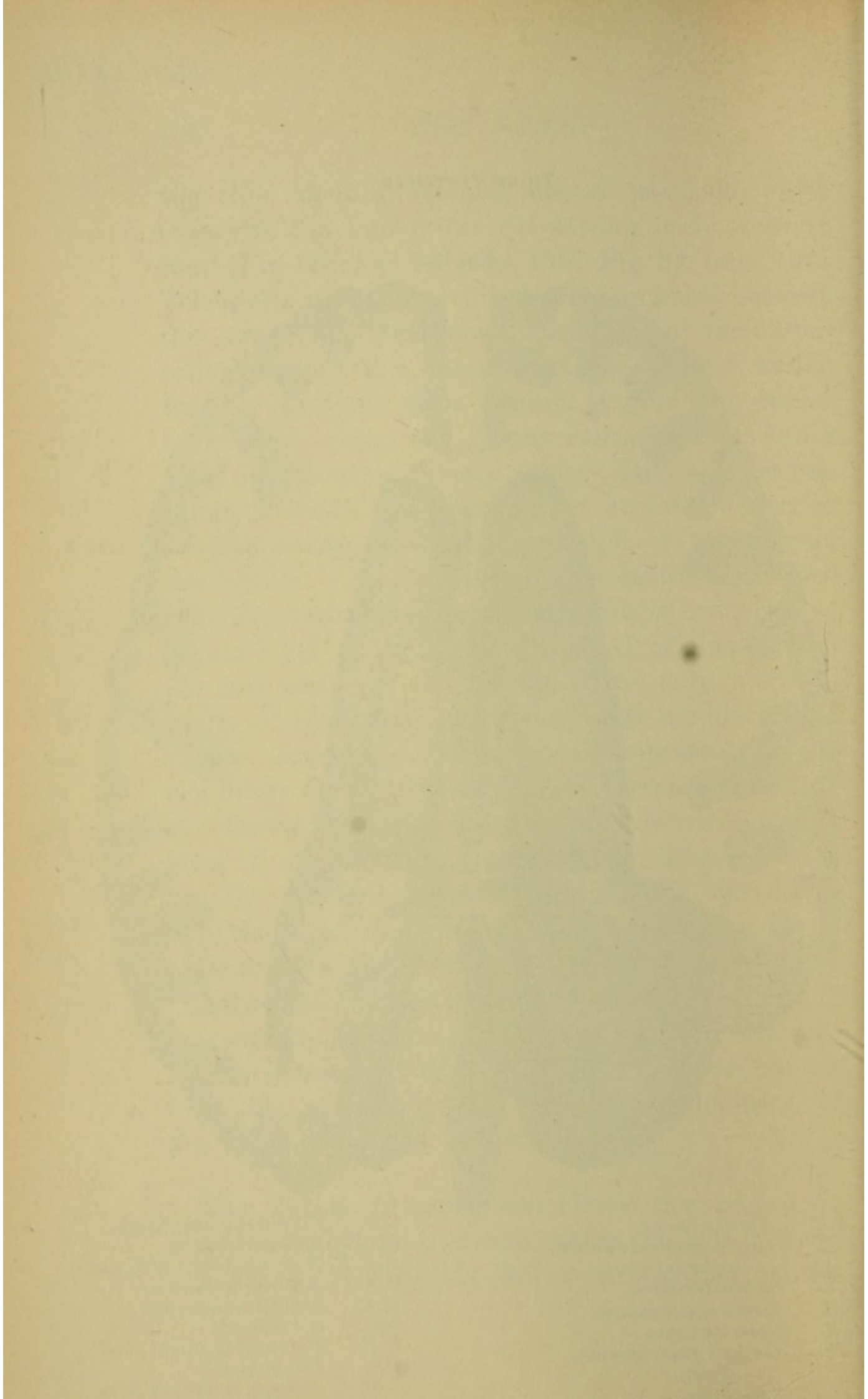
THIRD VENTRICLE

FIG. 85.



A.C. Anterior cornu.
 C.S. Corpus striatum (nucleus caudatus).
 S.L. Septum lucidum.
 T.S. Tænia semicircularis.
 O.T. Optic thalamus.
 C.Q. Corpora quadrigemina.
 n. Nates.
 t. Testes.
 A.V. Arbor vitæ.

C.C. Corpus callosum (cut).
 5th V. 5th ventricle.
 A.P.F. Anterior pillars of fornix.
 C.A. Anterior commissure.
 M.C. Middle commissure.
 3rd V. 3rd ventricle.
 P.P. Peduncles of pineal gland.
 P.G. Pineal gland.
 S.M.V. Superior medullary velum.
 4th V. 4th ventricle.
 P.C. Posterior cornu.



floor of the lateral ventricles (Plate XXXIIIA., page 150). It is a double fold of pia mater, which enters the brain through what is known as the great transverse fissure of the cerebrum, thus appearing in the 3rd and lateral ventricles, though separated from their cavities by the epithelium of the ependyma. Triangular in shape, with the apex forwards and its base backwards, the velum interpositum has the same extent as the body of the fornix, so that it reaches from the foramina of Monro in front to the splenium of the corpus callosum behind, beneath which, after investing the pineal gland, it will be seen to be continuous with the rest of the pia mater on the cerebrum and cerebellum (Fig. 84, page 146). At the sides, the free edges of the velum interpositum project into the floor of the lateral ventricles, and rest on the upper surfaces of the optic thalami, round the hinder ends of which they pass down the descending horns of the lateral ventricles, being still continuous with the pia mater of the rest of the brain.

Choroid Plexus (Plate XXXII., page 146; Plate XXXIIA., page 150).—The choroid plexus consists of tortuous ramifications of small blood-vessels, covered with vascular papillæ, over which is a layer of epithelium. Projecting downwards along the middle line of the under aspect of the velum interpositum are two of these vascular fringes—the choroid plexuses of the 3rd ventricle—covered everywhere, however, by the epithelium which forms the roof of that cavity. In each lateral margin of the

velum interpositum are similar vascular fringes—the choroid plexuses of the lateral ventricles, which extend from the foramina of Monro in front (through which they are continuous with the plexuses of the 3rd ventricle) to the apex of the descending cornu of the lateral ventricles, where the velum interpositum, as we have just seen, becomes continuous with the rest of the pia mater through the great transverse fissure. As the vascular fringes pass down the lateral horns they give a prolongation into the posterior horn.

The Veins of Galen (Plate XXXIIA., page 150) are two veins which gather the blood from the corpora striata and choroid plexuses, and run backwards, side by side, between the layers of the velum interpositum. Ultimately uniting to form a single vein, they discharge their blood into the straight sinus.

The Great Transverse Fissure of the cerebrum (Fig. 84, page 146) is the large artificial cleft which is made into the lateral ventricles when the pia mater and choroid plexuses, with the epithelium covering them, are torn away from the posterior part of the brain beneath the fornix, and from the descending cornua of the lateral ventricles. The fissure thus formed is horse-shoe shaped: its central part corresponds to the base of the fornix, its lateral parts to the descending horns of the lateral ventricles. Through this fissure the pia mater and choroid plexuses project into the ventricles, though, as we

FIG. 1

VELUM INTERPOSITUM

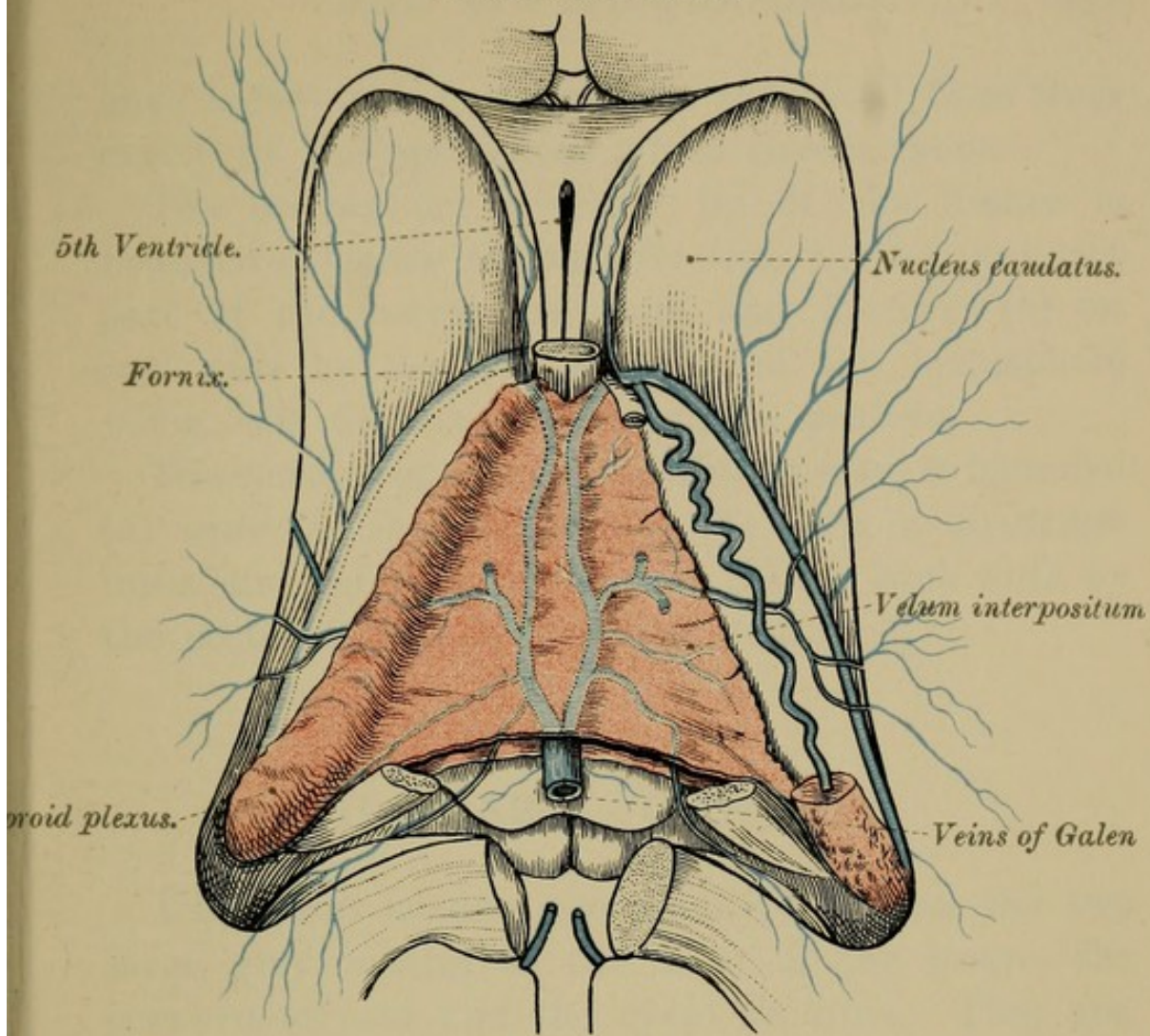
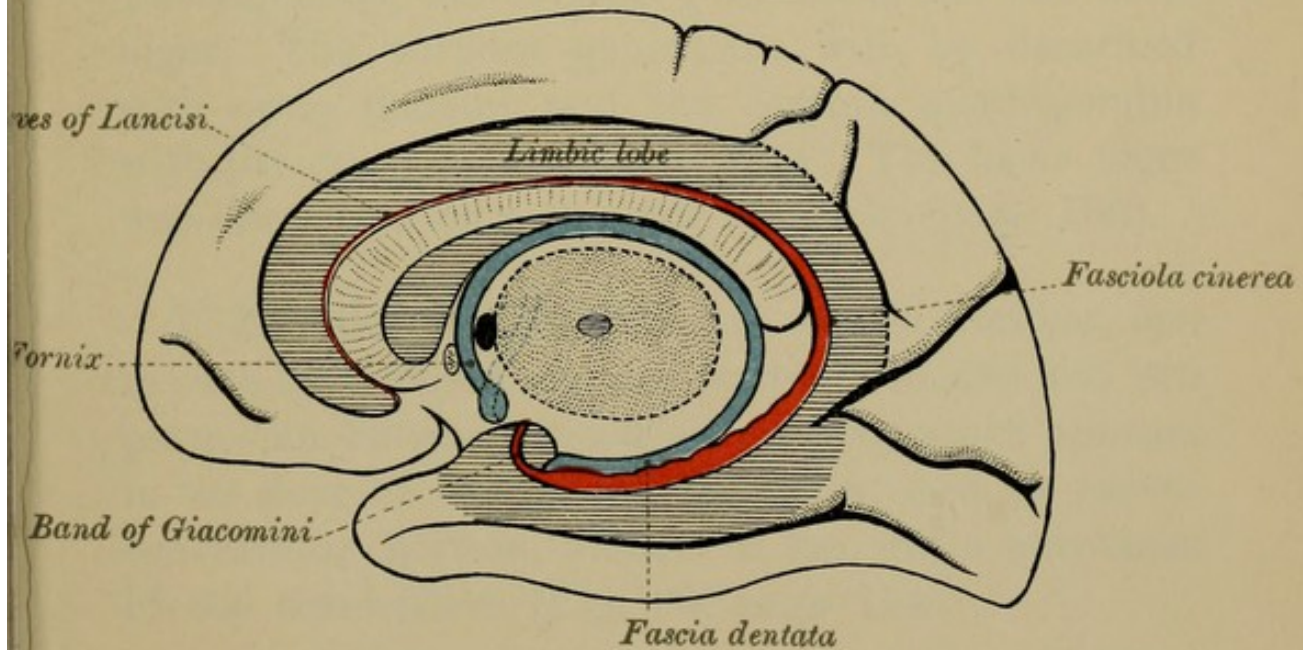



FIG. 2

FASCIA DENTATA AND FORNIX





have before noted, everywhere separated from their cavity by the epithelium which covers them.

The convex or posterior lip of the fissure is bounded (*a*) *near the middle line* by the posterior part of the corpus callosum and fornix; (*b*) *on each side* by the free margins of the hemisphere—viz., the fimbria and the fascia dentata.

The concave or anterior lip of the fissure is bounded (*a*) *near the middle line* by the corpora quadrigemina and cerebral peduncles; (*b*) *on each side* by the posterior part of the optic thalami.

II.—BASAL GANGLIA.

Under this heading are usually described the two large grey masses at the base of the brain—the *corpora striata* and the *optic thalami*. They are, however, quite distinct in their origin. The term moreover, is often made to include the corpora quadrigemina, the corpora geniculata, and the locus niger. The corpora geniculata will be described with optic thalami, and the corpora quadrigemina with the crura cerebri (page 165). The locus niger was described with the 4th ventricle (page 106).

1. **The Corpora Striata** are two in number, one in each hemisphere, and are each sub-divided into two parts—an *intra-ventricular* portion, which appears in the floor of the lateral ventricles; and an *extra-ventricular* portion, hidden in the white substance of the hemisphere (Fig. 86, page 154).

The Nucleus Caudatus—the *intra-ventricular* portion of the corpus striatum—so called from its shape, has been described as a pear-shaped, kite-shaped, pyriform or pyramidal eminence, of a pinkish grey colour, which appears in the fore part of the floor of the lateral ventricles. Covered on the surface by a layer of white substance, each nucleus consists of a grey core streaked with white fibres, hence the name corpus striatum. Its larger end or head is directed forwards, and its posterior end or tail, gradually tapering to a point, passes backwards outside the optic thalamus, where it turns downwards, forwards, and outwards, into the roof of the descending horn of the lateral ventricle, and can be traced as far as the tip of the temporal lobe. It may thus be said to form an arch with its concavity forwards, one end of the arch being formed by the head of the nucleus, the other end by its tail (Fig. 90, page 160).

The Nucleus Lenticularis—the *extra-ventricular* part of the corpus striatum—can only be seen in sections of the hemispheres (Fig. 86, page 154; Fig. 93, page 164). In horizontal sections it appears as a longitudinal grey mass, shaped like a double convex lens (*lenticularis*). It is placed external to the nucleus caudatus, and is separated from it by a strand of white nerve fibres, called the *inner capsule* (Fig. 86, page 154; Fig. 93, page 164). In vertical transverse section it is triangular in shape, and is intersected by two white laminæ, which divide it into three parallel strands—internal, middle, and external, of a somewhat different colour (Figs. 86, 93).

The internal and middle are pale in colour, hence the name *globus pallidus* applied to them; the external segment is darker, and is called the *putamen*—clippings, shells (Fig. 93). The nucleus caudatus and the nucleus lenticularis are continuous with each other in front and below.

Clastrum.—External to the nucleus lenticularis will be seen a narrow band or streak of grey matter—the *claustrum*—separated from the nucleus lenticularis by a white strand of fibres, the *outer capsule* (Fig. 86), and from the contiguous grey matter of the isle of Reil by a second white strand. Thus, enumerated from within outwards we have :—

1. The nucleus caudatus.
2. The inner capsule.
3. The nucleus lenticularis.
4. The outer capsule.
5. The claustrum.
6. A strand of white fibres—white matter of the isle of Reil.
7. The grey matter of the surface—grey matter of the isle of Reil.

The nucleus lenticularis, the claustrum, and the tail of the caudate nucleus are continuous below and in front with the amygdaloid nucleus, which is a thickened part of the cortex of the temporal lobe. It is seen at the anterior end of the descending horn of the lateral ventricles.

2. The Optic Thalami are two large, oval, convex prominences placed above the crura cerebri, but behind and internal to the corpora striata, from which

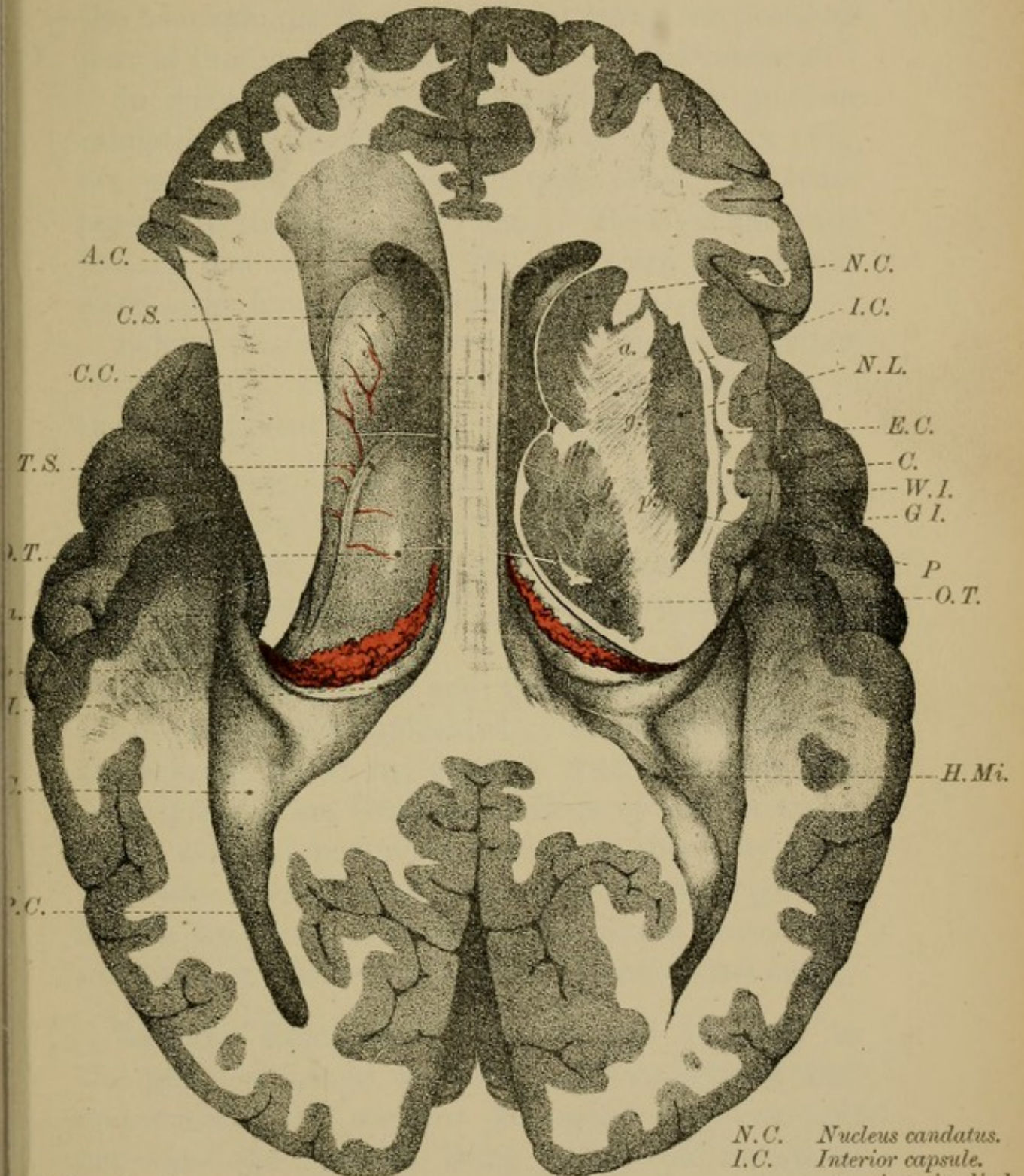
they are separated by the *tænia semicircularis*. Forming part of the floor of the lateral ventricle and the walls of the 3rd ventricle, each optic thalamus consists of a central grey core, covered on the surface by a stratum of white matter. They have four surfaces and two ends, and, where they enter into the formation of the ventricular cavities, they are clothed by ependyma and epithelium. Their anterior end is rounded—*anterior tubercle*—and their posterior and external end swells out into a prominence—the *posterior tubercle* or *pulvinar*, which overhangs the brachia of the corpora quadrigemina (Fig. 98, page 168); and the two oval nodules called the *corpora geniculata interna* and *externa* (Fig. 98). The pulvinar, where it is free, also forms part of the roof of the descending horn of the lateral ventricle.

The *upper surface* of the thalami optici appears in the floor of the lateral ventricles, and resting upon it are the velum interpositum, the choroid plexus, and the edge of the fornix. The *under surface*, in its hinder part, is placed above the crus cerebri (tegmentum, Fig. 98), while more in front it lies over the corpus albicans and the tuber cinereum.

The *inner (mesial) surfaces* of the optic thalami are vertical and form the lateral walls of the 3rd ventricle. Along them run the peduncles of the pineal gland, and above these we see a shallow groove, the sulcus of Monro, which marks the upper limit of this surface. Passing transversely between the optic thalami is the grey or soft commissure. *Externally* the optic thalami blend with the substance of


CAPSULES

FIG. 86.



A.C. Anterior cornu.
 C.S. Corpus striatum (nucleus caudatus).
 C.C. Corpus callosum.
 T.S. Tertia semicircularis.
 O.T. Optic thalamus.
 H.Ma. Hippocampus major.
 C.P. Choroid plexus.
 T.H. Tertia hippocampi.
 E.C. Eminentia collateralis.
 P.C. Posterior cornu.

N.C. Nucleus caudatus.
 I.C. Interior capsule.
 a. Anterior limb.
 g. Genu.
 p. Posterior limb.
 N.L. Nucleus lenticularis.
 E.C. External capsule.
 C. Claustrum.
 W.I. White matter of Isle of Reil.
 G.I. Grey matter of Isle of Reil.
 P. Putamen.
 O.T. Optic thalamus.
 H.Mi. Hippocampus minor.



the hemispheres, their outer limit being the posterior part of the inner capsule and the nucleus caudatus.

In front of the optic thalami are the nucleus caudatus and the anterior pillars of the fornix (Fig. 80, page 136; and Fig. 85, page 148), the latter passing to the base of the brain. Between the optic thalami and the pillars of the fornix are the slit-like clefts—the foramina of Monro (Figs. 80, 85).

Behind the optic thalami are the posterior pillars of the fornix, winding down the descending horn of the lateral ventricle (Fig. 83, page 144).

STRUCTURE.—The optic thalami are chiefly composed of grey matter arranged as three nuclei— anterior, outer, and inner (Fig. 86, page 154). The course and relations of its white tracts are not yet understood.

Both the functions and the morphology of the basal ganglia are undecided. Anatomical appearances seem to be in harmony with the view that these ganglia are terminal stations of certain tracts of the cerebral peduncles. In man they may probably take the place of the corpora quadrigemina in the frog, and, like them, exercise a restraining influence on the reflex centres of the spinal cord.

Corpora Geniculata. — Below and external to the pulvinar are, as we have said, two pairs of oval eminences — the *corpora geniculata interna* and *externa*—the internal being below and mesial to the external, and separated from it by a band of white fibres, one of the roots of the optic tract (Fig. 98, page 168).

These geniculate bodies consist of a grey core, and a white cortex. From each proceeds a white band which joins the optic tracts. The band from the internal pair has, however, nothing to do with sight. Similar bands connect the external bodies to the anterior, and the internal to the posterior pairs of corpora quadrigemina.

The Pineal Gland (or body) is a reddish, vascular, oval body, situated in the middle line above the orifice of the aqueduct of Sylvius, in the longitudinal groove between the corpora quadrigemina. Firmly attached to the velum interpositum, which gives it a special covering (Fig. 84, page 146), this so-called gland is a backward prolongation of the 3rd ventricle and is connected to the cerebrum by two white bands—the *peduncles*—which, as we have already seen, run one along the inner surface of each optic thalamus. The peduncles end in front by joining the anterior pillars of the fornix. On its ventral aspect, the pineal gland is connected with the posterior commissure.

In **STRUCTURE** the pineal gland is composed of follicles, separated by connective tissue, and filled with cells (neuroglia - cells), calcareous particles (brain sand), and corpora amylacea. It is probably a rudimentary eye.

III.—WHITE STRANDS.

White Matter.—Beneath the grey matter lies the white nerve substance of the brain, which, like that of the spinal cord, is composed both of grey and of white or medullated nerve fibres. The medullated fibres are transverse and longitudinal, the latter predominating. They are the axis-cylinder processes of the nerve cells of the various layers of the cortex, or of cells at lower levels of the cerebro-spinal system.

They are divisible into three groups.

(1) *Commissural fibres*, which connect identical parts of the two hemispheres.

(2) *Association fibres*, which connect different parts of the same hemisphere.

(3) *Projection fibres*, which connect the grey matter of the hemispheres with the lower parts of the cerebro-spinal axis.

I. The COMMISSURES of the brain are the corpus callosum, the anterior, middle, and posterior commissures.

CORPUS CALLOSUM.

(Fig. 80, Plate XXVIII., page 136.)

The Corpus Callosum.—As you already know, the corpus callosum is the white transverse band of nerve fibres which arches from before backwards, in the middle line, between the cerebral hemispheres, and connects them together. About four inches long, it forms the floor of the great longitudinal fissure and the roof of the lateral ventricles, and

reaches further forwards than backwards. It is thicker at the ends than in the middle of its extent, and is thickest and widest behind.

Anteriorly, it turns downwards and backwards upon itself in the great longitudinal fissure, making a knee-shaped bend—the *GENU* (Fig. 80, page 136). Becoming gradually smaller it then forms a narrow median band—the *ROSTRUM* (Fig. 80)—which ends below at the base of the brain by bifurcating into two tapering processes—the *PEDUNCLES*—which, you will remember, could be traced to the anterior perforated spot at the root of the fissure of Sylvius, and were there lost. Between them lies the lamina cinerea.

Posteriorly, on the other hand, the corpus callosum ends in a thickened, free, rounded border or base—the *SPLENIUM* (Fig. 80). From the outer ends of the splenium two horn-shaped bundles of fibres, the *forceps major*, diverge into the occipital lobes; and two similar bands, the *forceps minor*, can be traced from the genu into the frontal lobes.

The *upper surface* of the corpus callosum is marked along the middle line by a longitudinal groove—the *raphé*—parallel to which, on each side, you will see two or more faint lines—the *median longitudinal striæ* (nerves of Lancisi). Externally, under cover of the overhanging edge of the gyrus fornicatus, are similar longitudinal striæ—the *lateral longitudinal striæ* (*tæniæ tectæ*, covered bands). The median striæ, when traced forwards, are joined in front by a prolongation of the lateral striæ, and pass with them round the anterior end

of the corpus callosum to the peduncles of the corpus callosum ; behind, on the other hand, the striæ can be traced into a fine grey lamina—the fasciola cinerea—and then into the fascia dentata (Fig 2, page 150). The striæ longitudinales, the fasciola cinerea, and the fascia dentata form the abortive convolution (connected with the sense of smell), and referred to on page 127.

The *under surface* of the corpus callosum rests, in the posterior half of its extent, upon the upper surface of the body of the fornix, to which it is closely adherent, especially near the splenium. In its anterior half, it is connected below with the vertical mesial partition—the *septum lucidum*—filling up, as we have seen, the space left between the fornix and concavity of the knee-shaped bend of the corpus callosum (Fig. 89, page 160).

Laterally, the transverse fibres of the corpus callosum form the roof of the lateral ventricles, and diverge into the white substance of the hemispheres.

STRUCTURE.—The corpus callosum consists of white nerve fibres, which are in the main transverse, a few only being longitudinal. As they pass into the hemispheres they diverge in all directions, and probably go, along with the fibres of the *corona radiata*, to the grey matter of the cortex. They start from some of the pyramidal cells of the one or other side of the cortex, and end in ramifications in the pyramidal and molecular cell layers of the opposite hemisphere. Many of them are collaterals of the projection systems of fibres.

It is worthy of note that the corpus callosum may be absent without any ill effect (HOLDEN).

The *anterior, middle, and posterior commissures* are connected with the 3rd ventricle (Fig. 80, page 136).

The Anterior Commissure is a round white cord which passes transversely across the middle line in front of the anterior pillars of the fornix, between them and the lamina terminalis. It connects together the limbic lobes of the two sides.

The Middle (Grey) Commissure crosses the 3rd ventricle between the optic thalami. It is a delicate band of grey matter connected with the grey matter of the thalami optici.

The Posterior Commissure, situated in front of and below the pineal gland, but above the commencement of the passage into the 4th ventricle, is a rounded band which stretches between the optic thalami. It is not known whence its fibres come nor where they end.

II. The ASSOCIATION FIBRES (see page 157).—Of these the chief is the *fornix* (Figs. 89, 91, page 160; Plate XXXIIIA., Fig. 2, page 150).

THE FORNIX.

Beneath the corpus callosum, and more or less blended with it, especially behind, is a longitudinal system of association fibres—the FORNIX. It is an arched white band, which can be traced from the

FIG. 87.

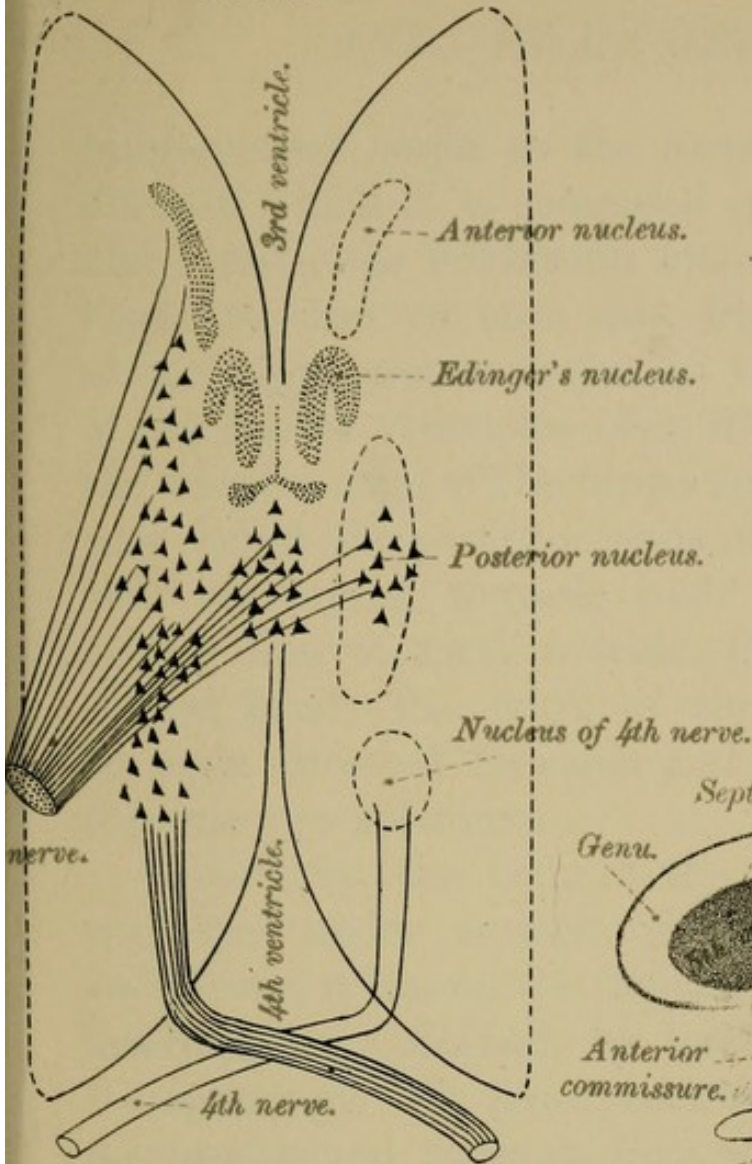


DIAGRAM OF NUCLEI OF 3RD AND 4TH NERVE.

FIG. 88.

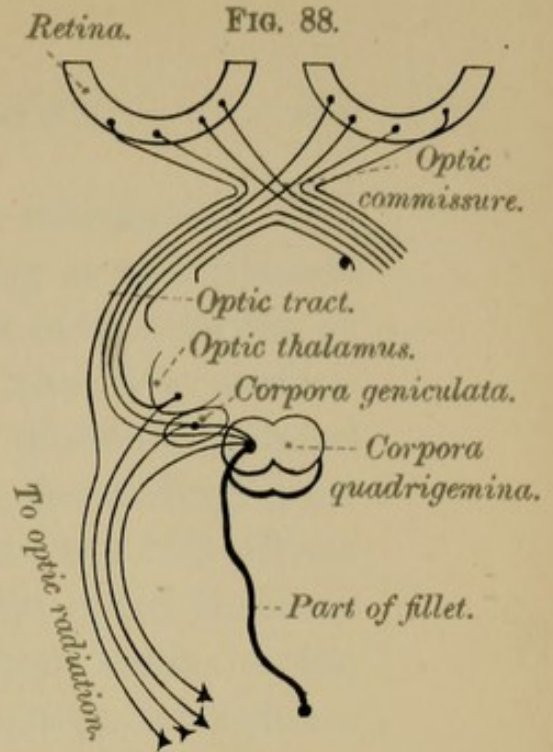


DIAGRAM OF OPTIC NERVES AND OPTIC TRACT.

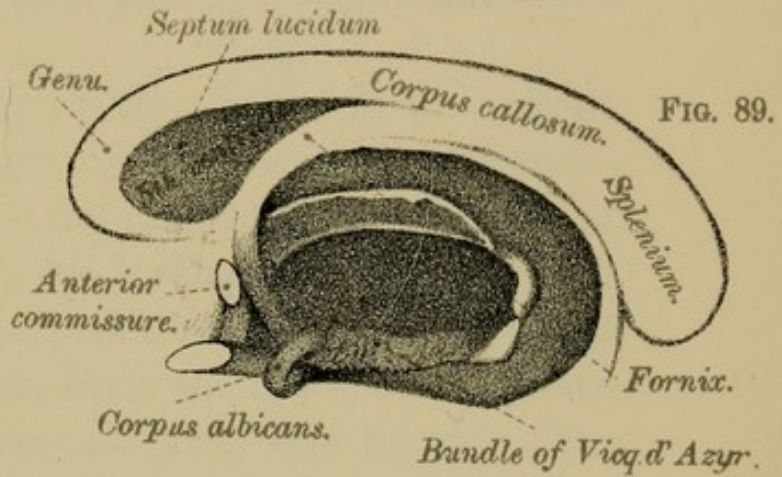
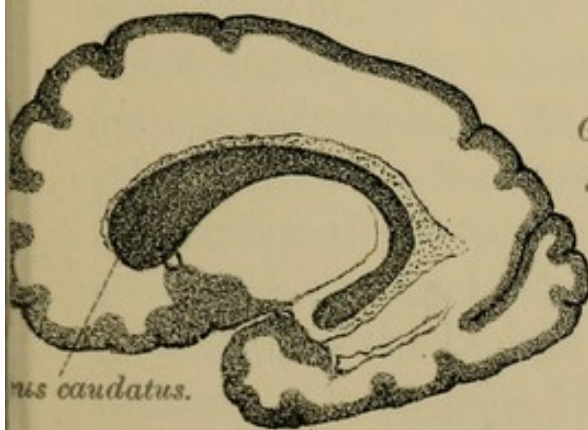


FIG. 89.

FIG. 90.



g. of the shape of the nucleus caudatus.

FIG. 91.

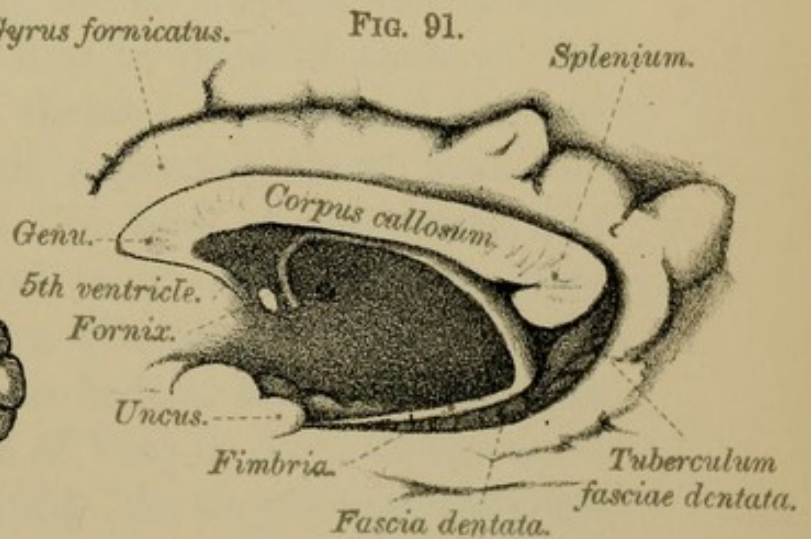



FIG. OF FORNIX—THE OPTIC THALAMUS REMOVED.



hippocampus major to the corpora albicantia. The fibres of which it is composed spring as two ribband-like bands—the POSTERIOR PILLARS of the fornix or FIMBRIÆ—one on each side, from the free surface of the hippocampus major, in the descending horn of the lateral ventricles (Fig. 91). Ascending from the concave edge of the hippocampus the two pillars pass round the posterior ends of the optic thalami, and, converging towards each other, meet in the middle line to form a wide, flattened, triangular-shaped band—the BODY of the fornix—which has its apex directed forwards and its base backwards towards the splenium.

Superiorly, the body of the fornix is in contact with the under surface of the corpus callosum; *inferiorly*, it lies on the delicate lamina—the velum interpositum. *Behind*, by its base it blends with the splenium. *In front*, its fibres diverge and pass downwards and forwards from the apex of the body, as two cylindrical processes—lying side by side—the ANTERIOR PILLARS of the fornix, which can be traced to the base of the brain, to the *corpora albicantia*. In this course they lie first in front of, then in the substance of, the optic thalami, but behind the anterior commissure which separates them from the lamina terminalis. At the base of the brain, the pillars make an 8-shaped twist on themselves, form the cortex of the corpora albicantia, and end in the grey core of these white bodies, from which fibres re-ascend, as the bundle of Vicq d' Azyr, to the optic thalami (Fig. 89, page 160). As they descend in front of the optic thalami, the anterior pillars of the fornix

form, as already explained, one of the boundaries of the small circular foramina—the foramina of Monro.

At *the sides*, the fornix appears as a thin, free, sickle-shaped edge, which rests upon the velum interpositum and the optic thalamus, and enters into the formation of the floor of the lateral ventricles.

Originally the fornix consisted of two separate divisions, right and left, but these ultimately fuse in the middle line to form the body, their ends remaining free as the anterior and the posterior pillars of the fornix.

Where the posterior pillars of the fornix diverge from each other, there will be found a triangular space filled up by transverse fibres of white matter. It is called the *lyra*. Sometimes the fornix is entirely blended with the posterior part of the under surface of the corpus callosum; at other times a small interval, called the *ventricle of Verga*, is left between them.

The Tænia Semicircularis is the narrow white band which lies in the groove between the nucleus caudatus and the optic thalamus. In front, it joins the corresponding pillar of the fornix; behind, it passes into the substance of the roof of the descending horn of the lateral ventricle (nucleus amygdalæ).

III. PROJECTION FIBRES (see page 157).—The chief projection systems of fibres are contained in the internal and external capsules.

INTERNAL AND EXTERNAL CAPSULES.

(Fig. 86, Plate XXXIV, page 154).

In treating of the Basal Ganglia you will remember we referred to two strands of white fibres, the INNER and OUTER CAPSULES, the former lying internal to, the latter external to the nucleus lenticularis. Of these so-called capsules, the internal is of the greatest clinical importance, for through it pass the chief motor and sensory tracts.

The Internal Capsules (Fig. 86, page 154).—Seen in horizontal section each internal capsule appears as a longitudinal semi-lunar shaped band of white matter with its convexity directed towards the middle line. It can be divided into three portions—an *anterior*, a *middle*, and a *posterior*. The ANTERIOR DIVISION lies between the nucleus caudatus and the nucleus lenticularis; the POSTERIOR DIVISION lies between the optic thalamus and the nucleus lenticularis, and forms with the anterior division a sharp angle, or knee-shaped bend—the *middle portion*, called the GENU. The inner capsule therefore has three parts—(1) a knee-shaped bend, the genu; (2) a part in front of the knee; and (3) a part behind the knee. This capsule contains all the fibres of the crura of the crus cerebri of the same side except those that go to the nucleus lenticularis. Emerging from between the nucleus lenticularis and the tail of the caudate nucleus, and reinforced by fibres from the optic thalamus and the region below

it, the fibres of the crusta form a radiating, hollow, fan-shaped mass of nerve fibres—the CORONA RADIATA—which spread out into the cerebral cortex.

In the internal capsule there are four sets of fibres.

(1) The tracts forming the knee, and the anterior two-thirds of the posterior limb of the inner capsule are *motor* in function, and are in relation respectively, from before backwards, with the centres for the ocular, oro-lingual, facial, brachial, trunk, and crural muscles. Injury to this portion of the inner capsule results in loss of motion on the opposite side of the body.

(2) Mingled with the motor fibres are others which connect the central convolutions (ascending frontal and parietal) with the nucleus pontis, and, through this nucleus, with the cerebellum of the opposite side. This tract is called the *secondary motor tract*, or *cortico-pontine tract* (Plate XLI., page 184). It is ultimately connected, though the exact route is unknown, with the anterior spinal nerve roots of the opposite side to that at which it left the brain.

(3) The posterior third or more of the hinder division of the inner capsule contains *sensory strands*; for, when injured or diseased, there ensues loss of sensation, general and special, on the opposite side of the body, the motor powers not being affected, unless the lesion implicates the motor tracts also.

(4) The anterior limb of the internal capsule, in front of the knee-shaped bend, carries fibres from

FIG. 92.

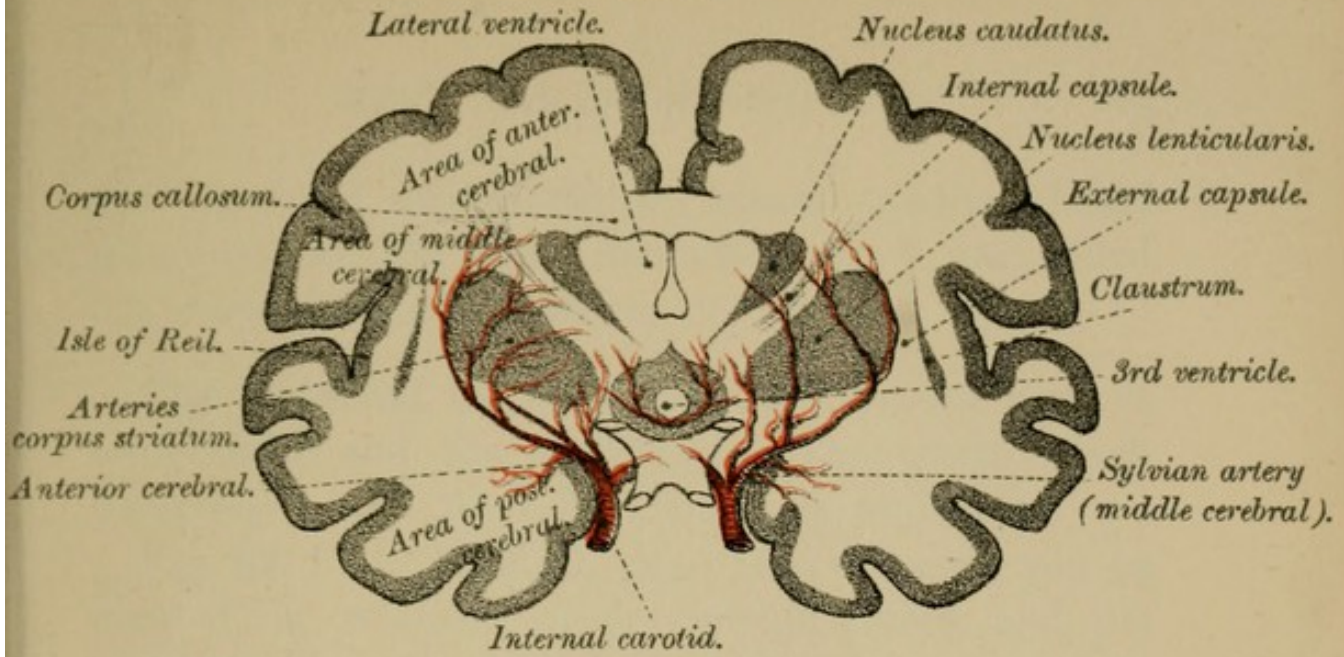


FIG. 93.

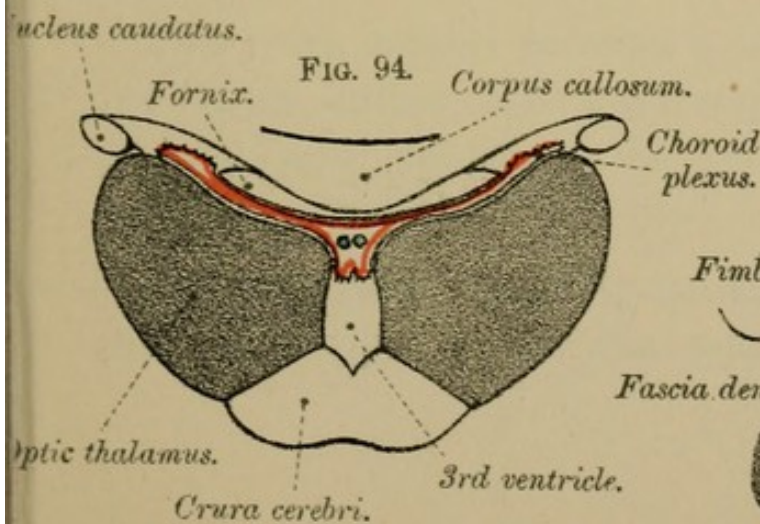
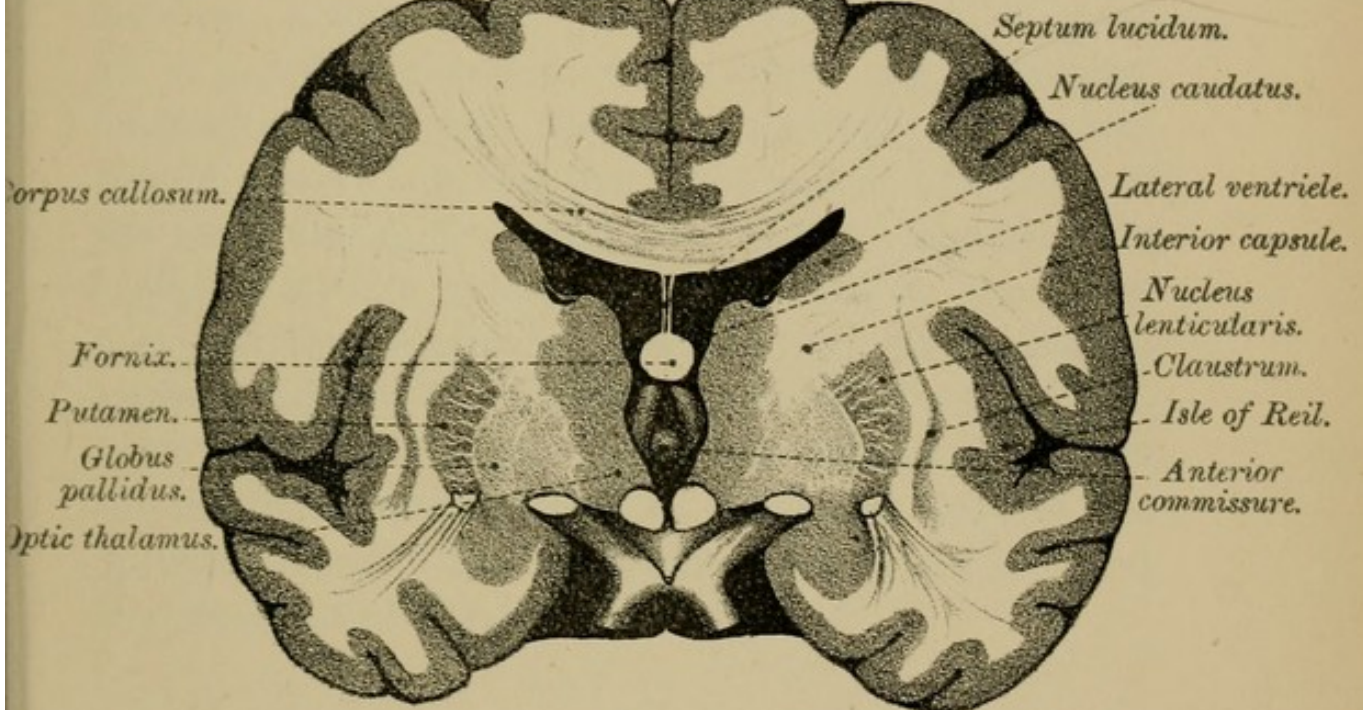
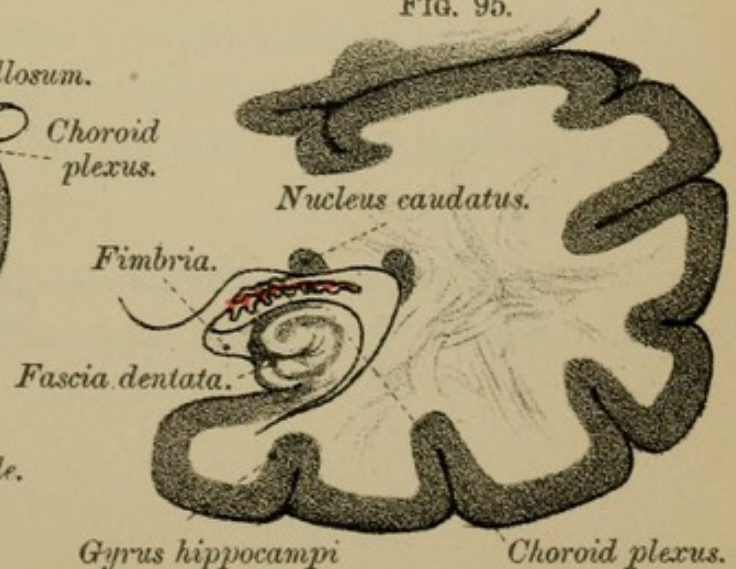



FIG. 94.

FIG. 95.





the sensorial areas—tactile, visual, auditory, and olfactory—to the optic thalamus: they are called the *cortico-thalamic* fibres.

The External Capsule lies between the nucleus lenticularis and the claustrum. The tracts which compose it, and their functions, are undecided.

Fig. 92, Plate XXXVI., page 164, will give you an idea of the relations of the Sylvian artery, and the distribution of its branches to the capsules, and to the contiguous nuclei. When describing the middle cerebral artery, page 58, we saw that it gave off a ganglionic system of arteries—the lenticular, lenticulo-striate, and the lenticulo-optic. The *lenticular* artery supplies the inner and middle parts of the lenticular nucleus and the internal capsule; the *lenticulo-striate* artery is distributed to the outer part of the lenticular nucleus, to the external capsule, and to the caudate nucleus; the *lenticulo-optic* artery goes to the outer and posterior part of the lenticular nucleus and to the outer part of the optic thalamus. The lenticulo-striate artery is called the artery of cerebral hæmorrhage.

IV.—CRURA CEREBRI.

The crura cerebri belongs to that sub-division of the brain called the mesencephalon. This sub-division also comprises the corpora quadrigemina and the aqueduct of Sylvius.

I. The Crura Cerebri, or Cerebral Peduncles (Fig. 46, page 66), are the two cylindrical masses

which you see springing in front from the upper margin of the pons. Diverging from each other, and enlarging as they ascend, they soon enter the base of the cerebral hemispheres, burying themselves in the optic thalami.

Between the peduncles, where they diverge from each other, will be found the posterior perforated spot and two little white bodies, the corpora albicantia (Fig. 98, page 168); winding round the outer side of the crura are the optic tracts above, and the 4th nerves below; on their inner side is a groove, the oculomotor groove, from which the 3rd nerve takes its superficial origin; and on their dorsal aspect are four rounded tubercles—the corpora quadrigemina—with the lamina quadrigemina, beneath which runs the aqueduct of Sylvius.

STRUCTURE.—A section at right angles to the crura cerebri will show you that they each consist of two portions, a posterior or dorsal, called the **TEGMENTUM**, and an anterior or ventral, called the **CRUSTA**, **PES** or **BASIS**. These two parts of the crura are separated from each other by a narrow stratum of grey matter, called, from its dark colour, the **LOCUS NIGER** (substantia nigra), the position of which is indicated on the surface by the oculomotor groove internally, and by another slight groove, the lateral sulcus, externally (Fig. 61, page 90).

(1) **The Tegmentum** (Fig. 61, page 90), is the larger division of the crus, and, like the *formatio reticularis* of the medulla and pons, is composed of a reticulum of longitudinal and transverse fibres interspersed with

grey matter. We shall study, first, the grey, then the white matter of the tegmentum.

(a) The *grey matter* of the tegmentum consists of scattered cells, and of two definite collections, the one being the grey matter of the aqueduct of Sylvius, the other lying beneath the anterior pair of corpora quadrigemina, and known as the RED NUCLEUS or *nucleus tegmenti* (Fig. 61, page 90). This latter nucleus consists of multipolar nerve cells, and is probably the primary termination of the superior cerebellar peduncles.

(b) The *white matter*.—The longitudinal fibres come from the anterior and lateral columns of the spinal cord, and form the superior cerebellar peduncles. The best marked tracts are the POSTERIOR LONGITUDINAL BUNDLE and the TRACT OF THE FILLET; the former appearing in sections of the crura as two well marked strands, one on each side of the aqueduct of Sylvius; the latter, the fillet, appearing as a tract of oblique white fibres on the outside of the red nucleus (Fig. 61). The transverse fibres are as yet little understood.

(2) **The Crusta, Pes or Basis**—the ventral part of the peduncles—lies in front of the locus niger, and is chiefly composed of the pyramidal tracts of the medulla, though other strands are superadded, for transverse sections of the crusta are much larger than those of the pyramids. The following are the various tracts of fibres of the crusta:—

(1) The *pyramidal tracts*, motor strands from the cortex, occupy the middle and inner part of the

crusta. They are divisible into two parts—an external, the pyramidal tracts proper; an internal, the *geniculate fasciculus*. The latter comes from the genu of the internal capsule, and contains fibres connected with the motor part of the 5th nerve, with the 7th and 12th nerves, and hence with the muscles of mastication, of the face and of the tongue. (See Fig. 61, Plate XIX., page 90).

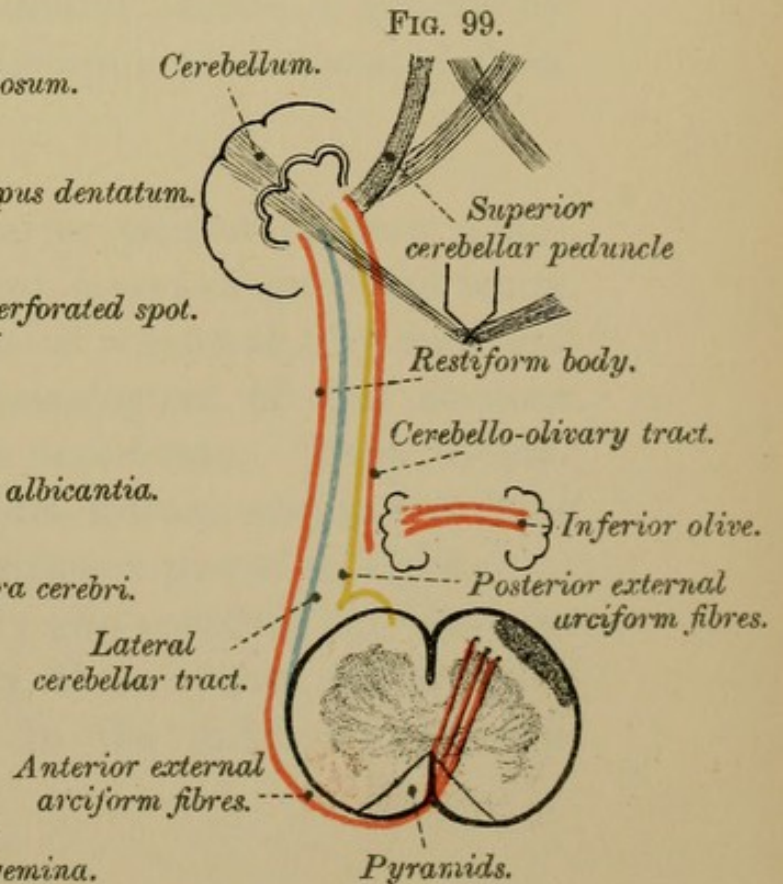
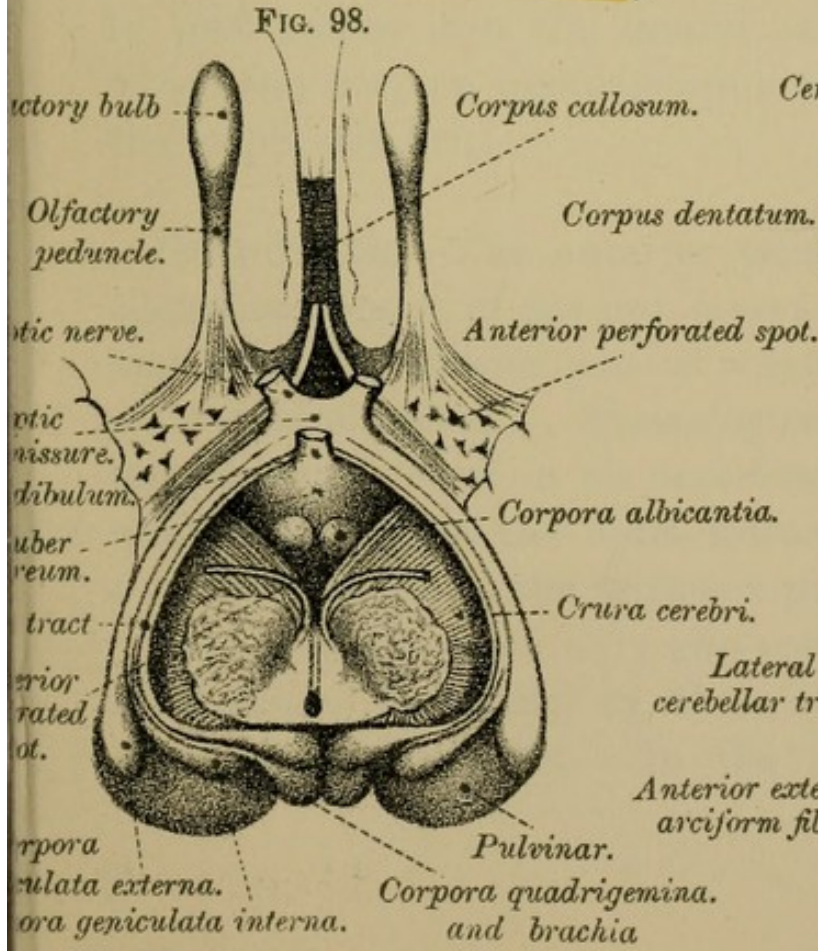
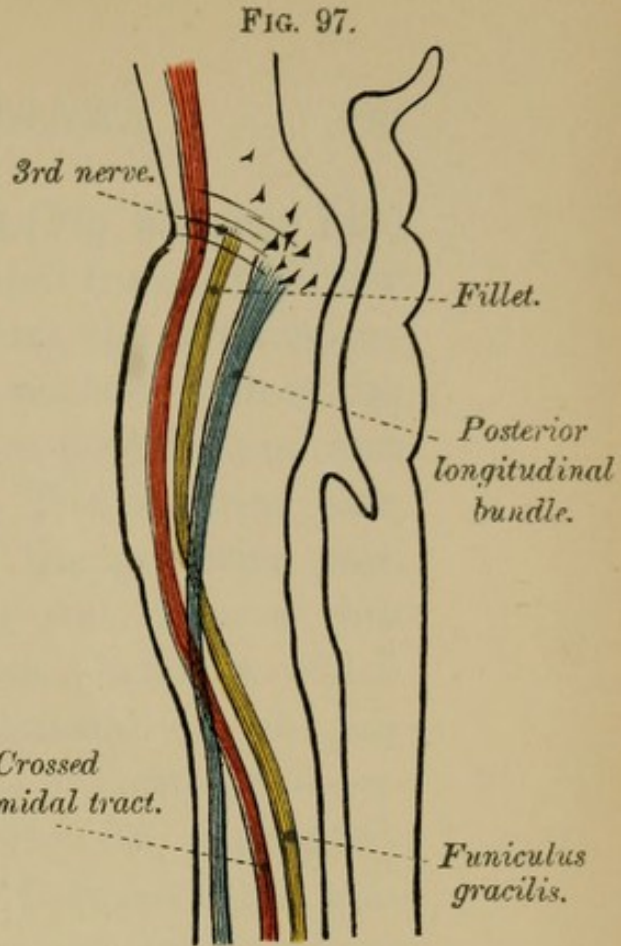
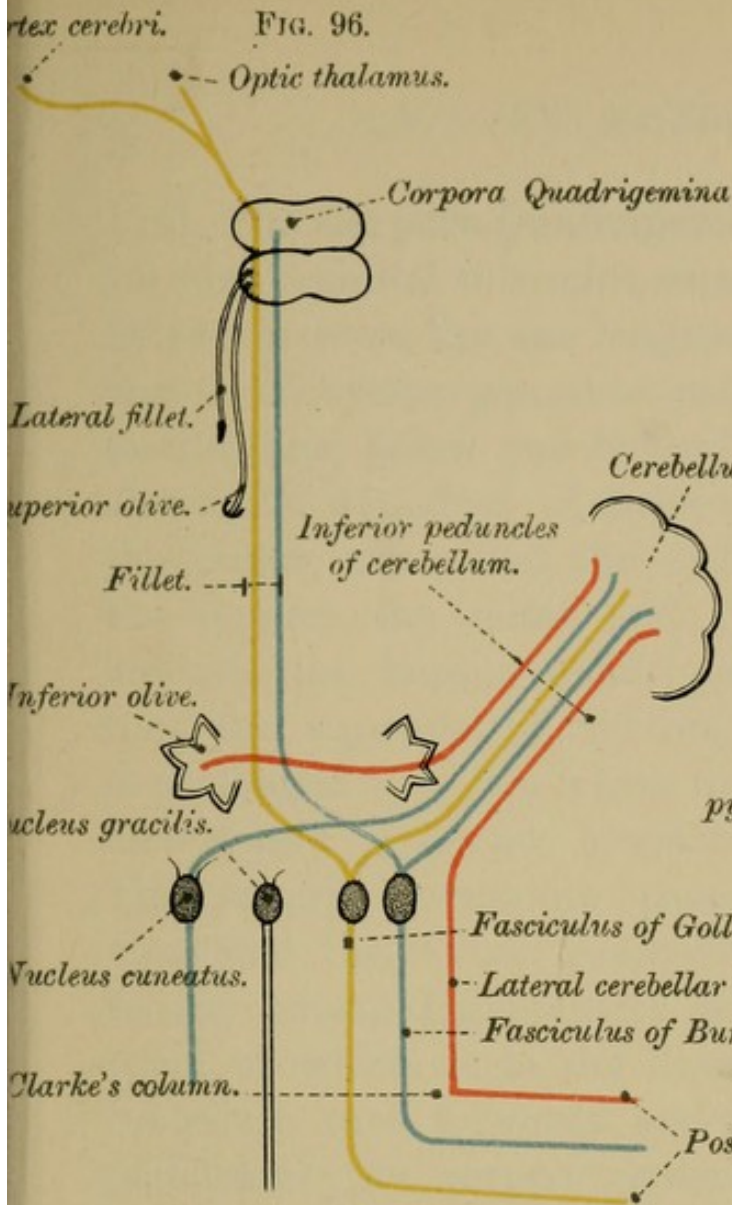
(b) The *cortico-pontine tract*, which passes from the cerebral cortex to the nucleus pontis, and then to the opposite half of the cerebellum. As they travel through the crus, these cortico-pontine fibres form two groups; the one occupies the posterior external part of the crusta, and is called the *fasciculus lateralis*; the other group mingles with the geniculate and pyramidal fibres.


(c) The *caudate cerebellar fibres*, or boundary layer of the pes, probably come from the caudate nucleus.

The relative positions of these tracts to each other will be understood by reference to Fig. 61, page 90.

(3) **The Substantia Nigra** is a semi-lunar band of grey matter placed between the two divisions of the crus. It is characterised by darkly pigmented cells—hence the name. Through it pass the roots of the 3rd nerve before they emerge at the oculomotor groove (Fig. 61). Its connections and uses are unknown.

The two pedes are quite distinct from each other, whereas the two tegmenta are merely separated by the median raphé.





II. The Corpora Quadrigemina (Fig. 85, page 148) are four rounded tubercles, separated from each other by two grooves, the one longitudinal, the other transverse. They are placed in pairs, on each side of the middle line, below and behind the pineal gland and above the aqueduct of Sylvius. The anterior pair, the larger, are called the *nates*, the posterior pair, the smaller, the *testes*, and they rest upon a thin lamina—the lamina quadrigemina—beneath which runs the aqueduct of Sylvius. Laterally, each pair is prolonged into two white bands or cords—the *anterior* and *posterior brachia* (Fig. 98, page 168). The anterior brachium passes between the pulvinar and the corpus geniculatum internum, thence to the external geniculate body and to the optic tract, of which it is the direct root; the posterior brachium runs forwards and outwards, and in part penetrates the corpus geniculatum internum, and in part passes into the lateral sulcus, a groove by which the corpora quadrigemina are separated from the crura cerebri.

STRUCTURE.—The anterior pair of corpora quadrigemina consist of several layers of grey and white matter; the posterior pair of a central grey core and of a white cortex. Homologues of the corpora quadrigemina exist in all vertebrata. They invariably give origin to the optic nerves, and in size bear a direct relation to the animal's power of sight.

In birds there are only two corpora, but they are very large, especially in those birds which have great powers of sight. In the mole the posterior

pair are well developed; the anterior pair are rudimentary.

Injury to the optic nerves causes the anterior pair to waste, but leaves the posterior pair unaltered.

III. **The Aqueduct of Sylvius** is the narrow passage between the 3rd and 4th ventricles (Fig. 80, page 136). Above, it is roofed over by a thin lamina—lamina quadrigemina—so called because it supports the corpora quadrigemina. Its floor and lateral walls are formed by the dorsal part of the cerebral peduncles. Internally it is lined by ciliated columnar epithelium, outside which is a thick layer of grey matter continuous with the grey matter—(locus cæruleus)—of the 4th ventricle. From this grey matter arise the 3rd, the 4th, and part of the 5th nerves.

SUMMARY.—Thus we see that the cerebrum consists of a convoluted cortex, of basal ganglia, of ventricles united by narrow passages, and of white strands formed of commissural, projection, and association fibres.

ORIGINS OF THE CRANIAL NERVES.

The Cranial Nerves have *superficial* and *deep* origins.

By the term *superficial origins* is meant the points at which the nerves are attached to the surface of the brain. Their *deep origins* (sub-cortical) are the several deep-seated nuclei to or from which they can ultimately be traced. Each

nerve has, moreover, a cortical representation (cortical origin).

1. The Olfactory Nerves—1st pair—spring from the olfactory bulbs, and pass through the holes in the cribriform plate of the ethmoid, to be distributed to the upper part of the olfactory mucous membrane. The roots of the olfactory peduncles have already been noticed (page 118). They are two in number, a *mesial root* and a *lateral root*. The *mesial root* passes in part to the callosal gyrus (gyrus of the corpus callosum), in part to the area of Broca: the *lateral* or *outer root* can be traced to the extremity of the temporal lobe, where it blends with the anterior end of the gyrus hippocampi. By means of these two roots the olfactory peduncle is connected with the two ends of the limbic lobe. The trigonum olfactorium is sometimes regarded as a third root, and a well-marked bundle of fibres can be traced to it from the peduncle. Besides the above distinct roots, some of the fibres of the olfactory tract go to the anterior end of the thalamus, others pass through the anterior commissure to the opposite cerebral cortex, and to the opposite olfactory bulb.

It is worthy of note that in animals with well-developed organs of smell, the gyrus hippocampi, the striæ longitudinales, and the fascia dentata are well marked; whereas in man, with small olfactory lobes, they are relatively small. Injury to the olfactory bulb causes atrophy of the uncinate gyrus of the same side. This gyrus, therefore, is the *cortical centre*.

2. **The Optic Nerves**—2nd pair—can be traced back from the eyeballs, through the optic foramina to the outer sides of a mesial band—the optic commissure—in which they partially decussate. From this commissure they run backwards as the *optic tracts* round the outer sides of the crura cerebri, and then bifurcate into an internal limb which goes to the corpora geniculata interna, and an external limb which can be traced to the pulvinar, to the corpora geniculata externa, and to the anterior pair of corpora quadrigemina (Fig. 98, page 168). In the optic tracts and commissure there are *four* sets of fibres—(1) an outer set, the *direct fasciculus*, to the eyeballs of the same side; (2) a middle set, which come from the macula lutea, and are partly crossed and partly uncrossed—*fasciculus macularis*; (3) a *crossed set*, which decussate with the fibres of the opposite side, *e.g.*, those of the right tract going to the left eye, and those of the left tract going to the right eye; (4) an internal set, which pass from one tract to the other and then back to the brain without entering the eye; this set is known as the commissure of Gudden.

The deep origins of the optic nerves are two-fold—sub-cortical or ganglionic, and the cortical.

(1) The *ganglionic centres* were named above, and are the pulvinar of the optic thalamus, the corpora geniculata externa, and the anterior pair of corpora quadrigemina (Fig. 88, page 160). These several nuclei degenerate when the eye of a young animal is destroyed.

FIG. 1

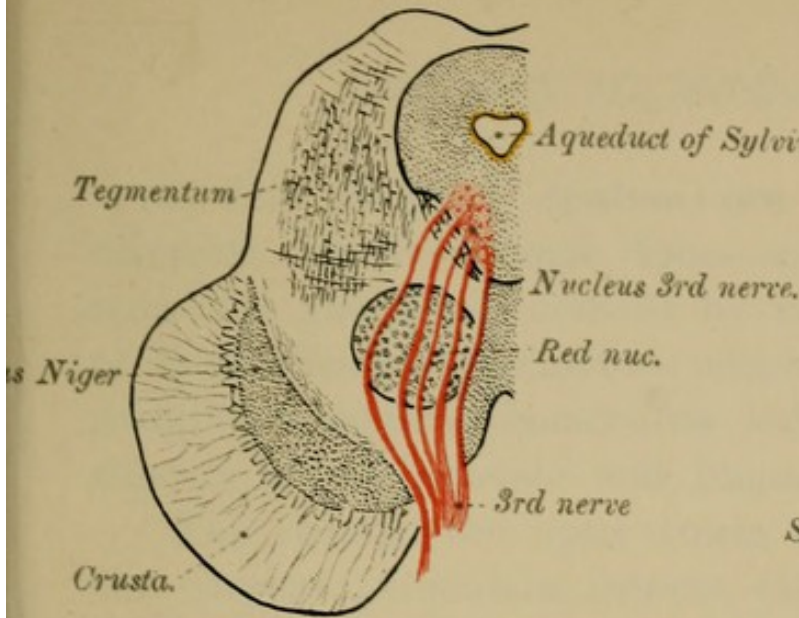


FIG. 2

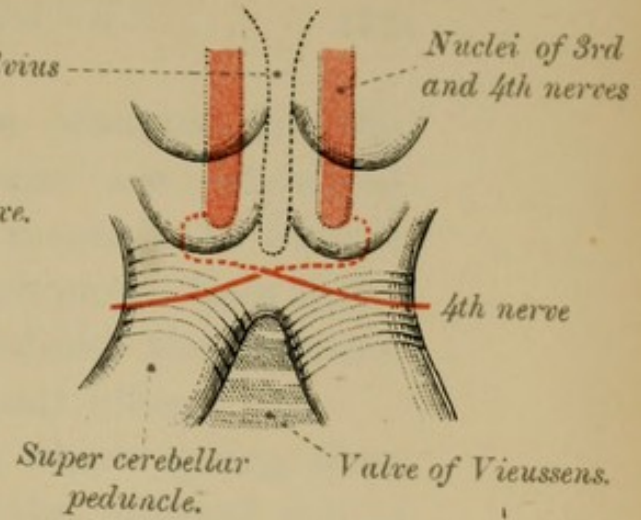


FIG. 3

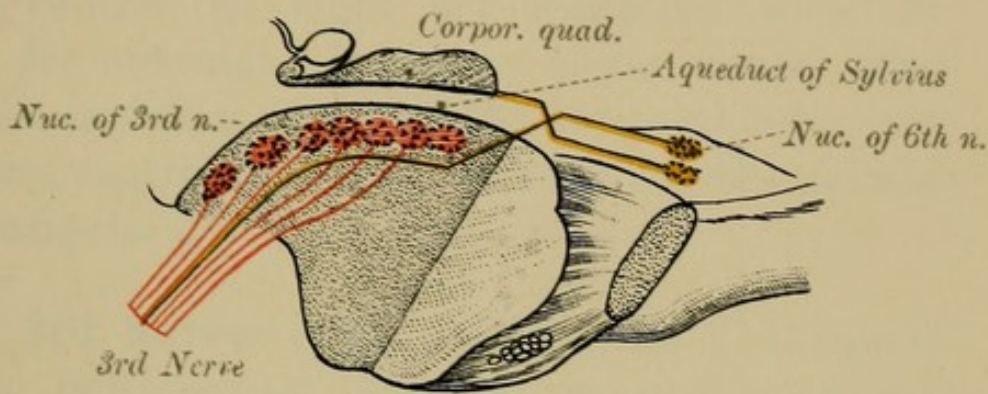


FIG. 4

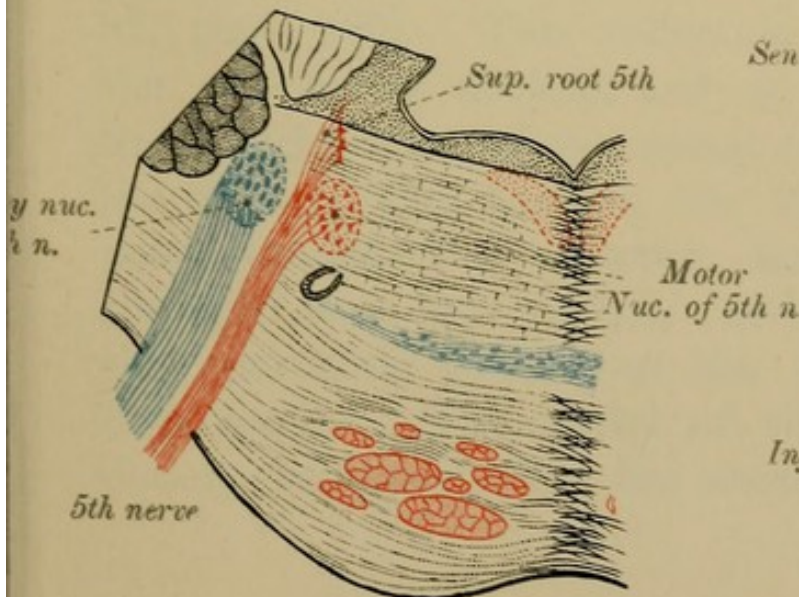
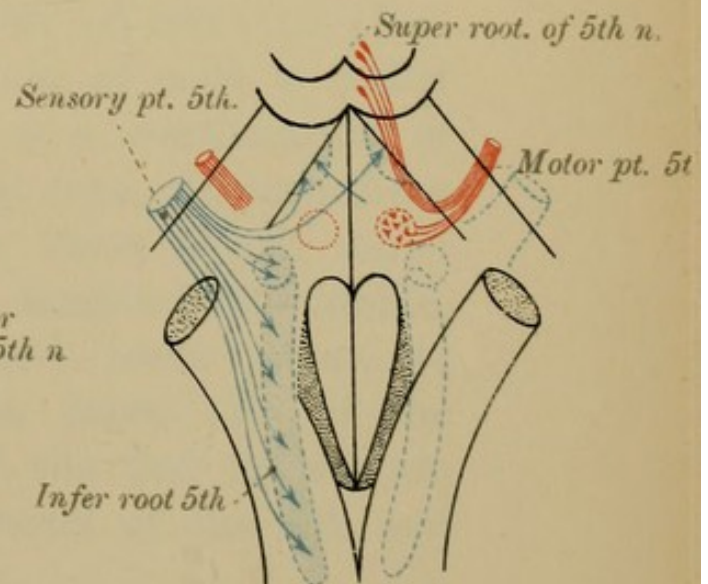



FIG. 5





(2) The *cortical centres* are situated in the occipital lobes—cuneate lobe—and are connected with the ganglionic centres by means of a bundle of fibres, *the optic radiation*, which passes from these ganglionic centres backwards behind the internal capsule to the cuneate and lingual lobes.

“The roots of the optic tracts which spring from the corpora geniculata interna (the internal set of fibres named above) have no real connection with vision, as they do not undergo atrophy like the other roots when the eyes are destroyed” (FERRIER).

The centres for sight are connected with the centre for articulate language in the frontal lobe; with the auditory centre in the temporal lobe; and with the centre for visual memory in the parietal lobe—angular gyrus.

The 3rd Nerves (Figs. 1, 2, 3, page 172) appear at the OCULOMOTOR GROOVE, on the inner side of the crura cerebri, close to the pons Varolii. They spring from a longitudinal column of cells, on each side of the middle line, in the grey matter of the FLOOR of the AQUEDUCT of SYLVIVS (Fig. 87, page 160). This collection of cells is called the oculomotor nucleus, and is a continuation of the anterior horn of the spinal cord. Traced from the cells of this nucleus, the fibres of the nerve pass through the posterior longitudinal bundle, through the red nucleus and locus niger, to the oculomotor groove, on the inner side of the crus cerebri. The nuclei of the 3rd nerves are closely connected with the nuclei of the 4th and

6th nerves, the nucleus of the 6th nerve of the one side being united by means of the posterior longitudinal bundle with the opposite 3rd nerve (Fig. 3, page 172, and Fig. 4, page 176). There is probably a partial decussation of the fibres of the 3rd nerve. The nucleus of the 3rd nerve gives rise to two sets of fibres—

(1) To the extrinsic muscles of the eyeball, except the external rectus and the superior oblique.

(2) To the intrinsic muscles of eyeball, viz., the sphincter pupillæ, and the ciliary muscle.

The 4th Nerves will be seen on the outside of the crura cerebri, between the cerebrum and cerebellum (Fig. 79, page 134). They are small and slender, and arise from a nucleus in the wall of the aqueduct of Sylvius behind that of the 3rd nerve (Fig. 2, page 172). The 4th nerve is connected with the nucleus of the 6th nerve of the opposite side. After leaving their nuclei of origin the 4th nerves pass backward and decussate in the superior medullary velum (superficial origin), so that the left nerve comes from the right nucleus, and *vice versâ* (Fig. 2, page 172).

The 5th Nerves spring from the sides of the pons, near its upper margin, by two roots—a large one, *sensory (ganglionic)*, and a small, *motor (aganglionic)*. The small—**MOTOR ROOT**—is the higher of the two, and is separated from the larger root by some of the transverse fibres of the pons. Followed backwards, this smaller part is seen to arise from the principal nucleus—motor nucleus—lying just below

the LATERAL ANGLE of the 4TH VENTRICLE (Fig. 57, page 82). It is joined by the superior or descending root of the 5th nerve, which comes from the accessory nucleus—a column of grey matter at the sides of the aqueduct of Sylvius (Fig. 5, page 172). Some of the motor fibres come from the opposite side.

The large or SENSORY ROOT.—The nucleus of this root is the Gasserian ganglion, situated on the apex of the petrous part of the temporal bone. The uni-polar nerve cells of this ganglion give off two branches, one of which passes into the peripheral nerve; the other enters the cerebro-spinal axis, and there divides into ascending and descending branches. The ascending branches terminate amongst the cells forming the sensory nucleus of the 5th nerve—a nucleus lying close to the outer side of the motor nucleus (Fig. 5, page 172). The descending branches form the descending or inferior root of the 5th nerve, and can be traced down the spinal cord as far as the first cervical nerve.

The 6th Nerves take their superficial origin near the middle line from the groove between the anterior pyramids of the medulla and the lower border of the pons (Fig. 79, page 134). Their deep origin is situated underneath the outer part of the FASCICULUS TERES in the fore part of the floor of the 4th ventricle, in front of the striæ acusticæ (Fig. 57, page 82). The nucleus of the 6th nerve is connected by means of the posterior longitudinal bundle with the fibres of the third nerve of the opposite side (Fig. 3, page 172, and Fig. 4, page 176).

The 7th Nerve consists of two parts—the FACIAL nerve proper (*portio dura*) and the PARS INTERMEDIA. The FACIAL nerve proper (7th) springs from the groove between the olivary body and the restiform body, just below the pons (Fig. 79). Its deep origin is the facial nucleus in the *formatio reticularis* of the dorsal aspect of the pons, near the nucleus of the 6th nerve, but external and deeper in beneath the floor of the 4th ventricle (Figs. 1, 2, page 176). The fibres leave the nerve cells of this nucleus, and are at first directed backwards and inwards towards the middle line, internal to the nucleus of the 6th nerve. They then ascend for a short distance behind the nucleus of the 6th nerve, close to the floor of the 4th ventricle, forming part of the *eminentia teres*, and, bending down and out over the upper end of the nucleus of the 6th nerve (Fig. 2, page 176), they run forwards, outwards, and downwards to the lower border of the pons—their superficial origin. In the pons the facial nerve is joined, through the posterior longitudinal bundle, by fibres from the nuclei of the 3rd and 12th nerves.

The *pars intermedia* of the facial nerve is a small bundle of nerve fibres which lies between the facial and auditory nerves, and is connected with both. It probably carries taste fibres to the glosso-pharyngeal nucleus, the sensory impulses travelling from the tongue to that nucleus through the *chorda tympani*, and through the *pars intermedia* of the facial nerve.

The Auditory Nerve—8th nerve—takes its superficial origin in the same groove with, but behind, the

FIG. 1

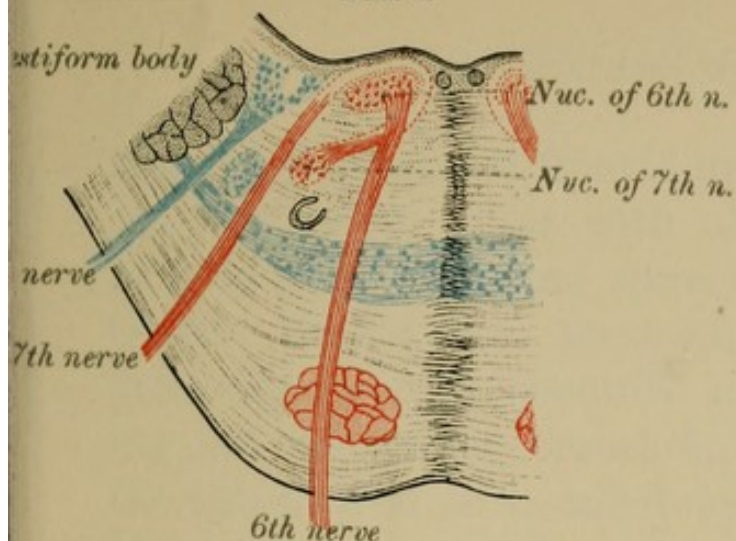


FIG. 2

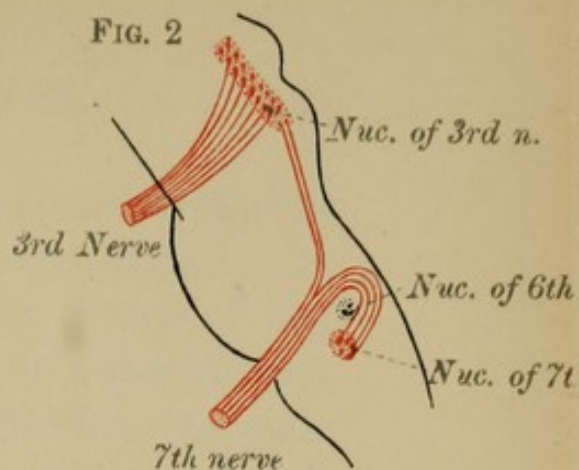


FIG. 3

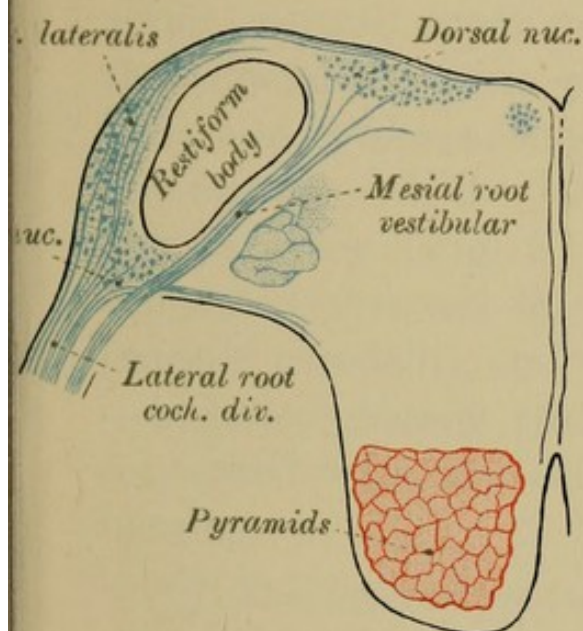


FIG. 4

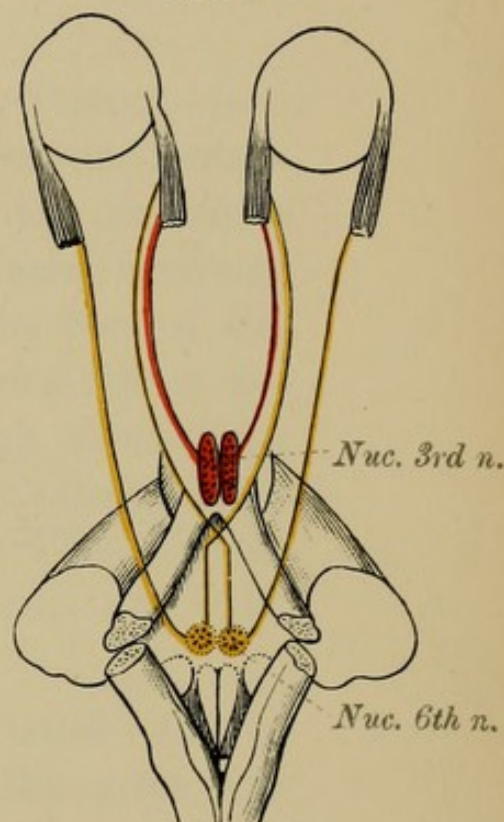


FIG. 5

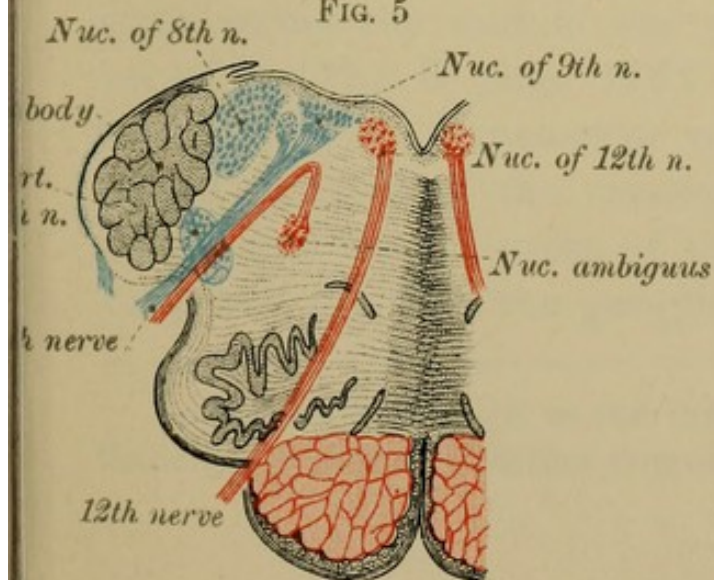
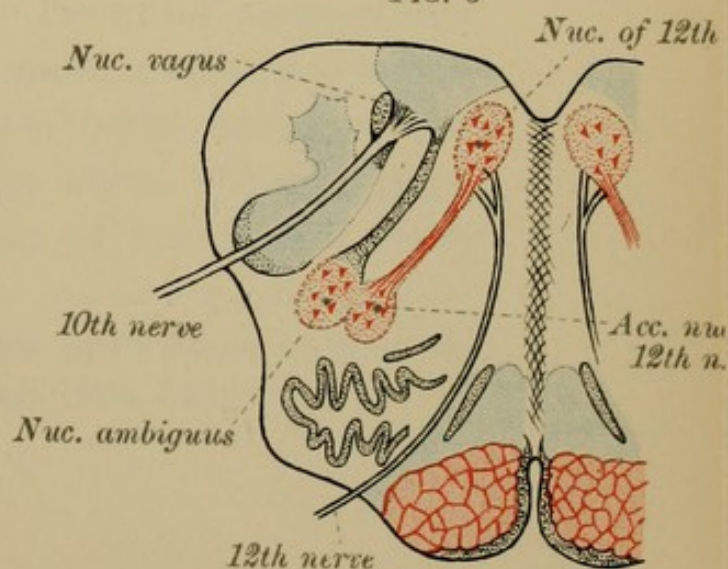



FIG. 6





facial, and separated from it by the *pars intermedia*. Its true origin is, as with all sensory nerves, the ganglia (vestibular and spiral) on the course of the nerve. Traced from these ganglia the axis-cylinder processes enter the medulla and divide into ascending and descending branches, which end in tufts at the sub-cortical or so-called deep origin of the nerve. The auditory nerve has two roots—a mesial and a lateral root (Fig. 3, page 176).

(1) The *mesial root*—VESTIBULAR DIVISION—(anterior, ventral, upper root) passes backwards through the substance of the pons internal to the restiform body, and becomes connected with the dorsal auditory nucleus beneath the lateral angle of the floor of the 4th ventricle (Fig. 3, page 176). Some fibres are connected through the raphé with the cerebellum (vermis cerebelli), and with the inferior olivary body—*acustico-olivary tract* of Bruce.* This root is concerned with the sense of equilibrium, not with hearing.

(2) The *lateral root*—COCHLEAR DIVISION—(lower or posterior root) can be traced round the outer side of the restiform body and through the auditory striæ across the middle line of the floor of the 4th ventricle (Fig. 3, page 176). Its chief connections are (1) with the accessory or ventral auditory nucleus placed in front of the restiform body, between the mesial and lateral roots of the nerve (Fig. 3, page 176), and (2) with the ganglion of the lateral root,

* See magnificent work on the Brain by Dr Bruce, Lecturer on Pathology, School of Medicine, Surgeons' Hall, Edinburgh.

a collection of cells found amidst the lateral root as it winds round the outer side of the restiform body (Fig. 3, page 176). This is the true nerve of hearing, being alone distributed to the organ of Corti. Some of the fibres of the accessory nucleus can be traced to the opposite fillet, and through it to the posterior pair of corpora quadrigemina; others go to the superior olive of the same and of the opposite sides.

The Glosso - pharyngeal—9th pair of nerves. The motor part of this nerve takes its deep origin from the nucleus ambiguus or accessory vagal nucleus (Fig. 5, page 176). The sensory fibres start in the ganglia on the nerve (the petrous and jugular ganglia), and on entering the medulla divide into descending branches which join the fasciculus solitarius, and ascending branches which end in a special nucleus, common to this nerve and to the vagus, beneath the inferior fovea of the lower half of the floor of the 4th ventricle (ala cinerea).

The Vagus—10th nerve. The motor portion of this nerve springs from the nucleus ambiguus or accessory vagal nucleus (Fig. 6, page 176) of the same and opposite sides. The sensory fibres arise in the ganglia of the root and of the trunk of the vagus, and after entering the medulla divide into descending branches which join the fasciculus solitarius, and ascending branches which end in tufts in the vagal nucleus beneath the ala cinerea. Its superficial origin is the groove behind the olive.

The Spinal Accessory—11th nerve—is a pure motor nerve. It has two parts—a spinal part and an accessory part.

(1) The *spinal part* arises from a column of cells in the spinal cord—the lateral horn—and extends as far down as the 5th cervical nerve.

(2) The *accessory* or *bulbar part* has a similar origin to the vagus, viz., from the nucleus ambiguus, and from the column of cells lying beneath the ala cinerea of the 4th ventricle. This column of cells is common to the glosso-pharyngeal, to the vagus, and to the bulbar part of the spinal accessory. This last should really be regarded as part of the vagus, and not as a separate nerve.

The Hypoglossal—12th nerve—springs by several filaments from the groove between the anterior pyramids and the olives (Fig. 79, page 134). Its fibres can be traced backwards through the formatio reticularis to its deep origin, a column of cells lying near the middle line, close to the surface of the floor of the 4th ventricle, beneath the lower part of the FASCICULUS TERES. This area is often called the trigonum hypoglossi (Figs. 57, 58, page 82, and Fig. 5, page 176).

It is worthy of note that the motor faculties occupy the anterior part, the sensory the posterior part, of the brain; just as in the spinal cord and medulla the motor tracts and nerves and their nuclei are anterior, the sensory posterior.

GENERAL SUMMARY.

In the preceding sections we have described the several parts of the brain and spinal cord; in this chapter we shall, for the sake of clearness, take a general survey of the whole system, both grey and white matter.

I. **Grey Matter.**—The grey matter of the cerebro-spinal nervous system is, as we know, composed of a countless number of superimposed neurones—motor, sensory and intellectual—with their *cell bodies* and their *protoplasmic* (centripetal) and their *axis-cylinder* (centrifugal) processes, by means of which the different parts of the nerve-axis are brought into relation with each other and with every part of the rest of the body. The several neurones are, however, independent, their processes being contiguous only, not continuous. The cell bodies, supported by neuroglia, and nutritive in function, constitute the grey matter; their processes, especially their axis-cylinder processes, form the various white strands.

(1) In the cerebrum the grey matter constitutes the *cortex* and the *sub-cortical* ganglia (basal ganglia).

(a) The *cortex* cerebri can be mapped out into specific areas—motor, sensory, and intellectual.

The MOTOR AREAS are the paracentral lobule, the ascending frontal, and the ascending parietal convolutions. Figs. 44, 45, page 62, will give you an idea of their several positions.

The SENSORIAL AREAS are—

For *common sensibility*—the same regions as for the motor faculties.

For the *sense of sight*—the cuneate lobe and the angular gyrus.

For the *sense of smell* and *of taste*—the tip of the temporal lobe (hippocampal and uncinate gyrus).

For the *sense of hearing*—the upper temporal convolution.

The ASSOCIATION AREAS—the true intellectual centres, holding in subjection the lower centres—constitute two-thirds of the total cerebral cortex, and occupy most of the frontal, temporal, parietal and occipital lobes. They cannot be stimulated from without.

(b) The *basal ganglia* occupy the interior of the cerebrum. Their functions and connections are as yet undecided. The pulvinar of the optic thalamus, the corpora geniculata externa, and the anterior pair of corpora quadrigemina, are the sub-cortical centres for sight, and are by means of the optic radiation connected with the cuneate lobes (cortical centres).

The posterior pair of corpora quadrigemina, and the corpora geniculata interna are probably associated with hearing.

(2) The *grey matter of the cerebellum* is united by its several peduncles with the cerebrum, medulla, pons, and most of the cranial nerves. Of its functions we are as yet ignorant. The table below, page 184, will give you the chief constituents of its peduncles.

(3) The *rest of the grey matter* extending from the aqueduct of Sylvius to the filum terminale—is arranged in a *dorsal part* (sensory in function) behind the central canal, and a *ventral part* (motor in function) in front of the central canal. In the pons, medulla, and crura cerebri, this grey matter forms the nuclei of origin of most of the cranial nerves; thus from the grey matter of the aqueduct of Sylvius arise the 3rd and 4th nerves: from the pons the 5th, 6th, 7th, and part of the 8th: from the medulla the 8th, 9th, 10th, 11th, and 12th nerves; finally at the lower part of the medulla are the nuclei of the fasciculus gracilis and cuneatus, the primary terminations of the long sensory tracts of the posterior columns of the spinal cord.

In the *spinal cord* the grey matter assumes the form of long columns of cells—vesicular columns—connected with the deep origins—motor and sensory—of the spinal nerves.

II. White Matter.—The white substance of the central nervous system, consisting principally of the axis-cylinder processes of the nerve cells which constitute the grey matter, can be arranged in two distinct strands of fibres—short strands and long strands.

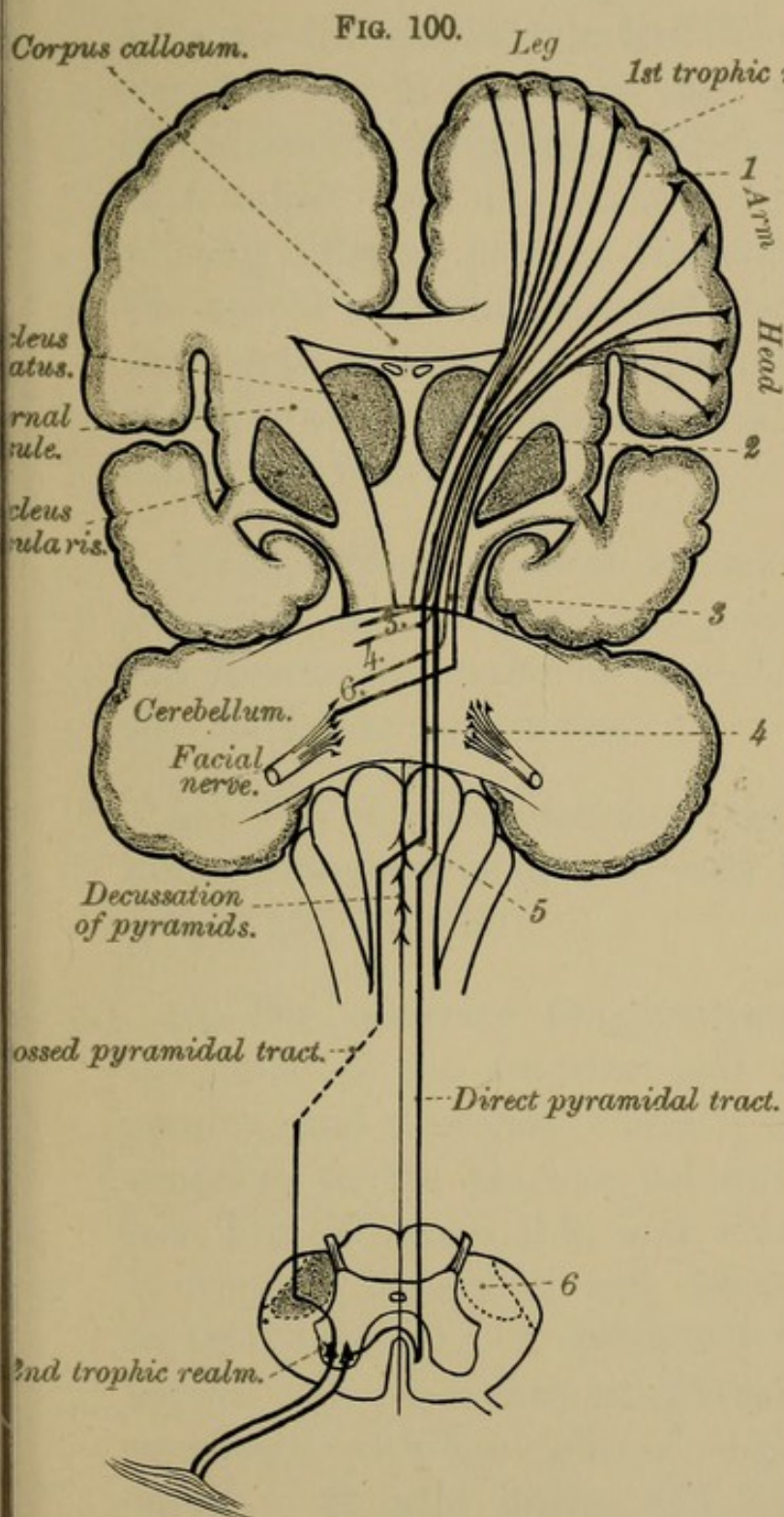


DIAGRAM OF MOTOR TRACTS.

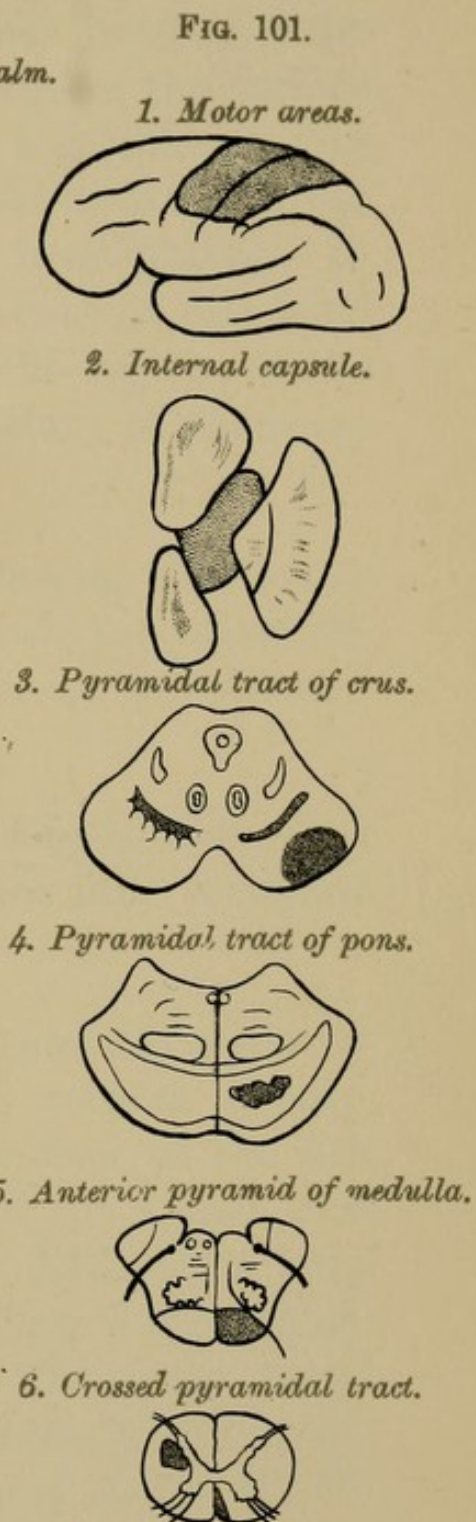



DIAGRAM OF A DESCENDING DEGENERATION.



(1) The SHORT STRANDS are mainly commissural between different segments of the same divisions of the nerve axis. In the brain they comprise the various *commissures*, connecting different hemispheres with each other; and the strands of *association* fibres uniting different parts of the same hemispheres. In the spinal cord they connect segments at one level with those at another, and occupy the regions of the cord known as the mixed zones. Many of them are concerned with reflex acts.

To this group of short strands belong the *corpus callosum*, the *anterior* and *posterior commissures*, the *fornix*, the *posterior longitudinal bundle*, and the *cerebellar peduncles*.

(a) The corpus callosum, the fornix, and other minor commissures have already been fully described (pages 157 and 160).

(b) The *posterior longitudinal bundle* starts in the cells of the anterior pair of corpora quadrigemina, and descends beneath the floor of the 4th ventricle to the anterior column of the spinal cord (see Fig. 97, page 168, and Plate XLI., page 184). It contains ascending and descending fibres which, on their way, give off collaterals to the motor cranial nerves. By its means peripheral sensory nerves are connected with the cells of origin of motor cranial nerves. It also unites the cerebellum with the nuclei of origin of the cranial nerves, and the cranial nuclei with each other; especially the 3rd nerve of the one side with the 6th nerve of the opposite side.

(c) The *peduncles of the cerebellum* are three in number—the superior, the middle, and the inferior.

The *superior peduncles* contain ascending and descending fibres, most of which decussate. Their ultimate destinations are the red nucleus, the cortex of the cerebrum, the optic thalamus, and the lenticular nucleus.

The *middle peduncles* pass to the nucleus pontis, to the posterior longitudinal bundle, to the fillet, to the corpora quadrigemina, to the antero-lateral tract of the spinal cord, and to the pyramids of the same and of the opposite side.

The *inferior peduncles*.—Their fibres can be traced to the opposite olivary body, to the fillet, to the posterior longitudinal bundle, and to the antero-lateral column of the spinal cord.

(2) The LONG STRANDS—*projection fibres*—connect the motor-sensorial areas with lower centres. They are arranged in two groups: the one motor, the other sensory.

(a) The MOTOR STRANDS are twofold: the *principal motor strand*—cortico-spinal; and the *secondary motor strand*—the cortico-cerebellar-spinal. Both these motor strands consist of two sets of neurones, the one *central—crossed*; the other *peripheral—uncrossed*.

(1) The *principal motor strand*, starting as the axis-cylinder processes of the nerve cells of the motor regions of the brain cortex (first trophic realm), descends through the corona radiata, through the

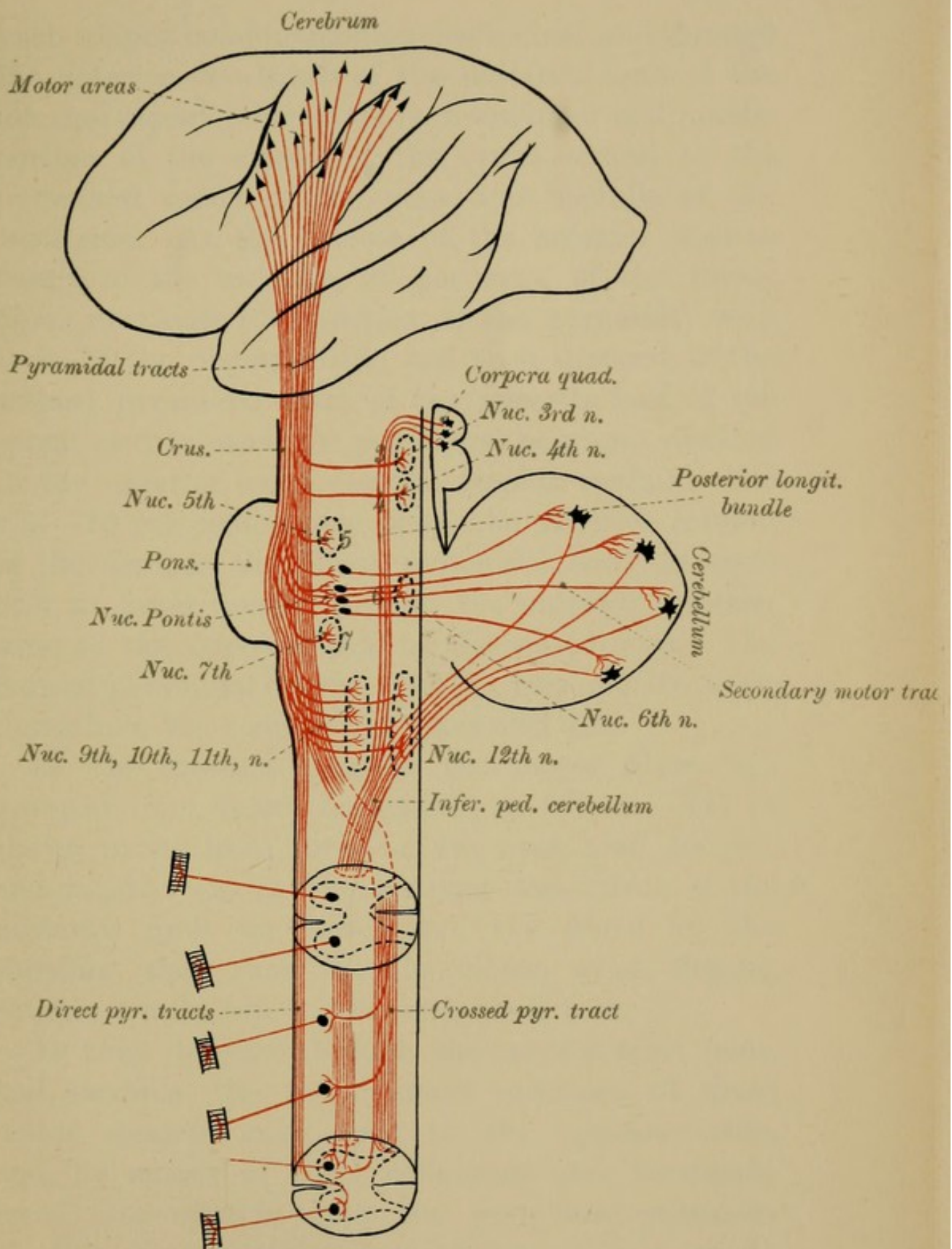



DIAGRAM (AFTER VAN GEHUCHTEN) OF MOTOR TRACTS



knee-shaped bend (geniculate fasciculus), and through the anterior two-thirds of the posterior limb of the internal capsule, thence through the inner and middle portion of the crusta of the crura cerebri to the pyramidal tracts of the pons and medulla of the same side. At the bottom of the anterior median fissure of the medulla, 90 per cent. of the motor fibres decussate (decussation of the pyramids) with those of the opposite side, and then descend in the crossed pyramidal tract of the opposite half of the spinal cord to reach the peripheral neurones situated in the anterior horns (second trophic realm). The rest—10 per cent.—pass down the anterior column of the cord, as the direct pyramidal tract, to cross over at lower levels, through the anterior commissure, to the opposite side of the spinal cord. The crossed pyramidal tracts, however, also receive a few fibres from the cerebrum of their own side.

In the internal capsule the motor fibres are grouped, from before backwards, as follows:—(1) in the genu we have fibres for the eyes, head, tongue, and mouth; (2) in the anterior two-thirds of the posterior limb we have, first, the fibres for the shoulder, then those for the elbow, wrist, fingers, thumb, trunk, hip, ankle, knee, and toes.

As they descend through the crura cerebri, pons, and medulla, the axis-cylinder processes of these motor strands cross over to the opposite side, and, by means of their collaterals and terminals, come into relation with the peripheral neurones of the several motor cranial nerves, just as at lower levels the fibres intended for the spinal nerves

decussate in the pyramids (Fig. 100, page 182, and Plate XLI., page 184). The central neurones therefore carry the impulses for the brain to the cranial and spinal peripheral motor neurones of the opposite side, which in turn transmit them to the muscles. Thus, for example, the right side of the face or arm is worked from the right facial or spinal nucleus (sub-cortical origin), but from the left cerebral cortex (cortical origin).

Hence it follows, as we have said, that all *peripheral* motor neurones are *uncrossed*, whereas the *central* ones are *crossed*.

The following cranial nerves are, however, exceptions to this rule: the 3rd, the 7th, the motor part of the 5th, 9th, and 10th nerves are partially crossed; the 4th nerves are totally crossed, decussating in the superior medullary velum; the 6th nerves are direct, and, as far as we yet know, the same is true of the 12th nerve and of the bulbar part of the vagus, these also being uncrossed.

(2) *Secondary motor strand*.—The cells of the central neurones of this strand are found in the same areas as the cells of the principal motor tracts, and their axis-cylinders descend mingled with those of the chief motor tract through the internal capsule and crura cerebri to the pons, where they leave that strand and end in branches amidst the nerve cells of the nucleus pontis. The axis-cylinders of the nerve cells of this nucleus (nucleus pontis) then cross over to the opposite half of the cerebellum, to terminate at the neurones of the cerebellar cortex, which transmit the impulses through the inferior peduncle

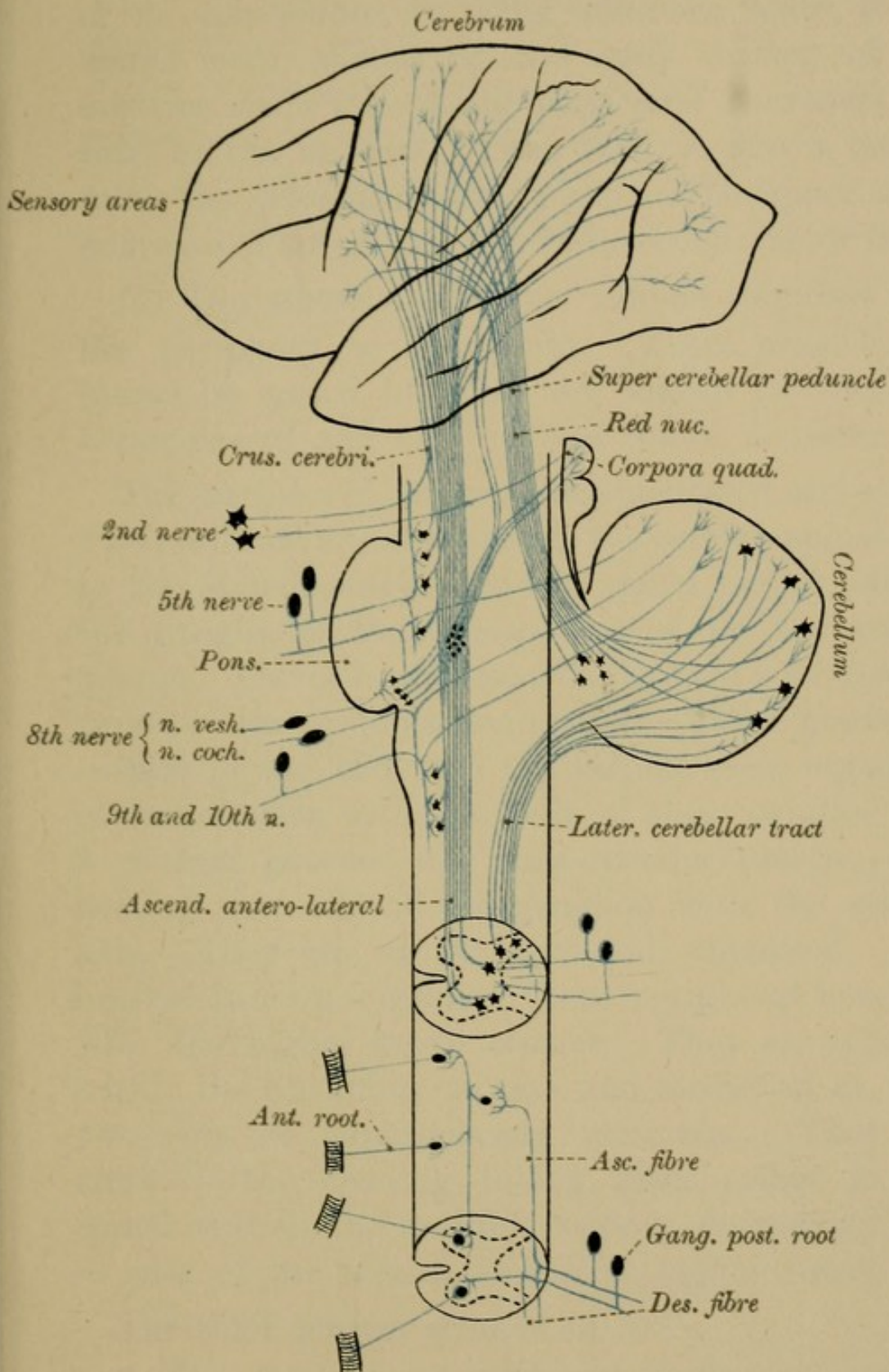



DIAGRAM (AFTER VAN GEHUCHTEN) OF SENSORY TRACTS,



of the cerebellum, by some unknown route, to the spinal cord, thence to the grey matter of the anterior cornu (the motor peripheral neurones), and thus to the muscles. This, then, is also a crossed tract, the crossing taking place in the upper set of neurones (Plate XLI., page 184; second: motor tract).

(b) The SENSORY STRANDS conduct impulses from the periphery to the brain. Their exact course cannot be traced, but they are known to consist of a *peripheral* and of a *central* set of neurones.

The *peripheral neurones* are uncrossed and single. Their cells are situated outside the cerebro-spinal axis, in the spinal ganglia, for the spinal nerves, and in the ganglia of the sensory nerves, for the cranial nerves. The cells of these ganglia have a *peripheral process*—the protoplasmic process—which places the surface of the body and the various sense organs in communication with the cells of these ganglia; and a *central process*—the axis-cylinder process—connecting the cells of the ganglion with the central axis. They are, as we have said, uncrossed. The *central neurones* connect these peripheral neurones with the higher nerve centres. They are situated within the central nerve axis, and consist of at least two sets of superimposed neurones. They are crossed—the crossing taking place either in the spinal cord, in the medulla (sensory decussation), or in case of the cranial nerves, at higher levels.

The chief sensory strands are:—

1. The fasciculi of Goll and of Burdach, which were traced into the medulla as the fasciculus

gracilis and the fasciculus cuneatus. They end in the nuclei of these fasciculi. A second relay of cells, situated in these nuclei, carry the impulse one of two ways, either (1) through the inferior cerebellar peduncle to the cerebellum of the same side or opposite side, or (2) through the medulla (sensory decussation), through the pons and crura cerebri (fillet), and through the posterior part of the internal capsule to the opposite cerebral hemispheres. Some of these latter fibres go direct to the cerebral cortex (to the ascending frontal and ascending parietal convolutions); others first pass through the optic thalamus.

The *fillet*, the constitution of which is given, for reference, in the following table, is seen as a flat band (Figs. 60 and 61, page 90), in the tegmental part of the pons and crura cerebri. It consists of three portions—(1) the lateral fillet, which receives its fibres from the antero-lateral tract of the spinal cord, and from the nucleus gracilis and cuneatus of the opposite side (superior pyramidal decussation); it ends in the posterior pair of corpora quadrigemina: (2) the mesial fillet which goes into the crura of the crura cerebri and ends in the lenticular nucleus: (3) the intermediate fillet which obtains its fibres from the cerebellum, from the antero-lateral column of the spinal cord of the same side, and from the nuclei gracilis and cuneatus of the opposite side (superior pyramidal decussation); it ends partly in the anterior corpora quadrigemina and partly in the cerebral cortex (Fig. 96, page 168).

(2) The *ascending antero-lateral tract of Gowers*, lying, as you know, on the surface of the lateral aspect of the cord in front of the direct cerebellar tract, can be traced through the superior peduncles of the cerebellum to the lingual lobe of the vermis of its own side (Bruce). Other fibres go direct to the brain, probably carrying sensations of temperature and of pain. It is a crossed sensory tract, though the cells of the cord from which it starts are undecided.

(3) The *direct cerebellar tract* (dorsal cerebellar) ascends along the lateral margins of the cord and medulla to the inferior peduncle of the cerebellum, thence to the upper part of the superior vermis. Most of its fibres end in the same side (Bruce). This tract is connected, as we have seen, by means of the cells of Clarke's column with the posterior spinal nerve roots.

The course followed by the several nerves of special sense is too complicated for any elementary work. (See "Deep Origins of Cranial Nerves.")

SECTION III.

OUTLINE OF DEVELOPMENT.

In this section we shall give an outline of the development of the brain and spinal cord.

One of the earliest steps in the development of the human embryo is, as you know, the formation of the *blastoderm* or *germinal membrane*. This membrane is composed of three distinct superimposed layers of cells, the *epiblast*, the *mesoblast*, and the *hypoblast*. Of these, the EPIBLAST is the one from which the central nervous system is developed.

PRIMITIVE GROOVE.—On the dorsal aspect of the embryo, at a very early date, appear two ridges, separated from each other by an intervening furrow—the *primitive groove*. Gradually increasing in size, these two ridges grow upwards and ultimately meet in the middle line on the dorsal aspect of the embryo. Blending together they form a closed cylindrical longitudinal tube — *primitive medullary tube*—with walls composed of epiblastic cells. From this primitive tube the brain and

spinal cord are formed; the walls giving rise to the *solid parts*, the cavity remaining as the central canal of the spinal cord, and as the *ventricles* of the brain.

I.—THE SPINAL CORD.

(Fig. 103, &c., Plate XLIII., page 192.)

The spinal marrow is developed from the hinder part of the primitive medullary tube. The lateral walls of this portion of the tube increase in thickness, so much so, that the cavity of the tube is reduced to a mere slit. Its roof and floor, however, remain thin. The walls are at first composed of columnar epithelial cells, their inner free ends being ciliated, their attached ends resting on a basement membrane. Soon, however, this layer of cells differentiates, and gives rise to three different kinds of cells. They are known as spongioblasts, germinal cells, and neuroblasts.

1. The SPONGIOBLASTS are branching cells, the processes of which anastomose with those of neighbouring cells, and thus form a network called *myelo-spongium*. The inner part of the cells still retains its columnar character.

2. GERMINAL CELLS.—Between the deep ends of the spongioblasts we find many rounded nucleated cells with much clear protoplasm, and with their nuclei in some stage or other of division. They give origin to the next group of cells—the neuroblasts, hence they are called *germinal cells*.

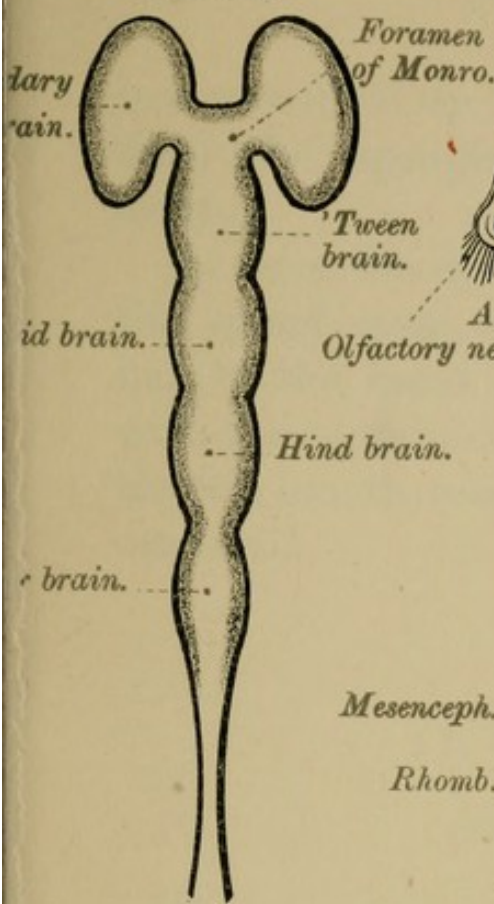
3. NEUROBLASTS. — These cells have a large oval nucleus, and little protoplasm. They are arranged in masses, which are transformed into the grey matter of the spinal cord (*nerve cells* and *grey crescents*). The cells have distinct prolongations towards that part of the surface of the embryonic cord from which the future anterior nerve roots spring. These prolongations are the commencement of the axis-cylinder processes of these nerve roots. The posterior roots are a subsequent development from the spinal ganglia connected with these roots.

Externally, on the surface of the cord, in the region in which the *white matter* of the cord (the various columns) is developed, we find no nuclei, this part of the embryonic cord being composed of the reticular and radiating *processes* of the spongioblasts. The anterior columns are the first to appear, then the posterior, then the lateral.

As we have already seen in the account of the spinal cord, these white strands acquire their medullary sheaths at different dates, thus enabling us to map out the course they take through the spinal marrow (see page 41).

At first there are no indications of the anterior and posterior median fissures of the cord. The former, the anterior median fissure, is the cleft left between the enlarging lateral halves of the cord. The anterior commissure is developed at the bottom of the fissure, and thus separates it from the central canal of the cord. The posterior fissure is probably the constricted dorsal part of the original canal. It

FIG. 103.



Cerebral hemispheres. FIG. 104.

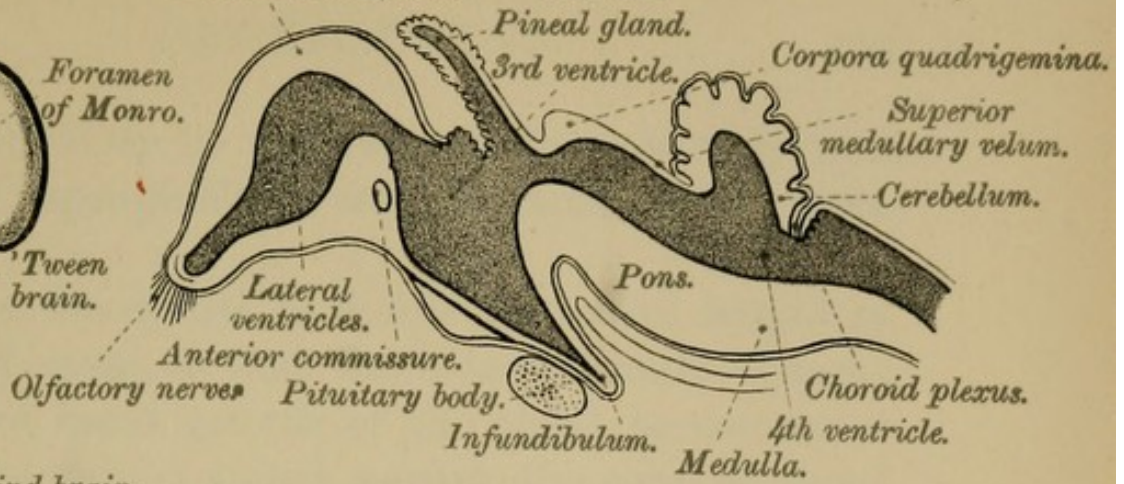


FIG. 105.

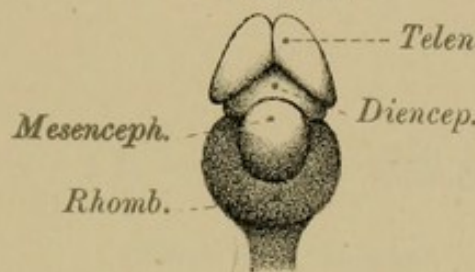


FIG. 106.

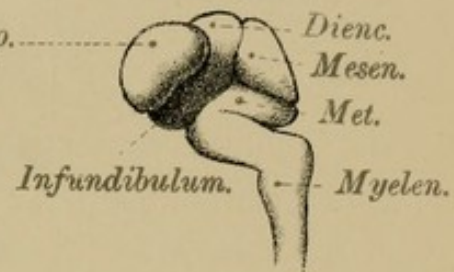


FIG. 107.

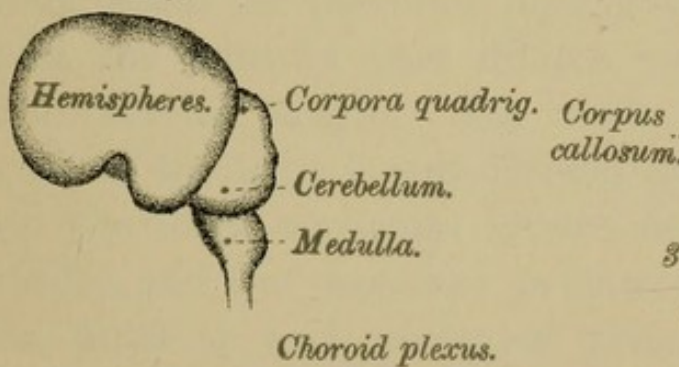


FIG. 108.

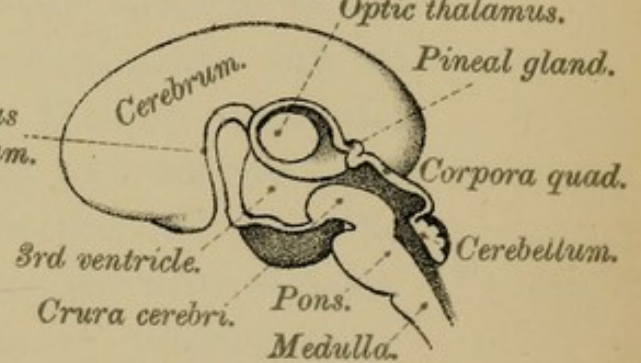
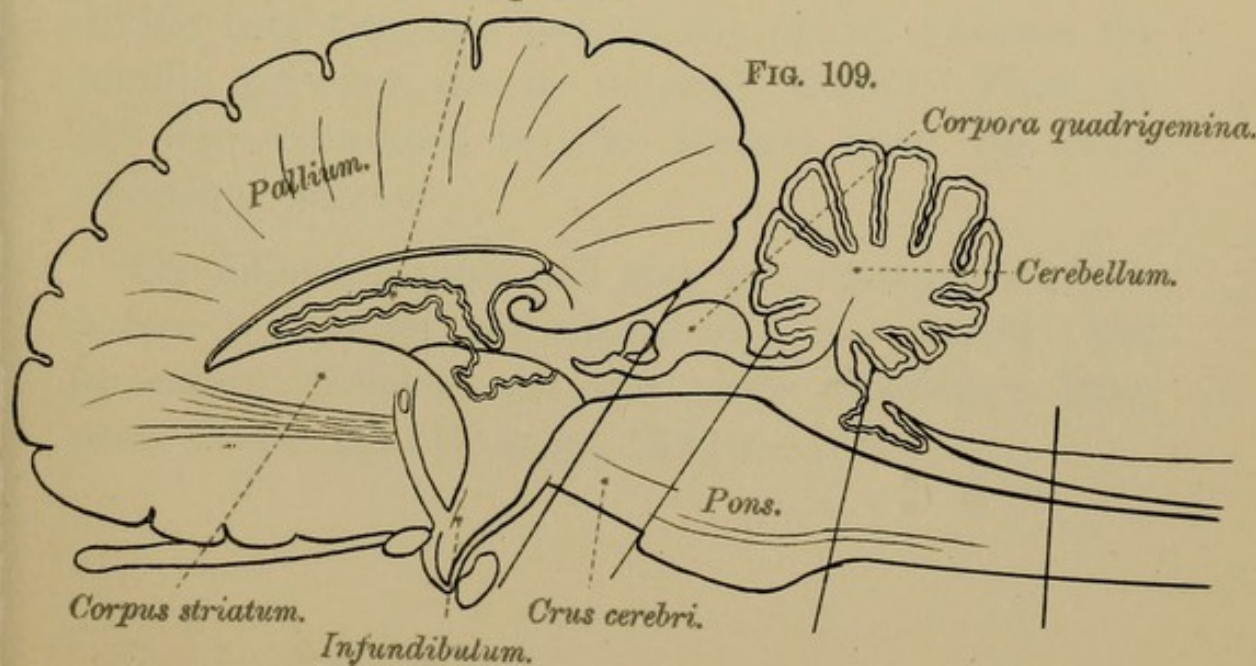



FIG. 109.





becomes filled up by a growth of *neuroglia*, derived from the spongioblast, and remains as a mere septum.

At first the spinal cord fills the entire length of the spinal canal, so that there is no cauda equina; but by the rapid growth of the canal, as compared with the contained spinal marrow, the cord, at about the 9th month, reaches only as low as the 3rd lumbar vertebra.

II.—THE BRAIN.

(Plate XLIII., page 192.)

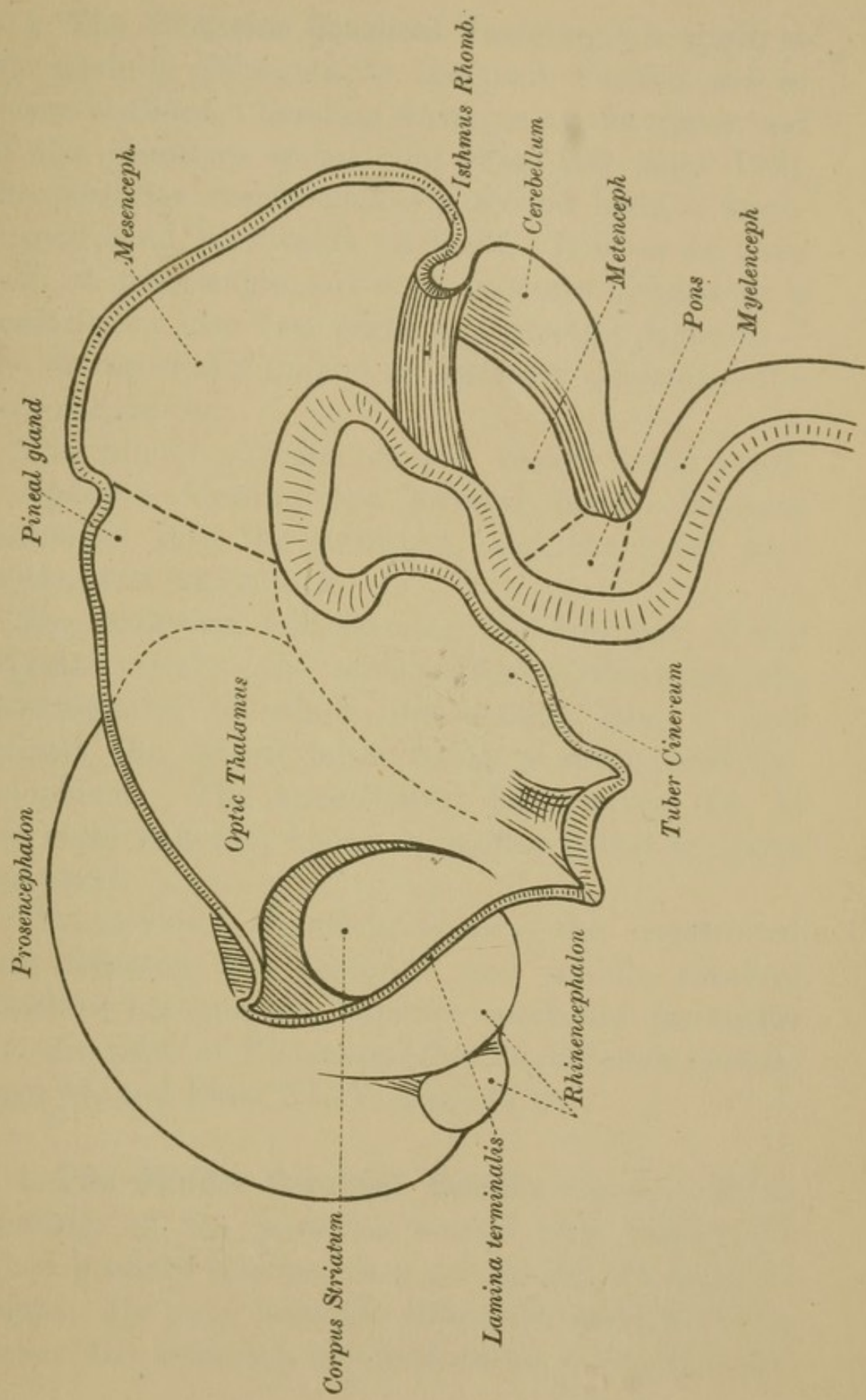
The brain is formed from the fore part of the primitive medullary tube. At the period of development, when the posterior part of this tube is as yet open, the anterior part dilates considerably, but at first remains single. Its walls thicken, and the cavity of the tube is sub-divided by two constrictions into the three segments known as the *anterior*, the *middle*, and the *posterior primary cerebral vesicles*. The anterior and posterior primary vesicles soon divide into two, one behind the other, whereas the middle primary vesicle remains single. Thus we get *five secondary vesicles* formed from the *three primary vesicles*.


The following table will give you, enumerated from before backwards, the names of these primary and secondary vesicles and the parts developed from each (Plate XLIV., page 194):—

TABLE OF THE CEREBRAL VESICLES AND THE PARTS
DEVELOPED FROM EACH.

PRIMARY VESICLES.	SECONDARY VESICLES.	PARTS DEVELOPED FROM THE VARIOUS VESICLES.	
1. Prosen- cephalon	1. Telencephalon	Cerebral Hemispheres. Cor- pora Striata. Corpus Cal- losum. Fornix. Lateral Ventricles. Optic Chi- asma. Olfactory Lobe.	7
	2. Diencephalon	Optic Thalami. Pineal Body. Infundibulum. Pituitary Body. 3rd Ventricle. Corpora Albicantia. Optic Tracts.	7
2. Mesen- cephalon	3. Mesencephalon	Corpora Quadrigemina. Cru- ra Cerebri. Aqueduct of Sylvius.	3
3. Rhomben- cephalon	4. Isthmus Rhomb- encephali	Superior Cerebellar Ped- uncles. Valve of Vieus- sens.	2
	5. Metencephalon	Cerebellum. Pons Varolii. Anterior part of the 4th Ventricle.	3
	6. Myelencephalon	Medulla Oblongata. Pos- terior part of 4th Ven- tricle.	2

The Isthmus Rhombencephali (Plate XLIV., page 194) is the constricted portion between the mesencephalon and the rhombencephalon. Thus we get six rings with epiblastic walls composed of histological elements similar to those which give origin to the spinal cord. By subsequent changes in these rings the brain and its sub-divisions are built up.





1. **The Posterior Cerebral Vesicle** gives origin to the medulla oblongata, to the pons Varolii, and to the cerebellum. Bending forwards at the upper end of the primitive spinal cord (Fig. 106, page 192), the posterior vesicle makes a second bend, a knee-shaped bend, backwards on itself. It is, as we have seen, at first single, but soon becomes divided by a constriction into two parts, a *posterior division*—the *myelencephalon*, and an *anterior division*—the *metencephalon*.

The hinder division of the vesicle—the *myelencephalon* forming the forward bend—becomes developed into the MEDULLA, and the lower part of the 4TH VENTRICLE.

The backward fold, forming the fore part of the original vesicle—the *metencephalon*—becomes the CEREBELLUM, of which the central lobe is first formed, the lateral lobes being a subsequent development. The knee-shaped bend gives rise to the PONS VAROLII; hence it is often called the pons curvature.

The *isthmus rhombencephali*—the constricted part between the posterior and middle cerebral vesicles—becomes the superior cerebellar peduncles and the valve of Vieussens (Fig. 34, *isthmus rhomb.*, page 44, and Plate XLIV., page 194).

2. **The Middle Cerebral Vesicle** likewise bends forwards on the posterior vesicle, but, unlike the other primary vesicles, does not divide, but remains single. Its *roof* becomes thickened, and in it are formed the CORPORA QUADRIGEMINA. Its *floor* and

sides give rise to the CRURA CEREBRI, while the original CENTRAL CANAL, much narrowed by the growth of these parts, remains as the AQUEDUCT of SYLVIUS—iter a tertio ad quartum ventriculum.

3. **The Anterior Cerebral Vesicle**, like the posterior, becomes sub-divided into two portions—a posterior, the *diencephalon*, and an anterior, the *telencephalon*. The entire vesicle, at first straight, bends forwards on the middle vesicle, which now forms the most prominent part of the head. From each side of its *posterior segment* are developed the OPTIC VESICLES, which ultimately become the optic nerves. With the formation of the optic nerves and the optic tracts, the stalk of the optic vesicles becomes solid, and by the growth backwards of the tracts becomes connected with the mid-brain. In the lateral walls of this segment—*diencephalon*—are developed the two OPTIC THALAMI, separated from each other by a median cleft—the 3RD VENTRICLE (Plate XLIV). Across this cavity subsequently grows the middle or grey commissure. Anteriorly, the floor of the ventricle is prolonged downwards as a funnel-shaped tube—the INFUNDIBULUM—connected with the PITUITARY BODY; behind, on the other hand, the cavity communicates with the 4th ventricle through a narrow channel, the continuation backwards of the original cavity—the AQUEDUCT of SYLVIUS. The roof of the vesicle rapidly becomes thinner and is reduced to a mere lamina of epithelium connected with the pia mater and choroid plexus in the roof of the 3rd ventricle.

The posterior part of the roof, however, has a transverse thickening—the POSTERIOR COMMISSURE; and in front of this the roof grows upwards and forwards, then backwards as a hollow process—the PINEAL GLAND—*epiphysis cerebri*—which is regarded as a rudimentary third eye.

The *fore* part—*telencephalon*—of the original anterior cerebral vesicle bulges forward as a median mass, which is at first single, but soon becomes divided by a longitudinal cleft into two lateral segments. These *lateral segments* form the hemispherical vesicles, and become the CEREBRAL HEMISPHERES. The cavities within them remain as the LATERAL VENTRICLES, which are connected with the 3rd ventricle, and, through it, with each other, by a constantly narrowing neck, the FORAMEN of MONRO (Fig. 103, page 192). In the *floor* of the ventricles appears a grey mass—the CORPUS STRIATUM—streaked with white matter, giving it the striated appearance from which it takes its name. Outside this grey mass we find the grey and white matter of the island of Reil. The OLFACTORY LOBES are hollow outgrowths of the lower and lateral parts of the hemispherical vesicles.

The *roof* and *walls* of the hemispherical vesicles are at first an evenly expanded mass of grey matter, which, however, soon becomes convoluted and furrowed, giving rise to the *fissures*, *lobes*, and *gyri* of the cerebral hemispheres. Increasing rapidly in size these hemispheres grow backwards, and, finally, completely overlap and hide the other sub-divisions of the brain.

In front and for some distance backwards the mesial surfaces of the cerebral hemispheres come in contact, and at certain places partly grow together. The CORPUS CALLOSUM, the FORNIX, and the small commissures are developed from these united parts of the mesial aspect of the hemispherical vesicles. The anterior commissure is the first formed, then the fore part of the fornix, and afterwards its posterior pillars. Finally, the corpus callosum appears, the anterior part being the first developed, its growth extending backwards with the growth of the hemispheres. That portion, however, of the walls of the hemispherical vesicles which lies between the fore part of the corpus callosum and the fornix is left, as the mesial walls unite, as a triangular interval, bounded on each side by a layer of grey and white matter derived from the hemispheres. These laminae form the SEPTUM LUCIDUM, the vertical partition separating the lateral ventricles. Between the two layers of which this septum is composed is enclosed the cavity of the 5TH VENTRICLE, or ventricle of the septum, which you will readily understand is never connected with the rest of the ventricles, and is not, like them, part of the primitive medullary cavity. It is merely a portion of the great longitudinal fissure which has become enclosed in the process of development.

INDEX.

- Ala cinerea (*cinereus*, ash-coloured), 108, 112, 178
 Eminentia, 108, 112
 Amygdalæ (*amygdala*, an almond) of cerebellum, 96
 Nucleus, 153, 162
 Apex cornu posterioris, 28
 Aqueduct (*aquæductus*) of Sylvius, 110, 139, 170
 Arachnoid (*ἀράχνιον*, a spider or spider's web) membrane of—
 Spinal Cord, 9
 Brain, 50
 Structure of, 10, 51
 Arbor vitæ (from resemblance to the shrub so-called) of cerebellum, 102
 Arcuate fibres, or arciform fibres of medulla, 75, 83
 Areas of brain, see also convolutions, 116, 117, 120, 122, 127, 181
 Areas of medulla, 67
 Arteries—
 Auditory, internal, 59
 Basilar, 59
 Brain, 57
 Carotid, internal, 57
 Cerebellar, 59
 Cerebral, anterior, 57
 middle, 57
 posterior, 60
 Choroidal, anterior, 58
 Circle of Willis, 60
 Communicating, anterior, 57
 posterior, 58
 Meningeal, 56
 Special characters of the cerebral circulation, 61
 Spinal, 11
 Vertebral, 58
 Association areas, 181
 fibres, 160
 Astrocytes, 30
 Ataxy, locomotor, 23
 Band of Giacomini, 127
 Basal ganglia, 139, 151
 Basis bundle, 20
 Basis pedunculi, 167
 Blastoderm (*βλαστος*, a germ; *δέρμα*, skin), 190
 Brachia of corpora quadrigemina, 169
 Brain, (See Cerebrum and Encephalon), 43
 Arteries of, 57
 Base of, 132
 Development of, 193
 Membranes of, 45
 Sub-divisions of, 63
 Veins, 61
 Brain sand, 156
 Broca's convolution, 117
 Bundle of—
 Posterior longitudinal, 113, 183
 Vieq d'Azyr, 161
 Bürdach, fasciculus of, 22, 23, 69
 Calamus scriptorius (a writing pen), 107
 Canal, central, of Spinal Cord, 29
 Capsule, external, 153, 165
 internal, 153, 163
 Caryochromes, 35
 Cauda equina (a horse's tail), 5
 Cells—
 Brain, 128
 Cerebellar, 102
 Column, 37
 Comet, 34
 Deiters, 30
 Germinal, 191
 Golgi, 131
 Molecular layer, cerebrum, 128
 Nerve cells, Structure, 34, 102, 128

Cells—

- Polymorphous, 131
- Processes, 35
- Purkinjé, 103
- Pyramidal, 129
- Root, 37
- Solitary, 34
- Spider, 30
- Spinal cord, 34

Centres—

- Motor, 121
- Sight, 120, 122

Centrum ovale, 138

- minus, 140
- magus, 140

Central lobe, 117, 123

Cerebellum (dim. of cerebrum, the brain), 92

Development of, 195

Fissures of, 93

Great horizontal, 93

Folia of, 95

Functions, 105

Grey matter of, 101

Hemispheres of, 93

Lobes of, 95

Medullary vela, 100

Minute structure of, 102

Peduncles of, 97, 184

Position of, 92

Vallecula of, 94

Vermiform process of, 93, 96

White matter, 105

Cerebral vesicles, 193

Cerebro-spinal fluid, 5, 10

Cerebrum (the brain), 113

Base of, 132

Commissures of, 157

Convolutions of, 116

Crura of, 165

Development of, 193

Exterior of, 114

Fissures and furrows of, 114

Grey matter, 114

Ganglia of, 151

General outline, 113

Hemispheres of, 113

Interior of, 138

General outline of, 138

Cerebrum—

Layers of cells in cortex, 128

Lobes of, 116

Peduncles or crura of, 165

Relations of, to cranial sutures, 128

Structure of, 128

Ventricles of, 138, 141

White matter of, 157

Choroid plexuses of, 149

Fourth ventricle, 111

Lateral ventricle, 145, 149

Third ventricle, 149

Circulation, special characters of cerebral, 61

Clarke's Column, 33

Clastrum (which shuts off), 153

Clava (a club), 68, 109

Collaterals, 26

Column or Columns—

Anterior, 19

Clarke's, 33

Ganglionic, 32

Inter-medio-lateral tract, 28

Lateral, 20

Posterior, 22

Spinal cord, 18

Vesicular, 32

White, 18

Anterior, 19

Lateral, 20

Posterior, 22

Column Cells, 37

Comet Cells, 34

Comma Tract, 24

Commissure (union) cerebral, great (corpus callosum), 157

Commissure of—

Brain, 139, 157

Anterior, 160

Middle or soft, 160

Posterior, 160

Spinal Cord, grey, 29

white, 25

Conus medullaris, 4

Convolutions (*con.*, together; *volvo*, I roll)—

Cerebellum, 95

Cerebrum, 116

- Convolutions—
 Angular, 120
 Corpus callosum, 125
 Dentate, 127
 Frontal, 117
 Hippocampal, 125
 Island of Reil, 123
 Marginal, 125, 126
 Mesial surface, 124
 Occipital, 121
 Occipito-temporal, 123
 Orbital, 118
 Parietal, 119
 Post-parietal, 120
 Relations to Scalp, &c., 128
 Supra-marginal, 120
 Temporal, 122
 Uncinate (hippocampal), 125
 Cornu Ammonis (from its resemblance to horns of Zeus-Ammon), Hippocampus major, 144
 Cornu of lateral ventricles, 140, 143
 Cornua of Spinal Cord, 28
 Lateral, 34
 Corona radiata, 164
 Corpora albicantia (white bodies), 134, 161
 Formation of, 161
 Corpora geniculata (*genu*, a knee), 154, 155, 172
 Corpora quadrigemina (four), 139, 169, 172
 Corpora striata, 139, 151
 Corpus callosum (*callosus*, thick or hard), 113, 133, 142, 157
 Development of, 198
 Dissection to expose, 140
 Peduncles of, 158
 Structure of, 159
 Corpus dentatum cerebelli, 102
 Olivi, 81,
 Corpus restiforme (*restis*, rope), 70, 99
 Cortex of brain, structure of, 114, 128
 Cortex of cerebellum, structure of, 102
 Course of nerve fibres, 105
 Crura ad cerebrum, 97
 ad medullam, 97
 ad pontem, 97
 Cerebri, 64, 113, 165
 Crusta, Basis, Pes, 167
 Fornicis, 161
 Crusta of Crura Cerebri, 167
 Cuneus, 126
 Decussation (*decusso*, I cut cross-wise) of pyramids, 73
 Sensory or superior pyramidal, 81, 83, 186
 Deiters, Cells of, 30
 Development of—
 Brain, 193
 Spinal Cord, 191
 Diencephalon, 194
 Dissection to expose—
 Corpus callosum, 140
 Fornix, 141
 Interior of Brain, 140
 Lateral ventricles, 140
 Membranes of Brain, 43
 Pia mater, 6
 Septum lucidum, 141
 Spinal Cord, 3
 Velum interpositum, 141
 3rd Ventricle, 141
 5th Ventricle, 141
 Dissection to remove—
 Brain, 44
 Dorsal ridges, 190
 Nucleus, 33, 177
 Dura mater of—
 Brain, 45
 Spinal Cord, 4
 Structure of, 6
 Eminentia collateralis, 145
 Teres, 108, 176
 Vascularis, 134
 Encephalon (*ἐν*, in; *κεφαλή*, the head), 43, 64
 Arteries of, 57
 Development of, 193
 (See Cerebrum, Cerebellum, Medulla, and Pons)

Enlargements—

- Cervical, 13
- Dorsal, 13
- Lumbar, 13
- Ependyma (*ἐνδυμα*, clothing) of
 - Cells, 30
 - Ventricles of brain, 110, 145
 - Spinal Cord, 30

Falx Cerebelli, 47

- Cerebri, 46

Fascia dentata, 127, 145

Fasciculus—

- Cuneatus, 22, 69
- Gracilis, 68
- Geniculate, 168
- Solitarius, 87, 178
- Teres, 111, 179

Fasciculus of—

- Bürdach, 23
- Goll, 22, 68
- Rolando, 69
- Türk, 19

Fasciola cinerea, 127, 159

Fibres—

- Association, 157, 160
- Commissural, 157
- Projection, 157, 162, 184
- Arcuate, or arciform, 71, 75, 83
- Moss, 105

Fillet, 83, 89, 90, 188

- Lateral, 24

Filum duræ matris spinalis, 5

Filum terminale, 5, 8, 13

Fimbria (a fringe), 126, 145

Fissures of—

- Cerebellum, 95
- Cerebrum, 114
- Medulla oblongata, 66
- Mesial surface, 124
- Spinal Cord, 14

Fissures—

- Callosal, 124
- Calloso-marginal, 124
- Calcarine, 126
- Collateral, 123
- Dentate, 126
- Great horizontal of Cerebellum, 93

Fissures—

- Great transverse, 150
- Hippocampal, 126
- Inter-lobular, 115
- Intra-lobular, 116
- Intra-orbital, 118
- Intra-parietal, 120
- Longitudinal, 63, 113
- Parallel, 122
- Parieto-occipital, 116, 120, 121, 126
- Relation of, to cranial sutures, &c., 128
- Rolando, 115
- Sylvius, 115, 122
- Transverse, great, 150
- Triradiate, 118
- (See also Sulci of Brain) 114
- Flexures, cranial, of embryo, 195
- Flocculus (dim. of *floccus*, a flock of wool), 96
- Folia of cerebellum, 93
- Foramen cæcum of medulla oblongata, 66
- Foramen of Majendie, 52, 109
- Monro, 146, 147, 155, 197.
- Fore-brain, 194
- Formatio reticularis, 71, 77, 80
- Fornix (an arch or vault), 143, 146, 160
- Dissection to expose, 141
- Fossa Rhomboidalis (4th ventricle), 106
- Fourth ventricle, 106
- Nuclei of, 111
- White matter of, 113
- Fovea (a pit)—
 - Inferior of 4th ventricle, 108
 - Superior of 4th ventricle, 109
- Funiculus—
 - Cuneatus (wedge-shaped), 69
 - Gracilis (slender), 68
 - Rolando, 69
 - Teres, 108
- Furrowed band, 96
- Galen, veins of, 150
- Ganglia, basal, 139, 151

- Ganglionic columns of the
 Spinal Cord, 32
 Geniculate body, inner, 154, 155
 outer, 154, 155
 Genu (knee) of—
 Corpus callosum, 158
 Facial nerve, 176
 Internal capsule, 163
 Gland Pineal, 156
 Glandulæ Pacchionii, 49
 Globus pallidus, 153
 Goll, Fasciculus of, 68
 Gowers' Table, 42
 Granular layer of cerebellum,
 104
 Grey matter of—
 Brain, 114, 128
 Cerebellum, 93, 102
 Cerebrum 114, 128
 Medulla, 77
 Spinal Cord, constituents of, 30
 Groove, primitive, 190
 Gyri (*γυρὸς*, a circle) of brain
 (See Convolutions), 114
 Operti, 123
 Gyrus, angular, 120
 Dentatus, 127
 Fornicatus (arched), 125
 Hippocampi, 125
 Rectus, 119
 Uncinate, 125
 (See Convolutions)
 Hippocampus (after the fish of
 that name)—
 Major, 141, 144
 Minor, 141, 144
 Horn—
 Lateral, 34
 Spinal Cord, 28
 Ventricles—
 Anterior, 143
 Lateral, 144
 Posterior, 144
 Infundibulum (funnel), 134, 146,
 196
 Insula, 123
 Island of Reil, 123
 Isthmus, 125
 Interior of cerebrum, 138
 General outline, 138
 Lamina—
 Cinerea (grey layer), 133, 135
 Quadrigemina, 169
 Terminalis, 133, 135
 Lateral recess of 4th ventricle,
 107
 Ligamentum denticulatum, 7
 Ligula (dim. of *lingula*), 110
 Linea splendens, 7
 Lingula (tongue), 100
 Lissauer's Tract, 23
 Lobes of—
 Cerebellum, 95
 Cerebrum, 116
 Central (Reil), 123
 Frontal, 117
 Limbic, 125
 Occipital, 121
 Olfactory, 119
 Parietal, 119
 Temporal, 122
 Lobules of—
 Cerebrum, 116
 Cuneate, 126
 Lingual, 125
 Paracentral, 126
 Parietal, 120
 Quadrangle, 126
 Locomotor ataxy, 23
 Locus cæruleus, 92
 Perforatus anticus, 134
 Perforatus posticus, 135
 Lyra (a lute), 162
 Majendie, foramen of, 52, 109
 Marginal zone, 23
 Matter—
 Grey—Brain, 114
 Spinal Cord, 27
 White—Brain, 157
 Spinal Cord, 18
 Medulla oblongata, 65
 Anterior area of, 72
 Anterior columns of, 72
 Development of, 195

- Medulla—
 External characters of, 65
 Fissures of, 66
 Grey matter of, 77
 Internal structure of, 77
 Isolated nuclei of, 81
 Lateral area of, 70
 Posterior area of, 67
 Pyramids of, 67
 Raphé of, 82
 White matter of, 67
 Fourth ventricle, 113
 Medulla spinalis, 65
 Medullary velum, 100
 inferior, 101
 superior, 100
 Membranes of—
 Brain, 43, 45
 Spinal Cord, 3
 Meninges (μήνιγξ, a membrane),
 3, 43
 Mesencephalon (μέσος, middle;
 ἐγκέφαλον, the brain), 194
 Metencephalon, 194
 Mid-brain, 194
 Mixed zone, 22, 71
 Monro, foramen of, 146, 147
 Motor centres, 121
 Myelencephalon, 194
 Nerves—
 Cranial, 136
 Origins—deep, 170
 superficial, 136,
 170
 Table of, 136
 Fibres—white structure, 26
 Roots, 16
 Spinal,
 Anterior spinal, 37
 Posterior spinal, 38
 Origins—deep, 37
 superficial, 37
 Nerve Cells—
 Classification of, 36
 Processes of, 35
 Structure of, 34
 Nerve Cells of—
 Cerebellum, 102
 Nerve Cells of—
 Cerebrum, 128
 Spinal Cord, 31
 Neuroblasts, 192
 Neuroglia (νεῦρον, a nerve;
 γλῖα, glue), 26, 30, 132
 Cells, 30
 Fibres, 31
 Neurones, 31, 40, 180
 Spinal, 31, 40
 Nodule of Cerebellum, 96
 Nuclei of—
 Arciform fibres, 82
 Fourth ventricle, 111
 Medulla, 67
 Origin of nerves, 37, 170
 Nuclei pontis, 91
 Nucleus—
 Accessory olivary, 81
 Amygdalæ, 162
 Arciform, 82
 Caudatus, 152
 Cuneatus, 80
 Dorsal, 33, 177
 Gracilis, 80
 Intermedio-lateral tract, 28
 Lateralis of medulla oblon-
 gata, 79
 Lenticularis, 152
 Of nerves—
 Auditory, 112, 176
 Fifth, 112, 174
 Fourth, 174
 Glosso-pharyngeal, 112,
 178
 Hypoglossal, 79, 111, 179
 Olfactory, 171
 Optic, 172
 Seventh, 112, 176
 Sixth, 112, 175
 Spinal-accessory, 112, 179
 Third, 173
 Vagus, 112, 178
 Olivary body, 72, 81
 Optic thalamus, 153
 Pontis, 91
 Red, 167
 Superior olivary, 92
 Tegmenti, 167

- Obex (a bar), 109
Olfactory bulb, 118
 Groove, 118
 Lobe, 119
 Tubercle, 118
Olivary body (*oliva*, an olive), 72
 Nucleus of, 72
 Peduncle, 81
Olives, accessory, 81
Operculum (covering or lid)
 of insula, 123
Optic Commissure, 133, 172
 Thalami, 139, 153
 Tract, 134, 172
Origins of Nerves—
 Cranial, 170
 Spinal, 37

Pacchionian bodies, 49
Pallium, 114
Paracentral lobule, 126
Parasinoidal sinus, 53
Pars Opercularis, 118
 Orbitalis, 118
 Triangularis, 118
Peduncles of—
 Cerebellum, 97, 184
 Cerebrum, 64, 113, 165
 Corpus callosum, 158
 Pes of crura cerebri, 167
 Pineal gland, 156
Perforated spot, anterior, 134
 posterior, 135
Pia-arachnoid, 9, 51
Pia mater of—
 Brain, 49
 Septa, 6
 Spinal Cord, 6
 Dissection, 6
 Structure of, 8
Pineal (*pineæ*, a pine-cone) body
 or gland, 156
Pituitary (*pituita*, phlegm or
 mucus) body, 134, 135
Plexus, choroid, 111, 145, 149
Pons Tarini, 135
Pons Varolii, 87
 Formatio reticularis, 91
 Grey matter of, 91

Pons—
 Raphé of, 91
 White matter of, 89
Præcuneus, 126
Primitive groove, 190
Processes—
 Axis-cylinder, 35
 Protoplasmic, 36
 Reticularis, 28
Projection fibres, 157, 162, 184
Prosencephalon (*πρός*, before;
 ἐγκέφαλον, the brain), 194
Pulvinar (a couch), 154
Purkinjé, cells of, 103
Putamen, 153
Pyramidal cells, 129
Pyramidal tracts of medulla
 oblongata, 70, 71, 73
 Tracts of Spinal Cord, 18
 Crossed, 20
 Direct, 19
Pyramid of cerebellum, 96
Pyramids, medulla oblongata, 67
Pyramids—
 Anterior, 72
 Inferior decussation of, 72
 Posterior, 67
 Superior decussation of, 81,
 83, 187

Raphé (*ῥαφή*, a seam) of—
 Corpus callosum, 158
 Medulla, 82
 Pons, 91
Realm, trophic, 33, 184
Recapitulation of medulla, 85
Recess, lateral, 107
Relations of fissures of cerebrum
 to scalp, &c., 128
Removal of Brain, 44
Restiform (*restis*, a rope) bodies,
 70, 99, 184
Rhinnencephalon, 114, 125
Rhombencephalon, 194
Rolando, Funiculus of, 69
 Tubercle of, 69
Root zone, 20
 Ascending of 5th nerve, 80
Rostrum of corpus callosum, 158

Rust-coloured layer of cerebellum, 104

Senses—

Hearing, 181

Muscular, 24

Pain, 24

Smell, 181

Sight, 122

Taste, 181

Temperature, 24

Touch, 24

Sensory decussation, 81, 83, 187

Septum Lucidum, 147

Posticum of Spinal Cord, 8

Sinuses—

Basilar, 55

Cavernous, 54

Circular, 55

Lateral, 54

Longitudinal, inferior, 53
superior, 53

Occipital, 56

Parasinoidal, 53

Petrosal, inferior, 55
superior, 55

Straight, 54

Transverse, 55

Venous, 52

Solitary cells, 34

Somatochromes, 35

Spaces—

Inter-peduncular, 133

Perforated, anterior, 134
posterior, 135

Sub-arachnoid, 4, 9, 51

Sub-dural, 4, 9, 51

Spinal Cord, 12

Anatomy of, 12

Arachnoid, 9

Arteries of, 11

Central Canal, 29

Columns or Tracts of, 18

Anterior, 15, 19

Antero-external, 20

Antero-internal, 19

Antero-lateral—

ascending, 21

descending, 21

Spinal Cord—

Columns or Tracts of—

Basis bundle, 20

Bruce's, 24

Bürdach, 22

Crossed pyramidal, 20

Direct lateral cerebellar, 21

Direct pyramidal, 19

Goll's, 22

Intermedio-lateral, 28

Lateral, 15, 20

Limiting layer, 22

Lissauer's, 23

Mixed zones, 22, 71

Posterior, 15, 22

Postero-external, 23

Postero-internal, 22

Postero-marginal, 23

Pyramidal crossed, 20
direct, 19

Commissures of—

Grey, 15, 29

White, 14, 25

Cornua of, 28

Development of, 191

Dura mater, 4

Enlargement of, 13

External form of, 13

Filum terminale, 8, 13

Fissures of, 14

Grey matter of, 17, 27

Structure of, 30

Ligamentum denticulatum, 7

Lymphatics, 12

Membranes of, 3

Nervous constituents of, 31

Neuroglia of, 30

Origin of nerves from—

Deep, 37

Superficial, 37

Parts of, 13

Pia mater, 6

Tracts of, 18

(see Columns), 18

Veins, 12

White matter of, 17, 18

Structure of, 26

Spinal—

Arteries, 11

- Spinal—
 Nerves, 16
 Veins, 12
 Vessels, 11
 Splenium (*σπληνίον*, a compress)
 of the corpus callosum, 158
 Spongioblasts, 191
 Spot, perforated, 134, 135
 Strands—
 White, 157
 Motor, 73, 184
 Sensory, 187
 Striæ acusticæ, 66, 107
 Longitudinal, lateral, and
 mesial of corpus callosum,
 158
 Structure (minute) of—
 Arachnoid of Brain, 51
 of Spinal Cord, 10
 Dura mater of Brain, 48
 of Spinal Cord, 6
 Grey matter of Brain, 128
 of Cerebellum, 102
 of Spinal Cord, 30
 Nerve Cells, 34
 Pia mater of Brain, 50
 of Spinal Cord, 8
 White matter of Spinal Cord,
 26
 Sub-arachnoid fluid, 10, 51
 Space, 4, 9, 51
 Trabeculæ, 8, 9
 Sub-divisions of Brain, 63
 Sub-dural space, 4, 9, 51
 Substantia gelatinosa, 28
 Nigra, 168
 Sulci (furrows) fissures of the
 cerebral hemispheres, 114
 Calloso-marginal, 124
 Callosal, 124
 Calcarine, 126
 Inter-lobular, 115
 Intra-lobular, 116
 Intra-parietal, 120
 Island of Reil, 123
 Lateral dorsal, 67
 Olfactory, 119
 Paramedian, 67
 Parieto-occipital, 116, 120, 126
 Sulci—
 Præcentral, 117
 Temporal, 122
 Triradiate, 118
 (see also Fissures)
 Sulcus—
 Lateral (*crus cerebri*), 166
 Lateral dorsal, 69
 Oculomotorii, 166, 173
 Paramedian, 67
 Summaries—
 Brain, 170
 General, 180
 Medulla, 75
 Spinal cord, 40
 Sylvius, Aqueduct of, 170
 Tables—
 Ascending and Descending
 Degenerations, 41
 Cerebral Vesicles, 194
 Convolutions of,
 Frontal, 119
 Mesial surface, 127
 Occipital lobe, 122
 Parietal lobe, 121
 Temporal lobe, 123
 Cranial nerves, 136
 Dura Mater—Agreements and
 Differences, 48
 Gowers', 42
 Grey Matter of Medulla, 82
 Tracts of conduction, 41
 Objects on base of Brain, 137
 Objects on surface of Medulla,
 75
 Order in which Tracts get
 their Medullary Sheath, 41
 Relations of Tracts of Cord
 and Medulla, 76
 Superficial Origins of the
 cranial nerves, 136
 Vesicular Columns, 34
 White tracts of Spinal Cord,
 25
 Tænia (*ταινία*, a band), 110
 Hippocampi, 126, 145
 Semi-circularis, 144, 162
 Tarini Pons, 135

- Tegmentum (covering) of crura cerebri, 166
 Nucleus of, 167
 Telencephalon, 194
 Tentorium (a tent) cerebelli, 47
 Thalamus (bed) opticus, 153
 Trabs (a beam) cerebri (corpus callosum), 157
 Trabeculæ sub-arachnoid, 8, 9
 Tracts of Spinal Cord, 18
 Tract—
 Antero-external, 20
 Antero-lateral ascend., 21, 71
 descend., 21, 71
 Goll's, 22, 68
 Optic, 134, 172
 Lateral Cerebellar, 21
 Pyramidal, direct, 19, 73, 185
 crossed, 20, 71, 185
 Spinal Cord, 18
 Intermedio-lateral, 34
 Trapezium of Pons Varolii, 90
 Trophic realm, 33, 184
 Tuber cinereum, 134
 Olfactorium, 118
 Valvulæ, 96
 Tubercle—
 Amygdaloid, 96
 Cuneate, 69
 Rolando, 69, 80
 Tubercula quadrigemina, 169
 (see Corpora Quadrigemina)
 Tuberculum acusticum, 112
 Türk, Fasciculus of, 19

 Uvula (dim. of *uva*, a cluster of grapes) of Cerebellum, 96

 Vallecule of Cerebellum, 94
 Valve of Vieussens, 100, 174
 Varolii, Pons, 87
 Veins—
 Cerebellar, 61
 Cerebral, 61
 Emissary, 56

 Veins—
 of Galen, 150
 Spinal, 12
 Velum, inferior or posterior medullary, 100
 Interpositum, 148
 Superior or anterior medullary, 100
 Venous Sinuses, 52
 Ventricles (*ventriculus*, dim. of *venter*, a belly)—138, 141
 Dissection to expose, 140
 Epithelial lining of, 145
 Fifth, 147
 Fourth, 106
 Lateral, 138, 142
 Medullary portion of 4th, 107, 108
 Nuclei of, 111
 Third, 146
 Upper portion of 4th, 107, 108
 Verga, 162
 Vermiform process, 93, 96
 Vesicles—
 Anterior Cerebral, 196
 Middle Cerebral, 195
 Posterior Cerebral, 195
 Vesicular Columns, 32
 Lateral, 28
 Table of, 34
 Vessels—
 Spinal, 11
 of Brain, 57
 Vicq d'Azyr, bundle of, 161
 Vieussens, Valve of, 100

 White Matter—
 Brain, 157
 Cerebellum, 105
 Medulla, 67, 113
 Spinal Cord, 18
 Willis, Circle of, 60, 132
 Wyllie's Trophic realms, 33, 184

 Zone, mixed, 22, 71

CATALOGUE
OF
E. & S. LIVINGSTONES'
MEDICAL
PUBLICATIONS, &c.



15 Teviot Place,
EDINBURGH.

CATALOGUE
OF
PUBLICATION
OF
Medical and Scientific Works.

THE SUBSCRIBERS are prepared to undertake the Publication of MEDICAL and SCIENTIFIC WORKS on terms advantageous to Authors.

The rapid sale of Works hitherto placed in their hands enables them to guarantee a favourable reception in the Profession, and by the Trade at home and abroad.

The Printing of their Publications is carried on within their own premises, thereby saving unnecessary expense, and receiving more careful attention.

E. & S. LIVINGSTONE,
MEDICAL AND SCIENTIFIC PUBLISHERS,
EDINBURGH.

Price £2 : 2s. Super-Royal Folio, Cloth.

THE
Topographical Anatomy
of the Child

BY JOHNSON SYMINGTON, M.D.,

F.R.S.E., F.R.C.S.E.,

*Professor of Anatomy, Queen's College, Belfast; formerly Lecturer
on Anatomy, School of Medicine, and Examiner in
Anatomy, University of Edinburgh.*

**Illustrated by 14 beautiful and correctly Coloured Plates (nearly
all of which are life size) and 33 Woodcuts.**

'Dr Johnson Symington has well filled a gap in our Topographical Anatomy. This department of anatomical science has been worked at most extensively and ably by Pirogoff, Braune, Luschka, and others, in the adult; but the method of frozen sections has hitherto been systematically applied to the child, in one case only, by Professor Dwight. Dr Symington has added to our knowledge by presenting us in this work with fourteen coloured lithographic illustrations, all life-size, and thirty-three woodcuts taken from sections of male and female children, aged four years and a half, five years, six years, and thirteen years, and has given us a large number of very accurate observations on the position of the various organs and viscera, and the changes which they undergo in the earlier periods of life. The horizontal sections have been taken from a girl six years of age, whilst the vertical sections (both coronal and sagittal) are from children of both sexes and various ages. In addition to the illustrations, the work is most valuable for excellent letterpress, treating very fully and minutely of the position of structures at all periods of early life, and it is evident that many of the views generally held in regard thereto will have to undergo considerable alteration. For example, Dr Symington shows that the external auditory meatus is relatively as long in the child as in the adult, when examined in the fresh state in subjects with the entire head frozen; that the spinal cord in the newly-born child ceases at much the same point as in the adult; that the child's neck is not relatively short, but that it is higher in relation to the vertebral column than in the adult. The common assumption that the position of the stomach in the child is vertical is also shown to be erroneous, and is proved by figures taken from an infant four days old, and from a girl six years of age. The portion of the book devoted to the position of the pelvic viscera in male children is of great importance to surgeons, and will be carefully studied in view of operations on the urinary organs in early life. Too much praise cannot be bestowed upon the author for the obvious care and industry with which he has pursued his investigation, and the accuracy and fidelity with which he has reproduced its results. Its dedication to Professor Braune is a most graceful compliment to an anatomist who has done more to advance the knowledge of Topographical Anatomy than any other worker in this special branch.'—*The Lancet*, 22nd October 1887.

Just Published, price 15s. net.

Profusely Illustrated.

A TEXT-BOOK
OF
Medical Jurisprudence, Toxicology,
AND
Public Health.

BY
JOHN GLAISTER, M.D.,
D.P.H.(Camb.), F.R.S.E.

*Professor of Forensic Medicine and Public Health in the University
of Glasgow.*

‘Taking this work as a whole we can unhesitatingly pronounce it to be one of the best text-books dealing with Medical Jurisprudence, Toxicology, and Public Health which we have met with. It is well written throughout, the information contained in it is full and accurate without being redundant, and the illustrations are appropriate and well executed. We can cordially recommend it to medical practitioners and students, and also to members of the legal profession who will find therein a useful guide in a class of cases which are often perplexing to the legal mind.’—*Lancet*.

‘This text-book will add a welcome unit to those with which Professors of the Faculty of Medicine in the University of Glasgow have enriched the literature of the profession. . . . A novel feature of this work, as compared with similar works published in former years, is the description of the Bertillon method of identification, and of Galton’s finger print system. The illustrations are numerous, many consisting of photo reproductions, and therefore giving life-like pictures of the various objects or features detailed. Altogether, Dr Glaister may be congratulated on having produced a very useful text-book, and one to which both the medical student and practitioner may turn for information with all confidence.’—*Glasgow Herald*.

Third Edition, in 2 vols., price 18s.

ILLUSTRATED WITH 238 USEFUL ENGRAVINGS.

Applied Anatomy

BY

JOHN M'LACHLAN, M.D., B.Sc., F.R.C.S.E., &c.

The Book includes what is usually known as—

1. SURGICAL ANATOMY. 2. MEDICAL ANATOMY.
3. OPERATIVE SURGERY.

USED AS A TEXT-BOOK IN THE PRINCIPAL UNIVERSITIES & MEDICAL COLLEGES.

'It deserves every success.'—SIR GEORGE MACLEOD, Professor of Surgery, University of Glasgow.

'If the medical student of to day comes to an examination unprepared, and retires without his diploma, he certainly cannot lay the blame of his failure on want of instruction. To help the student in his difficulties, to guide him in the waste wilderness of his poor lecture-room notes, and to give him a chance of learning something, the student has to find for himself men that can really teach him, and books that convey useful information, information that will bear not only on the work of the examination, but also on his future professional life. Dr M'Lachlan is such a teacher, and his book is of the kind we mean. It is a successful attempt to show how the facts of Anatomy are necessary as a ground-work both of Surgery and Medicine. If mastered it will do the student more good than acres of MSS. dealing with theory and fad, for it makes his anatomy interesting, and the bedside or the operating theatre intelligible, and, except where vested interests in fees come in, it is pretty generally acknowledged now that the dissecting-room, the laboratory, and the hospital are the real places of study.'—*Edinburgh Medical Journal*.

'The text is copiously illustrated with well executed engravings, numbering altogether 238 as against 74 in the former edition. The author has produced a work which is more fitted to meet the wants of the student and the practising surgeon in the application of anatomy to practice, than any other which has come under our notice.'—*Hospital Gazette*.

'The book is written specially with a view to the requirements of students preparing for the higher examinations; and its successive editions have, in this regard, been each one more perfect than the last. In this issue much new matter and many new illustrations have been added. The work may be cordially recommended to students as a complete and practically useful text-book.'—*Scotsman*.

Just Published, Fifth Edition, price 10s. 6d. net.

The Students' Handbook
OF THE
PRACTICE of MEDICINE

Designed for the use of Students and
Junior Practitioners.

By H. AUBREY HUSBAND, M.B., C.M.,

B.Sc., F.R.C.S.E., M.R.C.S., L.S.A.,

FORMERLY LECTURER ON MEDICAL JURISPRUDENCE AND PUBLIC HEALTH
IN THE EXTRA-ACADEMICAL SCHOOL, EDINBURGH.

MEMBER OF THE GENERAL COUNCIL OF THE UNIVERSITY OF EDINBURGH ;

EXTRAORDINARY MEMBER OF THE ROYAL MEDICAL

SOCIETY, EDINBURGH ;

AND CORRESPONDING FELLOW OF THE MEDICO-LEGAL SOCIETY
OF NEW YORK.

Illustrations, Tables, Prescriptions, and Glossary.

‘The book before us is an excellent example of its class; the whole of medicine is digested and tabulated, and in fact served up ready prepared at infinite pains to render it easily assimilated.’—*Lancet*.

‘The distinguishing features of Dr Husband’s handbook are condensation and clearness of diction—qualities which are certain to ensure for the book a favourable reception by those for whom it is intended. We have pleasure in recommending it to our readers as a most useful work to peruse immediately before presenting one’s self for a Medical Examination.’—*Students’ Journal*.

‘The book is not put forth as a systematic treatise upon diseases and their treatment, but under each section will be found a brief statement of the main points connected with all the diseases enumerated in the nomenclature of the Royal College of Physicians, London. From the point of view of the uses to which this Manual is designed, we know of no work that can be put in comparison with it.’—*Provincial Medical Journal*.

‘Whether as a handbook for use as an introduction to the systematic study of disease, or for the purpose of refreshing the memory on the eve of an examination, the work is equally to be commended, and one may safely assert that it will retain its well-earned popularity.’—*Hospital Gazette*.

Sixth Edition, Revised and considerably Enlarged.

Illustrated by Coloured Plates, price 10s. 6d. net.

THE STUDENTS' HANDBOOK
OF
Forensic Medicine, Toxicology, and
Public Health

By H. AUBREY HUSBAND, M.B., C.M.,

B.Sc., M.R.C.S., L.S.A., F.R.C.S.E.,

Author of 'Student's Handbook of the Practice of Medicine,' etc.

Used as a Text-book in the principal Universities and Medical Schools in
Great Britain, India, and the Colonies.

'It is intended for students, and is for them very convenient. This edition fully sustains the acceptableness of the work.'—*Lancet*.

'The work is an excellent epitome of the subjects on which it treats, and contains all that the student need know to pass his examinations, or that the ordinary practitioner will require in the course of his practice. . . . As a trustworthy and readable guide to the study of forensic medicine, we can strongly recommend it to both students and practitioners.'—*Student's Journal*.

'The book is one which can be commended, and will in the future, as in the past, doubtless smooth the passage of many medical students through the difficulties of the examination room.'—*Public Health*.

'The work has long enjoyed a pre-eminent reputation as a book useful to students about to proceed to examination in the subjects of which it treats; and men have been known to boast of having secured academic degrees by no more than a cursory perusal of its pages. They toiled not; but, being possessed of this handbook, neither were they spun. The new edition gives the book in an improved shape. The text has been revised, new matter has been added; and some professionally beautiful illustrations now appear in the work. For the rest, this edition keeps the handbook well abreast of its reputation.'—*Scotsman*.

Just Published, Second Edition, price 12s. net.

Elementary Textbook of Zoology

BY

ARTHUR T. MASTERMAN,

M.A.(Cantab.); D.Sc.(Lond. and St And.); F.R.S.E.;

LECTURER ON ZOOLOGY AND BIOLOGY IN THE
SCHOOL OF MEDICINE OF THE ROYAL COLLEGES, EDINBURGH;

JOINT-AUTHOR OF

"THE LIFE-HISTORIES OF THE BRITISH MARINE FOOD-FISHES";

EXAMINER IN BIOLOGY TO THE
ROYAL COLLEGE OF PHYSICIANS, EDINBURGH, ETC.

PROFUSELY ILLUSTRATED.

Just Published, price 4s. net.

HANDBOOK of PUBLIC HEALTH

BY

JOHN ORR,

M.D.; F.R.C.P.E.; M.R.C.S.(Eng.);

'The medical student in particular will be the gainer by the publication of Dr Orr's manual, but the general reader also may glean useful instruction from its pages.'—*Glasgow Herald*.

Just Published, price 2s. 6d. net.

Illustrated by numerous Woodcuts Plain
and in Colour,

Midwifery Notes

FOR THE USE OF STUDENTS.

BY T. A. GLOVER, M.D.(Edin.)

Fellow, Obstetrical Society, London, &c.

'The author distinctly states that the object of these Notes is to help the student in his Practical Midwifery Training; to this end only matter which is likely to be exemplified in the ordinary run of cases is included and this in such a manner as to be easily digested and as easily retained. This book will be found to be a useful introduction to the Art of Midwifery.'—*Guy's Hospital Gazette*.

Price Five Shillings.

THE STUDENTS' Handbook of Gynecology

PROFUSELY ILLUSTRATED.

THE MOST PRACTICAL HANDBOOK EVER PUBLISHED.

Used as an Introductory Text-Book in all the
Universities and Medical Schools.

'Everything is stated in a most clear and concise way, and as the volume is nicely illustrated, it should be of great assistance to final men especially.'—*Dispatch*.

'It is clearly and concisely written, and it is surprising to find that it has succeeded so well, in the small space at its disposal, in covering the ground necessary for an elementary knowledge of this progressive and important branch of medical learning.'—*Scotsman*.

Just Published, price 4s. 6d. net.

The Conservative Treatment
OF
Tubercular Joint Disease
and Cold Abscess

AS CARRIED OUT AT Breslau BY

Prof. J. von MIKULICZ, LL.D. Edin.

BY

DR A. HENLE,

Chief Assistant at the Surgical Klinik, Breslau.

WITH PREFACE BY PROFESSOR J. von MIKULICZ.

TRANSLATED FROM THE GERMAN BY

CHARLES W. CATHCART, F.R.C.S.,

SENIOR ASSISTANT SURGEON, ROYAL INFIRMARY, EDINBURGH.

'We regard this as a most important contribution to the literature of a most important department of surgery. Every practising surgeon should learn for himself what the modes of treatment are which find favour with Professor Mikulicz in a domain wherein he ranks as an authority of no undeniable weight. In this handsomely bound and well-printed octavo, he will find discussed the "congestion" treatment, the "orthopædic" treatment, the "iodoform" treatment, and all the other preliminary methods of avoiding the more advanced procedures of erosion, excision, &c., which may be employed before sacrificing a whole limb. We strongly recommend this volume to the attention of every practitioner.'—*The Medical Press.*

Demy 4to., price 7s. 6d.

Illustrated with 10 Coloured Plates.

Nerves of the Human Body

By ALFRED W. HUGHES, M.B. & C.M. Edin.;

F.R.C.S. Edin.; M.R.C.S. Eng.;

Late Professor of Anatomy, King's College, London.

'An excellent work of reference for students, quite in place in a Medical School library. The drawings are large and bold, demonstrating the distributions and connections of the cranial and spinal nerves with clearness and accuracy. The cranial nerves in particular are well represented. . . . The preparation of "Nerves of the Human Body" must have cost its author much trouble, and Dr Hughes may be congratulated on the result of his labours.'—*British Medical Journal*

'As regards the work little is left to be desired. As far as the diagrammatic and literal description of the nerves goes, this work is undoubtedly good; and there is no doubt that the anatomical details are an improvement on those usually given. It will be found a help to students in their practical work, and of equal help to the practitioner in his pathological and therapeutic investigations.'—*Provincial Medical Journal*

Price 4s. 6d. net.

ILLUSTRATED WITH 8 COLOURED PLATES.

MANUAL OF SURGICAL ANATOMY

By ALFRED W. HUGHES, M.B. & C.M. Edin.;

F.R.C.S. Edin.; M.R.C.S. Eng.;

*Late Professor of Anatomy, King's College, London. Author of
'Nerves of the Human Body,' &c.*

Used as a Handbook in all the Universities and Medical Colleges.

'This little book contains very terse descriptions of the anatomical facts most important to students about to present themselves for their Final Examination in Surgery. Clearness sometimes, and elegance of diction often, have been sacrificed to brevity. It will recommend itself to those for whom it is specially prepared.'—*Lancet*.

'Dr Hughes evidently possesses the faculty of condensing a large amount of information into a small space in a clear and methodical manner. The student will find it a very reliable guide. The work contains a number of excellent illustrations, which will greatly assist the student in learning the relative positions of various structures which he would encounter in the ligature of the principal arteries.'—*Edinburgh Medical Journal*.

Second Edition, price 6s.

Revised and Enlarged, with 12 Tinted Plates and 40 Woodcuts.

MANUAL OF THE Minor Gynecological Operations and Appliances

BY J. HALLIDAY CROOM, M.D.,

F.R.C.P.E., F.R.C.S.E.,

*Lecturer on Midwifery and Diseases of Women, School of Medicine;
President of the Obstetrical Society, Edinburgh; and
Examiner in Midwifery in the University of Edinburgh and Royal College
of Physicians, Edinburgh.*

'The descriptions and recommendations of Dr Croom seem entirely familiar, intelligible, and wholesome. A number of well-executed lithographic plates, giving various relations of the pelvic organs, add to the value of the book.'—*American Journal of Obstetrics.*

'We are glad to see that this valuable Manual has run into a Second Edition. Its arrangement is such as will commend itself both to the student and busy practitioner. We finish the perusal of this work impressed with its simplicity of arrangement and lucidity of expression.'—*Liverpool Medico-Chirurgical Journal.*

Price 10s. 6d.

THE STUDENTS' Handbook of Medicine AND Therapeutics

BY ALEXANDER WHEELER,

*Clinical Assistant, Out-Patient Department, Edinburgh Royal Infirmary.
Author of "OUR UNSEEN FOES," &c.*

Used as a Text-Book in the principal Universities and Colleges.

'It is distinctly designed to refresh the memory on salient points, as well as to enunciate the leading principles of treatment. These aims have been faithfully carried out, and that too with an originality for which it might be thought there could be little scope. Clear, concise, and accurate.'—*Lancet.*

3rd Edition. 5th Thousand, price 5s. net.

Illustrated by about 40 Plates (many Coloured) or 109 Figures.

Anatomy of the Brain and Spinal Cord

By J. RYLAND WHITAKER, B.A., M.B.(Lond.)

F.R.C.P., L.R.C.S.(Edin.);

Lecturer on Anatomy, Surgeons' Hall, Edinburgh; Examiner for the Triple Qualification.

Used as a Text-Book in the principal Universities and Medical Colleges in Great Britain, India, the Colonies, U.S.A., and Italy.

'The book is an excellent Manual for the use of Students and makes a good introduction to the heavier text-books. This Edition is made more valuable by the inclusion of some new matter in the text, and by the addition of many new figures and tables.'—*Scotsman*.

Price 4s. 6d. net.

Notes on Pathology

By J. RYLAND WHITAKER,

B.A., M.B.(Lond.), F.R.C.P., L.R.C.S.(Edin.);

Lecturer on Anatomy, Surgeons' Hall, Edinburgh; Examiner for the Triple Qualification.

Vol. I.—GENERAL.

Used as a Handbook in the principal Universities and Colleges.

'These "Notes," which traverse the whole range of General Pathology, have evidently been compiled with great care. Together, they form an outline of the subject of which it will not be difficult for the student to fill in such details as he gathers from his lecturer or his text-book. The author himself recognises this as the main object of his publication, and we may say at once that he has done his work well, and that it should prove of much utility. In these days of "compendia" of knowledge, where the aim often seems to be to condense into as small a space as possible the facts of science, so that the student may be saved the trouble of learning them step by step, it is gratifying to find a writer who takes a higher view of the kind of assistance that the student needs. The information he conveys in his little work is considerable, and also accurate; in parts even—e.g., in the sections dealing with Inflammation and the Parasites—it is almost, if not quite, as full as is to be found in many a text-book. But it would be difficult for the student to use the work simply for the purpose of "cram." We believe, moreover, that teachers also may be glad of so concise a summary of the subject as Mr Whitaker has given.'—*Lancet*.

Demy 8vo, price 4s. 6d. net.

Vaccination Eruptions:

ORIGINAL RESEARCH.

By THOMAS DOBSON POOLE, M.D.,

Master in Surgery, University of Edinburgh; Fellow of the Obstetrical Society.

'The title of this very interesting work concisely indicates its contents. A good acquaintance with the literature of the subject is shown on every page, and the cited cases are of great interest, especially those in connection with the subject of generalised vaccine eruption (*vaccine généralisée*). The differential diagnosis between vaccination, ulcers, and primary chancres, also between vaccination eruptions and secondary syphilitic manifestations, is given *in extenso* from Portalier's summary of Fournier's lectures. In conclusion, this work deserves perusal by all who are interested in the subject of vaccination, therefore by all medical practitioners.'—*British Medical Journal*.

Second Edition. Price Two Shillings net.

Revised in accordance with the British Pharmacopœia, 1898.

96 pp. Crown 8vo. Bound in Cape Morocco.

The Students' Practical Materia Medica

BY

G. HAXTON GIFFEN,

L.R.C.P.E., L.R.C.S.E., L.F.P. & S.G.;

'Bathgate' Gold Medallist in *Materia Medica*, Royal College of Surgeons.

'We recommend this little book.'—*Dublin Journal of Medical Science*.

'It contains a vast amount of information in small compass and is likely to become popular with students preparing for an examination.'—*Edinburgh Medical Journal*.

'This is a very concise and practical manual, a summary and resumé of the principles of pharmacology, and the nature and uses of drugs with their doses. The method of the arrangement of the chapters is simple and intelligible and the doses of officinal preparations are stated under a system of classification which prevents reiteration and more readily impresses the memory.'—*Glasgow Herald*.

'It is at present the most succinct, lucid, and suggestive of all the manuals on the subject.'—*Scotsman*.

'It contains much useful information.'—*Medical Press*.

Quarto. Price Sixpence net.

SCHEDULES FOR
PLANT DESCRIPTION
(ILLUSTRATED)

BY JOHN WISHART,

*Lecturer on Zoology and General Biology in Robert Gordon's College, Aberdeen ;
Herbarium Medallist of the Pharmaceutical Society of Great Britain.*

~~~~~  
USED IN ALL UNIVERSITIES AND COLLEGES.

---

'The use of these Schedules by pupils will train their powers of observation and reasoning, and prevent them from being contented with book knowledge.'—*Dublin Journal of Medical Science.*

'These tables are admirably adapted and arranged on a scientific principle for building up an instructive record of plant examination.'—*Aberdeen Daily Free Press.*

-----

BY THE SAME AUTHOR,

Price Two Shillings net.

THE  
Botanists' Vade Mecum.

---

'A very handy little pocket guide to the classification of plants, intended for use during botanical excursions. The matter is very concise and well arranged, and the value of the book is very materially enhanced by an ingenious and novel form of index.'—*Guy's Hospital Gazette.*

'This little manual, of a size suitable for the pocket, will form a useful companion to students of botany in their field-days. Its arrangement is concise, and its information conveniently scheduled. A useful ledger-index adds to the convenience of the manual.'—*Glasgow Herald.*

'We commend this Vade Mecum as a very useful guide to all botanical excursion students, who will find it an invaluable aid to recognising the characters of the various divisions and natural orders.'—*British and Colonial Druggist.*

Price 2s. 6d. net.

THE ROTATORY MOVEMENTS  
OF THE  
HUMAN VERTEBRAL COLUMN  
AND THE  
SO-CALLED MUSCULI ROTATOIRES.

By ALFRED W. HUGHES,

M.B. & C.M. Edin.; F.R.C.S. Eng.; F.R.C.S. Edin.;

*Late Professor of Anatomy, King's College, London; Author  
of 'Nerves of the Human Body' and 'Manual of Surgical Anatomy.'*

'The entire work bears evidence of careful observation, and forms a useful contribution to the mechanism of the human skeleton.'—*Edinburgh Medical Journal*.

NEW EDITION.

Revised in accordance with the British Pharmacopœia, 1898.

Price One Shilling net.

PHARMACOLOGICAL TABLES;

*Appendix on Poisons; Index of Diseases;  
and Medicines arranged according to their Actions.*

By WILLIAM CRAIG, M.D.,

C.M., F.R.S.E.,

*Lecturer on Materia Medica, School of Medicine, Surgeons' Hall, Edinburgh  
Late Examiner in Materia Medica, Edinburgh University;  
Examiner, Royal College of Surgeons.*

Being a Tabular Arrangement of all the Medicines contained in the  
British Pharmacopœia, with Dose, &c.

'This is a useful little book, containing a tabular arrangement of all the Pharmacopœial preparations, with their doses and methods of administration. A table on Poisons and an Index of Diseases with Appropriate Remedies are included.'—*Lancet*.

Price 1s. 6d. net.

## Materia Medica Tables.

*Designed for the Use of Students.*

BY A. HERBERT BUTCHER,

L.R.C.P., L.R.C.S. & L.M.,

*Honorary Surgeon to Birkenhead Borough Hospital.*

'This is a small work intended to supply a long-acknowledged want, and will be found to contain much information arranged in an admirably simple manner.'—*Publisher's Circular.*

Price 2s. 6d. net.

## THE STUDENTS' HANDBOOK OF Diseases of the Skin.

*Illustrated by Coloured Plates and Wood Engravings.*

'It is clearly and systematically arranged, and the student who masters its contents will have acquired a useful general knowledge of the pathological classification, course, and methods of treatment of all but the rarest diseases of the skin.'—*Manchester Guardian.*

'It will prove of service to the young practitioner, and also to older men in country practices, whose work leaves them but little time for the study of books of greater pretensions. A number of well-executed illustrations increase the working value of the book.'—*The Publisher's Circular.*

Second Edition. Price 6d. net.

Revised in accordance with the British Pharmacopœia, 1898.

## Dose Tables of Materia Medica

Containing all the Doses required for Examinations and Prescribing.

BY T. HOMER, L.R.C.S., L.R.C.P. Edin.

B 8/02.

Price 1s. 6d. in Paper Boards; or in Cloth, 2s.

## THE CHILD—HOW TO NURSE IT;

*Or the Management of Children and their Diseases.*

By ALEXANDER MILNE, M.D.

'Dr Milne not only describes how the Child should be managed from the hour of birth, but he notes the distinctive characteristics of all the ailments to which Children are liable, and gives instruction as to their proper treatment. A great many works have been published of late years, but there is certainly not one which is more likely to be of use to inexperienced or conscientious parents.'—*Scotsman*.

'This little work will be found to contain copious details on the management of infancy, expressed in language singularly free from technicalities.'—*Courant*.

'We heartily recommend the careful study of Dr Milne's invaluable work.'—*Ladies' Own Journal*.

'To emigrants and others who are at a distance from medical aid, we believe the book will be a "present help in time of trouble."'—*North Metropolitan*.

Price Threepence.

## The Monthly Nurse:

A FEW HINTS ON NURSING.

By H. AUBREY HUSBAND, M.B., C.M., B.Sc., &c.

'It can scarcely be said that a handbook of this kind is not required, and it is certain that a more clearly-arranged little work of the kind could not be found.'—*Scotsman*.

'A little Manual written in the simplest possible style, but containing invaluable advice and instruction for those who have to act as midwives. District visitors who should distribute copies of this pamphlet to poor mothers would save them much unnecessary misery.'—*Literary World*.

'We have very great pleasure in bearing testimony to this excellent little pamphlet. Monthly nursing, as it at present exists, is not at all in a satisfactory condition, and it is a relief to be able to get at some sensible advice and suggestions—Dr Husband supplies them here.'—*Medical Review*.

We supply the above two Works on special terms to District Visitors and Institutions using quantities for distribution.

---

Fourth Edition. Price 2s. net.

---

## BOTANY NOTES

SPECIALLY adapted for Students preparing for Professional Examinations in Medicine and Science. The various divisions considered in accordance with the several University Syllabuses.

BY ALEXANDER JOHNSTONE, F.G.S.,

AUTHOR OF 'ZOOLOGY NOTES,'

*Lecturer on Botany, School of Medicine, Edinburgh; and Natural Science Master, Blair Lodge.*

---

In reviewing 'Botany Notes,' and 'Botany—a Manual,' *The Lancet* says 'This little volume entitled "Botany Notes" traverses the same ground as the other book, but is rather more suitable for use on the evening preceding Exam. It is not too much to believe that, if the student does not receive material aid from the "Botany Notes" now before us, he has but small prospect of receiving assistance from any printed matter whatever.'

---

Price 3s. 6d. net.

---

## ZOOLOGY NOTES

SPECIALLY adapted for Students preparing for Professional Examinations in Medicine and Science. The various divisions considered in accordance with the several University Syllabuses.

BY ALEXANDER JOHNSTONE, F.G.S.,

AUTHOR OF 'BOTANY NOTES,'

*Lecturer on Botany, School of Medicine, Edinburgh; and Natural Science Master, Blair Lodge.*

---

'This useful little manual is divided into three parts. The first part is devoted to General Morphology, Histology, and Physiology, and to the Protozoa and Vermes; the second part treats of Vermes, Mollusca, and Arthropoda; and the third is occupied with Classes from Arthropoda to Man. The plan pursued is that a brief account of each class is given, then in succession the sub-classes and divisions are described, and finally a detailed account of some animal, as the anodonta amongst mollusca, and nephrops amongst crustacea. The descriptions, though short, are accurate.'

—*Lancet.*

## THE CATECHISM SERIES.

(NEARLY ALL THE PARTS ARE ILLUSTRATED.)

Price One Shilling net, each Part.

### ANATOMY.

Part 1—Upper Extremity.

" 2—Lower Extremity.

" 3—Head and Neck.

Part 4—The Abdomen.

" 5—The Thorax.

" 6—Bones and Joints.

### BOTANY.

[TWO PARTS.]

### BACTERIOLOGY.

[ONE PART.]

### CHEMISTRY.

[TWO PARTS.]

### FORENSIC MEDICINE.

[ONE PART.]

### MATERIA MEDICA.

Part 1—Mineral Waters, Foods, and Inorganic.

" 2—Inorganic.

" 3—Orders and Plants and Vegetable.

---

‘The reading of these books just before going in for an examination will be of considerable use in recalling the most important points to memory.’—*Illustrated Medical News.*

## THE CATECHISM SERIES.

Price One Shilling net, each Part.

### MIDWIFERY.

[TWO PARTS.]

~~~~~  
 'To say that these small books will be of help in memorising important points, and of special service when preparing for an examination, is but to reiterate what has been so often expressed in regard to other volumes in this capital series.'—*Dispatch College Column*.

PHYSIOLOGY.

- Part 1—Chiefly Histology.
 " 2—Circulation.
 " 3—Blood; Respiration.
 " 4—Digestion.
 " 5—Intestines; Blood Glands; Kidneys.
 " 6—The Skin, Animal Heat, Voice and Speech, Smell and Taste.
 " 7—Eye, Ear, and Cranial Nerves.
 " 8—Spinal Cord, Brain, Reproduction, Physiological Chemistry.

PUBLIC HEALTH.

- | | |
|--------------------------|-------------------------------|
| Part 1—Water. | Part 5—Medicine, Food, Water- |
| " 2—Air and Ventilation. | Closets, Disinfectants, |
| " 3—Sewage. | Warming, Hospitals, |
| " 4—Vital Statistics. | etc. |

~~~~~  
 'We have pleasure in recommending the series to all who are interested in a certain impending and rapidly approaching event.'—*Student*.

'These manuals are the best things of the kind in existence.'—*Scottish Review*.

## THE CATECHISM SERIES.

Price One Shilling net, each Part.

### SURGERY.

Part 1—Hæmorrhage—Repair—Inflammation—Suppuration—  
Ulceration—Mortification—Erysipelas—Wounds  
—Burns.

- " 2—Fractures and Dislocations of the Upper Extremity.
- " 3—Fractures and Dislocations of the Lower Extremity—  
Diseases of Blood-Vessels and Lymphatics.
- " 4—Tumours—Diseases of Bones—Diseases of Joints.
- " 5—Injuries and Diseases of Muscles and Nerves (Club-  
Foot, Whitlow, Ganglion, &c.)—Venereal Diseases.  
—REGIONAL SURGERY: Injuries and Diseases of  
the Head.
- " 6—REGIONAL SURGERY: Face, Nose, Mouth, and Tongue;  
Oesophagus, Hare-Lip, Neck, Tracheotomy, &c.;  
Thorax and Mamma.
- " 7—REGIONAL SURGERY: Vertebral Column, Abdomen  
Rectum, Urinary and Genital Organs, &c.

### SURGICAL ANATOMY and OPERATIONS.

[TWO PARTS.]

### TOXICOLOGY.

[ONE PART.]

### ZOOLOGY.

[TWO PARTS.]

'They cannot fail to be popular with students.'—*Hospital Gazette*.

'We recommend these little books to students, for we feel sure they will help to refresh the memory, specially if about to pass an "exam."'—*Journal of Microscopy*.

'We must commend the general accuracy and clearness of the descriptions.'—*Glasgow Medical Journal*.

---

*THE CATECHISM SERIES.*

---

Price 1s. net, each Part.

---

Examination Questions

IN

Practice of Medicine

WITH ANSWERS.

---

PART 1.—GENERAL DISEASES.

PART 2.—SKIN DISEASES.

PART 3.—FEVERS.

---

Adapted for those who are Preparing themselves for the  
Final Examination.

---

‘These little books are very valuable in refreshing the mind of  
the student.’—*Daily Free Press.*

---

[Other Parts will follow.]

## THE CATECHISM SERIES.

Price 2s. 6d. net, each Part.

### PATHOLOGY.

Part 1. GENERAL.      Part 2. SPECIAL.

---

Price 2s. 6d. net.      Illustrated.

## PHYSICAL TRAINING:

### ITS THEORY AND PRACTICE.

Being an Elementary Treatise on the necessity and effects of exercise.

By H. RIPPON SEYMOUR

*Gymnastic and Fencing Master, George Watson's College, Edinburgh.*

With an introduction by

WILLIAM TAYLOR, M.D., F.R.C.P.E.

‘It gives so much instruction in anatomy and physiology as is necessary for an intelligent understanding of the useful series of exercises it enumerates, and sets forth in a clear and interesting way the advantages that come of a scientific study of physical culture.’—*Scotsman*.

‘I can heartily recommend this book to all athletes. It will well repay perusal.’—*The Athletic Times*.

‘This is a very praiseworthy attempt to connect the theoretical and practical physical training in one book, and it easily succeeds in being both concise and intelligible.’—*Publishers' Circular*.

Second Edition, price 12s. 6d.

# THE Principles and Practice of Midwifery

By ALEXANDER MILNE, M.D.,

*Ex-Vice-President of the Edinburgh Obstetrical Society.*

'The very favourable reception accorded to the first edition was well merited, the work being thoroughly practical, and very readable—not too diffuse nor exhaustive, yet containing sufficient details for all examination purposes. The Second Edition has been carefully revised, and such additions made as were rendered necessary through recent advances in the obstetric art. We have no doubt that the Second Edition of Dr Milne's Manual will be more popular with medical students than the first.'—*Student's Journal*.

'Dr Milne has contrived to condense a great amount of obstetric doctrine, both physiological and pathological, into his book.'—*Lancet*.

'I estimate highly the thought, the labour, and the courage expended in the work.'—Dr J. MATTHEWS DUNCAN, London.

'A very excellent and comprehensive Manual.'—Professor GRAYLY HEWITT, London.

'An admirable digest of the subject.'—Professor A. R. SIMPSON, Edinburgh.

Price 4s. net.

## YELLOW FEVER

By JAMES W. MARTIN, M.D.

ILLUSTRATED.

'It gives a very clear and concise account of the chief facts about yellow fever and its congeners among the malarial fevers of the tropics, and discusses its etiology and treatment at some length.'—*Lancet*.

## TEMPERATURE CHARTS:

Suitable for Hospitals, Dispensaries, or  
Private Cases.

SPECIMEN COPIES FREE ON RECEIPT OF TWO STAMPS.

SPECIAL SIZES OR KINDS PRODUCED TO ORDER AT MODERATE RATES.

Third Edition. Greatly Enlarged and Improved.

Price One Shilling net.

## THE URINE

*In Health and in Disease, together with its Chemical Examination.*

By H. AUBREY HUSBAND, M.B., C.M.,

B.Sc., F.R.C.S.E., etc.,

*Formerly one of the Medical Officers of the Royal Dispensary, Edinburgh.*

*Author of the 'Students' Handbook of the Practice of Medicine,'*

*'Students' Pocket Prescriber,' &c.*

~~~~~  
WITH NUMEROUS PLATES.

Price 1s. 6d. Illustrated by 26 Woodcuts.

THE PHYSIOLOGY of the EYE,

With an Introductory Chapter on Optics.

By H. CAMPBELL, M.B.,

B.Sc. Lond., M.R.C.P. Lond., M.R.C.S. Eng.

New Edition. Revised and Greatly Enlarged.

Price 1s. 6d. net.

The Students' Pocket Prescriber

By H. AUBREY HUSBAND, M.B., C.M.,

B.Sc., etc.,

Author of 'The Students' Handbook of the Practice of Medicine,' 'The Urine, in Health and in Disease,' etc.

~~~~~  
This Book is intended for Students and young Practitioners, and contains much useful information. The Prescriptions are arranged thus:—Alteratives, Antacids, Antispasmodics, Aperients, Cathartics, and Anthelmintics, Astringents, Caustics and Counter Irritants, Diaphoretics and Diuretics, Emetics and Expectorants, Gargles and Inhalations, Lotions, Liniments and Ointments, Narcotics and Sedatives, Refrigerants and Salines, Stimulants, Tonics, and Uterine Therapeutics; with an Index to the Prescriptions.

Price One Shilling net.

## Puberty and the Change of Life.

A BOOK FOR WOMEN.

By J. C. WEBSTER, M.D., M.R.C.P.E.,

*Assistant to the Professor of Midwifery and Diseases of Women in the University of Edinburgh.*

'It should be read with profit by both mothers and daughters; its teachings are sound, and always on the side of that educated common sense which is but another name for science itself. The author's remarks on the evils attending the educational competition among girls deserve the attention of mothers especially. The health directions set forth in this manual, if followed out, cannot fail to avert much of the preventable pain and misery so characteristic of our modern civilisation.'—*Glasgow Herald*.

'The book is well written; some parts of it unquestionably are calculated to do good to suffering womankind.'—*Birmingham Medical Review*.

Price One Shilling and Sixpence net.

## DISEASES OF THE EYE.

A Manual for Senior Students and Young Practitioners.

By J. ARTHUR KEMPE, F.R.C.S.,

*Late Senior Demonstrator of Anatomy, Surgeons' Hall, Edinburgh.*

USED IN THE EDINBURGH MEDICAL SCHOOLS.

'It is a book for those who now require to show a knowledge of the more common eye diseases before passing the final examinations. The arrangement is good, the information explicit, and after the student is done with it as an examination guide he will find it very useful in general practice.'—*Glasgow Herald*.

'This book gives a pithy digest of the symptoms and diagnosis of the commonest diseases of the eye with practical hints as to treatment.'—*Daily Free Press*.

Price Sixpence net.

## Case-Taking Book for Hospitals;

With Hints on Case-Taking, Normal and Abnormal  
Temperatures, Weight of Adult Organs, etc.

*The Synopsis used in the Royal Infirmary, Edinburgh.*

Price One Shilling net.

## REFERENCES TO NERVES:

Being Tabular Views of the Motor Nerves to Muscles, the Nervous Supply of the Principal Articulations and of the Skin, the Deep and Superficial Origins of the Cranial Nerves, etc.; with the most important effects following Solution of Continuity of Nerves.

~~~~~  
INVALUABLE TO THE ANATOMICAL STUDENT.

Price One Shilling net.

MORPHOLOGY OF THE VERTEBRATA;

DOG-FISH, COD, PIGEON, AND RABBIT;

WITH DEVELOPMENT OF THE DOG-FISH.

By D. KNIGHT,

OF THE MUSEUM OF SCIENCE AND ART, EDINBURGH.

~~~~~  
ILLUSTRATED.  
-----

Part I.—Price Sixpence net.

## ATLAS OF CHEMISTRY:

Inorganic and Organic,

*Designed for the use of Medical and Science Students, and Science Teachers in Schools and Evening Classes.*

By VICTOR V. BRANFORD, M.A.

-----  
Third Edition, Revised, price Sixpence net.

## HANDBOOK OF ANIMAL CLASSIFICATION

For the Use of Medical and Science Students.

By VICTOR V. BRANFORD, M.A.

-----  
Price One Penny.

## ALCOHOL: Its Action on the Body in Health.

By ALEXANDER WALKER, M.D..

*Late Medical Officer of Health, Putney.*

Price Two Shillings net.

## Handbook of Deductive Logic:

Designed specially for the use of Medical Students preparing for their Preliminary Examination.

By REV. DUNCAN STEWART, D.D.,

MINISTER OF SPOTT, DUNBAR.

'Brevity and simplicity are the cardinal virtues in this book, because it has been designed specially for the use of young men intending to study medicine and preparing for their Preliminary Examination. A new feature in it is that not a few of the illustrations are medical, but the fundamental principles of logic being the same the world over, it is adapted to any other class of students. Brevity has been aimed at, but not to the detriment of perspicuity, and whatever help has been had from other writers on logic is mainly due to Jevons. As the work has been confessedly prepared for a purpose, the student is recommended not to pass over any of the questions on the several sections given at the end of the book till he is able to answer them. The questions and exercises are numerous and searching, and fitted to acquaint the student with the likely subjects of examination.'—*Glasgow Herald*.

-----

Price One Shilling net.

## A Manual of Dental Education

With some General Notes upon the Modern Curriculum of the Dental Student.

By ARTHUR TURNER,

*Licentiate in Dental Surgery of the Royal College of Surgeons, Edinburgh; Dental Surgeon to the Buckinghamshire General Infirmary; Fellow of the Chemical Society.*

'We can recommend it as affording much valuable information to those who think of studying dentistry.'—*Manchester Guardian*.

This is an epitomized guide for those about to enter upon the study of Dental Surgery with a view of obtaining the diploma, and will be found useful.'—*Edinburgh Medical Journal*.

'A manual such as we have now before us will be found most useful for intending dental students. It is a welcome and useful guide.'—*Glasgow Herald*.

NOW READY.

Second Edition, price 2s. 6d. net; post free, 2s. 10d.

# Walter Crichton

OR

*Reminiscences of George Heriot's Hospital.*

BY JAMIESON BAILLIE.

PROFUSELY ILLUSTRATED.

*With Portraits, Sketches, and Wash Drawings*

BY J. R. ABERCROMBY, and Others.

'The descriptions are exceedingly good. . . . Such an institution as George Heriot's Hospital with all its ancient customs lent itself to a book of this kind, and this volume is one of the best books of school life we have seen.'—*Edinburgh Evening News.*

-----

Just Published, price 7s. 6d. net.

# Memories of a Modern Monk

OR

*Reminiscences of George Heriot's Hospital.*

BY C. B. GUNN, M.D.Edin.,

With a Description of the Hospital from an Architectural Standpoint

By HIPPOLYTE J. BLANC, R.S.A., F.R.I.B.A.,

And a Short Sketch of the late Dr Bedford (House Governor),

By his son, Major CHARLES HENRY BEDFORD,

D.Sc., M.D.Edin., M.R.C.S.Eng.;

Indian Medical Service; Professor of Chemistry, Calcutta University, &c.

PROFUSELY ILLUSTRATED.

ILLUSTRATED WITH OVER 100 CHARACTERISTIC SKETCHES & PEN & INK PORTRAITS.

Price 2s. 6d. net.

[An EDITION DE LUXE, printed on Dutch hand-made paper and bound in half-morocco, price 5s. net—only 100 copies printed.]

CHEAP EDITION—(Words only)—Price 3d.

*The Awful and Ethical Allegory*

OF

DEUTERONOMY SMITH

Or, The Life History of a Medical Student.

'This excellent series of University sketches are a sort of Pilgrim's Progress of Edinburgh University studentdom, recording the gradual development of the medical, from the crude and chrysalis stage to that of his full-grown and perfect butterfly existence, and the moral of the tale lies in this, that it is of universal application; and the medical of to-day can read in it lessons for himself just as sound as the generation for whom it was written. The humour of the narrative lies largely in this, that it is written in the Biblical style, which gives to the incidents related a *naivete* that is often irresistible.'—*College Column*.

Crown 8vo., 411 pp., price 3s. 6d.

CLAUDE GARTON

*A Story of Dunburgh Student Life.*

By THOMAS J. HENRY, F.R.C.S.E.,

AUTHOR OF 'DEUTERONOMY SMITH.'

'This highly interesting story by the author of "Deuteronomy Smith," itself an excellent testimonial, deals with the life and adventures of a medical student. We are introduced to many whose names are curiously familiar. The story is interestingly written, and will be read with avidity by Edinburgh men in particular and medical students in general.'—*The Student*.

'Mr Henry has given us a very striking book, even more powerful, in its way, than George Moore's masterpiece, "Esther Waters." It describes the experiences of a medical student in Edinburgh, from his entry to the day when he is "capped" for his diploma, and each scene stands out distinct and clear, a triumph of detailed and effective realism. To read these chapters is never to forget them; it is as though we had been present at the scenes described. Conan Doyle has done nothing better. Mr Henry has done for the Medical School of Edinburgh what Tom Hughes did for Rugby.'—*Sheffield Daily Telegraph*.

'The story is one of extraordinary fascination and dramatic power.'—*St James Gazette*.

**PUBLISHED ANNUALLY.**

Crown 8vo, price 2s.; by post, 2s. 3d.

**EDINBURGH**

# Medical School Calendar

*Is the only book that contains all the information required for Graduation in Medicine, Surgery, and Public Health at Edinburgh University; Fellowship, Licence, and Licence in Dental Surgery of the Royal College of Surgeons; Fellowship, Membership, and Licence of Royal College of Physicians; Triple Qualification of Scottish Conjoint Board; Classes in the University and School of Medicine; Dispensaries, Students' Societies, &c.; also the*

## **Preliminary and Professional Examination Questions**

*set by the University, Educational Institute of Scotland, Royal College of Surgeons, Royal College of Physicians, and the Triple Board, for several years past.*

~~~~~  
'It is full of the most useful information. It ought to be a most valuable work of reference for the medical student.'—*Edinburgh Medical Journal*.

'Much time and money may be saved by a careful perusal of this book.'—*Medical Press and Circular*.

'The Medical School Calendar maintains its reputation for comprehensiveness and accuracy of information.'—*Scotsman*.

The book is crammed with information on all subjects which a student requires to know in piloting his way through a course of medical study. A page of well-compiled advice to the student as to the most advantageous method of study is given. A glance through the pages of the Calendar shows the extensive provision for medical education in Edinburgh, and is itself the most convincing argument for the necessity of the publication.'—*Edinburgh Evening News*.



