

**The anatomy of the brain : a text-book for medical students / by Richard H. Whitehead ... illustrated with forty-one engravings.**

**Contributors**

Whitehead, Richard H. 1865-1916.  
Augustus Long Health Sciences Library

**Publication/Creation**

Philadelphia, New York [etc.] : F. A. Davis company, 1900.

**Persistent URL**

<https://wellcomecollection.org/works/t8rfvckk>

**License and attribution**

This material has been provided by This material has been provided by the Augustus C. Long Health Sciences Library at Columbia University and Columbia University Libraries/Information Services, through the Medical Heritage Library. The original may be consulted at the the Augustus C. Long Health Sciences Library at Columbia University and Columbia University. where the originals may be consulted.


This work has been identified as being free of known restrictions under copyright law, including all related and neighbouring rights and is being made available under the Creative Commons, Public Domain Mark.

You can copy, modify, distribute and perform the work, even for commercial purposes, without asking permission.

**wellcome  
collection**

Wellcome Collection  
183 Euston Road  
London NW1 2BE UK  
T +44 (0)20 7611 8722  
E [library@wellcomecollection.org](mailto:library@wellcomecollection.org)  
<https://wellcomecollection.org>

COLUMBIA LIBRARIES OFFSITE  
HEALTH SCIENCES STANDARD



HX64084477

QM455 .W58

The anatomy of the b

**RECAP**

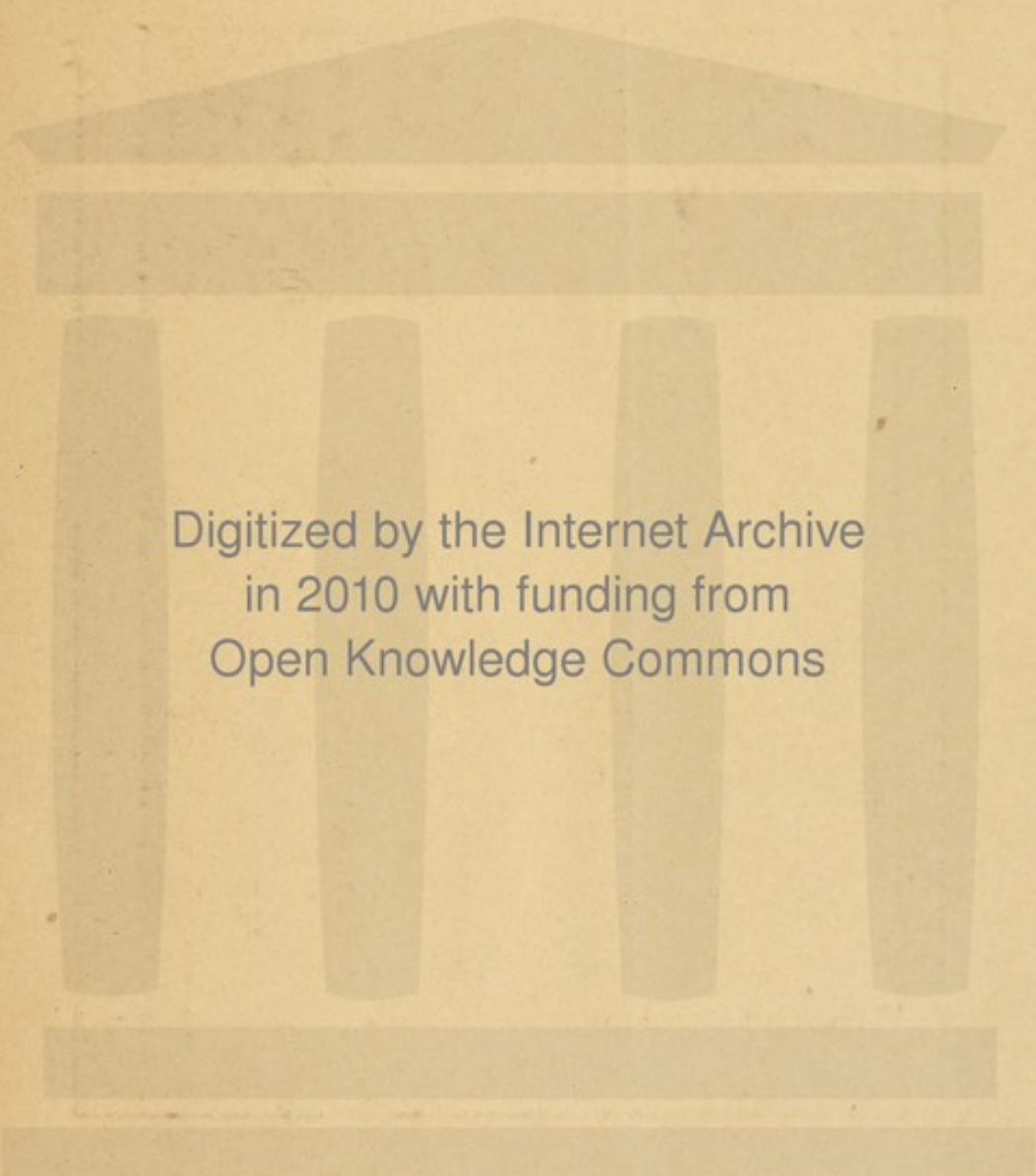
THE ANATOMY  
OF THE  
BRAIN

---


R.H. WHITEHEAD.


QM 455 - W 58






Digitized by the Internet Archive  
in 2010 with funding from  
Open Knowledge Commons







THE  
ANATOMY OF THE BRAIN

A TEXT-BOOK FOR MEDICAL  
STUDENTS

BY

RICHARD H. WHITEHEAD, M.D.

PROFESSOR OF ANATOMY IN THE UNIVERSITY OF NORTH CAROLINA

---

**Illustrated with Forty-one Engravings**

---



PHILADELPHIA. NEW YORK. CHICAGO  
THE F. A. DAVIS COMPANY, PUBLISHERS

1900

LIBRARY OF THE  
FEDERAL BUREAU OF INVESTIGATION  
WASHINGTON, D. C.

QM455  
W58

---

COPYRIGHT, 1900,  
BY  
THE F. A. DAVIS COMPANY.

---

[Registered at Stationers' Hall, London, Eng.]

---

---

Philadelphia, Pa., U. S. A. :  
The Medical Bulletin Printing-House,  
1916 Cherry Street.

---

## PREFACE.


---

IN the preparation of this little book it has been the author's aim to furnish medical students with a clear, accurate, and concise account of the anatomy of the brain, to be used as a guide in their study of that organ. From a work of this character it has been thought best to omit minor details, and to exclude, so far as seemed possible, subjects which are still matters of controversy.

Recognizing the value of a uniform nomenclature, use has been made of the Latin terms adopted and recommended by the German Anatomical Society at its meeting in Basel, to the extent that they have been inserted, parenthetically, after the names commonly employed in this country.

UNIVERSITY OF NORTH CAROLINA,

APRIL, 1899.



CONTENTS.

---

CHAPTER I.

THE DIVISIONS OF THE ENCEPHALON..... 1

CHAPTER II.


THE SURFACE ANATOMY OF THE ENCEPHALON..... 6

CHAPTER III.

THE INTERNAL ANATOMY OF THE ENCEPHALON..... 34

CHAPTER IV.

THE CONDUCTING-PATHS OF THE ENCEPHALON..... 86



## CHAPTER I.

### THE DIVISIONS OF THE ENCEPHALON.

As the division of the encephalon, or brain, into its several parts is based upon the embryological development of that organ, it will be necessary to briefly consider the early development of the central nervous system.

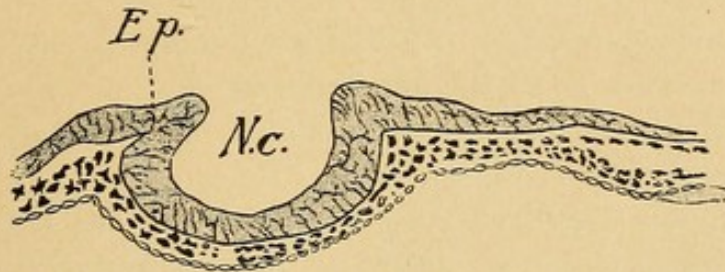


Fig. 1.—Transverse section of first-day chick (after Duval).  
*Ep.*, Epiblast. *N. c.*, Neural canal.

The cerebro-spinal nervous system makes its first appearance as two ridges of epiblast bordering a groove in the median line (Figs. 1 and 2). As these ridges increase in elevation, they soon meet over the back of the groove, which

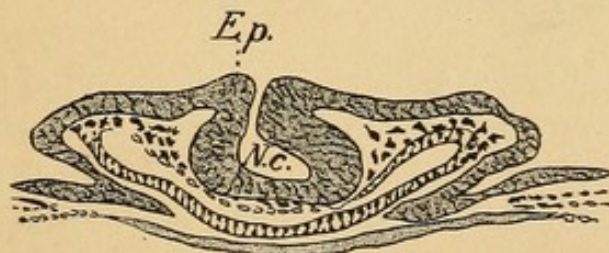


Fig. 2.—Transverse section of first-day chick (after Duval).  
Reference letters as in Fig. 1.

thus becomes a canal: the neural canal. At this period the embryonic nervous system may be represented as a cylinder whose walls are formed by epithelial cells; in this stage it is called the neural axis. While the great majority of the cells become differentiated into neurones and their supporting

tissue,—the neuroglia,—some remain as a lining to the canal, forming the ependymal epithelium. The neural canal persists throughout life under different names, and varies much in size in different portions of the nervous system.

That part of the neural axis which is contained within the embryonic cranium and which is to become the brain is seen, at a very early stage, to be dilated into three sacs, or vesicles, known from behind forward as the rhombencephalon, mesencephalon, and prosencephalon. A little later the first and third of these vesicles are differentiated into two each, the rhombencephalon becoming divided into the myelencephalon and metencephalon, while the prosencephalon gives rise to the diencephalon and the telencephalon. Thus, there are now five vesicles from behind forward: the myelencephalon, the metencephalon, the mesencephalon, the diencephalon, and the telencephalon (Fig. 3).

From these five vesicles are developed all the parts of the encephalon which we are about to study. Moreover, since the five primary divisions maintain their individuality more or less distinctly in the fully developed brain, those parts of it which a given vesicle produces are called collectively by the same name as the parent-vesicle. In other words, the vesicle bears the same name both in the undeveloped and in the mature state.

The encephalon is divided into five parts, then, as follows (Figs. 3, 4, and 5):—

1. The myelencephalon, or the medulla oblongata.
2. The metencephalon, composed of the pons Varolii and the cerebellum. The pons Varolii is developed from that portion of the metencephalon which lies ventral to the neural canal, the part which lies dorsal to the canal producing the cerebellum. The most anterior portion of the metencephalon may be individualized into a separate division under the name of the isthmus of the rhombencephalon. The neural canal in the region of the rhombencephalon becomes the fourth ventricle.
3. The mesencephalon, consisting of the corpora quadrigemina dorsal to, and the peduncles of the cerebrum ven-

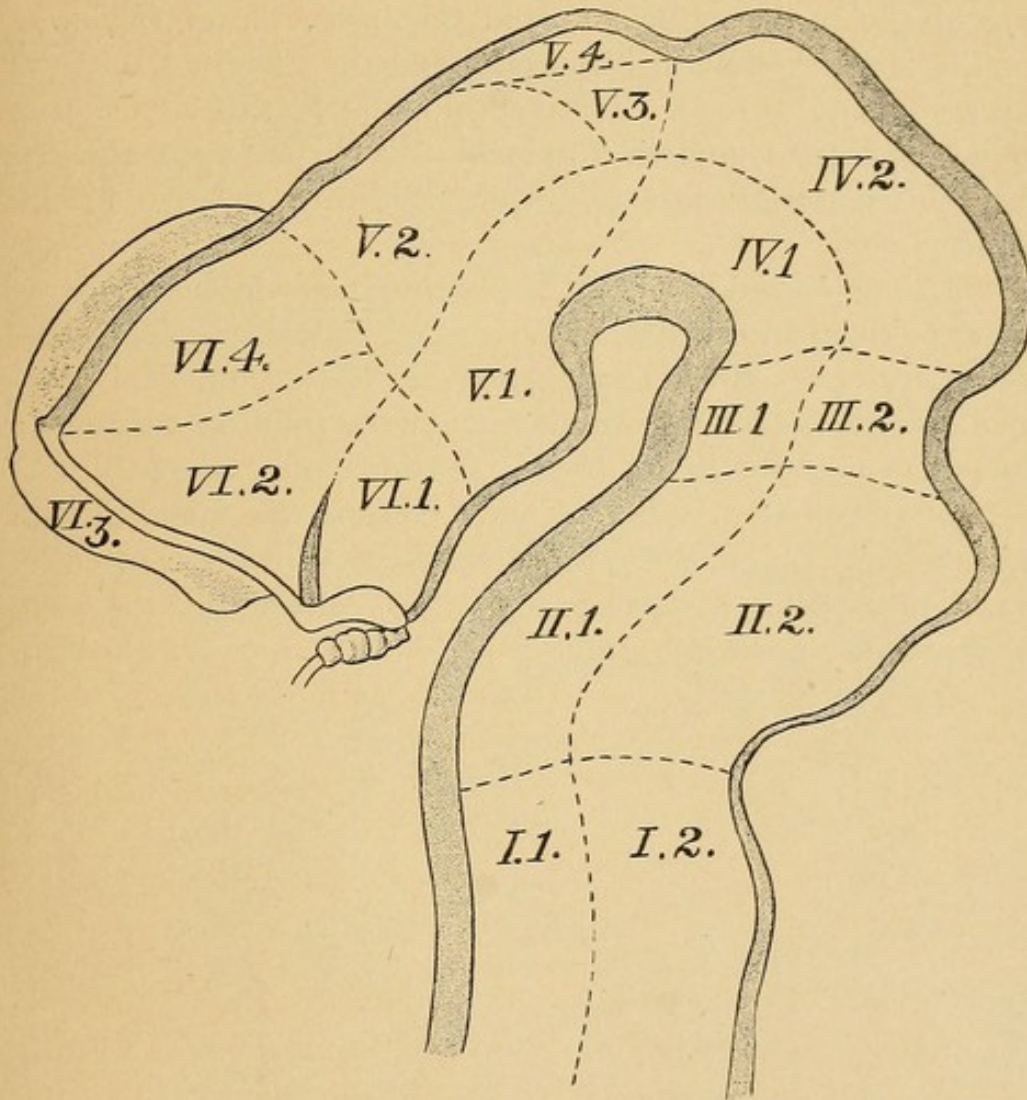


Fig. 3.—Sagittal section of brain of one-month human embryo (after His). *I.* Myelencephalon: *I.1*, Ventral portion; *I.2*, dorsal portion. *II.* Metencephalon: *II.1*, Pons Varolii; *II.2*, cerebellum. *III.* Isthmus rhombencephali: *III.1*, Ventral portion; *III.2*, dorsal portion. *IV.* Mesencephalon: *IV.1*, Pedunculi cerebri; *IV.2*, corpora quadrigemina. *V.* Diencephalon: *V.1*, Pars mamillaris hypothalami; *V.2*, thalamus; *V.3*, metathalamus; *V.4*, epithalamus. *VI.* Telencephalon: *VI.1*, Pars optica hypothalami; *VI.2*, corpus striatum; *VI.3*, rhinencephalon; *VI.4*, pallium.

tral to, the neural canal, which here is called the aqueduct of Sylvius.

4. The diencephalon. This is divided into the thalamencephalon dorsal to, and the hypothalamus ventral to, the neural canal. The thalamencephalon is subdivided on each side of the median line into the thalamus, the epithalamus (or the pineal body and habenula), and the metathalamus (or the geniculate bodies). The neural canal in this situation is called the third ventricle. Ventral to it is the hypothalamus, only the posterior part of which, however, belongs to the diencephalon.

5. The telencephalon. This consists of the hemispheres dorsal to the neural canal, while a small ventral portion forms the anterior part of the hypothalamus. Here the neural canal develops into the lateral ventricles. As the result of very rapid growth, especially in its lateral portions, the telencephalon soon outgrows its neighbors, and overlaps the diencephalon and mesencephalon. To these three divisions—telencephalon, diencephalon, and mesencephalon—collectively the term cerebrum is commonly applied.

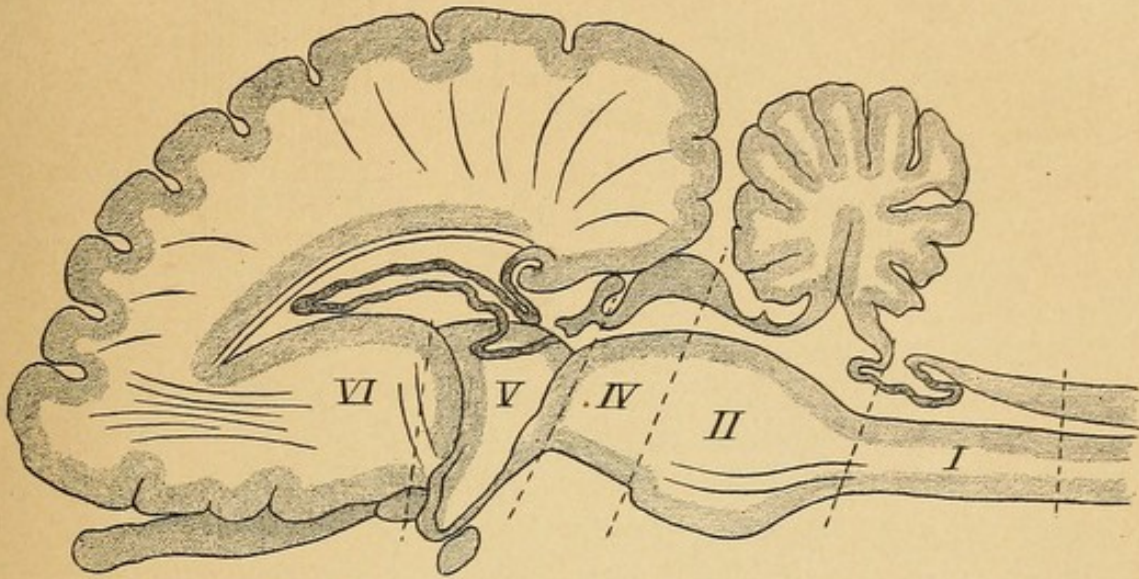


Fig. 4.—Sagittal section of brain of mammal (after Edinger).  
Reference numbers as in Fig. 3.

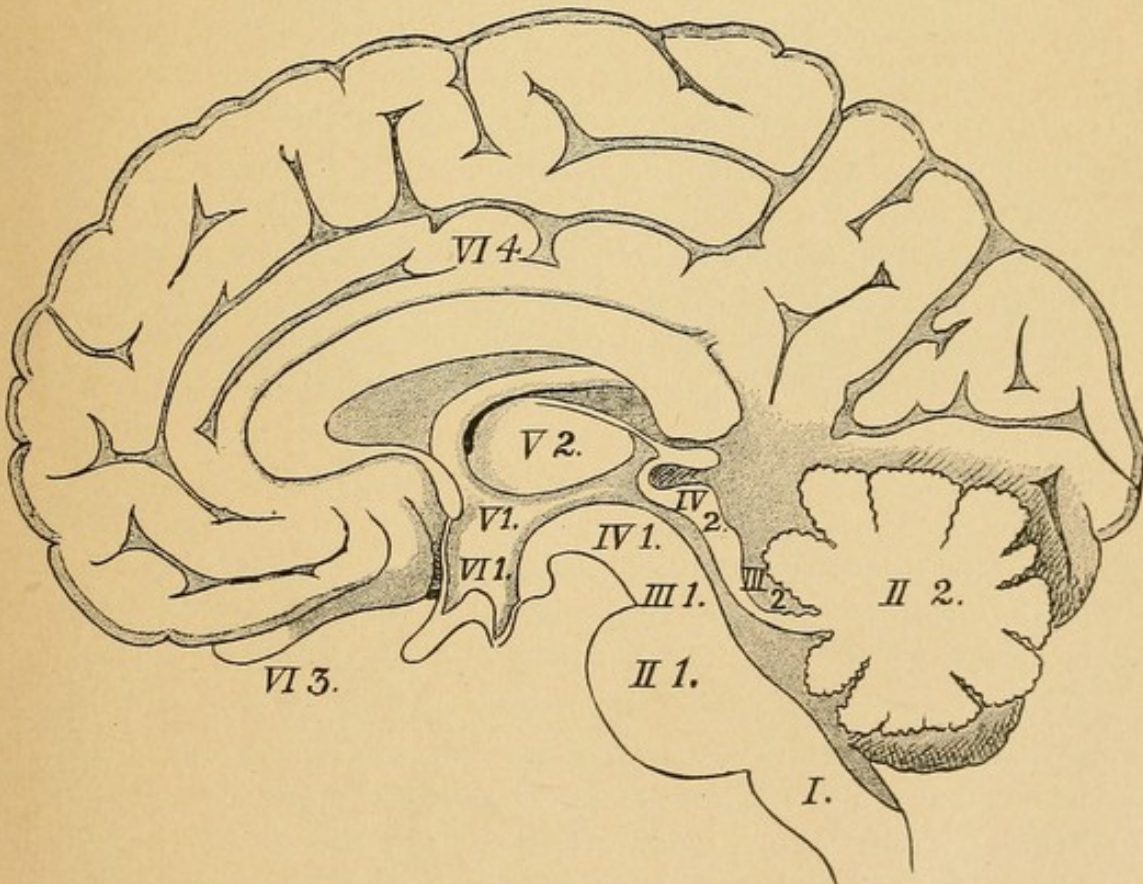


Fig. 5.—Sagittal section of human brain (after His).  
Reference numbers as in Fig. 3.

## CHAPTER II.

### THE SURFACE ANATOMY OF THE ENCEPHALON.

#### THE SURFACE ANATOMY OF THE MYELENCEPHALON.

THE myelencephalon or the medulla oblongata extends between the spinal cord behind and the pons Varolii in front. It is somewhat conical in shape, with its base forward and on a plane dorsal to the smaller extremity, which is continuous with the spinal cord. It is about one and one-quarter inches long, and its widest diameter measures nearly one inch. It rests upon the posterior part of the concave surface of the basilar process of the occiput. For purposes of description it may be divided into a ventral surface, a dorsal surface, and two lateral surfaces.

The ventral surface (Fig. 6) presents in the median line a well-marked longitudinal groove,—the ventral median fissure (*fissura mediana anterior*),—on each side of which is a rounded band, the pyramid (*pyramis*). Near the spinal cord the fissure is almost obliterated by fibres which pass across from one pyramid into the other; this is called the decussation of the pyramids (*decussatio pyramidum*). Lateral to each pyramid and separating the ventral from the lateral surface is the ventro-lateral sulcus (*sulcus lateralis anterior*), from which emerge the root-fibres of the twelfth cranial, or hypoglossal, nerve (*nervus hypoglossus*).

The lateral surface (Fig. 6) in its posterior half is known as the lateral tract (*funiculus lateralis*). Its anterior half is occupied by an oval mass called the olive (*oliva*). Each lateral is separated from the dorsal surface of the medulla by the dorso-lateral sulcus (*sulcus lateralis posterior*), from which many nerve-fibres escape to soon unite and form three nerves; from before backward these are the ninth (*nervus glosso-pharyngeus*), the tenth (*nervus vagus*), and the accessory portion of the eleventh (*nervus accessorius*) cranial nerves. It will be noticed that the posterior part of this sulcus is in-

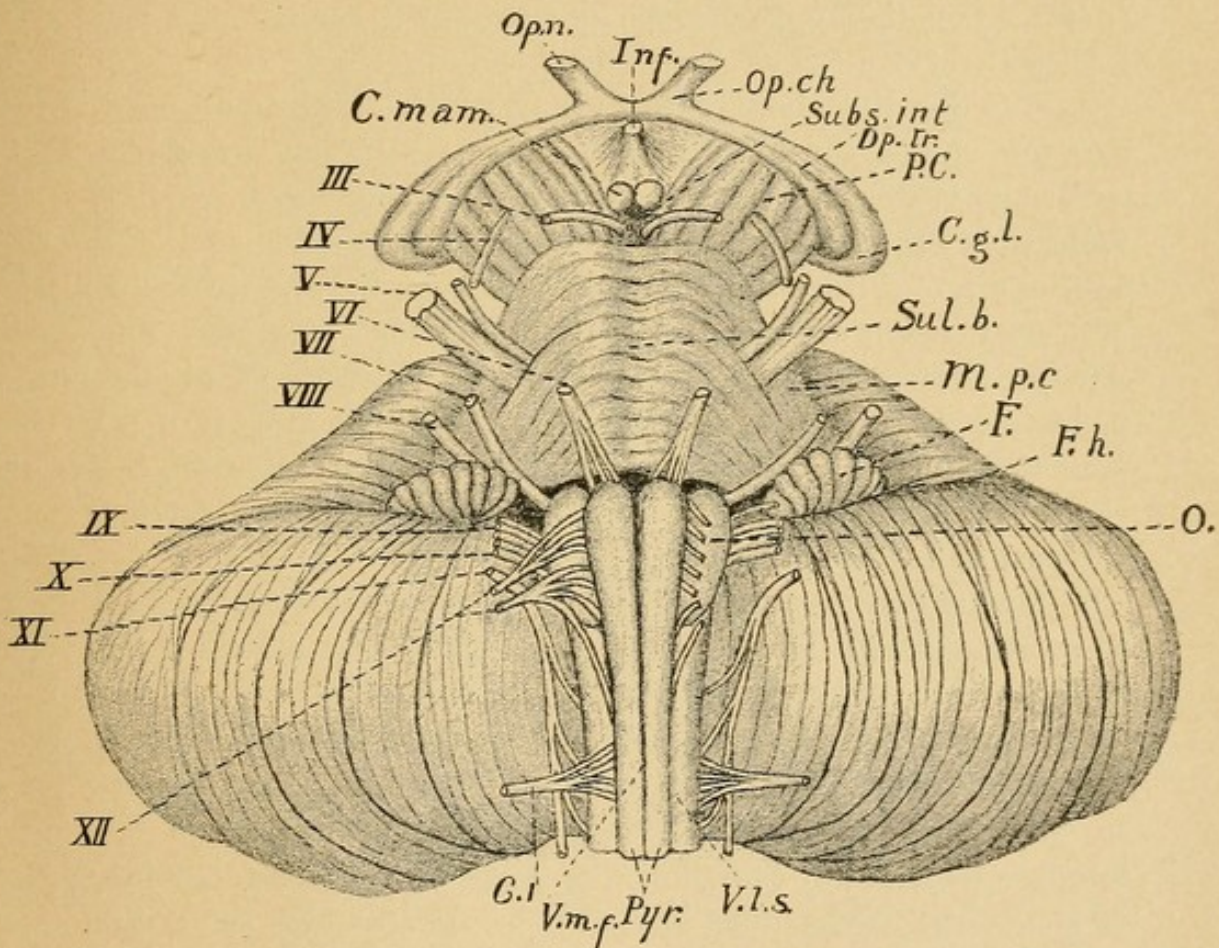


Fig. 6.—Roman numerals refer to cranial nerves. *C.1.*, First cervical spinal nerve. *C. mam.*, Corpus mamillare. *Op. n.*, Optic nerve. *Inf.*, Infundibulum. *Op. ch.*, Optic chiasm. *Subs. int.*, Substantia interpeduncularis. *Op. tr.*, Optic tract. *P. C.*, Peduncle of cerebrum. *C. g. l.*, Lateral geniculate body. *Sul. b.*, Basilar sulcus. *M. p. c.*, Middle peduncle of cerebellum. *F.*, Flocculus. *F. h.*, Horizontal fissure. *O.*, Olive. *V. l. s.*, Ventrolateral sulcus. *Pyr.*, Pyramid. *V. m. f.*, Ventral median fissure. (After Van Gehuchten.)

interrupted by the passing of a part of the lateral tract to the dorsal surface of the medulla.

The ventral and lateral surfaces of the medulla are clearly limited from the pons Varolii by a transverse groove. In this groove appear the root-fibres of three cranial nerves: the sixth (*nervus abducens*), opposite the pyramid; the seventh (*nervus facialis*), opposite the dorso-lateral sulcus; and the eighth (*nervus acusticus*), still farther lateral.

The dorsal surface (Fig. 7) may be divided into an anterior and a posterior half. The latter resembles the spinal cord; here we find in the median line the dorsal median fissure (*fissura mediana posterior*), and on each side of it the continuation of the dorsal funiculi of the cord,—the funiculus of Goll (*funiculus gracilis*), next to the median fissure and separated laterally from the funiculus of Burdach (*funiculus cuneatus*) by the paramedian fissure. These two funiculi terminate forward, the former in a small elevation called the *clava*, the latter in a less distinct elevation extending farther forward called the *cuneate tubercle*.

Owing to the termination of these dorsal funiculi and to an increase in the transverse diameter of the neural canal at this point, the anterior division of the dorsal surface presents a depression, which is bounded laterally by a white cord: the *corpus restiforme*. The two *corpora restiformia* diverge to enter the cerebellum, leaving thus between them a triangular depression, which is the floor of the neural canal, and is called the *calamus scriptorius*. As it is also the posterior (inferior) part of the floor (*fossa rhomboidea*) of the fourth ventricle, which is the neural canal of the rhombencephalon, it is called the *pars inferior fossæ rhomboideæ*. The base of the triangular depression is forward, and nearly corresponds to some fibres seen crossing the floor of the ventricle on each side: the *striæ acusticæ* (*striæ medullares*). These emerge from the longitudinal median sulcus, which is continuous, not with the dorsal median fissure of the medulla, but with the floor of the central canal continued from the cord into the medulla. Between this sulcus and the *corpus restiforme* the dorsal surface on each side may be divided into three triangles, as follows: Bordering the sulcus is a

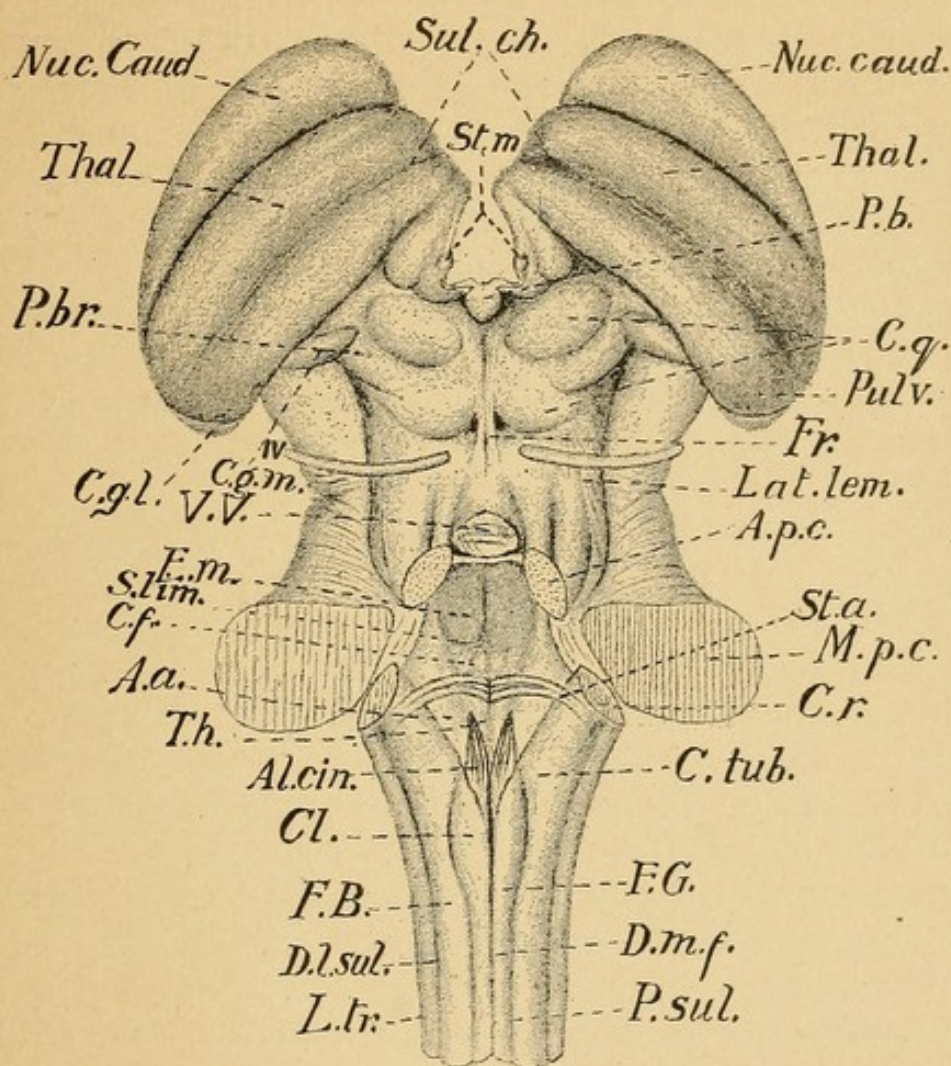


Fig. 7.—*Sul. ch.*, Chorioid sulcus. *Nuc. caud.*, Nucleus caudatus. *Thal.*, Thalamus. *St. m.*, Stria medullaris. *P. b.*, Pineal body. *C. q.*, Corpora quadrigemina. *Pulv.*, Pulvinar. *Fr.*, Frenulum. *Lat. lem.*, Medial lemniscus. *A. p. c.*, Anterior peduncle of cerebellum. *M. p. c.*, Middle peduncle of cerebellum. *St. a.*, Acoustic striæ. *C. r.*, Corpus restiforme. *C. tub.*, Cuneate tubercle. *F. G.*, Funiculus of Goll. *D. m. f.*, Dorsal median fissure. *P. sul.*, Paramedian sulcus. *L. tr.*, Lateral tract. *D. l. sul.*, Dorso-lateral sulcus. *F. B.*, Funiculus of Burdach. *Cl.*, Clava. *Al. cin.*, Ala cinerea. *T. h.*, Hypoglossal triangle. *A. a.*, Acoustic area. *C. f.*, Colliculus facialis. *S. lim.*, Sulcus limitans. *E. m.*, Eminentia medialis. *V. V.*, Anterior medullary velum. *IV*, Trochlear nerve. *C. g. m.*, Medial geniculate body. *C. g. l.*, Lateral geniculate body. *P. br.*, Posterior brachium of mesencephalon. (After Van Gehuchten.)

small triangular area with its base forward; this is the landmark of the nucleus of the twelfth cranial or hypoglossal nerve, and is called, therefore, the hypoglossal triangle (*trigonum nervi hypoglossi*). The hypoglossal triangle is bounded laterally by a faint sulcus, the *sulcus limitans*, which separates it from the second triangular area, which is somewhat darker in color, and is known as the *ala cinerea*; this has its apex forward, and is the landmark of the sensory nuclei of the ninth and tenth cranial nerves. The third triangle is found between the *ala cinerea* and the *corpus restiforme*; it has its base forward at the *striæ acusticæ*, and is the posterior portion of the acoustic area (*area acustica*), containing nuclei of the eighth cranial, or acoustic, nerve.

#### THE SURFACE ANATOMY OF THE METENCEPHALON.

The metencephalon is composed of the pons Varolii and the cerebellum.

THE PONS VAROLII.—This presents for study two surfaces: a ventral and a dorsal.

The ventral surface (Fig. 6) is situated between the cerebral peduncles in front, the medulla oblongata behind, and the cerebellum laterally. It is constituted by a broad layer of transverse fibres, which contracts on each side, and enters the cerebellum as its middle peduncle (*brachium pontis*). In the median line is an antero-posterior groove,—the basilar sulcus (*sulcus basilaris*) for the basilar artery,—and on each side of this a ridge thrown up by the passage of the fibres which constitute the pyramid in the medulla. Laterally appear the root-fibres of the fifth cranial, or trigeminal, nerve (*nervus trigeminus*), piercing this surface of the pons.

To examine the dorsal surface it is necessary to remove the cerebellum. It is then seen that this surface consists of an elevated cord on each side, with a depression between (Fig. 7). The cords are the anterior peduncles of the cerebellum (*brachia conjunctiva*), which converge toward the mesencephalon, where they disappear. Lateral to the peduncle a band of fibres can be seen winding forward and dorsalward to reach the mesencephalon; this is the lateral lemniscus (*lemniscus*

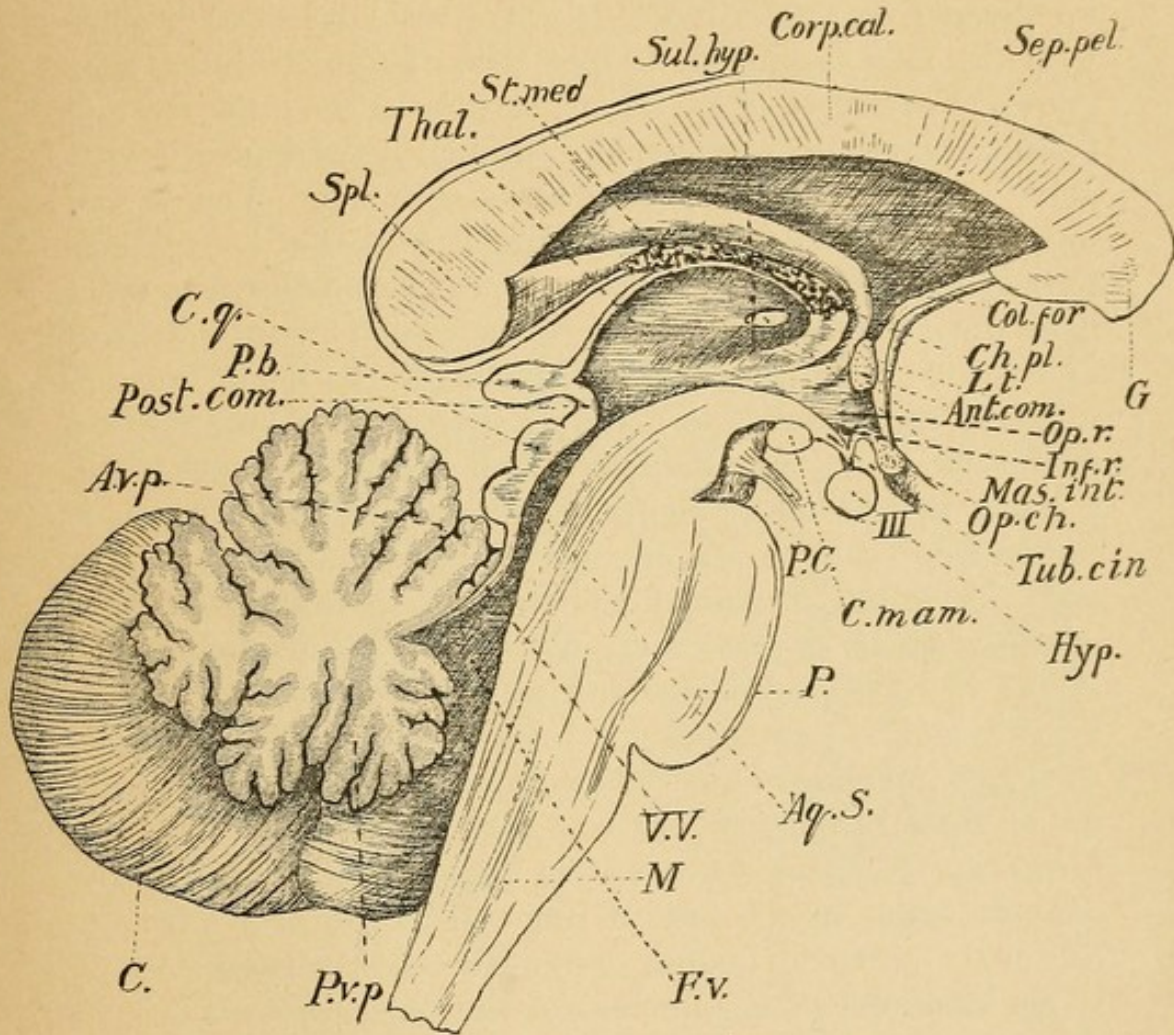


Fig. 8.—*Spl.*, Splenium. *Thal.*, Thalamus. *St. med.*, Medullary stria. *Sul. hyp.*, Sulcus hypothalamicus. *Corp. cal.*, Corpus callosum. *Sep. pel.*, Septum pellucidum. *G.*, Genu of corpus callosum. *Col. for.*, Column of fornix. *Ch. pl.*, Chorioid plexus of lateral ventricle. *L. t.*, Lamina terminalis. *Ant. com.*, Anterior commissure. *Op. r.*, Optic recess. *Inf. r.*, Recess of infundibulum. *Mas. int.*, Massa intermedia. *Op. ch.*, Optic chiasm. *Tub. cin.*, Tuber cinereum. *Hyp.*, Hypophysis. *III*, Oculomotor nerve. *C. mam.*, Corpus mamillare. *P. C.*, Peduncle of cerebrum. *P.*, Pons Varolii. *Aq. S.*, Aqueduct of Sylvius. *V. V.*, Anterior medullary velum. *M.*, Medulla oblongata. *F. v.*, Fourth ventricle. *P. v. p.*, Posterior vermiform process. *C.*, Cerebellum. *A. v. p.*, Anterior vermiform process. *Post. com.*, Posterior commissure. *P. b.*, Pineal body. *C. q.*, Corpora quadrigemina. (After Van Gehuchten.)

lateralis). The depression between the peduncles is triangular in shape, and forms the anterior part of the floor of the fourth ventricle. It is covered over by a thin, white lamina, stretching across from one peduncle to the other, continuous in front with the mesencephalon, behind with the cerebellum; it is known as the valve of Vieussens, or anterior medullary velum (*velum medullare anterius*), and through it the fourth cranial nerve (*nervus trochlearis*) escapes on each side. The depression has its base backward, coinciding with that of the *calamus scriptorius* of the medulla, between which and the pons there is no distinct boundary on the dorsal aspect. In the median line is seen the forward continuation of the dorsal median sulcus of the medulla, and laterally the forward prolongation of the *sulcus limitans*. These two sulci inclose between them a ridge, the medial eminence (*eminentia medialis*), which is the landmark of the nucleus of the sixth cranial nerve. On each side of the median sulcus at about its middle the floor of the ventricle is thrown up into a small rounded eminence by the root-fibres of the seventh cranial nerve, called the *colliculus facialis*. In front the *sulcus limitans* deepens somewhat to form the anterior fovea (*fovea superior*); behind, on the medulla, at the apex of the *ala cinerea*, it, in like manner, forms the posterior fovea (*fovea inferior*). Lateral to the anterior fovea, at the line of junction of the floor with the side of the ventricle, is a bluish spot, the *locus cœruleus*, which is the landmark of the nucleus of the trigeminal nerve. In the angle formed by the *corpus restiforme* behind and the anterior peduncle in front, lateral to the *sulcus limitans*, is the acoustic area (*area acustica*), which is situated partly on the pons and partly on the medulla, and is bisected by *striæ acusticæ*.

THE CEREBELLUM.—On external examination the cerebellum appears laminated, consisting of plates of nervous matter separated by narrow sulci. In shape it is rather oblong, and is about four inches wide and two inches in its dorso-ventral diameter. It occupies the inferior occipital fossæ of the skull. It may be divided into an anterior, a posterior, and a ventral surface. The anterior surface (Fig. 8) is marked in the median line by an elevated portion called the anterior

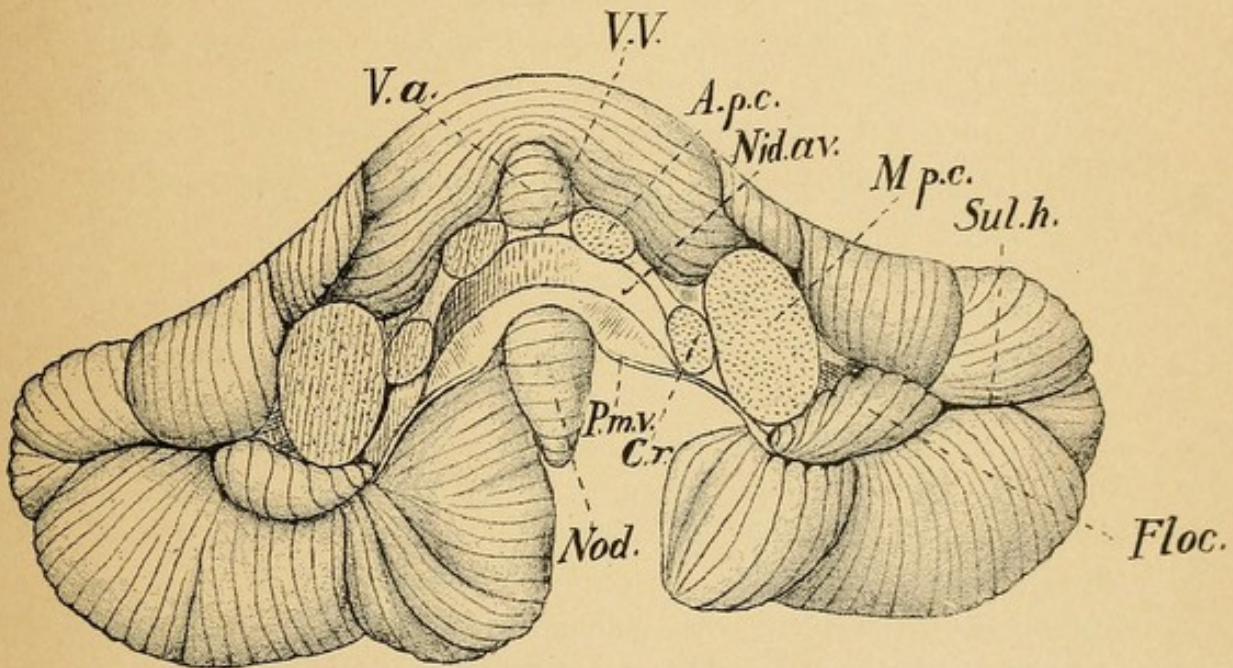


Fig. 9.—*V. a.*, Ventral extremity of anterior vermiform process. *V. V.*, Anterior medullary velum. *A. p. c.*, Anterior peduncle of cerebellum. *Nid. av.*, Nidus avis. *M. p. c.*, Middle peduncle of cerebellum. *Sul. h.*, Horizontal sulcus. *Floc.*, Flocculus. *C. r.*, Corpus restiforme. *P. m. v.*, Posterior medullary velum; *Nod.*, Nodulus. (After Van Gehuchten.)

(superior) vermiform process (vermis superior), terminating ventrally at a notch,—the ventral incisure (incisura anterior),—and dorsally at a deeper notch,—the dorsal incisure (incisura posterior). On the posterior surface opposite to the anterior vermiform process is a deep groove, the vallecule, in the bottom of which is the posterior (inferior) vermiform process (vermis inferior). It will be noticed that the two vermiform processes are continuous dorsally and form one lobe, which is termed the worm (vermis). The worm and the notches form the landmarks for dividing the remainder of the cerebellum into two hemispheres. The cerebellum has been further subdivided into numerous lobes, but, as our knowledge of the functions of the cerebellum is so imperfect, their names, which are in many instances fanciful, may be here omitted.

To examine the ventral surface, the cerebellum must be removed from its connections by severing its various peduncles. When this has been done (Fig. 9) we find in the median line the ventral extremity of the anterior vermiform process in front, and the ventral extremity of the posterior vermiform process, called the nodulus, behind. The former rests upon a thin sheet of white matter, which will be recognized as the anterior medullary velum, over which the worm sends forward a thin strip: the lingula. On each side the velum is attached to the anterior peduncle, the cross sections of which are here seen. Posterior to the anterior medullary velum is the transverse fissure (fissura transversa), leading into a cleft, or *cul-de-sac*, called the tent, or “bird’s nest” (*nidus avis*). Lateral to this is the section of the corpus restiforme, and lateral to it the larger section of the middle peduncle. Still farther lateral is the beginning of a fissure which can be traced around the circumference of the cerebellum to a corresponding point on the opposite side: the horizontal fissure (fissura horizontalis). In the commencement of this fissure is a quite distinct lobule: the flocculus. From the flocculus a delicate layer of white matter runs toward the median line, and crosses on the anterior aspect of the nodulus to gain the flocculus of the opposite side; this is the posterior medullary velum (velum medullare posterius). It is thus seen that the tent is a cleft in the white matter of

the cerebellum between the two medullary vela. It is prolonged on each side as far as the middle peduncle, which lateral prolongations, as we shall hereafter see, are the lateral recesses of the fourth ventricle, toward which cavity this surface of the cerebellum looks.

#### THE ISTHMUS OF THE RHOMBENCEPHALON.

The isthmus of the rhombencephalon (isthmus rhombencephali) is the name given to the most anterior part of the rhombencephalon, uniting that vesicle to the mesencephalon. In the embryo it exists as a separate vesicle, but in the developed brain it has no distinct boundaries. Its dorsal portion consists of the anterior peduncles of the cerebellum and the anterior medullary velum; these we have described as a part of the pons Varolii. Its ventral portion is furnished by the beginning of the cerebral peduncles, including the nuclei of the fourth pair of cranial nerves; these we shall study in connection with the mesencephalon.

#### THE FOURTH VENTRICLE.

The fourth ventricle (*ventriculus quartus*) is the neural canal in the rhombencephalon (Fig. 7). It may be considered as having a floor, a roof, and two sides. The floor (*fossa rhomboidea*) is diamond-shaped, and is furnished by the triangular depression on the dorsal surface of the pons in front, and by the *calamus scriptorius* of the medulla behind. If we regard the isthmus of the rhombencephalon as a separate division, there are three contributors to the floor: the isthmus furnishing the anterior portion (*pars superior*); the pons forming the middle portion (*pars intermedia*),—the part included between lines embracing the middle peduncles of the cerebellum; while the medulla contributes the posterior portion (*pars inferior fossæ rhomboideæ*). The appearances in the floor of the ventricle have been already described in the accounts of the medulla and of the pons.

The sides or lateral boundaries of this diamond-shaped space are furnished in front by the anterior peduncles of the cerebellum and behind by the *corpora restiformia*.

The roof of the ventricle in its anterior portion is the anterior medullary velum; the posterior part of the roof is furnished by a reflection of the pia mater known as the tela chorioidea. To gain a correct conception of this part of the roof it will be necessary to revert, for a moment, to the development of the rhombencephalon. The epithelial cells forming the dorsal wall of the embryonic rhombencephalon produce the anterior medullary velum in front, and the worm and posterior medullary velum of the cerebellum in the middle; but, along a line corresponding to the free edge of the posterior medullary velum, this epithelium ceases to develop nervous tissue. In the mature brain, therefore, the dorsal wall of the rhombencephalon reaches, in its primitive condition as a layer of epithelial cells, from the edge of the posterior medullary velum in front to the medulla behind (Fig. 4). This layer is consequently triangular, with its base at the edge of the velum, its apex continuous with the epithelium lining the dorsal wall of the central canal of the medulla, and its sides attached to the medial surfaces of the corpora restiformia, where the production of nervous substance is resumed. Now, the pia mater, adhering closely to the encephalon at all points, enters the space between the cerebellum and the medulla, and invaginates this epithelial membrane, pushing it ahead as far as the lateral recesses. This fold of pia mater is the tela chorioidea. The epithelium adheres to its ventricular aspect, and is therefore called the lamina chorioidea epithelialis. As a matter of fact, the epithelium is the true roof of the ventricle; but, since it is adherent to the tela, and is torn from its other attachments when the tela is removed, the latter is commonly called the roof. On its ventricular surface the tela presents a row of vascular tufts on each side of the median line: the median chorioid plexus (*plexus chorioideus ventriculi quarti*). Near its anterior margin the plexuses turn and run lateralward, and in this situation are called the lateral chorioid plexuses. There is frequently an opening in the tela known as the foramen of Magendie; so that the cavity of the fourth ventricle communicates with the space between the pia mater and the arachnoid.

The ventricle has four angles: an anterior, where it is con-

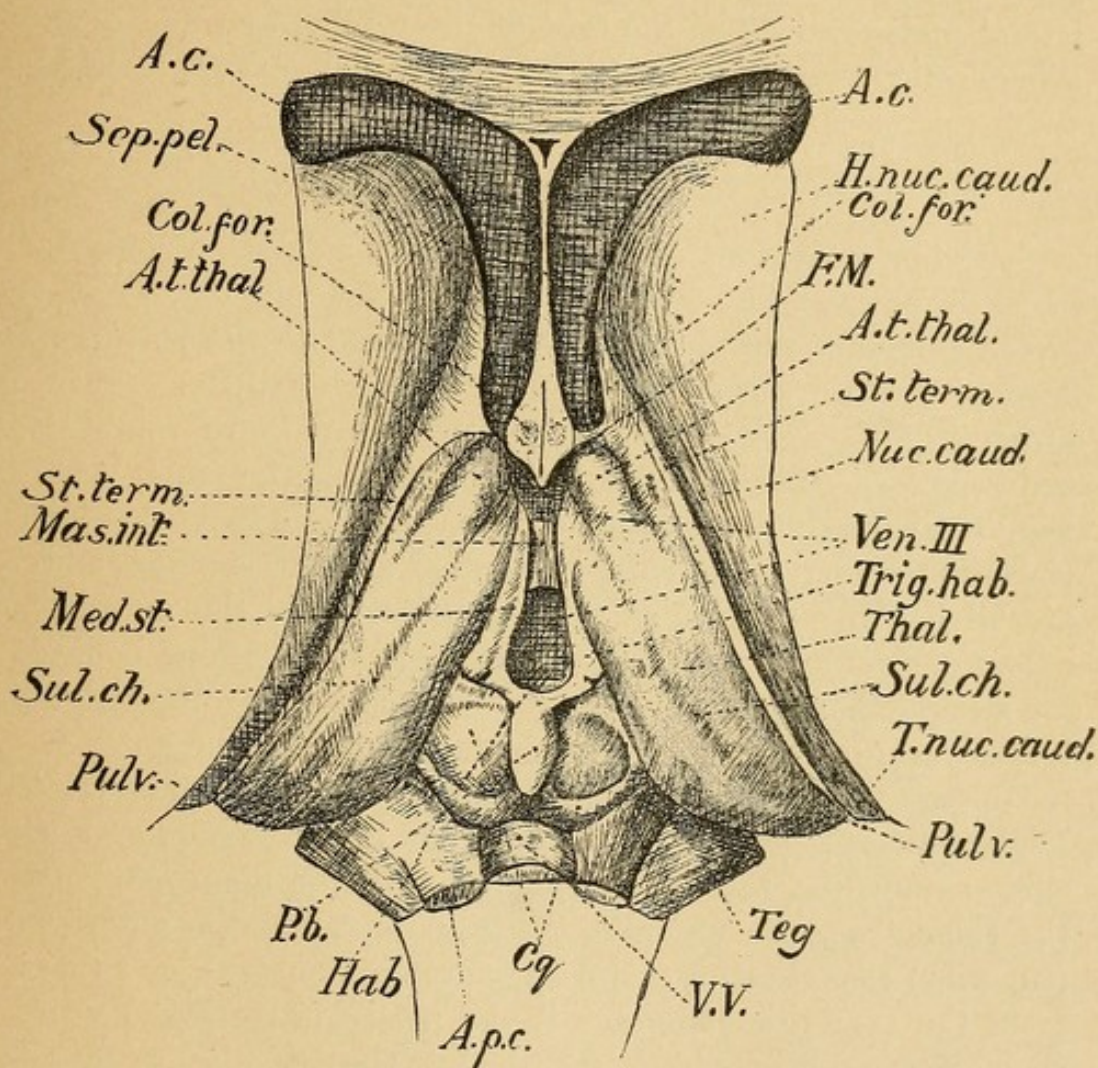


Fig. 10.—A. c., Anterior horn of lateral ventricle. *H. nuc. caud.*, Head of caudate nucleus. *Col. for.*, Column of fornix. *F. M.*, Foramen of Monro. *A. t. thal.*, Anterior tubercle of thalamus. *St. term.*, Stria terminalis. *Nuc. caud.*, Nucleus caudatus. *Ven. III*, Third ventricle. *Trig. hab.*, Trigonum habenulae. *Thal.*, Thalamus. *Sul. ch.*, Chorioidal sulcus. *T. nuc. caud.*, Tail of nucleus caudatus. *Pulv.*, Pulvinar. *Teg.*, Tegmentum. *V. V.*, Anterior medullary velum. *C. q.*, Corpora quadrigemina. *Hab.*, Habenula. *P. b.*, Pineal body. *Med. st.*, Medullary stria. *Mas. int.*, Massa intermedia. *Sep. pel.*, Septum pellucidum. *A. p. c.*, Anterior peduncle of cerebellum. (After Van Gehuchten.)

tinuous with the aqueduct of Sylvius; a posterior, where it is continuous with the canal of the medulla between the two clavæ; and two lateral. The latter are the angular intervals between the diverging corpora restiformia and the anterior peduncles of the cerebellum. As we have seen, these are the lateral prolongations of the tent of the cerebellum, and each is here called a lateral recess (*recessus lateralis*) of the ventricle.

#### THE SURFACE ANATOMY OF THE MESENCEPHALON.

The mesencephalon has four surfaces: a dorsal, a ventral, and two lateral. The dorsal surface (Figs. 7 and 10), which, in the complete encephalon, lies just ventral to the posterior extremity of the corpus callosum and anterior to the ventral incisure of the cerebellum, consists of two pairs of rounded bodies known collectively as the corpora quadrigemina, each body individually being called a colliculus. The two posterior (inferior) colliculi (*colliculi inferiores*) are the smaller, and are on a plane ventral as well as posterior to the anterior (superior) colliculi (*colliculi superiores*). These four bodies are separated from each other by a crucial sulcus; the longitudinal arm of this groove terminates behind on the anterior medullary velum, its edges here forming the frenulum veli. Each colliculus has running forward and lateralward from it a ridge connecting the mesencephalon with the diencephalon; the ridge from the anterior colliculus is called the anterior (superior) arm (*brachium quadrigeminum superius*), and that from the posterior colliculus is the posterior (inferior) arm (*brachium quadrigeminum inferius*). The brachia are separated by an interbrachial sulcus (*sulcus interbrachialis*).

The ventral surface (Fig. 6) presents two large rounded cords emerging from the pons Varolii: the cerebral peduncles (*pedunculi cerebri*). These diverge from each other to disappear under the diencephalon after a course of about half an inch. The triangular depression left between them is the interpeduncular fossa (*fossa interpeduncularis*), in the bottom of which is a thin lamella of nervous tissue containing many foramina: the posterior perforated substance (*substantia perforata posterior*). The foramina are produced by blood-vessels,

which pierce the lamella and are pulled out when the pia mater is removed. Through the fossa the third pair of cranial nerves makes its escape from the mesencephalon.

The lateral surface is marked by a longitudinal sulcus,—the sulcus lateralis,—which indicates the separation of the quadrigeminal from the peduncular portion of the mesencephalon.

The cavity of the mesencephalon is the aqueduct of Sylvius (aquæductus cerebri), opening behind into the fourth, and in front into the third ventricle.

#### THE SURFACE ANATOMY OF THE DIENCEPHALON.

The diencephalon is divided into the thalamencephalon and the hypothalamus. The neural canal here is the third ventricle.

**THE THALAMENCEPHALON.**—The thalamencephalon (Fig. 10) is subdivided on each side of the median line into the thalamus, the metathalamus, and the epithalamus.

*The Thalamus.*—This is an elongated oval mass of gray matter having four surfaces: dorsal, ventral, lateral, and medial; and two extremities: anterior and posterior.

The dorsal surface is marked by an obliquely lateral antero-posterior groove, the chorioid sulcus, in which lies, as we shall see hereafter, the chorioid plexus of the lateral ventricle. At its line of junction with the medial surface is a narrow white band,—the stria medullaris,—which can be traced backward to a small triangular swelling: the trigonum habenulæ. Laterally the dorsal surface is separated from another gray mass,—the caudate nucleus of the corpus striatum of the telencephalon,—by a groove which lodges a vein,—the vena terminalis,—and a small bundle of fibres: the stria terminalis.

The medial surface (Fig. 8) forms the lateral wall of the third ventricle. It is marked by an antero-posterior sulcus,—the sulcus of Monro (sulcus hypothalamicus),—which indicates the division of the thalamus from the hypothalamus. The lateral surface of the thalamus is fused with the telencephalon; the ventral surface with the hypothalamus and with the mesencephalon behind. The anterior extremity of the

thalamus is the smaller; its most prominent portion is called the anterior tubercle (tuberculum anterius).

The posterior extremity projects backward and lateralward so as to overhang the neighboring part of the mesencephalon; this projecting portion is called the pulvinar. On its ventral aspect the posterior extremity is continuous with a white cord,—the optic tract (tractus opticus),—which can be traced winding forward, first lateral and then ventral to the cerebral peduncle, and then medialward into the postero-lateral angle of a square white body,—the optic chiasm (chiasma op-

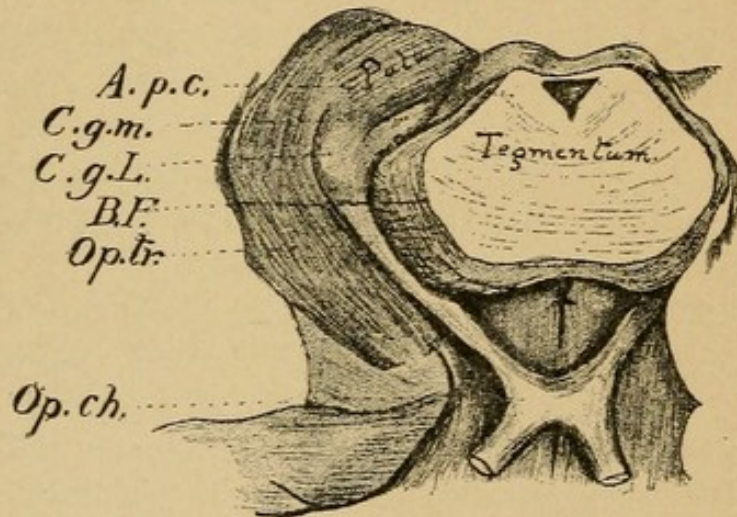


Fig. 11.—*A. p. c.*, Anterior peduncle of the cerebellum. *C. g. m.*, Corpus geniculatum mediale. *C. g. L.*, Corpus geniculatum laterale. *B. F.*, Base of the peduncle of the cerebrum. *Op. tr.*, Optic tract. *Op. ch.*, Optic chiasm. *Pulv.*, Pulvinar of the thalamus. (After Gegenbauer.)

ticum),—from the antero-lateral angle of which another white cord—the optic nerve—proceeds forward and lateralward.

*The Metathalamus.*—The metathalamus (Fig. 11) consists of the two geniculate bodies, lateral and medial (corpus geniculatum laterale; corpus geniculatum mediale). These are two small oval bodies which lie ventral to the posterior extremity of the thalamus. The corpus geniculatum laterale is situated on the course of the optic tract, and is connected with the anterior arm (brachium quadrigeminum superius) of

the mesencephalon; the corpus geniculatum mediale is found at the lateral end of the interbrachial sulcus, and is connected with the posterior arm (brachium quadrigeminum inferius).

*The Epithalamus.*—The epithalamus (Fig. 10) comprises the pineal body (corpus pineale) and the region of the habenula. The pineal body is a small flattened oval mass somewhat reddish in color, and about one-quarter of an inch in diameter; it rests in the median line on the anterior (superior) colliculi of the mesencephalon. From its anterior aspect there runs on each side a slender cord, the peduncle of the pineal body, forward to the habenula. To the unaided eye the peduncle of the pineal body and the habenula seem to be one and the same structure, with the trigonum as a swelling on it; but, as it is known that the peduncles connect the trigonum of one side with that of the other side, they are called the commissure of the habenulæ (commissura habenularum).

**THE THIRD VENTRICLE.**—The third ventricle (ventriculus tertius) is the neural canal in the diencephalon, which exists here as a narrow space between the medial surfaces of the two thalami, the latter constituting its lateral walls. Its anterior boundary is furnished by the anterior pillars of the fornix and by the anterior commissure of the cerebrum. These structures are parts of the telencephalon, and will be described in the appropriate place. The pillars of the fornix show here as two white cords running toward the ventral surface of the encephalon; they diverge in their course and allow the anterior commissure in front of them to come into view. The posterior boundary is a transverse bundle of fibres: the posterior commissure (commissura posterior). Passing between the adjacent surfaces of the thalami about the middle of the ventricle is a delicate gray layer, formerly called the middle commissure, but now known as the massa intermedia.

The roof of the ventricle is an epithelial structure. The dorsal wall of the embryonic diencephalon between the striæ medullares remains undeveloped, and stretches between these as a layer of epithelial cells. This epithelium, however, is adherent to a fold of pia mater interposed between the diencephalon and the telencephalon: the tela chorioidea of the third ventricle hereafter to be described, which is often con-

sidered the actual roof. The floor of the ventricle is formed by the hypothalamus.

THE HYPOTHALAMUS.—The hypothalamus (Figs. 6 and 8), when examined from before backward, presents the following appearances:—

If, with the brain inverted, one lifts up the optic chiasm, there is seen in the median line a sheet of nervous matter: the terminal plate (*lamina terminalis*). Posterior and ventral to this is the square mass of the optic chiasm, with the optic nerve entering it on each side in front and the optic tract leaving it on each side behind. Behind the chiasm is a dark swelling, the tuber cinereum, from the ventral surface of which runs a slender tube: the infundibulum. The latter terminates in an oblong mass about one-half inch in diameter: the pituitary body (*hypophysis*). The hypophysis rests in the sella Turcica of the sphenoid bone; it consists of two portions, or lobes, the anterior of which is the larger. Behind the tuber cinereum on each side is a small, shining, rounded body: the mamillary body (*corpus mamillare*).

If a sagittal section be made through the diencephalon (Fig. 8), it will be noticed that the floor of the third ventricle is considerably depressed in front, and that the bottom of this depressed portion is thrown up into a transverse ridge by the optic chiasm. In this way there are produced two small depressions by the chiasm: one in front,—the optic recess (*recessus opticus*), whose anterior wall is the *lamina terminalis*; and the other behind,—the recess of the infundibulum (*recessus infundibuli*), whose posterior wall is the tuber cinereum. The recess of the infundibulum leads into the infundibulum, which, it is now seen, is hollow. Roughly speaking, only that portion of the hypothalamus which lies behind the infundibulum belongs to the diencephalon; it is called the mamillary portion of the hypothalamus (*pars mamillaris hypothalami*). The remainder of the hypothalamus is the ventral part of the telencephalon, and is called the optic portion of the hypothalamus (*pars optica hypothalami*). For the sake of convenience they have been described together here.



## THE SURFACE ANATOMY OF THE TELENCEPHALON.

As a result of the rapid growth undergone by the lateral portion of the telencephalon in early foetal life, that vesicle is greatly elevated on each side of the median line; there is thus formed a deep sulcus separating the lateral portions from one another. This condition is maintained during subsequent development; so that in the fully developed encephalon we find two more or less symmetrical halves,—the hemispheres (*hemisphæria*),—separated by a longitudinal fissure (*fissura longitudinalis cerebri*). This fissure is complete in front and behind, but for its middle two-fourths is interrupted ventrally by a white body: the corpus callosum.

THE HEMISPHERE.—Embryologically each hemisphere may be divided into the pallium, or the superficial gray matter, and the white matter directly connected therewith; the rhinencephalon, or the central olfactory apparatus; and the corpus striatum; but for the purpose of this book it is more convenient to first consider the hemispheres as a whole, giving attention to its separate parts later.

The hemisphere is ovoid in shape. It has two surfaces,—one lateral and one medial,—and two extremities,—the anterior, or frontal, pole (*polus frontalis*); and the posterior, or occipital, pole (*polus occipitalis*).

The lateral surface (*facies lateralis*) is convex; it is folded in such a way as to present numerous eminences called convolutions (*gyri*) separated by grooves called sulci. Certain of the sulci are large and deep, and fairly constant, so that they may be taken as boundaries by which to divide the hemisphere on its lateral surface into portions called lobes (*lobi*). Such sulci are commonly called fissures, but in the new nomenclature that term is applied only to such sulci as produce corresponding elevations in the cavity of the hemisphere. The most prominent of the fissures is the fissure of Sylvius (*fissura cerebri lateralis*), which may be located in the following way:—

On the ventral aspect of the telencephalon lateral to the optic chiasm there is found a lamina of nervous matter perforated by many foramina for blood-vessels: the anterior per-

forated substance. Just lateral to this substance the fissure of Sylvius begins; whence it proceeds lateralward to gain the lateral surface of the hemisphere, where it divides into three branches (Fig. 12). The longest of these, the ramus posterior, runs dorsalward and backward, to become gradually lost upon the lateral surface; the other two are both short and both anterior, the one running nearly vertically dorsalward and called the ramus anterior ascendens, the other running nearly horizontally forward and called the ramus anterior horizontalis.

A second fissure is the so-called fissure of Rolando (*sulcus centralis*). It begins on the lateral surface near the longitudinal fissure at a point a little behind the junction of the anterior with the posterior half of the hemisphere, and proceeds forward and ventralward nearly to the posterior ramus of the fissure of Sylvius.

A third fissure is the parieto-occipital (*fissura parieto-occipitalis*). It begins on the medial surface of the hemisphere behind the posterior extremity of the corpus callosum, and passes dorsalward and slightly backward to reach the lateral surface, where it disappears after a forward and ventralward course of about half an inch. This latter part is frequently called the lateral limb of the fissure, the part on the medial surface being the medial limb.

By means of the fissures mentioned the lateral surface is divided into five lobes. That portion which lies dorsal to the fissure of Sylvius and anterior to the central sulcus of Rolando is called the frontal lobe (*lobus frontalis*); that ventral to the posterior ramus of the fissure of Sylvius the temporal lobe (*lobus temporalis*); that bounded ventrally by the posterior ramus of the fissure of Sylvius, in front by the central sulcus of Rolando, and behind by the lateral limb of the parieto-occipital fissure the parietal lobe (*lobus parietalis*); while the portion posterior to the lateral limb of the parieto-occipital fissure is the occipital lobe. The fifth division is the island of Reil (*insula*). This is found in the depths of the fissure of Sylvius where that fissure is dividing into its rami. The island can be brought into view by drawing aside the neighboring overhanging convolutions, which collectively are called the operculum. It will be observed that this division into lobes is far

from complete, since, except in the case of the island of Reil, each lobe is connected with its neighbors by convolutions passing between them, which for this reason are called gyri transitivi. This statement is especially true of the parietal and occipital lobes, between which there is scarcely any well-marked boundary.

Each lobe is divided into several convolutions by sulci as follows: The frontal lobe is marked by a sulcus, often atypical, running parallel with and anterior to the central sulcus of Rolando,—the ascending frontal, or precentral, sulcus (sulcus præcentralis),—cutting off between itself and the sulcus of Rolando a large convolution: the ascending frontal or anterior central convolution (gyrus centralis anterior). From the precentral sulcus there proceed forward two other smaller sulci, the dorsal, or superior (sulcus frontalis superior), and the ventral, or inferior, frontal sulcus (sulcus frontalis inferior), toward the frontal pole; these divide the remainder of the frontal lobe into three convolutions: the dorsal, or superior; the middle; and the ventral, or inferior, frontal convolutions (gyrus frontalis superior, medius, et inferior). The ventral frontal convolution at its ventral margin is divided into three parts by the indentations of the anterior rami of the fissure of Sylvius: the posterior division, behind the ascending ramus, is the pars opercularis; the middle, between the rami, is the pars angularis; and the anterior division is the pars orbitalis. In the course of development the anterior extremities of these three frontal convolutions are bent forward and ventralward, and then backward; so that they come to lie upon the orbital plate of the frontal bone (Fig. 13), in which situation they are called orbital convolutions (gyri orbitales). The dorsal frontal here becomes the medial orbital, the middle frontal becomes the anterior orbital, and the ventral frontal becomes the posterior orbital convolution. The medial orbital convolution borders on the anterior extremity of the longitudinal fissure, and contains an antero-posterior groove,—the olfactory sulcus,—which lodges a white band,—the olfactory tract; the portion of the gyrus medial to this sulcus is known as the straight convolution (gyrus rectus).

The parietal lobe contains a fairly-constant sulcus, the

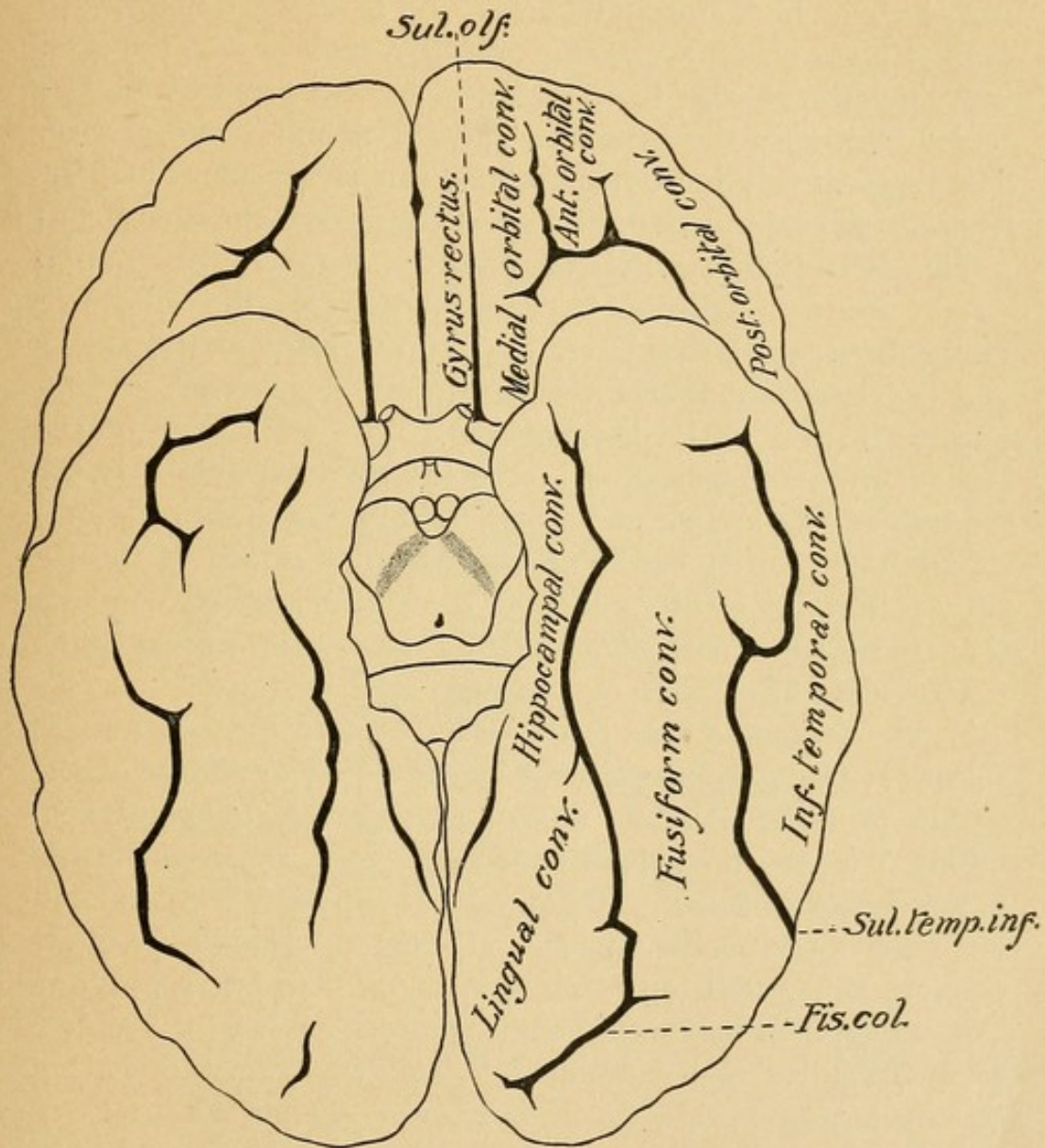


Fig. 13.—Scheme of convolutions of ventral aspect of cerebral hemisphere (after Van Gehuchten). *Sul. olf.*, Olfactory sulcus. *Sul. temp. inf.*, Inferior temporal sulcus. *Fis. col.*, Collateral fissure.

interparietal (sulcus interparietalis), by means of which it is divided into three convolutions. This sulcus begins near the posterior ramus of the fissure of Sylvius, and first runs parallel with the fissure of Rolando, and then turns backward to terminate near or in the occipital lobe. As it makes its backward turn it gives off an ascending branch, which is sometimes an independent sulcus,—the postcentral (sulcus postcentralis),—which continues the course of the parent-sulcus dorsalward. The long convolution lying between this latter sulcus and the interparietal behind, and the central sulcus of Rolando in front is the ascending parietal, or posterior central, convolution (gyrus centralis posterior). That portion of the lobe contained between the posterior part of the interparietal sulcus and the longitudinal fissure is the dorsal, or superior, parietal lobule (lobulus parietalis superior). The remainder of the lobe ventral and posterior to the interparietal sulcus is the ventral, or inferior, parietal lobule (lobulus parietalis inferior); its anterior portion bordering the posterior ramus of the fissure of Sylvius is often termed the supramarginal convolution (gyrus supramarginalis) while the posterior part is called the angular convolution (gyrus angularis).

The temporal lobe is divided into five convolutions as follows: The portion adjacent to the posterior ramus of the fissure of Sylvius is the dorsal, or superior, temporal convolution (gyrus temporalis superior). It is separated by an antero-posterior sulcus,—the dorsal, or superior, temporal sulcus (sulcus temporalis superior),—from the middle temporal convolution (gyrus temporalis medius). The latter convolution is separated by another antero-posterior sulcus, the middle temporal sulcus (sulcus temporalis medius), from the ventral, or inferior, temporal convolution (gyrus temporalis inferior). The last two convolutions are especially badly defined. At this point the lobe makes a ventral bend toward the median line, so as to present upon the ventral aspect of the encephalon. Here we find two convolutions (Figs. 13 and 14). The first is large and spindle-shaped, the fusiform convolution (gyrus fusiformis), and is limited laterally by the ventral, or inferior, temporal sulcus (sulcus temporalis inferior). On its medial side it is bounded by a long fissure extending

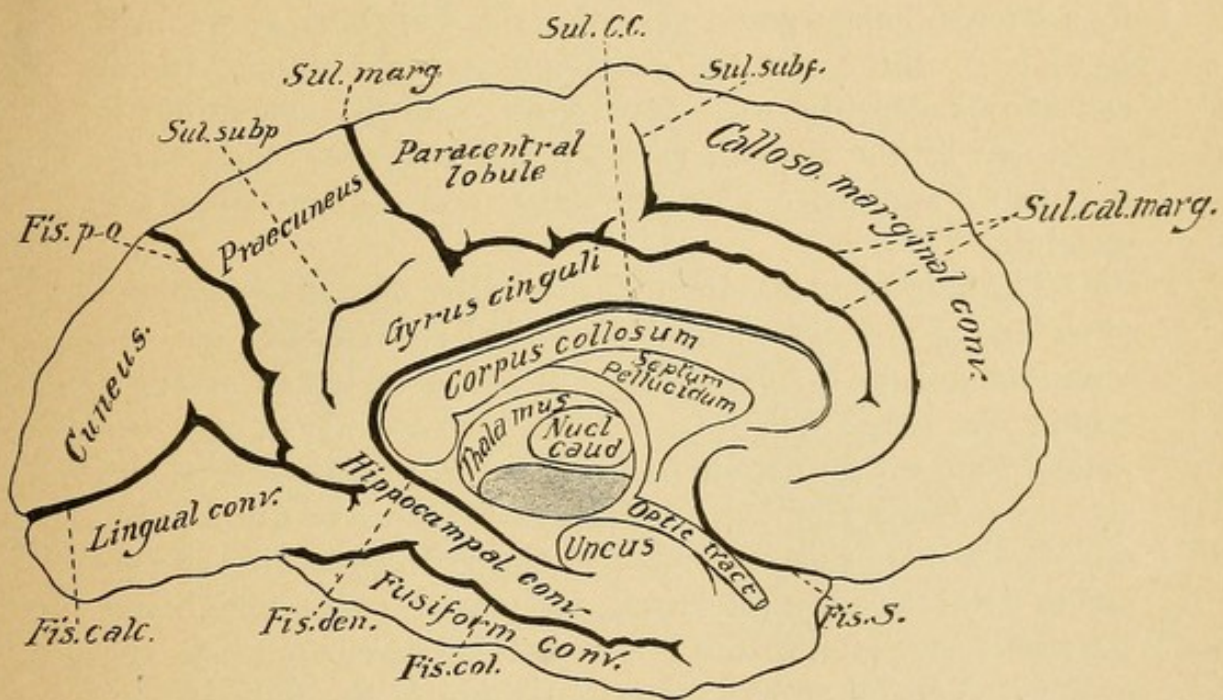


Fig. 14.—Scheme of convolutions on medial surface of cerebral hemisphere (after Van Gehuchten). *Fis. S.*, Fissure of Sylvius. *Sul. cal. marg.*, Callosomarginal sulcus. *Sul. subf.*, Subfrontal sulcus. *Sul. C. C.*, Sulcus of corpus callosum. *Sul. marg.*, Marginal sulcus. *Sul. subp.*, Subparietal sulcus. *Fis. p.o.*, Parieto-occipital fissure. *Fis. calc.*, Calcarine fissure. *Fis. den.*, Dentate fissure. *Fis. col.*, Collateral fissure.

almost to the anterior extremity of the lobe, the collateral fissure (*fissura collateralis*), medial to the posterior part of which is the lingual convolution (*gyrus lingualis*).

The occipital lobe may be roughly divided into three convolutions: dorsal, or superior; middle; and ventral, or inferior. Some make only two divisions of this lobe, with several small convolutions in each division; in this case the dorsal division is composed of the gyri occipitales superiores, and the ventral of the gyri occipitales laterales.

The island of Reil contains three convolutions surrounded by a circular sulcus (*sulcus circularis*). This lobe, as we have seen, is overhung by the neighboring convolutions, which collectively constitute the operculum. As the operculum is furnished by the frontal, parietal, and temporal lobes, there is a pars frontalis, a pars parietalis, and a pars temporalis operculi.

The medial surface (*facies medialis*) of the hemisphere (Fig. 14) is convoluted like the lateral surface, but its convolutions are, as a rule, larger and less complex in arrangement. As limits for these convolutions we have, first, the medial limb of the parieto-occipital fissure; beginning at the ventral extremity of this fissure and running backward usually to the posterior extremity of the hemisphere is the calcarine fissure (*fissura calcarina*), included between which and the parieto-occipital fissure is a wedge-shaped convolution, the cuneus. Ventral to the calcarine fissure is the lingual convolution already described as a part of the temporal lobe. This convolution is continuous in front with a narrow convolution limited ventrally by the collateral fissure, the hippocampal convolution (*gyrus hippocampi*), the anterior extremity of which is recurved so as to resemble a hook, and which, therefore, is known as the uncus. The hippocampal convolution is limited dorsally by the dentate fissure (*fissura hippocampi*), which begins just ventral to the posterior extremity of the corpus callosum, and curves forward and ventralward nearly to the uncus. In the middle of the medial surface is seen the sagittal section of the corpus callosum. It is separated from the adjacent convolutions by a sulcus,—the sulcus of the corpus callosum (*sulcus corporis callosi*),—which, be-

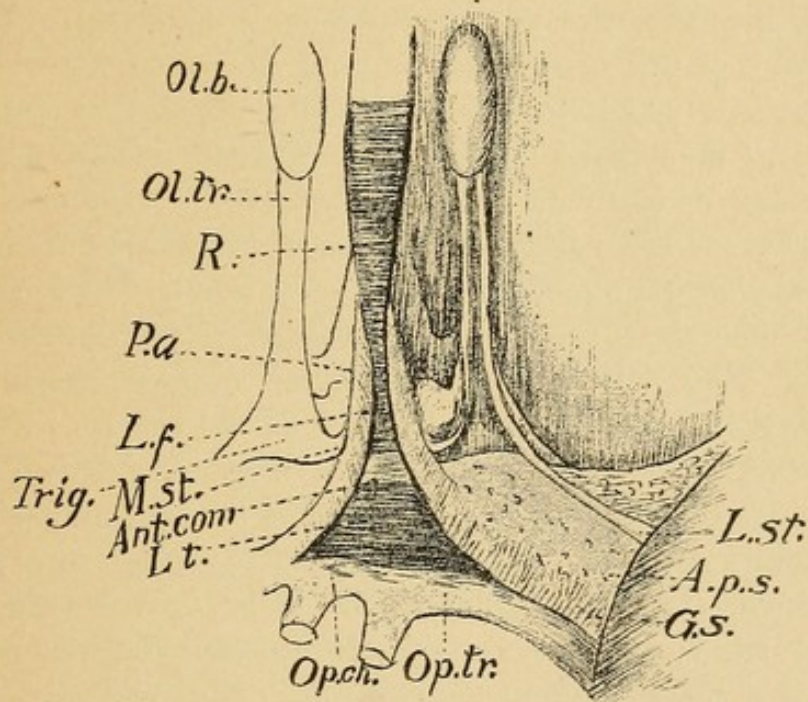


Fig. 15.—*Ol. b.*, Olfactory bulb. *Ol. tr.*, Olfactory tract. *R.*, Rostrum of corpus callosum. *L. f.*, Longitudinal fissure. *P. a.*, Parolfactory area. *Trig.*, Olfactory trigonum. *M. st.*, Medial stria. *Ant. com.*, Region of anterior commissure. *L. t.*, Lamina terminalis. *Op. ch.*, Optic chiasm. *Op. tr.*, Optic tract. *G. s.*, Gyrus subcallosus. *A. p. s.*, Anterior perforated substance. *L. st.*, Lateral stria. (After His.)

ginning ventral to the anterior extremity of that body, arches backward over its dorsal surface to terminate behind its posterior extremity by opening into the dentate fissure. Beginning in front of the anterior extremity of the corpus callosum is the calloso-marginal sulcus (*sulcus cinguli*), which winds dorsalward and backward to a point dorsal to the posterior extremity of the corpus callosum; about the middle of its course it sends off an ascending branch,—the subfrontal sulcus (*sulcus subfrontalis*),—and near its termination another ascending branch: the marginal sulcus (*sulcus marginalis*). The portion of the hemisphere cut off dorsal to the calloso-marginal sulcus is often called the calloso-marginal convolution; it will be noticed that it is merely the medial surface of the dorsal, or superior frontal, convolution. Between the subfrontal sulcus in front and the marginal sulcus behind is the paracentral lobule (*lobulus paracentralis*), which is the combined medial surfaces of the anterior and posterior central gyri. The calloso-marginal sulcus (*sulcus cinguli*) is sometimes continued backward nearly to the parieto-occipital fissure, and this part of it is called the subparietal sulcus (*sulcus subparietalis*). Between it, ventrally, the parieto-occipital fissure behind, and the marginal sulcus in front, is a large square convolution: the *præcuneus*. Between the sulcus of the corpus callosum ventrally and the calloso-marginal sulcus dorsally is a long, narrow convolution: the convolution of the corpus callosum. It will be seen that this is continuous with the hippocampal convolution around the posterior extremity of the corpus callosum. These two convolutions together have been called the limbic lobe of Broca; in the nomenclature now employed they constitute the *gyrus fornicatus*, divided into two parts,—the *gyrus cinguli*, corresponding to what was called the convolution of the corpus callosum, and the *gyrus hippocampi*,—while their point of union around the posterior extremity of the corpus callosum is the *isthmus gyri fornicati*.

*The Rhinencephalon.*—The rhinencephalon (Fig. 15) is developed as an offshoot from the anterior ventral portion of the telencephalon. The medial orbital convolution, as we have seen, contains an antero-posterior sulcus parallel to the

anterior extremity of the longitudinal fissure: the olfactory sulcus (*sulcus olfactorius*). In this lies a white band, the olfactory tract (*tractus olfactorius*), which, when followed forward, is seen to emerge from a small oval enlargement: the olfactory bulb (*bulbus olfactorius*). Behind, at the edge of the orbital convolution, the tract develops a small triangular swelling: the olfactory triangle (*trigonum olfactorium*). From this triangle set out two small cords: the olfactory roots, or *striae*. The medial root (*stria olfactoria medialis*) runs backward toward the median line, to enter a small gray area: the olfactory area of Broca (*area parolfactoria*). The lateral root (*stria olfactoria lateralis*) runs backward and lateralward to enter the anterior extremity of the hippocampal convolution. In its course it crosses the anterior perforated substance (*substantia perforata anterior*): a thin, gray lamella containing numerous foramina for vessels. Limiting this lamella medially and behind is a narrow white cord running between the anterior extremity of the corpus callosum and the hippocampal convolution; it has been called the peduncle of the corpus callosum, but it is more in accord with our present knowledge to regard it as a convolution, called, from its position, the *gyrus subcallosus*. By its means the two anterior extremities of the limbic lobe, or *gyrus fornicatus*, are connected.

It is customary to divide the rhinencephalon into two portions: an anterior (*pars anterior*) and a posterior (*pars posterior*). The former contains the bulb, the tract, the triangle, the medial *stria*, and the *area parolfactoria*; the latter the perforated substance, the lateral *stria*, and the *gyrus subcallosus*.

THE VENTRAL PORTION OF THE TELEENCEPHALON.—The divisions of the telencephalon which we have been studying are all developed from that part of the embryonic vesicle which lies dorsal to the neural cavity. The ventral portion of the telencephalon produces the optic part of the hypothalamus (*pars optica hypothalami*); this has already been described in the account given of the diencephalon.

## CHAPTER III.

### THE INTERNAL ANATOMY OF THE ENCEPHALON.

#### THE INTERNAL ANATOMY OF THE MYELENCEPHALON.

IN tracing the continuity of structure between the medulla oblongata and the spinal cord we shall find that a gradual, but marked, rearrangement of both gray and white matters occurs; moreover, we shall find structures in the medulla which are lacking in the cord.

This rearrangement of matter begins even in the cord. If a section through the first cervical segment of the cord (Fig. 16) be examined, it will be noticed that the dorsal horn of the gray matter has been bent ventro-laterally in such a manner as to describe a curve, the concavity of which is ventral. The neck of the horn is much thinned, while the gelatinous substance of Rolando (*substantia gelatinosa*) is enlarged, and is capped laterally by the cross-section of a bundle of slender nerve-fibres. These fibres are derived from the fifth cranial, or trigeminal, nerve. In the study of the surface anatomy of the pons Varolii we have seen that this nerve pierces the ventral surface of the pons; in its substance the sensory fibres of the nerve, after the manner of sensory nerves in general, bifurcate into ascending and descending branches; the latter run as far as the first segment of the cord. They constitute the spinal tract of the trigeminal nerve (*tractus spinalis nervi trigemini*), the cross-section of which appears very distinctly all through the posterior portion of the pons and through the entire extent of the medulla. It is accompanied by the gelatinous substance, which is situated medial to it, and is the terminal nucleus of its fibres (*nucleus tractus spinalis nervi trigemini*). In the cervical region of the cord the gray matter exhibits the so-called lateral horn, from which the fibres of the eleventh cranial, or spinal accessory, nerve arise. This nucleus is continued

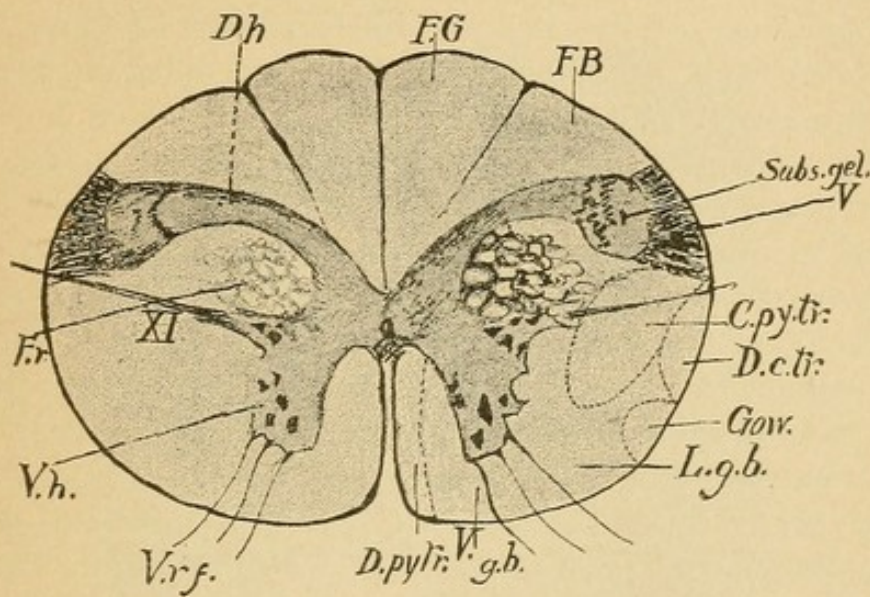


Fig. 16.—*D. h.*, Dorsal horn. *XI*, Spinal accessory nerve. *F. r.*, *Formatio reticularis*. *V. h.*, Ventral horn. *V. r. f.*, Ventral root-fibres. *V.*, Spinal tract of trigeminal nerve. *Subs. gel.*, *Substantia gelatinosa*. *F. G.*, *Funiculus of Goll* (*funiculus gracilis*). *F. B.*, *Funiculus of Burdach* (*funiculus cuneatus*). *C. py. tr.*, *Crossed pyramidal tract* (*fasciculus cerebro-spinalis lateralis*). *D. c. tr.*, *Direct cerebellar tract* (*fasciculus cerebello-spinalis*). *Gow.*, *Tract of Gowers* (*fasciculus antero-lateralis superficialis*). *L. g. b.*, *Lateral ground-bundle* (*fasciculus lateralis proprius*). *V. g. b.*, *Ventral ground-bundle* (*fasciculus anterior proprius*). *D. py. tr.*, *Direct pyramidal tract* (*fasciculus cerebro-spinalis anterior*).

into the posterior part of the medulla, where it keeps the same relative position.

Lateral to the gray matter in the cervical portion of the cord appears the *formatio reticularis*: a net-work of transverse and longitudinal fibres, which attains much fuller development in the medulla.

An important factor in the rearrangement of the white and gray matters is the decussation of the pyramids (Fig. 17). The pyramids of the medulla are composed of fibres which arise in certain convolutions of the telencephalon, and convey impulses to the nuclei of origin of the motor peripheral nerves. On arriving at the spinal end of the medulla the great majority of these fibres cross the median line to the lateral column of the opposite side of the cord, where they form the crossed pyramidal tract (*fasciculus cerebro-spinalis lateralis*); a few remain uncrossed, and descend in the ventral column of the cord as the direct pyramidal tract (*fasciculus cerebro-spinalis anterior*). The decussating fibres, crossing from the pyramid of one side to the lateral column of the other, pass through the base of the ventral horn, and sever it from the central gray matter. If we follow these fibres in the opposite direction,—*i.e.*, from the cord to the medulla,—it will be seen that in the medulla they occupy the region corresponding to that which the ventro-lateral ground-bundle occupies in the cord. The latter bundle continues its course into the medulla, and there lies dorsal to the pyramid and ventral to the central canal. The other tracts of white matter maintain the same relative positions in the posterior part of the medulla as in the cord.

Ventral to the funiculus of Goll (*funiculus gracilis*) is a gray mass continuous with the dorsal horn; a similar, but more rounded, mass is ventral to the funiculus of Burdach (*funiculus cuneatus*). As we follow these objects through the medulla (Fig. 18), the gray masses steadily increase in size, the lateral one extending farther forward, until they terminate in the enlargements which we have called the clava and the cuneate tubercle. The funiculi of white matter dorsal to them, however, become gradually thinner, until at the level of the clava and cuneate tubercle, respectively, they

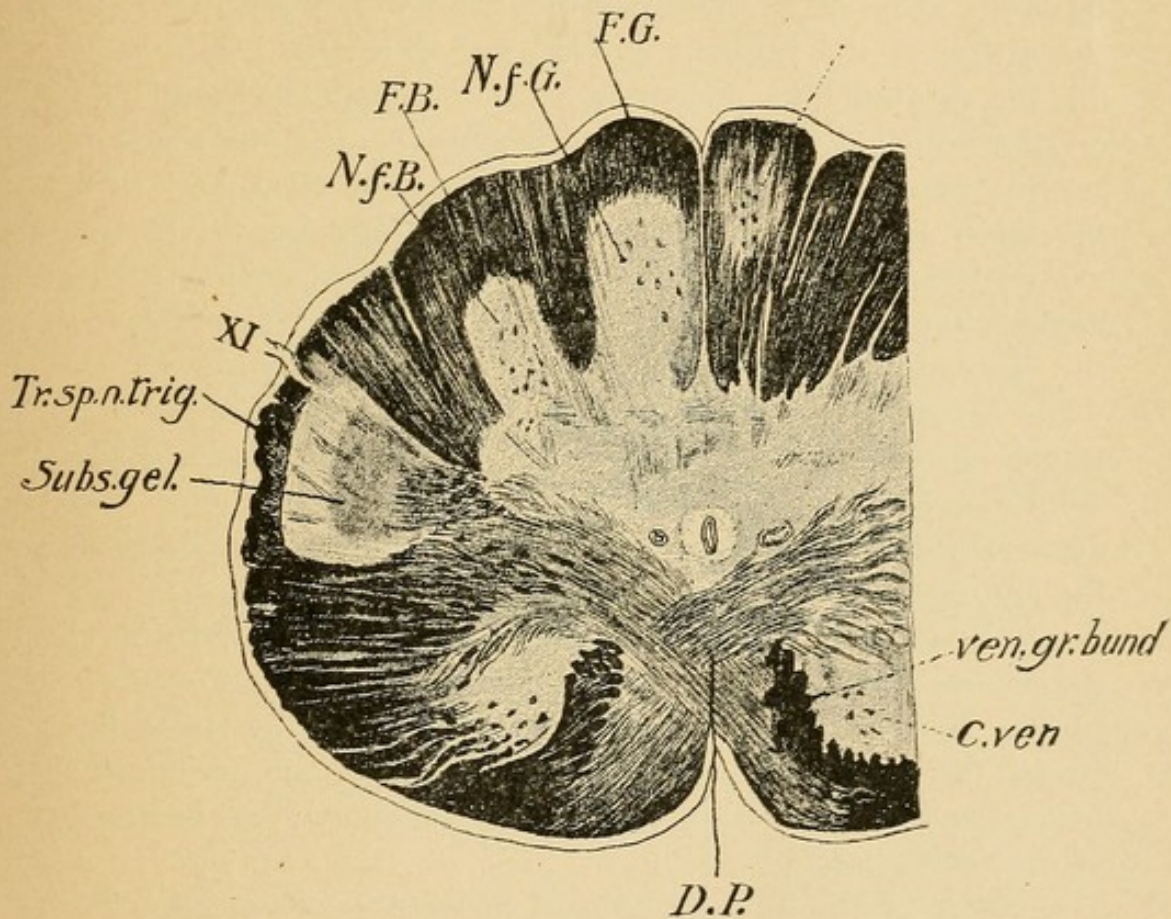


Fig. 17.—*F. G.*, Funiculus of Goll. *N. f. G.*, Nucleus of the funiculus of Goll. *F. B.*, Funiculus of Burdach. *N. f. B.*, Nucleus of the funiculus of Burdach. *XI*, Spinal accessory nerve. *Tr. sp. n. trig.*, Spinal tract of the trigeminal nerve. *Subs. gel.*, Substantia gelatinosa. *C. ven.*, Ventral horn. *D. P.*, Decussation of the pyramids. *Ven. gr. bund.*, Vento-lateral ground-bundle. (After Henle.)

cease altogether. The gray masses, then, are the terminal nuclei of the funiculi of Goll and Burdach (nucleus funiculi gracilis; nucleus funiculi cuneati).

Numerous fibres are seen sweeping across each half of the section toward the median line in curves with the concavities dorsal: the internal arcuate fibres (fibræ arcuatæ internæ). They are in great part the axones of cells situated in the nuclei of the funiculi of Goll and Burdach. On reaching the median line, they cross to the opposite side and take a longitudinal direction forward, occupying the same region as the ventro-lateral ground-bundle from the cord, and with the latter form the prominent tract of fibres known as the medial lemniscus (lemniscus medialis). The crossing in the median line of these arcuate fibres from both sides constitutes the decussation of the lemnisci (decussatio lemniscorum), while the median line in which they decussate is called the raphé. Since many of the fibres of the lemniscus are derived from the terminal nuclei of the funiculi of Goll and Burdach of the opposite side, each lemniscus may be regarded as the indirect continuation of these funiculi. Here, then, in the posterior part of the medulla are two great decussations: the ventral one of motor fibres, the dorsal one of sensory fibres. These fibres are the principal conducting-tracts between the cortex of the telencephalon and the peripheral nerves, and we shall meet them in all the succeeding portions of the encephalon.

Many of the internal arcuate fibres are axones from the cells in the substantia gelatinosa, the terminal nucleus of the spinal tract of the trigeminal nerve. Farther forward many are likewise derived from the nuclei of other sensory cranial nerves. These arcuate fibres from the nuclei of sensory nerves also cross the raphé, but the course pursued by them thereafter is not definitely settled, some holding the opinion that they travel in the medial lemniscus, while others believe that they form separate tracts in the dorsal part of the formatio reticularis. Certainly some of them, at least, join the lemniscus of the opposite side from that in which they arise. In the case of the nerve of hearing we shall see hereafter that the fibres which arise in its terminal nuclei form a separate tract.

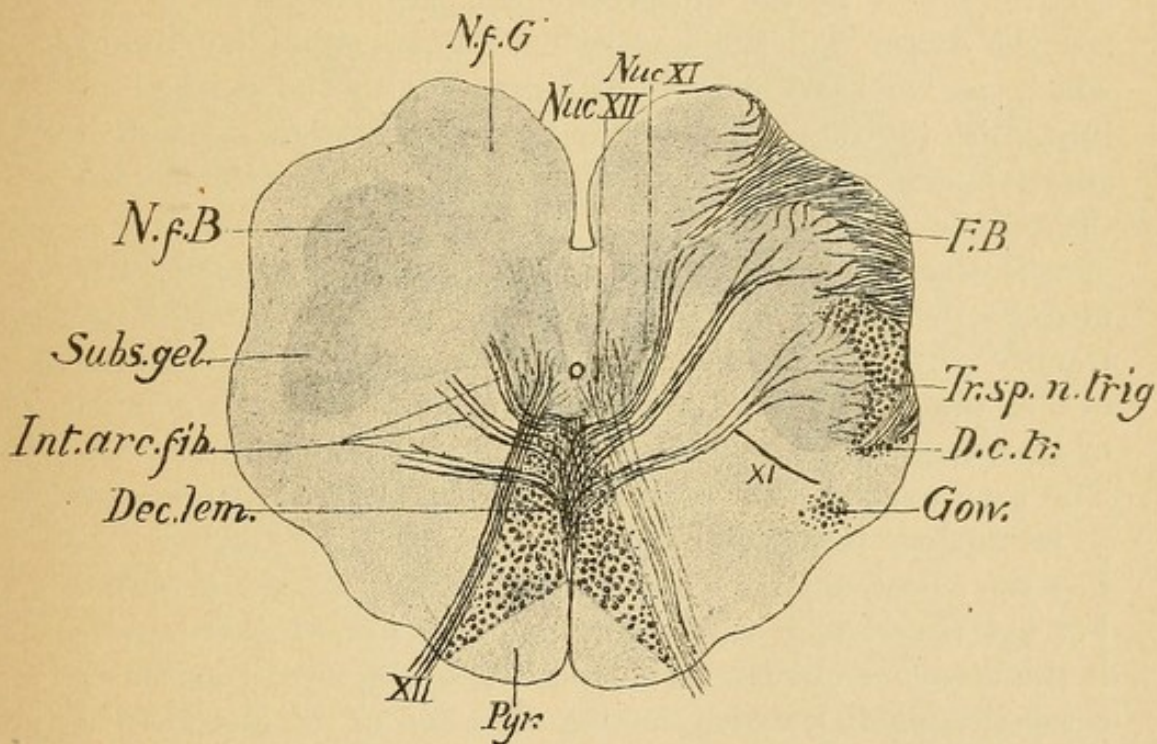


Fig. 18.—*Nuc. XII*, Nucleus of hypoglossal nerve. *Nuc. XI*, Nucleus of spinal accessory nerve. *F. B.*, Funiculus of Burdach. *Tr. sp. n. trig.*, Spinal tract of trigeminal nerve. *D. c. tr.*, Direct cerebellar tract. *Gow.*, Tract of Gowers. *XI*, Spinal accessory nerve. *Pyr.*, Pyramid. *XII*, Hypoglossal nerve. *Dec. lem.*, Decussation of lemniscus. *Int. arc. fib.*, Internal arcuate fibres. *Subs. gel.*, Substantia gelatinosa. *N. f. B.*, Nucleus of funiculus of Burdach. *N. f. G.*, Nucleus of funiculus of Goll.

Many of the arcuate fibres are derived from the pyramids, crossing the median line to reach the nuclei of origin of the motor nerves, and still others are fibres connecting the sensory with the motor nuclei.

Finally we have to note the changes which occur in the central canal. As the fourth ventricle is approached, the diameter of the canal increases, until at the level of the termination of the funiculus of Goll in its nucleus the canal is covered only by the thinned, dorsal, gray commissure. At last the dorsal wall becomes reduced to its epithelial lining, which, as we have seen, is continuous with the epithelium lining the ventral surface of the tela chorioidea of the fourth ventricle, and the canal is now said to have "opened out" into the ventricle.

Proceeding to the study of the anterior portion of the medulla, we begin with a section through the posterior extremity of the calamus scriptorius (Fig. 19). The funiculus of Goll and its nucleus have ceased to exist, but the funiculus of Burdach, though much smaller than before, is still present. The semilunar section of the trigeminal nerve lying lateral to its nucleus is a prominent feature. It will be noted that this tract does not here reach the periphery of the medulla, but has lateral to it a bundle of oblique fibres; this bundle is the direct cerebellar tract from the spinal cord (fasciculus cerebello-spinalis), which, having ascended in the lateral tract of the medulla, in this region makes a dorsal bend to enter the corpus restiforme. The tract of Gowers (fasciculus antero-lateralis superficialis) keeps the same position ventral to the direct cerebellar tract.

Farther ventral is the section of the olive, which here shows as three pieces: a dorsal, or dorsal accessory olivary nucleus (nucleus olivaris accessorius dorsalis); a medial, or medial accessory olivary nucleus (nucleus olivaris accessorius medialis); and a central portion, or inferior olivary nucleus (nucleus olivaris inferior). The latter is by far the largest; it is a convoluted lamina of gray matter with an opening, the hilus, toward the raphé, through which pass numerous fibres which connect it with the cerebellar hemisphere of the opposite side: the cerebello-olivary fibres.

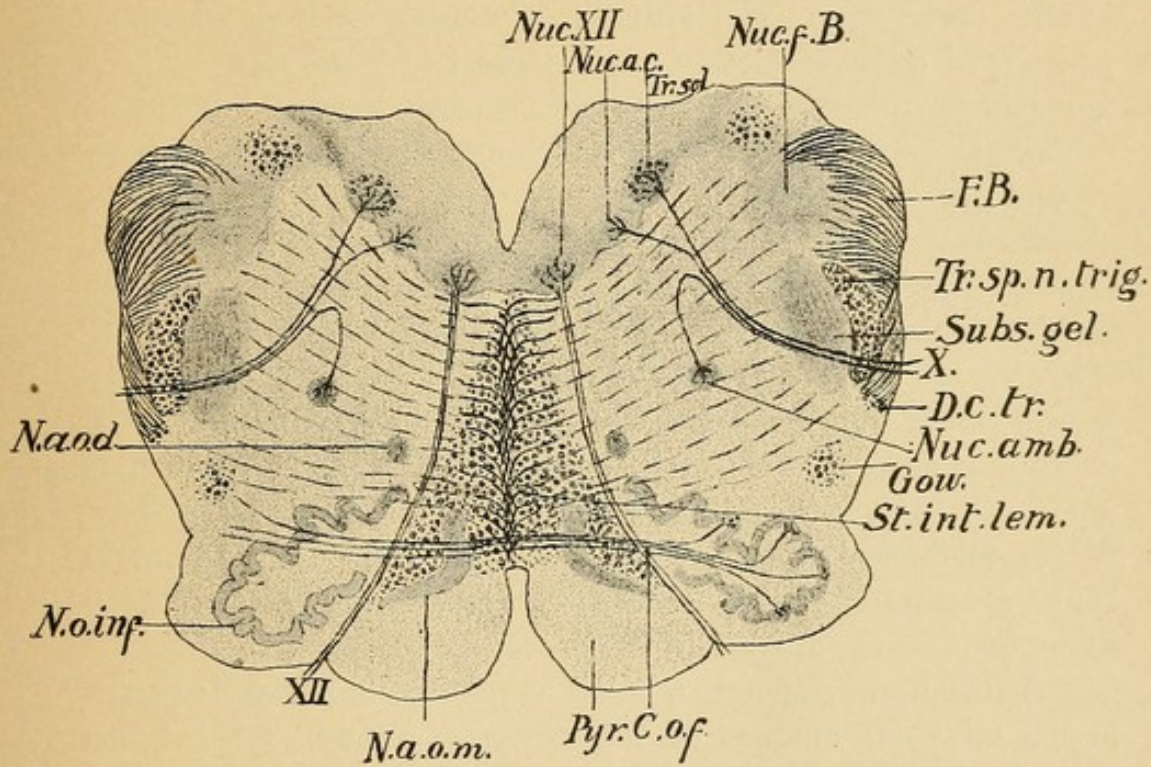


Fig. 19.—*Nuc. XII*, Nucleus of hypoglossal nerve. *Nuc. a. c.*, Nucleus of ala cinerea. *Nuc. f. B.*, Nucleus of funiculus of Burdach. *F. B.*, Funiculus of Burdach. *Tr. sol.*, Tractus solitarius. *Tr. sp. n. trig.*, Spinal tract of trigeminal nerve. *Subs. gel.*, Substantia gelatinosa. *X*, Vagus nerve. *D. C. tr.*, Direct cerebellar tract. *Nuc. amb.*, Nucleus ambiguus. *Gow.*, Tract of Gowers. *St. int. lem.*, Interolivary stratum of lemniscus. *C. o. f.*, Cerebello-olivary fibres. *Pyr.*, Pyramid. *N. a. o. m.*, Medial accessory olivary nucleus. *XII*, Hypoglossal nerve. *N. o. inf.*, Inferior olivary nucleus. *N. a. o. d.*, Dorsal accessory olivary nucleus.

On each side of the ventral median sulcus is the pyramid. Dorsal to the pyramid is the bundle of sensory fibres which farther forward goes to form the medial lemniscus, seen as a triangular tract between the olives and hence known as the interolivary layer (*stratum interolivare lemnisci*); the most dorsal of the fibres near the raphé in this situation are continuous farther forward with the medial longitudinal bundle (*fasciculus longitudinalis medialis*): a tract of fibres which will become much more evident as we proceed. These fibres correspond to those of the ventral ground-bundle of the spinal cord. In the floor of the ventricle are the nuclei of some of the cranial nerves. On each side of the median line is a collection of large cells: the nucleus of origin of the twelfth cranial or hypoglossal nerve. The root-fibres of the nerve are conspicuous, running ventro-lateralward medial to the olive to escape from the medulla through the ventro-lateral sulcus. This nucleus consists of a long column of cells extending from the level of the decussation of the pyramids nearly to that of the *striæ acusticæ*. In the posterior part of the medulla the nucleus lies ventro-lateral to the central canal; in the anterior portion it corresponds to the *trigonum hypoglossi* in the floor of the ventricle.

Lateral and somewhat dorsal to the nucleus of the twelfth is the terminal nucleus of the sensory portion of the tenth cranial, or pneumogastric or vagus, nerve (*nucleus alæ cinereæ*). Most of the sensory fibres of the nerve end in this nucleus, but some descend after the manner of the spinal tract of the trigeminal nerve, forming a part of a small bundle dorsal and lateral to the nucleus of the *ala cinereæ*: the *tractus solitarius*. Around the latter is a column of gray matter in which the fibres of the tract end: the nucleus of the solitary tract (*nucleus tractus solitarii*). These two nuclei are really common to both the tenth and the ninth (glosso-pharyngeal) cranial nerves, the latter terminating in their more anterior portions. The *tractus solitarius* consists, in the main, of fibres derived from the glosso-pharyngeal nerve. Moreover, both of these nerves are mixed nerves: *i.e.*, they contain both motor and sensory fibres. Now, the nucleus of origin of the motor fibres is the *nucleus ambiguus*. The ven-

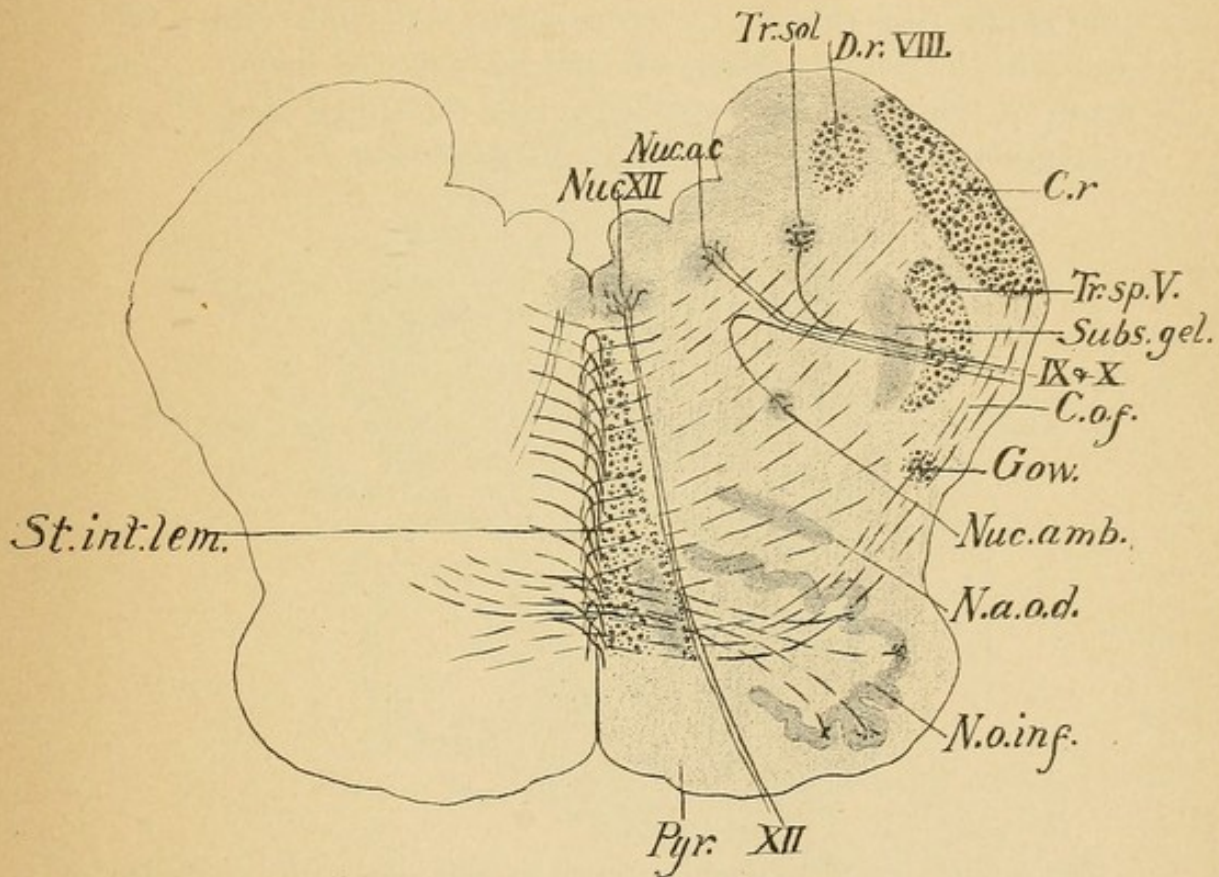


Fig. 20.—*Nuc. XII*, Nucleus of hypoglossal nerve. *Nuc. a. c.*, Nucleus of ala cinerea. *Tr. sol.*, Tractus solitarius. *D. r. VIII*, Descending root of vestibular nerve. *C. r.*, Corpus restiforme. *Tr. sp. V.*, Spinal tract of trigeminal nerve. *Subs. gel.*, Substantia gelatinosa. *IX*, Glosso-pharyngeal nerve. *X*, Vagus nerve. *C. o. f.*, Cerebello-olivary fibres. *Gow.*, Gowers' tract. *Nuc. amb.*, Nucleus ambiguus. *N. a. o. d.*, Dorsal accessory olivary nucleus. *N. o. inf.*, Inferior olivary nucleus. *XII*, Hypoglossal nerve. *Pyr.*, Pyramid. *St. int. lem.*, Interolivary stratum of the lemniscus.

tral horn of the cord, after being cut off by the decussating pyramid, does not disappear entirely, but continues forward in the medulla, to furnish nuclei for several cranial nerves. It thus furnishes that for the ninth and tenth cranial nerves,—the nucleus ambiguus,—which is located about midway between the olive and the gelatinous substance and dorsal to a line connecting them. Its axones take a dorso-lateral route, and join the sensory fibres. It will be observed that the root-fibres of these two nerves run through the spinal tract of the trigeminal nerve and the gelatinous substance.

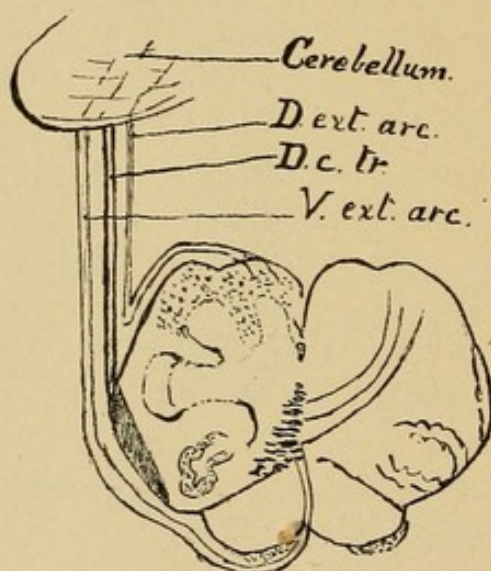


Fig. 21.—*D. ext. arc.*, Dorsal external arcuate fibres. *D. c. tr.*, Direct cerebellar tract. *V. ext. arc.*, Ventral external arcuate fibres. (After Edinger.)

The internal arcuate fibres are very numerous, sweeping across the section from all the sensory nuclei. That portion of the section through which they pass—between the floor of the ventricle, the medial lemniscus, the inferior olive, and the gelatinous substance—is the fully-developed *formatio reticularis* of the medulla: a mixture of white and gray matter believed to be associational in function.

The next section (Fig. 20) passes through all three of the triangular areas into which the *calamus scriptorius* is divided, the *trigonum hypoglossi* containing the nucleus of

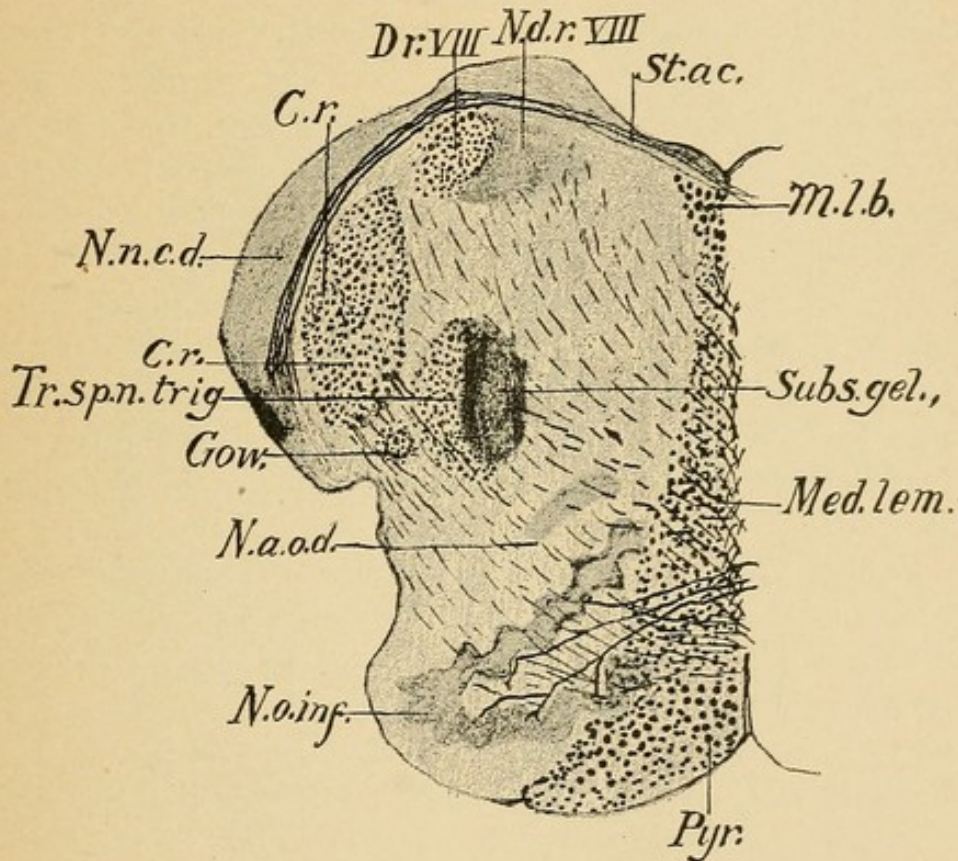


Fig. 22.—*M. l. b.*, Medial longitudinal bundle. *Subs. gel.*, Substantia gelatinosa. *Med. lem.*, Medial lemniscus. *Pyr.*, Pyramid. *N. o. inf.*, Inferior olivary nucleus. *N. a. o. d.*, Dorsal accessory olivary nucleus. *Gow.*, Gowers's tract. *Tr. sp. n. trig.*, Spinal tract of trigeminal nerve. *C. r.*, Corpus restiforme. *N. n. c. d.*, Dorsal nucleus of cochlear nerve. *D. r. VIII*, Descending root of vestibular nerve. *N. d. r. VIII*, Nucleus of descending root of vestibular nerve. *St. ac.*, Acoustic striæ.

the hypoglossal nerve, the ala cinerea containing the terminal nuclei of the ninth and tenth cranial nerves, and the acoustic area. In this situation the latter contains the descending root of the vestibular nerve and its accompanying nucleus medial to it. Lateral and ventral to this is seen the cross-section of the corpus restiforme. It is composed of fibres from several sources: first, the direct cerebellar tract from the cord, which is here seen entering it; second, the cerebello-olivary fibres; and, third, the external arcuate fibres. The cerebello-olivary fibres connect the cerebellar hemisphere of one side with the olive of the opposite side. They run in the corpus restiforme, appear among the most ventral of the internal arcuate fibres, traverse the olive of the same side, cross the raphé, and enter the olive of the opposite side. The external arcuate fibres consist of two sets (Fig. 21): a dorsal, derived from the nuclei of the funiculi of Goll and Burdach, and a ventral, which emerge from the interolivary layer of the lemniscus to wind around the lateral surface of the medulla and enter the corpus restiforme.

In Fig. 22 the section passes through the acoustic striæ. Laterally these fibres are connected with a semilunar mass of gray matter dorso-lateral to the corpus restiforme: the acoustic tubercle, or dorsal nucleus of the cochlear nerve (*nucleus nervi cochleæ dorsalis*). The acoustic nerve at the medulla is composed of two parts: a postero-lateral, or cochlear, portion (*radix cochlearis*); and an antero-medial, or vestibular, portion (*radix vestibularis*). Now, the acoustic tubercle is one of the terminal nuclei of the cochlear portion. The axones from the cells of this nucleus form the acoustic striæ, which arch in the floor of the ventricle first dorsalward and then ventralward toward the median line; just ventral to the median sulcus most of them cross the median line, and their subsequent course will be described hereafter.

The nuclei of the twelfth, tenth, and ninth cranial nerves have ceased to exist at this level of the medulla, while the descending root of the vestibular nerve is larger in volume.

The medial longitudinal bundle here begins to show as a distinct tract; it will be noticed that its fibres are larger than those of the medial lemniscus.

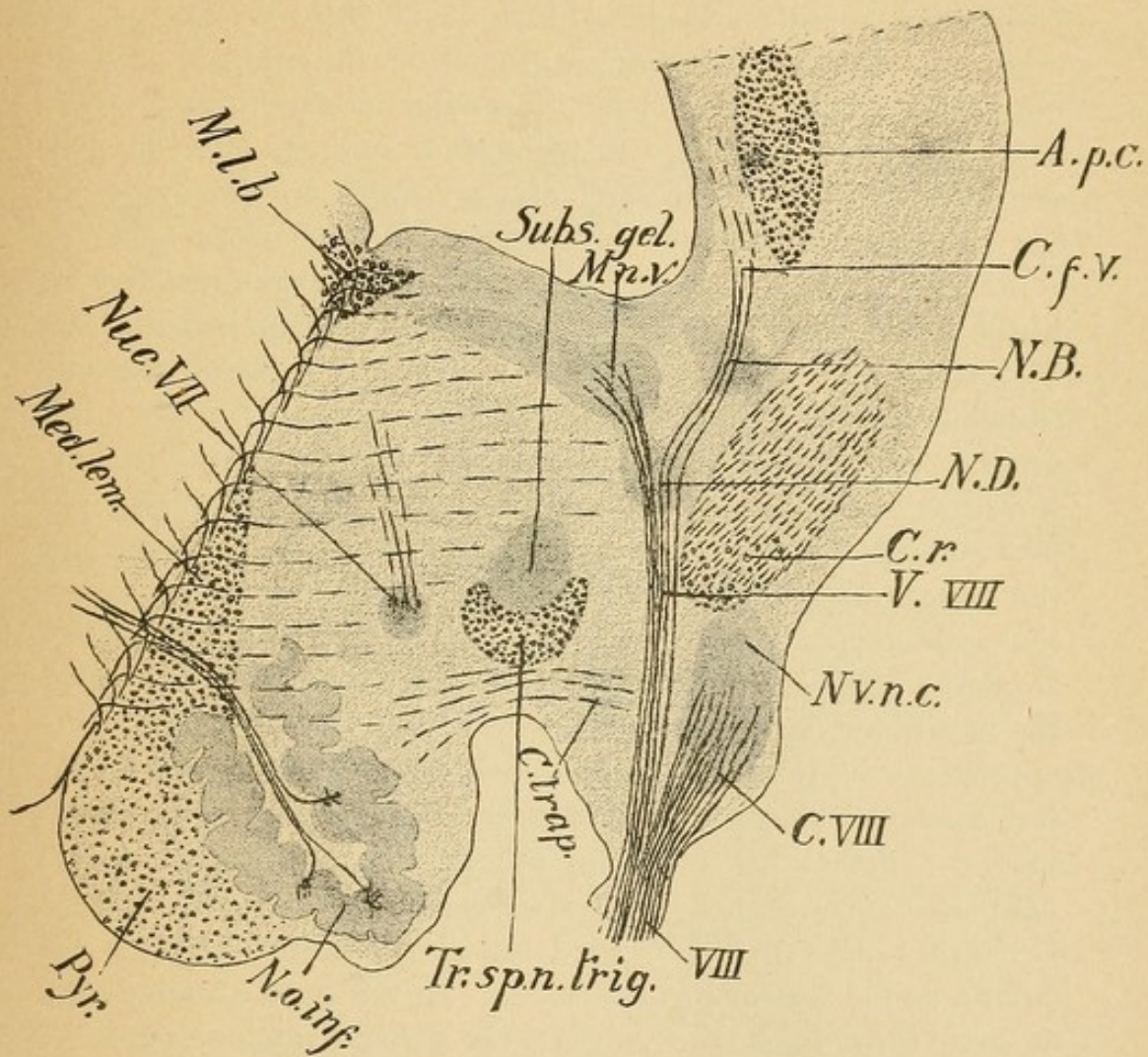


Fig. 23.—*A. p. c.*, Anterior peduncle of cerebellum. *C. f. v.*, Fibres from vestibular nerve to cerebellum. *N. B.*, Nucleus of Bechterew. *N. D.*, Nucleus of Deiters. *C. r.*, Corpus restiforme. *V. VIII*, Root-fibres of vestibular nerve. *N. v. n. c.*, Ventral nucleus of cochlear nerve. *C. VIII*, Cochlear portion of acoustic nerve. *VIII*, Acoustic nerve. *C. trap.*, Trapezoid body. *Tr. sp. n. trig.*, Spinal tract of trigeminal nerve. *N. o. inf.*, Inferior olivary nucleus. *Pyr.*, Pyramid. *Med. lem.*, Medial lemniscus. *Nuc. VII*, Nucleus of facial nerve. *M. l. b.*, Medial longitudinal bundle. *Subs. gel.*, Substantia gelatinosa. *M. n. v.*, Medial nucleus of vestibular nerve.

## THE INTERNAL ANATOMY OF THE METENCEPHALON.

THE PONS VAROLII.—We shall begin the study of the pons by examining a section through the transition-plane between the medulla and pons (Fig. 23). Here we find, as in preceding sections, the pyramid, the olive, the internal arcuate fibres and medial lemniscus, the medial longitudinal bundle, and the spinal tract of the trigeminal nerve; but the predominant feature of the section is presented by the nuclei of the eighth cranial or acoustic nerve. The acoustic tubercle is no longer seen, but ventro-lateral to the corpus restiforme, which is now entering the cerebellum, is the principal nucleus of termination of the cochlear nerve, the ventral nucleus (*nucleus nervi cochleæ ventralis*), characterized by the large number of nerve-fibres contained in it and by their “basket-work-like” arrangement around groups of cells. The acoustic nerve consists of two distinct bundles: the one arises from the ganglion of Corti in the cochlea, and is therefore called the cochlear nerve (*nervus cochleæ*); while the other springs from the ganglion of Scarpa in the vestibule, and is termed the vestibular nerve (*nervus vestibuli*). As the acoustic nerve approaches its termination, the cochlear nerve enters the ventral nucleus, where it bifurcates, sending a part of its fibres into the dorsal nucleus, the others ending in the ventral nucleus. A series of sections shows that the dorsal nucleus is continuous with the ventral nucleus, although it does not extend as far forward as the latter. In the dorsal nucleus the acoustic striæ take their origin; the ventral nucleus sends its axones, seen better in the next section, nearly transversely into the pons, where they form the trapezoid body (*corpus trapezoideum*).

The fibres of the vestibular nerve enter the pons and run toward the floor of the ventricle; near it, in the area acustica, they reach their principal nucleus of termination, the medial (*nucleus nervi vestibuli medialis*): a large gray mass extending in the floor of the ventricle from its lateral wall almost to the median line. Here the vestibular fibres divide into their ascending and descending branches. Most of the former terminate in the medial nucleus, but some turn laterally to

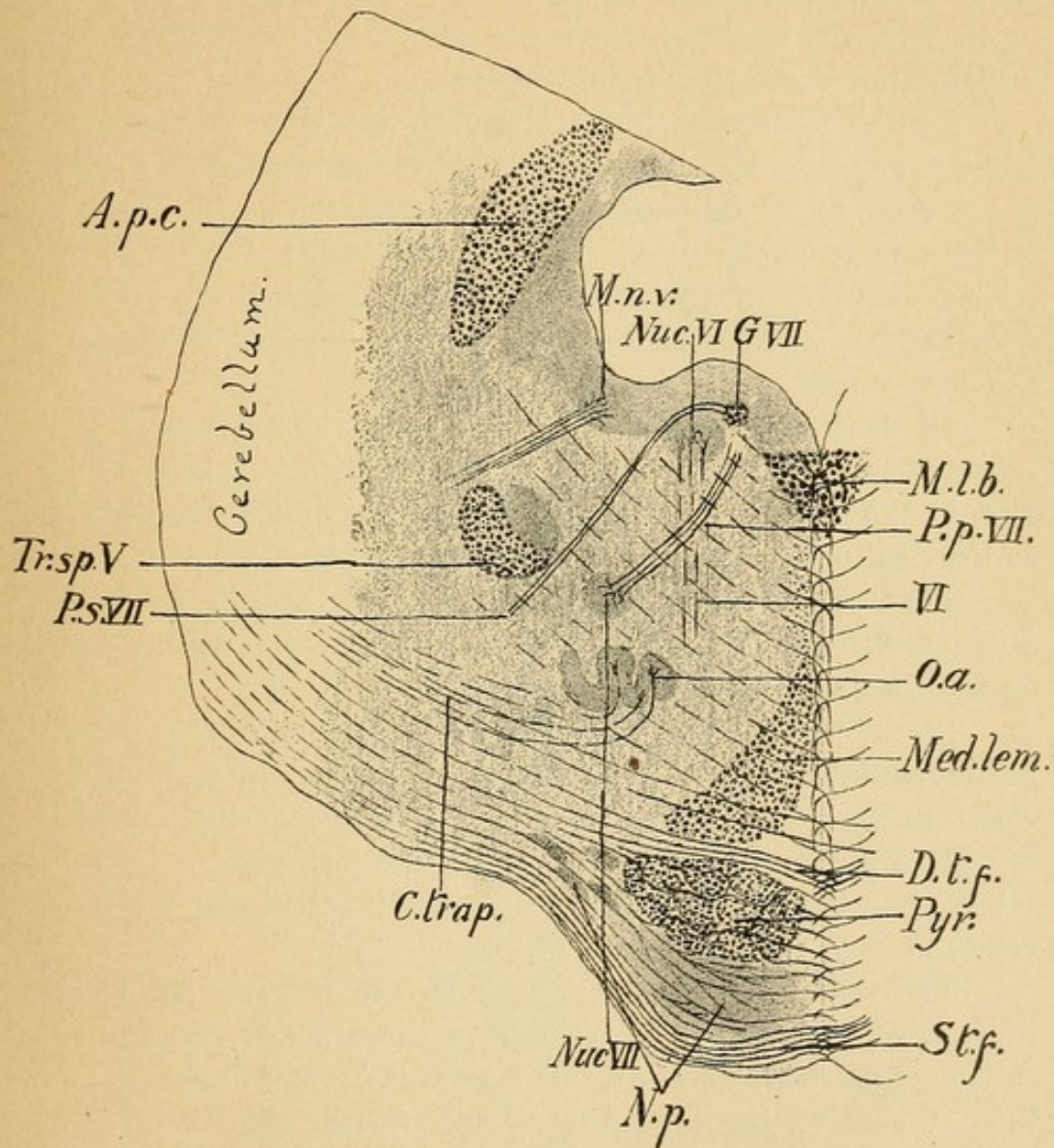


Fig. 24.—*M. n. v.*, Medial nucleus of vestibular nerve. *Nuc. VI*, Nucleus of abducens nerve. *G. VII*, Genu of facial nerve. *M. l. b.*, Medial longitudinal bundle. *P. p. VII*, Pars prima of facial nerve. *VI*, Root-fibres of abducens nerve. *O. a.*, Anterior olive. *Med. lem.*, Medial lemniscus. *D. t. f.*, Deep transverse fibres of pons. *Pyr.*, Pyramidal tract. *S. t. f.*, Superficial transverse fibres of pons. *N. p.*, Nuclei pontis. *Nuc. VII*, Nucleus of facial nerve. *C. trap.*, Trapezoid body. *P. s. VII*, Pars secunda of facial nerve. *Tr. sp. V.*, Spinal tract of trigeminal nerve. *A. p. c.*, Anterior peduncle of cerebellum.

disappear in the superior nucleus of Bechterew and in the cerebellum. The descending branches form the descending root of the vestibular nerve, which we have seen extending as far as the termination of the funiculus of Burdach accompanied by its terminal nucleus, which lies medial to it and which is a prolongation from the medial nucleus.

As the vestibular fibres approach the floor of the ventricle they traverse a scattered collection of large cells medial to the dorsum of the corpus restiforme known as the nucleus of Deiters (*nucleus nervi vestibuli lateralis*); similarly the cerebellar fibres of this nerve pass through another nucleus dorso-lateral to that of Deiters: the nucleus of Bechterew (*nucleus nervi vestibuli superior*).

Another new feature of this section is the nucleus of origin of the seventh cranial, or facial, nerve. It may be looked upon as a forward continuation of the nucleus ambiguus, and occupies the same relative position as that nucleus.

The next section (Fig. 24) is entirely within the pons. Sections of the pons are divided into two parts: dorsal (*pars dorsalis*); and ventral, or basilar (*pars basilaris*).

In the ventral portion we find two sets of fibres: longitudinal and transverse. The former are, in the main, the fibres which in the medulla constitute the pyramids, and which may be still called the pyramidal tracts; they are broken up into several bundles (*fasciculi longitudinales*) in the pons by transverse fibres.

The transverse fibres are divided into two sets according to their relation to the longitudinal: those which run ventral to the pyramidal tracts (*fibræ transversæ superficiales*), and those dorsal to the pyramidal tracts (*fibræ transversæ profundæ*).

Interspersed among these transverse fibres are several masses of gray matter: the nuclei of the pons (*nuclei pontis*).

Some of the transverse fibres pass entirely across the section, being fibres which connect the two hemispheres of the cerebellum; others come from the cerebellum and end in the nuclei pontis; and still others run from the nuclei pontis to the cerebellum.

The ventral portion of the pons maintains essentially the

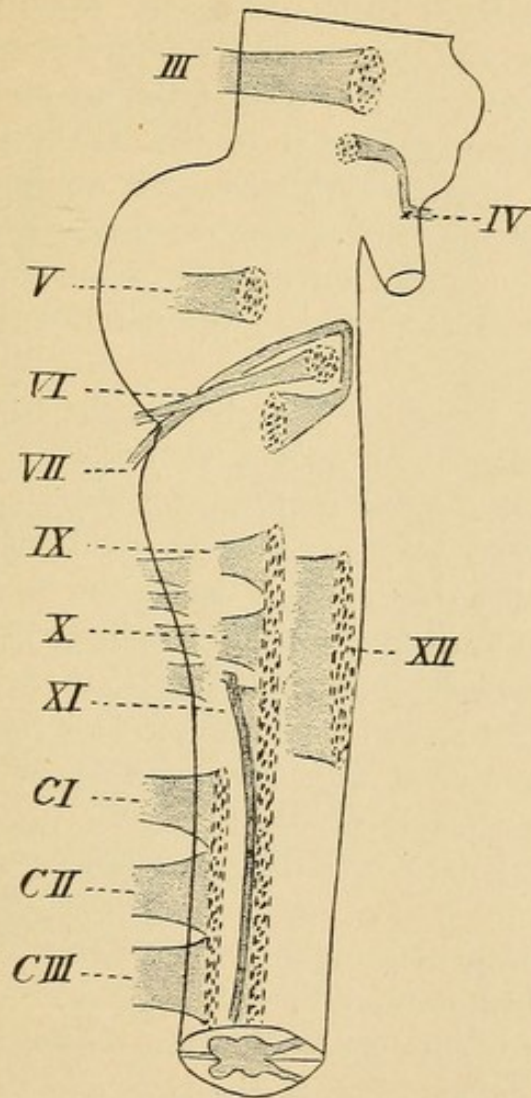


Fig. 25.—Scheme of the nuclei and root-fibres of the cranial nerves (after Edinger).

same appearance throughout the pons, and need not be described again.

Turning now to the dorsal portion of the pons, it is seen that the medial lemniscus occupies the same position as in previous sections, but is somewhat flattened. The inferior olivary nucleus has disappeared, and the medial lemniscus is now clearly separated from the medial longitudinal bundle. Lateral to the medial lemniscus is a folded sheet of gray matter: the anterior (superior) olive (nucleus olivaris superior). Running transversely ventral to this are the fibres of the trapezoid body, which, as we have seen, are, in the main, the axones of cells of the ventral cochlear nucleus. Some of them terminate in the anterior olive of the same side, while others cross the median line to end in the anterior olive of the opposite side.

Dorsal and lateral to the olive is the nucleus of origin of the facial nerve. In this section the root-fibres of this nerve have been divided in three places, owing to the fact that they pursue a very complex course in the substance of the pons (Fig. 25). After their origin the fibres take a dorso-medial direction until they reach the floor of the ventricle near the median line (*pars prima*); then they run longitudinally forward to make a lateral bend and curve dorsal to the nucleus of the sixth cranial or abducens nerve (*genu*); and finally assume a ventro-lateral direction to pass between their own nucleus and the gelatinous substance (*pars secunda*), and make their exit.

In the hollow of the *genu* of the facial is the nucleus of origin of the sixth cranial, or abducens, nerve. Its root-fibres run ventralward, with an inclination backward, to escape in the transverse sulcus between the pons and the medulla.

Lateral to the *pars secunda* of the facial is the spinal tract of the trigeminal nerve, with its terminal nucleus; and in the extreme lateral area of the floor of the ventricle is still a portion of the medial vestibular nucleus, with a few root-fibres entering it.

Bordering the ventricle is the cross-section of the anterior peduncle of the cerebellum (*brachium conjunctivum*).

The next section (Fig. 26) passes through the domain of

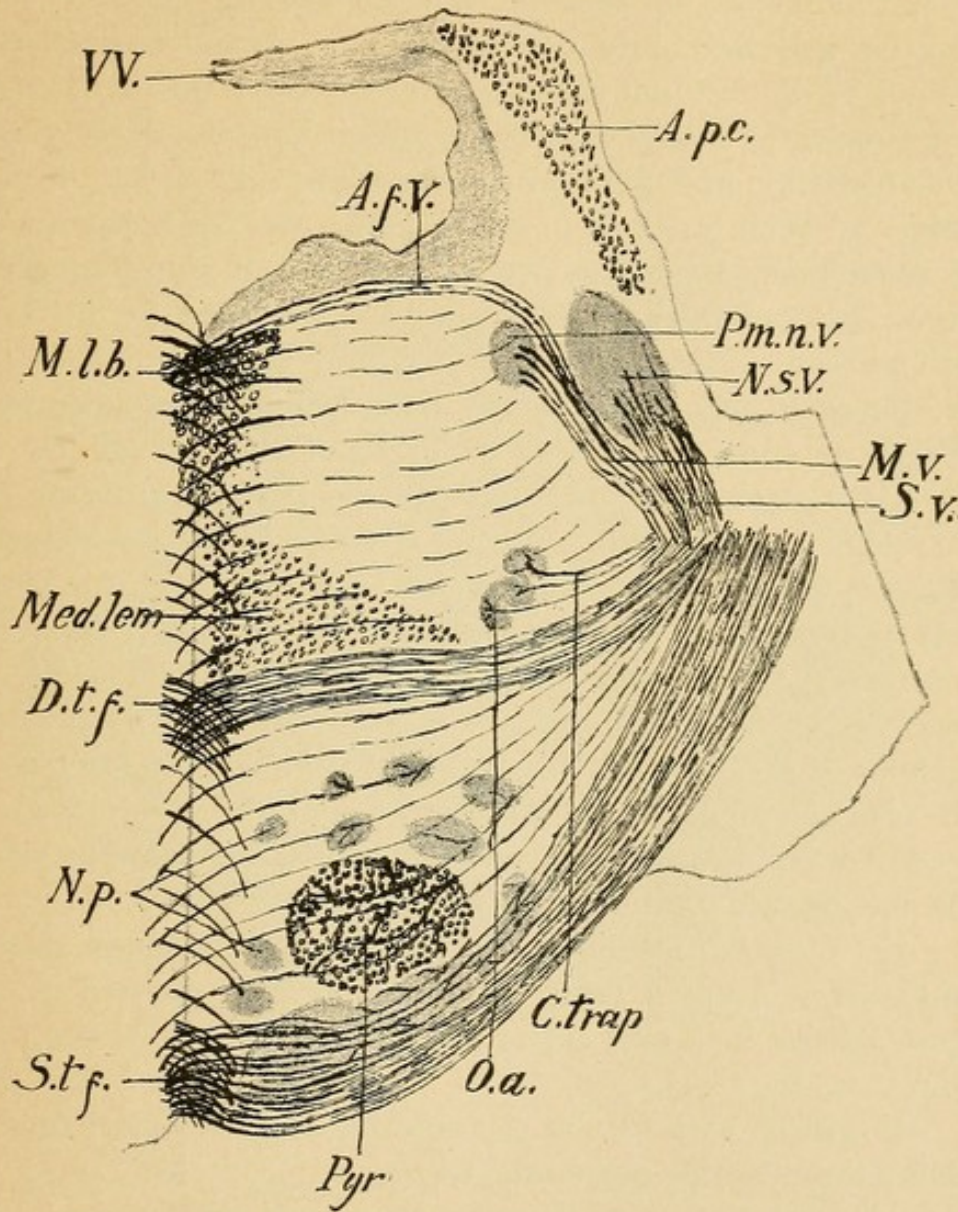


Fig. 26.—V. V., Anterior medullary velum. A. p. c., Anterior peduncle of cerebellum. P. m. n. v., Principal motor nucleus of the trigeminal nerve. N. s. v., Sensory nucleus of trigeminal nerve. M. v., Motor root-fibres of trigeminal nerve. S. v., Sensory root-fibres of trigeminal nerve. C. trap., Trapezoid body. O. a., Anterior olive. Pyr., Pyramidal tract. S. t. f., Superficial transverse fibres of the pons. D. t. f., Deep transverse fibres of the pons. N. p., Nuclei pontis. Med. lem., Medial lemniscus. M. l. b., Medial longitudinal bundle. A. f. v., Arcuate fibres of the trigeminal nerve.

the nuclei of the trigeminal nerve. As that nerve appears at the ventral surface of the pons it presents two divisions or roots, the larger, or sensory, portion (*portio major*) being posterior and lateral to the smaller, or motor, root (*portio minor*). The terminal nucleus of the sensory portion is situated deep in the lateral area of the pons; here the fibres divide into ascending and descending branches; the latter accompanied by their nucleus of termination we have seen in all the preceding sections as the spinal tract of the trigeminal nerve. Most of the ascending branches terminate in the large nucleus seen in this section, which may be regarded as the anterior extremity of the *substantia gelatinosa*, but some turn laterally to enter the middle peduncle of the cerebellum.

The anterior, or motor, root of the trigeminal nerve has two nuclei of origin, the principal one of which is seen in this section (*nucleus motorius princeps nervi trigemini*) as a small mass of large cells medial to the sensory nucleus. Between these two nuclei a band of fibres runs toward the floor of the ventricle, then turns medialward, and, passing just beneath the floor of the ventricle, decussates with a similar tract from the other side. These fibres are often called the arcuate fibres of the trigeminal, but neither their origin nor their termination has been definitely determined.

Between the medial longitudinal bundle and the medial lemniscus is quite a large collection of gray matter in the *raphé* and on each side called the central nucleus of the pons (shown in Fig. 27).

It will be noticed that the anterior olive is placed farther lateral than in the preceding section.

The last section of the pons that we shall examine (Fig. 27) is through the extreme anterior part of the fourth ventricle. In the anterior medullary velum covering the ventricle is the decussation of the fourth cranial, or trochlear, nerve. The trochlear nerve springs from a nucleus in the floor of the aqueduct of Sylvius farther forward at the level of the posterior (inferior) colliculi; it then runs in a dorsal and posterior direction to gain the anterior medullary velum, in which it entirely crosses to the opposite side.

Lateral to the ventricle is a small bundle of fibres semi-

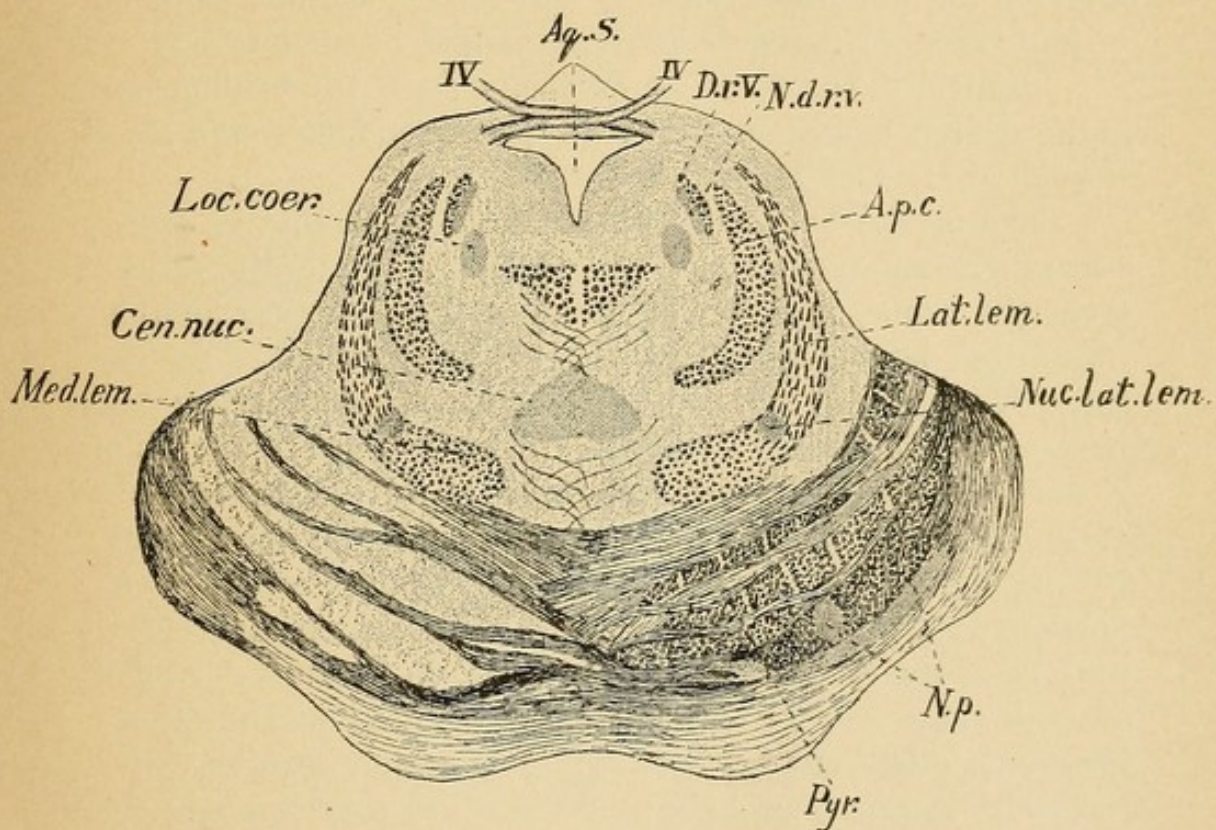


Fig. 27.—IV, Trochlear nerve. *Aq. S.*, Aqueduct of Sylvius. *D. r. V.*, Descending root of the trigeminal nerve. *N. d. r. v.*, Nucleus of descending root of trigeminal nerve. *A. p. c.*, Anterior peduncle of the cerebellum. *Lat. lem.*, Lateral lemniscus. *Nuc. lat. lem.*, Nucleus of lateral lemniscus. *Med. lem.*, Medial lemniscus. *Cen. nuc.*, Central nucleus of pons. *Loc. coer.*, Locus caeruleus. *Pyr.*, Region of pyramidal tract. *N. p.*, Nuclei pontis.

lunar on cross-section; this is the descending root of the trigeminal nerve (*radix descendens nervi trigemini*). It arises from cells in the neighborhood of the *locus cœruleus*, which lies medial and ventral to it. These cells constitute the minor motor nuclei of the trigeminal nerve (*nuclei motorii minores nervi trigemini*). The descending root can be traced in the lateral wall of the aqueduct of Sylvius as far forward as the level of the anterior (superior) colliculi. Its fibres descend to join those springing from the principal motor nucleus.

Ventral to the ventricle on each side of the median line is the medial longitudinal bundle, prominent on section as a triangular tract of large fibres.

The medial lemniscus is now so flattened that its transverse diameter exceeds the vertical; moreover, it has retired from the *raphé*, and joined nearly at right angles another tract: the lateral lemniscus (*lemniscus lateralis*). At the angle of junction is situated a small mass of gray matter: the nucleus of the lateral lemniscus (*nucleus lemnisci lateralis*). A series of sections through this region shows that the nucleus of the lateral lemniscus is continuous with the anterior extremity of the anterior olive. Now, we have seen that the fibres of the trapezoid body, derived in part from the ventral nucleus of the cochlear nerve, terminate in the anterior olive of both sides. From each olive and nucleus of the lateral lemniscus arises another set of fibres, which together with the *striæ acusticæ*, probably, of the other side compose the lateral lemniscus. Consequently the lateral lemniscus is regarded as the path toward the cerebrum of impulses brought to the pons by the cochlear nerve: *i.e.*, as a part of the auditory conduction-path.

In the ventral portion of the section it will be noticed that the aggregate area of the longitudinal fibres is greater than in the preceding sections of the pons; this is due to the fact that many of the longitudinal fibres are distributed to the motor nuclei of cranial nerves and to the *nuclei pontis* in the anterior portion of the pons. Since the fibres distributed to the *nuclei pontis* arise in the cortex of the telencephalon, they are called cortico-pontile fibres.

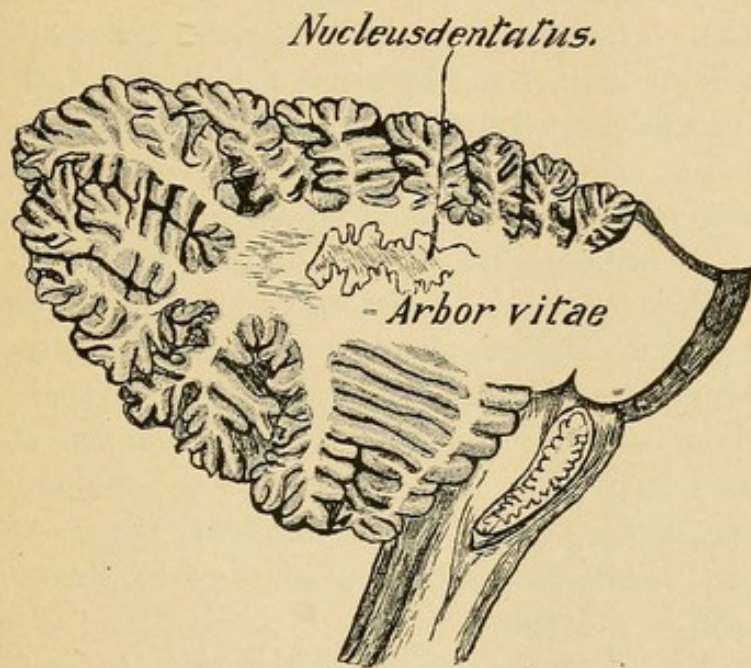


Fig. 28.—Longitudinal section of the hemisphere of the cerebellum  
(after Gray).

## THE INTERNAL ANATOMY OF THE CEREBELLUM.

An antero-posterior median section through the worm of the cerebellum shows the characteristic arrangement of its white and gray matters (Fig. 8). The white matter is internal, and consists of a central mass, or trunk, from which prolongations or limbs proceed in various directions, the whole constituting the arbor vitæ. The primary branches emit still smaller secondary branches, which are invested by the superficial gray matter, or cortex (*substantia corticalis*). The depth of the larger sulci separating the various lobules can now be appreciated. The white matter of the worm is continuous on each side with that of the hemisphere, and in front with the anterior medullary velum, resting on the dorsum of which is a small lobule of the worm called the lingula.

In the hemispheres the arrangement of the two matters (Fig. 28) is quite similar to that in the vermis. The trunk of the arbor, however, is larger, and contains a folded lamella of gray matter—named, from its serrated appearance, the nucleus dentatus—situated just lateral to the worm. A much smaller nucleus is found in the ventral extremity of the anterior vermiform process on each side of the middle line: the nucleus fastigii. Lateral to the nucleus fastigii are located two other nuclei: the nucleus globosus and the nucleus emboliformis.

In addition to the fibres which connect the two hemispheres and to those which connect different parts in the same division, the white matter of the cerebellum consists of fibres which bring it into communication with other portions of the central nervous system. Although much study has been devoted to the termination of the fibres which enter the cerebellum as well as to the destination of those which originate in its gray matter, our knowledge in both particulars is far from exact; so that at the present time only a provisional account can be given of the connections of the cerebellum. These connections are established mainly through its several peduncles. We begin with the inferior peduncle, or corpus restiforme. This, we have learned, contains three sets of fibres: the direct cerebellar tract from the cord; the cere-

bello-olivary fibres, running both ways between the inferior olivary nucleus of one side and the hemisphere of the cerebellum of the other; and the external arcuate fibres, ventral and dorsal. Thus, the cerebellum is connected by the direct cerebellar tract with Clarke's cells (nucleus dorsalis) of the cord, by the cerebello-olivary fibres with the olive of the opposite side of the medulla, and by the external arcuate fibres with the terminal nuclei of the dorsal funiculi of the cord on the same and on the opposite side. It has been generally thought that the direct cerebellar tract terminates in the nucleus fastigii of the worm; but recent investigations render it probable that this tract ends, in part at least, in the cortex of the hemisphere, and that, indeed, all the fibres which enter the cerebellum by way of the corpus restiforme may reach the cortex.

The middle peduncle of the cerebellum (brachium pontis) contains two sets of fibres: the ponto-cerebellar fibres, which arise in the nuclei pontis and terminate chiefly in the hemisphere of the opposite side; and the cerebello-pontile fibres, which run from the hemisphere to the pons, where some of them terminate in the nuclei pontis and others go to an unknown destination.

The anterior, or superior, peduncle (brachium conjunctivum) is composed of fibres which arise, according to some authorities, in the nucleus dentatus; according to others, partly in the cortex of the hemisphere. They enter the mesencephalon, where they decussate, and terminate in a gray mass there found, called the red nucleus (nucleus ruber).

In addition to these the cerebellum has two other connecting tracts. In studying the sections of the pons and medulla we saw that the vestibular nerve sends a fasciculus into the cerebellum; the trigeminal, glosso-pharyngeal, and vagus nerves possibly do the same thing. In the case of the vestibular nerve the bundle has been traced to the nucleus fastigii of the worm. Some fibres, then, of the sensory cranial nerves run directly into the cerebellum.

The second is the tract of Gowers from the cord. Although this tract is in reality very complex, a large proportion of its fibres runs forward as far as the level of entrance of

the sensory portion of the trigeminal nerve. The fibres then turn dorsalward, and, having reached the level of the anterior medullary velum, run backward medial to the anterior peduncle to end in the cortex of the worm.

Finally, the results of many investigators point to the existence of fibres which, originating in the gray matter of the cerebellum, establish connection with the cells of the ventral horns of the cord. Unfortunately, our knowledge concerning them is quite indefinite. It would seem that one important connection is established by way of Deiters's nucleus.

#### THE INTERNAL ANATOMY OF THE MESENCEPHALON.

We begin the study of the mesencephalon by examining a transverse section through the posterior, or inferior, colliculi (Fig. 29); the ventral portion of such a section, however, passes through the anterior margin of the pons. The fourth ventricle has now given place to the aqueduct of Sylvius (*aquæductus cerebri*): a narrow canal whose walls contain a considerable amount of gray matter. In this gray matter ventro-lateral to the aqueduct lies the nucleus of origin of the fourth cranial, or trochlear, nerve (*nervus trochlearis*). Its root-fibres curve dorsalward with an inclination toward the median line, then take a posterior direction to enter the anterior medullary velum, where they cross the median line and appear as the nerve lateral to the peduncle of the cerebrum.

Lateral to the root-fibres of this nerve is still seen the descending root of the trigeminal nerve, with its nuclei, and ventral to the nucleus of the fourth nerve is the prominent medial longitudinal bundle.

The *formatio reticularis* is traversed by numerous fibres from the anterior peduncle of the cerebellum (*brachium conjunctivum*), which decussate in the *raphé* (*decussatio brachii conjunctivi*), and take a forward course to end in the red nucleus, as we shall presently see. It will be noticed that the ventral fibres of the peduncle are the first to decussate. These ventral fibres are in reality not connected with the cerebellum, but form a commissure between the superior vestibular nuclei of the two sides.

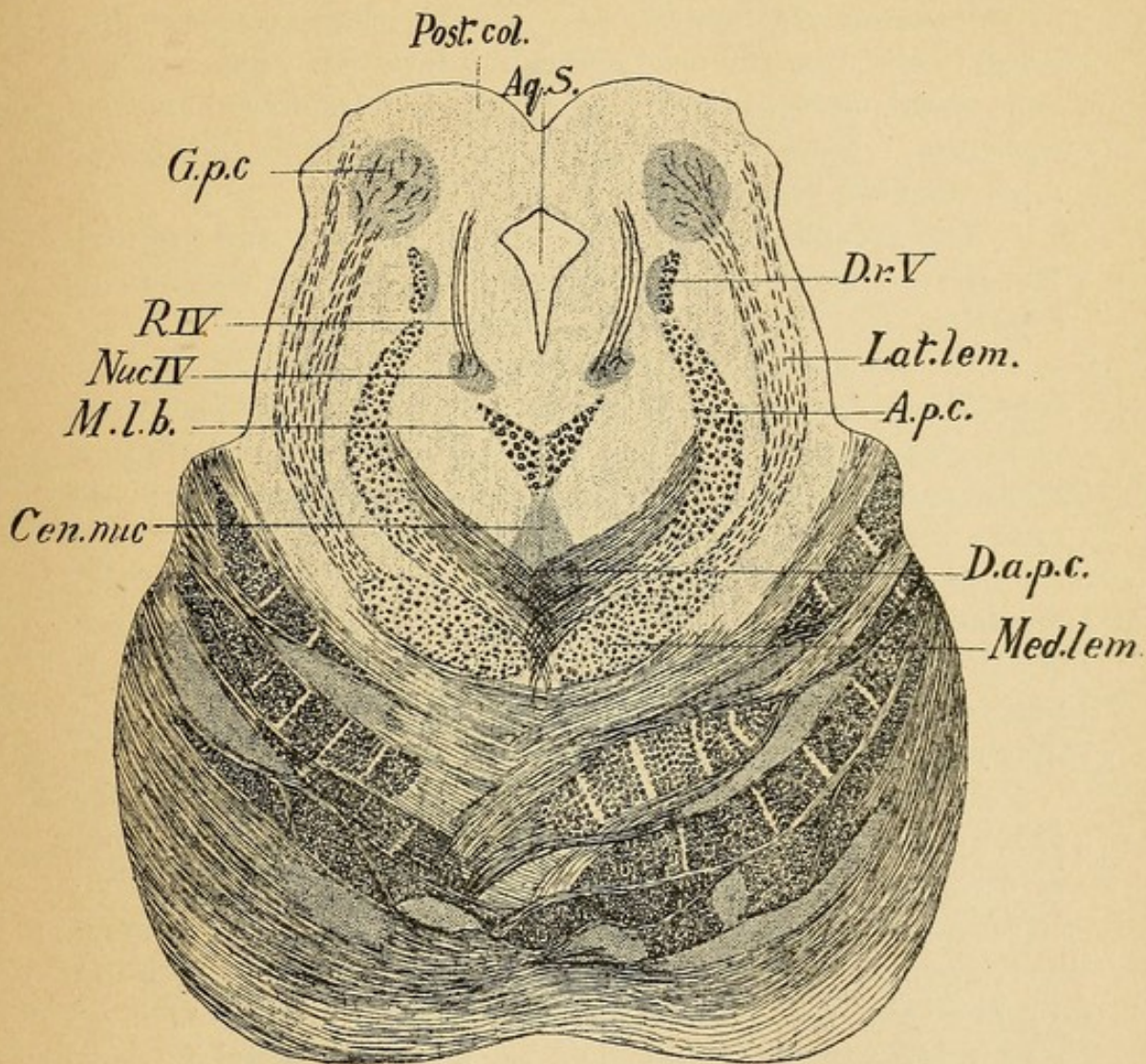


Fig. 29.—*Post. col.*, Posterior colliculus. *Aq. S.*, Aqueduct of Sylvius. *D. r. V.*, Descending root of the trigeminal nerve and its nucleus. *Lat. lem.*, Lateral lemniscus. *A. p. c.*, Anterior peduncle of cerebellum. *D. a. p. c.*, Decussation of anterior peduncle. - *Med. lem.*, Medial lemniscus. *Cen. nuc.*, Central nucleus. *M. l. b.*, Medial longitudinal bundle. *Nuc. IV*, Nucleus of the trochlear nerve. *R. IV*, Root-fibres of the trochlear nerve. *G. p. c.*, Gray matter of posterior colliculus.

Ventral to the peduncle is the medial lemniscus, still continuous laterally with the lateral lemniscus. The latter tract has here a decided dorsal inclination, and terminates by abandoning some of its fibres to the medial geniculate body through the posterior brachium, and others to the central gray matter of the posterior colliculus—the nucleus of the posterior (inferior) colliculus (*nucleus colliculi inferioris*). Some of the cells of this nucleus send their axones forward to the anterior colliculus, while others enter the lateral lemniscus and pursue a posterior direction in that tract.

The second section (Fig. 30) is through the anterior (superior) colliculi, and is entirely confined to the mesencephalon.

We have seen that the mesencephalon may be divided superficially into the corpora quadrigemina and the peduncles of the cerebrum. In sections each peduncle is divided into a dorsal portion—the tegmentum—and a ventral portion: the crusta, or base of the peduncle (*basis pedunculi*). The ground for this division is the substantia nigra, a mass of heavily-pigmented cells, which appears, to the unaided eye, as a black streak across the section of the peduncle. The tegmentum is separated from the corpora quadrigemina by an arbitrary line drawn through the aqueduct.

Taking up these parts separately, it will be seen that the fibres contained in the base of the peduncle are longitudinal in direction; they are derived from the cortex of the telencephalon, and we have seen most of them before as the pyramidal tract and the cortico-pontile fibres. In the tegmentum dorsal to the substantia nigra is situated the reddish mass of gray matter to which we have referred as the red nucleus (*nucleus ruber*), in which terminates the anterior peduncle of the cerebellum after its decussation. Its medial margin is marked by the section of a small bundle of fibres,—the fasciculus retroflexus,—which connects the trigonum habenulæ of the diencephalon with the ganglion interpedunculare: a mass of gray matter found between the beginning of the peduncles (not shown in the figure).

Lateral to the red nucleus and dorsal to the lateral extremity of the substantia nigra lies the lemniscus, its section

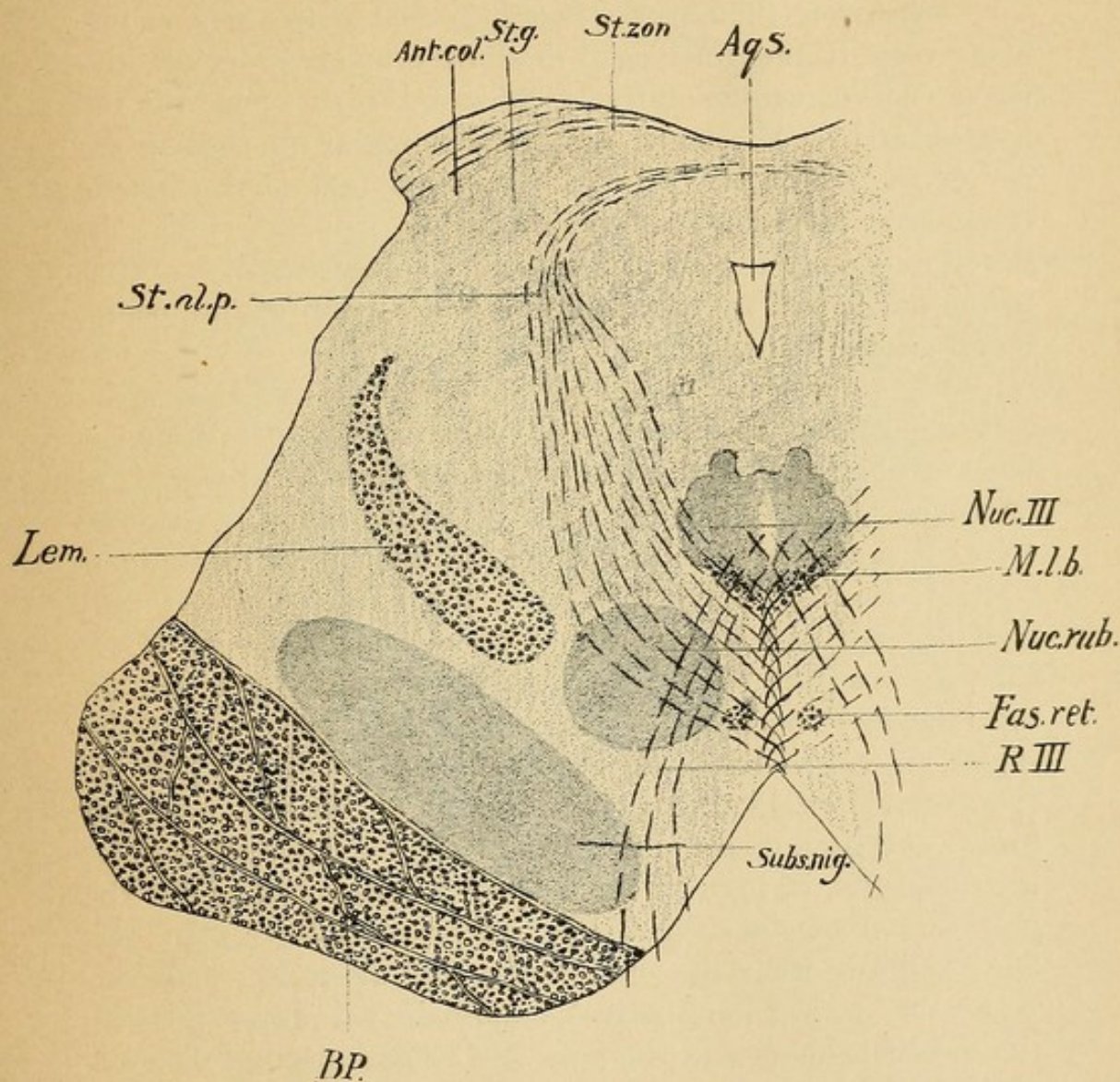


Fig. 30.—*Ant. col.*, Anterior colliculus. *St. g.*, Stratum griseum. *St. zon.*, Stratum zonale. *Aq. S.*, Aqueduct of Sylvius. *Nuc. III*, Nucleus of the oculomotor nerve. *M. l. b.*, Medial longitudinal bundle. *Nuc. rub.*, Red nucleus. *Fas. ret.*, Fasciculus retroflexus. *R. III*, Root-fibres of the oculomotor nerve. *Subs. nig.*, Substantia nigra. *B. P.*, Base of peduncle. *Lem.*, Lemniscus. *St. al. p.*, Deep layer of white matter.

being somewhat comma-shaped, with its small extremity pointing dorsalward. In this situation the bundle gives off some fibres to the anterior colliculus, but most of it is continued on to the diencephalon.

Ventral to the aqueduct on each side of the median line is the very striking nucleus of the third cranial, or oculomotor, nerve (*nervus oculomotorius*); its root-fibres traverse the red nucleus and the substantia nigra, to emerge at the medial border of the peduncle. It will be noticed that some of these fibres arise from the nucleus of the opposite side: *i.e.*, the nerve undergoes a partial decussation. Immediately ventral to the nucleus of the third nerve is the section of the medial longitudinal bundle.

The anterior colliculus is covered by a thin sheet of white matter,—the stratum zonale,—which consists, to a large extent, of fibres from the optic tract on their way to terminate in the central gray matter of the colliculus (*stratum griseum colliculi superioris*). Limiting this gray stratum medially is another zone of white matter,—the deep white stratum (*stratum album profundum*),—which is composed of fibres that, arising from the cells of the gray stratum, curve around the aqueduct to enter the tegmentum and decussate in the raphé ventral to the medial longitudinal bundle. Many of them are believed to enter the medial longitudinal bundle and form a constituent part of it. The medial longitudinal bundle, then, consists, in part, of the axones of cells contained in the gray matter of the colliculi, in which, as we have seen, terminate fibres from the optic tracts and from the lemnisci. Now, the medial longitudinal bundle in its course through the mesencephalon and the pons can be seen giving off fibres to the nuclei of the motor cranial nerves, especially those which innervate the ocular muscles. It is, therefore, not improbable that this bundle is, to a large extent, a connecting tract between the corpora quadrigemina and the nuclei of motor cranial nerves, thus permitting certain reflex acts due to visual and acoustic impressions. Another source, however, for the fibres of this bundle is found farther forward in the mesencephalon in the shape of a small nucleus lateral to the aqueduct, and known as the nucleus of the medial longitudinal bundle (*nucleus fasciculi longitudinalis medialis*).

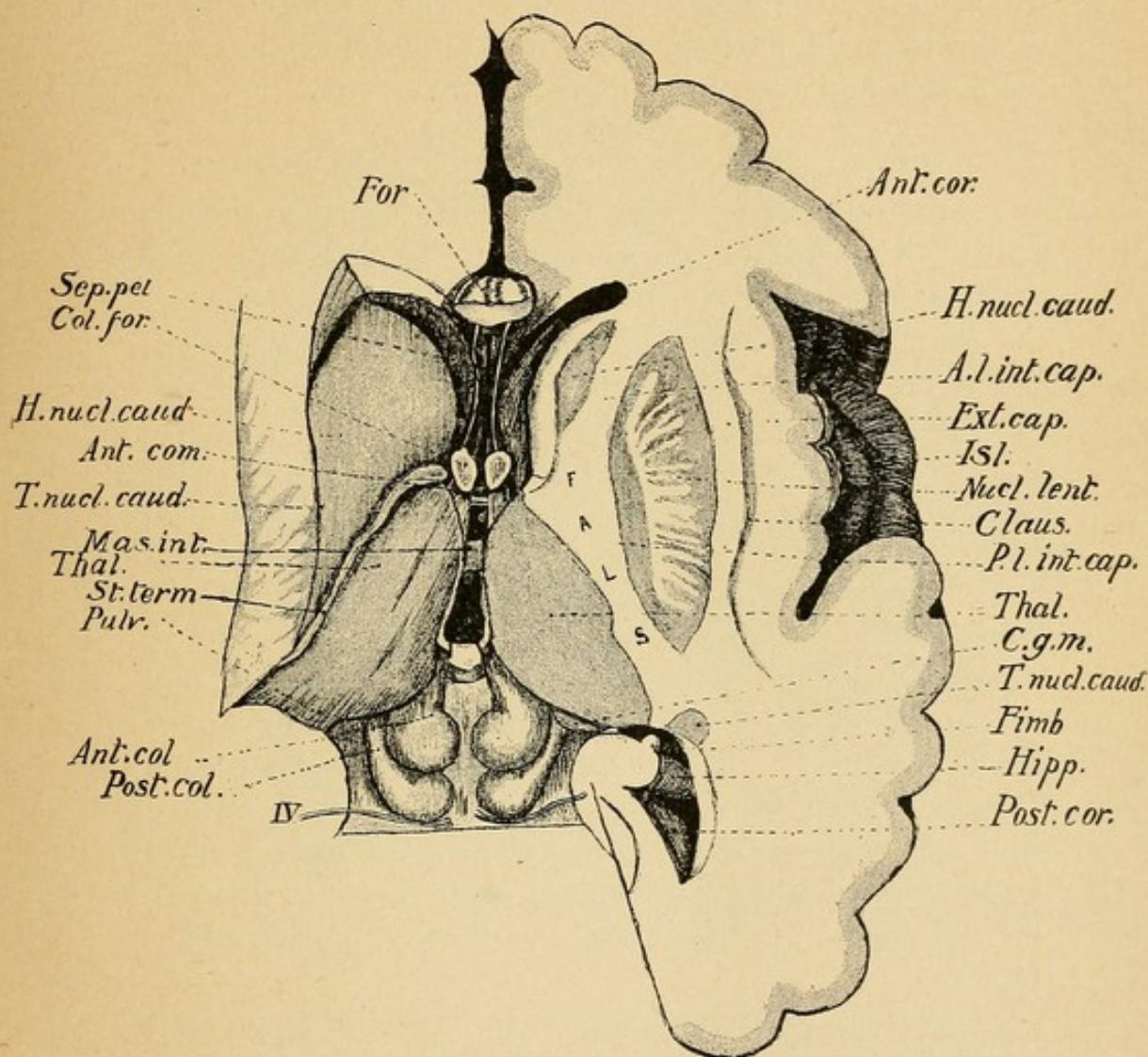


Fig. 31.—*For.*, Fornix. *Sep. pel.*, Septum pellucidum. *Col. for.*, Column of fornix. *H. nucl. caud.*, Head of nucleus caudatus. *Ant. com.*, Anterior commissure. *T. nucl. caud.*, Tail of nucleus caudatus. *Mas. int.*, Massa intermedia. *Thal.*, Thalamus. *St. term.*, Stria terminalis. *Pulv.*, Pulvinar. *Ant. col.*, Anterior colliculus. *Post. col.*, Posterior colliculus. *IV*, Trochlear nerve. *Ant. cor.*, Anterior cornu of lateral ventricle. *A. l. int. cap.*, Anterior limb of internal capsule. *Ext. cap.*, External capsule. *Isl.*, Island of Reil. *Nucl. lent.*, Nucleus lentiformis. *Claus.*, Clastrum. *P. l. int. cap.*, Posterior limb of internal capsule. *Hipp.*, Hippocampus. *Post. cor.*, Posterior cornu of lateral ventricle. (After Landois.)

In addition to the fibres derived from the medial longitudinal bundle numerous fibres enter the nuclei of the third and fourth cranial nerves; some of them are possibly fibres which have come down from the cortex of the telencephalon in the pyramidal tracts, and thus make connection between the cortex and the nuclei of these two nerves.

#### THE INTERNAL ANATOMY OF THE DIENCEPHALON.

**THE THALAMUS.**—The dorsal surface of the thalamus is white, owing to the presence of a thin stratum of fibres (stratum zonale) derived mostly from the optic tract.

The medial surface is gray, and continuous with the gray matter lining the third ventricle and, through the massa intermedia, with the opposite thalamus.

The lateral surface of the thalamus is fused with the telencephalon. To appreciate this it is necessary to examine a horizontal section through the cerebrum (Fig. 31). Such a section discloses, in addition to the thalamus, two gray bodies, which, together, constitute the corpus striatum of the telencephalon; the anterior is the caudate nucleus, and the one lateral to the thalamus is the lentiform nucleus of the corpus striatum. The thalamus and the corpus striatum are often called the "basal ganglia" of the cerebrum. The lentiform nucleus is separated from the caudate nucleus and from the thalamus by an elbow-shaped layer of white matter: the internal capsule, consisting of two limbs, anterior and posterior.

A vertical transverse section through the thalamus (Fig. 32) shows that it is composed of three nuclei more or less indistinctly separated by thin lamellæ of white matter; they are distinguished as the lateral, medial, and anterior nuclei of the thalamus (nucleus lateralis, n. medialis, et n. anterior thalami). Some anatomists make another nucleus out of the ventral part of the lateral nucleus, and speak of it as the ventral nucleus. From the cells in this latter portion of the thalamus arise numerous fibres, which, having passed through the posterior limb of the internal capsule, finally terminate in the cortex of the telencephalon; they represent, as we shall see hereafter, the indirect continuation of the medial lemniscus.

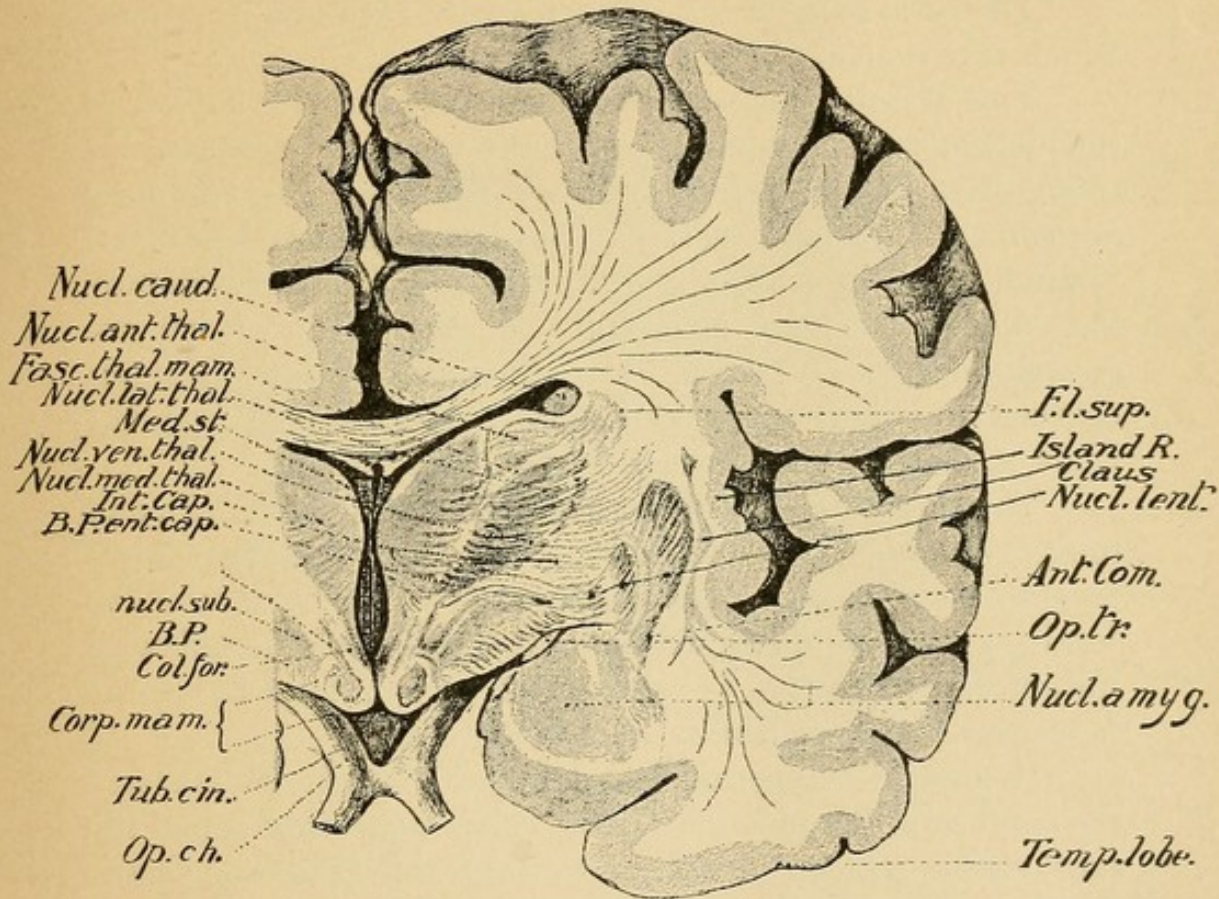


Fig. 32.—*Nucl. caud.*, Nucleus caudatus. *Nucl. ant. thal.*, Anterior nucleus of thalamus. *Fasc. thal. mam.*, Fasciculus thalamo-mamillaris. *Nucl. lat. thal.*, Lateral nucleus of thalamus. *Med. st.*, Medullary stria. *Nucl. ven. thal.*, Ventral nucleus of thalamus. *Nucl. med. thal.*, Medial nucleus of thalamus. *Int. cap.*, Internal capsule. *B. P. ent. cap.*, Base of peduncle of cerebrum entering the internal capsule. *Nucl. sub.*, Nucleus hypothalamicus. *B. P.*, Base of the peduncle of cerebrum. *Col. for.*, Column of fornix. *Corp. mam.*, Corpus mamillare. *Tub. cin.*, Tuber cinereum. *Op. ch.*, Optic chiasm. *F. l. sup.*, Fasciculus longitudinalis superior. *Island R.*, Island of Reil. *Claus.*, Clastrum. *Nucl. lent.*, Nucleus lentiformis. *Ant. com.*, Anterior commissure. *Op. tr.*, Optic tract. *Nucl. amyg.*, Nucleus amygdalæ. (After Edinger.)

Another bundle of fibres, which runs through the anterior limb of the internal capsule, connects the thalamus with the cortex of the telencephalon; about these not much is known, but it is held by some that the thalamus is connected with every region of the cortex.

The basal ganglia are connected with each other by fibres which run ventral to these bodies.

**THE HYPOTHALAMUS.**—Our knowledge of this region of the diencephalon is so imperfect that a very brief account will suffice here. The lamina terminalis and the tuber cinereum are composed of gray matter. The infundibulum is a diverticulum from the floor of the third ventricle to the hypophysis. The latter body is peculiar in that its two lobes are entirely different in structure; the posterior lobe contains nervous substance, while the anterior, being derived from the vault of the pharynx, consists of epithelial tubules.

The corpora mamillaria are gray internally (Fig. 32), and the gray matter in each is divided into three nuclei (nuclei corporis mamillaris). Each corpus receives the column of the fornix, as will be described hereafter, and is connected with the anterior nucleus of the thalamus by a bundle of fibres, the fasciculus thalamo-mamillaris of Vicq d'Azyr.

Behind, the hypothalamus is fused with the peduncle of the cerebrum, the plane of fusion being commonly called the subthalamic region. A section through this (Fig. 33) shows, lateral to the red nucleus, a gray body not seen hitherto: the subthalamic nucleus (nucleus hypothalamicus). The white matter dorsal to this nucleus consists largely of the fibres of the medial lemniscus. This tract terminates to a large extent in the ventral nucleus of the thalamus, from the cells of which run axones that continue the course of the lemniscus to the cortex of the telencephalon. Here we can also see the base of the peduncle continuous with the internal capsule.

**THE METATHALAMUS.**—The interior of the geniculate bodies is formed by gray matter known as their nuclei (nuclei corporis geniculati lateralis; n. c. g. medialis). The fibres of the optic tract terminate largely in the gray matter of the lateral geniculate body, but the tract also sends some fibres into the pulvinar of the thalamus, the anterior colliculus, and

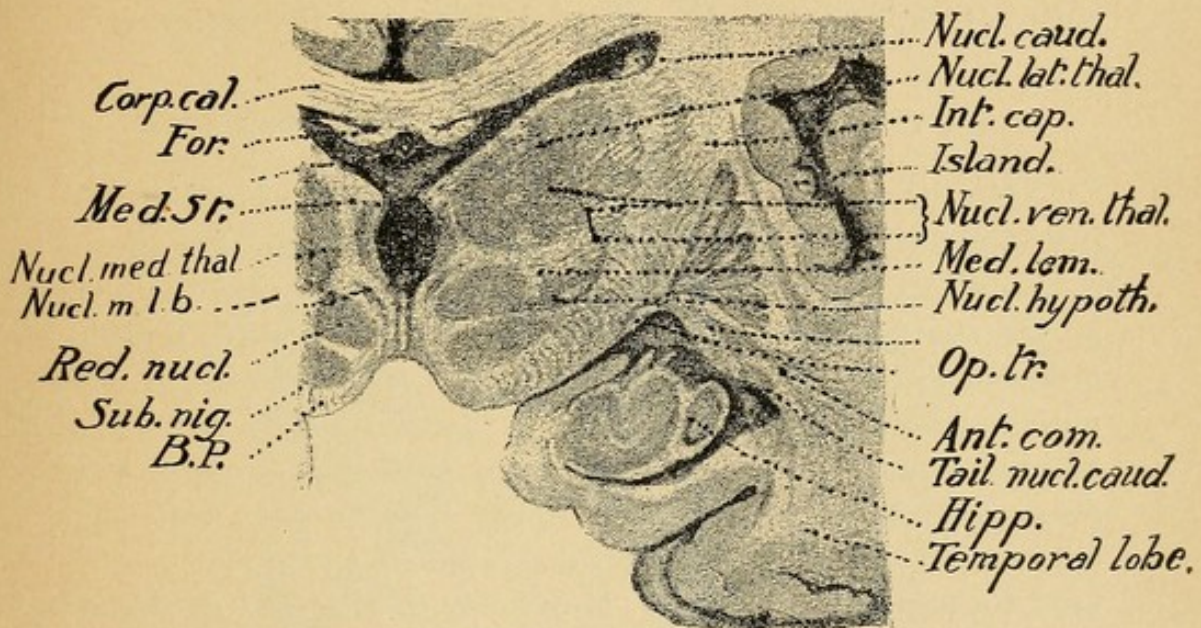


Fig. 33.—*Corp. cal.*, Corpus callosum. *For.*, Fornix. *Med. str.*, Medullary stria. *Nucl. med. thal.*, Medial nucleus of thalamus. *Nucl. m. l. b.*, Nucleus of medial longitudinal bundle. *Red. nucl.*, Red nucleus of the tegmentum. *Sub. nig.*, Substantia nigra. *B. P.*, Base of the cerebral peduncle. *Nucl. caud.*, Nucleus caudatus. *Nucl. lat. thal.*, Lateral nucleus of thalamus. *Int. cap.*, Internal capsule. *Island*, Island of Reil. *Nucl. ven. thal.*, Ventral nucleus of thalamus. *Med. lem.*, Region of the medial lemniscus. *Nucl. hypoth.*, Nucleus hypothalamicus. *Op. tr.*, Optic tract. *Ant. com.*, Anterior commissure. *Tail nucl. caud.*, Tail of nucleus caudatus. *Hipp.*, Hippocampus. (After Edinger.)

possibly into the medial geniculate body. The latter body receives most of the lateral lemniscus. From the gray matter of the lateral geniculate body, the pulvinar, and the anterior colliculus spring fibres which run through the posterior limb of the internal capsule, continuing the course of the optic tract to the cortex and forming the so-called occipito-thalamic radiation of Gratiolet; while those from the medial geniculate body continue the course of the lateral lemniscus to the cortex, terminating in the superior temporal convolution.

#### THE INTERNAL ANATOMY OF THE TELEENCEPHALON.

If a horizontal section be made through the hemispheres just dorsal to the level of the corpus callosum (Fig. 34), there is brought to light in each hemisphere the appearance known as the centrum semiovale, or central mass of white matter, dotted in the fresh specimen by sections of blood-vessels: the *puncta vasculosa*. The centrum is bordered by a thin convoluted margin of gray matter: the cortex, or cortical substance (*substantia corticalis*). It can now be seen that each convolution consists of a central mound of white matter covered by cortical substance. Moreover, the cortical substance lines even the deepest sulci, in the bottom and on the sides of which numerous small secondary convolutions are seen. The two centra semiovalia are connected by the broad band of white matter previously mentioned as the corpus callosum.

**THE CORPUS CALLOSUM.**—This body should be studied in sagittal (Fig. 38), as well as in horizontal, sections of the encephalon. It consists of a central portion, or trunk (*truncus*), and two extremities, anterior and posterior. The dorsal surface of the trunk presents on each side of the median line a slender longitudinal band, the nerve of Lancisi, or medial longitudinal stria (*stria longitudinalis medialis*); and laterally at the junction with the centrum a similar band, the lateral longitudinal stria (*stria longitudinalis lateralis*). Between the two striæ stretches an exceedingly delicate gray lamella: the *fasciola cinerea*.

The ventral surface of the trunk is concave, and forms the roof for a cavity in each hemisphere: the lateral ventricle.

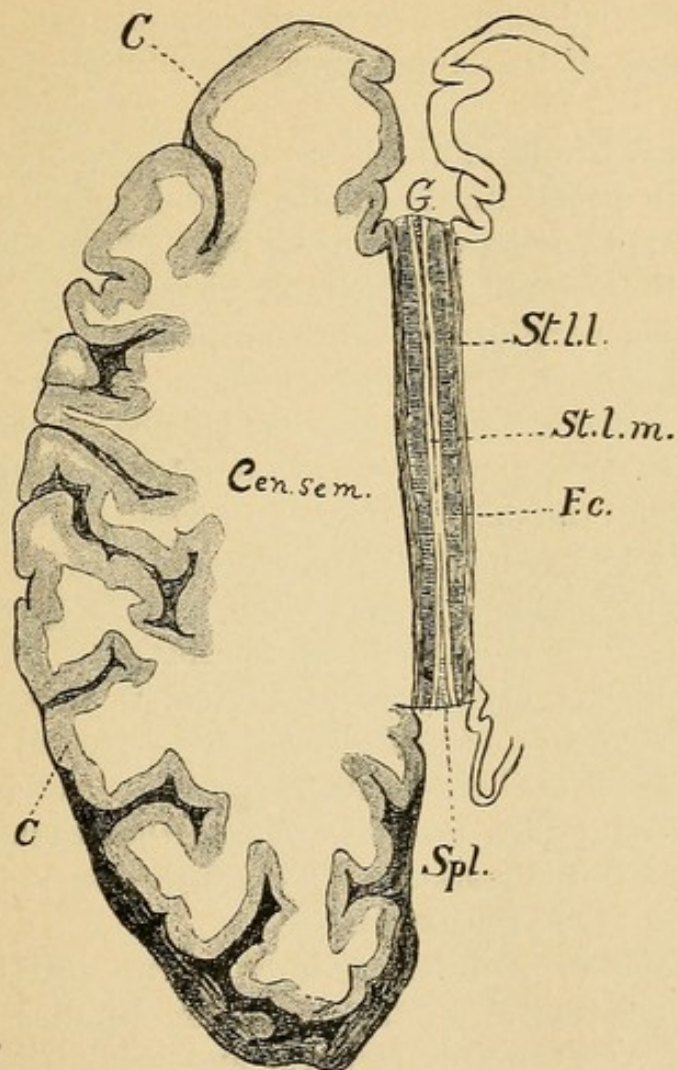


Fig. 34.—*G.*, Genu of corpus callosum. *Spl.*, Splenium of corpus callosum. *St. l. l.*, Lateral longitudinal stria. *St. l. m.*, Medial longitudinal stria. *F. c.*, Fasciola cinerea. *C.*, Cortex. *Cen. sem.*, Centrum semiovale. (After Rauber.)

The posterior extremity is thickened, and is called the splenium.

The anterior extremity is the knee (*genu*); here the corpus callosum makes a ventral bend, which is continued backward under the name of rostrum. The longitudinal striæ accompany it in this course, and under the name of peduncle of the corpus callosum, or *gyrus subcallosus*, pass to the anterior extremity of the hippocampal convolution, as previously described.

The great bulk of the fibres of the corpus callosum are transverse in direction: they radiate into the *centra semiovalia* in all directions, going to almost all parts of the cortex. They belong to the class of commissural fibres: *i.e.*, they connect corresponding parts of the two hemispheres.

THE LATERAL VENTRICLES.—The lateral ventricle (*ventriculus lateralis*) of each hemisphere may be exposed by carrying an antero-posterior incision through the corpus callosum on each side of the median line, and severing the attachments of that body in front, behind, and laterally. It is a wide and shallow cavity divided into a central portion (*pars centralis*) and three prolongations, or horns (*cornua*).

The anterior horn (*cornu anterius*) is directed forward and lateralward into the substance of the frontal lobe.

The posterior horn (*cornu posterius*) runs backward, lateralward, and then medialward into the substance of the occipital lobe; it is marked by a ridge thrown up by the calcarine fissure: the *calcar avis*.

The middle, or inferior, horn (*cornu inferius*) curves posterior and ventral to the thalamus, winding backward, lateralward, ventralward, forward, and medialward into the temporal lobe nearly to its anterior extremity. In its floor is a ridge, produced by the dentate fissure, following the course of the horn throughout its length, and called Ammon's horn, or the hippocampus.

Returning to the central portion of the ventricle, its roof is formed by the corpus callosum. Its lateral wall is formed by the junction of the corpus callosum with the white matter of the hemisphere. In its floor are seen the following objects, starting at the lateral wall and proceeding toward the median

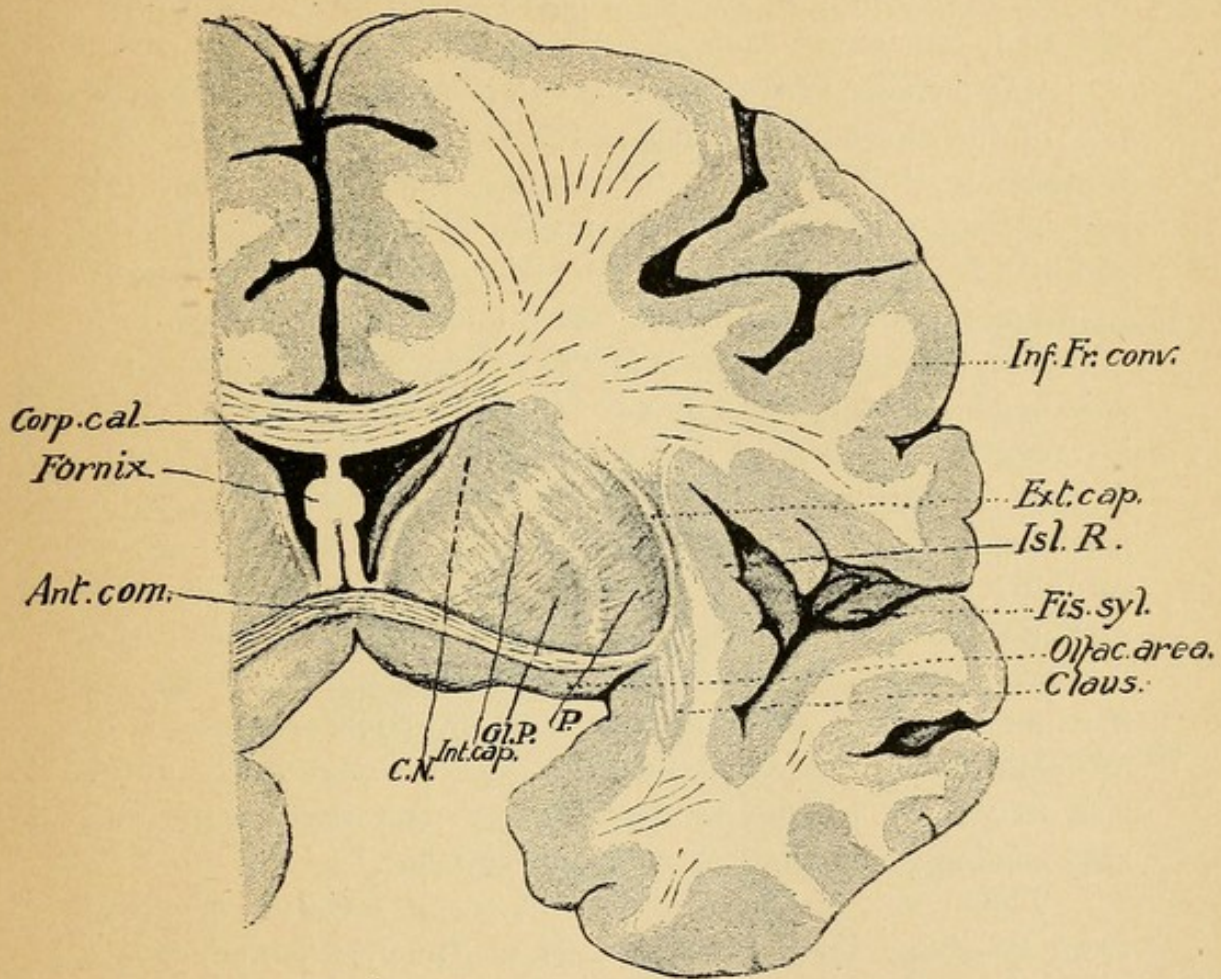


Fig. 35.—*Corp. cal.*, Corpus callosum. *Ant. com.*, Anterior commissure. *Inf. Fr. conv.*, Inferior frontal convolution. *Ext. cap.*, External capsule. *Isl. R.*, Island of Reil. *Fis. syl.*, Fissure of Sylvius. *Olfac. area.*, Olfactory area. *Claus.*, Claustrum. *C. n.*, Caudate nucleus. *Int. cap.*, Internal capsule. *Gl. p.*, Globus pallidus. *P.*, Putamen. (After Edinger.)

line: A large gourd-shaped mass of gray matter,—the caudate nucleus of the corpus striatum; then the stria terminalis and vena terminalis; then the lateral half of the dorsal surface of the thalamus; next a fringe of blood-vessels rolled in pia mater; the chorioid plexus (plexus chorioideus) of the lateral ventricle; and, finally, one-half of a triangular sheet of white matter, the fornix, which has a half in each lateral ventricle. We shall now study each of these objects separately.

*The Corpus Striatum.*—To obtain a satisfactory conception of the corpus striatum and the neighboring parts of the hemisphere it is necessary to examine a series of transverse and horizontal sections of this region (Figs. 31, 32, 33, 35, and 36), from which we learn the following facts: The corpus striatum contains two distinct collections of gray matter, one of which is seen in the floor of the ventricle, while the other is imbedded in the white matter lateral to the ventricle. The intraventricular portion is the caudate nucleus (nucleus caudatus); it begins with an enlarged anterior extremity,—the head (caput),—and rapidly tapers backward to a long, narrow column: the tail (cauda). The tail first arches backward, running dorsal and then lateral to the thalamus; it then turns forward ventral and lateral to the thalamus, and can be traced in transverse sections along the roof of the inferior horn of the ventricle to a thickened portion of the cortex in the anterior extremity of the temporal lobe: the amygdaloid, or almond-shaped, nucleus (nucleus amygdalæ).

The extraventricular part of the corpus striatum is called from its shape the lentiform nucleus (nucleus lentiformis). It lies in a plane lateral and posterior to the caudate nucleus, from which it is separated by a narrow sheet of white matter: the anterior limb of the internal capsule. On its medial side is the thalamus, which, however, extends farther backward than the lentiform nucleus; from this it is separated by the posterior limb of the internal capsule. In transverse sections it is seen that the lentiform nucleus is composed of three divisions separated from each other by thin planes of white matter; the lateral and highest of these divisions is called the putamen, while the other two constitute the globus pallidus. Lateral to the nucleus lentiformis is a sheet of white matter

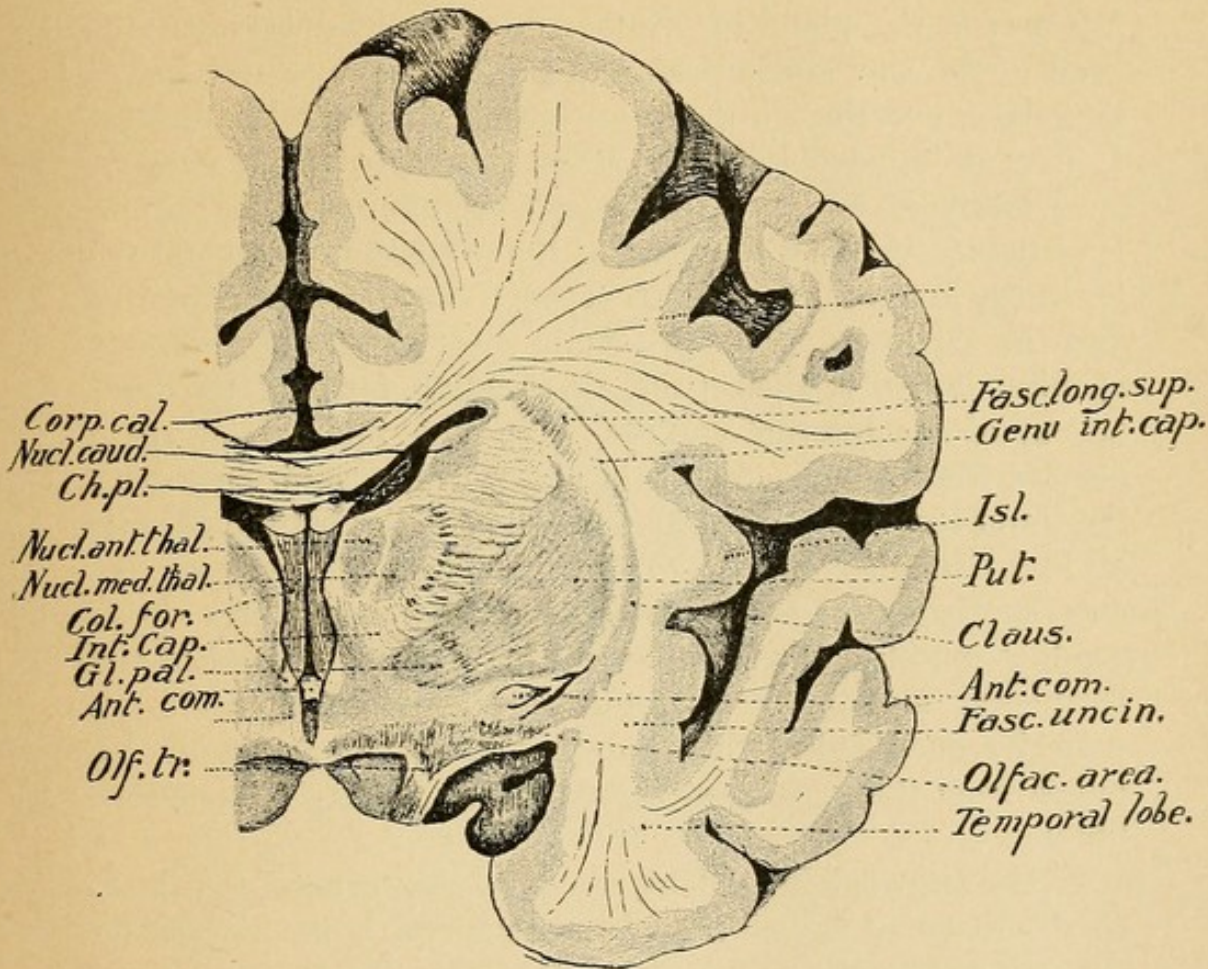


Fig. 36.—*Corp. cal.*, Corpus callosum. *Nucl. caud.*, Nucleus caudatus. *Ch. pl.*, Chorioid plexus. *Nucl. ant. thal.*, Anterior nucleus of thalamus. *Nucl. med. thal.*, Medial nucleus of thalamus. *Col. for.*, Column of the fornix. *Int. cap.*, Internal capsule. *Gl. pal.*, Globus pallidus. *Ant. com.*, Anterior commissure. *Olf. tr.*, Olfactory tract. *Fasc. long. sup.*, Superior longitudinal bundle. *Genu int. cap.*, Genu of internal capsule. *Isl.*, Island of Reil. *Claus.*, Claustrum. *Put.*, Putamen. *Fasc. uncin.*, Fasciculus uncinatus. *Olfac. area.*, Olfactory area. (After Edinger.)

known as the external capsule, and bordering this laterally is a thin layer of gray matter, the claustrum, which is continuous ventrally with the amygdaloid nucleus; still farther lateral we recognize the convolutions of the island of Reil.

*The Internal Capsule.*—The internal capsule (*capsula interna*) is the plane of white matter situated between the head of the caudate nucleus and the thalamus as the medial boundary, and the lentiform nucleus as the lateral boundary. It may be divided into two limbs, or portions: an anterior (*pars frontalis*) and a posterior (*pars occipitalis*). The former is contained between the head of the caudate nucleus and the lentiform nucleus, the latter between the lentiform nucleus and the thalamus. The two limbs meet at an obtuse angle, opening laterally, their point of junction forming the knee (*genu*) of the internal capsule. Through this narrow space pass the fibres which connect the cortex of the hemisphere with the lower-lying parts of the brain. The anterior limb consists of fibres which connect the thalamus with the cortex; the anterior two-thirds of the posterior limb contain fibres which conduct impulses to the motor nuclei of the pons and of the peripheral nerves,—*i.e.*, motor fibres,—while through the posterior one-third of this limb pass fibres which convey impulses from the peripheral nerves to the cortex: *i.e.*, sensory fibres.

The amygdaloid nucleus, previously mentioned, is a thickened portion of the cortex of the temporal lobe: it receives the stria terminalis, and is continuous with the claustrum and with the tail of the caudate nucleus.

*The Fornix and the Hippocampus.*—The fornix is formed by two cords which are triangular on cross-section, with the bases facing each other, the thin edges looking lateralward. These cords diverge behind, converge in front; the diverging portions are connected with each other and with the ventral surface of the corpus callosum by transverse fibres known as the lyra (*commissura hippocampi*). Owing to these fibres, the fornix appears triangular, with its apex forward and its base backward. At the apex of the fornix, about midway between the two extremities of the corpus callosum, the cords separate, and, under the name of columns of the fornix (*col-*

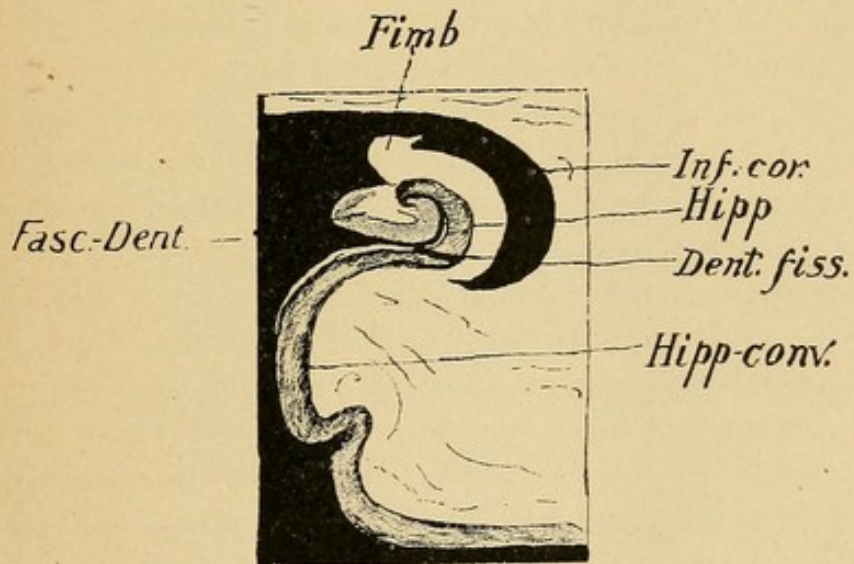


Fig. 37.—*Inf. cor.*, Inferior horn of lateral ventricle. *Hipp.*, Hippocampus. *Fasc. Dent.*, Dentate fascia. *Dent. fiss.*, Dentate fissure. *Hipp. conv.*, Hippocampal convolution. *Fimb.*, Fimbria. (After Edinger.)

umnæ fornicis), run toward the hypothalamus to terminate in the corpora mamillaria. Anterior to them as they diverge can be seen the transverse band called the anterior commissure (commissura anterior cerebri). Between the column of the fornix and the anterior tubercle of the thalamus on each side is the opening of a Y-shaped canal connecting the third with the lateral ventricles; it is called the foramen of Monro. From the point where the fornix ceases to be adherent to the ventral surface of the corpus callosum by means of the lyra appears a new structure,—the septum pellucidum,—forming the dividing wall between the lateral ventricles. On section it is found to consist of two laminæ separated by a very narrow cavity: the cavum septi pellucidi.

Posteriorly, each cord of the fornix, under the name of crus, enters the inferior horn of the ventricle, where it becomes continuous with the hippocampus, and takes the name of fimbria; it is accompanied by the chorioid plexus from the central portion of the ventricle.

To examine the hippocampus a horizontal section should be made through the region of the inferior horn (Fig. 37). It will be seen that the hippocampus is a ridge thrown up by the dentate fissure on the medial surface of the hemisphere, and that it is continuous with the hippocampal convolution (Fig. 38). In other words, it is an infolded portion of the cortex. Both gray and white matter are folded, but the white ceases sooner than the gray, which, continuing, bends first lateralward and then toward the median line, to terminate in a free edge, which, because of its serrated appearance, is known as the dentate fascia (fascia dentata). It is not in the cavity of the lateral ventricle, but is continuous over the posterior extremity of the corpus callosum with the fasciola cinerea and the longitudinal stria, and through them with the gyrus subcallosus. All these structures—fascia dentata, fasciola cinerea, longitudinal striæ, and gyrus subcallosus—may be considered as a rudimentary, or “aborted,” convolution, and together represent the free edge of the cortex of the hemisphere.

Many of the axones of the cells of the hippocampus enter the fimbria of the fornix, whence some of them cross the

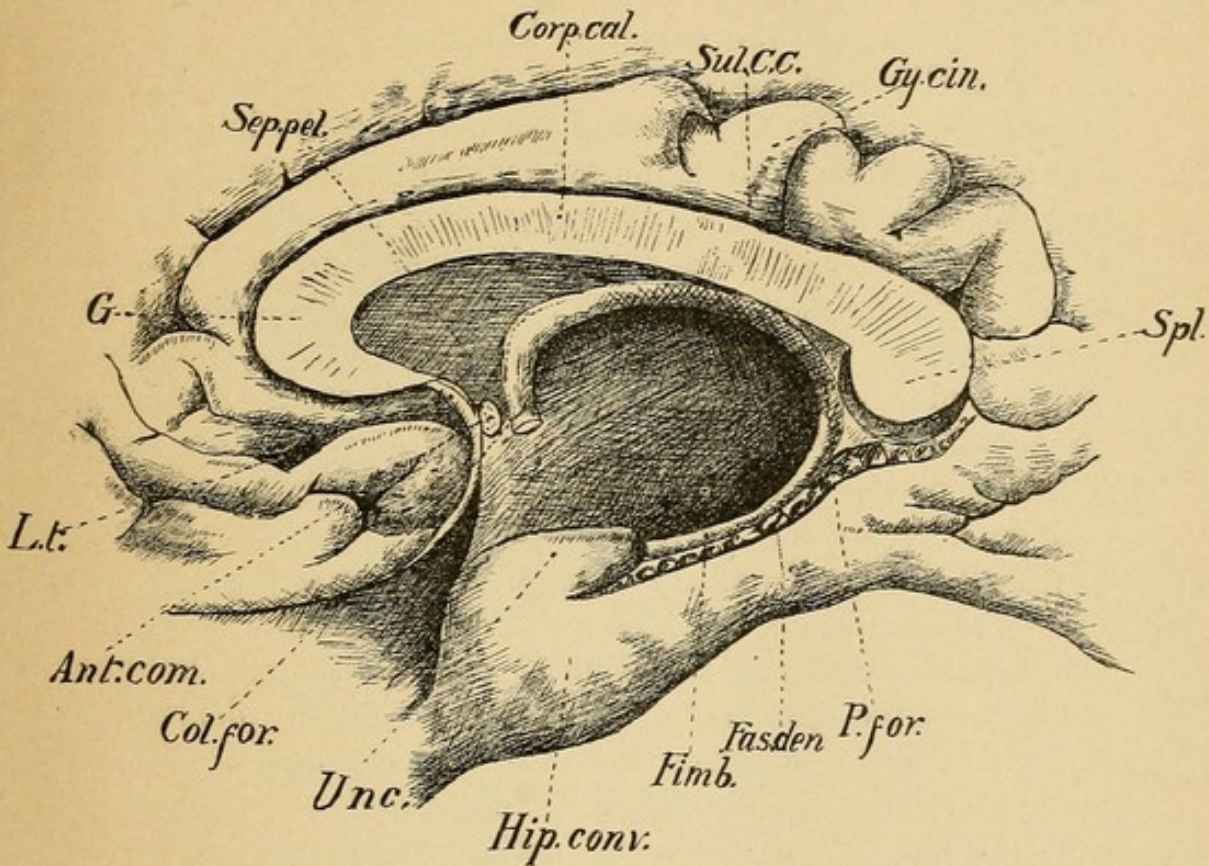


Fig. 38.—*G.*, Genu of corpus callosum. *Sep. pel.*, Septum pellucidum. *Corp. cal.*, Corpus callosum. *Sul. C. C.*, Sulcus of corpus callosum. *Gy. cin.*, Gyrus cinguli. *Spl.*, Splenium of corpus callosum. *P. for.*, Crus of fornix. *Fas. den.*, Fascia dentata. *Fimb.*, Fimbria. *Hip. conv.*, Hippocampal convolution. *Unc.*, Uncus. *Col. for.*, Column of fornix. *Ant. com.*, Anterior commissure. *L. t.*, Lamina terminalis. (After Van Gehuchten.)

median line in the lyra to enter the fimbria of the opposite side and end in the hippocampus. Others continue forward in the fornix to the column, by which most of them are conducted to the corpus mamillare; but some enter the septum pellucidum and pass to the uncus of the hippocampal convolution, while still others probably turn backward in front of the foramen of Monro, and run through the stria medullaris of the thalamus to the trigonum habenulæ.

*The Chorioid Plexus, Velum Interpositum, and Transverse Fissure.*—To the unaided eye both the chorioid plexus and the lateral half of the dorsal surface of the thalamus appear to lie in the floor of the lateral ventricle. As a matter of fact, both are outside of that cavity, being covered dorsally by a layer of epithelium passing between the free edge of the fornix and the stria terminalis. Just as we saw in the study of the fourth ventricle that the dorsal wall of the rhombencephalon ceases to form nervous tissue along a line corresponding to the free edge of the posterior medullary velum, so here, along a line corresponding to the free edge of the fornix all the way from the foramen of Monro to the termination of the fimbria in the inferior horn, the dorsal wall of the telencephalon ceases to lay down nervous tissue, and stretches in its primitive epithelial state over the chorioid plexus and the thalamus to the stria terminalis, where, again, nervous tissue—*i.e.*, the diencephalon—is developed. As it passes over the plexus and the lateral half of the dorsal surface of the thalamus it becomes firmly attached to these structures. At the edge of the fornix and at the stria terminalis it is continuous with the general ependymal epithelium of the ventricle.

If the fornix be cut across near its apex and turned backward (Fig. 39), there is exposed the triangular flap of pia mater called the velum interpositum (*tela chorioidea ventriculi tertii*). Its apex is forward just behind the apex of the fornix, while its sides, which are elevated into the vascular tufts which we have called the chorioid plexuses, project beyond the edge of the fornix, and invaginate the epithelium both in the central portion and in the inferior horns of the ventricle. It is composed of two layers. Bearing in mind

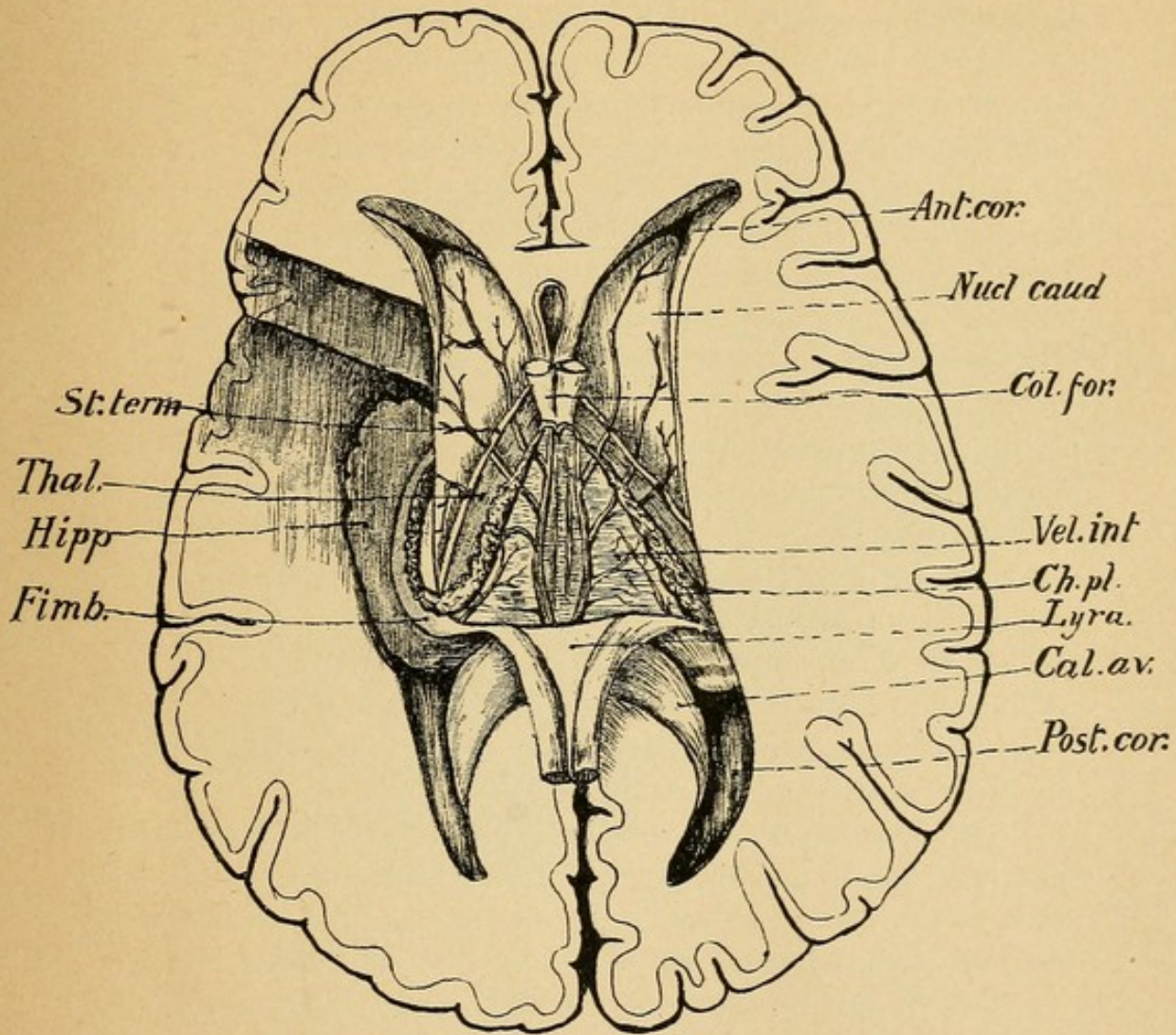


Fig. 39.—*St. term.*, Stria terminalis. *Thal.*, Thalamus. *Hipp.*, Hippocampus. *Fimb.*, Fimbria. *Ant. cor.*, Anterior cornu of lateral ventricle. *Nucl. caud.*, Nucleus caudatus. *Col. for.*, Columns of the fornix. *Vel. int.*, Velum interpositum. *Ch. pl.*, Chorioid plexus. *Cal. av.*, Calcar avis. *Post. cor.*, Posterior cornu of lateral ventricle. (After Gray.)

that the hemispheres in the embryo undergo great growth in the posterior direction and that the pia mater closely invests the surfaces of the encephalon, it will be understood that in the course of development two layers of the pia, one covering the dorsal wall of the telencephalon and the other that of the diencephalon, would be early brought together, and caught, as it were, between these two growing vesicles. The space through which the velum enters the cerebrum is the transverse fissure of Bichat (*fissura transversa cerebri*). It may be compared to a horseshoe in shape, the dentate fissures furnishing the lateral arms of the shoe, while the cross-bar is the space between the posterior extremity of the corpus callosum dorsally and the pineal body and the mesencephalon ventrally. It is not a fissure in the sense of a cleft opening into the lateral ventricles, for, as we follow the space toward these cavities, we find that its bottom is closed by the epithelium before described as extending between the edge of the fornix and the stria terminalis, and investing the chorioid plexuses and the lateral half of the dorsal surface of the thalamus.

The ventral surface of the velum is adherent to the epithelial roof of the third ventricle, which constitutes its lamina epithelialis. Between this epithelium and the pia there runs, in an antero-posterior direction, on each side of the median line the chorioid plexus of the third ventricle.

**THE ANTERIOR COMMISSURE.**—This band of fibres has been referred to as running transversely in front of the columns of the fornix. As it is chiefly concerned with the connections of the rhinencephalon, it will be considered later.

**THE WHITE MATTER OF THE PALLIUM.**—The pallium is the name given to the gray cortex and the central white matter. The latter may be divided into three classes of fibres as follows:—

(A) Fibres of association, or those which connect two parts of the same hemisphere. Of these there are two sets: the long and the short. The latter are all those innumerable fibres which connect neighboring points of the cortex (*fibrae propriae*). The long connect two or more lobes, and are arranged in four fairly distinct bundles (Fig. 40):—

1. The superior longitudinal bundle (*fasciculus longi-*

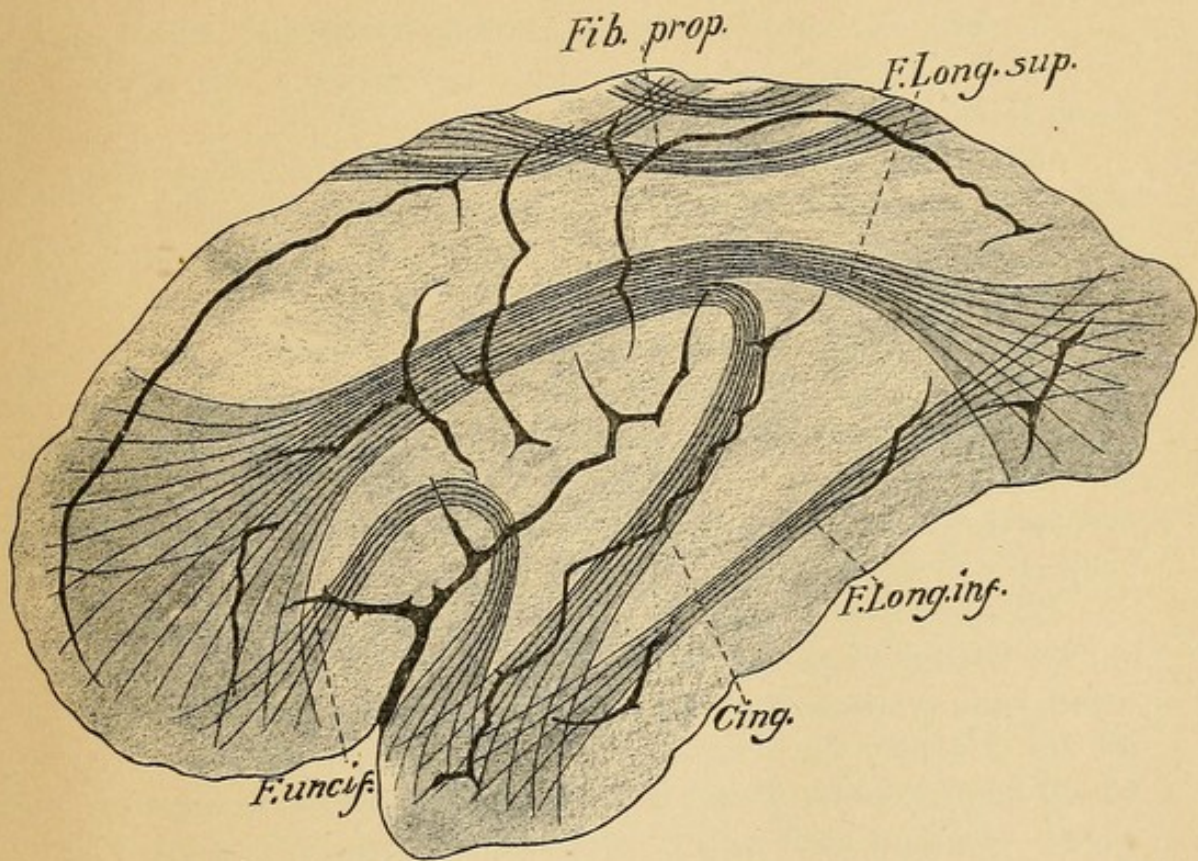


Fig. 40.—Scheme of fibres of association of cerebral hemisphere (after Van Gehuchten). *Fib. prop.*, *Fibræ propriae*. *F. Long. sup.*, *Fasciculus longitudinalis superior*. *F. Long. inf.*, *Fasciculus longitudinalis inferior*. *Cing.*, *Cingulum*. *F. uncif.*, *Fasciculus uncinatus*.

tudinalis superior), which connects the frontal with the occipital and temporal lobes.

2. The inferior longitudinal bundle (fasciculus longitudinalis inferior), connecting the occipital and temporal lobes.

3. The cingulum, which arches in the gyrus cinguli from the frontal to the temporal lobe.

4. The uncinata bundle (fasciculus uncinatus), uniting the ventral frontal convolution with the uncus of the temporal lobe.

(B) Commissural fibres, or those which connect convolutions in one hemisphere with corresponding convolutions in the other, such as the corpus callosum and the lyra (commissura hippocampi).

(C) Projection-fibres, or those which connect the cortex with lower-lying portions of the central nervous system. These, as we have seen, pass through the internal capsule; their radiation from the cortex to the capsule is called the corona radiata. They are of such importance that a separate chapter will be devoted to them.

THE RHINENCEPHALON.—There are many deficiencies in our knowledge of the rhinencephalon, but the following statements seem warranted at present. The principal constituents of the olfactory bulb are the numerous large cells around whose dendrites the fibres of the olfactory nerves terminate. These cells send their axones backward to form the olfactory tract; on arriving at the trigonum, they separate into two roots, or striæ. The medial root ends in the trigonum and the gyrus subcallosus. The lateral root enters the uncus of the hippocampal convolution, where most of its axones terminate; but some after crossing in the anterior commissure turn forward into the lateral stria and tract of the opposite side, to end in the bulb. The anterior extremity of the hippocampal convolution is connected with the hippocampal convolution of the opposite side by the anterior commissure, and with the hippocampus of the same side by fibres running in the fornix, as already described. The hippocampus, in its turn, is connected by the column of the fornix with the corpus mamillare, by the stria medullaris with the trigonum

habenulæ, and by the lyra with the hippocampus of the opposite side. In man the olfactory apparatus must be regarded as, to a large extent, rudimentary, but from analogy with certain of the lower animals in whom the apparatus receives full development, there seems no doubt that the entire gyrus fornicatus, the hippocampus, the fornix, the anterior commissure, the fascia dentata, and the fasciola cinerea are all concerned with the sense of smell.

## CHAPTER IV.

### THE CONDUCTING-PATHS OF THE ENCEPHALON.

THE cortex of each hemisphere of the telencephalon is in communication with the opposite half of the body by means of fibres conducting impulses to and from it. These fibres may be divided into two sets, according to the direction of conduction: centrifugal, or motor, which conduct excitations from the cortex to the various muscles of the body; and centripetal, or sensory, which convey excitations from the skin, mucous membranes, bones, special sense-organs, etc., to the cortex, where are produced in an unknown way what we call sensations. Each half of the body is thus represented in or projected upon the cortex of the opposite hemisphere; hence the name of "projection-fibres" given to those fibres of the telencephalon through which the communication is maintained. They are in many instances collected into distinct bundles; so that we may speak of motor and sensory paths or tracts, meaning thereby definite groups of fibres along which motor or sensory impulses, as the case may be, habitually travel. Moreover, these groups of fibres often arise from or terminate in fairly-definite areas of the cortex, which areas are usually called centres. Thus, that area from which spring the fibres that conduct impulses to the muscles which produce the movements of the hand may be called the motor "centre" of the hand; that which receives the fibres along which visual impressions travel is the "centre" of sight.

THE PRINCIPAL MOTOR PATH.—This path is formed by two groups of neurones. The cell-bodies of the first group are contained in the cortex, and their axones terminate in the nuclei of the motor peripheral nerves on the opposite side of the nervous axis,—in the mesencephalon, pons, medulla, and spinal cord,—where they enter into conduction-relation with the second group of neurones, whose medullated axones constitute the motor peripheral nerves. We are directly concerned in this place only with the first, or cortical, neurones.

Their cell-bodies are found in the cortex of the convolutions around the central sulcus of Rolando: the anterior central convolution and the posterior extremities of the other frontal convolutions, the posterior central convolution, and the paracentral lobule, which collectively are called the "motor area" of the cortex. In a general way, we may say that the ventral portion of this area is the motor centre for the head, the middle portion that for the upper extremity, and the dorsal portion that for the lower extremity. The axones of the cells in this area converge toward the internal capsule, and pass through the anterior two-thirds of its posterior limb. In the capsule the fibres destined to reach the nuclei of the facial and hypoglossal nerves occupy the genu, and hence are called the geniculate fasciculus. Posterior to them are the fibres for the upper extremity, and behind these are those for the lower extremity (Fig. 31). From the capsule the fibres of this path enter the base of the peduncle of the cerebrum; here the geniculate fasciculus occupies the medial border of the peduncle, while the other fibres of the path lie in the middle of that structure. In the mesencephalon, it will be recalled, are the nuclei of the third and fourth cranial nerves; they probably receive fibres from this path, but neither the cortical origin nor the course of such fibres is known.

From the peduncle the path reaches the pons, where some of its fibres cross the median line to terminate in the nuclei of the motor nerves there found. Next, the path appears in the medulla as the pyramid, for which reason it is frequently called the pyramidal tract throughout its extent. In this region fibres are distributed to the motor nuclei of the ninth, tenth, eleventh, and twelfth cranial nerves, chiefly of the opposite side. At the spinal extremity of the medulla the majority of the fibres cross to the lateral column of the opposite side of the spinal cord, in which they constitute the crossed pyramidal tract (*fasciculus cerebro-spinalis lateralis*), which traverses the whole length of the cord, abandoning fibres to the ventral horn as it goes, thus making connection with the spinal lower motor neurones. The small part of the tract which does not cross in the medulla at the decussation forms the direct pyramidal tract (*fasciculus cerebro-spinalis*

anterior) in the ventral column of the cord, whence its fibres, in large part, cross successively in the ventral white commissure, to end in the ventral horn of the opposite side.

**THE SECONDARY MOTOR PATH.**—There exists an anatomical basis for a second motor path from the cortex of the telencephalon to the motor nuclei of the peripheral nerves, though it cannot be traced with the same distinctness as the preceding, nor is much known concerning its function. It is formed by at least four groups of neurones, three of which are in the encephalon. The cells of the cortical neurones lie in the same area as those of the principal path, and also in the cortex of the temporal lobe. They send their axones through the anterior two-thirds of the posterior limb of the internal capsule, whence they enter the base of the peduncle of the cerebrum. Here those which arise in the "motor area" occupy the same position with the principal motor path, while those which arise in the temporal lobe lie in the lateral part of the peduncle (Fig. 41). All these fibres terminate in the nuclei pontis; whence the name of cortico-pontile given to them. The cells of the nuclei pontis, which are the second group of neurones, send their axones across the median line to enter the cerebellar hemisphere and terminate around Purkinje's cells in the cortex. These Purkinje cells constitute the third group of neurones, but the course pursued by their axones is undecided; there is good reason for believing that they reach the ventral horn of the spinal cord, either directly or indirectly through the olive.

**THE PRINCIPAL SENSORY PATH.**—The portions of each half of the spinal cord believed to conduct the various centripetal impressions from the skin, muscles, and viscera are the funiculi of Goll and Burdach, and the ventro-lateral ground-bundle. The latter of these is formed by fibres which spring from cells in the gray matter of the opposite side of the cord, while the two funiculi first mentioned contain the central axones of the ganglia on the dorsal roots of the spinal nerves of the same side. It will be recalled that the ventro-lateral ground-bundle on reaching the medulla lies dorsal to the pyramid, and that the two dorsal funiculi of the cord terminate in their respective nuclei, the cells of which send axones

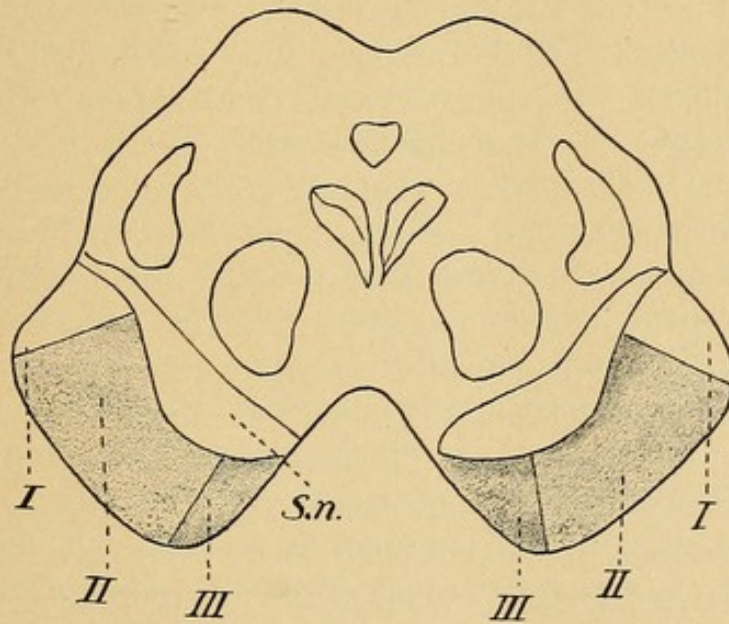


Fig. 41.—*I*, Region of temporo-pontile fibres. *II*, Region of pyramidal tracts. *III*, Region of geniculate fasciculus. *S. n.*, Substantia nigra. (After Dejerine.)

across the median line as internal arcuate fibres, to enter first the interolivary layer and later the medial lemniscus. This medial lemniscus is the principal sensory path in the encephalon. We have traced it through the medulla, where it lies medial to the olive and lateral to the raphé; thence into the pons, where it becomes flattened and lies dorsal to the deep transverse fibres; and thence into the tegmentum of the mesencephalon, where it fuses laterally with the lateral lemniscus. In its course through the rhombencephalon it is joined by fibres derived from the terminal nuclei of the sensory nerves there found; these, as we have seen, constitute many of the internal arcuate fibres, and join the lemniscus of the opposite side from that in which they arise. The axones from the nuclei of the cochlear nerve, however, have a separate path. From the mesencephalon the medial lemniscus enters the diencephalon, where the majority, at least, of its fibres end in the ventral nucleus of the thalamus. Here are the cells of the last group of neurones, whose axones pass through the posterior third of the posterior limb of the internal capsule to terminate in the cortex of the telencephalon over an area—the somæsthetic area—which practically coincides with that which we have termed the motor area. It will be noticed that this path, like the principal motor path, is crossed. It is formed by three superimposed groups of neurones as follows: (1) the peripheral, whose peripheral axones form the peripheral sensory nerves and whose central axones build up the dorsal funiculi of the cord; (2) the spinal and rhombencephalic, whose axones form, respectively, the ventro-lateral ground-bundle of the cord and the internal arcuate fibres and medial lemniscus; and (3) the thalamo-cortical, whose axones complete the connection with the cortex.

**THE SECONDARY SENSORY PATH.**—As in the case of motor impulses, so, for the sensory, there exists the anatomical basis of a complex secondary path. The two cerebellar tracts from the cord—the direct cerebellar tract and the main mass of Gowers's tract—terminate in the cerebellum; moreover, some of the sensory cranial nerves, notably the trigeminal and the vestibular portion of the acoustic, send some fibres into the cerebellum, as do also the terminal nuclei of the dorsal fu-

niculi of the cord. Thus there are numerous fibres conducting centripetally as regards the cerebellum. From the latter fibres run in the anterior peduncle to the red nucleus of the mesencephalon on the opposite side; the red nucleus sends fibres into the thalamus of the same side, and from the thalamus, as we have seen, many fibres proceed to the cortex. So that it seems quite possible that certain sensory impressions may reach the cortex by this roundabout path.

**THE ACOUSTIC PATH.**—The path traveled by auditory impressions is composed of four groups of neurones. The central axones of the peripheral neurones form the cochlear portion of the acoustic nerve, which terminates in the two gray masses known as the dorsal and ventral nuclei of the cochlear nerve. These two nuclei contain the cells of the second group of neurones. Those of the ventral nucleus send their axones into the pons, to form the trapezoid body. The fibres of this body undergo a partial decussation, some of them terminating in the anterior olive of the same side, while others cross the raphé to reach the anterior olive of the opposite side. This olive furnishes the third group of neurones; their axones run forward, and, aided, perhaps, by the acoustic striæ from the dorsal nucleus of the opposite side, form the lateral lemniscus, which ends in the medial geniculate body and in the posterior colliculus. In these two bodies the fourth group of neurones is found; their axones enter the posterior third of the posterior limb of the internal capsule, and terminate in the dorsal (superior) convolution of the temporal lobe. It should be borne in mind that the acoustic path is only partially crossed, since the trapezoid body only partially decussates; in other words, each dorsal temporal convolution is in communication with both ears.

**THE OPTIC PATH.**—In this path there are three sets of neurones. The cells of the first set are contained in the retina; they are the bipolar cells of this membrane. The cell-bodies of the second set are also found in the retina; they are the so-called ganglion-cells of the retina; their axones run backward and medialward as the optic nerve to enter the chiasm. In the chiasm the optic nerve partially decussates. The usual statement is that the nerve undergoes a semidecussation, in

process of which the fibres from the temporal half of the retina emerge from the chiasm as the lateral half of the optic tract of the same side, while the fibres of the medial half of the tract are derived from the medial half of the opposite retina. However, anatomical investigation has thus far not been able to establish anything much more definite than that a partial decussation occurs in the chiasm. The optic tract, formed thus by fibres from both retinae, runs backward and lateralward, winding first ventral and then lateral to the cerebral peduncle, to gain the diencephalon, where its fibres terminate in the lateral geniculate body, the pulvinar of the thalamus, and the anterior colliculus of the mesencephalon. In the gray matter of these structures are the cell-bodies of the third group of optic neurones. Their axones, having entered the posterior third of the posterior limb of the internal capsule, turn backward, run through the occipito-thalamic radiation, and terminate in the cortex of the cuneus, especially in the vicinity of the calcarine fissure.

It seems established that the optic tract and nerve also contain fibres which conduct centrifugally: *i.e.*, fibres which run from the lateral geniculate body, anterior colliculus, and thalamus to the retinae.

**THE OLFACTORY PATH.**—This path is constituted of two sets of neurones. The axones of the peripheral set, the olfactory nerves, terminate in the bulb, where the cells of the second, or central, set are situated. The axones of these are directed backward as the olfactory tract, which divides into the two olfactory roots, or striæ. The medial stria ends in the olfactory trigonum, the gyrus subcallosus, and the adjacent portion of the gyrus fornicatus; the lateral stria terminates in the hippocampal convolution, especially in the neighborhood of its uncus. Hence these areas of the cortex may be considered olfactory centres. From them proceed paths which throw the lower motor neurones under the influence of the sense of smell, thus accounting for olfactory reflexes.

## INDEX.


---

- Ala cinerea, 10, 46.  
 Aqueduct of Sylvius, 4, 19, 60.  
 Area, parolfactoria, 33.  
   the acoustic, 10, 12, 46.  
 Axis, the neural, 1.
- Basis pedunculi, 62.  
 Body, the pituitary, 22.  
 Brachium quadrigeminum inferius, 18.  
   "superius, 18.  
 Bulb, the olfactory, 33.
- Calamus scriptorius, 8.  
 Calcar avis, 72.  
 Canal, the central, of medulla, 40.  
   the neural, 1.  
 Capsule, the external, 76.  
   the internal, 66, 74, 76.  
 Centrum semiovale, 70.  
 Cerebellum, 2.  
   connections of, 58, 59.  
   internal anatomy of, 58.  
   surface anatomy of, 12.  
 Cerebrum, 4, 24.  
 Chiasm, the optic, 20, 22.  
 Cingulum, 24.  
 Claustrum, 76.  
 Clava, 8.  
 Colliculus, facialis, 12.  
   inferior, 18.  
   internal anatomy of, 64.  
   superior, 18.  
 Columns of fornix, 78.  
 Commissure, anterior, of cerebrum, 78, 82.  
   of the habenulæ, 21.  
   of the hippocampus, 76.  
   posterior, of the cerebrum, 21.  
 Convolution or convolutions, angular, 28.  
   ascending frontal (precentral), 26.  
   ascending parietal (postcentral), 26.  
   calloso-marginal, 32.  
   fusiform, 28.  
   hippocampal, 30, 32.  
   inferior frontal, 26.  
   inferior temporal, 28.  
   middle frontal, 26.  
   middle temporal, 28.
- Convolution or convolutions, occipital, 30.  
   of corpus callosum, 30.  
   orbital, 26.  
   straight, 26.  
   superior frontal, 26.  
   superior temporal, 28.  
   supramarginal, 28.  
 Corpora quadrigemina, 2, 18, 62.  
 Corpus callosum, 24, 70, 72.  
   geniculatum laterale, 20, 70.  
   mediale, 20, 70.  
   mamillare, 22, 68.  
   pineale, 21.  
   restiforme, 8, 18, 46.  
   striatum, 24, 66, 74.  
   trapezoideum, 48, 52.  
 Crura of fornix, 78.  
 Cuneus, 30.
- Decussation of anterior peduncles of cerebellum, 60.  
   of lemnisci, 38.  
   of optic nerves, 91.  
   of pyramids, 6, 36.  
 Diencephalon, 2.  
   internal anatomy of, 66.  
   surface anatomy of, 19.
- Eminentia medialis, 12.  
 Encephalon, the divisions of, 1, 2.  
 Ependymal epithelium, 2.  
 Epithalamus, 4.  
   surface anatomy of, 21.
- Fascia dentata, 78.  
 Fasciculi longitudinales of pons Varolii, 50.  
 Fasciculus, inferior longitudinal, 84.  
   medial longitudinal, 42, 46, 56, 64.  
   retroflexus, 62.  
   superior longitudinal, 82.  
   thalamo-mamillaris, 68.  
   uncinatus, 84.  
 Fasciola cinerea, 70, 78.  
 Fibres, association of telencephalon, 84.  
   cerebello-olivary, 40, 46.  
   commissural of telencephalon, 84.  
   cortico-pontile, 56.  
   external arcuate, 46.

- Fibres, internal arcuate, 38, 40, 44.  
   projection of telencephalon, 84.  
   transverse of pons Varolii, 50.
- Fissure, calcarine, 30.  
   collateral, 30.  
   dentate, 30, 72.  
   dorsal median, 8.  
   horizontal, 14.  
   longitudinal, of cerebrum, 24.  
   of Sylvius, 24.  
   paramedian, 8.  
   parieto-occipital, 25, 30.  
   transverse of Bichat, 82.  
   transverse of cerebellum, 14.  
   ventral median, 6.
- Flocculus, 14.
- Foramen, of Magendie, 16.  
   of Monro, 76.
- Formatio reticularis, 36.
- Fornix, 76.
- Fossa interpeduncularis, 18.  
   rhomboidea, 8, 15.
- Fovea inferior, 18.  
   superior, 18.
- Frenulum, 18.
- Funiculus of Burdach, 8.  
   of Goll, 18.
- Ganglion interpedunculare, 62.
- Globus pallidus, 74.
- Gyri transitivi, 26.
- Gyrus, fornicatus, 32.  
   subcallosus, 33, 72.
- Habenula, 21.
- Hemispheres of telencephalon, 24.  
   lateral surface of, 24.  
   medial surface of, 30.
- Hippocampus, 72, 78.
- Hypophysis, 22.
- Hypothalamus, 4, 14.  
   internal anatomy of, 68.  
   surface anatomy of, 22.
- Incisure, dorsal, of cerebellum, 14.  
   ventral, of cerebellum, 14.
- Infundibulum, 22, 68.
- Island of Reil, 25, 30, 76.
- Lamina, chorioidea epithelialis, 16.  
   terminalis, 22, 68.
- Lemniscus, the lateral, 10, 56, 62.  
   the medial, 38, 52, 56.
- Lingula, 14.
- Lobe, frontal, 24, 26.  
   limbic, of Broca, 32.  
   occipital, 24, 30.  
   parietal, 24, 28.  
   temporal, 24, 28.
- Lobes of cerebellum, 14.
- Lobule, inferior parietal, 28.  
   paracentral, 32.  
   superior parietal, 28.
- Locus cœruleus, 12.
- Lyra, 76, 80.
- Mesencephalon, 2.  
   internal anatomy, 60.  
   surface anatomy, 18.
- Metencephalon, 2.  
   internal anatomy, 48.  
   surface anatomy, 10.
- Myelencephalon, 2.  
   internal anatomy, 34.  
   surface anatomy, 6.
- Nerve, abducens, 8.  
   acoustic, 8, 46.  
   cochlear, 48.  
   facial, 8.  
   glosso-pharyngeal, 6.  
   hypoglossal, 6.  
   oculomotor, 64.  
   optic, 20, 91.  
   spinal accessory, 6, 34.  
   trigeminal, 10, 54.  
   trochlear, 60.  
   vagus, 6.  
   vestibular, 48.
- Nidus avis, 14.
- Nodus, 14.
- Nucleus or nuclei, ambiguous, 42.  
   amygdaloid, 74, 76.  
   caudatus, 66, 74.  
   central, of pons Varolii, 54.  
   dentatus, 58.  
   dorsal of cochlear nerve, 46.  
   emboliformis, 58.  
   fastigii, 58.  
   globosus, 58.  
   hypothalamicus, 68.  
   lentiformis, 66, 74.  
   of abducens nerve, 52.  
   of Bechterew, 50.  
   of Deiters, 50.  
   of facial nerve, 50, 52.  
   of funiculus of Burdach, 38.  
   of funiculus of Goll, 38.  
   of glosso-pharyngeal nerve, 42.  
   of hypoglossal nerve, 42.  
   of lateral lemniscus, 56.  
   of oculomotor nerve, 64.  
   of olive, 40.  
   of spinal accessory nerve, 34.  
   of thalamus, 66.  
   of tractus solitarius, 42.  
   of trigeminal nerve, 54.

- Nucleus or neuclei, of trochlear nerve, 54, 60.  
of vagus nerve, 42.  
of vestibular nerve, 48.  
pontis, 50.  
red, 59, 60, 62.  
superior olivary, 52.  
ventral of cochlear nerve, 48.
- Olive, 6.
- Operculum, 25, 30.
- Pallium, 24, 82.
- Path, conducting, 85, 86.  
acoustic, 91.  
olfactory, 92.  
optic, 91.  
principal motor, 86.  
principal sensory, 88.  
secondary motor, 88.  
secondary sensory, 90.
- Peduncle, anterior, of cerebellum (brachium conjunctivum), 10, 18, 52.  
middle, of cerebellum (brachium pontis), 10.  
of cerebrum, 2, 18.
- Plexus, chorioid, of fourth ventricle, 16.  
of lateral ventricle, 78, 80.  
of third ventricle, 82.
- Pons Varolii, 2.  
internal anatomy of, 48.  
surface anatomy of, 10.
- Process, inferior vermiform, 14.  
superior vermiform, 14.
- Prosencephalon, 2.
- Pulvinar, 19.
- Putamen, 74.
- Pyramid, of medulla oblongata, 6.
- Radiation, occipito-thalamic, 70.
- Raphé, 38.
- Recess, lateral, 15.  
of infundibulum, 22.  
optic, 18.  
Rhinencephalon, 24.  
internal anatomy of, 85, 86.  
surface anatomy of, 32.
- Rhombencephalon, 2.  
isthmus of, 2, 15.
- Root, descending of trigeminal nerve, 56.  
descending of vestibular nerve, 46, 50.
- Root-fibres, of abducens nerve, 52.  
of acoustic nerve, 46.  
of cochlear nerve, 46.  
of facial nerve, 52.
- Root-fibres, of oculomotor nerve, 64.  
of trigeminal nerve, 54.  
of trochlear nerve, 60.  
of vestibular nerve, 46.
- Septum pellucidum, 78.
- Stratum interolivare lemnisci, 42.
- Stria or striæ, acoustic, 8, 46.  
lateral longitudinal, 70.  
medial longitudinal, 70.  
medullaris, 19.  
olfactory, 33.  
terminalis, 19.
- Sulcus, basilaris, 10.  
calloso-marginal, 32.  
central, of Rolando, 25.  
chorioid, 19.  
circularis, 30.  
dorso-lateral, 6.  
inferior frontal, 26.  
inferior temporal, 28.  
interbrachialis, 18.  
interparietal, 28.  
lateralis, 19.  
limitans, 10, 12.  
marginal, 32.  
median longitudinal, 8, 12.  
middle temporal, 28.  
of corpus callosum, 30.  
of Monro, 19.  
olfactory, 26, 33.  
post-central, 26.  
precentral, 26.  
subfrontal, 32.  
subparietal, 32.  
superior frontal, 26.  
superior temporal, 28.  
ventro-lateral, 6.
- Substantia, corticalis, 70.  
gelatinosa, 34.  
nigra, 62.  
perforata anterior, 24, 33.  
perforata posterior, 18.
- Tegmentum, 62.
- Tela chorioidea, of third ventricle, 21, 80.  
of fourth ventricle, 16.
- Telencephalon, 2.  
internal anatomy of, 70.  
surface anatomy of, 24.
- Tent, 14.
- Thalamencephalon, 4.
- Thalamus, internal anatomy of, 66.  
surface anatomy of, 19.
- Tract, crossed pyramidal, 36.  
direct cerebellar, 40.

- Tract, direct pyramidal, 36.  
  lateral, 6.  
  of Gowers, 40, 59.  
  olfactory, 33.  
  optic, 19, 20, 22, 68.  
  solitary, 42, 44.  
  spinal, of trigeminal nerve, 34.
- Trigonum, habenulæ, 19, 21.  
  hypoglossal, 10, 46.  
  olfactory, 33.
- Tuber cinereum, 22, 68.
- Tubercle, anterior, of thalamus, 20.  
  cuneate, 8.
- Vallecula, 14.
- Valve of Vieussens, 12.
- Velum, anterior medullary, 12, 14, 18,  
  54.  
  interpositum, 80.  
  posterior medullary, 14.
- Vena terminalis, 19.
- Ventricle, fourth, 3, 15, 16.  
  third, 4, 21.  
  lateral, 4, 72.
- Worm, 14.



DUE DATE

NOV 3

1991

NOV 24 1991

DEC 1 1991

Printed  
in USA

COLUMBIA UNIVERSITY LIBRARIES



QM455

w58

Whitehead

