Surgery / by John Allan Wyeth.

Contributors

Wyeth, John A. 1845-1922.
Augustus Long Health Sciences Library

Publication/Creation

New York : M.S. Wyeth & co., 1908.

Persistent URL

https://wellcomecollection.org/works/r58ary5b

License and attribution

This material has been provided by This material has been provided by the Augustus C. Long Health Sciences Library at Columbia University and Columbia University Libraries/Information Services, through the Medical Heritage Library. The original may be consulted at the the Augustus C. Long Health Sciences Library at Columbia University and Columbia University. where the originals may be consulted.
This work has been identified as being free of known restrictions under copyright law, including all related and neighbouring rights and is being made available under the Creative Commons, Public Domain Mark.

You can copy, modify, distribute and perform the work, even for commercial purposes, without asking permission.

Wellcome Collection
183 Euston Road
London NW1 2BE UK
T +44 (0)20 7611 8722
E library@wellcomecollection.org
https://wellcomecollection.org

Dr A. A. Eggleston
with the compliments of
John A Wyeth
1919


Digitized by the Internet Archive
in 2010 with funding from
Open Knowledge Commons

http://www.archive.org/details/surgeryw00wyet

SURGERY

SURGERY

BY

JOHN ALLAN WYETH, M.D., LL.D. (UNIVERSITY OF ALABAMA)

PRESIDENT OF THE NEW YORK ACADEMY OF MEDICINE; PRESIDENT OF THE MEDICAL FACULTY OF, AND SURGEON-IN-CHIEF TO THE NEW YORK POLYCLINIC MEDICAL SCHOOL AND HOSPITAL; EX-PRESIDENT OF THE AMERICAN MEDICAL ASSOCIATION, OF THE NEW YORK STATE MEDICAL ASSOCIATION, AND OF THE NEW YORK PATHOLOGICAL SOCIETY; FORMERLY ATTENDING SURGEON TO MOUNT SINAI AND TO ST. ELIZABETH'S HOSPITALS; HONORARY MEMBER OF THE TEXAS STATE MEDICAL ASSOCIATION AND OF THE MEDICAL SOCIETY OF NEW JERSEY; AUTHOR OF "ESSAYS IN SURGICAL ANATOMY AND SURGERY"; AWARDED THE FIRST AND SECOND PRIZES OF THE AMERICAN MEDICAL ASSOCIATION IN 1878 AND THE "BELLEVUE ALUMNI ASSOCIATION PRIZE" IN 1876, ETC.

WITH 864 ILLUSTRATIONS

MARION SIMS WYETH & COMPANY, PUBLISHERS
244 LEXINGTON AVENUE, NEW YORK CITY
1908

Spec Coll
Hist Coll
RD
31
.W97
1908

Copyright, 1908, by
MARION SIMS WYETH & COMPANY



TO THE MEMORY OF HIS FRIEND

J. MARION SIMS, M.D., LL.D.

WHOSE BRILLIANT ACHIEVEMENTS

CARRIED THE FAME OF AMERICAN SURGERY

THROUGHOUT THE CIVILIZED WORLD

THIS BOOK IS AFFECTIONATELY DEDICATED

BY THE AUTHOR

PREFACE

The author's original "Text-book on Surgery" was published in 1887, and was followed by two subsequent editions, the last of which appeared in 1900. These editions were published by D. Appleton and Company, from whom, in 1907, by an arrangement mutually satisfactory, he became the owner of the illustrations, with the right to publish an entirely new work.

In this book, "Wyeth's Surgery," all of the original illustrations which are related to modern technic and as much of the text as deals with the science and art of surgery as accepted and practiced at this date have been retained, and many new illustrations have been added, making 864 in all, of which 57 are colored.

It has been the author's aim to present not only the major operations so concisely that this work may be made available for quick and ready reference, but to include as well the details of minor surgery, so much of which falls to the lot of the general practitioner. Beyond this he has endeavored to arrange the various subjects so as to make them attractive to teachers for their undergraduate pupils.

While in a single volume it is scarcely possible to deal exhaustively with subjects of such importance as surgical pathology and the process of repair in the various tissues, the author has endeavored to present concisely the essential features of infection and repair.

In the chapter devoted to the eye, he begs to acknowledge his indebtedness for many valuable suggestions to his colleague, Dr. R. O. Born, professor of ophthalmology in the New York Polyclinic Medical School and Hospital. He has, however, taken the liberty of so presenting this chapter as to relieve his colleague of any responsibility in regard to whatever may be expressed. That portion which deals with refraction is reproduced from his former book, and is the work of his friend and colleague, Dr. David Webster, professor emeritus.

In the chapter on the ear, with the consent of the author and publisher, he has made free use of the excellent work on "Diseases of the Ear" (D. Appleton and Company), by Dr. E. B. Dench, formerly professor of otology in the New York Polyclinic Medical School and Hospital, and now occupying this chair in the University and Bellevue Medical College.

The chapters on the blood and urine have been carefully revised by Prof.

F. M. Jeffries, of the Polyclinic Laboratory, to whom, and to Dr. J. C. Taylor for valuable assistance in the chapter on diseases of the female genital organs, he here makes formal acknowledgment.

He is deeply indebted to the various publishing firms and to his many professional friends for their permission to use the illustrations from books or periodicals issued by them. He has drawn extensively upon his former publishers, D. Appleton and Company, with whom his relations have always been most satisfactory, and also from W. B. Saunders Company, William Wood and Company, Cloyd J. Head and Company, the publishers of "Murphy's Year Book on Surgery," the "Journal of the American Medical Association," "Surgery, Gynecology, and Obstetrics," the "New York Medical Record," and the "Annals of Surgery." He has endeavored in each instance to credit, either in the text or in the lines explanatory of the illustration, the source from which it was obtained.

To his faithful and efficient assistant, Dr. Charles R. Hancock, he is indebted for the carefully prepared Index.

THE AUTHOR.

BOROUGH OF MANHATTAN, GREATER NEW YORK.

WYETH'S SURGERY

CHAPTER I

A SURGICAL OPERATION—THE PREPARATION OF THE PATIENT, ASEPSIS, ANTISEPSIS, THE OPERATING ROOM, INSTRUMENTS, DRESSINGS, ETC.

LIFE is a struggle for existence between the tissues of the body and the myriad organisms which are constantly seeking to devour them. That which we call health is the *normal resistance* of the tissues to the destroying organisms of disease. Since the chief rôle in defense is played by the leucocytes (phagocytes), recovery in large measure depends upon proper nutrition and the absence of those conditions, chiefly local, which favor the lodgment and proliferation of pathogenic organisms.

It follows that in the performance of an operation not only should that essential principle of surgical technic—viz., THE LEAST POSSIBLE TRAUMATISM—be regarded, but that by careful nutrition the resistance of the tissues should be brought as near the normal as possible.

It also follows that when an emergency does not make an immediate operation imperative, the careful preparation of the patient does away with many of the dangers of the operation and the discomforts of the anæsthetic.

The time required will vary with the condition of the subject and the character of the proposed operation. The alimentary canal should under all circumstances be thoroughly emptied, preferably by calomel triturates one half grain each, given every half hour until two grains are taken, to be followed in from ten to twelve hours by one or two tablespoonfuls of castor oil.[1]

Next in order of preference is Epsom salts, taken upon an empty stomach and, as generally advised, in the early morning one or two hours before eating. The employment of Seidlitz powder, or any agent which develops gas within the alimentary canal, is objectionable.

Should an operation upon the alimentary canal or within the abdominal cavity be intended, this treatment may be repeated in twenty-four hours, and again, if deemed advisable, always carefully guarding against too great tissue waste by

[1] The disagreeable taste of this invaluable agent may be entirely disguised by pouring into the bottom of a glass one or two ounces of syrup of sarsaparilla, aerating this with carbonic-acid gas discharged from a siphon, pouring the oil carefully into the center of this mixture and drinking at once. There is no more efficient and useful purgative in the Pharmacopœia. Nothing can equal the combination with calomel as above directed in preparing a patient for a surgical operation or in a general cleansing of the alimentary canal.

The thoughtful physician or patient will realize the necessity of eating slowly and of thoroughly masticating and insalivating all *ingesta*. Even liquids should be slowly sipped. By thorough mastication that which is swallowed is more readily taken hold of by the digestive fluids, while coarse and indigestible substances are recognized in the mouth and may be expelled. The conditions in the alimentary canal after about the fortieth year differ from those of earlier life, and suggest certain modifications of diet. The strength of the involuntary bowel muscle begins to be impaired, as well as the voluntary system; the digestive fluids are not so efficient, which with diminished peristalsis favors the putrefaction of ingesta and the development of toxines from bacterial proliferation. Any mental disturbance or overstrain interferes with digestion. The shock of an operation, the effects of an anæsthetic, or even confinement in bed adds to the inertia of the alimentary canal, and suggests the necessity of limiting the quantity of ingesta from all of which bacteria should be excluded. It follows that age, accident, or disease suggests the minimum of meats or any nitrogenous articles, and that cleansing the alimentary canal both by irrigation and by purgation is more than ordinarily essential in any of these conditions.

excessive purgation. If chronic or acute colitis should prevail, or if the patient suffers from habitual constipation, a thorough irrigation of the large bowel with normal salt solution, the injections being made with the patient in the knee-shoulder position, should be made.

In many instances the stomach requires to be emptied not only of ingesta, but of mucus, when, as so frequently is the case, gastric inertia is present. Abstinence from *solid* food for at least twelve, and preferably twenty-four, hours before an operation is advisable, although a concentrated liquid or semi-liquid nourishment, partially or completely predigested if necessary, should be given. Gastric lavage should also be practiced, especially in operations upon the stomach or the upper two feet of the alimentary canal.

When the operative procedure is confined to the anal outlet (as in hæmorrhoids) or to the external genitals, no purgation should be administered later than twenty-four hours before the operation. It is always advisable to give a thorough colon irrigation twelve hours before, so that this may be discharged or absorbed before the anæsthetic is begun.

In all of these procedures the introduction and inflation of a Barnes' dilator to a depth of six inches in the bowel will prevent any possible soiling. Should the dilator not be convenient, a gauze plug, to which a strong cord is attached, should be lubricated with vaseline and passed deeply into the bowel along the concave side of a Sims' speculum.

If tonics are needed to improve the condition of the blood, they should be carefully selected as well as a diet list, which latter should, so far as possible, exclude bacteria and all foods not readily digested.[1] By rest and careful feeding the hæmoglobin should be brought to the proper percentage.

A careful study of the heart, lungs, and kidneys should also be made. The mental condition of the patient should be the subject of careful consideration, and the most hopeful view as to the outcome of the proposed operation should be taken, even to the extent of concealing (at least from the patient) any extreme danger which, in the judgment of the surgeon, is about to be incurred.

In preparing the *operative field,* a wide area should be thoroughly shaven, preferably twelve hours before the operation, scrubbed with sterile soap, brush, and warm water, mopped well with mercuric chloride 1–1000, and protected by several layers of sterile towels, gauze, or cotton, held in place by a bandage. When exposed for the operation, the skin should be again mopped in mercuric-chloride solution, dried, and then thoroughly wet with ether to dissolve the infected fat in the sebaceous follicles, and with alcohol, and lastly again with the mercuric-chloride solution.

Under no circumstances should an excessive quantity of water or any solution be employed. To permit a patient to remain soaked in solutions during an operation is reprehensible in the extreme. It is an inexcusable lowering of the body heat and the patient's resistance. The parts should be mopped with ether and alcohol by the use of cotton pellets soaked in these materials, and not poured on.

When the umbilicus is in the operative field, this should in addition be filled with iodine solution.

All parts of the patient's body not exposed for operation, as well as the operating table, should be covered with sterile sheets or towels.

[1] This *diet list* may be modified to suit any particular case. *Drinks*: Water that has been boiled and allowed to cool, not ice water. The purest milk obtainable; if in doubt about its purity, Pasteurize by heating, not quite to the boiling point. Weak Ceylon tea, drinking it with a large proportion of hot water. Do not drink a great deal of water while eating. Take as much as you can conveniently dispose of between meals, beginning one hour after each meal. *Soups*: Simple, clear soups; consommé, chicken broth, beef broth, lamb broth, cream of celery. *Meats*: Beef (roasted or broiled). Mutton, lamb, chicken, turkey, birds, venison (roasted, broiled, or boiled). Lean of fish, preferably tender white meat and not oily. No sweets. *Cereals*: Well-cooked rice, mixed with beaten whites of egg, flavored, and baked in a hot oven; served warm. Wheatena; shredded wheat (browned); Pettijohn's breakfast gem; crust of roll; crust of bread; dry toast. Fresh butter. *Vegetables*: All uncooked vegetables should be avoided. A very limited quantity of white potatoes, mashed and baked, with a little cream. Beans, peas, carrots, *cooked* celery. *Fruits*: Stewed prunes occasionally. Very ripe peaches in moderate quantities, without sugar or cream. A few Malaga or Tokay grapes, not swallowing the hulls or seeds.

Asepsis implies the absence of infective organisms from the tissues; *antisepsis,* the effort to destroy those already present.

When it is known that cell proliferation in the process of repair in a wound from which septic organisms are excluded (or in which their proliferation is prevented) does not differ materially from the original development of the tissues in embryo, the vast importance of asepsis is evident, and while *cleanliness* is not all that is necessary to secure the best possible result in the healing of a wound, it is of sufficient importance to deserve the most careful consideration.

It follows that not only should the atmosphere of the room and all materials brought in contact with the wound be germ-free, but that the operator and all assistants should carefully sterilize the hands and prevent the possibility of infection from their person or clothing.

In *cleansing the hands* the nails should be trimmed closely, and, even if short, should always be freshly clipped. Three basins, which have just been taken from boiling water and placed on a table covered with a sterile cloth, should be filled with

a—1–1000 mercuric-chloride solution, *colored blue to prevent error.*[1]

b—Water that has been boiled, or warm sterile salt solution (one tablespoonful of salt to one pint of water).

c—Clear water that has been boiled and is quite warm, soft soap that has just been boiled and allowed to cool, and a brush and nail cleaner taken from the boiler for each basin.

Soak the hands for several minutes in the soap-and-water solution, rubbing them and the forearms thoroughly with the lathered brush, rinse and brush in the sterile salt solution, and cleanse thoroughly beneath the nails with a cleaner. Brush the hands again in the soap-and-water solution, then in the sterile salt solution, and next soak them from three to five minutes in the 1–1000 mercuric chloride. This being done, it is advisable until the operation is commenced to protect the hands at once from accidental contact with an unsterilized material by putting on a pair of sterile hop-picker's gloves. Tight-fitting rubber gloves of smooth or rough surface, which may be thoroughly sterilized by boiling, are a valuable addition to modern technic. It is my preference to wear these as a protection to the hands under septic conditions and to use the hands free in clean surgery. To the general practitioner, who of necessity frequently subjects his hands to contact with infectious material, it is advisable to use sterilized rubber gloves in all operative work. Once in contact with septic material, these should be thoroughly washed on both sides, first under running warm water and then with brush and soap and warm water, and finally boiled by being placed in tepid water gradually heated to the boiling point. Upon cooling sufficiently they should be wrapped in a sterile towel and put aside, to be boiled again just before the next operation.

The operator and first assistant should be protected with a clean rubber apron and over this a full-length sterile operating gown, preferably with long sleeves, coming within eight inches of the wrist.

If they be bearded or mustached, these and the face and hair should be rendered aseptic by bathing in 1–1000 mercuric-chloride solution.

The hair should be covered with a sterile cap, and in all serious operations it is advisable to wear a veil of gauze over the nose, mouth, and beard. Every few minutes during the operation the surgeon should rinse his hands with a 1–1000 mercuric-chloride solution, wiping them dry with a sterile towel before touching the wounded surfaces. This practice protects both patient and surgeon from infection.

Should the operator be especially susceptible to the irritation of the mercuric solution, it may be weakened to 1–2000 or 1–3000. All material brought in contact with or near the wound should be absolutely sterile.

[1] One grain to one ounce is approximately 1–500. One commercial tablet to one pint of warm water is 1–1000.

When a large steam sterilizer is not available, the small one shown in Fig. 1 may be substituted. A supply of gauze, towels, sheets, etc., can be sterilized in this apparatus, and transported in the metal box without being opened. In an emergency, boiling in any clean vessel will thoroughly sterilize all cloth material, which should be immediately wrapped in clean sheets or towels and kept from exposure to dust. Absorbent cotton cannot be boiled, but can be sterilized in steam or by dry heat. It is more convenient to obtain this from a reliable manufacturer.[1]

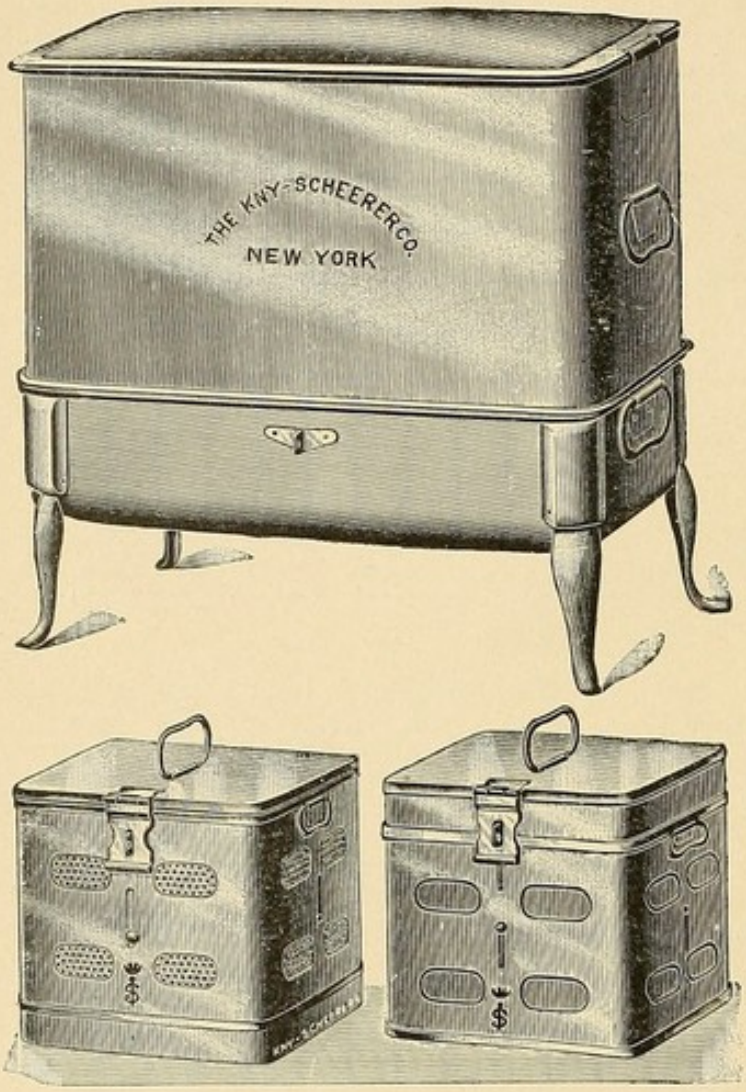

FIG. 1.—Combination sterilizer with portable metal dressing-holders.

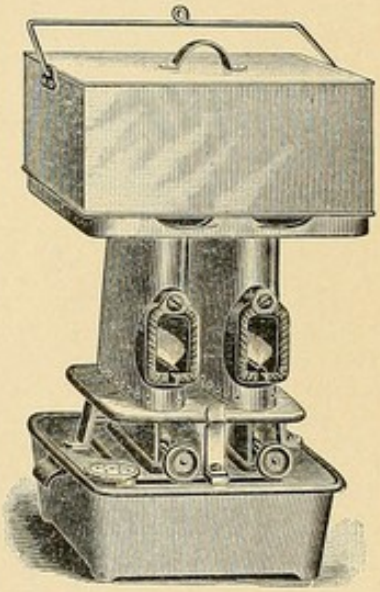

FIG. 2.—Coal-oil emergency boiler.

Ligatures and sutures are animal, vegetable, and metallic. Of the former, catgut and the tendons of the kangaroo or other animals are most important. Horsehair is very useful in securing the perfect adjustment of the edges of incisions upon the face and other exposed surfaces. Horsehair is prepared by washing thoroughly several times a day for two or three days in sterile soap and water, and then soaking for twenty-four hours in 1–1000 mercuric-chloride solution. After this it should be boiled for three or four minutes, and then kept in a solution of alcohol 60 parts, water 40, and crystal iodine 1 part.

[1] 1. In the sterilization of gauze, cotton, towels, sheets, etc., these should be placed in a steam-pressure sterilizer, and after the door is closed and the steam turned on, the outlet should be opened so as to permit the escape of air. The steam pressure should then be raised to between twenty-three and thirty pounds, when an outlet in front of the sterilizer should be opened sufficiently to allow the steam to escape in a quantity not greater than the amount being generated in the jacket. This gives a continuous circulation of steam at the above pressure, which should be maintained from one half to one hour and is much more efficacious than the same pressure without circulation.

2. Linen, silk, silkworm gut, horsehair, and silver wire may be sterilized in the steam sterilizer with the dressings, or wrapped in gauze and boiled with the instruments.

3. In preparing chromic-acid catgut, the simplest way is to soak the catgut in chloroform or ether for a month, wind it loosely on the spools, and let it soak for twenty-four hours in a one-per-cent solution of chromic acid in water, after which the spools may be rinsed in sterile water and the catgut further sterilized as for plain gut as directed by Dr. Moschcowitz.

Silkworm gut (preferably dyed black) is one of the cleanest, strongest, and best materials for closing skin incisions, and is much less apt to invite infection from the *staphylococcus epidermidis albus* than any other non-metallic suture. This material is sterilized by boiling, and is kept in the same solution in which the sterilized horsehair is preserved.

Irish linen, plain or, preferably, coated with celluloid or gutta-percha and dyed black, is the best of the vegetable fibers, and has almost superseded silk—No. 50 for intestinal suture and 25 for buried sutures in uniting aponeuroses. Silver wire is now rarely employed except in operations for the cure of cleft palate, in ununited fractures, and in exceptional cases of ventral hernia and vesico-vaginal fistula.

For the closure of the skin incision, where subdermal or buried sutures (usually kangaroo tendon or chromicized ten-day catgut) have been employed, small metallic clamps (Michel) may be employed. In their application, care should be taken not to pinch the skin hard enough to cause pain or pressure-necrosis.

All ligature and suture material should be made and kept aseptic under the immediate supervision of the responsible operator or an expert assistant, or purchased from a reliable manufacturer. This is especially important with animal material, the preparation of which requires great care and skill.[1]

In preparing catgut in large quantities the methods of Dr. Willard Bartlett or Dr. A. V. Moschcowitz may be followed. Both assure a safe and strong material which has been thoroughly tried. The Bartlett gut is softer and somewhat more pliable or threadlike, and is generally preferred.[2]

The preparation of chromicized catgut has been given in a preceding foot-note.

[1] The material sterilized in closed glass tubes by Van Horn and Sawtell, of New York City, has given perfect satisfaction in the author's experience. In the extensive clinic of Drs. W. J. and C. H. Mayo the catgut prepared by the method of Bartlett is exclusively used.

[2] Bartlett's method. The ordinary commercial 10-foot catgut strand is divided into four equal lengths, each of which is made into a little coil about an inch and a half in diameter. By twisting the last free end about four times around this little coil, the coil will maintain its shape. These coils are strung like beads on a thread, and hung in a metal can, or beaker glass without being allowed to touch the bottom or sides. They may be suspended by carrying the two ends of a thread through a small opening in a pasteboard cover placed over the receptacle. The same opening serves to admit a thermometer, which is carried down exactly to the point where its mercury bulb is on a level with the topmost coils. Liquid petrolatum is now poured in, the quantity being sufficient to immerse the catgut and the bulb of the thermometer. The vessel is set on a pan of sand, under which is placed a tiny gas flame of merely sufficient intensity to raise the temperature of the oil to 212° F. within one or two hours. The temperature should remain at about 212° F. for twelve hours, when the heat should be increased to such an extent that it will run up to 300° F. in an hour. The gas is then turned off, and the temperature of the oil allowed to return to about 212° F. The pasteboard cover, with the string of coils, is lifted out, the superfluous oil allowed to drop off, and then the thread is cut, allowing the untouched coils to fall into the following mixture:

Columbian spirits, 100 parts.
Iodine flakes, 1 part.

This catgut is now ready for immediate use, and will keep for any length of time. The jar may be opened any number of times, so long as a sterile instrument is used for removing the coils, since the iodine protects the coils left behind from accidental contamination. This catgut is as strong and as supple as silk, is easily seen on account of its color, will not untwist when wet on account of the oil in it, and for the same reason is more than usually resistant to absorption.

Dry iodine catgut is prepared as follows by the method of Dr. A. V. Moschcowitz, and has been used with perfect satisfaction in the extensive surgical service of Mt. Sinai Hospital. ("Annals of Surgery," May, 1903.)

The catgut just as bought from the dealer—i. e., without removing the fat—is loosely wound on the spool, preferably in a single layer, and tied at both ends to prevent unraveling. Immerse for eight days in a solution of iodine one part, iodide of potassium one part, distilled water 100 parts. This solution is prepared by dissolving the iodide of potassium in a small quantity of water, to which the iodine, previously finely pulverized, is added, and the whole diluted up to one hundred parts. At the end of eight days the catgut is removed from the solution, and preserved thereafter dry, in a sterile vessel, preferably in one not exposed to the light.

The catgut thus prepared and kept is used dry, just as it is cut from the spool, and after the operation any unused catgut may be put through the original process and is resterilized.

For one gallon of the solution, six hundred grains each of iodine, finely powdered, and an equal amount of iodide of potassium is required, the whole costing about fifty cents.

It is important to keep the solution in well-stoppered bottles or jars, because the iodine is volatile.

A good solution is not purple, it should in bulk have a deep brown almost black color; any solution not corresponding to these physical requirements should be discarded.

This suture has replaced kangaroo tendon to a considerable extent, but the latter is still preferred by more cautious operators as holding longer and therefore giving greater security in hernia operations and in uniting aponeuroses which may be subjected to post-operative tension. In using sealed glass tubes containing ligatures, these should be washed in clean water and placed in a solution of mercuric

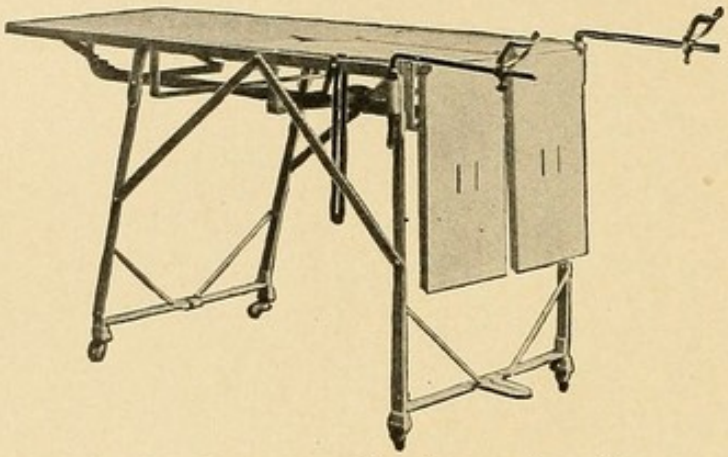

FIG. 3.—Downey's combination operating table.

chloride, 1–1000, from which they are taken by the assistant when the tube is to be broken. It is never advisable to expose the ligature material any longer than is necessary.

In addition to the foregoing, the aseptic healing of a wound in large measure depends upon the performance of the operation with the least possible injury to the tissues. Violent retraction, unnecessary tearing and bruising, or scraping the surface of a wound with a swab or sponge all tend to weaken the normal resistance of the tissues and encourage the proliferation of any chance septic organisms.

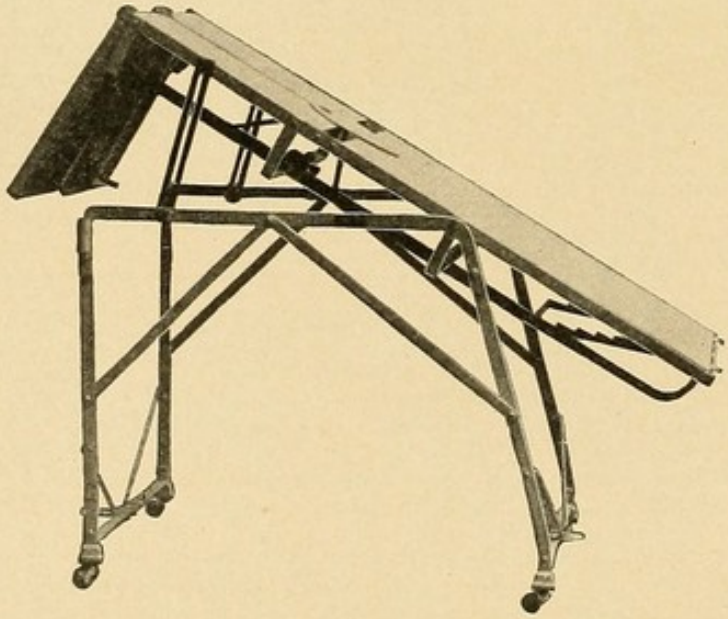

FIG. 4.—The same adjusted to the Trendelenburg position.

The fingers of an assistant should never come in contact with the wounded surface, nor those of the surgeon, when an instrument may be substituted. For this reason, in swabbing, I prefer either to use gauze swabs held in forceps, or large swabs which cover the ends of the fingers, or a roll of gauze which is unwound as it is needed, and rerolled or cut off as it becomes wet.

Since all pathogenic organisms proliferate in moist media, it is essential that a wound be left as dry as possible. For this reason it is often safer to unite the

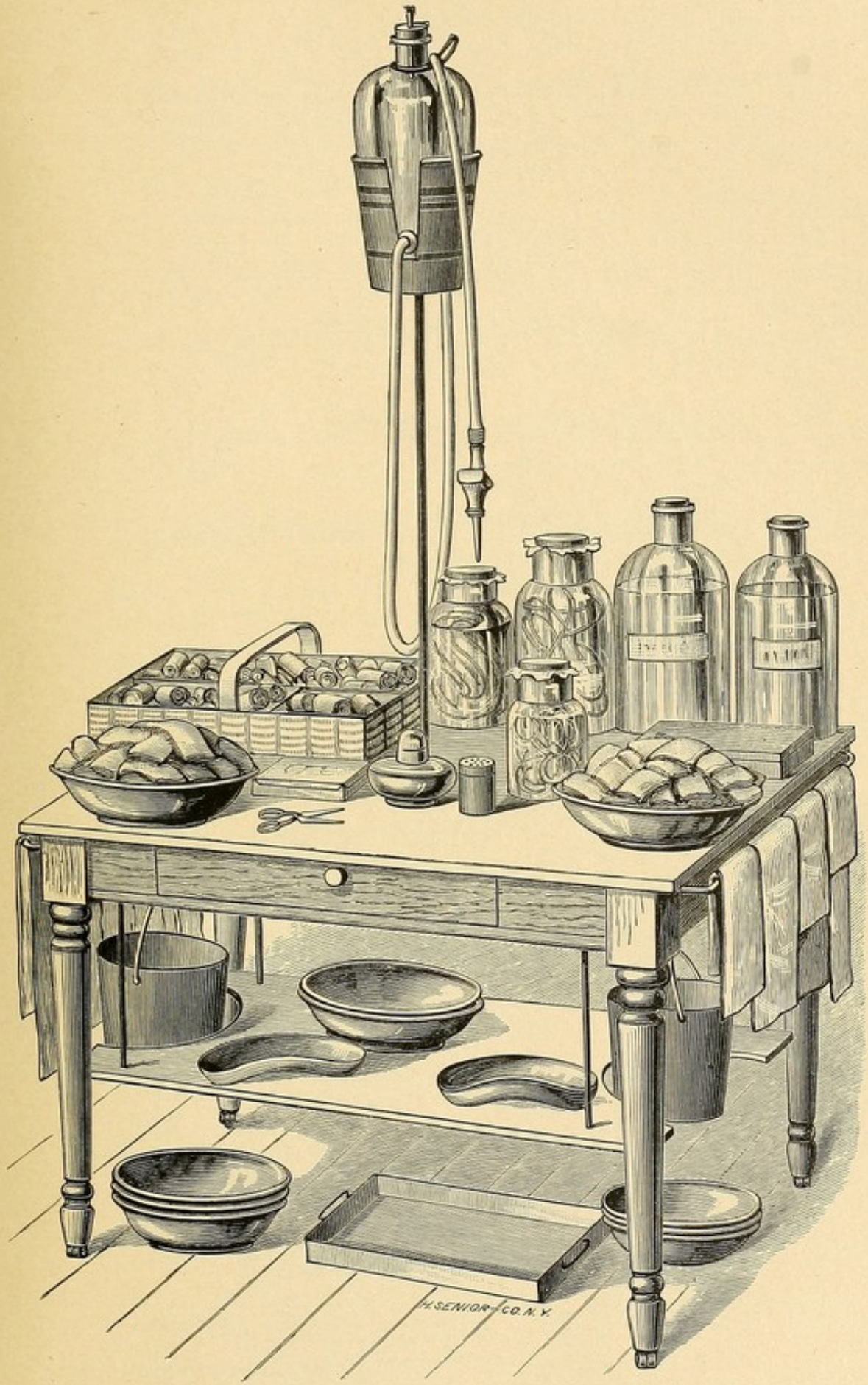

FIG. 5.—A single operating room and dressing table.

various layers of tissues by separate rows of sutures (usually absorbable), drying each carefully before the overlying row is inserted, and where there is a thick layer of fat this should be approximated by one or more separate rows of subcutaneous catgut.

When the superficial sutures are tied, the skin is finally washed with 1–1000 mercuric chloride and dried, and the dressing (usually dry sterile gauze reënforced with absorbent cotton) adjusted and held with moderate compression until the roller-bandage or adhesive strips are applied.

The *operating room*, large, warm, thoroughly ventilated, and well lighted with side windows and skylight (as well as the best obtainable artificial illumination), should be as clean and free from dust as possible. To precipitate particles of infection-carrying dust from the atmosphere a steam spray is ideal, though not absolutely necessary. Next in order is sprinkling the floor, walls, and furniture. The author has operated for years in a public lecture room, where it is impossible to secure ideal conditions, and yet by taking certain simple aseptic precautions, in the proximity of the operative field, the infection of clean wounds is practically unknown.

The accessories of an operating room should be of the simplest possible construction, and of material that will permit of boiling or scouring with very hot water or mercuric-chloride solution, 1–1000. A good strong operating table[1] is essential, preferably one of white-painted metal and glass, so constructed and arranged that the patient may be made to assume any necessary surgical position. In many procedures the Trendelenburg posture is required, while in others the head, neck, and chest need to be elevated.

There should be two or three side tables of the same or any cleansible material. Adjustable stools (preferably metal) for the use of the anæsthetist and operator; a capacious irrigator, with long rubber tube and glass tip or pipette, arranged for adjustment at various heights to secure the necessary pressure in irrigation; basins and bottles for solutions; pus and waste basins, etc., by preference made of metal and porcelain-lined (Fig. 5). Agate or ordinary commercial china ware vessels will serve in an emergency, the essential being that they should be subjected to boiling before using. A boiling apparatus should be a part of (or very convenient to) every operating room. This may be heated by gas, coal oil, or, preferably, when gas is not obtainable, by alcohol, which is now so cheap as to justify its use under all conditions. In addition to the boiling-water sterilizer for instruments, towels, gloves, and other boilable material, a modern steam- and dry-heat sterilizer are great conveniences. In their absence the water boiler may be substituted.

It is well to keep on hand certain solutions which may be required for emergency work. Normal salt solution, made of sterile filtered water (one teaspoonful of salt to one pint of water) should be kept in large glass bottles, with tight-fitting stoppers of glass or sterile cotton. Before being used they should be flushed with warm or hot water in order to remove dust. Mercuric-chloride solutions colored blue, 1–1000, 2000, 3000, and 5000, should be kept on hand or made as required. For flushing, especially in abdominal operations, some surgeons prefer pouring in the warm salt solution from pitchers rather than the slower method of the irrigator.

In the perfection of modern surgery, a tank of oxygen ready for use is always available; also a galvanic or galvano-faradic battery for purposes of resuscitation; one or two hypodermic syringes sterilized and ready for use if needed, together with whisky and tablets or solutions of morphine, strychnine, nitroglycerine, etc. While these various remedies are rarely called into use, they are in occasional crises of inestimable value, and moreover tend to protect the surgeon in case of disaster.

Instruments should be of the very best quality, well selected, with handles preferably of light metal and large enough to be grasped firmly without cramp-

[1] The table devised by Dr. James H. Downey can be adjusted to any surgical position and combines with these, a mechanism for extension and counter extension for the application of plaster-of-Paris dressings to fractures of the thigh and leg and the Sayre extension in fitting the gypsum jacket in Pott's disease.

ing. They should be smooth and polished, and so constructed as not to be injured by boiling. While the character and extent of his work should guide every surgeon



Fig. 6.



Fig. 7.

in the selection of an armamentarium, the following list will be found useful and satisfactory:

From six to twelve *scalpels*, the blades varying in length from one to two and a half inches. Major amputations may be done with these simple instruments, although a longer amputating knife is preferred by some operators.



Fig. 8.



Fig. 9.



Fig. 10.

Two curved *bistouries*, one sharp, the other probe pointed, with three and one half inches of cutting edge.



THE KNY-SCHEERER CO., N. Y.

Fig. 11.

For the subcutaneous division of a tendon or fascia, a sharp and a dull-pointed instrument (Figs. 6 and 7), while those for cleft palate are illustrated in Figs. 8,

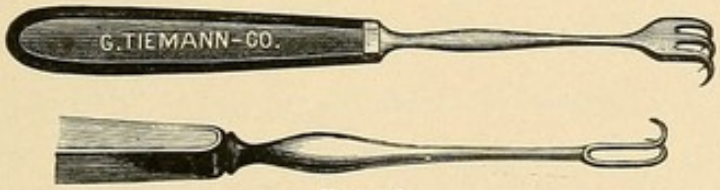

Fig. 12.

9, 10.[1] All knives should be in metal boxes and firmly held to protect the points and cutting edges, and in which they may be boiled (Fig. 11).

[1] These illustrations are made from instruments in the author's general operating case. The name of the maker appears only in the engraving.

Retractors should be long enough to keep the hands of assistants well away from the wound.

An excellent improvised retractor may be made of a strong silk or linen thread inserted through the tissues at the edges of the wound, and held by assistants two or three feet distant.

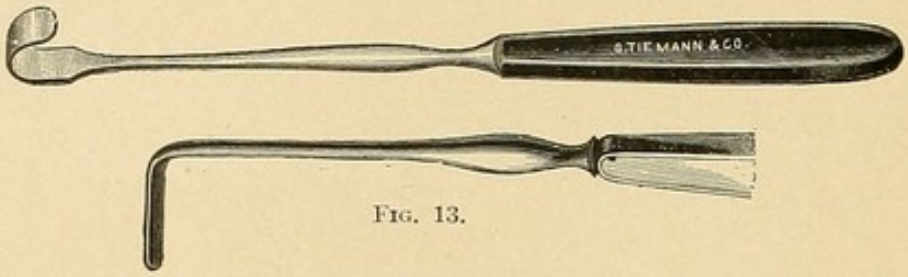

FIG. 13.

Metal retractors should have two or more sharp and dull prongs, or a broader surface bent on the flat (Figs. 11, 12, and 13).

The *tenaculum* and *aneurism needle* (Figs. 14 and 15) are often employed for retraction.



FIG. 14.



FIG. 15.

For general use the *bow-saw* (Fig. 16) will meet all ordinary requirements. The *keyhole saws* (Fig. 17) may be at times needed for minor work, while the Gigli *steel wire saw* is essential in osteoplastic operations on the skull.

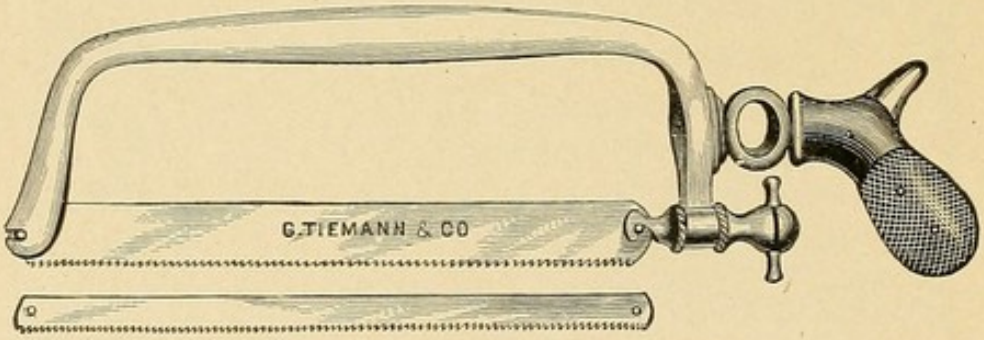

FIG. 16.—Bow-saw, with two blades.

A number of different shaped *chisels* are required for cutting or dividing bones in the correction of deformities. Vance's osteotome (Fig. 18) is an excel-

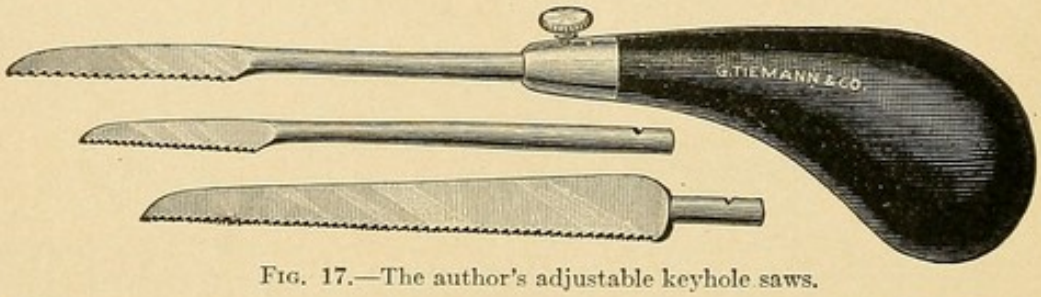

FIG. 17.—The author's adjustable keyhole saws.

lent instrument, and in its use requires a fairly heavy metal or hardwood mallet. In *osteomyelitis*, for exposing the medullary canal, the author uses by preference, the ordinary curved joiners' or sash-makers' chisel, with wooden handles. They

are cheap, durable, easily sterilized by boiling, and can be readily obtained in all required sizes.



Fig. 18.—Vance's osteotome.

Volkmann's sharp spoons (Fig. 19), for scraping the diseased surfaces of bone, are invaluable. They should be in two or three sizes, the middle one of which



Fig. 19.—Volkmann's sharp spoon.

should be very long in the shank for curetting the long bones in cases of amputations for osteomyelitis.

Sayre's periosteal knife (Fig. 20), and a smaller sharp periosteal elevator are needed, while for cleft-palate operations Brophy's periosteotomes are indispensable.



Fig. 20.—Sayre's periosteal elevator.

Drills of small size are necessary in wiring fractures; in an emergency a shoemaker's awl will suffice. For extensive work a drilling machine should be employed.

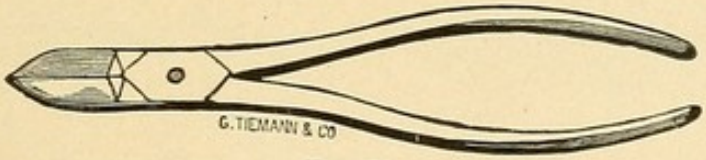

Fig. 21.

Fig. 21 represents a useful instrument for bone-cutting on the flat, while the *rongeurs* shown in Figs. 22 and 23 are of value, especially in operations upon

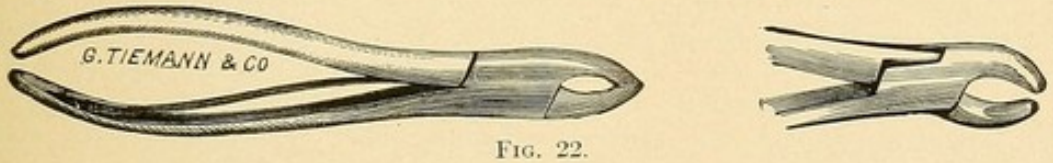

Fig. 22.

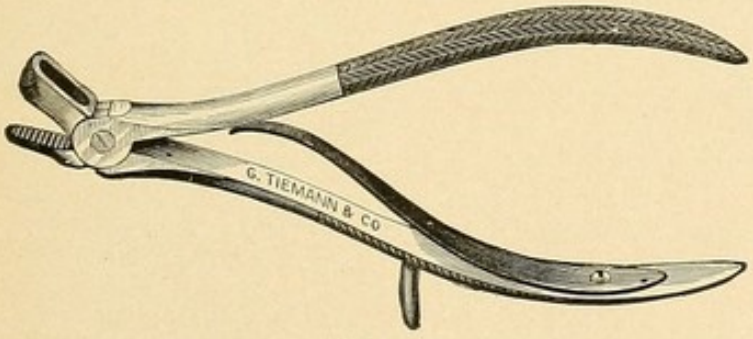

Fig. 23.

the cranium. For troughing in the trap-door operation on the skull, the De Vilbiss instrument shown in Fig. 24 is useful.

Fig. 25 represents an excellent holding or *sequestrum forceps.*

In *trephining*, the dura may be exposed by the careful use of a small sharp curved chisel and light mallet, although the *trephine* (Fig. 26) is more satisfactory.

Galt's instrument has a conical burr five eighths of an inch in diameter at the cutting edge, gradually enlarging to seven eighths at the base. It is so constructed

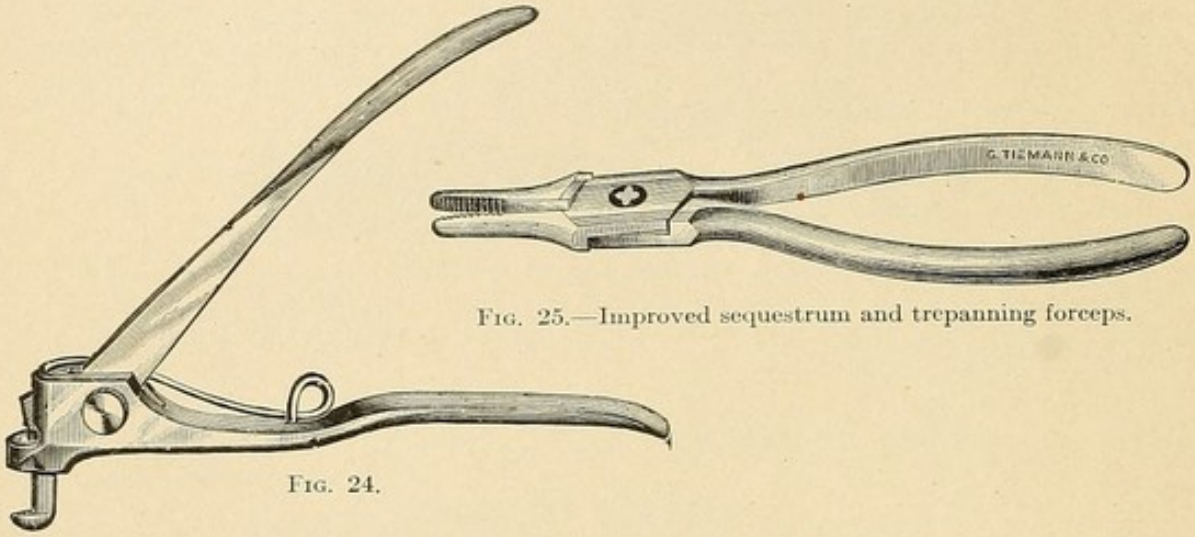

Fig. 25.—Improved sequestrum and trepanning forceps.

Fig. 24.

that as soon as resistance in front ceases, the side teeth take hold so greedily that further rotation is difficult, and the operator is thus warned that the dura has been reached. Undue force will, however, injure this membrane. In its employment, the central bit should be advanced about one eighth of an inch beyond the level of the teeth, so as to fix and steady the instrument in the bone until a



Fig. 26.—Galt's trephine.

well-marked circle is cut. The bit is then withdrawn, as the trephine can be held in place in the circular trench already made. In osteoplastic operations on the skull where rapid work is necessary a machine trephine is very desirable.

In controlling hæmorrhage, the flat elastic *Esmarch bandage* or rubber tubing may be employed. For squeezing the blood out of an extremity this apparatus is invaluable. For simple constriction, the plain rubber tube is preferable, although the Esmarch may be used for both. The danger of injuring nerves and producing paralysis by too strong constriction should not be overlooked.

Hæmostatic Forceps.—The scissor-handle clamps of various sizes and shapes (Fig. 27) are in general use. An operating outfit should have from twelve to twenty-four of these, also *dissecting forceps* with mouse-tooth and corrugated points. The author's *suture forceps*, with perfectly smooth and non-cutting point, is useful for holding the first knot of a suture or ligature immovable until the second knot is tied. A *needle-holder*, one or two of the best modern patterns, should be had, and should be constructed to hold any size or shaped needle, from the very smallest curved instrument to the large square Hagedorn.[1] *Scissors* curved on the flat, and dull pointed, and others fashioned straight, are very necessary. Much cutting and practically all dry or dull dissection may be done with the scissors. Some of these should be long, others short. *Probes* of malleable material, preferably silver, of various sizes and dull pointed, are required, and there should be a *grooved director* of the same material. Other instruments for special operations will be given later.

[1] The author's combination needle-holder and Reichert's are in general use.

Every operating set should have one or two razors for preparing the skin of the operative field.

All instruments to be used in an operation should be boiled, and when taken from the boiler laid upon and covered with sterile towels. Occasionally throughout an operation they should be dipped in hot sterile water.

Dressings.—The ordinary dressings are made of gauze and cotton, covered over at times with rubber-tissue protective or oiled silk. Plain gauze is made of cotton cheese-cloth, is absorbent, and should be in sterilized packages. It is used now altogether for sponging, having entirely displaced the sea sponge formerly employed. When it has been exposed, it should be resterilized before using, either in wet steam or by being boiled for twenty minutes, then wrung out and kept in sterile sheets or towels for drying. It may at times be used when moist.

While it is advisable to purchase these various materials from reliable manufacturers, in an emergency it may be prepared as follows: Take a bolt of cheese-

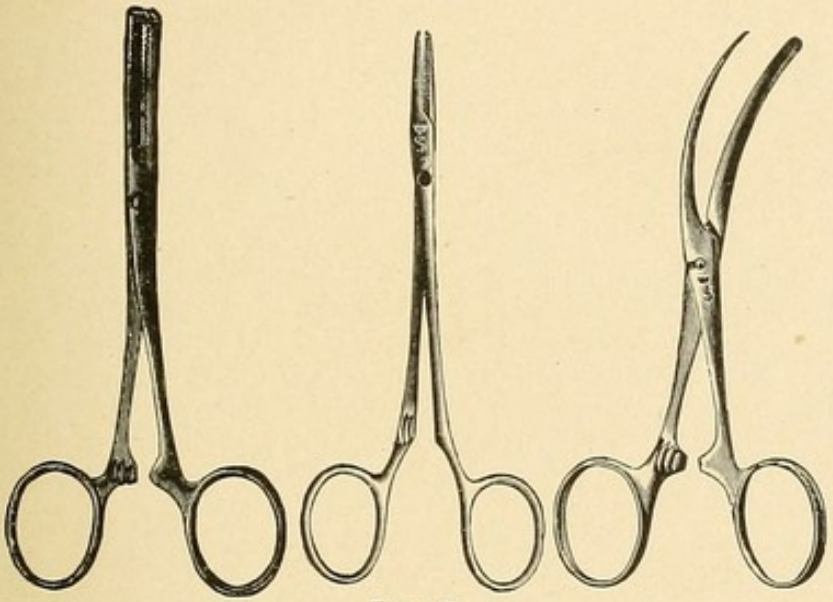

Fig. 27.

cloth and cut it into pieces one or two yards long; place in boiling water for two or three hours; rinse in cold water and soak in liquor sodii chlorinatæ (one part to five of water) for twenty-four hours. Rinse again in clear water and fold the gauze away in towels in a clean drawer. When about to use the gauze for a dressing it is placed in a sterilizer and boiled. If a dry-heat sterilizer is at hand, it should be placed in that and subjected to a high degree of heat.



Fig. 28.—Ribbon of gauze in sealed tube for wick-drainage or deep packing.

Mercuric chloride gauze is no longer used as a dressing. *Iodoformized* gauze is rarely employed, except in certain packings in the pelvis after operations through Douglas' cul-de-sac for the relief of pelvic peritonitis. It should be made of cheese-cloth and impregnated with iodoform in crystals, and sterilized by a reliable manufacturer. It is best carried in metal tubes (Fig. 28).

Absorbent cotton is so difficult of preparation that the practitioner is obliged to purchase it as prepared for the market. It can be sterilized in the dry-heat or wet-steam sterilizer. This material forms such an important part of surgical dressings that it should be prepared with great care. None should be used that has not been submitted to thorough sterilization after manufacture.

A very convenient dressing for any general operative wound is made of about twelve layers of sterilized gauze, in squares or parallelograms to suit varying conditions, and over this one layer of absorbent cotton, and over this one layer of cheaper cotton-batting. It is very exceptional that rubber-tissue protective or oiled silk is used. When a wet or moist dressing is applied, this covering is advisable.

Rubber tissue should be kept in a cold, dry place, and should be submerged in 1–1000 bichloride solution one hour before it is used in contact with an exposed or abraded surface. It is very rarely applied next to the skin, except as a dressing for burns or in Thiersch grafts.

For the drainage of wounds, catgut and soft sterile rubber tubing are in general employed. An ideal catgut drain is made by placing parallel with each other 12 to 30 or 40 strands of No. 2 or No. 3 catgut, using plain or chromicized, owing to the length of time that drainage may be required, the plain for one or two days and the ten-day chromic gut for the longer drainage. It is better to arrange these in bundles, the strands parallel rather than twisted, as twisting interferes with their capillarity. Rubber-tube drains may be used for the gall ducts or the urinary bladder. For peritoneal drains, soft rubber tubes, varying in diameter from one fourth to as much as an inch or more, are invaluable. The smaller drains are preferable. They are prepared by splitting the tube from end to end either in a straight line or spirally. Within the lumen of the tube a loose wick of sterile gauze, which should not more than half fill the cavity of the tube, is placed. The gauze should not come nearer than one fourth of an inch from the inner end of the tube. Outside the tube is loosely wrapped with two or three layers of gauze, and over this a layer or two of rubber-tissue protective. The peritonæum and the intestines do not adhere to the rubber tissue, which makes the removal of the tube painless and easy. A cigarette drain is made by wrapping a loosely rolled ribbon of absorbent gauze in three or four layers of rubber-tissue protective.

In using these tubes, especially in gall-bladder and gall-duct operations, in order to hold the end of the tube at the proper drainage point it is often necessary to fasten the rubber to any convenient tissue by a small No. 0 or No. 1 plain catgut suture. This prevents accidental displacement as the dressing is being applied and the patient put to bed. Within thirty-six hours the suture softens and the tube may be withdrawn.

CHAPTER II

ANÆSTHESIA

GENERAL CONSIDERATIONS—ETHER, CHLOROFORM, NITROUS OXIDE, COCAINE, QUINIA AND UREA, RECTAL ANÆSTHESIA, AND SPINAL ANALGESIA

WHILE no anæsthetic is absolutely safe, with a proper knowledge of the effects of the various agents upon the tissues in health, and especially in disease, together with a careful study of the conditions of the tissues at the time, and *always presuming that the patient has been properly prepared and that the administration is in the hands of an experienced and careful anæsthetist,* the danger is exceedingly slight.[1]

In the effort to condense in the smallest possible space the essentials of surgical practice as accepted by the author, there will only be considered ether, chloroform, nitrous oxide, cocaine, and quinia and urea.

The full measure of the benefit of surgery to mankind will never be realized until the science and art of anæsthesia are more thoroughly understood and more skillfully practiced. Knowing that the danger to life under proper conditions is infinitesimal, and that almost all the disagreeable features connected with anæsthesia as at present induced—namely, the natural dread of suspended consciousness, the anxiety or fright, and the distressing sense of suffocation, together with the equally annoying and perplexing after-effects—may be avoided, there is made a sad confession of the crudeness of our art and the necessity for its improvement.

Surgery can never reach that millennium toward which the eyes of all must turn who feel

> That touch of nature which makes the whole world kin,

when all in physical distress will seek relief when their troubles are just commencing and when they are safely and easily remediable, until anæsthesia is robbed of its present well-founded and widely felt distrust. The essentials to this end are:

1. A knowledge of the effects of the various agents employed upon the organs and tissues in health and in disease.
2. A knowledge of the condition of the organs and tissues at the time of administration.
3. A careful, systematic preparation of the patient.
4. A trained anæsthetist, sufficiently cautious and reliable to entirely relieve the operator of all the responsibility as to the narcosis.

Heretofore the agents almost exclusively employed have been ether and chloroform. Speaking entirely from the standpoint of the clinician (without regard to laboratory deductions), it is known that the vapor of ether or chloroform in the blood, even in small quantity, lowers the normal resistance, and is capable of serious injury to the tissues. Both are irritants to the respiratory organs in the process of administration, and to the kidneys in the process of elimination, and of the two, ether is more capable of injury to these organs. On the other hand, chloroform, at times and under conditions which the most careful preliminary

[1] Reference is made to a most instructive paper by the late Dr. Ernest J. Mellish, of El Paso, Texas, which was read at the Fifty-fourth Session of the American Medical Association, published in the Journal of that organization December 5, 1905, *et seq.*

study may not reveal, exerts an alarming and occasionally fatal influence upon the heart. This is especially true as regards children. The author has had two sudden deaths, both in the first stage of chloroform inhalation, when the anæsthetic was being administered with all possible caution and by an experienced anæsthetist. He has knowledge of four other cases in children who died from this anæsthetic, and all but one in the first stage of its administration. As between these two agents, it should follow that in weak heart action, due to atheroma of the coronary arteries or to fatty degeneration of the heart muscle, or in subjects who have had repeated attacks of rheumatism, or with chronic valvular lesions of the heart, ether or some other anæsthetic should be preferred to chloroform. Upon the other hand, when nephritis is present, especially in an acute form, or when a patient has had any recent inflammatory lesion of the kidney, as between ether and chloroform the latter is preferable, provided always that the condition of the heart does not contra-indicate the employment of chloroform. In laryngitis, bronchitis, pulmonary emphysema, extensive pleuritic effusion, with or without adhesions, and in patients who have chronic pneumonia or any consolidation of the lung due to tuberculosis or gumma, chloroform should be preferred to ether, provided that the condition of the heart will justify its use, *and always provided that analgesia or anæsthesia may not be secured by some other means less injurious to the organs than either.*

Formerly, in operations within the peritoneal cavity, there being no positive contra-indications, chloroform was preferred for the reason that during and after the operation vomiting was less apt to occur. It has, however, been demonstrated that the disagreeable after-effects of ether, as well as chloroform, may be greatly lessened by combining with ether nitrous-oxide gas and oxygen in certain proportions, and thus diminishing the quantity of the more noxious vapor.

It has also been demonstrated that a prolonged and satisfactory narcosis can be induced and maintained by the combination with ether, of morphia hypodermically, and nitrous-oxide gas and oxygen, together with the mechanical induction of cerebral anæmia by Professor Dawbarn's method of temporarily confining a good portion of the volume of blood in the extremities. In expert hands, after the narcosis is once complete, operations lasting an hour or more have been performed with the anæsthetic discontinued, the patient seemingly in natural sleep.

As before stated, in children ether is, in general, safer than chloroform, and this without regard to the greater irritation of the respiratory tract from ether.

Patients with atheroma of the blood vessels, especially when this condition of arteritis has been due to prolonged alcoholic addiction, take any anæsthetic badly, and in these subjects local anæsthesia is always to be employed when possible. The same is true in lesser degree of very fat subjects, who are generally of low resistance.

In an emergency, where it becomes necessary to perform an operation within one or two hours after the ingestion of a quantity of solid food, if local anæsthesia is not possible and only chloroform and ether are at hand, the former may be given preference, since *per se* it is less apt to induce vomiting. Under such conditions it is advisable to practice gastric lavage.

Chloroform has been found so safe in obstetrical practice that by common consent it is employed in parturition.

When an experienced assistant cannot be had, there being only ether and chloroform available, the former should be employed for the reason that an untrained anæsthetist is capable of less harm with it than with chloroform.

When we realize that the accepted death-rate from chloroform is about one in two thousand administrations, and from ether about one in five thousand, we must appreciate the necessity of not using these agents when safer methods are possible, or of endeavoring to secure the necessary anæsthesia by using smaller quantities of these more powerful agents which, in combination, may not only be made less dangerous to life, but less objectionable in their after-effects.[1] The storm-center

[1] Mellish quotes Bouffleur's statistics, of over 1,000,000 chloroform, and 500,000 ether anæsthesias, with a mortality of 1 in 3355 for the former and 1 in 16,768 for the latter. As employed up to within a recent period, in the author's opinion, the death-rate was greater than

of major surgery is the alimentary canal, and every clinician knows that even small quantities of ether or chloroform have a deleterious effect upon the secretions of the digestive apparatus, weakening if not paralyzing the muscle of the intestinal wall, and on this account interfering materially with the comfort and the recuperative power of the patient.

Even nitrous oxide should not be carelessly or indiscriminately given. Hewitt reports seventeen deaths from this agent, while cocaine, even in weak solutions and in the hands of experts, by reason of idiosyncrasy or special susceptibility, has frequently produced alarming and occasionally fatal results.

There is an agent, nitrous-oxide gas, which, administered with the free admixture of air or oxygen (of the former fifteen to eighteen per cent, and of the latter five to eight per cent—Gwathmey), is practically without danger; and so few are the disagreeable features connected with its administration that even timid children can be easily taught to submit to it willingly and, when necessary, repeatedly. The death-rate from nitrous oxide is estimated at one in from fifty to one hundred thousand. With oxygen no deaths have been reported, and it is held to be safer than the admixture with air. It may be used to the exclusion of chloroform or ether in a large number of procedures which heretofore have required these agents. With nitrous oxide the frequently repeated passive motion so essential to success in the treatment of certain fractures communicating with the joints (more particularly of the elbow) may be made with the best possible results. In the prevention of ankylosis in all forms of joint involvement it is of inestimable value, for the reasons that it is safe, the narcosis is induced in a minute without a disagreeable sensation, entire consciousness is restored within a minute after its discontinuance, and there is not a suggestion of nausea or unpleasantness; and, most important of all, patients will not hesitate to repeat it as often as necessary to secure the best possible results.

In the setting of minor fractures, where muscular rigidity is not extreme, it can be used to great advantage and with the minimum of inconvenience. However, in all fractures of the thigh and near the hip, or elsewhere, when complete muscular relaxation is essential to the successful reduction and maintenance of the parts in apposition until the plaster-of-Paris fixation dressing can be hardened in place, the more profound narcosis of ether is essential.

A long list of minor surgical procedures where cocaine infiltration is not done, such as the extraction of teeth, removal of adenoids, incision of an abscess, felon, pleural empyema with resection of one or more ribs, fistula *in ano*, fissure, isolated hæmorrhoids, in all short exploratory operations of the abdomen, suprapubic cystotomy, nephrotomy, strangulated hernia, minor amputations, moderate-sized tumors, and all minor and many other major procedures where complete muscular relaxation is not absolutely essential, this agent may be employed with perfect satisfaction. Operations lasting from a half hour to an hour, including colostomy, gastrostomy, and enterostomy, have been repeatedly and successfully performed with no other agent than this with the free admixture of air or, preferably, oxygen.[1]

If at any time in the administration of this agent a more complete temporary relaxation or quiescence is demanded, a few whiffs of ether or chloroform, as may be indicated, together with the judicious use of Dawbarn's sequestration, and the preliminary injection of a small quantity of morphine and atropine ($\frac{1}{8}$ to $\frac{1}{4}$ gr. of the former, $\frac{1}{100}$ to $\frac{1}{150}$ of the latter), will enable the surgeon in at least fifty per cent of all operations to dispense with the dangers and disagreeable effects of the major anæsthetics, ether and chloroform.

Nitrous oxide, on account of the persistence of the reflexes during its administration, is at times contra-indicated in certain procedures where perfect muscular relaxation is essential.

Again, the general profession has not as yet shown a proper appreciation of

would appear from these statistics, but within the last few years, with improved apparatus, the employment of expert anæsthetists, and a more careful selection of cases for a given anæsthetic, the ratio of mortality is fully as low as that given in Bouffleur's statistics, and doubtless will be much further reduced.

[1] Arthur D. Bevan, "Trans. Am. Med. Association," 1907.

the value of local anæsthesia as induced by the skillful injection of cocaine hydrochlorate and quinia. Practically all of the minor operations and many major procedures heretofore requiring general narcosis may be safely and satisfactorily performed with these agents.

Ether.—The vapor of ether is inflammable, and may possibly ignite if a flame or cautery be brought too near the inhaler. It is primarily a cardiac stimulant,

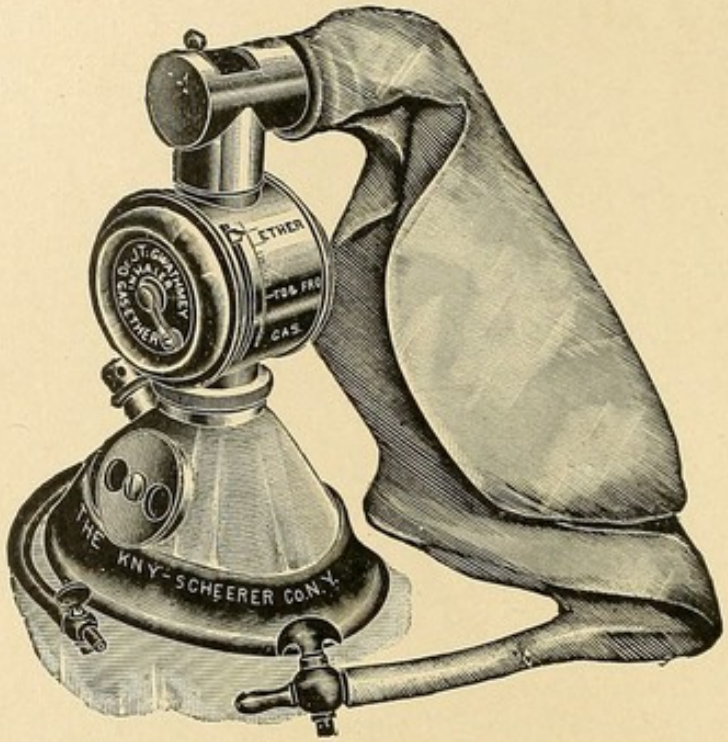

Fig. 29.—Gwathmey's balloon inhaler for ether alone or nitrous oxide and ether.

and increases arterial tension. On the nervous system it acts as a paralyzant, affecting first the cerebrum, next the cerebellum, later the sensory and motor functions of the cord.

It may be given alone or in combination with nitrous oxide. While in an emergency it may be given by the open or drop method, on account of the low temperature of the vapor as thus inhaled, which not only acts as an irritant to the



Fig. 30.—Gwathmey's warm-vapor apparatus for chloroform or ether.

respiratory tract, favoring the development of bronchitis or pneumonia, but diminishes the body temperature and therefore weakens the normal resistance, it should, when possible, be warmed before inhalation, preferably by a thermal (hot-water) apparatus or by one of the closed or balloon methods in which the expired air is in a measure used to raise the temperature of the vapor.

The anæsthetist should have at hand (1) a wedge- or screw-shaped piece of

wood or hard rubber, for forcing and holding the jaws apart (Fig. 31); a Sayre periosteal elevator is a good substitute. (2) A mouth gag (Figs. 32–33) with which to keep the jaws permanently open, if necessary. (3) A tenaculum or forceps



Fig. 31.—Hard-rubber oral screw.

for drawing out the tongue (Fig. 34*a*). (4) A large-sized curved needle, armed with a stout silk thread, for transfixing this organ should the emergency arise. (5) Forceps, with small sponges or swabs for mopping out the pharynx and throat. (6) A bottle, graduated, so that the exact quantity of the anæsthetic taken is known. (7) Whisky or brandy for hypodermic use. (8) A sterilized hypodermic syringe. (9) A pus basin or pan, in case of vomiting. (10) Towels to cover the patient's face as a guard against infection of the operating wound. (11) A cylinder of oxygen ready for inhalation. (12) A tube for the trachea.[1]

In the administration of ether alone the safer method is to employ the thermal inhaler (Fig. 30). In this apparatus the ether vapor is forced out by a hand-ball

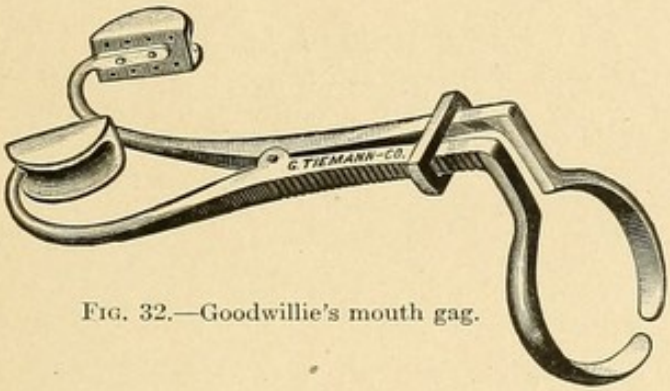

Fig. 32.—Goodwillie's mouth gag.

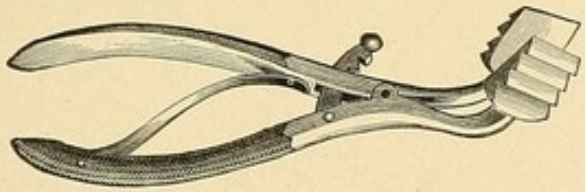

Fig. 33.—Gross' speculum oris.

pump through the hot-air chamber, and thus enters the respiratory tract near the body temperature. Should this be unavailable, the next in order of preference is the Ormsby, or some form of inhaler to which a rubber balloon is attached (Fig. 29). The expired air coming in contact with the ether in the balloon raises the temperature very considerably before it passes into the lungs. The partial asphyxia which may result from breathing over and over again the expired air, while more objectionable than warmed oxygenated vapor, is not dangerous, and any symptoms of suffocation may be quickly relieved by tilting the mouthpiece to one side during two or three inspirations. Should the pulse, color, or respiration suggest it, the necessary quantity of oxygen may be administered.

Since the passage of inspired air over ether vapor carries this into the lungs at a temperature so low that it tends to excite irritation, the *open air* or *drop method* is only advised in an emergency or under conditions which make the thermal methods impossible.

[1] A galvano-faradic battery may in very exceptional cases be of service.

In the "drop" method, the Esmarch screen, covered with several additional layers of gauze or a gauze mat, may be used. The eyes and chin are protected by towels or gauze, and the ether (preferably warmed in a basin of hot water), drop by drop in rapid succession, is made to moisten the screen.

The quantity of ether necessary for a given operation will vary in different individuals, but in general it is largely dependent upon the skill and experience

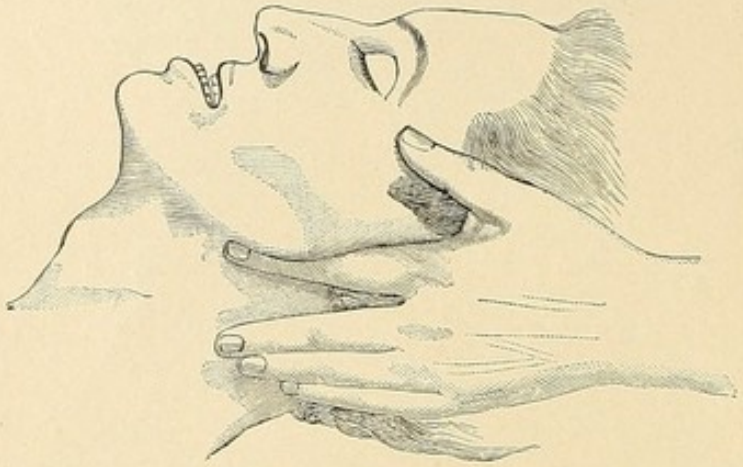

FIG. 34.—Pressing the lower jaw and base of the tongue forward. (Esmarch.)

of the anæsthetist. An operation lasting an hour should not require more than from two to four ounces, especially when a preliminary injection of morphia and atropia has been made.

Professor Dawbarn has recently demonstrated a method of prolonged narcosis with the minimum of ether, by confining a portion of the blood supply in the lower extremities during the operation, in this manner not only lessening the blood pressure and hæmorrhage in the wound, but at the same time causing a temporary

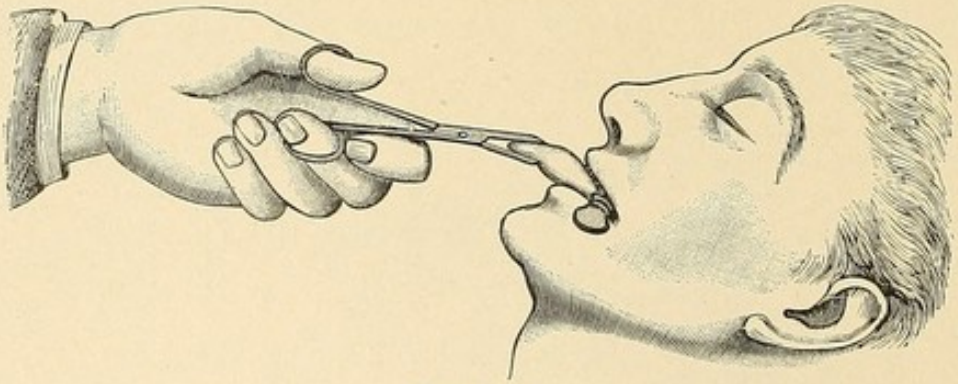

FIG. 34*a*.

cerebral anæmia, which induces an almost natural sleep. In operations lasting an hour it is possible to discontinue the anæsthetic after the first incision. Elastic bandages are wound around the thighs at the crotch, the pressure being so adjusted that the return of the blood through the veins is retarded, while it can still flow out through the arteries. This method is worthy of most serious consideration.

The anæsthetist should always have at least one assistant, and when help is scarce, especially in dealing with an alcoholic subject or a strong, excitable patient, holding straps should be thrown over the chest and knees and around the table. As a routine practice this precautionary method of restraint is advised.

In order to prevent the possibility of infection from the mouth and nose of the patient, a curved wire should be fastened to the operating table at the level of the chin, and on this a towel so arranged that the face is entirely screened from the field of operation.

In the *first stage* of ether anæsthesia the face is usually flushed, the pulse in-

creased in force and frequency, and there may develop a slight delirium from the intoxication. This stage lasts only two or three minutes, when the character of the breathing, becoming more regular, indicates that the stage of excitement is passing into the *second stage*, that of relaxation and unconsciousness. The respiration becomes regular and soft, and the corneal reflex is lost. Should the breathing become sonorous on account of the base of the tongue falling back upon the larynx, the index-finger inserted just beneath the angle of the jaw, pressing this gently forward (Fig. 34), lifts the tongue and permits the uninterrupted ingress of the anæsthetic. Should vomiting occur, the apparatus should be removed to prevent its being soiled, and immediately applied when the mouth has been cleansed. If mucus collects in the nose, mouth, or larynx, it should be removed with sponges on holders. Should the patient turn blue suddenly, the jaw should be pried open with a screw or wedge, and the tongue drawn forward. Plenty of fresh air should be admitted to the room, and the oxygen tank (which it is always proper to have near at hand) may be brought into requisition. In the event of respiration being entirely suspended, artificial respiration should at once be performed.

Sylvester's Method.—Slide the patient over the end of the table until the head hangs down, tilt the foot of the table up by placing the lower legs on a stool or

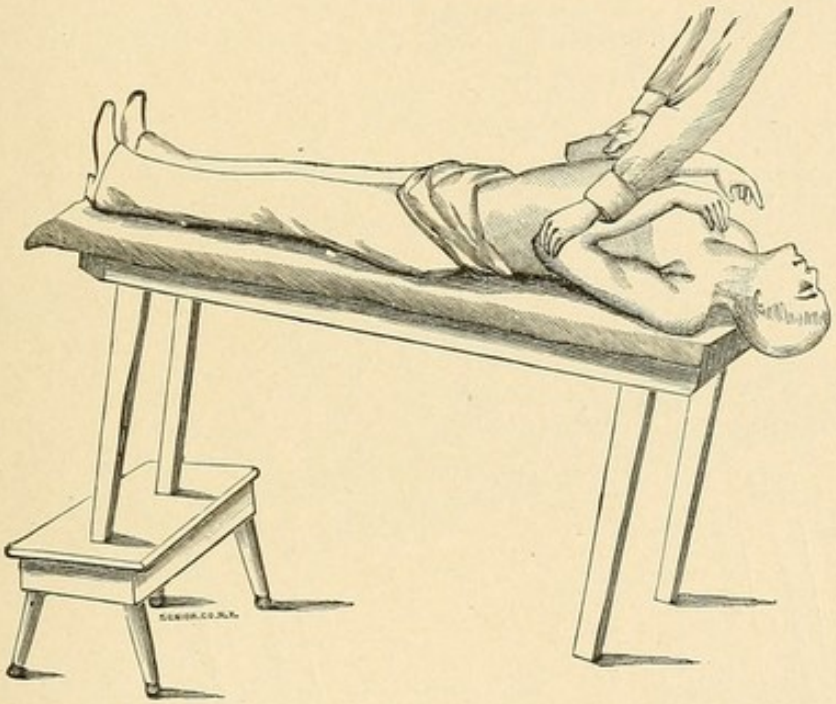

Fig. 35.—Forcing the dead air from the lungs by pressure upon the walls of the chest.

chair. Stand at the patient's head as he rests upon the inclined plane, and seize the arms at or near the elbows, pressing them down upon the thoracic walls, thus forcibly emptying the lungs (Fig. 35), and immediately thereafter extending them upward parallel with the long axis of the body, aiding in the expansion of the chest (Fig. 36); this is repeated eight or ten times a minute, and kept up by relays of assistants, if necessary, until voluntary respiration is established or the heart has ceased to beat. It is important that these manipulations should in no way interfere with the assistant who is holding the tongue out of the mouth and the gag in place. If, in the judgment of the surgeon, the respiratory failure has been caused by occlusion of the larynx or trachea, a rapid tracheotomy should be done. The insertion of a tracheotomy tube is not, under such circumstances, advisable, it being safer to grasp the edges of the incised trachea with tenacula, or insert a silk suture through the skin and trachea on either side and hold the wound gaping while an effort is made to clear away the obstruction.

Heart failure is exceedingly rare in ether narcosis. A weak heart is, in general, stimulated. Occurring later, it is indicated by gradual weakening in the force with increased rapidity of the pulse, or by the rapid supervention of pallor. One or two

drams of whisky or brandy may be administered hypodermically, or an ounce of whisky in a half pint of warm water may be thrown into the rectum and colon. In certain instances, where hæmorrhage has been quite profuse, Esmarch's elastic bandage should be thrown around the extremities, from the foot to the hip and from the fingers to the shoulder, in order to force the blood in them into the general circulation. The patient's head should be placed lower than the body, by allowing it to hang over the upper end of the table (Fig. 35); if the heart should cease to beat, striking sharply upon the ribs near this organ with the palm of the hand, at the same time showering the chest and epigastrium with cold water or ether, may act as a stimulant.

If within a few seconds this does not succeed, it is the imperative duty of the surgeon rapidly to incise the chest wall in the fourth intercostal space near the sternum, open the pericardium, and massage the heart between the thumb and index-finger. Several cases are recorded in which resuscitation has been effected by this heroic method. Artificial respiration by Sylvester's method and the inhalation of oxygen should be practiced, and when hæmorrhage has been severe, the rapid injection of salt solution in a vein should be added.

If respiration alone ceases, a sharp slap immediately over the sternum will almost invariably cause the patient to breathe (Gwathmey). In elderly persons, and in all patients in whom for any reason rigidity persists with the usual tendency to asphyxia, it will be advisable to change to the warm ether drop method, adding from time to time a drop or two of chloroform, also kept warm by placing the bottle in a basin of hot water.

Great care should be taken to keep the ether inhaler clean. After each operation it should be taken apart, cleansed with soap and brush, and submerged in

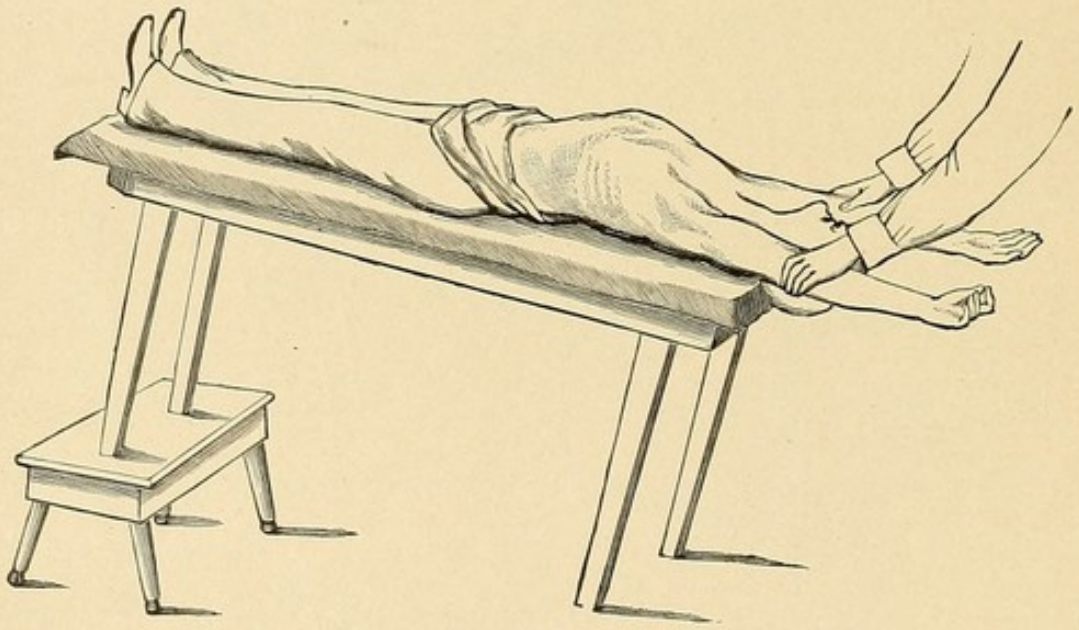

Fig. 36.—Expanding the chest and filling the lungs with fresh air.

1–1000 or 2000 mercuric-chloride solution, or boiled. The infection of the respiratory tract by germs conveyed from one patient to another may result if this precaution be not taken.

Chloroform.—Pure chloroform is more irritating to the skin than ether. If prevented from rapid evaporation, it produces vesication. An ordinary test of purity is a mixture with equal parts of pure sulphuric acid, which should produce no discoloration. The impure article colors the acid brown. It is not inflammable, and on this account it may, in certain cases, be preferred to ether.

The preparations for chloroform narcosis differ in no essential feature from those given for ether. A much smaller quantity is necessary, and, in general, it is a wise precaution, except in the very young and very old, to give a hypodermic of morphia (gr. $\frac{1}{4}$) with atropia (gr. $\frac{1}{150}$) twenty minutes before the anæsthesia.

The open *warm* vapor method with the Gwathmey apparatus (Fig. 30) regulates the quantity administered, and brings it in contact with the respiratory surfaces at nearly the normal temperature. It also permits the induction of oxygen as required or the change to ether.

Next in order of preference is the Esmarch screen (Fig. 37), but a napkin or gauze mat will suffice. Chloroform should be warmed by placing the bottle every

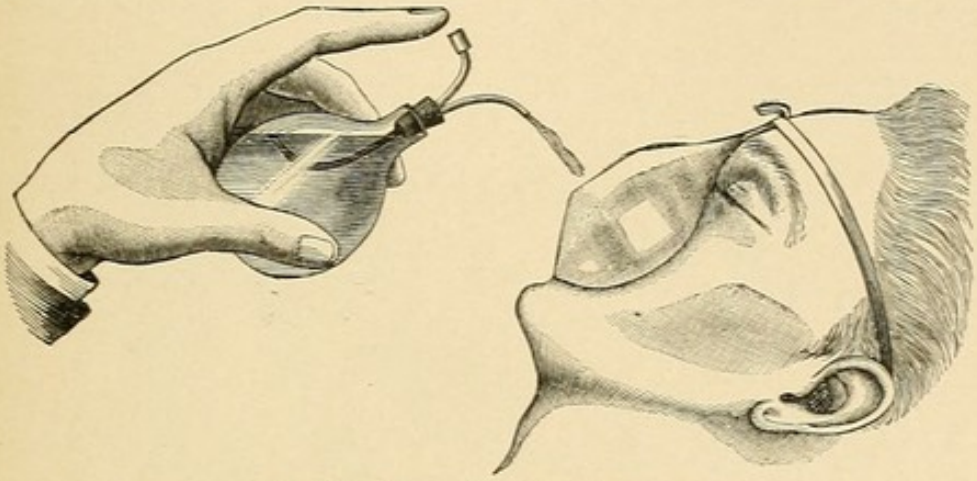

FIG. 37.—Esmarch's chloroform screen.

minute or two in a basin of hot water. It is believed to possess less danger when heated, and to be safer in warm weather or in a warm climate than in regions of low temperature.

The administration is begun by pouring five or ten drops upon the inhaler, permitting a free admixture of air. It is advisable to smear the skin about the mouth and nose with vaseline, to prevent irritation. The anæsthetic is added drop by drop until consciousness is lost. At no one time should more than a few drops be added. In the *first*, or *stage of excitation*, the pulse is increased in force and frequency, the face flushed, the pupil normal or at times contracted. Delirium may be present, with muscular rigidity varying in degree with different subjects. It is almost always well marked in patients of the alcohol habit. As given on a preceding page, ether should be substituted with threatened heart failure or asphyxia. The *second stage* is that in which sensibility and consciousness are lost, the functions of the heart and respiratory organs being performed in an almost natural manner. The pupil is slightly dilated, and arterial tension diminished. In the *third stage*, that of profound relaxation, the breathing becomes more shallow, and at times stertorous; the heart beats rapid and weak, and arterial tension is markedly diminished.

The *second* is the *operative stage*, the third should be avoided. It is more important to administer a preliminary injection of morphia and atropia in chloroform than in ether narcosis. Death during the inhalation of chloroform occurs more frequently from heart failure, although respiratory paralysis may ensue. Death from chloroform due to heart failure is very sudden. There are no premonitory symptoms, and restoration of function is almost always hopeless. When this accident occurs the heart should be massaged as just described.

Nitrous oxide is not only safe,[1] but simple in administration, producing in one or two minutes complete insensibility. In expert hands, with the admixture of air or oxygen, as may be indicated, an anæsthesia lasting two hours or longer may be satisfactorily maintained.

Nitrous oxide of the purest quality, condensed in portable cylinders containing a sufficient quantity for twenty ordinary administrations, can be obtained from reliable manufacturers.

When gas alone is to be administered, the tube at the end of the balloon is

[1] One operator in New York City has employed it in more than 100,000 instances without an accident.

connected with the tube leading from the cylinder, the cylinder cock is opened, and a sufficient quantity of gas allowed to flow in until the balloon is about three fourths distended. The face piece is now closely applied over the mouth and nose, so that no air can be admitted, and the patient is told to breathe deeply and somewhat more rapidly than normal. In from thirty to sixty seconds the color of the skin changes to a dark red, at times almost purple hue; there is usually muscular tremor or momentary rigidity, with incoherent speech, but in a very short time these symptoms pass, with complete insensibility to pain. If the lifted arm falls

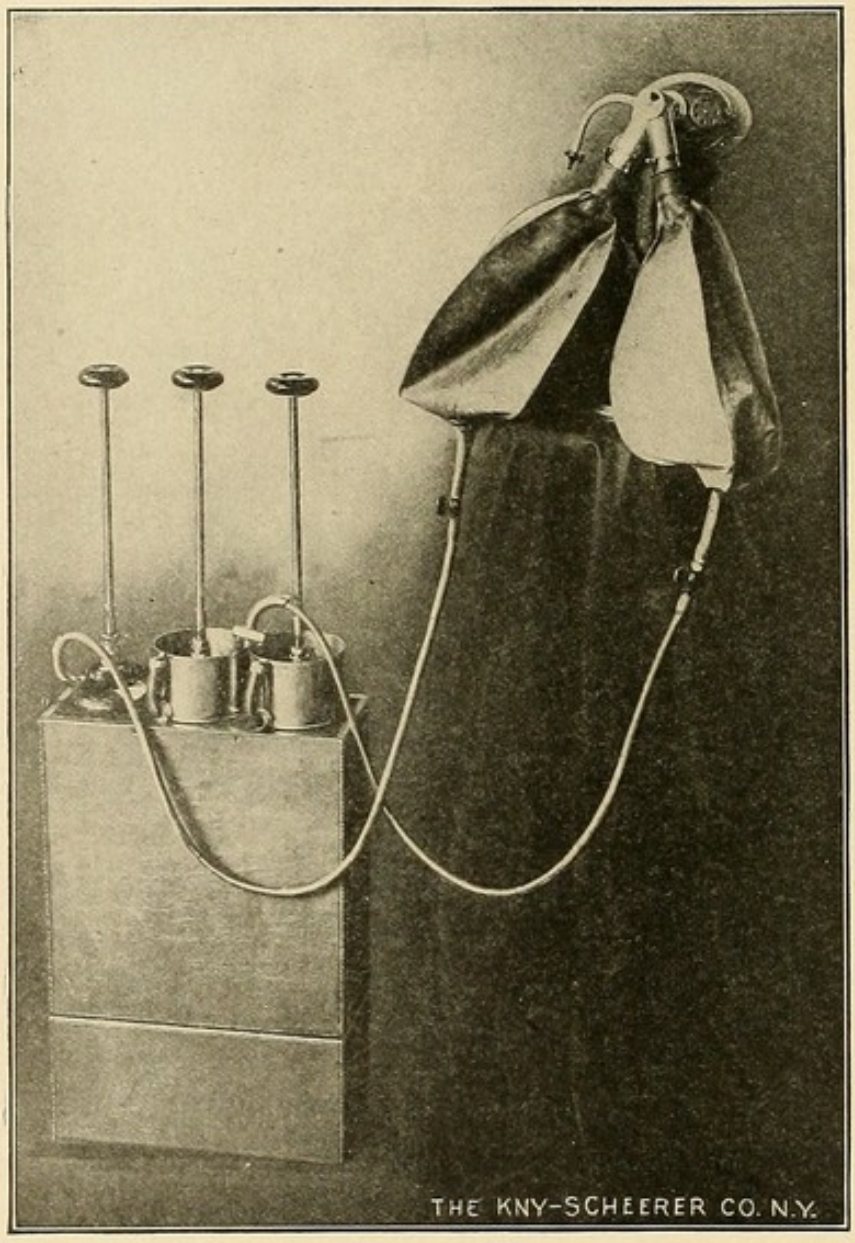

Fig. 38.—Portable combination heated nitrous oxide and oxygen apparatus.

to the patient's side, the surgeon can proceed with the operation. By allowing the patient to take two inspirations of the gas and one of free air (fourteen to eighteen per cent for men and eighteen to twenty-two per cent for women), the narcosis may be safely continued for an hour or more. When given alone, or in combination with ether, it is advisable to employ the thermal mechanism devised by Dr. Ernest Brown (Fig. 38), in which apparatus the gas passes through a coil of pipe in contact with hot water.

In addition to its usefulness alone in the long list of operations above given, it is invaluable when combined with ether for prolonged anæsthesia. The patient within a minute or two becomes unconscious from the gas, and does not feel the

irritation of the larynx nor the sense of strangulation and anxiety which ether alone produces.

For its administration a close-fitting mouth-and-nose piece is essential, to which is attached a rubber balloon. This combined ether and nitrous oxide inhaler (Fig. 29) is so arranged that the patient, for the first minute or two, inhales only gas, and when rendered insensible by this agent the ether is turned on very gradually, so as not to irritate the larynx. The quantity of gas is then gradually diminished until, within from three to five minutes from the commencement of the administration, ether alone is given and the gas reservoir entirely disconnected.

In expert hands this method is so satisfactory that patients become fully unconscious and relaxed without a struggle, and with the use of the smallest possible quantity of ether.

When a combination gas and ether inhalation apparatus is not at hand, a compromise can be made by employing any open inhaler, such as the Allis, around one end of which an ice-bag or oil silk has been tied. The nitrous oxide can be administered at first through the gas inhaler, and as soon as the patient is unconscious the modified ether apparatus applied.

Nitrous Oxide and Oxygen.—The proper admixture of nitrous oxide and oxygen produces a most satisfactory anæsthesia. The combined apparatus is shown in Fig. 38. It is so arranged that by turning a key any desired admixture of the two gases may be obtained. The usual proportion of oxygen is from five to eight per cent.

The nitrous oxide escaping from the cylinders passes through a metal coil submerged in hot water, which warms the gas to the proper degree. So cold is this vapor under pressure that the lower portions of the cylinders are frequently entirely congealed. The author has used this method in a very considerable number of cases (gallstone, varicose veins, etc.), and has found it satisfactory in every respect.

The narcosis is induced without excitement or any disagreeable sensation, the color of the skin is normal, and the ordinary suggestions of asphyxia so common to other anæsthetics are absent. The pulse is usually accelerated, being about 80 to 90 beats per minute. In no instance has it been followed by vomiting or any symptoms of inertia in the alimentary canal. It carries with it no danger to the kidneys, the respiratory apparatus, or the heart, and when its value is fully appreciated it will supplant in large measure the administration of ether or chloroform.

In patients of high tension it is advised to administer a preliminary injection of $\frac{1}{8}$ to $\frac{1}{4}$ of a grain of morphia thirty minutes before the anæsthesia is commenced. This should not be done as routine practice, but only in exceptional cases. It is, in general, better not to use morphia before or after a surgical operation, on account of its tendency to produce intestinal paralysis and to interfere with the normal secretory apparatus.

If, in the course of an operation, by reason of extreme muscular resistance (as in laparotomy), a more complete relaxation is required, the addition of a small quantity of ether (℥ss–℥j) will produce the necessary relaxation and a sufficiently profound narcosis. In no instance has the author used in any operation more than ℥jv of ether, and in the large majority of instances in which it was combined with nitrous oxide and oxygen the quantity was not over ℥ij.

One of the chief values of this narcosis is that none of the distressing after-effects of ether or chloroform upon the heart, lungs, or kidneys are present, and vomiting is absent. The apparatus is so arranged that the ether can be poured into the chamber of communication between the oxygen and nitrous oxide cylinders, and can be turned on or off as required.

Cocaine.[1]—Applied to the cornea and conjunctiva by dropping one or two minims of a two-per-cent solution into the eye or upon any mucous surface, within a few moments it completely deadens local sensibility. Upon the unbroken integument

[1] The human race will ever be indebted to Dr. Carl Koller, of New York, who discovered the anæsthetic properties of this agent when applied to the eye and mucous surfaces, and to Dr. J. Leonard Corning, of New York, who first demonstrated its use by hypodermic injection.

it has no effect. Injected into the tissues through a hypodermic needle, it produces anæsthesia within the range of contact. In the substance of a nerve it is rapidly absorbed, and within a few minutes produces complete anæsthesia in all parts in the range of distribution of the nerve trunk *beyond the point of injection.* So employed, it lessens, and may prevent, shock from the traumatism of an operation by paralyzing nerve conductivity and preventing the registration by the brain cells of the sense of injury in the field of operations. For this reason Crile advises its employment as a preliminary to amputations or other major operations upon the extremities, even when general narcosis is to be employed.

The quantity to be used will vary with the susceptibility of the individual and the extent of the dissection. By the infiltration method with the weaker solutions, introduced by Schleich, and more thoroughly developed by J. A. Bodine in the operation for the radical cure of hernia, etc., all danger from cocaine poisoning is practically removed. The solutions should be sterile, and should be prepared immediately before injection, for the reason that they rapidly develop a fungus. It is, moreover, not safe to employ a cocaine solution which has been boiled. In an emergency a fairly sterile product may be secured by dissolving clean crystals in normal salt solution heated for a few minutes just short of the boiling point (about 190° F.).

Bodine uses a preparation of sterile crystalline cocaine, plus sufficient sodium chloride, enclosed in a sealed tube;[1] the quantity in each, when dissolved in an ounce of water that has just been boiled and allowed to cool to about the body temperature, makes a 1–500 cocaine normal salt solution. This stock solution is used to anæsthetize the skin in the line of incision (endermic), and *nerve trunks* when encountered, but for subdermic infiltration a 1–1000 solution is employed.

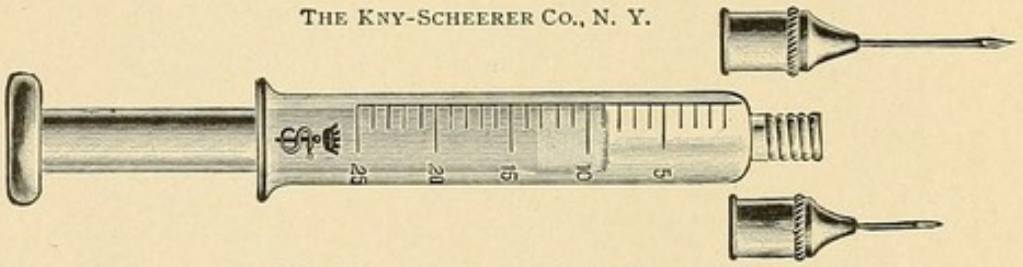

FIG. 39.—Glass syringe for infiltration.

This is secured by partially filling the glass syringe with the 1–500, and then drawing into the barrel an equal quantity of sterile salt water. Any hypodermic syringe and needle, if properly sterilized, may be employed, although the simple glass instrument (Fig. 39) is preferable. Two or three of these (holding ʒj or ʒij) should be kept at hand so that the infiltration may be rapidly accomplished.

Since, in operations under cocaine anæsthesia, the patient is entirely conscious, and naturally more or less apprehensive, it is exceedingly important that the operator should take every possible precaution to allay anxiety and to prevent panic. He should carefully note the peculiarities of the individual, and deport himself accordingly. By speech and manner he should convey the impression to the mind of the subject that the operation is not only entirely free from danger, but painless withal. This statement may be, in a measure, qualified by the suggestion that in case there should be the least sensation of pain, the attention of the operator be called to it by word, and not by movement.

With the majority of patients it is advisable to keep instruments and apparatus concealed, and under no circumstances to permit the patient to view the operative wound. When an instrument is desired, the operator should pick it up, or indicate it without speaking. The call for a knife or scissors, as well as the sight of blood, may unnecessarily excite apprehension. Although no pain is experienced, the click of the scissors may compel the operator to dissect with the knife.

[1] Parke, Davis & Co.

Individuals who are naturally nervous and overexcitable, and children who are unable to control themselves, are not suitable subjects for cocaine surgery.

In all instances where a prolonged operation is undertaken under cocaine anæsthesia, a hypodermic of $\frac{1}{4}$ of a grain of morphia is advised five or ten minutes before the infiltration is given. Morphia is not only an antidote to cocaine poisoning, but tends to allay anxiety.

For the first injection into the skin a very delicate needle should be used. This should be shown to the patient, with the statement that there will be no pain beyond the initial prick of the needle, for it is very important, in order to retain the confidence of the subject throughout the operation, to minimize even the small pain of the initial puncture. In a timid and overexcitable subject, so important is it that implicit confidence be won at the very threshold of the operation, it is a wise precaution to deaden sensation of the initial morphia and cocaine punctures by applying a spray of ether from the Richardson atomizer, or by holding a piece of ice to the skin for a few minutes. The hypodermic needle should be entered almost parallel with the surface of the skin to be anæsthetized, the point and shaft being *scarcely beneath the epidermis*, for here the end organs of the sensory nerves are most successfully paralyzed with the minimum of solution. When pressure is made upon the piston and three or four minims have been forced out, the skin is slightly distended, becomes pale, and is anæsthetized. It should then be further introduced to its full length, and more solution injected. It should now be withdrawn, a larger needle quickly substituted, and inserted through the edge of the anæsthetized area, and in the track of the proposed incision. This should be repeated *ad finem*. The underlying fat in the field of operation should then be thoroughly infiltrated with the weaker 1–1000 solution *before the skin is incised*.

Should a sensitive area be encountered, as when a blood vessel or nerve trunk comes in the line of dissection, one or two minims of the stock solution should be injected into or immediately about the nerve.

When operating upon the extremities it may, in certain conditions, be advisable to produce blood stasis by the use of the rubber tourniquet. When this is done, the cocaine solution remains for the time being stagnant, and in actual contact with the sensory end organs. When the operation is finished, and when a considerable quantity has been used, it is a wise precaution not to remove the tourniquet and allow all the solution to be carried too rapidly and in too large volume into the general circulation. This can be avoided by loosening the tourniquet for about ten seconds, tightening it again for a minute, and repeating this through five or ten minutes, thus giving an opportunity for the gradual distribution and elimination of the cocaine.

Cocaine infiltration, either free or in stasis, when properly done, does not interfere with the process of repair in the field of operation.

Any variation from the technic above described will be given in connection with the operations in which the change may be deemed advisable.

As heretofore stated, with these cocaine solutions properly employed, operations of the magnitude of thyroidectomy may be satisfactorily done. The Kochers of Berne have performed nearly two thousand thyroidectomies with no other anæsthetization than cocaine infiltration. All operations upon bone can be done with perfect insensibility after cocaine anæsthesia, provided the periosteum is thoroughly infiltrated. All the abdominal viscera are entirely insensible to pain, and unless the mesentery be dragged upon, all explorations and extensive operations may be done with cocaine anæsthesia, provided the peritonæum of the abdominal wall, which is exquisitely sensitive, be thoroughly anæsthetized.

Quinia and Urea Hydrochloride has been demonstrated by Dr. H. Thibault, of Arkansas, to be a local anæsthetic of great value. Injected into and beneath the skin in the same way as advised for cocaine infiltration (a two-per-cent solution for the endermic and one-per-cent for the hypodermic injection), it rapidly produces analgesia, the anæsthetic effect lasting longer than that of cocaine. Ten grains dissolved in one ounce of normal salt is approximately a two-per-cent solution. It may be rendered entirely sterile by boiling just before using, and so far, in the large number of cases in which it has been successfully employed, no constitutional

symptoms have been observed.[1] A fifteen-per-cent solution applied on pledgets of cotton to an ulcerated surface will render curetting painless (Thibault).[2] A ten- to fifteen-per-cent solution applied to the mucous surfaces will also produce analgesia.

Rectal Anæsthesia.—Ether vapor, absorbed by the mucous membrane of the colon, will produce narcosis. A number of fatal cases have been reported, and it is now rarely employed. Carefully administered in properly selected cases, it has its place in surgery.

The warmed vapor is carried into the bowel through a soft rubber tube, one end of which is introduced into the rectum as high as the sigmoid colon, the other being connected with the vessel holding the ether. This is placed in warm water, about 100° F., at which temperature it is rapidly vaporized. A very small quantity of vapor should be allowed gradually to enter the bowel, and should overintoxication occur, a second tube of larger caliber should be introduced to permit the excess of gas and vapor to escape.

This method was formerly recommended in operations about the mouth and upper air passages, since it did away with the inhaling apparatus and allowed uninterrupted access to the operative field, but since the introduction of Dawbarn's sequestration method, after the narcosis is complete, the quantity of the anæsthetic necessary is so insignificant that operations in this region can be done without interference.

Spinal Analgesia.—It has been demonstrated that a sterile cocaine solution, injected into the cavity of the arachnoid, will produce a general analgesia. Its administration is considered somewhat more hazardous than chloroform or ether narcosis, or local cocaine infiltration, and for this reason the method has not been more widely adopted. Under certain conditions, where ether or chloroform may not be tolerated, and where infiltration will not suffice, it may be properly and satisfactorily employed.

It requires from 10 to 25 minims of a two-per-cent solution to produce a satisfactory anæsthesia, and in some instances this may have to be repeated. In children from twelve to sixteen years of age, from 10 to 15 minims will suffice; in older persons, 20 to 25 minims (W. S. Bainbridge).

The patient is seated upon the operating table, leaning forward so as to separate as widely as possible the laminæ of the lumbar vertebræ, or resting upon the side, this position may be assumed. The point of election is between the laminæ of the first and second or second and third lumbar vertebræ, and *careful asepsis is imperative.*

Superficial infiltration may be employed to prevent pain. Through a skin puncture with a bistoury a needle three or four inches long is carried obliquely from below upwards, until it strikes the lamina on one or the other side of the spine; it is then slightly tilted and carefully guided through the space between the laminæ, and is slowly pushed through the dura into the cavity of the arachnoid. The entrance of the needle point into this cavity is indicated by the escape of a few drops of clear fluid. *Without moving the needle point*, the syringe is now attached to it, and the cocaine forced gently in. The quantity of solution injected should about equal that of cephalo-rachidian fluid which is permitted to escape.

[1] It occurs as colorless crystals or as a white powder that is soluble in about an equal part of distilled water and also freely soluble in alcohol. It contains seventy per cent of alkaloidal quinia and about seventeen per cent of urea hydrochloride. The ordinary dose subcutaneously as an antiperiodic is 5 to 15 grains, injected in concentrated (about fifty per cent) solution; but doubtless considerably greater quantities can be used hypodermically. Urea pure is used as a diuretic *per os* in doses of 10 to 20 grains three or four times daily. The urea in the quinia double salt is considered to be void of toxic action. (E. R. Squibb & Sons.)

[2] Dr. Thibault reports sixty-five minor operations in which the anæsthesia was perfect, and in various procedures in which it has been employed at the New York Polyclinic Medical School and Hospital, the results have been very satisfactory.

CHAPTER III

BANDAGING

BANDAGES are employed in surgical practice to retain dressings in position, to secure compression and support to any portion of the body, to maintain any required degree of immobility, and to render an extremity partially or completely bloodless.

They are made of cotton muslin of various degrees of fineness, crinoline, woolen goods, and India rubber. Cotton bandages are most generally employed, but, on account of the greater elasticity of flannel, these are preferable for certain special dressings. Crinoline is used chiefly for plaster-of-Paris bandages. Martin's rubber bandage and Esmarch's bloodless tourniquet are very useful in maintaining the firm compression of a part, either as a means of support or of emptying the vessels.

The muslin should be soft, not starched, and of two kinds—a fairly heavy quality, and the light cheese-cloth. Both should be cut in pieces from eight to ten yards in length. The former can be torn; the latter must be cut. The selvage edge is removed, and the cloth divided into strips varying in width from four, three, two and a half, and two inches, with some one inch or less in width. For the chest and abdomen the wide bandages are needed, the two- and three-inch strips for the arms, legs, head, and neck, and the narrow strips for the hands and fingers. All the loose ravelings along the edges should be pulled off, and the bandages made into compact, smooth rollers.

Bandages may be rolled by hand, but the work can be better and more rapidly done by machinery. In Fig. 40 is pictured a bandage roller, simple in construction and cheap. It should be fastened to the edge of a solid table by screws or movable clamps. The end of the strip to be wound is passed in and out over the four bars at the base and apex of the machine, and then around the shaft, so that one edge of the bandage touches the end of the upright. As the crank is turned, the strip is held tightly, and, as it runs over the rods, wrinkling or folding is prevented. A home-made apparatus may be constructed as follows: Take a cigar-box, remove the top and one end, bore a hole in each side-piece near the open end, and through these pass a piece of telegraph wire bent in the shape of a windlass and crank. Wires may be run through at other points to serve the same purpose as the four rods in the other machine, or a chink cut in the end through which the bandage travels toward the spindle.

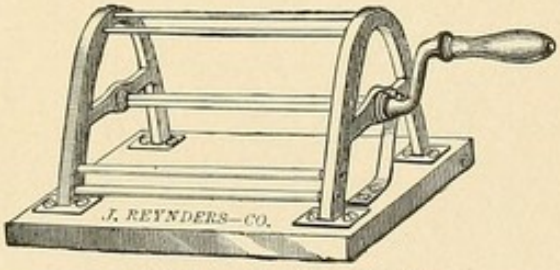

FIG. 40.—Bandage roller.

In making plaster-of-Paris bandages, these same machines may be employed, but the crinoline must be loosely rolled, and the powdered plaster worked in with the hands so well and thoroughly that the meshes of the cloth cannot be seen. Considerable experience is required to prepare a good plaster bandage, and a poor one will spoil a dressing. Plaster bandages should be made from fresh gypsum on the day they are to be applied. Cotton and flannel bandages should be kept in a chest or closet away from dust and moisture. Plaster or plaster bandages which have deteriorated from absorption of moisture should be subjected to dry heat in an oven to drive out the excess of moisture. These bandages are now prepared

and kept in hermetically sealed cans, in which they are preserved indefinitely. They are of inestimable value in the treatment of fractures.

Methods of Applying Bandages.—The various portions of the body may be bandaged by the *simple spiral, reverse spiral, simple figure-of-8,* and the *figure-of-8 reverse.*

The *simple spiral* turn is most useful in bandaging those parts of the body where there is no sudden increase in the diameter and volume of the part. It is impracticable under other circumstances.

Hold the bandage in the hand most convenient, with the back of the roller toward the limb (see Fig. 41); with the unoccupied hand take the free end of the bandage, lay and hold it upon the inner border of the limb, and carry the turn by the front to the outer side of the part to be bandaged.

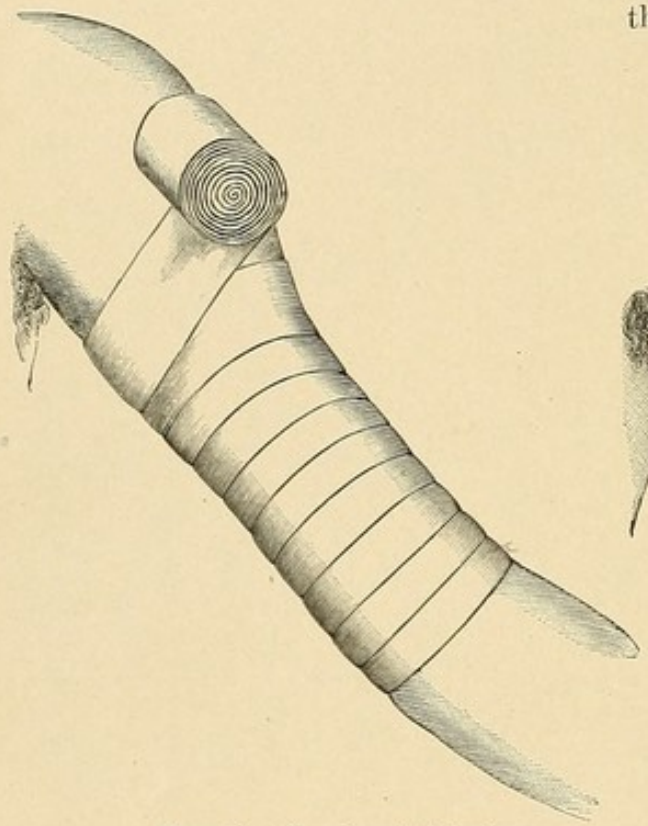

FIG. 41.—Simple spiral bandage.

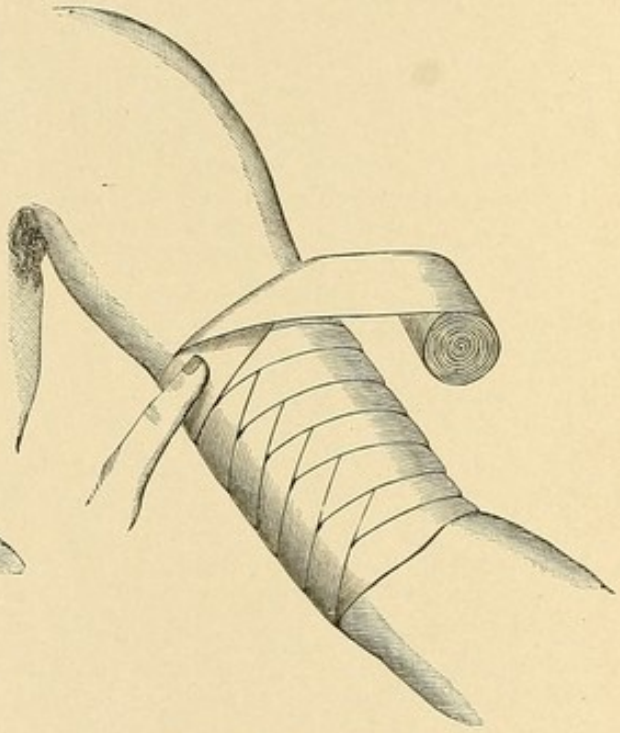

FIG. 42.—Reverse bandage.

Having carried the roller twice around the part to secure it, ascend the limb spirally, leaving about one third of each turn uncovered by the last.

The *reverse-spiral* turn (Fig. 42) is applied as follows:

Taking the left arm to be bandaged, hold the roller in the right hand, with its convexity toward the limb, and carry it from the inner or ulnar border, by the front, to the outer or radial border, and thus around the arm by two circular turns to secure the roller. Then, having carried the bandage to the outer side, ascending the limb gradually, lay the thumb of the left hand upon the lower edge of the bandage, press it firmly against the limb to prevent slipping, loosen the roller considerably in the right hand, at the same time turning it one-half turn toward the operator. This process is to be repeated as often as necessary, keeping the reverses well upon the outer border and anterior aspect of the extremity.

The Simple Figure-of-8 Turn.—After the bandage is secured, as heretofore described, ascend the limb sharply, from the inner to the outer border, so that at this outer border the lower edge of the roller shall be several inches above the starting-point. Carry the roller directly across and *behind* the limb to the same point on the opposite side; then obliquely downward in front, crossing the ascending turn at a right angle. When the outer border is again reached, carry the roller behind and directly across the limb to the starting-point (see Fig. 43).

The Figure-of-8 Reverse.—Commence exactly as for the simple figure-of-8 until the bandage has passed across the posterior aspect of the limb, and is about to descend obliquely along the inner aspect to the front. With the index-finger of the unoccupied hand hold the lower edge of the bandage tightly against the part, while the roller is slackened and turned half over in a direction away from the limb. This reverse in the figure-of-8 may also be made anteriorly, and, when the conformation of the part demands it, may be made both anteriorly and posteriorly.

Of these four methods, the *simple spiral* is more readily applied. When the diameter of the extremity increases rapidly it will not suffice, since it grasps the part at the upper edge of the roller while the lower stands out free and loose.

For all purposes the *spiral reverse* is more generally useful. In competent hands it can be applied to all portions of the body except where the members join the trunk, when it must give place to the *simple figure-of-8 turn*. Thus, the *spica* at the groin and shoulder, the occiput and chin dressings, and the neck and shoulder bandages, must describe this shape. The *figure-of-8 reverse* is of great use in getting over the calf of the leg in very muscular subjects, where not infrequently all the other methods will fail to hold.

The important rule in bandaging is to *equalize the pressure from periphery to center*. The circumstances of the case will determine the degree of compression.

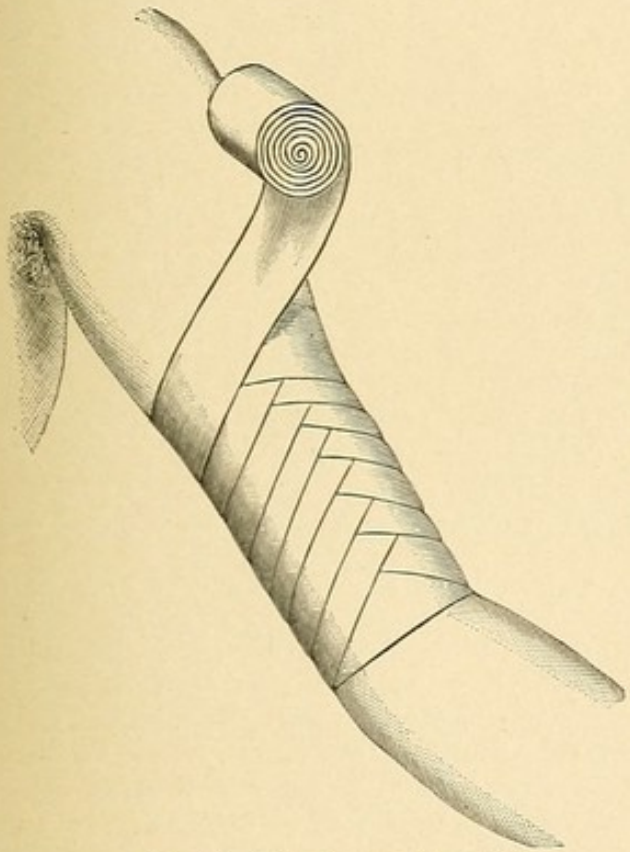

Fig. 43.—The figure-of-8 method.

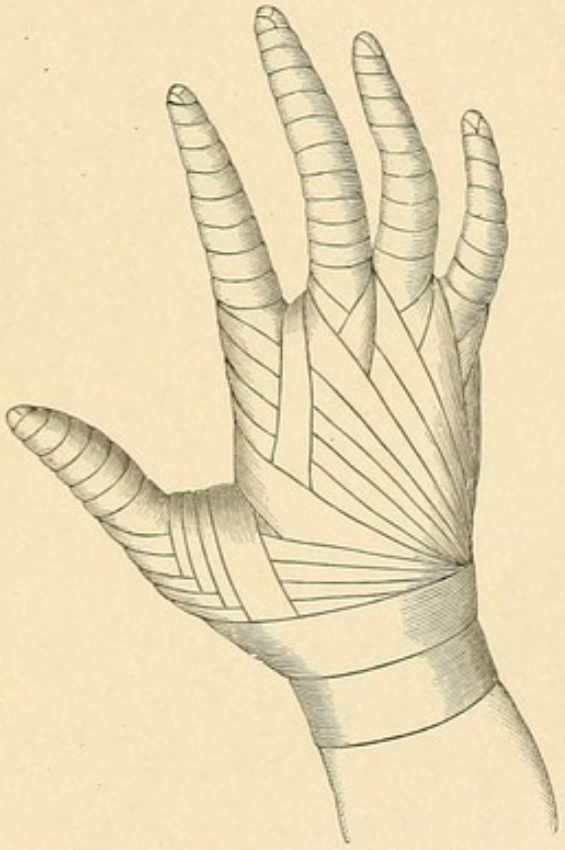

Fig. 44.—Hand-, thumb-, and finger-bandage. (The author's modification of the old method.)

It requires a great deal of study and practice to become expert in applying dressings. One should thoroughly familiarize one's self with each of the methods, for not infrequently a part to be dressed will require a combination of several methods. The question of how tight to apply the bandage may in part be left to the sense of the patient when an anæsthetic is not employed. After an extensive operation, in which Esmarch's bandage has been applied, a very considerable degree of compression is often required to prevent the oozing which otherwise would follow the use of this tourniquet. No amount of description will impart this sense to the inquirer; it can only come from personal experience. One precaution is imperative: the tips of the fingers or toes of the extremity bandaged must always be left open

for observation, for if strangulation is threatened it will always be earliest indicated here. A watch should be set on every case where there is ground for anxiety, with directions to slit the dressing with the appearance of any symptom of strangulation.

Special Bandages—The Hand and Fingers by the First Method (Fig. 44).—Take a roller between three fourths and one inch in width, and ten yards in length. Let the hand to be bandaged be pronated, and commence by taking two or three turns of the roller around the carpus, going from the radial over the back of the wrist to the ulnar side. Having in this manner secured the roller, carry it from the radial side of the wrist obliquely across the dorsum of the hand to the ulnar border of the root of the little finger, then spirally around the little finger two turns to its extremity. Next, return by careful spiral turns, or a spiral reverse, if necessary, to the root of the finger, covering it equally and nicely. From the radial border of the base of the finger the bandage is carried over the back of the hand to the ulnar side of the carpus, then under the wrist, by the front, to the radial side, and again over the dorsum of the hand around to the ulnar side of the same finger, repeating the figure-of-8, as before. Two turns are then thrown around the wrist to secure the former bandage, and the roller is carried in the same manner to the remaining fingers.

When the index-finger is reached, on account of the great space between its root and the thumb, it is advisable to make four or five extra figure-of-8 turns around its base, carrying the bandage a little lower with each successive layer toward the thumb.

Having reached the thumb, the roller is carried spirally to its extremity, as in the other fingers, but in returning, when the last, the interphalangeal, joint is reached, the figure-of-8 turn is commenced at this point, and continued until the ball of the thumb is completely covered.

This method may be applied to the thumb alone, or to any one or more of the fingers, when the remainder of the hand does not need to be bandaged, and is equally efficient in securing splints to these organs.

One objection to it, and a very formidable one to the practitioner, is the length of time necessary to apply it. A more rapid and almost equally effective way is the hand-bandage by the *second method* (Fig. 45).

Place pellets of cotton between the fingers, and a fair-sized tuft in the palm of the hand. Take a bandage from one to two inches in width, carry it one or two turns around the hand where the phalanges join the metacarpus, until it is secured, and then by nicely adjusted figure-of-8 turns (the crossings on the dorsal aspect of the fingers) cover the hand from the tips of the fingers back. When the bandage reaches the thumb in the crotch between it and the index, and begins to roll up, it should be clipped with the scissors deeper and deeper along the edge nearest the thumb with each successive turn until the cut extends to the middle of the roller. Then a split should be made in the middle parallel with its long axis, and the thumb stuck through this; the next split is nearer the distal edge, while with the succeeding turn it may be brought clear of the thumb on its carpal aspect. A spiral, with or without the reverse, will hold on the incline from the thumb to the carpus.

The Forearm, Arm, and Shoulder.—From the carpus to the elbow the spiral reverse or figure-of-8 will usually be required, on account of the pyramidal shape of the part. When the elbow is reached, if the right-angle position (Fig. 46) is determined upon, the figure-of-8 around the humerus and forearm will suffice to climb along the elbow; or the simple spiral, carried over the same ground in the flexure of the joint, and gradually ascending over the convexity, will accomplish the same purpose. For the arm the spiral, simple or reverse, will carry the bandage to the axilla. When the projection caused by the tendon of the pectoralis major is reached, the roller is carried from the inner side by the front, over the point of the shoulder, around the back, and underneath the opposite arm, across the chest to the anterior and outer surface of the humerus, then underneath the arm, making a figure-of-8 turn, one loop of which surrounds the arm, and the other the thorax. These turns are continued, gradually ascending until the root of the neck is reached.

It is best to fill the axilla of both arms with absorbent cotton to prevent chafing, when this dressing is to be worn for any length of time.

The Toes, Foot, Leg, and Thigh.—The great toe may be bandaged by carrying a narrow roller spirally around it, from the tip to the metatarso-phalangeal joint, and thence by a figure-of-8 around the ankle. This last turn should be several times repeated, in order to hold the dressing firmly. It is customary to include all of the toes in the general foot-bandage.

To bandage the foot, begin by placing bits of absorbent cotton between the toes. Take a roller from two to two and a half inches wide, and about ten yards long. Lay the end of the bandage parallel with the axis of the leg, half-way between the two malleoli in front, and carry the roller by the inner side to the heel, so that the middle of the bandage will be over the center of the heel's convexity, and on to the starting-point. Next, make another turn around the ankle, carrying

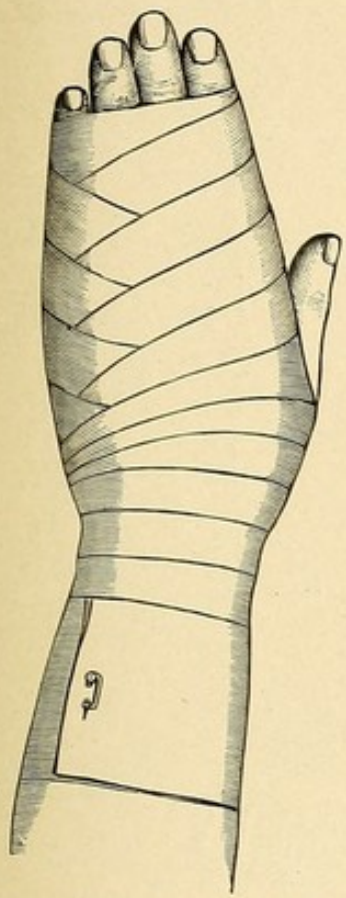

Fig. 45. — Figure-of-8 single bandage for the hand.

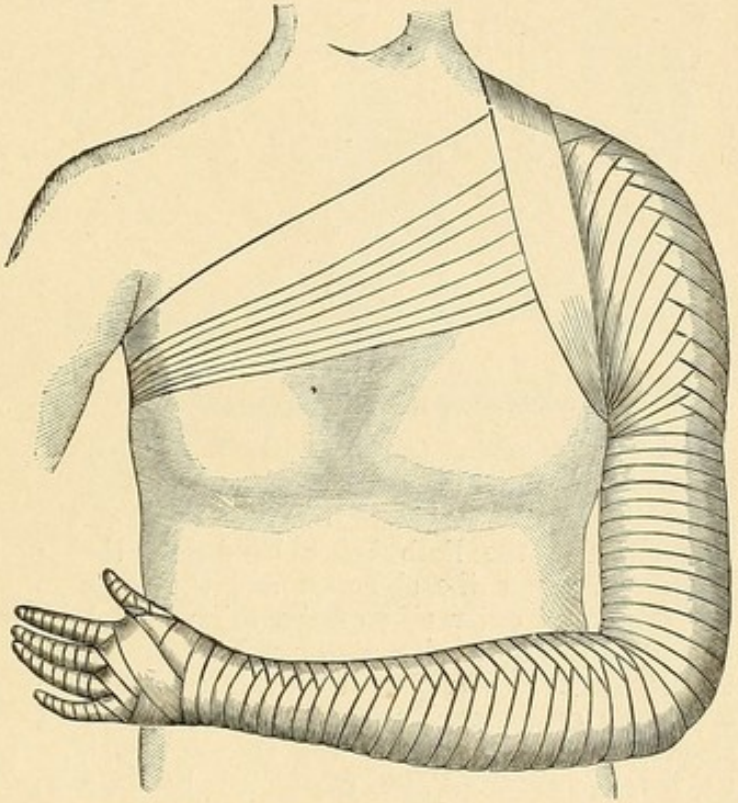

Fig. 46.—Bandage for the shoulder and upper extremity.

the posterior edge of the bandage over the center of the turn that has just preceded it, and make one or two other turns in front of this until the heel is completely covered (Fig. 47).

The bandage is then carried around the heel in the same direction, so that its anterior border rests on the middle of the *first* turn, and the roller is carried from the fibular side of the heel across the dorsum of the foot to the tibial side of the great toe. It then travels under the bases of the toes to the little toe, making a couple of complete turns around the foot at this point, and, when the roller has again reached the fibular side of the little toe, it is made to cross the dorsum of the foot obliquely to the tibial side of the heel, keeping the lower edge of the bandage about a quarter of an inch above the bottom of the heel. Repeat this figure-of-8 turn until the entire foot is thoroughly concealed. It is best to cut with the scissors each turn of the roller about half through just when it crosses the front of the ankle, so that the accumulation of the bandage at this point may not interfere with the movements of the ankle-joint.

The crossings of the figure-of-8 bandage on the dorsum of the foot should be kept a little to the fibular side of the median line.

When the ankle is reached, the bandage should be carried up the leg by the spiral reverse until the sudden prominence of the muscles of the calf is reached, when, if necessary, the figure-of-8 reverse should be practiced to just below the knee. From this point up to the trochanter the simple figure-of-8, spiral, or spiral reverse, may be employed, according to the shape of the limb. When the level of the gluteal fold is reached, carry the roller obliquely upward and outward about half-way between the trochanter major and anterior iliac spine, on across the sacro-lumbar region to just above the upper margin of the iliac crest of the side opposite the limb being bandaged, thence downward across the abdomen and the groin to the front and outer side of the thigh, and back behind to the inner side at the point of starting. This manœuvre is repeated until the entire hip and groin are covered, when the roller is carried spirally around the pelvis and abdomen as high as the umbilicus. The completed bandage is shown in Fig. 48. The portion of this bandage which goes around the thigh, groin, and pelvis is called the *single spica* for the groin, and is admirably adapted to the retention of a dressing upon a bubo or wound of this region, and also makes an efficient temporary compress for the support of an inguinal hernia. A *double spica* with a single roller may be made by carrying the roller, which has already partially covered in the groin and hip of one side, directly across the back to a point half-way between the trochanter and anterior iliac spine of the opposite side, over the front of the thigh to the inner side, and thence behind and outward, describing a figure-of-8 around the thigh and pelvis in a direction the reverse of the preceding (Fig. 49). A modification of this for controlling hæmorrhage after internal urethrotomy is shown in the chapter on urethrotomy.

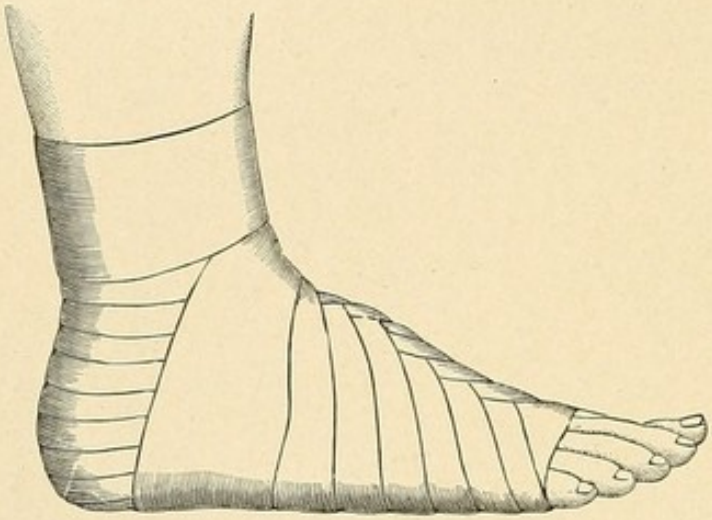

Fig. 47.—The author's foot-bandage with a single roller.

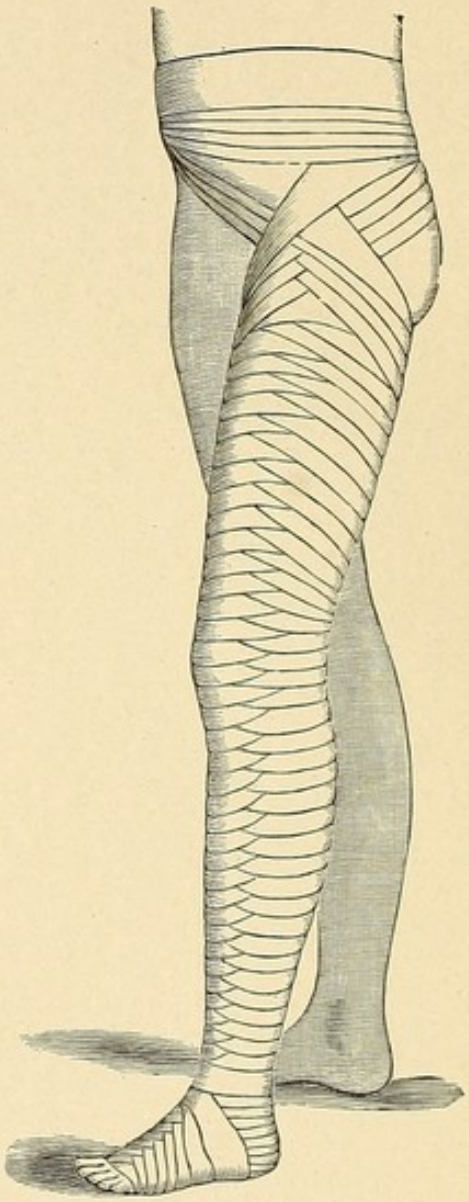

Fig. 48.—Hip and abdominal spica and bandage for the lower extremity.

The abdomen and thorax should be bandaged by the simple or reverse spiral until the axilla is reached in the male, and the mammary gland in the female.

To bandage the mammary gland it is best to place a thin layer of absorbent cotton over this organ, and under the axilla as well. The roller, about three inches wide, should be carried two or three times around the thorax just below the breast, which, if pendulous, should be lifted well up toward the clavicle. If the right breast is to be bandaged, the operator, standing in front, should carry the roller

from the patient's right to the left side, around the body, and then obliquely upward across the front of the chest, catching the under surface of the gland, passing over the left clavicle, making a figure-of-8 around the shoulder and

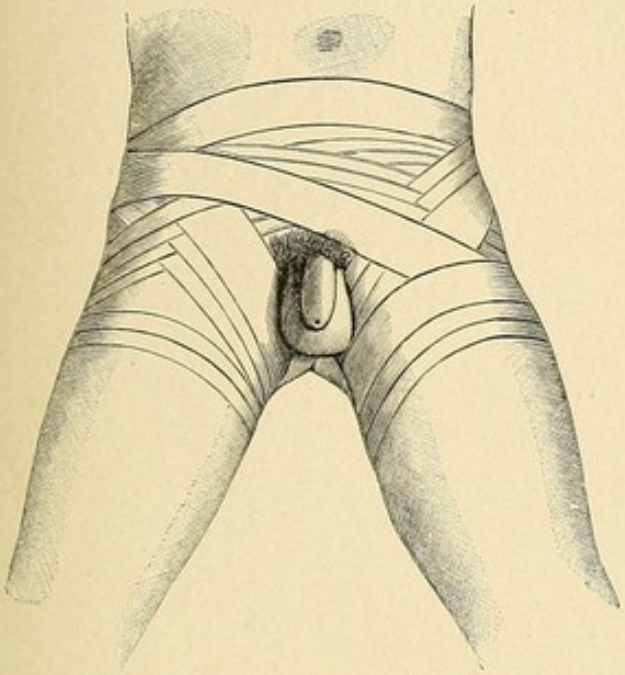

Fig. 49.—Double spica. (After Fischer.)



Fig. 50.—Bandage for support and compression of the breast. (After Fischer.)

axilla, and then across the back to the starting-point (see Fig. 50). It is now carried directly around the chest, and, when the circuit is completed, again travels obliquely upward on a plane about one inch higher than the preceding turn. This is repeated until the organ is entirely covered. When both breasts require support, the second may be bandaged in the same way by an additional roller, or, as shown in Fig. 51, a single bandage may be thrown around the thorax and neck in figure-of-8 fashion, so as to support both organs.



Fig. 51.—Double bandage for the breasts. (After Fischer.)



Fig. 52.—The hood-bandage.

Bandages for the Head and Face.—For retaining ice-caps, or other dressings to the head, the hood-bandage will be found convenient, while its modifications will suffice to keep a dressing upon any limited portion of the scalp (Fig. 52).

To apply this, take a roller twelve yards long and two and a half inches in width, rolled from both ends to the center. Holding one head of the roller in

each hand, the surgeon, standing behind the patient and laying the middle of the bandage across the forehead just over the eyebrows, carries one roller in the right and the other in the left hand around the head, above the ears, and crosses them under the occiput, so that the roller which went to the rear in the left hand will travel again to the front over the same path. The roller in the right hand is then carried over the head, in the median line, from the occiput to the nose, and at this point it is caught and held down by the encircling turn carried in the left hand. Then carry the roller which came over the median line of the head back again to the rear, so that its right edge will rest on the middle of the first turn. It is again caught under the encircling turn at the occiput, is carried to the front on the opposite side, and continues to travel from before backward in an ellipse that is constantly increasing, until it blends with the encircling turn upon the sides of the head, near the ears. Each successive turn of the elliptic should leave about one third of the turn that preceded it uncovered in the center. Of course, the ends will meet at the same point, before and behind, where the reverses are made.

If it is only required to maintain a dressing in the median line of the scalp, it will suffice to carry a circular turn or two around the head, just above the eyebrows and ears, and below the occiput, while an antero-posterior strip is pinned to this in front and behind.

The Head and Chin Bandage (Fig. 53) may be made to serve several purposes —namely, to retain a dressing on the chin and lower face, the same upon the scalp at any portion, and also for temporary fixation of the lower jaw after fracture of this bone. It is applied as follows:

The end of a bandage from one inch and a half to two inches in width is held about half-way between the left ear and the occipital protuberance, while the roller is carried to the front and obliquely across the head, just in front of the right ear, under the chin, up in front of the left ear, then across the scalp, passing backward between the right ear and occiput to beneath this protuberance, when it is carried beneath the left ear straight across the front or labial aspect of the chin, and around by the right side to the point of commencing. This manœuvre should be repeated several times, and the dressing then completed by carrying the roller twice around the head above the ears and eyebrows, and beneath the occiput, and pinning a strip along the median line of the scalp at the various points where the turns cross each other.

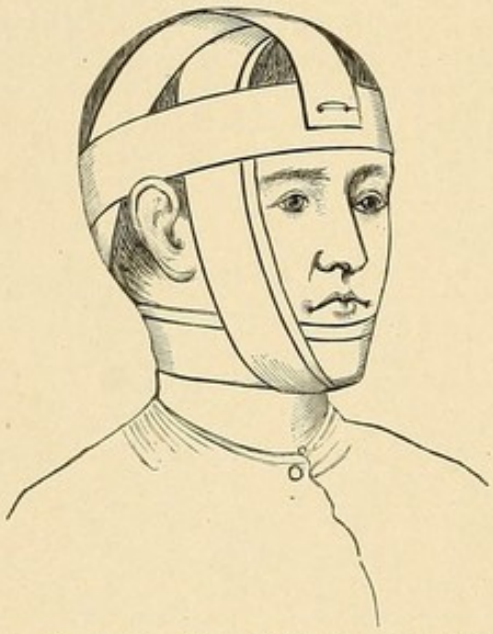

Fig. 53.—Head-stall and bandage for fracture of the lower jaw.



Fig. 54.—Compression bandage for arrest of hæmorrhage. (After Berkeley Hill.)

Knotted Bandage.—This dressing (Fig. 54) is sometimes employed in the arrest of hæmorrhage from wounds of the temporal and other vessels of the scalp.

Take a piece of cork or wood, about an inch in diameter and one quarter of an

inch in thickness, and wrap it with sublimate gauze or lint to make a compress. Apply this to the bleeding point, and lay over it the center of a double-headed roller, carrying the turns around the head, above the ears. They are then crossed over the compress, one end is carried under the chin, the other over the top of the head, and are again crossed on the opposite temple. Having carried the rollers again around the head, and crossed them firmly over the compress, the ends are pinned securely and cut off. A horizontal slip may then be pinned to the anterior, middle, and posterior slips of the knotted bandage, beginning in the median line on the forehead, then back to the center of the middle slip, and then to the slip underneath the occiput, to hold the dressing securely in position.

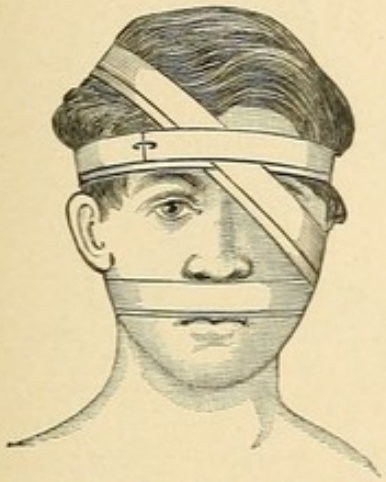

Fig. 55.—Bandage for the eye and upper lip. (After Esmarch.)



Fig. 56.—Handkerchief bandage.

To bandage the eye (the left, for example), hold the end of the strip half-way between the right ear and occiput, and bring the roller forward over the left eye and malar eminence, and around backward beneath the ear and occiput to the point of starting, and repeat once. When the second turn arrives at the right ear it should pass above this and completely around the skull, just above the eyebrows and below the occiput, in order to secure the oblique turn. Complete the dressing by alternating between the horizontal and the oblique direction of the roller (Fig. 55).

For the upper lip a dressing is readily secured by a narrow bandage passing horizontally around beneath the nose and ears, and held in place by the head-stall attachment, as in Fig. 53.

Handkerchief Bandages.—In addition to the foregoing, emergency dressings for different parts of the body may be extemporized from pieces of cloth cut in various shapes—the so-called *handkerchief bandages.*

Head and Face.—A simple hood (Fig. 56) may be made as follows: A piece of soft muslin is cut, 27 by 23 inches, folded over for 6 or 7 inches along its greatest measurement, and laid upon a table, with the short piece underneath. Place the index-finger at the middle of the folded edge, and turn the nearest corners toward the center, forming a pyramid. Now roll the remaining straight edge up until it is on a level with the edge which was turned under, and place upon the head, so that this edge will be put above the eyebrows, while the rolled portion comes across the occiput, and the ends are pinned beneath the chin. The conical tip may be pinned down if desired.



Fig. 57.—Four-tailed bandage.

The *four-tailed cap* is made from a piece of muslin, 45 inches long by 10 wide, split from each end to within 4 inches of the center. Each of the four tails is 5 inches in width. Lay the center of the piece across the vertex, carry the posterior tails forward over the ears, and tie them under the chin and the anterior backward beneath the occiput (Fig. 57).

The *head and face hood* is made as follows: A piece of soft, light cloth, 40 inches square, is folded and laid across the head in such a manner that the



FIG. 58.—Head and face hood. (After Esmarch.)



FIG. 59.—The same completed. (After Esmarch.)

shortest fold which is on top comes to the level of the eyebrows, while the longer reaches to the tip of the nose (Fig. 58). The corners belonging to the fold which is parallel with the line of the eyebrows are tied snugly beneath the chin. The longer fold is now turned up to the level of the eyebrows, while the corners belonging to it are drawn forward until freed, and are then carried back and tied beneath the occiput (Fig. 59).

For holding an ice-bag or dressing upon the head, the *skull-net* (Fig. 60) will be found of use. It is made of cotton threads, is tightened around the head by a



FIG. 60.—Ice-bag net. (After Esmarch.)



FIG. 61.—Four-tailed bandage for fracture of the lower jaw.

tape, which draws it together like the strings of a reticule, and is further secured by a strap tied under the chin.

The *four-tailed dressing for the chin and lower jaw* is made by splitting a strip of muslin, 6 inches wide and 45 inches long, from each end to within $1\frac{1}{2}$

inches of the center, placing its middle over the chin, and turning the posterior tails upward in front of the ears to be tied over the vertex. The anterior tails are now carried back below the ears, crossed once, and pinned beneath the occiput, while the ends are carried upward and forward and tied upon the forehead (Fig. 61).

Other special dressings will be described in the chapters on Regional Surgery.

The T bandage, made by sewing the end of one piece of muslin, 7 inches wide and about 4 feet long, to the middle of a second piece of the same width and about 5 feet in length, is essential in holding a dressing over the anal or perineal region. One belt is fastened around the waist and the tail brought between the legs and pinned in front to the belt. For abdominal dressings a wide piece of muslin may be snugly drawn and pinned around the body.

CHAPTER IV

HÆMORRHAGE, WOUNDS, AND WOUND SUTURE

Repair and the Occlusion of the Arteries. Process of Repair. Method of Suturing. Intravenous Infusion. Poisoned Wounds. Snake Bites.

HÆMORRHAGE is *arterial, capillary,* and *venous.* Occurring with the injury, it is *primary. Secondary* hæmorrhage occurs during the process of repair, and usually after infection.

The natural arrest of hæmorrhage may result from the contraction and retraction of divided vessels and the formation of coagulum. Diminution in the volume of blood and weaker heart action favor the formation of clot. In certain conditions, as in atheroma of the vessel walls and in some tissues (as the tongue, scalp, bone), vascular retraction and contraction is insufficient, and hæmorrhage is more apt to be continuous, unless arrested by the ligature or by compression.

The surgical means for the arrest of hæmorrhage are:

1. Direct compression of the bleeding surface with a clean towel or any soft aseptic material.

2. Compression over the artery of supply above and of the vein below the bleeding point.

3. Elevation, when the hæmorrhage is from an extremity, or the upright posture when from the head or neck.

4. Constriction with a handkerchief, towel, belt, or, preferably, piece of rubber tubing or Esmarch bandage over the artery of supply above the seat of injury. If the hæmorrhage be only venous, compression should be made on the distal side.

5. When the hæmorrhage is from the trunk and the bleeding point cannot be immediately reached by operation, pressure may be taken from the bleeding point by constricting the arms near the axilla and the thighs near the crotch with bandages tightened sufficiently to check the venous current, while they permit the flow of blood through the artery. This facilitates coagulation at the bleeding point.[1] When the bleeding is arrested, the bandages should be carefully loosened, one at a time, to prevent a sudden influx of a large volume of blood, which might dislodge the clot.

6. Hot or cold applications. After an injury or during an operation, capillary oozing may be controlled or arrested by elevation of the bleeding part, flushing with hot water or salt solution (120° F., or about as hot as the submerged hand can endure), or by compression with towels dipped in the hot solution. If heat cannot be obtained, cold in the shape of ice or very cold water may be substituted.

7. Torsion and the ligature. During a surgical operation the artery forceps is chiefly relied upon to control bleeding. Vessels seen in the course of a dissection should be clamped on either side with and divided between the forceps. The vessel should be at once occluded by torsion or the ligature. In applying a forceps no more tissue should be caught in the grasp of the instrument than is necessary to secure the vessel. By applying a number of instruments, much time can be saved in an operation, since smaller bleeding points are permanently occluded by permitting the forceps to remain in place from ten to twenty minutes. In general, only a small proportion of the forceps applied in the course of an operation require

[1] Method of Detmold.

the ligature. Twisting a small vessel for five or six rotations is an excellent and rapid method of arresting hæmorrhage. Properly applied retraction, without injuring the tissues, will control and may permanently arrest bleeding in the track of the incision.

For the larger vessels or bleeding points, and in all operations within the cavities, the ligature is the chief reliance of the surgeon. Catgut and silk or linen thread are commonly used. Plain catgut will usually suffice, though in tying the larger vessels (carotids, iliacs, and femorals), ten-day chromicized gut is preferable. Linen or silk is chiefly relied upon in tying pedicles or larger masses traversed by good-sized vessels, especially in abdominal work.

In tying a branch of a vein close to the parent trunk, or in applying a lateral ligature to a vein, very fine silk or linen thread should be used. In operations where

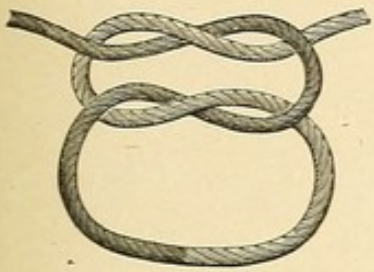

FIG. 62.—Reef knot.

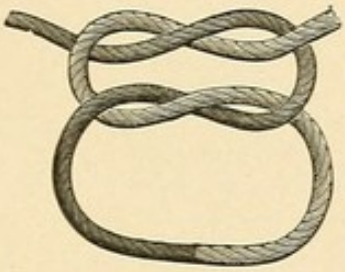

FIG. 63.—False knot.

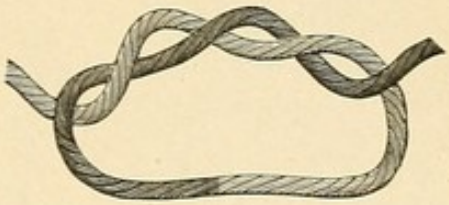

FIG. 64.—Friction knot.

the vessels are friable, as in the extirpation of goître, silk or linen may at times be preferred. In tying the exposed ends of a divided artery, these should be seized with dissecting forceps, and drawn out so that the ligature may be thrown around the vessel *and its sheath* one quarter of an inch from the end. By this precaution not infrequently a small collateral branch is caught, which otherwise would require a second ligature. Provided contiguous nerves are eliminated, it is not objectionable to include a certain amount of extravascular tissue in the grasp of the ligature. In arterial degeneration (sclerosis, atheroma, calcareous deposits) this practice is necessary to prevent the ligature from cutting through. On many occasions the author has included a large vein and artery (as the femoral) in the same ligature.

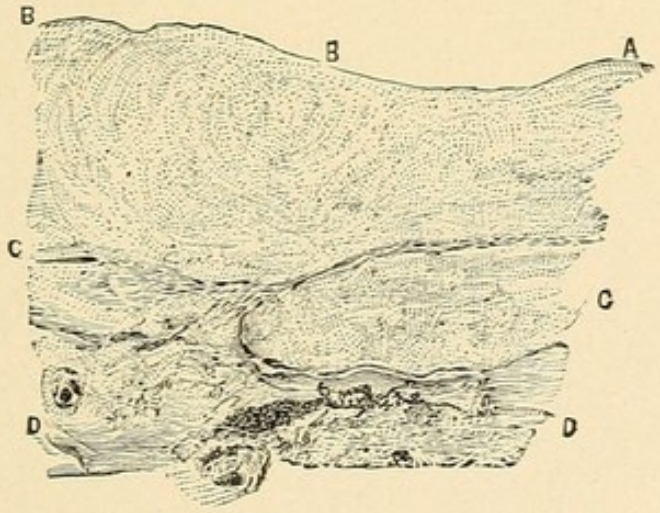

FIG. 65.—Traumatic endarteritis. Section from the common carotid of a horse, tied with a broad nerve ligature, showing at B B the proliferation of the intima. The inflammatory new formation is projected into the lumen of the vessel, and has caused partial atrophy of the media, C; A B, the intima; B B, portion of the intima in the grasp of the ligature; D, the adventitia, slightly changed, with small-cell infiltration. (Drawn by Dr. W. L. Wardwell, from the author's specimen. Magnified about forty diameters.)

The tension should be such that the occlusion is complete and the ligature buried deeply enough to prevent slipping. The *reef-knot ligature* (Fig. 62) will usually hold, although occasionally the *friction knot* (Fig. 64) may be required to prevent the first loop from slipping. This danger may, however, be entirely elim-

inated by grasping the first turn of the ligature with a pair of smooth forceps (the author's ligature forceps), which holds the first loop secure until the second is tightened.

In tying a vessel in continuity, the ligature is usually passed by the *aneurism needle* within the sheath, but this is immaterial, provided all contiguous nerves or other structures are excluded. Tightening the ligature just enough to arrest the passage of blood will suffice. A division of the inner coats by the ligature is not essential to permanent occlusion. The author first demonstrated in 1883 that a clot had nothing to do with permanent vascular occlusion after the ligature, but that this process was the result of cell proliferation and the organization of a new connective tissue, which by fibrillation made a permanent cicatricial occlusion. In tying arteries in the flaps of an amputation, the ligature must be drawn very tight to prevent the possibility of slipping.

Wounds

A wound is a sudden solution of continuity in the soft tissues of the body; such lesions in bone or cartilage are *fractures.*

Wounds are *operative* and *accidental*, and may be classed under four heads: *incised, punctured, lacerated,* and *contused.* When inoculated with a virus or venom, as in snake bite, they are *poisoned* wounds. Injuries from missiles projected by guns demand especial consideration as *gunshot* wounds.

An *incised* wound is made by a clean cut with a sharp instrument; a *punctured* wound, by a narrow instrument which does not cut laterally; a *lacerated* wound, by a dull instrument which tears; while in *contused* wounds the tissues are more bruised than divided.

When the soft tissues are divided, capillaries, arterioles, and venules contiguous to the injury instantly contract, and immediately thereafter become dilated beyond their normal caliber. The divided tissues retract, the intervening space fills with blood, and if no large vessels are divided, hæmorrhage may be arrested spontaneously by coagulation. The chief factor in rapid coagulation is the leucocyte, the number of which is vastly increased within the irritated zone. The paraglobulin of these corpuscles combines with the fibrinogen of the blood plasma, not only in the blood extravasated, but in the lumen of the capillaries and other vessels from the surface of the wound to the nearest anastomosis.

From this period on the changes which occur in the process of repair vary with the presence or absence of septic organisms. In *aseptic* wounds, while there can be no reunion of atom to atom with resumption of function without cell proliferation, this process takes place with the minimum of disturbance and with the restoration of the maximum of function. If the hæmorrhage is entirely arrested, the wound thoroughly dried under aseptic precautions, the parts brought together by properly adjusted pressure from deep as well as superficial absorbable sutures, the surface of the skin carefully dried and immediately coated with a thick layer of sterile collodion, the changes which the tissues undergo in the effort to restore their integrity include; with hyperæmia, an increased number of leucocytes, and their *diapedesis* (or passage from the vessels through their walls to wander in the intervascular spaces), and *general* cell proliferation. Vascular buds project themselves from the proliferating endothelial cells of the blood vessels (capillaries) at their divided and occluded ends, which, meeting those from opposing surfaces, unite to form new vessels. In like manner, from the original cells which composed other divided tissues, nerve, connective tissue, epithelial, etc., new cells are thrown out. In from five to ten days the process of contraction begins, and some of the new blood vessels may be obliterated by this normal process of connective-tissue fibrillation. In the process of repair, under aseptic conditions, any excess of new tissue undergoes granular metamorphosis. When, however, *infection* occurs, liquefaction of the new embryonic tissue (suppuration) takes place in varying degree. The process of repair is prolonged, cicatrization or fibrillation is increased, and the restoration of function less complete. By cicatrization much of the vascular supply is obliterated, giving the bleached appearance common to scar tissue. In an open

granulating wound in which the edges are not too widely separated, a new integument is formed by the projection of epithelium from the edges.

Treatment.—The arrest of hæmorrhage is the first indication. The methods have already been described.

In closing a wound by sutures, the points of chief importance are to bring all parts of the opposing surfaces in apposition with moderate pressure equally distributed; overpressure, especially in the skin, produces pain and impairs nutrition.

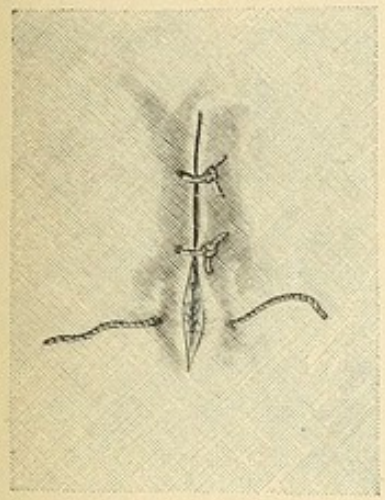

FIG. 66.

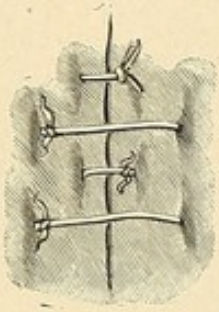

FIG. 67.—Alternating deep and superficial sutures.

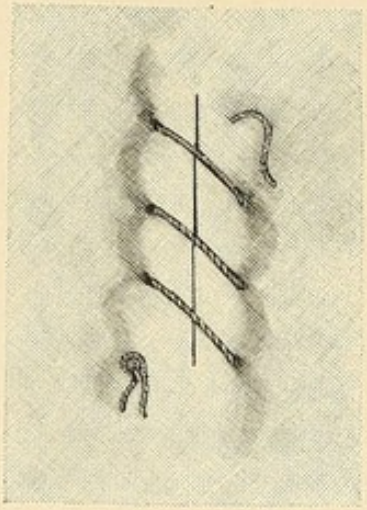

FIG. 68.

No clot, serum, or dead tissue should be left, since these encourage the proliferation of septic organisms. When oozing cannot be controlled, a temporary catgut drain should be inserted. These absorbable drains are made preferably of ten-day chromic-acid catgut, with the strands from ten to fifty in number, parallel, *not twisted.*

When possible, drainage should always be by gravitation from the most dependent portion of a wound as the patient rests in bed. The edges of the wound, through the skin, should be carefully brought in apposition; and to avoid a scar, especially upon the face or other exposed surfaces, the very finest needles and silk- or linen-suture material should be used.

In closing shallow wounds, it will suffice to enter the needle one eighth of an inch from the edge, and out at the same distance from the opposite margin, as

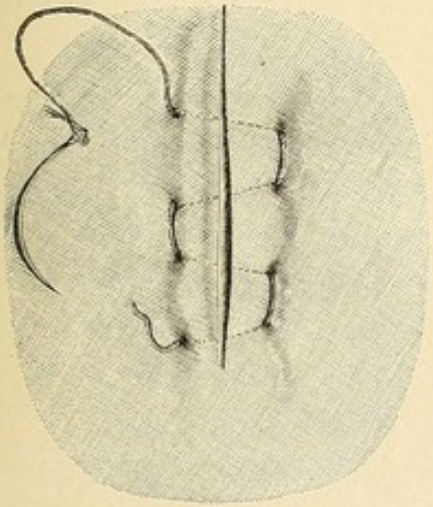

FIG. 69.—A mattress suture.

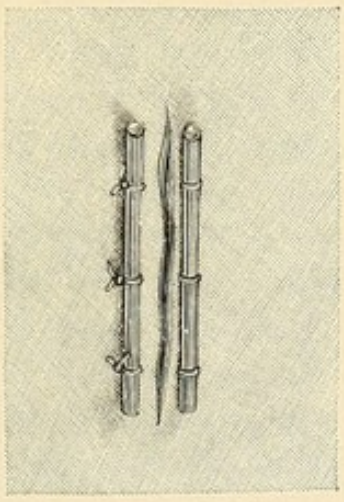

FIG. 70.—Quill or lead-plate suture rarely employed except in cleft-palate operations.

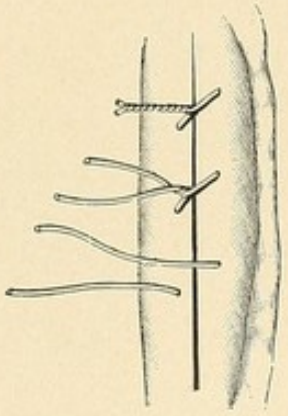

FIG. 71.—Silver-wire suture.

shown in the *interrupted* suture (Fig. 66). For rapid work the *continuous* suture (Fig. 68) is more frequently employed on unexposed surfaces. In tying a suture the edges of a wound should be brought together with just sufficient tension to

approximate and hold them in contact without bleaching or wrinkling. *Infolding* should be avoided. Silkworm gut makes, in general, one of the cleanest, most aseptic, and reliable suture materials for the skin.

In approximating a three-cornered wound, the methods shown in Figs. 72 and 73 are useful. Many superficial small wounds may be closed and held together by pressure with the fingers until collodion has been applied and allowed to harden. This dressing alone, or at times supported by narrow adhesive strips, will render suturing unnecessary. Small metal clips (Michel), which partially perforate the skin and hold the edges of the incision in apposition, are preferred to sutures by some operators. For general work, however, the suture, properly employed, is the better method.

A subcuticular suture of silkworm gut may be used with great advantage in the rapid closure of extensive operative wounds. It is inserted as follows:

The needle, being made to enter through the skin about one quarter of an inch from the upper end of the incision and to come out in the wound, is carried through



Fig. 72.

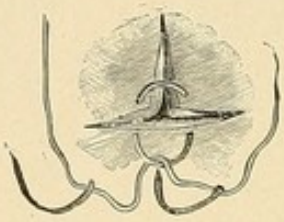

Fig. 73.

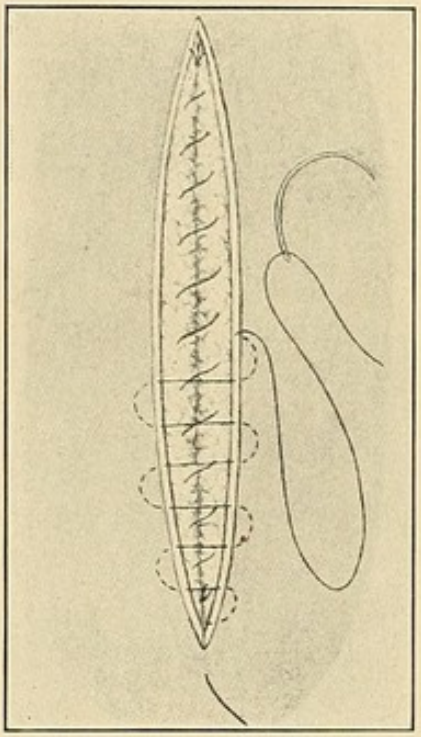

Fig. 74.—Showing the running subcutaneous catgut suture which has approximated the thick layer of fat and the subcuticular suture of silkworm gut which is being inserted. (Charles P. Noble.)

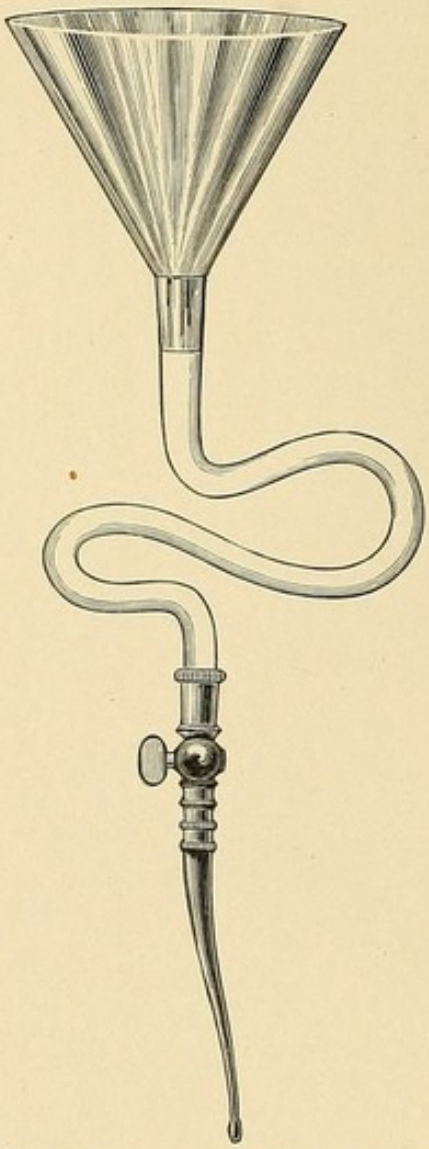

Fig. 75.—Apparatus for the intravenous infusion of normal salt solution.

the edge of the true skin (the corium) on one side for one quarter of an inch, thence directly across to the opposite side, where it is inserted for the same distance, and so on in zigzag fashion for the entire length of the incision until the suture is brought out through the skin just beyond the lower angle (Fig. 74). Drawing upon the two exposed ends in different directions approximates the cut surfaces

throughout their extent. These ends should be loosely tied over a swab or other dressing laid upon the wound.

Suture needles are of various patterns and sizes: straight, curved, half curved, angular, etc. Those without cutting edges are preferable (round embroidery needles and the modified Hagedorn). For rapid work, long half-curved needles, large enough to be used without a needle holder, are essential.

Hæmorrhage.—Should bleeding be so profuse that syncope is imminent, the head should be lowered so that gravity may carry enough blood to the brain to maintain its function. The administration of whisky by the mouth or rectum or hypodermically is indicated. A tablespoonful or more of black coffee may be administered per rectum with the whisky.

Intravenous injection of normal salt solution, heated to about 110°–115° F., should be done. The quantity thrown in will be determined by the improvement in heart action, as shown by the pulse. One or two pints will usually suffice, though twice this quantity may be used. When convenient, an open vein should be utilized, or the median basilic or cephalic near the elbow may be exposed and the pipette inserted under cocaine analgesia.

A simple apparatus for infusion is shown in Fig. 75. It consists of a glass funnel, to the tip of which a rubber tube is attached, while at the end of the tube is a canula for introduction into the vein. The funnel should be filled and a certain quantity allowed to run through to exclude the air. The stopcock is now closed or the rubber tube compressed, holding the canula and tube full of fluid.

When the canula is carried into the vein, it should be held in place by a ligature tied around it and the vessel. The introduction should be slowly and gradually accomplished. By keeping the funnel filled with the solution, no air can enter. The effect upon the heart is at once noticeable. The pulse is reduced in the number of beats and increased in force. If the apparatus described is not at hand, a fountain syringe which has been carefully sterilized by boiling may be substituted. A pocket-case canula or an ordinary glass medicine dropper will suffice as a substitute for the special transfusion canula.

This method has practically superseded the direct transfusion of blood. When the condition of the patient is not extreme, the salt solution may be injected into the subcutaneous fat.

Poisoned Wounds—Snake Bite.—The prognosis in snake bite is grave in proportion to the source of the venom and the quantity and rapidity of introduction. That of the *cobra* in India is considered almost inevitably fatal, while the *rattlesnake* is classed with the more venomous reptiles of this country.

When the venom is lodged in the skin or subcutaneous tissues, where absorption takes place through the lymph vessels and capillaries, the prognosis is more favorable than when the fang pierces a vein.

The order of toxicity in serpent venom, so far as known at this date, is as follows: 1. Cobra (*Naia tripudians*), a native of India; rattlesnake (*Crotalus durissus* and *C. adamanteus*), of southern North America; *Bothrop jararacassa* and *B. jararaca*, closely allied, according to Dr. Robert Fletcher,[1] in the intensity of its venom to its congener, the North American rattlesnake; American copperhead (*Trigonocephalus contortrix*); the American moccasin (*Toxicophis atrapiscus* and *T. piscivorus*); the spreading adder, of the order *Vipera berus*.

The venom of snakes is excreted by a gland situated near the eye. In the act of striking or biting it is forced by a compressor muscle along a channel, or groove, in the fangs. In the quiescent state the fangs (one on either side) are folded backward, and are buried in grooves in the mucous membrane of the roof of the mouth. When ready for use, they are drawn forward by erector muscles. Rattlesnake venom, according to Dr. S. Weir Mitchell,[2] has a specific gravity of 1.044, and an invariably acid reaction. Its color is from a greenish to a straw tint. Conjointly with Dr. Edward T. Reichert,[3] he has isolated three proteids—namely, venom peptone, venom globulin, and venom albumen. Venom globulin is

[1] "American Journal of the Medical Sciences," July, 1883.
[2] Smithsonian Contributions, 1860. "New York Medical Journal," 1868.
[3] "Philadelphia Medical News," 1883.

intensely toxic, producing rapid extravasations of blood; venom peptone is less poisonous, but produces, when injected into the breasts of pigeons, intense sloughing. The albumen venom is not yet fully understood. Bromine, iodine, sodium, and potassium hydrate and potassium permanganate destroy chemically the toxic property of the venom of the rattlesnake, copperhead, and moccasin. Serpent venom produces no poisonous effect in the tissues of the reptile which produces it, or in the tissues of any venom-producing reptile. It is poisonous to non-venomous snakes.

Pain of a sharp or stinging character is usually felt in the wound. Fright or shock may mask this symptom. Swelling rapidly ensues, and in rattlesnake bite ecchymosis is not uncommon. The swelling extends in all directions, but is most marked in the line of the lymphatics toward the center. Headache, fever, rigors, irregular breathing, and a low, feeble pulse, with nausea, may be present. Adenitis, abscess, or sloughing usually occur. If death does not ensue, the case may terminate favorably in two or three days, or last for weeks and months.

Treatment.—Suck the venom from the wound at once, constricting the member between the wound and body to retard absorption, and quickly apply a tight ligature or tourniquet. Make a free crucial incision, and again use labial suction. As soon as possible, and before the tourniquet is released, infiltrate into the tissues within a radius of an inch from the markings of the fangs a free quantity of permanganate-of-potash solution (for the rattlesnake, gr. x to xv to ℥j of water, and for the cobra, gr. xxv to ℥j). Whisky is advised as a cardiac stimulant in adults.

Within a recent period experiments have encouraged the hope that a serum has been produced which neutralizes the deadly effects of serpent venom. That for the cobra and the rattlesnake are already reported as successful demonstrations. Unfortunately, these agents are not easily obtainable, and the more ready methods will have to be employed.

When great swelling occurs, and gangrene is threatened on account of tension, free incisions or puncture should be made.

The venom of some of the lizard family, as the Gila monster[1] (*Heloderma suspectum*) and the toad[2] (*Bufo vulgaris*), also possesses toxic properties. The treatment should be about the same as given above for serpent venom, though not quite so energetic.

Venom introduced with the sting of the *scorpion* is reported as causing death in the Orient, although the sting of the variety common to North America is not dangerous.

That of the *tarantula* is occasionally fatal, a case having been reported by Dr. Thomas A. Pope, of Texas. Death was caused by asphyxia, due to closing of the larynx and trachea from swelling, but not to changes in the blood.

In scorpion and tarantula stings, immediate labial suction is advised, and the local application or injection of bicarbonate of potash or any alkali.

The stings of *bees, wasps, hornets,* etc., possess a venom which, while rarely fatal, is painful. The prompt application of an alkaline solution will neutralize the poison and prevent swelling. If the sting remains, it should be removed.

The venom of the *centipede* (*Myriapoda*) produces a slight irritation, which may be neutralized by the application of an alkaline solution.

Gunshot wounds, in general, produce *contusions* and *lacerations.* They are at times *complicated* by fragments of cartridge, clothing, powder, or other foreign matter carried in with the projectile. The degree of laceration is usually less when the ball is traveling swiftly. It may also depend upon the shape of the missile. The small-caliber, long projectile used in modern warfare (Mauser, Krag-Jorgensen, etc.), traversing skin and muscle "end on," as a rule does little damage. The hole of entrance is small, that of exit larger. Should it strike a bone, it may pass through, leaving a small-sized hole with a longitudinal split. If, however, it becomes tilted and begins to turn upon its axis, it is apt to produce extensive comminution in bone and widespread laceration and destruction of the soft tissues.[3]

[1] Mitchell and Reichert, "Medical News," Philadelphia, 1883.

[2] "Gazette des hôpitaux," 1881, p. 598.

[3] During the Spanish-American war, a number of these wounds came under the author's observation. In one instance a Mauser missile entered the pectoral muscle over the fifth rib,

Wounds of the liver, spleen, and other friable organs, caused even by these smaller missiles traveling at great speed, are characterized by widespread destruction, and are almost of necessity fatal.

In civil life, injuries received from a shotgun at close range are most destructive, and more apt to be immediately fatal.

Treatment.—Arrest of hæmorrhage is the first indication. In military service indelible tracings are employed to indicate to the common soldier where compression may be made to control the blood supply. Practical instruction is given in the application of a tourniquet by means of a belt, coat-sleeve, bridle rein, etc., tied about the limb and twisted by bayonet, sword, or stick. Each soldier carries a well-protected bit of sterile gauze to apply immediately over the wound.

Hæmorrhage from wounds of the cavities not directly accessible may in a measure be controlled by Detmold's method of constriction of the extremities. (See Hæmorrhage.)

Immediate operation is rarely indicated in gunshot wounds, except for the arrest of hæmorrhage from the larger vessels, or in exceptional instances where there is serious interference with respiration, or in cases of perforation of the hollow viscera. Special consideration of these wounds will be given in chapters which treat of regional surgery.

made its exit near the axilla, reëntered the muscular substance of the deltoid, and passed out end-on, doing practically no harm, the holes of entrance and exit being very small. In another instance a missile which traveled through the same tissues, on the opposite side, inflicted very serious results. This bullet had struck an obstacle and was tumbling on its long axis when it struck. The hole of entrance was over an inch long and one half of an inch in width. It passed through the right pectoral muscle, left the chest wall by an opening about half the size of that of entrance, entered the arm, fractured the right humerus, turning up at the point of exit a U-shaped flap of integument. In another Mauser wound the ball entered just above the left ilium near the lumbar vertebra, passed directly through the abdomen, and made its exit through the left inguinal canal. The wounds of entrance and exit were small, and it is believed the bowels escaped injury. The patient received no treatment, and made a prompt recovery.

CHAPTER V

AMPUTATIONS

An amputation is said to be in *continuity* when the bone is divided; in *contiguity* when the member is removed through an articulation.

An amputation for the removal of parts which are useless or deformed is one of *expediency*; under more urgent conditions, of *necessity*. Amputations of necessity are subdivided into those following *accident* and those from *disease*.

Amputations after accident are *immediate, primary,* and *secondary*. *Immediate*, when done during shock, usually from two to six hours after the injury; *primary*, after reaction from shock and before the symptoms of infection are present, usually within twenty-four hours of the injury; *secondary*, when performed after this limit of time, and during the prevalence of inflammation.

The *prognosis* depends upon the character of the injury, the *location* of the line of section, and the condition of the patient as the result of hæmorrhage, shock, sepsis, or any dyscrasia or disease. In general, the gravity is proportionate to the diameter of the part divided and the proximity of the line of section to the trunk.

As to *age*, the death-rate gradually increases with each decade.

Immediate or *primary* operations are more dangerous than the *secondary*.

In determining when to operate, it is well to bear in mind that nervous and fretful patients, chronic alcoholics, heavy smokers, those suffering with kidney lesions and arterial sclerosis, the very old and the very young, are not favorable subjects for conservatism.

"In estimating the gravity of the prognosis, based upon laceration of the soft tissues, muscular lacerations should receive less consideration than injury to the skin. Limbs with extensive laceration of muscle and comminution of bone with slight injury to the skin may be saved, but where there is extensive injury to the skin, however slight the laceration of muscle, I have rarely succeeded in saving a compound comminuted fractured extremity. If the muscles are pulpified, amputation is indicated. Violent injury to a principal set of vessels does not always call for amputation, especially when the injury is fairly well removed from the shoulder- and the hip-joint" (W. L. Estes).

The thick muscular portion of the extremities will resist injury better than the thinner parts, where nerves, vessels, etc., are nearer the skin and bone.

In the forearm and leg, if only a single artery and vein is severed and the skin not extensively destroyed, it is advisable to wait; under other conditions, amputation should be done at the earliest possible moment. When, after a crush, more or less severe, a single artery and vein (brachial, femoral) is severed, delay is dangerous. As soon as reaction is well established, operation is advised.

In these major injuries the immediate indication is the arrest of hæmorrhage by elevating the bleeding point (posture), by direct compression of the lacerated tissues, the application of a tourniquet, the thorough cleansing by irrigation with hot salt solution, followed with a 1–3000 mercuric-chloride (wet) dressing. In an emergency, plain hot water which has been boiled and cooled down to 120° F. will suffice.

In applying the Esmarch bandage around a mangled stump or over the crushed portion of a limb, it should be placed as near the injury as possible, and once applied, should not be removed until, in amputating, the soft parts have been divided on its proximal side. This precaution is necessary to prevent septic organ-

isms from entering the lymphatics and veins. If necessary, short transfixion pins may be employed to prevent the rubber tourniquet from slipping downward.

When extravasations have occurred beneath the skin, with marked swelling and tension, this should be relieved by multiple punctures, covering the injured area with a wet mercuric-chloride dressing, 1–3000.

Shock.—After an injury which may necessitate an amputation a condition of collapse often ensues, which is called *shock*, in which the functions of the nervous system are more or less completely suspended. Shock occurs from two causes, *hæmorrhage* and *fright*. *Psychical shock*, though comparatively infrequent and usually of short duration, is occasionally fatal. *Hæmorrhagic shock* is common, is very frequently fatal, may last for hours, and in rare instances, after an interval of reaction, may recur. In psychical shock, general anæsthesia (ether) is not contra-indicated, as it is in the more serious exhaustion following hæmorrhage. Nitrous oxide with oxygen or air should be preferred when narcosis is necessary.

When, following these grave injuries, *syncope* is threatened, the lower extremities should be elevated, and, if necessary, an Esmarch bandage applied upon the uninjured members, in order to force toward the heart and brain all the blood in the extremities.

To bring about reaction from hæmorrhagic shock, an immediate injection into a vein of a quantity of normal salt solution at about 110° F. is indicated (Fig. 75). From eight ounces to two or three pints (or more) may be employed, the quantity required being determined by the improvement in the character of the pulse and the general symptoms of reaction.

A vein already exposed, or one of the superficial veins of the arm, may be used. The hypodermic infiltration of a large quantity of hot salt solution over the chest and abdomen may also be considered. Caffeine and camphor, hypodermically, are among the most reliable stimulants. One or two ounces of black coffee in an equal quantity of whisky may be injected *per rectum*. Normal salt may be used by enema with or without the coffee and whisky when the condition of the patient is not extreme.

The prognosis in operations of *expediency* is, in general, favorable, since the line of section is made through uninfected tissues, and, as a rule, the general condition of the patient is good. When infection is present, as in osteomyelitis, tuberculosis, etc., the gravity of the prognosis is increased. Amputations on account of malignant neoplasms are more dangerous, since the resistance of these subjects is below the normal.

In determining the point at which an amputation should be made (with only few exceptions, which will be noted in treating of special amputations) the general rule should be to save as much of the length of limb as possible. For the upper extremity disarticulation at the shoulder-joint is most fatal, while from this point to the middle of the forearm the risk is about the same. Amputations through the knee or through the tibia within three or four inches of this joint are more dangerous than those between this point and the ankle. From the knee-joint upward, the danger increases practically for every inch in the approach to the hip-joint.

Operation.—An amputation may be made entirely bloodless by using the elastic bandage (Fig. 76), which is wound

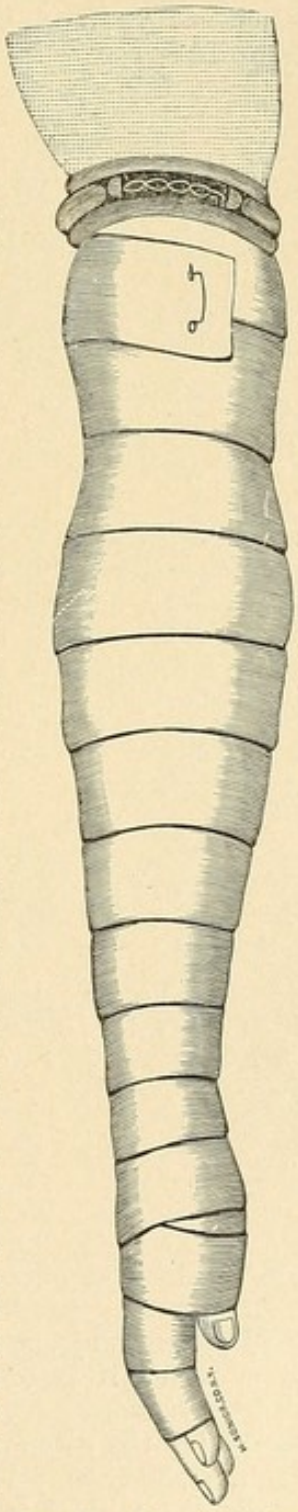

Fig. 76.—Esmarch's elastic bandage and tourniquet. (Esmarch.)

tightly around the limb from the extremity to the trunk. While in position, a rubber-tube tourniquet is applied at the upper limit of the Esmarch, which is then removed.

Since hæmorrhage is the chief cause of shock, this method should be generally employed. When septic infection (phlebitis, osteo-arthritis, etc.) is present, compression should not be made nearer than within six inches of the infected area, for fear of forcing pathogenic organisms into the circulation. The next best method is to hold the member at right angles to the body for five or ten minutes before the tourniquet is applied or to employ the full Trendelenburg posture.

For the same reason, a malignant neoplasm should not be subjected to pressure in applying the elastic bandage. It is well to note that capillary oozing is more persistent after the use of this bandage.

In the formation of *flaps*, whether of *skin* alone or of *skin and muscle*, the first essential is that they be made sufficiently long. Careful measurements, with

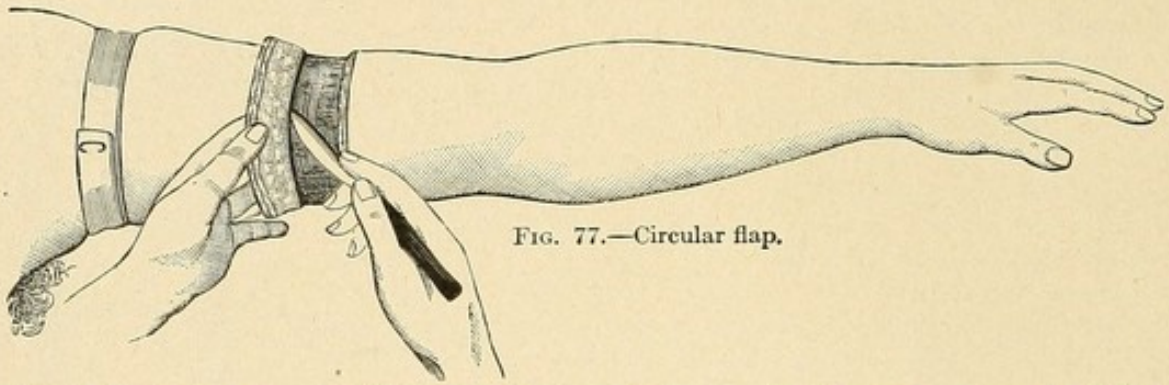

FIG. 77.—Circular flap.

a fair extra allowance, will prevent error. In general, the flap composed of skin, with just enough of the subcutaneous fat to insure its vitality, will be found most satisfactory, and when sufficiently long to prevent adhesions to the end of the bone, the location of the cicatrix is immaterial.

The *combination skin and muscular flap* is now little in vogue. In amputations through the leg, especially in diabetic subjects or in senile gangrene, it may be

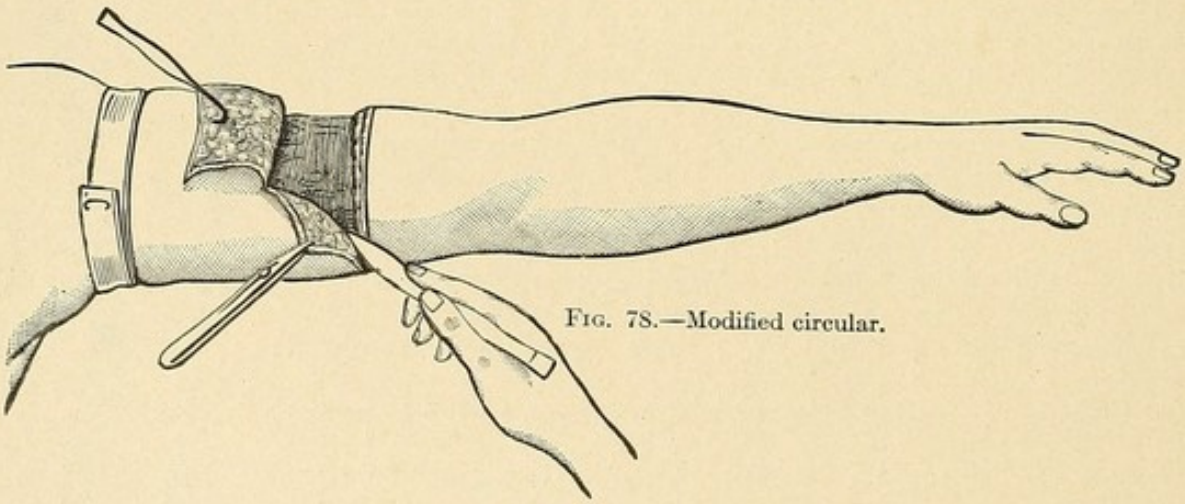

FIG. 78.—Modified circular.

preferred. The *circular* (Fig. 77) or *modified circular* (Fig. 78) method will fill almost every requirement.

In thin subjects the circular incision should extend down to the deep fascia, from which it is separated by careful dissection with the scalpel or the blunt-pointed scissors. A longitudinal slit for a sufficient distance, as shown in Fig. 78, facilitates the dissection, minimizes traumatism, and, moreover, serves as an exit for drainage. One half of an inch in front of the point at which the bone is to be divided, with the flap held out of the way, all the soft tissues should be squarely divided down to the bone, and, without disturbing the periosteum, the muscles lifted from the bone by dry dissection for another half inch, so that the latter

may be sawed this much nearer the body than the line of section through the soft parts. A gauze mat, or sterile towel split half-way, should now be laid over the end of the stump, to serve as a retractor as the saw is being used. In applying this instrument it should be placed against the bone close to the retractor, taking care to hold its blade in such relation to the shaft that the sawn surface will be at right angles to the axis of the bone. A few short, light strokes will suffice to cut a trench or hold for the saw, which may then be more rapidly used. The operator steadies the stump with his left hand, while an assistant holds the extremity. When the section is about complete, the strokes of the saw should be very light, in order to avoid splintering. No periosteal cuff should be used. With a bone cutter or cartilage knife the sharp edge of the cut surface is smoothed and rounded off. In doing this, the force applied should always be toward the center of the bone, to prevent stripping the periosteum or splintering.

The end of the bone should be flushed with salt solution, the retractor removed, the entire stump irrigated with the saline solution and thoroughly dried. The larger arteries and veins may be readily found, and their ends seized with the forceps and drawn slightly out, any contiguous nerves excluded by blunt dissection (grooved director), and *plain* CATGUT LIGATURES applied.[1] Minor bleeding points may be discovered by grasping the limb a few inches above the line of section and milking out the small quantity of blood which has remained in the vessels.

The entire wound should now be filled with dry sterile gauze, covered with towels, and firmly compressed, while the assistant entirely loosens, but does not wholly remove the tourniquet. After waiting two or three minutes for the vessels to fill, the packing is carefully removed, and any bleeding points immediately caught with the forceps. Should an unexpected hæmorrhage occur, the tourniquet is at once tightened.

It is essential that all bleeding or oozing be stopped before the wound is closed.

Under certain conditions, especially where the muscular surfaces are extensive and oozing is free, time may be saved by passing catgut sutures attached to long straight Hagedorn needles through several inches of the ends of the divided muscles, tying these just tight enough to arrest the bleeding.

In sewing up the cuff, alternate deep and superficial silkworm-gut sutures—inserted one eighth and one fourth of an inch respectively from the edge of the flap—are preferable. The edges should be accurately in apposition. Just before the final dressing is applied the limb should be elevated in the position in which it will rest in bed, and a catgut bundle drain[2] brought out at the upper angle of the longitudinal incision (in this position the lowest point).

In applying the dressing no pressure should be made against the end of the bone. The bandage should be just tight enough to control oozing and quiet muscular quivering without interfering with the vitality of the flaps. A light board splint is usually needed, and a wire arch to hold the bedclothes from contact. The dressing need not be changed for eight or ten days unless for pain, hæmorrhage, temperature, or odor. The sutures may be removed about the tenth day.

When an amputation is made through infected tissues, it is often advisable to treat the stump by the open method either with moist 1–3000 mercuric-chloride gauze, frequently changed, or a more or less continuous irrigation with warm normal salt solution.

SPECIAL AMPUTATIONS

Hand and Fingers.—A primary amputation of any portion of the hand is rarely justifiable. If there is only a small strip of tissue, the integrity of which is evident, an effort at the restoration of the nutrition and function of the part beyond should be attempted. If any doubt exists as to the result, the benefit of this should be

[1] Nothing but plain catgut, No. 2 for the larger vessels. Single knot a fourth of an inch from the end so snugly drawn that it cannot slip, the first loop not permitted to loosen, while the second is being run down. Always a third knot with all *animal* ligatures or sutures. When haste is indicated, an artery and vein may be included in the same ligature. When the arteries are atheromatous and brittle, include a protecting sheath of connective tissue in the ligature.

[2] Ten to twenty strands of No. 2 chromicized catgut arranged parallel, *not twisted*.

given to the side of conservatism. It is essential to arrest hæmorrhage, cleanse the wounds under strict antisepsis, and especially by thorough immersion in a basin of warm sublimate solution (1–3000), secure drainage, and place the parts in the best position for usefulness in case of recovery. Amputation may be done when necessitated by gangrene or necrosis.

Fingers—Interphalangeal Operations.—Between the second and third phalanges of the fingers, proceed as follows: Flex the terminal phalanx at about an angle of ninety degrees to the axis of the second bone, and one eighth of an inch anterior to the angle on the dorsal aspect, with a small, sharp-pointed scalpel make a transverse incision, extending half-way down the sides of the finger. From this point carry the incision forward, parallel with the axis of the digit, to within a quarter of an inch of the end, then across the palmar aspect of the tip to the opposite side, finishing the incision at the angle of the transverse cut (Fig. 79). Dissect the palmar flap up, keeping close to the bone, lifting the flexor tendon with the skin back to the articulation; divide the tendon opposite the joint, and disarticulate. The flap is now turned back, trimmed with the scissors to fit nicely, and sutured with fine linen. By this method the acute tactile sense of the palmar aspect of the finger is preserved. This, and other amputations of the fingers, may be made without general anæsthesia, and with perfect insensibility, by the local use of cocaine. Just anterior to the metacarpo-phalangeal joint insert on each lateral aspect of the finger the needle of a hypodermic syringe, and inject in the entire circumference of the finger 30 to 50 minims of a one-per-cent solution of cocaine hydrochlorate. As soon as the anæsthesia is complete the rubber tubing should be applied to control bleeding.

If a considerable quantity of cocaine has been required, it is advisable to loosen the elastic ligature for only a few seconds and then tighten it, and to repeat this procedure several times in the space of above five minutes, so that the cocaine in the tissues will be GRADUALLY liberated and carried into the circulation.

In dressing these amputations the pressure on the end of the stump should be light, for fear of slough in the long flap. Usually no vessels need to be tied. The covering of cartilage does not require to be removed. When only a slight portion of the anterior tip of the second phalanx is involved, the remaining portion should not be sacrificed by a disarticulation. The line of section through the bone should be about at the junction of the middle and anterior third of the phalanx. The incisions and flap are made as in the preceding operation.

In amputation with disarticulation at the posterior interphalangeal joint, flex at an angle of ninety degrees, make a transverse incision over the dorsum of the finger, from one eighth to one fourth of an inch in front of the angle, which includes half the circumference of the member. From the ends of this line carry the incision directly forward on each lateral aspect of the finger to the crease on the palmar surface opposite the anterior interphalangeal joint. A second transverse incision in this fold completes the rectangular flap, which is now dissected back,

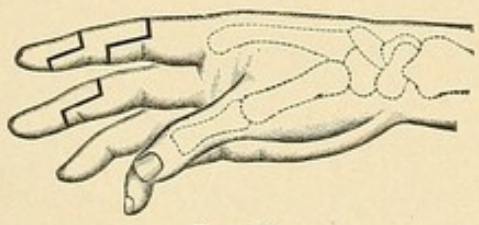

FIG. 79.

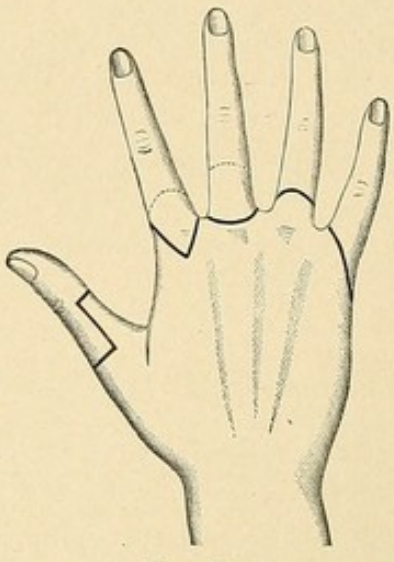

FIG. 80.

and the disarticulation effected by placing the ligaments on the stretch and dividing these with a narrow, sharp scalpel. If any difficulty is found in

entering the joint from the sides or front, it may be easily done by division of the extensor tendons over the dorsum, for these take the place of posterior ligaments. The method of amputation, as given for the operation at or near the articulation of the first and second phalanges of the finger, applies also to the thumb in amputation at the last joint, or through the first phalanx, within one fourth of an inch of its anterior extremity.

At the Metacarpo-phalangeal Joint—Thumb.—When the condition of the soft parts will permit, proceed as follows:

First Method.—Just over the joint, and in the middle of the dorsal aspect of the thumb, commence an incision and carry it along the surface next to the index-

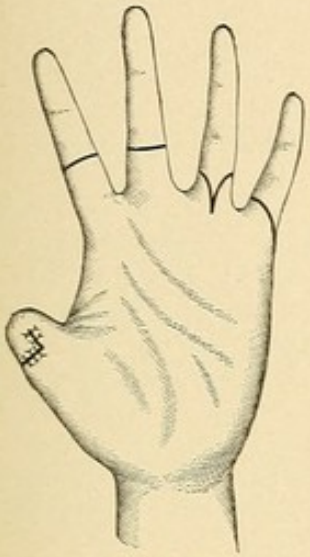

Fig. 81.

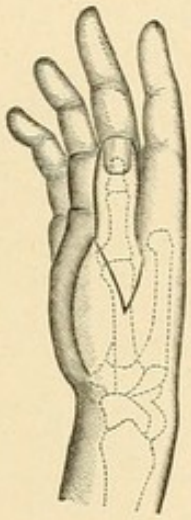

Fig. 82.

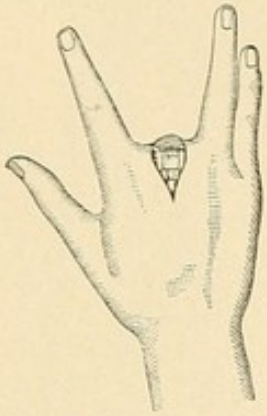

Fig. 83.—(After Esmarch.)

finger until half the circumference of the member is included. Along the dorsal and palmar aspects carry parallel incisions forward until near the interphalangeal joint, and connect these by a straight transverse cut across the palmar surface. Dissect the flap back, divide all tendons opposite the joint, disarticulate, tie the *dorsales pollicis* (one on either side of the back of the thumb), and the *arteria princeps pollicis*, which lies along the side of the metacarpal bone nearest the index-finger and divides into its terminal branches opposite the metacarpo-phalangeal joint. When the flap is stitched, the scar will be in good part concealed on the ulnar aspect of the stump.

Second Method.—A transverse dorsal incision is made over the articulation, extending half around and ending at opposite points on the external and internal lateral aspects of the thumb. Parallel lateral incisions are made as far forward as the interphalangeal joint, and the anterior extremities of these are joined by a transverse palmar cut (Fig. 80). The end of the metacarpal bone of the thumb should be left undisturbed, when not necrosed and when there is sound skin enough to cover it. Under other conditions it may be divided with a fine saw. It is especially important to a laborer that the end of the metacarpal bone be preserved (Fig. 81). For one not compelled to do manual work, a more symmetrical appearance may be obtained by an oblique section of the metacarpal bone about half an inch behind the articular surface. The incision through the skin should be such that the long part of the flap is obtained from the radial and palmar aspect of the thumb, while the line of sutures is situated well on the dorsal surface of the stump (Fig. 82).

Index-Finger—At the Metacarpo-phalangeal Joint—First Method.—When possible, the following method should be adopted, the object being to preserve the tactile sense and to leave the scar less prominent:

From the ulnar side of the knuckle, and just over the joint, make an incision which extends from this point forward as far as the web between the index- and middle finger, and, in case of a large knuckle, a little beyond this point at the

side of the digit. From the anterior end of this incision make a second cut directly across the palmar aspect of the phalanx until the middle of the radial side of the finger is reached, and complete the flap by cutting in a straight line from this point to the commencement of the first incision. When the disarticulation is completed, the *dorsalis* and *radialis indicis* arteries, and the *external digital* branches, tied with fine catgut, the corner of the flap is carried into the receding angle on the dorsal surface of the metacarpal bone and secured by sutures. When the head of the metacarpus is to be removed, the section of this bone should be slightly oblique, and the line of incision a partial oval, beginning at the web between the two fingers, and traveling along the crease formed by flexion of the finger on the metacarpus well up on the dorsum of this bone, about three fourths of an inch back of the joint. An incision, almost in a straight line, should now be made between the ends of this curved line (Fig. 80). Dissect the flaps clear and without making a disarticulation, expose the bone, and with a fine saw divide it obliquely from before backward, and from the ulnar toward the radial aspect. In amputation of the middle or the ring-finger, the following method should be preferred:

Middle Finger.—Locate the articulation exactly, and over this point make a transverse incision extending on either side to the middle of the depression between this digit and the index- and ring-fingers (Fig. 80). From either end of this cut carry a lateral incision directly forward about half-way up the first phalanx, and connect these by a transverse incision across the palmar aspect of the digit (Fig. 81). Disarticulate and fold the palmar end of the flap back upon the dorsal transverse incision where it is stitched.

Another method is the oval incision, shown in Fig. 83. By the first method the tactile surface is better preserved. The head of the metacarpal bone should be left intact for laborers. When the round expansion of this bone is removed, the

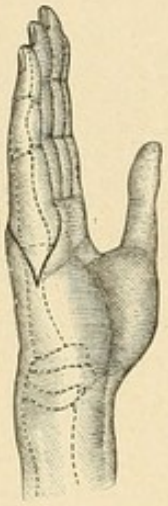

Fig. 84.

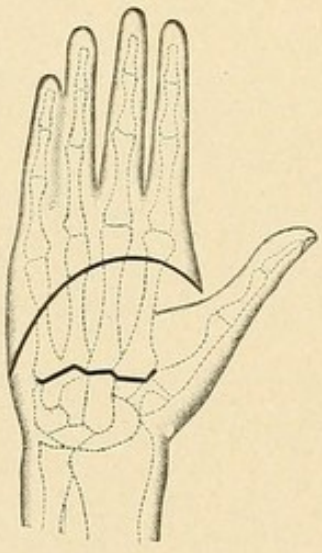

Fig. 85.

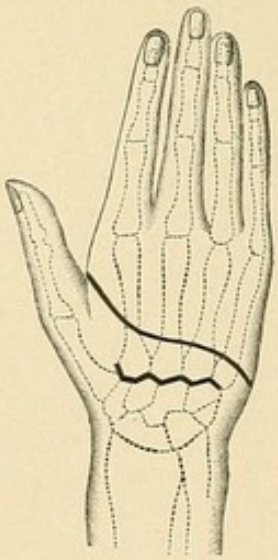

Fig. 86.

gap between the index- and ring-fingers is not so wide. The bone should be sawed squarely across a half inch behind the articular surface. All that has been said of this digit applies with equal force to the ring-finger.

Little Finger.—The method recommended in amputation of the index at the metacarpal joint should be preferred in removing the little finger at the same level. The flap should be so shaped that the cicatrix will fall on the dorsum and toward the ring-finger. When the metacarpal bone is to be divided it should be cut with a slight obliquity. In this operation the oval incision shown in Fig. 84 should be made.

When two or more fingers require to be removed at the metacarpo-phalangeal joint, each one may be amputated by the methods described as especially suited to it, or a common antero-posterior flap may be made. As to the propriety of removing

the ends of the metacarpal bones, the same rules apply as already given for the single amputations.

Through the Metacarpus.—When the end of the metacarpus cannot be saved, these bones should be divided at any point three fourths of an inch or more anterior to the carpo-metacarpal articulation. If the injury extends behind this line, it is better to disarticulate at the carpo-metacarpal junction. In amputation through the metacarpus, the flap should be made chiefly from the palmar tissues, so that the line of sutures and the scar will be well on the dorsum of the hand, and as much of the tactile sense preserved as possible.

Carpo-metacarpal Disarticulation.—When all the bones of the metacarpus require to be removed, on account of a lesion not involving the anterior row of the

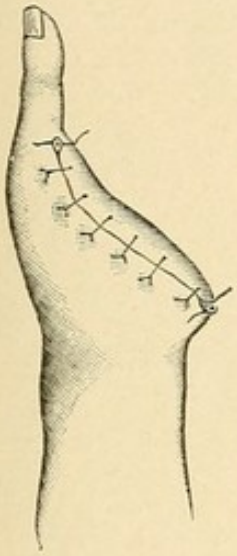

Fig. 87.

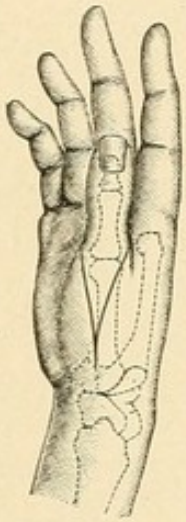

Fig. 88.

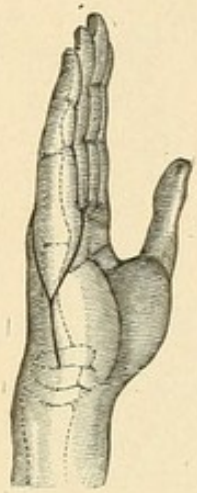

Fig. 89.

carpus, the amputation should be made through the metacarpo-carpal line. If the anterior row is involved, the entire carpus should be removed. When the thumb is intact, and the metacarpal bones of the four fingers require removal, the incision as given by Esmarch should be followed. A curved incision is made across the palm, beginning at the middle of the web between the thumb and index-finger, and carried outward to the ulnar side of the base of the fifth metacarpal bone (Fig. 85). The dorsal incision commences at the web between the thumb and finger, and is carried obliquely upward toward the carpus until the junction of the middle and upper third of the metacarpal bone of the index-finger is reached, whence it travels across the back of the hand to join the end of the palmar incision (Figs. 86, 87).

Amputation of the thumb with disarticulation at the carpo-metacarpal junction should be done as follows: Just over the carpo-metacarpal joint on the dorsal aspect of the hand commence an incision, and carry it directly along the metacarpal bone until half-way to the metacarpo-phalangeal articulation, from which point it is made to travel along the groove between the thumb and index-finger to the middle of the web between these two members, thence on around the base of the thumb until the dorsal incision is reached (Fig. 88). In amputation of the little finger, at the carpo-metacarpal joint, a similar incision is made (Fig. 89).

The character of the injury, the general condition of the individual, the vitality of the parts involved, may necessitate various modifications of the foregoing methods. *In the surgery of the hand, the rule in practice should be never to amputate when possible to avoid it, and never to remove any more than is absolutely necessary.* Fig. 90 is that of an amputation after an injury from the explosion of a shotgun, in which the thumb, index- and middle fingers, and their respective metacarpal bones, were blown off. The line of incision was a lateral one, and the disarticulation was at the carpo-metacarpal joint.

Radio-carpal Joint.—In amputation at the wrist the carpus should be removed, even when all the bones of this group are not involved. The line of incision will

depend upon the extent of the healthy tissues available for forming the covering to the stump. The long palmar and short dorsal flaps are preferable on account of the finer tactile sense of the covering thus secured. Moreover, the vitality of the palm is so great that, if ordinary precautions are observed in its dissection, sloughing will not occur.

First Method.—Place the thumb and finger of the left hand respectively upon the styloid of the radius and ulna, and make an incision across the dorsal surface of the wrist which shall divide everything straight down to the bones and into the cavity of the joint. This incision reaches half-way down the lateral aspects of the wrist. At the radial end of this cut enter the scalpel, and, in shaping the long flap, follow the center of the dorsum of the metacarpal bone of the thumb as far as the metacarpo-phalangeal articulation. From this point cut directly across the palm to the ulnar side of the fifth metacarpal bone, and back along this



Fig. 90.

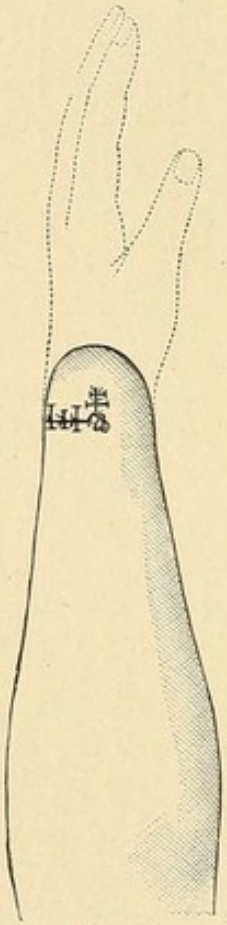

Fig. 91.

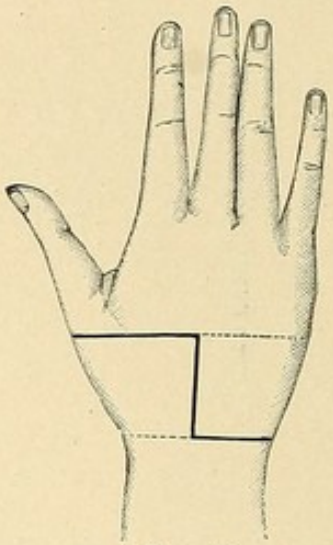

Fig. 92.

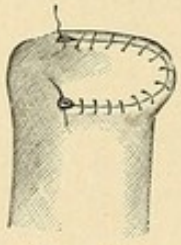

Fig. 93.

to join the dorsal incision. Dissect the flap closely from the flexor tendons, and divide all tendons opposite the wrist-joint. Apply a cloth retractor, and saw through the styloid of the radius and ulna just at the level of the articular surface of the radius, but not necessarily taking a section from this surface. The *radial, ulnar, anterior,* and *posterior carpal* vessels are tied, the palmar flap is trimmed down to fit snugly, and stitched in proper position. The catgut drainage comes out on either side (Fig. 91).

Second Method.—If the condition of the soft tissues is such that the long palmar flap cannot be obtained, the circular method may be practiced. It is always advisable to make a longitudinal split in the cuff along its ulnar aspect, from the angle of which the drain is brought out. Under other conditions, a lateral flap may be utilized, after the third method (Figs. 92, 93), in the flap from the thumb side; or the fourth method in which the flap is taken from the ulnar aspect of the hand.

Forearm above the Wrist.—In amputations through the forearm, the circular or modified circular skin-flaps are preferable.

The anatomical relations are shown in Figs. 94, 95, 96, and 97, which, with only slight modifications, I have copied from Prof. Braune's magnificent work.

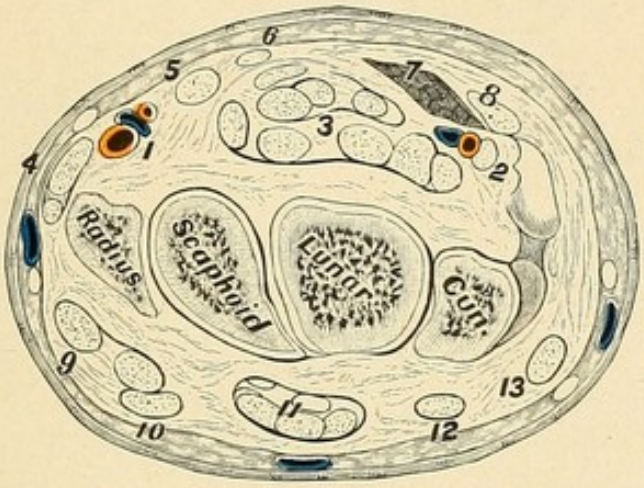

FIG. 94.[1]—Transverse section through the right upper extremity, one fourth of an inch anterior to the plane of the radio-carpal articulation. Looking at the surface of the stump. 1, Radial artery and veins. 2, Ulnar artery, veins, and nerve. 3, Tendons of deep and superficial flexors. 4, Tendon of extensor ossis metacarpi and primi internodii pollicis. 5, Flexor carpi radialis. 6, Palmaris longus. 7, Fibers of the flexor brevis minimi digiti, from the annular ligament. 8, Flexor carpi ulnaris. 9, 10, Extensor carpi radialis longior et brevior, and tendon of secundi internodii pollicis. 11, Extensor communis digitorum. 12, Extensor minimi digiti. 13, Extensor carpi radialis. Superficial veins and nerves are seen in the subcutaneous tissues.

When the line of amputation is so close to the elbow-joint that division of the bones is necessitated within an inch of the articular surface of the head of the radius, the operation to be preferred is a disarticulation at the elbow, with removal of the olecranon. When the bones can be preserved at the level of the lower border of the bicipital tuberosity of the radius, the joint should not be invaded.

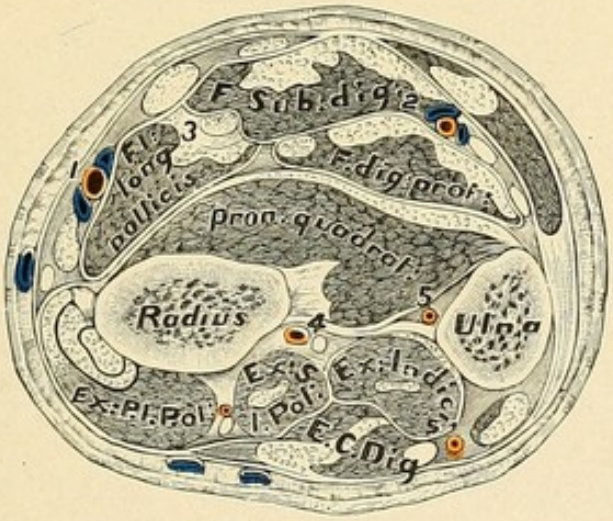

FIG. 95.—Transverse section showing the relations of the tissues divided in amputation through the lower third of the right forearm. Looking from below upward. 1, Radial artery and veins. Just below this, tendon of supinator longus, radial nerve, and close to the radius the tendons of the extensor ossis metacarpi pollicis and extensor carpi radialis longior and brevior. 2, Ulnar artery, veins, and nerve. 3, Median nerve. 4, 5, The posterior and anterior interosseous arteries.

Amputation at this level (Fig. 97) should be made subject to the rules just given for other portions of the forearm between the wrist and the insertion of the *biceps humeri*.

[1] All of these cuts represent the surface nearest tne patient's body, i.e., the surface on which the vessels are searched after an amputation.

At the Elbow-joint—First Method.—Make a circular incision through the skin from one inch to one inch and a half below the level of the internal condyle. Along

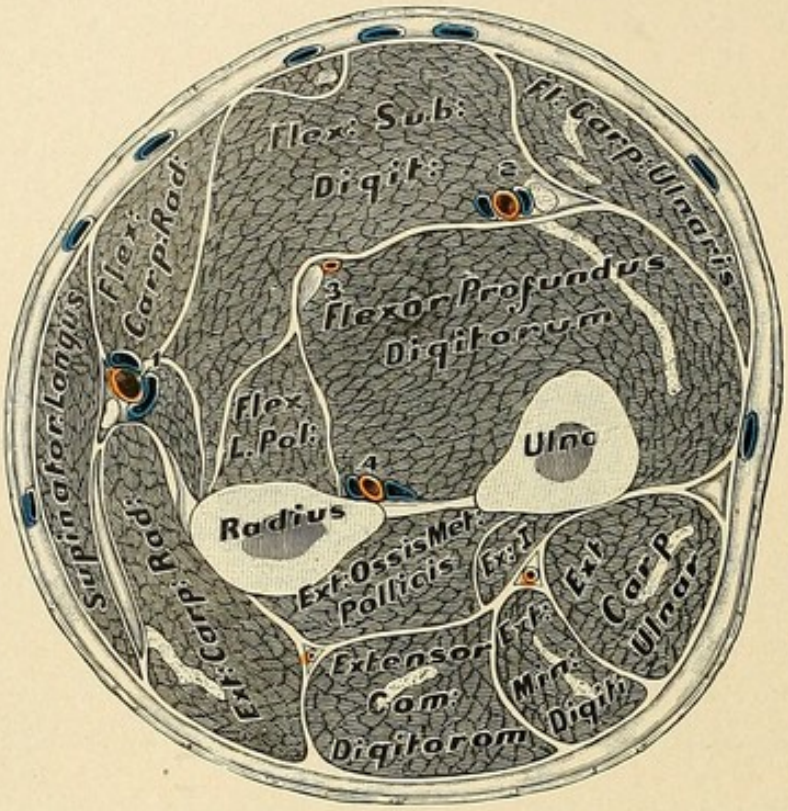

FIG. 96.—Transverse section through the middle of the right forearm. Looking from the periphery toward the center. Showing the relations of the tissues divided in amputation at this point. 1, Radial artery, veins, and nerve. 2, Ulnar ditto. 3, Median nerve. 4 Anterior interosseous vessels.

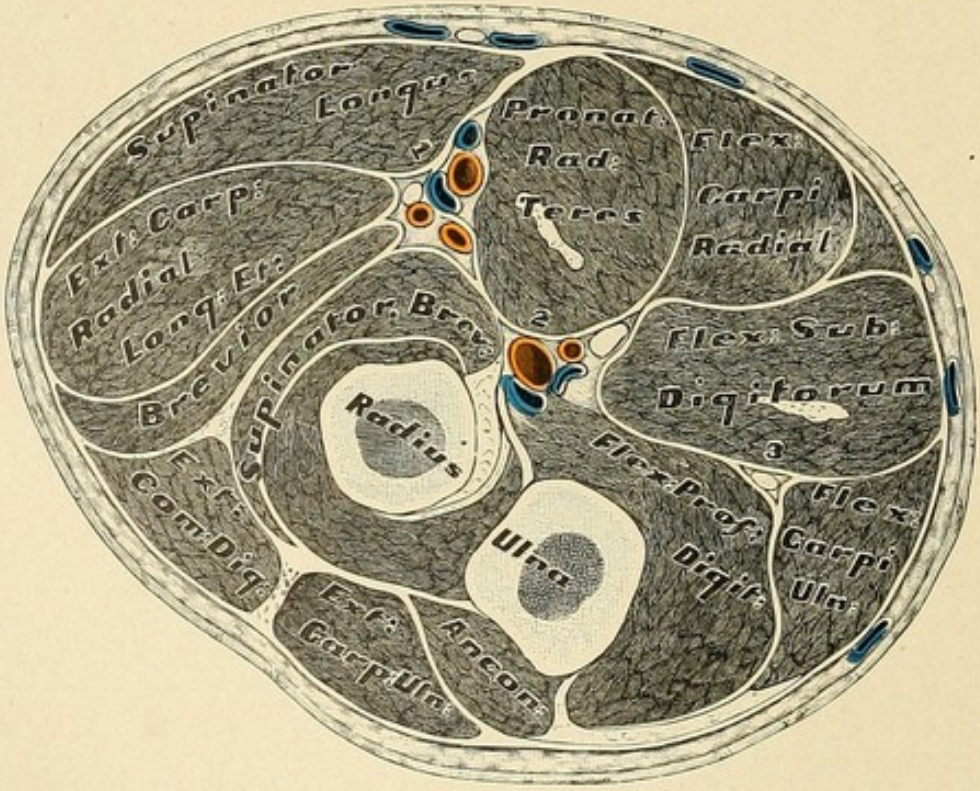

FIG. 97.—Transverse section through the upper third of the right forearm. Looking from the periphery toward the center. 1, Radial artery, muscular branches, veins, and radial nerve. 2, Ulnar and interosseous arteries, veins, and median nerve. 3, Ulnar nerve. The tendon of insertion of the biceps is seen with the radius.

the posterior aspect of the ulna make a second incision, splitting the sleeve of skin as far back as the end of the olecranon. Dissect up the flap from the muscles and deep fascial attachment until the joint is exposed in front, and the olecranon posteriorly. Extend the forearm fully, enter the articulation between the head of the radius and the humerus, disarticulate, and saw off the articular surface at the level of the lower portion of the internal condyle. The drainage is from the highest point in the perpendicular incision.

Second Method.—Make a circular incision down to the deep fascia from one to two inches anterior to the tip of the internal condyle of the humerus, and, when the skin has retracted, at the level of the line of retraction divide all the tissues to the bones. Along the posterior surface of the ulna make an incision extending as high as the olecranon process. Dissect the soft tissues neatly from the periosteum and capsule back to the condyles on the lateral and anterior aspects of the humerus,

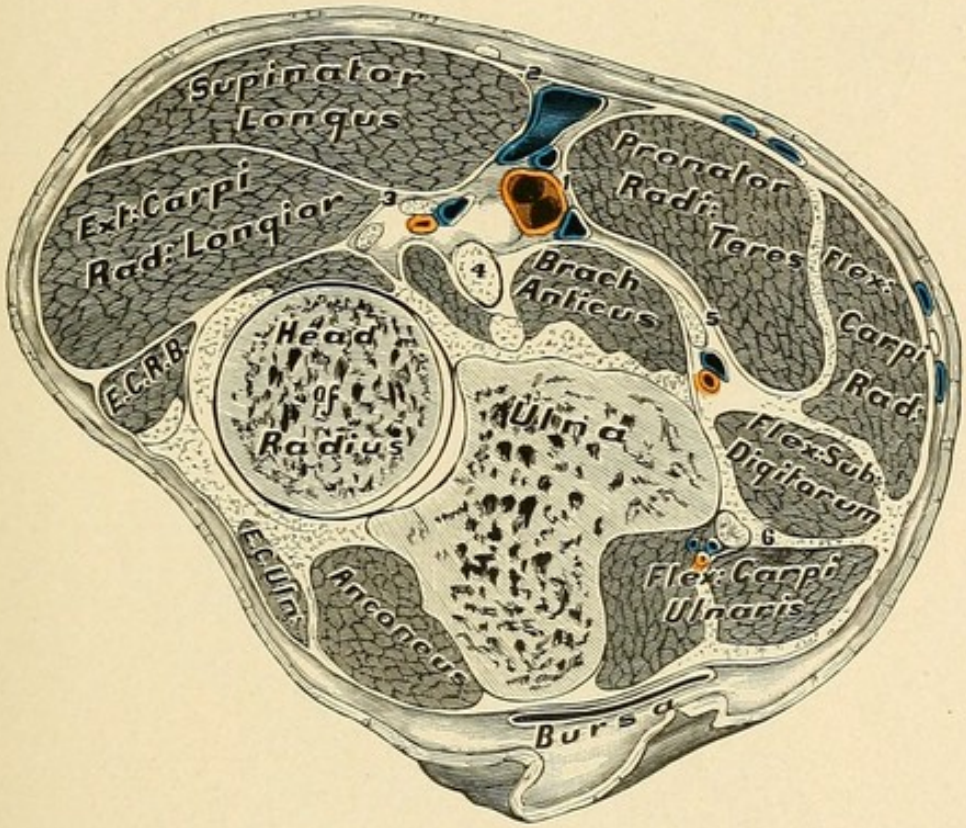

Fig. 98.—Transverse section of right arm just below the elbow-joint. Looking at the surface nearest the body. 1, Brachial artery at the point of division into ulnar and radial. 2, Median basilic vein communicating with brachial. 3, The radial and interosseous divisions of the musculo-spiral nerve and radial recurrent artery. 4, Tendon of biceps. 5, Median nerve and anterior ulnar recurrent artery. 6, Ulnar nerve and posterior ulnar recurrent artery.

and along the olecranon somewhat higher, in order to facilitate disarticulation and the complete removal of the synovial bursa, beneath the insertion of the triceps. When the disarticulation is completed, apply a cloth retractor and saw a portion of the articular surface off at the same level as given in the preceding operation. The flaps are now sutured, leaving the drainage at the upper limit of the incision, over the olecranon.

Fig. 98 shows the anatomical relations near the line of section of the soft parts involved in this amputation.

Arm below the Shoulder-joint.—The circular skin-flap is always preferable.

First Method.—Make a circular cut down to the muscles, and a longitudinal incision to the same depth along the outer side of the arm. Dissect the sleeve of skin carefully up to the line of section of the humerus, and at this point divide the muscles and bone.

The anatomical relations in the several regions of the arm are shown in Figs. 99, 100, and 101.

When the line of amputation is so near the shoulder-joint that section of the bone is required at the anatomical neck, the head of the humerus should be disarticulated.

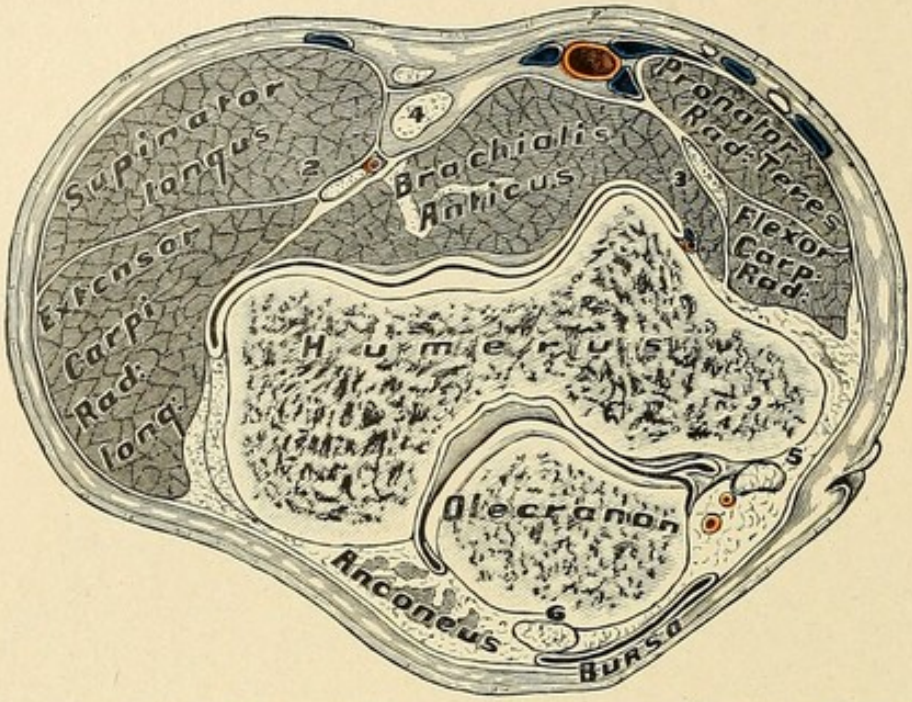

FIG. 99.—Section through the condyloid expansion of the right arm. Looking at the surface nearest the body. 1, Brachial artery and veins, and the median basilic vein. 2, Musculo-spiral nerve and superior profunda artery about the point of anastomosis with the radial recurrent. 3, Median nerve. 4, Biceps tendon. 5, Ulnar nerve. 6, Triceps tendon.

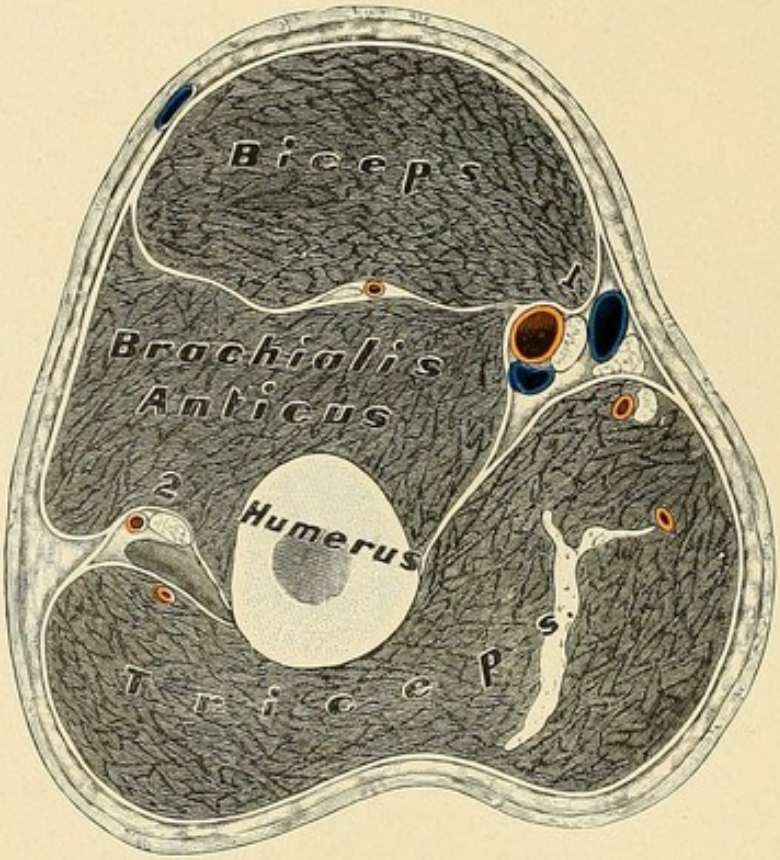

FIG. 100.—Transverse section through junction of middle and lower thirds of right arm. Looking from below upward. 1, Brachial artery, vein, median nerve, and basilic vein. Near by the ulnar nerve and inferior profunda artery. 2, Musculo-spiral nerve, superior profunda artery, and supinator longus muscle. Cephalic vein to outer side of the biceps muscle.

Second Method—Circular Skin and Muscle Flap.—Make a circular cut through the skin at a point sufficiently below the line of section through the humerus to permit a suitable covering. Allow the skin to retract up the arm, and at this point divide everything smoothly and squarely down to the bone. Render the skin and muscles tense, push the point of the scalpel down to the bone on the outer side of the arm, and lay the flap open by an incision which is parallel with the axis of the humerus. Dissect the tissues closely from the periosteum up to the point where the saw is to be applied, and, after protecting the soft parts with a retractor, divide the bone. The drainage should be from the upper extremity of the per-

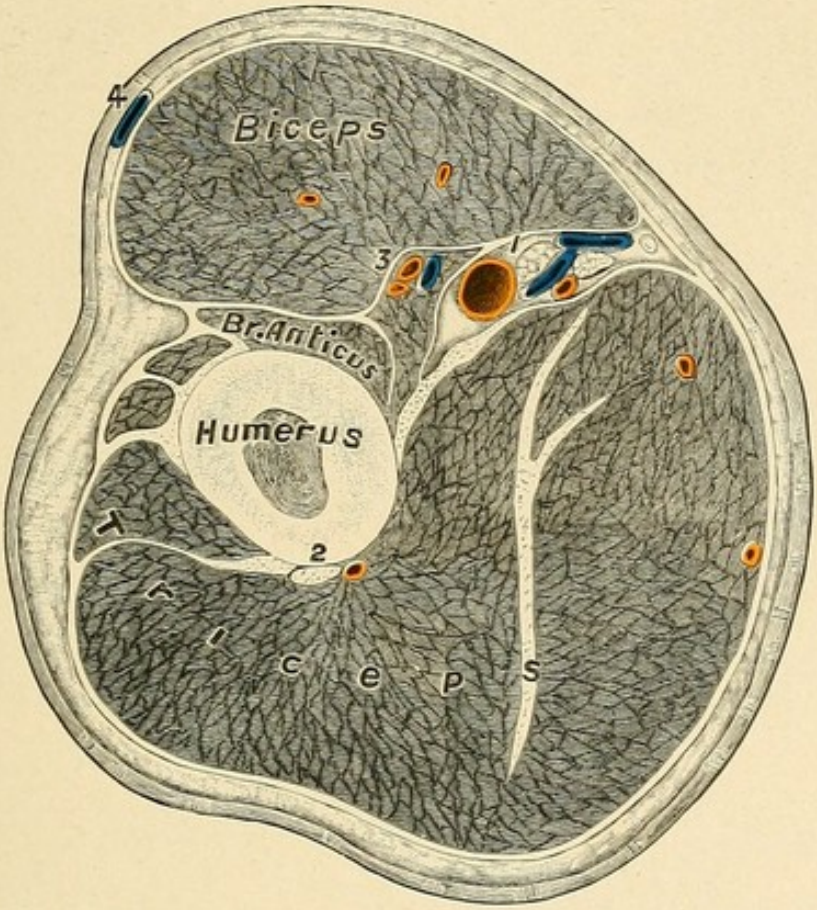

FIG. 101.—Transverse section showing the relations of parts divided in amputation just above the middle of the humerus. Right side. Looking toward the center. 1, Brachial artery. Near this the median nerve and brachial veins. Internal to it the ulnar nerve and inferior profunda artery. More superficial, the basilic vein. 2, Musculo-spiral nerve and superior profunda artery. 3, Nutrient artery in the substance of the coraco-brachialis muscle. 4, Cephalic vein.

pendicular cut, which, with the stump properly elevated, will be the most dependent portion of the wound.

Amputations through the humerus, especially in young and growing bones, not infrequently fail of success by reason of so-called conical stump—a projection of bone through the tissues of the flap. This condition supervenes in a proportion of cases sufficient to justify the surgeon in stating at the time of such an operation that a conical stump may result even with very long flaps.

AMPUTATION AT THE SHOULDER-JOINT—THE AUTHOR'S METHOD

In 1888, at the New York Polyclinic Medical School and Hospital, I removed the outer portion of the clavicle, the glenoid, acromion and coracoid processes, and a small portion of the body of the scapula, together with the upper extremity of a patient suffering from a large sarcoma of the upper articular end of the humerus by the following original method: With a stout mattress needle I transfixed the skin and a portion of the pectoralis major muscle about three inches from the shoul-

der, and at about the same distance from the joint on the dorsum scapulæ I introduced a second needle in such a way that when I carried a strong white-rubber

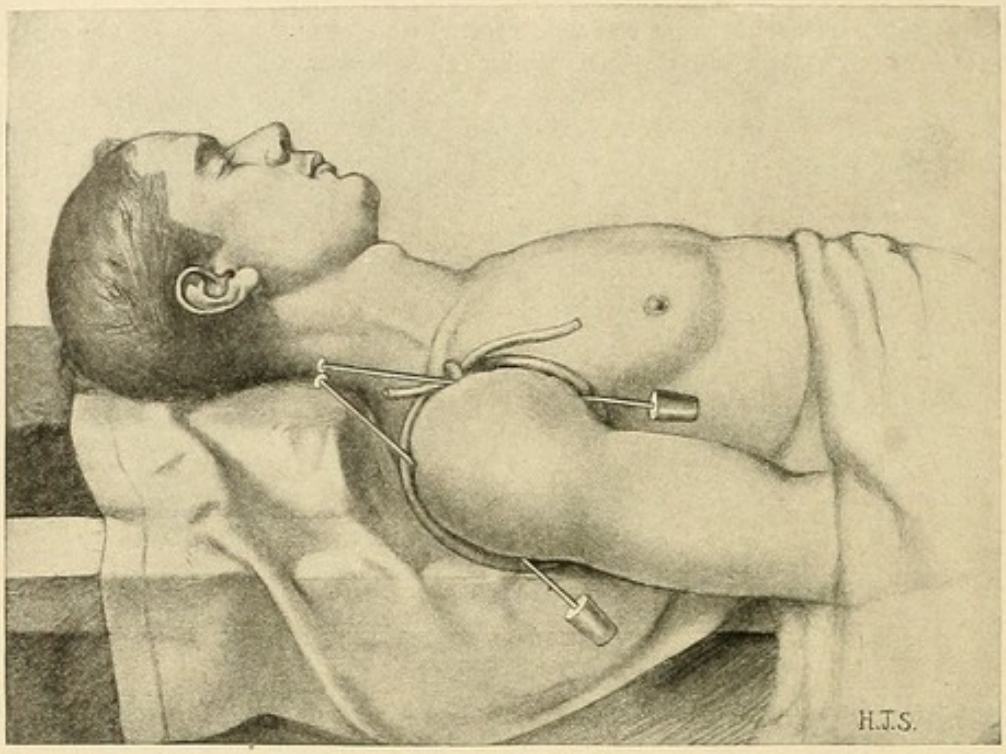

Fig. 102.—Shoulder-joint amputation. Pins and rubber-tube tourniquet in position. The Esmarch bandage has been removed. (From drawings by H. J. Shannon.)

tube four or five times around the shoulder above these needles, making strong traction, the compression was so great that the blood vessels going to the arm were entirely occluded (Fig. 102).

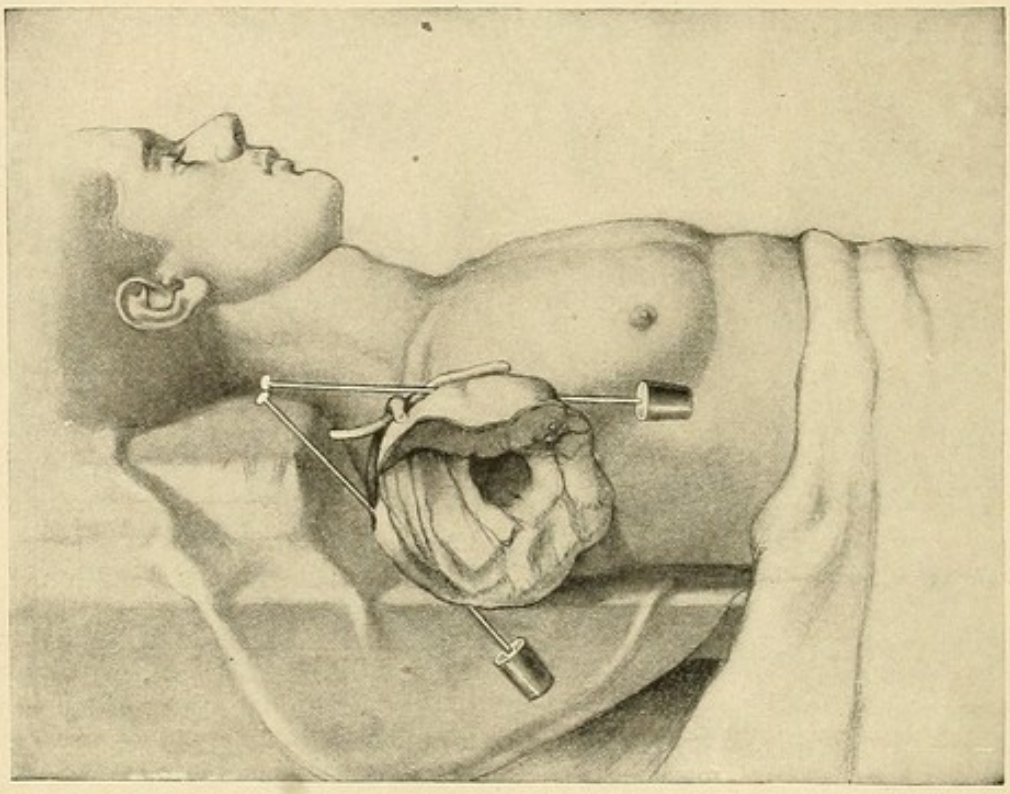

Fig. 103.—The same after disarticulation and ligature of the vessels.

Since that date this method has been repeatedly employed with invariable success in the control of hæmorrhage. After the extremity has been exsanguinated by Esmarch's bandage, the pins should be introduced, the rubber constrictor applied, and the Esmarch bandage removed. The incisions for the flap should be made to conform to the conditions which demand the operation. When possible, the ideal amputation at the shoulder is a circular incision through the skin down to the deep fascia, about four inches beyond the joint. A longitudinal incision is then made from the acromion process directly down to the circular incision, and the flap dissected back to the level of the joint and the latter disarticulated. When permissible, after disarticulation I leave the tissues upon the inner aspect of the humerus a little longer in order to get as much of the blood vessels beyond the constrictor as possible. The operation is completed with the tourniquet in position (Fig. 103). Silkworm-gut sutures with a bundle of sterile catgut for capillary drainage will suffice for closing and draining the wound, which, as a rule, should be redressed about the seventh day.

Removal of the Upper Extremity with All or a Portion of the Clavicle and Scapula

When it becomes necessary to remove portions of the scapula or clavicle, or all of these bones, it is advisable to tie the subclavian artery (third division) and the transversalis colli and subscapular branches of the thyroid axis. When the disease extends so far upon the shoulder that it is impossible to secure flaps sufficient to cover the exposed surface, cut well away from the disease and allow the wound to heal by granulation, relying upon subsequent plastic procedures to cover in the stump.

Lower Extremity

Amputation of the Toes.—The same methods given for the fingers should be employed in amputation of the toes. The long plantar flap is preferable in these operations, not so much for the preservation of the more perfect tactile sense of this surface in covering the stump, but chiefly to bring the cicatrix on top and away from pressure. When an amputation is necessitated for a lesion near the

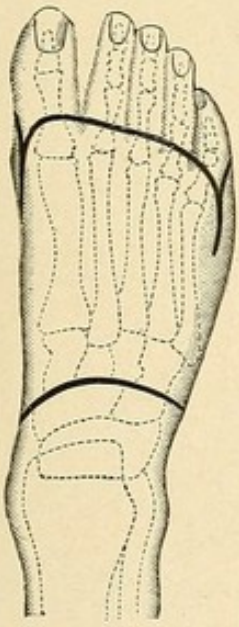

Fig. 104.

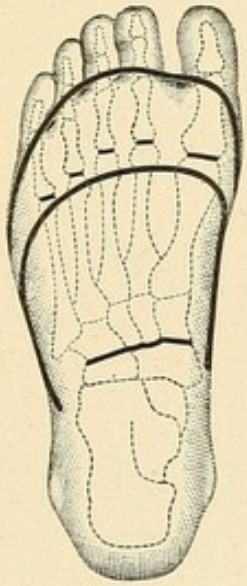

Fig. 105.

articulation between the first and second phalanges in which only the anterior extremity of the first phalanx is involved, section through the bone should be preferred to disarticulation at the metatarso-phalangeal joint, provided that the line of section is through the anterior third of the phalanx. Disarticulation of two or

more consecutive toes at the metatarso-phalangeal joint may be effected by a continuous incision. Amputation of all the toes at this articulation is performed as follows: Grasp and forcibly flex the toes, and make an incision, commencing just posterior to the inner aspect of the metatarsal joint of the great toe, curving forward along the side of the first phalanx to a point as far advanced as the web between the toes, and then across the base of each digit on this plane until the outer side of the metatarsal bone of the fifth toe is reached at a point corresponding to that at which the incision was begun. With the toes now fully extended, a symmetrical flap is next cut along the plantar aspect by an incision which almost merges into the first line at the anterior margin of the web (Figs. 104, 105). Dissect up each flap as far back as the metatarso-phalangeal articulation, leaving the tendons to be divided at this point. The disarticulation may be best effected with a strong narrow scalpel, while the ligaments are made tense by forced flexion.

Second Method.—A separate amputation may be made for each toe.

Through the Metatarsus.—When the loss of tissue requires an amputation behind the metatarso-phalangeal articulation, section of one, or even all, of the metatarsal bones should be effected rather than unnecessarily sacrifice any portion of the foot by disarticulation at the tarso-metatarsal joint. The line of section should always be as near the anterior extremity as possible, and when it falls within three fourths of an inch from the tarso-metatarsal joint, a disarticulation should be made at this point.

Amputation through the entire metatarsus should be made with a long plantar and short dorsal flap, so that the scar will fall on the dorsum of the foot and away from pressure. The dorsal incision should be made almost directly across the foot, and on a line with the plane of section through the bones. The plantar flap should begin on the inner side of the first metatarsal bone, and follow this forward as far as is necessary to secure a flap of sufficient length. It is always wise to make this a little too long, so that it may be trimmed down and made to fit nicely as the sutures are being adjusted. The incision is next carried across the sole of the foot to the outer surface of the metatarsal bone of the little toe, and back along this to the point of junction with the end of the dorsal cut. All of the tissues should be divided directly down to the bones in this incision, and the flap dissected up, keeping the knife-point always in contact with the periosteum, so that the vessels may be avoided. After the bones are sawn through, the lower flap is turned into position and suitably trimmed. The vessels are next secured, the sutures applied, and the drainage-tubes brought out at each side.

At the Tarso-metatarsal Articulation—First Metatarsal.—Amputation of the great toe, with disarticulation of its metatarsal bone at the tarsal joint, is effected as follows: At a point about half an inch behind the articulation of the metatarsal bone with the internal cuneiform, and immediately between the dorsal and internal lateral aspects of this bone, commence an incision which is carried forward to the

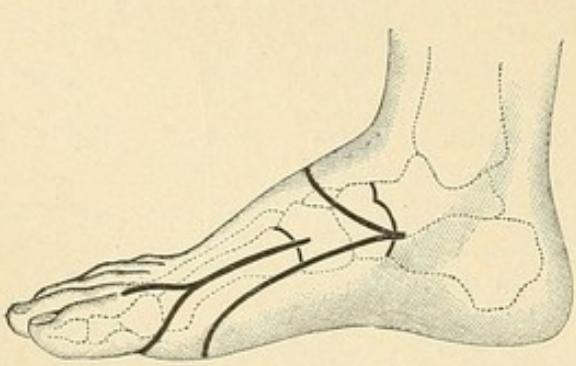

Fig. 106.

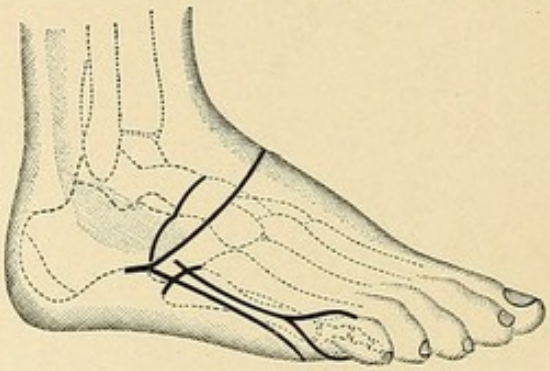

Fig. 107.

phalangeal junction. Thence it is continued around the base of the toe, across its plantar surface, and back through the web between the first and second digits, and back to the end of the straight incision over the metatarso-phalangeal joint (Fig. 106). Dissect the soft parts closely from the bone, taking care not to wound the

plantar vessels, and disarticulate. The preservation of the posterior portion of the first metatarsal bone is always desirable, on account of its giving insertion to the peroneus longus and partially to the tibialis anticus muscle, the former being a strong supporter of the transverse arch of the foot, and the latter offering the chief resistance to the sural muscles.

Fifth Metatarsal.—One fourth of an inch behind the tubercle of the fifth metatarsal, and over the center of the dorsal aspect of this bone, commence an incision, which is carried directly forward until near the first phalanx, when an oval is described around the base of the little toe (Fig. 107). Keep close to the bone in the dissection. The disarticulation is more easily effected by division of the peroneus brevis and peroneus tertius, and by entering the articulation from the outer side. The importance of the posterior portion of this bone is less than that of the metatarsal bone of the great toe, but it should never be needlessly sacrificed.

One or more of the intervening metatarsal bones may be removed in an amputation of their respective toes in practically the same manner as the preceding. The incision should be begun far enough behind the tarso-metatarsal joint to thoroughly expose the ligaments and facilitate disarticulation—not an easy process when only a single bone is to be removed. The incision should be made exactly along the middle line of the dorsal aspect.

Amputation of the entire metatarsus should always be made through the articular plane (Lisfranc).

Method—Dorsal Incision.—Place the thumb and index of one hand respectively half an inch behind the articulations of the first and fifth metatarsal bones with the cuneiform and cuboid, and at the most convenient one of these points commence the dorsal incision, carrying it directly forward to the base of the meta-

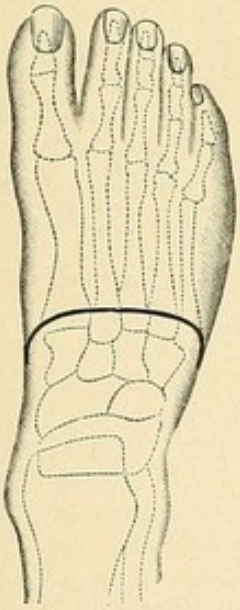

Fig. 108.

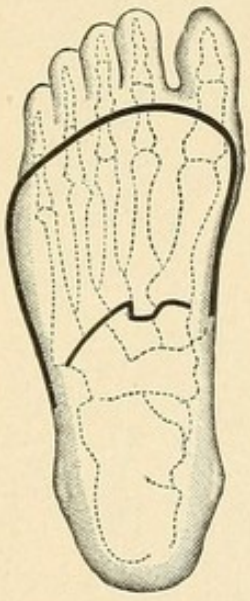

Fig. 109.

tarsus, and then across the foot one fourth of an inch in front of the tarso-metatarsal articulation, finishing at the opposite side (Fig. 108). This incision should have a slight forward convexity, and should divide all tissues down to the bones. Dissect the flap closely from the periosteum to about one fourth of an inch behind the line of articulation.

Plantar Flap.—From the same point as for the dorsal incision, carry the knife directly forward on the lateral aspect of the metatarsal bone to the metatarso-phalangeal joint, where the line of incision should begin to describe a curve until the interdigital web is reached, along which it travels across the foot, and thence back along the opposite metatarsal bone to the level of the tarsus (Fig. 109).

This flap should be lifted by deep dissection, keeping close to the under surface of the bones, in order to interfere as little as possible with the vascular supply. An

assistant should now hold both flaps well back, while with a narrow, short scalpel the disarticulation is effected as follows:

Grasp the metatarsus with one hand and forcibly depress it until the ligaments are put upon the stretch. Enter the knife just behind the tip of the fifth metatarsal bone and carry it inward with a slight forward inclination, disarticulating on this plane, and in succession the fifth, fourth, and third bones, until the knife is arrested by the outer surface of the second metatarsal. The line of this articulation is almost parallel with that just followed, but it is placed from one eighth to one fourth of an inch posterior to it, and may be readily found by moving the metatarsal bone upon the cuneiform. The joint between the metatarsal bone of the great toe and the internal cuneiform is about one fourth of an inch anterior to that of its fellow, being continuous with the line of the three outer bones. The flaps should now be trimmed and nicely fitted, and any ragged ends of tendons clipped off by the scissors, after which the vessels are tied and the sutures adjusted, leaving the drainage-tubes out at each angle.

One point of precaution is essential, namely, to avoid division of that part of the tendon of the tibialis anticus which is inserted into the internal cuneiform near its metatarsal articulation. One of the objections to this operation is the elevation of the heel, and the consequent depression of the stump by the action of the sural muscles, which action is practically unopposed if the insertion of the tibialis anticus is divided. Should this occur, or should the heel be too greatly elevated, the tendo Achillis should be divided as in talipes equinus.

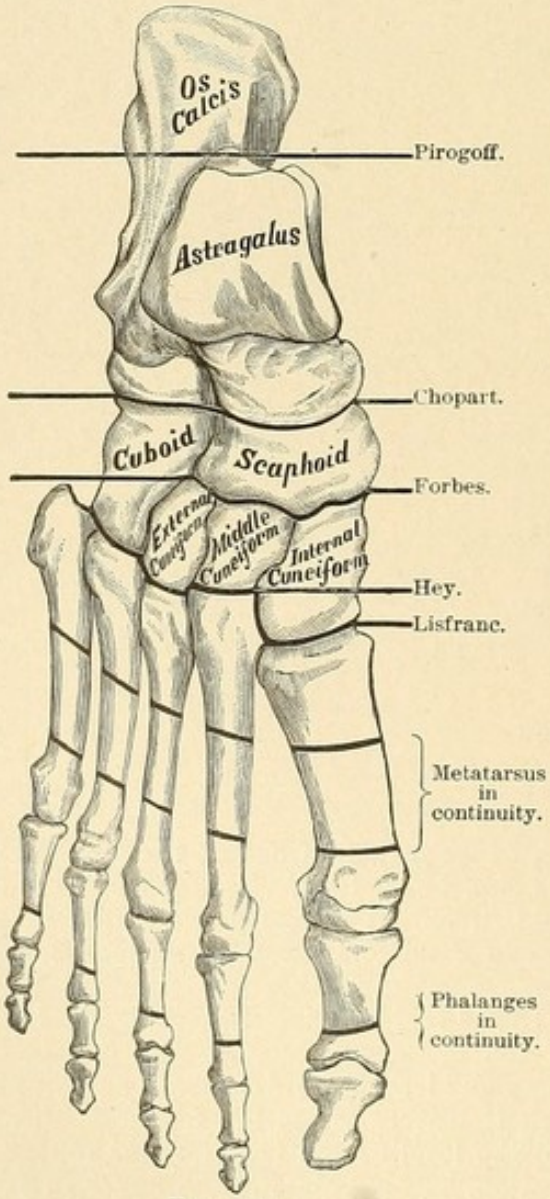

Fig. 110.

Through the Tarsus.—When removal of any part of the anterior row of tarsal bones is required, the following rules should be adopted: If the internal cuneiform is involved only on its anterior articular surface, it may be sawn through on the line of Hey (Fig. 110). If the middle or external cuneiform is involved only to a limited extent upon its anterior portion, as much as one fourth of an inch of this surface may be sawn or scraped off. Behind this limit a disarticulation from the scaphoid should be made. Through the cuboid the section should pass, as first advised by Dr. S. F. Forbes, of Toledo, Ohio (who performed this operation in 1863), through the middle of this bone on the line of the anterior surface of the scaphoid (Fig. 110).

Medio-tarsal—Operation of Chopart.—The dorsal incision is begun on a level with and an inch posterior to the



Fig. 111.

tip of the base of the fifth metatarsal bone (for the adult foot). This point is about one fourth of an inch behind the articulation between the cuboid and calcaneum (Figs. 107 and 111). With a slight forward convexity the incision is carried across the top of the foot to the posterior margin of the tuberosity of the scaphoid, and then directly back from one fourth to half an inch (Fig. 106). The skin, tendons, vessels, and nerves are divided on this line, and the flap lifted until the joints between the astragalus and scaphoid and the calcaneum and cuboid are well exposed. From the ends of this first incision a long plantar flap is fashioned by cutting forward, as in shaping the flap for the operation of Lisfranc (Figs. 106, 107). Disarticulation is effected with a short, strong scalpel, while forcible extension is employed. The flaps are now to be properly trimmed, and the vessels secured. Division of the tendo Achillis may be done later. When required, this operation may be modified by sawing off the anterior half-inch of the astragalus and calcaneum. The incisions are practically the same.

Calcaneo-astragaloid Disarticulation.—When in an amputation of the foot at the medio-tarsal joint it is discovered that the *os calcis* must also be removed, and

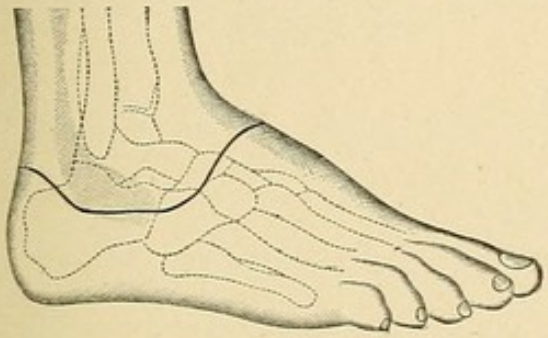

Fig. 112.—(After Malgaigne.)

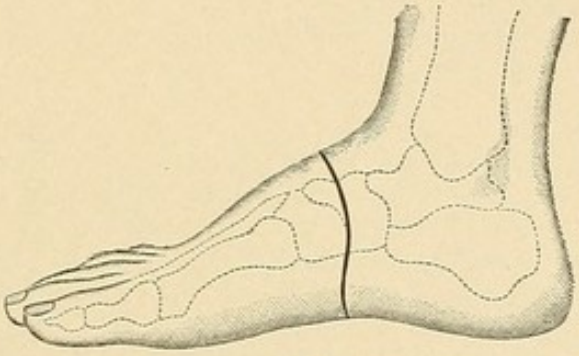

Fig. 113.—(After Malgaigne.)

if the astragalus is sound, the subastragaloid operation should be preferred to the amputation of Syme at the tibio-tarsal joint. The inequalities on the under surface of the astragalus may be removed with the chisel or saw. By this method a shortening of about two inches is prevented, and experience has shown that a useful stump results. Moreover, the degree of mobility maintained at the tibio-astragaloid articulation adds to the ease and comfort of locomotion.

Seize the foot with the left hand, and with a strong scalpel commence the incision by dividing the skin and tendo Achillis just at the level of the upper surface of the *os calcis*. From this point the incision is continued along the fibular side of the foot forward, dividing everything down to the bone, and curving slightly downward until, as it passes below the tip of the external malleolus, it is four tenths of an inch below this point (Fig. 112). The line of incision is now carried directly forward until near the tuberosity at the base of the fifth metatarsal bone, where it curves to the dorsum of the foot, crossing to the inner side over the anterior edge of the scaphoid, and then straight down and under the foot a half inch beyond the middle of the sole (Figs. 113, 114). From this point a straight incision is made directly back to the point of beginning at the inner edge of the tendo Achillis (Fig. 114). Lift the plantar flap by deep and careful dissection from the bone, leaving nothing but the periosteum, until the calcaneo-astragaloid articulation is well exposed. The flaps being held by an assistant, the disarticulation is begun by opening the astragalo-scaphoid joint and removing the anterior part of the foot at the medio-tarsal joint. The *os calcis* should now be seized with a lion-tooth forceps, and the disarticulation of this bone effected. The exposed tendons should be smoothly divided with the scissors at the higher portions of the

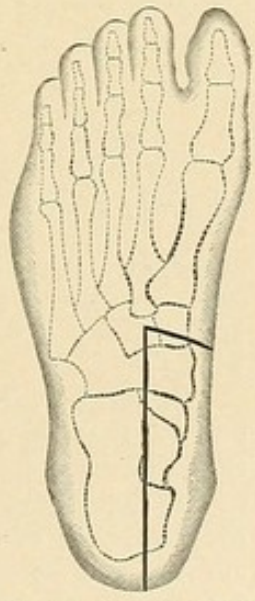

Fig. 114.—(After Malgaigne.)

incision. After deligation of the vessels the flap is properly trimmed and sutured, the cicatrix falling upon the dorsal and external lateral aspects of the stump.

Amputation of the Foot—Tibio-tarsal (Syme's).—When the astragalus must be removed, together with the foot, the amputation of Syme, which involves a disarticulation of the tibio-astragaloid joint, and a subsequent section of the articular surfaces of the tibia and fibula, should be made. In its successful performance certain precautions are necessary, chief among which is the preservation of the proper vascular supply to the posterior flap. The failure to appreciate the importance of making the plantar incision far enough forward, as laid down by Syme, has brought this procedure somewhat into disrepute, for Prof. Stephen Smith, in his comprehensive report, says the necessity for reamputation is three per cent greater in this than in any other amputation.

In 1876 [1] the author demonstrated that the arterial distribution to the calcaneo-plantar flap was chiefly derived from the external plantar artery, and from the posterior tibial so near the bifurcation of this vessel into its terminal branches, that any line of incision in the formation of this flap which necessitated the appli-

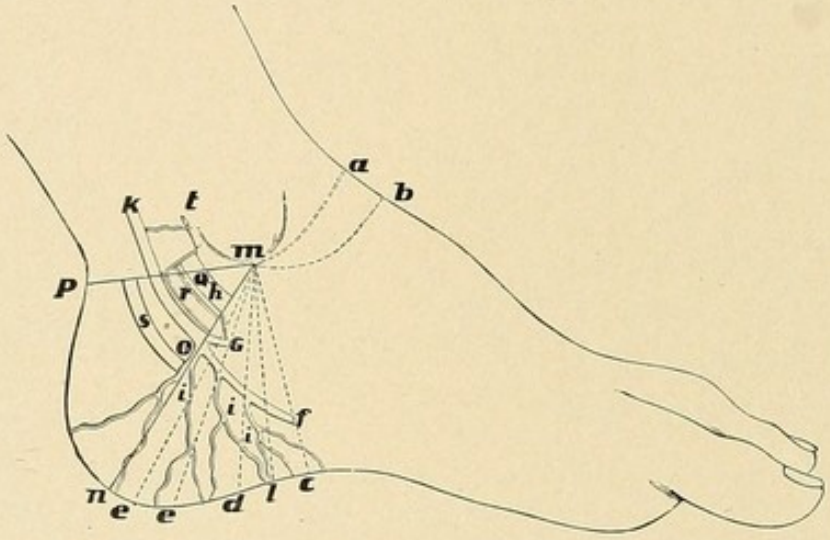

Fig. 115.—Diagram showing the arterial supply to the calcanean region, on the tibial side of the foot. (Drawn by the author, from the average of eighty-seven dissections.) *m*, Internal malleolus. *p m c n*, Tibio-tarsal quadrilateral, the surgical region of this articulation. *k*, Posterior tibial artery. *o*, Its point of bifurcation into *g*, Internal plantar, and *f*, External plantar artery. *i i i*, Calcanean branches of external plantar. *t*, Articular branches from posterior tibial. *h*, Articular branch from internal plantar. *g*, Tendon of tibialis posticus muscle. *r*, Tendon of flexor longus digitorum. *s*, Tendon of flexor longus pollicis. *m c*, The line of incision of Gross. *m l*, *m d*, *m e*, *m e*, Lines of incision showing that the nearer the incision approaches the heel, the more danger is incurred of cutting off the principal blood-supply to the calcanean flap, in amputation. *m n*, Line crossing the usual point of bifurcation of the posterior tibial. *m a*, *m b*, Anterior incision.

cation of a ligature at or very near its bifurcation was not justifiable. The sloughing so often met with at this point is caused by carrying this incision too far back toward the tuberosity of the calcaneum. The arterial supply is shown in Fig. 115.

Modified Procedure.—With the foot held at an angle of ninety degrees to the axis of the leg, place the thumb at the tip of one malleolus, and the index at the other, and from the center of the malleolus internus carry an incision directly across the sole of the foot to a point one fourth of an inch anterior to the tip of the malleolus externus. This incision should divide all the tissues to the bones, and, as will be seen in Figs. 116 and 117, its perpendicular portion descends in a direction slightly anterior to the axis of the tibia. The ends of this cut are united by a second, which arches sharply upward about on the line of section of the bones, and should also divide tendons and all intervening structures, opening into the joint. The foot should now be firmly grasped and extended, so as to make tense the anterior ligament of the ankle, which is easily divided. Carrying the knife to either side of the articular surfaces of the astragalus, the lateral liga-

[1] "Essays in Surgical Anatomy and Surgery," William Wood & Co., 1879.

ments are cut, and the joint thus widely exposed. An assistant now holds and depresses the foot, while the operator carefully dissects the tissues closely from the astragalus and calcaneum. Care should be taken not to bruise the flap by too great traction. In dissecting along the inner surface of the ankle, the knife should be kept close to the bones, so that when the lesser process of the calcaneum is reached it will slide behind and under this process, passing between it and the flexor tendon and the vessels. If this precaution is not taken, the arteries may

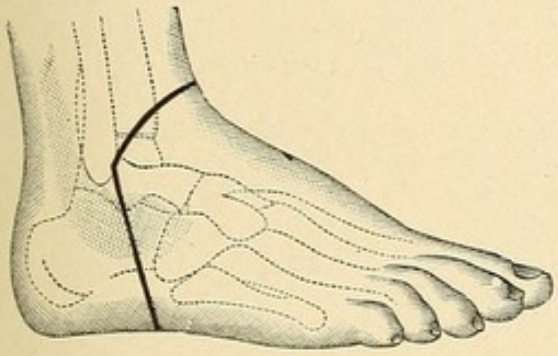

Fig. 116.

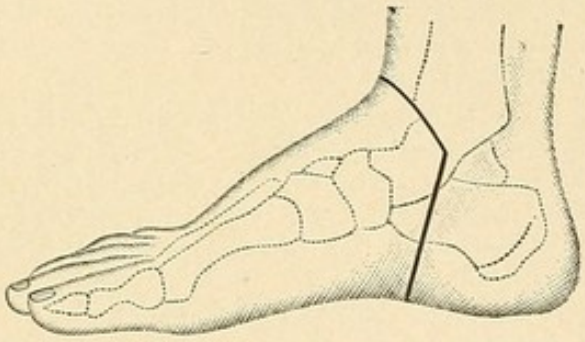

Fig. 117.

be wounded and the nutrition of the flap seriously impaired. As the dissection proceeds, the foot is further depressed, and the tendo Achillis separated from its insertion into the tuberosity of the calcaneum, in doing which care must be taken not to button-hole the flap. The posterior portion of the *os calcis* may now be brought through the joint, and the dissection continued in this direction or finished by working back along the under surface of this bone. After the foot is removed, the flaps are lifted from the tibia and fibula until a section of these bones can be

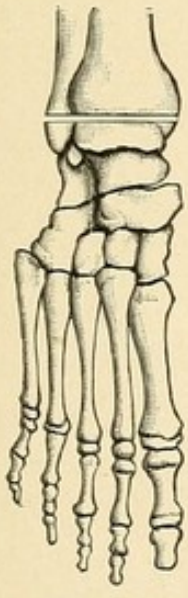

Fig. 118.

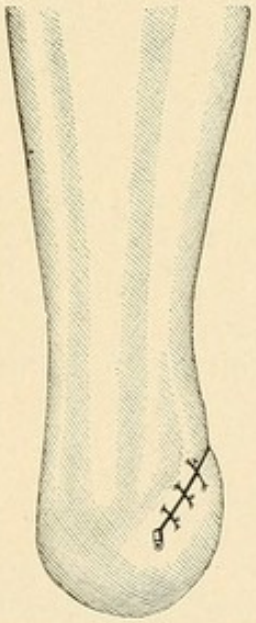

Fig. 119.—Stump after the author's modification of Syme's amputation.

made just on the level of the anterior articular margin of the tibia (Fig. 118). It is not necessary to remove the articular surface. The flaps should now be trimmed and fitted, and the vessels tied. As the sutures are applied, it will be noticed that there is a redundancy of tissue in the long flap, leaving a cup-shaped cavity; but this can be thoroughly drained from the angles of the wound, and disappears when the stump is healed (Fig. 119).

The great improvement in the construction of artificial apparatus has made the various osteoplastic operations of Pirogoff, Le Fort, and others unnecessary. The stump after the modified Syme's (Fig. 119) will prove most satisfactory.

Summary.—In amputations of the foot the following rules should be observed: The terminal phalanges of all the toes should be removed by disarticulation when it becomes necessary to remove a portion of the entire thickness of these bones. The same rule applies to all the second phalanges, except that of the great toe, which should be sawn through at any point anterior to its middle. If a section posterior to this is required, disarticulate from the metatarsal bone. What has been said of the second phalanx of the great toe applies with equal force to the proximal phalanges of all the other toes.

None of the metatarsal bones should be disarticulated from the tarsus when a section is possible not less than three fourths of an inch anterior to each tarso-metatarsal joint.

When a section posterior to this line is required, a tarso-metatarsal disarticulation should be effected. *Hey's* operation is only justifiable when the anterior face of the internal cuneiform is diseased. As much as the anterior fourth of each cuneiform bone, and the anterior half of the cuboid, may be sawn off, in preference to the sacrifice of the bony framework, by Forbes's or Chopart's operation.

When the cuneiform bones must be removed, and the posterior half of the cuboid is sound, Forbes's operation should be preferred to Chopart's. Chopart's procedure is next in order. The subastragaloid operation follows and then Syme's as modified. (See Fig. 110.)

Leg.—Amputation at any portion of the leg above the line of section in Syme's operation may be made as follows:

1. *Modified Circular Skin Flap.*—At a sufficient distance beyond the point at which the bones are to be divided make a circular cut through to the deep fascia, split the flap directly over the fibula, up to the point of section through the bones, and carefully dissect up the cuff. When the flap is reflected, at the level of its base divide all the soft tissues squarely down to the bones, which are next sawn through. The spine of the tibia should be trimmed down, to prevent too acute pressure and sloughing of the skin at this point, a not infrequent occurrence when this precaution is omitted. The drainage is at the fibular side, and, as the leg should be elevated, the tube should come out at the highest point of the perpendicular incision.

2. *Method of Prof. Stephen Smith.*—Commence an incision in the center of the anterior surface, and carry it downward along the side of the leg, so as to make a slightly curved flap, with its convexity below; when the incision passes over the prominent part of the leg toward the posterior surface, incline it upward until the middle of the limb is reached, where it should be continued directly up to the point at which the bone is to be divided; make a similar incision on the opposite side (Fig. 120); the flaps, consisting of the skin and fascia, are dissected

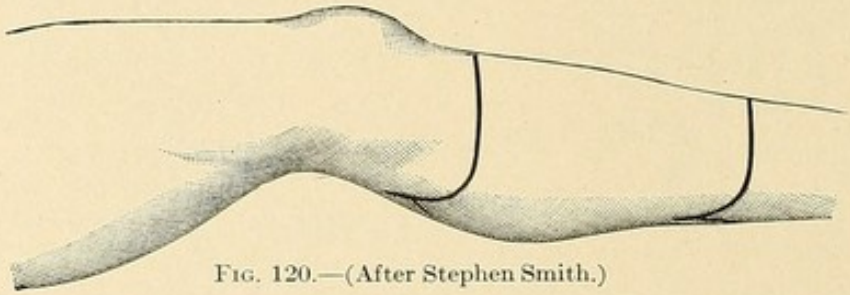

FIG. 120.—(After Stephen Smith.)

upward about an inch, at which point the muscles are divided squarely down to the bones. After the bones are divided, the hood is brought over the stump and sutured, leaving the drainage at the upper part of the posterior incision.

In very emaciated subjects, to forestall the liability of sloughing in the flaps, the first circular cut should go directly through all the tissues down to the bones, and the perpendicular incision along the fibula also down to this bone. All the tissues should then be lifted closely from the periosteum and interosseus membrane, forming a solid flap, reflected up to the point at which the bones are to be divided.

The time to apply an artificial limb is just as soon after an amputation as it can be borne. Waiting means only a loss of time, and causes the stump to become enervated from want of use.

If amputation is done for malignant disease, it is better to wait longer in order to see if there will be a recurrence of the neoplasm.

When the line of amputation approaches nearer than three inches from the upper articular surface of the tibia, a complete disarticulation at the knee should be performed. At or below this point the upper portion of the bone should be preserved, and the end of the fibula exsected. After recovery from the operation it

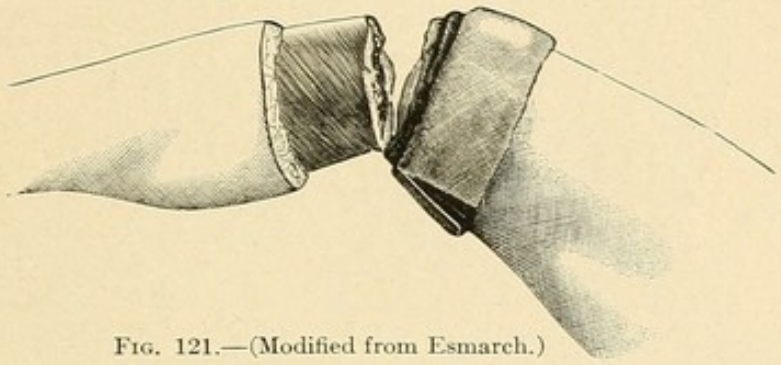

Fig. 121.—(Modified from Esmarch.)

will be found that the tibia is flexed upon the femur, so that, in the adjustment of an artificial limb, the chief pressure may be comfortably borne upon the normal tissues in front of the patella and the tuberosity of the tibia. The greater pressure in any prothetic apparatus used after amputation, at or above the knee, falls upon the ischio-perineal region.[1]

[1] The older operations, which consisted in making a long and a short flap on opposite sides of the leg, are now fallen into general disuse. They are the methods of Teale, Lee, Sedillot, and others.

Method of Teale—Long and Short Rectangular Flaps.—The long flap, folding over the end of the bone, is formed of parts generally devoid of large blood vessels and nerves, which structures are left in the short flap. The size of the long flap is determined by the circumference of the limb at the place of amputation, its length and breadth being each equal to half the circumference of the limb at this point. The short flap is one fourth as long as the other. The incisions and stump after Teale's method, are shown in Fig. 122.

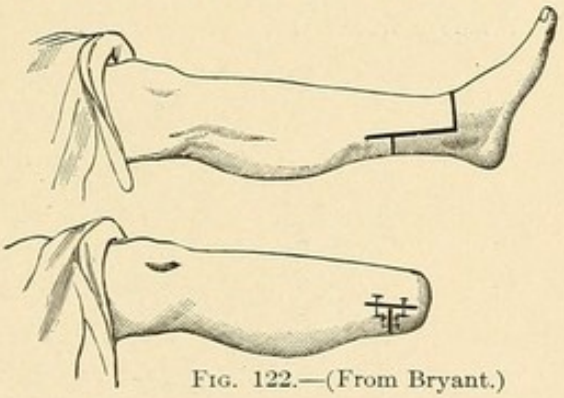

Fig. 122.—(From Bryant.)

Sedillot's Method—Long Fibular, Short Tibial, Flap.—Opposite the point at which the bones are to be divided insert a long, thin amputating knife, the point of which shall graze the spine of the tibia and the outer surface of the fibula, and come out through the outer aspect of the calf. Cut downward close to the bones, and make a long, rounded flap. The short flap is made by an incision with a slight downward convexity (Fig. 123).

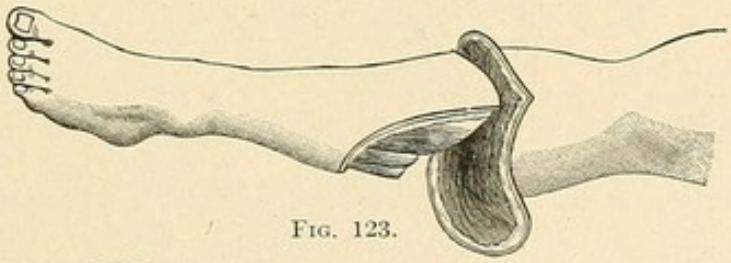

Fig. 123.

Lee's Method.—The length of the flaps is determined as in Teale's amputation. The long flap is posterior, and includes the skin and sural muscles. The deep muscles and the vessels are divided squarely at the base of the flap (Fig. 124).

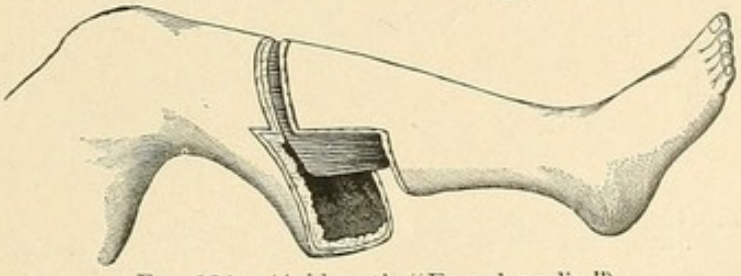

Fig. 124.—(Ashhurst's "Encyclopædia.")

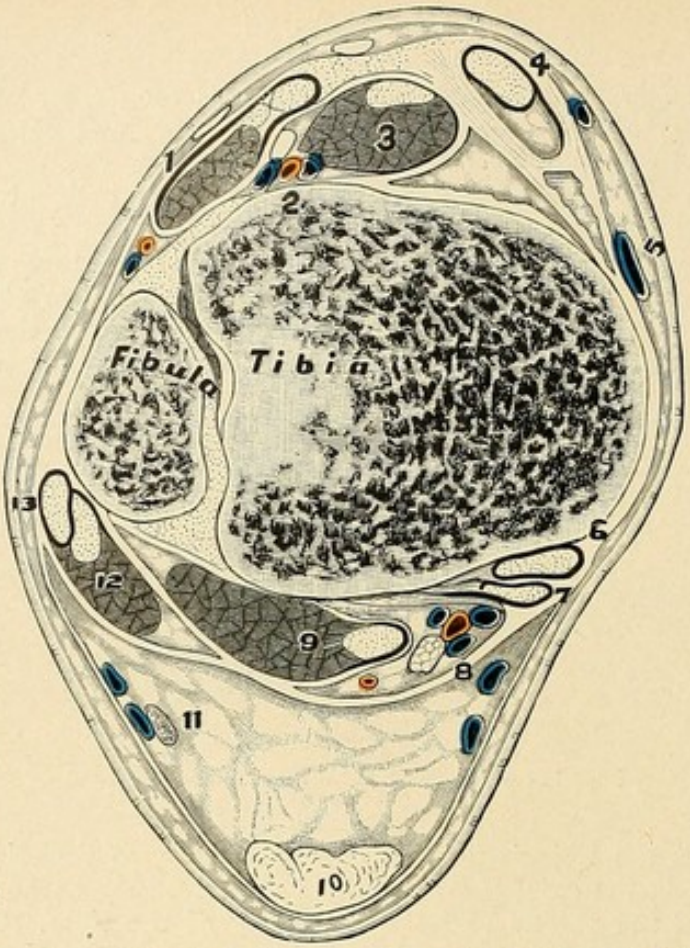

FIG. 125.—Transverse section of the right leg just above the ankle-joint, showing the relation of the parts on the plane of section through the malleoli in Syme's, Pirogoff's, Le Fort's, Gunther's, and Bruns's amputations. Looking at the surface nearest the body. 1, Extensor longus digitorum. 2, Anterior tibial vessels and nerve. 3, Extensor proprius pollicis. 4, Tibialis anticus. 5, Internal saphena vein. 6, Tibialis posticus. 7, Flexor longus digitorum. 8, Posterior tibial artery, veins, and nerve. 9, Flexor longus pollicis. 10, Tendo Achillis. 11, External cutaneous nerves. 12, Peroneus brevis. 13, Peroneus longus.

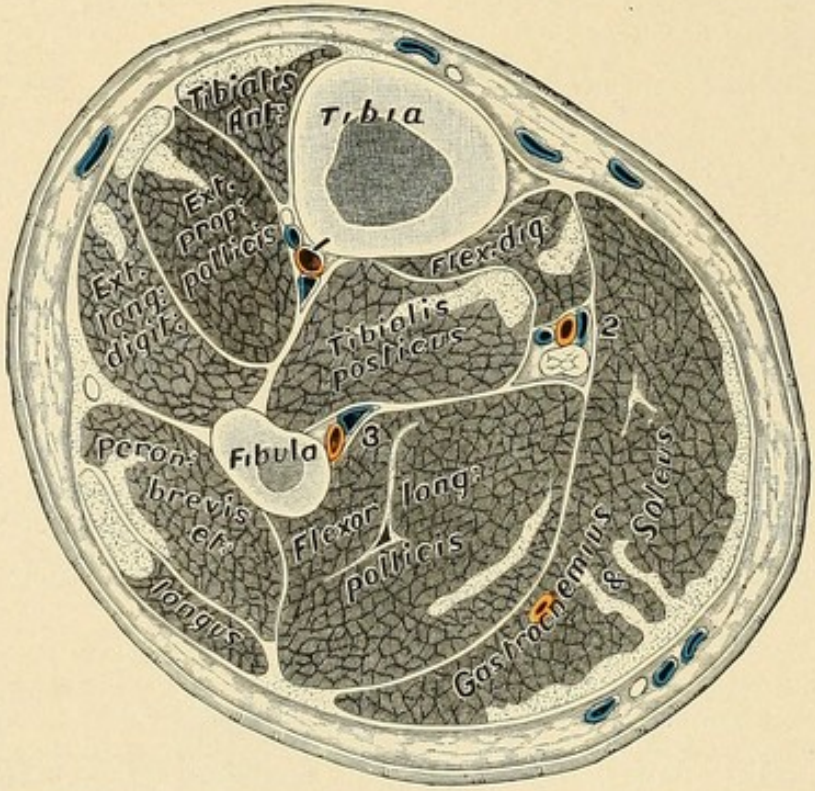

FIG. 126.—Section through lower third of right leg. Looking toward the center. 1, Anterior tibial nerve, artery, and veins. 2, Posterior tibial artery, veins, and nerve. 3, Peroneal artery and veins.

Knee-joint.—First Method—Modified Circular Skin Flap.—About three inches below the patella make a circular sweep around the leg, dividing the skin and fascia. Join this by a perpendicular incision in the middle line of the posterior aspect of the limb, extending through the skin and fascia, and at least as high as to the level of the top of the patella. Dissect the skin back carefully, keeping close to the anterior surface of the patella, as the skin over this bone is usually very thin. It is not necessary to dissect the cuff as high on the lateral and posterior aspects as in front, since the anterior incision is made to allow of the removal of the patella and dissection of the synovial sac just above it. Divide the tendon of the quadriceps at the upper limit of the patella, turn this down,

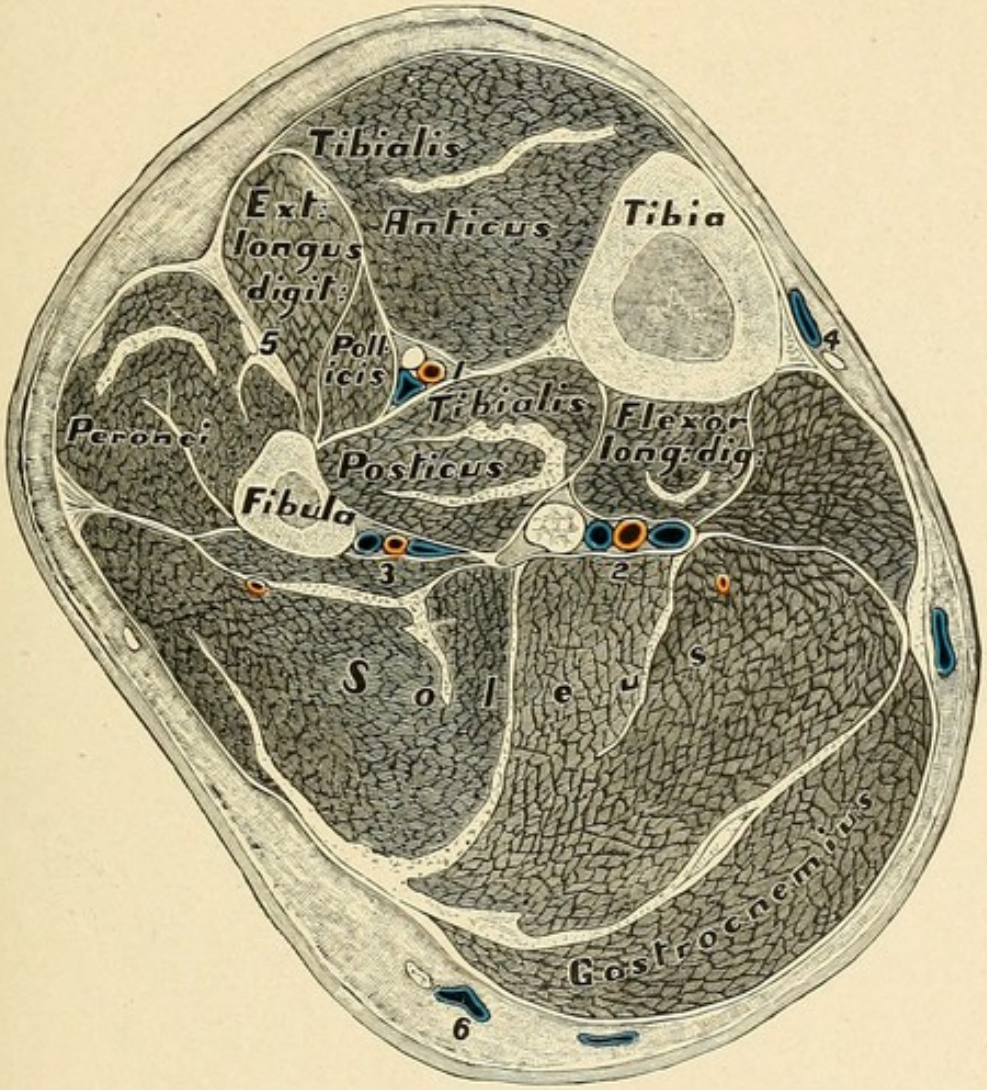

FIG. 127.—Section through the middle of the right leg. Looking from below upward. 1, Anterior tibial artery, veins, and nerve. 2, Posterior tibial artery, veins, and nerve. 3, Peroneal artery and veins. 4, Long saphena vein and nerve. 5, Musculo-cutaneous nerve. 6, Short saphena vein and nerve.

cut the lateral ligaments and capsule along the edges of the condyles of the femur, flex the leg strongly on the thigh, divide the crucial ligaments, and, as soon as the posterior ligament of Winslow is exposed, introduce a long knife and remove the leg by cutting squarely through the soft tissues at the back of the articulation. A cloth retractor is now applied and a slice of bone removed with the saw, leaving a smooth surface. Should the articular end of the femur be diseased, the section may be made high enough to remove this, provided the saw does not enter the medullary canal. With the cutting-forceps round off the sharp edges of bone, tie the vessels, and close the flaps.

Second Method (Operation of Prof. Stephen Smith).—With a large scalpel commence an incision about an inch below the tubercle of the tibia, and cut to

the bone; carry it downward and forward beyond the curve of the side of the leg, thence inward and backward to the middle of the leg, thence upward to the middle of the popliteal space; repeat this incision upon the opposite side; raise the flap, consisting of all the tissues, down to the bone until the articulation is reached, divide the ligaments, and remove the leg as in the previous operation. The flap should be lifted from the patella, and this bone removed.

"Care should be taken that the incision is inclined moderately forward down to the curve of the side of the leg, to secure ample covering for the condyles, and that upon the internal aspect it should have additional fullness for the purpose of insuring sufficient flap for the internal or larger condyle" (Smith).[1]

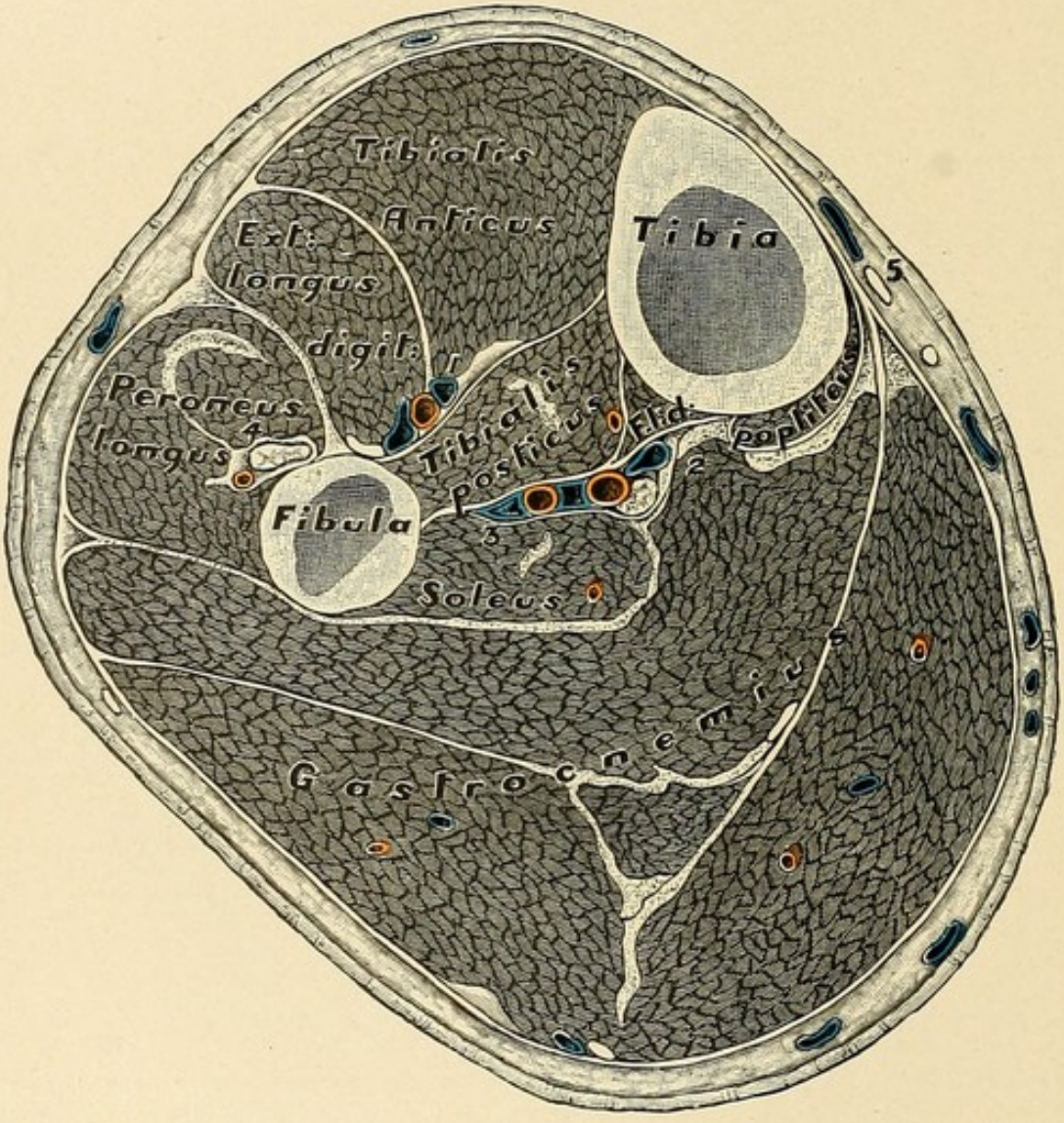

FIG. 128.—Section through upper third of right leg. Surface nearest the body. 1, Anterior tibial vessels and nerve. 2, Posterior ditto. 3, Peroneal vessels. 4, Musculo-cutaneous nerve. 5, Internal saphena vein and nerve.

After the flaps are stitched the drainage-tube makes its exit through the upper posterior angle of the wound.

When in amputation near the knee the femur is the seat of osteomyelitis, the indications are to thoroughly cleanse the canal by means of a long Volkmann's spoon and irrigate with sublimate solution; introduce a long drainage-tube the full length of the canal and bring this out through the flap exactly in line with the axis of the canal (Fig. 129).

[1] The osteoplastic operation of Gritti, in which the under surface of the patella is freshened and attached to the end of the femur, is not advised.

In this way the danger of a higher amputation is avoided and a longer stump secured. In two instances of amputation just above the knee, after exsection of this joint in which osteomyelitis occurred in the femur, I carried out this practice successfully.

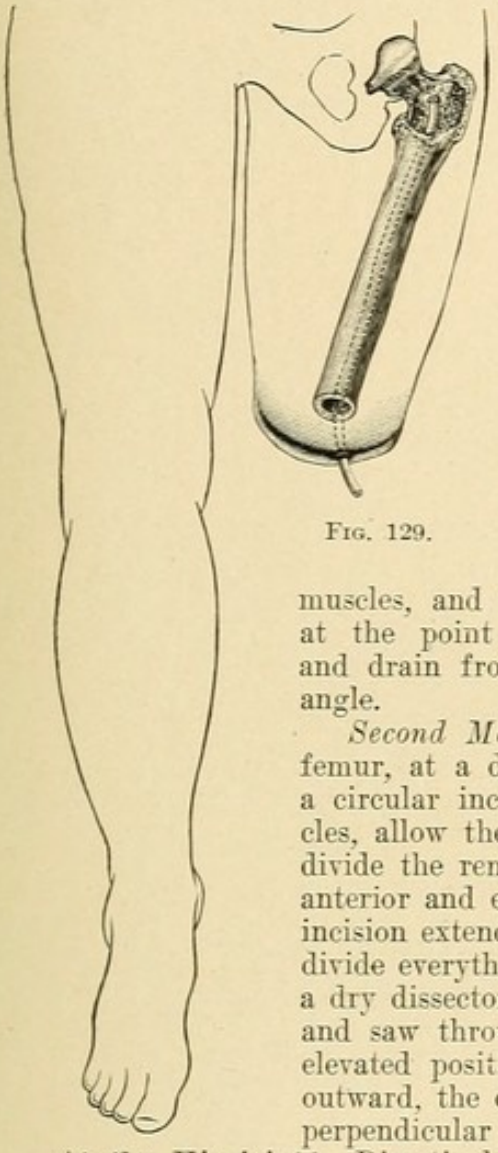

Fig. 129.

Irrigation through the tube should be practiced about the seventh day and every three or four days after this, and the tube gradually shortened.

Thigh.—The method to be selected in amputations through the lower two thirds of the thigh will depend upon the size of the member at the point of election. In limbs of ordinary size, and particularly in emaciated persons, the operation advised in the arm should be followed here.

First Method.—Make a circular incision through the skin and fascia, joined by a perpendicular cut on the lower external aspect of the limb. Dissect up the flap from the muscles, and divide all the remaining soft tissues squarely at the point of section of the bone. Suture the flap, and drain from the outer upper (and, if necessary, lower) angle.

Second Method.—Below the line of section through the femur, at a distance sufficient to furnish an ample flap, by a circular incision divide the integument down to the muscles, allow the skin to retract, and at the line of retraction divide the remaining soft tissues down to the bone. On the anterior and external aspect of the thigh, by a perpendicular incision extending as high as the point of section of the bone, divide everything to the bone, and from the periosteum, with a dry dissector, lift the solid flap. Apply the cloth retractor and saw through the bone. As the stump is placed in an elevated position, with the thigh also abducted and rotated outward, the drainage is naturally at the upper angle of the perpendicular incision.

At the Hip-joint.[1]—Disarticulation at the hip-joint is by far the most formidable in the list of amputations. In 1881 Prof. John Ashhurst, Jr., wrote: "The removal of the lower limb at the coxo-femoral articulation may be properly regarded as the gravest operation that the surgeon is ever called upon to perform, and it is only within a comparatively recent period that it has been accepted as a justifiable procedure. The most pressing risk is that of hæmorrhage."

In 1890 I applied for the first time, and with success, in an amputation at the hip-joint, the method which I had used for more than a year previous in amputation at the shoulder-joint. Since that date I have performed the operation a number of times, and it has been done in hundreds of instances by other operators. The method is as follows:

The patient should be placed with the sacrum resting upon the corner of the operating table, the sound limb and arms being wrapped with cotton batting and thoroughly protected from unnecessary loss of heat. The limb to be amputated

[1] At Bardstown, Ky., in August, 1806, Dr. Walter Brashear amputated at the hip in a negro lad, seventeen years of age, on account of a severe fracture of the femur and laceration of the soft parts. A circular incision was made, the muscles divided well below the hip-joint, and the vessels secured as the operation progressed. Then a longitudinal incision along the outer side of the limb exposed the remainder of the bone, which, being freed from its muscular attachments, was disarticulated at the socket (Prof. D. W. Yandell, "American Practitioner and News," 1890). Dieffenbach's name has been prominently associated with this operation among surgeons, but Dieffenbach did not take his degree in medicine until 1822, sixteen years after the pioneer Kentuckian had performed his operation, which was the first hip-joint amputation in the United States.

should be emptied of blood by elevation of the foot and by the application of the Esmarch bandage, commencing at the toes. Under certain circumstances, the bandage can only be partially applied. When a tumor exists, or when septic infiltration is present, pressure should be exercised only to within five inches of the diseased portion for fear of driving the septic material into the vessels. After injuries with great destruction—crushing or pulpefaction—one must generally trust to elevation, as the Esmarch bandage cannot always be applied. While the member is elevated, and before the Esmarch is removed, the rubber-tubing constrictor is applied. The object of this constriction is the absolute occlusion of

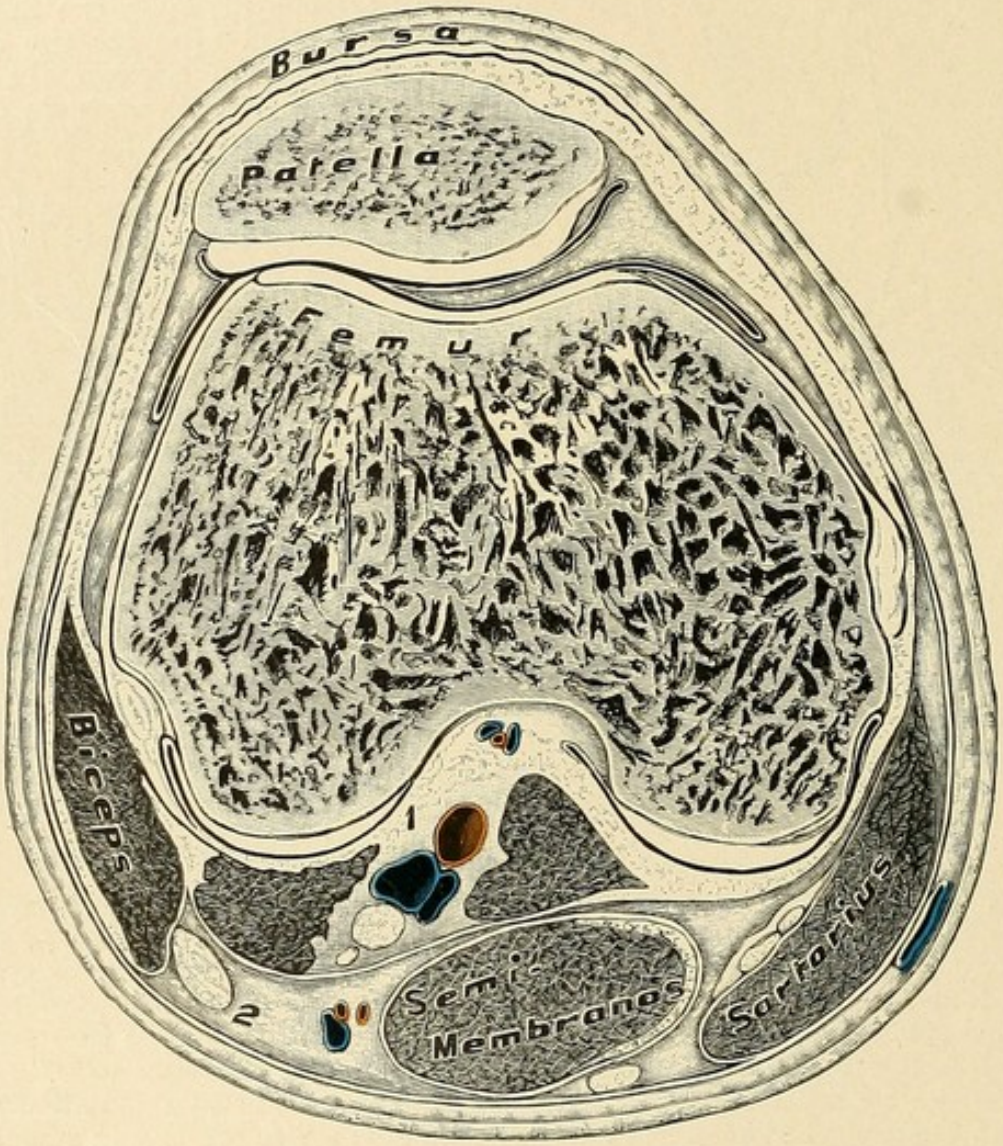

Fig. 130.—Section through the right femur at the condyles and at the middle of the patella. Looking at the central surface as exposed after amputation at this point. 1, Popliteal artery, vein, and internal popliteal nerve. 2, External popliteal or peroneal nerve. The capsule and the synovial cavities are admirably shown, as well as the *bursa mucosa patellæ*.

every vessel above the level of the hip-joint, permitting the disarticulation to be completed and the vessels secured without hæmorrhage and before the tourniquet is removed. To prevent any possibility of the tourniquet slipping, I employ two large steel needles or skewers, three sixteenths of an inch in diameter and ten inches long, one of which is introduced one fourth of an inch below the anterior superior spine of the ilium and slightly to the inner side of this prominence, and is made to traverse superficially for about three inches the muscles and fascia on the outer side of the hip, emerging on a level with the point of entrance (Fig. 131). The point of the second needle is thrust through the skin and tendon of origin of the adductor longus muscle half an inch below the crotch, the point emerging

an inch below the tuber ischii. The points should be shielded at once with a cork to prevent injury to the hands of the operator. No vessels are endangered by these skewers. A mat or compress of sterile gauze, about two inches thick

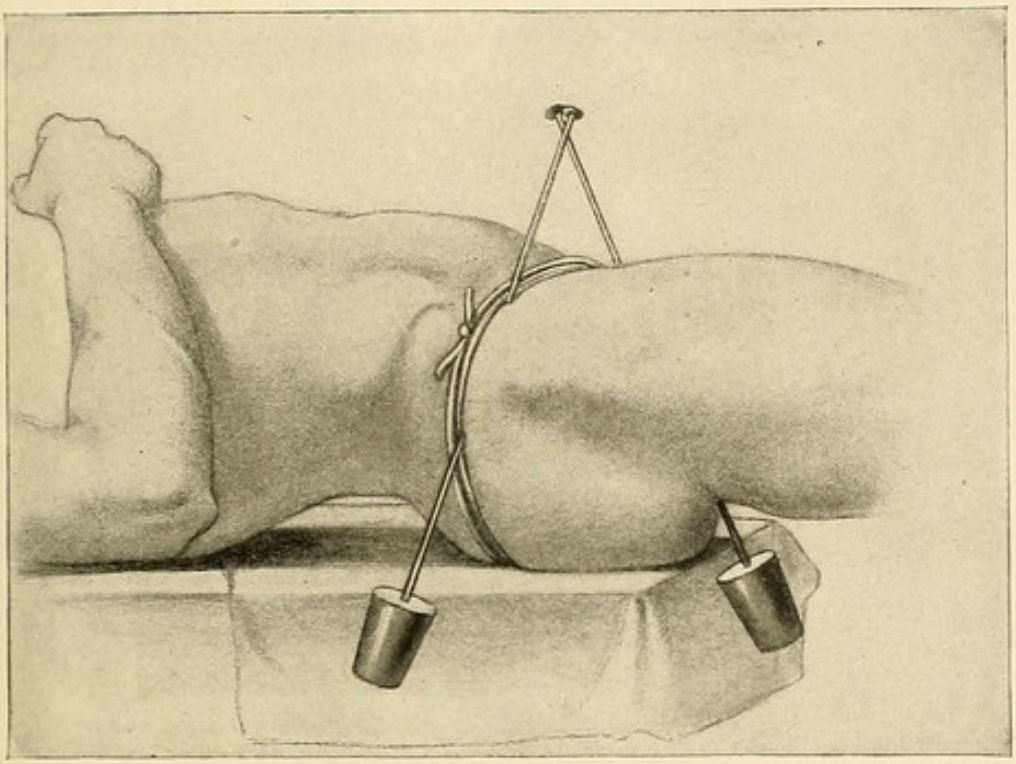

Fig. 131.—Hip-joint amputation. Pins and rubber-tube tourniquet in position. The Esmarch bandage has been removed.

and four inches square, is laid over the femoral artery and vein as they cross the brim of the pelvis; over this a piece of strong white-rubber tubing, half an inch in diameter when unstretched and long enough when in position to go five or six times around the thigh, is now wound very tightly around and above the fixa-

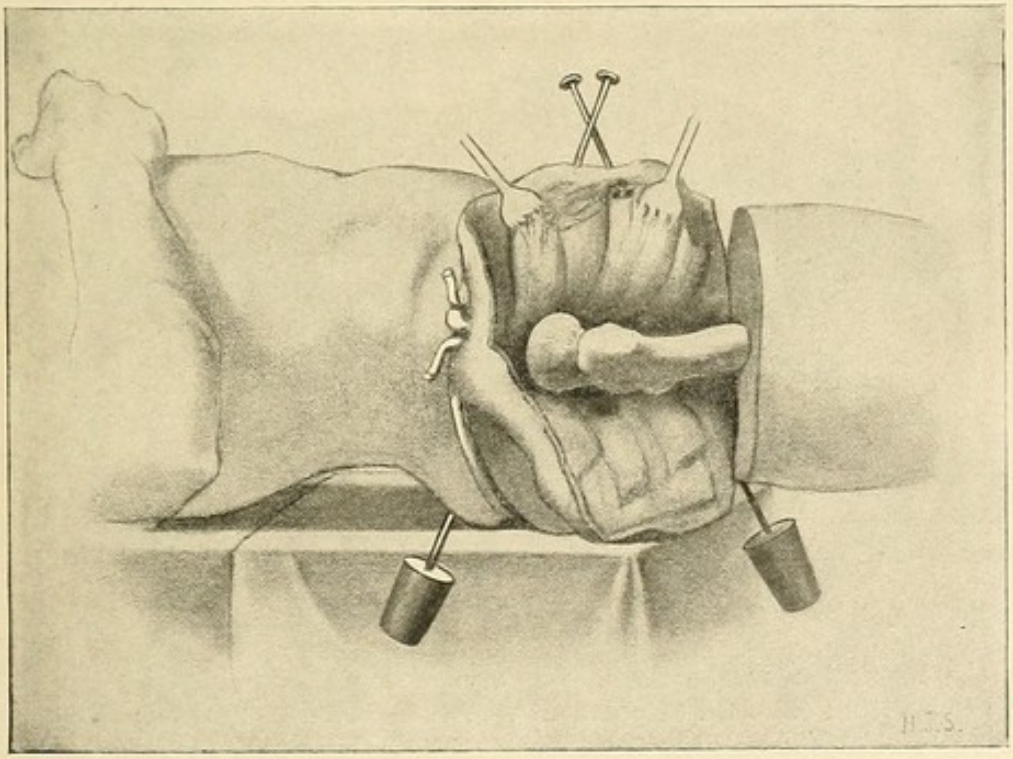

Fig. 132.—The same, showing the soft parts dissected from the bone and the capsule exposed.

tion needles and tied. If the Esmarch bandage has been employed, it is now removed. Excepting the small quantity of blood between the limit of the Esmarch bandage and the constricting tube, the extremity is bloodless and will remain so.

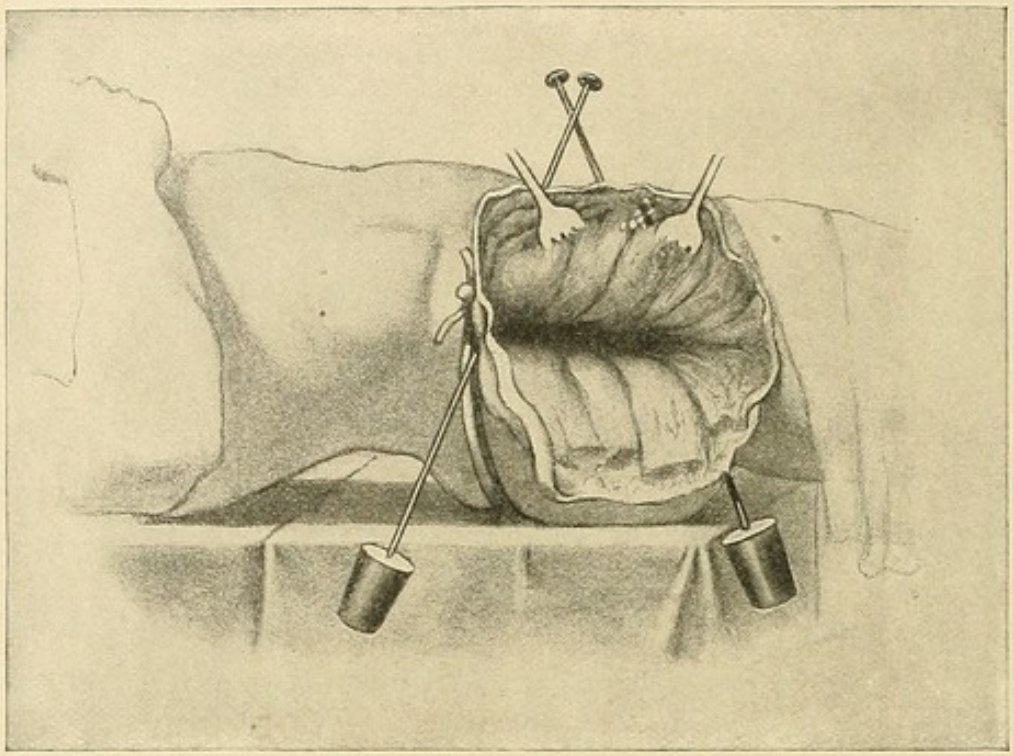

FIG. 133.—The same, with the disarticulation complete. Constrictor still in position.

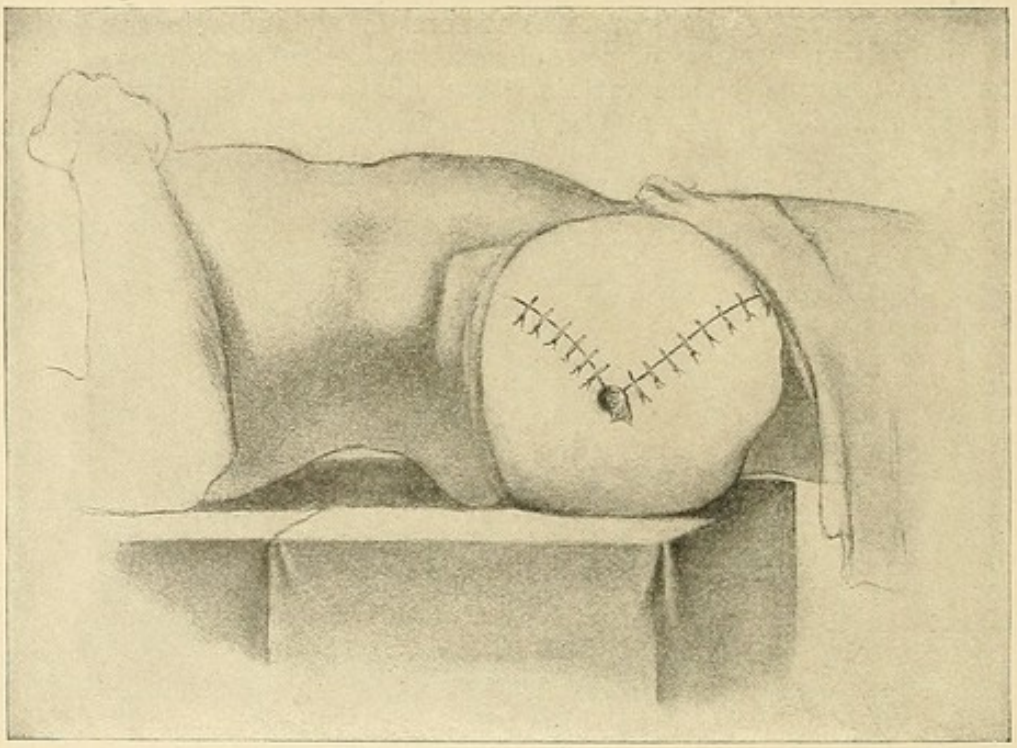

FIG. 134.—The operation completed.

In the formation of the flaps, the surgeon must be guided by the condition of the parts within the field of operation. When permissible, the following method seems ideal:

About six inches below the tourniquet a circular incision is made down to

the muscles, and this is joined by a longitudinal incision commencing at the tourniquet and passing over the trochanter major. A cuff that includes everything down to the muscles is dissected off to near the level of the trochanter minor. At about this level, the remaining soft parts, together with the vessels, are divided

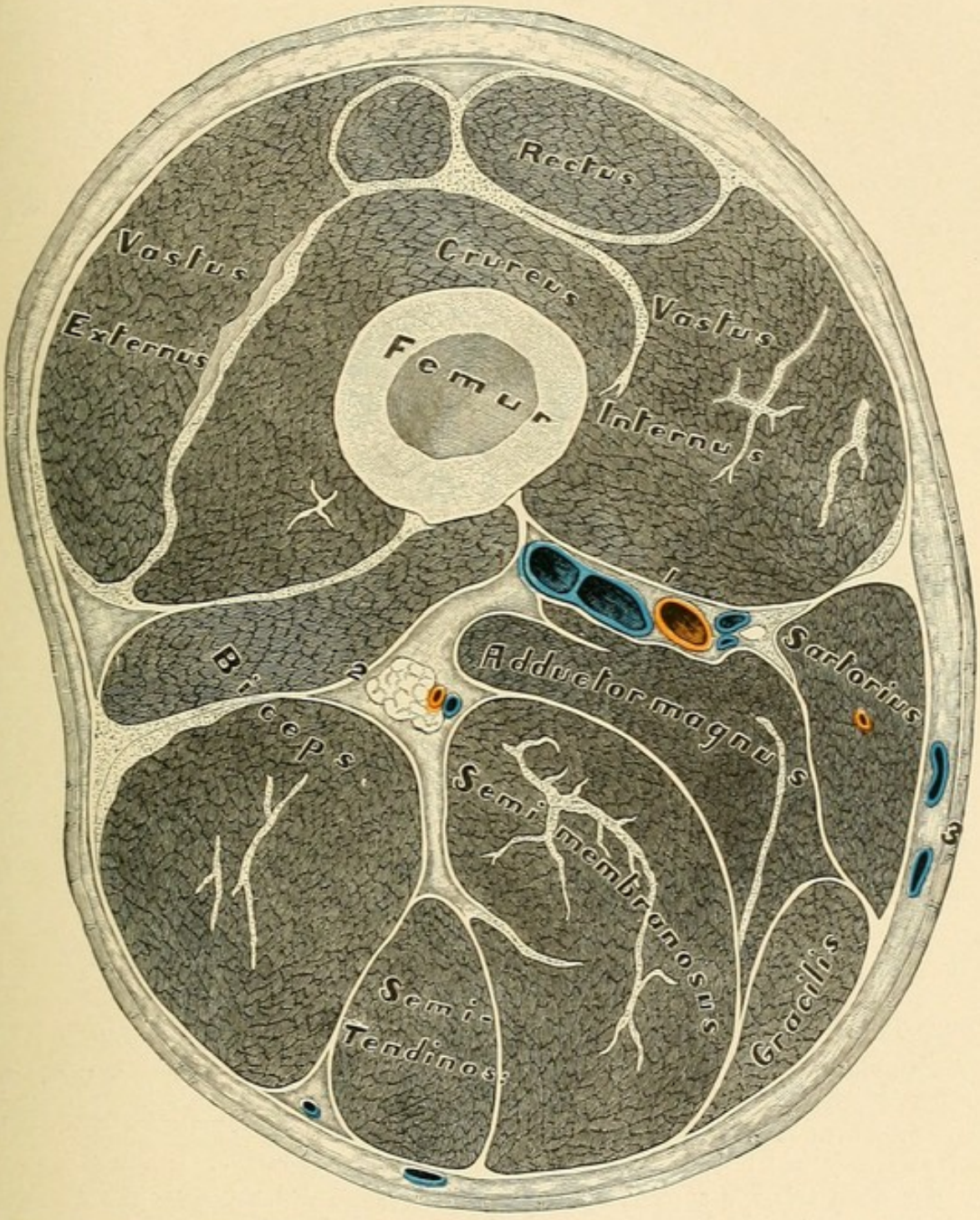

FIG. 135.—Section through right thigh at Hunter's canal. Looking at the surface attached to the body. 1, Femoral vessels and long saphenous nerve. 2, Great sciatic nerve and arteria comes. 3, Long saphenous vein.

squarely down to the bone by a circular cut (Fig. 132). At this stage of the operation the central ends of the divided superficial and deep femoral veins as well as arteries are in plain view and should now be tied with good-sized catgut. This done, the disarticulation is rapidly completed by lifting the muscular insertions from the trochanters and digital fossa, keeping very close to the bone with knife or scissors and holding the soft parts away with retractors. The capsular liga-

ment is now exposed and divided, and, by forcible elevation, adduction, and rotation of the femur, it is widely opened, the *ligamentum teres* ruptured, and the caput femoris dislocated (Fig. 133). If properly conducted up to this point, not a drop of blood has escaped except that which was in the limb below the con-

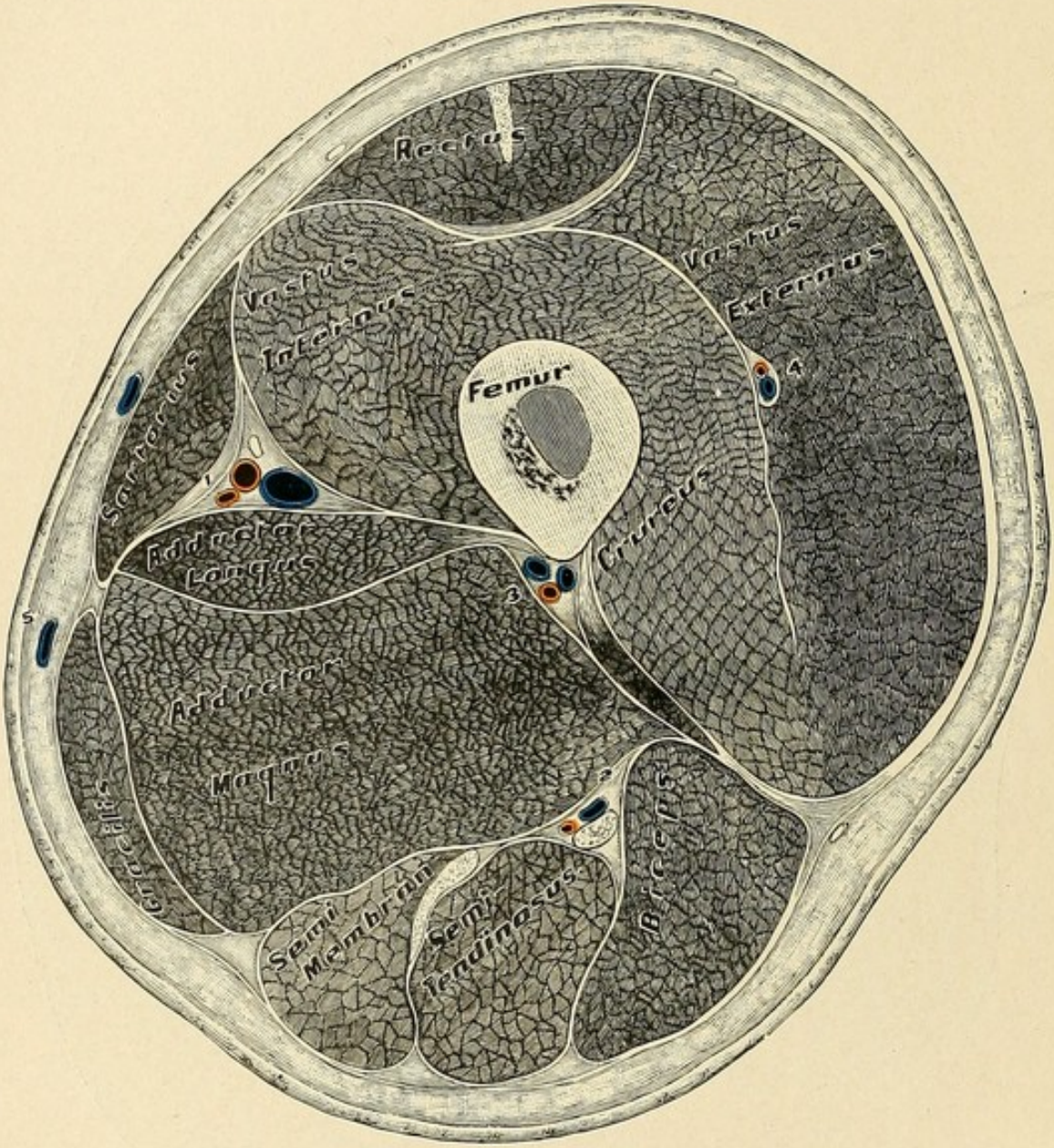

FIG. 136.—Section through left thigh at its middle. Looking at the surface attached to the body. 1, Superficial femoral artery, vein, and saphenous nerve. 2, Great sciatic nerve, and the arteria comes nervi ischiadici. 3, Terminal branch of profunda femoris. 4, Descending branch of external circumflex. 5, Long saphenous vein.

strictor when this was applied. The remaining vessels which require the ligature should now be sought for and secured. They are, first, the *saphena vein*, which, on account of its proximity to the main trunk, should be tied; the *sciatic artery*, which will be found near the stump of the sciatic nerve; the *obturator*, which is situated between the stump of the adductor brevis and magnus, usually about half-way from the center of the shaft of the femur to the inner side of the thigh, the vessel being on a level with the anterior surface of the femur; the *descending branches* of the *external circumflex*, two or three in number, usually found about an inch and a half outward and downward from the main femoral vessels beneath the rectus and in the substance of the cruræus and vastus externus. The *descending branches* of the *internal circumflex* are insignificant and are usually found on

the level of the femoral vessels in the substance of the adductor longus and between it and the adductor brevis and pectineus (see Fig. 138).

In tying the larger femoral vessels, I make it a rule to dissect both the superficial and deep femoral stumps back from a half to three fourths of an inch so that I can apply the ligature behind any of their branches which may have been divided close to their points of origin, and I do not hesitate to include the large veins in the same ligature in order to save time. With the vessels I have mentioned quickly secured, there is really no necessity for even temporarily loosening the tourniquet. If the operator is not sure that he has found and securely placed the ligatures upon these larger vessels, it is a simple matter to loosen slowly the grasp of the tourniquet until the pulsation of the larger trunks is perceptible. No attention should be paid to the general oozing from the large muscular surfaces which have been divided. If every oozing point were ligatured, from half an hour to an hour would be consumed in securing a dry wound in the majority

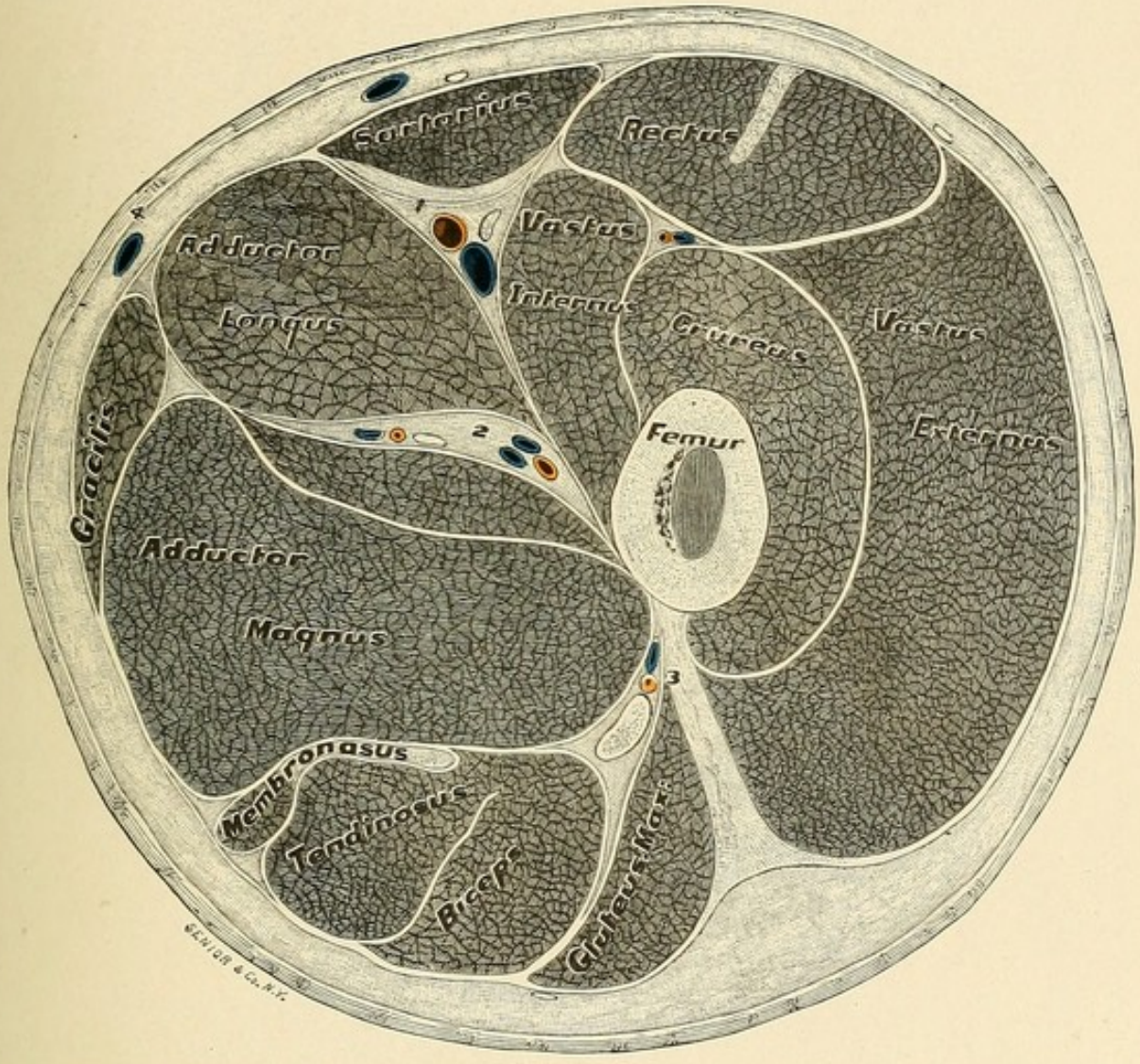

FIG. 137.—Section through left thigh in the upper third. 1, Superficial femoral artery, vein, and saphenous nerve. 2, Deep femoral vessels; near-by the obturator nerve and vessels. 3, Sciatic nerve and vessels.

of instances. In order to hasten the operation and stop the oozing, I introduce a snug packing of sterile iodoform gauze ribbon into the cavity of the acetabulum and the space between the muscles from which the bone has been removed, leaving one end of the ribbon to pass out between the flaps for the purpose of its removal. With a long, half-curved Hagedorn needle, armed with good-sized catgut, deep sutures are passed through the stumps of the divided muscles in such a way that

large masses of muscle are brought tightly together when these sutures are tied, taking two or three inches into the grasp of each suture. The needle is not passed in the proximity of the large vessels or the sciatic nerve. This effectively and rapidly controls all oozing. Nothing remains but to close the flap with silkworm-gut sutures, dry and cleanse it off thoroughly, seal it with collodion in its entire extent to prevent any infection from the genital or anal region, apply a large, loose dressing of iodoform and then sterile gauze, and a tight bandage over the first light dressing. The pins are then removed and the remainder of the dressing completed. Preliminary pressure of the light dressing prevents oozing and the wound remains dry.

When, from destruction of the parts, by accident or disease, or by the proximity of a neoplasm, this ideal method is not practicable, any modification may

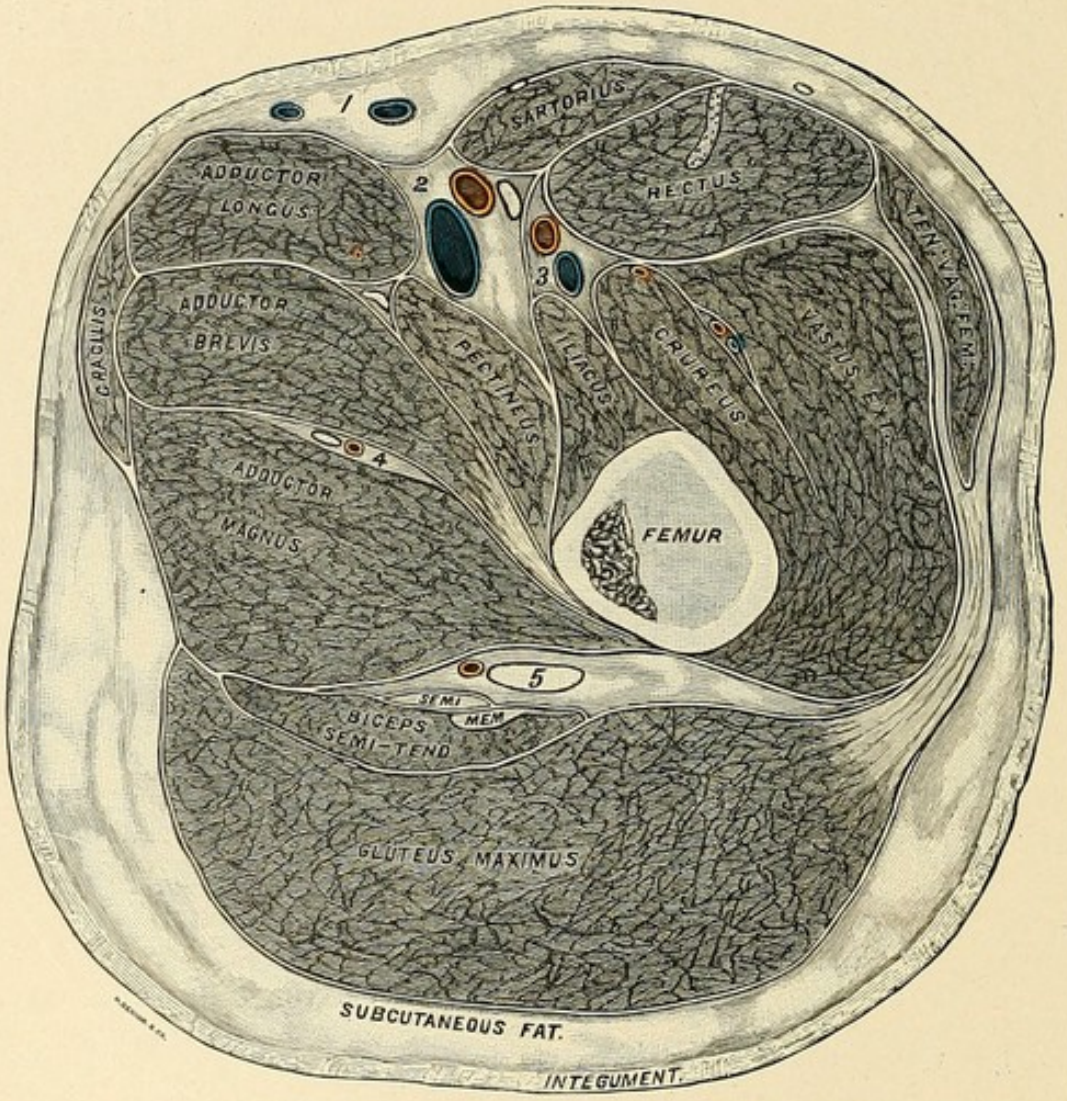

FIG. 138.—Transverse section of left thigh through lesser trochanter. Looking from below upward. 1, Saphenous vein. 2, Superficial femoral vein and artery. 3, Profunda femoral vein and artery, anterior crural nerve between the two arteries. 4, Obturator nerve and artery. 5, Sciatic nerve and artery.

be employed, preference being given to the incision which keeps farthest from the tumor and gives the healthiest flaps. When there is not sufficient material to cover the stump, it is even safer to err on the side of an unclosed wound and trust to granulation or grafting for ultimate closure.

In the first two operations I did, I divided the femur on a line with the incision through the muscles, tying the vessels, removing the tourniquet, and then dissecting out the upper fragment of the femur. I found it exceedingly difficult to disarticulate the head of the bone, and, at the suggestion of the late Dr. J. B.

Murdock, of Pittsburg, Pa., who witnessed the operation, I have since left the femur intact in order to facilitate the disarticulation.[1]

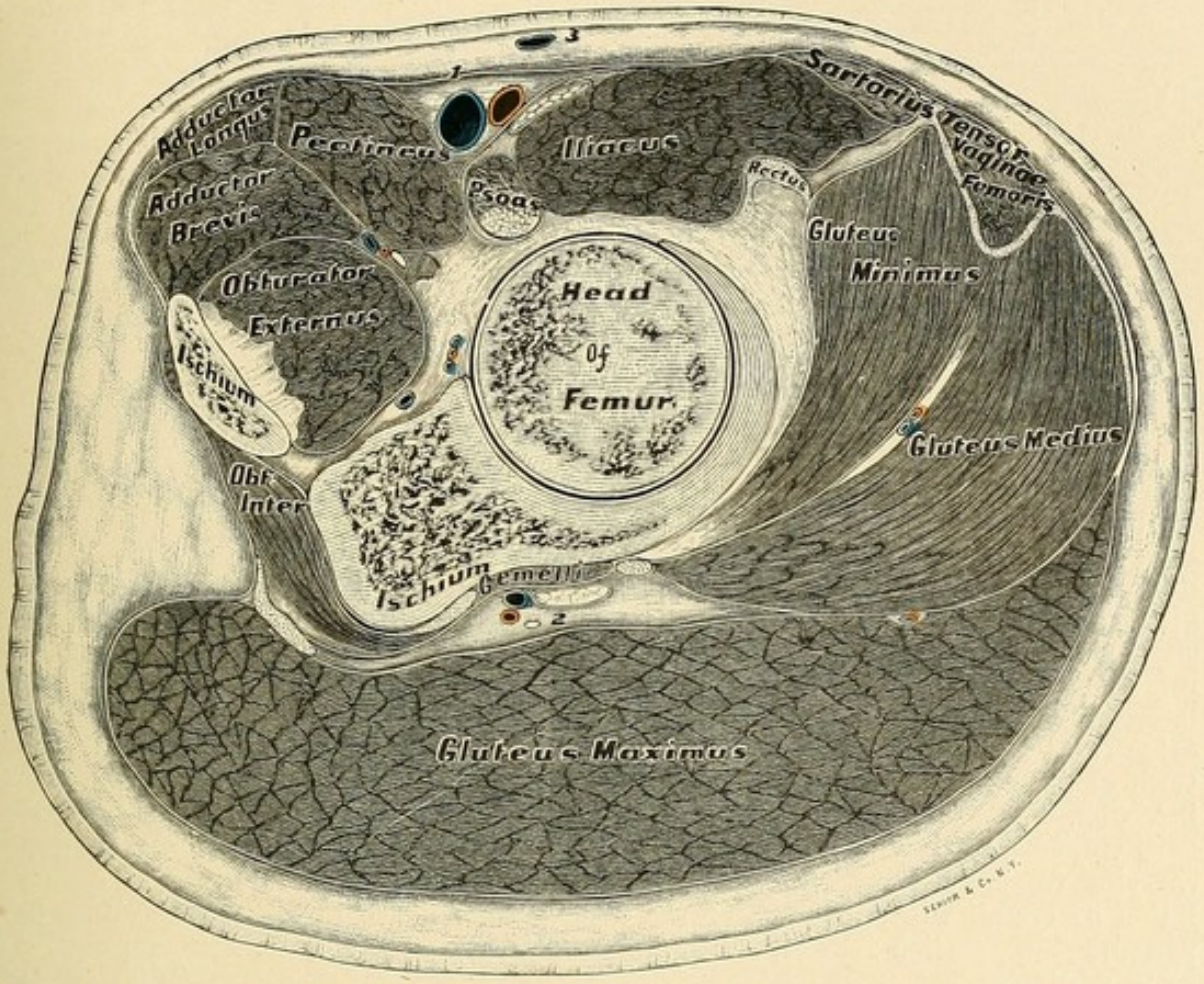

Fig. 139.—Section through the left hip. Looking from below upward. Reduced from life size. 1, Femoral vein, artery, and crural nerve in order from within outward. 2, Great sciatic nerve, artery, and vein. 3, Epigastric vein. 4, Vessels to acetabulum.

[1] During the Civil War of the United States (1861–1865) the death-rate from amputation at the hip-joint, following gunshot wounds was ninety-three per cent.

Dr. John F. Erdmann, in the "Annals of Surgery," September, 1895, says that from January, 1884, to January, 1895, there were eighteen hip-joint amputations done in Bellevue, Roosevelt, St. Luke's, Mount Sinai, Chambers Street, German, and Presbyterian Hospitals, with eight deaths, a mortality of 44.4 per cent. If from this list are eliminated seven cases done by my method—all of which recovered—it leaves the mortality ratio by other methods in the hospitals of New York 72.7 per cent.

I would not imply that such a death-rate as this would follow any other method of operation, for I know that in the hands of careful and thorough operators much better results would follow.

In a large number of cases tabulated by the author in which his method of hæmostasis was employed, the ratio of mortality after hip-joint amputation on account of disease did not exceed eight per cent.

In an emergency a single pin may suffice (Dr. Emory Lanphear), and large mattress needles or pins extemporized from telegraph wire may be substituted (Dr. George Emerson Brewer).

In a case where the pins were not available, Dr. John B. Deaver held the rubber-tube tourniquet in place by passing a loop of bandage around the tubing in front and behind and making upward traction to prevent slipping when the disarticulation was made.

The condition will be exceedingly rare when the performance of abdominal section in order to make digital compression of the common iliac to prevent hæmorrhage in amputation at the hip, as suggested by Dr. Charles McBurney, will be justifiable.

With the pins and tubing, complete hæmostasis has been secured in every instance, and the cases now reported run into the hundreds. The disarticulation may be done in five minutes and the entire operation be completed in three quarters of an hour.

Of this method, Prof. W. W. Keen, reporting one of his successful cases, said: "It was reserved for an American surgeon to devise what is undoubtedly the best method, and in fact which I think we can now call the only method, of hæmostasis in amputation at the hip-joint."

CHAPTER VI

THE LYMPHATIC VESSELS AND GLANDS, THE VEINS AND ARTERIES

Lymphangitis. Phlebitis. Arteritis. Adenitis. Vascular Tumors. Treatment by the Injection of Boiling Water. Varicose Veins. Mayo's Operation. Babcock's Procedure Modified. Excision.

THE pathology of the lymphatics closely resembles that of the veins with which they are intimately associated. One difference of great significance is that the lymphatic vessels in many portions of the body are closed tubes, for at varying intervals in their route to pour their contents into the veins each trunk breaks up into smaller branches, ending in blind capillaries in the substance of a lymphatic gland. (It is held that there is no direct communication between the afferent and efferent vessels in these glands.) It follows that where this arrangement prevails infectious material in the lymph current cannot rapidly enter the systemic circulation. These glands may be compared to breastworks, behind which the leucocytes rally for the defense of the tissues. In the lymphatic channels, near the vault of the diaphragm and with the veins, there are no obstacles to direct systemic infection.

Lymphangitis implies an infection of all the structures of the wall of a lymph-carrying vessel. Hyperæmia and cell proliferation occur, and there may be coagulation of lymph with occlusion of the ducts. Should the infecting organisms be pyogenic, suppuration follows, or the inflammatory process may be non-suppurative as in erysipelas.

Symptoms.—Following the inoculation upon an abrasion of any septic organism, there is within a few hours a painful sense of throbbing and burning in the wound, usually proportionate to the rapidity of swelling. In from ten to twenty-four hours the redness, locally and along the lymphatics leading toward the center, may be recognized. While the outline of the injected vessels can rarely be made out by palpation, there is none the less a thickening in the tissues of the vessel wall, and often in the perivascular tissues. In these pain is present in a fair proportion of cases, while in others it cannot be elicited even by direct pressure. The same is true of the nearest lymphatic glands, which by palpation are easily recognized.

The febrile movement, which usually begins within twenty-four hours after infection, is generally introduced by a chill or a series of chilly sensations. In the progress of the infection the temperature may rise rapidly. Nausea, vomiting, delirium, and the train of symptoms which accompany septicæmia may follow. If, however, the conditions are unfavorable to the progress of the disease—that is, if the resistance of the tissues is approximately normal—the temperature gradually declines with the destruction of the invading organs by the leucocytes, and the symptoms of infection disappear.

In the *differentiation* of *lymphangitis* from *phlebitis* it is well to bear in mind that in the latter the lines of discoloration are wider and follow the track of well-known and appreciable veins, and that in general these veins are very painful to pressure.

The *treatment* of acute lymphangitis is local and general. Immediate free incision of the infected focus is imperative. This can be done painlessly by local anæsthesia with cocaine, or general narcosis with nitrous-oxide gas. In cocaine infiltration (for example, in finger infection) the needle should be entered at a

point slightly removed from the infected and painful area, and anæsthesia effected by careful approaches to the line of incision. Should this be through the palmar surface, which is normally hypersensitive, the needle should be entered on the dorsum of the finger and carried just beneath the skin to be incised. A moist bichloride dressing (1–3000), or an antiseptic flaxseed or other poultice, should be applied.[1]

If incision has been delayed, or if infection is traveling along the lymphatics, every point of induration should also be freely incised not only to permit the escape of septic matter, but to relieve tension and prevent sloughing. These incisions should be treated as just advised.

With the first symptoms of infection the bowels should be emptied by calomel triturets (grains 3 to 5 in one dose), to be followed in six or eight hours by castor oil or salts. Rest in bed, nutritious diet, and fresh air are essential.

The process of repair in *wounds* of the lymphatic vessels does not differ essentially from that in the veins. It has been demonstrated that lymph and chyle may be carried into the veins by collateral circulation after occlusion of the larger vessels, even of the thoracic duct.

Varicosities may occur in these vessels, as in the veins. In some instances cystic dilatations occur, most frequently in the tongue, lips, and about the neck. These are sometimes congenital. In their structure they are trabeculated, the caverns being filled with lymph.

New formations of lymphatic vessels are occasionally met with (lympho-angeioma). The treatment of varicosities does not differ from that advised for the same lesions of the veins. Lymphatic new growths may be dealt with as advised in the treatment of angeiomata.

Adenitis.—In acute infection of a lymphatic gland the changes in its structure are very rapid. The cells of the reticulum and endothelia proliferate, and, in the presence of pyogenic organisms with their well-known property of liquefaction, suppuration rapidly supervenes. Necrosis of tissue is facilitated by the great pressure which rapid cell proliferation causes within the non-elastic capsule.

The local symptoms are pain, redness, and swelling. The general symptoms are as given in lymphangitis. If incision be delayed, the infective organisms may pass through the gland, enter the efferent vessels, and find their way to general vascular system.

The *treatment* of *acute adenitis* should be the same as that given in lymphangitis. Though the infection be seemingly mild in character, early incision in indicated.

In children, cervical adenitis is very frequently observed when suppuration does not ensue and when tuberculous infection is not present. In these cases there is a mild infection from a catarrhal pharyngitis or tonsilitis. The pyogenic germs are either not present or, being present, do not find conditions favorable for proliferation. The swelling which ensues is due to excitation and proliferation of the normal cells of the gland. This form of adenitis is met with chiefly in cold and damp climates, and in young subjects who are improperly fed and housed. The enlarged glands are very slightly, if at all, painful, and there is at first little or no constitutional disturbance. The symptoms do not differ very widely from those of incipient tuberculous adenitis, yet before advising extirpation the mouth, tonsils, and nasopharynx should be carefully examined. With the removal of adenoids or tonsils which are infected, together with tonics, proper feeding, and improved hygienic surroundings, these lymphomata very frequently disappear, while those caused by tuberculous infection persist.

Tuberculous adenitis is more frequently met with in the glands of the neck beneath the jaw, in the chain of lymphatics following the deep jugular vein, and along the upper posterior border of the mastoideus muscle. The bacilli find their way into the lymphatic channels through abrasions of the buccal wall or alveolus, and more frequently from foci of infection in the tonsil. Reaching the substance of the nearest gland, their progress is temporarily arrested, and here they undergo

[1] This poultice is made by mixing flaxseed in warm mercuric-chloride solution (1–3000).

a more or less rapid proliferation. There results an inflammatory process, mild in character, unless there is a mixed (pyogenic) infection. In uncomplicated tubercular infection the normal cells of the gland also undergo proliferation—the so-called lymphoid cells. The pathogenic organisms in the deep portions of the inflamed area continue to proliferate until the capsule of the gland itself is reached. In a certain proportion of cases at this stage the nodules undergo caseous or calcareous degeneration, and the bacilli perish without *spore* formation. When, under other conditions, the spores of tuberculosis are developed, these may lie dormant for a varying period until, under conditions again favorable to their proliferation, a fresh outbreak occurs and other glands in the chain are invaded. In most cases of tuberculous adenitis mixed infection occurs, due to the presence of pyogenic micro-organisms, and suppuration supervenes with all the symptoms of acute adenitis.

The *chief* symptom of tuberculous adenitis is a gradual and persistent enlargement of the lymphatic glands leading from the original focus of infection. Pain is not characteristic of these enlargements unless pyogenic infection has occurred. As a rule, there are no constitutional symptoms of sepsis, the pulse and temperature remaining normal. When the disease assumes a chronic character, and a number of glands are involved, the processes of nutrition are seriously disturbed.

As soon as the diagnosis of tuberculous adenitis is confirmed, a thorough removal of all infected glands should be advised; and it is proper to state that, no matter how thoroughly the operation may be done, a revision may be necessary, for the reason that the infective organisms have already passed into the efferent channels, where they cannot be recognized until proliferation is present in other glands.

The *adenitis* of *syphilis* will be considered with that disease.

In addition to acute and tuberculous adenitis, there is a condition of glandular enlargement known as "Hodgkin's disease," and another form of malignant lymphoma known as "Billroth's disease." Clinically, it is difficult to distinguish between these two forms, and recent authors claim that they are practically identical with lymphosarcoma.[1]

Adults from twelve to twenty-five years of age are most frequently affected. The glands in any part of the body may be the seat of lesions, although the name of Billroth is associated more particularly with lymphomata of the neck. The skin becomes pale and waxy, the spleen enlarged, and lymphatic metastases occur in the lungs, spleen, liver, and other organs. The red blood discs are greatly diminished and the leucocytes increased. Pain is absent unless the tumors press upon contiguous organs.[2]

Phlebitis means an inflammation of the tissues which form the walls of a vein. Endo-, meso-, and peri-phlebitis are terms used to designate inflammation involving respectively the inner, middle, and outer layers of the vessel wall. A vein is a tubular structure, made up in general of an inner layer of flat, polygonal cells (*tunica intima*), a middle layer (*media*), composed chiefly of elastic tissue, and an outer layer (*externa*), containing elastic loops, connective tissue, and unstriped muscle. The vasa vasorum and nerves are distributed to the outer and middle tunics.

The changes induced are first noticed in the two outer layers. The vasa vasorum are dilated, the leucocytes appear in the extravascular spaces, while the normal connective-tissue cells undergo proliferation, resulting in thickening of the venous

[1] See "N. Y. Med. Jour.," March 30, 1907, Dr. W. B. Coley.

[2] An exceedingly rare form of disease of the lymphatics is that caused by *filaria* (sanguinis hominis). The presence of this parasite in the lymph channels often leads to obstruction, and from the parent nest a crop of organisms may escape into the blood vessels. In the blood they are rarely detected during daylight, but if a specimen be examined several hours after dark, they may be discovered. The filaria, about 1–80 of an inch in length, is constantly in motion. In the blood they do not produce any particular disturbance, but those which lodge in the lymph ducts cause connective-tissue hyperplasia and swelling (elephantiasis). There is as yet no known method of relieving the body of these parasites. It is probable that, in common with certain other organisms found in the blood, they may be destroyed by a prolonged high temperature, as in typhoid or remittent fever.

wall. Should the infection be mild in character, resolution may occur without involvement of the intima. In the more severe types of phlebitis the lining membrane is involved, thrombosis results, and new capillaries protect themselves into the coagulum.

When phlebitis is complicated with thrombosis there is always danger that the coagulum may be carried to the heart and lodged in the pulmonary arteries with fatal result. Septic organisms passing through the pulmonary capillaries enter the systemic circulation and produce the general symptoms of septicæmia.

Phlebitis is one of the most serious of the surgical diseases. The vessels involved are swollen, tense, and less elastic than normal. They may be traced by the dull red color of the skin immediately over the diseased vein. Pain is constant, and is rendered intense by pressure. The œdema on the distal side of the lesion is in proportion to the obstruction to the return circulation and the infiltration of the perivascular tissues. The febrile movement varies with the virulence of the infection and the rapidity of its progress.

Treatment.—Complete rest is the first essential. Manipulation or movement is dangerous, not only because it exaggerates the inflammatory process, but may possibly cause the dislodgment of thrombi. With the first suggestion of pus formation, or when œdema is extensive, free incisions parallel with the veins should be made. These wounds should be treated by the open method, applying a moist 1–5000 bichloride dressing, with warm irrigations at intervals, until the symptoms have disappeared. Careful attention to the alimentary canal, nutritious diet, mild stimulation, and a free supply of pure air will complete the constitutional treatment.

Arteritis is an inflammatory process which involves the entire thickness of the arterial wall. When the intima is alone involved, it is designated *endarteritis*; the outer coat, *periarteritis*; the middle coat, *mesarteritis*.

Arteritis may be a local or general disease, and of traumatic or idiopathic origin. Simple endarteritis is more frequently met with in the aorta and other large arteries near the heart. It may be caused by syphilis, rheumatism, gout, alcoholism, chronic nephritis, or any chronic morbid process which poisons the blood and impairs its nutritive qualities.

The sequelæ of arteritis may be fatty degeneration, atheroma, calcification, partial or complete occlusion, or dilatation (aneurism).

Though not as frequent as in phlebitis, *thrombosis* and *embolism* often result from arteritis.

Vascular Tumors

Vascular new formations (*angeiomata*) may be considered clinically under three heads:

1. Arterial angeioma (cirsoid aneurism). 2. Capillary angeioma (mother's mark). 3. Venous angeioma (cavernous nævus).

In arterial angeioma there is an elongation and dilatation of the terminal arterioles. A single vessel may be affected or several arterioles of a given area may be involved. It is most frequently observed upon the scalp, the neck, and the hands, and may be congenital or acquired.

On account of hæmorrhage, it has been found impossible to remove them by dissection, and ligation of the arteries leading into the tumors has almost without exception failed to be of benefit.

In 1901 the author devised a method of treatment for these neoplasms which has proved successful in every instance in which it has been employed. The technic is given in the following history: Miss S. C., aged twenty-seven. In 1885, in her tenth year, she noticed a small pulsating tumor in the temporal artery above the ear. This was tied, but without benefit. Two years, and again five years, later attempts were made to strangulate the mass by subcutaneous ligatures, but without success. Twelve years later there was a large pulsating mass covering one half of the left side of the scalp, which measured five by six inches, and was elevated above the level of the normal scalp from one half to one inch.

Leading into the tumor were five arteries much larger than normal—two from the left temporal, one from the right temporal, and one from each occipital trunk.

The author's metal syringe (Fig. 140), taken from the boiler, was immediately filled with boiling water. With the hands protected by two pairs of heavy gloves, the needle was entered along the course of the arteries leading into the mass two inches from the tumor, and fifteen or twenty minims of boiling water were injected at each point, causing an immediate arrest of pulsation in these vessels. The long needle was then thrust from one side of the tumor to near the opposite surface, and about a dram of hot water forced out. Withdrawing the needle, for every half-inch this was repeated. It was then reëntered one half inch from the first line of injection, and this was repeated until the entire mass was consolidated. About five ounces of boiling water were used. No reaction followed. There was no pain, but a very considerable œdema of the scalp and face developed.

Despite the high temperature of the water and the thorough subcutaneous coagulation, there was no sloughing of the scalp. More than five years have elapsed; there has been no return of the growth, and the patient is entirely cured.

Venous angeioma (cavernous nævus) is much more frequently met with than cirsoid aneurism. I have treated a large number of these tumors by the injection of boiling water, so far without accident, and with a cure in every instance.

C. G., a well-developed child nine years old. At birth there was a "mother's mark," or blue spot about as large as a quarter of a dollar, on the back just above the right shoulder. At the age of two years it began to grow perceptibly. In the fifth year, when the tumor was about seven inches in length and half as wide, an effort was made to remove it by operation, but was abandoned on account of



Fig. 140.—The author's all-metal syringe for injecting hot water.

hæmorrhage. A year and a half later a second attempt was made, and again abandoned. When she came under my observation (February, 1902) there was a large venous angeioma occupying the back from the edge of the trapezius muscle, above the right shoulder, reaching to the middle line between the two scapulæ, extending downward as far as the twelfth rib and well over to the right side. The surface of the mass was from one and a half to two inches above the level of the body. To the touch it was soft and compressible, the venous channels remaining empty under pressure and refilling as soon as this was removed.

Under ether narcosis the boiling-water injections were made as in the former operation, a very long needle being carried crossways through the tumor at eleven different points. The child complained of no pain after consciousness was restored, and there was no elevation of temperature. Coagulation seemed to be perfect throughout. Seven months later the entire growth had disappeared, with the exception of a rounded mass about three inches in diameter, which is shown in the center of the area of the accompanying illustration (Fig. 141). This was then treated in the same way. Five years have elapsed and the patient is entirely cured. For these larger tumors a larger instrument may be employed.

In 1907 I operated upon a large venous angeioma which occupied the left side of the neck below the angle of the jaw. It involved the external and deep jugular veins, and the tumor measured three by four inches and projected outward about two inches beyond the level of the neck. For fear that the hot water might produce embolism in the deep jugular or internal carotid, in either of which a fatal issue would result, I attempted to extirpate the mass by dissection. Extensive coils of large veins were soon encountered with such profuse bleeding that compression had to be employed and the operation abandoned. A week later a separate temporary ligature was thrown around the common carotid artery and the internal jugular

vein just above the clavicle, and then were twisted and held with forceps, completely shutting off, for the time being, the circulation in both. By this procedure not only was the blood in the vein held stagnant and dammed back, hyperdistending the coils in the tumor, but at the same time the ligature of the common carotid, the tightening of which was synchronous with a pinhole contraction of the pupil of that side, caused reversal of the current in the internal carotid by reason of the free anastomosis through the circle of Willis with, and the increased supply from, the artery of the opposite side.

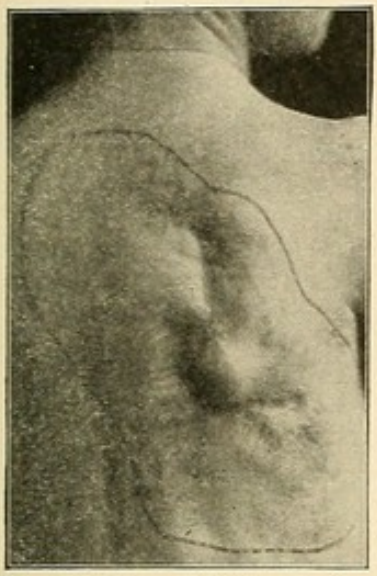

FIG. 141.—Case of C. G., extensive cavernous nævus of the back, after the second injection.



FIG. 142.—Inoperable venous angeioma, before injection.



FIG. 143.—The same, one year later.

No coagula could now reach the heart or brain, and, superficially occluding the external jugular by digital pressure, the entire mass was solidified by the careful instillation of boiling water. Every effort was made to keep the heat as far as possible from the pneumogastric, facial, and other contiguous nerves. After fifteen or twenty minutes, there being no evidence of coagulation in the vein at the seat of ligature, the ligature on the internal, and the compression of the external, jugular were removed. The common carotid was next unlocked, and the circulation in that side of the brain restored, as shown by the immediate dilatation of the pupil. Within two months the solidified mass had entirely disappeared, and the patient, a lad of nineteen years, is well. The growth was congenital, but had grown rapidly within the last few years.

In the use of an agent so capable of doing harm every precaution should be taken to prevent scalding. Water so hot that a single drop falling on the skin will destroy the epidermis, when injected under the skin will coagulate the blood without injury to the integument. While the boiling point (212° F.) is not always necessary, not infrequently, in order to maintain the proper temperature, an alcohol lamp should be held under the barrel of the syringe. All parts of the patient's body near the field of operation should be protected from scalding by thick layers of towels or gauze. A mass of gauze should be kept below the needle point, which, at the proper moment, is thrust through the gauze into the tumor. An assistant should be immediately at hand with a sponge saturated in cold water, so that in case of an unexpected leakage the cold can be instantly applied and prevent scalding. The operator should be careful to hold the instrument beneath his hand in order to be out of the way of any leakage. While so far no accident has occurred, it is well to bear in mind, and to explain to patients subjected to this procedure, the danger, however remote, of embolism.

When the tumor is located upon an extremity, this danger can be obviated by the application of a tourniquet on the proximal side, which should not be removed until coagulation has been assured. In all cases firm compression should be made upon any vein between the tumor and the heart until the mass is solidified. This method should never be employed where an important nerve trunk may be injured by the heat.

Capillary angeiomata are very much more often met with than either of the two varieties above given. They are frequently congenital, but may be ac-

quired. They may appear as reddish or blue stains or injections beneath the normal epidermis, or as strawberrylike elevations without an epidermal covering. They are usually seen on the face, a favorite location being the muco-cutaneous borders of the lips, the wing of the nose, the eyelid, and upon the forehead. Their tendency is to enlarge until puberty when, as a rule, they remain stationary. I have treated a large number of these neoplasms by the hot-water injections, a very delicate needle and a small syringe being employed. More than ordinary precautions are necessary on account of the importance of protecting the face. Only a few minims are injected at any one point. It is best to proceed slowly and note the changes which are produced. As a whole, the results are not so satisfactory as in the treatment of cirsoid aneurism and cavernous nævus. The majority of capillary tumors, not being protected by a normal epidermis, break down under the hot water and become infected. Some of these have been cured, while others have been markedly reduced in size.

Closely related to the more superficial forms of vascular tumor are the abnormal, circumscribed hypertrophies of the skin, known as moles, which may be congenital or acquired. They may occupy any portion of the skin, but are usually found on exposed surfaces, as the face, neck, and hands. The most frequent variety is that which appears as a simple elevation from which a few stiff hairs grow. As a rule, they are not stained with pigment. While benign in character as a result of irritation, these neoplasms may become infected, or even develop into malignant growths.

Nævus pigmentosus is characterized by an extensive deposit of pigment in and immediately beneath the epidermis, in color varying from slate-gray to purple, mahogany, or wine-color, and at times extending over a large area. The lobule of the ear and the integument between the eyes and over the temple is a common location. It is sometimes called "*port-wine mark.*"

Treatment.—When the pigment area is so small that it can be excised and the edges of the wound brought together by carefully adjusted sutures without too great tension, this may be done. When a muco-cutaneous border is not involved, transplantation of skin is indicated when after excision apposition cannot be secured. Moles, papillomata, etc., should also be excised. These operations can be done painlessly with cocaine anæsthesia. The smallest curved round needles and the finest silk or linen should be used when union by suture is necessary. Small incisions may be maintained in apposition without suturing by covering with collodion, pressing the edges together until the collodion sets.

Venous varix consists of a dilatation and elongation of the veins. It may involve the deep as well as the superficial veins, but those immediately beneath the skin are most seriously affected. Varicosities are especially prone to occur in the superficial veins of the lower extremities (saphenous). Hæmorrhoids and varicoceles are common forms of varix. Unusual types are dilatation of the jugulars, due to stenosis of the vena cava descendens, and that of the superficial abdominal veins from stenosis of the ascending cava. While a chain of veins is usually involved a limited portion of a single vessel may be the seat of varix. This form is due to paralysis of the muscular tissue in the walls either from atrophy or from interference with the function of the *nervi vasorum.*

Poorly fed individuals, especially those who work in the standing posture, are more frequently affected. Pregnant women, multipara, and persons suffering from large abdominal tumors or any interference with the venous return through the ascending cava, are apt to develop varicose veins in the legs.

Occlusion of the popliteal vein or of the femoral below the entrance of the internal saphena will also produce a varicose condition in the veins of the leg and lower thigh. This condition, however, is entirely compensatory and not operative, as it differs from the ordinary varicose veins of the lower extremity, which are due to diminished resistance in, and dilatations of the walls of, these vessels.

In well-marked *varix* the veins are increased in caliber and in length, being coiled and twisted upon themselves in knotted masses. They are narrowed in caliber at frequent intervals, opening into expanded pouches, in appearance not unlike the sacculated large intestine. As the result of dilatation the valves are

wholly inefficient, the walls are weakened, and rupture may occur. Calcareous deposits are occasionally met with in the vessel walls, while the lumen is not infrequently occluded by thrombi.

As the result of injury, blood stasis, or the low resistance which results from impaired nutrition, inflammation (phlebitis) frequently occurs as a complication of varix. One of the greatest dangers, however, from *varicosities* when thrombi form is the not infrequent dislodgment of a clot, which is rapidly carried with the venous current to the heart and into the lungs (embolism), causing obstruction of a terminal artery or larger trunk, and, not infrequently, sudden death. Many cases of so-called deaths from heart failure result from this form of embolism. When phlebitis or thrombosis and embolism do not occur, ulcers, especially along the anterior surface of the leg, are very common complications of varicose veins.

Treatment.—The treatment is palliative and operative. In the early development of a varicosity mechanical support, carefully and persistently applied, may arrest the progress of dilatation and render operation unnecessary. For the lower extremity an elastic stocking, preferably of silk, or of some soft material, affords great relief. The tension in the rubber should be no more than is necessary to support the veins. When the stocking cannot be had, Martin's rubber bandage is a fair substitute. The chief objection to any apparatus of this kind is the discomfort experienced in warm weather from perspiration. No matter what mechanical device is adopted, great comfort will be derived from the relief of intra-abdominal pressure by free evacuation of the bowels. When occlusion of the popliteal or femoral vein has occurred, reliance must be had solely upon elastic compression, since gangrene would almost inevitably follow excision of the superficial veins. In the earlier development of varicosities due to other causes they can be readily and safely cured by excision with cocaine anæsthesia. By this simple and painless procedure prolonged discomfort and remote complications may be avoided. In delayed cases where phlebitis has occurred, infection is so apt to follow surgical intervention that the strictest aseptic precautions are imperative.

The entire extremity in the field of operation, and well beyond, should be thoroughly shaved and scrubbed, the sebaceous and hair follicles rendered sterile by ether and alcohol, and the limb enveloped in a 1–3000 bichloride dressing, preferably for twelve hours before the operation. When the procedure is very extensive, and the patient's condition will tolerate prolonged narcosis, this should be preferred, with nitrous oxide and air or oxygen as the anæsthetic. Pneumonia or nephritis are more than ordinarily frequent on account of the low resistance in these subjects. As the veins are not easily recognized when the extremity is emptied of blood in the recumbent posture, it is advisable to compress the internal saphena or femoral vein, hyperdistend the varicosities it is intended to excise, and make tracings of these with sterile iodine parallel with, and one half of an inch away from, the course of the vessel.

The operative treatment consists in excision, ablation, or multiple ligature of the enlarged vessels. When practicable, one of the methods of ablation should be selected. The following ingenious procedure is that of Dr. C. H. Mayo:

His special apparatus consists of a ring vein enucleator (Fig. 144). The ring has a diameter of about one fourth of an inch, and is bent upon the tip of the shaft at an angle of about seventy degrees. The saphena vein is exposed in the



FIG. 144.—C. H. Mayo's vein enucleator.

upper portion of the thigh, above the high point of the lesion, the proximal end tied, and the distal section clamped an inch from the end, which is passed through the ring of the enucleator, while the clamp is transferred to the end of the vein. With the vein held in tension, the ring is forced down, tearing off the lateral branches

for six or eight inches. An incision may now be made directly over the end of the instrument, the stripped vein pulled through, and the procedure repeated, or, in order to save an extra wound, the vein may be exposed at a point six inches lower, and the first step reversed until the two tunnels meet, when the entire section of at least twelve inches of the vessel is drawn out through either opening.

During this operation the leg is held in an elevated position, so that the veins are practically emptied and the bleeding from the torn lateral branches is insignificant, and, if occurring, may readily be controlled by direct pressure. As soon as the vein is drawn out of the wound, sterile gauze is applied, and a roller adjusted sufficiently tight to compress the small superficial veins and arrest hæmorrhage. The entire extremity should be covered with a thin layer of cotton batting, and pressure equalized by bandaging from the toes to the crotch.

The author has found very satisfactory in this operation the employment of the ordinary urethral bulbous bougies used for locating stricture. The method is practically that of Dr. W. Wayne Babcock,[1] with the exception that while he carries the instrument from above downward, the author inserts the instrument below and carries it upward so as not to meet with any impediment from the valves. Dr. Babcock recommends a longer instrument than the ordinary urethral bougie-a-boule.

The saphenous vein is exposed well up in the thigh, clamped, and tied with ten-day catgut one half of an inch above the clamp and divided between the ligature and the instrument.

At a sufficient distance lower down to suit the length of the instrument employed, a second opening is made, the vein exposed, and divided between two clamps. Into the proximal end the bougie is inserted until it comes in contact with the forceps at the first incision. A silk or linen thread should now be tied around the vein just behind the bulb, after which the instrument is drawn downward, tearing off the collateral branches and bringing the vein out at the lower opening.

When the traction is begun, sterile gauze with firm compression should be laid on following the vein as it is torn loose. If this be done, and a roller bandage at once applied, no extravasation will occur. The author considers this a very important part of the technic. The remaining varicosities may be treated in the same manner.

Neither of these procedures is applicable where the veins are greatly enlarged and very tortuous or occluded here and there by firm thrombi, or where, as a result of phlebitis strong adhesions have formed. Such veins, as a rule, require the open incision, removing long or short sections as may be necessary.

As heretofore stated, bleeding may be controlled by elevating the foot, which should be secured by a bandage to a steel upright attached to the operating table. Temporary digital compression of the femoral artery will soon empty the extremity in this position. Should hæmorrhage prove serious, the tourniquet may be employed. Schaede's operation of circular incision of the leg dividing the skin and veins (and nerves) down to the deep fascia should not be performed.

Where the disease is limited to a small area, a simpler procedure, under perfectly satisfactory cocaine infiltration, is, through a very small incision, to tie the main efferent vein without section and repeat this as often as required, no two ligatures being nearer than two inches. After the incisions are closed by running ten-day catgut sutures, and each incision dried out by pressure, dry sterile gauze should be applied with cotton over this, and a bandage applied from the toes to the crotch with firm compression, in order to prevent any oozing along the line of the excised veins. The foot and leg should be kept elevated for the first twelve hours. The treatment of varicosities in connection with ulcers of the leg will be given in another chapter (Ulcers).

[1] "New York Medical Journal," July 27, 1907.

CHAPTER VII

ANEURISM—LIGATURE—COMPRESSION—ARTERIORRHAPHY—SPECIAL ANEURISMS

An aneurism is a sacculated tumor, the cavity of which communicates with an artery, and in rare instances also with a vein.

They may be classified as *spherical*, *fusiform*, and *dissecting*.

A *spherical* aneurism is one in which the tumor is well defined, its diameter being larger than that of the opening of communication with the vessel. It may spring from any portion of the arterial wall (Fig. 145, *e*) or, in rare instances, the vessel walls may yield in all directions to form the tumor (Fig. 145, *c*).

A *fusiform* aneurism is one in which there is a gradual and general dilatation of an artery in its entire circumference (Fig. 145, *a*, *b*). A spherical aneurism may occasionally develop from the wall of a fusiform dilatation.

A *dissecting* aneurism is one in which, owing to pathological changes in the intima, the blood insinuates itself between the inner coat and the adventitia, dissects the intima from the media and adventitia, and reënters the vessel at a distant opening.

Aneurisms are further divided into the *true* and *false*. To the former belong all tumors the walls of which are composed of the walls of the vessels from which they spring; to the latter belong those tumors the walls of which are composed of inflammatory new-formed tissue.

Cause.—A true aneurism is always preceded by *arteritis*, which results in atheromatous degeneration of the normal elements which compose the arterial wall.

The *pathology* of arteritis and the relation of this condition to various dyscrasiæ—as syphilis, nephritis, gout, rheumatism, etc.—have been given in a preceding chapter. Syphilis improperly treated induces aneurism in a large proportion of cases. The relation of violence to these tumors is important. No matter how severe the dyscrasia and the general condition of arteritis, which is a part of it, it is well known that in the large majority of cases aneurisms develop at those points in the arterial system which are subjected to the greatest violence from heart action, or muscular or mechanical pressure. Thus the arch of the aorta, and that portion of the arch in the direct axis of the left ventricle, is very prone to aneurism, as are the great vessels near their origin from the aortic curve. The popliteal arteries, subjected as they are to violence in forced flexion of the legs, are frequently the seat of aneurismal dilatations.

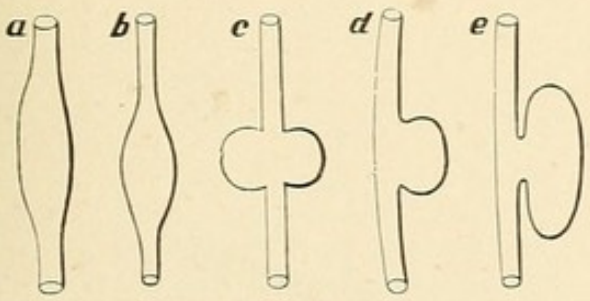

Fig. 145.



Fig. 146.
Varicose aneurism.

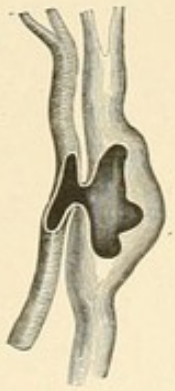

Fig. 147.
Aneurismal varix.

From a study of the various conditions which produce aneurisms, it is evident that the *normal* wall of an artery cannot form the sac of the aneurism. Some of

the normal anatomical elements may be present in the sac, but the integrity of the whole is impaired.

An aneurism may in rare instances communicate with a vein (*varicose aneurism*) (Fig. 146). The direct communication of a vein and artery without a sac is known as *aneurismal varix* (Fig. 147).

If an aneurismal tumor be examined, it will be found to contain coagulated blood in all stages of fibrillation. The peripheral portion of the clot is composed of irregular laminæ, and, if examined with the microscope, the laminated appearance is found to be due to alternate layers of white corpuscles, and upon these a deposit of fibrin. As the center of the tumor is approached, the coagulation is evidently more recent, while in the cavity of the aneurism a soft post-mortem clot is usually found.

Fusiform aneurism occurs most frequently in the thoracic aorta, with especial preference for the arch. It may affect the entire aorta, and the great vessels derived from it. Not only is the diameter of the arteries increased, but the hypertrophy results in a considerable increase in their length. Not infrequently a group of fusiform expansions may be seen with strips of sound and non-dilated artery intervening. Calcareous deposits occur in patches, and seem to give strength to the walls, since those portions give way more readily which are not the seat of calcification.

Coagulation is not apt to occur, as in sacculated aneurisms; in fact, it is a rare condition. Fusiform aneurisms develop slowly, and, as a rule, are painful and dangerous only when, by reason of their large growth, they exercise undue pressure upon important organs. Thus, in dilatation of the transverse arch, or of the right subclavian, spasm of the glottis occurs from irritation of the recurrent laryngeal nerves, or respiration and deglutition may be seriously embarrassed by direct compression of the trachea or œsophagus. Fusiform dilatation of the abdominal aorta may produce serious results from disturbance of the vaso-motor system, by compression of the sympathetic ganglia near the diaphragm, by partial or complete occlusion of the thoracic duct, etc.

Dissecting aneurisms are rare as compared with the other two varieties. The dissection or lifting of the thin lining membrane of the artery from the media usually occurs in the long axis of the vessel. If the middle and outer coats do not become involved in the degeneration which has affected the inner coat, this form of aneurism may continue indefinitely, without leading to a fatal termination, although the danger of embolism cannot be overlooked.

If the other layers give way, a sacculated aneurism is formed, with the adventitia for the sac, or rupture may occur, leading to fatal extravasation.

A *false*, or so-called "*diffuse*," aneurism results from the solution of continuity in all the coats of the vessel wall, and the sudden diffusion of blood into the periarterial tissues. The extravasation continues until the resistance of the surrounding tissues is equal to the pressure of the column of blood within the vessel. As a result of the extravasation, an inflammatory process, of variable intensity and usually non-infective, is established, which results in the formation of a limiting membrane, or aneurismal sac.

The *prognosis* in aneurism varies under widely differing conditions. In general it is a grave affection, the gravity depending, in a great degree, upon the location and character of the tumor and the physical condition of the individual affected. An aneurism of the cranial cavity will produce rapidly serious effects by compression of the brain. The gravity of a prognosis diminishes as the location of the tumor is removed from the cavities. Aneurism (especially the sacculated variety) of the aorta, innominate, subclavian, or iliac arteries, is an exceedingly dangerous affection, while the same condition in the distal arteries yields readily and safely to surgical interference in the great majority of cases. The prognosis may also, in part, depend upon the degree of discomfort experienced by the patient, from the effects of pressure upon contiguous organs. Neuralgia of the most painful and obstinate kind, resulting from pressure of the tumor upon a neighboring nerve, may hasten a fatal termination by loss of sleep and rest, and the general impairment of nutrition. Occlusion of the accompanying vein may

occur, producing œdema and gangrene. Again, the gravity of the prognosis is increased when, by reason of its location, the sac of an aneurism is in contact with a bony surface, since rupture is not infrequently precipitated by attrition against the roughened bone.

The *symptoms* of aneurism are, in great part, *local*. They refer to the direct development and effect of the tumor. A sense of unusual throbbing, pain more or less severe, and swelling in the line of an artery (when the aneurism is outside of a cavity) which pulsates with the cardiac systole, which, when not resting upon a hard surface, is expansile in all directions, and which gives to the sense of touch a *tremor* not easily described but readily appreciated, are symptoms which point in general to the diagnosis of aneurism. The stethoscope, applied to the tumor, conveys to the ear the peculiar sound (*"bruit"*) caused by the passage of the blood current from the narrow vessel into the expanded aneurismal sac and out again. If the tumor be situated upon one of the arteries of the extremities, compression upon the cardiac side will cause a cessation of the pulse tremor and bruit, and diminution of the swelling, while pressure upon the distal side will temporarily exaggerate these symptoms.

When an aneurism is developed as a result of a wound of an artery, the immediate symptoms of hæmorrhage and swelling, with the pulsating character of the tumor, will clearly indicate its presence. The differentiation is chiefly between solid or cystic tumors, which develop along the line of the artery, and are lifted by the arterial pulsation. Abscesses, or serous cysts, are the most difficult to recognize. In the formation of an abscess there is a previous history of inflammation. An aneurismal tumor expands equally in all directions, while any other tumor travels with the arterial pulse in one direction only—that of least resistance. In cases of great difficulty of diagnosis it will be justifiable to aspirate the tumor with the finest hypodermic needle.

Left to nature, the progress of an aneurism is, with rare exceptions, to a fatal termination. The deposit of fibrillated fibrin within, and the inflammatory new-formed tissue without, may retard, but rarely arrests, the progress of the disease. Added to the danger of death from rupture of the sac, or compression of neighboring organs, is that of inflammation and sloughing as the result of infection or overtension of the skin as the tumor approaches the surface. The hope of recovery is in the gradual deposition of fibrin within the sac, causing its ultimate occlusion, or that of the vessel or vessels immediately connected with it. The danger of gangrene in the parts beyond the tumor is lessened with the gradual establishment of the collateral circulation, while the sac and its contents are less apt to inflame than when the occlusion is sudden and the clot recent.

The *treatment* of aneurism is *constitutional* and *local*. The constitutional treatment is directed toward the judicious support of the physical powers of the patient, the relief from pain, and the production of a condition of the blood favorable to a deposit of fibrillated fibrin in the tumor.

The local measures are directed to the mechanical control and arrest, either gradual or immediate, of the circulation in the aneurism, with the same end in view, namely, the formation of fibrin within the sac.

Constitutional measures alone offer little hope of a cure, and are applicable only to cases where the dangers of operative interference are sufficient to contra-indicate any surgical procedure. In this plan of treatment rest in bed is the first and essential requirement. In conjunction with this there may be administered certain remedies which diminish the rapidity of the circulation, or affect the blood vessels or blood in such a manner that the gradual deposit of fibrin in the sac is produced. *Valsalva's* method of rest in bed, venesection, and gradual starvation, in order to slacken the blood current and thus cause coagulation in the aneurism, is now almost entirely abandoned.

Tufnell modified Valsalva's method by omitting bloodletting and substituting a restricted diet, with the minimum of fluids. Rest in the recumbent position must be *rigidly enforced*. Among the remedies which have been recommended for internal administration, iodide of potassium is most important. It is especially efficacious in syphilitic aneurism, and it is often essential to combine mercury with it.

In the local treatment of aneurism the most approved measures are *compression*, the *ligature* with or without excision, and *arteriorrhaphy* (Matas).

Compression may be employed on the cardiac side of an aneurism, close to the tumor, without an intervening collateral branch, or at a distance from the sac, with one or more intervening branches. It may be employed on the distal side, with or without intervening anastomosis, or directly to the surface and back of the tumor, or, again, on both peripheral and central sides, with or without direct compression of the aneurism.

The *ligature* may be applied on the *cardiac side* of the tumor, there being one or more branches given off between the ligature and the sac (Hunter's method), or without an intervening branch (Anel), or on the *distal side* without (Brasdor), or with an intervening branch (Wardrop), or close to the tumor on both the distal and cardiac side, with or without extirpation of the tumor (Antyllus) (Fig. 148).

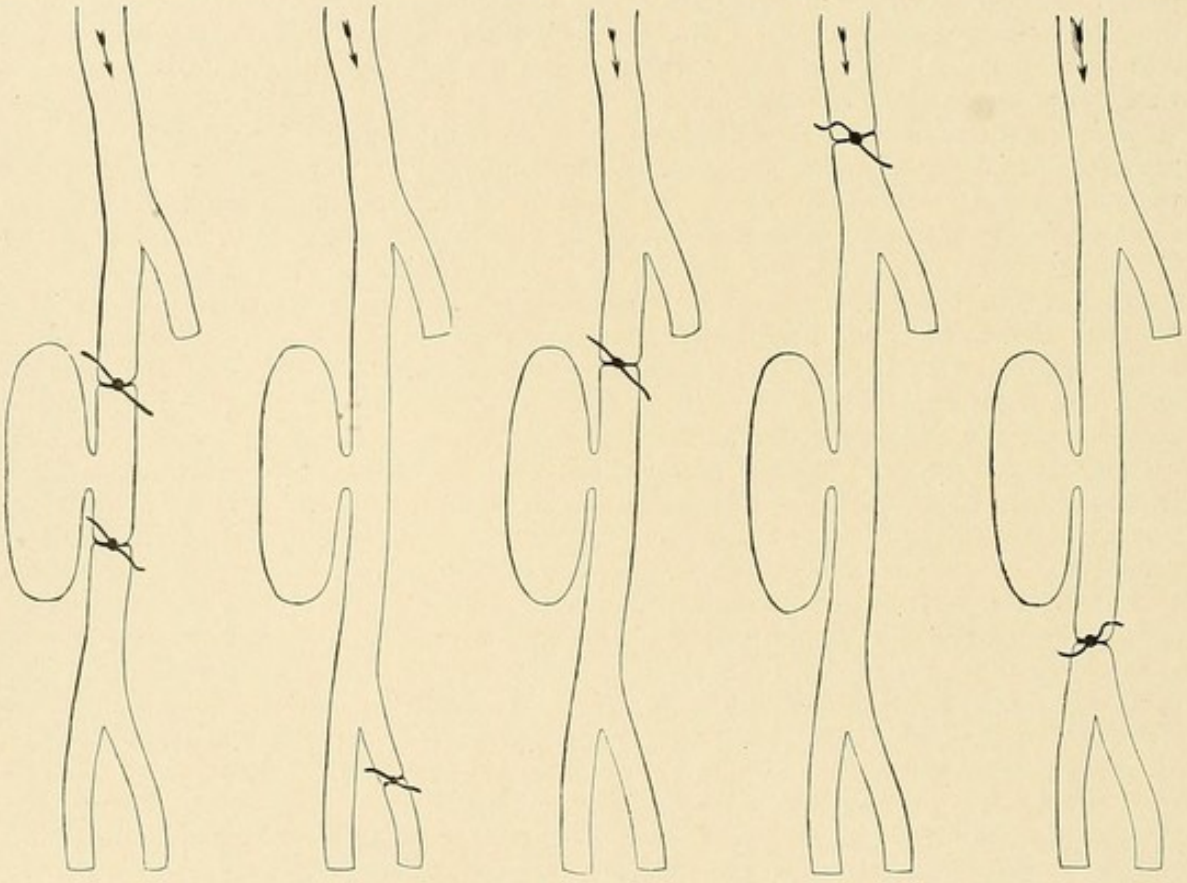

Antyllus' method. Wardrop's method. Anel's method. Hunter's method. Brasdor's method.

Fig. 148.

When interrupted pressure upon the main trunk, on the cardiac side of an aneurism, is possible, it is the first method of treatment to be adopted. It can only be contra-indicated when the tumor is so near to the great cavities from which the arteries emerge that there is not sufficient room for its accomplishment, or when, on account of the anatomical arrangement of contiguous nerves and veins, compression is painful or inexpedient, or when, as will occur only in exceptional instances, rupture is imminent; then the ligature is demanded.

It is, in general, advisable to apply compression on the cardiac side of, and some distance from, the tumor, where the vessel wall is more apt to be normal. For example: In a popliteal aneurism the patient is placed in the position of least discomfort to himself and most convenient for the operator. Should the pressure cause pain, cocaine infiltration, to which morphia may be added, will usually suffice, but in extreme cases a general anæsthetic may be employed for an hour or two if necessary. Compression is made by the thumb directly over the femoral artery, where it crosses the rim of the pelvis, and it should be firm enough to very appreciably diminish the pulsation in the aneurism and to entirely arrest the

current for a minute or two at frequently repeated intervals. Relays of assistants are required with the digital method, which should be continued for one or two or three hours, and repeated daily, or oftener, if necessary to produce consolidation.

The elastic bandage skillfully adjusted will enable the operator to dispense with the more tiresome digital compression. The small rubber ball or compress resting immediately upon the artery should be so adjusted that the circulation in the vein is not interfered with. The pressure should be very slight at first, and gradually increased as it may be tolerated. It is not intended to be sufficient to entirely occlude the artery. Should pain be felt in the skin or in the anterior crural nerve, which lies just to the outer side, it may be relieved by careful cocaine infiltration repeated every half hour or hour without removing the compress; and should soreness result, the point of pressure may be changed to Scarpa's space or Hunter's canal.

This method may be used continuously or interruptedly until, as a result of slowing the current, the deposit of fibrin in the cavity of the aneurismal sac has resulted in complete solidification.

Direct pressure upon the tumor has also been employed with success, but it is not so safe as compression on the proximal or distal side.

Should pressure fail and the application of the ligature become necessary, the surgeon may choose between the method of Hunter and Antyllus, Wardrop, Anel, or Brasdor (Fig. 148).

A commendable feature of the Hunter method is that the ligature is applied at some distance from the aneurism, where the artery is more apt to be in a healthy condition; but for this, the method of Anel would be preferable, since the danger of gangrene would be less.

If, on account of pressure upon contiguous organs, excision of the tumor is demanded, the method of Antyllus should be employed.

Deligation on the distal side of an aneurism has been done with more or less success in aneurism of the large vessels springing directly from the arch of the aorta, and is justified on account of the very great danger when a ligature is applied between the tumor and the heart.

Wardrop's method is the reverse of Hunter's, while Brasdor's is the reverse of Anel's (Fig. 148).

Within recent years Prof. Rudolph Matas has devised the operation of *endoaneurismorrhaphy.*

Under favorable conditions—i. e., when the aneurism is sacciform in type, and in which the parent trunk retains its continuity and normal outline, the aneurism being simply a sac grafted on the vessel—the operation is *restorative.*[1] The blood supply is controlled either by digital compression or the sterile tape passed around the vessel and twisted just enough to arrest the current, but not to injure the intima and media. The sac is incised in its longest axis and the clot washed out. The opening leading from the sac into the artery is then exposed inside the aneurism, and is readily closed by a continuous suture of fine chromicized catgut, which penetrates through all the coats of the sac at the margin of the orifice of communication. The sac is then obliterated by bringing its endothelial surfaces together with buried sutures of the same material. The constriction is now removed and the wound dressed in the usual manner.

Reconstructive arterioplasty is applicable in a fusiform aneurism in which the coats of the sac are firm, elastic, and resistant, the two openings leading to the main artery being on the same level, in close proximity, and situated at the bottom of a superficial or readily accessible sac. The continuity of the parent artery may be restored by making a new channel out of the sac walls, which can be brought together by suture over a guide of suitable size (velvet catheter or drainage tube) inserted into the proximal and distal openings of the aneurism. Before tying the last sutures, the guide is removed, leaving behind a channel corresponding to the outline of the original artery (Fig. 149). The sac is then obliterated by

[1] Matas reports seven operations of this character by American surgeons, all successful, and two from foreign sources.

approximating its surfaces with buried catgut sutures, as in the preceding operation.[1]

Obliterative arteriorrhaphy is especially applicable to aneurisms situated so near the aorta that the danger from the ligature in continuity is very great, or elsewhere, in the course of an artery, the walls of which have undergone atheromatous or calcareous degeneration. It consists in opening the sac freely without in any way disturbing its surroundings, and in closing all arterial orifices by suture. The sac

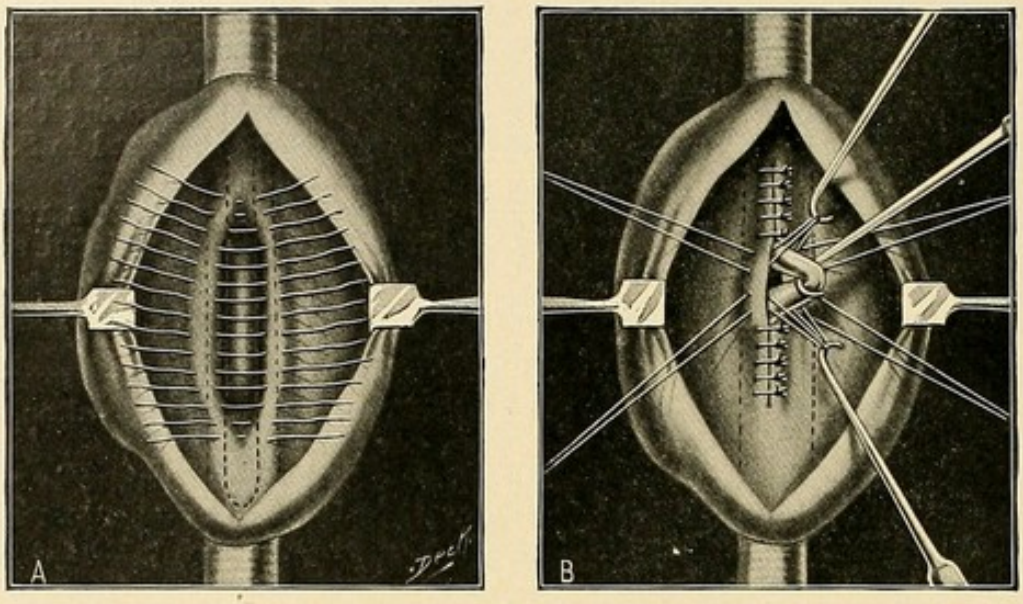

FIG. 149.—Matas' operation of reconstructive arterioplasty. *A*, Showing the method of closing the orifices and constructing a new arterial channel in a fusiform aneurism; *B*, removal of the guide. (*Fowler's Surgery.*)

is then obliterated by approximating its walls by buried sutures as before, and closing the wound with or without drainage. According to Matas, this procedure is indicated in aneurisms in which the sac is of fusiform type, with two or more orifices of supply, and in which the parent artery is entirely lost at the seat of the aneurism by blending with the aneurismal sac.

This procedure should largely reduce the mortality which has heretofore resulted in deligation of the innominate, the first, second, and third portions of the subclavian arteries, and the common iliacs, for the cure of aneurisms distal to the ligature. It has already been successfully performed in a case of subclavio-axillary aneurism.

Teasing the Sac.—Macewen successfully practiced this method, which consists of the introduction of a long, delicate sterile needle into the cavity of the sac, bringing the point of the needle along the wall in various directions, by this means exciting more rapid formation of coagulum in the roughened wall. In aneurisms at the root of the neck, as of the ascending or transverse aorta, of the innominate or carotid arteries, or of the subclavians close to the carotid, the danger of clot being washed into the vessels leading to the brain should not be overlooked.

Acupuncture consists in the introduction of needles or, preferably, silver pins. In one case of large thoracic aneurism of the ascending aorta, in which I was afraid to employ Macewen's method for fear of clot being carried to the brain, under careful aseptic precautions, I introduced about two dozen silver pins, two inches long, to their full depth into the aneurismal sac, the pins being about one fourth of an inch apart. They were left in from twelve to twenty-four hours, and produced well-marked coagulation. The operation was repeated twice in this case; the aneurism diminished rapidly in size, and the patient was discharged much improved. He returned to his work, and a year later died from dislodgment of a clot which was swept into the carotid artery, causing fatal cerebral anæmia.

[1] Five cases of this procedure are reported by American surgeons, in two of which relapses have occurred.

Massage or *kneading* has been successfully performed in a few instances. The aneurism is manipulated with the intention of detaching from the sac enough of the fibrillated clot to plug up the efferent vessel and thereby practically tie the artery on the distal side (Brasdor). It is of doubtful propriety except in small aneurisms situated in the arms or legs. The danger of embolism in the cerebral circulation is too great to justify this or any similar procedure upon an aneurism connected with a vessel leading toward the brain.

Flexion or *posture* is practically a method of direct *compression*, using the normal tissues for a pad. It is employed in popliteal aneurism, where the knee is flexed and fastened so as to compress and partially occlude the tumor between the tibia and fibula, and the femur. It is a justifiable method in rare instances. The same practice may be instituted at the elbow, but is impracticable at the axilla on account of the arrangement of the nerves.

The introduction of *watch-spring, silver-wire, horsehair, catgut coil,* or any other foreign solid substance into the cavity of an aneurism will rarely be justifiable except as a last resort in cases where the ligature or compression is impossible. For its execution a pointed canula is usually employed, which, having been introduced into the sac, the wire or gut is pushed through. The quantity used varies from two or three feet up to several yards. More of the catgut may be introduced than of the metal, and the animal ligature should always be preferred if this procedure is adopted.

Special Aneurisms

Aneurism of the Thoracic Aorta.—The ascending and transverse portions of the arch are most frequently affected. If the dilatation is *fusiform*, both of these segments are apt to be involved; if it is a *sacculated* aneurism, it is usually confined to one or the other segment. Sacculated aneurism of the ascending arch high up, or of the transverse arch, usually involves the orifice of one or more of the great vessels which originate here, although, as in the specimen figured below (see Fig. 151), not infrequently the mouth of the sac opens close to these vessels, but does not involve them.

The diagnosis of aneurism of the arch is generally obscure until the dilatation has advanced to such an extent that pressure symptoms are evident. Pain of varying intensity may be present in the earlier stages of development of both fusiform and sacculated aneurism. A symptom of great diagnostic value is disturbance of the laryngeal muscles, due to pressure upon the recurrent laryngeal nerve of the left side. This occurs in dilatation of the transverse or descending segment of the arch. The aneurismal bruit may be recognized as soon as the sacculation is well advanced. Interference with respiration, or deglutition, or the return circulation in the veins, is among other and important pressure symptoms.

The appearance of a tumor with an expansile pulsation synchronous with the cardiac systole, in the upper thoracic region, determines the diagnosis of aneurism. The differentiation of dilatation of the arch, from a similar condition of the innominate, left carotid, or left subclavian in the thorax, is difficult, and at times impossible. A number of errors in diagnosis by competent and honest observers are on record.

The following points will aid in arriving at a diagnosis: The tumor in aneurism of the ascending arch is usually first appreciated to the right of the sternum, between the clavicle and the third rib. The pressure symptoms do not affect the voice until the tumor is recognizable in the right side of the root of the neck, where it involves the right recurrent laryngeal nerve. Respiration may be interfered with, or cough produced by compression of the right bronchus. This condition will be recognized by the hissing râles distributed over the area of the right lung. Aneurism of the transverse arch is usually first recognized to the left of the sternum on about the same plane as for the ascending segment. Laryngoscopical examination will demonstrate that whatever of muscular paresis exists is confined to the left vocal bands. If the tumor rises into the neck, its appearance will have been preceded by pressure symptoms of longer duration and greater severity than in either innominate, carotid, or subclavian aneurism.

Innominate aneurism usually appears at the upper margin of the sternum in the space between the two tendons of origin of the right sterno-mastoid muscle, or in the interclavicular notch. The disturbance of the circulation through this vessel so affected may be recognized by the difference in the force and character of the pulse wave in the radial arteries of the two arms. In *aortic* aneurism, when the innominate is not compressed by the tumor, the pulse wave will be the same in both arms. It must, however, be borne in mind that in sacculated aneurisms, springing, as they not infrequently do, from the arch in immediate proximity to the orifice of the innominate, and rising to the root of the neck, in front of or behind this artery, a positive diagnosis is scarcely possible. The pressure on the innominate may retard or weaken the right radial pulse, when this vessel is not involved, while the aneurismal bruit is present in the exact location of this vessel.

Aneurism of the left carotid artery will first appear at the left sterno-clavicular articulation in the line of this vessel. The murmur will be transmitted toward the distribution of this vessel, and will not be heard in its fellow opposite.

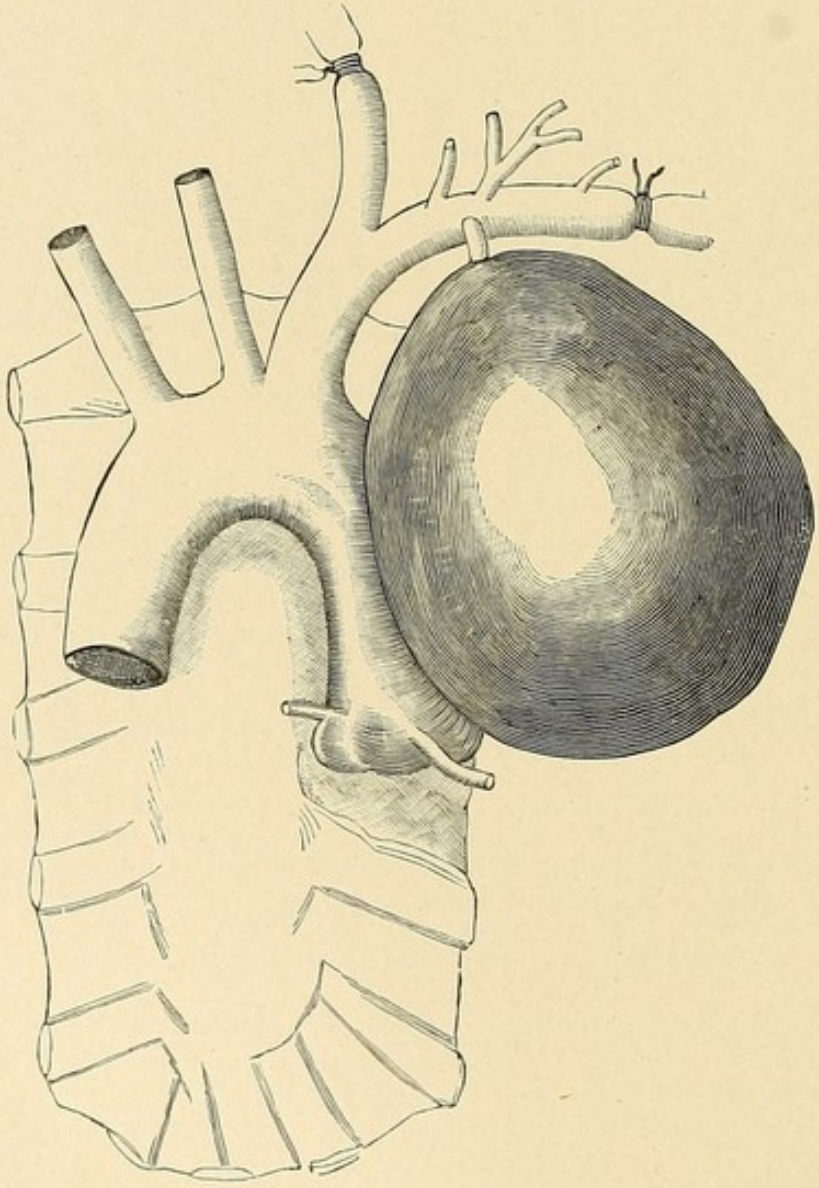

FIG. 150.—The author's case of aneurism of the ascending aorta.

When the left subclavian is involved, the swelling will usually appear to the left of the sterno-mastoid muscle, and the pulse in the left radial will differ from that of the right. When the descending aorta is the seat of aneurism, the diagnosis is still more obscure. The peculiar murmur is most easily recognized by placing the stethoscope to the left of the vertebral column in the interscapular space.

The chief pressure symptoms are those which affect deglutition and lift the heart forward.

The *clinical history* of aneurism of the thoracic aorta usually ends in the death of the individual. In addition to the symptoms given in the method of diagnosis, the gradual expansion of the tumor leads to more painful and graver conditions. Anxiety, loss of sleep, pain, and cough usually prostrate the patient; erosions of

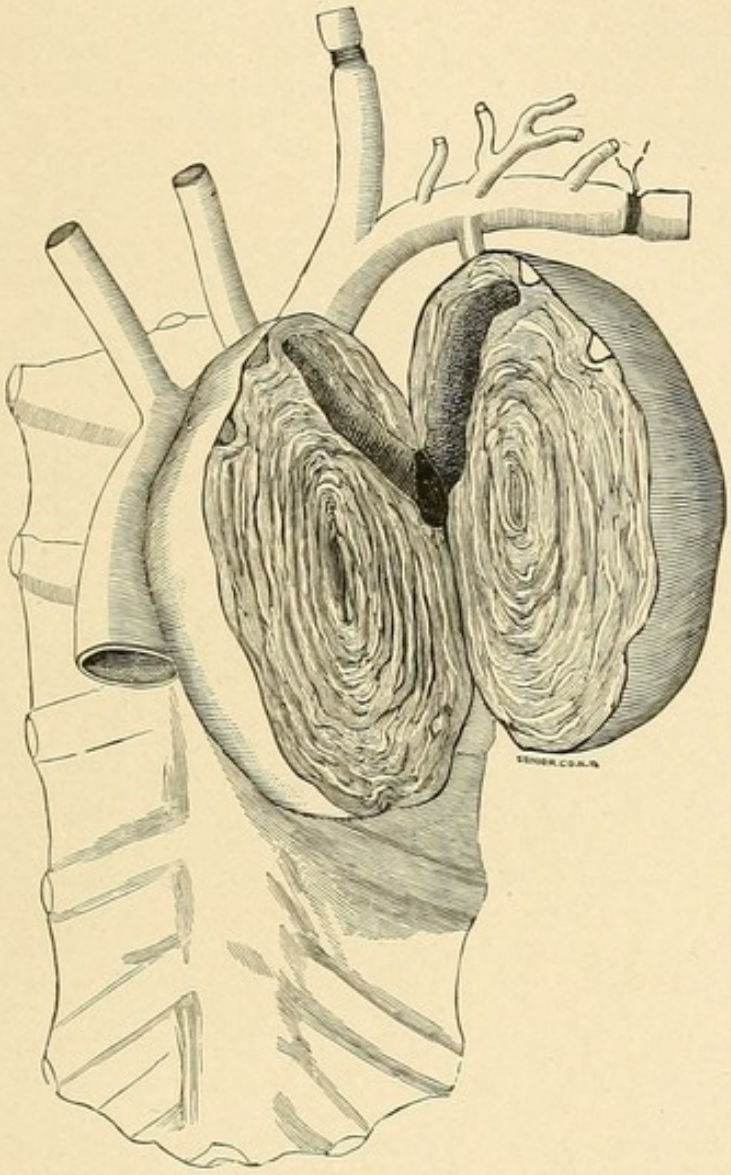

Fig. 151.—Section through the long diameter of the tumor.

the ribs, sternum, clavicles, and vertebræ occur, and sloughing, septic absorption, or hæmorrhage may produce a fatal termination.

The *medical treatment* is rest in bed, and the safe and judicious combination of Valsalva's and Tufnell's methods as given. The *surgical* treatment is of the most heroic order, and should not be instituted until a reasonable trial of the other methods has proved them as inefficient, as death is inevitable. This treatment is the deligation of one or more of the great vessels which are derived directly or indirectly from the arch—i. e., *the distal operation.*

That this operation is justifiable, under certain conditions, has been demonstrated. Among a number of cases in the statistics of this procedure, the following are from personal experience:

On the 21st of September, 1880, I tied the right carotid and subclavian arteries simultaneously for the relief of an aneurism of the ascending portion of the aorta.[1]

[1] For a full report of this, and all the other cases up to that date, see paper by the author in "American Journal of the Medical Sciences," January, 1881.

The history of the aneurism dated back sixteen months. Having developed rapidly, it projected through the right second intercostal space, causing such pain that the operation was undertaken. This was the second operation which had knowingly been undertaken for the relief of aneurism of the ascending aorta. Despite the prostrated condition of the patient, she recovered, the tumor diminished perceptibly in size, became more solid, and her general condition was much improved. One month after the operation she was discharged from the hospital, and traveled to a neighboring State, where she died, one year later, from acute diarrhœa. I secured an autopsy, which revealed an aneurism (Figs. 150, 151) as large as an orange springing from the ascending aorta, at its junction with the transverse segment. The orifice of the tumor was an oval, about half an inch by one inch in extent. The tumor was solidified with permanent clot on its lateral and posterior aspects. On the upper anterior surface, which had worn away the sternum and second rib, the sac was thin, with a recent clot which filled a cavity not quite an inch in diameter. The tumor was practically solidified, and had this patient not returned to her dissipated practices (alcoholism), I do not doubt that her recovery would have been complete.

Aneurism of the thoracic aorta beyond the transverse segment is not amenable to surgical treatment.

Aneurism of the Innominate Artery.—The symptoms of this formidable lesion have been given on a preceding page. It is frequently complicated with aneurismal dilatation of the aorta, or of the two vessels into which it usually bifurcates. It will be interesting to study the results of operative procedures under the following subdivisions:

1. *Innominate Aneurism.* 2. *Aortic Innominate Aneurism.*—For innominate aneurism, (*a*) the double simultaneous distal ligature (carotid and third division of the subclavian); (*b*) the double non-simultaneous distal operation; (*c*) distal deligation of the carotid artery alone; (*d*) distal deligation of the subclavian artery alone.

For the relief of innominate aneurism, simultaneous deligation of the *right common carotid* and the *right subclavian* artery in its third division has been done twelve times. Recovery with a cure more or less complete took place in five cases, while death occurred in seven. It is probable that if in some of these fatal cases the operation had been performed earlier, the ratio of mortality would have been lower.

In one instance the *subclavian* artery was tied a year before the *right carotid*, resulting in a cure, the patient dying from phthisis three years after the last operation. In a second case the *carotid* was tied, with temporary improvement. Two years later the *subclavian* was ligated; the aneurismal bruit disappeared, resulting in the consolidation of the tumor, as proven by an autopsy four months later, the patient dying from pleuritis caused by a fall while intoxicated. In a third case the interval was two months and nine days. Immediate and temporary relief followed each procedure. The sac ruptured on the forty-fourth day after the last operation. In a fourth case the patient was not benefited by tying the *carotid*. Three months later the *subclavian* was tied, followed by death from rupture of the sac on the twenty-first day.

In fourteen cases the *distal* ligature was applied to the *right carotid* for the relief of innominate aneurism. In only one instance was a cure effected, and in this only after suppuration occurred in the sac. Of the *fourteen* cases, *eight* ended fatally.

In three instances the *subclavian* artery in the third division has *alone* been tied for innominate aneurism. Each case recovered with marked improvement, and in each there was more or less complete solidification of the tumor.

With any of these operative measures, the postural, dietetic, and medicinal treatment should be combined; in fact, this, the Tufnell method, enforced with extreme rigor is entitled to a fair trial for a considerable period before operation is done.

Aneurism of the Common Carotid Artery.—Aneurism of the carotid may occur in any part of the course of this vessel, being in rare instances intrathoracic (when the left trunk is involved).

The diagnosis of aneurism of the left carotid, low down, depends upon the presence of the aneurismal bruit over the tumor, this murmur being carried along the artery. Pressure symptoms are referable to the pneumogastric or recurrent laryngeal, or to distention of the left internal jugular, and in rare instances the left subclavian vein. The presence of the swelling is usually first recognized in the space between the two tendons of origin of the left sterno-mastoid muscle.

Aneurism of the vertebral artery, in its lower portion, may be differentiated from that of the carotid by compression of this latter vessel high up. If the thumb be placed over the carotid, at its bifurcation, and pressed firmly and directly backward against the vertebral column, such compression will not affect the circulation in the sac of a vertebral aneurism, while if involving the carotid it would be visibly affected. Then, again, vertebral aneurism is, in nearly every instance, of traumatic origin, while aneurism of the carotid is almost always idiopathic.

In the differential diagnosis of these two lesions higher in the neck, the same method is applicable. It should not be forgotten that careless manipulation of a carotid aneurism may detach a clot. If the tumor involve the carotid or its branches, compression of the primitive trunk, low down, will arrest the pulsation in the sac. This is best accomplished by relaxing the sterno-mastoid muscle of that side, and grasping the vessel between the thumb and finger carried behind the muscle. On account of the deep seat of the vertebral artery its compression by this manœuvre is impossible. This last vessel may be compressed by placing the thumb one inch directly below the transverse process of the sixth cervical vertebra, and pressing backward. Above this point it is impossible, since the vessel runs into the vertebral foraminæ.

The ligature between the aneurism and the heart is the safest method of dealing with an aneurism of the common carotid artery. *Direct* or *indirect* compression is not only difficult, but dangerous, since cerebral embolism may occur from the separation of a fragment of clot.

When the ligature cannot be applied on the cardiac side, distal deligation should be done.

Aneurism of the *external carotid* artery should be treated by the ligature on the side nearest the heart; when the walls of the common trunk and the beginning of the external branch are normal, the ligature may even be safely applied directly in the crotch of bifurcation. The author has performed this operation three times, without accident. Should this, however, be impracticable, the common and internal carotid should be tied simultaneously. The external carotid artery may be tied at any point in its course, regardless of the origin of its branches.[1]

Aneurism of the internal carotid, in the neck, should be treated by the deligation of this vessel, between the sac and the common trunk. Should this be not feasible, the common and external carotid should be tied, *together with all branches of the external, on the cardiac side of the ligature.* I performed this operation in one instance, resulting in the rapid and permanent cure of a large extra-cranial aneu-

[1] The author demonstrated the practicability of tying the external carotid artery and the surgical necessity for this operation for the relief of all lesions in the distribution of the external carotid, rather than ligation of the common trunk, which up to that time was almost universally practiced.

When his essays on the arteries were published (in 1878), the external carotid artery to that period had been tied in only 91 instances, with a death-rate of 4½ per cent. There was not a text-book in any language that did not, at that time, advise the ligature of the common trunk, rather than the external carotid, for a lesion within the distribution of the latter vessel.

As an indication of the influence which these essays had in determining the future of operations upon this vessel, the following is quoted from the Third American Edition of "A Manual for the Practice of Surgery," by Thomas Bryant, F.R.C.S., 1881:

"In this connection the views of Dr. John A. Wyeth, of New York, deserve great attention, for, in his prize essays, presented to the American Medical Association in 1878, he has investigated the subject of ligation of the primitive carotid artery and its branches with such painstaking accuracy that his paper will deservedly become classical. He has collected and analyzed 789 cases of ligation of the common carotid artery, 91 instances of ligation of the external, and 18 of ligation of the internal carotid. In addition, he has given accurate measurements of the arteries in 121 subjects, showing the range of variation and the position of branches. His inferences from this astonishing amount of research are at variance in some respects with the surgical teaching and practice of the day; but it would seem that the profession must be in the wrong, rather than he who has considered the subject in such a thorough and scientific manner."

rism of the internal carotid. The common trunk was first tied, then the superior thyroid, and external carotid, just above its origin.

Aneurism of the internal carotid may occur in the cavernous or cerebral portions of this vessel. In the petrous canal dilatation is practically impossible. Not infrequently an arterio-cavernous aneurism occurs from the giving way of the septum between these two vessels. The cause may be traumatic, as in fracture at the base of the skull, or the communication may be established without appreciable cause.

The symptoms of aneurismal dilatation here are of two kinds: those referable to pressure upon the brain and nerves, and those due to interference with the return venous current through the ophthalmic vein. If the arterio-venous communication has occurred, exophthalmus is marked, and the eyeball is projected forward with each arterial pulse. Ringing in the ears, dizziness, with varying loss of function due to pressure, are other symptoms.

The *ophthalmic* artery may be the seat of aneurism within the cranial cavity or in the orbit. True sacculated intra-orbital aneurism of this artery is extremely rare,[1] although pulsating tumors (arterio-venous aneurisms, angeiomata, cirsoid arterial tumors, etc.) are not infrequent in this locality. The chief point in the diagnosis, and the one which has an important bearing in treatment, is compression of the carotid. If pulsation ceases, and the other symptoms disappear, the indication is clear that the ligature should be applied to this vessel. The common trunk should be tied, in order to cut off the free communication between the branches of the external carotid and the ophthalmic in the orbit. In my Essays are given fifty-two instances in which this operation was done for pulsating non-malignant tumors of the orbit, with a death-rate of 11.5 per cent.[2] About seventy-five per cent of recoveries after this operation result in cures. In severe cases extirpation may be necessitated.

Aneurism of any *branch* or *branches of the external carotid* should be treated by the ligature of the branch involved, or the external trunk.

Aneurism of the Subclavian Arteries.—The subclavian arteries may be affected in any portion of their extent, although, on account of the pressure exercised by the two scaleni muscles, this division is less frequently involved. The seat of this disease is by preference in the third portion, the first division being next in order. Exposure to violence or muscular effort has much to do with the development of subclavian aneurism, since males are more frequently affected. The tumor is found on the *right* side in the majority of cases.

The first portion of the right subclavian is also frequently involved in the progress of an innominate aneurism. Upon the left side aneurism of the thoracic portion of this vessel is rare.

Subclavian aneurism is first recognized as a pulsating tumor behind the clavicle, and to the outer side, or behind the sterno-mastoid muscle. It may be mistaken for a glandular or other tumor. The symptoms which have been detailed will serve as a guide for differentiation. Difficulty may arise, even after the aneurismal character of the swelling has been recognized, in determining from what vessel the tumor springs. As has been said, the progress of aortic aneurism gives rise to pulsation and pressure symptoms, located in the thorax for a considerable period prior to the appearance of the tumor at the root of the neck. In fact, aneurism of the aorta, in many instances, produces death before it attains such magnitude. On the right side, this knowledge will aid materially in recognizing the seat of the lesion, and, fortunately, aneurism of the arch and subclavian occurs most often on this side of the body. The differentiation of aneurism of the thoracic portion of the left artery, from the same lesion of the arch, near the origin of the subclavian, is more difficult. When the tumor involves the subclavian its appearance in the neck is more rapid than in aortic aneurism, while interference with the return circulation in the arm, which may appear early in the history

[1] Prof. Sattler's classical paper in Graefe and Saemisch's "Handbuch der gesammter Augenheilkunde," Leipsic, 1880.

[2] "Prize Essays of the American Medical Association, 1878," William Wood & Co., New York.

of subclavian aneurism, is rare when the aorta is the seat of this lesion. Again, in aneurism of the second or third portion of the arch, which does not involve the subclavian, the pulse wave in the left radial will be of equal force and synchronous with that of the right side.

In the *treatment* of *subclavian aneurism* [1] the methods may be divided into the surgical, the postural, medical, and dietetic, and the palliative or expectant. The employment of any of these means will, again, be in great part determined by the portion of the artery involved. The surgical treatment comprises the ligature or compression on the cardiac or distal side; or pressure applied directly to the sac, and massage.

Deligation of the *arteria innominata* for the relief of subclavian aneurism presents an array of disasters which makes it imperative in the surgeon to exhaust all less radical measures before attempting it. It has, however, been done successfully, and conditions may arise which will justify the procedure. When it is performed, I would advise a removal of the sternal end of the clavicle, in order to expose not only the innominate close to the bifurcation, but also the branches which arise from its *first* and *second* surgical divisions of the subclavian, which, with the common carotid, should also be tied at the same operation.

I would also advise the employment of a broad ligature, which would be less liable to cause the artery to cut through from the impact of the current coming with such force at this point directly from the left ventricle. A ligature made of several strands of catgut, ranged side by side, would suffice, or, preferably, a portion of the sciatic nerve of the calf treated aseptically. I have used this soft, yet strong, ligature in a number of instances with complete satisfaction; not, however, in tying so large a vessel as the innominate. I would not hesitate to employ it in this dangerous operation, using catgut for the carotid and the smaller branches. If all the branches of the subclavian were tied, and this vessel ligated in its third surgical division and the carotid tied, coagulation would of necessity take place in the innominata.

Ligature of the subclavian artery in its first or second surgical divisions has also proved disastrous in a very large proportion of cases in which it has been performed. Under aseptic conditions it will be justified in extreme cases, the branches given off from the first and second divisions being tied at the same time. Before resorting to any such procedures, however, the danger of gangrene to the upper extremity should be seriously considered.

It is safe to conclude, from a careful study of the results in the treatment of subclavian aneurism, that the ligature on the proximal side—that is, to the innominate, carotid, and first or second portions of the subclavian artery—should not be attempted until the most persistent and careful application of more conservative measures have been tried and have failed.

The combination of the postural, dietetic, and medicinal treatment, with absolute rest under strict surveillance, combined with compression when possible upon the cardiac side of the tumor, and when this cannot be done, directly upon the tumor, will, in the majority of instances, render it unnecessary to resort to operation. Digital compression may be practiced at varying intervals, as well as mechanical, and pain can be relieved by infiltration with one half of one per cent cocaine solution. The adjustment of the elastic bandage compress is perfectly feasible, and has been used successfully.[2]

[1] See classical paper by Prof. Edmond Souchon, of New Orleans, "Annals of Surgery," November and December, 1895.

[2] A baseball pitcher, twenty-five years old, developed an aneurism involving the third portion of the right subclavian and the axillary artery. A large pulsating tumor was distinctly recognized, extending from about one inch above the clavicle into the axilla and for about three inches along the axillary artery. Appreciating the dangers of tying the subclavian in the first or second division the patient was put to bed, placed upon a restricted diet of nutritious food in small quantities at frequent intervals, with the minimum of liquids, and strict attention to the alimentary canal. He was not permitted to leave the bed, but was allowed to sit upright or recline on pillows. The least possible motion of the affected arm was permitted. Direct compression was begun by means of a soft ball of absorbent cotton laid over the tumor and held by an elastic bandage, with only sufficient pressure to hold it in place for the first few days. This was gradually tightened until it became painful. A hollow rubber ball was substituted for the cotton. At varying intervals the

Aneurism of the brachial, radial, and ulnar arteries.

Aneurism of the *brachial* artery should be treated by compression on the cardiac side when possible, next on the distal side, or by either of these methods combined, with direct compression of the sac.

In applying compression directly upon or on the distal side of an aneurismal sac, the possibility of rupture and hæmorrhage should not be overlooked, and a tourniquet (preferably a piece of rubber tubing) should always be in readiness to be tightened on the cardiac side at the first suggestion of this accident.

One of the great advantages in a patient trial of compression, even if the ligature should ultimately have to be applied, is that it tends to develop a collateral circulation and thus removes the chief danger of gangrene, when occlusion occurs either from consolidation in the sac or the ligature. This applies with especial force to single vessels, as the brachial or femoral.

What has been said of the *brachial* applies in equal measure to the *radial* and *ulnar* arteries. Here, however, since there are two vessels of small size, the ligature is advised. Either of these can be tied with cocaine anæsthesia; in fact, the conditions are rare when any of the large arteries, with the exception of the innominate, first portions of the subclavian, and the iliacs may not be exposed and the ligature applied with perfectly satisfactory cocaine analgesia.[1]

Aneurism of the vertebral artery is very rare, and is almost always caused by a penetrating wound. It may be mistaken for carotid aneurism. If the head be flexed upon the chest, completely relaxing the sterno-mastoid muscle, the carotid artery can be compressed by grasping the muscle and artery between the thumb and finger. While this would cause pulsation to cease in a carotid aneurism, it would not interfere with the circulation through the vertebral, which, as it passes deeply through the foramina in the transverse processes of the cervical vertebræ from the sixth upward, cannot be compressed. Although the deligation of this vessel before it enters the foramina of the sixth cervical is a very difficult operation, it should be undertaken for the cure of aneurism. Direct compression upon the sac incurs a very considerable risk of death from embolism.[2]

Aneurism of the *internal mammary* and of the *intercostal arteries* does not demand especial consideration. The latter occurs occasionally as a result of fracture of the rib. They may be readily exposed as they lie in the groove along the lower border of the ribs.

Aneurism of the *thoracic aorta*, exclusive of the arch, does not come within the province of surgery. The method of Tufnell is advised.

Aneurism of the *abdominal aorta* is most frequently met with near the diaphragm. The tumor may be sacculated, or there may be a fusiform dilatation of the entire vessel.

The *diagnosis* is difficult, unless the subject be thin and the alimentary canal emptied so that palpation and auscultation may be made immediately over the tumor. The expansile pulsation, the aneurismal tremor and bruit, together with the history of the case, should lead to a recognition of the lesion.

The *treatment* should be a persistent trial of the postural and dietetic method. As a last resort, the introduction of steel wire, fine watch-spring, or catgut may be tried.

In this operation the tumor should be exposed by a median incision and the displacement of any interposed viscera. A small trocar-canula is introduced into the sac, the trocar withdrawn, and the material selected is rapidly introduced in quantity about equal to one half of the capacity of the sac. The presence of the foreign body tends to cause coagulation. The prognosis is exceedingly grave.

When the *visceral or parietal* branches of this vessel are involved, if the character of the lesion cannot be recognized, an exploration under strict asepsis is

bandage was loosened and digital compression was made upon the artery where it passes over the first rib. When this and the mechanical pressure could no longer be endured, a hypodermic of morphia or instillation of cocaine was advised. The tumor gradually diminished in size, the expansile pulsation was less noticeable, the mass became firmer to the touch and, later, became completely solidified, and was cured.

[1] The author has tied the subclavian in its third surgical division with this anæsthetic.

[2] This artery has been tied here by Smyth, Parker, Alexander, and the author.

justifiable. Deligation upon the cardiac side, if there is room, or if not, upon the distal side, is the operation of election.

Aneurism of the *common iliac arteries*, or of the two primary divisions of this trunk, may be diagnosticated by the stethoscope, combined with careful palpation and digital exploration by the rectum or vagina.

The mortality following deligation of the aorta or of the common iliacs for the cure of aneurism is so great that the conservative methods heretofore described should be first persistently employed. Mechanical compression with the horseshoe tourniquet has been employed. Digital compression of the aorta under spinal anæsthesia (cocaine) may also be advised. This may be done through a small incision in the *linea alba*, or a general narcosis lasting from one to two hours may be substituted if necessary, and this operation may be repeated at intervals of two or three weeks until an organized coagulum is secured.

Ligation of the abdominal aorta is one of the most fatal of all surgical procedures. Should it be deemed necessary in extreme cases, immediate occlusion by the ligature should not be attempted. The gradual closure of this vessel should be tried by surrounding it with a broad animal ligature, which would reduce the lumen one third. After an interval of several weeks, a second ligature at a point beyond the first should be applied, which would still further but not completely close the vessel, while at a third operation an attempt at final occlusion may be made. By this operation it is intended to develop a collateral circulation, which would lessen the strain upon the final ligature.

In iliac aneurism, situated near Poupart's ligament, compression by means of a hand introduced into the rectum may be tried, or Davy's lever may be employed in the same way. Should no other alternative be presented, and the external iliac alone is involved, this vessel may be tied, or the ligature may be placed upon the common iliac. Aneurism of the internal trunk is amenable to treatment by compression of the common iliac or by deligation of the primary trunk.[1]

Aneurism of the branches of this vessel is usually confined to the gluteal and sciatic, and results from a severe blow or a penetrating wound of this region. The author successfully operated upon a case of aneurism of the gluteal by cutting down upon the tumor, and tying this vessel just as it emerged from the pelvis.

Aneurism of the superficial femoral artery is comparatively frequent. It is usually seen in the upper half of this vessel, and almost always in males. As the artery is superficial, the diagnosis is not difficult, since the expansile pulsation of the tumor can be readily appreciated by palpation and auscultation. Aspiration with a very fine hypodermic needle will, if necessary, make clear the diagnosis.

Treatment.—Aneurism of the *femoral* artery will, in the vast majority of cases, yield to judicious and patient compression combined with absolute rest in bed and restricted diet. Should the tumor be located as high as Poupart's ligament, the chances of success diminish, since pressure will have to be applied to the common or external iliac. Under such conditions direct compression by means of Holmes' hollow elastic ball, held in place by Esmarch's bandage, should be employed. The pressure should be very gradually increased. Ligation of the common or external iliac should never be done until after a long and patient trial of the more conservative methods, and when there is a choice between these two measures the external iliac should be selected.[2]

When the tumor is so situated that compression of the femoral can be made at or below the rim of the pelvis, this treatment should be adopted. Should all conservative measures fail, and should the indications be not clear for the pro-

[1] Prof. J. D. Bryant, "Annals of Surgery," vol. xvii, 1893, reports the cure of a large aneurism of the right iliac after Macewen's method. Delicate needles were introduced, and the sac teased by drawing the point of the needle along the wall of the aneurism opposite to the point of introduction. The teasing lasted about half an hour, and two of the needles were left in for twenty-four hours.

The author induced coagulation in a large aneurism of the ascending arch of the aorta by this method. The patient died very suddenly a year later with all the symptoms of cerebral embolism.

[2] It would be safer to apply the distal ligature (after the method of Wardrop) before resorting to ligation of the common or external iliac.

cedure of Matas, the ligature becomes necessary, and the effort should be made to reach the artery below the origin of the *profunda femoris*, since the danger of gangrene is greatly lessened if this collateral route be left open.

The treatment of aneurism of the lower portion of the *femoral* does not differ materially from that advised for the upper portion.

Aneurism of the *profunda femoris* is rare, and is usually the result of a punctured wound. The treatment is the same as given for the common trunk. In properly selected cases, when the aneurism has been recognized early, the method of Professor Matas may be employed. The technic will be given in connection with popliteal aneurism.

Aneurism of the Popliteal Artery.—This vessel is frequently the seat of aneurism, caused by the compression to which it is subjected in extreme flexion of the leg on the thigh. It occurs most frequently in males, and in the active period of life—from twenty-five to fifty years of age.

The characteristic symptoms are pain due to pressure on the popliteal nerve and the posterior surface of the joint, and expansile pulsation, with the peculiar rushing sound of the blood as it passes through the sac. The differentiation from glandular enlargements, exostoses, or overdistended bursæ may be made by digital compression of the femoral at the rim of the pelvis, which will cause the tumor to diminish in size and pulsation to cease.

In abscess of the popliteal space pain, more or less diffused redness and swelling, with the usual symptoms of sepsis, and the absence of pulsation, will exclude aneurism.

Treatment.—If conservative measures are to be tried, the patient should rest in the recumbent posture, with the leg of the affected side slightly flexed. The mattress should be soft, and the limb held in a comfortable position by means of a pillow beneath the popliteal space. Sand bags should be packed on either side to prevent motion. Mechanical compression should be applied to the femoral, preferably at the rim of the pelvis or in Scarpa's space, and changed from place to place to prevent soreness.

In applying pressure it is not intended to completely occlude the artery, and care should be taken not to compress the vein which lies just to the inner side. The elastic bandage and a small rubber ball will be found most useful in carrying out this plan of treatment. Should this fail, one of two operations may be selected: viz., tying the vessel below the origin of the profunda femoris, at Hunter's canal, or attempting to restore the integrity of the artery by the method of Matas.

Aneurism beyond the popliteal is rare. The *anterior* and *posterior tibials* are deeply situated, and direct compression is difficult. As the ligature of either one of these vessels incurs no risk of gangrene, it should be advised. Should the *dorsalis pedis* be effected, direct compression with the elastic bandage should suffice.

Arterio-venous aneurism usually occurs as the result of a *gunshot* or *punctured* wound. The communication may be *direct* (aneurismal-varix, Fig. 147), or indirect (varicose-aneurism, Fig. 146).

As a rule, the vein involved becomes dilated and tortuous, and pulsates with each systole of the heart, while the pulsation in the artery beyond the point of communication is perceptibly diminished. Should the lesion involve a *single* artery and vein, as the *femoral* or *brachial*, where there would be danger of gangrene from the ligature, the member should be rendered bloodless by Esmarch's bandage, a careful dissection made in the effort to separate the vessels, and to close each opening by the finest linen sutures. Should this be impossible, the catgut ligature should be applied to each vessel above and below the lesion.

CHAPTER VIII

WOUNDS OF THE BLOOD VESSELS—LIGATION

Wounds of *arteries* and *veins* may be successfully closed by sutures as well as by the ligature, and under certain conditions end-to-end anastomosis should be performed. The dangers are considerable, not alone from hæmorrhage, due to failure of close apposition and leakage during the process of repair, but to the possible formation of a thrombus with the detachment of an embolus (always disastrous in a vein), or the gradual occlusion of an artery resulting from cell proliferation and the deposit of fibrin at the suture line. When, however, an important single trunk is involved (vein or artery), as the vena cava, aorta, either of the iliacs, common femoral, popliteal axillary, and brachial, this more heroic procedure is entitled to trial. The same is true after division of the two arteries of an extremity. In one instance the radial and ulnar of one side have been reunited and the circulation successfully reëstablished.

The technic requires the control of bleeding by digital compression or by a tape one fourth inch wide twisted and held by forceps just tight enough to occlude the vessel without crushing the intima, or by complete local exsanguination with the Esmarch bandage. Very fine and perfectly round half- and quarter-curved needles, the finest silk, linen (or chromicized catgut No. 0) are required. The animal suture has the advantage of being absorbable and of swelling enough to plug the needle hole. It does not, however, have the same holding power, and this fact justifies a general preference for linen or silk.

If the wound is transverse and the division incomplete, the delicate needle and thread should, if possible, be entered on one side one sixteenth inch from the edge, and made to pass through the adventitia and media, and come out on the cut edge between this and the intima, and, at a point exactly opposite on the other end, to enter between these coats and emerge through the adventitia. The sutures should not be more than one sixteenth inch apart, and should be carefully and evenly adjusted and tied in equal tension. When possible, these should be reënforced by suture of the sheath. The sheath should never be lifted farther than is absolutely necessary for fear of interfering with the nutrition of the coats (vasa-vasorum). When the conditions do not favor this ideal method the sutures may be carried directly through all the coats. The intima will, in all probability, be cut through in the act of tying, and the suture within a few hours entirely imbedded in a mass of plastic exudate and new cell proliferation.

Should the wound be longitudinal or oblique, the same technic is employed, but when a considerable portion of the wall is destroyed, end-to-end suture may be required. In complete division (as by a bullet wound) trim the edges smooth; arm two very fine needles with a single silk or linen thread; pass one needle in a direction parallel with the long axis of the upper end, entering one sixteenth inch from the edge and coming out between the media and intima on the cut edge. Both needles are now carried into the lumen of the lower end for one third inch, and are brought up through all the coats of the vessel wall one sixteenth inch apart (Figs. 152, 153). Two other similar sutures are inserted equidistant. The lower end is now split at one point in its long axis not quite to the point of exit of the twin needles. By traction on the sutures the upper end is invaginated into the lower, where it is held by tying the threads. The slit is closed by one or two interrupted stitches and the rim of the lower (the

outside) segment is then stitched in four or five places to the adventitia of the upper end, taking very great care that the needle does not penetrate the intima of the inner segment.[1] The sheath should be carefully readjusted and stitched by way of reënforcement, and the wound closed with all aseptic precautions.

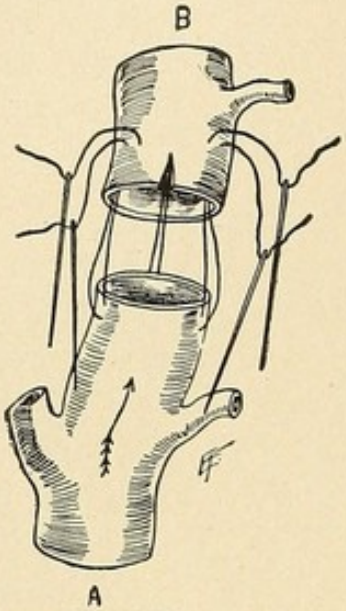

Fig. 152.

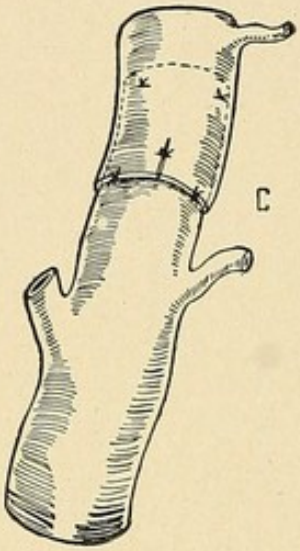

Fig. 153.

The after-treatment demands the greatest watchfulness. If the operation has been done on an extremity, this should be kept warm with cotton batting, and elevated and bandaged to diminish the blood current to the minimum required to maintain nutrition.

A tourniquet should be applied ready for use, and the eye of an attendant kept constantly upon the dressing.

For fear of embolism, suture of the common carotid artery should not be attempted. Sutures are applied to the veins in practically the same way as to the arteries. The danger from thrombosis and embolism is greater than in arterial suture, and therefore every effort should be made to so insert the thread as to leave no portion in contact with the blood current (Fig. 154). Infolding the edges after the method of Lembert should be attempted. In a small puncture the lateral silk ligature should be preferred (Fig. 155), as it is practically safe. In the treatment of arterio-venous aneurism favorably located, the foregoing technic may also be applied.

The Surgical Occlusion of Arteries and Veins.—In order of preference in the permanent occlusion of an artery or vein is the *ligature, torsion, crushing,* and the *actual cautery.* Ligatures are absorbable (catgut, plain or chromicized) and non-absorbable (linen and silk). (Silkworm gut or kangaroo tendon are only used for sutures.) Plain catgut of proper size is employed almost to the exclusion of all other ligature material. It is usually applied as a single strand, although in the deligation of a very large vessel (as the aorta or innominata) where a broader distribution of pressure may be required, a *broad ligature* may be made of six or a dozen medium-sized threads arranged parallel or very loosely twisted. Occasionally where the process of repair may be delayed (as in an infected area) the ten-day chromic-acid catgut may be substituted.

Linen or silk are never necessary in tying an artery, but for the lateral ligature of a vein that has been punctured or is bleeding from a collateral branch severed close to the parent trunk, fine linen is invaluable. They are much less apt to slip than the softening animal material, and in certain dissections, as along the jugular or axillary veins, should always be preferred (Fig. 155).

[1] The author, while without actual experience in this new and brilliant procedure of Prof. John B. Murphy, is of the opinion that the danger from this through and through suture is overestimated, as has already been proven in intestinal suture.

In tying an artery either in continuity or near the end of a divided vessel, the plain reef-knot is usually preferred for the reason that the degree of tension in the first knot can be more accurately determined. In almost all instances this will hold, but should it slip or yield it may be firmly held by the suture forceps especially designed for this purpose. A second and a *third* knot should always follow in using an animal ligature or suture.

When the vessel to be secured is so deeply situated that the suture forceps cannot be used the double or friction knot may be substituted.

While the occlusion of an undivided artery may result from a ligature so loosely applied that the opposing surfaces of the intima are barely held in contact, it is always advisable to use force enough with the first knot to crush the fragile intima and media. Imbedding the ligature in this way is always required to prevent slipping when the exposed stump of an artery is tied. The strong connective-tissue layer (adventitia) will prevent accident until permanent occlusion results from cell proliferation in the process of repair.[1]

Torsion, in which the end of an artery is seized by a forceps and twisted several times on its axis, crushing the intima and media and spinning the connective tissue of the outer coat into a loosely twisted thread, is useful especially in arresting hæmorrhage from smaller vessels (arterioles, etc.), when haste is necessary. In an emergency it may be applied to vessels as large as the femoral or brachial.

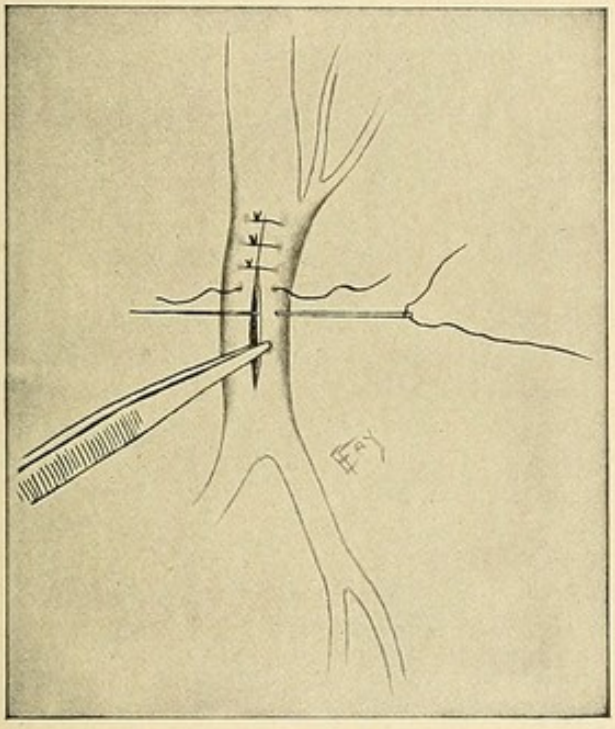

Fig. 154.—(After Bickham.)

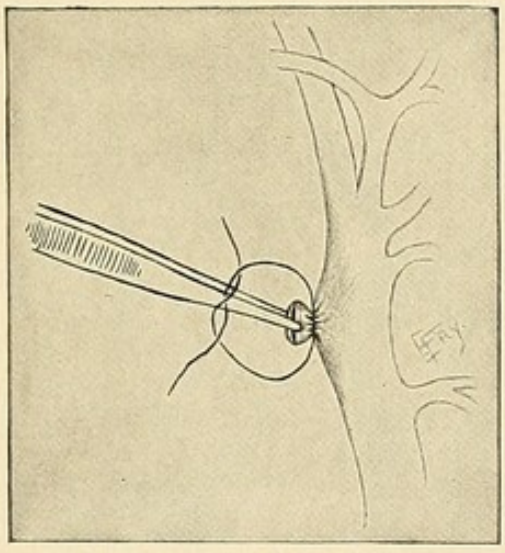

Fig. 155.—(After Bickham.)

Crushing with the angeiotribe, with or without the addition of the *actual cautery* is occasionally employed in the division of vascular pedicles (tubes, ovaries, etc.), though more expeditious than the ligature, silk, linen, or strong chromi-

[1] In 1883, in experiments upon animals, the author demonstrated that when under aseptic conditions an animal ligature was applied to an artery in continuity in such a way that opposing surfaces of the *intima* were held in apposition without breaking through this coat or the media, an active cell proliferation was precipitated in the zone of hyperæmia which followed the traumatism, and that permanent occlusion resulted from the fibrillation (contraction, cicatrization) of this new formed connective tissue.

This result proved the correction of the theory previously advanced (but not demonstrated) that the clot was an accident of and not an essential factor in arterial occlusion. In other words, that the process of repair in an artery did not differ from that of any other structure under corresponding conditions.

Fig. 65 from the common carotid of a horse shows the rich cell proliferation of the intima and adventitia following the presence of a broad animal ligature which did not quite close the lumen of the vessel.

Under septic conditions the result is ultimately the same provided that infection does not cause the vessel wall to break down.

cized catgut is more deserving of confidence. However, this method is still in general use in the *clamp* and *cautery* operation for hæmorrhoids.

The methods applied to arteries may be used as well in the closure of *veins*. In order to prevent the influx of air the proximal end should first be carefully secured, especially in operations near the root of the neck. Even the *vena cava ascendens* has been successfully deligated, the patient four years later being able to work in the upright posture without inconvenience.

Ligation in Continuity.—In tying an artery, while the incision should be along the line of the artery, it should lean as far from the accompanying vein as

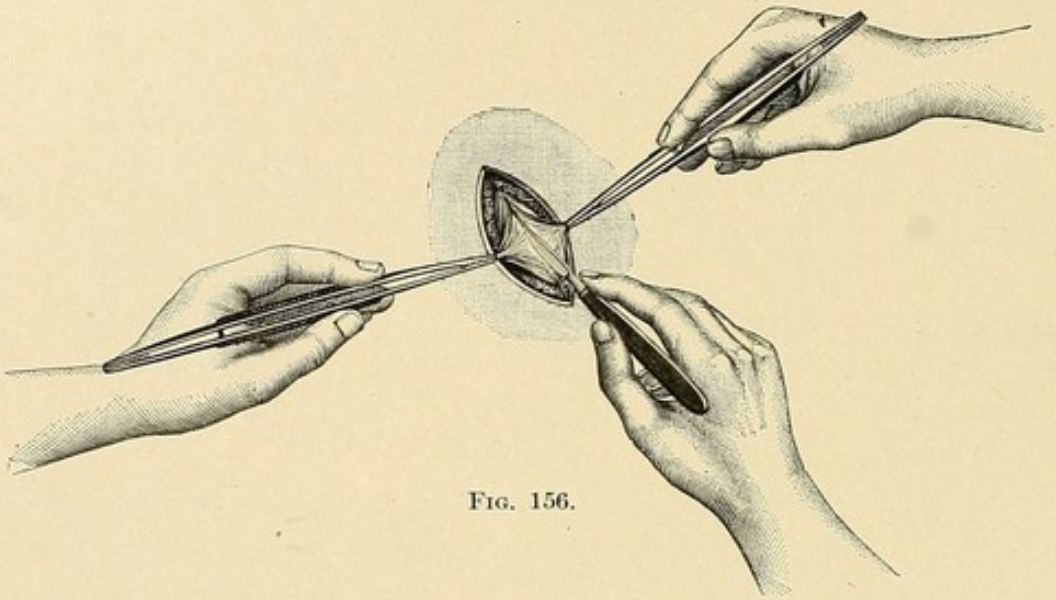

Fig. 156.

possible. In approaching the vessel after the skin is divided, the fascia and all intervening tissues should be grasped between two long, delicate dissecting forceps (Figs. 156, 157), until the sheath is reached, and this is opened in the same manner. As soon as the wall of the artery is exposed the sharp-pointed instruments should be laid aside. A dull-pointed aneurism-needle, or a flexible silver probe, should now be passed between the sheath and the vessel, and carried care-

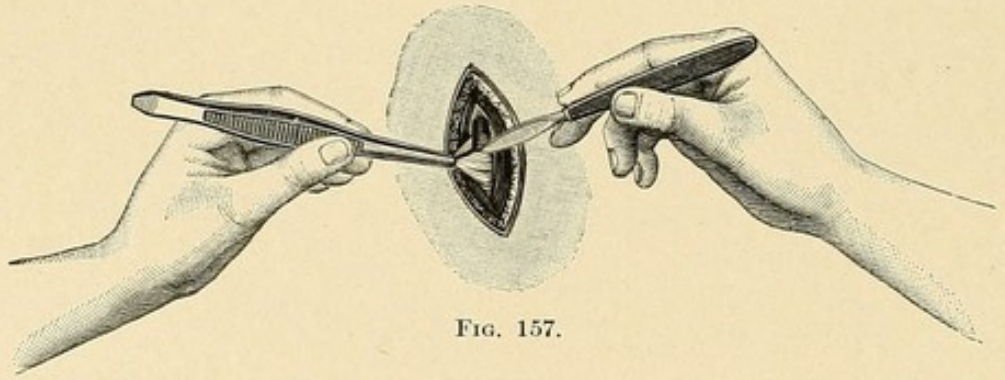

Fig. 157.

fully around the artery, keeping the point close to the wall of the vessel. When a nerve or vein is in close relation, the instrument should be introduced on the side nearest these, thus insuring their exclusion. The dull-pointed probe, bent to the proper curve, may be used to great advantage in almost all operations upon the arteries. After the point is carried around the vessel and brought up out of the sheath, the ligature may be tied over the slight bulbous expansion of this instrument, which, when withdrawn, leaves the ligature around the vessel. The force employed should be sufficient to occlude the vessel and prevent slipping, yet not enough to inflict unnecessary violence upon its walls. The single reef-knot should be preferred, and if necessary the ligature forceps should be used to hold the first knot while the second is being tied. In using animal ligatures a

third knot should always be made. The ends should be cut off for one fourth to one half of an inch from the knot, and the wound closed for a permanent dressing.

Ligation of the Innominate Artery—Anatomy.—The *arteria-innominata* is derived from the transverse segment of the arch of the aorta, immediately in front of the trachea, just behind the middle of the sternum, at a level varying from one half to one and a half inches below the upper margin of the manubrium.

From this origin it travels obliquely upward, backward, and to the right (crossing the trachea from its center), and bifurcates, near the upper margin of the clavicle, between the *sternal* and *clavicular* origins of the *sterno-mastoideus* into the *carotid* and *subclavian arteries*, the first of these coming from its anterior aspect, the last a direct continuation of the *arch of the innominate*. The *innominata* in rare instances originates to the left of the trachea; more frequently it is given off before it reaches the windpipe. As a rule, it is longer in females than in males.

In twenty-eight cases in which I measured the distance of the origin of the innominate from the commencement of the aorta, the average was three inches and a half. In thirty-seven measurements made to determine the length of the innominate artery, the average was one inch and a half, the shortest specimens being three fourths and the longest two inches.

Operation.—Place a firm cushion crosswise beneath the shoulder-blades, so that the head will fall well back, and thus draw the artery upward. Have an assistant draw the arm and shoulder of the right side forcibly downward, while the chin is elevated and the face turned slightly to the left.

With the patient completely anæsthetized, and every arrangement made for expedition, make, from the center of the interclavicular notch, an incision about three inches in extent along the clavicle. A second incision, commencing at the inner border of the sterno-mastoideus, about two inches and a half above the clavicle, is made to unite with the first incision at the middle of the interclavicular notch. Dissect the flap upward until the sterno-mastoid muscle is exposed, the sternal and two thirds of the clavicular origins of which should be divided upon a grooved director carefully introduced. Superficial to the muscle some small veins will be found, and underneath its clavicular portion is the junction of the subclavian and jugular veins, in dangerous proximity. The anterior jugular veins will be seen immediately beneath the muscle, and should be tied and divided. Dissecting carefully, with the handle of the scalpel, the connective and areolar tissue in which these veins are imbedded, the origins of the *sterno-hyoid* and *sterno-thyroid muscles* will be reached, and, when these are divided carefully upon the director, the right carotid will be seen near the center of the wound. Following this down, the *arteria innominata* will be found just behind the *sterno-clavicular* articulation (Fig. 158). Being exposed with the scalpel-handle, or any dry dissector not likely to wound the vessel, the aneurism-needle should be passed from right to left behind the artery, care being taken to avoid wounding the right *vena innominata* and the *pneumogastric nerve*, or puncturing the *pleura*, in which the artery is *partly imbedded*. It is well to bear in mind that the left innominate vein crosses this artery, although usually very low down. When the aorta is situated low in the *thorax*, it may be necessary to remove the sternal end of the clavicle and a segment of the sternum.

An element of danger in this operation is the origin of an abnormal branch from the innominate. In thirty-four consecutive subjects which I examined as to this feature, I found an abnormal branch to be derived from the innominate in five. When the necessity for occlusion of the arteria innominata arises, and the conditions are such as to permit it, the following method should be followed: The right common carotid should first be tied one inch above its origin. By a careful dissection the first division of the subclavian and its branches should then be exposed, drawing the internal jugular to the outer side until the vertebral is secured. Avoiding the phrenic nerve, as it descends to the inner side of the scalenus anticus, the internal mammary and branches of the thyroid axis should be secured, and finally a ligature of large, smooth catgut, placed around the sub-

clavian artery, about the middle of its first portion. A careful study of the anatomy and surgery of this region leads me to conclude that this procedure, though difficult of execution, offers a better prospect of success than deligation of the larger and primitive trunk, nearer the heart.

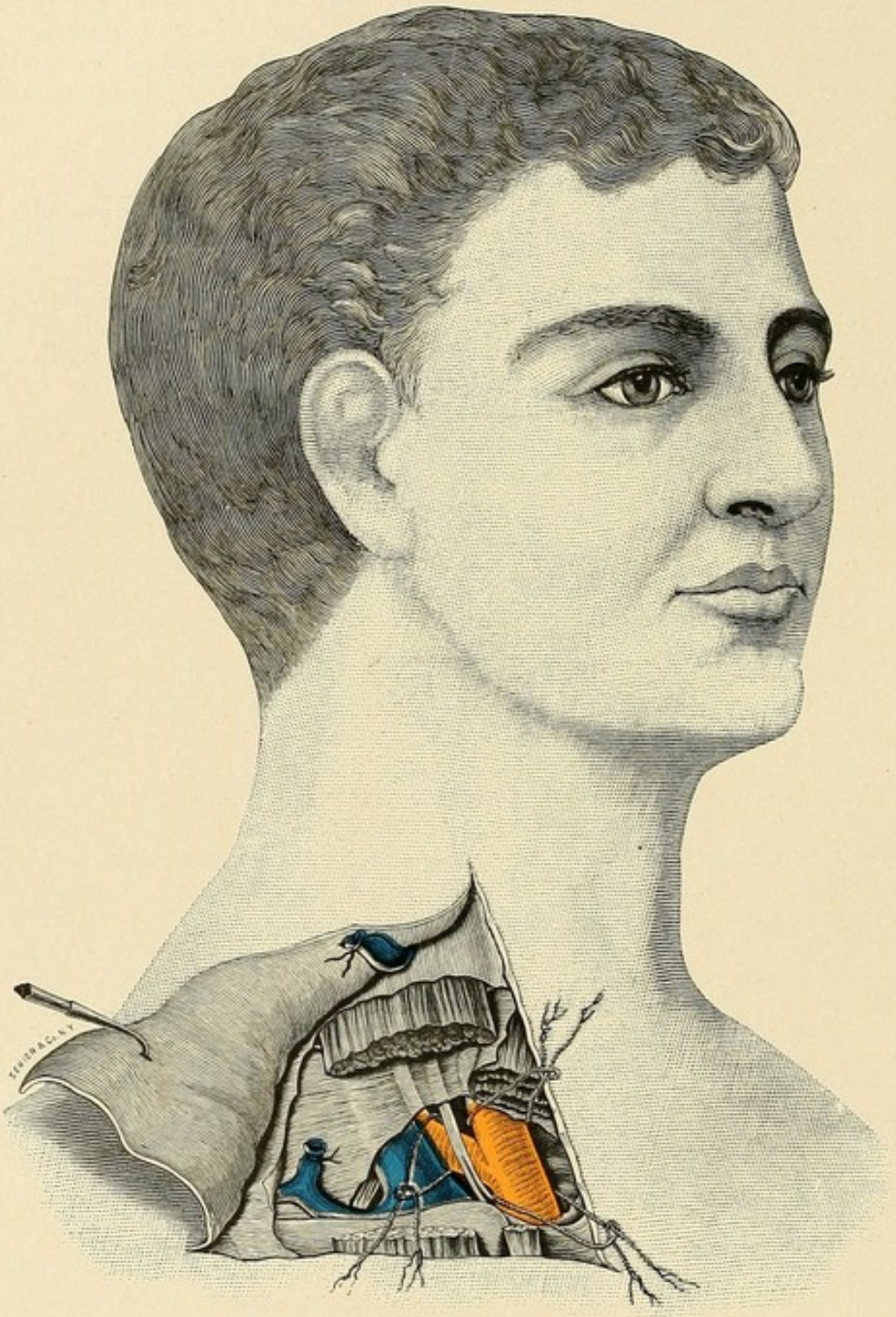

FIG. 158.—Showing the relations of the parts involved in deligation of the innominate artery; the right subclavian and carotid in their first divisions.

Ligation of the Common Carotid Arteries and the Internal Jugular Vein—Anatomy.—In one hundred and twenty dissections I found the *common carotid* artery to bifurcate on a level with the notch between the two alæ of the thyroid cartilage in one hundred and sixteen. The anomalies of this vessel are so rare that they do not deserve mention in this work.

Operation.—A firm cushion should be placed under the shoulders and lower part of the neck, with the chin elevated, and the face turned in the direction away from the side upon which the operation is to be performed. A line extending from the tragus of the ear to the sterno-clavicular articulation will cover, and be

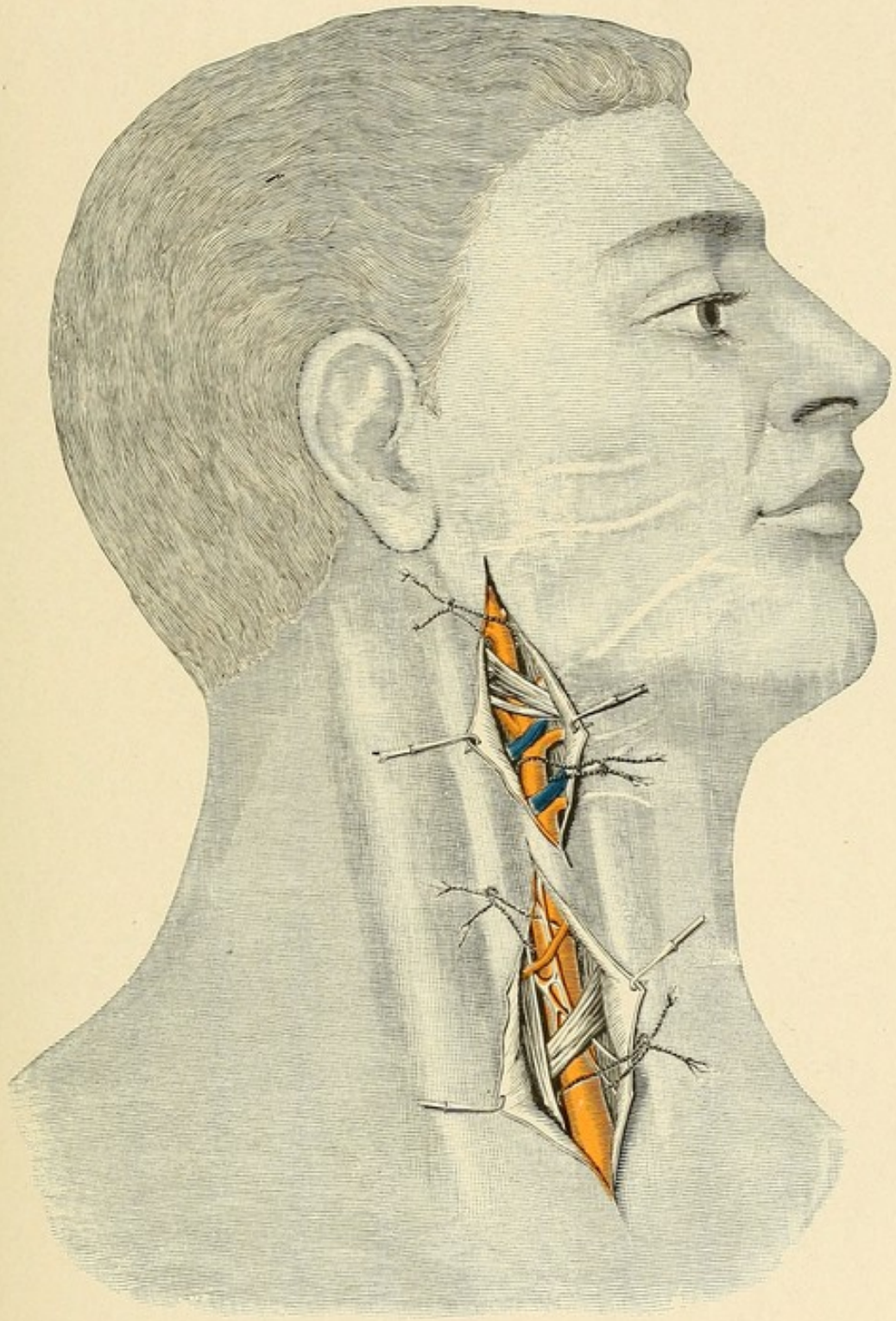

FIG. 159.—Showing lines of incision and relation of parts involved in deligation of the common carotid, above and below the anterior belly of the omo-hyoid, and the external carotid below the lingual and above the facial.

parallel with, the *internal* and *common carotid* arteries in their surgical length. This line will strike the center of bifurcation of the primitive carotid almost invariably on a level with the upper border of the thyroid cartilage, and the anterior edge of the *sterno-mastoideus* from one inch and a quarter to one and a half below

this level. The point of election is about one inch below this bifurcation, and at the upper border of the anterior belly of the omo-hyoid muscle.

The incision, being made with its direction as above given, its center about one inch below the bifurcation, extending from one and a half to two inches above and

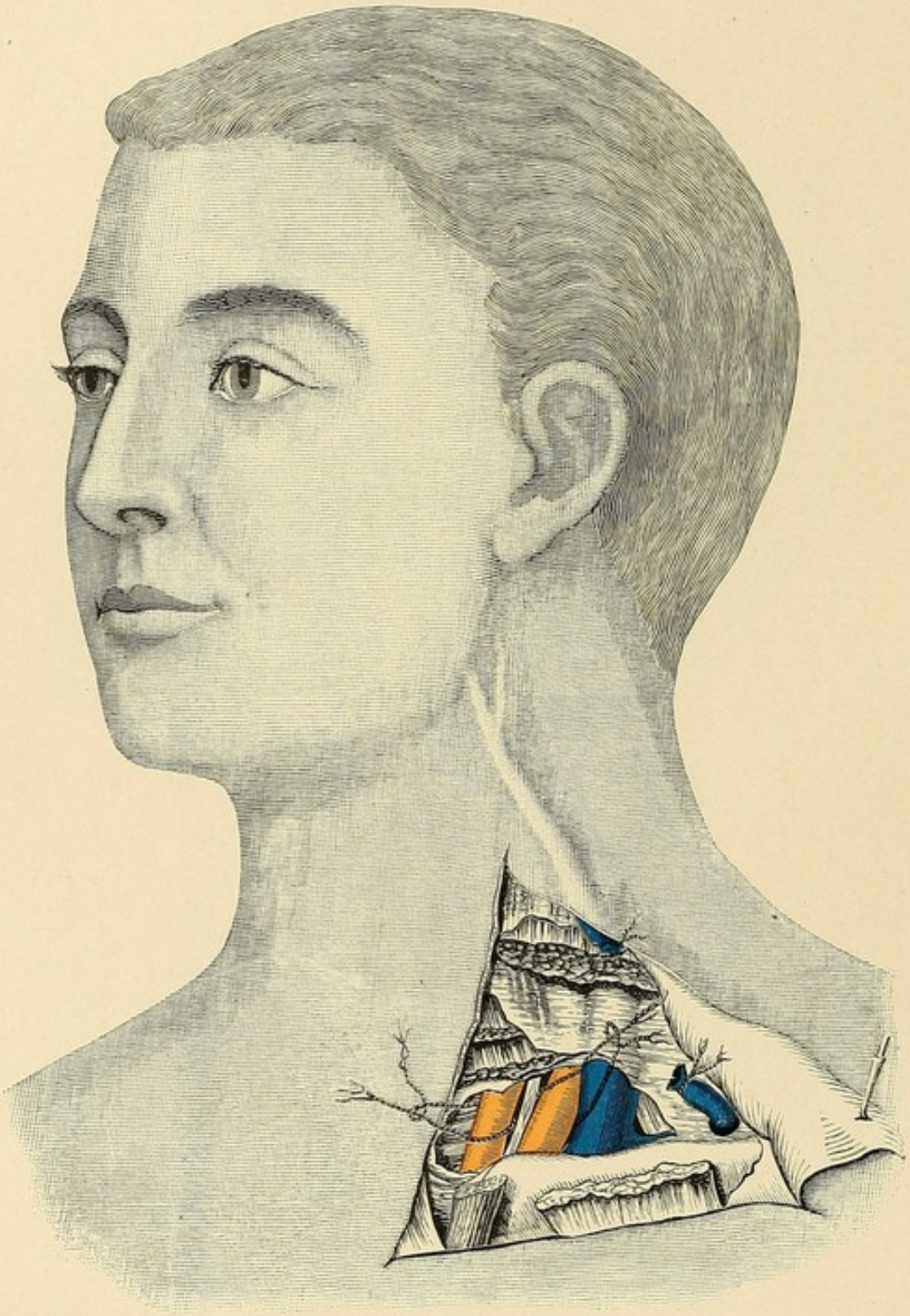

FIG. 160.—Showing the relations of parts involved in deligation of the left carotid, at the root of the neck, and the left subclavian in its first surgical division.

below this point, will divide first the integument, and with this the thin *platysma myoides*, some filaments of the *superficialis colli* nerve, of no importance, and some small veins passing from the *anterior*, either to the *internal* or *external jugular veins*. About the center of the wound the edge of the *mastoideus* will be seen,

and below this (usually) the anterior belly of the *omo-hyoideus* (Fig. 159, lower half). The sheath of the *carotid* and *jugular* vein is now exposed, often crossed

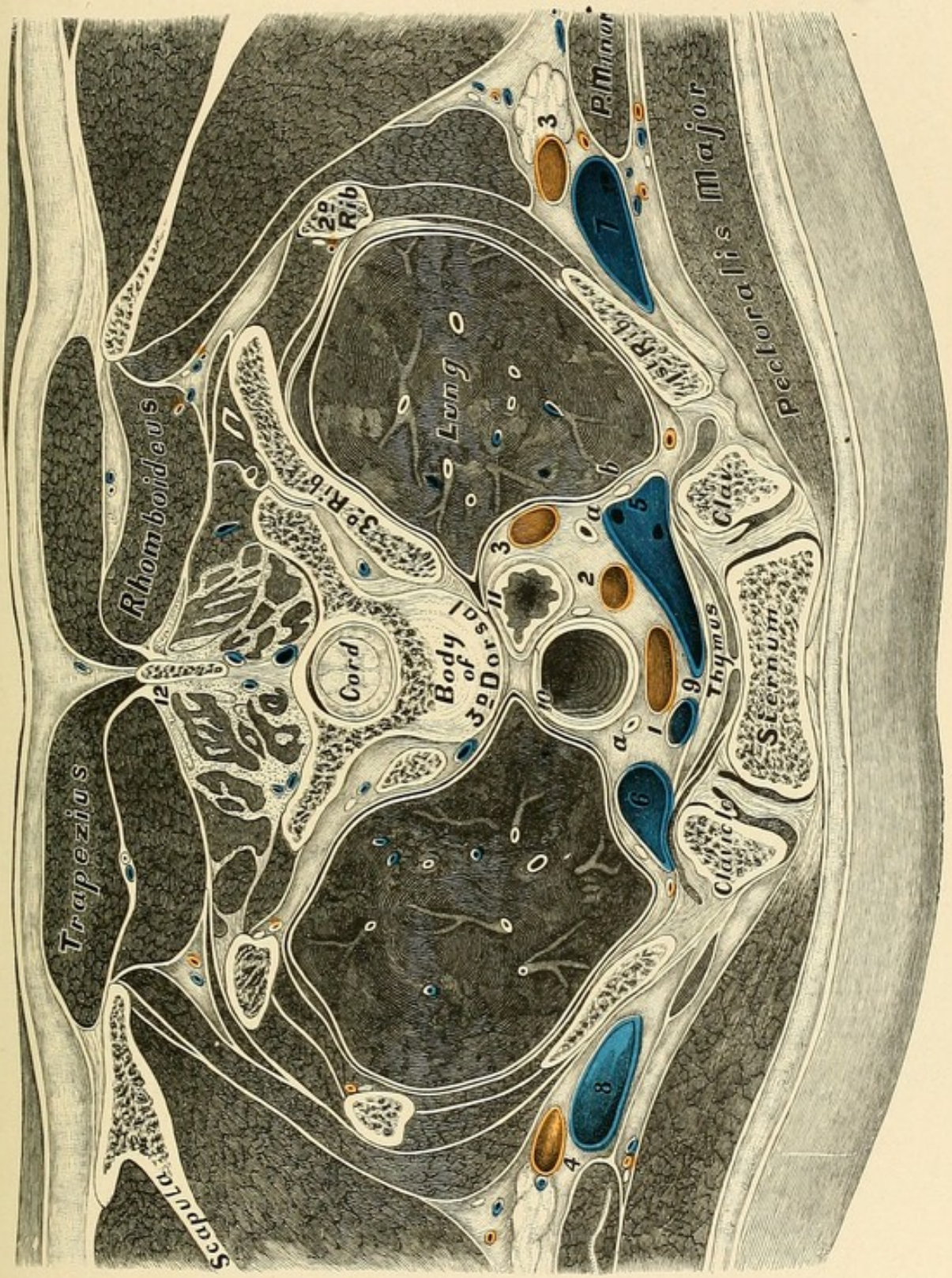

Fig. 161.—Showing the relations of the important organs at the root of the neck and apex of the thorax. Frozen horizontal section at the level of the third dorsal vertebra. (After Braune.) 1, Innominate. 2, Left carotid. 3, Left subclavian. 4, Right subclavian arteries. 5, 6, Left and right innominate veins. 7 and 8, Subclavian veins. 9, Inferior thyroid vein. 10, Trachea. 11, Œsophagus. 12, Spinous process of second dorsal vertebra. *a a*, Pneumogastric nerves. *b*, Phrenic nerves.

by the *thyroid* veins, and the *cervicalis descendens* artery, the *descendens noni* nerve almost invariably lying upon the center of the sheath, being parallel with

the axis of the *common* and *internal carotids*. In two instances I have seen the *superior thyroid* artery turn directly down, in front of the *common* trunk, for an inch or more, and then turn abruptly inward to be distributed to the thyroid body. Under such abnormal conditions this vessel would probably be divided. The *communicans noni* is occasionally found crossing the sheath from without inward, to anastomose with the *descendens*. These nerves will be drawn to the outer or inner side of the wound, as is most convenient. The sheath should be opened on its *tracheal* side, as far as possible from the *jugular vein*, and the needle passed from without inward, being kept close to the artery in order to avoid wounding the *vein* or including the *pneumogastric* or *sympathetic nerves*. The sheath should be well opened, and the artery clearly exposed, so that the needle may be manipulated with more of certainty and less danger from these too common and unfortunate accidents. In several instances the artery has been transfixed; the *jugular* has been wounded; the *pneumogastric* or *sympathetic* nerves included in the ligature, for want of precision in separating the artery from the vein. Certainly the danger of slough in the artery is not so great as the dangers above enumerated. Just as the needle is being introduced, pressure above upon the vein would empty it of blood, and of course diminish the danger of wounding it.

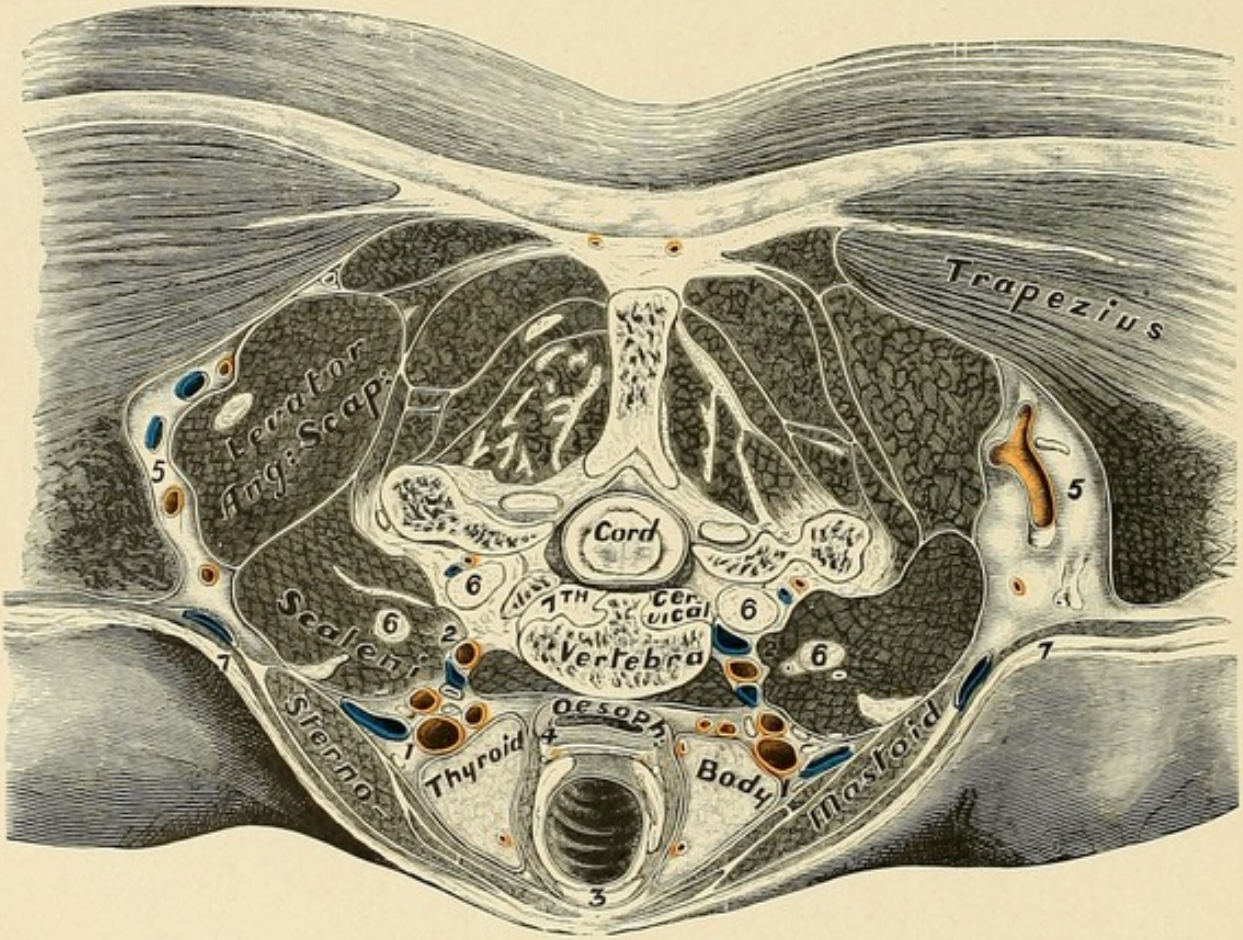

FIG. 162.—Horizontal section at the level of the seventh cervical vertebra. 1, 1, The right and left common carotid arteries and the internal jugular veins. 2, The right and left vertebral arteries and veins. Directly between the vertebral and carotid arteries is seen the sympathetic nerve and the inferior thyroid artery and some of its branches. The pneumogastric nerves are seen between and slightly posterior to the internal jugular veins and the common carotids. 3, Trachea. 4, Œsophagus. 5, Transversalis colli artery and veins and descending branches of the subclavian artery. 6, Cords of brachial plexus. 7, 7, External jugular vein. (After Braune.)

The operation of tying the carotid, just below or behind the omo-hyoid, is practically the same as that just described (Fig. 159).

In order to secure this vessel at the root of the neck, an incision should be made in the carotid line, extending from the sterno-clavicular articulation upward a distance of three or four inches, and between the two heads of origin of the sterno-mastoid muscle. This will divide the integument, superficial fascia, platysma, and

deep fascia, and some descending superficial nerves. The fibers of the sterno-mastoid may be separated and held to either side by retractors. Immediately beneath it will be found the anterior jugular vein, and some small branches emptying into it. If not easily displaced, they should be secured with a double liga-

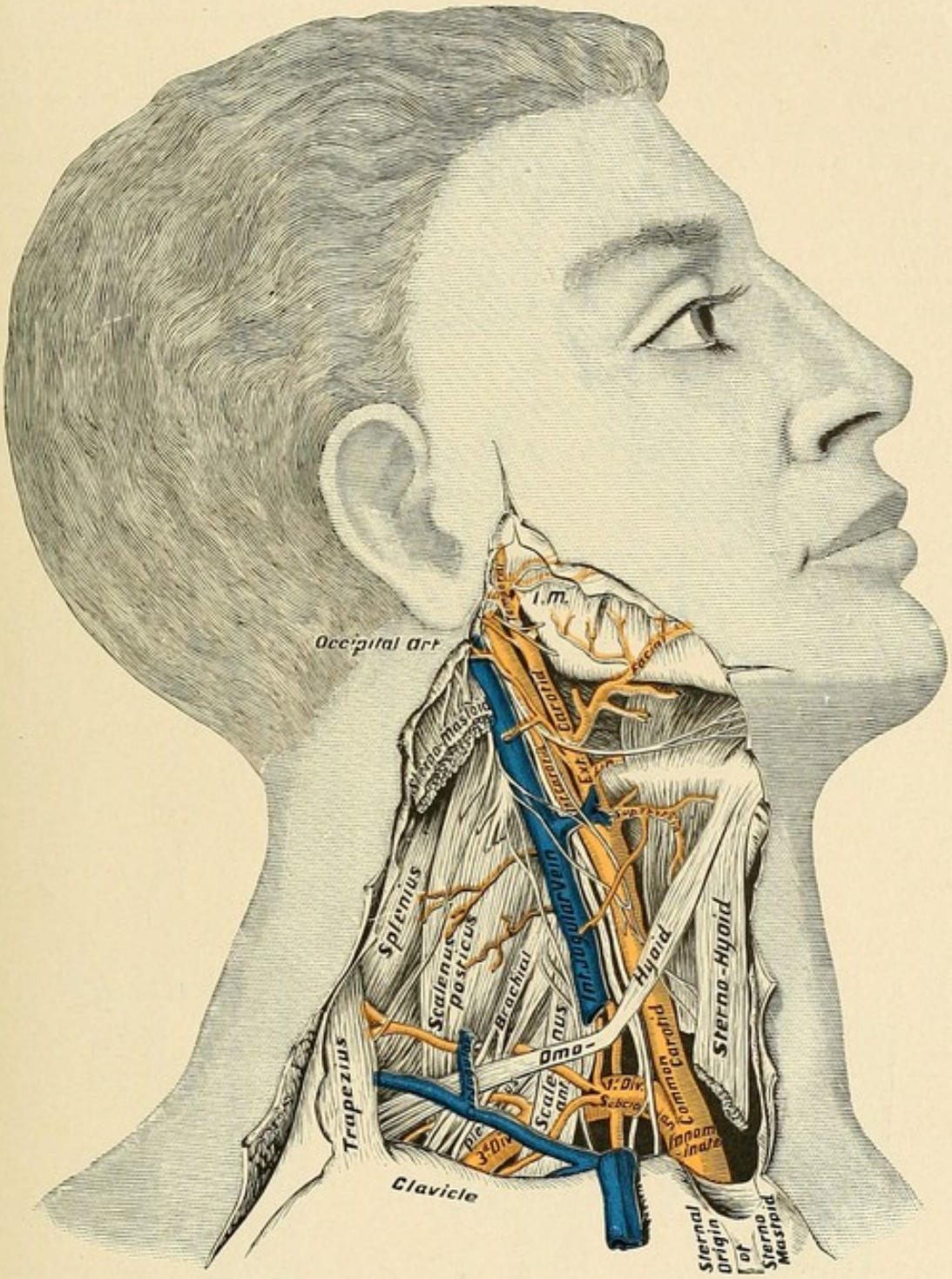

Fig. 163.—The usual relation of the contents of the surgical triangles of the neck. From the author's dissections.

ture, and divided between the threads. The fibers of the sterno-hyoid or sterno-thyroid muscles should next be divided on a grooved director, and turned aside or separated in the line of the artery. The vessel will be seen deeply situated in the line already given. The ligature should be passed from the outer side. Or an L-shaped incision, similar to that made for deligation of the innominate (Fig. 158) may be made, and the carotid found by separating the sternal tendon of the mastoideus muscle and turning this outward. For the left carotid, see Fig. 160.

The approach to the vesssel in this region should be very cautious, especially upon the left side of the neck, since the internal jugular vein crosses from the outer to the inner side by the front. On the right side the vein is a little more external. The pneumogastric nerve lies behind and to the outer side of the artery, while the inferior thyroid artery and sympathetic nerve are more deeply situated. The aneurism-needle should be passed around the artery, from the outer toward the inner side.

In the "Prize Essay" of the American Medical Association for 1878 I collected histories of seven hundred and eighty-nine cases in which the common carotid artery had been tied for all causes, of which three hundred and twenty-three, or forty-one per cent, died. The death-rate will never again reach this alarming figure.

Thirty-four cases are on record in which both trunks were tied, of which twenty-five recovered.[1]

Ligation of the Internal Carotid Artery—Anatomy.—This vessel is a direct continuation of the common trunk, and, while straight in its lower portion, it becomes slightly tortuous as it approaches the carotid canal. An abnormal branch was found to be derived from its first portion in seven of one hundred and twenty dissections.

Operation.—The position is the same as for tying the common trunk. The incision should be made in the carotid line, with its center from one half to

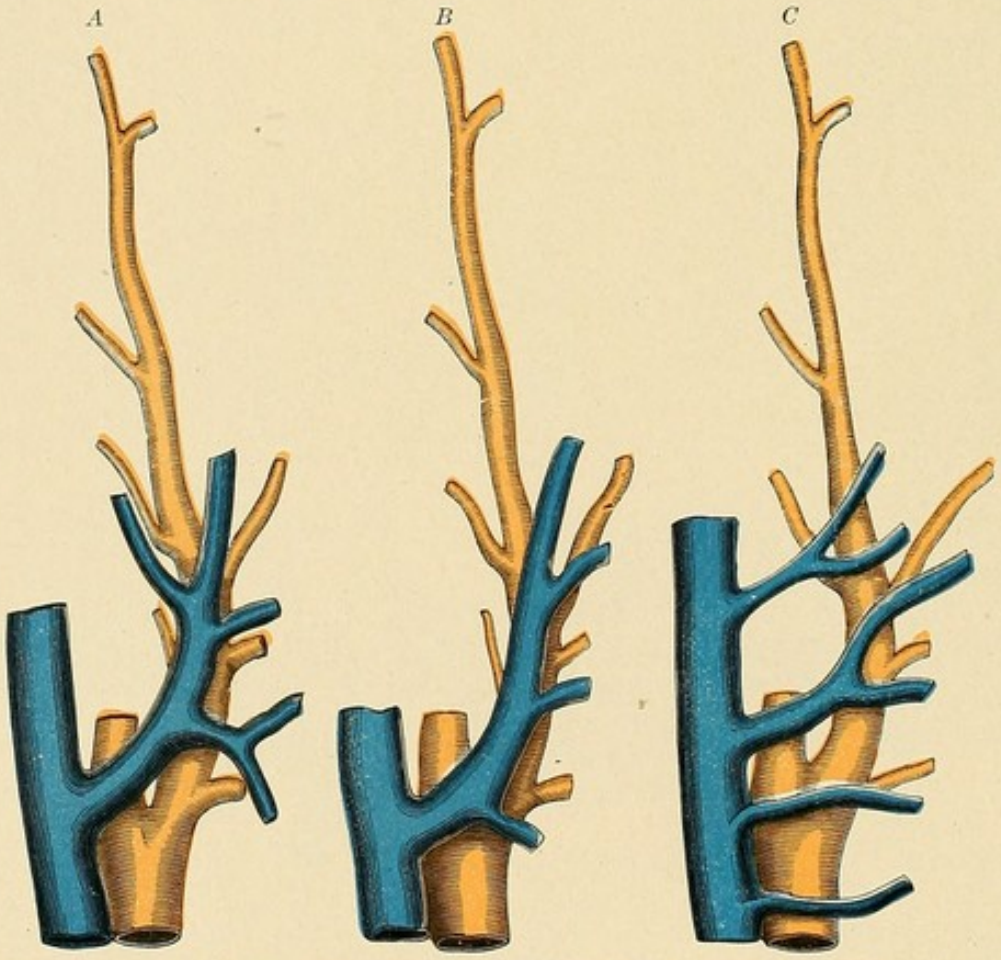

Fig. 164.—Relation of the veins to the carotids, right side. (Life size.)

three quarters of an inch above the upper border of the *thyroid cartilage.* The same structures will be divided superficially, and the veins will be seen superficial to the artery. As shown in *C*, Fig. 164, they may cross the internal carotid almost at a right angle, or (as in *A* or *B*) they may empty into a single trunk, and run parallel with the *external carotid.* This last is the most usual way, but it

[1] *Op. cit.* See also Riegner's case, "Centralblatt für Chirurgie," No. 26, 1884.

will be scarcely possible to ligate the *internal carotid* without ligature and division of some of these veins. The *descendens-noni* nerve will be seen running along the artery, the *hypoglossal* crossing it about one inch from the bifurcation. The vessel being exposed, the needle is introduced on the outer side, avoiding the *jugular* vein and *pneumogastric* nerve externally, the *external carotid* internally, and the *hypoglossal* nerve superficially. The *pharyngea ascendens* is in intimate relation to the *internal carotid*, running parallel with it on its inner aspect. Occasionally the first cervical ganglion of the sympathetic extends as low as this point. It will be avoided by keeping the needle close to the artery.

Ligation of the External Carotid Artery.—From the extensive distribution of its branches to the exposed portions of the neck and face, the *external carotid*

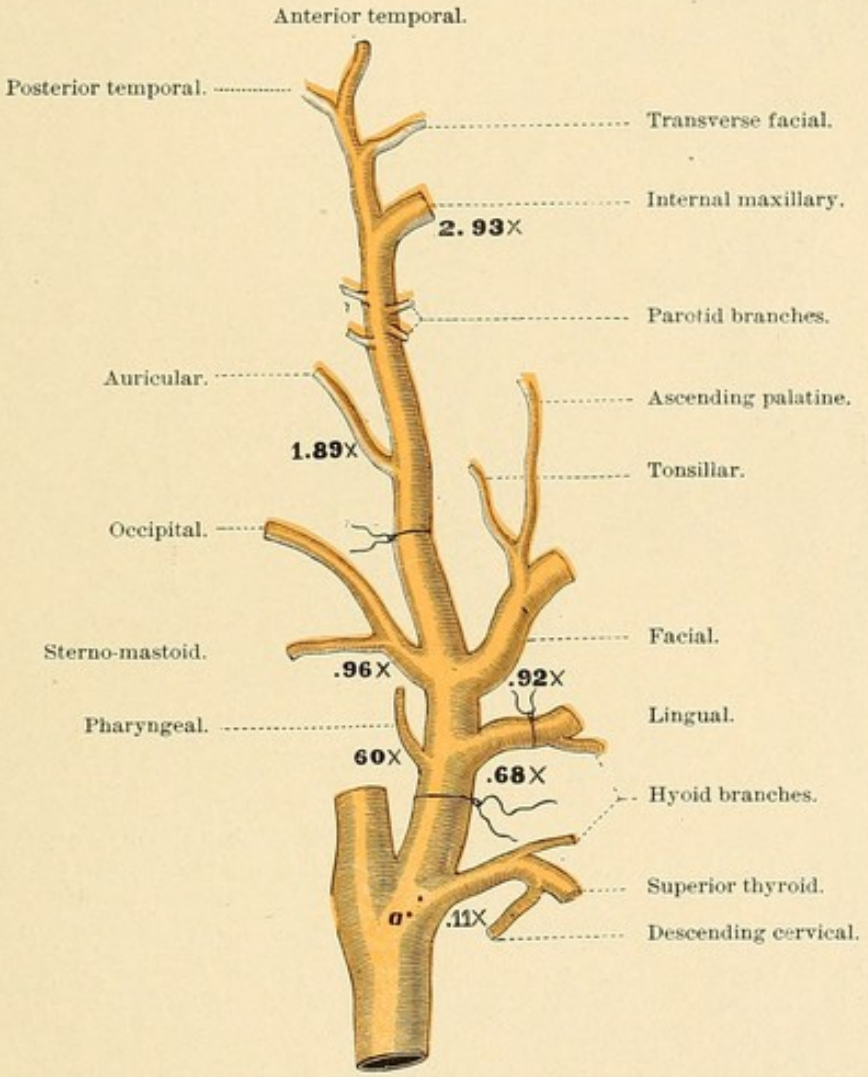

FIG. 165.—The external carotid and its branches. The average arrangement of one hundred and twenty-one dissections by the author. (Life size.)

artery demands a more careful consideration than any single vessel of the human body.

Anatomy.—Leaving the *common* trunk at the upper border of the *thyroid cartilage*, well forward of the anterior border of the *sterno-mastoid* muscle, this vessel arches forward and upward (its concavity looking toward the lobule of the ear) until, on an average of .92 inch above the bifurcation, after giving off the *facial* branch, it turns obliquely upward and backward to a point opposite the insertion of the *external pterygoid* muscle into the neck of the condyle of the lower jaw, where it terminates by dividing into the *temporal* and *internal maxillary* arteries.

Eight regular branches belong to this vessel. On its anterior aspect arise from below, upward, the *thyroidea superior, lingualis, maxillaris externa,* and *maxillaris*

interna. On its posterior and internal aspect the *pharyngea ascendens*, and posteriorly the *occipitalis, auricularis,* and *temporalis*.

The usual arrangement of these branches is seen in Fig. 165, which is the average of one hundred and twenty-one dissections. Abnormal deviations from this

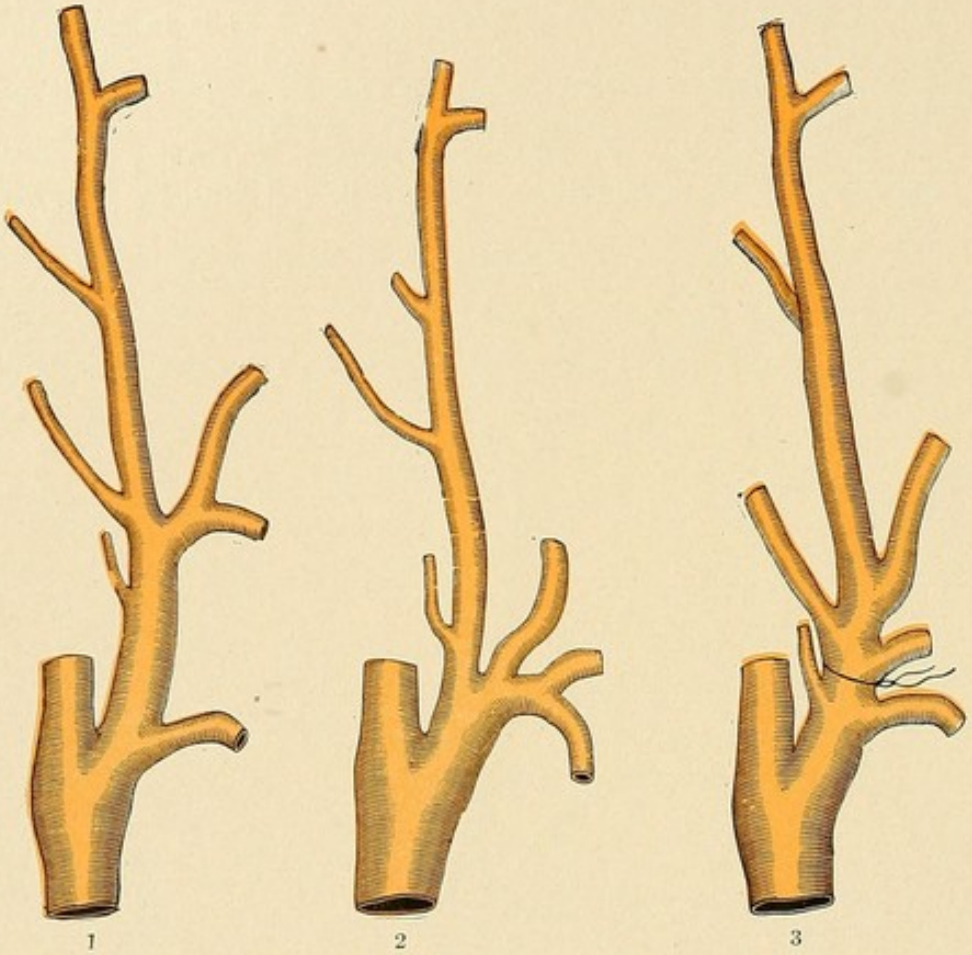

FIG. 166.—Unusual arrangement of the branches of the external carotid. 1, The lingual and facial from a common origin. 2, The lingual, facial, and superior thyroid from a common origin. 3, Close relation of first five branches to each other.

relation of the branches to the parent trunk occur occasionally, and types of these may be seen in Figs. 166 and 167. The relations of the veins to these arteries are shown in Fig. 164.

Operation.—The external carotid may be tied at any point. In the lower half the operation is the same as for ligature of the *internal carotid* on the same plane, except that the *external carotid* is usually from one quarter to one half inch nearer the median line than the *internal*.

For the upper half, i. e., above the posterior belly of the digastric, the incision should extend from the lobule of the ear along the ramus of the jaw, down to the level of the thyroid cartilage. Cutting through the superficial structures, the artery will be found just behind the posterior belly of the digastric muscle.

Above this level—that is, after the artery enters the parotid gland—it is so situated that it should not be cut down upon. The incision would involve the *facial nerve*, causing paralysis of the muscles of expression. In malignant disease of the parotid, where this gland is removed, the vessel may as well be secured here as not, since the operation itself usually destroys the *facial nerve*.

It is a remarkable fact that, notwithstanding the close proximity of the branches of the *carotid*, in a large number of instances in which it has been ligatured without the precaution of securing immediate collateral branches, there has not followed a secondary hæmorrhage.

On account of the importance of maintaining the integrity of the circulation to the brain, ligation of the common carotid, for a lesion in the distribution of the

external carotid, should never be performed when a sufficient distance remains between the lesion and the bifurcation of the common trunk to allow of the application of the ligature.

Ligation of the Superior Thyroid Artery—Anatomy.—This branch was present in every instance in one hundred and twenty-one dissections. It originated almost invariably on a level with the thyroid notch. In one of twenty-five cases it will be found to have a common origin with the lingual, or the lingual and facial. See Fig. 166.

Operation.—With the neck in the surgical position, i. e., with the head thrown back and the face turned to the opposite side, make an incision two inches long, parallel with, and one fourth of an inch in front of, the *carotid line*. The center of this incision must be on a level with the thyroid notch. Immediately beneath the skin and *platysma myoides* will be seen the *thyroid, lingual, hyoid*, and other veins, which may assume either of the forms or relations shown in Fig. 164, A, B, being most common. These being tied and divided, the artery will be found opposite the point above indicated.

The thyro-hyoid nerve will occasionally be seen passing across this artery, although usually nearer the median line. The external laryngeal passes beneath it.

Ligation of the Lingual Artery—Anatomy.—From its origin, usually opposite the cornu of the hyoid bone, it ascends obliquely upward and inward, and is superficial until it passes underneath the *stylo-hyoideus* and *digastricus* (posterior belly), and then more deeply behind the *hyo-glossus*.

In two of one hundred and twenty-one cases it originated in common with the superior thyroid, and in two other instances with this vessel and the facial. In thirty-one of one hundred and twenty-one cases it arose from a trunk common to it and the facial, being abnormally associated in one in every three and a half dissections.

Operation.—The lingual artery may be secured either below the digastric or above this point, where it passes beneath the hyo-glossus.

For the low operation make an incision as in the case of the *superior thyroid*, except that its *center* should be *opposite the os hyoides*. The artery will be found in the *lingual triangle*, bounded posteriorly by the *external carotid*, above by the *digastric* muscle, below by the *os hyoides*. The *middle constrictor* muscle is behind it; the *platysma myoides* in front, and under this the veins above noted. The hypo-glossal nerve is usually *just above* it as it crosses the *carotid*, while the *thyro-hyoid* branch of this nerve crosses the artery on its way to the muscle it supplies.

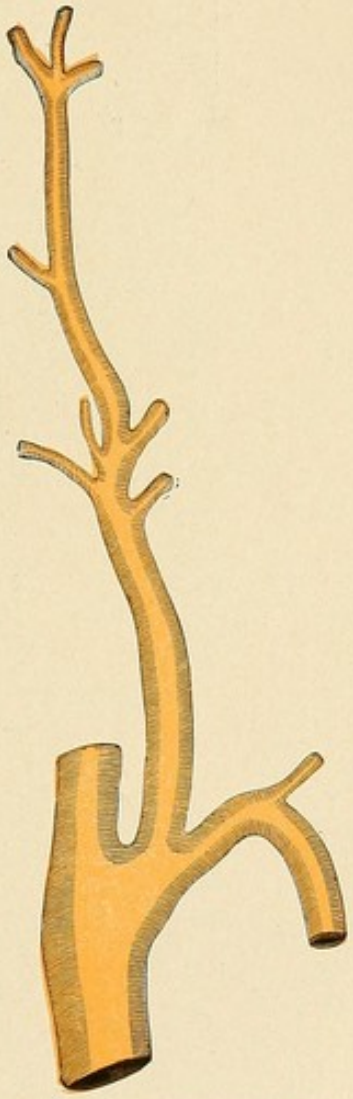

Fig. 167.—An enlarged superior thyroid artery.

The high operation is one of considerable difficulty. The face should be well turned to the opposite side, the chin elevated, and held perfectly immovable. Beginning immediately over the os hyoides, near the median line of the neck, an incision is made outward, and parallel with this bone as far as the great cornu, where it is curved upward to the angle of the jaw (Fig. 153). This crescentic flap is turned up, and with it the sub-maxillary gland, in a groove on the under surface of which the facial artery runs. As soon as the hyoid bone is exposed it should be fixed with a tenaculum and drawn steadily down. The posterior belly of the digastric will now be seen passing obliquely downward and forward to the central tendon in the hyoid bone. Passing beneath this muscle, and superficial to the

hyo-glossus, is seen the hypoglossal nerve, which runs parallel with and above the artery. Depress the posterior belly of the digastric, insert a director beneath the posterior fibers of the hyo-glossus, and divide these. The artery will

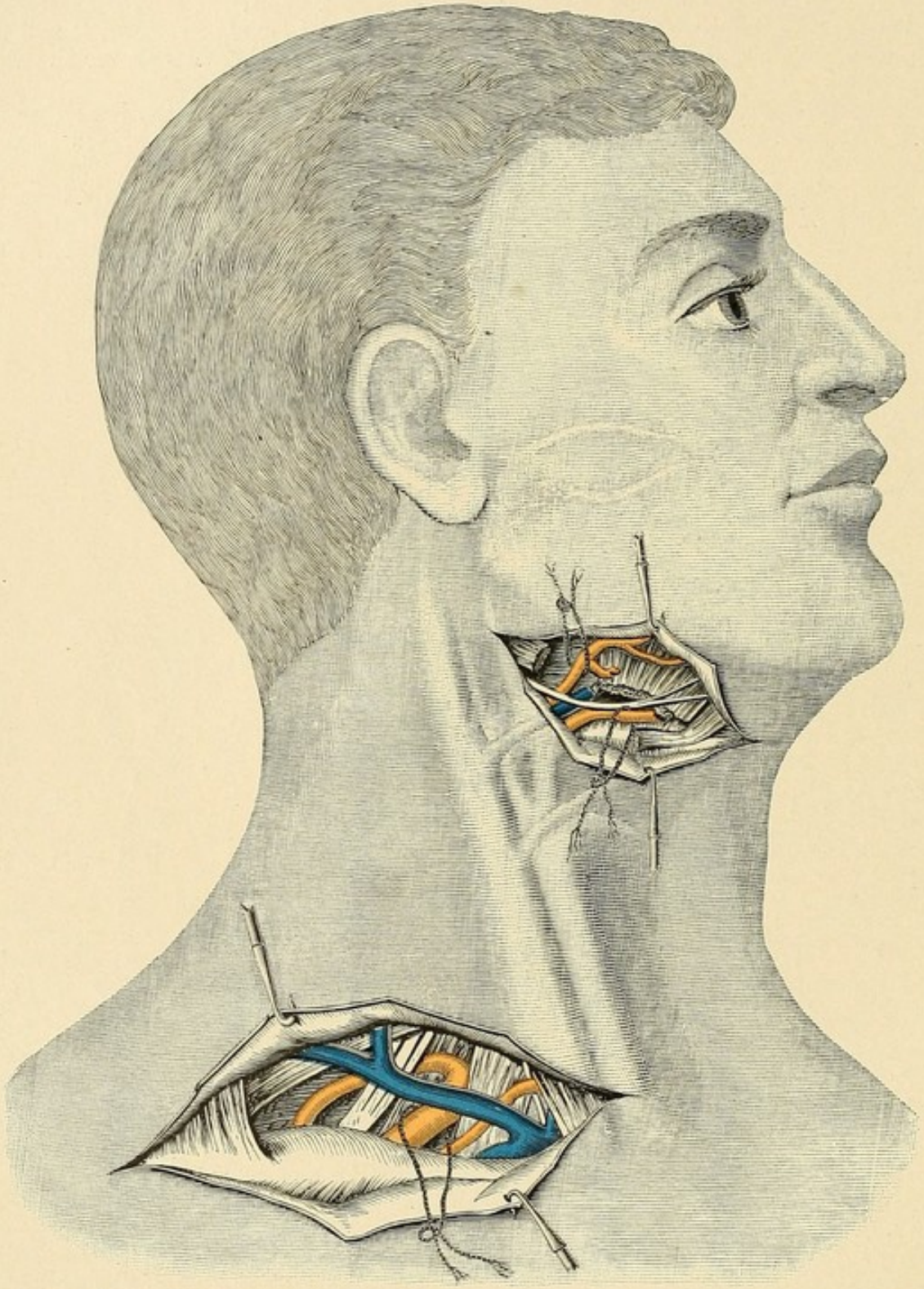

Fig. 168.—Ligation of the right subclavian in its third surgical division; the facial in the neck and the lingual beneath the hyo-glossus muscle.

be found just beneath this muscle, resting upon the middle constrictor of the pharynx.

The ligation of this artery is frequently practiced preliminary to excision of the tongue for malignant disease, and occasionally to arrest hæmorrhage.

Ligation of the Facial Artery—Anatomy.—The facial artery was present in one hundred and twenty of one hundred and twenty-one dissections. In the instance in which it was missing its facial distribution was taken by the *transverse facial* from the *temporal,* and its cervical by branches from the *lingual* and the *external carotid.* Its origin is usually about one fourth of an inch above the *lingual.* It is the longest branch of the *external carotid.* In thirty-one of one hundred and twenty cases it arose in common with the lingual, and in two instances it was from a trunk in common with this artery and the *superior thyroid.*

Operation.—In its cervical distribution this vessel will require to be tied at or near its origin from the *carotid.* The incision along the axis of the *carotid,* as

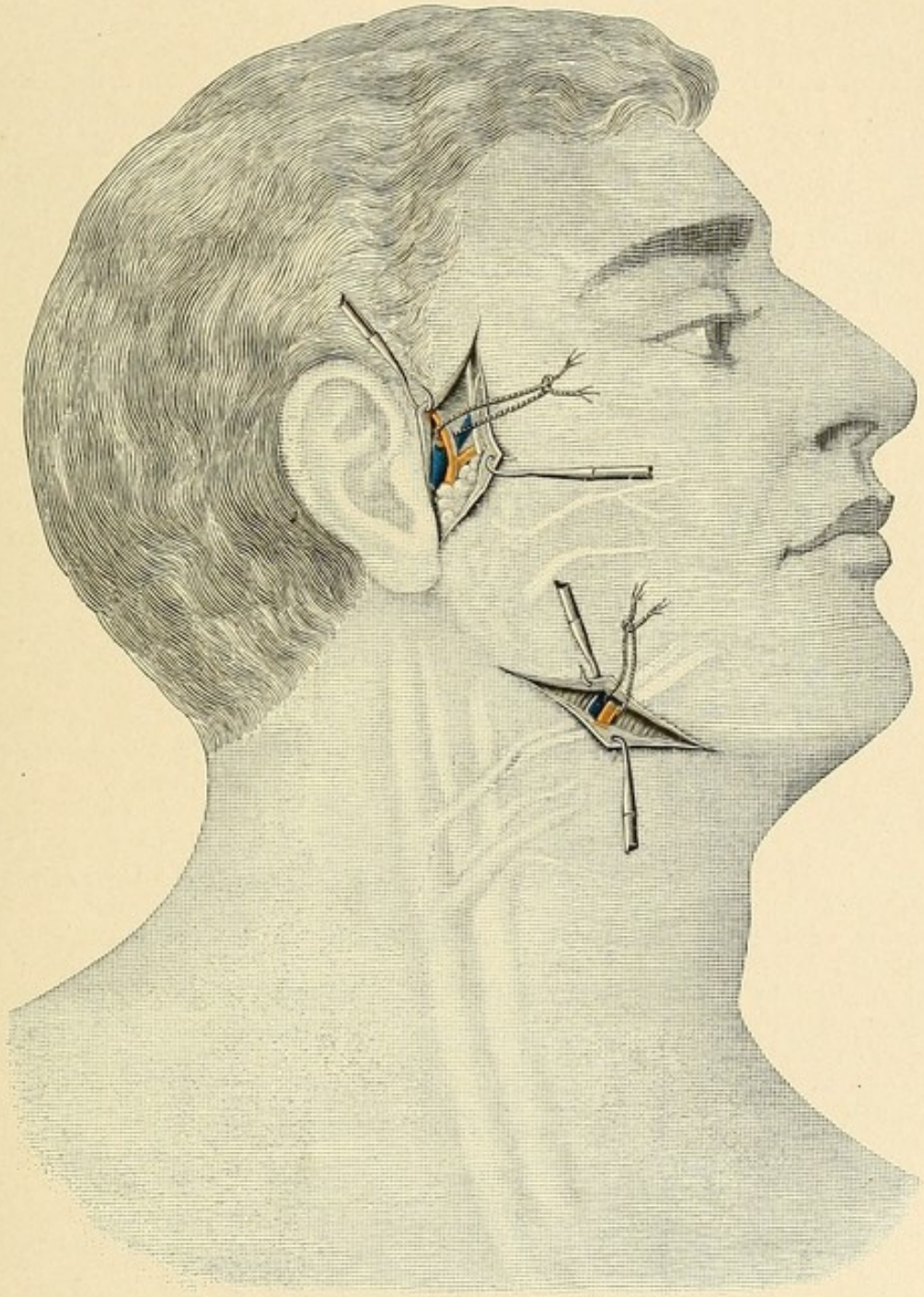

Fig. 169.—Ligation of the posterior temporal at the zygoma, and of the facial upon the inferior maxilla.

given before, with its center a quarter of an inch above the hyoid bone, will lead to the facial. The posterior belly of the *digastricus* will be found with its center usually above the origin, but soon crossing the artery. The ninth nerve is just

below. For lesion of this vessel in the face it can be readily secured as it crosses the *inferior maxilla* in the depression at the anterior border of the *masseter* (Fig. 169). Before making the incision, which should be parallel with the horizontal portion of the inferior maxilla, the skin should be well pulled up from the neck, so that, after healing, the cicatrix will fall below the jaw.

Ligation of the Ascending Pharyngeal—Anatomy.—This artery was derived from the *external carotid* in one hundred and eleven of one hundred and twenty-one cases, and from the *internal carotid* in four others. It usually comes off at a point opposite the origin of the *lingual*, and occasionally from the bifurcation of the *primitive carotid*. A pharyngeal branch is not uncommon from the occipital.

Operation.—The *external carotid* must be exposed by an incision the center of which is opposite the level of the hyoid bone. The vessel will be seen ascending between, and parallel with, the *external* and *internal carotids*.

One fatal case is recorded from hæmorrhage after a wound of the *ascending pharyngeal*.

Ligation of the Occipital Artery—Anatomy.—The *occipital* was present in one hundred and twenty of one hundred and twenty-one dissections, and it was found to be opposite the facial in the majority of cases. In the subject in which it was missing, a large branch from the *inferior thyroid* (not the *ascending cervical*) took its distribution. Not infrequently the *posterior auricular* or a *pharyngeal* branch arose from this vessel.

Operation.—It may be secured near its origin, or behind the mastoid process. For the low operation, make an incision in the *carotid line*, the center of which is about one inch above the thyroid notch. After dividing the deep fascia the hypoglossal nerve will be seen, which, if followed backward, will lead unerringly to the artery, underneath which it winds. The posterior belly of the digastric muscle will usually require to be lifted upward.

Behind the mastoid the occipital may be tied where it passes beneath the cranial attachment of the sterno-mastoid muscle (Fig. 170). From one half to three fourths of an inch behind the mastoid process an incision about two inches long should be made, extending upward and backward. The aponeurosis of the sterno-mastoid muscle is divided on a director, and the artery exposed. The constant relation of this vessel to the groove on the under surface of the mastoid process will serve as a valuable guide.

Ligation of the Posterior Auricular—Anatomy.—In eleven of one hundred and twenty-one dissections this vessel arose from the *occipital*, and in four it was absent. Its origin is usually one inch and four fifths above the thyroid notch.

For anatomical reasons, in lesions of this artery the *external carotid* should be tied, just above the posterior belly of the digastric, between its origin and that of the *occipital*. It runs under the parotid gland, is crossed by the facial nerve, and has beneath it the spinal accessory.

Ligation of the Temporal and Internal Maxillary Arteries—Anatomy.—The *temporal* and *internal maxillary* arteries begin at the terminal bifurcation of the *external carotid*, in the substance of the parotid gland, at an average distance of two inches and nine tenths from the thyroid notch.

Operation.—The *temporal* artery may be secured by a perpendicular incision immediately in front of the tragus of the ear, where it crosses the zygoma superficially (Fig. 170). For lesions of this vessel above the temporal fossa, and often in wounds in this region, the ligature will be unnecessary, since direct compression, by means of the knotted bandage, will suffice. When either this artery or the *internal maxillary* are wounded in the substance of the parotid gland, the *external carotid* should be tied at the posterior belly of the digastric. The same procedure is indicated in lesions of the *internal maxillary*, in its deeper portions.

Ligation of the Internal Jugular Vein.—The intimate relation of this vein to the *internal* and *common carotid* arteries renders it accessible by the same incisions laid down for the ligation of the arteries. The vein is contiguous to the artery, and is external and slightly superficial to it. On the left side, at the root of the neck, the jugular comes more to the front, while on the right side it tends to the outer side.

The rules which apply to the ligation of arteries apply with equal force to the ligation of veins. In tying the *internal jugulars* the aneurism-needle should be passed from the inner side.[1]

The anterior, external, and posterior jugular, and other veins of the neck, do not demand especial consideration. When, in operations in the neck, it becomes

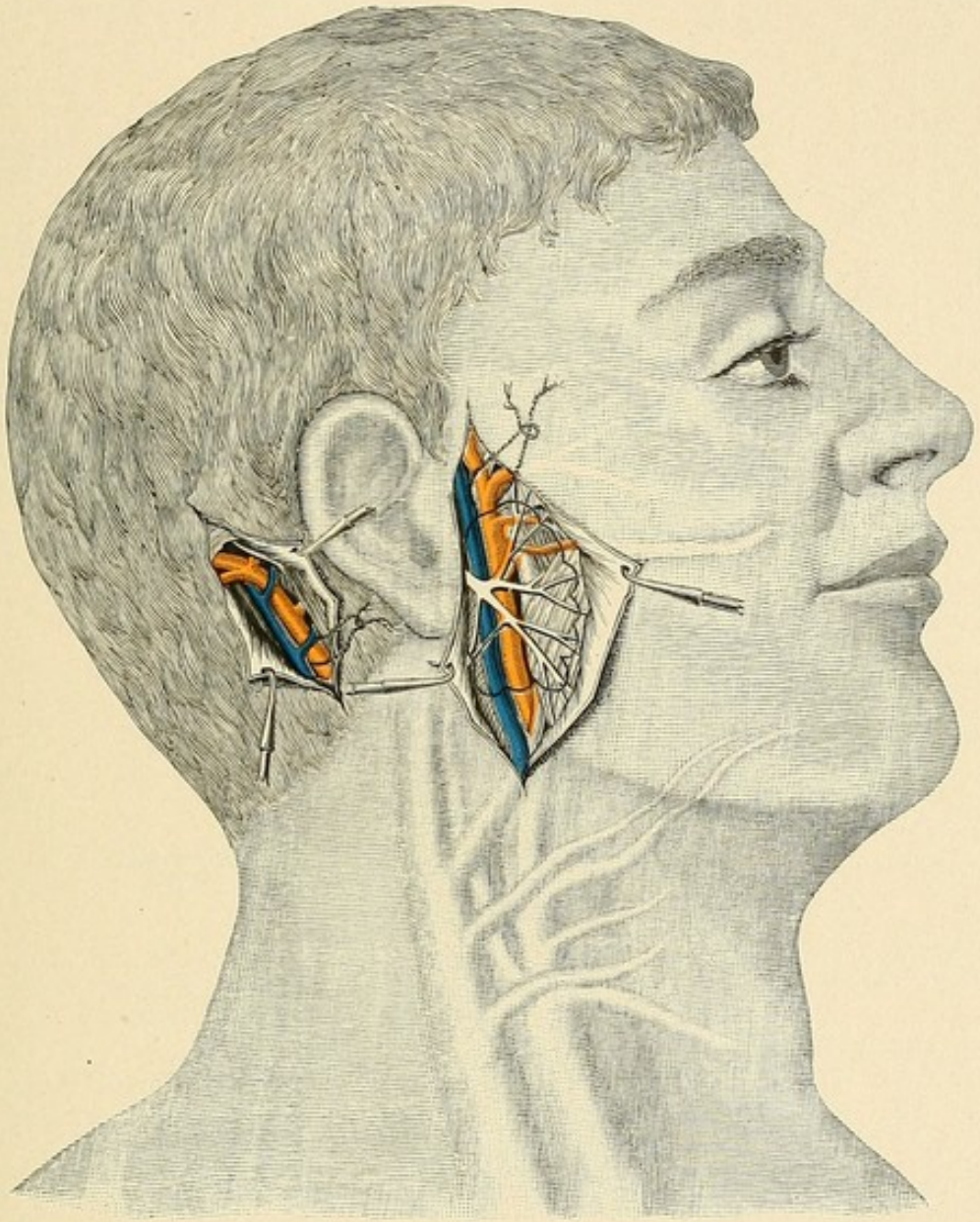

FIG. 170.—Ligation of the occipital behind the mastoid process and the common temporal near the zygoma, also showing the relations of the facial nerve to the terminal portion of the external carotid.

necessary to divide them, a double catgut should be applied, and the vessel divided between the two ligatures.

The Subclavian Arteries and their Branches—Anatomy.—The *right subclavian,* larger, shorter, and more superficial at its origin than the left, is derived from the *innominate behind* the origin of the carotid, about the level of the upper margin of the clavicle (more frequently above than below this line), behind the interval between the two tendons of the *sterno-mastoideus.* It is the direct continuation backward, upward, and outward of the *arch of the innominate,* and is continuous with the *axillary artery,* at the lower edge of the first rib. Its average length is 2.83 inches.

[1] See Prof. S. W. Gross's admirable article in "American Journal of the Medical Sciences," 1867.

The *left subclavian*, derived 1.23 inch beyond, to the left of, and more deeply situated in the thorax than the innominate, travels almost vertically upward, until it mounts above the upper surface of the first rib, when it curves very abruptly outward and downward, passing behind the scalenus anticus and thence to the lower edge of the first rib. Its length, in the average, is 3.74 inches.

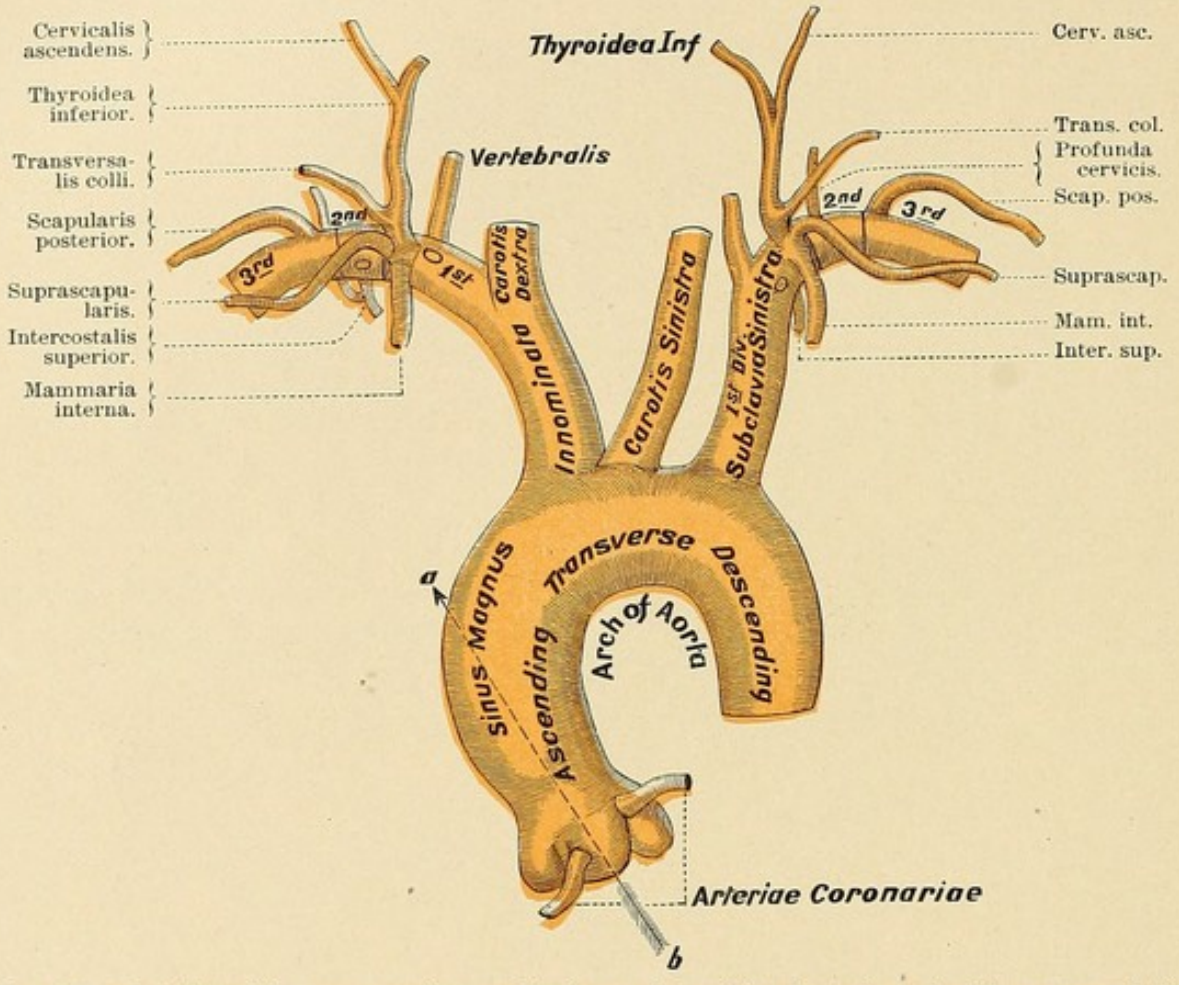

Fig. 171.—Relation of the great vessels to each other at their origins from the arch of the aorta, and the relation of the branches of the subclavian arteries to each other. From the author's dissections.

Each subclavian has three *surgical divisions*. The *first division* of the right artery is from its origin from the *innominate* to the inner border of the *scalenus anticus*. That of the left artery, from its origin at the arch of the aorta to the inner border of the *left scalenus anticus* (Fig. 171).

The second and third portions of both vessels are identical as regards direction and relation, being different in the origins of their respective branches. The *second surgical division* of each is entirely to the *inner* side of the *inner border* of the first rib. The *third portion* rests chiefly on the upper surface of the first rib, and extends from the outer border of the scalenus anticus to the lower border of this rib.

The *first portion* of the *right subclavian* varies from three fourths to one inch and a half in length, the average length being 1.15 inch.

The *first portion* of the *left* artery varies from one inch and a half to three inches, the average length being 2.06 inches.

The *second portion* of the *right subclavian* averaged .58 inch, the same division of the *left subclavian* being .56 inch in length.

The *third portion* of the *right* artery is a little less; the same division of the *left subclavian* a little more than 1.11 inch in length.

Nine important branches arise directly or indirectly from the *subclavian* arteries: the *vertebral, internal mammary, transversalis colli, suprascapular, inferior thyroid, cervicalis ascendens, superior intercostal, profunda cervicis,* and *posterior scapular.*

The *right vertebral*, the branch most constant in origin, arises from the superior and posterior aspect of the main trunk (Fig. 172) and passes upward to the vertebral foramen, in the sixth cervical vertebra; at times to the fifth; less frequently to the fourth. The relation of this branch is important. In the vast majority of subjects it will be found between one fourth and three fourths of an inch to the inner side of the inner margin of the scalenus anticus.

The *left vertebral* (Fig. 171) arises, in four per cent of cases, from the aorta. In most subjects it will be found within three fourths of an inch of the left scalenus muscle.

The *internal mammary* artery arises at the inner border of the scalenus anticus. It is occasionally from the thyroid axis. The phrenic nerve passes usually in front, occasionally behind it. Behind the costal cartilages it runs parallel with the edge of the sternum, about half an inch external to it.

The *thyroid axis* arises also just within the scalenus. The *inferior thyroid* branch arises from the axis, in almost every case on the left side. On the right, in twenty-six cases examined, it originated from the *innominate* in three, and directly from the subclavian in three instances. It passes upward (inclining at first a little inward) until it arrives at a point between the third and seventh (incomplete) rings of the trachea, where it turns abruptly inward, going behind the *common carotid* and *jugular*, in front of the *vertebral*, and is distributed chiefly to the lower portion of the thyroid body.

The *transversalis colli* passes outward in front of the *scalenus muscle* and the *phrenic nerve*, underneath the *omo-hyoid*, and in front of or between the cords

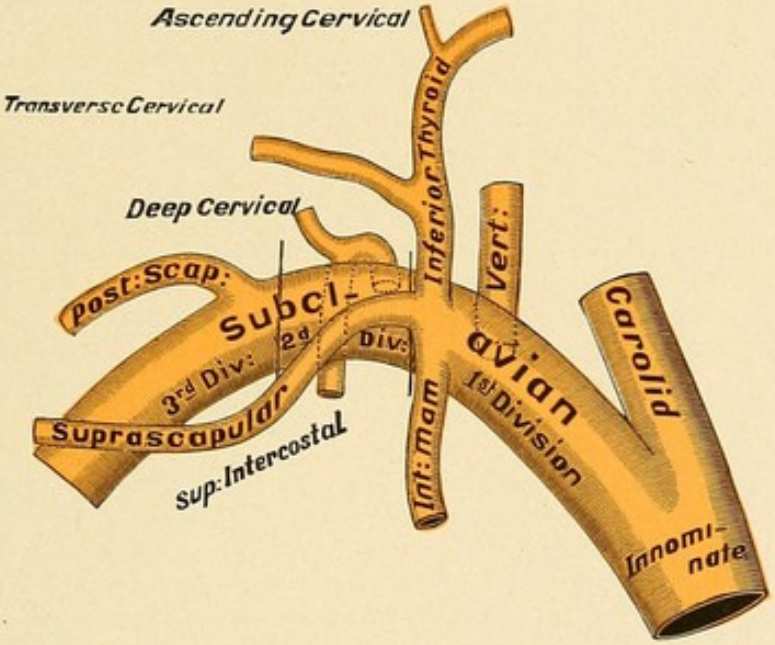

FIG. 172.—Plan of the right subclavian artery and its branches. From the author's dissections. (After Quain.)

of the brachial plexus, and is distributed to the *trapezius* muscle, sending a branch in the direction of the posterior border of the scapula, which anastomoses with the *posterior scapular artery*; and, when this last vessel is not present, this descending branch is continued along the border of the scapula to anastomose with the subscapular branch of the axillary.

The *suprascapular artery*, intimately associated with the preceding, travels suddenly downward and outward from its origin near the inner edge of the *scalenus anticus*, passes between the *subclavian artery* and *vein*, in front of the *phrenic nerve*, crosses in front of the third division of the main trunk, and goes to the suprascapular fossa under the protection of the clavicle, anastomosing with the *dorsalis scapulæ* of the *subscapularis*. It gives off a branch (frequently wounded in operations in this vicinity) which passes behind the *sterno-mastoideus* and along the upper border of the manubrium. (It is not usually mentioned.)

The right *superior intercostal* artery comes from the second division of the subclavian in almost every instance; occasionally from the first. The left is usually from the first division.

The *posterior scapular*, one of the most important branches of the subclavian, in a surgical view, since it must be in dangerous proximity to a ligature applied in the third surgical division (not given in many standard text-books, except as an occasional branch of this artery), was present in thirty-six of fifty-two dissections, or sixty-nine per cent. It was present in nineteen of twenty-six on the *right* side, and in seventeen of twenty-six on the left. In twenty-three of the thirty-six cases in which it was present it was derived from the third division; in the remaining thirteen, from the second division, close to its outer limit. On the *right* side seventy-four per cent came from the subclavian, within one fourth of an inch to the outer and inner side of the external border of the scalenus muscle; twenty-six per cent external to this.

On the *left* side eighty-two per cent were within one fourth of an inch to the outer and inner side of the line dividing the middle and external thirds of the main trunk; eighteen per cent were to the outer side of this. The tendency of this important branch is to originate near the scalenus, i. e., within one fourth of an inch of its outer edge. When this vessel is present the *transversalis colli* is small, and when absent the descending branch of the transversalis takes its distribution. Passing outward behind the most superficial cords of the brachial plexus, it turns sharply downward, along the posterior border of the scapula, to anastomose with the *subscapular* branch of the *axillary*.

Operation—The Right Subclavian in its First Surgical Division.—The incisions are the same as for the *arteria-innominata*. When the sterno-hyoid and sterno-thyroid muscles have been divided on the director, the *internal* jugular vein will be seen directly in front of the artery. It may be drawn to the inner side (or outer, if more convenient), carefully using for this purpose a dull retractor. Care must be exercised not to injure the pleura which rises against the artery in deep inspiration. A dull-pointed aneurism-needle may now be passed around the vessel, taking care not to wound the subclavian or innominate vein, or the recurrent laryngeal nerve. The *vertebral, internal mammary*, and branches of the *thyroid axis*, should also be secured.

The conditions which will justify this operation will rarely occur, yet, when the operation is demanded, every source of danger from hæmorrhage should be avoided. The necessity of securing the carotid at the same operation must be determined by the operator. I am of the opinion that it is safer to occlude this vessel also.

Ligation of the Left Subclavian Artery in its First Surgical Division—Operation.—From a point on the clavicle one fourth the distance from the center of the interclavicular notch to the acromion process commence an incision, and carry it to the inner border of the sternal tendon of the mastoid muscle. From the inner extremity of this line carry a second incision for three inches along the anterior border of the sterno-mastoideus. In dissecting this flap lift with it the mastoid muscle divided upon the director, then divide the sterno-hyoid and thyroid muscles, and feel for the pulsation of the artery, which ascends deeply behind and a little outside the sterno-clavicular articulation. The *internal jugular* vein will be drawn outward, and, passing the finger along the inner border of the *scalenus* muscle, the artery will be felt to pulsate. The *thoracic duct* usually is to the right of and a little behind the artery opposite the upper border of the *sternum*. On a level with the insertion of the *scalenus* it arches to the left, crosses in front of the *subclavian*, in front of the *scalenus*, behind the *internal jugular*, and curves downward to empty into the *subclavian* at its junction with the *jugular* to form the left *innominate* vein. On account of the intimate relations of the *thoracic duct* to the *left subclavian* artery as this vessel goes behind the *scalenus*, the ligature should not be attempted close to this muscle, nor should the dissection be carried fully to the *scalenus*. The artery should be tied as low down as possible, the *duct* being less likely to be injured here, since in passing behind the aorta it is deeper than the artery. It will be found behind and to the right, the pneumogastric in front and

to the right, the left *vena innominata* crossing in front, while the pleura is directly behind.

The *vertebral* and other branches of the left subclavian are in such proximity to the thoracic duct that it will be dangerous to attempt to tie them at this point.

Ligation of the Subclavian Arteries in their Second and Third Surgical Divisions—Operation.—The procedure is essentially the same on the two sides. Place the shoulders upon a cushion, pull downward on the arm of the side to be operated upon, and turn the patient's face to the opposite side. Find the location of the scalenus anticus, as in the preceding operation. Slide the skin well down upon the clavicle, and along this bone make an incision three or four inches in length, commencing one inch to the inner side of the scalenus muscle and terminating near the anterior edge of the trapezius. Allowing the skin to resume its normal relations, the incision will be carried above the clavicle. Upon a director divide the outermost of the clavicular fibers of the mastoid muscle. The internal *jugular vein,* seen in the anterior portion of the wound, will be carefully drawn to the inner side, the operator keeping well above the junction of this with the subclavian, and thus avoiding the *lymphatic duct.*

A prominent plexus or group of veins, viz., the *external jugular, transversalis colli,* and *suprascapular,* will be seen traversing the wound, coming from their respective origins, toward the *subclavian,* near the *jugular.* These should be secured with a double ligature, and divided or held aside. Dissecting carefully, the *suprascapular* and *transversalis colli* arteries will be observed running, in general, in the direction of the first incision. The posterior belly of the *omo-hyoid* may be found in the upper margin of the wound, crossing the scalenus at about a right angle. The *transversalis colli* and the *suprascapular* may be secured or held to one side, the finger passed along the scalenus until the tubercle on the first rib is felt, immediately behind which the artery will be found. If it shall have been determined to tie the artery in its second portion, the *scalenus anticus* muscle will be cut upon a director, the operator being careful to avoid the *phrenic nerve,* which crosses the muscle in front, coming from above downward and inward. (It is between the layers of the sheath of this muscle.) The ligature is next passed around the artery from before backward, care being taken not to wound the pleura.

If the third division of the artery is to be secured, the part of the above operation relating to the division of the *scalenus* will be omitted. The nearest cord of the brachial plexus must be carefully excluded, posteriorly to the artery; the subclavian vein in front and below (Fig. 168).

Ligation of the Vertebral Artery—Operation.—Locate by pressure the carotid tubercle (the transverse process of the sixth cervical vertebra). The point at which the artery is to be secured is one inch directly below this bony prominence, which must be the center of a perpendicular incision, four inches in length. Commence the incision at the outer border of the sterno-mastoid muscle, where the external jugular vein crosses. The internal jugular is seen and drawn inward. The transverse cervical artery, and one or two smaller veins, are met with next, and drawn to the outer side of the wound. The scalenus anticus muscle is now brought into view, and to the inner side of this a depression between this muscle and the longus colli. In this sulcus the artery lies, the vein being in front of it. In my case I had to tie the vein with a double ligature, divide, and turn the ends aside in order to secure the artery.

Ligation of the Internal Mammary—Operation.—This vessel may be secured, as has been described, close to the parent trunk, or it may be tied in one of the intercostal spaces. In the third or fourth space make an incision, about two inches in length, obliquely from without inward and downward, the center of which should be about half an inch external to the edge of the sternum. Divide the fibers of the pectoralis major and the intercostal muscle, and clear away the tissues with a blunt-pointed instrument. The artery, with its venæ comites, will be seen in front of the fibers of the triangularis sterni, which separates it from the pleura on the right and the mediastinum on the left side. In separating the veins from the artery, care should be taken not to break through the thin structure between the vessel and the cavity.

The other branches of the *subclavian* artery do not require especial consideration. The *inferior thyroid* is often tied in the removal of goître. I have, in six operations, found and deligated it prior to ablation of a bronchocele. It will usually be seen on the tracheal side of the *common carotid*, just below the anterior belly of the omo-hyoid.

Ligation of the Axillary Artery—Anatomy.—This artery may be tied at any part of its course. On account, however, of the difficulty of approach of that portion beneath the pectoralis minor, it is usually secured in the axilla, below this point, or between the upper margin of this muscle and the lower border of the first rib.

Operation.—With the head thrown back and the shoulders elevated, allow the arm to remain by the side of the body. About two inches from the sternal end of the clavicle, and half an inch below its inferior border, carry an incision outward, parallel with this bone, a distance of from three to four inches. This incision may divide a superficial vein which passes from the cephalic over the clavicle. The clavicular fibers of the pectoralis major and the costo-coracoid membrane are divided upon the director. The axillary vein will then be seen in the anterior portion of the wound, lying in front of the artery, which may be felt to pulsate, or seen just external to it. More external still may be seen the anterior cord of the brachial plexus, while in the lower portion of the wound the cephalic vein crosses over to empty into the axillary, below the clavicle. Beneath the clavicle the subclavius muscle may be seen. The needle should be passed from before backward. If necessary, a second incision may be made, beginning in the center of the first and carried in the direction of the axilla.

This operation is somewhat more difficult than ligation of the *subclavian* in its third division, but it is preferable. An incision beginning at the junction of the middle and outer third of the clavicle, and separating the deltoid and pectoralis muscles, will expose the commencement of this vessel.

Operation Below the Pectoralis Minor.—Shave and cleanse the axilla, and extend the arm at a right angle to the body. Divide the distance between the two

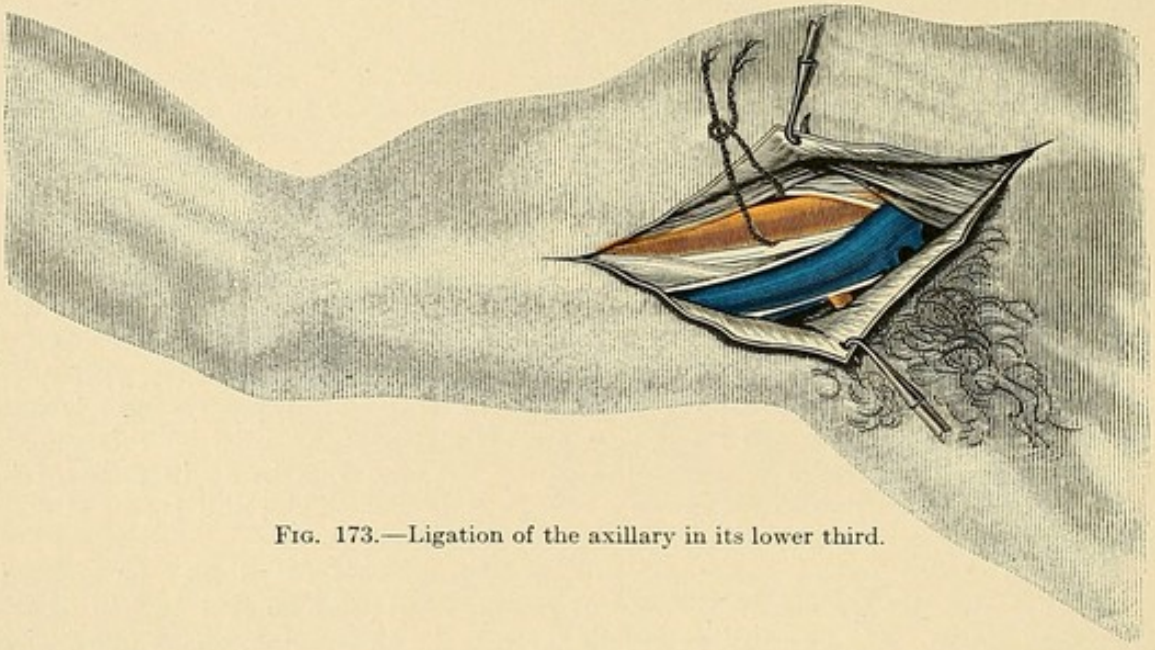

Fig. 173.—Ligation of the axillary in its lower third.

folds of the axilla into thirds, and the junction of the anterior and middle thirds will indicate the position of the artery. On this line make an incision in the axis of the arm, well up into the axilla. Cutting through the skin and fasciæ, the contents of this space will be seen. The vein lies internal to the artery, often overlapping it, and should be drawn carefully backward. The median nerve overlies the artery, or is on its anterior aspect, and should be drawn forward when the needle is passed from behind forward (Fig. 173).

Ligation of the Brachial Artery—Anatomy.—This artery lies in the furrow along the inner border of the coraco-brachialis and biceps muscles, tending more and more to the front as it nears the elbow-joint. In the lower half or three fourths of its course it has its venæ comites on either side, with occasional communications across the track of the artery. The median nerve crosses it by the front, from the outer side, on its way to the forearm, while the basilic vein is well to the inner side. As this vein passes up toward the axilla it pierces the deep fascia, and lies on the inner side and close to the artery, joining with the venæ comites to form a single large trunk.

Operation.—A line drawn from the junction of the middle and anterior thirds of the axillary space (as above given) to the middle of the elbow-joint, in front, will pass over the brachial artery in its entire length. The place of election is the middle of the arm. At this point make an incision, three inches in length, over the artery and in its axis. Dividing the skin and deep fascia, the white cord of the median nerve will be first seen, on the outer side of the brachial, overlapping the companion vein on this side. Just internal to this is the artery, with the other accompanying vein and the basilic in close relation (Fig. 174). The ligature should be passed from the inner toward the outer side. The operation above this point is essentially the same. In the lower third of the arm proceed as follows: On a level with the condyles of the humerus, and between the median basilic vein and the tendon of the biceps, commence an incision, which is carried upward three inches in the brachial line. Cutting through the deep fascia, the artery is readily found to the radial side of the median nerve, and surrounded by its veins (Fig. 176). The needle is passed from the inner side. Occasionally the brachial artery is double, while more frequently it bifurcates into the radial and ulnar, at a varying distance above the elbow.

Ligation of the Ulnar and Radial Arteries.—The *radial* artery may be tied immediately above the wrist, or in the upper third of the arm.

Operation at the Wrist.—A vertical incision, one inch and a half long, is made in the center of the depression, between the outer border of the radius and the radial border of the extensor carpi radialis muscle. Immediately beneath the deep fascia the artery will be observed, with its *venæ comites*, from which it is separated and tied (Fig. 175).



FIG. 174.—Ligation of the brachial near the middle and the lower third.

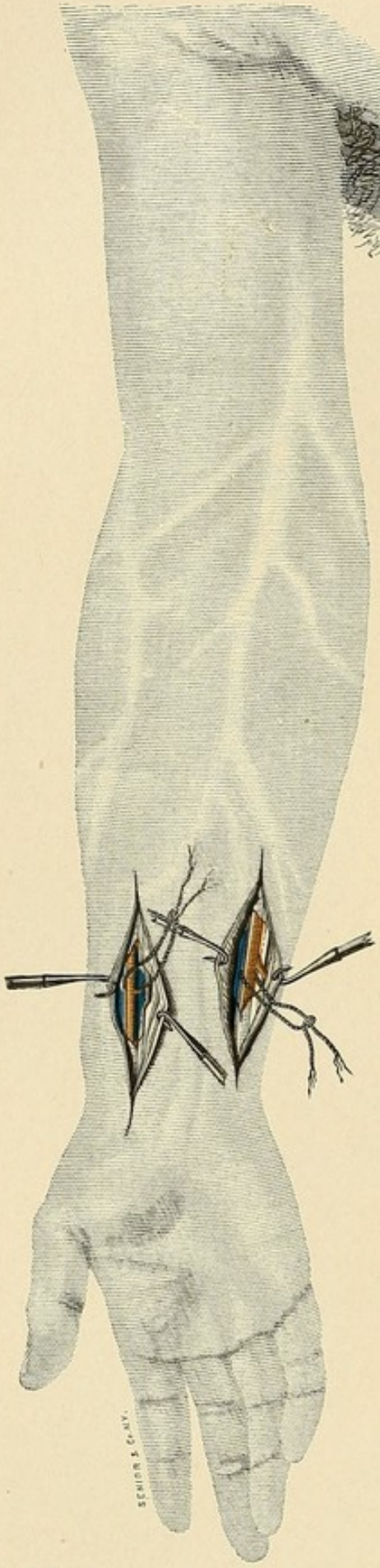

FIG. 175.—Ligation of the ulnar and radial arteries at the wrist.

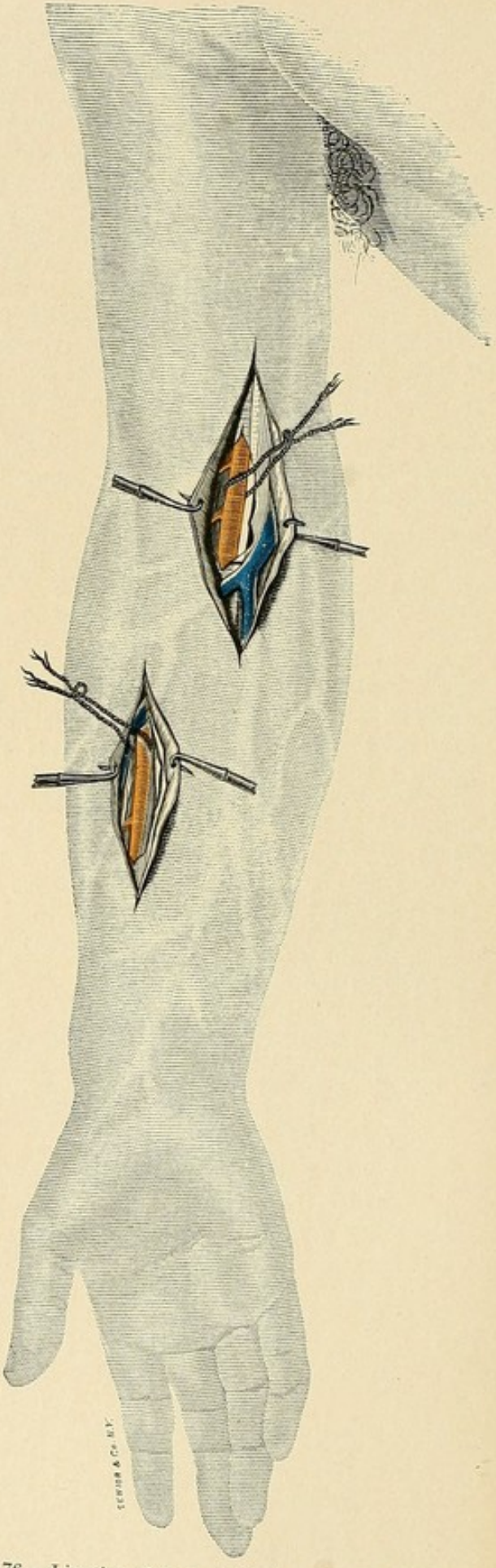

FIG. 176.—Ligation of the radial in the middle of the forearm and of the brachial at the bend of the elbow.

To find the artery in the upper third, draw a line from the middle of the elbow-joint, in front, to the styloid process of the radius. Along this line make an incision, about three inches in length, avoiding the superficial veins, if possible. Cutting directly down, the artery will be found between the supinator longus externally and the pronator radii teres on the ulnar side. The radial nerve is well to the radial side, and the venæ comites on either side (Fig. 176).



Fig. 177.—Dissection showing the relation of the right common, external and internal iliac arteries and veins. The ureter is seen crossing the iliac near the bifurcation.

The *ulnar* artery may be tied at the bend of the elbow, and near the wrist. As it passes beneath the pronator radii teres and flexor muscles, it is so deeply situated that an attempt to deligate it here is not justifiable. Above this point it may be secured by a downward extension of the incision given for ligature of the brachial at the bend of the elbow (Fig. 176).

Near the wrist-joint an incision should be made about a quarter of an inch to the radial side of the tendon of the flexor carpi ulnaris muscle. This incision should commence one inch above the level of the pisiform bone, and extend upward

one inch. The ulnar nerve will be seen partly concealed by the tendon, while the artery and its accompanying veins are immediately on its radial side (Fig. 175).

Ligation of the Intercostal Arteries—Anatomy.—The artery lies behind and near the lower border of the rib, the vein above, and the nerve below it. From near the angle of the rib to the vertebral column it is separated from the thoracic cavity by the pleura alone, but in front of this it runs between the two layers of intercostal muscles.

Operation.—An incision should be made just along the lower border of the rib. After passing through the outer plane of intercostal muscles the artery may be seen and secured. Or, failing in this, take a long, curved aneurism-needle, and through a puncture near the lower border of the rib pass it behind the artery and around the rib, taking care not to puncture the pleura. When the point of the needle is felt at the upper margin of the bone, another puncture is made to allow



FIG. 178.—Ligation of the gluteal, internal pudic, and sciatic arteries.

its escape. The needle is now armed with a strong catgut and withdrawn. A pellet of sublimate gauze is laid over the skin, between the points of exit and entrance, around which the ligature is tied. In exceptional cases it may be necessary to remove a portion of the rib.

Ligation of the Abdominal Aorta—Anatomy.—The aorta usually bifurcates upon the body of the fourth lumbar vertebra, a little to the left of the median

line. This point is on a level with the highest point of the iliac crests, and is a little to the left of and below the umbilicus. The point of election is one inch above the bifurcation.

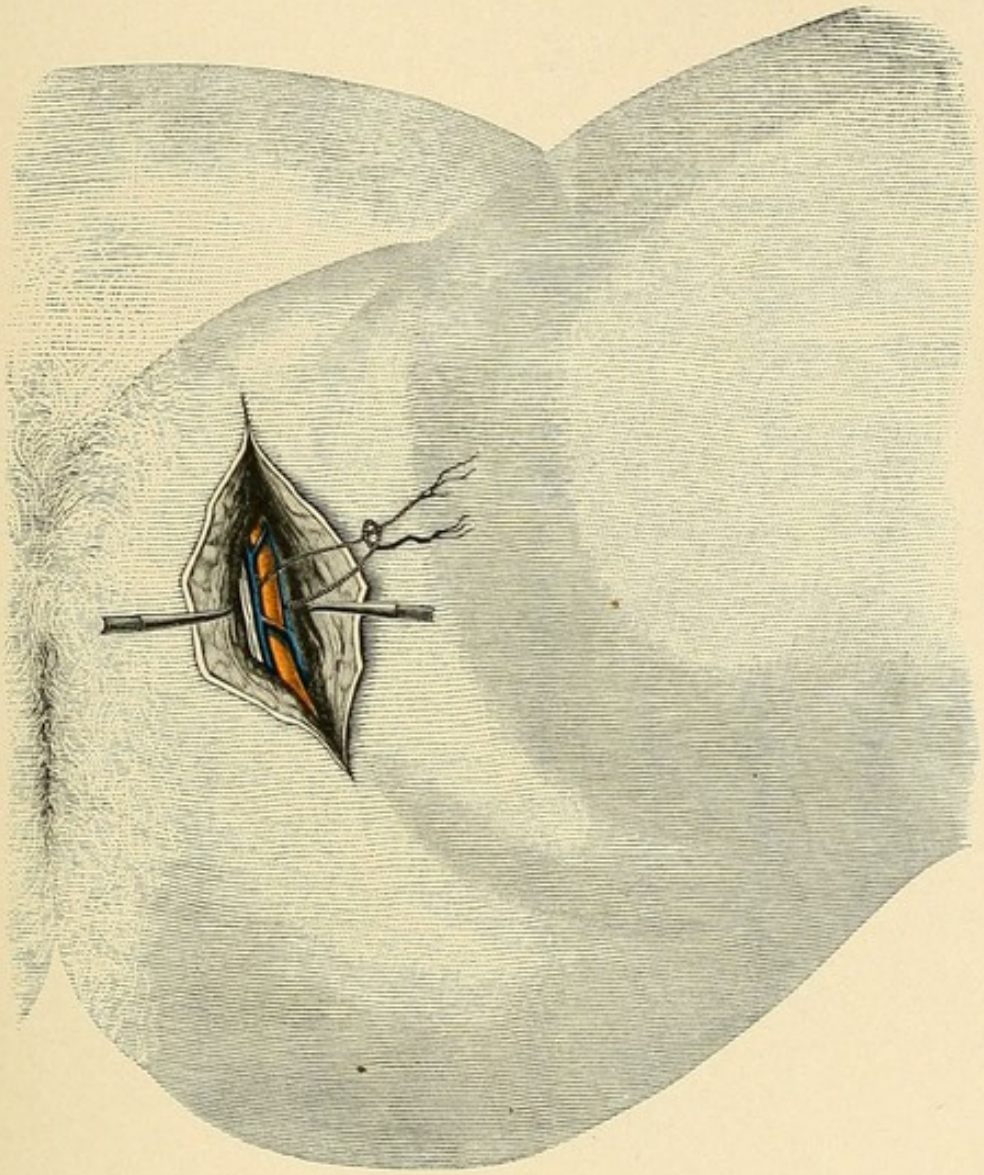

FIG. 179.—Ligation of the internal pudic in the perinæum.

Operation.—Through the left rectus muscle one inch from the *linea alba* make an incision, six inches long, the center of which corresponds to the umbilicus. Divide all the tissues down to the parietal peritonæum, and then arrest all bleeding before opening this. The transverse colon and omentum should be displaced upward, and if by posture or otherwise the small intestine cannot be displaced so as readily to expose the aorta, the interposed coils should be brought out through the wound and kept warm with sterile towels. With a blunt director scratch through the peritonæum and expose the aorta, around which a large animal ligature should be passed from the right side. (See aneurism of the common iliac artery.)

Ligation of the Common Iliac Artery—Anatomy.—The common iliac arteries extend from the left side of the body of the fourth lumbar to the sacro-lumbar junction. It is crossed by the ureter in front, near its bifurcation, and by some filaments of the sympathetic nerve higher up. The left common iliac vein lies wholly internal, and is on a plane somewhat deeper than the artery. The inferior mesenteric vein crosses the left artery, but is within the peritoneal folds. The right iliac artery crosses in front of both the iliac veins, passing at a right angle to the left vein and obliquely over the right, until near its termination the artery is in front of and external to the vein (Fig. 177).

Operation.—Make an incision one inch from the median line through the rectus muscle corresponding to the artery to be tied, extending from about one inch above to about five inches below the umbilicus. Deal with the viscera as just directed. The posterior wall of the peritonæum is scratched through by means of two dissecting-forceps and the aneurism-needle passed from within out.

Ligation of the Internal and External Iliac Arteries—Anatomy.—The *internal iliac* artery, less than two inches in length, has the ureter in front, its accompanying vein and the lumbo-sacral nerve behind.

Operation.—For the internal iliac and the upper portion of the external proceed as in the operation for the primitive iliac.

For the lower portion of the external iliac proceed practically as for the radical cure of oblique inguinal hernia. Split the aponeurosis of the external oblique, from the external inguinal opening. Make traction on the arch of the conjoined tendon and the internal oblique and transversalis muscles, and incise the peritonæum. The modified Trendelenburg posture will displace the intestines. The inferior epigastric vessels should be avoided. Approach the iliac from the outer side, as the vein is internal to it. Unite the peritonæum with running catgut, and if the incision is of necessity such that the abdominal wall may be weakened, close the canal as in the Bassini operation.

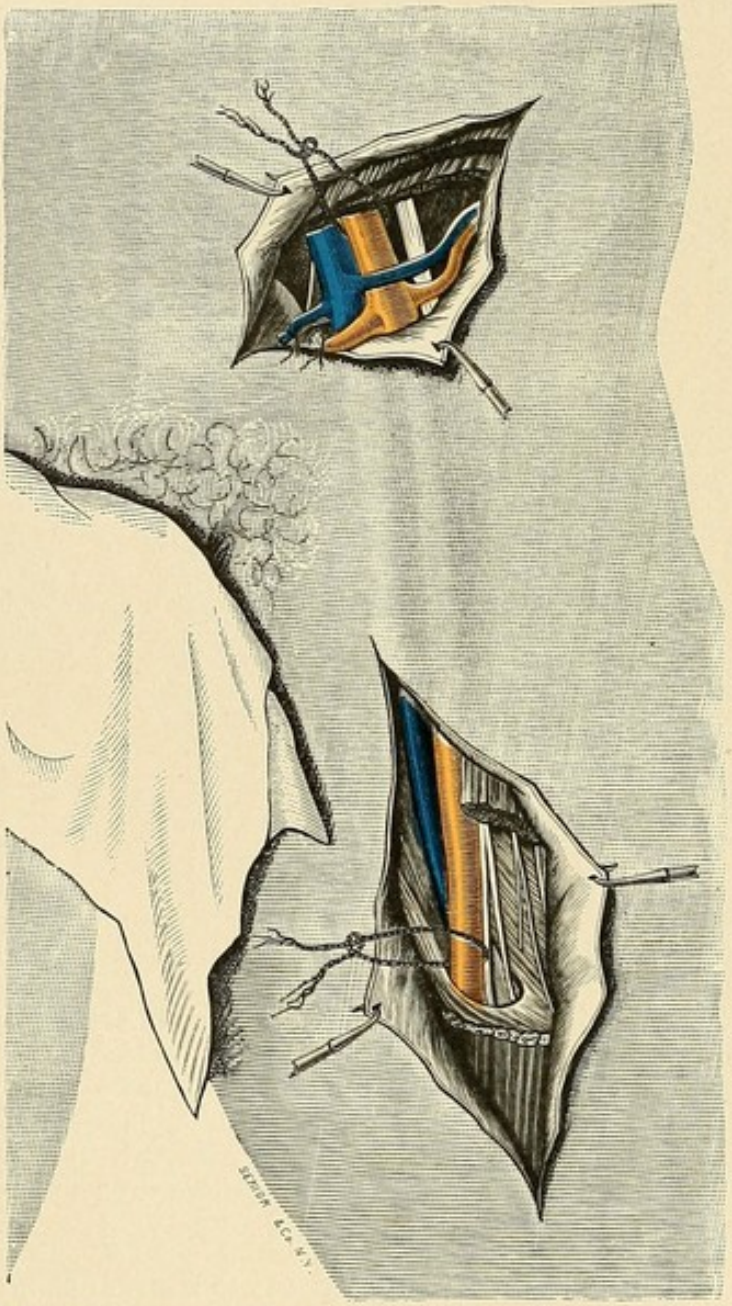

Fig. 180.—Ligation of the external iliac in its lower portion, and of the femoral in Hunter's canal.

The Gluteal Artery.—Make a five-inch incision, on a line extending from the spine of the last lumbar vertebra to the trochanter major. The center of this line will indicate the point at which the artery emerges. Separate with a dull instrument the fibers of the gluteus maximus, displace anteriorly the gluteus medius, and find the groove between the minimus and the pyriformis. Follow this groove upward to the bony edge of the notch, and the artery and veins will be found (Fig. 178, upper incision).

The Sciatic.—Make an incision, five inches long, on a line from the middle of the sacral spines to the trochanter major. Separate the fibers of the gluteus maximus and find the lower border of the pyriformis. The great cord of the sciatic nerve will now be seen emerging from beneath the muscle, and immediately in front of this the small sciatic nerve and the sciatic artery. The *internal pudic* artery is just anterior to this, upon the spine of the ischium (Fig. 178, middle incision). The

sciatic artery may also be secured opposite the *tuber ischii*, along the outer border of which it runs (Fig. 178, lower incision).

The Internal Pudic in the Perinæum.—With the patient supine and the thigh abducted, make an incision in a line with the symphysis pubis and tuber ischii. The artery will be found as it runs along the inner margin of the ramus of the pubis (Fig. 179).

Ligation of the Femoral Artery—Anatomy.—At Poupart's ligament the vein is on the same plane as the artery, and immediately internal to it. One quarter

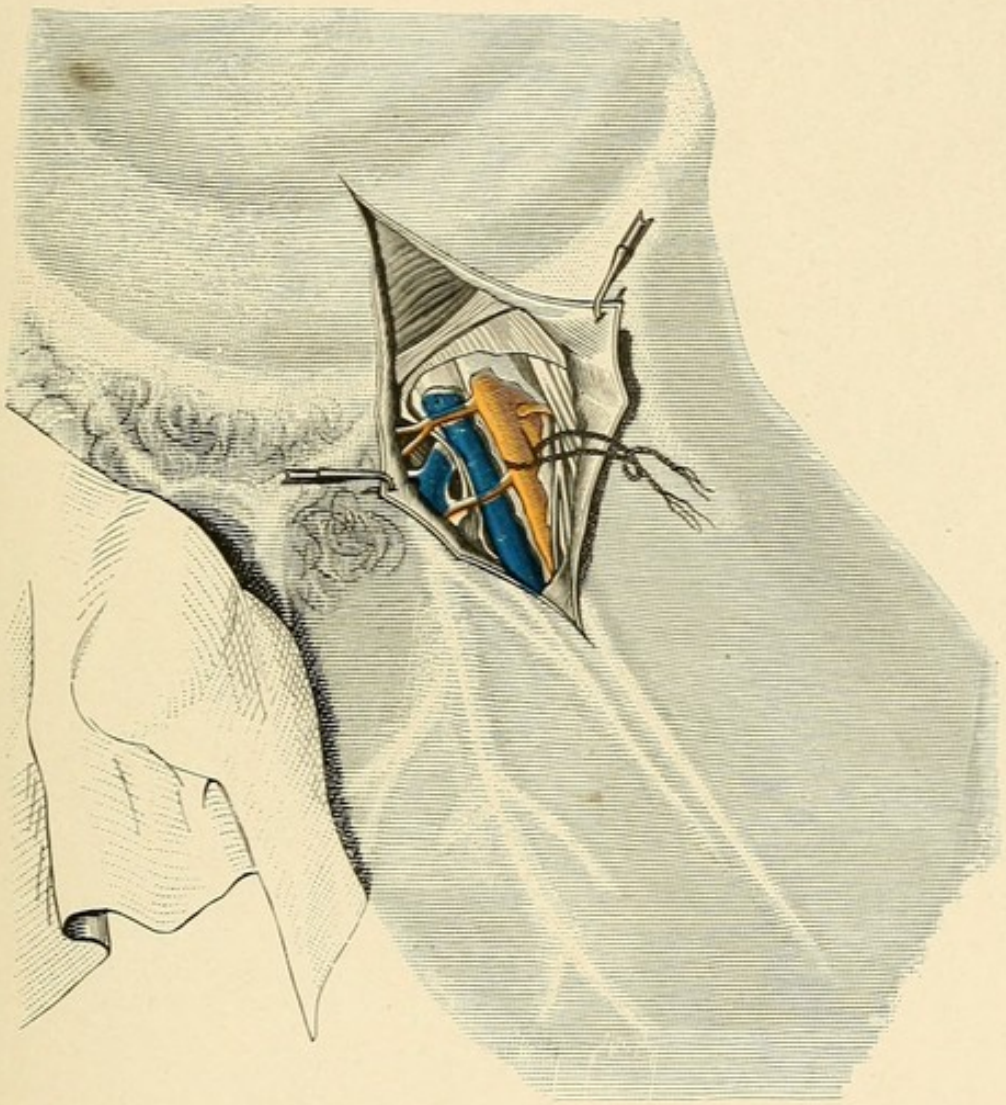

Fig. 181.—Ligation of the superficial femoral in Scarpa's space.

of an inch to the outer side, and deeper than the artery, lies the anterior crural nerve. One inch and a half from the ligament the *profunda femoris* arises from the outer aspect of the common trunk, and from one to two inches lower passes behind the superficial femoral. Four inches from Poupart's ligament the relations have changed to such an extent that the femoral vein is deeper and slightly behind the artery. The long saphenous nerve lies upon the sheath of the artery, in its middle third, and occasionally sends a branch through *Hunter's* canal. The *sartorius* muscle covers the femoral artery in all of its course except the first four inches, where it is superficial.

Operation.—A line from a point half-way between the symphysis pubis and the anterior superior spine of the ilium to the internal condyle of the femur will run over and parallel with the femoral. It may be secured in any part of its course.

In Scarpa's Space.—The point of election for tying the superficial femoral is from four to five inches below Poupart's ligament. With this as the center, make

an incision three inches long on the line already indicated. Beneath the skin and fascia some superficial and unimportant vessels may be divided; the fibers of the sartorius will be seen in the lower portion of the wound, and should be drawn downward with a retractor. The saphenous nerve will next be seen on the outer side of the common sheath of the vessels. The sheath should next be incised, and the artery carefully isolated by inserting a dull director beneath and around it from the inner side. The ligature is passed the same way. In this same plane an incision may be made to expose the artery lower down, where it is completely hidden by the sartorius. This muscle may be drawn to the side most convenient to the operator (Figs. 181, 182).

In Hunter's Canal.—Find the junction of the middle and lower thirds of the thigh. In the femoral line, with this point as the center, make an incision, about

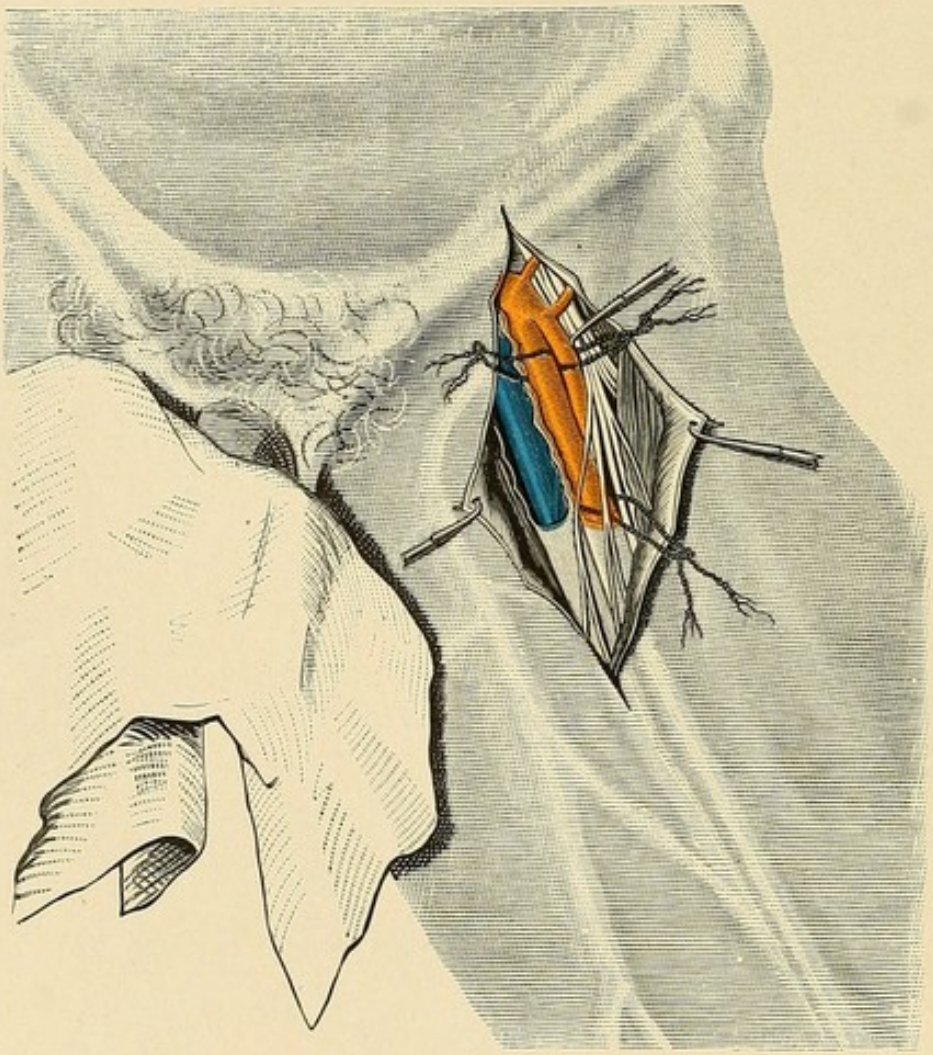

Fig. 182.—Ligation of the deep and superficial femoral near the bifurcation of the common femoral, and in the apex of Scarpa's triangle.

four inches in length, directly down to the sheath of the sartorius, which is incised and the muscle displaced outward. Immediately upon opening the posterior layer of the sheath of the muscle, the oblique aponeurotic fibers which pass from the adductor magnus to the vastus internus—forming the anterior wall of Hunter's canal—are seen. These may be divided on a director, or the sheath opened half an inch above this point. The saphenous nerve is on the sheath, and the vein is behind and to the outer side (Fig. 180).

The Common Femoral Above the Profunda.—Make an incision in the femoral line, from three fourths of an inch above Poupart's ligament downward for three inches and a half.. Do not divide the ligament, but approach the artery one half inch below. The superficial epigastric vein and artery may be wounded. Divide

the fascia lata, and pass the ligature from within out. (Dissection shown in Figs. 181, 182.)

The Profunda Femoris.—Make an incision in the femoral line, three inches and a half long, the center opposite a point one inch and a half to two inches below Poupart's ligament. As above, approach the common trunk and search along its outer border for the origin of the profunda [1] (Fig. 182). Pass the ligature from within out, one inch from its origin. Avoid the branches of the anterior crural nerve.

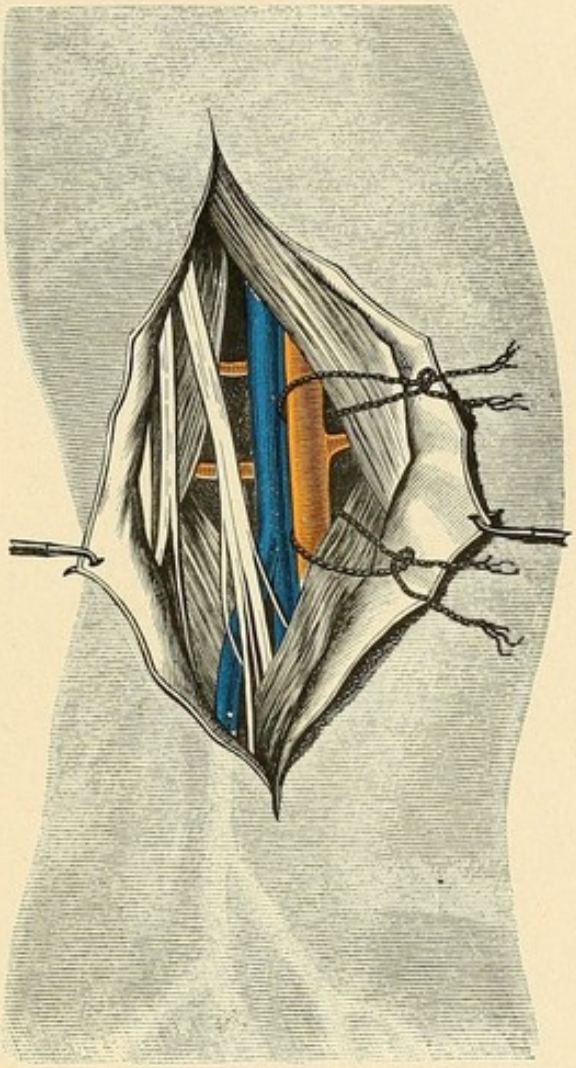

FIG. 183.—Ligation of the popliteal artery. Relations of contents in the left lower extremity.

In wounds of the posterior femoral region it may be necessary to tie this vessel as well as for aneurism. Ligation of the *common femoral* is rarely called for, and should only be done in extreme cases. In modern surgical practice, deligation of the superficial femoral is comparatively free from danger.

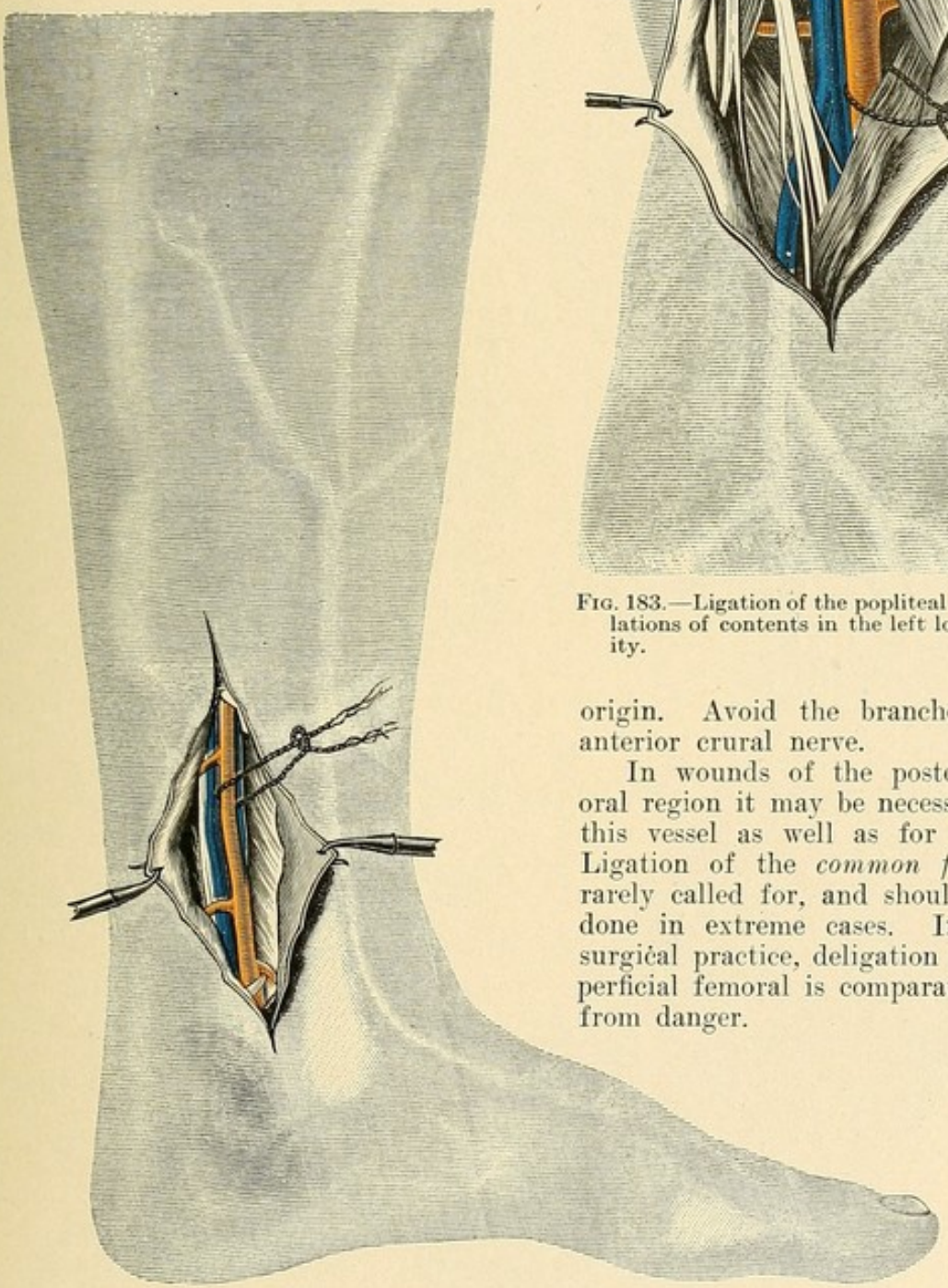

FIG. 184.—Ligation of the posterior tibial above the malleolus.

[1] In a large majority of subjects I have found this branch given off one inch and a half below the ligament.

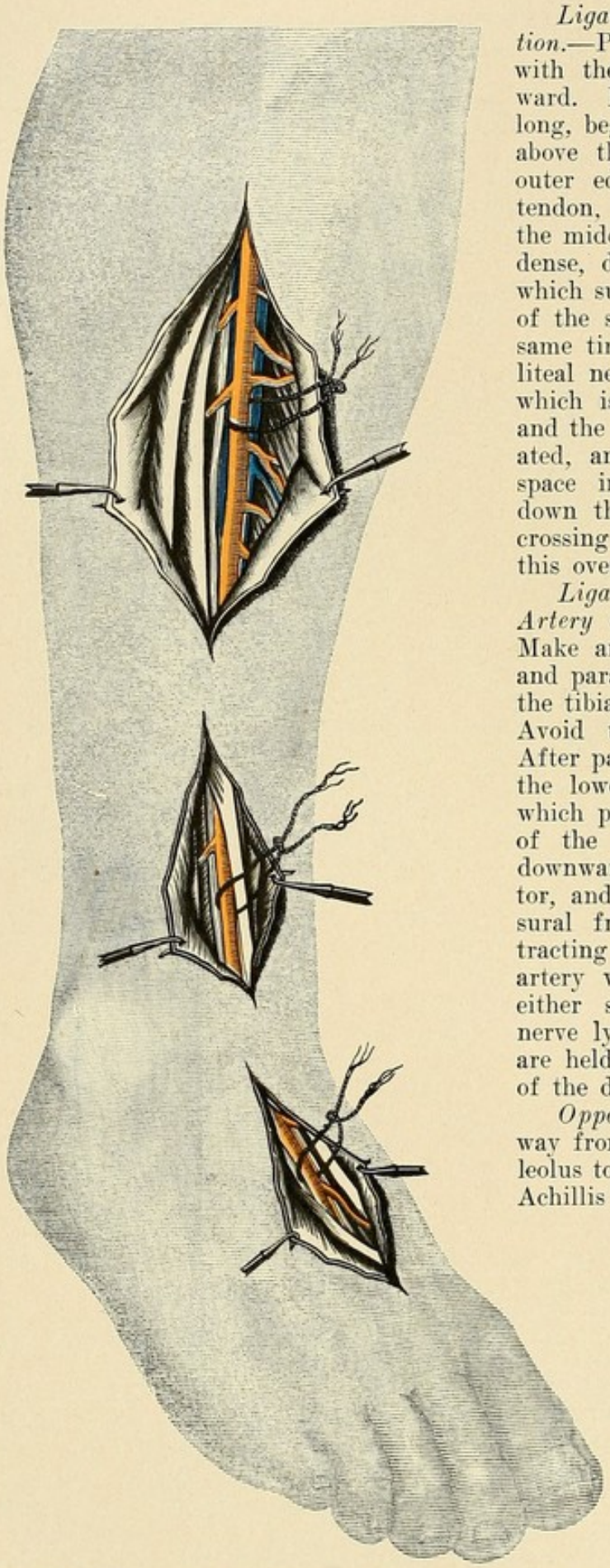

Fig. 185.—Ligation of the anterior tibial in the middle and lower third of the leg, and of the dorsalis pedis artery.

Ligation of the Popliteal—Operation.—Place the patient on his belly, with the popliteal space looking upward. Make an incision, four inches long, beginning two inches and a half above the level of the joint, at the outer edge of the semi-membranosus tendon, and extending down through the middle of the space. Dividing the dense, deep fascia, the areolar tissue which surrounds the vessels and nerves of the space will be seen, and at the same time, and superficially, the popliteal nerve. Draw this and the vein which is immediately below outward, and the artery will be seen deeply situated, and in the upper part of the space internal to the vein. Lower down the relations change, the nerve crossing superficial to the vein, and this overlying the artery (Fig. 183).

Ligation of the Posterior Tibial Artery at the Middle of the Leg.—Make an incision, half an inch from and parallel with the inner margin of the tibia, three inches and a half long. Avoid the internal saphenous vein. After passing the deep fascia, look for the lower tibial fibers of the soleus, which pass obliquely from this border of the tibia backward and slightly downward. Divide these on a director, and with the finger separate the sural from the flexor muscles. Retracting the edges of the wound, the artery will be seen, with a vein on either side and the posterior tibial nerve lying just behind. The vessels are held down by the common sheath of the deep muscles (Fig. 184).

Opposite the Ankle-joint.—Halfway from the tip of the internal malleolus to the anterior edge of the tendo Achillis commence an incision, which extends directly upward for one inch and a half. Dividing the skin and fascia upon a director, cut the dense internal annular ligament. The artery, with its two veins, will be found with the posterior tibial nerve and tendon of the flexor longus pollicis behind, and the flexor longus digitorum and tibialis posticus in front. As the artery curves around the malleolus it will be found

one third the distance from the tip of the malleolus to the convexity of the heel.

The Anterior Tibial at the Middle of the Leg.—A line from a point half-way between the anterior tuberosity of the tibia and the head of the fibula to a like point between the two malleoli, in front of the ankle, will indicate the position of this artery. At the middle of the leg make a four-inch incision in this line, dividing everything down to the dense fascia immediately over the muscles. Split this on a director and dissect it up carefully, searching for the interspace between the tibialis anticus internally and the extensor proprius pollicis externally. Finding this, discard the knife, and with the finger separate the muscles, and the artery, veins, and nerve will be found deep down upon the interosseous membrane, the nerve being external and slightly in front, and the veins wound about the artery. In order to relax the muscles and admit the light, flex the tarsus on the leg (Fig. 185).

At the Lower Portion.—One inch above the tip of the internal malleolus begin an incision, and carry it two inches upward, in the tibial line above given. This incision is along the fibular border of the extensor pollicis, between which and the tendon of the extensor communis digitorum the artery will be found, with the nerve on the fibular side, and its companion veins on either side.

The Dorsalis Pedis.—One fourth of an inch to the fibular side of and parallel with the tendon of the extensor pollicis make an incision, one inch long, over the tarsus. The artery and veins will be seen on a plane slightly deeper than the tendon, with the nerve on the tibial side of the vessels. This line is a continuation upward of the first metacarpal interspace (Fig. 185).

CHAPTER IX

THE SURGICAL DISEASES AND SURGERY OF THE BONES

Ostitis.—Inflammation in bone may be acute or chronic, general or circumscribed, traumatic or idiopathic. It may involve the periosteum (*periostitis*), the compact and cancellous substance (*ostitis*), or the medulla (*endostitis* or *osteomyelitis*). Endostitis and periostitis may occur independently, while ostitis must almost of necessity involve the periosteum or the endosteum and medulla.

Periostitis may be *suppurative* or *non-suppurative.* The so-called "*serous*" periostitis is a mild form of infection, the transudate containing only a few pus cells. It does not deserve to be considered as a separate type. Non-suppurative or fibrous periostitis is a subacute inflammatory process resulting in more or less permanent thickening of this membrane, with a varying degree of new bone formation (osteogenesis). It is a part of the late stages of the syphilitic process, and will be considered with that disease.

Tuberculous periostitis and ostitis are practically always associated.

Acute periostitis is usually a local disease involving a limited surface of the periosteum, although at times the entire covering of a bone may be affected. It is of more frequent occurrence upon exposed surfaces, as the spine of the tibia, upon the skull and the phalanges. It is always accompanied with great pain and febrile movement, requiring at times immediate relief by incision and evacuation of underlying pus or serous transudate. The incision should be free, and for the bone immediately beneath the area of infection the chisel or gouge should be freely used, in order to determine the extent of involvement. Not infrequently it will be found, even where the disease has existed only a few days, that the deeper structures, even the medulla (osteomyelitis), is involved.

The termination of inflammation in bone is in *resolution* or local *death.* In resolution the inflammatory embryonic tissue undergoes granular metamorphosis and is absorbed, or it may be in part converted into new bone. Should the bone die, it may be cast off as a *sequestrum,* or remain imprisoned in a shell of new-made osseous tissue, the *involucrum.*

When the inflammatory process is severe, or the arrest of nutrition sudden and complete, *necrosis* or death in mass occurs; under other and milder conditions, the process is known as *caries.*

In *necrosis,* which is aptly compared to *gangrene* of the soft tissues, the cast-off tissue retains something of its original form, while in *caries,* which is molecular death, the cell elements disappear by granular degeneration, leaving no trace of the original structure.

Periostitis and ostitis are infectious diseases, due to the presence of certain micro-organisms, chief among which is the streptococcus pyogenes aureus. Staphylococci, pneumococci, the bacilli of typhoid, of tuberculosis, and the colon bacilli, have also been observed. All of these are pyogenic except the bacillus tuberculosis, which is, however, very susceptible to mixed infection.

Acute osteomyelitis is one of the most serious diseases of bone, occurring chiefly in the period of rapid growth, from the eighth to the seventeenth year. It is exceedingly rare in infancy, and not more than three per cent of all cases occur after maturity (W. A. Dennis). It is met with in males oftener than females, in the proportion of three to one. The tibia is most frequently involved, and next in order the femur; after that the humerus. The short, spongy bones are compara-

tively immune. The process begins by preference at or near the epiphysis of the upper end of the tibia, or it may be the lower end of the femur. Kocher pointed out the fact that pyogenic ostitis started on the central side of the epiphysis, while the focus of tuberculous infection was located in or on the joint side of the epiphysis.[1]

Osteomyelitis is almost in all cases an extremely painful affection. From the fact that the medulla is soft and non-resistant, the infective process spreads rapidly; and since the surrounding bone is non-expansile, absorption takes place rapidly through the Haversian canals, with all the constitutional symptoms of septicæmia. Pain is exaggerated by any movement of the extremity, or by striking the bone which is involved. Immediate evacuation of the purulent contents is imperative. The incision should be free, the periosteum lifted on either side and a trough cut through the compact tissue for the entire length of the medulla involved. In recent cases (acute pyogenic osteomyelitis) it is best not to use the curette or sharp spoon, relying for disinfection of the medullary canal more upon forcible irrigation with hot salt solution, followed by 1–1000 mercuric-chloride solution, the excess of which is finally washed out with the salt water. The after-treatment consists in packing the cavity loosely with sterile gauze, and then covering in the entire area with gauze and sterile cotton. The operation is rendered entirely bloodless by the use of the Esmarch bandage, which should only be applied above the seat of the disease for fear of forcing septic matter into the circulation.

There is a rare form of subacute or chronic ostitis or osteomyelitis in which the infectious area is limited, the febrile movement slight and accompanied with little or no pain (Brodie's abscess).

Upon the discovery of these infected foci, the contents should be evacuated by curetting with Volkmann's sharp spoon.

Tuberculous inflammation of bone is a subacute process, not as rapidly destructive as acute osteomyelitis, oftentimes going on without exacerbations of temperature and without pain sufficient to attract the attention of the patient or surgeon. The presence of a rich granulation tissue, which is part of the tubercular process, produces molecular disintegration of the substance of the bone (*caries*), at times causing death *en masse* of more or less of the bony tissue (*necrosis*). When the granulation tissue is exuberant, the name of *ostitis interna fungosa* has been applied. When caseous, it is called *ostitis interna caseosa*, and in rarer instances, where the granulation tissue is scant, the bone may break down in practically a dry molecular disintegration, known as *caries sicca*.

Tuberculous ostitis, or osteomyelitis, is not infrequently converted into an acute infectious process by mixed infection, the pyogenic organisms finding in the tuberculous granulation tissue a suitable medium for their proliferation and development. Whether it be an acute or chronic myelitis, operative interference is demanded. In tubercular disease of the vertebral column direct interference is not possible, and this form of tubercular disease of bone will be considered in the treatment of Pott's disease. In all accessible locations the indications are exposure of the part affected by incision as free as possible, and a thorough removal by the chisel or spoon of all diseased bone. It is better in all cases to treat such wounds by the open method, changing the dressing every two to four days as indicated.

Osteomalacia—Rachitis.—Osteomalacia (*mollities ossium*) is a disease of adult life, and is especially apt to occur in child-bearing women. The chief pathological change is the disappearance of the earthy constituents from the bones, and their presence in the blood and excretions in abnormal proportion. Softening is often present to such an extent that marked distortions occur from muscular contraction and superincumbent weight. The medulla of the bones is the seat of congestion, often resulting in extravasation of blood. In the later stages the bony lamellæ disappear by absorption, the process commencing from within.

The *treatment* consists in the prevention of fracture and deformity by proper precaution, and the restoration of the osseous system to its normal condition by generous diet, studied hygiene, tonics, and the administration of the hypophosphites of lime and soda, with cod-liver oil and iron.

[1] "General Surgery," J. B. Murphy, 1907.

Rachitis, or "*rickets*," is strictly a disease of childhood and youth. Although it attacks the entire osseous system, its disastrous effects are chiefly observed in the bones of the skull and the long bones of the lower extremities. The bones of the skull become thickened and prominent, the sternum is advanced and angular ("pigeon-breast"), and the bones of the lower extremities are curved antero-posteriorly or laterally. While the diameter of a rachitic bone is usually increased at all points, the enlargement is more marked near the extremities. Rickets is a disease of malnutrition. Its chief pathological feature is the formation of an embryonic tissue, which in the normal condition is converted into bone, but in the rachitic diathesis only partially (if at all) undergoes ossification. The cells of the periosteum are unusually active in this proliferation, as are the cartilage bone-making cells; yet this new tissue remains in great part embryonic, without the formation of the osseous lamellæ.

The *treatment* of rickets is, first, to prevent deformity, and, secondly, to relieve the dyscrasia. Rachitic children should be kept in the recumbent posture, or, if allowed to stand or walk, artificial support should be given to the lower extremities and spine. The medical indications are nutritious diet, out-of-door life, and the administration of the hypophosphites of lime and soda, with cod-liver oil and tonics. The correction of the deformities which may result from rickets will be considered in the chapter on Orthopædic Surgery.

Acromegaly.—This term is applied to a condition of hypertrophy of certain bones of the body, as well as an increase of the soft structures. The hands and feet in many instances become enormously enlarged and out of proportion to the rest of the body, while in others the bones of the head and face, especially of the lower jaw, are affected. The central viscera are, as a rule, not involved. It is usually a symmetrical disease, the corresponding bones of the two sides of the body being alike affected. It gives to the individual a peculiar and unnatural appearance.

Actinomycosis of bone is a rare affection, but should be borne in mind, as it is occasionally met with, especially in the lower jaw, infection taking place through the alveolar process from a decayed tooth.

Hydatid cysts and cysts due to hæmatoma have also occasionally been met with in the bones.

Syphilitic ostitis and *periostitis* are given in the chapter on Syphilis. Periosteal gumma is met with most frequently upon the bones of the skull and upon the tibia, this painful affection being more marked when the patient retires at night. The deeper gumma of bone, also due to the presence of the lymphoid tissue of the syphilitic process, in common with periosteal gumma, does not suppurate unless mixed infection occurs.

Ostitis deformans (Paget's disease) may occur in any of the bones. In some cases this affection resembles osteomalacia, in which, from pressure or superincumbent weight, the bones give way, producing all kinds of deformities. It is a general disease and symmetrical, the bones of the two sides being alike involved. After the deformities have occurred, a supernatural hardening (sclerosis) takes place, leaving the bones harder than normal.

Exostoses, or new formations of bone, are occasionally met with. They occur quite frequently after a fracture near the insertion of a group of muscles (as at the trochanter), and are the cause of much inconvenience and pain. Upon the skull they usually result from an injury or a subacute periostitis. They form here dome-like or sessile tumors, while on the long bones they are often stalactite in shape. All such neoplasms should be thoroughly removed by the chisel or Volkmann sharp spoon as soon as discovered. The tendency of these growths to undergo malignant change (sarcoma, carcinoma) has long been recognized.

Fractures

Fractures are partial or complete; transverse, oblique, or longitudinal; single, double, or multiple; simple, comminuted, compound, complicated, and impacted.

Partial, when a bone breaks on one side (convex surface) and bends without

breaking on the opposite side (green-stick fracture, chiefly in the very young). *Complete*, when the break extends entirely through the bone. *Transverse*, when the break is at right angles to the axis of the shaft. In *oblique* fracture the direction of the line of cleavage is usually from before, upward and backward. *Longitudinal* fracture or split in the long axis of a bone is most frequently caused by penetrating wound (gunshot); occasionally by a fall with great violence, when the cleavage commences in an articular surface.

A *single* fracture is one break in a bone; *double* when two bones of one member (ulna and radius) are broken; *multiple* when two or more separate breaks occur in one or more bones.

A *simple* fracture is a single break of one bone, without injury of any contiguous organ, and without perforation of the skin. When there are two or more fragments, it is *comminuted*; if a fracture communicates with the air, it is *compound*; if it communicates with the joint, or involves an injury of any important organ (artery, vein, nerve, lung, etc.), it is a *complicated* fracture. When the fragments interlock with more or less complete immobility, it is *impacted*, and when for any cause bony union does not occur, it is an *ununited* fracture.

Fractures are caused by external violence directly or indirectly applied, or by muscular contraction. In *direct violence*, the bone breaks immediately where the injury is received. An example of *indirect violence* is fracture at the hip from a fall on the feet, or at the base of the skull from a blow on the vertex. Muscular contraction not infrequently fractures the patella; this bone is also frequently broken by direct violence (a fall on the knee).

Certain conditions of the bones predispose to fracture. Those of the aged break more readily and repair more slowly than the young and middle-aged. There is often a fragility of the bones in certain forms of insanity; also in osteomalacia, and occasionally in rachitis.

Men suffer more frequently than women, on account of exposure, and the bones of the right side are more frequently broken than the left.

Symptoms and Diagnosis.—The loss of function, absence of normal contour, shortening, abnormal mobility, crepitus, and pain are the usual symptoms. When not impacted, a broken bone no longer acts as a support, or sustains muscular contraction. Displacement of the fragments causes loss of the normal contour or shape. Overlapping will be recognized by careful manipulation, while comparative measurements will show shortening. *Crepitus* or grating may be felt when the broken ends are moved upon each other.

The diagnosis of *impacted* fracture is more difficult, since crepitus and mobility are not present. Measurement will reveal shortening, which with partial loss of function and pain where the break has occurred will aid in the recognition of the lesion. A *longitudinal* fracture or fissure is difficult of recognition, and may escape detection unless the Roentgen ray be employed. The X-ray either with a fluoroscope (preferably a radiograph carefully taken) is of inestimable value in recognizing the exact nature of a fracture, and should be employed in all obscure cases.

Prognosis.—A guarded prognosis should be the rule of practice. While an uncomplicated fracture in a young or middle-aged person, in good physical condition, if skillfully treated will unite promptly and oftentimes without appreciable deformity or loss of function, a large proportion of fractures do not terminate so favorably. This is especially true when the lesion is near a joint or when an important nerve or vessel or other organ is involved by contiguity.

Simple fracture of the humerus is not infrequently followed by paralysis, partial or complete, to those muscles which receive their motor impulse through the musculo-spiral nerve; the splintered bone may injure the nerve, or later callus may press upon it.

Fractures at the elbow, under most competent management, are frequently followed by impairment of function. The same may be said of fractures at the hip. In the aged, or in patients with rachitis or osteomalacia or any constitutional disease, delayed union or non-union may occur.

When the displacement is extreme, and where the soft tissues interpose, or when

the fracture has occurred in that part of a bone normally deficient in nutrition (as in the humerus and tibia above the nutrient foramina), callus is often deficient and the process of repair imperfect.

In compound fractures, which are infrequently complicated by infection, union is delayed and may fail entirely, while in extreme cases amputation on account of gangrene or septicæmia becomes imperative. This fracture when communicating with a joint is one of the most serious surgical lesions.

Treatment.—To prevent infection and to readjust the broken and displaced ends to as near the normal as possible, and hold them there immovably until reunion occurs, is the end and aim of treatment. To do this it is essential to recognize the exact conditions at the point of fracture by means of the X-ray, when necessary, or a careful examination under the relaxation of complete narcosis.

While in some of the simpler lesions (fracture of the clavicle) an anæsthetic is not absolutely necessary, and while in other lesions (as in Colles' fracture) the brief narcosis of nitrous-oxide gas may suffice, in fractures of the long bones, especially in muscular subjects, and in compound or complicated lesions, complete narcosis is imperative.

While the mechanism of reduction and treatment will be given in connection with special lesions, it may be said in general that in fractures of the long bones a plaster-of-Paris dressing, carefully adjusted and watched, yields the most satisfactory result; and since this material can now be obtained in prepared roller-bandages, hermetically sealed to prevent the absorption of moisture, there can be no good reason why it may not be employed. There is no objection to its immediate application on account of swelling, and no danger of gangrene when the ordinary precautions are taken. In its application an ordinary bandage-roller is usually applied next to the skin, while the moistened plaster-roller is wound rather loosely around the member and immediately molded to its surfaces by the hands of the operator. It hardens so rapidly that only a few minutes are required to secure immobility.

It is a wise precaution, when the patient is at a distance, as soon as the cast hardens to cut it in its entire length, and divide with a scissors a turn or so of the underlying bandage at the upper and lower ends. Should swelling occur, the nurse or attendant should be instructed to divide the remaining turns of the roller next to the skin, and to separate the margins of the plaster cast in the line of section. Strips of bandage tied around the cast every few inches of its length will hold the broken limb practically as immovable as if it had not been cut.[1]

Process of Repair.—In *simple* fracture, the immediate result is hæmorrhage from the vessels of the periosteum, the compact substance and medulla, as well

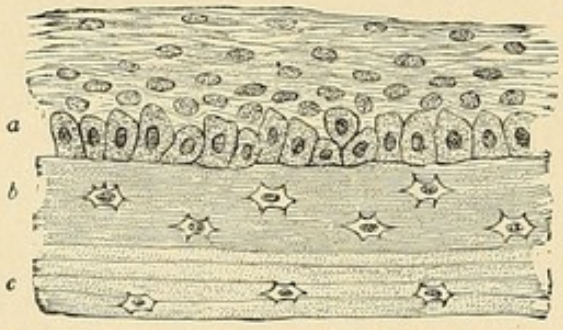

FIG. 186.—Periosteal formation of bone from osteoblasts *a*; *b*, newly formed bone; *c*, old bone. × 300. (After Tillmanns.)

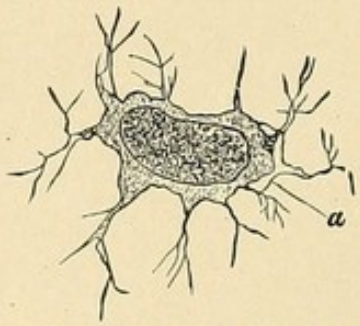

FIG. 187.—A bone cell isolated and highly magnified. *a*, Proper wall of the lacuna, shown at a part where the corpuscle has shrunk away from it. (After Joseph and Quain.)

as the accidental bleeding from the contiguous soft structures. The coagulum of blood and lymph covers the broken ends, extends a short distance into the medul-

[1] Plaster-rollers should be submerged in warm or tepid water for about one minute, or until the bubbles have ceased to rise. The excess of water is squeezed out and the application made at once.

lary cavity and Haversian canals, pressing back the medulla and infiltrating the space about the point of fracture. Into this clot and throughout the inflamed area the emigrating leucocytes crowd, and all the phenomena of cell proliferation which

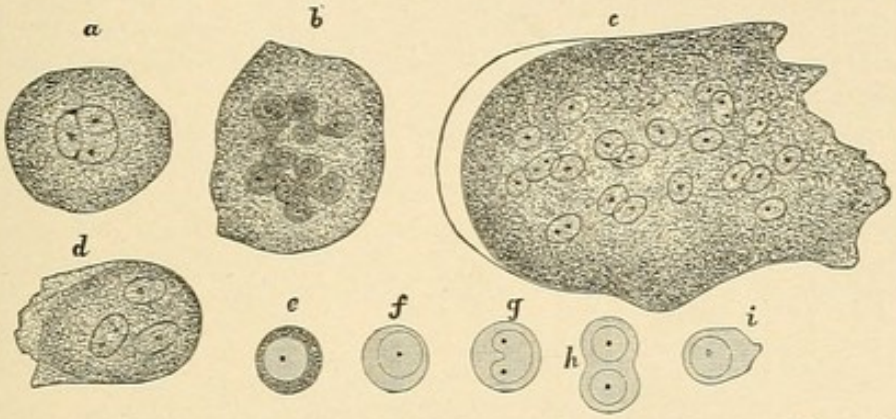

FIG. 188.—Multinuclear cells from bone marrow, highly magnified. *a*, A large cell the nucleus of which appears to be partly divided into three by constriction; *b*, a cell the enlarged nucleus of which shows an appearance of being constricted into a number of smaller nuclei; *c*, a so-called giant cell (myeloplaxes) with many nuclei; *d*, a smaller cell with three nuclei; *e–i*, other cells of the marrow. (After Sharpey and Quain.)

their presence excites takes place. The periosteal osteoblasts (Fig. 186), the bone corpuscles (Fig. 187) which fill the lacunæ, the "giant cells," or *myeloplaxes* of Robin (very large masses of protoplasm, containing usually many nuclei, Fig. 188 *c*), or, if only one, this very large, and the common and very much smaller mononuclear cells of the medulla (marrow cells, Fig. 188) (found not only in

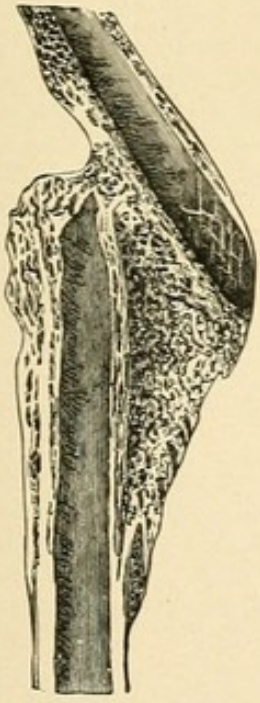

FIG. 189.

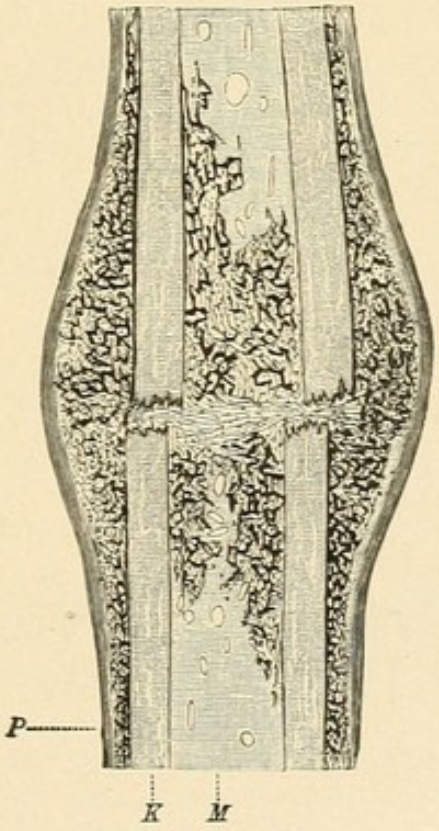

FIG. 190.

FIG. 189.—Fracture healed with deformity (callus luxurians.) (After Tillmanns.)
FIG. 190.—Longitudinal section through a fracture of the femur three weeks old. *P*, periosteum; *K*, bone; *M*, medulla. Periosteal callus and medullary callus. The intermediary callus consisting of periosteal granulation tissue, which is ossified only in some places and is partly cartilaginous. (After Tillmanns.)

the central medulla, but also in the Haversian canals, and possessing the amœboid properties of the leucocytes), all undergo active proliferation. The deeper cells of the periosteum are at first most active and throw out a rich mass of embryonic

tissue, which envelops and surrounds the broken ends and by the tenth day begins to be infiltrated with lime salts to form a callus. From the fifteenth to the twentieth day this (Fig. 190) ensheathing callus is complete and holds the fragments immovable while the process of ossification is going on. There forms also about the same time, in the young, a weaker callus from the central medulla cells (pin callus) and from the marrow cells of the Haversian canals—the interosseous callus. In older persons, after about fifty years, it is held that no central or pin callus forms. It is probable that in all cases the chief factor in the regeneration of bone is the *bone corpuscle* (Fig. 187). It is well known that the periosteal cells (osteoblasts, Fig. 186)) will reproduce bone in children and in early adult life, and in inflammation this doubtless assists in the process, but the bulk of their product usually disappears by absorption, as does the medullary callus. In that portion of the embryonic tissue which springs from proliferating bone-corpuscles and usually

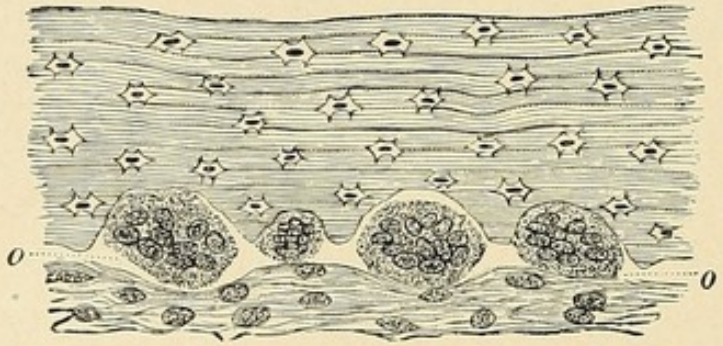

Fig. 191.—Lacunar absorption of bone by osteoclasts (*O*), which lie in Howship's lacunæ. × 250. (After Tillmanns.)

is interposed between the contiguous surfaces of fractured bone, the cells are transformed into *hyaline* substance, in which *cartilage* cells appear. As in the original development of bone, this cartilage is soon infiltrated by true osteoblastic tissue, forming the osseous lamellæ. In addition to the osteoblasts there appear multinucleated cells (myeloplaxes of Robin and osteoclasts of Kölliker) which arrange themselves in rows or circles and cause partial absorption of the osseous substance, giving, according to Sharpey, the festooned appearance to the Haversian spaces (Fig. 191). Through these canals, thus produced by absorption, the new-formed vessels make their way.

While the process of repair in bone, as just given, is closely analogous to the formation of bone from the blastoderm—namely, primary formation of cartilage and the replacement of this by osteogenic tissue—this does not always occur. In certain bones of the skeleton (the flat bones of the skull) osteogenesis is not preceded by cartilage formation. In inflammation with loss of substance, when suppuration has occurred, as in an infected compound fracture, embryonic tissue is *directly* converted into bone.

When overlapping occurs or when soft tissues intervene, the formation of callus and new bone is interfered with and the fracture may remain ununited. In from thirty to sixty days the greater part of the ensheathing callus is absorbed. The intermediate callus is formed into permanent bone, and while the pin callus may occasionally occlude the medullary canal by permanent osteogenesis, it is usually absorbed.

Special Fractures—Cranium.—Fractures of the skull are usually caused by direct violence, but not infrequently a blow received on the upper portion of the skull may cause a fracture at the base without breaking the bone at the point of injury. The base of the skull is occasionally fractured by a fall on the buttocks, the force being transmitted along the spinal column.

With these injuries there may or may not be *compression* of the brain or meninges. Indentation of the skull may occur without depression of the inner or vitreous table; more frequently both tables are involved.

Diagnosis.—When the scalp is unbroken, fracture may be determined by palpation, although a fissure, or a fracture without marked displacement, may escape

detection unless the X-ray is employed or an exploratory incision made. In fractures at the base, hæmorrhage or the escape of serous fluid from the ears or bleeding from the nose is a symptom. Sudden swelling of the vault of the pharynx (hæmatoma) is significant when a basilar fracture is suspected. Interference with vision or the sense of smell points to a lesion in the anterior fossa. The loss of consciousness and paralysis, partial or complete, points to *concussion* or *compression* of the brain, or both.

In general, the symptoms of *compression* are those of paralysis, usually unilateral with symptoms more pronounced than those which follow *concussion*. In *concussion* the patient may be aroused to partial consciousness, the buccal walls are equally relaxed, the pupils are equal, and vomiting is of frequent occurrence. In other words, both sides of the brain are involved. In *compression*, stupor is apt to be profound and prolonged. The facial muscles are drawn to one side, while the buccinator of the affected side is puffed out with the expiratory effort more than its fellow. The pupils are apt to be unequal, and vomiting is not the rule.

In the treatment of concussion, the first indication is rest, in the recumbent posture with the head elevated; with marked coldness of the skin and great prostration or collapse, heat should be applied locally and stimulants administered by hypodermic injection or enema. When shock subsides, cold applications may be essential.

When compression exists, operation is strongly indicated. In most instances it is advisable to wait until shock has disappeared and reaction established.

Occasionally, however, immediate operation is imperative, and, should the patient be wholly unconscious, no anæsthetic need be administered.

In comminuted fracture, with depression, under careful aseptic precaution the fragments should at once be lifted to their normal position. If infection can be prevented, the vitality of these fragments is such that they readily survive, and reunite to form a solid plate of bone. It is always better to operate early, since the danger of permanent injury to brain substance is increased by delay.

Operation.—The scalp within two or three inches of the incision (or wound, if such exist) should be shaved and thoroughly scrubbed with sterilized brush and soap, mopped with ether on clean absorbent cotton, and then with 1–1000 sublimate solution. The incision may be longitudinal, crucial, or horseshoe shaped, as required. Hæmorrhage from the scalp may be temporarily controlled by strong retraction while the operation is in progress, and permanently by deeply inserted continuous sutures of No. 2 chromic-acid catgut in closing the wound.

When the fissure is sufficiently wide to admit a thin, dull-pointed instrument, this may be employed to lift the depressed piece, using the sound edge as a fulcrum. With a narrow fissure, the dura will need to be exposed by a half-inch trephine or chisel. Preference for Galt's trephine is based on the fact that its conical shape makes it easier to avoid wounding the dura. Before applying it, the periosteum should be incised, lifted, and held aside over a space large enough to admit the trephine.

The bit of this instrument projected about one-eighth of an inch beyond the level of the teeth, is now applied near the fissure on the sound side, so that about one third of the disc will be removed from the depressed bone. After the first few turns, when the disc has been well outlined by the teeth, the bit should be withdrawn for fear of penetrating the dura.

When the vessels situated between the outer and the inner plate (diplöe) are reached, slight hæmorrhage will occur. After this, pressure upon the trephine should be cautiously employed. It should be removed at frequent intervals, in order to cleanse its track of bone-dust with the "eye-end" of a Hagedorn needle, so that the first point of exposure of the dura may be seen. Through this the needle or a stronger instrument, as an elevator, should be inserted, and the button removed.

On account of the small diameter of the disc, it is not necessary to replace it. Osteogenesis takes place from the periosteum and dura within a few weeks, forming permanent bony protection.

In closing the scalp wound, a catgut drain should be left at each angle.

Fractures at the base of the skull rarely require operation, although injuries in the lower occipital region, over the temporal bones, and occasionally in the anterior fossæ, will justify surgical interposition. Should infection supervene, with symptoms of meningitis or intra-cranial abscess, exploration is demanded. The same procedure is imperative when symptoms of compression from hæmorrhage are present.

Nasal Bones.—A blow upon the nose may break one or both nasal bones, the septum, and occasionally the cartilages. This fracture is almost always compound, and depression with deformity the rule. Hæmorrhage is usually severe, chiefly from the mucous surface, and may require compression by plugging. Before resorting to this, a spray of adrenalin or the injection of cold or very warm water should be tried, unless the operator has decided that plugging is necessary to hold in position the replaced fragments. It is in general advisable to employ an anæsthetic before reposition can be satisfactorily effected. A strong, narrow, blunt instrument should be passed along the septum until it is in contact with the inner surface of the depressed fragments, which should be pressed outward to their normal position.

When the fracture is multiple, and especially when both bones of the septum are involved, the following method is advised:[1]

After reposition, a large, round sewing needle is passed so as to transfix the nose, being made to enter through the line of fracture and forced through the unbroken bone and skin of the opposite side. A second or third needle may be required when there is a severe comminution. A soft silk thread may be carried in figure-of-8 fashion between the two ends of each needle, which are shielded with wax. They may be removed about the seventh day.

When one bone is broken and the depression is slight, a satisfactory local anæsthesia may be obtained by a spray of five-per-cent cocaine solution to the mucous surface, combined with the instillation of a two-per-cent solution beneath and into the skin.

It is important that fractures of the nasal bones be reduced within a few hours after the injury before swelling supervenes to such an extent as to render it difficult accurately to replace the fragments. Deformities of the nose due to old and badly united fractures of the nasal bones may be greatly relieved by comminution of the deformed bones and reshaping them. A special forceps, which is inserted under the skin and mucosa, is employed.

Malar Bones.—Fracture of these bones, though rare, is always the result of great violence, which frequently involves the superior maxilla. Reposition by means of an elevator should be made at once. None of the fragments should be removed, since the vitality of the bones of the face is so great that necrosis after injury is exceptional. When the impaction is firm, the bullet-screw elevator may be employed to replace the fragments, or through a small incision a narrow instrument may be passed beneath the zygomatic arch, in order to lift the bone into place.

In fracture of the *zygomatic process* (malar or temporal), a strong silver wire may be carried, by means of a full-curve Hagedorn needle, through the soft tissues beneath the bone, and used as a means to pull it back to its normal position.[2]

A narrow splint, resting on a pad of gauze and held in place by the wire twisted over it, will hold the bone in position until union occurs. In ten days or two weeks the splint and wire may be removed.

Superior Maxilla.—A blow received upon the upper teeth may fracture the alveolar and palatal arch, at times involving the antrum maxillare.

The treatment consists in early reposition of the fragments to their normal position.

When there is a wound through the cheek, this should be closed aseptically with drainage into the mouth, in order to prevent an eschar of the face.

When the teeth are displaced and reposition effected, the soft gutta-percha interdental splint may be required as in fracture of the lower jaw.

[1] Method of Dr. Lewis D. Mason, of New York.
[2] Method of Prof. Rudolph Matas.

Lower Jaw.—Fracture of the *inferior maxilla* may occur in rare instances through the symphysis, but much more frequently the break is near the mental foramen.

Fracture of the *angle* or *ramus* is infrequent, and is usually the result of a blow upon the side of the jaw.

The *coronoid process* is rarely broken, except by a penetrating body. The *condyle* may be broken by a fall or blow on the chin, or by a powerful force applied laterally at or near the angle.

Diagnosis.—Pain at the point of fracture, with loss of function and displacement are the chief symptoms of this injury; crepitus may at times be elicited. Loss of sensation points to fracture of the jaw, with interference with the function of the inferior dental nerve. When the condyle is broken, the chief symptom is pain in this region, with partial or complete loss of function.

Treatment and Prognosis.—Pressure from within the mouth, aided by counter-pressure from without, will easily effect a reduction of the displaced fragment. When this is done, the four-tailed bandage (Fig. 61) should be applied. A piece of soft sole leather or gutta-percha, about one eighth of an inch in thickness, should be cut from three to three and one half inches wide and from six to seven inches long, and split from each end in the long axis to within three quarters of an inch of the center. One strip should be left about one half inch wider than the other. The material should be dipped in warm water for a few minutes, until it becomes thoroughly softened. It is then laid across the chin, the upper and narrow ends are turned back parallel with the body of the jaw, while the lower strips are turned upward and made to cross outside the horizontal strips. There is thus shaped a close-fitting cup over the chin and lower jaw, and over this the four-tail bandage is to be firmly applied. Within a few hours this cup will harden into an unyielding dressing.

Before applying the bandage, interdental splints, made of gutta-percha strips one and one half inch in length and about one half inch in width, are softened in hot water and placed between the upper and lower teeth, bridging over the line of fracture. While the gutta-percha is soft, the teeth should be driven into its substance by closing the jaws. These splints keep the upper and lower incisors separated a distance sufficient to permit of semiliquid food being taken through a pipette.

The best apparatus is Hamilton's (Fig. 192), which consists of a chin and head strap made of strong, soft leather, shaped as shown in the illustration. The anterior part of the chin piece consists of strong, soft cloth sewed to the leather strip which passes beneath the jaw. By means of buckles the pressure can be accurately adjusted. The interdental splints are added to this dressing.[1]



Fig. 192.—(After Hamilton.)

A patient suffering from this fracture should not be allowed to talk, and when in bed should be required to rest upon the back, so as to avoid lateral pressure upon the injured bone.

The prognosis is usually favorable. Union occurs in three to four weeks. There may, however, be a delay in union, and in a certain proportion of cases non-union occurs.

In ununited fracture of the lower jaw, the broken surface should be exposed by incision, thoroughly freshened by scraping, one or two holes drilled about one quarter of an inch from the fractured margins of each section, and fixation secured by means of silver wires. After union has taken place it is usually necessary to remove the wires.

Larynx.—Fracture of the *cartilages* of the *larynx* is a rare occurrence. The prognosis is grave in proportion to the danger of asphyxia from inflammatory

[1] Prof. Frank Hastings Hamilton.

swelling, or emphysema, or from loss of voice due to injury to the muscles or nerves of this organ. Very serious shock may follow extensive comminution of the cartilages of the larynx. The operative treatment requires replacement of fragments and perfect rest. Tracheotomy may, in rare instances, be required.

Hyoid Bone.—When the *os hyoides* is broken, the fragments may be brought into position by introducing one finger in the mouth and pressing with the other hand from without. The application of a retentive apparatus is practically impossible, and fibrous union is the rule.

Clavicle.—Next to the radius, the collar bone is most frequently the seat of fracture. The break occurs in the large majority of instances in the middle third; in children it is rarely complete. It may be caused by direct violence or indirectly by a fall upon the shoulder or the extended arm. The classical displacement is shown in Fig. 193. The sterno-mastoid muscle and costo-clavicular ligament hold the inner fragment practically immovable. The weight of the arm and shoulder drags the outer fragment downward, while contraction of the pectoralis major and latissimus dorsi and subclavius muscles carry it toward the middle line beneath the inner fragment.

The *diagnosis* may be determined by pain at the seat of lesion, possible crepitus, loss of function and symmetry, shortening when compared with the opposite side, and recognition of displacement by palpation.

The *prognosis* is good as to restoration of function, although in complete fracture, overlapping and a certain amount of permanent deformity and shortening are almost inevitable.

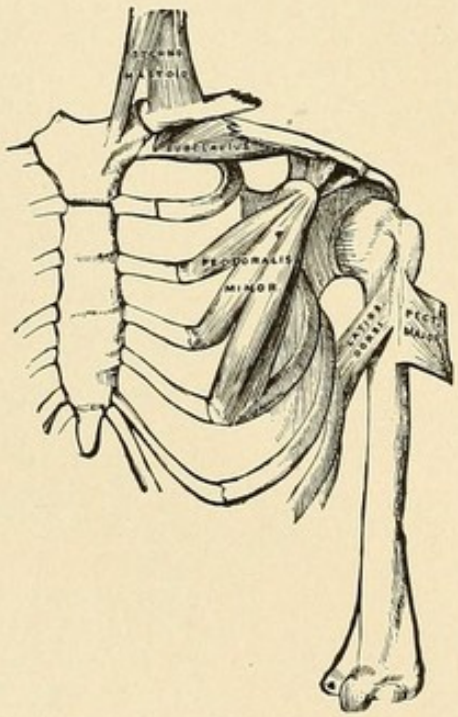

Fig. 193.—(From Gray.)

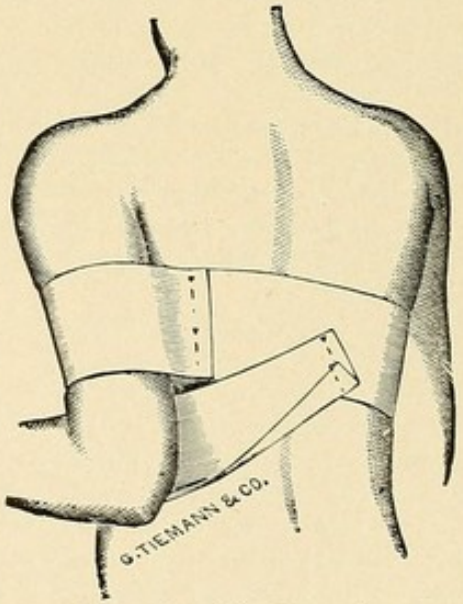

Fig. 194.—The first strip.

Treatment.—Cut two strips of strong adhesive plaster (mole-skin) three inches wide and of sufficient length. Just above the elbow of the injured side, one strip with adhesive surface nearest the body (the non-adhesive surface in contact with the arm) is passed around the arm, and secured with a safety pin, so that it will not constrict (Fig. 194). The patient's hand is now placed over the middle of the sternum, while the operator, placing his hand under the elbow of the affected side, lifts the arm and shoulder, at the same time carrying it well backward, and while securely held in this position, the plaster is drawn directly around the body, first across the back, then in front and beneath the elbow of the injured side, until the end is made to adhere to the first turn in the middle of the back (Fig. 194). This position disengages the outer fragment from beneath the inner, and it is now ready to be lifted to the level of the internal fragment. The second strip, split near its middle for about three inches for the accommodation of the elbow, is now

applied, and the arm and shoulder again lifted upward until, by passing the fingers along the inner fragment to the point of fracture, the outer fragment is felt to be on the same level. The second piece of adhesive plaster is then carried in front and behind over the shoulder of the opposite or sound side, and snugly drawn and secured so that the shoulder of the injured side remains well lifted (Fig. 195).[1]

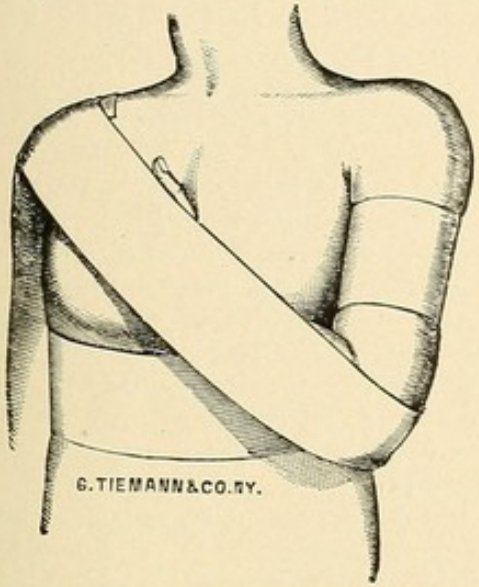

Fig. 195.—Sayre's dressing for fractured clavicle. Front view.

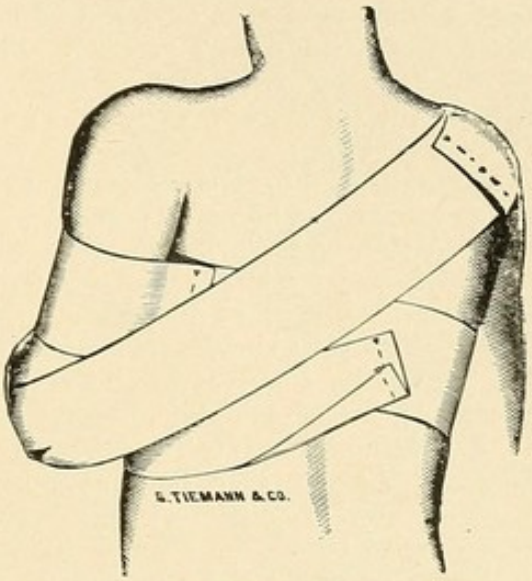

Fig. 196.—Back view.

An effective ready method[2] may be substituted as follows: A strip of cotton sheeting, eight inches in width and three yards long, is held near its center across the palm of the operator, who, for the left clavicle, grasps the elbow of this side from behind. The posterior end of the strip is passed between the arm and chest, then up in front of and over the clavicle of the injured side, obliquely across the back, under the opposite axilla, thence upward across the right clavicle, and to the back.

The opposite end is passed to the front of the arm at the elbow, between the first strip and the chest, and is then carried around the back. An assistant now carries the elbow backward and upward (as in the Sayre position), and while thus held the ends are tied. A sling to support the forearm is added. This is practically a figure-of-8 bandage around the elbow of the broken side and the shoulder of the sound side. The hand is carried across the chest, slightly elevated, and is held in a sling. Safety pins should be inserted at the points of crossing.

In green-stick fracture, occurring chiefly in children, especially during the summer months, the plaster tends to produce irritation of the skin, and Moore's strip or Velpeau's bandage (Fig. 197) is preferable.

The dressing may be removed at the end of four weeks in adults, and in children with green-stick fractures fourteen days will suffice.

Scapula.—Fractures of the shoulder blade are caused almost always by direct violence, occasionally by muscular contraction.

The *acromion process* is usually broken by a fall on the shoulder or a blow received from above. It may be recognized by crepitus, mobility, and depression of the outer end of the clavicle.

In the treatment it is advised to bend the forearm at a right angle to the arm, carry a roller bandage under the forearm at the elbow and over the clavicle and shoulder of the injured side, forcing the head of the humerus into the upper part of the shoulder-joint, and thus lifting the acromion into its normal position. The plaster-of-Paris dressing is to be preferred. If union should fail, and the func-

[1] This is Prof. Louis A. Sayre's method. Fig. 195 shows the arm drawn too far to the front; the elbow should occupy a position several inches posterior to that given in the drawing.

[2] Professor Moore, of Rochester, N. Y.

tion of the shoulder be in any way impaired, the fragments may be united by wiring.

When the *coracoid process* is broken, the pectoralis minor, coraco-brachialis and short head of the biceps displace the fragment downward; the displacement is usually very slight.

The treatment requires the hand of the injured side to be placed on the chest near the opposite shoulder, and to be held in this position by the application of the Velpeau bandage (Fig. 197). Fibrous union is the rule.

Fracture of the *glenoid process*, in the few instances recorded, involves the base of the coracoid as well. It is difficult of recognition, and requires a careful X-ray photograph.

Treatment.—Flex the forearm at right angles to the arm, carry it across the chest, leaving the humerus parallel with the axis of the body. A pad is now placed in the axilla and the humerus forced directly upward toward the coraco-acromial ligament, and while held in this position a roller-bandage is carried around and under the forearm at the elbow, and then over the shoulder of the same side. Every other turn should be carried horizontally around the body. By this means the head of the humerus keeps the fragment in position. Plaster-of-Paris bandages should be carried over this dressing in order to secure immobility.

Fracture of the spine or other portions of the scapula is infrequent. Velpeau's bandage or a plaster-of-Paris dressing is indicated.

Humerus.—Fracture of this bone within the capsule of the shoulder-joint is exceedingly rare. Epiphyseal separation occurs occasionally in young adults. Without the X-ray the diagnosis is very difficult. Shortening is scarcely perceptible, and crepitus may not be present. The free motion at the joint will eliminate dislocation.

The treatment will be the same as that given for fracture at the surgical neck.

Surgical Neck.—Fracture at the surgical neck—i. e., just below the tuberosities—is not infrequent, and may be caused by a fall on the shoulder or a blow applied directly at this point, or to force transmitted from the forearm or elbow.

The displacement of the lower fragment is inward toward the chest and upward, while the upper remains poised between the contractions of the opposing muscles attached to the outer or inner tuberosities.

Diagnosis.—There is shortening, motion at the joint and fracture line, crepitus and usually deformity due to the action of the pectoral and latissimus dorsi muscles which carry the shaft toward the chest. The head of the bone may be felt in its normal position. Comparative measurements from the olecranon to the tip of the acromion process will reveal shortening. The Roentgen ray should be employed in all doubtful cases.

In dislocation there is always stiffness; the muscles of the shoulder and arm are rigid, the humerus is not parallel with the chest wall, while measurement over the acromion and around through the axilla will show at least one inch more than on the normal side. If the hand of the affected side is laid upon the opposite shoulder (Dugas) the elbow cannot be made to touch the chest, while in fracture it readily falls to this level.

Treatment.—The reduction should be made by extension and counter-extension, under complete narcosis.

Counter-extension is secured by a towel or narrow sheet folded under the axilla and firmly held, while the arm and forearm are drawn in a direction parallel with the axis of the body. While in this position the forearm should be bent at right angles to the arm, and a plaster-of-Paris dressing applied from the middle of the forearm over the humerus, shoulder, and around the neck and chest. No other dressing gives such complete immobility and insures such success. If plaster is not at hand, a shoulder-cap and splint of leather, gutta-percha, or bookbinders' board may be made as follows: A pattern is first secured by cutting a piece of paper to fit over the shoulder and down the arm beyond the elbow and as far as the middle of the forearm. This cap should be large enough to spread over part of the scapular and pectoral regions, to embrace at least two thirds of the circumference of the arm and forearm, and to reach up to near the base of the neck.

The material selected is cut to correspond to this pattern, is then immersed in hot water until it is soft and pliable, when it is lined with a thin layer of absorbent cotton and molded over the arm and shoulder, where it is immediately secured by a roller-bandage snugly applied. The inner side of the arm is protected by cotton batting. The forearm at right angles to the arm should be included in the dressing and supported by a sling around the neck (Fig. 198).

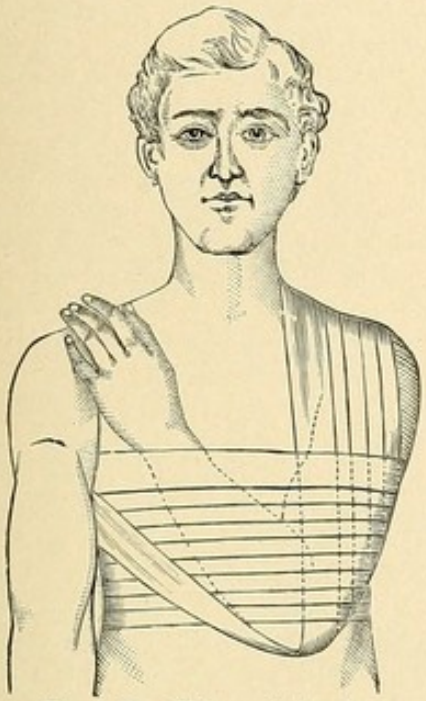

FIG. 197.—Velpeau's bandage. (After Stimson.)



FIG. 198.—Apparatus for fracture of the humerus at any point above the condyles. (After Hamilton.) The shoulder-cap should extend farther on the chest and neck, as well as the scapular region, than shown in the drawing.

Fracture at or near the surgical neck is occasionally complicated with dislocation. It may be recognized by a marked depression beneath the acromion process, indicating the absence of the head of the humerus, which may be felt in the axilla or beneath the clavicle. Preternatural mobility at the line of fracture and crepitus will determine the dual character of the injury. The crucial test of the Roentgen ray will assure a correct diagnosis.

Treatment.—An incision should be made directly over the dislocated fragment, which is exposed by dry separation of the muscles, not necessarily exposing the line of fracture. Near the level of the tuberosities a good-sized hole is drilled at a right angle to the general direction of the shaft, deeply into its substance; into this hole a stout metal retractor shaped like the letter "L," with a handle at the long end large enough for the firm grasp of the hand, is inserted. By careful manipulation of this instrument, with traction in the direction of the rent in the capsule aided by pressure upon the head of the bone, the dislocation is readily reduced and the wound closed. The fracture is then treated after the method just described.[1]

The operation in these cases should be performed at the earliest possible moment, as every day of delay adds to the difficulties of reduction.

Shaft.—Fractures of the shaft of the humerus, although chiefly caused by direct violence, are not infrequently the result of force transmitted from the elbow or hand and forearm, and may in rare instances be caused by muscular contraction alone. The displacement will in great part be determined by the direction of the line of fracture. If broken above the deltoid insertion the lower fragment is drawn upward, while the upper is carried toward the chest by the latissimus dorsi and pectoralis muscles. If the break is below the deltoid tubercle, the lower fragment is apt to be drawn behind the upper portion (Fig. 199).

[1] Method of Prof. Charles McBurney.

Injury to one or more of the nerves which are in intimate relation to the humerus not infrequently occurs. This is especially true of the musculo-spiral nerve, which for a considerable distance rests upon the periosteum. Partial or complete paralysis of the extensor muscles of the forearm may ensue, not only from direct injury at the time of the accident, but from compression of the nerve by callus. The possibility of this complication should be imparted to the patient.

If at the time of the accident there are evidences of injury to the nerve, it is advised to treat the fracture in the ordinary method and await developments. If, after five or six weeks, when union has been obtained, paralysis persists, resection and suture of the nerve ends should be considered. Exploration will determine the necessity for resection. When due to pressure from callus or new-bone formation at the line of fracture, this should be chiseled away, leaving the nerve free.

The treatment of all of these fractures is practically the same. Forced extension and counter-extension under the complete relaxation of an anæsthetic is essential. While this is being done, the operator should by careful manipulation satisfy himself that the fragments are in apposition, and while so held the whole member, including at least half of the forearm, the humerus, shoulder, and the chest should be enveloped in plaster-of-Paris bandages. The method of application is shown in Fig. 46.

Fractures of the humerus at the elbow may be subdivided into (1) those of the external epicondyle, (2) those of the internal epicondyle, (3) transverse *above* the capsular attachment, (4) transverse *within* the capsular attachment, (5) those of the external condyle, and (6) those of the internal condyle.

The *external* and *internal epicondyles* are always broken by direct violence, the force not being great enough to carry the line of fracture into the joint. These minor lesions may be recognized by the X-ray, and occasionally by a slight crepitus, with perceptible mobility of the fragment. The movements of the joint are not affected. The prognosis is favorable, since the capsule is not involved, and there is rarely any interference with the function of the joint. The treatment requires a light plaster-of-Paris dressing from near the wrist to the axilla, with the arm at a right angle to the forearm, the forearm being in full pronation for the internal and in full supination for the external epicondyle. In this position the muscles in relation to either condyle are most relaxed. The splint should be removed at the end of each week, and passive motion made. All dressings should be discontinued after the third week.

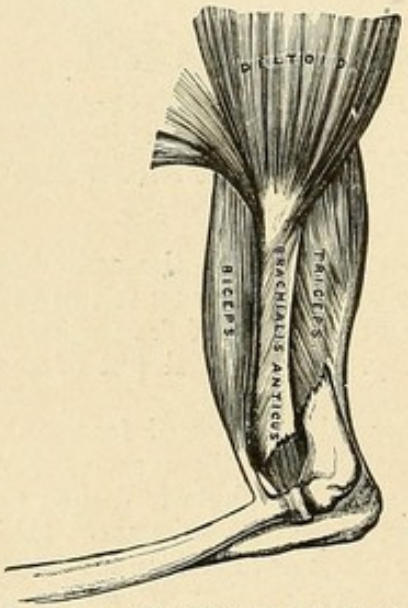

FIG. 199.—Showing mechanism of displacement in fracture above the condyles. (After Gray.)

In *transverse fracture above* the capsular attachment there is usually an obliquity from before upward and backward, the lower fragment being displaced upward and behind the longer portion of the shaft (Figs. 199–202). As a rule, the nearer the line of fracture approaches the capsular attachment, the obliquity is less marked and the displacement not so great. The diagnosis of this, as well as of all fractures which may possibly complicate the elbow-joint, should be carefully made by the use of the Roentgen ray. If this cannot be utilized, the patient should be completely relaxed by full ether narcosis and the character of the injury carefully studied by palpation. If swelling has occurred and sepsis is not present, the transudate may be forced into the circulation by the application of the Esmarch bandage, and the limb reduced to about its normal size.

Not infrequently a transverse fracture of the lower end of the humerus *above* as well as *within* the capsule involves the articulation by a split from the fracture line into the joint surface (Y fracture) (Fig. 200). It is exceedingly important to make an accurate diagnosis, since the treatment must be determined by the conditions present. If there has been a split into the joint, treatment in the posi-

tion of full extension is essential. If, however, the operator is convinced that he has to deal with a transverse fracture above the capsule, in no way communicating with it, the position of flexion of the forearm at a right angle to the humerus may be assumed. All of these injuries should be treated by a plaster-of-Paris dressing, snugly applied, and carrying the gypsum not only over the shoulder of the broken side but also that of the opposite side, as given on a following page (O. H. Allis).

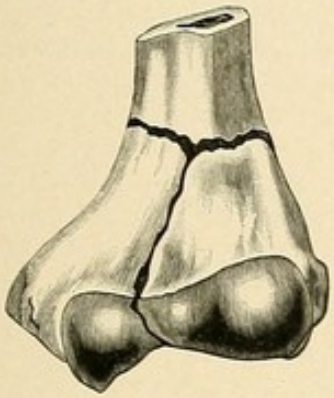

Fig. 200.—Double condyloid or T-fracture of the humerus. (Helferich.)

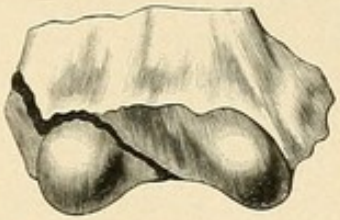

Fig. 201.—Fracture of eminentia capitata and external condyle by force transmitted along the radius from a fall on the hand. (Helferich.)

Fractures of the *external* condyle occur from direct violence by a fall or blow upon the elbow, or by force transmitted by the radius from the hand in falling forward, the forearm usually being bent at a right angle to the shaft of the humerus. The eminentia capitata and the external condyle are usually displaced

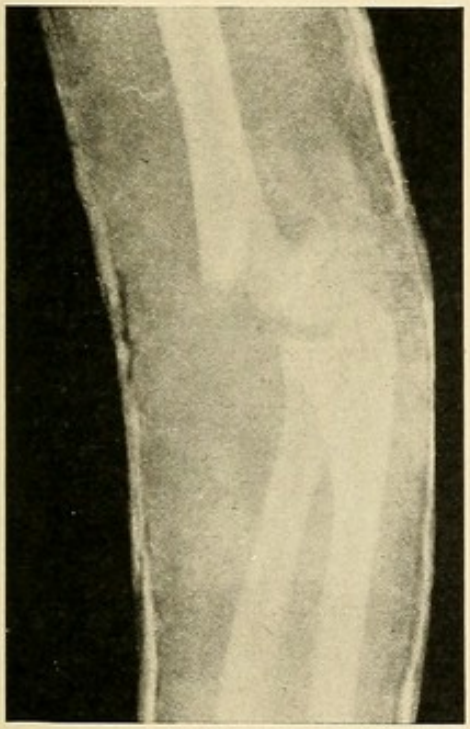

Fig. 202.—Charles Isaacson, aged twelve. Double fracture with backward displacement.

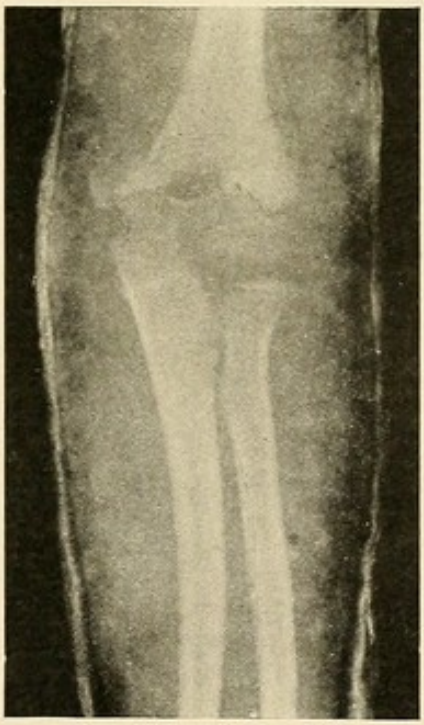

Fig. 203.—The same; front view showing fracture line entirely across the humerus above the articular surface and a second line of cleavage from the external condyle to the trochlea. Treated in full extension.

backward. The line of fracture begins, as a rule, near the center of the intercondyloid notch, and runs obliquely upward and outward, crossing the external condyloid ridge at a varying distance from the capsular attachment.

Fracture of the *internal* condyle is more apt to be caused by a fall upon the elbow, although it may result from force transmitted along the ulna from the hand. The symptoms and method of diagnosis of these fractures are considered,

with transverse fractures occurring within the capsule and communicating with the joint.

Should the Roentgen ray be not available and the parts not swollen, with the patient in ether narcosis, the relation of the fragments to the expanding condyloid ridges will by careful manipulation and comparison with the uninjured member be readily appreciated. If swelling has occurred and there are no symptoms of local infection, the application of the Esmarch bandage (A. G. Gerster) will remove the transudation and reduce the arm to near its normal size.

In certain of these elbow fractures occurring as the result of great violence, and especially in children, where the epiphyseal lines are yielding and the several centers of ossification are still present, the displacement of one (or more) of the condyloid fragments is often extreme, and reduction with partial restoration of function may only be hoped for after an open operation with or without pinning or wiring.[1]

The classical picture of transverse fracture within the capsule with a break through the articular surface is given in Figs. 202 and 203, taken at the time of

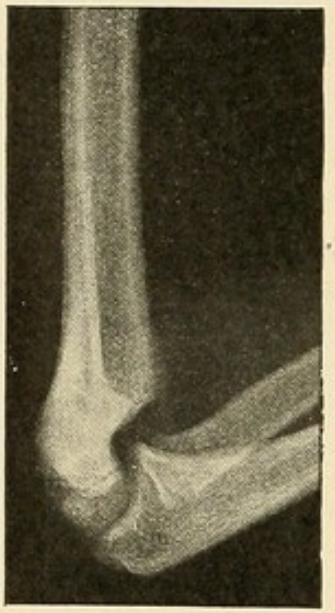

FIG. 204.—The same, six months later, showing free voluntary flexion. The coronoid process not fully drawn into the fossa.

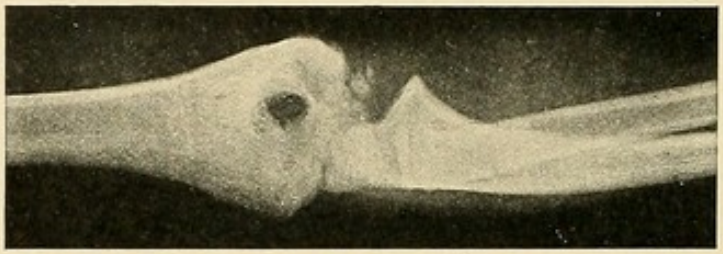

FIG. 205.—The same showing full voluntary extension. The relations of the forearm to the arm are normal.

the injury. There is shown in the side view (Fig. 202) the tendency to upward and backward displacement of the lower fragment, a displacement which is not easy to entirely overcome, and which requires strong and direct pressure forward, with counter-pressure on the shaft, to hold in reduction as the plaster-of-Paris is setting. Fig. 203 shows the transverse break through the olecranon and coronoid fossæ, and a separate fracture through the external condyle into the articular plane at the trochlea.

Treatment.—The diagnosis being clear with the line of fracture passing through the fossæ, the following method of treatment was carried out: Under ether narcosis strong extension was made from the wrist with counter-extension by means of a folded towel passed beneath the arm at the axilla.

With the limb in full extension and nearly parallel with the side of the body, the fragments were brought into alignment with the condyloid ridge of either side. At the same time the lower fragments were pushed forward while the shaft of the humerus was forced in the opposite direction. While held in this position a plaster-of-Paris dressing was rapidly applied from the wrist over the entire arm and shoulder, around the chest beneath the axilla of the opposite side, and finally a few turns of the roller were carried over the clavicle of the sound side.[2] As the plaster was setting the tendency of the upper fragment to override the lower was resisted by firm pressure and counter-pressure.

The weight of the plaster cast thus applied falls upon the clavicular regions and relieves the broken arm of pressure. On the eighth day the cast was split,

[1] Dr. Carleton P. Flint, New York Academy of Medicine, 1906. Among these interesting cases in one the X-ray had revealed the complete somersault of the fragments, the articular surface looking upward.

[2] The superiority of this dressing and method has long been maintained by Dr. O. H. Allis.

nitrous-oxide gas administered, and while the fragments were firmly grasped by one hand and held immovable the forearm was flexed to about eighty degrees, carried back to full extension, and the same dressing readjusted and snugly held by adhesive strips. Seven days later this was repeated, increasing the flexion to ninety degrees and a new dressing applied. At the end of another week (the twenty-second day after the first application) the splint was removed, flexion and extension made several times, and the arm left perfectly free. There was at this time well-marked resistance to flexion beyond a right angle, but force was not employed to overcome this for fear of breaking through the line of union. Twice a week regularly after this gas was administered, the forearm fully extended, and gradually increasing flexion made until by voluntary muscular action the finger-tips could be made to come within an inch of the shoulder.

Review.—Fractures of the humerus wholly or partly within the capsule at the elbow offer greater obstacles to a restoration of function than any other fracture. During and after the process of repair in most cases full extension is more difficult to secure than extreme flexion. As the line of cleavage almost always involves the fossæ, and as the olecranon is larger, deeper, and therefore more important, the olecranon process should always occupy this fossa to the exclusion of callus, new bone, or new connective tissue. Treatment in full extension better meets this requirement than partial or extreme flexion. Displacement of one or the other condyle with ultimate cubitus varus or valgus is less apt to follow the method of full extension. In all uncomplicated cases passive motion should be begun at the end of the first week and repeated at the end of the second and third weeks when the splint is discontinued.

Without regard to treatment in extreme flexion as advocated by some, or in full extension as advised here, rather than immobilize the joint for three weeks it were better to apply no splint. In achieving a result as nearly perfect as possible *nitrous-oxide gas is invaluable.* Even a timid child, if carefully managed, will soon lose any sense of dread of this agent. The complete relaxation of ether narcosis (chloroform has great danger for children) is essential to a first dressing. Young and old will run from the frequently repeated administration of ether or chloroform, preferring the alternative of impaired function. The double strength of the flexor muscles as compared with the extensors makes a temporary impairment of flexion easier to overcome than an impediment to extension.

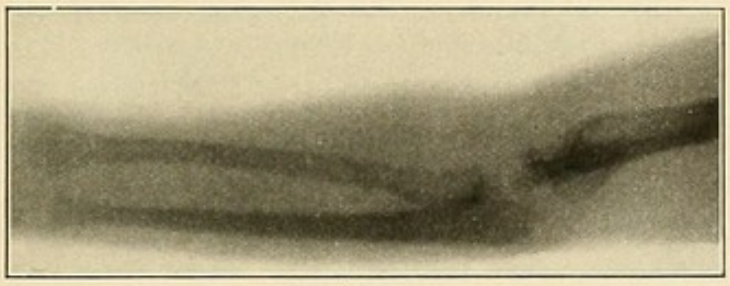

FIG. 206.—Case of Talcott Chittenden, three years of age, taken one year after compound extra and intracapsular fracture of the humerus at the elbow. Treated in full extension. Power of extension and function perfect.

The rare forms of transverse fracture of the humerus which communicate with the capsule but do not involve the articular surface should also be treated by this method of full extension. Figs. 206 and 207 show the complete restoration of function in spite of a rich new-bone formation which followed a compound fracture on this plane.

Forearm—Ulna.—Fracture of the olecranon process is usually caused by a fall on the elbow or a direct blow; occasionally by contraction of the triceps muscle. The line of fracture is usually found at or near the epiphyseal junction, and the displacement is upward (Fig. 208). The abnormal lateral mobility of the upper fragment and the depression between it and the shaft will render the diagnosis easy.

Treatment.—The following technic of J. B. Murphy strongly commends itself to the author. An incision is made on the lateral aspect of the ulna, long enough to expose the bone, three fourths of an inch anterior to the line of fracture, and

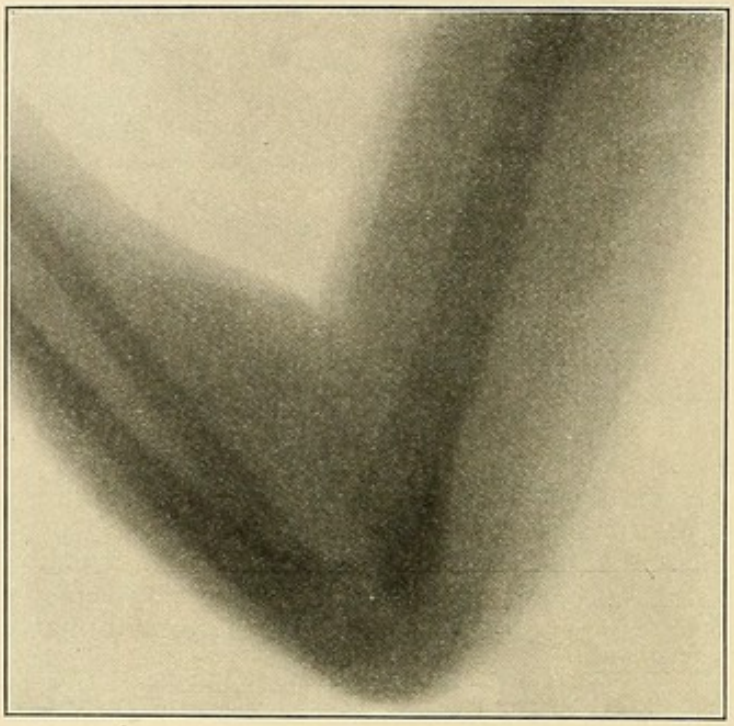

Fig. 207.—The same, showing no impediment to flexion. Function perfect. The extreme range of flexion is not fully shown in the skiagraph.

on exactly the opposite side a second incision is made, the bone exposed, and a hole drilled through for the passage of a strong silver wire. A long straight needle threaded with linen for carrying the wire is passed through this hole, reintroduced beneath the skin and other tissues close to the bone, and carried toward the tip of the olecranon process, where it is drawn out, reinserted, and carried across through the tendon of the triceps just where it takes hold of the process. It is then reintroduced beneath the skin and brought out at the lower wound, where the ends are twisted, thus drawing and holding the fragments firmly together. The forearm should be maintained in full extension for three weeks, removing the splint once a week for well-guarded, passive motion at the elbow. Should this procedure be declined, the fracture should be treated after the method of Hamilton.

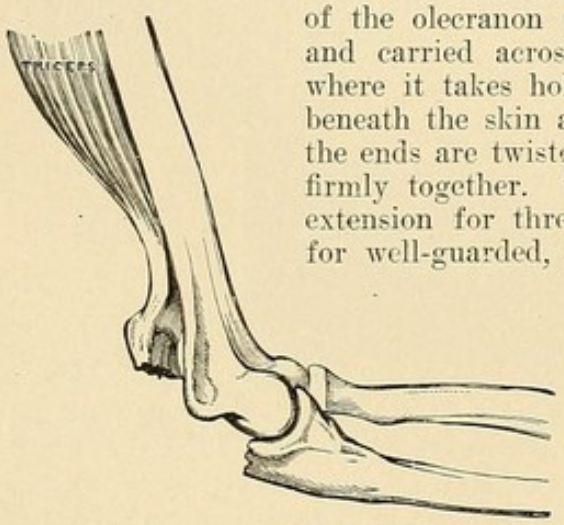

Fig. 208.—Displacement of the upper fragment in fracture of the olecranon. (After Gray.)



Fig. 209.—Hamilton's olecranon splint. (After Hamilton.)

A board splint, two or three inches wide and long enough to extend from the wrist to the axilla is notched as shown in Fig. 209. It should be padded with cotton batting, made twice as thick at the bend of the elbow as elsewhere. Lay the splint on the anterior surface of the arm and forearm, and secure it near the ends by several turns of the roller. Then with a flannel bandage (on account of its elasticity), commencing below, cover the forearm and splint by circular turns until the notch is reached, at which moment the roller is carried just above the upper fragment, around the posterior aspect of the arm, and down again, to be

secured in the notch on the opposite side of the splint. This oblique turn is repeated until the fragments are in apposition, when the whole is secured by as many circular turns as are needed (Fig. 210). Strips of adhesive plaster may be employed with equal advantage in making downward traction upon the upper frag-

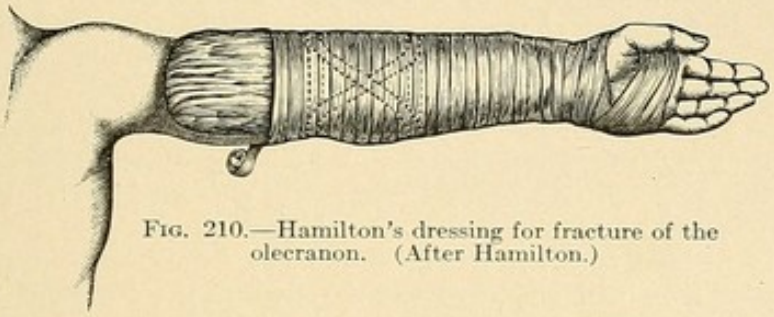

FIG. 210.—Hamilton's dressing for fracture of the olecranon. (After Hamilton.)

ment. A snug figure-of-8 bandage over the whole, including the shoulder, will aid in holding the triceps muscle perfectly quiet.

Passive motion should not be made until the end of the third week, and then very slightly, gradually increasing the degree of flexion until firm union is assured (sixth to eighth week). In commencing motion the short fragment should be firmly held in place. Osseous union by this method is exceptional.

Fracture of the coronoid process is exceedingly rare, and a diagnosis, unless revealed by the X-ray, difficult; it should be treated by fixation, with the forearm well flexed upon the arm.

Fracture of the shaft of the ulna alone is caused almost always by direct violence. In complete fracture the diagnosis is not difficult. If compression be made by grasping both bones of the forearm at a point remote from the fracture, pain or abnormal mobility or crepitus will be caused at that point. Inspection with the fluoroscope is advisable. The displacement of the upper fragment is usually slight, while the lower is drawn toward the radius by the pronator quadratus. The obliquity of the line of fracture and the direction of the force which produced the lesion will almost always determine the displacement.

The treatment is the same as for fracture of the shaft of the radius alone or of both bones; the prognosis is, however, more favorable, since in fractures of a single bone of the forearm its fellow acts as a retaining splint.

Radius.—Fracture of this bone, above the bicipital tuberosity is exceedingly rare, and is difficult of recognition, except by the Roentgen ray. It is caused by direct violence. Displacement of the upper fragment is slight, unless the fracture is complicated with a dislocation at the radio-humeral joint. The action of the biceps will tend to draw the lower fragment forward. The best position for immobilization is to flex the forearm on the arm, with the palm turned slightly upward. A plaster-of-Paris dressing should be applied to hold the member in this position.

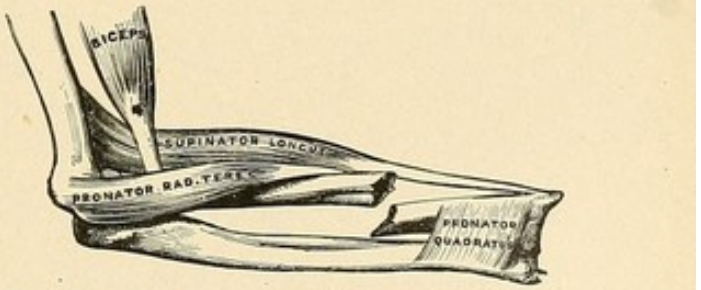

FIG. 211.—Displacement of the fragments in fracture of the radius in its lower third. (After Gray.)

Fracture of the radius between the bicipital tuberosity and the insertion of the pronator radii teres usually results from a direct blow, although it may be caused by a fall on the hand, or in very rare instances by muscular action. While the obliquity of the line of fracture will in great part determine the displacement, the tendency is for the lower fragment to be carried toward the ulna by the action of the pronator quadratus, while the upper fragment is drawn upward and slightly rotated outward by the biceps. When the bone is broken below this point, the lower fragment is also carried toward the ulna, while the upper is lifted by the biceps muscle (Fig. 211).

Treatment.—When both bones of the forearm are broken, the loss of function is so complete, together with the deformity, which is always present, that the diagnosis is readily made.

The treatment of a fracture of the shaft of the radius between the tuberosity of the biceps and the insertion of the pronator quadratus, or of the shaft of the ulna, within the same limit, or of both bones, is the same.

The forearm is flexed at about a right angle to the arm, and under the complete relaxation of an anæsthetic, extension from the hand, with counter-extension from the arm at the elbow, is made with such force that any overlapping of the fragments is overcome. The forearm should then be brought in a position half-way between supination and pronation, the thumb pointing directly upward, and while firmly held in this position two board splints long enough to extend from the end of the metacarpus to the elbow, and each *wider than the forearm in its widest portion*, properly padded with cotton batting, are so firmly applied over the flexors and extensors that they will compress the muscles of the forearm into the interosseous space and thus prevent any possible union of one bone to the other. While everything is firmly held, the splints are secured by adhesive strips, snugly applied, and over this is a firmly applied roller-bandage. After three or four days this dressing usually becomes somewhat loose on account of muscular atrophy, and requires to be tightened by applying another roller over the first without removal of the splints. These should be allowed to remain in place for three weeks in children, four or five weeks in middle-aged adults, and five weeks or longer in elderly persons.

Fracture of the Carpal End of the Radius (Colles' Fracture).—In falling upon the hand, as the metacarpus and carpus are forced backward a great strain is thrown upon the anterior radio-carpal ligament. When fracture occurs the bone begins to yield on its anterior aspect close to and parallel with the attachment of the ligament, the line of fracture traveling upward and backward, with usually very slight obliquity. In the majority of instances the anterior fragment is forced upward, and either overrides the upper or is oftener impacted into it without overriding (Fig. 212). This displacement causes the peculiar bowed or silver-fork deformity to the wrist. With this upward displacement of the lower fragment, a strong fibrous band spread over the dorsum of the radius at its carpal extremity, and which serves to hold the extensor tendons in place, is lifted frequently for half an inch or more (Fig. 212). It is this fibrous band, together with the partial impaction of the fragments, which makes reduction by direct extension and counter-extension practically impossible. With this posterior, there is at times a lateral displacement, the lower fragment being carried outward beyond the normal level of the radius; in very rare instances the line of fracture communicates with the articular surface, in other instances one or more bones of the carpus



Fig. 212.—Colles' fracture, showing the fibrous band which prevents reposition.

are involved in the fracture. The ulna is also sometimes broken, and the tendon of the extensor carpi ulnaris is displaced from its groove near the styloid process of this bone. A fracture at the wrist exactly the reverse of Colles' may take place when the force is applied to the dorsum of the hand (John B. Roberts).

Diagnosis.—Nothing is so satisfactory as an X-ray picture of the region involved in determining the exact character of the fracture. Complications such as fracture of the carpal bones, the end of the ulna, a lateral displacement, or a comminution of the lower fragment, can only be accurately determined by this

method. The upward displacement and sharp sense of pain which is elicited by pressing with the thumb nail, usually about one half inch above the edge of the articular surface on the dorsum radii, will aid in demonstrating the presence of the line of fracture. Crepitus may also be felt in the majority of instances.

Treatment.—Prof. L. S. Pilcher's method of reduction is as follows: With the patient fully anæsthetized (nitrous-oxide gas will suffice in the majority of cases, although in alcoholics, morphia and ether may be required), with the back of the patient's hand turned upward, the operator grasps the hand and forearm so that the thumb nails of the two hands are in touch immediately over the line of fracture. The patient's hand is now subjected to extreme extension by bending it backward at the line of fracture until the dorsum of the hand and the surface of the anterior fragment is practically at right angles to the axis of the forearm. This manipulation entirely relaxes the heretofore tense fibrous band which has prevented reduction, and unlocks any partial impaction. If now, at this juncture, the thumb of the operator's upper hand is pushed down in the general direction of the back of the radius until it comes in contact with that which is holding the lower fragment, this pressure will slide the broken piece forward to its position, and at this moment the patient's hand is carried into its normal position.

In rare instances, where the impaction is severe or the displacement marked, it may be necessary to repeat this manœuvre.

When there is lateral displacement, this should be corrected while the hand is held at right angles to the forearm, and before the fragment is finally reduced by flexion.

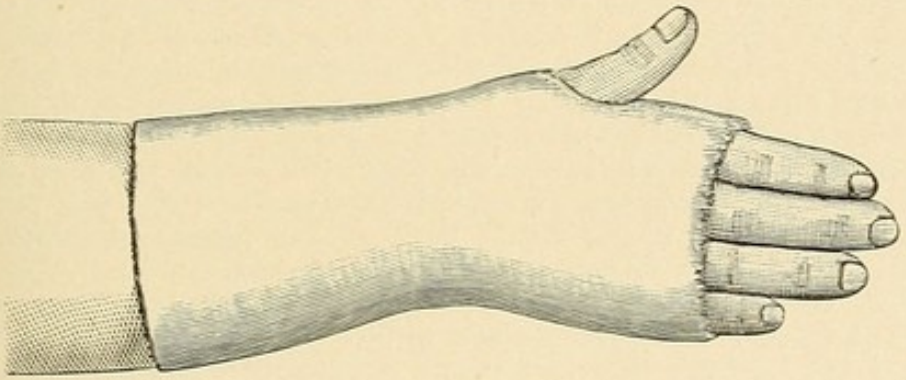

FIG. 213.—Plaster-of-Paris dressing for Colles' fracture. The mitten extends an inch too far along the fingers.

The application of a plaster-of-Paris mitten (as shown in Fig. 213) is an ideal dressing for this fracture; the thumb and fingers are left free so that they may be kept in motion in order to prevent adhesion of the tendons to their sheaths as they pass over the broken end of the radius. If plaster-of-Paris may not be had, a posterior board splint, properly padded and long enough to extend from the middle of the forearm to the end of the metacarpal bones should be applied and held in position by a snugly fitting roller-bandage. These dressings should remain undisturbed for about two and one half weeks in children, and from three to four weeks in adults and elderly persons.

Carpus, Metacarpus, Phalanges.—Fractures of the carpus should be restored as near to the normal position as possible, and immobilized by the plaster-of-Paris mitten figured above.

The same treatment will apply to one or more of the metacarpal bones, the ends having been carefully placed in apposition.

Fractures of the phalanges require to be placed accurately in position and held by a board splint, properly padded. It is frequently advisable to couple an uninjured finger with the broken member in order to use it as lateral support to hold the splint in position.

Sternum—Ribs—Vertebræ.—Fracture of the *sternum* is rare. It may be recognized by mobility at the point of fracture and by depression. Dangerous hæmorrhage from the internal mammary arteries may occur when great violence has been inflicted. Reposition may be effected by lifting with a blunt hook or an elevator.

In the treatment the most perfect quiet should be enforced. No special dressing is required.

The *ribs* or their cartilages may be broken by direct violence, or indirectly, as by a blow upon the sternum or crushing between the sternum and the spinal column, or from muscular contraction. The longer ribs are most liable to fracture, and when the force is applied to the sternum the break most frequently occurs just anterior to the middle of the bone. The displacement is usually slight. Hæmorrhage from rupture of the intercostal vessels is one of the immediate dangers, while puncture of the pleura or lung may occasionally result.

A *diagnosis* is based upon pain elicited by pressure at a point remote from the fracture, occasionally by a peculiar click or crepitus felt by laying the hand over the injured region during the full respiratory act. As a rule the respiratory movement is less full upon the affected side.

Treatment.—Fixation of the chest wall, as far as possible, is the indication in treatment. This may be secured by applying adhesive strips, cut one and one half inches wide and long enough to reach from the sternum to the vertebral spines. These should be tightly applied and extend far enough above and below the broken rib or ribs to cover the three or four adjacent bones. The strips should overlap about one half of their width.

Vertebral Column.—Fracture of the *vertebræ* frequently occurs from indirect violence, as in the act of diving, the patient striking squarely on the head, or by falling from a height and striking upon the feet or buttocks; or the bodies may be crushed by extreme flexion or extension, or by direct injury with or without penetration. The character of the injury, the displacement of the spine, pain, and the symptoms of pressure upon the cord or nerves will aid in a correct diagnosis.

Treatment.—When the symptoms of pressure upon or injury to the cord or any of the nerve trunks has caused paralysis of motion, or of sensation, immediate operation is advisable, for the reason that when the cord is not torn or divided, pressure upon its substance from depressed bone or blood clot will rapidly lead to degenerative changes, which become more or less permanent, whereas if the pressure be immediately removed these changes are not apt to occur. If the operation be done under careful asepsis, the dangers are slight, especially when it is not necessary to open the dura. When several months have elapsed after the injury the prognosis after operation is not so favorable; however, in several instances very marked improvement has followed the removal of depressed bone.

Operation—Laminectomy.—With the patient in the prone position, reclining somewhat upon one side in order to interfere as little as possible with respiration, an incision seven or eight inches in length, the center of which is over the seat of fracture, is made directly along the spines. Strong retraction will, in great measure, control the bleeding. The attachments of the muscles should be lifted from the bones with a periosteal elevator when possible, in order to avoid wounding any vessels. Certain attachments will need to be divided with the scissors. When the laminæ are exposed, one of these should be divided with a small *rongeur* and removed with others until the dura is sufficiently exposed. If depressed bone has been found and the dura has not been penetrated, it may not be necessary to proceed further. Opening into the dura should be avoided if the operator is satisfied from careful inspection that there is no hæmorrhage within the dural sac.

If it be deemed necessary to proceed further, the dura should be opened by a sharp-pointed knife, cutting carefully in the middle line until there is an escape of a drop or more of clear cerebrospinal fluid. Through this puncture a small dull-pointed grooved director should be inserted, and the dura divided exactly in the middle line as far as necessary. With the escape of fluid the edges of the dura can be held apart by a mouse-tooth forceps and the cord inspected. A small dull-pointed silver probe may be passed up and down from this point of opening, to determine whether or not there is compression from depressed bone.

The dura should be closed by fine interrupted catgut sutures passed about three sixteenths of an inch apart. The muscles should be brought back into position by ten-day catgut sutures. Silkworm-gut sutures are used for the skin by the subcuticular or interrupted method. It is a wise precaution to leave a few strands

of catgut as a capillary drain from the most dependent angle of the closed dura, coming out at the lowest angle of the wound.

The patient should remain upon the back for the first week or ten days after the operation. Dressings may be changed on the third or fourth day, or whenever necessary.

Removal of the laminæ of two or three vertebræ seems to cause no inconvenience to patients after their complete recovery.

The operation just described gives the best results when the laminæ or the articular or transverse processes have been fractured and are impinging upon the cord. Fractures of the bodies of the vertebræ rarely cause compression.

In crushings of the bodies, extension of the spinal column, by placing the patient in bed upon the back with cushions or pillows immediately under the broken point, will secure the fullest possible extension and the most complete rest while the process of repair is taking place.

In any of these lesions of the spinal column, when for any reason operation is not performed, the patient should be put to bed with carefully adjusted extension and counter-extension made from the head and thighs. Every care should be taken to prevent pressure sores on the back, buttocks, and heels, and when paraplegia is present strict aseptic care in relieving the bladder is essential. When recovery is sufficient to justify the upright posture, the Sayre plaster-of-Paris jacket or the Schaffer brace may be applied.

Fracture of the articular process is of less frequent occurrence. It may result from extreme dorso-lateral extension or from direct violence.

When the spinous processes are broken the lesion may occur near the extremity, but more frequently the laminæ are involved.

Sacrum and Coccyx.—Fractures of the *sacrum* are rare, and are caused by direct violence, usually by penetrating bodies or falls from a height so great that other and serious complications render the prognosis grave. Enforced quiet, the arrest of hæmorrhage and replacement of the broken fragments when this is possible, are the indications.

Fracture of the *coccyx* with forward displacement is common, the accident occurring from a fall or blow directly upon the tip of the spine. The symptoms are pressure upon the rectum, causing at times difficulty in defecation, and more or less pain from pressure, not only upon the bowel, but upon the fifth sacral and coccygeal nerve.

Treatment.—Removal of this bone is the only way of obtaining permanent relief from these painful symptoms. The incision is made directly over the bone in the median line, the muscular attachments being closely divided. Care must be taken to avoid wounding the posterior hæmorrhoidal plexus of veins or the rectum.

Os Innominatum.—The ilium, ischium, or pubes may be broken singly, or in rare instances the three bones may be involved in a common lesion. Fracture in the acetabulum may be caused by a fall on the foot or great trochanter, the head of the femur being driven violently into the socket, or by violence directly applied.

When the iliac crest is broken the diagnosis may be determined by the mobility of the fragment, with crepitus and pain. When more deeply situated, digital exploration by the rectum or vagina may be necessary to determine the line of fracture. Bloody urine, drawn by catheterization, is strongly indicative of fracture with perforation, and this condition demands immediate operation. When the intestinal tract is perforated shock is usually present and peritonitis rapidly develops. The X-ray should be used on all occasions.

The treatment demands reposition, as far as possible, and complete rest. When the acetabulum is involved, extension from the lower portion of the femur and counter-extension by elevating the foot of the bed (Buck's method), should be practiced. It is advisable to have the bed so arranged that defecation may be accomplished without lifting the pelvis; a modification of Crosby's fracture bed would answer this purpose. Fixation of one or both thighs, including the pelvis and lower portion of the spine and abdomen, can be secured by a plaster-of-Paris

spica. The prognosis will depend in great measure upon the extent of the injury sustained by the pelvic viscera. Rupture, not only of the bladder, but of the deep urethra is an occasional complication.

Intra-peritoneal rupture will require suture, and a careful toilet of the pelvic peritonæum, with suprapubic drainage when necessary. After suture of the blad-

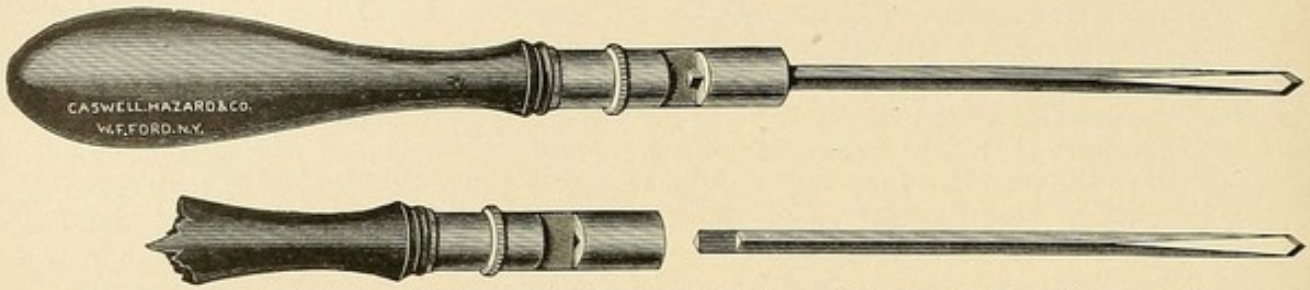

Fig. 214.—Wyeth's drills with adjustable handle for fixation of the bone in knee-joint exsection.

der in men, it is a wise precaution to drain for a week or ten days through the deep urethra and perinæum; in females a catheter introduced through the urethra may be left in place.

Femur.—Fractures of the neck of this bone may be intra- and extra-capsular, or partially within and without the capsule. The extra-capsular variety may involve one or both trochanters.

Fractures of the femur are clinically divided into three groups, viz.: (1) of the upper extremity, including the neck and trochanter, (2) of the shaft, (3) of the lower or condyloid extremity.

In fracture of the neck of the femur, the line of cleavage may lie wholly within or without or partly within and partly without the capsule. In children and young adults there may occur (though rarely unless in hip disease) an epiphyseal separation. Fractures of the neck are apt to be complete in elderly persons, but not infrequently they are partial or impacted in children and others under forty years of age. The Roentgen ray has demonstrated that this fracture is much more com-

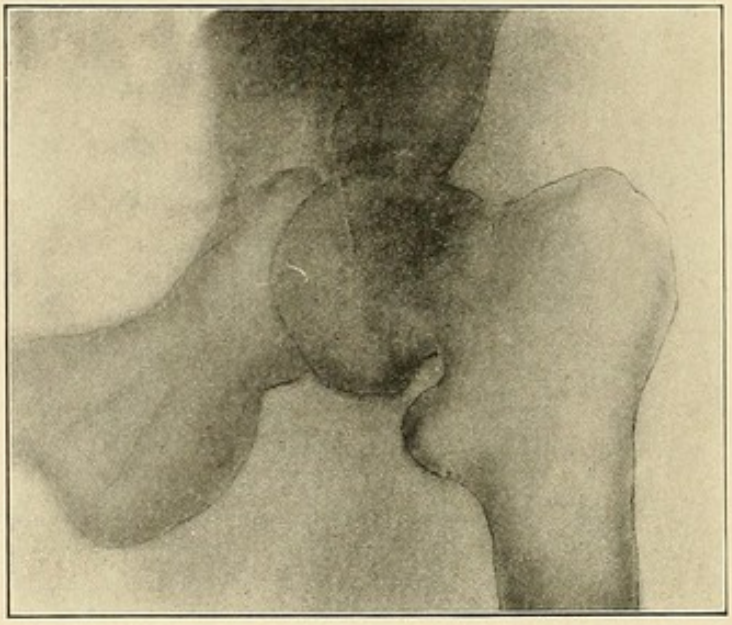

Fig. 215.—Impacted fracture of the neck of the femur partly within and without the capsule. United. About three fourths inch shortening. Male, about forty-five years of age.

mon in children and young adults than was formerly suspected (Whitman). In the old it is due to the common condition of rarefaction in bone, which begins about the fiftieth year of life, and to the change in the relation of the axis of the neck to that of the shaft, the angle being less oblique and the bone therefore

less able to stand a sudden impact from above. It is usually caused by a force transmitted from below upward along the shaft of the femur. In many instances with the aged the cause is trivial, as in the act of kneeling or even while turning in bed. It also occurs from direct violence, as in a fall upon the trochanter.

Diagnosis.—If, after a fall upon the foot or knee or directly upon the trochanter, there results pain in the hip with eversion of the foot, shortening, loss of function with or without crepitus, fracture is probable. All of these symptoms, however, are not always present. Pain is the most constant, together with eversion unless impaction has occurred. The outward rotation is due in part to gravity, but chiefly to contraction of the powerful external rotators at the hip (Fig. 216). Shortening is present practically in all cases, with or without impaction. It is determined by comparative measurement of the two sides, from the anterior superior spine of the ilium to the inner malleolus. The internal malleoli should be made to

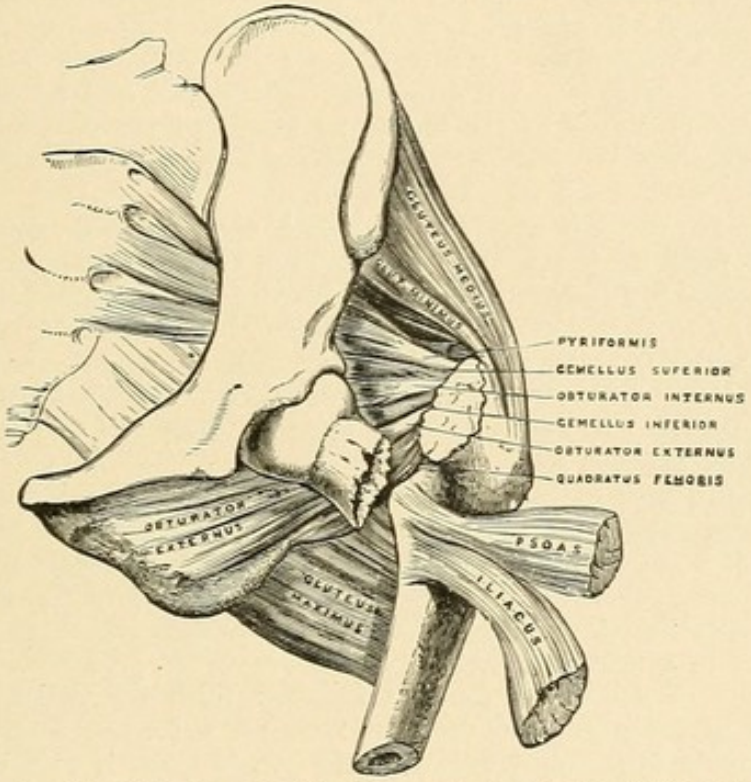

Fig. 216.—Showing the displacement of the fragments in fracture of the neck of the femur. (After Gray.)

touch, and should be directly in a line with the symphysis pubis, umbilicus, and interclavicular notch. The end of the tape should be held on the thumb nail, and pressed well into the notch, just under the anterior superior spine. It is then carried along the inner side of the thigh, knee, and leg, to the under edge of the inner malleolus. The degree of shortening will vary from one fourth of an inch up to two or more inches. The occasional normal inequality in the length of the two lower extremities should be remembered. To determine that the shortening is between the trochanter and the acetabulum, apply *Nélaton's* test; a line drawn from the tuberosity of the ischium to the anterior superior spine of the ilium passes over the upper surface of the great trochanter. The distance the tip of the trochanter may be above this line will give the degree of shortening. Bryant's test is, with the patient resting upon the back, the legs parallel and extended, to drop a line from the anterior superior spine and to measure the distance between this line, at its nearest point to the trochanter and this tuberosity. If the fracture is above the trochanter the tuberosity will be found nearer the line than on the sound side. Crepitus is absent with impaction, and is, in fact, not essential to a diagnosis.

In all the outward *dislocations*, in addition to *immobility* there is *inversion* of the foot. In the rare thyroid or pubic variety, the displaced head of the bone is easily recognized.

Loss of function does not always occur, for in some instances with firm impaction the patient has been known to walk unaided a considerable distance.

The *prognosis* after this formidable injury should always be guarded. The result depends in large measure upon the age and condition of the patient, the exact location of the line of cleavage, the prompt recognition of the lesion and appropriate treatment. In practically all cases the function of the joint is never performed so satisfactorily after as before the injury. There must of necessity be shortening, and should solid union be obtained the inequality in length of the lower extremities will need to be corrected by the elevation of the sole of the shoe on the short side to prevent muscular strain and spinal curvature. In the very old and infirm, and in heavy obese individuals, absorption of the upper fragment occurs with loss of one or two inches in length, and a lameness which necessitates the use of crutches or of some artificial support. In a certain proportion of cases death ensues from shock, while others condemn themselves to the lifelong imprisonment of a chair or the bed on account of timidity.

By reason of the increased blood supply the prognosis is more favorable as the line of fracture approaches the trochanter. In children and adults, with prompt recognition of the character of the lesion, by means of the Roentgen ray, and the institution of proper treatment, a fairly satisfactory restoration of function with the minimum of shortening may be expected.

Treatment.—In the old and feeble, where operative intervention is contraindicated, that plan of treatment which will give the minimum of discomfort should be instituted. Extension and counter-extension are only indicated for the relief of pain due to muscular spasm. At times it will suffice to apply long, narrow bags of sand to the side of the thigh and leg, holding the extremity as near the normal position as possible. Should extension be required, Buck's method is advised, and to this may be added the long splint of Hamilton if needed. Its application is given on another page.

Fracture of the neck of the femur in an aged person who is otherwise in good physical condition should be treated by immobilization with the gypsum dressing, and to this may be added in properly selected cases the operation of spiking the fragments together. Bony union and a fair restoration of function is possible in a certain proportion of cases which under less efficient methods have heretofore been condemned to a crutch or cane.

The operation of spiking is done as follows: With the patient placed in the proper position of extension and counter-extension and anæsthetized upon a suitable operating table (preferably Downey's (Fig. 217), or, if this is not available, T. H. Hancock's apparatus for the application of the complete plaster-of-Paris dressing), an incision is made exposing the great trochanter. The dissection is

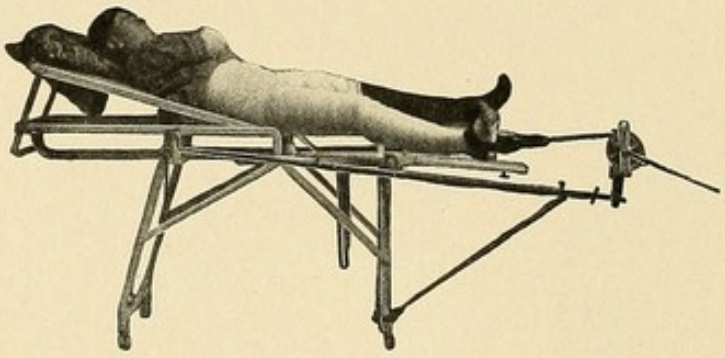

Fig. 217.—Plaster-of-Paris dressing, extension, counter-extension and abduction done mechanically by Downey's operating table.

only continued far enough to enable the operator to determine the exact direction of the neck. The thigh is then well abducted and rotated slightly inward until the foot assumes the normal position. If the fluoroscope is at hand, the surgeon should by its use satisfy himself of the alignment of the two fragments, and while thus held the author's drill (Fig. 214) is inserted through the trochanter,

in line with the general direction of the neck, and carried in until by accurate measurement it is determined that the point of the drill has passed into the distal fragment and head of the bone. The handle of the instrument is now unshipped and the drill left in place, with the end of the shaft projecting slightly beyond the skin incision, which is closed. A light gauze dressing is applied, the extremity is adducted to its normal relation to the body and its fellow, and the plaster-of-Paris immobilization at once effected.

The drill should be extracted without removing the plaster-of-Paris dressing about the end of the fourth week. This can readily be done, as the end projects beyond the skin and can be exposed by cutting away a small circle of the gypsum. At the end of the sixth week the plaster from the knee down should be removed, and passive motion made of this joint and the ankle. In two weeks more the cast may be discarded, but the hip should be carefully guarded for two or three months. In senile cases, where it has not been deemed advisable to use the drill or the gypsum method, the period of quiescence should be determined by individual comfort. In general, the sooner this class of patient is up and about the better, as there is a strong tendency to become bedridden.

In all cases in children and young adults, the method of Dr. Royal Whitman is advised. It is practically as follows: The chest, abdomen, and extremity of the injured side are fitted with muslin undershirting. The patient, fully anæsthetized, is placed on the table, rigged with a sacral and shoulder support for applying a complete plaster-of-Paris dressing. Counter-extension is made from the crotch and perinæum and extension directly from the leg and foot. The limb under gentle traction is slowly abducted, an assistant at the same time abducting the sound limb to prevent the tilting upward of the pelvis. If the fracture is complete, the shortening is first entirely overcome by the traction and counter-traction. The limb in the extended attitude, under traction, is slowly abducted by the assistant until the trochanter is fairly apposed to the side of the pelvis, the operator meanwhile pressing the trochanter downward and inward (Fig. 218). In some instances there is a distinct snap as the outer part of the neck slips beneath the rim of the acetabulum. The primary object of the abduction is by leverage against the upper border of the acetabulum to overcome the deformity; the second is by tension on the capsule to remove folds, to appose the fragments and to oppose redisplacement.

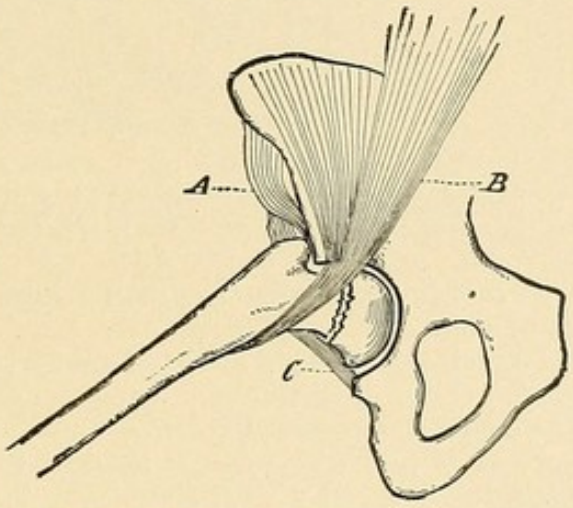

Fig. 218.—Whitman's position. Reduction and fixation in abduction, showing security from direct bony contact of the neck and trochanter with the pelvis, also the effect of this position on muscular action. *A*, Abductor group. *B*, ilio-psoas. *C*, capsule. (After Whitman.)

The limb being held in this attitude, the pelvis, the ribs, the bony prominences of the knee and foot are protected with layers of sheet wadding, and the limb and body are covered in carefully with cotton flannel bandages. A plaster spica is then applied, extending preferably from the mammary line to the toes. This should be drawn snugly about the hip, and most important of all, should completely enclose and support the buttock, not only to provide antero-posterior support, but to prevent the excoriations that are inevitable if the tissues are allowed to hang over the edge of the plaster. The insertion of thin strips of wood or iron about the hip and knee permits of a lighter bandage than would otherwise be possible. When the bandage is completed it is carefully cut away to allow complete flexion of the sound limb, the shirting is drawn over the edges of the bandage, carrying beneath it the cotton, and is sewed preferably to an outer cover of shirting drawn over the bandage.

For greater precaution it may be advisable to cut openings in the plaster at all points where pressure is feared, and a part may be cut away from the front of the body part if the constriction is too great (Fig. 219). At the end of four weeks the plaster cast should be removed from the knee down, to permit movements in this joint and the ankle, and at the end of eight weeks the entire gyp-

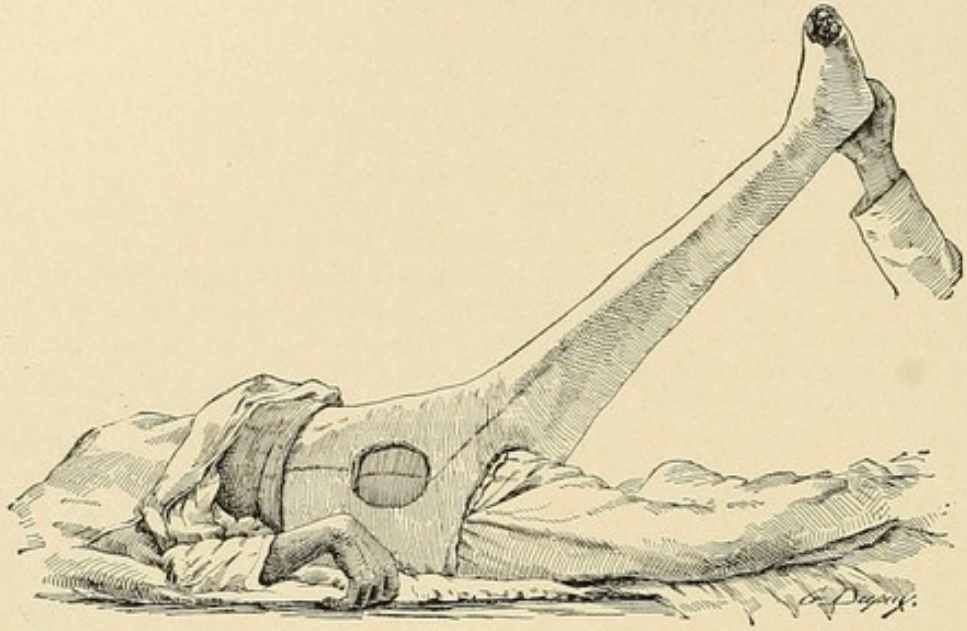

FIG. 219.—Whitman's position. The long spica as applied for fracture of the neck of the femur in the adult; illustrating the advantage of an appliance which permits movement without danger of displacement of fragments; an opening has been made to lessen the constriction of the abdomen. (After Whitman.)

sum cast is discarded. The limb should not be used to support weight for at least four months.[1]

Fractures through the trochanters are very often partially or completely impacted. For this reason crepitus may be absent (Fig. 215). Whether or not impaction has occurred rotation outward is not so marked a feature of this fracture as of that which occurs through the neck. The absence of the symptoms of dislocation, together with shortening and pain, should determine the diagnosis.

Fracture of the femur at this level is occasionally met with in the new-born, and is caused by traction on the flexed thigh in breach presentations, the bone breaking near the level of the lesser trochanter. In this particular fracture (at or immediately below the lesser trochanter) there is even in adults a marked tilting forward or flexion of the upper fragment (with external rotation) due to contraction of the psoas and iliacus muscles, with outward rotation caused by the action of the powerful external rotators (Figs. 220 and 216).

This is much more marked in the newly born for the reason that the psoas and iliacus muscles have never been stretched. In treatment with plaster-of-Paris around the extremity and abdomen the proper position is to flex the thigh well upon the abdomen with slight outward rotation and abduction.[2] In adults flexion at about forty-five degrees, with slight abduction, will suffice and will generally be the position of least discomfort to the patient, giving a satisfactory result if extension and counter-extension are maintained while the plaster-of-Paris is setting (Fig. 221).

Fractures at the middle of the femur and for the next six or eight inches below, may be treated in the straight position with the thigh and leg in the axis of the body, although there is no special objection to the position of partial flexion which has been advised in treating fractures above the middle. Below this point

[1] Dr. Royal Whitman, "Med. Record," March 10, 1904.

[2] The author has treated one case of this fracture at birth by this method with perfect success, the patient being now twenty years old, fully developed and with lower extremities of equal length. A similar experience has been reported by Dr. Edgar Wilkinson, a distinguished practitioner of Bermuda.

and including the condyloid fractures, the straight position parallel with the axis of the body and without abduction is in general preferable. The gypsum dressing should be applied in full narcosis, with strong extension and counter-extension continued until plaster is hard. Mechanical extension is much more satisfactory than that by hand (Fig. 217).

While it may not be absolutely necessary in every case of fracture at or below the middle of the femur to apply the plaster-of-Paris dressing from the foot and around the body as high as the line of the nipples, it should come at least as high as the navel. One very considerable advantage in the plaster-of-Paris dressing is that it permits the patient after three weeks to be up and about on crutches.

When the fracture line approaches the knee-joint (within about five inches) and the patient declines an anæsthetic, the position of flexion will be found advantageous, since it reduces muscular resistance to the minimum. With strong extension and counter-extension, aided by direct pressure forward of the lower fragment and counter-extension on the upper, the broken ends may be brought into accurate position (Fig. 221). The action of the muscles which cause displacement in this fracture are shown in Fig. 224.

When in a fracture in any portion of the thigh an anæsthetic may or may not be employed, and the gypsum dressing cannot be utilized, Buck's extension with Hamilton's long splint (Fig. 222) may be substituted. It is applied as follows:

Place the patient upon a hard mattress. If the bed is too soft and yielding, place wide boards underneath the top mattress in order to hold it smooth and firm. Elevate the foot of the bedstead from six to ten inches by placing the legs at this end upon blocks of wood or bricks. Cut two strips of strong adhesive plaster (Maw's moleskin is preferable) about two inches wide and long enough to extend from the hip to beyond the sole. Lay one of these upon the inner and outer surface of the thigh and leg, exactly opposite each other, and hold them in place by a well-adjusted roller. The strips can be more nicely applied if they are partially divided with the scissors in a direction

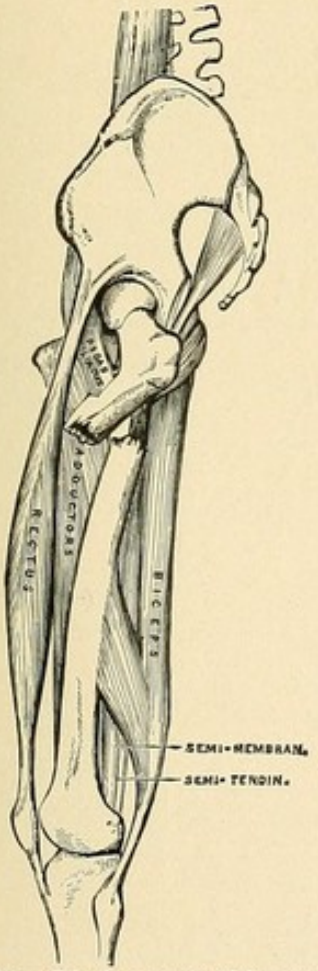

FIG. 220.—Displacement of fragments in fracture of the thigh in the upper third. (After Gray.)

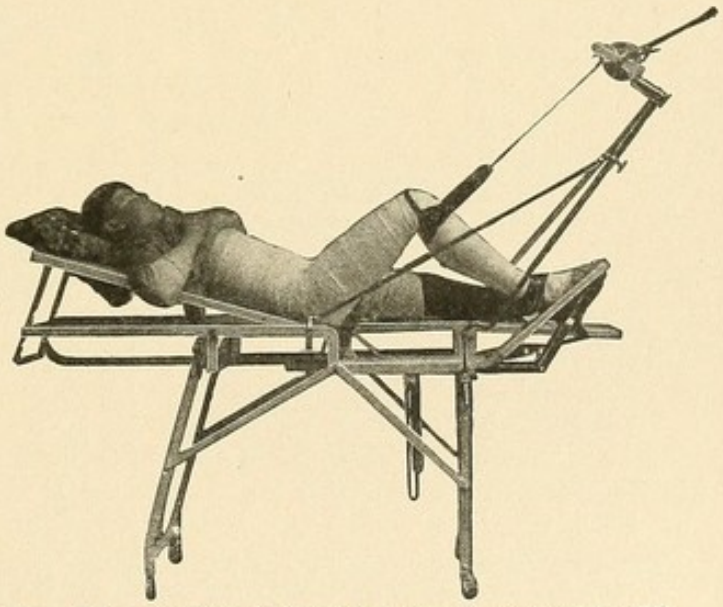

FIG. 221.—Mechanical extension, counter-extension with slight abduction, and gypsum dressing with Downey's table.

upward and inward, at intervals of about two inches. Six inches below the knee the bandage is interposed between the strips and the integument, for no traction should be made from the leg. In order to prevent pressure upon the malleoli, a stick about six inches in length is placed between the ends of the adhesive strips,

and the extension weight is attached to this. It is intended by this method to make the traction from the femur and not from the leg.

A piece of board provided with a pulley is next fastened to the foot of the bed, so that the tip of the pulley will be on a level with the malleoli. The weight will vary from two or three up to eighteen pounds. A pound for every year of life

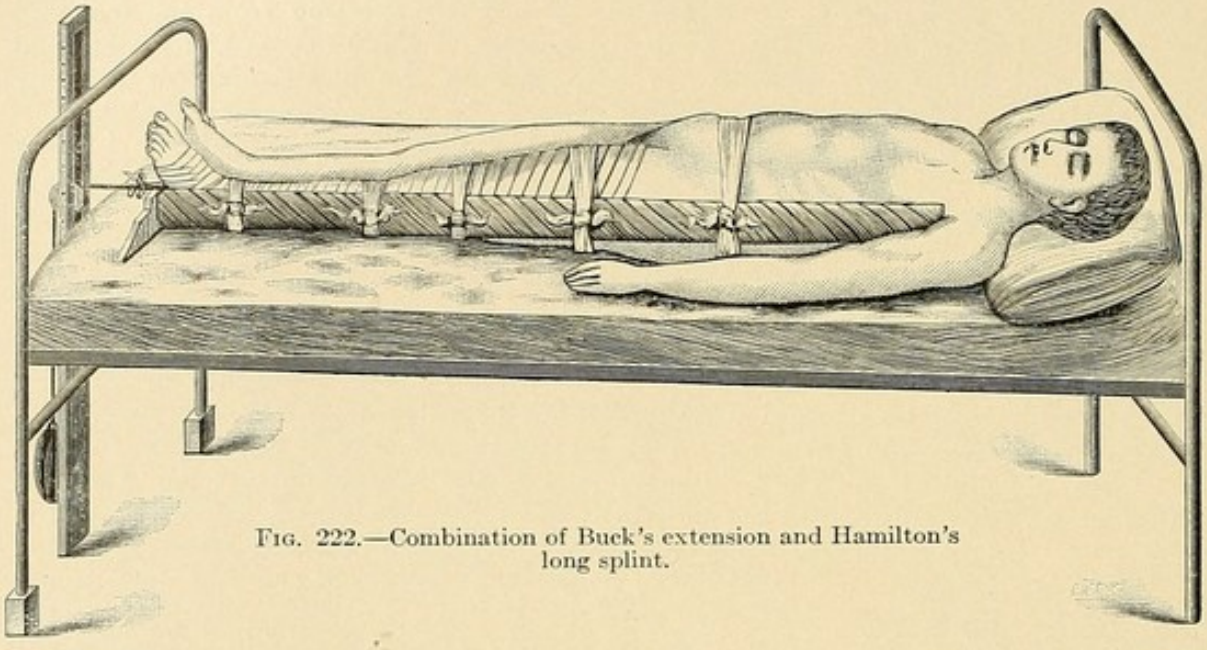

Fig. 222.—Combination of Buck's extension and Hamilton's long splint.

up to eighteen is the rule; but this is too much for fracture above the trochanter. About ten pounds is sufficient for all ordinary cases. Shot in a bag, or smoothing-irons, are usually employed for the extension weight, which is tied to the string (Fig. 222). The patient's body serves as the counter-extending force, the gravitation toward the head of the bed being about counteracted by the weight attached to the foot. Additional benefit and comfort may be obtained by laying small, long bags, filled with sand, on

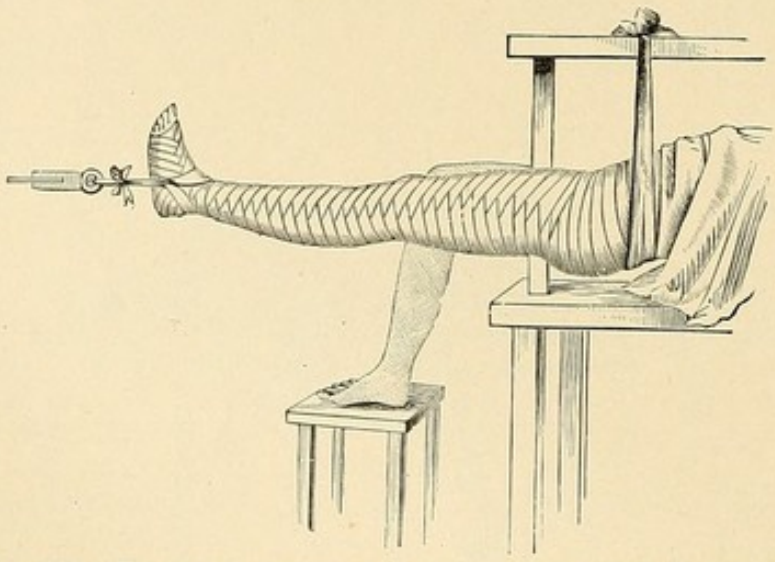

Fig. 223.—Emergency apparatus for swinging the pelvis in applying gypsum dressing in fracture of the thigh from the middle to the knee-joint.

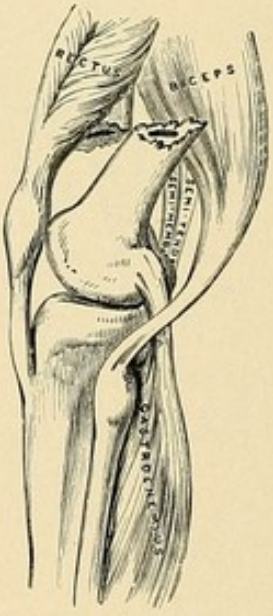

Fig. 224.—Displacement of fragments in fracture of the thigh in the lower third. (After Gray.)

either side of the thigh and leg. When the limb tends too strongly to outward rotation (or inversion) this may be corrected by the sand-bags, or by Professor Hamilton's long splint, which is shown in Fig. 222, and which is tied by strips of bandage from the axilla to the ankle. The foregoing is practically Buck's extension, to which may be added Hamilton's long splint.

In some instances it may be found advantageous to use Volkmann's sliding foot piece, seen in Fig. 225. This consists of a posterior splint for the leg, to which is attached a foot piece having the angle shown in the cut. This splint

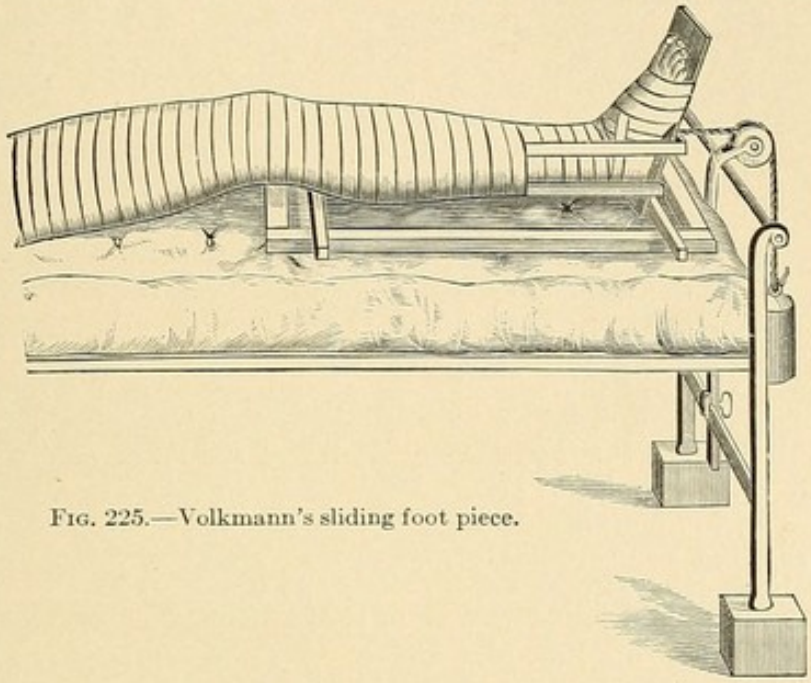

Fig. 225.—Volkmann's sliding foot piece.

should be perforated for the heel, and rest upon two cross-bars of wood, which in turn slide up and down on a rectangular frame. Upon the upper edge of these parallel bars a tongue is cut, and a corresponding notch or groove in the cross-bars.

In order to prevent the bedclothing from coming in contact with the fractured limb, a wire screen (Fig. 226) may be employed.

Patella.—Fracture of the knee-pan is usually caused by violent contraction of the quadriceps extensor muscle, while the leg is in extreme flexion. It may be

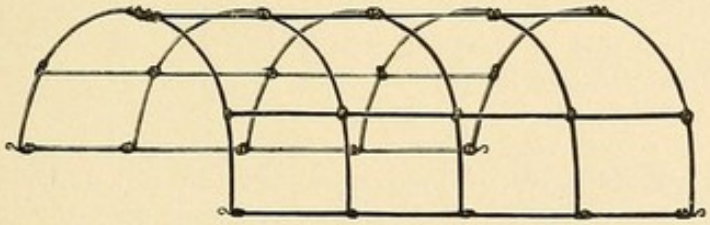

Fig. 226.—Wire screen. (After Esmarch.)

broken by a direct blow or a fall on the knee, or a blow and muscular action may combine to break it. The line of fracture is usually transverse or nearly so just below the middle of the bone, although it may break above or below this plane. It is occasionally split longitudinally by direct violence, or it may be comminuted. This fracture is rarely incomplete, the separation of the fragments varying from the smallest fraction of an inch to as much as two or more inches. The separation is somewhat wider at the inner than the outer border. It occurs in the majority of instances between the twentieth and fortieth years of life, and in males more frequently than females. Owing to its superficial location, by reason of the depression between the separated fragments, the diagnosis is easy. Should the separation be very slight, lateral motion of one fragment upon the other will elicit crepitus.

The treatment is operative or non-operative. Under strict asepsis and careful technic, the former is preferable, although in a large proportion of cases a satisfactory result will be obtained by the latter.

The following operation is advised: After thorough cleansing, the upper edge

of the lower fragment having been located, a transverse incision is made one fourth of an inch below this line, exposing the whole length of the broken surfaces. In order to turn up a sufficient skin flap, a short perpendicular incision may be made at either end of the transverse cut. The clot between the two fragments is now removed, preferably by irrigation with hot salt solution, 115° or 120° F. Under no circumstances should the finger be introduced, and it is better not to use forceps or gauze, unless the latter be necessary to remove any excess of solution.

Two subcutaneous sutures, one for the upper and one for the lower fragment, are now introduced through the wound beneath the flaps, near the inner border of the patella at the line of fracture. For the upper one of the two loops, the needle is made to emerge through the skin at a point just above the upper margin of the patella. It is reintroduced through this same puncture, and carried across the upper margin of the patella *through the substance of the tendon of the quadriceps extensor* muscle, at the outer limit of which it emerges through the skin, to be again reintroduced through the hole of exit, and to come out finally in the wound beneath the flap at the outer border of the patella at the line of fracture. The inferior loop is introduced in the same way, its transverse portion passing through the substance of the ligamentum patellæ at the lower border of this bone. Traction upon these two loops brings the two fragments in perfect apposition. The torn edges of the periosteum are now carefully everted with forceps, and reunited by a running suture of very fine linen. The two outer and inner ends of the strong linen loop sutures are now tied, as the fragments are pressed very firmly together. The superficial wound is closed with silkworm gut, the line of union being well below the line of fracture. A light sterile gauze dressing and a strong plaster-of-Paris cast from the ankle to the crotch are applied. This may be fenestrated over the patella, in order to remove the superficial sutures, about the tenth day. This operation may be done with perfect satisfaction under cocaine infiltration.

In a longitudinal fracture the periosteal sutures only are necessary, since slight lateral compression with adhesive plaster will hold the broken surfaces in apposition. When the bone is comminuted (stellate fracture), several rows of periosteal sutures may be required, and the double loop subcutaneous suture should be employed. When muscular rigidity cannot be overcome by the measures just indicated, the complete relaxation of ether narcosis will be necessary, and at times the insertion of silver wire through drill-holes will be required. This applies especially to ancient fractures of the patella in which there is a wide separation. The drill should enter about one half of an inch from the broken edge, and pass obliquely to emerge on the fractured surface well above the joint surface. In certain instances, which are fortunately extremely rare, in order to secure approximation in widely separated fractures of long standing, the subcutaneous section of the quadriceps extensor tendon and the contiguous fascia on either side is necessary.

When for any reason the suture operation may not be done, proceed as follows: Cut a piece of strong adhesive plaster (moleskin is preferable, or, if this cannot be obtained, double the ordinary adhesive plaster) about ten inches in length and broad enough to cover the whole front of the thigh, fitting snugly above the upper limit of the patella. To the center of this stitch a strong piece of webbing about an inch in width and several inches in length; a second piece of plaster, somewhat smaller than the first, is applied from the lower limit of the patella and extending down the leg eight or ten inches. To the center of this, at the middle of the *ligamentum patellæ*, a buckle corresponding to the size of the tongue of webbing is stitched with silk thread. With the leg in extension, these strips of adhesive plaster are bandaged snugly to the thigh; by passing the tongue into the buckle and pulling upon it, the fragments are not only closely applied to each other but the webbing prevents the fragments from tilting. The whole extremity from the perinæum, including the foot, is now invested with plaster-of-Paris, and a window is made over the knee-joint in front so that the fracture may be kept under observation. From day to day the strap may be tightened as the condition of the patient may demand (Fig. 227). Should the cast become loosened by shrinkage of the limb, a strip of sufficient width should be cut out

in front for the whole length of the cast, and an ordinary roller-bandage applied to make it fit more snugly. In this way the action of the quadriceps extensor is temporarily paralyzed. In five or six days the patient may move about carefully on crutches, and after he becomes accustomed to the use of these he can walk about and attend to business without danger to the limb. This dressing should remain undisturbed for from eight to ten weeks, at the end of which time it should be removed, and while the fragments are held closely in apposition by the hand of the surgeon, passive motion is made flexing the leg, not farther than twenty-five degrees from the anterior plane of the thigh. A lighter plaster dressing is then applied, and the patient can go another month without its removal, when the same passive motion is repeated, and this should be continued for as much as six months from the date of injury. After this time a posterior splint of light and strong shellac board or leather may be applied in the morning and removed upon going to bed, the patient going about with the aid of a cane. The atrophy of the muscles of the thigh and leg should excite no concern. In fact, a firm ligamentous union depends in good part upon this muscular atrophy. The functions of the muscles and of the joint are fully reëstablished as soon as the apparatus is left aside and the patient begins to use the limb. The essential point in the treatment of fracture of the patella is to prevent stretching of the ligament or fibrous tissue which is to hold the pieces together, and if this is properly attended to, a union will be obtained of such character that the functions of the leg will be practically restored. The failures which have occurred in the treatment of these injuries have been due chiefly to lack of appreciation of this fact.

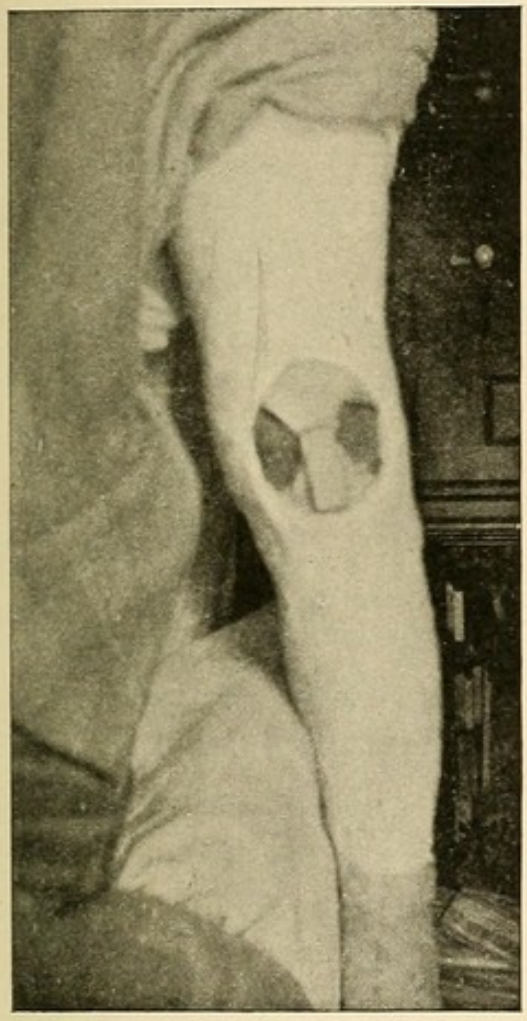

FIG. 227.—Fracture of the patella.

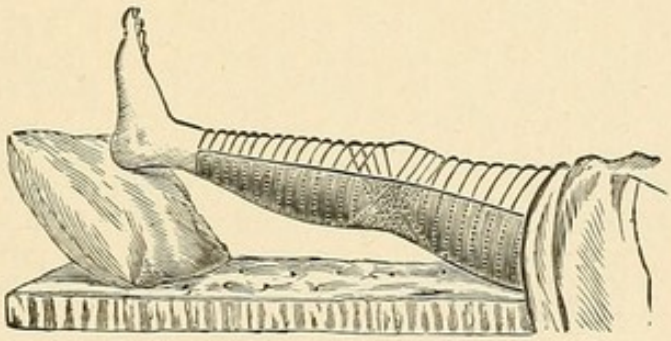

FIG. 228.—Hamilton's apparatus for fracture of the patella. (Hamilton.)

When this apparatus cannot be obtained, the method employed by the late Frank H. Hamilton should be employed. It is as follows:

A posterior splint is made to extend from near the heel to the gluteal fold. Shellac board is best suited for this purpose, but sole leather, gutta-percha, or a piece of plank will suffice, if these lighter articles cannot be obtained. If either of the first three articles is employed, the piece should be cut wide enough to envelop from one half to two thirds of the circumference of the limb. Three inches above and below the center of the knee-joint a tongue, one inch wide and two inches long, should be cut, and turned out so that the attached end is nearest the joint. This splint is dipped in warm water until soft enough to be molded to the part, when it is lined with a sheet of absorbent cotton and applied on the posterior

aspect of the limb. The cotton or padding material should be considerably thicker opposite the popliteal space, in order to prevent complete extension of the leg. Secure the upper and lower ends by turns of the roller thrown around the thigh and leg, and next begin the oblique or approximating turns by carrying a flannel bandage around the leg, so that it catches behind the lower tongue, whence it is carried obliquely upward above the upper fragment, across the quadriceps, and back to the starting-point. This is continued until the upper fragment is brought into apposition with the lower. For the lower fragment the bandage is made to catch behind the upper tongue upon the splint. When the fragments are approximated the entire limb is invested by the roller.

After the dressing is applied the same position is maintained for two weeks. The portion of the bandage immediately over the fracture should be opened on the fifth or sixth day, and a careful inspection made, in order to determine whether the roller has slipped and reseparation occurred. If the bandage is at all loose it should be tightened, but never drawn so tightly that it produces any discomfort.

This inspection should be repeated every five or six days, but the splint is never taken off until the eighth week, when passive motion at the knee-joint should be made.

The after-treatment is the same as just given.

After this procedure, six weeks should elapse before any effort at flexion is made. At this time the plaster cast should be removed, and the fragments held firmly together while the leg is bent on the thigh at an angle not beyond twenty-five or thirty degrees. The cast should be readjusted and passive motion repeated weekly for the next four weeks, when the area of motion may be gradually increased to and beyond ninety degrees. It is advisable to wear a protecting cap of sole leather or shellac board for several months to prevent the possibility of accident. This apparatus may, of course, be removed while the patient is in bed.

Leg.—Fracture of one or both bones of the leg occurs next in frequency to that of the radius, the clavicle, and ulna. The upper end of the tibia is usually broken by direct violence, although a fall from a height upon the foot may produce a longitudinal or oblique fracture communicating with the joint. The separation sometimes takes place through the epiphysis. The most common point of fracture is the junction of the middle and lower third. The fibula may be broken at the same level, or at a point removed from the line of fracture in the tibia, or this last bone alone may be broken.

Near the ankle-joint, partial fracture of the internal malleolus and a complete break of the fibula is comparatively frequent. In this (Pott's) fracture (called also railroad or street-car fracture, since it is often caused by jumping from a car in motion) the foot is powerfully everted, and the principal strain falls upon the internal lateral ligament of the ankle-joint. As the force is continued, as a rule, a crescent of bone is usually torn off with the ligament, or the entire malleolus is wrenched off at a higher point. The pressure upon the inner aspect of the external malleolus forces this outward, and the fibula above is bent inward and usually breaks about two or three inches above the tip of the malleolus. If great force is exercised in the production of this fracture, the inferior tibio-fibular ligament may be torn away, or, more likely, the outer lip of the articular surface of the tibia broken off. In exceptional instances, inversion of the foot will produce fracture of the inner malleolus by direct pressure of the astragalus, and of the external malleolus or fibula by traction on the external lateral ligament.

In fracture of the tibia alone the displacement will be determined by the direction of the line of fracture. Marked overlapping or displacement is prevented by the unbroken fibula. In the upper portion, with a transverse fracture, the deformity is slight. At the lower and middle third the obliquity is usually considerable, and from below upward and backward (Fig. 229). The upper fragment is tilted forward by the action of the quadriceps extensor, and partly by the pressure of the upper end of the lower fragment, which is thrown in the same direction by the contraction of the sural muscles and the consequent lifting of the heel. The deformity in Pott's fracture is shown in Fig. 230. In complete fracture of both bones of the leg, overlapping and displacement are the rule.

Diagnosis.—Fracture of the fibula alone may exist without detection unless the X-ray is employed. A careful examination, with direct pressure, will usually elicit crepitus or reveal the point of fracture by abnormal mobility and pain. Fracture of the tibia is easily made out by palpation along the spine, crepitus, loss of symmetry, and pain. These symptoms, together with the history of the accident, will leave little room for doubt in any case. Pott's fracture is recognized by the peculiar eversion of the foot, the abnormal prominence of the internal malleolus, pain, and loss of function. Crepitation of the fragments of the malleoli may be elicited, and preternatural mobility of the fibula, at a point two or three inches above the tip of the outer malleolus, is present. In *inversion* of the foot with fracture the outer malleolus is prominent. Fracture of both bones is easily made out by the deformity, abnormal mobility, and crepitation.

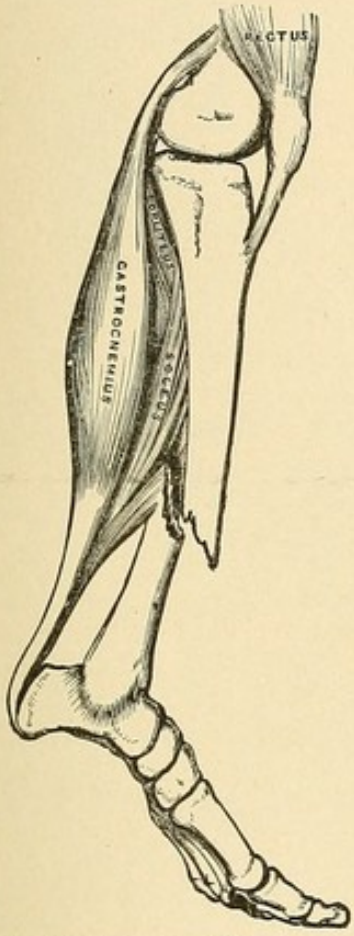

FIG. 229.—Displacement of fragments in fracture of the tibia, near the junction of the lower and middle third. (After Gray.)

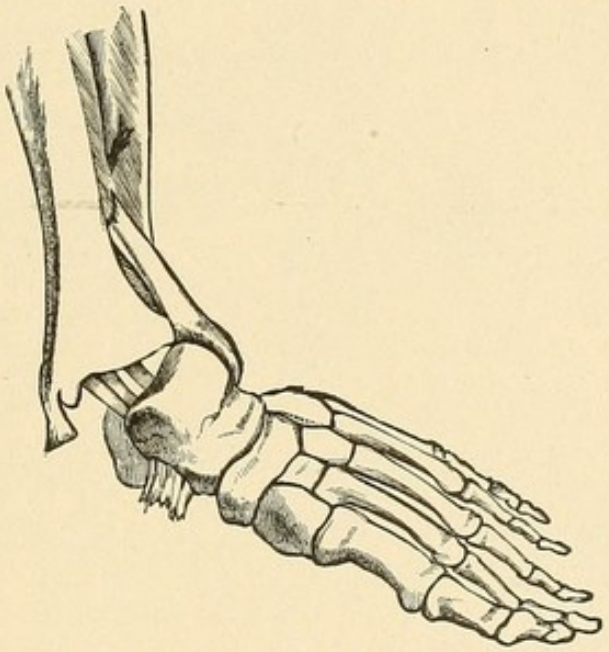

FIG. 230.—Displacement of the fragments in Pott's fracture. (After Gray.)

Treatment.—In most cases of fracture of one or both bones of the leg it is the best practice under anæsthesia to reduce the displacement by extension and counter-extension, and apply the plaster-of-Paris dressing at once.

This should extend at least half-way up the thigh, in all cases, in order to fix the knee-joint. It is applicable to all fractures of one or both bones, from the knee down to and including the malleoli. Extension can usually be made from

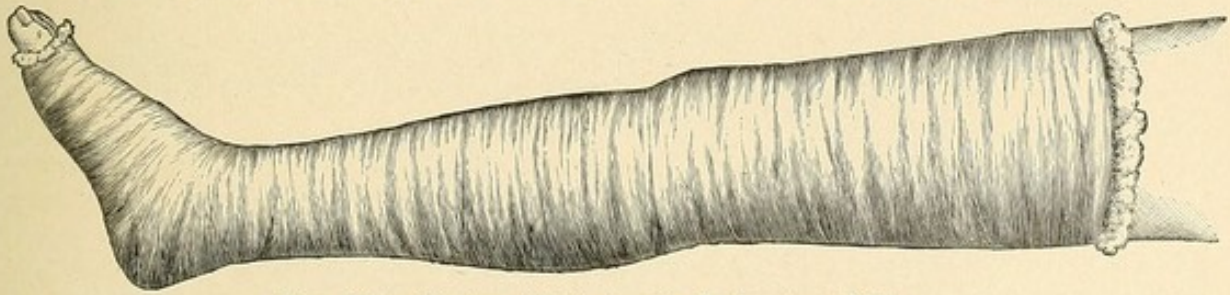

FIG. 231.—Plaster-of-Paris dressing in fracture of leg.

the heel and ankle by an assistant. A layer of cotton batting is placed next to the skin, a dry muslin or flannel roller, making firm compression, is applied, and

the plaster bandages over this (Fig. 231). The plaster cast should be split down the middle line, in front, to guard against even the remote danger of swelling. At the end of six or eight weeks all splints should be removed, passive motion made at the knee and ankle, and the apparatus reapplied and worn for at least two weeks more.

In applying the plaster in *Pott's* fracture the eversion needs to be overcome and the straight position maintained while the gypsum is hardening. Where the deformity is extreme the foot should be held in a position of slight overcorrection until the cast hardens.

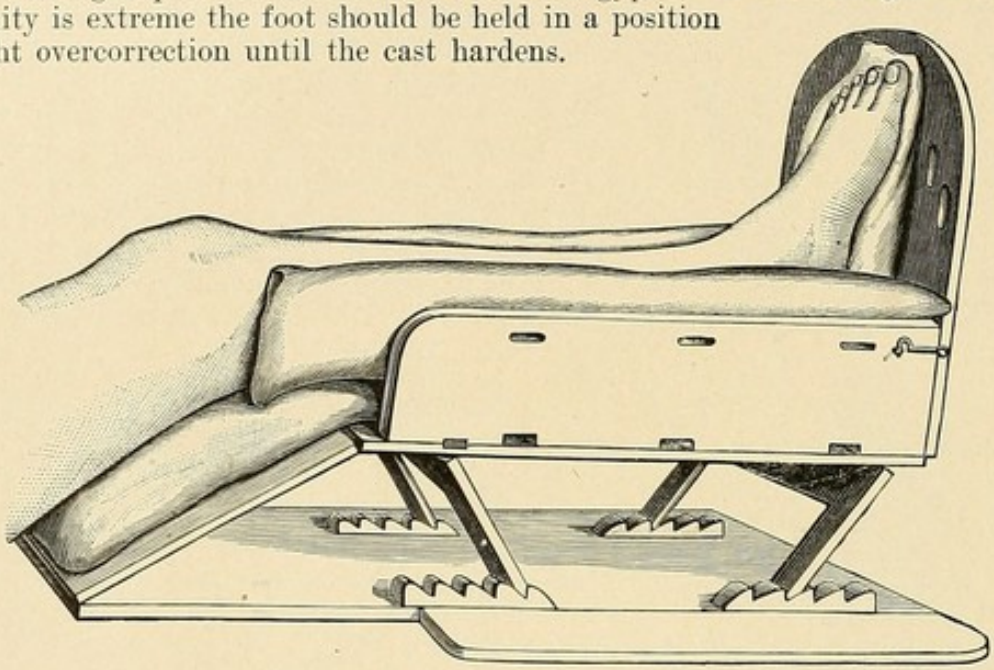

Fig. 232.—Petit's fracture box. (After Stimson.)

When plaster-of-Paris cannot be had, starch is next in order, or splints of felt, leather, bookbinders' board, metal, or wood may be employed. When swelling has occurred the fracture box (Fig. 232) is a most useful apparatus. This may be placed upon a pillow or box to give it a slight elevation, since the position of partial flexion is usually more comfortable.

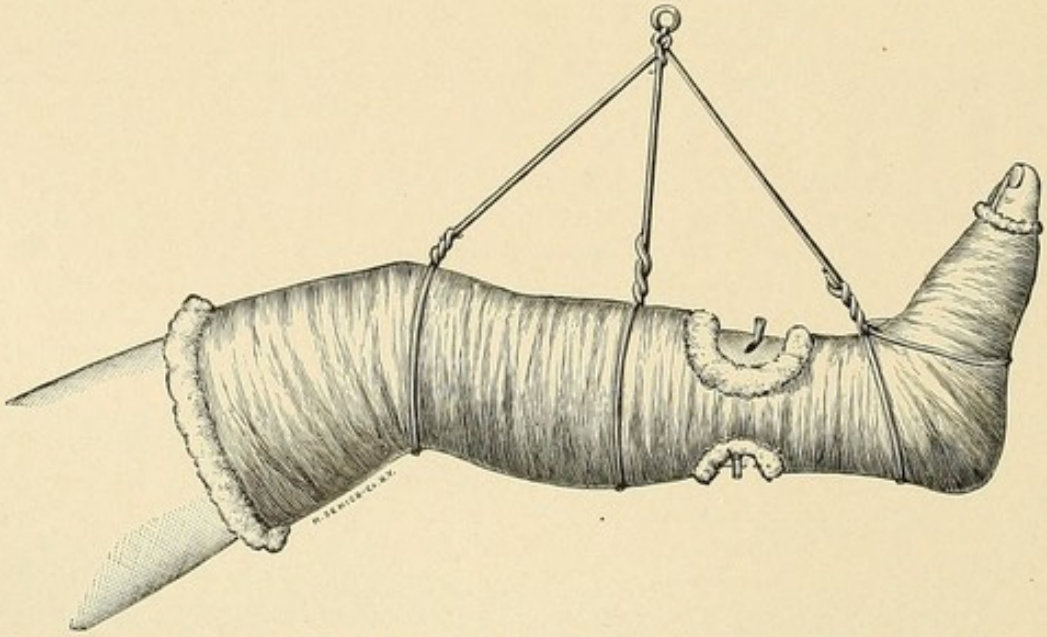

Fig. 233.—Fenestrated plaster-of-Paris dressing for fixation and through-drainage in infected compound fractures. Tin or metal strips should be inserted on either side of the limb opposite the windows to strengthen the weak points in the dressing.

If extension is needed it may be secured by a bandage around the ankle and foot, which is also passed through the holes in the foot piece. In fixing the leg

in this fracture box the sides are turned down, a thick layer of cotton or some soft material arranged for the leg to rest upon, and shaped to fit the natural contour of the calf. The sides are also packed, turned into position, and fastened. As soon as the first swelling subsides, or as soon as it is evident that no marked swelling will occur, the plaster-of-Paris should be applied.

In fractures of the tibia near the knee when an anæsthetic is not administered and muscular resistance is strong, flexion of the leg on the thigh and mechanical extension and counter-extension as shown in Fig. 234, will accomplish much in the

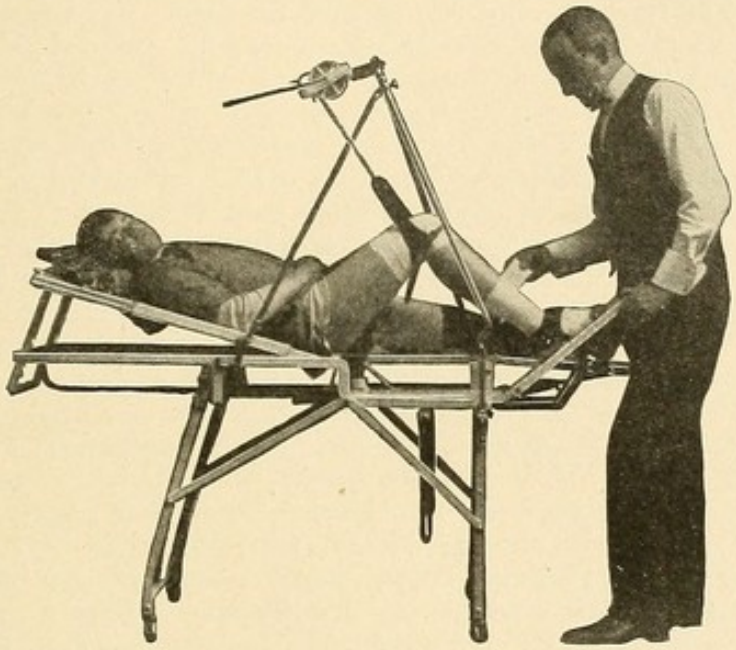

Fig. 234.—Mechanical extension and counter-extension (in flexion) by Downey's apparatus.

effort at reduction. The gypsum dressing should extend from the ankle and foot to the crotch.

Foot.—The bones of the tarsus may be broken by direct or indirect violence.

The diagnosis is not always easily made unless the X-ray is employed. The best method of treatment is fixation with a plaster-of-Paris dressing. When the os calcis is broken, and the tuberosity drawn up by the sural muscles, the leg should be flexed well upon the thigh, and the tarsus extended in order to relax this group of muscles, or the tendo Achillis divided.

Fracture of the astragalus is rare, and is at times difficult of reposition. Should the condition as revealed by the Roentgen ray demand a radical procedure, an open operation may be done.

Fracture of the metatarsal bones and phalanges should be treated in the same manner as the corresponding bones of the upper extremity.

Ununited Fractures—Fibrous Union.—In a certain proportion of cases union between the ends of broken bones is delayed beyond the time usually required for ossification, and may remain permanently ununited.

The *causes* of ununited fracture are: (1) Failure to secure immobility; (2) presence of muscle, tendon, nerve, or other substance between the fragments; (3) violent and prolonged inflammation of the broken bones and the surrounding soft parts in which granular degeneration occurs with considerable loss of bone substance; (4) any intercurrent disease which interferes with nutrition; (5) a too great separation of the fragments. If the ends of broken bones are not kept in contact, and at the same time immovable, fibrous union may result, for by motion the provisional callus is injured, and may disappear by absorption as a result of continued irritation. If the fragments overlap, so that no portion of the broken surface of one side is in contact with that of the opposite end, no matter how well adapted the dressing may be, muscular contraction may retard or prevent union.

The intervention of any of the soft tissues, or any foreign substance, may prevent the formation of callus, and lead to fibrous union.

Ostitis after fracture may lead to destruction of the fragments, and of the shafts of bone, to such an extent that union cannot occur. Instances are on record where, resulting from fracture, rarefying ostitis has destroyed the entire bone.

Any general condition of impaired nutrition increases the liability to fibrous union. Rickets, osteomalacia, syphilis, tuberculosis, or any acute febrile disease supervening upon fracture, tends to interfere with or to delay bony union.

The *diagnosis* of fibrous union is determined from continued preternatural mobility at the seat of fracture after two months have elapsed. Crepitus is not to be depended upon, as the ends of the fragments may be rounded off by absorption, and covered over with the inflammatory new-formed material, or at times with cartilage.

Treatment.—Any constitutional disease, especially syphilis, or any impairment of nutrition, must be specially treated. In the administration of tonics, cod-liver oil, with the hypophosphites of lime and soda, should play an important part.

It is of importance to fix the broken part immovably by the plaster-of-Paris or other solid dressing. This should not be removed for eight or ten weeks, when passive motion of any articulation near the seat of fracture, and necessarily included in the dressing, should be made. After the first movement of the joint the dressing should be reapplied and the passive motion repeated every second week. Great care should be preserved to prevent motion at the seat of fracture. If, after the lapse of from ten to fourteen weeks, there are no indications of union, a mild inflammation should be induced in the tissues immediately about the fracture. This may be accomplished by forcibly rubbing the ends of the bones together (after an anæsthetic has been administered), and then investing the member with a gypsum dressing. If this does not succeed, more radical measures must be adopted.

The line of non-union is exposed by a free incision usually longitudinal and at a point farthest removed from important blood vessels and nerves. The broken ends are exposed by forcible bending at the point of fracture, and all new tissue scraped or chiseled from the fractured surfaces. Should the line of fracture be oblique, a collar of heavy silver wire may be easily slipped over first one end and then the other, the surfaces brought in coaptation, and firmly held in place by twisting the wire, the ends of which are cut and turned toward the bone. This collar of wire requires very much less time in its application than drilling and wiring, and is far superior.

When, however, the line of fracture is transverse, a drill hole at least one eighth of an inch in diameter and one fourth or one half inch from the broken surface should be rapidly made, preferably with a machine drill, in order to save time and labor, and one or two threads of good-sized silver wire passed through and twisted. In an emergency a shoemaker's awl may be substituted.

It is not always necessary to carry the drill hole entirely through the bone, the wire being brought out through the medullary canal and reinserted through the canal on the opposite side. As a rule the wire remains imbedded and harmless in the reunited bone. In all of these operations for ununited fracture, the importance of the chromicized catgut bundle drain should not be overlooked. It should be inserted in such a way that the wound will be immediately emptied of blood or serum.

In certain cases where absorption has occurred and the fragments are pointed and narrow, instead of dividing the ends squarely across to secure a broad surface, thereby losing in length of limb, it is advisable to bevel the fragments on opposing surfaces, and hold them together by a collar of silver wire. In ununited fractures of the tibia, a bone in which they not infrequently occur, it may in rare instances be necessary to utilize the fibula, in order to secure a firm union in the weakened tibia.[1]

[1] Illustrative Case. F., male, thirty-two years of age, received a compound fracture of the tibia near the junction of the lower and middle third, in which non-union resulted. Six months later an effort was made to secure union by inserting an ivory pin in the medullary canal at the line of fracture. This also failed, and resulted in a further absorption of the broken ends necessitat-

When a fracture is complicated by the *injury* of a *nerve*, or *blood vessel*, or when the muscles are severely torn, it frequently becomes necessary, even if the wound be not open, to convert it into a compound fracture in order to reunite a divided nerve, or to tie or close by suture the wound in an artery or vein. The suture of muscle is not so important, although a divided muscle or tendon in general requires suture. Nerve trunks, when not disturbed at the time of fracture, are occasionally pressed upon, and their function partially or completely lost from the pressure of callus, new bone, or cicatricial tissue.

Upon the first symptoms of paralysis, operative intervention is imperative, with or without complete division of the injured nerve as the conditions may require, and end-to-end suture, as directed in the chapter on the Surgery of the Nervous System.

A *compound fracture* is always a grave injury, and the danger of complication is increased when a joint is laid open, and is exposed to infection. In general the treatment of a compound fracture requires the most careful antisepsis, and the reduction of the fragments to as near the normal position as possible. In order to accomplish this it is often necessary to remove portions of projecting bone. Immobilization by a heavy plaster-of-Paris dressing and the institution of drainage will meet the indications. This latter is one of the most important features in the treatment of compound fractures. It is not always possible to asepticize a compound fracture. Moreover, it is impossible to control bleeding from the broken ends, and on this account there is always apt to be more or less blood or serum in the deeper portions of the wound, which, if allowed to remain, would serve as a breeding place for septic organisms. Drainage can only be efficient when it leads downward from the deepest portion of the wound area as the patient lies in bed after the operation. After cleansing and reposition have been effected a dressing forceps should be pushed through from the deepest portion of the wound to the skin below, which latter is incised and the point of the forceps projected through the opening. By separating the jaws a drainage tract is established, and through this either a drainage-tube or, preferably, when long-continued drainage may not be required, a bundle drain of chromicized catgut is inserted. This latter drain will usually suffice. It should be about one fourth of an inch in diameter and made of twelve to twenty-four threads of No. 2 chromicized catgut parallel with each other, forming a loose bundle (not twisted). The ends should be cut one fourth inch from the level of the skin, and a sterile gauze dressing applied. While the extension and counter-extension (which has at no time been relaxed) is still made, the plaster-of-Paris dressing is applied.[1] Windows may be cut

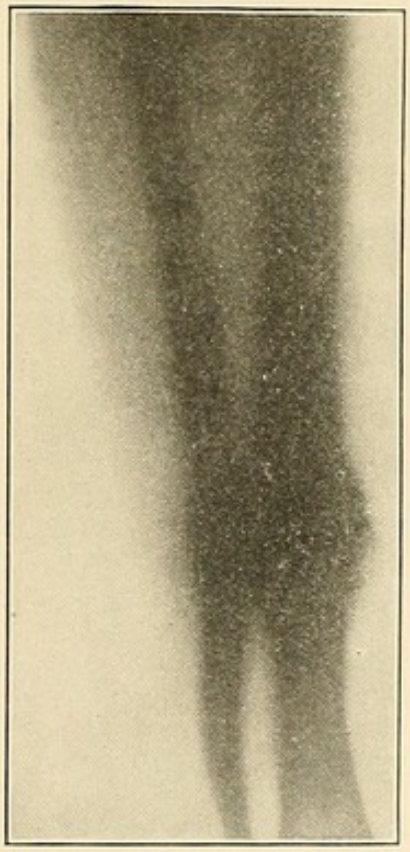

Fig. 235.—Union of the fibula with the tibia to strengthen a weak spot in the latter. (Case of F.)

ing the following operation: Through a free incision, the opposing surfaces of an ununited and somewhat oblique fracture were freshened by scraping with Volkmann's sharp spoon. The surface of the tibia nearest the fibula was also thoroughly scraped and the contiguous surface of the fibula treated in the same way. This latter bone was then broken and firmly fastened to the tibia by the author's drills, which after four weeks were removed. Union of the fibula to the tibia and of the tibial fragments to each other resulted with a restoration of function, as shown in Fig. 235. This patient now, after several years, has perfect use of his limb.

[1] Illustrative Case. Mrs. M., about forty years of age, in good physical condition, received an injury which resulted in fracture of the fibula at the external malleolus, the bone projecting an inch through the torn integument, complicated by a dislocation at the tibio-tarsal joint, the bone and the ankle-joint being exposed to infection. Under ether narcosis, the bone, joint and soft tissues were thoroughly cleansed with 1–1000 mercuric chloride solution, a number of pieces of broken bone removed with the rongeur, the dislocated bone and joint reduced. A crescent-shaped fringe of bone which had been torn away with the external lateral ligament was

as shown in Fig. 233. Upon the first indication of sepsis, the dressing should be changed, the wound carefully examined, and a more thorough drainage instituted.

brought back to its natural position and held in place by compression. A catgut bundle drain was inserted from the middle of the ankle-joint and carried downward through a fresh wound made for this purpose. A sterile gauze dressing was applied, and over all plaster-of-Paris immobilization, the foot being fixed in the position of slight eversion. This dressing was not removed for four weeks, when the wound was found entirely healed. No infection had occurred and the catgut drain had disappeared. Later a prothetic apparatus was adjusted to support the weakened ankle as the patient walked.

CHAPTER X

THE JOINTS—DISLOCATIONS

Dislocations are *traumatic, pathological*, and *congenital*. They may be partial or complete, and are described as simple, complicated, and compound.

Traumatic dislocations may occur from a blow or fall directly upon the joint, or by force transmitted along one or more bones forming the articulation. *Pathological* dislocations are caused chiefly by tubercular osteo-arthritis, with pyogenic infection, which results in a more or less extensive destruction of the cartilages and bones entering into the joint, together with rupture of the capsule through which the disarticulation takes place. A *congenital* dislocation is due to a failure of development in the joint structures, in which the normal contiguity of the articular surfaces cannot be maintained. A dislocation is said to be *partial* when any portion of the articular surfaces are still in contact; *complete* when one articular surface overlaps the other; *simple* when there is no other lesion than displacement and injury of the capsule; *complicated* when there exists with the dislocation a fracture into the joint; *compound* when, by reason of a wound, the air is in contact with the dislocated surfaces. Again, a dislocation may be *recent* or *ancient*, the limit of the former variety being from a few hours to two or three weeks. A *primitive* luxation is one in which the dislocated surfaces retain the same position as at the time of the accident, *secondary* when another position is assumed.

In dislocation the capsule is almost always ruptured, but occasionally, on account of extreme relaxation of the ligaments, the articular surfaces may be widely separated and become displaced from their normal relations without capsular rupture. In addition to rupture of the capsule, the violence which produces the dislocation is at times so great that muscles, tendons, nerves, vessels, and at times the fascia and skin about the joint may be torn or perforated.

Dislocations occur chiefly in adult life, and are more frequent in those joints which enjoy normally the greatest freedom of motion, and at the same time are subject to heavy strains. Patients with poorly developed muscles and relaxed ligaments are more prone to these lesions than the well-developed and vigorous.

The *diagnosis* of dislocations rests chiefly upon *abnormal immobility* and *asymmetry*. *Pain* and *swelling* are usually present. The Roentgen ray is indispensable to an absolutely correct picture of the injured articulation.

Special Dislocations—Inferior Maxilla.—Displacement of the condyles of the lower jaw, from its articulation with the temporal bone, may occur on one or both sides; usually it is bilateral. The condyles slip forward and are engaged partly beneath the zygoma, in front of the *eminentia articularis*, and partly between the zygoma and the temporal fossa. Muscular action alone may produce this luxation, or it may be caused by external violence.

The *symptoms* are great pain, difficult deglutition, and indistinct articulation (especially of the labial sounds). The lower teeth are unusually advanced, the mouth is opened, and the saliva trickles over the lips.

In unilateral luxation the chin points toward the sound side, and the teeth are less widely separated.

In the diagnosis the chief point of differentiation is fracture at or near the condyle. In fracture the condyle may possibly be recognized in its normal position by palpation; immobility is not marked; the mouth is not opened; crepitus may be obtained.

Reduction.—In bilateral displacement, wrap the thumbs with several layers of bandage or cloth, to protect them from being bitten when reduction is accomplished. Place one thumb along the inferior molars of each side, and the fingers beneath the body of the jaw; press downward and backward with the thumbs, while the fingers lift the chin upward.

Or place a thick roll of leather, piece of wood, or firm cork, between the upper and lower posterior molars of each side, and upon these, as a fulcrum, lift the chin upward, and at the same time push backward in the direction of the socket.

If both of these methods fail, they should be repeated under anæsthesia. It may sometimes be advisable to attempt the reduction of one side by either of the above methods, and retain it in position while reducing the other.

After reduction is completed put on a head and chin figure-of-8 bandage, and allow it to remain for a week (Fig. 53), or apply Hamilton's head-stall for fracture of the lower jaw (Fig. 192). In several instances, where the dislocation has become permanent, the symptoms have gradually subsided, and a fair degree of motion and usefulness acquired through the false joint.

Clavicle.—The sternal end may be displaced *forward* on the manubrium, *upward* above the sternum, *backward* behind the manubrium. The last two varieties are rare. The cause of the first form is usually force applied to the shoulder with the arm thrown backward. In the case of a boy fifteen years old, treated by myself, the displacement was caused by a comrade catching him by both shoulders, placing his knee in the middle of the back, between the shoulder-blades, and violently pulling the shoulders back.

The diagnosis is not difficult, the reduction easy, but the maintenance of the bone in position difficult. A compress, covered with adhesive plaster to prevent slipping, placed upon the bone after reduction, and firmly held in place by a roller, is a proper method of treatment. The arm should be fixed with Sayre's apparatus for fractured clavicle, in order to prevent a repetition of the luxation.

The outer end of the clavicle may be displaced above or below the acromion process, and above or in front of the coracoid process. Displacements under the acromion and in front of the coracoid are very rare.

The *symptoms* are very distinct, and the reduction not surrounded with great difficulty. When replaced, however, the bone is not easily maintained in position. By drawing firmly outward upon the shoulder of the affected side, and pressing the clavicle downward into position, reduction will be successfully accomplished. Place a firm compress over the end of the bone, bend the forearm at right angles to the arm, and carry one or two strong strips of adhesive plaster over the compress, behind the shoulder, along the arm to the olecranon, and again by the front over the compress. Reënforce this by a bandage, and place the arm in a sling. If luxation recurs, tighten the adhesive strips, and place the arm in a Velpeau's bandage. To apply this bandage, place the hand of the affected side almost upon the opposite shoulder, fixing a wad of cotton beneath each axilla. Lay the end of a roller on the shoulder-blade of the sound side, and carry the bandage over the acromial end of the clavicle of the injured side, and the front of the arm for a short distance, passing obliquely to the under surface at the elbow, and around beneath the well axilla to the point of starting. Repeat this to secure the roller, and then carry the bandage horizontally around the chest and over the tip of the elbow. The oblique and horizontal turns are alternated until the shoulder and arm are completely enveloped (Fig. 197).

Shoulder-joint.—Dislocation at this joint may take place in any direction, but in the vast majority of instances the head of the bone is carried through the inner aspect of the capsule and is lodged in the axilla beneath the coracoid process, or is pushed farther inward, lying beneath the clavicle; it occasionally rests at the margin of the glenoid fossa.

These three varieties are known as the *subglenoid, subcoracoid,* and *subclavicular.*

Occasionally the dislocation is backward (*subspinous*), the head of the bone resting beneath the base of the acromion process or the spine of the scapula. In

very rare instances the bone may be displaced directly upward, carrying the acromion process with it.

In *subcoracoid* dislocation a diagnosis may be made by a careful comparison of the injured with the uninjured side. It will be observed that while the arm of the uninjured side in relaxation falls directly downward, the humerus parallel with and practically in contact with the chest wall, on the opposite side the humerus is tilted outward so that the elbow of the dislocated side is several inches farther from the surface of the body than upon the normal side. Efforts at motion will reveal stiffness or marked immobility on the affected side. Firm pressure with the end of two fingers directly under the acromion process of this side will, in subjects not overfleshy or of extraordinary muscular development, demonstrate absence of the head of the bone which under ordinary conditions may be recognized in its abnormal position in the axilla. In doubtful cases, comparative measurement around the shoulder-joint, over the acromion, and through the axilla will show the circumference from one to two inches greater upon the side of dislocation than upon the normal side, even when there has occurred no swelling (Callaway). Moreover, if the hand of the affected side is placed upon the sound shoulder, the elbow cannot be carried down to the chest wall as upon the other side (Dugas).

When the dislocation is posterior (*subspinous*), the head of the bone may without difficulty be felt in this abnormal and more superficial position.

Treatment (Kocher's Method)—Inward Dislocations.—In these dislocations it has been demonstrated by Professor Kocher, of Berne, that the obstacles to replacement of the head of the bone could be overcome by manipulation, as follows:

The patient, under complete narcosis, is placed upon the back upon a hard table or the floor, with an assistant holding the shoulder of the sound side firmly down. The operator grasps the member of the injured side at the wrist and elbow and brings the humerus well against the wall of the chest (Fig. 236). Outward

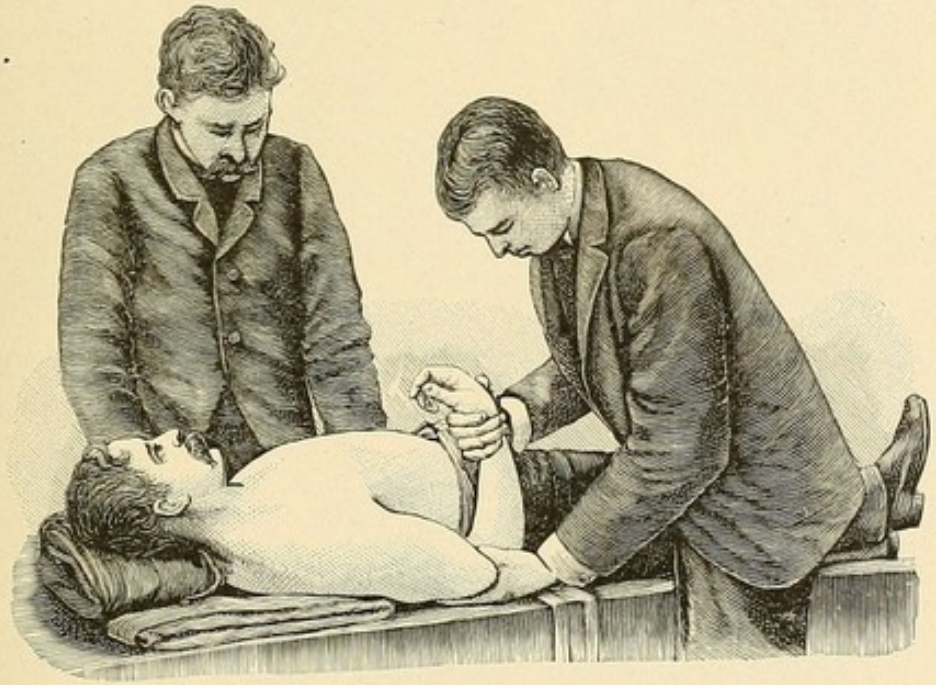

FIG. 236.—First Movement. The elbow is adducted to the body and drawn downward. (The arm and wrist should be firmly grasped, as shown in the figure.) (After Dr. C. A. Powers.)

rotation is made until the long axis of the forearm points directly outward (Fig. 237), when the elbow is brought along the front of the chest to the median line (Fig. 238) and the humerus rotated inward until the hand of the affected side is placed on the sound shoulder (Fig. 239). If this fail, repeat the procedure. It is always advisable to operate with the patient fully relaxed by an anæsthetic. In exceptional cases it may be successfully reduced without narcosis. Should this method fail, that of using the foot in the axilla, as given for subglenoid luxation, may also be tried.

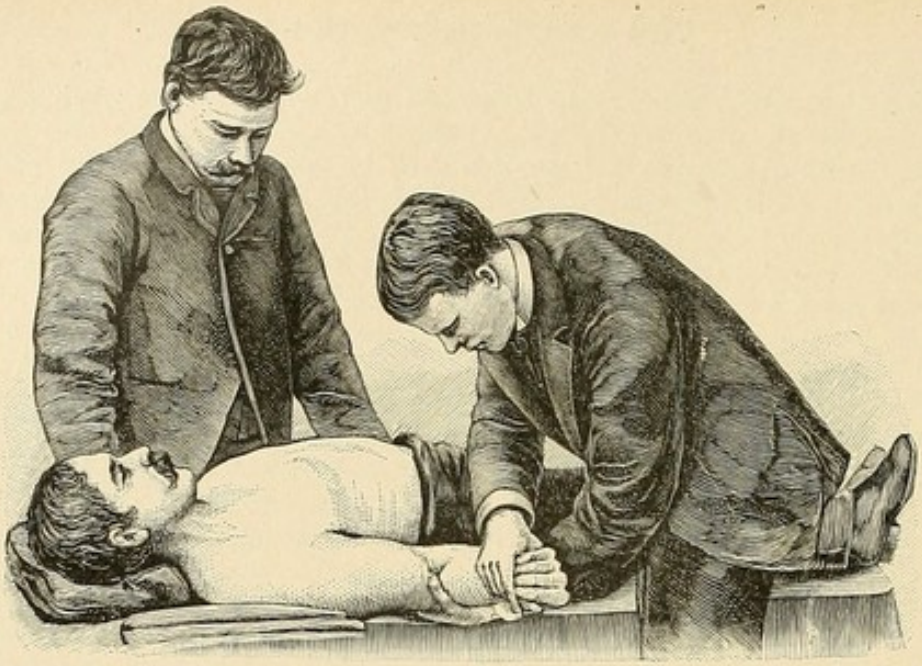

Fig. 237.—Second Movement. The arm is rotated out until firm resistance is met. (Practically until the long axis of the forearm points directly outward.) (After Dr. C. A. Powers.)

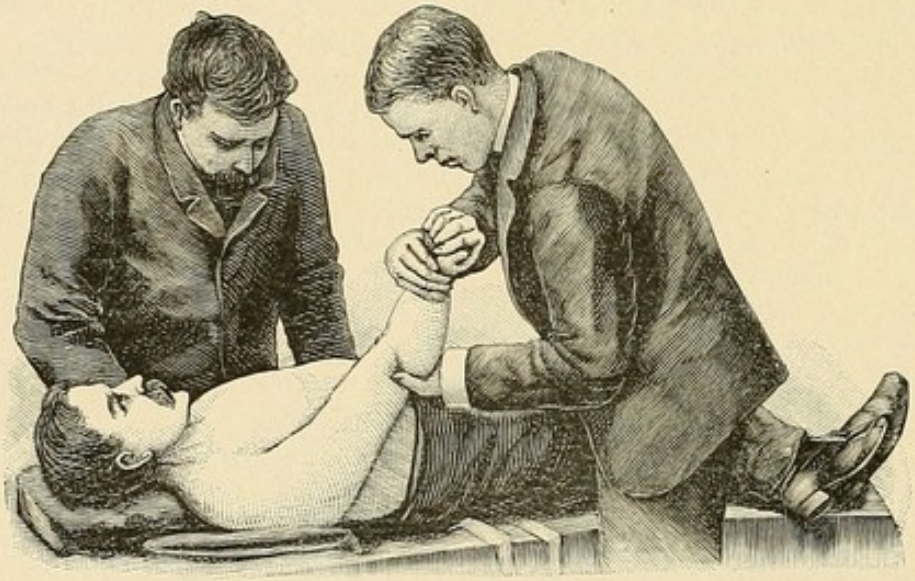

Fig. 238.—Third Movement. With the external rotation of the arm still maintained, the elbow is carried forward and upward on the chest. (After Dr. C. A. Powers.)

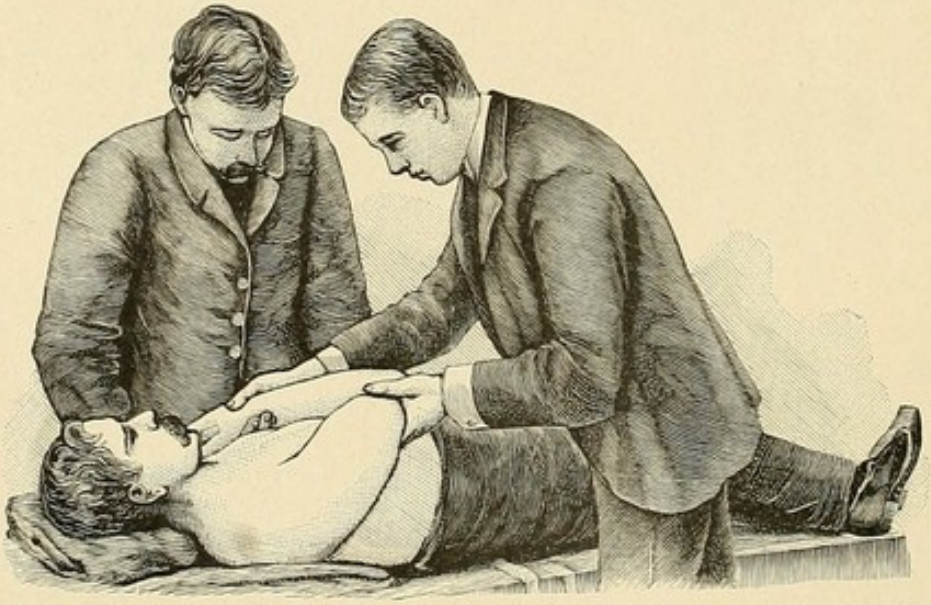

Fig. 239.—Fourth Movement. The hand is placed on the sound shoulder. (After Dr. C. A. Powers.)

The *subclavicular* variety of this forward dislocation is an exaggeration of the subcoracoid, in which the head of the bone slips underneath and internal to the coracoid, and rests against the serratus magnus and behind the pectoralis minor, below the clavicle (Fig. 242). The causes are the same, and the symptoms differ in little else than the presence of the head of the humerus nearer to the clavicle. The arm stands out from the body, and the elbow is tilted backward. The tension on the posterior scapular muscles is greater, and rupture of their attachments often occurs, while the anterior insertion of the subscapularis may be torn. Pressure on the axillary vessels and nerves is more marked in this luxation. Reduction may be effected by the means just described.



Fig. 240. Subacromial and subspinous. (Bryant.)

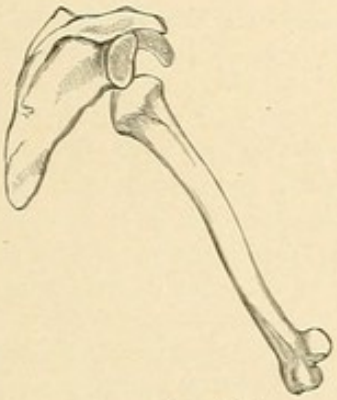

Fig. 241. Subglenoid. (Bryant.)

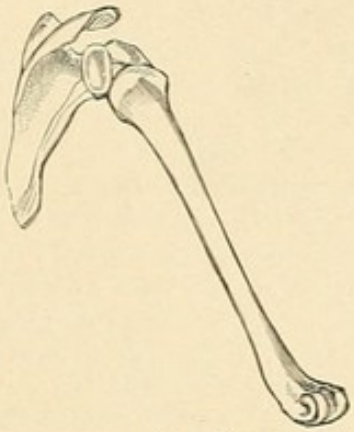

Fig. 242. Subcoracoid. (Bryant.)



Fig. 243. Subclavicular. (Bryant.)

Subglenoid Dislocation.—In the subglenoid luxation the capsule is stretched or torn along its lower surface, and the head of the humerus rests on the margin of the glenoid cavity, or, if the rent in the capsule is sufficiently extensive, it may slip in front of the long tendon of the triceps, and be lodged upon the axillary border of the scapula, immediately below the articular surface (Fig. 241). The supraspinatus muscle is severely stretched, and either suffers rupture of its tendon or substance, or it may tear off a rim of the upper facet of the greater tuberosity. The long head of the biceps and the coraco-brachialis are also subjected to great strain or possible rupture, while the tension of the deltoid holds the arm in a position with the elbow slightly tilted from the side of the body.

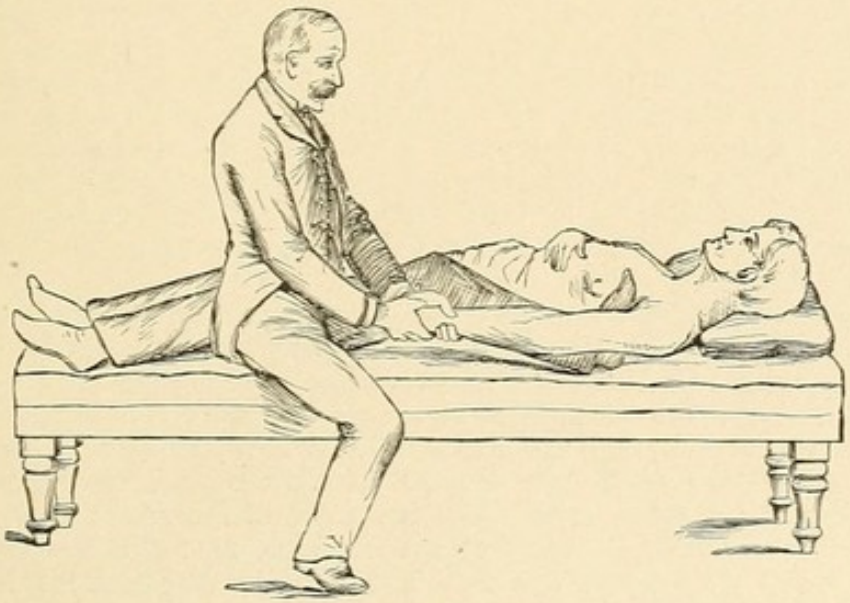

Fig. 244.—(Erichsen.)

Among the less frequent complications of this lesion may be mentioned pressure upon the circumflex and axillary nerves, and injury or rupture of the great vessels.

Should Kocher's method fail, place the patient upon a table, bed, or upon the floor. For the left shoulder the operator removes the shoe from the left foot and places it in the axilla, against the thorax. He now seizes the arm and forearm of the patient, carries it out at a right angle to the axis of the patient's spine, and makes powerful traction in the direction of the glenoid cavity. While this is being effected the arm is brought inward, parallel with and against the side of the body (Fig. 244). The foot not only serves to effect counter-extension, but is also used as a fulcrum for lifting the head of the bone over the edge of the glenoid facet into the articular cavity of this process. After reduction a shoulder-cap of bookbinders' board, leather, or gutta-percha should be applied, and worn for at least one week.

The *subacromial* and *subspinous* dislocations are reducible by extension and counter-extension in the line of displacement. Counter-extension may be made by an assistant holding the arm of the sound side, or by the folded sheet (already described) applied just in the axilla. The operator makes extension from the arm and forearm, imparting to the humerus a slight axial rotation.

General Considerations.—Even with an experienced operator and the proper employment of anæsthesia, occasionally a dislocation at the shoulder is found impossible of reduction without an operation which exposes the joint. Under such conditions and under strict asepsis, this is imperative when all else fails. The incision should be in the general axis of the arm along the anterior inner aspect, sacrificing as few of the fibers of the deltoid as possible. Hæmorrhage should be controlled as the operation proceeds, so that important structures may be recognized and avoided. When reduction is effected the wound should be closed with catgut wisp drain in the lower angle.

The danger of injury to the nerves and vessels of the axillary region in the efforts at reduction should always be carefully considered.

In all cases the difficulties increase when reduction is delayed. The formation of adhesions, muscular shortening, and the contraction of the rent in the capsule add ever-increasing obstacles to reposition. If operation has been delayed longer than forty-eight hours, these dangers should be carefully stated in the prognosis. Reduction after two or three weeks will fail in the majority of instances, and after six weeks it is almost impossible of accomplishment.

In cases properly selected, where an ancient dislocation exists, and where motion is so restricted that the usefulness of the arm is seriously impaired, the open operation may be advised. Failing in all efforts at reposition after the head of the bone is exposed, the propriety of excision may be considered not only to relieve pressure upon the nerves and vessels of the axilla, but in the hope of increasing motion.

When the dislocation is complicated with fracture of the surgical neck, McBurney's operation as given in connection with fractures of this bone should be performed. When the presence of the head of the bone in the axilla does not cause pain or paralysis by pressure upon the nerves, and does not interfere with the circulation in the arm, it has been demonstrated that surgical fracture at the neck of the humerus followed by regular and long-continued passive motion, will develop a false joint at the point of fracture and restore in great measure the movements of the arm.

Passive motion should be made once or twice each week, or less frequently should any considerable degree of inflammation or soreness be developed.

The employment of nitrous-oxide gas anæsthesia is invaluable in the treatment of these cases. Its administration is so simple and safe, and as the effects pass off immediately patients will not hesitate to present themselves for treatment, which is rarely the case when ether or chloroform are repeatedly employed.

Dislocations at the Elbow-joint.—The upper end of the radius may be displaced forward on to the anterior surface of the humerus, near the coronoid fossa, or backward upon the olecranon process. The anterior displacement is met with somewhat more frequently than the posterior.

In the displacement forward the orbicular and a portion of the external lateral and anterior ligaments are ruptured; in the opposite luxation only the first two are lacerated.

The *forward* displacement is caused by direct violence applied to the posterior aspect of the upper end of the radius, or by falling upon the palm of the hand, the full force of the contraction of the biceps being thus added to the force transmitted along the shaft of the bone.

Diagnosis.—Careful palpation will reveal the abnormal presence of the head of the radius near the center of the humerus, while pressure along the outer condyle will demonstrate its absence from its natural position. The forearm is semiflexed and slightly pronated. The fluoroscope will reveal the exact nature of the displacement, and should be utilized to demonstrate the success of the reduction.

Treatment.—Flex the arm and push the head of the bone forcibly downward in the direction of the articulation. When reduction is accomplished, place a compress over the upper end of the bone and the external condyle, and bind it firmly in position. The arm should be snugly bandaged, and carried in a sling for several weeks.

The *backward* dislocation is recognized by the presence of the head of the bone in an abnormal position near the olecranon, behind the external condyle.

Treatment.—While an assistant makes strong extension and counter-extension from the hand and arm, the operator makes direct pressure upon the head of the bone, forcing it in the direction of the articulation. As the displacement is being corrected the assistant should carry the forearm in a position of supination. The after-treatment consists of a compress and bandage, worn for several weeks.

The *prognosis* of this injury is generally not favorable, since it is very apt to recur after reduction, and may become permanent. A fair degree of usefulness is maintained, however, in many cases of chronic luxation of this end of the radius. The production of a rich callus, more or less permanent, resulting from raising the periosteum as the ligaments are torn is a frequent cause of impaired motion after this injury.

Complete forward dislocation of the ulna alone, at the elbow, cannot occur without fracture of the radius or extensive laceration of the radio-ulnar ligaments.

Subluxation of the Head of the Radius.—This lesion is met with usually in children from nine years old and under, and is much more common than complete dislocation at this joint. It is caused by sudden traction on the hand or forearm in lifting a child by a single arm or in saving it in the act of falling.

The symptoms are loss of function, the arm often hanging as if it could not be moved. Motion at the wrist, however, may be free. Pressure over the head of the radius causes sharp pain. Passive flexion at the elbow is permitted to about sixty degrees, when resistance may be met with. Complete extension is also painful. With the forearm flexed at a right angle to the arm, pronation is possible, but is slightly resisted, while supination causes great pain. If, however, this movement is carried to the extreme, a distinct click may be heard and felt at the head of the radius, with which the pain suddenly ceases and free motion is reëstablished (W. W. Van Arsdale).[1]

Reduction.—With the patient sitting or standing in front of the operator, he grasps the arm just above the elbow with one hand, while with the other the forearm is seized near the wrist. The forearm is now flexed to an angle of ninety degrees with the arm, and steadily rotated into a position of extreme supination. As above stated, the reduction is accompanied by a perceptible slip or click. A splint should be applied to hold the arm quiet in the right-angle position for four or five days.

Dislocation of *both radius and ulna* at the elbow may take place in all directions.

The dislocation backward may be produced by falling upon the hand with the forearm almost extended; by a blow upon the anterior aspect of the forearm, near the elbow, a blow upon the posterior surface of the humerus, in its lower portion, or force applied at the same time, in opposite directions, upon these surfaces. The coronoid process will be found lodged in the olecranon fossa, the upper end of the radius resting on the posterior aspect of the external condyle.

The anterior ligament and the anterior fasciculi of the external and internal

[1] "Annals of Surgery," June, 1889.

lateral ligaments are torn loose, and in extreme cases the orbicular ligament may give way, although the yielding of the external ligament usually saves the circular ligament from being torn. The tendon of the brachialis anticus is stretched or is broken loose from the coronoid process. Pressure upon the brachial artery may be so great that pulsation at the wrist is diminished or absent, while in extreme cases the median, ulnar, or musculo-spiral nerves may be injured.

The usual position of the forearm is one of almost complete extension, with pronation. Measurement from the inner condyle to the styloid process of the ulna will demonstrate shortening. Muscular rigidity is marked, and motion of the displaced bones difficult and painful. From these symptoms the diagnosis can be readily made. If swelling has ensued, and the tumefaction is great, it is not always easy or possible to recognize the character of the injury. It is best under such conditions to anæsthetize the patient, determine the exact nature of the injury, and treat it at once rather than wait until the swelling is reduced.

Reduction.—The patient, fully anæsthetized, should be placed upon the back on a firm table, and a chair so placed that the knee of the operator, pressing against the lower anterior aspect of the humerus near the elbow, may be used in counter-extension to the force employed by traction on the forearm.

The forearm, flexed at an angle of ninety degrees upon the humerus, is now grasped near the wrist by the operator and strong traction made, accompanied by slightly increasing flexion. This increased flexion unlocks the coronoid process from the olecranon fossa, while extension carries both bones forward into position. When reposition is affected, a right-angle splint should be applied and worn for a week or ten days.

A cloth or sheet folded around the patient's arm just above the elbow may also be employed for counter-extension. Should reposition not be effected in the position of flexion, Liston's method of making extension from the forearm and counter-extension from the shoulder with the arm and forearm held straight may be substituted.

Dislocation of the radius and ulna *forward*, without fracture of the olecranon, is of rare occurrence, and is always the result of great violence. Rupture of the posterior and lateral ligaments occurs, and the triceps tendon is torn or greatly stretched, while the brachialis anticus and biceps are relaxed. The posterior portion of the olecranon rests upon the anterior articular aspect of the humerus, or may slip into the coronoid fossa. The forearm is bent at an angle varying from ninety to one hundred and twenty degrees to the anterior surface of the humerus, and is well supinated. Motion is painful and limited. The character of the injury may be determined by the absence of the olecranon projection, the smooth, broad, posterior surface of the lower end of the humerus being readily appreciated.

Reduction.—An anæsthetic is required. With the forearm held at a right angle to the arm, make extension from the wrist, and counter-extension from the lower anterior surface of the humerus, in order to disengage the olecranon process from the coronoid fossa, and, when this is effected, make direct pressure downward upon the anterior aspect of the forearm, near the elbow. After the bones slip seemingly into position, careful examination should be made to see that the radius is in its proper relation to the external condyle, for the ridge between the two sigmoid cavities of the ulna may lodge in the groove between the trochlear surface and the articular surface for the head of the radius.

In the *outward lateral* dislocation the luxation is usually partial. The cause is direct violence applied to the inner aspect of the forearm, near the joint, or to the outer aspect of the humerus, low down, or to force applied simultaneously, in opposite directions, upon these two surfaces.

The *diagnosis* will rest chiefly upon the increased prominence of the inner condyle, and the difficulty of recognizing the outer condyle by palpation. The angle at the elbow is about one hundred and twenty degrees, motion is wanting, and the hand is pronated. Reduction is best effected by strong extension from the forearm, counter-extension from the humerus, and direct lateral pressure in the direction of the displacement.

Inward dislocation is always incomplete (Hamilton). The causes are direct violence in the opposite direction to that given for the luxation outward. The internal condyle will be less prominent, the external more prominent, the olecranon will be seen crowded over to the inner aspect of the joint, while the head of the radius rests near the middle of the articular surface of the humerus. The position of the forearm is that of flexion. Reduction is difficult, and should be effected in ether narcosis. Extension and counter-extension should be made in the flexed position, and the arm gradually brought out straight, while at the same time direct pressure is made, in proper and opposite directions, upon the humerus and forearm, near the joint.

Dislocation of both bones backward is the most frequent form of displacement at the elbow. Incomplete external and incomplete internal luxation are next in order of frequency, while the forward dislocation is rare.

In the posterior variety the direction of the force may be such that a deviation to one or the other side may occur. The treatment is practically the same. Direct lateral pressure in the line of the normal position of the bone may be required in addition to the mechanism of reduction above given. Partial ankylosis is not infrequent after these lesions. Passive motion should be begun within two weeks after the injury, and repeated daily if no acute inflammation is produced.

Wrist-joint.—Dislocations at the carpo-radial joint are very rare. Only a few instances of complete *backward* or *forward* luxation of the carpus are on record. Lateral dislocations are considered impossible without fracture of the styloid process of the radius or ulna. The two principal displacements occur with about equal frequency. In the *backward* variety the anterior aspect of the carpus rests upon the dorsal rim of the cancellous expansion of the radius, the reverse being true in the dislocation *forward*. The anterior and posterior ligaments are partially or completely ruptured, and the annular ligament, which binds the tendons down, may be torn and the tendons displaced.

The *cause* of the *backward* displacement is a fall on the back of the hand, or a blow upon the dorsum of the radius, just above the wrist, while the hand is in extreme flexion. Violence of a similar character, applied in the opposite direction, will produce the *forward* luxation.

The *diagnosis* must be made between Colles' fracture and dislocation. In *dislocation* the deformity from the overriding carpus is much greater than after fracture. In Colles' fracture the swelling on the dorsum of the wrist is smooth and rounded. When impaction has not occurred crepitus may be obtained.

Reduction is effected by extension and counter-extension from the forearm and hand, to which direct pressure in the line of displacement should be added.

Dislocation of the *metacarpal* bones, at their carpal extremities, is rare. Luxation of the metacarpal bone of the thumb is most frequently observed. The carpal end of this bone may be displaced partially or completely, in a *forward* or *backward* direction. When the end of the bone rests upon the dorsum of the trapezius it can be easily recognized.

Extension and counter-extension, with direct pressure, is usually sufficient to accomplish reposition. A clove-hitch or snare may be thrown around the thumb to insure extension. Reduction is at times difficult, and the history of this accident is not without a record of failure both as to replacement and retention when replaced.

In the displacement forward, on account of the thickness of the soft parts, the end of the bone cannot be easily recognized. An unusual depression may be observed on the radial and dorsal aspects of the wrist, just in front of the os trapezium.

Strong extension with counter-extension is necessary, and to this should be added direct pressure, applied near the end of the displaced bone.

Luxation of the remaining metacarpal bones occurs rarely, and, when met with, the displacement is usually partial, and toward the dorsum of the carpus.

The *phalanges* may be dislocated either *backward* or *forward* at the metacarpal articulations, or at the interphalangeal joints. The character of the lesion is easily recognized, and the reduction, as a rule, is not difficult. Extension with a

clove-hitch, or with the apparatus shown in Fig. 245, will effect reduction. In some instances operative interference is demanded when reposition by extension and pressure cannot be effected. Careful asepsis should be observed. On opening into

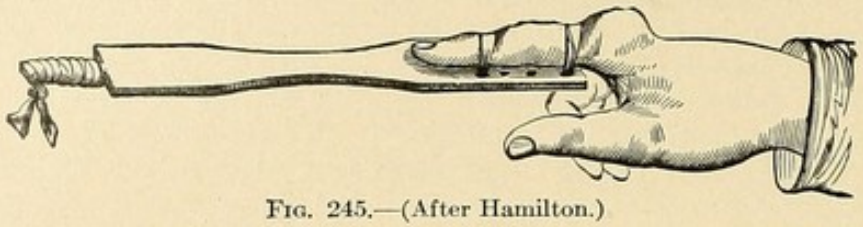

Fig. 245.—(After Hamilton.)

the joint, the resisting ligaments should be snipped with a sharp bistoury, when the displacement may be easily corrected.

Hip-joint.—While the head of the femur may be displaced from the cotyloid cavity in any direction, it is customary to consider *four* distinct luxations: (1) *Upon the dorsum ilii;* (2) *into the ischiatic notch;* (3) *into the obturator foramen;* (4) *upon the os pubis.* Practically these lesions occur in each of the quadrants of a circle, the center of which is the center of the acetabulum.

As shown in Fig. 246, about fifty per cent of all luxations at the hip occur in the iliac quadrant, thirty per cent in the ischiatic, eleven per cent in the obturator, and seven per cent in the pubic. Two per cent occur beyond these regions. Cases are on record where the head of the bone was lodged on the tuber ischii, in the perinæum, and just beneath the anterior superior spine of the ilium.

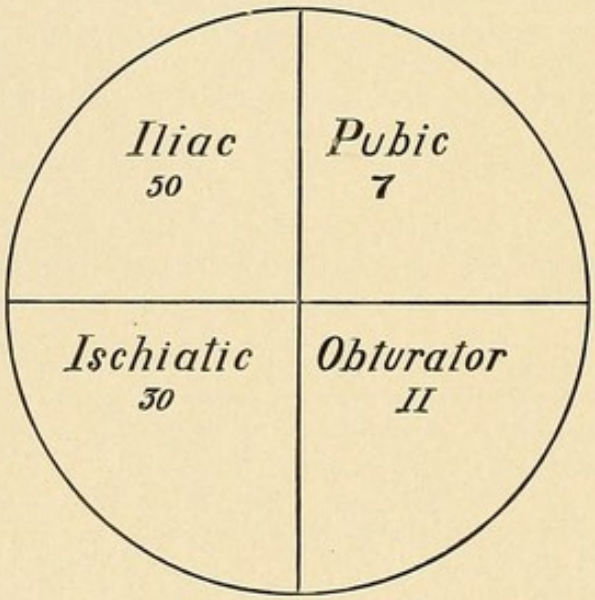

Fig. 246.—Showing the proportion of displacement in the four quadrants of a circle about the acetabulum.

The capsule is usually torn at its inferior and posterior surface. It may be a slit or tear in the long axis of the ligament, or frequently a broad rupture occurs along the edge of the cotyloid cavity. The ligamentum teres (when present) is always torn. The ilio-femoral (or Y) ligament is very rarely completely ruptured. The injury to the muscles and surrounding structures is always severe, and varies in proportion to the degree of violence which caused the luxation, together with the particular direction of the displacement.

In the displacement upon the *dorsum ilii* the glutei muscles may be lacerated, bruised, or lifted from the ilium by the head of the bone, but not by tension on their tendons, for, with the exception of the lower fibers of the maximus, their axes are slightly shortened in the new position. The obturator internus, externus, gemelli, and quadratus femoris are greatly stretched, or torn entirely loose. The pyriformis is not so apt to suffer. The pectineus, iliacus, and psoas are carried upward and outward. When the head of the bone is projected into the *ischiatic notch*, the conditions as to the muscles are practically unchanged. The sciatic nerve and vessels are pressed upon and may be contused or lacerated. In the displacement upon the pubes the psoas and iliacus may be injured, while the femoral vessels and anterior crural nerve are more or less pressed upon. When the head of the bone is lodged in the *obturator foramen*, the obturator externus muscle and the obturator vessels and nerves are more or less contused, while the glutei and the remaining external rotators are put upon the stretch.

Causes.—Dislocations at the hip may be congenital, pathological, or traumatic in cause.

Congenital luxations, rare in occurrence, are the result of interference with normal development. Failure to complete the process of ossification in the three bones which compose the acetabulum leaves a soft and fibro-cartilaginous cup or sac, through which, when the weight of the body is sufficient, the head of the femur is more or less completely displaced into the pelvic cavity. Abscess of the ligamentum teres is not alone sufficient to account for displacement when the bones, capsule, and muscles are normal, for it is not infrequently absent in cases which have never suffered a luxation. Moreover, the majority of cases in which this ligament has been ruptured by one luxation do not suffer a second displacement. An abnormally long, loose, or relaxed capsule will lead to subluxation or displacement without rupture of the capsule. Failure of development from the cervical epiphysis is another cause of congenital dislocation at the hip.

Pathological dislocations are caused by chronic arthritis. The bones are more or less destroyed, and the capsule breaks down, permitting dislocation of the head of the bone as a result of muscular action or slight violence.

Traumatic luxations are direct or indirect. The most frequent cause is a fall from a height or from a carriage in motion, the person striking upon the foot or knee, with the thigh carried in such a direction that its axis is at a considerable angle to that of the spinal column.

Anatomically considered, the most favorable position for the two posterior, and by far the most frequent, displacements is when the thigh is flexed at about an angle of ninety degrees to the axis of the body. If the thigh be adducted, the tendency is to rupture the capsule on its posterior inferior surface, with escape of the head on to the *dorsum ilii*, or into the *ischiatic notch*. When in a position of abduction, the rupture is likely to occur on the lower anterior aspect of the capsule.

A fall directly upon the trochanter, with the thigh in adduction or abduction, with extreme outward or inward rotation, is apt to produce rupture of the capsule and luxation.

Symptoms.—In dislocation upon the dorsum ilii, with the patient standing erect upon the uninjured extremity, the trochanter of the displaced femur will be nearer the anterior superior spine of the ilium than that of the opposite side; the thigh is slightly flexed upon the abdomen, adducted, and rotated inward. The head of the bone may be appreciated in the new position. The shortening is from one to two inches, and in the vast majority of cases the great toe of the injured side is directed to or rests upon the instep of the opposite foot, while the knee of the luxated side is in front of, and slightly above, its fellow (Fig. 247). Muscular rigidity and fixation are extreme. In very exceptional cases there is eversion of the foot, with slight abduction, which Professor Bigelow holds to be due to extensive and unusual laceration of the ilio-femoral ligament.

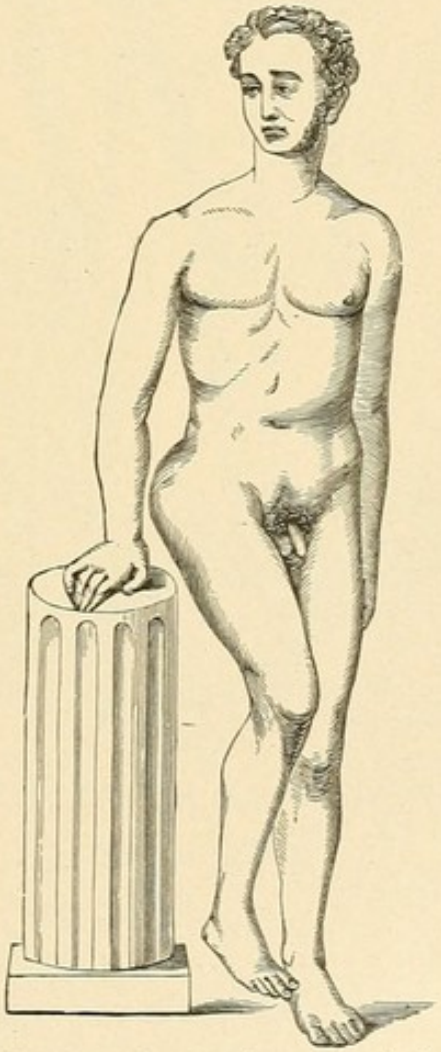

Fig. 247.—Position of extremity in dislocation of the head of the femur upon the dorsum ilii. (After Hamilton.)

When the head of the bone is lodged in the *ischiatic notch*, the general characters of the deformity are the same, yet not so well marked. The degrees of flexion and adduction are less extreme, the trochanter is less prominent, and there is not so much shortening.

In the *thyroid* displacement the extremity is increased in length, and the thigh is abducted and slightly flexed upon the abdomen. The toes may be turned slightly

in or out, although they usually point to the front. The hip is less prominent than normal. The head of the femur may at times be recognized in the new position, although, on account of the tense condition of the adductor muscles, this is in some instances impossible (Fig. 248).

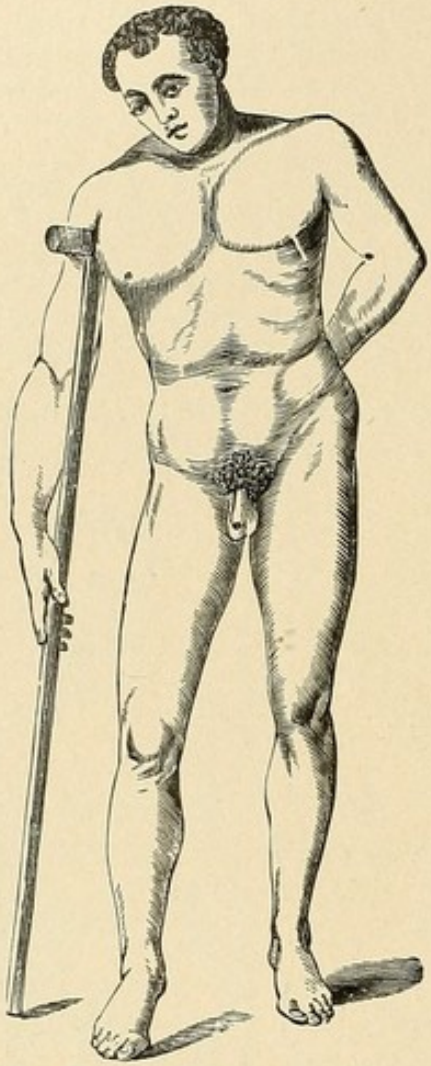

Fig. 248.—Position of extremity in dislocation of the head of the femur into the thyroid foramen. (After Hamilton.)

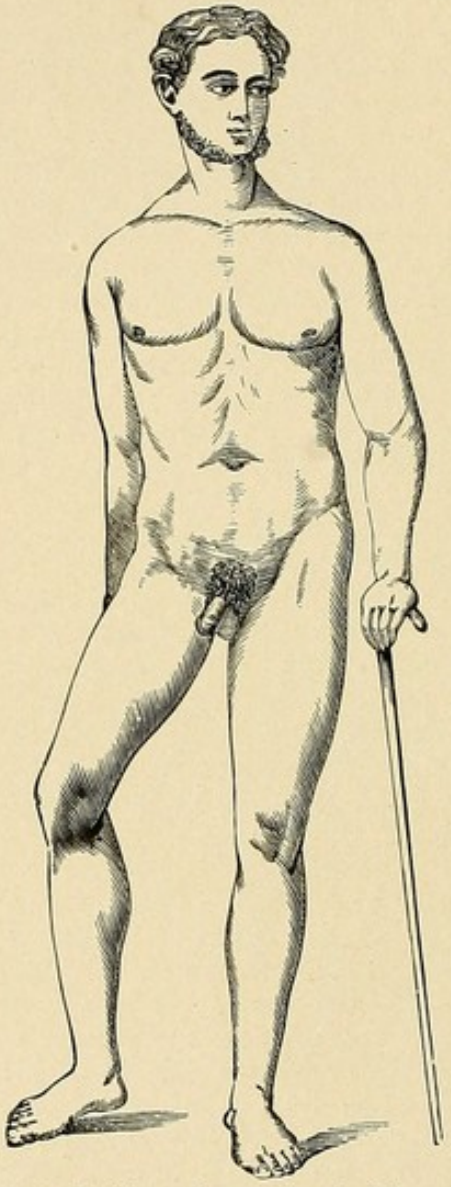

Fig. 249.—Position of extremity in dislocation of the head of the femur upon the pubes. (After Hamilton.)

When the dislocation occurs *on the pubes* there is abduction, slight flexion, and slight outward rotation. The foot is carried away from that of the sound side, and the toes are pointed outward. The chief diagnostic feature of this displacement is the presence of the head of the bone at Poupart's ligament (Fig. 249).

The differential diagnosis is between muscular spasm or rigidity and fracture.

Spasm or rigidity of the muscles about the hip may occur as a result of an acute or subacute inflammatory process in the joint, or in the periarticular tissues, or in certain cases of ostitis of the lumbar vertebræ, sacrum, or ilium, in the neighborhood of the psoas and iliacus muscles. This condition of partial immobility may be differentiated from that of dislocation by the absence of the *shortening*, which is present in the displacement on the dorsum ilii and into the ischiatic notch, the *lengthening* in the thyroid luxation, while the head of the bone on the pubes will determine the character of this lesion. The absence of the characteristic deformity of each of these forms of dislocation will determine the diagnosis of muscular spasm or rigidity. The symptoms of fracture near the hip have been

given. *Shortening, preternatural mobility,* and *crepitus* are to be chiefly relied upon in differentiation. The careful employment of the X-ray will enable the operator to determine the exact condition of the joint.

Reduction—Dislocation on the Dorsum Ilii —Bigelow's Method.—In complete ether narcosis, place the patient upon a strong, low table, or upon the floor, in the dorsal decubitus. With the pelvis held firmly, grasp the leg of the dislocated side just above the ankle, with one hand, and near the knee with the other, flex the leg on the thigh, and the thigh on the abdomen, to nearly an angle of ninety degrees with the surface of the floor, adduct the thigh until the knee of this side is carried to about the middle of the sound thigh, and then cause the knee to describe a circle *outward* and *downward* until the leg is brought to the floor in its normal position (Fig. 250). If the luxation is not reduced the manœuvre should be carefully repeated. This method of reduction by manipulation is based upon the resistance to reduction which is made by the ilio-femoral ligament (when this is not torn).

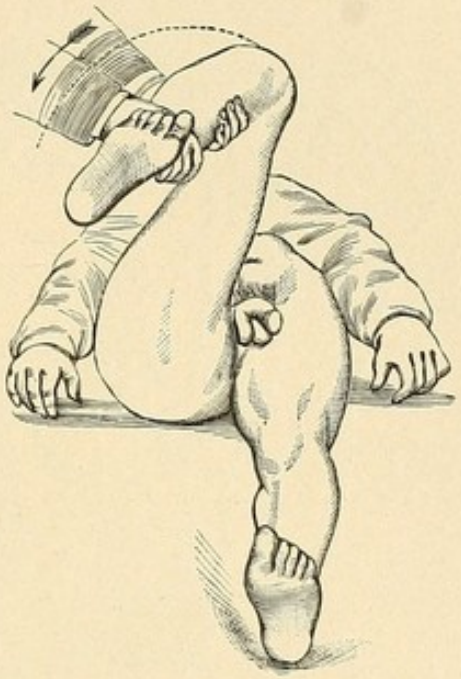

Fig. 250.—Reduction of dislocation on the dorsum ilii by manipulation. (After Bigelow.)

The normal position of this ligament is shown in Fig. 251, and its relaxation by flexing the dislocated thigh upon the abdomen is shown in Fig. 252; and it is readily seen that if, with the thigh in this position, abduction, with outward rotation, is practiced, the head of the bone will be lifted over the margin of the acetabulum and carried in the direction of the socket.

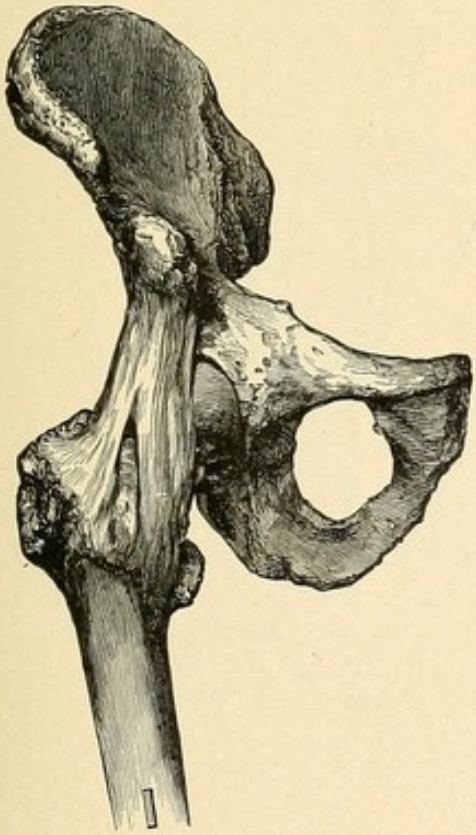

Fig. 251.—The ilio-femoral or Y ligament. (Bigelow.)

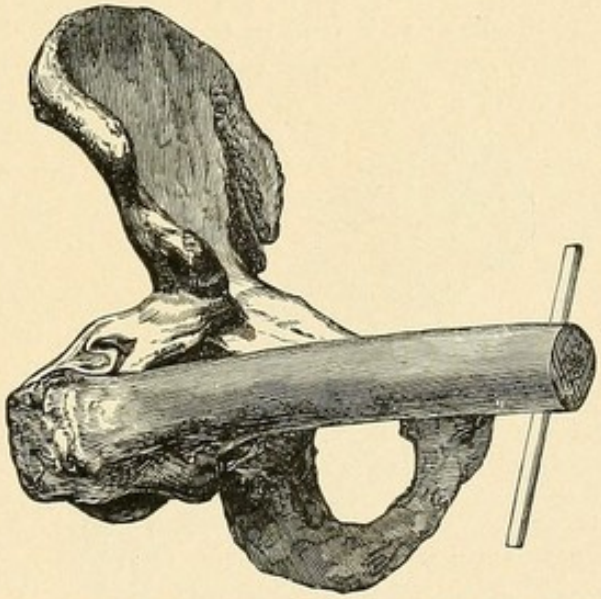

Fig. 252.—Relaxation of the ilio-femoral ligament by flexion and adduction of thigh. (Bigelow.)

In reducing posterior dislocations Prof. L. A. Stimson says:

"The plan which I have habitually employed for many years is to place the patient face downward upon a table, with his legs projecting so far beyond the edge that the injured thigh hangs directly downward, while the surgeon grasps the ankle, the

knee being flexed at a right angle. The other limb is held horizontal by an assistant. The weight of the limb now makes the needed traction in the desired direction, and the surgeon has only to wait for the muscles to relax and the bone to resume its place without further effort on his part than a slight rocking or rotation of the limb. Occasionally I have added the weight of a small sandbag at the knee or have made sudden slight pressure at the same point. It will often succeed without anæsthesia, and sometimes so quietly that there is no jar or sound indicating its return to place. In only two cases has it failed in my hands; both were then reduced by traction in the axis of the partly flexed limb."

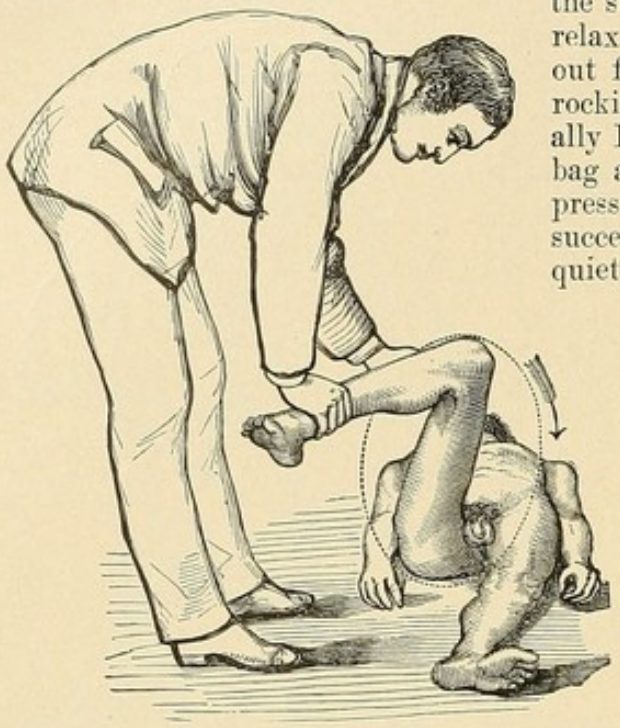

Fig. 253.—Reduction of dislocation into the thyroid foramen. (Bigelow.)

Reduction of Dislocations in the Thyroid Foramen—Method of Bigelow.—Place the patient upon the floor, in the dorsal decubitus, flex the leg on the thigh, and the thigh on the abdomen, making, at the same time, slight abduction. Then rotate the femur inward, adduct, and carry the knee to the floor.

The steps advised by Stimson are as follows:

1. Make strong traction in the axis of the limb as it lies, in order to bring the head below the brim of the pelvis; it is rarely necessary to aid this by increasing the extension, abduction, and outward rotation. By this means the posterior portion of the capsule is made tense, and its point of attachment to the back of the neck of the femur is thereby made the center for the following movements:

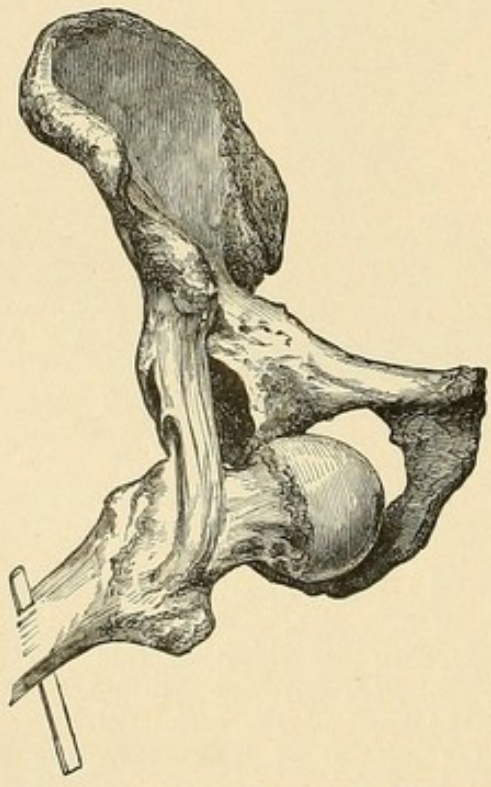

Fig. 254.—Showing the relation of the ilio-femoral ligament in dislocation of the head of the femur into the thyroid foramen. (Bigelow.)

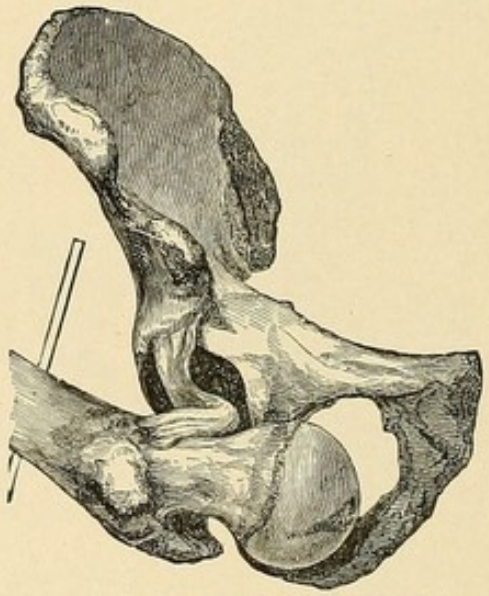

Fig. 255.—Showing how flexion of the thigh on the abdomen relaxes the ilio-femoral ligament in dislocation into the thyroid foramen. (Bigelow.)

2. Pressure with the hand upon the head of the femur to prevent its return upward during flexion. Sometimes this is sufficient to make reduction.

3. Flexion, in order to relax the Y ligament; it should not be carried to a right angle, otherwise too much strain will be made upon the posterior portion of the capsule.

4. Rotation inward, by which the head is returned to the socket.

The *after-treatment* of hip-luxation involves fixation of the muscles about the joint for from two to six weeks. A gutta-percha, heavy pasteboard, or leather splint, molded to the side of the pelvis, thigh, and down to the ankle, applied upon a thin layer of absorbent cotton, and held in place by a leg-, thigh-, and spica-bandage, should be employed.

The *prognosis* as to rapid restoration of function is not always favorable. The injury to the capsule, and more especially to the muscles around the joint, may lead to an impairment of the hip, more or less permanent. In permanent luxations, in some instances, a fair degree of mobility may be developed. Reduction has been successfully performed as late as four and six months after the injury.

The treatment of *congenital* dislocations of the hip, and of *pathological* luxations, will be given later.

Dislocations at the Knee—The Tibia from the Femur.—Displacement of the femoral end of the tibia may occur as a result of *congenital malformation, disease,* or *accident.*

Congenital luxation is rare, and is usually partial. As a rule, the tibia is displaced forward, although the opposite condition may prevail. Absence of the patella has been observed in several of these cases.

Pathological dislocations will be given under the head of diseases of this joint.

Traumatic luxation at the knee is comparatively rare. The tibia may be completely or partially displaced, and in any direction. Partial dislocation is the rule. Complete luxation is apt to be complicated with a wound. A compound dislocation usually occurs forward or backward. The *cause* is direct violence. A blow upon the anterior aspect of the tibia, near the joint, or the posterior-inferior portion of the femur, may cause a *backward* displacement of the tibia, while violence from opposite directions may produce a *forward* dislocation. The same force applied laterally may also produce the *lateral* displacements. A favorable condition for luxation is the application of violence when the leg is in extreme flexion. A sudden twisting or wrenching of the femur upon the tibia when the foot is so caught that rotation on the heel is impossible, is favorable to rupture of the ligaments, and lateral or oblique incomplete luxation.

The *symptoms* of dislocation at the knee are usually clear. In the *backward* variety the antero-posterior diameter of the knee is increased, the tibia projects into the popliteal space, and the condyles of the femur are unusually prominent. In the *forward* variety the antero-posterior measurements are also increased, the anterior edges of the tibia are easily detected in the advanced position of this bone, while the condyles of the femur are unusually prominent posteriorly. The tibia may be rotated upon its axis. In the *lateral* displacements the condyle of the femur is recognized as projecting on one side, while the flat end of the tibia is felt on the opposite side. The transverse diameter of the joint is increased in proportion to the degree of displacement, which is, however, rarely complete.

Treatment.—Reduction is readily effected by extension and counter-extension, with direct pressure and counter-pressure in the proper directions. Once reduced, fixation should be secured by Buck's extension, with sand-bags applied to the limb, or an investing splint should be employed.

The *prognosis* after this injury is unfavorable. The function of the joint is rarely fully restored. The question of *amputation* after dislocations of the knee, where there is extensive injury of the surrounding structures, is one of great importance. Shock is more profound in this luxation than in dislocation at any other joint. A primary amputation will rarely be justified except after laceration of the popliteal vessels. All antiseptic measures should be employed, and amputation only advised after every effort consistent with the safety of the patient's life has been made. Exsection is preferable, and offers not only a greater degree of safety but a more useful result.

Dislocation of the Patella.—This bone may be displaced by muscular action, without the aid of external violence, or by an injury alone. When the ligamentum patellæ is ruptured, it is carried *upward* for a varying distance by the contraction of the quadriceps. It can only be displaced *downward* by a blow received upon its upper margin sufficient to tear it loose from its muscular attachments. Dislocation *outward* is the more frequent variety, and occurs as a result of muscular contraction and from violence. Displacement *inward* is the result of a blow received upon the outer margin of the bone. In the *lateral* dislocations, in rare instances, the patella is turned obliquely on its edge, or it may possibly be completely inverted.

The *symptoms* of these various luxations are unmistakable, and the reduction, by relaxing the quadriceps and pressure, not difficult.

The after-treatment is directed to the prevention of recurrence.

Dislocations at the Ankle-joint.—Dislocations at the tibio-tarsal articulation may occur in four directions, viz., *forward*, *backward*, *inward*, and *outward*. In the last two forms fracture of one or the other malleolus is apt to occur.

Dislocation of the tibia *inward* is caused by a fall upon the foot at a time when it is turned outward, the body-weight being brought to bear upon the inner aspect of the heel and great toe. This form of sprain is frequently caused by leaping from a wagon or car in motion. It may also result from a heavy blow upon the fibular side of the leg, near the ankle, when the foot is solidly fixed against the ground. The displacement is usually partial. A complete luxation is apt to be compound.

The *symptoms* of *inward* dislocation are the great prominence of the inner malleolus and the peculiar twist of the foot, so that the inner side of the heel and the great toe rest on the floor while the sole looks obliquely outward and upward. The only displacement it may be mistaken for is that of the astragalus from the os calcis.

The *treatment* is to bring the foot into the normal position by pressure and counter-pressure, and fix it with a splint and bandage. On account of the great swelling which is likely to occur, an immovable dressing should not be applied until the acute symptoms of inflammation have subsided.

The *symptoms* of *outward* displacement are the reverse of the inward, and can without difficulty be recognized. Displacement of the tendons of the long and short peronei muscles, from their sheaths behind the external malleolus, is likely to occur in this accident. After reduction at the joint these should be pushed into place, and an effort (rarely successful) made to hold them in position by a compress and bandage, applied before the splint for the luxation is adjusted.

Forward dislocation may occur as the result of a blow upon the back of the leg, near the ankle, while the foot is firmly placed upon the ground; by falling forward with great violence, when the momentum of the body is suddenly arrested by the foot striking against the ground; or by falling backward, with the foot so fixed that great and unusual extension of the tarsus takes place.

The *symptoms* are unnatural prominence of the heel and shortening of the distance between the toes and the front of the tibia, on the displaced side.

Reduction.—Place a clove-hitch around the heel and instep for extension, and make counter-extension from the thigh. Flex the leg so as to relax the sural muscles, and make forcible extension from the foot. As soon as the extension is well begun the operator places his foot against the front of the patient's tibia, just above the ankle, and pulls forward on the foot, at the same time flexing it on the tibia.

Backward displacement is caused by violence applied in a direction opposite to that which produces the *forward* luxation, and the *symptoms* are exactly the reverse.

The *treatment* demands reduction by extension and counter-extension, and direct pressure.

Dislocations at the ankle are often complicated with fracture, or may be compound. In any form of injury an effort should be made to save the foot and joint. The ankle is exceedingly tolerant of surgical interference, and, with strict cleanli-

ness and antisepsis, amputation on account of complicated or compound dislocation will be rarely necessary.

The fibula may be displaced from its articulation with the tibia at its upper or lower end. At the upper end it is usually luxated forward, as a result of direct violence from behind, although it is possible to have the reverse occur. The bone will be felt in the abnormal and anterior position, and may be pushed directly back into place. In the backward displacement the biceps muscle may produce the luxation, or it may be from violence applied from the front. Strong and continued pressure must be employed to retain the bone in position until adhesions occur. During the treatment the leg should be flexed on the thigh in order to relax the biceps.

At the lower end dislocation of the fibula alone, without the tibia, is exceedingly rare. Anatomically, it may occur in both directions. Reduction may be affected by direct pressure. The fibula may be displaced outward from the tibia by the astragalus being driven upward between these bones.

Dislocations of the Bones of the Tarsus.—The *astragalus* may be partially or completely dislocated forward, backward, outward, or inward. The luxation is usually incomplete. On account of the great violence necessary to its production it not infrequently is compound, or complicated with a fracture. Violence of the same character as that which produces displacement of the tibia will cause dislocation of the astragalus.

Treatment.—Luxation of the astragalus is a serious accident. The efforts at reduction do not always succeed, and, even when reduction is effected, the injury to the joint may be such that loss of function results. Direct pressure and counter-pressure, while the patient is profoundly anæsthetized, offer the best means of successful reduction. Displacements of the metatarsal bones and phalanges of the toes are treated in the same general way as described for similar lesions of the hand.

The Vertebræ.—Dislocation may occur at any articular surface of the vertebral column. The accident is always serious, the gravity being proportionate to the degree of displacement and the injury to the cord and nerves. Fracture is a frequent accompaniment.

Luxations are more common in the *cervical* region. One or both articular processes may be displaced forward or backward upon the vertebra below. In the *unilateral* displacement the fibro-cartilage between the bodies is only slightly involved, and, while there is pressure upon the nerves passing out of the intervertebral foramen, there is no pressure upon the cord. In the *bilateral* form the cartilage is torn, the body more or less involved in the luxation, and the cord compressed.

The *causes* are muscular contraction, or violent twisting of the neck by accident.

The *symptoms* of unilateral displacement are pain—which may be referred to the distribution of the nerves passing through the intervertebral foramen involved—at the seat of luxation and rotation of the head, in a forward dislocation, so that the chin points to the side opposite to that upon which the injury exists. When the luxation is backward, the face is turned toward the seat of injury. Paralysis is proportionate to the compression or laceration of the cord or nerve roots.

In bilateral luxation careful extension and direct pressure and counter-pressure should be practiced.

Dislocation of the condyles of the occipital bone from the atlas, and luxation at the atlo-axoid joint with fracture of the odontoid, is exceedingly apt to be fatal.

Ribs.—The ribs may be displaced from their vertebral articulations. The cause is direct violence, and the displacement usually forward. The true ribs may be dislocated at the junction of these organs with their cartilages, near the sternum. The treatment for these luxations is the same as for fracture.

Pelvis.—The *coccyx* may be dislocated by a fall or blow received directly upon the tip of the spine. It is very apt to be complicated with fracture. Displacement is usually forward. Pain is severe, on account of pressure upon the nerves. In these forward displacements, the introduction of a thumb or finger properly protected in the rectum by direct pressure backward will replace the bone, which is evident by the instantaneous relief from pain. Backward dislocations should be

treated by direct pressure upon the dorsum of this bone. Any lateral displacements would be subject to the same general method of treatment.

Dislocation at the *symphysis pubis* is not accompanied with marked displacement. The lateral movement of one bone upon another will demonstrate that the interosseous ligaments have given way.

Treatment.—The dorsal decubitus with lateral compression should be employed. If this should fail and the inconvenience should be such as to demand an operation, the bones may be reunited by wiring. Displacements at the sacro-iliac synchondrosis are very rare, and are the result of great violence, which would almost of necessity be complicated with fracture. Any obscurity in diagnosis may be cleared away by the employment of the Roentgen ray. The treatment should be rest and immobilization.

Diseases of the Joints in General

Inflammation.—Septic infection of a joint may involve the entire anatomical structure of the articulation (arthritis or osteo-arthritis), or the capsule and its lining membrane (syndesmitis), or the synovial lining alone (synovitis).

The modern pathological definition of inflammation of a joint is not complete without infection. There is, however, a *hyperæmia* accompanied by heat, pain, redness, and swelling, without the demonstrable presence of septic organisms, as in the ordinary *sprain.*

True arthritis is caused by the presence of certain infectious organisms which have found their way through the blood or lymph channels, as in *tuberculosis* of these cavities, *gonorrhœal arthritis* and *suppurating* or *pyogenic osteo-arthritis*; or have entered directly through a *penetrating wound* or after a *compound dislocation.*

The most frequent form of joint disease is tuberculosis, which in a large proportion of cases becomes a *mixed* (tubercular and pyogenic) infection. Colonies of the *bacillus tuberculosis* may lodge on any part of the joint surfaces, but usually the original focus of infection is in the bone, in or on the articular side of the epiphyseal line, and from this starting-point the joint is gradually invaded.

That form of arthritis due to *specific urethritis* will be described elsewhere.

Sprain.—In traumatic synovo-arthritis there may be simply a bruising of the cartilage or an overstretching of the ligaments, or these may be more or less separated from their bony attachments, carrying generally with them a crescent or rim of bone torn from the point of insertion. At other times (as in Pott's fracture) a sprain may be complicated with a fracture of one or more bones which enter into the composition of the joint.

The first symptom is *pain* and *swelling*, generally proportionate to the severity of the traumatism; there ensues capillary dilatation (hyperæmia), emigration of leucocytes into the intercapillary spaces, as well as into the cavity of the joint in which there is also a transudation of serum. This fluid is not infrequently discolored by red blood corpuscles or free hæmatin. Not only is the capsule distended, but frequently the communicating bursæ are also abnormally filled with fluid. Within a period varying from a few days to two or more weeks, the inflammatory symptoms subside, absorption of the exudate takes place, with restoration of function.

Treatment.—The first essential in treatment of *sprain* is rest. This is best secured by the recumbent posture and elevation of the part involved. The ice-bag or other method of applying cold will be found beneficial. Immobilization is best effected by plaster-of-Paris dressing, beneath which, over the injured area, a considerable layer of absorbent cotton should be interposed. At the end of a week the fixed dressing should be removed and passive motion made. The dressing may, as a rule, be discarded after one or two weeks.

When infection supervenes, in addition to absolute rest, the closest attention should be given to the general nutrition of the patient. If pain is severe, the joint hyper-distended and the temperature sufficiently elevated to indicate marked septic absorption, the joint should be aspirated with a large needle, washing the cavity freely with normal salt solution, evacuating this finally and sealing the

opening through which the needle was introduced. This operation may be repeated on one or more occasions, and incision deferred until found absolutely necessary.

In gunshot or punctured wounds of joints it is advisable to apply a sterile dressing, and under no circumstances to probe or explore the wound or cavity; in fact, to do no surgery unless hæmorrhage demands it or unless infection has occurred.

Dry Synovitis, or Synovo-arthritis, is occasionally met with in surgical practice, especially in rheumatic or gouty subjects. It is an inflammation of the synovial membrane of the capsule in which there is not only no transudation of fluid into the capsule, but the normal synovial secretion is diminished, and in many cases, even when properly cared for, ends in loss of function or ankylosis. These cases require rest so far as the joint is concerned, and an effort to correct the diathesis which causes the inflammation.

Diseases of Special Joints

Of the Hip.—Arthritis of the hip, hip-joint disease (*morbus coxæ*, or *morbus coxarius*), is a frequent and formidable affection, and one which, in many instances, will baffle the best medical and surgical care through months and years of suffering, ending in destruction of the joint, and frequently in death. It is a disease of childhood, occurring chiefly in the period of rapid growth. It rarely occurs after the twelfth year. It may occur at any time prior to this age, the majority of cases being between the ages of three and six years.

The pathology of *morbus coxæ* will vary with the peculiar character of the lesion. The morbid changes which occur in that variety which is most frequently met with are those of tubercular *ostitis*, followed by destructive *arthritis*. The initial lesion occurs as an interference with, or arrest of, nutrition, near the diaphyso-epiphyseal cartilage (Fig. 256 *a*), due to the lodgment and proliferation there of colonies of bacilli tuberculosis. It may begin on the diaphyseal or epiphyseal side or in the several centers of ossification about the same time. The cancellous cavities become filled with embryonic cells, absorption of the lamellæ occurs, the inflammatory new products may undergo a slow process of fatty metamorphosis, may become caseous, or with mixed infection the process may terminate in pus formation. The development of the bone is arrested, the ostitis, commencing in the deeper portions, travels in all directions, destruction of the diaphyso-epiphyseal cartilage occurs, with separation of the epiphyses (*diastasis*). While these changes are going on, the lining membrane of the capsule becomes involved, the process being one of *chronic synovitis*, which, as has been stated, terminates inevitably in inflammatory changes in the tissue proper of the capsule. The joint becomes filled with the products of inflammation, the capsule, overdistended and weakened, ruptures either spontaneously or as a result of motion, and dislocation may occur. With separation of the epiphysis and destruction of the neck of the femur shortening ensues.

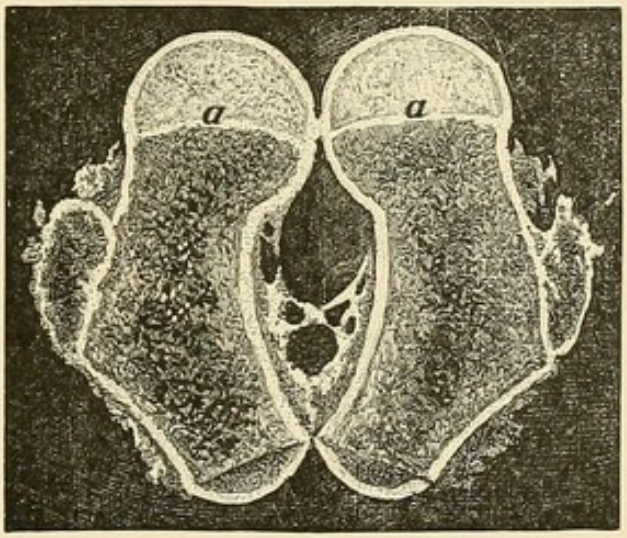

Fig. 256.—Section of normal femur of a boy eight years old. (After Gibney.) [1]

Occasionally the initial ostitis may be situated in the bones which form the cotyloid cavity. It is also held that hip-joint disease may, in very rare instances, result from a peri-articular inflammation.

[1] "The Hip and its Diseases," Bermingham & Co., New York, 1884.

Causes.—The causes of hip disease are chiefly predisposing. Any dyscrasia which impairs nutrition in general favors the lodgment and proliferation of the bacillus tuberculosis and tends to destructive ostitis and arthritis. Traumatism may, and undoubtedly does, precipitate the inflammatory process in many cases, yet the ordinary violence to which this joint is subjected will rarely induce *coxitis*, except in children affected with some constitutional disease. Excessive use or a blow may produce synovitis, but, in a healthy patient, rapid recovery is almost certain. If diastasis occurs as a result of accident, *ostitis* ensues, and impairment of the joint follows, yet this is an exceedingly rare injury. Rupture of the ligamentum teres, which must occur in a traumatic luxation, could not induce destructive arthritis in an otherwise healthy individual.

The *symptoms* of hip disease are divisible into *two stages*. The *first stage* embraces all the phenomena of inflammation, up to a positive and appreciable destruction of the structures which enter into the formation of this joint. The *second stage* embraces the phenomena of destruction, namely, shortening of the neck, diastasis, rupture of the ligamentum teres and capsular ligament, and luxation.

Among the earlier signs of this disease is pain, referred directly to the hip-joint, or it may be to the hip- and knee-joints, of the affected side, and in some instances the pain is felt wholly in the knee of the same side. This symptom is most exaggerated at night and in the early morning hours, and after the child begins to move about may disappear. The distribution of the obturator nerve to both articulations will account for the reflex sensibility in the knee. In a certain number of cases the patients will deny all sense of pain, and even under pressure may not exhibit signs of suffering. In children this effort at concealment (not uncommon) is incited by the fear of being subjected to surgical treatment. If, however, a careful examination is made, rigidity of the muscles about the hip will be evident. In standing erect, the weight of the body will be brought upon the sound extremity, the gluteal fold on the affected side is partially obliterated (Fig. 257), and in walking there is almost always a perceptible limp. The iliacus, psoas, and adductor muscles are usually in an abnormal state of tension; hence the initial flexion of the thigh, and outward rotation or eversion of the foot.

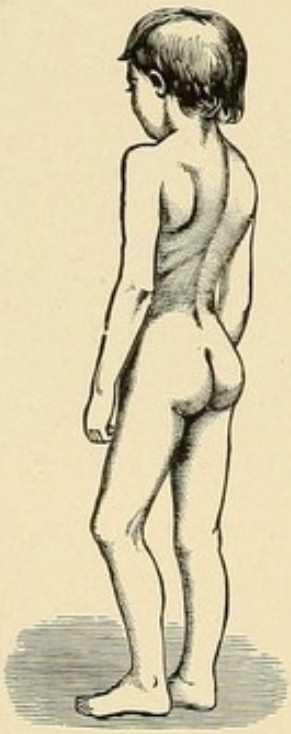

Fig. 257.—(After Sayre.)

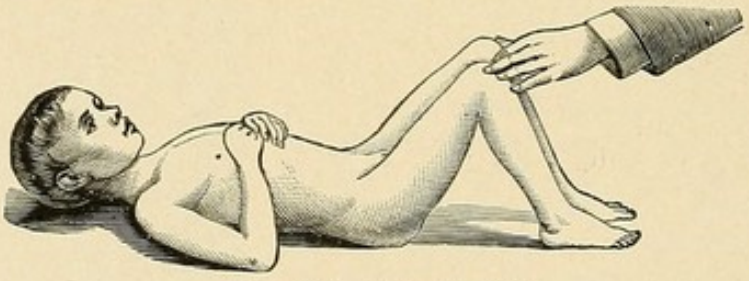

Fig. 258.—(After Sayre.)

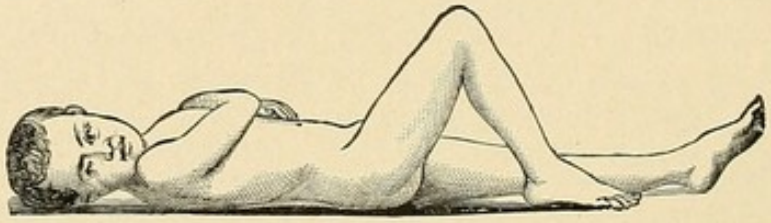

Fig. 259.—(After Sayre.)

Rigidity of the psoas and iliacus muscles—one of the more positive early symptoms of hip disease—may be demonstrated in the following manner: If the patient be stripped and laid flat on the back, on a hard, level surface, and both legs drawn up (Fig. 258), it will be seen that the sacrum, spines of the vertebræ, the scapulæ, and occiput rest in contact with the table. If the sound leg be now extended and

the popliteal space brought well down against the surface of the table, the lumbar spine is only very slightly, if at all, lifted from the table (Fig. 259). If there be rigidity of the muscles named, as a result of hip disease, on the suspected side, when the effort is made to bring this leg into a position parallel with the sound one, it will be seen that extension of the thigh is limited, and that the motion of

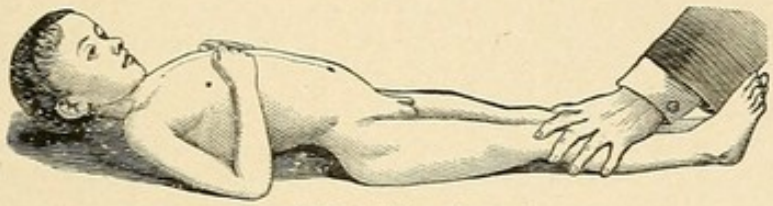

FIG. 260.—(After Sayre.)

the hip-joint is transferred to the lumbar vertebræ, so that when the popliteal space touches the table the lumbar spines are lifted from one to three inches from the surface (Fig. 260).

The duration of the first stage varies from two or three months to as much as one year, and in exceptional cases longer.

In the *second stage* the thigh is further flexed on the abdomen, adduction is more pronounced, and shortening is present in a degree varying with the extent of destructive ostitis in the acetabulum, or head and neck of the femur, and to the character of the luxation. In the usual position of the foot of the affected side, in this stage, the great toe or inner surface of the tarsus rests upon the dorsum of the well foot, or on the spine of the tibia. The shortening—which may be determined by measuring from the anterior superior spine of the ilium to the inner malleolus—will vary from half an inch to several inches. Nélaton's or Callaway's test—already given in the articles on fractures of the femur—will demonstrate that the shortening has occurred above the trochanter.

When suppuration occurs, the capsule gives way, and sooner or later, if surgical interference is delayed, sinuses open through the skin, about the trochanter, or in the groin. Perforation of the acetabulum takes place in a certain proportion of cases.

Diagnosis.—Disease of the hip-joint may be differentiated from bursitis, periarticular inflammation, rheumatism, neuralgia, sacro-iliac disease, or ostitis of the trochanter or ilium. It is also important to determine whether the initial lesion is a *synovitis* or an *ostitis*.

Synovitis may be caused by excessive use of the joint, by strain or concussion, by sudden exposure to cold, or it may result as a symptom of gout or rheumatism. It is a painful affection from its incipiency, and the pain increases with the march of the effusion into the joint and the distention of the capsule. Motion increases the pain, which is usually so severe that all movement of the joint is firmly resisted. The cause may usually be traced to an injury. Synovitis due to gout or rheumatism occurs usually in adults; coxitis is practically a disease of childhood.

When *ostitis* is the initial lesion, the approach of the disease is insidious and much less painful. When present, the pain in ostitis of the head and neck of the femur is deep-seated and dull, and motion is comparatively free. Rotation and pressure of the head upon the capsule and in the acetabulum do not produce the sharp sense of pain felt in synovitis. Ostitis is the rule in children, synovitis in adults.

Bursitis about the hip is rare. The sac between the capsule and the conjoined tendon of the psoas and iliacus muscles, and those situated between the tendons of the gluteus maximus, medius, and minimus and the great trochanter, and that between the quadratus femoris and the lesser trochanter, may one or all be involved. Inflammation in one or more of these bursæ may be recognized by the limited extent, as well as the acuteness of the pain elicited by direct digital pressure immediately over the known position of the sac. Pain in the knee is not present in bursitis at the hip. Rigidity is not general in the muscles about the joint.

Peri-articular inflammation is a painful affection, causing marked lameness from the start; it is accompanied by local swelling and tenderness if superficial, and usually by exacerbations of temperature, all of which will render it easy of recognition.

Muscular rheumatism is rarely confined to the muscles of the hip. It is an expression of a constitutional condition which cannot but be elicited by a careful history and study of the case. The pain is more severe and more early recognized than in coxitis. The painful territory may be outlined by fixation of the joint and digital pressure upon the muscles involved.

Neuralgia occurs very rarely in children, in the period when hip disease is most likely to appear. The exacerbations of pain are more sudden in development and acute in character, and occur with greater frequency and regularity than in hip disease. Motion is tolerated better in neuralgia than in coxitis. The symptoms of ostitis which lead to arthritis, if carefully studied, will show a wide difference from neuralgia about the hip.

In *arthritis* or *ostitis* at the sacro-iliac junction pain is caused by forcibly pressing the ilium against the sacrum. The same symptoms may be elicited by direct pressure posteriorly over the sacro-iliac articulation. Motion at the hip is only slightly if at all embarrassed.

Prognosis.—In hip-joint disease commencing—as is the rule—in *ostitis* or *epiphysitis*, the prognosis is bad as regards restoration of function. Partial or complete ankylosis, with a variable degree of shortening, will result, in the vast majority of cases, no matter how skillfully treated. The proportion of fatal cases can scarcely be determined. It is safe to say that at least five per cent of all cases in which the lesion begins as an ostitis end in death in from one to six years.

In traumatic synovitis of the hip the prognosis is favorable. A restoration of function is the rule.

Treatment.—The treatment of hip disease may be divided into *mechanical, operative*, and *constitutional*.

In the early stage of coxitis *rest* to the inflamed articulation, in the position of least discomfort, is essential. A diseased joint demands protection not only from traumatism in the effort at locomotion, but from reflex and involuntary muscular spasm. Fixation of the muscles which act upon and about this joint can be best secured by extension from the lower part of the thigh and counter-extension from the perinæum. It has been shown by Bradford and Lovett, of Boston, that in order to gain the full benefit of extension at the hip, the femur should not be brought out entirely straight, but should rest about five degrees short of full extension (175°).

If a child with hip disease be seen very early in the history of this affection, flexion of the thigh upon the abdomen will not have occurred to any extent, but, in cases where the inflammatory process has gone on for some time, the iliacus and psoas and adductor muscles will have become rigid and shortened to such an extent that the thigh cannot be immediately brought out straight.

In the former class of cases the apparatus about to be described can be at once adjusted; in the latter, extension in the recumbent posture is necessary until the shortening in the ilio-psoas muscles is overcome.

In fact, since in all cases some time must elapse between the discovery of the lesion and the preparation of the mechanical apparatus, it is a wise practice to put the patient to bed at once, and apply the extension as follows: Cut two strips of moleskin plaster from one inch and a half to two inches wide, and long enough to extend from six inches above the trochanter to below the sole of the foot. Adjust one to the outer and one to the inner aspect of the thigh, allowing the upper end, which is to be doubled back upon itself and woven in with the roller, to extend four or five inches above the level of the trochanter. Mold them carefully to the contour of the limb, bringing the strips exactly over the inner and outer condyles of the femur, and hold them by a well-adjusted bandage, beginning from above. In order to prevent the plaster from wrinkling, it is necessary to clip it with the scissors, obliquely upward from each edge, at intervals of an inch or two. As the extension is exerted only from the femur, the adhesive strips should

not be applied to the skin below this point. The bandage is commenced just at the level of the great trochanter, and that portion of the strips which extends above this is to be turned down and worked in with the roller.

That part of the plaster which is exposed from the knee down should be doubled by laying a second strip of equal width on this, the adhesive surfaces coming together. In this way it is not only strengthened, but is prevented from sticking to the dressing.

The extension weight—varying from seven to fifteen pounds—is applied as in Buck's apparatus. The dorsal decubitus should be maintained, for, if the sitting posture is assumed, the iliacus and psoas muscles are not materially affected by the extension. To secure this result the long splint of Hamilton should be applied from the axilla along the thigh and leg, and firmly secured by a bandage carried around the chest, pelvis, and thigh. Or a pillow slip may be pinned to either side of the bed, passing over the chest.

As soon as the thigh is fully extended the following mechanism should be adjusted. It embodies the principle of extension from the pelvis and counter-extension applied to the *femur* from the trochanter down to the condyles. It can be so arranged as to take advantage of any degree of deformity, correcting flexion, abduction or adduction. It consists, first, of a pelvic band (Fig. 261) so curved behind and in front as to make the shortest possible perineal pads. This band should be made of annealed steel strong enough to bear the weight of the body of the patient. Attached to this is the cylinder which extends down the leg along the outer side to a point opposite the ankle-joint. Accurately fitted into the cylinder is a traction rod with a

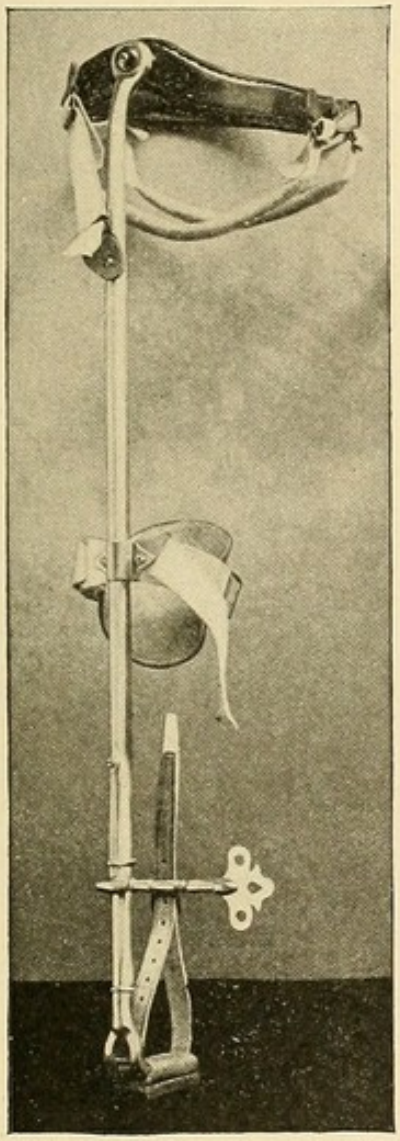

Fig. 261.—Shaffer's modification of Taylor's hip splint.

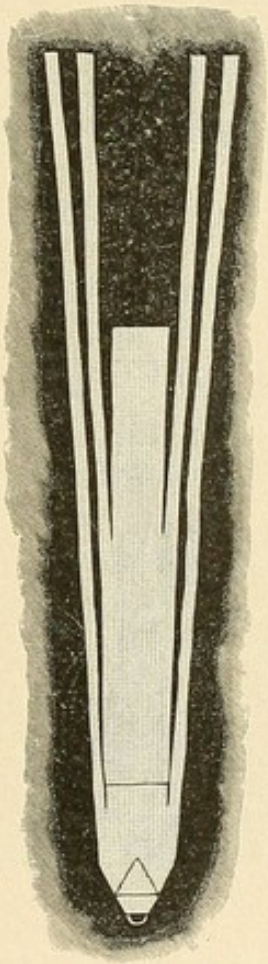

Fig. 262.—Four-tailed adhesive strip, with buckle ready for application.

foot piece, and the connection between the cylinder and the traction rod is regulated by an adjustable rack and pinion. The pelvic band, accurately adjusted, is fixed by two short perineal pads attached to it in front and behind, and the entire leg is connected with the traction rod by adhesive plasters which envelop it entirely and extend high up on the thigh, making practically all the traction

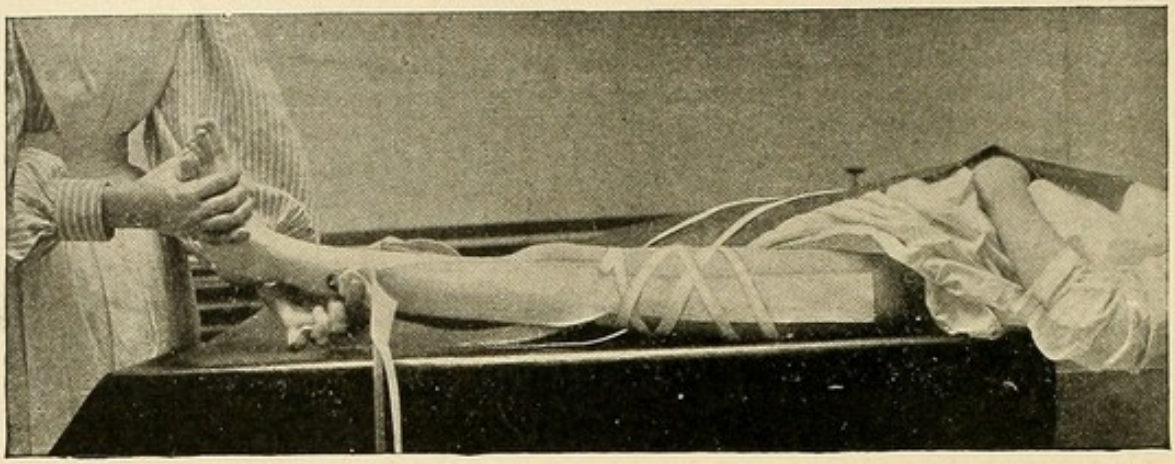

FIG. 263.—Showing the manner in which the tails are interwoven. First step.

from above the knee. The connection between the adhesive plasters and the foot piece is made by leather straps (Fig. 261).

This apparatus may be used in various modifications, not only in the treatment of the deformity, but after the deformity has been modified, in which latter case it is so adjusted that the weight of the body falls entirely upon the perineal straps—in other words, forming a double ischiatic crutch. When the deformity is removed or essentially modified, the patient may walk with or without crutches, as the conditions may demand. After a certain length of time has elapsed, the joint reaches a stage of convalescence where simple protection is necessary rather than traction. The modified apparatus then becomes very useful. The modification consists in adjusting the foot piece and cylinder into a well-fitting shoe, which takes the place of the adhesive-plaster traction. The end of the cylinder is inclosed in the shoe

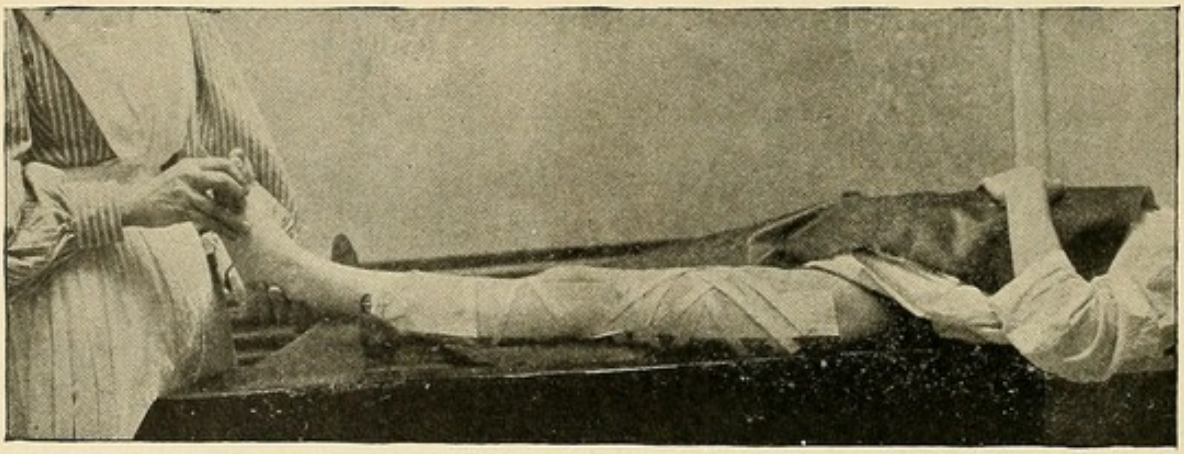

FIG. 264.—The same, before the bandage-roller is applied. Second step.

worn by the patient instead of passing on the outer side, and, in addition to the outer bar, an inside bar is added with thigh and calf bands and an automatic knee spring, which enables the patient to bend the knee as occasion may require. It has the same hip-joint and perineal pads, and affords a modified traction support to the hip-joint. When strong abduction is necessary the instrument shown in Fig. 265 will be found useful.

Among many orthopædic specialists the question of preference between this

form of apparatus and some modification of H. O. Thomas' method of treating hip-joint disease is not easily decided. Of all the applications of Thomas' idea which have been carried into effect, the following is the most commendable: It consists of a long malleable iron bar, which extends from near the axilla down the back parallel with the spinal column, over the buttocks, and down the posterior aspect of the thigh and leg, curving beneath the heel, and terminating opposite the center of the plantar arch (Fig. 267). At this termination a crossbar from three to four inches long is welded, from the tips of which the extension straps are adjusted. At the upper end of this perpendicular bar there is a metal bar or belt which encircles the thorax for two thirds of its circumference, terminating in straps of strong webbing fastened together with a buckle. At a point opposite the anterior superior iliac spine a pelvic band, similar in construction to the thoracic band, is adjusted for fastening the instrument around the pelvis at the iliac prominences. To this band buckles are attached behind and in front for double perineal pads. Opposite the gluteal fold a metal band is attached, which encircles the thigh at this point. Farther down, at the junction of the inferior with the middle third of the tibia, another metal band is attached. When adjusted accurately to the contour of the back, buttock, thigh, and leg, it should extend three inches below the extremity, so that when the patient stands, the instrument will rest upon the floor while the foot swings free and clear.

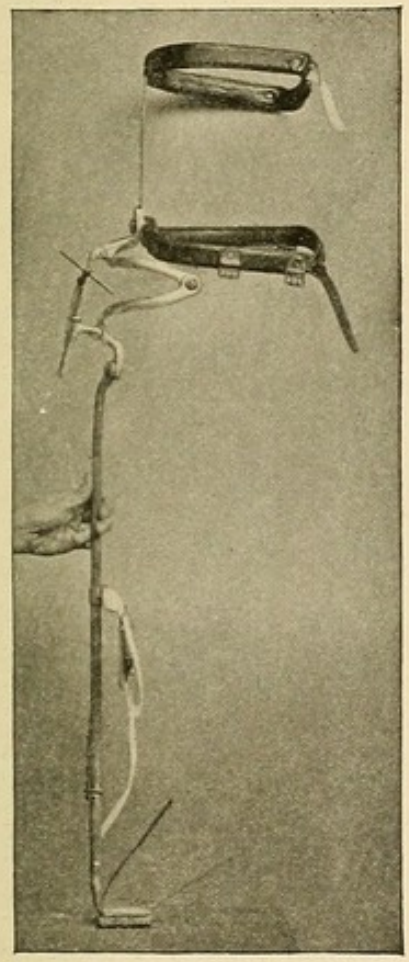

FIG. 265.—Shaffer's abduction hip apparatus.

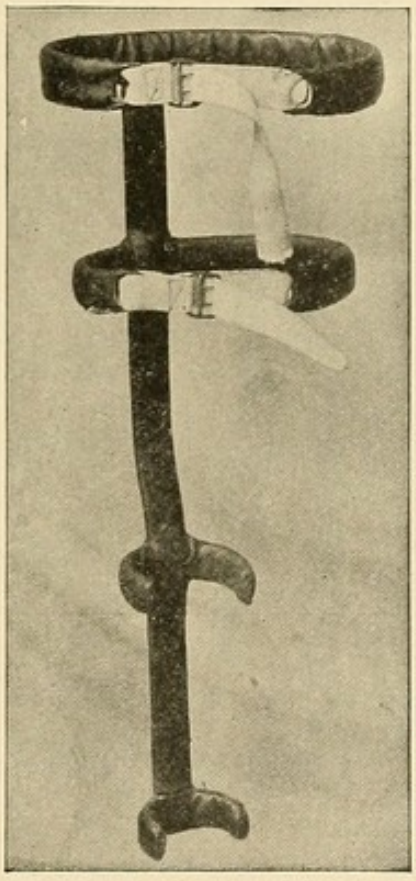

FIG. 266.—Thomas' hip splint.



FIG. 267. — Thomas' hip splint (with American extension).

The apparatus is applied as follows: The four-tailed adhesive plasters are applied to the leg as above directed; the splint is then adjusted by fastening, first, the perineal straps snugly, so that the pelvic band will come just below or on a level with the anterior superior spines; the thoracic and pelvic bands are connected by means of the webbing straps; the leather straps attached to the foot piece of the brace are then fastened into the buckles attached to the plaster on the leg, and firm, steady traction made. The entire limb and brace are then incased in a lightly applied muslin bandage so as to prevent any wabbling of the limb. A high shoe

is adjusted to the opposite limb, and the patient allowed to walk with this and a pair of crutches.

The length of time for which this treatment should be continued will be determined by the result achieved. It is often a necessity for one, two, or three years, and sometimes even longer, and should be worn for several months after all active symptoms of coxitis have disappeared.

Conditions may arise in which the apparatus just described cannot be applied. A fairly good substitute, and one which secures fixation, is the plaster-of-Paris dressing, which is applied from the line of the nipple around the abdomen and over the hip, thigh, and leg, including the foot of the affected side. In order to apply it while the leg is in a condition of fairly good extension, the patient may be made to stand on the sound foot upon an elevated stool, allowing the lame foot to be pendant. An assistant on either side holds the patient upright, and another makes traction downward as the plaster is applied. The bony prominences should be carefully padded. The child should be allowed to go about after the plaster has hardened, and should wear an elevated shoe, four or five inches high, on the sound foot. This will permit locomotion without danger to the integrity of the affected hip.

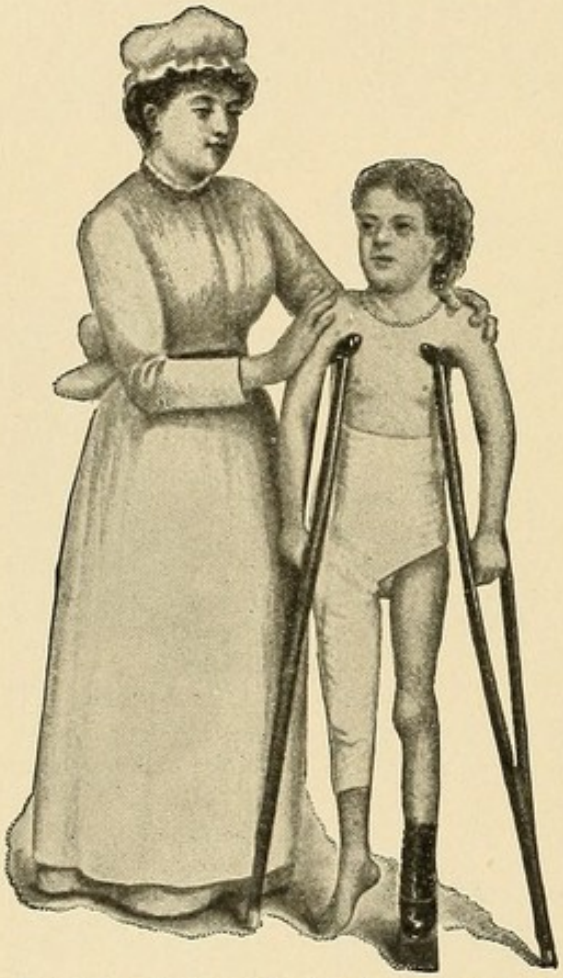

Fig. 268.—Plaster-of-Paris splint with suspension in hip disease.

Vance, of Louisville, Ky., has invented a molded-leather splint, which is applied in the same way, and covers the abdomen, hip, and thigh down to and below the knee, and answers the same purpose as the plaster-of-Paris; but as this latter is so much more readily obtained and more generally applicable, it may be relied upon in the early stages of hip-joint disease and in the later stages after extension and counter-extension in dorsal decubitus has brought the leg down to the proper plane.

When sinuses exist as a result of disease of the hip-joint, some slight change in the application of the apparatus selected will be necessary. It is always essential that the openings of the sinus or sinuses be properly protected by absorbent dressings in such a way that free discharge may be secured without soiling the apparatus.

The constitutional treatment of this disease is of great importance. Carefully selected diet, out-of-door life, cod-liver oil, the hypophosphites of lime and soda, and tonics are indicated.

In the *second* stage of hip disease operative interference may in rare cases be demanded: (1) To relieve pain on account of suppuration and the retention of pus, or to prevent sepsis from insufficient drainage; (2) to arrest ostitis in the head and neck of the femur, and in the acetabulum.

When pain is so severe that fixation with extension will not afford relief, it is safe to conclude that distention of capsule exists, or that in the structures which form the joint, or are immediately around it, suppuration has occurred to such a degree that free incision is necessary.

The question of performing a radical excision of the hip-joint is one upon which a divergence of opinion still prevails. I am convinced, however, that this operation should not be done except as a last resort and when the symptoms of septic absorption are so well marked and severe that radical interference is de-

manded. Careful conservative treatment by well-adjusted apparatus, incision and drainage of all pus accumulations, and careful general treatment of these patients will result not only in securing the recovery of the patient, but will give a more useful joint in the vast majority of cases. In the rare cases in which excision of the hip-joint is deemed necessary the wound should be packed with iodoform gauze and treated by the open method, not even partially closed by sutures.

The gauze may be changed every few days, the wound irrigated with 1–3000 sublimate solution, and again filled. Extension by the weight and pulley, in the dorsal decubitus, is necessary for from three to six weeks after the operation, unless the child is strapped in the wire breeches recommended by Professor Sayre (Fig. 269) immediately after the exsection. The chief recommendation of this apparatus is that it allows the patient to be carried out of doors or about the house with perfect freedom from motion or pain. The objection is its costliness, which puts it out of the reach of many patients. The extension in bed is very satisfactory in its results, and, with attention to ventilation and the amusement and entertainment of the little patient, the confinement need not be a formidable objection.



Fig. 269.—(After Sayre.)

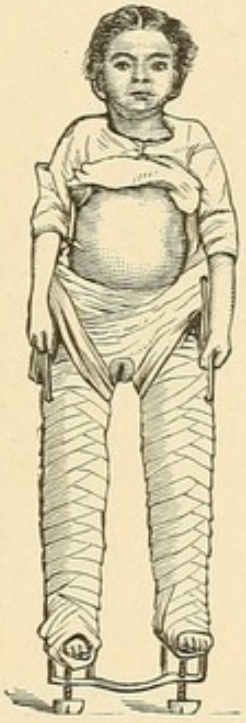

Fig. 270.—(After Sayre.)

When the wire apparatus is used the following directions should be carried out: Pad the instrument well, so that too great pressure at any one point may not occur. Place the patient in it so that the anus will project well over the crotch. It is well to insert a piece of protective under the sacrum and buttocks to prevent soiling. Fasten the well leg and the body to the instrument by rollers. Lay the extremity of the affected side in its splint, and screw the foot piece up until it touches the sole. Apply two strips of adhesive plaster in the same manner as heretofore given, attach these to the foot piece, and make the necessary extension by turning the screw in the proper direction (Fig. 270). After from four to six weeks, no matter whether the wire apparatus is used or extension in bed employed, the long splint of Shaffer or Thomas or the high shoe and crutches should be adjusted, and the case treated as given for the first stage.

Within the last few years the operation of drilling into the neck and head of

the femur, in certain cases where the initial lesion is an ostitis, has been advocated and performed in a number of instances by Mr. Macnamara.[1] The object of the operation is to give escape to, and secure drainage of, the products of the inflammatory process, at or near the epiphysis, and thus prevent disintegration of the bone and invasion of the joint. To be beneficial it must be done early in the disease.

The operation is neither dangerous nor difficult. A longitudinal incision, from two to three inches in extent, is made along the middle of the trochanter, down to the bone. The wound should be deep enough to permit the fingers to locate the neck of the femur, on its upper and lateral surfaces, so that the drill may be directed along its center. The chief danger to be avoided is entering the cavity of the joint by carrying the drill too far. The small Volkmann spoon is well adapted to this operation.

Knee-joint.—Acute synovitis of the knee is frequently of traumatic origin, resulting from the excessive strain to which this joint is subjected, and also on account of its exposed position. It may occur in the history of gout, rheumatism, gonorrhœa, and other diseases.

The chief *symptoms* are pain and swelling. Pain may be elicited by motion, or by direct pressure at any part of the joint, but it is, as a rule, emphasized over the coronoid ligaments, along the articular margin of the tibia, on either side of the *ligamentum patellæ.*

The *treatment* consists of *rest* by *fixation.* As a rule, the most agreeable position is that of slight flexion, with the limb elevated and the leg resting over a pillow. Fixation may be best secured by extension from adhesive strips, reaching from just below the knee to beyond the sole. The weight will vary from three to fifteen pounds, according to the age of the patient. It must not be forgotten that the ligaments of the knee-joint are susceptible of overstretching from too great and prolonged extension. Permanent relaxation or flail joint may result from overweight employed for too long a time. Cold, applied by means of the ice-bag, is a most useful remedy during the acute stage of inflammation. When pain is very severe, and when the capsule is greatly distended, aspiration may be indicated. This should be done with all antiseptic precautions, and with great care in preventing the entrance of air. The needle may be introduced on either side of the patella, at the point of greatest distention, or where fluctuation is most marked. The diagnosis may be made positive by a small exploring hypodermic needle and aspirator. Or, when the tumefaction is evident above the patella, the needle may be carried from above downward, behind this bone. After the excess of fluid is withdrawn a fair degree of compression should be exercised by enveloping the joint with borated cotton, held firmly down by a roller. Passive motion of the joint may be omitted for as long as six weeks, with or without a fixed dressing as may be required.

When an acute synovitis of the knee becomes infected and pus is present, incision and evacuation of the pus, with irrigation, and drainage of the joint are indicated. As a rule, a single lateral incision made near the posterior level of the joint, as the patient rests in the recumbent posture, will suffice. A sterile rubber drainage tube, about two inches long with a diameter of a quarter of an inch and stiff enough to resist being occluded by contraction of the incision, should be inserted. The joint may be irrigated as often as indicated, probably once a day, with salt solution. When pus ceases to flow, the tube may be removed and a small catgut bundle drain inserted for from two to six days.

The danger of ankylosis after acute synovitis of the knee-joint, lasting not longer than from one to six weeks, is slight. It is always great after *suppurative* synovo-arthritis, or *osteo-arthritis.*

Chronic Effusion in the Knee-joint.—Following gonococcus infection, and not infrequently when this disease has not existed, a persistent transudation into the capsule of the knee-joint may be present. This fluid varies in color from a pale amber to a darkish brown, and is at times so viscid that it will not flow through an ordinary canula. It is almost always an accompaniment of general malnutrition,

[1] "Gibney on the Hip," Bermingham & Co., New York, 1884.

and local measures are not apt to be successful unless combined with general constitutional treatment. The transudate has its origin from the endothelia lining the general synovial surface of either the quadriceps bursa or the capsule, and also from the synovial fringes beneath the patella.

Treatment.—Under strict asepsis an incision should be made upon the outer or inner lateral aspect of the joint, at that point where the fluid can be most readily reached, usually at the level of the upper margin of the patella. All bleeding should be arrested before the capsule is incised. When this is done a thorough irrigation of the entire joint and bursa cavities should be made with normal salt solution at a temperature of 115° F., the pressure being sufficient to hyperdistend the sac. A small swab of gauze is now securely held in a suitable clamp or forceps, and with it introduced through the incision the lining membrane of the quadriceps bursa, capsule, and the patella fringes are scraped. Some bleeding usually follows this procedure, but it is readily arrested by repeating the hot salt solution irrigation, which should be continued for five or ten minutes in order to thoroughly cleanse the joint. The excess of fluid is now pressed out, the capsule closed by a chromicized catgut running suture, with which the superficial incision is also reunited. A light gauze dressing with cotton batting over this and a snug immobilization gypsum cast is applied from near the ankle to half-way up the thigh. The general nutrition of the patient should be carefully prescribed. The joint should remain immobile for five or six weeks, and then gradually permitted to resume its normal function. Should this operation and treatment fail, it should be repeated by larger incision on each side, and the fringes of the patella entirely removed.

Destructive *osteo-arthritis* of the knee-joint may commence as a synovitis, either traumatic or idiopathic, or it may begin as an ostitis (tuberculous) in or near the epiphysis of the tibia or femur, the joint being secondarily involved. The latter is by far the more frequent source of chronic knee-joint disease.

Symptoms.—Pain is not, as a rule, a prominent symptom of ostitis near the knee, and, when the joint has become involved and the cartilages eroded, in many instances the degree of pain felt is far from being proportionate to the gravity and extent of the destructive process. In exceptional cases pain may be excessive, and may be felt in the hip as well as the knee, or may be referred entirely to the acetabulum. As the disease progresses the swelling increases, and is due not only to effusion into the capsule, but also to thickening of the ligaments, and, to a certain extent, to changes in the ends of one or both bones which enter into the formation of this articulation. Later the ligaments give way, and dislocation of the tibia backward, with slight outward rotation, occurs (subluxation). In the earlier stages of the ostitis certain constitutional symptoms appear, and remain throughout the course of the disease.

Treatment.—When tubercular arthritis of the knee-joint is recognized in the early stages, the indications are as complete rest as possible for the joint surfaces. This can be obtained in a moderate degree by simple fixation with plaster of Paris,

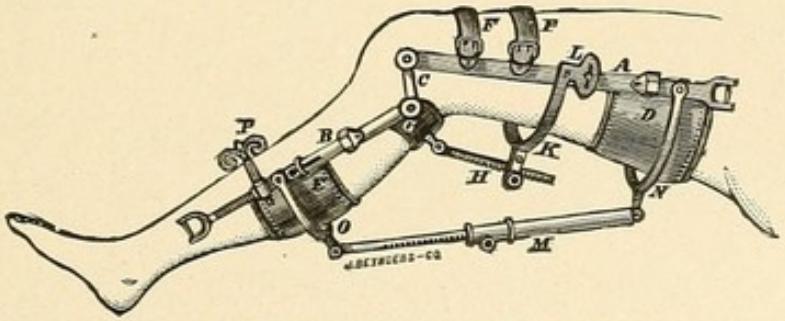

FIG. 271.—Shaffer's extension knee splint for knee-joint disease with subluxation.

but this does not give the degree of extension which is essential to success. If, however, no extension apparatus can be obtained, the leg should be incased in plaster of Paris, closely applied while extension is being made, from the level of

the perinæum down to and including the foot. It is better to leave the knee a little short of full extension—about five degrees of flexion. Shaffer's knee splint or brace (Fig. 271) is capable of meeting the various indications of extension, fixation, and rotation.

A simple, less costly, and very efficient apparatus is Thomas' knee splint. It consists of a metal ring at the upper or perineal end, joining two parallel bars of iron, the ring having an angle of about forty-five degrees to the inner bar. These bars project below the foot, and the instrument terminates in a ring of iron (Fig. 272). The upper or thigh ring is well padded and fits closely upon its inner aspect against the perinæum and tuberosity of the ischium. It is fastened to the leg by leather straps and corset lacing or by an ordinary roller-bandage. A shoulder strap or suspender, intended to hold the instrument against the perinæum, passes over the shoulder of the side opposite to that of the disease. A high shoe is placed upon the sound foot, and the patient walks at once with and later without the aid of crutches, the weight of the body falling upon the perinæum and end of the brace, allowing no concussion in the knee-joint. This apparatus, chiefly commendable for simplicity and cheapness, does not give as satisfactory extension as the Shaffer splint.

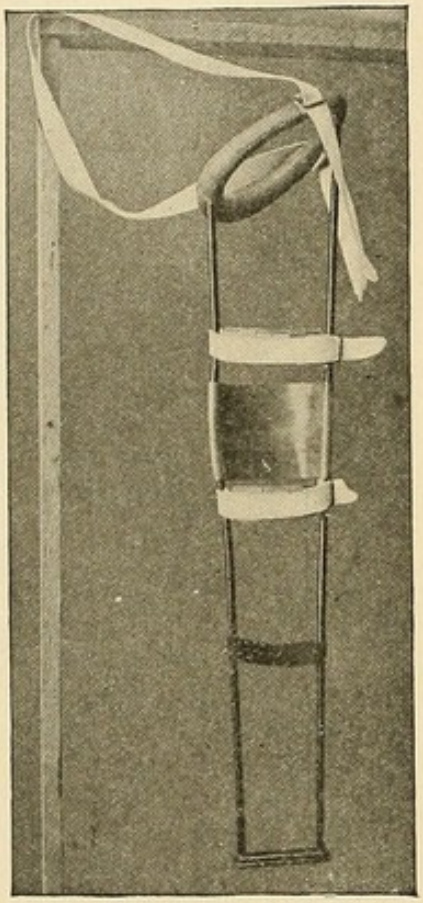

Fig. 272.—Thomas' knee and ankle brace.

In cases of knee-joint disease which have not received proper attention in the earlier stages there will very frequently be found a condition of subluxation of the tibia (Figs. 271 and 273). Extension in bed in two directions, as shown in the accompanying cut, will have to be made until the extremity is straight enough to wear either the Shaffer or Thomas splint.

Operative interference at the knee-joint should not be adopted until a thorough trial has been made of a carefully applied and well-attended orthopædic apparatus. Sometimes it requires three or four years to arrest the disease and effect a cure by these means, but it is often accomplished with a very fair degree of motion left in the joint. Operation, when it becomes necessary, may consist of incision of the capsule and drainage when, as determined by high temperature and great pain and constitutional disturbance, pyogenic infection has taken place, or excision of

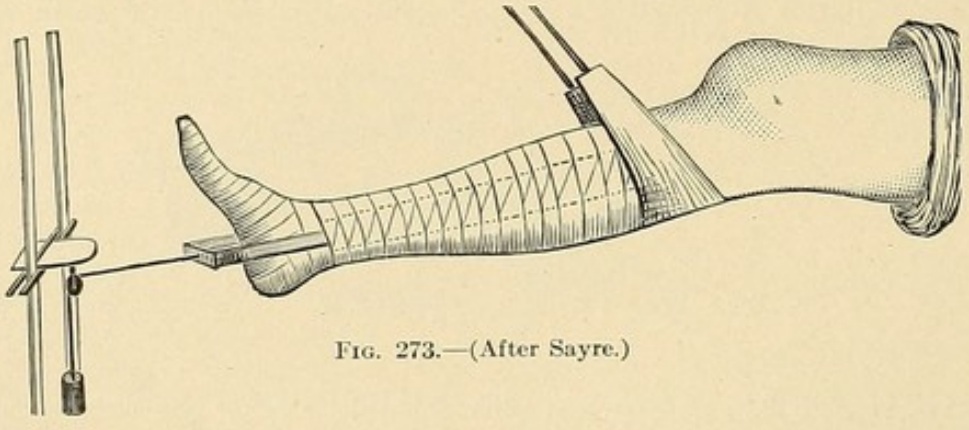

Fig. 273.—(After Sayre.)

the joint. Gouging will suffice in some instances where the destruction of bone is limited, but generally, when forced to a radical step, it will be found better to make a clean excision of the parts, according to the rules laid down for excision at the knee-joint.

Charcot's Disease.—The knee-joint (and less frequently other articulations) is occasionally the seat of a subacute type of osteo-arthritis which is in all probability a trophic disturbance, since it comes as a prodroma of locomotor ataxia (Charcot's disease). There is no history of injury, little or no pain, and very slight constitutional disturbance. The knee becomes weak, the ligaments relax, and there is more or less deformity. The muscles of the limb become atrophied, and finally there is a disintegration of the bone substance.

The indications in treatment are to protect the joint by a brace or plaster cast, and later, if necessary, to remove the offending member by amputation.

Wounds of the knee-joint do not require special consideration. The same general principles which have already been dealt with apply to this joint, which on account of its broad surfaces and exposed position is frequently injured.

Diseases of the Ankle-joint.—The pathology, causes, and symptoms of disease at the ankle do not differ from those at the articulation just considered.

Synovitis is oftener *traumatic* than *idiopathic*. The exposed position of this articulation, which is called upon not only to sustain the entire body weight, but is also frequently subjected to great lateral strain, renders it exceedingly liable to injury.

The symptoms of acute traumatic synovitis at the ankle are usually not obscure. Swelling, pain, and heat, following prolonged or violent exertion, a twist, sprain, or other injury, bear strong evidence of inflammation within the joint.

The injury most difficult to differentiate from intra-articular synovitis, and one which frequently complicates synovitis here, is inflammation of the sheaths of the tendons which play around the joint. The evidence of *thecitis* is pain in the track of the tendon, either elicited by direct pressure or by placing the foot slowly in a position which will cause the greatest tension of the tendons, and then requiring the patient to move the foot in various directions which are resisted by the operator. To test the peronei muscles, carry the foot well inward, hold it firmly, and ask the patient to turn the foot out. Thecitis in the track of these tendons will arrest the effort at abduction and outward rotation. The reverse of this manœuvre will serve to demonstrate a similar condition in the flexors and internal rotators.

Tuberculous synovitis of the ankle-joint is less painful and comes on slowly. Synovitis from exposure to cold, gout, or rheumatism is frequently symmetrical, attacking either both ankles at the same time, or first one and then the other. Traumatic and tuberculous synovitis, on the other hand, are almost always unilateral.

The *prognosis* of simple synovitis of the ankle, when proper, vigorous, and prompt treatment is instituted, is in general favorable.

Treatment.—Acute synovitis, whether of traumatic or idiopathic origin, demands rest, with an elevated position of the foot. Simple cases will require no more than this, with hot or cold applications, or lead-and-opium wash, applied by soft cloths laid loosely around the ankle, or blotting paper kept wet with vinegar. The employment of compression will depend upon the sense of relief it may give the patient. Absorbent cotton or soft sponges may be used, applied carefully with a flannel or muslin roller.

Aspiration of the joint to relieve extreme tension from effusion applies here as in other articulations. The needle should be entered in front, between the anterior margin of the external malleolus and the contiguous surface of the tibia, away from the vessels and nerves which are opposite the middle of the joint.

In subacute or chronic synovitis, or in gonorrhœal arthritis, compression is indicated, and will often cause absorption of the excessive effusion in the joint. It is especially demanded after aspiration, to give support to the parts and to prevent a further effusion.

Extension is indicated when its employment gives relief from pain, which rest and fixation without extension do not afford. Fixation with plaster-of-Paris secures rest to the joint in most cases, and permits of locomotion on crutches.

Arthritis of the ankle is more often due to tuberculous *ostitis* of the tibia or the astragalus.

The *symptoms* are those of ostitis, elsewhere given, and the *diagnosis* and *prognosis* do not differ materially from similar lesions in other articulations.

When osteo-arthritis with pyogenic infection is evident, operative interference is indicated, for the reasons that (1) early incision, by giving discharge to the contents of the capsule, retards or arrests the destructive process; (2) the common experience of surgeons is that the invasion of this joint is practically without danger to the patient's life.

Complete exsection of the articular ends of the tibia and fibula, and of the upper half of the astragalus, is rarely called for. An incision upon the side which, from the symptoms present, will give the best access to the diseased bone, and the free use of Volkmann's spoon in removing the dead tissues, will usually suffice. The foot should be kept at rest, and the patient directed to go on crutches until several months after the discharge has ceased and the sinus closed. The operation of gouging is more successful in osteo-arthritis at the ankle than in any other articulation. Complete exsection is only admissible when the destruction is very extensive.

Synovitis and osteo-arthritis of the articulations of the tarsus and metatarsus are treated upon the same general principles as just given for the ankle.

The Shoulder-joint.—Synovitis of the shoulder is usually general; in rare instances it may be local. It may affect the general synovial surface of the capsule, be reflected into the synovial sheath of the long head of the biceps, the bursa under the tendon of the subscapularis, or that beneath the infra-spinatus, or in rare instances, especially in the earlier stages, one or more of these bursæ may be inflamed, while the joint is not invaded. The bursa between the deltoid and the capsule may also be the seat of bursitis, although this sac does not communicate with the joint. The diagnosis of inflammation in one or more of the bursæ about the shoulder may be determined as follows: 1. Direct digital pressure upon any single bursa will indicate the sensibility of the part. 2. Extend the forearm fully, grasp the hand and elbow of the patient, and, while the head of the humerus is pulled away from the glenoid cavity, direct the patient to make strong flexion, which the operator firmly resists. If inflammation of the sheath of the long head of the biceps exists, pain will be experienced in the anterior and outer portion of the joint as this tendon is made tense. 3. When the bursa under the infra-spinatus is inflamed, if the arm is rotated inward, and held in this position, pain will be felt when the tendon of this muscle is made to press strongly on the bursa, in any effort at outward rotation.

An opposite manœuvre will serve as a test for the bursa beneath the tendon of the subscapularis. In *general synovitis* each of these movements will be productive of pain, and the differentiation is chiefly between neuralgia and muscular rheumatism. In *neuralgia* pain is rarely constant, the exacerbations appearing at intervals of comparative regularity, and extending in the recognized course of the nerves. Motion is not painful in the degree which characterizes either synovitis or rheumatism, and, if persisted in, the sense of pain may entirely disappear. Swelling is not a feature of a neurosis. In rheumatism of the muscles about the joint the pain is superficial, and may be elicited by digital pressure upon the substance of the muscles.

The treatment of synovitis is the same at all joints. Artificial extension is indicated when the weight of the extremity is not sufficient.

Aspiration is a safe and efficient means of relief from pain, and is indicated when there is marked capsular tension. The needle should be entered through the center of the joint in front. Fixation of the joint by a shoulder cap of felt, cardboard, or leather, should be secured immediately after aspiration. When ready for application, lay upon the surface of the board which is to be nearest the skin a layer of absorbent cotton, which shall be wide enough to extend entirely around the arm and over the shoulder, place it in position, and secure snugly by a figure-of-8 bandage around the arm and shoulder.

Acute *suppurative* synovitis demands an immediate evacuation of the purulent contents of the capsule by incision and drainage. The line of incision is from the anterior internal tip of the acromion, parallel with the fibers of the deltoid along the anterior margin of the great tuberosity. The capsule is opened external to the long head of the biceps, and, while traction is firmly made upon the edges,

the cavity may be thoroughly explored and cleansed. It is of vital importance that in this, as in every cavity which is the seat of purulent inflammation, drainage should, when possible, be established from that portion of the wound which is most dependent. As the patient rests in bed the posterior and outer part of the capsule is lowest. A dull-pointed dressing forceps should be carried into the capsule through the anterior incision and bored through the inferior posterior wall and all the tissues to the skin, and when this is pushed ahead of the instrument an incision should be made to allow the escape of the instrument. The wound is stretched by opening the jaws of the instrument, and a rubber tube pulled into place as the instrument is withdrawn. In *tuberculous osteo-arthritis* of the shoulder-joint exsection may be called for, after all conservative measures have failed.

The Elbow-joint.—Synovitis of this articulation need not be separately considered. The same general principles of diagnosis and treatment apply here as in other joints. Tuberculous osteo-arthritis demands gouging or exsection when careful corrective mechanical treatment has failed. The operation will be given hereafter.

The Wrist-joint.—Inflammation of the synovial membranes of the wrist or in the immediate neighborhood of this joint is of frequent occurrence. It is often traumatic in origin, and not infrequently tuberculous. It may attack the synovial sac between the ulna and radius; that between the radius and the fibro-cartilage and the first carpal row; the general synovial sac between the first and second rows and the metacarpus; or that between the base of the first metacarpal bone and the trapezius (Fig. 274). Inflammation of the sheaths of the tendons on the dorsum of the carpus or on the palmar surface may also complicate a carpal synovitis, or exist alone. The contiguity of these various structures renders a positive diagnosis of great difficulty. If, when the bones of the forearm are grasped near their center and pressed together, sharp pain is elicited at the wrist, synovitis of the radio-carpal sac is indicated. When the swelling is well defined at the edge of the articular end of the radius, extends across the wrist, and is limited to the situation of the first row of the carpus, the radio-carpal sac is probably alone involved. When the several capsules are involved the swelling is general. In *thecitis* the pain is superficial, and usually extends for some distance along the tendons above and below the joint. Contraction of the muscles, the tendons of which are involved, will point to the location of the inflammation. Differentiation of synovitis from Colles' fracture will depend upon a study of the symptoms of this lesion already given. *Tuberculous osteo-arthritis* in its earlier stages is comparatively a painless process, and even after the capsule is invaded is rarely as painful as an acute synovitis.

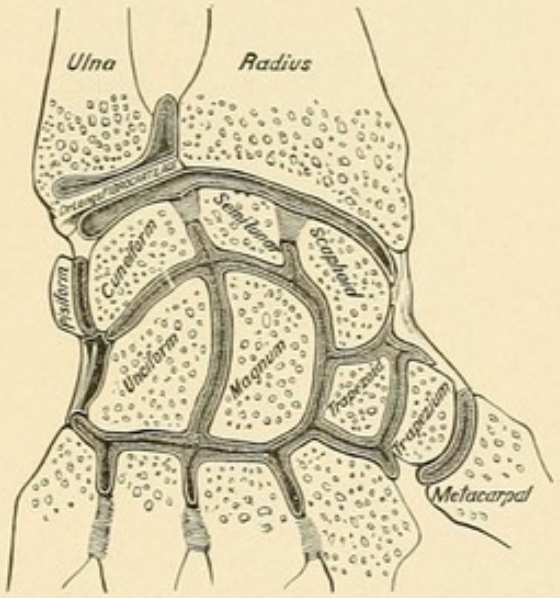

FIG. 274.—(After Gray.)

Treatment.—Synovitis of the wrist does not demand separate consideration. Destructive osteo-arthritis requires gouging rather than exsection. Synovitis of the metacarpal or interphalangeal joints should be treated on general principles of rest and fixation.

EXSECTIONS OF THE JOINTS

The Hip—Sayre's Operation.—Place the patient on the sound side; carry the point of a strong scalpel perpendicularly down to the bone exactly half-way between the anterior superior spine of the ilium and the tip of the trochanter major;[1] cut along the neck of the femur, keeping the knife firmly in contact with the bone,

[1] The extremity should be held parallel with the axis of the spine, with the foot normally rotated outward.

carrying the incision midway between the center and posterior aspect of the trochanter, and then curving it slightly forward as it passes about an inch below the tuberosity (Fig. 275). Through this incision, which divides the capsule and thickened periosteum, insert the elevator and lift the periosteal investment from the diseased bone. When the trochanters are involved, the tendons, inserted into these eminences and into the digital fossa just above the great tuberosity, usually require to be detached with the knife, the point of which, in order to avoid wounding any vessels, should be kept in close contact with the bone. As soon as the periosteum is freely raised, the bone should be divided, with the author's exsector, the Gigli wire or the keyhole or metacarpal saw, and the upper fragment lifted out with the elevator. The sawed surface should be carefully inspected in order to see if the disease extends farther down the bone, necessitating a second division. The acetabulum should next be examined, thoroughly scraped with a Volkmann's spoon, and all dead tissue removed. Hæmorrhage is usually insignificant, and, if occurring, should be arrested as the operation progresses. The wound should be thoroughly irrigated with 1–3000 sublimate, all shreds of tissue and particles of bone removed, and the entire cavity, after being thoroughly dried, filled with sterile gauze, well packed in, and held in place by a thigh and pelvic spica. The patient should now be put to bed with an extension apparatus applied as given for the early treatment of hip disease. Sand-bags may be laid along the leg to hold the foot in the proper degree of outward rotation, or a splint may be used. The long splint from the axilla to the heel is often required to prevent a child from sitting upright in bed. The first dressing is changed usually about one week after the operation, and once or twice a week thereafter. After four or five weeks the case should be treated as in the first stage. Professor Sayre prefers the wire breeches for the first few weeks after the operation (Fig. 270).

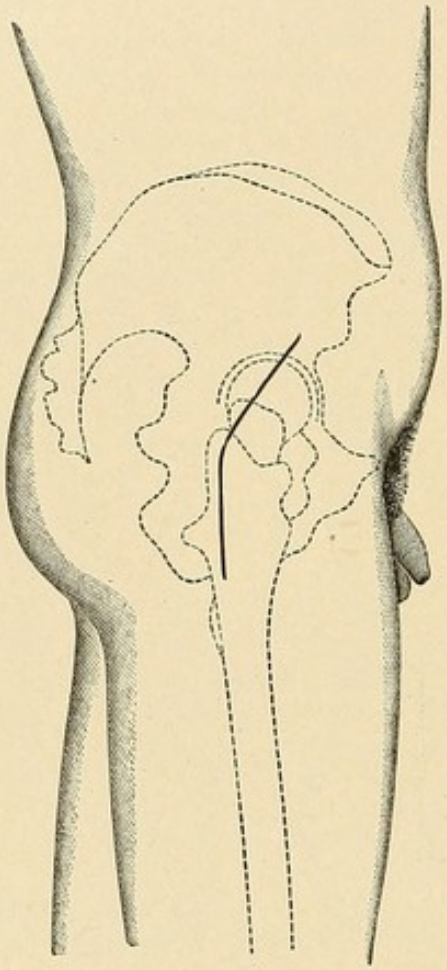

Fig. 275.

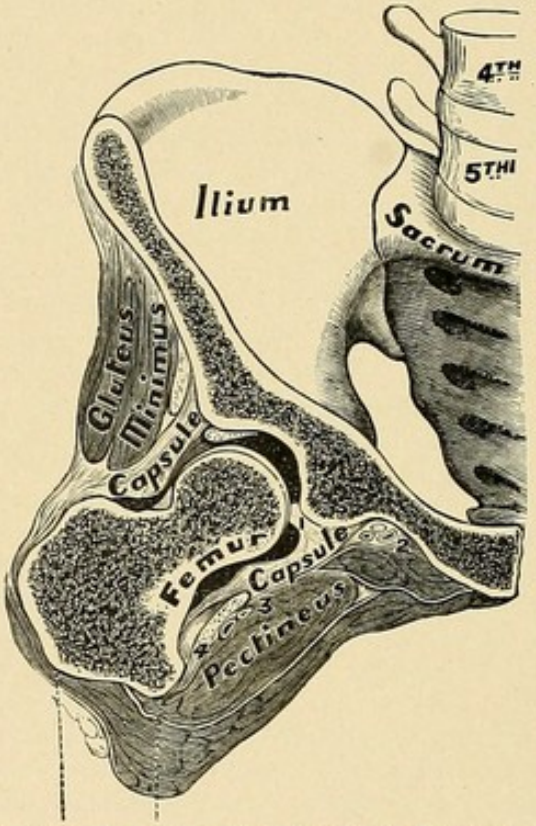

Fig. 276.—1, Ligamentum teres. 2, External obturator muscles and obturator vessels. 3, Circumflex vessels. 4, Conjoined tendon of psoas and iliacus. (After Braune.)

In a certain proportion of cases the disease is not arrested by the first operation, and a second is required.

The outline of the parts involved in this operation is well shown in Fig. 276.

Excision of the Knee-joint—Operation.—Under rigid asepsis elevate the foot in order to empty the extremity of blood, and after a minute or two apply the rubber tourniquet above the middle of the thigh.

With the leg straightened out, or slightly flexed (Fig. 277), an incision is made across the center of the patella and down on each side until the level of the posterior surface of the tibia is reached. These points must be low in order to secure drainage. The skin flaps or cuffs are now dissected and rolled up until the upper one is turned back about three inches, the lower two inches. As the flaps are held well away by assistants, the operator cuts down to the femur

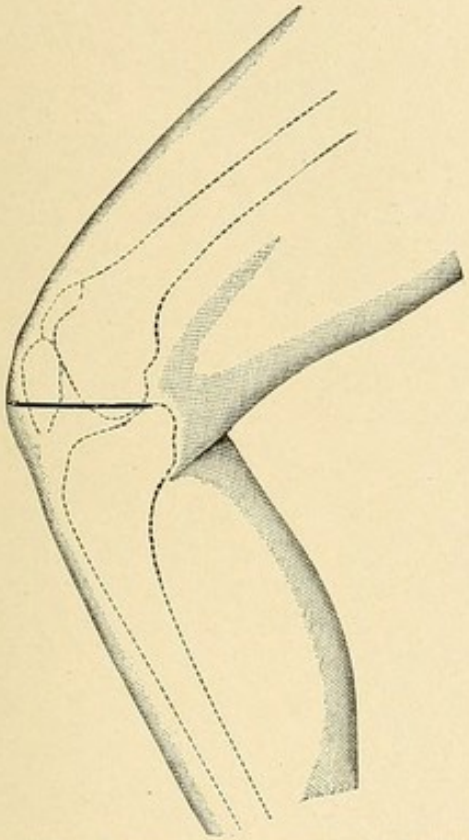

Fig. 277.—Incision for exsection of the knee.

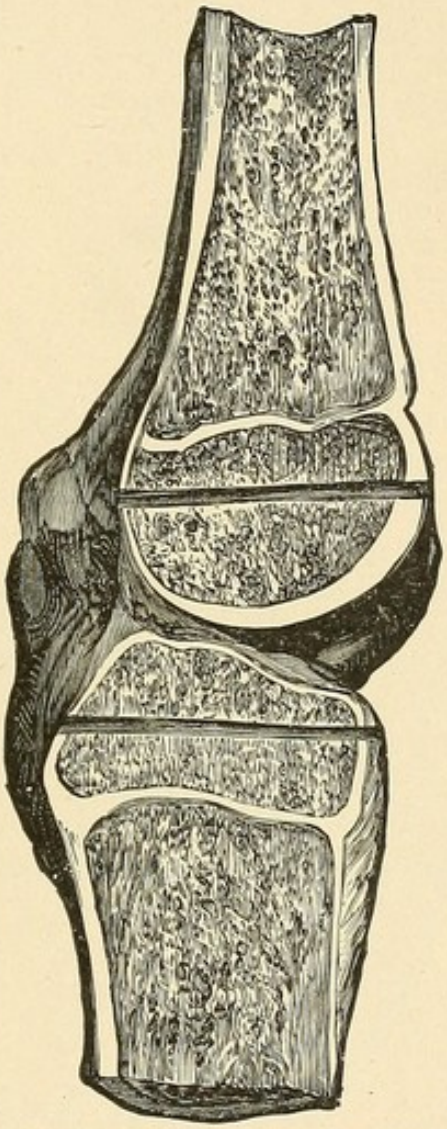

Fig. 278.—Showing the proper line for sawing between the epiphyses of the tibia and femur and the joint cavity.

through the tissues, parallel with the attached edge of the reflected upper flap, lifting everything from the anterior aspect of the femur and its condyles together with the patella, the attached fringes, ligamentum patellæ, and coronary ligaments —thus clearing in one mass all the tissues which envelop the anterior three fourths of the joint.

By sharply bending the knee the crucial ligaments are exposed and divided, the lateral ligaments cut away, and the disarticulation effected. In stripping the attachments of the ligamentum posticum Winslowii from the tibia and femur, the operator should closely hug the bone and thus avoid wounding the vessels. This dissection posteriorly should extend about three fourths of an inch below the level of the tibia and one and a half inch above the lowest surface of the condyles. Determining now the amount of bone necessary to be removed, a cloth retractor is applied so as to protect the soft parts from bone detritus or injury, and a slice thick enough to freshen the head of the tibia is sawed away, as nearly as possible parallel with the normal plane of the articular surfaces, or at a right angle to the

perpendicular axis of this bone. Should the section expose a focus of disease which dips down into the bone, this should be gouged out with a scoop or Volkmann's spoon, and finally mopped with a strong bichloride solution (1–500). It is im-

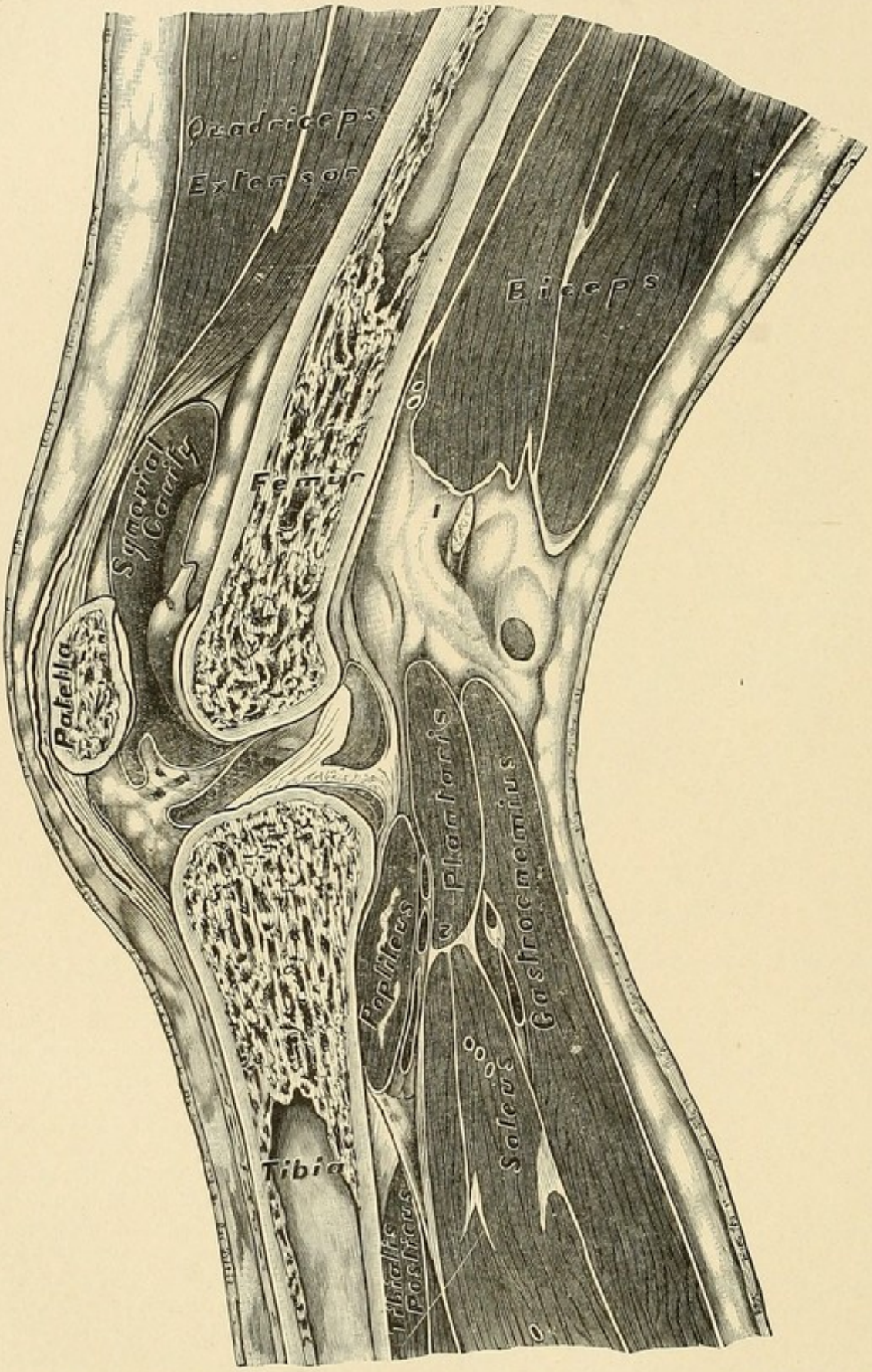

Fig. 279.—Longitudinal section through the knee-joint. 1, Peroneal nerve. 2, Popliteal vessels. (After Braune.)

portant, and especially in children and young adults, that the section should not involve the epiphyseal lines (Fig. 278).

The section through the end of the femur should now be made (Fig. 278). It follows that if the limb is to be straight in the position of ankylosis, the sawed surfaces of the two bones must be parallel. I have found it of great value to employ this method. By pulling on the foot the limb is fully straightened, and the articular surface of the femur separated from the sawed surface of the tibia. If the operator will now start the saw into the femur, sighting by the flat face of the tibia, the instrument will cut directly parallel with this. If by error the section of the tibia has been slightly oblique, that of the femur will have a like obliquity, and therefore the bones will fit snugly with the extremity straight.

The next step is to dissect away with forceps and curved blunt scissors all the diseased capsule. This should be done thoroughly, and even the bursæ that communicate with the joint should be cleaned out. If care is not taken, a portion of the sac which extends up beneath the quadriceps tendon will not be removed. All bleeding points should be tied with catgut and hæmorrhage stopped. The bones are now brought in exact apposition, and while so held the steel drills (Fig. 214) are introduced. I usually carry two of these in from below upward, passing them through the skin about two inches below the sawed surface of the tibia and directing them obliquely through the tibia into the femur. When the end of the drill has reached the compact substance of the femur, it is stopped, the handle unshipped, and the drill left in position. Three are used, one on either side from below, and one directly down the median line from above, entering the femur and passing into the tibia.

As the leg is now held steady the edges of the incision in the skin are sewed together with catgut and two short catgut drains inserted at the lower angles. Sterile gauze is applied and one thickness of absorbent cotton from near the ankle to the crotch. Over this successive layers of veneering on thin wooden splints are placed, and firmly adjusted to the leg and thigh by compression with a bandage, the whole to be enclosed with a light plaster-of-Paris cast. This dressing is allowed to remain on for six weeks, and when changed the drills are pulled out. Should it for any reason become necessary to remove it about the fourth week, the pins may then be extracted. The indications for a change of dressing are hæmorrhage, high temperature, and decomposition of the discharge beyond the zone of asepsis.

The roller should be firmly drawn, so that a considerable pressure may be exercised upon the parts to prevent oozing. The elasticity of the cotton distributes the pressure equally, and controls hæmorrhage without causing discomfort. It is the practice of some surgeons not to apply a single ligature in this operation, but to rely wholly upon compression for the control of bleeding. It is better to search for and tie the larger vessels which may have been divided. Recovery, with ankylosis in the straight position, is the result desired. This operation has met with remarkable success within late years. The drills are preferable to nails in fixation. They are carried into position by steady pressure on the handle, with a slight half-rotary movement. When they cannot be obtained, the parts may be held in apposition by wiring or by nails.

The Ankle-joint.—For the complete exsection of the articular ends of the tibia and fibula and the astragalus, proceed as follows: Commence an incision on the internal surface of the tibia, about two inches above the tip of the inner malleolus, and carry it directly down to this point, and thence forward, from one inch to one inch and a half along the tarsus, in the direction of the metatarsal bone of the great toe (Fig. 280). A similar L-shaped incision is made upon the fibular side of the joint (Fig. 281). These incisions divide all the tissues down to the bone. With the Sayre elevator lift the periosteum, with its attachments to the superjacent soft tissues undisturbed, from the diseased portions of bone. Expose the outer malleolus and fibula as high as it is deemed necessary to remove this bone, and divide it with the exsector (or chisel). As soon as the piece is removed the joint is thoroughly exposed to view. Now, further lift the periosteum of the tibia and tarsus, and, by forcibly bending the foot inward, dislocate the tibia and

inner malleolus outward, through the wound on the fibular side. The diseased surface may be sawn off with an ordinary saw, or with the exsector. The section through the astragalus may be made with a gouge, chisel, or a keyhole saw. Usu-

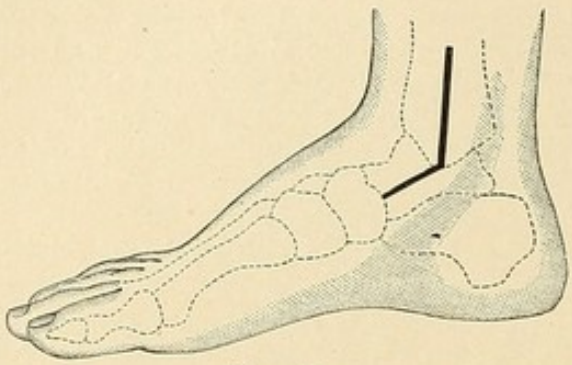

Fig. 280.

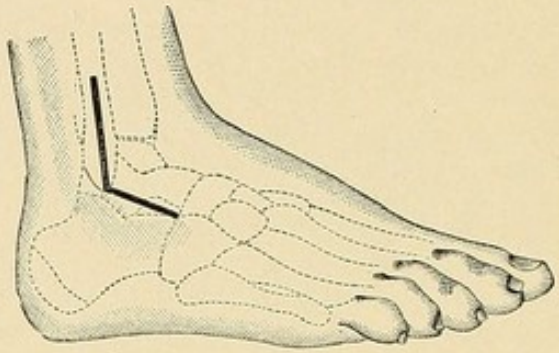

Fig. 281.

ally no vessels of importance are wounded in this dissection, since, by keeping beneath the periosteum, they are lifted with the tissues. The periosteum should not be elevated over the healthy bone. The sawed surfaces are now brought in apposition, so that the foot will be at an angle of ninety degrees with the axis of the leg. Fixation may be secured by transfixion with small steel drills, carried obliquely from above downward, entering on the internal aspect of the tibia and the external surface of the fibula, and passing into the astragalus (in the same manner as at the knee). The wound should be closed with catgut, leaving a small catgut drain to pass out on each side. An aseptic dressing should be applied, and over this plaster of Paris.

If the drills are not employed, the parts should be held in apposition while a plaster-of-Paris dressing is applied. Or a Volkmann's splint (Fig. 282) may be

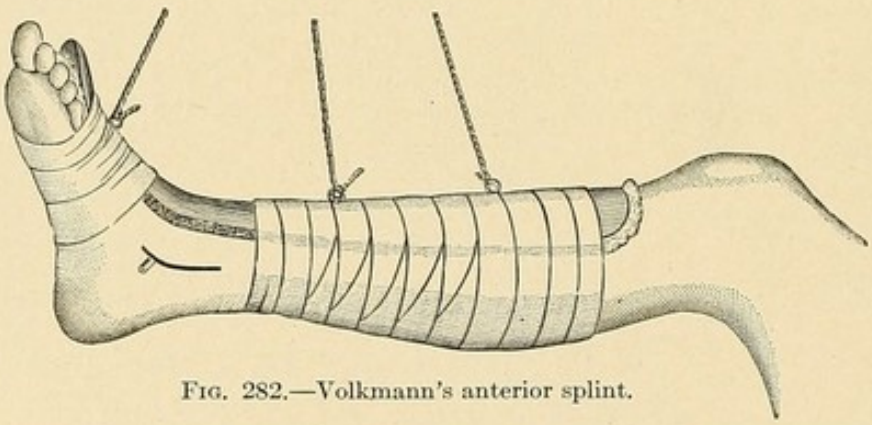

Fig. 282.—Volkmann's anterior splint.

applied to the anterior extremity of the foot and leg, and the parts fixed with plaster of Paris, or simple roller. This splint may be made of wood, or sheet or hoop iron, properly padded with sterile gauze.

If the bones are not extensively involved, a single L-shaped incision will suffice to expose the joint, and the dead bone can be removed with the gouge or Volkmann's spoon and a counter-opening made for drainage. This operation is always to be preferred at the ankle.

When, in an exsection of the ankle, the astragalus is so much involved that its removal is necessary, the upper surface of the *os calcis* should be smoothed off with the chisel or keyhole saw, and brought up in apposition with the plane surface of the bones of the leg.

The Shoulder-joint.—Exsection of the head of the humerus is readily effected by a single straight incision, about five inches in length, made from the acromion process directly down the arm, parallel with and splitting the fibers of the deltoid (Fig. 284). The periosteum should be carefully lifted as far as the ostitis extends,

and the soft tissues about the capsule raised with the elevator. The edges of the wound should be held wide apart by blunt retractors, and the tendons of insertion of the supra- and infra-spinatus, teres minor, and subscapularis divided close to the tuberosities with the curved blunt scissors. The sheath for the long head of the biceps should be laid open, and this tendon held aside. The bone should now be divided at the limit of the disease. When the section is completed a strong hook should be fastened into the end of the upper fragment, in order to lift it and

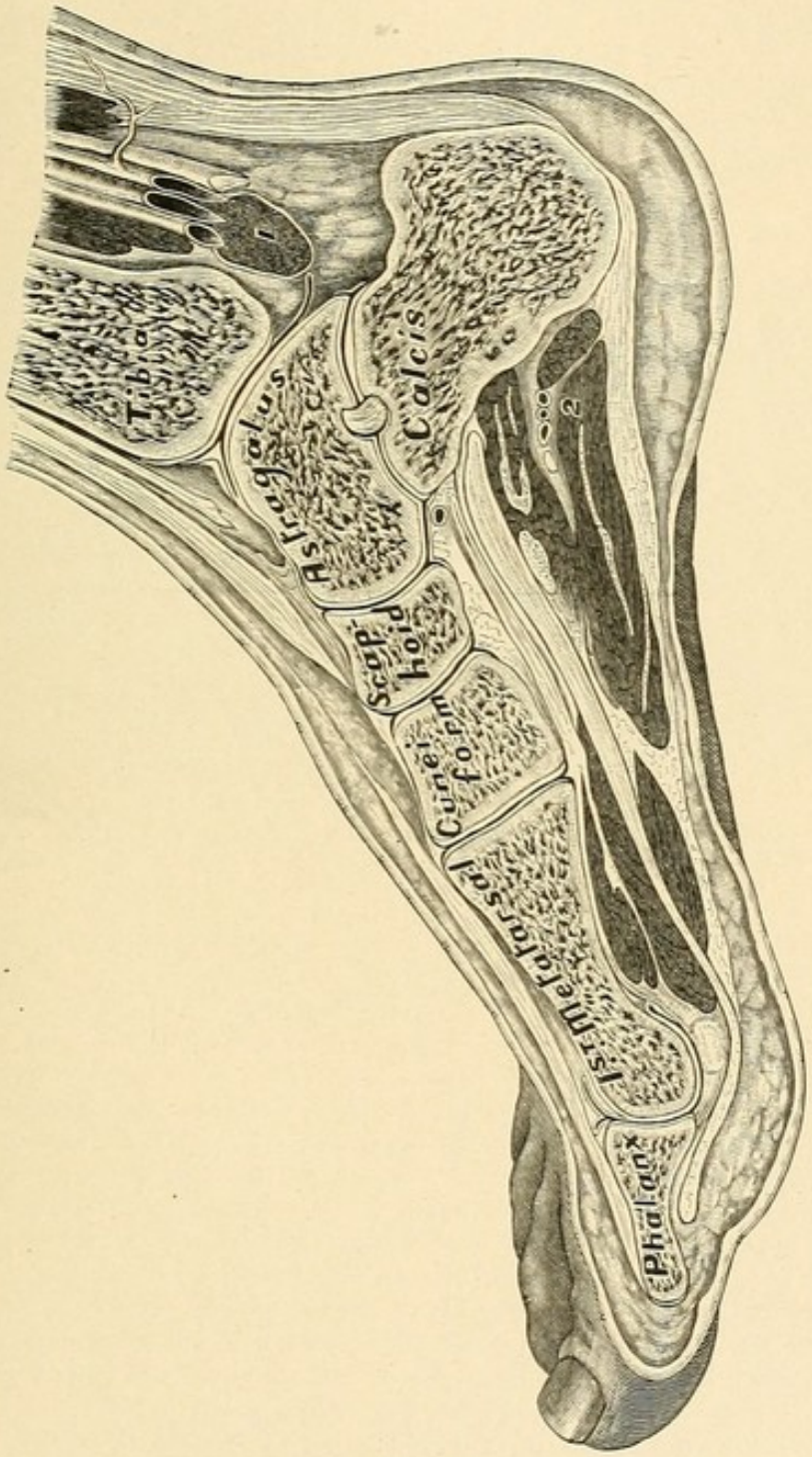

Fig. 283.—Section through the lower portion of the leg and foot, showing the relations of the parts in exsection of the ankle-joint. 1, Posterior tibial artery, veins, and nerve. 2, External plantar vessels. (After Braune.)

facilitate the separation of the soft tissues on the inner and under surface from the bone and capsule. The capsular ligament should be trimmed from the margins of the glenoid cavity and removed with the head of the humerus. All diseased tissues should be dissected out with the curved scissors, and, if the head of the scapula is involved, all disorganized bone should be scraped away with the spoon or rongeur. The capsule should now be divided and the head of the bone dislocated

upward through the wound. The division is then made with a narrow saw, taking the precaution to protect the soft parts from injury. Upon examining the wound left after this operation, it will be seen that the deepest portion is behind and to the outer side of the end of the shaft. Into this depression carry a closed dressing forceps, and bore through to the skin, pointing the instrument to the inferior and outer aspect of the arm. Divide the skin over the point of the forceps, dilate the opening by separation of the handles, and draw a catgut drain from below upward through the hole. A second shorter one should make its exit through the anterior and lower angle of the incision, and the wound closed throughout with catgut. The forearm should be held in a sling or fastened across the abdomen. The application of Esmarch's bandage, and the rubber tubing in the axilla and over the clavicle and scapula, renders this operation practically bloodless. The rate of mortality is exceedingly low.

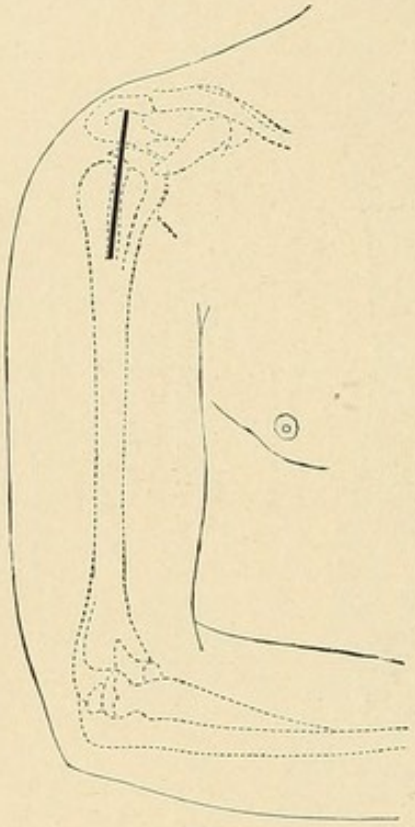

Fig. 284.

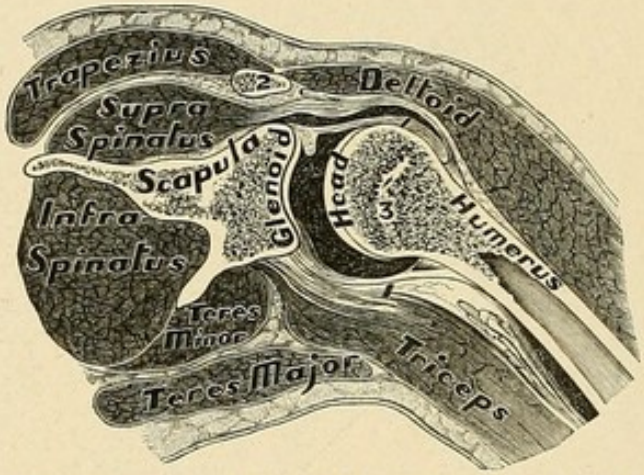

Fig. 285.—Longitudinal section through the shoulder-joint, showing the relations of the bones, ligaments, and muscles immediately about the articulation. 1, The capsular ligament. 2, The acromion. 3, Epiphysis. (After Braune.)

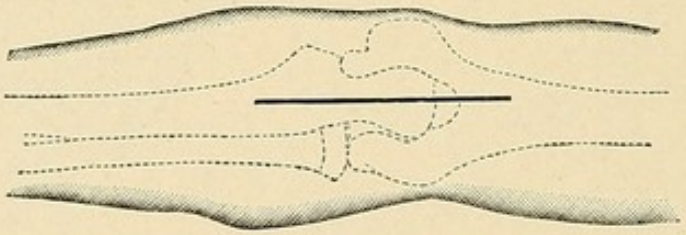

Fig. 286.

The Elbow-joint.—Flex the forearm on the arm and make a straight incision, commencing in the middle of the posterior aspect of the humerus, about one inch above the condyles, and extending over the center of the olecranon process, along the ulna for from two to three inches (Fig. 286). The tissues should be carefully lifted from the bone and capsule, and held to either side by blunt retractors. When the trough between the olecranon and internal condyle is approached, extra care should be taken not to wound the ulnar nerve, which passes in this groove. It may be avoided by keeping close to the bones with the knife or elevator. The articular end of the humerus should be exposed, as high as the point of section, by peeling off the soft tissues with the periosteum, after which a retractor is applied and the bone divided at an angle of ninety degrees to the shaft of the humerus. The ends of the ulna and radius may now be readily displaced backward, exposed to the point of section, and divided on a line parallel with that through the humerus. As in all the joint exsections, a careful dissection of all the diseased capsule and soft parts must be made. The wound is drained from the most dependent portion by means of catgut, and closed with sutures of the same material. An anterior splint, previously fitted to the arm and forearm, and fashioned so as to hold the forearm half-way between flexion at a right angle and complete extension, is

wrapped with gauze and laid on the anterior aspect of the extremity, and fixed by a roller to the arm and forearm, to within a few inches of the incision. A sterile dressing is next applied to the wound, with cotton and protective, and a bandage over this to effect compression and to hold it in position. When a change of dressing is required, this last bandage only is removed. After the sixth week passive motion should be commenced, and should this not produce a too painful inflammatory reaction it should be repeated once or twice a week for two or three months. Anæsthesia is essential. A very considerable degree of mobility may be gained by this practice, although the rule in this exsection is fibrous ankylosis, with limited motion of the joint and function of the extremity.

Exsection of the elbow is not a dangerous procedure, and, although not usually attended with the success which follows some other operations (as those upon the

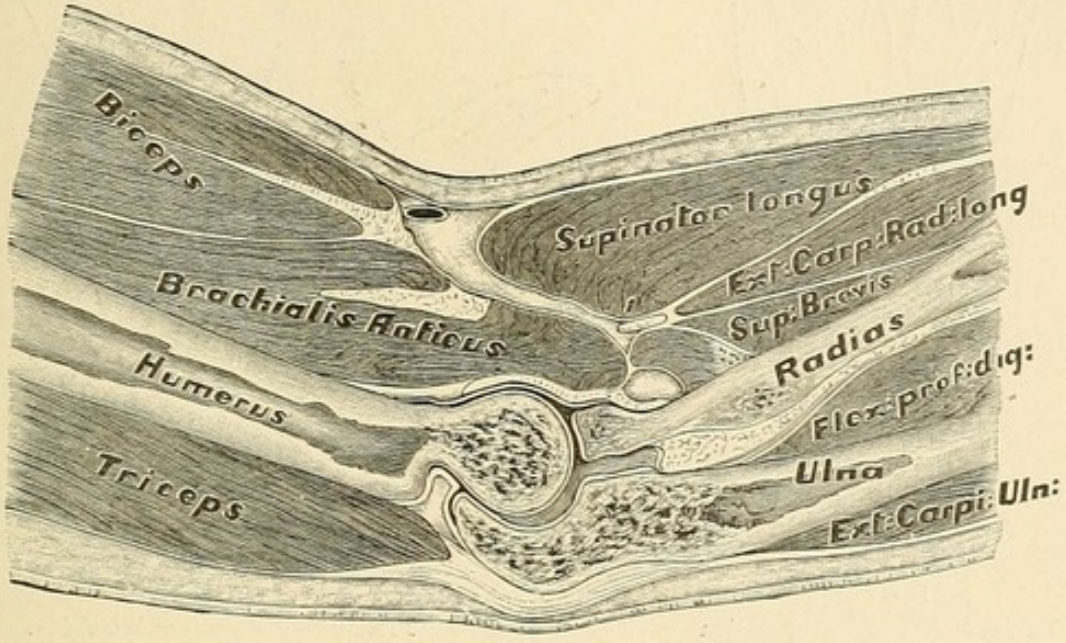

Fig. 287.—Longitudinal section through the elbow-joint. 1, Radial nerve. Superficially on the flexor surface the median basilic vein is seen cut across. (After Braune.)

shoulder and ankle), it should be preferred to amputation. The anatomical relations at this joint are shown in Fig. 287.

The Wrist-joint.—The exsection of this joint is attended with considerable difficulty, not only in the performance of the operation, but in the after-treatment. Of the two procedures—viz., the double lateral and parallel incisions (Fig. 288) and the single longitudinal dorsal incision (Fig. 289)—the latter is preferable when the destructive process is not so extensive, and when the spoon or gouge may be used, while the former will give the freest access to the bones when the saw or exsector is to be employed in the removal of a large portion of the bones which enter into the composition of this joint.

In the operation with a single dorsal incision the wrist should be made prominent, by flexing the hand on the forearm, and the integument divided along the tendon of the extensor communis digitorum, which goes to the index-finger, the incision extending from the middle of the metacarpus to one inch and a half above the tip of the styloid processes. The tendon may be retracted to the side most convenient. The posterior segment of the annular ligament is divided, and the tissues lifted from the bones with the elevator. The end of the radius should be removed with the exsector or gouge, when the carpus may be displaced backward through the incision, and removed wholly or in pieces. When the section is completed, the surfaces should be brought in apposition and fixed upon a well-adjusted anterior splint. Or an interrupted dressing may be applied by incasing the forearm in plaster of Paris to within an inch of the incision, and the fingers and hand in the same material, back as far as the anterior limit of the wound. A piece of

hoop iron (or several pieces of telegraph wire twisted into a single piece) is shaped as shown in Fig. 290, incorporated into the plaster upon the arm, and made to loop over the wrist to the tips of the fingers, where it is turned back

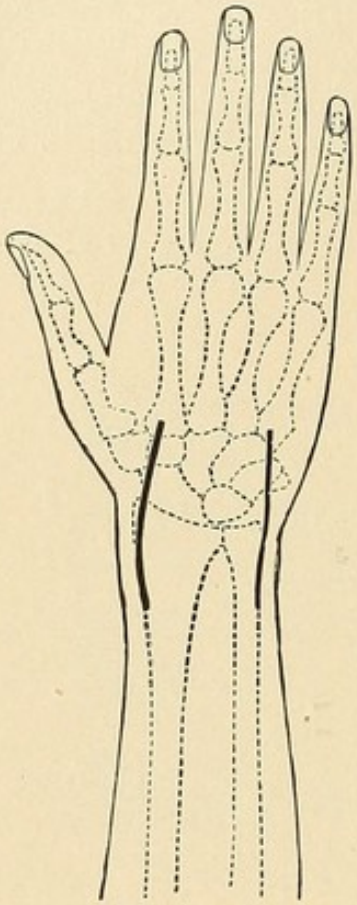

Fig. 288.—Bourgery's operation (modified).

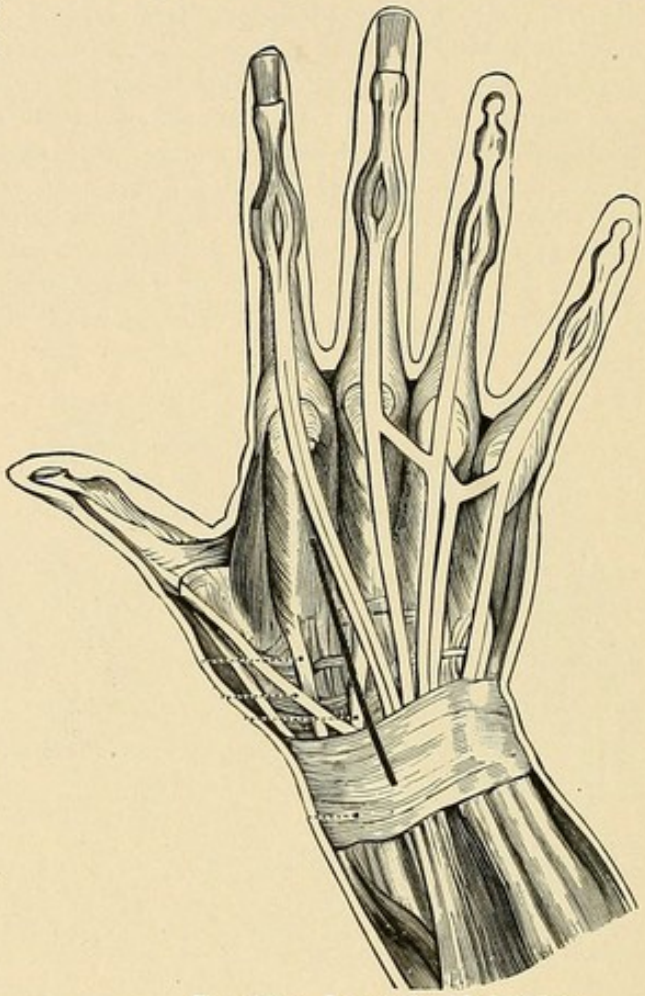

Fig. 289.—Langenbeck's incision. (After Esmarch.)

underneath the hand, and is fastened to the plaster here by an additional gypsum bandage (Fig. 291).

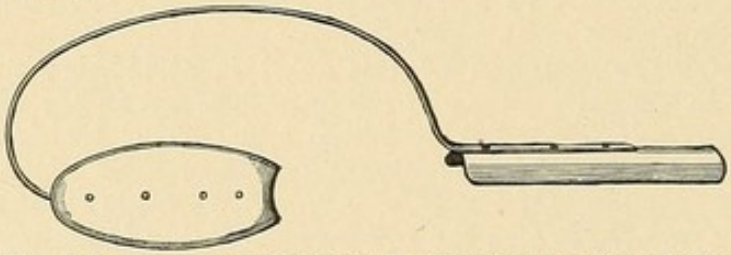

Fig. 290.—Esmarch's interrupted splint for exsection of the wrist.

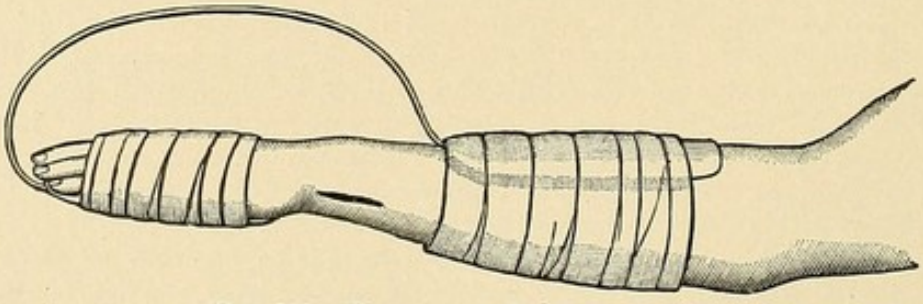

Fig. 291.—The same applied.

In the other operation one incision is made along the outer and dorsal aspect of the metacarpal bone of the little finger, over the styloid of the ulna, and one

inch along this bone. The radial incision should commence on the dorsum of the metacarpal bone of the index-finger, pass backward and slightly toward the radial surface of the forearm to a point half an inch above the tip of the styloid process, and thence directly upward along the dorsal aspect of the radius. In extensive operations it may become necessary to divide the tendon of the extensor ossis metacarpi pollicis, which is crossed by the incision. When done, the ends should be reunited by silk sutures when the operation is finished. The tissues are lifted from the bones and capsule as before, and the sections made with the exsector or keyhole saw.

Metacarpo-phalangeal and Inter-phalangeal Joints.—Excision of the metacarpo-phalangeal, on the inter-phalangeal articulations, may be done when the destruction of bone is limited. The same general rule, viz., that an excision is preferable to amputation, is applicable both to the hand and foot. At the terminal joints, however, the small size of the last phalanges will rarely permit of any operation except amputation.

Muscles and Tendons.—Of the diseases which affect the tendons or their sheaths and which require surgical interference, tuberculosis is by far the most important. It may affect any tendon of the body, but is chiefly met with in the sheaths on the dorsum of the wrist. The symptoms are usually those of swelling, which gives a puffy appearance to the entire back of the hand. Pain, although at times severe, is not a constant symptom. The only operative procedure which promises success is that which exposes the tendons involved by an incision, usually longitudinal, and a thorough dissection of the sheath from the tendon. The use of an Esmarch bandage facilitates the operation. Most careful asepsis should be practiced, the wound closed, and the patient should be directed to move the fingers while the process of repair is going on, in order to prevent adhesions of the tendon to the integument or bone.

In rupture or division of tendons it is essential to unite these at once by operation. Two sutures of fine silk are passed entirely through the substance of the tendon, about one eighth of an inch from the end, then tied and left in position.

Rupture of the tendon of the *quadriceps extensor femoris* is the most important injury connected with tendons.

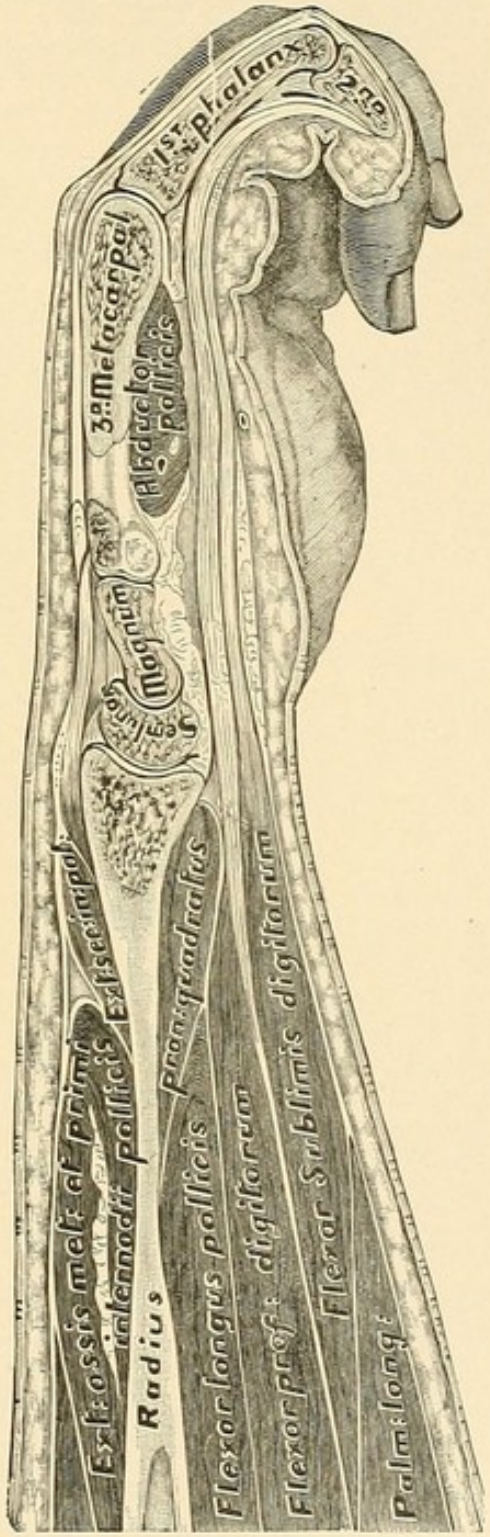

FIG. 292.—Longitudinal section through the forearm, wrist, and hand. (After Braune.)

The rational treatment and the only one that appears to offer any hope of success with restored function, is to expose the seat of rupture under the most careful asepsis and reunite the ends by direct suture. Silk is the best material to employ. When a sufficient fragment of tendon has been left attached to the patella, the sutures should be passed through this. When rupture has taken place close to the bone, two holes should be drilled in the upper

segment of the bone, as practiced by Buchanan, of Pittsburg, and the tendon of the muscle firmly united to this by a double set of silk sutures. The sooner the operation is done after the injury, the better. The limb should be immobilized in full extension after the operation.

When the *ligamentum patellæ* is torn, suture should be attempted, as for the quadriceps tendon. The prognosis is even more unfavorable.

In certain forms of paralysis, especially of the muscles which move the fingers, hands, and feet, it may at times be required to *transpose* a portion of the tendon of a non-paralyzed muscle and unite it to the tendon of one which has lost its function, the method of Dr. B. F. Parrish (New York Medical Journal, October 8, 1892). The tendon, or one half of the tendon, of a live muscle is in this operation sutured to the divided tendon of a dead or paralyzed muscle. Whether the union shall be end to end or lateral (overlapping) must be determined by the conditions to be corrected.

Elongation of the tendons of contracted or shortened muscles may also be effected by partial division on opposing surfaces at a given distance, splitting the intervening portion and uniting the half ends by suture.

The reunion of torn or incised muscles should be effected by immediate suture with linen, silk, or kangaroo tendon. The sutures must of necessity take hold in the sheaths, aponeuroses, or other dense connective tissue, as the fasciculi proper are too friable to resist tension. After suture the position must be selected which will reduce the tension to the minimum.

CHAPTER XI

THE SCALP—SKULL—BRAIN—CRANIAL NERVES, SPINAL CORD AND NERVES

Tumors of the Scalp.—Tumors of the scalp are *congenital* and *acquired.*

Congenital cysts are deeply situated, being beneath the skin, and not infrequently below the fascia and muscles. Their contents are chiefly white or yellow fluid, and at times hairs (*dermoids*). Each tumor may consist of a single cyst, or there may be several grouped together (multilocular), the mass rarely attaining a size greater than an inch in diameter.

If left alone they may ulcerate from pressure or injury, or, in rare instances, may cause atrophy and perforation of the calvaria and dura mater. They should be removed in early childhood. The operation consists in dissecting out the sac, with its contents. As a rule, small wounds of the scalp, situated where a scar will not be apparent, do not need to be stitched. The edges should be approximated and held thus by a dressing of sterile gauze and a bandage.

Acquired cysts, commonly called "wens," are of two varieties, one due to retention of sebum in a sebaceous follicle, the duct of which has been obstructed; the other caused by extravasation of blood, where the clot has been absorbed, leaving the serum more or less stained by the decomposition of hæmatin. They are round, smooth tumors, are superficial, and found most frequently upon the upper and posterior portion of the scalp. They are mostly multiple, are unilocular, and contain a granular, cheesy substance. The treatment is removal with the knife. The hair should be shaved from the tumor, and for a slight distance beyond its base. Complete anæsthesia can be obtained by cocaine infiltration. With a sharp bistoury transfix the mass through its base, and lay it open. The integument over the center of the tumor will be found exceedingly thin (not thicker than ordinary writing paper), and may be easily separated from the thickened sac, which should now be seized with a strong pair of forceps and torn out of its bed. If any strong adhesions are found they should be divided with the blunt scissors.

Sebaceous cysts occasionally become inflamed, the capsule breaks down, the contents escape, and a mass of *granulation tissue* replaces the original tumor. The new-formed capillaries in this tissue frequently give way, causing repeated hæmorrhage. They should be scraped out with a sharp spoon, and the sac removed by dissection.

Horns, or dense epithelial outgrowths, are occasionally seen upon the scalp and face. Some of these excrescences attain large size. They should be removed by an elliptical incision through the entire thickness of the integument.

Lipomata are of infrequent occurrence beneath the scalp, and, on account of the dense integument, they grow very slowly and rarely attain large size. The diagnosis between sebaceous and fatty tumors of this region is not always easy. The treatment is removal by dissection, which is easily effected by lifting the tumor from its capsule with the finger or the blunt scissors. The capsule need not be removed.

Nævi, *port-wine marks*, and other *vascular tumors*, are quite common upon the scalp. They have been considered in a previous chapter.

Papillomata, or *warts*, occasionally covering a large area, are found in this region. They should be clipped closely with the curved scissors, their bases burned with the actual cautery or nitric acid, and the operation repeated until a cure is effected.

Ulcers from *syphilitic gumma* of the skull are quite frequently met with in the scalp.

Tuberculosis (lupus) of the skin is rare in this region.

Elephantiasis, or general thickening of the scalp from connective-tissue new formation, is, fortunately, rarely met with. Ligation of the vessels feeding the diseased area will afford temporary relief, and may be followed by partial or complete extirpation.

Hæmatoma has been considered in the chapter on Wounds of the Scalp.

Abscess of the scalp requires free incision, irrigation, and drainage. Any doubts as to the character of the swelling may be dissipated by exploration with the hypodermic syringe and a good-sized needle.

Pneumatocele, or "*air tumor*," is occasionally met with beneath the scalp. It results from disease or fracture of some of the bones, permitting communication with the cavities, as the frontal sinus, or the Eustachian tube, etc., and the escape of air beneath the skin. Evacuation of the contents by pressure, with or without puncture, and a compress to prevent recurrence, will produce inflammatory adhesions and effect a cure.

Ostitis, or *periostitis*, is not uncommon in the calvaria. The causes are the same as for ostitis elsewhere. Great care should be observed in the treatment, on account of the proximity of the meninges and brain. Ostitis with exfoliation demands early recognition and immediate operative interference. The rubber tourniquet around the skull may be employed to control bleeding. A free horseshoe or crucial incision should be made, and all the diseased bone removed with the sharp spoon. When the exfoliation is confined to the outer table of the skull the prognosis is favorable. The wound should be kept open, well drained, and allowed to heal by granulation. If pus is found beneath the inner table, enough of the bone should be cut away with the rongeur to permit the free escape of all the products of inflammation. The patient should be required to rest in the position which secures most perfect drainage. A loose aseptic dressing should be applied.

Abscess of the Frontal Sinuses.—Chronic inflammation of these sinuses demands, as a rule, energetic and thorough operative measures. The accumulation of pus may interfere with the integrity of the eye, often breaking out through the orbit. Headache, great discomfort, and frequent and dangerously high temperatures indicate the sepsis which is occurring.

Operation.—Shave the eyebrow of the affected side and make an incision through the middle line of the brow so that when the hairs grow out the scar will be concealed. The incision should be free, extending across the root of the nose, if necessary. When the bone is exposed, the sinus is entered by chiseling with a small curved instrument through the anterior lamella of the frontal bone at the inner angle of the supra-orbital arch. A light mallet should be employed and the chisel should be held with the point directed toward the root of the nose, so that a slip would not injure the eye or brain. Continuing into the sinus, an opening one fourth of an inch in diameter should be made and the walls of the cavity thoroughly scraped with the sharp spoon.

A strong dressing forceps should now be carried into this opening, against the upper turbinated bones, and made, by boring, to crush through into the nasal cavity. A probe is next carried through this hole and brought out at the nostril of the affected side, and by this a strong silk thread is carried through. A good-sized piece of gauze—so twisted that while the end is as small as a cord the middle portion is as large as the little finger—is tied to the string and drawn through the sinus into the nasal cavity and out at the nostril. The entire twist of gauze is now pulled through. This breaks away the turbinated bones, does not cause annoying hæmorrhage, and leaves perfectly free drainage into the nose and mouth.

The edges of the wound should be united with fine silk sutures. In cases where the disease is unusually extensive and the discharge profuse, it will be advisable to carry a small soft-rubber drainage tube in through the wound down into the nose, leaving one end projecting through the nostril and the other at the inner angle of the incision above. For one or two weeks after the operation irrigation through the tube with warm salt solution should be practiced once a day. When

the tube is removed it should be drawn out through the nose. If both sinuses are involved, an incision on one side may suffice by breaking down the shell of bone which intervenes, and curetting the opposite sinus with the sharp spoon.

The effort to cure abscess of the frontal sinus by incision and drainage at the angle of the orbit is not only apt to fail, but it endangers the integrity of the eye.

Osteoma, or *exostosis*, occurs quite frequently upon the bones of the skull. When not due to syphilis it should be removed early, by the gouge or chisel, as there is always danger of pressure upon important organs if allowed to remain. Syphilitic hyperostosis requires the specific treatment given for this dyscrasia before resorting to operation.

Encephalocele, or *hernia cerebri*, is a protrusion of the brain substance through an opening in the calvaria. This condition usually occurs in children suffering from *hydrocephalus*, the protrusion taking place through the abnormally enlarged *fontanelles*. The dura mater surrounds and is carried in front of the mass, lying in contact with the pericranium. When the meninges alone protrude, the tumor is known as a *meningocele*. While this variety of tumor may occur at any point in the line of sutures, a favorite seat is in the median line of the skull, below the occipital protuberance. It may be covered with integument, or, as with certain forms of *spina bifida*, the meninges form the outer covering.

Meningocele is often incurable. Careful compression may limit the further development of the tumor, and in rare instances the opening in the skull closes spontaneously and a cure results. When the mass is covered with integument and the pedicle small, a rubber ligature gradually tightened is advisable.

Hernia cerebri may occur after perforation of the skull from any cause, as fracture or necrosis. More frequently the mass which protrudes is made up of a granulation tissue containing no elements from the brain substance, while at times these masses are composed of both brain and granulation tissue. The character of the tumor will be recognized from its rapid development after perforation of the calvaria.

Treatment.—When the mass is small, and is just beginning to project, compression should be employed to prevent a further protrusion. It is not safe to attempt a reduction of the tumor. The hair should be shaved from the scalp near the opening and disinfection accomplished by sublimate irrigation, and a compress of sterile gauze and absorbent cotton applied. If the tumor does not rapidly slough away, it should be removed at the level of the scalp with the elastic ligature or the actual cautery.

Sarcoma of the dura mater is a grave condition, fortunately of infrequent occurrence. In the process of development the tumor is apt to cause absorption of the calvaria, and finally perforation. This usually occurs long after symptoms of pressure from within have been developed. Should the patient survive the compression of the brain, the tumor ultimately undergoes necrosis and breaks down into a dirty mass, in which the process of ulceration is accompanied by frequent hæmorrhage.

Carcinoma of the meninges may occur as a result of metastasis, although rarely if ever occurring primarily in this situation.

In sarcoma and carcinoma of the dura mater little more can be done than to relieve pain by the employment of narcotics. The injection of the toxines of erysipelas with or without the mixture with the bacillus prodigiosus should be tried in this as in sarcoma elsewhere.

Hydrocephalus is primarily a tubercular disease of the arachnoid and pia mater in childhood. The gross lesion is a transudation of the serous fluid from the pia and arachnoid into the cavities of the ventricles, the arachnoid, and subarachnoid spaces. Distention of the ventricles, compression of the brain substance, separation of the sutures, enlargement and deformity of the head, projection of the eyeballs, downward squint, and loss of cerebral function, are the symptoms, invariably ending in death.

Treatment.—Tapping will at times relieve the more urgent symptoms of distention and compression. Careful antisepsis should be practiced, and the aspiration made through one of the lateral angles of the anterior fontanelle. A small needle should be introduced, and three or four ounces slowly withdrawn, the opera-

tion occupying from fifteen to thirty minutes. This treatment is palliative, and is only justifiable in the effort to relieve the suffering of the patient. A cure is impossible.

Microcephalus

Failure in development of the brain may be due to organic defect in brain cells, or to compression of this organ by non-expansion of the skull. With the former conditions surgery has nothing to do, but with the latter, a condition of true microcephalus, operation is indicated. The author has operated on a large number of these unfortunate children, and while none have been made normal, the physical and mental conditions have been materially improved in a sufficient number to justify its repetition. The death-rate is high (about fifteen per cent), but in view of the hopeless condition of these patients, when there is a prospect of betterment any risk seems justifiable.

There is usually a history of absence of the fontanelles. The skull and the head is small and cocoanut shaped. Lannelongue proposed cutting out a strip from a quarter to a half inch wide on either side of the median line and about an inch away from it. This operation does not relieve the pressure, and should be modified to include the removal of the entire top of the skull by the following technic: An incision is made from the middle line of the forehead, at the edge of the hair, back to near the occiput, the hæmorrhage being at once controlled by forceps, clamps, compression, or a running catgut suture. A button of bone is removed with the Galt trephine or hand gouge, and the opening immediately enlarged with the cutting forceps, which are laid aside and the bone rapidly broken and torn off in large pieces by the ordinary holding bone forceps. As the superior longitudinal sinus in children is not attached to the under surface of the skull, the entire roof of the calvarium can be removed for at least two inches on either side of the middle line. The dura mater is not disturbed, and the periosteum is removed with the bone. The edges are smoothed by clipping off the angular points of bone. The compression is further relieved by catching the remaining rim of skull to the depth of one half or three fourths of an inch between the jaws of the holding forceps, and straightening or prying it outward (not unlike a half-peeled orange). The operation is completed by reuniting the scalp in the middle line with a running catgut suture and applying a light sterile dressing. There is in almost all cases a noticeable improvement within a week or two. In one instance, in the case of a child a year old, a double talipes equinovarus disappeared within three months after the pressure was relieved.

Wounds of the scalp should be rendered aseptic, and closed by silk or linen sutures, or the edges brought into apposition by a sterile-gauze compress and bandage. The hair should be trimmed for a fourth or half inch from the edges of the wound. When no large vessels have been divided, the introduction of the sutures will suffice to arrest the bleeding. Cocaine anæsthesia will suffice.

Lacerated wounds of the scalp are at times very extensive and formidable. Several instances are reported of complete avulsion of the female scalp from the entanglement of the hair in machinery. In such cases transplantation of integument becomes necessary, in order to prevent ostitis from denudation of the calvaria. Ordinary lacerated wounds should be rendered aseptic, and may be treated by a compress of sterile gauze, or sutures employed, after the torn and bruised edges have been trimmed off with the scissors.

Contused wounds of the scalp are usually followed by marked swelling, due to extravasation of blood (hæmatoma) beneath the pericranium. The treatment consists in cold applications, by means of the ice-bag or cloths taken from ice water. If suppuration occurs, incision should be promptly made. A form of serous cyst sometimes results from hæmatoma of the scalp. It should be treated by aspiration, and, if one or two evacuations do not effect a cure, it should be incised and the cyst wall dissected out.

Penetrating Wounds of the Skull and Brain—Gunshot.—When a foreign body has penetrated the cranial cavity and passed out, the wounds of entrance and exit should be cleansed of loose fragments of bone or any foreign substance. Every

effort should be made to prevent infection. It is often imperative to enlarge both openings with a rongeur to secure free exit for the escape of blood or other fluids in the track of the missile. No effort should be made to arrest intracranial hæmorrhage by plugging, for fatal compression of the brain might result. If the vessels involved cannot be reached by forceps without injury to brain substance, the head of the patient should be elevated, and Dawbarn's sequestration method applied to lower blood pressure. Under no circumstances should a probe be introduced.

When there is only a single opening and the missile is lodged within the cranium, this wound should be cleared as above described, and the patient allowed to rest until the ball is located by a careful X-ray picture of the brain.

In gunshot wounds, and in other injuries of the brain, respiration is often suspended by the shock to this organ, while the heart still beats. With this knowledge in mind, artificial respiration should be practiced as long as there is hope of resuscitation. The introduction of a tube through an incision in the trachea and the bellows should be called into requisition when necessary to maintain prolonged oxygenation of the blood.

In locating a foreign body within the cranium by the Roentgen ray, great care must be taken to secure a correct picture.

In punctured wounds the propriety of operation will be determined by the conditions present. If there are symptoms of compression, either from hæmorrhage or the presence of a penetrating body, or should sepsis supervene, operation is indicated upon the first appearance of the symptoms.

Brain Centers.—Successful brain surgery depends largely upon (*a*) accurate knowledge of the various centers as determined by measurements upon the scalp and skull; (*b*) a careful study of the symptoms present in any given lesion; (*c*) the strictest asepsis; (*d*) rapidity of work; and (*e*) last, but not least in importance, the control of bleeding.

A useful scheme of localization is that of Chipault, an outline of which is given in Fig. 293. The patient's head should be smoothly shaved and scrubbed with soap and water. A careful measurement is made from the root of the nose at the naso-frontal suture *A*, along the median line of the skull to the occipital protuberance *B*, and this line is divided into hundredths: $\frac{45}{100}$ of this distance from the naso-frontal suture marks the precentral point; $\frac{55}{100}$, the Rolandic point; $\frac{70}{100}$, the Sylvian point; $\frac{80}{100}$, the lambdoidal point; and $\frac{25}{100}$, the lateral sinus point. From *C* the retro-orbital tubercle, which can be readily made out by the finger just behind the outer angle of the orbit, three primary lines are drawn to the $\frac{70}{100}$, $\frac{80}{100}$, and $\frac{95}{100}$ points, respectively named, from above downward, the Sylvian, the superior-temporo-sphenoidal, and the lateral sinus lines, and these are again subdivided into tenths. From the second tenth of the upper, or Sylvian line, to the forty-fifth or precentral point, is drawn the *precentral* line, and from the third tenth of the *Sylvian line* to the fifty-fifth, or Rolandic point, is drawn the *Rolandic line*. These two (the most important) lines are also subdivided into tenths. The various centers, as at present recognized, are indicated in the description of Fig. 293.

Given the symptoms of compression of the brain from hæmorrhage between the skull and the dura, beneath the dura, and within the brain substance, or from a collection of pus or an exostosis, depression of bone, or neoplasm within the cranium, a careful analysis of all the symptoms present will enable the surgeon to locate with reasonable certainty that portion of cerebrum or cerebellum which is involved.

In all extensive operations upon the brain it is advisable to have at hand the means of artificial respiration—namely, a trachea tube and bellows and a tank of oxygen, the latter not only to be used in an emergency, but to be combined with the inhalation of the anæsthetic, for there is less bleeding with than without this combination. It must be remembered that *shock* is one of the great dangers in brain surgery, chiefly on account of hæmorrhage, but also from traumatism. Next in importance is the prevention of sepsis, as well as the careful preparation of the patient. If possible, at least a week should be given to this, in which period the resistance should be brought as near to the normal as possible. Two days before the operation the scalp should be shaved and thoroughly scrubbed with warm water

and sterile soft soap that has just been boiled, the sebaceous matter and hair follicles cleaned out with the free use of ether, the whole surface thoroughly mopped with 1–3000 mercuric-chloride solution, and a moist 1–3000 mercuric-chloride dressing laid on and held in place by a capelline bandage. Just before the operation the scalp should be again shaved, and the cleansing process as above given repeated.

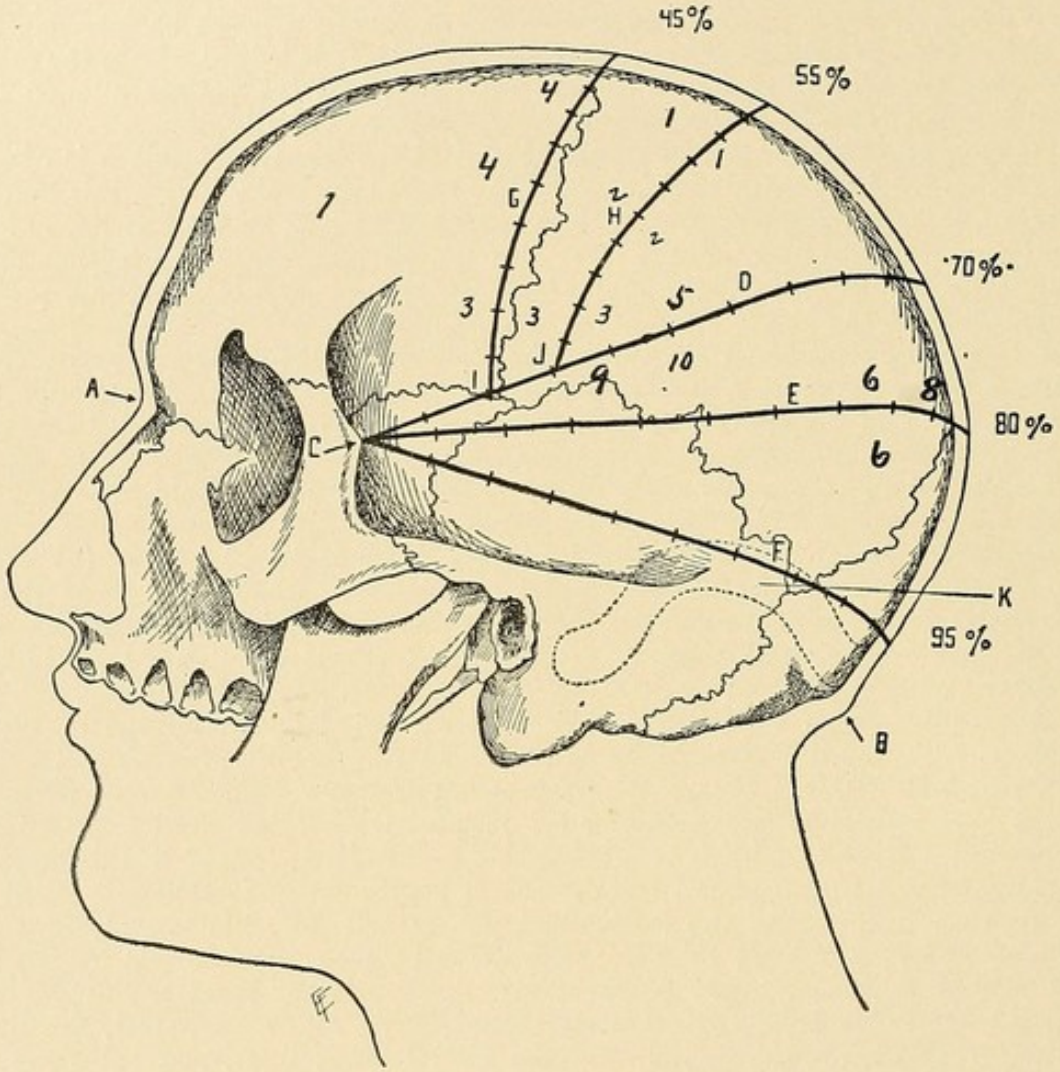

FIG. 293.—Localization after Chipault. A. Fronto-nasal junction. B. Occipital protuberance. C. Retro-orbital tubercle. D. Sylvian fissure line. E. Superior temporo-sphenoidal line. F. Lateral sinus line. G. Precentral line. H. Rolandic line. I. Junction of second and third tenths of Sylvian line. J. Junction of third and fourth tenths of Sylvian line. K. Lateral sinus. 45. Precentral point. 55. Rolandic point. 70. Sylvian point. 80. Superior temporo-sphenoidal point. 95. Lateral sinus point. 1. Motor and sensory disturbances, lower extremities. 2. Motor and sensory disturbances, upper extremities. 3. Motor and sensory disturbances, face, tongue, jaw, pharynx, vocal cords. Motor aphasia in right-handed people and vice versa. Upper 4. Movements of the body (posterior part of the first frontal convolution). Lower 4. Movements of the head and neck (posterior part of second frontal convolution). Lower 4. Associated movements of the eyes and head. 5. Tactile and muscular sensibility. 6. Hemianopsia and word-blindness, agraphia and paraphasia. 7. Intelligence. 8. Storage of visual images (cuneus, lingual lobe and calcerine fissure cannot be seen). 9. Audition. 10. Images for words heard and musical tones (left side). In this same region on both sides, the sensory motor auditory center exists. The internal frontal convolution lies in the longitudinal fissure, opposite the superior frontal convolution. The paracentral convolution lies in the longitudinal fissure opposite the ascending frontal, between the 45% and 55% points. The quadrate lobe lies in the longitudinal fissure opposite the ascending and inferior parietal convolutions, between the Rolandic and Sylvian lines, that is, the 55% and 70% points. The cuneus, lingual, and the fusiform lobes, first, second, and third occipital convolutions, are between the 70% and 95% lines. (After Ayer and Spitzka, Hartley, Kenyon and Bickham.)

Before commencing the operation all measurements should be carefully made and the various lines which may bear upon the procedure to be carried out indicated by sterile iodine or fuchsin stain.

In the selection of the anæsthetic, ether with oxygen should be used.

The position of the patient on the table should be the one most convenient to the operator, with the head and body slightly elevated. A rubber tube-tourniquet,

or flat band, is applied around the head beneath the occiput, above the ears and eyebrows, and is kept from slipping over the eyes by a sterile tape passing along the median line of the skull from before backward. If to this Dawbarn's sequestration method be added, the hæmorrhage will be materially lessened.

For the removal of tumors, or for any operation requiring the extra- or intradural exposure and exploration of a considerable brain area, the solid horseshoe-shaped or irregularly quadrilateral flap of scalp and bone is preferred. It is essential that the arterial supply to the flap be preserved. For this reason, the temporal and meningeal arteries are usually included in the base or hinge when operating laterally, and the occipital and frontal arteries when operating upon other portions of the skull. Guarding against hæmorrhage should commence with the operation. The incision through the scalp should be rapidly made down to the bone, and the bleeding at once arrested by compression or by the use of Kredal's steel plates.[1] The structure of the scalp is such that it is extremely difficult to grasp the end of bleeding vessels with the forceps, and clamping it tightly is apt to produce tissue necrosis. For this reason, when clamps are not at hand, a temporary running suture of linen will control this source of hæmorrhage. By the time the operation is finished most of these bleeding points will be stopped by coagula. The periosteum should be stripped back one eighth of an inch toward the flap to be elevated, and two eighths of an inch on the opposite side of the incision, and at certain points slightly wider for the trephine. A half-inch trephine (a smaller opening will suffice with Masland's saw) is now inserted at one of the upper angles of the wound (see

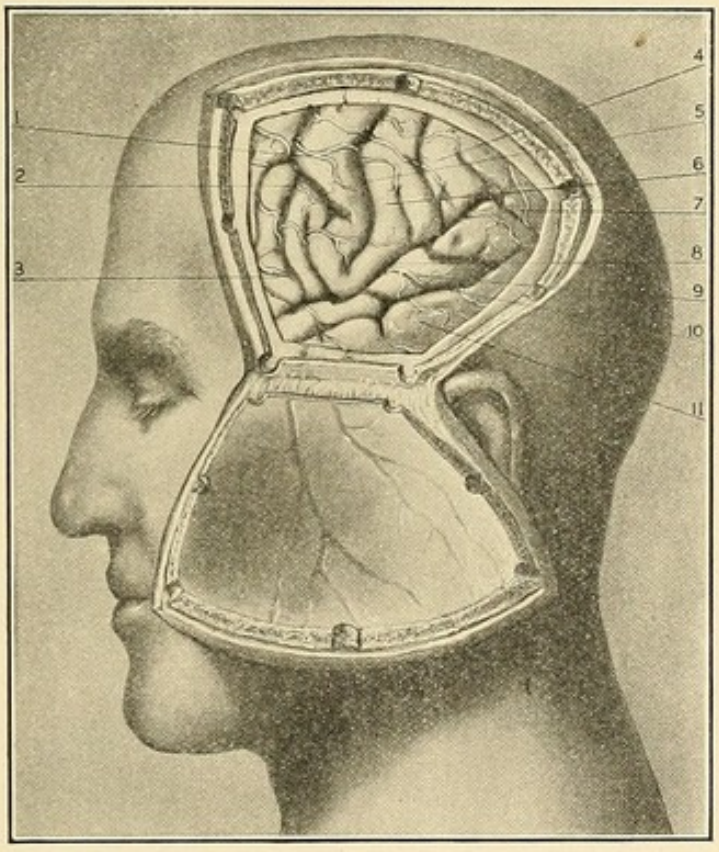

Fig. 294.—1, Ascending frontal convolution. 2, Precentral sulcus. 3, Ascending limb of the Sylvian fissure. 4, Inferior parietal convolution. 5, Fissure of Rolando. 6, Ascending parietal convolution. 7, Supramarginal convolution. 8, Fissure of Sylvius. 9, Superior temporo-sphenoidal convolution. 10, First temporo-sphenoidal sulcus. 11, Second temporo-sphenoidal convolution. (Hartley and Kenyon.)

Fig. 294), and a button of bone removed down to the dura. The concussion of the mallet stroke makes the chisel objectionable. Two other smaller trephine holes are cut in the same line, and along the descending planes of the proposed incision through the bone other holes are made (Fig. 294).

[1] "Centralblatt für Chirurgie," No. 43, 1906, Hartley and Kenyon.

In rapidly dividing the skull in these operations, the Masland saw [1] or Hartley's apparatus [2] in the hands of an expert are invaluable, for time is exceedingly important in this field of surgery. In their absence the next best method is the Gigli wire saw, which will require a larger trephine. Through this larger trephine hole a dull-pointed flexible, grooved director should be inserted, and the dura mater carefully separated from the bone in the line to the nearest trephine opening. Along the trough of the director the guide for the introduction of the wire saw is inserted, and this instrument pulled through, the director protecting the dura from injury. A few strokes should divide this strip of skull, preferably with a slight outward bevel. This technic is rapidly repeated until the section of bone is complete. In breaking the bone flap at the base, proceed as follows: Insert two strong, narrow instruments at the two lower angles, and make slight pressure with these, while a third and larger elevator is placed in the center of the upper line, where greater lifting force is exercised. If this be deftly done the line of fracture will be between the points of the two lower instruments. This trap-door flap, composed of bone and undisturbed periosteum and scalp, is now enveloped in gauze wet in hot normal salt solution and turned down and kept warm. The hæmorrhage from the bone is at times severe, necessitating rapid use of the saw, so that the bone may be quickly fractured and the flap turned down in order to expose the bleeding surfaces. All bleeding points should be packed at once with Horsley's sterile wax, or preferably a strong bone forceps should be used to pinch the two edges of the calvarium together over the bleeding points, crushing the vessel walls together with the diploë. Any severe oozing should be stopped by applying hot salt solution, either by irrigation or gauze pads, before the dura is opened. In case the Gigli saw, or the more modern apparatus of Hartley and Masland, are not used, the bone between the trephine openings may be cut away with the De Vilbiss cutter (Fig. 24), a very excellent instrument for this purpose; or, in an emergency, the old-fashioned von Bruns' bone cutter may be employed. The objection to these last two instruments is that they remove a rather wide strip of bone.

At this stage of the operation a careful note should be made of the patient's condition—the pulse, the character of the respiration, etc. The pulse is deemed so important an index that Hartley advises the use of a sphygmograph throughout the operation, with an indicator so arranged that any marked changes in heart action may be at once observed. If everything be favorable, the operation may proceed, but if there be doubt in the mind of the operator, he should rather lean to the side of conservatism and consider this the first stage in the operation, replacing the flap temporarily and applying an aseptic dressing, and waiting two or three days for complete reaction and recovery to continue the operation by opening the dura. With the modern saws and trephines run by electric motor power, the time consumed in reaching the brain surface is so much shorter that operations in two stages are now comparatively infrequent. In cutting the dura, the section should be about one quarter of an inch from the bone, so that resuture may be easier. In turning the dural flap, the hinge should be where the *meningeal* vessels enter. Any hæmorrhage should be arrested at once by fine catgut ligatures, and in lifting the dura great care should be taken to avoid the delicate plexus of vessels upon the cortex. Should there be found an extra-dural clot it will, of course, be unnecessary to expose the brain by opening the dura. The coagulum should be carefully removed, preferably by irrigation with hot salt solution. If subdural, the same method should be employed, and in brain clot irrigation from a small pipette, with force well regulated, is preferable to removing it by gauze.

Should a tumor be discovered, this, of course, must be removed with more or less injury to contiguous brain substance, and usually can be best accomplished with a dull-pointed curved scissors, or with the finger of the operator. Hæmorrhage should be arrested before the dura is resutured. Fine catgut ligatures will control larger points of bleeding, while hot salt solution will arrest oozing. The dura should be closed with a running catgut suture, and in case of persistent oozing, delicate bundles of this material may be left at one or two points to facilitate the escape of any transudate. The trap-door flap should now be brought into its nor-

[1] "Annals of Surgery," August, 1906. [2] *Ibid.*, April, 1907.

mal position, where it will remain with no other sutures than those passed deeply through the scalp and periosteum. Additional chromic-acid catgut bundle drains should be inserted at one or two points for drainage, and an aseptic dressing applied over all.

The lines of incision and field of exposure shown in this lateral operation may be extended forward or backward, as required. The occipital arteries are left in

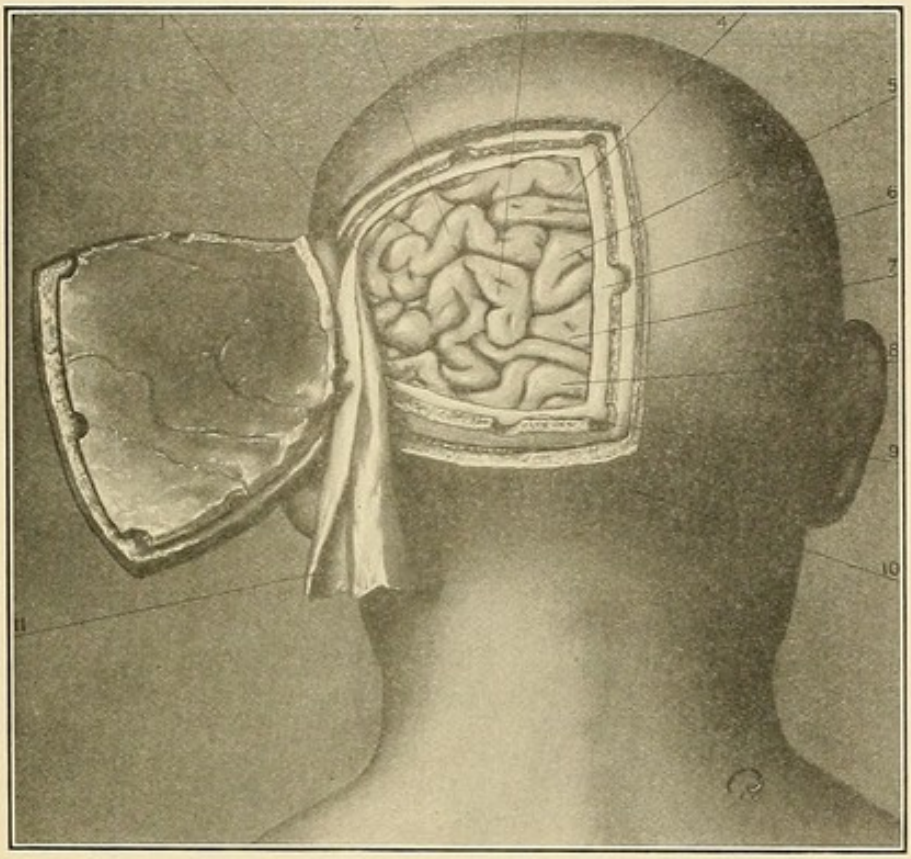

Fig. 295.—Trap-door exposure of the occipital region. 1, Supramarginal convolution. 2, Inferior parietal convolution. 3, Angular convolution. 4, External parieto-occipital fissure. 5, First occipital convolution. 6, Superior longitudinal sinus. 7, Second occipital convolution. 8, Third occipital convolution. 9, Lateral sinus. 10, External occipital protuberance. 11, Dural flap. In this region of the skull exposed by this flap, we have one case. (Hartley and Kenyon.)

the pedicle of the flap for the posterior operations (Fig. 295). When an extension of the lateral operation forward may not meet all the indications, a frontal bone flap may be made, leaving one or both frontal arteries in the pedicle.

Intercranial Lesions—Tumor—Hæmorrhage—Abscess

Compression of the brain, in addition to that caused by foreign bodies or depressed fractures, or traumatic hæmorrhage may also be due to neoplasms, collections of pus connected or not with an injury, and by hæmorrhage as well, which occurs at times without appreciable cause. One of the most frequent forms of compression is that due to collections of tuberculous material while the lesions of syphilis (gumma and various lesions of the arteries) and glioma, cysts, carcinoma, sarcoma, and fibroma are found.

Tumors.—The ordinary symptoms of brain tumor are headache (worse on waking), vomiting of a projective type not associated with ingesta, vertigo (developing upon change of position), optic neuritis, and mental dullness. If to these symptoms are added either Jacksonian epilepsy, paralysis, at first limited to one group of muscles or to a single limb and extending gradually to other parts, or if there is some form of aphasia or hemianopsia, with staggering or uncertainty of balance, the diagnosis of a tumor is reasonably certain, although its location may not be assured. When the localizing signs are absent, operation gives little or no

promise (Starr). This author concludes that about ten per cent of tumors are open to surgical treatment.

Those which lie in or near the Rolandic and Sylvian fissures are more readily diagnosticated, and give better results as to operation and improvement than when more deeply seated. With the foregoing symptoms present, and with evidences of the compression of a recognized brain center, an operation is imperative. The indications as to localization already given should suffice to lead the operator to the area of disease. When there exists severe and continuous pain, with increasing mental dullness, although there are no well-defined symptoms of localization present, an exploratory operation is justified, and should no lesion be discovered *decompression* is indicated.

Exploration.—In undertaking an exploratory operation upon the brain, it is important to utilize that point of the cranial surface which, by the smallest possible opening, will give the largest scope for intracranial search, and at the same time prevent the possibility of serious post-operative cerebral hernia.

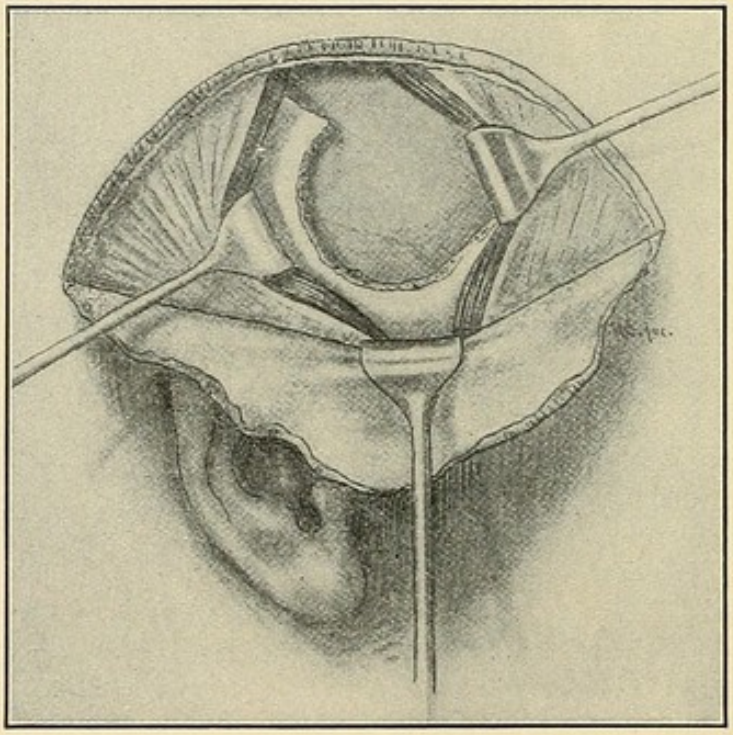

FIG. 296.—Sketch of the intermusculo-temporal field of operation, showing exposure with bone defect partially made.

Two methods may be followed—the trap-door procedure already given or the intermusculo-temporal operation of Dr. Harvey Cushing (Fig. 296):

"A curved incision is made over the side of the head concentric with and about one centimeter within the line of origin of the *M. temporalis* at the temporal ridge (Fig. 297). In order not to divide the filament of the facial nerve which supplies the frontal portion of the occipito-frontalis muscle, it should not extend anterior to the hair margin and its posterior angle may be advantageously carried somewhat lower than the anterior. The scalp and the aponeurotic membrane are reflected downward, leaving bare the temporal fascia. An incision is made through this semi-transparent fascia in the line of the fibers at about the central part of the muscle where the fibers run in an oblique direction downward and forward. Less room will be had if a point is chosen where the fibers are more vertical, and their course from origin to insertion consequently shorter. The fascial edges are retracted, exposing the muscle bundles. The incision is carried down to the bone in an interspace between the muscle bundles which are not divided. The anterior and posterior borders are retracted as widely as possible and at the same time lifted from the skull, while the periosteum, as far as it can be reached, is scraped back with an elevator from the bony surface that underlies the muscle. A small primary

opening is made through the exposed squamous portion of the temporal. This is enlarged with rongeurs or ordinary bone forceps to the desired size, the dura having been separated in advance (Fig. 296). It is necessary to have rather flat instruments, as the fascia and muscle cannot be lifted away from the bone sufficiently far to allow of the introduction of thick-bladed instruments under them. The opening may be about six centimeters in its vertical by eight centimeters in its antero-posterior diameter.

"Bleeding from the diploë may be particularly troublesome, and frequently necessitates the use of wax. Care must be taken while biting away pieces of bone from under the muscle anteriorly, lest injury to the meningeal be occasioned."

The extent of the incision in the dura will be determined by the nature of the operation. If an abscess is suspected, a small puncture at some point near the center of the field where the vessels may be avoided will suffice for the introduction into the brain substance of the dull-pointed grooved director, or preferably Jackson's exploring dilator (Fig. 296*a*).

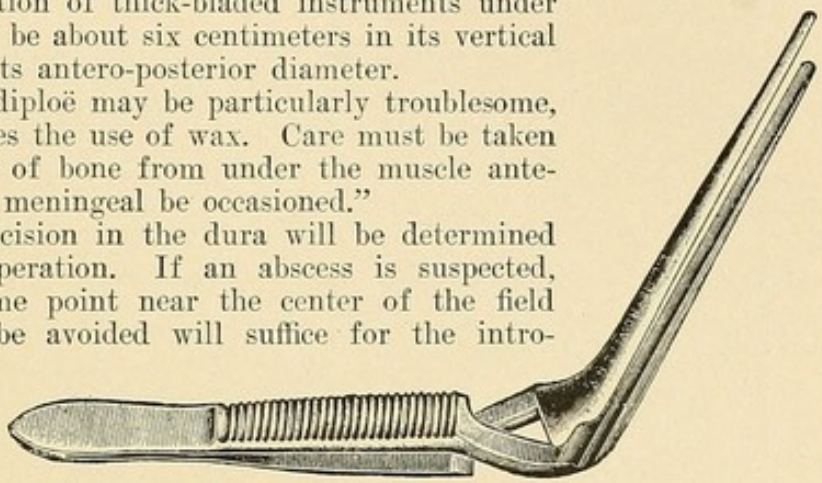

Fig. 296*a*.—Jackson's exploring dilator.

Should an abscess be discovered, if it can be drained to advantage from this level, a suitable incision of the dura should be made and drainage instituted, or a

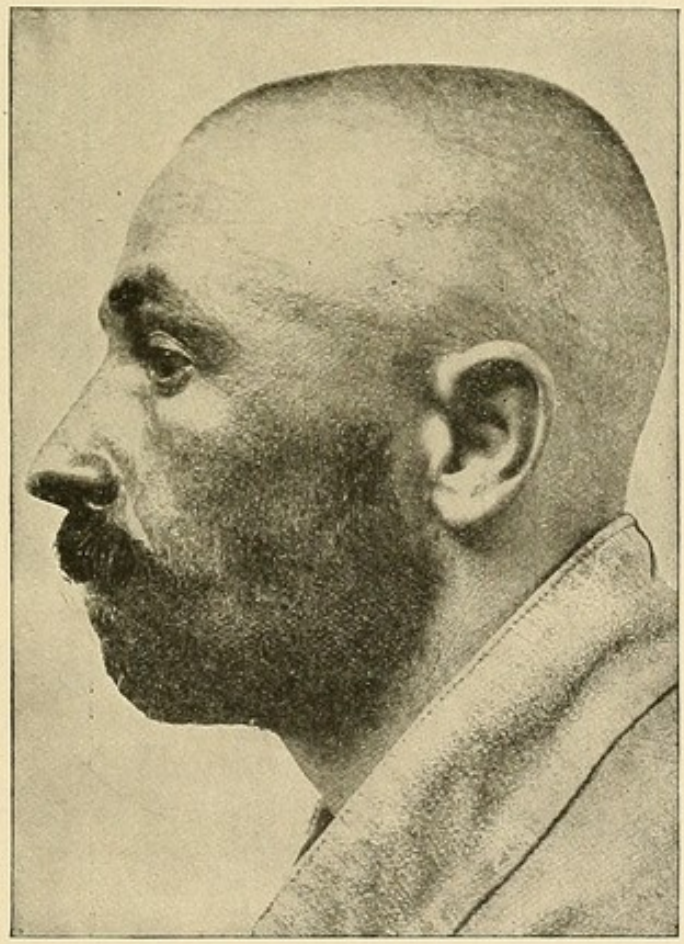

Fig. 297.—Photograph of patient four days after a decompressive operation by the temporal route. Note anterior limit of the incision at the hair line, stopping short of the nerve to the occipito-frontalis. In Cushing's operation for the extirpation of the Gasserian ganglion the curve ends near the upper attachment of the auricle, not behind the concha. (After Cushing.)

second bone incision may be made. An operable tumor would probably require an osteoplastic flap, but if inoperable and *decompression* is indicated, the bone defect

should be enlarged to the requisite size and "the dura should be incised and cut away to its very margins. Here, again, some care must be exercised, for with a tense brain, which bulges tightly against the dura, cortical injuries may be occasioned; an accident which always increases the amount of subsequent protrusion,

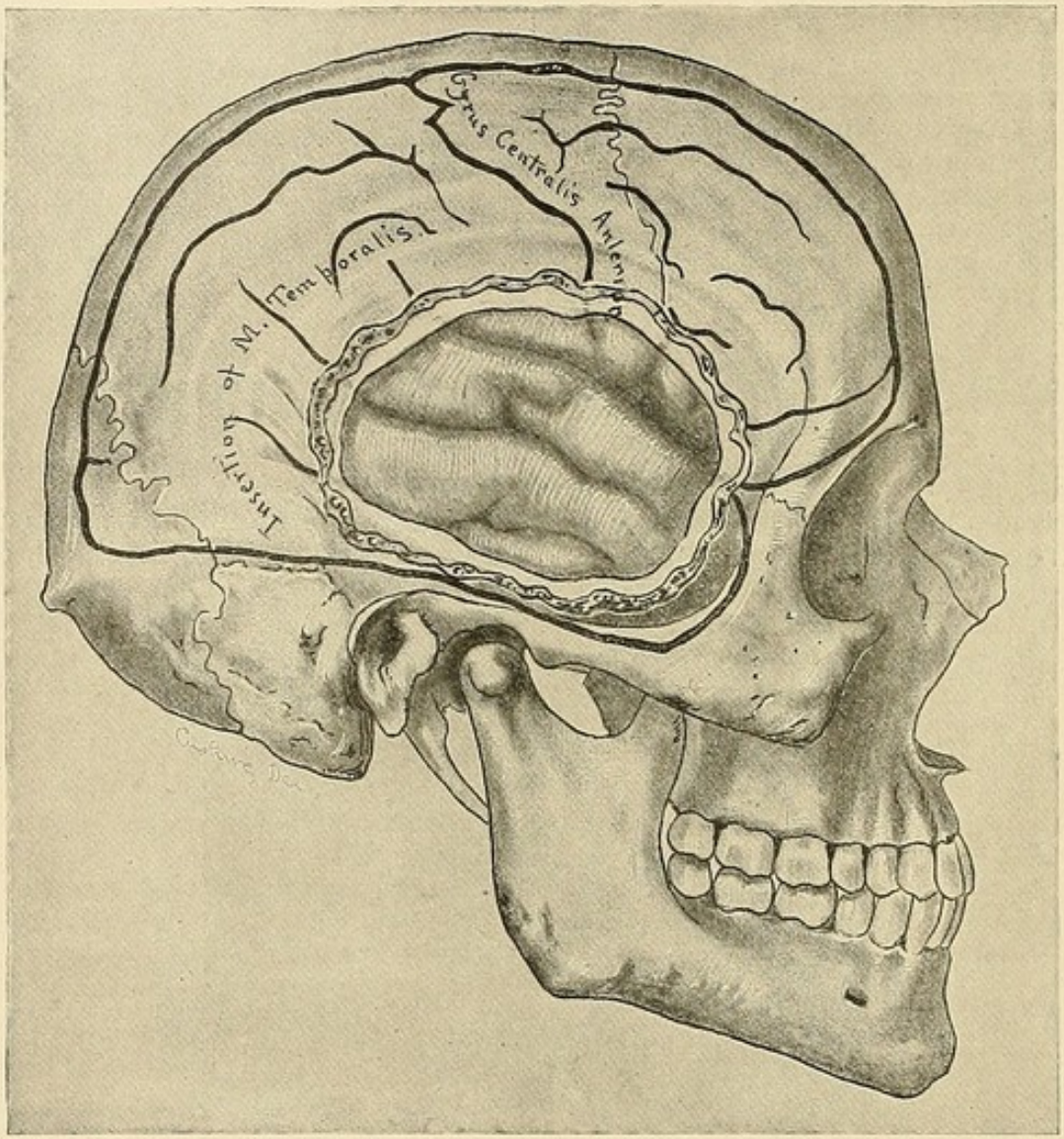

FIG. 298.—Sketch to show the relation of the temporal bone defect to the underlying cortex and the denuded area which will form the protrusion in Cushing's decompression operation. (After Cushing.)

owing to the consequent hæmorrhage and œdema. The dural incisions, too, should radiate in line with the posterior branch of the middle meningeal artery, after its ligation and division in the midfield, lest accidental injury of the vessel far under the muscle edge give annoying hæmorrhage. With the exception of this main vessel, the pressure of the protruding brain against the edge of the bone defect should control the oozing from the intervening fringe of dura. The area of the cortex which protrudes and makes up the hernia is shown in Fig. 298. It will be seen that the temporo-sphenoidal lobe constitutes the chief portion. Over the denuded bone, the split temporal muscle is then brought together with fine black silk sutures. The fascia is similarly closed, and it is necessary to place the sutures at the very edges of the incision, else the inelastic fibrous membrane will not be satisfactorily brought together. A few sutures may then be placed in the occipito-frontal aponeurosis before closing the scalp. For the scalp, accurate approximation of flat surfaces is desirable for the sake of controlling hæmorrhage—very rarely are any ligatures placed in the scalp—though there is less reason here

for the extreme precautions which closure of the scalp demands when it alone, without any underlying muscle and fascia, must withstand the pressure of the resulting protrusion. The sutures in all cases are removed in forty-eight hours and the wound protected, if need be, with collodion gauze strips."

Through this approach, as will be described later, it is possible to reach the sensory branches of the trifacial, and in the employment of alcohol injections this may be considered a more accurate route in guiding the needle to the foramina ovale and rotundum without danger to other organs. In this latter procedure the cavity of the skull would, of course, not be entered.

Dr. Harvey Cushing has, in a number of instances in fractures of the base, successfully drained the subdural space through this route. He commends it highly in exploration for extra-dural meningeal clot or abscess of the temporal lobe.

There can be no clearer surgical indication than to relieve compression in these hopeless cases of intracranial tumor. A large proportion of these neoplasms cannot as yet be accurately located, and when found many are inoperable. Nothing remains but to lift the skull and dura and permit expansion.

The author had done this operation as early as 1890 with immediate return of consciousness after prolonged coma. In these cases the trap-door operation was done, leaving the bone and dura standing well away from their former relations and reuniting the more elastic scalp. The procedure of Cushing when available is to be preferred.

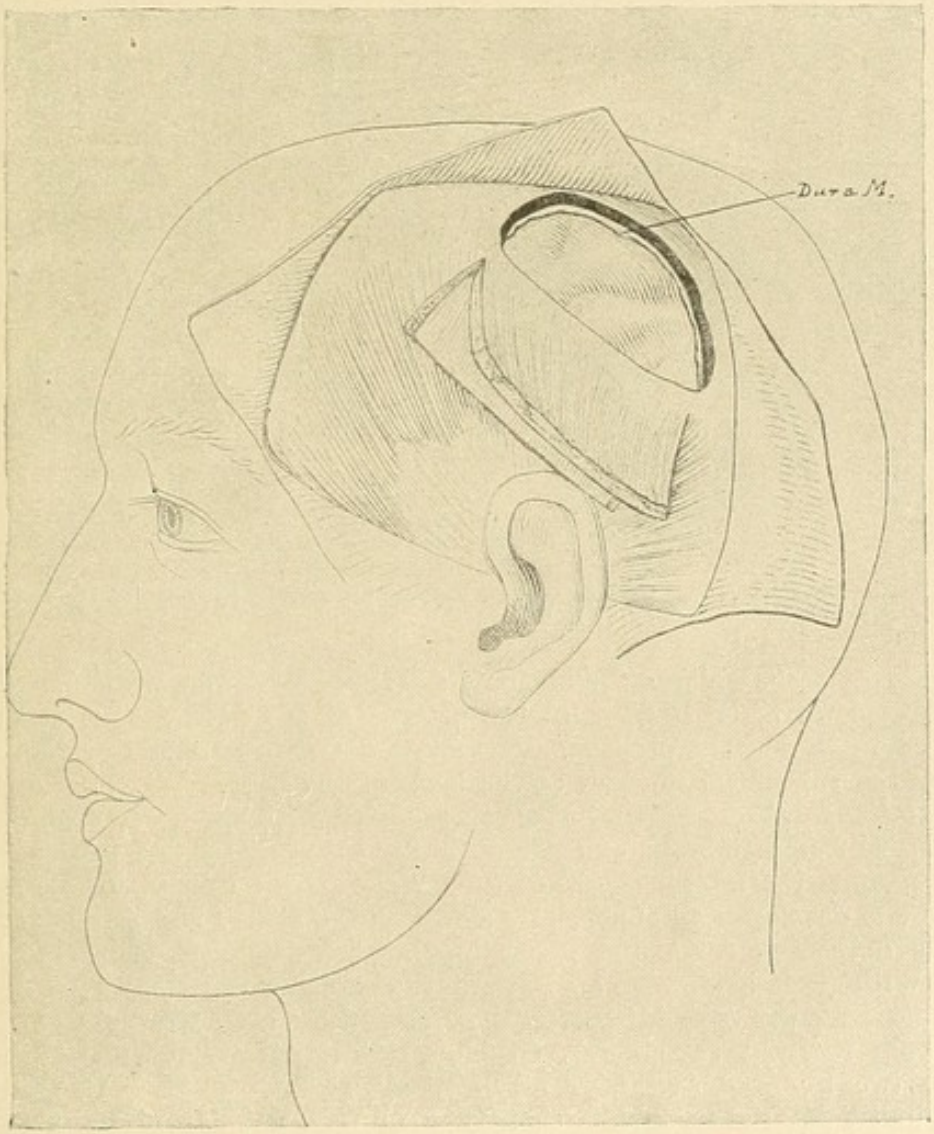

FIG. 299.—Solid flap of periosteum and temporal fascia lifted and ready to be turned bottom-side up to cover cranial defect. (Carl Beck.)

Cranial Defects.—Under other conditions than compression from neoplasms, the prevention of cerebral hernia is important. After fractures with ostitis or after extensive destruction of the skull from syphilis or necrosis, the muscular and fascial coverings of the cranium may be utilized in plastic procedures to cover such defects and limit or prevent hernia. Fig. 299 illustrates an operation devised

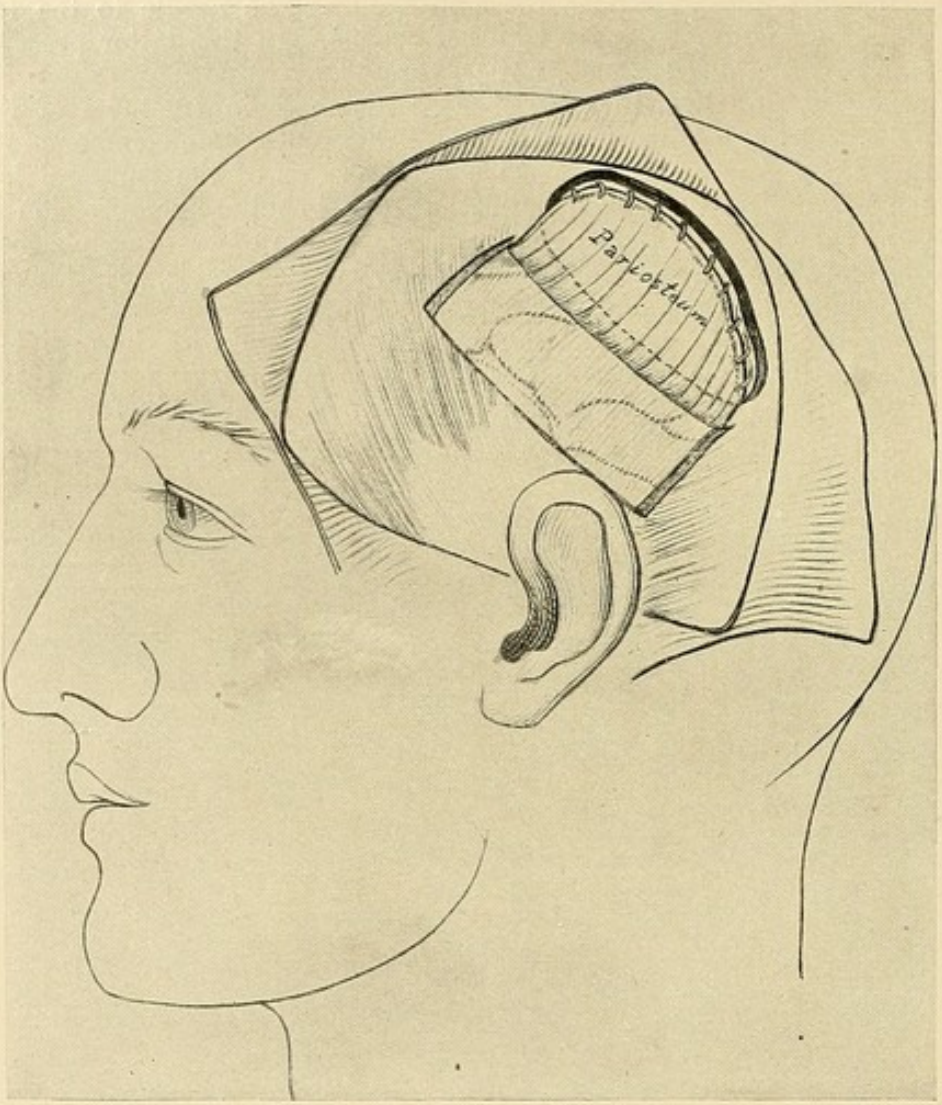

FIG. 299*a*.—The temporal fascia, muscle, and periosteum sutured to the edge of the dura mater. (After Beck.)

by Prof. Carl Beck, in which a solid flap of the temporal fascia, muscle, and periosteum, is turned up to be stitched to the margin of the dura mater, the scalp to be resutured in its normal position. A similar use may be made of the occipito-frontalis or the superficial muscles of the back of the head.

Cerebral Hæmorrhage.—Hæmorrhages associated with the dura, whether immediately beneath this membrane or extra-dural, may be readily diagnosticated when, after a blow upon the lateral aspect of the skull over the course of the meningeal vessels, there is developed an abnormally slow pulse, a steady rise in blood pressure, a gradually deepening coma and increasing hemiplegia, with Cheyne-Stokes respiration. With these symptoms an immediate operation is imperative.

In deeper hæmorrhages, intracerebral or cerebellar, even when no external injury has been received (apoplexy), Cushing states that when the pressure rises steadily to two hundred and fifty millimeters,[1] and when with this rise there is a slow pulse, falling to as low as fifty a minute, a fatal result is inevitable and justifies exploration. Under such conditions a large trap-door flap should be

[1] Measured on the Riva Roca apparatus.

turned down on the side opposite to the paralysis, the dura divided, the brain explored, and, if necessary, the exploration completed as a decompressive procedure, or the intermusculo-temporal operation may be substituted.

In another form of hæmorrhage-compression, in the new-born occurring with protracted and difficult labor, whether or not instruments have been employed, the surgeon should advise immediate lifting of the skull and removal of the clot. In many of these cases, and in other deeper hæmorrhages of the brain, the aspiration by lumbar puncture of bloody cerebro-spinal fluid, will confirm the suspicion of central hæmorrhage.

Abscess.—When not connected with a penetrating wound, or the presence of a foreign body, or a fracture, abscess of the brain is in such a large proportion of cases connected with infection of the middle and internal ear, or of the mastoid process and lateral sinus, that this lesion will be considered with the surgery of the ear. Abscess of the brain, of traumatic origin, which produces definite cerebral symptoms, can be diagnosticated and should be operated on as soon as recognized. In cases of fracture of the skull, or concussion, followed within two or three weeks by the development of symptoms suggestive of abscess, it is imperative to trephine, even though the symptoms are purely subjective.

These are headache, vertigo, vomiting, slow pulse, marked change in the mental state, dullness, irritability of temper, defective memory, despondency, tenderness on percussion, irregular pupils, and optic neuritis (Starr). When meningitis occurs, as a rule lumbar puncture will reveal an increased number of leucocytes in the cerebrospinal fluid, together with the micro-organisms of sepsis. The blood count is essential, since sudden and great increase in the leucocytes is an indication of a cerebral complication. The leucocyte count in meningitis is usually higher than that in abscess.

Aspiration of the Ventricles.—In exploration of the brain it is occasionally desirable to aspirate the lateral ventricles. Prof. W. W. Keen has laid down the following rules of procedure:

To aspirate the lateral ventricle: I. Trephine half-way from the external occipital protuberance to the upper end of the fissure of Rolando, half to three

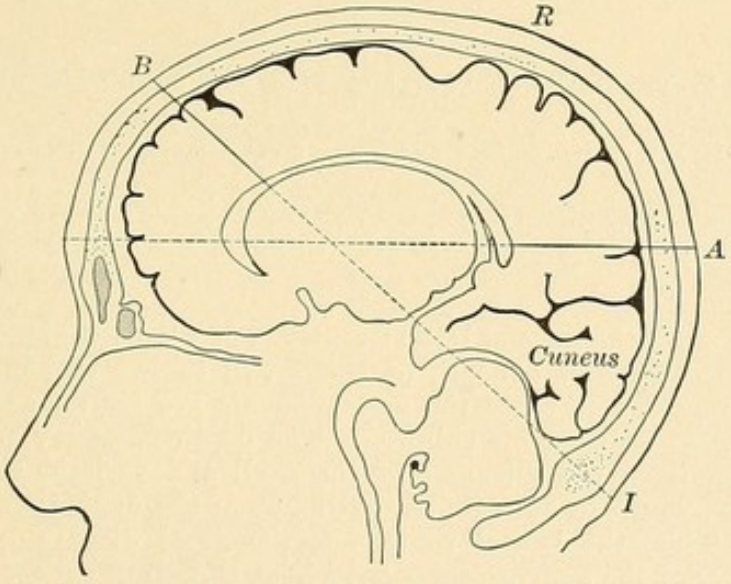

FIG. 300.—Antero-posterior section of the head half an inch from the median line. *R*, Fissure of Rolando. *I*, Inion. *A* and *B*, (solid) lines of puncture, the dotted lines showing their imaginary continuation to the fixed points. (After Keen.)

quarters of an inch to either side of the middle line. Puncture toward the inner end of the supra-orbital ridge of the same side (Fig. 300 *A*). The puncture will pass through the precuneus, and the normal ventricle will be struck at some point in the posterior horn at from two inches and a quarter to two inches and three quarters from the surface of scalp.

II. Trephine at one third of the distance from the glabella to the upper end

of the fissure of Rolando and half to three quarters of an inch to either side of the middle line. Puncture in the direction of the external occipital protuberance (Fig. 300 *B*). The puncture will traverse the first frontal convolution well in front of the motor zone, and the normal ventricle will be struck in the anterior horn at about two inches to two inches and a quarter from the scalp.

III. Trephine one and one fourth inch behind the meatus and one and one fourth inch above Reid's base line. (This line extends from the lowest part of the infra-orbital margin through the middle of the external meatus to the ear.)

Puncture toward a point two and one half inches directly behind the opposite meatus (Fig. 301). The puncture will traverse the second temporo-sphenoidal

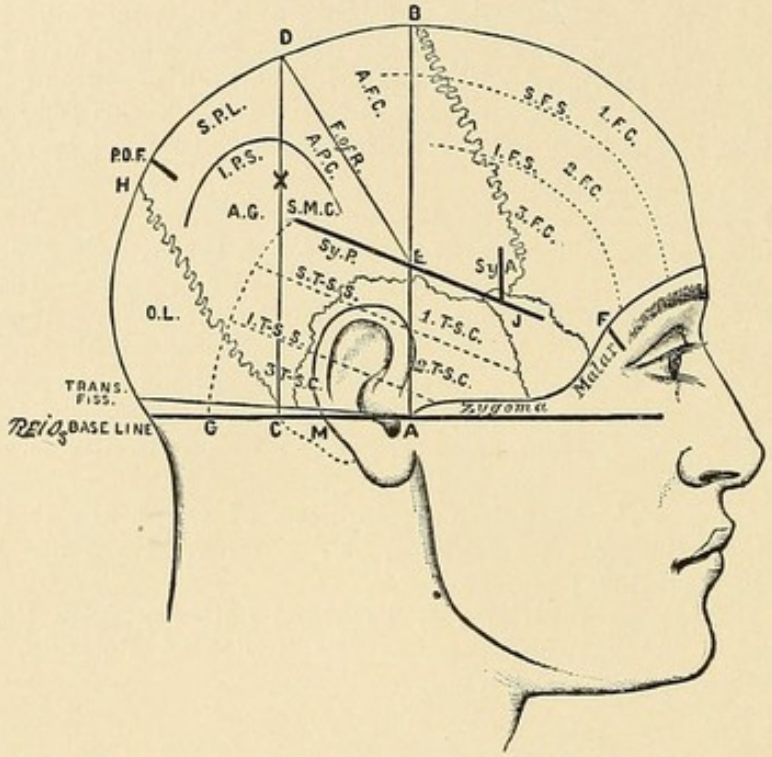

FIG. 301.—Diagram to show the relations of the brain to the skull (modified from Reid). J B, Coronal suture; B, bregma; F, external angular process; H, lambda; H C, lambdoid suture; J, pterion; M, mastoid process; X, parietal eminence; Sy. A., Sy. P., anterior and posterior limbs of Sylvian fissures; F. *of* R., fissure of Rolando; A. F. C., A. P. C., ascending frontal and ascending parietal convolutions; S. F. S., I. F. S., superior and inferior frontal sulci; 1 F. C., 2 F. C., 3 F. C., frontal convolutions; S. T.–S. S., superior and inferior temporo-sphenoidal sulci; 1 T.-S. C., 2 T.-S. C., 3 T.-S. C., temporo-sphenoidal convolutions; I. P. S., intraparietal suture; S. P. L., superior parietal lobule; S. M. C., supra-marginal convolutions; A. G., angular gyrus; P. O. F., parieto-occipital fissure; O. L., occipital lobe; G, C, M, A, Reid's base line.

convolution and enter the normal lateral ventricle at the beginning or in the course of the descending cornu at a depth of about two to two and one fourth inches from the surface. In this route the measurements are for an adult skull. They should be somewhat reduced for children. The depth necessary for puncture will depend somewhat upon the thickness of the skull and variations in the diameter of the skull from youth to old age, as well as upon the distention of the ventricle with effusion. This, the lateral route, has the great disadvantage that it will develop an abscess of the temporo-sphenoidal lobe, as well as dropsy of the ventricle. It is well to state that the center for hearing of the opposite side may be penetrated through this opening, but, as it has been done a number of times without impairment to the hearing, this objection should not prevent the operation. At the ventricular end of the puncture the optic thalamus may be injured, but this risk must be taken.

The Surgical Treatment of Epilepsy.—In about ten per cent of all epileptics the convulsions are due to a focus of irritation caused by an injury or to inflammatory adhesions, or to the presence of a neoplasm of the bony envelope, the membranes, or the brain substance proper. When it can be demonstrated by cere-

bral localization that a given point in the brain is affected, it is justifiable to explore the suspected focus of disturbance. When epileptic seizures habitually begin with twitching of a single muscle or group of muscles (as of the thumb, hand, or facial muscles of one side) before the general convulsion is precipitated, it is quite probable that the area from which these motor impulses originate is involved. The same is true of sensory phenomena, although these are comparatively rare.

The operative technic differs in no essential feature from that already given. The osteoplastic flap is in general to be preferred, and its shape and position may be modified to suit the region of the skull to be temporarily lifted. Should permanent removal of bone be considered advisable, the bone flap may be partially or completely cut away and the dura and scalp resutured, or the bone may be not quite restored to its original level, the scalp being stretched and resutured over the elevated fragment. On account of the great danger of cerebral hernia, an area larger than an inch in diameter should not be entirely removed unless protected by a covering of muscle or strong fascia.

Trifacial Neuralgia.—Neuritis of one or more of the branches of this nerve or of the Gasserian ganglion is one of the most painful of human maladies, and its relief one of the most perplexing problems in surgery.

The one most generally successful procedure is the removal by excision of the entire ganglion and its three offshoots, or its destruction by direct or indirect avulsion. The former procedure is so formidable and hazardous, involving an invasion of the cranial cavity, that in view of even the qualified success which has been reported by less dangerous methods, these are first entitled to a thorough trial. They are the *injection of alcohol* into or in contact with the two principal branches just after they leave the floor of the skull and *indirect* or *distal avulsion.*

A thorough knowledge of the regional anatomy of this part of the subcranial space is essential, and great care is necessary in applying the remedy.

Eighty per cent alcohol is used for the injection and a special needle is employed (Fig. 302). It is sharp at the point for penetrating the skin and dense



FIG. 302.—Levy and Baudouin's needle with removable stylet. (Hecht.)

fascia, and is provided with a stylet which converts it into a dull-pointed instrument to guard against wounding any vessel which may be in the line of penetration.

Levy and Baudouin give the following technic: "For the superior maxillary branch, to determine the point of puncture, a line is drawn vertically from the posterior border of the orbital process of the malar bone to the inferior edge of the arch of the zygoma. (See Fig. 302*a*.) The needle is to be introduced at a point 0.5 cm. posterior to this line tangentially measured on the lower edge of the zygomatic arch. It is then directed slightly upward, and when introduced to the required depth of 5 cm. it is well in the pterygo-maxillary fossa (Fig. 302*b*).

"At a depth of 2 cm. a bony obstacle in the form of an abnormal coronoid process may interfere, and still deeper an anomalous external pterygoid plate may obstruct. In either event the needle must be inclined forward, but not too far, since there is danger of entering the orbit and puncturing the eyeball. It must also be kept well above the spheno-palatine foramen which leads into the nasal fossæ. The skin, cellular tissues, anterior fibers of the masseter muscle, and temporal tendon are penetrated in the course of the needle.

"For the inferior maxillary branch, the point for puncture is ascertained on the cheek by measuring off 2.5 cm. along the inferior border of the zygomatic arch in front of the descending bifurcation of the longitudinal root of the zygoma (Fig. 302*a*). The needle inserted here to the prescribed depth of 4 cm. arrives at the foramen ovale (Fig. 302*b*) after having passed through skin, subcutaneous tissue,

the zygomatic insertion of the masseter, posterior portion of the temporal tendon, superior border of the external pterygoid muscle, and lastly in front of the temporo-maxillary articulation, which latter enables one to avoid the transverse facial

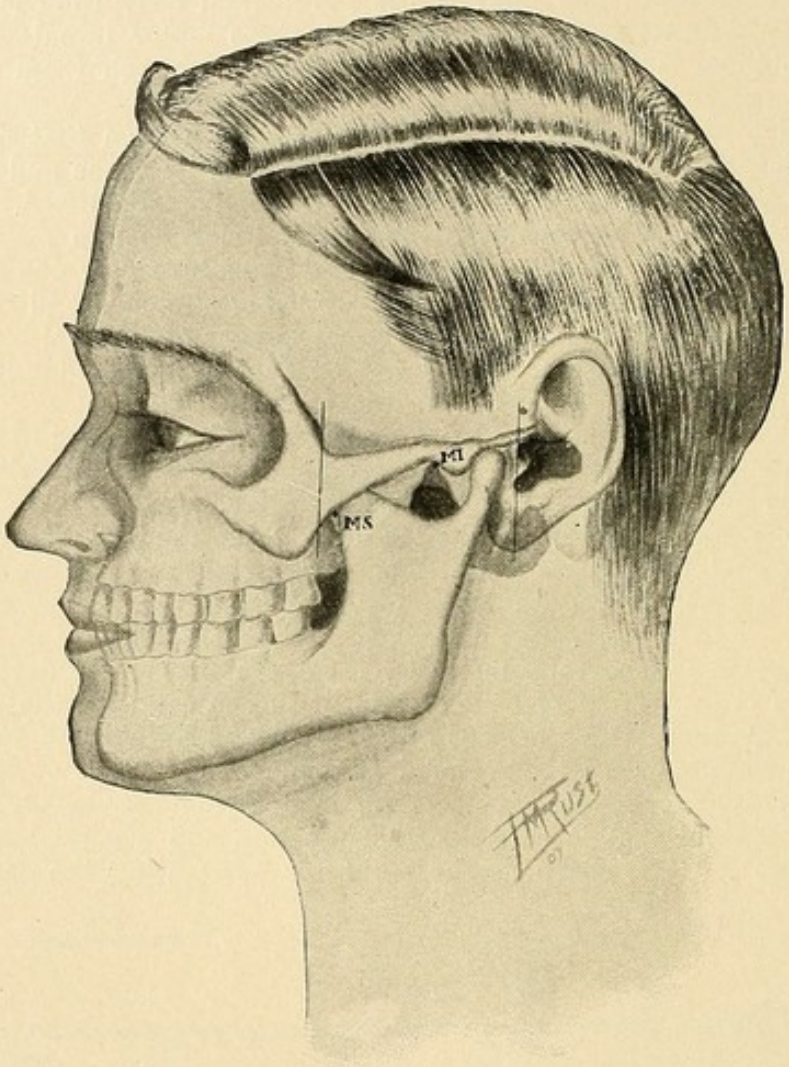

FIG. 302*a*.—M.S., Point of entrance for the needle for penetrating to the superior maxillary branch. M.I., The inferior maxillary. (Hecht.) ("Journal of the American Medical Association.")

artery, the internal maxillary artery and veins, and the middle meningeal artery which emerges from the foramen spinosum" (Hecht).

On account of the danger to the optic nerve, the author does not advise the injection into the ophthalmic branch.

The average depth of penetration of the needle to reach the neighborhood of the foramen ovale is 4 cm. It would be well to make a part of the injection at this depth, withdraw the needle for a very short distance ($\frac{1}{3}$ cm.) and force out the remainder. The quantity usually employed is from 1 to 2 c.c. of eighty per cent alcohol. The strictest aseptic precautions are essential. The patient's head should rest easily on a level plane, either sitting upright or lying on one side of the face. Local anæsthesia for the skin is advised. The hand of the operator should rest firmly on the bones of the face, and the needle with the stylet slightly withdrawn from its tip is introduced to the depth of about 1 cm., when the stylet is pushed forward and the needle insinuated to the proper depth. When this is reached the stylet is entirely withdrawn and the syringe containing the proper amount of alcohol is attached. The contents should be forced out rather slowly, taking probably as long as a minute for the entire injection. If the pain is not entirely absent on the succeeding day, the operation should be repeated.

Hecht reports that except for the œdema which followed the orbital injection, there was not the least unpleasant effect after the treatment. As before given, the

author insists that great caution is necessary in any effort to inject the ophthalmic branch for fear of wounding the optic nerve.

The alcohol renders the procedure aseptic; furthermore, it has the peculiarity of relieving pain without giving sensory or motor paralysis, or, if any, it is slight and temporary. The paresis may persist a few hours or a few days; exceptionally, a few weeks, and rarely a few months. The neuralgic pains are sometimes relieved instantaneously while the needle pricks the nerve. The rule, however, is that the first injection gives considerable relief, but that in severe neuralgia, two, three, or more injections must subsequently be given.

Ostwalt, of Paris, practiced several hundred injections, the patients being affected with very severe neuralgia dating back six, seven, nine, ten, thirteen, sixteen, and even twenty and thirty years. In one third of all patients there was a return of symptoms in four to five months. A few subsequent injections, however, relieved the neuralgia permanently.

Should the injections fail, the surgeon must choose between distal avulsion as practiced by Prof. Ernest Laplace, or the radical procedure of excision of the ganglion.

Avulsion is confined to the two inferior branches and the supra-orbital filaments of the ophthalmic division. The superior maxillary branch is exposed at the infra-orbital foramen, and without being divided is grasped with a delicate forceps which is very carefully and slowly turned, winding the nerve as a double thread is wound upon a spool. So deliberately must traction be exercised that two minutes should be taken for a single turn, and it takes from twelve to twenty minutes to complete the procedure. Laplace has succeeded in this way in extracting practically all of each division of the fifth nerve, not only back to the ganglion, but removing with the trunk a large proportion of the anterior filaments of distribution. In removing the inferior maxillary division the ramus of the lower jaw must be exposed and the canal opened (as hereafter described) for at least one inch of its extent. Plugging the canal with sterile gold-foil or a rubber-tissue pack has been recommended to prevent reproduction and reunion.

In the event of failure of these methods, intracranial section with removal of the ganglion of Gasser will be necessary.

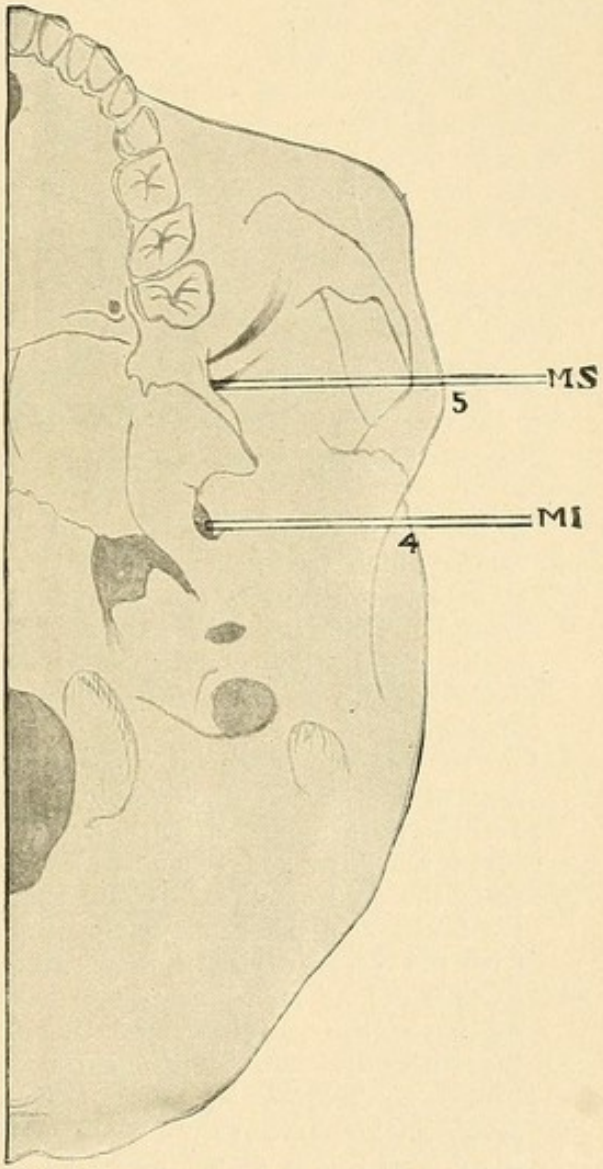

Fig. 302*b*.—Basal view of same. M. S., Needle at foramen rotundum; M.I., Needle at foramen ovale. (Hecht. "Journal of the American Medical Association.")

Two operations are accepted, viz.: the osteoplastic trap-door flap of Hartley and Krause and the bone-sacrificing procedure of Cushing. In the former a horseshoe incision is made, the ends of which are practically over the outer and inner ends of the zygoma, while its greatest convexity is from two and one half to three inches above at the temporal ridge (Fig. 303).

The incision is carried down to the periosteum in all portions except one inch above the zygoma. The divided soft tissues are retracted, and with a small curved chisel a groove is cut in the bone corresponding to the divided periosteum and

extending only to the vitreous plate, except at the highest point of the rounded portion, where the entire thickness of the skull is removed sufficiently to admit the point of an elevator. A periosteal elevator is here inserted and used as a lever to break the bone on a line between the "corks" of the horseshoe incision. In this way a "trap-door" flap, consisting of skin, muscle, periosteum, and bone, is turned down, exposing the dura mater over a circular area three inches in extent. A catgut ligature is now thrown around the middle meningeal artery, the dura carefully lifted from the bone, and the floor of the middle fossa of the skull exposed. Broad retractors are used to lift the dura with the brain, in order to expose the round and oval foramina. Any hæmorrhage which occurs can be stopped by pressure. The second and third divisions of the fifth nerve should now be isolated at their respective foramina, and by slight pressure the dura mater can be stripped from the nerve to beyond the ganglion of Gasser. With a tenotomy knife the nerve should be cut at the foramina, and that portion between these points and a point on the central side of the Gasserian ganglion excised. Care should be taken not to injure the third, fourth, and sixth nerves, which are in close proximity, and also the motor filament to the muscles of mastication which passes beneath the ganglion but is not connected with it. A good-sized catgut drain is put in and allowed to come out at the lower angle of the wound. The trap-door flap of bone, muscle, and periosteum is now placed in position and stitched with catgut sutures. Hartley has used the same method in exploring the posterior fossa, in a case of suppurating meningitis following otitis media.

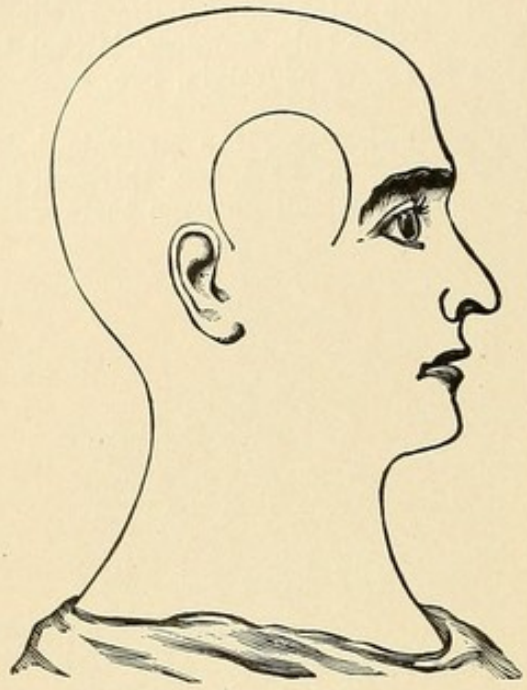

Fig. 303.—(After Hartley.)

In this procedure an observation of Tiffany is of great practical value. He noticed that, when first opening the cranium, the brain entirely filled the cavity, and the dura appeared tense, due to the presence of cerebrospinal fluid. He punctured the dura and evacuated the fluid, "after which the brain fell quite away from the field of operation and the dura mater rested, wrinkled, on the surface of the brain, as a sheet loosely thrown over a bed." In removing the nerve, he begins with the second division. Separating the dura from it, he passes a ligature around it with a long aneurism needle with a short curve, then strips back the dura to reach the third division and the ganglion. A similar ligature is passed around the third division. With gentle traction upon the ligature, with a long, sharp curette he separates the nerves and takes away the adjacent portion of the ganglion, dividing the nerves at the round and oval foramina last. In none of his cases has there been injury to the *third* cranial nerve, and all recovered. In one case, fourteen months after the operation, the anæsthesia was disappearing. The sense of taste was preserved after division of the second and third nerves. Sensations of heat and cold were appreciable after division of these nerves of ordinary sensation. He suggests the use of the electrode to recognize and avoid section of the motor branch of the third division of the fifth nerve. Cushing has pointed out an objectionable feature of this incision, viz., the division of the filament of the facial nerve which supplies the frontal portion of the occipito-frontalis muscle (Fig. 297). He limits the anterior extent of the curved incision through the scalp at the hair line, and thus avoids paralysis of this muscle. From this point in Cushing's operation "the posterior limb of the incision is carried down to the zygoma over the temporal vessels, which usually must be ligated. The skin flap is then reflected down-

ward and forward by blunt dissection, the handle of the scalpel sufficing for this purpose. The temporal fascia, thus exposed, is incised in a line concentric with the skin incision and likewise reflected. The zygoma, which has been brought into view at the lower angle of the wound, is shelled out of its periosteal sheath, not as formerly described by making an incision along its external surface, but by crowding forward its coverings *en masse*. The exposed fibers of the temporal may then be divided as usual by a horseshoe-shaped incision, and the muscle scraped away with a periosteal elevator as far down as the base of the skull. In order to satisfactorily expose the skull, a little deeper retraction of the flap is necessary than by the older method, the ordinary small appendix retractor being used for the purpose of holding down the cutaneous and fascial part of the flap as well as the muscle."

The objective point in either of these intracranial operations is the space on the floor of the skull between the round and oval foramina, or directly inward from a point just in front of the *eminentia articularis* or tubercle on the posterior root of the zygoma where it fuses with the main temporal bone. The cranial surface in this plane is the thin squamous portion of the temporal, and through this a trephine opening is made which is enlarged with the rongeur sufficient to give the necessary exposure. The dura is not divided, but may be punctured (Tiffany) to relieve tension.

Bleeding from the diploë may be particularly troublesome, and frequently necessitates the use of wax. Care must be taken while biting away pieces of bone from under the muscle anteriorly, lest injury to the meningeal be occasioned.

When the bone is removed to a sufficient extent to permit the unincised dura to be lifted from the base of the skull, this is carefully done until the ganglion is exposed. Should the dura or any blood vessel be torn, a temporary packing with sterile gauze will be necessary in order to control hæmorrhage.[1] The branches of the nerve will be seen at their points of exit at the foramen rotundum and foramen ovale. The second and third branches should be divided at the foramina and followed back to the ganglion, which is now raised from its bed and its connection with the bone severed close to the dura, if possible without injury to the motor root.

Facial Paralysis.—As a result of accident or disease, especially in connection with destructive ostitis following infection of the middle ear, as it passes through the aquæductus Fallopii to emerge at the stylomastoid foramen the facial nerve may be permanently impaired. The resulting paralysis of the muscles of expression leads to such disfigurement that anastomosis should be made between its distal end and the proximal end of the motor branch of the spinal accessory distributed to the mastoid and trapezius muscles. "This nerve at its exit from the jugular foramen passes backward behind the jugular vein and descends obliquely behind the digastric and stylo-hyoid muscles to the upper part of the sterno-mastoid" (Gray).

The following procedure is advised by Dr. J. B. Murphy:

"An incision is made from the anterior border of the mastoid process parallel with the belly of the digastricus down to the level of the hyoid bone. The deep fascia is divided, hugging close to the anterior border of the sternocleido-mastoid muscle. Blunt scissors are employed in the dissection between the digastric and stylohyoid muscles. The spinal accessory will be found at the upper angle, passing across the field over the tip of the transverse process of the atlas. The hypoglossal is just beneath the tip and runs parallel with the digastric muscle. Hugging the mastoid closely, *the stylomastoid foramen, where the facial nerve makes its exit as a single trunk, is found.*

"The parotid gland should not be disturbed. It is avoided by keeping close to the sheath of the sternomastoid muscle. The facial nerve is divided as close to the foramen as possible, the end swung down and joined to the end of the com-

[1] In the middle fossa, the middle meningeal artery entering through the foramen spinosum grooves the floor of the skull passing between the opening in the cranium and the foramina ovale and rotundum about a half inch from the former and three fourths of an inch from the latter. It is the principal obstacle to a dry dissection.

pletely divided spinal accessory by a paraneural (No. 0) catgut suture. An exceedingly delicate half-curve round needle should be carefully passed into the nerve sheath about one eighth of an inch from the cut end. Every effort should be made to avoid piercing the nerve substance. For protection, the point of union should be imbedded in the belly of the sterno-hyoid muscle, and completely hidden from view by a few stitches of catgut."

As a dry dissection greatly facilitates this delicate operation, should bleeding be annoying Dawbarn's sequestration should be practiced. An adrenalin may be employed.

CHAPTER XII

THE EYE

Wounds of the eyelids and of the circular muscle should be thoroughly disinfected by the careful use of warm salt solution and 1–5000 mercuric-chloride solution. Any irritating effects from the mercuric solution upon the conjunctiva or cornea may be neutralized by dropping plain, warm water under the lid. Preliminary cocainization by instilling five or six drops of two-per-cent solution will prevent pain. Hæmorrhage may usually be controlled by suture. When the orbicularis muscle is severed the ends should be carefully approximated. If the lids are divided, the sutures should be of horsehair or the finest linen, and passed through all of the tissues of the lid close to the margins of the incision. In order to prevent a nick at the palpebral margin a short lateral incision may be made, as in the operation to correct this deformity in harelip.

Contusions about the eye should be treated by cold applications, using a light ice-bag or soft linen cloth or gauze taken from ice.

New Formations.—Vascular new growths, usually of the capillary variety, are occasionally situated near the eye and involve, as a rule, the muco-cutaneous border.

They may be treated by injection of boiling water, as advised for these neoplasms elsewhere. More than ordinary care should be taken to prevent a possibility of leakage of the hot water into the eye or upon the skin. Not more than five to ten drops should be injected at one sitting.

Capillary angeioma, on account of the absence of an epidermal covering, is apt to break down and become infected, resulting in the formation of scar tissue. This, following repeated injections, reduces the size of the area formerly occupied by the new growth, and as soon as all the dilated vessels have disappeared, the resulting scar may, if deemed necessary, be removed by dissection. It is usually more satisfactory to close the open wound by sliding and stretching the integument.

As the palpebral artery runs just beneath the skin of the eyelid about one eighth of an inch from the free border, an incision should not cross this line unless it is absolutely necessary.

Warts or *cutaneous* horns on the lid should be clipped off with the scissors. *Small tumors* filled with *sebaceous* matter occurring here (molluscum contagiosum) should be incised and the contents squeezed out. When near the palpebral margin infection not infrequently occurs, forming a sty or *hordeolum*. The treatment is puncture with a sharp, clean knife, and the removal of the contents by pressure or curettage. Professor Webster recommends sulphide of calcium (gr. ss.) twice each day as a cure and preventive.

Cysts connected with the eyelids, either upon the mucous or cutaneous surfaces, often require complete removal of the sac to effect a cure.

Epitheliomata may be cured by the application of Marsden's paste even when they involve the free border of the lid. Careful attention will prevent the irritation of the conjunctiva by arsenious acid.

Obstructions of the ducts of the Meibomian glands (chalazion) are indicated by redness and swelling of the conjunctiva along the surface of the tarsal cartilage. They should be treated by puncture through the edge of the lid with evacuation of their contents by pressure upon both surfaces of the lid directly toward the free border. In obstinate cases a thorough curetting of the walls of the sac renders a recurrence less liable. Any incision on the under surface of the lids should

be made at right angles to the free border. On the outer cutaneous surface the incision should be parallel with this border.

A rare form of cystic tumor occasionally develops in the substance of the tarsal cartilage. It may be cured by incision with removal of the sac or by burning with a drop of pure carbolic acid, carefully guarding against contact of the cornea with this substance.

Blepharitis or inflammation of the lids may affect all or a limited portion of these organs. It most frequently involves the ciliary margins, and is known as *blepharitis ciliaris*. In rare instances the cartilages are involved. *Acute blepharitis* demands rest and local antiphlogistic applications. Cloths dipped in warm water are in general more agreeable. In *chronic blepharitis ciliaris* the scaly covering of the inflamed borders of the lids should be removed by the prolonged use of warm boric-acid water and a mop of soft lint, having first trimmed the lashes closely. When this is done the inflamed surface should be lightly touched with a pencil of lunar caustic. At night the lids should be lubricated with a small quantity of cosmoline.

When removal of the eyelashes (*epilation*) becomes necessary, they should be grasped with broad-ended forceps which have finely roughened blades, and removed by pulling gently and carefully in the normal axis of the lash. Lateral movements tend to break the hairs and leave the stubs *in situ*.

Blepharospasm, or spasm of the *orbicularis palpebrarum* muscle, results usually from irritation of the conjunctiva or cornea. It may, in rare instances, occur without any inflammatory exciting cause (idiopathic blepharospasm). The treatment is rest and the removal of the cause of the spasm. In rare cases division of the muscle through the outer canthus (*canthoplasty*) is demanded to relieve pressure on the conjunctiva, cornea, and globe.

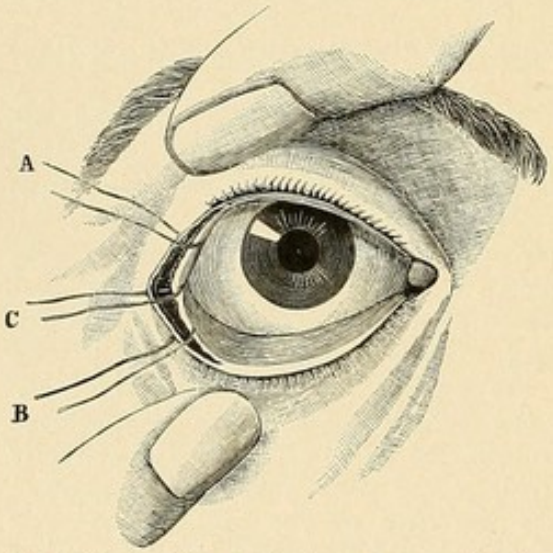

FIG. 304.—Incision and sutures in operation for blepharophimosis. (De Wecker.)

Blepharophimosis, or narrowing of the palpebral opening, is due to contraction of the lids at the outer canthus or angle. It may be relieved by an incision commencing in the outer angle and carried directly out through the entire thickness of the commissure for the required distance, extending the cut in the skin a short distance farther than that in the conjunctiva. The edges of the skin and mucous membrane are then united by silk sutures, as shown in Fig. 304.

Lagophthalmos.—Inability to close the eyelids may be due to protrusion of the globe from tumors of the orbital cavity, or of the globe; it occurs in the disease of which enlargement of the thyroid body and "exophthalmos" are symptoms; in staphyloma and in paralysis of the facial nerve. It is a serious condition, on account of the liability of ulceration of the cornea from prolonged exposure of the anterior surface of the globe. The indications in *treatment* are first *palliative* in keeping the lids closed by bandaging, or uniting the edges by sutures. When the condition is permanent, the operation of *tarsorrhaphy* is to be performed as follows: Introduce a horn spatula between the globe and the lids at the outer canthus; make the tissue tense, and with a sharp knife remove the free borders of the upper and lower lid for a distance sufficient to close the eye to the desired extent. The incision should remove the roots of the ciliæ. The opposing edges are now united with silk sutures.

Blepharoptosis.—Ptosis, or inability to lift the upper lid, may be due to partial or complete paralysis of the third nerve, or the filament which supplies the levator palpebræ; to adhesions from inflammatory affections of the lid; to the presence of neoplasms or to acquired or congenital weakness of the levator muscle. Ptosis

due to paralysis may be corrected by excising an elliptic-shaped piece of the skin of the upper lid, including the areolar tissue and the fibers of the orbicular muscle. The lower incision should run parallel with the margin of the lid and about one quarter inch above it. The edges of the two incisions should be united with silk sutures.

Should this operation not prove satisfactory, the procedure of Everbusch may be tried. The tendon of the levator palpebræ is freely exposed by an incision at the base of the tarsal cartilage, and the tendon shortened by inserting three ten-day catgut sutures so as to loop it upon itself; or the procedure of Wolff, which resects a piece of the levator tendon and reunites the cut end to the upper border of the tarsus, may be substituted. It is advisable to proceed cautiously, since overcorrection is to be avoided.

Symblepharon is a term applied to adhesions of the lids to the ocular conjunctiva. Limited adhesions may be broken up repeatedly until a cure is effected by

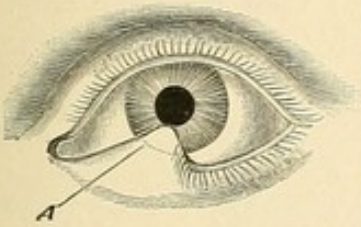

Fig. 305.
Symblepharon. *A*, Incision through the attached conjunctiva at the corneo-sclerotic junction. Teale's operation. (Swanzy.)

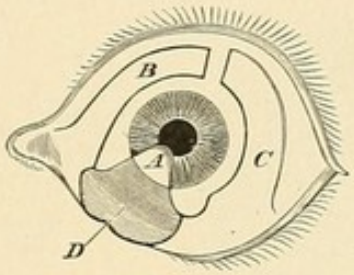

Fig. 306.
The same. *D*, Adherent conjunctiva dissected down. *B*, *C*, Incision for flaps to cover this wound. (Swanzy.)

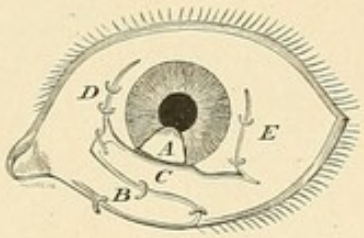

Fig. 307.
The same. *A*, Tip of symblepharon left to disappear by absorption. *C*, *B*, Flaps turned and sewed into new position. *D*, *E*, Wounds closed by sutures. (Swanzy.)

the extension of an epithelial covering over the granulating surfaces. When the adhesions are extensive, Teale's operation may be performed. Supposing the condition shown in Fig. 305 to exist, the symblepharon is cut through at *A*, in the line of the corneo-sclerotic junction, and the lid is dissected up to the normal fold of palpebral and ocular conjunctiva (*D*, Fig. 306). Two flaps (*B* and *C*, Fig. 306) are now dissected up from the conjunctiva and turned down and stitched in position to cover the raw surface left by the dissection of the adhered lid. The spaces left by lifting the flaps are closed at once by fine silk sutures (Fig. 307). The island of tissue left on the cornea is allowed to disappear by atrophy.

Ectropion, or eversion of the lid, may be *partial* or *complete*, and is due first to weakness of the orbicularis palpebræ muscle, especially to the palpebral fibers;

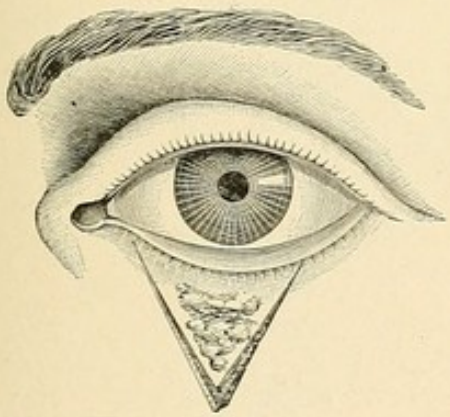

Fig. 308.—Wharton Jones' operation for ectorpion of the lower lid. (De Wecker.)

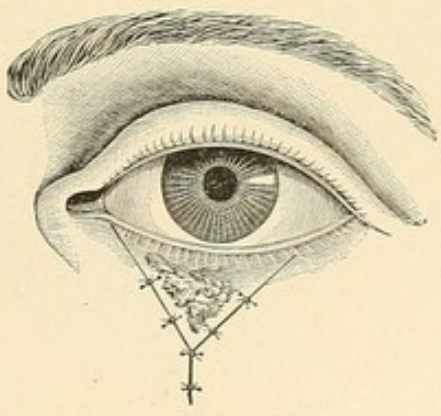

Fig. 309.—The same, after the flap is dissected up and the sutures tied. (De Wecker.)

second to cicatricial contractions due to injury or disease of the soft parts above the eye, or of the bones surrounding the orbital cavity. The lower lid is usually involved.

The milder cases may be relieved by repeated cauterizations of the conjunctiva with the nitrate-of-silver stick or the carefully used electrical cautery along the lid border. If this treatment does not succeed, and deep cicatricial adhesions have occurred, Wharton Jones' V Y operation may be adopted.



Fig. 310.—Complete ectropion of lower lid, due to cicatricial contractions after ostitis of the orbital margin.

As shown in Fig. 308, a V-shaped incision is made so as to include the scar, the flap dissected up, and the underlying cicatricial adhesions cut out. The lid is lifted into its normal position, stitched to its upper fellow, if necessary, to hold it in place, and the edges of the wound sutured from below upward, leaving a Y-shaped scar (Fig. 309).

In more extensive adhesions (Fig. 310), in which neither of the foregoing methods will meet the indications, a plastic operation is inevitable. Make one incision, parallel with the free border of the lid, which shall extend beyond the cicatricial tissue to be removed. Dissect out freely all adhesions and cicatricial material until, when left to itself, the remaining edge of the lower lid rises into its natural position. In order to fill the deep oval cavity (Fig. 311) left by such dissection, a flap may be turned from the cheek, forehead, or arm. The plan of the flap from the cheek is shown in Fig. 312. It should be cut by measurement, so as to fit without tension. As soon as it is turned across to its new position, the eyelids should be stitched together, and the flap accurately and carefully sutured

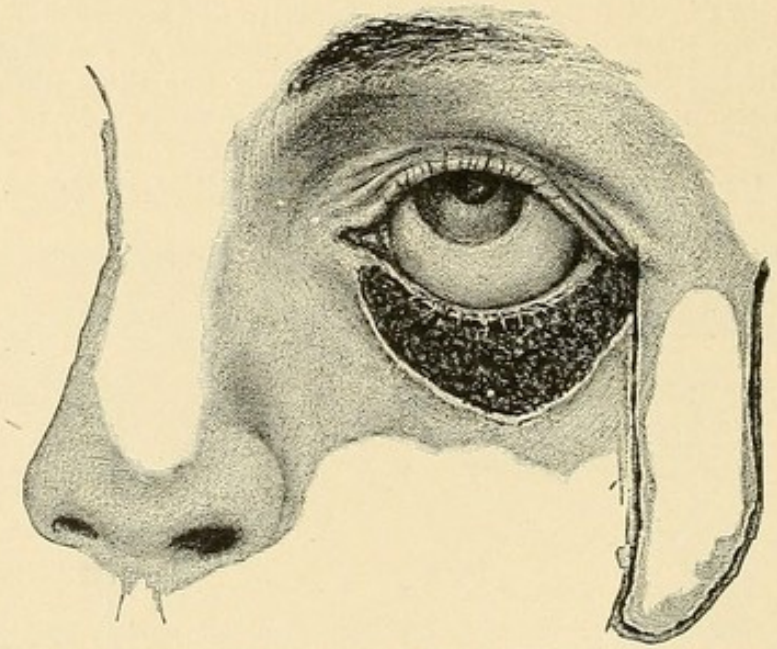

Fig. 311.—Showing the cicatricial tissue dissected out, and the flap to be turned from the cheek outlined.

to the margins of the elliptical wound. Before the lower row of sutures is inserted, the edges of the perpendicular wound from which the flap was removed should be approximated by sutures of fine silk, which material should be used throughout.

The stitches are to be removed about the fifth day. If any puffing remains at the seat of the pedicle of the flap, it may be relieved, after a few months, by dissecting out a small elliptical piece and bringing the edges together.

When the cavity from which the flap has been taken cannot be entirely closed by suture, small Thiersch grafts should be employed to prevent a broad cicatrix.

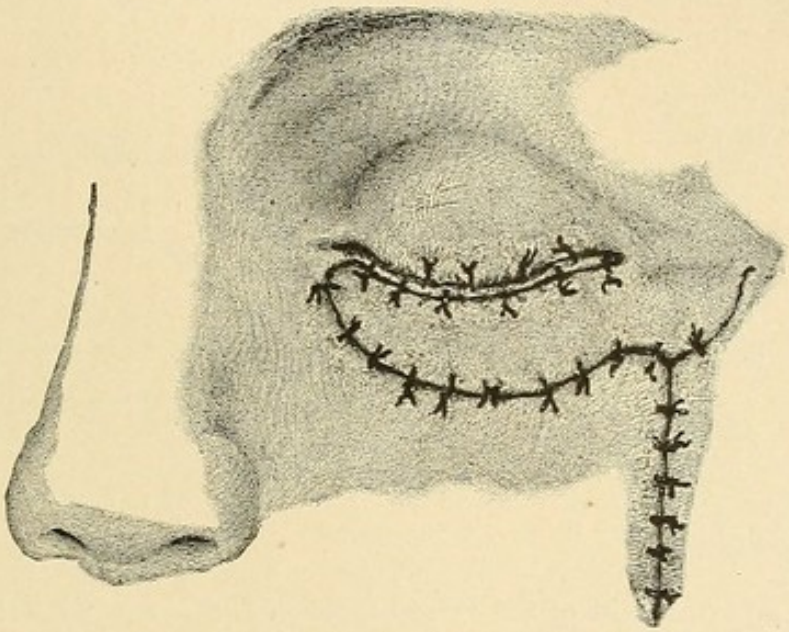

FIG. 312.—The flap stitched into position, and the wound formed by its removal closed. The lids temporarily sutured.

Entropion, or inversion of the lid, usually results from chronic inflammation of the conjunctiva and tarsal cartilage. It is more frequent in the upper lid. In mild cases relief may be obtained by epilation, or by splitting the edge of the lid

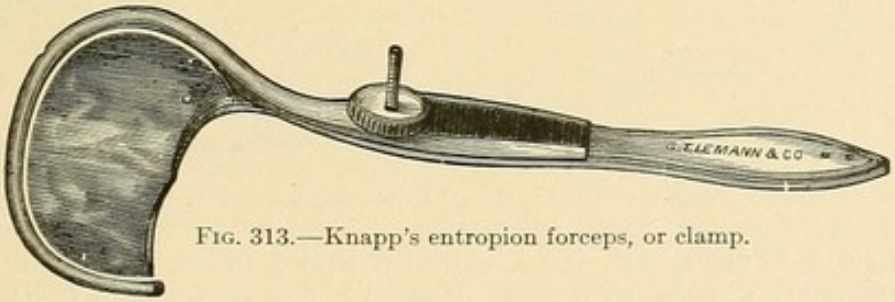

FIG. 313.—Knapp's entropion forceps, or clamp.

and destroying the hair follicles, or by excising an elliptical strip of the integument of the lid and stitching the edges of the wound together. When the tarsal cartilage is involved, Snellen's method will prove more satisfactory.

With Knapp's clamp applied, make an incision through the skin one eighth of an inch from and parallel with the whole length of the margin of the lid. Lift



FIG. 313*a*.—Lid scalpels.

the *skin-flap*, expose the fibers of the orbicularis muscle, and excise a strip of the muscle about one twelfth of an inch wide for the full length of the incision. The tarsal cartilage is now seen, and from it as far as it is exposed a wedge-shaped piece is excised with a sharp knife (Fig. 314). The apex of the wedge points toward the conjunctiva, but the section should not extend entirely through the cartilage.

Three sutures are now inserted, each entering from without inward, traversing the skin and muscle (Fig. 315) of the strip left at the palpebral margin; then in the same direction it is carried across the wound into the upper bevel of the incision in the cartilage, from which it emerges (without transfixing the integument of the flap), to be again brought out through the tissues it first entered, about one eighth of an inch distant from the point of entrance. Each end of the suture is fastened with a shot, to prevent it cutting through.

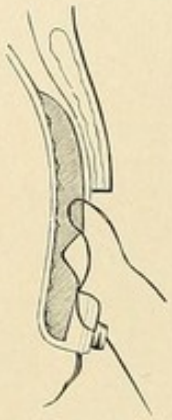

Fig. 314.—Perpendicular section showing character of dissection. The muscular strip and a triangular strip of the tarsal cartilage are removed. (De Wecker.)

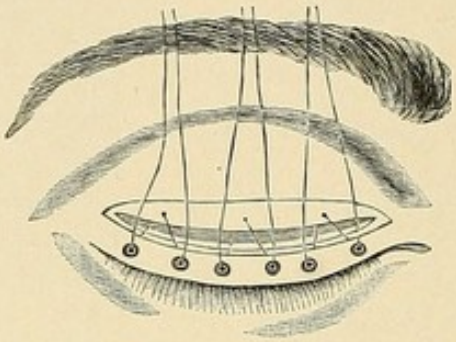

Fig. 315.—Front view of the same, with sutures inserted ready to be tied. (De Wecker.)

Trichiasis, or turning in of the eyelashes, occurs with entropion, but may exist independently. Occurring with inversion of the lid, it does not require any other interference than that given for the cure of entropion. When the ciliæ turn in without inversion of the lid, the proper method of treatment is total excision of the hair follicles. This should be accomplished by two parallel incisions made along the margin of the lid, one on either side of the row of hairs, and extending deep enough to insure the complete removal of the roots of the ciliæ. When only a few hairs are at fault, the follicles may be destroyed by the galvanic needle.



Fig. 316.—Gruening's depilating forceps.

When depilation is demanded, the instrument shown in Fig. 316 will be found of great service. In *distichiasis* there is an extra row of ciliæ; these require removal by the method just given.

Eczema of the eyelids is not of very frequent occurrence. Swanzy recommends the daily removal of the crusts by bathing the parts in a warm solution of bicarbonate of potash, drying, and then painting with solution of nitrate of silver (gr. xx to water ℥j); after this an ointment of boracic acid (gr. xxx to ℥j) is applied.

Epicanthus.—This term is applied to a congenital defect which consists of a fold of skin stretched across the inner canthus and the caruncula. It may be relieved by excising an elliptical piece of integument in the long axis of the nose just between the eyes. The width of the excised portion must be sufficient to remove the deformity when the edges of the wound are drawn together by sutures.

Restoration of the Eyelids.—In destruction of the lids by accident or disease it becomes necessary to restore the covering to the globe. Flaps may be turned from the neighboring healthy integument or borrowed by a plastic operation from the arm. In many cases much damage may be prevented by applying good-sized and numerous grafts to the exposed surfaces while granulation is going on.

The Lachrymal Gland and Ducts

Disease of the *lachrymal gland* is rare. In inflammation of this organ (*dacryo-adenitis*) tenderness and swelling may be observed in the upper outer portion of the orbital cavity. In well-marked enlargement from any cause, the eyelid is pushed forward and the globe displaced downward and inward. An abscess here should be opened by puncture through the base of the lid at the most convenient point. When a neoplasm develops in the gland, extirpation should be done by incision in the fold of the upper lid, just beneath the brow.

Epiphora, or continual overflow of tears, is caused by obstruction in the system of canals which normally should conduct the secretion of the lachrymal gland from the margins of the lids into the nasal cavity, or by displacement of the *punctum lachrymale*, so that the tears cannot enter the orifice. On account of its position, the lower canaliculus is of much more importance to the drainage of the eye than the upper.

Epiphora due to disturbance of the canaliculus may be present as a symptom of any displacement of the lower lid, from swelling, paralysis, or cicatricial contraction, the direction of the puncture being so changed that neither gravity nor the normal suction-force will carry the secretion into the opening. Occlusion, partial or complete, may occur either from lodgment of foreign substances, products of inflammation, pus, epithelia, etc., and occasionally to calcareous formations (*dacryoliths*).

The most common form of obstruction is, however, met with in the nasal portion of the excretory apparatus. Catarrhal inflammation of the mucous membrane lining the canal or cyst may occlude the duct either by approximation of the walls or by excessive secretion of tenacious mucus. Such condition is met with in patients of all ages, occurring chiefly in the poorly nourished and scrofulous or tuberculous subjects, who suffer from chronic nasal catarrh and ophthalmia, or ostitis of the neighboring bones. As a result of obstruction in the nasal duct, *dacryo-cystitis*, or inflammation of the lachrymal sac, may ensue with distention, the swelling showing beneath the skin at the inner angle of the eye (*mucocele*).



Fig. 317.—Agnew's canalicula knife.

The *treatment* of displaced *punctum lachrymale* should be directed to the restoration of the lid to its normal position. In partial obstruction, due to catarrhal conditions, relief may be obtained by slitting the canal with the canaliculus knife or scissors, and frequently repeated irrigations with the lachrymal syringe. When obstruction occurs, dilatation by means of probes is indicated. Should the stricture be close and resisting, the knife should be carefully introduced and a division effected, the dilatation being continued by inserting the probes at intervals of two to six days. The prognosis in many cases, no matter how faithfully and skillfully treated, is not favorable.

In slitting up the canaliculus the delicate probe-pointed knife or scissors should be introduced at the inferior punctum, and carried toward the canthus for a dis-



Fig. 318.—Theobold's lachrymal probes.

tance of about one sixth of an inch, the slit extending for this distance. The wound should be kept open by forcibly separating the edges once or twice a day, until the cut surfaces are covered with epithelium and the trough becomes perma-

nent. Some operators in chronic *dacryo-cystitis* prefer to slit the upper canaliculus and pass the probes by this route. The bulb-pointed dilating-probes should now be carefully introduced, beginning with the smaller sizes (Fig. 318). As soon as the bulb enters the sac, it should be gently and slowly directed along the nasal duct until it is arrested by the floor of the nose. The larger sizes may be introduced as in the treatment of stricture of the urethra. After full dilatation is secured

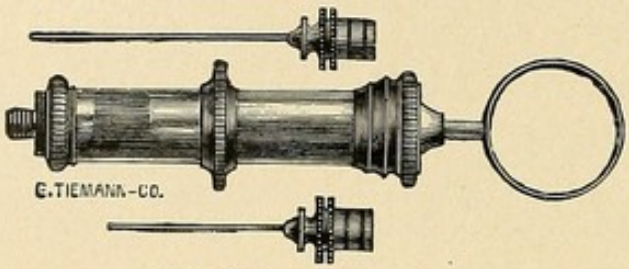

Fig. 319.—Anel's syringe.

the channel should be washed out daily, for about ten days, with a one per cent boracic-acid solution. For this purpose Anel's syringe (Fig. 319) will be found useful. The probe-pointed nozzle is introduced into the sac and the water forced through until it flows freely into the nose. If the obstruction recurs, the probes should be reintroduced at regular intervals, gradually increasing until a permanent opening is effected.

The Conjunctiva and Cornea

Conjunctivitis may be acute or chronic, and circumscribed or diffuse. *Simple conjunctivitis* may result from prolonged strain or overuse of the eyes, from the lodgment of foreign particles, or exposure to strong winds. The hyperæmia may be confined to a limited portion of the mucous membrane, or spread over the entire palpebral and ocular conjunctiva.

The treatment consists in the instillation of two or three drops of cocaine, two to four per cent solution, at intervals of from one to several hours, the removal of any foreign matter, rest by closure of the lids, or the dark room and the application of soft cloths taken from cold boracic-acid solution (grs. x to ℥j) or from a block of ice.

Follicular conjunctivitis may follow an acute simple inflammation, and is characterized by the development of small red points or elevations scattered over the deeper portions of the palpebral surfaces of the mucous membrane and the contiguous reflection of the ocular conjunctiva. The elevations are swollen and distended lymphatic channels and follicles. The disease is characterized by considerable pain, inability to use the eyes, and a sensation as if a gritty or sandy substance were present. In *treatment* the condition of the general system should be improved by tonics and nutritious diet; rest to the diseased organs, and the daily application, by means of a camel's-hair brush, into the conjunctival sac of a small mass, about one eighth inch diameter, sulphate of copper gr. ss. to ij in ℥j vaseline (Swanzy).



Fig. 320.—Granular lower lid. (Eble.)

Granular Conjunctivitis (*Trachoma*).—It is not yet positively known whether there is any real pathological difference between follicular and granular disease of the conjunctiva. Trachoma is chiefly met with among the poorly fed, who live in unwholesome surroundings. It is held to be contagious at all times, and, when a muco-purulent discharge is plentiful, the contagious nature of the affection is evident.

In the earlier stages there appear upon the lower lid round, granular elevations, scattered here and there, or the whole mucous membrane may be thickly studded. As a result of the chronic inflammation the lid is at first thickened. As the process

is continued, the usual cicatrization and contraction results, causing, in obstinate cases, deformities of the lids and great and persistent discomfort.

The treatment includes the measures just given for follicular conjunctivitis. In addition, either the sulphate-of-copper stick or nitrate of silver in strong solution —grs. x–xx to ʒj—or the *mitigated lunar caustic*. Nettleship advises the following strength: "Nitrate of silver, one part; nitrate of potash, two parts, fused together and run into molds to form short pointed sticks; used for granular lids and purulent ophthalmia." Applied daily, or less frequently, as may be demanded. When these measures fail, canthoplasty may be done and the diseased tissue dissected from the lids.

In both varieties of trachoma the cure is greatly accelerated by the operation of *expression*, or squeezing out the contents of the granular elevations by means of Prince's forceps. More can be accomplished by this operation when done thoroughly than by any other method of treatment (Webster).

Gonorrhœal Ophthalmia.—Conjunctivitis caused by the introduction of the virus of gonorrhœa into the eye should be treated with great care and persistency from the first symptom of this painful affection. Usually a single organ is attacked. It is important that, while the effort to cure one eye is being made, the other should be protected from the contagion. To effect this, a watch glass, to the edge of which adhesive plaster is attached, is placed over the sound eye and closely fastened to the skin about the orbit by the plaster, so that it is hermetically sealed. This should not be removed until the other eye is well.

In the local treatment of the affected eye it is required to remove the purulent discharge by frequent irrigation with warm boracic-acid water or by the pellets of lint or absorbent cotton, and to brush over the everted lids once or twice a day, as the attack is light or severe, a solution of nitrate of silver (grs. xx to ʒj). The excess should be immediately washed off with tepid water. Cold applications are of great importance, and a very efficient method is to apply frequent changes (every one or two minutes) of pieces of lint about two inches square, which are taken directly from a block of ice and laid over the inflamed organ. In this form of conjunctival inflammation, as in others where the injection is marked and the thickening great, and where painful *blepharospasm* occurs, or where a free discharge of purulent matter cannot be effected by ordinary means, *canthoplasty* is required. This operation consists in slitting the outer canthus in the direction of the ear, and in this way dividing the fibers of the orbicular muscle.

In gonorrhœal conjunctivitis the impairment of function in the muscle is not intended to be of long duration, and the wound is left open. In some cases of spasm of this muscle, and where a chronic inflammation exists, the mucous membrane is stitched to the skin along the edges of the wound, thus preventing a reunion. Reunion may be effected later by paring the edges and bringing the parts together after the lesion for which the canthoplasty was performed is healed. Cocaine should be used to relieve pain, and all adhesion between the ocular and palpebral mucous surfaces should be broken up as soon as discovered.

Conjunctivitis in the newborn (*ophthalmia neonatorum*) is a form of purulent ophthalmia which usually results from the inoculation of the conjunctiva with septic matter present in the genital passages of the mother. It may come from carelessness on the part of the nurse, herself affected with a leucorrhœa, etc., or from the lodgment of any virus in the eye of the child. The *treatment* is *prophylactic* as well as *curative*.



Fig. 321.—Drop-glass for the eye.

The eyes of a child born of a mother known to be suffering from a vaginal discharge of a purulent character should, as soon as possible after birth, be washed or mopped out with clean warm water, or boracic-acid solution, to be followed with one or two drops of a two per cent nitrate-of-silver solution (grs. x–ʒj) once or twice a day, for three or four days.

The pus should be gently removed by pellets of absorbent cotton, dipped in warm boracic-acid solution, the lids everted, and nitrate-of-silver solution (grs. v–x to ℥j) applied to the inflamed surfaces by means of a camel's-hair brush. The excess should be immediately washed away by the free use of warm water. This should be repeated every day until the purulent discharge is notably diminished.

The eyes should be carefully cleansed with warm solution of boracic acid every half hour day and night, or as often as any secretion appears between the edges of the eyelids.

Croupous conjunctivitis is a contagious disease met with in children, and characterized by injection of the mucous membrane and the deposit of a film or membrane upon the conjunctiva.

The *treatment* consists chiefly in frequent washing of the eye with warm boracic-acid water in the earlier stages. When suppuration supervenes, the indications are the same as for purulent ophthalmia.

Diphtheritic Conjunctivitis.—In this disease, which is exceedingly contagious, the inflammatory process is rapid and often hopelessly destructive. The lids soon become greatly swollen, and the mucous membranes are glazed over with a tough, closely adherent diphtheritic membrane. The period of infiltration varies from six to ten days, and is followed by the stage of suppuration.

Treatment.—The immediate danger is destruction of the cornea, the circulation being more or less interfered with by the false membrane. Since all pressure should be eliminated, in extreme cases it will be advisable to perform *canthoplasty*. Cold-water dressings should be employed in the early stages. Leeches to the temples are advised. When suppuration ensues, astringents are indicated.

Pterygium is the name given to a vascular network which extends from the ocular conjunctiva on to the cornea. It is usually situated on the inner side, less frequently on the outer portion of the globe. It is commonly triangular in shape, the apex encroaching more or less upon the corneal surface. It is caused by constant irritation from dust or sand, or fine particles of matter floating in the air, and is therefore chiefly met with in sandy, arid regions.

When small and not progressive, it is advisable not to interfere with pterygium. When it is growing steadily, it should be tied off or removed by dissection. For the first method the pterygium is lifted at the margin of the cornea, and a fine silk thread carried beneath it here. A second is carried beneath the base of the mass at the conjunctival fold. The ligatures are tied and cut short. In a few days they come away, and the vascular tuft disappears; or a dull instrument, as a strabismus-hook, may be inserted beneath the pterygium, which is gradually detached and divided with the scissors. One or two sutures are inserted to close the wound, where the base of the growth is cut away from the conjunctiva.



Fig. 322.—Pinguecula. (Swanzy.)

Pinguecula.—This is a small, yellow elevation occasionally met with at the inner or outer margin of the cornea (Fig. 322). It occurs usually in the aged, and should not be molested unless it seriously interferes with vision or comfort. It is a simple hypertrophy of the tissues of the conjunctiva.

Lupus of the conjunctiva is exceedingly rare, and does not require special consideration.

Epithelioma here does not differ from this affection on other mucous surfaces.



Fig. 323.—Sichel's iris knife.

Cystic tumors occur in the conjunctiva in a certain proportion of cases, and demand extirpation.

Polypus develops occasionally on the semilunar fold, or caruncula, and should be clipped off.

Lithiasis, or calcification of the secretion of the Meibomian glands, appears in the shape of little white spots or elevations on the inner surfaces of the lids. As they produce considerable irritation of the conjunctiva and cornea, they should be picked out with a needle-point after anæsthesia with cocaine is secured.



Fig. 324.—Daviels' curette.

Xerosis is a term applied to a dry condition of the conjunctiva resulting from changes in the structure of this membrane and deficient supply of the secretions which moisten this surface. The indications are to remove, if possible, any chronic inflammatory condition, and keep the eye moist by artificial means.

Cornea

Foreign Bodies and Wounds.—Non-penetrating wounds of the cornea should be thoroughly cleansed with warm boracic-acid solution, and the lids closed with a bandage until repair is effected. A penetrating wound should be treated on the same principle as the incision for cataract.

A foreign body lodged upon or buried in the cornea should be at once removed. Anæsthesia with cocaine is essential. Oblique illumination by means of the convex lens is of value in locating the body. A clean needle or knife-point may be used in lifting the foreign substance out.

Keratitis, or *corneitis*, may originate from injury or disease of the cornea proper or by extension of the inflammatory process from the conjunctiva or sclerotic, iris or choroid. The symptoms are pain variable in character, interference with vision, especially if the infiltration occurs toward the center of the cornea, and the appearance of a cloudy film upon the normally clear and transparent membrane.

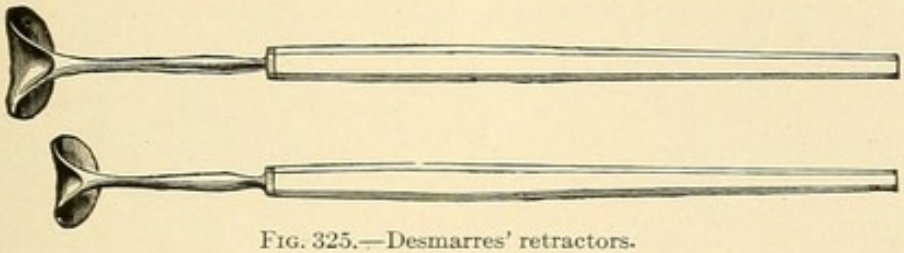

Fig. 325.—Desmarres' retractors.

Diffuse idiopathic keratitis usually commences at the periphery and travels toward the center. Occurring as a feature of a constitutional dyscrasia (syphilis, tuberculosis, etc.), both eyes are usually, though not simultaneously, involved.

Abscess of the cornea may be recognized by the grayish-yellow color of the pus collection and the greater density of the membrane at this point. In many cases the transudation or escape of the purulent liquid takes place into the anterior chamber, and may be seen to occupy the lower portion of this space (*hypopyon*).

Treatment.—In *traumatic keratitis* the removal of all irritation, disinfection with warm boracic-acid solution, relief from pain by cocaine locally or morphia internally, and the exclusion of light by the dark room, bandage, or shade, are the indications.

When the disease is *secondary* to inflammation in other parts of the globe or conjunctiva, the treatment should be directed to the original malady as well as to the protection of the cornea.

Diffuse keratitis demands active constitutional treatment to increase nutrition and neutralize the virus of general infection. In *abscess*, tension should be relieved by careful puncture. Penetration of the anterior chamber with the instrument should be avoided, unless the pus here is rapidly increasing; it should then be evacuated.

Pannus is a term applied to a condition of opacity of the cornea due to the formation of a vascular network beneath the epithelial covering of this membrane.

It is associated with a conjunctivitis, the vessels really extending from the conjunctiva into the cornea.

If the disease is due to chronic granular lids, entropion, distichiasis, etc., the cause should be at once eliminated. In milder cases of persistent pannus a cure may be effected by excision of a zone of conjunctiva and subconjunctival tissue from around the cornea (Nettleship). In severer cases the local use of jequirity-bean is advised. Prof. David Webster recommends the following:

One jequirity-bean coarsely powdered is placed in an ounce of water for four hours. The patient is then required to bathe the affected eye very freely with this solution for ten or fifteen minutes, letting some of it get into the eye. One thorough washing will usually produce the characteristic membrane of the conjunctiva. If this does not succeed, the operation should be repeated. Or the bean, very finely pulverized, may be applied to the whole palpebral conjunctiva.

A convenient shade or screen for the eye is shown in Fig. 326.

Ulcus Corneæ.—Ulcers of the cornea may follow injury, or the eruption of herpes or small-pox; they are met with in conditions of general malnutrition (syphilis, tuberculosis, etc.), and may also occur with inflammation of the other structures of the eyeball, or of the lids or conjunctiva.

Herpetic vesicles occur at times upon the cornea, either as *herpes zoster ophthalmicus* or *herpes corneæ febrilis* (Swanzy). They appear as groups of clear vesicles, the superficial covering of the vesicle giving way within a few hours and leaving a shallow ulcer. In *treatment*, herpes, or the resulting ulcer, demands little beyond protection from light, the removal of all irritation by the bandage, and the prevention of infection by careful aseptic irrigation.

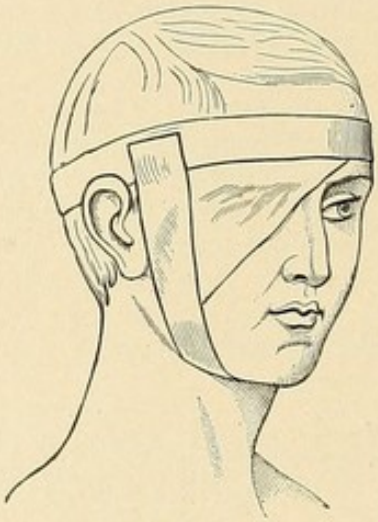

Fig. 326.

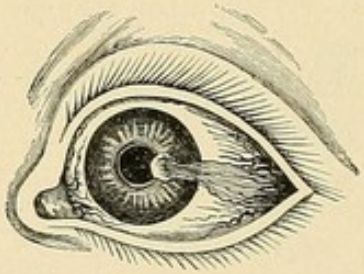

Fig. 327.—Phlyctenula of the conjunctiva and cornea. (Travers.)

Phlyctenulæ of the Conjunctiva and Cornea.—Phlyctenular ulcers occur almost invariably in strumous subjects, either with or without any direct exciting cause. When first noticed they are usually papules or pustules on the conjunctiva or cornea or both. There is, however, a localized hyperæmia in and near the spots where the elevation occurs which precedes the papule or pustule. Breaking down and discharging their contents, ulcers of variable extent are formed. They frequently develop on the conjunctiva and sclerotic without invading the cornea. Not infrequently, however, the process of ulceration travels on and toward the center of the cornea, leaving behind a trail of enlarged vessels, giving to the whole a comet-like appearance (Fig. 327). Perforation may follow in a certain proportion of cases. These ulcers may occur in all ages, but are chiefly met with after the third year and before the twenty-fifth year of life.

Ulcus Serpens.—The acute serpiginous ulcer is probably due to infection. It commences as a grayish film or spot, breaking down from the center, leaving sharp, precipitous edges (as in phagedenic chancre), "one part of which is more densely opaque than the rest; this infiltrated advancing edge is the distinguishing mark of the ulcer" (Nettleship).

Treatment.—In phlyctenular keratitis and conjunctivitis warm applications of boracic-acid water are useful. Pain should be relieved as heretofore directed. If

blepharospasm is present, *canthotomy* may be necessary. The ulcers should be stimulated locally by use of nitrate of silver to those on the conjunctiva, the mitigated stick; while weaker solutions (gr. v–x, ℥j) may be used for the corneal ulcers. In given cases the ulcers may be scraped out or burned with the fine galvano-cautery platinum wire. The prevailing dyscrasia should be corrected by appropriate remedies. The nutrition should be increased, and an out-of-door life advised.

In acute serpiginous ulcer active measures are often imperative, the phagedenic process marching rapidly to perforation and collapse of the globe. Hot boracic-acid water applications at intervals of an hour or two are advised for relief of pain. Cocaine may also be instilled. If the ulcer does not remain stationary, it should be carefully and thoroughly burned with the cautery needle upon the same principle as for chancroidal ulcer of the skin. When the serpiginous ulcer dips down into the deeper corneal tissue and undermines it, it should be laid open by incision in its entire extent.

Staphyloma Corneæ.—Bulging of a portion of the corneal surface may result from intra-ocular tension upon a point weakened by ulceration or cicatrization. *Conical cornea* differs from this in being due to atrophic (not inflammatory) changes in the central portion of the cornea, this part projecting by reason of intra-ocular tension. When perforation takes place, the aqueous humor escapes and usually carries the iris with it, this latter structure being caught in the opening, where it adheres. This condition is known as *anterior synechia.*

When the staphyloma involves a limited portion of the cornea, iridectomy should be done, making the artificial pupil behind the best remaining surface of the cornea. In complete staphyloma, vision being lost, Critchett's operation is advisable. Five half-curved needles, threaded with fine strong silk, are passed from above downward through the sclerotic, being made to enter and exit half-way between the insertions of the recti muscles and the posterior edge of the staphyloma. When the point of each needle has emerged about one quarter inch, it is allowed to remain, and the staphyloma is divided by a horizontal incision. The flaps are now snipped off with the scissors about one twelfth inch in front of the needles, this line (see the dotted line, Fig. 328) being through the sound sclerotic. The needles are next drawn through and the sutures tied, as in Fig. 329.

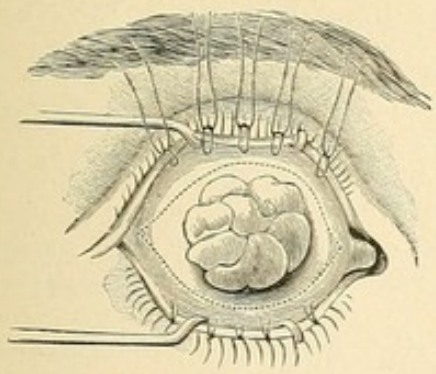

Fig. 328.—Needles introduced in Critchett's operation for staphyloma. (Abadie.)

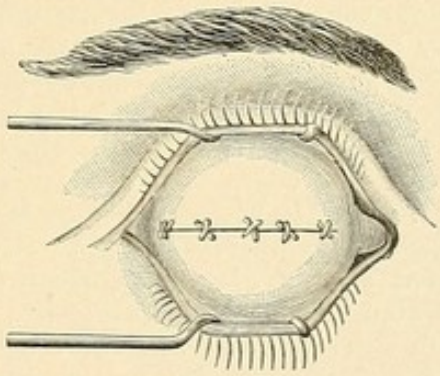

Fig. 329.—The same, after the sutures are tied. (Swanzy.)

In *conical cornea,* if any operative interference is deemed advisable, the conicity should be reduced by inducing cicatrization at and about the apex of the projection.

Von Graefe's Method.—Just to one side of the apex of the cone remove with the knife a small bit of the surface of the cornea without penetrating the anterior chamber. Every third day for about two weeks this wound should be touched with the mitigated pencil of nitrate of silver. Then puncture through this scar every second or third day for one week, evacuating at each puncture the aqueous humor. The wound is now allowed to heal.

Nebula, macula, and *leucoma,* are terms used to designate degrees of corneal opacity—the first being so slight as to be scarcely discernible, the second a more serious lesion, while in leucoma the opacity is complete. The grayish ring seen at the corneal margin in many old persons—*arcus senilis*—is due to fatty degenera-

tion of the cells of the cornea, near the sclerotic junction. This condition occasionally exists in the middle-aged and in young children. While not a contra-indication to operative interference, that it suggests faulty nutrition should not be forgotten in prognosis.

Sclerotic

Simple incised wounds of the sclerotic heal readily. Lacerations are more serious by reason of the greater violence accompanying such injuries. No special treatment is demanded beyond rest and cleanliness.

Scleritis.—Inflammation of the sclera is usually circumscribed, and may or not be accompanied by an appreciable thickening of this tunic. As a rule, the affection is not painful, unless it extends so widely that the choroid, cornea, or iris is involved.

Treatment should be directed to the prevailing dyscrasia. It is met with as a late manifestation of syphilis, and is also a symptom of rheumatism. No local medication is advisable, beyond the limited instillation of atropine to prevent iritis. Rest, and light cloths wet in warm boracic-acid solution locally, are advised. A single thorough application of the actual cautery will frequently abort this disease, which under other methods of treatment usually lasts many months.

Iris

Iritis is most frequently seen as a late manifestation of syphilis or in chronic rheumatism. It also may occur with inflammation of the cornea or sclera. The symptoms are abnormal immobility, thickening and cloudiness of the organ, irregularity of the pupillary margin, and adhesions to the anterior surface of the capsule of the lens (posterior synechiæ). The injected zone is usually of a pinkish color. Vision is more or less affected; and pain, though not always a symptom, is usually present. In rare cases the pupil is *occluded* by the formation of a membrane from the products of inflammation.

The *treatment* of iritis is local and general. To prevent permanent adhesions and to relieve pain, the instillation of atropine solution—gr. iv to water ℥j—is imperative. From one to two minims should be dropped in the conjunctival sac every hour, in the first few days of the attack. The degree of synechia is evident as soon as the iris is affected by the atropine, and even when the adhesions between the capsule of the lens and the iris are not completely relieved, firmer and more injurious adhesions will be prevented. Bloodletting at the temples, either by scarification and cups, or dry cupping, hot fomentations, etc., are local remedies of value. Rest to the eyes should be complete, and exposure to draughts or extreme changes in temperature are to be avoided. Any constitutional disease should be treated or any diathesis corrected by internal medication. Saline laxatives are indicated, as in other inflammatory affections.

In extreme cases, when all other remedial agents fail, *iridectomy* may be necessitated. This operation will be described hereafter. The permanent changes to which the iris is subject, after iritis, are adhesions (*synechiæ*), atrophy of the curtain at one or many points as the effusion disappears, and changes in color due to absorption of the normal pigment.

Choroid and Ciliary Body

Choroiditis is occasionally of traumatic origin. The lines of rupture are seen most frequently near the optic disk, and in recent injuries may be concealed by extravasation. *Idiopathic choroiditis* occurs often in the tertiary step of syphilis. A less frequent variety is of tuberculous origin.

The diagnosis rests chiefly upon examinations with the ophthalmoscope. Disease is evident from the abnormal paleness due to atrophy and diminution of the blood-supply. It may be general and symmetrical in the two eyes (*syphilis*), or confined to one or more isolated patches (*tuberculosis*). In the syphilitic variety,

changes in the retina are more evident. In very old persons an extensive area of atrophy may occasionally be observed, situated, as a rule, at the fundus.

The indications in treatment are to correct the prevailing dyscrasia, by specific remedies and tonics, and to give the eye as complete rest as possible.

Cyclitis occurs rarely except as in conjunction with inflammation of the sclerotic choroid or iris.

Sympathetic ophthalmitis is a term applied to inflammation in one eye, followed by a like disturbance in and threatened destruction of the other. It is very apt to occur, after *traumatic cyclitis*, from a penetrating body. Dislocation of the lens, iritis, or any inflammatory process, without penetration, and the entrance of air or a foreign substance, may also cause this form of ophthalmitis.

The invasion from one eye to the other is now believed to be by means of septic bacteria traveling along the optic nerve and chiasm. When once declared, the remedy of most avail is enucleation of the diseased eye. It is important that this operation be not too long postponed. The chief difficulty to be surmounted is to determine when it is necessary to operate. The following rules may serve as a guide:

When a penetrating septic body has entered the eye and destroyed vision, it would be wise to enucleate even before iritis and cyclitis are established, and if these symptoms of ophthalmitis are present, operation is imperative. Enucleation is indicated in an eye in which a foreign body is lodged with vision not materially impaired when the earliest symptoms of irido-cyclitis supervene.

Idiopathic inflammation of the interior of the globe, which destroys vision, also indicates enucleation.

Operation.—Seize the conjunctiva with a mouse-tooth forceps near the margin of the cornea, and with delicate scissors divide the conjunctiva evenly all the way



Fig. 330.—Jaeger's angular keratome.

around close to the cornea. Introduce the strabismus-hook and divide the internal muscle at its insertion into the globe. The other recti muscles are then successively



Fig. 331.—Beers' keratome.

divided. The ball is then carried toward the nose and a dull-pointed scissors curved on the flat is carried (concavity to the globe) backward and the nerve divided close to the ball. The attachments of the oblique muscles are next cut through.

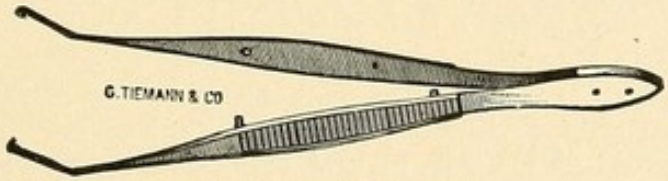

Fig. 332.—Iris forceps.

An artificial eye should not be worn until the stump is healed, which requires about five weeks.

Glaucoma.—This disease is almost always met with after the fortieth year, and is more common in the hypermetropic than in the myopic eye.

The prevailing symptom is an increased tension of the eyeball.

Glaucoma may be acute, subacute, or chronic. In rare instances, it occurs with great rapidity (*g. fulminans*). More frequently it is slower in its progress. The earliest symptom is dimness of vision. Patients usually complain of indistinctness of sight, as if they were looking through frosted glass. These attacks are at

first commonly periodic, but the interference with vision soon becomes permanent. Halos or rainbows are seen when an artificial light is looked at. The cornea has a dead and glazed appearance, the pupil is dilated, the anterior chamber shallow, and

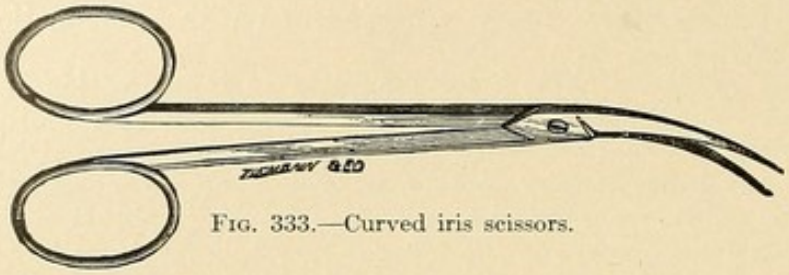

Fig. 333.—Curved iris scissors.

the iris is not so movable as normal. If the pulp of the finger is pressed upon the eyeball, it is felt to be hard and abnormally inelastic. Pain is not always present. Inflammation may or may not occur. Blindness sooner or later supervenes, unless

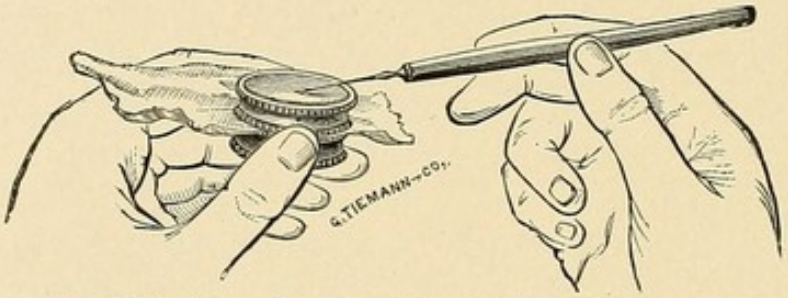

Fig. 334.—Drum for trying the edge of eye instruments.

prevented by treatment. The causes of glaucoma are, as yet, not satisfactorily explained. It is more generally held that obstruction of the efferent lymph-channels, or of the vessels which carry off the intravascular fluids, is the chief cause of this disease.

Treatment.—The chief reliance is in *iridectomy.* With the iridectomy knife, enter the anterior chamber by cutting through the sclerotic near the corneal border, exposing the upper margin of the iris for at least one fifth of its circumference. Divide the iris at one end of the incision in a line radiating from its pupillary margin to its ciliary attachment, by traction tear it from the ciliary attachment and divide with the scissors at the other limit, severing one fifth of the membrane (Fig. 335). No particle of iris should be allowed to be caught and remain in the wound. The after-treatment consists in bandaging the eye, and complete rest.



Fig. 335.—Iridectomy for glaucoma. (De Wecker.)

In mild cases, a smaller section of the iris should be made. The edge may be drawn out with the forceps and a loop of iris clipped off with the scissors.

Crystalline Lens

Cataract, or opacity of the lens, although chiefly encountered after the fortieth year of age, may occur at any period of life. It may be divided into—1, *congenital* or *infantile cataract*; 2, *cataract of adult and middle life* (before forty); 3, *senile cataract.*

Cataracts are also classified according to their location in the lens—*nuclear*, or central; *cortical*, or peripheral; and *capsular.*

Nuclear cataract occupies the center of the lens, either permanently, or spreads gradually until the organ is entirely involved. It is at first observed as an opacity or cloudiness immediately behind the pupil, white or amber-brown in color.

Cortical cataract commences near the margin of the lens, behind the iris, and is characterized by grayish-white lines or streaks projected toward the center of the pupil.

In the *capsular* variety the cloudiness or opacity is confined to the anterior shell of the capsule, the substance of the lens not being affected.

Cataracts which are congenital, or only observed in early infancy, are classified as *anterior polar*, or *pyramidal*; *lamellar*, or *zonular*; *central, posterior polar*, and *fusiform*. All of these types are comparatively rare.

The *anterior polar* variety is due to the formation of a chalky concretion in the center of the anterior lamellæ of the lens, caused by inflammation and perforating ulcer of the cornea in the early days of life. Operative interference is not called for.

In *lamellar* or *zonular* cataract the opacity is limited to a thin layer of lens-substance, about half-way between the nucleus and the anterior and posterior surfaces. The nucleus and peripheral portions are normal. When vision is seriously interfered with by this form of opacity, it may be improved by *iridectomy* or incision through the anterior layer of the capsule (*discission*). In some cases extraction is advisable.

In *central* cataract the deeper fibers of the lens only become opaque. It may be treated in the same way as the zonular opacity. *Posterior polar* cataract is seen deeply behind the center of the lens. Operative treatment is rarely demanded, and when indicated discission is advised.

Fusiform opacity extends from the posterior to the anterior pole. It is very rare.

Cataracts are *primary* when the opacity is developed independent of any other lesion of the eye, and *secondary* when some other lesion exists. A *traumatic* cataract occurs as a result of rupture of the capsule, with or without perforation, allowing the aqueous humor to invade the crystalline substance. A *Morgagnian* cataract is one in which partial liquefaction of the cortex has taken place, and the nucleus drops to the lowest portion of the capsule. The opacity occurring in *diabetes mellitus* is called *diabetic* cataract.

Cataracts are also termed *senile*, *hard*, and *soft*. Senile cataract occurs, as its name implies, in old persons, usually very late in life, but not unfrequently as young as the fortieth year. This variety, though usually firm or *hard*, is at times soft. Under forty years cataracts are usually *soft*. A cataract is said to be "ripe" when the entire lens has become opaque.

Symptoms and Diagnosis.—With senile cataract the earlier symptoms are disturbance of vision. Indistinctness of vision for distant objects is usually first noticed, and, in certain cases, multiple images of one object are observed. If the cataract is *nuclear* or central, vision is improved by shading the eye, thus allowing the pupil to dilate. In *cortical* cataract this is not the case, but by dilatation of the pupil with atropine the presence of the peripheral opacity may be detected. When a cataract is general and ripe, blindness for objects is complete, although light and darkness are appreciable.

Examined in ordinary light a well-marked nuclear cataract may be recognized; but it is by focal illumination and by the ophthalmoscope that a diagnosis is positively made. The pupil should be dilated.

A large nucleus with very fine radiating striæ indicates a hard cataract, while a small nucleus and large striæ suggest a soft opacity. If the cataract be *ripe*, no clear space will be discovered between the nucleus and the iris, and no shadow will be thrown upon the nucleus by the iris. Focal (oblique) illumination—i. e., concentrating by means of a prism the rays of a strong light let fall obliquely upon the cornea—is essential in this examination. By the ophthalmoscope the normal red reflex from the fundus is absent (Swanzy).

As it is important to have a cataract ripe when an operation is undertaken, *Foster* submits the following general guide: Cataracts which are ripe, according to the tests just given, and in which there are *no sectors shining like mother-of-pearl*, are considered ripe for operation. In color they are white, yellow, or gray; also when the lens is wholly occupied with a brownish-yellow nucleus. This may be semi-transparent, and the iris throw a distinct shadow.

Treatment.—When a cataract is not ready for operation, the vision may be improved by glasses, which shade the eyes, allowing the pupil to dilate, and by the

instillation of weak atropine solution. These measures apply to opacities at or near the antero-posterior axis of the lens.

Opacities of the lens may be removed by three methods: *Solid extraction*, *absorption after discission*, and *suction*. The first method is applicable to all forms of ripe cataract; the lamellar, central, posterior polar, and fusiform varieties are treated by discission when any operative interference is indicated; soft opacities are removable by suction.

Extraction is not imperative when only one lens is affected, vision being about perfect in the other, unless the cataract is becoming overripe. It is advisable to remove only one lens at a single operation, even in double ripe cataract.

Operation is not advisable when any serious intra-ocular complication exists, or when insurmountable opacity of the cornea is present. It is always advisable to allay any existing inflammation of the ball or appendages before an operation for cataract. When a cataract is not ripe, its solidification may be hastened by *massage* of the globe—that is, by pressure applied over the ball with the tips of the fingers. The massage should last a few minutes, and be repeated every few days as indicated.

Operation of Extraction.—Two principal methods of extraction are at present employed, viz., (1) *simple extraction* and (2) *extraction after iridectomy*. The

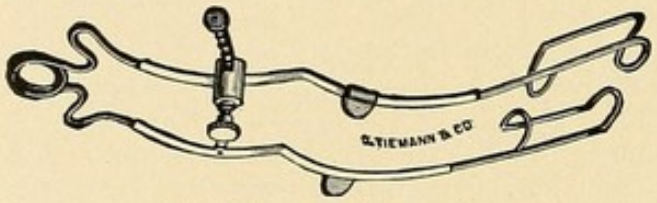

Fig. 336.—Graefe's speculum.

former is the ideal operation, and, although at this date not so generally employed, is fast gaining in popularity.

Simple Extraction.—The most careful asepsis is demanded. The eye should be irrigated with warm boracic-acid solution (gr. x–xv to $\bar{3}$j). The instruments should be thoroughly cleansed by boiling and immersion in alcohol. Anæsthesia is obtained by dropping several minims of two-per-cent cocaine hydrochlorate into



Fig. 337.—Graefe's fixation-forceps.

the eye, five minutes, and again three minutes, before the operation. The head should be so held that the cocaine rests in contact with the upper surface of the cornea through which the incision is made. When ready to operate, the eye and conjunctival sac should be dried with absorbent boracic-acid cotton pellets. The speculum is introduced and secured, and the conjunctiva seized with fixation-forceps just below the center of the lower margin of the cornea. The ball is drawn



Fig. 338.—Graefe's linear knife.

slightly downward and steadied, while the knife, cutting edge upward, is entered *through the cornea* just at the corneo-sclerotic junction, carried carefully across in front of the iris, which must not be touched, and out at a point corresponding to that of entrance (Fig. 339). By careful to-and-fro movements, the flap is made by cutting upward through the cornea just anterior to the sclerotic junction. The line between the angles of this flap should cross the cornea a little more than one third the distance from the upper to the lower margin. As this section is being

made, and before the aqueous humor escapes, an assistant should slightly lift the speculum, so that no pressure may be made by it upon the ball.

The cystotome is now carried through the wound, kept clear of the iris by the operator, who very cautiously scratches through the anterior capsule, through the whole width of the pupil. Care must be taken not to press so hard against the lens as to dislocate it. As soon as the capsule is opened, gentle pressure in an upward direction should be exercised by means of the spoon against the lower margin of the cornea, or pressure with the finger on the lower lid may suffice to deliver the lens through the pupil and out through the wound of incision. The pressure should be carefully gauged to effect only the exit of the cataract, and not to rupture the zonula. The wound should now be examined, and no particle of iris, lens, or capsule should be left in the incision. A drop of eserine solution (gr. ij–$\bar{3}$j) is now instilled into the conjunctival sac in order to contract the pupil. The eye is finally irrigated with the boracic-acid solution and the dressing applied, and both eyes closed by bandaging. The patient is required to remain quiet in a light room for a week. The first change of dressing should be made on the second day, and daily thereafter. Strict asepsis is essential at each change of dressing. The light should be excluded only from the eyes by bandages and shades, and *not* from the room. At the end of a week or ten days a black silk shade may be substituted for the bandages, and in from two to three weeks the

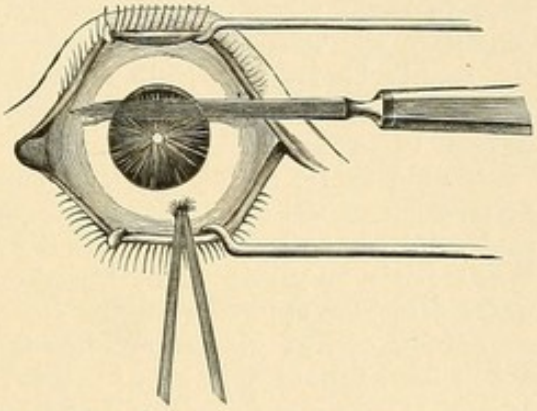

FIG. 339.—Introduction of Graefe's knife showing size of corneal flap in extraction of cataract. (Swanzy.)



FIG. 340.—Cystotome and Daviels' spoon.

patient will need only medium smoke coquilles to protect his eyes from the strong light. He should not be fitted with cataract glasses until all signs of redness and sensitiveness have disappeared.

Extraction with Iridectomy.—The speculum is introduced and secured, and the ball steadied by grasping a fold of the conjunctiva, just below the center of the lower margin of the cornea (Fig. 339), with a mouse-tooth fixation-forceps. The ball is drawn slightly downward, and the Von Graefe knife, edge upward, is made to enter the cornea, just at the sclerotic junction, at a point three millimeters (about one eighth of an inch) below the highest margin of the cornea (or about one third of the distance between the upper and lower margins of the cornea). The point is then made to emerge accurately opposite the entrance, when, by a gentle movement of the knife, the flap is completed by cutting through the cornea, just anterior to its junction with the sclerotic. As this flap is made, a certain proportion of the aqueous humor escapes. The fixation-forceps being, at this stage, transferred to an assistant, the iris-forceps are introduced, and the iris seized at a point corresponding to the center of the incision, and carefully drawn out through the wound. A narrow strip, including the entire depth of the iris, is then excised.

As soon as the iridectomy is completed the operator relieves the assistant of the fixation-forceps, directs that the speculum be lifted, so that no pressure is made on the eyeball, while, with the cystotome carried into the anterior chamber, he freely scratches through the anterior layer of the capsule. Care must be taken not to press so hard against the lens as to dislocate it. It is also important to see that no shred of the capsule is dragged out into the wound in withdrawing this instrument. The globe should now be depressed, either with the forceps or by

the patient's volition, and the cataract extracted by gentle pressure with the spoon from the lower margin of the cornea upward. The pressure should be carefully gauged, and the wound examined as above described. Should bleeding occur, this may be checked by a light compress of cold boracic solution. The after-treatment is the same as just given.

If the primary incision should not be large enough to allow the easy escape of the lens, it should be enlarged, preferably with the iris-scissors; it should be free, to begin with. If any fragments of the lens adhere to the capsule or are caught in the wound, they must be worked out by careful manipulation. Should the zonula be ruptured, allowing the vitreous to escape, the lens should be extracted with the scoop. The vitreous should be divided with the scissors at the level of the wound.

Should septic infection occur, suppuration of the wound follows, with usually destruction of the eye. The treatment should be frequent irrigation with boracic-acid solution, and the galvano-cautery wire applied to the margins of the wound. When iritis is precipitated, atropine should be instilled and warm boracic-acid water dressings applied.

Strong convex glasses are necessary after the operation, but the eyes should not be used for reading, etc., for three or four months. Two pairs of glasses should be prescribed—one for reading and another for vision.



FIG. 341.—Beers' straight needle.

Discission.—After dilatation with atropine, and with ether narcosis to prevent any movement which might displace the lens, the speculum is introduced, and the field of operation rendered aseptic.

The point of the cataract-needle is made to pass through the cornea near the outer margin, and the point carried to the center of the pupil, where it enters the capsule of the lens (Fig. 342). The capsule and the anterior superficial layers of the lens are torn open by gentle movements of the point of the instrument, which is then withdrawn, being careful not to injure the iris. The pupil should be kept fully dilated, renewing the instillation every few hours, if necessary, for several days. Cold applications and a dark room are the chief indications in the after-treatment. If successful, the lens becomes opaque after a week or more, and gradually disappears by absorption. A second operation may be necessary.

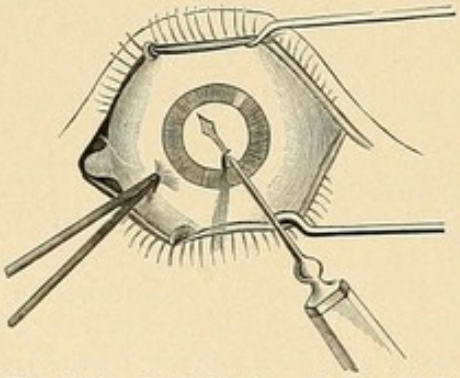

FIG. 342.—Introduction of the needle in discission. (Swanzy.)

Suction.—Dilate with atropine, administer ether, incise the cornea half-way between its center and margin, perform discission, and introduce the nozzle of the syringe into the lens, when it and the capsule are broken up. The softened lens is sucked into the cylinder by steady and gradual traction on the piston. Strict asepsis is essential. A single introduction of the instrument is advisable. The after-treatment is the same as for discission.

THE VITREOUS

Hyalitis, or inflammation of the vitreous, may result from traumatism, with or without the presence of a foreign body, or by the extension of some idiopathic inflammatory process from the choroid, iris, or any portion of the globe. Syphilitic choroiditis is especially apt to produce hyalitis. The immediate symptom is opacity due to extravasation of blood, or the exudation of the products of inflammation. The vitreous breaks down, becoming more fluid than normal (*synchisis*). Flakes

or small collections of more solid matter may be seen to change position as the position of the globe is changed. "Spots before the eyes" (*muscæ volitantes*) occur chiefly in myopic subjects, and are due to changes in the vitreous.

The exact condition of the vitreous can usually be made out by careful examination with the ophthalmoscope.

Foreign bodies, when composed of small bits of metal, may be removed by the electro-magnet. Should the wound in the sclerotic be not sufficient, it should be enlarged and the middle of the magnet carried into the vitreous. The metal, if not impacted, adheres to the magnet and is withdrawn. When the foreign body is non-metallic, operative interference is of doubtful propriety unless general inflammation is taking place. Idiopathic hyalitis should be treated by rest to the eye and by special medication.

The Retina

Inflammation of the retina (*retinitis*) may occur independently of lesion of any other portion of the eye, or it may be part of an inflammation of the choroid, ciliary body, iris, vitreous, or by extension from the optic nerve. It is not uncommon in syphilis, and follows thrombosis and embolism of the vessels. It is met with in nephritis, in diabetes, and in severe cerebral hyperæmia.

Detachment of the retina from the choroid may be due to extravasation of blood or transudation of serum.

All these conditions may be determined by a careful analysis of the symptoms present and by ophthalmoscopic examination. The indications in treatment are chiefly to correct the general condition of disease on which the retinitis depends. When of traumatic origin, the chief reliance is upon complete rest and warm fomentations. In certain morbid conditions of the external portions of the retina, objects appear unusually small (*micropsia*). The opposite of this condition is known as *megalopsia*.

Night-blindness (*hemeralopia*) is usually only a symptom of *retinitis pigmentosa*, but sometimes occurs in other diseases of the retina and optic nerve.

Day-blindness (*nyctalopia*) is generally due to exposure to strong light, as the glare of the ocean in the tropics, and may occur in persons of faulty nutrition.

Optic Neuritis.—The optic nerve is at times the seat of neuritis which may originate here, or descend from the brain along the nerve; it may be secondary to retinitis, or become involved by contact with morbid changes occurring in the lymph spaces and other tissues contiguous to it. The subjective symptoms are varying degrees of interference with vision. *Amblyopia* (dimness of sight), or *amaurosis* (complete blindness), may be present. These symptoms may be present without perceptible change in the appearance of the retina or optic papilla. When the lesion is beyond the disk, atrophic or other changes of the papilla may be recognized by the ophthalmoscope.

In some instances the obliteration of the retinal image is confined to a portion of the field of vision, usually one half (*hemianopsia*). If one eye only is involved, the lesion is peripheral and limited to the nerve or retina of the affected eye. If binocular, the lesion is in or posterior to the optic chiasm. The inner half of one and the outer half of the other eye are usually obscured.

Color-blindness.—There is a congenital defect of the retina in which the individual is incapable of recognizing certain colors, as *red, green,* and *blue*; a little more than three per cent of males are so affected. Of thirteen hundred and eighty-three men in the employment of the Pennsylvania Railroad Company examined by Dr. William Thomson, fifty-five were absolutely color-blind. It is less common in women. The usual method of testing is that with Professor Holmgren's colored woolen threads. If the patient is wholly color-blind, he will be unable to differentiate between the principal colors. Partial color-blindness may be detected by a careful test with the woolen threads, requiring the suspected person to match to the leading colors those which to him appear of the same or nearly the same shades.

Strabismus

Strabismus, or "squint," may be *convergent* or *divergent*. The former is by far the more frequent variety, and is usually observed in young children. It results from a loss of the normal equilibrium in the muscles of the eye, and when first noticed is often intermittent, appearing in one eye and then the other (*alternating*). As a result of prolonged and repeated efforts at *accommodation* (contraction of the ciliary muscle causing relaxation of the zonula, with consequent increase in the antero-posterior diameter of the lens), the internal rectus becomes permanently shortened.

The degree of convergence may be determined by the strabismometer (Fig. 343). Let the patient fix his vision on a distant point directly in front of him; place the

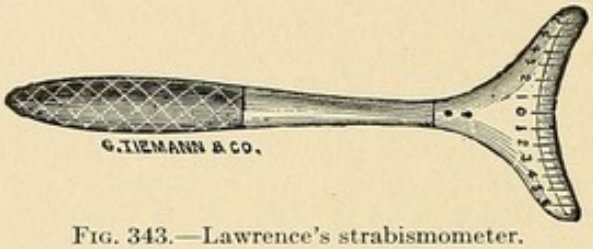

Fig. 343.—Lawrence's strabismometer.

center of the instrument directly beneath the center of the pupil, and measure the distance from this point to the inner angle of the eye. The same measurement on the affected side will determine the degree of convergence on that side.

Treatment.—Tenotomy is indicated in convergent strabismus for the relief of deformity, as well as for the correction of vision. The prospect of a perfect result is better in recent cases than in those of long standing, in which the external rectus has been overstretched and permanently weakened. In children, about the seventh year is the best period for operation. Tenotomy of the internal rectus is



Fig. 344.—Von Graefe's strabismus-hook.

thus done: The conjunctiva is first anæsthetized with cocaine solution, and two to four minims may be injected into and beneath the conjunctiva, immediately about the insertion of the muscle. The speculum is introduced, and the conjunctiva, just on the inner side of the eye, picked up with the forceps and divided with the scissors. The strabismus-hook (Fig. 344) is next carried into this opening and guided beneath and behind the tendon of the rectus internus, which is pulled

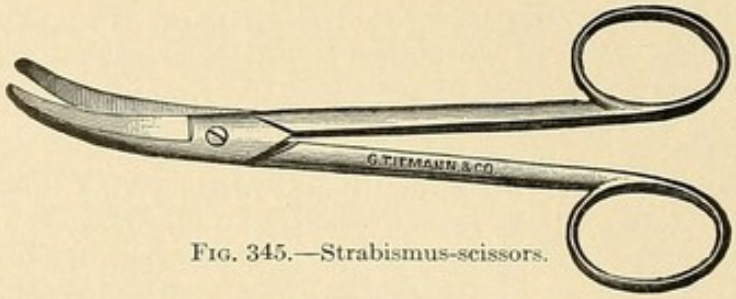

Fig. 345.—Strabismus-scissors.

forward and divided at its insertion into the sclerotic. The hook should be again introduced, to make sure that a thorough division is effected. A pad of cotton dipped in boracic-acid solution, held in place by a dry cotton compress and bandage, should be worn for one or two days. When strabismus makes its appearance in adult life, it is usually due to paralysis, partial or complete, of one or more of the orbital muscles. The lesion producing paralysis may be situated in the brain

or in the orbit. Disease of the bones about the foramina of exit of the nerves which supply these muscles, the presence of syphilitic gummata, or any neoplasm, will produce, by pressure on the nerves or muscles, a more or less complete paralysis. Rheumatism is occasionally a cause of strabismus.

In the *treatment* of strabismus due to paralysis, operative interference is not indicated until all other remedial agents have been exhausted in vain. When operation is demanded, not only should division of the contracted muscle be effected as just described, but the weaker muscle may be shortened by *advancing its insertion.*

Take, for example, the external rectus. Perform tenotomy as heretofore described. A small curved needle is threaded with fine silk and carried from the ocular side out through the divided muscle and conjunctiva. Each end of this double suture is now threaded to a curved needle and passed beneath and through the conjunctiva, coming out near the margin of the cornea and about one eighth of an inch from the vertical meridian of the eye above and below (Fig. 346). The needles are cut away, and the two ends of the lower threads tied together, at the same time that an assistant ties the upper ends. These sutures are allowed to remain about forty-eight hours. The amount of shortening in the muscle advanced can be increased by carrying the first needle farther back through the muscle. In order to get the best possible result, the shortening should be slightly more than appears necessary at the time of operation.

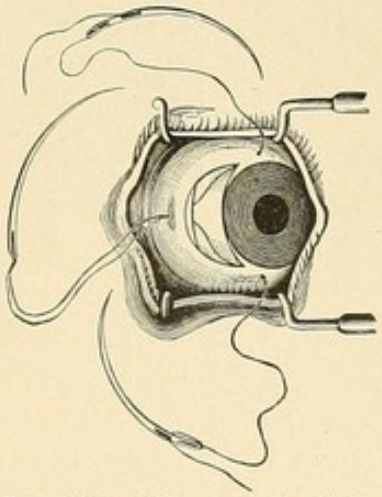

Fig. 346.—Advancement of the rectus. (De Wecker.)

Refraction—The Ophthalmoscope [1]

By the *refraction* of the eye we mean its power, when in a state of rest, of bringing parallel rays of light to a focus. In normal refraction, or *emmetropia,* the focus for parallel rays is upon the retina (Fig. 347). When the focus for parallel rays is not on the retina, there is said to be an error of refraction. The term *ametropia* includes all the errors of refraction. The principal forms of



Fig. 347.—Showing concentration of rays of light (*a, b, c*) on the retina (*d*) in normal refraction. (Swanzy.)

ametropia are: (1) *myopia*; (2) *hypermetropia.* All the other forms of ametropia are included under the head of *astigmatism,* in which the refraction differs, in degree or kind, in opposite meridians of the same eye.

The difference in refraction of eyes is due to their difference in shape. While the emmetropic eye is nearly spherical, the myopic eye is egg-shaped—too long in its antero-posterior diameter; and the hypermetropic eye turnip-shaped—too short in its antero-posterior diameter. Thus, while the principal focus of the emmetropic eye is upon the retina, that of the hypermetropic eye is behind the retina (Fig. 348), and that of the myopic eye in front of it (Fig. 349).

Astigmatism is usually due to asymmetry, or irregularity of surface, of the cornea, probably sometimes to a like condition of the lens. The varieties of astig-

[1] The author desires to acknowledge his indebtedness to his friend, Prof. David Webster, M.D., by whom this article on Refraction was written.

matism are six in number: (1) *simple myopic*, (2) *compound myopic*, (3) *simple hypermetropic*, (4) *compound hypermetropic*, (5) *mixed*, and (6) *irregular astigmatism*.

In simple myopic and simple hypermetropic astigmatism, the principal focus of one meridian of the cornea is upon the retina, while the principal focus of the



FIG. 348.—Showing rays converging to focus (at *a*) behind the retina (*b*, *c*). The hypermetropic eye (Swanzy.)

opposite meridian is anterior to the retina or behind it, accordingly as the astigmatism is myopic or hypermetropic.

In compound myopic astigmatism all the meridians of the eye are myopic, but one of them more so than any of the others, and the meridian at right angles to it less so than any of the others.

In compound hypermetropic astigmatism all the meridians of the eye are hypermetropic; but one of them more so than any of the others, and the meridian at right angles to it less so than any of the others. In mixed astigmatism one

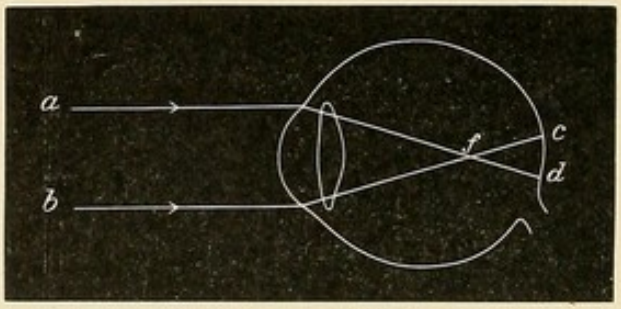

FIG. 349.—Showing concentration at (*f*) of rays of light (*a*, *b*) in front of retina (*c*, *d*) in myopia. (Swanzy.)

meridian of the eye is myopic, while the opposite meridian is hypermetropic. In irregular astigmatism different parts of the same meridian possess different degrees of refraction. Hence this form of astigmatism is the only error of refraction, which cannot be corrected by glasses. It is, in every sense of the word, irremediable.

It is obvious that persons with emmetropic eyes, and with unimpaired accommodation and well-balanced ocular muscles, do not need spectacles. Persons with any of the different forms of ametropia are liable to become the subjects of asthenopia from eye-strain. Such persons complain of inability to use their eyes, pain in their eyes and temples, headache, nausea, and various nervous disorders.

Hypermetropia is congenital, as a rule, and is said to be due to an arrest of development of the globe in its antero-posterior axis. It is sometimes the result of changes in the refractive media, as in the hardening of the crystalline lens that occurs in old age, or the removal of the lens by operations for cataract.

Parallel rays of light passing through the hypermetropic pupil do not meet on the retina, but converge toward a point behind it. Objects are therefore seen under circles of diffusion; and such eyes, in order to see distinctly, contract their ciliary muscles sufficiently to so increase the convexity of the crystalline lens that the focus will be brought forward upon the retina. This act is involuntary, and produces more or less strain upon the eyes. For such persons the *strongest convex* spherical glasses should be selected with which they can distinctly see objects distant twenty feet or more. If the asthenopic symptoms only accompany or follow

the use of the eyes for reading and other near work, it may be sufficient to wear the glasses only for the near. But when the asthenopic symptoms are constant, and are only aggravated by near work, the glasses should be worn constantly.

In selecting glasses for the relief of asthenopia, no matter what the error of refraction, it is always well to examine the eyes with the pupil dilated. While sulphate of atropia is the most reliable mydriatic, if used in solution sufficiently strong to paralyze the accommodation, it incapacitates the eyes for near vision for at least ten days.

When the object is to ascertain the true refraction with as little inconvenience to the patient as possible, it is sufficient for all practical purposes to drop into the eyes a few minims of a three-per-cent solution of homatropine hydrobromate at intervals of fifteen minutes, until seven or eight instillations have been made, and to test the refraction ten or fifteen minutes after the last instillation. If the homatropine produces redness of the eyes, as is often the case, this may be relieved by a single instillation of a four-per-cent solution of cocaine hydrochlorate, which, at the same time, increases the effect of the homatropine in paralyzing the ciliary muscle. The effect of these mydriatics passes off inside of twenty-four hours. In cases where it is desirable that the patient should have the benefit of a prolonged rest of his accommodation, regardless of inconvenience, it is better to use the sulphate of atropia (a one-per-cent solution).

In some cases of asthenopia from hypermetropia, glasses correcting the total error of refraction are worn with comfort from the start. In the majority of cases, however, when the accommodation reasserts itself, such glasses make the eyes practically myopic, and the indistinctness of vision thus produced so annoys the patient that he rejects them. It is safer, therefore, to wait until the hypermetrope has recovered from the effects of the mydriatic, and then to order the strongest convex glasses that he can wear with comfort. When his eyes have become accustomed to these, they should be exchanged for stronger ones, and these changes should be repeated at intervals of two or three months until the total hypermetropia is corrected. After that it is probable that the patient will need no further change of glasses, and that the relief of his asthenopia will be permanent.

Myopia may be apparent or real. Apparent myopia is due to spasm of the ciliary muscle, and may be diagnosticated from true myopia by ascertaining the true refraction under the effects of atropia. Spasm of the ciliary muscle is usually the result of overuse of the eyes. Such patients should be kept under atropia for several weeks, wearing medium smoked coquille glasses to protect the retina from excessive light. When the spasm of the ciliary muscle fails to reassert itself after the use of the mydriatic is stopped, convex glasses, correcting the hypermetropia, which almost always exists in such cases, should be substituted for the coquilles, and the patient should be cautioned not to resume the excessive near use of his eyes. True myopia is the result of the lengthening of the antero-posterior diameter of the eyeball, and is rarely congenital. There often exists a hereditary tendency to myopia; and it is a matter of common observation, that where the father or mother is myopic the children are apt to develop the same condition during school-life. Myopia is frequently developed in children, however, where there is no traceable hereditary tendency. It almost invariably first shows itself during early school-life, and the first intimation of it is that the child fails to see the letters and figures on the blackboard across the school-room. It is encouraged by the use of the eyes by insufficient light in a vitiated atmosphere, and in a stooping position, during the period when the eyes are undergoing rapid development along with the other organs of the body. It is of the greatest importance that it should be arrested as soon as possible; for highly myopic eyes are nearly always diseased eyes, and are in great danger of developing staphyloma posticum, retinal, and choroidal changes, floating bodies in the vitreous, and detachment of the retina. Myopic patients should be fitted with glasses at as early a period as possible, the weakest concave glasses being selected for them, with which they can see distant objects distinctly. They should wear such glasses constantly; by so doing, arrest of development of the ciliary muscle will be avoided, as will also excessive strain upon the interni. Attention to their general health should not

be neglected, and the amount of use of their eyes for near work should be limited. Their eyes should be tested at least once in six months, and a careful record kept of the results of such testings, for it is only in this way that we can tell whether the myopia is stationary or progressive, and, if the latter, whether rapidly so or not. If the myopia is increasing rapidly, near work should be entirely stopped, and the patient should be put upon atropia and colored glasses, and turned out into the open air. Myopia usually ceases to be progressive somewhere between the ages of twenty and thirty. Aside from all consideration of the health of the eyes, myopes should wear the correcting glasses for educational reasons.

Astigmatism, especially when only slight and correctible by an unequal contraction of the ciliary muscle, is a prolific source of asthenopia. When it exists in the higher degrees, the patient makes no attempt to correct it; sees indistinctly at all distances, and is comparatively free from asthenopic symptoms. The slighter degrees, then, should be corrected with glasses for the relief of asthenopia; the higher degrees for the purpose of procuring distinct vision. Of course, in fitting patients with glasses for the correction of astigmatism, convex and concave cylin-



Fig. 350.—Nachet's trial-set.

drical lenses are necessary. For simple hypermetropic astigmatism that convex cylindrical glass should be selected which brings the focus of the hypermetropic meridian forward upon the retina, and this makes distinct vision possible without an effort of accommodation. For simple myopic astigmatism the concave cylindrical glass should be selected which throws the focus of the myopic meridian back upon the retina, and thus renders the eye practically emmetropic. For compound hypermetropic astigmatism a convex spherical with a convex cylindrical glass is necessary, while in compound myopic astigmatism the error of refraction is corrected by the combination of a concave spherical and a concave cylindrical glass. Mixed astigmatism is corrected by a convex cylindric and a concave cylindric combined, and with their axes at right angles to one another.

In prescribing glasses for astigmatism the greatest care should be taken to

adjust the axes properly. The cylindric trial-glasses should always be placed before the eyes in trial-frames made for the purpose, and the direction of the axes read in degrees from the frames. Ophthalmologists use Snellen's test-types in examining for errors of refraction, and the cases of trial-glasses made by Nachet (Fig. 350) are as good as any.

Testing for Glasses

For determining errors of refraction and fitting patients with spectacles, the surgeon should provide himself with Snellen's and Jaeger's test-types and with a case of trial-glasses, including spherical and cylindrical glasses, convex and concave, trial-frames with the degrees of a semicircle marked upon them, etc. The patient should be placed at a distance of twenty feet from Snellen's test-type, with the light shining upon the test-type and not upon the face of the patient. Each eye should be tested separately, the other being kept open and covered with a screen.

Snellen's test-type is so constructed that the letters in each line subtend an angle of five minutes at the distance marked in feet above the line. The line marked 100 should therefore be read at one hundred feet; that marked 20, at twenty feet, etc. Vision is recorded *fractionally*, the distance from the test-type being set down as the *numerator*, while the number of the line read is set down as the *denominator*. Thus, if a person with his right eye reads Snellen No. 70 at twenty feet, the vision would be recorded thus: R. V. $= \frac{20}{70}$. If with his left eye he reads Snellen No. 20 at twenty feet, it is recorded L. V. $= \frac{20}{20}$. The vision of the right eye would be two sevenths of the normal, while that of the left eye would be one, or normal. If a patient reads $\frac{20}{20}$ with each eye, we know that his vision is perfect in both eyes, but still he may be *hypermetropic*, and straining his accommodation in order to see distinctly. We should always test such a patient with convex spherical glasses. If the weakest glass blurs his vision, he has no manifest hypermetropia. The vision and refraction of such a patient should be recorded thus:

R. V. $= \frac{20}{20}$; E. L. V. $= \frac{20}{20}$; E. (emmetropic).

If the patient can read Snellen No. 20 at twenty feet through a convex spherical glass, the *strongest* one through which he can read it represents his manifest hypermetropia. Thus—

R. V. $= \frac{20}{20}$; Hm. 1.75 D. L. V. $= \frac{20}{20}$; Hm. 1.50 D.

would mean that the patient had perfect vision without a glass, or with any convex spherical glass from the weakest up to + 1.75 D., right eye, and + 1.50 D., left eye; but that stronger glasses than those indicated would blur his vision. Those glasses should, therefore, be prescribed. If the patient sees less than $\frac{20}{20}$, we may suspect myopia or astigmatism. For instance, the formula—

R. V. $= \frac{20}{200}$; $\frac{20}{20}$ with − 4 D. L. V. $= \frac{20}{100}$; $\frac{20}{20}$ with − 3 D.

means that, without glasses, the patient sees $\frac{20}{200}$ with his right eye, and $\frac{20}{100}$ with his left eye, and that − 4 dioptries is the *weakest* concave glass with which he can read $\frac{20}{20}$ with his right eye, and − 3 dioptries the weakest with which he can read $\frac{20}{20}$ with his left eye.[1]

Again, the patient may be astigmatic. Suppose we find—

[2] R. V. $= \frac{20}{40}$; $\frac{20}{20}$ with + 1.25 D. c. ax. 90°.
L. V. $= \frac{20}{50}$; $\frac{20}{20}$ with + 1 D. s. ⌒ + 1.50 D. c. ax. 90°.

We have here simple hypermetropic astigmatism in the right eye, and compound hypermetropic astigmatism in the left. In the right eye, the vision is brought up to $\frac{20}{20}$ by a convex cylindric, one and a quarter dioptries, axis 90°; while in the left the combination of a convex spherical and a convex cylindrical is required.

[1] In the dioptric scale of numbering spectacle-lenses the unit is a weak lens of 100 centimetres focal length, or D. (one dioptry). A lens with focal length of 50 cm. = (2 D.), etc.

[2] This reads: Right vision equal $\frac{20}{40}$; $\frac{20}{20}$ with convex 1.25 Dioptries, cylindric, axis 90°. Left vision equal $\frac{20}{50}$; $\frac{20}{20}$ with (+) convex 1 D. spherical, (⌒) combined with convex 1.50 D. cylindric, axis 90°.

In another case—

R. V. = $\frac{17}{200}$; $\frac{20}{20}$ with − 3.25 D. c. ax. 180°.
L. V. = $\frac{3}{200}$; $\frac{20}{20}$ with − 3.75 D. s. ⌒ − 2 D. c. ax. 180°.

Here we have simple myopic astigmatism in the right, and compound myopic astigmatism in the left. In mixed astigmatism the refraction may be corrected and the vision brought up to the normal by either of three different combinations of lenses. Thus—

R. V. = $\frac{20}{50}$; $\frac{20}{20}$ with + 1 D. c. ax. 90° ⌒ − 1 D. c. ax. 180°.
L. V. = $\frac{20}{70}$; $\frac{20}{20}$ with + 2 D. c. ax. 90° ⌒ − 2 D. c. ax. 180°.

The equivalent glasses would be—

R. + 1 D. s. ⌒ − 2 D. c. ax. 180°.
L. + 2 D. s. ⌒ − 4 D. c. ax. 180°. Or,
R. − 1 D. s. ⌒ + 2 D. c. ax. 90°.
L. − 2 D. s. ⌒ + 4 D. c. ax. 90°.

In fitting patients with cylindric glasses the direction of the axes is read from the degrees marked on the trial-frames toward which the axes point in giving the best vision.

Presbyopia, or old sight, is an impairment of the accommodation due to the gradual hardening of the crystalline lens, the result of age. Persons who are emmetropic, or slightly hypermetropic, usually need glasses for near purposes when from forty to forty-five years of age. The higher degrees of hypermetropia necessitate the use of glasses for reading much earlier. In the lower degrees of myopia the use of glasses for reading may be deferred considerably longer, while in the higher degrees they may never be needed at all. Presbyopes, no matter what their refraction, should be suited with the glasses, generally convex, with which we find experimentally they can read most comfortably. Generally the weaker convex glasses are selected in the early stages of presbyopia, and these are exchanged for stronger ones as the patient advances in life.

Heterophoria.—Insufficiency of the extrinsic ocular muscles—latent or dynamic squint.

When the extrinsic ocular muscles are not well balanced, as when the interni are relatively stronger than the externi, or one of the inferior recti weaker than its fellow of the opposite side, there is a tendency of one eye to deviate in the direction of the relatively stronger muscle. If the eye should actually deviate, *diplopia* (double vision) would result, and would be productive of great annoyance. Therefore, single, binocular vision is always maintained as long as possible, and in order to its maintenance, an extra innervation has to be supplied to the weaker muscle. This constant strain causes asthenopia, headache, nervousness, etc. In some cases the strain can be removed by the use of prisms worn with their bases toward the weaker muscles, alone, or combined with the lenses which correct any existing error of refraction. But in many cases it becomes necessary to restore equilibrium of the muscles by a tenotomy of the stronger or a tendon resection of the weaker muscle.

The different kinds of correctible heterophoria (tendency to deviation of the visual lines) are: 1. Hyperphoria (a tendency upward of one eye). 2. Exophoria (a tendency outward). 3. Esophoria (a tendency inward).

In order to ascertain with accuracy the kind and amount of heterophoria, the surgeon should provide himself with a phorometer (an instrument of precision invented by Dr. George T. Stevens, of New York), and a set of square prisms, of one degree and upward.

The patient is seated facing a lighted candle, which is situated on a level with his eyes, and twenty feet, or more, distant. The horizontal bar of the phorometer is placed in front of his eyes and a few inches away from them. In a slot in this horizontal bar is placed a frame containing two prisms of four degrees to eight degrees each, bases toward the nose, and on looking at the candle through these prisms,

the images are thrown to the nasal side of the macula, and the patient has homonymous diplopia. If both inferior recti are of equal strength, and likewise both superior recti, neither eye will deviate upward, and the two candles will appear in a horizontal line, or on a level. But if one eye deviates upward, the image will be thrown upon the supero-nasal quadrant of the retina of that eye, and will be seen on a lower level than that seen with the other eye. The prism placed before the eye that sees the lower candle, base down, which brings the candles on a level, measures the amount of hyperphoria.

Having tested for hyperphoria, the horizontal prisms should be removed and replaced by a prism base down in front of one eye. This will produce vertical diplopia by throwing the image of the candle-flame on the retina below the macula, so that it will be projected above. If the two flames are seen in a vertical line, there is no insufficiency of the interni or externi. But if the images are homonymous, there is insufficiency of the externi; and the prism, base out, that makes them vertical, measures the esophoria.

If the images are crossed, there is insufficiency of the interni; and the prism, base in, that makes them vertical, measures the exophoria. In making these tests, the horizontal bar of the phorometer must be carefully adjusted by means of the attached screw or ratchet and spirit-level.

In order to arrive at a more positive idea as to the relative strength of the ocular muscles, it is necessary to measure (1) the abduction, (2) the adduction, and (3) the sursumduction.

The abduction is measured by the strongest prism that can be overcome by the externi—that is, the strongest prism, base in, through which the patient can see singly at twenty feet or more. In like manner, the strongest prisms, base out, through which the patient has binocular single vision, measure the adduction; and the strongest prism, base down, over one eye, through which the patient sees singly, measures the sursumduction.

In hyperphoria of one degree or more, the superior rectus of the hyperphoric eye may be divided; in esophoria of two degrees or more, the internus may be cut; and in exophoria of two degrees or more, the externus may be snipped. But if the surgeon would avoid an overcorrection, thus leaving the eyes in a worse condition than before, he must follow the method advocated by Stevens:

1. Make a small opening in the conjunctiva over the tendon to be cut.

2. Seize the center of the tendon with delicate but strong forceps, made for the purpose, and buttonhole it with delicate probe-pointed scissors.

3. Introduce one blade of the same scissors between the tendon and the sclera and the other blade between the tendon and the conjunctiva, and cut transversely to one border of the tendon, and then, reversing the scissors, cut transversely to the other border of the tendon.

4. The eyes should now be tested with prisms, and if the heterophoria is not nearly corrected, the scissors may be again introduced and the loosening up of the insertion be carried a little further. Thus by cutting cautiously, a little at a time, and then testing with candle and prisms to ascertain how much effect has been obtained, it is not difficult for the dexterous operator to correct the deviation with considerable accuracy. No surgeon should undertake these operations with the ordinary clumsy instruments in vogue. The necessary instruments particularly adapted to the purpose, and to tendon-resection, are made by Messrs. Tiemann & Co., of New York. Tendon-resection is practiced in cases where the heterophoria is too great to be corrected by a graduated tenotomy of the stronger muscle without limiting the excursion of the eye in that direction. In such cases it is better to partly correct the deviation by tenotomy and to correct what remains by tendon-resection of the weaker muscle. In performing this operation, by Stevens' method, the tendon is divided as in graduated tenotomy. A delicate hook is then slipped beneath and caught into the under surface of the divided tendon which is now drawn out of the conjunctival aperture and caught some lines from its extremity with delicate fixation-forceps. A small, very sharp, curved needle, armed with a fine silk thread, is now passed through the muscle from without inward, as far back as the operator thinks necessary, and then the portion of the muscle anterior

to the needle is excised with scissors. The needle is then carried through the stump of the insertion of the muscle, including the capsule of Tenon and overlying conjunctiva, and the thread drawn through and loosely tied.

The patient should now be placed in the position for testing with prisms, and the knot drawn just tight enough to correct, or slightly overcorrect, the deviation. In both these operations the lids may be held open by a speculum, an elevator, or the fingers of an assistant. The stitch may be removed at the end of three or four days. No after-treatment is required, as there is rarely any inflammatory reaction.

Tenotomy and tendon-resection for the correction of heterophoria should be resorted to only after all other means for the relief of asthenopia have been exhausted.

Ophthalmoscopy

The general practitioner should familiarize himself with the use of the ophthalmoscope sufficiently to be able to diagnosticate gross lesions of the globe situated posterior to the crystalline lens. He should provide himself with an ophthalmoscope with tilting mirror and convex and concave lenses ranging from one to twenty dioptries. The pupils should be dilated with homatropine or cocaine, two-per-cent solution in either case. The patient should be seated in a darkened room, with a lamp placed on a level with the eye to be examined, a little behind and to one side. The observer then rests the ophthalmoscope against the inner angle of his orbit and throws the light into the eye with the mirror, at the same time looking into the pupil through the aperture in the mirror. He thus gazes at the papillary area while the patient looks up, down, right, and left. If the reflex from the pupil is, in all positions of the eye, of a uniform clear pinkish or reddish color, it is to be inferred that there are no gross lesions of the refractive media. If the red reflex from the fundus is interrupted by dark spots, there are opacities of the media, and the surgeon must proceed to locate them. If they move while the eye is fixed, they are floating bodies in the vitreous. If they move with the eye and stop when the eye stops, they are opacities either of the cornea or of the crystalline lens. If of the cornea, they will be seen by oblique illumination. This is also true of opacities situated on the anterior capsule and in the front portions of the crystalline lens. If in the posterior portions of the lens, they will appear to move in an opposite direction to the eye. Opacities in the periphery of the lens are seen only when the eye is so turned that the observer looks through the pupil very obliquely. For more minute examination of any opacity already discovered, the observer should turn on over the aperture of his ophthalmoscope a + 10. D., and approach the eye to within its focal distance, about four inches. In this way he will obtain a greatly magnified view. In high degrees of myopia and hypermetropia pigment patches in the fundus may be mistaken by the novice for opacities of the media. These are excluded by seeing them in their true position while examining the fundus.

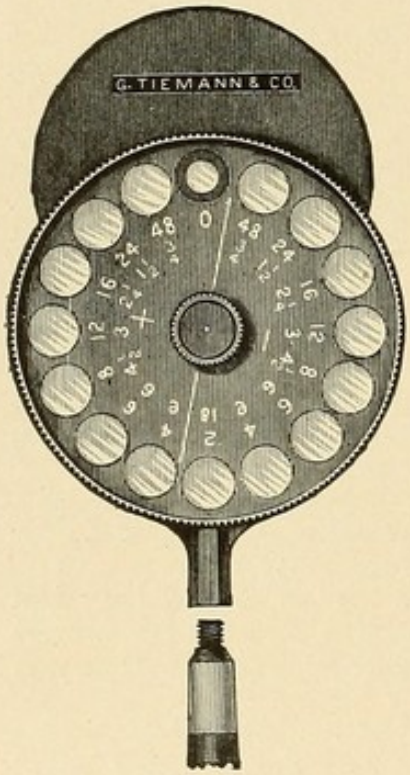

Fig. 351.—Loring's student's ophthalmoscope.

There are two methods of examining the fundus: (1) The indirect, (2) the direct.

In examining the eye by the indirect method, the observer interposes a two-inch or two-and-a-half-inch lens between his ophthalmoscope and the patient's eye, at about its focal distance from the eye, his own eye being twelve to fifteen inches away. In this manner he gets an inverted image of the fundus, magnified some

three or four diameters. By directing the patient to look successively in different directions, he thus easily scans the whole fundus.

In using the direct method, the observer approaches his eye with the ophthalmoscope as close as possible to the eye he is examining, often touching the brow or nose of the patient with his instrument. In this way he sees only a small portion of the fundus at a time, but that is in its true position and is magnified some seventeen diameters, more or less. The examined eye being myopic, he must turn on the *weakest* concave lens with which he can see the fundus distinctly; and this, while it enables him to see the fundus clearly, at the same time measures the amount of myopia. If the patient is hypermetropic in a moderate degree, the fundus will be well seen without any lens; but if the observer would estimate the amount of hypermetropia, he must turn on the strongest convex lens through which he can see the fundus distinctly. In astigmatism only one meridian of the fundus is seen distinctly at a time, the opposite meridian being seen through a stronger or weaker lens. If the observer has an error of refraction, he must take it into account in estimating refraction with the ophthalmoscope. Some of the grosser lesions to be looked for by the surgeon are:

1. *Optic Neuritis.*—Here the ophthalmoscopic appearances vary. In the milder cases only the nasal, or upper, or lower, border of the disk is obscured by swelling, while in the severer cases the whole papilla is greatly swollen and its outline entirely obliterated. The retinal vessels are tortuous, while the veins are enlarged and the arteries are either of normal size or diminished. There may or may not be ecchymoses upon the disk or in the retina. Rarely the central vision and visual field are perfect. In most cases, however, both are impaired, and often vision is reduced to perception of light. In optic neuritis or "choked disk" of both eyes intracranial tumors should always be suspected. Optic neuritis may, however, depend on a variety of causes, such as kidney disease, lead-poisoning, meningitis, syphilis, etc.

2. *Atrophy of the Optic Nerve* is recognized by the paleness of the optic disk and the smallness of the retinal blood vessels. It may be consecutive to optic neuritis, or it may be ushered in as "primary" atrophy. Therefore the conditions which produce optic neuritis should be sought in cases of atrophy. It frequently

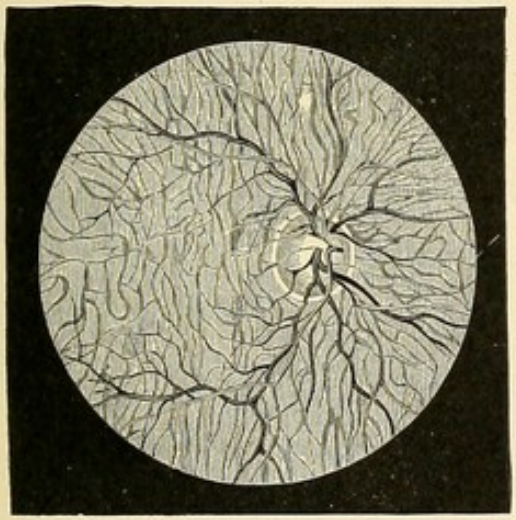

FIG. 352.—Ophthalmoscopic appearance of healthy fundus in a person of very fair complexion. Scleral ring well marked. Left eye, inverted image. (Wecker and Jaeger.)

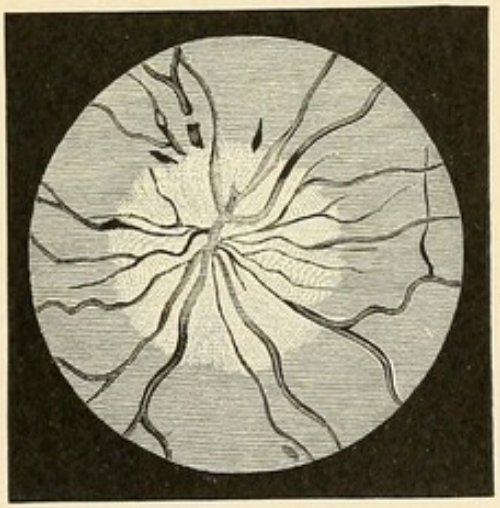

FIG. 353.—Ophthalmoscopic appearance of severe recent papillitis. Several elongated patches of blood near border of the central inflammatory area. (After Hughlings Jackson and Nettleship.)

occurs in poisoning by tobacco and alcohol, and is often a symptom of progressive locomotor ataxia. It is found in advanced stages of retinitis pigmentosa.

3. *Retinitis* is distinguished by bright or whitish patches in the retina. When these arrange themselves about the macula lutea in a stellate form, the cause is generally found to be kidney disease. They are often accompanied by retinal hæmorrhages. Diabetes and syphilis are among the other causes of retinitis.

4. *Choroiditis* is known by white patches in the fundus, generally bordered irregularly with black pigment, and with the retinal vessels passing over them. The cause is often obscured. It is sometimes due to syphilis.

5. *Glaucoma simplex* is always characterized by excavation, or cupping of the optic disk. The retinal vessels appear to end abruptly at the discal border. The bottom of the excavation can be seen through a sufficiently strong concave lens. Around the disk is a ring of choroidal atrophy exposing the white sclera. There is often pulsation of the retinal arteries. Central vision is usually impaired, and the visual field limited, especially on the nasal side.

CHAPTER XIII

THE EAR

The Auricle.—*Wounds* of the auricle should be treated with the view of preventing the least possible deformity. Lacerations of the lobule, even of long standing, may be corrected by paring the edges and uniting them by fine linen or horsehair sutures carried directly through all the tissues of this organ. Cocaine infiltration will secure perfect anæsthesia in practically all the operations upon the auricle.

Drooping of the ears may be corrected by proper care in infancy, strapping the auricle against the scalp by means of a light elastic band carried around the forehead and occiput. In extreme cases it may be necessary to excise an oval-shaped piece, including the entire thickness of the cartilage from the posterior surface of the concha, leaving the anterior cutaneous surface uncut. It is advisable to make a small section at first and insert trial sutures, gradually enlarging the wound,

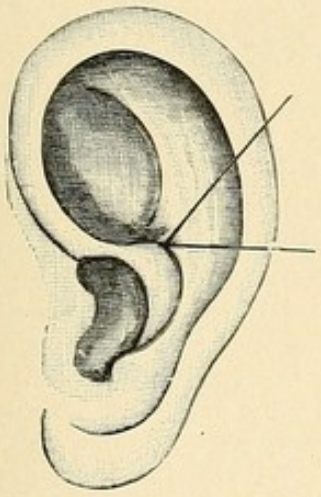

FIG. 354.—(After Reeves.)

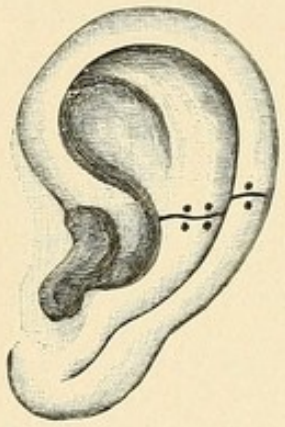

FIG. 355.—(After Reeves.)

until the proper correction is secured. In children this operation necessitates ether narcosis.

Hypertrophy of either one or both auricles may be corrected by excision of a triangular piece, as shown in Figs. 354 and 355.

Adhesion of the auricle to the scalp requires to be freed by dissection, and the raw surfaces covered by transplantation of skin with healthy epidermis.

Benign neoplasms of the auricle are occasionally observed at or near the tragus. They are chiefly cartilaginous, and should be clipped off with the scissors, under cocaine anæsthesia.

Angeioma may be cured without incision by carefully injecting the vascular area with a few minims of water at a very high temperature, by the author's method.

Epithelioma of this organ occurs usually along the upper border, and is not infrequently caused by frostbite. Taken early it is readily cured by the application of Marsden's paste. (See Epithelioma.)

A not infrequent cutaneous disease of the outer ear (*intertrigo*) occurs chiefly in children, and is caused by the uncleanly habit of wearing a tight-fitting cap

or bonnet continuously over the ears, plastering the auricles against the scalp, and resulting in excoriations which become infected. Correction of the habit, washing with 1–3000 mercuric-chloride solution once or twice daily, and the application of an aseptic drying powder will effect a cure.

The External Auditory Canal.—In adults the length of this canal is about one and a half inches, of which the inner five eighths of an inch is bony, the remaining portion cartilaginous. The general direction of the cartilaginous portion is upward, backward, and inward, while that of the bony portion is downward, forward,



Fig. 356.—Sexton's hard-rubber double probe.

and inward. In order to straighten the canal in examination, it is necessary to draw upon the auricle upward and backward.

In infants the upper and lower walls are in contact.

The drum is placed obliquely to the axis of the meatus, appearing as a continuation of the upper and posterior walls. In other words, the superior and posterior margins of the membrane are nearer the orifice of the meatus than the inferior and anterior.

To examine the deeper ear satisfactorily, a strong light is essential. The order of preference is the electric arc, the Argand or Welsbach gas-burner, and the duplex coal-oil lamp. Unless direct electric illumination is employed, a reflecting

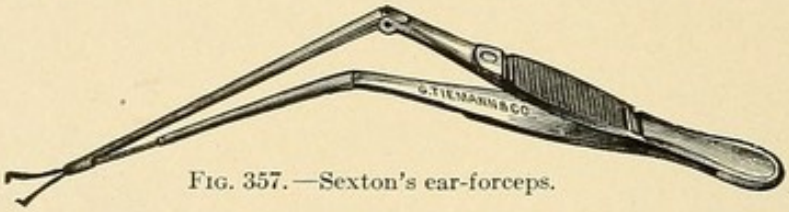

Fig. 357.—Sexton's ear-forceps.

forehead mirror is necessary. That in general use has a focal distance of eight to ten inches. Aural specula should be made of thin *polished* metal.

The patient should be seated with the head resting firmly against the back of the chair, the affected ear turned toward the surgeon, who should occupy a position slightly to one side. The light should be on the left of the examiner, and slightly above the horizontal plane, passing through the ear to be examined. The condition of the canal should be carefully studied before the speculum is introduced. The auricle should be grasped firmly at its upper posterior margin between the third and fourth fingers of the left hand, and traction made upward, outward, and backward. In examining the right ear, the hand lies behind the auricle; for the left, above and anterior to it. The speculum is held between the left thumb and index-finger, the auricle being grasped between the third and fourth fingers of



Fig. 358.—Sexton's double ear-hook, to extract foreign bodies.

the same hand. In this position the speculum is carried in gradually by rotation upon its axis. It should not be passed beyond the cartilaginous canal, and should expose without stretching the meatus. As the superior wall is followed inward, there will be seen just below the center of the line marking its inner termination a prominent projection, white or grayish-white in color, having the appearance as though the soft parts covering it were pushed upward into the lumen of the canal. This is the short process of the malleus, the position of which changes but little, no matter how much the system of ossicles may be displaced under abnormal

conditions. On account of its rich vascular supply, it often resists extensive caries of the tympanic wall and of the ossiculæ. Extending downward, and somewhat backward from this point through the middle of the membrane as far as its center, the handle of the malleus is recognized. The flattened termination of the handle at the center of the membrane is known as the *umbo*.

Between the short process of the malleus and the superior wall of the meatus, the membrana tympana presents a distinctly triangular form, the apex being at the short process, the sides of the triangle diverging to lose themselves in the superior walls of the canal. The sides of this triangle are clearly marked, and this portion of the drum membrane is known as the *membrana flaccida*, or Shrapnell's membrane.

Should the meatus be hairy, these may be made to adhere closely to the wall of the canal by applying vaseline on a cotton-tipped probe.

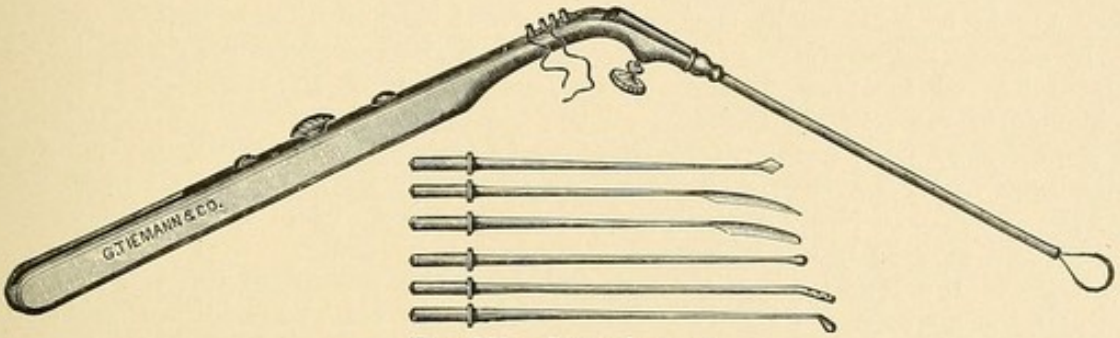

FIG. 359.—Sexton's snare.

Lesions of the External Auditory Meatus.—When inflammation is present, the exact location of infection should be determined, carefully watched, and freely incised upon the first indication of the retention of pus, and the canal irrigated with 1–5000 warm mercuric-chloride solution. Cocaine, applied locally or by infiltration, entering the needle from the outside skin, will secure perfect anæsthesia.

Not infrequently, certain *vegetable parasites* lodge and proliferate in this canal. They may be recognized by the microscope, and are almost always associated with partial or complete occlusion of the meatus by aggregations of epithelium, sebaceous crusts, etc. In chronic cases, the periosteum lining the bony portion of the canal may become involved and thickened. A thorough cleansing with the dull curette and repeated irrigation with 1–5000 mercuric-chloride solution in fifty-per-cent

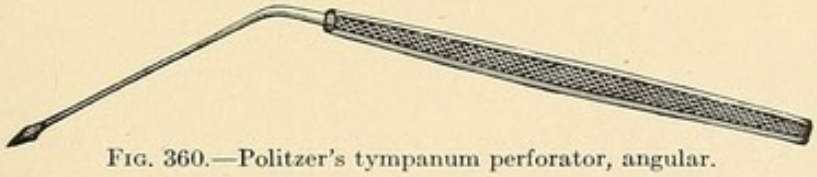

FIG. 360.—Politzer's tympanum perforator, angular.

alcohol will suffice, while sterile vaseline or olive oil, applied once or twice daily, will allay local irritation (Dench).

Impacted cerumen is best removed by irrigation with a lukewarm solution of 1–8000 mercuric chloride. If the entire meatus is filled, an opening should be carefully made by a small, dull-pointed instrument, so that the fluid may be thrown through this behind and around the mass, to soften and force it out.

Foreign bodies may be removed preferably by irrigation through a delicate pipette carefully introduced beyond the foreign substance. It is at times necessary to put the patient in complete narcosis to effect the removal without injury to the drum membrane. In exceptional instances, where the canal is abnormally small, it may be necessary to perform the operation advised by Dench: Under strict asepsis an incision is made from just below the insertion of the lobule, upward along the line of attachment of the auricle to a point just above the meatus, and then forward as far as the helix; the fibro-cartilaginous canal is then loosened from its attachment by means of the periosteum elevator, the instrument being applied

first below and then behind, the superior wall being detached last. In the same way the periosteum of the canal is separated from the bone, and the fibro-cartilaginous tube is divided transversely as near the drum membrane as possible.

This anterior flap, consisting of the auricle and the soft parts of the meatus, is turned forward, and entrance is thus gained to the bony meatus, and the foreign body may be extracted at once after the flap has been turned forward. In case the object is found so firmly fixed in the canal that efforts at extraction are still futile, the lumen of the meatus can be enlarged with a chisel by carefully chipping away the bone from the posterior wall until sufficient space is obtained. It is better to enlarge the passage by the removal of a portion of the osseous wall than to attempt to extract the body by forcible manipulation. The wound is closed with silk sutures and a small drainage-tube inserted through the canal. Repeated antiseptic irrigations are advised.

Bony new growths from the osseous canal require no special consideration. They should be removed by the most convenient method of approach.

Wounds of the *membrana tympani*, whether incised or lacerated, should be made aseptic by the local application to the membrane of an alcoholic solution of bichloride of mercury, 1–3000.

Inflation of the Tympanum.—In order to test the permeability of the Eustachian tube, and the normal mobility of the membrana tympani, as well as to recognize the presence of liquid (serum or pus) in the middle ear, the following methods of inflation may be practiced:

1. Close the nostrils and mouth, and have the patient attempt to force air through the nostrils. If the tube is permeable, the air will enter the middle ear and act upon the drum.

2. Politzer's air-bag consists of a rubber bulb attached to a tube, with a nozzle to be inserted in one nostril, the other being tightly closed. The lips are firmly compressed, and the patient is directed to swallow in order to throw the soft palate firmly against the posterior pharyngeal wall, and at this moment the bag is suddenly compressed, forcing the air into the pharyngeal vault and through the Eustachian tube.

3. By far the most satisfactory method is through the Eustachian catheter (Fig. 361), which should be made of pure silver, as this is more flexible. To the expanded outer end of the catheter a rubber tube is attached before its introduction. The other end of this rubber tube is attached to an ordinary atomizer bulb. "The



FIG. 361.—The Eustachian catheter.

inflating bulb is held in the palm of the right hand, while the catheter is grasped lightly between the thumb and index and middle fingers of this hand. The patient should be seated in a chair with a high back, the head inclined forward slightly, while he should close the lips tightly and breathe slowly through the nostrils. The operator, either standing or sitting at the right of the patient, tilts the tip of the patient's nose upward with the ball of the left thumb, the index and middle fingers resting upon the nose just below the bridge. From this moment the left hand is not removed from the patient's nose until inflation has been accomplished and the catheter has been removed. The tip of the nose being elevated, the extremity of the catheter is introduced into the nostril (Fig. 362); as soon as the instrument has passed the slight ridge at the nasal orifice the operator carries the hand holding the instrument upward until the catheter assumes a horizontal position. In this position, with the tip kept constantly upon the floor of the nasal cavity, the catheter is passed directly backward through the inferior meatus until the posterior pharyngeal wall is encountered (Fig. 363); it is then drawn forward about three eighths or one fourth of an inch, and, remembering that the guide ring on the shaft indicates the direction in which the pharyngeal extremity points, the instrument is rotated upon its long axis until the ring points almost directly outward toward

the side to be inflated. The hand is then elevated a little and carried slightly toward the opposite ear, causing the pharyngeal extremity of the instrument to descend, and at the same time to press lightly against the lateral pharyngeal wall.

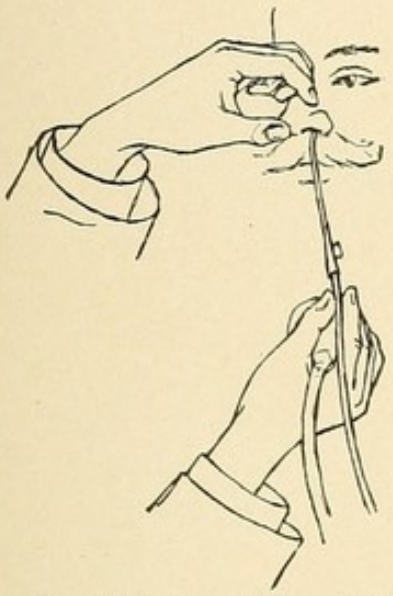

Fig. 362.—Introduction of the Eustachian catheter (first step).

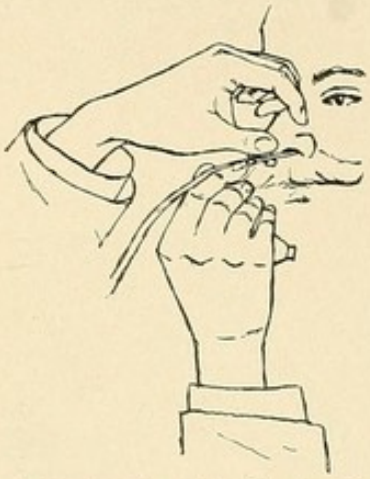

Fig. 363.—Introduction of the Eustachian catheter (second step).

By drawing the catheter a little outward, the tip will be felt to impinge upon the posterior lip of the tube; it is to be drawn over this, the tip being turned slightly downward, if necessary, to effect this without undue force. As soon as the operator knows by the sense of touch that the prominent posterior lip has been passed, the catheter is rotated upon its long axis until the guide ring points upward and outward toward the ear, while at the same time the outer extremity of the instrument is moved toward the opposite side, thus pushing the pharyngeal extremity well into the mouth of the tube. When carefully placed, the sense of fixation imparted to the hand is unmistakable. At this juncture the left thumb is moved so as to pass beneath the catheter and support it. The instrument is thus held firmly against the margin of the nostril, by the thumb below and the first three fingers, resting upon the bridge of the nose, above (Fig. 364); at the same time the tip of the nose is pressed upward as before. The right hand is now free to compress the bulb, forcing the air through the catheter into the middle ear, its entrance being recognized by sounds heard through the auscultation tube." (Dench.)

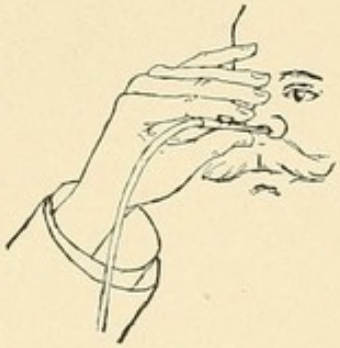

Fig. 364.—Introduction of the Eustachian catheter (the instrument fixed in the mouth of the tube). (After Dench.)

A soft-rubber tube, with a proper tip at each end, is inserted, one into the meatus of the patient, the other into that of the examiner. When the bulb is compressed, if the air enters there is a short click or sound of impact conveyed to the surgeon's ear as the drum is pushed out. If the middle ear contains fluid, instead of the "click" there is heard at irregular intervals a series of sharp, crackling, or churning râles. The quality of these râles suggests the nature of the fluid.[1] If high-pitched, the fluid is watery or serous; if low in pitch, it is thick—probably purulent. Should the cavity of the tympanum be overdistended, no crepitation is heard, but the impact sound, though distant and indistinct, is observed just as the current of air through the tube strikes the contained fluid.

A perforation of the drum is indicated by a high-pitched, whistling sound as the air escapes through the rent.

At times a deformity of the septum may render it impossible, even by the use of adrenalin and cocaine, to introduce the catheter through the lower meatus. The

[1] In old persons in whom adhesions have occurred this crackling sound is practically lost.

curve of the instrument may be changed to conform to the route through the middle meatus or, in extreme cases, through the opposite nostril. Failing in all attempts, the Politzer method may be substituted. The employment of a proper solution of cocaine, usually ten per cent. not only contracts the swollen mucous membrane,

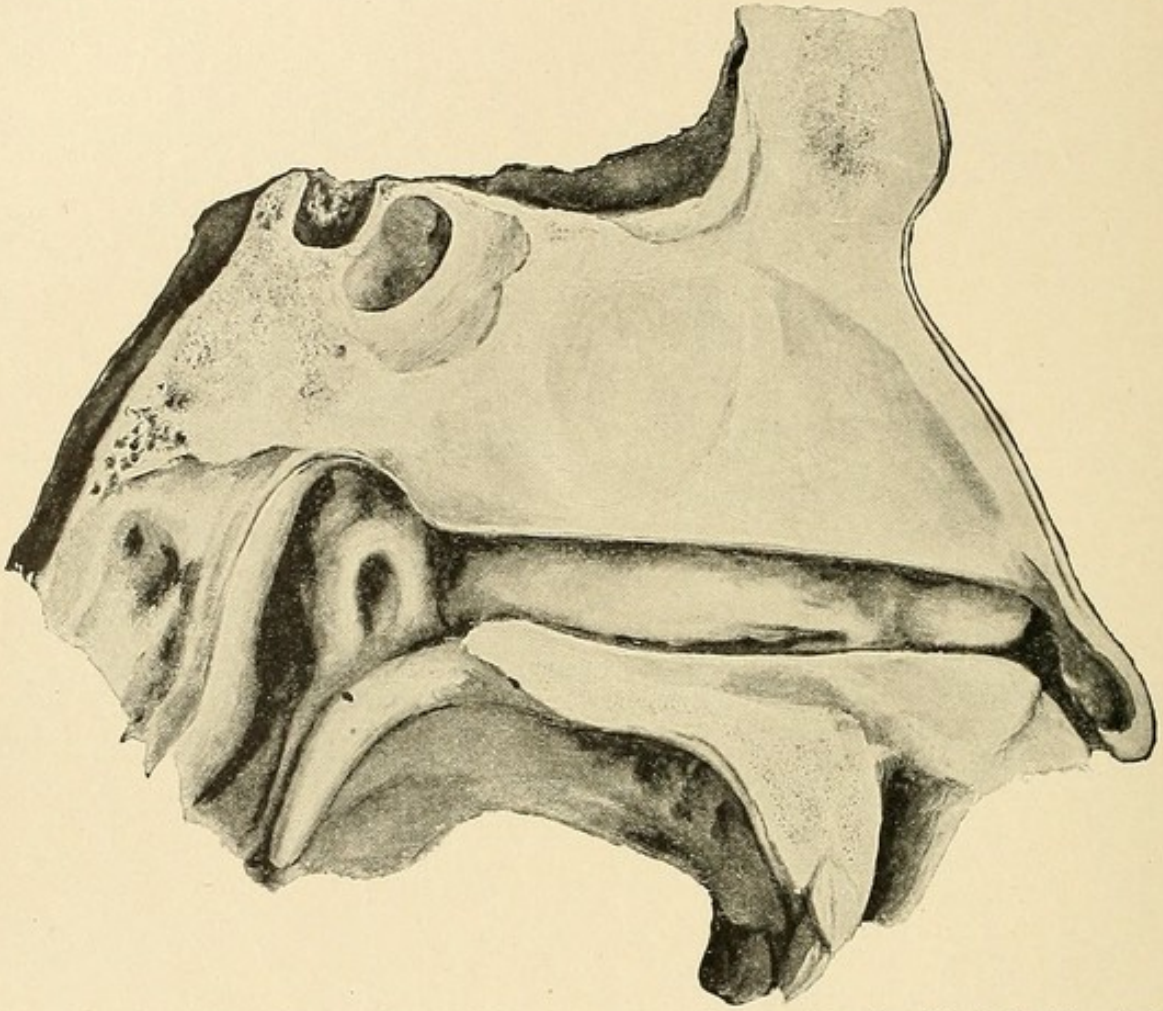

Fig. 365.—Vertical section showing the inferior meatus and posteriorly the elliptical orifice of the Eustachian tube and its relation to the posterior wall of the pharynx. (After Dench.)

leaving more space for inspection and the passage of the instrument, but at the same time lessens the pain of the operation, which should always be done with gentleness and skill. Applying the spray will deaden the sensibility of the meatus, while a small pledget of cotton, moistened in the cocaine solution and passed through the inferior meatus on a probe properly curved to reach the orifice of the tube, will render the whole procedure practically painless. If necessary, the contiguous surfaces of the pharynx may also be touched with this solution. In treating a patient for the first time, the susceptibility to cocaine absorption should be cautiously determined.

When catheterization is clumsily done there is some danger from emphysema, due to air forced underneath the mucous surfaces.

Very frequently patients will complain of dizziness as the air is forced in. They should be forewarned of this and assured that there is no need for alarm. It should not be forgotton that the drum of the ear has been ruptured by too great pressure, especially in the use of the Politzer apparatus.

On account of the difficulties in the way of catheterization of the tube in children, the Politzer bulb is preferable. Employed for diagnostic purposes, the meatus of the opposite ear should be stopped with the finger, so that the only sound conveyed to the ear of the operator will be from the affected tympanum.[1]

[1] A careful examination of the nose, nasopharynx, and pharynx, is an essential feature of the study of the condition of the middle ear.

Myringotomy.—The technic of the operative procedure upon the drum membrane under varying conditions is given by Prof. E. B. Dench as follows:

"The site of election for perforating the drum membrane varies according to the manifestations in each particular case. If fluid is to be evacuated the incision should commence at the most prominent point, and should extend either upward or downward through the bulging portion. If the bulging involves chiefly the upper part of the drum membrane, the knife should be carried into the canal with the cutting edge upward. Its point is entered at the apex of the tumefaction, and carried rapidly through the drum until it impinges upon the internal tympanic wall, after which it is made to cut upward toward the periphery as far as may seem necessary (Fig. 366). As the most prominent region is almost invariably in the posterior quadrant, and usually in the postero-superior, care must be taken to avoid striking the long portion of the incus with the point of the knife. When the primary incision is made the malleus shaft can usually be sufficiently well made out to be avoided; but if the knife impinges upon this, the operator will have failed to secure a proper opening, the resistance being firm and the knife seldom gliding off so as to pass through the membrane and evacuate the contents of the cavity. To avoid injuring the incus and stapes it is necessary that the operator should hold the instrument delicately between the thumb and finger in making the upward stroke, when contact with these structures will be immediately recognized, and the blade may be slightly turned so as to avoid them. Where the most prominent area corresponds to the lower half of the tympanic cavity incision in the opposite direction is usually more convenient. In this case the knife is introduced in the canal with the cutting edge downward. Here no important structures can be encountered, and the procedure is relatively simple. It is usually wise to make this incision somewhat curvilinear, following the peripheral attachment of the membrane, the incision passing close to the cartilaginous ring. Approximation is more perfect when the wound is located here, and cicatrization correspondingly more rapid. In all cases attended with congestion or an inflammatory process the inner tympanic wall should be incised at the same time to

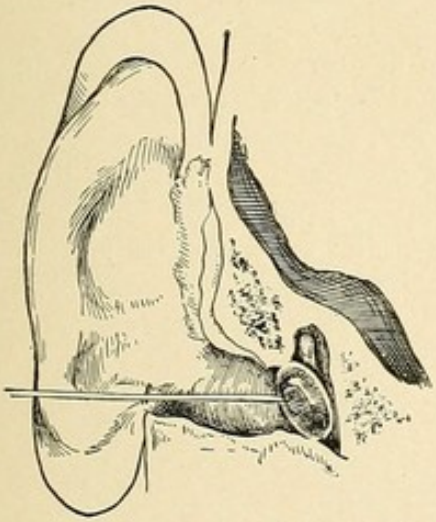

Fig. 366.—Method of incising membrana tympani to evacuate fluid in the atrium (natural size).

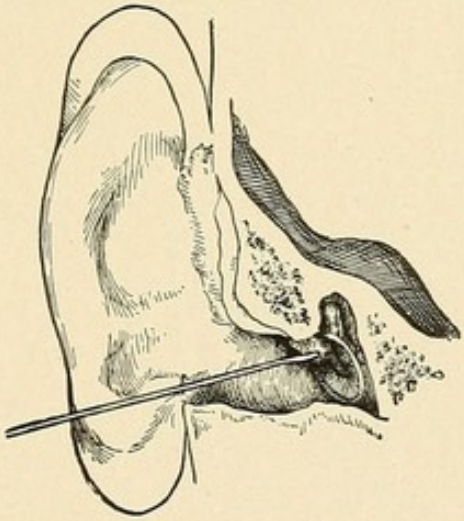

Fig. 367.—Incision of Shrapnell's membrane in the early stages of acute purulent otitis. (The continuation of the incision upon the superior wall of the canal is indicated by the dotted line.)

secure local depletion. Regarding the absolute extent of the incision, it is seldom wise that this should be shorter than one fourth of the long diameter of the membrane if lying in a vertical direction, or less than one eighth of the periphery if located near this.

"It is well to remember that the plane of the membrana tympani is obliquely placed to both the horizontal and vertical transverse planes of the body. An instrument introduced into the meatus and carried horizontally inward will frequently not pass through the drum membrane, but will be deflected from its surface

and inflict but a superficial wound. This is particularly true when the bulging involves the superior segment, and in children. In order to enter the tympanic cavity the knife must be passed not only inward, but inward and upward, and even after the point has passed through the membrane the handle should be strongly depressed, so as to carry the blade well up into the cavity. In an infant the *plane of the membrane is nearly horizontal,* and unless particular attention is given to this fact the operation will be inefficiently performed. It is well in operating upon a young child, and even upon an adult where the canal is narrow, to employ a curved knife rather than a straight one, as an extensive incision is more easily made if this is done.

"Where myringotomy is performed for depletion alone in those cases where the acute inflammatory process has begun in the vault of the tympanum, the atrium remaining free, success in aborting the attack will depend largely upon the thoroughness with which the connective-tissue structures lying in the tympanic vault are divided. In such a case the knife should be introduced with the blade lying in the horizontal plane, the cutting edge looking backward (Fig. 367). The point punctures the drum membrane just above and behind the short process of the malleus, the knife being passed upward and inward and a little backward, to avoid the body of the incus. The incision is then carried horizontally backward to the periphery, when the cutting edge of the knife is turned upward and the incision extended for a short distance along the superior wall of the canal (as shown by the dotted line in Fig. 367). This severs the numerous reduplications of mucous membrane, and efficiently depletes this region and the lining membrane of the mastoid antrum."

Otitis Media.—Infection of the middle ear, by reason of the importance of the organ involved, the complicated and delicate mechanism crowded into such a limited space, and its location practically in contact with the brain, is fraught with such great danger that it is entitled to be classed with the most important surgical lesions. The route of infection is through the Eustachian tube, rarely through the drum, less rarely through the blood. It may be said that the failure to take reasonable care of the nasopharynx and tonsils is the most common cause of the Eustachian tube inflammation and otitis. The prompt removal of enlarged and habitually infected tonsils, of adenoids and diseased turbinated tufts, *would make impossible* a large proportion of these distressing infections. Usually following a more or less persistent pharyngeal inflammation, otitis media is ushered in with an overwhelmingly acute pain, with high fever, deafness, tinnitus, and with commencing involvement of the internal ear, nausea, dizziness, and vomiting.

Inspection will show a bulging drum, and inflation through the tube will give the churning râles of thick fluid in the tympanic cavity.

In order to forestall mastoid involvement, incision of the drum is imperative. With everything in readiness, nitrous-oxide gas is administered.

"In order that the drainage may be perfect, the lowest point of the opening must lie near the inferior pole of the drum membrane. Since the upper and posterior part of the cavity is the most capacious, an effusion sufficient in amount to demand evacuation usually causes a bulging of the drum membrane in this locality. I prefer, therefore, to insert an exceedingly sharp but delicate knife close to the periphery of the membrana at a point opposite the short process; the knife is then carried downward close to the periphery to the lowest point of attachment of the membrana tympani. The section lies entirely within the clear membrane, and should not wound the cartilaginous ring. When considerable congestion is present it is advisable to secure local depletion by carrying the knife sufficiently inward to make it impinge upon the internal tympanic wall so as to divide the soft parts which cover it, throughout the entire extent of the incision through the drum membrane. If the parts above the short process are intensely congested, the incision is to be extended upward so as to enter the vault and deplete the engorged tissues. In these cases it is usual to incise from below upward (Fig. 366). A few vigorous efforts at inflation by means of the Politzer method clears the cavity completely of fluid, the divided parts fall readily into place, approximation being practically perfect, and it is not unusual to find complete union at the

end of thirty-six hours. The only possible untoward result following this procedure is accidental infection at the time of the operation. To avoid this the canal should be first syringed with a solution of bichloride of mercury (1–8000), while the instruments employed should be sterilized by boiling. After the fluid has been evacuated the canal should be closed by a plug of aseptic cotton and the patient should on no condition interfere with it. Carried out in this manner, there is absolutely no danger in adopting this method of treatment for an effusion of any kind within the tympanic cavity. When spontaneous perforation has taken place, it is usually necessary to enlarge the opening. This measure should be carried out according to the rule which governs the primary incision.

"Upon the appearance of discharge after spontaneous rupture, or after surgical interference, the canal must be kept as free as possible by frequent irrigation with a warm antiseptic solution." (Dench.)

The Mastoid Cells.—With the first symptoms of mastoid inflammation, incision and drainage of these cells should be done. If the operator is in doubt as to their involvement, this procedure should be advised, as it gives an assurance of safety.

The arrangement of the mastoid cells, which are more or less in direct communication with the middle ear, vary at different periods of life and in different individuals. At times this process is eburnated, containing practically no cavities; under other conditions it is spongy and permeated with recesses.

"Owing to the invariable presence of the mastoid antrum, its location is a matter of importance. It is best located by bearing in mind its relation to the superior and posterior walls of the external auditory meatus. If two lines be drawn—one horizontal, tangent to the superior wall of the external auditory canal, the second vertical and tangent to its posterior wall—the point of their intersection will be the apex of a triangle the base of which will be formed by that portion of the curvilinear outline of the meatus included between the points of tangency of these lines. This triangle lies immediately over the antrum and an artificial opening within this space will enter the cavity." (Dench.)

In infants the mastoid is poorly developed, consisting usually of a single cell—the antrum. As the vault of the tympanum in the child is nearly as large as in the adult, it may be opened if great care is not exercised. Mastoid infection is caused almost always from the extension of septic process involving the middle ear. It may possibly occur as a direct infection through the blood. If not evacuated early, the septic material may find its way through the roof of the antrum, or tympanic cavity, to the middle cranial fossa, or to the meninges of the posterior cerebrocerebellar fossæ, or into the general circulation through the small veins and the lateral sinus. The symptoms are usually intense pain, severe at night, rendered more acute by percussion upon the mastoid. It has almost always been preceded by Eustachian tube involvement. Although not of real diagnostic value, the temperature is usually elevated. In addition to the local tenderness, there is often seen a depression, or sagging, of the superior posterior wall of the canal, close to the tympanic ring. The ophthalmoscope should be used in the early recognition of choked optic disk, one of the most important signs of cerebral involvement.

The Mastoid Operation.—Although a septic area is to be laid open, on account of the immediate proximity of the meninges, brain and lateral sinus, every possible antiseptic precaution is imperative. Shave in every direction for three inches from the mastoid, irrigate the meatus with 1–1000 mercuric chloride, and follow with hot salt solution; plug the meatus with sterile gauze, and apply moist 1–3000 bichloride dressing until the patient is anæsthetized.

Beginning one half inch below the tip of the mastoid process, carry an incision upward and forward, curving it to run about an eighth of an inch from and parallel with the normal curve of the auricular crease, so that the resulting scar may be concealed. It should divide everything, including the periosteum, which, when elevated, lifts the solid flap. Arrest all bleeding, retract the auricle forward, and with dull half-curved scissors closely clip the muscular insertion from the tip of the mastoid.

The *antrum*, located just behind the posterior margin of the meatus and just below its upper margin, is now opened by light strokes on a small curved chisel.

From this point of entrance the entire septic area may be exposed. The cutting edge of the chisel, or rongeur, should be guarded from the lateral sinus, the jugular vein, or the facial nerve. Upon opening the antrum the route to the middle ear is determined by passing a small probe, slightly bent at the tip, forward, downward, and inward for about three quarters of an inch. This passage into the tympanum is curetted with a small, sharp spoon, and the spongy tissue of the mastoid thoroughly removed with the rongeur and sharp spoon.

From this initial incision any of the various complications may be dealt with.

Should the necrotic process have involved the contiguous skull bone, the operative field may be enlarged by extending the horizontal incision backward for an inch or more from the middle of the primary mastoid incision. In lifting the periosteum, a short vein leading into the lateral sinus is often wounded, and may require compression or a temporary plug to control hæmorrhage. If the inner table is involved, it should also be removed, and the dura carefully examined and incised, if there are symptoms of local meningitis. In this operation the lateral sinus may be opened, but hæmorrhage from this source may be readily controlled by packing. Such is the necessity for free exposure and drainage in this important operation, that opening the lateral sinus or the dura is of small consequence when compared with the dangers from imprisoned septic matter.

In the after-treatment it is exceedingly important to take every precaution to prevent infection of the sinus or dura. The facial nerve as it crosses the tympanic cavity may be wounded, especially where it has been necessary to remove the bone to a sufficient depth to expose the internal wall of the middle ear (Dench). It is therefore important to bear in mind the relation of the internal wall of the tympanic cavity over which the aquæductus Fallopii passes.

The relation of the lateral sinus to the antrum varies in different individuals. It is usually just behind the antrum, and when for any reason it is necessary to expose it, this can be done by extending the opening in the bone backward, care being taken to avoid the removal of the bone beyond the occipito-temporal suture. The groove lodging the knee of the sinus is located in the mastoid process, and an extension of the opening to the occipito-temporal suture gives abundant room for examining the sinus and the posterior fossa, both above and below the tentorium cerebelli.

Sinus Thrombosis.—In addition to pain and preëxisting otitis or mastoiditis, wide fluctuations in temperature is considered one of the most important characteristic features of sinus thrombosis. As the disease progresses, the symptoms of general sepsis are more appreciable, on account of the dislodgment of septic particles and their dispersion by the jugular vein through the general circulation. When meningeal symptoms supervene, the temperature is remittent rather than intermittent, and as the thrombus extends down the jugular, the line of tenderness corresponds to the location of this vein. Careful watch should be kept upon the retina, since the recognition of a choked disk goes far to confirm the diagnosis of sinus thrombosis in doubtful cases.

Operation.—Expose the sinus by perforating the skull at a point approximately half an inch behind the posterior margin of the external auditory meatus. As soon as the dura is exposed, introduce a dull-pointed, grooved director, and carefully separate the dura from the skull; after which enlarge the opening upward and downward with a rongeur. Uncover the sinus for about one inch. In a normal sinus distinct pulsation is usually felt. If the blood is flowing through, pressure on the lower portion will cause a slight dilatation. If there is any doubt in the mind of the surgeon as to the presence of a clot, an exploratory incision should be made; a puncture will not suffice. Compress the vessel above and open the wall of the vein longitudinally about a quarter of an inch, making immediate compression below to prevent the induction of air. If free hæmorrhage does not occur, occlusion of the vessel by clot is evident. The incision should then be enlarged and a blunt curette introduced, and the clot carefully but thoroughly removed. This instrument should be passed well downward into the bulb until bleeding from that direction takes place. This may be controlled by a pledget of gauze packed over the lower portion of the opening. The curette should then be used in the opposite direction toward the torcular, and the clot removed in this

direction until free hæmorrhage results. If free hæmorrhage from below does not occur, it indicates that the internal jugular vein is occluded. This vein should now be exposed by the proper incision along the anterior border of the sterno-mastoid muscle, carefully separating it from the pneumogastric nerve and the common carotid artery.

Below the limit of the thrombus two ligatures of No. 2 chromicized catgut are passed around the vein one half inch apart, and the vessel divided between them. The upper diseased portion is dissected out, tying off and dividing all tributary branches as high as possible, when it is again tied about one inch below the jugular fossa and divided. No irrigation of the sinus from the jugular should be attempted. The entire wound should now be flushed with hot salt solution, and closed by silkworm-gut sutures, with catgut bundle drains, as indicated. In dressing the mastoid wound, care should be taken to separate the antrum from the open sinus by a carefully inserted gauze packing.

Infection, following mastoid involvement or purulent otitis media, may cause *extra-* or *intradural abscess*. The symptoms of extradural abscess are: severe, continuous, localized headache, with a temperature which, as a rule, does not rise above 101° or 102° F., and which while undergoing slight fluctuations slowly drops to the normal. As no portion of the motor tract is involved, there are no localizing symptoms.

In arriving at a diagnosis of cerebral abscess the history of the case is important. Where chronic otitis has existed, or where several acute attacks have occurred, if these are followed by persistent sleeplessness and a temperature remaining steadily at about 99° F., von Bergmann insists that these are sufficient indications for opening the cranial cavity for the purpose of exploration. Dench advises, however, to await some localizing symptoms or some more pronounced condition of hebetude. An argument in favor of early intervention is advanced from the fact that cerebral abscess is usually deeply situated and is apt to rupture into the lateral ventricle. Vomiting is more persistently a symptom of cerebellar than of cerebral involvement. The patient is dull, apathetic, complains at times of severe headache, although this is not always a prominent symptom.

The most frequent site of an abscess from middle-ear suppuration is the temporo-sphenoidal lobe; second the cerebellum.

The first step is to enter the mastoid antrum and expose the roof of the tympanum and the antrum, entering the cranial cavity just above the external auditory meatus, where the skull is usually very thin. The bone should be eaten away with a rongeur, making an opening at least one inch in diameter. The dura should be carefully lifted with a grooved director from the upper surface of the petrous portion of the temporal bone, and careful exploration made with the finger. If no pus is discovered the opening should be enlarged downward and backward by removing the floor of the middle fossa sufficiently to expose the lower surface of the temporo-sphenoidal lobe. A U-shaped incision should be made in the dura, and the flap reflected upward. Exploration of the brain substance may now be made, preferably with a small grooved director in the hope of finding the abscess cavity. The use of a knife is objectionable on account of danger of dividing a blood vessel. If the grooved director reveals nothing, a good-sized aspirator needle may be employed. When pus is discovered a dull-pointed dressing forceps should be carried into the abscess and free drainage secured through the opening in the dura and skull. Irrigation is not advised. Ten-day catgut bundle drainage on a film of gauze may be used. A loose dressing of sterile gauze should be applied, and this should be changed only for purposes of cleansing or a threatening elevation of temperature or other urgent reason.

In suspected cerebellar abscess, the point of election for an exploratory opening is one and one half inches behind the center of the external auditory meatus, and one fourth inch below the horizontal plane passing through the center of the external auditory canal. After the periosteum is raised the bone, which is quite thin here, may be readily opened by a few strokes of the chisel, which should be enlarged by means of the rongeur forceps. A dural flap should be made and exploration done as in the preceding operation.

CHAPTER XIV

THE NOSE

Fractures of the bones and cartilages of the nose have already been considered.

Epistaxis, or hæmorrhage from the nose, may be arrested by spraying the bleeding meatus with a small quantity of a five-per-cent cocaine solution, followed by adrenalin solution (1–1000) in normal saline. One or both of these local applications cause the mucous membrane to shrink. If not arrested the bleeding point may now be recognized with the aid of the speculum and reflected light, and a concentrated astringent applied, such as powdered alum, on a pledget of sterile gauze or cotton. Plugging or tamponing the nares will only be necessary in extreme cases. The technic is as follows:

First, determine accurately the nostril in which the bleeding is occurring. Take a piece of fine sponge at least an inch in diameter when dry (and it should be introduced without being moistened, so that when in position in the posterior nares it will expand as the blood moistens it), and tie around its center three strong silk threads. A soft catheter or bougie is now introduced into the nostril from the front, keeping the point of the instrument well on the floor of the nose. As soon as the end is seen or felt behind the soft palate, it is drawn out of the mouth by the forceps or fingers. Two of the three threads are attached to the point of the instrument, which is then pulled back through the nostril. When the threads come out of the nose in front they are seized by the fingers of one hand while the sponge is carefully guided into position *behind* the soft palate with the other. Once well in the posterior nares it is held in position and made to exert the necessary compression by tying the two anterior strings over a softened sponge packed into the nostril in front. The third thread is brought out of the mouth, and is to be used in dislodging the tampon when the hæmorrhage has ceased. Lint, soft rags, or cotton may be used for plugs when a sponge cannot be obtained. A long probe or a loop of soft wire may be used instead of the bougie.

In this, as in all other internal hæmorrhages, the arrest of bleeding is facilitated by ligation of the extremities. This consists in applying an elastic bandage (or an ordinary roller, if the rubber cannot be obtained) around the thighs and arms close to the trunk, and making the pressure strong enough to arrest, in great part, the return of blood through the veins without arresting the circulation in the arteries. When the hæmorrhage ceases the ligatures should be gradually loosened, so that the volume of blood which has been confined in the extremities may not be too suddenly returned to the heart.

Foreign Bodies.—Buttons, seeds, and other substances are often lodged in the cavity of the nose. The usual seat of lodgment is in the anterior part of the inferior meatus, or between the lower turbinated bone and the septum, and occasionally they are pushed beyond this into the middle meatus.

Any foreign body should be removed at once, as it is not only painful, but tends to produce inflammation of the lining membrane and not infrequently ostitis. Its presence may be indicated by a change of the voice from its natural to a nasal tone. If the mucous membrane is swollen, spraying with weak cocaine and adrenalin solutions, aided by the speculum and reflected light, will enable the surgeon to locate it. Strong slender forceps bent at an angle so that the hand of the operator will not shut out the light, is the most suitable instrument to be employed in extraction. Should the body be lodged well back, it may be pushed into the nasopharynx, to be ejected through the mouth.

Rhinolites, or nasal calculi, are occasionally seen, and probably originate in the lachrymal apparatus. Lachrymal concretions (dachryolites) sometimes plug the tear passages. These bodies should be removed with forceps as soon as discovered.

Neoplasms.—The most frequent variety of tumor within the nasal cavity is the *myxoma*, or so-called *gelatinous polypus*. Next in order of frequency is the *fibroma* or *fibrous polypus*. Both of these belong microscopically to the connective-tissue tumors, the myxomata being allied to the embryonic, the fibromata to the more developed connective-tissue tumors. *Papillomata*, or *warts*, are not infrequently seen at the edges of the mucous membrane of the nostrils. Lastly, there may be a general *hypertrophy* of the mucous membrane of the nose, causing a tumefaction of the turbinated tufts, and partial, or may be complete, occlusion of the nares.

Gelatinous nasal polypi are usually pear-shaped, the bulk of the tumor tending toward the floor of the nose. The pedicle is attached to one of the thick velvety tufts, most frequently in the upper or middle meatus. There may be a single tumor, although the rule is for them to be multiple. They are of light-grayish color, and are colored by mucous exudation.

The *symptoms* are chiefly those due to pressure and obstruction of the nares. Changes in the voice are not marked until the presence of the tumor has been suspected from pressure and irritation. This irritation gives rise to an excessive secretion and discharge from the nose, and occasionally to prolonged and violent fits of sneezing.

The *diagnosis* may be rendered positive by physical exploration. The shrinkage of the turbinated tufts, following the local use of cocaine hydrochlorate, renders inspection more easy.

Treatment.—The only rational method of treatment is removal and destruction of the pedicle and contiguous mucous membrane. Avulsion may be effected by seizing the growth with a long, delicate polypus forceps, and twisting the tumor around until the pedicle is wrung off, then applying pure nitric acid or the galvanocautery to the stump. The wire *écraseur* or *snare* of Jarvis is greatly to be preferred (Fig. 369). After the wire loop has been passed around the tumor, and slipped up to the pedicle, it should be slowly tightened, since by this method the danger of hæmorrhage which always follows the use of the forceps is avoided. From one to two hours may be consumed in the division of the growth, the screw being turned from time to time. Nitric acid or the cautery should be applied to the stump in all cases, since without this recurrence is almost certain.

Fibromata, or *fibrous polypi*, are much less frequent than the *myxomata*. As a rule they are deeper situated. They require the same treatment as above given. Occasionally large tumors of the nasal cavities require for their complete removal section of the nasal and superior maxillary bones.

Papillomata, or *warts*, which occur at the junction of the mucous membrane of the nares with the integument, should be clipped off with curved scissors and their bases burned with pure nitric acid.

Fissures of the nares may be relieved by the repeated local use of the lunar-caustic pencil. The application of cold cream at bedtime will aid in preventing a recurrence.



FIG. 369.—Jarvis' snare.

Ozæna.—Ozæna is the name given to a chronic inflammation of one or more of the nasal cavities, or the sinuses communicating with them. It may be confined to a process of ulceration of the soft tissues alone, but the bone is usually involved. Syphilitic ozæna is probably the most common form. It frequently

occurs with other dyscrasiæ. It is accompanied by a fœtid odor and a muco-purulent discharge, partially liquid and partially solid. Atrophy, or destruction of the turbinated tufts, is not infrequent, so that there is abnormal space within the nares.

The *treatment* is local and general. The removal of diseased or dead bone is imperative, and irrigation with the weaker sublimate solutions should be regularly made.

Dobell's solution will be found of use: Carbolic acid, gr. x; biborate and bicarbonate of soda, each, ℈j; glycerine, ʒx; to this add water to make ℥x. This should be used five or six times a day as a douche. The general condition of the patient should be improved by the administration of well-selected tonics and food, and by out-of-door life.

Superficial epithelioma, situated upon the nose or face, should be destroyed by the application of Marsden's paste. If the first application is not sufficient, it should be repeated in three weeks.

Hypertrophic rhinitis consists in a general connective-tissue hypertrophy of the lining membrane of the nose, with relative increase in the number and size of the blood vessels. It almost invariably coexists with deviation of the septum, and is most marked on the side least obstructed. In order to determine the degree of hypertrophy, the preliminary examination should be made without the use of cocaine or adrenalin, since these cause shrinkage and disguise the condition of turgescence.

The first essential in treatment is the correction of the deflected septum. Any marked angular projection may be removed under the anæsthesia of cocaine, applied at first by a spray, followed by direct local application with a pellet of cotton moistened in a ten-per-cent solution, and the additional submucous infiltration of a weak solution by means of a hypodermic needle. If only a small projection is to be removed, the mucous membrane may be sawed through with the bone, but when any extensive operation is to be performed the mucous covering should be incised and lifted to be replaced after the deformed bone has been removed.

This minor procedure may not always suffice, and for the more extensive operation for the correction of a badly deflected septum the method of Prof. John B. Roberts is recommended.

Make a long incision at the most prominent portion of the deviation, and supplement this by chopping the septum full of incisions with the stellate punch. If there is an angular deviation close to the palatal process of the superior maxillary bone, make an incision from front to back at the most prominent part, and do not chop the upper portion with the punch. If the deviation is a curved one, split the cartilage along the most prominent portion and then chop the rest of the septum until it has lost its resiliency. Afterward cut away with the chisel or saw any horizontal bony edge that may remain at the bottom. If some small triangular pieces are removed by the interlacing of the incisions made with the forceps, it makes no difference, since the openings left are very small and will soon become closed. To hold the septum in place, use steel pins (Fig. 370), either those with spherical heads of glass, or the flat-headed pins. When the head of the pin is to be within the nostril, those with the glass heads are better; when the head is to lie against the exterior of the nose, the flat heads are preferable.



Fig. 370.—Roberts' nasal pin.

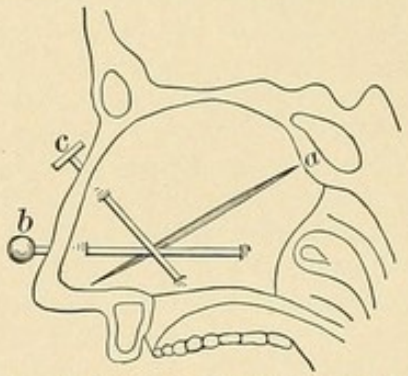

Fig. 371.—Roberts' method of holding the septum in correct position by means of pins. The upper part of the septum, immediately above the oblique incision, projected too far this way (i. e., toward the reader). It is now pressed the other way (i. e., from the reader) and is held there by the pins. *a*, Incision through the septum. *b*, *c*, Pins in position.

After having divided the septum (*a*, Fig. 371), as above described, introduce a pin (*b*) into the more open nostril and thrust its point through the anterior part of that portion of the divided septum. Displace this part into the desired position, thrust the point of the pin onward and bury its point deep in the tissues at the back part of the nasal chamber which was formerly occluded. This holds the septum firmly in its new location. The head of this pin will be just inside of the anterior naris which was not obstructed, and will lie against the columella. It should be allowed to remain about one week, for if left a longer time its head will probably cause ulceration from pressure, and may become deeply buried in the tissues. It is often well to introduce a second pin (*c*, Fig. 371), from the external surface of the front of the nose just below the nasal bones, which aids in keeping the septal cartilage pinned into proper place. If this pin has a flat head, it may be covered with a small square of court-plaster.

In many instances hypertrophy of the turbinated bones, or permanent thickening of the vascular membrane covering them, obstructs the nose to such an extent that the passage of air by these channels is difficult or impossible, or deviation of the septum may result. Under such conditions, removal of the turbinated bones and tufts is indicated. Removal of the inferior bone and tuft will usually suffice. The inferior tuft is commonly implicated. A sufficient degree of anæsthesia may be obtained by the use of cocaine hydrochlorate as above directed. The turbinated process should be divided with the delicate saw close to its attachment to the superior maxilla. Should hæmorrhage be troublesome, it may be arrested by plugging the nostril.

When the bone is not involved in the hypertrophy, the thickened mucous membrane may be sufficiently destroyed by means of the galvano-cautery or by the repeated application of chromic acid. Before applying the acid care should be taken to dry the nasal mucous membrane with a pledget of cotton. The membrane should first be exsanguinated with cocaine spray, and then a small bit of chromic acid melted upon the tip of a metal probe should be applied over an area of about one fourth of an inch in diameter.

Any excess is to be immediately removed by means of a dry pledget of cotton. "The slough separates at the end of from five to ten days, after which the operation is repeated over another portion of the turbinated body. These applications are continued until the patency of the passage has been restored. When the hypertrophy is excessive the cold wire snare may be used to remove redundant portions. The membrane is first anæsthetized with cocaine and the loop made to surround the mass. The wire is then drawn into the tube and cuts through the tissue which it surrounds. When the mass is situated in the posterior nares the wire loop should be made to cut through slowly by using the screw. In this manner hæmorrhage is avoided. As cocaine exsanguinates the membrane, it is well to use only a sufficient quantity to produce anæsthesia, in order that the snare may remove as much of the swollen mucous membrane as possible. After the operation is completed a little iodol is to be insufflated upon the cut surface, and the patient directed to avoid forcible efforts at clearing the nostril for at least twelve hours. In this way hæmorrhage is avoided, and prompt recovery is the rule." (Dench.)

Atrophic Rhinitis.—In this condition the nasal cavities are covered with crusts, which often render the breath extremely offensive. Although frequently incurable, this distressing condition may be ameliorated by using two or three times daily a nasal douche composed of a quart of weak saline solution as hot as can be borne. This not only washes away decomposing crusts, but exercises a certain stimulating action upon the membranes. During the day the nasal chambers may be cleansed at frequent intervals with an alkaline spray, composed of

℞ Sod. bicarb. ..... gr. xx;
Acid. boric ..... ʒss.;
Acid. carbolic ..... ♏iv;
Glycerin ..... ʒj;
Aqua .....q. s. ad ʒviij.

M. Sig.: Dilute with an equal volume of water, and use in an atomizer as a nasal spray.

Later, irrigation may be employed but once daily. If faithfully continued, this treatment will prevent the discomfort attendant upon the nasal affection. The use of the nasal douche in these cases seldom produces aural symptoms, as the nasal passages are free and there is but little danger of the fluid entering the tympanum. It should always be remembered in employing the douche that the current should enter by the occluded nostril if there is any difference in the patency of the two sides. (Dench.)

Adenoid Vegetations.—In addition to the neoplasms and hypertrophies which interfere with the respiratory functions of the anterior nasal cavity, the presence of vegetations located chiefly in the vault of nasopharynx are deserving of serious surgical consideration. They are very common in children, especially in those living in cold, damp climates, and in unhygienic surroundings. These new growths and hypertrophies not only prevent natural breathing through the nose, but they lead to constant infectious processes which involve almost inevitably the Eustachian tube, induce otitis, and are responsible in large measure for the serious disasters not only to the functions of the ear, but the greater dangers which follow purulent otitis. For the welfare of a child it is imperative that these growths be removed as soon as discovered.

In ordinary cases the operation can be readily done under nitrous-oxide gas anæsthesia, the whole procedure not lasting over two minutes. When by reason of neglect a more formidable operation is necessary, ether anæsthesia is preferable, and since adenoids of the nasopharynx are almost always accompanied by enlargement of the tonsils, these should be clipped with the tonsilotome just before the removal of the adenoids.

The head of the patient should be thrown backward over the edge of the table or over a pillow, in this position making the vault of the pharynx occupy a lower level than the larynx, reducing to a minimum the danger of the accidental introduction of blood into the trachea.

"The jaws are held apart by a properly constructed mouth-gag, and the surgeon, standing upon the right of the patient, introduces the left forefinger behind the palate, where it remains until the operation is completed. The closed forceps held in the right hand is now passed along the left forefinger as a guide into the nasopharynx, where it is opened and made to grasp as much of the growth as possible, the manipulation being directed by the left index-finger. In this way the growth is removed piecemeal, and the operation is not considered complete until the examining finger fails to discover any masses projecting into the nasopharyngeal space. The operation is completed by passing the curette into the space and sweeping it along each lateral wall and along the posterior wall of the cavity. The child is then turned over on the face to facilitate the discharge of blood which has accumulated in the nasopharynx during the progress of the operation, the mouth-gag not being removed until this position has been assumed. No after-treatment is necessary." (E. B. Dench.)

Nasopharyngeal Catarrh.—A prominent symptom of this distressing condition is a viscid secretion from the pharyngeal vault which is drawn back into the mouth for expulsion. It is another common source of infection of the Eustachian tube.

The treatment consists in the local application to the pharyngeal mucous surfaces of a solution of nitrate of silver, applied by means of a cotton-tipped probe introduced through the anterior nares, this passage having been previously anæsthetized with cocaine. The strength should vary with the intensity of the inflammation. In the early or most acute stage a solution of thirty grains to the ounce, thoroughly applied, may arrest the disease. In the later stages a weaker solution should be employed. (Dench.)

Angular depressions, caused by fracture of the cartilage or bones of the nose, may be remedied by lifting the skin by careful subcutaneous dissection to about its normal position, and holding it by inserting beneath it a thin plate of platinum.

Under careful asepsis an incision is made, splitting the skin near the mucocutaneous junction of the nostril on either side as far as the middle line of the tip of the nose with a delicate, long, narrow-bladed knife. The dissection is con-

tinued upward between the cartilage and bones of the nose, and the integument, until the whole cutaneous covering of the nose is loosened and freely movable as far as the level of the lower eyelid. Bleeding will soon cease under direct pressure. A piece of thin platinum cut in diamond shape and bent along the middle line at an angle something like the roof of a house, carefully sterilized and held by a delicate narrow forceps, is pushed upward from the superficial incision until it rests over the depression in the cartilage or bone. Upon this the skin rests, and the depression is no longer perceptible. The incision is closed by a few interrupted horsehair sutures (Fig. 372). The subcutaneous injections of paraffin have been

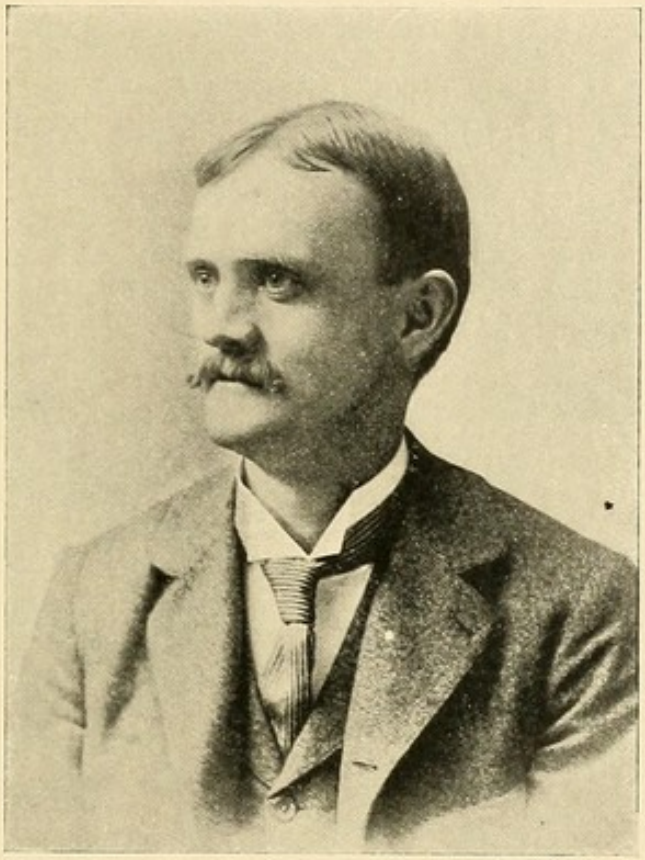

FIG. 372.—Subcutaneous platinum support restoring the normal outline of the nose.

employed successfully by Drs. W. H. Luckett and F. I. Horn, but the method is still in the experimental stage. Moreover, several serious accidents are reported as a result of the injections.

Loss of substance may occur from the accidental or surgical ablation of all or a portion of this organ, or from its destruction by disease. The diseases which most frequently produce loss of substance are *syphilis*, *lupus*, and *epithelioma*. *Sarcoma*, *elephantiasis*, or any neoplasm may involve the nose and cause loss of tissue in its removal. One of the most distressing lesions in neglected cases of (tertiary) syphilis is necrosis of the cartilages and bones of the nose, resulting in great disfigurement. Occasionally sloughing occurs, from the presence of a phagedenic syphilide during the second stage of this disease.

Rhinoplasty may be partial or complete. Complete rhinoplasty is performed when the skin, cartilages, and bones of the nose have been carried away. In such cases nothing remains but an irregular sunken pit, leading almost directly into the pharynx.

The successful and satisfactory restoration of this organ is rarely accomplished. It would be well, in all cases of complete loss of the nose, to consider some form of prothetic apparatus before resorting to a plastic operation.

The operation consists (1) in paring the margins of the opening and the integument immediately around the opening, in apposition to which the transplanted

flap is to be brought; (2) in the transportation of a properly shaped piece of skin, with its underlying tissues, from its normal to the new position.

The flap may be taken entirely from the forehead, or one half from each cheek, or from the arm. One of the most frequent causes of failure in this operation is the caving-in of the ridge of the new nose, and, in order to better prevent this, the platinum support to be described may be employed.

Complete Rhinoplasty from the Forehead.—Cut a piece of chamois-skin, or soft, thin leather, of the shape represented in Fig. 373. Adjust this to the line of the nasal cavity to see if it is large enough and of proper shape. Bear in mind the following points: 1. The flap once dissected up tends to contract. It should therefore be considerably larger than a pattern which fits exactly. 2. The isthmus (*d*, Fig. 373) must not be too narrow, for fear that the vitality of the flap may be insufficient. It should always be cut so as to include the angular artery, and should be broader than represented in the accompanying cut. It should take in a portion of the hair-covered eyebrow, since this insures a width of pedicle sufficient to nourish the flap, and the hairy stump, when turned back after the circulation is established, restores the normal brow. 3. The distance from the isthmus (*d*) to e′, where the lower edge of the new nose is to be, should be considerably less than the distance from *d* to *a c*, in order to prevent tension of the flap and interference with the circulation through the pedicle, *d*. Lay the pattern on the fore-

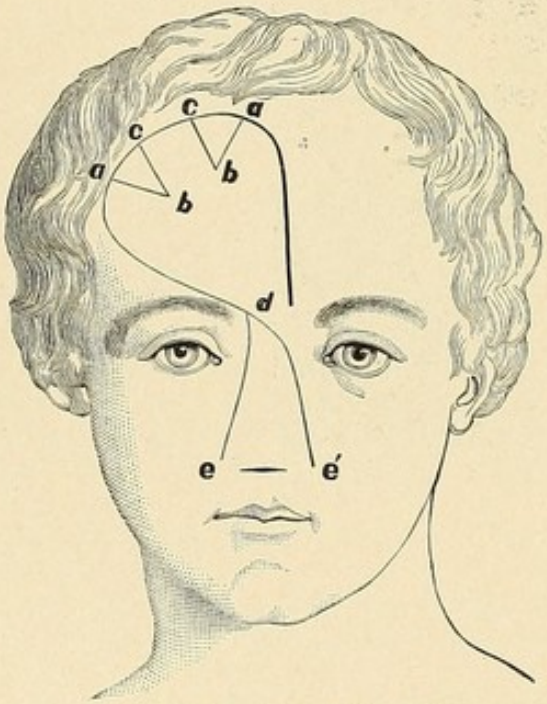

Fig. 373.—(After Linhart.)



Fig. 374.—(After Malgaigne.)

head and outline the flap by making punctures at intervals of every fourth of an inch along its edges. The incision, made through the tissues and periosteum, should begin at *d* and be carried to *a c c a*, and then down to a point in the eyebrow farther outward than represented by the dark line at *d*. The smaller incisions in the flap *a b* or *c b* are made to provide for the septum and alæ of the new nose, when the platinum support is not to be used. The flap is now dissected up with the periosteum as far as the pedicle, when it is turned down and sewed into position with fine silk sutures. The operation is completed when the entire flap has been accurately stitched to the freshened edges of the cavity, as shown in Fig. 374. Pieces of rubber tubing may be inserted in the nostrils to hold the alæ in position, or a plug of sterile gauze not too tightly packed in may be substituted. It should be changed as often as it becomes moistened. The upper part of the wound on the forehead is drawn as near together as can be done, with silkworm-gut sutures, and an iodoform-gauze dressing is applied. No pressure must be exercised upon

the pedicle, or flap, which should be loosely enveloped in the dressing. In about two weeks the circulation will have been sufficiently established between the flap and the edges of the cavity to permit the section of the pedicle, the stump of which is used in filling up the gap upon the forehead. In returning the pedicle to its original position, it is advisable to dissect out the granulation tissue in the wound, so that the returned portion will sink to the proper level. The exposed surface which remains upon the forehead should be covered in by grafting after the methods already given.

Partial Rhinoplasty.—When there is a limited loss of substance confined to the ala, the cicatricial edges of the wing of the defective nostril should be trimmed and a small flap turned from the contiguous integument of the upper lip and cheek.

The pedicle should be left wide enough to insure nutrition, and the flap should be carefully patterned before any incision is made. The farthermost portion of the wound from which the flap has been removed should be closed at once with linen or horsehair sutures, while the nearer portion should be left open. In about ten days the pedicle may be divided and the stump reimbedded in the remaining open portion of the wound.

Should the integument and cartilage along the middle line be destroyed, leaving an opening here, it may be covered in by a long flap turned from the forehead and the pedicle replaced after vascular connections have been established between the tissues of the nose and the transplanted portion. With proper care the resulting scar upon the forehead does not seriously disfigure.

When the integument of the nares is intact and the tip of the nose is shriveled and sunken, the employment of the three-legged platinum support or ridgepole advocated by Dr. Robert Weir will relieve to a considerable extent the deformity. The upper lip and nasal attachments are lifted freely from the bones of the face by subcutaneous dissection with curved scissors, commencing along the attachment of the upper lip to the alveolus of the superior maxilla, and by this route detaching the alæ nasi and contiguous integument from the maxilla and nasal bones. The ridgepole of platinum is now inserted from underneath the lip, the lateral prongs or legs resting upon the superior maxilla of either side, while the upper prong rests between the skin and the nasal bones. The greatest care is essential to prevent the accidental displacement of the apparatus.

Congenital Lesions of the Nose.—Occasionally the lateral halves of the nose fail to unite, resulting in the deformity known as bifid nose. There may be *partial* or *complete absence* of this organ, or when present the nares may be occluded, or it may be complicated with the extreme cases of harelip. The operative procedure for the relief of this last deformity will be given in connection with congenital cleft of the lip. Occlusion of the nares may be relieved by cutting through the membrane in the direction of the normal opening. For the correction of forked nose, or the absence of this organ, no fixed rule of practice can be laid down.

CHAPTER XV

THE FACE, LIPS, AND CHEEKS, PAROTID GLAND AND DUCTS, JAWS AND TEETH

INCISED wounds of the face usually bleed profusely. The essential features in treatment are to arrest hæmorrhage and secure repair with the least possible cicatrix. When the bleeding is only slight, bringing the edges together, preferably with horsehair sutures or the very finest celluloid linen will arrest it. Should a ligature be required, the finest catgut should be used.

Every wound of the face should be treated with the strictest asepsis. The approximation of the edges of the divided skin should be accomplished with exactness, and the sutures carried in with the smallest needles. In superficial incisions, after the hæmorrhage has entirely ceased, the edges may be brought in apposition and held by pressure some distance from the wound while sterile collodion is being freely applied. As this usually contracts, it holds the wound in apposition without sutures.

Contusions of this region require, as in other parts of the body, local applications, usually of cold water or the ice-bag. Ecchymosis is, as a rule, present, and is persistent in the tissues about the eyes.

Lacerated wounds of the face are serious, on account of the danger of disfigurement after repair. If the procedure does not involve much loss of tissue, the edges may be pared smoothly and united with horsehair sutures, under careful asepsis. If there has been extensive contusion, a small catgut drain should be left at each end.

Punctured wounds require no special consideration. Deligation of the external carotid may be necessitated to arrest bleeding from deep wounds of the spheno-maxillary fossa.

Shot wounds of the face are not, as a rule, dangerous to life, even in military practice. In civil practice the rate of mortality is still lower.

When the missile has penetrated the spheno-maxillary fossa, or divided any deep-seated vessels, the necessity of tying the external carotid may arise. A ball or any foreign body lodged in the bones or tissues of the face should be immediately removed, when this can be accomplished without an operation which may incur the danger of deformity. When, however, the missile is deeply lodged, and is of small size, it should not be molested until there is evidence that it will not remain encapsuled and harmless.

Bones or fragments of bone which have been displaced in part, but not entirely stripped of periosteum and vascular attachments, must not be removed, since, if replaced and held in proper position, they usually become reunited to the sound bone.

Accidental *wounds* of the lips are usually incised or lacerated. If badly torn, the ragged edges should be smoothly trimmed, washed with sublimate solution, and secured with interrupted silk sutures. When the wound is through the entire thickness of the lip, the sutures should include the mucous membrane. A very fine suture should be used in the vermilion border to insure absolute approximation here. Adhesive strips are not reliable.

Diseases of the Lips.—Among the diseases which involve the lips and the contiguous structures are *epithelioma, lupus, papilloma, nævus, cysts, lipoma, adenoma, phlegmon, ulcers,* and *general hypertrophy* and *fissures.*

Epithelioma.—One of the most frequent causes of removal of portions of the lips is the presence of *epithelioma.* It is a disease of middle and old age, involves

usually the lower lip, and occurs in the great majority of instances in males. Epithelioma may attack the lip without any appreciable cause, but in most cases the appearance of the neoplasm is preceded by prolonged irritation at the place involved. A jagged or projecting tooth, the habitual use of a pipe stem or cigar, are frequent causes of this disease. It will also result from the irritation caused by chronic fissure or ulcer of the lip.

Symptoms.—It begins as a small ulcer with rather abrupt margins, in the bottom of which is a dirty granulation tissue partially hidden by thin pus. In its earlier stages it is not readily distinguished from the benign ulcer which may be found upon the lip. The preceding history of a prolonged irritation should always suggest epithelioma, especially if it occurs after the age of thirty, and upon the lower lip. Labial chancre may be differentiated by the indurated base, which is characteristic of this lesion. Adenitis in the line of lymphatics along the lower jaw comes on in the earlier stages of syphilis, while in epithelioma the sore may exist for months without perceptible enlargement of the lymphatic glands. In syphilis the appearance of the eruption, together with the history of the case, will lead to correct differentiation.

Epithelioma of the lip is a dangerous affection. Left alone, it destroys life within a period varying from one to four years. It spreads at times with rapidity, eating away the tissues in all directions. It may confine itself to the soft parts, or attack the maxillary and nasal bones. Engorgement of the submental, sublingual, submaxillary, and cervical glands is almost inevitable if the disease is not destroyed in the first few months of its existence. The glandular enlargement is at first not always due to metastasis, but may result from simple adenitis following the inflammatory process in the margins of the ulcer.

Treatment.—Epithelioma involving mucous or muco-cutaneous surfaces, especially of the lips, buccal cavity, and tongue, is more dangerous by reason of the tendency to rapid glandular infiltration in this situation. The greatest safety lies in the early and free excision of the diseased tissues. Marsden's paste, while preferable in epithelioma of the skin, is in general second to the knife in the treatment of this disease in the locality under consideration. The incision should be well away (about half an inch) from the infiltrated margin, and if any lymphatic glands are enlarged, they should be thoroughly extirpated. In closing the gap left by removal of a good portion of lip, the principles of plastic surgery hereinafter given should be employed in restoring the part to as near the normal condition as possible.

The prognosis as to permanent cure will depend in great part upon the time which has elapsed between the appearance of the *initial epithelial ulcer* and the date of operation. If infiltration of the lymphatic channels or glands has occurred, these should be thoroughly removed. Recurrence is almost inevitable.

Lupus.—Lupus erythymatosus and vulgaris usually attack the tissues of the nose, cheeks, and lips, at times producing extensive loss of substance. The erythematous variety is first seen as small red papules, projecting slightly above the epidermis, and covered with scales. It is a disease of the sebaceous glands and ducts, causing chronic inflammation of the skin and atrophy of all the elements of the cutis. Its progress is slow, and the prognosis is usually favorable when the disease is confined to a limited area. It does not affect the general health of the patient, and often heals spontaneously, leaving a flat, smooth scar. When disseminated it is more dangerous, not infrequently ending in fatal complications. The *treatment* requires generous diet, tonics, and out-of-door life. Among the local agents recommended in lupus erythematosus is green soap, which should be spread on lint and pressed closely upon the affected part, or rubbed in with the finger every day. Prof. A. R. Robinson, in addition to the above, also recommends a ten-per-cent solution of oleate of mercury brushed over the diseased surface.

If the disease does not yield to these milder measures, the sharp spoon should be employed and the broken-down tissue thoroughly scooped out. Emollients, cold applications, or poultices may be used afterward, according to the requirements of the case.

Lupus vulgaris is a more formidable affection. In its earlier stages it con-

sists of a number of soft red dots in the deeper layers of the integument, which gradually appear as papules upon the surface. The characteristic lesion is the infiltration of the skin with an abundant small cell new-growth. It is believed to be a tuberculosis of the skin. The integument breaks down and is cast off as a slough. The new-formed cells also undergo granular metamorphosis, and disappear with the other destroyed tissues. The only disease likely to be mistaken for common lupus in the adult is epithelioma. Lupus begins usually in childhood, while epithelioma is exceedingly rare before the age of thirty. The ulcer of lupus is not so painful as that of epithelioma, nor its edges so hard and elevated. The *treatment* of this affection is often unavailing. The constitutional treatment is the same as for lupus erythematosus. Locally, a ten-per-cent ointment of pyrogallic acid, spread upon linen and closely laid upon the diseased surface, is a useful remedy. It should be applied twice daily for several days, and then poultices or ointments used until the slough is removed. In certain cases it is advisable to scrape the ulcer well with a sharp spoon, and then apply the pyrogallic acid for one or two days. Within recent years the X-ray has been highly recommended as a curative agent. The protection of all parts not diseased is essential.

Angeioma of the lip should be treated by the injection of very hot water, as already described. Should cicatrization result the deformity may be corrected by excision and a plastic operation.

Moles are less formidable, and rarely require an extensive reparative operation after excision.

Papilloma, *lipoma*, *adenoma*, and *fibroma* do not, as a rule, require extensive incisions and loss of tissue in their removal.

Cystic tumors of the lip are not infrequent, occurring as spherical swellings beneath the mucous membrane. They are caused by obstruction of the duct of a labial follicle, and contain a thick, ropy fluid. The treatment involves a careful and thorough excision of the sac.

Fissures, or "*chaps*" of the lip may occur independently of any constitutional disease. They may be cured by a local astringent, as alum, or caustic nitrate of silver, applied once a day for two or three days. When these more simple remedies are without avail, excision should be practiced. When fissure of the lip is allowed to remain, and the general condition of the patient is bad, necrosis of the mucous membrane immediately contiguous ensues, causing a grayish-red ulcer. The treatment consists in the local use of astringents and the improvement of the patient's nutrition.

Phlegmon of the lip is rare. It is a painful affection, and not devoid of danger. The pathology of carbuncle has been given. The proper treatment is early and free incision through the skin, deep fascia, and muscles, and the employment of aseptic poultices.

Hypertrophy of the lip is occasionally met with. It may be confined to the mucous and submucous tissues, or the entire thickness of the lip may be involved. It occurs usually in the upper lip, but may be seen occasionally in the lower lip. When extensive enough to require operative interference, the proper method is to dissect out in the long axis of the lip a portion of the tissue between the skin and mucous membrane, and approximate the edges of the wound with silk sutures.

Hair on the Lips of Women.—Permanent epilation may be effected by introducing into the follicle of each hair the point of a fine platinum needle, which is then heated by the galvanic current. The employment of cocaine renders this operation painless.

Reparative Surgery of the Lips.—A plastic operation may be demanded in acquired or congenital lack of tissue in the upper lip. In the lower lip congenital deformity is exceedingly rare.

In addition to congenital defects (harelip, which will be considered with cleft palate) as the result of accident or disease, restoration of the upper lip becomes necessary.

When the defect is small (Fig. 375) the flaps are shaped by the incisions *a d*. The lip and cheek are freely dissected from the maxilla and sutures inserted as shown in Fig. 376. If after the dissection the tension is still so great that the

parts do not come well into position, a horizontal incision should be made on either side, beginning near the root of the nose, and carried directly outward, or slightly outward, and downward, as the shape of the flap may require. Where there is greater loss of substance an incision, *c a* (Fig. 377), is carried from the alæ of the

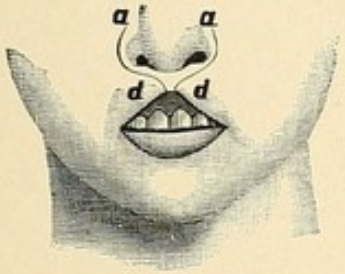

Fig. 375.—(After Roser.)

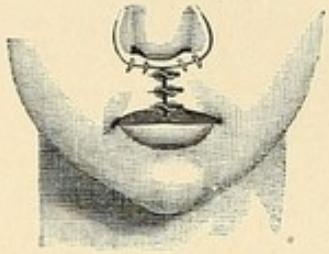

Fig. 376.—(After Roser.)

nose upward and outward. The length of this cut and its obliquity depend upon the distance to be filled between the normal line of the lip and the nose. A second incision, *a b*, is now carried deeply forward and outward, making a quadrilateral flap which hinges at *b d*, and is dissected up, and the edges, *c a*, are brought in apposition and secured to the median line.

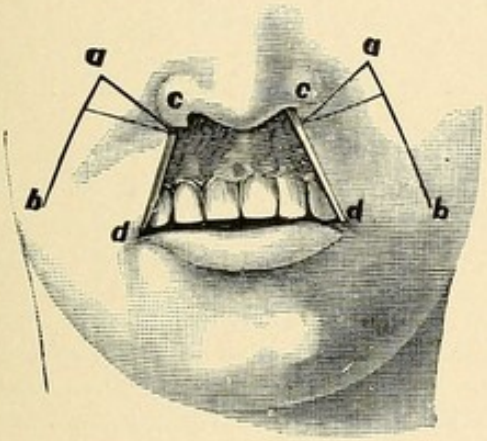

Fig. 377.—(After Linhart.)

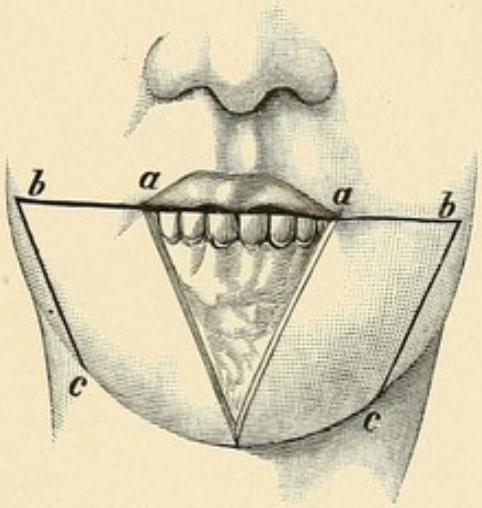

Fig. 378.—(After Linhart.)

Lower Lip.—When the loss of tissue has left a cavity triangular in shape, as in Fig. 378, that one of the following methods may be selected which in the judgment of the operator is best adapted to the case:

1. A horizontal cut, *a b* (Fig. 378), is made outward from the angle of the lip, and a second one, *b c*, parallel with the freshened edge of the fissure. Both flaps are now loosened and slid toward the median line, and united by sutures.

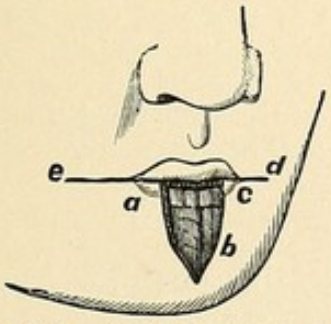

Fig. 379.—(After Szymanowsky.)

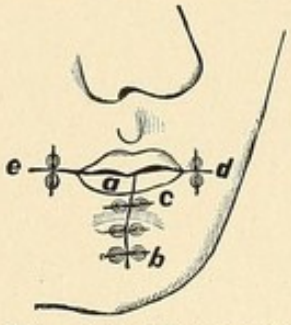

Fig. 380.—(After Szymanowsky.)

Along the free border of the new lip stitch the mucous membrane to the skin with fine silk sutures. The gap left on either side is also wholly or partially closed by sutures or grafts.

2. If the fissure is less extensive, make a horizontal incision from each angle of the mouth through the entire thickness of the lip for a sufficient distance (Fig. 379), *a e*, *c d*, dissect up the triangular flaps, and adjust with sutures, as shown in Fig. 380.

3. When the apex of the triangular defect does not dip down too far from the teeth, the unilateral sliding operation of Blasius may be practiced. From the apex

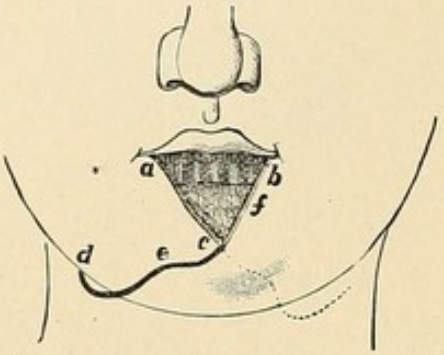

FIG. 381.—(After Szymanowsky.)

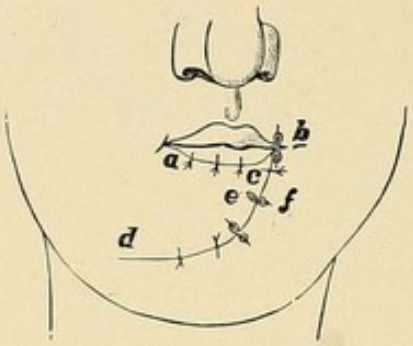

FIG. 382.—(After Szymanowsky.)

of the angle, *c* (Fig. 381), make a deep cut, *c e d*, downward and outward over the side of the chin, in the main a continuation of the line of the defect, *b f c*. The flap, *a c e d*, is dissected up and slid so that *c* is attached to *b* (Fig. 382).

In *contraction* of the mouth the orifice may be enlarged by incising the angles in a horizontal direction, finishing the operation by stitching the skin and mucous membrane together.

In the selection of any of the plastic methods heretofore given, the surgeon must be guided by the requirements of each case. It is a wise precaution to make a guarded prognosis, for, no matter how successful from the surgical standpoint, the operations do not, in the majority of instances, secure the expected improvement in the personal appearance of the patient.

Very extensive defects involving the lower lip and chin and the cheeks may be very satisfactorily repaired by various modifications of this sliding method of skin transplantation. It is especially applicable in correcting the deformities resulting from cicatricial contractions after burns. The lower lip may be drawn well toward the lower margin of the jaw, leaving the teeth exposed and the retention of saliva impossible. The cicatricial tissue should be thoroughly removed and the liberated vermilion border of the lip stitched back to its original position. The gap left open is then filled by sliding a flap of suitable size from the neck. Careful measurements should be made, and if necessary a chamois pattern should be modeled in order to secure accuracy. The shape of the flap must conform to that of the space to be filled. The defect in the neck is in turn filled by a second flap from below, and so on until the last flap and scar is low enough to be concealed by the collar. On account of the elasticity of the flaps, by stretching each somewhat beyond the normal, a considerable gain is made in covering surface, until by the time the chest is reached the gap is insignificant. In all these plastic procedures not only is asepsis essential to rapid and satisfactory repair, but the position must be such that there is no strain on the sutures or tension or pressure on the flaps. The sutures are of silkworm-gut or fine linen or silk.

PAROTID GLAND AND DUCT

Salivary fistula may be confined to the main parotid duct in any part of its course, or to the primary ducts within the substance of the gland.

It may result from a wound or any inflammatory and necrotic process due to obstruction from salivary calculi or other disease of the parotid and buccal regions. Exploration of the duct with a delicate blunt probe is accomplished thus: Find the outlet at the papilla on the mucous membrane of the buccal cavity near the junction of the second bicuspid and first molar teeth of the upper jaw. Introduce

the probe, carrying it at first slightly outward. When it is arrested by the natural curve of the duct, pull the corner of the mouth and the cheek directly outward, thus straightening the tube. The general direction is backward, toward the auditory meatus.

The diagnosis of salivary fistula or of obstructed duct may be determined as follows: By means of absorbent cotton or lint remove all moisture from the mucous surface where the papilla is situated, and place some sapid or acid substance on the tongue. If there is no obstruction, the flow of saliva is immediately perceived. In case of fistula the secretion will flow out through it. *Calculi* of Steno's duct, or of any of the salivary ducts, should be removed by dilatation, if this is possible, and if not, by incision. The prominent feature of stone is swelling of the cheek from retention of saliva.

In the treatment of salivary fistula the object aimed at is to stop the flow of saliva on the outside and turn it into the mouth. Arm a probe with a silk seton and carry it through the fistula into the buccal cavity, bring the thread out through the mouth, and tie the two ends together. In about ten days the flow into the mouth will be fully established, when the seton should be removed and the outer opening closed by a compress until cicatrization occurs. It may, at times, be necessary to freshen the edges and bring them together with a suture.

Riberi operated successfully by cutting through the integument down upon the duct behind the opening, passing a ligature around it, and carrying this and the end of the duct into the buccal cavity, where it was left open. The wound in the integument was immediately sutured.

In a case recently treated by the author, the following method was successful in restoring the flow of saliva into the mouth: A boy twelve years old had scarlatina at seven, which was followed by obstruction of the left duct of Steno. A fistulous opening occurred spontaneously behind the ear. Cutting down through the cheek in the anatomical line of the duct, this was discovered to be obliterated for the last half inch of its course. It was divided just posterior to the limit of occlusion, and an incision opposite this point made directly through into the buccal cavity. Two fine silk threads were inserted in the wall of the duct at the end, and these sutures were stitched to the mucous membrane of the cheek at the edges of the incision just made. The wound in the integument of the face was closed, excepting the anterior angle, where a small rubber tube was inserted. This tube projected into the cavity of the mouth by the side of the new opening for the duct. This was done to form a fistula in case the wound in the mucous membrane should close and obstruct the duct. A compress was placed and worn on the fistulous opening behind the ear. The tube was removed in five weeks, and the external outlet closed by silk sutures. At this time, also, the old fistulous opening was closed. The saliva up to this time flowed about equally out of the hole behind the ear and the opening in front. After this it came only through the end of the duct in the mouth.

Fistula of the primary ducts within the substance of the gland may require the forced atrophy or ablation of this organ. An effort at occlusion should be made by direct pressure upon the abnormal opening, or by careful dissection in the line of the fistula, when this can be safely done. When, however, the fistulous tract is deeply situated, it will be found almost impossible to effect a cure without serious risk of interfering with the integrity of the seventh nerve, the motor filaments of which are in intimate relation with this gland. Removal of the parotid gland, for any cause, becomes a serious operation, since it necessarily implies paralysis, more or less complete, of the muscles of the face; when it is entertained, the patient should be thoroughly acquainted with the prospect of paralysis which will follow. In non-malignant cases the greatest care should be exercised in avoiding division of the filaments of the facial nerve. Even in the arrest of hæmorrhage, as the operation proceeds, the application of the forceps should be carefully made, so that the branches of the nerve may not be injured or included in the ligature. When the seat of malignant disease, a thorough ablation is essential, and the nerve is necessarily sacrificed.

Tumors of the Parotid.—About thirty per cent of all neoplasms of this organ are enchondromata, twenty-five carcinomata, while the remaining forty-five per cent are about equally divided between sarcomata, fibromata, myxomata, and cystomata. Enchondroma, carcinoma, and fibroma occasionally are found developing at the same time in this organ. Simple hypertrophy is rare, although hyperplasia of the gland tissue occurs in a varying degree in the progress of most of the neoplasms which attack this organ.

Tumor of the parotid is rare prior to the thirtieth year of life, being met with chiefly between the thirtieth and fiftieth years. As to the period when the various forms appear, it may be said that carcinoma occurs generally after the fiftieth year, while enchondroma, sarcoma, myxoma, and fibroma develop in the earlier decades. Sarcoma is apt to develop in childhood or early adult life.

Diagnosis.—All forms of tumor of the parotid, as a rule, develop slowly. In the earlier stages of their development they are movable within the limited area of mobility of the gland. This is true of both the benign and malignant growths. Later, even the benign neoplasms may become fastened between the temporal bone and fascia and the ramus of the jaw, but not to the overlying integument. The malignant growths are more rapid in development, and earlier in their history are bound down to the surrounding tissues, may become adherent to the integument, and produce great pain and disturbance by reason of pressure upon the nerves and vessels with which the gland is in close relation.

The cartilage tumors are nodular, hard, and slightly elastic to direct pressure. Cancer is also nodular at times, but not so hard as enchondroma. Cancer comes, as a rule, after the forty-fifth to fiftieth year, and the other neoplasms before this period. The lymphatic glands are involved in cancer, and rarely enlarged in any other form of neoplasm. Sarcoma occurs earliest of all. Cysts are elastic, may present fluctuation, while the exact character of this variety may be determined by exploration with the aspirator. If of great importance in determining the plan of treatment to be pursued, a section of the diseased organ sufficiently large for microscopic examination should be removed; in this way a positive diagnosis is assured.

Removal of the parotid gland is a difficult operation. In many cases of tumor of this organ in which the neoplasm is developed at the expense of the under portion of the gland, the internal jugular vein, internal carotid artery, and the important nerves and ganglia situated here become so involved that complete extirpation is impossible. When the tumor is of small size, it may be entirely removed. Section of the various divisions of the facial nerve or of the main trunk is almost inevitable.

Operation.—Make a crucial incision over the mass, the perpendicular cut being in the line of the external carotid artery. Turn the flaps back from the anterior aspect of the tumor, and approach its deeper portions from below in the line of the vessels. As soon as the external carotid can be exposed, it should be secured with a catgut ligature. All bleeding should be arrested as the operation proceeds. The reversed Trendelenburg posture and Dawbarn's sequestration will aid greatly in diminishing bleeding and the recognition of the nerve filaments. In lifting the under surface of the tumor from its bed, the operator should keep close to the mass, using a dull instrument for fear of wounding the internal jugular vein and other important vessels or nerves. The blunt scissors curved on the flat, the handle of the scalpel, or the thumb and finger nail may be utilized for this purpose. The facial nerve and its branches which run through the neoplasm should be saved, if possible. As before stated, if the tumor is extensive, this is scarcely possible on account of the great length of time it would require. If, in the course of the operation, it is discovered that the neoplasm dips down beneath the jaw and styloid process, and surrounds the vessels and nerves, its complete extirpation is impossible. As much of the mass as can be lifted should now be transfixed near the middle with a double elastic ligature, tied, and the part external to the ligature cut away.

The *prognosis* in cancer and sarcoma of the parotid is always grave, even after removal. The probabilities of recurrence, and the certainty of facial paralysis should be fully explained before operation. In benign tumors which show a tend-

ency to increase, operation should be advised. It is always important to attempt the removal of the neoplasm early in its history.

In sarcoma and in all doubtful inoperable tumors the injection of the mixed toxines as advised by Coley should be faithfully tried before extirpation is attempted.

Parotitis—"Mumps"

Inflammation of the parotid gland occurs chiefly in children, but is occasionally met with in adults. In males it is, at times, accompanied by orchitis, and in females the mammary glands and ovaries are affected. The symptoms are pain and swelling of the gland, difficult deglutition, and slight febrile movement. The prognosis is favorable, the disease yielding to warm applications, quiet, and the judicious employment of laxatives. In rare instances atrophy of the testicle has been known to follow the inflammation of this organ, occurring as a complication of "*mumps*."

Abscess of this organ may occur as a complication of the eruptive or continued fevers. Under these last conditions the prognosis is always grave. The presence of pus is recognized by the intense character of the pain experienced, the febrile movement, the doughy condition of the skin and areolar tissue in front of the organ, and by aspiration. The abscess should be evacuated by aspiration, puncture, or incision.

Submaxillary Gland

This organ may become inflamed and suppurate, or be the seat of neoplasms. Its removal is a simple procedure, and may be accomplished by a crescentic incision commencing at the angle of the jaw, dipping three quarters of an inch toward the hyoid bone, and ending one and a half inch in front of the angle at the lower border of the jaw. The flap of skin should be raised with the platysma muscle as far as the jaw, and the deep cervical fascia divided. The gland rests beneath and internal to the bone and upon the mylohyoid and hyoglossus muscles. The submaxillary branch of the facial artery may be divided.

The Jaws

Superior Maxilla.—Periostitis, ostitis, and abscess of the upper jaw may be caused by infection through a carious tooth, or in the upper jaw from the antrum, or pathological changes within the bone proper. Ostitis of the maxilla is more apt to occur in children, and especially in those of a tuberculous diathesis. Phosphorus poisoning and the syphilitic dyscrasia lead also to inflammation and caries of this bone.

The *symptoms* of ostitis and abscess here do not differ from those already given in the general chapter on bone diseases. Pain is, perhaps, more acute in ostitis within the distribution of the trifacial nerve. It is elicited by direct pressure, and, when the process is associated with a carious tooth or its roots, the exact location may be determined by striking the tooth sharply with a metallic substance.

The *treatment* is to relieve the tension by puncture or incision, or by extraction of one or more teeth in case they are connected with the diseased surface. The removal of dead bone is demanded. When exfoliation has occurred, the operation is much simplified. If free drainage is secured by early incision, the arrest of the spread of the disease is practically insured. *Chronic alveolar abscess* is often cured by extraction of an offending tooth. When this fails, the diseased surface should be exposed by incision, and a thorough removal accomplished. When possible, all sequestra should be removed from within the oral cavity in order to avoid a scar upon the face.

Syphilitic ostitis, and that variety which occurs from absorption of the fumes of phosphorus, require specific constitutional treatment as well as operative interference.

Abscess of the antrum of Highmore may occur as the result of an inflammatory process in the mucous membrane lining this cavity, by extension of an infection

from the nose, or in connection with ostitis of the upper jaw, or from the presence of foreign bodies or neoplasms within its cavity. The chief symptom is pain, referred to the region of the antrum. The febrile movement of acute abscess is usually present. The pus may force its way through the opening into the meatus, or cause necrosis in the bone and discharge in any direction.

Treatment.—Free drainage must be established in all cases. This can be accomplished in two ways: First, and preferably, by making an opening directly into the antrum from beneath the cheek and just above the roots of the first molar tooth. For temporary drainage in the suppurating antrum, this opening will suffice. It may be enlarged by biting away a portion of the wall of the antrum around the hole made by the drill. It is important to explore the cavity with the probe or finger in order to determine the presence of dead bone or any tumor or other offending substance. Drainage must be maintained until the discharge of pus has ceased. The old method of drainage was to extract the anterior molar tooth and break through directly into the antrum; but, on account of the annoyance from the easy entrance of food through this opening, it will be better to employ the higher drainage.

Among the many other diseases to which the antrum is subject are myxoma, fibroma, papilloma, sarcoma, and carcinoma. The differentiation of these growths is extremely difficult. The small electric arc light introduced in the pharynx, nose, or mouth will illuminate the normal antrum and thus aid in diagnosis. When doubt exists as to the character of the neoplasm, an exploratory operation for the purpose of positive diagnosis should be made.

Operation for Removal of a Tumor from the Antrum of Highmore.—For the removal of small neoplasms of the antrum, the method already given of incision underneath the lip and cheek and above the roots of the molar tooth will be found sufficient as advised and practiced by Prof. Robert C. Myles. For larger growths, the following simple method I have found extremely satisfactory, and have removed through this incision tumors entirely filling the cavity of the antrum of Highmore, and projecting into the nose and pharynx. A horizontal incision is made about one fourth of an inch below and parallel with the inferior orbital margin, and extending from the outer angle of the orbit to near the canthus of the eye. A second incision joins the inner extremity of this cut at a right angle, and divides all the tissues down to the bone, extending to the level of the wing of the nose. The filaments of distribution of the fifth nerve are divided and all the tissues are lifted with the periosteum. The anterior wall of the antrum is broken through by a small chisel, and the opening enlarged with the rongeur until the entire anterior wall is removed piece by piece. The antrum is now exposed, the tumor removed, and the hæmorrhage arrested by a packing with gauze, which is then removed and the wound closed, leaving a small catgut drain at the anterior inferior angle, when this is deemed necessary. The loss of the anterior wall of the antrum produces very little deformity.

When a nasopharyngeal tumor of large size has developed into the antrum and is pressing into the spheno-maxillary fissure, producing bulging of the eye, and into the zygomatic and pterygo-maxillary fossa, the following operative method, which was first performed by the writer in 1894, may be employed: In the patient upon whom it was first done the tumor was a large vascular fibroma which sprung from the base of the pterygoid process of the sphenoid bone, filled the nasopharynx, and had broken through the posterior wall of the antrum. It projected upward into the sphenoid fissure and zygomatic and pterygo-maxillary fossæ. The eye was pushed well out of the socket and toward the nose, and the cheek and temporal region were greatly swollen. The patient was a young man, nineteen years of age, and in bad condition from frequent hæmorrhages from the tumor, loss of appetite, and sleeplessness.[1]

[1] An incision was made beginning along the temporal arch two inches back of the outer angle of the orbit, following the temporal arch to the edge of the orbital cavity, along the frontal process of the malar bone, curving parallel with and one-eighth of an inch from the orbital margin, until the point of the knife reached half an inch to the inner side of the infra-orbital foramen; then downward to the level of the ala nasi and outward through the cheek until the point of the knife neared the opening of Steno's duct (Fig. 383). This incision was down to the bone from the point

Operation for Removal of the Upper Jaw

A quarter of an inch below the inner canthus of the eye commence an incision and carry it downward along the naso-maxillary groove, curving in the contour of the ala nasi, then horizontally beneath the ala to the median line of the lip, where it turns directly downward, dividing the lip in the median fissure. From the point of beginning carry a second incision one fourth of an inch below and parallel with the inferior margin of the orbit out to the prominence of the malar bone (Fig. 384). Dissect up the soft tissues of the cheek, and turn the flap downward and outward. If the disease is so extensive that the incision does not

of beginning to the lower point of the superior maxilla, where the antrum of Highmore rests upon the alveolar process of the upper maxilla opposite the first molar tooth. Hæmorrhage was carefully stopped throughout the entire incision by pressure and by ligating with catgut the larger vessels which were divided, but the soft tissues were in no way dissected up from the bone, except when it became necessary to enter the orbital cavity in its outer half, where the tissues were carefully lifted from the bone and the eye displaced toward the median line (taking care not to press upon or injure this organ), until the anterior commissure of the spheno-maxillary fissure came into view. I then passed in this a keyhole saw with the teeth turned upward, and sawed through the junction of the malar with the frontal bone. The saw was then turned over with the teeth directed downward, and beginning at the same point I rapidly cut through the floor of the orbital cavity, traversing the infra-orbital foramen until I had sawed through the antrum of Highmore at the level of the alveolar process of the lower maxilla. A hook was then placed in the outer angle of the orbit, and a quick, sharp jerk fractured the zygomatic process of the temporal bone, displacing the side of the face, completely exposing the antrum of Highmore, the zygomatic fossa, and the pterygoid and spheno-maxillary fissures. The hæmorrhage was severe, but was controlled by packing sponges into the wound and making firm compression. So sudden was the hæmorrhage that the pulse jumped from 85 to 140, and the patient, who was before the operation in a condition of extreme exhaustion, seemed about to expire in collapse. As a precautionary measure I had inserted into the median cephalic vein a pipette for injecting hot salt solution, and had everything in position for immediate use. At this juncture the faucet was turned on, and one pint of the saline solution, already prepared and kept so hot that the hand could scarcely be borne in it with comfort (temperature 110° to 120° F.), allowed to run into the vein. Under the pressure of this solution the heart rallied and came down to eighty-five beats to the minute. The tumor was again exposed, and with a periosteal elevator lifted out of the antrum of Highmore, and from its attachments to the pterygoid process of the sphenoid bone. By opening the patient's mouth, which depressed the coronoid process of the inferior maxilla, the ptery-go-maxillary fissure and the zygomatic fossa were well exposed. The whole antrum was packed with a long wick of sterile gauze, which was allowed to project at the anterior inferior angle of the wound, from which it was drawn on the third day after the operation. The bone, which had been temporarily displaced with the soft parts adherent, was then brought back into position and held there by stitching the soft parts along the line of incision. A bandage and compress were applied in order to maintain approximation. No sutures were inserted in the bones. The patient made an uninterrupted recovery. He is now, thirteen years after the operation, entirely well. The bones have all united in their normal position; he has perfect use of the eye, and, although the filaments of the facial nerve were divided, he still has motion of the orbicularis palpebrarum muscle.



Fig. 383.—Dotted line indicates the incision for the author's osteoplastic resection of the malar bone and wall of the antrum maxillare. Case of Charles Bull. One year after operation.

expose the parts sufficiently, a horizontal cut may be made outward from the angle of the mouth. This is rarely necessary.

The bone may be divided by the saw inserted in the spheno-maxillary fissure, cutting through the nasal process with a chisel. Extract an incisor tooth, and with a chisel or bone-cutting forceps divide the alveolus and the palate process by inserting one blade in the nose and the other in the mouth. These sections being accomplished, avulsion is made by means of elevator and forceps. The operation is completed by the closure of the wounds with fine silk sutures. If, in section of the palate, the Paquelin cautery is used, hæmorrhage will be less annoying.



Fig. 384.—(After Roser.)

Preliminary tracheotomy and plugging the pharynx and larynx with sponges in order to prevent hæmorrhage into the trachea is rarely, if ever, required.

If the patient be placed well upon the side and the neck twisted over so that the mouth is dependent, the blood will gravitate easily out of the mouth, and thus dispense with the necessity for a trachea tube. This position and sequestration should be employed in all cases of operation upon the mouth where hæmorrhage is serious.

For simple osteoma, or for necrosis of the upper jaw, this bone may be removed without incision in the cheek. I removed the left superior maxilla, except the orbital plate, entirely *from within the mouth*, without external incision. In necrosis, when the subperiosteal operation is permissible, the procedure is devoid of great difficulty.

The Lower Jaw

Ostitis of the inferior maxilla is of frequent occurrence.

Various forms of fibroma, fibro-myxoma, encysted fibroma, enchondroma, and, in rare instances, angeioma, have been observed in this bone, but of new formations sarcoma is most frequent. Cystic formations resulting from failure of normal development of the teeth are not uncommon.

Ostitis occurs most frequently in children. It is usually secondary to disease of the teeth, and in very rare instances is caused by inhalation of the fumes of phosphorus. While this process may be located at any portion of the jaw, the neighborhood of the angle seems to be most frequently affected.

The *symptoms* are pain, followed by swelling of the jaw and contiguous soft tissue, ending in abscess, which, if left alone, eventually opens and discharges.

Treatment.—As soon as the character of the disease is evident, an incision or puncture should be made through the overlying tissues and periosteum, in order to give free exit to pus and loose particles of bone. The operation for removal of the dead bone may be delayed for several weeks until exfoliation has taken place. Diligent effort should be made to reach the diseased bone from within the mouth, and this can be done in a large proportion of cases. With the patient well over on the side, the blood will flow out and not interfere with the larynx. Incision, when necessary, should always be made below the line of the jaw, if this is feasible, so that the resulting scar will be less apparent. Usually by following the track of the abscess it will lead directly to the dead bone surrounded by an *involucrum*. This often requires to be chiseled or forced open to allow the extraction of the *sequestrum*, which may be readily removed with ordinary bone- or dressing-forceps. The cavity should be well scraped with a Volkmann's spoon, a drainage-tube left in, and the edges of the wound adjusted with silk sutures. The deformity due to the rich deposit of callus disappears with the absorption of this material. When all or any portion of the entire thickness of the jaw requires removal for ostitis, the subperiosteal operation is imperative, since by this means alone is it possible to have a reproduction of the bone. The method of procedure,

when the bone is the seat of a neoplasm, depends upon the character of the new formation. If there is any doubt as to the benign character of the tumor, a piece should be removed and examined microscopically before operation.

In sarcoma, cancer, and enchondroma of the jaw, the subperiosteal operation cannot be performed, since the sound tissues must be included in the ablation, in order to secure immunity from recurrence. Enchondroma, though not intrinsically malignant, tends to recur if not freely excised. In the experience of the author, sarcoma of the upper and lower jaw is not so apt to recur as in other bones.

Operation.—When it is safe and possible, the diseased portion of the lower jaw should be removed without breaking the continuity of the bone. If a portion of the entire thickness of the organ is removed, the tendency to displacement is inward, thereby interfering with mastication. The entire thickness of the jaw should be included in exsection for malignant neoplasm.

Resection of the lower jaw may be accomplished from within the buccal cavity, as done by J. Marion Sims in 1845 ("American Journal of the Medical Sciences," October, 1847).[1]

I have in women twice performed the operation of dividing the inferior maxilla in the middle line at the chin with the wire saw, and disarticulating at the temporo-maxillary joint without external incision. In one case the disease was osteomyelitis, and the operation was practically subperiosteal. Hæmorrhage was insignificant. The patient recovered with very slight deformity, as shown in Fig. 385. In these cases, as soon as the diseased jawbone is removed, in order to prevent displacement of the remaining portion toward the median line, it should be wired to the teeth of the upper jaw and held in proper position until the wound of operation has healed enough to permit the insertion of an artificial apparatus.



FIG. 385.—Complete removal by disarticulation of the right half of the lower jaw from within the mouth. Six months after operation.



FIG. 386.—Osteo-sarcoma of inferior maxilla. Disarticulation from within the mouth.

In the second case the same operation was successfully performed for osteo-sarcoma, in which the disease was as yet entirely confined to the central portion of the left half of the inferior maxilla (Fig. 386). No effort was made at subperiosteal removal, as it was essential to freely dissect away with the mass the soft tissues on either side. The girl recovered, and one year after the operation

[1] Dr. Sims writes: "There are several considerations to recommend this operation in preference to the usual one with its extensive incisions: (1) There is no external mutilation; (2) as the third branch of the fifth pair of nerves was divided at the outset of the operation, its subsequent stages were comparatively free from pain; (3) as no important blood vessels are cut, no ligatures are required; (4) there is no trouble with the after-treatment; (5) it is just as easy of performance as the old operation."

there was no sign of a recurrence, and very slight deformity (Fig. 387). The danger from hæmorrhage is slight, and the flow of blood into the larynx can be easily prevented by placing the patient upon the side corresponding to that on which the operation is to be performed, keeping the mouth well open with retractors, and the head tilted in such a position that the blood runs freely out of the mouth. Silk-suture retractors inserted through the lip at various points in the entire circumference of the mouth will stretch this orifice and materially aid in rapidity of the operation. As soon as the disarticulation is completed the wound should be tightly packed with sterile gauze,
in order to arrest hæmorrhage.



FIG. 387.—One year after operation.



FIG. 388.—(After Roser.)

When the danger of bleeding is past, usually in forty-eight hours, the packing should be removed, and not replaced.

If there is extensive malignant disease and the attachments to the soft parts are firm, the intra-oral operation is not indicated, and external incision is necessary. The simplest method is the incision of Roser (Fig. 388) through the median line in front of the chin and underneath the jaw, since the scar is less prominent in this position.

In all formidable operations about the mouth where rapid work is imperative, Dawbarn's sequestration method should be practiced, and morphine should be given so that the ether inhaler may be only occasionally required.

Resection of the inferior dental nerve may be performed at the mental foramen, or at the commencement of the dental canal at the angle of the jaw.

The *mental foramen* is situated about half-way between the inferior border of the bone and the alveolus. A line let fall perpendicularly from the interspace between the two bicuspid teeth of the lower jaw will pass over the opening. A curved or crucial incision will expose the nerve at this point.

The foramen of entrance of the inferior dental nerve is very near the center of the quadrilateral formed by the anterior and posterior margins of the ramus, the lower horizontal border of the angle, and an imaginary horizontal line on a level with the lowest portion of the sigmoid notch.

In order to avoid section of the branches of the facial nerve an incision as long as may be required should be made along the lower border of the jaw, cutting directly down to the bone. The dissection should keep close to the bone, clipping the insertion of the masseter muscle from the periosteum, with strong upward

traction. The trephine should be applied over the center of the quadrilateral. The best indication of having reached the nerve is the bleeding through the track of the trephine when it passes into the cancellous tissue of the jaw. This comes from the wounded inferior dental vessels. An elevator placed in the cut will now lift the button of bone, and expose the nerve. The entire portion in the limit of the trephine should be excised. Temporary relief is almost invariably secured, although a recurrence of pain is not uncommon after several months. Packing the dental canal with metallic foil is advised to prevent regeneration and reunion of the nerve. As before stated, the exsection of the Gasserian ganglion is the final resort.

Ankylosis.—Motion of the jaw may be limited or entirely prevented by muscular rigidity, cicatricial contractions, or true ankylosis at the temporo-maxillary articulation.

The area of motion in partial ankylosis may be increased by forcible separation of the lower from the upper jaw by the mouth-gag or screw. This should be repeated at frequent intervals, gradually increasing the pressure. In severe cases a false joint may be successfully established by section of the bone anterior to the point of fixation, usually at or above the angle. Care must be taken to make frequent passive motion in order to prevent bony union at the point of section.

The Teeth

Extraction.—Dental forceps should be of different patterns, the jaws bent at various angles to the shaft, and the handles large enough to be grasped firmly and securely by the operator.

The gum immediately around the neck of the tooth should be freely incised with a lancet, since if this precaution is not taken it may be unnecessarily torn away with the tooth. The injection of cocaine around the tooth will render the cutting painless, while nitrous-oxide gas should be given for the extraction. The

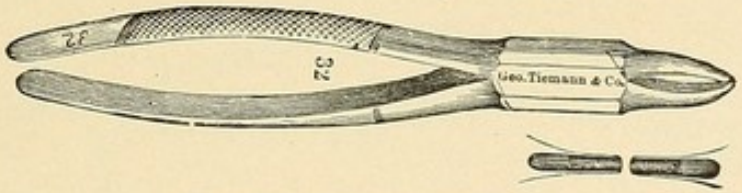

Fig. 389.—Incisor, straight root.

jaws of the forceps are applied on either side of the neck, and forced down toward the root until they grasp the tooth firmly, and yet not forcibly enough to cause crushing, at the margin of its alveolar insertion. The direction of traction is determined by the normal direction of the axis of the tooth. In extracting the

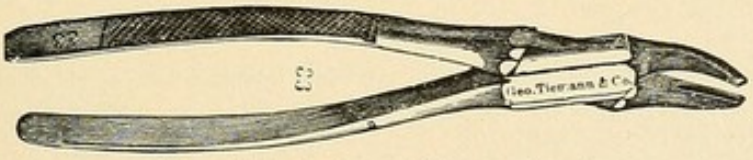

Fig. 390.—Incisor, half-curved root.

incisors and canine teeth, the forceps represented in Figs. 389 and 390 are applied as described above, and, when firmly fixed, a slight forward and backward movement, with limited rotation, will loosen the root, while traction should at the same time be made in a direction upward and slightly forward for the lower jaw, and downward for the teeth of the upper row. For the bicuspids and molars, the instruments shown in Figs. 391, 392, and 393 are preferable.

The bicuspids and molars may be loosened by lateral motion or rocking. The direction of traction is slightly inward for the lower teeth, and slightly outward for those of the upper jaw.

Fracture of a root or shelving of the alveolus will occur at times in the most

skillful hands, and abscess and necrosis may ensue. Fragments of the teeth should be gouged out by using an elevator. Hæmorrhage, usually insignificant, may at times be dangerous, death having occurred from this cause in one or more in-

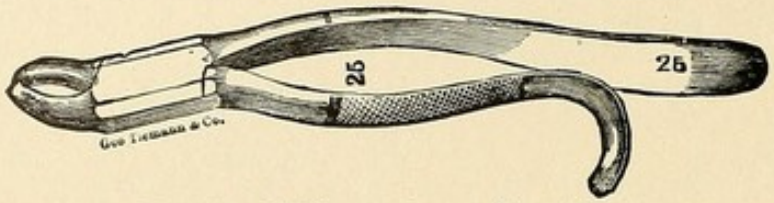

FIG. 391.—Wolverton's upper bicuspids.

stances. Cold or heat, or packing the cavity with a compress of cotton or lint, will effect its arrest. In extreme cases the compress may be saturated with Monsel's solution, or alum, or any astringent, and left in for forty-eight hours. Nitrous

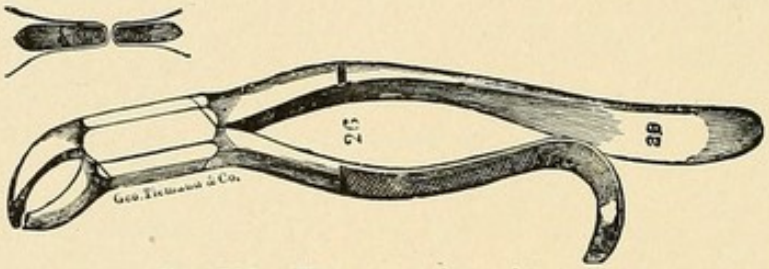

FIG. 392.—Wolverton's lower bicuspids.

oxide may be employed with great safety in dental surgery. A number of fatal cases are recorded in which chloroform had been administered in extracting teeth. Careful attention to the teeth and gums is an essential feature of preventive

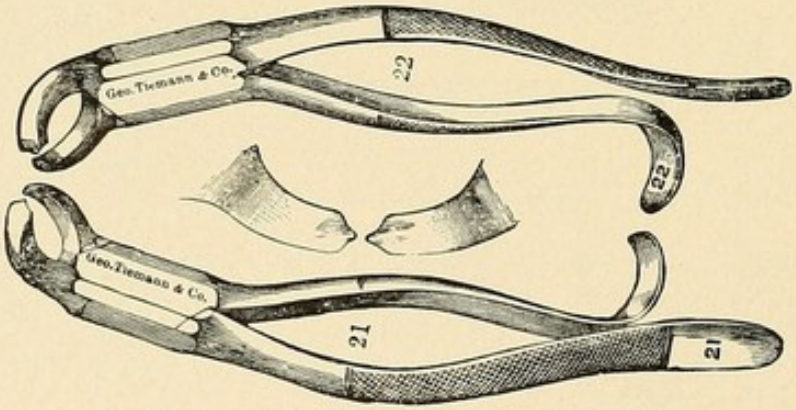

FIG. 393.—Harris' lower molars, for the two sides.

medicine. Malignant neoplasms are frequently caused by the irritation from projecting teeth. Tuberculous and pyogenic infection is a common occurrence from exposed abrasions in the mouth.

Dentigerous cysts, resulting from defective development of the teeth, are occasionally present. They appear as round or sessile swellings of the alveolus or jawbone near the roots of the teeth. As the covering of bone is thin, it gives under pressure with the finger a feeling of resiliency. If not subjected to operation early, they lead to extensive deformity, and tend to undergo malignant transformation.

From an incision within the mouth they can be exposed, and by breaking through the soft curtain of bone the cyst is opened and the glairy contents escape. The sac should be carefully removed by dissection and the cavity mopped with pure carbolic acid on a wisp of cotton. Any misplaced tooth should be removed. A gauze pack should be inserted, and renewed as required until the cavity is closed by granulation. The process is usually tedious, and requires care and patience on the part of the surgeon and patient.

CHAPTER XVI

THE UVULA, DISEASES OF THE PALATE, CLEFT PALATE AND HARELIP, TONGUE, BUCCAL CAVITY, AND TONSIL

Uvula.—On account of elongation or hypertrophy of this portion of the soft palate, its excision is at times required. It may be accomplished by taking hold of the tip with a mouse-tooth forceps, and with a long curved scissors removing as much as required. Local anæsthesia may be obtained by mopping the uvula with a small quantity of a four-per-cent solution of cocaine hydrochlorate at intervals of three minutes for fifteen minutes before the operation.

Tumors of the palate, abscess, necrosis, and ulceration are not infrequent, and demand the same treatment as in other portions of the body.

Malignant neoplasms of the palate should be thoroughly destroyed by the Paquelin cautery. In two cases which came under my care this was done with no recurrence in five years and one year respectively.

Since harelip is so frequently complicated with cleft palate, and since the success of any operation for the correction of a deformity caused by harelip must depend upon a reconstruction of the alveolar arch, naturally a consideration of the cleft palate should precede that of the deformity of the lip.

Cleft palate may be complete or incomplete, lateral or bilateral. The fissure may occupy only the anterior or the posterior portion, or, in rare instances, there may be only a cleft in the uvula or velum pendulum palati. It is almost invariably congenital, and is not caused so much by a deficiency in the blastodermic cells which enter into the formation of the bones of the roof of the mouth and the floor of the nose, as by the spreading apart of the two superior maxillæ during the formative period.

The rare cases of acquired cleft palate are due usually to syphilis or to non-specific necrosis of the hard palate.

An illustration of unilateral cleft of the palate is shown in Fig. 394, while a complete bilateral cleft is shown in Fig. 395. In the latter figure it will be observed that the intermaxillary bone, that portion of the alveolar arch from which the four upper incisor teeth normally protrude, is attached to the vomer, and is

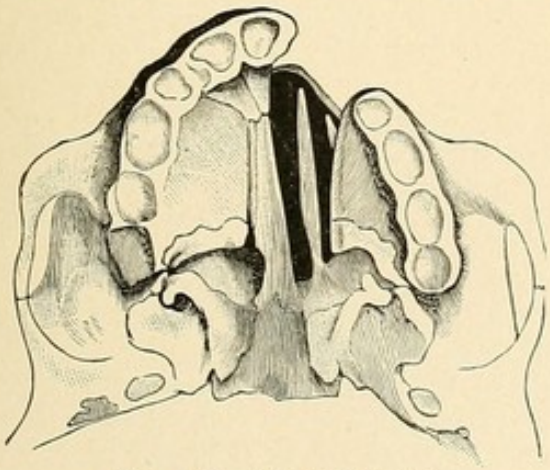

FIG. 394.—(After Koenig.)

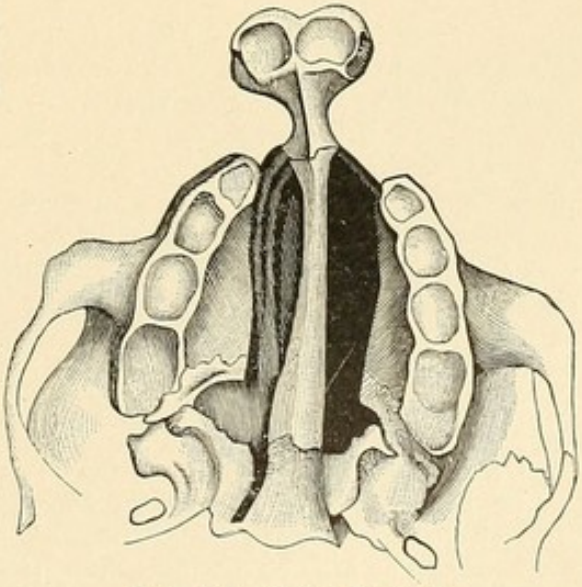

FIG. 395.—(After Koenig.)

projected far beyond the normal contour of the arch, while, in the preceding figure, the intermaxillary bone is attached to the alveolar arch on one side, being deflected from the median line toward that side, while, as is the rule in practically all these cases, the fissure is exaggerated by a deflection outward of both of the superior maxillæ. The same condition is shown in Fig. 396, where the vomer is seen to occupy its proper place in the median line, while each alveolus is abnormally divergent. A careful study of these abnormalities must convince the operator that no procedure intended to correct the deformity in the lip and nostril (for the ala nasi is always involved in these displacements) which does not take into consideration the necessity for a more or less perfect reconstruction of the bony framework, can give a satisfactory result.

In the newly born with cleft palate, it will be noticed that pressure of the lower jaw upward tends to increase the space between the already separated maxillæ, while even light pressure with the thumb and finger upon the cheeks will partially or completely close the fissure. From this it is evident that the proper time to commence the treatment of this deformity is immediately after birth, and no operation upon the lips or nose should be undertaken until the best possible correction of the deformity of the bones has been made.

In bilateral cleft (Fig. 395), the first step of importance is to bring the projecting intermaxillary bone back into its normal place in the alveolar arch. This

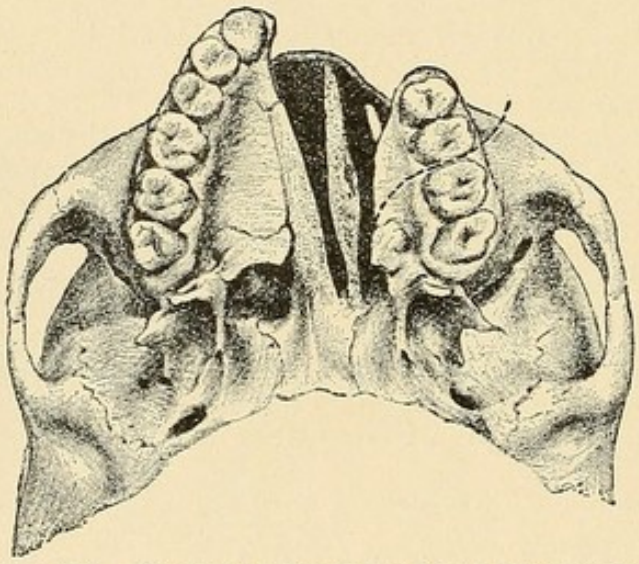

Fig. 396.—Showing at dotted line where the alveolar process is divided prior to advancement.

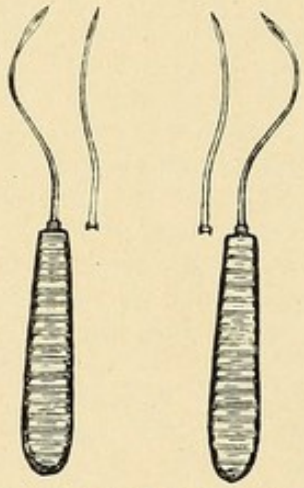

Fig. 397.—Brophy's strong needles used in the introduction of silver tension sutures through the maxillary bones.

may be done in very young infants by pressure with the thumb directly backward, the force employed crushing the vomer, or it may be necessary, with strong scissors, to cut the lower thickened portion of this bone, permitting it to overlap as the prominence is pushed back into position. It is not advisable to cut out a triangular section. Once restored to its normal position, it should be held in place by the proper insertion of silver wire sutures.

Lateral compression to approximate the two separated superior maxillæ may in many instances be continued until complete union occurs; while in others, especially in cases that have not been operated upon early in life, it will be found that if lateral compression be continued until the fissure is closed, the alveolus of the upper jaw will not be accurately in contact with the lower. The operator must guard against this error, and while a slight absence of alignment may be permissible, it should not be too great. The method here recommended is that practiced by Dr. Truman W. Brophy, which is as follows:

Beginning within a few days after birth, a lead plate should be carefully fitted to the outer contour of each alveolar arch, and through this there should be as many perforations as may be needed to accommodate the silver wire sutures. In complete cleft four sutures are usually required, while in a partial separation only two may

suffice. A strong needle (Fig. 397), threaded with silk, is forced through the soft bones, passing just above the floor of the nose, and by means of this silk thread the silver wire sutures are carried into place. The ends of the two sutures of each of the two sets are brought through the lead plates, underneath the buccal wall, and while lateral compression is made upon the superior maxillæ, the ends are tightly twisted and the edges of the fissure approximated. In patients between five and six months of age this tightening process may be repeated once or twice each week, making an additional twist upon one or both ends of the sutures. The relation of the sutures to the alveolar arch and the floor of the nose are shown in the schematic diagrams 398 and 399. The bones approximated, the operation upon the soft parts can be most successfully performed when the child is about fourteen to eighteen months old. Among the advantages given by Dr. Brophy in favor of early operation are the following:

(*a*) The surgical shock is less in an infant. (*b*) Before the bones are hardened, they may be bent or moved without fracture. (*c*) If the muscles are brought into action early, they develop instead of undergoing atrophy from disuse, and hence a good velum is secured with plenty of tissue. None of the muscles of the soft palate can be developed when the parts are not united. (*d*) As a consequence of early operation, there is much less deformity. (*e*) A most beneficial result of an early operation is that it permits a normal development of the speech function.

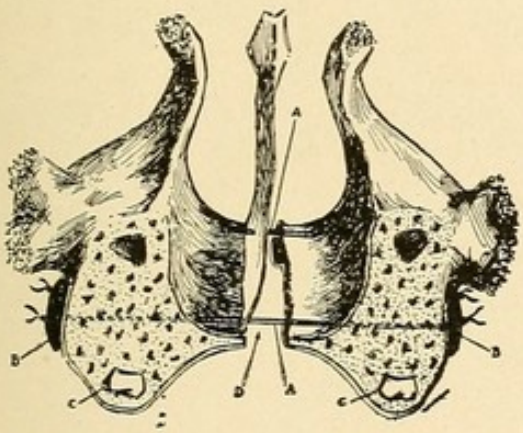

FIG. 398.—Vertical section of the superior maxillary bones of a child five weeks of age, showing congenital cleft palate. A, A, silver tension sutures; B, B, lead plates; C, C, germs of the first temporary molar teeth; D, cleft palate.

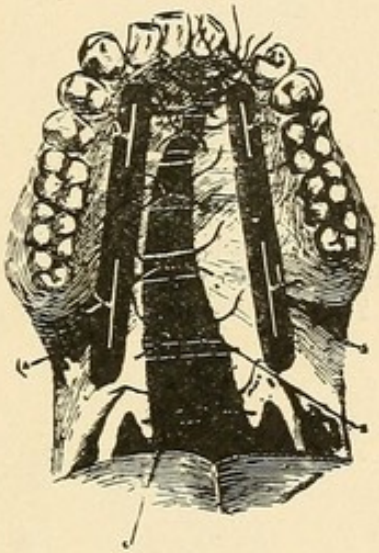

FIG. 399.—Palatal surface of adult's mouth, showing congenital cleft of the hard and soft palates, plates and sutures in position ready for tightening. (Brophy.)

In dealing with delayed cases—i. e., adults—while a perfect restoration of the palate is possible, the faulty habits of speech are so fixed that even with special treatment in phonation it is often very difficult to overcome speech defect. In all cases, however, it is important, as soon as possible, to place the patient under the special instructions and care of a speech specialist.

The operation upon the young does not differ materially from that advised for adults, which will be first described. Fig. 399 illustrates a congenital cleft of the hard and soft palates in an adult. Dr. Brophy's operation is as follows:

Beginning at the edge of the cleft on either side, the periosteum, together with its covering of mucous membrane, is lifted for the whole length of the palate well back to the alveolar arch, and the attachment of the soft parts to the posterior margins of the horizontal portion of the palate bones is divided so that the mucous membrane and the periosteum lining the roof of the mouth, together with the uvula and the muscles of the palate, are entirely loosened (Fig. 400). This is best accomplished with Brophy's periosteotomes, which instruments (Fig. 401) have different angles, suited to the different shapes of the palate.

The next step is to freshen the edges of these two curtains throughout their

entire length. In the majority of cases, if this operation is properly done, the soft parts readily come together in the middle line without undue tension, and there is no necessity for making lateral incisions. Two narrow lead plates, as shown in Fig. 402, are now fitted to each half of the loosened palate, and perforated in

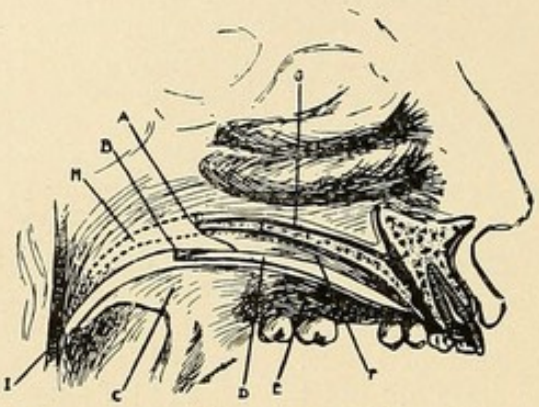

FIG. 400.—Left superior maxillary bone with associative parts, illustrating surgery of the palate; A, Posterior border of horizontal plate of left palate bone; B, velum separated from muco-periosteum of nasal surface of palate bone; C, velum separated from the hard palate, and the palate lengthened so as to restore palatal function; D, periosteum denuded from hard palate; E, palatal mucous membrane; F, bones denuded of membrane; G, nasal muco-periosteum; H, position occupied by palate before operation; I, posterior wall of the pharynx. (After Brophy.)

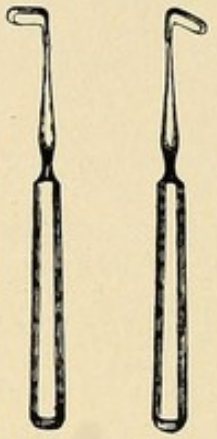

FIG. 401.—Brophy's curved periosteotomes used in the elevation of the soft tissue of the hard palate. There are a number of these instruments, varying from a right angle to the acute angle shown in the drawing.

four places to admit the passage of a permanent silver wire suture. With a proper curved needle, as shown in Fig. 403, four silk sutures are carried through the tissues, and these are to be used for the purpose of drawing the silver wire (No. 22) into place. They are temporarily left long and in place until small coaptation sutures of horsehair or gutta-percha linen are inserted. The two pairs of silver wire sutures are

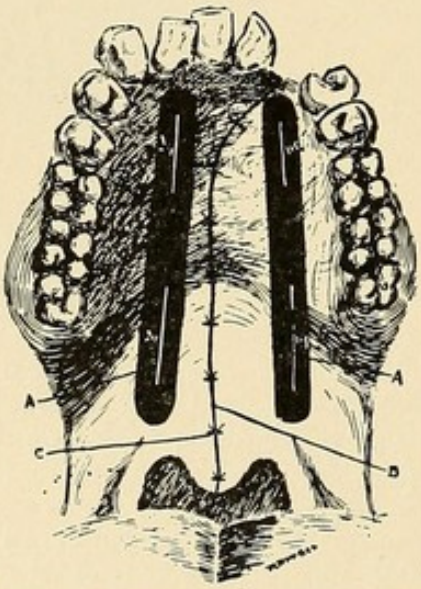

FIG. 402.—Palatal surface of adult's mouth after the sutures have been tightened, the muco-periosteum approximated, and the coaptation sutures tied; A, A, lead plates; B, closed palate; C, coaptation sutures. (Brophy.)

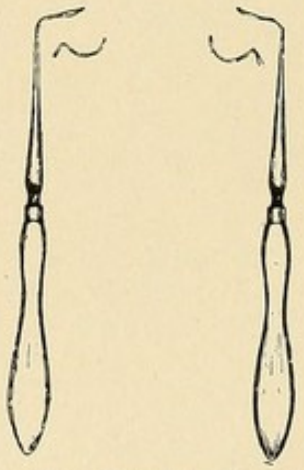

FIG. 403.—Deschamp's needles used in the introduction of the sutures. (Brophy.)

then drawn into place and twisted over the plates until the proper degree of coaptation and tension is secured.

The space left between the loosened lining membrane of the roof of the mouth and the two shelves of the hard palate will eventually be filled in by new bone, or as a result of new connective-tissue formation the united soft parts will readjust themselves in contact with the bone.

The lead plates pressing upon such a broad extent of surface prevent the cutting out of the tension sutures. They also serve as splints, rendering the palate immovable during the process of repair. The horse-hair sutures may be removed on the eighth or tenth day, and the tension sutures at the end of ten days or two weeks.

The proper after-care of these cases is very important, and no ingesta should be permitted to come in contact with the line of union.

When, after an operation, or as a result of accident, the soft palate has not a sufficient length to perform its functions, this defect may be overcome by a plastic

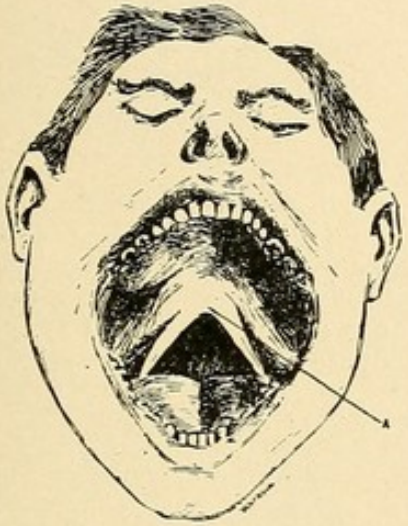

FIG. 404.—Drawing from life showing congenital defect of velum, and complete absence of azygos uvula (A). (Brophy.)

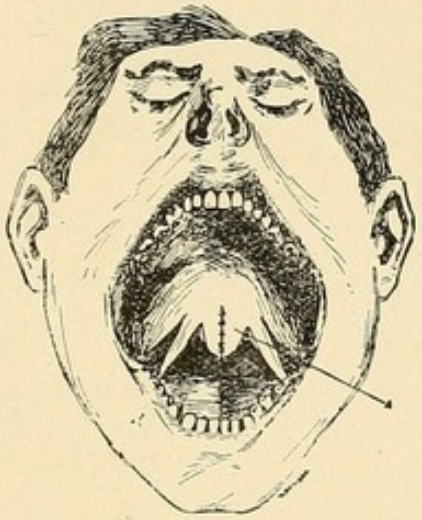

FIG. 405.—Drawing from life of the same case after operation for lengthening velum and making uvula by uniting in the center one half of the overdeveloped palato-pharyngeal muscles (A).

operation on the palato-pharyngeal muscles, as advised by Dr. Brophy. These muscles may be seen as broad, flattened bands of muscular tissue, extending from the palate downward and outward, to be inserted in the posterior part of the thyroid cartilage (Fig. 404). By utilizing two thirds of each muscle, and bringing these flaps to the median line, and uniting them by sutures, the palate may be lengthened as required (Fig. 405).

HARELIP

Harelip is a congenital defect in which the upper lip in one or two places is partially or completely divided in the embryonic tissues from which it is developed. This deformity is usually single and to one side of the median line. According to Dr. Brophy, eighty-five per cent of single harelip cases are on the left side. A cleft in the median line is a rare exception.

Harelip is complete when the fissure connects with the naris (Fig. 412), incomplete as shown in Fig. 410. It may or may not be complicated with a partial cleft of the hard palate and alveolus. Double harelip (Fig. 415) almost always occurs with cleft of the hard and soft palates. When the line of separation communicates with the nostril or approaches it, even when there is no cleft of the bone, the nostril of that side is always larger than its fellow, while the nose is drawn over in the opposite direction.

As stated in the article on cleft palate, no operation should be attempted on the lip until the alveolar arch has been reconstructed and the cleft in the palate closed. When this has been done, or when an uncomplicated harelip is present, the following methods of operation are advised:

In the simpler form shown in Fig. 407, where the nose is not involved, the nick in the vermilion border may be obliterated by making a curved incision practically parallel with the contour of the nick and about three sixteenths of an inch from it, as shown in the illustration. This incision should be made with a very narrow

knife, which is carried directly backward through the entire thickness of the lip. Bleeding may be readily controlled by having an assistant grasp the lip at the angles of the mouth between the thumb and the finger of each hand. If the lip is in any way adherent to the gum, it should be thoroughly dissected loose with the

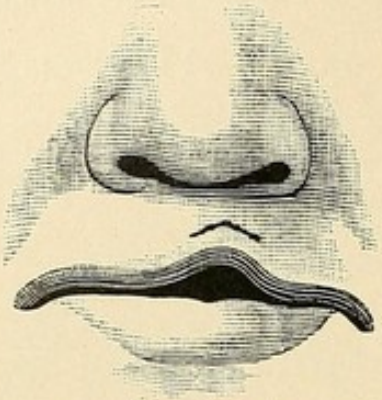

Fig. 407.

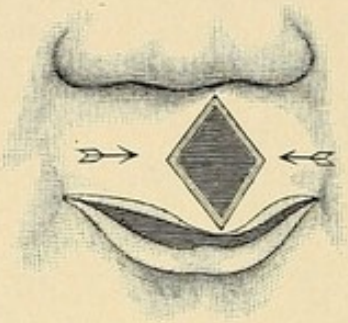

Fig. 408.—(After Koenig.)

scissors. A tenaculum is then inserted in the center of the incision, and the strip drawn down as shown in Fig. 408. The sutures are next inserted, passing squarely through the entire thickness of the lip, and about one eighth of an inch away from the margin of the incision. When there is practically no tension in these minor procedures, horsehair is preferable. The first suture should be inserted as indi-

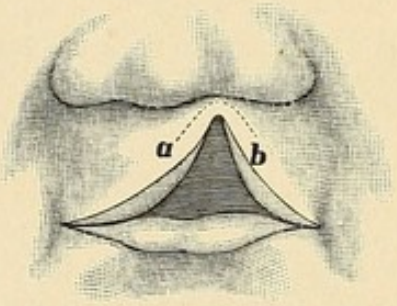

Fig. 409.—(After Nélaton, Koenig.)

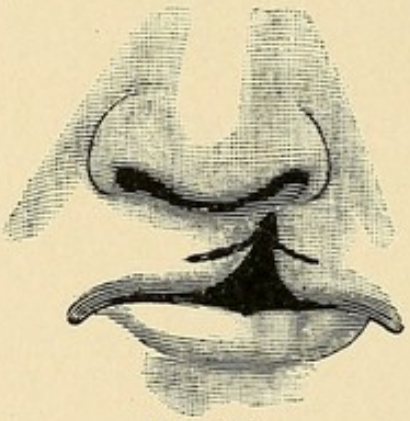

Fig. 410.

cated by the arrows in Fig. 408, while one or more may be required above and below this point. It is usually advisable to insert them with a fine needle and at intervals of about one eighth of an inch. No dressing should be applied, and every effort

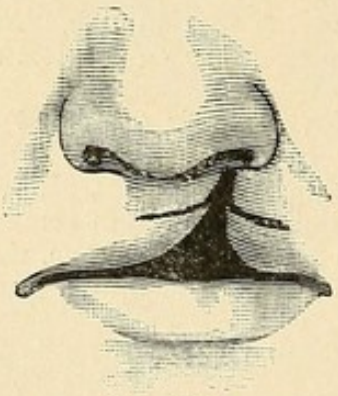

Fig. 411.

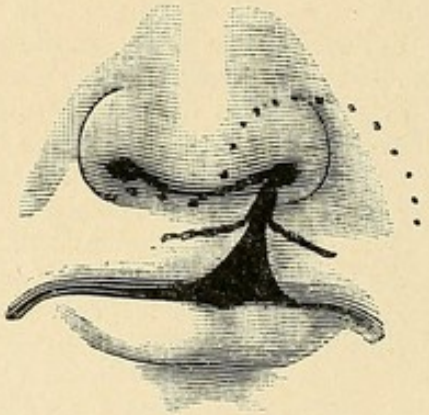

Fig. 412.

should be made to prevent infection. In the case of a child, the arms and hands should be confined within an undervest, so that they cannot disturb the sutures. The patient should be fed with a spoon, and under no circumstances should be permitted to nurse or feed from a bottle.

In the second form of single harelip (Fig. 409) practically the same operation is indicated, the incision extending somewhat further than for the preceding form. After the cut is commenced it is well to insert the tenaculum and draw down the strip, in order to see just what may be the shortest possible limit of the incision. When the fissure extends higher, as shown in Fig. 410, and especially in the complete form (Fig. 412), a more extensive operation is indicated. As the fissure approaches the nostril, or when it communicates with it, the first step in the operation is to dissect the lip freely along the lower level of the nose as high as the septum, and to the edge of the nostril of the unaffected side, while the nostril of the flattened or affected side should be freely lifted from the underlying maxilla. The operation for the form of harelip shown in Fig. 410 is indicated in the drawing. The margin of the fissure should be freshened through the entire thickness of the muco-cutaneous tissues for one third of the distance from the angle of the cleft toward the normal level of the vermilion border. From this point an incision is made outward through the entire thickness of the lip, as shown in the drawing, the flap on the long side of the lip being made longer. In making these incisions, the operator should feel his way by fitting the flaps from time to time, in order to avoid cutting farther than is necessary.

In all these procedures the new-made lip should project a little beyond the level of the vermilion border, since a certain amount of atrophy will always take place. In an operation of this character (Fig. 410) one or two sutures of gutta-percha linen will be required, while intermediate sutures of horsehair may be employed. The apposition should be very exact, and it is often necessary to insert one or two very fine horsehair sutures at the vermilion border. In Fig. 412 the dotted lines represent the extent of the separation of the lip and nostril from the maxillary bones, while the black lines indicate the distance for which the edges of the fissure should be freshened, with the incisions through the lip for the correction of the deformity. In these more difficult operations, there is very apt to be a small nick remaining in the lip, at the line of union, which will have to be closed at a subsequent operation. The method shown in Fig. 407 may be employed to correct this defect. In the operation shown in Fig. 412, the freshening should extend well up into the nostril on either side, and when the flaps have been made, the first step of importance is to introduce the sutures and shape the nostril to correspond in size with its fellow. The defect in the lip may then be closed, as in the preceding operation.



Fig. 413.—Single U-shaped harelip.

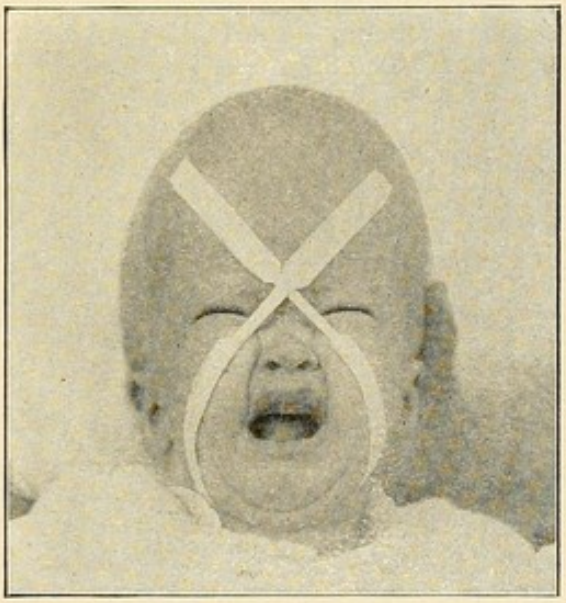

Fig. 414.—Method of applying adhesive strips to lessen tension on the sutures.

When by reason of the width of the defect as shown in Fig. 413, where the harelip is U-shaped, and in almost all cases of double harelip the tension on the stitches is so great that lateral support is needed during the process of repair. To prevent movements in the lip, and to relieve the tension, the method illustrated in Fig. 414 may be employed.

Double Harelip.—The operation for double harelip is as follows: The defect in the alveolar arch having been corrected, the edges of the central portion of the defect are pared, as indicated by the black line in Fig. 415. The edges of each lateral

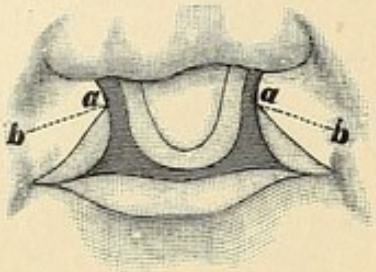

Fig. 415.—(After Koenig.)

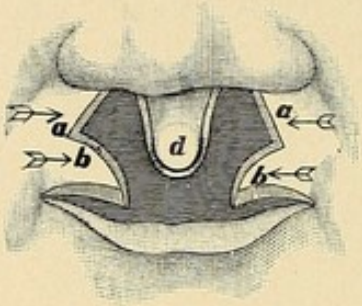

Fig. 416.—(After Koenig.)

portion of the lip from the letter *a* upward into the nostril are also thoroughly freshened, while the lateral incisions from *a* to *b* are made to extend as far as is necessary to correct the deformity. The condition of the tissues after these various freshenings and incisions is shown in Fig. 416. The sutures are then inserted first from the angle between the two arrows, each suture passing from one side of the lip to the central piece. A free dissection of the central piece, the lips, and of both nostrils from the maxillæ is also indicated.

In certain neglected cases of double harelip in adults, where there is marked deformity of the nose, in order to correct the flattening of the nostrils, it is first necessary to fill in the wide gap in the alveolar arch. The operation shown in Figs. 396 and 417 has been devised by the author and is as follows:

On account of the hardening of the bones, it will be found impossible to carry the alveolus and the intermaxillary bone over to the middle line. The inner surface of the intermaxillary bone and the opposing margin of the receding alveolus of the opposite side are freshened with the knife by removing the mucous covering. Between two of the teeth, as shown in the dotted line (Fig. 396), a chisel is introduced and the bone freely divided upward between these two teeth. A strong wire or heavy silk cord is now inserted into this fissure, and by strong traction on this the superior maxilla is fractured and carried forward, where it is wired as shown in Fig. 417. The fissure in this method is transferred from the alveolar arch in front,

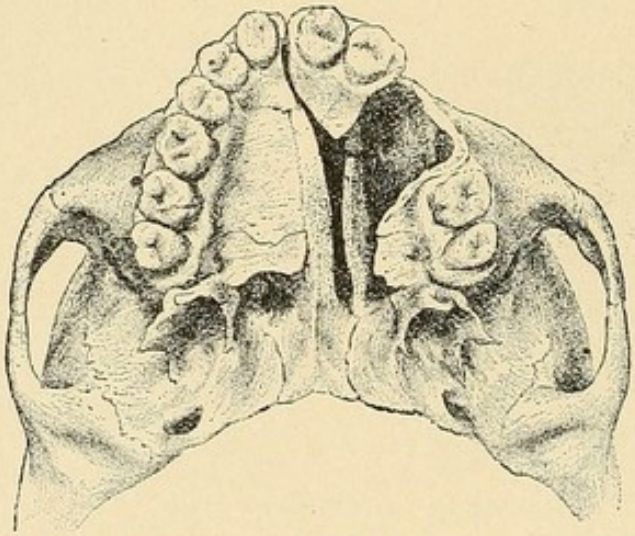

Fig. 417.—Showing the method of advancement by which the anterior alveolar arch is restored.

back within the mouth, where it is not observed. The author has performed this operation in two instances with success. Fortunately the conditions which make it necessary are rare.

The Tongue and Buccal Cavity

Wounds of the tongue bleed profusely, especially if the larger vessels along its under surface are divided. The arrest of hæmorrhage is easily and safely accomplished by introducing the index-finger back over the dorsum to the root of the tongue, and bringing the organ forward and forcibly compressing it against the symphysis menti. The tip of the organ should be turned upward, and the forceps applied at the bleeding points. In the substance of the tongue the vessels are also readily secured in the same manner. Should any difficulty arise, a silk thread may be carried around the bleeding vessel by means of a curved needle, or it may be transfixed with a tenaculum and the thread tied around the hook. The operation of tying the linguals or external carotids is elsewhere given.

Glossitis.—Inflammation of the tongue may result from the same causes and assume all the phases of inflammation common to the soft tissues in other portions of the body. It may be acute or chronic, ending in ulceration or hypertrophy. The process may begin superficially, as after the ingestion of some irritating substance, or it may commence in the deeper portions of the organ as a diffuse phlegmonous process. In some instances only one lateral half of the organ is involved.

Treatment.—Inflammation of the tongue from any cause should be closely watched, on account of the danger of asphyxia from rapid enlargement of this organ. In this emergency tracheotomy should be performed. If abscess forms, incision or puncture is demanded. Scarification may be required in rapid enlargement from engorgement of the vessels.

Hypertrophy of the tongue is both congenital and acquired. It may exist in adult life, although it is in general a condition of childhood. The enlargement is due to hypertrophy of the lymphatic plexuses of this organ and to a general hyperplasia of the connective-tissue elements. The muscular substance undergoes granular metamorphosis. The cause of this disease is not understood. The organ may become so large that it protrudes from the mouth, pushes the teeth out of their normal position, and interferes with deglutition and respiration to such an extent that its partial or complete removal becomes necessary. In a child of twelve years with congenital macroglossia tremendous hæmorrhage occurred in an effort at removal. Not only was the operation discontinued, but intravenous injection of salt solution was necessary to prevent a fatal issue. Cystic tumors of the tongue may be mistaken for hypertrophy. A diagnosis may be made by exploration with a good-sized aspirator needle.



Fig. 418.—Author's case of macroglossia.

In mild cases deligation of the lingual artery of one or both sides may be done, and this may be followed by excision of a portion of the organ. The tip may be amputated, or a triangular section may be removed from the central portion, the sides being brought together by sutures. Coagulation of the contents of the lymph and blood vessels may be done in these lesions of the tongue by the careful employment of the author's hot-water injection method.

Atrophy is a rare disease, and is due to diminution of the blood supply, or to lesions of the trophic nerves of this organ.

Cystic tumors of the tongue may be caused by closure of the outlet to any portion of the follicular apparatus (retention cysts), or less frequently by the lodgment in this organ of a parasite, the *cysticercus.*

The *diagnosis* is made positive by exploration. The *treatment* required is excision of the sac with the scissors, or the less bloody operation of opening it with the Paquelin cautery, burning the lining membrane thoroughly, and packing the cavity with gauze. The precaution should be taken to make the packing from one piece of gauze, and of securing it by a thread attached outside, in order to prevent its accidental escape backward.

Angeioma of the tongue is rare. When present, the treatment is by the hot-water injection procedure.

Abscess of the tongue should be treated by incision and drainage.

Ulcers of the tongue appear as a symptom of various conditions. They occur in syphilis with frequency. They may occur as a result of general catarrh of the pharynx and mouth, or as a result of any violence. If an ulcer exists as an expression of a dyscrasia, the treatment must be chiefly constitutional. The local treatment consists in cleanliness and the application of nitrate of silver, or other stimulating remedies.

The tongue is at times the seat of *papilloma*, *lipoma*, *fibroma*, *sarcoma*, and one or two instances of *enchondroma* in this organ are reported. *Epithelioma* is not infrequent, and is the most important of the neoplasms of this organ, not only on account of its greater frequency, but also on account of its grave character and the necessity of arriving at an early diagnosis. The late manifestations of syphilis (ulcers, gumma, fissures), ulcers of tuberculosis, and some specific ulcers, and papilloma, may be mistaken for this neoplasm.

If a patient has a syphilitic history, gumma or specific ulcer will naturally be suspected. If large doses of potassium iodide and mercury be administered for two or three weeks, the specific ulcer will respond to this remedy. If no impression is made upon it, it should be treated as malignant. As regards all other suspicious sores of this organ, it will be the wiser practice to treat them also as malignant growths, for it is a well-recognized fact that papillomatous, tuberculous, and simple ulcers of the tongue (as elsewhere), chronic in character, are capable of transformation into epithelioma. If these sores are removed early in their history, no mutilation is required, the operation is without danger, only a small portion of the organ need be sacrificed, and the focus of disease is removed before its malignant nature is declared or metastasis occurs. If an epitheliomatous ulcer exists, its character may be determined by microscopical examination, as given by Butlin.[1] If the scraping from a tuberculous, syphilitic, or simple ulcer is placed in a drop of water on a slide, pus- and blood-corpuscles, particles of food, bacteria, and a few normal or almost normal epithelial cells are observed. If the scraping from an epitheliomatous ulcer be examined, in addition to the above will be seen a great number of abnormal epithelia, varying in size and shape, some flattened scales, others round or oval, others elongated, with caudate prolongations. The cells are generally granular, and possess from two to three or more nuclei, much larger than the normal nuclei of these cells. In some instances the "swallow's-nest" arrangement may be observed.

If no ulcer is present, a section for microscopical examination may be removed from the indurated mass.

Operation.—The method of procedure must be determined by the extent of the organ to be removed. If the induration is confined to the tip, and does not extend more than one inch behind this point, the line of section should be at or near the center of the tongue. It should always be well away from the disease. An inch from the nearest induration will be safer than to allow the line of section to approach the neoplasm in order to save more of the tongue. When the lateral aspect of the anterior half is involved, the line of section need not pass at right angles to the axis of the organ, but may curve around parallel with the limit of induration at a sufficient distance from it. In this way the anterior portion of the opposite half may be, in part, preserved. If the floor of the mouth is infiltrated, it should be dissected from its attachments to the jaw, and the diseased part removed with the tongue. If the disease extends to the middle of the tongue, and involves its entire width, the organ should be removed at its base, and the floor of the mouth thoroughly cleared of all suspicious tissue. The lymphatics in the middle line below the symphysis menti, in the submaxillary region, and down the neck, should be examined and removed if metastasis has occurred.

When the floor of the mouth, together with the anterior two thirds of the organ, are involved, and metastasis is evident in the deeper lymphatics, the propriety of surgical interference may be questioned. A cure is not probable, and the operation formidable and dangerous. The removal of the ulcerating portion may be done as a palliative measure.

[1] "Diseases of the Tongue," Lea Brothers & Co., Philadelphia, 1885.

Ether and morphia combined with sequestration should be employed. It is essential for the teeth to be held widely separated by the gag, and the lips held out of the way by flat, blunt retractors.

When the tip of the tongue is to be removed the écraseur may be employed. It should be applied well posterior to the ulcer. Bleeding from the stump is controlled by forceps and silk ligatures.

When a more extensive operation is required, the following method will be advisable:

A strong silk thread should be passed through the sound tissues of the tongue near the end and intrusted to an assistant. It is to be used in lifting the organ as the dissection proceeds. The attachment along the lower jaw should first be divided with the scissors or knife and the tissues dissected up until the tongue can be lifted freely to a point at least one inch behind the induration. The écraseur loop should now be placed around the organ and the division made. Any bleeding points on the stump can be readily seized with the long-nosed narrow forceps and tied with silk ligatures. In the after-treatment no dressing is applied to the wound in the mouth.

If, for any reason, more space is required in the ablation of this organ than can be obtained through the natural orifice, one of the following procedures may be adopted:

1. *Gant's* incision through the cheek, from the angle of the mouth in the direction of the lobe of the ear as far as required (Fig. 419, *a*). This incision gives a full view of the lateral aspect of the tongue, and may be made upon both sides when the disease is bilateral and extends beyond the middle of the organ. The edges of the wound are afterwards brought together by silk sutures.

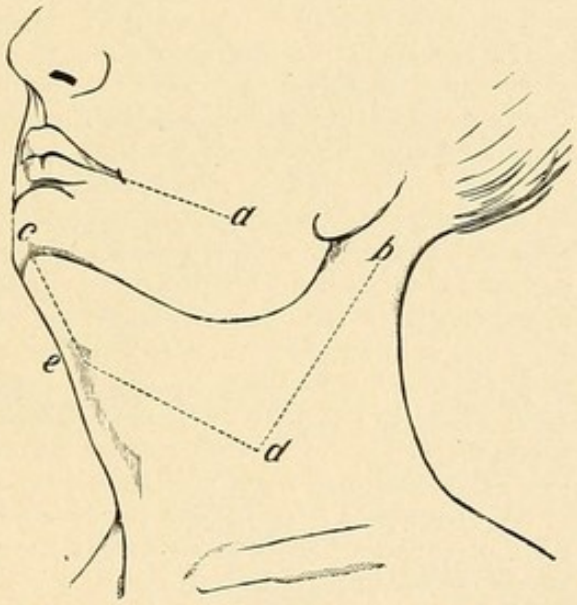

Fig. 419.—Incision of Gant and Kocher. (After Butlin.)

2. *Kocher* has lately devised an operation the incision in which is shown by the line *b d e c* (Fig. 419). A preliminary tracheotomy is done and the pharynx stuffed with a plug of sterile gauze to which a string is attached. The excision extends along the anterior border of the sterno-mastoid muscle, from the level of the lobule of the ear to the level of the hyoid bone, along this bone to near the median line, and thence to the symphysis menti. The skin and platysma are turned up on the jaw, the lingual and facial arteries and veins are tied as they are encountered, all enlarged glands are extirpated, and the muscles and floor of the mouth separated along the attachments to the lower jaw to any required extent. If the entire tongue is to be removed, the opposite lingual is also tied. Through this opening the tongue is drawn out, dissected from its anterior and lateral attachments, surrounded with the cautery loop and divided, or cut off with the écraseur or scissors.

If necessary to a thorough command of the operative field, these two incisions may be combined, and in extreme cases of metastasis employed upon both sides. Such is the rapidity of metastasis in cancer of this organ that the widest possible ablation of all the structures in the floor of the mouth and the throat should be made.

In the after-treatment the trachea tube is left in place, and the pharynx, mouth, and wound filled with gauze. The wound is dressed as required, and liquid nourishment given at each change of the dressing. Colon alimentation is an important adjuvant.

The operations in which the organ is removed through the mouth are simpler,

and require much less time in execution, but in general unless the disease is very recent (four to six weeks) the radical procedures give a better assurance of success.

The after-treatment consists in rinsing the mouth at frequent intervals with a warm solution of permanganate of potassa (gr. ss. to ℥j), anodynes to relieve pain, and generous liquid diet.

Ranula.—This name is applied to certain tumors, cystic in character, which are situated immediately beneath the anterior and lateral portions of the tongue. Ranula is usually acquired, although it may be congenital. The tumor is almost always single; occasionally there is one on either side of the organ. Commencing as a result of obstruction to the outlet of one of the subdivisions of the sublingual gland (rarely as a result of occlusion to one of the terminal ducts), it may grow, when left undisturbed, to great size, crowding the tongue out of its position, rising above the level of the teeth, and protruding through the muscles of the chin until it appears beneath the skin above the hyoid bone.

The treatment is to evacuate the contents and dissect out the sac or cause its obliteration by inflammatory adhesion. The Paquelin cautery is the best instrument to employ in removal. Etherize the patient, introduce the gag, lift the tongue upward with the forceps, protect the lips and teeth by means of flat retractors, seize the wall of the cyst with a mouse-tooth forceps, and with the platinum knife at a red heat dissect away the anterior wall. After the fluid escapes, dilate the cavity, and make a thorough digital exploration of the sac. The cautery knife should now be carried slowly back to the deepest portions, searing all sides of the cyst wall. The wound should be well packed with a single ribbon of gauze. The after-treatment consists in changing the packing every twenty-four to forty-eight hours, and at each dressing irrigating the cavity with 1–2000 sublimate solution.

If the Paquelin thermo-cautery is not convenient, seize the cyst wall with the forceps and dissect it out with curved, blunt scissors, and apply pure carbolic acid freely neutralizing the excess with alcohol. Pack the wound firmly with gauze, as above. Hæmorrhage may be controlled as directed in wounds of the tongue.

Tongue-tie.—When the frænum extends an unusual distance toward the tip of the tongue, or is so narrow that it checks the free movements of this organ, it should be divided in the following manner: Seize the tip of the tongue with a dry towel, carry it upward so as to put the bridle on the stretch, and, with a curved scissors, divide the frænum from one eighth to one quarter of an inch nearer to the floor of the mouth than to the surface of the tongue. This precaution is necessary to avoid wounding the ranine vessels. The gag may be used if required. This procedure should be made painless by cocaine infiltration. The strip of raw surface left by the cutting should be closed over by chromicized catgut sutures to prevent recurrence from adhesions.

A *congenital* defect, very rarely observed, is the adhesion of the tongue to the floor of the mouth. The adhesions should be broken up at birth and the raw surface covered as just described.

Equally rare is the bifid or snake tongue, which results from arrest of development or failure of union of the two halves from which this organ is formed. The edges should be pared, and the two halves united in the median line by sutures.

Tonsils.—*Acute tonsillitis* is of very frequent occurrence, causing, in a varying degree, pain, difficulty of deglutition, and interference with phonation, deglutition, and respiration.

The *pathology* of this affection consists in dilatation of the blood and lymph vessels, emigration of leucocytes, and proliferation of the connective tissue and other cell elements of the tonsil. The gland rapidly enlarges, producing great tension of the pillars of the fauces, and projects toward the median line, at times filling the pharynx and crowding the velum upward and backward.

Acute tonsillitis may end in resolution, the gland rapidly diminishing to its normal size, or in ulceration or suppuration (abscess), or the acute process may subside into a chronic form of inflammation, which induces permanent hypertrophy of the organ.

The local *treatment* of acute tonsillitis consists in the application of hot water as a gargle, and scarification of these organs when the tension is sufficient to produce

great pain. The internal administration of aconite tincture and quinine is highly recommended.

Abscess of the tonsil should be opened as soon as its presence is detected. The discharge of pus always brings great relief. If the symptoms lead to the suspicion of pus, exploration with the hypodermic aspirator needle should be made to determine the diagnosis. The internal carotid artery and jugular vein are well back from the tonsil, on a level with the posterior wall of the pharynx.

The object in operating early is to prevent œdema of the glottis, which may occur when the abscess is large or situated behind the body of the tonsil. A more remote danger is rupture of the abscess during sleep, and escape of the contents into the larynx.

Chronic hypertrophy of the tonsils should be treated by partial or complete excision. The presence of these enlarged organs forces the patient to breathe through the mouth, a habit which often induces a catarrhal condition of the mucous membrane lining the respiratory tract. The constant presence of infectious organisms in chronic hypertrophy of these organs is a source of grave danger. Glandular enlargements in the neck (tuberculosis), diphtheria, and other infections are apt to result, while nasopharyngeal catarrh and Eustachian-tube involvement and ostitis media are natural sequences. The follicles of the tonsils discharge a dirty, cheesy secretion, which at times becomes retained in the gland and undergoes calcification. Calculi one fourth of an inch in diameter have been removed from this organ.

Tonsillotomy.—Excision of the tonsils is an operation practically free from danger. In children who cannot control themselves, anæsthesia should be used, the gag introduced, and the tongue depressed by an assistant. The operator seizes the exposed portion of the organ with a long mouse-tooth forceps or a tenaculum, pulls it slightly toward the median line, and with a long-handled pair of scissors, curved on the flat, clips off from one third to one half the tonsil. A sponge, fixed in a holder, dipped in ice water and pressed on to the bleeding surface, will arrest the hæmorrhage.

In adults local anæsthesia may be insured by cocaine hydrochlorate, and the operation performed as above, with much greater facility, since the intelligent coöperation of the patient is of great value. If the long scissors cannot be had,

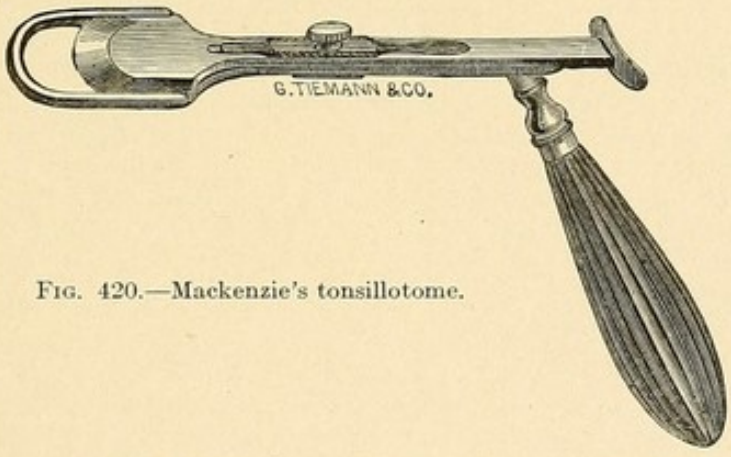

FIG. 420.—Mackenzie's tonsillotome.

a long, curved, probe-pointed bistoury may be used instead. The tonsil is lifted from its bed by a tenaculum, and the knife carried through as above.

Various tonsillotomes have been introduced, and for some cases are very useful, but for simplicity and general application the instruments above selected will answer all purposes. Among the best of the tonsillotomes is that of Mackenzie (Fig. 420), and Tiemann's instrument (Fig. 421).

The tonsil is also occasionally the seat of malignant neoplasms, as sarcoma and carcinoma, while cystic tumors, fibroma, and lymphoma are among the benign new formations which attack this gland. They require early and thorough excision in all cases.

When this organ is the seat of inoperable sarcoma the inoculations with the toxines of erysipelas or the mixed products of the bacillus prodigiosus and Fehleisen's coccus are advised.

With these procedures in all cases of inoperable tumors of the nasopharyngeal and tonsillar regions, Professor Dawbarn's complete removal of the external carotid

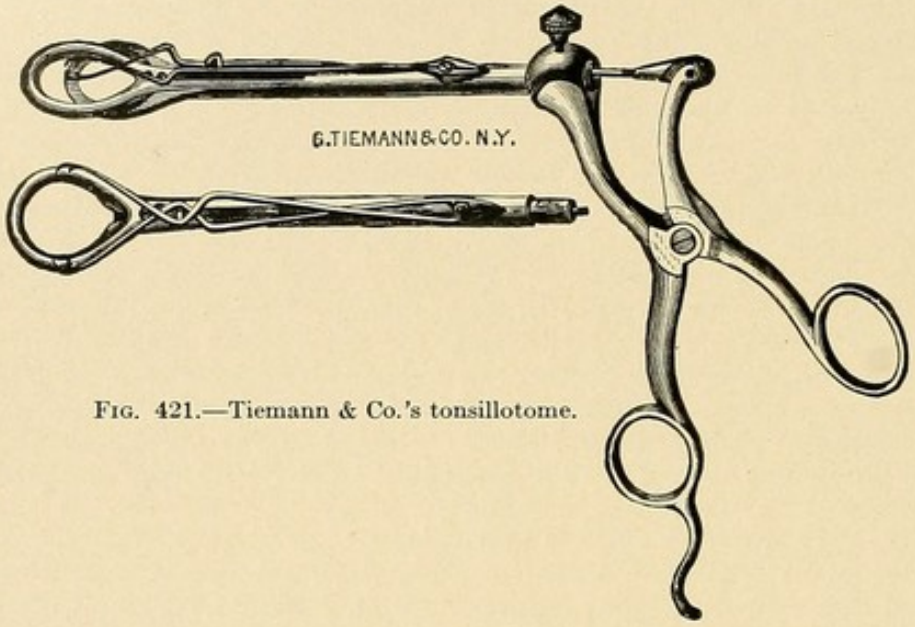

FIG. 421.—Tiemann & Co.'s tonsillotome.

artery and its branches on both sides of the neck will by starvation greatly lessen the dangers of further growth and in some instances cause shrinkage and disappearance of the neoplasm.

CHAPTER XVII

THE NECK—WOUNDS, INFECTION, TUMORS, GOÎTRE, LESIONS OF THE LARYNX, TRACHEA AND ŒSOPHAGUS, GASTROSTOMY

Wounds.—Wounds of the neck may prove rapidly fatal from hæmorrhage inducing syncope; from hæmorrhage into the trachea, causing fatal asphyxia; from the entrance of air into the veins; or from injury to the cord, at or near the medulla. Death from sepsis may occur as a more or less remote sequence of a wound in this region.

Treatment.—The immediate indications are to arrest hæmorrhage at once, and prevent asphyxia, or the admission of air into the veins. Hæmorrhage should be controlled by pressure directly in the wound, until the injured vessels can be secured by the ligature. The entrance of air into the veins must be carefully prevented, by constant pressure on the cardiac side of the lesion, until the forceps have been successfully applied to the bleeding point.

When the wound is *incised* or *lacerated*, and is above the hyoid bone and has severed the hyoid muscles, in addition to the prevention of hæmorrhage into the larynx the tongue must be drawn forward, for when these muscles are divided it falls back upon the glottis, and may occlude the larynx. If the trachea is opened, the edges of the wound should be held apart with tenacula, the head dropped over the end of a table, any clots removed, and artificial respiration practiced by Sylvester's method. When the pneumogastric, hypoglossal, or other important nerves have been divided, the ends should be brought together by suture. It is also necessary to unite the ends of divided muscles. An incised wound of the œsophagus should be closed immediately. If infection has occurred it should be left open and kept thoroughly cleansed. The patient should be nourished by colon alimentation. Lacerated wounds of this tube should be allowed to close by granulation. Difficulty in deglutition follows severe wounds of the throat, not infrequently necessitating the introduction of liquid food through the œsophageal tube, or feeding by the rectum.

Punctured wounds of the neck should be dressed antiseptically, and compression employed to arrest hæmorrhage. If this does not succeed, the ligature should be applied.

Gunshot wounds should be treated in practically the same manner. Missiles of small caliber deeply lodged should be left alone, since they usually become encapsuled and remain harmless. When superficial and readily detected, they should be extracted by the forceps. In the effort to locate a bullet the X-ray should be the chief reliance. Unless infection has taken place, probing is rarely if ever indicated. Gunshot wounds traversing the outer lateral and superficial posterior regions of the neck are not, as a rule, dangerous. If the vertebral column is involved, the prognosis becomes grave. A missile traversing the tissues of the neck laterally, and in front of the vertebral column, is apt to inflict fatal injury.

Abscess.—Abscess of the neck occurs most frequently in children. It is met with in infective adenitis, or periadenitis, tonsillitis, and in caries of the upper cervical vertebræ, or base of the skull (retro-pharyngeal abscess). Collections of pus in the upper cervical regions, and in the superficial portions of the root of the neck, tend to become encapsuled, or may open ultimately through the integument. Retro-pharyngeal abscess, if left alone, not infrequently travels downward along the deep fascia of the neck, and may open into the mediastinum.

The *diagnosis* of abscess in the neck, from the various tumors which are found in this region, depends upon the febrile movement present in abscess, the acute and persistent character of the pain, and fluctuation. The value of exploration, with an aspirator needle large enough to carry pus, should not be lost sight of in the effort to arrive at a positive diagnosis.

The *treatment* is evacuation, either by the method of aspiration and hyperdistention already given, or by puncture or incision, and free drainage. When the abscess is situated in a portion of the neck rich in vessels, it should be opened by cutting carefully down upon it, so that any hæmorrhage encountered may be immediately and readily controlled. If a puncture is determined upon, the knife should be introduced in the part farthest from the vessels, and along the aspirator or exploring needle as a guide. As soon as the sac is entered by the instrument it is withdrawn and a dull-pointed dressing forceps, tightly closed, is carried into the abscess, when, by forcible separation of the jaws, the puncture is enlarged.

The finger may now be introduced, or, if this cannot be done, the forceps or probe will indicate the size and most dependent portion of the sac. If the first opening has not been made at the lowest part of the abscess, or is not so situated that thorough drainage is secured, it should be enlarged so as to extend this far, or a counter-opening made by boring through with the forceps until the skin is distended over the point of the instrument, when it can be safely incised. Drainage should be maintained, and the cavity irrigated with 1–3000 sublimate solution.

The *diagnosis* of retro-pharyngeal abscess depends upon the following symptoms: Pain, a feeling of soreness and stiffness in the neck, swelling, with protrusion of the posterior wall of the pharynx if the disease is high up, interference with deglutition and respiration. In the earlier stages all of these symptoms will not be present, but as soon as this dangerous condition is suspected an effort should be made to locate the abscess by palpation and aspiration.

In evacuating the pus an incision should be made in the pharynx, as near the median line as possible. When a large quantity of fluid is present the head should be inclined downward as the incision is made, so that the contents of the abscess may not gravitate into the larynx. This danger may be obviated by partially emptying the sac by the aspirator before the incision is made. When the sac extends low down the neck it should be entered and drained from below. Deep retro-pharyngeal abscess may be reached, as a rule, by the incision and dissection laid down in the operation of *œsophagotomy*.

Phlegmon of the neck demands free incision in all cases, when such incision does not encroach upon the important organs of this region.

Infection of the superficial cervical glands is easily recognized, and the treatment by incision and drainage comparatively easy. Involvement of the deeper lymphatics or of the glands in general is often rapidly overwhelming. In individuals of low resistance the infecting organisms entering from the buccal or naso-pharyngeal cavities rapidly pass from the gland substance and carry widespread infection into the tissues of the neck. (*Ludwig's Angina.*)

The prognosis is unfavorable. The treatment demands multiple incision to relieve tension and the active improvement of the patient's nutrition.

Tumors of the Neck—Solid and Cystic—Lymphoma.—Pathological changes in the lymphatics of the neck account for the large majority of swellings in this region. Lymphoma of the neck may be solid or cystic, benign or malignant.

Tumors of the cervical glands may comprise simple lymphoma, the result of hypertrophy and hyperplasia; tubercular lymphoma, lympho-sarcoma, and lymphangiectasis.

Tubercular lymphoma occurs most frequently in the submaxillary and upper carotid triangle, and next in order of frequency along the line of the great vessels beneath the mastoideus, and lastly in the subclavian region. In some instances these tumors attain enormous proportions, filling in the neck to the level of the lower jaw and clavicle, and, if not removed, produce annoying pressure upon the respiratory apparatus or the œsophagus. They should be removed by operation at the earliest possible moment if a cure is to be effected. When left until they are of considerable size and numerous the prognosis, even after thorough operation, is

unfavorable, since the infection in these cases will have passed already into the mediastinal and bronchial glands.

Excision is not indicated in the rare cases of lymphoma of the neck known as Billroth's disease. The local injection and internal administration of Fowler's solution, the details of which are given elsewhere, is highly recommended. (See Sarcoma.)

Fatty tumors are apt to occur upon the posterior aspect of the neck, and occasionally in the clavicular region. They are comparatively rare in the anterior and upper triangles.

Cystic Tumors.—Cysts of the neck are congenital and acquired.

Congenital cysts are rare. The form most frequently observed is that already mentioned as a dilatation and hypertrophy of the lymphatic vessels (lymphangiectasis). They are usually multilocular, and may extend deeply and, at times, assume enormous proportions.

Occasionally the *carotid body*, a small glandlike organ, made up of small lobular collections of cells [1] without definite arrangement, enclosed in a fibrous capsule and located at or near the angle of bifurcation of the common carotid artery undergoes hypertrophy. It becomes formidable by reason of the involvement in its substance of the carotid and its primitive divisions. It grows slowly, and is not painful until it causes pressure upon contiguous nerves.

The diagnosis depends chiefly upon the location of the neoplasm, which is movable laterally but not vertically. It is lifted by the pulsation in the artery, but is of itself non-expansile.

Branchial cysts and *fistulæ* are congenital and result from the failure of closure in a portion of one or more of the branchial clefts, most commonly the third, occasionally the fourth.[2] These fistulæ traverse the tissues of the neck, open into the pharynx, and becoming infected discharge externally a varying quantity of slightly purulent fluid.

They may be cured by extirpation, but it is often difficult to trace the tract to its deeper opening. The careful injection of very hot water would tend to destroy the lining secretory membrane. The author has employed this method successfully in old sinuses elsewhere which were otherwise incurable.

The Thyroid Body—Goître

The abnormal conditions of the thyroid body which bring this organ within the province of surgery are (1) traumatism, (2) infection, (3) hypertrophy, (4) neoplasm, (5) functional disturbance.

Normally the thyroid is richly supplied with blood vessels, and in any form of hypertrophy and in almost all functional disturbances its vascularity is increased. In most of these pathological changes the plexuses of veins are not only more distended and tortuous, but their walls become abnormally friable. In all operative procedures this peculiarity of the thyroid should be borne in mind in the selection of the anæsthetic. Ether or chloroform narcosis always increases the engorgement of the veins of the neck, and with these the vessels become more than ordinarily turgid, and necessitating clamping and dividing between the forceps, with immediate application of the ligature.

In order to lessen this blood pressure, general narcosis should as far as possible be avoided, relying, as demonstrated by Kocher in several thousand operations, upon the anæsthetic effect of cocaine or quinia and urea infiltration combined with the hypodermic use of morphia. It may be advisable in certain cases to add adrenalin (1–1000 or 1–2000) to the cocaine infiltration, and should temporary general narcosis become necessary nitrous-oxide gas with oxygen or the smallest possible quantity of chloroform or ether with oxygen should be employed. To these precautionary measures may be added the elevation of the patient's head

[1] J. Chalmers Da Costa, "Annals of Surgery," 1906; W. W. Keen and J. Funke in the "Journal of the American Medical Association," vol. xlvii; report twenty-nine cases of this body. It was first described by Marchand in 1891.

[2] M. J. Cheever, "Annals of Surgery," June, 1906.

(reversed Trendelenburg) or Dawbarn's sequestration method, which will be found a most valuable adjunct in diminishing blood pressure in the operative field.

Wounds of the thyroid may be contused, incised, punctured, or gunshot. *Contused* wounds rarely cause injury sufficient to demand surgical intervention. Should hematoma occur it should be left undisturbed unless compression and continued bleeding necessitates incision, turning out the clot and the ligature. *Incised* wounds are mostly suicidal, and require the immediate arrest of hæmorrhage, with disinfection. *Infection* of the thyroid body occurs occasionally in connection with general infection of the anterior portion of the neck, in rare instances by metastasis in typhoid fever and other general septic processes. The indications are to drain at once any septic focus. The thyroid is richly supplied with lymphatics which act as ducts to its secretory apparatus and are capable of rapidly conveying toxic material into the circulation. By reason of the peculiar arrangement of the capsule which surrounds the œsophagus and trachea, a sudden swelling of this organ may cause dangerous compression. Closely related to the four thyroid arteries which supply this body are some important structures, namely, the recurrent laryngeal nerves and the parathyroid bodies. The recurrent laryngeal nerve on the right side is in close relation to the inferior thyroid artery, while on the left it is somewhat more deeply seated.

The parathyroid bodies, usually four in number, are situated posteriorly upon or just within the capsule in close relation to the thyroid arteries as they break up into smaller branches to penetrate the gland substance (Fig. 422). It is of very great importance that these bodies be not only not removed, but that they be not roughly handled or damaged by surgical traumatism. By keeping well within the capsule at the lower and upper posterior portions of this organ they may be avoided. The upper one is usually at the side of the larynx and œsophagus, while the lower one may be seen just below the inferior thyroid artery. They are, however, subject to variation in number as well as location, and while most frequently situated behind the capsule, they may be enclosed within it, in which case even with proper care they may not escape removal or injury. According to S. P. Beebe, the parathyroids and the thyroid body are different in their histological structure, and entirely different in their functions. Complete removal of the thyroid causes cachexia, which may in large part be relieved by the administration of thyroid substance, while removal of the parathyroids, if complete, is followed by acute fatal tetany.[1] In sixteen cases examined by MacCallum the cells of all varieties found in the normal gland were seen in these in the usual proportions, showing that they were not changed by the diseased condition of the thyroid body.

Hypertrophies of the thyroid may be clinically divided into simple, solid, semisolid, and cystic. (The variety known as exophthalmic goître is not included here, but will be considered with functional lesions of this organ.)

Simple goître is a form which occurs in young adults, almost always in females, coming on usually about the sixteenth or eighteenth year, seemingly associated with the menstrual function, enlarging at times and diminishing at others, and continuing on in this way for five to ten years, when the swelling disappears. In a certain proportion of these cases, however, the enlargement remains more or less permanent, and may ultimately require surgical intervention. This form occurs also during pregnancy in a small proportion of parturient women. Under proper dietetic and medical treatment these simple hypertrophies may be held in abeyance or cured.

In the *solid* form of goître there is a proliferation of the connective-tissue stroma at the expense of the cell elements. It grows comparatively slowly, but as the capsule becomes tense the symptoms of compression upon the trachea and recurrent laryngeals are more marked than in the larger and softer tumors. As the glandular cell elements become atrophied there are apt to develop symptoms of hypothyroidism.

[1] Transactions of the American Medical Association, 1907. According to E. H. Poole ("Annals of Surgery," October, 1907), each parathyroid consists of a mass of cells and is completely invested with a thin fibrous capsule beneath which a fine anastomosis may be seen. In size they vary from 3 to 15 mm. and in color from brown-red to reddish-yellow.

In the *semi-solid* goître there are isolated foci of connective-tissue hyperplasia with neighboring cystic expansions of the normal elements, which contain a colloid material in varying quantities.

In *cystic* goître proper there are, as a rule, from one to three large cysts, at times the whole gland being occupied by a single cavity, the liquid contents of which are considerably changed as compared to the colloid material of the semi-solid variety. The fluid, when withdrawn by aspiration for examination and

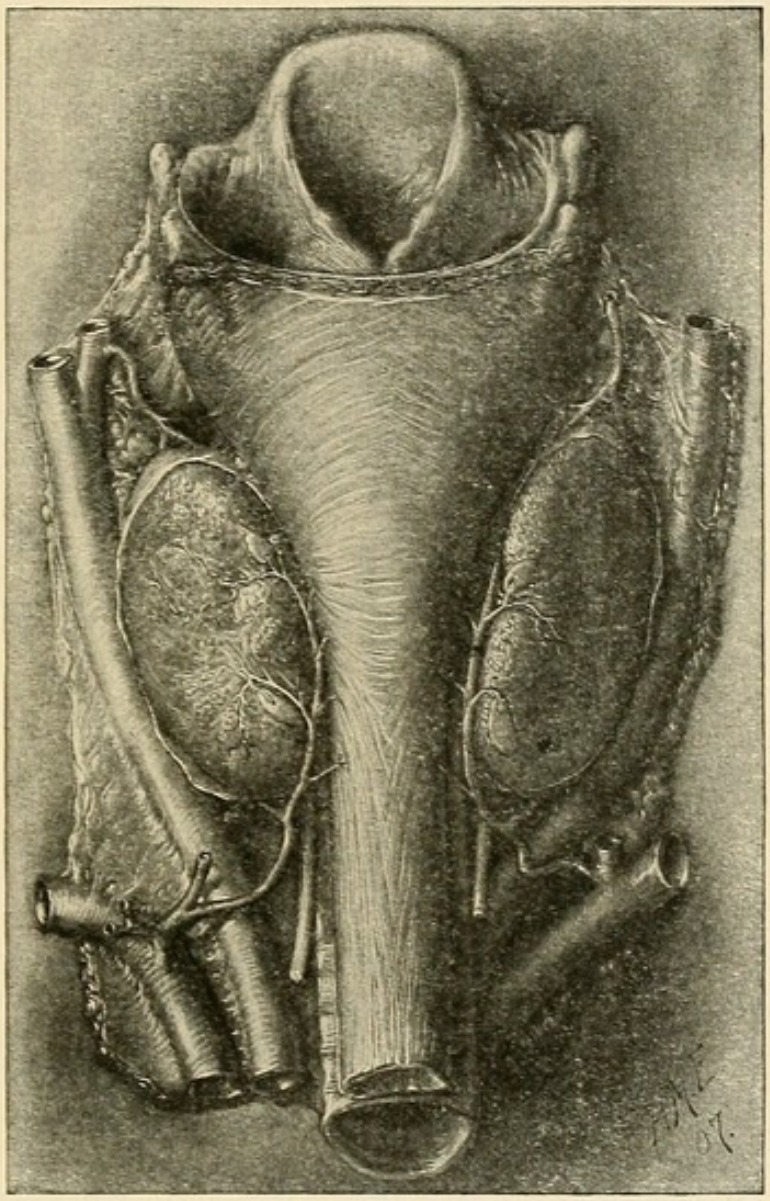

Fig. 422.—The posterior wall of the œsophagus, showing the relations of the parathyroid bodies to the thyroids. The posterior capsule of each thyroid has been removed, showing the two bean-shaped parathyroids of each thyroid. (After W. S. Halsted and H. M. Evans, "Annals of Surgery," October, 1907.)

diagnosis, is dark coffee-colored, and shows under the microscope crenated, red-blood cells in large numbers, together with leucocytes and the very large compound granular corpuscles of Glüge, and not infrequently cholesterin crystals.

Neoplasms of the thyroid body are comparatively rare, those usually met with being *sarcoma* and *carcinoma*.

Sarcoma and *carcinoma* of this organ are hard, solid tumors of rapid development, steadily increasing in size, and in their growth binding the invaded organ to the integument, muscles, and fascia of the neck. *Abscess* would give a previous history of inflammation, pain, and febrile movement. *Aneurism* of the carotid appears usually to the outer side of the thyroid region, and presents the

symptoms of expansion with the heart's systole, the aneurismal thrill and murmur, all of which symptoms disappear after pressure upon the artery on the cardiac side of the tumor. In the earlier history of thyroid tumor it is movable with the trachea in the act of deglutition.

Tubercular lymphomata are recognized by their anatomical locations, and by their slow process of development. In many instances these tumors of the glands remain quiet for a variable period, when pyogenic infection occurs, with the formation of acute abscess. They are found most frequently along the lower border of the inferior maxilla in the lower carotid region, along the under surface and posterior border of the sterno-mastoid muscle, and in the subclavian triangle.

Metastatic lymphomata secondary to epithelioma or other malignant disease of the face, will be recognized by the history of the case. Lympho-sarcoma of the neck is, in its earlier stages of development, with difficulty differentiated from simple adenoma. It grows, however, with much greater rapidity, and, by its tendency to become fixed to the surrounding tissue, suggests its malignant nature. It is most usually located along or beneath the sterno-mastoid muscle.

Functional Disturbances.—There is a condition of abnormal increase in thyroid secretion (hyperthyroidism) known as exophthalmic goître, Graves's, or Basedow's disease, which is in almost all cases accompanied by enlargement of this gland, with other symptoms, among the more prominent of which are increased rapidity in heart action, protrusion of the eyeballs, muscular tremor, and emaciation. According to Dr. W. G. MacCallum [1]: "The most characteristic change is enlargement of the thyroid, though as a rule not to great size, in some cases not larger than the normal, in a very few actually decreased in size. Usually the gland tissue is harder and more resistant than normal. The surface of the organ is somewhat nodular and rough, there being observed fine strands of fibrous tissue traversing the glandular substance, separating it into nodules. In these nodules the alveoli are smaller than normal, and are no longer lined with low cubical epithelium and filled with colloid material." This careful investigator concludes:

"On the whole, therefore, the only lesions in this disease which are palpable and constant are those of the thyroid and of the lymphoid apparatus and thymus. All of the others are so indefinite and so often completely missed that it is difficult to convince oneself that they play a primary rôle in the disease.

"From what has been said it is seen that with the appearance of definite symptoms of exophthalmic goître there is always the same change in the thyroid. In very mild and indefinite cases it may be possible to find only the beginning of this change in some part of the walls of some of the alveoli. In more severe cases in the early stages the change in the thyroid may be in foci only, while the rest remains normal, but in the more advanced cases the typical change with proliferation of the epithelium and folding of the walls of the alveoli is invariably found."

Diagnosis.—The diagnosis depends chiefly upon the enlargement and visible pulsation of the goître.

The pulse-rate is rarely below ninety, and may exceed two hundred beats to the minute (tachycardia).

Exophthalmus is entirely absent in about one third of the cases, and oftentimes not sufficiently marked to attract attention.

The character of the tremor is rapid and vibratory, noticeably differing from the slow tremor of paralysis agitans. Disturbances of digestion are the rule with marked emaciation, despite liberal feeding. Perspiration, often profuse, is a common symptom of hyperthyreosis. Barker, in the "American Medical Association Symposium," says: "An important part of the physician's function lies in the diagnosis of the indications and contra-indications for surgical interference. Though nearly all patients improve on rest and a diet which does not stimulate the thyroid (milk), sodium phosphate, and fortnightly X-ray exposures, and although occasionally a patient will get well, the majority go backward again as soon as treatment is discontinued. In the very early cases surgery is capable of curing nearly one hundred per cent. Even in the outspoken cases, seventy-five per cent can be cured by operations judiciously planned and skillfully performed, and the mor-

[1] "Journal Amer. Med. Association," June, 1907.

tality, now about five per cent, can be further reduced. In general, medicine up to this time has been utterly unable to obtain results comparable with these."

Thyroidectomy.—The lowering of blood-pressure in the neck is essential. The patient should be strapped to the table, which is well elevated at the head, or Dawbarn's sequestration method should be practiced. In removing a *solid* (fibrous) goître, it is advisable to confine the operation to a single lobe and the isthmus, the removal of which usually relieves pressure and seemingly retards or arrests the hypertrophy of the remaining lobe. The microscopical examination of the part removed should at once be made in order to determine the necessity of a complete extirpation, which should be done at once if cancer or sarcoma is discovered. The same conservative method should be applied to the semisolid form of goître, removing only the body of one side (not the isthmus unless seriously involved), or, if possible, after opening the capsule, enucleating the various cysts which may be most superficial, in this way not endangering the parathyroids or the laryngeal nerves.

In *cystic* goître a cure may be effected by drainage without resorting to the more serious operation of complete extirpation. These drainage operations are

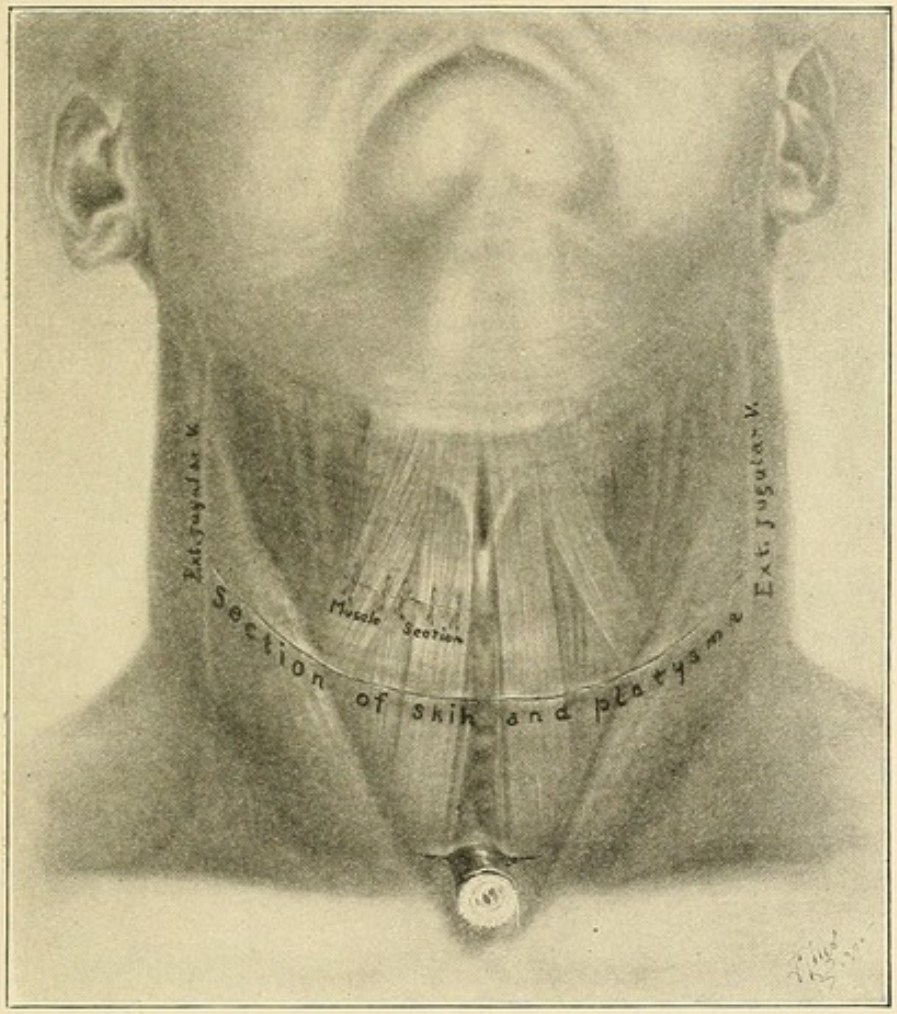

FIG. 423.—Kocher's collar incision dividing the skin and platysma myoides. When necessary to divide the sterno-hyoid and sterno thyroid muscles note the division on a higher plane and the short cigarette or catgut bundle-drain at the interclavicular notch. (After C. H. Mayo, "Journal of the American Medical Association," January 26, 1907.)

done under careful antisepsis, introducing one or more soft-rubber tubes, the number dependent upon the size and number of cysts to be drained (in my experience never more than two) and irrigating daily with hot salt solution. A mild infection occurred in several of the author's cases toward the latter part of the treatment, but produced no discomfort or septicæmia. In very large cysts where, on account of long-endured pressure with cachexia, the patient's resistance is

low, this operation is preferable to extirpation, which, if necessary, can be done later with better prospects of success. For complete and for practically all partial extirpations the transverse or "collar" incision of Kocher is advised. This incision should be slightly crescentic in shape, as it crosses the neck over the middle of the thyroid body, having a downward curve about parallel with the crease below the chin (Fig. 423). When the dissection is to be unilateral, it need only extend as far beyond the median line as is necessary to give *ample room*, which is essential to satisfactory work upon this vascular organ. The platysma myoides should be incised with and included in the skin flaps reflected up and down as far as may be required. It is best not to divide the hyoid muscles which cross the operative field when the organ can be properly exposed by retraction, but in cases of great enlargement they should be divided an inch or more higher than the incision through the skin. When the gland is exposed the capsule should be carefully differentiated from the overlying layers of fascia and opened on its lateral aspect (Fig. 424). If the disease is not malignant it may easily be stripped from the body, either with the curved blunt scissors or wiped off with a gauze swab. All blood vessels encountered should be clamped at two points

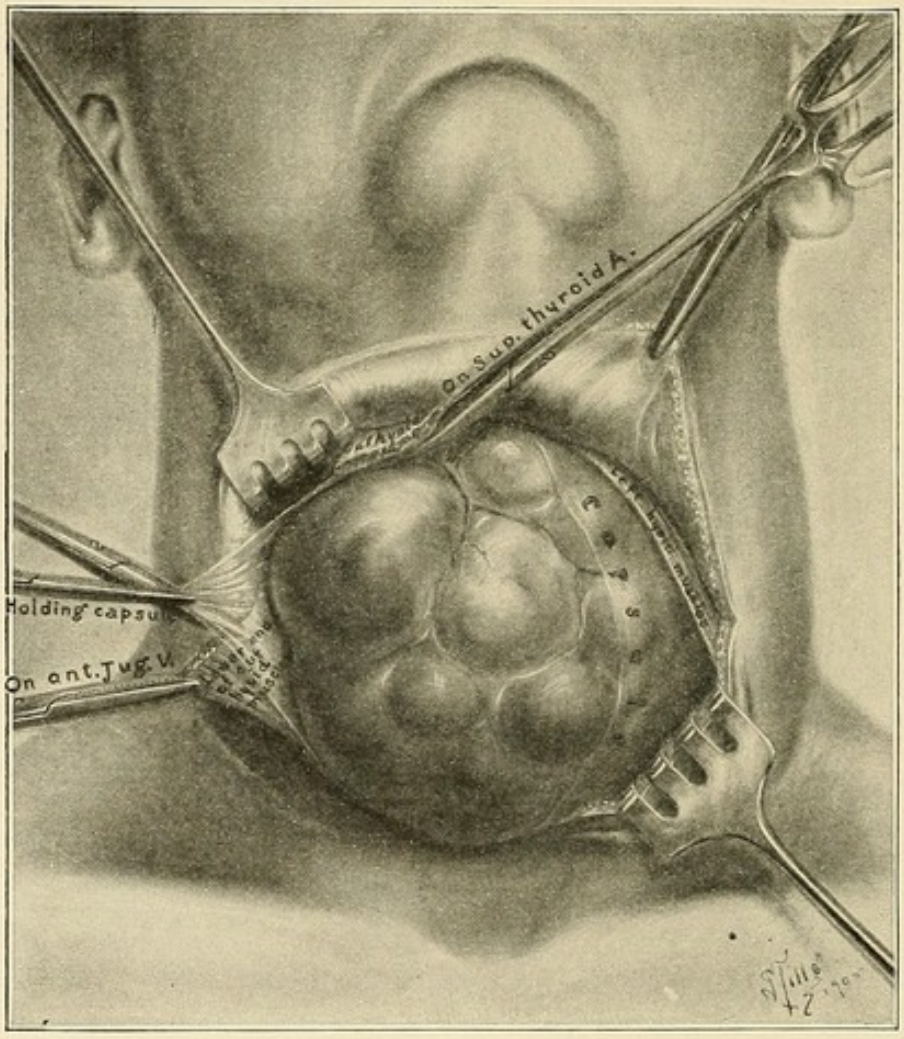

FIG. 424.—The capsule opened on its lateral aspect, exposing the thyroid body and the superior thyroid artery. (After C. H. Mayo, "Journal of the American Medical Association," January 26, 1907.)

with forceps, divided, and tied as the operation proceeds. On account of the structures to be avoided it is advisable to apply all forceps parallel with the axis of the trachea. By working well in behind the lobe to be removed and lifting it toward the middle line, the thyroid vessels as they break up to be distributed to the gland above and below can be seen, and closely associated with these, usually behind the capsule, are the parathyroids. Moreover, by hugging the capsule closely in the

lower quadrant (Fig. 425) the recurrent laryngeal nerve need not be seen. In order to prevent post-operative oozing a catgut ligature should be tied around the isthmus before separating it from the extirpated lobe. In closing the wound the muscles should be carefully reunited with ten-day catgut, and a drainage puncture made in the middle line at the lowest portion of the cup-shaped cavity formed

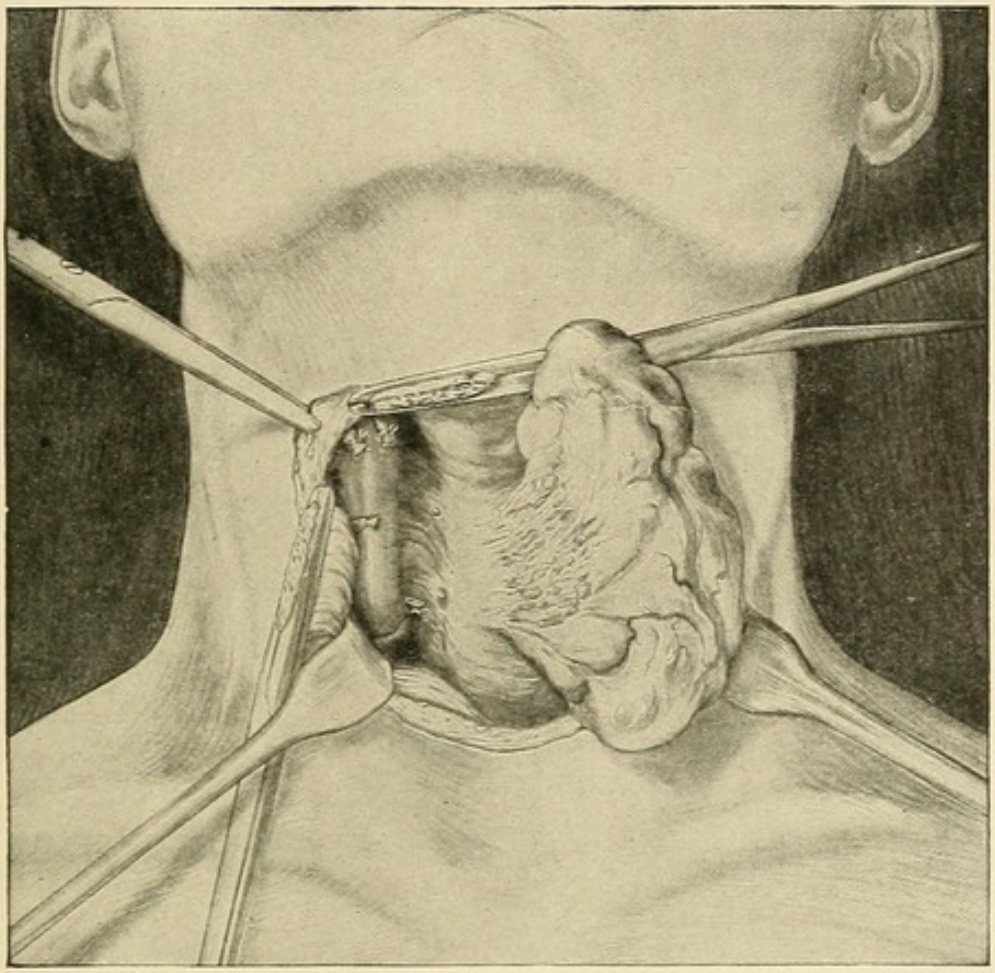

Fig. 425.—The thyroid lifted and reflected toward the median line in order to lessen hæmorrhage. Note the posterior layer of the capsule undisturbed, thus minimizing the danger of injury to the parathyroids and the recurrent laryngeal nerve. (After C. H. Mayo, "Surgery, Gynecology, and Obstetrics," July, 1907.)

by turning down the inferior flap (Fig. 423). A ten-day catgut bundle drain should be employed.

In *fibrous*, and in those forms of *semisolid* goître, where the enlargement seems chiefly upon one side and involves a very considerable portion of the gland, the operation just described should be performed, but so important is the function of the thyroid body that when the cysts are few in number, and form only a small portion of the tumor and are accessible, it is advisable to attempt the separate removal of these cysts in order to leave as much of the functionating organ as possible. This may at times be accomplished with insignificant bleeding which can be controlled by the use of adrenalin solution, and by the method of suture with catgut, as shown in Fig. 426.

In *cystic* goître, where there is one large, or perhaps two or three smaller separate cavities filled with the coffee-colored material common to this form of thyroid tumor, extirpation should not be attempted until a careful and thorough effort has been made to obliterate the cysts by drainage. In six cases the author has followed this method without an accident and with a satisfactory result in each instance. The rubber-tube drainage was made from the lowest point, as determined by careful aspiration. Irrigations with hot salt solution should be used once or twice every day.

On account of the low resistance of individuals affected with Basedow's or Graves' disease, even greater precautions in treatment are essential than for other lesions of the thyroid. In view of the results reported by Drs. Rogers and Beebe,[1] from the use of a specific serum, this agent in conjunction with a careful dietetic and rest treatment, should be thoroughly tried before resorting to a surgical operation.

In no department of surgery has more gratifying progress been made than in the operative treatment of lesions of the thyroid. Within the last half century it was considered a procedure so formidable as to be practically forbidden until the courage and skill of Green of Maine forced its recognition. To-day two surgeons of Switzerland, Kocher, father and son, have performed several thousand thyroidectomies with a death-rate in all cases not exceeding three per cent.

Even in *exophthalmos*, where the cachexia is well marked and the resistance is low, by thorough preparation and the exercise of proper care a successful issue

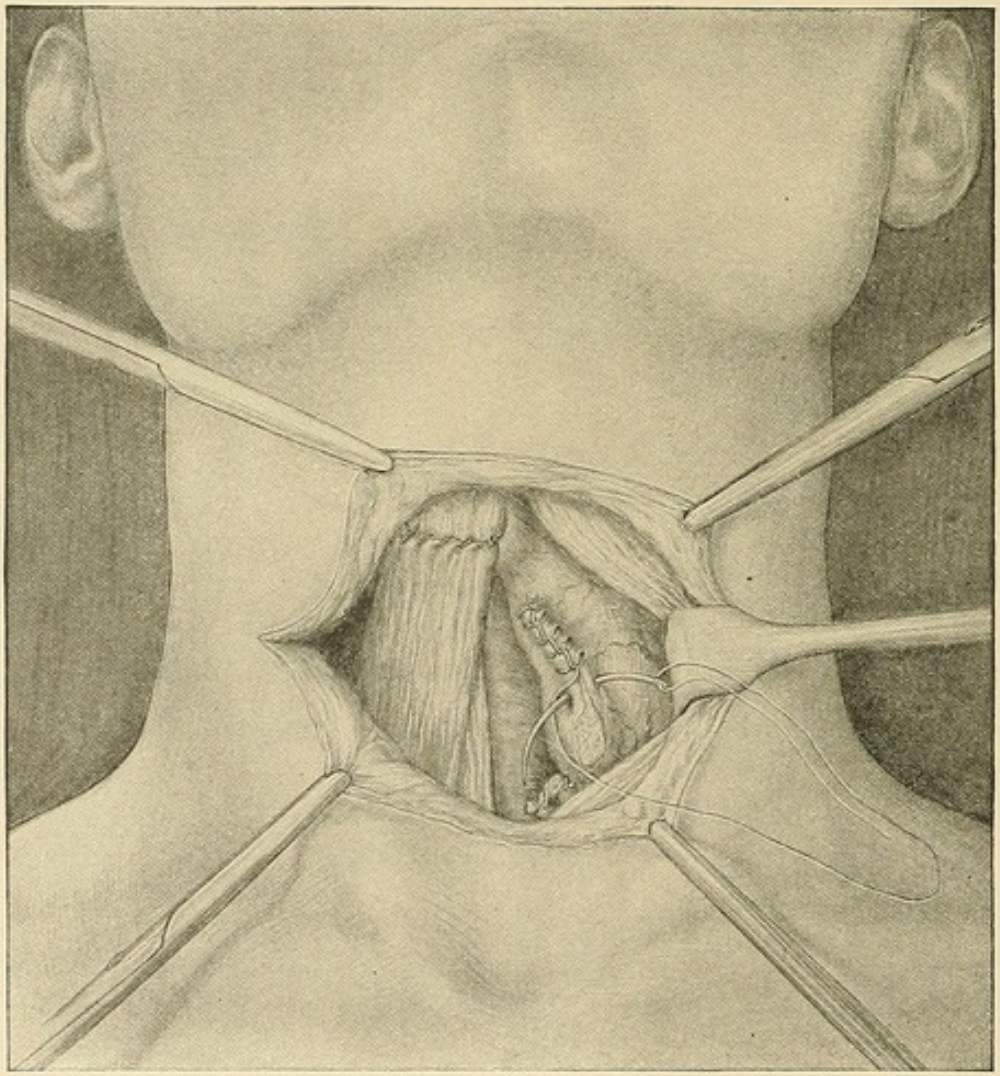

Fig. 426.—Muscle suture and interlocking suture of cut gland with ten-day chromicised catgut. (C. H. Mayo, from "Journal of Surgery, Gynecology, and Obstetrics," July, 1907.)

is the rule. Avoiding when possible even the small risk of shock from ether or chloroform narcosis, using cocaine infiltration and morphia instead, and in extreme cases resting content to cut off the circulation of a single thyroid artery, are among the conservative measures which are advised. Symptoms of diminished thyroid toxæmia will follow this lessening of the blood supply, and with the pa-

[1] J. A. Booth, "Med. Record," June 15, 1907, p. 980; "Transactions of the American Medical Association," 1907.

tient's improved condition the operation can be carried on in various sittings to a complete and safe removal of the organ. The vast majority of cases of exophthalmus taken early will not require this extreme precaution, but the necessity of great care cannot be too strongly expressed.

In all operations where the substance of the diseased thyroid is exposed, frequently repeated irrigation with hot salt solution should be made in order to

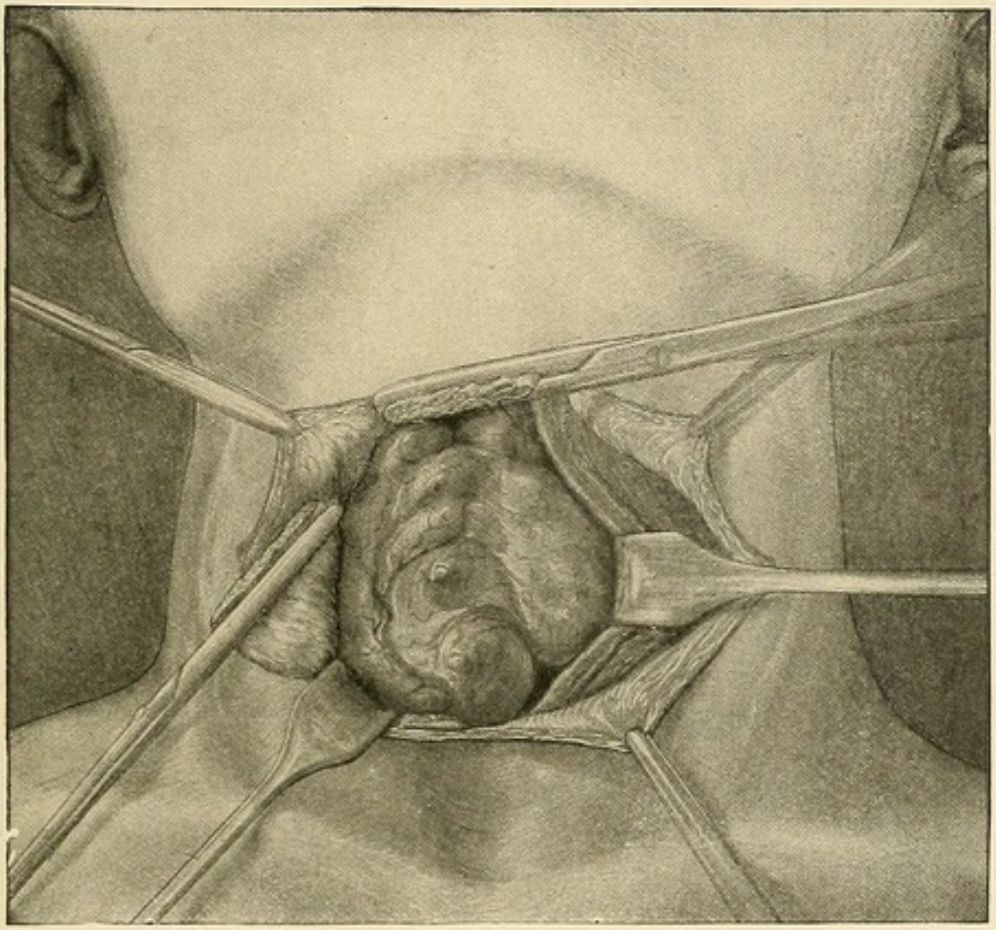

FIG. 426*a*.—Greatest exposure of thyroid with high muscle section. (C. H. Mayo, from "Journal of Surgery, Gynecology, and Obstetrics," July, 1907.)

prevent the possible absorption of an excess of thyroid secretion which may come in contact with the wound as the result of traumatism.

In the after-treatment, when all parts of the gland have been removed, the administration of thyroid extract is considered necessary in postponing the condition of myxœdema which results in many of these cases.

Hydatid cysts are occasionally met with in the thyroid. The diagnosis will be determined by aspiration, and they should be treated by incision and drainage.

THE LARYNX AND TRACHEA

The operations upon these organs in the neck are *subhyoid pharyngotomy*, *thyrotomy*, *laryngotomy*, *laryngo-tracheotomy*, *tracheotomy*, and *exsection* of the larynx or *laryngectomy*.

In the removal of large tumors situated in the laryngo-pharynx, subhyoid pharyngotomy, as advised by Dr. Walter F. Chappell,[1] may be performed. A transverse incision is made and the thyro-hyoid membrane opened, permitting the operator to pull the epiglottis forward. The tumor may now be removed, either by transfixing or tying the pedicle with strong ten-day chromicized catgut. If small and non-vascular, the electro-thermal cautery may be substituted for the ligature.

[1] "Med. Record," July 13, 1907.

As a precautionary measure, tracheotomy may be performed, and if this is not deemed necessary, every preparation should be made for its immediate performance. In closing the wound, the thyro-hyoid membrane, the various muscular layers, and the skin should be closed by separate rows of sutures.

Thyrotomy is indicated in the removal of neoplasms or foreign bodies from the larynx, which cannot be reached through the mouth by the aid of the laryngoscope and forceps or snare. The patient should be placed upon the table, with the head well depressed. Make a perpendicular incision from near the center of the hyoid bone, in the median line of the pomum Adami, as far down as the cricoid cartilage. The bleeding is thoroughly arrested, and the two wings of the thyroid cartilage divided exactly in the angle of union. This should be done with great care, in order to avoid wounding the vocal bands, which are attached on either side of the median line, in front. If at this stage of the operation a tenaculum is inserted, on either side, the alæ may be drawn apart, freely exposing the interior of the larynx. In closing the wound the cartilages are not included in the sutures, it being sufficient to bring the edges of the skin together.

In *laryngotomy* the opening is made through the crico-thyroid membrane. It is indicated in œdema of the glottis, obstruction of the larynx by new growths, foreign bodies, and exceptionally in rapid inflammatory swelling of the tonsils or pharynx, with occlusion of the larynx.

When the emergency demands it, rapid laryngotomy may be performed as follows: Make a single incision from the notch in the upper margin of the thyroid cartilage, in the median line, to the lower edge of the cricoid ring, then turn the knife edge upward and thrust the point through the crico-thyroid membrane. A hook should now be quickly inserted on either side, and the edges of the wound separated. Traction not only opens the wound in the membrane to admit the air more freely, but it also arrests the bleeding. When tenacula cannot be had, a fair substitute may be extemporized from wire, or the ordinary metal hairpin. The opening in the membrane may be enlarged by a transverse incision when necessary.

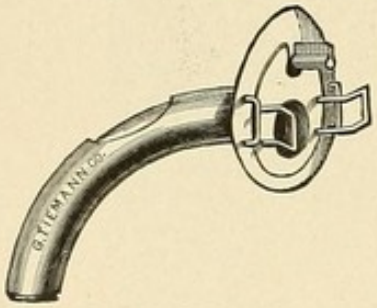

Fig. 427.—Double trachea tube, silver, plain.

When expedition is not urgent, the bleeding from the wound in the integument should be arrested before the opening into the larynx is made.

If it is necessary to keep the wound open, a silver trachea canula (Fig. 427) should be inserted. This instrument is secured by a tape tied around the neck. When it becomes obstructed, the inner canula should be withdrawn, cleansed, and reinserted, and, if necessary, the larger tube remaining in the larynx should be brushed out with a small brush or mop. When this instrument is worn it should be carefully watched, as long as any danger of its becoming obstructed exists. It may be worn indefinitely in cases of permanent laryngeal stenosis.

Laryngotomy without a Tube.—When a canula is not at hand, a needle, armed with fine, strong silk, should be passed, on either side, through the integument and cricoid membrane, brought out through the opening in the larynx, and the suture tied. It is best to employ two sutures in each side of the wound. These may be tied behind the neck, or attached to bits of adhesive plaster and fastened to the integument, so as to keep the wound open. A strip of plaster should be laid on each side of the wound, to prevent the thread from cutting into the integument.

Laryngo-tracheotomy (an operation rarely performed) consists in extending the incision of laryngotomy through the cricoid cartilage, and the upper one or two rings of the trachea.

Tracheotomy is more frequently done than either of the operations just given. The trachea may be opened (1) above the isthmus of the thyroid body, the upper three or four rings being divided; (2) the isthmus may be tied with a double ligature, divided, and the trachea opened beneath it; (3) the opening into the tube may be altogether below the isthmus.

It will rarely be found necessary to divide the isthmus. The operation above the isthmus is simpler, and should be preferred in all cases where the obstruction is in the larynx. For the removal of a foreign body lodged in the bifurcation of the trachea, or in either bronchus, the lower procedure should be adopted. This operation should also be preferred in diphtheritic croup when all other measures have failed. The results achieved with the laryngeal tube of Dr. O'Dwyer, of New York, justifies a faithful trial with this instrument before resorting to the formidable operation of tracheotomy in diphtheritic croup.[1]

High Operation.—Place the patient on the back, in such a position that the head falls well over the end of the table. If an anæsthetic is not given, one assistant should hold the extremities immovable, while a second steadies the head. The operator should stand to the patient's right, facing the light. It is important that the head be held so that the nose and symphysis menti will be directly in line with the interclavicular notch and umbilicus, for if this precaution is not taken the trachea may be displaced, an accident which might lead to great annoyance, especially in children, in whom this tube is always very small. The incision should be exactly in the median line, commencing at the center of the thyroid cartilage and extending downward one inch and a half, or more if necessary. The edges of the wound should be separated by retractors, and the incision continued down to the tube. All bleeding should be arrested by the forceps and ligature before the trachea is opened, for fear of suffocation from the entrance of blood.

In some subjects it will be found that the isthmus of the thyroid body is situated so high that an opening sufficiently long cannot be made without displacing it downward. This may be done by dividing with the curved scissors the muscular and ligamentous bands which are attached to the isthmus below, and the hyoid bone and thyroid cartilage above. This section should be made on either side of the incision, opposite the first ring of the trachea. After all bleeding has ceased, the knife should be carried into the trachea with the edge directed upward, and the two or three upper rings divided.

Low Operation.—The incision through the integument extends from the cricoid cartilage to the level of the interclavicular notch. Separate the sterno-hyoid muscles in the median line, and carry the dissection carefully down to the trachea, avoiding the isthmus of the thyroid body and the inferior thyroid vein, a branch of which is in front of this tube. The anterior jugular vein occasionally is in the median line. Any of these vessels coming within the line of incision should be secured with a double ligature before being divided. The trachea will be found deeply situated, and should be incised through four or five rings, in the same manner as advised in the preceding operation. If a trachea tube is not at hand, the operation may be completed, as advised in laryngotomy, without a tube.

Foreign Bodies in the Larynx, Trachea, and Bronchi

Foreign bodies in the respiratory tract are, in almost all instances, introduced by way of the larynx, into which they may fall by gravity or be drawn in by the suction force of the inspiratory effort. Occasionally they enter directly from without, as in stab or gunshot wounds, or may make their way in from the œsophagus by perforation or from the rupture of an aneurism or abscess. Pieces of coin, buttons, teeth, seeds, threads, pins, blow-gun darts, shot, particles of food, etc., are among the most frequent substances lodged in the air passages. A foreign body may lodge just behind the epiglottis, across the rima glottidis, in the ventricle between the true and false bands, between the vocal cords, or, passing these, it may descend into the trachea or bronchus. If it be a solid and smooth body, it will pass into the bronchus and continue to descend until the smaller diameter of the tube arrests its progress. Any substance with projecting, sharp edges, or long and pointed, as a pin or fish bone, may become lodged across the windpipe at any point.

The symptoms of a foreign body in the air passages are immediate and remote.

[1] See Chapter on Diphtheria.

Strangulation, cough, and cyanosis immediately after the escape of any substance backward from the mouth or nose, or matter which has been regurgitated from the stomach, always suggest the entrance of foreign matter into the larynx or trachea. In some cases death ensues almost instantly from asphyxia. In others the symptoms of strangulation last for a few moments and then disappear, leading the patient or attendant to believe that the foreign body has been coughed out or swallowed. The momentary cyanosis and strangulation are caused by spasm of the laryngeal muscles, induced by direct irritation from the foreign body. As soon as these relax a forcible inspiratory effort may carry the substance downward to the trachea or bronchus, or the expiratory cough may have discharged it into the mouth. In any event, the symptoms of asphyxia disappear unless the offending substance is so large that, even when sucked into the trachea, it completely occludes this tube. The remote symptoms of foreign bodies in the air passages are chiefly inflammatory. Trachitis, bronchitis, pneumonia, gangrene, and abscess may ensue. Abscess and gangrene are rare. Bronchitis is inevitable, and localized or lobar pneumonia is not infrequent.

The *diagnosis* may be determined by the X-ray or by laryngoscopic inspection, palpation (either direct or intermediate), and by auscultation, together with a due regard for the sensations experienced by the patient. Direct palpation is only possible when the substance is lodged in the larynx, since the tip of the finger cannot be carried beyond this point.

Auscultation is of great aid to diagnosis, especially when the body has passed deep into the respiratory tract. Diminution or absence of the normal vesicular murmur over one entire lung indicates the partial or complete occlusion of one primary bronchus by the foreign body. If this interference is limited to only a portion of the lung, the indication is that the body has passed into one of the subdivisions of the bronchus.

The compensatory increase of the normal vesicular respiration in the opposite lung will be proportioned to the interference with the function of the affected side. When a narrow body becomes lodged in the trachea or bronchus, its presence is indicated by a sibilant or hissing sound, heard with greatest intensity over the point of lodgment, and carried upward and downward with the expiratory or inspiratory movement.

The presence of pain persisting in a given locality points to the seat of lodgment of the foreign substance. Persistent spasm of the larynx until tolerance is acquired suggests lodgment in the ventricle of this organ.

Treatment.—The immediate indication is the prevention of fatal asphyxia, and this may require rapid laryngotomy or tracheotomy, and, in exceptional instances, the resuscitation of the patient by the method of Sylvester. As soon as this danger is obviated, the removal of the foreign body may be undertaken. It is well to remember that symptoms of asphyxia may be produced from the presence of viscid mucus adhering to the rima glottidis, causing obstruction and spasm.

When fatal asphyxia is not threatened, no immediate operation is indicated. The patient should be turned head downward and violently shaken, and at the same time made to cough or sneeze. If the substance is smooth or heavy, it may be dislodged and expelled in this manner.

If this procedure is unsuccessful, the question of operation should be considered. If the body can be located in the larynx, it can readily be removed by the operation of thyrotomy if the patient is a child, or by laryngotomy and the introduction of the little finger into the organ through the wound in the adult, pushing the offending substance upward into the pharynx. Either of these procedures is practically free from danger. When the foreign body has passed into the trachea or bronchi, the necessity for operation will depend upon its size, shape, and location. If it is small, and produces no marked disturbance of respiration, and is deeply lodged, no effort should be made to remove it, for the following reasons: When small it is not apt to inflict serious damage; tracheotomy and the introduction of instruments into the respiratory tract are not without risk; lastly, the uncertainty of finding or dislodging a small body should be taken into consideration.

When, however, the character of the foreign body is such that its presence is

a source of great danger to the patient, and it cannot be removed without operation, surgical interference is demanded. The position for the patient is the same as for tracheotomy, and this operation should be done as low down as possible. When the trachea is opened, the little finger should be carried downward to the bifurcation in the hope of locating the body, and, if discovered, it should be grasped with a pair of forceps and removed. If it is not encountered below, the upper portion of the tube should be examined in the same way. If it cannot be reached by the finger, the angular alligator forceps (Fig. 428) should be carried into the bronchial tubes, carefully regarding any arrest in the progress of the instrument.

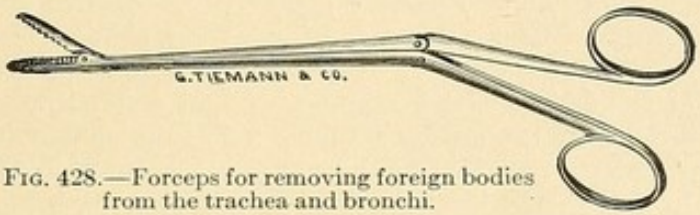

FIG. 428.—Forceps for removing foreign bodies from the trachea and bronchi.

A solid or large body may be felt and seized without great difficulty. A small, light substance may be touched without any sense of resistance to the hand of the operator. If it cannot be recognized, the point of the instrument should be carried into the bronchus in which the body is located, the jaws separated, and, while open, carried about half an inch farther in, and then closed and withdrawn in order to see if the object has been grasped. This manœuvre is repeated several times until the whole length of the bronchus has been searched. If the foreign body is not found, it will be judicious to search in the opposite bronchus, for it is possible for it to have been dislodged in the course of the exploration, and carried by the respiratory effort into the trachea and down into the other tube. If proper forceps cannot be obtained, a loop of silver wire may be used.

The exploration of the trachea should be done with great care not to inflict unnecessary violence upon the mucous membrane.

If the body is removed, the wound may be left to heal by granulation, simply closing it with adhesive strips, or, if the patient has borne the anæsthetic well, it will be better to stitch the trachea with catgut, and the edges of the wound separately with the same substance. If the object is not found, the tracheal wound should be kept open by inserting a large trachea tube, or by sewing the tracheal rings to the edges of the divided integument and keeping the wound open by tying the strings behind the neck.

When a foreign body is lodged deep in the lung and is producing dangerous inflammation of this organ, or the pleura, and is so situated that it can be reached by resection of one or more ribs, surgical interference may be entertained.

Laryngectomy, or exsection of the larynx, although a formidable operation, is, under certain conditions, justifiable. It may be partial or complete.

The conditions which justify this procedure are the invasion of this organ by malignant neoplasm, and, in rare instances, destructive chondritis, with infiltration and threatened occlusion of the respiratory tract. If, after a careful study of the case, the surgeon is convinced that there is a fair probability of relief from pain and prolongation of life by the removal of the diseased structures, greater than he would be likely to obtain by the palliative operation of tracheotomy, he is justified in advising the operation. When the tissues about the larynx are widely infiltrated with the malignant neoplasm, the operation is not justifiable.

Complete laryngectomy is performed as follows: Under chloroform narcosis an incision is made from above the hyoid bone in the median line over the *pomum Adami* and downward in the direction of the middle line of the manubrium. A transverse incision crosses this at the level of the coracoid cartilage, taking care not to wound the great vessels and important structures lying on the side of the neck. A careful dissection is made and all hæmorrhage controlled as the operation proceeds. The wound should be perfectly dry when the division of the trachea is effected. After this is exposed and dissected free from the œsophagus by the

finger, a probe-pointed, curved bistoury should be carefully inserted between the œsophagus and the trachea at the point at which the windpipe is to be divided, and when everything is ready, a quick division of the trachea is made and the dissection completed from *below* upward. In this way no bleeding can escape into the respiratory tract. By placing the patient with the head considerably lower than the feet, I have done this operation without the use of the Trendelenburg or any similar tube. In fact, this complicated apparatus is a hindrance rather than an aid to rapidity in this procedure. It is usually necessary to treat these wounds by the open method, closing only the angles of the incisions. Great after-care is essential in preventing the descent of saliva or ingested liquids into the trachea. When the operation does not of necessity demand the removal of a portion of the anterior wall of the œsophagus or that portion of the pharynx immediately below the tongue, and this is opened into the upper portion of the operative field, this part of the wound should be closed at once so that the patient may be able to swallow without the use of the stomach tube. The tube should be held in reserve in all cases for the purpose of feeding. It is always advisable to sew the integument either to the edges of the tracheal wound or to leave this projecting from the partially closed wound to prevent septic infiltration as well as to obviate the danger of emphysema.

Partial laryngectomy is performed in the same general way as the complete operation. The value of morphine as an adjuvant in securing profound narcosis with the minimum of chloroform or ether cannot be overestimated, especially in connection with this particular operation. If to this be added the tactful and judicious employment of sequestration and cocaine, there will be very little need of either of the general anæsthetics.

Neoplasms of the Larynx and Trachea.—Almost every form of new growth has been removed from the larynx. No portion of the organ is exempt. The symptoms are referable to the location of the neoplasm and to its size, and in a certain sense to its shape. Those situated upon the vocal bands are first noticed, on account of interference with the voice. A neoplasm may develop in the ventricle, and not be noticed until it encroaches upon the cords. Dyspnœa occurs earlier, when the tumor is situated upon the rima glottidis.

Cough is not a prominent symptom, for the reason that the slow and progressive development of the neoplasm gradually accustoms the larynx to its presence. Spasmodic cough does, however, occur in pedunculated growths, which are moved to and fro as the air rushes in and out of the larynx.

The *diagnosis* may be made from the symptoms detailed, but chiefly by palpation and the laryngoscope. The location is simple, but the differentiation as to the character of the growth is at times difficult. *Papillomata* are most frequently met with, and papilloma in the larynx possesses the same general properties observed in these growths in more exposed quarters. They are most commonly found upon the vocal bands. The tumor may appear in the mirror as a single wartlike fungus, or pinkish-gray tuft upon the cords or laryngeal wall, or there may be several which fill a great part of the opening. The fibroid laryngeal polypi (*fibromata*) are chiefly pyriform, pedunculated, and smooth, in location and color resembling the papillomata.

Enchondromata of the larynx, less frequently observed than the two preceding neoplasms, are developed from the cartilage proper of the larynx. They are usually seen in the vicinity of the crico-arytenoid articulation. *Cystic* tumors are rare. Occlusion of the duct of the *sacculus laryngis* will lead to the appearance of a tumor in the ventricle, between the true and false bands. Other cysts may result from simple follicular occlusion. *Telangiectasis*, or *angeioma*, is a still rarer form of laryngeal tumor. *Carcinoma* (*epithelioma*) is, unfortunately, not a rare disease of this organ. *Sarcoma* is very rarely met with. *Epithelioma* of the larynx, in common with all malignant (as well as benign) neoplasms, occurs chiefly at the upper portions of the organ.

The treatment of all forms of benign tumors of the larynx is their removal with the knife, scissors, the snare, or caustics. Removal of malignant growths, to an extent sufficient to prevent recurrence, without a total or partial laryngec-

tomy, is rarely possible. Benign growths, especially the smaller new formations, may be removed best by chromic-acid crystals directly applied at frequent sittings. A small pellet of cotton is attached to the end of the applicator, and a particle of chromic acid, of convenient size, is picked up on this and carried down to the tumor. The crystals adhere to the lint until they come in contact with a moist surface. In carrying the instrument through the mouth, care must be taken to avoid touching the mucous surfaces. Epithelioma in its early development may be successfully destroyed by this escharotic. The operator should take advantage of the anæsthetic properties of cocaine to render the pharynx and larynx tolerant of manipulation. Nitrate of silver may also be used, but is inferior to chromic acid.

Avulsion, or tearing away the neoplasm, is a useful and frequently employed method. For this purpose various forms of forceps have been used. Pedunculated tumors may be snared and cut away with the wire loop of Jarvis. Fibromata often adhere so tenaciously that they cannot be torn away without damage to the larynx. Care should be taken to regulate the force so that injury to the vocal bands or the smaller cartilages may be avoided.

The operations of *thyrotomy* and subhyoid pharyngotomy—heretofore described—gives the best command of the cavity of this organ, and allow the more thorough and safe removal of the neoplasm.

Neoplasms similar in character to those found in the larynx may occur in the trachea and bronchi. The location of the new growth may be determined from the physical signs.

The treatment is strictly surgical, and involves physical exploration of the respiratory tract, with avulsion or excision of the growth, or the introduction of the trachea tube to prevent asphyxia.

Pharynx and Œsophagus

Pharynx.—Neoplasm of the walls of this cavity are comparatively rare. They occur usually in the vault, and are attached to the mucous membrane, or periosteum, beneath the basilar process. The treatment consists in removal by the forceps, the snare, or galvano-cautery, or, if the tumor is of considerable size, by the knife. In some instances deligation of both external carotid arteries is advisable, or Dawbarn's more radical procedure of excision of these arteries with all their upper branches and anastomoses.

Foreign bodies are not infrequently lodged in this organ. They may be discovered by inspection with the pharyngoscope, or felt with the index-finger.

The *treatment* is removal by the aid of the mirror and curved forceps.

Œsophagus

Rupture of the œsophagus, though several instances are recorded, is exceedingly rare. The accident occurs in forced efforts at deglutition after overdistention of the stomach. The *symptoms* are intense pain in the region of the rupture—which is usually in the long axis of the tube and near the diaphragm—followed by rapid and fatal collapse. Vomiting does not occur, although the contents of the stomach may be emptied, in part, into the mediastinum.

Foreign Bodies.—The lodgment of bodies in the œsophagus, resulting in partial or complete occlusion, is of frequent occurrence. The *symptoms* depend in great part upon the character of the foreign substance. A sharp and narrow body—as a bone, pin, needle, or splinter of wood—will produce pain at the seat of lodgment, but will allow the passage of liquid and semisolid ingesta. Soft, compressible particles of large size may completely occlude the tube, and cause pressure upon the trachea sufficient to induce marked asphyxia. The diagnosis must, in part, be based upon these symptoms and the history of the accident. Pressure over the seat of lodgment of a sharp substance will exaggerate the sense of pain, while the inability to swallow liquids will indicate the complete occlusion

of the tube. The introduction of the elastic œsophageal sound (Fig. 429) will demonstrate the presence of any occluding body.

In order to introduce this instrument, lubricate it with the white of an egg, or glycerin, and cause the patient to throw the head back so as to bring the axis of the mouth and pharynx in line with that of the œsophagus. Insert the bougie

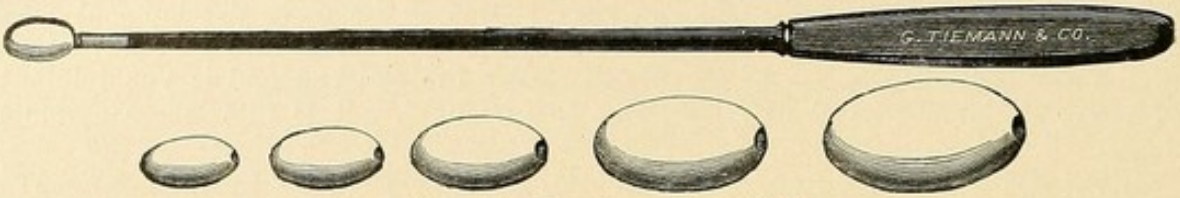

Fig. 429.—Œsophageal sound and bulbs.

so that the point will glide over the root of the tongue and strike the posterior wall of the pharynx behind the larynx. The tongue should not be drawn out of the mouth. Spasm of the glottis will prevent the instrument passing into the larynx, while, if kept in the median line and pushed carefully down, it will pass into the œsophagus. The location of the foreign body will be indicated by stoppage of the sound. *A proper use of the radiograph will render all manipulation unnecessary.*

The *prognosis* is usually favorable when the occlusion is not complete. If the distention is great enough to interfere with respiration, the gravity of the accident is increased. Inflammation, abscess, and perforation of the œsophagus may occur if the obstruction is not removed within the first few days.

Treatment.—When a foreign body is lodged in the œsophagus, and does not completely occlude its caliber, it may usually be dislodged by producing emesis.



Fig. 430.—Bristle probang, for removing foreign bodies.



The ingestion of corn-meal mush or a cereal mixed with cotton fiber has been successfully used, the plug of cotton forced upward in the act of vomiting dislodging the foreign substance. If there is complete obstruction, vomiting should not be excited, nor is the employment of a sound or bougie to push the object into the stomach permissible.

When the substance lodged does not occlude the œsophagus, and emesis has failed to dislodge it, the umbrella probang (Fig. 430) should be introduced. This instrument is lubricated, closed, and passed into the œsophagus until the bristles are well beyond the point of lodgment, when they, by pressure upon the whalebone handle, are projected, completely filling the tube, and the probang withdrawn. If the introduction of this instrument is difficult or painful, an anæsthetic should be administered.

In case of complete obstruction, where the danger of inanition is threatened, or where pressure upon the trachea must be relieved, *œsophagotomy* should be performed.



Fig. 431.—Artificial plate. Natural size.

Illustrative Case.—A man fifty years old swallowed an artificial plate of vulcanized rubber to which two false upper incisor teeth were soldered. This plate,

crescentic in shape, measured from point to point along the arch two and a half inches, the direct diameter between the two points of the crescent was one inch and a half, the widest measurement of the plate at the center, including the teeth, was five eighths of an inch (Fig. 431). Six weeks later the foreign body was located behind the manubrium by the X-ray.

An incision five and a half inches in length was made along the anterior border of the left sterno-mastoid muscle, extending one and a half inches on to the surface of the manubrium. The fibers of the sterno-hyoid and the sterno-thyroid muscles were separated by dull dissection, the left lobe of the thyroid body turned upward, and careful traction made on this in order to avoid injury to the parathyroids or overtension of the recurrent laryngeal nerve, which was clearly seen as it came from behind the carotid artery and passed upward and inward in the general direction of the inferior thyroid vessel of that side.

In the exposure of the œsophagus at this low level very considerable care was necessary to avoid injury to this nerve. A bougie was carried into the œsophagus, and on this as a guide I made an incision three quarters of an inch in length through the gullet on its left posterior aspect. This was gradually dilated by inserting the index-finger which, carried down to its full length, barely came in contact with the upper rim of the plate. On the finger as a guide a pair of dull-pointed scissors, curved on the flat, was passed anterior to the plate and slightly beyond it. With this on one side and the finger opposing it, the upper corner of the plate, which was deeply imbedded in the walls of the œsophagus, was carefully loosened and tilted upward, and in that way dislodged and brought up lengthways to the wound and extracted without any further difficulty. The wound in the œsophagus was left open, while the upper portion of the superficial wound was closed with four or five silkworm-gut sutures. The deeper wound was filled with a light packing of sterile gauze. There was no vomiting during or after the operation.

After-treatment.—The patient was placed in bed on the back, the foot of the bed elevated about twelve inches in order to facilitate drainage upward and away from the mediastinum. Every four hours he received six ounces of normal salt solution by the rectum for the first twenty-four hours. After this the quantity was increased to eight ounces, and in the intervals two nutritive enemata were given. He suffered practically no pain after the operation.

Nothing entered the œsophagus for four days, when a tube was easily introduced through the mouth and œsophagus and sixteen ounces of milk carried into the stomach. This was repeated on the next day. On the sixth day after the operation he began to swallow liquids, and of sixteen ounces of milk given four ounces came out through the wound. The proportion which leaked through gradually diminished, and twelve days after the operation the œsophageal wound was entirely healed.

Colonic Alimentation

The value of alimentation by the colon in all conditions where the upper portion of the alimentary canal requires absolute rest cannot be overestimated.

For conveying water by the lower bowel to the blood, normal salt solution should be employed (one teaspoonful of salt to one pint of water which has been boiled and allowed to cool down to the temperature of the body). From six to eight ounces to as much as a pint, and at times more than this, may be employed if absolutely necessary. The foot of the bed should be well elevated so that the liquid will gravitate away from the rectum and thus avoid pressure which induces an effort at evacuation. When there is intolerance of the lower bowel smaller quantities should be employed with more frequent repetition, or the fountain syringe elevated only a few inches. (See General Peritonitis.)

Milk Prepared by the Warm Process.—One of the most useful foods given by the colon is milk. When the bowel is irritable the warm process, which is as follows, should be employed: Put a teacupful (gill) of cold water and the powder contained in one of the peptonizing tubes (of Fairchild Brothers & Foster) into a clean quart bottle and shake thoroughly; add a pint of cold fresh milk and

shake again; then place the bottle in a pail or kettle of warm water—about 115° F. —or not too hot to immerse the whole hand in without discomfort. Keep the bottle in the water bath for from thirty to forty minutes or longer if a greater degree of predigestion seems necessary, then put it immediately on ice. As a portion is needed, shake the bottle, pour out the quantity—usually four ounces—and heat gently to blood warmth. Avoid hasty heating and overheating.

Six, eight, or twelve ounces may be given every four or five hours, or a larger quantity if the case is urgently in need of nutrition and the bowel is tolerant. In rectal feeding it is of great importance not to overcrowd the colon sufficiently to produce irritation.

Cold Process.—In cases where the enema can be retained for some time without irritation, the milk may be peptonized by the cold process. Put a teacupful (gill) of cold water into a clean quart bottle and dissolve it by shaking thoroughly the powder contained in one of the peptonizing tubes; add a pint of cold fresh milk, shake the bottle again and immediately place it directly in contact with the ice.

Warm each portion as it is required for injection, being careful to avoid hasty heating or overheating.

Or, only a sufficient quantity to use may be prepared each time by the following method: In two tablespoonfuls (one ounce) of cold water dissolve one quarter of the contents of a peptonizing tube; add eight tablespoonfuls (four ounces) of cold milk; warm to the proper temperature and inject at once.

Eggs.—In administering eggs the following formula is advisable: Dissolve the white of an egg in three times its bulk of warm water; to this add the contents of one of the peptonizing tubes, stir well, and inject at once. The water should be just warm enough to make the mixture the proper temperature for the injection, not hot enough to coagulate the albumin.

Another method of using the whole of the egg is to beat the white and the yellow well together, with a pint of milk, adding a gill of water in which the contents of a peptonizing tube has been dissolved. It may be employed cold, but if it is thought best to use the warm method, warm water can be used as in the formula immediately preceding.

Beef Juice.—In using beef for rectal feeding, to a tablespoonful of minced lean beef add four tablespoonfuls of cold water, and gradually heat to boiling. Strain all through a fine sieve or colander. When it becomes lukewarm add the contents of one of the peptonizing tubes, and it is ready for injection. More water may be added should it seem desirable.

Peptonized Food and Whey.—Panopepton in rectal feeding should be diluted in two or three parts of lukewarm water, or, preferably, normal salt solution.

If it be desired to employ whey, it can be combined with panopepton at times as follows: Put one pint of cold fresh milk in a clean saucepan and heat it to not over 100° F. Add two tablespoonfuls of essence of pepsin and stir just enough to mix. Let it stand until firmly jellied, then beat with a fork until it is finely divided, and strain. Warm to the proper temperature and inject without dilution. Panopepton and whey may be used in conjunction by adding three parts of whey to one of panopepton.

Panopepton and peptonized milk may be used by mixing one tablespoonful of panopepton with two or three of peptonized milk prepared by the warm process. Mix the panopepton and peptonized milk when required for use.

As a variation from the foregoing, the following formulæ have proved very satisfactory: The yolk of one egg whipped thoroughly in one half ounce of whisky. To this is added one half ounce of Valentine's meat juice and four ounces of peptonized milk. The mixture should be warmed to about the temperature of the blood before being injected into the colon. If whisky is not desired, use two teaspoonfuls of Valentine's meat juice thoroughly mixed with the yolk of one egg in ℥ij of lukewarm water, or normal salt solution ℥vi, red wine, and Valentine's meat juice each ℥ss. and the whites of two eggs.

Stricture.—Stricture of the œsophagus may be spasmodic or organic. The irritation caused by an organic stricture may not only exaggerate the degree of

constriction by exciting spasm of the muscular fibers of this tube in the immediate vicinity of the stricture, but also at points remote from the seat of the organic lesion.

Organic stricture is comparatively rare. It may result from inflammation of the œsophagus caused by the ingestion of scalding water, strong acids or alkalies, the lodgment of foreign bodies, by wounds of the neck, the presence of a neoplasm, an aneurism, or by the local expression of some general dyscrasia, as in syphilis.

The *diagnosis* is determined by interference with deglutition and by physical exploration with the bulbous bougies.

The *prognosis* is unfavorable, although a fatal termination may not be reached for a considerable period.

The *treatment* consists in dilating the stricture by means of elastic bougies, introduced at intervals of two or three days. These instruments should be softened by being placed in warm water for a few minutes before they are used. The mechanism of introduction is the same as for the bulbous bougies just described. An extra long whalebone bougie, after the pattern of Bank's dilating urethral filiform bougie, will prove of service in strictures of such small caliber that the ordinary œsophageal bougie cannot be introduced.

Internal œsophagotomy is a justifiable procedure in cases of organic stricture which will not yield to careful and persistent efforts at dilatation. In its performance, the œsophagotome of Professor Sands (Fig. 432) has been successfully employed. As described by this surgeon,[1] the shank of the instrument, which is fifteen inches and a half in length and four millimetres in diameter, is a flexible tube, made of narrow, spiral steel plate, secured within by two pieces of fine wire,



Fig. 432.—Professor Sands' œsophagotome.

in order to prevent stretching or separation of the spiral coil. The instrument is provided with a variable number of steel bulbs, each bulb being furnished with a corresponding knife blade. The bulb is firmly fastened by a screw to the distal end of the shank, and the knife is attached to an inner flexible steel rod, manipulated by a thumbscrew at the proximal end of the instrument. By turning this screw, the knife is drawn out from its concealed position within the bulb, the back of the blade sliding over a firm inclined plane. An index on a dial plate indicates the amount of projection of the blade, the maximum being two millimetres and a half. A small sliding ring on the spiral tube is used to indicate the distance of the stricture from the incisor teeth. The bulb being conical, the operator can readily perceive when it comes in contact with the stricture, before he projects the blade. In operating, a bulb must be employed which exactly fits the stricture; the depth of the incision will then just equal the distance to which the blade is projected by the action of the screw in the handle. The bulb is introduced beyond the stricture, and the instrument withdrawn until the shoulder of the bulb indicates that it is in contact with the inferior or gastric border of the stricture. It is then turned so that the knife is posterior, the screw in the handle which projects the blade is turned to the required extent, and the constricting band divided by pulling the instrument outward until resistance ceases. The blade is then concealed and the œsophagotome withdrawn. The dilating bougies may be introduced at once, or this may be postponed for twenty-four hours. The danger to be guarded against is an incision through the wall of the œsophagus. With the instrument of Prof. Sands this is scarcely possible, especially when the smaller bulbs are used, since the greatest projection of the blade is only a little more than one twelfth of an inch.

When the occlusion is so complete that the œsophagotome cannot be employed,

[1] "New York Medical Journal," February, 1884.

or if for any reason this method of procedure is contra-indicated and inanition is threatened, the operation of *gastrostomy* is imperative. It is not only to be commended in permanent occlusion of the œsophagus from stricture, a diverticulum, or neoplasm, but in those cases in which extensive inflammation has resulted from the ingestion of corrosive substances. In this last condition the operation is intended to keep the organ at rest during the process of repair, in which nothing but water is passed through the œsophagus. It is always advisable to operate early in all conditions.

Operation.—Two operative methods may be entertained. The most modern, the operation of Sebanijew and Frank, which has met with considerable favor in late years and which has for its chief aim the establishment of a valvular fistulous opening for the prevention of regurgitation of food from the stomach, consists of an incision, four or five inches in length, beginning near the xyphoid appendix, parallel with and a little less than two inches distant from the costal cartilages of the left side. All bleeding should be stopped as the operation proceeds. When the anterior sheath of the rectus muscle is opened in the line of this incision, retractors are inserted and the edges of the wound held apart. The fibers of the rectus are separated in their normal perpendicular arrangement by a blunt instrument, and the posterior sheath of this muscle and peritonæum are then incised in the same (perpendicular) direction. The stomach is now drawn out through this opening and the silk suture passed through the peritoneal and muscular coats (not entering the cavity) at a point near the fundus, which is used in drawing

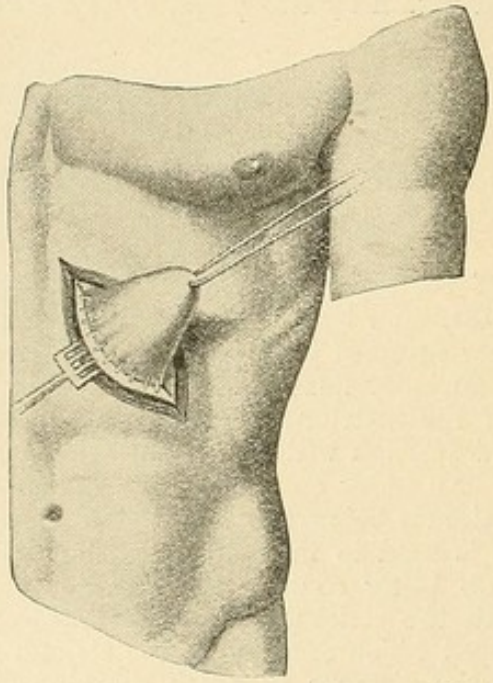

Fig. 433.—Incision made and cone of fundus of the stomach drawn out. A row of sutures have stitched the peritonæum of the abdominal wall and the posterior sheath of the rectus to the stomach. Sebanijew-Frank method.

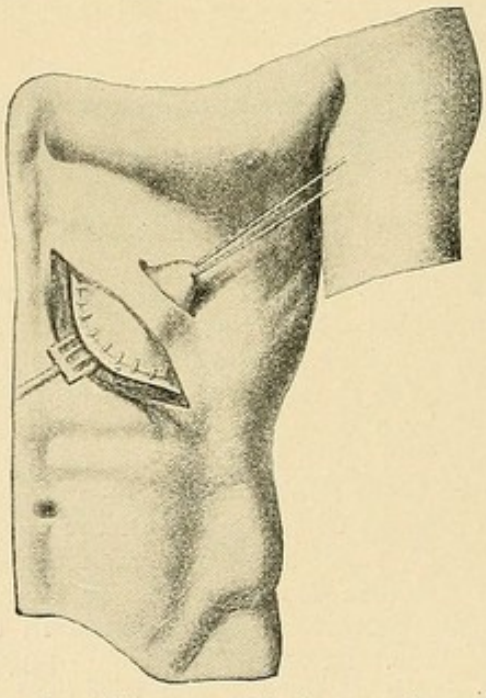

Fig. 434.—The same with the second parallel incision made, skin raised, and stomach drawn through.

out a conical pouch of the stomach about an inch and a half in extent (Fig. 433). At this stage of the operation the edges of the parietal peritonæum, including the posterior sheath of the rectus, are stitched carefully with fine silk to the peritoneal surface of the stomach entirely around this cone, the sutures going deep to take good hold in the muscular coat. A second incision an inch in length, parallel to the first and slightly above the ribs, is now made through the skin. By a careful dissection which lifts only the integument, this wound is made to communicate with the first incision, and the silk suture passed into the stomach is brought up underneath the loosened integument and out of the last and smaller incision, pulling the apex of the conical pouch of the stomach out of this opening

(Fig. 434). The first incision is now closed with silkworm gut, and the apex of the cone of the stomach incised for about half an inch and sutured with fine silk to the wound in the integument, the stitches passing entirely through the coats of the stomach and the skin (Fig. 435).

The patient may be fed at once if the condition demands it, but it is usually safer to wait for at least twenty-four hours in order to secure peritoneal adhesions.[1]

When operations for the establishment of gastric fistula are undertaken in cases in which there has been œsophageal stenosis of long standing, it must be borne in mind that the stomach is always greatly contracted, and that the fundus is lifted higher up toward the diaphragm than normal. In some instances it is difficult to lift even the fundus of the stomach up to the edges of the wound, and the operation just detailed is not practicable.

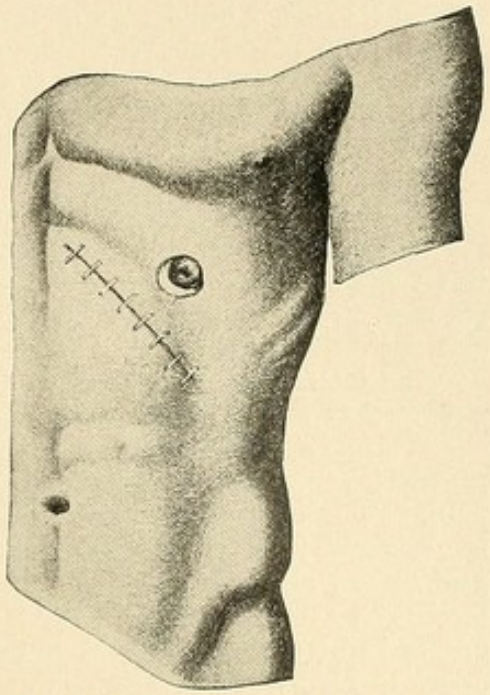

FIG. 435.—The operation completed.

The older method, which is simpler, requires exposure of the stomach by an incision similar to that described in the foregoing operation. When a temporary fistula is required it should be preferred to the operation of Frank. The stomach is immediately drawn into the wound and sutured with fine silk to the parietal peritonæum and skin, including the posterior sheath of the rectus muscle, in the entire circumference of the wound. A continuous suture may be employed, although the interrupted suture is generally used. This suture should also include the muscular coat of the stomach with the serous, but should not perforate the mucous coat. Silkworm-gut sutures may now be inserted in the upper and lower angles of the incision in the integument, partially closing this wound. It is best not to open into the stomach until twenty-four or forty-eight hours have elapsed, by which time union will have occurred between contiguous peritoneal surfaces, thus avoiding infiltration into the peritoneal cavity. Should the necessity for nutrition be extreme and rectal alimentation not to be relied upon to sustain the patient, a quantity of milk may be injected by means of a large aspirating needle into the stomach at the point of attachment.[2] In several instances after a fistula has been established by firm adhesions I have used an hour-glass-shaped hard-rubber nipple with a lumen of one third of an inch inserted into the opening, in order to keep it patulous. A cork fitted to this prevented regurgitation.

In certain cases of stricture of the œsophagus in which only the finest filiform bougies can be introduced it may be found necessary to operate from the *gastric* instead of the pharyngeal end of the œsophagus. A small-sized bougie to which a strong silk thread is attached is carried into the stricture, through the cardiac orifice of the stomach and brought out at the mouth, or an opening in the œsophagus, drawing the silk thread with it. Strictures have been divided by a sawing

[1] This method proved very satisfactory in a patient operated upon by the author in 1896.

[2] Liquid or semisolid articles of food may be introduced directly into the stomach, or, as practiced in the remarkable case of Dr. L. L. Staton, of North Carolina, the food may be masticated and thus submitted to the action of the saliva, and may then be forced from the mouth into the stomach through a tube.

A woman about forty-five years of age who came under my observation had accidentally swallowed a corrosive substance, producing acute closure of the œsophagus. I performed the operation of gastrostomy, and through the artificial opening she was nourished for about ten months. An interesting feature of the case was that at the time of the accident the woman was three months pregnant, and went to full term and was delivered of a healthy child. After the acute inflammatory symptoms subsided, the strictures which resulted were successfully treated by interrupted dilatation by œsophageal bougies.

motion of the string (Abbe) or by pulling through a series of bulbs (Maydl), gradually increasing in size, which are attached to the string at regular intervals. Dr. Lange has successfully employed this method, having a blade (œsophagotome) attached to each bulb. The subsequent treatment in these cases consists of the introduction of œsophageal bougies, gradually increasing in size. Of these methods, that of Dr. Robert Abbe is to be preferred. For its performance, an opening in the œsophagus in the neck is not required. The sawing motion of the thread divides the stricture and permits the introduction of soft dilating bougies.

New Formations.—Epithelioma is the most common neoplasm met with in the œsophagus. *Sarcoma* is rarely met with. Cancer occurs usually between the thirty-fifth and sixty-fifth year of life. The favorite location is near the diaphragm. The symptoms of malignant growth are chiefly those due to obstruction and the development of the cancerous cachexia.

Non-malignant neoplasms are slower in development, and, beyond the dysphagia they may produce, do not affect the general condition of the patient.

Treatment.—Malignant new growths of the œsophagus always justify a grave prognosis, especially so when situated in the lower portions of this organ. Beyond palliative treatment by dilatation with bougies, or gastrostomy after deglutition is seriously impaired or impossible, nothing can be done. Non-malignant neoplasms are also not amenable to surgical interference when situated below the level of the upper border of the sternum. When the upper portion of the œsophagus is involved, operation is indicated, not only to relieve dysphagia, but in the effort to remove the disease.

Œsophagectomy, or exsection of a portion of this organ, may occasionally be justified in the removal of a malignant growth of limited extent and situated in the upper portion of the tube. The probability that, before the character of the neoplasm is discovered, infiltration of the neighboring tissues will have occurred, almost precludes a favorable result, and is therefore a strong argument against the propriety of the operation.

Diverticula, or pouches communicating with the cavity of the œsophagus are occasionally observed. They may be congenital, but are more frequently acquired. They communicate with the œsophagus usually on its posterior wall. Cervical œsophageal diverticula open into the main tube at the junction of the œsophagus with the pharynx, whence the pouch may extend between the vertebral column and the œsophagus as far down as the bifurcation of the trachea. Thoracic œsophageal diverticula occur most frequently opposite the origin of the bronchi.

The *causes* of these abnormal pouches are various. As stated, they may be the result of a failure in normal development. A stricture of the œsophagus may lead to a dilatation and pouching of this organ in that portion immediately above the seat of constriction. Degeneration of the muscular fibers of the tube in a limited area may lead to a hernia of the mucous membrane, in which, by the impaction of ingested matter, a diverticulum is formed. Ulceration of the lining membrane at any point, and from any cause, may lead to the development of a sac or pouch by the infiltration of ingesta behind the mucous membrane.[1]

The diagnosis of these diverticula is made with great difficulty, and little hope of relief is offered, even when the character of the lesion is recognized.

The presence of the tumor is indicated by dysphagia, and this symptom may vary in severity with the act of deglutition which carries food into the pouch. Dyspnœa may be present as the result of pressure upon the trachea and bronchi, and phonation may be interfered with if the pneumogastric or recurrent laryngeal nerves are involved.

The *treatment* is chiefly palliative, and consists in the use of liquid diet.

Fistula of the œsophagus may occur as a result of a penetrating wound, or from an abscess or ulceration which destroys a portion of the œsophageal wall. A few instances of supposed congenital fistula have been reported.

[1] Rokitansky has advanced the theory that thoracic diverticula result from atrophy of the bronchial lymphatic glands, which are situated on the anterior and lateral aspects of the œsophagus.

The *diagnosis* will depend upon the passage of ingested matter through the outer opening, or the successful introduction of a probe from without.

The *treatment* is surgical, and on the same principle as applied to all fistulous tracts; they should be laid open by incision, packed to arrest bleeding, and afterward allowed to close by granulation. Or, as in the recent procedure for the relief of fistula in ano, the lining membrane of the fistula may be dissected away and the wound closed throughout with catgut sutures.

CHAPTER XVIII

THORAX

MAMMARY GLAND—ABSCESS OF CHEST WALL—EXSECTION OF CLAVICLE—WOUNDS —PLEURA, LUNGS, AND BRONCHI—THE HEART

Mammary Gland—Congenital Defects.—One or both of these organs may be absent; one may develop fully while the other remains in its primitive condition; there may be three, four, or five, the supernumerary glands being placed upon the back, abdomen, axilla, or thigh.[1] The nipple may be absent or retracted, and may be bifid or multiple, as many as half a dozen occurring within the limit of the areola.

Inflammation of the nipple occurs, as a rule, in the early period of lactation, abrasions produced by the gums of the infant affording lodgment to septic organisms. Tuberculosis and syphilis may also be acquired through these abrasions.

The first indication in treatment is to give the organ rest. Pain may be relieved by emptying the milk ducts by artificial means. A child should not nurse at an infected nipple or breast. Thorough cleansing with warm sterile water or boric-acid solution should be done at frequent intervals. When suppuration is present, incision and drainage are essential. A circular shield should be adjusted to prevent friction from the clothing.

All incisions should be made in the direction of the efferent ducts in lines radiating from the nipple.

Eczema, or *fissure* of the nipple, is of frequent occurrence during lactation. It is always annoying, and at times causes severe pain. Every source of irritation should be removed. Boric-acid solution is indicated in the early stages, and later glycerite of tannin or other astringent. Chronic inflammatory processes of the nipple which are intractable, resisting all constitutional and local remedies, demand free incision and ablation of the diseased area.

Epithelioma is the most frequent form of malignant neoplasm of the nipple. When of recent growth and superficial in extent, Marsden's paste will give the most satisfactory result. If the deeper ducts or substance of the gland are infiltrated, the entire breast should be removed, with the axillary glands and subjacent muscles.

Papilloma, *fibroma*, *angeioma*, *cysts*, etc., may occur in this organ, and should be removed by the knife as soon as discovered.

Mastitis.—Inflammation of the breast frequently follows infection of the nipple, the pathogenic organisms traveling along the galactiferous and lymphatic ducts. A single lobule or subdivision of the gland or the entire organ may be involved. In the more severe forms of inflammation the process may extend backward into the submammary tissues and axilla.

Traumatic mastitis is usually circumscribed, the integument and subcutaneous areolar tissue being also involved. The deeper tissues escape unless great and unusual violence has been inflicted.

Non-traumatic mastitis is almost always connected with lactation, occurring usually during the first few weeks after parturition. Mastitis is also a symptom of *parotitis*, although pyogenic infection is exceedingly rare as a complication of "mumps."

[1] The author presented to the New York Surgical Society a case in which a supernumerary gland was situated in the axilla. The development of this organ simultaneously with the normal breasts produced great pain by pressure upon the branches of the axillary plexus. Relief followed extirpation of the abnormal gland.

Symptoms.—The first indications of inflammation of the mammary gland are pain and localized induration. The pain is constant, and usually severe in character, and may extend along the ribs to the axilla. It is due, in great part, to obstruction of the milk ducts and hyperdistention from retained excretion. The induration is usually well defined, and may consist of one or more nodules. Injection of the skin is marked over the area of induration. The temperature is elevated one or two degrees, the pulse increased in frequency, and a well-pronounced chill or a series of rigors is apt to be a feature of the earlier stages of this disease.

Treatment.—As soon as inflammation is threatened the breast should be supported by a bandage, or long, soft towel, or handkerchief thrown around the neck and shoulder and beneath the gland, holding it in the position of least discomfort. In the stage of hyperæmia the application of a light ice-bag, with limited compression of the organ, is advisable. Artificial means should be employed to empty the breast. It is important to recognize the earliest collection of pus, and to relieve it by incision. When the induration is localized and well marked, it is good practice to explore under cocaine with the large hypodermic needle to determine the presence of suppuration.

When *abscess* exists the pus should be freely evacuated. The incision should be parallel with the direction of the galactiferous ducts. When the cavity is opened the nozzle of the irrigator should be introduced and the abscess thoroughly washed out with 1–3000 permanganate-of-potash or 1–5000 sublimate solution. Drainage should be secured, and a loose dressing applied. The point of incision should be made in the lower portion of the sac, so that drainage may be free. At times it may be necessary to make a counter-opening. Less frequently abscess may form in front of the glandular tissue beneath the integument or between the capsule of the gland and the thorax. Ostitis or periostitis of the ribs may be the cause of deep-seated submammary abscess.

Hypertrophy of the mammary gland is a physiological process, usually occurring at puberty and during pregnancy and lactation. In rare instances there is an extensive pathological hyperplasia of the connective-tissue elements of this organ, resulting in great enlargement. The *diagnosis* may be based upon the hard character of the mass, there being none of the softness and elasticity which belong to the normal breast. The hyperplasia is general, involving the entire framework of the organ, which will render it easy of differentiation from any form of neoplasm, for these grow from recognized centers of induration. The diagnosis meets with confirmation if the enlargement takes place after puberty, and in a non-pregnant woman.

In the *treatment* of this condition in the earlier stages well-adjusted and prolonged compression should be tried. This may be effected by a thick layer of absorbent cotton laid over the breast and held firmly down upon it by a roller. In advanced cases excision of the organ is demanded.

Tumors of the Breast.—New formations in the mammary gland are among the more frequent surgical diseases. Unfortunately, they are more frequently *malignant* than *benign*. Although tumors of the breast occur chiefly in females, they are not uncommon in males. Among the non-malignant tumors are *adenoma, myxoma, fibroma,* and *enchondroma*. Various forms of cysts are also met with, while syphilitic gumma and tubercular deposits may occur in this organ. Carcinoma (scirrhus, encephaloid, colloid, and epithelioma) and sarcoma are the malignant neoplasms which are found in the breast.

Adenoma of the mammary gland is comparatively rare. The pathological change, a hyperplasia of the glandular tissue proper, is usually circumscribed. The tumor is of small size, freely movable with the breast, and does not form adhesions with the capsule, integument, or submammary fascia. There is no inflammatory process connected with its development, no enlargement of the axillary glands, no dilatation of the veins of this region, and little or no pain. It is found in nursing women, but is also not uncommon in early puberty and in women who have not borne children. It is not the rule for cystic degeneration to take place in this neoplasm, although such cysts may be met with in rare instances

as a result of degeneration of the new-formed cells of the deeper portions of the growth.

Adenoma, of itself a benign neoplasm, is believed to be capable either of developing into carcinoma or of exciting the carcinomatous change in the organ. Not only in the simple circumscribed form of this neoplasm, but in that variety sometimes called tubular adenoma, in which the hyperplasia of the glandular cells is not confined to the acini and terminal ducts, but extends into and involves the galactiferous ducts as far as the nipple, and which is more generally diffused than in the simpler form above described, it is admitted that the transformation into carcinoma is possible and at times rapid.

Treatment.—The tumor should be excised. If it is small it may be removed by sacrificing only that part of the gland tissue immediately around it. Upon the recurrence of the growth, the entire breast should be excised.

In removing adenoma or other small tumor of the breast, it may be exposed by linear incision through the skin and subcutaneous areolar tissue. As a rule, this incision should radiate from the nipple toward the circumference of the breast, parallel with the galactiferous ducts. When the tumor is well exposed by retraction of the edges of the wound and subcutaneous dissection, it should be removed, taking care to go beyond the limit of the disease about half an inch, cutting through sound breast tissue. When the hæmorrhage is arrested, strong subcutaneous catgut sutures should be introduced into the breast tissue on either side of the space left by removal of the tumor. When these sutures are tied, the edges of the wound in the breast are approximated, and the depression which otherwise would exist and cause a deformity is prevented. The edges of the incision in the integument should be closed by a separate row of sutures.

When a benign tumor involves more than half of the breast it is safer to remove the entire organ. It is advisable not to sacrifice the nipple in these cases. If the incision through the skin be carried along the fold or crease between the under surface of the breast and the chest wall, the integument of the breast, including the nipple, may be raised and the tumor and glands thoroughly exposed and removed. When the wound is closed, it will be seen that the scar is concealed in this fold. Small tumors of this nature occupying the lower half of the breast may easily be removed through this incision, leaving no visible scar.

Myxoma is very rarely met with in the mammary gland. It may occur as a single nodule and develop slowly from a single center, or it may develop from several centers and rapidly invade the entire organ. It is not adherent to the skin until inflammatory adhesions occur preliminary to ulceration of the mass. Infiltration of the axillary glands occurs only as a result of inflammation. The nipple is not retracted.

The prognosis is favorable if the tumor is discovered early in its development, and if in the excision a sufficient portion of healthy tissue is removed with the neoplasm. The *treatment* is free excision. The entire gland should be sacrificed, and, if the organ is wholly involved, the line of incision should be well out from the limits of the tumor in the healthy tissues.

Fibroma of the mammary gland may occur at any period of life. It is rarer in the aged than in the young, occurring mostly in persons under forty, and occasionally under puberty. This form of connective-tissue hyperplasia may affect the entire organ (as in general hypertrophy, already described) or a circumscribed area. A nodular or circumscribed fibroma is a hard, dense tumor, freely movable with the gland, and may or may not be painful. Shrinkage of the breast occurs at times as a result of the cicatricial contraction of the new-formed tissue, and, when near the nipple, its retraction may resemble that of scirrhus. As a rule, this variety of tumor is of slow development. Not infrequently it undergoes cystic degeneration. The axillary glands are not involved, nor do adhesions occur until after atrophy of the gland with retraction of the new-formed connective tissue. It should be removed by the same wide and free excision as recommended for myxoma.

Enchondroma of the breast is very rare. It is apt to be circumscribed. Calcification has been observed in some of the few recorded cases of this neoplasm.

Occasionally it is found with carcinoma. Enchondroma of the breast should be freely excised.

Cysts.—Among the forms of cystic tumors found in this gland are galactocele, sanguineous, dermoid, and hydatid cysts, and the forms which occur in the degeneration of adenoma, fibroma, myxoma, and carcinoma.

Galactocele is a cyst caused by obstruction of the ducts which convey the milk toward the nipple. The obstruction is followed by distention of the tubes and *acini*. Examined with the microscope, the contents of these cysts consist of epithelial cells in various stages of granular metamorphosis, and milk globules.

The diagnosis may be determined by aspiration. The treatment consists in incision and evacuation of the contents with drainage until the cysts may be obliterated by the process of granulation.

Dermoid and *hydatid* cysts are exceedingly rare in this situation. The diagnosis may be determined by aspiration, and the proper treatment is excision. Cysts may occur in the breast from the extravasation of blood after contusions, or from the non-traumatic rupture of blood or lymph vessels. They heal readily after incision and drainage.

Tuberculosis of the breast is rare. It is probably due to infection through the nipple. The nodules may be disseminated generally through the gland or beneath the capsule, or there may be one or more large collections. They are hard to the touch. The history of the case will aid in determining the character of the lesion. If there is no general dissemination of tubercular matter—that is, if the disease is limited to the mammary gland—this organ should be freely excised.

Sarcoma of the breast attacks usually the young and middle-aged. It is rarely general in its development, but commences as a single nodule, more apt to occupy the upper portion of the organ than the lower, whence it invades the gland and circumjacent structures in every direction. The rapidity with which it grows depends in part upon the microscopical character of the neoplasm, and in part upon the age of the patient. Sarcoma develops more rapidly in the young, and the round-cell variety, which is most frequently met with in the breast, is more rapid in its development than the spindle-cell sarcoma. In the earlier stage this tumor, though firm and nodular, is freely movable with the gland. Its growth, however, is often so rapid that the skin and subcutaneous tissues, the submammary fascia, and the muscles of the chest become involved, the breast stands out full and tense, and becomes immovable. The superficial veins are greatly enlarged. As a rule, the lymphatic glands of the axilla are not involved until infection and suppuration of the mass induces axillary adenitis.

Differentiation between round and spindle-cell sarcoma is difficult unless the tumor is examined with the microscope. Practically, the differentiation is not important. The first variety is softer to the touch, more rapid in growth, and is more vascular. It is apt to occur in the younger class of patients.

Both forms of sarcoma tend to the formation of cysts within their structure. As stated, they may be due to fatty degeneration of the embryonic elements of the tumor, or may result from caverns of blood which have become cut off from the general circulation through the new growth.

The diagnosis depends upon the age of the patient, the rapidity of development, and the absence of axillary engorgement. The treatment consists in free excision. The action of pyogenic and erysipelatous organisms upon sarcoma will be given in the chapter on tumors.

Carcinoma is by far the most common form of neoplasm met with in the breast. The order of prevalence of the four varieties is *scirrhus, encephaloid, colloid*, and *epithelioma*. Cancer of the mammary gland occurs in rare instances in males. In women it is met with most frequently in the period from the fortieth to the sixtieth years of life. It may occur later than this, and is rarely seen earlier than the age of thirty. Women who have never been pregnant are affected, though probably not so liable as those who have borne children.

Scirrhus of the breast appears usually as a single hard nodule or lump, situated in the substance of the gland, movable with this organ, but firmly imbedded in it; or two or more nodules may appear simultaneously in different parts of the

gland, which eventually approach each other so as to form a nodulated mass. The growth of scirrhus is, as a rule, not rapid in the earlier stages of its development, but, after reaching a certain size, it spreads with increasing rapidity. The length of time which may elapse between the commencement of the neoplasm and metastasis in the subpectoral and axillary lymphatics varies in different individuals. It is, however, in general proportionate to the rapidity of the growth of the neoplasm. Pain, which is a symptom of this disease, is lancinating in character rather than dull and continuous. It is usually more severe in tumors which develop rapidly.

Cancer of the breast may assume the form of a single large, rounded, and nodular mass, or nodules of various sizes may develop in the organ or be scattered in knots or groups beneath the integument, in the pectoral muscles, or along the line of lymphatics leading into the axilla. If left unmolested, scirrhus soon invades the tissues around the breast, the muscles of the chest becoming infiltrated, the skin attached to the mass, and the nipple retracted. On account of pressure the circulation in the most remote portions of the invaded gland is interfered with, and ulceration ensues, giving rise to a more or less extensive granulating surface, from which there is a discharge of a serouslike fluid containing blood-corpuscles, embryonic, pus, and cancer cells. In the later stages lymphatic engorgement is more extensive, and the effects of compression upon the thoracic and axillary nerves more evident. Not infrequently the subclavicular, supraclavicular, and cervical lymphatics become engorged. Pressure symptoms are not alone confined to the nerves, but the interference with the return circulation in the axillary vein may produce general œdema of the extremity.

Encephaloid cancer of the breast differs only in degree from the scirrhus variety. It is softer under pressure, grows with much greater rapidity, ulcerates earlier and more extensively, is more prone to hæmorrhages, and tends to a more rapidly fatal termination. It is more apt to recur after removal.

Epithelioma of the breast is rare. It commences in or near the nipple, and may extend along the epithelial lining of the lactiferous ducts, or spread along the integument of the areola. Although ulceration begins earlier, its progress is slower and less painful than in either of the forms of cancer just given, which attack the deeper structures of the gland. If not extirpated, the entire gland may be infiltrated, metastasis occurs, and death follows from general exhaustion.

Prognosis and Treatment.—The prognosis of cancer of the breast is always grave, the gravity varying with the character of the neoplasm, the general condition of the patient, and the length of time the tumor has existed before excision. Left without surgical interference, a fatal termination is reached usually within one to two years after the appearance of the disease. Encephaloid is most rapidly fatal, scirrhus next in order, and epithelioma last. Death ensues from exhaustion caused by toxæmia, suppuration, pain, anorexia, and infiltration of the various organs by metastasis. In isolated cases scirrhus of the breast reaches a certain point and remains stationary for a number of years before again enlarging and producing a fatal issue.

With the operation as performed in modern practice the prognosis is much more favorable. This implies early recognition of the presence and character of the neoplasm, immediate and wide extirpation of the invaded organ, and a careful dissection of all metastatic foci in the glands of the axillary plexus. As to the selection of cases in which operation is justifiable, it is imperative in all cases in which the lymphatic engorgement has not extended beyond the axillary region, and in which the invasion of the pectoral and thoracic muscles is not so deep or extensive that a clean excision is possible without opening into the thorax. Even when metastasis of the cervical lymphatics has occurred, relief may be obtained. It is well to bear in mind that a simple non-malignant enlargement of the glands may occur before true metastasis has taken place.

Treatment.—It is advisable to prepare the patient as if the most radical procedure were intended, but when the diagnosis is uncertain to incise the tumor. At times cysts with thick walls or when tense from overaccumulation may be mistaken for malignant neoplasms. If the suspicion of malignancy is confirmed the incision should be tightly packed.

In general, the following rule of practice is submitted:

A tumor of the breast occurring in either sex after the thirtieth year of life should be excised as soon as discovered. The contra-indications to this procedure are: (1) a condition of prostration so extreme that a surgical operation would involve great and unusual risk to life; (2) metastasis to such an extent that complete removal of the neoplasm is impossible.

The incision and dissection should be far away from the limit of the tumor in the healthy tissues. When only a small portion of the organ is involved, it is advisable to extirpate the entire gland. When the patient is under thirty years of age, and when the tumor is thought to be benign in character, the less radical operation of enucleation of the neoplasm may be undertaken. Any new formation so removed should be carefully examined *at once*, and, if found to be malignant, the radical extirpation completed at this operation.

Operation.—The patient is placed upon the table with the chest slightly elevated, the breast and axilla of the affected side near the edge. The arm, entrusted to an assistant, should be held at a right angle to the body, and the head directed to the opposite side. Extreme elevation of the arm may overstretch the nerve trunks and cause paralysis.

In removal of the mammary gland for cancer, two important points present themselves to the surgeon. First and most important is that the operation be done at the earliest possible moment. If this were properly done within the first two to four months in every case of neoplasm of the breast, few would perish, where a great many are sacrificed by delay.

Secondly, and of equal importance, the operation should be thoroughly done. It is as important to remove the entire lymphatic apparatus from the clavicle through the axillary space down to and with the breast as it is to remove the breast itself. It is very exceptional when metastases have not occurred in the lymphatics of the pectoralis minor and axilla, if a tumor has existed in the breast for two or three months. The glands in the neck should also be examined and removed when involved.

No special incision will apply to all cases. It should always be well away from any suggestion of cancerous infiltration. When the neoplasm is of moderate size and is deeply situated in the breast substance, the skin as yet not being involved and freely movable, nor the nipple well retracted, the operator can afford to leave a larger margin of skin for the purpose of covering up the wound than under other conditions. When the mass is of considerable size, or is superficially located, and when the nipple is retracted and the skin infiltrated for one or two inches on either side of the center of induration, it is advisable to go two or three inches in all directions from the edges of induration. Fig. 436 (J. Collins Warren) fairly represents the extent of this incision. When it becomes necessary to remove the infiltrated glands from the supraclavicular regions, a perpendicular cut coming from the neck and crossing the clavicle should be added to the incision given in the illustration. The posterior curved incision there shown is not always essential; it is only used when so much of the integument over the breast proper has of necessity been removed that a plastic or sliding operation is necessary to cover in the gap. No manipulation of the breast should be permitted, for fear of forcing cancer cells into the lymphatics. As soon as the skin is divided it is advisable to closely remove the subcutaneous fat, working always as far away from the tumor as possible, through an entirely healthy zone. After the incision has been outlined and made through the skin, the dissection should commence in all cases at the clavicle (Fig. 436 *a*). As a rule there is no superficial infiltration in this region, and the incision may be made in such a way that after the dissection is completed the skin readily comes together. The essential point to be borne in mind is that the contents of the axilla and the pectoral muscles must be well exposed. The incision most commonly adopted is one which begins at the point of insertion of the tendon of the pectoralis major muscle into the humerus, curved slightly inward in a direction which will go wide of the edge of the tumor and around the breast, describing a circle which meets with the first portion of the incision. A second incision is made from above the center of the

clavicle and joins this at a right angle, when it becomes necessary to remove any infiltrated glands in the supraclavicular region. The surgeon should see *that the cephalic vein is not endangered.* Hæmorrhage is arrested in the line of incision as the operation proceeds (Fig. 436*a*). The flap in the upper portion of the

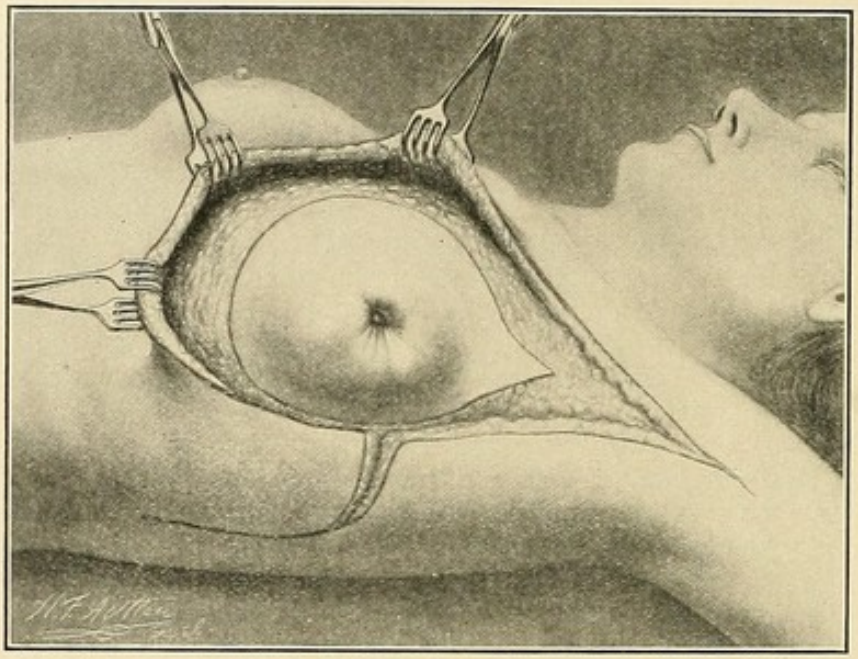

FIG. 436.—General plan of incision for the removal of a cancerous breast with the pectoral muscles and the axillary contents. (After J. Collins Warren.)

dissection is stripped of fat, leaving nothing but the skin, and this is reflected out of the way. The flap in the axilla is lifted in the same way, being freed from fat, keeping the scissors or knife close to the under surface of the integument, and is reflected downward. The pectoral muscles are exposed and the upper and

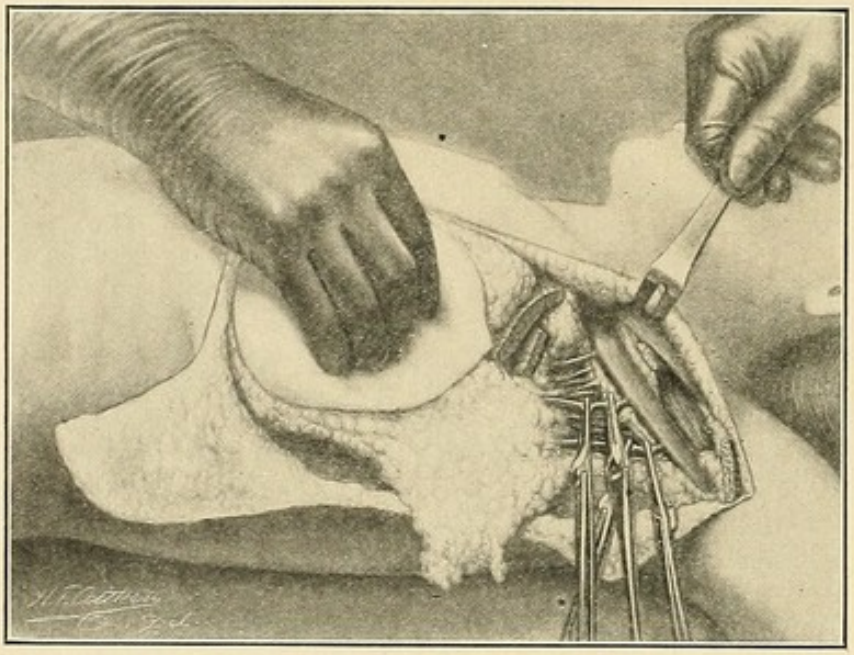

FIG. 436*a*.—The same, showing the method of hæmostasis as the axilla is being cleared. (J. Collins Warren.)

most important portion of the field of operation is in view. The pectoralis major muscle should be separated from the humerus through its tendon and close to the point of insertion. (In the case of a small tumor with limited infiltration of the lymphatics, the clavicular portion of the pectoralis major may be left. The

thoracic portion and the pectoralis minor should always be removed.) (Fig. 436*a*.) This can safely be done, since the finger can be inserted between it and the vessels of the axilla to serve as a guide to its division. This muscle is then reflected toward the chest. The operator now carefully removes that portion of the pectoralis major muscle which is attached to the clavicle immediately over the point where the axillary artery and vein rest under this bone. This accomplished, and all hæmorrhage arrested by the application of forceps and ligatures when required, with the greatest care the operator strips all the fat, lymphatics, and loose tissue from the fascia of the axillary vein and artery, tying with fine silk the venous branches, which must be divided usually within one eighth to one fourth of an inch of the point of entrance into the parent trunk. When the pectoralis minor muscle is reached in the dissection, its insertion into the cora-

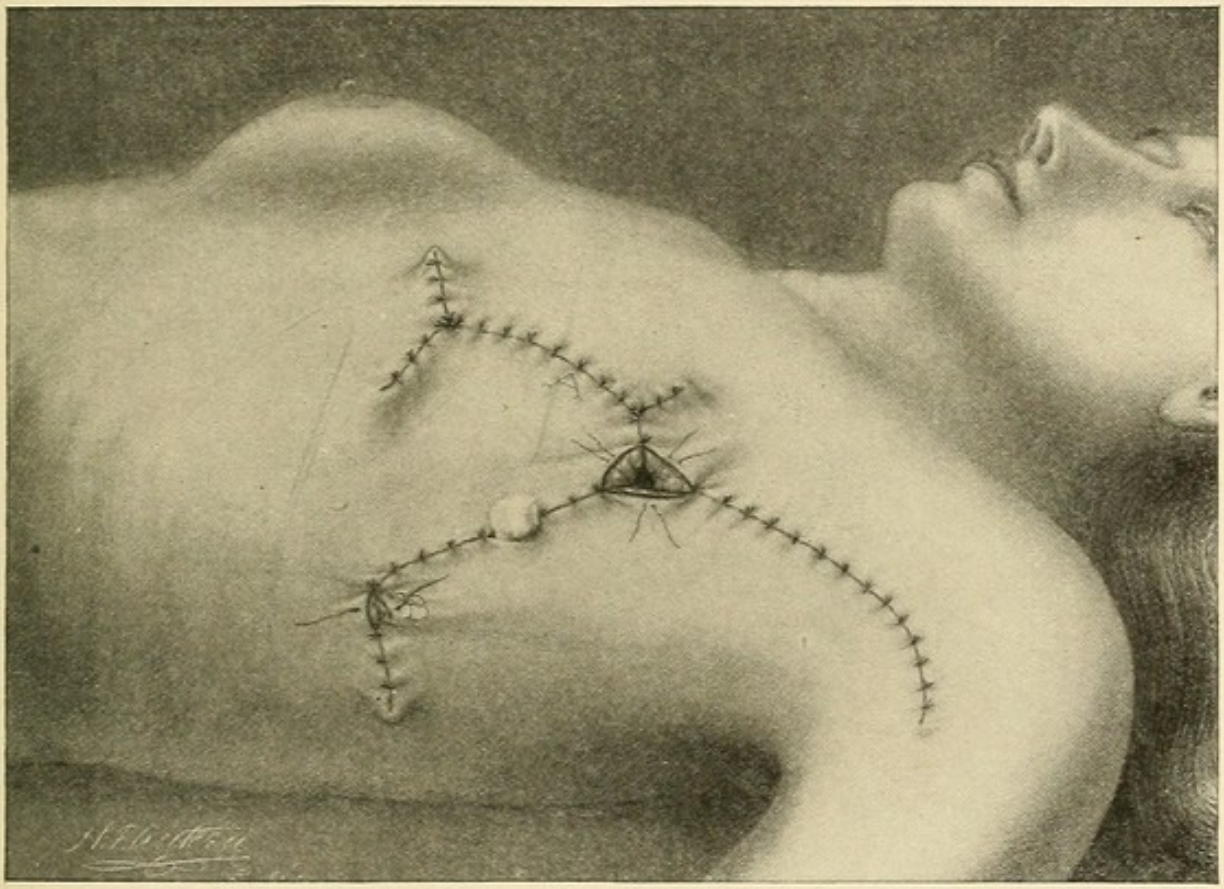

FIG. 436*b*.—The same, after the sutures have been inserted. A cigarette gauze or catgut drain should be placed in the lower angle of the wound nearest the back. (J. Collins Warren.)

coid process should be divided, and it in turn reflected inward toward its point of origin from the chest. The dissection is then continued down the vein and artery until the lower boundary of the axilla is reached. At this stage of the operation it is well to pack the wound with sterile gauze. Then, beginning from above downward, the connective tissue and lymphatics which rest upon the chest wall and the under surface of the pectoralis minor muscle are carefully removed, dividing the small pectoral muscle well out toward its origin. The upper fibers of the pectoralis major are removed in the same way, and, lastly, the lower portion of the pectoralis major is dissected from the ribs, and with it the breast, which still remains attached. When the axillary vein is studded with infected lymphatics this vessel should be tied at the clavicle and entirely removed with all of its branches. The danger of seriously wounding the axillary vein is not great. When in the course of the dissection a branch coming into this vein is wounded close to the parent trunk, the stump of the branch may be grasped with an Esmarch forceps and a fine silk or linen ligature tied around it on a level with the wall of the vein. By taking care not to injure the cephalic vein in the primary

incision, this vessel will carry on the circulation in the arm even after the axillary is obliterated. Silk should be used in preference to catgut for this particular ligature. In cleaning out the axilla, the dull-pointed scissors, or dulled grooved director will be found the most suitable instruments. In closing this wound, the upper portions of the flap fall easily together, and by bringing the arm down to or slightly upon the chest, and sliding a broad skin flap from the chest wall, the large space left by removal of the breast may be in great measure closed. Any raw surface left should heal by granulation, but may ultimately have to be closed by grafting.

After the entire pectoral muscles have been removed, the clavicular fibers of the deltoid enable the arm to be carried across the chest.

In uniting the flaps (Fig. 436*b*), silkworm gut is the best suture. It is advisable to carry a good-sized catgut drain out of the lowest portion of the axilla

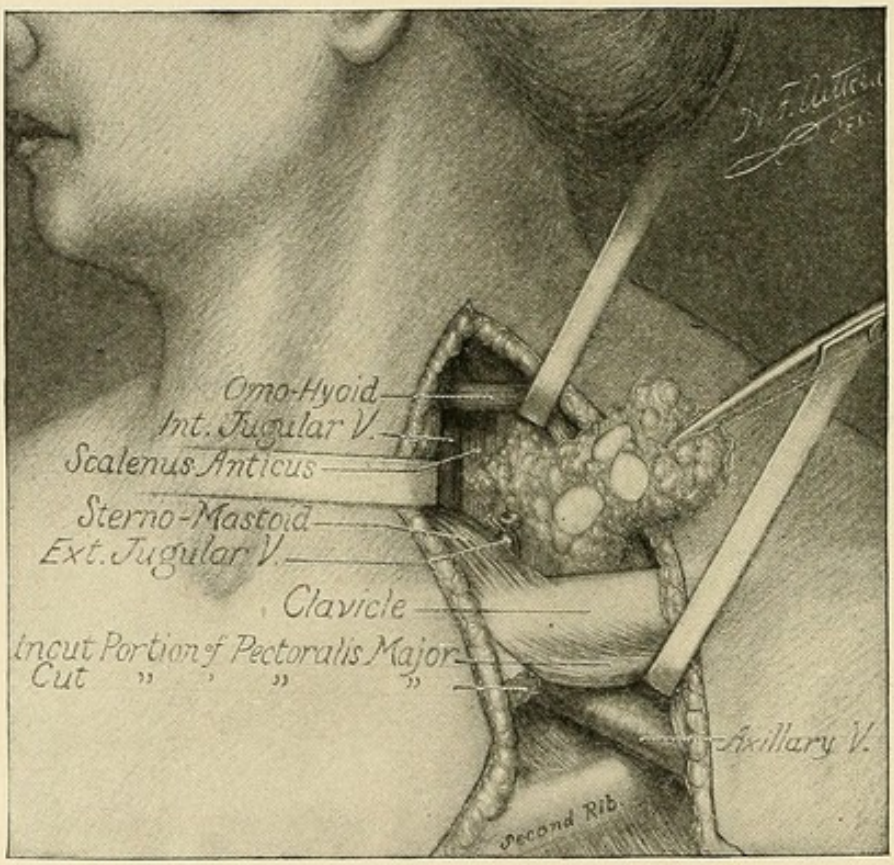

Fig. 436c.—The supraclavicular dissection. (J. Collins Warren.)

through the skin, to give escape to any oozing. The dressings often require to be changed on the second or third day.

When it becomes necessary to extirpate the infiltrated cervical glands this should be done as shown in Fig. 436*c*.

Abscess of the thoracic walls usually results from ostitis of the clavicle, sternum, ribs, scapula, or vertebræ, or enchondritis of the costal cartilages of tuberculous origin. If not incised, it opens spontaneously through the integument and discharges pus and at times particles of bone and other detritus. Spontaneous cure may occur, although this is the exception. Sinuses usually result, and continue until the diseased tissues are excised. The most common seat of ostitis is in the sternum and the sternal ends of the ribs. The indications in treatment are to lay the sinuses open, carefully following each to its terminus, scrape the indurated lining membrane away with the scoop, and remove all dead bone by scraping with the Volkmann spoon or exsection in mass. Opening into the pleura or mediastinum should be avoided. When the abscess leads behind the sternum a segment of this bone should be removed in order to expose and drain the cavity.

In exsection of a portion of one or more ribs, the incision should be made along the center of the bone, the periosteum lifted with the elevator first from the anterior surface and then from behind, taking great care not to enter the pleural cavity, and the bone divided with the cutting forceps. All of these wounds should be packed with gauze.

Exsection of the clavicle may be demanded in ostitis of this bone. In a case operated upon by myself for necrosis, the incision extended the entire length of the bone, and the excision was subperiosteal throughout. A new and strong clavicle formed, with perfect motion at the sternal and acromial articulations. The shortening was half an inch. Six years after the operation the function of the injured side was perfect.

Wounds of the Chest

Wounds of the chest are divided into penetrating and non-penetrating. A penetrating wound is one which opens into the pleural cavity or mediastinum. Pneumothorax, with hæmorrhage into the pleural sac, may occur, however, without an external opening, as when, after a contusion of the chest, a fractured rib penetrates the lung, the inspired air filling the pleural cavity and causing collapse of the lung.

Contused wounds of the chest may be accompanied by fracture of the ribs, lacerations of the muscles, or followed by pleuritis with or without either of the above complications.

Non-penetrating wounds of the chest, whether incised, lacerated, or punctured are treated as directed for such lesions in other parts of the body. The same may be said of gunshot wounds which do not involve the bony framework of the thorax or pass into the cavities.

Penetrating wounds of the thorax are dangerous in proportion to the size of the entering substance and the organs invaded.

Punctured wounds, not involving the heart, great vessels, bronchi, trachea, and œsophagus are not usually fatal, while death is apt to follow even small lesions of these organs. *Incised* wounds are more dangerous, while *gunshot* wounds are still graver lesions.

Passing in any direction into or through the mediastinum, a gunshot wound is apt to inflict fatal violence. In the lungs and pleuræ the prognosis is not so grave, being proportionate to the size or shape of the missile and to the nearness of its approach to the great vessels at the root of the lung.

Again, if a rib is fractured at the point of entrance, the gravity of the prognosis is increased from the destruction by and the lodgment of particles of bone driven into the lung. Wounds produced by round missiles of small caliber, not fatal within a few hours, are apt to end in recovery unless an uncontrollable sepsis is established. Conical missiles which strike the chest wall and turn or "plunge" on their long axes produce extensive and usually fatal injury.

Surgery of the Pleura, Lungs, and Bronchi.—Inflammation of the serous membrane covering the lungs and lining the inner surface of the thoracic cavity may result from infection primarily in the lung (tuberculosis, pneumonia, foreign body, etc.); from the costal side by contact with ostitis of a rib, the sternum, or vertebræ; from an abscess of the liver or spleen (subphrenic) or any subdiaphragmatic infection; from a traumatism with or without fracture of a rib; not infrequently from the end of a broken rib driven through the pleura into the lung; and lastly pleuritis may occur from infection through the general circulation.

As the result of pleuritis there frequently collects an accumulation of serum or pus either in the general pleural cavity or in an isolated portion (encapsulated) which may require evacuation.

This should be done by careful aspiration as soon as even a small accumulation has been recognized. In using this instrument every precaution should be taken to prevent puncture of the lung, which is always apt to be followed by pneumothorax with infection.

A short hypodermic needle should be used to demonstrate the presence of fluid, gauging carefully the depth to which the needle penetrates when the fluid is

reached. A trocar-canula should then be introduced to the same depth, withdrawing the trocar as soon as the instrument is felt to enter the cavity. By taking this precaution, as the fluid escapes and the lung finally comes in contact with the instrument, no puncture can be made. The fenestrated canula should be used. As much of the fluid should be withdrawn as will be tolerated by the patient, the degree of toleration being determined by the condition of the patient's pulse or any suggestion of collapse. When a large quantity has accumulated, compressing the lung and displacing the heart from its normal position, it is not safe entirely to empty the cavity at one sitting, since death has followed in several instances from this procedure.

If the fluid withdrawn is serum, containing no pus, nothing further should be done except to carefully seal the puncture through the skin by a bit of sterile gauze and adhesive plaster. The remainder of the fluid should be removed in one or two subsequent aspirations. Should serum continue to accumulate, or if pus is present, after a proper amount has been withdrawn there should be injected, taking great care to exclude any possible influx of air, from two to four ounces of a two-per-cent solution of formalin in glycerin. This should be repeated every three to six or seven days, until the fluid ceases to be purulent, and every two or three weeks until it ceases to collect. Prof. J. B. Murphy asserts that this treatment will cure ordinary hydrops in from two to four injections, and recommends it highly as the ideal treatment in pleural empyema. To avoid the danger of collapse of the lung, drainage should never be instituted in these simpler cases until it is absolutely demonstrated that aspiration with the injection of the formalin-glycerin solution has failed.

In chronic encapsulated abscess, where the danger of lung collapse does not exist, drainage may be employed and frequently exsection of a considerable portion of one or more ribs is necessary in order to effect a cure.

Pneumonotomy.—Incision of lung substance may be required in evacuating a pulmonary abscess. It is advisable to exsect a part of at least one rib, and if adhesions between the costal and pulmonic pleuræ exist, the aspirating needle should be used to indicate the depth of the incision. A puncture with the scalpel is then made, and through this a closed dressing forceps forced until the cavity of the abscess is entered and the opening enlarged by separation of the handles of this instrument.

Irrigation with hot saline solution should be made and free drainage established. When no adhesions are present, and if delay is permissible, an effort should be made to secure agglutination of the opposing pleural surfaces by depressing the costal pleura by means of a gauze pack snugly held in place with a roller-bandage around the chest. In five or six days adhesions should form over an area large enough to permit incision and drainage without collapse of the lung or general pleuritic infection.

In *pulmonary gangrene* a thorough curettage should be done and free drainage established. Packing the cavity with sterile gauze may be necessary to prevent hæmorrhage.

Pneumonectomy, or the removal of a part of one or more lobes of the lung, is occasionally necessary on account of neoplasm, hernia, gangrene, or hæmorrhage. Dr. Lewis Rassieur reports the ligature *en masse*, and excision of about one and a half square inches of the lower lobe of the left lung on account of hæmorrhage from a pistol-shot wound which also penetrated the wall of the heart. The hæmorrhage was at once arrested and the patient recovered.

Pneumorrhaphy, or suturing the lung with catgut, has been successfully performed in a number of instances in operations for the removal of foreign bodies, for hernia, gangrene, cysts, or new growths (Ricketts).

In operating for wounds of the pleura and lung a large curved incision is advised, the wound of penetration being about the center of the circle. One or two ribs should at first be divided for exploration, and a larger trap-door made as required. These operations must always be done with great haste, and it may at times be necessary to instil into a vein normal salt solution to prevent collapse while the chest is being opened. The bleeding lung should, when possible, be

brought up through the opening in the chest wall and ligated *en masse* with chromicized catgut.

The lung is occasionally the seat of *malignant neoplasms*, carcinoma and sarcoma. Cysts, especially those caused by echinococcus, when recognized should be subjected to operation.

Bronchotomy.—Foreign bodies in the bronchus may be recognized by the X-ray as well as by auscultation and percussion. When removal through the trachea is impossible, the incision through the chest wall should be at the nearest possible approach to the location of the body. Lodgment is more frequently in the right than the left bronchus.

Surgery of the Heart

Cardiamorphia, or malformations of the heart, are scarcely within the province of surgery.[1] *Ectocardia*, or malpositions, may be congenital or acquired. The heart may be located in any part of the thoracic cavity, and two instances are recorded in which it was in the abdomen. In transposition of the viscera it occupies the right side of the chest. Acquired ectocardia occurs as the result of pleural effusion, aneurism of the aorta, or pressure displacement from a mediastinal tumor.

With aneurism or congenital displacement, operative intervention is scarcely advisable. In effusion into the pleura the evacuation of the fluid permits the heart to resume its normal position. This should be done very carefully by aspiration, since fatal results have followed rapid and complete evacuation at one operation. (See Pleura.)

Cardioclasia, or rupture of the heart muscle, has occurred in rare instances from crushing or squeezing, and not infrequently from intrinsic weakness resulting from fatty degeneration.

Wounds of the heart are usually caused by gunshot missiles or knife stabs. The *diagnosis* depends chiefly upon the location and direction of the wound of entrance and hæmorrhage with the systole. The patient is usually cyanotic on account of interference with respiration due to hæmorrhage into the pericardium, pleura, or lung. There is an expression of great anxiety, often with severe pain. The pulse is rapid and weak, while the temperature is usually subnormal. The indications in *treatment* are rapid exposure of the heart and suture of the wound. Stimulants should be given with great discretion, since increased heart action is apt to increase hæmorrhage. Application of heat to the body is advised. The patient should not be moved any more than absolutely necessary, and should then be carefully lifted by hand.

If, upon opening the cavity, the heart has ceased to beat, it should be gently and rhythmically massaged between the thumb and finger, and artificial respiration practiced with any indication of arrest of breathing.[2]

Wounds of the heart may be penetrating, or may divide the muscular substance without entering any of the cavities. Severe hæmorrhage into the pericardial sac may cause fatal paralysis of the heart muscle from compression. As far as the prognosis is concerned, recoveries from wounds which penetrate and those

[1] There are recorded instances in which the heart has contained two, three, five, and six separate cavities. The author acknowledges his indebtedness to the "Surgery of the Heart and Lungs," by B. Merrill Ricketts, Ph.D., M.D., The Grafton Press, New York, for valuable data derived therefrom and used in this chapter.

[2] *Illustrative Cases.*—A man forty-seven years old, who had received a knife wound of the chest, suddenly went into collapse as the lung was exposed during an operation. Only a small quantity of ether had been administered. Notwithstanding stimulation and artificial respiration, the patient seemed dead. The operator grasped the heart between the thumb and forefinger and manipulated it from forty to sixty seconds, when it began to contract. Soon after a second pulsation occurred, and the circulation was gradually reëstablished.—Dr. W. S. Conkling, "N. Y. and Phila. Med. Jour.," September 2, 1905.

Direct Massage of the Heart in Chloroform Collapse.—After taking chloroform for some time the patient stopped breathing during a laparotomy and the heart ceased to beat. Artificial respiration was done while the operator grasped the apex of the heart, through the diaphragm, by taking advantage of the laparotomy wound. The heart was stroked regularly with the thumb in front and the fingers behind, and after five minutes of this rhythmic massage, its spontaneous contractions were resumed. The wound was sutured immediately, with recovery.—Sensert, "Journal de Médicin de Paris," September 24, 1905.

which do not are about equal. Ricketts reports fifty-six cases operated upon, with twenty recoveries. In one of the recoveries the coronary artery was included in the suture.

For reaching the heart in an emergency (chloroform narcosis or wound) where massage is indicated, a long incision between the fourth and fifth ribs will suffice. This can be extended if necessary by rapid division of the costal cartilages (Wilms).[1] By strong retraction up and down a fairly good view of even the posterior surface of the organ can be had after opening the pericardium. In one instance a bullet wound, involving the anterior and posterior wall of the left ventricle, was sutured through this incision, the pericardium being closed without drainage with recovery. The following flap method is, however, the best for wounds on the anterior surface of the heart:

Stab Wound of the Heart. Illustrative Case.—Dr. L. L. Hill, Montgomery, Ala., operated on a boy thirteen years of age for a stab wound received at five o'clock Sunday afternoon, September 14, 1902. The knife blade entered the fifth intercostal space about one fourth inch to the right of the left nipple and penetrating the apex of the heart passed into the left ventricle. There was no external bleeding, the radial pulse was almost imperceptible, and the heart sounds were heard with difficulty. There was dyspnœa and restlessness, and the extremities were cold. Eight hours after the stabbing an incision was made, beginning five eighths of an inch from the left border of the sternum, which was carried along the third rib for four inches. A similar and parallel incision was made along the sixth rib, the outer terminals of the two being joined by a vertical incision along the anterior axillary line. The third, fourth, and fifth ribs were cut through with the pleura. The musculo-osseus flap was raised, the cartilage of the ribs acting as hinges. There was no bleeding in the pleural cavity, but the pericardium was enormously distended. The opening in the pericardium was enlarged to two inches and a half, and about ten ounces of blood evacuated. The pulse immediately improved. The heart was lifted from the pericardial sac by the hand and steadied, while a catgut suture was passed through the center of the wound in the wall of the left ventricle, which was three eighths of an inch long. This controlled the hæmorrhage. The pericardial sac was cleansed with normal salt solution, emptied, and the opening closed with seven interrupted catgut sutures. The pleural cavity was also cleansed with a similar solution and an iodoform gauze drain inserted. The musculo-osseus flap was stitched in position. The operation lasted forty-five minutes. After the patient was put to bed, strychnine was injected hypodermically, and hot salt solution thrown under the skin and in the colon. The patient recovered.

Morris[2] reports a stab wound of the heart and pleura in which the fourth costal cartilage was resected, the wound of the pleura enlarged, and sterilized gauze placed in the cavity of the pleura to steady the heart. The pericardial wound was also enlarged, exposing a stab wound three quarters of an inch long on the antero-lateral aspect of the left ventricle, two inches above the apex. Three stitches of fine silk were passed deeply into the heart muscle, the needle being inserted during systole while the knot was tied during diastole. It was necessary to steady the heart in the hand in order to introduce the sutures. The pleura was next cleared of blood, and the patient recovered.

Lænormant[3] reports 128 cases of cardiac suture with 47 recoveries. Of these, in 58 the wound was in the left ventricle, in 49 the right, while 5 were in the apex. Of those wounded through the left ventricle, 25 recovered; through the right, 14. There were 3 cases of wounds of the right auricle with 2 recoveries, 3 of the left auricle with 2 recoveries.

As far as the post-operative treatment was concerned, in 23 cases there was no drainage, while in 65 either the pericardium, the pleura, or both were drained. Of the 65 drained cases, in 35 infectious pleuro-pericardial complications ensued, with 22 deaths. Of the 23 not drained, infection occurred in only 5, with four

[1] "Centralblatt für Chir.," July 28, 1906.
[2] "Gazette des Hôpitaux," September 13, 1906.
[3] "Year-Book of Surgery," J. B. Murphy.

deaths. From this it seems proper to conclude that drainage should be avoided in all cases when possible, unless infection has occurred.

Ricketts concludes that: "Whenever the location of a wound (with attending symptoms) justifies the suspicion of penetration of the heart, it is the duty of the surgeon to determine the nature of the injury and the possibilities of relief by an exploratory operation. The wound should never be probed. The heart should be steadied before attempting to suture it. Chromicized catgut interrupted sutures should be used and should not include the endocardium."

Adhesions may form between the pericardium and the pleura or chest wall, and interfere with heart action to such an extent as to require operation. The indications are the exsection of the rib or ribs to which the membrane is adherent, guarding against an opening into the pericardial sac (J. B. Murphy).

Dropsy of the Pericardium.—The removal of fluid from the pericardium is demanded whenever the muscle of this organ is interfered with by compression. Careful aspiration with a fine needle through the fourth or fifth intercostal space should be done, keeping close to the sternum.

In purulent pericarditis, which at times complicates a pneumonia, paracentesis is indicated (Dr. R. G. LeConte).

Aneurism may occur in the substance of the heart muscle or in the coronary artery. This condition is not amenable to surgical intervention.

Foreign bodies are extremely rare in this organ. Hamilton records the case of a bullet which, being lodged in the neck, worked its way into the jugular, and dropped into the heart, where, becoming encysted, it remained over twenty years and did not cause death. *Cardioliths* may exist and have produced obstructive symptoms acting as emboli.

Tumors.—In addition to *gumma* due to syphilis, the heart may be the location of neoplasms, *fibroma* being the most common. *Lipoma* and *angeioma* have been reported. *Polypoid* growths are found adherent to the endocardium, and occasionally on the external muscular surface. *Sarcoma* and *cancer* are also reported, while the *echinococcus* has been observed and has proved fatal. In extreme cases exploratory incision, revealing the presence of an echinococcus cyst or any tumor which may be removed, would justify a radical procedure.

CHAPTER XIX

THE ABDOMEN

CŒLIOTOMY—ABDOMINAL INJURIES IN GENERAL—WOUNDS OF THE VISCERA

In abdominal section the character of the operation to be performed will have much to do with determining the line of the incision. The natural route would seem to be through the median line, since there are fewer blood vessels to be encountered here and practically no nerves to be divided.

Experience has shown, however, that there is greater danger of post-operative hernia following an incision exactly in the median line than when this incision is made slightly to one or the other side of the linea alba.

This is especially true when the opening is made below the umbilicus, since from this point to the symphysis pubis all the aponeuroses of the oblique and transverse muscles pass in front of the rectus. Above the umbilicus the aponeuroses divide, running partly in front and partly posterior to the recti muscles, and in suturing the peritonæum from the navel to the xiphoid appendix the posterior sheath of the rectus and peritonæum are included in the same suture.

Post-operative ventral hernia is therefore less apt to occur above than below the navel. Moreover, the suture line below the navel is subjected to more strain on account of the greater weight of the abdominal viscera which the lower halves of these muscles are called upon to bear.

For these various reasons, while the incision above the navel may be made in the linea alba that below the level of the umbilicus should be made about three fourths of an inch from the inner border of one or the other rectus muscle, usually the right.

Taking this for purposes of demonstration, the sheath is incised for the required length, exposing the muscle, the fibers of which should not be separated, but the inner edge of the rectus through the entire length of the incision lifted and held outward by retractors, thus exposing the peritonæum exactly in the line of the anterior incision. In this way no nerves are divided and there is no subsequent paralysis of the muscle, whch, after the peritonæum is closed, is allowed to fall back to its original position.

The peritonæum should be reunited by a separate running suture of catgut. Ordinary gut will suffice in the majority of instances, but when in operations above the navel the posterior sheath of the rectus must be included in the peritoneal suture, a No. 2 ten-day chromicized catgut is preferable. The closure of the peritonæum is greatly facilitated by the following procedure:

When the full length of the peritoneal incision is reached, retractors of linen or silk thread of good size should be introduced from within out through the abdominal peritonæum and all the tissues of the abdominal wall. One of these should be near each end of the incision and one about half an inch from the edge of the wound on either side and near its middle.

Should there be distention of the intestines or a tendency of the omentum to protrude, the sutures can be inserted without risk of wounding these organs by using a sterile spoon. The spoon, convex surface downward, serves as a shield for the introduction of the half-curved Hagedorn needle (Monks), and the ends are tied to form a loop about ten inches in length.

These looped thread retractors are of great value, not only in lifting the abdominal wall and exposing the viscera to view, but in facilitating the introduction of gauze mats and the rapid and safe closure of the peritoneal incision.

The author insists upon this precaution in view of the many cases, especially after appendectomy, in which he has been called upon to do a secondary operation for the relief of imprisoned omentum or mesentery caught in the peritoneal sutures at the time of operation.

After the peritonæum is sutured, the chief reliance in the prevention of hernia is in overlapping the edges of the aponeuroses or sheaths of the recti muscles and of holding them firmly in apposition until thorough union is secured.[1]

Prof. John Collins Warren has called attention to the fact that in connective-tissue proliferation under aseptic conditions, the time required for the organization or fibrillation of the new connective tissue is about three weeks. This he regards as a "surgical unit of time" so far as the completed healing of wounds under the most favorable conditions is concerned.

It should, therefore, be imperative to keep these muscles as much at rest as possible and to take every precaution to prevent them from being subjected to pressure or strain, for at least this length of time.

In limited incisions and in simple operations, such as may be done through the small McBurney incision for appendectomy, a patient may be permitted to be up and about at an earlier date, within ten days or two weeks from the operation, but in extensive incisions the conditions are entirely different, and the practice of permitting these patients within a few hours or two or three days to get out of bed and move about is not advised.

For a strip one half inch in width for the entire length of the incision, the fat is dissected from the anterior surface of the aponeurosis or sheath on the left side.

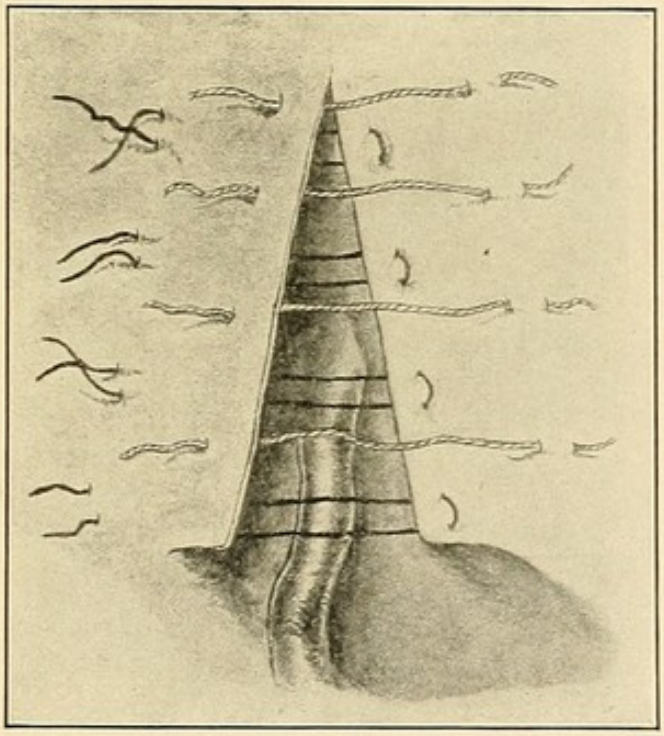

Fig. 437.—Four mattress and four single overlapping sutures for approximating the aponeuroses. (After Championnière and Noble.)

The sheath upon the right side of the wound is lifted from the rectus muscle for an equal width and distance. This is the overlapping layer. The fasciæ are now overlapped and securely held by strong kangaroo-tendon, mattress, or U-shaped sutures, as employed by Championnière in his operation for inguinal hernia (Fig. 437).

[1] Within recent years, partly upon the initiative of Lucas-Championnière, and later, E. Wyllys Andrews, of Chicago, who applied the overlapping method for closure of the external abdominal ring in herniotomy, but more particularly to Dr. Charles P. Noble, of Philadelphia, who first demonstrated the practical results of overlapping the aponeuroses as applied to the abdominal wall in general, this great advance in abdominal surgery has been made.

The needle, as shown in Fig. 437, is first introduced from without, in through the right aponeurosis, one half inch from the cut edge, and up through the opposite aponeurosis an eighth of an inch from the edge, back again in a loop suture a fourth of an inch wide, to come out finally in line with and one fourth of an inch from the original point of entrance. These sutures should be half an inch apart. An intermediate kangaroo-tendon suture is inserted as shown in the drawing. Fig. 438 illustrates the overlapping secured by tying the U-shaped or mattress suture. The reënforcing or tension suture is not yet tied.

This method of overlapping the aponeurosis may be varied to suit different conditions. When the abdomen is flaccid the overlapping surface need not be more than one fourth of an inch, and a simpler running suture of kangaroo tendon

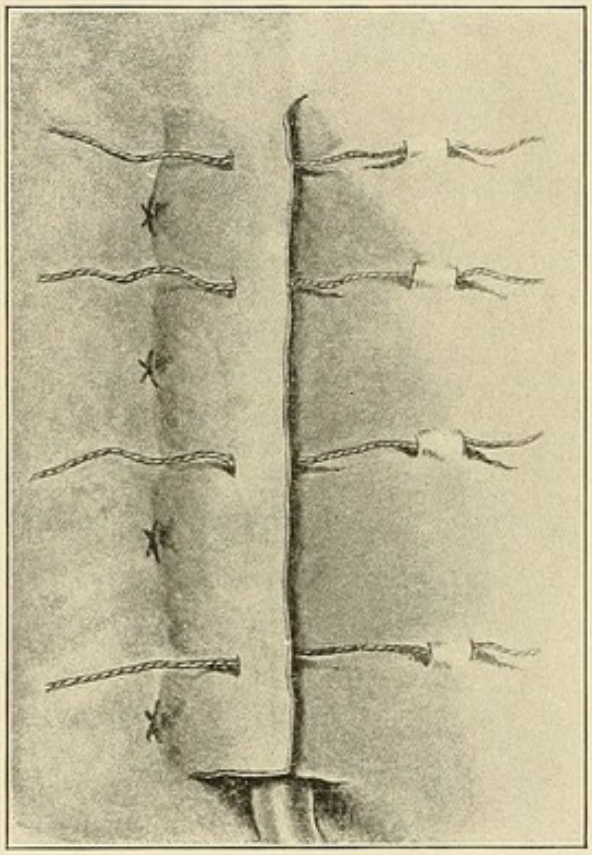

FIG. 438.—The same. The four single sutures not yet tied.

the method of insertion of which is shown in Fig. 439, will suffice, or the modified mattress suture, as shown in Fig. 440, may be substituted.

Sutures directly in the muscle substance are of doubtful propriety, for the reason that the fasciculi are apt to cut through from too great tension in their insertion, or as a result of muscular contraction after the operation. If used at all they should be interrupted and only loosely tied.

Where there is considerable fat in any abdominal incision it should be brought together by a subcutaneous suture, as shown in Fig. 74, while the skin itself may be united by the endocuticular suture.

Incisions through the linea semilunaris are objectionable for the reason that not only are the same nerves divided that would be cut in splitting the rectus, but there is also not enough muscular and aponeurotic tissue here to give a firm and resistant union. When this part of the abdominal wall is in the field of operation, it would be better to lean to one side or the other of this line, splitting the sheath of the rectus and temporarily displacing this muscle by preference, or the McBurney method of separating the fibers of the aponeurosis of the external oblique and the muscle fibers of the internal oblique and transversalis. For draining an appendicular abscess or removing the appendix in the uncomplicated cases of interval operations, this incision is ideal. The muscle-splitting incision

of Deaver is, however, preferable in the vast majority of cases, for the reason that no matter what complications are encountered it can be enlarged to any extent without the danger of hernia. Other special incisions of the abdominal wall will be considered with the operations of which they are a part.

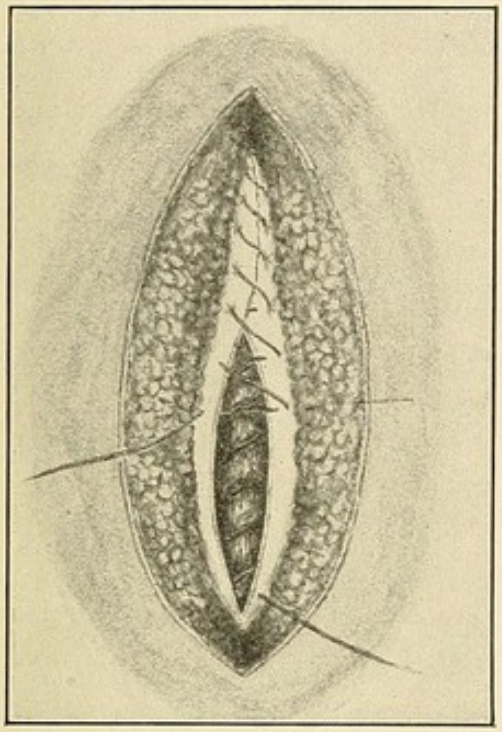

FIG. 439.—Showing method of introducing the continuous or running suture for overlapping the aponeuroses. (Noble.)

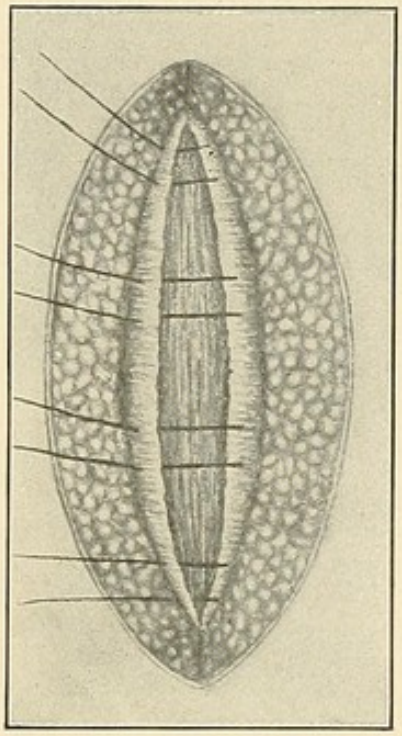

FIG. 440.—Showing method of introducing four mattress tendon sutures for overlapping the aponeuroses. (Noble.)

Abdominal Injuries in General.—Extensive injuries may be inflicted upon the abdominal viscera without outward signs, and at times with no immediate symptoms proportionate to the gravity of the internal lesion. The bowel has been completely severed by a wagon wheel, the patient walking immediately after the injury a considerable distance without shock or pain. In the majority of instances, notwithstanding the abdominal wall is stronger below the navel than above it, the injuries are found in the lower abdomen. Seemingly slight accidents cause serious and fatal injury. Senn reports a case of rupture of the intestine due to the patient's slipping to the ground, striking on the buttock. In the same way the liver and spleen may be ruptured. Two cases of intestinal rupture have occurred from a blow on the back near the spinal column. In thirty-six cases of horse kick upon the abdomen, intestinal rupture occurred in thirty-five. In determining the gravity and location of the injury, although the site of impact does not always guide one to the lesion, this should be considered. If a blow has been received over the right hypochondrium, followed by a weak pulse and other signs of anæmia, with shock, hepatic rupture should be suspected. The same would be true in regard to a blow received over the spleen, which is the most readily ruptured of all the abdominal viscera.

The careful consideration of the general condition of the patient at the time of accident is of importance. An enlarged spleen or liver, distended stomach or bladder, or presence of a large hernia, as well as the expectedness of the blow, are all important factors. If injury is even momentarily expected, muscular tension will do much to prevent rupture.

Treves suggests that the thickness of the fat over the part struck is to be considered in arriving at a diagnosis, as well as the position of the patient at the time of accident.

In the majority of instances initial shock is present, although its severity and

duration are not reliable criteria as to the extent of intra-abdominal injury. Severe and persistent shock is suggestive of hæmorrhage, and when this is accompanied by a rapid, weak pulse, restlessness, sense of suffocation, thirst, cold perspiration, a diagnosis of hæmorrhage is practically sure. In most cases pain is present. According to Dr. Robert Le Conte, one of the most valuable signs is muscular rigidity. He states that the characteristic of visceral injury is progressive rigidity, usually of boardlike hardness.

Persistent vomiting is of great diagnostic value. If bloody, the stomach and upper intestinal tract are naturally under suspicion.

Increasing pulse-rate is ominous. Fowler claims that a gain of from ten to fifteen beats an hour is significant of intra-abdominal rupture.

Facial expression should always be carefully considered.

Brewer asserts that deep-seated, localized pain following an abdominal injury, especially if increased by pressure and accompanied by local and general rigidity, is one of the most common symptoms of visceral injury.

Lesions of the small intestine are more serious than the large, by reason of the mobility of this part of the alimentary canal and the greater danger of the general dissemination of intestinal contents.

The *prognosis* depends upon the time which elapses between the injury and the operation, as well as the character of the treatment. In all cases of doubt exploration should be advised. If the symptoms of acute hæmorrhage are present, and there is shock, the additional risk of operation may be incurred, since death is inevitable from bleeding. Ligation of the extremities, and the sequestration of as much blood as is possible in the legs and arms, should be part of the emergency treatment in all cases of profuse internal hæmorrhage. The head should be lowered in order to maintain the cerebral circulation.[1]

Wounds of the abdomen are divided into *penetrating* and *non-penetrating*, and both of these varieties are again divisible into those which involve the viscera and those in which the organs escape.

Contusions may involve the integument, produce extravasation in the subcutaneous tissues, rupture of the muscles, or displacement or rupture of a viscus and death without any external evidence of injury.

Simple contused wounds of this region demand no especial consideration. If abscess or hæmatoma occurs, the same rule of treatment which applies elsewhere is applicable here. *Rupture* of one or more of the muscles may occur as the result of a blow on a muscle in tension, or by muscular action alone. The rectus abdominalis is most frequently torn. Hernia is apt to follow this injury unless immediate union is secured by freshening the ruptured surfaces and uniting them by suture. The overlapping technic (Noble) applied to muscular tissue and the aponeuroses is essential. Perfect rest and well-adjusted support are also of great importance in insuring success.

Displacement or rupture of an organ (as the kidney, spleen, etc.) may be caused by direct violence or by a severe fall. The diagnosis will, in the first lesion, depend upon the absence of the organ from its normal place and the recognition of the tumor in the new position. Laceration is followed by hæmorrhage, at times profuse, which is evident from great pallor and a rapid and weak pulse. If the intestine is involved, the escape of gas or fæces is followed usually by profound shock, tympanites, and peritonitis. Emphysematous crackling may be recognized on palpation.

The first indication in treatment of a displaced viscus is to place the patient in such a posture that gravity will aid in the restoration of the organ to its normal position. A compress and bandage may be useful in some instances. In rupture of a solid organ profound quiet should be maintained. When hæmorrhage is alarming, deligation of the extremities is advisable. If the symptoms of rupture of the alimentary canal are present, the abdomen should be opened in the median line, the rupture closed, or an artificial anus established, and the peritoneal cavity carefully cleansed.

[1] The author acknowledges his indebtedness to the excellent contribution of Dr. H. C. Dalton in the "Journal of the Missouri State Medical Association," vol. iii, Nov. 8, 1907.

Non-penetrating *incised*, *punctured*, or *shot* wounds of this region do not demand especial consideration. The former should be closed, while it is usually safer to treat the punctured and shot wounds by placing a sublimate compress over the opening.

Penetrating Wounds.—Wounds of the abdomen which penetrate without wounding any internal organ should be closed in the same manner as directed for the closure of surgical wounds through the belly. If an internal organ is involved the abdomen should be opened, the character of the lesion ascertained, and proper surgical treatment instituted. Among the symptoms which aid in arriving at a diagnosis are the following: If the injury is followed by the vomiting of blood it is fair to conclude that the stomach or duodenum is involved; if blood is passed by the rectum, that the wound is farther along the bowel; or, if hæmaturia exists, that the kidney, ureter, or bladder is injured. If the odor of intestinal gas or fæces is present, the inference is clear that the alimentary canal is opened. Bile, gastric juice, or recently ingested matter seen in the wound or recognized by the sense of smell indicates the character of the injury and the location of the perforation. The crackling sound peculiar to emphysema, elicited by palpation, indicates the presence of intestinal gas in the loose tissues, beneath the peritonæum (Dennis). Tympanitic resonance over the liver, which has appeared suddenly and which is persistent, is a diagnostic sign of perforation of considerable value. Shock is usually severe, although in some cases it may be slight and of short duration.

In shot wounds the location of the wound of entrance (and exit, if it exists), together with the known direction of the missile and the force with which it was propelled, will be of aid in determining the character of the lesion within. A bullet passing directly or obliquely into the abdomen, at or below the level of the umbilicus, can scarcely miss the intestinal tube, and will be more apt to make a number of holes than a single wound. Above this point the chances of escape are more favorable, yet so fortunate a result is exceptional. The direction and depth of a stab wound may also be determined by the appearance of the wound and an examination of the instrument with which it was inflicted. The persistence of pain in a given point within the abdomen is a recognized symptom of a penetrating wound.

Many of the foregoing symptoms may not be present within the first few hours after the receipt of a wound which has penetrated the alimentary canal, and beyond the external wound and a varying degree of shock there may be no symptom of perforation. Temporary contraction of the muscular fibers of the stomach or intestine, or prolapse of the mucous membrane into the wound, may prevent, for a time, the escape of gas or ingested matter, and the appearance of the more pronounced symptoms of perforating wounds of the alimentary canal.

Treatment.—When there is a wound in the wall of the abdomen, the immediate indication is to determine whether it opens into the cavity. In order to do this, the disinfected finger, or preferably the light and porcelain-tipped Nélaton probe, should be introduced, and, if necessary, the opening enlarged. Cocaine anæsthesia may be sufficient for this procedure. The peritonæum lining the abdominal wall will require careful infiltration. If the wound is confined to the abdominal wall it should be treated in the aseptic method advised for ordinary wounds of the soft tissues. If it extends through the wall, the abdomen should be opened and the condition of the viscera examined. As to whether the incision should be an enlargement of the accidental wound or made in the median line, the location and direction of the wound must determine. The section should be, preferably, near the linea alba. (See Cœliotomy.) If the lesion is not more than six inches from this line, and if the direction of the wound is backward or tending toward the center, this incision should be chosen. Under other conditions the section may be through the wound of entrance or elsewhere. (See Cœliotomy.)

In this procedure the details of the antiseptic method should be carried out, as directed in operation for the relief of intestinal obstruction. When the peri-

toneal cavity is opened, if it contain clotted blood which is known not to have entered from the wound of operation, or ingested matter, or if gas escape through the opening, the penetrating character of the wound is evident. If none of these signs are present the disinfected hand should be introduced and the internal surface of the wall examined at the supposed point of entrance. In examining the intestinal canal it is usually advisable to begin with the loop which presents at the incision.

This should be marked for identification by a loop suture passed through the mesentery and around the gut, leaving the ends tied long. In the search for perforations it is best to pass the bowel from the starting point in one direction on and on through the fingers without drawing the loops outside the abdominal cavity. This procedure may be greatly facilitated by inserting the loop suture retractors, which it is advisable to introduce through the abdominal wall on either side of the center, and at each end of the incision. Traction on these loops, at the same time lifting the abdominal wall forward, gives much more room for inspection and manipulation within the abdomen. When a perforation is encountered it should be temporarily closed with a small clamp shielded with rubber, which should not compress the bowel hard enough to produce necrosis. If necessary the loop, in the center of which is the perforation, may be drawn out of the abdominal incision and immediately covered by gauze or towels taken from hot salt solution. Any extravasated matter from this particular perforation should be carefully *mopped* up with gauze, wet in 1–2000 mercuric-chloride solution and squeezed so that the mercury may not be left in the peritoneal cavity. In using swabs or sponges in a toilet of the peritonæum rough swabbing should not be done, since hyperæmia and an inflammatory exudate with adhesions is very readily induced in this membrane. The search should now be continued until all of the intestinal tract above the starting point has been examined, or as far as the character of the injury will indicate as necessary. The same method of search should be employed on the other side of the starting point.

In closing intestinal perforations or penetrating wounds, the following method should be employed: For a small incision or stab wound the Lembert suture, shown in Fig. 443, is ideal. The needle is introduced into the peritoneal covering of the bowel wall one eighth of an inch from the cut edge, and is made to pass just deep enough to include the muscular layer down to the mucous, and is brought out through the serous surface right at the edge of the incision. It is carried across to the opposite side and inserted reversely in the same manner. It includes a bite one eighth of an inch wide, and when tied brings in close apposition this much of peritoneal surface, which quickly unites to prevent leakage. The peritoneal surfaces thus approximated and held in contact will, by the exudation of plastic lymph and cell proliferation, form adhesions within six hours of the introduction of the sutures. These stitches should under no circumstances be more than one eighth of an inch apart throughout the length of the wound to be closed, and at the ends it is a wise precaution to insert an additional suture more than might possibly be required, as the angles are the weak points in intestinal suture. If the loss of substance is extensive, necessitating a wide excision, and there should be danger of tension upon the sutures, it would be a wise precaution to introduce one row of the Mayo-mattress ten-day catgut one sixteenth inch from the edge, and reënforce this by the Lembert or the Cushing linen suture. A small stab or incised wound of a hollow viscus may practically always be closed without regard to the direction of the opening through the wall, and when there is no loss of substance the Lembert suture above described sacrifices such a small strip of

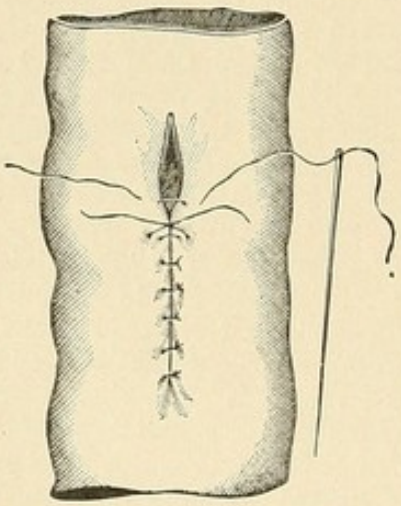

Fig. 443. — Lembert's suture for closing wounds of the intestines. (After Esmarch.)

bowel that the caliber of the gut is not materially lessened. In gunshot wounds which are more or less lacerated, and which may at times pass through the bowel in such a way as to necessitate the excision of a considerable portion of the bowel wall, the question may arise whether an immediate resuture should be made or whether an excision is preferable. If the hole has been made by a bullet and has rough or torn borders, the edges should be trimmed smooth with curved scissors and then closed. Should a very narrow strip of tissue separate two openings, it is generally safer to convert them into a single elliptical wound. In uniting a considerable wound of the wall of the intestine, the line of sutures should, when possible, be transverse to the axis of the bowel, for while the sutures in this direction may slightly kink or angulate the bowel, they do not impinge upon the lumen of the gut so much as those in which the line of suture is parallel with the long axis. Rather than diminish the lumen of the bowel beyond one third of its normal capacity, it would be better to excise and reunite by suture or by use of the Murphy button should the patient's condition be such as to contraindicate the longer operation. If a Murphy button is not at hand and the condition of the patient is bad, Bodine's temporary artificial anus method should be substituted.

When the small intestine only is involved, in the hands of one expert with the needle, end-to-end anastomosis is advised, provided always that the condition of the patient will justify any operation. In anastomosis between large and small intestine lateral union is preferable. In an emergency the Murphy button (round or oblong) is of great value.

When visceral extravasation has occurred the method of cleansing the peritoneal cavity should be determined by the extent and location of the extravasation. If there is only a perforation at one point, with a very limited leakage, which is not infrequently the case where a small caliber bullet has passed, it would be better to make a careful local toilet, mopping the extravasated matter away carefully with swabs taken from 1–2000 hot mercuric-chloride solution, the excess being squeezed out before using. This mopping should be followed with a second cleansing with hot salt solution in order to remove or neutralize any excess of mercury. Unless a general widespread peritonitis has already been established, irrigation is not advisable, for fear of spreading a localized infection to portions of the peritoneal cavity not yet involved. In all of these traumatic infectious processes below the navel the Fowler posture is very essential. Above this level an effort should be made by the recumbent posture to confine the infection to a limited area. If there has been a gravitation of extravasated matter into the pelvis, a free near-median line incision should be made in order to permit of the most thorough inspection and cleansing of the peritonæum.

In a toilet below the umbilicus a certain amount of hot salt solution may be safely employed, provided that the Fowler position is carefully maintained and that pelvic drainage is established when indicated. Drainage of the pelvis is best secured in females by opening through Douglas' *cul-de-sac*, inserting here a Van Buren Knott rubber and gauze drain, and in males the double supravesical drainage. (See Diffuse Suppurative Peritonitis.)

No especial treatment can be laid down for wounds of the solid viscera or of the great vessels. The arrest of hæmorrhage, the removal of extravasated blood, and the establishment of drainage when needed are the indications.

The argument in favor of operative interference in penetrating or supposed penetrating wounds of the abdomen may be briefly stated as follows:

1. The enlargement of a wound sufficiently to demonstrate whether or not it opens into the cavity of the peritonæum is a simple procedure, practically without danger. Cocaine anæsthesia should suffice.

2. Abdominal section is not a difficult, nor, under ordinary conditions, when properly performed, a dangerous operation.

3. A penetrating wound of the abdomen, left without surgical interference, is always attended with extreme danger.

4. If any vessels of size are divided, hæmorrhage is an immediate danger, and peritonitis a serious and probably fatal complication.

5. If the alimentary canal is opened, death is almost inevitable. The few recorded cases of recovery form such an infinitesimal proportion of the whole that they should carry no weight against interference.[1]

[1] It may be justly claimed that to American surgery is due the great advances which have been made in the treatment of penetrating wounds of the abdominal cavity. In 1847 Dr. Newell, of New Brunswick, N. J., "made an abdominal incision and sutured the intestine in a case of gunshot wound, cleansed the cavity, closed the wound, and the patient recovered."

A similar operation was done by Kinloch, of South Carolina, in 1882, and by Kollock, of the same State, in 1884, who sutured two pistol-shot wounds of the colon and one of the small intestine, with a successful result.

The operation was not brought prominently before the profession until the celebrated paper of Dr. J. Marion Sims was read before the New York Academy of Medicine, on October 6, 1881. This paper attracted widespread attention, and may truly be said to be the starting point in the surgical invasion of the abdominal cavity for penetrating wounds.

In 1884 Dr, Bacon Saunders, then of Bonham, Texas, opened the peritoneal cavity after a stab wound with symptoms of hæmorrhage, tied the mesenteric artery, which had been divided, and cleansed the cavity, with a successful result. A brilliant case of (intraperitoneal) gunshot wound of the bladder, the first on record, was reported by Dr. Amos B. Walker, of Texas, and is given in the chapter on injuries of the bladder. In 1885 Dr. W. T. Bull successfully performed his operation for multiple perforation by a pistol ball. In 1886 Dr. W. O. Roberts, of the University of Louisville, operated for a stab wound of the intestine, with success. Following this pioneer work, successful cases have been reported of late years in many instances.

CHAPTER XX

THE STOMACH

PENETRATING WOUNDS—FOREIGN BODIES—CICATRICIAL CONTRACTIONS—TUMORS—GASTROTOMY—ULCERS—PARTIAL OR COMPLETE GASTRECTOMY—GASTRO-ENTEROSTOMY — GASTRO-PYLORECTOMY — DUODENO-GASTROPLASTY — GASTROPTOSIS —GASTROPLICATION — CARCINOMA — SARCOMA — DUODENAL ULCER — PERFORATION

Among the surgical lesions of the stomach are the lodgment of *foreign bodies*, *penetrating wounds*, *obstructions* due to *congenital malformation* or *cicatricial contractions* (hour-glass stomach, pyloric stenosis) *adhesions* and *tumors*.

Certain conditions of *dilatation* and *displacement* due to hyperdistention or atony are also at times properly considered amenable to surgical intervention, while *gastric ulcer*, the most important of all the pathological conditions of this organ in recent years, has been accorded an unusually prominent place in the list of surgical diseases.

Foreign Bodies.—The presence of foreign bodies in the stomach may be recognized by the X-ray when the substance is metallic; by palpation, as in the case of gastroliths of considerable size formed by the accretion of ingested matter; by the endoscope or gastroscope; and lastly, when other means fail, by surgical exploration. For their removal the operation of *gastrotomy* is necessary.

In this operation the organ is exposed by the incision which splits the left rectus half-way between the xiphoid appendix and navel, usually enlarged in whatever direction may be required after the situation, size, and shape of the body to be removed has been ascertained. When the stomach is fully exposed, an effort should be made to draw it up into and through the wound as far as possible, where it is held by silk threads inserted into the walls, the needle which introduces these not passing into the lumen. The organ may then be incised, and the foreign body extracted either by the finger or a suitable instrument. Great care should be taken to so protect the margins of the abdominal incision with mops of gauze as to prevent the entrance of any septic matter into the peritoneal cavity. The wound in the stomach should be closed by the Mayo-Cushing double mattress suture method. If the stomach cannot be drawn up into the wound, the abdominal incision may, if necessary, be further enlarged and sterilized pads inserted in such a way that the contents of the stomach cannot come in contact with the peritonæum after it has been incised. The same method of suture for the stomach wall should be employed.

It is an essential feature of either procedure that the stomach be thoroughly washed out before the operation and that no food be taken for at least twelve hours preceding the anæsthetic. For washing out the stomach, the ordinary œsophageal tube and pump or the stomach siphon may be used.

Wounds.—In the treatment of gunshot or other penetrating wounds of the stomach, the incision will be determined in a measure by the location of the wound of entrance. As a general proposition, the whole stomach area may be best exposed by an incision which splits the left rectus, beginning about half-way between the umbilicus and the xiphoid cartilage, and which may be enlarged as necessary. When more room is required, lateral retraction upon the recti muscles, when one or the other is split or when the median incision is made, may be increased by dividing transversely the muscle-sheath which allows the uncut fibers

to stretch. Should the lesion be near the cardia and otherwise inaccessible, the Meyer costoplastic procedure may be necessary.

The stomach should be drawn up into the wound as far as possible, the opening in the anterior wall temporarily clamped to prevent further extravasation, while the

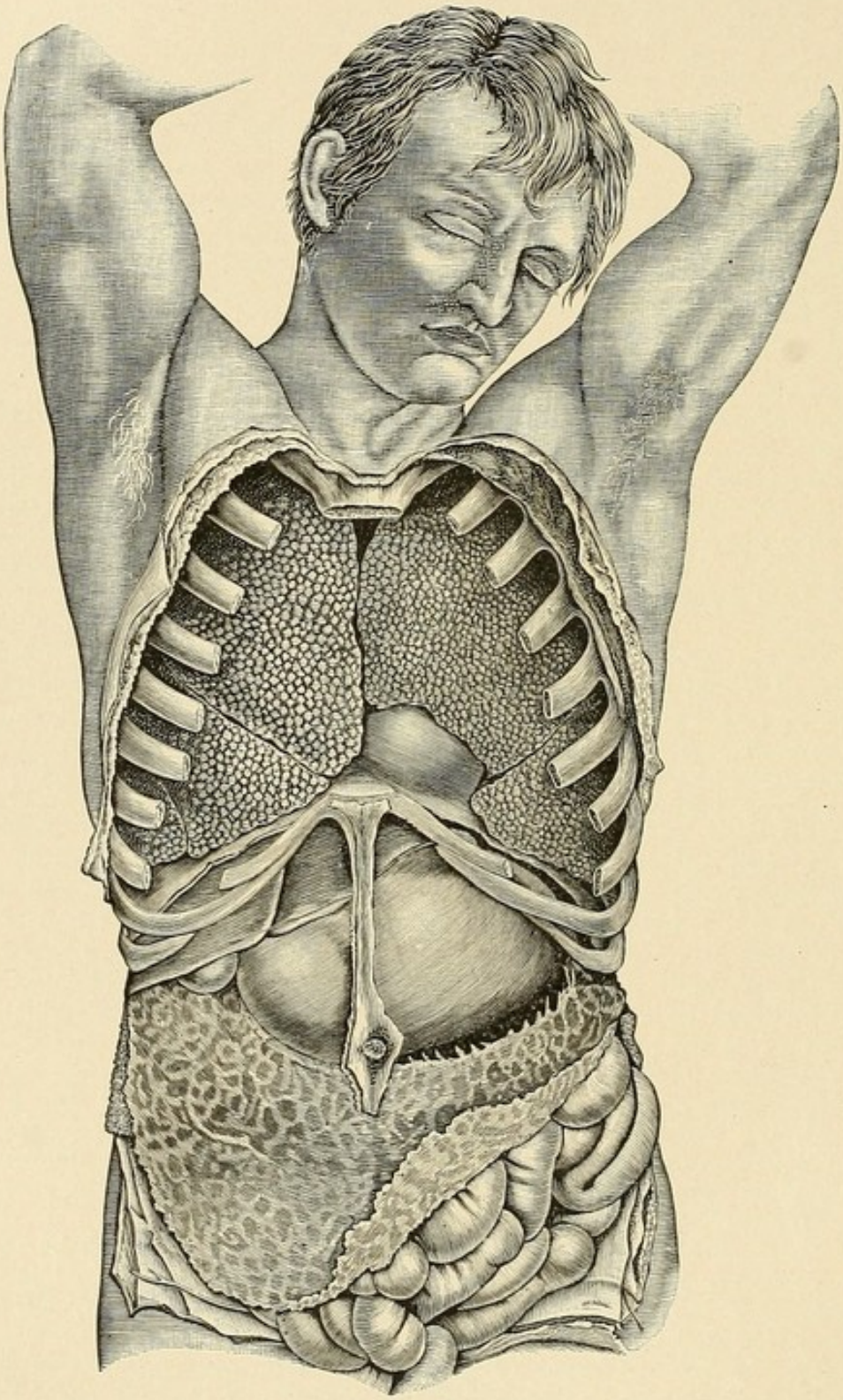

Fig. 444.—(After Maclise.)

colon and omentum are rolled up and search made for the posterior wound. If this is found it should be clamped, all extravasated matter carefully removed, and disinfection made with swabs moistened in 1–3000 mercuric-chloride solution, followed immediately by the free use of hot salt solution. The question of packing or

draining must depend upon the conditions present. If in serious doubt as to infection, it is wiser to lean to the safer side of drainage, notwithstanding the objectionable features of the adhesions which are apt to follow. In closing wounds of the stomach, a moderate-sized pistol-shot opening may be closed with a very carefully inserted purse-string suture of chromicized catgut, reënforced by a Cushing linen peritoneal mattress suture, or when great haste is required a single purse-string suture of linen (somewhat less safe) will suffice. The anterior wound should be treated in the same way.

In the case of incised wounds or large punctures, the Mayo muco-serous and the Cushing musculo-serous sutures are advised.

When extensive injuries have been inflicted upon the walls of the stomach, after closing any posterior points of leakage and instituting packing or draining, as may be necessary, in order to give the greatest possible degree of rest to the organ during the process of repair and at the same time to insure the patient's nourishment, a temporary gastrostomy may be done. If the anterior penetrating wound be favorably situated, this opening may be utilized by carefully stitching the peritonæum of the abdominal wall to that of the stomach, so that no leakage into the peritoneal cavity may occur. Supporting sutures of No. 1 or No. 2 linen should be carried through the entire thickness of the stomach wall, external to the peritoneal row of stitches, and the needle then carried through the integument around the margins of the superficial incision.

In these rare emergencies the insertion of a soft-rubber tube through this opening and beyond the pylorus will permit the introduction of nourishment to the duodenum and small intestine without risk to the posterior wound in the stomach wall.

Should this procedure be deemed inexpedient, colon alimentation should be relied upon for a week or ten days after the operation. Under favorable conditions, liquids in very small quantities may be given by the mouth after three or four days. It is safer, however, to rely upon nourishment by the rectum until the wounds in the stomach wall have safely healed.

Ulcer.—Ulcers of the stomach may be divided clinically into two classes: The *acute, superficial erosion*, limited to the first few layers of lining epithelia, and the *deep or chronic ulcer*, occasionally round in shape, more often with jagged, irregular outlines, which invades all of the mucous coat, involves the muscle, producing with or without perforation a general or local peritonitis.

The superficial ulcer is difficult of recognition, and unless discovered by the gastroscope it may heal without attracting especial attention, and often without recurrence. It is, however, prone to recur, and unless proper treatment is instituted will merge gradually into the chronic form.

One of the occasional symptoms of superficial ulcer is hæmorrhage, usually slight. It occurs in individuals of low resistance, and is apt to follow an abrasion of the epithelial lining caused by hard ingesta, the broken surface becoming more and more irritated in the presence of hyperacidity.

Insufficient mastication and overingestion are in all probability the principal factors in causing the production of gastric ulcer.

Since it is much more common in men than in women, the inference seems clear that overeating, induced by the indulgence in drinks, has an important bearing in the etiology. It is, however, not infrequent in infants. Between the ages of seven and thirteen it is not at all rare. (Prof. A. Jacobi, *Albany Medical Annals*, June, 1907.)

Chronic ulcers may be recognized by the feeling of distress which is always constant after eating, even when a small quantity of food is taken. This distress gradually develops into well-marked pain, often intensely cramplike in character. There is tenderness or extreme pain on direct pressure, especially over the pyloric end. Nausea and vomiting are the common indications of the progress of this lesion, and are usually present fifteen or thirty minutes after ingestion. With these earlier symptoms, the later occurrence of hæmorrhage points with almost unerring certainty to ulcer.

The endoscope, an instrument which should prove of inestimable service in

the early recognition and the prompt and intelligent medical treatment of these lesions, should be employed as an aid in diagnosis as well as in treatment. The one laboratory diagnostic test of value is the presence of high values of hydrochloric acid, which indicate ulcer, while low values suggest cancer (W. J. Mayo).

As to location, ninety-four per cent of all ulcers are on the pyloric side of Mayo's line (a perpendicular let fall from the cardiac orifice), and of these over seventy per cent occupy the lesser curvature and the posterior wall.

Treatment.—The medical treatment of ulcer of the stomach requires a perfect rest of this organ. This can only be secured by colon alimentation, and if after from four to eight weeks of this careful treatment with lavage and local remedies the symptoms of gastric distress are not relieved, an exploratory incision should be made in the median line half-way between the umbilicus and xiphoid cartilage. This should be large enough to permit the introduction of at least two fingers for careful palpation of this organ and for inspection.

In properly selected cases this exploration can be made with cocaine infiltration, provided that the abdominal peritonæum, which is very sensitive, is well anæsthetized; or nitrous-oxide gas with oxygen or air will be found entirely satisfactory in these shorter operations. If from the finding a more extensive procedure is necessary, ether narcosis may be superadded. By inspection, chronic ulcer of the stomach is easily recognized by the induration which is present and the milky opaque appearance of the peritoneal covering.

While in sudden *hæmorrhage* or *perforation* an immediate operation is imperative, in all other cases a patient should be carefully prepared. Lavage with the stomach tube should be systematically performed for at least a week before the operation, and during this period the patient should be fed with the most nourishing and readily assimilated articles of food. Should the conditions of this organ contra-indicate ingesta, colon alimentation should be practiced.

Should an ulcer be discovered, its free excision is demanded, and since ulcers are frequently multiple and often coalesce, a partial gastrectomy should not be begun until other lesions are located or excluded by inspection.

In multiple ulcer it is often safer and easier to excise a considerable portion of the stomach wall than to attempt a separate excision of several lesions.

The operation consists in a rapid enlargement of the incision through the abdominal wall, bringing the stomach forward into the wound, and a careful protection of the peritoneal cavity from infection by the escape of gastric contents. Sterile mats taken from hot normal salt solution should be inserted, carefully isolating the operative field, while clamps guarded by soft-rubber tubing should, when possible, be applied in such manner as to control hæmorrhage during the operation and prevent leakage from the cavity of the organ.

The entire area of induration should be excised and the edges united, preferably in a direction at right angles to the long axis of the stomach, employing the preliminary through-and-through catgut muco-serous stitch of C. H. Mayo, reënforced by the sero-muscular mattress sutures of H. W. Cushing. The technic of these sutures is thoroughly demonstrated in Fig. 445*a*.

Should it become necessary to perform *gastrectomy*, the area to be excised having been determined by careful examination, the gastrocolic and gastrohepatic omenta are tied off with catgut sutures as far as the disease extends, and "a straight elastic holding clamp is placed on the proximal side across from the greater to the lesser curvature about one inch back from the proposed line of section. On the distal side the clamp is applied obliquely from above down, right to left, to increase the diameter of the cut surface, saving from the greater curvature. In this way we have been able to secure on the distal side an opening two thirds the size of the proximal one for suturing. By having one inch or more of the tissue projecting beyond the clamps, the slack on the large or proximal side is taken up with each suture, the bits of the thread taking only two thirds of the amount of tissue on the distal portion, a difference in diameter of one third being disposed of without seam or puckering. If the ulcer is situated close to the pylorus, an end-to-end union is quite easy to obtain" (W. J. Mayo). The division should be made by a clean cut with long straight scissors or a sharp knife.

In view of the improved technic and the insignificant death-rate which in careful and expert hands follows this procedure, when any lesion of the stomach (especially at the pyloric end, where practically all begin) requires an excision the closure of which causes deep puckering or *hour-glass* contraction, a *resection* which includes the diseased area in its zone as advocated by Prof. W. L. Rodman is advised.

If direct reunion is not easily accomplished, the open ends should be closed and gastro-jejunostomy performed. Should the operator prefer gastro-duode-

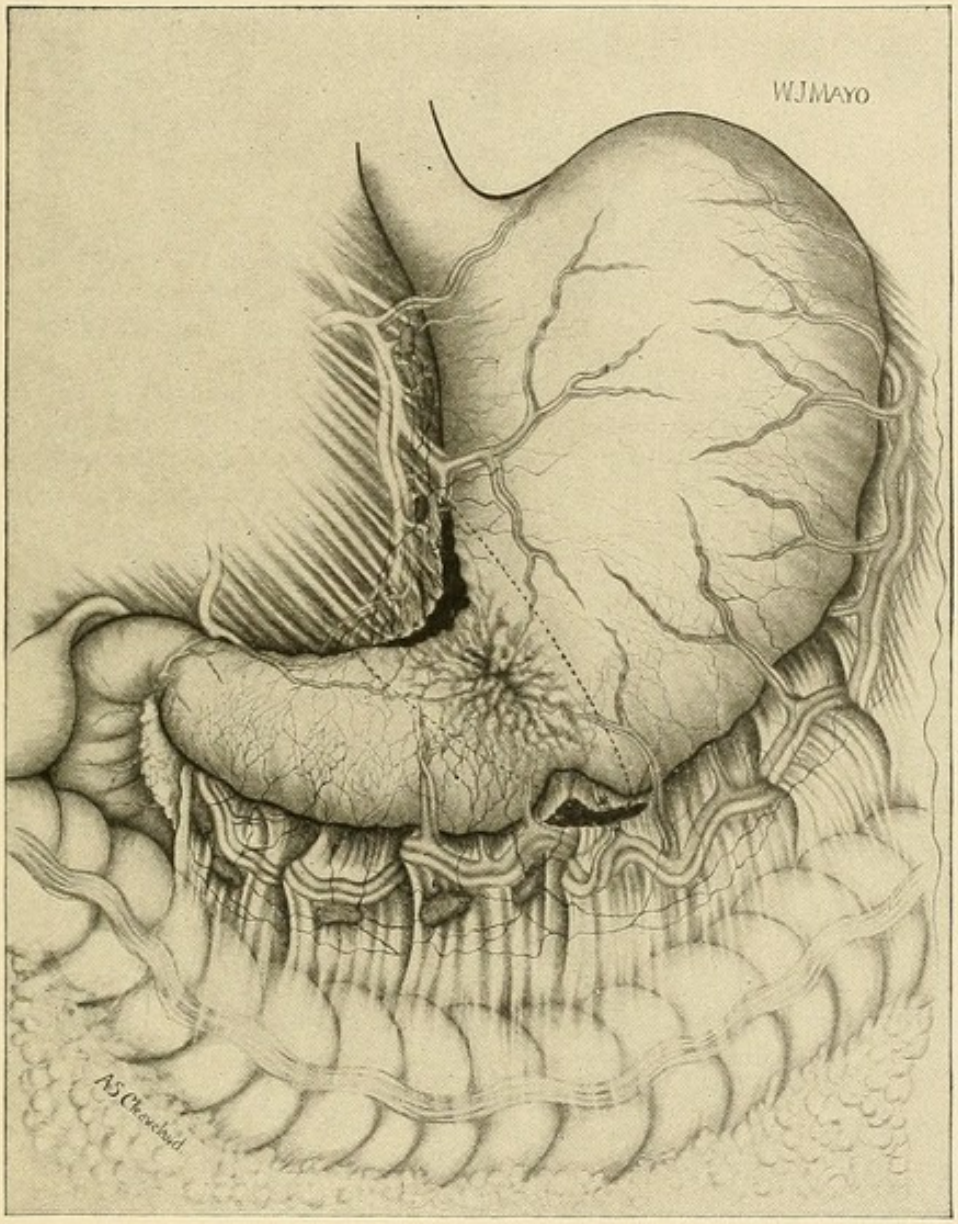

FIG. 445.—Showing lines of section in partial gastrectomy for large ulcer. The gastro-hepatic and gastrocolic omenta have been tied off. (Mayo.)

nostomy, the technic of these two procedures is practically identical. As there is only five inches of the duodenum below the entrance of the common duct, and as the second portion of this gut is not readily movable, the "no-loop" operation of gastro-jejunostomy, as advised by W. J. Mayo, is to be preferred.

Gastro-jejunostomy is also indicated where rest and drainage of the stomach is necessary to restore its function, where stricture, either of the pylorus or of the upper two or three inches of the duodenum or the last several inches of the stomach exists, and where an excision with immediate end-to-end anastomosis does not commend itself to the surgeon.

In this operation anastomosis should be made as close to the origin of the

jejunum as possible. The landmarks, as laid down by W. J. Mayo ("Annals of Surgery," 1906), are as follows: "The origin of the jejunum is at the point where the duodenum passes through the transverse mesocolon (Fig. 445*b*). The distal end of the duodenum lies behind the stomach when the latter is moder-

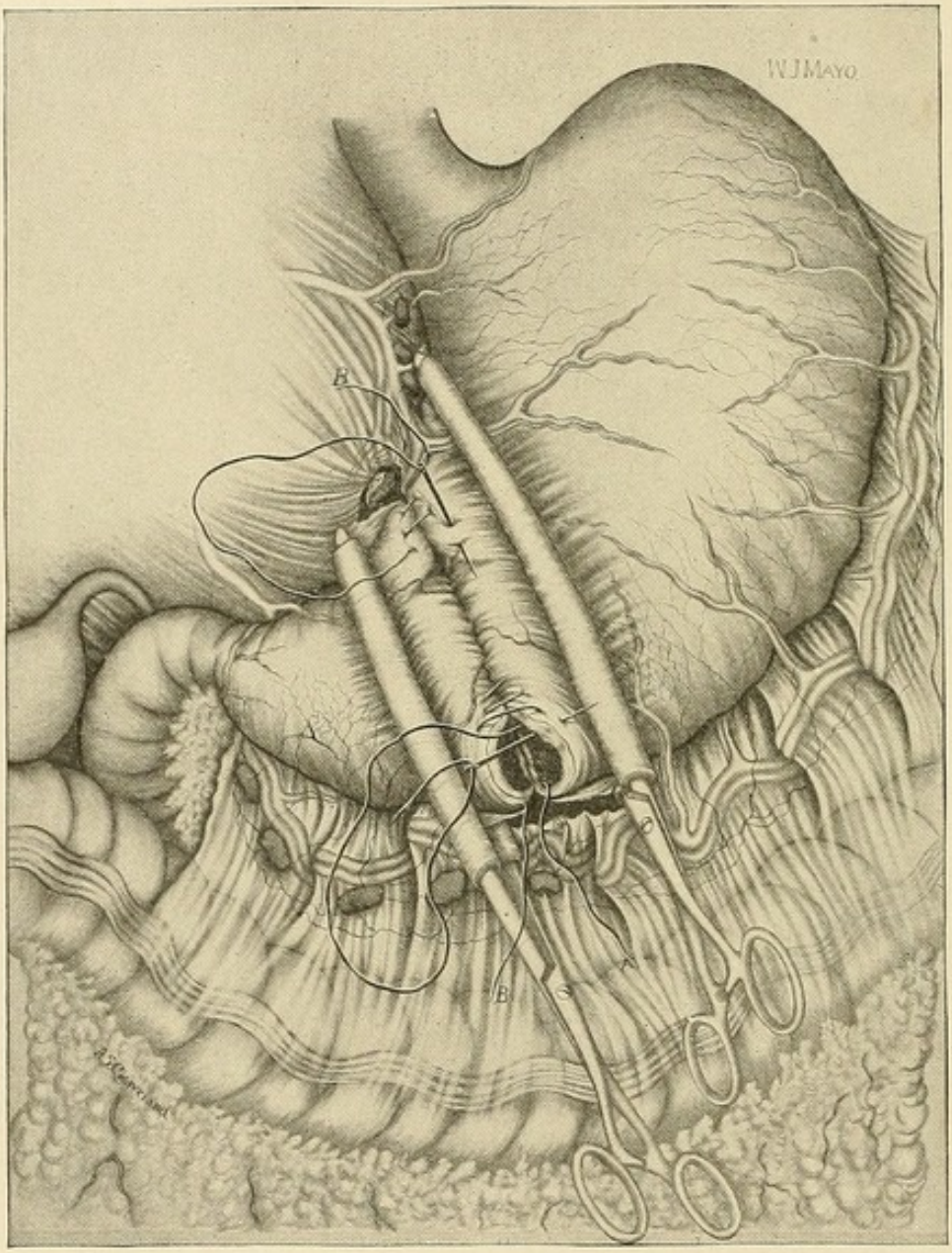

Fig. 445*a*.—Showing the excision accomplished, the clamps in position and the technic of the Cushing musculo-serous suture near the lesser curvature and the Mayo sero-mucous suture below. (Mayo.)

ately distended, and about one and a half inches to the left of the middle line and from one and a half to two inches above the umbilicus. The duodeno-jejunal juncture is within about two inches as high as the pylorus. It is here directed upward and to the left. The jejunum from this origin drops at once into the left abdominal fossa, gravitating backward to the left kidney, underneath the splenic flexure of the colon. The proper site for gastric incision is somewhat to the left of a line let fall perpendicularly from the cardiac orifice of the stomach. (See Fig. 445*b*.) The operation now recommended is figured in the accompanying illustration. Anastomosis is direct, without looping the jejunum—the "no-loop" operation. The following is the technic of the Mayos:

"*Steps of the Operation.*—For benign disease the abdomen is opened from three fourths to one inch to the right of the median line, splitting the fibers of

the rectus muscle. The transverse colon is drawn out of the abdominal incision and by a steady traction to the right and upward the mesocolon is brought out until the jejunum comes into view, and the intestine is grasped at a point three or four inches from its origin. On drawing the jejunum tight the fold of peritonæum which covers the ligament of Treitz (a small band containing muscle fibers) is developed. This peritoneal band has its origin on the transverse mesocolon and extends down on to the beginning of the jejunum, acting as a suspensory ligament; it will be found to lead to the base of the vascular arch of the middle colic artery, and *accurately marks the place where the transverse mesocolon is torn through to secure the posterior wall of the stomach* (Fig. 445*c*). The

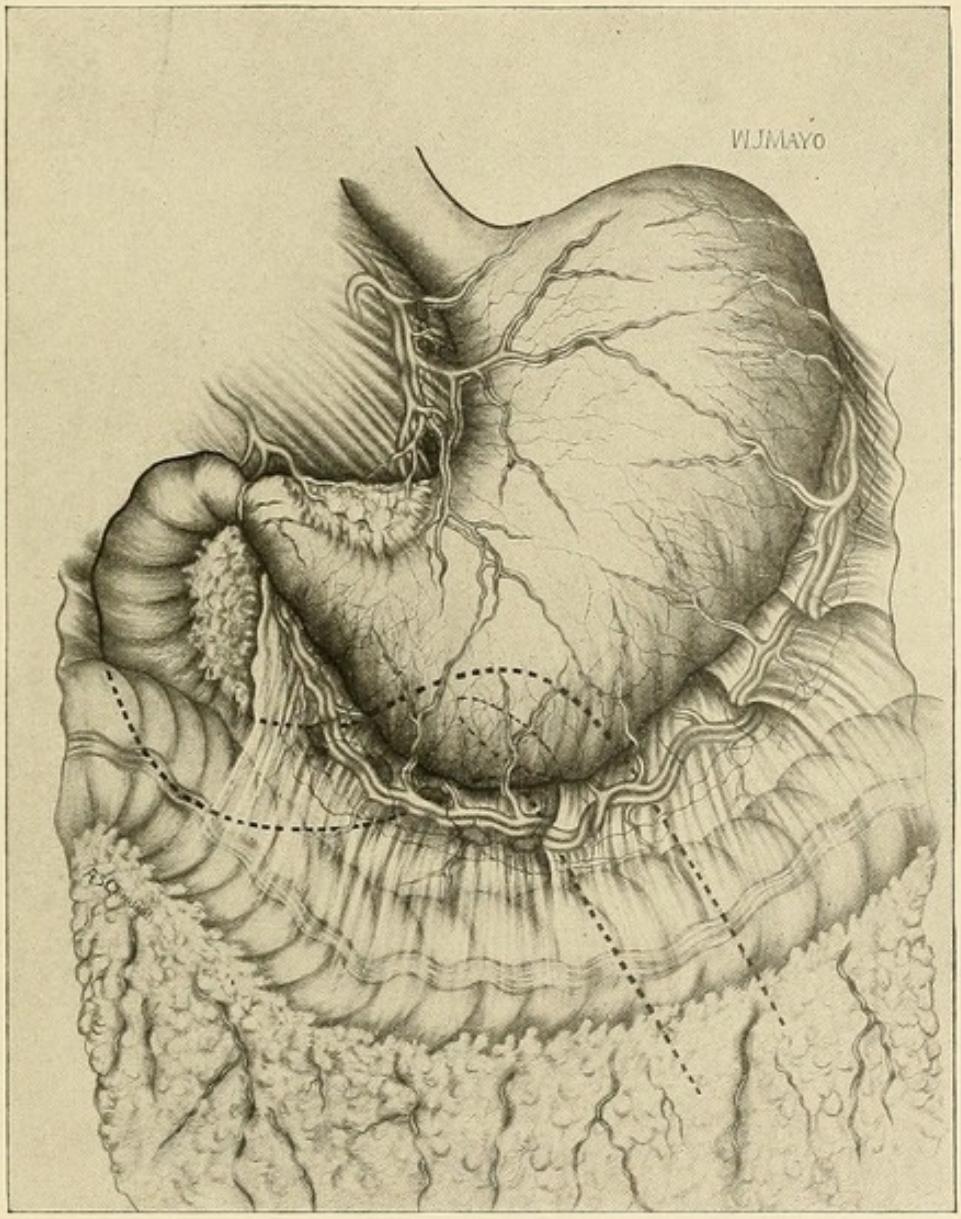

Fig. 445*b*.—Showing the location of the opening of communication between the stomach and jejunum in posterior "no-loop" gastro-jejunostomy. The dotted lines represent the last portion of the duodenum and the jejunum as they lie behind the transverse colon the stomach and the gastrocolic omentum. (Mayo.)

stomach is drawn through this opening and the anastomosis performed, beginning at a point one inch above the greater curvature on a line with the longitudinal portion of the lesser curvature and ending at the bottom of the stomach, two and one half inches to the left. To secure a proper low point a small opening is made in the gastrocolic omentum and one half inch of the anterior wall pulled through behind. Having these features in view a considerable portion of the posterior

wall is drawn into a pair of light elastic curved holding clamps. We prefer the Doyen (Fig. 445*d*). The handles lie to the right and about transverse with the axis of the body. Beginning one and one half to three and one half inches from its origin, the jejunum is drawn into a similar pair of clamps with handles to the right.

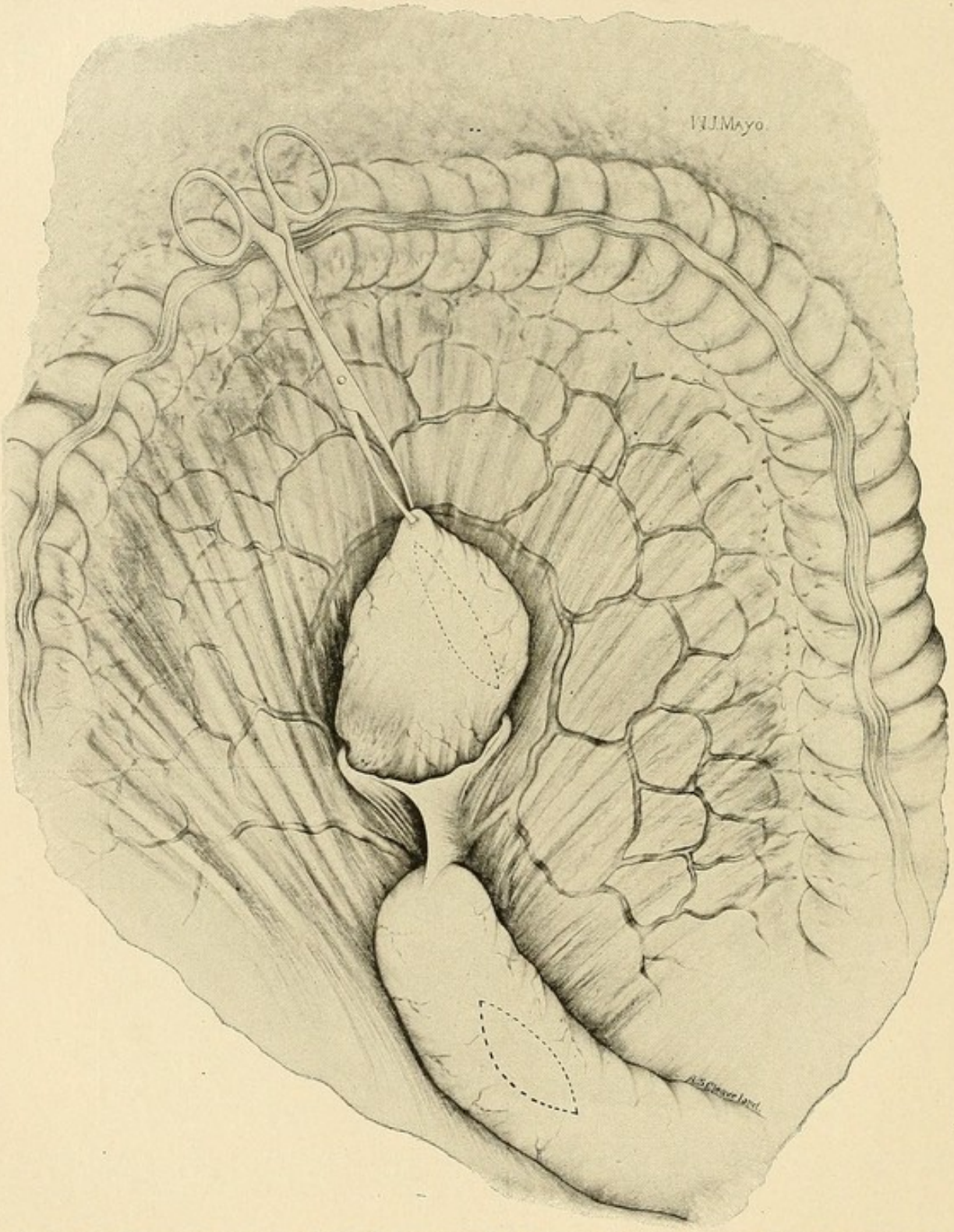

Fig. 445c.—The transverse colon is lifted, the mesocolon perforated, and a portion of the posterior wall of the stomach drawn through and held by forceps. The dotted lines indicate the direction of the opening of communication. The ligament of Treitz is seen between the stomach and jejunum. (Mayo.)

It will thus be seen that the left low point on the stomach lies in the tip of the clamps and the distal point of the jejunum lies also to the left. By placing the two clamps side by side the operation is completed in the usual manner by

two-row suturing, chromic catgut suture being used for the inner through-and-through mucous stitch, as silk or linen may hang ulcerating for months before passing away. In applying this suture on the posterior row behind *we use the Connell or buttonhole suture.* On the anterior we use the *method advised by Dr.*

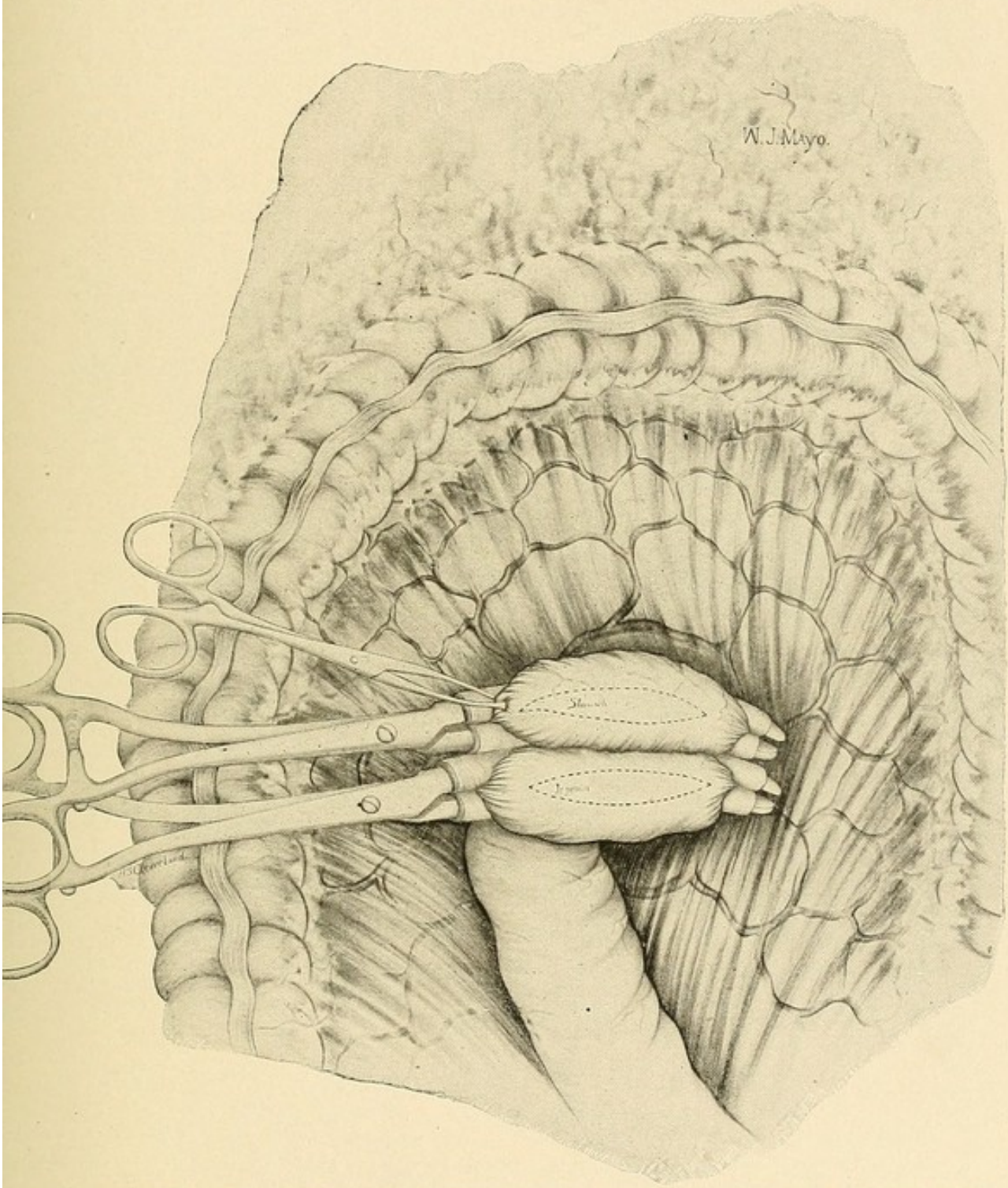

FIG. 445*d*.—The same with clamps applied preparatory to insertion of the sutures. In the trough where the stomach and jejunum are in contact the Cushing stitch is first placed for the length of contact. The two organs are then incised and the Mayo suture inserted for the entire circumference of the openings. The Cushing stitch is then completed. (Mayo.)

Charles H. Mayo, which consists in entering the needle on the peritoneal side through to the mucous and directly backward from mucous to peritonæum on the same side. By doing this alternately, first on one side and then on the other, with this first chromic catgut suture the peritoneal surfaces are rolled into contact, the parts to be united are held firmly in apposition, and the hæmorrhage

checked. The outer row consists of No. 1 celluloid linen (Pagenstecher). Flattening the intestine (Cannon and Blake) should be avoided by grasping the intestinal wall close to the margin of the incision with the suture so as to turn in a narrow seam from the intestinal side. On the gastric side, on the contrary, there need be no hesitation in taking a free grasp of the tissues. The rent in the mesocolon is fastened to the suture line with three or four mattress sutures of linen. This should grasp the peritoneal coat close to the margins of the rent in such manner that when tied all the raw surfaces shall be turned in behind the stomach, and the peritonæum folded smoothly against the gastro-jejunostomy opening so that there shall be nothing to cause adhesions to form between the mesocolon and the jejunum beyond the anastomosis."

While in the hands of one who, by reason of large experience, can work with rapidity and accuracy in performing anastomosis by suture, under other conditions the employment of Murphy's oblong button may be preferred.

The technic is as follows: After the jejunum has been clamped on either side of the point where the incision is to be made, two floss needles, two and one half inches in length, on a single thread of Pagenstecher linen or silk No. 2, are in-

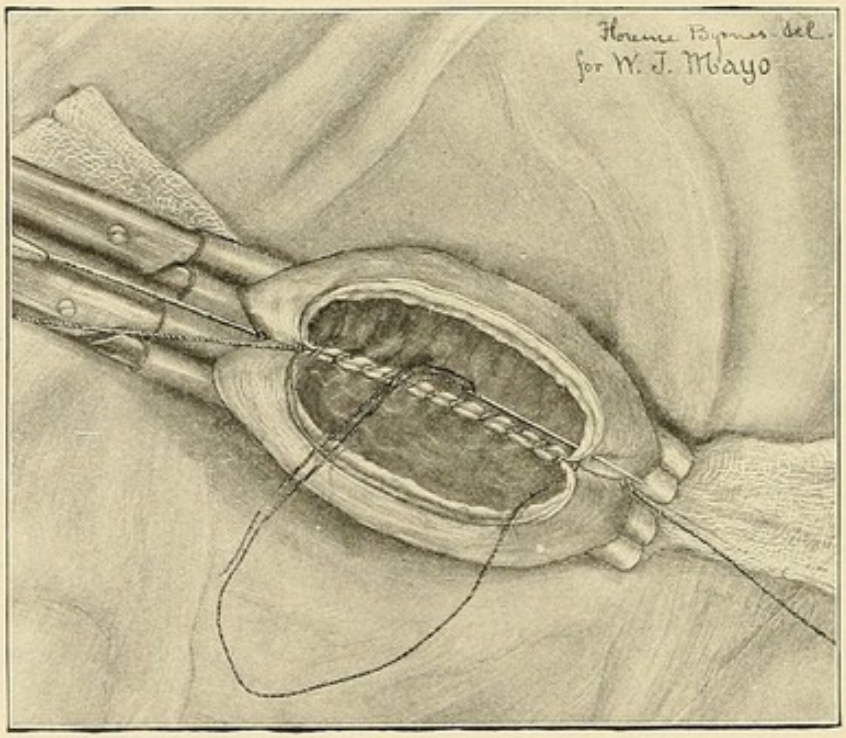

Fig. 445e.—The same. The posterior half of the Cushing suture has been completed, a straight incision has been made into the cavity of both viscera, the C. H. Mayo stitch has been superadded and is being continued along the entire circumference of the anastomosis. When completed the remainder of the Cushing stitch will be superadded. (Mayo.)

serted on the convex portion of the stomach (or bowel), so that each needle penetrates the wall four or five times in a space of about an inch and a quarter.

They should be a quarter of an inch apart, and while the needles are still in the wall of the bowel or stomach a scalpel is used to divide the wall midway between the needles for the distance of three quarters of an inch.

A tissue forceps then grasps the entire thickness of the bowel (or stomach) at the needle-eye-end of the incision, and the needles are drawn through until the loop comes quite up to the forceps.

One half of the oblong button (Fig. 446), grasped at the end of the cylinder with an ordinary hæmostat, is then slid entirely into the bowel or stomach, with the invaginating tube projecting through the incision (the cap entirely within the viscus).

The thread is then tied *fairly firm only* on the intussuscipiens or inner tube, and the thread cut short close to the cylinder.

The button-holding forceps (Fig. 447) is then applied to the cylinder, grasping the ends and extending outward at right angles from the button, and pushed as far down on the cylinder as the tissue will permit.

The other half of the button is inserted in a similar manner, and the other holding forceps applied to the ends, but in the opposite direction from the first, so that when the buttons are approximated, one holding forceps will be to the right and one to the left of the operator.

The holding forceps then twists the button around into position and the cylinders are invaginated.

The holding forceps of the inner cylinder is removed first, so as to permit it to invaginate and catch in the outer cylinder.



FIG. 446.—Murphy's oblong button and key.

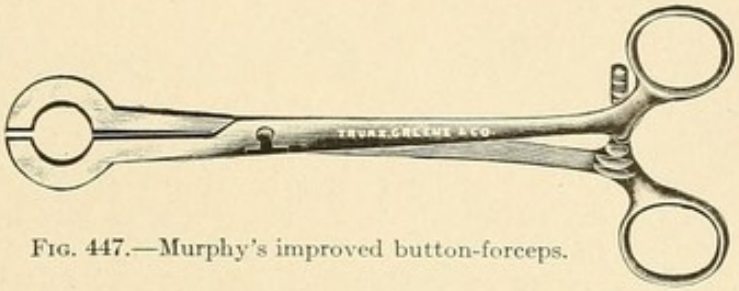

FIG. 447.—Murphy's improved button-forceps.

Then the other holding forceps is removed and the button is slowly pressed home, until there is a firm compression of the cups.

The reason that the thread on the inner cylinder is not tied so tight as on the outer cylinder is that on invaginating it it is desirable that the outer tube can pass between the thread and the inner cylinder.

To relieve the approximated surfaces of tension, one or two catgut sutures should now be inserted one third to one half inch from the button, so as to prevent traction during the process of repair.

It is entirely unnecessary to surround the button with a row of sutures.

In doing a gastro-enterostomy, Professor Murphy divides the stomach wall parallel to the long axis of the vessels—i. e., transverse to the midline of the stomach curvature—and makes the approximation as near to the pyloric end of the stomach as the anatomic conditions will permit. After exposing the stomach wall through the mesocolon, the edges of the mesocolon are anchored to the stomach by four stitches, an inch or an inch and a half apart, so as to secure a complete closure of the lesser peritonæum by the subsequent agglutination and adhesions of the mesocolon to the stomach.

"As the ligament of Treitz draws the first portion of the jejunum from left to right, and not from right to left as so erroneously stated, I always make the approximation of the stomach wall run from left to right in consonance with the normal anatomic direction of the first portion of the jejunum.

"The button is voided in gastro-enterostomies, as a rule, on an average from the eleventh to the fifteenth day. In side-to-side unions of the intestines it is usually voided earlier" (Murphy).

Gastro-duodenostomy is recommended in those cases of mucous lesions which interfere with pyloric drainage on account of spasm.

Hour-glass Stomach.—Gastroplastic operations for the relief of hour-glass contractions are not satisfactory, and *resection* is to be preferred. After exposing the organ by the incision through the left rectus, it is drawn up through the wound and the gastrohepatic and gastrocolic omenta are tied off as shown in Figs. 445 and 452.

The method of applying the clamps and of suturing is indicated in Fig. 445*a*, where at *B* on the lesser curvature is shown the final sero-muscular stitch of Cushing, while in the lower portion of the wound the muco-serous suture of C. H. Mayo is in process of insertion. The posterior wall is first united by the Mayo

stitch, the Cushing suture being superadded, and then the anterior wall of the stomach is sutured, thus completing the entire circumference of the organ.

When the closure shall have been completed, the forceps removed, and a careful toilet performed, the rents in the gastrohepatic and gastrocolic omenta should be reunited with catgut sutures in such a way that adhesions will not be possible. The technic here described is applicable to the removal of a part of one wall or to complete section.

Gastro-pylorectomy, an operation formerly done for pyloric stenosis with limited cicatricial narrowing of the pyloric end of the stomach, is now practically abandoned. The suture of the duodenum to the lower portion of the opening in the stomach wall left a point at which leakage was always an element of great danger. The better procedure is to close separately the upper ends of the duodenum and the stomach, as shown in Fig. 454, and perform a separate no-loop gastro-jejunostomy, as recommended by Rodman and Mayo.

Adhesions of the stomach to the abdominal wall, the colon, duodenum, or other contiguous viscera, are occasionally met with. As they limit the peristalsis of the stomach, they interfere seriously with digestion and demand operative intervention. Incision through the left rectus is indicated, the adhesions should be separated, and if possible the raw surfaces should be covered by direct peritoneal suture or by stitching a layer of omentum over the exposed surfaces. In several instances where neither of these methods was available, Van Buren Knott has successfully employed Cargile membrane.

In the rare instances when *duodeno-gastroplasty* is required, the pylorus is exposed by splitting the right rectus with any of the modifications already given for a wider opening. The visceral incision usually extends from an inch to an inch and a half in the stomach tissue and the same distance over the pylorus into the duodenum. The stricture is divided in this incision, and the posterior in-

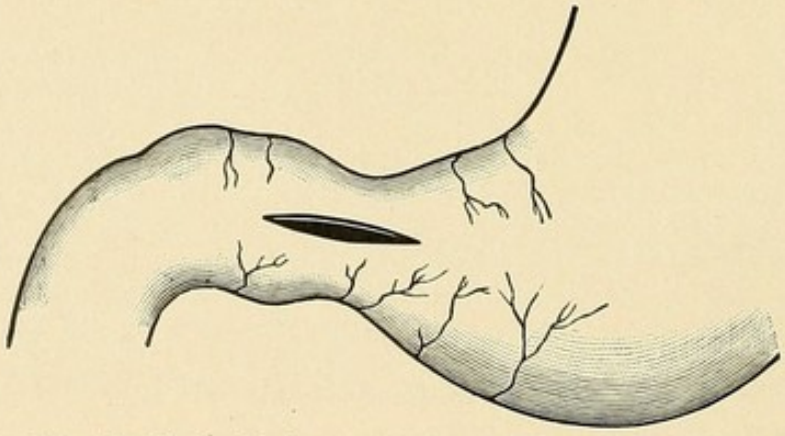

Fig. 448.—Incision in duodeno-gastroplasty. (From Park's "Surgery.")

ternal surface of the wall of the stomach, the pylorus, and duodenum are brought well into view by inserting a tenaculum above and below in the center of the incision, and widely separating the edges of the wound. Holding the wound thus open in diamond shape, the duodenum is brought over upon the stomach and Mayo-Cushing sutures are inserted, beginning at the upper and lower angles made by retraction with the tenacula. The duodenum is folded over and sewed on to the opening in the stomach in such a way that a stricture no longer exists, the contents of the stomach falling directly into the duodenum beyond the pylorus. Should any difficulty be experienced in uniting the edges of this longitudinal incision, excision of the pylorus and direct end-to-end suture should be substituted.

Gastroptosis, or falling of the stomach, is due to the stretching of the gastrohepatic omentum from inherent weakness of this structure, general relaxation or atony of the muscle due to malnutrition and to overloading and distention of this organ, and *transverse colon*, which aids in the downward displacement of the stomach.

The diagnosis of displaced stomach can be determined by careful percussion combined with auscultation. The greater curvature can be made out by having the patient drink a considerable quantity of water upon an empty stomach. The percussion notes will give the water level as distinguished from the tympanitic resonance of the intestinal tract. Oscillation will elicit a gurgling sound of the liquid contents. Hyperdistention of the displaced and usually dilated organ by swallowing air, or by the administration of a gas-producing powder, will, by percussion notes, give the upper and lower outlines of the organ. With these objective symptoms there are subjective signs of indigestion or gastric distress, since it is difficult for the stomach to discharge its contents through the pylorus.

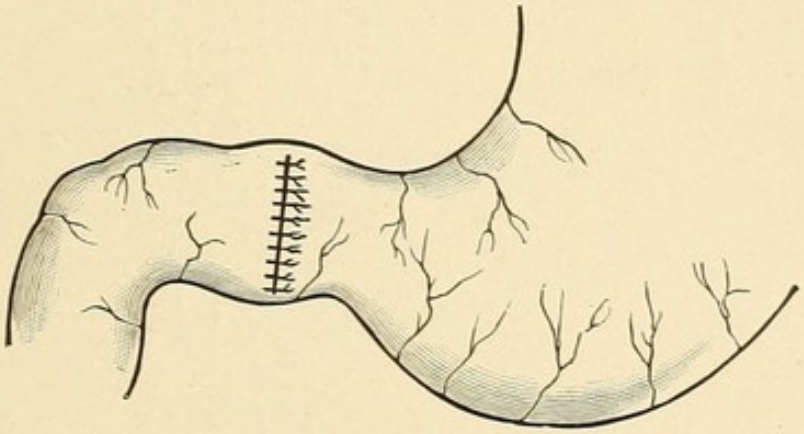

FIG. 449.—The same after suture. (From Park's "Surgery.")

The operative methods look to the shortening of the gastrohepatic omentum. As a rule, this is thin and difficult of successful replication. The operation of F. S. Eve[1] commends itself, and is as follows:

A free incision is made through the rectus muscle, one inch to the left of the (patient's) median line. A sand-bag placed beneath the back, opposite the stomach, raises the liver and holds it out of the way. Celluloid linen sutures, five or six in number, are now inserted through the lesser curvature of the stomach, taking firm hold on the muscle and serous covering but avoiding in their grasp the blood supply of the lesser curvature. The needle is next carried through the attachment of the lesser omentum to the liver, taking hold quite deeply in the liver substance. The stomach is then lifted so as to bring the lesser curvature in contact with the under surface of the liver, and the sutures are tied. Eve suggests (and has carried out the suggestion) that when the liver has also been dragged downward, the passage of a series of interrupted sutures through the anterior surface of the left lobe, and then through the margin of the costal cartilages, will hold the liver in a more nearly normal position and give an additional guarantee to the anchorage of the stomach.

Gastroplication.—When the stomach muscle has been hopelessly stretched and weakened by prolonged neglect and overdistention, this operation may at times be beneficial. It consists in exposing the organ by splitting the left rectus, bringing the stomach forward into or through the incision if possible, laying a long steel urethral sound parallel with its long axis, folding the peritoneal surfaces over this instrument and introducing chromicized catgut sutures, as shown in Fig. 450. Several parallel rows of these sutures may be required.

Hernia of the stomach is one of the rarest accidents to this organ.[2] The diagnosis can only be assured by exploration. The indications are reduction of the hernia and closure of the opening. If through the diaphragm by chromicized catgut sutures, and in reaching the vault of the diaphragm the osteoplastic section of the costal arches, as advised by Prof. Willy Meyer, may be necessary. If through the abdominal wall, direct incision and closure is indicated.

[1] "British Med. Journal," April 7, 1906; "General Surgery," Murphy, 1907.
[2] G. S. Gordon, M.D., "Annals of Surgery," May, 1907.

Carcinoma.—The causative relation between ulcer and cancer of the stomach is evident from the fact that the latter almost always occurs in that portion of the organ where ulcer is common.

In 1890, 48, and in 1900, 60 per 100,000 died from this disease in the United States. The age limit varied from thirty-one to seventy-five years, it being most

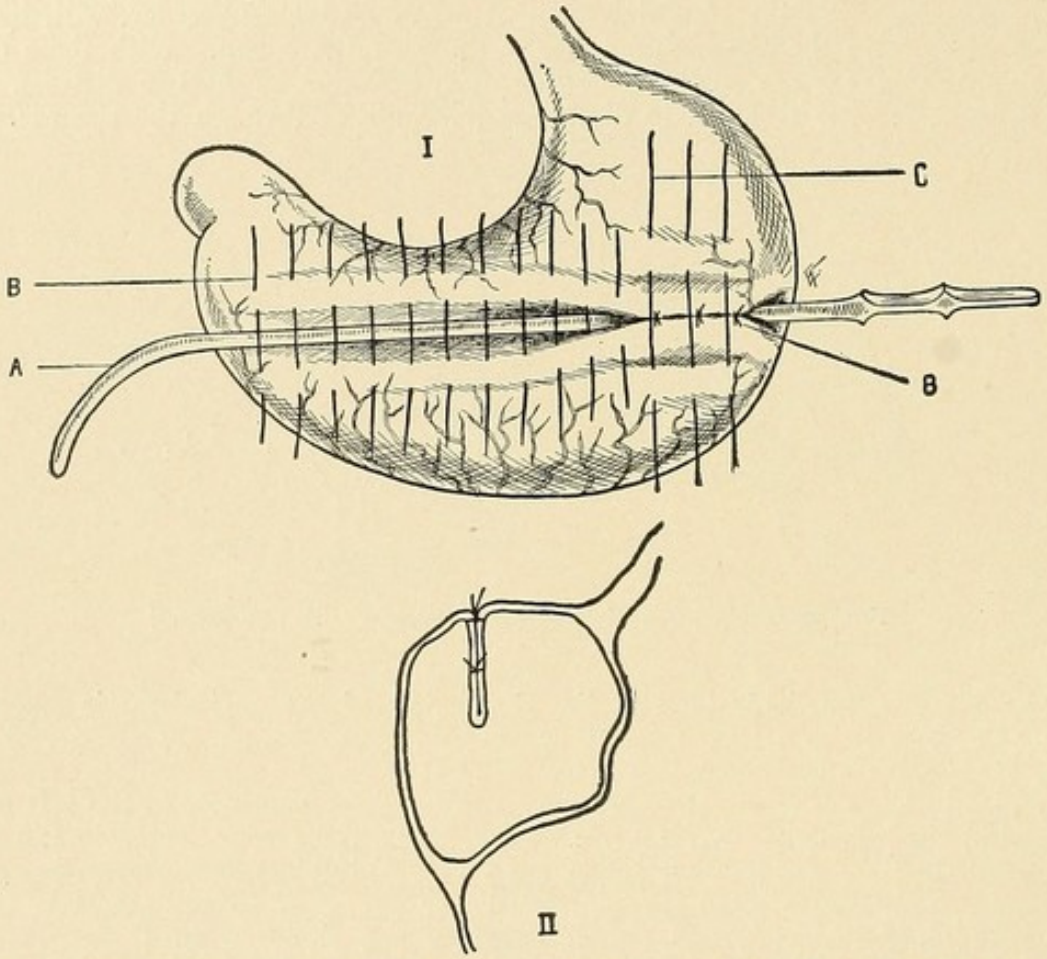

FIG. 450.—Gastroplication (Weir's modification of Bircher's operation); I. A, Sound infolding anterior stomach-wall; B, B, First tier of Lembert sutures burying in sound; C, Second tier of sutures ready to bury in sound for second time, when latter is placed upon first tier. II. Sectional view of stomach after the two tiers have been tied. (Bickham.)

frequent from forty to sixty. In very rare instances it has occurred under the twentieth year of life (W. Gilman Thompson).[1]

The ratio of mortality will only be materially decreased when greater intelligence is shown in our methods of nutrition, and when by means of the gastroscope and the careful analysis of symptoms *ulcer* is recognized in its earlier stages and subjected to skillful medical and dietetic treatment.

Diagnosis.—In delayed cases the enlargement and induration may be recognized by palpation. The patient should be seated leaning forward in complete relaxation of the abdominal muscles, with the knees drawn up, thus allowing the stomach to fall to the lowest possible level. At times when no tumor may be felt, gastric tenderness, as shown by muscular rigidity, is a strong indication of an underlying lesion (W. Gilman Thompson).

According to Thompson:

"Loss of muscular strength and weight, even without definite phenomena, are among the most constant early symptoms, but bear no definite proportion to the size or position of the growth. Dilatation of the stomach, developing rather suddenly, suggests pyloric cancer. Failure to improve radically under treatment is an important diagnostic indication. As to the blood examination, the early char-

[1] "Ohio State Medical Journal," 1907.

acteristics are a moderate leucocytosis (12,000 to 16,000), polynucleosis, moderate anæmia, with red cells rarely below 3,000,000, and hemoglobin sixty per cent.

"Vomiting is an early symptom in a large number of cases, not infrequently with hæmatemesis. The stools should be examined for occult blood.

"Epigastric pain is a variable symptom. The analysis of gastric contents should be several times repeated before arriving at a conclusion. The dread of the first passage of the stomach tube may inhibit secretion. The variations from hyperacidity to hypoacidity differ in other lesions as they do in gastric cancer." (Thompson.) [1]

Gastrectomy for Cancer.—In an operation of itself formidable, and rendered more grave by reason of the low resistance which insufficient nourishment induces the smallest possible quantity of ether should be given. In view of the fact that the stomach is entirely insensible to pain, and that the abdominal peritonæum is the only exquisitely sensitive tissue involved, the skillful combination of morphia, nitrous oxide gas and ether, with the employment of sequestration, should secure a perfect anæsthesia with the minimum of ether.

The following technic of W. J. Mayo is preferred:

1. *Exploration.*—A short incision is made in the midline half-way between the umbilicus and the ensiform cartilage. Two fingers are introduced and the growth explored with reference to other structures. Next the extent of glandular involvement is ascertained (Fig. 451). If the case seems fairly reasonable for operation, the incision is rapidly enlarged and the growth drawn out of the abdomen. This manœuvre permits of careful examination of the lesser curvature, and especially as to whether the infiltration in this vicinity extends beyond the possibility of removal. The transverse mesocolon is then inspected, as it is often infiltrated from behind. The posterior surface of the stomach and its relation to the pancreas are palpated with fingers passed through a rent in the gastrohepatic omentum.

2. *Mobilization of the Lesser Curvature* (Fig. 452).—The stomach is drawn firmly downward and to the right, the left lobe of the liver raised by the fingers

[1] This author gives the following summary of conditions which combine to make operation desirable. I cannot but insist that since delay is the gravest of all surgical dangers any doubt as to the exact character of the lesion should lean to the side of exploration.

1. The patient's age should be within the average cancer developing period, for gastric cases, i. e., between forty and sixty-five years.
2. There should be a rapid and decided loss of weight and strength, without other assignable cause, such as chronic gastric catarrh, neurasthenia, mental strain or worry, or chronic general disease, such as diabetes, etc.
3. There should be evidence of some degree of stagnation of food contents in the stomach.
4. There should be failure to improve in marked degree under treatment after a few weeks' trial.

With these four conditions fulfilled, exploration should be seriously considered, despite the absence of gastric pain or other marked gastric symptoms. In addition there may be:

5. A leucocytosis of 12,000 to 15,000 with polynucleosis and a moderate secondary anæmia, with low color index.
6. Decided dilatation of the stomach.

With these two additional factors, operation is distinctly indicated. Still further there may be:

7. Occasional attacks of vomiting without definite relation to food ingestion.
8. Occult or visible blood in the vomitus or stools.
9. Epigastric or right hypogastric rigidity and tenderness on deep pressure.

With these symptoms added, the diagnosis can admit of practically no question. In this order of relative importance of symptoms I have purposely left until the last, as being often unreliable:

10. The demonstration of hypoacidity or anacidity, and
11. The so-called carcinomatous cachexia, which, while plain enough toward the fatal ending, is often wanting as an early definite appearance.

By thus grouping the train of symptoms and conditions in the relative order of their appearance and importance, it becomes possible to recommend operation at a period when there is hope of accomplishing something more definite than mere exploration. As to what is to be gained by early operation, there is first always the relief of uncertainty as to the extent and nature of the disease, and as to any possibility of error in diagnosis. Second, there is the possibility of complete extirpation of the growth and the prolongation of life for three or four years before a fatal and inoperable return. Third, there is the certainty not only of some prolongation of life, but of relief from much increasing suffering, and particularly from that most wretched of deaths, by slow starvation, with constant nausea, regurgitation and pain from a dilated and useless stomach. Even in the later cases in which a growth of considerable size is obvious, operation may be of advantage as a palliative measure whenever the growth obstructs the pylorus, causing dilatation.

of an assistant, and the gastric artery tied with catgut on a needle at the highest possible point well beyond the lymphatic nodes. A pair of clamps are caught on the opposite side, and the artery and that portion of the gastrohepatic ligament which has been ligated with it are cut. With a few nicks of the knife the pedicle is partly detached from the stomach and allowed to retract. This permits of mobilization of the gastric wall and obtains a clear space near the œsophagus for the division of the stomach. The superior pyloric artery and the remainder of the gastrohepatic ligament are now doubly tied and cut between, leaving the glands

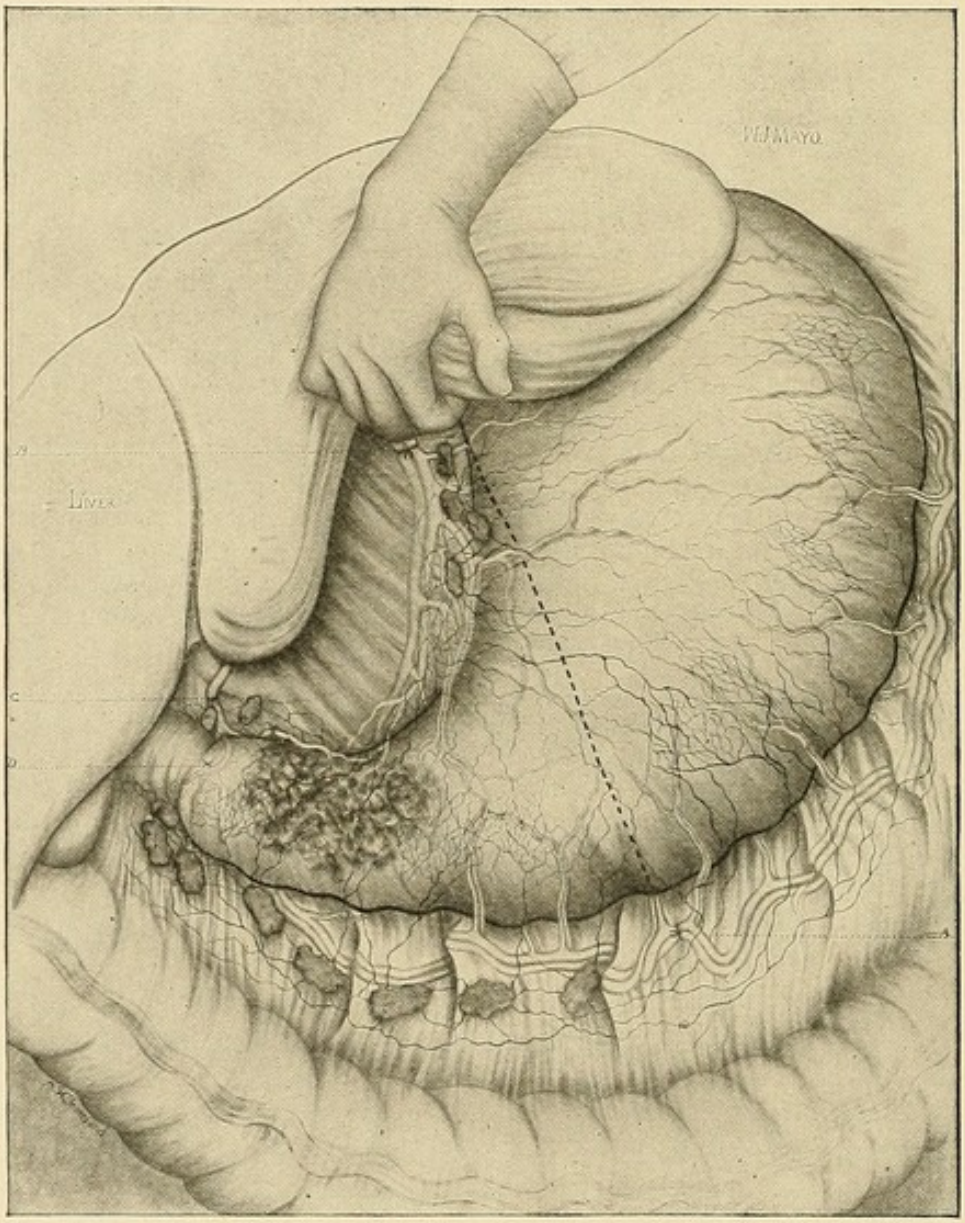

Fig. 451.—Showing the line of section through the stomach beyond the infiltration of the glands in the gastro-hepatic and gastro-colic omenta. The liver is lifted to expose the lesser curvature and the gastro-hepatic omentum. (Mayo.)

attached to the duodenum. This mobilizes the entire lesser curvature and makes the remainder of the work outside of the body.

3. *Separation of the Pyloric End of the Stomach.*—The hand is passed into the lesser cavity of the peritonæum behind the stomach, adhesions are carefully divided, and bleeding points ligated (Fig. 452). Hot moist gauze pads are now placed in this space. Two pairs of narrow crushing clamps (Ferguson) are placed on the duodenum well below the disease (as a rule, an inch below the pylorus) and the duodenum is divided between. The glands lying in the omentum immediately below the pylorus are carefully dissected upward so as to remain attached to the pyloric

end of the stomach and a few bleeding points caught and ligated. The forceps on the stomach side with these glands is now lifted sharply upward, exposing the gastro-duodenal artery in the groove between the head of the pancreas and the

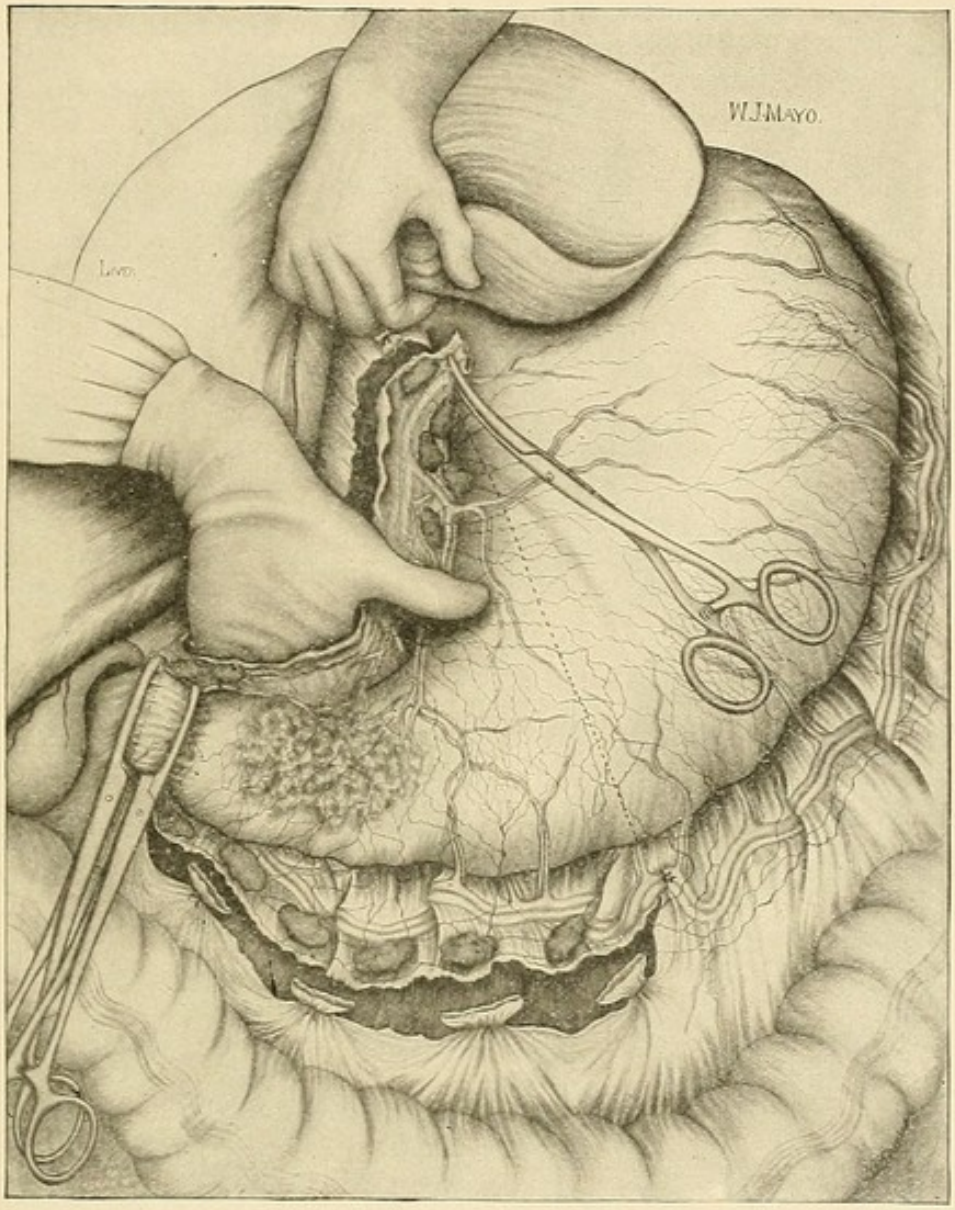

Fig. 452.—Showing ligation of gastro-colic and gastro-hepatic omentum, leaving all the lymph nodes attached to the part to be excised. Also lines of section of stomach and duodenum. The gastric vessels of the lesser curvature are clamped. (Mayo.)

duodenum; this vessel is doubly tied and divided between ligatures. The glands in this region are dissected upward with the fat and hot gauze compresses placed in the space.

4. *Freeing the Greater Curvature.*—The gastrocolic omentum is tied and divided in sections below the inferior coronary vessels, care being taken to avoid the middle colic artery; accidental inclusion of this vessel has caused gangrene of the transverse colon, of which it is the sole blood supply in seventy-five per cent of the cases (Kronlein). The lymph nodes lie close to the blood vessels, and at a point well beyond these structures the left gastro-epiploic vessel is caught and tied.[1] Care should be taken not to destroy its branches to the stomach beyond the point of ligation as it will be the sole blood supply for the contiguous stomach wall.

[1] Cuneo showed that no lymph glands existed to the left of the middle of the greater curvature, and that the circulation in these was from left to right. He also showed that the lymphatics of the lesser curvature lay in the wall of the stomach itself. In this way the entire lymph absorbents of the pyloric end of the stomach can be extirpated *en masse*.

5. *Removal of the Diseased Structures.*—Light elastic holding clamps are now placed on the stomach an inch or more back of the proposed line of resection, a second pair grasping the tumor side and the growth with the glands and fat removed *en masse*. As it is cut loose, several catch forceps should be applied to

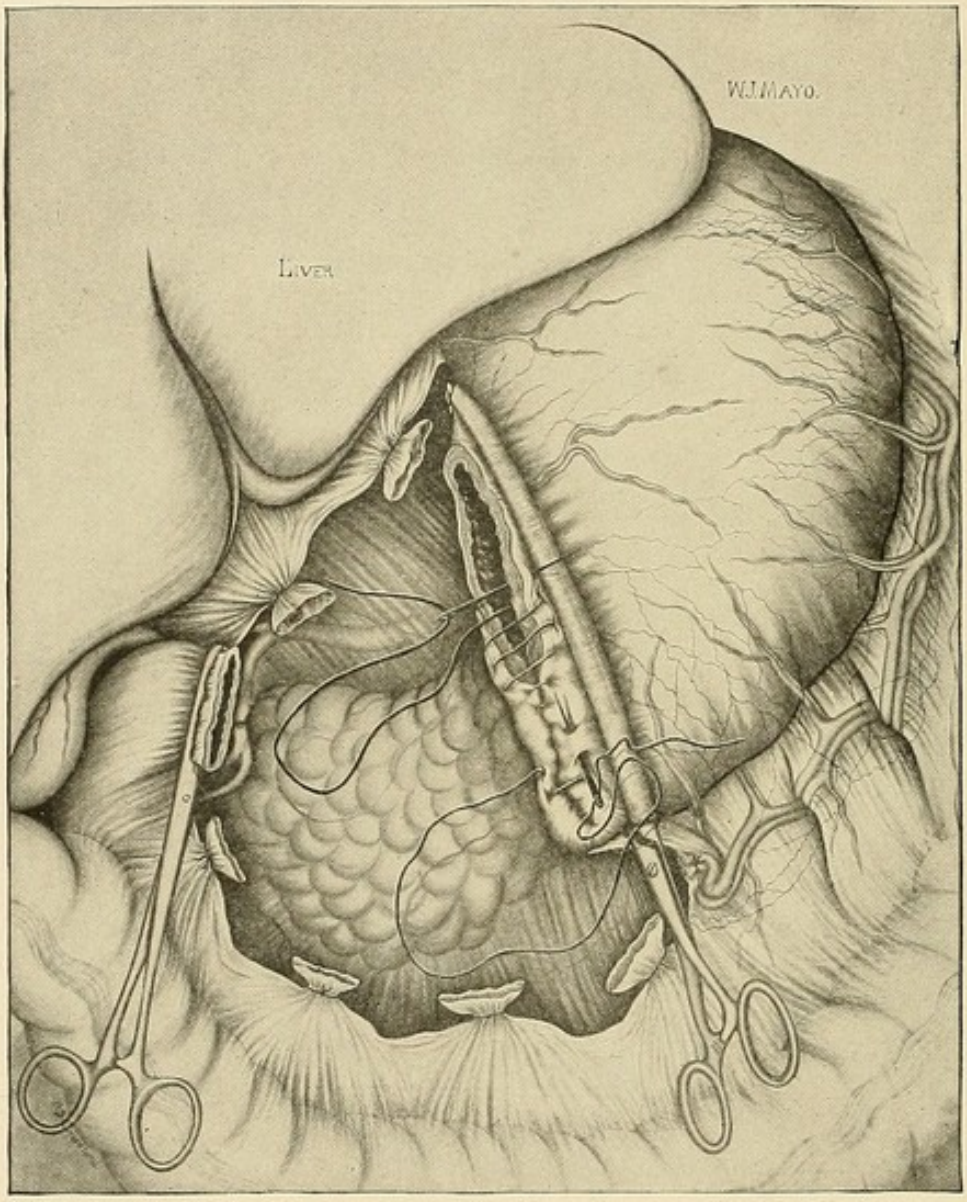

FIG. 453.—Showing above the technic of C. H. Mayo's sero-mucous right-angle suture and below Cushing's right-angle sero-muscular stitch. The cancerous portion of the stomach and the infiltrated glands have been removed, together with the other two clamps between which and those still in position the sections were made. (Mayo.)

the margins of the cut stomach surface projecting beyond the clamp to prevent retraction. This clamp is straight, quite elastic and rubber covered so that it will not crush or injure the stomach wall. We have found those of Scudder very satisfactory. The cut gastric wall is now lightly gone over with the actual cautery, particularly at the upper part, at which point we are most liable to fail to get well beyond the disease (Fig. 453).

6. *Suture of the Gastric Stump.*—After rearranging the hot moist packs, to furnish ample protection, with No. 2 chromic catgut on a straight needle, beginning at the greater curvature, a running suture is placed through all of the coats after the method of Charles H. Mayo. The needle enters on the peritonæum at one margin, passes through to the mucous coat, and directly back on the same side from mucous coat to peritonæum. By doing this alternately, first on one side and then the other, by a single suture the peritoneal surfaces are rolled into contact, the parts being firmly brought into apposition and the hæmorrhage checked.

On approaching the lesser curvature it will usually be found that the clamps are too close to the edges of the wound to permit of this manœuvre, and it may be necessary to unclasp them in suturing the last inch. As this situation is also under considerable tension, it is well to place one or two mattress sutures of linen at once at the upper end to completely and permanently secure it, rolling the first catgut suture in by a wide grasp of the gastric wall far enough back to permit of union without tension. Any point not well turned or showing a tendency to ooze is secured by an independent mattress suture of linen. Beginning now at the greater curvature, a fine linen continuous Cushing suture turns in the gastric wall without tension over the first row (Fig. 453).

The duodenal stump is turned in by a circular suture after ligature in the groove made by the forceps and a posterior gastro-jejunostomy is performed without a loop, that is, within three inches of the origin of the jejunum (Fig. 454). The opening in the stomach, however, should run from above down, right to left,

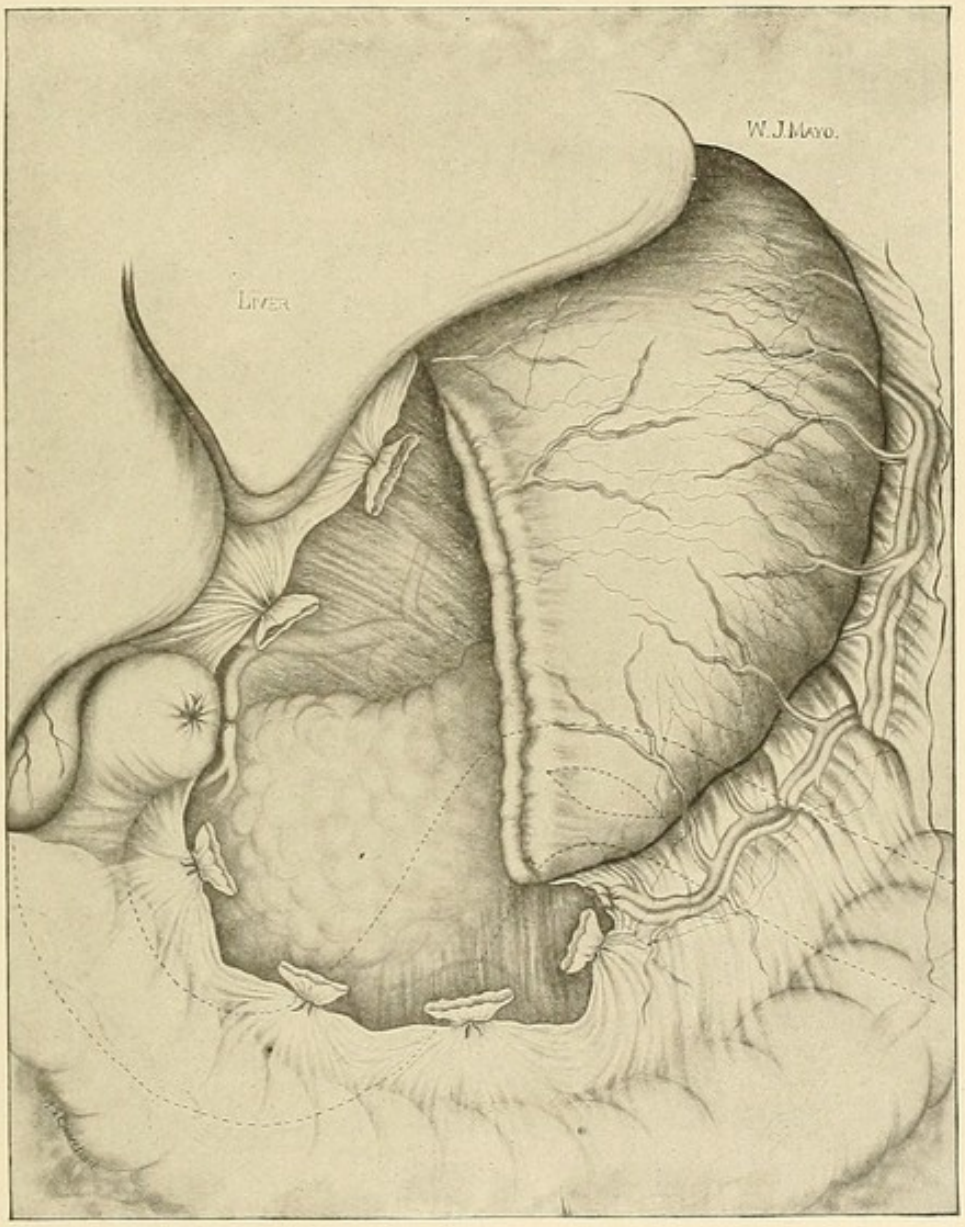

Fig. 454.—Showing the duodenum inverted and closed, the stomach sutured and the posterior "no-loop" gastro-jejunostomy completed. (Mayo.)

so that the proximal end of the jejunum shall lie close to the suture line, the distal end at the lowest point and passing to the left. After completion of the gastro-jejunostomy in the usual manner, the jejunum at once drops down into the left iliac fossa in its normal position. A few sutures close the rent in the trans-

verse mesocolon in such fashion as to protect the suture line. If the patient is in a poor condition, an anterior or posterior Murphy button operation can be made to save time. The button must be protected, however, by at least four mattress sutures of linen at intervals to prevent separation.

8. *After-care.*—After resection the patient should be placed in bed, the head and shoulders elevated to the semisitting posture, and a glass female douche point introduced above the internal sphincter, through which from one to four quarts of one half strength normal saline solution is allowed slowly to enter the rectum for absorption from a gravity bag, thirty minutes to three hours being used in this process (Murphy). This is repeated in twelve hours with a lesser amount. From one half to one ounce of hot water is allowed by the stomach every hour after sixteen hours, and the usual experimentation of liquid foods begun after twenty-four to forty-eight hours, the rectum being used as an auxiliary for four or five days.

Gastro-enterostomy should not supplant gastrectomy as a palliative procedure unless the glandular infiltration is too extensive. The latter operation in proper hands, even in incurable cases, will give a greater prolongation of life.

Sarcoma of the stomach, either as a secondary or primary growth, is rare. It has, however, been observed in a child of three and a half years and in a subject of seventy-eight. Primary sarcoma is most infrequent, originating in the submucosa or muscularis, and at times growing to large size. This lesion occurs in the average at an earlier period than cancer.

The *diagnosis* can only be made clear by exploration, and the indications are gastrectomy, cutting well away from the disease. Recovery from the operation should be followed by prolonged injections of the mixed toxines as advised by Coley. (See Sarcoma.)

The Duodenum.—The surgery of the duodenum in its first portion is intimately associated with that of the stomach, while the second portion is not infrequently involved in lesions of the head of the pancreas and the common gall duct. It is the most immovable part of the small intestine, has no mesentery, and in its second portion is only partially invested by peritonæum.

Ulcer of the duodenum occurs almost altogether in the upper three inches, and is frequently associated with the same lesion in the pylorus and pyloric end of the stomach. They may be single or multiple. The causes are practically the same as those which produce gastric ulcer. The diagnosis is more difficult, for the reason that gastroscopy, however perfect, has not yet been able to examine satisfactorily the duodenum on account of the contractions of the pylorus. According to Graham [1] the most prominent symptom is pain, which is felt farther to the right than that which is caused by ulcer of the stomach. It is generally sharp and severe, and comes on suddenly with a decided relation to ingestion, although the pain and distress after eating are felt at a period somewhat later than that experienced in stomach ulcer. Pain is due to localized peritonitis or to the irritant action of the stomach juices on the abraded mucous surface. The intensity of pain is almost always in direct ratio to the degree of hyperacidity. In thirty-two of forty-six cases reported by him, vomiting was a prominent symptom. Hæmorrhage is an indication, especially when blood is found in the stools, for in these forty-six cases bleeding occurred and was noticed in the vomit or the stools or in both in sixteen. In most cases there will be a history of gastric or pyloric disturbance for some weeks or months preceding the symptoms just given. The pain which is felt in cholelithiasis, although in practically the same area, is much more intense and spasmodic in character, and in addition is apt to be accompanied with jaundice, while this latter condition is not a part of ulcer of the first two or three inches of the duodenum. The only positive means of diagnosis is by exploration, which should be done just as soon as the symptoms justify, to be continued by excision if the character of the lesion renders this necessary.

For the relief of this condition a free incision splitting the right rectus muscle near its middle is advised, and if greater space is needed, A. D. Bevan's lateral

[1] Christopher Graham, M.D., St. Paul "Medical Journal," 1904.

curved prolongation of the incision, either at the upper or lower end or both will suffice. A transverse division of the sheath of the rectus at any point will also permit of a wider retraction of this muscle. The technic described in the excision of isolated ulcer of the stomach will apply equally well to ulcer of the duodenum. It is important always in excising any portion of the alimentary canal to insert the sutures parallel with the long axis of the bowel so as not to diminish its caliber. Slight angulation will not materially interfere with the passage of ingesta. In case of perforation an immediate incision, with closure of the opening and cleansing of the infected area, is imperative. The treatment given for perforative ulcer of the stomach is practically the same as for perforation of duodenal ulcer.

Should a single ulcer be extensive, with well-marked cicatrization, or should there be a number of ulcers covering an area too large for partial excision, or should an ulcer of the duodenum be continuous through the pylorus, with a like condition of the stomach, it would be more conservative to exsect all of the diseased bowel and stomach, performing a direct anastomosis should this be feasible, or a gastro-jejunostomy,[1] which will in general best meet the indications.

Perforation of any point in the wall of the alimentary canal into the cavity of the peritonæum is one of the gravest surgical conditions. It is especially dangerous when the wall of the stomach is involved. The gravity is in general proportionate to the size and location of the lesion, and to the promptness and thoroughness of the operative treatment. The prognosis is always in a measure dependent upon the condition of the patient's resistance at the time of the accident.

Peritonitis, which follows perforating gastric and duodenal ulcer, is more apt to produce an overwhelming septicæmia, for the reason that the larger lymphatics of the central diaphragmatic region absorb toxic products very much more rapidly than those lower down. Moreover, an infectious process starting above naturally tends to spread downward by gravitation, and unless checked at once, rapidly involves the entire peritoneal cavity.

Perforations of the gall bladder, or those of the ileum resulting from typhoid fever or from other causes elsewhere, will be considered later.

Gastric and duodenal perforations may be precipitated by vomiting or any extra exertion, or by overdistention of these organs with gas or ingesta. A number of instances are, however, recorded in which the rupture or perforation took place while the patient was resting quietly in bed. The accident is almost always preceded by certain symptoms of pain due to developing peritonitis, and there is in the vast majority of cases a history of gastric distress which may have given rise to a suspicion of ulcer. When the perforation takes place and the contents are escaping, there is always acute and overwhelming pain, which at the moment is felt at the point of leakage. Within a few minutes it is often referred to an area so wide that this symptom is of little value as a guide to the seat of perforation. This is due to the fact that by gravitation the extravasated contents are spreading the peritoneal infection.

It is exceedingly important that this condition be recognized and operated upon immediately. The patient should be placed in the recumbent posture and not permitted to move until all necessary preparations are made for the administration of the anæsthetic.

If taken within the first five hours of perforation, a fairly favorable prognosis may be made. After ten hours it is exceedingly grave. What is here said applies equally to duodenal as well as gastric ulcer. The most careful cleansing should be made, and if there is any doubt as to the thoroughness of the toilet, one or more rubber tissue gauze wick drains should be inserted, or in more serious cases a temporary packing made. The ulcer should be excised and the incision closed by the technic already described.

The treatment of *general peritonitis* will be considered in another chapter.

[1] It must not be forgotten that after this operation there is no longer a pyloric muscle to prevent the entrance of undigested particles into the intestines. As the food passes from the œsophagus almost directly into the small intestine, careful mastication and possibly predigestion of certain articles of diet are indicated.

CHAPTER XXI

THE LIVER

GALL BLADDER AND DUCTS—THE SPLEEN, OMENTUM, AND MESENTERY

Neoplasms.—Surgical intervention is rarely demanded on account of new growths of the liver. *Carcinoma* is almost always *secondary* to involvement of the alimentary canal or mesentery, and, as a rule, develops slowly. The history is that of progressive emaciation with the peculiar cachexia of carcinoma. It occurs usually after the fortieth year of life, and when the tumor develops sufficiently to project below the free border of the ribs its nodular character may be appreciable to the touch. It may or may not be complicated with ascites. The occurrence of abdominal dropsy points to the location of the cancer near the transverse fissure with pressure upon the portal vein. Widely disseminated metastases rarely produce abdominal dropsy. Operation is not called for unless it be to remove excess fluid from the peritoneal cavity.

The symptoms of *ascites* are distention of the abdominal cavity, first observed in the lower portion as the patient sits upright or stands. The line of dullness on percussion ends abruptly from below upward at the limit of the fluid, while above this the note is immediately tympanitic in character, as the small intestines floating on the surface of the fluid are encountered. By placing one hand upon one side of the abdomen, and tapping with a finger on the opposite side, a wave or tremor is imparted to the liquid. If the patient be now placed upon the back the tympanic resonance will extend over the entire front of the abdomen from the pubes to the xyphoid. These symptoms differentiate ascites from ovarian cysts, a solid tumor, or any other comparatively immovable lesion of the abdominal cavity.

Tapping the Peritoneal Cavity in Ascites.—The integument should be thoroughly cleansed in the middle line half-way between the umbilicus and the symphysis pubis, *and the bladder emptied.* With the patient sitting upright, preferably in a chair, fifteen or twenty minims of one-per-cent cocaine should be injected into and beneath the skin in the proposed line of puncture. A broad sterile abdominal binder is applied and split just enough to expose the point where the instrument is to be introduced. With a sharp scalpel the skin is incised for one fourth of an inch, and through this a good-sized trocar-canula is slowly introduced until resistance ceases as it is felt to pass into the cavity of the peritonæum. As the trocar is withdrawn the fluid immediately escapes through the canula. The most satisfactory canula should have an oval window one eighth inch from the end, as the omentum or intestine is apt to come in contact with the open end and arrest the flow. Should the patient show signs of syncope the chair may be temporarily tilted back, care being taken to keep the finger over the end of the canula to prevent the entrance of air. If the stream is suddenly stopped by the omentum or intestine falling over the mouth of the pipette, a slight movement of the instrument may serve to remove the obstruction, or it may be necessary to introduce a sterile probe through the canula in order to clear it. As soon as the stream begins to break up into drops, showing that the fluid above the level of the perforation has escaped, the abdominal binder should be drawn tighter until the flow ceases. The canula should be removed and the opening immediately covered with sterile gauze held in place by adhesive strips and a binder around the abdomen.

Sarcoma of the liver is even rarer than cancer. This neoplasm may be located in the gastrohepatic omentum, and involve the liver by extension. This occurred in a very remarkable case operated upon by the author. Five gallons of fluid by measurement were removed by tapping the abdomen as just described. The mass, as large as the head of an infant, could be distinctly felt, attached to the lower border of the left lobe of the liver and extending five or six inches along the gastrohepatic omentum in the direction of the stomach. Under complete narcosis a free exploratory incision was made over the most prominent portion. The tumor was of reddish-brown color, hard and very vascular. No attempt was made at removal. The wound was treated by the open method and packed with sterile gauze in order to secure adhesions between the peritonæum and the surface of the neoplasm for the purpose of streptococcus inoculation. Seventy-two hours later the packing was removed and infection of the mass was secured by changing the dressings without aseptic precautions. The tissues about the wound became red and inflamed, but the suppuration was not profuse. Under this novel treatment the tumor diminished gradually in size, pressure on the portal vein ceased, and the ascites did not return. Ten years have elapsed since the operation, and the patient is now (1907) in excellent health and actively engaged in large business enterprises.

Hydatid Cysts.—Cystic tumors caused by the presence of the larva of the tapeworm (*echinococcus hominis*) are met with in the liver more frequently than in any other part of the body. They may be multiple or single, and may grow so large that they break through the diaphragm, emptying their contents into the pleural cavity or lung, or, extending downward, may occupy a large part of the abdomen. They occasionally open into the stomach or other hollow viscus.

The differentiation of hydatids from abscess of the liver is not difficult. In the former there is no tenderness nor any symptoms of sepsis.

In hyperdistention of the gall bladder there is pain, and jaundice is apt to exist. Aspiration with a delicate needle will make the diagnosis positive. Hydatid cysts contain a watery fluid, clear or of light-straw color, and in some instances fragments of the *hooklets* may be discovered.

Treatment.—The contents should be drawn off with the aspirator, and the procedure repeated as often as necessary. A single operation may effect a cure. The needle should be introduced at the most superficial portion of the tumor. As the fluid ceases to flow the canula should be withdrawn and the opening stopped by gauze held in place by adhesive strips. Local anæsthesia will suffice in this operation. Complete rest in the recumbent posture should be enforced for at least a week after the operation. In the event of sepsis, incision and drainage are imperative. Should repeated aspirations fail to effect a cure, a drainage-tube should be inserted, as advised by Verneuil, after adhesions have been secured.

Hepatic Abscess.—A circumscribed collection of pus in the liver is comparatively rare. It occurs more frequently in tropical or semitropical countries on account of the greater frequency there of intestinal diseases. Any infectious process in the alimentary canal may produce hepatic abscess from pyogenic organisms carried into the radicles of the portal vein. Appendicitis may cause suppuration in this organ either by direct extension or through the portal system. These metastases are generally multiple. Direct infection through a penetrating wound may also cause abscess of the liver. In exceptional cases ingested substances, such as bone, etc., have been known to pass from the alimentary canal into the substance of this organ, producing fatal pyogenic infection.

Abscess (*subphrenic*) located upon the upper surface of the liver occurs in a certain proportion of cases as the result of gastric or duodenal ulcer.

Symptoms and Diagnosis.—The early recognition of hepatic abscess is difficult. Pain is not a prominent symptom. Exacerbations of fever, with chills or rigors, are apt to occur, and there follows a gradual impairment of health. Jaundice is not present unless the collection of pus is near the transverse fissure, where it may partially or completely occlude the hepatic duct.

Empyema of the pleura or of the gall bladder or subphrenic abscess may be mistaken for abscess of the liver. In pleural empyema, where encapsulation does

not exist, a change of posture will change the percussion sounds. An overdistended gall bladder may be eliminated by bearing in mind its location in front and low down where abscess is extremely rare, and also from the fact that a distended gall bladder may be moved independently of the liver.

The differentiation from hydatid cyst has just been given. Should the infected area be near the upper surface and free border of the liver, deep palpation may develop soreness. As a last resort the exploring needle will positively determine a diagnosis, but this should not be used until everything is ready for immediate operation.

The prognosis is unfavorable. Left alone, a fatal termination is almost inevitable, either from rupture into the peritonæum or pleura or from prolonged septicæmia.

Treatment.—Evacuation is the only rational treatment. An effort should be made to locate the most superficial portion of the abscess. At this point the aspirator needle should be passed through the most convenient intercostal space into the substance of the liver, in the supposed direction of the pus cavity. As soon as by withdrawing the piston pus appears in the barrel of the syringe, this should be unscrewed and the needle left *in situ*. Enough pus should be withdrawn to relieve tension. An incision about four inches long parallel with and over the center of the nearest rib is made, the center of the cut being near the needle. A subperiosteal exsection of three inches of the rib should be made and the costal pleura incised for two inches. The edges of the incision in the costal pleura are carefully sutured with a chromicized catgut continuous suture to the reflection of the pleura which covers the diaphragm, forming a buttonhole, in the center of which is the needle. This may now be withdrawn, a slight puncture with the scalpel point made in the diaphragm, and a dressing forceps carried through this into the abscess cavity. By careful separation of the handles of this instrument the opening will be sufficiently enlarged to give a free discharge of pus. A single or double drainage-tube should now be inserted. If irrigation is done, normal salt solution should be used and great care taken not to overdistend the cavity. By this operation infection of the pleural cavity is avoided, while the peritoneal cavity is not opened.

Subphrenic abscess situated above the liver at any point may be evacuated by this procedure.

Displacement.—As the result of accident, or at times from tight lacing, the liver is occasionally displaced downward. A properly adjusted compress and support must be relied upon to hold the organ near its normal position. In a single instance which came under the observation of the author, this organ was sutured in position with a very satisfactory result by practically the same method as advised in the cure of floating kidney. The patient was kept in bed in a modified Trendelenburg posture for a number of weeks in order to secure firm adhesions. The same method of securing adhesions between the upper surface of the liver and the diaphragm in establishing a collateral portal circulation in cirrhosis may be practiced in anchoring this organ.

Gunshot or other *penetrating wounds* of the liver may demand operation for the arrest of hæmorrhage as well as for drainage in sepsis. A number of instances are on record where free incision into the peritoneal cavity has been made and hæmorrhage arrested by packing the wound in the liver with sterile gauze, and walling off the general peritoneal cavity until protecting adhesions were secured. For the arrest of hæmorrhage here blood pressure should be lowered at once by Detmold's method of constriction of the thighs and arms. The author has successfully controlled severe hæmorrhage from the liver by suturing a cut or abraded surface, and by uniting the torn edges with catgut.

Operation for the Relief of Ascites.—In cirrhosis, when the portal circulation is hopelessly obstructed, the following operation is advised in the effort to establish a collateral venous route. The fluid should be removed by tapping, from twelve to twenty-four hours before the operation. A free incision in the middle line is made, commencing at the ensiform cartilage and extending to the umbilicus, and, if necessary, half-way between that point and the pubis. Any fluid

found in the cavity should be removed by mopping. The peritonæum lining the abdominal wall and diaphragm should be irritated by friction with a coarse crash laparotomy pad or swab, and the upper surface of the liver scraped with a scalpel or teased with needles. The entire surface of the omentum and any mesentery, the circulation of which may be utilized by adhesions with the abdominal wall, should be also irritated by friction. The round ligament of the liver should be shortened by suturing it in folds and attaching it to the parietal peritonæum and the rectus muscle by as many chromicized catgut sutures as may be required. The anterior edge of the liver should also be sutured to the parietal peritonæum, and the operation completed by passing a number of stitches through the omentum, attaching this in a transverse direction to the parietal peritonæum by several parallel rows of sutures. On account of the low resistance of these subjects the operation should be completed as rapidly as possible with the minimum of the anæsthetic, relying in large measure upon morphia and nitrous oxide gas. It is well to practice extraordinary care in asepsis. The success of the operation will be determined by the extent and thoroughness of the adhesions of the opposing surfaces and the new formation of blood vessels which will carry the circulation from the radicles of the portal vein to the heart by way of the veins of the diaphragm and the abdominal wall.

The Gall Bladder and Gall Ducts.—Cholecystotomy is indicated for the removal of stones from the gall bladder and to secure drainage in empyema under conditions which contra-indicate the removal of this organ.

While pain is a frequent symptom of stone it is not so prominent as when these concretions are lodged in the cystic or common duct. In common duct obstructions jaundice is a prominent symptom, and although it may occur in those cases of calculus in the gall bladder which by reason of their size, weight, or location partially or completely obstruct the hepatic duct, under other conditions the gall bladder may contain a large number of stones without icterus. It is also true that biliary calculi may remain for years without attracting the attention of the patient or surgeon as far as pain is concerned, and unless infection with symptoms of septicæmia result they may entirely escape notice.

In addition to the symptoms just given, the diagnosis may be facilitated by local tenderness, or in hyperdistention by the presence of a tumor just below the free border of the liver in a direct line, usually between the right nipple and the umbilicus. The presence of hydatids may also produce tumefaction, but the absence of pain, jaundice, and any suggestion of infection will exclude the echinococcus cyst.

Treatment.—Opening the gall bladder under ordinary conditions is not a very difficult or dangerous procedure. It only becomes serious when the patient is exhausted by long-continued sepsis, pain, and starvation.

In all operative procedures upon the gall bladder and ducts the incision is that given in describing the operation of *cholecystectomy*, but for the removal of stones or simply establishing temporary drainage for empyema, a much smaller opening will suffice. This smaller opening should, however, be in the line of the larger incision, so that should the necessity for a major procedure arise it can be extended in both directions until sufficient room is secured. The center of this primary incision should be over the gall bladder, and should split the right rectus muscle in this location. If the gall bladder is enlarged and has been subjected to repeated infection, in many instances adhesions will have occurred between its peritoneal covering and that of the abdominal wall, so that in cutting down at this location the summit of the gall bladder will be encountered and may be entered without opening into the general peritoneal cavity. When this condition is present immediate incision may be made, and two loop sutures passed from within the gall bladder outward through the abdominal wall on either side of the opening, to be tied long and used to support the bladder and prevent its being torn loose during any necessary manipulation. In removing calculi from the gall bladder a dull scoop may be employed, or a small Blake forceps, which should be made of light, springy steel and fenestrated so that the stones may be readily caught and not crushed by overpressure. Another useful method, especially for

dislodging small calculi which are more or less impacted in the deeper portions of the gall bladder and in the cystic duct, is to attach a fairly stiff rubber tube to an ordinary syringe, distend the gall bladder by throwing in a sufficient quantity of hot salt solution, and immediately drawing it back into the syringe by suction. In this way small calculi in the deeper portions of the neck of the gall bladder may be removed. A very careful search should be instituted for concretions which are frequently lodged in the valvelike pockets at the junction of the cystic duct with the bladder. These will require a dull fenestrated curette, or scoop for their dislodgment. When this latter condition exists, the complete removal of the gall bladder will in general be a more satisfactory procedure.

When drainage is necessary, and when there are no firm adhesions between the summit of the gall bladder and the peritonæum of the abdominal wall, and in all cases where this organ cannot be brought into the opening of the rectus, the following operation is advised:

A drainage-tube of soft rubber, with a diameter of about one quarter of an inch and of sufficient length to extend from near the neck of the gall bladder, well out through the abdominal incision, is fenestrated (fish-tail) on opposite sides one fourth of an inch from the inner end. It should be wrapped or wound with two or three layers of absorbent gauze, and over this one or two layers of rubber-tissue protective.

The abdominal incision having been sufficiently enlarged, the summit of the gall bladder is, if possible, brought into and partially through the wound. If it is too short to protrude, it should be brought up as near the incision in the abdominal peritonæum as possible.

A purse-string suture of No. 2 chromicized catgut is inserted with a half-curve needle completely around that portion of the summit of the gall bladder (about one inch in diameter) through which the drainage incision is to be made. Gauze mats or a gauze pack should be carefully inserted to prevent any possible leakage into the peritoneal cavity. If the gall bladder is hyperdistended, it is advisable to introduce an aspirator and draw off a portion of the fluid in order to prevent overflow. The incision into the gall bladder is now made within the circumference of this first purse-string suture. As the bladder is firmly held by forceps its liquid contents may be removed by wisps of absorbent gauze on forceps. A search should be instituted for calculi, and any present should be removed. The drainage-tube should next be carried in to a depth of three fourths of an inch and the purse-string suture snugly tied, the peritoneal surfaces of the gall bladder being enfolded and brought into contact, as they grasp the tube, where the fenestræ have been made. The sutures should be tied tight enough to hold snugly, but not sufficiently tight to diminish the caliber of the tube.

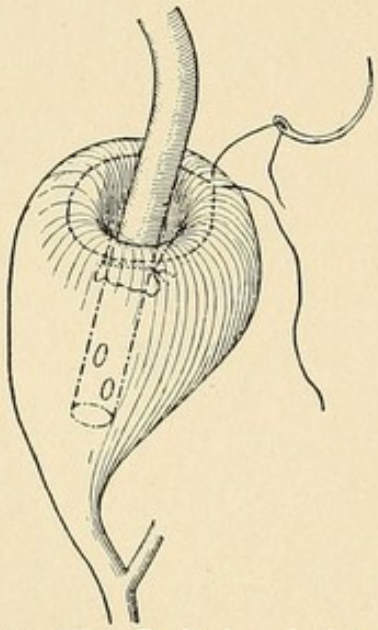

Fig. 455. — Rockey's valvular method of closing the gall bladder for drainage. (Murphy's General Surgery, 1906.)

The tube should be pushed in deeper, invaginating the gall bladder for one half or three quarters of an inch (see Fig. 455). A second purse-string suture of No. 2 ten-day chromic-acid catgut is introduced at this level, taking great care that the point of the needle does not penetrate the cavity of the gall bladder. This purse string is tied snugly about the tube, and in this way leakage into the peritoneal cavity is practically impossible. By attaching a longer piece of rubber tubing, all the drainage may be carried away from the dressing into a receptacle properly adjusted.

Within a week or ten days firm adhesions will have formed, which will prevent leakage when the drainage-tube is removed. Drainage should be continued as long as any suppuration is present. After the tube is removed, the discharge will usually continue for several days or weeks before final closure.

If for any reason this procedure may not be carried out and the summit of the

gall bladder can be brought into the wound, it should be held there while sutures of fine black linen (No. 50) or silk are inserted in such a way as to stitch the peritonæum lining the edges of the abdominal wall to that covering the gall bladder, taking care not to permit the needle to pass into the cavity of this organ.

An interrupted suture with an interval of about three sixteenths of an inch is preferable, and one end should be left two inches long to facilitate removal by traction after adhesions have taken place. If the necessity for drainage is not urgent, the wound should be left open and packed for twenty-four or, preferably, forty-eight hours, when adhesions will have formed and the gall bladder may be incised. For this secondary incision cocaine anæsthesia will suffice. It is a wise precaution, when the operation of stitching the gall bladder to the margins of the peritoneal incision is completed, to insert two long loop sutures into the summit of this organ on opposite sides of the wound. These sutures will serve as a guide to the incision which is later to be made.

In this operation drainage is secured by the use of one or two pieces of plain soft-rubber tubing, which should be allowed to remain until all inflammation has subsided.

Cholecystectomy.—Complete removal of the gall bladder is destined to take the place of many operations for drainage which have heretofore been preferred. Infection through the communication of this organ with the alimentary canal is of frequent occurrence, and when as a result of the presence of calculi or repeated temporary or the permanent obstruction of the common or cystic duct this condition becomes a danger to the welfare of the individual, extirpation rather than drainage of the gall bladder should be done if the resistance of the patient will justify the procedure. If not, drainage may restore the normal resistance, and later cholecystectomy done. According to W. J. Mayo, "a gall bladder once infected remains infected, needing only a disturbing element to produce its original intensity."

Operation.—If cholecystectomy is found necessary after the incision which has just been advised for purposes of drainage, this should be enlarged by splitting the rectus as may be required to give ample room, but in general, in all operations upon the deeper portions of the gall bladder and the bile ducts, Robson's technic, as employed at the Mayo clinic and as modified by A. D. Bevan, should be preferred. A sand-bag is placed under the patient's back in order to increase the forward convexity, lift the arches of the ribs, and aid in carrying the liver and diaphragm as far out of the way as possible. A longitudinal incision is made through the right rectus muscle, with division of its inner half parallel with the costal arch as far as the ensiform cartilage, when necessary (Bevan). When a larger space becomes absolutely necessary (and unless an operator is more than ordinarily expert a free exposure is essential), a transverse division of the sheath of the outer half of the rectus will permit a wider retraction. With proper retraction, and elevation of the left lobe of the liver, together with the costal arches, the gall bladder is clearly in view. The cystic duct and vessels should be made out and clamped with a single forceps (Fig. 456), while a second curved forceps of sufficient grasp closes the apex of the gall bladder and prevents leakage as the duct and vessels are divided between the two clamps. Before this division is made it is a wise precaution to insert a gauze mat underneath to prevent peritoneal soiling.[1] The gall bladder is now easily dissected from below upward, and removed. The artery having been first secured, the bleeding is insignificant. A chromicized catgut ligature should be placed beyond the remaining forceps, tying duct and vessels with this single ligature. The stump of the cystic duct should be disinfected thoroughly with carbolic acid, carried on a wisp of cotton attached to the end of a delicate probe or holder. This is introduced into the funnel-shaped end and moved around until the acid has been brought thoroughly in contact with the inner surface. A

[1] So many cases are being constantly recorded where by oversight materials used in intra-abdominal operations have been left *in situ* after closure of the wound, that in no case should a mat or sponge be introduced without a tape or thread connected with it, which shall remain outside and have a forceps attached to it. It would be better when possible to use long rollers of gauze of suitable width so that a portion of it should of necessity remain without.

drop or two of alcohol may be added to neutralize any excess of the acid. The edges of the peritonæum on either side of the raw surface of the liver from which the gall bladder has been removed should be brought together by catgut sutures in order to prevent adhesions (Fig. 457).

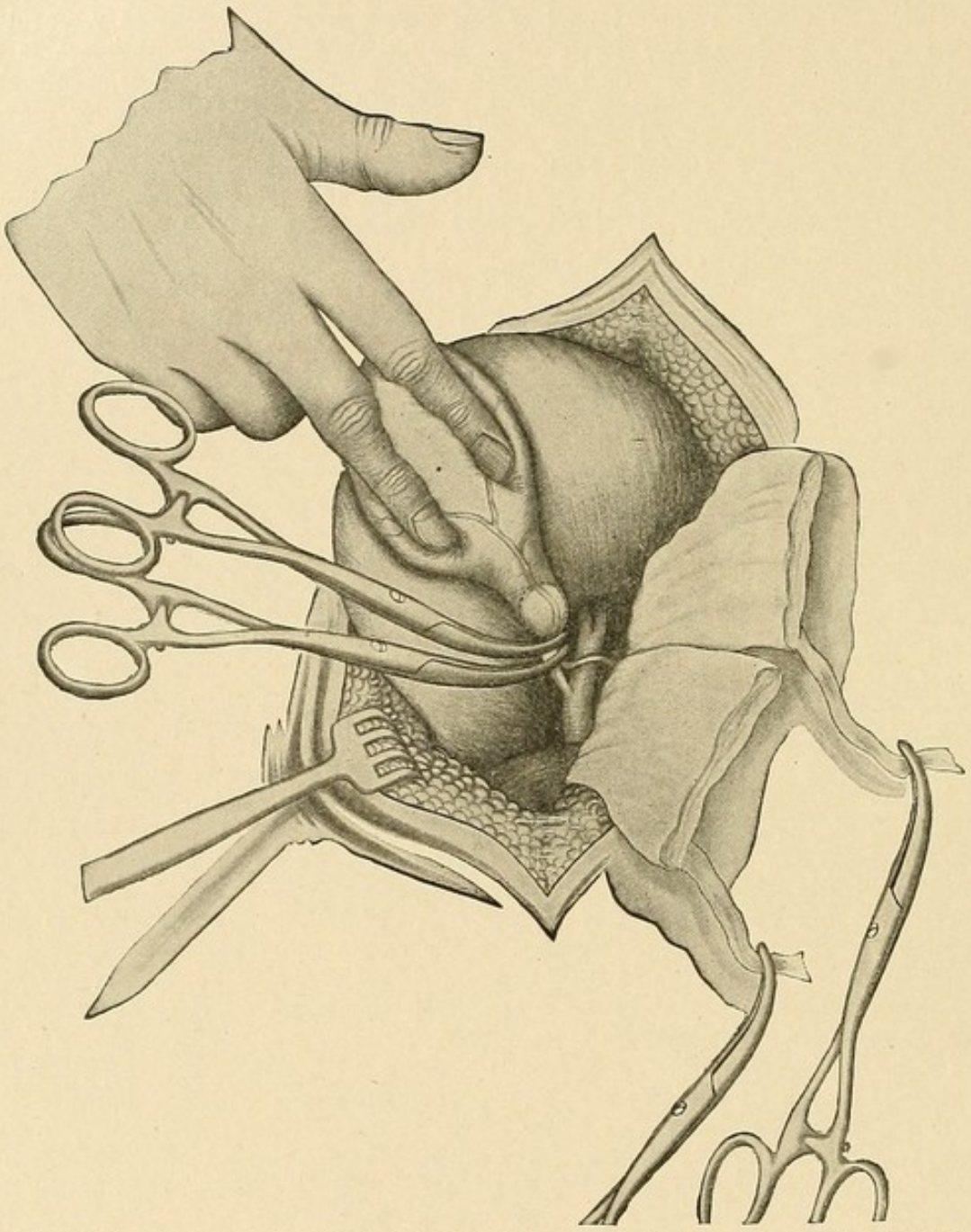

Fig. 456.—Cholecystectomy, showing clamps applied to cystic duct and cystic vessels. (After Mayo.)

A light cigarette drain should be allowed to remain in place for two or three days, the deeper end of which should be held in place by a small plain catgut suture which attaches it to the point where the duct has been tied.

These drains play an important rôle in the surgery of the bile ducts. They are made of a loose wick or light roll of absorbent gauze wrapped, in cigarette fashion, in one or two layers of rubber-tissue protective, loosely rolled. No threads should be tied about them.

When well-marked infection is present, a larger drain may be required. They are made of soft-rubber tubing split spirally from one end to the other, inside of which is placed a loose wick of absorbent gauze, while around the tube are one or two layers of absorbent gauze, and over this a layer or two of rubber-tissue pro-

tective. A drain should be long enough to project two or three inches from the abdomen, and in order to hold it accurately in place the lower end should be fastened by a plain catgut suture to the point from which drainage is desired.

Choledochotomy.—Operations upon the bile ducts are usually performed on account of the presence of gallstones, which may partially or completely occlude the common duct, and less frequently the cystic and hepatic ducts. At times a puttylike mass of decomposing bile salts and other waste material fills the common and hepatic duct well back into the substance of the liver. The author has met with two instances of this kind, in both of which there was an extraordinary condition of cholæmia, and in one of which he was enabled to empty the gall ducts by milking this soft material into the duodenum.

Intrahepatic Cholelithiasis.—The presence of gallstones in the branches of the hepatic duct within the liver is not altogether infrequent.[1] Of these reported, a large proportion doubtless formed in the small ducts within the substance of the liver.

The more consistent symptoms of stone in the common or hepatic duct is jaundice and pain. There may, however, be numerous calculi in these tubes without

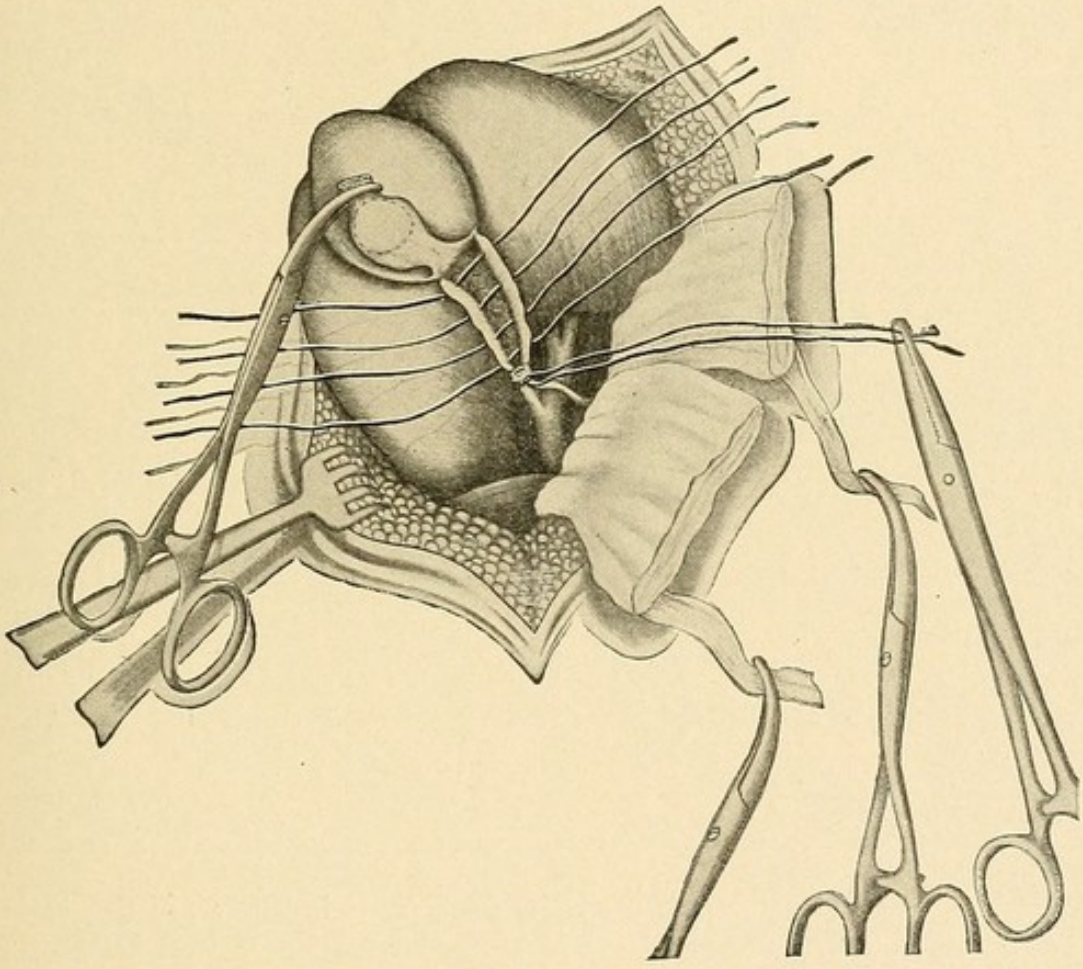

FIG. 457.—Cholecystectomy, showing cystic duct and vessels ligated. Gall bladder partially separated and sutures in position to cover the exposed liver substance. (After Mayo.)

producing jaundice, and in rare instances without causing sufficient pain to attract the attention of the surgeon directly to this locality. Small calculi which are producing symptoms of sepsis may even escape notice when the duct is laid open in the course of a surgical procedure. The Mayo technic of this operation is as follows:[2]

If the common duct contains stone, one is seized between the left forefinger

[1] Dr. Edwin Bier, of New York. Report from the Laboratory of Professor Weichselbaum, "Vienna Medical News," July 30, 1904.

[2] "New York Medical Record," April 30, 1904.

and thumb, and, using the stone as a guide (Elliot), two lateral mattress sutures are placed, leaving a free space between for longitudinal incision of the duct in its visible portion between the cystic duct entrance and the duodenum. These two threads with long ends act as tractors, and after removal of stones may be crossed to unite the duct margins, always leaving a little chance for drainage at the ends of the incision (Fig. 458). In the majority of cases, unless the cystic duct is

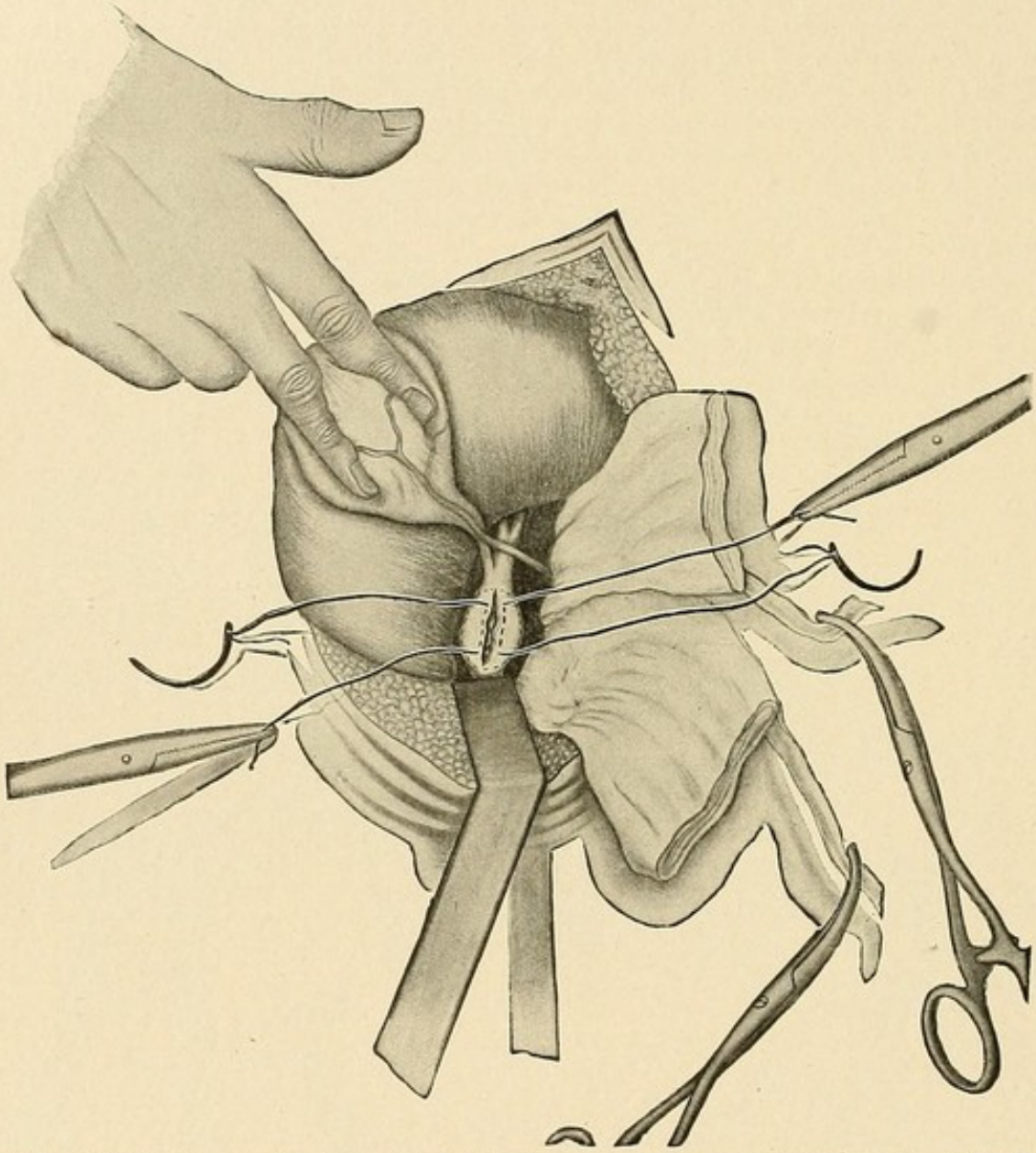

FIG. 458.—Choledochotomy, showing method of placing working sutures in common duct. (After Mayo.)

freely open for drainage through a cholecystostomy, it is better practice to leave the incision open, either completely or in part, and use the threads to fasten the drains in position. Fixing the drains prevents floating by biliary escape or derangement by diaphragmatic action exerted upon the liver. The gauze is surrounded on its inner and lower surface by rubber tissue to prevent peritoneal adhesions.

In septic cases a rubber tube one quarter to one third inch in diameter is cut fish-tailed and introduced into the dilated duct, and with a needle the tube is secured in position by the original catgut thread on each side. The outer end of the tube can be placed in a flattened flask, which is held in the dressing. A light gauze pack is placed about the tube and fastened with the same thread. The notch cut in each side of the deep end of the tube permits bile to pass on and out through the papilla at any time, and yet furnishes just as complete drainage.

In removing stones from the common duct the finger is the only reliable guide, and without it one cannot be sure that no calculi have been missed. The bile

pressure will cause an *obstructed* common duct to distend to a size sufficient to admit a medium forefinger of the left hand.

Calculi in the common duct are often so well concealed that they may even escape detection by the sense of touch. Where all the symptoms are present and where the duct is dilated and jaundice is present, having exposed this area and finding no adequate cause for the conditions which exist, the duct should be laid open and thoroughly explored. As to the danger of hæmorrhage from the portal vein and hepatic artery, Mayo asserts that in a well-conducted operation for common duct stones these structures are not seen.

"The cystic artery frequently comes off from the superior pancreato-duodenal (Brewer), and if cut bleeds sharply, and a large vein may cross the duct, and if wounded will cause the field to fill with blood, leading to erroneous belief as to origin. These vessels are easily caught and tied.

"It sometimes happens that no stone can be felt, yet from the symptoms we are morally certain they are in the common duct, while the parts are adherent, with the anatomy so disturbed that nothing, not even the duct itself, can be recognized. To find and open the common duct in such cases, split the gall bladder from top to bottom and extend the incision the entire length of the cystic duct, and from this point into the common duct. The adhesions are left intact to act as barriers to infection. After completing the common-duct work, the cystic duct is cut across near the common duct and the gall bladder removed from below upward, or, in some cases (where the adhesions render it necessary),[1] the mucous membrane may be entirely peeled off."

[1] The reparative power of the common duct is not exceeded by any mucous lined channel in the human body. One not infrequently encounters cases in which this channel after operation looks very badly with widely separated and ragged walls, and one fears that union will not take place, yet healing almost invariably occurs, whether the duct is sutured or not. During 1904 the following three cases, illustrating the reparative power of the common duct, occurred in St. Mary's Hospital. The first, a female patient, age twenty-two, with acute infectious cholecystitis and cholangitis, with stones in gall bladder. In emptying the gall bladder much puttylike material was forced into the deep ducts. To enable removal of this substance and proper drainage, it was necessary to split the hepatic and common ducts from the liver to the shelter of the duodenum; the gall bladder was also removed. The margins of the common duct were approximated in three places by catgut sutures, the balance being left open for drainage. Patient left the hospital in twenty days with a healed wound; no bile was discharged after fourteen days.

The second patient was a female of thirty-four years. In removing a gall bladder which was very adherent the common duct was completely severed and the ends separated to such an extent that it was difficult to locate the distal fragment. The proximal end was made manifest by escape of bile. The severed duct was sutured end to end in three fourths of its circumference with interrupted fine catgut sutures, through all the coats but avoiding the mucous membrane, excepting at its margin. The sheath was treated in a similar manner. It was not possible to introduce more than five to six sutures in all. One fourth of the severed duct was left open to avoid tension and secure free drainage. Bile ceased escaping from the wound on the sixteenth day, patient left the hospital on the twenty-second day.

The third case was most interesting. A female, fifty years of age, with stones in gall bladder and common duct. Gall bladder malignant, involving cystic duct and extending laterally upon common duct. Gall bladder, cystic duct, and one inch of common duct excised. The duodenum and head of pancreas were liberated by incising the peritonæum and loosening the cellular attachments. This enabled the distal end of the common duct, which barely projected beyond the duodenal shelter, to be brought to the short end of the hepatic duct. The duodenum was secured in this situation by sutures posteriorly. The common duct, which was dilated to the size of a lead pencil, was sutured as in the case just described. One fourth was left open for drainage. This patient was discharged in nineteen days with a healed wound. She remained well for seven months, but now has return of the malignant disease shown by nodular tumors of the liver.

In two additional cases the common duct was excised for malignant disease. In the first the proximal end of the duct was united to the duodenum by a new opening. The third, a malignant tumor of the common duct, was excised with end-to-end suture. Death followed from shock.

In removing stones impacted in the duodenal end of the common duct, great difficulty may be encountered, and in three of our cases it became necessary to open the duodenum (McBurney), for the purpose of extracting the stone. It was only by means of this double operation that the duct could be properly cleared. The duodenum was sutured and the common duct drained in the usual manner. In a fourth case the duodenum was opened for the removal of a cancer of the ampulla and papilla. All of these cases recovered. I cannot too strongly urge the complete removal of all stones at one sitting, if the patient can bear the operation, and in our experience it has been safer than half-way measures, followed by unavailing irrigations, probing, etc., and in the large majority of cases a secondary operation of greater magnitude than the first. [W. J. Mayo, "New York Medical Record," 1905.]

Cholecystenterostomy is an operation which may be necessary in certain rare cases of benign inoperable obstruction, or for malignant disease. The gall bladder

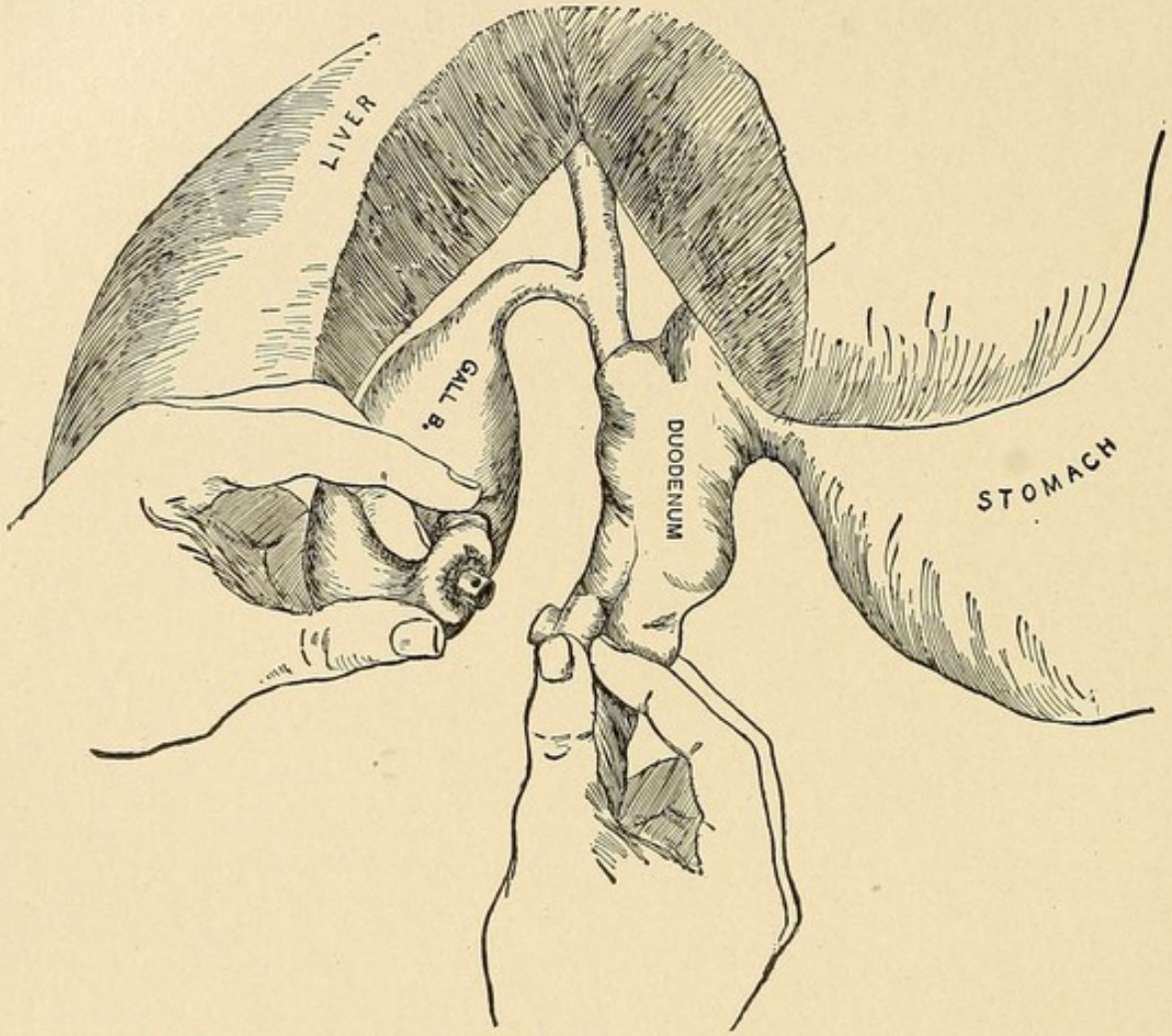

FIG. 459.—Button as held when pressed together when performing cholecystenterostomy.

should be attached to the duodenum either by direct suture or, preferably, by the employment of a button, the ingenious device of Prof. J. B. Murphy. The technic is as follows: A perpendicular incision is made three inches long and three inches from the right of the median line over the gall bladder. The duodenum and gall bladder are drawn into the wound, and an incision made in the duodenum large enough to admit one half of the button (Fig. 459). The method of inserting the suture to tie around the button is shown in the accompanying cuts (Figs. 460 and 461). The thread should be inserted before the bowel is opened, and every precaution should be taken to prevent the escape of any bowel contents into the peritoneal cavity. The same form of suture is then inserted into the gall bladder at a point which, after trial, will permit the two surfaces to come snugly together. Any gallstones that are present may be removed before the button is inserted. The other half of the button is then placed in the gall bladder, the suture tied, as in the intestine, and the approximation made. The bile passes through the

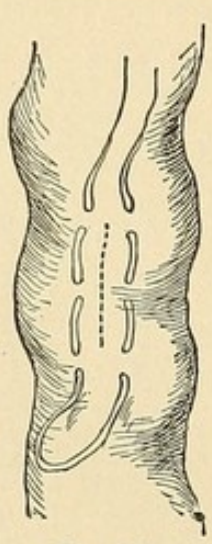

FIG. 460.

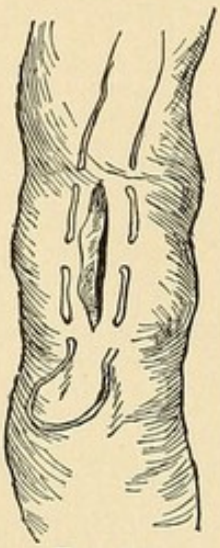

FIG. 461.

opening in the button into the duodenum, and usually the symptoms of jaundice disappear. After adhesion between the approximated bowel takes place, the button drops either into the intestinal tube or into the ball bladder. When it drops into the alimentary canal it is discharged with the fæces, but if it drops into the gall bladder it will cause discomfort, and may ultimately require removal.

In five cases in which it was found impossible to make this anastomosis with the duodenum, a loop of the transverse colon was substituted by W. J. and C. H. Mayo, using the Murphy button as for duodenal anastomosis. In each of these cases the result was as satisfactory as when the duodenum was used. There were no late infections of the bowel tract from colonic bacteria, and one patient lived six years, dying from an independent disease. The second was alive and well four years after the operation.

Occasionally it will be found that calculi have drifted so far toward the duodenum as to necessitate the incision of this intestine immediately over the opening of the common duct, removing the stone from the duct from within the bowel, as was performed by Dr. Charles McBurney.

When it becomes necessary to divide or exsect a portion of the common duct, the ends may be reunited by using ten-day chromic-acid catgut, the needle passing through all the structures of the wall of the duct one eighth of an inch from the cut ends. Careful capillary drainage should be secured during the seven or eight days in the process of repair.

When for any reason the lower end of the duct cannot be utilized, the upper end may be led directly into the duodenum by stitching this portion of the intestine to the adhesions which have resulted from the inflammatory process. In this way dragging away from the upper end of the duct, after it has been united at the opening in the duodenum by suture, may be prevented. This operation has been successfully performed by W. J. Mayo.

The Spleen

By reason of its friability, the spleen is more liable to rupture than any other organ of the body. Its substance may be torn as a result of a direct blow upon the abdomen or by an indirect injury, as a severe concussion received in a fall. Hæmorrhage is usually profuse, and often rapidly fatal. When caused by a penetrating wound, there is usually an escape of blood through the wound in the abdominal wall. The bleeding may, however, be entirely internal, as in the case of rupture without penetration. The symptoms are syncope, with more or less profound shock, which comes from sudden exhaustive hæmorrhage.

Treatment.—With a penetrating wound followed by hæmorrhage, the indications are to open the abdomen at once either through the wound of entrance or sufficiently near it to control the bleeding from the spleen. The temporary arrest of hæmorrhage may be secured by packing with sterile gauze, and, when possible, the injured portion of the organ should be brought through the abdominal incision. At times it has been found expedient to surround the torn portion with a ligature, this part ultimately separating. In small punctured wounds, packing with ribbon gauze should be done. The gauze is left in place, with one end brought out through the abdominal wound, and when adhesions have formed it may be removed. In order to reduce blood pressure from a bleeding spleen (or other internal organs), ligation of the extremities, after the method of Detmold, should be done. When the bleeding has ceased and shock is still threatened from loss of blood, the injection of hot normal salt solution into a vein may be done. In milder cases, two or three pints of this solution, to which is added a teacupful of strong coffee or an equal quantity of whisky or brandy, may be thrown into the colon. In rare instances, *splenectomy* may be necessary after infection following an injury.

A number of cases are recorded in which the spleen has been successfully removed on account of rupture, both with and without a penetrating wound.

Abscess of this organ may be single or multiple. The symptoms are those of tenderness elicited by deep palpation, with gradually developing sepsis. *Subphrenic* abscess of the left side is occasionally met with as the result of the extension of

an infectious process following gastric ulcer, or from a preëxisting abscess of the spleen. The differentiation of abscess between the diaphragm and the spleen and intrasplenic abscess is practically impossible without exploration. The treatment does not differ materially from that already given for hepatic abscess or subphrenic abscess over the liver.

Displacement of the spleen occurs quite commonly from tight lacing, and is apt to follow prolonged enlargements of this organ due to malaria or to simple hypertrophy, neoplasm, etc.

When possible, it should be resutured in its normal position, or, failing in this, splenectomy may be necessary.

Cysts of the spleen, when present, may be diagnosticated from abscess by absence of tenderness and the general symptoms of infection. Aspiration with a delicate hypodermic needle will assure a correct diagnosis, although this should not be done until every preparation is made for immediate operation.

Hernia of the spleen occurs at times through a wound of the abdominal wall. If the prolapsed portion has not become strangulated or hopelessly infected, it should be thoroughly cleansed with hot sterile salt solution, flushed with 1–3000 mercuric chloride, and again with a normal salt solution, dried, and returned to the peritoneal cavity, and the wound immediately closed. On account of its delicate structure, the most careful handling is required. If the organ is so lacerated that in all probability bleeding will ensue as soon as the stricture is released, it will be advisable to throw an elastic ligature around it at the level of the skin, apply an aseptic dressing, and remove at once the greater part of that portion projecting beyond the ligature.

Splenectomy.—This operation is contra-indicated in leukæmia, amyloid spleen, hypertrophy secondary to cirrhosis of the liver, for secondary malignant diseases, and in all the essential anæmias.[1] It may be considered in certain forms of localized tuberculosis and sarcoma. When the organ is displaced and the pedicle is long, the operation is not difficult, but when it is closely lodged beneath the vault of the diaphragm, a very long abdominal incision, which splits the left rectus muscle and permits of Meyer's costoplasty, will be advisable. The splenic vessels should be tied separately with silk or linen ligatures.

With abscess, if drainage can be successfully accomplished, it is preferable to splenectomy. In cysts, benign tumors, tuberculosis, and sarcoma, splenectomy is the operation of choice, unless in the non-malignant diseases a tumor is so small that partial splenectomy may be entertained. Davis states that in the severe type of malarial spleen, with failure of relief of the malaria or the extreme enlargement by medical treatment, splenectomy will often result in cure.

The Pancreas.—One of the most frequent lesions of this organ is an acute or chronic inflammation (pancreatitis), not infrequently associated with infection, with partial or complete occlusion of the common gall duct. Infection in all probability occurs through the communication of the pancreatic duct with the bile duct, although infection by direct extension through the tissues or by metastasis is possible.

In twenty-six cases operated upon at the Mayo clinic, a chronic infection of this organ was treated with satisfactory results by drainage of the bile ducts. The symptoms of pancreatic infection do not differ materially from those of a local peritonitis, and cannot be positively differentiated without exploration, which should be done upon the appearance of the first symptom of intra-abdominal infection in this region.

The operative route is transperitoneal,[2] following a free incision in the median line about half-way between the xyphoid appendix and the umbilicus, to be en-

[1] D. B. Davis, "Journal American Medical Association," 1905.

[2] In two cases operated upon by Dr. George E. Brewer, the following method was employed: A median incision 10 cm. long was made through the left rectus muscle. The transverse colon with its omentum was turned upward and the body of the pancreas palpated through the transverse mesocolon. As soon as the indurated area was appreciated, the intestines were walled off by gauze pads and the presence of pus discovered by an exploring needle. A long rubber drainage-tube about three sixteenths of an inch in diameter, was introduced into the small opening through the inferior layer of the mesocolon, and tightly packed about with a thin strip of folded gauze

larged upward or downward, or transversely if necessary, to meet the indications. The gastrocolic omentum should be incised or torn, and all bleeding promptly arrested. By traction upward upon the stomach and downward upon the transverse colon, the posterior layer of the peritonæum which covers the pancreas is incised and the organ exposed.[1] If there are evidences of extensive involvement of the head of the gland, in addition to drainage of the principal bile ducts one or more cigarette drains or a temporary gauze pack may be considered. If the tail of this organ is involved, removal of that portion is the only alternative.

Tuberculosis of the pancreas is occasionally met with, and may at times give rise to the ordinary symptoms of tumor. After exploration, any immediate surgical indications should be met and the proper general hygienic routine prescribed.

Calculus of the pancreas occurs in rare instances, and may possibly be diagnosticated by the X-ray. Much more reliable, however, is the careful palpation of this organ through an exploratory incision.

Carcinoma is located almost always in the head or larger portion. It is, as a rule, accompanied by chronic progressive jaundice, dilatation of the gall bladder due to obstructive pressure, and there is the usual wasting cachexia of carcinoma. Tumefaction is of slow development, and not readily appreciated on account of the great depth of this organ.

A not infrequent lesion of the pancreas is *cyst*, which may be of traumatic origin or result from hæmatoma due to extravasation. Cysts due to pathological changes in the glandular apparatus occasionally develop in the pancreas, and may assume very large proportions. When so extensive as to render extirpation impossible, they should be tapped through an incision and drained, but when seen early a complete removal is advised.

Mesentery and Omentum.—While cysts of the mesentery are not infrequently encountered, solid neoplasms are rare. Cancer may be primary, but is more often secondary. Sarcoma is most frequently observed. Fibroma and fibrosarcoma are the neoplasms which are most often brought to the attention of the surgeon. These tumors should be removed as soon as discovered, and this requires at times the resection of that part of the alimentary canal to which the blood vessels involved in the tumor are distributed.

There is a form of cyst found in this membrane which is so closely related to the lacteal system that it is supposed to originate in obstruction of these ducts, although one observer (Dowd) holds that they are of embryonic origin. They are multilocular, in color cream white, with large vessels traversing their walls. They may occur at any time of life, from ten years old and upward. Dr. Miles F. Porter[2] concludes from a careful study of this subject that chyle cysts of the mesentery are rarer than the serous variety. The treatment consists in removal by that technic which seems best adapted to the case in hand, as demonstrated by exploration (Porter).

The omentum is less frequently the seat of neoplasms than the mesentery, although primary sarcoma of the omentum is, in rare instances, encountered.[3] Cysts and other tumors are occasionally met with here, and in common with sarcoma require exploration for diagnosis, and, when possible, extirpation. In all cases of tumor which the microscope has demonstrated to be sarcoma, either with or without removal by operation, the injection of mixed toxines should be advised.

tape to prevent leakage. The tube and the gauze packing were secured in place by a single stitch of plain catgut. The distal extremity of the gauze tape and long drainage-tube were brought out at the lower angle of the wound leaving ample space for the transverse colon and small intestines to resume their normal place. The tube and tape were allowed to remain in place for eight days. Both patients recovered ("Surg. Gyn. and Obst.," September, 1907).

[1] F. Vilas, "Semaine Medicale," October 11, 1905. Murphy, General Surgery, 1906, reports 106 cases of acute pancreatitis surgically treated, of which more than 50 per cent recovered.

[2] "Annals of Surgery," 1906.

[3] F. Cobb, "Annals of Surgery," July, 1906.

CHAPTER XXII

OBSTRUCTION OF THE ALIMENTARY CANAL BELOW THE PYLORUS—FOREIGN BODIES—BILIARY CALCULI—INTUSSUSCEPTION—VOLVULUS—CONSTRICTION BY BANDS—STRANGULATION THROUGH SLITS IN THE OMENTUM AND MESENTERY—DIVERTICULA—NEOPLASMS—STRICTURE—ABDOMINAL SECTION FOR INTESTINAL OCCLUSION—RESECTION—INTESTINAL ANASTOMOSIS

PARTIAL or complete occlusion of the alimentary canal may occur from a variety of causes, namely: (1) impaction of fecal matter, (2) foreign bodies, (3) intussusception, (4) volvulus, (5) constriction by bands, (6) by adhesions, (7) omental and mesenteric slits, (8) diverticula, (9) neoplasms, (10) stricture, (11) true hernia.

The impaction of ingested matter may occur at any part of the alimentary canal, although this accident occurs in the great majority of cases in the large intestine. The cæcum and ascending colon are the most common seats of fecal impaction, the sigmoid flexure next in order.

The symptoms upon which a diagnosis is made are the presence of a tumor in the line of the colon, which is not painful on pressure, may be molded by firm and prolonged compression, is movable, and has formed gradually. In the sigmoid colon and rectum digital exploration or inspection will demonstrate the nature of the mass. Vomiting, tenderness, and shock, so common in acute obstruction, are absent, or, if present, only occur in the latter stages and in extreme cases.

The *treatment* consists in the repeated injection of warm water until the bulk of the tumor is softened, when laxatives may be given by the mouth. The method of injection is as follows: Place the patient in the knee-elbow position, or upon the right side with the pelvis elevated. In this position the pressure is in great part taken off the rectum, and a greater degree of tolerance is obtained. The fountain irrigator is the best instrument, and from two to four pints or more may be thrown slowly in at one operation. The water should be allowed to remain in the colon as long as possible. When the impaction is near the anus, it may be removed with the finger or by a spoon. Olive oil or some softening and lubricating agent should be added to the fluid injected.

Foreign Bodies.—Indigestible substances of various kinds, introduced by accident or intentionally, at times pass through the stomach into the intestinal canal and become lodged. In rarer instances they are introduced through the anus.

Biliary calculi which have passed through the common duct into the duodenum, or, causing ulceration of the gall bladder and duodenal wall, enter the canal in this manner, may also cause intestinal occlusion. Again, obstruction has been caused in a number of instances by *concretions* (enteroliths) composed of ingested material insoluble in the gastro-intestinal juices and from which the moisture has been absorbed. They are met with chiefly in the colon and appendix.

The symptoms vary with the suddenness or completeness of the obstruction, as well as with its location. Sudden occlusion is accompanied by a rapid pulse and by pain of a colicky and violent character, usually referred to the seat of the obstruction. Shock is also present in acute stoppage of the canal. Vomiting is an early and prominent symptom of occlusion of the small intestine, coming on at a later period, when the colon is involved. On the other hand, constipation is a feature of stoppage in the large intestine, while fecal matter in varying quantity may continue to pass *per anum* for several days after occlusion above

the ileo-cecal valve. In arriving at a diagnosis, palpation and percussion will be of value. The knowledge of the accident when a body has been swallowed will, of course, establish the character of the occlusion. Insane or hysterical individuals often indulge in such practices. Biliary colic and jaundice not infrequently precede occlusion from calculi which escape by the common duct, while tenderness in the region of the liver and duodenum must be present in a varying degree in cases of perforation of the duodenal wall by large calculi from the gall bladder.

Tenderness is also present in cases where delicate sharp objects (pins, needles, etc.) have passed through the walls of the intestine and are wandering in the cavity of the peritonæum or in the pelvis.

The *treatment* which should be instituted in obstruction by foreign bodies will depend in great part upon the symptoms which ensue. If the occlusion is complete and the symptoms are alarming, operative interference should not be delayed. The only doubt which may be thrown upon the propriety of operating is the presence of shock or collapse in an extreme degree. If this condition is present, morphia and whisky hypodermically should be administered in the effort to bring about reaction. If no urgent symptoms follow the presence of a foreign body in the alimentary canal, expectant measures may be employed in the hope that it may pass out by the rectum. When a foreign body has been swallowed and has gone beyond the stomach, and its shape is known to be such that it may cause perforation of the intestinal wall, or that the possibility of its being passed through is remote, it is the wiser policy not to lose valuable time by procrastination, but to operate at once. When introduced through the anus or lodged in the rectum or lower portion of the sigmoid flexure of the colon, it may be removed through the natural opening.

Intussusception, or the telescoping of one part of the intestinal canal into another may occur at any portion of the bowel.

It is most frequent in infancy, being at that time of life the most common cause of intestinal obstruction. In the small intestine, it is called *enteric*; in the colon, *colic*; and when occurring at the ileo-cæcal valve, *ileo-cæcal* intussusception. Multiple invagination in the small intestine is not infrequently found on autopsy in children in whom no symptoms existed before death, and which evidently occurred in the last few minutes of life.

Dr. L. Emmet Holt collected 385 cases of intussusception under three years of age. Of these, 28 were under four months old; 113 were between four and six months old; 71 between seven and nine months; 18 between ten and twelve months; 32 between one and two years; 96 between two and ten years. Three fourths of all the cases occurred in children in the first two years of life, and one half between the fourth and ninth months. It is more frequently met with in males than in females, in a proportion of 174 to 94. Its association with any general disease is too infrequent to be of any importance. It is caused by irregular action of the muscular walls of the intestines. One part of the tube, by reason of irritation, becomes stiff and small by contraction of the circular muscular fibers, while the part immediately below is relaxed, and into this the smaller and stiffened part telescopes or is propelled by the force of a downward peristalsis. The mesentery is drawn in with the bowel. Intussusception need not necessarily cause obstruction and strangulation, but in most cases both are present, and produce the usual symptoms of occlusion. Gangrene may occur, due to strangulation of the mesentery as it becomes crowded in with the invaginating gut. In some instances parts of the gangrenous intestine are passed by the rectum. The symptoms are those of sudden and severe pain and vomiting, almost always following enteritis or colitis which has induced straining at stool, shock, tenesmus, especially when the tumor is low down toward the rectum, and bloody and mucous evacuations. The tumor then may be felt on the left side along the sigmoid flexure, or by rectal examination. It is often felt near the cæcum. The abdomen is not distended in the early stages of the disease, but later, when obstruction becomes established, tympanites is well marked. The pain is usually intermittent, as in colic, and is excruciating during the attacks. The most marked symptom is the passing

of blood or bloody mucus. The temperature during the first twenty-four or forty-eight hours usually rises, but may be normal or subnormal in the early stages of the attack, due to shock. The prognosis depends on the age of the patient and the character of the invagination. If it is recognized within the first few hours and energetically treated, the death-rate will be very much lower.

Treatment.—Immediate operation is indicated. If the tumor can be recognized the incision should be as nearly over it as possible, always with due regard to the prevention of post-operative hernia (*vide* Celiotomy). If in doubt as to the exact point of invagination a limited exploratory incision should be made in the linea alba below the umbilicus, and this may be enlarged up or down as required. In recent cases, before adhesions have formed, traction and counter-traction will release the imprisoned segment. Should this be impossible, and the condition of the patient will justify a major procedure, excision and direct reunion is imperative; if not, an artificial anus should be made. In case gangrene has occurred, excision should be done without regard to the general condition of the patient, unless the entire necrotic portion can be brought outside the abdominal wall. When the invagination is recent, after the patient is completely relaxed by the anæsthetic, the following conservative measure may be cautiously tried:

The patient, completely relaxed, is placed upon the back with the thighs flexed, and the table inclined, so that the head may be considerably lowered. Inflation through the rectum and colon or the injection of liquid may be employed. Inflation is preferable for the reason that it is somewhat more easy to determine when reduction has been accomplished by air than by water. Danger of intestinal rupture is not very great, as it occurred only once in two hundred and twenty-five cases in children. An ordinary hand bellows can be used with a long catheter attached, introduced well up in the colon. The introduction of air should be effected gradually, and its escape prevented by pressing the buttocks closely together. Manipulation of the tumor is advised while the air is being introduced. The best guide as to the quantity of air to be introduced is the distention it produces. Fifteen or thirty minutes may be allowed for the effort. When bellows cannot be obtained, warm water, at a temperature of about 105° F., may be substituted. A fountain syringe may be used, and the pressure increased by elevation. The quantity of water should be determined by the degree of fullness felt along the line of the colon. The water should be allowed to escape, and if the tumor has not disappeared, it may be again tried, and, failing in a second attempt, laparotomy should be done. Recurring intussusception may be prevented by pleating or wrinkling the mesentery in two or more folds parallel with the weakened segment of gut, by inserting chromicized catgut sutures.

Volvulus, or twisting of a loop of intestine, occurs usually in the sigmoid flexure of the colon, although the remaining portions of the colon, or cæcum and small intestine, may be occluded by this accident. The loop may become twisted upon itself at its mesenteric attachment, or one loop may be twisted over a second. The last variety is more apt to occur in the ileum and lower jejunum. The principal cause of volvulus is an abnormally long mesentery, allowing unusual freedom of motion to the loop of intestine which is attached to it. This defect may be congenital or acquired. Constipation and the habitual distention of the sigmoid flexure by fecal matter is probably the most frequent cause of elongation of the mesocolon and increased length of this part of the large intestine. Volvulus occurs more frequently in men than in women, and is met with in adults more than in children. When the conditions are favorable, a suitable position or an accident in movement is sufficient to rotate the loop on its axis, causing occlusion by the weight of the loop and mesentery brought to bear upon a limited surface. The symptoms of volvulus are those of acute intestinal obstruction. Pain similar to that of colic is present from the start. Constipation is the rule, and indicates the sigmoid colon as the seat of the lesion. Tenesmus is present in a certain number of cases, and is additional evidence that the colon is involved. Distention of the abdomen to an extreme degree occurs in a large proportion of cases, developing more rapidly in volvulus of the colon. Vomiting is rarely present until late in the history of the case, and, when it appears early, it suggests

obstruction in the small intestine. A condition of shock more or less profound supervenes if relief is not obtained. Diminution in the quantity of urine is present in a certain proportion of cases.

Without interference the prognosis is fatal probably without exception in every case of complete volvulus. Strangulation of the loop and gangrene with enormous distention of the part involved occur.

Treatment.—If the symptoms point to the sigmoid flexure or colon as the seat of the twist, the introduction of warm water into the rectum is indicated. The patient should be placed in the knee-elbow position. The introduction should be made gradually, and may prove successful in recent cases where adhesions have not occurred, or where the distention of the gut is not too great. If this measure is not successful within a few minutes, abdominal section should be performed and the loop untwisted, or, if gangrenous, excised.

Constriction by Bands.—Bands of cicatricial tissue resulting from old as well as acute peritonitis may cause intestinal obstruction. This accident occurs chiefly in adults, about equally in both sexes, being due to pelvic inflammations in women and to appendicitis and traumatic peritonitis in men (Treves). The bands vary in length, breadth, and points of attachment. The lower jejunum and ileum are involved in almost all cases. The symptoms are in general those of acute obstruction of the small intestine. Pain is violent in the beginning, and in the majority of cases is referred to the part involved. Vomiting is an early and persistent symptom, and, as is common in obstruction above the ileo-cæcal valve, is apt to be stercoraceous. Shock is usually more prominent in this form of occlusion than in those heretofore given. The urine is diminished in quantity. The abdomen is not tympanitic as a rule, although the constricted loop may be greatly distended, and may be recognized as a distinct tumor by palpation or percussion, or by vaginal or rectal exploration.

The diagnosis must be made from the history of a former peritonitis and the presence of the symptoms above given. The prognosis is grave, and the indication for treatment is early operative interference.

In addition to inflammatory bands, intestinal occlusion is occasionally caused by the pedicle of an ovarian or uterine tumor, or the Fallopian tube may act in the same manner.

Adhesions between contiguous loops of intestine, resulting from peritonitis, may occur in such a manner as to lead to occlusion. The symptoms do not differ materially from those just given, and the treatment is the same.

Strangulation through Slits in the Omentum and Mesentery.—Occasionally a loop of intestine slips through an opening in the omentum or mesentery, becomes imprisoned and strangulated. The rent may be congenital or result from an injury, penetrating or non-penetrating. The small intestine (ileum) is most frequently involved, and the aperture occurs as a rule in the mesentery of the last part of this organ. Strangulation of the colon in this manner is exceedingly uncommon. With the exception of the presence of a tumor, the symptoms are the same as those in hernia of the small intestine with strangulation. Early operative interference offers the only hope of relief.

Constriction by Diverticula.—Pouches or cavities communicating with or attached to the intestines may be true or false—i. e., congenital or acquired. Meckel's diverticulum, which is attached to the last two or three feet of the ileum, may remain patulous and open at the umbilicus, or more frequently it ends in a blind extremity which may be continued as a cord to the umbilicus. When it exists it represents the vitelline duct of the embryo, in which the normal process of closure and obliteration has not taken place. The vermiform appendix may also be classed with the true diverticula. False diverticula occur in both the small and large intestine, being slightly more common in the colon. Their mode of origin is not as yet satisfactorily explained. They are found to project between the two layers of peritonæum along the mesenteric border of the small intestine, and into the appendices epiploicæ of the colon (Treves). They are herniæ of the mucous membrane projecting through an aperture in the muscular layer.

Constriction and strangulation of a loop of intestine by Meckel's diverticulum

are much more apt to occur than by the false pouches. The vermiform appendix in rare instances may become twisted upon its axis and strangulated, or it may cause the constriction of a neighboring loop of the ileum.

There are no symptoms peculiar to obstruction from true or false diverticula, and the nature of the lesion can only be discovered by abdominal section, which is indicated in this form of intestinal occlusion. W. J. Mayo has reported a number of cases of acquired diverticula of the colon in which infection occurred with inflammatory thickening of the walls of this gut and involving the peritonæum. The true nature of these lesions was only revealed by exploration which was followed by excision.

Neoplasms.—Various new formations, both benign and malignant in character, may occur in the intestinal canal and lead to obstruction by projecting into the lumen of the gut, or by pressure from without or by development within the wall proper, producing narrowing. *Fibroma*, *fibromyoma*, and *lipoma* are of rare occurrence. *Angeioma* is also exceptional in this location. *Adenoma* is a more common form, developing from the glandular apparatus, and more particularly from the follicles of Lieberkühn in the large intestine.

Sarcoma and *carcinoma* are also met with, both as primary and secondary growths. The symptoms of obstruction are, as a rule, gradual in development, and the presence of a tumor may be recognized by palpation with the abdominal muscles in complete relaxation. Cancer is the most common of these new formations, and is apt to be located in the colon or rectum. According to Haussmann and Treves, the variety of cancer met with in the large majority of instances is a *cylindrical epithelioma*, encephaloid and scirrhus being very exceptional. The growth may cause constriction by extending completely around the lumen of the tube, or, by developing on one side, cause stenosis by its bulk and by the contractions which result. The diagnosis of cancer may be made in those cases in which the disease is situated in the rectum or lower portion of the sigmoid flexure by digital examination or by the aid of the speculum. Situated higher up, the presence of a tumor, the age of the patient (over forty as a rule), and the peculiar cachexia will aid in arriving at a correct diagnosis.

Stricture.—The partial or complete occlusion of an intestine, by cicatricial contractions following inflammation or ulceration of its mucous and submucous or muscular layers, constitutes a true intestinal stricture. Constriction by peritoneal bands, or the infiltration accompanying cancer, is not considered as stricture proper.

Any disease which produces loss of substance in the inner layers of the wall of the gut may produce stricture. The ulcers of typhoid fever, tuberculosis, dysentery, syphilis, and chronic intestinal catarrh, or those resulting from injury by ingested matter, by traumatism, or the necrosis following strangulated hernia, are the chief lesions which precede true stricture of the intestine. Cicatrization in an ulcer which has its longest axis at a right angle to that of the intestine is more apt to lead to obstruction than one which has its long axis in an opposite direction. Stricture occurs in adults, of forty years or more, oftener than in the young, being rarely met with in children under ten years of age. No portion of the alimentary canal, from the pylorus to the anus, is exempt, yet stricture of the duodenum and upper jejunum is comparatively rare; the ileum, near the cæcum, is more frequently attacked, while the large intestine, and especially the sigmoid flexure and rectum, is the most common seat of this grave and painful affection.

The symptoms of stricture are those of progressive narrowing of the intestine. The intensity of the symptoms will be proportionate to the rapidity with which stenosis results and to the portion of the canal involved. Pain is not marked until the narrowing has arrived at a point where ingested matter passes through with difficulty. It is spasmodic in character, and occurs at varying intervals. Distention of the intestine above the seat of stricture, with consequent hypertrophy of the wall, follows sooner or later in all cases. The continued irritation of the bowel from the pressure of fecal matter induces ulceration of the mucous and submucous tissues at and above the seat of stenosis, and perforation may occur.

Vomiting is an earlier symptom in stricture of the ileum and jejunum than when the colon is involved. There may be diarrhœa or constipation, or these conditions may alternate, and are therefore of no diagnostic value. Tenesmus is rare, and the abdomen is not distended except in case of peritonitis. As far as the previous history may be of value in locating the seat of the lesion, it is known that dysenteric ulcers are usually found in the rectum, sigmoid flexure, and cæcum, and in the order of frequency in which these organs are given: typhoid ulcers (which rarely cause stricture) in the lower ileum and cæcum; those of chronic catarrh in the colon; syphilis (gumma) in the rectum and ileum; and tubercular ulcers in the lower ileum (Treves).

The diagnosis of stricture must be based upon a study of the symptoms above given, except the cases in which the lesion is in the rectum or lower part of the sigmoid flexure, where digital or instrumental exploration may be made.

Treatment.—Stricture of the rectum and lower part of the sigmoid flexure of the colon should be treated by dilatation or division. Above this point the only hope of relief is by *exsection* of the part involved with *end-to-end anastomosis*, or by *lateral intestinal anastomosis*. Enterostomy and colostomy (*fecal fistula*) are palliative surgical measures, to be instituted when other means are not indicated.

Abdominal Section for Intestinal Occlusion.—The rules governing the incision through the abdominal wall as given in the chapter on celiotomy, may in general be applied for the relief of intestinal obstruction. While in case the seat of the lesion is determined it is most convenient for the operator to make an incision directly over the point of obstruction, as before stated, this should not be done if such incision will permanently weaken the abdominal wall, provided there is another approach near by which can be so closed as to give a better guarantee against the danger of abdominal hernia.

When exploration is necessary, the linea alba is in general preferable. The opening should at first be just large enough to admit one or two fingers, and it may be enlarged or abandoned as required.

For the cæcum, the ileo-cæcal region, and ascending colon, splitting the right rectus is advised. To this may be added a separate opening farther out, after the method of McBurney. The hepatic flexure of the colon, the duodenum, and upper jejunum may be reached through the right rectus above, the stomach and transverse colon through the median line, while the splenic flexure and descending colon are best approached through the left rectus, with or without a combination with a McBurney separation on this side. For obstructive lesions in the left inguinal region for a major procedure, a split of the rectus should be preferred with the alternative of the McBurney method nearer the crest of the ileum.

In general, the smaller the incision the better, yet the opening should always be sufficient to admit of thorough exploration, and, if necessary, inspection. The patient should rest upon the back, with the head and shoulders slightly elevated, in order to relax the abdominal muscles. Under certain conditions the Trendelenburg posture more or less modified is advisable.

If, upon exposing the small intestines, some of the coils are found to be greatly distended while others are collapsed, it is pretty safe to conclude that the obstruction is near at hand, and the collapsed loops should be carefully passed between the fingers up to the obstruction. It is scarcely possible, in the condition in which the viscera will be found, to determine exactly which is the upward or downward direction of the coils, and it may be necessary to begin at the cæcum and work upward.

Senn determined by experimentation that by touching the peritoneal surface of the bowel with a little powdered chloride of sodium, a reversed peristalsis will ensue. In this way the upward direction of the bowel may be recognized.

Not infrequently the intestines are so enormously distended that they are protruded through even a small incision and seriously interfere with the exploration. Proceed with the method of Dr. George H. Monks as follows:[1]

The first distended loop of small intestine is brought out through the abdomi-

[1] "Annals of Surgery," October, 1903.

nal incision, and a No. 50 linen purse-string suture is inserted in the shape of an ellipse in the long axis of the gut, the ellipse being about three fourths of an inch wide and about an inch long. A gauze packing is used to protect the peritoneal cavity from soiling. A glass tube slightly curved near the end, the opening one half inch in diameter on the concavity of the curve (a straight tube about one half inch in diameter, or the ordinary glass drainage-tube will suffice in an emergency), to one end of which a long piece of rubber tubing is attached, is introduced into the lumen of the gut through an opening made along the center of the space within the elliptical purse-string suture, which is immediately tightened around the cylinder to prevent extravasation. The gaseous and semiliquid contents flow out through the tube into a receptacle. When the flow ceases, loop after loop of distended gut is drawn down upon the tube, the operation taking time enough to permit the escape of the contents of each loop. As soon as the upper end of the canal is emptied, the glass tube should be turned downward into the lower portion and the process of emptying repeated.

In this way the distention may be entirely relieved, and if necessary it may be applied to hyperdistention of the colon. The tube is then withdrawn and the purse-string suture immediately tied. There is scarcely any constriction of the lumen of the gut by tying the purse-string suture, and the slight degree of angulation which results will not interfere with the passage of ingesta. One or more Lembert sutures may be superadded to the purse string for security.

Emptying the intestines by this procedure not only diminishes tension and permits the return of the bowels to the peritoneal cavity, but it removes a large quantity of toxic material from the alimentary canal, and thus adds to the chances of recovery. If this apparatus is not at hand, multiple puncture may be substituted, but this method is unsatisfactory since a single puncture will rarely empty more than one or two feet of intestine.

When as not infrequently happens, by reason of procrastination, the condition of the patient is so critical that a prolonged operation is not indicated, it is the better practice to seize the first presenting loop of *distended* intestine, stitch it to the abdominal wound, and establish immediately an artificial anus. The alarming symptoms of obstruction may be thus allayed, and the occlusion dealt with at a subsequent operation. I have in a number of instances successfully employed this method, restoring later the continuity of the canal.

If the cæcum is found to be distended, the lesion is evidently in the colon, and this organ should be followed to the obstruction. If biliary calculi, a foreign body, or enteroliths are found, the part involved in the obstruction should, if possible, be brought out at the wound, protected by warm towels, the escape of matter into the cavity of the peritonæum prevented by napkins, and the body removed by an incision in the long axis of the gut, and, when possible, opposite the mesenteric attachment. The length of the opening should be sufficient to allow of the removal of the body without bruising or tearing. If the part cannot be brought out, it should be laid upon mats and the peritonæum in this way protected from the escape of fecal contents. This accident may be in great part prevented by compression of the gut above and below the obstruction. The wound in the intestinal wall is next closed by Lembert's suture.

If strangulation and necrosis exist, exsection of the necrosed portion should be made at once, if the condition of the patient is such as to justify a prolonged operation. If not, the dead loop or portion should be brought out at the incision in the abdomen, cut away, and a fecal fistula established. In this emergency Bodine's operation may be found of great value, since the restoration of the intestinal canal may be accomplished at a subsequent operation without general narcosis. If, however, operative interference has not been too long postponed, it will be advisable to proceed with the exsection at once.

Excision of a portion of the intestinal canal may be necessitated as a result of gangrene following strangulated hernia, intussusception, volvulus, vascular occlusion, stricture, neoplasm, or perforation with loss of substance so great that lateral closure is not possible.

The operative procedures are *end-to-end* or *lateral anastomosis,* or the estab-

lishment of a temporary *fecal fistula*. The choice of either one of these operations will depend upon the conditions which prevail. A restoration of the integrity of the canal by end-to-end suture is the ideal procedure, and it should be preferred. If the patient's condition is such as to contra-indicate a prolonged operation, the Murphy button or lateral anastomosis may be substituted, or the temporary fecal fistula should be established and resection performed at a later period.

As between end-to-end anastomosis by suture or the Murphy button, the suture should be preferred if the conditions of the operation are favorable and the operator sufficiently expert. If not, the button should be given preference.

In expert hands lateral anastomosis may be rapidly performed with the assistance of the double clamp, and this operation is given preference by a surgeon of such large experience as W. J. Mayo.

End-to-end Anastomosis by Suture.—The loop of the intestine which is the seat of lesion should be brought out through the incision in the abdominal wall. Gauze should be inserted to prevent infection of the peritoneal cavity, and that portion of the exposed loop not in the field of operation should be covered with towels wet in hot salt solution. At a convenient distance on either side of the proposed lines of incision through the bowel, it should be clamped by forceps shielded with rubber, or sterile tapes should be passed through the mesentery close to the bowel and tied in a loose half bow-knot sufficiently tight to close the lumen of the gut, while not exercising pressure enough to entirely arrest the circulation (Fig. 462). In excising the necrotic area the intestine should be cut across at a right

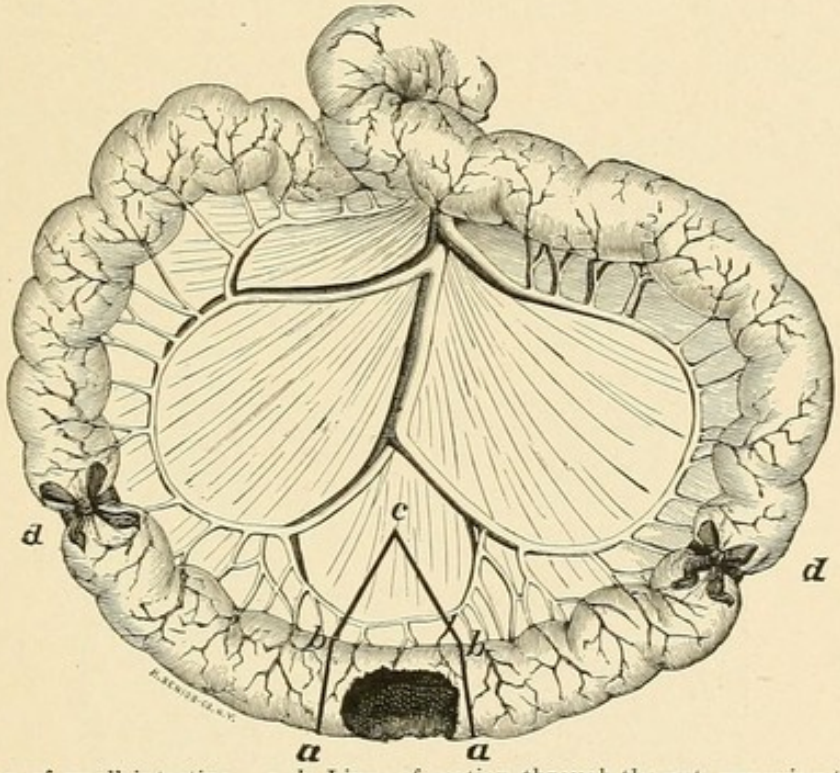

Fig. 462.—Loop of small intestine. *a*, *b*, Lines of section through the gut, removing the gangrenous portion. *b*, *c*, Same through the mesentery. *a*, *a*, Gangrenous portion of ileum. *d*, *d*, Occlusion of the afferent and efferent tubes by tape ligatures.

angle to its axis by a single stroke with straight scissors (Fig. 462, *a*, *b*), and these lines of section should be well in sound tissue. A triangular piece of mesentery is next removed (Fig. 462, *b*, *c*) in such a manner that the mesentery is left projecting nearly one quarter of an inch beyond the line of section through the intestine, in order to insure the vascular supply to the gut at this most important point. All bleeding points from the mesentery should be tied with plain catgut.

Of the suture methods the simplest and most rapidly executed is the author's through-and-through partly continuous suture, which is interrupted at four points in the circumference of the gut so that the threads, as later they become loose and hang in the lumen of the bowel, may not form festoons of too great length. The

material employed is a fine (No. 50) Pagenstecher's celluloided linen, and preferably dyed black, with a perfectly round ordinary embroidery or sewing needle, straight, and of as small size as will carry the thread. These needles can be used rapidly without a needle holder, and make only a small puncture, which is at once filled with the suture, so that the chances of leakage are infinitesimal. The two ends of the divided intestine are flattened and placed side by side with the cut surfaces parallel, the mesenteric attachments in the center of the approxi-

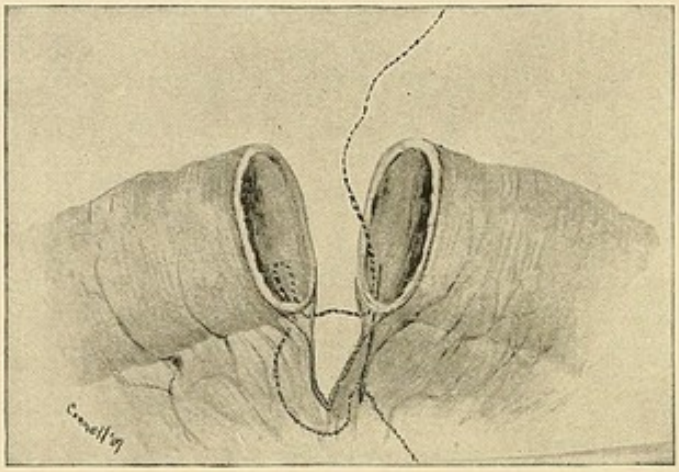

Fig. 462*a*.—Insertion of mesenteric stitch, which obliterates triangular space. (Connell.)

mated surfaces. This is the weak point in the operation, and considerable care must be taken to prevent leakage. At a point just to one side of the middle of the space which is uncovered by peritonæum (Fig. 462 *a*) and a little more than one eighth of an inch from the cut edge, the needle should be carried directly through the bowel wall and then out through the cut edge of the divided mesentery straight across to the other side through the layer of the mesentery of that side, then through the bowel wall into the lumen of the opposite end of the gut. At a point one eighth of an inch removed it is reëntered and made to pass again through the wall and out through that layer of the mesentery, across through the

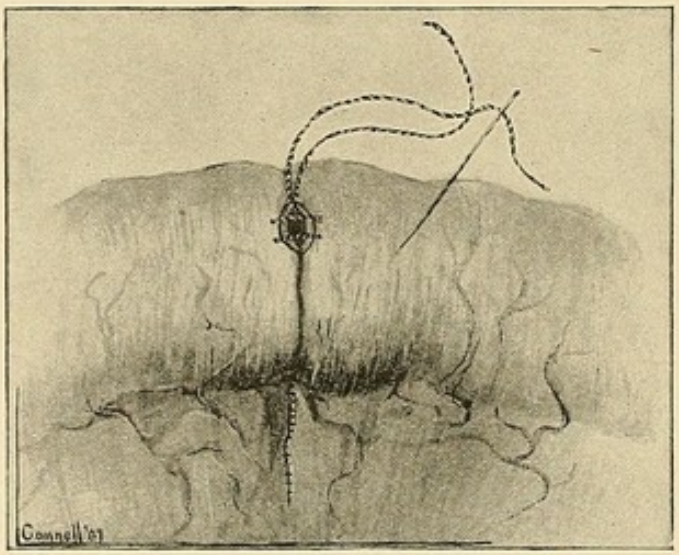

Fig. 462*b*.—Stitches inserted and all tied but the last two. These in place, with ends ready for tying. (Connell.)

opposite mesenteric layer, and then again through the bowel wall, coming out one eighth of an inch from where it was originally introduced. The route of this suture is clearly shown in Fig. 462 *a*. It should be tied at once.

If this Connell suture is not employed, the next best method at this point is to carry a single interrupted suture through the center of the inter-mesenteric

space and one eighth of an inch on either side, another which shall include both the bowel and the layer of mesentery. Either, if properly employed, should suffice to prevent leakage. The Connell suture is preferable, since it can be more rapidly introduced and time is always a factor of importance in intestinal surgery. With this suture inserted and tied, a through-and-through suture to be used as a holding loop should be inserted at the limit of the approximated bowel surfaces on either side of the primary suture. While an assistant holds these two

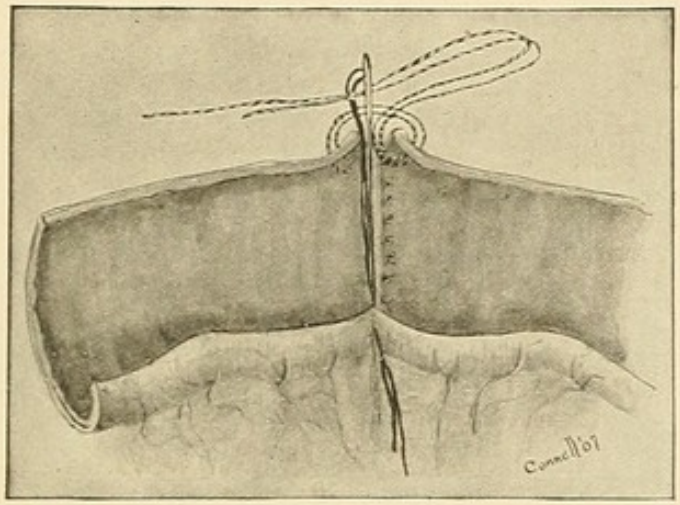

FIG. 462*c*.—The threaded needle presents at the location of the last stitch. The ends to be tied are inserted into the loop formed by the needle and its thread. (Connell.)

loops, the operator rapidly introduces a continuous suture, commencing one sixteenth of an inch from the first suture, each loop being one eighth of an inch long, and the needle introduced slightly more than one eighth of an inch from the cut edge. These loops should be drawn tight enough to firmly approximate the peritoneal edges, but not tight enough to pucker or contract the lumen of the bowel. When the holding sutures are reached, these should also be tied and one end of each thread used as a continuous suture until a space of about one

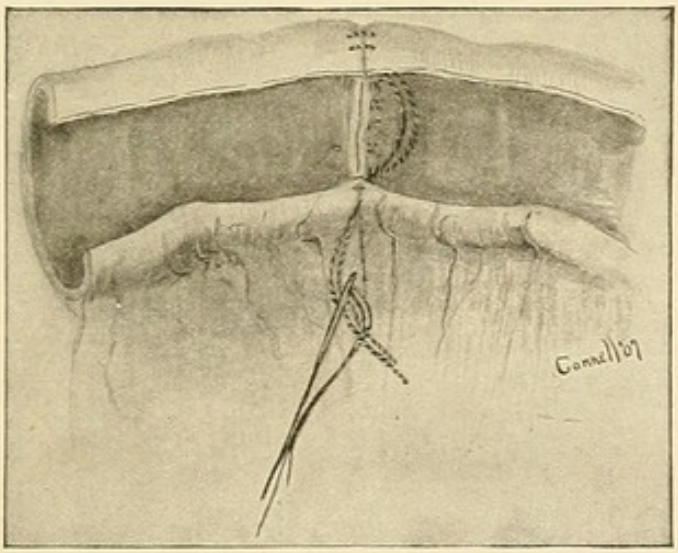

FIG. 462*d*.—By withdrawal of the needle and its loop, the cut ends at the site of the last stitch are inverted, and the ends to be tied are drawn to the outside through the opposite portion of the line of suture. (Connell.)

fourth of an inch is still ununited. Here they should be tied, the knots being upon the inner or mucous surface, and the remaining gap closed by two interrupted sutures inserted from the mucous side of the bowel, as shown in Fig. 462 *b*. In order to bring these last knots also on the inner side of the bowel, they are to be tied in the following manner: One of the needles, armed with a

loop of sufficient length is pushed eye-end foremost through the suture line at a point about opposite that at which the last sutures are inserted, and is carried through as shown in Figs. 462 *c* and *d*. Both ends of one of the final sutures is caught in the loop, which is then withdrawn, bringing both ends out through the bowel on the opposite side, where they are temporarily knotted to prevent confusion. This is repeated for the remaining suture, when the ends are tightly drawn and tied, which brings the knot on the mucous surface. The ends are cut short with the peritoneal surface, and as the bowel expands they slip into the lumen, leaving every knot tied upon the inner surface of the bowel.

If the technic of this through-and-through suture is carefully carried out as above given, it involves the minimum of risk, possessing as it does the one great advantage of rapidity of execution. When completed, if there should appear to be a weak point in the line of union a simple Lembert suture should be inserted by way of reënforcement.

In the hands of an expert operator, anastomosis by the combined Mayo-Cushing sutures may be preferred, especially if time is not of great importance, or if the surgeon is a rapid and skillful technician. These two stitches are clearly illustrated in Fig. 445*e*.

The needle carrying the Mayo catgut stitch should be inserted one sixteenth of an inch from the cut edge for the small and one eighth for the large intestine. It is commenced on one side of the mesenteric attachment, each loop of the suture being one eighth of an inch long. When the first stitch is tied, the end should be left about two inches long to be finally knotted with the main thread when the entire circumference of the cut edges have been united. Then it should be cut short and the knot pushed between the united edges into the lumen of the bowel. The Cushing seromuscular mattress suture is now superadded in the same manner as described by him when no other suture is employed.

This seromuscular suture line is intended to run parallel with the cut edge of the intestinal wall three sixteenths of an inch (4.5 mm.) from the edge. The needle is inserted parallel with the cut edge, passing through the serous and the muscular layers, taking care not to penetrate the mucous membrane, and is made to come out one eighth of an inch from where it entered. The needle is then carried *directly across* the wound to the other cut end of the intestine and the same procedure is there repeated. As it passes from one end of the gut to the other, it should be exactly at a right angle to the cut edge, hence Cushing calls it "the right-angled continuous suture." It is begun at one side of the mesenteric attachment by what he terms an inverted Lembert suture. This is tied at once, leaving a free end two or three inches long. The suture is then continued along that part of the intestine where the two layers of the mesentery split to surround the gut, and on to complete the circumference, when the thread forming the *last* stitch is tied to the free end of the *first* or Lembert suture. Both sides or layers of the mesentery are now sutured by inverted Lembert sutures one eighth of an inch apart. It is well to repeat that the weak point in end-to-end anastomosis is at that part of the intestinal circumference in close relation to the mesentery as it divides to surround the gut. Extra care should be given to this portion to see that no possible leakage may occur.

If the foregoing technic is carefully applied, leakage is practically impossible. The Mayo suture of absorbable catgut passing through the entire thickness of the intestinal wall is so inserted that as it is tightened a strip of peritonæum one sixteenth of an inch wide (in the small, one eighth in the large intestine) on each end of the gut is brought in close apposition. The Cushing suture superadded, approximates another strip of peritonæum one eighth of an inch wide, and as this suture line does not become infected it not only holds the peritonæum in apposition and secures rapid plastic union, but it remains innocuous until it is finally absorbed. In tightening this linen suture, Cushing advises that it be drawn just tight enough to firmly approximate the peritoneal edges without diminishing at all the lumen of the intestines. The same precaution holds good with the Mayo stitch.

The seromuscular suture of Cushing may also, when time is a matter of great importance, be alone employed. It has been successfully used in many instances.

After irrigation with warm salt solution the clamps are removed and the sutured loop returned to the peritoneal cavity (Fig. 463).

When the loop of gut cannot be drawn out through an incision, sterile mats should be used to wall off the general cavity to guard against infection.

In the after-treatment the bowels should be kept at rest from eight to ten days. Nourishing liquid diet and articles of food digested and absorbed in the

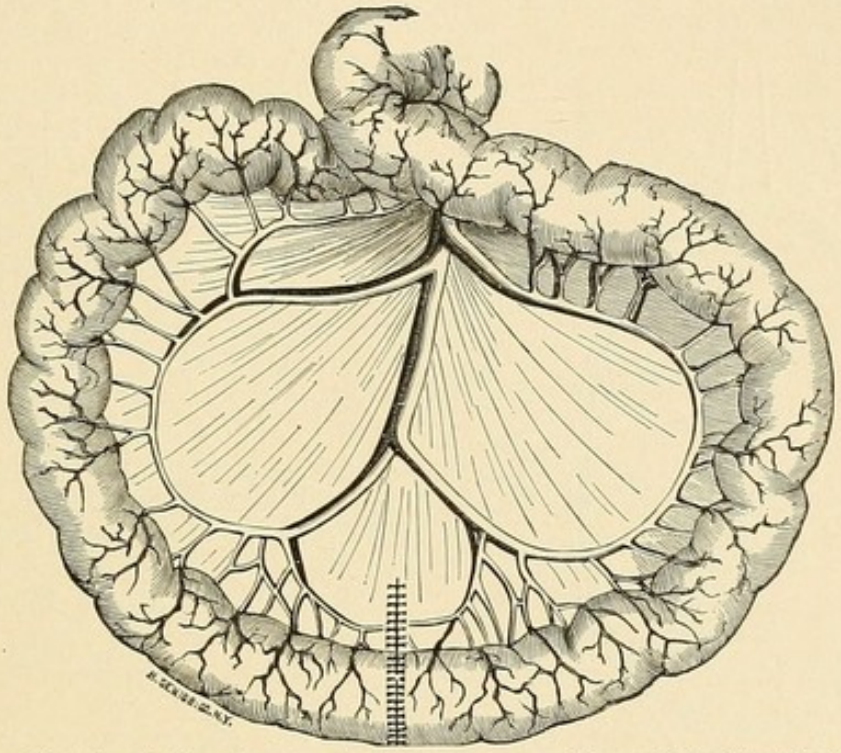

Fig. 463.—Showing the line of sutures in the mesentery and around the intestine in one of the author's cases.

stomach or high up in the alimentary canal, or in the lower colon when this is not the field of operation, will meet the indications.

In end-to-end anastomosis after a fecal fistula has existed for some time, the lumen of the bowel below the opening will be so much smaller than above that it will be necessary to insert the sutures somewhat nearer to each other in the lower circumference. The inequality will disappear as soon as the continuity of the canal is restored. When this inequality is present the author prefers to use the interrupted suture.

When the conditions are such as to demand a more rapid procedure than union by suture, as just described, the employment of the Murphy button may be substituted for the union by suture, or the establishment of a temporary artificial anus.

These buttons are made of various sizes to suit different portions of the alimentary canal.

They consist of two small circular bowls (Fig. 465) so arranged that when properly adjusted in that portion of the bowel where the anastomosis is to be made they close together by a double ratchet (Fig. 464) compressing the inverted peritoneal surfaces of the ends of the intestine and securely holding these in apposition until adhesion occurs. The thread, which has tied the end of the gut around the central portion of each segment of the button *and inverted the peritonæum,*

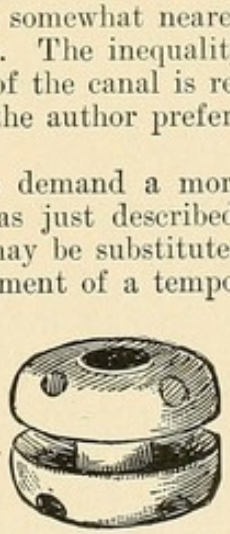

Fig. 464.—Murphy's button. The segments pressed nearly to complete closure.

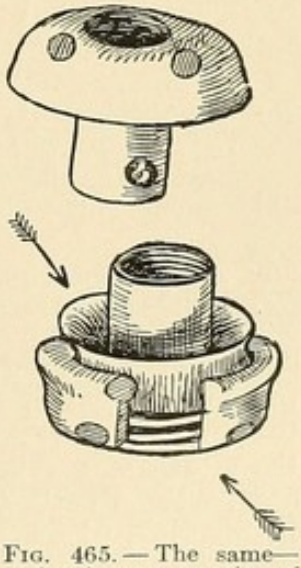

Fig. 465.—The same—showing construction of the separated segments.

becomes loosened by necrosis from pressure, and, with the button, in from seven to fifteen days drops loose in the alimentary canal and is carried along until it is passed through the rectum. At Fig. 466 the method of passing the suture in and out around the margin of the bowel is shown. With a straight needle, armed with a medium-sized linen suture, carry the needle through the bowel, a little more than one eighth of an inch from the cut edge passing through the peritoneal coat and into the lumen of the gut. One fourth of an inch farther on, the suture is carried on the same level through the mucous membrane and out through the peritonæum to the outside. It is then carried over the free (cut) edge of the bowel again to the inner side and through, and this in-and-over suture is continued (as shown in the drawing) until the bowel has been perforated by the needle from the mucous-membrane side out to the peritoneal surface just at the beginning of the attachment of the mesentery to the intestine. It is then carried over the cut edge of the mesentery around and back through this membrane at the same depth from the edge as for the intestine, then back again over the cut edge of the mesentery,

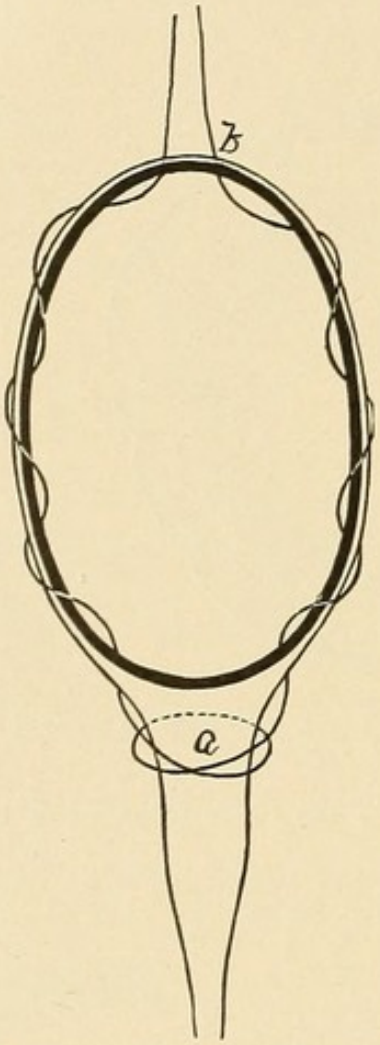

Fig. 466.—Showing the in-and-out method of inserting the silk suture around the end of the divided intestine and over and through the mesentery near its attachment. *b*, Point of beginning. *a*, Including the mesentery.

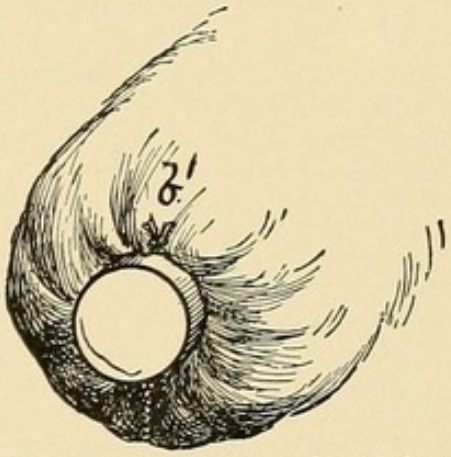

Fig. 467.—One segment of the button fastened in one end of the intestine (to be united) by the purse-string suture tied at *b*. The complete inversion of the peritoneal surface is properly accomplished.

and on in like manner as for the opposite side of the gut to a point of emergence about one eighth of an inch from the point where it entered. The two ends of the threads are now ready for the insertion of one segment of the button. This is grasped by the forceps and carried into the end of the bowel deep enough to allow the gut to be snugly folded around the central shaft or stem, when the two ends of the thread are tied into a single knot and are drawn upon. Like the mouth of a reticule that is being closed, the wall of the intestine is folded and puckered until it fits tightly around the central shaft of the button, as shown in Fig. 467, where the threads are cut off close to the knot.

Examining this end of the bowel, it is readily seen that when the opposite half of the button has been in like manner applied, and has been pushed into this, there would be nothing but the peritoneal surfaces of the gut in contact. If the mucous membrane should become everted, or if the thread is not so thrown over the mesentery as to invert this thoroughly, and bring peritoneal surfaces in apposition, there will be failure of union, sloughing, and perforation at these points. The

whole success of this operation rests upon the careful application of the button. The other half of the button is applied in the same manner, and then the two are brought together with the smaller invaginated into the larger. By pressing them steadily together they close until the peritoneal surfaces are snugly in contact, and the operation is completed. In this operation, as in end-to-end suture, the greatest care must be taken to prevent any foreign substance from entering the peritoneal cavity.

Exsection and reunion of the colon is somewhat more difficult than the operation upon the small intestine, on account of its irregularity in size and the deeper location of all of this organ except the transverse portion. It should be brought into or out of the incision if possible, or, if this cannot be done, the opening may be enlarged in the direction best suited to the case. Experience has demonstrated the fact that shock is less apt to follow a severe operation upon the colon than upon the smaller intestine.

Lateral intestinal anastomosis is especially indicated between the small and large intestine. When the parts in the operative field can be brought through

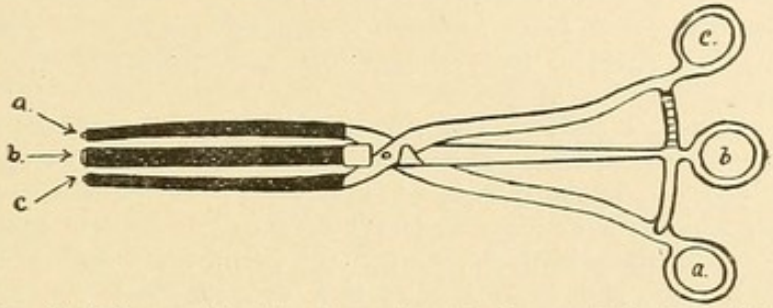

FIG. 467*a*.—C. F. Roosevelt's lateral anastomosis clamp. ("Jr. Am. Med. Assn.")

the abdominal incision, this should be done. After the required excision, the two open ends should be closed at once by a purse-string suture of No. 50 linen with two or three Lembert sutures superadded for security. A free portion of that side of the colon opposite the mesenteric attachment should be caught between two blades of the clamp (Figs. 467 *a* and *b*), while the same extent of the

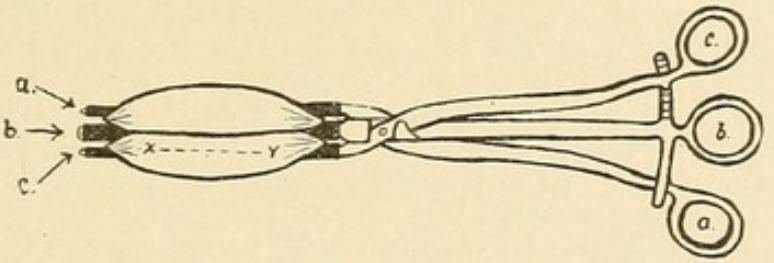

FIG. 467*b*.—The same, clamping both limbs of the gut to be united. X Y, Line of section through one limb.

smaller intestine is fixed between the remaining blades. The sutured line of union should be about two and a half inches long, leaving the opening of communication two inches in length, so that in the contraction which naturally follows there will still remain a free passage for ingested matter. The peritoneal surfaces of the two portions of gut which are in contact should be at first secured by the Cushing linen suture. About one fourth of an inch away from this first row an incision, parallel with the suture line and two inches long, is made into the wall of both limbs of intestine, and their contents carefully removed by bits of gauze so that no soiling may take place. C. H. Mayo's catgut mucoserous suture is now inserted as in resection of the stomach, or end-to-end anastomosis as already described, and should be continued throughout the entire circumference of the opening of communication, infolding the peritoneal covering and firmly uniting the cut edges. The remaining half of the Cushing seromuscular suture is now inserted and a careful toilet made.

CHAPTER XXIII

TYPHOID ULCER—TYPHLITIS—PERITYPHLITIC ABSCESS—COLITIS—APPENDICOSTOMY—FLEXURE—CARCINOMA OF THE COLON AND RECTUM (MAYO'S OPERATION)—TUTTLE'S OPERATION FOR COLOSTOMY—BODINE'S OPERATION—FECAL FISTULA

Typhoid Ulcer.—Perforations from typhoid ulcer, unless subjected to operation, are fatal in practically all cases. So low is the condition of resistance of patients who have suffered from typhoid toxæmia before perforation occurs, that even with immediate surgical intervention under the best possible conditions, the death-rate is alarmingly high.

Comparing Elsberg's statistics of the mortality ratio in children [1] with those given for adults, the prognosis is much more favorable in very young than in adult or elderly subjects. The death-rate at this date may be placed in general at about thirty per cent in children and about seventy per cent in adults.

Symptoms.—According to J. W. Long [2] the perforation occurs most frequently during the third week, and from this to the twenty-eighth day, although it may occur later. The chief symptoms are a rapid rise of temperature immediately after perforation, followed in some instances by a subnormal register. Pain, very severe in character, is usually present, with muscular rigidity and tenderness on pressure with rapidly developing tympanitis. Vomiting may or may not be present. With these symptoms in a patient suffering from typhoid fever occurring between the sixteenth and thirtieth day, the diagnosis of perforation is clear enough to justify exploration.

The incision should be made through the right rectus muscle, since ninety-five per cent of perforations occur in the last three feet of the ileum (Haggard), while seventy-three per cent are found in the last foot of the small intestine. According to Long, in exceptional cases it may occur at any portion of the alimentary canal, even in Meckel's diverticulum. This observer says:

"Another point to be borne in mind is the fact that in sixteen per cent the perforations are multiple. Upon opening the abdomen, the presence of free fluid and other evidences of peritonitis will usually be found. The distal portion of the ileum with the cæcum and appendix should be quickly and gently examined. Perforations should be closed with a purse-string suture, being careful not to make too great tension."

As time is an important factor, it is advisable that the edges of the ulcer be not trimmed, but simply inverted. If they are multiple and involve more than one half of the wall of the gut, the loops should be drawn through the incision and a temporary fecal fistula established.

If there has been any escape of intestinal contents, a careful peritoneal toilet is imperative. For this purpose the siphon-irrigating apparatus of Blake should be preferred. Drainage should be employed in all cases at the seat of the lesion, and, when there has been general peritonitis, also from the pelvis, as described in the article on general suppurative peritonitis. As an anæsthetic in these cases, nitrous oxide and oxygen should be employed, and when this is not available nitrous oxide and air, and, last in order of preference, ether.

Certain acute and chronic inflammatory lesions of the large intestine demand

[1] "Annals of Surgery," May, 1903.

[2] Paper read before the International Surgeons' Club at Rochester, Minn., September 21, 1906.

surgical intervention. Acute inflammation of the cæcum (*typhlitis*) is of frequent occurrence, and is at times so severe that the infection spreads either in the form of *peritonitis* or *perityphlitic abscess*. While the pus collection here is retroperitoneal, peritonitis, at first local, is always a complication of perityphlitis. The differentiation from appendicitis is not easy, and can rarely be made positive except by exploration, which should be done at the earliest possible moment in all cases of infection in this region.

In delayed retroperitoneal abscess the pus may drift toward the right lumbar region, where it can be reached by incision and drainage.

In cases operated upon early, the regular incision for appendicitis is advised, at which time the appendix if involved may also be removed, together with all septic fluid or exudate. The question of drainage must be determined by the conditions present. The methods given for the after-treatment of infection for appendicitis will apply equally well in perityphlitic abscess or beginning retroperitoneal infection.

In obstinate cases of chronic colitis, when irrigation by the rectum, together with careful dietetic treatment and medication have failed to afford relief, a cure may be effected by surgical drainage and irrigation from the cæcum to the rectum by the operation known as *appendicostomy*. Through a McBurney incision one or two fingers are introduced, the head of the cæcum lifted to the opening through the peritonæum, and the appendix drawn out until it is in contact with the abdominal peritonæum, where it is firmly held until the margins of the incised peritonæum are attached by sutures of fine silk or linen to the wall of the appendix just where it joins the cæcum. To prevent slipping, two safety pins are passed through each side of the appendix, and between these and the edges of the wound sterile gauze pads are temporarily inserted to prevent infection, and over this is adjusted an ordinary dressing. Forty-eight hours later, after adhesions have occurred, the appendix is clipped off near the level of the skin and three or four linen sutures carried through the entire thickness of its walls, which are stitched to the margins of the incision through the skin, thus firmly anchoring it. Into the cæcum through the appendix a soft velvet drainage-tube is inserted. In amœbic dysentery irrigations with solutions of quinia have been successfully employed. Normal salt solution at a high or low temperature, as indicated by the character of the infection, is also recommended. In catarrhal dysentery, with or without ulceration, nitrate of silver (1–5000) and one-half-of-one-per-cent solutions of ichthyol have given satisfaction. When irrigation is no longer required, the tube should be removed and the fistula left to close spontaneously.

Flexure.—Not infrequently following colitis, a localized peritonitis is developed, resulting in adhesions with more or less contraction of the new connective tissue which is a part of the process of repair under septic conditions, causing partial obstruction of the lumen of the gut by angulation (Fig. 468). While angulation may follow the healing of an ulcer or a local peritonitis at any point of the large intestine, it is almost always encountered in the sigmoid colon, since these septic processes are more frequently located here.

The *symptoms* are those of gradually increasing difficulty in emptying the large bowel. These patients complain of constipation, which can only be relieved by high irrigation. Pain is not usually acute in character, unless a quantity of ingested matter accumulates in the bowel above the bend.

The *diagnosis* depends upon a careful study of these symptoms, with the history of one or more attacks of colitis. With the patient in Tuttle's position—i. e., in the left lateral knee-chest posture on Martin's chair (Fig. 469)—by the employment of this surgeon's pneumatic electric proctoscope the diagnosis of this and other surgical lesions of the rectum and sigmoid colon may be made positive.

Treatment.—An incision should be made over the seat of the angulation, which is usually in the left iliac fossa and is practically a McBurney incision upon the left side. By separating the fibers of the various muscles with wide retraction, sufficient room can be obtained to liberate the imprisoned bowel without a resulting ventral hernia. The colon should be carefully separated from the adhesions, and the raw surface so made covered by bringing the peritoneal edges

together with a running suture of ten-day chromicized catgut. In extreme cases it may also be necessary to stitch the bowel to some point upon the abdominal wall in which the angulation will be entirely corrected. If stricture has resulted with narrowing of the canal to the point of obstruction, resection and end-to-end anastomosis should be done.

Obstruction, partial or complete, of the large intestine, more particularly of the sigmoid flexure, as a result of *diverticula*, has been considered on another page.

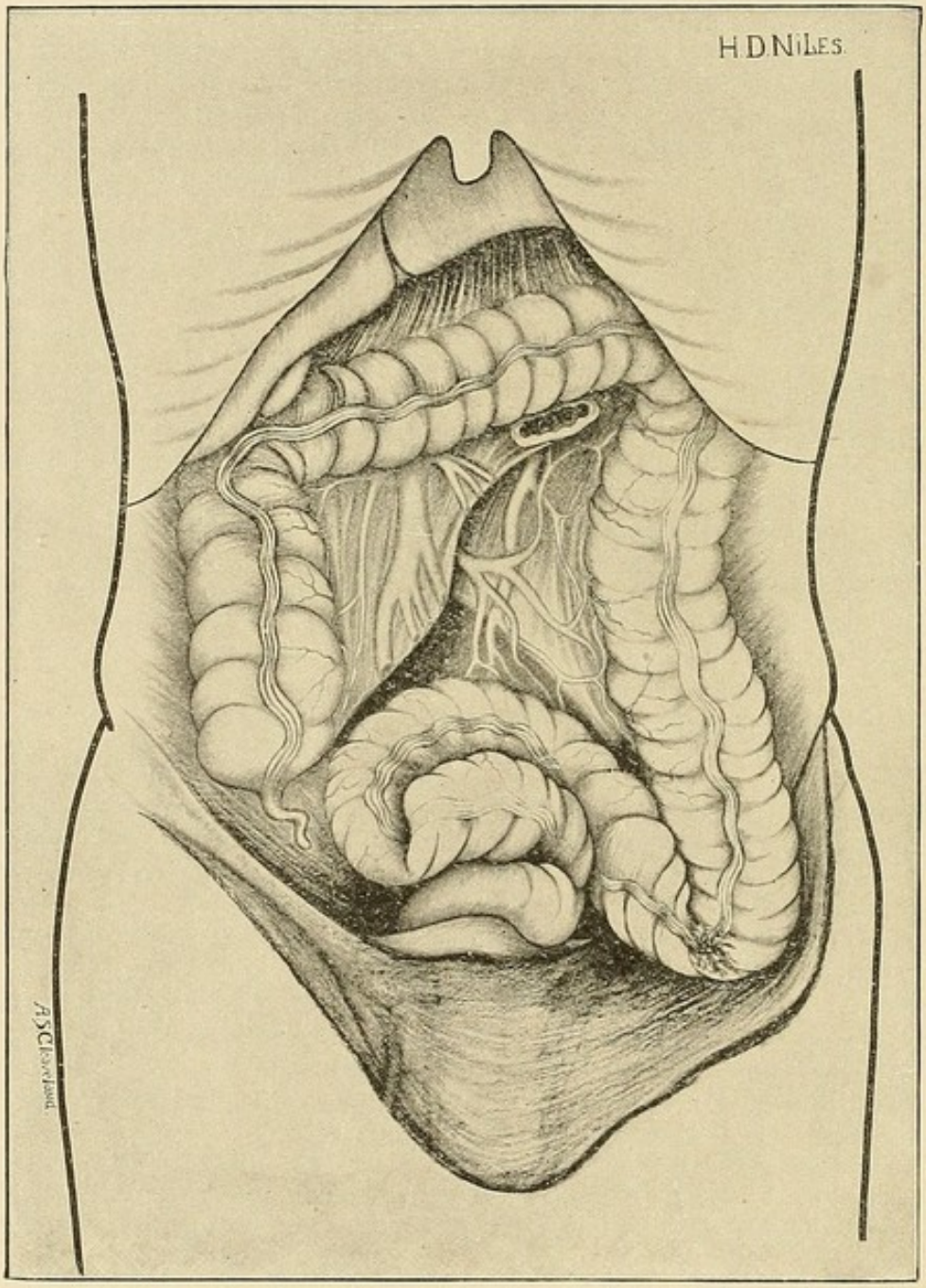

FIG. 468.—Showing commencing ulcer and angulation at proximal and distal ends of sigmoid. (Niles.)

Carcinoma of the large intestine, especially of the rectum near the anus and of the sigmoid flexure of the colon, is not infrequent. The ileo-cæcal junction is also a favorable location for malignant neoplasms. A large proportion of cases of cancer of the intestinal tract are found below the ileo-cæcal valve, and men are much more frequently affected than women.

The *symptoms* are those of gradually increasing obstruction, in which pain is not a marked symptom, until the narrowing of the intestine results in fecal accumulation with localized colitis and possibly peritonitis.

Later a tumor may be recognized by careful palpation. The passage of mucus and blood in the stools of patients without hæmorrhoids is indicative of a deeper and more serious lesion.

The history of chronic colitis with a tendency to localization should attract the attention of the surgeon in the effort to arrive at a correct diagnosis. When the



Fig. 469.—Patient in knee-chest posture on Martin's chair. (Tuttle.)

carcinoma is at or near the anus, its recognition by inspection and digital exploration is not difficult. When more deeply located, examination with Tuttle's proctoscope should reveal the presence of a neoplasm. The importance of the early recognition of such a grave disease cannot be overestimated, since whatever hope the surgeon may hold out is based upon early operative intervention.

Treatment.—Early and complete excision of that part of the alimentary canal involved in the disease is the prime indication in treatment. Upon the first suspicion of cancer, an exploratory incision should be made. A fair proportion of these cases, which otherwise are inevitably fatal, would be saved by an early wide excision, with the careful removal of all the lymphatics in the area of the disease, followed by immediate intestinal anastomosis.

The definite results desired, as tersely stated by Charles H. Mayo,[1] are permanent cure, low operative mortality, and a controllable anus, or its best substitute. He makes a clinical division of cancers of the lower bowel into those within two and one half inches from the anus and those which lie above the levator ani muscle.

The first group are removable by incision from the anal region, the depth and location of the incision being determined by the extent of the bowel to be excised. The procedure of James P. Tuttle is preferred (*vide* Cancer of the Rectum).

With the higher form of rectal cancer and in all cases of carcinoma of the sigmoid, the double operation is advised. Mayo gives the following in connection with the operation of choice for high rectal cancer:

"Bearing in mind that the lymphatics of the lower rectum first pass laterally with the middle hæmorrhoidal vessels and then converge posteriorly in the mesorectum with the superior rectal artery, it is evident that any operation, to be effective, must remove the entire chain of glands with all the fat as high as the promontory of the sacrum.

"The method of procedure is as follows: The patient is placed in the high Trendelenburg position and the abdomen freely opened in the middle line. The

[1] "Surg., Gyn., and Obstetrics," page 4. August, 1906.

upper limits of the growth and its relation to the surrounding tissues are noted. The possibility of the removal of all of the obviously infected glands is ascertained, and the liver examined for embolic carcinoma. If the case is a favorable one, the intestines, with the exception of the sigmoid, are carefully packed away with large gauze pads; two clamps are caught across the lower sigmoid on a level with the promontory of the sacrum and the bowel divided between. The mesosigmoid is liberated by lateral incisions and the proximal fragment brought up outside of the abdominal wound. A ligature is thrown around the bowel immediately below the forceps, which are removed as the ligature is drawn tight. A purse-string suture is placed an inch below the end of the stump, which is invaginated in a manner similar to that of the appendix. The ends of the ligature are left long. The threads and stump are carefully cleansed. The distal stump is treated by inversion in a similar manner, to prevent soiling. Lateral and anterior peritoneal incisions are now made, liberating the rectum from the bladder and prostate in the male and from the uterus in the female. The inferior mesenteric artery, which is the upper continuation of the superior rectal, is caught and tied above and to the left of the promontory of the sacrum at as high a point as can be safely done without interfering with the nutrition of the bowel used in the colostomy. The fat is carefully separated, the entire mass of gland-bearing fascia, with the fat, is wiped perfectly clean to the periosteum. The middle sacral artery is of considerable size in most cases, and should be caught and ligated near its origin from the abdominal aorta between the common iliac vessels. The dissection is continued downward, exposing the internal iliac vessels and the ureters. Most of this can be done by sponging. The middle hæmorrhoidal vessels are caught laterally, as they come off with the inferior. The entire area is now packed with hot moist gauze, and the patient put in the perineal position. In some cases, if the bowel is healthy for a space of four inches above the anus, it is clamped and ligated at this point, and cut above the ligatures, the diseased area being removed. The operator, or preferably a second operator, begins the lower part. A pair of forceps are passed into the blind pocket of bowel from below, the tied end of the bowel is pushed into the open forceps, and they are withdrawn through the anus, inverting the bowel.

"After cleansing, the thread of closure is cut, and the forceps are now passed through the invaginated bowel and anus into the pelvis to grasp the proximal end of bowel, which is withdrawn, and the two ends united by a circular end-to-end closure outside the anus and allowed to retract. Drainage is secured by a midline incision in front of the coccyx, through which tube drainage into the pelvis is made. This type of operation (Mansill) we were able to make in four cases. In some colostomies, the lower end of the rectum can be saved as a blind pouch, or temporarily employed for drainage of the pelvis. Should the disease require such extensive removal of the rectum as to destroy the lower rectal wall muscles and nerves, as well as straighten the sigmoid loop, thereby losing both retention and control, it is preferable to save the sigmoid loop as such and make an abdominal anus. To employ this method, a small gridiron incision is made on the left side, as would be done on the opposite side for appendicitis, and through this opening, using the ends of the threads as a tractor, the proximal stump is pulled out three fourths of an inch beyond the skin surface. Three or four linen sutures are quickly placed, uniting the bowel to the peritonæum on the inner side, and a silkworm-gut suture on the outside closes each angle of the wound, including in its bite the skin, aponeurosis of the external oblique, and the wall of the bowel, holding it securely in position. If this plan is followed, the operator from below, after inserting the gauze in the rectum to facilitate subsequent dissection, and closing the anus by a circular suture, circumscribes the anal margin with a deep incision, and dissects the perineal portion of the rectum with its muscles and fat free from the prostate and urethra, or from the vagina in women. This extends up to the levator ani muscle, which forms the boundary between the upper and lower dissections. The abdominal operator now passes down the fragment of lower sigmoid and the upper end of the rectum with its fat and glands into the perineal opening, where they are removed by the surgeon working below, or one operator, with changes of gloves, can accomplish the work in both fields. All bleeding points are caught and

ligated. A considerable sized gauze drain is passed from above downward, leaving its upper end just exposed on a level with the peritonæum, which is drawn together to cover as much as possible, the external gauze portion being brought out of the perineal wound. The sigmoid loop from above is placed over the exposed surface, and in the female the body of the uterus and broad ligaments are adjusted with a few sutures to aid in covering. The upper incision is completely closed, while the perineal opening is narrowed to proper dimensions for drainage by a few sutures.

"The end of the sigmoid is left completely obstructed for the first twenty-four hours, after which time the circular suture is cut and the stump everted by the ligature, which is tied around it, and the bowel opened.

"The advantages of the operation herein outlined are obvious. The disease is removed widely, with all of its tributary lymphatics, muscles, and related tissues. The anus is placed in a position easy of inspection and cleansing; the sigmoid trap obviates the necessity of frequent stools, and the intermuscular incision gives a fair degree of control."

Artificial Anus.—Unfortunately, in a large proportion of cases of malignant disease of the lower bowel which come to the notice of the surgeon, operative treatment has been so long delayed that a cure is impossible, and nothing remains but to give the greatest possible relief to the patient.

The establishment of a fecal fistula between the colon and the abdominal wall —*colostomy*—is usually performed in the lower part of the descending colon, or in the sigmoid flexure. It is indicated as a palliative measure in occlusion of the alimentary canal on the anal side of the operation by stricture, neoplasms, intussusception, volvulus, or any lesions for the relief of which exsection or lateral anastomosis is not permissible. In chronic *colitis* or *proctitis* it is a curative operation, in giving complete rest to the bowels until recovery ensues.

It is not so frequently performed now as formerly.[1] Many of the lesions for which it was done are now cured by resection of the intestine involved. Fecal fistula is attended with so much discomfort that a very considerable risk is justified in the performance of a radical operation in the hope of avoiding the annoyance of a constant discharge from an opening in the large intestine.

At a point about one inch above and one and one half inch inside of the anterior superior spine of the left ileum an incision about three inches long is made through the skin obliquely downward and parallel to the fibers of the external oblique muscle. These fibers and those of the muscle in each layer are separated by blunt scissors and held apart by retractors until the peritonæum is clearly seen. All hæmorrhage should be arrested, and an incision about two inches long made through the peritonæum in the same general direction as the superficial wound. The edges of the peritonæum should be firmly held by forceps, or better by two silk loops passed from within outward through the peritonæum and the entire thickness of the abdominal wall, and tied in a long loop, serving a double purpose as a retractor, and also to prevent the peritonæum from being stripped from the abdominal wall during the examination or operation. The patient should now be placed in the Trendelenburg posture, and the incision enlarged, if necessary to permit the introduction of more than one or two fingers, in order to insure a thorough examination. The sigmoid flexure and colon are easily recognized not only by the longitudinal muscular bands, but by the beads of fat (*epiploicæ*) which are attached along the border opposite the mesentery. If the artificial anus to be established is only a temporary expedient, the technic differs in an essential feature from that

[1] The old operation of lumbar colostomy on either the right or the left side is now practically abandoned. Left lumbar colostomy was done through a perpendicular incision in front of the left quadratus lumborum muscle or by an oblique incision just below the floating rib. The muscles were divided or separated by blunt dissection until the colon was reached. This was seized by forceps and pulled into the wound far enough to permit the insertion of two silk ligatures through the skin at the edge of the wound, then through the intestine embracing about one third of its circumference and out through the integument on the opposite side. The intestine is now incised longitudinally, and the loops of the two sutures pulled out through this incision, divided in the middle at each end, and tied so as to fasten the wall of the bowel to the edge of the skin, and additional sutures were inserted on either side to thoroughly anchor the gut in its new position.

in which a permanent opening is to be established. For temporary colostomy,[1] as soon as the sigmoid is drawn up and the point to be opened is selected, a small opening is made through the mesentery, avoiding the blood vessel, and a glass rod about one quarter of an inch thick by four inches long is passed through this, its

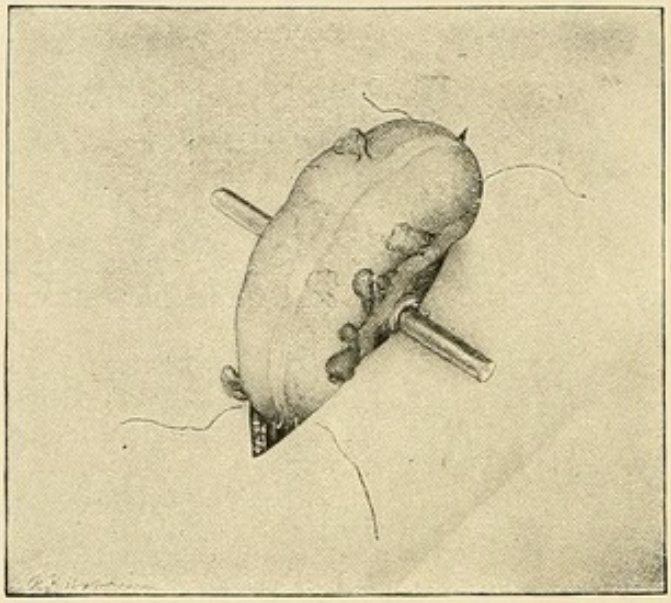

FIG. 469*a*.—Temporary inguinal colostomy. Gut supported on rod and sutures in position. (Tuttle.)

ends resting upon either side of the wound. "The lower angle of the wound is closed by silkworm-gut sutures passed through the abdominal wall until the lower limb of the intestinal loop is pressed against the glass rod. Fine continuous catgut sutures are now passed at the two angles of the wound through the skin and peri-

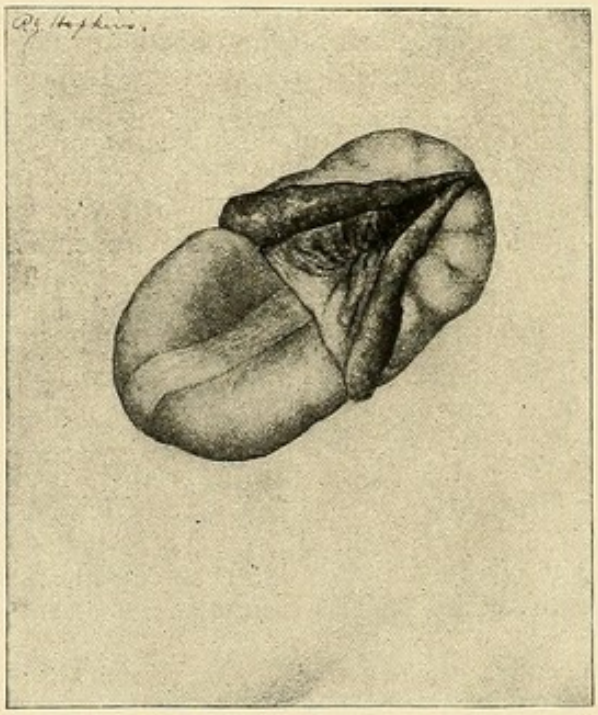

FIG. 469*b*.—Incision for opening the gut in temporary inguinal colostomy. (Tuttle.)

tonæum, then through the muscular wall of the gut, and again through the peritonæum and skin upon the opposite side (Fig. 469*a*). Small sterile pads are placed under the ends of the glass rod and along the edges of the wound close

[1] Prof. James P. Tuttle.

to the intestine. The projecting loop of gut and the entire wound is covered with protective tissue; over this gauze, adhesive strips, and a firm abdominal bandage. The gut is not opened, but if there is great distention by gas a trocar may be inserted to permit its escape and the opening closed by Lembert sutures. The patient is placed in bed, hips well elevated, is given sufficient morphia to control vomiting and quiet the peritonæum for ten or twelve hours. After six hours the intestine may be incised, but it is preferable to wait for two or three days in order to secure firm adhesions. The opening should be made through the longitudinal band opposite the mesentery, and should extend from the upper angle of the wound to one half inch below the glass rod. A transverse incision is then made at the lower end involving two thirds of the circumference of the gut (Fig. 469*b*). The straight flap in the lower segment falls downward like a trapdoor, practically closing the lower aperture, while the triangular flaps are naturally retracted outward. When the fistulous opening shall have served its purpose by simply suturing the edges of this T-shaped incision together without opening the peritoneal cavity, the integrity of the intestinal wall is restored. During the existence of the fistula, if it should at any time be deemed necessary to irrigate that part of the intestinal tract between the opening and the anus, the lower transverse flap can be raised and the irrigating tube inserted. It is important to bear in mind the necessity of making the artificial anus as high up in the sigmoid as possible when a resection is to be made below. The longer the loop left below the artificial anus the easier the subsequent procedure. The glass rod is retained in position for two or three weeks, and should be prevented from slipping out of place by adhesive plaster properly arranged. Should it become necessary to convert the temporary artificial anus into a permanent one, this can be accomplished by trimming off the projecting bowel wall to near the level of the skin." Since the colon is not sensitive, these incisions may be made without an anæsthetic.

When a permanent artificial anus is to be established, the procedure of Prof. James P. Tuttle [1] should be selected.

"The operation is begun by the ordinary incision for inguinal colotomy. The fibers of the external and internal oblique muscles are separated by a blunt instrument instead of being cut. The transversalis fascia and peritonæum are incised in a line parallel to Poupart's ligament. A loop of sigmoid sufficiently long to be drawn at least two inches outside of the abdominal cavity is selected, and a tape or loop of large silk is passed around it through a small slit in the mesentery, the ends being left long and held by an artery forceps. The lower fibers of the external oblique are then pulled downward, and the internal oblique is split laterally to the distance of about two centimeters (three quarters of an inch). A canal is then made between the skin and the external oblique downward to the extent of about two inches, opening through an incision in the skin just above Poupart's ligament (Fig. 470). This canal and incision should be large enough to admit of the loop of sigmoid being drawn through them without much compression. With the aid of the dressing forceps the knuckle of gut is then dragged through the lateral slit in the internal oblique and downward through the canal outside of the external oblique muscle until it emerges at the inferior opening in the skin. It is held in this position either by the passage of a glass rod through the opening in the mesentery, or by suturing it to the edges of the skin wound. The abdominal wound is then closed by chromicized catgut sutures in the muscular layers and a subcutaneous silk suture in the skin; it is then sealed by iodoformized collodion and dressed with sterilized gauze, over which a layer of rubber protective tissue is placed, and sealed to the skin with chloroform. This latter precaution is taken to avoid infection of the primary wound through the escape of fæces when the gut is opened. If necessary, the loop of intestine may be opened immediately, but ordinarily it is better to wait twenty-four to forty-eight hours before doing so. This is accomplished by a simple slit in the line of the longitudinal fibers of the gut. After ten days or more, the protruding portions of the gut should be trimmed

[1] This operation together with the technic of that just given are credited to Prof. James P. Tuttle. "A Treatise on Diseases of the Anus, Rectum, and Pelvic Colon," by James P. Tuttle, A.M., M.D., D. Appleton and Company, 1902.

down flush with the skin and the artificial anus will present itself as a double-barreled aperture, one opening of which connects with the proximal and the other with the distal end of the sigmoid (Fig. 471). The gut is brought outside of the external oblique muscle in order that it will rest upon a resisting plane, and a truss or compress can be placed upon it, thus absolutely occluding its caliber. Being passed through the slit in the external oblique, it is surrounded by muscular fibers, and thus obtains a certain amount of voluntary control. In the majority of cases no compressing apparatus is necessary, as the patient usually possesses almost complete continence without it. When it is necessary, an ordinary single spring hernial truss with an elongated pad placed somewhat outside of the usual position serves every purpose. Not only is the continence obtained by this method exceedingly satisfactory, but the site of the anus is very convenient for the patient.

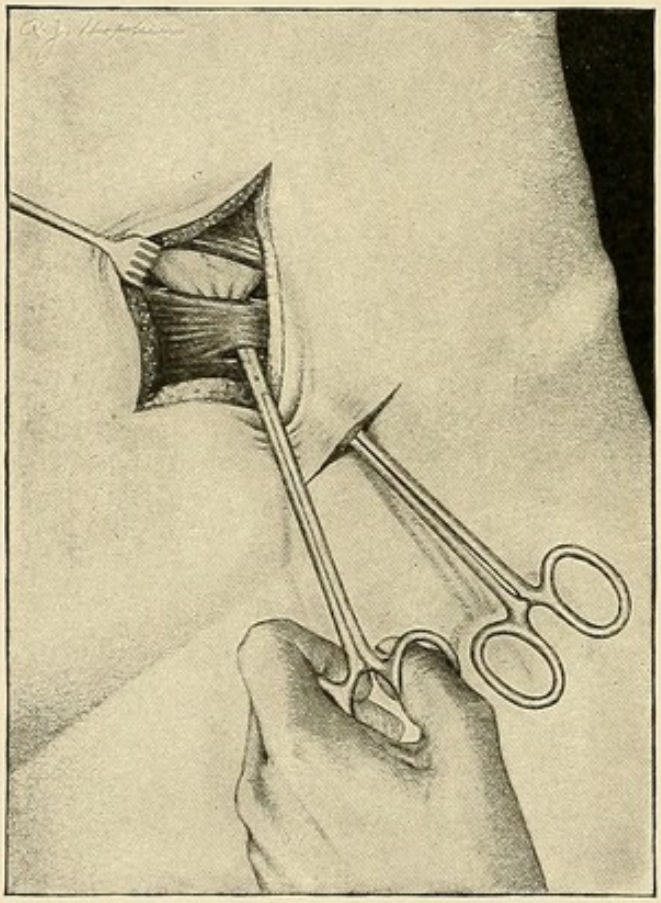

Fig. 470.—Permanent colostomy (Tuttle's method). The gut being dragged through the split internal oblique and then through the subcutaneous canal.

He can sit upon an ordinary toilet-seat with a pus basin held underneath the artificial anus and relieve his bowels with as little inconvenience as if the anus were in the normal position. The parts can be easily cleaned, and in the cases thus far observed there has never been the slightest tendency toward prolapse. The inferior segment of the sigmoid can also be washed out and irrigated through this type of permanent artificial anus, thus obviating the danger of collections of pus and putrefying substances in this portion of the gut."

While the operations advised by Tuttle both for a permanent and temporary colostomy are preferable, should the conditions be such as to render these procedures difficult of execution, the following simple operation of Prof. J. A. Bodine is well adapted for securing a temporary fistula, and for restoring the lumen of the gut when the artificial anus is no longer required.

When the continuity of the intestine is to be restored, of course the mesentery is excluded from between the two approximating rows of sutures. Later, when these walls have become agglutinated by inflammatory adhesions, the gut is divided

without interfering with the blood supply. The method is as follows: As soon as the proper incision through the peritonæum is made, a sterile pad is introduced while the operator stitches the parietal peritonæum to the integument with a continuous catgut suture. If there be a tumor, stricture, or necrotic focus upon the

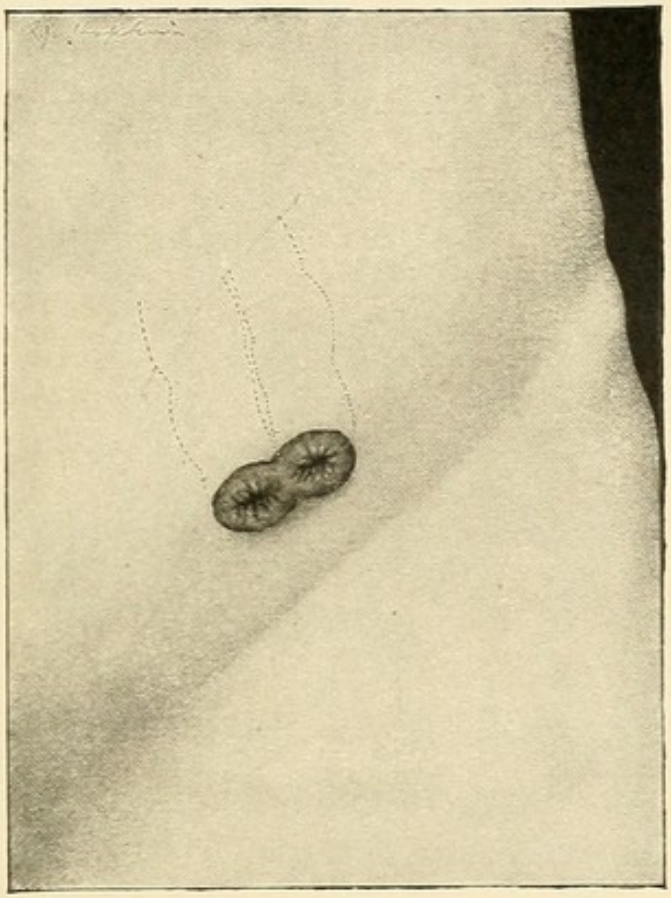

Fig. 471.—Permanent colostomy completed by Tuttle's method.

intestine, it is brought out through the wound until six inches of healthy intestine on each side of the part to be excised are exposed. The two limbs of the loop, with the lesion at the apex of the knuckle, are laid side by side, and a running stitch of fine silk, beginning at the point where the exsection is desired, is carefully inserted, uniting the two pieces of intestine close to and parallel with the mesenteric border for six inches (Fig. 472). If the fistula is to be permanent, the mesenteric attachment is half-way between the two rows of sutures. If temporary, the loops are approximated, leaving the mesentery free. There should be about an inch of space between the two rows of sutures. At the deepest portion of the approximation—that is, the portion most remote from the part to be excised—the sutures should be inserted across the bowel so as to insure a complete approximation at this point and prevent any possibility of leakage into the peritoneal cavity after the septum has been divided. The row of sutures should represent an elongated U. The sutured loop is then passed back into the abdomen until the point where the intestine is to be excised is on a level with the skin surface, and it is here stitched into the margin of the abdominal wound with a continuous suture of strong catgut. If the excision is to take place at once, as in cases where a fistulous opening is urgent for the patient's safety, this last suture should be of silk, but as peritoneal surfaces are brought together, if the opening can be left for twenty-four or thirty-six hours, adhesions will have formed in that time and catgut may be employed. Silk is, however, in my opinion, the safest suture. If waiting is permissible after twelve, twenty-four, or thirty-six hours, cocaine anæsthesia (two-per-cent solution) may, if necessary, be employed, and the protruding intestine snipped off with scissors on a level with the skin. After one or two weeks, or a longer period, if this

be required, the septum between the two rows of sutures may be divided by Grant's enterotome (Fig. 473) or a pair of straight scissors, introducing one blade into the upper and the other into the lower bowel channel, guiding the blades back by means of the finger, to the middle line between the two rows of sutures and cutting to the required depth. The passage of the fecal current prevents reunion of the divided septum, and in the course of time the fecal fistula closes by granulation. The same procedure would be advisable after strangulated hernia with necrosis of the intestine, where end-to-end anastomosis by direct suture is not permissible.

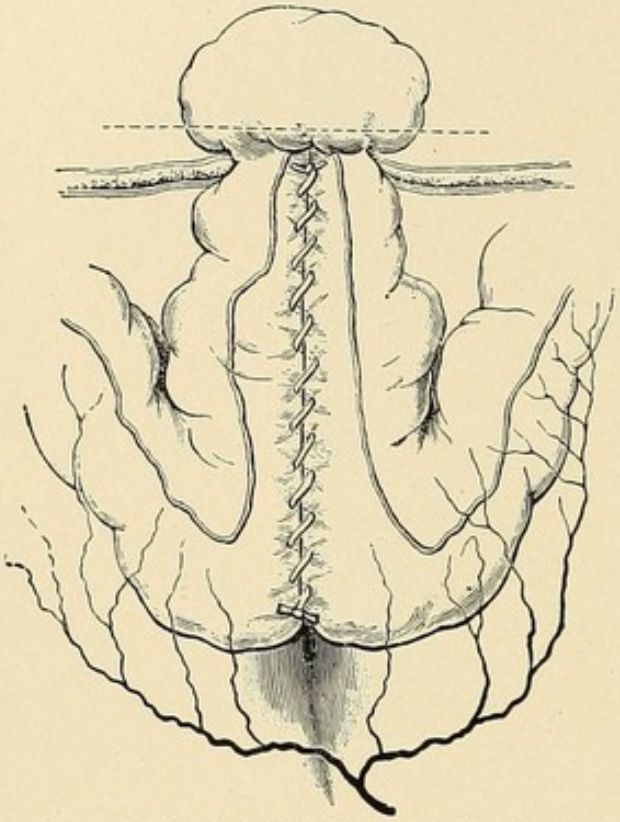

Fig. 472.—Prof. J. A. Bodine's operation for lateral anastomosis, with ultimate restoration of the continuity of the canal, showing one side of the loop after it has been sutured, passed back into the cavity, and stitched into the abdominal wound. The lesion is left protruding, and the dotted line indicates where the protrusion is to be clipped off.

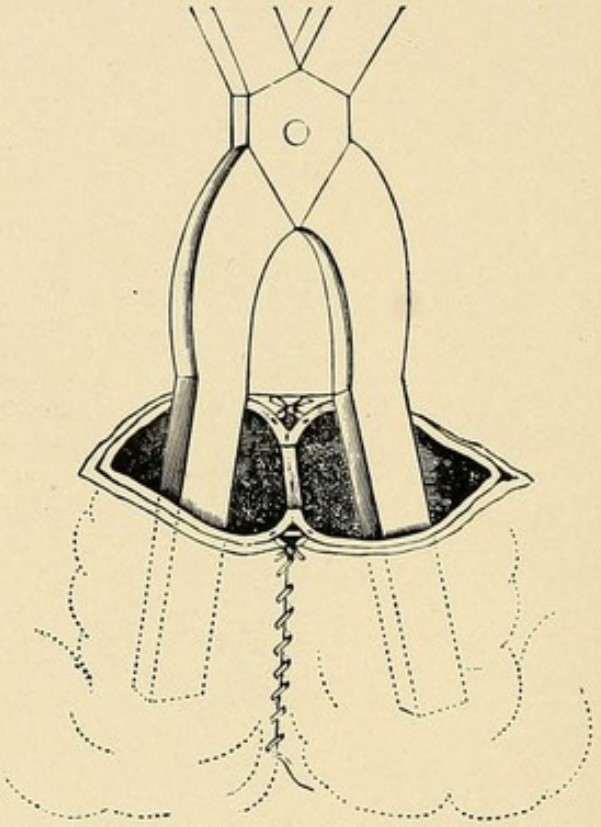

Fig. 473.—Intestinal anastomosis. Showing the septum to be divided in restoring the fecal current. Grant's clamp in position for the division. In permanent colostomy this septum remains as a rigid and effective spur.

Fecal Fistula.—A fecal fistula may exist between any portion of the intestinal canal and the exterior through the integument; from the intestine into a normal cavity, as the bladder or uterus, and thence to the exterior; into an abnormal cavity, as an abscess, and thence out through one of the hollow organs or directly to the skin; or it may lead into a *cul-de-sac* or blind pocket.

Fecal fistulæ are *congenital* and *acquired.*

Imperforate anus is the most frequent cause of congenital fistula. The pressure of accumulated matter at the extremity of the canal induces inflammation, ulceration, and perforation, with extravasation of the bowel contents. If the congenital obstruction is low down, the opening may occur through the perinæum, bladder, or vagina. If higher up, the fistula may open through the abdominal wall at the umbilicus, or below this point in the linea alba, or posteriorly near the spine. A rare cause of congenital fistula is the presence of the omphalo-mesenteric duct, or Meckel's diverticulum, which, as heretofore stated, opens at the umbilicus.

Acquired fecal fistulæ may be *surgical* or *accidental.* Colostomy and enterostomy are examples of the former, while the latter result from perforating wounds of the intestinal canal, either from the exterior, as by *gunshot* or *punctured wounds*, or by the passage of some ingested sharp or hard body through the intestinal wall; or by perforation of the intestine by an ulcer or abscess, or from gangrene due to strangulation, contusion, etc.

The *diagnosis* of a fecal fistula which communicates directly with the exterior is made evident by the escape of gas and ingested matter. Indirect fistulæ can also be determined by the careful examination of the discharges from the organs through which they pass. In a case reported by Dr. Krackowitzer, in the "Transactions of the New York Pathological Society," an ulcer of the appendix vermiformis had opened into the bladder. The diagnosis of entero-vesical fistula was established by the escape of a lumbricoid worm from the urethra. Blind fistulæ cannot often be made out until demonstrated by exploration.

In determining into what portion of the intestinal canal the fistula opens one must consider, first, the character of the discharge; second, the distance from the rectum, as determined by injections.

In *congenital fistulæ* opening into the perinæum the inference is natural and generally correct that the lower portion of the large intestine is involved. If bile is freely discharged through a *congenital* or *acquired* fistula, it is safe to conclude that the opening is not very far removed from the duodenum or upper portion of the jejunum. The odor of gas or ingesta escaping from the large intestine is usually more offensive than that from the small bowel.

When caused by a wound, the known direction and character of the penetrating body will aid in arriving at a correct idea of the gut penetrated.

A fistula resulting from appendicular or perityphlitic abscess occurs almost always in the cæcum, more rarely in the lower portion of the ascending colon or lower ileum. When the colon is involved the location may be determined by slowly injecting milk *per rectum*, having measured the quantity injected until it begins to flow out at the external opening.

The *prognosis* of fecal fistula depends upon its character. Congenital fistulæ are obstinate under treatment. Acquired fistulæ may be cured in the majority of instances.

Treatment.—Congenital fistulæ, resulting from imperforate anus, can be healed by the establishment of an opening in the perinæum which shall communicate with the most dependent portion of the blind gut. When this is done, a pad worn over the fistulous opening will lead to its gradual occlusion. When the fistula is the result of a patulous omphalo-mesenteric canal, it may be closed by sutures or by a compress.

Acquired fistulæ not infrequently heal spontaneously. The operation consists in cutting down upon the opening in the gut and laying freely open all sinuses which communicate with the fistulous outlet. As the track of the fistula is often tortuous, it is at times exceedingly difficult to follow it. A repetition of the method employed in the following case will be of service in the more complicated operations:

In 1880 a young man came under my observation on account of a pistol-shot wound. The ball had entered the abdomen on a level with and about one and a half inch to the inner side of the left anterior superior spine of the ilium. From the direction in which the weapon was aimed, the missile was thought to have passed directly back and lodged in the iliac fossa. There were no immediate symptoms of perforation of the intestine. An abscess formed which discharged from the wound of entrance, and, about six weeks after the receipt of the injury, a fecal fistula was established. The fistulous track was so long and tortuous that it could not be followed. After the anæsthesia was complete, warm milk was thrown into the bowel until it ran out at the opening. The stream of milk was then followed without difficulty, and the opening discovered. All communicating sinuses were laid open and packed with gauze. The wound closed within a month, and the patient was cured.

It will be advisable, in attempting to close the fistula, for the patient to maintain a position which will prevent the gravitation of ingested matter into the opening.

Closure of the external orifice by means of sutures is not advisable, since it may induce fecal infiltration. A recovery is usually hastened when the margins of the wound in the integument can be stitched to the edges of the opening into the bowel, as directed in enterostomy.

In persistent fistula of the cæcum as met with after appendicitis a lateral anastomosis between the small intestine and colon will effect a cure.

CHAPTER XXIV

APPENDICITIS,[1] PERITONITIS

APPENDICITIS is an inflammation of the *vermiform appendix*, through the diseased or perforated wall of which septic organisms penetrate, producing local or general peritonitis.

The appendix comes off from the inner posterior portion of the cæcum at its lower end, where the three longitudinal muscular bands of the colon unite. It is held in position usually by a small fold of peritonæum, which forms its mesentery (meso-appendix). It communicates with the cæcum by a small opening, which is partly guarded by a valvelike fold of mucous membrane. The average length of this organ is about three inches, but it may vary from one to nine inches. The diameter of the lumen varies from one eighth to one quarter of an inch, occasionally larger. Of one hundred and forty-four dissections by Prof. Joseph D. Bryant, in thirty-four its direction was *inward*; in thirty-two it was *inward* and *behind* the cæcum; in twenty-eight it pointed *inward* and slightly *downward*; in twenty-one, *downward* into the pelvis; directly *downward* and *inward* in nine; *upward* and *backward* in three; *upward* and *outward* in two.

The meso-appendix does not always entirely cover this organ with peritonæum, at times leaving a strip upon the posterior aspect, which, in common with that portion of the cæcum may be uncovered and in contact with the iliac fascia. Beneath the peritoneal covering is a thin layer of longitudinal muscular fibers; then a layer of circular muscular fibers, a submucous layer, and a thick mucous membrane which is studded with closed follicles and lined with cylindrical epithelia. The chief source of blood supply is a branch which arises from a loop of the *colica media*. This vessel runs along the border of the meso-appendix, giving off branches, which pass to the organ. When the meso-appendix is wanting the artery runs directly along the peritoneal covering of the appendix. Probably it is in these cases of *limited single arterial* supply that *rapid gangrene* occurs, the ulcer or primary focus of infection suddenly occluding this vessel.

Anatomically the appendix occupies an unfortunate position. It is subjected to distention from semiliquid ingesta, which enter it from the cæcum by gravitation. On account of muscular insufficiency it is unable to empty itself, and the resulting decomposition of its contents make of it even more than the blind gut from which it springs a breeding-ground for septic organisms. In addition to overdistention, the weight of the loaded cæcum, *with the strong reverse peristalsis of the ascending colon*, tends to interfere with the proper blood supply to its walls.

[1] Kroenlein in 1884 did the first appendectomy, placing a double ligature (material not stated) on the base of the appendix, which was removed, with fatal result ("Archiv f. klin. Chir.," p. 516, 1886). Dr. W. W. Grant placed a ligature upon and cut off but did not remove the appendix for appendicitis in 1885. The patient recovered. Dr. Reginald H. Fitz, of Boston, in 1886 published his classical article upon this subject. The late Dr. Richard Hall, of New York, in May, 1886, did a successful appendectomy, ligating the stump with a catgut ligature. The late Prof. T. G. Morton, of Philadelphia, operated upon the first case for which the diagnosis had been made and operation done with the intention of removing the appendix. The stump was tied with a silk ligature, and the patient recovered. Dr. Simon Baruch, of New York City, in 1887, after an experience based upon post-mortem examinations, diagnosticated appendicitis in a boy eleven years of age, and succeeded after much insistence in persuading the late Dr. Henry B. Sands to operate directly for this disease. This patient recovered. Dr. Charles McBurney's name is associated with one of the surgical approaches to this organ, and Dr. John B. Deaver, of Philadelphia, has demonstrated the great advantage of the route through the right rectus muscle, the "Deaver incision."

Appendicitis occurs more frequently in males than in females (four to one), and about one half of all cases are under twenty-five years of age. Dr. J. F. Erdmann reported sixty cases in children—twenty-five under two years, the youngest eleven months.[1] With adults, those who ingest large quantities of food and lead sedentary lives are more frequently attacked. As shown by Dr. H. A. Royster, under the same conditions of living appendicitis is as common with negroes as whites.[2] It is rarely caused by fruit seeds or foreign bodies. Small *fecal* accretions (enteroliths) are not infrequently present, and are doubtless etiological factors. There are a few cases on record in which a blow upon the abdomen directly over the organ was the immediate exciting cause.[3] Tubercular deposits (*bacilli tuberculosis*) are only in very exceptional instances to be accepted in the etiology of this disease.

The frequency of the infection of this organ may be accounted for by its low resistance due to interference with its blood supply; by the constant presence within its cavity of shoals of pathogenic bacteria, and by the more or less persistent overdistention with liquid, semisolid, or solid ingesta and the gaseous products of decomposition which its degenerate muscle cannot expel. Any breach in the endothelia lining the wall is an open door through which enter the ever-present organisms of disease.

Appendicitis may be considered clinically under the following heads: *Subacute, Acute, Chronic.*

In the *subacute* variety the infection is mild, and usually limited to a small area of the mucous membrane. Should the area of infection become larger and involve the submucous and muscular layers and peritoneal covering, with or without perforation, it passes into the *acute* form. Perforation or gangrene, with rapidly developing peritonitis, local or general, are forms of acute appendicitis.

Chronic appendicitis is practically nothing more than repeated attacks of the *subacute* variety, with intervening periods of more or less complete absence of inflammation. It has been called relapsing or recurring or "interval" appendicitis.

Symptoms.—Pain is the first symptom in practically all forms of appendicitis. In the subacute variety, and in the early stages of an *acute* attack, it may be mild in character. In the more rapidly developing cases it is apt to be severe and persistent. In the earlier stages it is often referred to the region of the navel, and later to the exact location of infection. If, however, direct and deep pressure with the end of a single finger be made at McBurney's point, the sharp sense of pain elicited will determine this to be the seat of inflammation. This point is from one half to one inch below the center of a line drawn from the anterior superior spine of the ilium to the umbilicus.

Nausea, with or without vomiting, is a frequent early symptom of appendicitis, and in general suggests an acute attack. Rigidity of the muscles directly over the organ is one of the most unerring symptoms of peritonitis from disease of the appendix. With a patient resting upon the back, if the hand be gently drawn across the abdomen from the left iliac spine to the right, the comparative rigidity of the muscles over the appendix will be appreciated. This muscular resistance is at times so strong and so sharply defined as to be mistaken for a peri-appendicular exudate or abscess. In very young children, in addition to overlying muscular rigidity the patient's hand will instinctively ward off the hand of the surgeon (Erdmann). In the diagnosis, a careful comparison with the symptoms of intussusception, gastro-enteritis, entero-colitis, or typhoid infection should be made.

The position usually assumed in the severer forms is upon the back, with the right thigh, or probably both thighs, flexed upon the abdomen.

In gangrene or perforation, or with rapidly developing peritonitis, local or general, in addition to tympanitis and general rigidity of the abdominal muscles there is noticeable an expression of anxiety or fright. Abdominal breathing is

[1] "Med. Rec.," May 11, 1907.
[2] "Mobile Med. and Surg. Jr.," January, 1907.
[3] Blow with a baseball in the author's practice.

diminished or absent, while the respiratory movements of the thorax are exaggerated.

The pulse is also usually increased in force and frequency in the earlier stages of acute appendicitis. Should perforation or gangrene occur, with the almost invariably accompanying shock, the pulse becomes at once weaker and more rapid. The average leucocyte count, as reported by Dr. Ghriskey in one hundred cases in the practice of Dr. John B. Deaver, was, in acute cases, 11,246; with pus accumulation (abscess), 18,500; in chronic cases, 8690. In the highest leucocytosis the streptococcus was found; next, staphylococcus, and lowest, the colon bacillus.

There is in general an elevation of temperature in proportion to the rapid spread of the infection. However, in a certain proportion of instances this does not hold good. In the first hour or so of gangrene, or immediately after perforation, the temperature may fall below the normal, and then rapidly rise as high as 103° or 104° within from six to twelve hours of the first symptom.

Nausea and vomiting are prominent symptoms of these more dangerous types, and if accompanied by intense pain should excite the gravest apprehension and *indicate immediate operation.*

The *morbid changes* which occur in the region of the appendix vary in proportion to the severity and rapidity of the septic process. In the milder forms a plastic exudate is thrown out over the inflamed area, and adhesions are formed with contiguous peritoneal surfaces—intestinal, omental, mesenteric, or mural. In the center of this exudate most frequently pus collects, forming an abscess of variable size. By this encapsulation general peritoneal infection may be prevented. Should operation be deferred, adhesions may continue to form between the abscess wall and the peritonæum lining the abdomen, either in front or laterally in the direction of the right iliac spine or lumbar region, until ultimately the abscess may be opened without entering the free peritoneal cavity; or, as not infrequently occurs, the adhesions give way with rapid general, and too often fatal, infection. In rarer forms, especially in those cases in which the cæcum is located at the edge of the pelvis, and in which the appendix has a direction downward, the abscess may encroach upon and become adherent to the rectum, bladder, or other pelvic organs. Examination per rectum or vagina will reveal the presence of the tumor, and it is often advisable to open such abscesses through the rectum or vagina by an operation to be described. In very exceptional cases suppuration does not occur, and instead of undergoing fatty metamorphosis and absorption the plastic exudate increases and persists for months, with all the symptoms and history of a rapidly developing malignant neoplasm,[1] at times enveloping the cæcum, appendix, and terminal portion of the ileum.

In other instances, usually with perforation or gangrene, the infection of the peritonæum is so rapid that adhesions cannot form in time to prevent a general (diffuse) peritonitis.

Treatment.—Appendicitis is strictly a surgical lesion, and in the hands of an experienced surgeon, without regard to the character of the attack, if recognized within the first twelve hours of the onslaught, *appendectomy* should be performed. By pursuing this seemingly radical course, the death-rate would be reduced to the minimum (probably not to exceed two per cent), while the serious after-consequences in recoveries where operation has been delayed, or where there has been no surgical intervention would be avoided. Even where the diagnosis may, in a measure, be doubtful, with an operator of experience and with competent assistants at hand, it is better to make the exploration necessary to determine the exact conditions and permit the indications to be met than to incur the always serious danger of delay.

With the first symptom of an attack, the patient should rest quietly upon the back, with a slight inclination to the right side. The bowels should be freely moved, castor oil (in syrup of sarsaparilla) being the remedy of choice. If this is not

[1] The author operated upon two cases of this character breaking up adhesions and removing thick organized masses of solid non-septic exudate in the center of which the remnant of the appendix was buried. Both recovered. In a third case reported to him excision and end-to-end anastomosis was done.

taken, *calomel* (in triturate form), grs. iij–v, followed in six hours by sulphate of magnesia, may be substituted. Morphia should never be given unless the pain is unbearable, and only then to give relief while preparation is being made for the operation.

Technic of Appendectomy.—In a *clean* case, as in the interval between attacks, or in acute appendicitis taken sufficiently early to forestall serious peritoneal infection, the following procedure is advised:

The skin incision is at least four inches long, parallel with the fibers of the right rectus muscle, about one inch toward the *linea alba* from the right edge of this muscle. The center of this incision should be one half inch below an imaginary line drawn from the umbilicus to the right anterior superior spine of the ilium. The anterior sheath of the rectus is opened on this plane, a pair of dull-pointed half-curved scissors carried between its fibers until they come in contact with the posterior sheath, when they are turned crossways and the blades sufficiently opened to separate the muscular fibers. In this opening a finger is inserted, and with it the separation is completed in the length of the incision. The nerve filaments crossing the line of separation should be held apart by gentle traction, and never divided unless it is absolutely necessary. Light retraction with dull-pointed instruments will expose the posterior sheath, and bring into view branches of the inferior epigastric artery and vein. When possible, these should be avoided, but when they cross the line of the posterior incision, they should be secured with two forceps, divided between, and tied with small plain catgut. All bleeding should be arrested before the peritonæum is incised. The posterior sheath and the peritonæum are now opened in the general direction of the anterior incision, but not for more than one inch. The posterior sheath may be sufficiently developed to be opened separately, or it and the peritonæum may be divided together. A Hagedorn needle, with long curve, armed with a No. 3 silk or linen thread, is entered on the peritoneal surface one half inch from the edge of the incision, and forced directly through the abdominal wall and out through the skin on each side of the wound. The ends are tied to form a long loop retractor. To prevent any possible injury to the omentum or intestine, these are displaced and shielded by the bowl of a small spoon introduced, convex surface downward. The omentum, which is usually encountered, should be carefully displaced toward the median line, and any overlying loops of small intestine similarly displaced. In certain instances this may be facilitated by half turning the patient on the left side. If through this small peritoneal opening the operation cannot be thoroughly accomplished without unnecessary manipulation, it should be enlarged upward or downward, as required. A free incision is much less harmful than the rough handling which is often necessary in separating adhesions and bringing the appendix through a small aperture. Should, however, the appendix present favorably, a small opening is preferable. When (as not infrequently occurs) it is not readily located by the touch, it may be found by following downward the longitudinal band, easily recognized on the anterior wall of the colon and cæcum.[1] This band terminates in the appendix. In children three or four years old the appendix may be near the costal arch (Erdmann). The end of the cæcum, with the appendix and meso-appendix attached, should be brought through the peritoneal opening, but no more of the cæcum exposed than is necessary to complete the operation of tying off the meso-appendix with two or three separate loops of plain catgut ligature, and of tying with a No. 2 silk or linen thread the organ to be removed. The meso-appendix is divided between the ligatures and the appendix, the end of which is held directly upward until it may be clamped by an artery forceps one half inch from its junction with the cæcum. A No. 2 silk or linen ligature is thrown around the appendix one quarter of an inch from the cæcum, and so tightly tied that there can be no possible chance for it to slip. The operator should be sure that the first knot holds firmly while the second is being secured. As soon as this is done and before the ends are cut away, a gauze swab split half-way with the scissors is carried on either side of the stump, and with this the operator firmly holds the cæcum. The appen-

[1] A few instances are on record where operators of large experience after prolonged search have failed to find the misplaced appendix.

dix is divided with the curved scissors one quarter of an inch beyond the ligature. The presence of the gauze prevents the possibility of infection. The funnel-shaped end of the stump is now thoroughly disinfected with a drop or two of pure carbolic acid carried upon a wisp of cotton on a small probe; the point should be carried to the apex of the funnel and rotated until all the surfaces are bleached by cauterization. One or two drops of alcohol are next applied in the same way to neutralize any excess of the acid. The stump should be thoroughly dried, the silk ligature divided one quarter of an inch from the knot, the swab removed, and the cæcum permitted to drop back to its normal position. Within a few hours the small aseptic raw surface on the end of the stump beyond the ligature is covered by a plastic exudate and the knot is buried. When the removal of septic exudate or fluid is necessary, the peritoneal incision should be larger. If the operation be clean, the omentum should be brought again to its normal position in front of the cæcum, and the peritoneal incision, with that of the posterior sheath, closed by a running suture of No. 2 chromicized catgut. This part of the technic is greatly facilitated by traction on the thread loops so as to lift the abdominal wall and peritonæum away from the protruding mesentery or intestine. When the incision is long, an additional loop retractor should be inserted near each angle. When the peritonæum is closed, the retractors are removed and the separated fibers of the rectus muscle are permitted to resume their normal position, where they remain without suture. The anterior sheath should be closed with a running suture of kangaroo tendon. If there be a superabundance of fat, a subcutaneous running suture of No. 2 plain catgut is advisable for its approximation. An endocuticular suture of silkworm gut should close the anterior incision. A light dressing of sterile gauze, held in place by firm pressure with adhesive strips or an abdominal bandage, will suffice. The silkworm-gut suture should be removed about the eighth day.

Preference is given the Deaver incision because it gives free access to the cæcum and appendix, and when, as is not infrequent, it becomes necessary to have more room for safe and thorough work, it can be extended indefinitely upward or downward, giving complete command of the peritoneal cavity with the minimum of risk of being followed by ventral hernia. The only objection to it is the occasional division of one (rarely more) of the dorso-lumbar nerve filaments which cross it to supply the rectus. The closure of the peritonæum, the strong muscular splint which guards this posterior incision, together with the firm union which can be obtained in the sheath, makes a ventral hernia a rare exception. I prefer it to the Kammerer method, which, making the same anterior and posterior incision, displaces temporarily the right edge of the rectus toward the median line. My chief objection to the latter is that when drainage is found to be necessary, the muscle resuming its normal position, forms a trapdoor over the posterior opening. Both are preferable to McBurney's incision, for the reason that it cannot be sufficiently enlarged to meet an emergency without great danger of ventral hernia.

Numerous accidents from hæmorrhage or giving way of the suture, some of them fatal, have followed other methods than the simple ligature. Any suture method is unnecessary, and violates an essential principle of surgery, viz., *the minimum of traumatism.*

When an *abscess* or *septic exudate* is encountered, the peritoneal incision should be enlarged so as to give a full view of and free access to the septic area, and, if necessary, the abdominal incision should also be further extended upward or downward. It is imperative to prevent, if possible, contact of all peritoneal surfaces not already involved with septic matter. To accomplish this it is often necessary to wall off the diseased area with sterile mats or loose absorbent gauze. A careful count should be kept of separate pieces so that by oversight none may be left in the abdomen, and it is a wise precaution to have a string or tape attached to each with a forceps fastened to the free end. By means of the author's loop retractors the abdominal wall may be lifted, when there will be space so free that these mats may be inserted with expedition and the minimum of traumatism. With this carefully accomplished, adhesions may now be broken up by the finger of the operator, and the appendix with the exudate and stump of the cæcum brought up to the edges of the incision. If in the process of breaking up adhesions pus is encountered, it

should at once be mopped out with sterile gauze swabs. The appendix should now be tied off and the stump treated as in the preceding operation, and all septic matter, either exudate or liquid, thoroughly removed with sponges or swabs. It may be necessary in rare cases to clip with the curved scissors masses or fragments of septic exudate, which adhere to the walls of the cæcum, ileum, or mesentery, and to tie off and remove any masses of omentum fouled with this exudate.

The question will now confront the surgeon whether or not he shall close the abdominal wound without drainage. If the patient is young and vigorous—in other words, if the resistance is near the normal—and if the area of infection is small and a thorough cleansing has been effected, the gauze pads may be removed and the wound closed as just described.[1]

If, on the contrary, there is serious doubt as to the propriety of closure without drainage, he should lean to the side of conservatism and drain, if only temporarily.

The objections to drainage are that it favors the formation of adhesions, and weakens the abdominal incision at the point through which the drain makes its exit. However, in severe infections these risks must be incurred rather than the greater one of diffuse peritonitis. As a rule, the ordinary cigarette drain is all that is necessary. This is made by enclosing one or several loose wisps or pencils of absorbent gauze in a layer of rubber-tissue protective, the gauze projecting slightly from both ends. One end is carried to the center of the infected area, usually at the stump, and passes directly upward to the most convenient point of the abdominal incision. In order to prevent displacement the inner end of the drain should be fastened at the center of infection by a single small plain catgut suture. The peritoneal and the abdominal wounds are then closed from either end up to the drain. As it is intended to remove this within forty-eight or seventy-two hours, it is a wise precaution to introduce one or two silkworm-gut sutures through the skin and sheath of the rectus, then through the peritonæum across to the opposite side, and out through the same tissues. These sutures are left long so that when the drain is removed they may be tied, and thus secure firm closure of an otherwise weak point in the abdominal incision.

If at any time a high temperature or tympanitis, accompanied by other symptoms of renewed infection and spreading peritonitis, should be present, the surgeon should without delay open the wound and meet the indications.

If the conditions are such as to require more than temporary drainage, a rubber drain may be required. A piece of soft-rubber tubing, varying in diameter from one quarter to one half inch, and at times larger, and long enough to reach from the stump of the appendix and to come out through the abdominal wall, should be split from end to end spirally (the spiral making about one turn), and loosely filled with wisps of absorbent gauze.[2] The size will depend upon the conditions which are present, but one a half inch in diameter will usually suffice. At times two of these tubes may be necessary, placed side by side.

In rare instances it may be deemed more advisable to wall off the uninvolved peritoneal surfaces with sterile gauze, either loose or in mats, leaving these in place about forty-eight hours until adhesions have formed. When the original pack is removed, which should be done under nitrous-oxide gas, a smaller secondary pack may be required, and this can be removed in twenty-four or forty-eight hours, generally without narcosis. In all these cases of packing it is my invariable practice to insert through-and-through silkworm-gut sutures one quarter of an inch apart for the entire length of the incision, leaving the ends long so that plenty of room may be had for removing and replacing the pack. With the first change one or two of the sutures at each end may be tied, followed from time to time by the others as the pack is gradually discontinued.

While with the Deaver incision (splitting the rectus) the danger of ventral hernia is reduced to the minimum, it may follow in these drainage cases, even where the precautions just advised have been thoroughly carried out.

[1] Should the patient be in a hospital where at any hour of the day or night, upon the first indication of recurring infection, a second operation may be done with the establishment of drainage, the surgeon will often be justified in adopting this plan.

[2] Dr. Van Buren Knott.

The operative measures above given will apply equally in all cases of perforated and gangrenous appendicitis, but not in general diffuse peritonitis.

In *delayed* cases, where an abscess of large size has been formed, temporary drainage through the smallest possible puncture or incision is safer than an effort to remove by a radical operation an extensive septic exudate. In these cases adhesions may exist between the abscess wall and the abdominal peritonæum, so that the abscess may be reached without passing through the peritoneal cavity.

When the focus of infection is below the rim of the pelvis, the wall of the abscess not infrequently is adherent to the rectum or vagina, through either of which it may be evacuated by puncture. When the tumor may be reached directly over the appendix, the McBurney incision is advised. A small cut not more than two inches long, parallel with and about one inch to the right of the linea semilunaris, exposes the fibers of the aponeurosis of the external oblique which are split and held apart by dull retractors. The fibers of the internal oblique and transversalis are also separated and held apart by retraction. If the peritonæum is agglutinated to the underlying mass, an aspirator needle should be carefully inserted in the direction of the center of the tumor in order to demonstrate the presence of pus and the thickness of the abscess wall. When pus appears the needle should be withdrawn, and a dull-pointed dressing forceps carried along the track of the needle until it slips into the cavity of the abscess, when by separation of the blades a free exit is established. One or two drainage-tubes should now be inserted and the pus allowed to discharge itself. Should irrigation be deemed advisable it should be done without undue pressure for fear of breaking through adhesions and spreading infection. If adhesions between the mass and the peritonæum have not formed, it is advisable to incise the latter for about an inch and insert a small pack of gauze, leaving this *in situ* for thirty-six to forty-eight hours to secure adhesions before opening the abscess.

If the pus has drifted toward the lumbar region the incision should be made there, and when digital examination recognizes the tumor in the pelvis, puncture and drainage may be made, preferably through the rectum or through the vagina.

The danger incurred in the effort to remove these very extensive areas of infection by an open radical operation is great for the reason that the subjects, as a rule, are exhausted by prolonged sepsis. It is safer to practice drainage until the discharge has entirely ceased or until the size of the infected area is reduced to the minimum, and the normal resistance of the patient is restored, and later in a period of quiescence through a Deaver incision to remove the appendix.

In cases of appendicitis where operation is declined or where, for any reason, the physician or surgeon in charge deems operation inadvisable, the method of treatment advised by Dr. A. J. Ochsner should be practiced.

This distinguished surgeon bases what may be called the treatment of *absolute rest* upon the claim, first, that "the distribution or extension of the infection is accomplished by peristaltic action of the small intestines, after the infection has extended beyond the appendix and before it has become circumscribed."

"Peristalsis can be prevented by prohibiting the use of every form of nourishment and cathartic by mouth, and by employing gastric lavage in order to remove any food substances or mucus from the stomach."

"The patient can be safely nourished during the necessary period of time by means of nutrient enemata. Large enemata should never be given, for they may cause the rupture of an abscess into the peritoneal cavity."

Ochsner notes that "when neither food nor cathartic are given from the beginning of the attack of acute appendicitis and gastric lavage is employed, the mortality is reduced to an extremely low percentage."

"In cases which have received some form of food and cathartics during the early portion of the attack, and are consequently suffering from a beginning diffuse peritonitis when they come under treatment, the mortality will still be less than four per cent if peristalsis is inhibited by the use of gastric lavage and the absolute prohibition of all forms of nourishment and cathartics by mouth. In this manner very dangerous cases of acute appendicitis may be changed into relatively harmless chronic cases."

Ochsner insists that even "during the beginning of this treatment no water should be given by mouth, the thirst being quenched by rinsing the mouth with cold water and the use of small enemata. Later small sips of very hot water, frequently repeated, may be given, and still later cold water in the same way. There is danger in giving water too freely, and there is great danger in the use of large enemata."

"It should be constantly borne in mind that even the slightest amount of liquid food of any kind given by mouth may give rise to dangerous peristalsis. The most convenient form of rectal feeding consists in the use of one ounce of any of the various concentrated liquid predigested foods in the market dissolved in three ounces of warm normal salt solution introduced slowly through a soft catheter inserted into the rectum a distance of two to three inches." He also states that "this form of treatment cannot supplant the operative treatment of acute appendicitis, but it can and should be used to reduce the mortality by changing the class of cases in which the mortality is greatest into another class in which the mortality is very small after operation."

In practicing lavage, which he considers so essential in the successful management of these cases, he advises spraying the pharynx with two-per-cent cocaine, waiting from five to seven minutes until a local anæsthetic effect is experienced, then introducing a stomach-tube and irrigating with warm normal salt solution. No food of any kind whatsoever or cathartic should be given by mouth until the patient has been normal for four days, no matter whether or not an immediate operation be performed. The enemata are given every three to four hours.

Peritonitis.—Infection of the peritonæum may be *traumatic* or *idiopathic, local* or *general.*

Penetrating wounds, or injuries which involve the muscular walls and become infected, are apt to induce peritonitis. Hard or pointed ingested substances occasionally penetrate the walls of the alimentary canal, permitting the escape of pathogenic organisms into this cavity. As already stated in the chapter which treats of appendicitis, complete rupture or destruction by disease of all of the coats which compose the wall of any portion of the alimentary tract, or in fact of any one layer, is not necessary to peritoneal infection. In gangrene due to sudden arrest of the blood supply, where there is no actual breach of continuity, the leucocytes are no longer present in force sufficient to resist invasion. In other words, the tissues have lost their normal resistance and infection ensues. An ulcer which destroys no more than the mucous lining may so impair the resistance of the intervening muscular layer that the peritonæum becomes involved.

Idiopathic peritonitis is almost always due to the spread of an infective process from one or more of the organs with which this membrane is in contact. While it is possible that the organisms of sepsis may be carried by the blood or lymph channels, and may find a lodgment on any portion of the peritoneal surface where the local conditions are favorable to their proliferation, such a method of infection is extremely rare. It occurs as a complication of diaphragmatic pleurisy, abscess of the liver, septic infarctions of the spleen, gastric and duodenal ulcer, empyema or ulcer of the gall bladder, inflammation of the gall ducts, pancreatitis, enterocolitis, appendicitis, peri-nephritic infection, and very frequently from specific or pyogenic infections of the genito-urinary organs. The necrotic process resulting from intussusception, volvulus, strangulated hernia, weakens the resistance of even the unbroken intestinal wall and permits the outward passage of septic micro-organisms.

The most common pathogenic organisms in acute peritonitis are the streptococcus, staphylococcus, bacillus coli communis, and gonococcus. The bacillus typhosus and pneumococcus are occasionally present, but even in peritonitis complicated with typhoid ulcer, with or without perforation, the severity of the symptoms is almost always due to the streptococcus and staphylococcus.

Symptoms and Diagnosis.—The symptoms of peritonitis vary in large measure with the virulence and rapid spread of the infection. In many instances the attack is so insidious and mild that the character of the infection is with difficulty recognized. Pain is usually the first symptom, and in the more rapidly developing cases is severe and persistent. It is usually referred to the focus of infection, although

in a certain proportion of cases the painful sensations are referred to the neighborhood of the umbilicus. As a rule, deep or point-pressure with a single finger will elicit a more acute sense of pain at the seat of the lesion than elsewhere. Muscular resistance or rigidity is one of the most unfailing indications of the location of a beginning peritonitis. Nausea, with or without vomiting, is a frequent early symptom, and if prominent as a symptom suggests acuteness and rapidity of the invasion. Shock is almost always present in varying degree with perforation, intussusception, volvulus, or gangrene. The expression of the face is one of anxiety in these more severe attacks (facies abdominalis). Abdominal breathing is less than normal, while the respiratory movements of the thorax are increased. In non-perforative cases the pulse is usually increased in force and frequency. In the early stages of acute localized peritonitis the temperature does not vary far from the normal. In many instances it is subnormal, and this is rather an alarming symptom. If with a suspected peritonitis there is a subnormal temperature, rising above the normal one or two degrees within as many hours, the indications for exploration are positive, although in a certain proportion of cases this symptom is deceptive. Knowledge of a preëxisting lesion should be considered in locating the focus of invasion. Ulcers of the stomach and duodenum not infrequently break down and induce overwhelming peritonitis from perforation. The same is true of ulcer of the gall bladder, and of any continuous infective process of the lining membrane of the alimentary canal (typhoid ulcer). The history of a specific infection of the genito-urinary apparatus, with deep-seated pains in the lower abdomen and even a slight rise of temperature, would justify the suspicion of commencing peritonitis.

Prognosis.—The prognosis in peritonitis depends upon the location of the infection, the rapidity of invasion, the condition of resistance of the patient at the time of the attack, and in large measure upon the promptness of surgical relief. Peritonitis resulting from perforation is always a grave condition. If the perforation is of large size, with free extravasation, the danger is greatly increased. A peritonitis due to perforation or infection in the subdiaphragmatic zone is extraordinarily dangerous, for the reason that the lymphatic absorption at this part of the abdomen, especially near the center of the diaphragmatic arch, is very rapid, and at times overwhelming. Moreover, the peritonitis is apt to spread rapidly by gravitation to other portions of the general cavity. Infection due to the escape of organisms from the region of the appendix and the first part of the colon is usually more virulent than that caused by escape of contents from the small intestine higher up, for the reason that the first part of the colon is the main breeding-ground of the most virulent septic germs.

Treatment.—The first indication in the treatment of peritonitis is absolute rest in that position which will best prevent the spread of infection until surgical relief can be obtained, or, failing in this, until adhesions with encapsulation of the infective process may be established. The logical treatment of a peritoneal infection is immediate incision, with removal of the focus of invasion and a careful local toilet of the peritonæum, removing all foreign or septic matter, and when possible immediately closing the abdominal incision. The question of drainage in any given case must be determined by the conditions which are found. In an individual in whom the resistance is near the normal, with a localized infection recognized within the first few hours of invasion and subjected to operation and a neat toilet, as a rule immediate closure without drainage may be done. When, however, the resistance is low and there is any suspicion in the mind of the operator of the ability of the peritonæum and its leucocytes to combat the invasion, it is better to lean to the side of conservatism and establish a temporary and usually restricted drainage. In cleansing a limited area of infected peritonæum it is advisable to use no irrigation, but to remove with swabs wet in sterile salt solution or mercuric chloride 1–3000 all extravasated or septic material, always taking the precaution when the mercuric solution is employed to remove any possible excess by a final cleansing with the swabs wet in the salt solution. When drainage is employed in incipient local peritonitis, the cigarette drain is usually sufficient. This is composed of a wick or film of absorbent gauze, wrapped loosely about with one or two layers

of sterile rubber-tissue protective. One end should rest at the seat of infection, and if necessary it may be anchored at that point by a single ordinary catgut suture passed through the end of the gauze, which should project slightly beyond the rubber tissue, stitching it to the tissues at the point of infection. The other end should pass out at the most convenient point upon the abdominal incision. As directed in celiotomy, when a drain is left projecting through an abdominal incision a through-and-through silkworm-gut loop should be inserted, and left long so that when the drain is removed at the end of twenty-four or forty-eight hours this suture can be tied, bringing the peritonæum and abdominal wound together, and thus preventing hernia. When the peritonitis becomes general or diffuse, more heroic measures of treatment are necessary. These will be given on another page.

Non-operative Treatment.—When for any reason operation is delayed, the patient should be placed in bed and in the position best calculated to prevent a spread of the infection. If there is a beginning peritonitis in the right iliac fossa (appendicitis) the patient should rest upon the back, with the shoulders well elevated (Fowler's position), with a slight inclination to the right side. In any lesion of the pelvis inducing peritonitis, the extreme Fowler position should be maintained. If subdiaphragmatic peritonitis is suspected, the patient should rest flat upon the back, with an elevation of the foot of the bed eight or ten inches, with an inclination to one side or the other if there is thought to be a lateral focus of infection.

When a lesion of any portion of the walls of the alimentary canal is thought to exist and to cause the peritonitis, a general purgative is not indicated, unless severe intestinal toxæmia is present. It is then advisable to empty the bowels by the administration of castor oil, or from three to five grains of calomel triturates. If the upper end of the alimentary canal is involved and the necessity for emptying the bowels is present, irrigation of the colon should be done. In non-operative cases where pain is severe, and where it is deemed advisable to keep the alimentary canal in quiescence, the administration of morphia may in rare instances be permissible. The local applications of cold or heat by means of a light rubber ice-bag or by means of the rubber hot-water bag, gives at times a sense of relief. The Ochsner method as advised in non-operative appendicitis should be equally beneficial in peritonitis.

General Suppurative Peritonitis.—In the treatment of widespread infection of the peritoneal cavity the immediate indication is to remove the focus of infection, together with all septic exudate which may be encountered. If the location of the original point of infection is satisfactorily established, the incision through the abdominal wall should of necessity be made so as to permit free access to this location. The rules governing these incisions have been given in the chapter on celiotomy. The method of removing the gas and semiliquid ingesta from the hyperdistended intestines has been given.

Such is, in general, the patient's low resistance, due to overwhelming septicæmia, that time is more than ordinarily an important factor in dealing successfully with this condition. The incision should only be large enough to give free command of

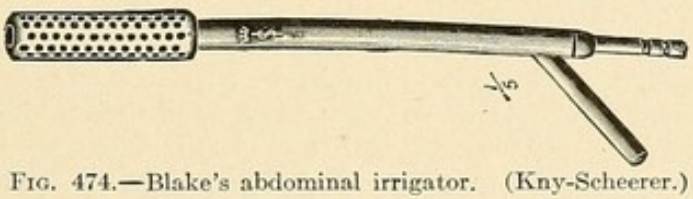

Fig. 474.—Blake's abdominal irrigator. (Kny-Scheerer.)

the infected area. In cleansing the general peritoneal cavity the abdominal irrigator devised by Prof. Joseph A. Blake will be found most satisfactory. It permits of a direct inflow through a straight central tube, while the return current is siphoned through the lateral perforations in the enlarged end, and escapes by way of the outer tube. "The combined area of the lateral perforations is much greater than that of the outflow, thereby preventing undue suction upon intestine or omentum." This instrument is made in two sizes: that for adults fourteen inches long, the smaller about one third less in all dimensions (Fig. 474). It can be entirely taken

apart for cleansing. In its employment it is connected to the reservoir with a large rubber tube, in order to get a rapid inflow. A short piece of rubber tubing, not over twelve inches long, is connected with the outflow. If this tube be too long, there is danger of injury to the intestines from violent suction. It should be held in the hand in such a way that the inflow and return can be easily controlled by pressure of the fingers.

In order for the instrument to work, it is necessary to establish a siphon action through the outflow, inasmuch as the end in the abdomen is usually lower than the part of the tube outside. If this is not done, it works only as an ordinary irrigator.

To establish the siphon the margins of the wound should be compressed about the shank of the tube, when the inflow will cause sufficient intra-abdominal pressure to force the irrigating fluid back through the outflow, thus making the siphon. If the instrument has to be withdrawn in order to insert it in another direction, and there is danger of air entering and breaking the siphon, it is only necessary to compress and fold the rubber outlet tubing against the metal with the fingers, thus closing it and preventing it from emptying. It is well, if possible, to pass the fingers of the left hand into the abdomen and partially surround the tube with them, thus preventing occlusion of the lateral apertures. The degree of cleanliness reached is at once evident by the character of the outflow, and when this becomes clear the irrigator is passed to another fossa of the abdomen. In this way each peritoneal pocket can be successively cleansed, and at the same time an accurate estimation of the diffusion of the exudate or foreign material be obtained. Foreign material too coarse to pass through the apertures will on account of the suction stick to them, and in this way large pieces of foreign substances may be removed, together with patches of fibrin, etc. It has the one very great advantage of being used with a very small incision.[1]

If this apparatus is not at hand, a fair substitute may be had in a piece of stiff rubber drainage-tube, from one quarter to one half inch in diameter and long enough to reach from a median-line incision to any part of the abdominal cavity. Irrigation with hot salt solution, at a temperature from 115° to 120° F., should be used, always beginning in the upper part of the abdomen, flooding the region behind and in front of the stomach, the liver, spleen, transverse colon, down along the region posterior to the ascending and descending colon, and a final thorough irrigation of the pelvis. As a part of this general peritoneal toilet and drainage, the extreme Fowler position should be maintained and free pelvic drainage instituted. When an irrigator or fountain apparatus is not at hand, the hot salt solution may be poured in from sterile pitchers held at a sufficient height above the gaping abdominal incision. A longer incision may be required than when the irrigator is employed. In women it is advisable to open freely through Douglas's *cul-de-sac*, and insert a large size Van Buren Knott rubber drainage-tube, which is loosely packed with iodoformized or sterile absorbent gauze. In males, two tubes should be inserted in the middle line, immediately above the symphysis pubis. The lower and larger of these should be at least one inch in diameter, split spirally from end to end, and filled with a strip of absorbent gauze. Above and in contact with this a second tube of smaller size should be inserted. This tube contains no gauze.

The question of a local cigarette drain at the focus of infection must be determined by the conditions which it is sought to correct. The irrigation with hot salt solution from above should be continued until the fluid which escapes through the points of drainage is satisfactorily clear and clean. The operative wound should be closed without any attempt to remove the excess of solution, some of which will escape by the drainage, the remainder being absorbed by the peritonæum. Any collection of fluid in the smaller of the two lower tubes should be carefully withdrawn by suction with a syringe and rubber tube every hour or so, an accumulation not being permitted.

In closing the incision, a rapid through-and-through silkworm-gut closure may be necessary rather than take the time required for separate layer sutures. The shortest time consistent with thoroughness and the minimum of ether or chloroform are all important.

[1] Prof. Joseph A. Blake, "Surg., Gyn. and Obstet.," May, 1906.

To this treatment there should be added the routine technic of continuous colon irrigation which has given admirable results in the hands of Prof. John B. Murphy[1]: "The vaginal hard-rubber tube of an ordinary fountain syringe is heated and bent two and a half inches from the end at an angle of about thirty-five degrees and inserted into the rectum. To this is attached a rubber tube secured to the side of the thigh by adhesive straps so as to prevent its possible displacement. A fountain syringe filled with normal salt solution, and kept at a temperature of about 100° F., with an elevation of from six to eighteen inches, as required, should be allowed to flow in until from one and a half to three pints have been taken. The influx of this solution should be very slow, requiring at least sixty minutes for the quantity above given, the inflow to be controlled by the elevation of the syringe and never by a forceps applied to the tube to lessen its lumen, as this will prevent a rapid return of flow to the can, or the escape of gas should the patient cough or strain. The quantity should be repeated every two hours. Never remove the rectal tube, except for defecation. When it is not retained, it is improperly given." Professor Murphy has succeeded in having a child retain and absorb as much as thirty pints in thirty-four hours. By this treatment it is intended to tide the patient over the immediate effects of toxæmia. Should emesis or gastric distention be present, lavage of the stomach will give great relief.

In a certain proportion of these cases of general peritonitis secondary pus pockets will form, and require to be opened. Obstructions due to adhesions, and ileus caused by partial intestinal paralysis, are not infrequently encountered.

Tuberculous peritonitis results from the lodgment in this membrane of the *bacilli tuberculosis*. These may be carried through the vessels and be generally disseminated (miliary), or the infection may be by direct invasion from an infected focus in any of the organs with which the peritonæum is in contact. It is most frequently observed from the twentieth to the fortieth year of life, although about eighteen per cent of all cases occur in children. Women are affected more than men in the proportion of 2 to 1. Clinically it exists in two forms, the moist (or ascitic) and the dry (fibroplastic or adhesive). In the former the peritoneal surface is studded with minute tubercular nodules, which may be localized or generally disseminated. Transudation of serum is a feature of this form, and the quantity of liquid is generally proportionate to the area involved. Occasionally the transudate becomes encysted in one or more separate cavities.

In the fibroplastic variety there is little or no serous effusion, but an exudate, in the presence of which the mesentery, omentum, and intestines become agglutinated.

An ulcerated form has also been described, but this is nothing more than a cheesy degeneration of the tuberculous nodules.

The symptoms of tuberculous peritonitis are not well marked in the early stages. It is not a painful disease. There is the disturbance of nutrition characteristic of tuberculosis in other organs. Usually the first symptom of the moist form is a collection of fluid in the pelvis and lower portion of the abdominal cavity. In the dry variety the agglutination of the viscera may be recognized by careful palpation.

The *treatment* is medical and surgical. Tonics, the open-air treatment, and careful nutrition are essential in all cases, and must be practically relied upon in the miliary form, in which there is apt to be a general dissemination.

As far as operative intervention is concerned, the best results have been obtained in tuberculous peritonitis with transudation resulting from limited infection. The operation consists in a small incision near the median line, splitting the rectus muscle. Irrigation with saline solution (110°–115° F.) may be added, using by preference the Blake tube, the excess of liquid being permitted to remain in the general cavity. No handling of the viscera should be permitted, and the abdominal wound should be immediately closed without drainage.

[1] Professor Murphy also recommends "10 to 20 c. c. of Stearn's streptolytic serum every twelve hours until from two to six doses have been given, depending on the conditions." In the present status of serum therapy the purity of the agent injected should be assured.

CHAPTER XXV

HERNIA

A HERNIA is formed by the protrusion of a portion or all of any viscus from its normal cavity. Although there may be a hernia of the brain, lung, bladder, spleen, etc., the term by common consent is almost wholly restricted to protrusions of intestine (enterocele), or omentum (epiplocele), or both.

Hernia may be *congenital* (when it exists *in utero* or at birth) or it may be *acquired.*

It is termed *complete* when the organ escapes entirely through the substance of the enclosing wall; *incomplete* when it has entered and has not yet escaped. A hernia is *reducible* when the contents of the sac can be returned to the peritoneal cavity, *irreducible* when this cannot be accomplished, and *strangulated* when the circulation in its contents is wholly or partially arrested by constriction (usually at the neck).

Herniæ are *classified* according to their place of escape: *inguinal, femoral, umbilical, ventral, diaphragmatic, gluteal, obturator, lumbar, vaginal, pudendal,* and *perineal.* The term *ventral* is applied to all herniæ occurring at points on the abdominal wall other than those indicated in the classification just given. Of herniæ in general, the inguinal variety forms about eighty per cent of all cases; femoral, ten; umbilical, five; the remaining varieties, five. Of every five patients affected with hernia four are males. Inguinal hernia in males occurs more often in the first ten years of life than in any subsequent decade, the period from the twentieth to the fortieth year being next in order of frequency. According to Kingdon, femoral hernia in *males* of all ages is met with in four of every hundred cases; in the first decade in one of every three hundred, in the second two per cent; in the third and fourth together, four and a half per cent; the fifth and sixth, six per cent; and after this, eight per cent. In *females* inguinal and femoral herniæ are met with in about equal proportions. The latter variety is rarely met with before puberty, but occurs chiefly during the child-bearing period (Thomas Bryant).

STRUCTURE OF HERNIÆ

The contents of the hernia are enclosed in a *sac,* almost always formed by the peritonæum lining the abdominal cavity. The sac may be carried immediately in front of the escaping intestine or omentum (femoral, umbilical, etc.), or these viscera may descend into a sac already formed by the escape of some other organ, as the testicle (inguinal, scrotal). In the rare cases of hernia of those portions of the large intestine not covered by peritonæum there is no true sac. That part of the sac which looks directly into the abdominal cavity is called the mouth, the constricted portion between this and the main cavity or *body* is the *neck,* while the deepest or most protruding portion is the *fundus.*

The sac varies in thickness generally in proportion to the age of the hernia. In a recent hernia it is exceedingly thin, while in some forms of scrotal hernia, of long duration, it may be as much as one sixteenth or one eighth of an inch in thickness.

SPECIAL HERNIÆ

INGUINAL HERNIA.—An inguinal hernia may be *direct* or *indirect, complete* or *incomplete, congenital* or *acquired.* The *indirect* or "*oblique*" variety is much

more frequently met with. In the *male*, the contents pass into the *internal abdominal ring*, and follow the *spermatic cord* along the inguinal canal, at times descending into the *tunica vaginalis testis*. In the *female*, the descent is in the canal of Nuck, following the round ligament in the inguinal canal, and at times as far as the labium. *The epigastric vessels are internal to the neck and behind the body of an oblique inguinal hernia* (1, Fig. 475, and Fig. 475 *b*).

A *direct* hernia does not enter the *internal* abdominal ring, but pushes the fascia which is to the inner side of the epigastric vessels and immediately behind the external ring directly in front of the *tumor and out at the external ring.*

Therefore the epigastric vessels are external to the neck, and may be displaced slightly in front and to the outer side of a direct inguinal hernia (2, Fig. 475, and Fig. 475 *a*).

An inguinal hernia is said to be *complete* when the contents protrude beyond the external ring; *incomplete* when the tumor is within this limit. A *complete*

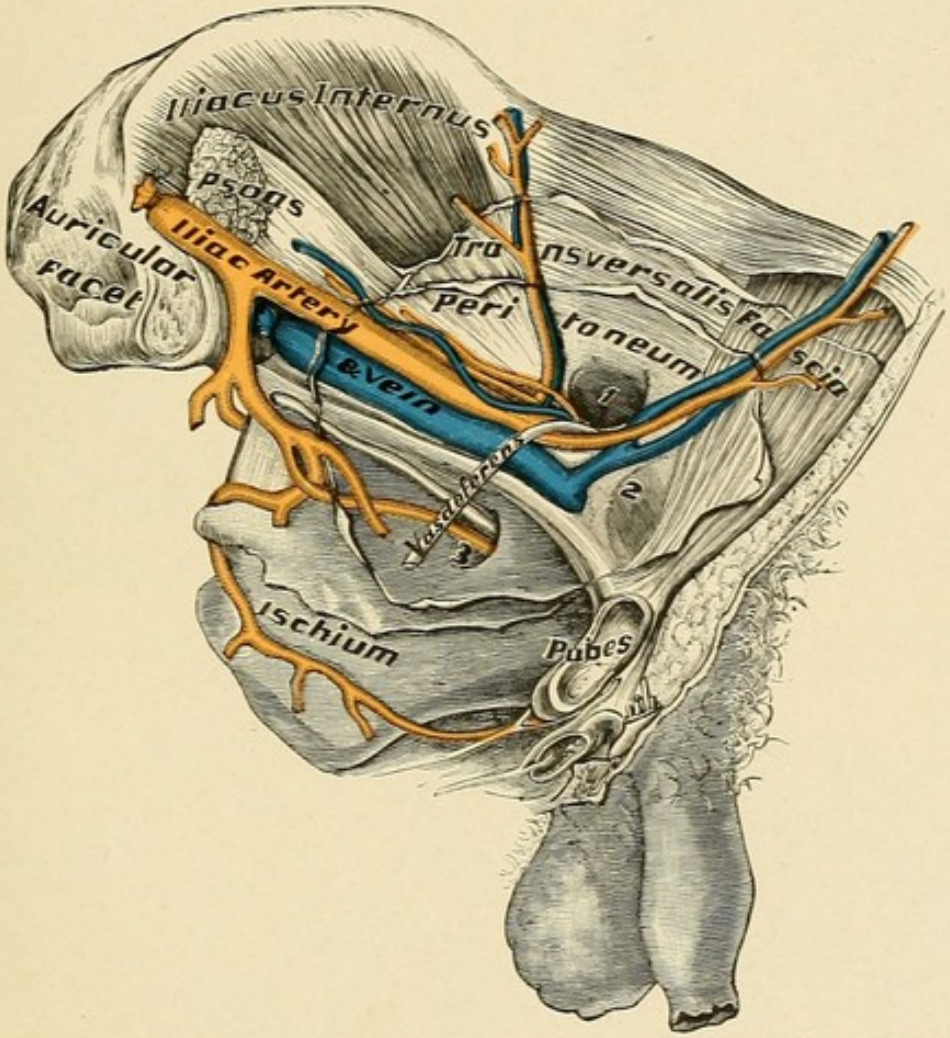

FIG. 475.—The relations of the points of escape of oblique and direct inguinal and obturator herniæ to the important vessels of the pelvis. 1, Internal abdominal ring. 2, Point at which a direct inguinal hernia commences. 3, Obturator canal, artery, and nerve. The epigastric vessels are seen passing upward between 1 and 2. (Modified from Maclise.)

inguinal hernia in the male may descend into the cavity of the tunica vaginalis testis, the contents resting in contact with the testicle (*congenital*) (Fig. 476), or it may be arrested in the tubular sheath which surrounds the spermatic cord (*infantile*), the contents not in contact with, but pressing upon, the testicle (Fig. 477).

There is a rarer form of inguinal hernia, known as the *encysted* hernia of Astley Cooper. This variety of hernia is produced as follows: The vaginal process on that part of the peritoneal pouch which surrounds the spermatic cord from the *internal* to the *external* ring, and which normally is closely adherent to the

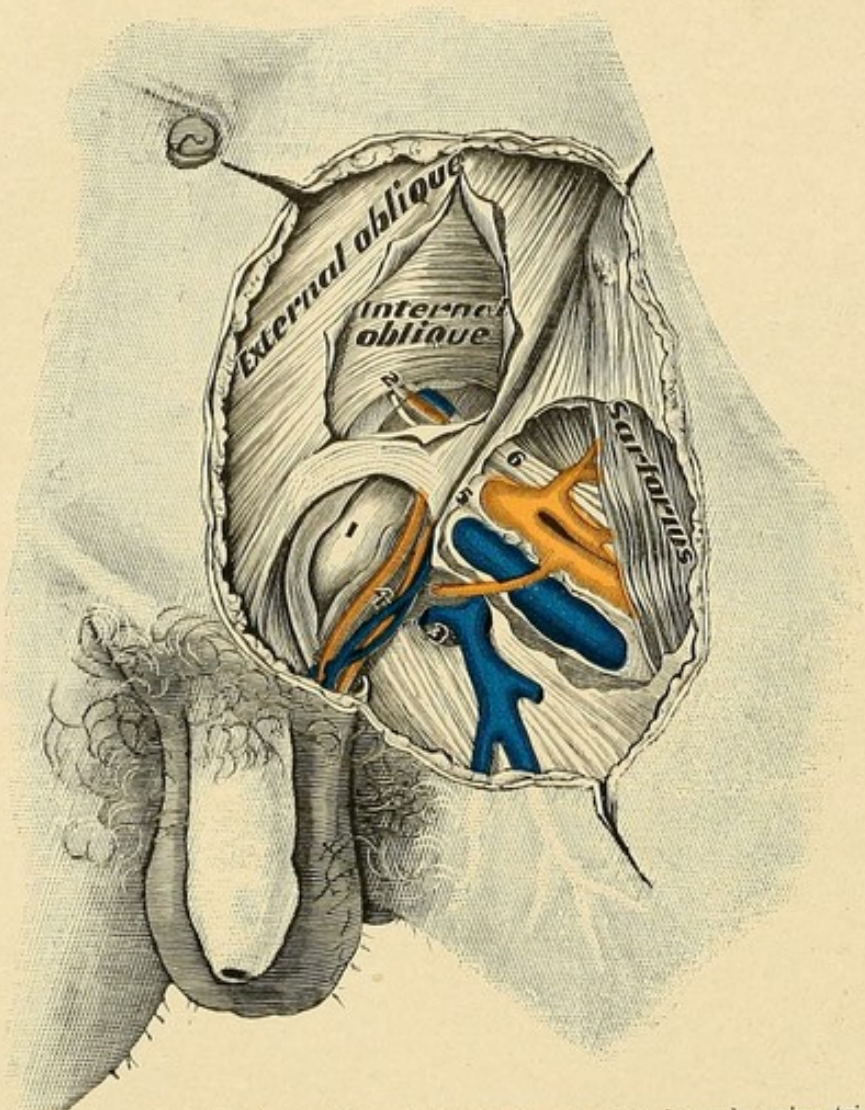

FIG. 475*a*.—Showing the relations of a direct inguinal hernia to the epigastric vessels and the spermatic cord. 1, Hernial tumor. 2, Epigastric vessels in front of and external to the neck of the tumor. 3, Saphenous opening and vein. 4, Spermatic vessels. 5, Femoral vessels. 6, Crural nerve.

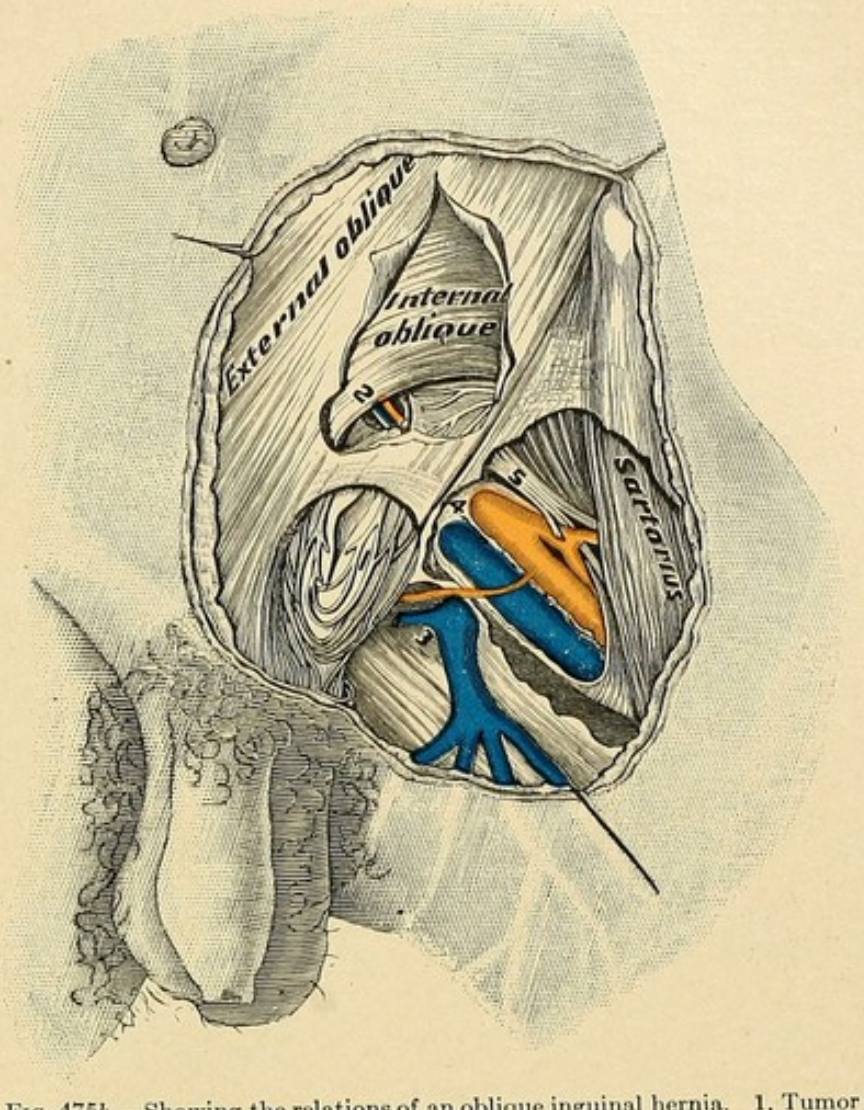

FIG. 475*b*.—Showing the relations of an oblique inguinal hernia. 1, Tumor covered by cremasteric fascia. 2, Epigastric vessels behind and to the inner side of the neck of the tumor. 3, Saphenous vein and opening. 4, Femoral vessels. 5, Crural nerve.

cord, not permitting the entrance of any of the abdominal contents, is closed at the *internal*, but remains unclosed at the *external* ring. The hernia descending, pushes before it the parietal peritonæum as in ordinary hernia, and carries it gradually downward until it is protruded into the unclosed vaginal process below, forming in this way two sacs.

Inguino-properitoneal Hernia.—A. E. Halstead[1] describes inguino-properitoneal hernia as "containing two sacs, or two divisions of one sac, the inner or intraparietal sac lying between the peritonæum and the transversalis fascia, and

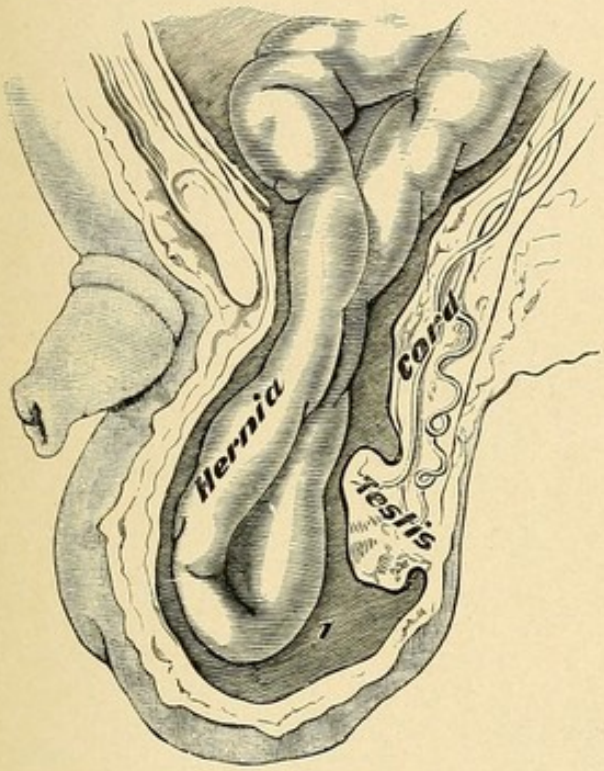

FIG. 476.—Congenital oblique inguinal hernia. Sac formed by the *tunica vaginalis et funiculi*. 1, Cavity of the tunica. (After Maclise.)

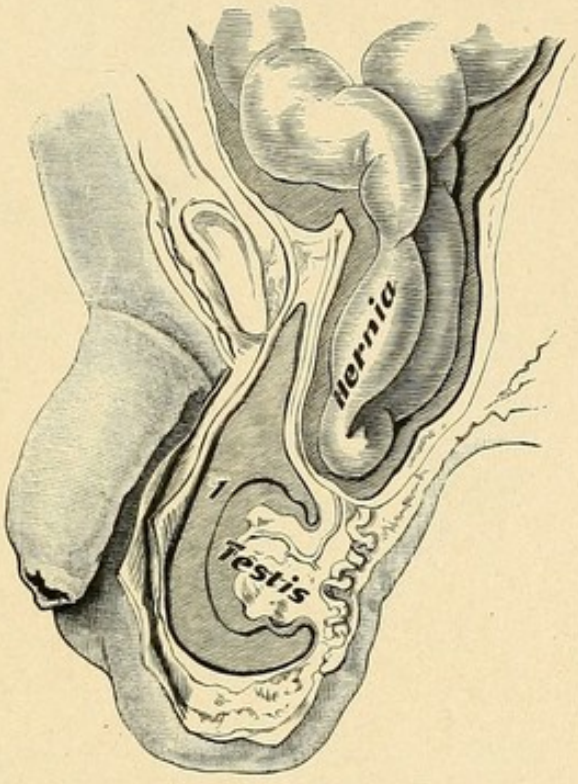

FIG. 477.—Infantile hernia (acquired), the intestine carrying with it a process of peritonæum by the side of the occluded spermatic tube. (After Maclise.)

the outer or inguinal sac, which occupies the inguinal canal or extends down into the scrotum for a variable distance. The origin of the two sacs is by a common funnel-like process."

In addition to this type, there is a form of interstitial hernia found at times between the internal oblique and the aponeurosis of the external oblique muscle, or the properitoneal sac may lie between the skin and the external oblique.

It will be seen that an oblique inguinal hernia is *congenital* when it follows exactly in the route traveled by the *testicle* in its descent and lies in contact with this organ. This form of hernia exists generally at birth, but it has been known to occur after birth and even in adult life in rare instances where the vaginal process and tunica funiculi have not firmly united and are easily broken through.

In an *infantile* hernia, which occurs, as its name implies, usually soon after birth, but which may also, in exceptional instances, occur later in life, the intestine descends along the tubular sheath which surrounds the spermatic cord, but finds this sheath closely attached to the cord at the upper margin of the testicle,

[1] This observer reports that "after exposing the external abdominal ring a sac was found extending from the ring down into the scrotum. This was freed from its attachments up to the external ring. The inguinal canal was opened by incising the aponeurosis of the external oblique. After freeing the inguinal sac up to the internal ring it was opened, and from it escaped a small quantity of bloody serum. On pulling down on the inguinal sac, the neck of a second sac was brought into view. This sac was opened by extending the incision made in the first sac. It was seen to contain a small knuckle of the small intestine and a piece of omentum."—"Annals of Surgery," May, 1906.

where it is arrested; and while by its weight it may descend into the scrotum and pass beyond the level of the testicle, it never lies in contact with it, as in the case of congenital oblique inguinal hernia. In general, therefore, we may say that an inguinal hernia is *congenital* or *acquired*, the *congenital* form existing at birth, while the *acquired* hernia (Fig. 478) is one which comes on after birth, and is caused chiefly by the pressure of the intestine or omentum from *gravity* and *muscular effort* combined.

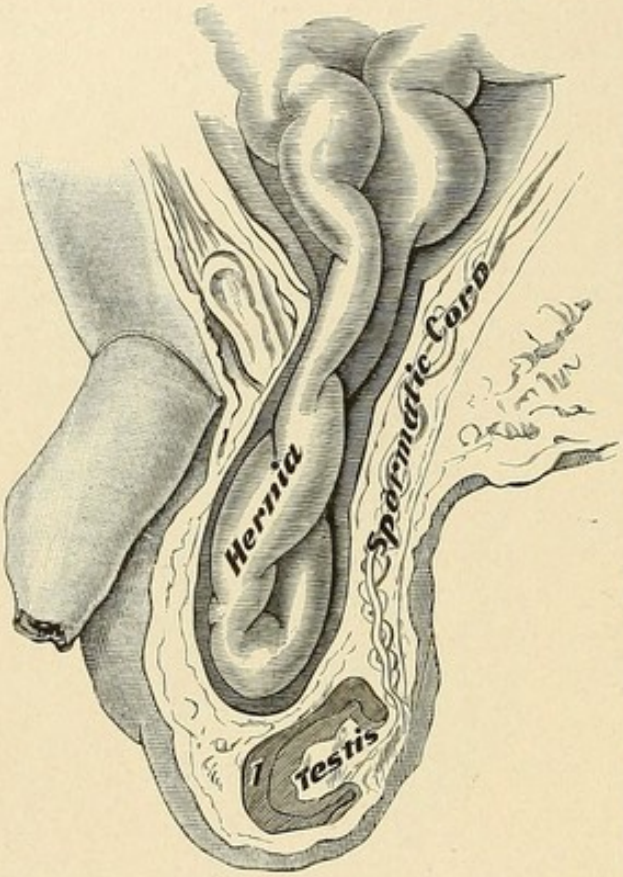

FIG. 478.—Complete (acquired) inguinal hernia as it occurs in the adult. Not communicating with the cavity of the *tunica vaginalis testis*. (After Maclise.)

FEMORAL HERNIA.—This is always an *acquired* hernia. The tumor enters the *femoral* or *crural* canal (1, Fig. 479) beneath Poupart's ligament just to the inner side of the iliac and femoral vein. If it remains in the crural sheath it is an *incomplete*, but if it protrudes at the *saphenous opening* (Fig. 480) it is a *complete* femoral hernia.

UMBILICAL HERNIA.—Umbilical hernia is either congenital or acquired. It exists not infrequently at birth in both sexes on account of the patulous condition of the omphalo-mesenteric duct. In this variety the only covering of the tumor is the *sheath* of the umbilical cord. In the acquired form the intestine escapes either directly through the navel or more frequently to one side of this contraction. The sac of an *acquired umbilical* hernia is composed of the *parietal layer of the peritonæum*, and the outer covering of *integument* and *subcutaneous fat*.

VENTRAL HERNIA.—This may also be congenital or acquired. The protrusion may occur at birth as a result of failure of development in the muscles of the abdomen. It is usually met with along the linea alba above the umbilicus. The acquired form may occur at any point, and results from accidental or surgical wounds of the muscles and fascia and occasionally from pregnancy. It is quite frequently met with in the wounds of incision in laparotomy.

RARER FORMS OF HERNIA

Diaphragmatic hernia is usually due to a wound or rupture of the diaphragm. It may result from a congenital defect in this muscle. It generally occurs on the left side on account of the protection afforded by the liver on the right side. The intestine or stomach may be imprisoned.

Gluteal hernia is extremely rare. The escape of the viscus is through the *sciatic* notch, and it may occur above or below the pyriformis muscle.

Obturator hernia takes place in the *thyroid* (obturator) foramen, usually in the upper portion of the canal which gives exit to the obturator vessels and nerves (3, Fig. 475). It is more common in women than in men.

Lumbar hernia occurs in the region situated between the twelfth rib and the crest of the ilium.

Hernia into the *vagina* occurs as a rule with partial or complete *prolapse* of the *uterus*, or after loss of substance allowing escape of the intestine.

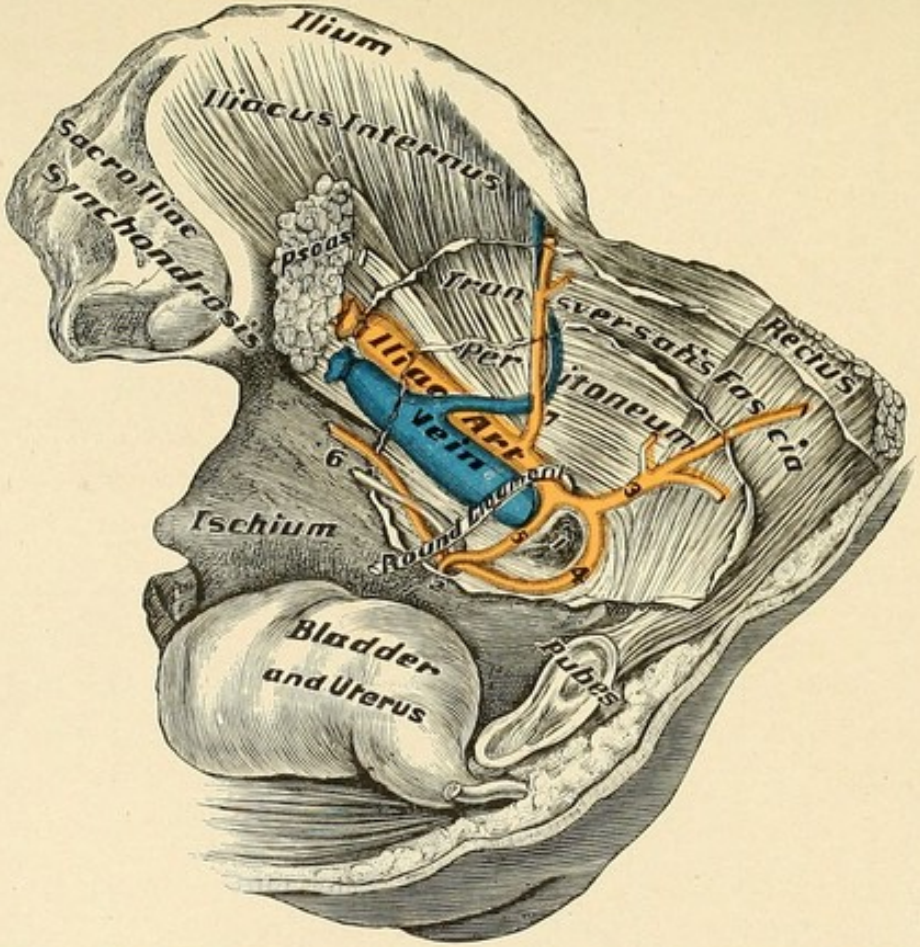

FIG. 479.—Showing the femoral ring and its relations to the iliac vein and the obturator artery when derived from the deep epigastric. 1, Femoral ring. 2, Obturator foramen. 3, Deep epigastric artery. 4, Abnormal origin of the obturator running internal to the neck of a femoral hernia. 5, The same descending external to the neck of a femoral hernia. 6, Normal obturator artery. 7, Circumflex branch of external iliac. (Modified from Maclise.)

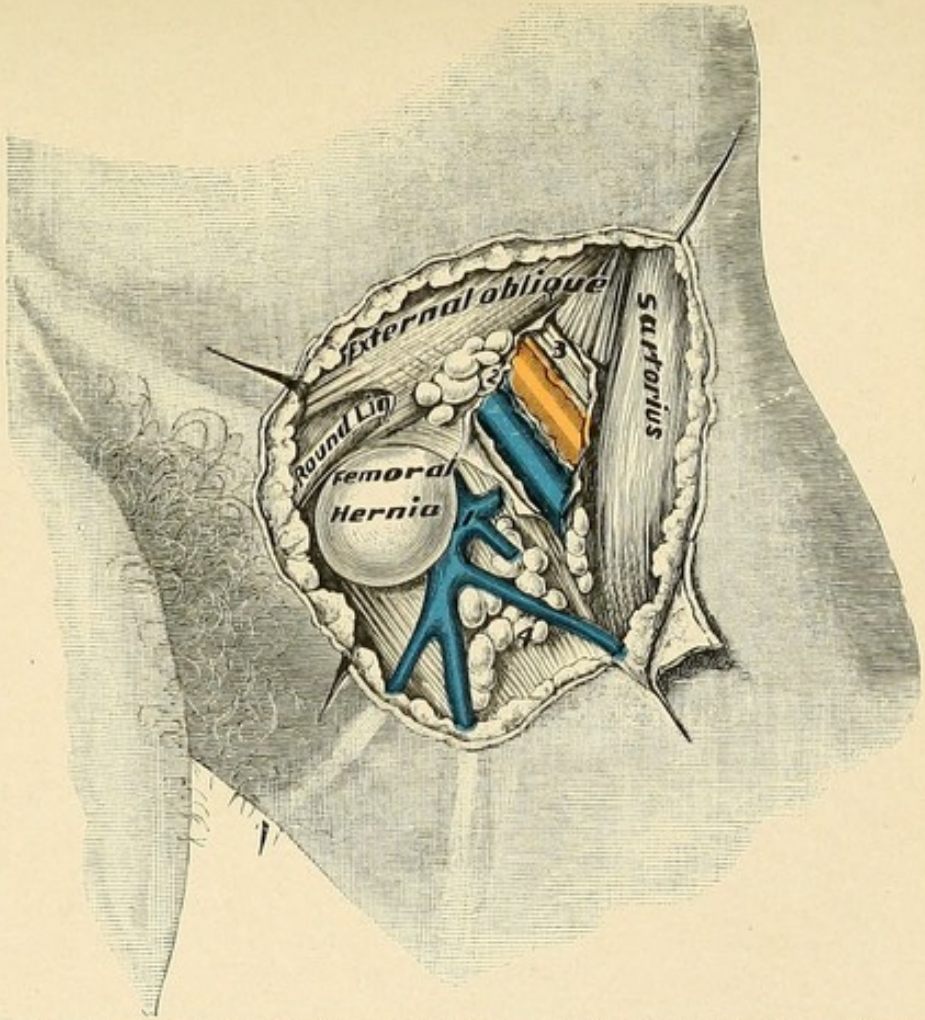

FIG. 480.—Showing the relations of a complete femoral hernia to the important organs of the groin. 1, Saphenous vein passing beneath the falciform process. 2, Femoral vein and artery. 3, Crural nerve. 4, Plexus of femoral lymphatic glands. (Modified from Maclise.)

Perineal hernia descends to one side of the median line of the perinæum between the *bladder* and the rectum in the male; between the *rectum* and the *vagina* in the female, traveling along the inner slope of the levator ani muscle. It is extremely rare, but has been known to follow the operation of lithotomy.

Pudendal hernia, in which the bowel passes down between the *ramus of the ischium* and the vagina, forming a tumor in the labium, and *sacro-rectal* hernia, which is described as having occurred in failure of the junction by ossification of the separate bones composing the sacrum, are rarely observed.

There is also at times a hernia of the *ovary* into the canal of Nuck, and there are two instances on record in which a hernia of the Fallopian tube alone existed in this canal. One of these cases was in the practice of the author, and, having become strangulated, caused the death of the woman by infectious peritonitis, the infection spreading through the disintegrating sac into the peritoneal cavity. The *bladder* has also been known to protrude into the inguinal canal and through the external ring, the author having observed several cases.

Symptoms, Diagnosis, and Treatment of Hernia

Symptoms and Diagnosis of Inguinal Hernia.—When gradually acquired, the presence of a small swelling or tumor near the center of Poupart's ligament, or a little to the inner side of this point, is usually the first symptom of *inguinal hernia.* In a certain proportion of cases the appearance of the swelling has been preceded by a feeling of weakness or uneasiness referred to this region, which only disappeared when the recumbent posture was assumed, or when strong upward pressure was made by the hand.

If suddenly acquired, the presence of the tumor is noticed soon after a violent strain of the abdominal muscles. Pain is almost always present, and the patient is generally aware that rupture has occurred.

The diagnosis of inguinal hernia involves (1) the differentiation between the *direct* and *indirect* variety, and (2) between inguinal and femoral herniæ and the various swellings which may occur in this region: varicocele, hydrocele, bubo, incarcerated testicle, ovary, cyst, Fallopian tube, new formations, abscess, and aneurism.

A *direct* inguinal hernia is exceptional. The tumor formed by it is apt to be spherical (Fig. 481), is situated nearer the median line, and the neck will be found to enter the abdominal cavity immediately behind the external ring.

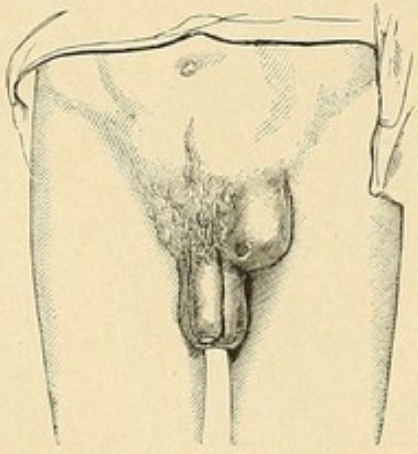

Fig. 481.—Direct inguinal hernia. (After Thomas Bryant.)

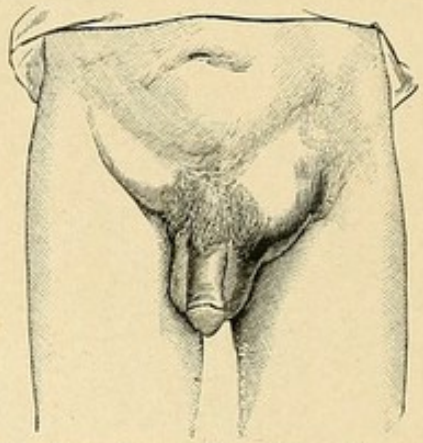

Fig. 482.—Incomplete oblique inguinal hernia. (After Thomas Bryant.)

The tumor formed by an *oblique inguinal* hernia is oval or elliptical in the incomplete (Fig. 482) and oval or pyriform in the complete variety. The history of the swelling, if gradually developed, will indicate that the tumor commenced at the middle of Poupart's ligament and traveled toward the pubes. In cases of long standing, and when the tumor is of large size, the diagnosis between the

direct and indirect form is scarcely possible, from the fact that the inner edge of the internal ring has been dragged down until it occupies a position just behind the external opening.

A *femoral* hernia is situated below Poupart's ligament, and near its attachment to the spine of the pubes, to the inner side of the femoral vessels (Fig. 483). In lean subjects the neck of the tumor can be readily traced to the canal at this point. In corpulent persons the diagnosis is more difficult.

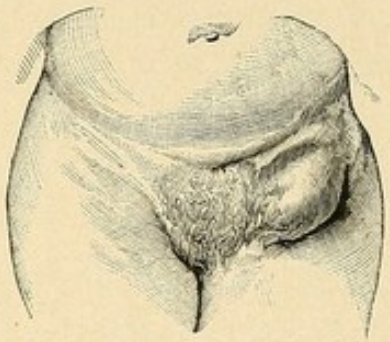

Fig. 483.—Femoral hernia. (After Thomas Bryant.)

The swelling of *varicocele* commences in the lower posterior portion of the cord and increases gradually upward. To the touch the distended veins feel like worms. The tumor has none of the elasticity of hernia. In the recumbent posture a *varicocele* and a *non-incarcerated* inguinal hernia will both disappear. If after the disappearance firm pressure is made with the fingers, and the patient is directed to resume the upright posture, the varicocele, despite the pressure, will return, while the hernia cannot descend. *Coughing* does not give an impulse to *varicocele*.

The accumulation of fluid in *hydrocele* of the *tunica vaginalis* is first noticed in the most inferior portion of the scrotum; the swelling is spherical at first, and becomes pyriform after the cord is involved. Hydrocele is translucent, and fluctuation may be detected. *Encysted hydrocele* of the cord near the external ring or within the inguinal canal may make differentiation more difficult. The impulse from coughing is not marked in hydrocele, the sense of weakness is absent, the cyst is small, and usually remains so. If, after full consideration, doubt still exists, aseptic aspiration with the finest hypodermic needle will clear up the diagnosis without danger.

Bubo.—In *chronic adenitis* the glandular character of the swelling can be made out distinctly. In *acute adenitis*, although the perilymphatic infiltration is so extensive that the glands cannot be recognized, the redness of the skin, the great tenderness on pressure, and the superficial character of the pain, with the coexistence of a urethritis or sore upon the penis or scrotum, will serve to establish the character of the lesion.

Incarcerated testicle may be suspected if there is absence of the organ on that side. If the testicle is not extensively atrophied, pressure will give the peculiar and characteristic sense of pain experienced in injury of this organ.

In *neoplasms* there is a history of progressive development entirely disassociated from that of hernia, as heretofore detailed. Incarceration, temporary or permanent, of an *ovary* in the canal of Nuck may be suspected when on coughing there is no marked impulse to the tumor, and when pain is increased coexistent with the menstrual period. *Cysts* of the canal of Nuck or of the inguinal canal are rare, but have been met with in a number of cases—four or five within the experience of the author. They differ from herniæ in general since they are irreducible, and do not impart well-marked impulse on coughing.

Abscess, which not infrequently appears above Poupart's ligament, is accompanied with inflammatory and septic symptoms which do not accompany hernia. Abscess of this region occurs with adenitis, as just stated, and with osteitis of the vertebræ or ilium. The recognition of either of these lesions will lead to the diagnosis of abscess.

In the manipulation of a hernial tumor, the sensation imparted to the fingers will vary with the contents of the sac and the condition of the mass. If it contain only *omentum*, it is doughy to the feel, and will yield dullness on percussion. If the mass is composed of *intestine*, it is elastic and more or less tympanitic on percussion. The "colicky" pain felt when the intestine is firmly compressed is of diagnostic value in determining the contents of a hernia. Whether a hernia is reducible or not, there is always a perceptible impulse imparted to the tumor in coughing or sneezing. In *strangulated* hernia the diganosis rests first upon the existence of a swelling, which is present in almost all cases. In very exceptional

instances there is no protrusion noticeable. The next symptom is pain at the seat of the hernia. In character it is compared to that of *intestinal colic*, and when not intensified at the point of strangulation it is usually referred to the umbilical region. The symptoms of occlusion are more remote, and while very strong in a diagnostic point of view, are practically not of much importance, because a diagnosis should be made and treatment instituted before the effects of obstruction are made evident. The cessation of fecal discharges may not occur in intestinal obstruction for several days after the occlusion, when the small intestine alone is involved, since the contents of the bowel below the constricted point may be evacuated. The *vomiting* of recently ingested food or drinks followed by stercoraceous matter is the last and strongest evidence of occlusion. *Distention* of the abdominal walls, with *tympanitic resonance*, is, when taken in connection with other symptoms, a strong link in the chain which makes the diagnosis conclusive. *Hiccough* is present in many cases, but is apt to be one of the later evidences of obstruction. *Shock* is present in a varying degree in almost all cases of strangulated hernia. It is evident in a rapid and weak pulse, occasionally missing a beat, or varying in exacerbations of rapidity and slowness; coldness of the skin with unnatural perspiration, lack of facial mobility, the eyes wide open and staring, the only expression being that of pain or great anxiety. In omental hernia the pain is not so intense as in intestinal hernia, and the symptoms of occlusion are always absent.

The treatment of inguinal hernia may be considered under the following heads: (1) the *reducible*, (2) the *non-reducible* (not strangulated), (3) the *strangulated*.

A *reducible inguinal* hernia should be returned to the abdominal cavity and retained within by a carefully adjusted truss or bandage and compress. Reduction is accomplished by placing the patient upon the back in the more or less complete Trendelenburg posture, with the thighs flexed upon the abdomen. If, after a few minutes, gravitation does not accomplish reduction, gentle pressure with the fingers should suffice. Overmanipulation of the hernia (*taxis*) is not advised. The retention apparatus should be applied while resting on the back. If a truss is to be worn the patient should be carefully instructed as to its proper use. It should never be applied unless the inguinal canal is entirely empty, and the pressure should be only strong enough to close the canal. Overpressure does harm, especially to the spermatic cord in males, and in both sexes by causing atrophy in the underlying muscles. Among the trusses, which for incipient hernia are worn with the minimum degree of discomfort, is some form of an elastic belt with a firm pad, held accurately in place by a perineal strap. The spiral spring truss, which has no perineal band, is preferred by some. In measuring for a truss, or in sending an order to a maker, the character of the hernia should be described and accurate measurements given. One end of a lead tape should be laid directly over the internal ring and carried across the abdomen to just below the anterior superior spine of the ilium, thence across the gluteal region to the same point below the anterior superior spinous process of the affected side. The malleable lead should be pressed closely to the skin in order to get an exact outline of the surface to which the truss is to be applied, and this should be immediately traced upon paper. In bilateral hernia a double truss should be worn.

An emergency support may be made as follows: A bit of soft cloth, cotton, wool, or oakum is made into a ball three inches in diameter, covered with adhesive plaster (adhesive surface outward), and laid immediately over the inguinal canal as the patient is recumbent. A figure-of-8 spica soft flannel bandage is carried around the pelvis and thigh, holding the compress firmly in position. The adhesive plaster covering adheres to the skin and spica. When plaster is not at hand safety pins may be used to fix the compress to the bandage.

The operation for the cure of all forms of herniæ (and especially inguinal) is now so free from danger and results in such a large proportion of cures that the vast majority of those afflicted should be advised to submit to it at once. Beyond the annoyance of a truss, the ever present danger of strangulation, *especially to those not within two or three hours' reach of an experienced surgeon*, fully justifies this conclusion, and now that very many of these operations, where the tumor

is not so large as to necessitate a long and extensive dissection, may be successfully done with the analgesia of quinia and urea or cocaine, the proportion of persons requiring trusses should year by year, as the laity learns this important lesson, become smaller.

RADICAL CURE OF OBLIQUE INGUINAL HERNIA—THE OPERATION OF CHOICE

Asepsis is so essential that the minutest details should be carried out. All parts in and about the field of operation should be thoroughly shaved (see preparation of patient), scrubbed, asepticized, protected from subsequent exposure twelve hours before the operation, and this repeated upon the table. In males a sterilized rubber bag should envelope the penis and scrotum or (not having this) rubber tissue or gauze should isolate these organs.

Locate with the index-finger the external ring, and especially its upper border. An incision, three inches long (to be lengthened if necessary) through the skin and superficial fat down to the aponeurosis of the external oblique muscle is made, commencing at the suprapubic skin fold, just above the center of the upper margin of the external abdominal ring, thence obliquely upward and outward toward a point about two inches internal to the anterior iliac spine. Below this level is a rich plexus of vessels which are thus avoided, while traction downward from the lower angle of the incision will thoroughly expose the external ring (and cord). The upper border of the external ring should be divided with dull-pointed scissors *near the internal pillar*, the object being to leave as much of an outer aponeurotic flap as possible.[1] The aponeurosis is carefully split between two parallel fibers to a point sufficiently high in the line of incision to expose the internal ring, the arched fibers of the internal oblique and transversalis muscles, the conjoined tendon, and the neck of the sac. With the dull-pointed scissors the aponeurosis of the external oblique is separated from the underlying tissues until its reflected portion (Poupart's ligament) is clearly exposed, while the inner flap is also lifted an inch. This being done and all bleeding arrested, the inguinal nerve will be seen and should be carefully avoided.[2]

The structures of the spermatic cord should be carefully separated from the hernial sac with the blunt-pointed half-curved scissors. Should adhesions have formed, the cord may be recognized by the peculiar shoestring feel of the *vas deferens*, its white appearance, and the *venæ-comites*. In separating the sac from the cord, care should be taken not to draw heavily upon the latter, and this is especially important in children. The sac of the hernia should be thoroughly freed in its entire circumference from all adhesions down to the internal ring and as far as the level of the peritonæum lining the abdominal wall. Immediately above the arch of the internal ring the peritonæum should be further separated from the muscles by the end of the index-finger until an extra-peritoneal pocket is formed as shown in Fig. 484. The hernial sac should now be carefully opened, the finger introduced, and the contents reduced. The index-finger should be carried the entire circumference of the neck of the sac upon the peritoneal surface to demonstrate the absence of adhesions. These, if present, should be carefully separated. When omentum forms a portion or all of the hernial con-

[1] It is not always necessary to divide this ring. The aponeurosis of the external oblique may be split to within one half inch of it and the outer portion retracted sufficiently to expose Poupart's ligament.

[2] The hypogastric branch perforates the external oblique above the external abdominal ring, to be distributed to the integument of this region. It is the least important of the nerves which come into the field of operation, and no very serious results follow its division. It should not be forgotten, however, that this nerve sometimes takes the place of the inguinal branch of the ilio-inguinal, and that the later is occasionally absent. It is always important to be on the lookout for all of these nerves, and to avoid them if possible.

The inguinal branch of the ilio-inguinal pierces the internal oblique above the inner ring, distributing filaments to the muscles, and in males accompanies the spermatic cord to escape at the external abdominal ring to be distributed to the internal surface of the scrotal or labial regions. The genital branch of the genito-crural nerve, descends along the external iliac artery, pierces the transversalis fascia, and passing through the internal abdominal ring descends along the back part of the spermatic cord, and supplies in the male the cremaster muscle.

tents, is hardened and thickened by agglutination, it should be drawn out, tied off in sections with No. 2 catgut, the abnormal portions removed, and the stump returned to the peritoneal cavity. In tying the ligatures a third knot should be used. The section should be one fourth of an inch beyond the ligature, and each stump should be carefully tested for bleeding before returning. It is advisable at this stage of the operation to have the patient placed in the modified Trendelenburg posture, so that gravity may carry the intestines and omentum toward the diaphragm and leave the inguinal canal free.

In dealing with the sac *the method of Macewen is preferable* (although many operators of large experience prefer simple ligation of the sac at the level of the abdominal wall with No. 2 catgut). If the sac is large and thick it should be cut away to within one inch of the internal ring. It is transfixed at the end with a long fourth-curved Hagedorn needle armed with a strong No. 2 ten-day catgut, which is at once tied. The needle is now carried through both walls of the sac from below upward one fourth of an inch from the knot, back again in an opposite direction one fourth inch lower, and finally from below upward the same distance beyond (or one fourth of an inch from the level of the peritonæum lining the abdominal wall at the internal ring),

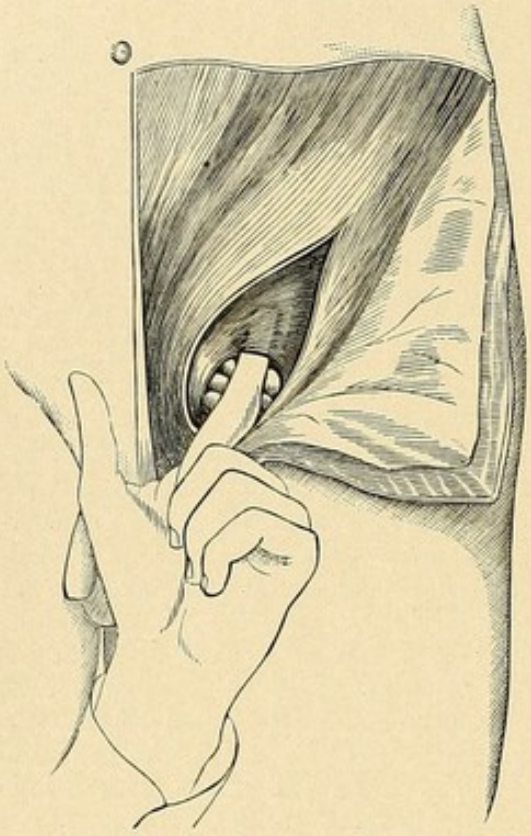

FIG. 484.—Showing the method of separating with the finger the sac from the margins of the internal ring and conjoined tendon. (After Macewen.)



FIG. 485.—Showing the sac folded up and covering the abdominal aspect of the internal ring. (After Macewen.)

the point directed upward. Pressing the back of the needle point into the tip of the palmar surface of the index-finger, it is carried by the introduction of this finger to the bottom or upper limit of the pocket, and thence is made to transfix the muscles and skin of the abdominal wall, coming out above the upper angle of the skin incision.

The operator should now assure himself that there is no imprisonment of omentum or intestine in the sac or its neck, and this done, traction upon the catgut suture folds the sac upon itself when it is drawn tightly into the pocket and against the wall of the abdomen (Fig. 485). It is held firmly in this position by attaching a large-sized forceps to the end of the suture until the operation is completed, when at the level of the skin it is wound in figure-of-8 fashion about a pencil of gauze an inch long and half an inch in diameter. Within twelve to twenty-four hours adhesions occur between the surfaces folded together by this method, and the sac is entirely obliterated. Instead of a funnel-shaped depression on the under surface, which is inevitable, no matter how high up the neck of the sac is tied, there is formed by Macewen's method a boss or projection where the neck of the sac was situated.

The next step in the operation consists in stitching the arched fibers or con-

joined tendon of the internal oblique and transversalis muscle to the shelving or scroll-like edge of Poupart's ligament (Bassini's plastic operation). Strong kangaroo tendon should be used. If this cannot be obtained, No. 3 or No. 4 chromic-acid catgut should be employed.

These sutures are inserted with a half-curved Hagedorn needle. The spermatic cord is held out of the way and slight upward traction made upon it by means of a thin strip of gauze or thread passed beneath it. The first suture is inserted into the internal oblique and transversalis muscle about one quarter of an inch from the arched border, and should be very near the upper limit of the cord. The inguinal nerve should be carefully excluded from the grasp of the suture. The needle is carried beneath the cord, readjusted in the needle holder, and the point carried through Poupart's ligament from below upward, coming out one eighth to one quarter of an inch from its free border. This first suture is the most important. An artery forceps is fastened to either end, and holds it in position until ready for tying. The next suture should be about one quarter of an inch farther down, and should be inserted on a plane somewhat farther from the edge than the first, also avoiding the nerve. It, too, is carried underneath the cord, and passes through Poupart's ligament one quarter of an inch below the first suture. In passing the point of the needle from below upward through Poupart's ligament, it must not be forgotten that the iliac vein is very near, and that it has been wounded in this operation. By retracting the free edge of the aponeurosis of the external oblique and bringing the ligament in clear view this accident should not happen. Two more ligatures are required, and a fifth may be inserted if necessary.

When (as occurs in large old herniæ where a truss has long been worn) the tissues are atrophied and thin from pressure, it may be necessary to include in the last one or two sutures a part of the outer edge of the rectus abdominalis muscle. In tying the first knot of the first suture (nearest the cord), it should be drawn and held fast for a few moments until the surgeon is convinced that too much tension is not being exercised upon the cord. In regulating the tension of these sutures the suture forceps is very useful. The author's instrument consists of an ordinary dissecting forceps without teeth or ridges, perfectly smooth, with no cutting edge.

When the first loop is drawn to the required tension the forceps grasps and holds it until the second knot is tied. A third knot should be tied in all animal ligatures. In tying this row of sutures very little, if any, tension should be exercised in approximating the arched border and edges of the transversalis and internal oblique and rectus muscles to Poupart's ligament, for the reason that any tension will soon cut through the soft muscular fasciculi. It is intended simply to hold them in apposition without tension until connective-tissue proliferation occurs and the tissues become permanently welded in this new position.

The wound is thoroughly dried, the spermatic cord resting upon the deep row of sutures while the split aponeurosis of the external oblique is reunited by a running suture of kangaroo tendon. In fat subjects a subcutaneous ten-day catgut suture should be used to approximate the edges of areolar tissue while a subcuticular silkworm-gut suture may be used to close the wound in the skin. The skin should be thoroughly cleansed and dried, all serum or moisture expressed from the wound, the dressing laid on, and compression continued as the dressing is applied.

The catgut ligature attached to the sac and drawn through the skin above the upper angle of the incision should be fastened as directed. A dry sterile gauze dressing and compress held in place by a snug spica completes the operation.

A certain proportion of cases of hernia in males are complicated with varicocele. When these varicosities are large, several of the veins should be removed, as in the operation for the cure of varicocele.

By this procedure the cord is reduced to the normal size, and is not so apt to be a factor in reproducing a hernia (Halsted). The patient should rest quietly in bed for at least two weeks after the operation, and the figure-of-8 bandage and compress should remain snugly adjusted in order to support the abdominal wall.

The upright posture should not be permitted until the end of the third week, and all movements should be carefully guarded and the compress and bandage worn for several weeks longer. When the hernia is large and of long standing, the canal greatly dilated, and the tissues are weak and thin, the period of rest in bed should be extended to four or five weeks and extra precautions taken to insure the best possible result.

The operation for the cure of *direct* inguinal hernia does not differ materially from that just given. In certain cases the peritonæum in front of the hernial protrusion is not sacculated, the tumor having a sessile appearance. The patient should be placed in the full Trendelenburg posture, the peritonæum incised as in an ordinary laparotomy, and made tense by overlapping the edges with the running catgut suture. The plastic work is the same, as advised by Bassini. When the aponeuroses are relaxed the overlapping suture method of Championnière should be used.

The contents of the sac may be omentum alone or small intestine and mesentery, or the cæcum and vermiform appendix, or occasionally the transverse colon. In a number of instances the author has removed the appendix in a hernial sac of the right side, treating the stump as advised in the technic of appendectomy. He has also removed the diseased appendix from its normal location through the ordinary hernial incision.

In the operation for the cure of congenital hernia, the technic differs for the reason that the spermatic cord is in the hernial sac (Fig. 476).

After opening the sac and reducing the contents, the sac is freed from the cord by clipping with the scissors to the level of the internal ring. The divided edges are reunited by a running catgut suture. The sac thus made is treated after Macewen's method, as already described.

In very rare instances the bladder forms a part of the contents of an inguinal hernia. Should the involvement of this organ be suspected, a sound introduced through the urethra will demonstrate the proximity of the bladder wall to the inguinal canal.

Treatment of Strangulated Inguinal Hernia.—With the first symptom of strangulation the patient should be placed in the semi-Trendelenburg posture while the pubes, scrotum, and integument in the field of operation is being shaved, scrubbed, and rendered aseptic. With the thighs flexed on the abdomen, if gentle manipulation combined with gravitation does not within a few minutes succeed in the reduction, immediate operation is imperative. The employment of force in the effort at taxis is not justifiable. Should the patient be capable of self-control, the analgesia of cocaine infiltration should be preferred to general narcosis. Should it become necessary, ether narcosis may be substituted.

The incision should be the same as above given, cutting directly down upon the mass, or pinching up the integument, transfixing, and cutting upward and away from the tumor. As soon as the sac is thoroughly exposed and freed from the overlying tissues down to the external ring, it should be carefully opened, and the tip of the index-finger carried down to the constriction. With the finger as a guide and as a shield between the knife and the intestine, a probe-pointed bistoury is carried along the palmar surface and the constriction divided. Or the external ring may be incised and the aponeurosis split as in the operation for the radical cure. Irrigation with hot salt solution should be done, and if the released bowel takes on its normal color it should be returned to the peritoneal cavity.

Should the condition of the patient justify it, the operation for the radical cure should at once be carried out as already given. If, on the other hand, gangrene has taken place and the patient's condition is such that no operation beyond the relief of strangulation is permissible, nothing further than the establishment of a temporary artificial anus should be attempted.

If adhesions have not formed and there is danger of the liberated intestine dropping into the peritoneal cavity, silk sutures should be inserted to hold it in place.

Within two or three days, or as soon as the conditions are favorable, resection

of the gangrenous section and end-to-end anastomosis should be done, as described on another page.

Inguinal hernia in the female has the same relation to the epigastric vessels as in the male. In the complete form the contents may descend into the labium. The technic is simpler for the reason that there is no spermatic cord. Cysts of the canal of Nuck not infrequently simulate a hernial tumor, or the ovary bladder and occasionally the Fallopian tube may be found in the sac.

Herniotomy with Local Anæsthesia.—Operations for the relief of strangulated hernia, and for the radical cure of a fair proportion of all varieties of herniæ, can be very satisfactorily done under local anæsthesia. Solutions of cocaine or quinia and urea are employed. If cocaine is used the endermic infiltration for the entire extent of the proposed incision is made with the 1–500 stock solution, while for the subcutaneous infiltration the 1–1000 solution is employed (J. A. Bodine). A one-per-cent solution of the hydrochloride of quinia et urea (gr. v to ℥j of a normal salt solution) will produce a very satisfactory analgesia, and without any danger from absorption. When the line of incision has been anæsthetized by endocuticular injection, the subcutaneous infiltration with either of these agents should be made before cutting through the skin.

The technic of the operation is practically the same as that already given. After the skin and subcutaneous fat is divided and the aponeurosis of the external oblique muscle is exposed, this should be split for about two inches in the direction of its fibers just over the known situation of the internal ring. By careful retraction of the edges the inguinal branch of the ilio-inguinal nerve, filaments of which emerge at the external ring, will be seen. It should be cocainized at once at the highest accessible point by injecting into or immediately in contact with the trunk, several minims of the stock solution. The painless splitting of the aponeurosis may now be continued until it opens into the external ring. The outer flap is carefully dissected up with the blunt scissors until the shelving process of Poupart's ligament is brought clearly into view, while the inner flap is also lifted for about an inch.

If the tissues are not clouded by unnecessarily rough swabbing, the ilio-hypogastric nerve may now be seen where it pierces the inner oblique muscle and at once cocainized. Should it not be seen and pain is felt, a free instillation of the weaker solution should be made into the arched fibers of the internal oblique and transversalis muscles.

The same solution may be freely infiltrated for the entire extent of the incision into the coverings of the hernial protrusions, and especially around but not into the spermatic cord where it comes through the internal ring. This infiltration is intended to anæsthetize the genital branch of the genito-crural nerve. The sac is now carefully separated from the cord with scissors and forceps, and treated as heretofore directed with all the details of the hernia technic.

Femoral Hernia.—A femoral hernia descends between Poupart's ligament above, the upper surface of the horizontal ramus of the pubes below, a sharp scythe-shaped reflection of Poupart's ligament toward the median line of the body called Gimbernat's ligament, and the femoral vein to the outer side, between which and the hernial sac is an arched reflection of the deep fascia of the thigh (Figs. 479 and 480). This (the femoral ring), of comparatively small caliber, is chiefly composed of bone and unyielding connective tissue, the sharp borders of which conduce readily to strangulation.

In front of the escaping sac there is a second reflection of the fascia of the thigh, which covers the saphenous opening and is attached above to the deep fascia which covers the aponeurosis of the external oblique muscle. In Fig. 480 it has been removed to show the hernial sac. It is this reflection of the deep fascia which arrests the downward direction of a femoral hernia and turns it upward, more sharply in contact with the edge of Poupart's and Gimbernat's ligaments.

These anatomical facts will explain the extraordinary danger of femoral hernia and make it imperative that the surgeon, with the first appearance of the tumor, advise immediate operation for the radical cure. It may be safely said that no form of truss is safe in femoral hernia, and none should be prescribed without

impressing this fact upon the patient's mind. At the first suggestion of *strangulation* there is no other alternative.

Diagnosis.—The protrusion is first noticed just below and near the center of Poupart's ligament. Its appearance may have been preceded either by distinct pain or an uneasy feeling, as of "something giving way." In the further escape of the hernia it is deflected upward by the superficial layer of the deep fascia of the thigh, and it may cross in front of Poupart's ligament, and appear as a tumor in the location of an inguinal protrusion.

A diagnosis is rendered difficult in fleshy individuals. The differentiation is chiefly between enlarged inguinal glands, abscess (psoas), and inguinal hernia. In thin subjects the line of Poupart's ligament can be readily followed, and a protrusion below this excludes inguinal hernia. Should an impulse be given to this protrusion in the act of coughing, the diagnosis is clear.

Lymphomata of the groin are usually hard, cover a considerable area, and their peculiar shape and mobility should render them easy of recognition. When infection has occurred, they are painful under pressure, which does not hold good in a hernia not strangulated.

Syphilitic adenitis is not painful, and may be determined as a sequence of the initial lesion.

Psoas abscess may point under Poupart's ligament and simulate a hernial protrusion, but with this collection of pus there is almost invariably a history of tuberculous osteitis of the vertebræ. The introduction of the tip of index-finger through the external abdominal opening into the inguinal ring, should feel the impulse imparted to an inguinal hernia. In the absence of this sign, a second protrusion slightly below this location to which an impulse is imparted would make clear the recognition of a femoral hernia.

Strangulated Femoral Hernia.—At the first suggestion of strangulation the patient should be placed on the back in the modified Trendelenburg posture, the thighs flexed on the abdomen and gentle pressure exercised in an effort at reduction. If within ten or fifteen minutes this cannot be accomplished (and under no circumstances should force be employed), immediate operation is imperative, and may be done with perfect satisfaction with local anæsthesia.

The technic of infiltration does not differ from that for inguinal hernia. The incision is the same as given for the radical cure.

As soon as the sac is reached and freed, it should be carefully punctured, and as the first few drops of fluid exude, a grooved director should be inserted and the opening made large enough to admit the index-finger. The sac and contents should be well flushed with hot normal salt solution (110° to 115° F.). The tip of the finger should be carried to the constricting edge of Gimbernat's ligament, and with the palmar surface as a guide, the finger being between the contents of the sac and the knife, a probe-pointed bistoury is carried through the constriction just at the *attachment of Gimbernat's ligament to the pubic bone*, and this divided by turning the edge of the knife toward the median line and cutting close to the surface of the bone, a distance of about one quarter of an inch. If the circulation in the hernial contents is not satisfactory within from two to five minutes, the constriction should be still further divided in the same direction, and the ring stretched by the finger. If the loop of intestines still remains black or dark brown, without any tendency to clear up within ten minutes after the strangulation is thoroughly relieved, one of two alternatives remains:

If the patient's condition is such that a prolonged operation is contra-indicated, a temporary artificial anus should be made by drawing the upper segment of the loop one half inch farther through the constriction and stitching it with linen or silk sutures to the edge of Poupart's ligament, or to the skin, to prevent infection of the peritoneal cavity. The loop should then be incised. If there is not a free escape of intestinal contents through this opening, a forceps should be introduced into the lumen of the upper segment, which should be stretched.

The operation of excising the gangrenous portion of the loop and reuniting the ends by direct anastomosis may be done at a later period, preferably at the

earliest possible moment, since the lower unused end soon becomes much smaller in diameter.

In performing this later stage excision for imprisoned hernia with fecal fistula, in order not too greatly to enlarge the femoral opening in the effort to disengage and bring out both ends of the open gut, a near-by incision through the rectus or linea alba may be utilized, and the imprisoned segments released and brought out here for suture. The femoral canal should always be closed by that method for the radical cure which may seem best adapted to the case in hand.

If, on the other hand, the conditions are favorable for immediate exsection and reunion, after careful disinfection of the contents and sac by free irrigation with hot salt solution, followed by 1–1000 mercuric chloride and again by the saline, both ends of the loop of intestine should be drawn well out from the canal and anastomosis performed as given on another page.

Should it be clear to the mind of the surgeon that a more hurried anastomosis should be made than that by suture, the Murphy button may be substituted.

In general these various operations can be successfully and satisfactorily performed with local anæsthesia unless the subject be extremely nervous or hysterical and loses self-control. Should complete narcosis become imperative the preliminary use of these agents is no bar to nitrous oxide and ether (or chloroform). When the anastomosis is complete and the intestine has been returned to the peritoneal cavity, the operation for the radical cure should be at once carried out.

The operation for the *radical* cure of *femoral* hernia has given results as encouraging as that for the inguinal variety.

An incision about four inches long is made parallel with the lower edge of Poupart's ligament, its center being over the femoral canal or neck of the sac. The inner end of this incision is over the sharp spine of the pubes, which may readily be felt. Carefully dissecting down upon the sac, this should be isolated well within the canal, opened, and its intestinal contents returned to the peritoneal cavity, any omentum tied off with strong catgut cut away, and the stump returned. The patient should now be placed in the Trendelenburg posture. The sac should be transfixed about three quarters of an inch in front of Gimbernat's ligament with a Hagedorn needle armed with a strong No. 2 ten-day chromic-acid catgut strand, the end of which is tied around the sac at the point of transfixion. Making tension on this ligature, the index-finger should be carried along the upper surface of the neck of the sac underneath Poupart's ligament, separating the peritonæum lining the abdominal wall from the free border of the ligament and aponeurosis, making a pocket in which the neck of the sac is to be inverted in the same manner as the method of Macewen in the inguinal hernia operation.

The back of the point of the long crescent-curved Hagedorn needle is now pressed well into the palmar surface of the index-finger, the point directed slightly toward the median line in order to avoid even the remote possibility of wounding the vein, and when the end of the finger is reintroduced through the femoral canal the needle is brought directly up through the abdominal wall, piercing the integument about one inch above Poupart's ligament, care being taken in male subjects to avoid the spermatic cord. Tension on this ligature, aided by direct pressure, inverts the sac and holds it firmly folded in the new position, where it is retained by twisting the ligature around a pencil of gauze at the point where it emerges through the integument.

The next step in the operation is to stitch the lower edge of Poupart's ligament to the periosteum and fascia along the origin of the pectineus muscle from the horizontal ramus of the pubes (Fig. 486). For this purpose kangaroo tendon should be employed, and considerable care is necessary in passing the outermost suture, which is practically in contact with the sheath of the femoral vein. This vessel should be pressed outward by the finger or a dull instrument while the outermost suture is being inserted. It will be found advantageous to loosen the periosteum with the fibers of insertion of the pectineus from the pubes by means of a small sharp elevator. Since the obturator artery in women rises from the deep epigastric in nearly fifty per cent of cases, and in males in twenty-five

per cent, a careful regard should be had for this vessel and its accompanying vein. The deep fascia which has been divided in the earlier part of the dissection is now also stitched to Poupart's ligament by chromic-acid catgut, and the wound closed by an endocuticular silkworm-gut suture. A loose gauze dressing and the figure-of-8 spica compress should be applied and worn for three weeks, the patient resting in the dorsal decubitus for at least a fortnight. It is not wise to assume the *upright posture under three weeks*, and this only when firm compression is being made, which should be worn for three or four weeks longer.

By this technic femoral herniæ are radically cured in about the same proportion of cases as in the Bassini-Macewen-Halsted procedure for inguinal rupture.

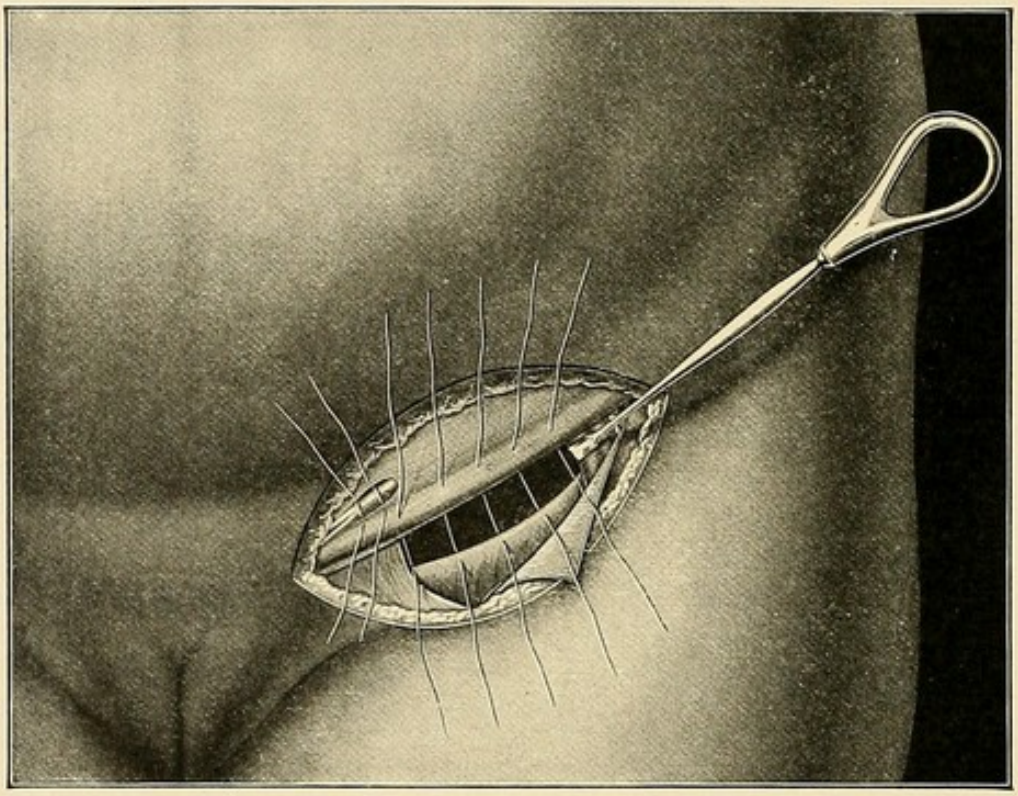

FIG. 486.—Radical cure of femoral hernia. Stitches to close lower opening of femoral canal inserted, but not tied. (Fowler's "Surgery.")

Prof. Joseph A. Blake has originated a method which is especially directed to the more perfect closure of the upper opening of the femoral canal. In herniæ of long standing, or where the canal has been more than ordinarily dilated, it may be preferred.

The chief feature of this technic is the introduction of a mattress suture *parallel* with Poupart's ligament in such manner that when tied it acts like a purse string around the internal orifice of the femoral canal.

After ligature of the sac and carrying it into the abdominal cavity, with the patient in a modified Trendelenburg posture, a needle armed with kangaroo tendon is "introduced through the aponeurosis of the external oblique muscle from one half to five eighths of an inch above its lower reflected margin on the mesial side of the canal directly through the anterior abdominal wall, and is made to pick up Cooper's ligament.[1] The needle is then brought out of the lower opening of the femoral canal. Then, the femoral vein being protected and pushed aside by the finger, the needle is passed into the canal and picks up Cooper's ligament again at the lateral side of the canal, and is passed from there directly forward through the anterior abdominal wall, emerging at a level corresponding to the point of

[1] Cooper's ligament is a fold of the *fascia transversalis* attached to the ileo-pectineal eminence and spine of the pubes. Gimbernat's ligament is the triangular expanse of the aponeurosis of the external oblique muscle anteriorly joined to Poupart's ligament and extending to the ileo-pectineal line.

introduction. This forms a mattress stitch, which, when tied closely, approximates the deep surface of Poupart's ligament to the dorsal margin of the femoral ring and completely closes the mouth of the femoral canal. The lower margin of the canal can then be stitched to the fascia of the pectineus muscle with a few interrupted sutures, thus closing the entire canal (Fig. 486).

"The mattress stitch passes through the outer pillar of the external inguinal ring, and with a little care the spermatic cord is easily avoided in the male."

Of the more recent procedures for the radical cure of femoral hernia, one which combines something of the method of Ruggi as applied to femoral hernia and Bassini's plastic inguinal herniotomy, is that devised and successfully demonstrated by Dr. A. V. Moschcowitz:

"The incision through the skin, about two and a half inches long, is parallel with and about one inch above Poupart's ligament. A short vertical incision is added to the lower and inner end (Fig. 487). The aponeurosis of the external oblique is exposed and split in the direction of its fibers, as in Bassini's operation. Retraction of the lower flap exposes the shelving edge of Poupart's ligament which forms a convenient guide to the neck of the femoral sac. Retraction of the upper flap exposes the conjoined tendon and the arched fibers of the internal oblique and transversalis muscles. These two muscles, as well as the exposed spermatic cord or round ligament are retracted upward by the blunt hook, exposing the transversalis fascia. This is also incised and retracted, exposing the neck of the sac (Fig. 488).

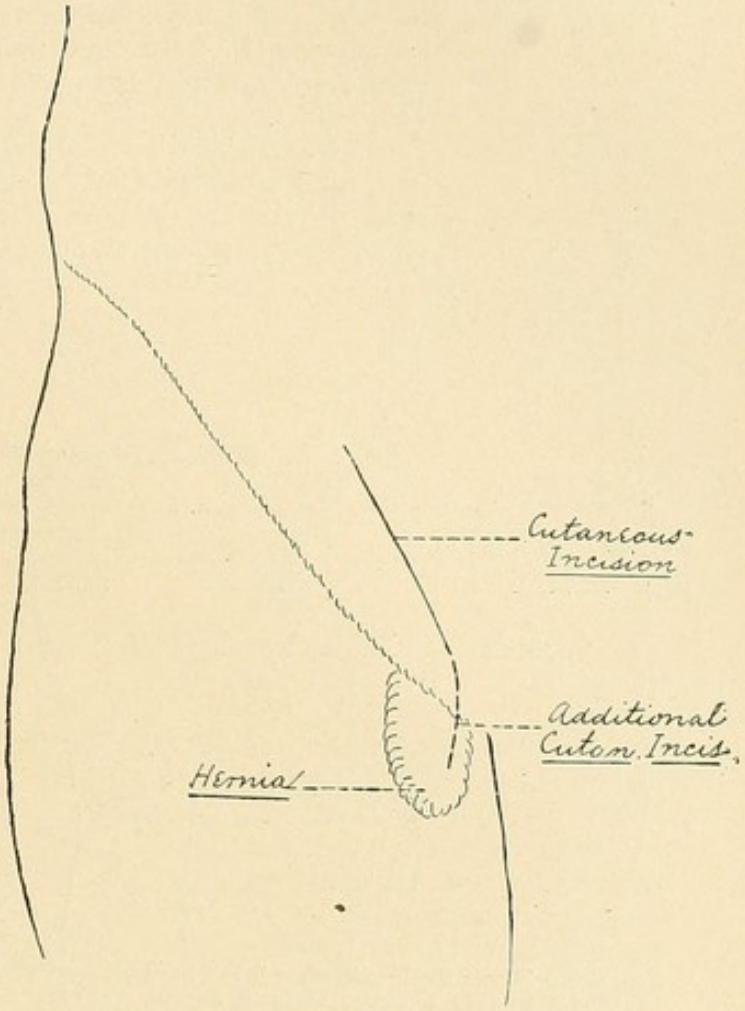

FIG. 487.—Showing the ordinary cutaneous incision; dotted line indicates the occasionally necessary supplementary incision. (Moschcowitz.)

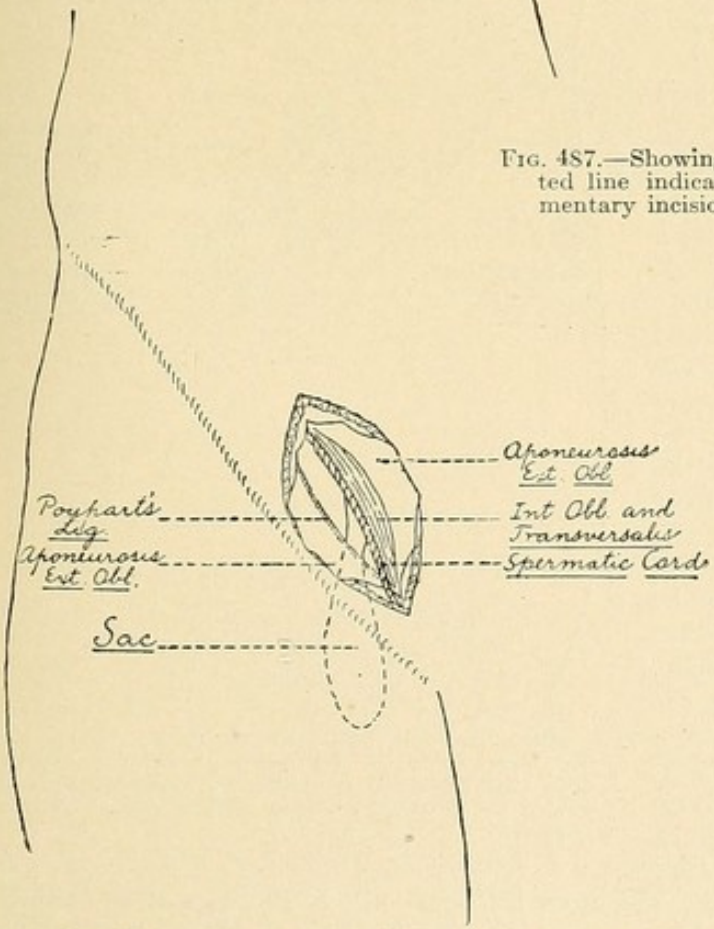

FIG. 488.—Shows the parts after division and retraction of the aponeurosis of the external oblique. (Moschcowitz.)

"The sac, just before it dips beneath Poupart's ligament, is now incised, and its contents are reduced in the usual manner.

"A dressing forceps is introduced through the internal femoral ring to the fundus of the sac, which it grasps, and if no adhesions are present the sac can be entirely inverted and pulled through the ring, so that the hernia is converted from a femoral into a direct inguinal hernia (Fig. 489).

"If adhesions have occurred, the sac should be dissected out, or if this is difficult cut off near the internal femoral ring. The neck of the sac is now obliterated flush with the peritonæum either by transfixion and ligature or by suture.

"In closing the internal femoral ring, in order to expose it properly, the peritonæum should be pushed bluntly upward with a broad flat retractor. The following anatomical structures are now in sight: Anteriorly Poupart's ligament, externally the external iliac vein and the deep epigastric vessels, internally Gimbernat's ligament, and posteriorly, but on a slightly higher level, Cooper's ligament and the pectineus muscle and fascia, while above is the retracted peritonæum, the transversalis fascia, internal oblique (and transversalis muscles), and the aponeurosis of the external ob-

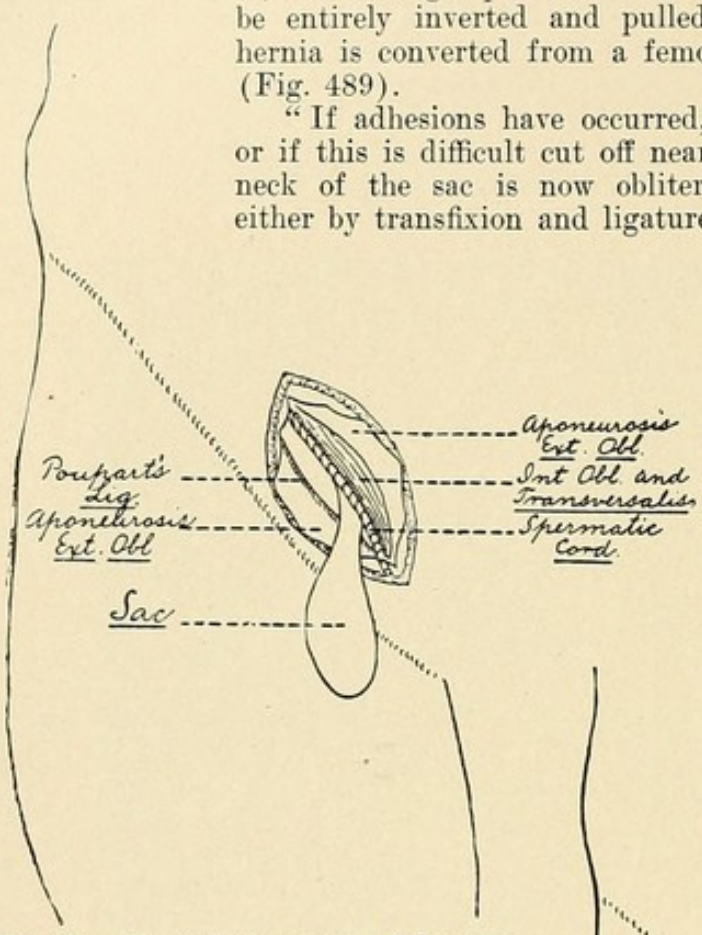

FIG. 489.—Shows the hernia after it has been converted into a direct inguinal hernia. (Moschcowitz.)

lique. The internal femoral ring is thus perfectly exposed, and with the greatest ease and safety it may be closed. With a strong, small, full-curved needle, armed with strong chromicized catgut (or kangaroo tendon), sutures are passed between Cooper's ligament and the periosteum of the pubic bone on the one hand, and Poupart's ligament on the other, over the site of the femoral ring (Fig. 490). When these sutures are tied it will be seen that Poupart's ligament has been approximated to the pubic bone, thereby completely obliterating the internal femoral ring. In a majority of instances two or three sutures will suffice to entirely close the ring. The most external suture goes as near as possible to the external iliac vein without constricting it, while the most internal suture includes also Gimbernat's ligament (Fig. 491).

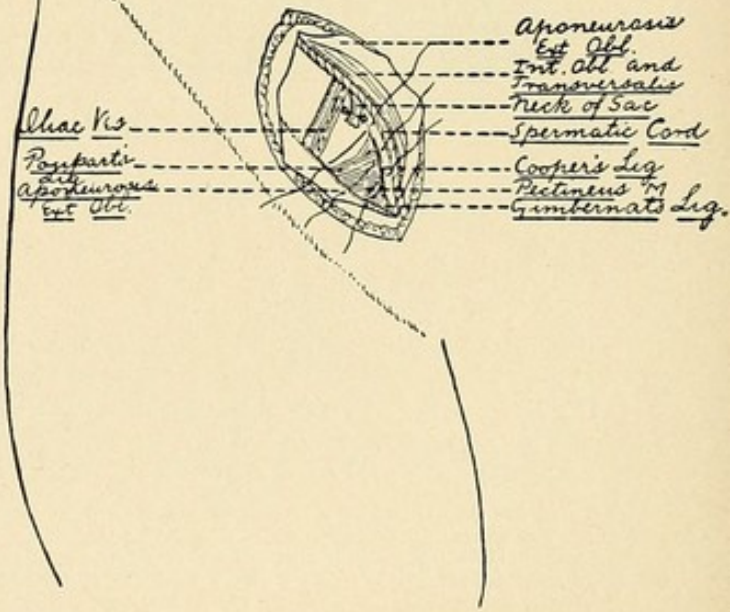

FIG. 490.—Shows the parts after the neck of the sac had been ligated and the peritonæum retracted. All the deep structures are exposed and three sutures are passed to close the internal femoral ring. (Moschcowitz.)

"The final closure of the wound is made by bringing the spermatic cord or round

ligament to the normal position and inserting chromicized gut (or kangaroo tendon) sutures to the number of four or five, including the internal oblique and transversalis on the one hand, and on the other Poupart's ligament just anteriorly to the first series of sutures. Care must be taken to leave just sufficient room at the inferior angle for the emergence of the round ligament or spermatic cord (Fig. 492). The external oblique is closed with a running kangaroo tendon suture and the skin as already advised." [1]

With the proper selection of cases and the application of the technic above given, which may be best suited to the conditions present, the percentage of failures should be exceedingly small.

Umbilical hernia may be *congenital* or *acquired*. The former is due to the failure of union in the development of the tissues, which compose the anterior wall of the abdomen at the navel. Its only covering is the thin amniotic layer of the cord.

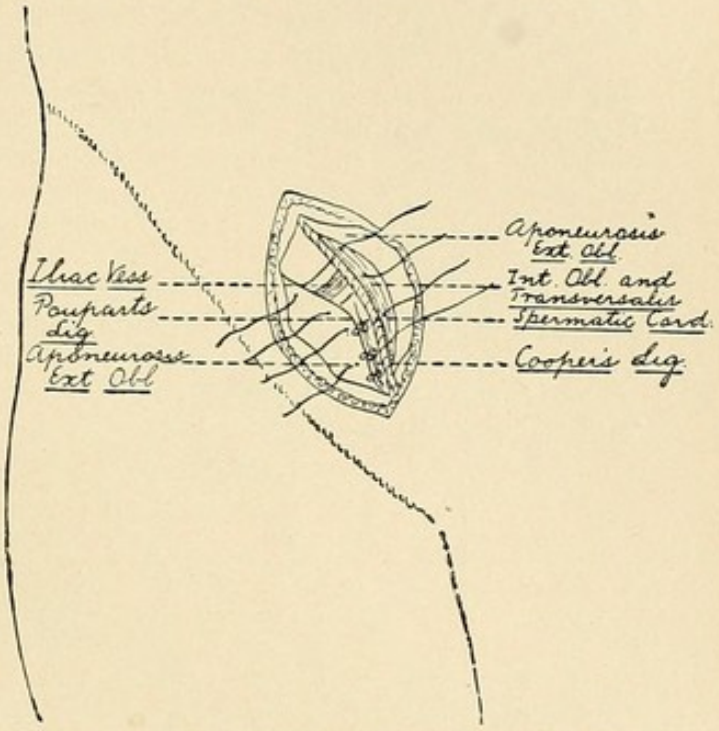

Fig. 491.—The deep sutures closing the internal femoral ring have been tied; and four sutures have been passed to prevent the occurrence of an inguinal hernia. (Moschcowitz.)

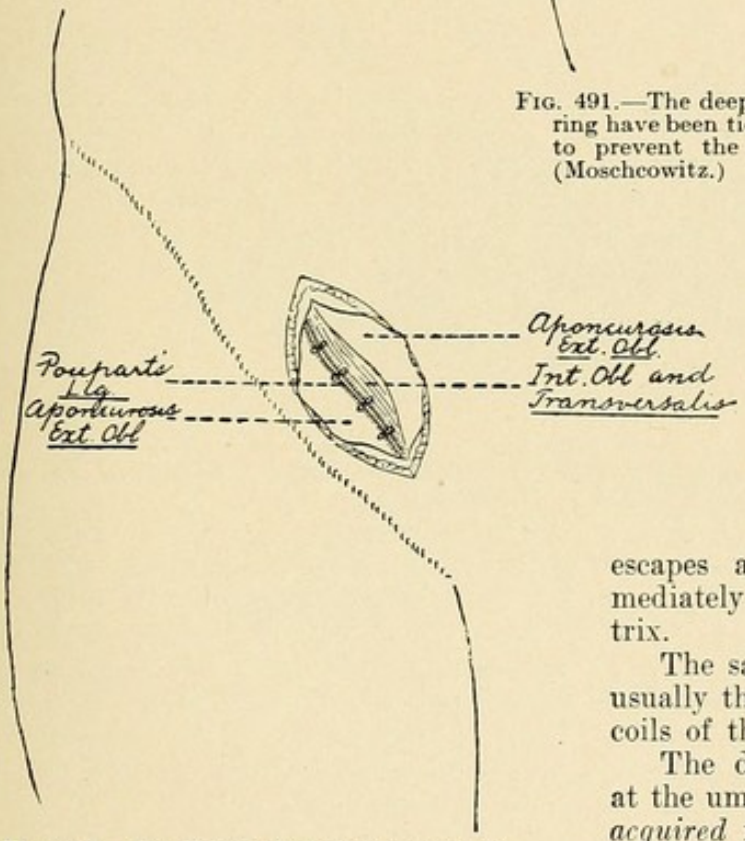

Fig. 492.—Condition after the approximation of the internal oblique and transversalis to Poupart's ligament. To be followed by suturing the cut edges of the aponeurosis of the external oblique and of the skin. (Moschcowitz.)

The *acquired* form rarely occurs before puberty, and is most frequent in women. Occasionally the protrusion escapes at the side of, but not immediately through, the umbilical cicatrix.

The sac may contain only omentum, usually the large intestine, and at times coils of the smaller gut.

The diagnosis of *congenital hernia* at the umbilicus is not difficult. In the *acquired* form the gradual development of the tumor and the impulse imparted to it in the act of coughing will point very directly to hernia. Should the tumor disappear with the recumbent posture, its character is evident.

The treatment of the congenital variety (omphalosis) consists in most careful asepsis, with protection of the thin covering from infection and rupture by a sterile dressing, around which is placed a soft ring of gauze, and over all a second sterile dressing, held in place by adhesive strips. A skin and muscle-plastic operation is indicated to cover the tumor.

[1] Dr. A. V. Moschcowitz, "New York State Journal," October, 1907.

In the *acquired* form, if reducible, a compress or pad fitted so that pressure is made in the hernial opening, will afford temporary relief. The pad and belt should be applied and tightened while the patient is lying down with the thighs flexed and recti muscles relaxed.

A reducible umbilical hernia is a constant menace to the safety of the patient, and when irreducible it becomes a graver danger and makes an operation for the radical cure imperative. The rational procedure requires the reduction of the mass, the ligation and removal of imprisoned and adherent omentum, closure of the peritoneal neck of the sac by suture, and, most important, overlapping of the connective tissues (aponeuroses and sheaths) forming the abdominal wall in the region of the navel.

Operation of W. J. Mayo.—Two transverse elliptical incisions are made, cleanly exposing the neck of the hernial sac and the aponeurotic structures for several inches above and below it (Fig. 493). The sac is opened, the intestinal contents returned, the omental contents ligated in sections with a strong catgut on a level with the abdominal orifice, and the stumps returned to the peritoneal cavity. *The*

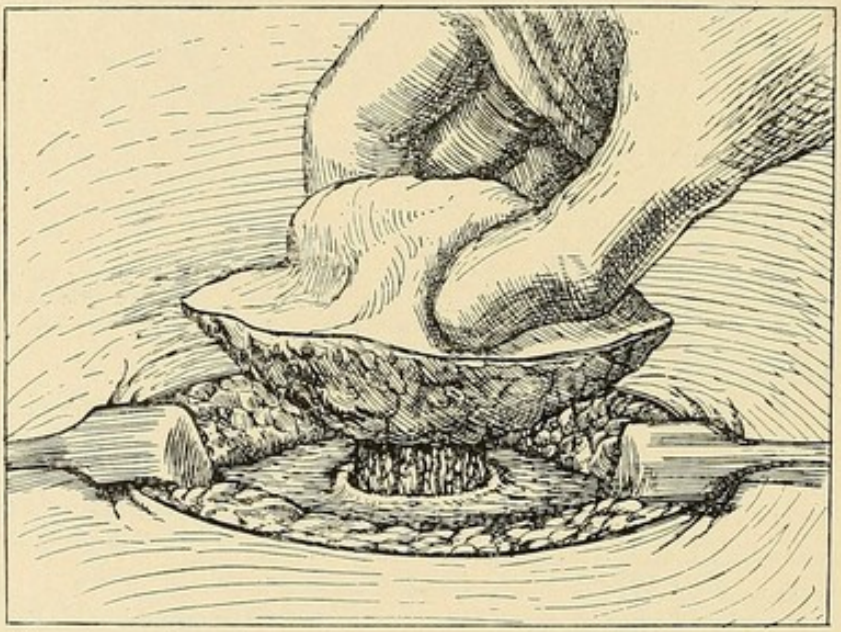

Fig. 493.—Mayo's operation showing the transverse elliptical incisions and exposure of the neck of the sac. (W. J. Mayo.)

sac, with all of the adherent omentum, including the skin, is cut away without further manipulation. A stout curved needle, with strong celluloiden linen is passed from without in through the aponeurotic structures and peritonæum from two to three inches above the margin of the opening. To guard the needle as it enters the peritoneal cavity, the bowl of a large tablespoon (Monks) is used, the underlying viscera being displaced by the convex surface of the spoon. The needle and thread is drawn down and out of the hernial opening. A firm mattress stitch is now caught in the upper edge of the lower flap about one quarter of an inch from the margin; the needle is then carried back through the hernial opening into the peritoneal cavity, and made to emerge one third of an inch lateral to the point of original entrance. On each side of this is introduced a similar mattress suture of strong chromicized catgut (or preferably kangaroo tendon) (Fig. 494). These three sutures are drawn tight, pulling the entire thickness of the aponeurotic and peritoneal structures behind the upper flap. The margin of the upper flap is retracted to expose the suture line, and if any gap exists it is closed with catgut or kangaroo sutures. The edge of the upper flap is sutured to the surface of the aponeurosis below (preferably continuous kangaroo tendon sutures) (Fig. 495).

When the fat is thick, which is almost always the case in these subjects, it should be approximated by subcutaneous chromic-acid gut. The superficial wound

is closed by interrupted silkworm gut or a running subcuticular suture of the same material. The patient should remain in bed without exercising unnecessary strain upon the abdominal muscles for at least twenty-one days, and longer if the opening was large and the tissues weak. The position in bed on the back, propped up with the shoulders well elevated, aids in preventing muscular strain.

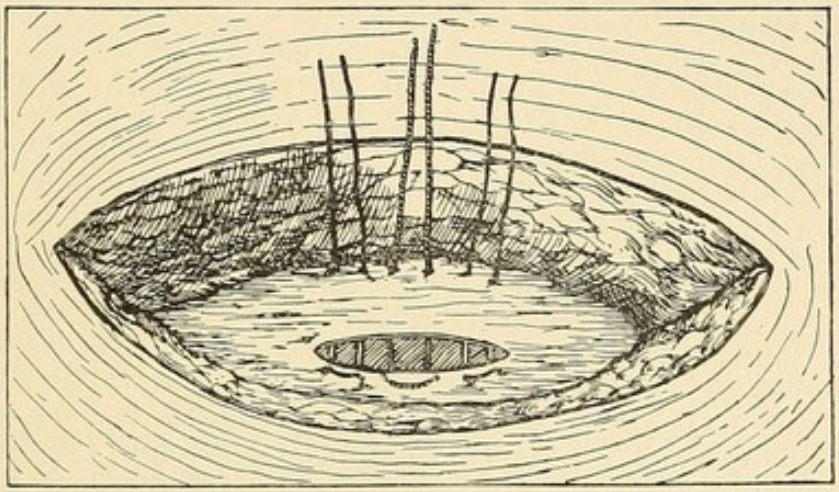

FIG. 494.—Three mattress sutures introduced. (Mayo.)

When strangulation occurs, immediate operation should be done. If, on account of ingesta in the stomach, general narcosis cannot be safely employed, local infiltration should be substituted. In expert hands, and with the patient under complete self-control, the use of this anæsthesia is very satisfactory.

Diaphragmatic hernia is fortunately of rare occurrence. The symptoms are those of acute pain, shock due to obstruction of the intestinal tract without the objective symptoms of hernia. A portion of the stomach is occasionally imprisoned in an opening of the diaphragm. In cases of grave doubt an exploratory incision is advisable. In relieving the constriction the probe-pointed bistoury should be used and the least possible incision made. Should the opening be

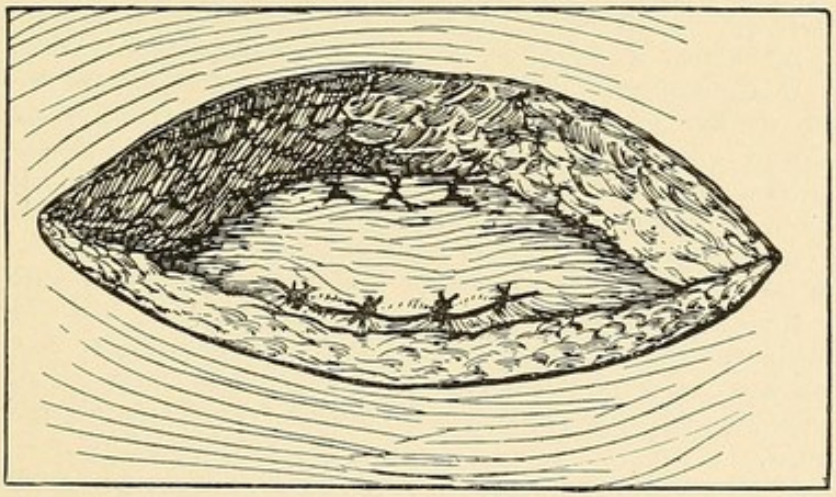

FIG. 495.—Mattress sutures tied above, and upper edge of incision stitched to surface of aponeurosis below. (Mayo.)

readily accessible it may be closed by sutures of chromic-acid catgut. The Meyer costoplastic operation may be utilized.

The recognition of *gluteal hernia* is difficult. If with the symptoms of obstruction there is pain in the region of the sciatic notch, and this is conveyed along the distribution of the gluteal or sciatic nerve, the presence of hernia may be suspected. Occasionally the tumor may be felt. The notch may be located by placing the patient in the recumbent posture, when a line drawn from the pos-

terior-superior spine of the ilium to the upper surface of the great trochanter will cross directly over the foramen.

The incision should be free, and the fibers of the gluteal muscles separated with the finger, as considerable care is necessary to avoid wounding the artery, which makes its exit here.

Obturator hernia may be present without any appreciable tumor. It may be recognized by digital exploration through the rectum or vagina. Pressure upon the obturator nerve may produce pain in the hip- or knee-joint. An incision through the linea alba above the pelvis will enable the operator to recognize with the index-finger whether or not this form of hernia exists. If necessary, a counter-incision may be made immediately over the foramen and the constriction divided from below. The fibers of the pectineus muscle will lie directly in front of the hernial tumor.

Lumbar, *vaginal*, and *pudendal* herniæ do not demand special consideration. The diagnosis will depend upon the appearance of the tumor with the symptoms of strangulation when the constriction is sufficient.

Hernia in children was formerly treated by the careful adjustment of a truss, but the low death-rate and the large proportion of cures by the Bassini operation has led to the abandonment of this method of treatment in favor of operation. The technic differs in no essential features from that already advised for adults. In young male children the spermatic cord should be handled with great care for fear of injury to the vas deferens and blood vessels.

For the radical cure of *ventral* hernia the incision should be made to conform in general to the shape of the opening through the abdominal wall. The contents are usually closely adherent to the deep fascia or cicatrix, and this to the integument, rendering great care necessary in order to avoid wounding the intestine. In general, it is advisable to enter the peritoneal cavity at one point close to the line of incision, and through this to introduce the index-finger in order to determine the extent and limit of the adhesions. These should be carefully separated and the contents of the sac freed, any imprisoned omentum tied off with ordinary catgut, and the stumps returned with the intestinal contents to the peritoneal cavity. The peritonæum lining the anterior wall of the abdomen which forms the hernial sac should be smoothly trimmed around the margins of the aperture, and separated for about one half inch from the under surface of the abdominal wall and closed by a separate running suture of chromicized catgut. The silk loop retractors described in the operation for appendectomy may be used here with great satisfaction. The aponeurotic or muscular layers should be closed with kangaroo tendon separately by the overlapping mattress sutures of Noble. If, on account of great tension, the lateral overlapping method cannot be employed, the up-and-down overlap method, as advised for umbilical hernia by W. J. Mayo, may be substituted.

In herniæ of long standing, where a large aperture exists, and where the muscular aponeuroses have become atrophied and weakened by pressure either from a supporting apparatus or the weight of the tumor itself, it will be found impossible successfully to utilize the tissues in any plastic work for the radical cure. This condition may occur at the umbilicus, the inguinal canal, or elsewhere. Under such conditions the silver wire wicker work or Bartlett's filigree may be successfully applied.

The technic is as follows:[1] An incision is made over the hernial protrusion, the sac is opened, and its contents reduced. The excess of the sac is cut away and the edges sutured as would be done in closing the healthy peritonæum. The peritonæum is now separated from the inner surface of the abdominal wall to a depth of about half an inch throughout the entire circumference of the hernial opening.

On the bed thus formed by the peritonæum a filigree (Fig. 496) slightly longer and wider than the opening is placed in position, being overlapped by all the tissues anterior to the peritonæum. It is held in position by catgut sutures at its

[1] Willard Bartlett, M.D., "Transactions of the American Medical Association," 1906.

extremities. If the defect is large and the tissues cannot be united over the filigree, they should be approximated as near as possible with kangaroo tendon sutures. All that is necessary is that the edges of the network should be covered for a short distance. Over this the fat and skin are closed in the ordinary manner.

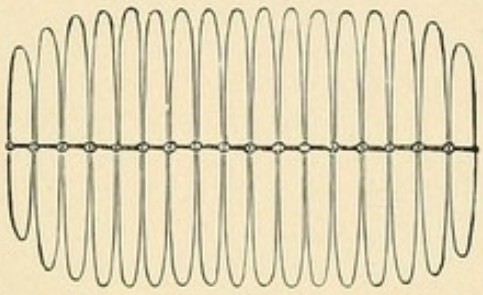

FIG. 496.—Bartlett's silver wire filigree. (Kny-Scherer.)

The patient should be kept in bed for at least three weeks (in severe cases longer), and a binder is worn for several weeks after convalescence.[1]

[1] Dr. Bartlett reports a number of cases successfully treated by this method, and Dr. Joseph Wiener, Jr., in the "Annals of Surgery," April, 1906, reports an additional group of successful cases and highly commends the practical success of the method. The filigree should be made of thin pliable wire, as shown in the illustration, not heavier than gauge No. 30.

CHAPTER XXVI

RECTUM AND ANUS—ATRESIA—CUTANEOUS LESIONS—PARASITES—FOREIGN BODIES—ABSCESS—FISTULA—GANT'S OPERATION—ULCERS—STRICTURE—NEOPLASMS—RESECTION—PROLAPSUS—NEURALGIA—HÆMORRHOIDS

RECTUM AND ANUS

Absence of the anus is one of the most frequent congenital lesions of the alimentary outlet. The rectum may be partially developed, and terminate within the pelvis in a blind pouch at a point more or less removed from the normal opening (Fig. 497); there may be a partial development of the anus (Fig. 498); the rectum may be entirely absent (Fig. 499); or it may be present in the pelvis, opening abnormally into the bladder, vagina, uterus, or urethra (Figs. 500 and

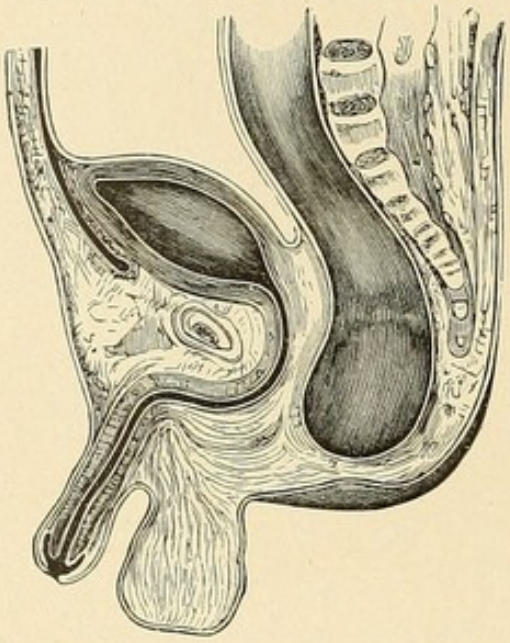

FIG. 497.—Atresia of the anus. (After Esmarch.)

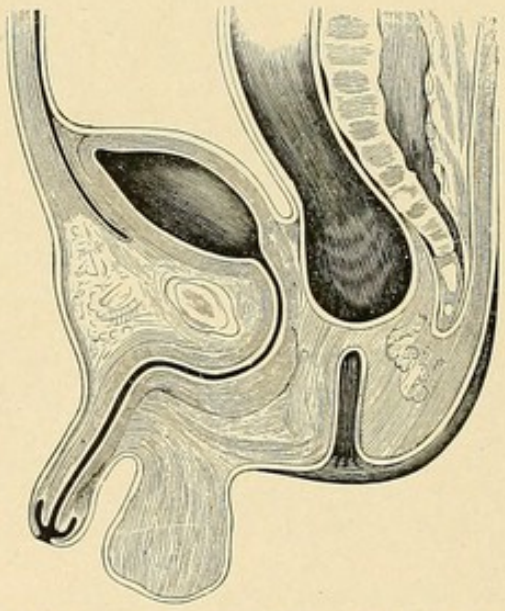

FIG. 498.—Atresia of the rectum, with a rudimentary anus. (After Esmarch.)

501). In the simpler forms of atresia ani only a thin membrane is stretched across the otherwise normal opening. The more complicated varieties are those in which a greater distance intervenes between the end of the defective intestine and the perinæum.

Diagnosis.—Absence of the anus is easily established by inspection. The more important and difficult point is to determine the distance from the perinæum to the end of the pouch. When the intervening tissue is thin, the accumulation of matter within the tube may cause a protrusion in the perinæum, which is exaggerated when the infant cries. If the finger be pressed into the perinæum, an impulse somewhat comparable to that felt in the expulsive efforts of a patient with hernia may be appreciated.

Exploration by the vagina, when the capacity of this tube will permit, will aid in diagnosis.

When the intestine opens into another hollow organ, or through the integument

in an abnormal position, the only diagnostic sign is the presence of fecal matter in the natural discharge from the organ or at the abnormal opening. In atresia recti in female children, the bowel opens most frequently into the uterus or vagina, and in males into the bladder. At times the communication is established between

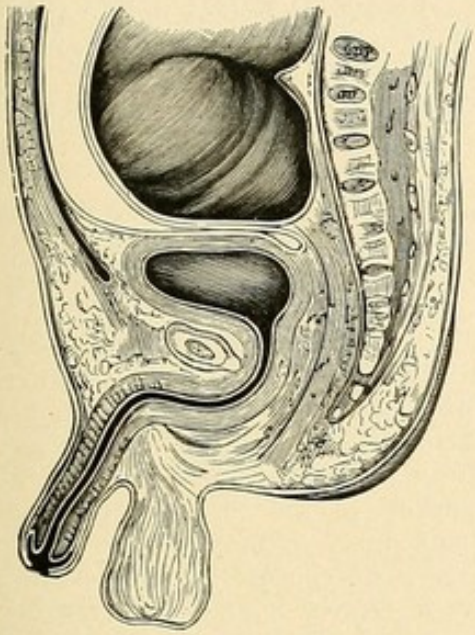

FIG. 499.—Atresia of the anus and rectum. (After Esmarch.)

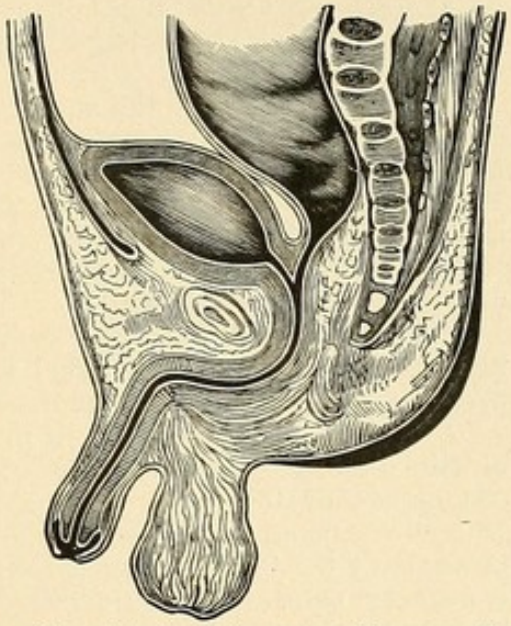

FIG. 500.—Atresia of the anus and lower portion of the rectum; the upper part opening into the urethra. (After Esmarch.)

the bowel and the urethra, or a false opening may occur at any point in the perinæum, and, in rarer cases, in some remote portion of the body.

Treatment.—The indications are to establish an opening as near the natural position of the anus as possible. If the blind pouch can be reached by the exploring aspirator, the needle should be left in place as a guide. The operative procedure is to dissect gradually toward the supposed location of the end of the gut, keeping an open and clear wound by using retractors and arresting all hæmorrhage. The incision through the integument should be in the median line, with its center just in front of the tip of the sacrum and coccyx, for, if the *sphincter ani* is present even in an imperfect condition, it is important to preserve it to aid in the voluntary control of the bowel when the operation is completed. When there exists only a thin septum, this muscle is usually well developed, and the operation is a simple incision and divulsion of the membrane. In more formidable operations, the location of the urethra and bladder, and in females the vagina and uterus, must be kept well in mind, for in infants the pelvic diameters are very small, varying from one to one and a half inch. It is a safe rule to proceed cautiously along the sacral curve. Moreover, it is wiser to dispense with an anæsthetic, since the expulsive efforts in crying may aid in finding the end of the gut.

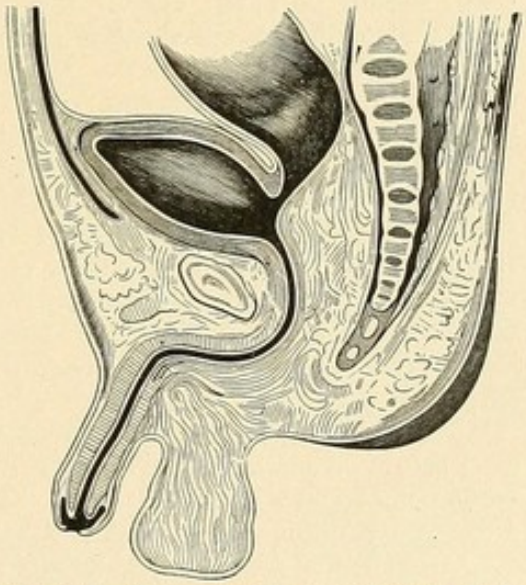

FIG. 501.—The same; the upper portion of the rectum opening into the bladder. (After Esmarch.)

When it is reached, if it is possible, the end should be loosened, drawn down, and sutured to the integument of the edges of the incision. If this is not done, the opening usually contracts, necessitating repeated dilatation by the use of the

finger, tents, or a divulsor. In some instances it has been found necessary to remove the coccyx in order to effect the union of the bowel with the skin.

When, after proceeding as far as the immediate safety of the infant will justify, the bowel cannot be discovered, the propriety of colostomy or enterostomy may be entertained. When the intestine ends directly in the uterus or vagina, and there is no pouching behind these organs toward the perinæum, it is best not to interfere. If, however, the bladder or urethra is involved, an opening should be made or colostomy performed.

In exceptional cases the anus is present in a condition of more or less perfect development, while at the same time the rectum does not communicate with it, but terminates in a blind pouch at a varying distance from the perinæum.

The effort should be made to establish a communication between the two pockets by dissection through the tissues which intervene.

When the opening from the rectum is abnormally small (a congenital stricture), dilatation, incision, or divulsion should be performed.

The prognosis in all these cases is unfavorable. Inflammation, visceral complications, dilatation of the bowel above with retained ingesta, insufficient assimilation, pain, etc., render a fatal issue exceedingly probable.

Pruritus Ani.—Persistent itching about the anus may be caused by a variety of skin diseases, as eczema, herpes, pityriasis, and erythema, or by irritation of the end organs of the sensory nerves from overdistention in the act of defecation. It is also a symptom of hæmorrhoids, fissure of the anus, or may be due to the presence of the thread-worm (*ascaris vermicularis*). The character of the itching is burning, painful, and aggravating, and the desire to scratch is almost irresistible. The successful management of pruritus ani will depend upon the recognition of the disease of which it is a symptom.

Eczema of the perinæum and anus is more apt to occur in a warm temperature, where perspiration is excessive, and in corpulent individuals, where considerable friction occurs between the folds of integument of this region. The skin becomes infiltrated and thickened, fissures are formed, and the mucous membrane at the anal opening may become involved.

Treatment.—The part affected should be kept clean and friction prevented as much as possible. In the acute eczema of the anal region a warm bath, without soap, should be taken two or three times a day, the parts thoroughly dried, and sprinkled with powdered starch or lycopodium. If excoriations exist, lead-and-opium wash should be tried. In chronic eczema of the anus, in order to effect a cure, it is often necessary to remove the accumulation of scales by the local use of green soap for a day or two, and then smearing the surface with diachylon salve.

Herpes may be recognized by the character of the eruption, which is vesicular, the vesicles being grouped in bunches around the anus. Those which rupture and are subjected to irritation present flat and slightly ulcerating excoriations. The treatment consists in thoroughly washing the surface involved with a warm solution of boracic acid, grs. xv–℥j of water, by means of pellets of absorbent cotton moistened in the solution. This should be followed by applying an astringent ointment, composed as follows: plumbi acetatis, grs. iij; acid. tannic, gr. j; morphiæ sulph., grs. iij; adipis, ℥j.

Erythema is a mild form of inflammation of the integument, occurring here as a result of friction between the folds of skin of the two sides and the irritation from perspiration or other fluids. The warm bath, followed by sprinkling the part affected with starch or lycopodium, will usually effect a cure.

Pityriasis versicolor occasionally exists in the ischio-rectal region. This disease can be recognized by the brownish slate color of the parts involved. The cause is a vegetable parasite, the spores and mycelia of which may be easily recognized by the microscope. It yields readily to pure sulphurous acid, which may be applied by means of a camel's-hair pencil. Corrosive sublimate (gr. j to water ℥j) may be applied by mopping with absorbent cotton dipped in this solution.

When pruritus occurs with hæmorrhoids or fissures, the treatment must be directed to these affections. If it is caused by overdistention or irritation of the rectum and anus, the use of enemata and laxatives will arrest the disease. The

local application of a four-per-cent solution of cocaine hydrochlorate will dull the sensibility of the part and temporarily stop the pain and itching.

Ascarides, or "thread-worms," are not an uncommon cause of pruritus ani. They vary in length from a quarter to half an inch, are somewhat lighter in color than the mucous membrane, and are not readily seen unless this membrane is everted and carefully examined. Santonin in full doses should be administered for two or three days, followed by a free purgation. When this is accomplished the bowel should be distended with an enema of lime-water, retained for fifteen minutes, if possible, and repeated. As soon as the last injection is evacuated, a pint of water, in which grs. xx of carbolic acid are thoroughly dissolved, should be thrown into the rectum and retained for about five minutes. The injection of lime-water and carbolic acid in solution should be repeated for several days to insure a thorough destruction of these annoying parasites.

Enemata of the infusion of quassia are also highly recommended in the extermination of the ascaris vermicularis.

Foreign Bodies.—Foreign bodies in the rectum are usually introduced through the anus, and not infrequently lodge here, having passed through the alimentary canal. Their presence may be recognized by digital exploration, or, when of small size, the speculum may be employed.

Digital exploration of the rectum may be performed with the minimum of discomfort by curving the thoroughly lubricated finger to conform to the shape of the lower portion of the bowel. The direction from the anus is upward and forward for the first inch and a half, and then upward and slightly backward.

If a speculum is employed, that of Sims (Fig. 502) should be preferred.

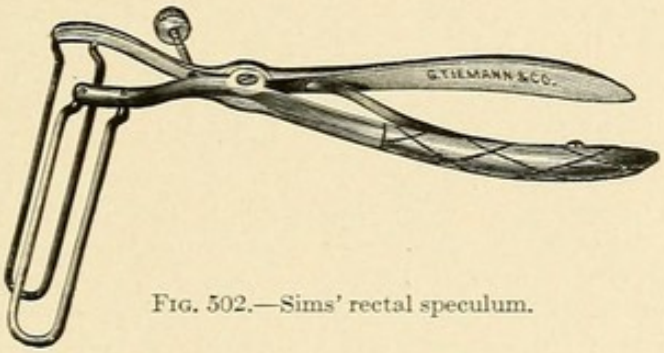

Fig. 502.—Sims' rectal speculum.

A small body may be readily removed by seizing it with a long forceps after dilatation with this instrument. A large substance may require anæsthesia, with forcible divulsion of the sphincter, or a posterior linear rectotomy before it can be removed. When the object is made of glass or any fragile substance, great care should be taken to prevent its breaking.

Fistula in Ano.—A fistula of the anus or rectum may be *complete* or *incomplete*. The last variety is further divided into the *incomplete external* and the *incomplete internal* fistula.

In the complete form the track of the fistula, more or less sinuous, leads from the wall of the rectum or the anal margin out through the integument of the

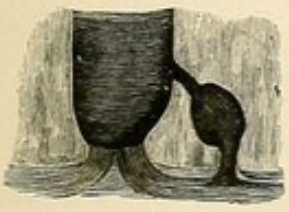

Fig. 503.—Complete fistula in recto.



Fig. 504.—Incomplete external fistula.

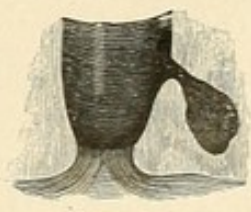

Fig. 505.—Incomplete internal fistula.

perineal, ischio-rectal, or gluteal regions (Fig. 503). In the incomplete external variety, the track opens through the skin, but does not communicate with the

rectum (Fig. 504); while in the incomplete internal fistula the track opens into the bowel only (Fig. 505).

Causes.—The loose areolar tissue which surrounds the lower portion of the rectum possesses a low vitality. Its nutrition is more or less impaired by over-distention of the bowel, which renders it a suitable nidus for the lodgment and proliferation of infectious organisms. If these do not find their way here through the blood channels, they may readily effect entrance by the lymphatic channels which communicate with abrasions (fissures, ulcerating hæmorrhoids), etc., which are common near the anal aperture. It is rarely by direct perforation of the bowel wall that infection occurs.

A not infrequent source of infection is the bacillus tuberculosis. As is well known, this organism is not pyogenic, nor does it produce inflammation of a painful nature, nor any recognizable exacerbations of temperature unless a mixed infection occurs and pus is produced. Whenever suppuration takes place, whether tuberculosis be present or not, pain is a prominent symptom, and there is a marked febrile movement. As the pus accumulates the tissues break down, and the abscess opens into the bowel or through the integument. A complete fistula may be developed from either of the incomplete varieties by partial occlusion of the original opening, thus causing the pus to seek an outlet elsewhere.

Abscess of this region may be superficial or deep. When superficial, it is apt to open through the mucous membrane, just above the junction of the skin and mucous membrane. When the deep variety opens into the rectum, it is usually at a point from three fourths of an inch to two inches from the margin of the anus. A single abscess may have one or more openings into the rectum or through the skin.

The *diagnosis* of fistula in ano is not difficult. It depends upon the history of an abscess followed by a constant or frequently recurring discharge of pus, the pain being severe until the abscess is evacuated, and recurring in a varying degree with the temporary closure of the outlet. An area of induration usually exists, and the opening may be discovered either through the skin or within the anus. If an external opening exists through which gas or fecal matter escapes, a complete fistula is demonstrated. When an external opening is formed, unless the abscess is very recent, there is almost always an internal opening, although it may not be found. The diagnosis may be further made clear by exploration with the probe, an operation which is rendered practically painless by the injection of a two-per-cent solution of cocaine hydrochlorate into the abscess cavity. If a single injection does not sufficiently dull the sensibility, it should be repeated.

No matter where the external opening is situated, the track will, in the great majority of instances, run just beneath the skin toward the anus. The probe should be allowed to find its own way, and when well in, the point at which it impinges upon or opens into the bowel can be determined by the finger in the rectum.

Treatment.—When seen early, a perirectal infection or beginning abscess should be incised (not punctured) and drained by loosely packing it with a ribbon of gauze. The incision can be made with cocaine infiltration. In the early stages there is very rarely any communication with the bowel, and the majority of such cases can be cured in this stage. If, however, the formation of pus is extensive, and the loose areolar tissue has been dissolved or dissected up until a large pocket is formed, it is extremely difficult to effect a cure without performing a more radical operation. Should circumstances necessitate postponement of the thorough procedure, the incision and drainage should be done immediately. Tuberculous fistulæ may exist without pyogenic infection, and often with very insignificant pain. The operative treatment of this variety is practically the same as that to be given for the radical cure of *fistula in ano.*

Operation.—A laxative should be administered and the bowels thoroughly emptied the day before the operation. The perinæum and region of the anus should be cleanly shaved. The patient should be placed upon the back, with the sacrum resting on the edge of the table, the legs flexed on the thighs, and the thighs on the abdomen, and separated; or upon the side in the Sims position. The probe should be carried into the fistula, the lubricated index-finger of the left hand into

the rectum, and the point noted at which the instrument strikes the rectum. The probe is now withdrawn and the grooved director introduced in the same track. If the opening into the bowel cannot be found, the operator should determine by the touch the thinnest point on the intervening wall, and at this location bore through into the rectum, supporting the mucous membrane near the point of the instrument with the finger in the bowel. As soon as the director is felt in the cavity of the gut, the point should be brought out at the anus, the sharp-pointed curved bistoury carried along the groove, and the fistula laid open by dividing the intervening bridge of tissue. If a second sinus exists, it should be incised in the same way, but it is always advisable to make only a single incision through the sphincters. The bleeding is usually insignificant, and may be arrested by pressure, or the ligature. The finger should now be carried into the wound, and, if it is discovered that the abscess extends higher along the wall of the rectum than the point at which the director was carried through, the intervening wall should be divided with the blunt scissors. It is important that the incision in the gut should extend to the depth of the abscess when this point is less than three inches from the anus. A careful search for any pockets or sinuses should be made, and these, if found, should be laid freely open. The fistulous tract and abscess wall should be thoroughly scraped out with the Volkmann sharp spoon, or the indurated and infected lining membrane dissected out with curved scissors or scalpel. In tuberculous infiltration, in order to effect a cure, it is essential that all the tissues invaded by the tubercular bacilli be thoroughly removed. The entire wound should be packed with plain sterile gauze, held in place by a compress of absorbent cotton and a T-bandage. This dressing should be allowed to remain in place for two or three days, when, with the first evacuation of the bowels, it is carried away. After this the wound is not repacked, but, for purposes of cleanliness, it may be washed out by allowing the patient to sit in a basin of warm water once or twice a day, or by irrigation, and an outside dressing applied.

The wound rapidly heals by granulation, and, in the vast majority of cases, a cure is effected by a single operation. Temporary incontinence of fæces results in all cases where both sphincters are divided, but a permanent loss of function is exceptional. It is more apt to occur in females, and for this reason a more guarded prognosis should be made in this class of patients. In the rare instances in which an internal incomplete fistula is present, the cavity of the abscess should be opened by incision through the skin, and the operation completed as just given.

A division of the external sphincter is not necessary in the mildest class of cases, in which the abscess is recent and small, and in which the sinus runs just beneath the skin and opens at the margin of the anus. Under all other conditions it should be partially or completely divided.

Prophylaxis.—Upon the first appearance of inflammation in the ischio-rectal or perineal region, the integument immediately over the most superficial point of the induration should be incised, and a free puncture made into the inflamed tissues. This should be followed by the insertion of a small packing of gauze, which should be changed daily. Too great distention of the rectum should be prevented by the administration of laxatives, and an enema of warm water should be given just before the bowel is emptied. By this method the tension is relieved and an outlet given to the products of inflammation before the process extends into the deeper tissues. A cure without further operation will be effected in a fair proportion of cases.

After an abscess is once formed, whether the fistula opens into the rectum or through the integument, or has both outlets, the case demands operative interference. The proportion of cures by the use of injections into the fistula, or the application of stimulating remedies, is very small. Of the radical operations, preference should always be given to that of free incision. The *elastic ligature* should only be tried on patients who are unwilling to remain in bed, or to be operated upon with the knife, to whom the merits of the two operations have been explained, and who relieve the surgeon of the probabilities of failure. It is also applicable to those cases in which the fistula enters the rectum so high up that incision is impracticable. A guarded prognosis should be made in this class of patients.

Operative interference is contra-indicated in multiple fistulæ in the aged, or in patients in a weak and debilitated condition. When the tubercular diathesis is well marked, an operation should not be done unless great discomfort is caused by the fistula, and, when performed, the prognosis should be guarded.

Fissure.—Fissure of the anus is most frequently met with on the posterior portion of the outlet. It may, however, exist at any part of the anal circumference, or in the rectum above the sphincter. The tear is usually through the mucous membrane, although the muscular fibers may be more or less involved. The chief cause is overdistention of the anus in the evacuation of hardened fæces, together with the presence of sharp substances in the matter discharged. In like manner, foreign bodies introduced into the rectum may produce it. Fissure may result from the inflammation and ulceration of a hæmorrhoid, or from any chronic inflammatory process in the rectum.

The chief symptom is pain of an acute character, exaggerated by an evacuation of the bowel, and continuing some time after the act in a violent spasm of the sphincter muscle. By careful and gentle dilatation of the anus, it may be seen or recognized by the touch as a line of induration running parallel with the axis of the bowel. The employment of cocaine will render the exploration more thorough, and will permit the introduction of the speculum.

Treatment.—The administration of laxatives, and the employment of enemata of warm water and olive oil, will remove the chief source of irritation, while the stimulating effect of the lunar-caustic pencil applied in the fissure, and repeated every two or three days, will usually effect a cure. Cocaine should be employed to deaden the sensibility before the silver is applied. If a more radical procedure is necessary, it will consist in a division of the sphincter in the line of the fissure, as advised by Prof. S. G. Gant.

The patient, previously prepared, is placed upon a low table in the lithotomy position. The operator seizes a fold of skin in the median line one inch posterior to the anal margin, and compresses it between the thumb and finger, to lessen the pain of puncture. In hypersensitive cases, a momentary spray with a Richardson ether atomizer will render the puncture and instillation of the cocaine solution entirely painless. The weak solution is used, as heretofore directed (see local anæsthesia). The anal circumference on either side of the fissure and proposed line of incision should be infiltrated, and the tissues immediately adjoining the fissure well anæsthetized. The anæsthesia should extend along the rectal wall in the line of incision for at least one and a half inches. Gant emphasizes the fact that it is a waste of time to try to locate the sensory nerves, since perfect anæsthesia is everywhere obtained by the infiltration. In the track of the fissure an incision is now made to the depth of about one half inch, dividing the skin, subcutaneous structures, posterior bowel wall, and sphincter. Any skin tags or piles should be excised, and the wound lightly packed with sterile gauze, to prevent bleeding. It is then covered by a gauze pad, kept in place by a T-bandage, well adjusted.

The post-operative treatment consists in cleansing the wound daily after each stool, and inserting a piece of gauze loosely in the cut as a drain and to keep the edges apart. After the first week the gauze is moistened with ichthyol or balsam of Peru. The patients are at no time confined to bed.

Ulcers.—The traumatic causes of ulcer of the rectum are the same as those given for fissure of the anus. Ulcer may also result from any acute or chronic inflammatory process of the lower bowel. It is a not infrequent sequence of dysentery, and may be met with in that form of proctitis which results from prolonged diarrhœa. Inflammation of a hæmorrhoidal tumor will produce ulcer of the lower portion of the rectum, and the same is true of the gummatous deposits of the late stages of syphilis. A primary chancre or a chancroid may be located at the anal margin, and less frequently in the bowel. These two varieties of ulcer are usually seen in women suffering with pudendal chancre or chancroid. Tubercular deposits in the rectum may also break down, and thus cause ulceration in the wall of this organ.

The symptoms of ulcer of the rectum vary with the character of the sore and with its location. If the lesion is situated within the grasp of the sphincter mus-

cles, tenesmus is apt to be a marked feature. The ulcer from a traumatism, or following an acute inflammatory process, is more apt to be painful than that which is a part of a subacute or chronic catarrh, or which occurs with tuberculosis or syphilis. A common symptom of all ulcers of this organ is the presence of more or less blood and mucus or pus in the discharges. The diagnosis may be confirmed by inspection with the speculum, and by digital exploration. Rectal illumination by reflected light or preferably by the electric proctoscope of Prof. James P. Tuttle, is a valuable aid to correct diagnosis of ulcer, stricture, neoplasm, or other lesions of the sigmoid flexure or rectum. Tubercular ulcer of the rectum very rarely exists before the symptoms of deposits in the lungs are present. Upon inspection they are recognized by their yellowish color, usually small size, and their dissemination over a considerable area of the mucous membrane. In the more fully developed ulcers the caseous degeneration of the inflammatory products may be observed.

Mr. Allingham describes a rare form of ulcer which he has occasionally observed in the rectum, and which he has named *lupoid*, or *rodent* ulcer, of this organ. Its usual location is near the anus. It tends to spread widely, the floor of the ulcer is red and dry, the margins irregular and precipitous. It is very probably tubercular in character.

Chancroidal ulcer of the rectum may be recognized by the precipitous margins of these sores, and by the rapidity with which they spread. In patients affected with phagedenic ulcers of the genital organs, the inoculation may occur by direct contact of the secretion of the venereal sore, or the virus may be conveyed through the medium of the nails in the act of scratching. Under such conditions the sore usually first appears upon the mucous membrane of the margins of the anus, and extends later into the rectum. The diagnosis must be based upon the peculiar appearance of the ulcer, together with the probabilities of infection from a contiguous venereal ulcer.

The hard syphilitic or true chancre is rarely observed in this region, and, when met with, is usually confined to the anal margin. It possesses here the same well-recognized features of the specific ulcer of the genital organs, from which source the virus is conveyed usually by the nails, and occasionally by immediate contagion.

Ulcers of the rectum resulting from the breaking down of the gummatous deposits of tertiary syphilis are chiefly seen just along the upper margin of the sphincter muscle. From this point they extend upward, and may involve the entire rectum and invade the colon. These ulcers are usually multiple, varying in size from a small point to a half inch or more in diameter, and in depth may involve only the mucous membrane, or the muscular and connective-tissue stroma may be destroyed, and in some instances perforation may occur. The process of destruction is greater in the older ulcers, and the various stages may be observed by examining the bowel from below upward. The appearance of the ulcers as above described, together with the history of syphilis, will enable the observer to arrive at a correct diagnosis. Traumatic ulcers, and those resulting from the breaking down of hæmorrhoidal tumors, will be recognized by the appearance of the sore and the history of an accident or hæmorrhoids.

As far as a cure of the ulcer is concerned, a favorable *prognosis* may be made in all ulcers of the rectum except the tubercular. These may be relieved by treatment, but, being expressions of an incurable dyscrasia, permanent relief cannot be expected. A more remote, as well as greater evil which often results from ulcer is stricture of the rectum, and the danger of stricture is usually proportionate to the extent of the destructive process. Phagedenic chancroidal ulcer, and the ulcers of gumma and dysentery, are especially prone to induce stricture.

Treatment.—The common indication in the treatment of all forms of ulcer of the rectum is to keep the bowel in as complete repose as possible. Every effort should be made to keep it clear of fecal matter. This may be accomplished by the repeated employment of enemata, and by the administration of proper articles of diet, all of which should be capable of absorption in the stomach and small intestines. Milk, meat juice, soft-boiled eggs, rice, wheatena, corn-meal mush, etc., will afford variety and sustain the patient's nutrition.

In irrigation of the diseased surface, warm or cold water may be used at the temperature which is most agreeable to the patient. The best apparatus for this purpose is the fountain syringe. The smallest glass nozzle, thoroughly warmed and oiled, should be employed, and from one to two pints of fluid may be introduced at one injection. A larger quantity may be employed when the colon is involved. If the patient is placed upon the left side, with the buttocks elevated, a greater degree of tolerance will be obtained in the rectum. The fluid should be retained for a few minutes, if possible. In obstinate cases which resist all ordinary means, appendicostomy and irrigation from the cæcum is indicated.

When the ulcer encroaches upon the sphincter muscle, causing painful tenesmus, the hypodermic use of morphia or opium suppositories may be required to relieve the spasm. In obstinate cases divulsion or division of the sphincter may be done as a last resort.

In the treatment of the ulcers which result from dysentery, catarrh of the rectum, an injury, or breaking down of hæmorrhoids, the plan just given should be adopted. It is often advisable to add from grs. v–x of nitrate of silver to the pint of water thrown in, and, if the ulcer can be reached, recovery will be hastened by the local use of the lunar caustic. An excellent remedy for the alleviation of pain and the relief of tenesmus is a suppository composed of gr. ij each of iodoform and cocaine hydrochlorate, introduced from three to five times in twenty-four hours. As already stated, in obstinate and extreme cases, colostomy may be necessitated.

Chancroidal ulcer of the rectum requires the most energetic treatment. Ether should be administered, the sphincter divulsed, the ulcer exposed by the speculum, its surface scraped with the curette, and a thorough cauterization effected with nitric acid. The cocaine and iodoform suppositories should be employed in the after-treatment.

True syphilitic chancre of the rectum rarely demands local treatment. It yields readily to the constitutional remedies employed in syphilis.

The specific ulcer of the later stages of syphilis requires the constitutional treatment recommended for the late manifestations of this disease, and, locally, irrigation and the cocaine and iodoform suppositories.

Tubercular ulcers should be treated chiefly by the administration of cod-liver-oil emulsions, the iron tonics, the hypophosphites of lime and soda, and carefully selected diet. Irrigation with warm water will be found useful. When pain and tenesmus exist, relief may be obtained by the means already given.

In rodent, or lupoid ulcer, the Paquelin cautery knife should be employed, and a thorough excision of the diseased surface effected.

Stricture of the Rectum.—Stricture of the rectum may be congenital or acquired. Partial and complete congenital occlusion of this organ has already been considered. Acquired stricture is usually the result of an inflammatory process in the walls of the rectum, and at times in the tissues which surround this organ (Fig. 506). New formations (cancer, etc.) may also cause a partial or complete occlusion of the rectum, not only by reason of the bulk of the cells proper of the neoplasm, but on account of the inflammatory process which it causes in the connective-tissue elements of the bowel.

The lumen of this portion of the intestine may be partially or completely occluded by pressure of a tumor not connected with the bowel, or by the presence of some displaced organ, as the uterus, bladder, etc. Lastly, spasmodic stricture may occur from contraction of the circular muscular fibers of the rectum.

As stated on a previous page, organic stricture frequently follows ulcer of the rectum, and is especially apt to occur in the process of cicatrization after dysenteric ulcers and those of the tertiary stage of syphilis. The accidents of parturition not infrequently tend to stricture, and this may account for the greater prevalence of this lesion in females than in males.

Stricture of the rectum may be *narrow* or *linear*, or *long* and *tortuous*. The usual location is about two inches above the margin of the anus, although any part of the organ may be involved. The earlier symptoms of this lesion are interference with the act of defecation, pain with the passage of fæces, and the presence

of blood or mucus in the discharges. In some instances the fæces are tapelike, or are abnormally shaped, although this symptom may not be present when the stricture is high up, since the fecal matter, after it passes through the constriction, may assume the shape of the bowel below. If the constriction is situated within the first four inches of the bowel, its presence and caliber may be determined by digital exploration. When with difficulty reached by the finger, the patient should be directed to strain as if at stool, in order to force the obstruction nearer the anus. Beyond this limit the bulbous bougies or direct illumination and the sigmoid speculum must be relied upon. The bougies are of all sizes, each consisting of an oval bulb of hard rubber, attached to the end of a flexible whalebone staff. In introducing them the patient should rest upon the back while the bougie, warmed and oiled, is guided up the bowel, upon the index-finger of the left hand, which is carried its full length into the rectum (Fig. 507). If resistance is met with, only careful and gentle pressure should be exercised, for undue violence may drive the bulb through the wall of the gut. The inferior limit of the stricture is indicated by the first obstruction encountered. If the bulb can be carried through the constriction, the resistance ceases, but is again experienced when, upon withdrawing it, the shoulder of the instrument catches at the upper limit of the obstruction. The lower border of the stricture is again indicated when all resistance ceases in withdrawing the bulb.

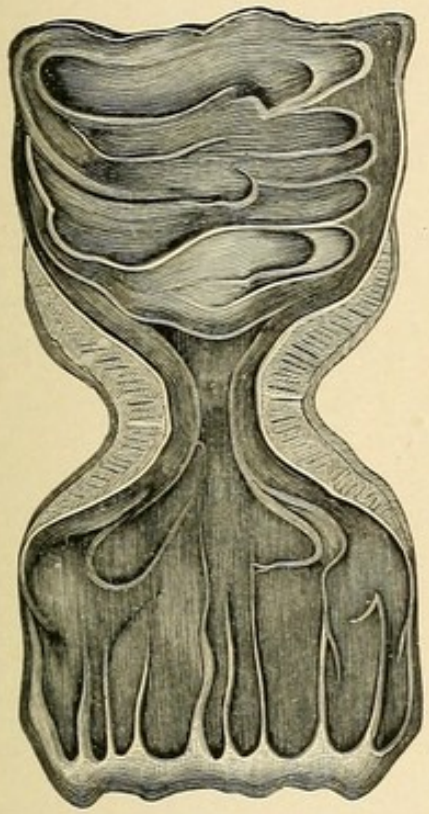

Fig. 506.—Stricture of the rectum from connective-tissue new formation in the submucous layer. (After Bushe.)

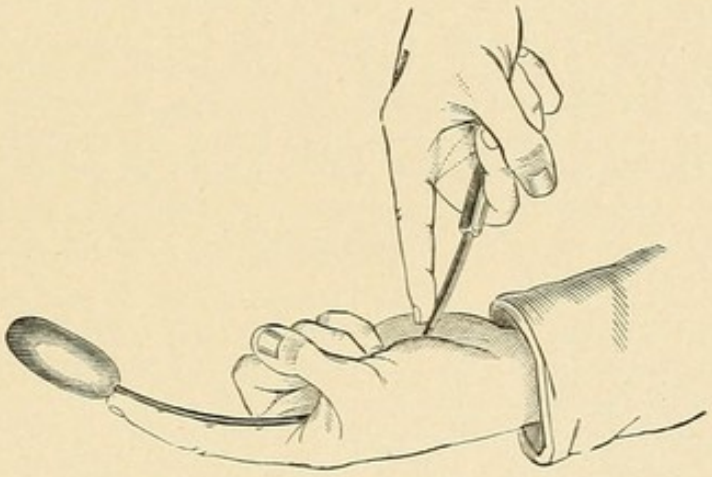

Fig. 507.—Method of introducing the bulbous bougie in exploration of the rectum. (After Bushe.)

Treatment.—The surgical treatment of stricture of the rectum may comprise *dilatation* or *division* of the cicatricial tissue or *colostomy*, or excision.

The character of the obstruction and its location will determine the means to be employed. When the stricture is linear, and is located near the anus, relief may be obtained by dilatation. For this purpose the finger should be employed, and the operation repeated at necessary intervals until a sufficient opening is secured. If the cicatricial tissue is dense, and does not yield in the effort at dilatation, it should be incised to a slight depth at four or five points of its circumference, and the finger again introduced. The incisions may be made with a probe-pointed bistoury, carried along the finger as a guide, or the anus and bowel may be stretched with the Sims rectal speculum up to the point of obstruction, and the knife introduced without a guide. If this procedure is not successful, the only alternative is *posterior linear rectotomy*. In performing this operation the patient is placed upon the back, with the anus at the edge of the table and the legs drawn up and separated. The parts below the obstruction are dilated with the speculum. A long, curved, sharp-pointed bistoury is carried through the stricture, keeping

the cutting edge toward the posterior median line of the gut. As soon as the point is beyond the obstruction, *but not more than four inches from the anus*, it is carried through the wall of the bowel, which, with the stricture, is completely divided out through the anus. If the first incision does not permit the introduction of the first two fingers side by side, it should be made deeper. Hæmorrhage is readily stopped by packing the wound and bowel with gauze, taking the precaution to insert a stiff rubber tube in the middle of the dressing to allow the escape of gas from the intestine. If any important vessel is divided, it may be secured with the forceps or by transfixation with a tenaculum. The dressing is allowed to remain in place for four or five days, and is not replaced after the bowels are moved unless bleeding should occur. Continence of fæces is restored after from three to six weeks. No matter how thoroughly divided, the tendency is to recurrence, which necessitates interrupted dilatation at intervals of from three to six weeks during the life of the patient. It is usually not necessary to practice dilatation within the first six or eight weeks after the operation.

When the stricture is situated more than four inches above the anus, proctotomy is not permissible on account of the proximity of the large hæmorrhoidal vessels, the peritonæum, and pelvic fascia. Dilatation with the *soft-rubber* bougies may be tried, and, if this fails, a rectotomy may be done as high as the limit already given, which will allow the introduction of the hand to this point and the finger into the stricture. This may now be nicked with the bistoury, as above described, and digital or instrumental dilatation effected. Rectal bougies before being used should be made thoroughly flexible by immersion in warm water. In their employment only a mild degree of force should be exercised, for fear of perforating the wall of the intestine.

When all conservative measures fail, exsection with end-to-end union should, if possible, be done, with *colostomy* as the last resort.

All strictures above the rectum should be treated by celiotomy, and dealing directly with the lesion by division of the stricture or by excision and anastomosis or colostomy.

Neoplasms of the Rectum and Anus

Carcinoma.—Of the malignant new formations which are found in this organ, *epithelioma* is the most common, *scirrhus* and *encephaloid* cancer being next in order of frequency. The latter is comparatively rare. Cancer of the rectum occurs about equally in the sexes, and almost always in the middle-aged and old, although in exceptional instances it has been observed before the age of twenty-five.

Epithelioma begins in the mucous membrane, scirrhus and encephaloid carcinoma in the submucous tissues.

The former is slower in development and less apt to recur after removal. The most common location of cancer of the lower bowel is at the upper margin of the sphincter muscle.

The *prognosis* is grave, the duration of life varying from one to two or three years, and in exceptional cases longer. Usually the earliest symptom of cancer of the rectum is pain with the act of defecation. If the disease is located at the margin of the anus, it can be recognized before there is any interference with the discharge of fecal matter. Later, hæmorrhage is of frequent occurrence, although, as a rule, it is not profuse in character. After an evacuation of the contents of the bowel, the pain, though less intense, remains for some time. A sense of fullness or "bearing down" is a marked feature of this disease in the majority of cases.

Diagnosis.—If operative interference is to be undertaken, it is important that an early diagnosis be made. Epithelioma, as has been said, begins in the mucous membrane, the cells of the new formation break down early, the ulcer being present in some instances before there is marked induration. On the other hand, induration and thickening are observed early in the history of scirrhus and encephaloid.

Non-malignant stricture of the rectum is always preceded by a history of chronic inflammation. To the touch, the cicatricial character of the tissue may be recognized by its firmness and sharp borders. It is not nodular, like cancer, nor is

there a deep and wide infiltration of the surrounding tissues in simple stricture, which condition is common to scirrhus and encephaloid, and the later stages of epithelioma. In doubtful cases it will be advisable to remove a portion of the mass for microscopical examination.

The *treatment* of cancer of the rectum may be *palliative* or *radical*. The former looks to the prolongation of life and the alleviation of pain by the employment of careful dietetic and medicinal measures. The regular daily introduction of warm water will prevent the lodgment of fecal matter and secure the greatest possible immunity from irritation. The iodoform and cocaine suppositories will be found useful in alleviating pain, and morphia may be employed if all other measures fail. As the disease progresses it will be found necessary to practice dilatation of the stricture at intervals which should be as far removed as possible, or partial or complete division may be required.

Colostomy is essential in the palliative treatment of carcinoma of the rectum. In forming the spur for a permanent artificial anus by this method, in order to stiffen it the mesenteric attachment should be left between the two rows of sutures. The *radical* cure consists in the free excision of the bowel at a point well above the tissues involved in the neoplasm. Formerly the death-rate after this operation was exceedingly heavy, but under improved methods the danger is materially lessened. The important question to be decided is whether the operation promises well for the complete cure of the patient. If the disease is limited to a small portion of the intestine, which condition prevails in cases seen early, the diagnosis may be confirmed by excision of a small portion under cocaine anæsthesia, for microscopic study; or if the clinical signs point—as these do in most cases (Mathews)—to the development of a malignant growth, then excision should be undertaken at once, when it can be done with more safety to the patient and without the loss of enough bowel to interfere too seriously with the function of the alimentary canal. When the disease is within three inches of the anus, and there is no infiltration toward the bladder or the vaginal wall and uterus, excision from the anal approach may be undertaken. Under other conditions celiotomy and the combined operation, as advised by Drs. C. H. and W. J. Mayo, and already given in Chapter XXIII, may be done.

Resection of the Rectum from the Anal Approach

The patient is prepared by the daily administration of calomel triturates and saline laxatives for three or four days before the operation. Intestinal asepsis is essayed by the administration of naphthalene and salol, each gr. x–xx three times a day, and, when stricture does not prevent it, high enemata of boric-acid solution are given twice daily. The parts are thoroughly shaved, all external antiseptic precautions taken, and, after the patient is anæsthetized, the rectum is thoroughly irrigated with 1–5000 bichloride solution. When an artificial anus has been established by colostotomy prior to the operation, it will only be necessary to give a purgative the day before the operation, and salol and naphthalene need not be given. Irrigation with boric-acid solution is, however, indicated.

The conditions are extremely rare when the method of Kraske or any modification of the operation which requires an osteoplastic section of the sacrum will be required. When the upper margin of the growth can be reached by the tip of the index-finger, Tuttle's modification of Quénu's operation will meet all the indications. When the disease extends beyond this limit, that method combined with the Mayo technic from above will be necessary.

The patient is placed in the combined Trendelenburg and lithotomy position. The rectum is thoroughly irrigated with normal salt solution, dried out, and loosely packed with gauze in order that one may recognize a close approach to its walls during the dissection. A circular incision is made through the skin around the anus, and this with the rim of the bowel is dissected up inside of the external sphincter for one half inch. A strong silk suture, the ends of which are left long for purposes of traction, is tied around, completely closing the freed end of the rectum. The mucous lining and margins of the anus below the ligature are now cauterized with the Paquelin blade, to destroy any infectious organisms. The

external sphincter is incised anteriorly and posteriorly entirely outside of the rectum, the posterior incision being carried back to the tip of the coccyx and well into the retrorectal space. The rectum is then dissected from its attachments laterally and posteriorly, the sphincter, if not involved in the growth, being left in the skin-flaps. In doing this, the levator ani muscle should be cut off as close to the rectum as possible (Fig. 507*a*). The skin and sphincter muscle having been incised in the anterior line as far as the junction with the scrotum, the rectum is drawn backward and dissected loose anteriorly up to the level of the levator ani, which is much higher here than posteriorly. The finger is then introduced from behind forward above the anterior fibers of the levator and the deep perineal fascia, and by gently dragging downward, these are separated from the rectum in the lines of cleavage. When this has been accomplished on both sides, the anterior attachment of the levator and ano-bulbar raphé to the rectum are cut through upon the finger, and the organ is thus freed in its entire circumference. The rectum is now easily separated by the finger in the superior pelvi-rectal space until the peritoneal *cul-de-sac* is reached in front (Fig. 507*b*). At this point the lateral

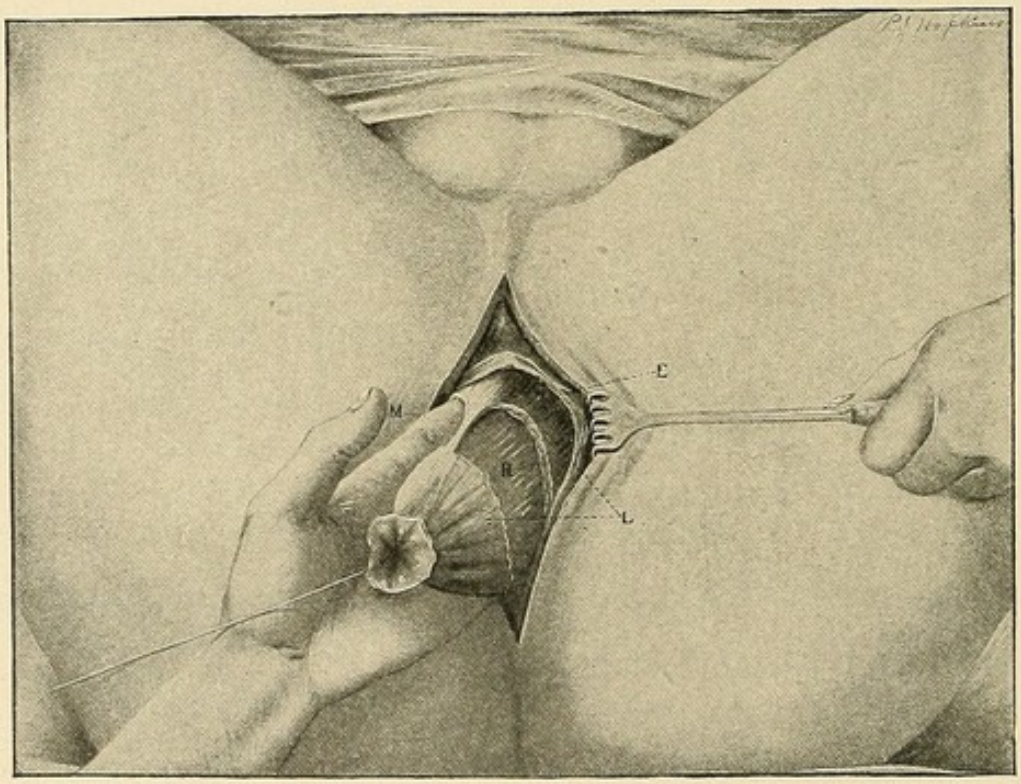

FIG. 507*a*.—Extirpation of the anus and rectum by the perineal approach. The dissection has been carried up within the external sphincter, which is widely retracted. The levator ani muscle has been divided near its inclusion of *R*, the bowel-wall. *L*, Levator ani. *M*, Median raphé. (After Tuttle.)

connective-tissue folds which support the rectum on the sides must be clipped with scissors, after which the gut may be dragged well outside of the wound. While the peritonæum can at times be stripped from the rectum, it is better when the growth extends well up to open the cavity at once. Before doing this it is advisable to disarticulate the coccyx and fold it backward, in order to obtain more room, and to separate the rectum from the sacrum by breaking up the attachments with the finger. The peritonæum on the anterior surface of the rectum is then incised, cut loose from its attachments close to the rectum back to the meso-rectum, which latter should be divided close to the sacrum in order to avoid wounding the inferior mesenteric artery. When the gut has been loosened sufficiently above the tumor to be brought down and sutured to the anus, the surgeon should close the peritonæum and restore the planes of the pelvic floor down to the levator ani with fine chromicized catgut sutures. This accomplished, the anus, which is now well outside of the operative field, should be reopened, the gauze packing in the rectum removed, and the gut flushed with a solution of mercuric chloride, 1–3000. It is

then amputated through the healthy tissue well above the tumor, and its upper end sutured at the original site of the anus. Quénu advises that, in amputating,

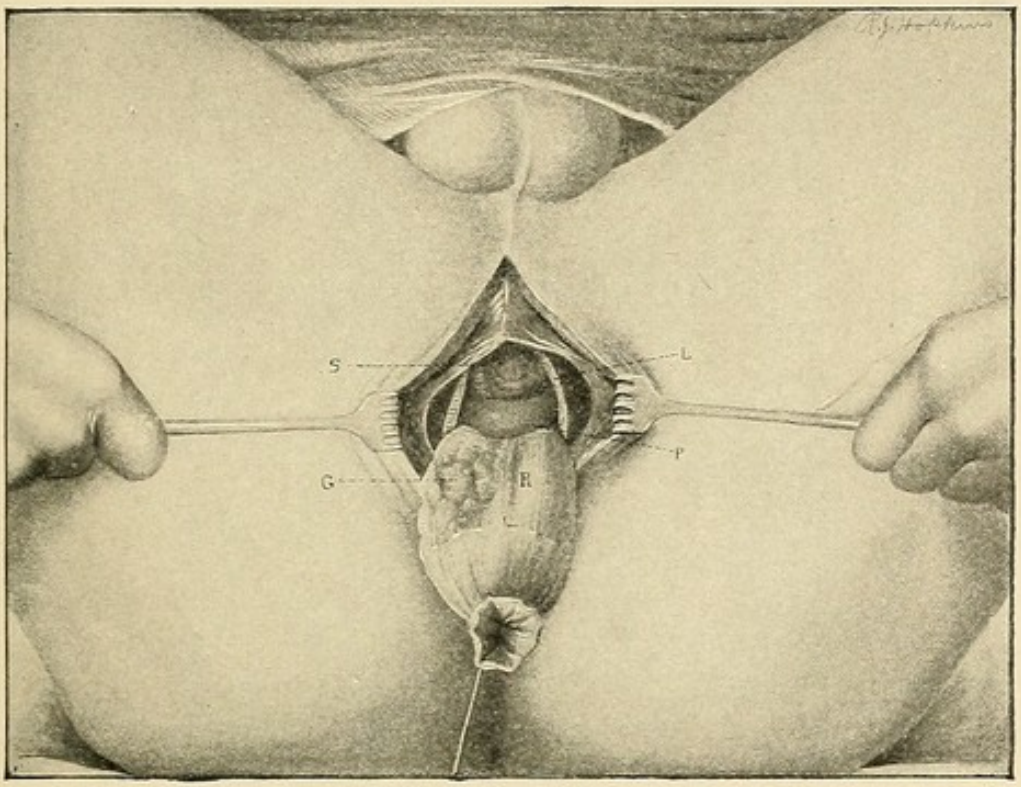

Fig. 507*b*.—Showing the deeper dissection. *L*, Levator ani; *G*, neoplasm; *P*, peritoneal pouch; *S*, seminal vesicles; *P*, prostate. (After Tuttle.)

each layer should be cut separately in order to avoid hæmorrhage. Tuttle holds that there is no advantage in this, "in fact, we are much more likely to meet with a rather deficient blood supply causing subsequent sloughing of the gut than with

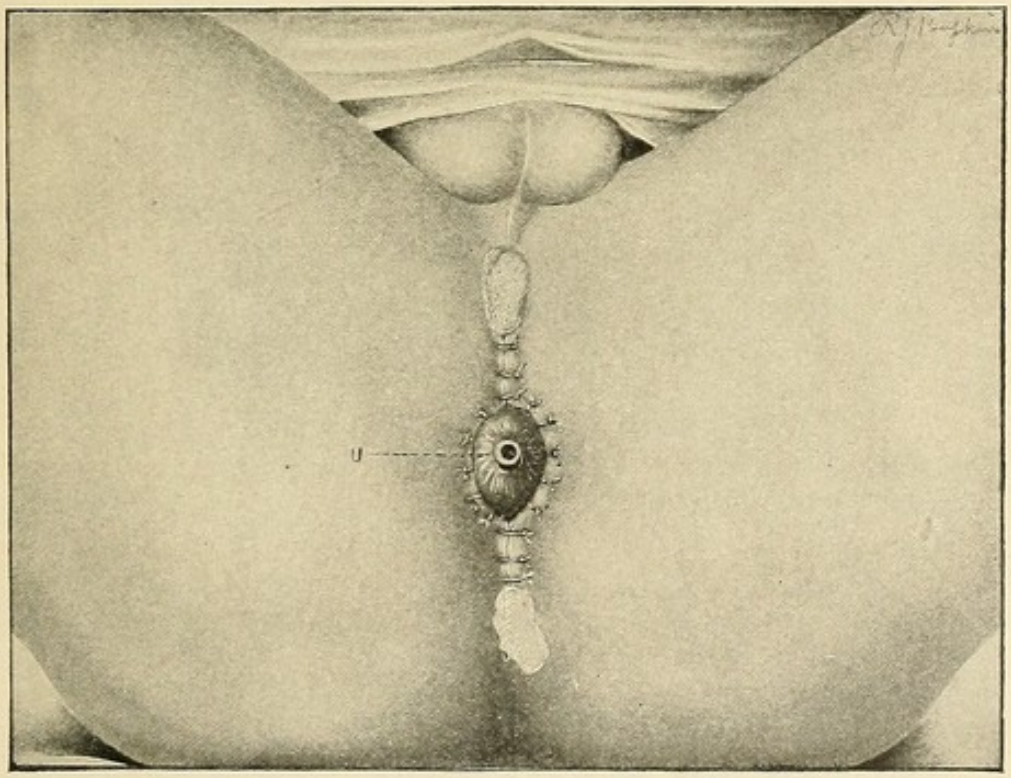

Fig. 507*c*.—The operation completed, showing the gauze packing and drains above and below, and at *U* the rectal tube. (After Tuttle.)

hæmorrhage." The posterior and anterior portions of the wound are packed with gauze, and left open to insure drainage (Fig. 507*c*), and the parts are covered with aseptic pads held into position by a well-fitting napkin or broad T-bandage. A large drainage-tube is passed well up into the rectum, its lower end extending outside of the dressings in order to convey the discharges and gases beyond the operative wound.[1]

In cancer of the rectum in women, the vaginal route is advised. The technic of the operation as given by Murphy is as follows: The position is the same as just given. The vagina is dilated with broad retractors, the cervix drawn down, and Douglas' *cul-de-sac* opened by a transverse incision just below the cervical juncture. The small intestines are pushed upward and the peritoneal cavity packed with large laparotomy sponges or pads, a careful count of which should be noted. The recto-vaginal septum is then divided by a vertical incision in the median line, extending from the first incision down to the margin of the anus and including the external sphincter (Fig. 507*d*). The vaginal wall is dissected from its attachments to the rectum, exposing this organ in its entire length, enabling one to exam-

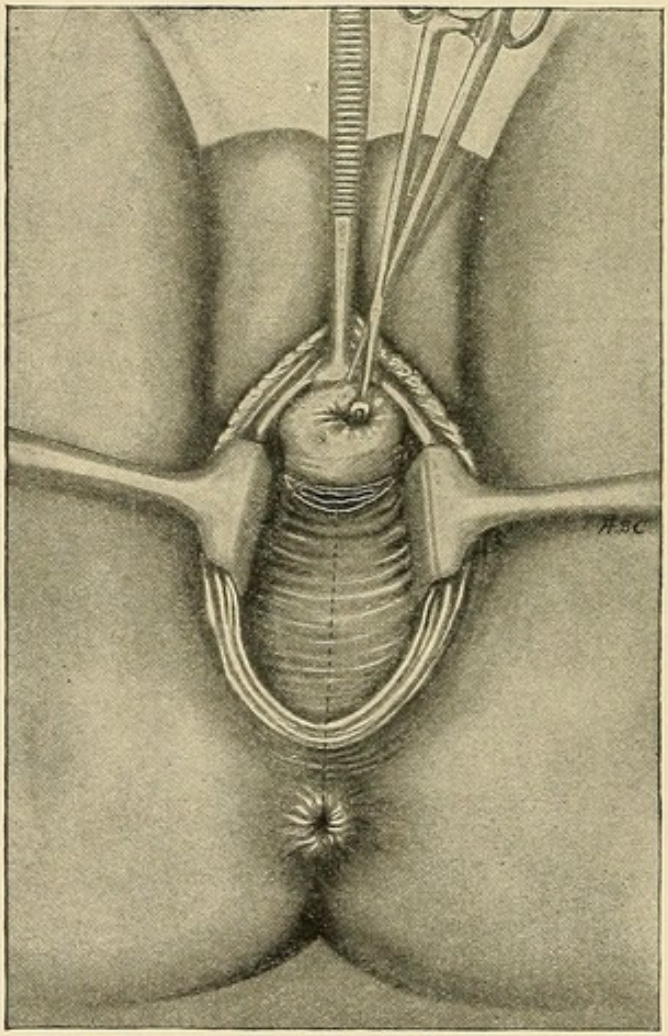

FIG. 507*d*.—The cervix drawn upward and outward, the *cul-de-sac* opened, and the long incision in the posterior vaginal wall outlined. (After J. B. Murphy and Tuttle.)

ine it and drag down the sigmoid flexure at will (Fig. 507*e*). The anterior rectal wall is now divided to the lower border of the tumor, and the gut incised transversely one inch below the lower limits of the growth, carrying the incision into the retrorectal tissue. The proximal end of the gut is grasped with forceps which close it, and by the use of the curved scissors it is separated from its posterior

[1] The foregoing technic is credited to Tuttle's "Diseases of the Anus, Rectum, and Pelvic Colon."

attachments as far as the promontory of the sacrum, or sufficiently far to allow the bowel to be drawn down and out until its healthy portion reaches the lower segment without undue tension. The gut is then amputated above the growth (Fig. 507*f*), and the upper and lower segments are united, end to end, by silkworm sutures. These sutures should be passed so as to permit the knots being tied upon

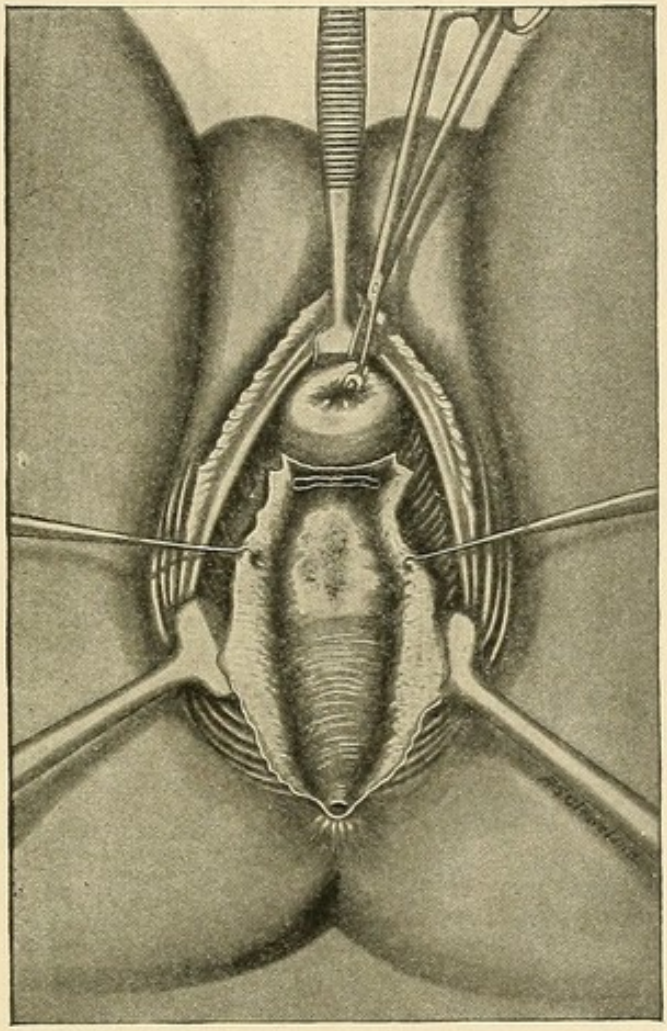

FIG. 507*e*.—The posterior vaginal wall lifted from the rectum. (After Murphy and Tuttle.)

the inside, and the ends left long to facilitate their removal. The anterior wound of the rectum is closed in a similar manner, and the ends of the sphincter are brought together by buried catgut sutures (Fig. 507*g*). After the laparotomy pads are removed, the peritoneal wound is closed with a continuous catgut suture, and the vaginal wound is brought together with silkworm-gut stitches. A large drainage-tube is introduced through the anus above the point of anastomosis and sutured in position, the vagina and external parts being dressed with sterilized gauze.

Tuttle has modified the above technic of Murphy by commencing the operation with a semicircular incision between the anus and coccyx, and extending this into the retrorectal space. With the fingers or a dull instrument the cellular tissues and rectum are separated from the anterior surface of the sacrum and the coccyx as high up as the growth extends. After this has been accomplished the wound and sacral concavity are packed with sterile gauze, to control the oozing, and the vaginal portion of the operation is then carried out as directed by Murphy, with the exception that the gut is not cut across until it has been freed from all its attachments, dragged down as far as is necessary, and the peritoneal cavity closed by sutures or firm packing.

Polypus.—Three distinct forms of polypi are found in the rectum, namely—the *villous*, *mucous*, and *fibrous*.

The first of these is the most important, for, while essentially benign in the earlier stages of its development, it may, as a result of the irritation to which it is subjected, become malignant. It is composed of newly formed villi, which resemble the normal villi of the rectum. They are very vascular, and differ from the mucous or fibrous polypus not only in their minute structure, but in gross appearances and the character of their attachment to the mucous membrane. While these latter are pedunculated, often hanging by a narrow stem, the villous growth has a broad attachment frequently as thick as the tumor is long.

The mucous or soft, and the fibrous or hard, polypus of the rectum does not differ in any essential particular from that already described in affections of the nasal cavities. In some instances the deeper portions of the tumor undergo cystic degeneration, forming the so-called *cystic polypus*.

Polypi of the rectum may occur at any period of life, being comparatively frequent in childhood. The most common location of these tumors is on the posterior wall of the bowel, just above the internal sphincter. The pedunculated variety in

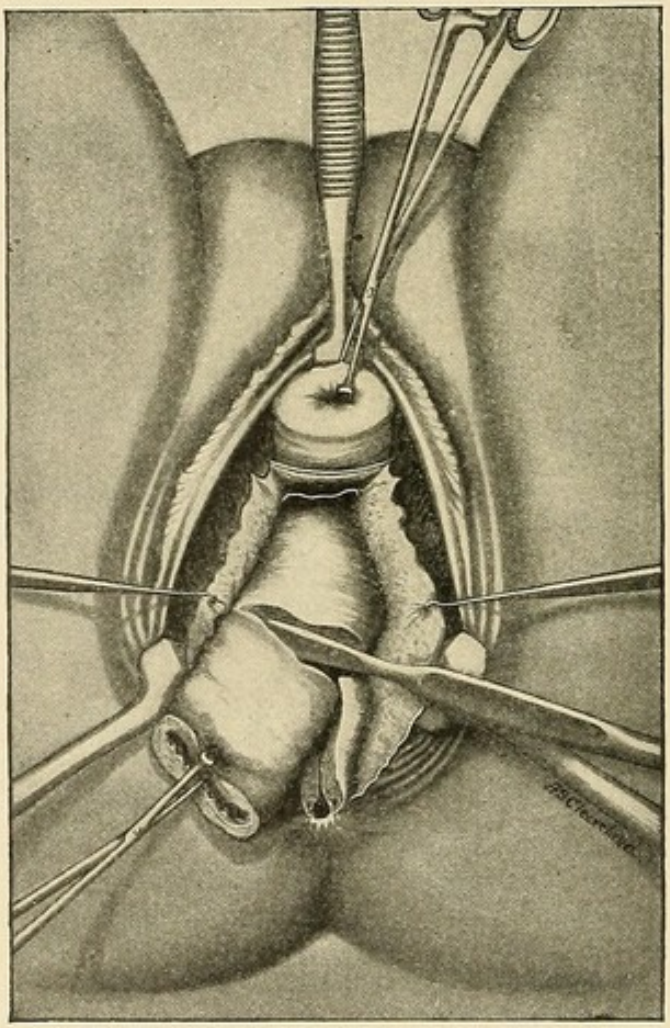

Fig. 507*f*.—Excision of the diseased segment. (After Murphy and Tuttle.)

some instances protrude through the anus, causing violent tenesmus. When not removed these neoplasms may break down, causing ulcer or fissure of the bowels, severe hæmorrhage, or by their weight cause prolapse of the mucous membrane.

The *diagnosis* is readily made by inspection or digital exploration, after the rectum is thoroughly cleansed by an enema. The *treatment* consists in removal of the tumor by the forceps, scissors, or ligature.

Villous papilloma, or "villous tumor," according to Mathews, is the rarest form of rectal neoplasm. "It is likely to be mistaken for polypus because it is pedunculated. In polypus the stem is round, in villous tumor broad." The clinical

feature of most importance is the frequent hæmorrhage which occurs from rectal papilloma, caused by the passage of ingested matter. The treatment consists in the removal of the mass after a ligature has been thrown around it close to the pedicle. It is a wise precaution after removal to thoroughly touch the base of the tumor with the Paquelin cautery. There is very little danger of hæmorrhage in such treatment.

Neuralgia.—Pain, neuralgic in character, is occasionally felt in the rectum or about the anus. In some instances it is caused by displacement of the *coccyx*, the

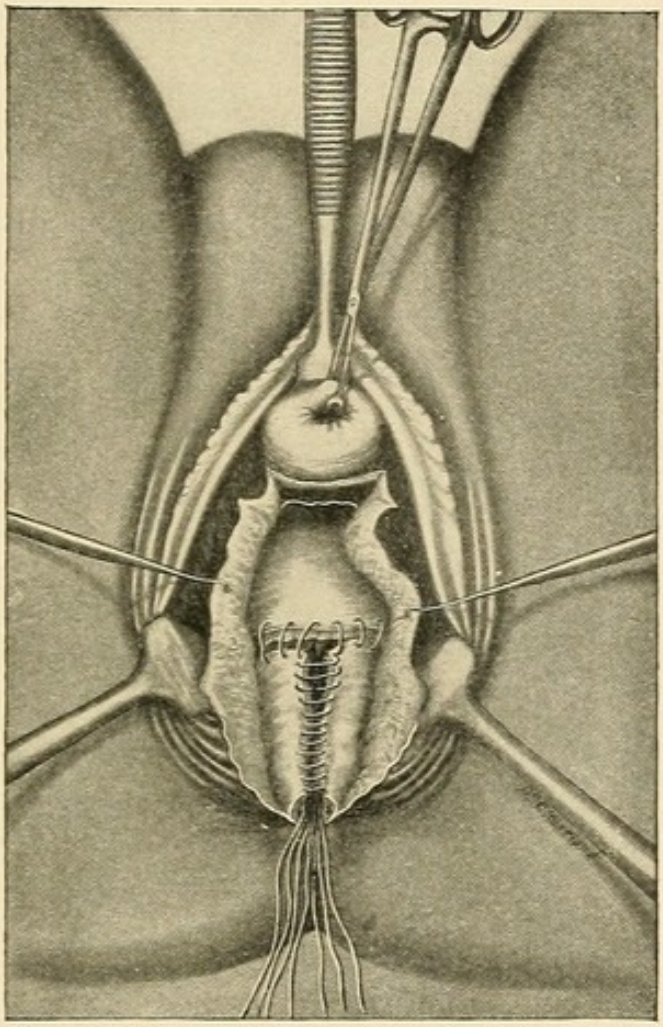

FIG. 507*g*.—Reunion of the upper and lower segments and closure of the anterior longitudinal incision in the rectum. (After Murphy and Tuttle.)

bone in the abnormal position pressing upon the fifth sacral or coccygeal nerve, or directly against the wall of the bowel. The diagnosis is readily made out by direct examination. The only means of cure is by removal of the displaced bone.

The operation is performed as follows: The patient is placed upon the side and an incision is made in the median line, from the tip of the coccyx to about one inch above the sacro-coccygeal articulation. The tissues are first lifted directly from the dorsal aspect of the bone, and then the anterior surface is exposed by beginning at the tip and keeping close to the smooth face of the coccyx. There is no danger of wounding the bowel if this precaution is taken. When the dissection is completed, the bone should be divided at the sacro-coccygeal junction with the cutting forceps or chisel.

Idiopathic neuralgia of the rectum and anus may occur as in other portions of the body. Spasm of the sphincter is occasionally due to this cause.

Prolapsus Recti.—Protrusion of the rectum may be *complete* or *incomplete*. In the incomplete variety the lining membrane of the bowel is alone protruded. The everted portion may include a narrow ring of the mucous membrane near the

anus, or it may measure an inch or more in width. In the complete prolapsus more or less of the entire thickness of the wall of the rectum is dragged downward and everted. The process commences usually near the anus, and in the complete form the fascia which attaches the rectum to the promontory of the sacrum is elongated, and the peritonæum dragged down toward the anal aperture. In the pocket thus formed a loop of intestine may descend and become strangulated.

Prolapsus recti may occur at any period of life, although usually met with in children. In a varying degree it exists as a complication in all cases of chronic hæmorrhoids. It is frequently caused by frequent and prolonged straining at stool. A predisposing cause in adults is habitual constipation, with the overdistention of the bowel which is the result of this condition. In children, it is thought that the peculiar shape of the sacrum, the curve of which is much less pronounced than in adults, renders this class of patients more liable to prolapsus. It is probable that indiscretions in diet, the lack of restraint, and the low, squatting posture too often permitted in children in the act of defecation, are more responsible for this accident than the straight position of the bowel.

Diseases of the bladder and prostate, uterus and ovaries, pregnancy, or the presence of a tumor, are also to be considered as exciting causes of this lesion. Finally, the weak and infirm are more liable to be affected than the robust.

When prolapsus occurs it is accompanied with a sense of distention, heaviness, and dragging down, which causes great pain and anxiety to the patient. In recent cases in which there is only an eversion of the mucous membrane, this will be seen projecting beyond the limit of the anus on one or both sides, or in severer cases including its entire circumference. The prolapsed fold or ring is of a reddish-purple color, varying with the degree of strangulation, and is broken at intervals by furrows or depressions which, in the main, seem to radiate from the center of the protrusion. When complicated with hæmorrhoids, these will be easily recognized by their shape and color, giving a swollen and nodulated appearance, which could not exist in simple eversion. In differentiating partial from complete prolapsus, the chief points are the thinness of the prolapsed ring in the partial form, and the radiating direction of the furrows. In complete prolapse the mass is markedly thicker, more strangulated, and the folds of mucous membrane are more nearly circular in arrangement.

Treatment.—In *acute* prolapsus the immediate indication is to relieve the strangulation and restore the prolapsed portion to its normal position. The removal of the cause or causes of the accident is next in importance. The first indication is met by placing the patient upon the left side, with the pelvis well elevated, the shoulders and head depressed, or in the knee-shoulder position, in either of which the return of the bowel is aided by gravity. The fingers of the operator and the protruded mass should now be well lubricated, and steady and gentle pressure exercised upon the tumor in the direction of the normal position of the bowel. In almost all cases this practice will succeed. When, on account of spasm of the sphincter, the strangulation is so great that gangrene is threatened and reduction impossible, an anæsthetic should be administered and forcible dilatation effected by the thumbs of the operator, after which the mass will readily return within the anus. Once reduced, the greatest pains must be observed to prevent the repetition of the accident. Fecal accumulation and straining should be prevented by the injection of cold water when there is a need or desire for an evacuation, and by the use of the bedpan. In children it is essential that they should not be allowed to squat upon a low vessel, or place themselves in a constrained position at stool. The position assumed should be one where gravitation will not carry the intestines toward the anus. Lying upon the side, with the buttocks slightly projecting over the edge of the bed or table, or defecating in the knee-elbow position, should be insisted upon. Any condition which contributes to the cause of prolapse must be removed or palliated. When, despite all conservative methods, the prolapse becomes chronic, growing progressively worse, operative interference becomes imperative. The preparation of the patient is the same as for other operations about the rectum. After the narcosis is complete, the patient is placed in the lithotomy position, with the pelvis elevated to such an

extent that the intestines will gravitate toward the diaphragm, the mass returned, and a large sponge introduced well up into the bowel. The sphincter ani and rectum should now be widely dilated with the speculum until the walls of the bowel are brought clearly into view. The Paquelin cautery knife, heated to a light-red color, is carried into the bowel as high as the limit of the prolapsed portion, and drawn straight down the wall of the gut to the margins of the anus, burning its way through the mucous membrane. The depth of the furrow must be determined by the extent of the prolapse. If the entire thickness of the rectal wall is involved, as in complete prolapsus, the wound should extend well into the muscular layer. In partial prolapse it will suffice to go down to the muscle. From four to six incisions should be made at equal distances from each other. Partial divulsion of the sphincter should be made before or after the operation, in order to prevent spasm and to secure rest. A complete recovery will follow in the large majority of cases. If the Paquelin cautery cannot be obtained, strong iron wire, or rod iron, may be used by heating in the ordinary furnace. The after-treatment is to keep the patient quiet with mild opium narcosis, and after five or six days to move the bowels with a cold-water enema, keeping the patient in the recumbent posture. The cure is effected by the formation of inflammatory adhesions between the mucous membrane and muscle, and between the outer wall of the rectum and the perirectal connective tissues and fasciæ. The older operation of excising a V-shaped piece of the mucous membrane and afterward uniting the edges by sutures, is bloody and troublesome, and not to be compared to the procedure above given.

In chronic prolapse, the most satisfactory procedure is the operation of Whitehead, carried out as if it were being done for hæmorrhoids instead of prolapse. It is well to bear in mind, as emphasized in the description of this operation for hæmorrhoids, the danger of cutting away too much of the mucous membrane. Whitehead's operation is better adapted to chronic prolapse than any other procedure.

In very exceptional instances celiotomy is indicated, with suture of the bowel to the pelvic fascia after the prolapse has been reduced. The lumen of the overdilated lower segment may also be narrowed by plication from the peritoneal side. Chromicized catgut sutures should be employed. In all essentials the procedure is the same as gastroplication.

Hæmorrhoids

Hæmorrhoids, or "piles," are vascular tumors or varicosities formed beneath the mucous membrane of the rectum and anus. They are divided anatomically into *external* and *internal* hæmorrhoids. Internal hæmorrhoids are again divided into *venous*, *arterio-venous*, and *capillary* hæmorrhoids.

The veins which are involved in hæmorrhoids belong to two plexuses, between which, ordinarily, there is not a free anastomosis. The inferior or external hæmorrhoidal plexus is situated in the last portion of the rectum, within about one inch of the anus, and the blood from this part returns by way of the middle and inferior hæmorrhoidal veins to the iliacs, and thence by the inferior cava to the heart. The superior or internal plexus occupies the rectum above this point, and from this portion the blood returns by the portal system, passing through the liver.

In their incipiency, *external hæmorrhoids* are simple varicosities of the inferior plexus. Later, as a result of engorgement and repeated inflammation, the walls become thickened from the presence of newly formed connective tissue, which, in the process of contraction peculiar to this product of inflammation, often causes obliteration of the vein within the tumor. The remains of these tumors are seen in almost all cases of chronic external hæmorrhoids, where they appear as tags of thickened skin of variable size and shape, collected around the margin of the anus.

Internal hæmorrhoids of recent development are also varicosities of the internal or portal plexus, but when of long duration the tumors very frequently contain arterioles of considerable size. The mucous membrane of the deeper portions of the rectum is at times studded with small, raspberry-like elevations, which bleed

profusely, are found to contain a rich network of capillaries, and for this reason are termed *capillary hæmorrhoids.*

External Hæmorrhoids—Acute and Chronic.—This form of tumor, commonly known as "dry piles," is of frequent occurrence. Few individuals live beyond the age of forty without being affected. The chief cause is habitual constipation and the overdistention of the lower portion of the rectum in the act of defecation. Prolonged straining at stool, even without the discharge of fecal matter, will also aid in the development of piles. Gravitation by reason of the erect posture is also entitled to a consideration in the ætiology of hæmorrhoids, since man is the only animal thus affected. Pressure upon the iliac veins or the inferior cava by the gravid uterus, or any form of tumor, will also aid in producing varicosities of the hæmorrhoidal veins as well as in those of the lower extremities.

A patient who is suffering from an acute external hæmorrhoidal tumor will usually give a history of constipation and straining at stool, with an unnatural sense of fullness and heaviness about the anus, and of considerable pain while the evacuation is taking place, for several days before the protrusion is noticed. Immediately after an evacuation a swelling is noticed just outside of the anus which is painful to the touch, and which cannot be pushed into the bowel. Upon inspection, a recent external hæmorrhoidal tumor usually appears tense and glistening on the surface, and red or reddish-blue in color. It is partly within and partly outside of the anus. There may be a single swelling, which is spherical in shape, or it may be crescentic, occupying half of the anal margin. If not observed until after several days have elapsed, and when the tension or partial strangulation has not been relieved, ulceration may have occurred, with inflammation and induration of the tissues near the base of the tumor. In other instances which do not come under the observation of a physician, the patient goes to bed, pushes the tumor within the anus, the symptoms disappear within a day or two, to recur again and again under the same conditions.

Chronic external hæmorrhoids differ from the acute form just described in the following particulars: They are brown or bluish in color, are not tense or painful, are loose and flabby, and have a thickened, leathery feel when pinched between the fingers.

Treatment.—This may be palliative or curative. Tension in the tumors may be lessened by placing the patient in the knee-shoulder position and making gentle pressure upon the mass until it slips within the anus. The cure of acute external hæmorrhoids, however, is so simple that it is rarely advisable to delay operation. There are rarely more than two or three of these masses, and by injecting directly into each one two to five minims of a one-per-cent cocaine, or two per cent quinia and urea, solution, all sensation is lost as the tumor is incised with a sharp-pointed curved bistoury, carried through its base, splitting it and turning out the clot, and inserting a little film of boric cotton or sterile gauze to arrest bleeding. The wound heals in the course of a week, and the hæmorrhoids do not recur. Should the patient be unusually apprehensive or the anal region more than ordinarily sensitive, ether spray by means of the Richardson atomizer will deaden sensibility to the needle puncture and the infiltration. In the case of chronic external hæmorrhoids with prolapsus ani, the operation of Whitehead is indicated. Old withered-up external hæmorrhoids may be easily removed by grasping the tumor with a pair of mouse-tooth forceps, and cutting it off with scissors. Local anæsthesia may be employed if deemed necessary.

Internal Hæmorrhoids.—Constipation, overdistention of the rectum, and prolonged straining at stool must also be considered as among the principal causes of internal piles. In addition to these, any disease of the liver which causes a retardation of the return of blood through the portal circulation will aid in producing internal hæmorrhoids.

Pressure upon the portal vein, or upon the inferior mesenteric vein, whether due to an overloaded condition of the alimentary canal or a tumor, will produce the same effect.

Symptoms.—Internal piles, as a rule, cause little or no pain or annoyance until they are sufficiently developed to be caught in the grip of the sphincter, or are

protruded through the anus. Previous to their descent, however, a variable amount of bleeding has usually occurred, often enough to attract the attention and excite the alarm of the patient. This is especially true of the arterio-venous and capillary tumor, although the venous tumor not infrequently gives rise to considerable hæmorrhage.

Upon digital examination the presence of the hæmorrhoids may be easily recognized, and ocular demonstration may be made by the careful dilatation of the sphincter with the Sims rectal speculum. If a free enema of warm water be administered, the tumors will usually protrude with the discharge of the water if the patient is placed in the squatting posture, and is directed to make a strong expulsive effort.

Treatment.—The preliminary treatment should be instituted seventy-two hours before any operative procedure for internal hæmorrhoids. A full dose of castor oil (two ounces) in sarsaparilla should be given at bedtime, and in the case of an ordinary individual this procedure should be repeated forty-eight hours before the operation. Twelve hours before the anæsthetic is administered, the patient should receive a full irrigation of the colon with hot normal salt solution. After this nothing should be done until the patient is unconscious and on the table. The subject should be in the lithotomy position, and when help is scarce the legs should be held by the Clover crutch. The operator should wear rubber gloves, and every precaution taken to prevent accidental soiling should the patient vomit or struggle. The internal and external sphincter ani muscles should be slowly and carefully stretched by an instrument, or preferably with the lubricated fingers of the two hands. The dilatation should be in all directions and so gradual that no muscular fibers are ruptured, and, if possible, the mucous membrane not torn. A rubber bulb (Barnes' dilator) should now be introduced several inches up the bowel and filled with water. This prevents the descent of soiling material, and by pressure on the veins causes a temporary distention of the hæmorrhoids. If the rubber bulb is not at hand, a sponge of the proper size or a plug made of absorbent gauze, to which a strong cord has been attached, is carried well up into the bowel along the trough of a large Sims speculum.

All that part of the bowel below the plug and the entire anal region should be cleansed with soap and water and 1–5000 sublimate solution. The operator by introducing one or two fingers and by pressure from above downward will cause the mucous membrane to prolapse and bring the hæmorrhoidal tumors well down to the margin of the anus. If varicosities are present in the entire rectal and anal circumference, and if, as is almost always the case with chronic hæmorrhoids, there is a prolapse of the mucous membrane, the ideal operation is complete excision of all the hæmorrhoidal varicosities, together with a section of the mucous membrane of the rectum (Whitehead's operation).

By the use of scissors and dissecting forceps the mucous membrane is divided at its junction with the skin throughout the entire circumference of the bowel, every irregularity of the muco-cutaneous junction being carefully followed. By commencing this incision at the most dependent portion of the anal circumference and proceeding upward, the line is not obscured by the bleeding which occurs. The assistant, who uses the irrigator with hot salt solution, should, from time to time, flush (not splatter) the wound in order to clear the field and retard bleeding. The external sphincter muscle, the circular arrangement of the fibers of which may readily be recognized if the wound be kept dry, should be carefully sought and the operator should keep to the inner or mucous side of this muscle. The forceps should be applied freely, and all bleeding points tied at once with very fine catgut. After the external sphincter muscle has been exposed, the dissection may be rapidly made with the dull-pointed scissors and with slight bleeding. It will usually suffice to remove a strip of the mucous lining membrane not more than one half to three quarters of an inch in width. Great care should be taken not to remove too much for fear the sutures may tear loose from too great tension and a cicatricial ring or band be formed, causing post-operative contraction. A No. 2 ten-day catgut suture is now introduced through the skin about one eighth of an inch from the edge of the incision. Avoiding the sphincter muscle, the

needle enters the mucous membrane passing one fourth of an inch beyond the point where it is to be divided. The mucous membrane is split directly down to one fourth of an inch from the point where it was penetrated by the needle, and this suture is immediately tied in such a way that the edge of the mucous membrane and the edge of the skin are in apposition. Half an inch beyond a second suture is inserted, and the mucous membrane is then divided transversely as far as this second suture, which is also to be tied.

This operation is repeated for the entire circumference of the bowel, tying each suture as it is inserted after the mucous membrane has been divided. Halfway between the first row of sutures a second row should now be inserted, and at any points where the apposition is not entirely satisfactory small intermediate sutures of plain catgut may be used. It is important that the sutures should be so closely applied that the mucous membrane and the skin are absolutely in

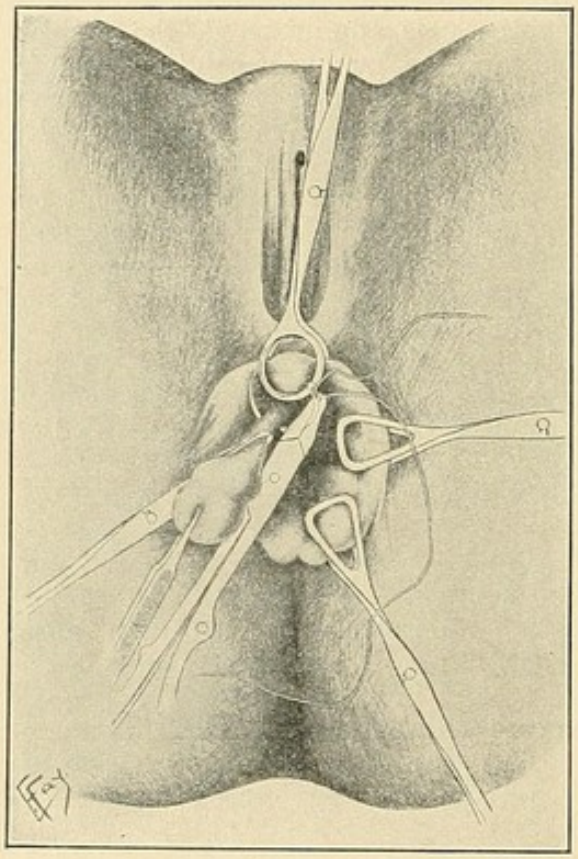

FIG. 508.—Pilcher's operation for hæmorrhoids, showing a single pile clamped with a long slightly curved forceps and a curved needle carrying a chromicized catgut suture passed beneath the mucous membrane and the vessel leading from the hæmorrhoid. (After Pilcher.)

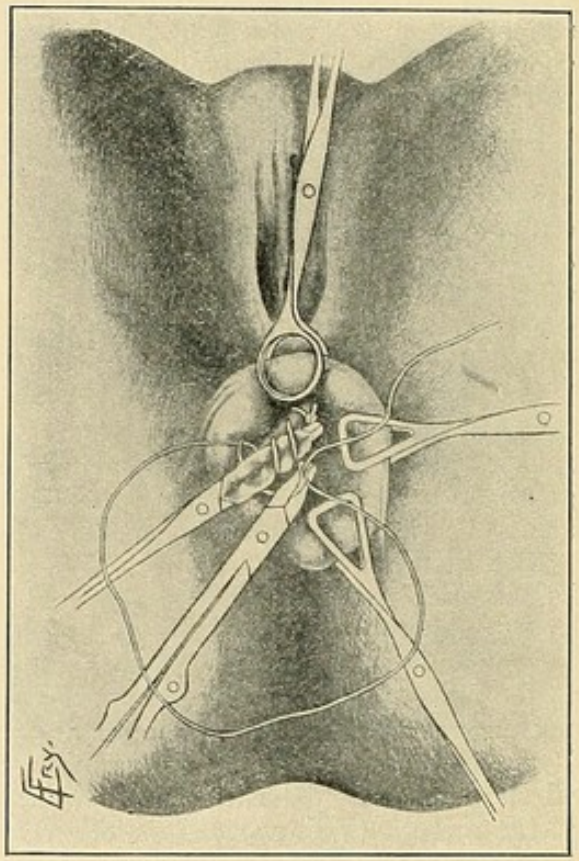

FIG. 509.—The same, showing the tumor clipped off with the scissors and the running suture continued through the base of the hæmorrhoid and over the forceps, which is to be removed and the suture drawn tight. (Pilcher.)

apposition throughout the entire circumference, and it is of greater importance that too much of the lining membrane be not sacrificed. The Barnes dilator or the plug should be removed and a dressing of light gauze applied.

It is a common practice, in order to permit the escape of gas without causing muscular spasm, to insert a small rubber tube not more than one quarter of an inch in diameter, four or five inches into the bowel, and to hold it in place by a safety pin secured in the outer dressing. The bowels should be moved within twenty-four hours of the operation by irrigation with hot normal salt solution.

For the first three days the diet should be liquids or very light semisolid ingesta. After this solid food may be taken. The bowels should be moved once in every twenty-four hours by the administration, preferably, of castor oil, next in order calomel triturates, 2 to 2½ grains, to be followed, if necessary, by Epsom

salts. Under no circumstances should fecal matter be allowed to accumulate and interfere with the process of repair by overdistention.

When there is no prolapse of the mucous membrane and when there are only two or three isolated hæmorrhoidal tumors, the rational method of treatment is to deal with each individual tumor as advocated by Earle and A. B. Mitchell and as modified by L. S. Pilcher.[1]

When the sphincter has been dilated and the hæmorrhoids stripped down to the anal margin, the tumor should be picked up by the mouse-tooth forceps, and the small narrow curved forceps, with a bite of about one and a half inches, should be made to grasp the tumor parallel with the long axis of the rectum and be tightly clamped (Fig. 508). It is not necessary to incise the mucous membrane around the base of the hæmorrhoid.

If there is a single tumor the forceps may take a free hold of the mucous membrane, but when there are two or more tumors to be removed, if too much tissue is included in the grasp of the instrument an uncomfortable narrowing of the bowel outlet may result.

It is better to err on the safe side and grasp not more than two thirds of the mass, as the remaining third will be constricted by the continuous suture. After the forceps has been clamped, the tumor and mucous membrane should be cut away with the scissors to within about one eighth of an inch of the instrument. A No. 2 ten-day catgut suture is now inserted as follows:

A full-curve Hagedorn needle is carried one eighth of an inch beyond the point of the instrument through the mucous membrane and out one quarter of an inch distant, and is tied. This suture secures the vascular supply of the hæmorrhoid and prevents subsequent hæmorrhage. A running suture, which passes underneath the forceps and then over it until the cut surface is all included, is inserted, and the forceps is then unlocked and withdrawn and the suture tightened by traction, and finally tied (Fig. 509).

The *clamp* and *cautery* operation is still preferred by many operators of large experience. It is performed as follows: After stretching the sphincter, the tumor is drawn out and grasped at its base between the jaws of the clamp (Fig. 510), and the blades closed by tightening the screw in the handles until the hæmorrhoid is strangulated. It is advised to grasp the hæmorrhoids in such a manner that the instrument points directly up the bowel. With the scissors the mass is cut away about one fourth of an inch external to the clamp, and the cut surface thoroughly cauterized with the Paquelin or the actual cautery. The ivory plates upon the jaws of the clamp protect the mucous membrane of the bowel from being burned. When this is done, the blades should be slowly separated, and, if any



Fig. 510.—Smith's hæmorrhoidal clamp (ivory-plated).

oozing is seen, the bleeding point should be again touched with the cautery. The after-treatment is the same as for the preceding operation.

In *capillary hæmorrhoids* the chief symptom is hæmorrhage. The bleeding occurs with and after each stool, or may follow violent exercise or straining. If the finger is carried into the bowel, no tumors are felt, and there is usually no tenesmus. If the speculum is employed, the mucous membrane will be seen to be studded with bleeding points or tufts projecting a slight distance from the normal level of the lining membrane of the rectum. They are red, not unlike small raspberries in appearance, and bleed profusely at the slightest provocation.

[1] "British Medical Jr.," February 28, 1905; "Annals of Surgery," August, 1906.

They are really new formations or chronic granulation tissue, rich in capillary loops.

The *treatment* consists in dilatation of the anus and rectum with the speculum, and in touching the bleeding points with the Paquelin or hot-iron cautery until all bleeding ceases.

Catarrhal Inflammation of the Rectum and Sigmoid.—Tuttle's rectal irrigator is used in applying either hot or cold water in irrigation, as may be indicated in the case under consideration. Tuberculosis is now recognized as the ætiological factor in a number of conditions about the anus and rectum. It may develop primarily or secondarily in the skin, muco-cutaneous, mucous and cellular tissues (Tuttle). The miliary form is rare, developing as minute nodules or infiltration, which feel like small shot or millet seed beneath the epidermis. Practically all varieties end in ulceration. The typical tubercular ulcer has ragged, irregular edges, with a tendency to spread from the cutaneous margin into the anal mucous membrane.

Treatment is local and constitutional. Local repair is scarcely possible unless the general resistance of the patient can be improved. As a rule, soothing local applications are better than drying powders.

Primary tuberculosis of the low portion of the intestinal tract is exceedingly rare, and is almost unknown in adults. Secondary to the disease in other organs, it is comparatively frequent. The diagnosis is difficult, and requires careful inspection with the proctoscope. They are, as a rule, not painful, and appear as irregular ulcers, with slightly elevated, sloping bases, surrounded by slightly thickened and undermined edges (Tuttle). The local treatment is to scrape out, cauterize, or stimulate the ulcers, and to improve the general condition.

Gonococcus proctitis is a rare affection, and will be treated of in another chapter. The parts should be kept clean by sponging or external irrigation with mercuric chloride, 1–2000, and intra-anal irrigation with permanganate of potash solution.

Anal chancroids are treated in the same way as are those of other portions of the body. Herpes of the anus appears as one or more groups of elevated vesicles, in which is an accumulation of clear, milky white serum. They sometimes coalesce, to form a large bleb (Tuttle). They usually break down and leave large raw surfaces. The bleb should be opened, the thin covering excised, the parts washed with 1–3000 mercuric-chloride solution, warm, and a drying powder, such as aristol, applied.

Eczema of this region should be treated by improving the general condition of the patient. Application of warm water, to which is added a small quantity of bicarbonate of soda, is one of the most soothing local applications. The surfaces should not be irritated. Oxide-of-zinc ointment is one of the best local remedies.

Pruritus Ani.—This distressing affection is a symptom of a number of diseases connected with the peritonæum, vulva, and anus. It is at times due to the presence of parasites, certain forms of pediculi, and to the *trichophyton* or fungus which produces eczema marginatum. It is found in the superficial layers of the epidermis, and is readily transmissible. The spores or mycelia may be recognized by examining under the microscope a small scraping of the epidermis, treated with diluted liquor potassi. The application of hyposulphite of sodium, one dram to the ounce of water, or an ointment of about the same proportion, will effect a cure. Eczema and herpes also cause itching. Not infrequently pruritus is caused by a small parasite, the ascaris vermicularis, which infests the lower end of the alimentary canal. Hæmorrhoids are another cause. Among various remedies, combination of carbolic acid, 2 drams, salicylic acid, 1 dram, and glycerine, 1 dram, applied by means of a camel's-hair brush or on a swab, after bathing in hot water, is highly recommended. Mathews recommends campho-phenyl, 1 dram, distilled water, 1 ounce, applied as a lotion after the application of hot water, repeating frequently if necessary. Chloral hydrate, 10 to 30 grains, in glycerine and water, often affords instant relief. When there is an erythematous or eczematous condition about the margins of the anus, ichthyol, 10 parts, boric

acid, 5 parts, and lanolin, 85 parts, will relieve the distressing symptoms. Diachylon ointment has also been found of use. Professor Tuttle recommends highly the following formula of Adler: Fluid extract hamamelis, ℥j; fl. ext. ergot, ℥ij; fl. ext. hydrastis, ℥j; comp. tinct. benzoin, ℥ij; carbolized olive or linseed oil, ℥j; and carbolic acid (five-per-cent strong), ℥j. Shake well before using and apply externally.

Nitrate of silver in solutions of from two to twenty-five per cent are among other more heroic remedies prescribed. When the parts are dry and fissured, Tuttle recommends painting with flexible collodion, and to mix one per cent of ichthyol with this in cases where there is considerable thickening of the skin. "With all these applications, the parts should be protected from rubbing on each other with pledgets of cotton or gauze. Every case of pruritus is a problem in itself."

Allingham noticed that pressure over the anus would relieve the sensation of pruritus, and advised the introduction of a specially formed plug into the anus at bedtime, keeping it there by a bandage throughout the night. Occasionally this brings relief. All local catarrhal conditions should be carefully treated, diseases of digestive disorders corrected, and general constitutional treatment combined with local measures.

CHAPTER XXVII

GENITO-URINARY ORGANS—KIDNEYS—PYELITIS, PYELONEPHRITIS, HYDRONEPHROSIS, NEPHROLITHIASIS—URETERS

Wounds.—Rupture of the kidney may occur not only *directly* from a *penetrating* wound, but from a blow without penetration inflicted over this organ, and *indirectly* as from a fall from a height, striking on a remote part of the body as the buttocks or feet. The immediate symptom is hæmorrhage, which is proportionate to the extent of the injury and especially to the location of the wound in the kidney. If only a limited area of the cortex is torn, the bleeding may not be dangerous, but where the larger vessels near the hilum are involved, alarming hæmorrhage may occur, while shock, vomiting, pallor, cold perspiration, rapid and weak pulse, are present in the majority of such cases. Pain is severe at times and is felt not only in the region of the organ, but is transmitted in the direction of the ureters into the bladder, producing tenesmus, extending down the leg, and in males to the testicle, of that side which is generally retracted toward the external ring. Extravasation of urine takes place, and when the capsule is torn it may find its way either through a posterior rupture into the loose areolar tissue of the retroperitoneal space, or, in cases of anterior rupture of the capsule, it may escape into the peritoneal cavity. Hæmorrhage occurs also into the uriniferous tubules and pelvis of the kidney, gravitating along the ureters into the bladder, where it may be in evidence in the discharged urine. At times blood clots form either in the ureters or in the pelvis of the kidney, preventing the urine from flowing into the bladder and producing what may be mistaken for partial suppression of urine, the urine from this kidney being discharged either into the retroperitoneal space or through an external wound, if such exists. There may be, however, as a result of injury and the consequent shock, a partial suppression of urine without regard to the occlusion of the ureter on one side. The more remote symptoms of rupture of the kidney, which are met with usually from twelve to twenty-four hours after the injury, are increased localized tenderness, distention or swelling in the lumbar region, and exacerbations of temperature, with or without rigors or chills, due to septic infection either from urine which is not sterile or through the external opening.

Treatment.—The immediate indication is the arrest of hæmorrhage, and when the conditions are alarming this should be done by immediate incision over the known location of the organ, and the hæmorrhage controlled either by packing with sterile gauze when the cortical substance alone is involved, or by direct suture with sterile catgut through the cortical substance when the location of the rupture and the character of the hæmorrhage will require. When the larger vessels near the hilum are involved, direct ligature at the bleeding point is advisable, or, in cases of great depletion, where valuable time would be sacrificed in the effort to find the bleeding points, a temporary ligature *en masse* to the pedicle of this organ will be justifiable. In counteracting the dangerous effects of such hæmorrhage, the immediate injection of a hot saline solution is of inestimable value. When septic infection has occurred, as will be determined by the symptoms just given, careful exploration with an aspirating needle, under cocaine anæsthesia, should be made at the point of selection (usually that of greatest tenderness), and if pus is discovered, an incision should be made, the pus evacuated, and the wound irrigated with mercuric-chloride solution (1–10,000) and drained with a rubber tube or iodoformized gauze wick. Even when pus cannot be discovered

by the aspirating needle, incision is indicated if there are pronounced symptoms of sepsis. The kidney may be easily reached by a perpendicular incision extending from an inch above the level of the last rib three or four inches downward parallel with the spines of the lumbar vertebræ and from three to three and a half inches from these spines. It is located just in front of the outer border of the quadratus lumborum muscle, its lower extremity reaching nearly to the umbilicus. Should the organ be practically destroyed as the result of injury, free drainage will secure safety, and some time should elapse—usually six weeks to three months—before removal of the disintegrated organ should be undertaken, in order to enable the remaining kidney to become accustomed to its increased function.

The kidney is often the seat of morbid changes, which occur partly from internal violence (calculus), or structural changes, which may at times demand surgical interference. *Pyelitis, pyonephrosis, hydronephrosis, nephrolithiasis, tuberculosis, gumma,* and certain new formations, as *cysts, carcinoma, sarcoma, rhabdomyoma, adenoma,* and *angeioma* are among the chief diseases of a surgical nature.

Pyelitis, Pyelonephritis, and Hydronephrosis

Pyelitis, an inflammation of the pelvis and calices of the kidney, is of frequent occurrence. When the substance of the kidney becomes involved it is known as pyelonephritis. In extreme cases the whole kidney may be converted into an immense abscess, divided and subdivided by trabeculæ, but limited by the original distended capsule. Inflammation of the renal pelvis, uncomplicated with any other lesion of the urinary apparatus, rarely develops symptoms appreciable to the patient or surgeon. When it assumes surgical proportions it is usually secondary to a pathological condition somewhere in the genito-urinary tract. A frequent cause is nephrolithiasis. A stone or calculus lodged in the pelvis induces inflammation by its presence or by obstruction of the ureter, and causes a distention of the pelvis with urine (hydronephrosis), or when pus is present with the retained urine (hydro-pyonephrosis). Or the disease may be due to an ascending inflammation, ureteritis, cystitis, or urethritis, or to an obstruction to the outflow of urine, caused by an enlarged prostate, or tumor, or urethral stricture, with overdistention of the bladder and ureters and renal pelvis, ultimately destroying the substance of the kidney.

The disease is usually bilateral unless caused by renal calculus or stricture of the ureter on one side. Another frequent cause of pyelitis and pyelonephritis is tuberculosis, which is often secondary to a tubercular focus in the lungs or elsewhere. The prolonged use of blennorrhetics—cantharides, turpentine, cubebs, etc.—improperly employed in the treatment of gonorrhœa, may cause an active congestion of the kidney, from which pyelitis or pyelonephritis results. The pregnant uterus, or uterus enlarged from other causes, may, by pressure upon the ureters, cause pyelitis. In rare instances violence from without may be a cause, and the disease may also result from a suppurative inflammation surrounding the kidney (perinephritis). Certain systemic infectious diseases, such as scarlet fever, diphtheria, osteomyelitis, etc., are associated with pyelitis and pyelonephritis. In these cases, however, the inflammation rarely proceeds to recognizable pus formation, and its presence is overshadowed by the gravity of the primary disease.

Direct extension of an acute gonorrhœal inflammation of the kidney, as given by Keyes, is not, as a rule, associated with appreciable renal symptoms.

Diagnosis.—Pyelitis and pyelonephritis are nearly always associated with symptoms of cystitis. A chill occurring during the course of a cystitis suggests pyelitis. The history of an antecedent attack of renal colic, a dull pain in the loin radiating down the course of the ureter and inner side of the thigh, with retraction of the testicle on that side, are strong evidence of the presence of this disease. In long-standing pyelonephritis a tumor may be made out by deep palpation. Tubercular pyelitis may be suggested by the presence of tubercular disease elsewhere. Careful examination of the urine is the most important step in diagnosis. The sudden disappearance of the pain, decline in temperature, and symptoms of sepsis, with an exaggerated quantity of pus in the urine, should con-

firm the diagnosis. These cases of explosive pyelonephritis are not uncommon. The reaction of the urine to litmus paper is of importance. In pyelitis the urine is excessively acid, remaining so for several days upon standing, with a greenish, oily deposit of pus and *débris*, while in severe cystitis, without involvement of the kidney, the urine is neutral or even alkaline from ammoniacal decomposition. Under the microscope, pus, mucus, occasionally hyaline and granular casts, blood corpuscles, and epithelial cells, peculiar to the renal pelvis, are found. In the diagnosis of this disease the cystoscope may be used with advantage to determine if it be unilateral or bilateral. The bladder should be thoroughly washed out with warm boric-acid solution to free it from all pus and mucus, then, with about half a pint of this solution in the bladder, the cystoscope should be carefully introduced through the urethra and inverted, holding the mirror well above the floor of the trigonum, the electric light turned on, and search made for the urethral outlet. The boiling up of pus, mucus, and shreds from the ureter which leads down from the diseased kidney can readily be seen. A ready means of diagnosis is to wash the bladder out thoroughly, and after fifteen or twenty minutes to collect the urine by the introduction of a clean Nélaton catheter. If the pus is abundant and evenly mixed with the urine, it undoubtedly comes from the kidney.

Treatment.—When pyelonephritis exists exploration and drainage are indicated with removal of the kidney, if the condition demands it. As a rule, however, it is safer to delay the nephrectomy until after several months of drainage in order not only to build up the condition of the patient by the arrest of septic absorption, but to accustom the opposite organ gradually to the additional labor placed upon it. In milder cases the treatment of the disease is usually the treatment of the cause. The cystitis should be treated by rest in bed, warm fomentations over the bladder and kidney to relieve pain, diluent drinks, and the administration of salol, oil of wintergreen, or other sterilizing diuretics internally; occasionally irrigation of the bladder with warm boric-acid solution is of advantage.

Urethral strictures should be divided, obstructing tumors removed, or the bladder drained; stone in the ureter or kidney pelvis, if made out, should be removed by direct incision. Tuberculosis of the kidney, if unilateral, cannot be cured other than by nephrectomy.

Hydronephrosis.—Hydronephrosis, the gradual distention of the pelvis of the kidney caused by an accumulation of the urine from an obstruction to its outflow, is usually attended by more or less atrophy of renal substance. It sometimes reaches enormous dimensions, and again may be so small as to escape observation. The condition is always a primary stage of pyelonephritis. Chronic hydronephrosis nearly always results in a suppurative inflammation. It is either a congenital or an acquired lesion. When congenital, it is the result of partial or complete occlusion of the ureter or urethra. When acquired, it is the result of an impacted calculus in the ureter, or stricture of this tube, pressure of pelvic tumors, growths in the bladder encroaching upon the urethral or ureteral outlet, flexion of the ureter due to movable kidney, enlarged prostate in old men, and urethral strictures.

The diagnosis is quite difficult unless the swelling is sufficiently large to attract the attention by its size or to cause symptoms of compression of the abdominal organs. In most cases where the obstruction is not permanent but recurs at intervals, the disappearance of the swelling with the discharge of an extraordinary quantity of urine is a positive symptom of hydronephrosis. Pain may be absent or excruciating in character. Pressure of the tumor upon the overlying colon may give rise to disturbance in this tube. Uræmia is at times present and of serious character when the disease is bilateral. A positive diagnosis can be made with safety by exploratory puncture with an aspirating needle. The disease may coexist with a hydatid or an ovarian cyst, or cyst of other organs in the region of the kidney, such as the pancreas or spleen, or with abdominal ascites. In the latter, however, the level of the fluid changes with the different positions assumed, and the history of an antecedent liver trouble almost always precedes ascites. Hydatid vesicles are found in the urine or obtained by exploratory puncture, and

enable us to diagnose this cyst, which is rarely bilateral, while hydronephrosis is frequently so. Cysts of the spleen and pancreas are rare, and the early history of their origin will point away from the kidney.

In the treatment of hydronephrosis, attention should be directed to prophylaxis. The diagnosis of nephrolithiasis, enlarged prostate, or urethral stricture should demand the surgeon's attention before hydronephrosis results. In the majority of cases, with moderate tumefaction, operative measures are not indicated. Symptoms of uræmia call for warm baths, diaphoretics, and purgatives, in the effort to eliminate by the skin and bowels the necessary quantity of urea. When large enough to interfere with the comfort of the patient, or when well-marked sepsis supervenes, the fluid should be evacuated. If suppuration has resulted in the sac, preference should be given to free incision. The wall of the cyst may be stitched to the abdominal wound, or if urgent symptoms be not present, the dissection may be carried down to the cyst capsule and the wound packed with sterilized gauze for a day or two, until adhesions have taken place, after which the contents should be evacuated. In milder cases a sterile aspirator needle should be introduced at the most prominent part of the obstruction near the last rib, and the contents removed. Injections of iodine, carbolic acid, and other irritating substances should not be practiced. Impacted calculus demands removal.

Nephrolithiasis

The most frequent condition of nephrolithiasis is where the urinary salts are precipitated in crystalline form within the kidney tubules, pelvis, or other portion of the urinary tract. A gouty or rheumatic diathesis predisposes to *gravel*. A renal stone is formed by these small urinary crystals aggregating around a nucleus of epithelium, mucus, blood clot, or other organic substance. Although chiefly composed of uric acid in various combinations, or oxalic acid in combination with lime, these calculi may be as variable in composition as those to be considered in connection with diseases of the bladder. According to analyses made by Taylor of the calculi in the Hunterian Museum, those occurring in children are chiefly muriate of ammonia; in adult life, uric acid; and after forty years of age, oxalate of lime. They may be found in the substance of the kidney, in the pelvis, or projecting from one into the other; more frequently, however, they are met with in the pelvis of the kidney. A kidney stone may be single, in size varying from small particles of sand to several ounces in weight; or there may be several hundred small ones of irregular size, round and smooth by mutual friction.

The symptoms are variable. Unless severe pyelitis supervenes, or mechanical obstruction to the outflow of urine from the pelvis by impaction in the ureter is evident, the patient's attention may not be attracted to the kidney. If, however, sudden occlusion of the ureter ensues, it produces symptoms of great distress. If the stone is small and smooth, it may find its way into the bladder without much pain; but when large enough to distend the ureter, or rough, pain is extreme. It may be constant or spasmodic, and is usually referred to the neighborhood of the impaction. In males the testicle of the affected side is drawn up toward the external ring, and the pain may radiate down the thigh and leg. Vomiting may be present. The duration of the attack varies from a few hours to days. When the stone escapes into the bladder the relief is as sudden as the attack. In some instances, however, it becomes hopelessly impacted. The presence of blood in the urine is important in connection with the pain, especially so when it is increased by exercise and diminished after rest in bed. The microscope may also show epithelial cells characteristic of the renal pelvis. The discovery of small calculi that have passed with the urine confirms the diagnosis.

Treatment.—In patients known to have the uric-acid diathesis, or when the characteristic brick-dust deposit is in the urine, the kidneys should be flooded by administering large quantities of alkaline water, and by sterilization of the urine with salol and gaultheria, as heretofore given; such patients should be advised to live on a low diet, largely vegetable, to abstain from alcoholic liquors, and to take plenty of outdoor exercise. The urine should be examined occasionally, and

if found very acid, thirty grains of citrate of potassium in a large tumbler of water should be given three times a day. When the paroxysms of pain, due to the passage of the stone through the ureter, occur, morphine or chloroform should be used to allay the extreme suffering. A hot bath and fomentations may be used with benefit. In extreme cases and when the stone is known to have become impacted, exploratory operation should be done and the stone carefully removed. Should the kidney be entirely destroyed by the presence of a large number of stones or by pyelonephritis and the disease be confined to one kidney, the question of nephrectomy may be entertained. If a portion of the kidney is still capable of excreting urine, it is advisable to pack the wound and allow it to heal by granulation. If the stone be not found in the renal substance or pelvis, the whole length of the ureter must be palpated. The operations of nephrotomy and ureterotomy are described on another page.

Cysts of the Kidney.—Cystic tumors are occasionally encountered in the kidney. They are caused by an obstruction along the course of the uriniferous tubules, causing a dilatation or cyst formation from retention of the urine, are usually small, and may be single or multiple. The conglomerate variety is a true cystic degeneration of the kidney, and is rare. Both kidneys are usually involved, and for this reason the prognosis is grave. The degeneration continues with the formation of cysts, until in course of time all trace of kidney substance disappears. When bilateral, surgical treatment is not called for. Hydatid cysts, due to the lodgment of the ova of the *Tænia echinococcus*, are met with occasionally in the kidney. The tumor may become so large as to be mistaken for an ovarian cyst. Pressure symptoms on the contiguous viscera or distinct bulging in the region of the affected organs will probably be the only indication of its presence. A differential diagnosis between these renal cysts may be made by aspiration. The fluid from a hydronephrosis would be urine; that from a simple or conglomerate cyst, albuminous; while fluid from a hydatid would contain the characteristic hooklets. It is a safe rule in practice, when a tumor of the kidney becomes large enough to be appreciated by palpation and inspection, and should prove to be cystic in character, to evacuate the contents. This may be done by aspiration or, better, by an incision into the cyst, stitching the cyst wall to the edges of the wound.

Solid Tumors of the Kidney.—Of the solid tumors which affect the kidney, *sarcoma* is the most frequent; it occurs chiefly in the young, and is occasionally congenital. Carcinoma of the kidney usually assumes the (so-called) *encephaloid* form, less frequently the *melanotic*. A rare form of tumor known as *rhabdomyoma* or *myosarcoma* sometimes occurs in this organ. In the differentiation between sarcoma and carcinoma of the kidney the only guide is the age of the patient, for, as just said, sarcoma occurs almost always in the young, and carcinoma rarely before the thirtieth year of life. The presence of a tumor solid in character in the region of the kidney, with symptoms of pressure upon the ureter, renal vein, or ascending vena cava, and displacement of the mass downward in the direction of the navel, would indicate the presence of a solid neoplasm. Pressure upon the spermatic vein in the male may produce varicocele. Exploration with a view to extirpation is the only way to confirm the diagnosis as soon as a solid neoplasm is recognized. In the removal of large sarcomata in children, and, in fact, in all operations upon large vascular tumors of the body, the Trendelenburg posture is preferable, since the gravitation of the blood to the chest and to the upper extremity lessens the danger of hæmorrhage. In some of these cases a long transverse incision from the middle line to the quadratus lumborum, combined with the perpendicular lumbar incision, is essential to the safe removal of renal neoplasms.

Fibroma of the kidney has been met with in few instances, and, while not a malignant growth, it should be removed, since it produces great discomfort by displacing the organ.

Movable and Floating Kidney.—The kidney may be displaced *directly* by a blow over the seat of this organ, or *indirectly* by a fall from a height, the individual striking upon the feet, stretching or rupturing the fascial attachments.

It may also be displaced by tight lacing in women, especially on the right side, where expansion of the chest is interfered with and the liver forced downward upon the kidney in the inspiration act. It may also be displaced, as just said, by increased weight due to hydronephrosis and the development of tumors in connection with it. Rapid absorption of the perirenal fat—as in pregnancy or in disease—adds to the tendency of this organ to gravitate from its normal position. Displacement of the kidney may also be congenital. In a case which came under my observation the kidney was found in the pelvis.

A kidney is said to be "floating" when it has descended so far that it has pushed the peritonæum ahead of it and is encapsulated in the peritonæum, in the same manner as the testicle in its descent. It is "movable" when it is displaced but not encapsulated by peritonæum.

Diagnosis.—A thickened and enlarged gall bladder, a tumor of the colon, or mesentery, or omentum, should be carefully excluded. In one instance a lobular prolongation of the right lobe of the liver, in shape not unlike the kidney, was mistaken by me for a floating kidney—which organ was found in its proper place. Opening into the peritoneal cavity, the tumor was found to be a projection from the liver with the gall bladder attached. It was connected with the liver by a well-defined isthmus about two inches wide and one fourth of an inch in thickness. The presence of a tumor in the lower portion of the hypochondriac or in the lumbar region, in shape conforming to that of the kidney reducible in the direction of the normal position of this organ, and disappearing by gravitation in the same direction when the pelvis is well elevated, are physical signs which point decidedly to a misplaced kidney.

Bimanual palpation will aid in the diagnosis. It can be best recognized with the patient in a semireclining position, with the abdominal muscles entirely relaxed. Certain symptoms, such as renal colic, due to overlapping or doubling of the ureter and its temporary occlusion, or a dragging, peculiar, and sickening sensation which accompanies this lesion, should be of value in arriving at a correct diagnosis.

The treatment of this condition is surgical in all cases in which the condition of the patient will justify operative interference.

Nephropexy by the following method is advised: The patient is placed in the prone position with an inflated rubber bag or soft cushion beneath the abdomen just above the umbilicus. The incision begins over the center of the twelfth rib and runs downward to the crest with a slight obliquity toward the anterior-superior spine of the ilium. The muscular fibers should be separated by blunt dissection as far as possible, and only divided when sufficient room cannot otherwise be obtained. Any blood vessels encountered should be clamped with two forceps divided between and immediately secured with catgut. The nerves should be held aside with retractors, and when it becomes necessary to divide one or more, each end should be marked at once by a fine silk or linen thread introduced by means of a small needle in the sheath near the end. When the wound is being closed, these ends should be carefully approximated.

When the kidney is exposed and drawn well into the wound, the fatty capsule should be stripped off by dry dissection and an incision made in the capsule proper throughout the whole extent of the convex border. With dull-pointed scissors the capsule should be lifted from the body of the organ for about one inch and everted. Two sutures of silkworm gut upon long quarter-curved Hagedorn needles should now be passed through the integument near the edge of the wound directly through the capsule, and the substance of the kidney from one half to three fourths of an inch from the convex border, and again through the skin near the point of entrance, where the two ends are tied together. These two sutures passing partly through the substance of the kidney will hold the organ in position better than those passing through the friable capsule. The eversion of the capsule is done to secure permanent adhesions between the kidney and the neighboring tissues. Four or five ten-day chromicized catgut sutures may be used in stitching the capsule to the lumbar fascia if deemed necessary. The wound should then be closed with the ordinary aseptic precautions. The silkworm-gut loops are removed

about the tenth or fifteenth day by dividing one end of the loop and making a traction upon the other.

Nephrectomy is a much more difficult procedure, and is, in fact, one of the more formidable operations and requires a larger incision. To the perpendicular lumbar incision, as just given, may be added a transverse cut running from near the center of the perpendicular incision. When the organ is greatly enlarged it may be necessary to open the peritonæum, carefully guarding from infection by packing with sterile mats. It is, of course, advisable not to open the peritonæum when this can be avoided, but so great is the danger from hæmorrhage in dealing with the large vessels of the hilum that it is safer in many procedures to adopt the transperitoneal route. It is at times necessary to apply a clamp to the entire pedicle, remove the diseased organ, and then secure the vessels separately before the clamp is removed.

In cases of tuberculosis of the *kidney* and *ureter* this should also be removed, and it may be necessary to extend the incision obliquely downward along the crest of the ilium in order to reach the ureter at its lowest point. In the removal of very large tumors the author has found the incision along the linea semilunaris preferable. This incision is continued until the peritoneal cavity over the kidney is freely opened. The intestines, especially the descending colon and the splenic flexure, are displaced toward the median line and carefully guarded with hot sterilized pads. After the kidney has been removed, the wound through the posterior layer of the peritonæum should be closed by catgut sutures and the anterior wound treated after the usual manner.

Ureters

Congenital lesions of the ureter rarely call for surgical interference. Occasionally this tube comes off from the kidney in a normal position and ends in a *cul-de-sac*, or a valve may be present which prevents the escape of urine into the bladder. Instead of entering the bladder, the ureter may open into the canal of the urethra in either sex; or occasionally it may terminate in the vagina. Cases have been reported where two or more ureters or prolonged calices proceeded from one kidney and united below in a single tube. If any of these conditions can be determined, the operative treatment would require either a removal of the kidney or the transfer of the end of the ureter, first, into the bladder, if this be possible, or out through the integument at the most convenient point to establish the urinary fistula. In all such operations it is essential before extirpation of the kidney to determine the presence and condition of the opposite organ. If there are two kidneys, one of these being normal, it is advisable to remove the offending organ rather than to lead the ureter into the vagina or intestinal canal, on account of the discomfort produced by this procedure and the danger of ascending infection.

There are three narrowings in the normal ureter, the first about one and a half inch from the pelvis of the kidney; the second, at the point of crossing of the iliac artery; the third, at the entrance into the muscular wall of the bladder. It is at these points that calculi or inflammatory matter, pus, etc., drifting downward from the pelvis are apt to lodge.

The ureter is a muscular cylinder, varying in length from ten to fifteen inches. It descends in a slightly curved line from the kidney to the urinary bladder, and its relation to the peritonæum should be carefully studied. Normally it is so firmly adherent to this membrane that when the peritonæum is lifted the ureter goes with it. In retroperitoneal operations it may be easily found attached to the peritonæum and running about half an inch external to the line of adhesion of this membrane to the spinal column.

Traumatic lesions of the ureter may occur from penetrating wounds and (in certain cases of fracture) from projecting particles of bone, or perforation may occur from the pressure of an impacted calculus. The treatment demands exposure of the seat of injury, suture of the divided ends of the canal, as will be described hereafter, or, if this is not possible, the establishment of an external urinary fistula, after which at some proper time the removal of the kidney of that side may be considered. Impaction of a calculus in the ureter may be determined

by the symptoms already given in the section on nephrolithiasis, and in addition the X-ray may be called into requisition.

Deaver advises opening the pelvis of the kidney and introducing a long probe or sound into the ureter until the stone is encountered. If the lodgment has occurred at the two lower contractions, palpation by the rectum or vagina for the lower, and direct palpation through the abdominal wall for the upper narrowing, may succeed in locating the stone. An incision may be necessary to a correct diagnosis, especially when the stone is located in the upper contraction, and, when found, if the stone cannot be crushed between the thumb and finger, the ureter should be opened and the calculus removed.

Willard Bartlett [1] advises an incision, which is not necessarily extensive, parallel to the external border of the rectus muscle, extending upward from near the pubis as far as required. The peritonæum is exposed, but not opened, and gently pushed toward the middle line, the hand of the operator keeping as close as possible to this membrane, which will drag the ureter into the wound, so intimate is the attachment between them.

With the tube between the thumb and first finger of the left hand, the ureter is followed and the stone located. The stone is tightly held between the thumb and first finger of the left hand while the wall of the ureter, which is stretched over the stone, is nicked with the point of a sharp knife, and the foreign body is then squeezed through the tiny opening which stretches to accommodate its passage. No stitches are taken in the ureter, the small wound closing spontaneously. A fine cigarette drain is carried down to the vicinity, and the abdomen closed except at the lower angle.[2]

Longitudinal wounds of the ureter which communicate with the peritoneal cavity should be closed by direct suture, and in all such operations thorough

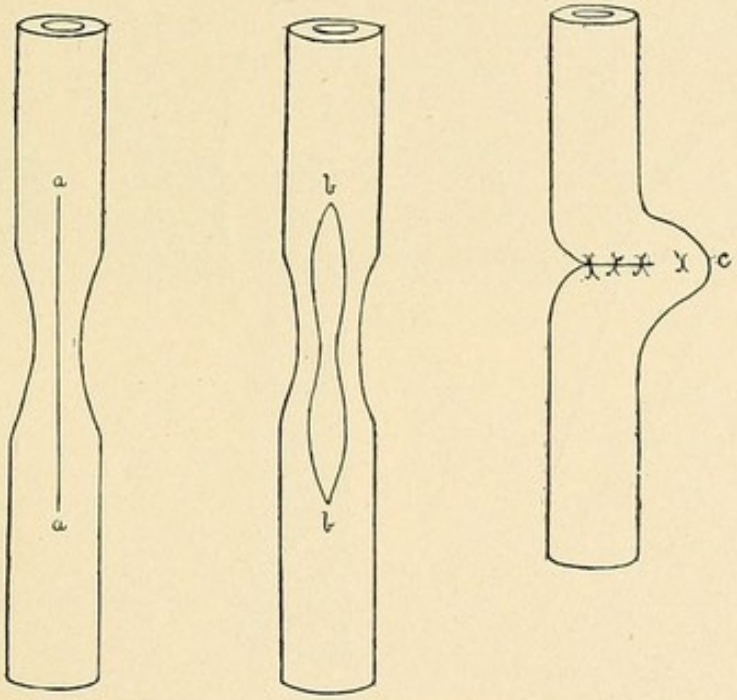

FIG. 511.—Fenger's method for relief of stricture of the ureter.

drainage should be secured. When longitudinal wounds of the ureter, accidental or incised, do not open into the peritonæum, it is not necessary to employ sutures, since such wounds usually close by granulation.

In dealing with the ureter, the extraperitoneal route should be used whenever possible. Cicatricial stenosis, if not too extensive, should be treated by Fenger's method. Make a longitudinal incision through the contracted portion; bring the

[1] "Surg., Gyn. and Obst.," September, 1907.
[2] Bartlett reports four operations successful in this manner, with no leakage.

upper and lower ends of the incision together by folding the ureter upon itself, and unite the contiguous surfaces to each other with silk sutures (Fig. 511).

To expose the ureter in the retroperitoneal space, make an incision from the last rib to near the iliac crest, parallel to and three and a half inches from the vertebral spine. From the anterior spine, when necessary, the incision should be extended inward and downward to near the center of Poupart's ligament. Upon reaching the peritonæum, this is carefully detached and raised by the finger until its line of adhesion to the spinal column is reached. The ureter will be found adhering to the peritonæum from half an inch to one inch from the line of adhesion of the membrane to the spinal column. On account of the position of the vena cava ascendens on the right side, the line of adhesion is somewhat more external.

In *transverse* wounds with complete division, efforts at direct suture and reunion have all failed on account of the great difficulty of manipulation in so deep a situation and the retraction and separation of the ends. The more rational procedure is to form a fistula by transferring the end of the upper portion of the divided tube to the integument at a convenient point, usually near the kidney

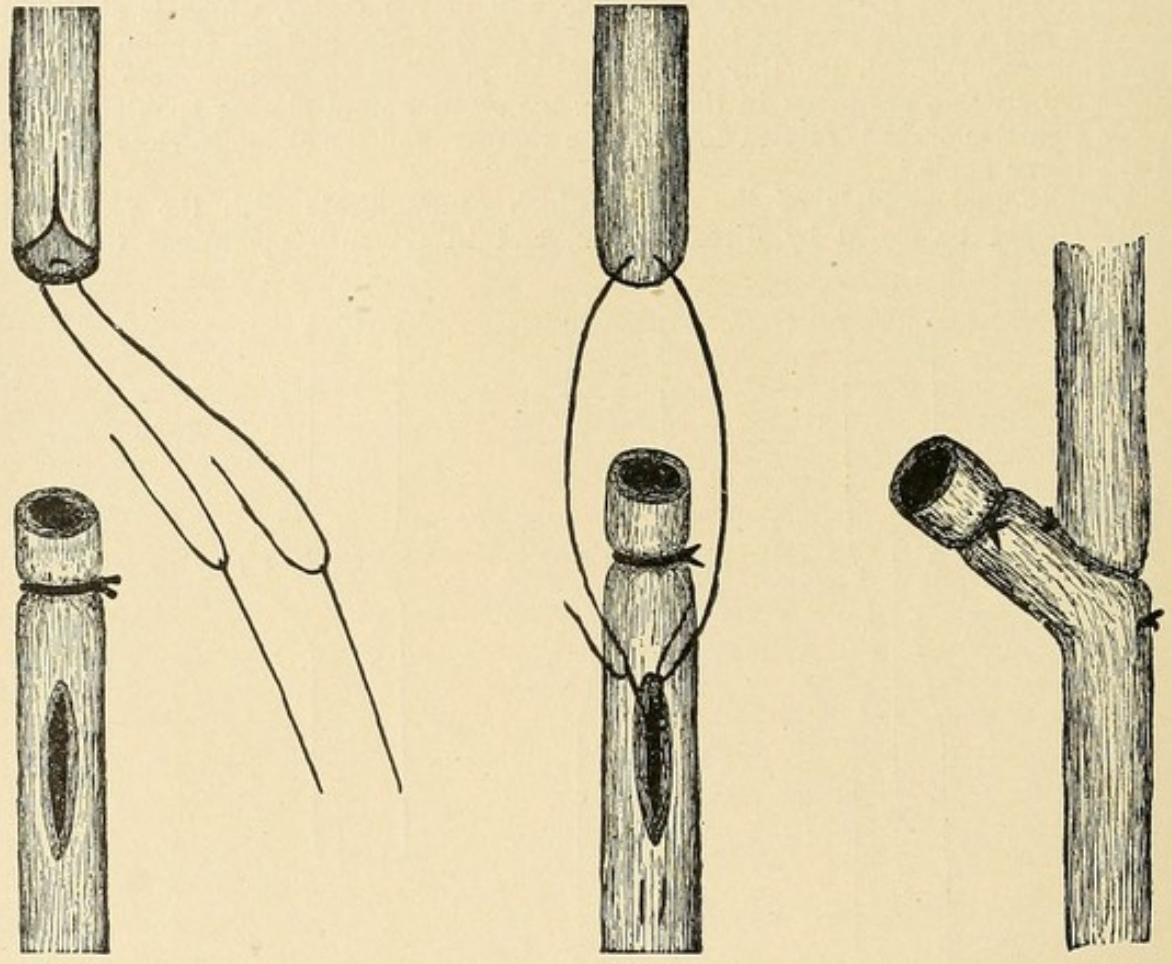

No. 1. No. 2. No. 3.

FIG. 512.—Van Hook's method of anastomosis of the divided ureter.

posteriorly. For security, a ligature may be applied to the lower end. The question of nephrectomy will be a later consideration.

Implantation into the bowel is such a great inconvenience to the patient, as a rule, and accompanied by such risk of ascending infection, that it is scarcely advisable.

In Van Hook's operation invagination of the upper into the lower segment has been successfully performed. "Ligate the lower portion of the tube one eighth or one fourth of an inch from the end with silk; with fine, sharp-pointed scissors, make a longitudinal incision beginning one fourth of an inch below the ligature,

the opening to be twice as long as the diameter of the ureter. In the upper portion of the ureter, with scissors, make an incision beginning at the open end of the duct and carrying it up one fourth of an inch. Pass two very small cambric sewing needles, armed with a single catgut thread, through the wall of the upper end of the urethra, one eighth of an inch from the extremity and from within outward, the needles to be one sixteenth to one eighth of an inch apart (Fig. 512). These needles are now carried through the slit in the side of the lower end of the ureter into and down the tube for half an inch, where they are pushed through the wall of the duct side by side. By traction upon this catgut loop pulling upon the two cambric needles, the upper segment of the duct is drawn into the lower

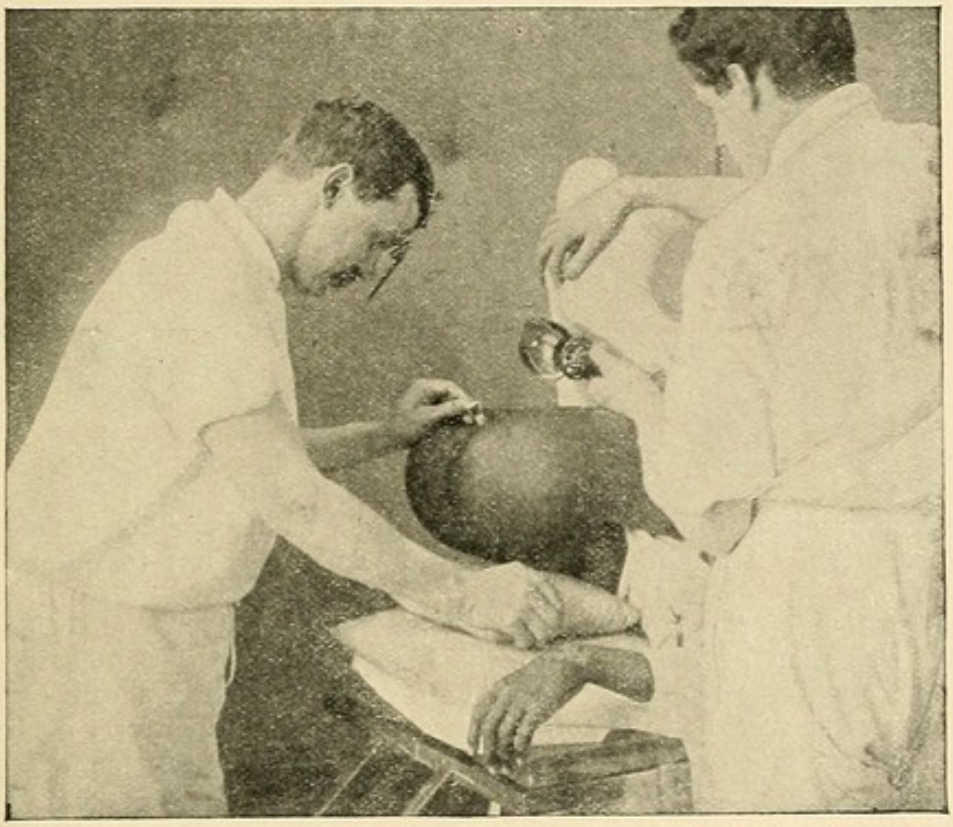

FIG. 513.—Direct ocular inspection and catheterization of the ureters in the female. (Howard Kelly.)

segment. This being done, the ends of the catgut thread are tied together securely. The ureter is now carefully enveloped with peritonæum and fine silk sutures inserted, passing only through the muscular layer" (Figs. No. 2 and 3).

When only the lower portion of the ureter is to be explored, an incision parallel with Poupart's ligament, beginning about at its center and extended upward in the general direction of the anterior-superior spine and the fibers of the aponeurosis of the external oblique will be sufficient. The peritonæum is displaced inward as soon as it is encountered, the whole procedure being retroperitoneal. When removal of the ureter at its attachment to the bladder is necessary, it may be divided, and the ligature is not essential for the reason that the valvular arrangement of the entrance of this tube into the bladder prevents regurgitation of the urine. A cigarette drain or tube should always be left in place as a matter of precaution. This may be removed in two to four days as indicated.

In several instances in which a ligature has been placed upon the upper end of the divided ureter, where so much has been removed that end-to-end reunion was impossible, and where the upper end could not be transplanted into the bladder, it has resulted in an arrest of the function in the kidney on that side.

When a calculus is extracted by any of these methods, the wound should be packed and careful gauze-wick drainage established, the wound being allowed to heal by granulation.

It is at times essential to transfer the end of a divided ureter into the bladder. The method suggested by Van Hook and successfully performed by Prof. Florian Krug is as follows: The left ureter having been divided, a small opening was made into the bladder and the end of the upper section of the ureter carried through this wound. Several rows of carefully inserted silk sutures attached the tube to the wound in the bladder, care being taken not to permit the needle to penetrate through the muscular layer into the lumen of the tube. Careful cathe-

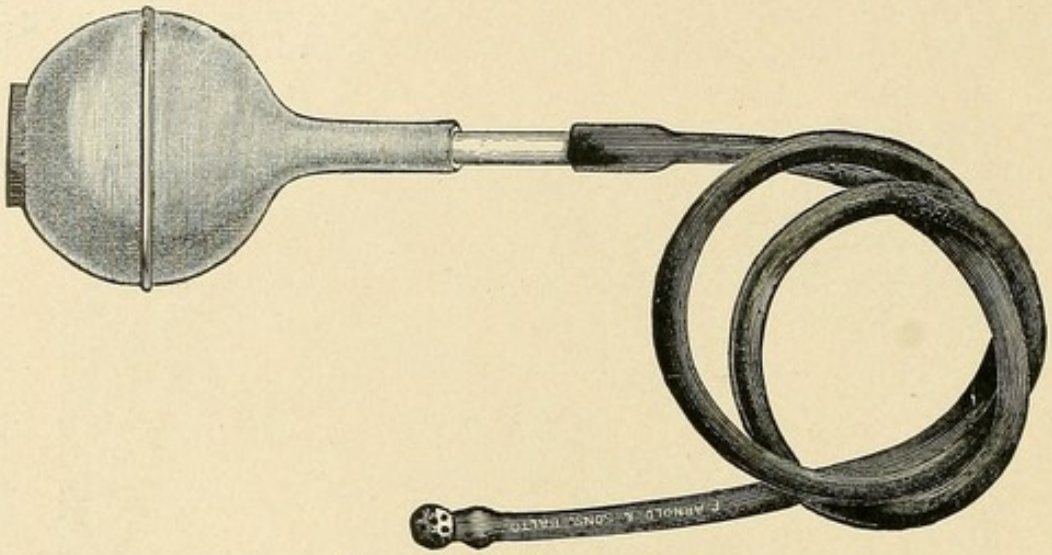

Fig. 514.—Suction apparatus.

terization was practiced in order to keep the bladder empty and to prevent leakage by hyperdistention. Ascending infection of the kidney is apt to follow ureteral transplantation.

Catheterization of the Ureters—Method of Kelly.—Direct exploration of the ureter and irrigation of the pelvis of the kidney through this tube is done as follows: The apparatus required consists of a female catheter, a conical urethral dilator and several specula with obturators, a common head mirror, a lamp with an Argand burner or electric droplight, a pair of long, delicate mouse-tooth forceps, a suction apparatus for completely emptying the bladder, a ureteral searcher, a ureteral catheter without any handle, cushions for elevating the pelvis, or an inclined plane.

Careful cocainization of the urethra will in many instances enable the operator to examine the bladder and catheterize the ureters practically without pain. Should necessity demand, general narcosis may be employed.

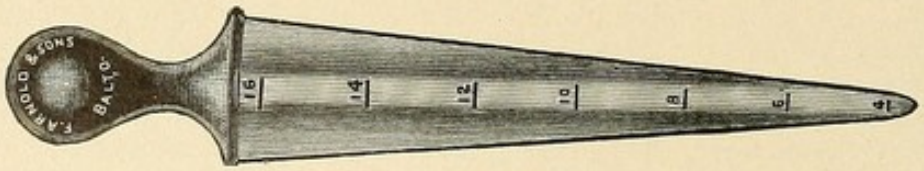

Fig. 515.—Dilator.

The patient is placed upon the back near the edge of the table with the pelvis elevated as shown in Fig. 513. The bladder is completely emptied by catheter and the suction apparatus (Fig. 514). The conical graduated dilator (Fig. 515) is gently bored into the external orifice of the urethra until it is dilated as much as eight or ten millimetres. A speculum corresponding to the size indicated by the dilator is next introduced, holding the handle at first well above the level of the external meatus, carrying the end on through the urethra and into the bladder by gently sweeping the hand downward and inward over the symphysis. The obturator is now withdrawn, and the bladder at once fills with air, with an audible suction sound. If the air does not rush in, the hips of the patient are

still further elevated (from twelve to sixteen inches above the level of the table, Fig. 513). With the head mirror attached, an electric droplight or bright lamp is held close to the patient's symphysis pubis to make the angle of reflection as

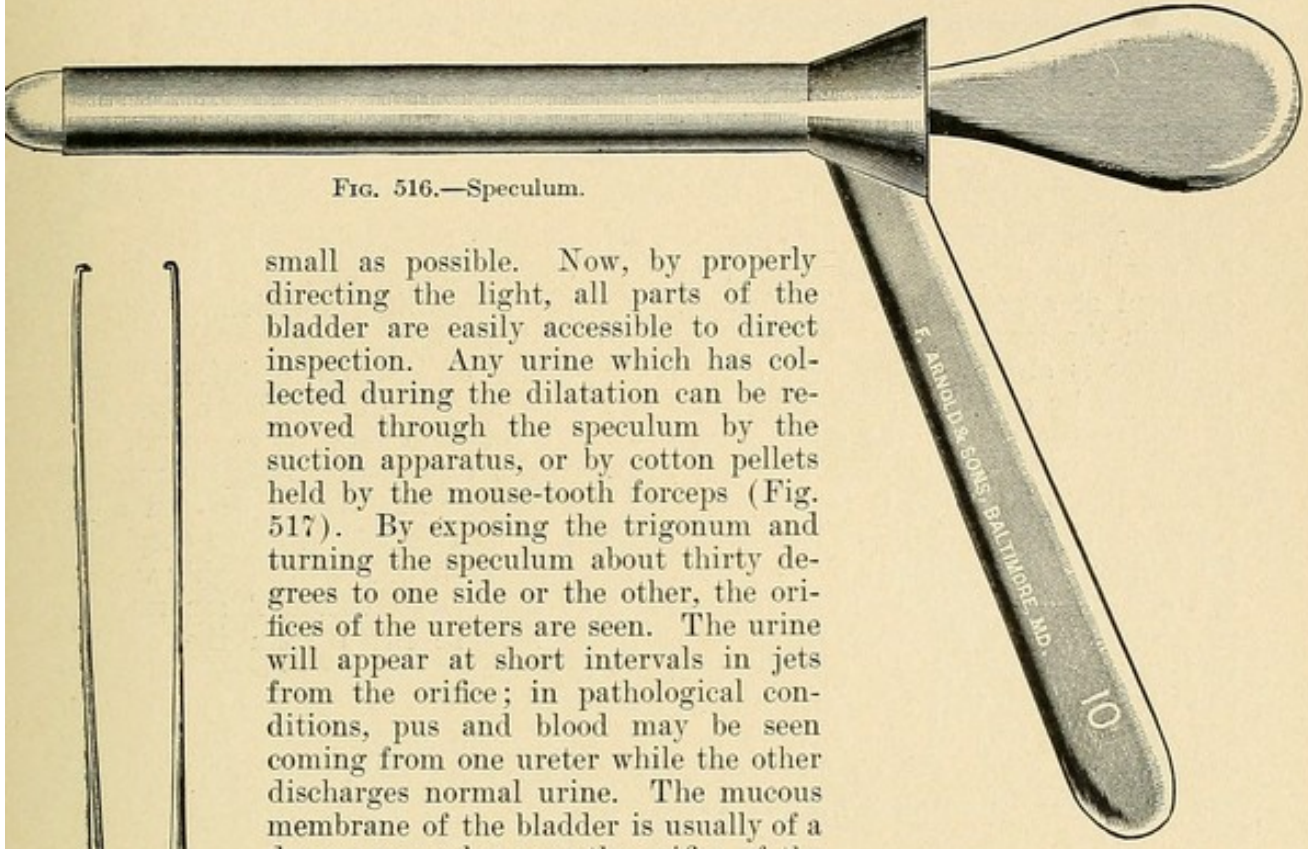

Fig. 516.—Speculum.

small as possible. Now, by properly directing the light, all parts of the bladder are easily accessible to direct inspection. Any urine which has collected during the dilatation can be removed through the speculum by the suction apparatus, or by cotton pellets held by the mouse-tooth forceps (Fig. 517). By exposing the trigonum and turning the speculum about thirty degrees to one side or the other, the orifices of the ureters are seen. The urine will appear at short intervals in jets from the orifice; in pathological conditions, pus and blood may be seen coming from one ureter while the other discharges normal urine. The mucous membrane of the bladder is usually of a deeper rose-color near the orifice of the ureter; at times it is deeply injected. The searcher (Fig. 518) may be introduced through the speculum into a suspected ureteral orifice, which, if found, will allow the searcher to pass in for several centimeters. The latter is then withdrawn and the ureteral catheter (Fig. 519) introduced. By leaving this catheter in the ureter for a few minutes, the urine which descends from the kidney of that side will be discharged through it, while the urine from the opposite side collects in the emptied bladder, thus affording an opportunity to make a separate analysis of the urine of each kidney. The diagnostic value of this practice is evident. If the patient is stout, or if the bladder for any reason does not readily distend with air, the inspection will be best conducted in the knee-breast posture.



Fig. 517.
Forceps.

Pawlik's Method.—Free-hand ureteral catheterization is practiced in the following way: The patient is brought with the buttocks to the edge of the table, with the legs and thighs sharply flexed. The vulva and vagina are cleansed with soap and water and the urine drawn from the bladder and preserved for inspection. The bladder is then injected with a solution of methyl blue, about six ounces. The posterior vaginal wall is now retracted with a Sims speculum, which exposes the anterior wall. On close inspection two prominent folds will be seen sweeping over the anterior wall about half-way up and out to the sides on to the lateral walls toward the cervix. These are the "ureteral folds" of Pawlik, the pioneer in this method. Parallel to and just above these folds the ureters are to be sought. Kelly's ureteral sound is now introduced through the urethra into the bladder and held with the concavity of its tip toward the floor of the bladder. A little pressure on the floor reveals its position to the eye, which is kept on the vaginal wall. It is now guided in the direction of the ureteral

folds, and, should it catch in the ureteral orifice, it will at once be felt to have a determinate direction as it slips backward and outward toward the posterior pelvic wall. The ureter may now be palpated on the sound. If the catheter is in the



Fig. 518.—Searcher.

Fig. 519.—Catheter.

ureter, after waiting a few minutes, the urine begins to flow, drop by drop, clear and unmixed with the methyl solution, demonstrating that it is being collected at a point above the bladder. For the recognition of stricture or stone in the lower portion of the ureter, this method is invaluable.

There is always such a very considerable danger of introducing infection into the ureter by catheterization that when any other method of securing a specimen of urine from one or the other ureter for differentiation may be employed, this should be used. This may be done by the Luys separator. This instrument, shaped like a catheter, is introduced into the bladder, and should be held accurately in the median line imbedding the convex surface of its curve deeply in the trigonum and posterior bladder wall. The bladder should be thoroughly washed out and all the residual fluid removed. The mechanism of Luys' separator is so arranged that the diaphragm or partition may be lifted from the concave surface of the instrument, and this prevents the urine descending from one ureter to be mixed with that from the other. As it trickles into the bladder it is carried out on either side of the diaphragm through a separate catheter. In this way a differential study can be made of the excretion from the two kidneys without any danger of infecting a healthy ureter.

CHAPTER XXVIII

THE BLADDER — CONGENITAL MALFORMATIONS — WOUNDS — HERNIA — CYSTITIS — SUPPRESSION — INCONTINENCE — NEOPLASMS — THE URINE — CALCULUS — LITHOTRITY — CYSTOTOMY — FOREIGN BODIES

CONGENITAL malformations of the bladder are fortunately rare. There may be complete absence of this organ, the ureters opening directly on the surface or into the vagina or rectum; there may be more than one bladder or a normal bladder divided into two parts by a septum. In these cases in the male there may be a double penis with a separate urethra to each bladder. In the case of the child (Fig. 520) born in 1894 there are two organs, "each penis perfectly formed, one

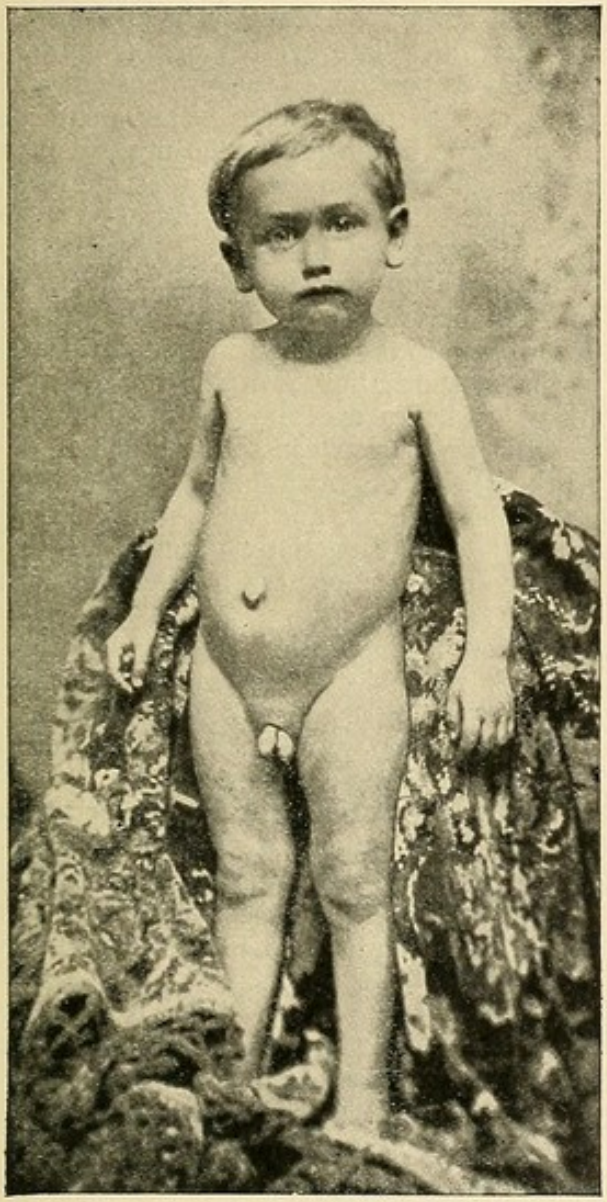

FIG. 520.—Double penis. Case in practice of Dr. J. D. Cole, of Tennessee.

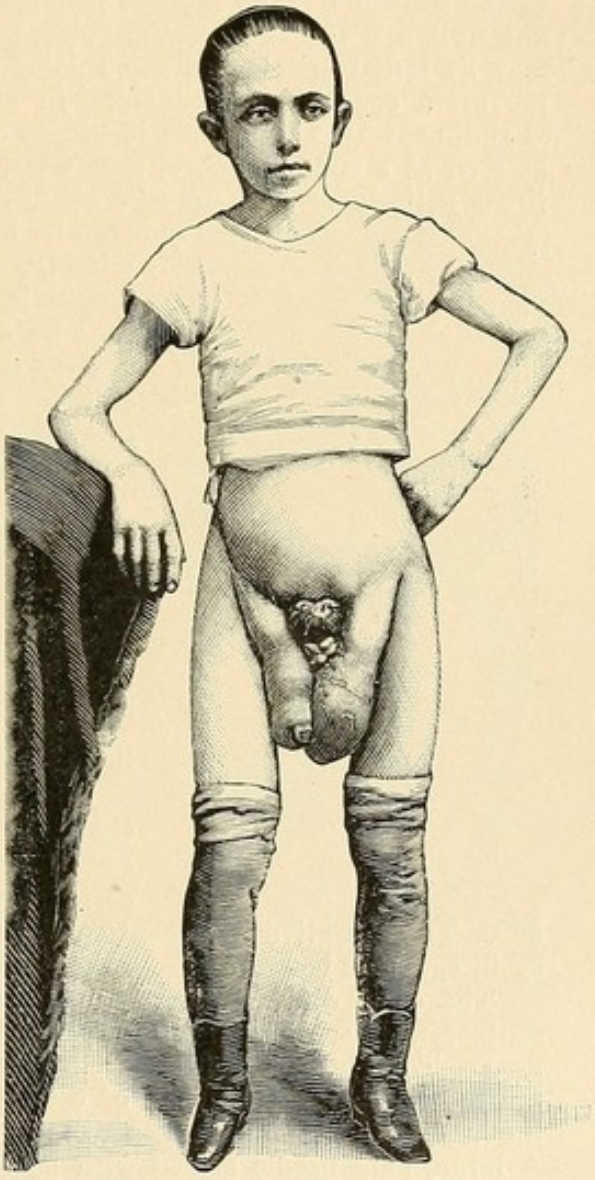

FIG. 521.—Exstrophy of the bladder. So-called hermaphrodite.

a little to the left of the median line and a little lower than the other, which is nearly in the middle line. They are one fourth of an inch apart at the level of the skin. He passes a good stream of urine through both urethræ at the same time. A single urethra in the perinæum bifurcates into a channel for each penis. The scrotum is divided into three compartments. The right and left compartments contain each one testicle, and in the middle pouch is something which feels like a testicle. The anus was imperforate. I operated by an incision three inches in depth, when the blind end (*cul-de-sac*) of the rectum was found and freely opened." [1] The child recovered, and is now living at two years of age.

Exstrophy, or eversion of the bladder (Fig. 521), is almost always met with in males. It is caused by a failure of development in the anterior pelvic and abdominal regions. The integument, muscles, pubic bones, and anterior part of the bladder wall are missing. Through this gap the part of the bladder which may be present is protruded, as a mass of variable size (depending upon the extent of the deformity and upon the position of the patient), from one inch up to three or four inches in diameter. In the erect posture it is always largest, being pushed out by the descent of the abdominal viscera, and may be complicated by hernia of the intestine. The mucous membrane, which covers the mass, is in appearance not unlike a recent non-strangulated *prolapsus ani*. The orifices of the ureters may be found opening at some point on the lower portion of the protrusion, and are often considerably dilated. In all cases of exstrophy the genital apparatus is rudimentary. The penis is wholly or in great part wanting. The urethra may be seen as a simple groove, into which the seminal ducts enter. The scrotum, at times entirely absent, may in other cases be present, lodging the testicles, or it may be bifid, with one organ in each sac, or entirely missing, the testes remaining in the abdomen, or lodged in the groin or thigh.

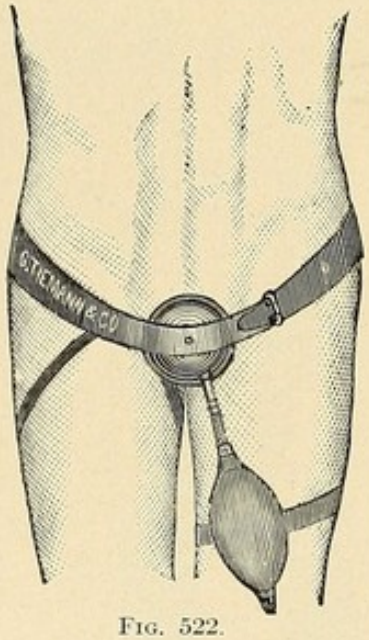

Fig. 522.

The degree of *exstrophy* varies in proportion to the extent of the malformation. In the more favorable cases the pubic bones are almost united at the symphysis, and the protrusion consequently small.

In females the genital organs are also rudimentary. The clitoris, nymphæ, vagina, and uterus may be absent or displaced, and only partially developed. The general appearances of the tumor are the same in both sexes.

In males the condition of bifid scrotum and absence of the penis resembles somewhat the normal genitals of the female, the so-called hermaphrodite.

Exstrophy of the bladder, even in a mild form, is a source of great annoyance.

The *treatment* is chiefly palliative, and consists in the application of an apparatus, with or without operative interference, to drain the urine and prevent excoriations. A suitable instrument is shown in Fig. 522. The operative treatment consists in an effort to cover in the protruding mass by integument borrowed from the immediate vicinity of the tumor.

The chief difficulty lies in protecting the flaps from suppuration excited by contact with septic urine. Silkworm-gut or silver-wire sutures are always to be used. To protect the flaps from the urine, Levis' procedure more nearly meets the indications. It consists of establishing a false urethra from that portion of the undeveloped bladder near the orifice of the ureters through the perinæum. A large, long needle armed with good-sized thread or wire is passed through the wall of the bladder just at the opening of the ureters and brought out in the perinæum just in front of the anus. The wire is allowed to remain as a seton, and through the fistula thus established, and enlarged by interrupted dilatation with bougies, the urine flows. If necessary, the testicles may be removed and the

[1] Personal communication from Dr. J. D. Cole, of Newbern, Tennessee, to author.

skin of the scrotum used to line this false passage. When this is accomplished, the second stage of the operation consists of covering the exstrophy with integument turned over from the immediate neighborhood of the deformity. Wood's method (Figs. 523 and 524) consists of three flaps, two lateral and one central.

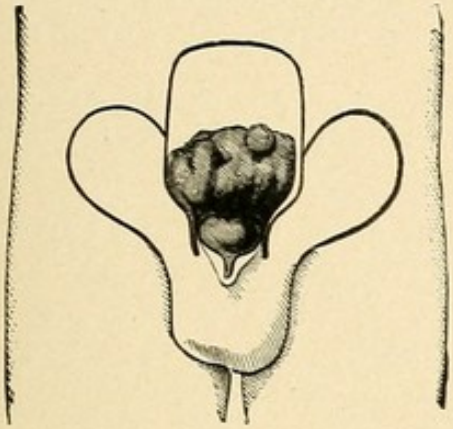

FIG. 523.—Wood's method. Outline of flaps.

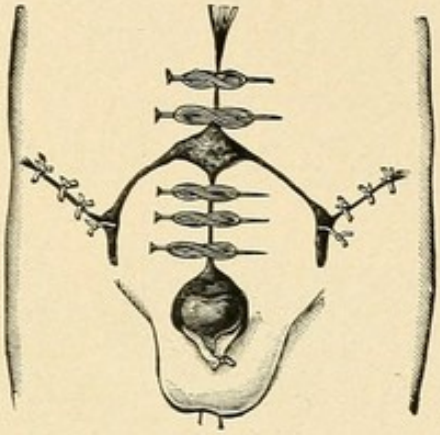

FIG. 524.—The same after the sutures have been applied.

The central one should be square, its width at least one third greater than the defect to be covered; its length sufficient to cover the bladder space completely when turned down, also allowing one third for contraction. The flaps should consist of skin and superficial fascia. The two lateral pear-shaped flaps are now dissected up from the groin with breadth equal to the length of the first flap and length equal to the width of the defect to be covered. These flaps when dissected up are reflected across the reversed abdominal flap, meeting in the median line and united with silver-wire or silkworm-gut sutures. These sutures should without complete perforation include a portion of the thickness of the abdominal flap, so as to keep the surfaces in contact. The deficiencies left after the removal of the flaps should be drawn as nearly together by sutures as possible. Any space which cannot be covered is allowed to granulate or is repaired later by grafting. A perfect functional result is not to be hoped for in view of the absent sphincter. Some form of apparatus to control the urine will always have to be worn.

HERNIA VESICÆ, OR CYSTOCELE

Hernia of the bladder is of very rare occurrence. In the male it usually occurs through the inguinal canal, and is almost always associated with some form of intestinal or omental hernia. It rarely descends into the scrotum. In the female it usually takes the form of a cystocele into the vagina. It occurs most often in the aged and in those who have atonic and dilated bladders. The bladder becomes top-heavy and flabby, and readily prolapses into the patulous inguinal canal. It is important that a correct diagnosis be made, as the condition may simulate hydrocele of the cord, and thus, under error of diagnosis, be incised. The practical point in diagnosis is the diminished size of the tumor after micturition or withdrawal of the urine by catheter.

The treatment consists in restoring the organ to the normal position, as the hernia which it complicates is cured by radical operation.

The prolapse of this organ in females (cystocele) will be considered in the chapter on gynæcology.

WOUNDS OF THE BLADDER—RUPTURE

Wounds of the bladder may be caused by penetration from without, as from a stab or gunshot wound, by rupture from overdistention, by violent concussion over the lower abdominal region when the organ is even only partially distended, by instrumentation, and by direct injury from displaced fragments of the pelvic bones. Penetrating wounds of the bladder are rare, not only on account of the

protection afforded by the pelvis, but because its usual condition is that of only partial distention. This is especially true of wounds received in military practice, since the majority of soldiers, under the excitement which attends going into action, voluntarily empty this organ.

A distinction should be made between bladder wounds which communicate with the peritoneal cavity and those which penetrate the organ in that part of its surface not covered with peritonæum.

Diagnosis.—The diagnosis of a penetrating wound of the bladder will depend upon the escape of urine through the external opening, should the situation of the external wound be favorable for the discharge of urine, the presence of blood or foreign matter of any kind in the urine drawn by catheter, severe pain over the region of the bladder, constant desire with inability to pass water, and usually profound shock. If these points are considered, together with the receipt of an injury, a penetrating wound, or the coexistence of a disease of the bladder wall, or an obstruction to the outflow of urine from any cause, the diagnosis should be readily made. It must be remembered that the symptoms differ considerably according to the location of the wound. If the posterior or peritoneal surface is perforated, the urine will escape into the peritoneal cavity, producing in most cases rapidly supervening symptoms of peritonitis, accompanied with extreme prostration ("abdominal shock"). This, however, does not occur in all cases, and in rare instances, when the urine is aseptic, it may remain in the peritoneal cavity for many hours without producing infection or any marked symptoms of peritoneal inflammation. When the perforation is through that part of the bladder wall not covered by peritonæum, there occurs usually rapid and widespread infiltration of the loose connective tissue of this region, followed by symptoms of œdema and, in the presence of septic urine, rapid rise of temperature, pain, and rigors, and the usual phenomena of septic infection and pus formation. Wounds of the bladder are rare in children, and naturally much more frequent in men than in women, the proportion being ten to one.

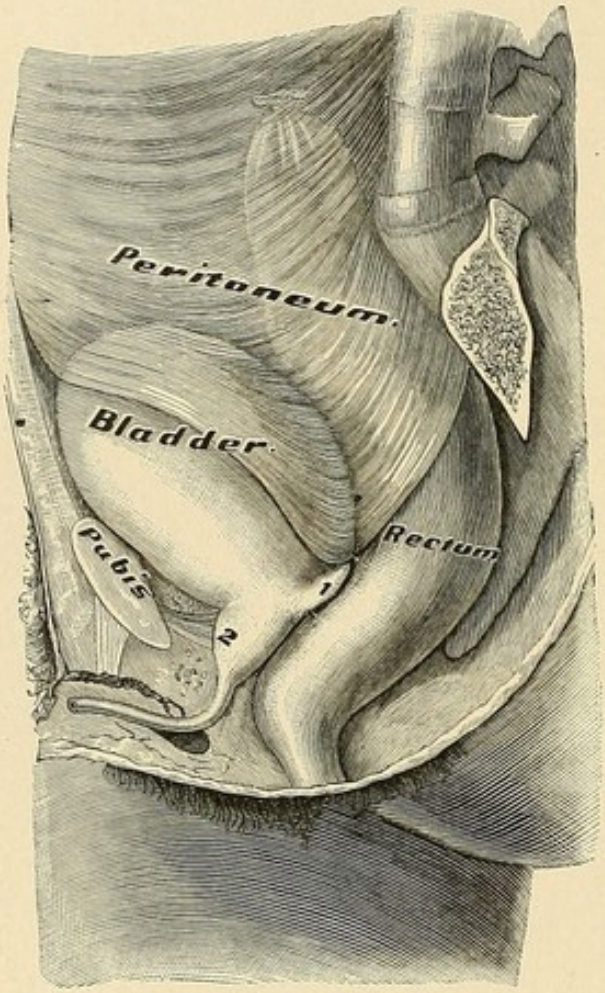

FIG. 525.—The relations of the peritonæum to the bladder when distended. (After Tarnier.) 1, The situation of the trigonum vesicæ. 2, Prostatic urethra.

The diagnosis may be confirmed by introducing a catheter through the urethra, which usually gives escape to a small quantity of bloody urine. If an aseptic solution, such as boiled water of proper temperature (120° F.), or boric-acid solution, be carefully measured and injected, it will be found, if there is a perforation, that the quantity returned through the catheter will be considerably less than that injected, as a certain portion will escape through the rupture, and will not reënter the bladder. If there be no rupture, the distention of the bladder by the injected liquid will be evident by percussion above the symphysis pubis.

In *rupture* of the bladder from overdistention where no injury has been received, the history of the case is one of long retention and overdistention, great suffering, constant desire to urinate, and finally a feeling as if something had given

way, followed by partial or complete temporary relief from the pressure within the bladder.

The *prognosis* in rupture of the bladder is always grave, the gravity depending in good part upon the location and extent of the opening. If the urine escapes into the peritoneal cavity, death is inevitable unless operation is performed in the first few hours of the extravasation, and even then, if the urine be markedly septic, the ratio of mortality is high. In extraperitoneal rupture the prognosis is more favorable.

Treatment.—The indications are to establish the diagnosis at the earliest possible moment after the receipt of the injury by the use of the methods just advised, and when these fail and the character of the injury is not clear, an exploratory operation is advisable. If the diagnosis be clear, operation is imperative. In intraperitoneal rupture, nothing is left but to perform laparotomy in the median line between the umbilicus and the symphysis pubis, taking care not to use the Trendelenburg posture or to elevate the pelvis, for fear that extravasated urine may be brought in contact with peritoneal surfaces not yet involved in the infection. The escaped urine should be removed by careful sponging, and the pelvic basin thoroughly flushed with hot saline solution, boiled water or boric-acid solution at 120°, and this carefully dried out with gauze mops. Any loops of intestine in contact with the urine should be brought out through the wound, protected with hot towels, and carefully cleansed with mops of sterile gauze. The abdominal incision should be free, in order to expose the rent in the bladder, which should then be sutured with fine sterilized silk, applied after the manner of the Lembert suture in intestinal surgery. If the edges of the wound are ragged, they should be clipped with scissors and the sutures inserted not more than one eighth of an inch apart, and should begin and end one fourth of an inch beyond each end of the rent, in order to insure perfect closure. It is safer in practically all cases after a bladder wound is closed to insert a Mikulicz gauze packing or drain, which consists in introducing a piece of sterile gauze, the size of an ordinary handkerchief, the center of which is pushed down into the deepest part of the pelvis behind the bladder in the form of a sac or stocking. Into this pocket a good-sized wick of gauze is carried and brought out at the lower angle of the abdominal incision. At this stage of the operation it is advisable to perform a perineal cystotomy, through which a drainage-tube should be inserted and secured in place to establish thorough drainage of the bladder. If the urine is in this way discharged, the bladder wall will unite readily. The abdominal wound should be closed from above downward, leaving a small portion of the lower angle open for the extraction of the Mikulicz drain. Perineal drainage should be continued for about ten days, and requires constant attention. Should the bladder even partially fill, leakage would probably occur with fatal peritonitis.

In those rare cases where the perforation is near the trigonum and intraperitoneal, it is advised by some operators to distend the rectum with a Barnes dilator, in order to lift the bladder and bring the wound into view.

In extraperitoneal perforations the indications are to secure immediate free drainage, which may be done through the perinæum at the most convenient point, and this, when necessary, should be reënforced by suprapubic incision and counter-drainage from the prevesical space. Wounds of this variety close spontaneously. It is better to rely upon the Mikulicz drain than to stitch the edges of an intraperitoneal rent of the bladder to the abdominal wound.[1]

[1] The first successful operation for gunshot wound of the bladder was performed by Amos C. Walker, of Fort Worth, Texas, March 3, 1890. Ten hours after the injury from a 38-caliber pistol ball the abdomen was opened. The pelvis was filled with blood clot and urine. The bladder was perforated near the summit, it having been distended with urine at the time of the shooting and thus lifted above the symphysis pubis. The ragged aperture in the bladder was held open by tenacula and the edges pared smooth. Silk sutures (Lembert) closed the wound. After careful peritoneal toilet, the abdominal incision was closed without drainage. Six hours after operation the catheter was introduced and some bloody urine removed. This was repeated in six hours, and after that period the patient passed his water voluntarily. The recovery was perfect. The only criticism of this brilliant pioneer work is that for the assurance of safety the catheter should have been used every three or four hours for as many days.

Cystitis

Cystitis, an infectious inflammation of the urinary bladder, is of frequent occurrence. It may be due to direct infection from septic inflammation of the urethra, as frequently occurs in gonorrhœa and after traumatism of this canal by the use of sounds, or by the downward extension of a pyelonephritis. It is present in practically all cases of tumor or persistent urethral obstruction, paralysis of the bladder, stone, etc. It may be superficial, involving only a portion of the mucous membrane, or at times the entire epithelial lining. Most frequently, however, the lesion is limited to the most dependent portion of the organ, the *trigonum*, the internal ureteral orifices and prostate, which is properly considered a part of the urinary bladder. It may be interstitial, involving the muscular coat, and, in very aggravated forms, it may invade the serous coat, producing pericystitis and peritonitis. According to the intensity and duration of the inflammation, cystitis should be considered as *acute* and *chronic*. Acute cystitis is most frequently caused by the extension of an infectious urethritis into this organ or by using an unclean catheter. Vaginitis and severe metritis may produce cystitis by direct extension of the infectious process. It may be caused in rare instances by sudden and unguarded exposure to cold and wet. Certain drugs, as cantharides, may produce it, and again it appears in connection with certain exanthematous fevers. In rare instances, a blow upon the abdomen immediately above the pubes or an injury in the perineal or rectal region will cause cystitis. Chronic inflammation is present as a rule in all cases of neoplasm of the bladder, vesical calculus, enlarged prostate, stricture or other obstruction, and is sometimes due to the irritation of concentrated urine. In tropical countries chronic cystitis is caused quite frequently by the presence of a parasite (*Bilharzia hæmatobia*), one instance of which disease is elsewhere given.

Acute cystitis is usually temporary and disappears under proper treatment, leaving no persistent lesion of the bladder. The most common pathological change is an injection of the blood vessels of the trigonum. This congestion may at times be so severe that rupture of the capillaries takes place, with hæmorrhage into the bladder. The mucous membrane is swollen and œdematous, and the superficial epithelial cells become loosened and detached. In very severe cases extensive ulceration, and even sloughing of the mucous membrane, may be present.

In the *chronic* form of cystitis the extreme pain which accompanies acute cystitis is usually absent. The urine becomes thick and alkaline in reaction, and flakes of mucus containing bacteria, epithelial cells, pus, and other *débris* are present. The bacteria convert the urea into carbonate of ammonia, producing the well-known ammoniacal decomposition of the urine, which intensifies the inflammation. The bladder wall itself becomes thickened. The normal folds or *rugæ* are hypertrophied. The thickening may be caused by an increase of the muscular elements. There is usually, however, atrophy of these elements with a hypertrophy of the connective tissues, in which the cavity of the bladder is lessened, *concentric hypertrophy*. When the cavity is increased and the walls thickened, it is called *eccentric hypertrophy*.

Causes.—Directly or indirectly, gonorrhœa may stand as the chief cause. Stricture of the urethra, especially in the membranous portion, enlarged prostate (*in which case it is more often the result of catheterization than of the actual obstruction*), calculus, vesical tumors, paralysis with decomposition of urine, gout, and rheumatism are other causes. An attack is precipitated by exposure to cold and wet, and pyelitis and pyelonephritis are nearly always accompanied by inflammation of the bladder.

Symptoms.—The most prominent symptom of acute cystitis is a constant desire to micturate with the passage of only a few drops of urine, accompanied by pain, burning, and straining (tenesmus). The pain may extend to the perinæum or above the pubes, radiate down the inner side of the thighs, or to the sacral region. Again, there may be pain at the head of the penis. The pain is increased at the close of the attempt to urinate, and reaches its intensity as the last few drops are forced out. The diagnosis is clear when frequent micturition, pain, and pus in

the urine are present. If there be rupture in the capillaries due to intense congestion, blood will be present in the urine, although it is only in severe cases that this is found, and its presence is usually discovered only by the microscope. The urine, as a rule, is neutral or alkaline in reaction, with a distinctly foul odor, and always contains albumin due to pus.

Microscopical examination of the urine is of great value in making the diagnosis and should always be employed. There may be fever or not. In mild cases there are no symptoms other than those referable to the bladder. In severe cases constitutional symptoms, such as chills and high temperature, may be present.

In chronic cystitis all of the symptoms described in the acute form are lessened; pain may be slight or entirely absent, but the urine is always thick and fœtid.

Treatment.—In acute cystitis it is of first importance to secure perfect rest in bed in that position which gives the least sense of discomfort. As the inflammation is usually confined to the most dependent portion of the organ, the trigonum and the prostatic urethra, it is advisable to elevate the foot of the bed and place a pillow under the patient's hips. By these means pressure upon the irritated viscus by the intestines, which usually rest upon it, is relieved. Morphia for the alleviation of pain and the enforcement of rest are necessary. Hot or cold applications, as found most agreeable to the patient, should be employed. The use of morphia *per os* or hypodermically, in my opinion, is preferable to suppositories, which must, of necessity, produce a certain amount of irritation when they are inserted so near a diseased organ. The rectum should be carefully emptied by a warm enema or by the administration of calomel triturates. The free administration of water—preferably alkaline waters, such as Vichy—and citrate of potassium in twenty-grain doses are advised. In both the acute and chronic forms of the disease it is essential to eliminate all alcoholic drinks.

In chronic cystitis, treatment should be directed first to the cause of the inflammation. When resulting from the presence of a stone or tumor of the bladder or prostate, from retention by stricture or any other obstruction, causing ammoniacal decomposition and a general cystitis, removal of the stone or tumor

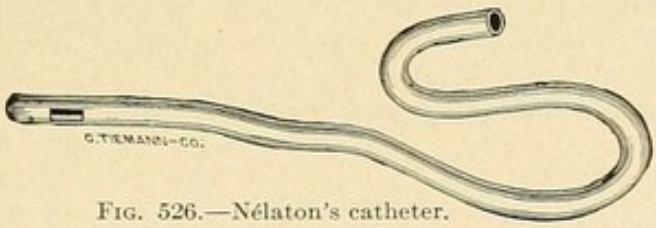

Fig. 526.—Nélaton's catheter.

and of the obstruction is imperative. Cystitis resulting from pyelitis cannot be cured unless the pyelitis is first relieved. In certain forms of retention resulting from paralysis or atony of the muscular walls of the bladder, the retention may be relieved by the employment of the soft catheter, and the condition of the organ temporarily relieved by irrigation. The soft-rubber catheter of Nélaton (Fig. 526) produces less irritation than the harder instruments, and should be pre-



Fig. 527.—Velvet-eyed gum catheters, curved and straight.

ferred. An instrument of good size, Nos. 12 to 14, United States scale, with a perfectly smooth point should be selected. It should be perfectly sterile, warm, lubricated with sterile sweet oil or glycerine, and introduced with the patient resting on the back. An effort should be made to carry the eye of the instrument

just deep enough to project well into the bladder without touching the posterior wall. The double-current soft catheter (Fig. 528) is a useful instrument for bladder irrigation, but is not necessary for successful treatment. Its objections are that it is costly and more difficult to keep thoroughly sterile than the simpler instrument. The advantage it possesses is that the inflow and outflow is constant. The ordinary simple catheter will, however, answer every purpose. It is important to prevent the admission of air into the bladder by filling the catheter with the

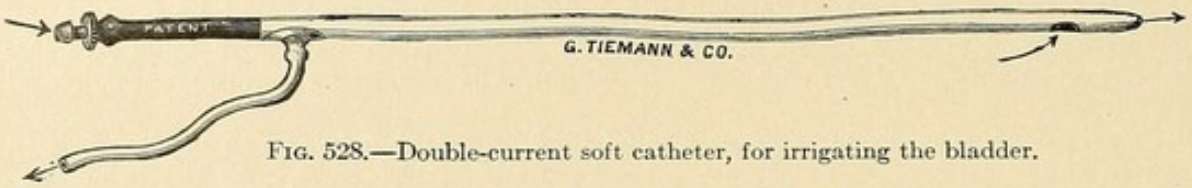

FIG. 528.—Double-current soft catheter, for irrigating the bladder.

fluid to be injected when the eye of the instrument is passed to the cut-off muscle. If the bladder should be partially filled with urine at the time of introduction, the air which is in the instrument will be forced out immediately by the outflow of urine. For the purposes of irrigation, a warm solution of permanganate of potassium, 1–5000 (three grains to the quart) is employed, and next in order a solution of boric acid, one dram to the pint, and, when these are not convenient, clean water which has been boiled and allowed to cool down to a temperature of 100° to 105° F. may be used. Several pints of the irrigating fluid are placed in a fountain syringe, a small quantity is allowed to run through the nozzle to displace the air, the point of the nozzle is then introduced on the end of the catheter and the irrigating fluid allowed to run in slowly, and the bladder distended to the point of tolerance. It is then allowed to empty itself through the catheter, and this is repeated until the fluid which escapes is clear. These irrigations may be repeated once or twice weekly if necessary.

A simpler method of irrigation of the bladder which obviates the use of the catheter is as follows: The nozzle of the irrigator should be carried into the meatus and the anterior urethra flushed out in order to render it aseptic. Then by firmer pressure of the nozzle at the meatus, the urethra is gradually distended by hydrostatic pressure, and in the course of a minute or more the cut-off muscle gives way

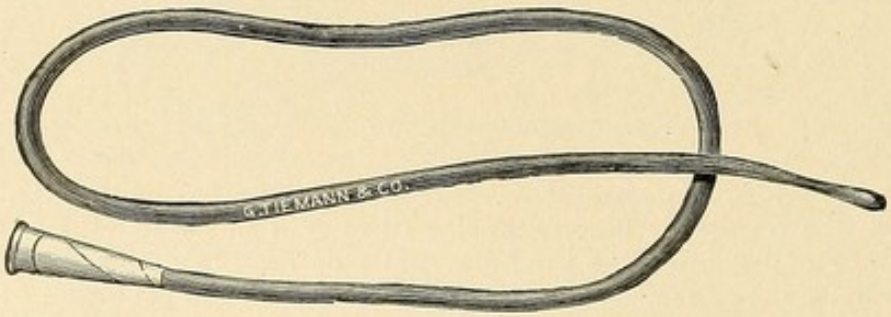

FIG. 529.—Filiform catheter.

and the fluid runs readily into the bladder. If there is marked resistance due to spasm of the compressor urethræ, if the patient is advised to attempt to empty his bladder, this muscle immediately gives way and the water flows back into the bladder. As soon as it is sufficiently distended, the patient is allowed to evacuate the injected fluid and the operation is repeated until the fluid returns clear.

In cases that resist all conservative measures, incision with drainage, preferably by the suprapubic method (or through the perinæum, as in the median operation for stone) is imperative.

My clinical notes contain twenty cases of suprapubic cystotomy for chronic cystitis uncomplicated by tumor or stone. This condition existed in all the cases of stone and tumor, making twenty-nine additional, or a total of forty-nine cases operated upon in which chronic cystitis existed. The shortest period of drainage was seventeen days; the longest, eight weeks. In twelve of the twenty cases of

drainage in uncomplicated cystitis a cure resulted; two others were improved, and in one permanent drainage was established on account of paralysis of the bladder; one case was not benefited by the operation.

Paralysis of the bladder may be partial or complete. It may be caused by violence inflicted directly to the organ or in its immediate neighborhood, by pathological changes in its muscular tissue, or by traumatic or idiopathic lesions of the cerebro-spinal axis; or it may occur under the influence of certain emotions in which no lesion is recognizable.

The prolonged overdistention of the organ which is common in prostatic hypertrophy will induce the same condition.

In the *treatment* of this affection the first indication is to prevent prolonged distention of the organ by catheterization, which should be repeated at least twice in twenty-four hours. If a catheter cannot be introduced, suprapubic aspiration



Fig. 530.—Black French catheter, blunt-pointed.

should be practiced. Cystitis may be avoided if the urine is carefully and regularly drawn off with careful antiseptic precautions. Attention should next be directed to the removal of the cause of the paralysis. If the paresis is permanent, suprapubic drainage is advisable.

Retention.—As just stated, paralysis of the muscular walls of the bladder is a cause of retention of urine. Lesions of the sensory nerves of this organ also induce retention, which is proportionate to the loss of sensibility. The chief cause, how-



Fig. 531.—Black French catheter, olive-pointed.

ever, is some form of obstruction at the neck of the bladder or in the urethra. As will be seen in treating of hypertrophy of the prostate, this is a frequent cause of retention. Organic stricture, spasm of the compressor urethræ (or "cut-off") muscle, and mechanical occlusion of the urethra, are also common causes of this affection.

Diagnosis.—Distention of the bladder may be determined by palpation, percussion, and exploration. In this condition it rises well above the level of the



Fig. 532.—Gummed silk-woven catheter.

symphysis pubis, at times as high as the umbilicus, and causes tension of the recti muscles or protrusion of the abdomen. In one instance I drew off six quarts of urine. By direct pressure, the desire on the part of the patient to urinate may usually be increased, and, if the abdominal walls are thin, the spherical character of the organ may be recognized.

In *treatment*, the evacuation of the contents is the immediate indication. The patient should be put to bed and given the benefit of a full dose of opium. This



Fig. 533.—Gummed silk-woven bougie.

agent is useful in alleviating pain, in securing relaxation of the muscular elements of the urethra and prostate, and—by producing diaphoresis—in diverting fluids from the kidneys to the excretory apparatus of the skin. A soft-rubber (Nélaton)

catheter should be preferred; but, if this cannot be introduced, a firmer, olive-pointed instrument (Fig. 531) should be employed. The silk-woven and gummed catheter (Figs. 532 and 533) is also a useful instrument, and if, on account of its elasticity, it cannot be introduced, the stylet of Professor Keyes (Fig. 534) should be inserted into the catheter to give it the required stiffness. The metal



Fig. 534.—Dr. Keyes' wire stylet.

catheter (Fig. 535), if properly constructed and carefully introduced, can be made to safely overcome any ordinary resistance. It should be of heavy silver, strong, perfectly smooth, and should have a curve corresponding to that of the normal urethra. In size it should correspond to No. 10, 12, or 14, U. S., and the larger sizes should be preferred.



Fig. 535.—Strong silver catheter.

The introduction of a metal catheter or sound through the normal urethra into the bladder is accomplished as follows: The patient is placed upon the back with the lower extremities parallel with the body. If about ʒj to ʒij of a two-per-cent solution of cocaine hydrochlorate is introduced, the normal sensibility will be lost as far back as the compressor muscle. The urethra is then flushed with warm boric-acid or permanganate-of-potash solution. The catheter is placed in water at a temperature of about 105° to 110° F., and, when warmed through, is lubricated with sterilized sweet oil or glycerine. If the operator is right-handed, it is best to stand on the left side of and facing the patient. The penis is seized with the left hand and held steady while the end of the catheter is carried into the meatus. At this stage of the procedure the shaft of the sound is parallel with Poupart's ligament, and, as soon as the first four inches have passed into the urethra, while it still descends, the handle is gradually brought toward the median line. The point is now engaged in the bulb, or at the anterior layer of the triangular ligament, and the shaft is about perpendicular to the plane of the abdomen. Without exercising any force to push the instrument in the direction of the bladder, the handle is slowly and steadily carried downward until the shaft is parallel with the anterior surface of the thighs. While this manœuvre is being effected, the point is tilted from the floor of the bulb into the membranous portion which offers the greatest resistance, not only because it is the narrowest part of the canal, but because the compressor-urethræ muscle must be overcome. All the time that the instrument is being pushed toward the bladder the penis should be pulled over the catheter, for in this way the lining membrane is put upon the stretch and the introduction greatly facilitated. When the neck of the bladder is reached, the instrument will usually have penetrated a distance of eight or nine inches. It should be borne in mind that even a silver catheter is capable of doing damage to the urethra if improper force is employed in its introduction. There is usually no resistance except by the compressor muscle, and this is only spasmodic. If the point of the instrument is kept well against this obstruction by depressing the handle between the thighs, it will slip by with the first relaxation of this muscle. The methods of introducing an instrument into the bladder in abnormal conditions of the urethra and prostate will be given later.

If it is found impossible to reach the bladder by the urethra, the urine should be evacuated by the aspirator. The apparatus shown in Fig. 536 will give general satisfaction. The needle should be carefully cleansed by boiling. The medium or smallest needle will suffice. If its introduction is preceded by a small hypo-

dermic syringe needle, and ♏x of four-per-cent cocaine are injected, the operation will be painless. The pubes being shaved and disinfected, and everything in readiness, the cock (*6*, Fig. 536) is closed; the air is exhausted from the receiver (*2*) by working the pump (*4*). The patient should be placed in the sitting posture, and the needle introduced a half inch above the symphysis and pushed directly backward a distance of two inches. The cock is now opened, and the urine flows into the bottle. If it becomes necessary to empty the receiver, the stopcock should be turned, to prevent the entrance of air into the bladder. When the aspirator is not convenient the small trocar and canula may be introduced. The danger of leakage at the point of puncture is insignificant.

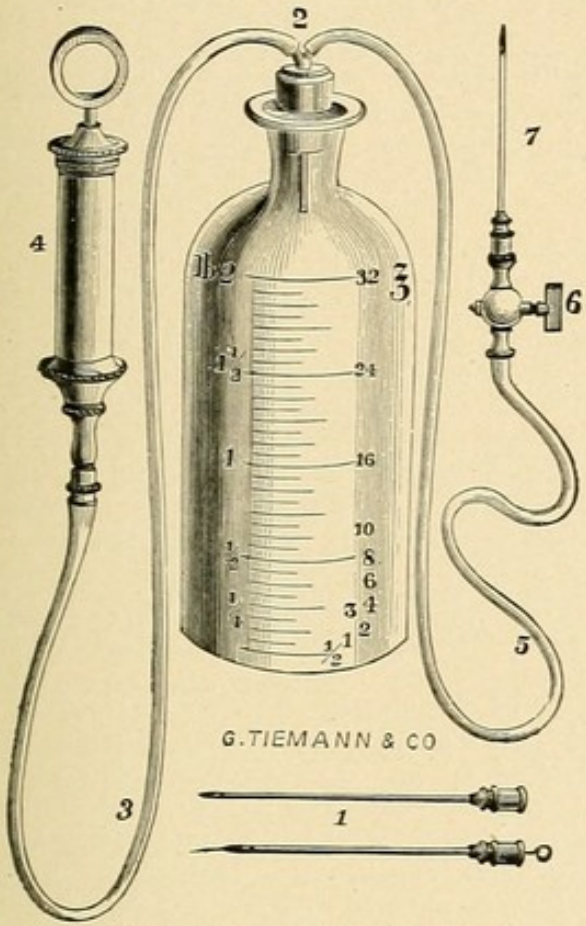

FIG. 536.—Tiemann & Co.'s aspirator.

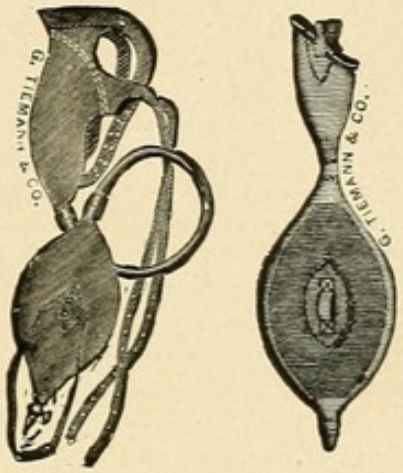

FIG. 537.—Female and male urinals, for incontinence.

When the character of the obstruction or disease is such that a permanent urinary fistula is necessary, suprapubic cystotomy is advised.

Incontinence of Urine.—Incontinence of urine occurs when the compressor urethræ is partially or completely paralyzed. It is also present in a proportion of cases of prolonged overdistention of the bladder (overflow), the pressure from behind overcoming the normal resistance of these muscles. Irritation of the bladder from any cause may produce tenesmus of this organ, and consequent inability to retain the urine. This is especially apt to occur in children during sleep, in the earlier hours of morning, when the bladder is full.

Women are more frequently affected with incontinence than men, which fact is explained not only in the better tone of the muscular system in males, but in the absence of the prostatic muscle in females, which, according to Henle, is of great aid in holding the urethra closed. The general relaxation of the pelvic muscles as a result of parturition may also account for the more frequent occurrence of incontinence of urine in women.

The palliative treatment consists in applying a urinal for the reception of the water as it dribbles away (Fig. 537).

Curative measures should be directed to a removal of the cause of incontinence. These will be given with the various lesions of which it is a symptom. In the nocturnal incontinence of children the habit may be corrected by causing the patient to be awakened and the bladder emptied once or twice during the night.

Dr. H. Marion-Sims reported to the New York Obstetrical Society a number of distressing cases of incontinence of urine in adult females. These cases were

cured by gradual and frequently repeated distention of the bladder. His method was to introduce, by means of a Davidson syringe through a catheter, cold or tepid water beginning with ℥j, holding this in for some minutes and then allowing it to be evacuated. The next day an ounce and a half was injected, and this was continued until one pint or more was easily contained. In this manner tolerance was established and a cure effected.

Suppression of Urine.—Not infrequently after prolonged operations under ether or chloroform narcosis, and especially on patients the subject of nephritis, the function of the kidneys is partially or completely suspended. Suppression may also follow an injury of any part of the body and as a result of any strong emotion. It may occur in subjects with no recognizable lesion of the kidneys, but, as said before, is especially liable to occur where these organs are diseased. The skin is usually hot and dry, the pulse rapid and full, there is great restlessness and anxiety, and the temperature is elevated several degrees above normal. The diagnosis may be confirmed by the introduction of the catheter, when the bladder will be found to be contracted and empty, or containing only a small quantity of urine. Suppression of urine is an extremely dangerous condition, and, if not relieved, rapidly induces uræmic coma and death. The best method of treatment is believed to be the intravenous injection of hot salt solution in the same manner as described in the article on transfusion. From one to two pints may be injected. The continuous influx of salt solution, as practiced by J. B. Murphy in the treatment of diffuse peritonitis, is advised when uræmia is imminent. In milder cases the urinary function may be restored by the hypodermic injection of morphia and of digitalis in the form of digitalin, reënforced by warm drinks and external applications to promote diaphoresis.

Neoplasms of the Bladder.—New growths of the bladder are classified according to the tissues from which they have their origin or of which they are composed.[1] In the epithelial group are papilloma, adenoma, carcinoma, and cysts. The connective-tissue groups are fibroma, myxoma, and sarcoma; the muscle group, myoma. A fourth or heterotopic group in which the tumor does not originate from the normal elements of the bladder wall has been suggested to include chondromyoma, rhabdomyoma, and dermoid, also adeno-carcinoma, myo- or myxo-sarcoma, when more than one variety of tissues are involved may be found.

The vast majority of neoplasms of the bladder occur in males (about ninety per cent), and the larger proportion are malignant. These may remain localized and practically unobserved for a very considerable period. Primary tumors of the bladder comprise less than one per cent of all new growths. The extension of the tumor to the bladder from a contiguous organ—the prostate, rectum, uterus, vagina, etc.—is not the rule, and tumors of the bladder by general metastasis are exceedingly rare.

While benign tumors may occur in any period of life, the malignant tumors, especially carcinoma, are most frequently observed between the fiftieth and sixtieth years of life.

Sarcoma, as is well known, occurs in old or young subjects, and may even be met with in very young children.

Papilloma, or more properly *papillary fibro-epithelioma*, may occur single or multiple, and may spring from any portion of the bladder wall. The typical form has a stem, or mushroom-like pedicle, springing directly from the mucosa, from the extremity or stump of which tufts of villi crop out, resembling in miniature a box shrub. When these spring from the trigone the pedicle is more closely attached to the submucous connective tissue, while on other portions of the bladder the attachment is less and the tumor more readily extirpated. From this it is evident that in the removal of a papilloma from the trigone very considerable care is necessary to destroy by cauterization the connections in the deep attachments in the submucous connective tissue.

[1] For this classification and the pathology which follows, the author is especially indebted to a very instructive paper read before the New York Academy of Medicine, 1907, by Dr. F. S. Mandlebaum, Pathologist to Mt. Sinai Hospital, and later published in "Surg., Gyn. and Obstetrics," September, 1907.

Occasionally these papillomata are sessile or nodular in shape, and contain an unusual quantity of fibrous connective tissue.

The softer or villous forms of papillomata at times occur with great rapidity, and may fill the entire bladder. They tend to recur after removal, and may appear in benign form or distinctly malignant. When the malignant transformation occurs it is first seen either in the deeper portions, or in the lower layers of epithelium of the villi.

A *papillary carcinoma* resembles a simple papilloma so closely that the microscope alone can differentiate. In the malignant form the epithelial cells lose the typical arrangement of papilloma, are polymorphous in character, showing an infiltration of the stroma.

Carcinoma of the bladder which is not of papillomatous origin is comparatively rare. There is sometimes observed a flat or squamous-cell carcinoma, which, breaking down, may appear in the form of an ulcer. Of this type Mandlebaum reports only two cases. The squamous carcinoma may be hard or soft, and in very rare instances the squamous and cylindrical cells are found side by side in the same neoplasm.

Fibro-carcinoma also occurs in this organ. Mandlebaum reports five cases occurring between the ages of fifty-two and sixty-five years, with infiltration of the bladder wall in each case. All terminated fatally. These tumors, which are hard and dense in structure, are confined mostly to the region of the trigone. This observer emphasizes the fact that almost all of the fibro-carcinomata (medullary or scirrhus malignant tumors) occur secondarily by direct extension from primary growths of the prostate. A knowledge of this fact suggests early operation upon the prostate in all cases of rapidly growing tumor of this organ.

Adeno-carcinoma may be found in the bladder. This type is infrequent and may also arise as a primary growth of the prostate. Mandlebaum's two cases were of this nature, and both ended fatally.

Simple adenoma and fibro-adenoma are quite rare in the bladder, and in all probability the latter form is always secondary to prostatic neoplasm.

Colloid carcinoma of the bladder is not common, and is supposed to originate from epithelial degeneration of the glandular tissues associated with the bladder mucosa, forming colloid cysts from which a carcinoma may arise.

Cysts other than those arising from the glands of Limbeck are sometimes found resulting from congenital defects of the urachus, Wolffian body, or Gärtner's duct. This form of tumor is fortunately very exceptional.

The *connective-tissue* tumors are less frequent than those just described. The most usual form, fibroma, is met with usually at the base of the bladder where it develops beneath the mucosa.

Myxoma is of more frequent occurrence, especially in childhood. It may occur as a simple pedunculated polypoid growth, or as multiple, rapidly growing nodules, having a marked tendency to recur after removal (Mandlebaum). Histologically it shows branching cells and mucous tissue, and is very vascular, the surface being usually covered with a seemingly normal mucous membrane. Its favorite site is near the urethral opening.

Myxo-sarcoma may develop from or be associated with this form of tumor.

Other *sarcomata* occurring in the bladder may be single or multiple, hard or soft. As a rule they are sessile in shape, at times pedunculated.

Myomata of the bladder are rare. They spring directly from the muscle fibers, either as single or multiple growths. As a rule they are covered with mucosa and are nodular in shape. It is almost always composed of unstriped muscle, but in exceptional instances the striated variety (rhabdomyoma) has been observed.

Dermoid of the bladder has been reported in only a single instance.

The *diagnosis* of the presence of tumor may be evident from symptoms of pressure, interference with urination, from bloody urine, from the microscopical examination of shreds of tissue discharged, by manual examination, and by the use of the cystoscope or sound. Under certain conditions where a tumor is suspected, such is the importance of its early recognition that a suprapubic cystotomy should be performed. This operation is especially commended in view of the fact that

it is practically without danger, and can be done for purposes of exploration with cocaine infiltration. The differentiation from the tumor of the prostate, or the recognition of a tumor partly prostatic and partly vesicular, may be at times determined, in the male by rectal, in the female by vaginal exploration with firm pressure above the pubis, with complete relaxation of the abdominal muscle.

Treatment.—Neoplasms of the bladder or prostate should be removed by operation at the earliest possible moment. When they are connected entirely with the bladder the route is by the suprapubic method. If they are intimately associated with the prostate and the neck or base of the bladder, the perineal route may also be combined with the suprapubic. In the operation for the removal of a tumor of the bladder the importance of a free opening in this organ should be borne in mind. The perpendicular incision in the median line should extend from below the level of the pubes at the symphysis at least as high as the peritoneal attachment, and should emergency demand, it should extend to the umbilicus or higher. The sheath of the rectus of either side may be divided for one half inch in a transverse direction, when it becomes absolutely necessary to have a wider opening. This transverse part of the incision should be closed with kangaroo tendon sutures to prevent a possible hernia. It is almost always advisable to dissect the peritonæum from the summit of the bladder for one or two inches or farther in order to permit of a free inspection. This is not difficult when the bladder has been filled with twelve to eighteen ounces of normal salt solution. Should an opening be torn into the peritonæum, this may be closed, or a careful walling off of the peritoneal cavity by gauze mats taken from hot salt solution may be done. Before incising the bladder two or three silk or linen loop sutures should be carried entirely through the walls of this organ on either side of the proposed line of incision. This can readily be done by using two full-curved Hagedorn needles. By having two needles threaded and inserting them rapidly, a very small part of the water in the bladder will escape through the puncture before the incision can be made. While the bladder is being firmly held against the abdominal wall by retraction on these loops, the incision is made by inserting the knife at the level of the pubis and cutting quickly upward in the middle line in the direction of the linea alba. Not infrequently one or two large veins are distributed to the anterior surface of this organ, and these can be avoided in the section. Should it be necessary to prevent loosening the anterior wall of the bladder from the abdominal wall, two or three additional supporting loop sutures should be inserted. The retractors are now inserted, and the internal surface of the bladder carefully examined. In order to prevent too great collapse of the bladder when it is incised and the salt solution escapes, flat retractors shaped like a fish hook have been devised, and are very serviceable. The tumor should be carefully removed, the mucous membrane being clipped off with the pedicle or base, and an application of a few drops of pure carbolic acid upon a tuft of gauze made to the wound from which the pedicle was removed. If the tumor is partly prostatic, the perineal incision and the operative method which will be given in connection with prostatectomy is advised. The after-treatment will depend in large measure upon the size and character of the neoplasm removed. For a small papilloma, the bladder being in fairly good condition, the bladder wound may be cleansed at once by a running or interrupted suture of No. 2 chromicized catgut, leaving the abdominal incision at the lower angle open for the distance of an inch, in case there should occur a leakage. A small bit of sterile gauze loosely packed into this wound will suffice. The introduction of the catheter every four hours for the first twenty-four hours, and every six hours after this, will suffice to keep the strain of overdistention from the sutures. Should the neoplasm prove to be a sarcoma, the use of the mixed toxines should be urged.

The Urine.—The average quantity of urine excreted in twenty-four hours is fifty-six ounces. This quantity varies with the amount of fluids ingested, the non-activity of the sweat glands, etc. Certain conditions of the nervous system —diabetes, chronic interstitial nephritis, chronic diffuse nephritis, and amyloid infiltration will increase the quantity.

The urine will be diminished when a small quantity of liquid is taken, by

free perspiration, fever, diarrhœa, vomiting, the early stages of acute diffuse nephritis, subacute glomerular nephritis, and toward death in all diseases (Ogden).

The normal specific gravity varies from 1.015 to 1.020, but even under conditions of health the range may be from 1.002 to 1.040. Usually the increase in quantity is accompanied by a smaller proportion of solids and a consequent lower specific gravity. This is not the case in diabetes, where the quantity is abnormally large while the urinometer may vary from 1.030 to 1.040.

The color of urine is amber or straw-color, due to the presence of indican, urobiline, etc. It is dark in proportion to the intensity of the destructive changes in the tissues, as in prolonged and violent exertion or during the progress of fevers. Carbolic acid and bile turn the urine brown or greenish-black and blood (hæmaturia) gives it its characteristic tinge. The normal odor of urine is peculiar to itself. An artificial aroma is easily substituted by the ingestion of certain foods and drinks, as gaultheria, turpentine, asparagus, etc.

Reaction.—Healthy, fresh urine is acid in reaction, changing litmus from blue to the faintest red or rose color. Acid urine will at times become alkaline within a few minutes after its discharge. The ingestion of alkaline substances in vegetable foods gives a neutral or alkaline character to the urine passed within a short time after eating. The same is true of the alkaline salts, potash, soda, etc. Urine, alkaline in reaction as it leaves the urethra—the alkalinity not due to food or medication—is an indication of disease of the bladder.

Urea.—Urea is the result of destructive tissue metamorphosis. It is increased by the ingestion of nitrogenized food and by excessive muscular exercise, and also before the chills of intermittent fever, in diabetes, chronic gout, and in the early stages of acute infection. It is also diminished after free perspiration, and as a rule during the later months of pregnancy. The quantity is diminished in practically all the diseases of the kidneys, functional as well as organic.

The average daily quantity excreted by the urine is about four hundred and fifty grains, which, with the estimate of the daily urine at fifty-six ounces, is about gr. j of urea to ℥j of the urine.

Any marked diminution of this proportion indicates failure in the elimination of the products of waste in the tissues and the danger of *uræmia*. The simplest quantitative test, and one sufficiently exact for practical purposes, is the following: To make it, it is required to have a Doremus ureaometer, which resembles a medium-sized test tube, the open end of which is dilated and also bent at an acute angle with the rest of the tube, about an inch and a half from the expanded end. The tube is filled with a twenty-per-cent solution of caustic soda and then one cubic centimetre of bromine is introduced through a pipette. A thorough admixture is secured by agitation. One cubic centimetre of urine is now carried through a pipette to the bottom of the dilated end of the ureaometer, well beyond the angle, and slowly liberated, so that the gas which is generated will rise in the long and closed end of the cylinder. The percentage of urea (which is represented by the volume of nitrogen evolved) is read off from the graduated scale fixed on the tube.

Albuminuria is of two varieties, the true due to renal derangement and the false due to blood, pus, or, lymph in the urine. The microscope will reveal the presence of these bodies and aids in differentiation. True albuminuria is usually due to a kidney lesion, probably arising from an increased permeability of renal epithelium. It is found in the urine in venous congestion, the anæmias, occluded ureter, vesical retention during epileptic attacks, in leukæmia, chloræa, severe diarrhœa and lead colic. It is most abundant in acute nephritis, when it may reach as high as one per cent or more. In chronic nephritis it is less abundant and is practically always present in severe infectious diseases.

Albuminuria is usually accompanied by casts, and ordinarily the more albumin the more abundant the casts. They are characteristic plugs formed in the renal tubules, and are easily recognized by the microscope. They are nearly all made up of a translucent hyaline substance (hyaline casts). When they are studded with epithelial cells they are known as epithelial casts and strongly suggest renal desqua-

mation. When they contain granules (granular casts) they indicate disintegration of the renal epithelium. When fat globules are observed in these bodies, they are known as *fatty* casts; when blood cells predominate, *blood* casts; and when white cells are present, *pus* casts.

Not so frequently seen is another, the waxy cast, which appears during the later stages of nephritis. It is commonly stained a light yellow from the pigments of the urine. Any or all varieties of casts may be present in the various forms of nephritis. They do not usually accompany the albuminuria of febrile or congestive disturbances.

Albumin is always present in urine which contains pus, independent of any affection of the kidneys.

It may be recognized by the tests with heat and nitric acid. To employ the heat test, fill a tube half full of urine, to which, if alkaline or faintly acid in reaction, one or two drops of acetic acid should be added. Hold the tube so that the flame of the spirit lamp will heat the upper inch of urine. If, just before the boiling point is reached, a cloudy white film pervades the heated mass, the presence of albumin is demonstrated.

The nitric-acid test is not so reliable as the preceding. When albumin is thought to be demonstrated by its use, the heat test should be applied to confirm it. Into a small test tube drop from ♏x–xx of pure nitric acid. Hold the tube slanting and allow the urine from a glass pipette to run gently down the side until it floats upon the acid. Albumin is indicated by a white or cloudy ring formed in the layer of urine immediately in contact with the acid.

Sugar.—The urine of *diabetes mellitus* has a high specific gravity, is passed in great quantity, and has a characteristic sweet odor. This form of sugar may be recognized by *Trommer's test*, in which an oxide of copper is produced by boiling diabetic urine (grape sugar) with a solution of potash and copper. Fill a test tube for one inch with the suspected urine, and add one or two drops of a solution of sulphate of copper—just enough to give the whole a pale-blue tint. Add the potash solution in quantity equal to one half the urine. When sugar is present, a pale-blue hydrated oxide of copper will be thrown down and immediately redissolved. If the mixture is now slowly heated to near the boiling point, a reddish-brown suboxide of copper will be precipitated. Objections to the copper tests are lack of stability of the solutions and the fact that excessive uric acid and creatinin occasionally produce the sugar reaction. The most satisfactory sugar test is Nylander's. The formula for the solution is: Rochelle salts, 4 parts; caustic soda, 10 parts; water 100 parts. Heat to the boiling point, add bismuth subnitrate to saturation (about two parts), and filter. To eight parts of urine in a test tube add one part of the solution, and heat until a white cloudy precipitate is produced, which, if sugar be present, turns an intense black on standing a few minutes.

When a quantitative analysis is desired, the fermentation test will be found simple and sufficiently accurate for practical use. Fill a wide-mouthed bottle with the urine, and register the specific gravity at the time. Place a small piece of yeast in the urine, and set it aside in a warm place for from twelve to eighteen hours, until fermentation has occurred, and again take the specific gravity. The difference in degrees of the urinometer, as registered before and after fermentation, will represent the number of grains of sugar in the ounce of urine.

Indican is a product derived from putrefactive changes in the alimentary canal, and usually follows overeating and indigestion. Its presence suggests a low resistance which should, if possible, be corrected before an operation is undertaken. It is also present as a result of obstruction in the small intestines, but not in obstruction of the colon.

Calcium oxalate is a normal constituent of the urine, and varies in quantity from ten to twenty milligrams per day. The crystals, when precipitated, are commonly small, octahedral, colorless bodies, occasionally oval and dumb-bell shaped. About sixty per cent of renal and vesical calculi are made up of calcium oxalate in whole or in part. Persons affected should refrain from tomatoes and rhubarb, and the general diet should be so restricted as to maintain a proper diges-

tion. In its elimination, in addition to regularity of diet, the imbibition of large quantities of water one or two hours after meals is indicated.

Acetone appears in the urine under various conditions, but it is only significant when found in diabetes, and under such conditions is of grave import.

A simple method of testing for acetone is to add to half a test tube of urine a few drops of a strong solution of sodium hydrate, and to this a few drops of a five-per-cent solution of nitroprusside of sodium, and if upon the addition of a few drops of glacial acetic acid to the mixture the color changes to a purple, acetone is present. In the absence of acetone the acetic acid causes no deepening of color.

Bile in the urine always imparts to it a high color which may vary from a dark yellow or light brown to a deep brown, or it may be greenish, especially if it has been allowed to stand. The foam of such urine is colored a light yellow, and the urinary sediments are also stained a deep yellow color. It may be further observed that whenever it comes in contact with linen it leaves a yellow stain.

A simple test for the presence of bile is to moisten a piece of filter paper with the urine and place on it a drop of nitrous acid. If bile be present a green color will appear at the margin of the drop. Other colors will appear even in the absence of bile, but the green only is significant of bile.

Albumin and casts are usually present in urines containing bile.

It is ordinarily noticeable in the urine before the jaundice is observed in the skin and mucous membranes.

It occurs in all instances of obstruction to the flow of bile from the gall bladder, hence it will be found in many of the liver disturbances, such as catarrhal jaundice, cirrhosis of the liver, gallstones, and cancer of the liver.

Pus- and Blood-corpuscles—Epithelia.—Pus cells in the urine may come from an inflammation in any portion of the urinary tract, from the kidney to the meatus, or from the communication of a sinus or abscess with the urinary apparatus. Urine containing pus may be acid, alkaline, or neutral in reaction. In acid urine the corpuscles are prominent and easily recognized; when the reaction is alkaline, they are usually destroyed, and appear as ropy or gelatinous strings, more resembling mucus than pus. If the urine is examined immediately after being passed, a few corpuscles may be recognized. When allowed to stand for some minutes the pus cells collect in the bottom of the vessel. Examined with the microscope, they are seen to be spherical and faintly granular. On account of the absorption of water they are swollen and less distinct than pus cells from a recent abscess. The addition of acetic acid renders the nuclei more distinct. The source of pus found in the urine may frequently be determined from the symptoms present, together with the microscopical appearances of the urine. If with the pus-corpuscles flat, large epithelia are abundant, the inflammatory process is in all probability situated in the bladder, where these epithelia belong. In females a larger, flat epithelium from the vagina often finds its way into the urine. The cells from the vagina are more often disposed in drifts or groups than the bladder epithelia. Large spherical or polygonal cells may come from the kidney tubules or the male urethra. They are about twice the size of a pus-corpuscle. Whether they are derived from the kidney or the urethra may in great part be determined by the presence or absence of urethritis. Conical or ham-shaped cells may come from the pelvis of the kidney, prostate, and glandular apparatus of the urethra. They are usually not so abundant as the other varieties.

Hæmaturia.—Blood in the urine may come from traumatic or idiopathic hæmorrhage into the Malpighian tufts or kidney tubules; from the pelvis or ureters as a result of calculi or ulceration; from the bladder as a result of instrumentation, calculi, wounds, foreign bodies, neoplasms, ulceration, parasites, or the hæmorrhagic diathesis; from the prostate or accessory organs and from the urethra.

The administration of certain remedies may account for the appearance of blood in the urine. Hæmaturia occurs at times as a symptom of malarial fever, and, in women, as a form of vicarious menstruation.

Blood in the urine may be recognized by its characteristic coagula, by the red or reddish-brown color it imparts to this fluid, the presence of the corpuscles

under the microscope, or the fibrinous casts of the tubules of the kidney or ureters. In rare instances the blood disks are entirely destroyed, and the coloring matter set free. This condition is apt to occur in ammoniacal urine.

When urine containing blood is boiled, a white or cloudy coagulum is formed, its density depending upon the quantity of blood present.

If bloody urine is allowed to stand without being agitated, the corpuscles settle to the bottom of the vessel, and may be recognized by their red or amber color. Under the microscope they may assume different shapes. In *acid* urine the disks retain their biconcave conformation for a long time. When the hæmorrhage is slight, they float isolated; if profuse, they may be caught in coagula or collect in rouleaux. If the reaction is feebly acid, or where the corpuscles are submitted for a considerable time to the action of the urine, they lose their biconcave shape, and become distended, swollen, and spherical. They may be recognized from pus-corpuscles by their smaller size, transparency, and in not containing granular bodies. At times they retain their flat shape and appear with serrated edges.

Blood casts usually come from the kidney tubules, and are composed of fibrin in which the red disks are entangled in varying proportion. In some, large clusters or groups of blood-corpuscles are seen, with an occasional epithelial cell from the kidney or urinary passages. When the disks have been completely destroyed, as in the decomposition of the coloring matter in ammoniacal urine, and the organic elements of the blood are not recognizable with the microscope, the spectroscope may be relied upon to demonstrate the presence of the coloring matter.

In determining the source of blood in hæmaturia the following points should be considered: When the bleeding is urethral, the first discharge of urine is most deeply colored. A clot of blood preceding or accompanying the discharge of urine indicates urethral hæmorrhage. In males, if spermatozoa are entangled in the coagula, the suspicion of hæmorrhage from the *vasa deferentia*, *vesiculæ seminales*, or prostatic apparatus is entitled to consideration, although the fact must not be overlooked that these elements may mingle in the urethra with blood from any part of the urinary passages.

When the bleeding is from the pelvis of the kidney pain and other symptoms of stone or pyelitis will often precede the hæmaturia. Not infrequently, however, the hæmorrhage is, next to the presence of pus in the urine, the first indication of pyelitis.

In hæmorrhage from the bladder there are often symptoms of cystitis which will point directly to this organ as the source of the bleeding. In differentiating the source of blood from the kidneys, ureters, and the bladder, the method of Thompson and Van Buren may be resorted to with success. Introduce a soft catheter just within the neck of the bladder, draw off the contained urine, and wash out the organ with clean water. If, during the irrigation, the water which flows away contains blood, the hæmorrhage is from the bladder walls. If it flows away clear, then empty the bladder, place the finger over the end of the catheter, allow it to remain introduced, and wait until a small quantity of urine has accumulated. This is drawn off, and, if it is bloody, and if the clear water now thrown in comes out unstained, the inference is fair that the bleeding is from the ureters or beyond. The cystoscope should be employed in cases in which doubt may exist after the foregoing methods have been tried.

Hæmorrhage from the urethra is rare except from violence, the lodgment of calculi, or from ulceration.

Hæmaturia due to parasitic lodgment in the walls of the bladder is exceedingly rare in this country. In 1883 a young man of white parents—a native of Natal, Africa—came under my care on account of chronic hæmaturia. He was at this time twenty-six years of age, and had had bloody urine at intervals for thirteen years. His health was not seriously impaired. The urine was faintly acid; specific gravity 1.020, with only a trace of albumin, which was readily accounted for by the slight amount of blood. About the middle and toward the last stage of the act of micturition a few strings of clotted blood were discharged.

Placing these under the microscope, I discovered a number of bodies (Fig. 538) shaped much like a watermelon seed, except that the small end was more pointed. These were evidently the eggs of the parasite known as *Bilharzia hæmatobia*, the hæmaturia resulting from the rupture of capillaries caused by the presence of nests of these ova in the mucous membrane of the bladder. This disease is frequent in Africa and Asia, but almost unknown in North America. The body of the male parasite is about four lines in length, threadlike, and flattened anteriorly (Aitken); the female a little shorter and more delicate. They inhabit by preference the portal vein and the walls of the bladder. In treating my patient I saturated him with large doses of santonin for a week, and injected the bladder daily with alcohol, beginning with a 1–20 solution, and increasing it to the extreme degree of tolerance by the bladder. The patient improved in every respect, but the hæmaturia was not entirely arrested when he returned to Africa, in November, 1883, since which time I have not heard from him.

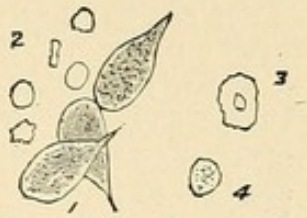

FIG. 538.—1, Ova of *Bilharzia hæmatobia*. 2, Crenated blood disks. 3, Epithelium. 4, Pus cell. (From the author's case.)

The parent distoma is killed by high febrile movement, and with its death the hæmaturia ceases.

Chemically blood may be detected by adding to some urine in a test tube about two cubic centimetres of tincture of guiac and the same amount of old turpentine. The mixture is then agitated, and if blood or pus be present the mixture will become blue in color.

The *treatment* of hæmaturia must be directed to the disease of which it is a symptom. The patient should be required to remain in the recumbent posture. Large doses of citrate of potash will prove beneficial in rendering the urine less irritating. Opium is advisable, not only on account of the relief from pain it affords, but because it secures complete quiet, which is essential, and prevents the too frequent evacuation of the bladder.

When the hæmorrhage is from this organ, and does not yield to the measures above given, the injection of cold or hot water, or of astringent solutions, may be employed. If villous growths are present, they should be removed by cystotomy.

Tumors of the kidneys, omentum, retroperitoneal glands, stomach, pancreas, and even the uterus and ovaries may interfere with the outflow of bile, and thereby cause its appearance in the urine.

Among the pathogenic bacteria found in the urine are streptococcus, staphylococcus, gonococcus, colon bacillus, typhoid bacillus, and tubercle bacillus. Of these, the gonococcus, streptococcus, and tubercle bacillus are easily discovered if the urine be thoroughly centrifuged and the sediment be examined in smear preparations as advised for these organisms. The typhoid bacillus is commonly present in the urine during the course of an attack of typhoid fever, and it occasionally persists for some time after recovery.

Parasites in the urine are not numerous. Perhaps the most common is the tricomonas, which is probably the same as the tricomonas intestinalis of the fæces. It has no diagnostic importance. In echinococcus cysts of the kidney the hooklets sometimes appear in the urine together with fragments of the cysts. Filaria sanguinis embryos are sometimes found in the urine of those afflicted with this parasite. Finally, as above given, the eggs of Bilharzia hæmatobia are found in the urine in countries where that parasite abounds.

The deodorization of foul urine is effected by the administration of oil of gaultheria 3ij, salol 3j, in doses of gtt. xx three times daily.

STONE IN THE BLADDER

Urinary calculi may form in any portion of the kidney, in the pelvis or ureters, in the bladder or urethra. They are concretions of the various inorganic substances which are common to the urine. Organic particles, such as epithelia, mucus, and various inflammatory products, often enter into the formation of

calculi. When an aggregation of the urinary salts occurs within the kidney tubules, the probabilities are that the stone so formed will remain imprisoned in this organ (renal calculus) until removed by ulceration or operation. Forming in the larger straight tubes of the pyramids, a urinary concretion may, while yet minute, escape into the calix and pelvis, and pass down the ureter into the bladder, or remain lodged in the pelvis or excretory duct.

It is, moreover, probable that the majority of calculi found in the bladder, or passed by the urethra, originate as concretions in the straight tubes, calices, or pelves of the kidneys, whence they drift outward to the bladder, and there by continued accretion become large enough to attract attention, even if the transit along the ureter was unnoticed. Undoubtedly a fair proportion of vesical calculi are formed in this organ proper, and the greater number of these may be grouped in the class of calculi which form around nuclei composed of foreign substances, or animal matter, such as epithelia, inflammatory products, etc. Conversely, it is admitted that animal matter may form the nucleus of a kidney or pelvic concretion, while a bladder calculus may also be formed by accretion of the purely inorganic elements of the urine.

A calculus is rarely of uniform composition, more frequently combining two or more inorganic as well as organic elements in its formation. In the nomenclature it is the practice to give to the stone the name of the preponderating element.

That most commonly observed is composed principally of *uric acid* and the urates. These stones are of fair consistency, yellowish or light brown in color, not very smooth when single, yet not so rough as oxalate-of-lime concretions. They may attain a diameter of two or three inches. As a rule, they form in urine which is distinctly acid in reaction.

The *mulberry* or oxalate-of-lime calculus is next in order of frequency, and relatively more so in children than in adults. It may exist in all sizes, and varies greatly in color. The smaller concretions are light in color and fairly smooth; the larger are exceedingly rough, with jagged edges, and are dark brown in color, in rare instances white. Oxalate-of-lime calculi usually commence in the kidney, and pass as small particles to the bladder. The most severe forms of "renal colic" are due to the slow and painful passage of these rougher concretions along the ureters.

Phosphatic calculi come next in order of frequency, and are divisible into three classes: the *ammonio-magnesian* and *phosphate-of-lime* (*fusible*), *neutral phosphate of lime*, and *ammonio-magnesian* calculi.

Fusible calculi are more often met with than the other two forms of phosphatic concretions. They are gray or white in color, readily friable, and light. The hardness is proportionate to the lime phosphate present. They attain large size, and conform themselves to the shape of the bladder.

The *neutral phosphate-of-lime* calculus is rare. It may form in the kidney, though it originates chiefly in the bladder. All the phosphatic calculi are chiefly vesical in origin, being found with ammoniacal urine, which is present with chronic vesical catarrh. The *ammonio-magnesian* phosphatic concretion is equally rare, and differs very slightly in its chemical and physical characters from that just described.

Other and still rarer forms of urinary concretions are the following:

Cystin.—This variety is usually smooth, occasionally corrugated, yellow in color when fresh, inclining to a greenish hue when long removed. They break readily, do not show a marked concentric arrangement, and are somewhat greasy to the feel.

Xanthic or uric-oxide calculi have only been reported in two or three instances. They are of concentric formation, smooth and greasy to the feel, and vary in color from gray to brown.

Carbonate-of-lime calculi are usually multiple, and are light gray in color and chalky in consistence.

Organic calculi, consisting of epithelia, blood, etc., are not infrequent as nuclei for other varieties, but exceedingly rare as independent forms.

Stone in the bladder is a misfortune that may befall every age and condition of human life, from the fœtus *in utero* to the old and decrepit. The period of greatest exemption is from twenty to fifty years of age. It is comparatively frequent in children, and here must be chiefly of renal origin and due to the excess of inorganic elements in the urine, since obstruction and inflammatory diseases of the urinary tract rarely exist at this age. After fifty, when prostatic, cystic, and urethral obstruction are more frequently met with, the formation of calculi, vesical in origin, is more common. As to sex, stone is more frequent in males. It was formerly argued that there was no difference in the frequency of stone in the sexes, but that the short and dilatable urethra of the female allowed a ready escape to the concretion before it became sufficiently large to produce any organic disturbance. When, regardless of the statistical evidence which shows that the number of deaths in males from urinary calculus is ten times greater than in females, we consider that one of the most frequent causes of stone is the gouty diathesis, and that gout is more frequent in men; and, again, that prostatic and urethral obstruction is peculiar to this sex—it must be conceded that the conditions for the formation of calculi are more frequently present in males.

In the *ætiology* of stone in the bladder two great factors are recognized: The one includes all conditions of the economy which favor precipitation of the inorganic elements of the urine; the second all obstructive and inflammatory lesions which produce decomposition of the urine in the bladder, the detachment of epithelia, and the accumulation of other organic elements which serve as nuclei around which the salts of the urine are congregated.

In the first category are hereditary tendencies, such as gout and rheumatism. Certain conditions of malnutrition undoubtedly lead to a precipitation of the urinary salts, for children poorly fed and cared for are much more apt to suffer from calculus than those who are well fed and comfortably clothed and sheltered.

In the group of local causes may be classed all cystic diseases in which the products of inflammation collect in the bladder and form nuclei, around which concretions occur; prostatic enlargement inducing retention, cystitis, and decomposition of urine; stricture, and all obstructive and inflammatory lesions of the urethra which may involve or affect the integrity of the bladder; the presence of any foreign matter in the bladder, or paralysis of the bladder from any cause.

The Symptoms and Diagnosis.—It may be stated at once that, however much has been and may be said of the value of the various symptoms of stone, the diagnosis rests upon one simple expedient, the introduction of a metallic instrument into the bladder, and in contact with the stone. For this purpose the ordinary steel sound is usually sufficient. The bladder should be allowed to contain about half a pint of fluid, and when the instrument is introduced it should be manipulated so that the convexity of the curve will glide over the floor of the bladder back and forth from the neck to the posterior wall of the organ, at the same time depressing the bladder toward the rectum. By this manœuvre the stone will be induced to gravitate to the deeper portions in contact with the instrument, or so close to it that a sharp, quick turn to right or left will bring the calculus and metal into appreciable contact. In certain cases of prostatic hypertrophy the calculus may remain concealed immediately behind the enlarged organ, and in such a position that the sound cannot be brought in contact with it. Under such conditions Thompson's searcher (Fig. 539) will be found useful. The objection to



FIG. 539.—Thompson's searcher.

this instrument is the difficulty of its introduction from the abrupt nature of the curve near the tip. When once introduced its value is readily appreciated. Turning its point downward and moving as if to withdraw it, there is no portion of the floor that it will not thoroughly search.

When a stone cannot be appreciated with a full or half-filled bladder it may be felt if this organ is completely emptied. Not only is the calculus driven toward the neck of the bladder when it is emptied of urine, but the hardness and weight are more readily appreciated, since it is held in the grasp of the organ, and cannot slip away when the sound touches it. In some forms of vesical calculus the stone becomes partially or completely *encysted* in some portion of the bladder wall. The calculus may drop into an abnormal pouch in the bladder; it may sink by a process of ulceration into the walls, and be partially or completely surrounded by a newly formed inflammatory tissue, or it may have been lodged in the ureter near its termination.

Again, a stone may be caught in the upper portion of the bladder without being sacculated. In sounding for stone in adults narcosis is rarely required, especially where there are no symptoms of severe cystitis and tenesmus. In children an anæsthetic should always be employed. When the calculus cannot be felt after careful search it is at times a successful expedient to introduce the finger into the rectum and make upward pressure upon the base of the bladder, and firm pressure downward upon the abdomen just above the symphysis pubis.

Vesical calculus may be suspected in a patient who has had renal colic, or has passed by the urethra particles of gravel, and afterward develops a cystitis. Not infrequently, however, a concretion goes from the kidney into the bladder without attracting the attention of the patient. If it lodges here and increases slowly in size, it may remain for months or years without giving any symptoms of cystitis, or marked annoyance. Usually, however, when a stone is present, and is so light and smooth that it does not affect the mucous membrane of the bladder, it attracts attention by mechanical interference with the escape of urine, dropping at times into the orifice of the urethra, and suddenly shutting off the flow during micturition.

When a stone, by reason of its size, weight, and roughness, begins to cause cystitis, frequent micturition is a prominent symptom. A burning or smarting pain, referred to the end of the penis, is a frequent symptom in this, as in idiopathic inflammation of this organ. At times the pain is referred to the scrotum, penis, uterus, and other organs, or along the nerve tracts in the lower extremities. In any jolting movement, as in riding on horseback or in vehicles without springs, or in walking about, the pain is increased. Tenesmus is often violent toward the end of urination, when the stone is grasped by the contracting bladder. The urine almost always contains pus, and blood is frequently present. Hæmaturia, with calculus, occurs chiefly during the waking hours, when the patient is moving about. It is more apt to be met with in oxalate-of-lime calculi than in the other varieties. In the rare instances in which stone exists with villous growths of the bladder, hæmorrhage is often excessive. When a calculus is of large size it may by pressure produce pain and symptoms of disturbance in other organs, as the vagina, uterus, or rectum. The size and character of a stone in the bladder may, in a measure, be determined by exploration with the sound, as well as by palpation.

A large stone is usually felt as soon as the sound enters the neck of the bladder. The sense of resistance is greater, and a fair idea of its proportions may be made out by passing the metallic sound along its surfaces. A small stone is often with difficulty recognized. Pressure above the symphysis pubis, and intravaginal or rectal exploration, are not without value in estimating the size of a calculus. If the click of the sound is sharp and clear, and if the surface is rough and grating to the sense of touch conveyed along the instrument, an oxalate-of-lime stone may be suspected, and, if the patient is a child, the suspicion is strengthened. Hæmaturia, and all the symptoms of cystitis, are, as a rule, increased with this form of calculus. In patients with the gouty or rheumatic diathesis, *uric-acid* stone is the rule. The acidity of the urine in a measure excludes phosphatic calculus. In the exceptional instances in which a portion of the surface of the bladder has become incrusted with the inorganic elements of the urine, this condition may be determined by the immobility of the concretion when the sound is brought in contact with it. The absence of a spherical calculus can be determined

by digital exploration through the rectum or vagina, combined with pressure from above the symphysis pubis.

The proper treatment of stone in the bladder may be divided into the *curative* and *palliative*. To the former belong the operations of *lithotomy* and *lithotrity*; to the latter are systematic medication and hygiene, together with the employment of all local means calculated to relieve pain and prolong life. *The conditions under which lithotrity should be preferred to suprapubic lithotomy are rare, and are given with the description of the operation.*

Lithotrity.—If the symptoms are not so distressing as to demand immediate interference, from ten days to two weeks should be devoted to the careful prepara-

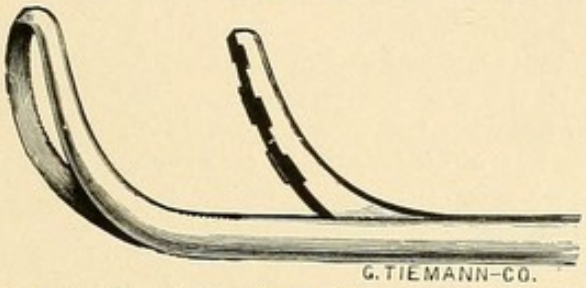

Fig. 540.—Fenestrated jaws of Thompson's lithotrite.

tion of the patient. It is not only important to improve the general condition, but also to accustom the urethra to the introduction of the sound. Strict adherence to the practice of antisepsis, as given for the bladder and urethra, is required.

The instruments required are the lithotrite and an apparatus for washing out the detritus.

Of the various crushing instruments which have been introduced, that of Sir Henry Thompson is to be preferred (Fig. 543). It is commendable for its light-



Fig. 541.—Male blade of Thompson's lithotrite.



Fig. 542.—Female blade of Thompson's lithotrite.

ness, strength, and smooth action. With the heavier instruments the sense of touch is not so delicate and acute. The lighter lithotrite is strong enough to crush any calculus which may be safely removed by this operation. Moreover, it is especially to be commended for the fenestrated jaw in the female blade, which allows the male blade to pass entirely through, and thus avoids the danger of



Fig. 543.—Thompson's lithotrite adjusted.

choking and fouling. It consists of a male blade (Fig. 541), or sliding rod, which fits into a fixed or female blade (Fig. 542), which is deeply hollowed out for its reception.

The seizing and crushing action of the lithotrite is double. When the male blade is carried through the hollow handle into the slot in the female blade, a simple and rapid to-and-fro movement can be executed by pushing or pulling on the male blade with the right hand, while the left steadies the female blade, to

which the handle is attached. This movement can be made very effective in seizing the stone and in crushing the smaller fragments without taking the extra time in sliding the catch which throws on the screw motion of the instrument.

When, however, a stone is caught in its grasp by the sliding movement just described, and is so solid and resisting that a sufficient and safe crushing force cannot be employed, the catch on the top of the handle is slipped upward. The sliding movement is now impossible, and the more powerful screw motion substituted. By turning the wheel at the end of the male blade to the right, the stone can be felt to give way under the crushing force.

In the removal of vesical calculi by this operation two procedures are recognized, viz., *complete* and *incomplete* lithotrity.

In the former, or Bigelow's method, narcosis is required; the stone is entirely crushed, and the fragments washed out at a single operation. In the latter, anæsthesia is not employed; the calculus is only partially comminuted, and the fragments are left to pass off with the urine.

Complete lithotrity has almost entirely superseded the older operation. It is preferable in all cases where the condition of the patient justifies the risk of shock from a capital operation under narcosis.

Operation.—The patient, being narcotized, is placed upon the operating table, in the dorsal decubitus, with the pelvis raised about half a foot by pillows placed under the sacrum. If the bladder has not been emptied just before the operation, the urine is now drawn off and about one pint of tepid water injected, thus distending this organ and rendering the mucous membrane less liable to injury from being picked up by the instrument. The lithotrite, having been properly warmed, oiled, and tested as to its working capacity and strength, is now prepared for introduction by sliding the male blade completely down until its tip passes into the fenestra of the female blade. As the convexity of the male blade is serrated, great care must be taken not to push the rough surface beyond the level of the female blade, since the introduction of the instrument, improperly adjusted, would do unnecessary violence to the floor of the urethra.

A right-handed operator should stand at the patient's right side. The instrument is locked and carried into the bladder by the same manœuvres as given for the introduction of the sound or metal catheter. When the beak is well into the bladder, it is carried along the floor, with the tip pointing upward, until it meets with the resistance of the posterior wall of the bladder, when it should be slightly withdrawn. The handle should now be elevated, in order to depress the floor of the bladder with the convexity of the curve. Held firmly in this position, the lithotrite is opened by withdrawing the male blade about two inches. The operator should now strike the handle of the instrument with the knuckles or hand hard enough to carry the concussion to the bladder, in order to dislodge the calculus and allow it to fall into the lowest portion of the organ, and within the grasp of the lithotrite, which is now closed by pushing the male blade down. If the stone is seized, it will be made evident by the failure to close the blades, and, when caught, it should be firmly held, the screw movement adjusted, and the wheel rotated slowly. Having thus secured the stone, the instrument should be moved to and fro, in order to assure the operator that the wall of the bladder is not caught. In crushing a calculus, the rapidity with which it is done should be determined by the sense of resistance experienced. It is not safe to employ force sufficient to spring the blades. A stone which can be safely crushed will yield perceptibly under a few turns of the screw. Phosphatic stone can often be rapidly comminuted without adjusting the screw. Uric-acid calculi require more power, while the oxalate-of-lime at times cannot be crushed at all.

If the manœuvre above described fails after being several times carefully repeated, search must be made in other quarters. Holding the instrument beak upward, the convexity still upon the floor of the bladder, separate the blades, turn the shaft half over to the right, and then close the blades. If the stone is seized, hold it steady, adjust the screw motion, tighten the grip by a slight turn of the wheel, and carry the instrument back to the middle line with the beak pointing upward. If it does not move freely, the indication is that the bladder has been

picked up, and of course the blades must be separated and another effort made. With the instrument shown there is little danger of this accident. The same manœuvre may be tried on the opposite side. If there is prostatic enlargement, it may be necessary to turn the beak downward into the pocket on the floor of the bladder. If, after a half hour's search, the seizure has not been effected, the operation should be discontinued.

When the stone has been seized and broken once, the same manœuvres should be carefully yet rapidly repeated until no large pieces remain. It will usually be found easy to crush the smaller pieces by the sliding movement alone. The instrument should now be closed until the blades have the same relation as when introduced, and then withdrawn. The *evacuator* consists of a rubber bulb capable of holding about one pint. At the upper end is a funnel and stopcock for filling and closing the apparatus. Below is attached a glass globe, in which the particles of stone gravitate as fast as they are drawn into the evacuator. Between this and the rubber bulb is a second stopcock, and a place for attaching the catheter. It is advisable to insert a piece of rubber tubing, about five inches in length, between the catheter and the evacuator, in order to prevent the jarring motion imparted to the bulb from being conveyed to the instrument in the bladder. The catheters (Fig. 544) are of different sizes and shapes, ranging from No. 14 to No. 25, U. S. The evacuation is much more rapid with the larger instruments. However, the urethra should not be overdistended. In general, the catheters which are only slightly curved near the tip, with the eye at the extremity, are preferable. In filling the bulb, in order to exclude the air, the glass ball is first detached, filled with clean warm water, and readjusted. Both stopcocks are now open, the end of the tube closed with the finger, and water poured into the funnel until the bulb and tube are filled to overflowing. The cocks are then closed, and the instrument entrusted to an assistant. The catheter, well oiled, is carried into the bladder, and as the water is escaping the lower end of the rubber tube attached to the evacuator is slipped over the end of the instrument. The bulb is grasped between the thumbs and fingers of both hands and squeezed, thus forcing the greater part of its contents into the bladder. It is now allowed to expand; the water rushes back out of the bladder and brings with it the smaller particles of stone which fall down into the glass sphere. This part of the operation may be expedited by rapidly half emptying the bulb into the bladder, and as rapidly allowing it to expand. When it is seen that particles of the calculus cease to fall into the receiver, the catheter should be withdrawn, the lithotrite reintroduced, and a second crushing done. The bladder is again washed out, and these operations should be alternated until all detritus is removed, unless alarming symptoms should supervene, when of course all operative measures should be discontinued. If the glass receiver becomes filled, it should be detached and emptied. At times particles of calculus become lodged in the catheter or tube, and require to be dislodged with a stylet. From one to one and a half hours may be allowed for this operation from the commencement of the anæsthesia. The prognosis will be more favorable with the shorter period, but it is wiser to proceed carefully and remove the stone thoroughly, even if a longer time is required. The absence of all fragments can be recognized by placing the ear over the bladder at the symphysis while the evacuator is being worked. The click of any fragments against the catheter can be distinctly heard. The introduction of a sound will also determine the presence of any pieces.

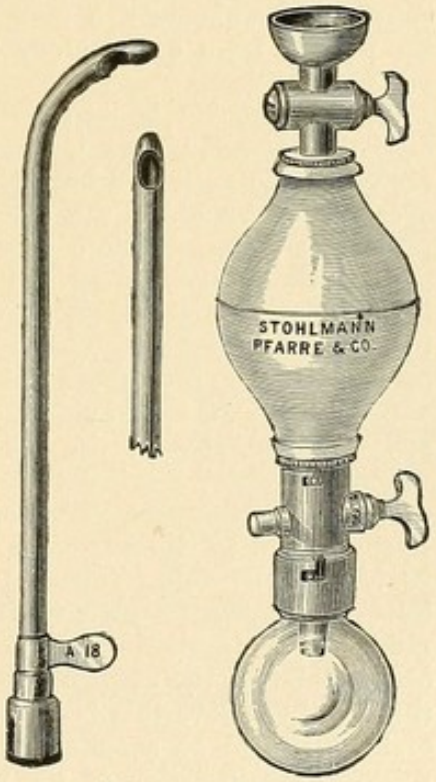

FIG. 544.—Thompson's improved evacuator and catheters.

In the after-treatment opium is essential to relieve pain and tenesmus. Citrate of potash, grs. xx, three or four times a day, with flaxseed tea, will render the urine less irritating. The soft catheter may need to be employed to evacuate the bladder.

In incomplete lithotrity the crushing is done in the same manner as just described. A fair degree of urethral anæsthesia may be secured by the employment of cocaine. The lithotrite is only introduced once, and not more than five or ten minutes are consumed in the operation. The evacuator is not employed, the detritus being expelled in the act of urination.

Cystotomy or Lithotomy.—Cutting into the bladder for the removal of stone is performed through the perinæum or through the abdominal wall, just above the symphysis pubis. Incision through the rectum in males is no longer a recognized procedure, while the vesico-vaginal operation is rarely, if ever, indicated, since it necessitates a second operation to close the fistula.

Suprapubic cystotomy is such a safe and simple procedure that it should be preferred to perineal cystotomy in practically all cases in which entrance to the bladder by an operative wound is desired. For the removal of all forms of neoplasm not involving the prostate, no other method is to be compared to it. For the extraction of foreign bodies so shaped or so large that they cannot be withdrawn by means of the small Thompson lithotrite without undue violence to the urethral canal it is to be preferred. *It is the better operation in all cases of vesical calculus, with the exception of very small and soft calculi in adults in whom the urethra is capable of freely admitting the lithotrite and the bladder is not affected with marked cystitis.* Under such conditions, in expert hands, *litholapaxy* is permissible, the fragments being removed either by the act of urination or with the evacuator. In all forms of cystitis due to prostatic hypertrophy the perineal operation cannot be compared to the suprapubic incision. In females it should absolutely supersede the establishment of a vesico-vaginal fistula, for, with proper care, a perfectly satisfactory drainage and rest to the bladder can be obtained by suprapubic siphonage, a method which will not only cure the cystitis, but saves the patient from a secondary and formidable operation in the closure of a vesico-vaginal fistula.

Operation.—It is important not only to shave those parts in the immediate field of operation, but the perinæum, the inner surface of the thighs, and the region of the anus and buttocks. It is almost impossible to prevent an occasional overflow of urine in the after-treatment, and if the hairs are all removed the parts can be much more readily cleansed and unpleasant odors prevented. The patient should rest upon the back, with the legs in full extension and upon a table so constructed that, at the proper moment, a modified Trendelenburg posture may be secured. The full Trendelenburg is not desirable, but, if the pelvis can be lifted a foot above the level of the shoulders, the weight of the intestines will be taken off the bladder, which is an advantage. There is no necessity under any circumstances to use rectal distention. For dilating the bladder, I prefer water. I employ a soft catheter and a glass-barreled syringe containing four ounces of warm salt solution, or water which has been boiled and cooled to about 110° F. From twelve to sixteen ounces are forced into the bladder, and in males this can be held in by tying rubber tubing around the urethra and catheter, in females by digital pressure upon the urethra from below upward against the arch of the pubis. The incision I prefer is the longitudinal, the lowest angle of which is one inch below the upper margin of the symphysis pubis and the upper angle about three inches above this bone. Separating the muscles in the median line, all hæmorrhage should be arrested as the operation proceeds. With dull-pointed, curved scissors, the insertion of the recti muscles are snipped away for from one fourth to three fourths of an inch on either side of the median line close to their attachment to the pubic bone. If the operation is for the removal of a stone of small size or a foreign body, or for exploration or drainage in uncomplicated cystitis, it is not essential to have a wide external wound or a large incision into the bladder. I therefore modify the incision and exposure of this organ as the operation may require. When there is a tumor, as the greatest possible room is required, I usually add to the longitudinal a short transverse incision parallel with

the pubic crest, which divides or nicks the *sheath* of the recti and permits a free retraction of the uncut muscle. When these muscles are held back with retractors, the loose areolar tissue situated between the bladder and the surface of the pubic bone and the abdominal muscles is readily seen and separated from its slight attachment to the bone. If, then, the finger is carried down with the dorsum in contact with the surface of the pubic symphysis, this prevesical fat can be easily detached from the bladder with the blunt scissors as a dissector, and carried upward for a distance of from one and a half to two inches, and, in certain cases of tumor of the upper posterior wall of the bladder, the peritonæum may be still further dissected off by lifting the prevesical fat and carrying the peritonæum up with it. However, the peritonæum is rarely seen. If torn through or incised it should be immediately sutured with catgut. If at this stage of the operation it is evident that the bladder is not sufficiently distended to bring it well under the touch of the surgeon or to lift the peritonæum high enough, four or eight ounces more of the fluid may be injected through the catheter, which has been left in. When a tumor is to be removed, or a stone of large size, requiring a good deal of operative interference within this organ, before opening the bladder I usually insert two loops of silk thread, which are carried by means of a short curved Hagedorn needle entirely through the bladder wall, one on either side of the proposed line of incision. A little fluid will escape through these punctures, but will not interfere with the operation. These loops are left long and tied at least a foot from the margin of the incision, and are intended to steady the anterior wall of the bladder by proper traction as the operator is at work within the bladder. In this way undue dissection of the anterior bladder wall from its normal attachments can be prevented. In rare instances, where one or more large veins appear on the anterior wall, if a line of incision cannot be secured to one side and safely removed from these veins, catgut ligature should be passed, by means of a short-curved needle, and the vessels secured and divided between the ligatures. In removing tumors it is very important to have a large incision through the bladder wall, and to dilate this widely in all directions by retractors so inserted that the cavity of the bladder is well exposed and the point of attachment of the tumor brought in sight. In removing papillomata they can usually be scraped off with the finger nail or an ordinary uterine curette. The point of attachment should then be thoroughly burned with the blunt Paquelin cautery. For small hypertrophies of the middle lobe of the prostate, no other portion of this organ being materially involved, it is not so essential to have the tumor exposed, since the cutting forceps can be applied directly by the sense of touch, placing the tip of the index-finger upon the mass to be removed, and carrying the forceps down with one blade on each side of the finger until the blades are guided on to the mass. The forceps I have had made for this purpose have double cup-shaped blades, which, when the tumor is seized, are closed but do not entirely cut off the section grasped.

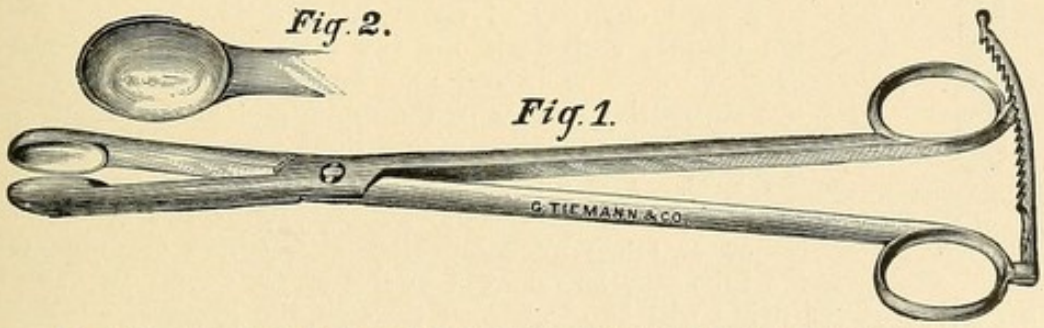

FIG. 545.—The author's forceps for removing tumors of the prostate and bladder.

The removal is made by twisting, in order to prevent the hæmorrhage which would result from a clean cut of these hard tumors. When any well-marked hæmorrhage is present, hot-water irrigation will aid in controlling it. I have on no occasion had to pack the bladder for hæmorrhage, but would not hesitate to do this if necessary. In operating for the removal of foreign bodies, a much

smaller incision is required, and for small calculi an incision an inch long in the bladder will suffice. I have found it much easier to remove these stones by slipping them along with the index-finger until they present at the wound in the bladder. My objection to using an instrument for removing calculi is the fear of breaking off small particles which may escape detection and remain in the bladder. I have never had any trouble in extracting stones in this manner. In one instance, where more than one hundred were removed, I used a good-sized bladder scoop, as it expedited the operation.

The after-treatment of these cases must, of course, vary. When there is no well-marked inflammation of the bladder, as after removal of a small stone or tumor or foreign body, or after exploration of the bladder in which no lesion was found, the operator may close the bladder by *immediate suture*. This is a very desirable method, for the reason that it does away with the necessity for suprapubic drainage and the slow process of closure of the wound, which, if left alone, takes from two to three weeks. In closing the bladder, I prefer firm small chromicized catgut, and the suture used is not unlike the Lembert suture employed in intestinal surgery. The needle is inserted about one eighth of an inch from the cut edge and comes out near the edge, yet not upon the cut surface, nor does the needle go into the cavity of the bladder. The sutures should be about one sixteenth of an inch apart. It is not safe to close the superficial wound over this line of sutures. A light packing of gauze will suffice.

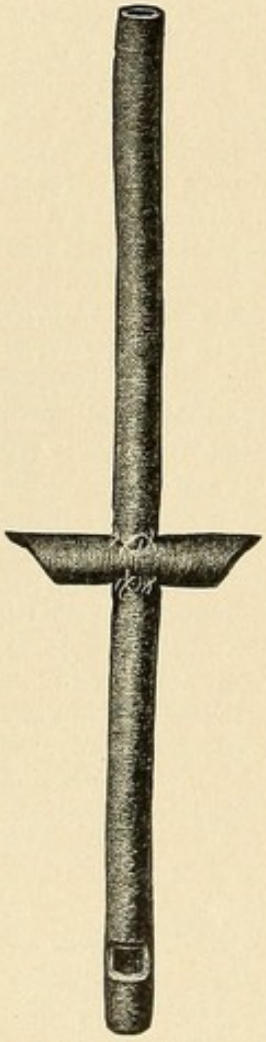

FIG. 546.—Bodine's modification of Trendelenburg's T-tube.

When the bladder is closed a catheter should be inserted and allowed to remain in for three days after the operation, or the water should be drawn by catheter every three or four hours in order to prevent any distention of the organ or strain upon the sutures. If for any reason the surgeon should deem it best not to undertake immediate suture of the bladder, he may rest assured that in from three to four weeks the wound will close by the ordinary process of repair in practically all cases.

In drainage, the use of the rubber tube is essential for the comfort of the patient. The ordinary T-shaped Trendelenburg tube is very unsatisfactory. Dr. J. A. Bodine has modified this by extending that part of the tube which projects into the bladder at least four and a half inches beyond the crosspiece, which is intended to catch within the bladder on either side of the incision in this organ. As the end of the tube is thus kept in the deepest portion of the bladder, the siphonage is more satisfactory. After the tube is introduced and before the wound is closed, it is better to throw in a good quantity of warm salt solution in order to flush the bladder and wash out any clots which may have been overlooked. The wound may be partially closed by one or two superficial sutures in the upper and lower angles, or left entirely open and filled with a light packing of gauze around the tube. The duration of drainage should be determined by the condition of the bladder. After the removal of a tumor or stone uncomplicated with severe chronic cystitis, the tube may be removed in five or six days. In five or six more a portion of the urine will be discharged through the urethra, and entirely by this route in ten days or two weeks more.

Since there is usually danger of overflow due to obstruction of the tube from blood clot during the first twenty-four hours after the operation, a generous quantity of absorbent cotton should be placed around and over the wound. When the tube is placed in position, it is attached to a long piece of tubing which is carried down the side of the bed and held in place by safety pins, and through this the urine is carried into a receptacle placed to receive it. Siphonage may be

started by injecting the solution into the long tube until the bladder is well filled, holding the end of the tube higher than the summit of the bladder, removing the syringe, and closing the tube by pressure of the finger; the end is brought down lower than the level of the bladder, the pressure released, and the fluid allowed to run out of the tube, thus establishing siphonage. The danger of infiltration of urine between the bladder and the abdominal wall or the pelvic bones is not to be considered when the abdominal incision is open and loosely packed.

Perineal lithotomy is now rarely performed, and should only be undertaken when the conditions are such that perineal drainage is essential. When necessary the operation of choice is the *median* or the combination known as the *medio-lateral*.

Median lithotomy or *perineal section* is performed as follows:

Two hours before the operation the rectum should be emptied by a free enema of tepid water, and the perinæum cleanly shaved. The patient should be placed upon the back, the sacrum resting near the edge of the table, the thighs flexed toward the abdomen, slightly abducted, the feet brought down and secured to the hands and wrists by several turns of a roller. Each leg is entrusted to an assistant, while a third, selected for his special fitness, and upon whom the duty of holding the guide devolves, stands beside the patient's abdomen, facing the operator.

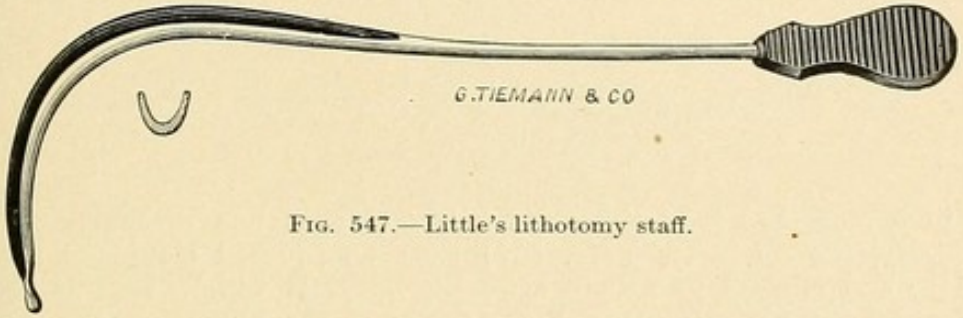

Fig. 547.—Little's lithotomy staff.

If the bladder is not fairly distended with urine, a Nélaton's catheter should be introduced, and about a pint of fluid injected. Little's guide, grooved in the middle (Fig. 547), is next carried into the bladder. The probabilities are that the stone will be felt by the sound. If the calculus has been recognized within a day or two, and if in the meantime the urine has been carefully watched and no solid substance has escaped by the urethra, no prolonged effort should be made at this juncture to demonstrate its presence.

The proper position for the guide is shown in Fig. 548. The shaft is held in such a position that the staff is perpendicular to the plane of the body, the

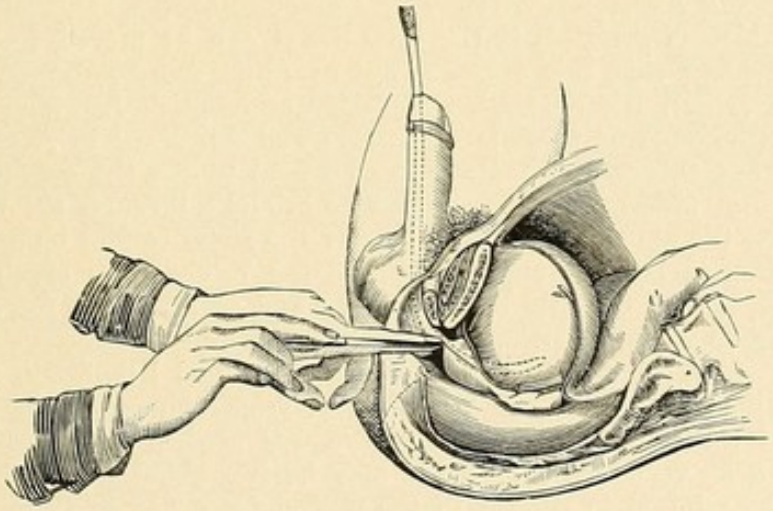

Fig. 548.—Guide in position. (After Bryant.)

tip well in the bladder, with the convexity of the instrument pressing firmly and steadily toward the perinæum. The finger is now carried into the rectum in order

to guard against puncture of the anterior wall of this organ. Little's lithotomy knife is entered just about one half inch anterior to the anus in the median line, the edge of the blade directed upward, and is pushed straight inward until the point strikes into the concavity of the groove in the staff at the anterior limit of the prostate. It is then made to cut forward and upward until the membranous

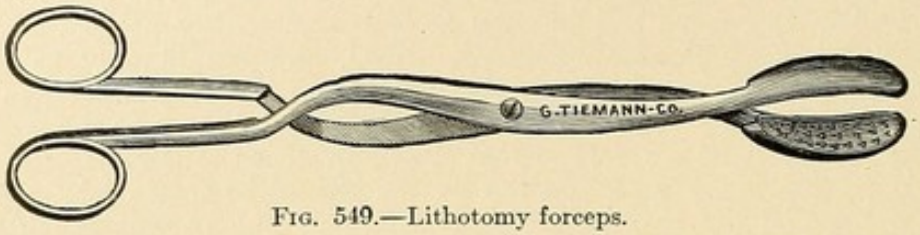

Fig. 549.—Lithotomy forceps.

portion is divided, and, as it is withdrawn, the incision in the perinæum is lengthened in all about one and a half inches. The finger is now introduced, the sound withdrawn, and the wound, prostatic portion of the urethra, and neck of the bladder dilated until the stone can be felt and extracted with a slender forceps.

The forceps (Fig. 549) should now be introduced and the stone removed. This instrument cannot always be carried in through the wound if the finger is

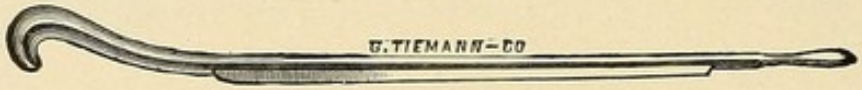

Fig. 550.—Scoop and conductor.

allowed to remain, and is at times difficult of introduction without a guide. To prevent delay, the conductor (Fig. 550) should be passed along the finger into the bladder and allowed to remain after the finger is withdrawn. If the blades of the forceps are now closed upon the flange of the conductor, the instrument



Fig. 551.—Lithotomy scoop.

can be made to slide accurately along the guide into the bladder, after which the conductor should be removed.

In removing a stone with the forceps two precautions are essential: (1) not to pick up the wall of the bladder with the calculus, and (2) not to employ force enough in grasping the stone to crush it.

When the stone is grasped, if the instrument can be moved freely within the bladder, it is evident that this organ is not caught.

With small calculi the extraction is easily accomplished. When the stone is large, a certain amount of force is justifiable and necessary to stretch the wound to its utmost; but this force should never be used unless the operator is satisfied that the stone and jaws of the forceps can be brought through the wound without serious injury to the bladder and prostate. If the stone cannot be extracted whole, it would be safer to make a suprapubic opening rather than crush it into fragments. Finally, a sound should be introduced and search made for a second stone lodged in the more remote portions of the bladder.

Among the accidents which may complicate perineal lithotomy, in addition to that of wounding the rectum, is hæmorrhage from the artery of the bulb and other vessels of the perinæum. The ligature will control all superficial bleeding, and, should a deep vessel be divided, it may be transfixed with a tenaculum and tied, or the hook allowed to remain in the wound for a day or two. If the oozing is free and general, an umbrella compress (Fig. 552) should be made by tying a piece of oiled silk or rubber tissue to a canula or bougie. This is carried into the wound and compression made by packing sponges beneath the cloth which is brought in contact with the bleeding surface.

The after-treatment of median or medio-lateral lithotomy is simple. The wound is left open and unmolested. The urine passes through this for a few days or weeks, and gradually resumes the urethral channel as the incision closes by granu-

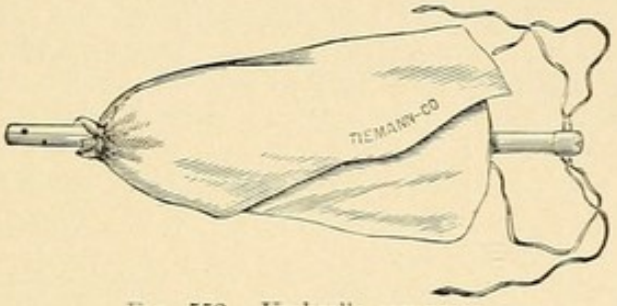

FIG. 552.—Umbrella compress.

lation. In some cases the urine passes through the urethra uninterruptedly. The patient should remain in bed for two or three weeks.

The anatomical relations of the parts involved in this operation are shown in Fig. 553.

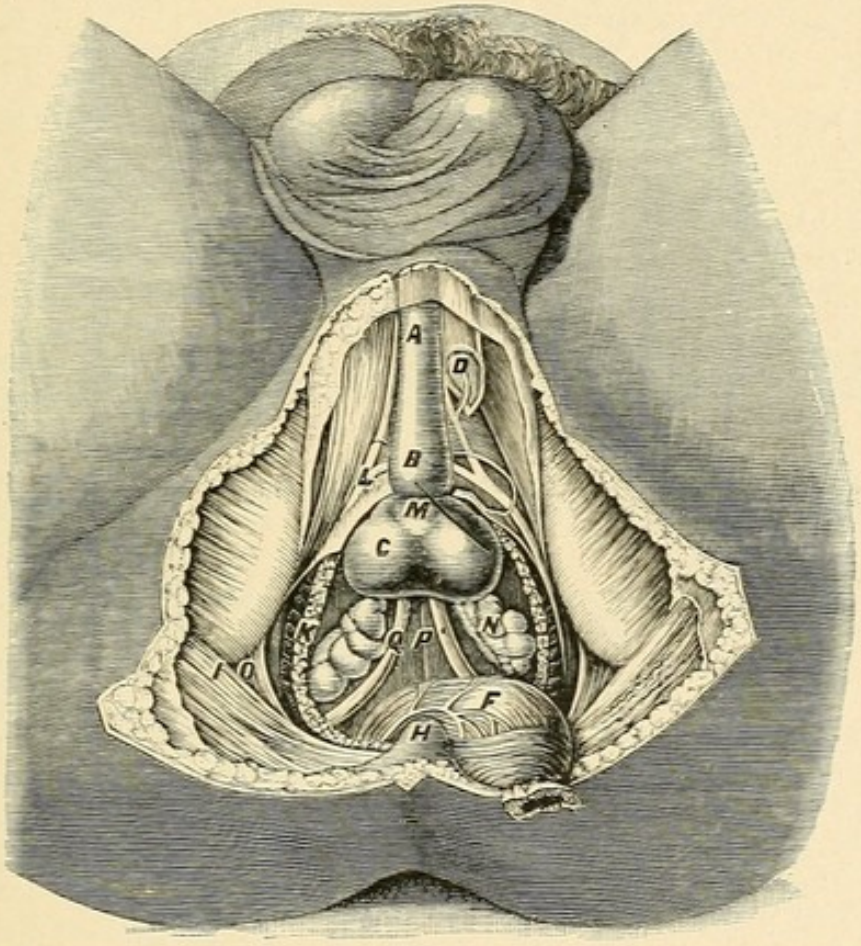

FIG. 553.—*A*, *B*, Bulbous portion of the urethra. *C*, Right lateral lobe of the prostate. *M*, Junction of bulbous and prostatic portions of the urethra. The line of section in median lithotomy extends from *A* to *M*. Should the necessity arise this incision may be extended obliquely along the dark line. *D*, Corpus cavernosum. *F*, Rectum. *N*, Vesicula seminalis. *Q*, Vas Deferens. *L*, Artery of the bulb. (After Maclise.)

Stone in the Bladder of Females.—Vesical calculi are not met with in females as frequently as in males. Many conditions which conduce to the lodgment or formation of stone in the male bladder, and are common in this sex, are either impossible to, or rarely occur in, females.

Another explanation of the comparative infrequency of stone in females is the short and dilatable urethra, allowing the escape of many small concretions which in men would lodge in the *cul-de-sac* behind the prostate. The symptoms

do not differ from those given in stone in the bladders of males. The *diagnosis* rests upon exploration with a searcher, combined with digital exploration *per vaginam*, and direct pressure over the pubes.

Treatment.—Small calculi found in the bladders of females may be readily removed by lithotrity. The short and distensible urethra permits of the introduction of the largest evacuating catheter, and greatly facilitates the operation. The older method of dilatation or divulsion of the urethra and extraction in mass by forceps is not justifiable. Large calculi and small oxalate-of-lime concretions, which may not be easily and completely crushed, should be removed by the suprapubic operation. Incision through the vesico-vaginal septum requires a second operation for its closure, and of itself is more complicated than the suprapubic method.[1]

Foreign Bodies.—Foreign substances in the bladder are usually introduced through the urethra. Less frequently they pass through the walls of this organ, as in gunshot wounds, etc. In exceptional instances foreign matter finds its way into the bladder through a fecal or vaginal fistula. Pus in a number of cases of appendicitis has found its way into this organ. In several cases of this character worms have escaped from the intestines and found an exit through the urethra.

The symptoms are usually those of stone in the bladder, with cystitis in a varying degree. The diagnosis may be evident from the history of an accidental or intentional introduction of the foreign substance. The matter can usually be recognized by the searcher. If a few weeks have elapsed, the foreign body will probably be coated with a deposit of urinary salts, and will impart to the sound the grating or click peculiar to stone.

The *treatment* consists in removal of the offending substance as soon as possible. If it is small, round, and smooth, it may be extracted through the urethra with the lithotrite. For this purpose the smallest instrument should be employed. If it is too large to be brought out in mass, it may be chopped up or crushed,



Fig. 554.—Gum catheter removed from the bladder by the lithotrite. (The author's case.)

and then extracted piecemeal, in the jaws of the lithotrite, or washed out through the evacuator. Fig. 554 represents an English gum catheter which was removed in this manner. The two larger pieces were grasped by the end and drawn out; the remainder was caught in the lithotrite, and brought out one piece at a time.

When the substance is so large or of such a shape that it cannot with safety be brought through the urethra, cystotomy is imperative.

[1] Prof. George Ben Johnston, of Richmond, Va., from a careful study of this subject, concludes that stone is 4.72 per centum more prevalent in whites than in negroes in the United States.

CHAPTER XXIX

THE PROSTATE — PROSTATITIS — HYPERTROPHY — PROSTATECTOMY — PERMANENT DRAINAGE — SPERMATORRHŒA — PROSTATORRHŒA — ASPERMATISM — TUBERCULOSIS — CARCINOMA — SARCOMA — CONCRETIONS — NEURALGIA — SEMINAL VESICLES—FULLER'S OPERATION

The Prostate Body.—Disease of the prostate is almost always a condition of adult life. This organ is rudimentary in childhood, and while, from direct injury, as in catheterization, lithotomy, or any form of violence, or by the extension of any of the rarer forms of disease which affect the bladder or urethra of children, this body may be involved, it only assumes its true importance after it has taken on its functional activity.

Prostatitis.—Inflammation of the prostate may be partial or complete, as well as acute or chronic. It may affect the epithelial and glandular or muscular and connective-tissue structure of this complex organ. Prostatitis rarely originates in the substance of this body, which is usually involved by the extension of an inflammation from the bladder, urethra, or other organs and tissues in its immediate neighborhood. Urethritis, cystitis, epididymitis, and proctitis are among the more common causes. To these may be added excessive venereal excitement, all forms of traumatism, whether by violence applied to the rectal or perineal regions, or by instruments in the urethra, and the presence of calcareous or amylaceous concretions.

The *symptoms* are usually well marked. Pain in the acute form of inflammation is usually intense and burning in character. There is a sense of fullness and throbbing in the organ. With the finger in the rectum the enlargement may be appreciated, together with abnormal heat and throbbing of the arteries. Pain is increased by direct pressure in the perinæum or rectum, and also in the act of urination. Fever is present in proportion to the severity of the local process. Suppuration and the formation of an abscess are usually indicated by exacerbations of temperature and by interference with micturition.

The first indication in the *treatment* of this painful affection is rest in the recumbent posture. The bowels should be kept open. The ice-bag to the perinæum will be found of value. If retention of urine occurs, it should be relieved by the use of the smaller soft catheter. Suprapubic aspiration may be demanded in severe cases. Scarification of the perinæum and the application of cups are highly recommended as local measures. If abscess exists, it should be evacuated by the aspirator or incision through the perinæum. Rupture may occur into the urethra, or the abscess may find an opening through the perinæum or rectum.

Hypertrophy.—Chronic progressive enlargement of the prostate occurs in about one third of all males who live through the period from fifty to seventy-five years of age. The increase in volume is not a true hyperplasia, for the glandular functions, as well as the muscular power of the organ, decrease with the hypertrophy. In some portions of the mass the muscular tissue is increased, but the bulk of the enlargement is due to the presence of newly formed connective tissue. The induration is in proportion to the excess of the new tissue over the normal muscular and glandular elements. In some instances, though rarely, the glandular elements are increased; but this is, in all probability, only observed in the earlier stages of hypertrophy, before the connective-tissue elements are in sufficient quantity to cause atrophy of the glandular apparatus. The enlargement may be local

or general. In general hypertrophy, while the increase in size is in all directions, it is more marked in the posterior portions, where it encroaches upon the neck of the bladder. Not infrequently one lateral lobe is greatly enlarged, or the hyper-

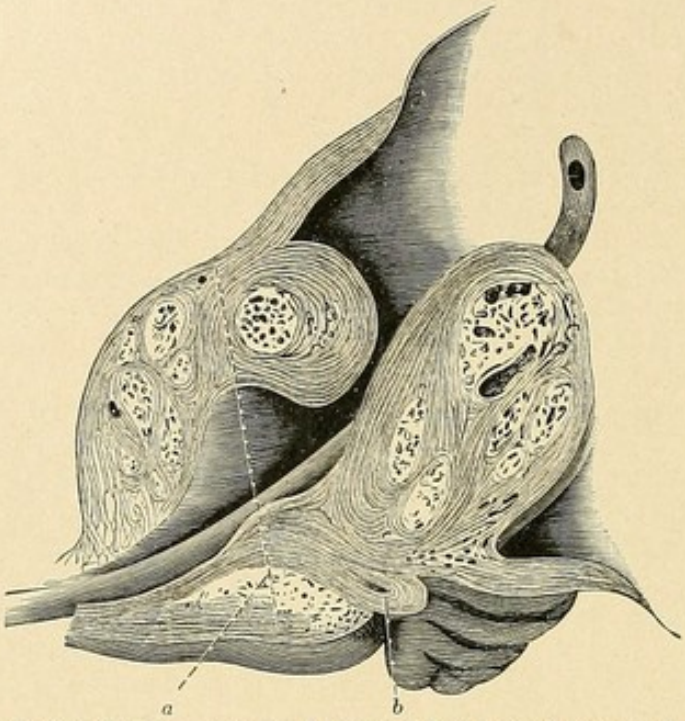

FIG. 555.—Longitudinal section of hypertrophied prostate in a patient seventy-four years of age, showing a false passage tunneled by a catheter. *b*, Line of transverse section shown in Fig. 556. *a*, Duct of vesicula seminalis. (After Socin.)

trophy may be central, resulting in the development of a middle or third lobe, which, by progressive enlargement, not only changes the axis of the normal urethra, but occludes, in a variable degree, the outlet of the bladder. This last condition is well shown in Fig. 555, and that

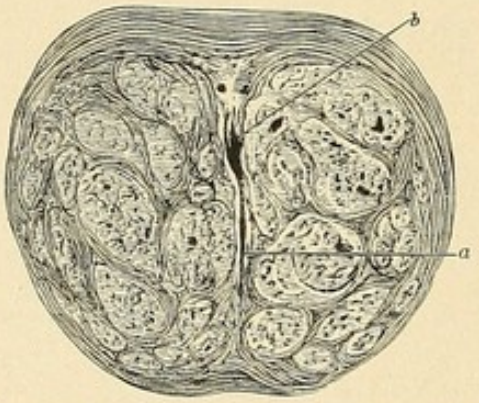

FIG. 556.—Transverse section through the center of the prostate of a patient seventy-four years old. Hypertrophy of fourteen years' duration. *a*, Urethra. *b*, Caput gallinaginis. (After Socin.)

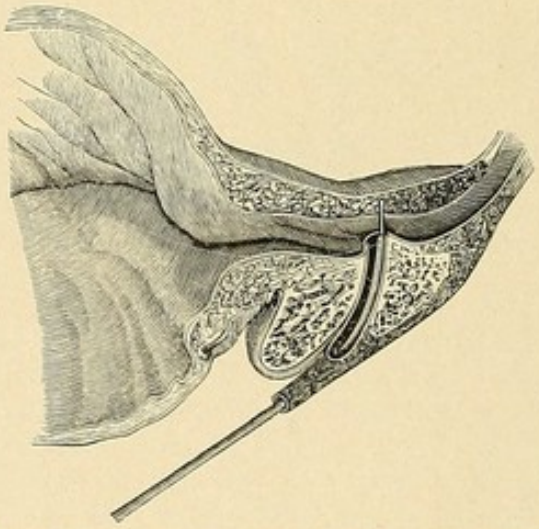

FIG. 557.—Showing the relations of the floor of the bladder to the prostatic urethra in the normal condition of this body. The bristle is passed from the ejaculatory duct into the urethra. (After Socin.)

of general hypertrophy of the muscular, fibrous, and glandular tissues, with narrowing of the urethra, in Fig. 556.

Symptoms.—The increase in size is usually so gradual that the condition of hypertrophy does not attract the attention of the patient until interference with the flow of urine occurs. As a result of retention the bladder is distended, the contractility of its muscular walls is diminished, and chronic cystitis inevitably

ensues. The changes which take place in this organ—thickening of the walls, occasional sacculation, the formation of calculi, dilatation of the ureters, etc.—have been given. In severe cases the functions of the rectum may be interfered with.

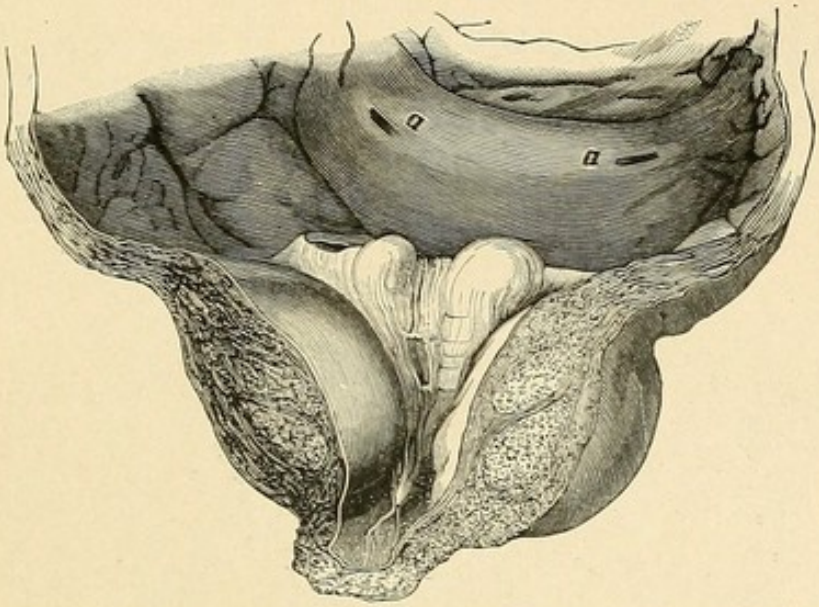

FIG. 558.—Hypertrophy of the prostate, showing the asymmetrical development of the middle or third lobe. *a*, *a*, Openings of ureters. (After Socin.)

The *diagnosis* may be determined by the presence of the symptoms just given, by digital exploration per rectum, and by the introduction of a sound or bougie through the urethra.

The *treatment* is palliative and operative. When recognized early in its history, every source of irritation should be removed from this organ. The bowels should be kept open, the irritability of the urine diminished by the administration of alkaline diluents, and all venereal excitement prohibited. In those affected

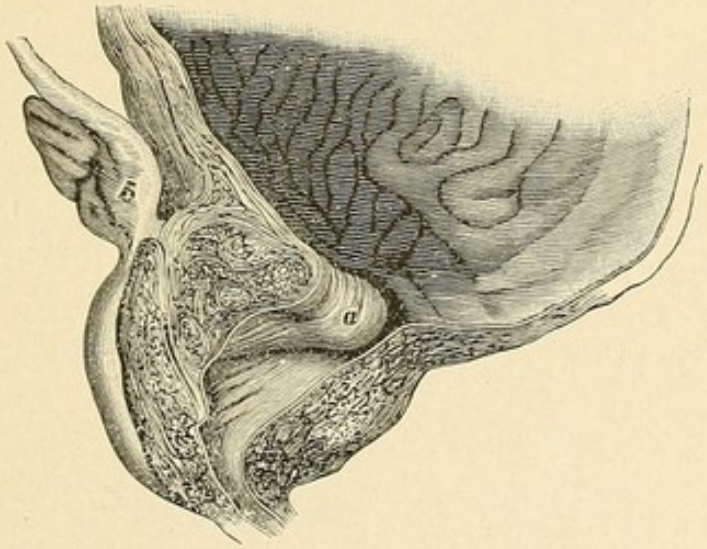

FIG. 559.—Antero-posterior section of the same specimen.

with gout or rheumatism, or any disturbance of the digestive apparatus, judicious diet and medication may arrest, or at least retard, the progress of the disease in the prostate.

When, however, the obstruction to the outflow of urine is such that hyperdistention of the bladder is taking place, together with cystitis resulting from decomposition of that portion of the bladder contents which cannot be expelled,

prostatectomy should be advised. This operation is a valuable contribution to the surgery of the male genito-urinary organs, and when properly done in the earlier stages of hypertrophy, before the pathological changes in the bladder have affected the ureters and the kidneys by direct or ascending infection, the mortality is insignificant.

Prostatectomy.—The prostate may be removed by either the suprapubic or the perineal incision, and under certain conditions it may be advisable to utilize both of these approaches. In very rare instances, when the obstruction to the outflow of urine is due almost if not wholly to a hypertrophy of what is known as the third or middle lobe of this organ, this hypertrophied portion may alone require removal. In this minor procedure, the suprapubic incision should be preferred, through which the obstruction to the escape of urine may be easily removed by the author's prostatic forceps, as heretofore given (Fig. 545). Suprapubic drainage will be

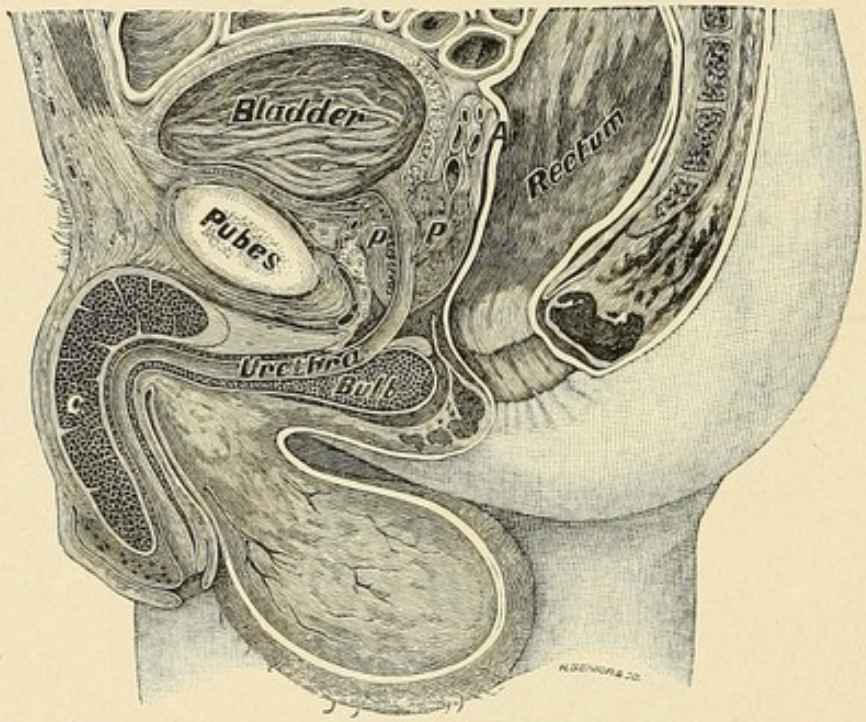

FIG. 560.—The normal urethra of the male adult. From a frozen section. Reduced from life size. (After Braune.)

necessary for a few days, after which the bladder incision may be left to close by granulation.

The suprapubic route should also be favorably considered when there is a general enlargement of the prostate with marked projection of the hypertrophied portion into the lumen of the bladder, as shown in Fig. 555. In some of the enormous hypertrophies, which are occasionally observed, it may be necessary to combine the perineal route with the suprapubic. In working from above, the mucous membrane covering the bulging prostate should be torn through by the dull-pointed scissors or by the nail of the index-finger of one hand, while with the other introduced through a perineal incision (if this has been deemed necessary) or into the rectum as a guide and for counter-pressure, the organ may be hulled out without danger to the large bowel.

In the opinion of the author, *perineal prostatectomy* (as advised by Dr. Hugh H. Young) is the operation of choice in a very large proportion of all cases of hypertrophy of the entire prostate. The patient should be placed in the lithotomy position, a sound having been first introduced into the deep urethra. An incision in the median line is made from near the scrotal crease to within half an inch of the anal margin. In fat subjects, or when more room may be needed, to this may be added a transverse curved incision half an inch anterior to and parallel with the circle of the anus. This incision should expose the bulb of the urethra,

the central tendon, and the edges of the levator ani muscle (Fig. 560*a*). The central tendon is then divided close to the margin of the levator ani and turned down. By keeping close to the capsule of the prostate in the dissection, wounding the rectum should be avoided. However, under certain exceptional conditions,

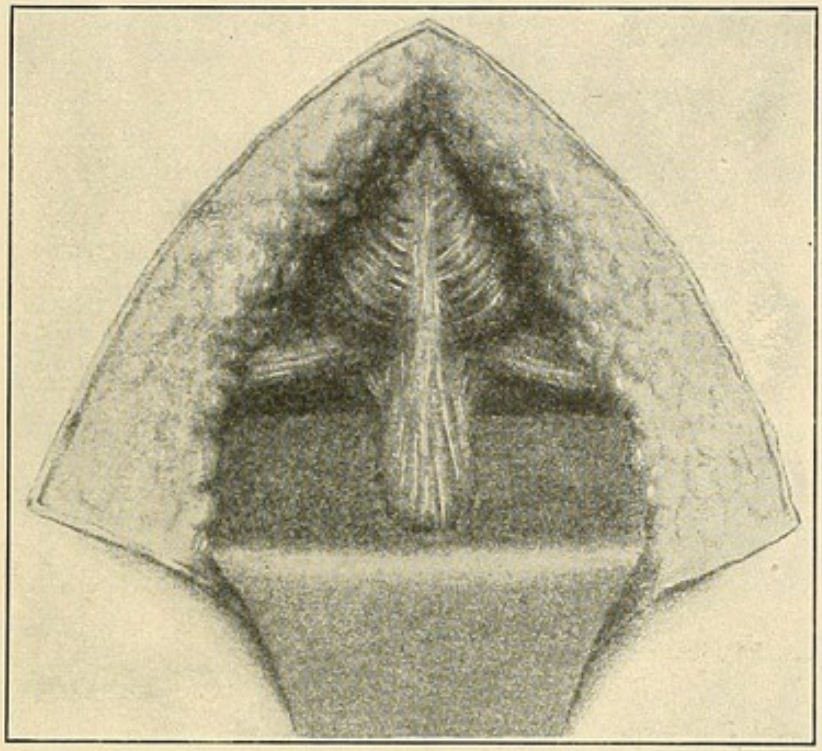

Fig. 560*a*.—Showing the bulb of the urethra above, the central tendon below, and laterally the edges of the levator ani. Young's bifid retractor in position. (After Young.)

when the enlargement is excessive and when adhesions due to preëxisting inflammation are firm and extensive, this accident may be unavoidable. When it occurs, the opening should be temporarily closed with the forceps to prevent infection, and as soon as the enucleation has been completed it should be repaired by suture.

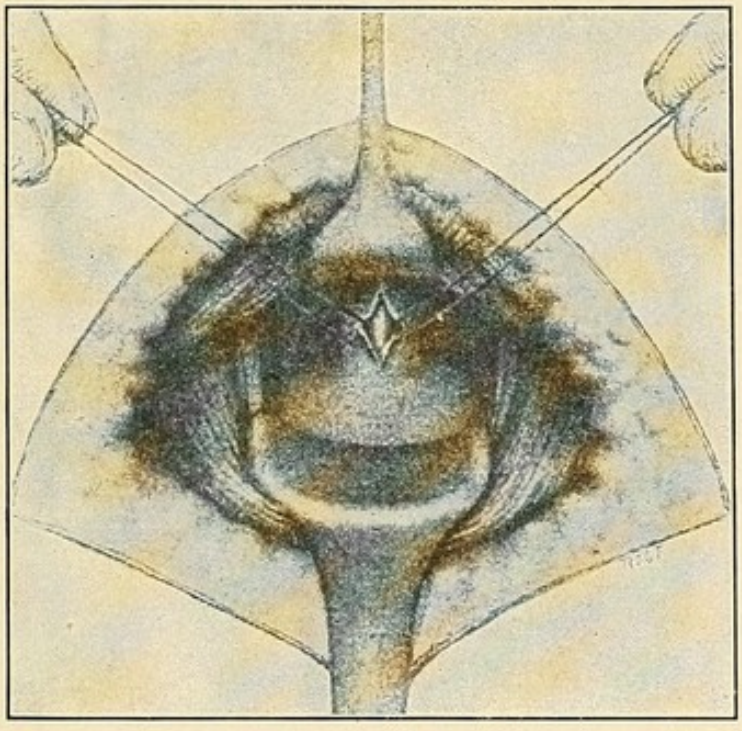

Fig. 560*b*.—Showing the incision into the urethra and the thread-loops inserted. (After Young.)

With the sound which has already been introduced as a guide, a small longitudinal incision is made into the urethra through the membranous portion, and two linen threads inserted, as shown in Fig. 560*b*. The sound is now withdrawn, and through this opening Young's tractor is inserted into the bladder, the blades turned, and the lateral and posterior retractors placed into position. The prostatic tractor draws the gland outward while the rectum is displaced backward, which, with strong lateral retraction, fully exposes the entire anterior and inferior surfaces of the prostate. An incision about 1.5 cm. deep is now made on each side of the median line for almost the entire length of the anterior surface of the prostate. These two lines diverge from before backward, being separated 1.8 cm. posteriorly and 1.5 cm. anteriorly (Fig. 560*c*). The bridge of tissues which lies between these two incisions contains the ejaculatory ducts, the preservation of which is important (Fig. 560*d*). Through these incisions in the capsule each lateral lobe is hulled out with the blunt dissector (Fig. 560*e*). The outer portion of each lateral half should be first separated from the capsule, and great care is necessary in separating the inner half to prevent tearing into the urethra, an accident which may occur, however, when the adhesions are strong. Enucleation of the inner portion is facilitated by seizing the tumor with forceps and making outward traction, as shown in Fig. 560*f*. At this stage of the operation the blunt dissector should be discarded, and the index-finger used. After the lateral lobes have been enucleated, a careful

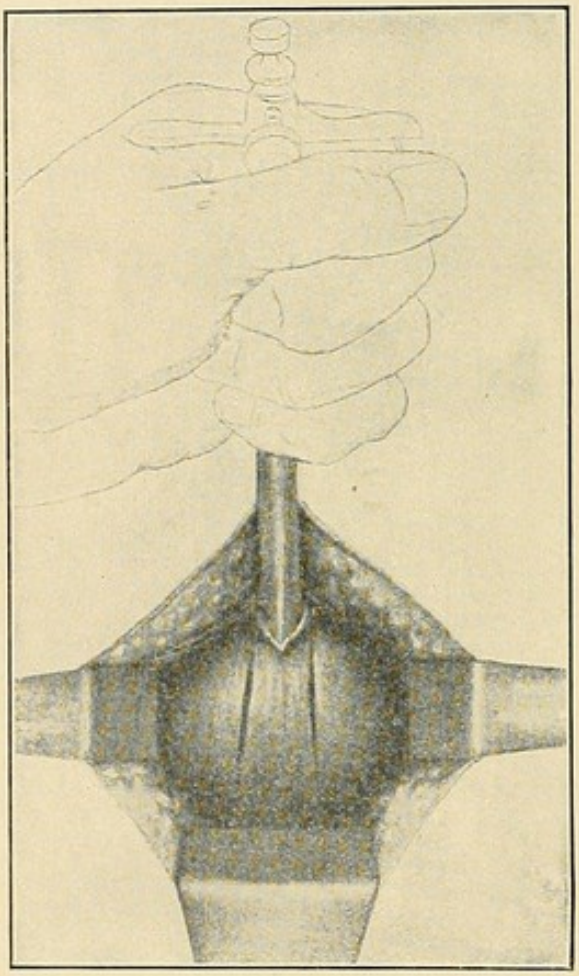

FIG. 560*c*.—Showing Young's tractor introduced and the lateral incisions into the substance of the prostate on either side of the urethral canal. (After Young.)

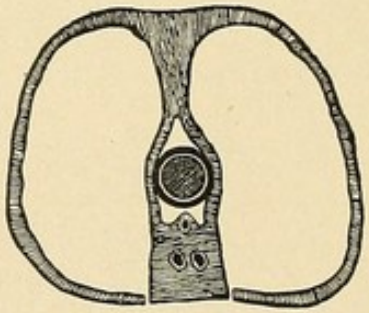

FIG. 560*d*.—Cross-section of the prostate and urethra, showing the strip of prostate which contains the ejaculatory ducts and which is not removed. (After Young.)

examination should be made and any median enlargement also removed through one of the lateral incisions.

Having removed the tractor and thoroughly irrigated the bladder and wound, the operator should carefully search for any injury to the bowel. The edges of the levator ani muscle should be approximated with a strong suture of chromicized catgut, No. 2, and the central tendon stitched back to its original attachment.

It is very important to see that the bladder is emptied of blood before the patient leaves the operating table, and that the drainage apparatus is thoroughly in place and kept in order after the patient is put to bed. This consists of a double current, soft-rubber tube, or two tubes which pass into the bladder through the incision in the membranous urethra. A light gauze pack is inserted laterally. Young advises in all cases a submammary infusion of one thousand cubic centi-

metres of salt solution, to be given while the patient is on the operating table. "This is considered so valuable, both as a preventive to shock and anuria and as a

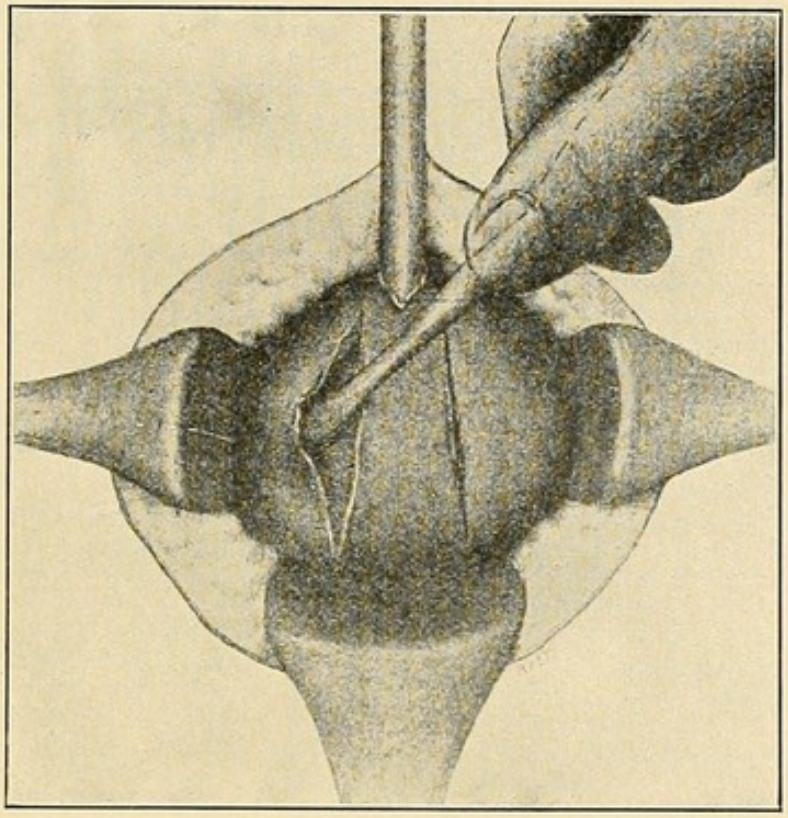

Fig. 560e.—Enucleation of the outer portion of each lateral lobe with the blunt dissector. (After Young.)

cure for post-operative thirst, that it is never omitted." The gauze drain is removed one day after the operation, and no more packing employed. The tube

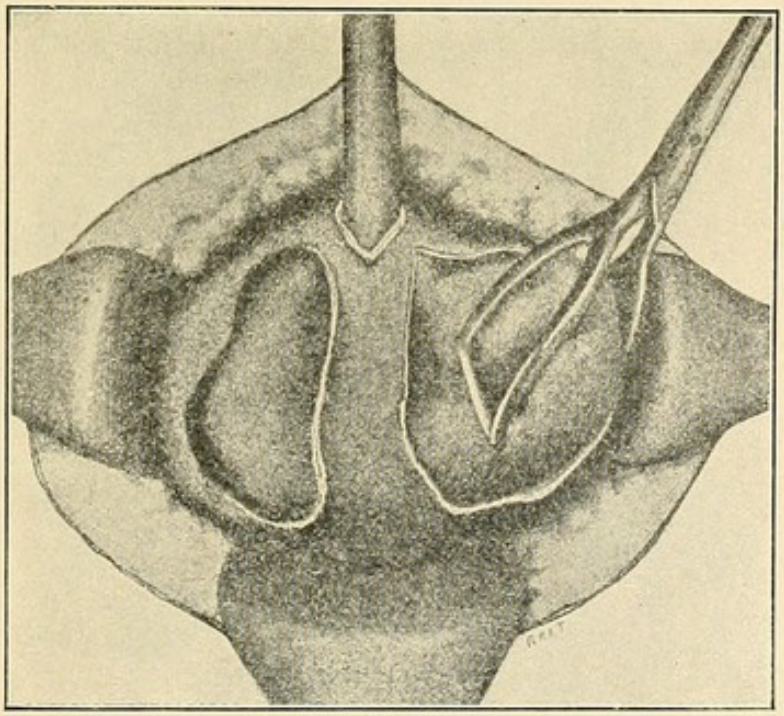

Fig. 560*f*.—Traction with the prostatic forceps. (After Young.)

is pulled out a few hours later, and the next day the patient is usually placed in a wheel chair and carried out-doors. No sounds are passed and stricture never

results. Urotropin is given early, and water in abundance. (Young.) The normal relation of the prostate is shown in Fig. 560, while the changes which are present in hypertrophy are given in Fig. 562. The relation of the ejaculatory duct is shown in Fig. 557. The impediment to the complete evacuation of the bladder in enlargement of the posterior and middle portions of this body is shown in Fig. 558.

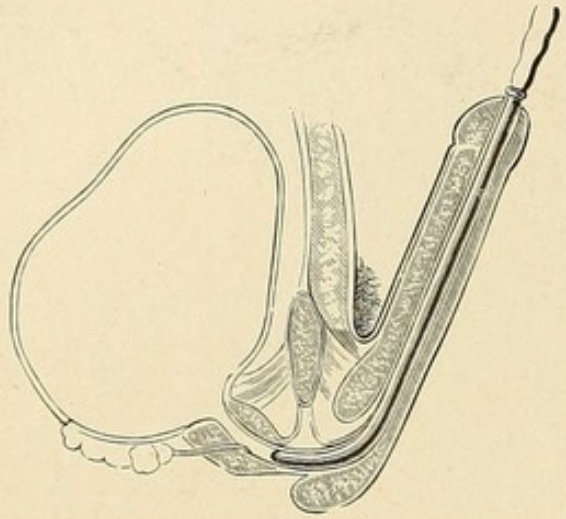

Fig. 561.—The sound passing around the normal curve of the urethra. (After Van Buren and Keyes.)

A reference to Fig. 562 will show the changes which occur in the general contour of the posterior urethra in connection with prostatic hypertrophy, more especially that form which projects backward into the bladder. Fig. 560 shows the normal curve, and the sharp forward curve of the deep urethra is shown in Fig. 562 as a result of the enlargement.

In hopeless cases of cystitis resulting from obstruction of the urethra from prostatic hypertrophy, malignant neoplasms, or any cause, in rare instances the establishment of a permanent urinary fistula may become necessary. After a suprapubic operation has been performed and the wound has contracted upon the ordinary drainage-tube, this may be removed and a permanent apparatus such as shown in Fig. 565 inserted.

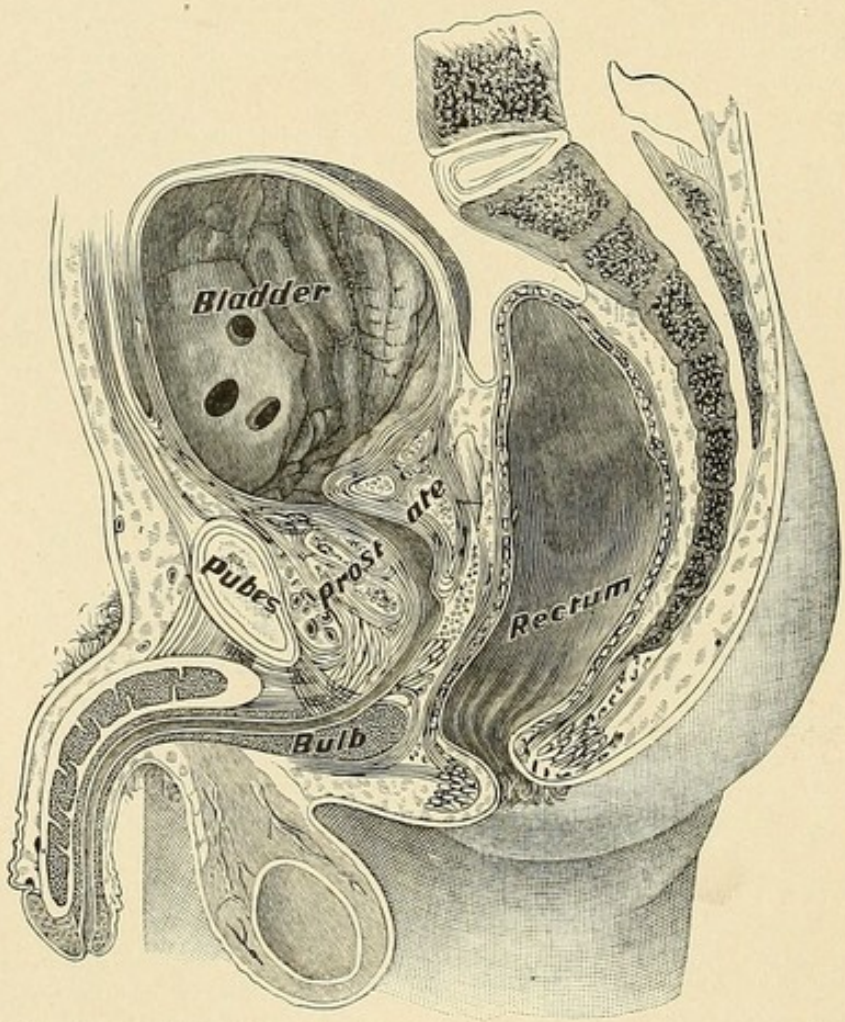

Fig. 562.—The change in the direction of the urethra caused by hypertrophy of the prostate. (After Socin.)

This consists of a large-sized soft Nélaton catheter, which is carried through the fistulous opening until it rests comfortably within the bladder, usually about three inches from the level of the integument. This catheter is made to pass through a perforated hard-rubber plate about three inches long and two inches wide. To the corners of this plate are fastened four tapes, two of which are carried around the body and tied, the other two passing under the perinæum, in the same way as the perineal straps of a truss, to hold the drainage catheter firmly in its proper position. When the wound is entirely healed, and the patient begins to move about, a rubber urinal, which receives the outer end of the catheter, is

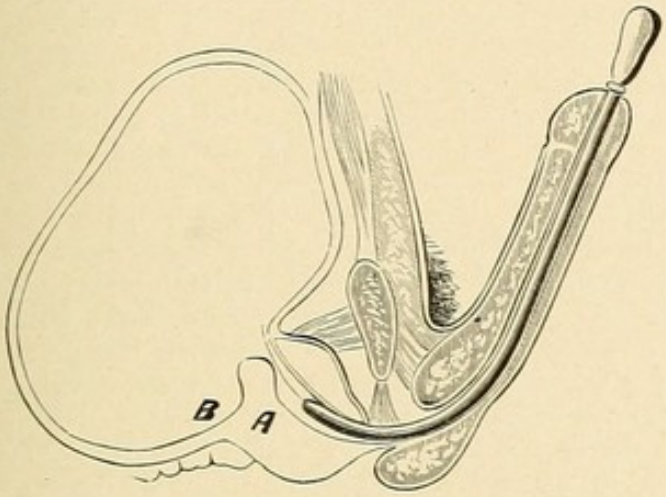

FIG. 563.—Showing the increase in the curve of the urethra in prostatic hypertrophy, and the necessity of a longer curve in the catheter. (After Van Buren and Keyes.)

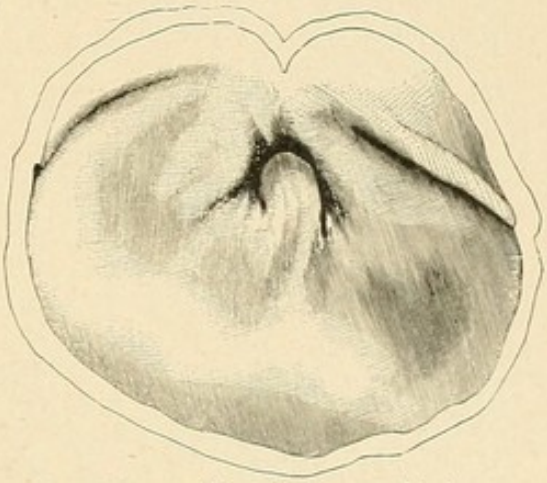

FIG. 564.—A ridge of hypertrophied prostate seen from within the bladder. (After Socin.)

fastened to the inner side of the thigh and leg. This urinal extends down the leg, and is so arranged that by turning a little stopcock situated near the ankle it may be emptied when necessary.

Prostatorrhœa.—Chronic prostatitis, or catarrh of the prostate, in a majority of cases follows an acute inflammation of this organ (gonorrhœa). Its chief cause is, therefore, an extension of a cystitis or urethritis to the epithelial lining of the glandular portions of this body. In a certain proportion of cases it originates as a subacute inflammatory process located in the glandular substance. It

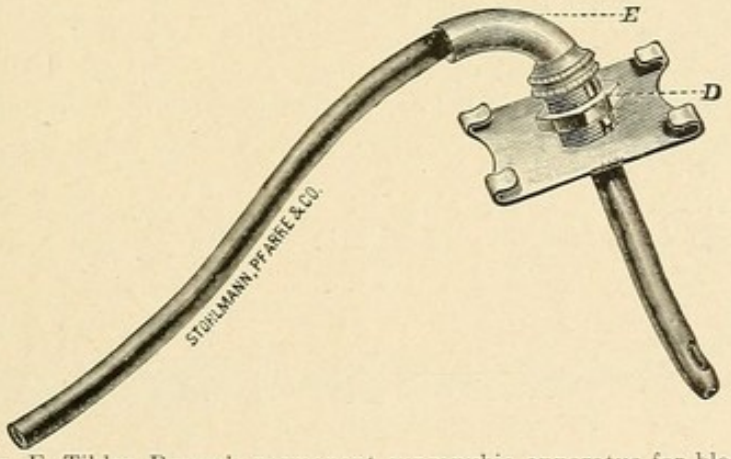

FIG. 565.—Dr. F. Tilden Brown's permanent suprapubic apparatus for bladder drainage.

is in this form most frequently seen in weak, scrofulous, or tubercular adults about the period of puberty. Prostatorrhœa is a symptom of general hypertrophy of this organ in the earlier stages of enlargement, gradually diminishing as the connective-tissue hyperplasia encroaches upon and destroys by compression the glandular apparatus.

The leading symptom of this disease is the discharge of a small quantity of bluish-white fluid from the meatus. It is noticed particularly by the patient before the first micturition in the morning, having accumulated during the night. A drop or two may be squeezed from the urethra by pressure along the under surface of the penis from the perinæum forward. It is carried out with the first flow of urine, and, if not observed previously, usually escapes notice. In the severer type of cases the prostatic fluid may be seen immediately after urinating or during the intervals of micturition, as a bluish mucus, moistening the meatus and prepuce, and slightly tenacious and stringy when wiped off. This fluid is also frequently observed when the contents of the rectum are discharged, especially if the fæces are hard and fully formed. Prostatorrhœa occurs in excessive or prolonged venereal excitement.

The *diagnosis* depends upon the exclusion of spermatorrhœa and urethritis. The symptoms of spermatorrhœa are in general so similar to those of prostatorrhœa that a positive differentiation can only be made by microscopical examination. The fluid which escapes may be examined alone, or the first ounce or two of urine passed after a comparatively long interval in urinating may be caught in a separate vessel, allowed to settle, and a drop of the sediment placed upon the slide. The presence of spermatozoa will confirm the diagnosis of spermatorrhœa. The urine first passed after a discharge of semen should not be examined, since under such conditions these elements are found in perfectly normal subjects. In differentiating between prostatorrhœa and gleet, the exploration of the urethra will be necessary. The absence of a stricture or of marked tenderness in the canal in front of the prostatic portion will exclude urethritis, with the exception of a rare form of chronic follicular urethritis, which, as will be seen farther on, may or may not be preceded by a gonorrhœa or stricture. In follicular urethritis, tenderness is not marked. If a large-sized bulbous wire bougie is carried back to the membranous portion of the urethra, and is then withdrawn while the urethra is held in close contact with it, the yellowish-white flakes or plugs of cheesy material will be squeezed out of the follicles and be seen adhering to the bulbs.

Treatment.—The correction of any diathesis which predisposes to a catarrhal condition of the mucous membranes is an important step in the general treatment of prostatorrhœa.

Among the local measures, distention of the prostatic urethra by the introduction of steel sounds is advisable. The larger sizes should be employed, and if the meatus is so narrow that it will not admit No. 20 or 21 (U. S.), it should be incised up to this point as a preparatory measure. When stricture exists, internal urethrotomy should be performed. The dilatation may be commenced with No. 17 and increased to No. 21 at a single operation; or, if the procedure is attended with pain of a severe nature, the larger numbers may be used at the third or fourth introduction. The point of the sound should not be carried farther than the neck of the bladder, which is between seven and eight inches from the meatus. The operation should be repeated from two to three times a week—not often enough to cause a general urethritis.

Local medication is at times of great value. The method which yields the best results is the deep injection of nitrate of silver, varying in strength from



Fig. 566.—Keyes-Ultzman syringe.

ten to forty grains to the ounce. As a rule, a ten-grain solution is the proper strength to commence with, and is increased as the exigencies of the case demand. The instrument employed is the Keyes-Ultzman syringe (Fig. 566). Under the ordinary aseptic rules the syringe is filled with the proper solution, lubricated with

glycerine, and carried back until the point can be felt to pass behind the cut-off muscle and rests in the deep or prostatic urethra. The quantity of the solution injected is usually from five to ten minims, repeated every two or three days. It is usually followed by a slight and temporary sense of irritation or burning.

Spermatorrhœa.—This term is used to designate the escape of semen from the ejaculatory ducts without an orgasm. This fluid may find its way into the bladder, but usually escapes by the meatus. The symptoms of this disease do not differ materially from those given in prostatorrhœa. The diagnosis can only be made certain by the recognition of the spermatozoa with the aid of the microscope. It occurs at times in conditions of great physical prostration, as a result of excessive and unnatural venereal indulgence, and from interference with the function of the muscular elements of the prostate.

The *treatment* is general and local. Measures looking to the improvement of the moral and physical condition of the patient should be adopted. The local treatment is the same as that given for prostatorrhœa.

Aspermatism.—The spermatozoa are wanting in adults whose testicles have been removed or destroyed by disease, in patients in whom both organs have failed to descend and have undergone atrophy; in all cases of complete obstruction of the *vasa deferentia* or ejaculatory ducts, and in certain cases of senile atrophy of these organs. These conditions are rarely amenable to surgical treatment.

Tuberculosis of the Prostate.—Tubercular disease of this organ, though rarely observed, may be primary, or more frequently is secondary, to tubercular deposit in other viscera, as the testis, epididymis, lungs, etc. It is more apt to occur in the young and middle-aged than in the old. The diagnosis cannot, as a rule, be easily made. In some cases there are no symptoms of tuberculosis. If with a subacute or chronic lesion of this organ there is a history of phthisis, the deposit of tubercular matter may be suspected. When the febrile movement, hectic flush, profuse sweats, and emaciation of this disease are present, a correct diagnosis is readily made. The enlargement and nodular character of the prostate may be made out by digital exploration by the rectum. The treatment is palliative if general tuberculosis exists, or operative if the disease is local.

Carcinoma.—Cancer of the prostate is also rare. It is more apt to occur primarily than by metastasis. Primary cancer of this organ is more frequently seen in young adults than in the old. In the middle-aged and old it is more likely to occur by invasion from a neighboring organ, as the rectum.

In the earlier stages the symptoms of this disease do not differ materially from those of simple hypertrophy. As simple hypertrophy is rare in the young and middle-aged, the presence of a tumor of this organ at this time of life should be regarded with a suspicion of malignancy. The absence of the symptoms of abscess is in some degree a confirmation of this suspicion. If the tumor develops rapidly, carcinoma or sarcoma may be diagnosticated, for, although the disease may continue for one or two years, or even longer, the invaded organ soon assumes a size not met with in non-malignant hypertrophy. Hæmorrhage of a profuse character is apt to follow the introduction of a sound or catheter when carcinoma or sarcoma is present.

Sarcoma is also rare in this organ (Fig. 567). It is more apt to occur in the young than in the middle-aged and old. The symptoms differ in no essential feature from those present in cancer. The *prognosis* of both diseases is grave, and the treatment palliative.

Prostatic Concretions.—Concretions in this organ are of two kinds—the *corpora amylacea* and *calculi*. The former are small bodies which frequently exist in the follicles of the prostate. Their mode of origin is unknown. They give the well-known amyloid reaction with iodine. Stone in the prostate may originate in the deposit of inorganic elements from the blood and fluids of this organ, either in the follicles originally (Fig. 568) or as accretions upon the amyloid bodies just described.

The *symptoms* of prostatic concretions are chiefly those due to the inflammation or enlargement which they produce. Corpora amylacea not infrequently exist in the prostate, causing little or no discomfort. When of large size, especially when

they grow by reason of a deposit of inorganic substances, they cause inflammation of the follicles and destruction of the glandular epithelia. A positive *diagnosis* can only be made by bringing a sound or catheter in contact with the concretion. When the stone is situated in the deeper portions of the organ it will escape detection by this method, but the tumefaction it causes may be recognized by digital exploration *per rectum*.

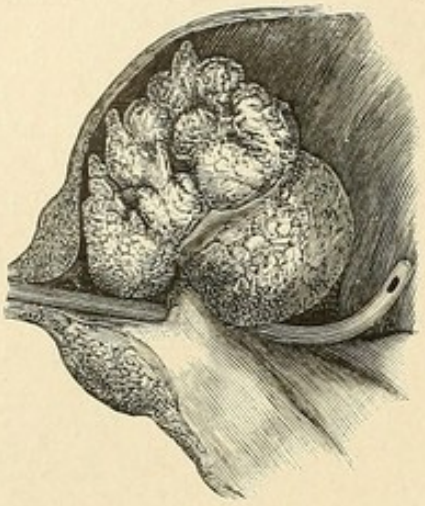

FIG. 567.—Sarcoma of the prostate and neck of the bladder, with obstruction. The catheter has tunneled the neoplasm. (After Socin.)

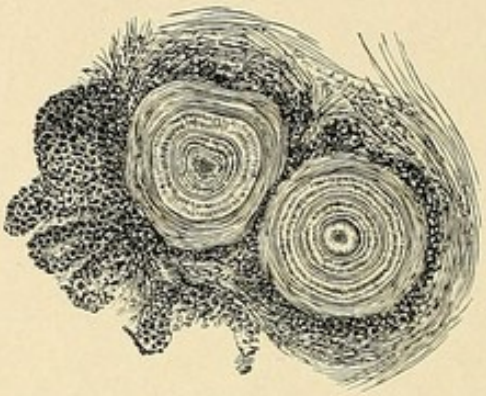

FIG. 568.—Calculi in the prostatic follicles. (After Socin.)

The interference with the escape of urine caused by calculi of the prostate is analogous to that which occurs with general hypertrophy of the body of this organ. The stream of urine is diminished, but remains about the same size, and escapes steadily throughout the act of urination. There is no sudden and complete interruption of the current, as in stone in the bladder, or in enlargement of the middle lobe of the prostate. Calculi of this organ may escape into the urethra and lodge there, or work their way back into the bladder, or pass out at the meatus.

The *treatment* is palliative until operative interference is necessitated on account of pain or dysuria. Either lobe may be incised and the concretions removed by following the technic given for perineal prostatectomy. Should hypertrophy be present, removal of the prostate may be advisable.

Neuralgia of the prostate and neck of the bladder is occasionally observed. Pain is present in this organ when no symptoms of inflammation are discoverable. It is usually exaggerated during and immediately after micturition, and after a seminal emission. The introduction of a sound shows great tenderness of the deep urethra. The instrument carried into the bladder does not produce the tenesmus and pain common to cystitis. An examination of the urine will demonstrate the absence of pus, which will also serve to exclude inflammation of the bladder or prostate. The causes of this infection are as a rule obscure. Irregular or excessive venereal indulgence is considered to be one of the most frequent causes of neuralgia in this organ. The treatment involves the removal of every possible source of irritation. The constitutional measures recommended in neuralgia in other parts of the body should be employed. Locally the galvanic current is especially indicated. If the urine is extremely acid and burning, benefit will be derived from the administration of large quantities of alkaline and diluent drinks.

Seminal Vesicles.—The seminal vesicles are occasionally absent from failure of development, or they may be obliterated as a result of cicatricial contraction after infection, while they are occasionally destroyed by operation.

Inflammation of the seminal vesicles is caused by the extension of an infection from the urethra, prostate, bladder, rectum, and *vas deferens*. In occlusion of the ejaculatory duct there is always an overdistention of these organs. Several cases of calculus in the ducts have been recorded. Gonorrhœa is, in all probability, the most frequent cause of serious seminal vesiculitis.

The specific organisms of this disease long after the first acute symptoms have subsided lie concealed in the deeper follicles of the prostate and probably in the seminal vesicles, to declare themselves by renewed outbreaks of infection under conditions favorable for their proliferation and dissemination.

In all probability the so-called prostatic neuralgia is due in large measure to chronic subacute inflammation of the seminal vesicles following gonorrhœa. These vesicles are also at times the seat of localized tuberculosis, and their function must always of necessity be more or less impaired by any hypertrophy of the prostate.

In the *treatment* of chronic vesiculitis with hyperdistention, intrarectal massage has been recommended. This can be done digitally or by the use of a large glass rod with proper curve and with a knoblike end. This is introduced into the rectum and kneading done from above downward. In a certain proportion of cases of chronic vesiculitis, where pain is persistent, operative intervention may be demanded. Prof. Eugene Fuller has devised the following operation, which he has practiced in a number of instances with satisfactory results:

The patient, properly prepared and anæsthetized, is placed upon the operating table in the prone position with the thighs abducted and flexed upon the abdomen.

The incision on the right begins a little above the upper border of the patient's coccyx, just inside the right ischium, then extends slightly downward, keeping just within the border of that bone and ending about three fourths of an inch anteriorly to the anterior margin of the anus. A similar incision is made on the opposite side, and these are joined in front of the anus by a transverse cut. The longitudinal cut should be deep enough to divide all the fatty tissues of the ischio-rectal space, and dividing above a few of the lower fibers of the gluteus maximus muscle. The transverse cut is then deepened, the anterior layer of the deep fascia being cut through. Great care should be taken in cutting down transversely to avoid wounding the sphincter ani muscle. The curved forefinger of the operator's left hand should be inserted into the rectum, the ball of the tip being turned downward against the anterior rectal wall, while the corresponding thumb presses against the loosely dissected rectum, the hand at the same time exercising upward traction. The bowel is thus held up in the grasp of the thumb and the forefinger, while the operator dissects more deeply, cutting through the levator ani muscle and the visceral layer of the pelvic fascia. As the narrow pathway of this dissection is between the urethra and the rectum, the knife or dull-pointed scissors should be kept well against the anterior rectal wall. When the fibers of the levator ani muscle are divided, the upper flap, which includes the rectum, spontaneously retracts or may be raised well out of the way. As the dissection becomes deeper, the operator's right forefinger may be used to separate the tissues instead of an instrument, and the path of the wound over the prostate divulsed by separating the fingers. In the deeper dissection it is comparatively easy to strip the loose rectal connections from the seminal vesicles and the posterior bladder wall. The vesicles are now opened by means of a free longitudinal incision, and their cavities thoroughly curetted. A light wicker drain is inserted in the trough of the opened vesicles. This may be removed within five days or a week. The operation being completed, the walls of the wound should be carefully adjusted by deeper sutures so as to bring the rectum back into its original position. A space for gauze packing should be left in the middle portion of the transverse cut. Temporary retention of the urine requiring the catheter is apt to follow, especially where extensive gauze packing has been found necessary.[1]

[1] Eugene Fuller, "Jour. A. M. A.," May 4, 1901; "N. Y. Med. Rec.," May 21, 1904.

CHAPTER XXX

THE URETHRA—PENIS—TESTICLES—SCROTUM—BALANITIS—POSTHITIS—PHIMOSIS—ORCHITIS—BUBO—GONORRHŒAL RHEUMATISM—CHRONIC URETHRITIS—STRICTURE—URETHROTOMY—DILATATION—DIVULSION—FOREIGN BODIES—URETHRO-RECTAL FISTULA—HYPOSPADIAS—EPISPADIAS—NEOPLASMS—HUMPHREY'S OPERATION—CIRCUMCISION—ULCER—HÆMATOMA—FISTULÆ—ELEPHANTIASIS—HYDROCELE—VARICOCELE—EPIDIDYMITIS—NEOPLASMS OF THE TESTICLE—MALPOSITION

GONORRHŒA will be considered in the chapter on infectious diseases.

Among the *complications* of gonorrhœa are balanitis, posthitis, paraphimosis, prostatitis, cystitis, epididymitis, orchitis, bubo, ophthalmia, arthritis, and retention of urine.

Balanitis and *posthitis*, inflammation of the glans and prepuce, are conditions existing in a varying degree in almost all cases of gonorrhœa. Among the circumcised, or those with short and retracted foreskins, posthitis need not occur, but the acrid discharge will always affect the epithelial covering of the glans in the immediate neighborhood of the meatus. When the foreskin is long and adherent, or not readily drawn behind the glans, it usually becomes swollen and tense, retains the irritating discharge, and inaugurates an exceedingly painful and annoying condition of phimosis. Even when thus swollen, if the prepuce can be retracted, it is apt to be caught behind the corona and become irreducible, with ensuing strangulation, if not relieved by operative interference. Preputial sloughing will occur in a certain proportion of neglected cases.

In the treatment of gonorrhœa certain measures were detailed looking to the prevention of these complications. When, however, they are present in a mild degree, balanitis and posthitis disappear with proper attention to cleanliness. The glans and prepuce should be irrigated by being submerged in a vessel of warm water. Soap should not be employed. The hip-bath, already given as useful in the general management of the disease, is especially so in this complication.

The inflammatory phimosis of gonorrhœa, as of non-specific *balano-posthitis*, demands active measures of treatment. In milder cases it may suffice to maintain cleanliness by the frequent subpreputial injection of tepid water. For this purpose a syringe with a delicate dull point or nozzle, about an inch in length, is needed. It should be oiled, carefully introduced between the glans and prepuce, and the contents slowly discharged. An irrigating apparatus may also be attached to the nozzle, and a continuous current applied, which does away with the irritation of repeated introductions of the nozzle. If these milder measures do not relieve the pain, tension, and threatened strangulation, an incision should be made. The prepuce may be nicked in several places, or a director introduced in the median line above, along the groove of which a bistoury is carried, and the division effected.

When inflammatory paraphimosis exists, adhesions rapidly occur at a point just behind the corona, on the dorsum penis, rendering a reduction impossible unless these transverse bands are divided. The reduction of a paraphimosis is undertaken in this manner. The organ is held in a vessel of cold water for a few minutes, or cold cloths are wrapped loosely over and around the swollen parts. When removed, the glans and prepuce are thoroughly lubricated, and the organ grasped so that while the soft parts of the thumbs press the glans backward, the

fingers are drawing the prepuce to the front. Or the penis may be grasped by the thumb and finger of the left hand, and the foreskin drawn forward while the glans is pushed backward by the thumb and fingers of the opposite member. When the reduction is accomplished, the patient should be directed to make every effort to prevent a recurrence of the accident.

If the efforts at reduction fail, the contractions on the dorsum, behind the glans, should be divided by one or more incisions in the long axis of the penis. Œdema of the prepuce, especially of the lower portion, is apt to occur, even in cases of recent paraphimosis, and, when the condition has existed for a day or two, infiltrations occur, which may persist for a long time after the constriction is relieved.

Prostatitis and cystitis, occurring with gonorrhœa, require treatment not differing from that already given. *Retention* must be relieved by the small soft catheter or by suprapubic aspiration. *Epididymitis*, or inflammation of the vas deferens and the globus major and minor, is one of the most painful complications of gonorrhœa. Perfect physical quiet, with support of the scrotum and testicle, are essential. At the earliest indication of an extension of the infection along the vas deferens, every effort should be made to arrest the disease before it reaches the epididymis or to confine it at least to the globus major. The anatomical arrangement of the globus minor, which is composed of a single tube in numerous convolutions, makes it more easy of occlusion by inflammation than the multiple tubules which compose the globus major. Sterility not infrequently follows an epididymitis which seriously involves the globus minor. The last of these measures may be secured by using the handkerchief sling, which is made as follows:

Attach a belt or piece of roller around the waist, above the pelvis; fold a good-sized silk handkerchief in a triangular shape, carry the center of the long

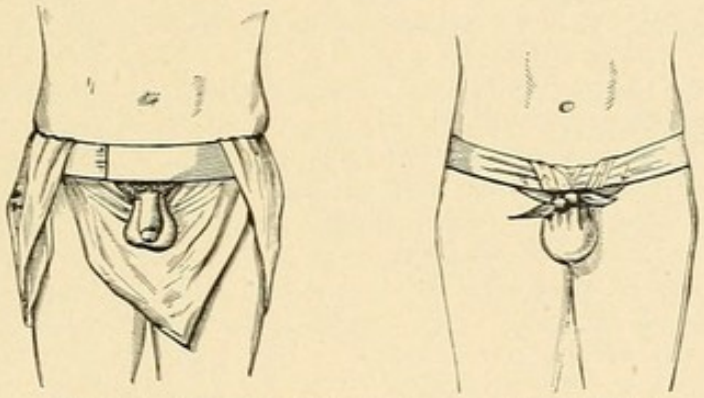

Fig. 569.—Handkerchief suspensory. (After Hill.)

side of this triangle beneath the scrotum, at the perineo-scrotal junction, attach one of the long ends to the belt, near the anterior superior spine of the ilium, on either side, and bring the short piece directly upward, in front of the scrotum and penis, and pin it to the belt in the median line; or the ends may be tied just above the root of the penis (Fig. 569).

Another method is to place a three-cornered cushion beneath the scrotum, close up to the perinæum, and allow the testicles to rest upon this support; or two thickly folded towels may be pinned together and carried tightly around the thighs at the level of the perinæum.

At times the tension of the parts is so great that, not only to relieve pain, but to prevent gangrene, puncture or incision is imperative. The most immediate relief will follow this operation. A sharp narrow blade is preferable, and, if the instrument is not made for this especial purpose, it may be extemporized by projecting the point of an ordinary sharp-pointed bistoury half an inch beyond the surface of a cork through which the knife is thrust. With this guard attached, the punctures may be made rapidly and without danger of penetrating too deeply.

Although the procedure is very painful, it is usually so rapidly accomplished

that an anæsthetic is not necessary. The injection of a two-per-cent cocaine solution will afford a fair degree of anæsthesia. The operator holds the scrotum and testicle so as to make tense the skin over the epididymis and to expose it properly to view, and then by well-directed and rapid thrusts punctures the organ in from two to four or six points, scattered over the induration. A free discharge of dark or black blood usually follows, and in from twenty to thirty minutes the pain is greatly if not entirely relieved. The antiseptic precautions should be carried out in this procedure.

Orchitis is an infrequent affection in gonorrhœa. The treatment is in general similar to that of the last-named disease. The diagnosis is readily made out by the touch, for, when hydrocele does not coexist, the induration of the organ cannot well be mistaken. Poultices of tobacco have long enjoyed a reputation in the treatment of orchitis and epididymitis, but when warm applications are indicated, well-saturated and frequently changed warm cloths will be found equally satisfactory in the effect produced, and much more cleanly than the poultices. In the majority of instances cold will be more agreeable than heat. The ice-bag may be utilized in the following manner with great satisfaction: A bladder or rubber bag is filled with crushed ice, placed upon the three-cornered perineal cushion, and the inflamed organ allowed to rest upon it. If the cold is too great for comfort (and the patient may usually be relied upon to determine this), a layer or two of lint or cotton may be interposed. It occasionally becomes necessary to puncture or incise the tunica albuginea in orchitis somewhat after the fashion given in puncture for epididymitis. Two methods are employed, namely: to carry a sharp-pointed long knife through a single puncture of the scrotum down to the testicle, and incise the fibrous capsule in one or more places parallel with its long axis and along its anterior surface; or to use an instrument similar to that employed in epididymitis, and make several punctures through the scrotum and the anterior portion of the capsule.

Inguinal adenitis, or *bubo*, occurs in a considerable proportion of cases of specific urethritis, and is apt to be bilateral. The disease is readily recognized by the swelling in the groin. The inflammatory process is usually so rapid in its invasion that the different glands in this group of lymphatics cannot be made out, the entire group being matted together in one mass of embryonic cells infiltrating the tissues around the glands as well as involving their substance. The gonorrhœal bubo tends naturally to suppuration. In mild cases, and where the proper measures are taken at the early appearance of the adenitis, this disaster may be averted; but in others, partly owing to the unfavorable condition of the tissues and to the continued irritation from motion, pus formation cannot be prevented.

In the treatment of acute inflammatory bubo, perfect rest is imperative, and the dorsal decubitus should be maintained. Local medication is of little value. The employment of cold will be found agreeable in the earlier stages and may serve to prevent suppuration. The ice-bag may be employed by laying it upon a circular pad placed around the bubo. In this way the pressure is entirely taken off the inflamed surface. After the formation of pus is inevitable, warm cloths or poultices should be substituted. When pus is formed, a free incision under cocaine anæsthesia should be made.

Chronic suppurative adenitis of the inguinal glands occasionally persists long after the gonorrhœa which caused it has disappeared. The only remedy is to dissect out the diseased glands with the curved scissors, or scrape them out with Volkmann's spoon.

Gonorrhœal *proctitis* is a rare affection, and does not call for especial consideration.

Ophthalmia resulting from the inoculation of the conjunctiva with the virus of specific urethritis, has been considered with lesions of the eye.

Gonorrhœal Rheumatism.—In a certain proportion of individuals suffering from gonorrhœal inoculation at a period varying from five or six days to several weeks from the date of the attack, symptoms not unlike those occurring in gout or rheumatism make their appearance in the joints, tendons, and bursæ, and less frequently in the nerves and eye. The parts involved become more or less swollen

and painful. The pain, however, is less than in ordinary rheumatism. The febrile movement is not high, and the character of the urine is unchanged, in both of which features it differs from ordinary rheumatism (Fournier). Neuralgia occasionally supervenes in the course of this disease. In a certain proportion of cases the eye is affected, but the ophthalmia here in no way resembles that of gonorrhœal conjunctivitis. The pathology of this disease is not understood. It is claimed by some observers that the diplococcus occasionally met with in the fluid removed from the joints in this affection is not the gonococcus of Neisser. The treatment is entirely expectant.

Gonorrhœa in females is usually less severe than in males, and yields more readily to treatment. The chief seat of the inflammation is in the vagina. The urethra and bladder may also become involved. From the vagina the infection often spreads to the uterus and tubes, resulting in sterility by occlusion of these ducts. In the treatment, quiet is of first importance. The warm hip-bath should be employed several times a day, and the vagina irrigated at regular intervals with warm permanganate-of-potash solution (1–5000), thrown in from a fountain syringe.

Non-specific urethritis may be caused by injury, as from the introduction of a catheter or any foreign body, the lodgment of a calculus, the injection of an irritating substance, or from without, as in striking the perinæum upon the saddle in riding, or excessive coitus. It may also result from infection from an unclean vagina or urethra in which pyogenic yet non-specific bacteria are present. It is usually of short duration, mild in character, and does not involve the entire length of the canal. In a medico-legal sense it may be necessary to determine whether specific infection is or is not present, and, as stated on a previous page, this can only be decided by the microscope, together with a careful study of the grosser symptoms of this disease already given, and in no other way. Non-specific urethritis should be treated by the removal of the offending substance, by rest and irrigation, as in the specific form of the disease, and sterilization of the urine is advisable.

Gleet, or Chronic Urethritis.—Gleet is a name given to the prolonged discharge from the urethra of a variable quantity of muco-purulent, bluish-white fluid. This discharge is a transudation from the mucous and glandular epithelia of the urethra. In gleet, all or any limited portion of this tube may be affected. The pathological change is a puffiness of the lining membrane, due to hyperæmia of the subepithelial vascular area, with a tendency to embryonic and connective-tissue formation. In some points patches of erosions or tissue necrosis occur. The epithelia lining the glandular apparatus—as those of the prostate, Cowper's glands, and the urethral follicles—become more or less involved. Not infrequently the outlets to these follicles become obstructed by the superficial inflammatory process, resulting in the formation of one or more retention cysts, which project into the lumen of the tube.

Any form of acute urethritis may pass into this chronic condition of gleet; or a urethritis subacute in its character from the beginning, may continue as a gleet.

Although chronic urethritis may exist without the presence of stricture of the urethra—as in follicular urethritis—the exceptions to this rule are extremely rare. Any chronic interference with the normal caliber of the urethra serves to induce a catarrhal condition of the mucous membrane of this canal, which, commencing near the seat of stricture, may involve any portion of the tube.

The *treatment* of gleet involves, primarily, the removal of the cause. Taking stricture as the chief cause, urethrotomy with dilatation, or dilatation without cutting, is demanded. In mild cases without close organic stricture, the introduction of the steel sound will often effect a cure. The methods of procedure will be given in full in the treatment of stricture of the urethra.

In *chronic follicular urethritis* it is best to examine carefully with the endoscope (Fig. 570) the urethral canal, and apply nitrate of silver directly to the diseased surfaces.

Stricture of the Male Urethra.—Strictures of the urethra may be divided into two classes: *true* or *organic*, and *false* or *spasmodic*.

A permanent diminution of the caliber of this canal, as a result of an inflammatory process, constitutes a true or organic stricture. A spasmodic stricture exists when the normal caliber is diminished as a result of contraction of the voluntary or involuntary muscular elements connected with the urethra.

Congenital non-inflammatory narrowing of the meatus does not constitute a stricture. The normal contraction of the compressor-urethræ or "cut-off" muscle is also excluded in the definition of spasmodic stricture.

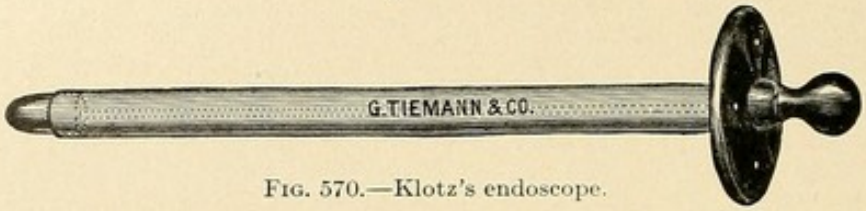

FIG. 570.—Klotz's endoscope.

An organic stricture may be *annular*, *tortuous*, *single*, or *multiple*.

In annular, or ring stricture, the cicatricial contraction involves the entire circumference. It may vary in width from a line to one inch.

In tortuous, or irregular stricture, an inch or more of the urethral canal is involved.

Two or more annular or lateral strictures may unite to form a tortuous or irregular stricture.

The *pathology* of stricture of the urethra is that of an inflammation of variable intensity involving the epithelial and submucous basement membrane of this canal, together with the deeper tissues of the corpus spongiosum, and occasionally of the corpora cavernosa. This process usually begins from within, but may originate in the deeper tissues of the penis and involve the urethra secondarily.

In a typical case there is first an increased vascularity of the submucous area, followed by emigration of leucocytes and cell proliferation. The lining membrane becomes puffy and swollen, and the diameter of the canal is diminished. As the acute inflammation subsides, the puffiness disappears, but the caliber of the tube is again diminished by the contraction which takes places in the newly formed connective-tissue elements (cicatrization).

Causes.—Among the causes of stricture, specific urethritis ranks first, a fact which emphasizes the importance of the early recognition and prompt treatment of this disease.

Any violence inflicted upon the urethra, either from without, as by a blow upon the perinæum or penis, or from within, as by the reckless use of instruments, the lodgment of calculi or other foreign bodies, may also cause a stricture.

Chancroidal ulcer within the meatus is a rare cause of this lesion.

Location.—The most frequent seat of organic stricture is in that portion of the urethra limited behind by the compressor-urethræ muscle, and in front by the suspensory ligament at the junction of the penile with the perineal urethra. Next in order is the first inch within the meatus. Stricture in the prostatic portion is rare. As stated in the consideration of diseases of the prostate, it may occur in general hypertrophy of this organ.

Diagnosis.—The symptoms of stricture are a gleety discharge, interference with the escape of urine or semen, and pain. A muco-purulent discharge continuing for several months is almost pathognomonic of this lesion, and justifies exploration in order to determine the presence of stricture. Interference with the escape of urine from the bladder when atony of this organ and hypertrophy of the prostate are eliminated is also a symptom of importance. A twisted or forked stream, when not of diminished volume, has no significance, for this may exist with a perfectly normal canal. Pain is not often a symptom of organic stricture, but, when present, is not without value as an indication of localized inflammation.

No matter what symptoms may exist, a diagnosis can only be arrived at by instrumental exploration, which can be done without pain, and the exact location and character of the stricture made positive.

For this purpose the Otis bulbous bougie is invaluable. This should be made of all sizes, commencing with No. 6 and ending with Nos. 21 or 23 (U. S. scale).



FIG. 571.—Otis' oval-tipped wire bougies for locating strictures of the urethra.

For practical purposes, every alternate size, from Nos. 6 to 23 inclusive, will suffice. The wire bougies are thoroughly satisfactory instruments, and incapable of injury to the urethra if ordinary care is taken. The bulbs are oval, the wire is flexible, and is screwed into the bulb for security.

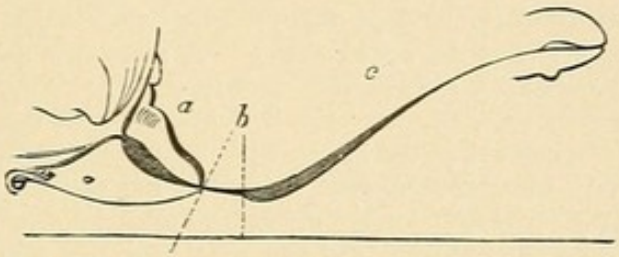

FIG. 572.—Longitudinal section of the urethra, showing the diameter of the canal at various points. *a*, Prostatic; *b*, membranous; *c*, penile portion. (After Thompson.)

In the effort to locate a stricture, the different diameters of the normal urethra at various points in this canal must be borne in mind. The meatus is least dilatable, and the membranous portion next in order. Immediately behind the meatus there is an expansion into the fossa navicularis, and from this point to the suspensory ligament (the junction of the penile and perineal urethra) the diameter is about the same. From the suspensory ligament to the anterior layer of the triangular ligament the diameter gradually increases. This, the bulbous portion, is the largest part of the canal. Behind the membranous portion there is a second expansion in the prostate (Fig. 572).

The patient should be placed upon the table or bed in the dorsal decubitus. In order to secure insensibility, from ʒj to ʒij of a two-per-cent solution of cocaine should be thrown into the urethra with the ordinary urethral syringe introduced no farther than well within the meatus. While a stronger (four-per-cent) solution may be required and with safety employed, the idiosyncrasy of each patient must be studied by commencing with ʒj of a two-per-cent solution and gradually increasing the quantity and strength as required. In five to fifteen minutes local anæsthesia is obtained. A bulb of medium size is selected and properly warmed and oiled. The wire is not curved in exploration of the urethra anterior to the membranous portion. The penis should be held at about a right angle to the plane of the body, and, as the instrument is being introduced, the organ should be elongated in order to obliterate any folds in the mucous membrane. This membrane is not so closely attached to the connective tissue of the corpus spongiosum but that it can be perceptibly displaced up and down and doubled upon itself if sufficient force is applied. If no stricture of caliber smaller than the bulb is encountered, it will glide smoothly and uninterruptedly down to a point about five inches from the meatus, where it will be arrested, having reached the end of the bulbous portion and lodged in a pocket just in front of the anterior layer of the triangular ligament. Withdrawing the instrument, it will in all probability return as smoothly as it entered. If, however, a stricture exists, and the bulb used is about the size of the lumen of the stricture, as it is carried into the urethra a slight resistance will be felt. As the instrument is withdrawn, the broad shoulder of the oval will come in contact with the posterior surface of the obstruction, where it will be arrested. The penis should now be allowed to retract, and the thumb and finger of the left hand slipped down to the level of the meatus, where the wire is grasped and slightly bent. The instrument is steadily drawn through the

stricture, and, as soon as the resistance ceases, the wire is again bent at the level of the meatus. The distance between the two points at which the wire is bent represents the extent of the stricture.

When it becomes necessary to search the urethra beyond the bulbous portion, the wire should be bent to correspond to the normal curve of the deep urethra. The handle of the instrument should be bent in an opposite direction in order to prevent the possibility of getting the point of the bougie turned toward the perinæum. It is introduced in the same way as the catheter or steel sound. When the triangular ligament and compressor urethræ muscle are encountered, by depressing the handle toward the thighs of the patient, the bulb is made to rise out of the pocket in front of the anterior layer of the ligament and to pass into the membranous portion. If a stricture is present the resistance, if not felt as the bulb goes through, will certainly be appreciated as it is withdrawn, if the instrument is large enough. If the patient is not narcotized, spasmodic contraction of the compressor muscle may arrest the bulb, and, in a certain sense, simulate stricture.

In the resistance of the muscle there is a roundness, smoothness, and elasticity which differ from the rough surface of cicatricial tissue and the inelastic grip of a stricture. When the obstruction is felt, the same method of measurement and location is to be observed. A stricture may be roughly estimated by the introduction of a catheter, ordinary bougie, or steel sound, but it cannot be intelligently or satisfactorily defined without the oval bulbs.

Not infrequently it will be found that the meatus is too narrow to admit a bulb of sufficient size to define the stricture, necessitating division of the meatus (*meatotomy*). This operation may be done with an ordinary scalpel or bistoury, but with nothing like the exactness and freedom from pain which is secured when the urethrotome is employed. The incision should be made in the median line, and should correspond to the floor of the urethra. It should not extend deep enough to wound the artery of the frænum, nor should it be any deeper than is sufficient to admit the larger bougies.

If the bistoury is employed, the operator grasps the glans between the thumb and finger of the left hand, introduces the knife, cutting edge downward, a distance of one half inch, and cuts carefully outward. The injection of cocaine solution into the tissues of the part incised or the local application of a few cocaine crystals within the meatus will render the incision along the floor painless.

The operation can be more accurately and satisfactorily done by the use of the Otis dilating urethrotome (Fig. 573). It should be introduced into the meatus until the knife is about three fourths of an inch from the opening, with the cutting edge of the concealed blade turned toward the floor of the urethra. The dilating screw at the end of the instrument is now turned until the meatus is put fairly on the stretch, when the knife is drawn quickly through and the division effected. If the blades are too widely separated, the opening may be too deeply slit. If the first incision is not sufficient, this manœuvre should be repeated. The small amount of bleeding which at times follows can be readily controlled by plugging the wound and the anterior half inch of the urethra with a small strip of iodoform gauze. To prevent a recontraction, it is necessary to introduce the straight sounds, at intervals of from two to four days, for two or three weeks after the operation.

Treatment.—The treatment of organic stricture of the urethra should be considered under two headings: first, those situated in any part of the urethra anterior to the membranous portion; and, second, those of the membranous urethra.

Internal urethrotomy is applicable practically to all strictures anterior to the membranous urethra, while those of the membranous portion, with rare exceptions, may be relieved by a modification of the same procedure.

External urethrotomy, or "perineal section," is indicated in the exceptional cases in which the stricture is so tight and tortuous that a dilating filiform cannot be introduced to make way for the urethrotome; when a fistula or abscess complicates the stricture, and when the cicatricial tissue is so extensive that recontraction takes place after one or more trials of the less radical operation. When properly performed it yields gratifying results. The method of *gradual dilatation* by the

repeated introduction of sounds was formerly much in vogue, and even now is practiced by some surgeons, but it is much more painful and requires a greater length of time to effect a satisfactory result than with direct urethrotomy followed by dilatation with sounds.

Complete divulsion or rapid dilatation of a stricture is rarely indicated, and is practically an obsolete operation.

Partial divulsion by the dilating filiform bougie of Banks is often necessary as a preliminary to internal division.

Internal urethrotomy in ordinary cases of stricture is performed as follows: The urethra should be thoroughly irrigated with a 1–3000 permanganate-of-potash solution or a saturated solution of boric acid. This may be done in the manner directed in the treatment of gonorrhœa. Or the tip of an ordinary urethral syringe may be pressed firmly into the meatus and its contents expelled until the urethra is fully distended, the fluid being thus forced into the follicles and deeper portions of the canal. This should be repeated four or five times, and the excess of fluid forced out by pressure before the cocaine solution is introduced. A very satisfactory anæsthesia can be effected by injecting into the urethra with the same syringe from one to three or more drams of a two- to four-per-cent solution of cocaine, which is forced in, and the meatus held tightly as the instrument is withdrawn to prevent the escape of the solution. In about five minutes the anæsthesia is complete, when by releasing the pressure on the meatus the cocaine runs out. As already stated, the employment of this agent in any manner, and especially in the urethra, should be made with care. When using it for the first time in a patient, the smaller quantity should be tried and the constitutional effect closely observed. A bulbous bougie is next introduced and the stricture definitely located. If the bougie produces pain and no constitutional effects have been observed from the cocaine, either the quantity of the solution may be increased or a three- or four-per-cent solution employed in order to effect a satisfactory anæsthesia. The distance from the meatus to the posterior boundary of the stricture is now measured on the urethrotome, beginning at the point where the knife is projected and extending toward the handle. Half an inch should be added to this in order to be sure that the knife is carried well beyond the stricture, and it is generally advisable to indicate this point on the instrument by a small ring clipped from a rubber tube and slid over the shaft. It is now ready for introduction.

The urethrotome consists of a shaft, handle, and blades. The shaft is composed of two bars, which can be separated or closed by turning a screw at the handle, where there is also arranged a dial which registers the exact degree of dilatation by the separation of the bars. In the upper bar of the shaft is a slide



Fig. 573.—Otis' dilating urethrotome, with the author's cog-wheel attachment.

or groove along which the knife is carried, and when this arrives near the point of the instrument the blade sinks into a depression and disappears. I have added to this instrument a cog-wheel apparatus attached near the handle, by the use of which the knife is carried steadily forward or backward as desired, and is made to cut with mathematical precision. In expert hands this addition is not necessary, the original instrument of Otis being eminently satisfactory. The patient should rest upon the back, with the legs fully extended, while the surgeon stands at the patient's right side. With the bars of the instrument closed, the knife inserted, and the blade concealed, the shaft is lubricated with glycerine as far as it is to be introduced. The glans penis is grasped between the thumb and finger of the left hand, the organ held in the same position as when the stricture was located, and the instrument with the cutting edge of the knife exactly in the middle line of the roof of the canal carried into the urethra until the rubber

ring touches the meatus. If the measurements have been correctly taken, the blade of the instrument is now a quarter of an inch beyond the posterior wall of the stricture. The left hand, releasing the penis, is made to grasp the urethrotome and steady it, while with the right hand the dilating screw is turned until the arrow on the dial indicates a separation of the bars nearly equal to the diameter of the bulb which located the stricture. The degree of resistance felt by the hand of the practiced surgeon will indicate whether or not the necessary dilatation is effected without consulting the dial. Taking hold of the end of the knife at the handle, this latter instrument is made to travel through the stricture from behind forward and accurately along the median line of the *roof* of the urethra. As the knife advances, the resistance of the stricture can be readily felt as it is steadily and firmly drawn through the cicatrix until all resistance ceases and the knife moves smoothly. Without changing the position of the instrument, the knife is rapidly pushed back to its original position and the dilatation increased by one or more turns of the screw, and the knife again carried forward and back as for the first incision. The bars should now be still further separated in order to part any cicatricial bands that may have escaped the knife (modified divulsion). When this is done, by reversing the screw the bars should be partially closed and withdrawn. If the bars are closely approximated, the mucous membrane may be caught and torn. A bulb equal in size to the caliber of the urethra is now introduced, and this should pass freely up and down the canal. If it catches at any point, further incision is required. Finally, a full-size, straight sound is carried through the stricture. The urethra should now be again irrigated. The most careful asepsis should be practiced in urethral surgery, and no instrument should be introduced which has not been cleansed and boiled prior to its use.

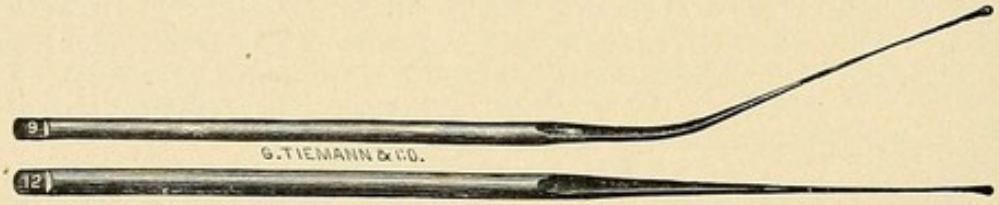

FIG. 574.—Banks' dilating filiform bougies.

Hæmorrhage after internal urethrotomy is usually slight. When the incision has been made in the pendulous part of the urethra, it may be readily arrested by turning the penis up on the belly, laying a handful of cotton or gauze on the organ and strapping it down by a bandage carried around the pelvis. In the posterior portion of the urethra a compress of cotton applied along the perinæum will control the bleeding (Fig. 575). The patient should be put to bed at once and remain quiet for several days. Not infrequently in from two to twelve hours after urethrotomy, or after the introduction of a sound or catheter, the patient is seized with rigors or pronounced chills followed by a considerable rise of temperature. This, the so-called "urethral fever," is due to septic infection in the wounds inflicted upon the canal. When the temperature rises to 103° F. or more it is a wise precaution to administer from two to eight grains of acetanilide and to give the patient an alcohol or cold-water sponge bath until the temperature is below 100° F. The repeated introduction of steel sounds or of gum bougies is essential in the after-treatment of internal urethrotomy. The dilatation should be commenced usually on the second or third day after the operation. If fever exists, the use of the sound should be postponed until there are no symptoms of infection. Cocaine anæsthesia should be employed, for, as a rule, the reintroduction of the sound is more painful than the primary operation. The quantity of cocaine used at this stage of the treatment should be less than for the original cutting operation. The urethra in the operative field is now covered with a granulation tissue capable, under too great pressure, of rapid absorption of the solution of cocaine and of carrying it into the system, producing constitutional and at times alarming symptoms. When it has required two or three drams of a two-, three-, or four-per-cent solution for the primary operation, before introducing the

sound for the first time I begin with the injection of one dram of a two-per-cent solution, carefully watching for the symptoms of systemic absorption, gradually increasing the quantity until a safe and satisfactory degree of anæsthesia is obtained. For the penile urethra the *straight* sounds are preferable to the curved instruments. Beginning with the proper size, usually about No. 17, the numbers are gradually increased until the urethra at all points is dilated to its normal caliber. This procedure should be repeated every third or fourth day for three or four weeks, and every fifth or sixth day for about two months following. It is essential to keep the walls of the incision through the strictured portion open by the interrupted dilatations until the wounded surface is covered with newly formed epithelium. Should cystitis, epididymitis, or orchitis ensue after urethrotomy, all operative measures should be discontinued until these symptoms disappear.

The *prognosis* after urethrotomy should be guarded. Many cases do not recur, but a stricture of long standing with extensive induration, no matter how thoroughly divided and carefully treated, tends to recontract. In some instances it thus becomes necessary to employ dilatation either with the sound in the hands of the surgeon, or with the soft bougie if this duty is intrusted to the patient, at intervals of from two to three weeks or months, as the case may require, during the life of the patient. In a certain proportion of cases the stricture will be found so tight that the urethrotome cannot be passed through it, necessitating partial divulsion by the *dilating* filiform bougie. This excellent instrument, devised by the late Dr. E. A. Banks, of New York, meets every indication. With the urethra cocainized as heretofore directed, it may be injected with a small quantity of glycerine or sterilized oil and the filiform carried into the meatus and down the urethra until it meets the obstruction. By careful manipulation it is made to find its way through the most tortuous stricture. As soon as the filiform portion is engaged in the stricture, continued pressure carries this portion into the bladder, while the larger dilating portion of the shaft stretches or tears the cicatricial bands sufficiently to admit the urethrotome. This small instrument, in the vast majority of cases of stricture, accomplishes in skilled hands, in five to thirty minutes, a greater degree of dilatation than the method of continuous dilatation employed by Sir Henry Thompson accomplished in a week. As it is elastic and readily bends back upon itself when an obstruction is encountered, it is a perfectly safe instrument in competent hands. When fully introduced, the filiform portion curls upon itself, producing no injury to the bladder. In rare instances, where the dilating filiform bougie cannot be made to pass beyond the obstruction, external urethrotomy is demanded.

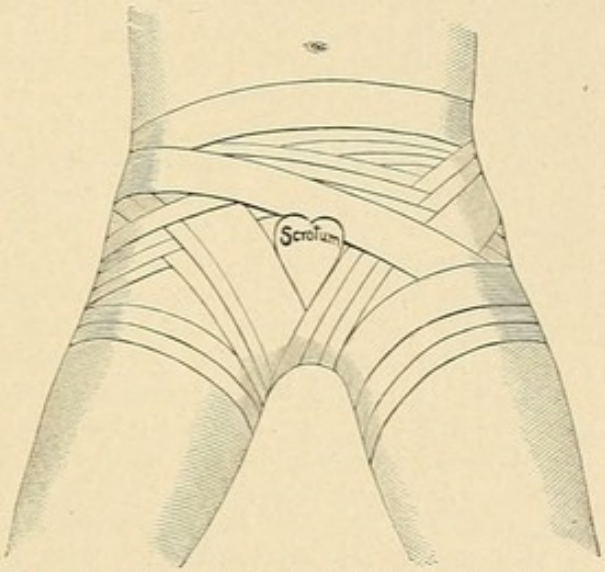

FIG. 575.—The author's method of compressing the penile and perineal urethra to control hæmorrhage after internal urethrotomy.

Modified Internal Urethrotomy.—When a stricture of the membranous portion of the urethra exists and a filiform bougie can be passed through it and there is no urethro-perineal fistula or abscess, relief from the obstruction may be obtained by this operation. The stricture is partially divulsed by the forced introduction of the Banks dilating filiform bougie, as just advised in very tight strictures of the pendulous portion of the urethra. If an ordinary-sized dilating filiform bougie is not large enough to make room for the urethrotome, it should be followed by a larger instrument of the same kind. As soon as the way is clear for the urethrotome, the ordinary straight instrument of Otis (Fig. 573) is carried into the urethra until the membranous portion is reached. Placing the left hand upon the penis over the pubic arch and pressing down upon the body of this organ,

putting the suspensory ligament upon the stretch, and at the same time depressing the handle of the instrument until the shaft is parallel with the surface of the thighs, the curved urethra is made into a straight channel and the point of the urethrotome with the slightest possible pressure is forced through the stricture until its tip rests in the neck of the bladder. As a rule, the stricture grasps the instrument in this position tightly. Without separating the bars, the knife is now drawn forward and backward along the middle line of the roof of this portion of the urethra, partially dividing the stricture. If the bars are then separated, in the majority of cases the stricture readily gives way by divulsion in the line of the partial incision. If the stricture is still unyielding, requiring greater force in the separation of the bars of the urethrotome than seems proper to the operator, a very slight dilatation may be made and the knife again drawn through in order to make a deeper incision, and thus enable the divulsion to be completed. Two objections may be made to this operation: first, the danger of hæmorrhage from the artery of the bulb or the artery of the corpus cavernosum; second, its lack of thoroughness in completely removing the cicatricial tissue. If the method is closely followed, there is no possible danger of hæmorrhage. The knife is used only in dividing the most prominent bands of the stricture—those farthest from the vessels—the remaining bands being torn through by the divulsing power of the instrument. The arteries which surround or arch over the urethra are elastic tubes which stretch under the divulsion; and while the unyielding bands of cicatricial tissue are torn across, the vessels are not injured.

I have employed this method in a large number of cases, and have never had any hæmorrhage. As to its inefficiency, necessitating the continued, interrupted use of bougies or sounds, the same may be said of many strictures of the anterior urethra which are treated practically by all surgeons in the same manner. Moreover, if a very long and dense stricture be encountered, which does not yield readily to the method of dilatation, perineal section may then be resorted to for the radical cure. I am convinced that this last-named operation is performed in a great many cases where modified internal urethrotomy would give relief and satisfaction. Hæmorrhage from the deep urethra, as well as from the perineal portion anterior to the triangular ligament, may readily be controlled by compression. A large wad of absorbent cotton is placed on the perinæum, extending from the anus forward to the scrotum; in front of the scrotum, along the penile urethra, a second cotton compress is applied, and a bandage passed around the pelvis in a figure-of-8 fashion over the iliac crests and around the hips. In case there were any bleeding backward into the bladder, the introduction of a large-size sound would act as a direct hæmostatic. The necessity for such a procedure will never be indicated when proper care is taken.

The after-treatment consists in interrupted dilatation by the introduction of straight or curved sounds.

External urethrotomy, or *perineal section*, is an operation for the relief of close organic stricture of the bulbous or membranous portions of the urethra which cannot be reached through this canal. With the exception of those cases where urinary fistula or chronic abscess exists as a result of stricture, the conditions which justify this operation are rare.

It is performed with or without a guide. When a sound or bougie can be carried through the obstruction into the bladder the procedure is much simplified. Without this guide the operation is surrounded with considerable difficulty. In external urethrotomy the patient is placed in the lithotomy position, being prepared as for this operation. After the anæsthesia is complete, a careful and final effort should be made to carry a filiform or soft bougie through the stricture and into the bladder. If this cannot be done, a good-sized sound should be carried down to the obstruction, and this will serve to guide the operator to the commencement of the stricture.

An incision is then made exactly in the median line, the anterior limit being slightly in front of the ascertained commencement of the stricture, the posterior extending toward the anus a sufficient distance. In making this incision the scrotum should be held up by an assistant, who is directed not to displace the

median raphe to either side. The legs must also be held in the same relative position.

The bleeding is usually considerable, as the vascular tissue of the bulb is divided. All vessels should be secured; but the oozing, which is general, need not retard the operation. As soon as the sound or filiform, at the anterior margin of the constriction, is seen, the division should continue along the guide until the healthy urethra is reached beyond the stricture. If no guide has been introduced, the dissection should be carried back in the known direction of the base of the bladder, guided by the location of the prostate with the finger introduced into the rectum. The first indication that the canal is reached behind the stricture will be a gush of urine. On account of the obstruction, the urethra between it and the bladder is widely dilated, and for this reason is more readily found. It is essential to the success of this operation that all cicatricial tissue be dissected out. A large-sized steel sound should now be introduced through the meatus and into the bladder. If any difficulty is met with in introducing this instrument, a flexible bougie may be substituted. It is not advisable to leave the instrument in the urethra. In order to prevent bleeding, the wound should be packed temporarily with gauze, held in position by a T-bandage. A fatal hæmorrhage occurred in one of the author's cases, the packing having become loose while the patient slept.

The urine usually escapes through the wound for the first few days, and afterward partly through the wound and partly through the urethra. In rare instances it escapes uninterruptedly through the urethra. The after-treatment consists in the introduction of the sounds or bougies (as above directed) through the urethra as far as the neck of the bladder. This operation should be repeated every three or four days until the urine ceases to escape through the wound, and once a week thereafter for several months. In urinary fistula and peri-urethral abscess the operation is practically the same. The urethra is opened in the area involved and the stricture incised and dissected out.

Interrupted Dilatation.—In the treatment of stricture of the urethra by this method there are required *steel sounds* and *flexible bougies.* Steel sounds are of two patterns, the straight and curved. The former are preferable for dilating strictures anterior to the membranous portion, and when properly constructed and in experienced hands they will suffice for dilatation of the deep urethra. The curved instruments may also be employed. The most satisfactory instruments are those constructed upon the United States scale,[1] which commences with the small-

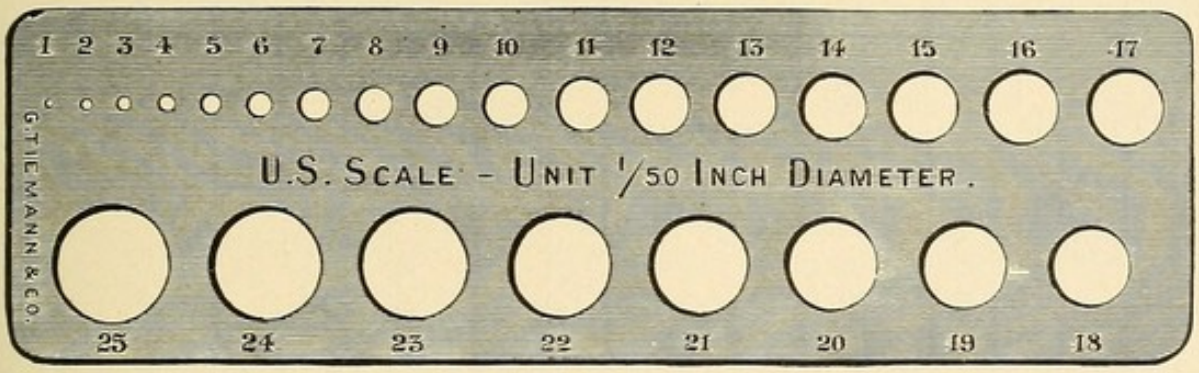

FIG. 576.

est steel instrument, $\frac{9}{50}$ of an inch in diameter, and increases $\frac{1}{50}$ of an inch in diameter for each successive sound to No. 25 inclusive, equal to $\frac{25}{50}$ of an inch. Nos. 1 to 8, inclusive, are filiform and elastic bougies.

A *straight sound* should be eight inches in length clear of the handle, slightly

[1] The unit of the French scale is one third of a millimetre (about $\frac{1}{75}$ of an inch), and each size up to No. 30, inclusive, increases one third of a millimetre in diameter. Divide any given number of this scale by three, subtract the quotient, and the remainder approximates the corresponding size on the above scale. Thus, No. 30 French, divided by 3 = 10; 30 − 10 = 20; or, No. 30, French = No. 20, U. S. The instruments on this scale are manufactured after the author's directions by Tiemann & Co., of New York City.

conical from the tip, back for a distance of one and a half inches. This conicity should increase one size for every half inch for this distance. Thus, a sound which measures No. 17 at the tip increases to No. 18 one half inch back, to No. 19 at one inch, and is No. 20 at one and a half inches from the point, and continues this size for the entire shaft.

A *curved sound* should be nine inches long clear of the handle. The curve should involve only the last two inches. The conicity extends also one and a

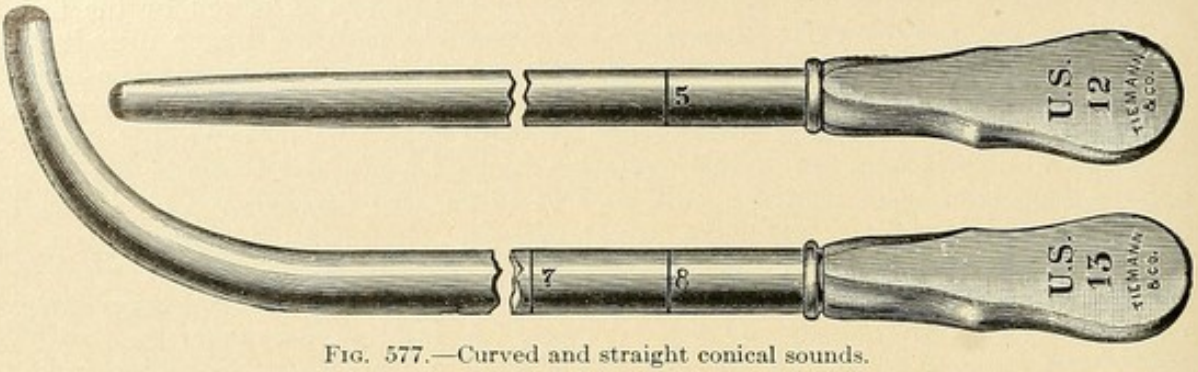

Fig. 577.—Curved and straight conical sounds.

half inches from the tip, increasing one size for every half inch until the full size is reached at one and a half inches from the point. Thus, an instrument the shaft of which measures No. 20, is 17 at the tip, 18 at one half inch, and 19 at one inch farther back.

The curve should be made to correspond to that of the normal deep urethra, which is that of a circle with a diameter of three and a quarter inches; "and the proper length of arc of such a circle to represent the subpubic curve is that subtended by a chord two and three quarter inches long" [1] (Fig. 578).

Flexible bougies are of various sizes, being conical for two or three inches, and olive-pointed. They are exceedingly useful instruments, and, when warmed before introduction, are incapable of injury to the urethra, even when an unusual degree of force is employed. The black French bougie is preferable. The filiform instrument has already been described.

In dilating a stricture with the conical steel sound, the method of introduction is identical with that given in using the metal catheter. In the interrupted dilatation a mild degree of force is exercised, and the *séance* is repeated on every second, third, or

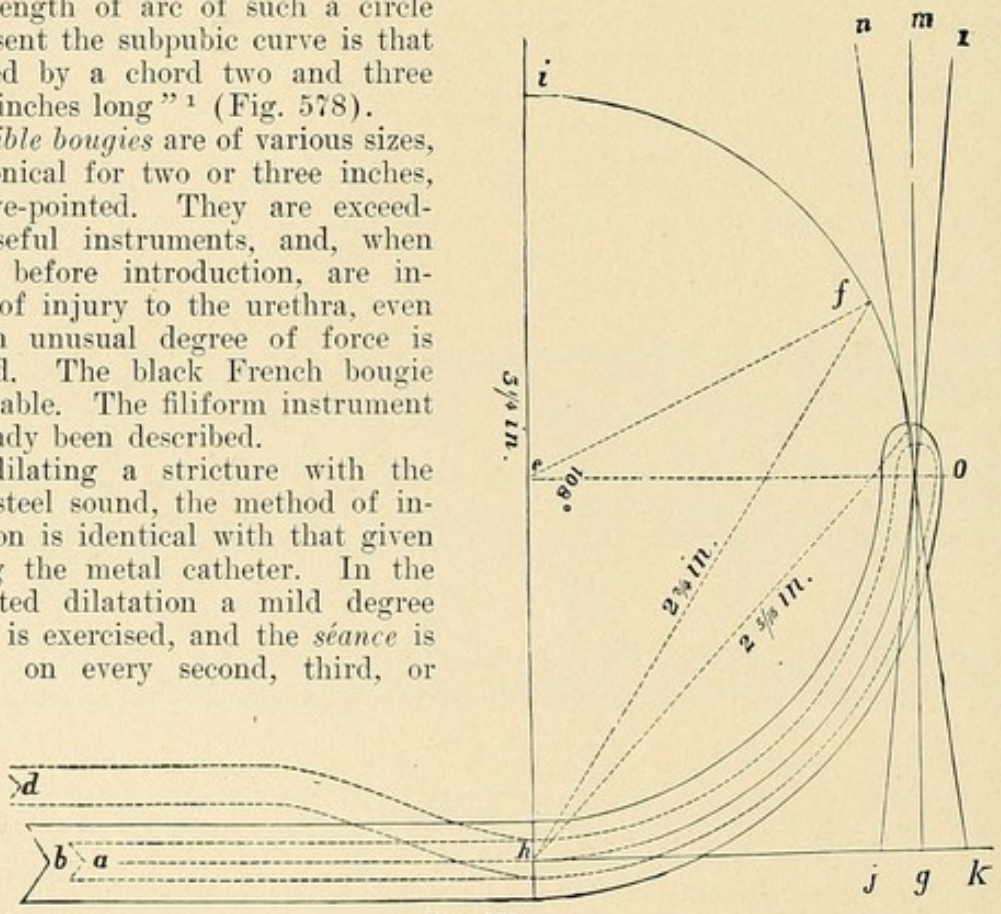

Fig. 578.

fourth day. The length of the interval between the introductions must be determined by the symptoms in each case, the object being to accomplish moderate divulsion at each sitting without producing marked inflammation. The sound

[1] Van Buren.

should never be carried beyond the point where its full dilating power is applied to the stricture. In this way irritation of the prostatic urethra and neck of the bladder may be avoided in all save the deepest variety of strictures.

The dilatation of strictures by the use of conical steel sounds should be limited to those cases in which the stricture is of sufficient caliber to admit at least No.



Fig. 579.



Fig. 580.



Fig. 581.



Fig. 582.

15, U. S., and is narrow or linear in character, so that it may be made to give way without the employment of too great force. The smaller sounds are capable of penetrating the walls of the urethra unless they are used with great skill and carefulness, while the larger instruments will not, within the limit of safety, succeed in the dilatation or rupture of a broad or tortuous stricture. Incision with the urethrotome is a safer and less painful operation, and the sounds serve an admirable purpose in the after-treatment.

In using the soft bougies in the anterior portion of the urethra, they may be passed in straight; but, when the deeper portion is invaded, they should be curved as much as possible, to correspond to the subpubic curve of this canal.

Foreign Bodies in the Urethra.—Calculi occasionally lodge in the urethra, and substances introduced through the meatus—as fragments of a catheter, etc.—may

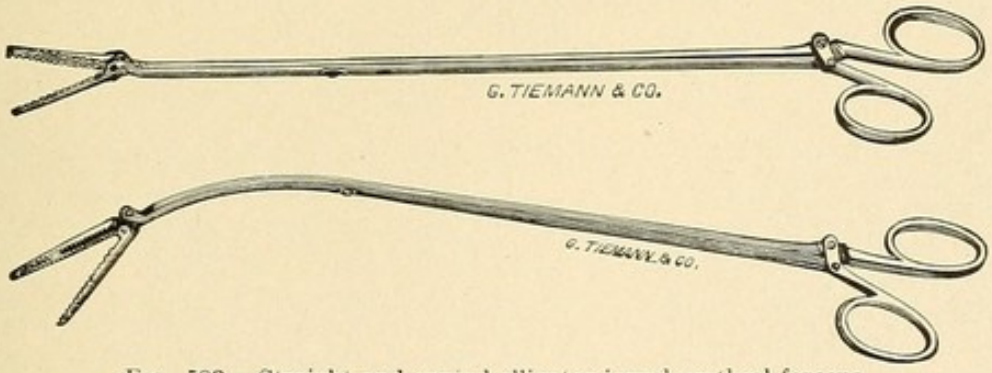

Fig. 583.—Straight and curved alligator-jawed urethral forceps.

require removal by the surgeon. The diagnosis will be evident from the symptoms of obstruction to the escape of urine, by recognition of the body by digital pressure along the canal, and by exploration through the meatus. Stone may be made out by the grating sound which is emitted, or by the sense of friction upon a rough



Fig. 584.—Hale's instrument for removing foreign bodies from the urethra. (After Linhart.)

and hard surface which is conveyed to the fingers along the sound: A metallic substance may also be recognized by the peculiar click which is elicited when it is brought in contact with the exploring instrument.

Removal with cocaine anæsthesia may be effected through the meatus, or by incision directly through the floor of the urethra at the point of lodgment. It is always desirable to avoid incision through the urethral wall when, by the use of forceps or any mechanism, the extraction can be effected through the meatus without doing too great violence to this canal. If the substance is narrow and smooth, it may be seized with the forceps (Fig. 583) and extracted. The straight alligator forceps, or the instrument of Hale, is preferable for the anterior portion of the urethra, while for the deeper part the curved instrument is more suitable. For a round body, the scoop or curette will prove more satisfactory (Fig. 585).

In using the forceps, the instrument closed should be carried down until its beak strikes the foreign substance, when the jaws should be slowly separated and pushed farther in, so that they may pass between the lining membrane of the urethra and the body. They should then be firmly closed and cautiously moved a slight distance to and fro in order to determine whether the mucous membrane has been caught in the instrument. This danger will in great part be obviated if, just at the moment when the jaws are applied to the foreign substance, the urethra is put upon the stretch by pulling upon and elongating the penis. The canal should be lubricated by an injection of sweet oil. If stricture exists, urethrotomy may be necessary before the substance can be extracted. In a case which came under my care, two strictures were divided with the urethrotome. From behind the first constriction two calculi were removed, and several after the second

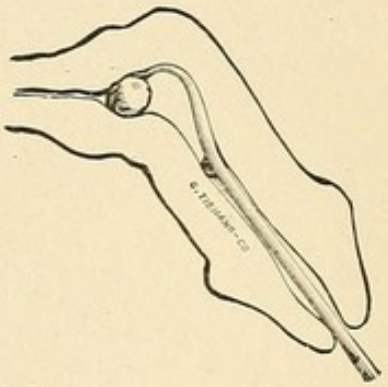

Fig. 585.—Curette, or scoop, for the removal of calculus in the urethra. (After Van Buren and Keyes.)



Fig. 586.—Calculi removed from the urethra. (The author's case.)

stricture was divided (Fig. 586). In this operation a scoop proved more serviceable than the forceps.

In a second operation I found it necessary to perform external urethrotomy, cutting directly down upon the calculi (two in number), which were easily removed through the incision. The direct injection of cocaine into the tissues secured complete anæsthesia. The wound should be left to close as in the ordinary operation of perineal urethrotomy.

Urinary Fistula Communicating with the Urethra.—In congenital or acquired urinary fistula communicating with the urethra the following operative measures are indicated: When the fistula opens in the perinæum or lower surface of the penile urethra, the method of Szymanowski offers the surest prospect of success. It is essential that all inflammation in and about the field of operation be allayed, sinuses slit up and healed, and all strictures divided, or stretched and cured. The bowels should be well emptied for two or three days before the operation. For perineal fistula the lithotomy position is preferable; the parts should be shaved and disinfected. Proceed as follows: Let the dark spot at *F* (Fig. 587) represent the opening of the fistula. A straight incision *A B* is made, passing along one edge of the fistula, extending three quarters of an inch each way from the opening. This incision passes through the skin and superficial fascia. The edge of this incision is raised, and, dissecting away from the fistula, the skin is lifted to form a pocket, the bottom of which is the dotted curved line *A C B*, and the lifted edge or entrance to this pocket the straight incision *A F B*. On the opposite side, corresponding accurately with the attached bottom of the pocket *A C B*, a curved

incision *A D B* is made, the greatest depth of the flap being from three quarters to one inch. From this flap, with a pair of small scissors curved on the flat, remove the epidermis, except over an area amply sufficient to cover the fistulous opening. (This area is represented in white between *F* and *D* in Fig. 587.)

The flap *A D B* is now dissected up, taking with it a generous allowance of subcutaneous fat and fascia, down to about an eighth or three sixteenths of an inch of

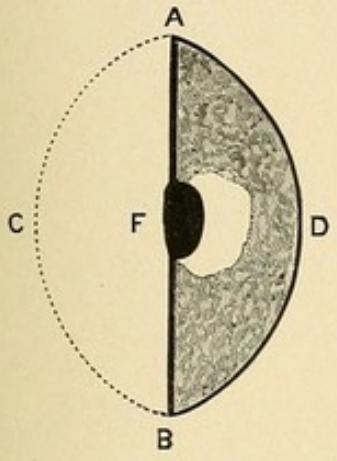

Fig. 587.

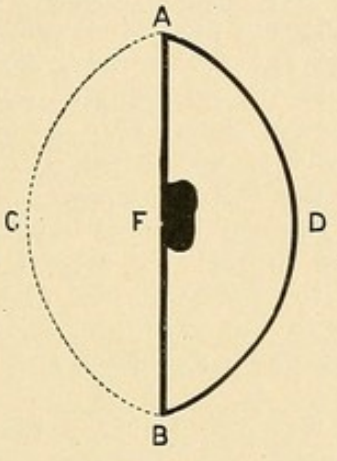

Fig. 588.

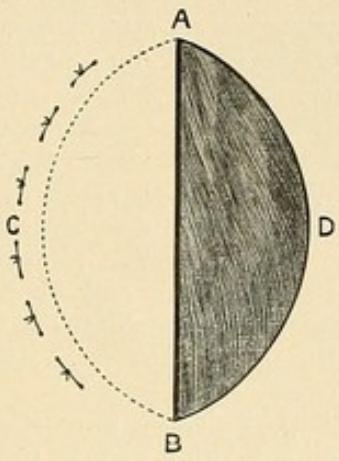

Fig. 589.

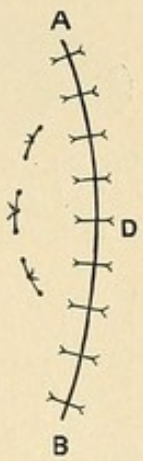

Fig. 590.

the original straight incision *A F B*, this attachment being left to give it a sufficient blood supply. As this *A D B* is turned over toward *C*, it hinges on the attached edge *A F B*, and, as it is slipped beneath the pocket *A C B F*, it will be seen that the undenuded (white) portion suffices to form the new floor of the urethra. It being ascertained that the flap fits accurately, it is brought out again and a series of five or six loops of fine catgut sutures are inserted by carrying the needle through the skin one eighth inch from the curved dotted line *A C B* into the bottom of the pocket, and beneath the integument, directly opposite and through the free edge of the flap *A D B*, and back again, being brought out finally one quarter inch from the point of entrance *A C B* (Fig. 589). As these sutures are tied, the flap is inverted and secured. It now remains to close the open wound by sutures of fine linen, which snugly approximate the lines *A B* and *A D B*. The result is shown in *A D B* (Fig. 590). It is important to keep the bowels from moving and the patient quiet with morphia for several days. Every three or six hours the soft Nélaton catheter should be inserted, the urine drawn off, and the bladder washed out with four or five ounces of warm boric-acid solution, gr. x–℥j. On withdrawing the catheter the end should be closed in order to prevent the escape of even a few drops of its contents in the urethra. The linen sutures should be removed about the seventh day, and the use of the catheter discontinued only when the wound is thoroughly united. Strict asepsis in the field of operation and sterilization of the urine are necessary. In rare instances the floor of the prostatic and posterior part of the membranous portion of the urethra may be destroyed, and the fistula open directly into the rectum.

The following case which came under my care will serve to illustrate this form of fistula:[1]

The patient, twenty-seven years of age, merchant, came under my care in August, 1887. He came of healthy stock, and had had no sickness of a serious character until 1883, when symptoms of vesical calculus supervened, for which a left lateral lithotomy was done in August, 1886. The stone removed was reported to be the size of a hen's egg.

A urethro-perineal fistula remained after this operation, and from August, 1886, to August, 1887, four attempts were made to close this opening, without success. In the last of these operations a drainage-tube about one and one half inches in length was inserted in the perineal opening and left with the deep end in the urethra. This tube, about three sixteenths of an inch in diameter, was

[1] Read before the Ontario Medical Association at Toronto, June, 1888.

lost sight of, the surgeon and patient supposing it had escaped externally and had been thrown away with the dressings. The last operation was followed by considerable pain, which was persistent. In the course of three months an abscess opened into the rectum through the anterior wall, and the urine began to flow freely in this new channel. About this time the perineal opening closed and an abscess formed in each tunica vaginalis. These were incised, and when I first saw the patient were entirely healed. At this date (August, 1887) nearly all the urine passed through the rectum. The patient suffered greatly, and had to be kept constantly under the influence of opium.



Fig. 591.—Calculus formed on a piece of drainage tube as a nucleus. (Actual size.)

An examination *per rectum* revealed the presence of a stone, the end of which was on a level with the anterior surface of the rectum, about one inch beyond the anal aperture. The opening was slightly dilated, and the stone was removed through the rectum by means of strong forceps. It had formed in and upon the drainage-tube, and is seen in natural size in Fig. 591. After consultation with Dr. Edward L. Keyes, it was determined to prepare the patient for operation, which was done, and on September 13, 1887, I operated as follows:

The patient, in ether narcosis, was placed in the Sims position and a large Sims vaginal speculum was introduced. The opening through the anterior wall of the rectum measured three fourths of an inch in length, with an irregular width of from one eighth to one fourth of an inch. It led directly into the urethra near the junction of the membranous and prostatic portions. The floor of the urethra was entirely destroyed. The right edge (patient's right) of the opening was seen to be undermined, as shown by the dotted surface *B* (Fig. 592).

I determined to attempt the formation of a new floor to the urethra by turning the mucous membrane of the rectum into this position. The operation performed was a modification of the method of Szymanowski. Two crescentic incisions were made, as shown at *A A* (Fig. 592), being about parallel with the edges of the

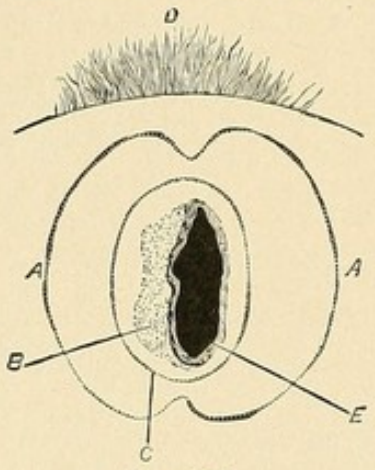

Fig. 592.

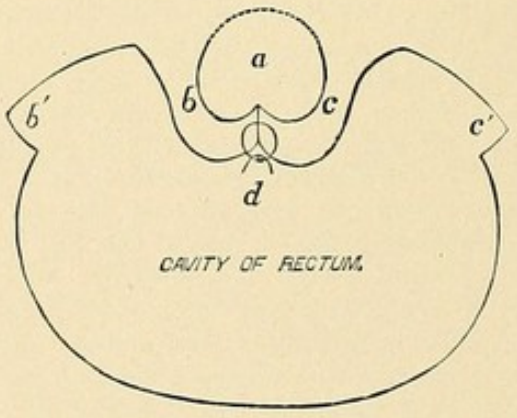

Fig. 593.

Fig. 592.—Showing the anterior wall of the rectum, and opening into it at *E*, a sinus from the membranous and prostatic urethra. *B*, *Cul-de-sac*, which undermined the right margin of the opening. *A A*, Line of incision, along which the flaps were dissected as far inward as *C*. For their nutrition the two lateral flaps depended upon the limit between the dotted line *C* and the margins of the opening *E*. *D*, The perinæum.

Fig. 593.—Schematic. Transverse section through the urethra and rectum, showing the method by which the flaps were turned from the mucous membrane of the rectum to make the floor of the urethra. *a*, Urethra. *b*, The right flap dissected from *b′*. *c*, The left flap from *c′*. *d*, The silkworm-gut suture in position (not entering the cavity of the urethra).

opening, but approaching more closely at its upper and lower angles. These incisions went deep into the wall of the rectum and included the mucous and muscular layers. The two lateral flaps were dissected up, the left to within an eighth of an inch of the edge of the opening; the right could not be carried so far on account of the pocket which undermined this side.

The flaps were now turned toward each other and their raw edges made to

meet in the middle line, while the raw surfaces looked into the rectum and the mucous surfaces into the urethra (Fig. 593). Sutures of silkworm gut were inserted, as shown at *d* (Fig. 593). These sutures were about three sixteenths of an inch apart, and were so inserted that they did not penetrate to the cavity of the urethra. On account of the thinness of the flap at one point I was compelled to pass one suture into the urethra.

A Nélaton catheter was carried through the meatus and urethra into the bladder, and through this the urine ran out at intervals. Whenever the urine accumulated enough to create a desire to expel it, about six ounces of Thiersch's solution were thrown in to dilute it; and when this, with the normal contents of the bladder, were evacuated, the same quantity was thrown in again and immediately expelled. In this way the wound was kept practically free from irritation by the urine. Divulsion of the sphincter ani removed all danger or annoyance from spasm of this organ. The bowels were kept quiet for nine days, and liquid diet was enforced. The patient had been placed on liquid diet for ten days prior to the operation.

The sutures were left *in situ*. The wound healed promptly, and the patient left for his home in three weeks after the operation. In April, 1888, seven months later, he returned, complaining of slight irritation in the rectum, and said he thought, at rare intervals, a few drops of water escaped into the bowel. On examination, three of the sutures were still in position, but no opening could, by most careful search, be discovered. The sutures were removed, and in a few days the patient was discharged. A second case, practically identical with this, was operated upon in the same way and cured.

Congenital Malformations of the Urethra.—In exstrophy of the bladder the urethra is absent, and, in certain rare anomalies, it may open into the groin, upon the side of the glans penis, in the median line of the dorsum penis (epispadias), in the median line below at any point on the corpus spongiosum (hypospadias).

Hypospadias is the most common of the congenital deformities of the urethra. When the opening is within one inch of the normal position of the meatus, operative interference for the purpose of establishing a new urethral canal is scarcely indicated. It will, however, in many instances be found necessary to enlarge the abnormal opening in order to permit the free escape of urine. When the false meatus is so far back that in sexual intercourse the semen cannot be ejaculated into the vagina, a plastic operation may be undertaken.

Clinically, *hypospadias* may be considered as *penile* or *peno-scrotal*. In the first variety the false meatus is more or less in front of the scrotal junction, while in the second variety the opening may be at or posterior to the anterior scrotal fold, the scrotum under these conditions often being bifid. It is exceedingly difficult to correct this deformity satisfactorily, and it is impossible to apply any given technic to either of these two varieties. The various methods should be thoroughly understood, and the features of each method which may be properly applied to a given case should be employed.

The first essential is to correct the bowing of the organ due to the contraction of a dense band of fibrous tissue which practically takes the place of the urethra. This should be divided transversely in one or more places at the point of the greatest curvature (Duplay). When this is completed, and the organ straightened, a diamond-shaped opening of raw surface is the result (Fig. 594).[1]

Should division not be sufficient to permit the organ to be thoroughly straightened, other contracted fibrous bands should be sought, and the more prominent of these should be dissected out, and any remaining portions, together with the tight portions of the sheaths of the corpora cavernosa, snipped with scissors as they are felt to be made tense by the upward traction on the glans. This process is continued until the penis is completely released and can be drawn out straight.[2] Should this be considered the first step in the operation, the exposed raw surface should be closed at once by fine linen sutures (Fig. 595), and the procedure con-

[1] C. H. Mayo, "Journ. of A. M. A.," April 27, 1901.
[2] R. Hamilton Russell, "Annals of Surgery," August, 1907.

tinued after an interval of about two weeks.[1] Should a longer time elapse, the penis should be frequently stretched to guard against retraction.

The first important step in the construction of the anterior portion of the urethra is to form a satisfactory channel through the glans with the meatus near

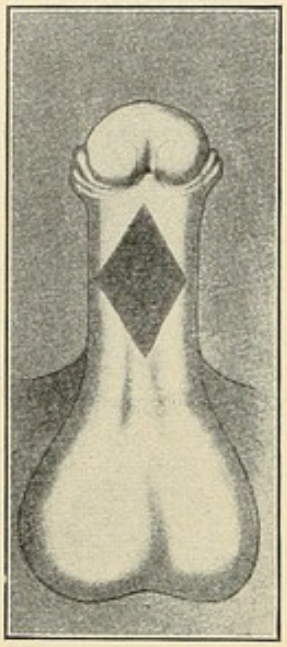

Fig. 594.—The contracted bands have been divided and the organ straightened. (After Duplay and Bouisson.)

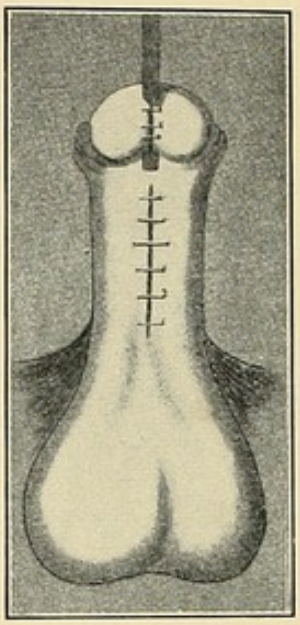

Fig. 595.—The same, after the incision has been closed. The plastic operation at the meatus is not done as shown in the illustration when Van Hook's method is adopted.

the normal position. Simple tunneling through this part of the organ and inserting a tube will not prove satisfactory, since such a tunnel is not lined with epithelium, and tends to close spontaneously.

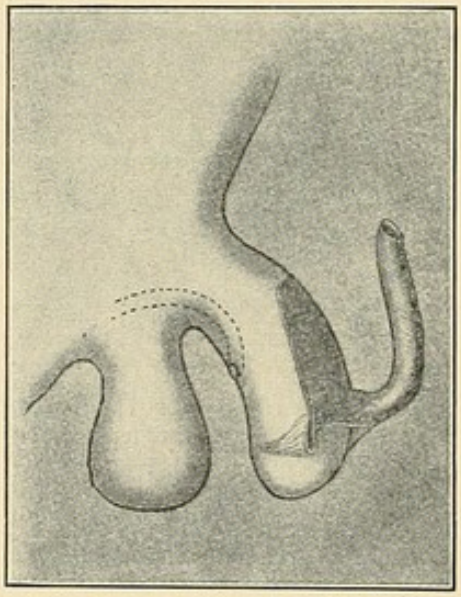

Fig. 596.—A new urethra for the anterior half of the penis formed from the skin on the dorsum. (After C. H. Mayo and Van Hook.)

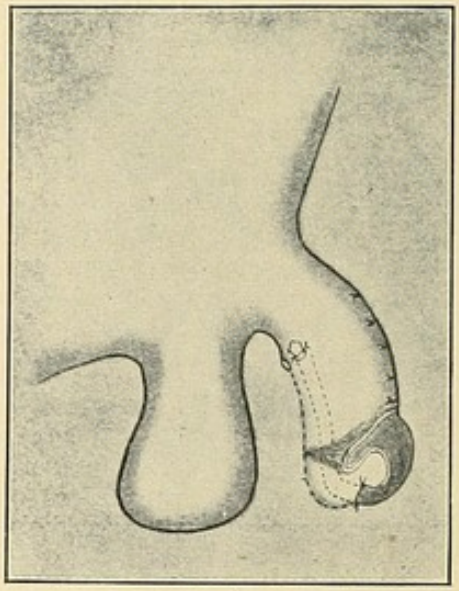

Fig. 597.—The same, after the new urethra has been carried through the tunneled glans.

C. H. Mayo's modification of Van Hook's method[2] of forming a new meatus and the anterior urethra gives a longer tube, and in general should be given preference for the reason that a sufficient quantity of skin may be borrowed from the

[1] The method of forming the meatus as shown in Fig. 595 is not advised.
[2] "Journal American Medical Association," April 27, 1901.

dorsum penis to form a new urethra which will extend back to or beyond the level of the abnormal opening.

A careful measurement should be made as to the required length of the new tube, and free allowance should be made for the loss in folding upon itself this flap which is made into a tube and is drawn through the newly made meatus. It is always better to allow something extra in plastic work on the skin.

"The prepuce in cases of hypospadias is usually redundant and situated on the dorsal surface, overhanging the glans like a hood. The skin of the penis is noted for its thinness, having no adipose tissue, also for its looseness of attachment and elasticity. Where it is folded upon itself at its cervical attachment its character very nearly resembles mucous membrane.

"The prepuce is extended as for circumcision and two incisions are made, about one inch apart, extending from its free border to its attachment at the penile cervix; the prepuce is unfolded, forming a loop of thin skin about two and one half inches in length. Should this not be considered sufficient to reach from its attachment to the hypospadiac opening, the two incisions are extended back along the dorsum of the penis until sufficient tissue is obtained, when the two incisions are connected by a transverse one, and the flap of skin lifted but left attached to the cervix by the inner surface. Several sutures now close the lateral integument of the penis over the denuded area (Figs. 596, 597).

"The pediculated flap of prepuce is constructed into a tube with its skin or outer surface inside, by means of a number of catgut sutures. The penis is tunneled by means of a narrow bistoury or medium trocar and canula, through the glans, above its groove, along the penis to a point beneath the hypospadiac opening, when it is made to emerge at one side of, but close to, the urethra; the tube of prepuce is drawn through the tunnel and sutured where it enters the glans, and also where it emerges (Fig. 597). At the end of ten days the flap of pedicle is cut through close to the new meatus. The second operation, made at a later period, consists of a perineal opening into the urethra and insertion of a Jacobs' self-retaining female catheter; this is the least irritating and can be left as long as needed, usually from five to eight days. An incision at the termination of the two urethras now admits of accurate coaptation by sutures, or the normal urethra may be mobilized (Beck method) to a sufficient extent to admit of its insertion into the caliber of the new urethra, where it is held by sutures and the external parts closed over this (Fig. 598). Occasionally a little urine escapes into the urethra and the entire canal is best drained by passing several silkworm strands through the urethra and out alongside the catheter in the perineal opening. When union of the canals is complete the drains are removed and the perineal drainage will usually close itself in a few days. Horsehair and fine catgut have proved the best suture material for this form of plastic work.

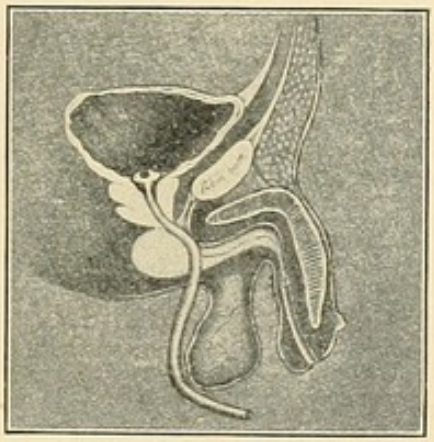

FIG. 598. — Perpendicular section, showing the new canal and perineal drainage of the bladder. (Mayo.)

"The advantages of this combined operation are: 1, a urethral tube of thin elastic skin nearly approaching mucous membrane, yet having no hair surface to occasion later complications; 2, a perineal drain for the bladder, with a self-retaining Jacobs' female catheter; 3, a silkworm drain for the urethra; and 4, in being a method capable of application to the worst types of hypospadiac cases."

When the skin on the under surface of the penis is loose and redundant, after the contractions have been overcome the following simple procedure in the author's practice succeeded in establishing a satisfactory urethral channel: On either side of the median line of the under surface of the penis from the abnormal opening to the glans the epidermis was removed with scissors for the space of about three sixteenths of an inch in breadth, leaving about three eighths of an inch of undenuded skin between the two parallel furrows of denudation. Passing the needle

in and out through the undenuded skin just at the edges of denudation, fine silk sutures (interrupted) were inserted in such a manner as to bring the vivified surfaces together to fold into a cylinder the strip of integument between these. As the urine was allowed to escape through the abnormal opening, infection did not occur, and prompt union was obtained.

In a second operation, made three weeks later, the same method was applied to close the abnormal opening. The urine was drawn by careful aseptic catheterization, and this wound also closed promptly.

Neoplasms.—Papillomata and fibromata are occasionally met with growing from the mucous membrane of the urethra. They produce symptoms of obstruction varying with their shape, size, and point of attachment. They may be observed by means of the urethral speculum (Fig. 599), or when deeply situated

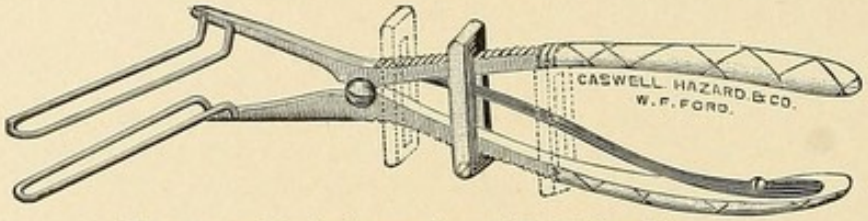

Fig. 599.—Urethral speculum of H. Marion-Sims.

the urethroscope (Fig. 570) will establish the diagnosis. The only treatment is removal, which may be done by the wire snare or by torsion with forceps. In extreme cases a longitudinal incision may be required in the median line of the floor of the penis in order to effect removal.

Cancer may originate in this canal, or more frequently may extend here from malignant disease of the prepuce and glans. Dr. Melville Wasserman has reported a number of cases of primary epithelioma of the urethra.[1] Tuberculosis also occasionally attacks the urethra.

The Penis.—The congenital malformations of the urethra just given may be included with deformities of the penis. The corpus spongiosum is at times arrested in development, while the corpora cavernosa are fully formed, causing the organ to bow when an erection occurs. One cavernous body is, in rare instances, not fully formed, and, when an erection takes place, the curve is lateral, with the concavity toward the affected side. The penis is occasionally double, with separate urethræ (Fig. 520). In hermaphrodites it is rudimentary.

Inflammation of this organ is rare, except as a result of traumatism. It occasionally becomes involved by the extension of a phlegmonous or erysipelatous process from the scrotum or abdomen, or from urethritis and posthitis. The organ becomes greatly swollen, and a painful condition of chordee is almost constant. Retention of urine may occur, as well as suppuration or gangrene.

In the treatment of mild inflammation of the penis, local applications will usually prove sufficient. The tendency to erection should be controlled by the use of opium or chloral and potassium bromide in full doses. When gangrene is threatened, free incisions in the long axis of the organ should be practiced.

Wounds of the penis, involving more than the integument, always bleed profusely. Hæmorrhage may be controlled by direct compression with a roller, or by throwing a few turns of an elastic ligature around this organ near the pubic junction. When the urethra is divided in whole or in part, it is best to stitch the separated walls together by close sutures of delicate silk. Catgut, though more desirable in one sense, is too readily absorbed to hold the edges of the wound in contact for a length of time sufficient to secure union. It is not usually necessary to insert a catheter, and it is best to dispense with this on account of the irritation it causes. Before and after each urination the urethra should be irrigated without distention. Should the operation by direct suture fail, Szymanowski's procedure will close the fistula. Any tendency to stricture may be treated later. When the dense capsule of the corpus cavernosum is divided, this should

[1] Epithélioma primitif de l'Urèthre, Paris, 1895.

be included in the sutures which are carried through the wound in the integument. A guarded prognosis should be made in all deep injuries of the penis. Distortion during erection, and stricture, are frequent results of such lesions.

Fracture of the *corpora cavernosa*, an accident which occurs in rare instances as a result of great violence to the erected organ, is a difficult injury to treat. Deformity, with more or less loss of function, is apt to ensue. The organ should be laid up on the abdomen, and kept in a condition of as perfect quiet as possible. Cold applications are indicated, and, in case of *strangulation* from effusion of blood or from any other cause, free longitudinal incisions may be necessitated.

Carcinoma.—Epithelioma of the penis is not an uncommon affection. It commences as a small pimple or erosion on the mucous surface of the prepuce or on the glans, gradually spreading until, if left alone, the entire organ is involved and destroyed. The margins of the ulcer are indurated, elevated, sinuous, and slightly everted. The induration, as a rule, is confined to the immediate borders of the sore, not extending into the deeper tissues unless inflammation supervenes. As the disease progresses, the center of the surface becomes studded with buds of newly formed cells and capillaries, giving it an appearance not unlike a cauliflower (Fig. 600). Ulceration occurs at various portions of the mass, and a dirty quality of pus is exuded. The odor from the decomposing tissues is peculiarly penetrating and offensive.

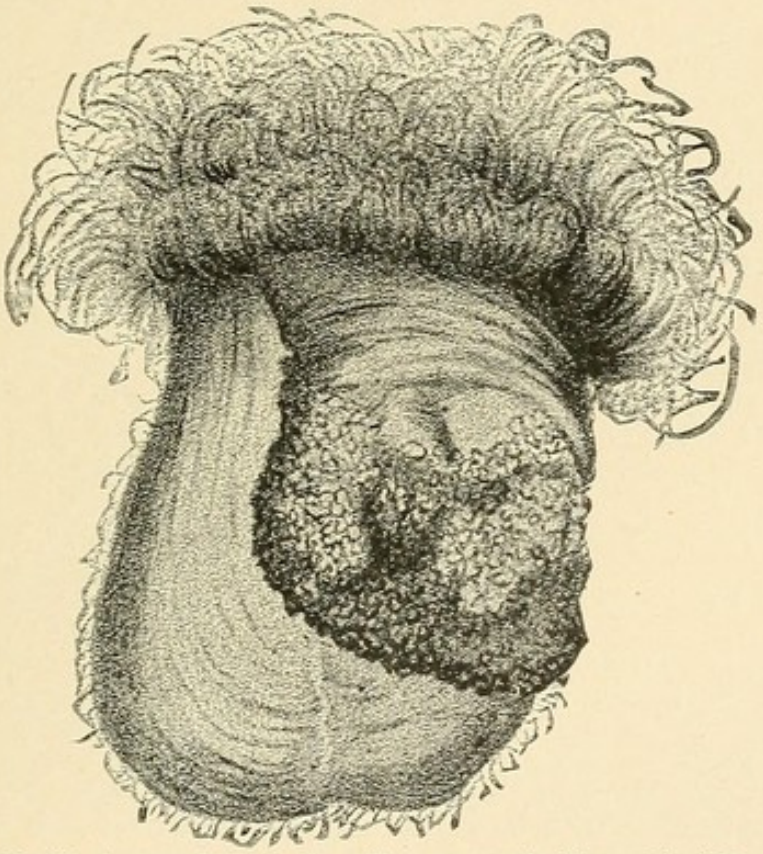

FIG. 600.—Carcinoma of the penis. (From a case in Mount Sinai Hospital.)

Within a period of time varying from two to six or eight months, enlargement of the inguinal glands is observed. This enlargement may be inflammatory or metastatic. As a rule, metastasis is not rapid in epithelioma of the penis, and induration of the glands does not, on this account, preclude the hope of cure after amputation.

The principal cause of epithelioma of the penis is prolonged irritation of the glans and prepuce from retained secretions. All the cases which have come under my observation have occurred in patients with unusually long and tight prepuces.[1] It is usually met with in the middle-aged and old, although it sometimes occurs in early adult life.

[1] In an experience of fifteen years in attendance at Mount Sinai Hospital, I observed only one case of epithelioma of the penis in an individual upon whom in early life circumcision had been performed.

The *diagnosis* of epithelioma is not very difficult after ulceration takes place. The indurated sinuous and everted borders of the ulcer, the red, cauliflower-like appearance of the mass, and the steady progress of the disease in the destruction of all the tissues in its path, are symptoms not met with in any other lesion of this organ. Warty growths (papillomata), when not seen early in their development, may at times simulate epithelioma, especially when these vegetations are luxuriant, are undergoing ulceration, are covered with purulent matter, and are the seat of repeated hæmorrhages. No matter how widespread the papillomatous neoplasm may be, at the outskirts of the mass will be found tufts or minute warts sufficiently isolated to be recognized. In the very earliest stages of development of the ulcer of epithelioma, it is scarcely possible to make a positive diagnosis between it and chancroid, or even a simple ulcer of the prepuce and glans penis.

Treatment and Prognosis.—In well-marked epithelioma of the penis the safest method of treatment is an immediate excision of the neoplasm by amputation. The line of amputation should always be wide of the limit of the disease. If the induration of the ulcer is well defined, and is limited closely to the margins of the erosion, the amputation may be made with one inch of sound tissue intervening. If the inguinal glands are enlarged, and if the surgeon has reason to be satisfied that the enlargement is due rather to inflammatory engorgement than to metastasis, the operation is still advisable, and the prognosis not altogether unfavorable. The inguinal glands should be dissected out at the same time as a precautionary measure. When metastasis of the glands is unmistakable, amputation may be done to rid the patient of the foul and ulcerating mass, although a favorable prognosis cannot be entertained. In the earlier development of the growth, where a sufficient extent of healthy tissue intervenes between the induration and the line of excision, amputation offers a strong hope of permanent relief. In the earlier period of development of the ulcer, if doubt exists as to its character, it is advisable to administer the iodide of potassium, together with proto-iodide of mercury, for a number of weeks. The application of Marsden's paste to the ulcer should, however, be made when it is first observed. If it be epithelial in character, the paste offers a strong hope of cure, and beyond the temporary inconvenience it produces no harm.

Operation.—Amputation of the penis may be performed by two methods: (1) simple amputation; (2) amputation with transplantation of the urethra to the perinæum. In the selection of the method, the operator must be guided by the nearness of the disease to the pubes and scrotum. Ordinarily, when the induration is limited to the glans, a simple amputation may be made at a point about one inch posterior to this. If the line of amputation must be chosen at or very near the level of the pubes, the second method will be preferable, for the reason that retraction of the stump will always occur, and the urine escaping over the scrotum will keep up a constant and annoying excoriation and condition of uncleanliness. In the operation with transplantation of the urethra, the urine is voided in the squatting posture, and escapes freely behind the scrotum.[1]

Simple Amputation.—Having shaved and thoroughly cleansed the pubes, scrotum, and penis, throw an elastic ligature around the organ at the level of the pubes. If the line of amputation is very near the ligature, this may be prevented from slipping by transfixing the penis with a large needle just in front of the tourniquet. Seize the mass with a double hook, and, holding it steady, with a long, thin-bladed knife cut the organ smoothly off at a point at least one inch behind the disease. A tenaculum should be in readiness to prevent the erectile tissue from retracting. The tube of the urethra should now be dissected up for half an inch, and the tissues of both cavernous bodies again divided on a level with the point to which the dissection of the spongiosum has been carried. The urethra is now split by passing the knife through its roof and floor, and a silk suture carried through the end of each lateral half. A thread is also passed through

[1] I have performed this, the operation of Humphrey, three times, and in none of these patients has any unpleasant symptom followed. Two of the cases were under observation three years after the operation.

the dense capsule of the corpora cavernosa to prevent their retraction when the elastic ligature is removed. All vessels which may be recognized before loosening the rubber band should now be secured with catgut ligatures, and the remaining bleeding points caught up as the tourniquet is gradually loosened. The sutures passed through each half of the urethra are now carried through the edge of the incision in the skin to which it is sewed. A simple dressing completes the operation.

Humphrey's Operation.—The elastic ligature is carried around the penis close up to the level of the pubes, as in the preceding operation, and the organ severed as near the ligature as possible. The vessels in the corpora cavernosa should be tied at once. An incision should now be made through the skin along the under surface of the corpus spongiosum, back to and splitting through the base of the scrotum, so as to expose the tube of the urethra for about two and a half inches. This tube is carefully dissected out from its attachment beneath and between the two corpora cavernosa for this distance, and is turned down on to the peri-

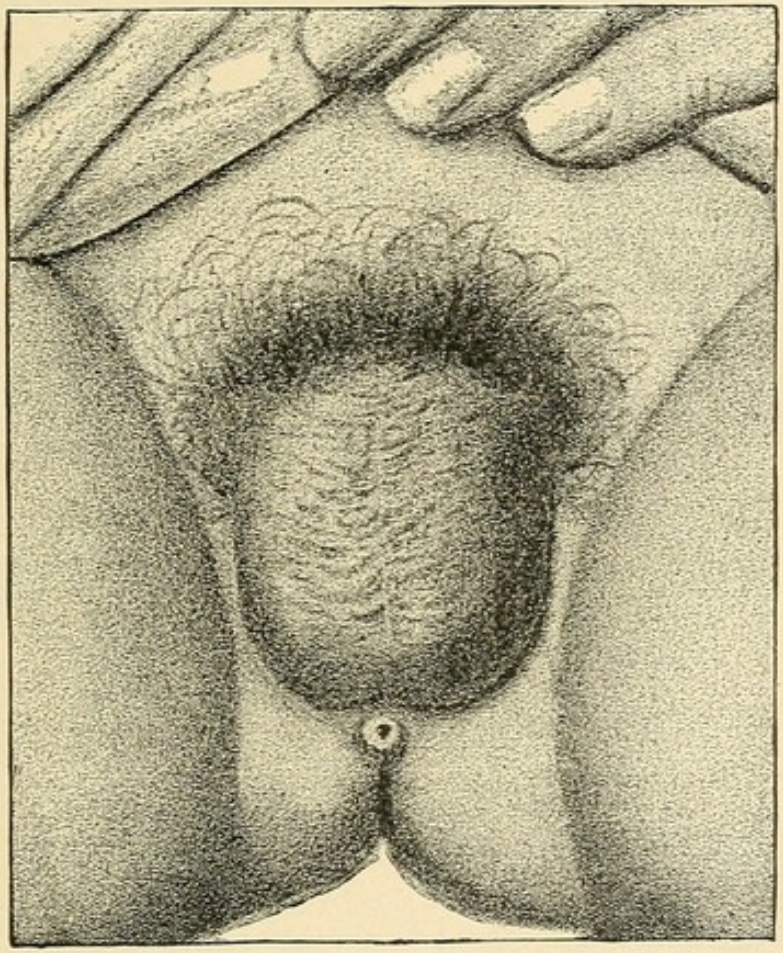

Fig. 601.—Humphrey's operation. (From a case of the author's at Mount Sinai Hospital.)

næum through the slit in the posterior wall of the scrotum. The urethra should next be split along the median line of its roof for a distance of half an inch back from the end, and the edges stitched to the margins of the wound in the integument of the perinæum. The operation is completed by closing the posterior slit through the scrotum, and stitching the margin of the wound in the skin of the anterior wall of the scrotum to that of the belly at the root of the penis, so as to cover in and include the stump of the amputated corpora cavernosa. The appearance of the parts after this operation is shown in Fig. 601.

Sarcoma of the penis is exceedingly rare. It may be recognized by its rapid development, the absence of glandular enlargement, the general invasion of the cavernous bodies—in certain cases producing a continuous and painful erection of the organ—and by its resemblance to the well-known appearance and behavior

of sarcomatous tumors in other portions of the body. The treatment should consist in immediate amputation.

Phimosis, or inability to retract the prepuce behind the corona glandis, is a frequent condition of childhood, often met with in adult life, and should always be corrected in early infancy. It is both a congenital and an acquired affection, and may be partial or complete. The prepuce may be adherent to the glans, or phimosis may exist without adhesions, the opening in the foreskin being so narrow that retraction is impossible. A prepuce ordinarily retractile may become irretractile as a result of any inflammatory process of the glans and foreskin. This condition is not infrequently met with in gonorrhœa and with chancroid.

Congenital phimosis is an unfortunate affection, preventing perfect cleanliness by retention and decomposition of the retained secretions and urine, and inducing a condition of irritation which it were better to avoid by timely operative interference. Inflammatory or acquired phimosis always requires careful attention, and very frequently a surgical operation, to prevent gangrene or to expose a subpreputial chancroid.

The operative measures may include: (1) amputation of the prepuce (circumcision); (2) dilatation of the preputial orifice with forced retraction; (3) incision of the anterior portion of the prepuce and retraction.

The first of these procedures should be preferred in all cases in which there is no inflammatory process present, while the latter is advisable in phimosis with acute balano-posthitis.

Operation.—In adults, circumcision may be done with almost perfect freedom from pain by the proper employment of cocaine. In children under six years of age, narcosis is advisable, although in selected cases local anæsthesia may suffice.

Proceed as follows: Cleanse the parts to be operated upon with 1–5000 sublimate solution. Grasp the upper end of the prepuce between the thumb and finger of one hand, make it tense, and insert a delicate hypodermic needle between the mucosa and the skin and force in a free quantity of a one-half-of-one-per-cent solution of cocaine. Using this weak solution, it is not necessary to employ a rubber tube

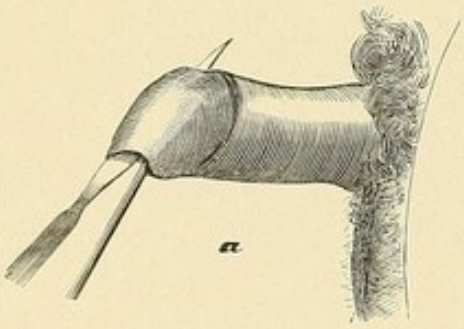

Fig. 602.

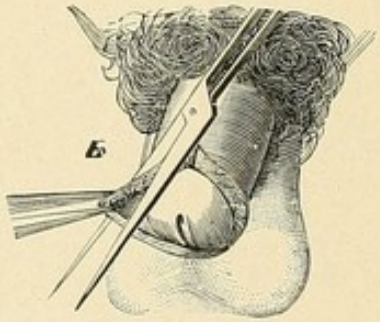

Fig. 603.

tourniquet, although this may be used should the operator prefer. The cocaine should be thrown in well back beyond the proposed line of incision, and having anæsthetized this space in the median line of the foreskin, the needle should be withdrawn, reinserted through the anæsthetized zone and both sides of the prepuce thoroughly infiltrated, taking special pains to throw an extra quantity of the solution into the region of the frenum.

In selecting the line of incision, the best rule is to allow the parts to assume their normal relation and mark the skin by repeated small punctures with the scalpel, parallel with and about one fourth of an inch anterior to the outline of the corona glandis. The prepuce is now divided, preferably with the scissors, exactly in the middle line of the dorsum as far back as already indicated by the line of punctures, and the sides are trimmed off following the lines already indicated down to the frenum (Fig. 603). The divided skin will retract to about the level of the corona, and the mucous membrane should next be folded back upon itself (not unlike a turndown collar), and carefully stitched to the edges of the skin incision in the following manner:

Four small ten-day catgut sutures are inserted above and below and one on either side directly through skin and mucosa, and tied in loops about six inches long to serve as retractors. While these are held fairly taut, intermediate sutures of the same material are inserted, making a close approximation of mucous membrane to the skin, as shown in Fig. 604. Should the operator prefer, the division of the prepuce in the median line may be made with the scalpel passed through on a grooved director, as shown in Fig. 602. When the four catgut loops are tied, the ends are still left long, and a loose roll of absorbent gauze about half an inch thick is made into the shape of the letter *O* and applied over the line of sutures, and is held in place by tying these four loops down upon it. This serves as a dressing, prevents oozing, and keeps the line of skin free from infection. The sutures disappear by absorption, and the union is completed in from four to ten days. When the prepuce is adherent to the glans, the adhesions should be broken up, usually with a dull-pointed grooved director, and the foregoing procedure carried out.

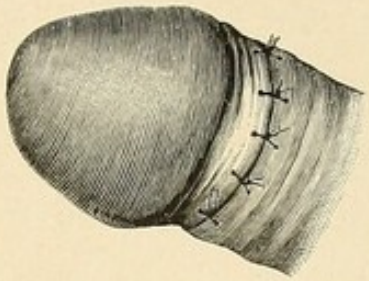

FIG. 604.—(After Malgaigne.)

Dilatation or *divulsion* of the prepuce yields a satisfactory result in young boys. Circumcision is not indicated, as a rule, since, if the prepuce is enlarged, the foreskin shortens by a normal process of atrophy. It is performed by introducing the point of a small, closed dressing forceps into the opening of the foreskin, and stretching or tearing this by forced separation of the blades. The operation is completed by retracting the prepuce and breaking up all adhesions. In the after-treatment it is essential to move the foreskin back and forth over the glans once or twice daily to prevent the reformation of adhesions.

Incision limited to the anterior half-inch of the foreskin, and in the median line of the dorsum, is advisable where the opening is very small and dilatation difficult. Retraction should be immediately effected.

Ulcers of the Penis.—Sores may occur upon the integument of the penis, usually near the prepuce; upon the mucous lining of the foreskin; the glans; within the meatus; and along the urethra. Venereal sores are occasionally met with upon the integument of the scrotum, abdomen, perinæum, and thighs. Ulcers of the penis only will be considered here. They are divisible into two classes—namely, the non-specific and the specific ulcer. To the former belong the sores which follow abrasions and the eruption of herpes. They are more or less phagedenic in character, the extent and rapidity of the process of necrobiosis being due to the degree of virulence of the inoculating micro-organism, and the impoverished condition of the tissues attacked. The *chancroid* belongs to this group. In the second class belongs the specific ulcer of syphilis.

Non-specific Ulcers.—A *simple* ulcer of the penis is extremely rare. It may occur here, as in other parts of the body, as a result of traumatism, or an inflammatory process not due to the inoculation of a virus. Thus, the molecular death of a variable extent of tissue may follow a simple abrasion if the part involved is not kept free from all irritation, and if there prevails a condition of impaired nutrition, in which, as is well known, the tissues yield readily to the destructive process. Under more healthful conditions, an abrasion of the glans or prepuce undergoes the simple process of repair seen in similar lesions of the integument and mucous surfaces elsewhere. Abrasions usually occur on the sides of the penis, close to the attachment of the prepuce, just behind the corona or near the frenum. The glans is rarely involved, although the meatus, especially at its lower angle, may be torn. Bleeding sufficient to attract the attention of the patient is rare, unless extensive laceration has occurred.

The *ulcer of herpes* is usually situated upon the surface of the mucous lining of the prepuce, less frequently upon its cutaneous surface, and the glans. It begins as a vesicular eruption. There may be one or many. Multiple herpetic vesicles may be scattered or in clusters, linear, semilunar, or circular in arrangement. In the recent state the herpetic vesicle is round at its base, measuring

from one twelfth to one twenty-fifth of an inch in width. It consists of a thin investing membrane resting upon a slightly red and irritated base, and containing a clear, serous fluid, which often escapes by rupture of the membrane before the vesicle is observed. Upon the skin they rapidly dry on account of evaporation of the fluid contents, and the floor of the patch becomes covered over with a light incrustation. Upon the mucous and moist surfaces incrustation does not occur. The circumference of the base exposed after rupture of the vesicle is usually round, with well-defined walls leading perpendicularly down to the bottom of a shallow excavation.

In typical cases of genital herpes the morbid process ends here, the sore healing without suppuration. Not infrequently, however, the floor becomes covered with a layer of pus, the walls are undermined and break down, forming an ulcer which is phagedenic in character. The character of the pain varies. In some instances there is a stinging, burning sensation felt in the part affected; in others there exists total insensibility.

Herpes is a neurosis due to a local irritation of the nerve terminations in the part attacked. In some instances a severe neuralgia of the branches of the sacral or lumbar plexuses exists at the time of the eruption on the glans and prepuce. Uncleanliness is a frequent cause of this disease. Any irritation of the glans or prepuce may induce it, and one attack is apt to be followed by a second.

In mild and ordinary cases it runs its course in from ten days to two or three weeks. In other forms, especially when infection occurs, it may last for a number of weeks, and is usually complicated by lymphangitis and adenitis.

Phagedenic ulcer of the genital organs was formerly held to be the result of the inoculation of a specific poison—the virus or micro-organism of "chancroid"; but, since ulcers which in appearance and behavior do not differ from the so-called chancroidal ulcer have been produced by inoculation with the infectious material taken from the pustules of acne, from gonorrhœal pus, etc., the specific nature of this virus cannot be maintained. Even the specific ulcer of syphilis will, as a result of repeated and prolonged irritation, take on a phagedenic character.

This ulcer results most frequently from direct contagion, the virus being lodged in an abrasion of the integument, prepuce, or glans. The period of incubation—that is, the length of time between the date of the contact and the recognition of the sore—will vary in different individuals. It has been seen within twenty-four hours, and, in rare instances, as much as twenty days have elapsed. In a very large majority of cases the inflammation is observed within the first nine days after the inoculation. The rapidity of its appearance depends chiefly upon the thoroughness with which it is brought into contact with the tissues in an abrasion, and the condition of the tissues at the time of the invasion. The ulcer is usually located on the side of the penis, just behind the corona glandis at the preputial attachment, at the points where abrasions are most frequent. It may be on the cutaneous surface of the prepuce, upon the body of the penis, the scrotum, or within the meatus. There may be one or more, owing to the number of abrasions and the distribution of the virus. A single ulcer may result from the confluence of several contiguous points of inoculation. It is first noticed as a light redness or flush, usually circular or elliptical in shape, or, if the abrasion is irregular in outline, it will conform to this. Within a few hours after the appearance of the redness its center becomes elevated and a pustule is formed, which soon breaks down, discharging a small quantity of matter.

If the sore is not seen early, the pustule may escape observation. When the inoculation occurs upon a surface denuded of its mucous membrane or epidermis, a pustule is not formed. The walls of a phagedenic ulcer are usually precipitous. At times the superficial layers of the skin resist disintegration longer than the deeper layers and subcutaneous tissues, giving the edges an undermined appearance. It tends to spread in width rather than in depth, although in a certain proportion of cases extensive destruction of tissue may occur in all directions. The floor of the ulcer is covered with a creamy pus and the broken-down tissues in various stages of decomposition. A small quantity of matter of creamy con-

sistence may be removed with a pellet of cotton. A membrane or film of a yellowish-brown color usually adheres to the floor with considerable tenacity.

A zone of redness extends along the edges of the ulcer in advance of the tissue destruction. In many ulcers this is not more than a line in width. If the sore is subjected to irritation, the inflammatory redness and induration may spread widely into the surrounding tissues.

Pain, which is always present, varies, as a rule, with the extent of the inflammatory process.

In a typical phagedenic ulcer of the penis, lymphangitis and adenitis of the inguinal glands are always present in a varying degree. In the simpler forms adenitis does not occur, although the lymphatic channels in the neighborhood of the sore may be involved. Inguinal adenitis or *bubo* is always a painful complication. It may be lateral or bilateral. If the sore is in the median line, or if there are ulcers on both sides, both groups of glands will be affected. Suppuration of the inguinal bubo of phagedenic ulcer is not uncommon. The violence of the inflammatory process here is subject to the same conditions as given for the primary ulcer. One or more glands may be involved and suppurate. In severe adenitis the inflammation extends to the tissues immediately surrounding the glands. The mass appears as one large swelling, over which the integument is red and œdematous, and to which it is adherent. Phagedenic bubo is apt to follow a virulent phagedenic ulcer of the penis.

Treatment.—Simple ulcer of the penis, if left without interference, usually heals within a few weeks; the ulcer of herpes is usually more obstinate. The process of repair may be greatly facilitated by a careful removal of all sources of irritation. Strict cleanliness is essential, no matter what form the ulcer may assume. Finally, powdered aristol, applied two or three times daily, affords protection and aids in the absorption of moisture.

In addition to the foregoing, it is essential to keep the sore uncovered by the prepuce, which should be worn back behind the corona. Circumcision may at times become necessary to obtain a permanent cure. If the simpler remedies just given do not succeed, the local use of the nitrate-of-silver pencil is indicated.

In phagedenic ulcer, as a rule, more vigorous measures are necessary. The severity in local treatment will depend, however, upon the rapidity of molecular death in the tissues. If its progress is slow, and the inflammation mild in character, recovery may be brought about by the treatment laid down for simple and herpetic ulcer. If within the first few days of its appearance the spread of the sore is rapid, or if, when first brought to the notice of the physician, it is more than a quarter of an inch in diameter, and the zone of redness spreads well out into the tissues, it should be treated as follows: By the introduction of a delicate hypodermic needle through the sound tissues, after which its point should be carried under the base of the ulcer, from ten to twenty minims of a one-per-cent solution of cocaine should be injected, by which means complete anæsthesia may be secured. The pus should now be removed from the bottom of the sore with a pellet of absorbent cotton on the end of a small piece of wood. The parts immediately about the ulcer should be coated over with vaseline or oil, to protect them from excoriation. A small quantity of carbonate of soda should be on hand to neutralize any excess of acid. In applying pure nitric acid, the ulcer should, if possible, be held so that it will contain the acid without letting it run over the edges. It is best applied by means of a wooden match or toothpick dipped in the acid, and the point immediately carried into the floor of the ulcer. It should be conveyed into every portion of the sore, and allowed to remain in contact with the virus for one or two minutes. The excess may now be soaked out with the cotton pellets, and the ulcer filled with soda. A piece of lint moistened in vaseline will serve as a dressing. When nitric acid cannot be had, the actual cautery should be employed.

Iodoform should not be used, on account of the disagreeable odor.

When phagedenic ulcer occurs beneath an irretractile prepuce, this should be incised and the sore treated as above. Ulcer of the meatus should also be burned with nitric acid. Complete rest is essential, and constitutional measures looking

to the improved nutrition of the tissues are strongly indicated. If suppuration occurs in the glands of the inguinal region, free incision should be made and free drainage established. Phagedenic bubo should be treated in the same manner as the phagedenic ulcer. Chronic adenitis, in which the glands are discharging at varying intervals, is rarely cured without a thorough extirpation.

Scrotum.—Wounds of the scrotum should be treated as similar lesions elsewhere. On account of the great vascularity of the tissues, repair is usually rapid. The contractility of the dartos and cremaster muscles will prevent early union unless the stitches are closely applied. If the testicle is protruded, it should be disinfected with 1–10,000 sublimate, returned to its normal position, and the cavity of the tunica vaginalis also washed out with the sublimate solution. In closing the wound with catgut sutures, the edges of the opening in the tunica should be included. A small catgut drain may be inserted into the cavity and emerge at the lower angle of the incision.

Contusions should be treated by rest in the horizontal posture, cold applications and mechanical support beneath the posterior aspect of the scrotum.

Œdema of the scrotum occurs with general anasarca and with ascites. The integument is tense, pale, and doughy; pits upon pressure, and, after puncture with the hypodermic needle, a clear, watery serum escapes. Besides the indications for constitutional treatment directed to the disease proper, puncture with the lancet in several points will temporarily relieve the tension and danger of gangrene.

Eczema and other cutaneous lesions of the scrotum do not demand especial consideration. The same general principles of treatment apply with equal force to all the cutaneous surface. The prognosis is unfavorable on account of the irritation to which this organ is subjected from friction with the clothing and thighs, and especially owing to the peristaltic movements of the dartos and cremaster muscles.

Cysts, due chiefly to the retention of sebum, are occasionally seen in the scrotum. They are usually situated near the raphé, or laterally and posteriorly upon the base of the scrotum. When large enough to cause inconvenience, incision and extirpation of the sac are demanded.

Erysipelas, although rare in this portion of the body, is met with, and is often obstinate under treatment. *Gangrene* is one of the chief dangers, and must be guarded against by free incision as soon as the tension is great. *Phlegmon* of the scrotum should be treated by warm applications, poultices, etc., and by early incisions to relieve tension and give escape to septic matter. Free drainage and sublimate irrigation are indicated.

Elephantiasis scroti, comparatively of rare occurrence in the temperate and colder zones, is frequently met with near the equator; and in some of the West Indies and the islands of the South Pacific Ocean it occurs with great frequency.

The pathology of this form of connective-tissue hyperplasia has been given. The only treatment is extirpation with the knife. No fixed rule of operating can be laid down. The penis is at times buried in the neoplasm, and should be carefully dissected out. The incisions should be made so as to give a cutaneous flap in front and behind sufficiently large to contain the testes and cord without pressure after the connective-tissue new formation has been dissected out. When the penis is included in the new growth, the integument should be saved, to cover this organ. If this cannot be done, flaps may be turned from the thighs and abdomen.

The hæmorrhage in this procedure may be controlled by working between fixation forceps, or by the adjustment of an elastic tourniquet around the scrotum near its attachment to the perinæum.

Fig. 605 represents a typical case of this affection which I successfully removed in two operations, with ten days' interval, in 1893. The patient, a negro fisherman from Bermuda, is entirely well. The entire scrotum, testicles, and penis were removed.

Angeioma of the scrotum is rare, and demands treatment similar to that advised in the chapter on these vascular formations.

Epithelioma is more frequently seen than either of the foregoing neoplasms, and calls for immediate excision. The so-called chimney-sweep's cancer is often located on the scrotum.

Fistulæ, or *sinuses* of the scrotum, may be caused by abscess of the tunica vaginalis testis, or by any lesion of the testicle. Abscess of the perinæum or urinary fistula may also cause fistula of the scrotum. Stony concretions are occasionally met with in fistulæ of the scrotum through which the urine makes its escape.

The treatment should be directed to a relief of the cause of the fistulous tracts. If this is accomplished, the sinuses should be laid open and allowed to close by granulation.

Hæmatoma.—Extravasation of blood may occur either in the tunica funiculi, in the tunica vaginalis testis, or in both. In the former it may be *diffuse* or

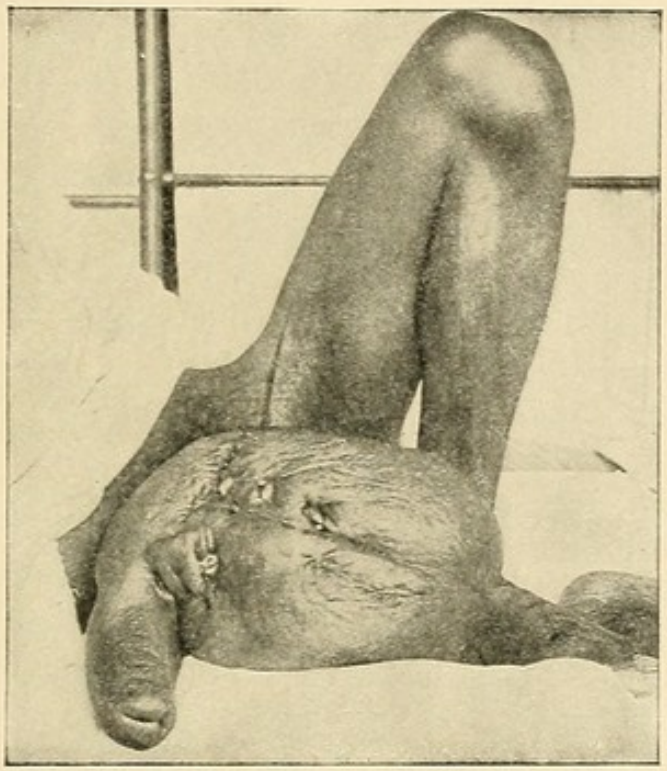

Fig. 605.—Elephantiasis of scrotum and penis. Native of Bermuda. Cured by complete ablation. (The author's case.)

circumscribed. It is usually diffuse, the extravasation extending from the abdominal opening to the epididymis. When only a portion of the sheath is involved, the hæmatoma is generally confined to the upper segment.

The chief causes of extravasation are rupture of one or more vessels by direct traumatism, or by overdistention from prolonged strain, which retards the return circulation, causing rupture of a vein.

Hæmatoma of the tunica vaginalis testis is rare, except as a complication of chronic *periorchitis serosa* (hydrocele) or direct violence.

The diagnosis of hæmatoma in either of these positions depends upon its sudden development, the tendency to enlarge progressively, and pain from the sudden distention. The tumor is not translucent. The exact nature may be determined by aspiration.

Serous effusion (hydrocele) into the sheath of the cord or testis progresses slowly and painlessly. The tumor is translucent. Exploration with the hypodermic needle and syringe is a safe, painless, and positive means of diagnosis.

Hernia may be eliminated by a consideration of the history of the case and the absence of impulse in the tumor upon coughing.

Treatment.—Hæmatocele may be treated by the expectant method, or by surgical interference.

Simple and limited extravasation requires rest in the dorsal decubitus, and the ice-bag locally. After the hæmorrhage is arrested, absorption may be expedited by judicious and well-applied pressure by strapping. When the extravasation is extensive, an incision should be made under strict antisepsis, the clot turned out, the bleeding point ligated, drainage secured, and the wound closed. Death has followed in some instances where operative procedure has been too long delayed.

Hydrocele and Spermatocele

Hydrocele (periorchitis) is a term employed to denote an accumulation in the sac of the testicle of a serous fluid (Fig. 606). It may be an *acute* or a *chronic* affection. The fluid contents may be contained in a single sac, or, as occurs in rare instances, there may be adhesions of contiguous surfaces to each other in one or more places, holding the fluid in two or more separate cavities.

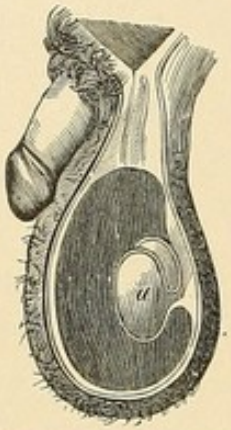

Fig. 606.—Hydrocele of the tunica vaginalis testis. (After Linhart.)

Acute hydrocele of the tunica vaginalis testis may occur from any acute inflammatory process of the epididymis or testis. The serous membrane appears red and injected, the capillaries enormously distended and filled with blood. The surface is less smooth than normal, the epithelium gradually disappears, and emigration of leucocytes occurs. A soft, pinkish, elastic substance is deposited upon the surface of the membrane. Similar flaky masses are also to be found in the fluid contents. Acute hydrocele is usually accompanied by pain, rarely goes on to suppuration, and disappears with the inflammatory process which precipitated it. The diagnosis, if necessary, can be confirmed by careful exploration with a very fine aseptic aspirating needle. The treatment is complete rest of the part involved.

Chronic hydrocele is by far the most frequent form which comes under the observation of the surgeon. It occurs at all times of life, and seems to have no preference for one side or the other, but frequently involves both serous cavities. It develops slowly, shows no tendency to disappear spontaneously, and may attain tremendous proportions.

The ætiology of this disease is not satisfactorily explained. It is frequently found occurring with chronic, subacute inflammation of the epididymis or testicle, but as often exists when no inflammatory lesions can be determined. The walls of the sac in most cases, and in all cases of long duration, appear thicker than normal, showing a proliferation of new connective tissue, and frequently there is much induration. In rare instances calcareous and even osseous deposits have been noticed. The epithelial covering is but little impaired. It is whiter than normal, but retains its peritoneal gloss. The quantity of fluid contained in the sac varies considerably, at times reaching a gallon or more. It is pale straw or amber-colored, and may be greenish-brown or chocolate color and opaque. Pus is not present unless some septic infection has occurred. It is neutral or slightly alkaline in reaction, and the specific gravity varies, being usually from 1.020 to 1.026. When the fluid is dark brown or red, it contains blood, due to rupture of small vessels upon the vascular granulation tissue which has developed upon the surface of the membrane.

The symptoms of the disease are little more than a gradual accumulation of fluid, the enlargement showing first in the lower part of the scrotal sac and extending upward. Pain is rarely present in chronic hydrocele. As the fluid accumulates, the testicle is generally pressed upward and backward.

In the diagnosis of this affection it is important to exclude the presence of hernia, which may complicate it. When the hydrocele is small and occupies the lower portion of the scrotal sac, differentiation is easy; but when it is of large size, extending as high as the external ring and lying in front of the spermatic cord, differentiation is not so easy. It is important to bear in mind that the history of a hernia is that of a swelling appearing first along the inguinal canal

and then out through the external ring, gradually extending downward in the direction of the testicle, and that a hydrocele begins below and extends up. The introduction of the finger into the external ring and the absence of any impulse on coughing will exclude hernia. Holding a bright light upon the opposite side of the scrotal sac, the serous fluid of a hydrocele becomes translucent, while a hernia would obscure all light. A hydrocele could scarcely be mistaken for a varicocele, the peculiar wormlike feel of this latter condition clearly pointing to its recognition. A varicocele disappears with the recumbent posture. Lastly, a positive diagnosis can be made by aspirating with an aseptic and very fine needle. Even if an error were made and an intestine punctured by this needle, no harm would result.

The treatment of chronic hydrocele has been greatly simplified in modern practice. In the vast majority of cases of ordinary size, containing less than one pint of fluid, the tumor can be cured by the method of Levis. The anterior aspect of the tumor should be thoroughly cleansed with soap and water and a little mercuric-chloride solution. In an area one inch in diameter, with a delicate hypodermic needle inject three to ten minims of a one-per-cent solution of cocaine. Through this anæsthetized area, after grasping the scrotum to make it as tense as possible, is thrust a trocar and canula which have just been taken out of the boiler. This canula should be threaded in order to fit the screw tip of an ordinary large-size hypodermic syringe. As soon as the point of the trocar and canula pass freely into the cavity of the sac, the trocar is withdrawn and the fluid allowed to escape. Gentle pressure applied to the sac, taking pains not to allow the canula to be extruded, will empty all but a few drops of fluid. The next step in the operation is the injection of liquid carbolic acid, ninety-five per cent pure. The quantity to be thrown in varies with the size of the tumor, twenty minims for a sac containing two to six ounces, gradually increasing to as much as sixty minims for a sac containing a pint. Care should be taken not to carry any air through the syringe into the cavity. The fluid having been evacuated and the proper quantity of carbolic acid placed in the syringe, the thread is now screwed into the corresponding threads of the canula, a little clean vaseline is spread upon the scrotum around the needle puncture to prevent any possible leakage of acid on the integument, and the contents of the syringe forced in. When the canula is withdrawn, gentle massage of the scrotum is practiced until the injected carbolic acid has been brought into contact with every part of the tunica vaginalis testis. Strange to say, this operation is almost entirely free from pain, and in many instances I have performed it as above described, the patient not knowing when the instrument was introduced or when the carbolic acid was injected. No dressing is required, and, while it is best for the patient to remain quiet for at least twenty-four hours after the operation, I have in a number of instances operated upon laboring men who would come into the clinic from their work and return to it afterward with the loss of only one hour. If properly done, this operation should cure about seventy-five per cent of all cases of hydrocele at a first injection. When it fails, it should be carefully repeated, increasing or diminishing the quantity of acid thrown in as is necessary to insure a perfect result. It is important that the strictest asepsis be carried out, since the introduction of any septic organism would produce a painful process of suppuration not without danger to the patient. Twenty-four or forty-eight hours after this operation the scrotum appears as large as ever, is heavy, and seems solid or doughy to the feel. After a week or ten days it begins to decrease in size, and, since the epithelial lining which furnished the serum has been destroyed by the injection, it does not again refill with fluid, but gradually contracts down, and adhesions form, thus effecting a cure. The walls of the scrotum, however, are usually much thickened by a chronic hydrocele, and never regain their former thinness.

When the accumulation of liquid is larger, as in chronic hydrocele with thickened walls, *Volkmann's* operation is advised. Shave the scrotum and pubes, and wash the parts thoroughly with brush, soap, and water, and afterward with mercuric chloride. The sac of the hydrocele is then opened by an incision varying in length from three to six inches or more, as the case may require, upon the anterior

surface of the tumor. All bleeding should be arrested as the operation progresses. When the sac is reached it should be incised to correspond to the length of the incision in the contracted scrotum. Allow the fluid to escape, and with a good-sized continuous catgut suture stitch the parietal layer of the tunica vaginalis to the edge of the wound in the integument, making a wound not unlike a button-hole. After irrigation with a 1–5000 mercuric-chloride solution insert a wick of gauze in the upper and lower portions of the cavity. A sterilized dressing is placed over all, which need not be changed before the fourth or fifth day, and often two or three changes will suffice to effect a cure. A shorter gauze wick may be inserted after each dressing.

The conditions are very rare which call for ether or chloroform narcosis in the performance of this operation. Even in cases in which a cure cannot be effected by the simple method of Levis it is not necessary to secure any better anæsthesia than that obtained with cocaine. A one-per-cent solution injected into the integument of the scrotum in the line of incision will give perfectly satisfactory anæsthesia in the vast majority of instances, enabling the operator to open the sac, discharge its contents, and irrigate and insert the wick drain without pain.

Hydrocele of the cord is much less frequently met with, and consists in the accumulation of a fluid in character similar to that of hydrocele of the tunica vaginalis.

Hydrocele of the tunica funiculi (Fig. 607) appears as a round, slightly elongated cyst or tumor, movable in all directions with the tissues of the cord, not communicating below with the tunica vaginalis or above with the peritoneal cavity. It rarely attains a large size, although as much as three ounces of fluid may be met with in rare cases.

The diagnosis between hydrocele of the tunica funiculi and spermatocele in this same region is exceedingly difficult, and cannot be positively made without aspiration. Fluid drawn off from a hydrocele of the cord is straw-colored, while that of a spermatocele is milky-white, and not unlike the fluid which is found in a cocoanut. Should the diagnosis be still doubtful, the microscope will demonstrate the presence of spermatozoa if the case is one of spermatocele. For all practical purposes the differentiation is of no moment, since the treatment is the

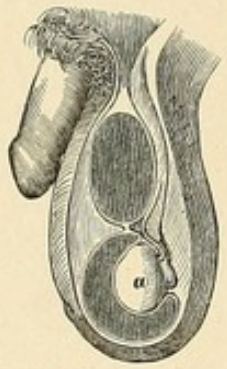

FIG. 607.—Hydrocele of the cord encysted.

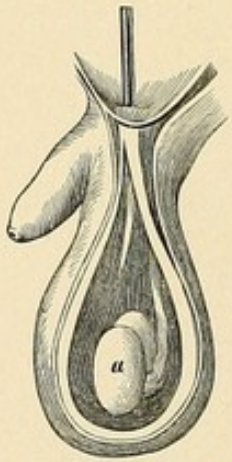

FIG. 608.—Congenital hydrocele. The tunica funiculi communicating with the tunica vaginalis testis and the peritoneal cavity. *a*, Testis. (After Linhart.)

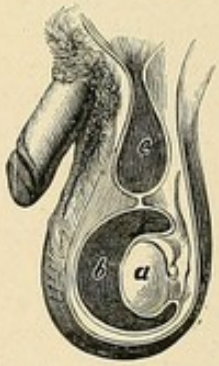

FIG. 609.—*c*, Hydrocele of the cord communicating with the peritoneal cavity. *a*, Testis. *b*, Small effusion into the tunica vaginalis. (After Linhart.)

same in both—incision under the same antiseptic precautions as given for Volkmann's operation, opening into the sac, irrigating with mercuric-chloride solution, packing with sterile gauze. Careful asepsis should be carried out in order to prevent suppuration, for the inflammation which can be secured by cleanliness will obliterate the sac in much less time than that which occurs with pus formation.

Hydrocele may sometimes be *congenital*, fluid descending from the peritoneal cavity and along the cord and extending into the tunica vaginalis (Fig. 608).

Hydrocele of this variety, however, is rarely met with, and does not require treatment unless it persists. It is occasionally met with in very young infants, and

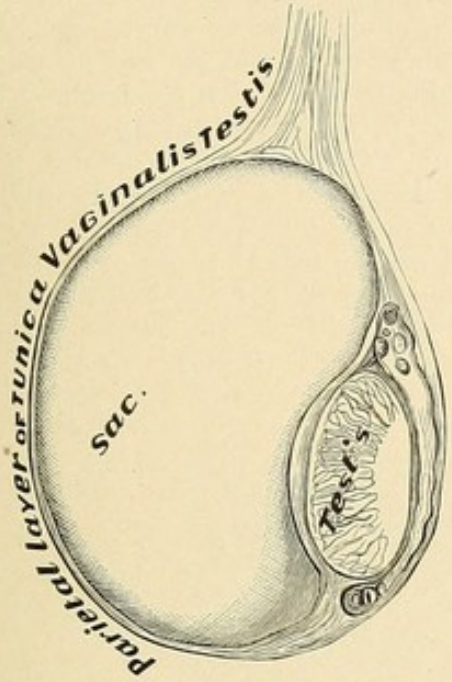

Fig. 610.—Usual form of hydrocele. (After Kocher.)

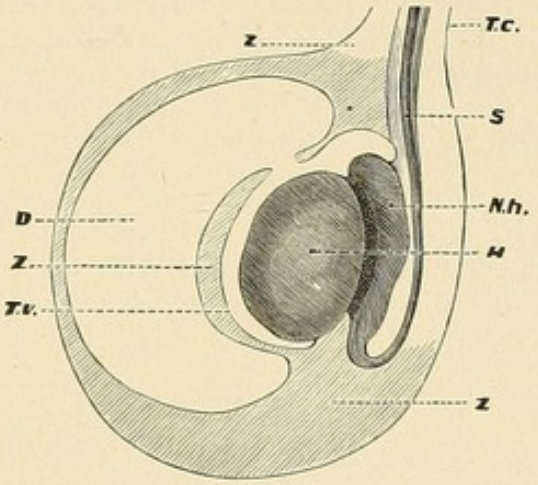

Fig. 611.—Bilocular hydrocele. *T c*, Parietal layer of tunica. *S*, Spermatic cord. *N h*, Epididymis. *H*, Testis. *D*, Cavity of diverticulum. *T v*, Cavity of the tunica vaginalis proprius. *Z z*, Inflammatory new formation between the visceral and parietal layers. (After Kocher.)

becomes separated from the peritoneal cavity by closure of the tunica funiculi in the inguinal canal. Hydrocele in children, when not congenital, is not infre-

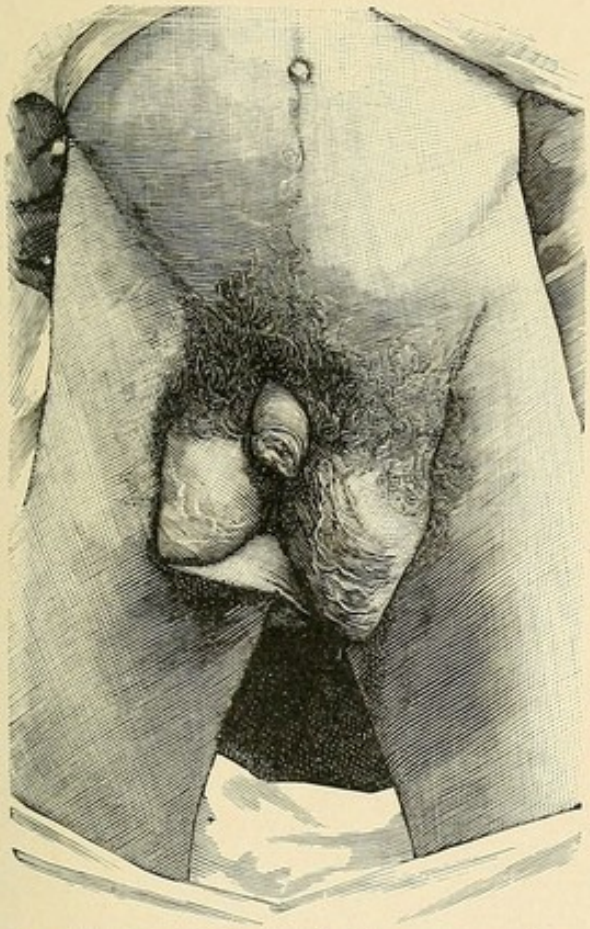

Fig. 612.—Double hydrocele of the tunica vaginalis testis. (From a patient operated upon at Mount Sinai Hospital.)

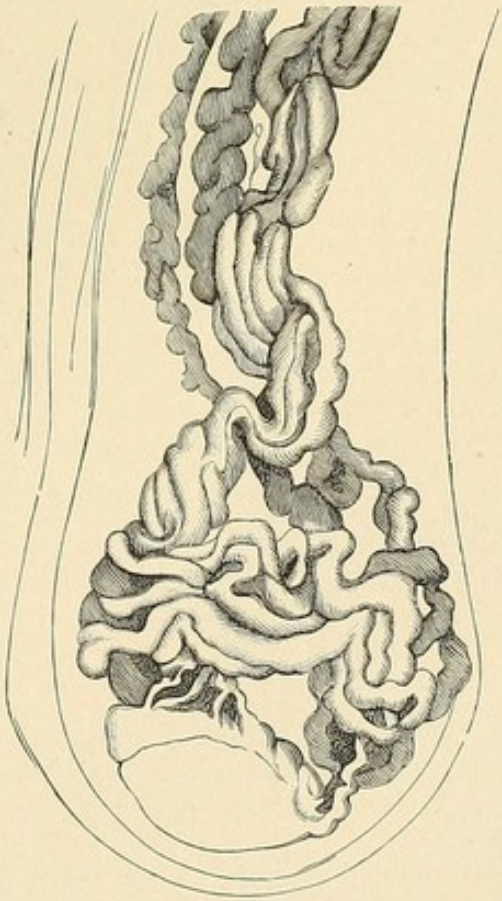

Fig. 613.—Varicosities of the spermatic plexus of veins, with atrophy of the testicle. (After Kocher.)

quent, and may often be cured by simple, clean evacuation of the fluid with a hypodermic apparatus without injection. It should be thus treated for one or two or three times, after which, should the fluid re-form, from one to three minims of pure carbolic acid should be thrown in after another aspiration.

Varicocele.—Varicosities of the veins of the spermatic plexus are not uncommon. Varicocele is chiefly caused by gravity and the mechanical interference with the return of blood through the spermatic veins. It occurs with greater frequency on the left side, where the vessels are pressed upon by the sigmoid flexure of the colon with its almost constant weight of fecal matter. In addition to this, the greater length of the left spermatic vein, which enters the renal vein at a right angle to its axis, and is poorly protected by valves, are causes which serve to produce varicosities upon this side more frequently than in the right plexus. Any occupation which necessitates the erect posture is apt to add to the susceptibility of this disease. Hereditary tendencies must be considered in its ætiology, for frequently members of a family through several generations will be affected.

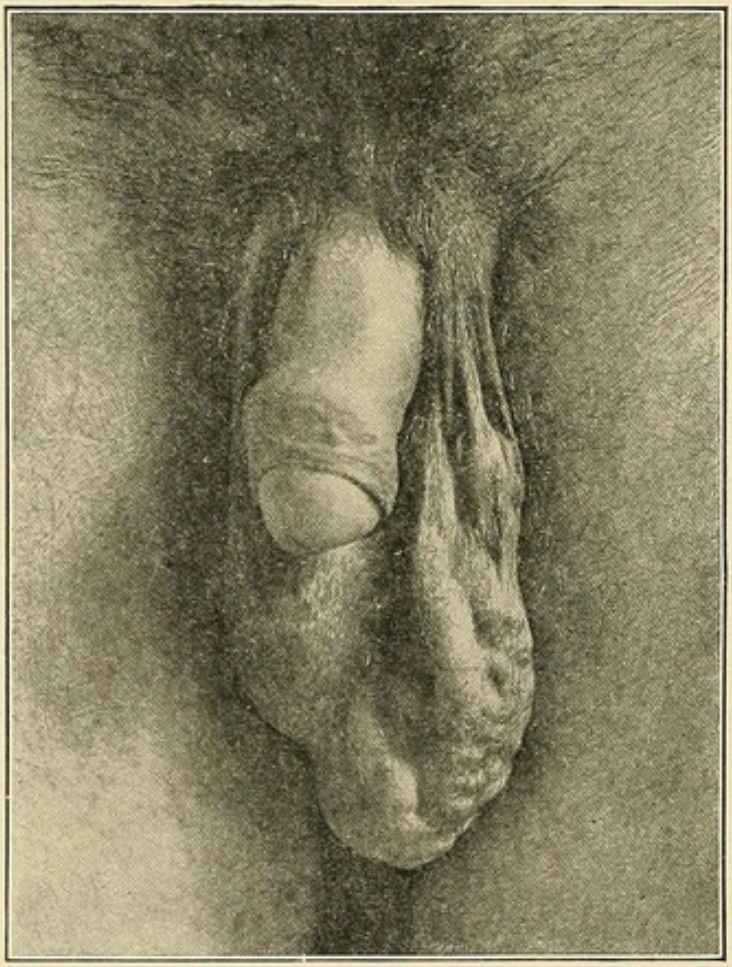

FIG. 613*a*.—Varicocele of extreme degree. Veins unusually large and distinct. Duration, fourteen years. Patient aged twenty-nine years. (Foote.)

The earlier *symptoms* are a feeling of heaviness or dragging down on the side affected, with the appearance of a small swelling in the line of the cord. Pain is variable, and is sometimes referred to the cord or to the inguinal region or down the leg. The testicle hangs lower than natural, and along the cord can be felt a network of turgid veins extending from the epididymis toward the external ring. To the touch they seem not unlike a knot of earthworms. The swelling is apt to be largest at the lower extremity (Fig. 613).

The *diagnosis* is not difficult. The swelling of inguinal *hernia* is spherical, and, when composed of intestine, it is resonant on percussion. If the hernia is reducible, and is returned into the cavity of the abdomen with the patient in the recumbent posture, and if the index-finger is carried into the internal ring and

held there while the patient is made to stand erect, the veins will again refill and demonstrate the varicocele, while the hernia will be prevented from descending. Hæmatoma, or hydrocele of the cord, can be recognized by aspiration with the hypodermic syringe.

Treatment.—In general, a well-adjusted suspensory apparatus constantly worn when in the erect position will obviate the necessity for an operation. A double elastic apparatus is advisable. When the annoyance of the suspensory bag is great, or if it is ineffectual, operative interference is demanded. There is but one method for the radical cure of varicocele that is advisable. It is as follows:

Shave and thoroughly cleanse with brush, soap, and water the entire field of operation and contiguous surfaces. An incision is made that should extend from one inch above the external abdominal ring, down along the spermatic cord, through the tissues of the scrotum to the upper margin of the epididymis. Careful dissection will expose the entire cord without wounding any veins which enter into its composition. The vas deferens can be easily recognized, not only by the sense of touch, since it feels like a round leather shoestring when pressed between the fingers, but by the eye. This should be carefully separated from all the remaining tissues of the cord, together with one or two veins, the artery of the vas deferens and the nerve, which are in one sheath, from the level of the epididymis to the external ring. A good-sized catgut ligature—usually the largest size—is now tied around the part to be excised near the epididymis, and a second ligature at the external ring. The intervening portion is cut through with scissors and removed. By leaving the ends of the two ligatures fairly long, these can be tied together, bringing the testicle up in proper position and holding it temporarily until adhesions occur. The wound should be carefully dried, closed, and sealed with sterile collodion. It is a wise precaution to insert a twist of two or three strands of catgut in the lower angle of the wound, in order to give exit to the serous transudate which nearly always follows this operation. The collodion can be lifted at this point to permit the escape of serum or blood.

In the majority of cases the scrotum will be found so elongated that amputation of the redundant portion is essential to comfort and cleanliness. In performing this operation the testicles should be pushed well up toward the external ring and a little more of the scrotum amputated than may seem necessary; the tissues are retracted to a much greater degree under the anæsthetic than normal. The operation is much facilitated by using the scrotal clamp (Fig. 614), which, if properly adjusted, will hold the tissues firmly while the amputation is being made, and the wound closed with strong catgut sutures, thus preventing all hæmorrhage and the necessity of applying any ligatures in the line of incision. If

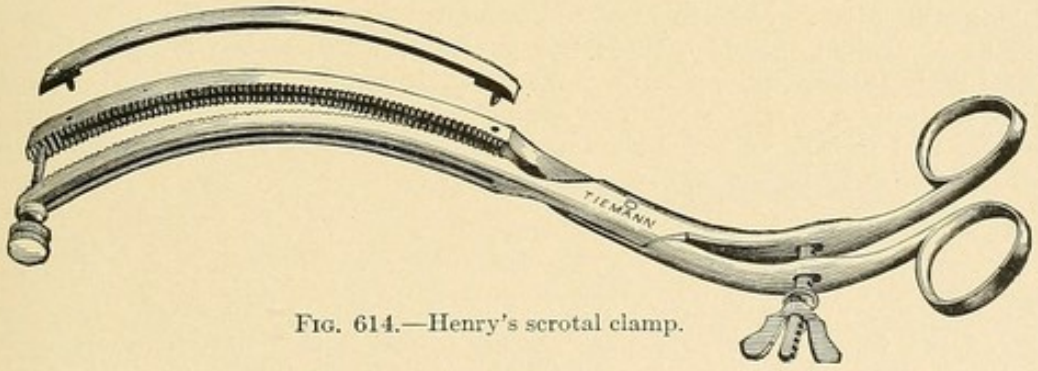

Fig. 614.—Henry's scrotal clamp.

this instrument cannot be obtained, Smith's hæmorrhoidal cautery clamp may be used, applying the clamp over a portion of the line of amputation, making the section about one fourth of an inch in front of it, and inserting and tying the sutures before further section is made. If no apparatus can be obtained, the fingers of an assistant will prevent hæmorrhage while the operation proceeds. This wound should be sealed at once with collodion.

Cocaine infiltration should give a perfectly satisfactory anæsthesia in this operation.

The *vas deferens* is more or less involved in all inflammatory processes which occur in the epididymis. It is also subject to invasion by inflammation from the urethra and prostate. Tuberculosis of this vessel may follow tuberculosis of the testes and epididymis.

In chronic vesiculitis benefit may be derived by the stimulation which results from digital pressure or massage. This is done by carrying the index-finger into the rectum until these organs are felt, and exercising gentle, steady pressure with the tip of the finger applied from behind forward.

Epididymis.—Neoplasms of the sheath of the spermatic cord are rare. Kocher mentions isolated cases of lipoma, fibroma, or myxofibroma and sarcoma.

Epididymitis results occasionally from direct violence, but is chiefly due to urethritis and the extension of the inflammatory process along the vas deferens. Metastatic or "sympathetic" inflammation of this organ is very rare. It may be acute or chronic. The inflammatory process may be confined to the epididymis or invade the testicle. Acute epididymitis always involves the tunica vaginalis (with which it is in contact), and very frequently the testicle. Specific urethritis stands first in order in the causation of epididymitis. The introduction of a sound or catheter, the lodgment of a calculus in the urethra or prostate, stricture, cystitis, and prostatitis may also cause this disease.

The *symptoms* of acute epididymitis are a sense of uneasiness or pain, varying in intensity in the organ affected, or in the cord or groin. It is increased by pressure, when the erect posture is assumed, or in walking.

In severe cases a chill or rigors occur, followed by a marked rise in temperature. Upon inspection there will be more or less induration along the posterior border of the testicle, with heat, redness, and tension. The testicle is more or less enlarged, and very frequently there is a serous transudation into the cavity of the tunica vaginalis testis.

The pathological changes consist chiefly of hyperæmia and infiltration of the connective-tissue framework with embryonic cells. The epithelial lining membrane is also thickened and injected.

The *diagnosis* depends upon the symptoms above given. The *prognosis* is usually favorable. One attack, however, predisposes to another. In some instances occlusion of the efferent apparatus results from contraction of the products of inflammation, and sterility follows. Spermatic fistula may result. As before stated, the prognosis is more serious when the globus minor is involved.

The *treatment* consists in the administration of saline laxatives in order to empty the alimentary canal. The patient should be placed upon his back, and the inflamed organ supported by either a three-cornered pillow between the thighs, or a towel pinned around both thighs just below the base of the scrotum. Upon this a small bladder filled with crushed ice may be placed, and the inflamed organ allowed to rest upon it. If cold is not grateful, warm cloths or a poultice may be substituted. The application of from three to six leeches will at times relieve the local congestion.

Usually rest in bed will alone suffice to effect a cure. In some instances operative interference is indicated.

The Testicle

The Testicle.—Wounds of this organ do not demand especial consideration. Hernia of the tubules not infrequently occurs from incision or puncture of the tunica albuginea. Reduction is practically impossible. The protruded portion should be tied off with a catgut ligature, the excess of substance beyond the thread cut off, and the organ returned to the normal position.

Inflammation of the testis (orchitis) may result from direct violence, from the extension of an epididymitis, or from metastatis. Orchitis is met with as a symptom of "mumps," but the relation between these two processes is not understood.

The *symptoms* are enlargement of the organ, with pain usually intense in the acute variety. The swelling is slow on account of the great resistance offered by

the tunica albuginea. The skin over the organ is tense and reddened, and at times œdematous, especially when an epididymitis precedes the inflammatory process in the testicle.

In severe cases gangrene may ensue, and the tunica vaginalis and scrotal walls may become involved. In mild cases the *pathological* changes are chiefly hyperæmia and the formation of a limited amount of embryonic tissue along the blood-vessels and in the connective-tissue septa of this organ. In the severer forms this process is greatly exaggerated, and as a result of the extensive hyperplasia the circulation is arrested, and death of the tubular structure ensues. Or, if gangrene does not occur, atrophy of the excretory apparatus follows as a result of contraction of the products of inflammation. In some instances the swelling subsides, leaving no marked changes in the organ.

Prognosis.—Mild cases, especially in the forms occurring with urethral epididymitis, generally terminate in one or two weeks in recovery and restoration of the organ to its normal condition. In cases where the symptoms are severe from the start, the prognosis is grave unless early relief is afforded, and even then it is not always favorable.

Treatment.—Rest in the dorsal decubitus should be insisted upon in even the mildest cases, for not infrequently dangerous orchitis is provoked by neglect of this precaution.

The position of the testicle should be elevated, as in epididymitis. The local application of cold is grateful and advantageous in most cases. The organ is, however, so sensitive that no pressure is tolerated. This can be obviated by making a ring of cloths wrapped around a small hoop, leaving a lumen large enough to include the scrotum and penis. The ice-bag is laid upon this ring, which prevents any pressure upon the testicle.

When the effusion is rapid, causing dangerous tension of the fibrous capsule, surgical interference is imperative.

The operation consists in seizing the organ with the left hand, so as to render it steady and the skin tense, puncturing the scrotum and parietal layer of the tunica vaginalis testis, and thus subcutaneously making a series of incisions through the tunica albuginea on its anterior and antero-lateral aspects. The incisions should be about half an inch in length, and are much preferable to simple puncture.

The danger of hernia testis does not contra-indicate this procedure.

Chronic orchitis, not due to syphilis, is comparatively rare. When it occurs, it usually follows an acute inflammation. The pathological change consists in a thickening of the tunica albuginea and of the connective-tissue septa. Embryonic cells, collected in groups or nests, in various stages of development, are crowded along and around the blood-vessels and seminiferous tubules, as well as scattered about in the intertubular spaces. As the process continues, the tubules disappear under the pressure of the new products of inflammation. In a certain proportion of cases cysts form in the following manner: The peripheral cells of one or more foci of the embryonic tissue organize into connective tissue and aid in forming the investing capsule. The cells within this new capsule undergo granular metamorphosis, and later liquefaction, by absorption of fluid from the surrounding vessels. In other cases foci of suppuration (multiple abscess of the testicle) may remain from an acute inflammation and be present in chronic orchitis long after the acute symptoms have subsided. The contents of these foci may also undergo caseous degeneration.

The *symptoms* of chronic orchitis are those of progressive enlargement of this organ. In some instances pain is wanting, in others it is present, though less intense than in the acute form, while in a third category may be classed cases of chronic orchitis with intercurrent attacks of acute inflammation and the accompanying exacerbations of pain. The organ varies in size from two to four or five inches in its greatest diameter. Much annoyance may be occasioned by the dragging upon the cord.

The *diagnosis* is between hydrocele of the tunica vaginalis, inflammation of the walls of this cavity, with exudation and thickening and adhesion to the testicle,

syphilitic orchitis, and tuberculous testis. Hydrocele is easily excluded by fluctuation, translucency, and aspiration. In periorchitis with exudation and adhesions, differentiation will at times be difficult. The obliteration of the cavity of the tunica vaginalis renders the superficial tissues less freely movable upon the body of the testis. In orchitis the surface of the enlargement is smooth, spherical, and of like consistence at all points; often in periorchitis ridges of new tissue can be made out; there are soft spots or depressions which can be recognized by careful palpation.

If syphilitic orchitis is suspected (even if the history of this disease is denied), it will be advisable to administer the protoiodide of mercury and the iodide of potassium for several weeks. The marked diminution of the tumor will be confirmatory of the suspicion of the syphilitic dyscrasia. The extraordinary weight of a syphilitic testicle should be borne in mind.

Tuberculosis testis is usually preceded by the deposit of tuberculous matter in the epididymis. Pain in this affection, when uncomplicated by pyogenic infection, is insignificant and entirely disproportionate to the rapidity of the infiltration and enlargement. Moreover, orchitis and epididymitis may usually be traced to some direct and exciting cause which is absent in tubercular disease.

The indications in *treatment* are, first of all, to remove every cause of irritation, to keep up the tone of the system by judicious feeding and medication, and to support the heavy organ by suspension. When these measures fail to arrest the disease, or when the pain becomes so great that the patient's comfort is interfered with, or when the disintegration of the organ is threatened, castration may be entertained. Before carrying out such an extreme measure, the precaution should be taken to explore the organ through an incision in the scrotum, in order to determine its exact condition before removing it.

Tuberculosis of the Testicle and Epididymis.—True miliary tuberculosis of the testicle and epididymis is comparatively rare. Many cases which have been recorded as tuberculosis must, upon analysis, be classed with a non-tubercular inflammation, the embryonic tissue of which has undergone caseous degeneration.

Primary tubercular disease of the testicle is the exception. The epididymis is usually first invaded, and from this point the new tissue spreads into the testicle, and not infrequently along the vas deferens to the seminal vesicles, as well as to the tunica funiculi and tunica vaginalis testis.

While it may be slow in some instances, as a rule the invasion is rapid, occupying from two to eight weeks in a general infiltration of both organs. The *symptoms* are, upon the whole, obscure. One point of great diagnostic value is that the pain is entirely disproportionate to the rapidity and extent of the tumefaction. In simple orchitis and epididymitis, pain is extreme and pressure unbearable. In *tubercular* orchitis pain is, as a rule, slight, and may not be present at all. In a certain proportion of cases there will be sudden and recurring exacerbations of pain indicating a circumscribed acute orchitis the result of irritation from the presence of the cell elements of the tubercular process or a mixed (pyogenic) infection. Ulceration and the formation of fistulæ occur in a certain proportion of cases.

In simple orchitis and epididymitis the cord is not involved, while not infrequently in tuberculosis the deposit rapidly travels along the vas deferens. Grasped between the fingers, the tubercular organ is felt to be hard, and its surface uneven and nodular.

The initial morbid change is the deposit around the seminiferous tubes of clusters or nests of lymphoid cells. Within the tubes the endothelia are thickened and are undergoing granular or caseous metamorphosis. Later, the connective-tissue septa become infiltrated with the new cells. The process ends in compression and destruction more or less complete of the tubules. The centers of these clusters of cells farthest removed from the vascular network undergo granular or caseous metamorphosis, forming at times cystlike caverns, or at other times abscesses and fistulæ.

Treatment.—The prognosis of tubercular disease of these organs is so grave that when an early diagnosis can be made out, extirpation of the diseased tissues

should be considered. If only one side is involved, and the other organ is fully developed, there should be no hesitation in advising the operation of castration.

When the diagnosis is doubtful, it will be wise to keep the patient under constant observation, with especial regard to the advance of the disease along the cord, and when this is evident, and when there is no positive evidence of tubercular deposits elsewhere, extirpation is indicated in order to prevent invasion of the prostate and general dissemination. When both organs are involved, the question of complete castration may be submitted to the patient.

Enchondroma of the testicle is not altogether infrequent. It occurs most often after injury. While it is prone to originate in this organ, it may spread from the epididymis to the testicle. The volume of the organ varies, at times reaching a large size. Enchondroma testis, as with almost all forms of neoplasm seated in this structure, is apt to undergo cystic degeneration.

The *diagnosis* must be based upon the hard, elastic feel peculiar to this form of tumor.

The treatment is either expectant or operative, as circumstances may demand. Castration is indicated when the disease is unilateral, and when the size of the tumor is such that the function of the opposite organ is threatened. The mixed treatment should be thoroughly tested in all instances where the diagnosis is obscure.

Adenoma testis occurs chiefly from the twentieth to the fortieth year of life. It has so far not been observed during childhood.

The development of the tumor is usually rapid, attaining a diameter of three or four inches or more. Only one organ is usually affected. Pain is not a prominent symptom in the earlier history of this neoplasm, but, after the growth attains a sufficient bulk, it causes more or less pain by pressure and weight. To the touch it is soft and compressible. The formation of cysts in various portions of the neoplasm is frequent (cysto-adenoma).

Under the microscope the epithelia of the seminiferous tubules are seen to be swollen while their caliber is more or less completely occluded with the round cells of the new (adenoid) tissue.

The *prognosis* is not favorable, and the *diagnosis* difficult. Since the function of the organ is wholly impaired, and since the rapid development of the tumor is of itself an indication of the gravity of the lesion, the matter of exact recognition of adenoma is not important. In all of these rapid and threatening neoplasms, especially when a single testicle or epididymis is involved, the safest course is in early and prompt excision.

Carcinoma.—Both scirrhus and medullary cancer may develop primarily in the testicle or epididymis. The encephaloid variety is most frequently encountered. The microscopical characters of these different varieties of cancer will be given in the chapter on tumors.

Carcinoma of the testis is apt to occur about the age of puberty, although it may be met with later in life. One organ is affected, as a rule. It is more apt to begin in the testicle than in the epididymis. In the early stages of the development cancer of the testes is not painful, but as the disease advances the suffering may be intense. Early removal offers the only hope of cure, and this, unfortunately, is not great.

Sarcoma testis occurs at all ages, but is chiefly confined to childhood and early manhood. Following the general law of sarcomata, that of the testicle is rapid in growth, attaining at times an enormous size. This is one of the chief diagnostic points of this tumor, which is hard, usually pyriform in shape, and of comparatively smooth contour. Castration offers the only hope of relief.

It will be seen from the foregoing that accurate diagnosis of the various neoplasms which develop in the testicle is difficult and often impossible. Almost all of these morbid processes lead to destruction of the organ and loss of function, and immediately or remotely threaten the life of the individual.

Thus tuberculosis, adenoma, carcinoma, and sarcoma may be classed as malignant. Enchondroma, although not intrinsically malignant, leads to loss of function, and in this particular justifies operative interference. The same applies

with greater force to cystic degeneration of this organ, since cysts often develop in malignant neoplasms of the testicle. In view of these facts, when only a single organ is involved, it will be advisable in the early history of any neoplasm of this organ to consider the propriety of castration.

The operation is thus performed: Shave the scrotum and pubes, and make an incision extending from the external abdominal ring along the anterior surface of the cord and testicle to the base of the scrotum. When the morbid process involves the scrotal tissues, and even when there is a suspicion of involvement, the primary incision should be carried well away from the suspected tissue into the healthy structures.

Two points of importance are suggested in the removal of this organ. The first is to make an incision into the mass in order to clear up the diagnosis; the second is to secure the vessels by the ligature applied near the external ring, and thus prevent the danger of forcing septic or metatastic matter in the lymph channels or vessels leading toward the center. The cord should be exposed at the ring, the vas deferens isolated, and a large, double catgut ligature thrown around so as to include the entire cord except the vas deferens. This is twisted around the cord while the exploratory incision is being made, and, if the diagnosis is confirmed, the catgut is tied and the cord divided between the two ligatures. The diseased organ is then dissected out, the hæmorrhage arrested, drainage secured, and the wound closed with catgut sutures. A single dressing will usually suffice. When the vas deferens is divided, the accompanying artery should be separately tied.

Malposition.—One or both of these organs may be absent from the normal position in the scrotal sac. The descent from the abdominal cavity may be prevented by narrowing or closure of the inguinal rings, or the inner ring may be passed, the testicle being arrested at the outer opening, and thus imprisoned in the canal; or, passing both rings, it may lodge beneath the skin near the pubic crest, or in the perinæum or groin. Occasionally the testicle remains entirely within the abdominal cavity. Another rare form of malposition is when the organ is turned obliquely or crosswise in the scrotum.

Misplaced testicle does not usually give rise to great inconvenience until the approach of puberty, when its normal development is interfered with by compression. If it is lodged in the inguinal canal, where it is acted upon by muscular contraction, it may cause pain at an earlier period. The descent of a hernia upon a testicle thus imprisoned gives rise to considerable annoyance. An imprisoned testicle is occasionally the seat of a neoplasm. The symptoms are those of pain, neuralgic in character and the diagnosis must depend upon the absence of the organ from its normal place and its recognition in the position of the abnormal swelling. The author removed in one patient, two, and in another one greatly enlarged intra-abdominal testicle in which sarcoma had developed. Both recovered, and there was no symptom of recurrence after two years.

When one or both organs are imprisoned in the inguinal canal or more deeply situated, an effort should be made to bring them into the scrotum. An incision of sufficient length should be made over the inguinal canal, a little lower down than that for oblique inguinal hernia. The aponeurosis of the external oblique should be divided from the arch of the anterior ring upward in the direction of its fibers, far enough to thoroughly expose the canal. In this will usually be found the imprisoned testicle and the cord. By careful manipulation the cord and testicle should be loosened. Care should be taken to preserve the gubernaculum testis, which is finally divided as far as possible from the organ, namely, near the pillars of the external ring.[1] When this is done, the testicle can usually be brought down into the scrotum. The scrotal pouch should be enlarged and an incision from the outside made into its cavity. Through this incision, a dressing forceps, carrying a long strand of catgut, is pushed upward into the open wound, where it is temporarily fastened to the gubernaculum and then brought back through the opening in the scrotum. This loop aids in the downward traction of the organ, and if necessary may be used as a suture to hold it in position. When

[1] W. M. Brickner, "Amer. Jour. of Surgery," March, 1906.

the cord is so short that the testicle cannot be made to descend into the scrotum, it should be brought outside the external ring.

The inguinal canal is now closed after the method of Bassini, as in hernia. In certain cases it may be advisable to operate upon only one organ at a time, rather than subject the child to a long procedure.

When both organs are abnormally situated, one or both should be brought out of the canal and carried, if possible, into the scrotum.

Traumatic dislocation of the testicle may also occur. Dr. Ramon Guitéras [1] reported a dislocation of this organ into the loose tissues between the integument of the penis and the body of this organ. A successful reduction was made by a long incision which exposed the testicle, and was continued until the contracted tunica vaginalis testis was opened.

[1] "Medical Record," January 4, 1896.

CHAPTER XXXI

THE GENITO-URINARY ORGANS IN FEMALES

THE examination of the genito-urinary organs should be preceded by thoroughly emptying the bowels by purgation or colon irrigation, and by a warm sitz-bath, followed by irrigation of the vagina with a 1–3000 mercuric-chloride solution. The vaginal douche should be given with the patient upon the back, the thighs flexed and the pelvis resting upon a Kelly pad or bedpan, with the fountain syringe elevated sufficiently to give considerable force to the irrigating fluid. This should be as hot as the patient can comfortably endure, and should, by using a long tube, be carried directly into the deeper portions of the vagina. The examiner should wear sterile rubber gloves, or cots of sufficient length to entirely cover the fingers. It is always advisable to have a 1–1000 mercuric-chloride solution on hand for immediate disinfection in case of accidental contact with infectious material.

An anæsthetic may be required in rare instances where pain is severe or in very young subjects whose sensibilities may preclude an examination without narcosis.

The momentary inhalation of nitrous-oxide gas will always give a perfectly satisfactory anæsthesia for a brief examination.

The patient should be thoroughly covered with a sheet, and placed in either the dorsal or lateral (Sims) position. For the former, the sacrum rests upon the edge of the table, the legs are flexed on the thighs, and these are separated and flexed upon the abdomen, while the knees are steadied by an assistant. The finger, properly lubricated, is introduced at the *lower* angle of the vulva, and should be carried along the floor of the vagina. Contact with the sensitive surfaces of the upper commissure, nymphæ, or vaginal roof should, when possible, be avoided.

It is important to note the direction and size of the cervix uteri, whether any erosions or lacerations are present, and whether tenderness is evident from pressure on either side over the known locations of the tubes and ovaries, or in the median line, where the urethra and bladder are located. With the right hand on the abdomen just above the symphysis, by making steady downward pressure with the fingers, and counter-pressure with the index-finger in the vagina, the body of the uterus may be palpated, and its size and the direction of its long axis determined. If it cannot be felt by this effort, it may be inferred that the fundus is in the hollow of the sacrum, with *retroversion* or *retroflexion*. The insertion of an instrument with proper curve into the rectum will enable the surgeon to lift the fundus until it may be felt by the index-finger in the vagina or the hand upon the abdomen.

If a tumor should be present, this may be palpated between the two hands, and a mental note made of its mobility and consistence. If the uterus be immovable, the indications are that an inflammatory process has preceded the examination, leaving extensive adhesion after the acute symptoms had subsided.

In the lateral or Sims position the patient rests upon the left side, with this hip near the edge of the table, and with both thighs flexed upon the abdomen, the right overlapping and in front of the left. The left arm is drawn beneath and behind the patient so that the upper portion of the body rests well over upon the chest.

This position is generally selected for inspection of the vaginal wall and cervix after the introduction of the Sims speculum. This instrument, after being lubri-

cated, is inserted with the convex surface in contact with the recto-vaginal septum. It is carried in to its full depth and is held with firm backward pressure by an assistant. While atmospheric pressure dilates the vaginal tube and usually brings the cervix into plain view, it is advisable to lift the anterior vaginal wall with a narrow retractor in order to obtain as much light as possible.

Vulvitis may be *simple*, *follicular*, and *gonorrhœal*. *Simple vulvitis* is seen chiefly in children and young adults, and is due to local irritation or to the presence of decomposing discharges. It is characterized by redness, more or less swelling, with an itching or burning sensation during urination. The orifices of the labial glands are usually swollen and prominent.

The treatment consists in irrigation with warm sterile water or 1–5000 mercuric-chloride solution, followed by local applications with a mild astringent such as four-per-cent argyrol or borolyptol. Salves or ointments are objectionable, as they tend to occlude the follicles.

Follicular vulvitis is more apt to accompany a dyscrasia which carries with it a general low resistance, such as diabetes. The orifices of the glands are prominent, and acne-like pustules are seen over the surface, and the labia are very much thickened. Itching is a marked symptom. The disease is most frequently met with in women who have passed the meridian of life.

Treatment.—A careful urinary analysis and blood examination is essential, and any constitutional conditions which they indicate should be carefully treated. Locally the parts should be kept clean, and an application of an ointment containing five-per-cent carbolic acid or ichthyol will be beneficial.

Gonorrhœal vulvitis is unfortunately the most common form. The urethra is swollen, and there is present a purulent discharge. The clitoris, urethra, and labia are red and swollen, and the glands of Skene are unusually prominent. The glands of Bartholin, when involved, discharge pus freely. The pus examined by Gram's method will, under the microscope, reveal the presence of the gonococcus. In neglected cases inguinal adenitis is usually present.

Gonorrhœa in the female, while not infrequently confined to the vulva and meatus urinarius, may extend to the vagina, uterus, and tubes, and to the bladder. The symptoms of inflammation supervene, as a rule, rapidly after the contact, there being first noticed a sense of burning over the meatus and along the urethra, especially severe during and immediately after micturition. There soon follows a purulent and occasionally a bloody discharge from the urethra and vagina. The diagnosis of gonorrhœa in the female is not so easily made as in the male, since a vaginal discharge not specific in character may conceal the true nature of the disease. The discharge directly from the meatus is the most direct symptom of gonorrhœa.

Treatment.—The first essential is to impress upon the patient and attendants the danger of infection of the conjunctiva or of conveying the disease by any method from one person to another. Locally, the parts should be irrigated with 1–8000 permanganate-of-potash solution, or mercuric chloride 1–10,000. The vagina should also be thoroughly flushed with these solutions, and in extreme cases the urethra may be carefully irrigated, under no circumstances permitting the small soft catheter employed from going farther than the cut-off or constrictor muscle. This should be followed by the local application of a five-per-cent solution of argyrol. The warm sitz-bath and complete rest are indicated.

Specific infection of the vulvo-vaginal glands is often more marked on one labium. If the ducts remain patulous, infection may run its course and the glands resume their normal function. With occlusion of the ducts, an abscess usually forms, and requires incision and drainage. Cocaine anæsthesia will generally suffice in relieving these conditions.

If commenced early in the disease, the invasion of the uterus may be prevented; this is of vast importance since serious lesions (*pyosalpinx*, *sterility*, etc.) may result from infection of the uterus and Fallopian tubes.

Vulvo-vaginal abscess may be caused by gonorrhœal infection. Incision and drainage is indicated, and when by this method a cure is delayed, curettage or a clean dissection of the glandular tissues involved should be done.

Pruritus vulvæ is a distressing and often an obstinate disease. The sense of itching, burning, or formication may be felt at the vulva, in the vagina, or over the entire pudendal region. It is paroxysmal in character; the attacks may occur at all times, but more frequently are severest immediately after the patient goes to bed. This condition is met with in females of all ages, but is more apt to occur about the cessation of the menses. In addition to superficial lesions of the genital organs, displacement of the uterus, chronic inflammation of the vagina, or any disorder of the deeper organs, may cause pruritus of the vulva. The indications in treatment are to correct any existing pathological condition. Grailly Hewitt advises a mixture of one part of chloroform to six of almond oil.

Hernia of the labium may be recognized from the history of the case, the tumor having first been noticed above at the canal of Nuck, descending more or less gradually into the labium.

Cystic tumors here originate in the substance of the labium.

Hernia of the *ovary* is occasionally met with. The *diagnosis* may be made as follows: In hernia of the bowel or omentum an impulse will be transmitted on coughing; it may be reducible; it is first observed in the canal of Nuck, extending subsequently into the labium. A prolapsed ovary is painful on pressure, giving a peculiar sensation not met with in compression of a cyst or loop of intestine. The character of a cyst may be positively determined by exploration with a very fine and thoroughly aseptic hypodermic needle and syringe. An exacerbation of pain in a tumor in this locality, about the menstrual period, would suggest the presence of a misplaced ovary.

The treatment of hernia in the female is given elsewhere. A prolapsed ovary should be extirpated, and a cyst of the labium or canal of Nuck should be removed.

The vulva and adjacent cutaneous surfaces may be the seat of syphilitic, chancroidal, tubercular, and epithelial ulcers, of ulcers resulting from abrasions or fissures which have been in contact with gonorrhœal virus, a leucorrhœal discharge, or the urine; and of warty excrescences (condylomata) and sarcoma.

The primary lesion of *syphilis* and the *chancroidal ulcer* in this location do not differ materially from those elsewhere given. *Tubercular* ulcers follow a chronic course; they are irregular in outline, and are characterized by a deeper infiltration of the subcutaneous tissues than in the acute forms of ulcers. *Epithelioma* of the vulva possesses the same characteristics as given for this condition on other mucocutaneous surfaces. Condylomata have already been considered. Epithelioma and sarcoma of the vulva are occasionally met with and demand early and wide removal with the knife.

Treatment.—A typical syphilitic ulcer requires no local treatment. When an ulcer of this region takes on a phagedenic character it should be at once thoroughly cauterized with the red-hot wire or Paquelin's cautery. If these agents cannot be employed, pure nitric acid will suffice. The injection into the tissues beneath and around the ulcer, of a two-per-cent solution of cocaine hydrochlorate, renders the free use of the cautery painless. After destroying the ulcer, an ointment of cocaine hydrochlorate, gr. ij; iodoform, gr. j; morph. sulph., gr. ss.; olei theobrom., q. s., may be applied as an emollient local anæsthetic.

Lupoid or *tubercular* ulcers should be dissected out, or deeply injected with pure liquid carbolic acid, until sloughing is produced. Mild forms of this ulcer may be cured by scraping with a sharp spoon or ring-scoop, and repeating this procedure at intervals of two weeks, until cicatrization ensues. *Epithelioma* and sarcoma should be freely excised. Arsenious acid may be successfully applied to epithelial cancer which has not extended too deeply within the vagina. *Papillomata* may be radically destroyed by clipping them off with curved scissors and burning the stump with nitric acid. In all forms of ulcer of the vulva complicated with vaginal discharge, repeated irrigation of this canal with warm sublimate solution (1–5000) should be practiced.

Vulvitis from direct injury should be treated by complete rest, aided by the sitz-bath of warm water and by emollient applications.

Among the acute surgical lesions of the labia which may call for operation are

hæmorrhage from wounds, and hæmatoma due to contusions, or to rupture of a blood vessel from an erosion (chancre, etc.).

Incised or *lacerated* wounds of the vulva are frequently accompanied by profuse hæmorrhage, especially when the venous plexuses which compose the *bulbs of the vestibule*, on either side of the vaginal orifice, or the large *connecting veins* which extend upward to the clitoris, are divided. Incision or rupture at or near the median line, the *posterior commissure* of the vulva, is not followed by hæmorrhage, as a rule, since the vascular network does not extend so low.

Bleeding may be arrested by direct compression with a pledget of gauze or lint, or, in case of extensive injury, by the ligature.

Contusions of this part of the genital apparatus may be followed by *hæmatoma* or *abscess*. Hæmatoma also occurs in rare instances in pregnant women from overdistention and rupture of the veins without direct violence.

In this variety of swelling operative interference is not advisable, unless the tumor is so large that it seriously interferes with the comfort of the patient, or

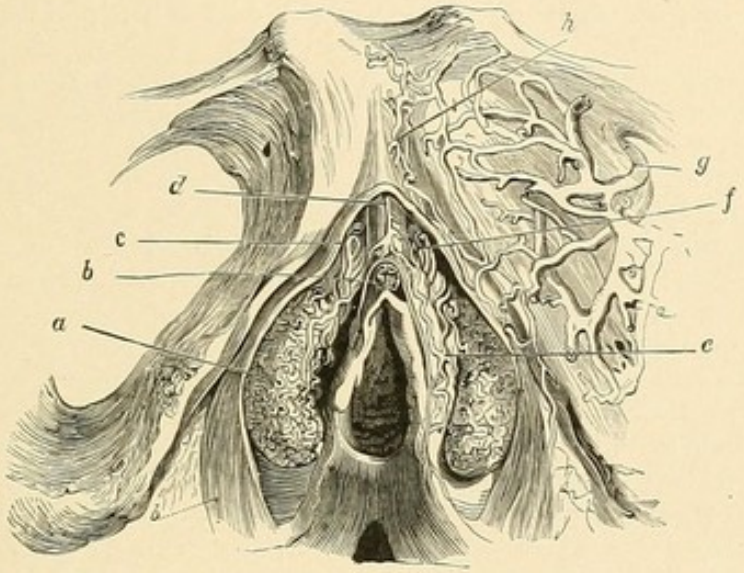

FIG. 615.—Showing arrangement of the erectile tissue and venous plexuses about the vulva. *a*, Bulb of vestibule. *b*, Clitoris. *c*, Connecting veins. *d*, Dorsal vein of clitoris. *e*, *f*, Deeper veins. *g*, *h*, Communication between obturator and vulvar vessels. (After Quain.)

unless sloughing is imminent or suppuration supervenes. *Boils* are not infrequent in this same location, and require to be opened, kept clean by constant care, and when sluggish in healing should be touched thoroughly with lunar caustic.

As a result of injury, and occasionally as a congenital affection, *adhesions* of the labia exist.

Adhesions of the *clitoris* are very frequently seen and should be broken up, since the retained secretion tends to decomposition and always produces a very annoying irritation. This may be accomplished by putting the parts on the stretch between the thumb and finger and using a dull-pointed instrument—such as a grooved director—for tearing through the adhesions.

Elephantiasis, not due to the presence of the filaria, is another of the rarer surgical diseases of the external genitals. The mass usually assumes a sessile shape, and appears to be an aggregation of hard nodules. It should be treated by excision.

Vaginitis.—By reason of its thick protective covering of squamous epithelium, the vaginal mucous membrane is not easily infected. While the gonococcus may find lodgment here and produce inflammation, the most frequent cause of vaginitis is the presence of an irritating septic discharge from the cervix uteri. It is more apt to be severe in the young than in the middle-aged and old.

Treatment.—As a cleansing and palliative measure, irrigation with a 1–8000 permanganate-of-potash or 1–10,000 mercuric-chloride solution should be made two or three times a day. A cure cannot be effected without dealing directly with the

focus of infection in the cervix or cavity of the uterus when the disease has passed beyond the internal os.

When ulcers occur upon the vaginal wall, they should be touched with a ten-per-cent solution of argyrol. In severe chronic cases, the vagina packed daily with five-per-cent iodoformized gauze wrung out of mercuric-chloride solution, 1–10,000, will bring the inflammation under control. It is imperative that the patient rest in bed.

There is a mild form of vaginitis which affects the aged, which is best treated by loose tampons soaked in lanolin or ichthyol. *Membranous vaginitis,* which is a complication of puerperal peritonitis, will be given elsewhere.

Endocervicitis.—On account of the racemose glands which are found lining the cervical canal, this portion of the uterus is very frequently the seat of infection. It is especially liable to chronic gonorrhœal inflammation, which is by far the most common form of infection, and is often so obstinate that amputation is necessary to effect a cure. In gonorrhœal endocervicitis the follicles about the external os appear as elevated red papillæ, the cervix is enlarged and red, and is usually bathed in pus. These patients usually complain of a sense of weight in the pelvis.

Treatment.—Vaginal irrigation, as just advised as a palliative measure, should be practiced in this disease. The chief reliance, however, is upon local applications. In using these great care should be taken not to convey the infection to the cavity of the uterus. A pellet of cotton upon a probe moistened in mercuric-chloride solution, 1–5000, should be covered with iodine crystals and introduced to, not through, the internal os, making a thorough application of the iodine to the lining membrane of the cervical canal. The same application should be made to the vaginal surface of the cervix and a glycerine tampon inserted, or the deeper vagina packed with iodoformized gauze wrung out of 1–10,000 mercuric-chloride solution. This should be repeated every second day, giving frequent irrigations on the intervening day. Should the condition become chronic and obstinate, amputation is indicated.

In those cases where cysts are frequently observed upon the vaginal cervix, multiple puncture, followed by the application of iodine, may effect a cure. *Tuberculous* endocervicitis almost always requires amputation. As this is but a local expression of a constitutional condition, every means should be employed to improve the nutrition of the patient.

Vaginismus, or "spasm of the vagina," is chiefly due to an abnormally sensitive condition of the vaginal orifice. Vaginitis is not usually present. Upon introducing the finger, the *hymen* will often be found tense and resisting. An effort to carry the finger into the vagina will be extremely painful, and will cause spasm of the sphincter-vaginæ muscle.

Treatment.—Place the anæsthetized patient on the back, with the sacrum resting on the edge of the table, the thighs separated and held by assistants, and make



Fig. 615*a*.—Sims glass vaginal plug.

the antiseptic toilet. With the hymen exposed by holding the labia apart, seize this membrane with mouse-tooth forceps and dissect it out close to its vaginal attachments. Introduce two fingers, dilate the vagina, and with the knife make two parallel incisions on the lateral aspects of the vaginal wall throughout its length. These incisions should extend about through the vaginal wall. Then introduce the Sims glass vaginal plug (Fig. 615*a*), adjusting the instrument so

that the urethra will fit into the concavity on its upper surface. It should be removed in six or eight hours, the vagina irrigated and the cylinder reintroduced. After the first twenty-four hours it may be worn three or four hours daily. This should be kept up for two or three weeks, or until all trace of the vaginismus has disappeared.

If the glass plug cannot be obtained, a moderate packing of strips of iodoformized gauze will suffice. In mild cases simple digital divulsion of the sphincter-vaginæ muscle may effect a cure. It is occasionally associated with endometritis, ovaritis, and salpingitis, and cannot be relieved until the deeper lesions are cured.

Stricture of the Vagina.—Occlusion of the vagina may be *partial* or *complete*, and may be *congenital* or *acquired*. The diagnosis is readily made by digital examination or by inspection. Imperforate or partially obliterated hymen need not be mistaken for true stricture, when it is borne in mind that this membrane is situated just at the entrance to the vagina, while stricture proper occurs beyond this point in a large majority of cases. The exact situation of the obstruction may be readily appreciated by making a digital exploration of the rectum, thus locating the cervix uteri, while the other index-finger is introduced *per vaginam* as far as the stricture. In complete obstruction (*atresia*), the absence of the menstrual discharge should be considered in arriving at a diagnosis.

Treatment.—In partial occlusion, due to bands or a membrane, these should be divided or ruptured, a thorough dilatation accomplished, and the glass cylinder of Dr. J. Marion Sims introduced, as in the treatment of vaginismus. When there is a narrowness of this canal, without well-marked contracting bands, it will suffice to dilate with bougies, gradually increasing in size until a cure is effected. The operation may be repeated two or three times a week, or less frequently should any severe inflammation supervene.

When the opening is so small that the finger cannot be introduced, a probe-pointed bistoury may be carried through and the obstruction divided in several directions, after which forcible dilatation should be practiced.

When complete occlusion exists, the canal should be opened up by cutting through the adherent walls in the ascertained direction of the *cervix uteri*. By dilating the canal as wide as possible to the point of obstruction then locating the cervix with the index-finger of the left hand in the rectum, while the sound is kept constantly in the urethra and bladder as an additional guide, the dissection may be safely accomplished. The Sims glass cylinder should be employed in the after-treatment.

Endometritis.—Septic organisms usually find their way into the cavity and lining membrane of the uterus by the extension of a vaginal or cervical infection. The instances are extremely rare when they are conveyed by the blood or lymph channels. *Gonorrhœal endometritis* is one of the most serious of these infections, not only dangerous to life by inducing peritonitis, but almost always ending in the sterility of the individual.

The onset of this disease is marked by uterine cramps, at first intermittent, but later these may become almost constant. Deep-seated pain is felt as the tubes and peritonæum become involved. The temperature is elevated two or three degrees beyond the normal, with a corresponding increase in the pulse-rate. The patient rests upon the back, with the thighs flexed upon the abdomen.

The diagnosis can only be made positive by a careful search for the gonococcus by Gram's method.

Treatment.—In the majority of cases a cure cannot be effected. The gonococci find a lodgment in the deeper follicles and layers of epithelium beyond the reach of any local applications, and where, after the subsidence of the acute inflammation, they may lay dormant for months or years, only to reassert their virulence under conditions favorable to renewed proliferation. Irrigation of the cavity of the uterus with 1–8000 permanganate-of-potash or 1–10,000 mercuric-chloride solution is indicated as a palliative measure. The operative treatment will be considered with salpingitis.

Non-specific endometritis may follow any operative procedure upon the cervix or body of the uterus. It is usually of short duration although the infection may

travel along the tubes, and in patients of low resistance salpingitis and peritonitis may result, necessitating operative intervention.

Puerperal endometritis results from infection, usually at the placental attachment, as a result of the introduction of staphylococci or streptococci. It often follows criminal abortions or even a normal parturition, in which strict antiseptic precautions have not been taken. In women who have suffered from gonorrhœa, infection of the endometrium during or after labor may, in rare instances, occur notwithstanding the fact that the strictest antiseptic practice has been followed.

The lymphatics are the principal channels through which the infection travels toward the broad ligaments and the peritonæum. The venous sinuses may also be involved, infected coagula being not infrequently swept into the circulation, to form metastases in the various organs. From this incipient lymphangitis pelvic peritonitis ensues, which may become general. The formation of abscesses or small pus foci in the body of the uterus, ovaries, or Fallopian tubes may also occur.

This process of infection differs from that in gonorrhœa, *which travels along the mucous lining of the tubes*, to involve the peritonæum.

Symptoms.—Puerperal sepsis is usually ushered in by a chill or frequent rigors, with a rapidly increasing pulse-rate which is in general disproportionate to the rise in temperature, the latter rarely going higher than 102° in the early stages. Pain, as a rule, is not severe, although the uterus will be found tender upon pressure. In the more overwhelming cases of infection, the expression of the face is characteristic of a severe intra-abdominal lesion. Upon examination, the external and deeper genitals are swollen, with frequently a large area in the vagina covered by an inflammatory exudate. It is a wise precaution to have a careful laboratory examination made of this membrane, and any transudate found in the deeper portions of the vagina.

Albumen is apt to be present in the urine and careful attention should be given to the kidneys. The urine should be tested for albumen hourly, if necessary, and upon the first appearance of nephritis saline solution should be introduced either by opening a vein in the arm or by permitting the necessary quantity of normal salt solution to flow *slowly* into the colon through a small, soft catheter, introduced as in the method of treatment of general suppurative peritonitis advised by J. B. Murphy in the article on appendicitis. As a heart stimulant, alcohol in some form and digitalis seem to be most efficacious.

The prognosis will depend upon the virulence of the infecting organisms and the resistance of the patient. At times the onslaught is so overwhelming that death ensues from acute septicæmia.

When drainage of the endometrium has been secured and the patient's resistance is sustained by careful nutrition and hygiene, the symptoms subside within a few days and recovery takes place with the minimum of damage to the pelvic viscera.

The *treatment* of puerperal sepsis consists in a thorough cleansing of the endometrium, removing putrid or dead particles of placenta or blood clot with the least possible traumatism to the lining membrane. On account of the adhesion of these particles and shreds of the placenta, it is practically impossible to remove all septic foci by irrigation.

The cavity of the uterus should be thoroughly swabbed with five-per-cent iodoformized gauze and then loosely packed with the same material. Under no circumstances should a sharp curette be employed.

With the cervix patulous, this will secure the necessary drainage, while the presence of the iodine in the gauze assures the best possible antiseptic application. In severe cases it is advisable to make free incision through the posterior *cul-de-sac*, in order to drain off any septic serous transudate.

This operation is performed by seizing the posterior lip of the cervix with blunt forceps, making upward traction and cutting through with blunt curved scissors at the line of union between the neck of the uterus and the posterior vaginal wall. If the precaution is taken to cut to the extent of about half an inch in the middle line at the junction of the vaginal wall with the cervix, no danger

can be done to any of the structures. Through this opening the gloved finger is introduced into the peritoneal cavity, and the opening dilated laterally.

If adhesions have formed between the posterior surface of the uterus and broad ligaments and the intestines, they should be freely broken up with the finger, keeping the palmar surface close to the uterus and ligaments in order to avoid injury to the walls of the intestines. In separating these adhesions the finger should be carried well out to the pelvic brim on either side. With this accomplished and having removed all possible fluid and exudate, the patient should be placed in the extreme Trendelenburg posture. By lifting the anterior vaginal wall with a trowel retractor and by gentle pressure with a gloved finger or a gauze swab on long forceps, any adhering loops of intestine may be loosened and allowed to gravitate out of the pelvis. The pelvis is now packed through the opening in Douglas' *cul-de-sac* by the following method of the late Prof. W. R. Pryor: Five-per-cent recrystallized iodoform gauze is folded so as to make loose

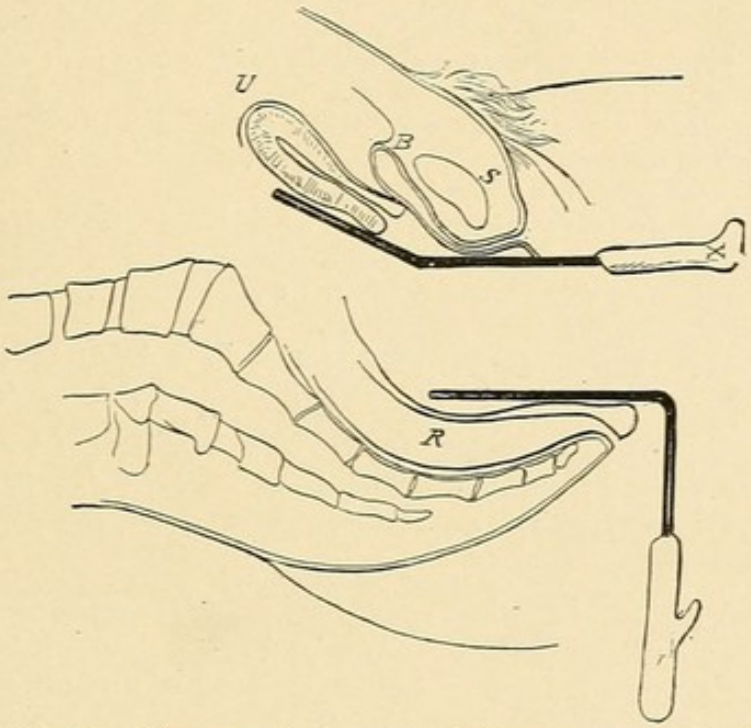

Fig. 616.—The Pean-Pryor trowels in position, lifting the uterus and bladder and depressing the rectum.

rolls about one inch wide and about one inch longer than the distance from the opening in the *cul-de-sac* to the top of the fundus of the uterus and the broad ligaments. These rolls, slightly flattened, are introduced through the vaginal incision, and carried upward laterally to the level of the broad ligament. Other pieces are placed side by side with these and held firmly until all are inserted, the whole making a dam or compress of gauze which entirely shuts off the pelvic organs from the general peritoneal cavity. In order to place these properly, it is best to use right-angle retractors, with long thin blades about one and one quarter inches wide. After the insertion of each piece of gauze, the retractor is withdrawn and pressed against the last piece inserted. The end of each gauze roll protrudes into the vagina. The loose packing of gauze in the uterus should be withdrawn after forty-eight hours. The *cul-de-sac* packing should be allowed to remain for one week, when it is withdrawn and two additional loose pieces inserted at this time to secure further drainage.

The precaution to be sure that no intestinal loops remain in the pelvis when this packing is inserted should be emphasized, since intestinal obstruction would almost inevitably ensue. Hence the necessity for exaggerating the Trendelenburg posture and the careful examination to determine the fact that no intestinal loops are caught by adhesion.

This second dressing should be changed every two or three days until the discharge has ceased and the wound is nearly closed, at which time the cervix is pressed backward and held by a transverse packing placed immediately over the anterior fornix. This packing is intended to bring the fundus forward and restore the uterus to its former position.

Salpingitis.—The most common cause of infection of the Fallopian tubes is the gonococcus; less frequently the streptococcus or staphylococcus. Such is the virulence of gonorrhœal salpingitis that the deep layers of tubular epithelia which line the tube are rapidly destroyed, the infecting process involving the deeper structures and the peritoneal covering.

Fortunately, the peritoneal opening of the tube is almost always closed by a rapidly formed exudate, thus encapsulating the septic focus. Should this not occur, the infection passes immediately into the peritoneal cavity, and a rapid ascending peritonitis results. When encapsulation occurs and an abscess forms, its contents may be discharged into the uterine cavity, to be drained off through the vagina.

In the earlier stages of infection the increased weight of the tube carries it into the deeper pelvis, often with the attached ovary, where both are apt to become permanently bound down by plastic lymph.

Symptoms.—Pain, which is increased when standing or walking, is one of the earlier symptoms of salpingitis. As a rule, the temperature is not markedly elevated unless general peritonitis has taken place.

In the diagnosis, careful attention must be given to the history of the case, and an examination made in order to discover any indications of a recent or remote gonorrhœal infection. Upon a vaginal examination, the fornices are found tense and pressure over the tubes is painful.

Treatment.—The palliative treatment is rest in bed in the Fowler position, with the application of ice-bags to the lower portion of the abdomen, and to this should be added vaginal irrigation with 1–10,000 warm mercuric-chloride solution. It is advised to keep the bowels open by free catharsis.

If at any time while these conservative measures are being tried there should develop well-marked symptoms of a further spread of the infection, an operation should be performed.

Operative Treatment.—The method of operating should be determined by the character of the infection and the conditions present. When a clean operation may be performed, the abdominal route with the patient in the Trendelenburg posture gives the surgeon the most complete command of the entire pelvis, enabling him to determine accurately by inspection the extent of the lesion and to operate with greater safety than can be done through a *cul-de-sac* incision.

When, however, an operation is urgent in an acute stage of salpingitis, where there is more or less widespread pelvic infiltration, a condition which usually demands drainage, a *cul-de-sac* operation is to be preferred. The procedure is identical with that described for drainage in puerperal sepsis. The tubes, as a rule, will be found near the opening, and may be felt surrounded by a varying thickness of lymph exudate, which may be readily broken up with the fingers.

The extreme Trendelenburg posture, with the legs and thighs flexed well upon the abdomen, will remove the coils of small intestines from the pelvis, and thus prevent their contact with any septic material to which they might be accidentally exposed by rupture of an abscess during the operation. When both tubes have been loosened, they may be seized with a pair of blunt forceps and drawn through the opening into the vagina, where they are clamped with long forceps close to their deep attachment, cut away with scissors, and the pedicle tied with No. 25 linen, and an iodoformized gauze pack inserted as described for puerperal sepsis. This should be removed in five or six days, and replaced with a smaller quantity of loose gauze, which is changed every three days until the wound is healed.

In chronic subacute salpingitis, the suprapubic incision should be selected, since it is often possible to remove all septic material, enabling the operator to close the abdominal incision without drainage.

If, during the operation by this incision, the surgeon finds drainage necessary, the *cul-de-sac* incision should then be made and drainage inserted here.

Ovaritis.—Primary inflammation of the ovary is an exceedingly rare lesion. Infection of this organ results almost always from the direct extension of a septic process from the tubes, body of the uterus, or peritonæum. In gonorrhœal endometritis it may be involved by direct contact with the fimbriated extremity of the Fallopian tube, since the infecting organisms reach the peritoneal cavity along the mucous lining of this tube.

Ovaritis from puerperal sepsis is caused by the transmission of the septic process along the lymphatic channel. There may be a general infiltration, causing the organ to become swollen, heavy, and spongy to the feel, with or without the formation of an abscess.

The treatment is a careful removal of the diseased organ. When exposed by incision, sterile mats should be carefully placed so that in case of rupture the septic contents may not come in contact with other organs. If any infection of the peritonæum has already occurred, it is a wise precaution on the part of the operator to drain as just advised through Douglas' *cul-de-sac.* Should both organs be involved, the question of drainage in the hope of preserving the functions of the ovary should be seriously considered.

Infection and abscess of the broad ligaments is not so serious as that of the ovary. Evacuation and drainage through the *cul-de-sac* is advised.

Deformities and Malpositions of the Uterus

Anteflexion.—In acute or well-marked anteflexion, the cervix occupies a relatively high position in the pelvis, owing to a contraction of the utero-sacral ligament, while the body of the uterus lies over the bladder close to the symphysis pubis. With the vaginal portion of the cervix in practically its normal relation to the axis of the vagina, the deeper portion, or internal os, is bent sharply forward.

This type of malposition or malformation of the uterus is frequently congenital and produces the dysmenorrhœa so common in younger women and those who have not borne children.

The chief subjective symptom is pain, which commences from one to four days before the menstrual flow, and is frequently so severe as to cause the patient to take to bed. When the flow is established the acuteness of the pain is less, and in a majority of cases it practically ceases with a free menstrual discharge.

Dysmenorrhœa is due not only to obstruction in the cervical canal, but also to a changed condition of the endometrium. This is evidenced by the nature of the menstrual discharge, which consists almost altogether of blood, while in the normal condition there is a large mixture of a transudate from the uterine lymphatics.

Treatment.—The operation consists in a thorough dilatation of the cervix either by the introduction of sounds, gradually increasing the size, or, when the cervix is unyielding, by first making an incision about one eighth of an inch deep on either side at the site of the internal os. This is best accomplished by inserting a curved probe-pointed bistoury into the cavity of the uterus, drawing the edge toward the side and making the necessary bilateral incision; or the dilator may be inserted and careful, forcible dilatation made.

Should there be the history of a persistent leucorrhœal discharge, it is advisable to make a careful curettage, after which a ribbon of iodoformized gauze should be inserted well into the cavity of the uterus, where it is allowed to remain for forty-eight hours.

The *after-treatment* consists in the introduction of a sound once or twice a month, in order to prevent a recontraction of the cervical canal. This is best accomplished by introducing under careful asepsis the ordinary curved male urethral sounds as often as required, or the cervical dilator may be employed.

Anteflexion of the uterus, as well as the narrowing of the cervix, is practically always benefited, and in many instances cured, as a result of gestation and parturition.

Retroflexion and Retroversion

Backward displacements of the uterus are also congenital and acquired. In the majority of instances there is a congenital defect which carries the fundus backward, and here, as a result of long-continued irritation, due chiefly to retained menstrual excretion, adhesions are apt to occur permanently, attaching the uterus to the peritoneal covering of the rectum and to the pelvic fascia.

For this condition the rational method of treatment is an operation preferably by the suprapubic route. When endometritis is present, a preliminary curettage should be done. The patient is then placed in the Trendelenburg posture and an incision made as for hysterectomy. This should be large enough to permit a careful inspection of the pelvic viscera, for a clear view is essential in preventing injury to the viscera in separating adhesions.

When this is done, all bleeding should be carefully arrested and an effort made to cover the raw surfaces left by separating adhesions with peritonæum. The uterus is now carried forward to as near the normal position as possible and held in place by shortening the round ligaments. The peritoneal surfaces of the round ligament which will come in contact when it is looped upon itself should be scraped with the scalpel or rubbed harshly with a gauze swab. It is then folded once or twice, as may be necessary to give the required shortening, and the loops stitched together with chromicized catgut or fine linen sutures.

When no adhesions exist, Alexander's operation is much simpler, since it is entirely extra-peritoneal: This consists of an incision which exposes the external abdominal ring, between the pillars of which and through the inguinal canal the round ligament makes its escape. By careful dissection this ligament is found and traction made upon the free end until the uterus is drawn well up toward the anterior abdominal wall. The round ligament is then stitched into the pillars of the ring in this new position, and the same procedure repeated on the other side.

If, as is not infrequent, salpingitis is a complication, or if there is any other lesion of the pelvic viscera, this should be subjected to operation before attempting to replace the uterus.

In properly selected cases, and especially in women who have passed the child-bearing period, and in whom the uterus is uncontracted and top-heavy, ventral suspension gives very satisfactory results in not only relieving the congestion due to displacement, but in giving increased support to the bladder.

In the performance of this operation an incision about two inches long is made in the median line beginning at a point about one and one half inches above the symphysis pubis, and is extended upward. The uterus is brought up, grasped by a vulsellum, and held in place while the sutures are inserted.

A large-sized half-curved Hagedorn needle is threaded with a strong suture of No. 3 chromicized catgut, and carried through the peritonæum from without in, entering half an inch from the cut edge. It is then inserted well into the muscular substance of the fundus of the uterus from one side to the other on its anterior aspect, the needle coming up through the peritonæum of the opposite side in the same relative position as that at which it was entered. This suture is repeated half an inch farther up, the needle this time traveling through the posterior aspect of the fundus. The peritoneal surface of all that part of the uterus which, when the ligatures are tightened, will be brought in contact with the peritonæum of the abdominal wall is now scarified with the point of the scalpel.

The peritoneal incision is closed with a running suture of ordinary catgut, after which the two suspension sutures are tied and the ends cut away. The wound is then closed in the ordinary manner.

Lacerations of the Vagina and Perinæum

These lesions in practically all cases result from parturition. A careful examination should be made immediately after delivery, in order to determine the

extent of any laceration which may have occurred, and if a tear is present, it should be repaired at once unless operation is positively contra-indicated by the condition of the patient.

Irrigation of the vagina with hot 1–3000 mercuric-chloride solution will tend to arrest oozing and assure a more thorough asepsis. If the rectovesical septum is extensively torn, salt solution should be used. If necessary, packing with a ribbon of gauze will arrest the bleeding from the cervix, which otherwise would cloud the operative field. The ribbon gauze is preferable, for the reason that it can be drawn out, as one unwinds a spool of thread, after the operation is completed, and does not subject the line of sutures to any strain.

In the ordinary superficial recent lacerations of the perinæum, after thorough cleansing silkworm-gut sutures are inserted, beginning at the upper angle of the tear. The needle is introduced about one quarter inch from the margin of the wound, taking a deeper hold if the tissues have been badly bruised. It emerges at the bottom or deepest portion of the wound, is immediately made to reënter beneath the lacerated surface, is brought out again at a point on the vaginal mucosa corresponding to the point of entrance.

The second suture is introduced about one third inch below this, with its loop directed toward the operator, and so on until the wound is closed. It is at times advisable to insert intermediate sutures of fine chromicized catgut. If, as is usually the case, an external tear is associated with an internal, the opening remaining on the skin surface is now reduced to a shallow pit, and is readily approximated by a few additional superficial sutures. Each suture should be tied as it is introduced.

These sutures should be removed about the tenth day. In the after-treatment Dr. Howard A. Kelly advises that the use of the catheter be avoided if possible, and that the bowels be opened within two days after the operation. In order to prevent too great strain upon the sutures, colon irrigation is advised.

The patient should remain in bed from two to four weeks, in order to secure a firm union before the tissues are subjected to any great strain.

Complete rupture of the recto-vaginal septum is fortunately a rare occurrence. It is frequently due to breech and other abnormal presentations, practically all of which are convertible into the normal by a careful study of the position of the fœtus within the last few weeks of pregnancy.

Complete rupture, however, is possible with a normal presentation when the head of the child is unusually large or when the tissues of the outlet are contracted and unyielding. An operation is demanded as soon after the accident as the condition of the patient will permit.

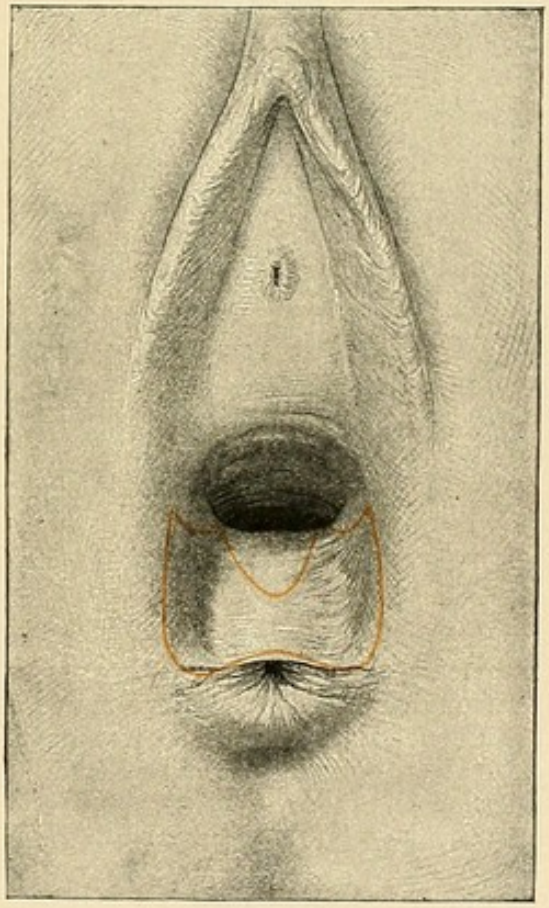

Fig. 617.—Complete tear of the recto-vaginal septum of long standing. The sphincter pits are seen below on both sides of the rectal orifice, the shortened sphincter muscle is much thickened, and there is a characteristic pit just below it. The red line incloses the area to be denuded; it must not be forgotten that the triangles seen extending up into the vagina are greatly foreshortened. (Kelly.)

Beginning at the upper angle, a row of interrupted chromicized catgut sutures should be inserted upon the rectal side, uniting the rectal mucous membrane. The needle should be entered about one fourth inch from the torn edge and passed deep enough to engage in the submucous connective-tissue stroma. Each

suture should be tied as it is inserted. The ends of the torn sphincter muscle should be accurately approximated, and for this purpose one or two tension sutures of silkworm gut are required. They should be inserted deeply and in such a manner as to hold the divided muscular fibers firmly together. The vaginal sur-

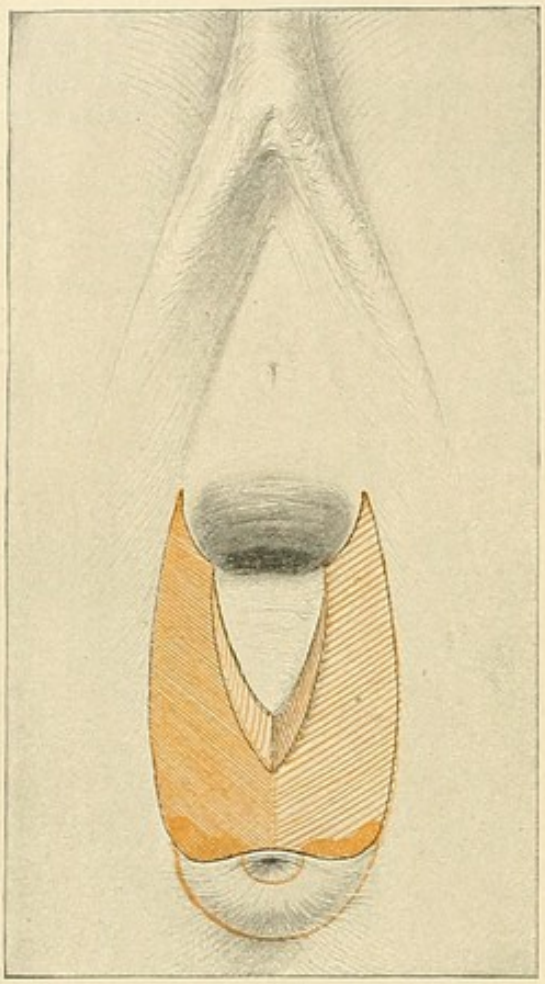

FIG. 618.—Complete tear of the recto-vaginal septum. Denudation completed. (Kelly.)

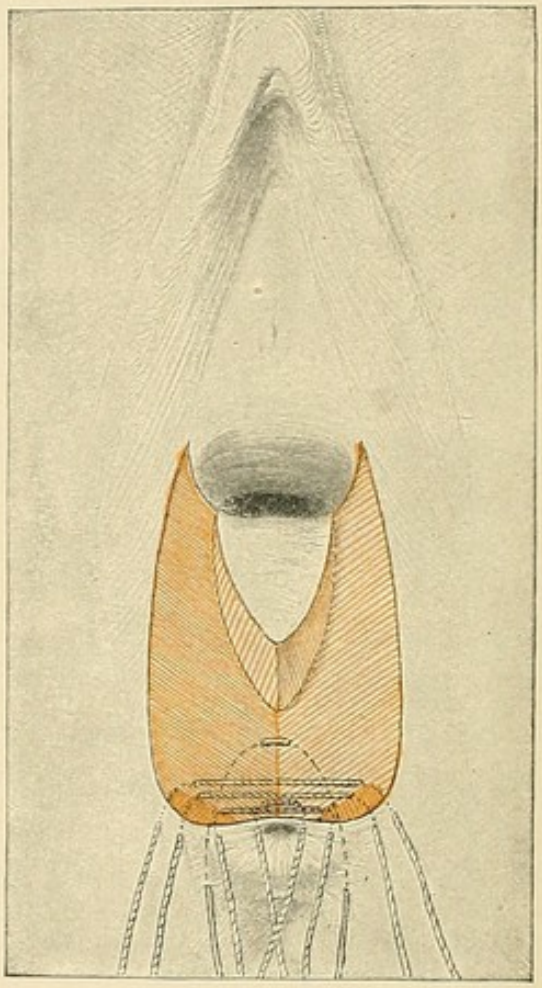

FIG. 619.—Complete tear of the recto-vaginal septum. Rectal sutures introduced, but not tied. Note the position of the silkworm gut tension suture introduced well behind the sphincter ends and passing up through the septum. (Kelly.)

face of the tear is now united from within outward by interrupted silkworm-gut sutures one third inch apart, inserted at sufficient depth to insure a firm hold laterally and to leave no tunnel or trough in the deeper portions of the wound.

Each suture should be tied as it is inserted, and, in order to insure a more perfect approximation, a few small chromicized catgut sutures should be inserted between the silkworm threads.

The bowels should be kept open from the start, softening the discharges by irrigation with warm water, to which sweet oil should be added. The sutures should be removed on the eighth or tenth day, and the patient should remain in bed for at least three weeks.

When operation has been delayed after complete rupture of the recto-vaginal septum, the changes which occur are such that a different procedure is necessary.

After a few weeks the torn surfaces are contracted, "forming a sharp ridge across the bowel, below which a few red folds of everted rectal mucosa project (looking like hæmorrhoids, and sometimes mistaken for them). In the absence of the perinæum, the rectum and vagina have a common outlet, or cloaca, characteristically pentagonal or triangular in outline. Notwithstanding this absence of the perinæum, prolapse of the vagina and uterus rarely occurs. This fact is irreconcilable with the view commonly held that the function of the perinæum is

to plug the pelvic outlet like a cork. The correct explanation is to be sought in the different locations of the tear; in most cases it extends up the median line, and only branches superficially into the sulci, leaving the lower fibers of the levator ani muscle uninjured. When, in rare instances, the rupture both passes through the perinæum centrally and extends deeply into one or both sulci, prolapse may occur.

"The sphincter ani muscle, in cases of complete tear, will vary in form, in different cases, from a simple broken circle, with its ends still bound together, all the way to a shallow arc, in which case the muscle is short and thick, with a deep dimple in the skin behind it. A smooth, glazed depression, at times puckered or pitted, at the lower angle of the perineal scar frequently serves as the sphincter landmark. It is sometimes difficult to identify the sphincter ends upon simple inspection, but by pulling on or pinching the muscle so as to stimulate a contraction, the position of the ends may always be discovered."

Dr. Howard A. Kelly,[1] from whose work the foregoing is quoted, gives the following operative technic:

After the bowels have been thoroughly emptied (preferably by medication and irrigation), in order to prevent contamination, sterilized gauze is pushed into the

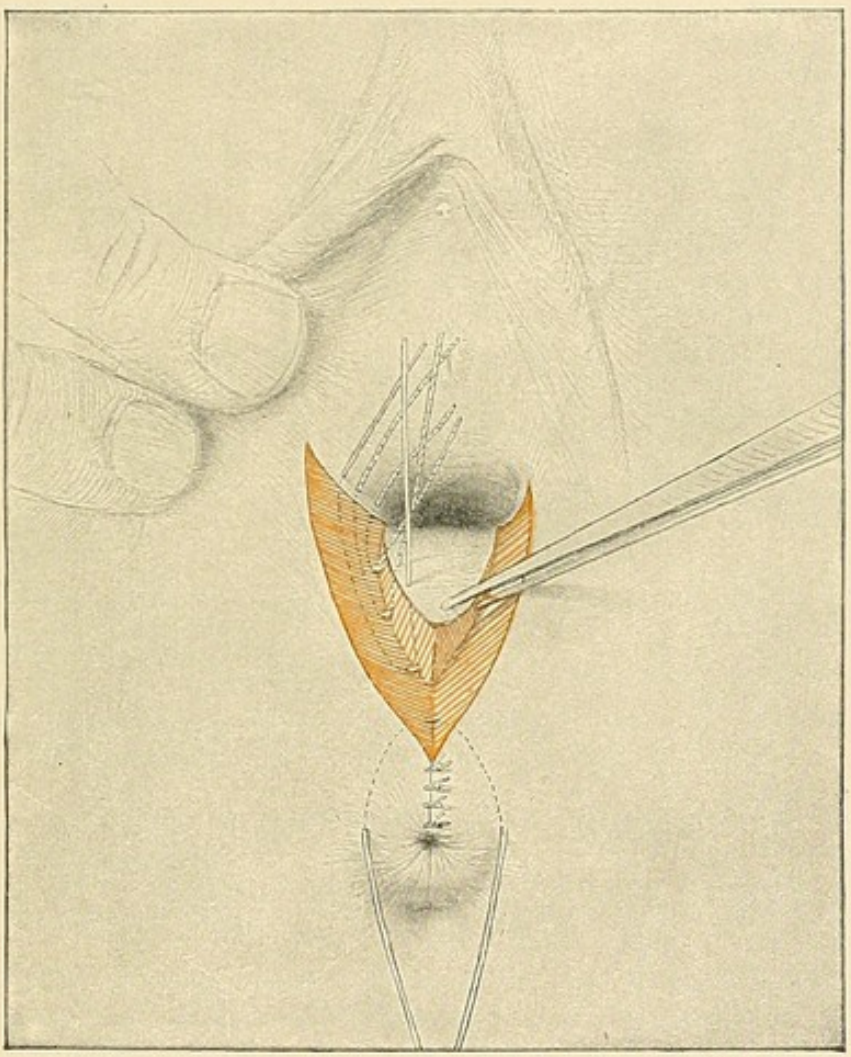

FIG. 620.—Complete tear of the recto-vaginal septum. The rectal sutures all tied except the silkworm gut tension suture. The sutures are introduced but not tied in the right vaginal sulcus, one of silkworm gut and two of catgut above it. (Kelly.)

lower bowel, which is plugged above the field of operation. (It is advisable to make the packing with a long ribbon of gauze rather than use this material in bulk, as the ribbon can be removed without putting the line of sutures on the

[1] "Operative Gynæcology." D. Appleton and Company, New York City.

stretch.) Fig. 617 gives the general appearance of an old case of complete rupture of the recto-vaginal septum. The posterior vaginal wall at the upper limit of the tear is here drawn down by contraction until it occupies the position of the normal perinæum.

The area of denudation required is outlined in Fig. 617, and in Fig. 618 it is shown as completed. The incision is begun by splitting from side to side the thin edge of the septum, which runs crossways just over the anal aperture. This

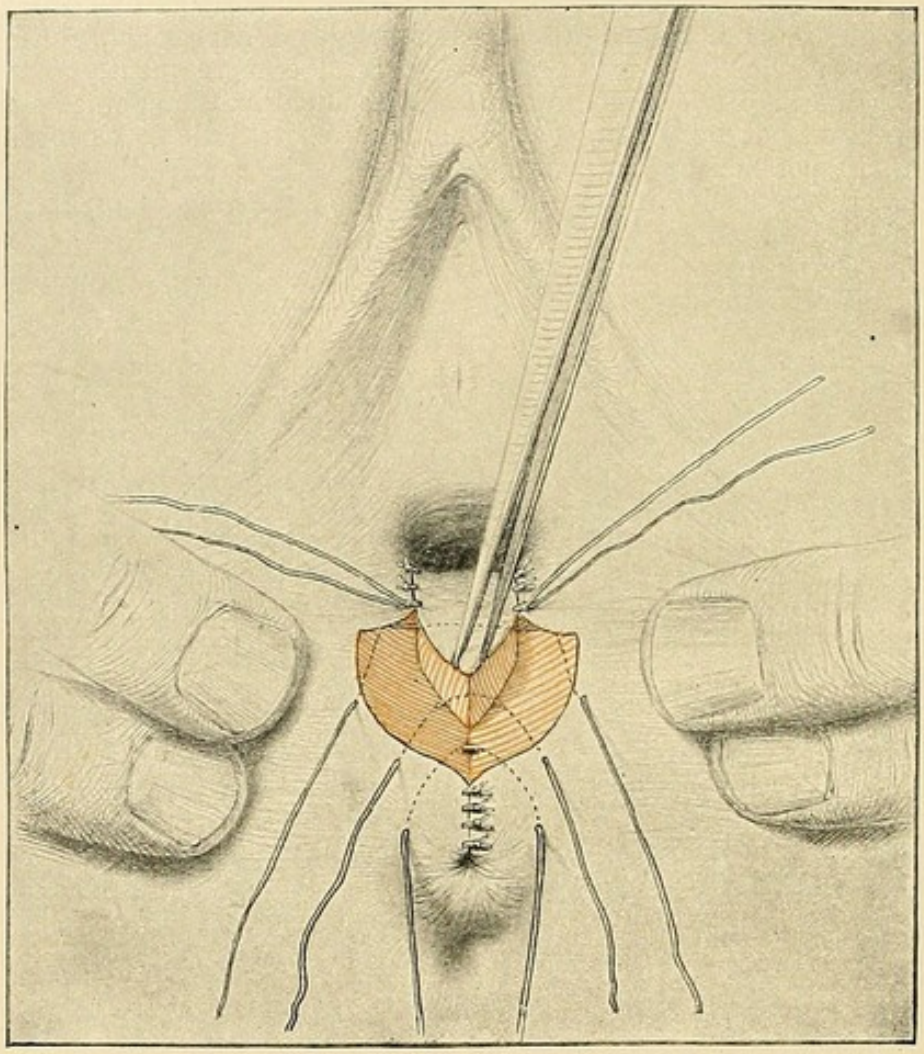

FIG. 621.—Complete tear of the recto-vaginal septum. Rectal and vaginal sutures all introduced and tied, and the perineal sutures in place, but not yet tied. (Kelly.)

incision is then continued upward in the direction of the upper surface of the vaginal opening as shown in Fig. 618. The angle of denudation, however, extends much farther upward than is indicated in the drawing. All of the mucous membrane, together with all scar tissue, within the limits of this incision is removed by the forceps and scissors (Fig. 618).

The manner of inserting the various sutures is shown in Fig. 619 *et seq.* The material used is silkworm gut and chromicized catgut. For the rectal side of the tear only the catgut is used, while silkworm gut is preferred for the vaginal surface and for uniting the ends of the sphincter.

"The complication of the torn bowel is first disposed of by a series of interrupted rectal sutures, commencing at the upper angle of the tear, entering each suture at the margin of the rectal mucosa, and emerging on the wound surface about two fifths of an inch distant, reëntering on the opposite side and coming out again on the margin of the mucosa at a point corresponding to that of entrance. This suture may be tied at once and dropped into the rectum, and so on every fifth of an inch until the whole of the rectal rent has been obliterated down

to the sphincter. It is exceedingly important to secure an accurate approximation of the sphincter ends by two or three sutures radiating from the rectal out on to the skin surface. The contractions of the sphincter render it necessary to assist these sutures with one of silkworm gut introduced well behind the denuded ends and passing up through the septum (Figs. 619 and 620).

"The next step is the repair of the vaginal wound by a silkworm-gut suture in either sulcus (Fig. 620), reaching down to the series of rectal sutures at the bottom of the wound. The loop of the suture should lie in a plane nearer to the operator than its points of exit and entrance, so as to lift up the tissues at the bottom of the wound when it is tied (Fig. 621). Superficial and half-deep catgut sutures complete the union within. There still remains an opening on the skin surface, which is readily brought together by a silkworm-gut suture, aided by a few superficial or half-deep catgut sutures" (Fig. 622).

The after-treatment is the same as just given.

Quite frequently in women who have borne a number of children there is, without a recognizable rupture, such a wide relaxation of the vulvo-vaginal outlet

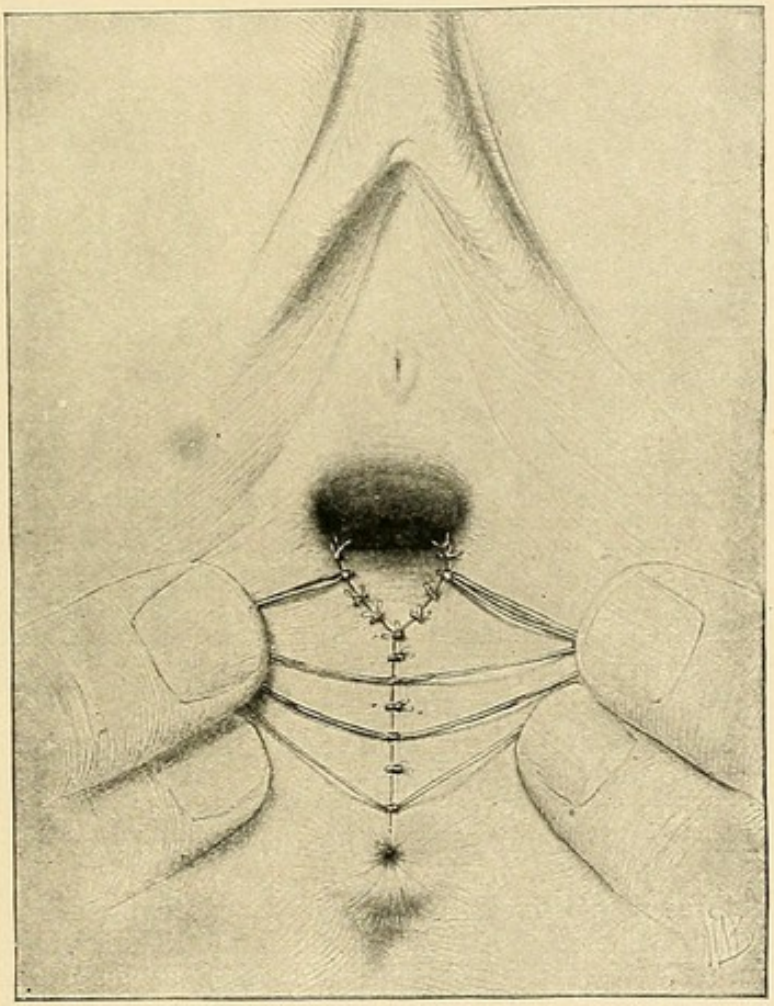

FIG. 622.—Complete tear of the recto-vaginal septum. All three sets of sutures introduced and tied, the catgut suture cut off and the silkworm gut left long. The outlet is pulled open a little in order to show the inside suture. (Kelly.)

that prolapse of the uterus, or rectocele or cystocele occurs. Either of these conditions require operation, as given by Dr. Howard A. Kelly.

"It is necessary to exaggerate slightly the effect of the operation in narrowing the vagina in order to counterbalance a slight relaxation which always follows.

"The first step is to determine the limits of the denudation; this is done by means of two tenacula shaped like a shepherd's crook, fixed on either side at the junction of the hymenal ring, or its remains, leaving sufficient tissue across the anterior vaginal wall between the tenacula to make a small outlet when the tenacula

are brought together. These points mark the upper lateral limits of the resection (Fig. 624). If they are fixed too near the urethra, too much tissue will be removed and the new outlet will be too contracted; on the other hand, if they are fixed too low down, the new outlet will continue to be too large, notwithstanding the

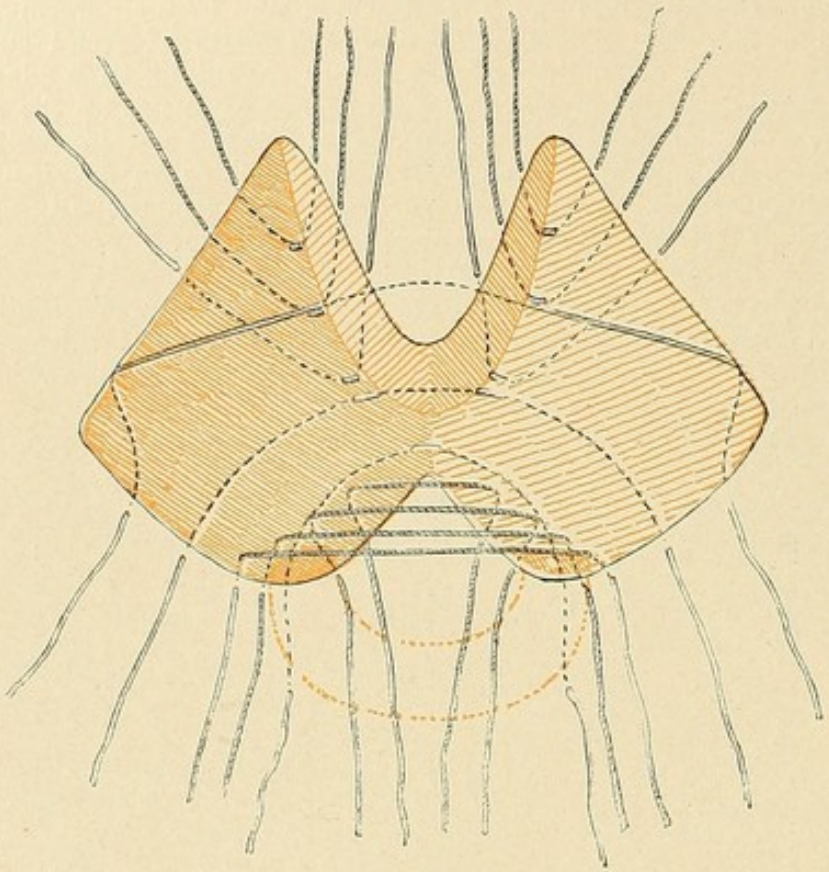

FIG. 623.—Scheme of the operation for complete tear of the recto-vaginal septum laid on a flat surface. The torn sphincter muscle is indicated by dotted red lines cross-hatched at each end. The deep indentation on the under side of the figure represents the rectal side of the tear, and the two red triangles above, one on each side, represent the denudations extending up into the vaginal sulcus. The sutures are passed first on the rectal side, *A*, radiating out into the perineum, then in the vaginal sulci, *B*, and finally on the perineal side, *C*. The cross-marked sutures are of catgut and the plain ones of silkworm gut. Note especially the silkworm gut sutures passed in behind the sphincter ends and up into the septum. (Kelly.)

operation. The correct pattern to have in mind in resecting is the nulliparous outlet.

"A third tenaculum is now fixed in the vagina in the median line posteriorly, on the crest of the vaulted prominence of the rectocele or posterior column (Fig. 625).

"With these three points fixed, the area of denudation must now be outlined with a sharp scalpel. The bloody outline obviates the liability to error in a free-hand denudation. No one pattern will fit all cases, as an excessive relaxation requires a more extensive resection than one of moderate degree.

"The surface to be denuded is irregular in outline and occupies several planes, making it difficult to represent it adequately in a picture. In making the outline the central tenaculum and one of the lateral tenacula are drawn widely apart, downward and outward, exposing one of the vaginal sulci. If there be a moderate degree of relaxation the apex of the triangle outlined in each sulcus is situated three centimeters (one and one fifth inches) within the outlet. By depressing the convex posterior vaginal wall a distinct line will be seen at the juncture of the anterior and lateral walls. An incision should be made down to the lateral tenaculum through the vagina, parallel to and just below the anterior wall. From the same point within, the second side of the triangle is made by an incision down to the tenaculum at the crest of the rectocele. A narrow triangular undenuded

area remains between the two triangles thus formed in the sulci (Fig. 626). The outline is now completed by a semicircular incision extending around the posterior wall, keeping within the hymen above, but embracing any scar tissue seen below. The center of this line falls three to four centimeters (one to one and one half inches) below the tenaculum fixed in the posterior column. The area thus outlined is rapidly denuded with Emmet's right-curved scissors, removing the whole thickness of the vaginal walls in long strips three to four millimeters (one tenth to one fifth inch) broad. At first the strip of tissue follows the line of the incision down to the apex of one of the triangles; then it continues back, and is carried to and fro across the front, and up into the other triangle; frequently the whole outlined

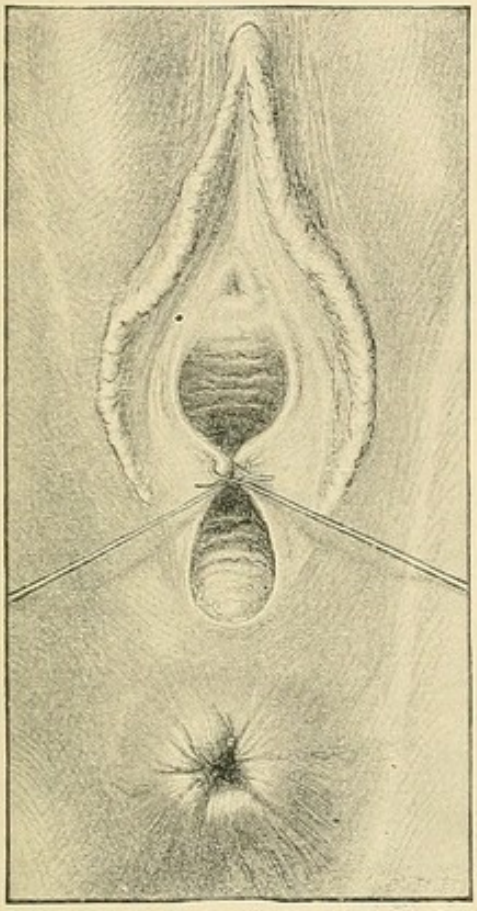

FIG. 624. — Relaxed vaginal outlet. Shepherd's-crook tenacula fixed in both sides just within the hymen, mark the limits of the denudation. The tenacula are crossed to show the size to which it is proposed to reduce the reconstructed outlet. (Kelly.)

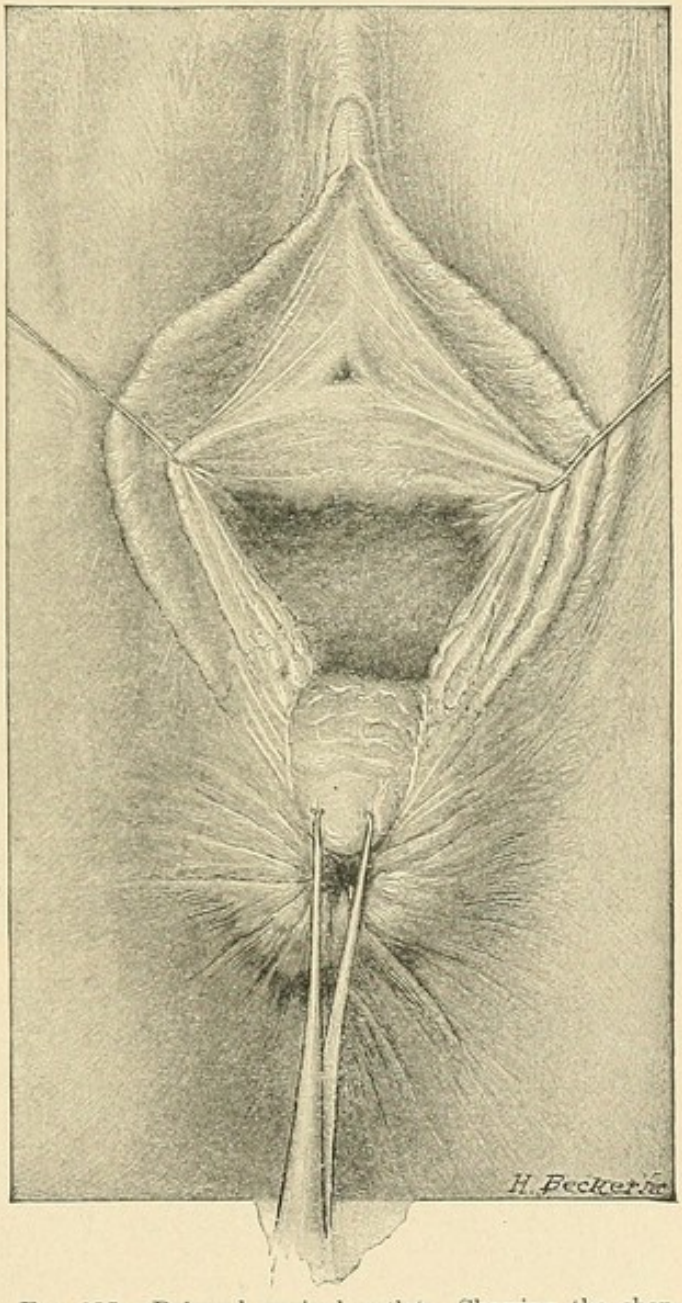

FIG. 625.—Relaxed vaginal outlet. Showing the shepherd's-crook tenacula fixed at the sides, below the urethra, and the tenaculum forceps drawing the posterior columna downward, so as to expose the lateral vaginal walls where the triangular denudations are made. (Kelly.)

area can be removed in a single strip. The dissection is often facilitated by running the ends of the scissors beneath the lax tissue on the floor of the vagina. Arterial and venous hæmorrhage from cut vessels is sometimes free, but the venous flow lasts only a short time, and ceases spontaneously. An actively spouting artery should first be clamped for a time in the artery forceps, and if it persists in bleeding after a few moments it may be tied with catgut. By judicious application of the deep tension and the approximation sutures, much hæmorrhage can be checked without the use of buried sutures at all (Fig. 627).

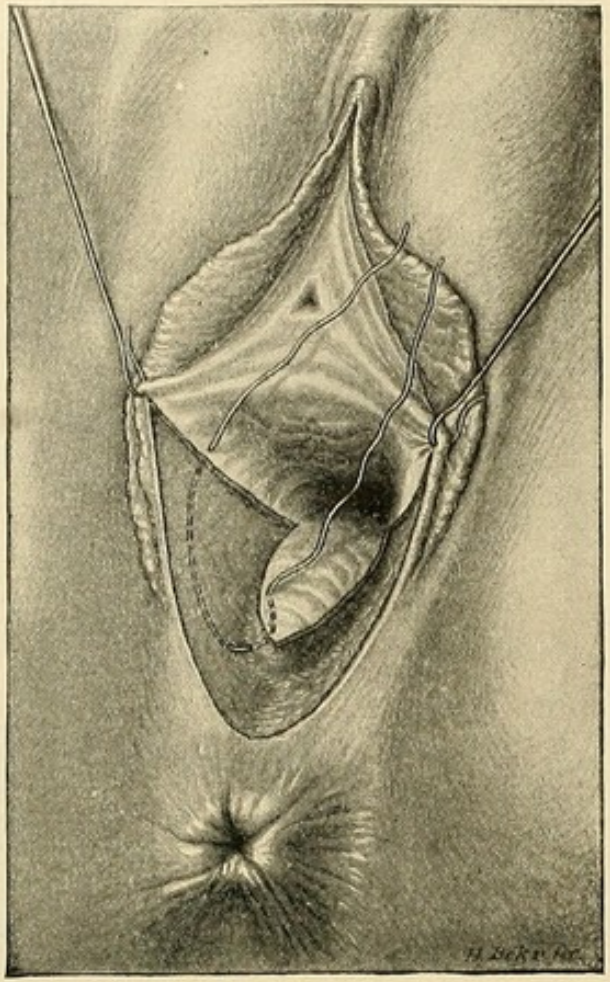

FIG. 626.—Relaxed vaginal outlet. The silkworm-gut tension suture is placed in the triangle on the right side. The dotted lines represent the part of the suture which lies concealed under the surface. The short piece of the suture visible as a white line at the bottom of the denudation is the part which is exposed by bringing the needle out at the bottom of the wound and reentering it close by. (Kelly.)

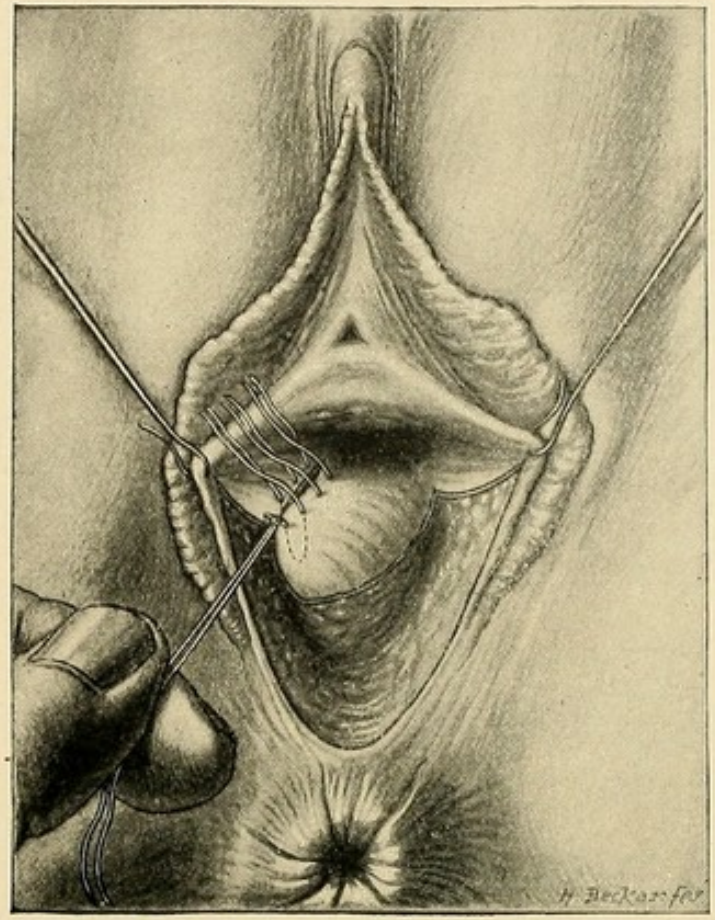

FIG. 627.—Relaxed vaginal outlet. The silkworm-gut suture is tied and pulled down, exposing the catgut sutures in place and ready to be tied, closing accurately the upper part of the denudation, already brought loosely together by the silkworm gut. These catgut sutures must pass deeply into the tissues so as not to leave a pocket in the wound below them. (Kelly.)

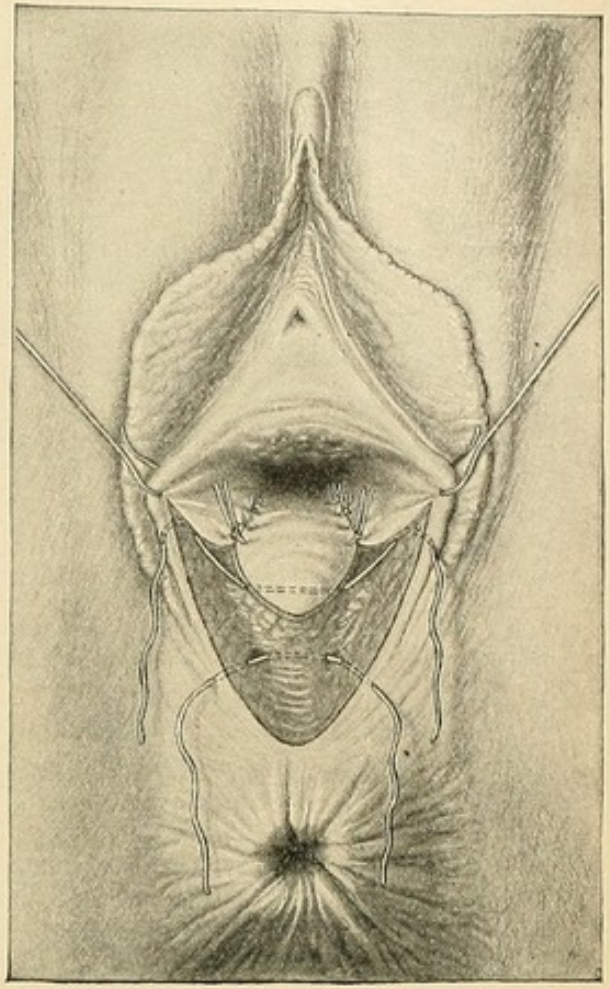

FIG. 628.—Relaxed vaginal outlet. The inside sutures are now introduced and tied in both sulci. The gathering suture of silkworm gut is introduced above across the angles, but is not tied. An auxiliary suture introduced to close the wound below this is also left untied. (Kelly.)

"The large wound area is now accurately approximated by means of from three to four silkworm-gut sutures, and from eight to twelve half-deep and superficial catgut sutures (chromicized). But one silkworm-gut suture is placed within the vagina, in either sulcus. An assistant exposes one of the triangular areas by drawing the tenacula at its base downward and outward; a carrier is entered upon the mucosa on the lateral vaginal wall near the incision, a little below the middle of the triangle, and carried under the tissue toward the operator, appearing at the bottom of the sulcus, considerably below the point of entrance; it is reëntered close by and carried in the reverse direction, finally emerging on the mucosa of the opposite side of the triangle (and opposite the point of entrance). A stout silkworm-gut suture, sharply bent upon itself, two centimeters (three quarters of an

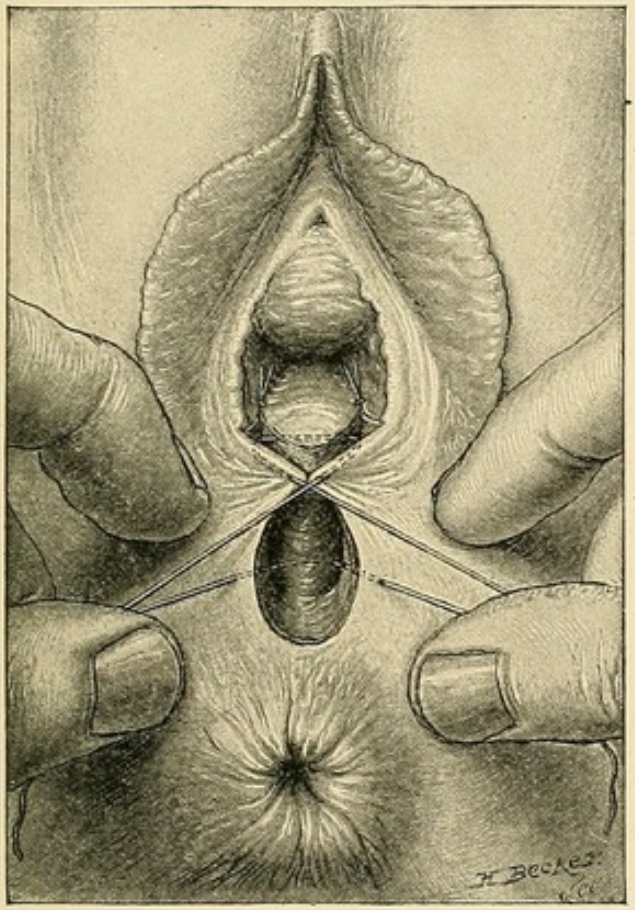

FIG. 629.—Relaxed vaginal outlet. Showing how the gathering suture above draws together the tissues. (Kelly.)

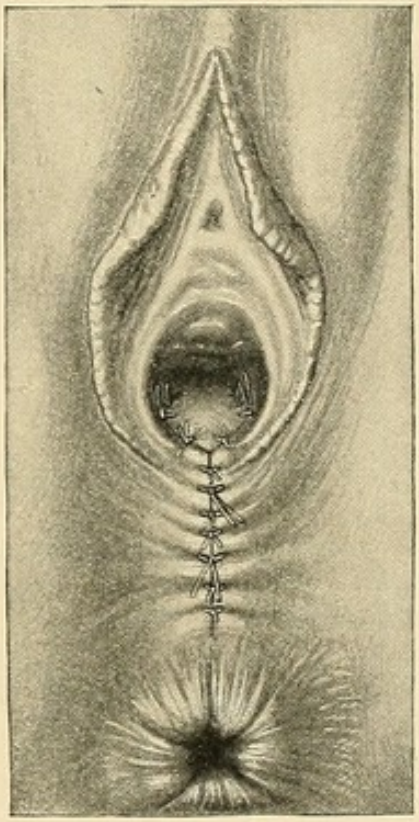

FIG. 630.—Relaxed vaginal outlet. Operation completed. The sutures with longer ends, two inside and two outside, are of silkworm gut; the others are all of catgut. (Kelly.)

inch) from the end, is hooked into the loop of the carrier and drawn through, then pulled up and tied in a square knot, care being taken to adjust accurately the edges of the wound before tying. The suture thus placed draws together a large area of tissue. To close the wound accurately above the suture, its ends are grasped between the third and fourth fingers, and by traction the upper part of the triangle is exposed, as a narrow ellipse, with loosely approximated sides. Perfect union is secured here by fine catgut sutures, carried deeply from side to side. The first is placed but a short distance above the one of silkworm gut, tied here, and used in its turn as a tractor, exposing the wound immediately beyond; then the next suture is passed and tied, and so on until the upper part of the triangle is closed and all bleeding has stopped. The opposite sulcus is closed in the same way with a single suture of silkworm gut and several of fine catgut. These sutures should check all hæmorrhage, but if there is persistent oozing it must be controlled by additional sutures tied tightly at the bleeding point. In this way a large part of the resected area within the vagina has been approximated, and the vaginal canal markedly narrowed within the pelvis. When the triangular

areas in the sulci are large, a half-deep catgut suture should be added below the one of silkworm gut. Most of the remaining area may be brought together by a single gathering suture of silkworm gut, embracing the upper angles on the sides and transfixing the rectocele (Fig. 628).

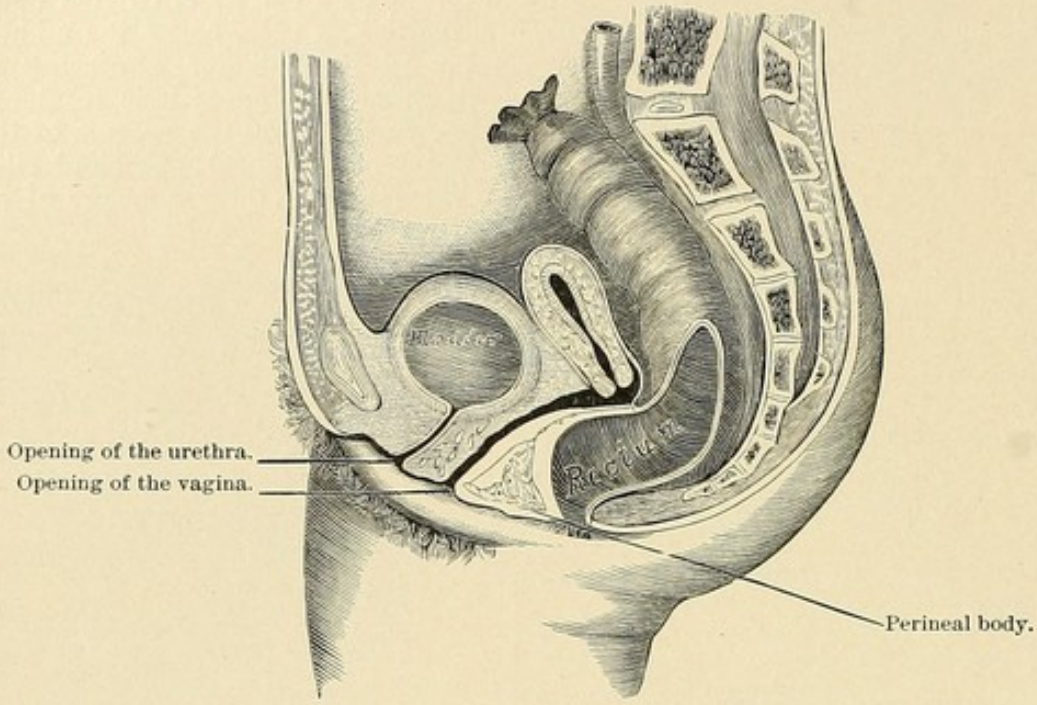

FIG. 631.—Showing in perpendicular section the relations of the perineal body to the bladder, vagina, and rectum. (After Thomas.)

"An additional silkworm-gut suture may sometimes be necessary on the skin surface extending through to the bottom of the wound. Half-deep and superficial sutures will complete the union (Figs. 629, 630).

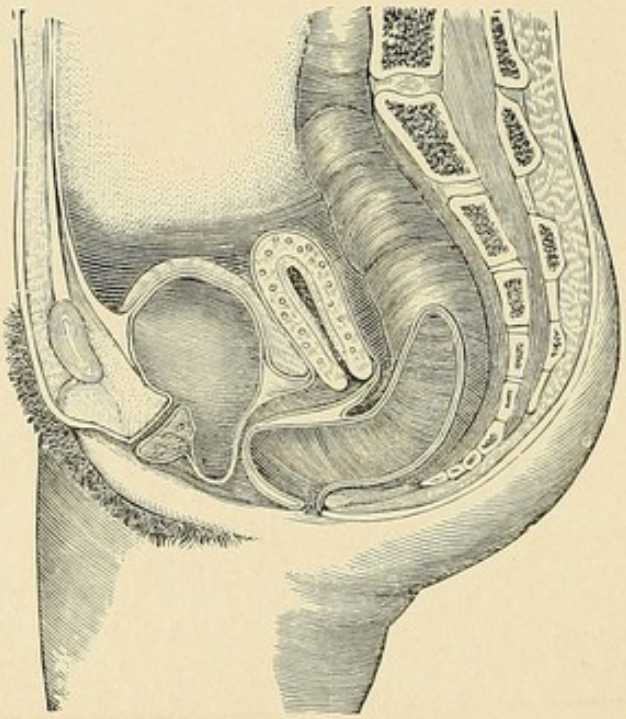

FIG. 632.—The same after rupture of the perinæum and the prolapse of the bladder and rectum (cystocele and rectocele). (After Thomas.)

"The external sutures should be removed from the eighth to the tenth day. Those in the inside may remain several weeks.

"The immediate result of this operation is a complete restoration, and even the hymen is often restored. Subsequent labors will not destroy the effects of the operation, unless unskillfully conducted or attended by complications."

Figs. 631 and 632 show in perpendicular section the relations of the various organs before and after rupture of the perinæum.

The Vagina

Absence of the vagina is a congenital affection which scarcely comes within the domain of the general surgeon.

An anomaly equally rare and yet operative in character is that of *double* vagina. There is a middle line septum which usually divides the canal into two chambers of about equal caliber.

The operative procedure consists in a division of the septum along the middle line throughout its entire extent. The hæmorrhage is usually not severe, but can be controlled by packing with sterile gauze or by a running loop of chromicized catgut suture.

Imperforate hymen is a more frequent congenital defect, and is readily recognized by careful inspection, and may be cured by incision, either dissecting out the membrane near its vulvo-vaginal attachment or by making a crucial incision, leaving the angles to retract and undergo atrophy.

In imperforate hymen there is usually a collection of thick fluid, dark in color due to retained menstrual flow. This fluid should be thoroughly removed by sponging or irrigation, and frequent post-operative antiseptic irrigation is advised to prevent possible septic absorption.

Of the *neoplasms* of the vagina, the cystic variety is more frequently encountered. They may grow from either wall, and occasionally have a thick covering which renders them not easy of recognition. Aspiration with a delicate, clean needle is the surest method of diagnosis.

These tumors should be removed, the sack being thoroughly dissected out.

Abscess of the recto-vaginal septum is a rare form of infection. The swelling is perceptible by vaginal as well as rectal examination, and should be removed by incision, preferably from the vaginal side. Drainage should be established until the cure is complete.

Of the solid neoplasms of the vagina, sarcoma, carcinoma, and myoma are occasionally observed. The malignant tumors may be differentiated by microscopical examination, and together with the non-malignant should be removed as soon as discovered.

The surgical lesions of the *female urethra* are rare. One of the most frequent is *caruncle*, which, according to Dr. Howard A. Kelly, is histologically made up of connective tissue and hypertrophied papillæ, with numerous dilated vessels, covered with pavement epithelium. It appears as a small, warty-like growth, usually red in color, and is almost always exceedingly painful to the touch.

Dr. Kelly recommends the thorough extirpation of the tumor, preferably by removal with the knife, and with cocaine anæsthesia. After infiltration with cocaine, it should be seized with the forceps and cleanly dissected from its base. Hæmorrhage may be controlled by chromacized-catgut sutures or by the ligature.

The various lesions of the female bladder do not differ materially from those of the other sex, and will be given in the general chapter devoted to the surgical lesions of this organ.

The one procedure which belongs more particularly to gynæcological surgery is that of vesico-vaginal fistula. The operation for the cure of this distressing affection was introduced and first successfully performed by Dr. J. Marion Sims, of Montgomery, Ala. It is performed as follows:

The edges of the fistulous opening are pared with sharp-pointed, one-half-curved scissors, the patient resting usually in the Sims position, with the vagina dilated by a large, duck-billed speculum. The freshening should extend well into the sound tissue. The opening thus made is closed by silkworm-gut sutures, inserted

about one eighth of an inch from the margin of the wound. The needle is made to come out between the mucous membrane and the muscular layer of the bladder wall, to enter and be brought out in the same relative position on the opposite side (Fig. 633). The sutures should be about one fifth of an inch apart, and

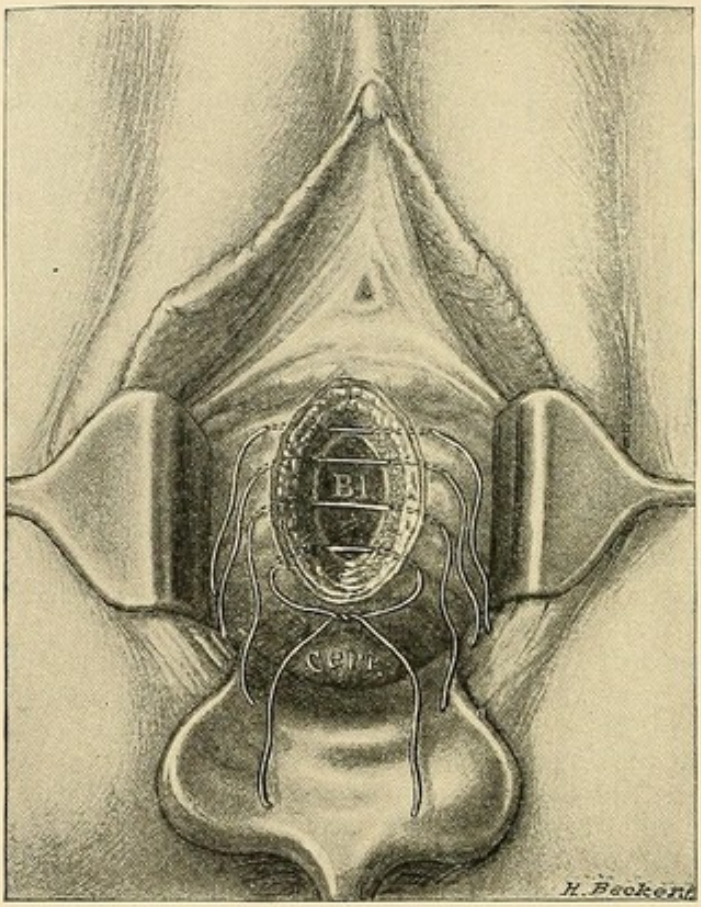

Fig. 633.—Classical operation, sutures inserted transversely, instead of vertically. (Kelly.)

any puckering of the vaginal mucosa between any two sutures should be closed by a very fine intermediate suture of chromicized catgut.

Kelly advises "the introduction of a soft gauze pack, to give gentle support to the vaginal wall and base of the bladder. A soft-rubber catheter is left in the bladder for from four to seven days, according to the size of the fistula. The vaginal pack should be replaced when it becomes soiled. The bowels should be opened on the third day by giving a purgative, followed by an enema. The silkworm-gut stitches may be removed in twelve to fifteen days."

Prolapse of the anterior vaginal wall, or *cystocele*, may be relieved by dissecting off the vaginal layer of the vesico-vaginal septum over an area of sufficient size, and uniting the edges of this wound in such manner as to shorten the vaginal arch and hold the bladder up in its normal position.

The outline of the bladder wall is accentuated and the separation of the vaginal layer from the bladder is more easily accomplished after a small quantity of liquid (normal salt solution, five or six ounces) has been injected. The cervix is grasped with traction forceps drawn down to the vaginal outlet, and lateral retractors introduced. A longitudinal median line incision is made through the vaginal half of the vesico-vaginal wall extending from the anterior limit of the cystocele (usually about one inch from the urethral meatus, where the internal urethral orifice is located) to the cervix. The vaginal layer of the vesico-vaginal wall is carefully separated from the bladder well out into the lateral fornices and from the cervix uteri up to the peritoneal reflection. A self-retaining soft-rubber catheter is carried into the bladder and its contents evacuated. The flaps lifted on either side of the median incision are now trimmed a sufficient distance on either side to

take in the slack of the anterior vaginal wall. In order to insure accuracy one or two trial sutures may be inserted to determine just how much narrowing of the vaginal roof is necessary to give the proper support to the bladder. Chromicized catgut sutures are used to approximate the raw edges. Beginning at the cervix, the needle should pass through a strip of the anterior cervical wall as far up as the peritoneal reflection beyond which point only the two flaps are sutured. The self-retaining catheter may remain for four days to guard against overdistention of the bladder which otherwise might interfere with firm union. A light vaginal gauze pack should be employed for the same length of time. Vaginal irrigations of 1–3000 mercuric-chloride solution may be made daily.

Cervix Uteri.—Lacerations of the cervix may be classified as unilateral, bilateral, anterior, posterior, and stellate. They are also complete or incomplete. The bilateral variety is most frequent, the unilateral next, the remaining forms being comparatively rare. In a complete laceration, the tear extends through all the tissues of the cervical wall into the vaginal vault; the incomplete variety extends into but not through the wall of the cervix.

The principal indications for operative interference are pain, constant in character, either local or reflex, hypertrophy or thickening of the tissues of the cervix, as a result of granulations along the line of the laceration, cystic degeneration of the cervix, sterility from occlusion of the internal os, inability to carry the fœtus to term, etc. The danger of epithelioma, resulting from prolonged irritation of a fissured surface, should never be lost sight of. The preparation of the patient has been given. When the narcosis is complete, she is placed in the Sims position and a large Sims speculum introduced. A strong tenaculum should now be hooked securely into the sound portion of the cervix and the uterus drawn toward the vulva. A second tenaculum is firmly inserted at the edge of the rent, the margin of which is now trimmed off with the Sims adjustable knife, or, if this is not at hand, Emmet's cervix scissors. In freshening the edges of the laceration, the section

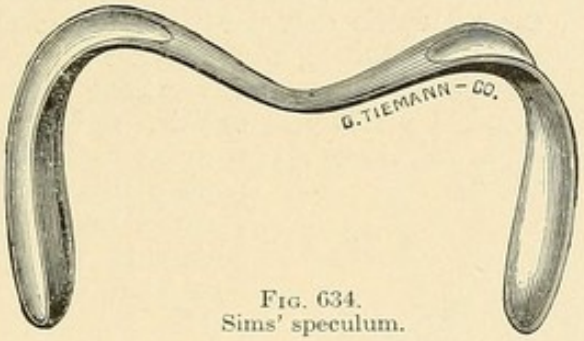

Fig. 634.
Sims' speculum.

should extend thoroughly into the angle of the tear, and all cicatricial or granulating surfaces should be most carefully removed. When the tissue along the line of the tear is densely cicatricial, it must be deeply excised, since restoration of the cervical canal cannot be accomplished when the cicatrix remains.

When a bilateral laceration exists, the denuded area should extend well out to the vaginal surface of the cervix and inward to the level of the internal os, or remaining cervical canal. It is usual to leave unfreshened a space of about one fourth of an inch wide, as shown at *a a*, Fig. 635, which space corresponds to the canal to be restored by the operation. The opposite fissure is prepared in the same manner, and the wire sutures are then inserted. The most suitable needle is short and strong, with a slight cutting edge on one side, this cutting edge limited to the first one fourth of an inch from the point. This should be armed with the silkworm gut, and passed through the vaginal portion of the cervix, one fourth of an inch from the edge of the wound, and brought out barely within the undenuded area *a a* left to form the walls of the canal (*1*, *1*, Fig. 635). The deep suture—that in the angle—should be first inserted. When all the sutures are passed, they should be tied in the order of insertion. It is important to bring the freshened surfaces accurately together.

After the sutures are all tied, they should be cut at one fourth of an inch from

the line of union and a sound introduced, to see that the canal is not by accident occluded.

The patient should be put to bed and kept perfectly quiet and the sutures removed on the eighth or tenth day. This is accomplished by placing her in the same position as for the operation, cleansing the parts thoroughly, lifting the deep-

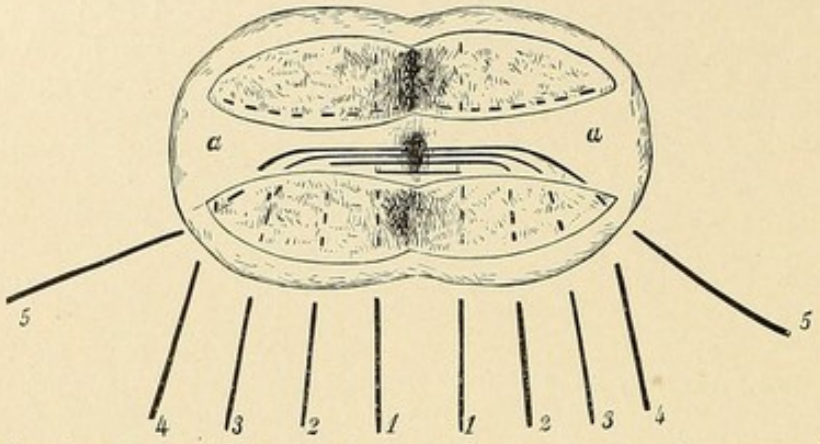

FIG. 635.—Showing the area of denudation and the method of passing sutures in bilateral laceration of the cervix. (Mundé.)

est suture with the forceps until one side of the loop is seen, and then dividing this with the sharp-pointed scissors. Great care and considerable skill are necessary to prevent the tearing apart of the freshly united surfaces. The patient should remain in bed for a week or ten days longer. When cystic degeneration exists with a single or double laceration it is advisable to substitute one of the following methods of amputation of the torn and diseased cervix.

Amputation of the Cervix.—This procedure is also recommended in hypertrophy of the cervix and general cystic degeneration. Cystic degeneration is caused by connective-tissue hyperplasia resulting from chronic infectious inflammation, the new tissue occluding the glandular outlets, and causing a retention of their normal secretion, which may remain a clear fluid, but in the majority of cases undergoes pyogenic infection. Not only the glands of the superficial, but of the deeper part of the cervix, are involved. As a result of

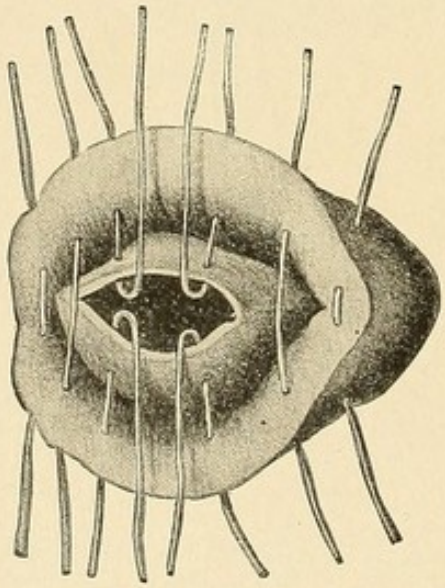

FIG. 636.—Wedge-shaped amputation of the cervix uteri. ("American Text-book of Gynæcology.")

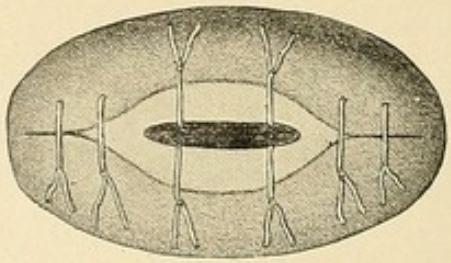

FIG. 637.—The same after the sutures are tied.

the retained secretion and the hyperplasia the cervix is greatly increased in size. When the hypertrophy or degeneration is extensive, and it becomes necessary to sacrifice practically all the tissues, the wedge-shaped operation should be performed as follows: A double volsella is fastened into the anterior and posterior lips of the cervix and the uterus dragged down until the cervix is near the orifice of the vulva. A short, broad speculum and retractors may be used when needed. With a knife or sharp-pointed scissors the cervix is completely incised on either side almost to the

cervico-vaginal junction. Depressing the anterior lip with the volsella, a transverse incision is made across this lip from right to left, the knife being inserted from one quarter to one half inch from the margin of the cervico-vaginal junction. The direction of the cut should be upward, passing a little more than half-way through the thickness of the cervix. The knife is then withdrawn, the anterior lip raised, and an incision made parallel with this on the inner or mucous surface of the cervix. In this way a wedge-shaped section is removed, leaving a trough on the stump which remains. The same incision is made on the lower or posterior lip of the cervix at the same plane, and sutures are inserted in order (Fig. 636) to bring the edges of the wound together, leaving a partial cervical canal lined with normal mucous membrane. The destruction of the cervical mucous membrane is always to be avoided for the reason that it never reproduces itself, as does the endometrium. After the sutures are inserted, the condition of the parts is as shown in Fig. 637. When endometritis is present, this should be cured by curettage at least one week before the operation on the cervix.

Curettage is performed as follows: The uterus is pulled down with the double volsella and the direction of the cervical canal determined by the sound. In the case of a narrow cervix, it should be incised on both sides by introducing a curved, probe-pointed bistoury. The dilator is next introduced and the cervix gradually and intermittently stretched. In the nulliparous uterus, a dilatation of half an inch will be sufficient. In multipara a larger opening, being readily secured, is desirable. The uterus is now irrigated with sterilized one-per-cent salt solution or a 1–8000 permanganate-of-potash solution. A curette is introduced and carried back to the fundus and withdrawn in the axis of the uterus, making moderate pressure, but not sufficient if a sharp curette is employed to penetrate into the muscular substance. Repeating this manœuvre so as to cover the entire cavity, the whole endometrium is scraped off. Particular attention should be paid to the deep angles where the Fallopian tubes enter, and, in order to reach these, a smaller curette is sometimes required. The furrow across the fundus uteri is scraped by carrying the curette transversely from one tubal orifice to the other. The curettage should not be so forcibly applied to the cervical canal as to destroy the mucous membrane, which, unlike that of the uterus, is not reproduced. The cavity of the uterus should be thoroughly dried or mopped with small tampons of iodoform gauze on forceps, after which it is packed full of gauze, using by preference a single long ribbon. A small uterus will hold about one yard of gauze one inch wide. In the after-treatment, if the patient can empty the bladder every six hours she should be permitted to do so; otherwise the catheter should be used. In non-septic cases, the gauze should be allowed to remain five days. In pus cases, it should be removed in three days. If the uterus does not measure more than four inches in depth, it need not be packed a second time, but in organs of greater depth than this a second, and often a third packing may be necessary. When the packing is removed, if the uterus is practically dry, irrigation is not necessary. The patient may be allowed out of bed on the sixth or seventh day. The vagina should be carefully packed with iodoform gauze, changing the packing about every two days for three or four weeks after this operation in order to prevent infection.

Inversion, in which the uterus is turned inside out and prolapses into the vagina, occurs usually after parturition, when the process of contraction of the muscular tissue of this organ is insufficient, and the cervix remains so widely dilated that the fundus falls into and passes through it. It is recognized by the presence of a pear-shaped mass, seemingly covered with granulations which bleed readily and which fills the vagina or may protrude beyond the vulva.

An effort should be made to replace it by pressing with one finger in the center of the projecting mass steadily backward in the axis of the normal position of the uterus. Complete narcosis is essential, and considerable time may be required to dilate the cervix sufficiently to allow an entire restoration of the uterus to its normal position. Once replaced, it is necessary to hold it in position by artificial support, usually a sterile gauze packing placed in the cavity of the uterus and vagina. This should be changed in two or three days, and a smaller packing

inserted until the uterus contracts. In changing the dressing care should be taken to prevent the prolapses from recurring.

Myoma of the Uterus.—Uterine fibroids are new formations of unstriated muscle which contain a variable quantity of connective tissue. When the latter element predominates, they are called fibro-myoma, or fibroids.

They are rarely present before maturity, and may develop within the muscular substance of the wall of the uterus, where they usually become encapsulated (intermural), or on the surface of the uterus just under the peritonæum (extramural). When they grow from the internal surface of the uterus and project beneath the mucous membrane into the cavity of this organ, they are called submucous myoma (intramural).

Growing from the peritoneal surface of the uterus, they may be round or sessile in shape or attached by a stem or pedicle of varying length and thickness to the wall of the uterus. This form of tumor at times becomes strangulated, and may undergo rapid necrosis as a result of a twist of the pedicle.

The submucous fibroids, especially those situated near the internal os, very frequently cause profuse hæmorrhage. In mural fibroids there are found at times numerous small cysts caused by dilatations of the lymphatic vessels.

In general, uterine fibroids are of firm consistency and more or less encapsulated, the chief blood supply being found in close relation to the capsule.

Symptoms.—Fibroids of the uterus, especially those growing beneath the peritonæum, may be present for months or years without attracting the attention of the patient or physician until they have grown so large as to produce pressure symptoms.

In the submucous variety, by reason of a progressive increase in the amount of blood lost at each menstrual period, they may be recognized earlier. The intramural fibroids are also liable to induce menorrhagia.

Loss of blood is in no way proportionate to the size of a tumor, being chiefly due to its location near the internal os. Moreover, those neoplasms which project into the cavity of the organ are more apt to cause uterine cramps, especially during the menstrual period, than the subperitoneal growths.

Intraligamentous fibroids are apt to produce pain in the hip-joint by pressure upon the obturator nerve. When the neoplasm is situated on the anterior wall, pressure upon the bladder often causes cystitis, while if it is on the posterior wall, and resting on the rectum or sigmoid colon, it may induce constipation, and at times colitis and hæmorrhoids.

When the tumor becomes of large size, pressure upon the iliac veins is apt to cause varicosities in the legs, with more or less œdema. In those cases in which the tumor rises rapidly out of the pelvis, these earlier pressure symptoms are not present.

The *treatment* of fibroids, which is operative, will be considered in the chapter on abdominal and vaginal hysterectomy.

Carcinoma.—Cancer of the uterus in about ninety per cent of all cases is located in the cervix. It is met with usually between the fortieth and fiftieth years of life, is exceedingly rare in women under thirty, but not infrequently occurs after the fiftieth year.

It is in all probability caused by a more or less constant irritation due to lacerations which have not been cured by operation, and to acrid or irritating discharges in contact with even slight abrasions. Microscopically, uterine cancer is of the epithelial type (epithelioma). Adeno-carcinoma is comparatively rare.

The new epithelial tissue grows rapidly, is of low resistance, and readily undergoes disintegration. The rank growth gives the lesion a cauliflower-like appearance, and often completely covers and conceals the vaginal cervix. It bleeds profusely under the slightest provocation.

Infiltration of the contiguous wall of the vagina, the bladder, and rectum occurs early in the history of the disease. Metastases take place through the lymphatic channels at an early period, a fact which adds to the hopelessness of a cure, unless a thorough extirpation is done within the first few weeks of the appearance of the epithelioma.

Adeno-carcinoma is usually located higher up in the cervical canal or in the body of the uterus, and is often far advanced before the attention of the patient or physician has been called to it.

The lining membrane of the deeper portions of the cervix is frequently broken down, while the external os is practically normal in appearance. By reason of its location in the upper portion of the cervical canal, this variety of uterine cancer is more apt to involve the bladder early in its development than epithelioma of the vaginal cervix.

Symptoms.—The first symptom usually observed in uterine cancer is leucorrhœa, which gradually increases and has a penetrating and offensive odor, due to the putrefactive changes in the particles of the new growth which are cast off. This discharge is more profuse in adeno-carcinoma than in epithelial carcinoma.

Pain is as a rule not severe, and may not be present in the early stages. Later, when the bladder or rectum becomes involved by extension, cystitis or proctitis results.

The *diagnosis* is usually not difficult when the neoplasm is situated at the external os. It may be made positive by the removal of a section and immediate examination under the microscope. Adeno-carcinoma of the deeper cervix or of the endometrium and body of the uterus is rarely recognized until lymphatic infiltration has taken place. In the differentiation between an epithelial ulcer and one due to syphilis or tuberculosis, or of a polypus which is undergoing disintegration, the following points should be borne in mind:

A careful history of the case will determine whether or not the patient has suffered a syphilitic infection. The ulcer of syphilis does not bleed so readily as that which is caused by epithelioma. Tuberculous ulcers are pale in color, not apt to bleed, and their borders are serpiginous. The presence of a polypus may be determined by dilatations of the cervix, after which the tumor may be traced back to its attached pedicle.

The *prognosis* is in general unfavorable, for the reason that lymphatic infiltration will have occurred before the ulcer has been recognized, making a thorough extirpation practically impossible. It is only favorable when the tumor is located in the fundus of the uterus and a complete hysterectomy has been performed before lymphatic metastases have occurred, or when with the first appearance of an ulcer of the cervix, the entire neck of the uterus has been amputated.

Treatment.—In this operative procedure (for incipient epithelial ulcer of the os and cervix) *vaginal hysterectomy* is advised, and the Paquelin cautery knife should be used. Clamps or ligatures may be applied laterally to the broad ligaments and tubes.

Even in more advanced cases, where infiltration is so extensive that a cure is impossible, amputation of the cervix with a Paquelin cautery will often render the patient less uncomfortable, and do away with much of the disagreeable odor of the discharge.

In the treatment of inoperative cases of cervical epithelioma, the following palliative treatment should be instituted:

In delayed cases, where the destruction of tissue is extensive, the local application of enzymol and pancreatis [1] will in large measure arrest putrefaction, diminish the discharge, and greatly lessen the offensive odor. In the author's experience, pancreatis, to which an equal part of water is added, applied on absorbent cotton twice daily directly to the surface of the ulcer is preferable. Enzymol may be substituted in the same dilution and applied in the same way every third day. The foot of the bed should be well elevated for two hours after each application. In the cases subjected to this treatment, the area of inflammation which circumscribes the epitheliomatous infiltration has in every instance been markedly lessened together with the pain, which is due in large measure to infection.

Cancer of the body of the uterus is usually located in the fundus near the cornu. One of the earliest symptoms of deep-seated carcinoma is an irritating discharge, which gradually increases in quantity. While not accompanied by marked bleeding, as in cancer of the cervical portion of the uterus, this discharge

[1] Fairchild Brothers & Foster.

is apt to be streaked with blood. It also carries with it evidences of putrefaction, as shown by the disagreeable odor.

Pain is more apt to be present in a cancer situated in this location than when the cervix is involved.

The *diagnosis* is extremely difficult and cannot positively be determined unless a thorough curettage is done, and a careful microscopical examination made of the tissues removed.

The *treatment* demanded is an immediate removal of the uterus with the adnexa, and in this operation the suprapubic route is to be preferred.

Sarcoma of the uterus is comparatively rare. It is exceedingly difficult to differentiate this neoplasm from myoma, although in general the sarcomatous tumors grow more rapidly than uterine fibroids. The ovary is occasionally the seat of sarcoma.

The *surgical treatment* is an immediate removal of the organ involved with the adnexa. As with sarcoma in any other portion of the body, the prolonged injection of the mixed toxines should follow the operation.

In preparing the operative field for *abdominal hysterectomy*, especial care should be given to cleansing the vagina and preventing any uterine discharge from escaping. The line of incision and the technic of closing the wound is given in the chapter on *Celiotomy*.

The incision should at first be large enough to permit the introduction of two fingers for careful exploration. It may be enlarged upward or downward to any extent demanded by the conditions which require to be remedied.

In case of uterine myoma, single or multiple, which are subperitoneal or pedunculated, if the patient be within the child-bearing period careful consideration should be given to the possibility of removing these from the wall of the uterus with the smallest possible detriment to the function of this organ.

In the performance of this operation, the peritonæum covering the attachment of the tumor should be incised and carefully reflected with the curved dull-pointed scissors on all sides down to and slightly beyond the attachment to the uterine wall. The pedicle or base of the tumor should then be excised and all hæmorrhage stopped by the insertion of sutures of strong chromicized catgut (Nos. 2, 3, or 4, as may be required), the needle being so inserted as to occlude all bleeding points. The peritonæum should then be carefully stitched over the seat of the attachment of the tumor, leaving a perfectly smooth surface which will not invite adhesions.

Should there be a large vascular tumor, all bleeding can be absolutely controlled by surrounding the uterus at its neck with a strong piece of rubber tubing, which is temporarily clamped, to be removed when the operation has been completed.

All of these procedures in the pelvis are simplified by a partial or extreme Trendelenburg posture. If the tumor fills the cavity of the pelvis, the incision is of necessity extended. It should always be large enough to enable the operator to see clearly the various organs and to lift the tumor out through the wound without traumatism to the intestines and other contiguous viscera.

In many of these cases adhesions between the tumor and omentum, mesentery or the intestines have occurred which should be carefully separated, tying on both sides with strong catgut all masses in which blood vessels are observed.

In lifting a large uterine fibroid from the pelvis, it is frequently easier to do this by grasping it with strong volsella, since it may be difficult to introduce the hand on account of the size of the mass.

The most important points to bear in mind in hysterectomy, especially for large fibroids, is the relation of the anterior surface of the uterus to the bladder, to the antero-lateral portions where the ureters are under normal conditions, and to the posterior portion in its relations to the rectum.

The safest way to proceed is to be certain that the bladder has been thoroughly emptied, and in all doubtful cases to ascertain its exact relations to the anterior surface of the uterus by introducing a sound into the bladder the point of which clearly maps out the summit of this organ. By dividing the peritonæum above this plane, and keeping close to the body of the uterus and the cervix, all danger

to the bladder and ureters may be avoided. All bleeding points encountered should be clamped temporarily, to be tied when the tumor has been removed. The same precaution posteriorly will prevent any possible injury to the rectum. The peritoneal covering may also be wiped off with a gauze swab. In the early part of the operation, when the tumor has first been exposed and lifted, the broad ligaments should be carefully clamped, always keeping close to the mass in order to shun the ureters, a careful lookout for which should be kept. Should the operator be short of assistance, it would be a wise precaution to tie at once the larger vessels, two or three in number, which occupy each broad ligament.

The operation, however, may be more expeditiously performed by applying clamps and dividing between them, first removing the tumor and then securing every possible source of hæmorrhage. This may be done either by ligature *en masse* with strong celluloiden linen, or preferably by Nos. 2, 3, or 4 ten-day catgut sutures carried along the raw edge with a tight button stitch tied every half inch or so with a firm knot, continuing the suture with the same piece of gut.

The operator should be absolutely sure that every source of bleeding is under assured control before closing the wound. When the uterus shall have been removed at the junction of the cervix with the vagina, this opening should be closed by a row of catgut sutures, continuous or interrupted, as the operator may prefer, and then the peritonæum, which has been stripped from the body of the uterus, should be sewed over this line of sutures in the vagina in such a way that there will be no raw surfaces for the adhesion of intestines.

Ovariotomy.—Should there be an ovarian tumor present, this may be removed through a much smaller incision than that required in hysterectomy on account of myoma. The cystic character of the neoplasm, if not determined before the incision, will be easily recognized, and its liquid contents evacuated through a trocar carefully inserted, the rubber tube attached to which conveys the fluid into a basin at the side of the operating table. The emptied sac can now easily be drawn through the incision and the pedicle of the tumor tied up with celluloiden linen. Should adhesions be present or should any complication arise, the incision may be extended and, if necessary, the Trendelenburg posture assumed.

In the suprapubic operation for the removal of septic foci in the pelvic organs, as in gonorrhœal salpingitis, etc., the same incision should be made and the Trendelenburg posture is advised. In this operation, infection being presumable, the first precaution is to see that all intestinal loops are carried out of the pelvis and a careful dam of sterilized gauze inserted in such a manner as to prevent the contact of any septic matter which may be liberated in the separation of adhesions from the peritonæum.

All hæmorrhage should be thoroughly controlled, and in case a considerable quantity of purulent fluid is encountered the question of drainage by an opening through Douglas' *cul-de-sac* is entitled to careful consideration.

In chronic or subacute cases of pyosalpinx, it is rarely necessary to take this extreme precaution, but where there are evidences of recent pelvic peritonitis, and where the resistance of the patient is low, it is advisable to lean to the side of caution and take advantage of this method of drainage, closing the upper wound as in a clean operation.

When an intraligamentous fibroid is encountered, complete hysterectomy should be done. It is important to secure the large vessels distributed to the ovaries and broad ligaments as the first step in the operation. The ureters are frequently misplaced by being carried over the upper limit of these tumors in the process of their development. They may be avoided by keeping beneath the peritoneal covering of the broad ligaments. It is safer to ligate the ovarian and uterine vessels separately rather than to tie them *en masse*.

When in these operations any portion of the cervix is left, the canal should be thoroughly curetted and a short catgut drain inserted in the os.

Hysterotomy and Abdominal Hysterectomy.—*Hysterotomy*, or cutting into the uterus for the extraction of the fœtus from the living mother, is an operation which has been greatly perfected within the last few years, chiefly owing to the labors of Saenger, Leopold, and Tait. It is indicated when at full term it is found

impossible, on account of insurmountable disproportion between the diameters of the pelvic outlet and the child, to effect delivery by the vagina, and when symphyseotomy will not give sufficient outlet for instrumental delivery. When this condition is evident, proceed as rapidly as possible in the following manner:

If the membranes are not already ruptured, break them. Disinfect the vagina and genitals with sublimate solution, 1–3000. Prepare the abdomen as for an ovariotomy, and make a long abdominal incision, controlling all bleeding with catgut ligatures as the operation proceeds. Having entered the abdominal cavity and made the opening large enough, place three or four silk sutures at the upper end of the wound in order to narrow the opening as soon as the uterus is drawn out of the incision, thus avoiding extrusion of the intestines. Drag the uterus outside the abdominal cavity, and close the upper portion of the wound by tightening the sutures already in position. If the intestines should be protruded, protect them with warm towels wrung out of sterile salt solution, and beneath the uterus pass sterile gauze mats or towels to protect the abdominal cavity from the entrance of blood. Around the cervix uteri pass a stout piece of elastic tubing, and draw it tight, thus arresting the circulation in the uterus. Immediately incise the uterus in the median line and in its long axes, limiting the incision below to the peritoneal reflection, thus avoiding the large circular sinuses about the os internum, and extending it upward if necessary. Remove the child, and hand it to an assistant to resuscitate. The uterus will now usually contract. Introduce the hand into the uterus and remove the placenta. The uterine cavity is next to be dried out with gauze. Unless the cervical canal is widely dilated (and this should be ascertained before the operation), the use of a utero-vaginal drainage-tube is indicated, and this latter must be of stiff rubber or glass. The next step in the operation is the insertion of the sutures in the wall of the uterus. First ascertain whether the peritoneal covering of this organ is sufficiently movable to allow it to be folded in between the sides of the incision. If need be, dissect it up from

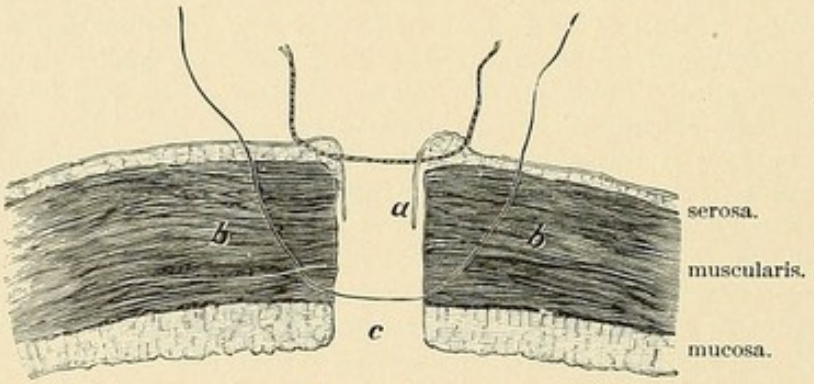

Fig. 638.—Sutures in Cæsarean section. Method of passing the sutures in closing the wall of the uterus after hysterotomy. *a*, The peritoneal covering dissected up along the edge of the incision and inverted by the catgut suture, after the method of Lembert. *b*, The muscular substance, with the silver-wire suture passed through. *c*, Decidua. (Drawn by Dr. W. R. Pryor.)

its attachment to the muscular fibers a slight distance and fold it in between the lips of the wound. The deep sutures of celluloiden linen are passed as shown in Fig. 638. They should be close enough to control hæmorrhage and secure accurate adjustment of the sides of the wound. They should enter the peritoneal covering about half an inch from the edge of the wound, and pass through it and the muscular wall to the decidua, which must not be included in the suture; then across to the other side through the muscular and serous coats. To secure perfect coaptation of the serous edges of the incision, ten-day catgut is employed. They are introduced in the same way as Lembert's suture of the intestine.

The incision in the abdominal wall is closed, as after ovariotomy. There are certain conditions which can only be determined by inspection through the incision in the abdominal wall which may contra-indicate the operation just given, and necessitate a modified procedure.

If the patient has been long in labor, and considerable time has elapsed after the membranes have ruptured; if there is a putrid discharge from the vagina; if

the symptoms of septic fever are present, with the perimetrium dulled and adherent to the muscular wall of the uterus, the operation of amputation of the uterus at the os internum may be indicated. If malignant disease of the cervix is present, the entire organ should be removed. If the pregnant uterus be the seat of a fibromyoma, and so situated as to render delivery impossible, or if a rupture of the walls of the uterus has occurred, which is so ragged in outline that it cannot be sutured, hysterectomy is indicated. The objects aimed at in all operations for the artificial delivery of children at term are preservation of the mother's life and future health, with, if possible, the non-mutilation of her generative organs and the delivery of a living child.[1]

Hysterectomy during Pregnancy.—Porro's operation, which is more often fatal than hysterotomy, is sometimes called for in the removal of an infected uterus at the same time that the delivery is effected by hysterotomy. In performing this operation, an abdominal incision is made similar to the one just described. As the bladder is usually high up in these cases, and in good part uncovered by peritonæum, care must be taken that the incision does not wound this organ. As soon as the uterus is exposed it should be drawn out of the abdominal cavity. A strong rubber ligature is now thrown around the uterus at the cervix. The intestines should be protected by sterile mats or warm towels, which have been boiled. These should also be placed underneath the uterus, in order to protect the peritoneal cavity from the entrance of blood or infectious material. As soon as the rubber ligature is securely tightened around the cervix the uterus should be rapidly incised and the child extracted at once. A linear incision is preferable. The uterus should now be divided as close to the rubber ligature as possible, and ligatures applied through the broad ligaments on each side to cut off all vascular supply to the stump of the cervix, which should then be excised. A careful toilet of the pelvic cavity should be made, after which it should be packed with a ribbon of iodoform gauze introduced either through the abdominal incision from above or through an incision in Douglas' *cul-de-sac*, and the abdominal wound should be closed. The iodoform gauze should be withdrawn through the vaginal opening five or six days after the operation. It is very essential in this operation that the vagina be rendered as aseptic as possible. It should also be repacked with iodoform gauze when the dressing is changed. When the gauze is removed from Douglas' *cul-de-sac* a second and much smaller packing should be reinserted.

Symphyseotomy.—This operation, which consists in the division of the cartilage between the two pubic bones in the median line at the symphysis, is indicated in a certain proportion of cases which, by abnormal narrowing of the pelvic outlet, would otherwise be subjected to the more formidable operation of abdominal hysterectomy or to cephalotripsy.

The operation may be performed subcutaneously or by the open incision. E. A. Ayers' method is as follows: After shaving the parts, under thorough asepsis, secure full dilatation of the cervix if possible without risk to the child. The patient is brought to the edge of the table and placed in the lithotomy position. A small male urethral sound is introduced into the bladder, and with it the urethra and lower portion of the bladder are held firmly to the patient's left side. The labia minora and clitoris are then drawn well up and also to the patient's left. The operator introduces the left index-finger into the vagina, and carries this along the posterior curve of the symphysis to the top of the joint in the median line. A small incision is now made about one half inch below the clitoris. A curved, probe-pointed bistoury is passed into this wound close against the joint to the top of the symphysis, until the probe point is felt against the end of the left index-finger, which is behind the bone. The cutting edge of the blade is turned downward, the back of the knife being toward the vessels of the clitoris. The bistoury is now worked carefully down through the cartilage of the symphysis. The success of the division is determined by the separation which ensues, the left finger being able to appreciate the space between the bones as they are separated. In dividing the subpubic ligament it is advisable to change the direction of the

[1] As regards statistics, Saenger gives thirty Cæsarean sections performed as above described, with a mortality of 26.7 per cent.

bistoury and cut up instead of down. In Dr. Ayers' cases the separation varied from two to two and a half inches, enabling the easy delivery of the child by the application of forceps. If for any reason the operator may not feel justified in attempting the subcutaneous operation, separation can readily and with perfect propriety be secured through an open wound made above the genital apparatus, exposing the symphysis pubis, by a modification of the incision given for supra-pubic cystotomy.

Vaginal Hysterectomy.—In this operation the patient rests upon the back, with the thighs and legs flexed well upon the abdomen, in which position they should be steadily held by an assistant or by strapping to the table.

The Trendelenburg posture, the body of the patient being prevented from slipping by shoulder supports attached to the table, is advised. Pryor's portable oper-

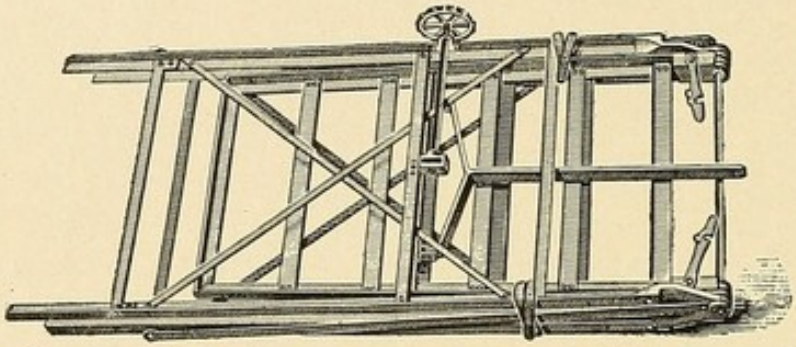

FIG. 639.—Prof. W. R. Pryor's operating frame folded for transportation.

ating table (Figs. 639, 640), to which these shoulder supports may be attached, will be found very satisfactory. A careful toilet of the vaginal cavity is essential, and the usual intravaginal scrubbing with soap, brush, and sterile water should be followed by the application of 1–1000 mercuric-chloride solution, the excess of which is washed out by hot salt solution. To prevent the possibility of any septic matter escaping from the uterine cavity, a plug of sterile gauze should be tightly inserted in the cervical canal.

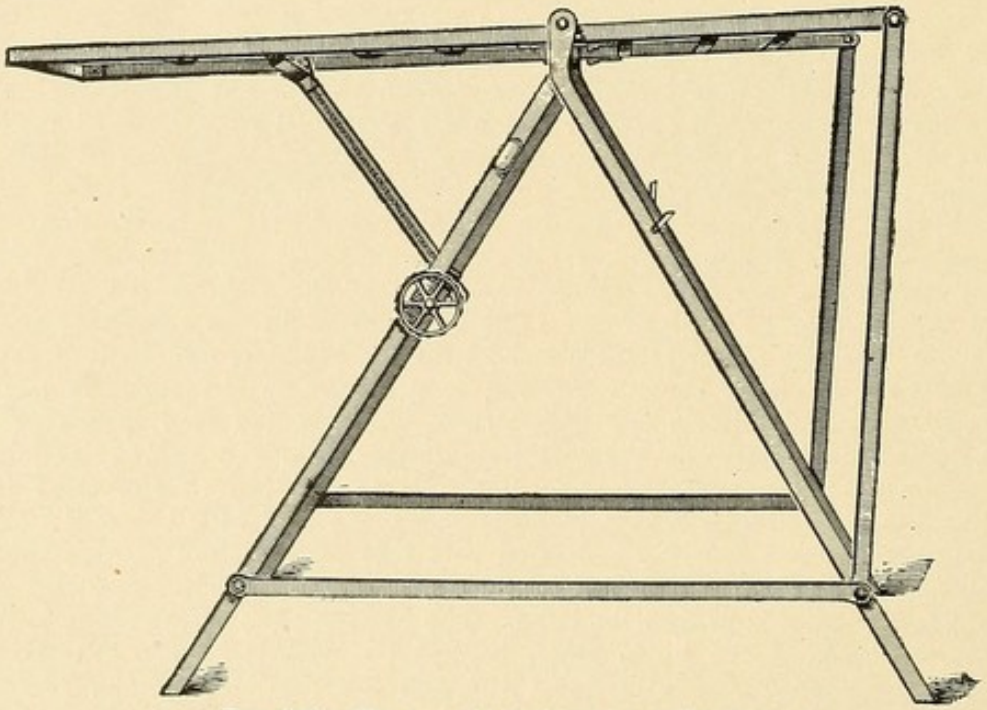

FIG. 640.—The same in position for ordinary uses.

Lateral retraction with the right-angle spatulæ will expose the cervix, which should be seized by a strong, double volsella, fastened into both lips and strong traction made, dragging the uterus well into the vulvo-vaginal outlet.

When the conditions will permit, in order to keep as far away from the base of the bladder and the ureters as possible, the separation of the vaginal attachment to the cervix should be made by keeping as close to the substance of the neck and body of the uterus. The same precaution on the posterior aspect of the uterus will preclude the possibility of wounding the rectum.

In malignant disease, where the infiltration has extended to the vagina, this cannot well be done, and the incision here must of necessity be well away from the limit of induration.

The instrument which will be found most generally useful is the short, curved scissors, which may be either dull- or sharp-pointed, preferably the former. As the dissection proceeds on the anterior surface of the body of the uterus, when the tissues begin to yield readily the dull-pointed scissors may be pushed along the an-

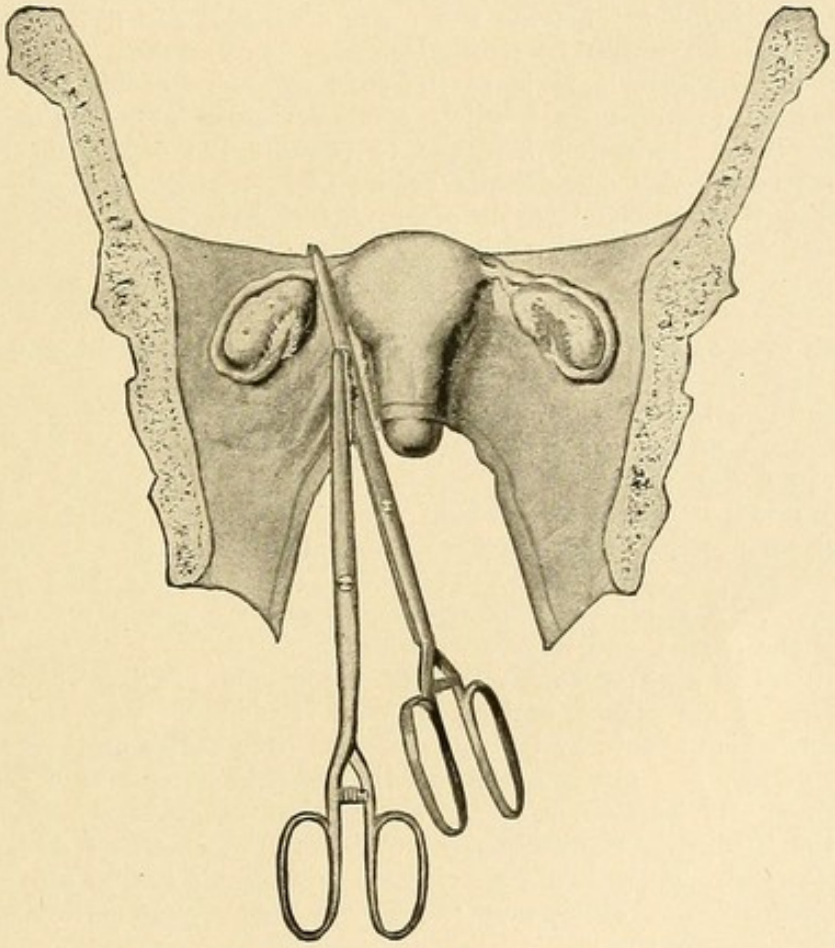

Fig. 641.—Application of Pryor's lock forceps.

terior wall of the uterus into the peritoneal cavity and the opening enlarged by forcibly separating the handles; or the index-finger may be used for this purpose.

As soon as the peritonæum has been entered on the anterior surface of the uterus, the dissection should be carried laterally on each side around the cervix, but not higher than one half inch for fear of cutting the uterine artery.

As soon as the peritoneal cavity is entered posteriorly through Douglas' *cul-de-sac*, the operator should introduce the index-finger in order to determine the presence of adhesions either to intestinal loops or to other organs.

The next step in the operation is the application of Pryor's lock forceps. These instruments are so constructed that they may be clamped in position and the handles removed, thus taking away much of the weight and the sense of dragging and discomfort which was caused by the earlier, heavier forceps. The first pair is applied on one side of the cervix, keeping close to the body of the uterus in order to prevent including the ureter in the clamp (Fig. 641).

A second clamp is applied in the same line as the first, but the point is directed

a little farther out. This second clamp is intended to include the remainder of the broad ligament and to control the ovarian artery as the first clamp did the uterine. Some operators prefer to apply these clamps from above downward.

Both sides being thus securely clamped, the broad ligament with the Fallopian tubes on either side is divided between the clamp and the uterus, and this organ removed. There should be no hæmorrhage, and any oozing which may have occurred should now be removed with gauze swabs, and the cavity packed with plain sterile gauze, as in the vaginal operation for puerperal sepsis. This should be changed on the fourth or fifth day.

The clamps should be removed at the end of forty-eight hours. In order to guard against hæmorrhage, the jaws should be slowly and carefully separated without dragging upon the broad ligaments.

When in an emergency vaginal hysterectomy is deemed necessary, and the lock clamps are not at hand, the uterine and ovarian arteries and other portions of the broad ligament may be secured by strong ligatures of celluloiden linen. When these are employed, it is advisable to leave the ends of each ligature in the vagina so that they may be removed by traction after occlusion of the vessels has been accomplished. This precaution is taken to prevent the possibility of prolonged infection or abscess which occasionally occurs when a non-absorbable ligature has been left within the peritoneal cavity after vaginal hysterectomy.

Tumors of the Parovarium and Ovary

Parovarian cyst originates in the remains of the parovarium between the layers of the broad ligament. In its growth it usually forces the uterus to one side, becoming intimately attached to this organ. In very rare instances a parovarian cyst will break through one of the layers of the broad ligament and become pedunculated. As a rule, however, the attachment of their base is broad. The Fallopian tube and ovary will usually be found on top of the tumor. The ureter is forced out of its normal position, and appears on the anterior surface of the mass. The growth of a parovarian cyst is slow. The early *symptoms* are those of pressure on the other viscera. A careful examination will detect a soft tumor situated close to the side of the uterus, and not very movable.

Treatment.—The high operation is preferable. The ovarian vessels are ligated near the cornua of the uterus, and an incision is made through one layer of the broad ligament, which should be bluntly dissected over the summit of the tumor.

If vessels of any size are encountered, they should be caught with the forceps and tied at once. If isolated, a strong chromicized catgut will suffice; but when portions of the ligament or other tissues are included (ligature *en masse*), linen is the safer material. There is almost always considerable oozing after the removal of a broad ligament cyst which may necessitate a *cul-de-sac* pack and temporary drainage.

Ovarian cysts develop chiefly from the cortex of this organ, in which they may remain small in size for a variable period and then rapidly develop into large tumors, at times almost completely filling the abdominal cavity. They are filled with fluid, which varies in color from a yellow to a dark green, usually of thick consistency and high specific gravity. This fluid is furnished by the epithelial lining of the cyst wall.

Diagnosis.—If the tumor is in the pelvis, it is nearly always found behind the uterus. In its growth it lifts the uterus forward, and is apt to produce pressure symptoms in the bladder. This form of tumor is usually pedunculated, easily movable, and not painful. When large enough to occupy the abdominal cavity, it may at times be mistaken for abdominal dropsy. It may be differentiated from this condition from the fact that the fluid in ascites changes its level with the position of the patient.

Treatment.—The operative procedure has already been given.

Dermoid cysts of the ovary contain hair, bone, teeth, and other rudimentary tissues. The tumor is usually small, with a thick wall and of firm consistency. They are apt to cause considerable pain, and if neglected or overlooked may rup-

ture and cause peritonitis. They should be removed as soon as recognized, and in case of rupture an immediate operation is imperative.

Ectopic gestation may take place in that portion of the Fallopian tube within the uterus (interstitial) or in the free portion of the tube (tubal) or beginning in the tube, it may escape between the folds of the broad ligament (intraligamentous pregnancy). In rare instances it is located between the tube and the ovary, or it may escape into the abdominal cavity. Occasionally an interstitial pregnancy may become freed from its original attachment and escape into the uterus.

Symptoms.—The patient may have all the signs of uterine pregnancy, or they may be entirely absent. Amenorrhœa is present in the larger proportion of cases. When rupture of the tube occurs there is usually a sudden and very sharp sense of pain, often followed by a shock and collapse due to a more or less profuse hæmorrhage.

Should infection occur, peritonitis is apt to develop with great rapidity. After rupture the destruction of the fœtus is inevitable, and operation should be done at the earliest possible moment in the effort to save the life of the mother.

Examination in tubal pregnancy will reveal a mass on one side close to the uterus, which is often quite sensitive under pressure.

Treatment.—Celiotomy should be performed at the earliest possible moment after the presence of ectopic pregnancy is recognized. The embryo and all blood clots should be carefully removed and a thorough toilet made, instituting *cul-de-sac* drainage when indicated.

CHAPTER XXXII

DEFORMITIES

DEFORMITIES OF THE SPINAL COLUMN

Any noticeable deviation from the normal curvatures of the vertebral column constitutes a deformity. They are *congenital* and *acquired*, *temporary* or *permanent*. They are divisible into two great classes, namely, those due to lesions of the column (bones or cartilages), and those due to lesions of the soft tissues (muscles and ligaments). To the former belong dislocations, fractures, destructive ostitis, and spina bifida; to the latter, muscular torticollis, lateral or rotary-lateral curvature (*scoliosis*), stoop-shoulder (*cyphosis*), curvature from pleuritic adhesions, collapse of the lung, contractions of cicatrices following burns, scalds, phlegmon, etc.

Lateral and Rotary-lateral Curvature.—Simple lateral curvature of the spine—that is, a bowing to one side without rotation of the vertebræ—is extremely rare. It may occur in any portion of the column to a slight extent, although rotation is very apt to take place with the curvature. It is more often observed in the cervical region than elsewhere, and is known as *torticollis*, or "*wry-neck.*"

The causes of wry-neck are—1, loss of parallelism, or balance of power between opposing muscles, and 2, cicatricial conditions.

Muscular torticollis is by far the most frequent form, and, in common with all deformities resulting from lesions of the muscles, the right side is usually affected. The right sterno-mastoideus muscle is the principal seat of tonic spasm, or there is partial or complete paralysis of the same muscle of the left side, causing this organ to stand out in relief; the right ear is drawn down toward the clavicle of that side, while the chin points well to the left (Fig. 642). The trapezius not unfrequently is contracted with the mastoid muscle. The splenius, scaleni, platysma myoides, or levator-anguli scapulæ, are less frequently involved. Loss of equilibrium between the muscles of the two sides occurs chiefly in chlorotic patients in whom the normal muscular tone is greatly diminished, rendering the organ of the left (or non-preferred) side unable to resist the more developed muscles of the right half of the body. In other cases the lesion may be situated in the central nervous ganglia, or in the track of the nerve.

Inflammation of the muscular substance (myositis), or of the tendons or sheaths of the muscles, is an occasional cause of wry-neck. Any inflammatory process may lead to shortening of the muscles, and to contractions in the fasciæ and connective tissues of the neck. Muscular torticollis is met with most frequently in the young, may exist at birth, is seen in females oftener than males, and in this class of cases is apt to occur about the age of puberty. In some instances, in addition to the tonic spasm of the muscles involved, a clonic or irregular convulsive movement occurs.

Diagnosis.—The recognition of torticollis is usually free from difficulty. The elimination of caries, dislocation, fracture, and wry-neck caused by cicatricial contractions is determined from the history of the case and by inspection and manipulation.

When one sterno-mastoid muscle is contracted, the chin is pointed to the opposite side, and the occiput made to approximate the clavicle of the side corresponding to the contracted muscle. The splenius capitis draws the mastoid process downward and backward toward the spine of the seventh cervical vertebra.

The *prognosis* in muscular torticollis is usually favorable—less so in clonic

than in tonic muscular spasm. In wry-neck due to contractions of the fasciæ, tendons, etc., the deformity is with difficulty relieved.

Treatment.—Chlorosis, or any dyscrasia, should be treated by tonics and internal medication, by properly selected diet and out-of-door life. The development of the muscles of the left (or weaker) side is essential. Kneading, massage, and electricity will be found useful adjuvants. Mechanical appliances should be used in overcoming the contractions in the offending muscles. Artificial muscles, composed of elastic bands or rubber tubing, more nearly fulfill the indications. The origin and insertion should correspond to that of the normal muscle. A thoracic belt or jacket of plaster of Paris, leather, or silicate of soda, properly adjusted, will serve for the points of fixation of the lower end of the elastic material. The upper insertion near the occiput is best secured by a stall carried around the head above the ears and across the forehead. In order to prevent it from slipping, the portion which rests upon the skin of the forehead should be made of strong adhesive plaster (as advised by Professor Sayre). The tension on the rubber muscle may be increased from day to day, if necessary. If this method does not succeed, the apparatus (Fig. 643) should be tried. The mechanism is well shown in the accompanying cut, the correction of the deformity being effected by means of a series of joints situated at the back of the neck, which are worked by a key, and can be fixed at any angle of flexion and rotation.



Fig. 642.—Muscular torticollis. (After Sayre.)

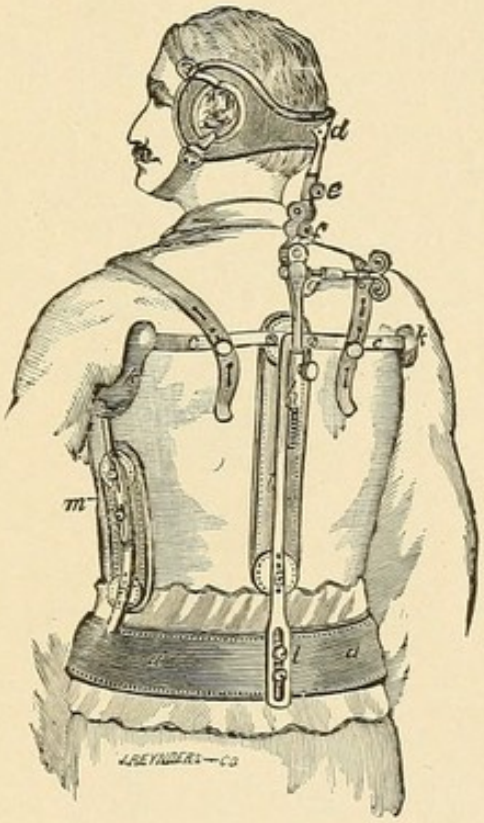

Fig. 643.—Apparatus for the correction of muscular torticollis.

The operative procedures include stretching or division of the muscle or muscles affected, tenotomy, neurectomy, division of the fascia, and the free dissection of cicatricial tissue. Of these operations, tenotomy of the sterno-mastoideus is most frequently demanded. A puncture is made a little to the outer side of the clavicular tendon of this muscle, and a long, probe-pointed tenotome slid flatwise (the cutting edge downward) upon the outer anterior surface of the clavicle. As soon as the point of the instrument has passed between the clavicular and sternal origins, the edge is turned outward, making the muscle tense, and the tendon is divided subcutaneously. The sternal origin is divided by an additional puncture. After tenotomy the prothetic apparatus should be employed until recovery is complete. In dividing the body of this muscle, or the trapezius, splenius, or levator-anguli scapulæ, the open method should be followed.

Violent and sudden stretching of the muscles, with or without anæsthesia, is not advisable. Exsection of that portion of the spinal accessory nerve which is supplied to the sterno-mastoid and trapezius muscles is occasionally performed in

order to paralyze the permanently contracted muscles. It is preferable to a simple division or to stretching of the nerve, for the reason that a divided nerve may reunite, and, after stretching, the function of the nerve is only temporarily impaired.

In order to expose this nerve, make an incision about four inches in length, following the posterior border of the sterno-mastoideus muscle, and commencing on a level with a point half-way between the lobule of the ear and the angle of the jaw. The fibers of the muscle should be sought, and, recognizing these, the posterior edge is exposed. By keeping the wound dry, and working close to the under surface of the muscle the vessels will be avoided and the nerve will be seen running obliquely downward and outward, and passing into the muscle. One or two superficial nerves are sometimes seen radiating from the cervical plexus. From one-half to one inch of the nerve should be excised. After this operation, mechanical treatment should be instituted for a short time.

In torticollis due to cicatrices, simple division of the contracting tissue affords only temporary benefit. The only legitimate method is to dissect out the offending tissue, slide sound skin over the wound thus made, and use mechanical treatment until the deformity is overcome.

Deformities due to *dislocations* and *fractures* of the cervical vertebræ have been considered, and those resulting from *caries* of this portion of the spine will be given hereafter.

Lateral and Rotary-lateral Curvature of the Dorso-lumbar Spine.—Simple lateral curvature of the dorso-lumbar spine is exceedingly rare. It is complicated in almost all cases by rotation of the vertebræ upon each other, and in deformity here from muscular causes, the rotation precedes the lateral curvature.

Lateral curvature is usually caused by an inequality in the length of the lower extremities. Fig. 644 was taken from a boy in whom the right extremity was one

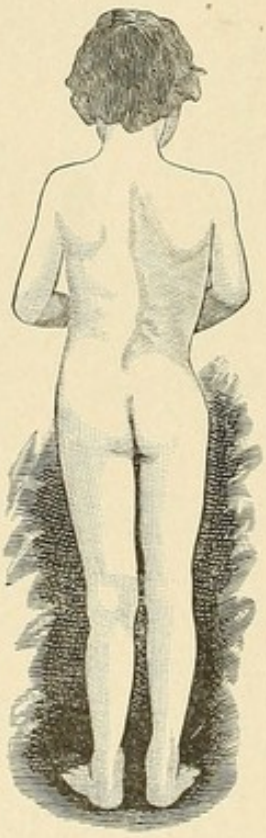

Fig. 644.

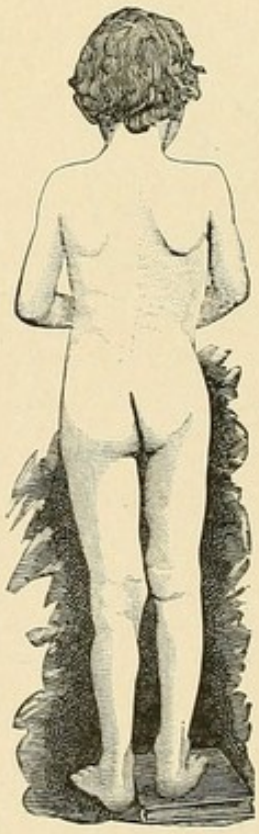

Fig. 645.

and a half inch shorter than the left. With both soles on the same plane, marked lateral curvature (convexity to the right) was observed. By placing the foot of the short side upon a book of the required thickness, the deformity disappeared (Fig. 645).

Inequality in the length of the lower extremities is not uncommon, even in

individuals who have not suffered from injury or disease. A difference of as much as one inch has been noted, while from one half to one fourth inch is quite common.

Cicatricial contractions on one side of the chest or abdomen, as after extensive burns or in chronic pleuritic adhesions with collapse of the lung, also produce this deformity. The treatment will be considered with that of rotary-lateral curvature.

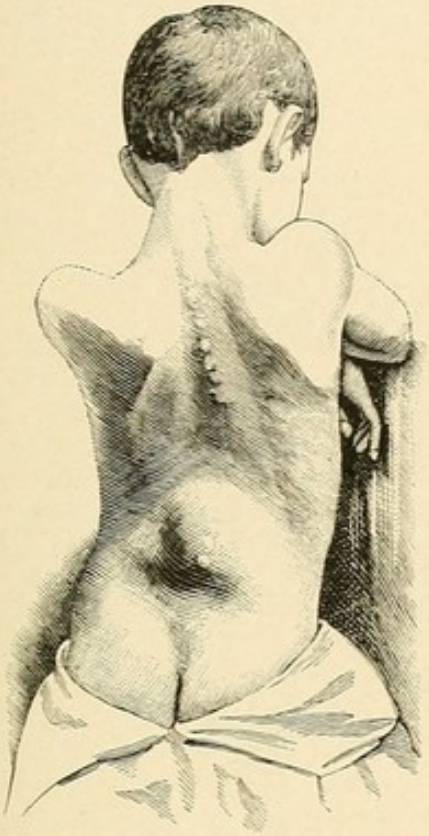

FIG. 646.—Lateral curvature after recovery from lumbo-sacral spondylitis.

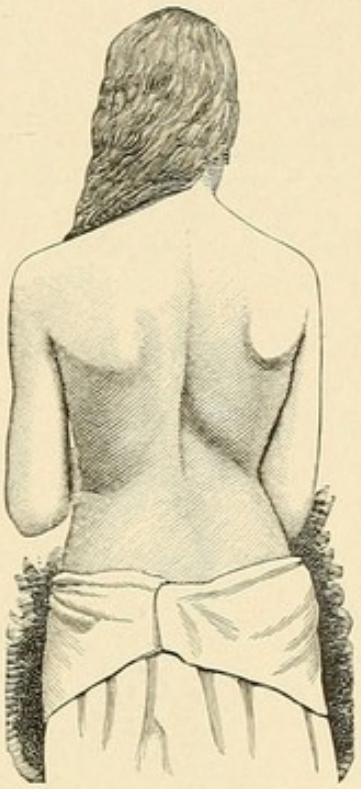

FIG. 647.—Rotary-lateral curvature in a girl fifteen years of age.

Rotary-lateral Curvature.—Rotation of the bodies of the vertebræ upon each other, and upon the sacrum and subsequent or simultaneous lateral curvature, is one of the most difficult deformities to correct. The chief cause is loss of the normal equilibrium of the muscles of the two sides of the trunk. The tendency to deformity is increased by the habit of sitting sidewise at the table or desk, with one shoulder drooping while the other is elevated, or in the twisted and unnatural position which females on horseback assume. A large majority of those affected are chlorotic girls, between thirteen and eighteen years of age, although this deformity is occasionally met with in muscular and healthy porters or laborers who habitually carry heavy weights upon one shoulder. The rotation most frequently commences in the lumbar region. The spines are pointed to the right, while the anterior aspect of the bodies of the vertebræ are made to look toward the left. The convexity of the curve is to the left, the right shoulder is prominent, the apex tilted outward, the angles of the ribs on this side project abnormally, and there is a folding in or wrinkling of the skin between the iliac crest and the thorax (Fig. 647).

The chief agent in this distortion is believed to be the latissimus dorsi muscle. Acting upon the tips of the long spines of the lumbar vertebræ from its insertion in the humerus (and indirectly through the pectoralis major, from the clavicle and sternum), the spines are twisted to the right, causing the rotation of the bodies to the left; the shoulder-blade is tilted outward, and the ribs are bent under the contraction of this long and comparatively powerful muscle.

In some instances the abdominal muscles take part in the unilateral contraction, while in others the deformity commences with the rotation of the dorsal vertebræ by the action of the serratus magnus, rhomboidei, and deep short muscles of the

back. No matter where the primary curve takes place, a second or compensatory curve follows in all chronic cases.

The *diagnosis* of rotary-lateral curvature will depend upon the prominence of the shoulder-blade, bulging of the ribs, and the approximation of the crest of the ilium and thorax of the right (or affected) side. Caries of the spine may be eliminated by the absence of abnormal temperature, freedom from pain when direct pressure is made from the head along the vertebral column, and absence of symptoms of compression of the cord or nerves in the intervertebral notches. Psoas abscess is present in a certain proportion of cases of ostitis of the vertebræ.

In *simple lateral* curvature the ribs are not projected, as when rotation occurs, nor is the tip of the shoulder-blade so prominent.

The *prognosis* varies with the character of the lesion. In recent lateral curvature, due to inequality of length in the extremities, it is favorable. In rotary-lateral curvature, within the first few months of the lesion, a cure may be effected. In old cases, while the deformity may be arrested, it is difficult and often impossible to restore the normal contour of the spine and ribs.

Treatment.—When the lesion is due to loss of equilibrium in the muscles of the two sides, especial attention should be directed to the development of the organs of the weaker side, and at times it is necessary to impair the nutrition of the muscles of the stronger half of the trunk. When the deformity is on the right side, the muscles of the left arm and side should be exercised by the use of the dumb-bells, elastic strap, swing, or horizontal bar. It is often advisable to place

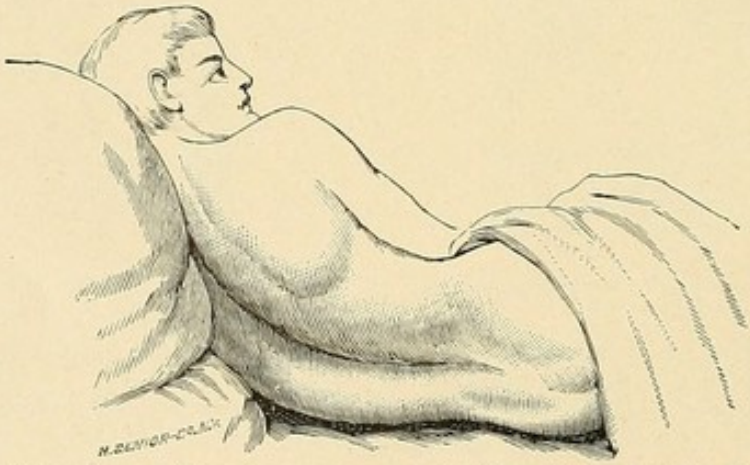

Fig. 648.—Patient lying in a position to overcome contraction of the muscles of the *left side* of the abdomen and thorax. (After Reeves.)

the right arm and hand in a sling, to prevent the further development of these muscles. Massage or kneading, confined to the left half of the body, and the galvanic current to the same region two or three times a week, will be advisable. Tonics, judicious feeding, and out-of-door life are essential features of treatment. The patient should be directed to sit squarely upon the buttocks, and not to droop or loll to one side. In reclining, the body should be placed in such a position that the offending muscles are put upon the stretch (Fig. 648). The deformity is temporarily overcome by the employment of Wolff's cradle (Fig. 649). The belt passes over the projecting ribs and shoulder-blade, thus bringing the weight of the trunk upon these parts, while gravity aids in overcoming the curvature in the lumbar region.

In a certain proportion of cases, mechanical support of the thorax is indicated, especially in those cases where from muscular weakness it is almost impossible to hold the spine erect. For this purpose the plaster-of-Paris jacket or the perforated corset may be used. The latter (Figs. 650, 651) I have found very satisfactory. It is to be commended, for the reason that it can be readily removed at night, and is more cleanly than a permanent plaster jacket. When the gypsum is applied it should be split down the front, taken off and fixed for lacing so that it may be removed when necessary.

This perforated corset is made as follows: A plaster-of-Paris jacket is applied as hereafter directed, and as soon as this hardens (in from ten to thirty minutes) it is split down the median line in front, removed from the body, and the cut

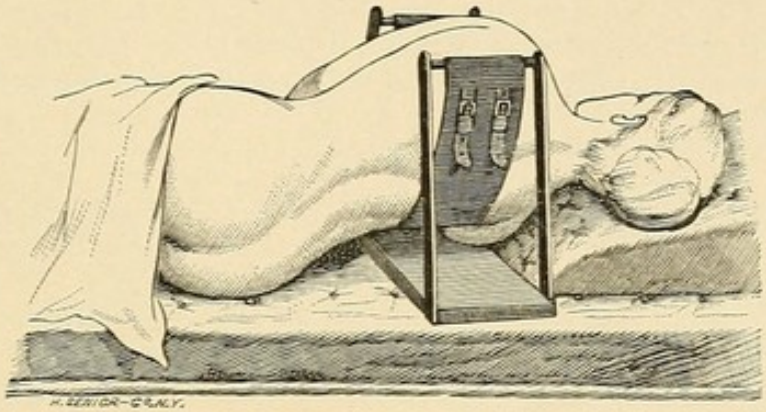

Fig. 649.—Wolff's suspensory cradle. Patient in position when the contraction is on the right side (with the right shoulder-blade and ribs projecting). (After Reeves.)

edges placed and held in apposition by a bandage carried around and over the entire jacket. This shell is to be used as a mold in which a cast of the deformed thorax is to be made. It is thoroughly greased on its inner surface, placed upon the floor, and filled with stiff plaster mortar. When this hardens, the shell is removed, leaving an exact cast of the thorax, upon which the corset is to be built.

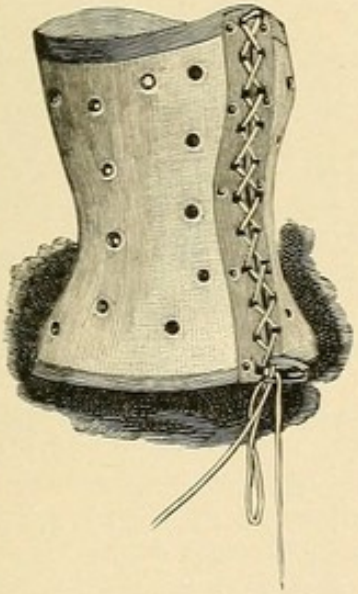

Fig. 650.—Corset made after Vance's method.

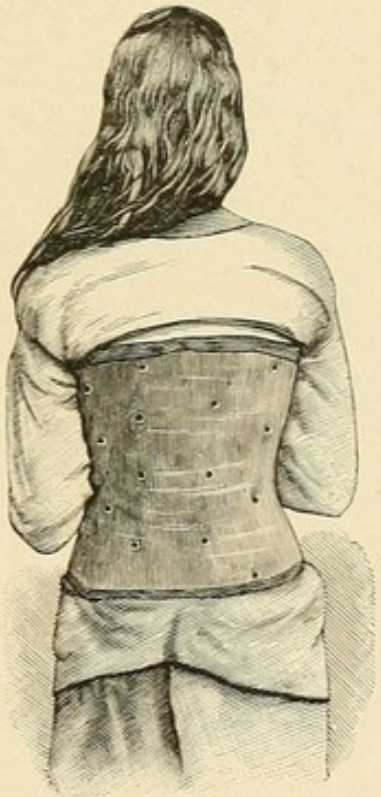

Fig. 651.—The same, applied.

The materials needed are white glue, ordinary muslin rollers, flat spring steel about one eighth of an inch wide and very thin, and one yard of Canton flannel. Place the flannel with the soft plush next to the plaster, and stitch this tightly to the model, so that it is not wrinkled. It should be sewed only along the middle line in front. The glue should now be dissolved in warm water. Strips of bandage about two feet long and two inches in width are dipped in the glue and laid on the flannel which is around the model. As soon as a single thickness has been applied, strips of the steel wire, cut not quite as long as the corset, are placed one inch apart over its entire surface, and held in place by a string wound around as

they are laid on. A long, dry roller is next carried around the model from above downward, and drawn so tight that the steel springs are made to conform exactly to the surface of the corset. Upon this two additional layers of the short strips of roller dipped in glue are laid. The corset should be left for several hours in the hot sun, or by a fire, until it is thoroughly dried. It is then split down the front, removed, and the edges bound with chamois skin. Hooks for lacing should be fastened along the edges in front. Perforations may be made between the springs with a wadding punch. This apparatus, when properly made, fits accurately about the body in the most favorable position for the correction of the deformity. It can be removed at night upon retiring, and for bathing, changes of clothing, massage, and electricity. It is lighter and cleaner than the plaster-of-Paris jacket. When the necessary materials cannot be had, the plaster jacket should be employed.

Dr. Newton Shaffer, of New York, recommends the apparatus used by him in a large experience, and shown in the accompanying cuts. The pelvic band and



Fig. 652. — Scoliosis or rotary-lateral curvature.

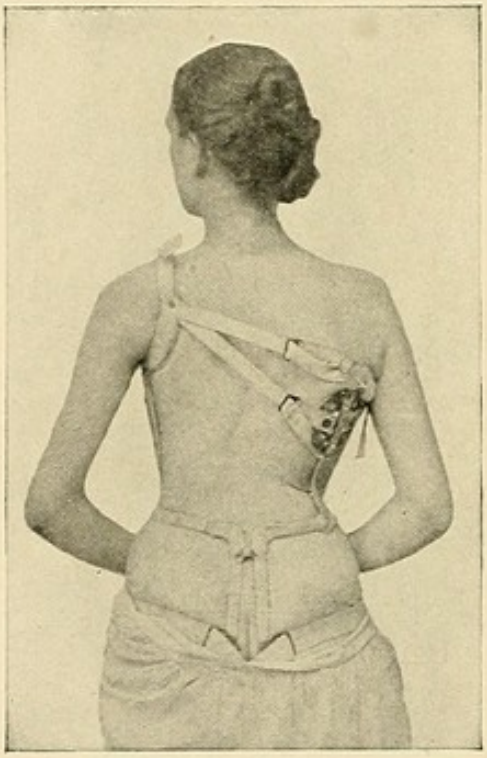

Fig. 653.—The same, with Shaffer's rotary-lateral curvature apparatus applied.

straps support a perpendicular bar, which terminates in the axilla of the unaffected side, and from this bar the traction force is exerted. The perforated metal shield presses upon the angles of the distorted ribs (Fig. 653).

Operative interference in muscular scoliosis is rarely called for. In extreme cases, when the latissimus dorsi of one side is greatly shortened and increased in development, correction of the curvature may be expedited by the subcutaneous division of this muscle.

When lateral or rotary-lateral curvature of the spine results from inequality in the length of the lower extremities, the first indication in treatment is to elevate the shoe of the short side, and thus bring the plane of the iliac crests at a right angle to the axis of the vertebral column. If the deformity is not entirely corrected by this plan, the measures just detailed should be also employed.

When the deformity is caused by superficial cicatricial contractions, their division is essential. In pleuritic adhesions, with collapse of the lung, the treatment given for rotary-lateral curvature due to muscular asymmetry should be adopted.

Anterior and Posterior Curvature of the Spine.—Anterior curvature, or "stoop shoulder," usually occurs in the dorso-cervical regions; occasionally the entire

column is involved. It may be caused by—1, partial or complete paralysis of the erector muscles of the back; 2, tonic spasm of the abdominal muscles; 3, from inadvertence, as in the habit of allowing the shoulders to droop forward, with or without the carrying of burdens; 4, cicatricial contractions in the anterior thoracic and abdominal regions; 5, heredity.

Complete paralysis of the muscles of the back is exceedingly rare. Unilateral paresis is not altogether uncommon. The most frequent condition is one of general impairment of muscular tone, the head and upper spine gravitating forward as the muscles yield, until the posterior ligaments are elongated and the anterior margins of the intervertebral disks narrowed by compression. The habit of carrying a heavy burden upon one shoulder is more likely to induce rotary-lateral curvature than *cyphosis*. The indications are to correct the deformity by the use of braces, and to increase the tone of the muscles, the nutrition of which is impaired.

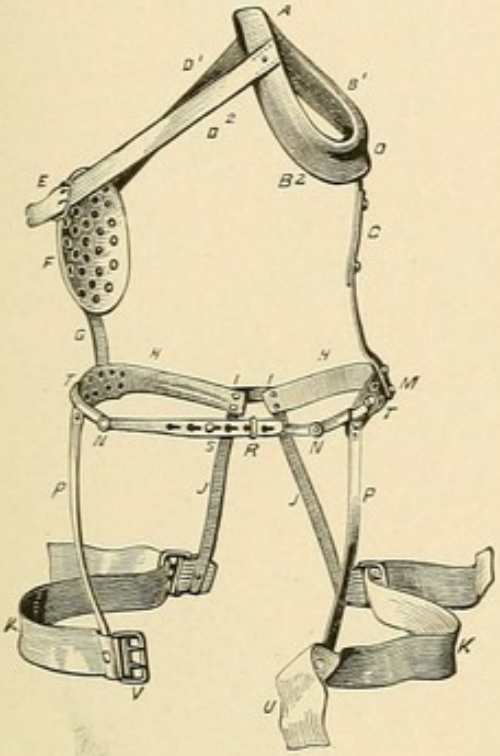

Fig. 654.—Shaffer's apparatus for correcting scoliosis.

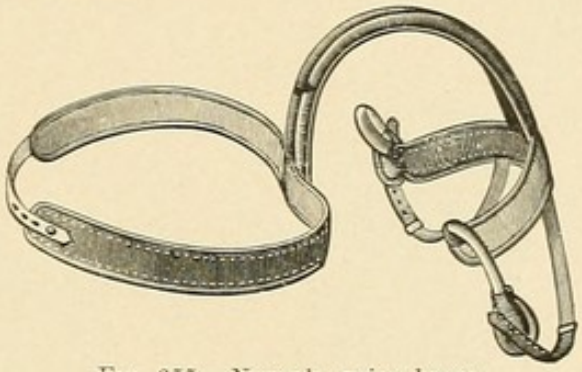

Fig. 655.—Nyrop's spring brace. (After Reeves.)

To meet the former, in mild cases a double elastic brace, such as is shown in Fig. 655, will be sufficient. Massage, electricity, tonics, and out-of-door life are also essential features of treatment.

Posterior curvature of the spine, *lordosis* or "sway-back," is far less frequent than the condition just described. It occurs almost always in the lumbar region. In the later months of pregnancy it is a common condition, and is met with in individuals with unusual development of the stomach and abdominal viscera, or in cases of chronic abdominal tumor (fibroid, etc.).

Spondylitis.—Destructive ostitis of the vertebræ, commonly known as Pott's disease, occurs usually between the third and fifteenth year of life. In exceptional instances it is observed prior to three years of age, while not more than one fifth of all cases occur after the fifteenth year. It is therefore eminently a disease of the growing period, when rapid nutritive changes are taking place in the bones.

While no portion of the spine is exempt, the disease is much more frequent in the dorsal vertebræ, which are involved in about two thirds of all cases. The lumbar and cervical portions of the column are about equally liable to destructive ostitis. Occipito-cervical disease is rare. Ostitis in the lower cervical region is apt to involve the upper dorsal by extension, and the same is true of ostitis of the lower dorsal in their relation to the lumbar vertebræ. Lumbo-sacral disease is not altogether uncommon. Destructive ostitis of the spine is divided into *occipito-cervical, cervical, cervico-dorsal, dorsal, dorso-lumbar, lumbar,* and *lumbo-sacral,* according to the recognized location of the disease.

Causes.—Tuberculous infection is the cause of Pott's disease in a large majority of cases. The bacillus tuberculosis is especially liable to attack the cancellous tissues of the vertebræ, which bones, together with the sternum and ribs, are the

last to take on the changes of adult life. In the pathology of ostitis it was shown that the medulla of these bones remains in the red or embryonic condition long after the marrow of other bones has undergone the adult or yellow change, and that consequently they are for a prolonged period liable to accidents consequent upon rapid nutritive changes, and especially to capillary rupture and extravasation. Although a fall upon the feet or hands, or violent flexion of the spine, or a blow upon the sternum or ribs, or a penetrating wound, may lead to destructive ostitis, yet destructive inflammation of these structures as a result of traumatism is comparatively rare. Carcinoma and sarcoma of the vertebral column is very infrequent. Destructive ostitis of one or more vertebræ is occasionally caused by pressure from aortic aneurism.

Clinically, destructive ostitis is met with in two forms—the dry and the suppurative. The latter variety is more common. In dry ostitis pyogenic infection does not occur, the bone cells undergo granular metamorphosis, and, together with the inorganic salts of this tissue, are absorbed. In these cases the breaking down of the bodies of the vertebræ, to the extent of marked deformity, may occur without recognized febrile movement. In the suppurative form, when mixed infection occurs, the destructive process is more rapid, and is accompanied by the formation of a variable quantity of embryonic tissue, the bone breaks down in bulk, and particles varying in size appear in the pus which results from the inflammatory process. The earliest pathological change in such cases is in the cancellous tissue of the body. In rarer instances the lesion commences as a synovitis in the costo-

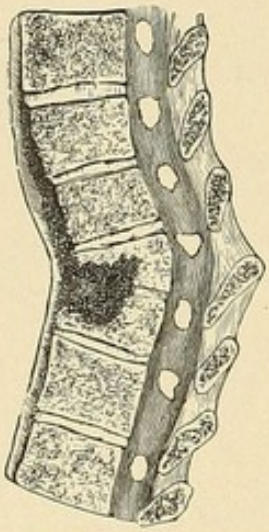

Fig. 656.—Destructive ostitis of the anterior portion of the bodies of the vertebræ. (After Noble Smith.)

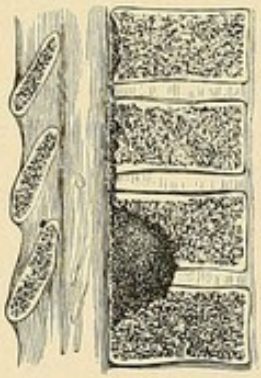

Fig. 657.—The same process in the posterior portion of the bodies of the vertebræ. (After Noble Smith.)

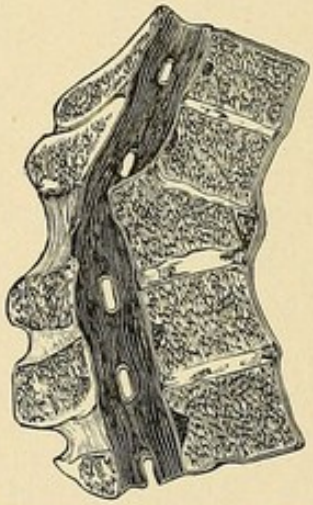

Fig. 658.—Deformity resulting from fracture of a vertebra. (After Noble Smith.)

vertebral or interarticular joints, whence the disease may invade the intervertebral disks and bodies. Primary inflammation of the intervertebral fibro-cartilage is believed to be very rare. As the destructive process continues, the cancellous tissue of the body, and chiefly of the anterior portions of the column, breaks down (Fig. 656), causing abnormal curvature, with sharp projection of the spinous processes. The angular deformity is less apt to be present when the disease attacks the posterior portion of the body, where the superincumbent weight in great part falls upon the articular processes (Fig. 657).

Symptoms.—The clinical history of Pott's disease may be divided into two stages: The *first stage* includes all the phenomena which occur up to the time when deformity is recognized; the *second stage* embraces all the changes met with after deformity. The usual symptoms of the first stage are pain and muscular rigidity, with varying exacerbations of temperature. *Pain* may be elicited when the patient assumes the erect posture, by direct pressure upon the spines of the vertebræ involved, and by concussion of the column transmitted from the head downward. When the bodies alone are involved (the usual condition) it may be lessened or

made to disappear entirely by suspension of the patient from a portion of the column above the lesion; by bending the spine backward, thus throwing the weight upon the healthy articular processes; or by laying the patient face downward across the surgeon's lap, and making extension by separating the knees.

Muscular rigidity is recognizable in a majority of instances, and in children may be observed as a symptom of pain, when the presence of pain is denied. Fixation of the dorsal muscles is evident in the stiff and unusual manner in which the back is held as the patient moves about, and in the awkward posture assumed while sitting down. If directed to bend the vertebral column, as in stooping to pick up something from the floor, the movements are cautious and constrained, altogether lacking in the celerity and suppleness which are seen in flexion and extension of the vertebral column in health. In the earlier stages pain is dull and steady in character, and is usually local, being confined to the neighborhood of the part affected.

Elevation of temperature may be present at any stage of Pott's disease. It is, as a rule, the index of pyogenic infection with inflammatory and destructive processes. The thermometer may register from the normal as high as 101°–102° F., and only in exceptional instances as high as 104°. In a fair proportion of cases in the early stages, and especially in the dry form of ostitis, no elevation of temperature can be detected.

The *second stage* of the disease, that of deformity, may be present in the course of a few weeks after the appearance of the first stage, or several months may elapse. All of the symptoms of the preceding stage are present in the second stage of Pott's disease. If proper treatment has not been instituted, interference with the functions of the cord at and below the seat of lesion, or of the nerves which pass out between the diseased vertebræ, is apt to occur, from displacement of the bones or as a result of inflammatory products pressing upon the spinal cord and nerves. Paralysis of motion and sensation, in a varying degree, occurs in a certain proportion of cases.

When deformity occurs the convexity of the curve is posterior in about ninety-five per cent of all cases. The "knuckle" may consist of a single spinous process (Fig. 656), or several spines may project, as in Fig. 658.

The degree of deformity depends upon the location of the disease, its extent, and in part to general relaxation of the erector muscles. It is greater when the lower cervical and upper dorsal vertebræ are involved (Fig. 659). The formation of pus and the resulting abscess and sinuses belong chiefly to the last stage of ostitis of the spine. The abscess may travel along the psoas muscle, opening near the middle of the groin above or beneath Poupart's ligament, the pus may escape through the inguinal canal, over the iliac crest, or through the sacro-sciatic notch; or it may be arrested at a higher point and escape recognition, unless careful examination is made under ether narcosis.

Spinal abscess is usually single, occasionally double. When occurring in the upper dorsal region it may be arrested by the diaphragm, or pass behind this into the sheath or fascia of the psoas muscle. Abscess in ostitis of the bodies almost always travels downward on one or the other side of the antero-lateral aspect of the spine. When the articular processes or laminæ are involved, the pus may penetrate the dorsal muscles and point posteriorly.

In occipito-cervical or upper cervical spondylitis, the pus collection often appears at the posterior wall of the pharynx (*retropharyngeal abscess*). Interference with deglutition and phonation is not infrequent. The contents of an abscess resulting from destructive ostitis of the cervical vertebræ may also descend along the deep fascia of the neck and pass into the thorax or the mediastinum. In this manner it occasionally finds its way into the pericardium.

Amyloid changes of the viscera are among the late symptoms of chronic spondylitis.

Diagnosis.—In general the recognition of the disease will depend upon a history in accordance with most of the symptoms just detailed. As to the portion of the column involved, the appreciation of localized pain by direct or indirect pressure is an indication of value. When the efferent nerves are involved by pres-

sure from the products of inflammation, certain disturbances in their course or distribution are of diagnostic importance. Spasm of the larynx, pharynx, diaphragm, pain down the arm, etc., naturally attract attention to the points of exit of the nerves supplying these parts. When tenderness in the region of the psoas muscles is evidenced by habitual indisposition to extend the thighs, lumbar ostitis

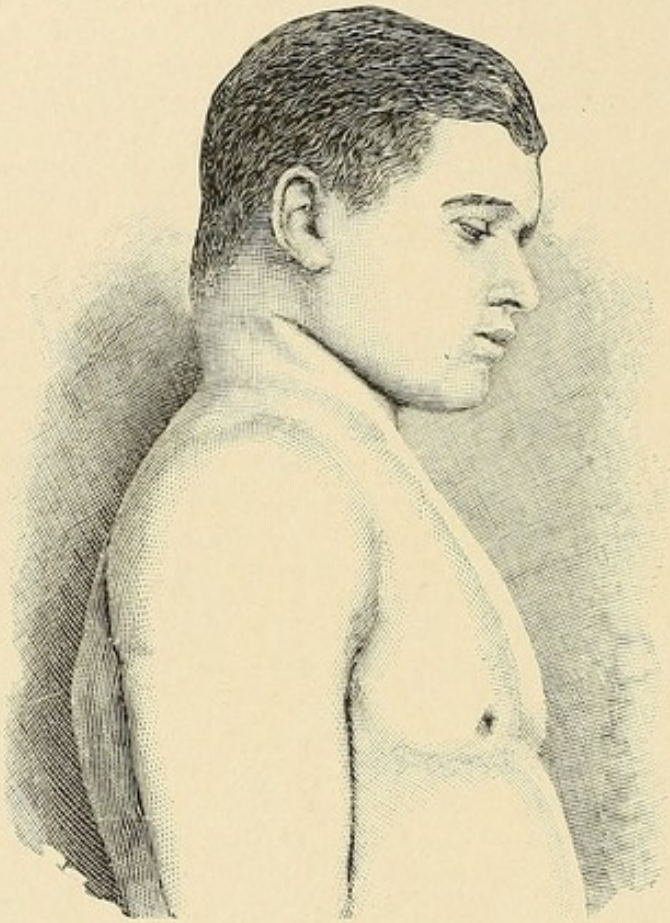

Fig. 659.—Caries of the bodies of the third, fourth, and fifth cervical vertebræ.

may be suspected. When the gibbosity is recognized, a diagnosis is no longer doubtful. The early recognition of abscess in the abdominal region is possible only by palpation under profound narcosis.

If the articular processes are diseased, bending of the spinal column backward will increase the pain. Placing the patient on the abdomen, with the head and lower extremities depressed, will diminish it. When the bodies and intervertebral disks are involved, bending the spine backward will reveal the pressure symptoms.

Treatment.—In the mechanical treatment the indications are to secure fixation of the spinal column in the position of least discomfort to the patient. Judicious medication, good food, and pure air are the indications in the constitutional treatment. The character of the mechanism to be used will depend in good part upon the portion of the vertebral column involved. It is essential, in order that any apparatus may fully meet the indications, that not only shall the diseased bones and the healthy tissues be held practically immovable, but the superincumbent weight be lifted. Fixation may be accomplished by any form of well-adjusted apparatus, but lifting the weight of the body, which is above the seat of disease, is a more difficult undertaking.

The downward pressure upon the bodies when, as is usual, these structures are involved and breaking down, can be in great part obviated by extension or backward bending of the spine, in which manœuvre the pressure is transferred from the bodies and intervertebral disks to the articular processes and pedicles.

Much of the apparatus devised for the arrest and cure of Pott's disease is based

upon this principle. Another method is based upon the principle of lifting the parts above the seat of the lesion, and removing in part the pressure, not only from the bodies but also from the articular processes (extension and counter-extension, or suspension).

To accomplish the former the spinal braces of Drs. Davis, Taylor, and Shaffer have been constructed. For complete extension or lifting, the plaster-of-Paris jacket or the jury-mast of Professor Sayre, and the suspension carriage of Dr. Meigs Case, more nearly meet all the indications.

In appropriate cases each of these forms of apparatus, if properly adjusted and intelligently worn, will accomplish all that is possible in the mechanical treatment of Pott's disease. Much of the discredit which is brought upon any particular apparatus can justly be charged to the lack of judgment in the selection of cases, want of skill in the adjustment of the instrument, and failure on the part of the attendant or patient in persisting in its use a sufficient length of time.

The selection of the apparatus best adapted to succeed will depend upon the location of the disease and the age and conformation of the patient. Clinically the spinal column is divisible into three regions: 1, embracing the occipito-cervical articulation, the cervical vertebræ, and down to the third dorsal; 2, from the third to the tenth dorsal; 3, from the tenth dorsal to the sacro-lumbar articulation.

The lower region is more amenable to treatment, the upper next, while the middle region, which is most frequently involved in ostitis, is the most difficult to manage.

Third Region.—In the mechanical treatment of Pott's disease in the third region, Sayre's plaster-of-Paris jacket, of light make and properly adjusted, will give great satisfaction. In its application the following articles are essential:

1, A suspension apparatus; 2, a tight-fitting, seamless, knit shirt; 3, plaster-of-Paris bandages. The suspension apparatus (Fig. 660) consists of an iron cross-

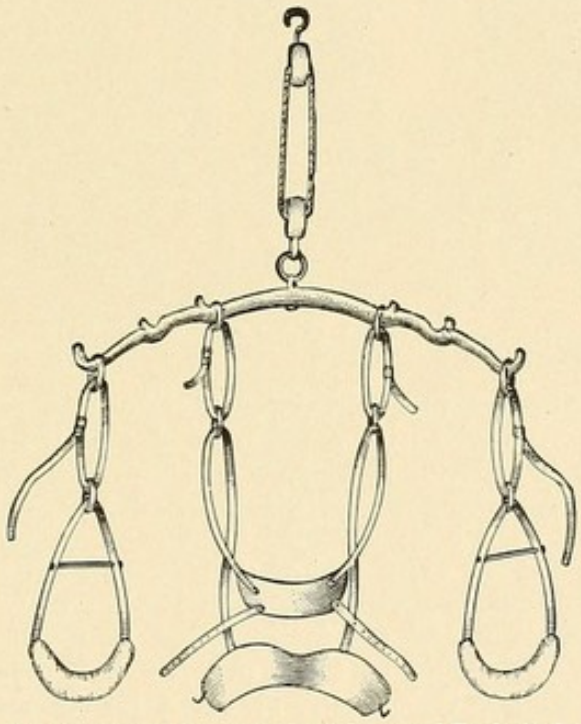

Fig. 660.—Suspension apparatus for applying plaster-of-Paris jacket. (After Sayre.)

bar from which are suspended padded loops for each axilla, and a chin and occiput swing for lifting from these points. The crossbar is attached at its center to a block and pulley. After the knit shirt is applied, the arms of the patient are slipped through the padded loops while the collar is buckled around beneath the chin and occiput. The center and lateral suspension straps should be adjusted so that when the lift is made the tension will be equally distributed. The block of the pulley apparatus may be fastened to a hook in the ceiling or to the tripod

(Fig. 661). The plaster bandages—the method of preparing which is given on page 29—should be perfectly fresh and well made, for a good deal of success depends upon the quality of the gypsum and the thoroughness with which it is worked into the meshes of the crinoline. As the direction for applying this jacket,

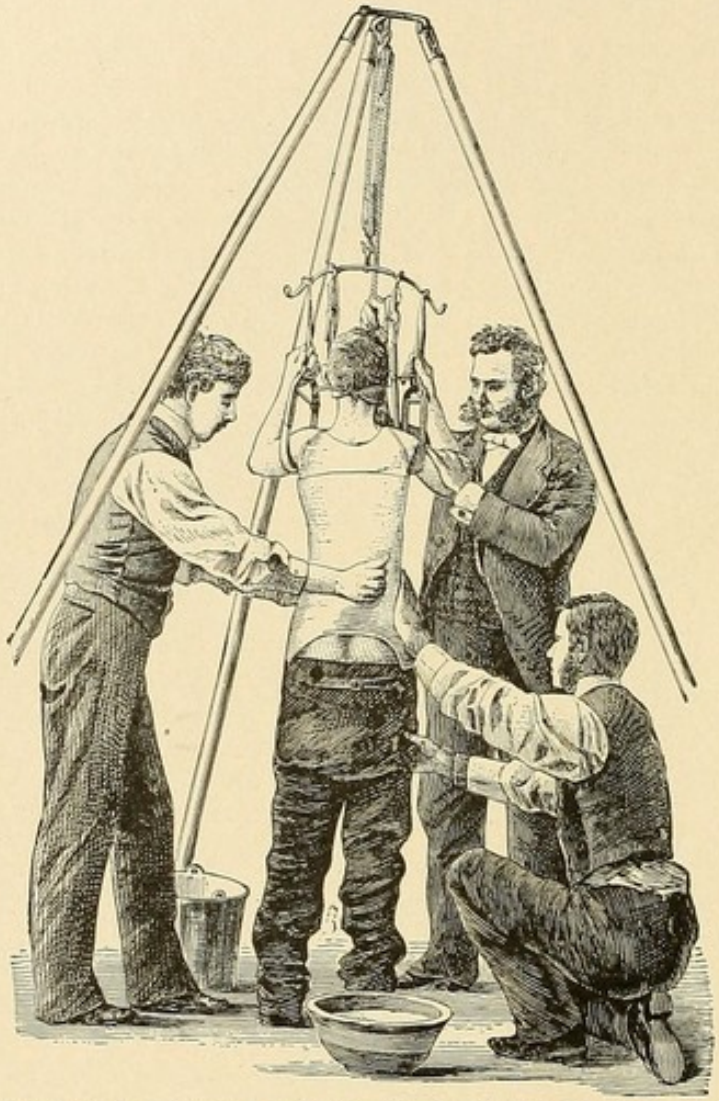

Fig. 661.—Suspension apparatus and tripod in position for lifting. (After Sayre.)

as given by Professor Sayre—to whom the profession is indebted for bringing it so prominently into use—cannot be improved upon, I give it in his language:

"Before applying the plaster bandage, I place over the abdomen, between the shirt and the skin, a pad composed of a towel folded up so as to form a wedge-shaped mass, the thin edge being directed downward. This is intended to leave room, when removed, for the expansion of the abdomen after meals, and so I call it the 'dinner pad.' It is important to make it thin where it comes under the lower edge of the jacket, or else the jacket would fit too loosely about the lower part of the abdomen. It should be taken out just before the plaster sets. It is always a good plan to get the patient to eat a hearty meal before the jacket is applied, but this precaution of allowing room for meals should never be neglected.

"If there are any very prominent spinous processes which, at the same time, may have become inflamed in consequence of pressure produced by instruments previously worn, or from lying in bed, such places should be guarded by little pads of cotton or cloth, or little glove fingers filled with wool placed on either side of them. Another detail, which I have found to be of practical value in some cases, is the application under the shirt, over each anterior iliac spine, of two or three thicknesses of folded cloth three or four inches in length. If these little pads be

removed just before the plaster has completely set, such bony processes will be left free from pressure.

"If the patient be a female, and especially if she be developing at the time, it will be necessary to apply a pad under the shirt over each breast before the plaster bandage is put on. These pads should be removed just before the plaster sets, and at the same time slight pressure should be made over the sternum for the purpose of indenting the central portion of the plaster jacket, and of thus giving form to the body, and of removing pressure from the breasts.

"The skin-fitting shirt having been tied over the shoulders, and then pulled down, and kept stretched by means of tapes applied, one in front, the other behind, near its lower edge, and tied tightly over a handkerchief placed on the perinæum, the patient is to be gently and slowly drawn up by means of the apparatus until he feels perfectly comfortable, and *never beyond that point*, and while he is retained in this position the plaster bandage is to be applied. A prepared and saturated roller, which has been gently squeezed to remove all surplus water, is now applied around the smallest part of the body, and is carried around and around the trunk downward to the crest of the ilium, and a little beyond it, and afterward from below upward in a spiral direction, until the entire trunk from the pelvis to the axillæ has been incased. The bandage should be placed smoothly around the body,



Fig. 661*a*.—Sayre's extension as employed on Downey's table.

not drawn too tight, and especial care taken not to have any single turn of the bandage tighter than the rest. Each layer of bandage should be rubbed most thoroughly with the hand by an assistant, that the plaster may be closely incorporated in the meshes of the crinoline, and bind together the various bandages which make up the jacket, thus making it much stronger than if attention is not paid to this particular. If you notice any spot which seems weak or likely to give way, pass

the bandage over it, and then fold it back on itself, and do this until you have placed several thicknesses of bandage over this point, being careful to wet all well together, and then pass a turn completely around the trunk to retain any ends which might have a tendency to become detached.

"In a very short time the plaster sets with sufficient firmness, so that the patient can be removed from the suspending apparatus, and laid upon his face or back on a hair mattress, or—what is preferable, especially when there is much projection of the spinous processes or sternum—an air bed. Before the plaster has completely set, the dinner pad is to be removed, and the plaster gently pressed in with the hand in front of each iliac spinous process, for the purpose of widening the jacket over the bony projections. In the case of a young child with a small pelvis it may happen that the circumference of the body at the umbilicus is as great as around the pelvis, but, as the soft parts in the lumbar region allow us to mold the plaster as we choose, you can still obtain a point of support at the pelvis; if, as the jacket hardens, you will press it in at the sides above the ilium, and in front and rear above the pubes, the antero-posterior diameter above will be the longer, while below it will be the transverse one."

When the angular projection is extreme, or when an ulcer exists, it will be advisable to cut a hole in the jacket at this point large enough to prevent any undue pressure. In case of abscess, a window of sufficient size to allow free drainage, and a frequent change of dressing, should be made.

The commendable features of this plan of treatment are the extension obtained by suspension, fixation by the plaster while in the most favorable position, and the cheapness and readiness with which it may be employed.

The objections are, uncleanliness by reason of the immovable nature of the apparatus, and the excoriations which are a cause of considerable complaint. The first objection may be met by splitting the corset down in front and reapplying it each time while the patient is suspended, and making it tight by a roller carried around the body several times; or a row of hooks may be fastened on either side of the line of section and corset-lacing used to hold the jacket closely adjusted. As for excoriations, it may be said that no apparatus which grasps the body tight enough to secure fixation is free from this danger. When they occur with the plaster jacket, the fault generally lies either in the improper manner of its application or carelessness on the part of the attendant.

Second Region.—When the middle or dorsal region is involved, the plaster jacket is not so serviceable as in ostitis of the vertebræ in the lower region of the spine, although much good will be accomplished by the partial fixation of the thorax as high as to the level of the axillæ. The efficacy of this method diminishes the higher the diseased process is located, and, when the lesion invades the sixth dorsal, or above this point, the jacket without head suspension is almost useless. In all cases of Pott's disease above the tenth dorsal, suspension of the head or elevation of the chin is an essential feature of treatment. A favorable result would be achieved in a greater proportion of cases if this point were insisted upon, and the prejudice against the suspension apparatus or chin-lift overcome.

In the application of the jury-mast the patient should be suspended as just described, and a plaster jacket applied from just above the trochanters up as high as the axillæ. After two layers of the plaster bandages have been applied, the jury-mast is adjusted, and its framework covered in with the succeeding layers of bandage. The jury-mast (Fig. 662) consists of a back piece, in shape not unlike the inverted letter U, made of soft iron, which enables it to be accurately molded to fit the surface to which it is applied. To this are fastened two or three strips of tin, made rough by a series of perforations with an awl. To the upper end of the back piece a curved bar of light steel is attached, in such a manner that it can be raised or depressed at will. At the end of this crane is a light cross-bar, hooked at each extremity, from which the collar is suspended. After the first two layers of plaster bandages have hardened, the apparatus is bent to fit the surface of the back, and is adjusted to the jacket, with the middle piece or crane exactly in the median line of the back of the neck and occiput, and its extremity over the center of the top of the head, so that traction by the strips will be directly

upward. It is fastened by carrying plaster rollers over the tin strips and back piece, and working in plaster mortar. When the plaster hardens, the apparatus is immovably incorporated into the jacket. The suspension collar should now be buckled beneath the occipital protuberance, and the strips tightened enough to lift the weight of the head from the neck. The jacket may be converted into a movable corset by splitting it along the middle line in front and attaching hooks for lacing (Fig. 662*a*). If the jury-mast cannot be applied in ostitis involving the vertebræ between the third and ninth dorsal, Shaffer's modification of Taylor's brace should be preferred.

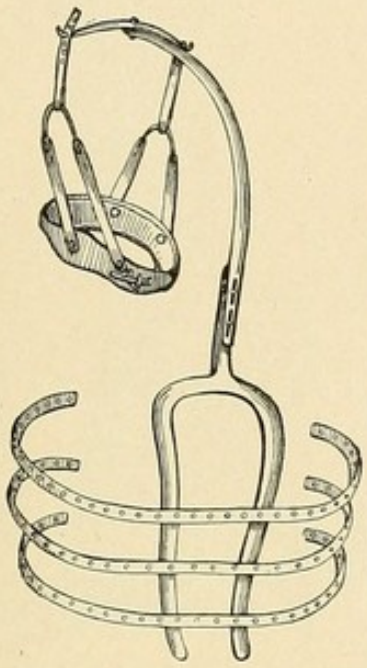

Fig. 662.—Sayre's jury-mast head-swing. (After Sayre.)



Fig. 662*a*.—Jury-mast apparatus applied. (After Sayre.)

"The patient is placed prone upon two tables of equal height, and the tables are then separated so that the diseased area may be freely accessible from all sides. One assistant grasps the patient under the axillæ, the other makes steady but easy traction at the thighs. While the patient is in this prone position the operator fits the uprights to the line of the transverse processes; in other words, adjusts the apparatus to the deformity. A pair of 'monkey-wrenches' may be easily used as a pair of levers with which to bend the annealed steel uprights into *any* shape. It takes but a few moments to adapt the uprights to the deformity. The traction is affording relief, and is not producing any injury. Then the apparatus is laid on the back accurately, traction is steadily maintained, and the thoracic and pelvic straps are fastened. When the operation is complete, the patient is firmly secured in an apparatus which affords a support that can be maintained by the thoracic, axillary, and pelvic straps, and the uprights are held, without undue pressure, in their position by the circular straps and bands." [1]

The value of this apparatus consists in the fair degree of fixation which it secures, but chiefly in the fact that, when properly applied, the dorsal spine is extended, that is, bent backward to such a degree that the weight from above is removed from the diseased bodies and transferred to the sound articular processes and pedicles. If this position is properly maintained, relief will usually follow in those cases where the bodies alone are involved. The chin-rest or elevator (Fig. 664) may be attached to this same apparatus.

First Region.—In ostitis of the vertebral column, from the third dorsal to the occipito-atloid articulation, the treatment should be by suspension from the chin and occiput, or by tilting or lifting the chin upward. In accomplishing this end

[1] "Pott's Disease," etc., N. M. Shaffer, M.D. G. P. Putnam's Sons, New York, 1879.

the jury-mast, or chin-rest, applied and worn as just described, will meet the indications. Much good may be obtained from the judicious use of extension in the recumbent posture (Fig. 665). This apparatus may be worn at night, when the head stall of the jury-mast, or chin-lift, is removed. In the worst class of cases it is advisable to employ the extension in bed until the symptoms of paralysis are relieved. Instead of the block and pulley, with weight, the extension may be made by elastic bands attached to

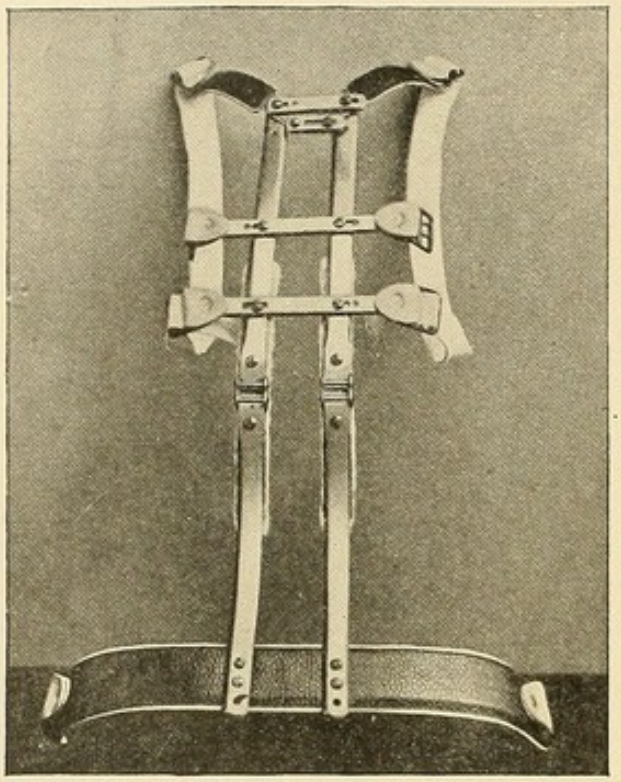

Fig. 663.—Shaffer's modification of Taylor's spinal brace.

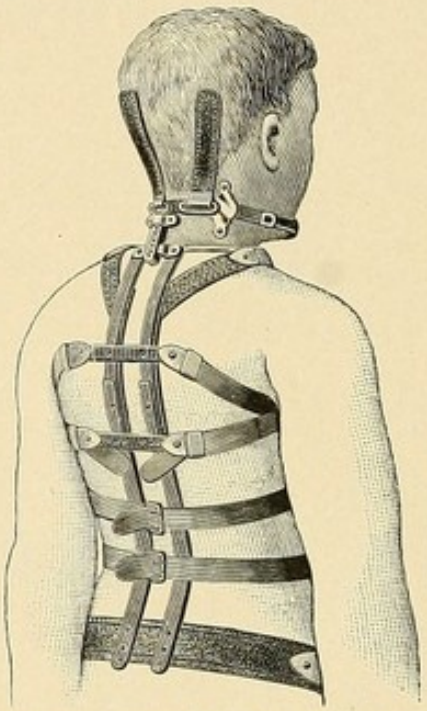

Fig. 664.—Shaffer's head and chin support added to Taylor's brace.

the chin-and-occiput collar, chin-piece, and the head of the bed, while, if necessary, fixation may be secured by elevating the head of the bed six or eight inches.

The suspension carriage of Dr. Meigs Case, which lifts from the axillæ, chin, and occiput (Fig. 666), is a valuable apparatus in the treatment of Pott's disease in the cervical and upper dorsal region. If the degree of elastic suspension from the chin and occiput which it affords during the waking hours is continued during

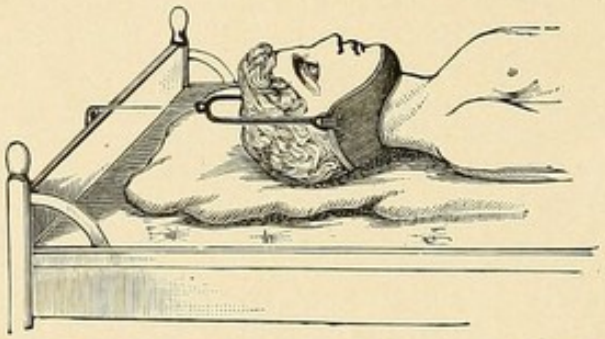

Fig. 665.—Extension in the recumbent posture. (After Reeves.)

sleep, by the method of extension in the recumbent posture above given, success will be achieved in the majority of cases. It is chiefly objectionable by reason of its high price, which places it beyond the reach of many who can obtain the jury-mast.

As to the value of the various mechanical devices, Professor Gibney concludes "that in very young children, from two to five years, the wire cuirass with a good rest for the head and means for making moderate traction, such as the swing in

the jury-mast, is an excellent apparatus. In older children some modification of the Taylor chin-piece or the Whitman chin-rest attached to a plaster-of-Paris jacket or corset should be employed. For the practitioner remote from a large city, and with no good instrument maker at hand, nothing is quite so good as the plaster-of-Paris jacket with the jury-mast."

The successful management of Pott's disease depends not only upon a thorough practical knowledge of the construction and application of the mechanical appara-



Fig. 666.—Dr. Meigs Case's suspension carriage, for both the standing and sitting postures.

tus required, but upon the careful and constant attention of a competent surgeon during the entire time, from the incipiency of the spondylitis until several months have elapsed after consolidation is effected. The prevention of chafing and sores, the renewal or tightening of the apparatus, require almost as much skill as in the diagnosis and first adjustment of the mechanism. As regards abscess in ostitis of the vertebral column, it may be said that incision and drainage, as shown by Dr. Shaffer, are not indicated unless pyogenic infection of the tuberculous abscess has occurred. Pain, high temperature, and other symptoms of septic absorption will indicate infection. Fresh air, well-selected articles of food, and tonics are essential. In the severer cases, in which a myelitis is developed from compression by the products of inflammation, potassium iodide, in full and continued doses, is

recommended by Professor Gibney. In all cases where the recumbent posture is assumed, an effort should be made to keep the patient on the back, with a pillow so arranged that the spinal column is bent well backward, and the pressure on the bodies in this way partially relieved. The suspensory cradle of Reeves will accomplish this end more successfully. A splint or shell is made of gutta-percha or sole-

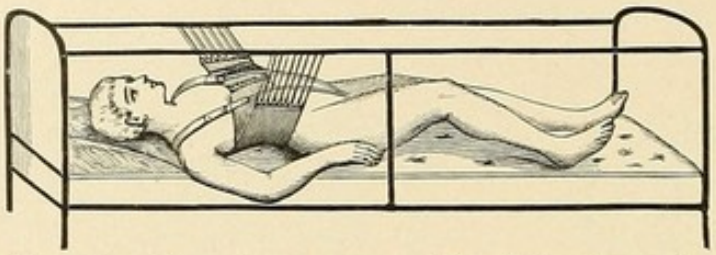

Fig. 666*a*.—Reeves' suspensory cradle. (After Reeves.)

leather, and molded accurately to the back, from the sacrum to the neck. With this held in position by a roller, the patient, while lying down, is supported by the swing, as shown in Fig. 666*a*.

Deformities of the Lower Extremity

The deformities of the lower extremity may be divided into those—1, of the coxo-femoral region; 2, of the shaft of the femur in its entirety; 3, of the condyles; 4, of the tibia and fibula; 5, of the tarsus and metatarsus; and, 6, of the phalanges.

In this classification, distortions of the pelvis, such as in malacosteon and rachitis, are excluded, since they concern the obstetrician rather than the surgeon.

At the *hip* there may exist preternatural mobility, or partial or complete immobility with malposition. Preternatural mobility may be due to the following causes: Arrest of development in the bones which form the acetabulum; congenital failure of development of the head of the femur, or atrophy of this portion; to both of these conditions combined; abnormal length of the capsular ligament, and absence of the ligamentum teres. In a majority of these cases of congenital dislocation the abnormally small and misshapen head of the humerus is found near the normal site of the rim of the acetabulum, which latter is rudimentary and often filled with fibrous tissue.

Immobility with malposition results from inflammation of the joint and ankylosis, with or without destructive ostitis and loss of substance. Contraction of the psoas and iliacus or other muscles about the hip which are not overcome before ankylosis ensues is the chief cause of deformity. Dislocation with failure at reduction always induces deformity, and the same is true of fracture.

In preternatural mobility at the hip-joint (*congenital dislocation*) the symptoms are chiefly a peculiar rolling gait, or oscillation to right and left in the act of walking, especially when the deformity is bilateral. While standing erect, the trochanters will be closer to the iliac crest than normal, which condition can be accurately determined by Nélaton's or Bryant's test. In these cases the anterior convexity of the curve in the lumbar region is exaggerated, giving the patient a sway-back appearance. If extension is made from the feet, while the trunk is fixed in the recumbent posture, the length of the patient will be considerably increased over that measured in the erect position. Absence of the head of the femur may be determined by palpation with outward rotation and by the X-ray. Perforation of the acetabulum may also be made out by digital exploration *per rectum*.

Treatment.—Congenital dislocation at the hip may be successfully treated by the method of Lorenz or Allis. Under anæsthesia, Lorenz, with counter-extension by means of a sheet in the perinæum, moves the thigh freely *in all directions, gradually increasing the force employed until every structure that resists reduction is broken down.* Such is the range of enforced movement that the toe with

the leg extended is made to touch the ear, then hyperdistended to the extreme limit of safety. When the deformity is recognized in infancy and early treatment instituted, this degree of violence is unnecessary.

When resistance is overcome and reduction is announced by the sudden passage of the head of the femur from an outward to an inward position, the thigh is flexed and abducted almost to the horizontal, while the pelvis and thigh are now enveloped in cotton and encased in plaster of Paris. In order to do this, the sacrum rests upon a specially devised support. The body and the thigh must be held steady in the proper position while the plaster hardens. It is then cut away from the perinæum and over the abdomen, in order to provide for cleanliness and to allow for abdominal distention. It is retained without change for five or six months, the child walking all the time upon the deformed member, hammering the caput femoris as much as possible into the acetabulum. It is this constant pounding and pressure of the weight of the body upon the thigh in the new position which effects a deepening of the acetabulum and permits the ligaments and muscles to contract and hold it permanently in the newly made socket. In applying the plaster of Paris between the first layer of ordinary bandage-rollers and the back and abdomen of the child, long strips of cotton-flannel bandage material should be laid, the ends being left out above and below. As the plaster remains on such a length of time, these bandage strips are used as "scratchers," and may be moved up and down over the loose epidermis, in order to cleanse the skin.

Allis' method is as follows:

"After full anæsthesia the pelvis of the child is firmly secured to the table by means of bandages and hooks placed at the perinæum and sides of the pelvis

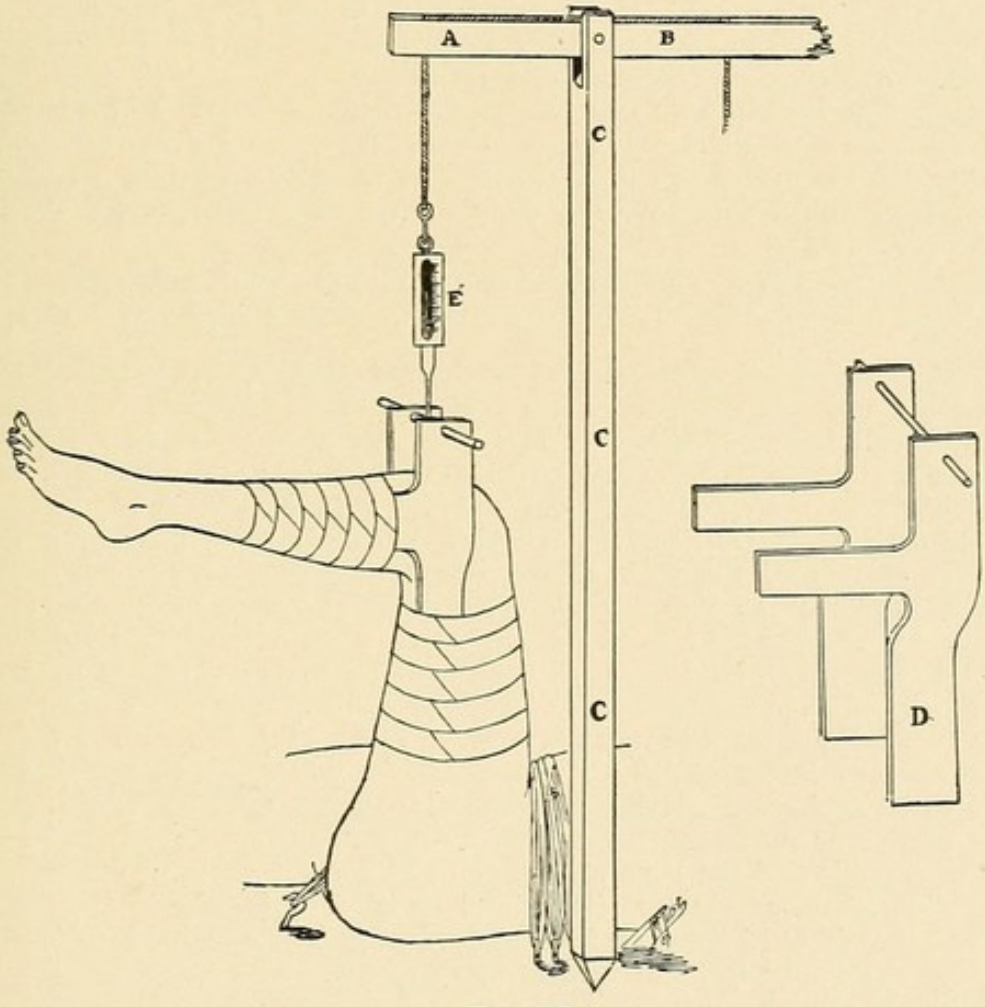

Fig. 667.

(Fig. 667). To prevent the bandages from interfering with the free manipulation of the hips, they are passed over a bent piece of iron as represented in Fig. 668.

After securing the pelvis to the table, angle irons (Fig. 667 *D*) are secured to the thigh and leg; this done, vertical traction through a lever is made (Fig. 667, *A B C*) for the length of time deemed desirable. With the spring balance (*E*) between the short arm of the lever and the angle irons attached to the limb, the exact amount of traction can be seen. Traction from twenty to thirty pounds may be made for from fifteen minutes to half an hour, after which the lever is detached and an effort made to replace the dislocated femur. This is done by seizing the thigh with the right hand, and lifting it upward until the head of the femur is on a level with the socket, and then making abduction against the thumb of the left hand, pressing against the great trochanter. The ease with which reduction is often accomplished, the entire absence of shock, the favorable condition the following day, all contrast strongly with the conditions I had witnessed in the reductions effected by Professor Lorenz. In the apparatus used, the long fulcrum (*C C C*, Fig. 667), whose base is near the pelvis, and which is parallel with the femur, permits of every motion that is desired in applying traction. Thus one is able to lift perpendicularly, abduct, adduct, flex, extend, circumduct, and rotate, all the time gently increasing the traction with a knowledge of the amount of traction being used."

Allis places his patients in plaster of Paris, after the method of Lorenz, for a month or six weeks, at the end of which time the child is put in an apparatus with adjustable wings to which the abducted thigh can be loosely bound and the abduction gradually increased until an angle of ninety degrees is reached. His apparatus permits a free motion save in abduction and adduction. After ten months this is removed and the child is allowed to have limited freedom, being still in the recumbent posture for two months more. It will be seen from this that Allis restrains his patients in the recumbent posture for a year, while in the method of Lorenz they are in plaster of Paris for six, eight, or ten months, but are permitted a certain degree of locomotion.

In *ankylosis* at the hip with malposition, the thigh is generally flexed upon the abdomen and adducted with outward rotation. When destructive osteo-arthritis has occurred the trochanter will be seen nearer to the iliac crest than on the sound side, a condition which does not exist when the ankylosis has occurred from non-destructive arthritis.

On account of muscular rigidity the exact condition of ankylosis cannot usually be determined without ether narcosis. A certain degree of mobility is present, as a rule.

Treatment.—When the malposition is such that usefulness is impaired or comfort interfered with, an effort to relieve the deformity by operation is justifiable, provided that all local inflammatory symptoms are absent and that the general condition of the patient is such that no risk is incurred by the procedure. Under ordinary conditions the operation is not attended with danger.

In osteotomy at the hip for the relief of deformity three procedures may be entertained: Section of the neck of the femur, just above the great trochanter (Adams, Fig. 668); the intertrochanteric section of Sayre (Fig. 669); or the subtrochanteric operation of Gant (Fig. 670). The objections to Adams' line of section is that often, on account of disappearance of the head and neck of the bone, it is impossible; and, secondly and chiefly, if disease has existed at the joint, this line of section is so near the old seat of osteo-arthritis that the process of inflammation may be reëstablished. In ankylosis, without osteo-arthritis at the hip, it is to be preferred. In the vast majority of cases, Gant's section—just at the lower portion of the lesser trochanter—is preferable. The objects to be accomplished are, a section of the bone at this point at a right angle to the axis of the shaft, rotation of the femur into its normal position, and abduction.

Subtrochanteric Osteotomy at the Hip.—The patient is placed on the sound side, so that the femur to be divided is well exposed. The strict details of antisepsis should be carried out.

The upper surface of the great trochanter is felt, and the femur grasped between the thumb and finger. Upon the outer portion of the femur an incision is made, commencing about one inch below the most superior surface of the tro-

chanter major, and extending downward about one inch. When the bone is exposed, the wound is held open by retractors, and Vance's narrow chisel introduced flatwise with the incision until the bone is reached, when it is turned so that the cutting edge is across the axis of the femur. In a child twelve years old the lower portion of the lesser trochanter (the line of section) is about one and a half inch below the tip of the great trochanter.

While the limb is steadied by an assistant, a few blows with the mallet drives the chisel into the bone, which is cut from one half to three fourths through.

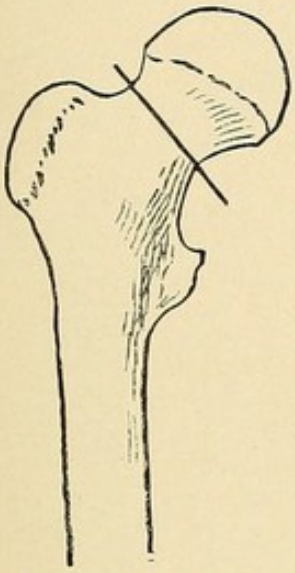

FIG. 668.—Adams' line of section. (After Poore.)

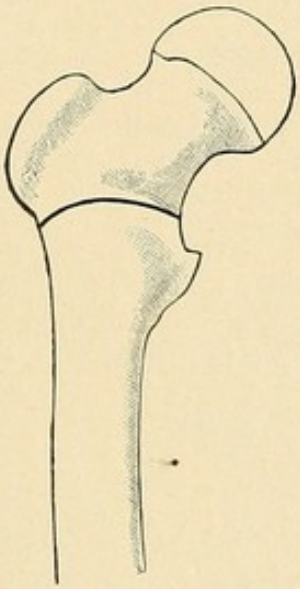

FIG. 669.—Sayre's intertrochanteric line of section.

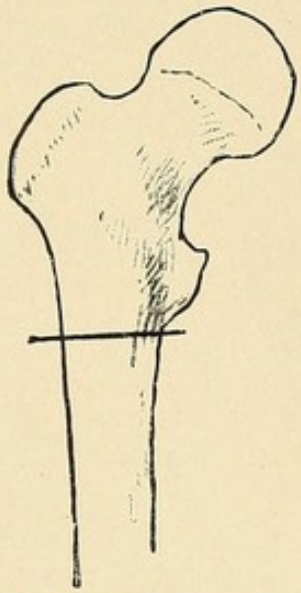

FIG. 670.—Gant's subtrochanteric line of section. (After Poore.)

Grasping the thigh near the knee with one hand, while the other steadies the part above the section, the remaining portion is readily fractured by carrying the thigh toward the median line. The wound is now thoroughly dried, closed with catgut sutures, and sealed with collodion. A sterile gauze dressing is applied. The thigh is rotated slightly inward, abducted to about five degrees from the axis of the spine, and flexed on the abdomen so that the axis of the femur joins that of the body at an angle of fifteen degrees (Fig. 671). If in the position of deformity the thigh is abducted—a condition which rarely exists—the corrected position should be that of adduction about five degrees beyond the normal. The after-treatment is the same as for fracture at this point, namely, Buck's extension and Hamilton's long splint, or the plaster-of-Paris spica may be used.

In order to secure the necessary five degrees of abduction, the padding to the splint should be made several inches thicker opposite the acetabulum than at the knee, and the thigh and leg should be elevated upon pillows enough to secure the fifteen degrees of flexion required. When consolidation occurs with the extremity in this position, locomotion is good and more comfort experienced in the sitting posture than when the leg is perfectly straight. At the end of four or five weeks the patient may be allowed to go about on crutches, and in eight or ten weeks to walk without them.

The result to be achieved is osseous reunion at the point of fracture with the limb in the improved position. A false or new joint is not to be attempted. The hæmorrhage is usually slight, and a few catgut ligatures readily control all bleeding points. Forcible breaking up of adhesions or fracture at the joint is not permissible. Adams' section is made through an incision in the line advised for hip-joint exsection. Its center should correspond to a point just above the great trochanter. The chisel should be preferred to the saw in making the section, on account of the bone dust and detritus left by this latter instrument.

Sayre's line is half-way between Adams' and Gant's lines. The bone should be divided squarely across. The attempt to form an artificial ball-and-socket joint

by making a concavity in the upper fragment, or rounding off the upper extremity of the lower fragment, is not advisable, because it prolongs the operation, and is apt to be followed by necrosis, with ultimate ankylosis. It is better to accomplish reunion in an improved position at once.

The deformities of the *shaft* of the femur are also congenital and acquired. An occasional congenital malformation is due to failure of development of this bone in its long axis. The femur may not be more than six inches in length, while the tibia and fibula are normal in development. As a consequence of rickets, the femur is occasionally curved outward, causing *genu varum*, or bowlegs, although, as will be seen later, the bones of the leg are chiefly involved in this deformity.

Shortening, with or without angular malposition, is sometimes seen after badly united fractures.

For the relief of these deformities osteotomy and osteoclasis may be done when the deformity is sufficient to justify the operation. In osteotomy the incision should be along the anterior and external aspect of the thigh farthest removed from the vessels. The only artery of importance here is the descending branch of the external circumflex. Osteoclasis is not permissible unless the fracture can be effected by manual force. In recent and badly united fractures, and in rachitic subjects this may be done. The osteotome is preferable to the osteoclast. In overlapping fractures, with marked shortening (two to five inches), if the union is not angular, the deformity may be corrected and lateral spinal curvature obviated by a compensating high shoe. If for æsthetic reasons the patient insists upon it, a section may be taken from the sound femur and the ends brought together, as was done by Weir in one instance. The conditions which will justify this procedure are, however, rare.

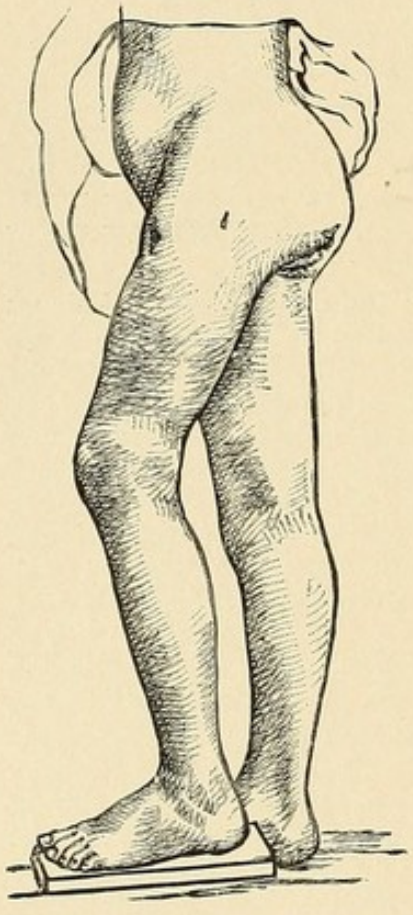

FIG. 671.—The proper position of the extremity after subtrochanteric osteotomy. (After Poore.)

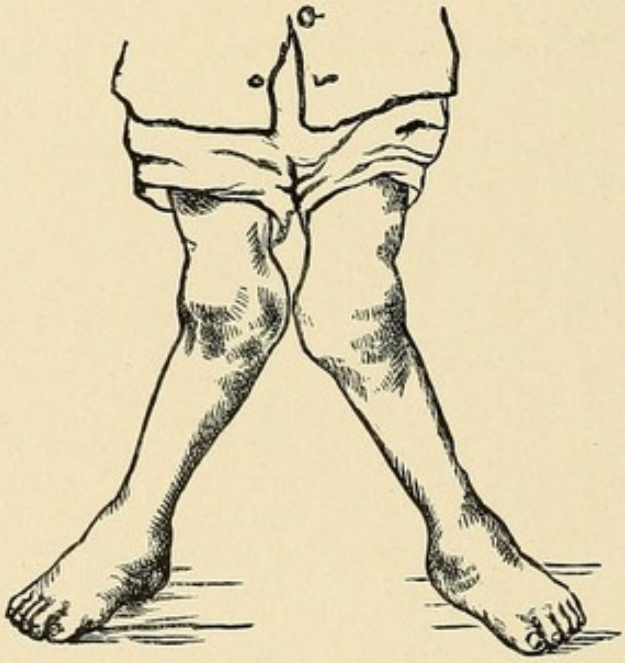

FIG. 672.—Genu valgum—Knock-knee or in-knee. (After Poore.)

Occasionally overlapping and badly united fractures of the thigh will be met with in which the callus, which persists, is so extensive that operation at the seat of fracture is impossible.

The deformities of the lower extremity of the femur are those of hypertrophy or elongation of one or the other condyle. The outer condyle is only exceptionally enlarged. The consideration of these pathological changes belongs properly to *genu valgum* and *varum*.

Genu Valgum.—When a normal subject stands erect, the inclination of the femur of each side is inward and toward its fellow, until the internal condyles are almost in contact. In other words, by actual measurement in a descent of eighteen inches from the head to the condyloid extremity, a separation of seven inches between the acetabula is reduced to three and a half inches from center to center at



FIG. 673.—Genu valgum and varum in the same patient, in Mount Sinai Hospital.



FIG. 674.—The same, after osteotomy of both femora. (The author's case.)

the knee. This obliquity is slightly increased in females, owing to the broader development of the pelvis.

If the articular facets of both tibiæ are brought firmly and evenly in contact with the condyles of the femur, it will be seen that the axis of the tibia is parallel with that of the spine.

Any outward deviation of this parallelism of the tibia with the axis of the body constitutes the deformity known as *genu valgum*, knock-knee, or in-knee (Fig. 672).

Knock-knee may occur on one or both sides, in both sexes and at all ages. In exceptional instances genu valgum may exist on one side and varum on the other, as shown in Figs. 673 and 674. *Knock-knee* is usually *acquired*; occasionally *congenital*. It is most frequently seen in children and young adults suffering from an acquired or hereditary dyscrasia. As to the *causes*, we must look chiefly to changes in the bones at or near the knee-joint. Any interference with the normal processes of nutrition and development in the bones will account for most cases of knock-knee, and the chief pathological condition is either that of rachitis, or one so closely allied to it that a distinction is difficult.

The most classical osseous lesion in genu valgum is the enlargement of the internal condyle as compared to the external, and the resulting increase of the normal obliquity of the tibio-femoral articulation. This increased obliquity may be due to hypertrophy of the inner condyle; or to hypertrophy of the inner half of the upper tibial epiphysis; to atrophy of the outer condyle, or atrophy of the outer half of the upper tibial epiphysis; to a combination of two or more of these conditions; to a curve of the femur (convexity inward) from rickets, and to a like curve of the tibia and fibula.

There is no anatomical reason why the internal condyle should enjoy a better nutrition and greater development than the outer. There is, however, a very good mechanical explanation in this, that by reason of the marked obliquity of the femoral axis and the perpendicular direction of the tibial shaft when the subject is standing erect, the line of gravity brings the greater weight upon the outer facet of the tibia and the corresponding condyle of the femur. The distribution of this pressure equally over the entire articular surface belongs to the muscles controlling this joint; but owing to the excessive number and greater power in the adductor as compared to the abductor group, the internal obliquity is maintained and the pressure upon the outer articular surfaces increased. In the rachitic condition the bones are softened, and become distorted under pressure, and as a result of muscular action, while such deformities are resisted by the normal bones.

Knock-knee from incurvation of the shaft of the *femur* alone is exceedingly rare. When not due to abnormal changes in the condyles, the cause of this deformity will usually be found in rachitic disease of the tibia and fibula, in which these bones are bent inward at the middle or lower third. The principal changes in the soft parts are elongation of the internal lateral ligaments, and a contractured condition of the biceps and popliteus muscles.

Symptoms.—The symptoms of knock-knee vary in different stages of the deformity. The approximation of the knees is a feature less noticeable than the divergence of the tibiæ. With the lower extremities fully extended, and the knees in contact, it will be noticed that the inner malleoli are separated from a few inches to a foot or more. When the lesion is due to changes in the inner condyle of the femur, it will be observed that, if the leg is flexed upon the thigh at an angle of ninety degrees, the deformity is less apparent; and if complete flexion is made in mild cases of in-knee, it will disappear altogether; i. e., the tibia in extreme flexion will be parallel with the femur. The patella is displaced outward, and locomotion is more or less impaired. Pain is often present, from the unnatural strain upon the tissues, and fatigue with the slightest exertion is often noticed.

The *diagnosis* rests upon the recognition of the symptoms just detailed, and the *prognosis* is generally favorable when judicious and persistent *treatment* is instituted. Constitutional remedies and mechanical appliances are indicated early in the disease, and operative interference is justifiable when mechanical treatment cannot effect a cure.

The first indication is met in out-of-door life, good food, diversion, tonics, cod-liver oil, and the hypophosphites of lime and soda.

The mechanical treatment should be insisted upon in all cases of children in which the deformity is not exaggerated, and should be persisted in for several years, if necessary. Any mechanism which is applicable in this deformity must afford a fixed point, opposite to and on the external aspect of the region of the knee-joint, from which constant traction may be made. The apparatus of Professor Sayre (Fig. 675) will be found of great use in meeting the chief indications. It consists of a pelvic belt of steel, padded so as not to excoriate, and a bar of steel hinged at the knee and passing down from the belt to the sole of the shoe, where it is fastened, as in the long hip splint already described.

Opposite each knee, and just above and below the joints—in order to distribute the pressure over a wider area, and thus prevent chafing or excoriations—are padded belts or bands which surround the limb; these are attached to the side-bars, and may be tightened at will in exercising the required traction to overcome the deformity. Elastic tension by means of rubber bands or webbing may also be utilized in this manner. The hinges at the knees allow the patient to bend these joints in walking, and to assume the sitting posture. The instrument should be worn during the waking hours, and at night it will be advisable to make extension from both legs by Buck's method. The cost of this apparatus places it beyond the reach of many patients, and in this class of cases renders early operative interference more justifiable.

Osteotomy of the femur for the correction of chronic cases of genu valgum is an operation practically free from danger, and yields excellent results. The section should be made above the joint, and away from it a sufficient distance to avoid

all danger of entering the articulation or injuring the epiphysis. Linear section should be preferred, since it is simpler than cuneiform osteotomy, and is equal to the correction of all cases excepting those in which there is extreme angularity at the seat of deformity. Such conditions rarely, if ever, occur in the femur. The older operations of Ogston, Reeves, Chiene, and Macewen, which involved the joint, are practically discarded. They are objectionable in this, that they invade the joint and endanger the functions of this important articulation. Transverse section above the epiphyseal line from the outside (MacCormac) or inner side (Macewen) should be preferred (Fig. 676).

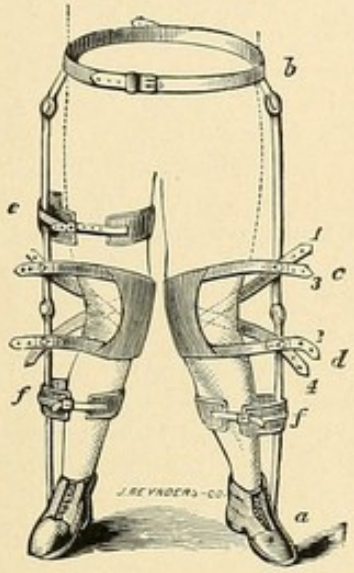

Fig. 675.—Sayre's apparatus for the correction of knock-knee. (After Sayre.)

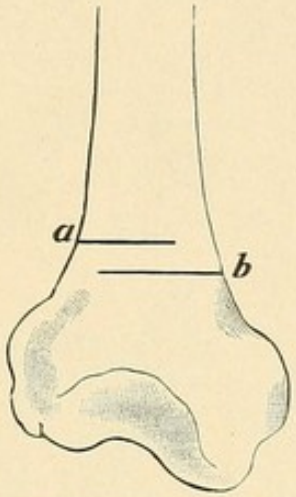

Fig. 676.—*a*, MacCormac's line. *b*, Macewen's line. (After Poore.)

Macewen's Operation.—In this procedure it is intended to divide the femur at a right angle to its axis through two thirds to three fourths of its thickness, at a point well above the level of the lower epiphysis. In a child ten years old the line of section should be one and three quarter inches above the most dependent portion of the articular surface of the internal condyle, and in an adult two and a half inches.

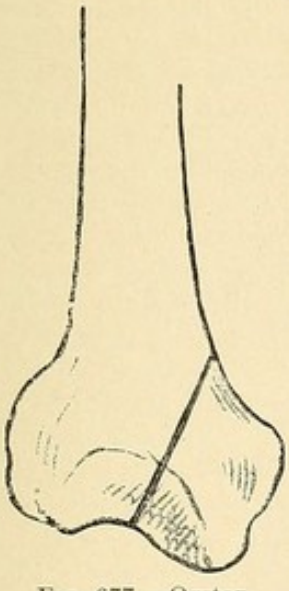

Fig. 677.—Ogston.

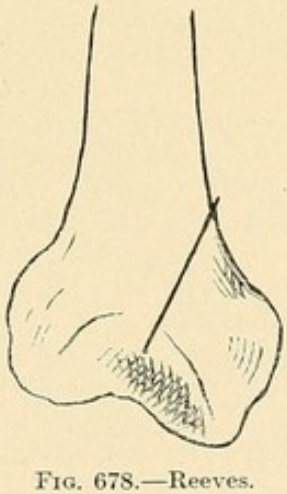

Fig. 678.—Reeves.

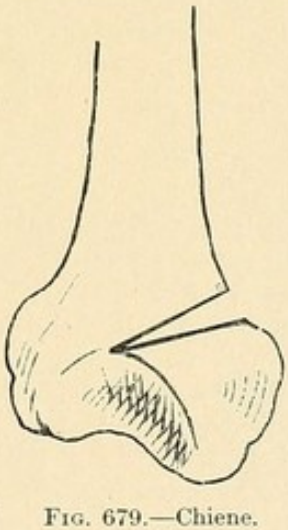

Fig. 679.—Chiene.

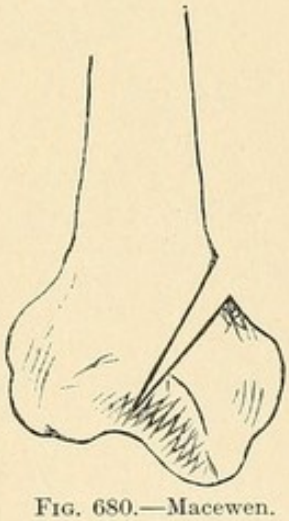

Fig. 680.—Macewen.

Strict aseptic precautions should be taken. If Esmarch's bandage is applied as high as the middle of the thigh, the wound will be kept dry and the operation greatly facilitated. Flex the leg on the thigh and rotate the thigh outward so as to bring the inner aspect of the joint upward. Make an incision one inch long, following the direction of the internal condyloid ridge. The center of this incision should be opposite the point of section above given. The internal saphenous vein

and the anastomotica magna artery should be avoided, and the tubercle for the insertion of the tendon of the abductor magnus felt. As soon as the bone is reached the chisel is carried down to it, parallel with the incision, and immediately turned with its cutting edge at a right angle to the axis of the femur. The inner and anterior shell of compact tissue should be first divided, and when the posterior portion is cut through the osteotome should be directed to the front so that when struck with the mallet it will be carried away from the vessels. As soon as the bone is cut through two thirds of its thickness, the remaining piece may be fractured by grasping the limb above and below the section, and using the other hand for a fulcrum and the leg as a lever, which is carried outward. As soon as the bone snaps, the leg is handed to an assistant, who is directed to steady it by making strong extension. The wound should now be thoroughly dried, a dressing of sterile gauze applied, and the tourniquet removed. Firm compression with the roller is essential to prevent bleeding. The limb should be brought into the straight position by extension, and steadily held until a plaster-of-Paris bandage is put on and hardened. This dressing is allowed to remain for four or five weeks, as in simple fracture, when it is removed, and passive motion made at the joint. It is reapplied for a week longer, and then, as a rule, may be discontinued. MacCormac's procedure is practically the same as the above, with the exception that the section is made from the outer side of the femur. Of these two operations the incision from the outer side (MacCormac's) is preferable, for the reason that there are no vessels in the way. On the inner side the long saphenous vein and the anastomotica magna artery are endangered. Moreover, it does not matter from which side the bone proper is divided, as far as the correction of the deformity is concerned. When the tibia and fibula are involved in the deformity, section of these bones may be required at the same or a subsequent operation.

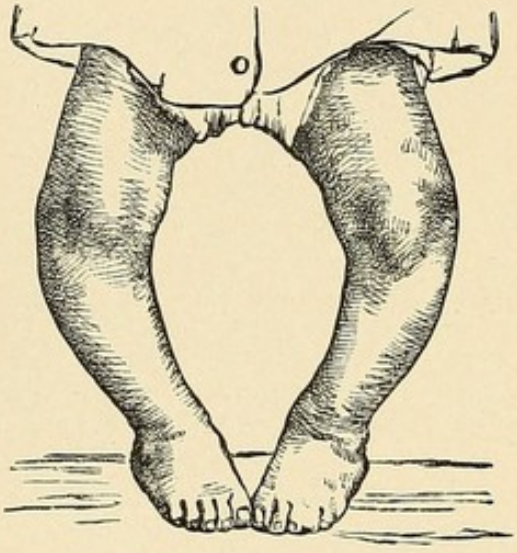

Fig. 681.—Genu varum, or bowlegs. (After Poore.)

Genu Varum.—In bowleg, or outward curvature of the lower extremity, one or both members may be involved. The bones of the leg are usually alone involved, although in some instances the femur may take part in the deformity (Fig. 681).

The principal cause of bowlegs is rickets, the softened bones yielding to the weight of the body or to muscular contractions. Genu varum is usually met with in childhood, but may occur in adults who are rachitic. In *treatment*, the indications are the same as for knock-knee. The adjustment of any mechanical apparatus is, however, more difficult. Splints should be adjusted to prevent further deformity, or the patient should be prevented from bringing the weight of the body upon the diseased bones. In the meanwhile every effort should be made to correct the dyscrasia. As long as the bones remain in the softened condition of rickets, operative interference is not indicated. Osteotomy of the tibia and fibula at the point where the outward curve is most pronounced will, in the majority of instances, correct the deformity. In extreme cases it may be necessary to make sections at two or more points. If the femur is involved it should also be divided, although this complication will rarely be met with. The details of the operation and the after-treatment are practically the same as for genu valgum.

Osteoclasis should be substituted for osteotomy in those cases in which the fracture may be accomplished with little force and with the hands of the operator. It is objectionable when performed with the osteoclast, for the reason that the soft tissues are bruised to an extent which does not occur in osteotomy. Moreover, the line of fracture cannot be directed with the same accuracy as in cutting with the chisel.

Ankylosis at the Knee, with Malposition.—For the correction of this deformity osteotomy is at times performed. When the degree of malposition is extreme, it may become necessary to divide the femur at a point from three to four inches above the most dependent portion of the articular surface of this bone. If after this section the limb cannot be brought out straight, division of the tibia just below the tuberosity may be done. Exsection of the knee is, however, a preferable operation; and, since in modern practice the danger of this procedure is so greatly diminished, it is believed that the operation through the articulation will supersede section of the bone in continuity.

Talipes.—Clubfoot is a deformity in which there exists either an abnormal relation between the bones of the foot to each other, or to the tibia and fibula.

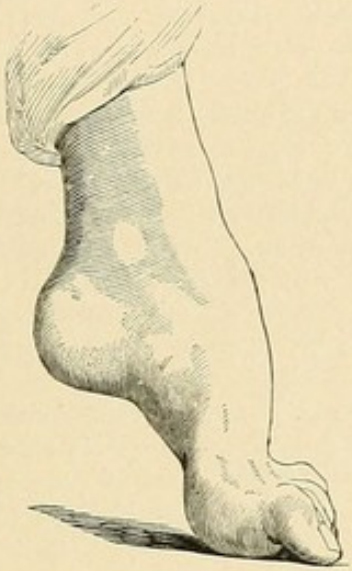

FIG. 682.

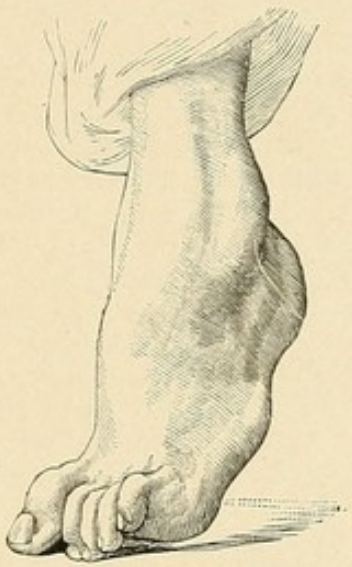

FIG. 683.

Congenital talipes equinus. (After Churchill.)

There are six simple and several compound forms of talipes. The simple varieties are *talipes equinus*, *calcaneus*, *varus*, *valgus*, *cavus*, and *planus*. Among the compound forms are those of equino-valgus, equino-varus, calcaneo-valgus, calcaneo-varus, etc.

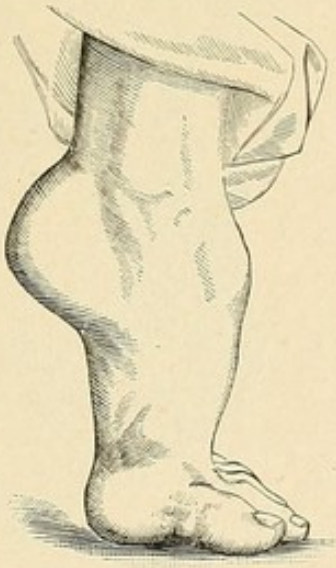

FIG. 684.

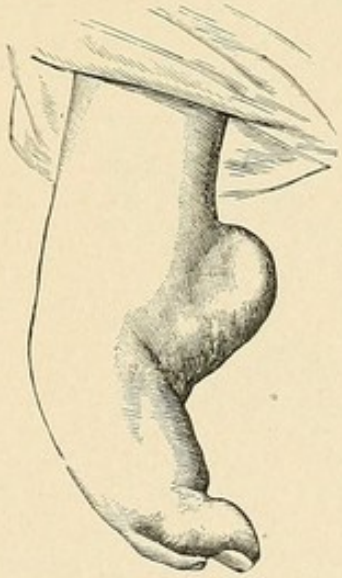

FIG. 685.

Acquired talipes equinus. In Fig. 685 there has occurred complete paralysis of the extensor muscles. (After Churchill.)

In *talipes equinus* the heel is drawn up and the weight of the body falls upon the plantar aspect of the metatarsus, the toes and phalanges; the gastrocnemius

and soleus are shortened, the tendo Achillis tense, and in extreme cases the heel cannot be brought down to the ground. Callosities are formed upon the sole of the foot along the metatarso-phalangeal line. When paralysis of the anterior muscles of the leg has taken place, the toes are turned under, as in Fig. 685. In this condition there are atrophy and complete loss of power in the tibialis anticus, peroneus tertius, extensor longus digitorum, and extensor pollicis muscles.

Simple talipes equinus is not of very frequent occurrence, since it is almost always complicated with inward rotation of the tarsus, or talipes equino-varus.

Treatment.—When complete paralysis has not occurred, and if taken early, talipes equinus, whether congenital or acquired, may be cured, or marked deformity prevented, by the institution of proper treatment. Section of the tendo Achillis is rarely necessary when the case has not been neglected. The propriety of tenotomy can be determined by the degree of resistance met with in the effort to bring the sole of the foot to a right angle with the axis of the leg. If this cannot be accomplished, or if, when the tarsus is firmly flexed on the leg, pressure upon the sural muscles produces a painful and marked spasm (Sayre), tenotomy is indicated, especially in those patients who cannot afford the long-continued expense of mechanical treatment, and who of necessity cannot remain long in the hands of an experienced surgeon. In simple equinus the indications are to overcome the muscular contraction by artificial appliances, and to restore the normal tonicity and power to the anterior tibial group of muscles.

When a child is born with talipes equinus (and all forms of congenital clubfoot should be treated from birth), deformity of the bones of the foot, and the too great stretching or elongation of the anterior muscles, may be prevented by the following simple means: Cut a piece of light board as wide as the sole and a little longer than the foot, and cover it with adhesive plaster in such a way that the sticking surface is next to the skin. This is laid along the sole of the foot, to which it is fastened by adhesive strips, and a light bandage, leaving the end of the board to project a little beyond the toes. From the end of the board traction may be made by a strip of plaster carried upward and fastened along the front of the leg near the knee, sufficient tension being exercised to draw the foot into its natural position. Or, if deemed necessary, artificial muscles (rubber tubing) may be attached from the tip of the board to insertions fastened near the knee on the antero-lateral aspects of the leg. The apparatus must be carefully readjusted whenever it becomes loose or causes pain.



Fig. 686.—Bones of the foot of an adult with talipes equinus. (After Chance and Noble Smith.)

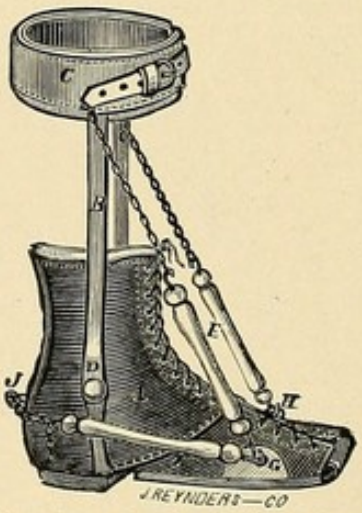

Fig. 687.—Sayre's clubfoot shoe. (After Sayre.)

When the patient is able to walk, simple cases of equinus may be corrected by wearing a stiff, solid, and well-constructed laced shoe, which will hold the instep well down and keep the sole of the foot in close contact with the sole of the shoe. The weight of the body, falling upon the anterior portion of the foot, will aid in carrying the heel to the ground with each step.

In more obstinate cases the Sayre shoe (Fig. 687) more nearly meets the

mechanical indications than any other apparatus. When there is no inversion of the foot (varus), the lateral rubber muscle *J G* is unnecessary. In ordering this shoe it is advisable to send to the instrument-maker the shoe at the time worn by the patient, and with this the distance from the sole of the heel to the upper articular margin of the tibia, as well as the circumference of the leg at this point. To this may be added the measurements around the foot, at the bases of the toes, and around the malleoli. In all cases of talipes in walking children and adults it is important that all excoriations be healed before any appliance is adjusted.

The idea must not, however, be entertained that the simple application of the shoe, or any mechanical appliance, will correct the deformity. The after-treatment is a most important feature in these cases. Electricity and massage are important adjuvants. The weaker galvanic current should be preferred, the positive pole being placed along the track of the nerve which supplies the affected muscles, while the negative sponge is carried over the bellies of these muscles. The application should be made about twice each week, while massage should be employed twice daily.

In those cases where tenotomy is deemed advisable, the operation is performed as follows: The patient being placed under the influence of an anæsthetic, the tarsus is flexed forcibly upon the leg, in order to place the tendo Achillis and plantar fascia upon the stretch; a slight puncture of the skin is then made, a little anterior to the tendon, and on the inner side of the leg, slightly above the malleolus; this opening is now carried to the edge of the tendon by traction upon the integument, and the tenotome introduced, with its flat surface toward the tendon. The tension upon the tissues is now relaxed, and the edge of the knife turned toward the parts to be divided; the tarsus is flexed strongly upon the leg, and the tendon again made tense, when the knife is pressed forward and outward through the tendon, which separates with a very audible snap. The thumb of the operator being placed over the tendon externally, acts as a guide and support, preventing the blade from passing through the integument and causing an open wound, an accident which should be carefully avoided. As soon as the division of the tissues is effected, the blade of the knife should be withdrawn, flatwise, and the thumb of the operator slipped over the slight puncture, which is at once covered with one or two strips of adhesive plaster; the plantar fascia can be divided in a similar manner, if desirable, the whole foot being then enveloped in cotton, and a snug roller-bandage applied. The foot is now secured, by mechanical appliances, at a right angle to the leg, as heretofore described. Division of the extensor tendons of the toes is not often required. The best point of section is just over the metatarso-phalangeal articulation.

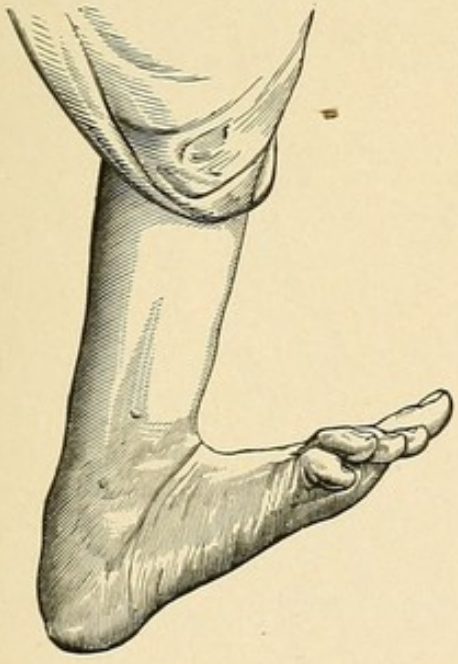

Fig. 688.—Congenital talipes calcaneus. (After Churchill.)

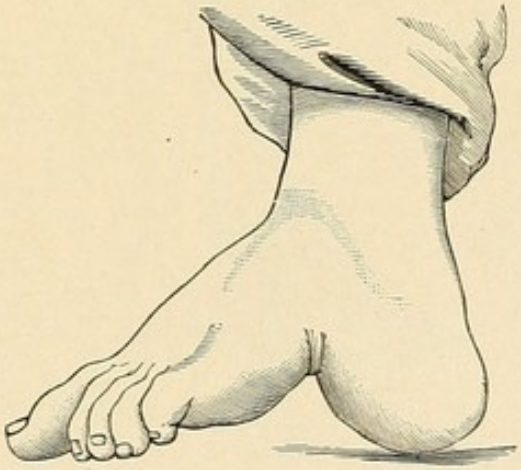

Fig. 689.—Acquired talipes calcaneus. (After Churchill.)

Talipes Calcaneus.—In this rare form of clubfoot the toes are drawn upward and the tarsus flexed upon the tibia; impairment of function exists in one or

more of the sural muscles; the tibialis anticus, peroneus tertius, extensor longus digitorum, and pollicis are shortened. This deformity may be either congenital or acquired (Figs. 688, 689). It is usually met with in children, or may occur at any period of life, from rupture of the tendo Achillis, or paralysis of the muscles of the calf of the leg, ununited fracture of the os calcis, etc. In this condition the mechanical and surgical appliances and treatment are exactly opposite to those of the preceding variety. An ununited section of the tendo Achillis should be corrected by cutting down upon this tendon at the seat of the division, freshening the divided ends, and sewing them together with silk sutures. Mild cases of calcaneus may be relieved by the wearing of a well-fitting laced shoe, the weight of the body aiding in correcting the deformity. When the toes cannot be brought down without the aid of additional pressure, the apparatus in construction similar to the one recommended for flat-foot can be applied. The object to be obtained is to elevate the heel and depress the toes by mechanical means. For this purpose, the shoe as devised by Dr. Sayre (Fig. 690) is admirably adapted. This is a strong laced shoe, with steel rods running up on either side of the leg to a collar below the knee, the rods being hinged at the ankle to allow of free motion at this joint; from the heel of the shoe a small steel spur is seen, to which is secured a strong piece of elastic, passing up to the collar around the leg. This rubber artificial muscle, taking the place of the gastrocnemius and soleus muscles, if made of sufficient tension, will elevate the heel and restore the foot to its normal position. There are, however, various instruments for the correction of this deformity, the surgeon modifying the shoe as may be required to suit each case. In addition to the mechanical appliances, the after-treatment, by electricity, massage, etc., should be carried out as in other forms of clubfoot where atrophy of the muscles and loss of power exists.

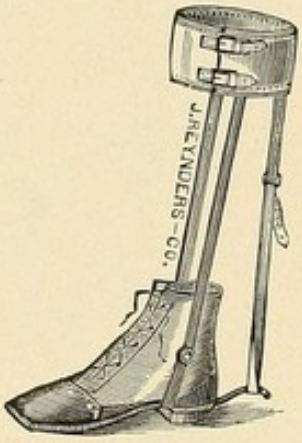

Fig. 690. — Sayre's shoe for talipes calcaneus. (After Sayre.)

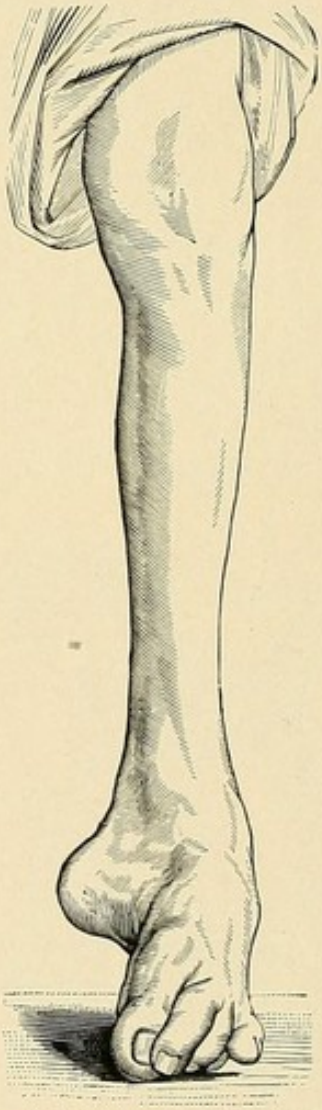

Fig. 691.—Talipes equino-varus in an adult. (After Churchill.)

Talipes Varus and Equino-Varus.—These deformities consist of an inward rotation of the foot, and are the most common forms of talipes (Figs. 691, 694). The majority of cases are those in which spastic contraction of the sural muscles also occurs (equino-varus). Talipes varus and equino-varus are more often congenital, but are frequently acquired, one or both feet being involved. The degree of de-

formity varies from slight inversion of the foot to the most exaggerated form in which the sole looks upward, while in the act of walking the dorsum rests upon the ground.

The changes which the structures of the foot undergo are shortening of the plantar fascia and the internal lateral ligaments, together with a contractured condition of the tibialis anticus and posticus muscles and permanent deformity of the bones. The displacement of the bones of the tarsus will correspond to the

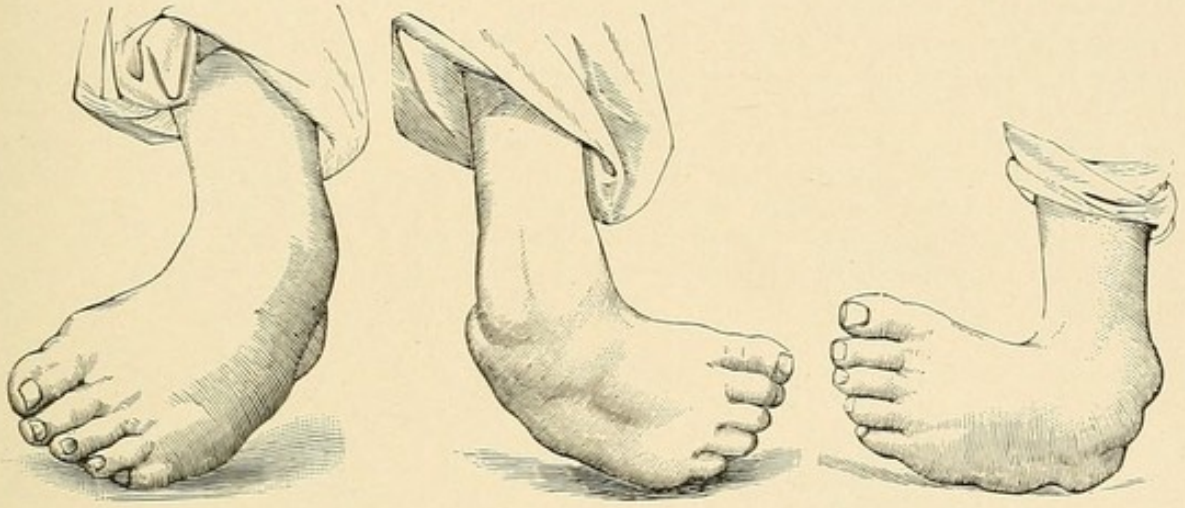

Fig. 692. Fig. 693. Fig. 694.

Three grades of talipes varus. (After Churchill.)

extent of the deformity; the astragalus being tilted downward, the scaphoid is displaced inward and downward by the action of the tibialis posticus, the tubercle on this bone becoming very prominent; there is in addition marked rotation at the astragalo-scaphoid and calcaneo-cuboid junctions, the displacement being especially marked in this last-named articulation.

When the deformity exists at birth, if not corrected early, the bones will become misshapen, and the deformity permanent.

The treatment of talipes equino-varus in the infant consists in the application of small rubber bands or pieces of tubing, which will make constant and gradual traction in the line of the weakened or paralyzed muscles. This (*Barwell's*) method is as follows:

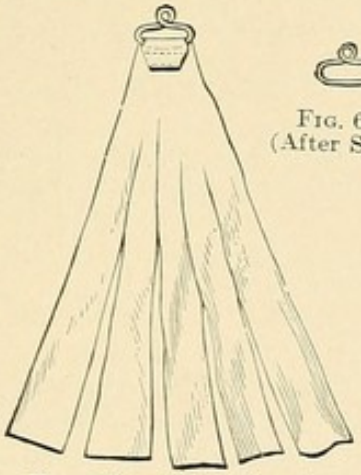

Fig. 695.—(After Sayre.)

Fig. 696. (After Sayre.)

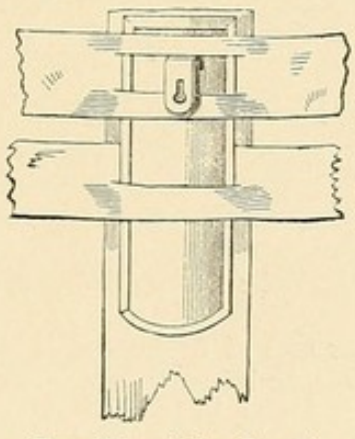

Fig. 697.—(After Sayre.)

Cut a piece of strong adhesive plaster into the shape of a fan, which is split into four or five strips converging toward the apex of the fan (Fig. 695). "The apex of the triangle is passed through a wire loop with a ring in the top (Fig. 696), brought back upon itself, and secured by sewing. The plaster is firmly secured to the foot in such a manner that the wire eye shall be at a point where we wish to

imitate the *insertion* of the muscle, and that it shall draw evenly on all parts of the foot when the traction is applied. Secure this by other adhesive straps and a smoothly adjusted roller.

"The artificial *origin* of the muscle is made as follows: Cut a strip of tin or zinc plate, in length about two thirds that of the tibia, and in width one quarter the circumference of the limb (Fig. 697). This is shaped to fit the limb as well as can be done conveniently. About an inch from the upper end fasten an eye of wire. Care should be taken not to have this too large, as it would not confine the rubber to a fixed point. The tin is secured upon the limb in the following manner: From stout (moleskin) plaster cut two strips long enough to encircle the limb, and in the middle of each make two slits just large enough to admit the tin, which will prevent any lateral motion; then cut a strip of plaster, rather more than twice as long as the tin, and a little wider; apply this smoothly to the side of the leg on which the traction is to be made, beginning as high up as the tuberosity of the tibia. Lay upon it the tin, placing the upper end level with that of the plaster (Fig. 698). Secure this by passing the two strips above mentioned around the limb (Fig. 699), then turn the vertical strip of plaster upward upon

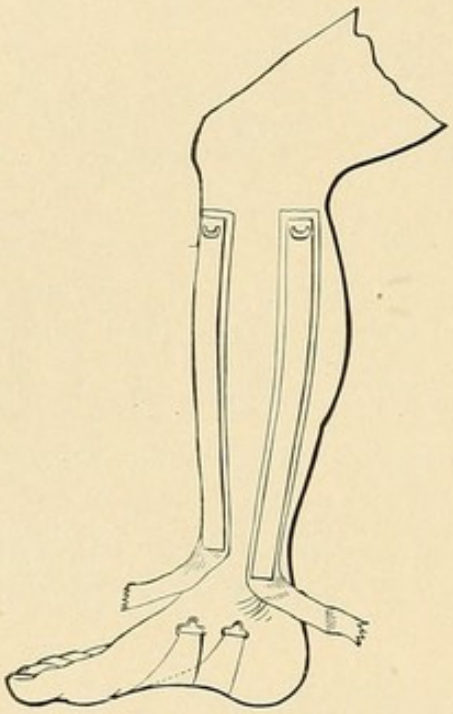

Fig. 698.—(From Barwell.)

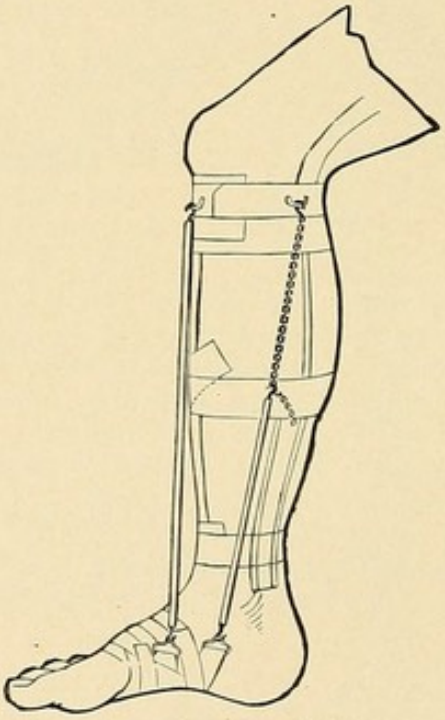

Fig. 699.—(From Barwell.)



Fig. 700.



Fig. 701.

the tin. A slit should be made in the plaster where it passes over the eye, in order that the latter may protrude. The roller should then be continued smoothly up the limb to the top of the tin. The plaster is again reversed and brought down over the bandage, another slit being made for the eye, and the whole secured by a few turns of the roller. A small chain, a few inches in length, containing a dozen or twenty links for graduating the adjustment, is then secured to the eye in the tin.

"Into either end of a piece of ordinary rubber tubing, about one quarter of an inch in diameter and two to six inches in length, hooks of the pattern shown in Fig. 700 are fastened by a wire or other strong ligature (Fig. 701). One hook is fastened to the wire loop on the plaster on the foot, and the other to the chain above mentioned, the various links making the necessary changes in the adjustment.

"The dressing, when complete, is shown in Fig. 699." (Sayre.)

A roller should now be carefully and smoothly applied over the plaster and between the leg and the artificial muscles.

When the muscles cannot be obtained, and in mild cases in which the foot may

be brought readily into position, a correction may be effected by means of one or more strips of adhesive plaster as follows: One end of the strip is laid upon the dorsum of the foot, near the bases of the third and fourth toes, whence it is carried in a slightly spiral direction to the inner border of the sole, and across the sole to the outer margin of the foot. As the foot is now brought into a normal position by the hand of the operator, the strip of plaster is laid along the outer and anterior aspect of the leg and thigh, and firmly secured by encircling strips of the same material. A bandage over all will hold the dressing in position.

When the patient is able to walk, the clubfoot shoe (Fig. 687) will give the greatest satisfaction. The rubber muscles should be applied and regulated in such

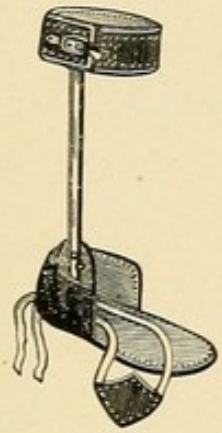

Fig. 702.—Iron shoe for talipes varus and equino-varus.



Fig. 703.—Iron shoe for talipes varus and equino-varus in position. The adhesive strips and bandage have been omitted in the cut.

a way that they will imitate as nearly as possible the normal action of the muscles they are intended to assist. A less expensive instrument, one which yields good results in the milder forms of talipes equino-varus, and which may be readily made by any ordinary worker in iron, is shown in Fig. 702. It consists of a sole-piece of sheet iron, which is riveted to a heel-piece of the same material, and is roomy enough to hold the heel of the patient without chafing. It should be nicely padded to prevent the danger of excoriations. To this heel-piece is attached, by a hinge joint with limited forward and backward motion, an iron bar which extends to the padded iron collar around the leg, near the knee. The foot of the patient is secured to the sole-piece by adhesive plaster, with the aid of the instep strap shown in Fig. 703, and a flannel roller carried over all. As the perpendicular bar is now carried parallel with the leg, and held in this position by buckling the collar around the leg at the knee, the foot is turned outward and held in its normal position. An ordinary lacing shoe should be worn over the brace.

An apparatus, the mechanism of which is somewhat similar to this, is highly recommended by Mr. Reeves, and is shown in Fig. 704.

The modification of Scarpa's shoe (Fig. 705) possesses some advantages over the iron shoe above described, and should be preferred to it when it can be obtained.

Tenotomy and *fasciotomy* will be found necessary in a large proportion of cases of talipes equino-varus, and, when not essential to ultimate success, it will greatly expedite the permanent restoration of the member to its normal position. The application of Esmarch's bandage from the toes to above the knee, though not essential, renders the operative procedure more rapid and easy of execution. The tendo Achillis is divided as heretofore directed. In addition, the tibialis anticus and the tibialis posticus will, as a rule, require to be divided. The tendon of the tibialis anticus should be cut subcutaneously about one inch above its insertion into the internal cuneiform bone by introducing the tenotome beneath it from the middle line of the foot. It can be made prominent by forcible eversion of the foot. Division of the tendon of the tibialis posticus is best effected by an

incision parallel with the inner border of the tibia just above the internal malleolus, where it lies in close relation to this surface of the bone. As soon as it is exposed, an aneurism needle should be passed beneath it, when it can be drawn out through the wound and divided with the scissors. Subcutaneous section of this

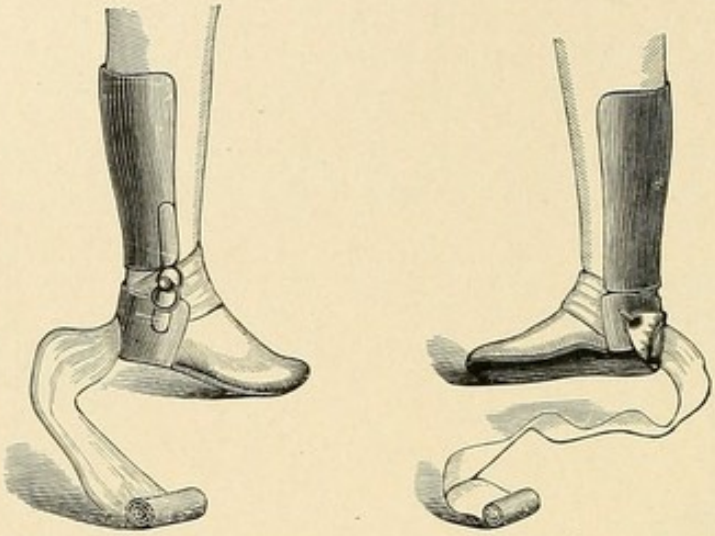

Outer view. Inner view.

Fig. 704.—Reeves' universal shoe, as it is being applied in the treatment of talipes equino-varus. (After Reeves.)

tendon is a very difficult and uncertain procedure, while no mistake is possible through an open wound. If careful antisepsis is practiced, and if the wound is at once closed with catgut sutures, no suppuration can occur. The plantar fascia should be divided by introducing the tenotome flatwise under the fascia from the inner border of the foot, turning the edge outward, and cutting the fascia as it is made tense. Several lines of section through this fascia may be made when necessary. Each puncture should be closed with aseptic collodion.

Tarsotomy.—In exaggerated and chronic cases of congenital talipes equino-varus a wedge-shaped exsection of a portion of the tarsus will at times permit a

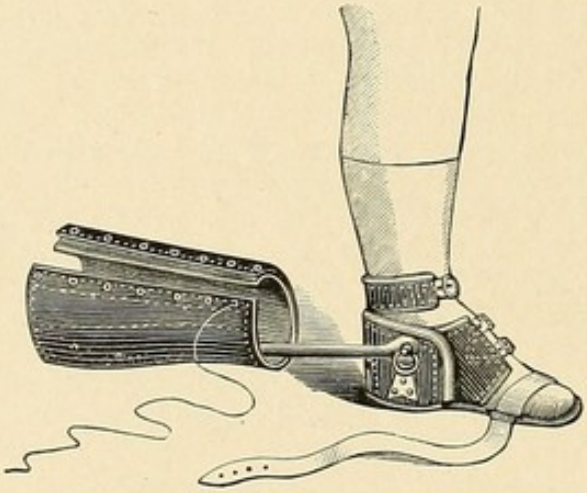

Fig. 705.—Modified Scarpa's shoe for talipes varus and equino-varus. (After Reeves.)

restoration of the foot to its normal position, and serve to restore in great part the usefulness of the member. In two recent cases in which I performed this operation the most gratifying results were obtained. In each case before operation the patient walked with the dorsum of the foot on the floor, and, in one instance, the toes pointed directly backward.

After Esmarch's bandage has been applied, a free incision is made along the fibular side of the foot, extending from below the external malleolus to the tarso-metatarsal junction. All the tissues should be lifted from the bones by the peri-

osteal elevator, and the wedge-shaped section of the tarsus removed by the gouge or chisel. The anterior portion of the astragalus will require to be removed, and as much of the tarsus should be exsected as is needed to permit the restoration of the foot to the natural position; for it is not only necessary to evert the foot, but to make at the same time a marked rotation of that part of the member anterior to the line of section. The tendo Achillis should now be divided, and, as soon as the proper position is obtained, the incision closed and covered with iodoformized gauze, and a light dressing and compression bandage applied tight enough to arrest all oozing. A plaster-of-Paris dressing is now put on, and the foot held in position until this hardens. This last procedure can be facilitated by adjusting two strips of adhesive plaster, one of which will serve to hold the foot at a right angle to the axis of the leg, and the other to keep it rotated outward while the plaster is being applied and is hardening. The dressing may be removed not earlier than the fifteenth day, and should not be disturbed for a month unless it is necessitated from soiling.

In a certain proportion of cases which, from neglect to institute treatment immediately after birth, will not yield to the measures heretofore advised, great benefit may be derived from forcible manual twisting of the foot into a proper position. The patient is usually anæsthetized and the foot is so held that no strain will be brought upon the ankle-joint while the process of twisting the bones of the tarsus is being carried out. While the patient is still under the anæsthetic a plaster-of-Paris dressing should be applied and the foot held in the improved position until the plaster is firmly set. This may be repeated from time to time, and should be considered one of the best methods in the treatment of all forms of talipes in which there is marked distortion of the foot and tarsus. If these means were carried out in all cases, the need for tarsotomy would be exceptional.

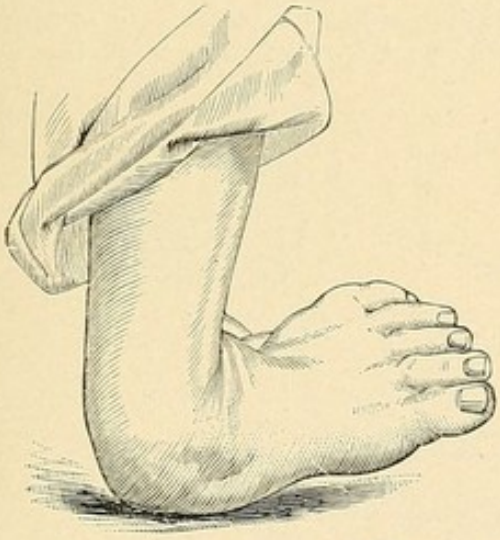

Fig. 706.—Congenital talipes valgus. (After Churchill.)



Fig. 707.—Acquired talipes valgus. (After Churchill.)

Talipes Valgus.—In this deformity the normal arch of the foot is lost, and the foot is everted (Figs. 706, 707). The contracted muscles are the peroneus longus and brevis, while the paralysis, as a rule, affects the tibialis posticus, anticus, and flexor muscles. When the tarsal arch gives way, the plantar fascia, calcaneo-cuboid ligaments, and short flexors become stretched, and the tibialis anticus is elongated. The yielding of these muscles may be due to paralysis, or to strain from the habit of carrying heavy weights.

Treatment.—In talipes valgus in an infant the eversion may be corrected by means of the adhesive strips applied as in the treatment of varus. The direction of traction is of course opposite. The artificial muscles, after the method of Barwell, are also as applicable here as in varus. The iron shoe, made with the

bar to come upon the inner side of the leg, is as serviceable in mild cases of valgus as in varus or equino-varus. This apparatus is always worn inside of an ordinary shoe. Nyrop's boot (Fig. 710) is highly recommended by Mr. Reeves. It consists of a stiff-soled lacing shoe, with a leg collar and iron or steel bar attached to the outer side of the shoe, with a lateral hinge opposite the outer malleolus. To the inner side of the sole, near the heel, is attached a strong piece of elastic web-

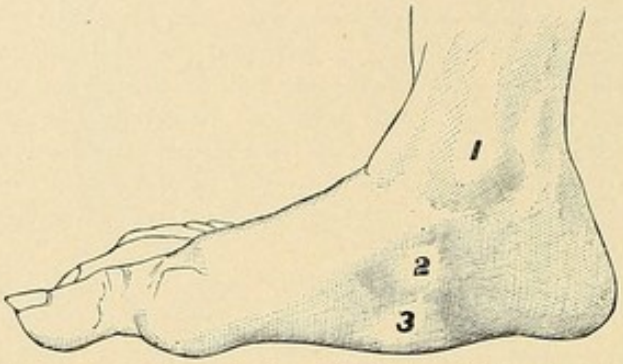

Fig. 708.—Inner view of a severe valgus of the right foot. (After Reeves.) 1, Inner malleolus. 2, Inner surface of head of astragalus. 3, Tubercle of scaphoid.

bing, by which inversion of the foot is effected by buckling the strap to the collar near the knee.

When tenotomy of the peronei muscles is indicated, they should be divided subcutaneously from three quarters to one and a half inch (owing to the age of the patient) above the external malleolus. Cuneiform tarsotomy may be applied to the correction of this deformity in exaggerated cases in adults. When the bones are thoroughly ossified it will be impossible to change the shape of these organs and restore the normal shape of the part by any mechanical apparatus, no matter how persistent in its use. The incision is made along the inner side of the foot, and the apex of the conical section must be at the outer border of the tarsus.

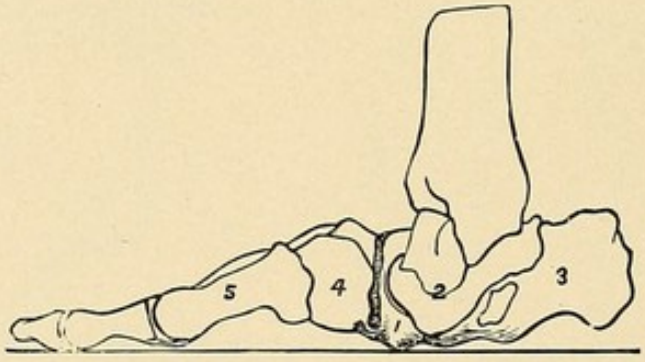

Fig. 709.—Inner view of the bones of a severe valgus. (After Reeves.) 1, Tubercle of scaphoid. 2, Astragalus. 3, Os calcis. 4, Internal cuneiform bone. 5, First metatarsal.

The details of the operation and the after-treatment are practically the same as given for equino-varus.

A very satisfactory and successful method of treating flat-foot is that of Dr. Royal Whitman, and is as follows:[1]

"The foot is first immersed in hot water, afterward vigorously massaged, especially about the dorsum, and is then slowly forced into a position of adduction. . . . This inward twisting is at first resisted by a mixed voluntary and involuntary muscular spasm, which gradually gives way under steady pressure. When the limit of adduction has been reached the foot is firmly held until all pain has subsided, when the patient is instructed to make voluntary movements of flexion and extension. The foot is then released and twenty minutes of voluntary exercises follow, and at intervals during the day the patient, by active mus-

[1] Dr. Walter C. Wood, "Annals of Surgery," vol. xvi, p. 407.

cular efforts and passive motion, constantly works to one end—namely, to regain the lost power of adduction—while once daily the twisting is performed by the surgeon.

"During the ten days, more or less, while this active massage is being performed, the patient is allowed to walk a little, wearing whatever support has been selected. The most satisfactory in practice and the most scientific in theory of any support with which I am acquainted is the brace advocated by Dr. Whitman. In each case it is made on an iron mold, with the cast of the foot in the corrected position as a model. The cast is taken a few days after the twisting by removing the plaster splint for the purpose. Another plaster splint is usually applied until the brace is ready. This steel brace extends from just behind the ball of the great toe to a point in front of the inner tuberosity of the os calcis; thus the foot rests on its normal supports, the inner flange reaches to a point in front of and a little below the internal malleolus, while the small outer one fits in behind the base of the fifth metatarsal. The weight on the outer border forces the inner part of the brace snugly up against the weak arch. The time required from the date of the anæsthesia until a patient can walk about with some comfort on these well-fitting supports is about three weeks. In a foot without stiffness, of course, they can be applied without the preliminary twisting and massage.

"These braces should be worn some six or more months, depending upon the severity of the case, during which time the patient should himself continue the twisting and massage. They can then gradually be laid aside. The ultimate result

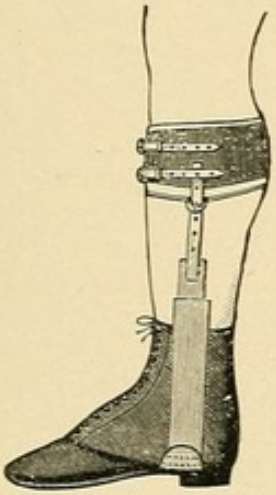

FIG. 710.—Nyrop's shoe for talipes valgus. (After Reeves.)



FIG. 711.—Showing the surface of the sole which rests upon the floor in a normal foot. (After Sayre.)



FIG. 712.—Cast of the right foot in a case of talipes planus, at the Polyclinic.

is a flexible foot in a correct position without pain, and can justly be considered a radical cure. Although the proper application of this brace requires some skill in the use of plaster of Paris and a wise attention to the details of massage, the results warrant its use in an important case."

Talipes Cavus.—Hollow-foot is almost always an acquired deformity, although it may be congenital. It occurs with talipes calcaneus, equinus, and, in a mild degree, may complicate varus and equino-varus. In this deformity the antero-posterior arch of the foot is exaggerated, the plantar fascia and the muscles of the plantar region which have their origin behind the medio-tarsal joint, and are inserted anterior to this articulation, are shortened. The plantar fascia and the calcaneo-cuboid ligaments are also shortened. The sole of the foot no longer rests upon the floor, as in the normal condition (Fig. 711), but touches only at the heel and along the metatarso-phalangeal line.

Any inflammatory process of the plantar region may induce contraction of the fascia or ligaments; or spastic contraction of the muscles of this region from local or remote causes may produce this deformity. Commencing before the bones are softened, the distortion of the foot is apt to become permanent unless exsection or crushing is performed. Of these two procedures, tarsoclasis is the most readily accomplished; but, when the tarsoclast cannot be had, section through the tarsus,

with a thorough division of the plantar fascia, will be justifiable. Fortunately, few instances will occur where such harsh procedures will be called for.

In recent cases the deformity may be relieved by wearing a plain shoe with a low, broad heel and straight, thick sole. The plantar fascia should be divided in all cases which do not readily yield to mechanical treatment.

Talipes Planus.—Flat-foot has been partially considered with talipes valgus, with which condition it is almost always associated. The antero-posterior arch of the foot is more or less obliterated, and in severe cases the anterior portion of the sole spreads out or widens in its transverse diameter (Fig. 712).

The plantar fascia and calcaneo-cuboid ligaments are stretched, the internal lateral ligaments of the ankle-joint are generally involved, while the tibialis anticus and the muscles of the plantar aspect of the foot are elongated. The principal cause of this deformity is the habitual carrying of heavy burdens, or pressure of the superincumbent weight of the body upon the arch of the foot, together with lack of tonicity in the muscles, and of strength in the ligaments and fascia.

Treatment.—It is exceedingly difficult and in the majority of cases impossible to correct this deformity. The best method is to support the arch of the foot by a comfortable adjustment of pressure by inserting a piece of felt in the sole of the shoe, just beneath the arch.

The *deformities of the toes* are congenital and acquired. The congenital deviations from the normal are the presence of one or more supernumerary toes (*polydactylus*), or the absence of one or more of these members (*syndactylus*).

In *polydactylus* the most frequent supernumerary toe is one connected with the great toe, attached usually on its inner or tibial aspect, near the junction of the metatarsal bone and phalanx. In a rare case of this deformity, reported by Professor Sayre, there were eight toes on the right and ten on the left foot.

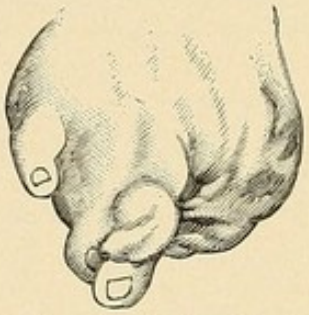

Fig. 713.—Syndactylus in the right foot of a boy. (After Reeves.)

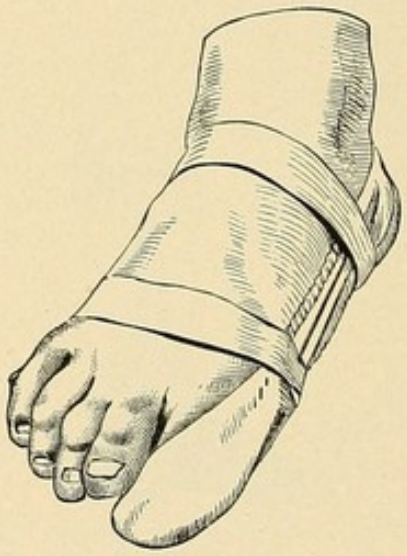

Fig. 714.—Sayre's method of treating hallux valgus. (After Sayre.)

Treatment.—All minor deformities the removal of which does not endanger the life of the individual, or diminish the usefulness of the member affected, demand amputation within the first year or two of life, before the patient is old enough to become conscious of possessing a deformity.

Syndactylus is a term applied not only to the partial or entire absence of one or more fingers, but also to the condition known as congenital *web-toe*.

Web-toes may be treated in the same way as web-fingers. If neglected until the child is old enough to become accustomed to the deformity, operation is of doubtful propriety.

When one or more toes are missing, even when the deformity is offensive to the sight, the question of operative interference (except for relief from pain) should depend upon the degree of usefulness enjoyed by the deformed member. An important principle in the surgery of the foot is to save every particle of surface for the support of the body. This conclusion gains additional force in the ability to conceal the deformity by a properly constructed shoe.

The acquired deformities of the toes result in almost all cases from improperly adjusted shoes. The displacement may be in all directions, although those of the great and little toes are usually toward the median line of the foot. The middle toes may be flexed in one joint, extended in another, or crossed over each other.

Hallux valgus, or displacement of the great toe toward the fibular or outer side of the foot, is a common deformity (Fig. 715). In exaggerated instances mechanical or surgical interference is demanded. Hallux valgus is caused chiefly by shoes which are pointed at the tip and are too short for the foot. It may also occur with clubfoot, and generally with talipes varus and planus. The action of the muscles inserted into the base of the great toe must not be altogether overlooked in the ætiology of this deformity. Of the five muscles which arise from the tarsus and metatarsus and are inserted into this toe, all but one tend to carry it toward the fibular side of the foot.

In being displaced, the great toe is usually carried above the second or third toe, occasionally beneath it. The phalanx is more or less completely dislocated from the original articular surface of the metatarsal bone, being twisted around to its outer lateral aspect. The cartilage of the old portion disappears, and a new joint surface is developed on the external aspect of the metatarsal bone. From pressure, a callosity of varying thickness develops over the tip of the metacarpus, adding greatly to the appearance of deformity.

Treatment.—Mild cases of hallux valgus may be cured by elastic tension steadily applied, as follows: A soft kid or chamois-skin cover is made for the affected toe, and to the end of this a piece of thin elastic webbing is attached. To the webbing a strip of adhesive plaster is stitched, and this is carried around the heel and is made to adhere along the outer side of the foot in such a way that the webbing is made to draw the toe outward (Fig. 714).

In severe cases, operative interference can alone restore the toe to its normal position. The operation consists in an incision made along the inner side of the foot, the center of which is over the angular projection at the end of the metatarsal bone. The callosity should be removed, the joint opened, a wedge-shaped segment removed from the end of the metatarsal bone and the phalanx. Enough should be removed with the exsector or metacarpal saw to permit the bones to be brought into proper position, where they should be held by a plaster-of-Paris dressing applied over light sterile gauze. The toe should be held well abducted until the gypsum is hard. It is removed at the expiration of three weeks. Fig. 715 is from a cast taken from a patient at Mount Sinai Hospital upon whom I did this operation in both feet. The degree of correction is shown in Fig. 716.

This operation is preferable to that of osteotomy of the first metatarsal bone just behind the articulation, for the reason that the callosity and projection opposite the joint can only be removed by excision.

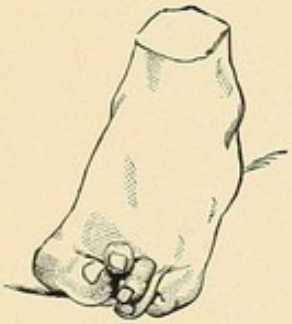

Fig. 715.—Hallux valgus. (From a patient at Mount Sinai Hospital.)



Fig. 716.—The same, after operation.

Hallux varus, or pigeon-toe, is a much rarer deformity, and occurs usually as a result of cicatricial contractions or from spastic action of the abductor-pollicis muscle. The treatment consists in adjusting a well-made shoe that will push the toe into its proper position. Division of any cicatricial tissue or the tendon of the abductor muscle may be necessary.

Displacement of the little toe is usually inward and beneath the fourth. The same treatment may be applied in this deformity as given for hallux valgus.

Flexion of the toes may be complete when there is paralysis of the extensor muscles. The most usual form is that in which the first phalanx is tilted upward, that is, seemingly extended, while the distal phalanx is drawn downward, so that the nail is to the front, and the tip of the toes rests upon the ground. This condition is also known as *hammer-toes.*



Fig. 717.—Apparatus for hammer-toes. (After Reeves.)

The cause is chiefly one of improper shoeing, by which the toes are not allowed to be fully extended, and, being held in this cramped position by the shoe, the muscles and fasciæ become permanently shortened. The plantar fascia is usually involved in chronic cases. The extensor muscles become shortened as well as the flexors, which are, however, the principal agents in producing the deformity.

Extension of the toes beyond the normal line is a rare condition. It could only be caused by paralysis of the flexors.

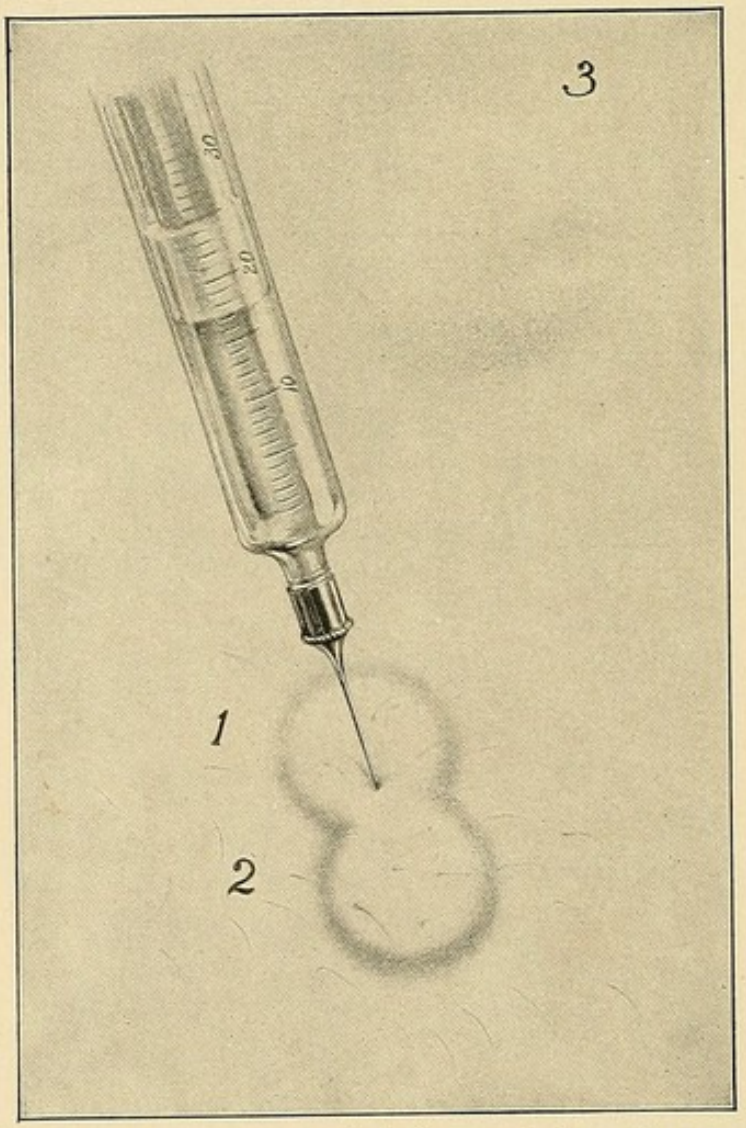

Fig. 717*a*.—Injection of cocaine for local anæsthesia in removing ingrowing toe-nail and other minor procedures. 1, The wheal caused by the first injection into (not under) the skin; 2, the wheal due to the second injection into the skin. The needle for this injection is inserted in the edge of the area already anæsthetized. It is shown in the correct position for the second injection. (Foote's "Minor Surgery.")

Treatment.—In mild cases of incipient hammer-toes a cure may be effected by wearing a shoe long enough to allow these members to be extended. In more

chronic and obstinate cases a metal sole should be adjusted so that an ordinary shoe can be worn over it. Just beneath the middle of the toes is a series of perforations in the sole, through which loops are passed. The toes are straightened by traction on the loops, which are tied below (Fig. 717). In some instances tenotomy of the long flexor and extensor muscles and of the plantar fascia is essential. The tendons of the extensor digitorum should be subcutaneously divided just over the bases of the toes; the flexor tendons near the middle of the plantar surface of these members.

Bunions are callosities resulting from intermittent pressure upon certain portions of the foot.

Corns are both *hard* and *soft*. A hard corn differs from a bunion only in size. Soft corns are small ulcers situated between the toes or in the fissures on the under surface. They are caused by friction of opposing surfaces and moisture.

Bunions and hard corns are to be treated by relieving the unnatural pressure which caused them. Comfortably fitting, yet not necessarily loose shoes, of soft leather, should be worn. Pieces of Canton flannel, cut into rings and laid upon each other so that the pressure will be distributed to the surfaces near the corn, will be advisable, in simple cases, even when loose shoes are adopted. A small tuft of cotton dipped in vaseline will aid in softening the hard covering. Soft corns may be readily cured by inserting pellets of absorbent cotton moistened with borax dissolved in glycerin, and applied so as to protect the raw surfaces and prevent friction.

Ingrowing nail, caused by tight shoeing and uncleanliness, usually occurs on the great toe.

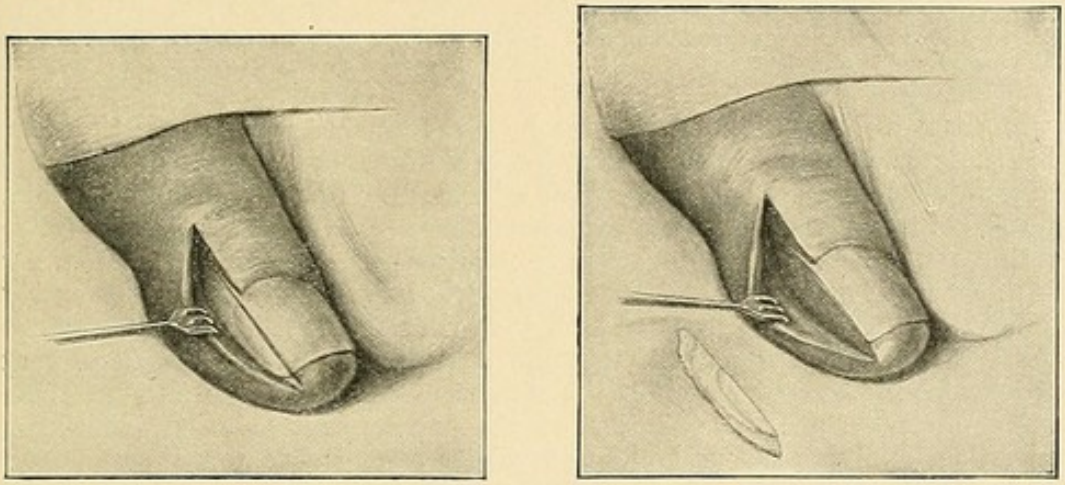

A B

FIG. 717*b*.—Operation for ingrown nail. A, the skin flaps reflected; B, the section of nail and corresponding matrix removed. (Foote's "Minor Surgery.")

The palliative treatment is to cut away portions of the nail near the inflamed surface, and to protect this by a pellet of lint moistened in Van Arsdale's mixture. The radical treatment requires the removal of a portion, and, in very rare instances, of the entire nail, with the matrix.

The following operation will usually suffice: The toes and foot should be thoroughly cleansed. Local anæsthesia is effected by introducing between the layers of the skin the hypodermic needle of the cocaine syringe (one-per-cent solution) on the dorsum of the toe, half an inch behind the nearest surface of the inner aspect of the nail. Three or four drops are forced out and the needle is pushed through and beneath the skin half an inch farther, injecting the same quantity and continuing this process along the inner side of the toe near the nail, waiting a moment for the anæsthesia to declare itself before withdrawing the needle, to reënter it through the anterior margin of the freshly anæsthetized zone (Fig. 717*a*).

The pain is insignificant, the discomfort experienced being due to the momentary distention of the tissues with the injected liquid. It is also necessary to inject about half of the matrix and to throw the cocaine between the nail and

the phalanx in order to get a perfect anæsthesia. In from three to five minutes insensibility is complete. The nail should now be split from before directly backward, usually removing the inner fourth, together with as much of the matrix as belongs to the strip removed. The operator should be careful to remove the matrix well down to the bone (Fig. 717*b*).

If there is any granulation tissue present, it should be scraped away with a curette, and the entire raw surface touched with a pellet of absorbent cotton dipped

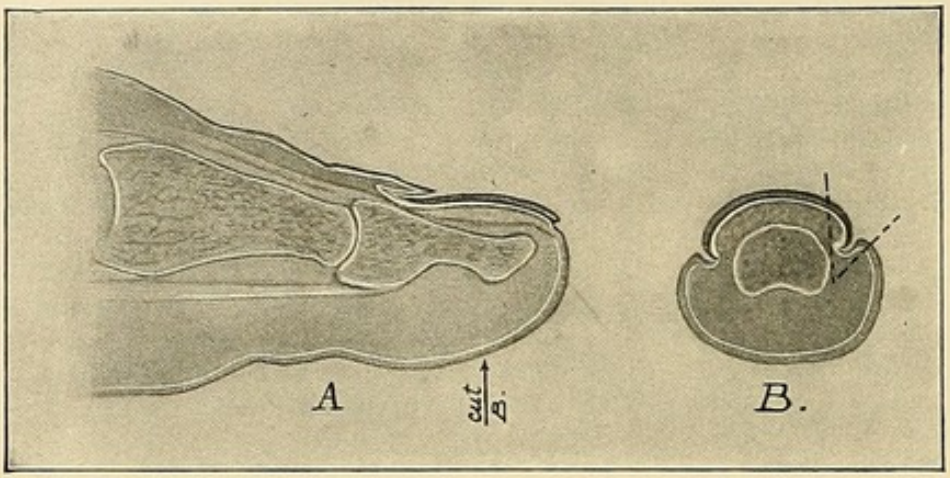

FIG. 717*c*.—Sections of the great toe to illustrate the pathology of ingrown nail on which successful operation is based. The nail is shown dark, the matrix light. Note that the matrix extends almost to the joint. *A*, longitudinal section; *B*, transverse section at point in *A* marked by the arrow. The dotted lines mark out the portion of the nail and matrix which should be removed. (Foote's "Minor Surgery.")

in pure carbolic acid. The acid is not only antiseptic, but analgesic. A little alcohol should be applied to neutralize the excess of carbolic acid. A pad of sterile gauze is laid on and held in place with a bandage. Fig. 717*c* shows the anatomy of the structures involved in this operation.

When a more extensive operation is required—that is, removal of the entire nail—the method just described may be modified to include the entire end of the toe, or the cocaine may be injected well back near the metatarso-phalangeal articulation. "Ringing" a digit with cocaine anæsthesia may be successfully accomplished by injecting here first into the skin for one half of the circumference and then the other a sufficient quantity of the one-per-cent solution, waiting for a minute, then applying a small piece of rubber tubing as a tourniquet behind the ring of cocaine. After this is temporarily applied, the syringe should be plunged more deeply, gradually infiltrating the toe on either side until all of the tissues have been subjected to the presence of cocaine. The tourniquet should now be loosened for thirty seconds, allowing the circulation to sweep the cocaine forward. It should then be tightened and the cocaine forced forward by pressure with the thumb and finger.

The employment of this method with the one-per-cent solution of cocaine will thoroughly anæsthetize all the tissues beyond the tourniquet, and by holding this in place bleeding is entirely prevented, while the tissues in line of incision are not distended by the injection.

Should there be any anxiety in regard to the quantity used of even so weak a solution of cocaine, constitutional symptoms may be avoided by loosening the tourniquet for ten or fifteen seconds, reapplying it for a minute, then loosening it again for fifteen or twenty seconds, and repeating this for four or five minutes. In this way the cocaine is gradually let into the circulation and creates no disturbance.

In removing the entire nail an incision is first made from the middle of the posterior margin of the nail directly backward for half an inch. A second incision across the top of the toe, extending as low down as the most inferior portion of the nail, on either side, uniting with the central end of the perpendicular cut,

gives the entire wound a T-shape. The two quadrilateral flaps of skin are now dissected up, turned one to the right and one to the left side, and held away by the weight of an artery forceps or by retractors. The nail should next be split from before backward in the middle line, the incision extending through the matrix as far back as the transverse incision through the skin. Both halves and the matrix should be thoroughly extirpated, all granulation tissue scraped out, and the foot dipped into a basin of warm sublimate solution, 1–2000. The flaps are now brought into position, the space formerly occupied by the horny part of the nail packed with sterile gauze, and the entire toe enveloped in the same material. A narrow bandage should be applied firmly enough to hold the gauze in place, and to exercise sufficient compression to prevent bleeding. Over this a generous piece of protective should be thrown and a second bandage applied. When, in applying this bandage, the elastic ligature is reached, it should be taken off and the roller carried on to the foot. A single dressing usually suffices, and it need not be removed for ten days or two weeks.

The same general technic will apply to the treatment of twisted or deformed nails.

Deformities of the Upper Extremity—Clavicle.—Congenital absence of portions of one or both of these bones may exist. No case of complete absence of the collar bone is as yet on record. The partial deficiency may occur on one or both sides, and is usually at the inner extremity. The indications in *treatment* are to use a figure-of-8 brace around the shoulders to prevent them from being approximated in part by the actions of the pectoral muscles.

Paralysis of the *deltoid* and *serratus magnus* muscles imparts to the shoulder a deformed appearance. In deltoid paresis the shoulder is flattened, and the acromion process more prominent and easily recognized. The arm is incapable of being lifted to a right angle with the spine. It may be due to injury of the circumflex nerve, or to a central nervous lesion. When the serratus magnus is paralyzed, the vertebral border of the scapula is tilted outward in a position of unusual prominence. Neither of these injuries is amenable to surgical treatment.

Ankylosis of the *shoulder* is more amenable to the operation of exsection than to forcible breaking up of the adhesions. This last procedure may be employed in cases of partial ankylosis in which no inflammatory process is going on. In *ankylosis* of the *elbow-joint* the same treatment is advisable.

Congenital dislocation at the shoulder is extremely rare, as is the *displacement* due to violence at birth. The *diagnosis* between either of these lesions and epiphyseal separation or fracture can with difficulty be made positive without the X-ray.

A more common deformity is that due to partial paralysis from injury to the fibers of the cervico-brachial nerves. According to Whitman, the fifth and sixth roots are more frequently compressed. The characteristic paralysis affects the deltoid, biceps, and supinators of the forearm, the arm as a result hanging by the side in an attitude of inward rotation and pronation. If seen soon after birth, there is tenderness over the injured nerves. Later these symptoms disappear. The extremity is smaller and shorter than its fellow, the deltoid more or less atrophied, and frequently the shoulder is ankylosed.

The indication is to overcome the inward rotation so that the power of supination of the forearm may be utilized. The technic is as follows:[1]

"The child, having been anæsthetized, is brought to the edge of the table. The shoulder is grasped firmly with one hand in order to restrain the movements of the scapula, and with the other the arm is drawn upward and backward over the fulcrum of the thumb, which lies behind the joint. This, the so-called pump-handle movement, alternately relaxing and stretching the contracted parts, is carried out over and over again with slowly increasing force, the aim being to force the head of the bone forward, and thus to overcome the resistance of the anterior part of the capsule. When this has been accomplished, there is a distinct depression behind, and the head of the humerus projects in front, at a point below its proper position.

[1] Royal Whitman, "Annals of Surgery," July, 1905.

"One then attempts to overcome the abduction and to force the head upward by changing the grasp on the scapula and using the thumb in the axilla as a fulcrum. When the arm can be carried across the chest to the normal degree of adduction, the final, and often most difficult, part of the process—namely, to stretch the tissues sufficiently to permit the proper degree of outward rotation—is undertaken. This is best accomplished by flexing the forearm and using this to exert leverage on the humerus, care being taken, of course, to avoid the danger of fracture. When the head of the bone has been replaced, it will often be noted that the tension on the anterior tissues causes flexion of the forearm; this must be overcome in the same manner, and, finally, the limitation to complete supination. The extremity is then fixed in the overcorrected attitude by means of a plaster bandage which includes the thorax. That is, the arm is drawn backward so that the head of the humerus is made prominent anteriorly, the forearm is flexed and turned outward to the frontal plane, while the hand is placed in extreme supination, the arm lying against the thoracic wall.

"In the more extreme cases it is impracticable to complete the operation at one sitting. When, therefore, as much force has been exercised as seems wise, a plaster bandage is applied, and after an interval of two weeks the further correction is undertaken.

"As has been stated, when the head of the bone is forced forward, a distinct depression and evident relaxation of the tissues is noted on the posterior aspect of the joint. The object of the fixation is to allow the contraction of the posterior wall of the capsule and the obliteration of the old articulation, consequently, the part must be fixed for a period of at least three months. When the plaster bandage is removed, the after-treatment is of great importance. This consists of daily passive forcible movements to the extreme limits in the directions formerly restricted; namely, outward rotation, backward extension, and eventually abduction of the humerus and supination and extension of the forearm. For in all these cases there is a strong tendency to a return in some degree to the original posture.



FIG. 718.—Congenital fusion of the radius and ulnar. (From a case at the Polyclinic.)

When motion has become fairly free, the disabled member must be regularly exercised and reëducated in functional use. Under this treatment the weakened and almost completely atrophied muscles usually gain surprisingly in power and ability, and the longer it is continued the better will be the final result. If the deltoid muscle is completely paralyzed, one cannot expect independent movement at the

shoulder, and the aim should be to gain fibrous ankylosis in the attitude of outward rotation in order to permit supination of the forearm."

Deformities of the forearm are comparatively rare. Of the congenital variety, occasionally there exists a fusion of the two bones. The length of the forearm is normal, as is the motion at the elbow-joint, but supination and pronation are impossible. In the only case I have ever seen, from which Fig. 718 is taken, the



Fig. 719.—Deformity resulting from subperiosteal exsection of the entire radius for ostitis. (From a case operated on at the Polyclinic.)

hands were in the prone position. Operative interference was not indicated in this instance.

Distortions due to rickets are at times met with, and may result from the action of the muscles upon the softened bones, or to pressure from the habitual carrying of burdens in the hands. In destruction of one of the bones of the forearm by ostitis, or after its removal, deformity usually results, the deviation of the hand being toward the side of the missing bone (Fig. 719).

Treatment.—In deformity after rickets, correction by osteotomy is justifiable after the disease is arrested. In the distortions due to loss of substance there is little hope of relief. If the loss on one side is limited, exsection of a portion of the sound bone and reunion of the divided surfaces by wire sutures might be entertained.

Clubhand.—Distortions of the hand, not unlike those already detailed as occurring in the foot, yet far less common, may be met with. The deformity may be at the wrist-joint, in the intercarpal or carpo-metacarpal articulations, and may

be due to failure of development in the bones of the forearm or hand, to muscular paralysis, to fracture, dislocations, or cicatricial contractions.

In the congenital deficiencies, the radius is more often wanting, or only partially developed, allowing the hand to be carried toward the radial side. The carpus is occasionally deficient. Not infrequently the congenital cases are symmetrical, and the lower extremities are also involved.

The muscles are deficient in some of these cases of osseous malformation. The usual condition in paralysis is that of flexion of the carpus and metacarpus upon the forearm.

This variety is termed *palmar*; the opposite, *dorsal* clubhand. When the displacement is lateral it is called *radial* or *ulnar*, as the hand is carried outward or inward. As in clubfoot, there are compound forms of clubhand.

As to frequency in the congenital types, the radius being chiefly at fault, the *radial* distortion is most frequent. When from any cause the equilibrium between the muscles is impaired, the hand is usually flexed upon the forearm, and the condition is known as palmar clubhand. With this there may be radio-palmar or ulno-palmar deformity.

Fracture of the radius (Colles'), or epiphyseal separation, may induce a mild form of radial clubhand. Unreduced dislocations will, of course, cause deformity. Deformities due to cicatricial contraction, as after burns, extensive phlegmons, etc., are occasionally met with.

The treatment of all these different varieties of clubhand will depend upon the particular cause. In the worst form of congenital deformity, amputation at or shortly after birth should be performed. Other and milder cases may be improved by mechanical apparatus constructed to meet the indications.

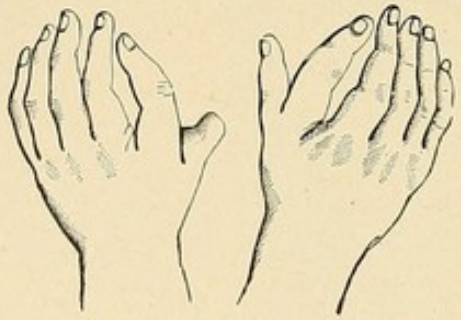

FIG. 720.—Supernumerary digits. (After Reeves.)

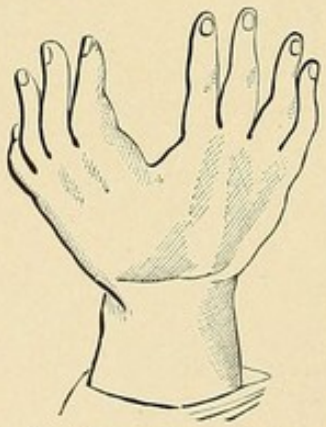

FIG. 721.—Double hand. (After Reeves.)

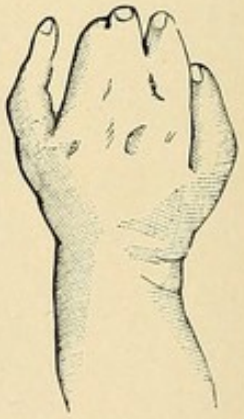

FIG. 722.—Stunted and webbed hand. (After Reeves.)

In muscular paralysis the same general rules of practice as laid down in clubfoot due to this cause should be followed. *Tenotomy* may be necessary. The extensors may be subcutaneously divided about the middle of the metacarpal bones. The flexors slightly above the wrist-joint. The lateral deformities also will justify in some cases division of the contracting muscles. The rule to be followed is to do subcutaneous tenotomy when the tendon to be divided is far enough away from any important nerve or vessel to allow a perfectly safe and sure division of the tendon; if not, the tendons should be exposed by incision under strict antisepsis, and each one picked up on an aneurism-needle and divided in plain view.

The propriety of breaking up adhesion in ankylosis with malposition, or of resection, should be determined by the condition of the parts and of the patient, and the necessities of the case.

The Fingers and Hand.—Among the *congenital* deformities of the fingers are polydactylus, syndactylus, and web-finger, or fusion of two or more digits. The *acquired* deformities are due to contraction of the palmar fascia, of the muscles and tendons, to paralysis of certain muscles, and to osseous and articular lesions, both traumatic and idiopathic.

Supernumerary Finger (*Polydactylus*).—The usual location of one extra finger is on the radial side of the thumb or ulnar aspect of the little finger, near the metacarpo-phalangeal junction (Fig. 720). It may or may not possess phalanges or cartilages. If the phalanges exist, a synovial cavity will be found at the junction with the metacarpal bone, or with the phalanx of the normal member.

A rare form of supernumerary fingers is shown in Fig. 721, in which there is practically a double hand. Amputation of the supernumerary members should be made soon after birth.

In syndactylus, all or a portion of one or more fingers may be wanting (Fig. 722). Amputation of the deformed portion is usually advisable.

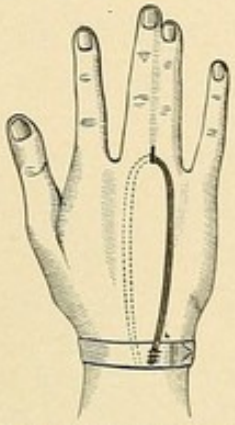

Fig. 723.—Elastic ligature passed through the web. (After Fort and Noble Smith.)

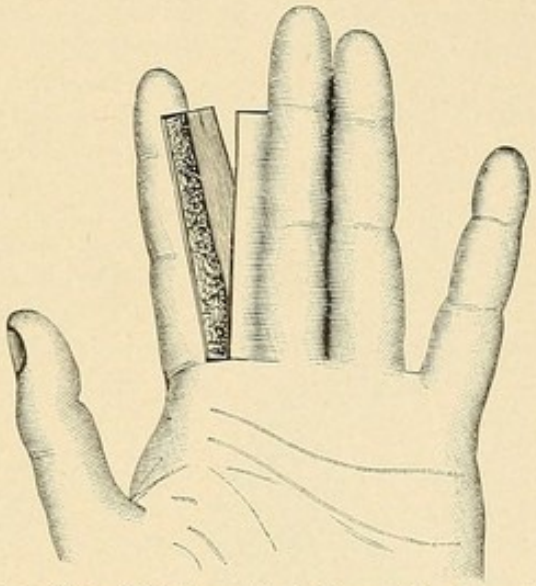

Fig. 724.—Didot's method of operating for web-fingers. (After Fort and Noble Smith.)

Web-finger is most frequently congenital, although it may be acquired. In mild cases, where the union between the contiguous surfaces is slight and the web is thin, the following method will succeed: A round elastic ligature or cord is carried through the web just in front of the metacarpo-phalangeal articulation, and the ends are turned back and attached by a band around the wrist (Fig. 723). This is allowed to remain for three or four weeks, until the hole made by the ligature is lined with epidermis. A second puncture should now be made about one inch in front of the first, the ligature passed through this, and the ends tied. The constant traction of the elastic gradually cuts through the web, yet so slowly that the track of the wound becomes covered with epidermis. This procedure should be repeated until all the web is divided.

When the fingers are solidly united, the method of Didot should be preferred. An incision is made down the palmar surface of one finger (the index, Fig. 724) and along the dorsal surface of the adjoining member (the middle finger). The flaps are dissected up so that the one removed from the palmar surface of the index-finger remains attached to the middle finger, while the posterior flap is attached along the dorsum of the index-finger. They are then sutured in position (Fig. 725).

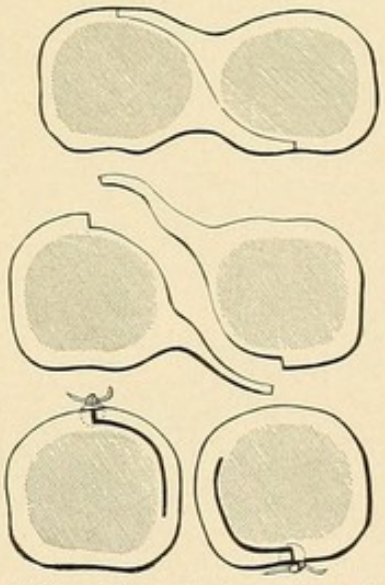

Fig. 725.—Transverse sections of the webbed fingers, showing in the upper figure the line of separation between the two flaps; in the middle, the outline of the separated flaps; below, the sutures are applied. (After Fort and Noble Smith.)

In those cases in which the bones are only slightly united, the line of union may be sawed through. When the bones are fused into one solid mass an operation is not indicated.

Chronic flexion of one or more fingers may result from paralysis of the extensor muscles, spastic contraction of the flexors, or from contractions of the palmar and digital fascia. Paralysis of the extensors may be temporary or permanent. Lead-poisoning not infrequently leads to temporary impairment of the function of this group of muscles.

In neglected cases of chronic extensor paralysis, permanent shortening of the opposing muscles, with contraction of the palmar fascia, occurs.

The indications in treatment are to restore, if possible, the functions of the paralyzed muscles, and to prevent deformity by the adjustment of an apparatus which will keep the fingers extended.

Contraction of the palmar fascia, as a result of any inflammatory process, gives rise to the most common deformity of the fingers. Penetrating wounds of the palm, or idiopathic phlegmon, are exceedingly apt to result in fascial contraction and chronic malposition of the fingers.

This process takes place at times in persons of the gouty or rheumatic diathesis without any marked symptom of local inflammation. The tendons are not affected, as a rule, in the earlier stages of *Du-*

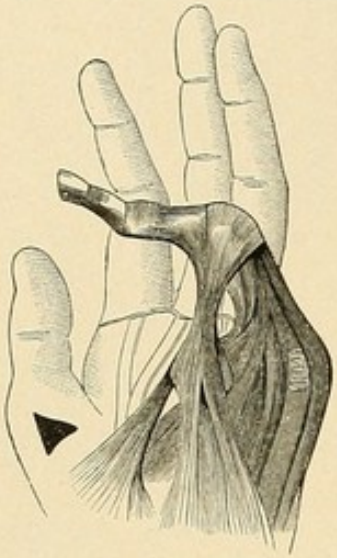

Fig. 726.—Dupuytren's contraction in the fascia of the palm and of the little finger. (After Noble Smith.)

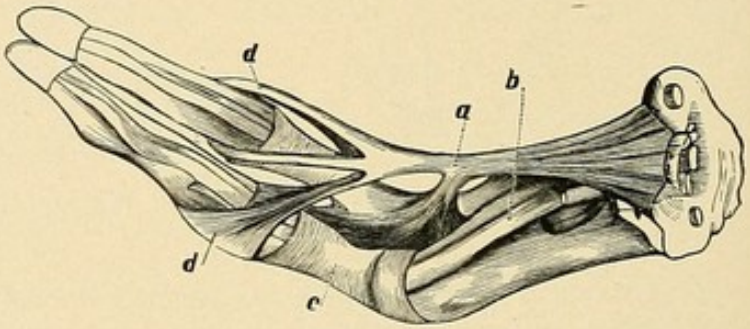

Fig. 727.—The same, in the middle and ring fingers. *a*, Contracted band of palmar fascia. *b*, Flexor tendons (not involved). *c*, Sheath of tendons. *d*, Digital prolongations of palmar fascia. (After W. Adams and Noble Smith.)

puytren's contraction. In old cases the muscles are shortened. The fascial contractions are well shown in Figs. 726 and 727.

Treatment.—In mild cases, taken early in the commencement of the affection, a cure may be effected by repeated stretching of the fascia by fully extending the fingers involved. The instrument shown in Fig. 728, devised by Dr. Battey, of

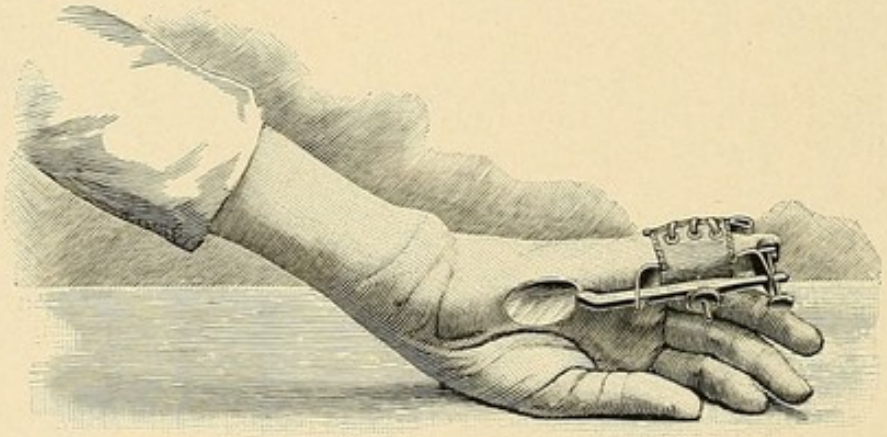

Fig. 728.

New York, will be found very useful in such cases. In obstinate cases fasciotomy is demanded. Division of the palmar fascia should be done as follows: The hand should be rendered thoroughly aseptic by washing in sublimate solution, and made bloodless by Esmarch's bandage. The hypodermic injection of four-per-cent co-

caine solution renders the operation painless. The delicate fascia knife should be introduced beneath the bands of fascia, which can be made prominent by extreme extension of the fingers, the edge turned upward, and a thorough division effected, taking care not to allow the knife to cut through the skin. Every resisting band should be divided until the fingers can be readily brought into a position of over-correction. Two or three lines of section may be made in the palm and one or two through the digital prolongations of the fingers involved. By carefully inserting the knife closely beneath the fascia, the vessels of the palm and fingers may be avoided. The palm should be covered with a thick layer of sublimate gauze, and a splint applied in order to keep the fingers perfectly straight. This should be worn for two or three weeks, at which time passive motion should be made and the splint reapplied for another week. After it is removed, thorough extension should be practiced at least once a day for several months.

Snap- or Jerk-finger.—This name has been used to designate a condition in which free extension and flexion of one or more fingers is more or less interrupted. As the affected digit is being flexed or extended, motion is arrested in a certain position, and if a violent effort is made, or if flexion is continued by aid from the other hand, a perceptible jerk occurs as the obstruction is overcome. A nodular swelling, to the touch resembling the ganglia often met with on the back of the wrist, may be felt along the line of the tendon at or near the metacarpo-phalangeal joint. Snap-finger may be due to a circumscribed thickening of the tendon, or a disproportion between the size of the tendon and sheath for a limited area. This condition is believed to exist, especially in the thumb, where the jerk occurs in one third of all cases. Mr. Reeves thinks that in the fingers it is chiefly due to the synovial fringes catching upon the transverse process of the palmar fascia. This may occur not only "from thickening of this process of fascia, but also from rolling up or displacement of the synovial sheaths."

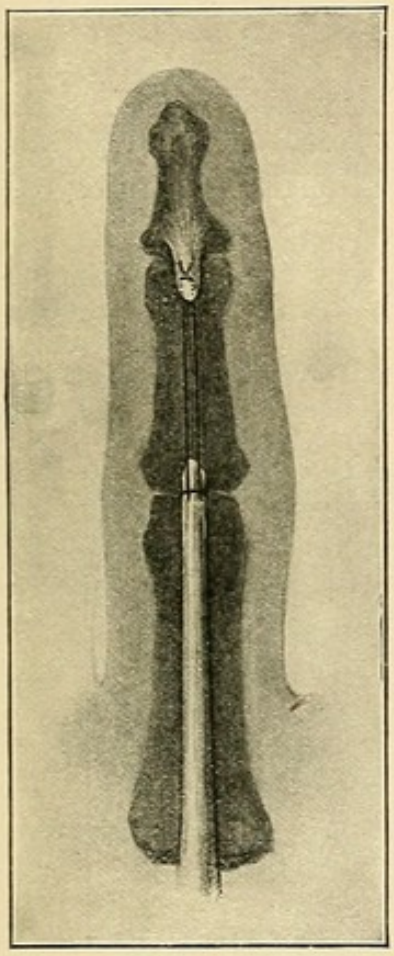

FIG. 728*a*.—Tendon suture. A long loop stitch left in place to act as a tendon. It becomes covered with fibrous tissue growing out from the cut ends of the tendon. (Foote's "Minor Surgery.")

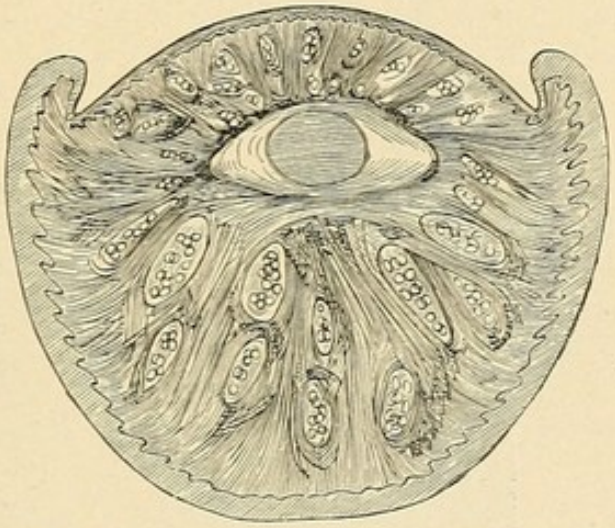

FIG. 729.—Showing the converging arrangement of the dense connective-tissue bundles in the finger around the last phalanx. (After Vogt.)

Snap-finger may be traumatic or idiopathic in origin. Strains on the tendons and fascia in the act of lifting, direct violence, as well as the gouty and rheumatic inflammations, are noted in the ætiology. The treatment consists in passive motion, and internal medication to correct any dyscrasia. If relief does not fol-

low ordinary measures, an incision should be made and the enlargement dissected out.

In certain cases in which adhesion of the tendons to their sheaths and to the palmar and digital fascia occur chiefly as a result of penetrating wounds, it will —in order to relieve the deformity—be required to make an open dissection and divide the adhesions in plain view. Such operations can be done with impunity, and with an extraordinary degree of success, if the strict antiseptic precautions

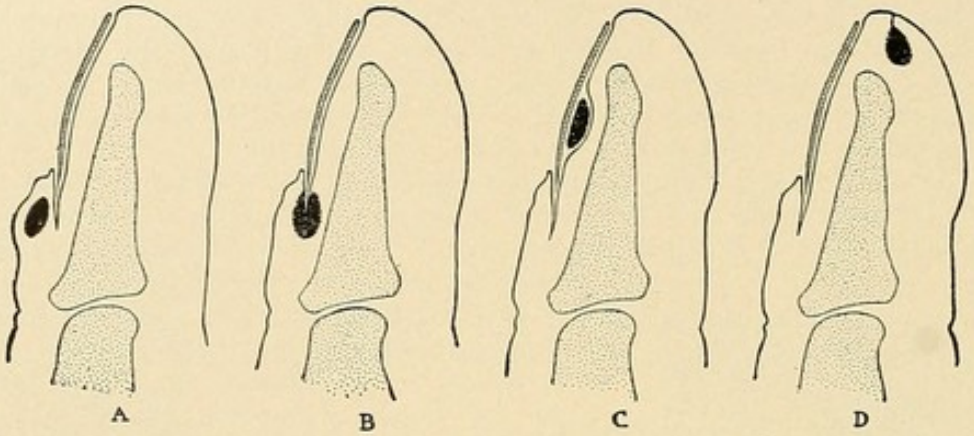

FIG. 729*a*.—Section of terminal segment of finger. An abscess may form between the dorsal skin and the matrix of the nail at *A*; or between the matrix and the formed nail at *B*; or between the nail and the underlying skin at *C*; or between the skin and the front of the phalanx, as shown in *D*. (Foote's "Minor Surgery.")

are observed. Esmarch's bandage is essential to the operation, and cocaine anæsthesia I have frequently demonstrated to be perfectly satisfactory in these procedures. The wound should be closed at once with fine silk sutures. Catgut is not sufficiently reliable in this region. The danger of inflammation and contractions of the fascia from opening into the hand under sublimate irrigation and careful

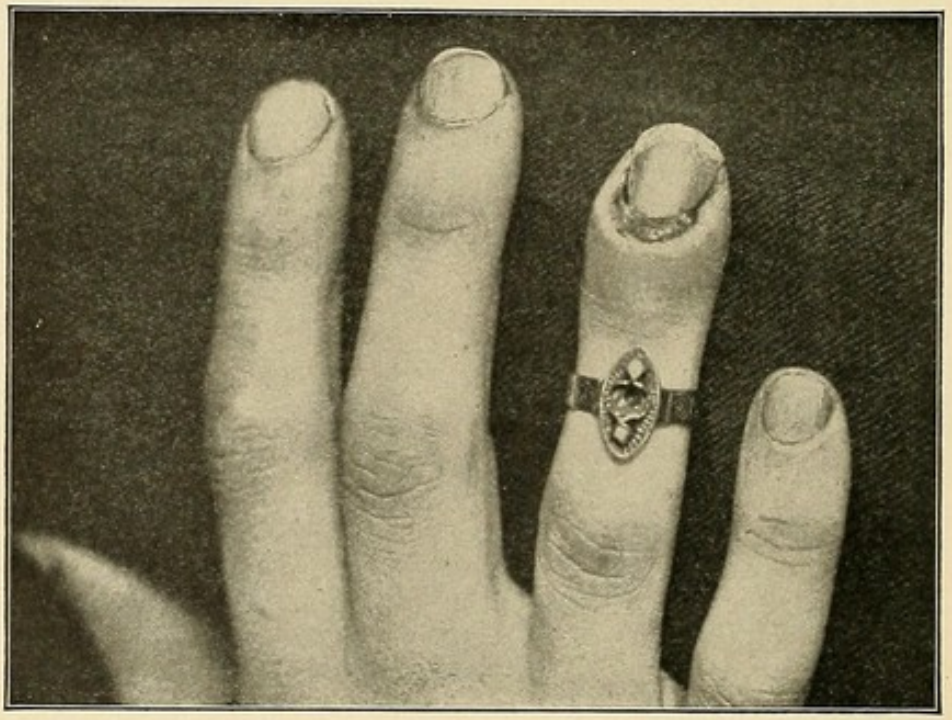

FIG. 729*b*.—Acute paronychia of three weeks' duration with spontaneous rupture of abscess. Pus in spaces marked *A* and *B*, Fig. 729*a*. Patient a woman aged twenty-one years. (Foote's "Minor Surgery.")

antisepsis are exceedingly remote. Even the most extensive injuries of the hand may be made to heal with as little deformity as often follows a simple wound in which inflammation and suppuration are established.

When the tendons are divided, either in the forearm near the wrist or in the palm or along the fingers, it is essential that the divided ends be stitched together with silk sutures. When there is loss of substance the ends should be united by a long linen or silk loop (Foote) (Fig. 728*a*). Cocaine anæsthesia and Esmarch's bandage should be employed.

Deformities of the hand and fingers also result from exostosis and new formations of cartilage in the digits. Amputation is indicated in the latter condition, while in exostosis relief may be obtained by direct incision and removal of the offending bone.

Phlegmon of the Hand and Fingers.—Phlegmon of the fingers is an exceedingly painful affection. Occurring, as it usually does, in the terminal phalanx, a knowledge of the arrangement of the fascia here is essential to proper treatment. Fig. 729 shows the intimate attachment of the connective-tissue fibers to the integument of the palmar aspect of the digit and to the matrix of the nail, the separation of the various layers to form spaces in which are contained quantities of fat. The general convergence of these bundles of connective tissue toward the center is well illustrated in the cut. They are intimately attached to the sheath of the tendon in front and to the periosteum posteriorly. The lymph-channels follow the layers of fascia from the skin toward the bone. Phlegmon of the finger ("*felon*," or "*whitlow*") may originate in the bone or periosteum, but most frequently begins in the soft tissues (Fig. 729*a*). On account of the arrangement of the fascia and lymphatics, the inflammation rapidly extends to the tendon or periosteum. The dense structure of the tissues here, which prevents their yielding to the pressure of the inflammatory infiltration, will account for the unusual degree of pain present in this affection. In *paronychia* (Fig. 729*b*), where the skin and matrix of the nail are involved, there is less pain and tension.



Fig. 730.—Showing by injection the continuity of the synovial sheaths of the little finger and thumb with the large sac beneath the palmar fascia. (After Vogt.)

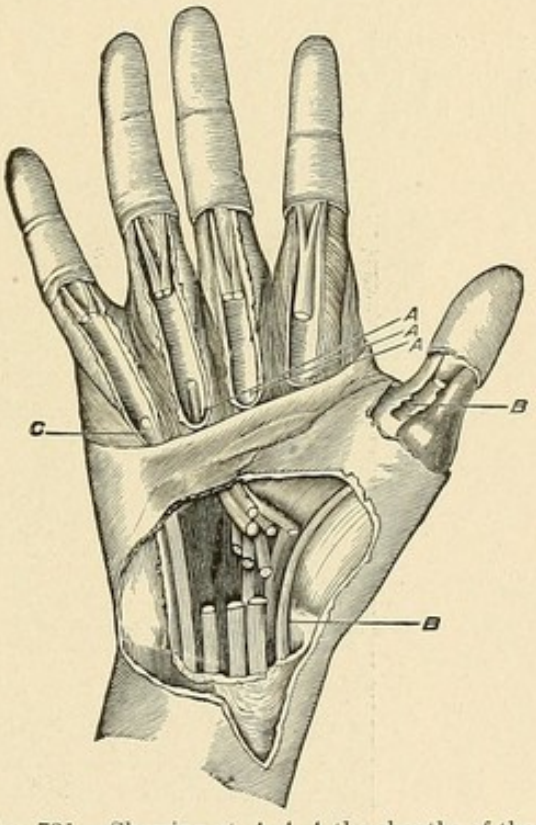

Fig. 731.—Showing at *A A A* the sheaths of the ring, middle, and index-fingers ending in blind extremities toward the palmar sac. (After Vogt.)

Phlegmon of the palmar aspects of the thumb or little finger, not relieved by early incision and disinfection, may extend along the sheaths of their tendons and invade the entire palmar fascia. Conversely, central phlegmon of the palm of the hand may radiate to these digits (Fig. 730).

By reason of the anatomical arrangement of the sheaths of the ring, index-, and middle fingers, closing as they do in blind extremities at the metacarpo-

phalangeal articulations, the inflammatory process does not extend, as a rule, into the large synovial sac beneath the palmar fascia (Figs. 730 and 731). Upon the back of the hand and fingers phlegmon behaves as it does beneath the skin in other parts of the body.

In the *treatment* of *whitlow* the first indication is to relieve tension at the earliest moment by puncture or incision. The exact point of inflammation in

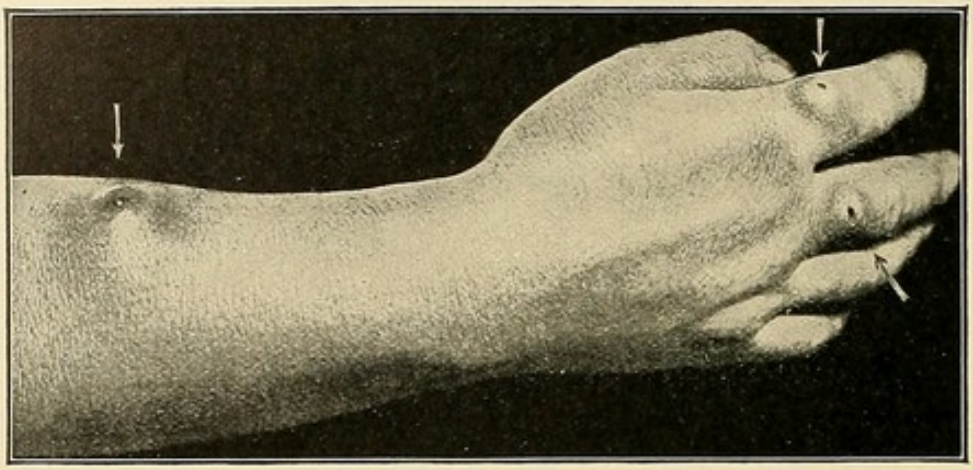

FIG. 731*a*.—Phlegmon of finger with abscess developing in the course of the lymphatic vessel. The arrows are directed to these points. Note the different appearance of tuberculosis as shown in Fig. 731*b* and in the late stages of syphilitic infection as shown in Fig. 731*c*. (Foote's "Minor Surgery.")

the earliest stage of phlegmon may be recognized by direct pressure with a small pointed instrument, as a probe or director. Cocaine may be utilized to prevent pain when the incision is made. A rubber ligature tied around the finger to arrest

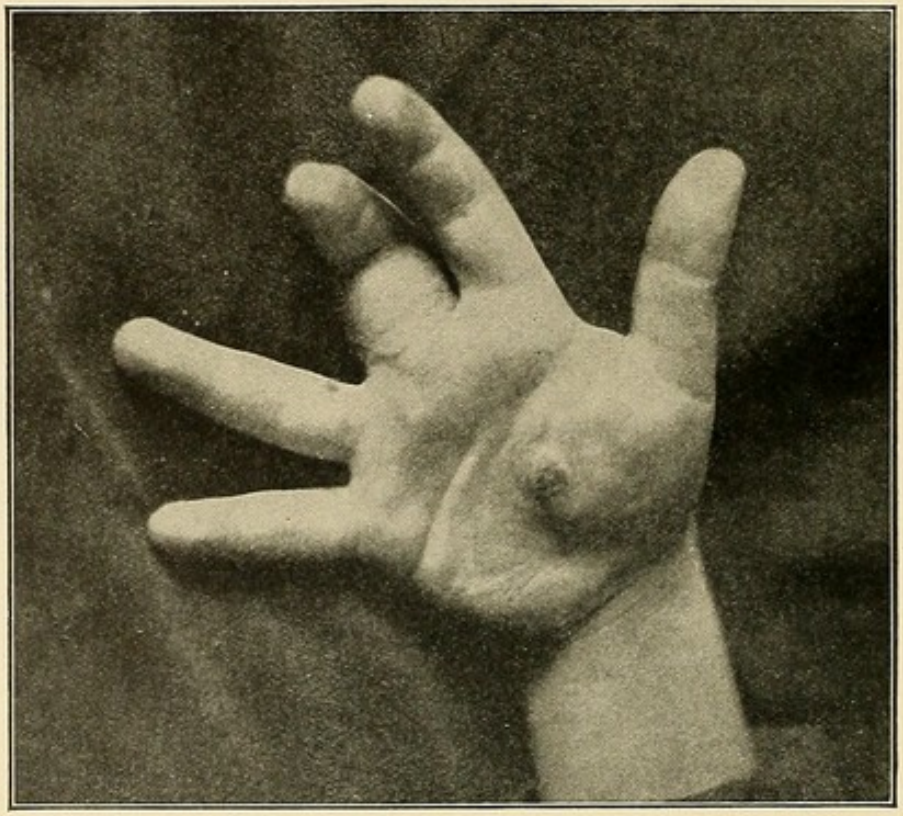

FIG. 731*b*.—Tuberculosis of flexor tendon sheaths of hand. Especial distention of sheath of middle finger; sinus in palm. Patient a boy aged six years. (Foote's "Minor Surgery.")

the circulation, and a few minims injected into the line of incision, will deaden all sensibility. The incision should be free, and down to the tendon or bone, to

insure relief of all tension. The part should then be submerged in warm sublimate solution, the ligature removed, and, after a minute or two of bleeding under water an iodoform strip should be packed into the wound, and a moist aseptic dressing applied.

When pus has formed and can be evacuated in this manner, the opening should be made upon the lateral aspects of the finger, in order to avoid the sheath of the tendon.

In phlegmon beneath the palmar fascia the same principles of incision and drainage should be applied, avoiding the larger vessels when possible.

When amputation of the finger is necessitated it is in general advisable to preserve the end of the metacarpal bone, thus securing a broader palmar surface (Fig. 731*d*).

Ganglion.—Ganglion is due to the localized collection of a variable quantity of synovial fluid in the sheaths of the tendons, or bursæ on the dorsum of the hand

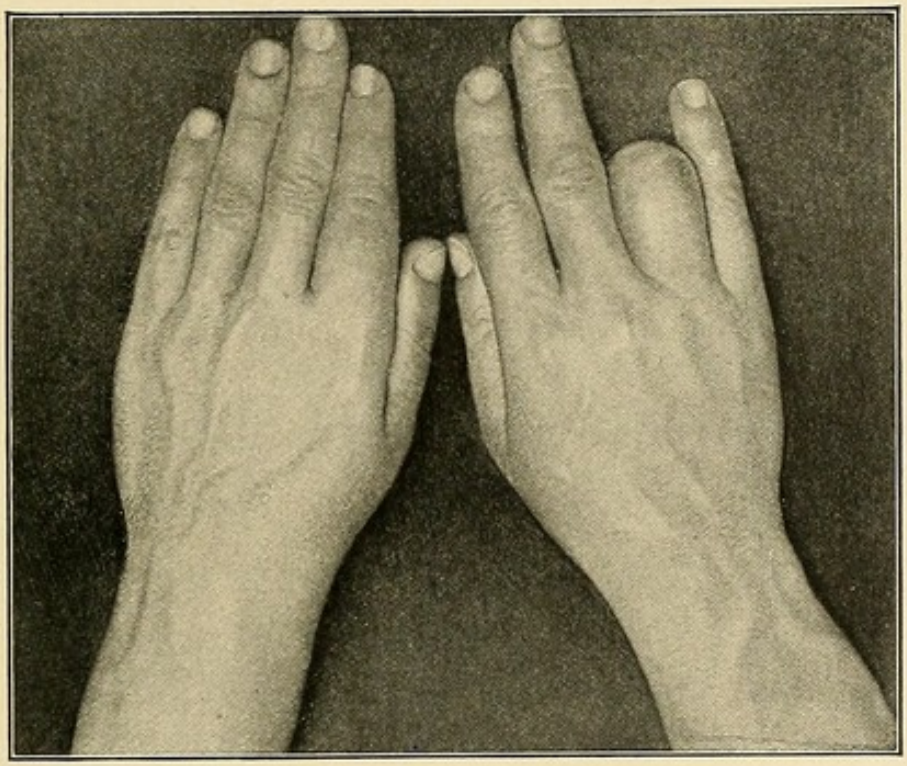

FIG. 731*c*.—Syphilis of left wrist, left forefinger and right ring-finger, commencing one year ago in the ring-finger, a part of which was amputated by a physician. Patient a woman aged thirty-six years. (Foote's "Minor Surgery.")

or wrist. Excision and dissection under cocaine anæsthesia, and strict asepsis, I have found to be the most satisfactory means of effecting a cure. They may be made to disappear by absorption, after subcutaneous rupture from a sharp blow with the back of a book or padded hammer.

Division of the tendons of any part of the hand or of the wrist near the hand demands careful asepsis and immediate suture of the tendons and nerves, if these be divided. When the wound is across the wrist, the skin should be freely dissected back in order to thoroughly expose the tendons, which usually are considerably retracted in the direction of the origin of the muscle; it also requires a thorough knowledge of anatomy in order to separate the various tendons and to unite the upper section to the proper tendon of insertion. I employ fine sterile silk sutures, using two threads to each tendon, and an additional thread when the tendon is unusually broad or strong, such as the flexor carpi ulnaris. The needle is passed entirely through the tendon between one eighth and one fourth of an inch from the divided edge. All sutures are inserted and approximation made gradually with the hand and arm in a position which will most thoroughly relax the tissues to be approximated. Nerve suture has been described. It is important

in uniting such a nerve as the median or ulna at the wrist, to use fine needles, a round one preferably, which will not cut the nerve fibers, and when tension is great to pass one needle and suture through the center of the nerve about one eighth of an inch from the cut surface; then on either side of this to insert a very delicate suture into the sheath of the nerve. Approximation should be very carefully made, not jamming the ends of the nerve together, but securing them snugly in opposition. The dressing should consist of sterile gauze with plaster of Paris over all, the hand being held properly flexed for six or eight weeks after the operation. The nerves reunite in from two to six weeks. Function may not always be early established, and in some instances months, and as much as two years, have elapsed before conductivity was restored.

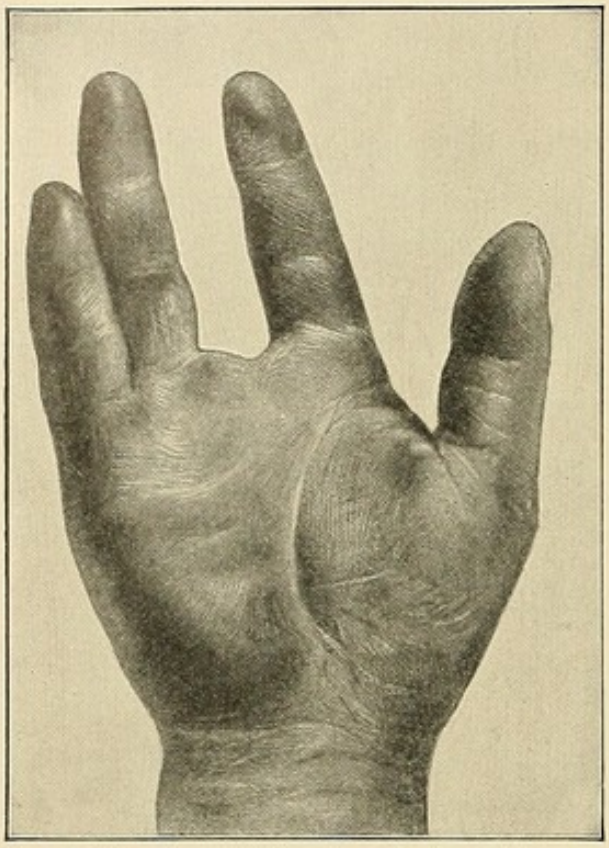

Fig. 731*d*. — Amputation through the metacarpophalangeal joint. The photograph taken some years later, shows the permanent wide gap between the remaining fingers and the broad palmar surface which is lost when the end of the metacarpal bone is removed. (Foote's "Minor Surgery.")

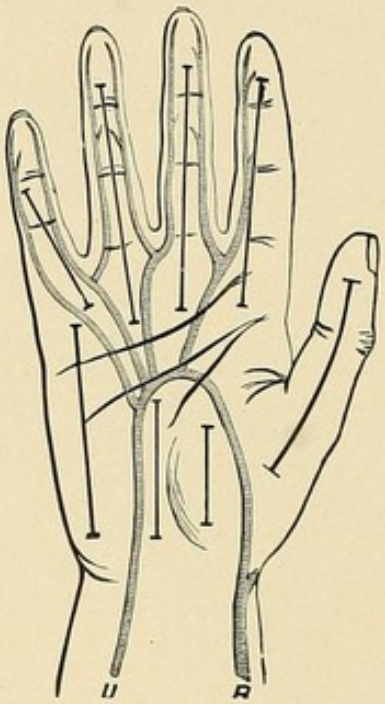

Fig. 732.—Showing outline relation of arteries, and line of incision which may avoid the more important vessels. (After Vogt.)

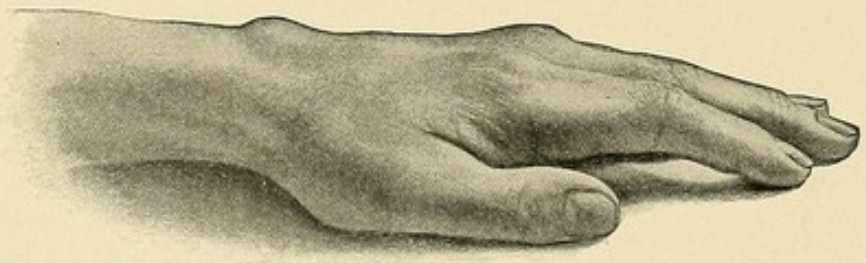

Fig. 732*a*.—Ganglion of the wrist. Lateral view to show the elevation of the tumor. (Foote's "Minor Surgery.")

CHAPTER XXXIII

THE SPINAL CORD[1] AND ITS MEMBRANES—THE NERVES[2]—THE MUSCLES AND TENDONS

THE *traumatic* lesions of the cord are classified as concussion, contusion, penetrating wounds, hæmorrhage, extra- or intra-dural, or in the substance of the cord proper, together with the various lesions of compression, or of partial or complete division which may follow dislocations or fractures of the vertebræ.

The *idiopathic* lesions are congenital and acquired. The chief congenitive lesion is spina bifida. Tuberculosis, affecting either the bones of the spinal column or the meninges, is the most frequent of the acquired lesions. In addition to these are the various neoplasms or tumors, and certain infective processes, as meningitis.

Concussion of the spine is defined surgically as a partial or complete, temporary or permanent loss of function without, so far as has yet been demonstrated, the presence of any recognizable anatomic changes in the minute or gross structure of the cord.

In *contusion* there are the same symptoms as in concussion, usually more pronounced, but here there is found, to account for loss of function, extravasation of blood from the capillaries of the cord substance, or from the peripheral blood supply, with pressure, and at times division of cord substances.

The symptoms of contusion and concussion are therefore clinically considered as the same.

Penetrating wounds are chiefly gunshot or knife injuries. The former usually cause comminution or limited fracture of bone, carrying with the missile spiculæ, which may be buried in the membranes or cord. Division of the cord as the result of these injuries produces paralysis, which is permanent, and which is referable to all parts of the body to which the nerve fibers or nerve cells so injured are functionally related. The track of punctured or stab wounds of this organ is usually through the intervertebral spaces, and they are most frequently met with in the neck.

Hæmorrhage within the spinal canal may in rare instances occur spontaneously. It is, however, in practically all cases of traumatic origin.

Dislocation and fractures of the vertebræ are apt to occur together, although one or the other may exist alone. They are caused by a direct blow, or indirectly, as by fall upon the buttocks, or by diving, striking upon the head, or in overflexion or extension. The cervical region is oftener the seat of these injuries. Fracture or dislocation of the atlas has been reported without symptoms of spinal cord injury.[3] The chief symptom connected with the injury of the spinal cord is paralysis of motion or of sensation. The sensory symptoms may be those of anæsthesia, or at times of hyperæsthesia. There may be a noticeable displacement of the spines, and in the cervical region interference with swallowing, due to pressure upon the œsophagus.

[1] Surgically the spinal cord may be considered as extending from the occipito-atloid articulation to the upper surface of the second lumbar vertebra.

[2] For many valuable suggestions used in this chapter, from "Neurological Surgery," published in "Surgery, Gynæcology, and Obstetrics," for April, 1907, the author is indebted to Prof. John B. Murphy.

[3] Dr. H. A. Wilson reports the case of a man who suffered a fracture of the odontoid process and a forward dislocation of the atlas as clearly demonstrated by the radiograph. There was no paralysis; the patient was unable to sleep lying down, but could do so sitting up with his head resting forward on a pillow; occasionally he had difficulty in swallowing because of the mechanical pressure of the displaced bone on the œsophagus.

Treatment.—The chief indication in treatment is relief of compression. If the cord has been divided, restoration of function never takes place. Compression from clot, the presence of a foreign body, or a displaced particle of bone will, however, produce paralysis when no cord elements are divided. The knowledge of this fact makes it imperative, unless extraordinary conditions contra-indicate it, to perform laminectomy, if for no more than an exploratory procedure. Properly conducted, this operation is not dangerous, and it gives the one opportunity of removing pressure and preserving the cord from degenerative changes which may be permanent if the compression is not soon moved. The technic of laminectomy is given on another page.[1]

Hæmorrhage.—In the diagnosis of a suspected hæmorrhage, lumbar puncture should be done. When pain is felt with this lesion, it is usually paroxysmal and burning in character, and may or may not be accompanied by muscular spasm.

Tuberculosis of the bones of the spinal column is considered in another chapter. Aggregations of tuberculous material, connected or not with breaking down of the bodies of the vertebræ, at times press upon the dura or the cord, so as to cause partial or complete hemiplegia, or, more commonly, paraplegia. Laminectomy is indicated as soon as this condition is recognized, and, taken early enough, will relieve the pressure symptoms with more or less restoration of function.[2] When the laminæ are removed, if the tumor is within the dura it should be opened carefully in the middle line, as elsewhere directed, and the tuberculous materials carefully scraped from the cord with a dull spoon or curette. In connection with the surgical treatment of the spinal column or cord for tuberculosis, the most thorough climatic and nourishing treatment should be combined. Proper support should be given to any functional weakness of the muscles or bones.

Neoplasms of the spine may be divided into those developed in the vertebræ, which are common to bones in general, and which produce paralysis by compression, and those originating directly in the cord or in its membranes.

Those of the meninges may be considered as extra- and intra-dural. The usual varieties are lipoma, sarcoma, carcinoma, and myxoma, while occasionally a cyst caused by the echinococcus is observed.

The symptoms of these various tumors are chiefly those of compression, either upon the cord proper, or the motor or sensory roots of the nerves given off from it. The location of the tumor is estimated usually as about four inches higher than the level of the sensory disturbance on the back (Starr).

Tumors of the cauda equina may be suspected when there is pain in the sacral region radiating to the leg, interfering more or less with the function of the bladder and the rectum, but more particularly producing muscular weakness in the lower extremities.

The indications in all of these various lesions are to operate early for the relief of compression.

Spina bifida is a condition resulting from the failure of development in the laminæ and spines in one or more of the vertebræ. Prof. Charles L. Dana classifies the varieties of spina bifida as follows:

(*a*) Meningocele; a protruding sac composed of meningeal membranes and cerebrospinal fluid only. This may be either: 1, Anterior, abdominal, or pelvic; or 2, posterior or dorsal tumor.

(*b*) Meningomyelocele; hydromyelia; a tumor composed of meningeal membranes, cerebrospinal fluid, and spinal cord, including cauda.

(*c*) Syringomyelocele; composed of meninges, cerebrospinal fluid, and spinal cord, with an enormous dilatation of the central canal.

To these Prof. John B. Murphy adds the rare form spina bifida occulta, in which there is a cleft of the spinal column without any visible protrusion of the contents of the canal.

[1] The author has performed this operation in some twenty instances, and in no case has a fatality followed as a result of the operation, nor has the permanent removal of the laminæ and spines of three contiguous vertebræ interfered with the supporting power of the spinal column.

[2] In one instance in the experience of the author a complete paraplegia of several months entirely disappeared after laminectomy, opening the dura and removing the tuberculous mass from the posterior surface of the cord.

In meningocele the cord elements may be intact, while in meningomyelocele they are involved in the tumor and are very frequently spread out and fused with the posterior and median surface of the sac, forming a part of the cyst wall.

In syringomyelocele there is usually a pressure atrophy of the cord, with partial or complete paraplegia.

Spina bifida is met with most frequently in the lumbo-sacral region, next in frequency in the neck, rarely elsewhere. One fissure may exist below and one above in the same child, though it is very rarely multiple.

The tumor may vary in size from one inch to six or eight inches in the longest diameter, and may be sessile or pedunculated. It is elastic to the touch, and when covered by the integument, this is thinner than normal. The skin is oftener wanting over the mass, the protruding *dura mater* forming the outside covering.

The character of the swelling may be recognized by its congenital origin, its location in the median line of the back, almost always in the lumbo-sacral region, its smooth contour, elasticity, and chiefly by its variable size. It becomes larger and more tense during the act of crying, and by pressure its contents may in part be forced back into the spinal canal and ventricles of the brain. Convulsive movements may follow too great and prolonged compression of the tumor. The prognosis is, as a rule, very unfavorable. Ulceration of the integument over the mass, followed by rupture of the sac, is apt to occur, usually ending in death. A recovery after this accident is rare, although such cases are reported. Or the tumor may remain indefinitely in about the same condition as at birth. Paralysis, more or less complete, in the lower extremities is the rule.

The treatment will depend in large measure upon the location and character of the tumor. When the fissure is small and the tumor is pedunculated, the cord elements not being prolapsed or in any way involved (meningocele), a cure may be effected by ligation at the level of the skin. In a case of this character situated in the cervical region, the author successfully performed this operation with complete cure, and without any subsequent paralysis. In the large majority of cases of spina bifida the more radical procedure of removal of the sac by dissection, covering in the cord by a plastic skin-flap operation is indicated. The prognosis is in general grave, both as to a fatal and functional result. The treatment by injections should not be considered. In the radical operation the dissection should begin from the lateral aspects of the tumor, for the reason that the cord elements are apt to be attached near the median line. Approached from the side, they are more easily recognized, and may be preserved by being enclosed in the new canal formed by suture of the membranous and cutaneous flaps from the sides.

The Nerves.—Partial and complete loss of conductivity in a nerve, or excessive pain, is not infrequently caused by changes in the nerve sheath or in the neurilemma. These new formations belong to the connective-tissue variety, and may or may not be malignant. They form perceptible enlargements, which are usually fusiform or spindle-shaped, and may often be recognized by palpation. The author has operated upon three cases of this character connected with the cervico-brachial plexuses. In two of these complete extirpation was made of all the nerve divisions involved, which relieved the painful symptoms entirely, but resulted in permanent paralysis in the distribution of the nerves removed. In the second case, on account of extreme pain and to prevent the acquirement of the morphine habit, an operation was undertaken which necessitated the surgical division of the clavicle. There were two separate tumors of the cervico-brachial plexus, from one half to one inch in diameter at their largest portion, tapering gradually four or five inches toward the axilla and up into the neck. On account of the extensive paralysis which would necessarily follow excision, the operation was discontinued, and the collar bone arched upward in such a way as to relieve pressure. The collar bone united in the new position, and the pain was entirely relieved. Ten years later the patient was in perfect health, with the exception of a very slight deformity caused by the elevated collar bone and the neoplasms, which are still appreciable.

As soon as a neuroma is recognized the nerve should be divided above and below the tumor at a sufficient distance to be safely in sound tissue and immediate reunion effected. The element of pain should also be considered as an indication

for surgical relief. When a nerve has been divided, or has been destroyed by pressure, excision of the degenerated or diseased stumps should be practiced, and end-to-end suture immediately performed. When ununited, the distal end begins at once to take on a swollen and bulblike appearance, with commencing degeneration, which extends rapidly toward its distribution. On the central end the same change takes place in lesser degree. In suturing a nerve the finest linen or silk or No. 0 chromicized catgut should be employed. On account of the firmer and better holding power of the former it is preferred. In reuniting a nerve not only should the bulbous ends be removed, cutting squarely across where the fibers are normal, but any cicatricial tissue or neighboring adhesions should be removed. Asepsis is imperative, since infection and the presence of scar tissue will retard or prevent restoration of function. A perfectly round and partly curved needle of the smallest practical size should be used. The sutures are introduced only through the sheath about one eighth of an inch from the edge, and come out beneath it at the free end, care being taken that the needle does not dip down among the nerve bundles. On a small nerve one of these sutures on opposing surfaces may suffice, while in the larger trunks four or more are required. Where there is difficulty in approximation, one or two sutures may be passed through both sheath and nerve substance, to be used as tension sutures. In a case in which the great sciatic nerve had been divided just at the bifurcation, this operation was successfully performed. One of the tension sutures passed through the middle of the external popliteal, the other through the internal, while both of them passed through the main trunk.

Even when the ends do not meet by a half inch or more, such is the reproductive and regenerative power of some of the nerves that if they be held steadily in place by long sutures and are embedded in contiguous muscle substance and kept perfectly at rest for a proper period of time (about two months), reproduction with functional restoration may occur. The first symptom of return of function is a change in the nutrition of the part affected, with the healing of trophic ulcers when these are present, then sensation, and lastly motion. Sometimes motion does not return for several months after a successful union has been accomplished.

In the paralysis resulting from anterior poliomyelitis, nerve transplantation is worthy of consideration, especially when a small group of muscles is involved. The operation should be done early in life, from the sixth month to the third year, and in general should be supplemented by tendon implantation, carrying all or part of the tendon of a live muscle over to one that is paralyzed. At times the shortening of the paralyzed and overstretched tendons, which cannot be reinforced by a live tendon, is advisable. In transplanting the peripheral end of a dead nerve into the side of a live nerve, it is important that the nerve fibers should be placed in close *end-to-end* apposition with those of the nerve which is still functionating.

Nerve stretching is recommended in the treatment of persistent neuralgia, and in a certain proportion of cases gives at least temporary relief. These operations may practically all be done with cocaine anæsthesia. In sciatica, in which disease it is most frequently recommended, exposure of the trunk is readily made between the trochanter major and the tuberosity of the ischium. Should it be necessary after the exposure of the nerve by cocaine, the stretching may be done under momentary nitrous-oxide anæsthesia.

Muscles and Tendons.—Of the surgical lesions of the muscles, contusions, rupture, and penetrating wounds are the most common. In contusions, in general, nothing more is required than to support the injured muscle or group of muscles by appropriate bandaging with a splint, if necessary, and permitting careful passive motion in order to prevent adhesions in the process of repair.

When a muscle is torn, if the injury is extensive and the function of the organ is seriously impaired by the separation of its fibers, an anæsthetic should be administered and careful suture made of the torn ends. The material best adopted for suture is a celluloiden linen for the muscular sheath, with ten-day catgut sutures for the muscle bundles. As these are buried sutures, the most careful asepsis

should be practiced. The fixation should be in that position which will give the most complete relaxation and rest to the injured member.

Muscles which with their tendons are occasionally dislocated demand only reposition and careful holding in position by bandage or splint until a cure is effected. Hernia of a muscle, in which some of the fasciculi protrude through the sheath, or the fascia or skin is rare and requires no special consideration.

Muscular neuralgia, so-called, is in all probability due to some general condition of the system (uric-acid or oxalic-acid diathesis), or to the exposure of a limited area of the body to sudden changes in temperature. Many cases of so-called myalgia are in reality neuralgia.

A painful condition of the muscles is present in certain forms of toxæmia, as in lead-poisoning, in the so-called gonorrhœal rheumatism, in syphilitic infection and tuberculosis, and also in the deposit of calcareous or inorganic substances in the muscle substance, usually near the junction with their tendons or aponeuroses. These calcareous deposits are sometimes converted into bone (myositis ossificans). A rare muscular lesion is hydatid cyst due to the presence of the ova of the tapeworm. It requires no special treatment except incision and removal of the contents by drainage.

The *treatment* in each of these varieties of muscular lesion must of necessity be directed to the prevailing dyscrasia. The elimination of uric and oxalic acid may be best effected by rigid and simple diet combined with thorough irrigation of the tissues by the free imbibition of water, by massage, judicious exercise and open-air life. A warm climate is advisable in order to aid elimination in keeping the pores of the skin freely open.

Muscular paralyses, in addition to constitutional and operative measures, directed toward the primary cause, may require surgical intervention.

In the choice of orthopedic or supporting apparatus, massage, and at times nerve or tendon transplantation—that is, the carrying of a part or all of a live nerve and suturing it to a dead one, or a tendon of a live muscle and uniting it to the tendon of one that is paralyzed—is employed. These procedures should not be undertaken until a most careful study is made of the condition of the organs involved.

In correcting the deformity due to partial or complete paralysis of one or more of a group of muscles, it not infrequently becomes necessary to elongate by division the tendons of the contractured group, or to shorten the tendons of the overstretched or paralyzed organs. Tendon division is a simple procedure, and when it can with perfect safety be effected subcutaneously, this should be done. However, with careful asepsis there is no objection to an incision which will expose the tendon, and this should be done when it lies in close contact with a nerve or vessel which otherwise might be injured. In shortening tendons, as a rule, overlapping and careful suture with fine linen will suffice.

In lengthening a tendon, the method most generally employed is to cut halfway through the tendon at a given point, split it in its long axis for the required length, and complete the section by dividing the half opposite to that which was first incised, and then uniting the two free ends by end-to-end anastomosis.

The lesions of the tendons which most interest the surgeon are those associated with contractions of the fascia of the hand and of the foot, or to cicatricial conditions resulting from extensive injuries, burns, etc., and the more common lesions connected with disease of the sheaths of the tendons. Dupuytren's contraction is given in the chapter on deformities, together with the various lesions of the bursæ.

CHAPTER XXXIV

NEOPLASMS (NEW GROWTHS, TUMORS)

A NEOPLASM is a *non-inflammatory mass, composed of new-formed elements which, having their type in the normal embryonic or adult tissues, are dependent upon these for nutrition, and yet are not amenable to the laws regulating and limiting the development of the normal structures.*

The efforts at classification of new growths upon a histological basis have not been generally satisfactory. Virchow, Foerster, Cornil and Ranvier, and other pathologists, with the same end in view, have arrived at conclusions scarcely reconcilable. A discussion of these various classifications belongs more properly to special works on pathology. Clinically, they admit of division into two heads—the *malignant* and *non-malignant.*[1]

Malignancy in a tumor means its tendency to become multiple by metastasis; the tendency of the elements of which it is composed to travel along the lymph

[1] The following classification of tumors is taken from "Modern Surgery," by Prof. Roswell Park, published by Lea Brothers & Company, Philadelphia, 1907, to which work the student is referred.

1. RETENTION CYSTS

TYPES.—*Hydronephrosis,* hydrocholecyst, due to obstruction of the ureter or gall duct.

Tubulo-cysts, found in the vitello-intestinal duct, connected with the remains of the Wolffian body, allantoic, etc.

Hydroceles, watery fluid collected in a previously existing serous cavity; tunica vaginalis, tunica funiculi; canal of Nuck. *Hydroceles* of the *neck,* cystic collections of congenital origin.

Glandular cysts, as ranula.

Pseudocysts, intestinal and vesical diverticula. (Sutton.) Synovial cysts, bursæ, ganglion, etc.

Neural cysts, found in the brain and central nervous system. (Sutton.)

Hydatid cysts, due to the ova of the tape-worm. Cysts due to blood extravasation, hematocele, etc.

2. DERMOIDS

Dermoids are cysts or tumors containing tissues and appendages which are developed from the epiblast. They contain skin, hair follicles, sebaceous glands, sweat glands, teeth, mucous membrane, etc. Sutton divides dermoids into three classes:

1. *Sequestration dermoids,* due to coalescence between two surfaces possessing an epiblastic covering.

2. *Tubulodermoids,* developing from obsolete canals and ducts, as the omphalomesenteric duct, branchial clefts, etc.

3. *Ovarian dermoids* and *teratomas,* unilocular or multilocular cysts lined with epithelium containing chiefly mucoid fluid. (Park.) In large tumors of this type, hair, teeth, etc., are found.

3. TERATOMAS

Tumors composed of tissues of epiblastic and mesoblastic origin, probably also hypoblastic. They form irregular tumors containing tissues or fragments of viscera of a suppressed fœtus which is attached to an otherwise normal individual.

Embryonal adenosarcoma connected with the renal and adrenal structures. They are congenital, usually appearing early but may come in advanced adult life.

4. TUMORS OF CONNECTIVE-TISSUE TYPE

Lipoma, or tumor composed of fat, is subdivided into subcutaneous, subserous, and subsynovial.

Fibroma, composed of fibrous tissue occurs in the ovary, uterus, intestine, gum (epulis), nerve-sheaths, skin, etc. *Epulis, keloid, dermoids,* are terms restricted to tumors which proceed

or blood channels, and, thus disseminated, to reproduce the parent tumor; or its tendency to invade and destroy the tissues in its vicinity, and to recur *in loco* after extirpation.

primarily from muscles, tendons, and aponeuroses or from ligamentary and periosteal tissue. (Park.) *Psammoma* is a hard fibroma of the dura mater.

Chondroma, composed of hyaline cartilage and osteoma or tumor of bone.

Exostoses are classified by Sutton as (1) Ossification of tendons. (2) Subungual exostoses. (3) Exostoses due to calcification of inflammatory exudations. (Myositis Ossificans.)

Sarcoma, tumor composed of immature mesoblastic or embryonic tissue in which cells predominate over intercellular material. (Park.) They are classified according to the shape of their cells and their disposition, into (*a*) round-cell; (*b*) spindle-cell; (*c*) myeloid, to which other varieties are added.

(A) *Lymphosarcoma*, a round-cell sarcoma in which there is a delicate meshwork resembling that of lymph nodes, not to be confounded with enlargements nor with specific granulomas involving these lymphatic structures.

(B) *Spindle-cell sarcoma*, the cells spindle-shaped, running in all directions. The largest spindle-cells are at times striated, and have been called rhabdomyoma. There is, however, no tumor of striped muscle fiber.

Alveolar sarcoma, a rare type, the cells assuming an alveolar arrangement.

(C) *Myeloid or giant-cell sarcoma*, the cells resembling those of the red marrow of young and growing bone containing a large number of multinuclear cells being involved in a matrix of spindle or round cells. They occur in the long bones and epulis, or spongy tumors springing from the gums. (Park).

(D) *Osteosarcoma* or sarcoma of the specific bone-forming connective tissue. There may also be a true osteofibroma. These are to be distinguished even clinically from the medullary sarcomas, which develop within the bone and expand it. (Park.)

(E) *Chondrosarcoma*, involving the stroma of cartilage, or the specific tissue which produces cartilage. White fibrous cartilage is found throughout the tumor. Chondrofibroma is also possible. (Park.)

(F) *Endothelioma*, composed of endothelial cells which line the lymph spaces, met with most frequently in the skin of the face, the genital glands, the bones, the lymph nodes, and dura.

(G) *Angeiosarcoma*, originating from the adventitia of the blood vessels. (1) Peritheliomas met with especially in the kidneys, the bones, and skin, originating in the perithelial cells between the capillaries and the perivascular lymph spaces.

(H) *Cylindroma*, angeiosarcoma, in which hyaline changes have occurred.

(I) *Melanosarcoma*, or pigmented sarcoma deservedly considered most malignant.

Myxoma, composed of mucous tissue. (1) Polypi, nasal, etc. (2) Cutaneous, may be sessile, or pedunculated. (3) Neuromyxoma, a mucoid tumor involving nerve trunks.

Myoma, composed of unstriped muscle fiber, develops only in this tissue; most frequently found in the uterus. It has been seen in the œsophagus, in the walls of the stomach, prostate, bladder, and skin.

Angeioma. (1) Capillary, mother's mark, or port-wine mark. (2) Cavernous, involving the veins. (3) Arterial, or cirsoid (aneurism).

Lymphangeioma, composed of lymph vessels, divided into three varieties:

(1) The lymphatic nevus, seen during childhood in the tongue, known as macroglossia. (2) Cavernous lymphangeioma cysts. (3) Lymph cysts, due to dilatation of the lymph vessels. The lower extremities and the scrotum and labia are often enormously enlarged (elephantiasis).

5. Tumors of Nerve Elements

Glioma, a malignant tumor developing directly from actual nerve structures or that of the original nerve elements. (Park.) Found in the brain, cord, and optic nerve.

Neuroma, originating from the structures of the nerve trunks.

(1) *Plexiform neuroma*, involving the branches of a nerve distributed to a particular area (rare). (2) *Malignant neuroma*, a sarcoma of the nerve structures. *Traumatic* neuroma is often seen in amputation stumps.

6. The Epithelial Tumors

Odontoma. (1) Epithelial. (2) Follicular (dentigerous cysts). (3) Fibrous. (4) Cementoma. (5) Follicular (containing immature teeth). (6) Radicular, developing in the roots of teeth. (7) Composite, a hard growth occurring in the jaws, made of enamel, dentine, and cement.

Papilloma or fibro-epithelioma. (1) Warts. (2) Villous, found in the bladder and kidney. (3) Intracystic, found in mammary cysts. (4) Ovarian, growing luxuriantly from peritoneal surfaces, contiguous to the ovary. (5) Cutaneous horns.

Mucous polypus, an epithelial tumor hanging from the mucous membrane, most commonly the rectum.

Goître (*struma*), neoplasm of the thyroid body. (1) Struma parenchymatosa nodosa. (2) Struma fibrosa.

Ovarian cystoma. (1) Glandular. (2) Papillary.

Adenoma and fibro-adenoma are the abnormal outgrowth of the normal secreting apparatus of a gland, occurring in the mammæ, parotid, thyroid, liver, and mucous membrane of the bowels and uterus. Adenoma occurs frequently in sebaceous glands. (Park.) (1) Sebaceous cysts or

The malignant neoplasms are grouped under two headings—*carcinoma* and *sarcoma.*

The non-malignant are as follows: *lipoma, fibroma, myxoma, osteoma, enchondroma, angeioma, neuroma, myoma, adenoma, papilloma,* and *lymphoma.*

Carcinoma.—A cancer may be defined to be a tumor, composed of *embryonic cell elements* of varying shape and proportions, collected in groups, which groups or clusters are *partially separated by a well-defined stroma.*

While the elements of the carcinomata do not always differ so widely from those of the sarcomata (especially the more embryonic cells of this latter neo-

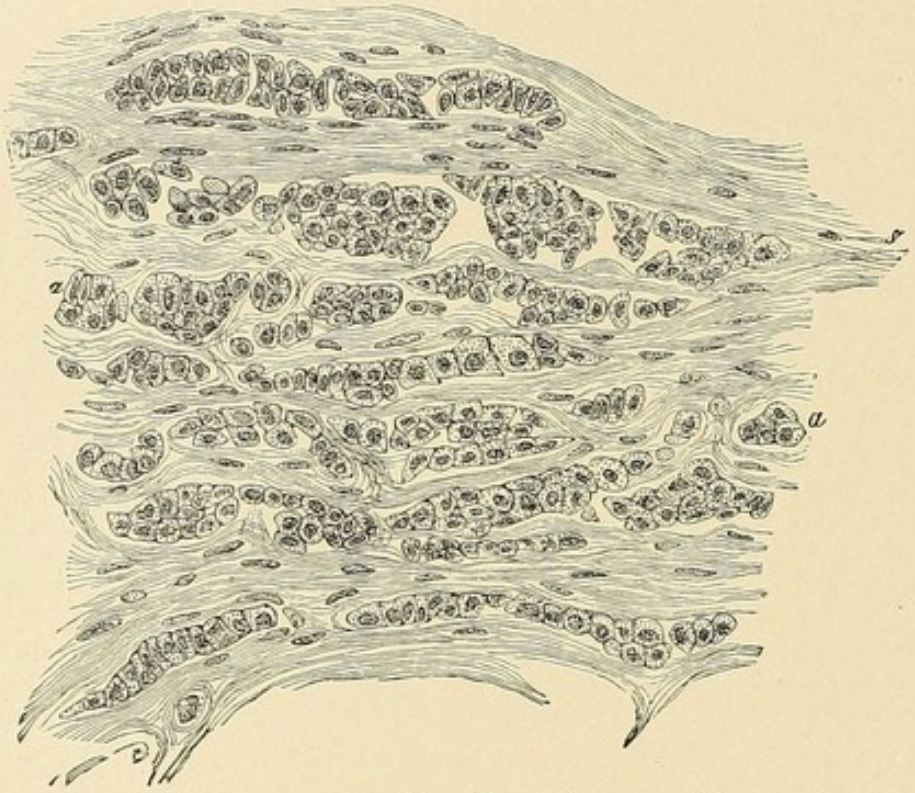

Fig. 733.—Development of carcinoma. *s*, Bundles of fibrous tissue containing occasional connective-tissue corpuscles. *a*, Cancer cells in groups or rows between the stroma. (After Cornil and Ranvier.)

plasm), the alveolar structure of the stroma of cancer will always render it easy of recognition.

Cancer cells vary greatly in shape and size, being round, flat, ovoid, fusiform, polygonal, and measuring from $\frac{1}{2500}$ to $\frac{1}{1200}$ and $\frac{1}{500}$ inch in diameter. Each cell may contain one or many nuclei. The nucleus is often of large size, at times occupying the greater portion of the cell space. The nucleoli are especially prominent. The cell elements of carcinoma are contained within the alveoli, and float in or are in contact with a juice of varying quantity and consistence.

The walls of the alveoli are composed of a fibrillated structure of modified connective tissue. In old tumors the fibers of the stroma are closely packed to-

wens. (2) Sebaceous adenomas arise from glands which are lobulated like those about the nose and ear. (Park.) (3) Adenocarcinoma, a rare tumor existing in the glands of Tyson. (*a*) Pituitary adenomas. (*b*) Those of the prostate. (*c*) Salivary glands; also in the mucous membrane of the stomach, the rectum, Fallopian tubes, etc.

Epithelioma occurs especially in the meso-cutaneous borders. A rapidly destructive type of this neoplasm was formerly known as *rodent* ulcer.

Carcinoma, a tumor springing from preëxisting gland tissue. Scirrhus and colloid, in the breast; considered as *acinous* and *duct* cancers. The former of the scirrhus type, may arise in any part of the breast, and when located near the nipple causes retraction. Lymphatic infection occurs early in this form. *Duct* carcinoma appears about the time of the menopause, and is most common in the terminal branches.

Malignant chorion epithelioma follow pregnancy generally within a few months and are often preceded or accompanied by a hydatidiform mole.

Suprarenal epithelioma, a tumor of the kidney springing from remnants of suprarenal tissue. Very rare. (Grawitz.)

gether, while in more recent neoplasms connective-tissue corpuscles are frequently observed between the clusters of cells (Fig. 733). The alveolar arrangement of the stroma is well shown in Fig. 734, in which the cancer cells have been removed.

The alveoli are not isolated cavities, but communicate more or less freely. In the connective-tissue walls of the alveoli the blood vessels and lymph channels are lodged. In the development of a carcinoma the proliferation among the cells proper of the neoplasm excites a similar condition in the connective-tissue cells of the neighboring and involved tissues, and, coincident with the multiplication of the cancer elements, the connective-tissue elements are developed. In this way the stroma is formed around and among the cancer cells, and in rare instances this proliferation is so rapid that clusters of adipose cells are caught within the neoplasm and remain as such in the process of growth in the tumor.

Carcinomata spread by direct invasion of contiguous tissues, and along the route of the lymph channels.

It is not uncommon (as established by Cornil and Ranvier) for induration and hypertrophy of the ganglia of the nearest lymph plexus to occur before metastasis has taken place, a fact of great interest to the surgeon. This early glandular hyperplasia is due to the irritation caused by the neoplasm, and though less acute is not unlike the adenitis of an ordinary inflammatory process.

Four chief varieties of cancer are recognized—the *scirrhus, encephaloid, mucoid* or *colloid,* and *epithelioma.*

Scirrhus, or hard cancer, is distinguished by the greater proportion and thickness of the *stroma,* in comparison with the cell elements. Many of the cells in this variety of neoplasm, especially those more deeply situated, undergo extensive granular metamorphosis, and appear as granular corpuscles, having lost all the characteristics of the cancer elements.

Encephaloid, soft, or medullary cancer is rich in cells and cancer-juice, while the stroma is very thin. It is more vascular, and in gross appearance is like broken-up brain matter; hence the name encephaloid. Owing to the embryonic character of the new-formed blood vessels and the lack of resistance from the scantily developed stroma, aneurismal dilatations of the vessels are common, and rupture frequently occurs.

Colloid cancer is characterized by the presence within the alveoli of a fluid rich in mucin, which substance also appears in all the foci that may be developed by metastasis. Many of the cells disappear, and those which remain are unusually large and swollen. The alveoli are also distended and the walls more translucent than in scirrhus.

The changes which cancers undergo are chiefly granular metamorphosis and ulceration. The cells of the deeper portions of the neoplasm, deprived of sufficient nourishment by reason of their central position, break down in a granular detritus, which is absorbed and carried away in part by the blood vessels, but chiefly by the lymph channels. In older tumors this gradual loss of cellular elements is followed by contraction of the stroma and sinking in or retraction of the integument. Inflammation and ulceration of a cancer may result from direct irritation from without, or may occur as a result of the growth of the neoplasm, which thus often cuts off its own nutrition. The process is not unlike ulceration in the normal tissues, only the granulations are often very exuberant and the death of tissue rapid. All forms of carcinoma are subject to the deposit of pigment, and under such conditions have been termed *melanotic* cancer.

Causes.—Cancer is a disease of adult and of late adult life. Scirrhus, encephaloid, or colloid cancer, under twenty years of age, is exceedingly rare. It occurs chiefly in the period of life between thirty and sixty. Women are more frequently attacked than men. Prolonged irritation is undoubtedly the chief exciting cause of the development of this neoplasm. In evidence of this conclusion is the fact that those portions of the body which are subjected to the greatest amount of irritation are most often affected. The mammary gland, pylorus, rectum, and uterus are the more common locations of cancer.

Diagnosis.—The recognition of cancer is positive only by microscopical examination, and depends in part upon the peculiar characters of the cells already

noted, but chiefly upon the appearance of the stroma. Clinically, the diagnosis will depend upon the age of the patient, the location of the tumor, its consistence, immobility, and the condition of the lymphatic glands in the line of the vessels toward the center. A tumor occurring after the age of thirty-five, of a mildly painful character, and increased when firm pressure is exercised; steadily, although at times slowly, enlarging, movable, it may be, beneath the skin or within the substance of the organ or part in which it is located, yet not freely so, should be looked upon with suspicion. If it has existed for several months, and there is retraction of the integument over a portion of the mass, together with induration of the nearest lymphatic glands, the diagnosis of cancer is almost positive. As between the three different forms of cancer, it may be said that scirrhus is much the more common, is slower in growth, and harder to the touch. Colloid cancer or the colloid degeneration of scirrhus is also hard, and grows slowly, and from palpation and inspection cannot be differentiated from scirrhus with any certainty. It is comparatively rare. Encephaloid is a soft, elastic tumor, not always of uniform consistence, but generally of smooth surface, and always of rapid growth. Its vascularity is therefore much more noticeable than that of either of the other varieties, and metastasis is more rapid. As between sarcoma, the chief diagnostic points are the age of the patient, sarcoma being more common in the young, cancer in the old and middle-aged; the lymphatics are not involved in sarcoma, except when extensive ulceration and septic absorption occurs; in general, the superficial veins of sarcoma are more dilated and perceptible, and the tumor more elastic.

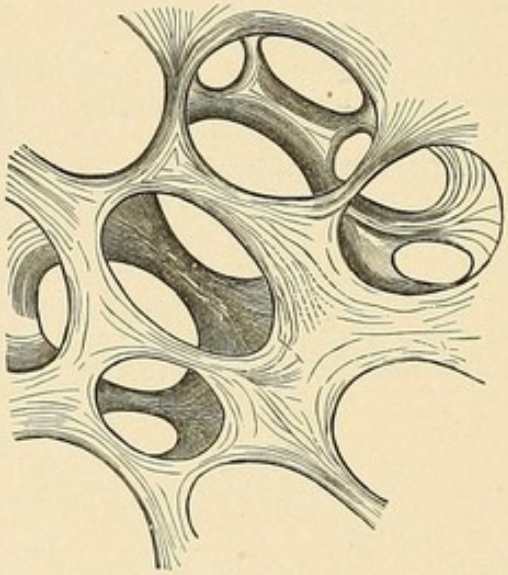

FIG. 734.—Stroma of cancer from which the cell elements have been removed. (After Cornil and Ranvier.)

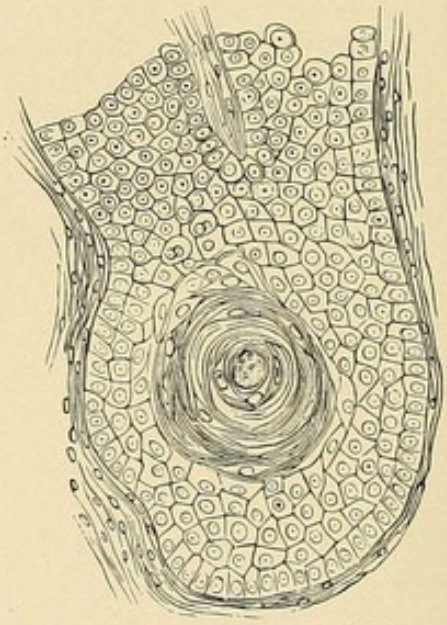

FIG. 735.—Lobular or spherical epithelioma, 250 diameters. (After Cornil and Ranvier.)

The excision of a portion of a tumor for immediate microscopical examination for purposes of diagnosis is indicated in all doubtful cases. Under proper conditions a few minutes should suffice to determine the proper operative procedure.

Epithelioma.—An *epithelioma* may be defined as a neoplasm, the embryonic elements of which assume, in a varying degree, the shape and arrangement of the normal epithelium. Developing usually in the skin or mucous membranes, they at times originate in tissues remote from them, as in the bones.

Malignant epitheliomata may be divided into two classes: 1, the flat or superficial; 2, the tubular or deep.

The first variety is by far the more common. It occurs by preference upon the muco-cutaneous surfaces, as the lips, prepuce, anus, vulva, etc., but may appear either upon the skin or mucous surfaces, remote from any line of union of these coverings, as the tongue, cheek, face, etc.

Flat epithelioma usually begins as a nodule or induration of small size, slightly reddened at its margin, the center of which very early in its history breaks down into a dirty ulcer which, when kept fairly clean, is reddish in color, and, when not cleansed, is covered with a grayish mass of pus and broken-down tissue, either solidified into a crust or scab, or in a softened state. The margins of the ulcer are sinuous, hard, and everted. It may limit itself to a small area, or develop steadily, and sometimes with great rapidity until, after extensive destruction of the tissues in its neighborhood, death ensues from hæmorrhage, sepsis, or metastasis. Pain, usually mild in character, is always a symptom of this disease. Lymphatic engorgement may occur in the first few weeks, but usually from four to eight months, and even a longer time, may elapse.

Examined microscopically, this form of epithelioma is seen to be composed of flattened cells, containing one or several nuclei, with a tendency on the part of the elements to form themselves in concentric layers (Fig. 735). In the center of these spheres of flattened epithelia are frequently seen a few cells which have undergone the colloid change. Farther out the surrounding cell elements are more embryonic in character, cylindrical, spherical, or polygonal from lateral compression, the mass being limited externally by a stroma of connective tissue, varying in quantity, which separates one epithelial nest from the others composing the entire neoplasm. In the process of ulceration an epithelioma is surrounded by a zone of embryonic tissues due to the cell proliferation of the inflammatory process.

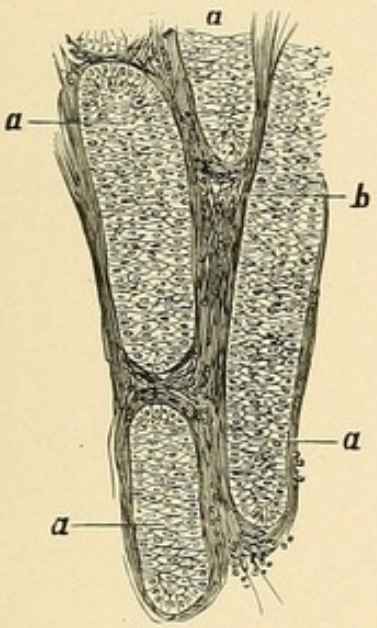

Fig. 736.—Tubular epithelioma. *a*, Tubules or cylinders cut obliquely. *b*, Connective-tissue stroma. (After Cornil and Ranvier.)

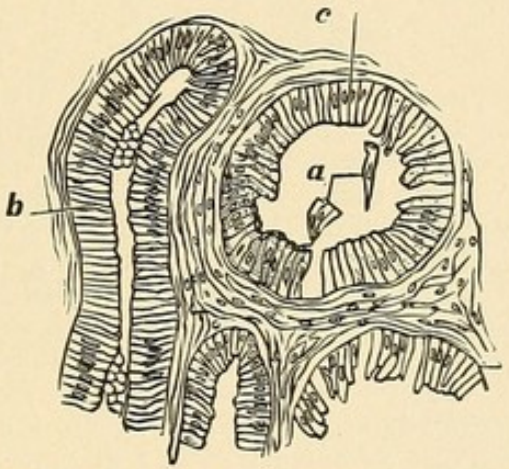

Fig. 737.—Tubular epithelioma with cylindrical elements. *a*, Tubule cut across. *b*, Tubule cut in its long axis. *c*, Cylindrical epithelia. (After Cornil and Ranvier.)

Tubular epitheliomata are considered somewhat less malignant than the lobular or bird's-nest variety just described. After reaching a certain stage in their development, they may remain stationary; but, in the majority of instances, the tendency is to grow, as well as to recur after removal. They are usually situated upon the skin, where they originate in the sweat or sebaceous glands or upon the mucous membranes, where they spring from the follicles of these surfaces. The antrum maxillare is occasionally the seat of this variety of neoplasm.

Microscopically, the flat-celled epitheliomata are composed of pavement or tessellated cells, crowded in tubules or cylinders, which are long, more or less irregular in shape, at times anastomosing with each other, and are held together by a stroma of connective tissue (Fig. 736).

The general shape of these neoplasms is oval or round.

Treatment.—The proper treatment of epithelioma will vary with the special character of the neoplasm and its location. The simpler forms of flat epithelioma developing away from a mucous surface—i. e., not communicating with a mucocutaneous surface—yield readily to the application of *arsenious-acid paste.* Even

when situated near the eye and practically communicating with the mucous membrane of the eyelid, it may still yield to this remedy without danger to the integrity of the eye. On the other hand, when an epithelioma is situated upon the lip, it should be removed by free excision at the very earliest possible moment. Epithelioma of the tongue is one of the most malignant of all forms of neoplasm and is amenable to no other treatment than early and wide extirpation of the part involved. After lymphatic engorgement and metastases, the application of Marsden's paste to the epitheliomatous ulcer is of doubtful propriety unless a thorough dissection of all the involved glands has been made prior to the application or at the same time. When, after metastatic invasion one or more of the lymphatic glands have been removed, it is advisable to apply arsenious-acid paste in the wound so made. The action of arsenious acid is to destroy the weak tissue of the epitheliomatous growth. In applying it, it is always essential that it rest in contact with a raw surface. If an epithelioma is covered with a thick crust, this should be removed either by the knife or by the application of caustic potash. The stick of caustic potash, when rubbed over these crusts, rapidly destroys them, and enables the surgeon to expose the underlying diseased surface in five or ten minutes. The formula employed is the following: Arsenious acid, two drams; powdered gum acacia, one dram; cocaine, eighteen grains. Mix and rub well together in a mortar. When ready for use, a sufficient quantity should be moistened into a paste about as thick as half-melted butter by adding water drop by drop. The paste should be laid about an eighth of an inch thick upon a piece of lint or gauze, and should extend about one eighth of an inch beyond the margin of the ulcer upon which it is applied. It is well not to cover more than a square inch of surface at a time, for fear of absorption of too much arsenious acid. The length of time the paste is to remain on will depend upon the result in a given case. I usually apply it about nine o'clock in the morning and leave it on until nine at night, when it is removed, and a simple dressing of vaseline applied. The next morning the paste is applied again and left on for about six hours. An application of eighteen hours with an interval of about twelve hours will suffice for ordinary cases. Upon the alæ nasi or eyelids four or five hours will be safer. The after-treatment is a simple vaseline dressing. In the very mildest form of epithelioma, such as is caused by friction of the spectacles upon the nose or that appearing in the form of little pimples upon the face, which have been converted into epithelioma by irritation, Marsden's old formula—equal parts of arsenious acid and gum acacia—will suffice.

Small scaly formations quite frequently observed on the face in elderly subjects will at times disappear if the area involved is thoroughly lubricated with vaseline cold-cream night and morning.

In the deep or tubular form the skin is usually not broken, the epitheliomatous elements having developed in the follicles and practically beneath the skin. The paste will not act directly upon the unbroken skin, and therefore in these cases it is often necessary to remove the overlying skin by dissection, usually under cocaine anæsthesia, applying gauze to arrest hæmorrhage, and then applying the paste after all bleeding has stopped. It is sometimes necessary after applying the paste to use the curette to scrape away the destroyed tissue. If the ulcer does not heal readily within two or three weeks after such application—i. e., if in one or two spots upon the margin there is any induration, the application may be repeated on these places. The practitioner may rest assured that by following the above method in properly selected cases the vast majority will be cured by one application.

It has been observed in a number of instances that these milder forms of flat epithelioma have undergone certain modifications during an attack of erysipelas which was either located at the ulcer or in another portion of the body. One such experience occurred in my own practice; an epitheliomatous ulcer on the temple became infected with erysipelas, which ran its usual course, during which time the ulcer disappeared and remained absent for several months. It recurred, however, and was cured by the arsenious-acid paste.

Lymphadenoma.—This variety of neoplasm is entitled to be classed with the malignant tumors. It consists of new-formed lymphatic gland tissue, and may

occur in preëxisting glands or in any of the tissues of the body. The liver, spleen, and kidneys, the testicle, the alimentary canal, the bones and integument, may all be the seat of these new formations. Coincident with the development of these neoplasms, the proportion of white blood-corpuscles in the volume of blood is enormously increased, until death ensues from leucocythæmia. These tumors may be of any size, from a millet seed up to several inches in diameter, are soft to the touch, and usually not well defined. They cannot be diagnosticated from other gland tissues unless examined microscopically, when they are seen to consist of a connective-tissue framework or reticulum, along the fibrillæ of which run the capillaries, and in the meshes of the reticulum the lymph corpuscles are situated (Fig. 738).

The prognosis is grave, and the condition does not justify surgical interference.

Sarcomata.—A sarcoma is a tumor the elements of which have their type in the normal connective tissues. The cells of a sarcoma may be purely embryonic, or may, in a certain sense, resemble the more developed elements. They are, however, not capable of organization into a permanent tissue.

Classified according to the shape and size of the cell elements which preponderate in their composition, they are called—1, *round*; 2, *spindle*; 3, *giant-cell* sarcoma.

The cell elements of the sarcomata not only vary in size and shape, but in the number of their nuclei, of which there may be from one to thirty or more. In the more fully developed or spindle-celled neoplasm the elements are arranged in bundles which run in all directions. These tumors possess little or no intercellular substance, the elements resting in contact or separated by the blood vessels which freely permeate them. The richness of the blood supply and the proportion of the tumor occupied by these channels are well shown in Fig. 739.

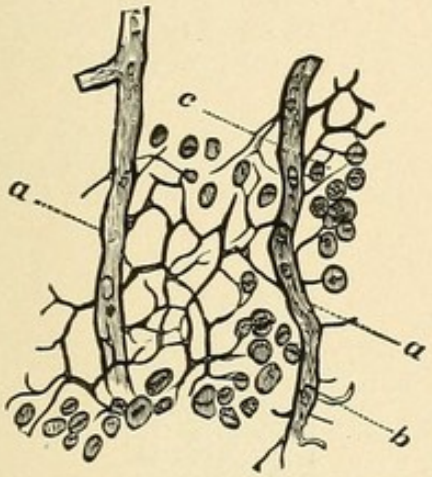

Fig. 738.—Reticular structure of a lymphatic intestinal follicle. *a b*, Capillary vessels with nuclei in their walls. *c*, Meshes of the reticular structure containing lymphatic corpuscles. (After Frey.)

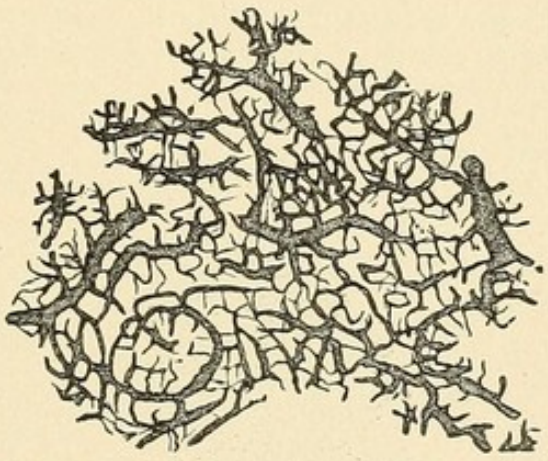

Fig. 739.—Injection of the vascular network of an osteo-sarcoma. (After Billroth.)

The size and number of the blood channels depend upon the structure of the tumor, the round-cell sarcoma being most vascular, while the vessels are less numerous and of smaller caliber in the spindle-cell variety.

The intercellular substance also varies in quantity, being scarcely perceptible in the round-cell tumor, and more distinct in the spindle or fusiform variety. In some of the sarcomata normal connective-tissue fibers may exist, and these are believed to have been caught in the development of the neoplasm.

The sarcomata in general develop with great rapidity, and tend to invade or infiltrate the structures in their immediate neighborhood. In this the different forms of tumor also differ. The round-celled neoplasm grows more rapidly than the others, and is more apt to invade the surrounding tissues than the fusiform-cell variety. It is not the rule for these neoplasms to become encapsuled, although this may occur in the spindle- or giant-cell variety.

The three varieties of cells may exist in the same tumor. According to Cornil and Ranvier, a careful search will reveal the presence of giant cells in varying numbers in almost all sarcomata.

The retrogressive changes which these tumors undergo are fatty and calcareous degeneration. The deeper cells of tumors of considerable size—in other words, those farthest removed from the supply of nutrition—very commonly undergo the fatty or granular metamorphosis. Not infrequently this granular metamorphosis proceeds so rapidly that the blood vessels of the tumor become occluded with the fatty detritus (granular infarction). In this way the nutrition in certain portions of the growth is interfered with, increasing the area of fatty metamorphosis, or inducing gangrene from a sudden arrest of the blood current.

Calcareous degeneration occurs in certain of the sarcomata irrespective of their being situated in the neighborhood of bone. Pigmentation occasionally occurs, and this form is at times separately classified as melanotic sarcoma. It is apt to take place in the small, round-cell tumors. Acute inflammation in a sarcoma is almost always followed by the proliferation of an exuberant granulation tissue, with more or less extensive gangrene and death of the mass. Excessive and at times fatal hæmorrhage may occur in the process of sloughing.

A common accident in the evolution of a sarcoma is the extravasation of blood from rupture of the walls of the new-formed vessels. Such is the crude condition of these tumors that even the cells which compose the vessels are embryonic, and readily give way, allowing the escape of blood among the cell elements and intercellular spaces. The more nearly the development of the cells approaches a normal tissue, the less probability there is of extravasation. The blood thus escaped may be absorbed or become encapsuled by pressure upon the cells near the point of rupture and become converted into a blood cyst.

Mucoid degeneration is also occasionally met with in these neoplasms. The cells of certain portions of the tumor disappear, leaving cysts or alveoli varying in size from the smallest up to as large as two or three inches in diameter in large



Fig. 740.—Alveolar sarcoma. (After Green.)



Fig. 741.—Round-cell sarcoma. (After Green.)

tumors. The cysts are occupied by an amber-colored or reddish-brown fluid, which, examined with the microscope, demonstrates the presence of blood-corpuscles in various conditions of degeneration. Chemically, the fluid yields *mucin*. The name *alveolar* sarcoma (Fig. 740) has been given to this form of tumor.

Special Forms of Sarcoma—Round-cell Variety.—The cells are analogous to the embryonic elements of the ordinary inflammatory process, from which they cannot be distinguished. They possess one or more nuclei and nucleoli, and are spherical, or with slightly irregular outlines from reciprocal pressure. The intercellular substance is homogeneous, and either very scanty or entirely absent (Fig. 741). The vessels and blood channels have been described. This variety of sarcoma occurs everywhere. In the neuroglia of the brain and the neurilemma it is called *neuro-sarcoma* or *glioma*.

Spindle-cell Sarcoma.—The cells of this variety are elongated or fusiform in shape, containing usually one, at times several, nuclei. The ends of the spindle may be single or bifurcated (Fig. 742). The cells vary in size from $\frac{1}{2500}$ to $\frac{1}{4000}$ of an inch in diameter, and are arranged in bundles running in various directions (Fig. 743).

Clinically, this is the most common form of sarcoma. They are slower in development, firmer to the feel, and less vascular, and of smaller dimensions than the preceding variety. As stated, they are somewhat less malignant. They may, in rare instances, be encapsuled, although the rule is to invade the surrounding tissues.

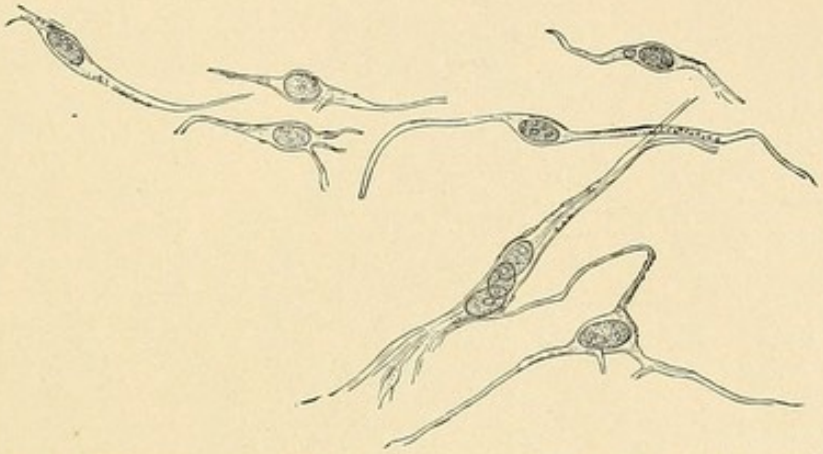

Fig. 742.—Multipolar cells of a sarcoma. (After Cornil and Ranvier.)

The favorite location for their development is the periosteum and in the substance of the bones.

They attack the glandular structures, not infrequently affecting the breast. While developing here, the increased vascularity of the neoplasms induces hyper-

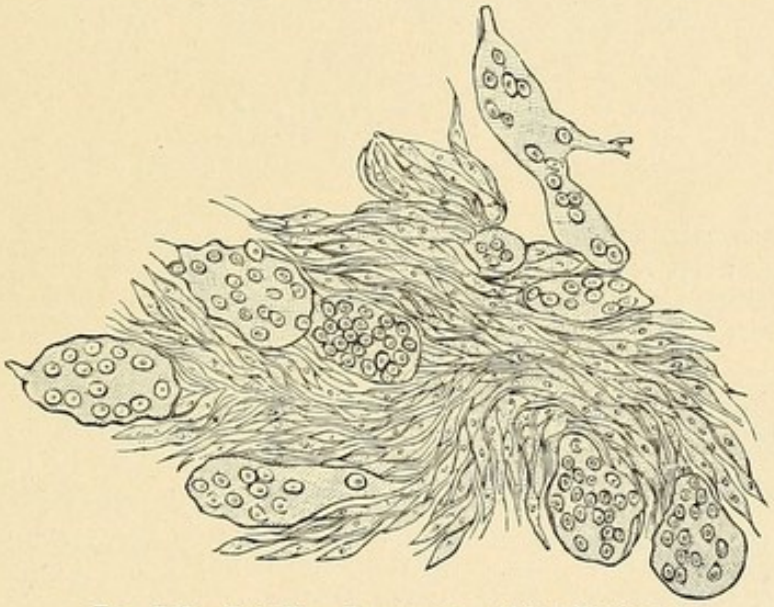

Fig. 743.—Spindle-cell sarcoma. (After Virchow.)

æmia of the glandular apparatus of the breast with consequent proliferation of the epithelia, a condition which has been termed by Billroth adeno-sarcoma.

Giant-cell Sarcoma.—The cells of this neoplasm are of all sizes and shapes: spherical, fusiform, and irregularly oval, having at times one, at others thirty or more nuclei (Fig. 744). They closely resemble the cells of the normal marrow of fœtal bones. Clinically, this form of sarcoma is met with usually in the bones, especially in the lower jaw and the long bones. It may develop to an enormous size, remaining practically confined to a single bone; less frequently spreading to the surrounding soft parts. Bones so affected at times become friable, being readily fractured from the body-weight, or yield a crackling sound upon palpation.

Clinical Features.—Sarcomata may be met with in all conditions and at any period of life. Comparatively speaking, they are rare in old age, occurring chiefly

in children, and adults under thirty. Occasionally they are congenital. Both sexes are equally liable to be attacked. They are, as a rule, idiopathic in origin, in rare cases being due to, or at least following, an injury to the part involved in the

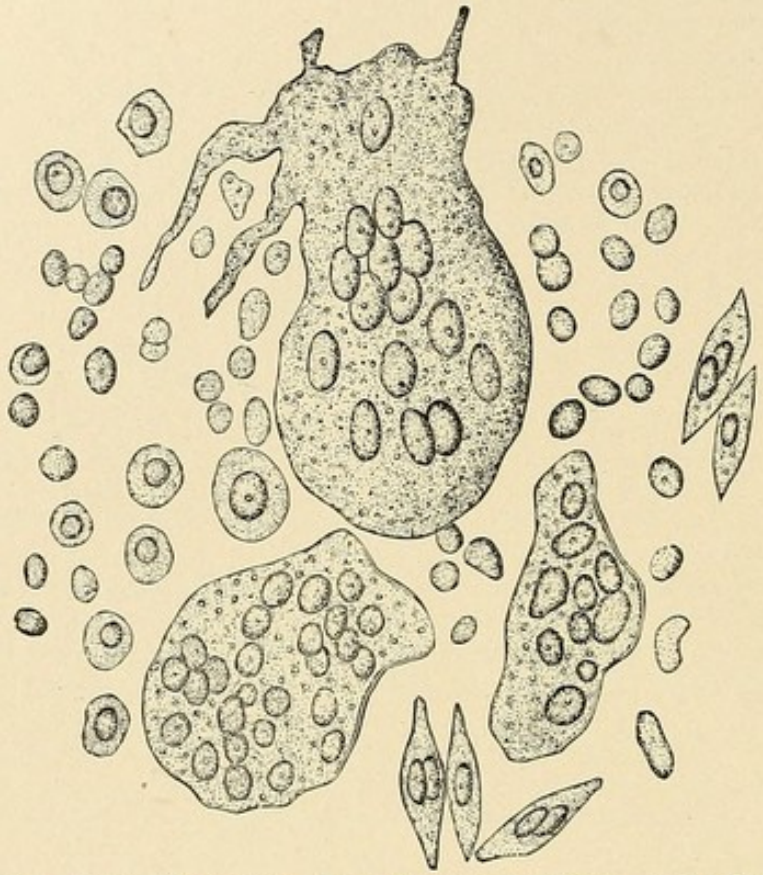

Fig. 744.—Giant-cell sarcoma. From a sarcoma of bone. (After Ordonez.)

neoplasm. Sarcomata are among the most malignant new formations, not only recurring *in loco* after removal, but tending to be disseminated by the blood vessels. Unlike the carcinomata, they have no lymph channels, and metastasis must occur by the blood vessels which enjoy free anastomoses with the caverns and sinuses of the neoplasm.

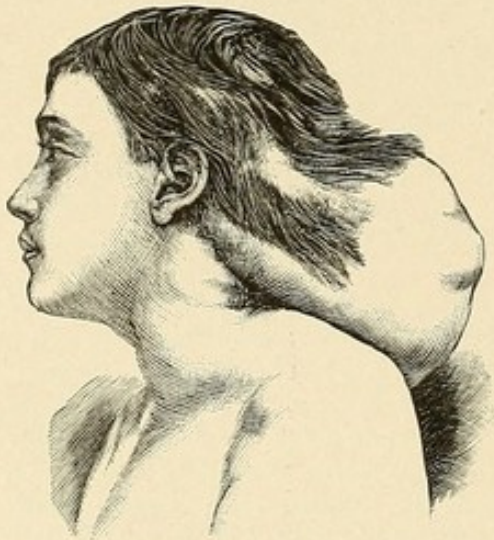

Fig. 745.—Sarcoma of the scalp and neck.

The degree of malignancy of a sarcoma is, in general, in proportion to the embryonic character of the elements of which it is composed. Thus, the round-celled tumors of rapid development are most malignant, the spindle-celled next, the giant-celled last in this order.

As to location, no tissue is exempt. They are frequently met with in the skin and subcutaneous tissues (Fig. 745); also the osseous tissues, especially the long bones, furnish a favorite seat for them. Those developing from within are chiefly the myeloid or giant-celled variety; those of periosteal origin are round- or spindle-celled.

Sarcoma of the bones is exceedingly malignant.

From the foregoing it is evident that the prognosis in any of the varieties of sarcoma is unfavorable. The gravity increases with the duration of the tumor, its location near the trunk, and with the rapidity of its growth.

The round-celled, especially those which have undergone the *melanotic*, *mucoid*,

or *alveolar* change, are most dangerous; next, the spindle-celled; and, lastly, the myeloid or giant-celled variety.[1]

Diagnosis.—In the differentiation of sarcoma from scirrhus and colloid cancers, lipoma, fibroma, cysts, and other non-malignant tumors, the following points are essential:

Cancer is a disease of adult life. It is extremely rare under the thirty-fifth year, while the large majority of sarcomata under this age and in general are seen in the growing period of life, or within the first years after maturity. Carcinomata as a rule affect the glandular apparatus, as the breast, stomach, and bowels. Sarcoma is exceedingly rare in these locations. Sarcoma involves usually the extremities, and a favorite location is in the bones or periosteum. When a gland is involved, it is by preference the parotid or glands of the neck. Sarcomata grow very much more rapidly than other neoplasms, are immovable, the skin covering is more or less tense, and usually a rich network of veins is observed. From a cyst, a diagnosis is made easily by aspiration. From fibroma of the skin in the young the diagnosis is difficult, and usually requires a section under microscopical examination for confirmation. These examinations should never be made until the patient is under the anæsthetic and prepared for a radical operation. Lipoma is soft and movable, usually develops superficially, and should not be mistaken for sarcoma.

Treatment.—Early and wide extirpation is the immediate indication, to be followed by a carefully managed streptococcus infection. Sarcoma in the bone of an extremity demands amputation well away from the tumor, usually through an articulation. Located in the lower end of the tibia, the knee-joint should be selected; in the condyles of the femur at or near the hip-joint, preferably disarticulation. If the tarsus or metatarsus is involved, and the neoplasm has not been recognized in its incipiency, amputation above the ankle is indicated. In the phalanges of the hand or foot, amputation of the membrane involved may suffice. When located at the lower end of the radius or ulna, disarticulation at the elbow is the safer course, while disarticulation at the shoulder is usually indicated when any portion of the humerus is involved. If the tumor has developed from the periosteum by a limited pedicle, and is so situated that the bony attachment can be deeply removed by the chisel without involving the supporting power of the bone, this conservative procedure may be considered, but if in doubt the operator should lean to the side of ultimate safety in dealing with this malignant disease.

A careful analysis of eighty-three cases by the author which required amputation at the hip-joint by his method on account of sarcoma, showed that recurrence, not in the stump but in the viscera, was the rule within the first two years after the operation.[2]

It is evident that the germs of the neoplasm had already been deposited in the lungs before the amputation, and were only awaiting conditions which favored their proliferation.

Should the tumor involve only the soft structures, it should be removed by as wide a dissection as possible, unless certain organs are involved the removal of which would produce a too serious mutilation. Under such conditions, and in fact in all inoperable sarcomas, the infection should be thoroughly tried.

It has long been known that under certain conditions sarcoma may be cured as the result of erysipelatous infection. In the experience of the author it has

[1] For a consideration of the various mixed varieties of sarcoma, viz., osteoid, neuro- and lipo-sarcomata, angeiolithic sarcoma, etc., the student is referred to the text-books on pathology, and especially to the excellent work of Cornil and Ranvier, which the author has drawn from extensively.

[2] One case, a boy of 14, was alive and well 9 years after operation, 3 survived 7 years and were still living, 2 five years, 3 four years, 3 three years, 3 two and a half years, 9 were surviving two years after operation, and 3 one year and over. The remaining five were well within twelve months of the operation. Of the fatal occurrences, the location of the metastasis was as follows: Lung, 23; lung and brain, 1; lung and pleura, 1; lung and abdomen, 1; pleura, 2; abdominal viscera, 3; liver, 1; abdomen and chest, 1; stump, 10; stump and mesenteric glands, 1; stump and general metastasis, 1; stump and iliac fossa, 1; lymphatic, just above Poupart's ligament, 1; sacro-iliac synchondrosis, 1; location not given, 4; apoplexy, 1. Total, 53.

been demonstrated that the streptococcus pyogenes also has an inhibitory action upon sarcoma, and will, under favorable conditions, effect a permanent cure.

While the larger proportion of sarcomata have not yielded to these infections, in view of the fact that without this treatment recurrence with a fatal issue is almost without exception the result, it should be advised in all instances. During the author's connection with Mt. Sinai Hospital, in the service of a colleague, Dr. A. G. Gerster, a young girl was admitted suffering from a sarcoma of the leg, for which amputation was done. The disease recurred and amputation at the middle of the thigh was performed; again there was a recurrence, and, finally, at the hip-joint disarticulation was done, but the disease recurred in the stump. The patient was abandoned, but fortunately contracted erysipelas in the wound. The recovery from the erysipelas was followed by complete and permanent disappearance of the tumor. Dr. Gerster informs me, November 27, 1907, more than twenty-five years after this experience, that this patient is entirely well, and still actively engaged in her work as a teacher.

Drs. B. F. Curtis and Andrew J. McCosh have also reported cases in which this malignant neoplasm has disappeared after erysipelatous infection.

That pyogenic infection also exercises a curative influence over sarcoma is evident from the following, which occurred in the author's personal experience.[1]

In the author's technic, preference is given to alternating infection by giving at first a series of injections of the pure cultures of streptococcus pyogenes,[2] followed by or alternated with pure cultures of Fehleisen's coccus (streptococcus erysipelatis).

In dealing with an inoperable sarcoma, the needle should not at first be introduced into the tumor on account of its vascularity and the danger of throwing the toxine too rapidly into the circulation. The first injection is not more than one minim of pure undiluted pyogenic streptococcus or the same quantity of the erysipelas toxine, diluted in five or ten minims of salt solution, and this should

[1] On May 20, 1884, at Mt. Sinai Hospital, a man about twenty-eight years of age was admitted with the following history: About one year previous he had received a blow upon the abdomen over the right iliac region which was followed by induration and the development of a neoplasm which, at the time of examination was 4 x 6 inches in surface measurement, and 3½ inches in thickness. On account of the involvement of the abdominal wall, it was found impossible to remove it. A section extending entirely through the mass was excised and examined by Dr. William H. Welch and two other competent pathologists. The diagnosis of each was spindle-celled sarcoma. Injections of Fowler's solution were advised and were continued for one week. They were so painful that at the patient's request, the treatment was discontinued. Fortunately as a result of these injections, pyogenic infection ensued. The tumor became intensely red and swollen. The skin did not have the glazed appearance of erysipelas although deeply injected. The infection proved to be pyogenic and several incisions were necessary to permit the free discharge of pus. The patient became much exhausted from the high temperatures and septic absorption, during which time the tumor began to diminish in size and gradually it disappeared. This patient survived eighteen years without recurrence and until a few days before his death, from acute pneumonia, was in the enjoyment of robust health, his weight then being 170 pounds.

On May 20, 1893, a gentleman thirty-five years of age consulted me on account of a large tumor occupying the right hypochondriac region. He had been tapped for dropsy on three occasions and I removed, by measurement, five gallons of fluid from the peritoneal cavity. With the collapse of the abdominal wall, a hard, round, slightly movable tumor with a transverse and antero-posterior diameter of about six inches and about eight inches in its longest measurement, was made out. The tumor was exposed by an incision about six inches in length. It was firm to the touch and occupied the space between the stomach and liver. It seemed to be developed from the gastro-hepatic omentum, was of a reddish-brown color, and covered in front with a network of large vessels. The abdominal wound was dressed so as to permit about one third of the anterior surface of the mass to present in the wound, with sterile gauze inserted, to secure adhesions and prevent general peritoneal infection. Three days later the packing was removed and the wound and exposed surface of the tumor were permitted to become infected. Suppuration rapidly supervened. The dressings were changed daily and within two weeks' time there was a marked diminution in the size of the mass. The wound was kept open and allowed to suppurate for about two months, at the end of which time, as well as I could estimate, the tumor was about one-half its original size. After the wound healed the shrinkage continued and at the end of six months the swelling had disappeared. Tapping was only necessary once in six weeks after the treatment was begun. The patient's general condition improved from day to day and he is now, fourteen years after the operation, perfectly well.

[2] The cultures used are those which have been prepared by Dr. Buxton of the Loomis Laboratory and by Dr. F. M. Jeffries of the Laboratory of the New York Polyclinic Medical School and Hospital.

be thrown partly into and partly beneath the skin, and the dose gradually increased daily until a localized redness is present or until a marked febrile reaction—101° to 103° F.—is observed.

In a certain proportion of cases it is impossible to obtain a reaction with the erysipelatous toxine until the resistance of the patient has been lowered by a series of injections of the pyogenic streptococcus.

In a few instances the author has employed a mixed toxine as recommended by Dr. Coley for lowering the resistance of a patient, in order to secure the proper reaction from the erysipelas toxine.

As the treatment progresses the injections can be carried more deeply, and finally, when the system has been accustomed to its presence, the agent may be thrown into the substance of the tumor. The author's method of injection after amputation is illustrated in the following case:

In an amputation through the thigh, on account of sarcoma, the wound healed promptly, and at the end of two weeks there was only a slight discharge through a gauze drain in one angle of the stump. A gauze wicker drain was saturated with the cultures of pure streptococcus and inserted into the drainage sinus. The wound became red and swollen, with marked exacerbations of temperature. Fehleisen's coccus was substituted at the end of two weeks, and two weeks later the pure streptococcus pyogenes was employed. This treatment was discontinued after six weeks and the wound allowed to heal. Two years have elapsed, and with no suggestion of recurrence. This is the technic advised in all cases of amputation. On account of the large exposed surface in an amputation through the thigh, together with the shock of an operation, it is deemed advisable to postpone infection until the wound has practically healed.

In addition to these cases, and others in the author's experience, Dr. W. B. Coley has reported a number of successful results following infection with the *mixed toxins*. The preparation of this agent as given by him is as follows:[1]

"Streptococcus culture in broth—three weeks' growth.....	100 c.c.
Prodigiosus suspension, containing 750 milligrams of prodigiosus proteid	30 "
Glycerine	20 "

"Each cubic centimeter of the mixture contains 5 milligrams of the prodigiosus proteid. Considering 1 oz. to be equal to 29.57 c.c., it contains 147.85 milligrams prodigiosus proteid; 1 c.c. equals about 17 minims, so 1 minim contains about 3 milligrams of prodigiosus.

"The prodigiosus suspension used is made and measured in the following way: Prodigiosus is grown on agar for ten days. There is then a thick red growth, which is scraped off with glass rods and rubbed up with a mortar and pestle to a smooth, rather thick suspension, using physiological salt solution as diluent. This suspension is sterilized by heat—one hour at 75° F. The total nitrogen per c.c. is determined and the weight of nitrogen per c.c. multiplied by the factor 6.25 gives the weight of proteid present. Thus the weight of prodigiosus proteid in each c.c. is known and the suspension is diluted to the required strength before mixing with the streptococcus culture. After mixing and bottling the toxines, the mixture is again sterilized two hours at 75° F."

Dr. Coley insists that it "is most important to begin in every case with a very small dose, not over one quarter minim (diluted with a little boiled water to insure accuracy of dosage). If the tumor in question is highly vascular, it is wiser to begin the injections remote from the same, until the susceptibility of the patient to the toxines has been ascertained. This varies considerably in different individuals. After a few doses it is safe, in most cases, to inject into the tumor itself.

"As a rule, when giving injections into the tumor, only about one fifth of the dose used for injections remote from the tumor is required to produce the same reaction. The dose should be increased by one quarter minim when given into the tumor; by one half minim when injected remote from the tumor, until the desired

[1] "Medical Record," July 27, 1907.

reaction is obtained. The best results are obtained by doses sufficiently large to produce severe reactions, say a temperature of 102° to 105° F.

"The frequency of the injections must depend entirely upon the strength of the patient, some being able to bear daily injections, while in others it may be unwise to push the treatment beyond three or four injections a week.

"In the successful cases the effect is usually very promptly noticeable. The tumor becomes smaller in size, much more movable, and very much less vascular. These changes appear very quickly, often within two to three days.

"The action of the toxines is both local and systemic. Sometimes the best results are obtained by giving the injections alternately into the tumor and remote from the same. In tumors in inaccessible regions—e. g., intra-abdominal sarcoma or sarcoma of the tonsil—a perfect cure may be obtained entirely by systemic injections." [1]

NON-MALIGNANT NEOPLASMS

The *non-malignant epitheliomata* are the dry, pavement, or pearl-like epithelioma, papilloma, the adenoma, and the cystic tumors.

The *pearl epithelioma* is of rare occurrence. Microscopically, it is found to be closely akin to the bird's-nest tumors, which are classed with the malignant growths. The cells of the non-malignant and rare neoplasm are, however, flat, and collected in little dry, pearl-like bodies, gathered in clusters, and held together, or surrounded by a connective-tissue stroma. Occasionally, cholesterine crystals are seen in these bodies, and this fact induced Müller to name this form of neoplasm "*cholesteatoma.*"

The proper treatment is removal with the knife, or Marsden's paste.

Papilloma.—A papilloma is a neoplasm, in structure not unlike the normal papillæ of the skin and mucous membranes. Each papilla possesses a connective-tissue framework which supports one or more new-formed vascular loops, and the whole is covered in with one or several layers of epithelia.

They may be met with upon the cutaneous, mucous, or serous surfaces.

The most frequent form of papilloma is the ordinary "wart." The hard or cutaneous wart is often seen upon the hands; the soft or mucous wart is frequently met with upon the prepuce, vulva, and anal margins. Corns are also classified as papillomata.

Mucous warts grow more exuberantly than those of the skin. Upon the prepuce, where they are kept moist and are subjected to irritating secretions and to friction, they form at times enormous masses. Hæmorrhage is a common accident, and sloughing, with the emission of a most offensive odor, is the rule in these larger neoplasms.

Essentially benign papillomata may, by long-continued irritation, be converted into, or replaced by, an embryonic neoplasm of a malignant type.

Treatment.—The indication is to destroy them at once. The best method to pursue is to grasp them with forceps, clip them off with scissors close to the attached margin, and apply nitric acid to the bleeding base of the neoplasm. Anæsthesia is obtained by moistening them for several minutes with a four-per-cent solution of cocaine hydrochlorate. The nitric acid leaves a yellow stain, which is objectionable when the growth is situated upon an exposed surface.

Adenoma.—Adenomata are neoplasms the structure of which is analogous to gland tissue. Following this analogy, they are of the racemose and tubular varieties. The racemose adenomata are extremely rare. They are composed of collections of acini held together by a varying quantity of connective tissue, and lined with epithelium. They may develop in all parts of the economy where the racemose glands are found. A favorite location is the mammary gland, occasionally the parotid, the lachrymal gland, and the roof of the mouth. They are slow in growth, are spherical in shape, and are freely movable in the structure in which they develop.

Tubular adenoma is more frequently observed than the racemose variety. The

[1] It is advisable to obtain the toxine as prepared in the laboratory.

tubules are in some cases separated by a layer of new-formed connective tissue, while in others there is no perceptible intertubular stroma. The tubules may be single, but are more frequently bifurcated, and, as in the normal glands, commence in blind extremities and open upon the mucous surface. They are lined with one or more layers of glandular epithelium. These tumors are seen in the rectum and colon, in the uterus, especially the cervix, and occasionally in the nose (Fig. 746).

They are spherical or pyriform masses, covered with mucous epithelium as long as they are contained within the cavities; but when, by reason of excessive growth,

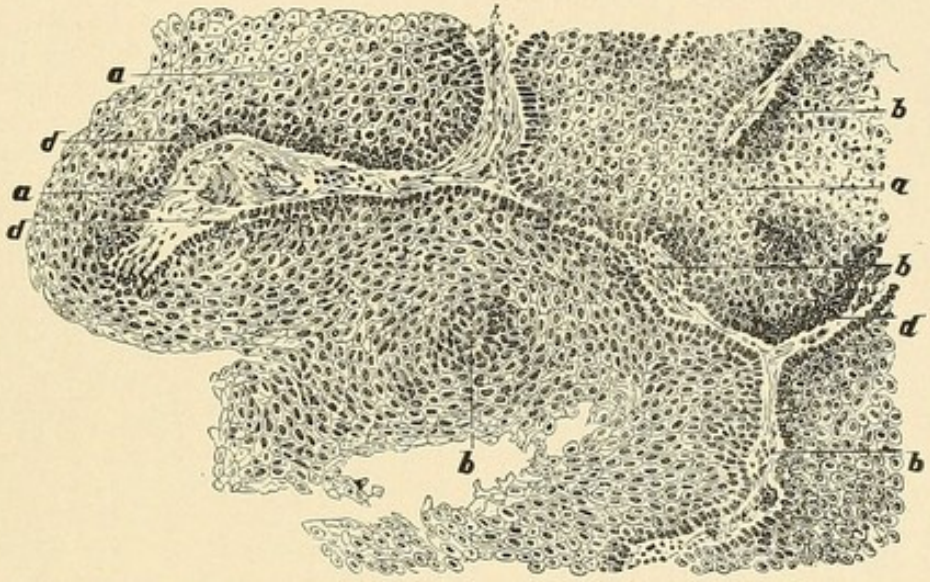

FIG. 746.—Nasal polypus. *a*, Pavement epithelia, of which the deeper layers, *d*, are cylindrical, and are arranged along the edges of the papillæ, *b*. A vessel is shown at *b*. (After Cornil and Ranvier.)

they are exposed to the air, the covering becomes hard and smooth, like the epidermis.

Cysts.—A cyst is a tumor composed of a limiting membrane or capsule of connective tissue, lined by epithelium and filled with fluid or semifluid contents. The contained matter may be mucoid or colloid material, or sebaceous matter and epithelial cells in various conditions of degeneration.

Sebaceous cysts occur upon all portions of the external surface, and in rare instances develop in the deeper tissues.

The external sebaceous tumors are seen very frequently upon the face and scalp, and vary in size, measuring at times an inch or more in diameter. They are spherical or flattened tumors, soft and elastic to the touch, and freely movable upon the subcutaneous tissues.

The contents may be a white, cheesy matter or more fluid, and of an amber or brown color. Examined microscopically, it is seen to be composed of epithelial cells which have undergone a more or less complete granular metamorphosis, loose granules, compound granular corpuscles, cholesterine crystals, rudimentary hairs, etc. The wall of the cyst varies in thickness, being at times very thin and closely adherent to the surrounding structures, and at others thick and easily detached. Those upon the hairy scalp, commonly known as "*wens*," are usually filled with an amber-colored, jellylike mass, which escapes upon section or puncture of the cyst. Upon the face, or other cutaneous surface, the contents are apt to be cheesy in character.

They are caused by cell-proliferation and the accumulation within the hair-follicle and communicating sebaceous gland of its normal secretion, which cannot escape, owing to the partial or complete occlusion of the excretory duct. Cutaneous cysts, from direct violence, and often without any appreciable cause, may inflame and suppurate.

Dermoid cysts are closely analogous to the preceding, although situated in the deeper structures. They consist of a limiting membrane, and liquid and solid con-

tents. In addition to the changed epithelial cells and granular matter, these tumors often contain tufts of hair, rudimentary teeth, etc. They occupy by preference the ovary, but are met with in all parts of the body.

Mucous cysts are usually seen upon the lips, buccal cavity, vulva, and anus. They may occur in any portion of the alimentary or respiratory passages, or in any of the cavities lined by mucous membrane. The wall is thin, lined with epithelium, and adhering to the surrounding structures. The contents are a viscid mucus, resembling the white of an egg. The cause of the tumor is obstruction of the normal excretory duct. The character of the tumor may be suspected from the location and the spherical shape. A slight puncture, with compression, will reveal the mucous character of the contents.

Serous Cysts.—Cysts of the smaller serous cavities may result from hypersecretion of the normal fluid by the epithelia lining the serous membrane, in which the excess is not reabsorbed. The swellings often observed upon the back of the wrist and hand, and sometimes upon the dorsal aspect of the foot, are typical serous cysts, and result from hyperdistention of normal serous bursæ.

Lipoma.—A fatty tumor is a circumscribed collection of adipose tissue growing independently of the other tissues. Lipomata usually develop in the subcutaneous cellular tissue, and are frequently met with about the back of the neck and shoulders. From this location they occasionally are carried by gravity toward the sacrum, slipping downward between the integument and deep fascia. Situated superficially, they grow to be irregular and spherical or pyriform tumors of varying size; are usually single, but may be multiple. Less often they are met with in the glands, muscles, bones, and in the abdominal viscera.

Microscopically, they are composed of vesicles filled with oil or fat. The vesicles are connective-tissue corpuscles, the nuclei of which are displaced to the periphery and compressed against the investing membrane of the vesicle. These vesicles are held together in clusters of various size by a stroma of fibrous tissue, in the meshes of which the blood vessels run. The whole tumor is in turn encapsuled.

Various names have been given to certain complex fatty tumors; when the intervesicular substance is myxomatous, *myxo-lipoma*; when the connective tissue is excessive, *fibro-lipoma*; in bone, *osteo-lipoma*; when very vascular, *angeio-lipoma*, etc.

Lipomata may undergo granular and calcareous metamorphosis, and may also become inflamed and break down as a very offensive and sloughing mass. They are altogether benign, and can only cause death by ulceration, sepsis, and hæmorrhage, or by pressure upon important organs.

The *diagnosis* depends upon the soft, uneven feel and the mobility of the mass. It is only to be differentiated from old abscesses or cystic tumors. If the history does not point to the diagnosis, the aspirator needle will be of service.

The treatment is removal with the knife. The incision may be straight for a small tumor, but should be elliptical for large growths, in order to do away with redundancy after the tumor is turned out. The capsule should be opened, and the tumor may be turned out almost wholly with the fingers.

Fibroma.—This variety of neoplasm is made up of fibrous tissue, the filaments of which are at times arranged in bundles which run in all directions; at others, there is little or no fascicular arrangement, the filaments being entangled in all directions. In the interstices of the bundles, or between the fasciculi, are found connective-tissue cells, the poles of which communicate with each other. The vascular supply is limited. Fibromata develop chiefly in the skin and subcutaneous tissues and periosteum, but may exist in any other portion of the body. They are usually single and small, occasionally multiple, and this form of tumor may attain an enormous size. In shape, those developing from the deeper tissues are spherical, and are hard to the touch. In the skin they are often pedunculated and pyriform. Fibromata may undergo a mucoid, granular, or calcareous degeneration, and are subject to inflammation and suppuration, as are other neoplasms. Possessing a low degree of vascularity, the danger of hæmorrhage is not great, unless a rich granulation tissue has sprung up as a result of prolonged irritation.

Simple fibroma is benign, and the indications in treatment are removal by the knife.

Myxoma.—This neoplasm is made up of primitive connective-tissue cells, similar to those observed in the umbilical cord at birth. The cell elements are spherical and fusiform in shape. The former are isolated and float freely in the gelatinous-like intercellular substance. The latter may possess two or more poles, and anastomose freely with each other, forming a continuous network or stroma throughout the mass. The vascular supply is rich. These neoplasms occur, as a rule, in the skin and subcutaneous tissues and upon the mucous surfaces, especially in the nose (mucous or soft polypi). They may develop, however, in any portion of the body, and have been observed in the muscles, bones, and nerves, the mammary gland, kidney, brain, etc. In shape they are usually spherical, of small size, and are soft and doughy to the touch, and not painful unless by accident the sensory nerves are pressed upon by the tumor. As a result of rupture of the blood vessels, cysts frequently occur in this variety of neoplasm.

The treatment is early and complete removal. Pure myxoma does not tend to recur after a thorough removal. In some instances, owing to the peculiar location of the neoplasm, a thorough extirpation is impossible, and in these cases the tumor may rapidly recur. The cases of general metastasis after supposed myxoma were probably instances in which the sarcomatous nature of the growth had been overlooked.

Myoma is a tumor composed of new-formed muscular elements. There are two varieties, namely, those composed of *striated* or voluntary, and those of *non-striated* or involuntary muscular fibers.

The first variety is extremely rare, and is of less clinical importance than the non-striated myoma.

In two instances the striated myoma has been seen in a congenital tumor of the testicle, and in a few other instances of tumors developed wholly or in part in the embryo or fœtus. Dermoid cysts at times contain traces of striated muscle.

A *diagnosis* can only be made out by the recognition, under the microscope, of the characteristic striated muscular fiber. The *prognosis* is favorable, owing to the benign nature of the tumor, which, nevertheless, should be removed as soon as recognized.

In the non-striated myoma the fusiform elements are arranged in all directions, either in bundles or groups which interlace, or there may be a general interlacing of the separate elements without fascicular arrangement, as in many of the organs in which the smooth muscle is found. Between these bundles true connective-tissue cells exist, and in these spaces the vessels are found. The nuclei of these new-formed elements, as well as the muscle-elements proper, do not differ materially from the normal non-striated muscular fibers.

Non-striated myomata are often met with in the uterus. In many of these neoplasms there is a variable quantity of connective tissue, more or less organized, and for this reason the term fibro-myoma has been given to these tumors. They may grow from the wall of the uterus, toward the peritonæum (*extramural*), or develop in the substance of the uterine muscle, become encapsuled (*intermural*), or project from the internal surface into the cavity of this organ (*submucous myoma, intramural*).

This variety of neoplasm has also been seen in various other localities, as the skin, alimentary canal at various points, the prostate, scrotum, etc. The diagnosis depends upon the recognition of the characteristic fusiform elements under the microscope. The method advocated by Cornil and Ranvier is to macerate the sections in azotic acid, twenty parts to one hundred of water, or caustic potassa, forty parts to one hundred of water. By this process the connective-tissue stroma is dissolved and the muscular elements liberated.

The prognosis in this form of myoma is favorable as far as recurrence is concerned when the removal has been thorough. They not infrequently produce death, either directly by pressure and interference with the normal functions of organs necessary to life, or indirectly by causing hæmorrhage, rendering the individual more likely to perish from some intercurrent affection.

Treatment.—They should be removed, when this can be done with a justifiable degree of safety.

Neuroma.—A tumor composed of new-formed nerve tissue is rarely met with. Many so-called neuromata are connective-tissue neoplasms springing from the neurilemma. They may be made up of *nerve cells* or *nerve fibers* (Fig. 747).

The former are even rarer than the latter. Small particles of gray matter have been seen in dermoid cysts, and in a few instances neoplasms of this variety have been seen in the brain and spinal cord.

Fascicular neuromata may occur in the nerves. They exist as slight elliptical swellings or enlargements of the nerve involved, may be single, or there may be a succession of nodosities in the course of the nerve.

The *symptoms*, in addition to the tumor, which may at times be made out by palpation, are those of pain or interference with the function of the part involved. A careful analysis with the microscope alone can determine an accurate *diagnosis*.

The *prognosis* is not grave, in so far as the life of the patient is concerned, but the removal of the neoplasm may of necessity involve an injury of the trunk in or upon which it is located, and in this manner may add an element of gravity to the result. They should be extirpated, and, where (as will almost always be the case) the positively benign character of the neoplasm is not evident, a section of the nerve below and above the tumor, as well as a portion of the surrounding tissues, should be removed.

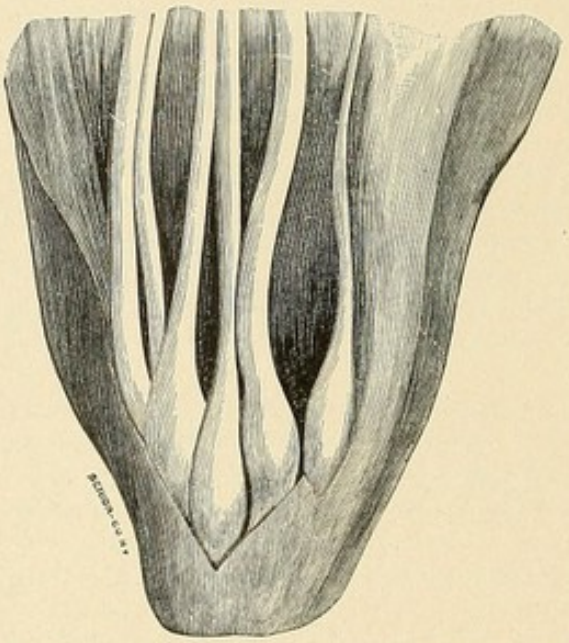

FIG. 747.—Neuromata developed in the divided nerve tissues after amputation of the member. (After Cornil and Ranvier.)

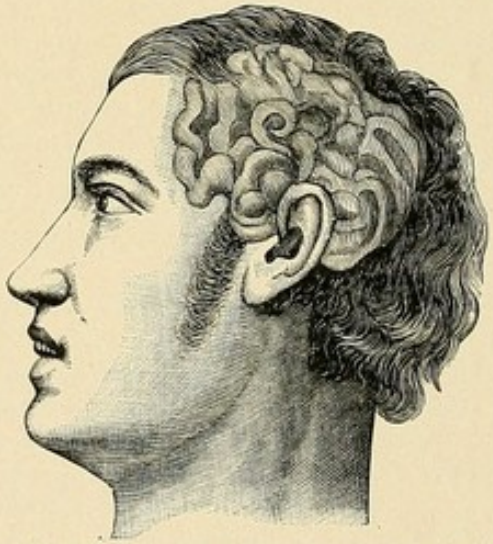

FIG. 748.—Angeioma (cirsoid aneurism) of the temporal region.

Angeioma.—The angeiomata are tumors of new-formed vessels, capillaries, arterioles, or veins. They are frequently congenital, and may also appear at any period after birth.

Microscopically, the simple forms are made up of capillaries, arterioles, and veinules in plexuses richer than the normal, and held together by a connective-tissue stroma of varying thickness. In the more formidable tumors—*cavernous nævi*—the vessels are larger, with thickened walls of dense connective tissue, and at times a quantity of non-striated muscular fibers. The *vasa vasorum* are also met with in the walls of the sinuses.

The former variety appear as red or bluish spots or stains in the skin, of various sizes and shapes, at times rising above the level of the integument.

The method of *treatment* is fully described in the chapter upon diseases of the vascular system.

Lymphangeioma.—Tumors composed of new-formed lymphatic vessels are very rarely met with. In their construction they do not materially differ from

the angeiomata. The new tissue consists of a capillary network of lymph channels, in arrangement analogous to the capillary vessels in the smaller angeiomata.

In the case shown in Fig. 749 I removed by dissection a plexus of lymphatic vessels about as large as a hen's egg. The walls were sacculated, and the vessels were distended with clear lymph. Situated in the cheek, this form of tumor may be mistaken for retention of parotid secretion due to stricture of Steno's duct or



Fig. 749.—Lymphangeioma of left buccal wall.

its occlusion by calculi. In other instances the lymph canals have a cavernous arrangement comparable to the structure of the cavernous nævus described in the article on vascular tumors.

Lymphadenoma.—Many forms of enlargement of the lymphatic glands are not true tumors, since they are not composed of new-made gland tissue, but are due to cancerous infiltration, to tubercle, to syphilitic adenitis, tubercular deposit, etc. Tubercular lymphomata should always be extirpated when tuberculosis of the deeper organs can be excluded, provided that the operation of removal does not involve a too great risk of life. The removal of enlarged glands from metastasis in cancer should also be done when there is a reasonable hope of cutting off the disease from the centers.

Chondroma.—New formations of cartilage develop in and from the connective-tissue cells of any portions of the body, excepting from cartilage proper. The bones and periosteum are favorite points of origin for these neoplasms. Developing from within the bone, a cartilaginous new formation is termed an *enchondroma*; if from the periosteum, a *perichondroma*. Quite a number of chondromata have been observed in the testicles and in the parotid glands. They may assume all sorts of shapes, growing into more or less spherical tumors, or the new tissue may be generally diffused in the normal tissue.

In the bones of the hand and fingers they give rise to marked deformities and to considerable pain, from displacement of the normal structures and interference with nutrition (Fig. 750).

The new formation of cartilage is preceded by an inflammatory process varying in intensity, usually of a mild nature, yet resulting in the proliferation of the cells of the part involved, and the formation of an embryonic tissue from which the cartilage is formed, as in the normal development of this tissue. Some of

these cells become the cartilage cells proper, and are collected in groups of different sizes, while others form a connective-tissue stroma around the collections of cartilage cells. The vessels find their way along these bundles of connective tissue.

The proportion of connective-tissue stroma varies in different tumors. When the cartilage cells and groups are plentiful, with a limited quantity of intervening fibrous tissue, the mass is strictly a *chondroma*. When the stroma preponderates, it is termed a *fibro-chondroma*. In certain forms of these tumors there is a paucity of connective-tissue fibers as well as cartilage cells, although both are present in quantity sufficient for recognition. The mass of tissue may be *embryonic*, and, under such conditions, the tumor may be sarcomatous in character. Simple chon-

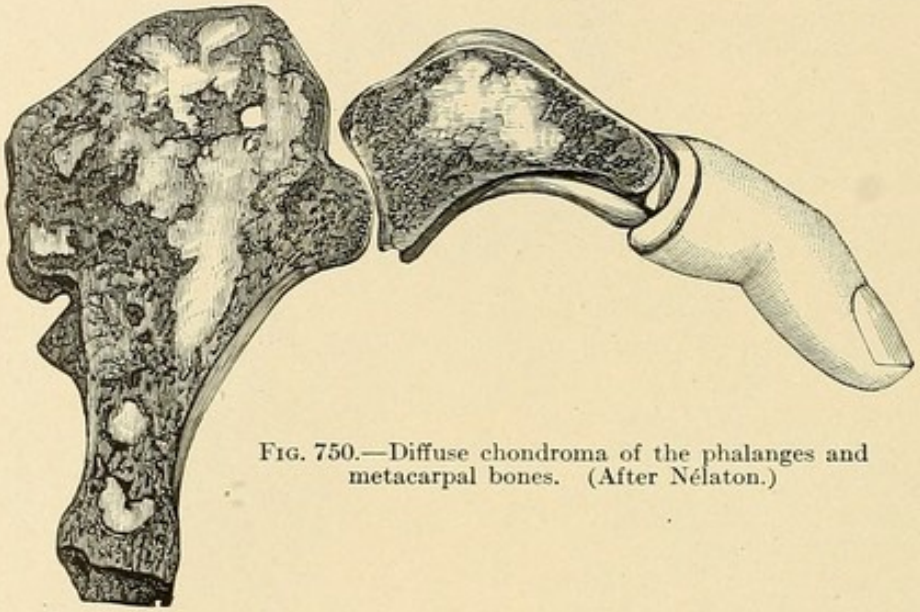

FIG. 750.—Diffuse chondroma of the phalanges and metacarpal bones. (After Nélaton.)

droma is benign, but a mixed chondroma of an embryonic-tissue type must be classed with the malignant neoplasms.

Chondromata may undergo fatty or granular degeneration, may ossify in part, may become infiltrated with calcareous matter, or undergo the mucoid change.

Treatment.—Removal is indicated when pain is unbearable, or when the sarcomatous nature of the neoplasm is evident.

Osteoma.—Tumors of new-formed bone tissue may develop from the normal bone and periosteum, or in the tissues removed from the bones. There are three varieties—the *eburnated*, *compact*, and *spongy*.

In the first, or ivorylike neoplasms, the bone is exceedingly dense and hard, and contains bone corpuscles and canaliculi, which, though well marked, are more irregular in arrangement than in normal forms. This new-formed bone tissue, however, does not possess blood vessels. These tumors are especially apt to be observed upon the bones of the skull, notably those of the frontal and parietal regions.

The compact or spongy neoplasms are in structure analogous to the normal compact or spongy bone substance. In the latter the bony framework is light, and the medullary spaces larger than normal.

An osteoma formed upon the outside of an old bone is called an *exostosis*; developed within the medullary space, an *enostosis*.

Exostoses grow as more or less well-rounded tumors beneath the periosteum, or as sharp spikes or thorns projecting from the bone. Such spines are in the great majority of instances directed upward (stalagmites) in the axis of the tendon in and about which they develop. In rare instances the direction is downward (stalactite).

Bony neoplasms may also develop in any of the cartilaginous tissues of the body, and this change is usually one of senility. Beyond this, bone may form in

the muscles, choroid, the serous membranes in all locations, and in the integument.

Osteomata are always benign. If dangerous at all, it is from compression of important organs. Those developed from the internal surface of the cranial bones and along the vertebral canal are especially dangerous in this respect.

Treatment.—Interference is not called for, unless pressure upon important organs renders it necessary.

Keloid.—Keloid, a formation of scar tissue either resulting from a traumatism—i. e., in the scar of a wound which is healing—or without any apparent cause, is frequently met with in surgical practice. According to A. R. Robinson, it is a circumscribed connective-tissue new growth of the skin characterized by the appearance of one or more irregular, elevated, firm, smooth, reddish, somewhat elastic tumors. The cause of keloid is not as yet understood. It is a connective-tissue proliferation of peculiar type, which, as the process of fibrillation goes on, occludes the vascular supply of the part, and yet not to such a degree as to cause retrograde changes or absorption of the new tissue. Traumatic or *false* keloid is elevated from one eighth to one fourth or one half inch above the level of the surrounding skin, and usually assumes the shape of the scar in which it has developed, while *true* keloid begins as a small nodule situated in the skin, becoming multiple in almost all cases. As a rule, these nodules develop to a certain size, growing for two or three years, then seem to reach their limitations and remain stationary for an indefinite period. Occasionally they undergo atrophy, but this is the exception; they usually last for life.

Treatment.—The treatment of keloid is one of the discouraging features of surgical practice. It is almost always an incurable disease, but rarely, if ever, destroys life. Sometimes the tumors disappear under the application of adhesive straps, which cause at least temporary atrophy, and the same result has been noticed in some tumors under the persistent application of flexible collodion. Dr. J. W. White reports a case of a young girl who received a lacerated wound of the face from broken glass. A disfiguring keloid developed in the cicatrix. All treatment was futile until she was given daily two to four doses each of five grains of thyroid extract. The scar was covered with a film of collodion to protect it from abrasions and to keep up gentle pressure. In six weeks the scar in its entire length had come down to the level of the skin, where it remained. The improvement seemed to be permanent.

I have removed these tumors in several instances, extirpating the skin and subcutaneous connective tissues freely away from the neoplasm, but recurrence took place in each case.

(*From Park's "Surgery"*)

TABLE 1.—DIFFERENTIATION BETWEEN BENIGN AND MALIGNANT GROWTHS

Benign Growths	*Malignant Growths*
Common at all ages.	Rare in early life.
Usually slow in growth.	Usually rapid in growth.
No evidences of infiltration or dissemination.	Infiltration in all cases, dissemination in many.
Are often encapsulated, nearly always circumscribed.	Never encapsulated, seldom circumscribed.
Rarely adherent unless inflamed.	Always adherent.
Rarely ulcerate.	Often ulcerate — nearly always when surface is involved.
Overlying tissue not retracted.	Overlying tissue nearly always retracted.
No lymphatic involvement when not inflamed.	Lymphatic involvement an almost constant feature.
No leucocytosis.	Leucocytosis often marked.
Elimination of urea unaffected.	Deficient elimination of urea (?).

TABLE 2.—DIAGNOSIS BETWEEN SARCOMA AND CARCINOMA

Sarcoma	*Carcinoma*
Occurs at any age.	Rare before thirtieth year of life.
Disseminates by the blood vessels (veins).	Disseminations by the lymphatics.
Arises from mesoblastic structures.	Arises from glandular (epithelial) tissues.
Distant metastases are more common.	Less so.
Contains blood channels rather than complete blood vessels.	Contains vessels of normal type.
Less prone to ulceration.	More so.
Involvement of adjacent lymphatics not common.	Almost invariably adjacent lymphatics are involved.
Secondary changes and degenerations are more common.	Degenerations not common; other secondary changes are.
(Sugar present in the blood?)	(Peptone present in the blood?)

TABLE 3.—DIAGNOSIS BETWEEN EPITHELIOMA AND TUBERCULOSIS (LUPUS)

Epithelioma	*Tuberculosis (Lupus)*
Preceded usually by continued irritation or warty growths.	Irritation plays no figure. Preceded usually by nodules.
Diathesis plays no known part.	Diathesis evident. Coincident evidences of tuberculous disease elsewhere.
Rarely multiple.	Often multiple.
Area of thickening ahead of ulceration.	Extension of ulceration not preceded by thickening.
Ulceration advancing from a central focus.	Various foci, which may coalesce.
Border usually raised and everted, regular in outline.	Border abrupt, eaten, irregular, thickened, firm, often inverted, irregular in outline.
Often assumes fungoid type.	Never fungoid.
Base may be deeply excavated.	Base nearly level with surface.
Usually painful.	Seldom painful.
Bleeds easily.	Seldom bleeds.
Never tends to cicatrize.	As marginal ulceration proceeds there is often cicatrization at center.
Most rare in the young.	Common in the young.
Discharge is very offensive.	Discharge rarely offensive.
Lymphatic involvement nearly always.	Rarely.

CHAPTER XXXV

THE SURGICAL DISEASES

INFLAMMATION AND THE PROCESS OF REPAIR—BACTERIA—SUPPURATION—SEPTICÆMIA

INFLAMMATION, from *inflammo*, "to set on fire," is a disturbance of nutrition in the tissues of a part of the body resulting from the presence of certain bacteria or pathogenic micro-organisms. This disturbance of nutrition is characterized by *hyperæmia* more or less prolonged, by the emigration of leucocytes through the vessel walls (*diapedesis*), the *transudation* of plasma and lymph, and by a tendency to *general cell proliferation* in the area involved. The grosser symptoms of inflammation are *heat*, *redness*, *swelling*, *pain*, and *loss of function*.

While it is claimed—and it seems to be demonstrated—that one or more of these symptoms may be present in certain aseptic conditions in which hyperæmia, diapedesis, transudation, and cell proliferation occur (as in the experiment of injecting an aseptic corrosive chemical beneath the skin of a healthy animal), so far as practical surgery is concerned the above definition is accepted.[1]

While the phenomena of inflammation are in general common to all the tissues, there are some variations by reason of structure, as in bone, which is only slightly expansile, and in cartilage and the cornea, in which no blood vessels exist.

In an animal body in which the processes of nutrition are approximately normal, the tendency in the tissues which are the seat of inflammation or local disturbance of nutrition resulting from the presence of bacteria or their toxic products is to restore as near as possible the original condition of these tissues. The

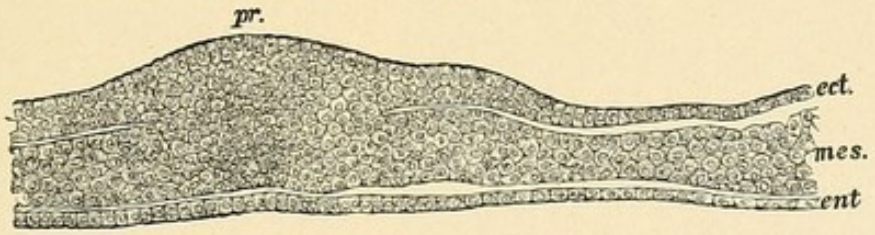

FIG. 751.—Karyokinesis of the fecundated ovum of the rabbit (the primary embryonic tissue) arranged in three layers—the ectoderm, mesoderm, and entoderm. At *pr.* the ectoderm and mesoderm have fused together. (Kölliker and Quain.)

success of this effort at repair must depend not only upon the condition of nutrition which prevails at the moment, but in large measure upon the quality and quantity of the toxic material and the violence to the tissues immediately involved.

In modern aseptic or antiseptic practice the conditions in the process of repair are so nearly physiological, that in order to comprehend these conditions the student must bear in mind the normal development of the tissues.

[1] In vascular tumors (angeiomata) there is a condition of hyperæmia, with redness without inflammation; blushing associated with certain emotions produces localized hyperæmia with redness and is a physiological process. *Active* hyperæmia occurs sometimes after injury of a sympathetic nerve and this may be accompanied by redness and swelling without inflammation. *Passive* hyperæmia due to interference with the return of the blood through the veins or the flow of lymph through their channels causes œdema or swelling which is non-inflammatory. In the hepatic vein under strict physiological conditions the blood is heated, at times to far above the normal temperature. Finally, pain is not infrequently felt as in neuralgia where no other symptoms of inflammation are present.

The fecundated ovum of the parent is a typical cell, which, by the process of primary division of the nucleus (karyokinesis [1]) indefinitely repeated, develops myriads of protoplasmic cells which compose the primary embryonic tissue, the *blastoderm*. These cells arrange themselves in three groups or layers—the outer, or *ectoderm*, the *mesoderm*, and the *entoderm*. The ectoderm, by continuous proliferation, is developed into the epithelia of the skin, buccal cavity, the epithelia of the organs of sense, of the ventricles of the brain, the canal of the spinal cord, and forms the nervous tissues. The entoderm, excepting the buccal cavity, forms the epithelia of the alimentary canal and the glands in connection with it. The mesoderm forms the renal epithelia and the epithelia of the vessels and serous surfaces, and all connective tissue, cartilage, bone, muscle, tendon, ligament, etc. (Quain).



FIG. 751*a*.—Three cells from the early embryo of the cat (highly magnified). *b*, protoplasm; *c*, nucleus with nucleolus; the lower one a double nucleated cell. (After Sharpey and Quain.)

In the normal processes of waste and repair, as epithelia or connective-tissue cells are worn out and disappear, new cells are proliferated by the parent stock to replace them. Epithelial cells by karyokinesis reproduce their kind, and in like manner the connective-tissue group reproduce connective tissue. In simple inflammation from the embryonic tissue which is the common product of the proliferation of all the fixed or resident cells in the area involved, the destroyed cells are replaced by new cells by proliferation of their parent stock, just as a grain of wheat produces wheat.

The ordinary phenomena of inflammation following an injury are as follows: There is a spasmodic contraction of the terminal arterioles, the capil-

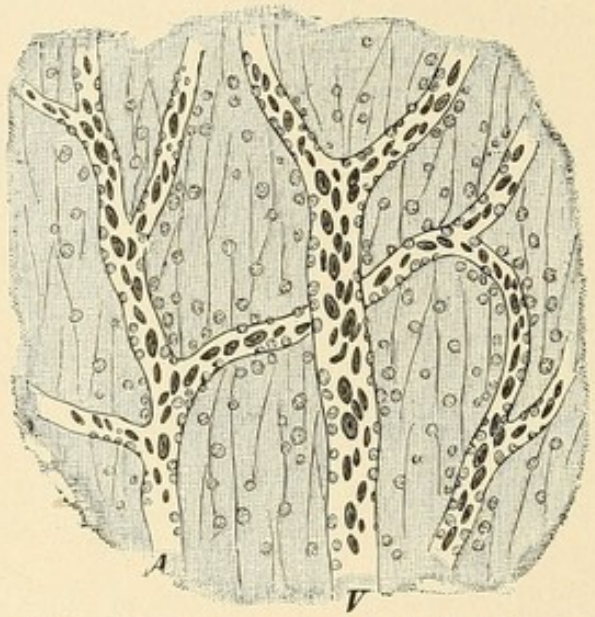

FIG. 751*b*.—Inflamed mesentery of a frog. *V*, vein; *A*, small artery and capillaries. The red corpuscles are seen in the center of the current; the white blood-corpuscles creep along their inner walls, some being in the process of emigration; the surrounding tissues contain many of these which have already emigrated from the vessels. (Tillmanns.)

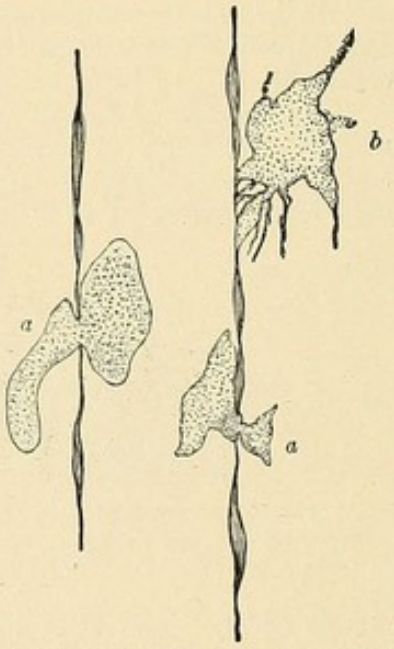

FIG. 751*c*.—Diapedesis or emigration of leucocytes through the walls of a venule. *a*, incomplete, *b*, complete emigration (schematic). (Tillmanns.)

laries, and venules in the injured area, followed almost instantly by dilatation of these vessels far beyond their normal caliber. The volume of blood is at once greatly increased to fill the enlarged channels, and the current is more rapid, since capillary resistance is less. After the lapse of about one hour the current begins to slacken, and gradually becomes slower than before the

[1] From *καρυον*, nucleus, and *κινησις*, movement.

injury. This slowing of the current is not due to recontraction of the vessels, but to a clogging of their channels with the corpuscular elements of the blood. The red blood-corpuscles and the plaques [1] floating in the plasma occupy the center of the vessels, while the white corpuscles (leucocytes), which normally exist in the blood in the proportion of from 1 to 1000 to 1 to 250 of the red corpuscles, are

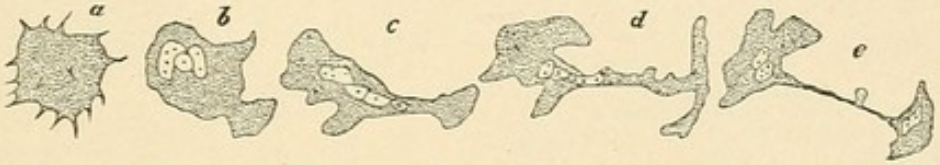

FIG. 751*d*.—A white corpuscle or leucocyte of the newt's blood with three nuclei. *a*—*e*, successive forms assumed at intervals of a few minutes. (After Klein and Quain.)

largely increased and are seen to adhere to the vessel walls (Fig. 751*b*). Since the force of the current is greatest in the arterioles and least in the venules (which have the capillaries between them and the heart to retard the circulation), the leucocytes cannot adhere to the lining membrane of the arterioles; a considerable number are seen attached to the capillaries, while the venules are practically choked with them, and it is through the walls of the venules that they emigrate (diapedesis, διαπήδᾶν, to ooze through) and wander into the intervascular spaces (Figs. 751*b*, 751*c*). Some few pass through the capillaries, but none have been observed to escape through the walls of the arterioles. The leucocyte, which has the power of changing its form (Fig. 751*c*), pushes through the line of union of the flat epithelium which composes the wall of the venule, displacing the cement substance, and finally emerging at the outer side of the vessel, which by its elasticity at once closes the aperture of escape. Coincident with the clogging of the venules and the emigration of the leucocytes, by reason of the force of the heart's action, the plasma oozes through the walls of the blood vessels, producing *active* œdema, and a little later pressure on the lymphatic vessels by the mass of newly formed cells causes a transudation of lymph—*passive* œdema—which, mingling with the escaped plasma, coagulates outside the vessels. In some instances red blood-corpuscles and



FIG. 751*e*.—White corpuscles or leucocytes treated with water and with acetic acid. 1, first effect of the action of water upon a white blood-corpuscle; 2, 3, white corpuscles treated with dilute acetic acid; *n*, nucleus.

plaques may also escape in the wake of the emigrating leucocytes without vascular rupture and produce slight discoloration due to the decomposition of *hæmatin*, the coloring matter of the red disk. *Ecchymosis*, however, is usually caused by rupture of the vessels, with free extravasation, and the formation of blood clot which is invaded by and probably serves as food for the proliferating cells. The appearance of the escaped leucocytes in the tissues is marked by a sudden activity in the various protoplasmic elements of the area involved. Every normal cell in the zone of irritation takes part in this activity of proliferation; but since the connective-tissue cells largely predominate, they have attracted the greatest attention of observers and furnish as well the greater portion of the embryonic tissue. The protoplasm of the fixed or resident cell increases in size, and the nucleus undergoes remarkable changes (Fig. 753). The connective-tissue cell (Fig. 752) consists of a minute particle of protoplasm in the center of which is a nucleus. The nucleus is made up of a network of nucleoli and threadlike bodies which are readily stained and

[1] The plaques or "third corpuscles" of the blood measure from 1.3 to 3.5 micromillimeters in diameter, and are supposed to be embryonic red blood-corpuscles. They consist of a colorless protoplasm, and are present in the proportion of about 1 to 20 of the red disks. A micron, or micromillimeter, is $\frac{1}{25000}$ of an inch. The Greek character μ will be used to denote a micromillimeter.

has an investing membrane of its own. In the normal condition of the tissues the fixed cell is somewhat flattened, but when excited to proliferation it rapidly swells and the threads in the nucleus form a thicker network, soon followed by an hour-glass contraction of these thickened threads[1] (karyomitosis), near the center of

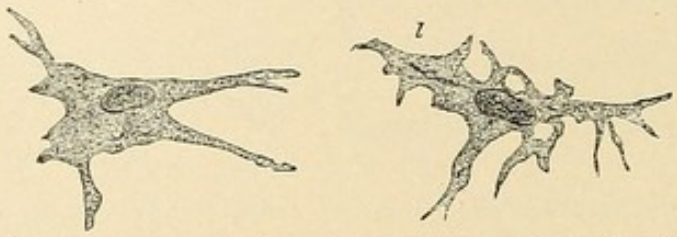

FIG. 752.—Two connective-tissue corpuscles from the subcutaneous connective tissue, highly magnified. The dark streak below *l*, in the right-hand corpuscle, is a lamella which happens to be projecting toward the observer, and is seen in optical section. (After Sharpey and Quain.)

the nucleus, where it rapidly divides in two, the thin capsular membrane closing in and surrounding each new, as it did the parent nucleus (Fig. 753). The main body of the cell may now divide and form two new cells, each with a single nucleus, or the protoplasm may simply enlarge without division, the nuclei dividing indefinitely within the cell. In this way the polynucleated or "giant cells" are formed.

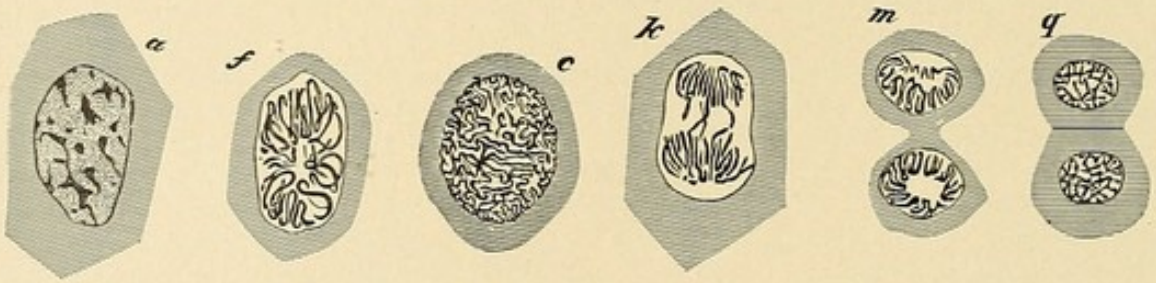

FIG. 753.—Karyokinesis in the cells of salamander larva. *a*, cell in rest, showing parts of the nuclear network colored black; the remaining portion of the nucleus is the nuclear matrix; *c*, nucleus transformed into closely contorted filaments; *f*, filaments converging toward the center with commencing separation into an upper and a lower portion; *k*, separation more advanced; *m*, a further step in the process in which the perinuclear protoplasm is taking part; *q*, two cells, the product of karyokinesis, the nuclear network again assuming the cell in repose. (After Flemming and Quain.)

It is now held that all cell proliferation takes place by this process of *karyokinesis*, or primary division in the nucleus. The dilatation of the blood vessels, with the increased supply in the part, the escape of leucocytes, plasma, and lymph, and the enormous cell proliferation, cause the *heat*, *redness*, *swelling*, and *pain* of inflammation, together with the *loss of function* in the part, as well as a partial or complete stoppage (*stasis*) of the circulation in the inflamed area. Stasis is always more pronounced at the center of the disturbed zone, and here the discoloration is deeper, gradually diminishing toward the periphery. The sudden contraction and immediate dilatation of the vessels is due to a momentary irritation of the vasomotor nerves and the paralysis which follows their injury. It is difficult to explain just why the leucocytes appear in such large numbers at the seat of inflammation. It is claimed that they are attracted there by some chemical change in the parts involved, and this is termed *chemiotaxis*.[2] In all probability their chief function is the protection of the injured tissues from bacterial invasion. That they are phagocytes has been clearly demonstrated. Under conditions of mild infection in tissues where the resistance is near the normal, the process of repair begins within a few hours after the injury. The phenomena of regeneration are practically identical in all vascular soft tissues. In bone, by reason of the

[1] Karyomitosis, from χαρυον, *nucleus*, and μιτος, *thread*. This term is applied to the increased size and changes in the *threadlike* contents of the nucleus.

[2] The property living cells exhibit, with reference to non-living organic material, by virtue of which they approach or recede from certain substances. In *positive* chemiotaxis the cell approaches, in *negative* it is repelled (Sternberg).

dense structure which surrounds the vessels and medulla, and in the two non-vascular structures, the cornea and cartilage, the process differs somewhat and will be specially studied. When the infection is virulent or when the tissues are of low resistance the destruction is much greater, the process of repair is slower, and



FIG. 754.—(After Paget.)

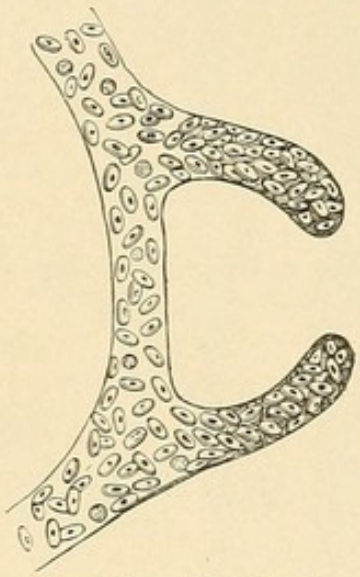

FIG. 755.—(After Paget.)

regeneration is always imperfect. Chemical and mechanical destruction of the tissues is always followed by the formation of a fibrillated connective tissue, producing a scar or *cicatrix*.

The most important step in the regeneration of injured tissue is the distribution of blood and nutrition by the new formation of vessels. From the stumps of the divided or occluded capillaries, buds (Fig. 756) of protoplasm, springing from the new cells of the proliferating endothelia, are projected into the mass of em-

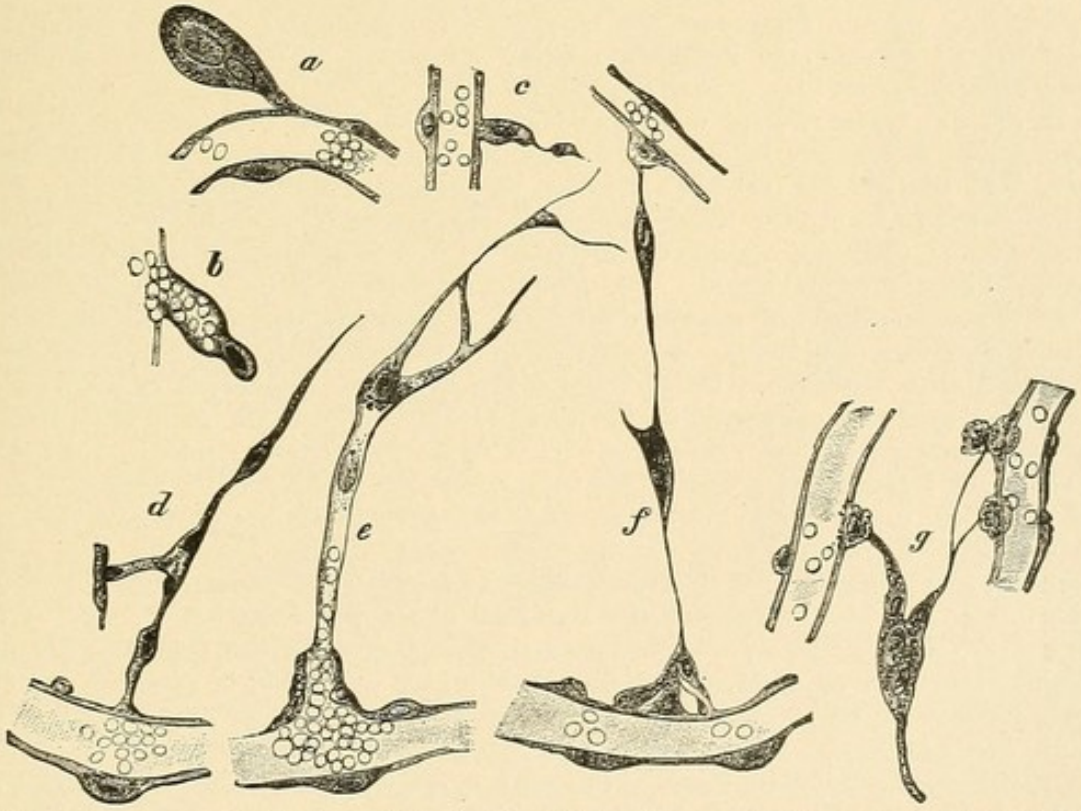

FIG. 756.—Development of blood vessels by budding; different forms of buds. *a*, *b*, *c*, first stages; *d*, *f*, *g*, simple and branching solid buds; *e*, vascular bud which is being made hollow and which already contains blood corpuscles. (After Tillmanns.)

bryonic cells. Some of these meet and fuse with similar buds projecting from opposing surfaces of the inflamed area, or at times two buds from the same surface unite to form a capillary loop (Fig. 755). Some of these embryonic vascular buds begin as tubules, communicating with the vessels (*e* Fig. 756), while others are more solid prolongations of protoplasm not yet canalized (*d* Fig. 756). According to Ranvier, the centers of these undergo liquefaction, and thus becoming canulated, they ultimately communicate at their extremities and become continuous with the vessels from which they spring. The cells of the embryonic tissue immediately in contact with the new canals aid in forming the walls of the newly made vessels. When hæmorrhage has occurred, the *coagulum* is rapidly infiltrated with the new cells and disappears after a variable time, either undergoing granular metamorphosis or is taken up as nourishment by the proliferating cells. Many of the capillaries and vessels disappear as the result of the contraction which takes place in the final stage of inflammation. This formation of connective tissue (Fig. 757)

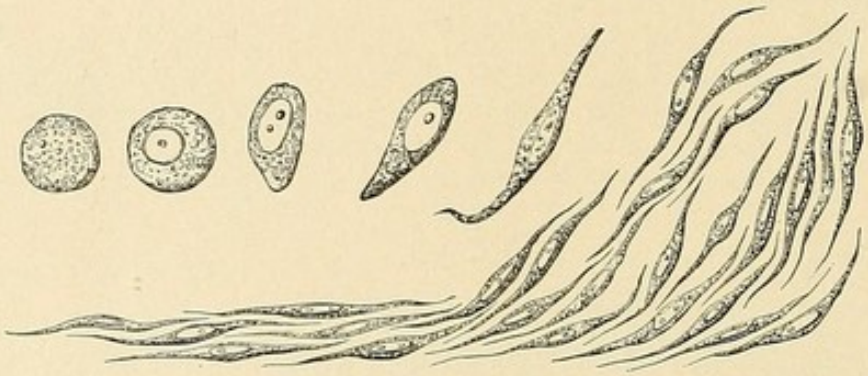

Fig. 757.—Steps in the fibrillation of connective-tissue cells. (After Paget.)

in inflammation is at times so extensive that occlusion of the newly formed capillaries is often complete, giving the peculiar bleached appearance to cicatricial tissue.

In the *skin* the repair in the deeper layers of the cuticle is carried on by the proliferating prickle cells and the elongated and granular cells of Langerhans, while in the corium the embryonic tissue springing from the fixed connective-tissue cells develops into a new connective tissue.

In *adipose* tissue the fat vesicles, when ruptured, allow the escape of their contents, which disappears by granular metamorphosis. The nucleus of the capsule enters into the general cell proliferation, the capsule itself being originally a connective-tissue cell. As the inflammatory process subsides, fat droplets again appear in certain of the new embryonic cells which are gradually distended and form new fat vesicles (Fig. 758).

In the regeneration of *muscle* the process is somewhat analogous to the budding in new forming capillaries. From the ends of the muscular fibers, which are infiltrated with embryonic cells (to the formation of which the muscle cells or *sarcoblasts* and the connective-tissue cells of the perimysium contribute), protoplasmic swellings or buds, which are rich in nuclei, are projected. By division of the nuclei (practically analogous to the formation of muscle plates from the mesoderm in the embryo) the new fiber is constructed, meeting and becoming continuous with the buds from the opposing surface. These formative cells arrange themselves in elongated or fusiform shape, in which, later on, fine longitudinal striæ are seen. The transverse striæ appear about the twenty-first day. Muscle has not the reproductive power of other tissues, and when the injury is extensive, or when infection or suppuration occurs, the lost substance is replaced by fibrillated, connective, or cicatricial tissue. Even when new fibers are produced, their arrangement is not so symmetrical as in the normal muscle.

In the regeneration of *tendon*, the tendon cells and the connective-tissue cells of the sheaths are the agents of proliferation and repair in inflammation as well as after surgical or accidental division. A tendon cell is a fusiform body of protoplasm containing a single nucleus in which are several nucleoli. They are

arranged in rows between the layers of fibers. From these rows tendon buds are projected, which, growing longer, become fibrillated and arrange themselves in parallel layers, interlocking with the growing fibers or buds from the opposite side.

The process of repair in inflammation or injury of the *ligaments* is practically identical with that of tendons, and need not be separately considered.

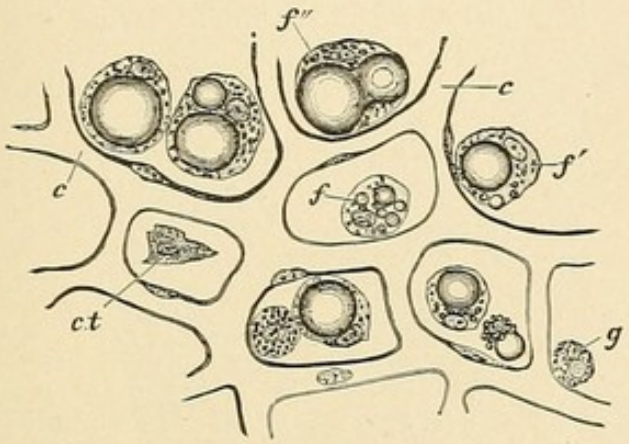

Fig. 758.—Deposition of fat in connective-tissue cells (adipose tissue). *f*, a cell with a few isolated fat droplets in its protoplasm; *f'*, a cell with a single large and several minute drops; *f''*, fusion of two large drops; *g*, granular cell, not yet exhibiting any fat deposition; *c t*, fat connective-tissue corpuscle; *c*, *c*, network of capillaries. (After Sharpey and Quain.)

In *nerves*, in exceptional cases, the repair or reunion takes place soon after extensive injury, with the resumption of function. As a rule, however, restoration of function takes place very slowly. The essential element of conduction is the *axis cylinder* (Fig. 760). In some nerves and at points in many nerve strands the outer sheath (nucleated sheath of Schwann) and the medullary sheath (white substance of Schwann) are absent, the axis cylinder alone being present. This axis cylinder is the greatly elongated branch of a central nerve cell (Fig. 761). When destroyed, that portion of the axis cylinder on the peripheral side of the lesion undergoes destructive metamorphosis, and the function of the nerve cannot be restored until the central end of the axial band buds out and is prolonged throughout the nerve to replace the cylinders which have been destroyed. In two or three weeks after the lesion, pale, delicate processes are seen budding out from the

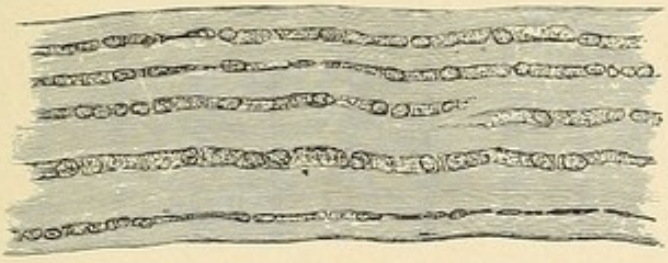

Fig. 759.—Tendon of mouse's tail, showing chains of cells between the tendon bundles; 175 diameters. (After Sharpey and Quain.)

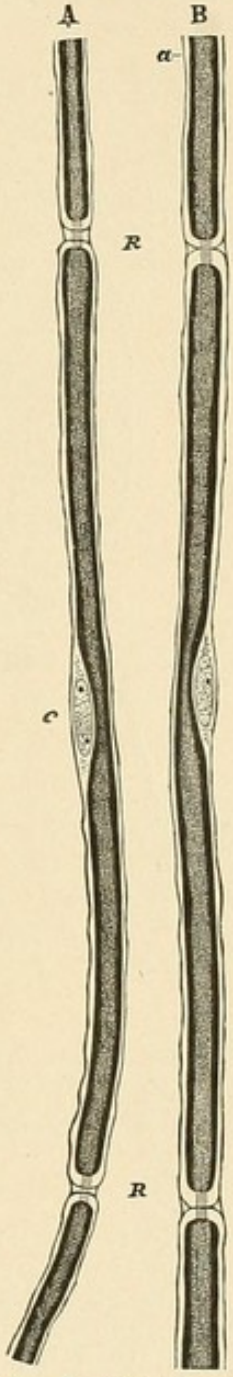

Fig. 760.—Portions of two nerve fibers stained with osmic acid (from a young rabbit). 425 diameters *R*, *R*, nodes of Ranvier, with axis cylinder passing through; *a*, primitive sheath of the nerve; *c*, opposite the middle of the segment indicates the nucleus and protoplasm lying between the primitive sheath and the medullary sheath. In A the nodes are wider, and the intersegmental substance more apparent than in B. (From a drawing by Mr. J. E. Neale, after Sharpey and Quain.)

axis cylinders of the central end into the inflammatory embryonic tissue. This process of budding is only from the central end of the divided nerve, and differs from that in the regeneration of capillaries, tendons, and muscle, in which the budding is from both the proximal and distal ends. (Bügner claims that the cells in the nucleated sheath, by their proliferation, aid in the restoration of the cylinder, and these he terms *neuroblasts*.)

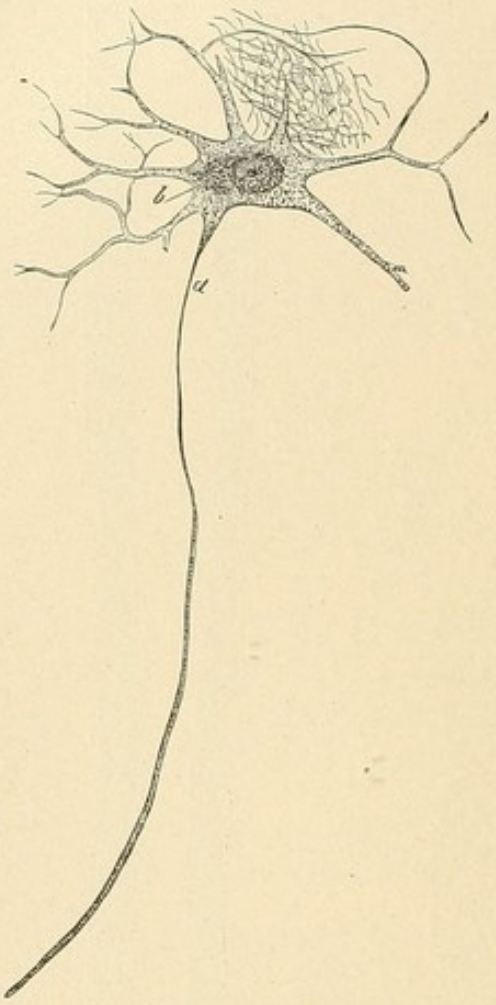

FIG. 761.—Ramified nerve cell from anterior cornu of spinal cord of man. *a*, axis-cylinder process; *b*, clump of pigment granules. Above the cell is seen part of the network of fibrils. (After Gerlach and Quain.)

The slowness with which nerve trunks—the seat of inflammation or injury—resume their function gives weight to the theory which holds that the projection of the axial band is alone from the central and parent nerve cell. As much as twelve months have elapsed after careful, aseptic reunion by suture before any restoration of function was observed in cases in which complete recovery resulted. In no other tissue is the process of repair so slow. It is evident that careful apposition without unnecessary tension of the sutures, is essential to successful union.

Periosteum and Bone.—Inflammation of the periosteum causes a rapid proliferation of the connective-tissue cells of the superficial or fibrillated layers of this structure, and of the rich supply of cells, the *osteoblasts*, of the layer nearer the bone. The nerve, blood and lymph vessels, and the contiguous bone must of necessity take part in the process, and when at the seat of injury the fascia or tendon perforates the periosteum to insert their fibrillæ deep into the meshes of the bone, they also contribute something to the production of the embryonic tissue. From the tenth to the fifteenth day after the injury in adults the cells which have remained soft begin to be infiltrated with calcareous matter (*callus*). From the twentieth to the thirtieth day, under ordinary conditions, this (provisional callus) begins to be absorbed and may disappear entirely by the end of sixty days. In some instances, however, it in part remains and is transformed permanently into bone to form a *node* or *exostosis*.

A typical non-infective inflammation of bone is seen in *simple* fracture, the immediate result of which is hæmorrhage from the vessels of the periosteum, the compact substance and medulla, as well as the accidental bleeding from the contiguous soft structures. The coagulum of blood and lymph covers the broken ends, extends a short distance into the medullary cavity and Haversian canals, pressing back the medulla and infiltrating the space about the point of fracture. Into this clot and throughout the inflamed area the emigrating leucocytes crowd, and all the phenomena of cell proliferation which their presence excites takes place. The periosteal osteoblasts (Fig. 763), the bone corpuscles (Fig. 764) which fill the lacunæ, the "giant cells," or *myeloplaxes* of Robin (very large masses of protoplasm, containing usually many nuclei, Fig. 765, *c*), or, if only one, this very large, and the common and very much smaller mononuclear cells of the medulla (marrow cells, Fig. 765) (found not only in the central medulla, but also in the Haversian canals, and possessing the amœboid properties of the leucocytes), all undergo active proliferation. The deeper cells of the periosteum are at first most active and throw out a rich mass of embryonic tissue, which envelops and surrounds the broken ends and by the tenth day begins to be infiltrated with

lime salts to form a callus. From the fifteenth to the twentieth day this (Fig. 767) ensheathing callus is complete, and holds the fragments immovable while the process of ossification is going on. There forms also about the same time,

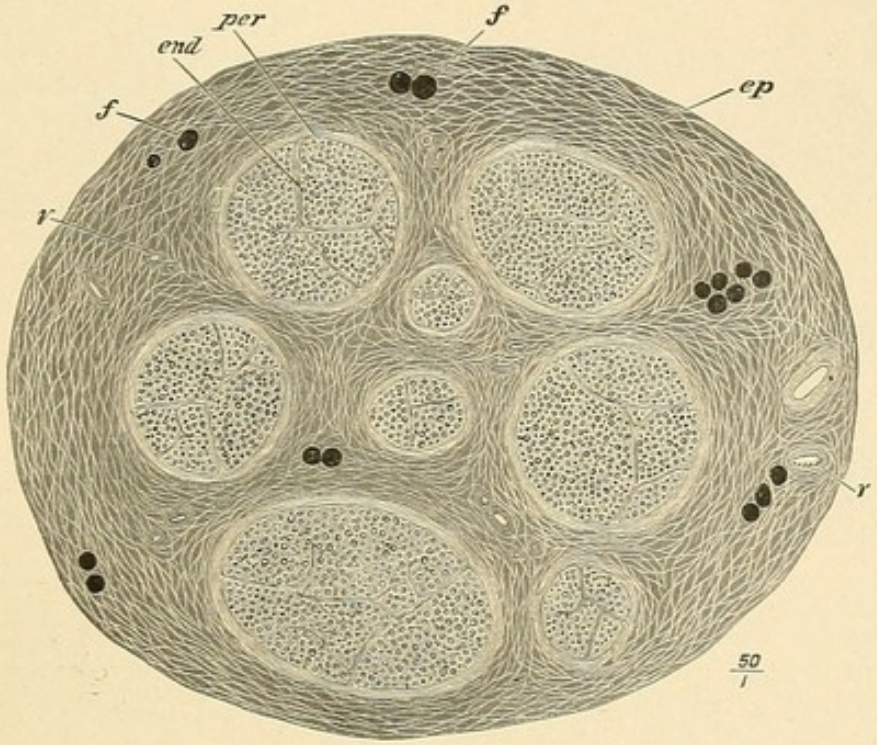

Fig. 762.—Section of the internal saphenous nerve (human), made after being stained in osmic acid and subsequently hardened in alcohol. Drawn as seen under a very low magnifying power. *ep*, epineurium, or general sheath of the nerve, consisting of connective-tissue bundles of variable size, separated by cleftlike areolæ, which appear as a network of clear lines, with here and there fat cells (*f f*) and blood vessels (*v*); *per*, funiculus inclosed in its lamellated connective-tissue sheath (perineurium); *end*, interior of funiculus, showing the cut ends of the medullated nerve fibers, which are imbedded in the connective tissue within the funiculus (endoneurium). The fat cells and the nerve fibers are darkly stained by the osmic acid, but the connective tissue of the nerve is only slightly stained. (After Sharpey and Quain.)

in the young, a weaker callus from the central medulla cells (pin callus) and from the marrow cells of the Haversian canals—the interosseous callus. In older persons, after about fifty years, it is held that no central or pin callus forms. It

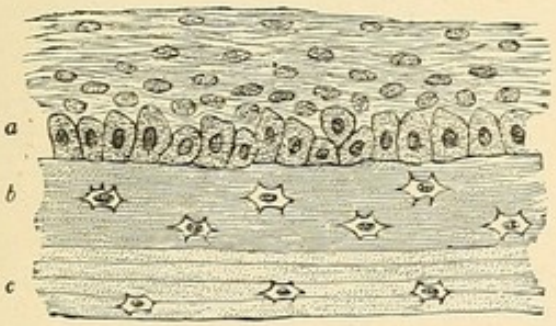

Fig. 763.—Periosteal formation of bone from osteoblasts *a*; *b*, newly formed bone; *c*, old bone. × 300. (After Tillmanns.)

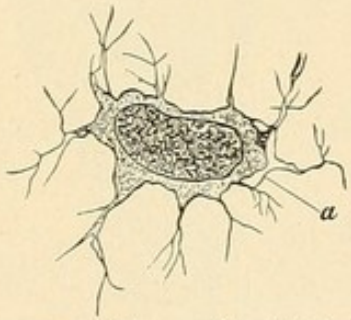

Fig. 764.—A bone cell isolated and highly magnified. *a*, proper wall of the lacuna, shown at a part where the corpuscle has shrunk away from it. (After Joseph and Quain.)

is probable that in all cases the chief factor in the regeneration of bone is the bone corpuscle (Fig. 764). It is well known that the periosteal cells (osteoblasts, Fig. 763) will reproduce bone in children and in early adult life, and in inflammation this doubtless assists in the process, but the bulk of their product usually disappears by absorption, as does the medullary callus. In that portion of the embryonic tissue which springs from proliferating bone corpuscles and usually is

interposed between the contiguous surfaces of fractured bone, the cells are transformed into *hyaline* substance, in which *cartilage* cells appear. As in the original development of bone, this cartilage is soon infiltrated by true osteoblastic tissue,

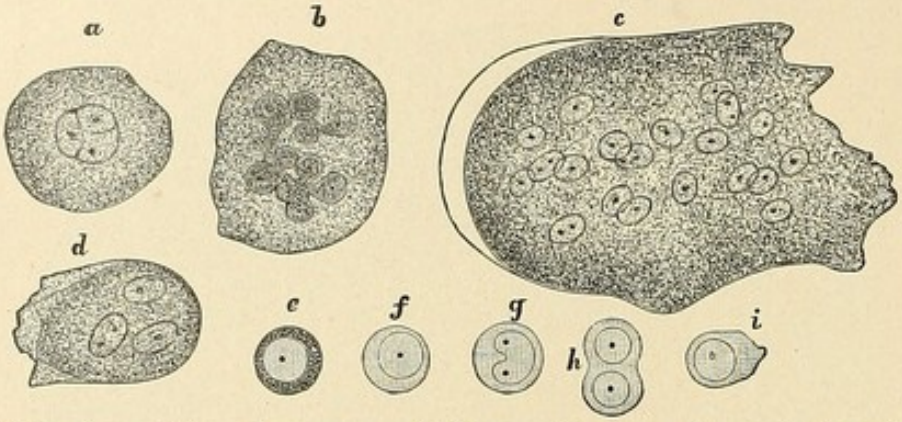

FIG. 765.—Multinuclear cells from bone marrow, highly magnified. *a*, a large cell the nucleus of which appears to be partly divided into three by constriction; *b*, a cell the enlarged nucleus of which shows an appearance of being constricted into a number of smaller nuclei; *c*, a so-called giant cell (myeloplaxes) with many nuclei; *d*, a smaller cell with three nuclei; *e–i*, other cells of the marrow. (After Sharpey and Quain.)

forming the osseous lamellæ. In addition to the osteoblasts there appear multinucleated cells (myeloplaxes of Robin and osteoclasts of Kölliker) which arrange themselves in rows or circles and cause partial absorption of the osseous substance, giving, according to Sharpey, the festooned appearance to the Haversian spaces (Fig. 768). Through these canals, thus produced by absorption, the new-formed vessels make their way.

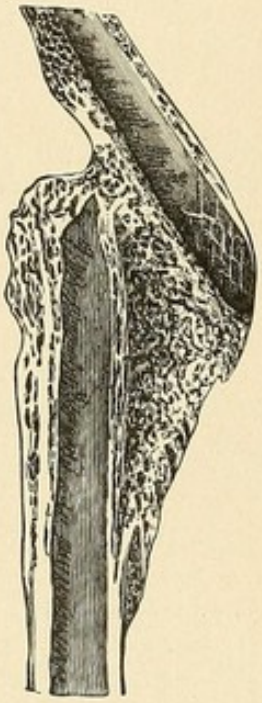

FIG. 766.

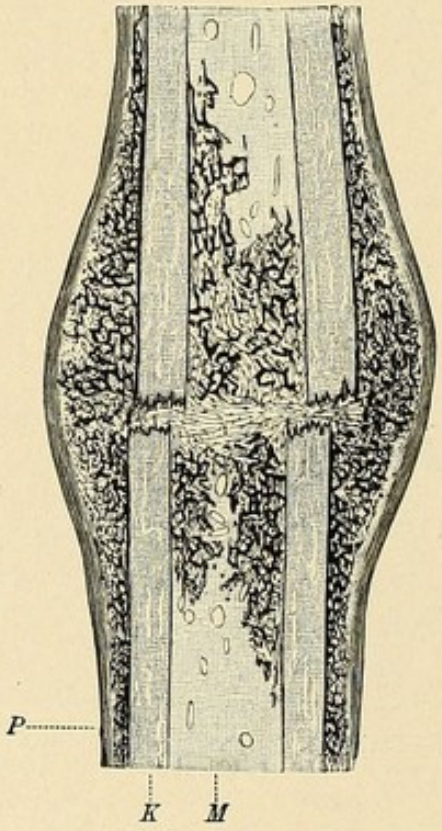

FIG. 767.

FIG. 766.—Fracture healed with deformity (callus luxurians). (After Tillmanns.)

FIG. 767.—Longitudinal section through a fracture of the femur three weeks old. *P*, periosteum; *K*, bone; *M*, medulla. Periosteal callus and medullary callus. The intermediary callus consisting of periosteal granulation tissue, which is ossified only in some places and is partly cartilaginous. (After Tillmanns.)

While the process of repair in bone, as just given, is closely analogous to the formation of bone from the blastoderm—namely, primary formation of cartilage

and the replacement of this by osteogenic tissue—this does not always occur. In certain bones of the skeleton (the flat bones of the skull) osteogenesis is not preceded by cartilage formation. In inflammation with loss of substance, when suppuration has occurred, as in an infected compound fracture, embryonic tissue is *directly* converted into bone.

In inflammation of the *cornea* (keratitis) the changes are very much the same as in inflammation of the tissues which possess blood vessels. While the blood does

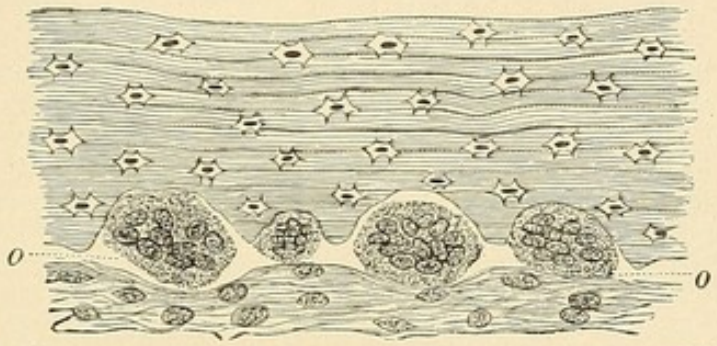

FIG. 768.—Lacunar absorption of bone by osteoclasts (*O*), which lie in Howship's lacunæ. ×250. (After Tillmanns.)

not circulate in the cornea proper, there are certain channels, called plasma canals, through which plasma and lymph convey nutrition from the blood vessels to the tissues of the cornea. These plasma canals undergo a dilatation in the earlier stage of inflammation analogous to that of the blood vessels in other tissues, and there is also a transudation of the increased fluid between the lamellæ of which the cornea is composed. General proliferation ensues in the corneal corpuscles, which is preceded by emigration of leucocytes from the blood vessels into the plasma canals. The presence of this new embryonic tissue causes opacity or clouding of the cornea. When the inflammatory process continues for a sufficiently long period blood vessels shoot out from the corneal margin into the cornea, projecting their capillary buds along the spaces formerly occupied by plasma canals, and the condition of *pannus* is established. If infection occurs, suppuration soon takes place with the widespread destruction which follows the presence of pus. The development of blood vessels into the inflamed area is a conservative process, in response to the demand for increased nutrition and for removing the inflammatory products which undergo granular metamorphosis. Ultimately these new blood vessels diminish in size and gradually disappear.

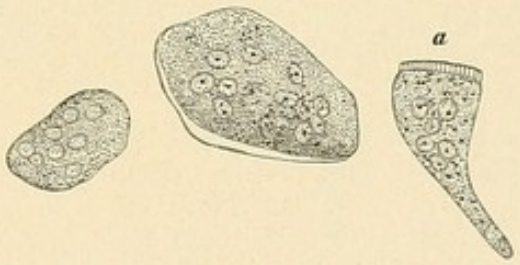

FIG. 769.—Three osteoclasts from absorption surfaces of growing bone. 400 diameters. *a*, with thickened striated border. (After Kölliker and Quain.)

In *cartilage*, inflammation is unlike that which occurs in the cornea, for in cartilage there are no vascular spaces whatever. Nutritive material is absorbed directly by the cartilage cells and hyaline substance from the blood vessels at the point of contact of the cartilage with the bone. In the early stages of chondritis, the cartilage cells are swollen, the nuclei enlarged, the intercellular substance (hyaline) becomes liquefied, or, in the milder form, may undergo molecular degeneration. If the inflammation be sufficiently prolonged, blood vessels may be projected into the area involved. Cartilage is a tissue of such low vitality that the process of repair is always slow. While it has not been demonstrated, it is in all probability true that new cartilage cells are produced from the embryonic tissue, the product of the original cartilage cells. When infection by bacterial invasion occurs, the destruction of the tissue is more extensive and the cartilage cells and hyaline substance are generally not reproduced, but are replaced by cicatricial tissue.

Inflammation may be clinically considered as moist (suppurative) or dry (non-suppurative).

Suppurative inflammation may be considered under four headings—i. e., (1) that which affects the mucous surfaces (gonorrhœa, conjunctivitis, etc.), (2) the serous surfaces (peritonitis, pleuritis, etc.), (3) the synovial surfaces (arthritis, thecitis), and (4) that which affects the cutaneous and subcutaneous tissues (boils, abscesses, osteomyelitis, etc.).

The non-suppurative inflammatory lesions may be subdivided in the same manner: Of the first, diphtheria is a type; the second, peritonitis and pleuritis with a plastic or dry (non-supportive) exudate; the third, a similar lesion of the joints; and fourth, those which affect the skin and deeper tissues (erysipelas, anthrax, glanders, tuberculosis, actinomycosis, syphilis, and leprosy, in none of which is pus formed without the presence of pyogenic organisms—mixed infection).[1]

Pathogenic Organisms.—Bacteria (*bacterium*, βακτήριον, a rod or staff) is a general term applied to all these minute organisms, and the science which treats of them is *bacteriology*. To attempt a classification of these organisms in the present condition of science would be unsatisfactory.

Bacteria have been named chiefly by reason of their shape. Those which under the microscope appear like bits of broken rods are called *bacilli* (*bacillus*, a little

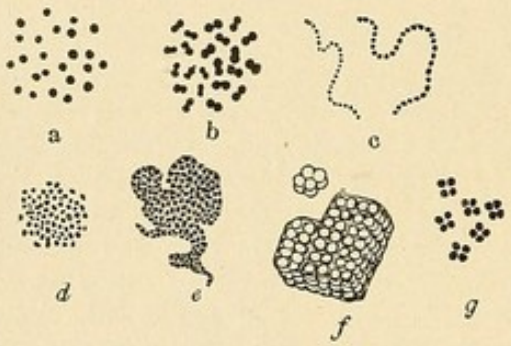

Fig. 770.—Different varieties of cocci. *a*, smaller and larger cocci; *b*, diplococci; *c*, chain coccus (streptococcus); *d*, *e*, clusters of cocci in the form of a bunch of grapes (staphylococci); *f*, sarcina (packet coccus); *g*, micrococcus tetragonus. (After Tillmanns.)



Fig. 771.



Fig. 772.

Fig. 771.—Staphylococcus pyogenes. (Pure culture.) (Modified from Landerer.)

Fig. 772.—Streptococcus pyogenes. (Pure culture.) (Modified from Landerer.)

stick). The very longest bacilli are sometimes called *leptothrix* or hairlike (λεπτος, slender; θριξ, hair). When curvilinear or spiral in outline, *spirilla* (*spirillum*, a curve). When round or near so, they are termed cocci (κοκκυς, a berry or kernel). Some of these divide in two and remain attached in a single envelope, and are called diplococci (διπλοος, double).

Those which divide in two directions, forming fours which adhere together in a single plane in the same gelatinous envelope, are called *tetragonus* or *tetrads* (τετρα, four, and γωνια, angle), a four-angled or four-cornered arrangement.

When they divide into spherical bodies, which at times cluster together by *surface* agglutination, they are called *staphylococci* (σταφυλη, a bunch of grapes).

When they proliferate in one direction indefinitely, like the links of a chain, and remain joined together, they are called *streptococci* (στρεπτος, a chain).

Adhering in groups or blocks, *zoöglœa* (ζῶον, animal, and γλοιος, a glutinous substance).

Arranged in cubes, they are *sarcina* (*sarcire*, to arrange in order, as a package or bale).

While bacteria are chiefly of vegetable origin, consisting, when fully developed, of an element of protoplasm, containing albuminous matter, fats, salts, and water, and enveloped in a shell of *cellulose*, recent investigators have described a form,

[1] Certain lesions of the skin due to the lodgment of micro-organisms and parasites in the hair follicles or upon or in the substance of the integument may also be classed as non-suppurative lesions. As they belong to the domain of dermatology they are not considered in this work.

the *mycetozoa* (μυκης, fungus), which seems to belong half-way between the vegetable and animal kingdoms, and the *protozoa* (πρῶτος, first or beginning) (animal), which are considered the very lowest form of animal life.

Bacteria reproduce their kind in two ways: by division (fission) and by spore formation (sporulation).

In fission the parent germ usually becomes elongated, and near its center a pale line may be observed in a direction transverse to the long axis of the germ. This line becomes clearer and clearer until it disappears entirely, and the two products are separated into independent organisms.

In sporulation the protoplasm of the germ seems to condense and harden and inclose usually a single spore. On account of the thickening of the capsule, the spore is able to resist destruction to a greater degree than the parent organism.

Many bacteria are capable of motion while a large group are non-motile. Those that are non-motile (certain of the cocci) are at times seen to sway *en masse*. This molecular motion is also called the "Brownian" movement. Quite recently Ali-Cohen, in two different micrococci, has demonstrated flagella with motion. By a recent method of staining, Loeffler demonstrated flagella—long hairlike fins—on many important pathogenic bacteria. These may be seen at one or both ends, and in some types, as the typhoid bacillus, they grow out in all directions. These flagella are often very long and have a wavy motion (Fig. 775).

Certain forms of bacteria can live without oxygen; they are called *anaërobic*. The greater number require oxygen and are termed *aërobic*, while others (comparable to the amphibious animals) can live with or without oxygen. Those which thrive best in a medium containing oxygen, yet can exist, however stunted, when this gas is absent, are termed *facultative aërobic* bacteria. All bacteria develop best in alkaline media. The rapidity of their proliferation is remarkable. Under favorable conditions a single organism will, within twenty-four hours, by dividing and redividing every hour, produce more than sixteen million of its kind, and they have been known to undergo fission in so short a time as twenty minutes. The presence of moisture is always required for their development, and, as a rule, they develop best where *light* is excluded.

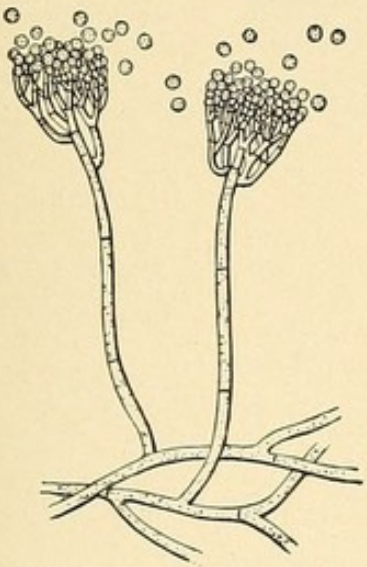

Fig. 773.—Penicillium glaucum. × 500. (Tillmanns.)



Fig. 774.—Yeast fungus. Saccharomyces cerevisiæ. Vacuoles are present in some of the larger cells.

Certain of these micro-organisms form coloring matter and are classed as *chromogenic* bacteria. Others produce rapid fermentation, and are called *zymogenic*.

Bacteria which exist outside of the living body in putrefying animal or vegetable matter are called *saprophytes*, while those which dwell in the living tissues are called *parasites*. Some of these organisms, ordinarily saprophytes, but capable of existing within the living body, are called *facultative parasites*.

Bacteria which possess the faculty of liquefying the tissues with which they come in contact produce pus and are called *pyogenic bacteria*.

The principal pathogenic bacteria of surgical interest are: Staphylococcus pyogenes aureus, epidermidis albus, citreus, fluorescens, cereus, flavus; micrococcus

pyogenes tenuis, gonococcus, micrococcus tetragonus, micrococcus lanceolatus; streptococcus erysipelatis (Fehleisen), streptococcus pyogenes; bacillus pyocyaneus and pyofluorescens, bacillus ruber and fœtidus, bacillus coli communis, bacillus tetani, anthracis, syphilis, tuberculosis, mallei, lepræ, typhi abdominalis, diphtheriæ.[1]

As yet little is known concerning the *mycetozoa* and *protozoa*. The former, sometimes called *myxomycetes*, are not distinctly animal or plant, but seem to be nearer to the *amœbæ*, the lowest form of animal life, than to *bacteria*, the most elementary plants. As *protozoa* are classed the following: Plasmodium malariæ, the germ of molluscum contagiosum, and a peculiar amœbic organism found in the discharges of dysentery (Tillmanns). The fungi or molds—viz., penicillium,

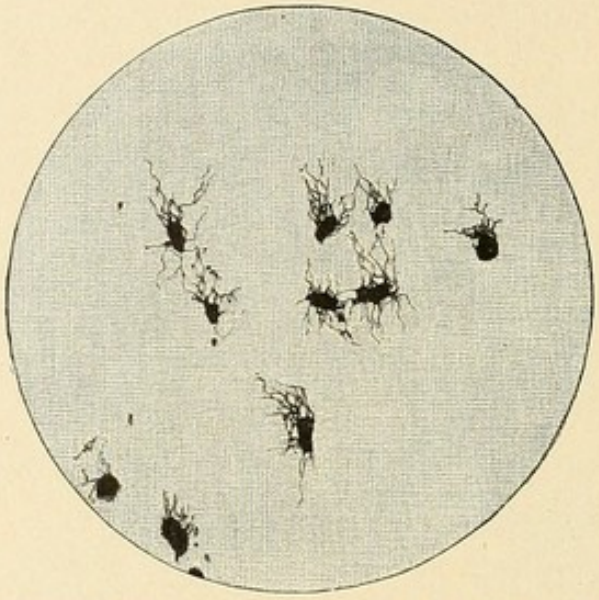

Fig. 775.—Typhoid bacilli with numerous fine flagella. (After Tillmanns.)

oidium, monilia, mucor, aspergillus, and especially actinomyces—are at times important. Certain skin diseases, such as favus, pityriasis versicolor, tinea tonsurans, etc., are caused by growing fungi. The fungus of thrush, which attacks mucous surfaces, has been found in multiple abscesses (metastases) in the brain. Aspergillus is occasionally met with in the cornea and external auditory meatus. Mucor mycelia has also been observed in multiple abscess of the brain, lungs, and bowels. Yeast fungi (blastomycetes, Fig. 774) are rarely, if ever, of special interest, excepting in gastric fermentation, where they play an important rôle.

Of the various micro-organisms of pus, the staphylococcus pyogenes aureus is the most common, being the chief factor in suppuration in about eighty per cent of all cases. This organism measures 0.7 μ in diameter, is killed at the boiling point—100° C. (212° F.) [2]—and in laboratory experiments at 58° C. (136.4° F.), but will resist desiccation for ten days. It is aërobic and practically universal in

[1] Sternberg gives the thermal death point in streaming steam of the more important organisms as far as known as follows: S. p. aureus, 58° C. = 136.4° F.; citreus and albus, 62° C. = 143.6° F.; m. tetragonus, 58° C. = 136.4° F.; streptococcus pyogenes, 54° C. = 129.2° F.; s. lanceolatus, 56° C. = 132.8° F.; b. typhi, 56° C. = 132.8° F.; anthrax, 54° C. = 129.2° F.; malleus, 55° C. = 131° F.; diphtheria, 60° C. = 140° F.; gonococcus and hydrophobia, each 60° C. = 140° F.; tuberculosis, 70° C. = 158° F.; all spores, 100° C. = 212° F.

[2] A simple rule for the conversion of Centigrade to Fahrenheit, and *vice versa*: 212° F.—32 × 5 ÷ 9 = 100° C.; 100° C. × 9 ÷ 5 + 32 = 212° F.

Example:

212° F.	100° C.
32	9
180	5)900
5	180
9)900	32
100° C.	212° F.

distribution, being found in the soil, upon clothing and hands, especially beneath the nails, but rarely in the air.

The next in order of importance is the staphylococcus pyogenes (epidermidis) albus, which from the researches of Welch, of Johns Hopkins, is of considerable surgical importance. According to this careful investigator, it should be considered an almost constant inhabitant of the epidermis. It lives deep in the follicles of the skin, and is usually the cause of stitch abscess. This demonstrates the necessity of careful scrubbing of the integument in the operative field, and the dissolution of sebaceous matter by the use of ether poured upon the skin.

The staphylococcus citreus, fluorescens, cereus, flavus, and the micrococcus pyogenes tenuis, are unimportant varieties. The gonococcus will be separately considered in the article on Gonorrhœa.

The bacillus pyocyaneus gives the color to blue pus; the bacillus pyofluorescens is found in green pus, and consists of small rods with slightly rounded ends, two or more of which are linked together and possess active movement. It does not sporulate.

The bacillus ruber (Ferchmin) is found in red pus.

The bacillus fœtidus is a rare form, found in abscesses chiefly of the perirectal region.

The bacillus coli communis (3 μ in length and 0.6 μ in breadth) is of great surgical interest, since it is considered the chief agent in pus formation in all suppurative processes in the peritoneal cavity, hepatic abscess, suppurating gall bladder, and appendicitis. Welch has found it in pure cultures in fifteen different inflammatory conditions.

The streptococcus pyogenes and the streptococcus erysipelatis, so far as microscopical appearance is concerned, cannot be differentiated. The former appears in chains of from four to six cocci, or at times a dozen or more, linked together in a single chain. It is facultative anaërobic, non-motile, and, in common with all cocci, reproduces itself by fission. It possesses great vitality in living tissues. There is one clinical point of difference which is of interest between the streptococcus pyogenes and the staphylococcus pyogenes aureus. This latter organism is associated with acute circumscribed inflammatory processes, with rapid pus formation (circumscribed abscess), while the streptococcus tends to produce a spreading suppurative process or a diffuse phlegmon or abscess. The different behavior of the streptococcus of erysipelas will be considered in the chapter on Erysipelas.

The micrococcus tetragonus, discovered by Gaffky in 1881, in the pus of acute abscesses, is found in the sputum of tuberculous subjects as a rule, as well as in the saliva of a certain proportion of healthy individuals. It is 1 μ in its longest diameter, and while usually grouped in fours (as its name implies) and inclosed in a jellylike capsule, it is occasionally met with in groups of two and three. It is aërobic and under certain conditions will produce fatal septicæmia. Experiments on animals show at times wide dissemination of the organism throughout the body, while in others local points of inflammation have been found.

The micrococcus lanceolatus was discovered by Sternberg in 1880 in the buccal cavity and saliva of otherwise healthy individuals in about twenty per cent of all cases. It is constant in the brick-dust sputum of fibrinous pneumonia. It appears commonly in the form of a diplococcus, although it may be in chains of from four to six links. In shape it is not unlike the unstriped muscular cell, being fusiform, somewhat sharper at one end than the other. When they join together they adhere by their broader ends. Fresh preparations from the blood of animals and saliva, examined under the microscope, show, although not invariably, a capsule surrounding these linked organisms. When injected into the peritoneal cavity or veins of animals a rapidly fatal septicæmia is produced. It is considered the specific germ of lobar pneumonia, and has also been found and is believed to be a factor in producing cerebro-spinal meningitis, pleuritis, arthritis, otitis media, endocarditis, and pericarditis.

The typhoid bacillus (Fig. 775) has been found in pure cultures in the pus of osteomyelitis of the ribs, in acute otitis media, empyema, localized peritonitis, either during or as a sequela of typhoid fever. It is oval or fusiform in shape,

with stubby, rounded ends, and has projecting from its surface in all directions very fine hairlike flagella, with which it propels itself in active motion. Stained by Loeffler's method it looks not unlike a cotton seed with particles of the lint still adherent. In typhoid fever it is found in the blood, fæces, and urine, showing the wisdom of the thorough sterilization of these excreta. After death the bacillus is found widely disseminated and chiefly crowded in the spleen, liver, kidneys, and lymphatics connected with the intestinal canal. In animal experiments Saronelli observed that when the *normal resistance was impaired* by injecting certain other organisms—as the bacillus prodigiosus, proteus vulgaris, or bacterium coli commune—fatal typhoid lesions resulted in animals in which he could not obtain a reaction prior to the preliminary inoculations. Similar results were obtained by placing the animals where they were compelled to breathe foul air for from five to thirty days. This bacillus may be destroyed in the urine and fæces by adding five, or preferably ten, times the quantity of boiling water.

The micrococcus of tetanus, anthrax, malignant œdema, syphilis, tuberculosis, glanders, leprosy, and diphtheria will be considered separately with those diseases.

The fungus of thrush and the mucor mycelia have also been found in metastatic abscesses of the brain, lungs, and intestines, and are entitled to be considered as possibly pyogenic organisms.

Suppuration.—Pyogenic bacteria possess the property of dissolving or liquefying the tissues with which they come in contact, especially those in which nutrition is disturbed by injury. The embryonic cells of the inflammatory process yield rapidly to their destructive presence. The coagulated exudate of lymph and plasma or extravasated blood is liquefied into *pus serum*, and the leucocytes, some living but mostly dead, float in the serum thus made, and with other cells of the embryonic tissue not yet disintegrated form the *cellular* elements of pus. The connective tissues are also dissolved and appear in shreds mixed with the pus cells and serum. This collection of pus is called an *abscess*. When well defined and held in position by a limiting membrane or wall it is a *circumscribed* abscess, and when without a barrier it infiltrates the tissues, a *diffuse* abscess; a rapid and recent collection of pus is an *acute*, a collection of long standing and free from pyogenic organisms (tuberculous fluid) is called a *cold* abscess. The lining membrane or wall of a circumscribed abscess is a new formation of inflammatory origin, the inner surface of which is a granulation tissue studded with capillary loops, as in the embryonic tissue of a wound undergoing repair. It is in part a *pyogenic* membrane (Fig. 776), since it furnishes the dead and cast-off embryonic cells which float in the pus serum, while the leucocytes, the pus cells proper, wander in from the capillaries as well as from the extravascular spaces. The deeper layers of this wall of defense against further invasion by micro-organisms is composed of rank after rank of connective tissue and other fixed cells, active in the proliferation of a common embryonic tissue.



FIG. 776.—(After Agnew.)

A *chronic*, *subacute*, or *cold* abscess differs from the preceding in the slowness of its development and the absence of those symptoms of local and constitutional disturbance which characterize the acute formation of pus. It occurs, as a rule, in diseases of the bone and joints, and in individuals of low vitality (diminished resistance), and is most frequently seen in connection with *caries* of the spine (Pott's disease), in other forms of tuberculous ostitis, and in tuberculous lymphomata. Such abscesses are, as a rule, of tuberculous origin, and do not contain true pus. While in gross appearance the contents may resemble pus, the microscope shows that the normal elements of pus are not present. Under such conditions the danger of general infection from the bacillus of tuberculosis is small. The bacillus tuberculosis produces a subacute inflammatory process, which results in a rich granulation tissue, the base of which is composed of newly formed cells, the embryonic tissue of the inflammatory process, which hedges in the tuberculous focus and tends to prevent systemic invasion. The tendency of these products of

the tuberculous process is to undergo rapid degeneration, due in part to the toxic product of the bacillus (chemical action) as well as by anæmia, both local and systemic. As a result of this retrograde metamorphosis, caseation and liquefaction of caseous material occurs, the product being a white liquid of varying consistence, resembling but not being pus.

Under favorable conditions these collections of tuberculous fluid tend to absorption. In the majority of instances the wall of embryonic cells offer sufficient resistance to invasion of the tuberculous germs into the general system. The liquid is absorbed ultimately and carried away as a harmless product, and the remaining caseous matter undergoes granular metamorphosis and of itself ultimately disappears. Such pathological processes do not have symptoms in any way in common with abscesses proper, which are the seat of acute inflammation caused by pyogenic germs. Pain is not a marked symptom, since they can exist for months and are not suspected until the collection of this milky fluid is sufficient to attract attention by pressure upon the abdominal viscera, or protrusion due to its size.

It is a recognized fact that these tubercular foci can become infected with pyogenic micro-organisms without direct communication with the air. Certainly, if the medulla of bone can become infected without a direct or external communication, it is just as easy to infect a deep-seated tuberculous fluid when conditions for infection are favorable, the germs traveling through the blood and being deposited in a suitable pabulum.

The treatment of the two classes is clearly indicated. The simple tuberculous focus, under ordinary conditions, when located in the epiphyses of the long bones or in the vertebræ or in deep situations, may be left alone to undergo absorption, taking pains by careful nourishment and hygienic precautions to increase the normal resistance of the tissues and prevent general infection. On the other hand, when in the lymphatic glands or in superficial locations readily accessible, or when a tuberculous accumulation is the seat of a mixed infection, as determined by the ordinary symptoms of septic infection, local and general, then a careful aseptic invasion and removal or evacuation is indicated.

Pus.—Pus is a liquid or semiliquid of varying color, for, while usually yellowish white, it may possess a well-marked hue of red, blue, orange, or green. It consists of a fluid portion, *pus serum*; cellular elements, to be described as *pus cells*; various micro-organisms; at times red disks, crenated, and in various stages of disintegration; fat globules, fibrin, and shreds of necrotic tissue not yet liquefied, and crystals of cholesterin. There are also found in pus, paraglobulin, serum albumin, myosin, leucin, tyrosin, and potassium albuminate (Fig. 777).

Recent pus is usually alkaline in reaction, but when exposed to the air it becomes acid. Moreover, it may be without odor, but when accompanied by decomposition of necrotic tissue, from which gases are evolved, or when proceeding from an inflamed area contiguous to the alimentary canal, it is often extremely offensive.

Surgical (septic or bacterial) pus does not coagulate. Pus serum, although furnished from the vessels of the inflamed area, is prevented from coagulation by the liquefying action of *bacterial peptone*, a product of bacterial ferment and decomposition.

Pus cells are chiefly white blood-corpuscles, which by chemical attraction (chemiotaxis) have crowded into the inflamed area. Treated with dilute acetic acid, they seem to possess two or three nuclei, rarely a single nucleus.

The single nucleated cells, found in large numbers in pus and classed as pus corpuscles, are cast-off products of the new embryonic tissue, due to cell proliferation. In recent pus, and in a warm medium, some of the corpuscles are capable of amœboid movement. Their number varies from four hundred thousand to one million six hundred thousand in one cubic millimeter.

The poisonous products of bacteria, if separated from the micro-organism from which they are derived, produce suppuration or toxic symptoms similar to those produced by the bacteria, but the poisonous effect is only transient, since the parent bacteria is essential to maintain prolonged septic infection.

Certain sterilized chemical substances, as well as sterilized bacteria, will, when injected into the tissues, cause inflammation and a liquefaction of the exuded plasma and connective and embryonic tissues with which they come in contact, and produce a creamy liquid which very closely resembles *true surgical pus.* The

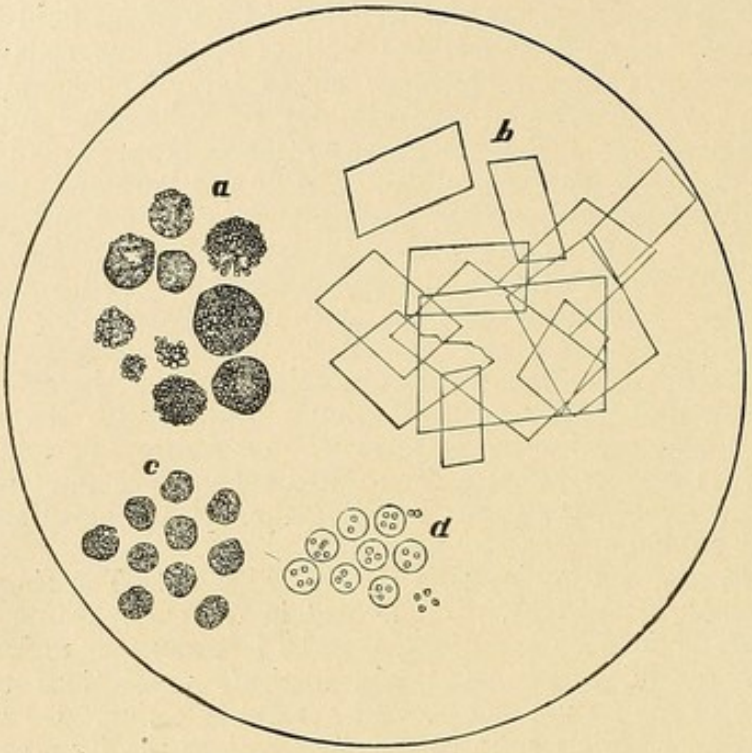

Fig. 777.—(Modified from Thomas.) *a*, compound granular corpuscles; *b*, crystals of cholesterin; *c*, pus cells; *d*, same after addition of acetic acid.

inflammatory process, however, is mild, and systemic infection does not occur. Surgical writers have termed this "laboratory pus."

Treatment.—In the treatment of inflammation the first great essential is rest, and this should be as complete as possible. If necessary to assure this, some form of fixation apparatus should be applied. In non-infective inflammation, as a rule, nothing further than this will be required to bring about absorption of the excess

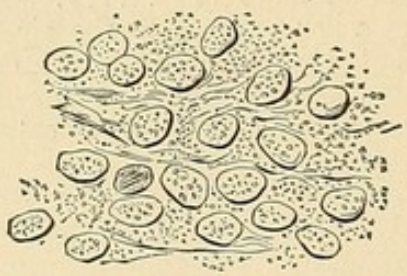

Fig. 778.—Pus from an acute abscess, showing pus cells, shreds of broken-down connective tissue and micrococci. (After Landerer.)



Fig. 779.—Bacilli of blue pus. (After Landerer.)

of embryonic tissue and coagulated exudates, and the repair or regeneration of the tissues which have been injured. As far as local applications are concerned, as a rule, patients prefer cold to heat. The neatest way to apply cold is by the rubber ice-bag, which can be laid directly upon the inflamed part, with a piece of lint or thin layer of cotton batting between the skin and the ice-bag. The cold-water coil (Fig. 780) is also very useful. In the absence of these preferable methods, benefit may be derived by applying towels dipped in cold water, partially squeezed out, and laid directly upon the inflamed surface. When one of the extremities is the seat of lesion, the painful throbbing, which is often a part of inflammation,

may in good part be relieved by elevation of the limb. For the upper extremity the Fluhrer swing (Fig. 781) is useful for this purpose, and adds to the patient's comfort. A very important feature in the treatment of all surgical lesions is a careful attention to the condition of the alimentary canal. It is of great impor-

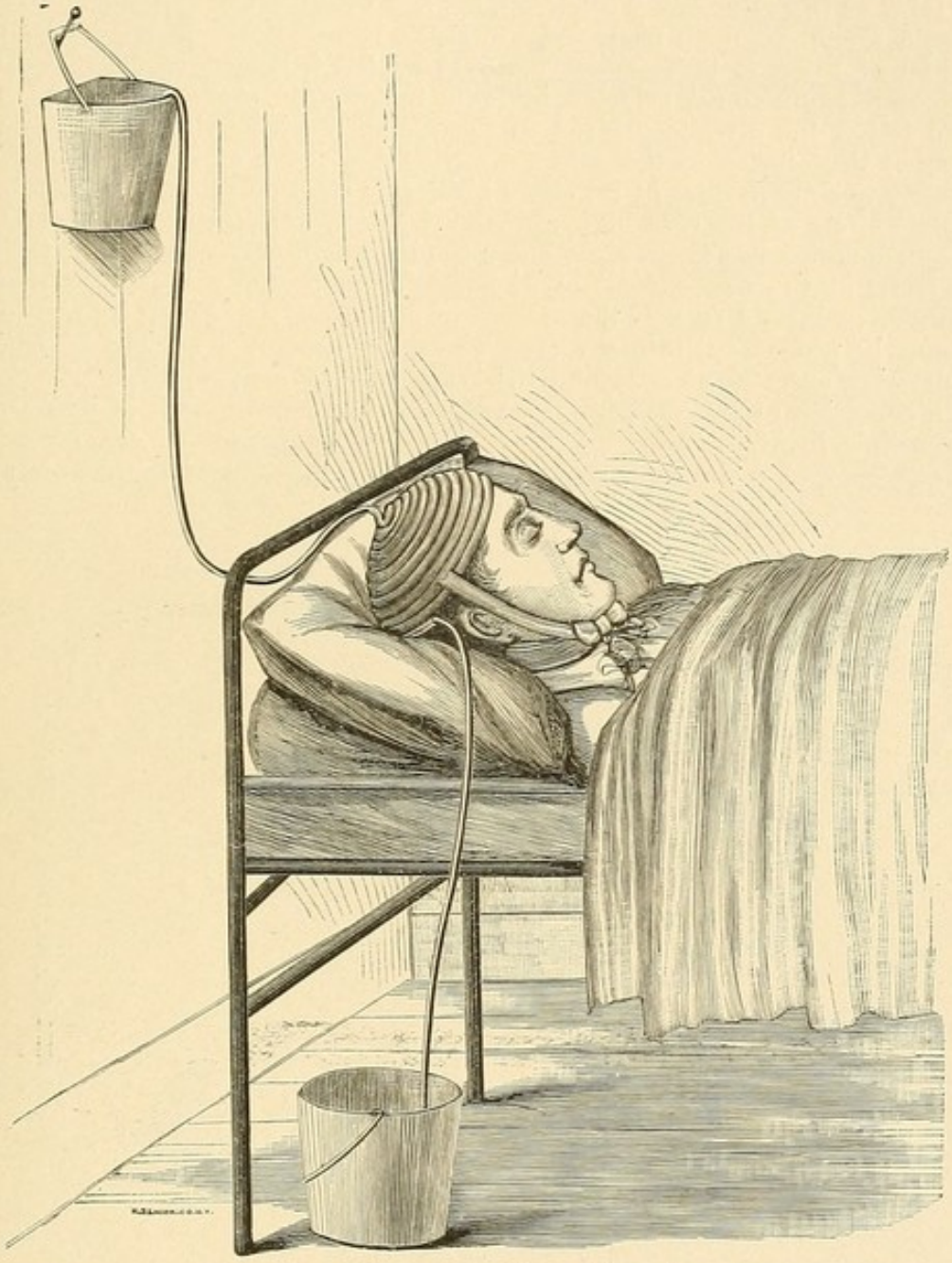

FIG. 780.—(Modified from Fischer.)

tance that the alimentary canal be carefully emptied, and kept empty to prevent intestinal toxæmia.

In *suppurative inflammation* more urgent measures are demanded. It is difficult to deal with any form of infective inflammation without the use of the knife, even in its early stages, and the sooner the knife is used in these cases, as a rule, the better. It is a surgical axiom that wherever infection has occurred and pus is forming, the sooner an incision is made the quicker will recovery follow and less danger ensue to the life and comfort of the patient and the usefulness of the part involved. The treatment of all abrasions or deeper wounds should be strictly antiseptic from the moment a wound comes under consideration. If the laity were thoroughly trained in the simplicity and safety of the sterilization of wounds, not one in a hundred of the serious accidents of infection would occur. Patients should

be instructed to keep on hand tablets of bichloride of mercury with directions for making a simple and safe solution in which any part of the body may be immersed or bathed; and, this being done, to dry the wound off with a clean towel that has been boiled, press the edges of the abrasion together, and cover the exposed surface with a layer or two of ordinary collodion, applied with a brush or poured on. When, however, a wound has been neglected and sepsis is established in the earlier stages, the next best thing is to cocainize the part by the injection of from one to ten minims of a two-per-cent solution into the integument about the wound, taking pains to follow the directions given in the use of cocaine in the chapter on local anæsthesia; then incise in the safest direction the focus of infection, and inject from thirty to sixty minims of a 1–3000 bichloride solution into the tissues, making a complete circle of the area of infection. When lymphangitis is established and septic inflammation has taken place along the lymphatic channels toward the center of the body, at the first indication of suppuration in the glands they should in like manner be incised so that the current of septic matter coming into them from below may be poured out into a wound where sterilization is secured by antiseptic moist dressing and infection beyond the lymphatic glands prevented.

In a condition of general cellulitis resulting from infection it is imperative to make multiple incisions, not only to relieve tension and prevent gangrene, but to give free escape to septic matter and to permit sterilization of the deeper portion

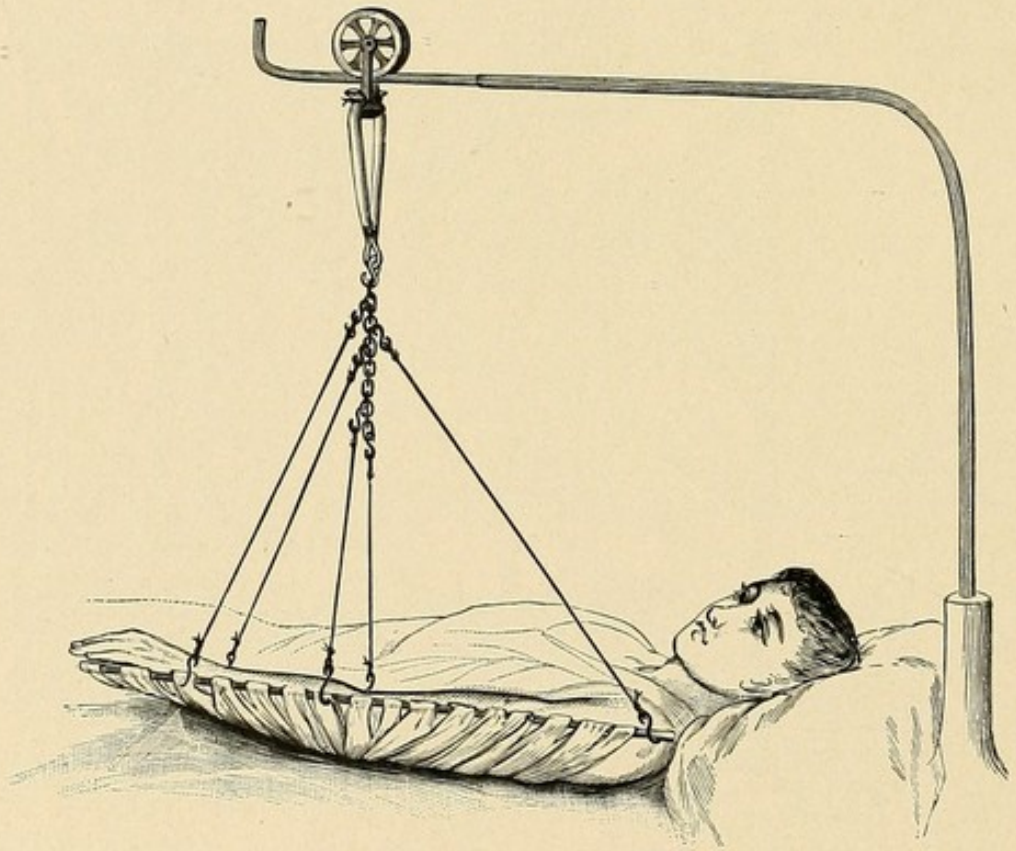

Fig. 781.—Fluhrer's swinging cradle (Mt. Sinai Hospital).

of the infected tissues and secure as thorough drainage as may be possible. On general surgical principles, all incisions should be made parallel with the axis of the body. Any variation from this practice should be made for the purpose of keeping away from any nerves or vessels which might run in another direction.

The recognition of an acute abscess will depend upon certain symptoms of a local as well as a constitutional character. The sudden rise of temperature, preceded by a chill or series of rigors, are symptoms of purulent infection. The local signs are those of inflammation—heat, pain, redness, and swelling. Fluctuation is also present in well-advanced cases. The integument and subcutaneous tissues about an abscess are often œdematous and doughy. The positive test is, however,

by *aspiration*. A hypodermic syringe (used only for this purpose) with a large-sized needle (Fig. 782) is invaluable. The needle should be held over a flame or boiled just before using. It is best to employ strict antiseptic precautions in aspiration as in other surgical procedures. A preliminary injection of one or two



FIG. 782.—Exploring-needle and syringe.

minims of two-per-cent cocaine solution with the finest needle will prevent pain. If incision is determined upon, the same anæsthetic may be employed.

In the neck or in any vascular region it is best to dissect carefully down to or near the abscess wall. In some cases it is safer to push a dressing forceps tightly closed through the tissues into the abscess, then separating the blades and stretching the opening, through which, after irrigating with 1–3000 bichloride solution, a drainage-tube is inserted.

The constitutional symptoms of septic infection should be combated by careful attention to the condition of the alimentary canal, as heretofore described, and the prompt and persistent effort by careful nourishment (and stimulation, if necessary), and by a bountiful supply of as pure air as can be obtained, to hold the tissues of the patient as nearly as possible in a condition of normal resistance. The survival of the patient depends upon the power of the tissues to resist destruction from the invading micro-organisms until, failing to find a suitable pabulum for their rapid proliferation, they perish. In suppurative cases, after incision a warm, moist dressing of weak bichloride or of plain sterilized gauze covered in with protective or oil silk to prevent evaporation, is often advisable. In exceptional instances an aseptic poultice, made by wetting flaxseed meal or any other substance in warm bichloride solution (1–5000), may be employed with benefit.

Septicæmia.—*Septicæmia* (σηπτικός putrid, αἷμα blood), or blood poisoning (with or without metastases), results from the entrance into the blood channels of either an infectious organism or the ptomaine or toxic product of such organism, or of gaseous emanations from the decomposition of diseased tissues of the body or of ingested material. The term *pyæmia* was formerly used to imply the entrance into the blood of the semisolid products of suppuration, while *septico-pyæmia* is now proposed by some writers to express a mixed condition of septicæmia and pyæmia. It seems to me, however, that an effort should be made to simplify the terms used in pathology, and that *septicæmia* would express a condition of blood poisoning in which metastases do not occur, while *septicæmia with metastases* would express all that is contained in the term "pyæmia." The term septico-pyæmia is entirely unnecessary.

Septicæmia, or blood poisoning, may be caused not only by the presence of bacteria in the tissues, but can also be produced by *ptomaines*,[1] or toxic products derived from these organisms entirely separated from the bacteria which produced them. When septic *bacteria* are present, the septicæmia is sudden, and may continue indefinitely, while the septicæmia resulting from the *toxic products* alone is temporary. Septic infection takes place in the vast majority of cases from an abrasion or wound of the skin or mucous membrane; bacteria, entering here, travel into the tissues, lymph spaces, and blood vessels, and in severe cases are rapidly disseminated by the blood. They attack by preference the white blood-corpuscles

[1] Various basic substances containing nitrogen and in chemical constitution resembling the vegetable alkaloids have been isolated by chemists from putrefying material and from cultures of bacteria concerned in putrefaction, as well as from certain pathogenic organisms. These products are called *ptomaines* (πτωμα, a corpse). In contra-distinction to the ptomaines are the *leucomaines* (λευκωμα, white of egg), which differ from the foregoing in that they are derived from tissue changes in the body independent of the presence of bacteria. Among the ptomaines are neuridin, cadaverin, putrescin, saprin, methylamine, dimethylamine, and trimethylamine. Also neurin, derived from decomposition of brain matter and putrefying muscular tissue; cholin, found in hogs' bile, in the yolk of eggs, etc.; muscarin, found in poisonous mushrooms and putrefying fish; peptotoxin, tyrotoxicon, typhotoxin, from cultures of typhoid bacillus; tetanin, from tetanus-bacillus cultures.

until these seem to be mere aggregations of bacteria. The red blood-corpuscles later become disintegrated, and after death the blood is dark in color and decomposes rapidly. Hæmorrhages occur in the gastro-intestinal tract and various organs; the spleen and liver are enlarged and softer than normal; the kidneys are seriously affected and seem, from the shoals of micro-organisms found in them, to be chiefly depended upon for the elimination of the bacteria. Septicæmia in severe cases is introduced by high and continuous fever, with, however, varying temperature, rapid pulse, great discomfort, and a feeling of prostration. In milder cases fever may be wanting. In some instances there are repeated chills, followed invariably by a rapid rise of temperature. From the point of infection the progress of invasion is marked by *lymphangitis* and at times by *phlebitis*, a condition favorable for the development of pyæmia and inflammation of the skin and subcutaneous connective tissue. The lymph glands between the wound of infection and the central organs become enlarged and break down in suppuration. When the cellulitis or phlegmon is extensive, gangrene may ensue on account of the tension of the parts involved and the interference with the circulation. The parts are swollen, and often extremely painful.

In the treatment of septicæmia it is of vital importance to regard all wounds as capable of conveying infection to the tissues; and if the principles of prophylaxis just given in the treatment of infective inflammation were carefully carried out, there would be no such thing as septic infection. When infection has taken place, and free incision been made, it is advisable, after making the incisions, to keep the hand or part involved submerged in a warm solution of bichloride of mercury (1 to 2000 to 3000) for at least half an hour after the incisions are made. Beyond this local treatment not much can be done except to support the patient in every way by careful nourishment and proper stimulation. When the lymphatic glands become engorged and are about to suppurate, they should be incised and treated as the original point of infection.

Septicæmia with Metastases.—In *septicæmia with metastases* (pyæmia) the symptoms just given as characteristic of simple septicæmia are exaggerated; the

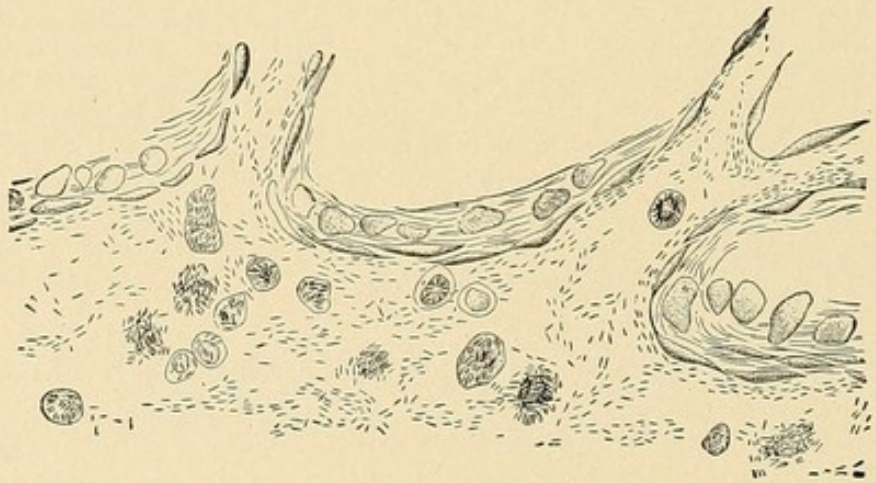

Fig. 783.—Bacilli of septicæmia in a vein of the diaphragm, taken from a septicæmic mouse. White blood-corpuscles, some containing bacilli and some changed into masses of bacilli. × 700. (After Koch.)

resistance of the tissues in the inflamed area seems lessened; the blood vessels are invaded by the bacteria (Fig. 783), and, as a result, clots or *thrombi* form upon the vessel walls, which, under the disintegrating action of the micrococcus of inflammation, break down, and thus purulent fragments are swept along the blood channels to the heart, from whence they are distributed through the lungs to the various organs of the body. They form *emboli*, or arrested clots, chiefly in the capillaries of the lungs, and each embolus may form a metastatic abscess. From here other thrombi are developed, and these are swept into the circulation and distributed by the left ventricle to the entire system. If the point of infection is in the area of the portal system the liver is apt to be the seat of metastatic abscesses.

In Mr. Thomas Bryant's analysis of two hundred and three cases at Guy's Hospital the lungs were involved in one hundred and eighty-seven, and in seventy-eight of these, infarctions occurred in no other organ. The fever in pyæmia is usually preceded by a chill, and this is apt to recur with more or less frequency during the disease. The febrile movement does not follow a regular course, but is generally intermittent. After a high temperature there is a sudden fall, often coincident with profuse and exhausting sweats. The thermometer not infrequently within a period of twelve hours will vary from 96° to 104° F. The condition of these patients is deplorable and the prognosis very grave. Recovery is extremely rare.

In addition to constitutional measures, all metastatic foci should be drained when possible.

CHAPTER XXXVI

THE SURGICAL DISEASES (*continued*).—ERYSIPELAS—DIPHTHERIA—TETANUS—HYDROPHOBIA—HOSPITAL GANGRENE—ACTINOMYCOSIS—ANTHRAX—GLANDERS—MALIGNANT ŒDEMA—FOOT AND MOUTH DISEASE—TUBERCULOSIS—LEPROSY

Erysipelas is an infectious inflammation of the skin and subcutaneous connective tissue, or of the mucous membrane and submucous tissue, involving especially the lymph channels which permeate the area involved. It is caused by a specific micro-organism (streptococcus erysipelatis) (Fehleisen) which effects an entrance through an abrasion of the skin or mucous membrane. It proliferates rapidly and spreads along the lymphatic channels (Fig. 784), which, becoming engorged, break down, permitting shoals of cocci to invade the intravascular spaces. They are here found within the protoplasm of the leucocytes (phagocytosis) (Fig. 785).

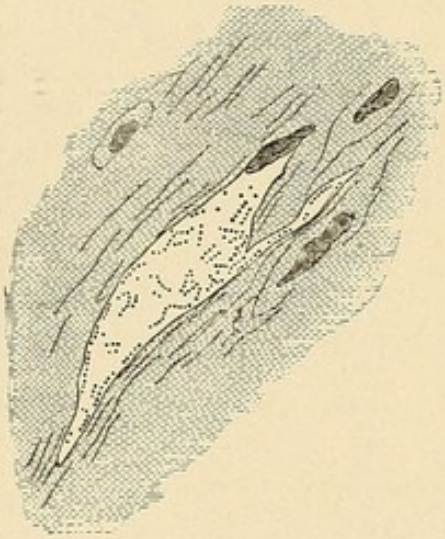

FIG. 784.—Streptococci of erysipelas. × 700. Section through a lymph vessel of the skin. (Flügge.)



FIG. 785.—Phagocytes (Metschnikoff). *a*, an anthrax bacillus about to enter a white blood-corpuscle; *b*, the anthrax bacillus within the white blood-corpuscle; *c*, white blood-corpuscle with anthrax bacilli which have become broken into pieces.

There seems to be a close relationship between erysipelas and puerperal fever. The organism found in this fever cannot, under the microscope, be differentiated from the streptococcus of Fehleisen. Senn claims that streptococci obtained from the puerperal uterus when injected into the skin cause erysipelas, and *vice versa*. While the coccus of erysipelas closely resembles the streptococcus pyogenes, experiments seem to demonstrate their essential difference. Injections of the pyogenic cocci produce a deep-seated, widespread inflammation with general infiltration, while the erysipelas cocci are chiefly found in the lumen of the lymph vessels.

In its incipiency the skin is in color a bright red, and presents a smooth and glazed appearance. The line of redness is usually sharply defined, not fading gradually into the normal skin as in simple dermatitis. The color is deeper in the center of infection, at times assuming a dark, mottled hue. There is marked increased local heat, with throbbing and sharp burning pain, with usually high temperatures, chills, or rigors.

In simple cutaneous erysipelas the symptoms are usually mild, and the tendency is to recovery in from four to six days. With a low resistance, and when the infection is virulent, *bullæ*, due to exudation of serum in the Malpighian layer, may appear, or, the subcutaneous connective tissues being involved, mixed infection with the formation of pus may result (phlegmonous erysipelas). In the

severer forms of infection, where the leucocytes are overwhelmed, gangrene may result (gangrenous erysipelas).

Diagnosis.—Erysipelas occurs more frequently upon the face, especially about the muco-cutaneous surfaces of the nose, where abrasions are frequent. It may be mistaken for dermatitis or simple erythema, phlebitis, lymphangitis, or cellulo-dermatitis. Dermatitis occurs, as a rule, from local irritation, and is not accompanied by any marked constitutional disturbance. While the skin is red, it does not present the glazed appearance which is typical of erysipelas, nor the sharply defined borders. In *erythema papulatum*, which usually attacks the exposed and extensor surfaces, as the dorsum of the hand and the posterior aspect of the forearm (almost always in children and adults), there is no focus of inoculation, and very slight infiltration of the skin. Moreover, the papules, commonly observed in erythema, are rarely found in erysipelas.

In phlebitis and lymphangitis the march of the infection is rapidly along the lines of these vessels. It does not spread in a circular area, as does erysipelas.

Diffuse cellulitis is caused by an infected wound, and is almost always accompanied by rapid pus formation.

Treatment.—The streptococcus of erysipelas is destroyed in 1–1000 mercuric-chloride solution. If the disease is recognized within the first few hours of infection, a hypodermic injection of the solution into the substance of the skin involved, and slightly beyond the area of redness, would retard, and might prevent, further invasion. If a one-per-cent cocaine solution were first injected, the sharp pain of the mercuric-chloride instillation would be lessened. This treatment could only be justified where the circle of injection would not require a sufficient quantity of the mercuric solution to endanger systemic poisoning.

Lattice-work incisions (Fig. 786), commencing one half inch from the margin of redness and completely surrounding the area of infection, tend to arrest the further spread of the disease. These incisions, made with a sharp scalpel, should not go deeper than about half-way through the skin. Cocaine instillation (one to one half of one per cent) should be employed to deaden sensation. It is advisable to cover these incisions with several layers of flexible collodion. Compresses, wet in 1–1000 sublimate solution, should be applied as an after-treatment. The bowels should be kept open, the patient carefully nourished. Ten to fifteen grains of quinia and tincture of chlorate of iron are recommended. Upon an extremity an elastic bandage, applied above and below the focus of infection, tight enough to constrict the superficial lymphatics and veins, will retard the spread of the disease and may, after the theory of Bier, produce localized leucocytosis with destruction of the special pathogenic organisms. Isolation and antisepsis are imperative. The hands of the attendant should be protected with rubber gloves, the body and clothing shielded with a gown moistened in 1–1000 bichloride solution. The head and face should also be protected when in attendance, and when this is not done, a careful washing with bichloride solution should be practiced.

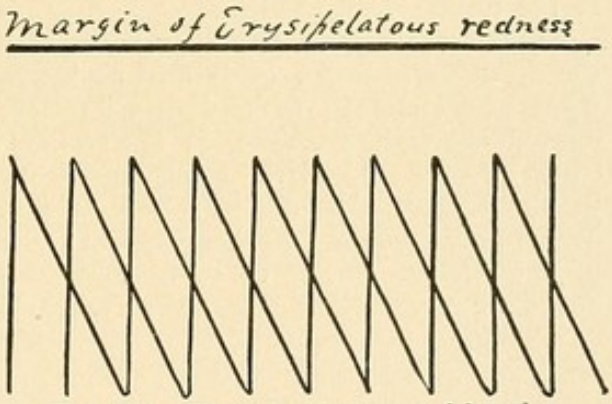

FIG. 786.—Zigzag incisions, actual length. (After Willy Meyer.)

A knowledge of the fatal character of puerperal fever resulting from streptococcus infection should forbid attendance upon an obstetric case by one in charge of an erysipelatous patient. All dressings should be burned or boiled, all instruments, bedding, clothes, etc., subjected to germ-destroying heat.

Diphtheria is an infectious disease caused by the Klebs-Loeffler bacillus diphtheriæ,[1] attacking usually the mucous membrane of the tonsils, pharynx, fauces,

[1] There is not infrequently found a pseudo-bacillus which infests the tonsils and contiguous mucous surfaces. It closely resembles the true diphtheritic germ. When discovered in cultures from a suspicious subject rigid antiseptic local treatment should be instituted.

larynx, and occasionally the nasopharynx. It may, however, effect a lodgment in an abrasion upon the skin or mucous membrane in any part of the body. This bacillus is slightly curved, with rounded ends, 2 to 3 μ in length, with a diameter of 0.8 μ. It is reproduced by fission, is aërobic and non-motile. It resists desiccation for weeks, and even when thoroughly dried will reproduce itself in a suitable medium. The toxic products of the bacillus diphtheriæ are readily absorbed by the blood, in severe cases impairing the function of the red blood corpuscles. This poison also affects the tissues in general, and especially disturbs the nutrition of the nerve cells, causing the frequent paralyses associated with diphtheritic sepsis. Mixed infection due to the passage into the blood of pyogenic cocci lodged on the area infected often occurs with diphtheria.

Symptoms.—The symptoms of diphtheria are local and constitutional. There is usually located on the tonsils a characteristic membrane spreading along the fauces, into the larynx, and upward in the nasopharynx. With the true diphtheritic exudate there is a peculiar odor and an irritating discharge, swelling of the nearest lymphatic glands (submaxillary, as a rule), and a tendency to bleeding where the membrane is becoming detached. It is closely adherent to and incorporated with the superficial epithelia of the mucous membrane. In non-diphtheritic exudates the membrane rests upon the epithelia, and is easily removed without the bleeding which follows the more virulent disease.

The diagnosis depends upon the presence of the specific bacillus as shown by cultures, together with the constitutional symptoms, the most positive feature of which is a profound prostration which is out of all proportion to the fever and the local manifestation. The pulse is usually rapid, the temperature is high, although in rapidly fatal cases it may be normal, and often subnormal. The kidneys are apt to be involved early in the disease. Albumin and casts appear in the urine within the first five days. There is occasionally an eruption of the skin, varying from a transient rash to dark-red spots or patches (maculæ).

A membranous inflammation located in the larynx is almost invariably true diphtheria (Holt). When, however, a laryngitis follows a pseudo-membranous inflammation of the tonsils, nose, and pharynx, occurring as a complication of measles or scarlet fever, it is more frequently due to a streptococcus infection than to the diphtheritic bacillus.

Treatment.—Serum therapy must be accorded the first place. That issued by the New York Board of Health or by Behring is preferable. It will keep from three to six months without deterioration. A slight turbidity and some floccular deposit are always present in the serum, but when it shows a milky turbidity or emits an odor suggestive of decomposition, it should not be used. It usually comes in phials containing 5 c.c., and is said not to be injured by freezing or extreme heat. It is best not to subject it to extremes of temperature, and it should be kept in a dark, moderately cool place. The injections should be made under careful antiseptic precautions. A glass syringe with a piece of rubber tubing attached,

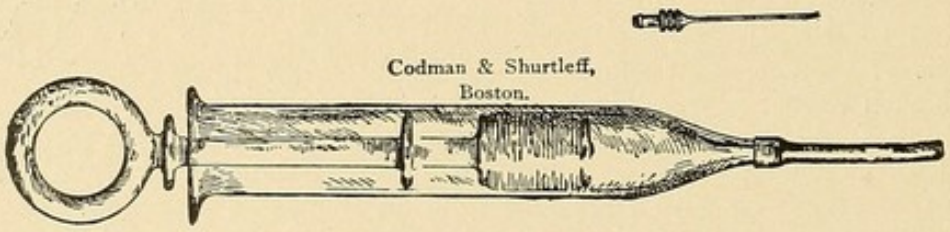

Fig. 787.—Syringe for serum injection.

and a good-sized needle, capable of carrying the serum into the tissues, makes a simple apparatus that can be thoroughly cleansed by boiling (Fig. 787). Professor Holt prefers to inject a small quantity of the concentrated serum. The dose is to be measured not by the amount of serum, but by the number of antitoxine units it contains. A child under two years of age should receive 1,000 units in a severe case and 600 in a mild case, repeating the dose in from eighteen to twenty-four hours if no improvement is seen, and again after a similar interval,

if necessary. A child over two years of age should have 1000 units in a mild case as an initial dose, a second one being rarely necessary, and from 1500 to 2000 units in a severe case, repeating the dose as above given. With a concentrated serum, 2.5 c.c. (38 minims) give 1000 antitoxine units. Formerly it required one third of an ounce of Behring's serum to obtain this number of units. The mortality ratio has been very greatly diminished by this treatment of diphtheria. The serum is essentially harmless, but to be of value it must be injected early, at least during the first three days, and earlier in a laryngeal case. Properly given, it neutralizes the toxæmia of diphtheria and controls the membranous formation due to this bacillus. It has no effect upon general septicæmia or streptococcus infection.

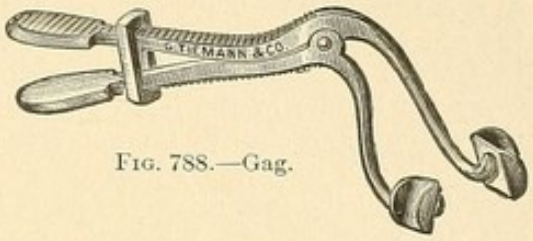

Fig. 788.—Gag.

In employing the antitoxine, heart stimulants are indicated whenever required by the condition of the pulse. Every child exposed to diphtheria should receive an immunizing dose of the serum, 100 to 300 units being given, according to the age of the child. This will usually afford protection for at least a month.

Local treatment is not advised for young and intractable patients. For others, nasal injections of warm salt solution (for cleanliness only) are to be recommended in nasal and nasopharyngeal cases.

Intubation.—In the surgical treatment of the tracheal or laryngeal stenosis of diphtheria, intubation has practically superseded the operation of tracheotomy.

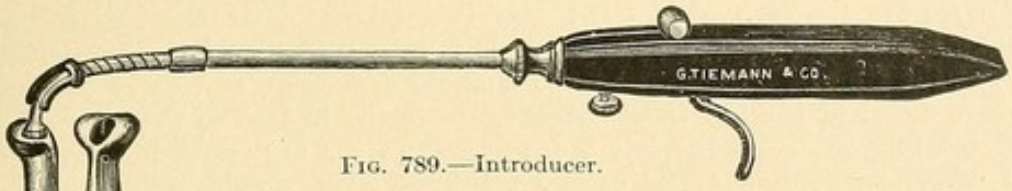

Fig. 789.—Introducer.


Tubes.

This innovation is due to the late Dr. Joseph O'Dwyer. It is indicated when there is progressive and persistent dyspnœa. It is performed as follows: The child should be covered from the chin down with a light blanket, the shoulders, arms, and hands included. The attendant holding the child should sit in a straight chair bolt upright, the child in her lap, and both facing the operator. The attendant grasps the child's elbows firmly, clasps its legs between the knees, securing the child in a firm grasp, immobilizing it without interfering with the expansion of the chest. The position of the child should be as though it were suspended from the top of its head. Another assistant stands behind the nurse and grasps the child's head between his hands in order to hold it firmly, and when the gag (Fig. 788) has been inserted includes it within his grasp to insure its steadiness. The operator, sitting squarely facing the child, inserts the gag, opens the mouth widely, and gives the handle to the assistant. With the introducer (Fig. 789), armed with the tube of proper size,[1] already threaded, the operator inserts the index-finger hooks up the epiglottis, crowds the finger to one side,



Fig. 790.
Scale.

[1] Dr. O'Dwyer's directions are as follows: The tubes are of various sizes, and are constructed on a scale (Fig. 790) somewhat like the urethral sounds. No. 1 is intended for a child eighteen months old, or less; No. 2, between eighteen months and three years; No. 3, for the fourth year; No. 4, for the fifth year, and so on.

When the proper tube is selected for the case to be operated on, a fine silk thread is passed through the small hole near its anterior angle, and left long enough to hang out of the mouth, its object being to remove the tube should it be found to have passed into the œsophagus instead of the larynx. The obturator is then screwed tightly to the introducing instrument, to prevent the possibility of its rotating while being inserted, and passed into the tube.

passes the tube beyond it until it engages in the chink of the glottis, elevates the handle, and gently presses the tube down till the head is within the box of the larynx and the introducer lies crowded upon the tongue. He then, with the trigger, loosens the obturator, holds the tube with the left index-finger while withdrawing the obturator, and with a gentle thrust presses the tube's head well into the larynx and removes the finger and gag. Always keep the introducer in the middle line, otherwise the obturator will pinch in the caliber of the tube and draw the tube with it as it is withdrawn. The handle of the introducer should be held most lightly between the end of the thumb and finger. In this way it is impossible to use enough force to make a false passage. It is easy for a right-handed operator inadvertently to carry his handle to the left of the child's middle line. Everything depends upon the coolness and skill of the operator and the absolute quiet of the child, who must be firmly and immovably held.

"Should the first attempt fail, it is better to make repeated short attempts than one prolonged effort. When the tube is properly lodged in the larynx, there will be some rattling on the first respiration and subsequent cough and expectoration. The cough argues well for the sensitiveness of the parts, and the gag may be removed as soon as the tube is in place, but the thread should remain until all obstruction to breathing has been overcome and the physician is assured that there is no partially detached false membrane in the trachea below the tube. An expert operator can remove the thread in the course of ten or twenty minutes, but since the removal of the tube requires a good deal of skill, it would be better ordinarily to leave the thread in for the purpose of removing the tube when the time comes. Children with teeth, however, are apt to chew the thread in two unless it is sunk down and buried between two teeth.

"To remove the tube when the thread is not left in, the child should be held in the same position as before; carry the left index-finger past the epiglottis, hook it up, rest the tip of the finger on the arytenoid cartilages, and carry the extractor point to the end of the left index-finger; elevate the handle so that the point will be directed forward from the left index-finger on the arytenoid into the aperture of the tube. The guard screw of the extractor lever should be carefully set to avoid injury to the tissues in case the extractor jaws should be opened by mistake

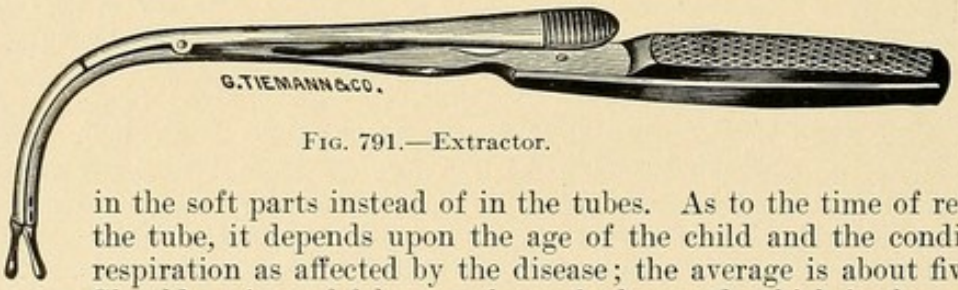

Fig. 791.—Extractor.

in the soft parts instead of in the tubes. As to the time of removing the tube, it depends upon the age of the child and the condition of respiration as affected by the disease; the average is about five days. Should a piece of false membrane be loosened, which is characterized by a croupy cough, rattling due to obstruction of outgoing air, and other symptoms of threatened asphyxia, the tube should be removed at once.

"Feeding a child after intubation is the great difficulty. When the effort of swallowing is accompanied by strangling, the child should be laid with the head lowered so that it swallows uphill, as any fluid which gets into the tube during the act of swallowing quickly runs out. The child should be fed either with a spoon or a nursing bottle."

Tetanus, or "lockjaw," is an infectious disease caused by the lodgment in a wound of the skin or mucous surface of a specific micro-organism known as the *tetanus bacillus* of Nicolier. It is one of the smallest bacilli and develops by sporulation. The spore or seed developing in one end causes this to swell, giving the rod a shape like a tack or drumstick (Fig. 792). Its habitat is the soil, decomposed fluids, manure, and in the purulent discharge of a person affected with this disease. The infection is most prevalent between May and October, and especially so in June, July, and August (Jacobson and Pease). It is slightly motile, and is classed among the obligate anaërobic organisms—that is, it cannot

live where it comes in contact with the oxygen of the atmosphere. It is difficult to destroy the spores, and pus containing them has been dried for sixteen months, yet produced lockjaw when introduced under the skin of animals. They are readily killed when exposed to a temperature of 100° C. (212° F.). The toxic product or ptomaine of the tetanus bacillus, separated from these organisms by germ-free filtration, will, when introduced into the blood of animals, produce typical tetanus, but, as with other toxic products, it is less apt to prove fatal, since the symptoms are only temporary, the bacillus itself being necessary to prolonged sepsis. The bacillus of Nicolier, so far, has not been found in the blood or in any of the central organs. It is evident, therefore, that it remains near the wound of infection, where it generates a violent poison, which is absorbed and produces rapid infection and the convulsions peculiar to this disease.



FIG. 792.—Tetanus bacilli with spores from an agar culture. × 1,000. (Kitasato.)

The time which may elapse between the receipt of the injury and the appearance of the muscular spasms varies from a few hours to several weeks; usually within the first three weeks after the injury. The earlier symptoms refer to an unusual degree of irritation and pain in the wound, which is apt to be out of proportion to the degree of inflammation present. The sense of pain is often referred along the sensory tracts toward the centers. Irritability, a sense of unusual muscular excitability, a feeling of malaise and apprehension, are among the symptoms which precede the convulsive attacks. The muscles supplied by the motor filaments of the fifth nerve are among the earliest to respond to this abnormal stimulus, hence the commonly accepted term of *lockjaw*. In the milder cases the tonic spasm may be altogether confined to these muscles. In severer cases the sense of distress is referred to the epigastric region, and this is followed by tonic muscular contraction, commencing with the diaphragm, and involving in quick succession the muscles of the jaws, larynx, and back of the neck and dorso-lumbar region. Respiration is interrupted, the expression of distress is extreme, the face becomes cyanotic, and death may occur from fixation of the respiratory muscles. The chief distortion is that of more or less complete extension of the spine (*opisthotonos*). When the tonic spasms are confined to the anterior muscles, and the body is bent forward, the condition is known as *emprosthotonos*, and if curved laterally, *pleurothotonos*. The spasm continues until the muscles are unable longer to contract, when a gradual and partial relaxation occurs. Successive attacks follow rapidly, being precipitated by the slightest cause, as the jar communicated by walking upon the floor, or the contact of the hair or clothing upon the hyperæsthetic integument. Occasionally the muscles near the infection are first seized with convulsions, as in the muscles of the calf when the foot is the seat of lesion.

Notwithstanding the violent nature of this affection, the mind, in the great majority of cases, remains clear until carbonic-acid poisoning occurs from prolonged fixation of the respiratory muscles. The pulse and temperature vary between great extremes, records of the former running from the normal up to 160 beats per minute, and of the latter from 98.5° to 112° F. The intense heat which is premonitory of a fatal termination, and which continues for a considerable while after death, is supposed to be due to coagulation of the albuminoid principle of muscle, the myosin (Fricke). Death may take place in a single paroxysm, or the patient may survive a number of attacks.

Prognosis.—The gravity of the prognosis usually depends upon the violence of the paroxysms, the rise in pulse and temperature being also proportional to the severity of the convulsions. The period which elapses between the receipt of the accident and the appearance of the tetanic spasms is not without importance in prognosis, the chances of recovery being increased with the longer interval.

Diagnosis.—Hysteria is more apt to be mistaken for tetanus than any other disease. In hysteria there is usually no elevation of temperature, and the symp-

toms of great and acute distress are wanting. Hysteria occurs chiefly in females; tetanus, in a large majority of cases, in the opposite sex. It may be necessary at times to differentiate between the tetanoid spasms of strychnia poisoning and true tetanus.

Strychnia tetanus ensues within a few minutes after the poison has been taken; the muscles of the jaw are not first affected as in tetanus, and are not always rigid during the attack. The convulsive movements in strychnia poison are of short duration, and complete relaxation occurs, while in tetanus the muscular rigidity is continuous.

Hydrophobia may be distinguished from tetanus in the character of the lesion which causes it, the peculiar clonic or interrupted spasm of the muscles, especially those of the larynx, and in the generally longer period of incubation in rabies.

The post-mortem changes are chiefly noticeable in the spinal cord where there occur extravasations of blood in the interstitial connective tissue of the cord and peripheral nerves and a granular infiltration of the nerve cells (Tillmanns). In the wound there is hyperæmia and swelling and usually great pain. Suppuration does not occur unless some pyogenic organism has produced in the wound a mixed infection.

Treatment.—The immediate immersion of a superficial wound in a solution of mercuric chloride, 1–500, within a few minutes of its receipt (especially if constriction has been applied) will destroy the tetanus bacillus as well as any other pathogenic micro-organisms. After a delay of fifteen or twenty minutes, or in a case of a deep wound or puncture, especially when earth or farmyard manure has been in contact, washing away of the dirt, the removal of all foreign matter, and thorough cauterization with fuming nitric acid, should be made as advised in hydrophobia. Cocaine infiltration should be employed to deaden sensibility.

The germs of lockjaw lodge immediately in the wounded area, where, under proper conditions, they proliferate and generate a toxine which is absorbed and carried into the tissues, producing the convulsions which are common to this disease. When there is a deep puncture, as from a nail thrust in the sole of the foot, this should be enlarged so that every portion of the wound may be subjected to thorough cauterization. If infection has been established before the wound is seen by the surgeon, several cauterizations may be necessary, the eschar from the first treatment being removed by the curette.

Within recent years treatment of this disease by the use of a tetanus antitoxine has been generally approved. According to R. T. Hewlett, tetanus antitoxine is obtainable in three forms, viz., (1) blood serum; (2) dry form, one gramme of which corresponds to ten cubic centimetres of the serum; (3) the serum may be precipitated with alcohol, and the precipitate dried (Tizzoni's antitoxine), which is the most concentrated form (Senn). The dose varies from five or six cubic centimetres to as high as one hundred and sixty-seven cubic centimetres. This quantity was given by Roux, and caused no general disturbance beyond producing urticaria. Such a large dose will rarely be required. Henle recommends from twenty to forty centimetres of the fluid serum for the first day, followed by ten to twenty cubic centimetres every six to twelve hours afterward. (One gramme of dry serum is equal to ten cubic centimetres of the fluid serum.) With Tizzoni's antitoxine the dose is two grammes to begin with, and 0.6 of a gramme in subsequent doses. It is administered by hypodermic injection with a syringe sufficiently large to necessitate only a single puncture. Antiseptic precautions should be taken in its administration. It should be given as soon as the disease is recognized. The quantity necessary will increase rapidly with the duration of the disease.

Antitetanic serum, which may now be readily obtained,[1] is administered by hypodermic injection in doses of ten cubic centimetres, repeated every six hours until improvement is manifest, and then at longer intervals until recovery is assured. Even in a wound such as that caused by the lodgment of a fragment of cartridge or shell, or any deep abrasion which has been in contact with foul

[1] Parke, Davis & Co.

earth, the prophylactic use of this remedy is advised, and at the same time the wound should be treated in the thorough manner already given.[1]

In seemingly hopeless cases the intraspinal injection of this serum may be entertained. Dr. W. H. Luckett has reported two cases in which this agent was employed and in which recovery ensued. Under careful asepsis the puncture was made between the third and fourth lumbar vertebræ. Twenty-two drops of cerebrospinal fluid were withdrawn and eight cubic centimetres of the serum injected. On the second day, twelve drops were withdrawn and eleven cubic centimetres of the antitoxine used. On the fourth day, forty drops were withdrawn and ten cubic centimetres injected. The injection should be made very slowly, consuming from five to ten minutes in emptying the syringe. In one case, Luckett withdrew, in all, one hundred and sixty-one drops of cerebrospinal fluid and injected in the course of the treatment a total of ninety-two cubic centimetres of antitetanic serum; in another, six hundred and five drops of fluid were drawn and fifty-nine cubic centimetres injected.

The general treatment is to keep the patient quiet, and by thoroughly emptying the alimentary canal to place the digestive apparatus in the best possible condition for absorbing nourishment.

The administration of chloral hydrate, from forty to seventy grains at a dose per rectum, has been recommended. The percentage of deaths among cases so treated, as given by Kane, was ninety-four out of one hundred and thirty-four. Tillmanns states that in ninety-three cases treated with chloral hydrate in combination with other remedies, there were thirty-three deaths. The patient should be placed in a dark room, the ears plugged with cotton in order to shut out all sound, and no one should be allowed to approach the bed except in the most careful and noiseless manner. The isolation should be as absolute as possible.

Dr. W. R. Bross, in a considerable experience in Central America, found the most efficient remedy to be tartar emetic, in doses of from one fourth to one sixth grain every two or three hours.

Dr. David St. John reports a number of cases of lockjaw (and also of cerebrospinal meningitis) successfully treated by this remedy.[2]

Dr. Joseph A. Blake ("Annals of Surgery," 1906) reports that magnesium sulphate modifies the convulsions and relieves the pain in a way no other drug has approached. It is injected into the areolar tissue, one cubic centimetre of a twenty-five-per-cent solution for every twenty-four pounds of body weight. An anæsthetic is required.

Hydrophobia is an infectious disease, acquired with the bite of a dog, wolf, cat, fox, or other animals in these groups. The specific organism belongs to the *protozoa*. In shape it is round or oval, varying in size, the largest measuring about twenty-five μ.[3] Under the microscope it appears to contain granules and is somewhat vacuolated. It is introduced with the puncture of the tooth, and ultimately finds a proliferating ground in the central nervous system, especially in the brain and in that particular portion of the cerebrum known as the hippocampus major (William Litterer). They are occasionally found in the substance of the spinal cord, in the spinal ganglia, and in the ganglion of Gasser, but nowhere with

[1] In the St. Louis City Dispensary, Dr. H. J. Scherck reports sixteen deaths out of fifty-six cases in 1903 when no antitetanic serum was used. In 1906, 170 cases were treated with the antitetanic serum with no deaths.

[2] "Transactions of the 140th Session of the Medical Society of New Jersey." The diagnosis of some of these interesting cases was confirmed by Dr. Carlos F. MacDonald and Dr. George F. Shrady. G. W., aged fifty-three years, had his finger crushed September 28, 1898; the wound became infected on October 10th, stiffness of the jaw developed and on the following day in the abdominal muscles and those of the right leg. By October 18th, the patient was much exhausted by frequent tetanic spasms, perspiration was profuse, thirst intense and respiration labored. Tartar emetic one quarter grain every two hours, with morphia was administered. On the following day the patient seemed somewhat less uncomfortable, and not so rigid. October 20th, pulse 118, temperature 100° F., catheterization necessary, several spasms during the day. October 21st under chloroform narcosis, the injured finger was amputated. October 23d the patient delirious, attempting to get out of bed and had severe convulsions with most marked opisthotonos. From this time he gradually improved under the continuous use of the tartar emetic and morphia and finally recovered.

[3] A micron (μ) is $\frac{1}{25000}$ of an inch.

such constancy as in the brain (Dr. Ira Van Gieson). According to Tillmanns, ninety per cent of cases in man result from the bite of the dog, four per cent from cats and wolves, two per cent from foxes.

The period of incubation varies from a few days to several weeks or months, occasionally longer. The earlier symptoms are a feeling of uneasiness and depression; in rare instances pain is felt in the scar of the wound, and this is followed by convulsive movements of the pharyngeal and respiratory muscles. The reflexes are all exaggerated. Convulsive seizures gradually increase in severity, and death follows from exhaustion due to inability to swallow as well as from the depressing action of the toxine.

Treatment.—The immediate indication is to neutralize the virus at the point of inoculation. In a superficial wound thorough cauterization within the first twenty-four hours will in all probability effect a cure. The proper remedy, according to Dr. D. W. Poor, is fuming nitric acid thoroughly applied to all parts of the wound by means of a capillary pipette, which is more satisfactory than the glass rod. As the application is intensely painful, preliminary subcutaneous infiltration with cocaine or quinia solution should be done. With a deep puncture of the tooth or an extensive tear, great care should be taken to have the acid find its way to the remotest portions of the laceration.

Dr. Poor advises the application of nitric acid even after twenty-four hours, adding that in cases where the Pasteur treatment cannot be applied, great benefit may be derived from the correct use of this agent.

When nitric acid is not obtainable, carbolic acid very thoroughly rubbed in, or the actual cautery, should be substituted. In view of the safety of this treatment, and in its assurance of immunization from the more remote and terrible consequences of hydrophobia, it would be a wise precaution to treat every case of dog bite by immediate cauterization with nitric acid.

The diagnosis can only be made positive by the examination of the brain of the animal which has inflicted the wound, and this should in all cases be done at once, so that the positive knowledge of the character of the lesion may be known and rigorous treatment instituted.

In 1903 Dr. A. Negri, of Italy, discovered certain bodies which he took to be protozoa and the specific organism of rabies. It is advised to make examinations from several portions of the brain, selecting first the hippocampus major, then other portions of the brain, and lastly the cord and ganglia, for it has been shown by Negri that when animals were inoculated in the sciatic nerve these bodies were with difficulty discernible in the hippocampus, but were abundant in the spinal cord and spinal ganglia (Litterer [1]).

The staining solution recommended by Dr. Ira Van Gieson and Dr. Williams [2] is Lœffler's methylene blue, two cubic centimetres; distilled water, ten cubic centimetres, and a saturated alcoholic solution of basic fuchsin, three minims. By this stain the protoplasm of the cell body is stained a light pink, the nuclei a light blue, the nucleoli a dark blue, the red blood cells a light yellow, while the Negri bodies stain a dark red. A well-stained specimen will show in these bodies a few very small dark-blue dots called chromatoid granules.[3]

In an emergency, where the diagnosis cannot be immediately assured by the destruction of the animal and by examination for these pathognomonic bodies, the wound should be treated as above directed. The animal should be killed and the brain preserved in fifty-per-cent alcohol, bottled, and shipped at once to the nearest laboratory.

[1] "Southern Practitioner," 1907.

[2] Dr. Van Gieson also recommends the following stain and method for the quick recognition of the Negri bodies: To ten cubic centimetres of distilled water, add two drops of a saturated alcoholic solution of rose anilin violet and two drops of saturated aqueous solution of methylene blue diluted one half with water. A portion of the suspected gray matter about the size of a bird shot is placed on one end of the slide covered with a cover-glass, gently squeezed out with the ball of the finger and the cover-glass shifted across the slide, making a smear. These squeeze smears are stained by pouring a few drops of staining solution over them, holding the cover-glass over the flame until the dye steams. They are next rinsed, dried in the air and are then ready for the microscope. "The Negri bodies take a distinctive deep crimson color with their chromatin particles blue."

[3] "Medical Record," August 11, 1907.

By experiments upon animals, Pasteur obtained an antitoxine of rabies which is now generally accepted in the therapy of this disease. By the use of this substance he was able to immunize healthy dogs from the bite of those known to be mad. This fluid of proper strength, which is injected subcutaneously, by preference in the abdominal wall, should be fresh and absolutely sterile. The injections should be mild in character for the first treatment, increasing the quantity gradually for three or four days.

Hospital gangrene has practically disappeared since the introduction of antiseptic surgery. Although it is believed to be due to a streptococcus infection, no special germ has yet been recognized. Among the wounded during the Civil War, and especially those long subjected to insufficient food and unhygienic surroundings, it created great havoc. The most successful treatment, as given by Prof. Frank H. Hamilton, who had a large experience in that period, was the destruction of the infected area with the actual cautery, or preferably by the free use of pure bromine.

Actinomycosis, a disease quite common in animals, is occasionally met with in man. It is caused by the presence of the ray fungus (Fig. 793). To the naked eye this is about the size and shape of a millet seed, yellowish-brown or greenish in color, soft in consistence. Under the microscope it consists of clusters of wavy, bushy shreds, or club-shaped projections. The most common seat of infection in man is the mouth. It may, however, be engrafted upon any abrasion of the skin. It is characterized by inflammation and swelling of a low and slowly developing type with the formation of serum and pus. The fungus is not a pyogenic organism, the pus being due to a mixed infection.

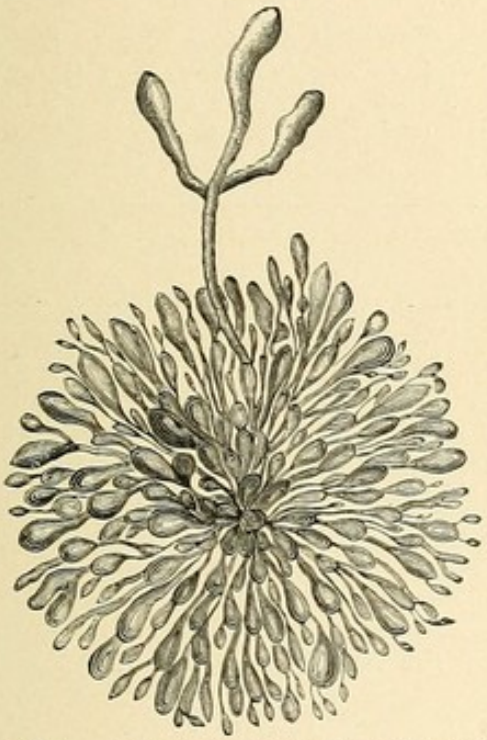

FIG. 793.—Actinomyces (ray fungus) with one branching filament separated from the others. (Ponfick.)



FIG. 794.—Blood from a mouse with anthrax, dried on the cover-glass and stained with methyl violet. Red blood-corpuscles and anthrax bacilli. × 700. (Koch.)

The diagnosis rests upon the recognition of the peculiar millet-seed particles found in the discharge. If not visible to the naked eye, the microscope will reveal its presence. The disease may attack the lungs through the respiratory tract, or find a focus of infection through the alimentary canal.

The indications in treatment are to destroy the focus of infection by the use of escharotics, such as nitrate of silver or mercuric-chloride solution. The iodine of potassium internally administered in large doses has proved curative in a number of cases, and should be faithfully tried before resorting to operation. Dr. A. D. Bevan advises sulphate of copper, gr. ¼–gr. j t. i. d. internally, while the sinuses are to be irrigated with one-per-cent solution of the same.

Anthrax ("milzbrand," "splenic fever," "charbon," "malignant pustule"), a disease of animals, is occasionally met with in man. It is caused by a specific germ, the bacillus of anthrax (Fig. 794). Infection in man is most frequently through an abrasion of the skin or the hair follicles, and occasionally through the respiratory tract. Those engaged in handling raw hides or caring for animals

are most frequently infected. The bite of flies has been known to convey this organism into the body. Incubation is from a few hours to as many days. As a rule, infection is rapid. When seen at the earliest stages the disease may be arrested by crucial incisions under cocaine anæsthesia and the injection of ten to fifteen minims of 1–1000 mercuric-chloride solution. In neglected cases the tissues become gangrenous, there is high fever, vomiting, and the usual symptoms of severe infection. The local application of a compress in ninety-per-cent alcohol is also recommended. In severe infection, Sclavo's serum, thirty to forty cubic centimetres injected hypodermically, has been successfully employed. In seemingly hopeless cases the intravenous injection of this remedy may be tried. It is claimed to be harmless even in very large doses.

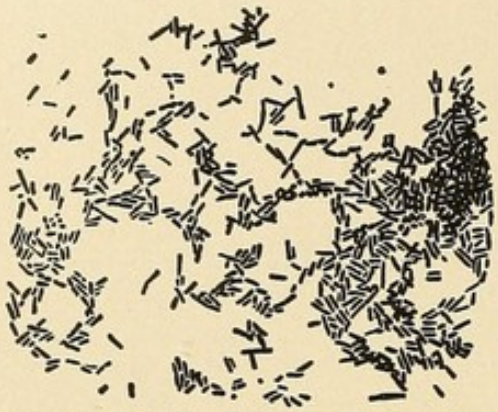

Fig. 795.—Bacillus of glanders. Pure cultures upon glycerin-agar, teased specimen stained with carbolic-fuchsin. × 100. (Frankel and Pfeiffer.)

Glanders (farcy) is a disease chiefly of horses, but it can be transmitted to man. It is caused by a specific non-motile rodlike bacillus (Fig. 795). Infection takes place through an abrasion of the skin or mucous membrane, and it is believed it may enter and effect a lodgment through the hair follicles. It not infrequently attacks the conjunctiva and the mucous membrane of the nose, although it is most frequently met with in the integument. The acute form is accompanied with all the symptoms of general sepsis. The lymph glands are enlarged and usual pyogenic infection is also present. Metastases in the spleen, liver and other organs may occur.

The diagnosis must depend upon the peculiar appearance of the nodes and the association of the person attacked with animals known to have the disease. In the treatment it is essential to destroy as early as possible the germs at the seat of infection. Free incision, the use of the Paquelin cautery, or the instillation of 1–1000 mercuric-chloride solution may be employed. Should the infection be upon the conjunctiva, this course cannot be followed. The parts may be bathed with strong bichloride solution, care being taken to wash out the excess.

Malignant Œdema.—The bacillus which causes this form of rapid gangrene resembles the anthrax bacillus. It is motile, anaërobic, and reproduces itself by sporulation, the spore being near the center of the organism (Fig. 796). Its

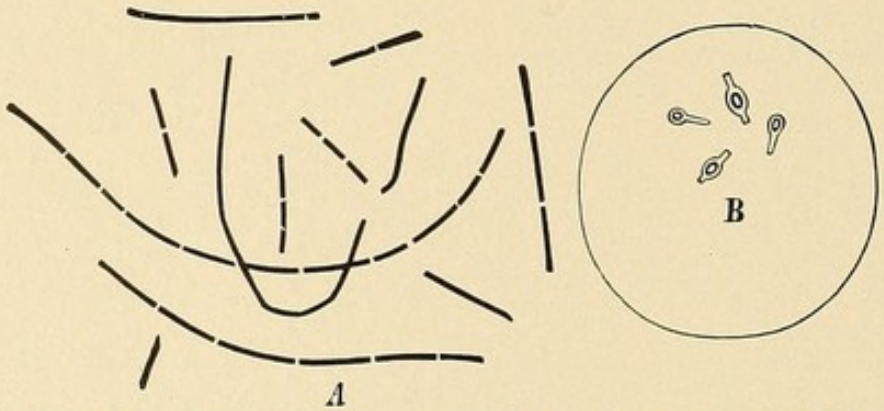

Fig. 796.—*A*, bacillus of malignant œdema. *B*, spore formation. (After Tillmanns.)

habitat is in fertile soil, foul water, and decomposing matter. It seems to possess the property of producing rapid decomposition of the tissues with which it comes in contact. The disease is rare in man. It is possible that the rapid gangrenous processes, of which many epidemics were reported in military hospitals (hospital gangrene), were due to the presence of this then unrecognized micro-organism.

Modern antisepsis has practically eliminated this disease from the category of surgical infections.

Foot and mouth disease, so named from the vesicular eruption found in the mouths or in the clefts between the hoofs in animals, is an acute infectious disease of rare occurrence, transmitted very occasionally to man from domestic animals, especially cows, sheep, and hogs. The symptoms as given by Tillmanns are stomatitis, gastro-enteritis with fever, and a vesicular eruption scattered over the body. As a rule, the disease is not fatal in adults, although children of low vitality succumb to it.

The treatment is chiefly local, and does not differ from that recommended in glanders.

Tuberculosis is an infectious inflammation of low grade, caused by the *bacillus tuberculosis* (Fig. 797). It is characterized by the formation of nodules (tubercles) which never suppurate unless there is a mixed infection with pyogenic bacteria. In surgical practice the lymphatic glands, bones, joints, skin, and mucous surface are the principal lesions. This specific organism was discovered by Robert Koch in 1882. It varies in length from 1.5 μ to 3.5 μ and 0.2 μ in breadth, and is slightly curvilinear in shape, with rounded ends. It is non-motile, does



FIG. 797.—Tubercle bacilli (lung). × 700. (Koch.)

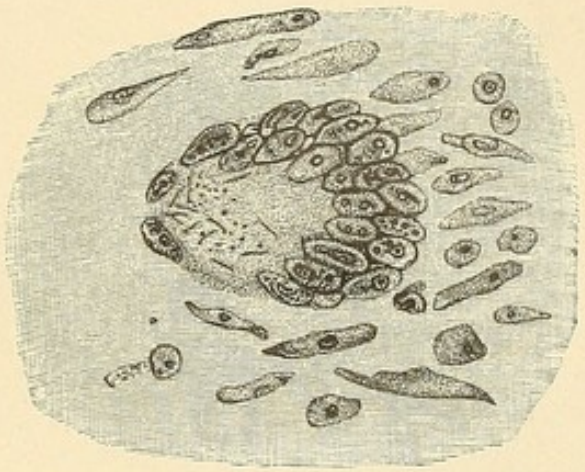

FIG. 798.—Giant cell with tubercle bacilli. × 700. (Koch.)

not form in chains, although it is frequently observed in pairs or bundles. It multiplies by sporulation, a single rod containing at times as many as six spores. It is aërobic, but can exist without oxygen. In the giant cells of the tuberculous process it is found in large numbers, usually in the periphery of these bodies (Fig. 798). In tubercular nodules or foci which have undergone cheesy degeneration the bacillus is rarely seen, but the caseous material found in the nodules is rich in spores capable of causing infection. This organism may be carried into the tissues through an abrasion of the skin or through the respiratory or alimentary tracts. The chief source of infection is the expectorated matter from individuals who are afflicted with pulmonary tuberculosis. It retains its vitality in the sputum which has been dried for three years. The dust about hotels and localities where consumptives congregate is rich in germs. Cow's milk is a source of infection of great importance, as this disease is exceedingly prevalent in cattle. The bacillus is found not only in the milk of cows whose udders are diseased, but in those affected with general tuberculosis with seemingly healthy milk-bags. The germs from unsterilized milk frequently enter the system through abrasions in the buccal cavity. From the mouth, pharynx, and tonsils they find their way into the lymphatic channels, and soon produce enlargements in the glands beneath the jaw and in the neck (scrofula). The vitality of the bacillus of tuberculosis is not impaired by the action of the gastric juice, nor even of the toxic products of decomposition.

In the tissues it produces a circumscribed inflammation of mild type. The fixed cells in contact with the invading organisms undergo proliferation, and thus are formed the nodules or tubercles. At the center of these nodules the bacilli first perish, while at the periphery their proliferation continues, and they advance with the process of inflammation toward the surrounding tissues. Examination under the microscope shows the nodule to be composed of leucocytes, "epithelioid," and large "giant" cells all held together in a nodular mass by a delicate reticulum. The aggregation of leucocytes which wander through the vascular walls to the intravascular spaces form the so-called "lymphoid" cells of the tubercular process.

In certain instances the connective-tissue proliferation predominates, forming a *fibrous* tuberculous nodule, which is grayer or more pearl-like in appearance and has no well-marked reticulum.

The hyaline nodule is also occasionally observed, the reticulum having undergone a waxy degeneration.

Tubercular nodules are prone to undergo cascation, the process beginning in the center and gradually involving the entire tuberculous area. This cheesy matter is composed of the débris of all the cells that have undergone destructive metamorphosis. Occasionally the investing (connective-tissue) capsule is found to have undergone a calcareous change in the effort to confine the infectious spores.

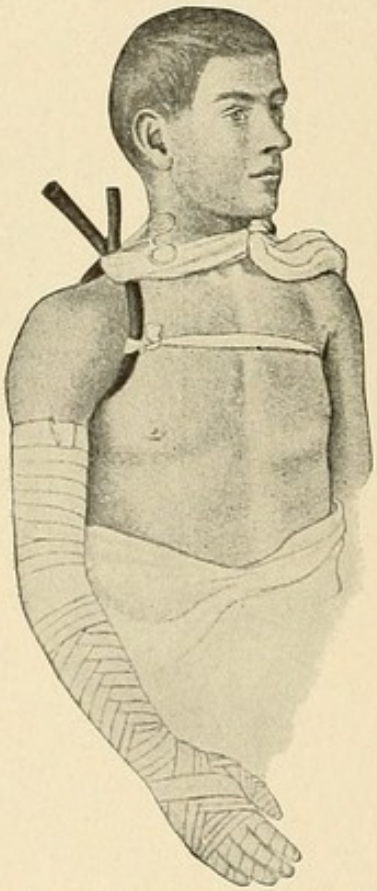

FIG. 798*a*.—Bier's method for the shoulder-joint. ("Journal American Medical Association," August 17, 1907.)

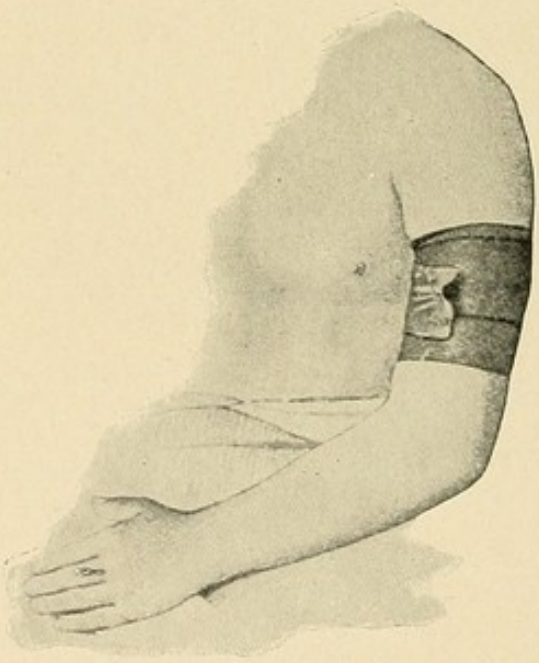

FIG. 798*b*.—The same for the elbow. The Esmarch bandage has not yet been applied below the joint. ("Journal American Medical Association," August 17, 1907.)

The early removal by operation of all infected lymphatic glands is imperative, and is easily accomplished and practically free from danger if done before a mixed infection has caused an agglutination of the infected glands to the surrounding tissues.

Prof. A. Bier, of Berlin (*Journal American Medical Association*, August 17, 1907) has demonstrated that the partial stagnation of the blood current in any part of the body affected by an inflammatory process will result in the gradual disappearance of the symptoms of infection, with complete recovery in a certain proportion of cases. Thus, in tuberculous osteo-arthritis at the shoulder, Esmarch's or Martin's elastic bandage is applied from the finger-tips to about the deltoid insertion. This should not be tight enough to arrest the radial pulsation. A piece

of rubber tubing is next applied at the axilla and over the collar bone behind the acromion process, where it is drawn sufficiently tight to retard but not completely arrest the return circulation in the veins in the area of inflammation. The arrangement for holding this constricting tube in place is shown in Fig. 798*a*. While maintaining the venous engorgement of the tissues between the two bandages, the pressure should be so adjusted as not to cause marked discomfort. It may be slight at first and gradually increased until the proper degree of "stagnant hyperæmia" is secured. The parts beyond the tourniquet should never be permitted to become cold or clammy. The bandage should remain in position from three to four hours. It may at times be worn without marked discomfort for as much as eleven continuous hours. After removal the part which has been subjected to compression by the Esmarch bandage should be thoroughly massaged in order to guard against pressure atrophy (Willy Meyer). The treatment may be continued for six months or a year, or longer if necessary. The method of applying the Esmarch bandage as a constrictor in lesions at the elbow-joint or below this is shown in Fig. 798*b*. The method is also highly recommended in inflammatory processes other than those of tuberculous origin.

The other forms of tuberculosis which come within the domain of surgery will be considered in the chapters which treat of the different regions of the body involved.

Leprosy, a disease caused by the bacillus lepræ, discovered by Hansen in 1879, is exceedingly rare in the United States. It belongs to the domain of dermatology rather than of surgery.

NOTE.—A consideration of the bacillus of typhoid fever does not come within the domain of surgical pathology, but deserves mention from the fact that it has been met with in abscesses, which, however, were probably due to mixed infection during the process of typhoid fever. The thermal death point of this organism is 56° C. (138.8° F.) in streaming steam.

DISINFECTION OF EXCRETA.—Under certain conditions, the surgeon may be called upon to advise in the disposition of infectious excreta: the discharges of dysentery, tuberculosis, diphtheria, yellow fever, scarlet fever, typhus and typhoid patients; the vomited matter in cholera, diphtheria, yellow fever, scarlet fever; the sputum in tuberculosis, diphtheria, scarlet fever, and pneumonia; and the urine of all patients with infectious diseases. The most efficacious method is by burning, and if this cannot be done, the next best thing to be done is to pour boiling water, in quantity five or ten times greater, upon the material to be disinfected. Chloride of lime of the best quality (which should yield twenty-five per cent of available chlorine and which costs about one cent a gallon) is an excellent disinfectant. Distilled or pure water (six ounces to one gallon of water makes a proper solution). One quart is necessary to disinfect each rectal discharge. Expectorated matter should be discharged into a vessel filled with this solution.

CHAPTER XXXVII

THE VENEREAL DISEASES: URETHRITIS—SYPHILIS

Urethritis—inflammation of the urethra—may be specific and non-specific. Specific urethritis (gonorrhœa) is a violently contagious disease affecting primarily the urethra in the male and the urethra and vagina in the female. It occasionally involves the rectum. From these points of initial infection the active organisms, reënforced by other pyogenic bacteria may invade the glandular apparatus connected with the prostate, vesiculæ seminales, vasa deferentia, testicles, bladder, ureters, and pelves of the kidneys. In the female, it may spread to the glandular apparatus of the vulva, the cervix, uterus, the Fallopian tubes, and peritonæum. It may be also conveyed to other mucous membranes. Upon the conjunctiva it establishes a rapidly destructive inflammation, occasionally spreading along the lachrymal canal into the nose and mouth.

The germs of specific urethritis have been found in peri-urethral abscesses, the pus of suppurating buboes, and in lesions of the joints (gonorrhœal rheumatism).

Gonorrhœa is one of the gravest diseases which afflict the human family. When it invades the deep urethra in men or the cervix and uterus, it is in very many instances incurable. It may lie dormant for months or years, springing up seemingly without cause and carrying with its recurrence the power of infection. The blindness of the new-born and fully eighty per cent of the operations done upon women for inflammatory lesions of the pelvic organs are due to this malady, while in men, its effects, immediate and remote, are equally disastrous. Such is the insidiousness and so terrible are the consequences of this infection that no one who has had gonorrhœa should consent to the sexual relation without the verdict of an expert that after a most careful test gonococci are no longer present.

The germ of urethritis (gonococcus) was discovered by Neisser in 1879. It is from 0.8 μ to 1.6 μ (a micromillimetre is $\frac{1}{25000}$ of an inch) in length and 0.6 μ to 0.8 μ in width. When single it is kidney- or bean-shaped, but it appears

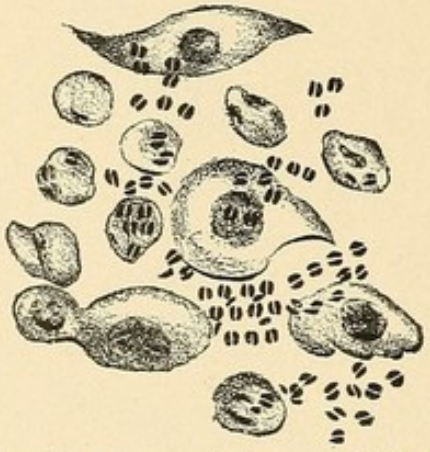

FIG. 799.—Pure gonococci, free and within the pus and epithelial cells.

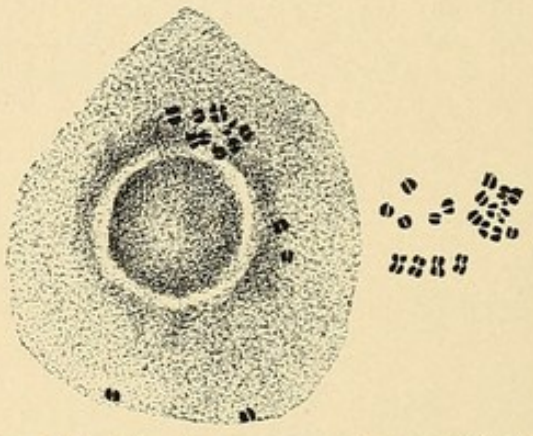

FIG. 800.—Pseudo-gonococcus in an epithelial cell and free.

almost always as a diplococcus, two of the bean-shaped bodies adhering with their concave surfaces toward each other (Fig. 799). Gonococci are found free in gonorrhœal pus and in large numbers within the pus corpuscles, never within the nucleus of the cell. They are also found in the epithelial cells of the urethral discharge.

In the urethra there are also found: (1) the smegma bacillus, which requires careful study to differentiate it from the bacillus tuberculosis; (2) pseudo-gonococcus, found at times in the cast-off epithelia and also within the pus corpuscles of a non-specific inflammation (Fig. 800); (3) the staphylococcus pyogenes aureus; and (4) the streptococcus pyogenes (Figs. 801–802).

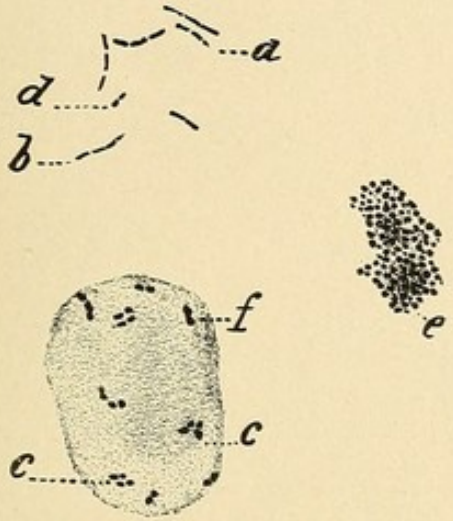

FIG. 801.—*a*, *b*, *d*, Smegma bacilli, which may be mistaken for tubercle bacilli; *e*, *f*, diplococci in small hyaline cell—pseudo-gonococcus; *c*, staphylococcus pyogenes aureus.

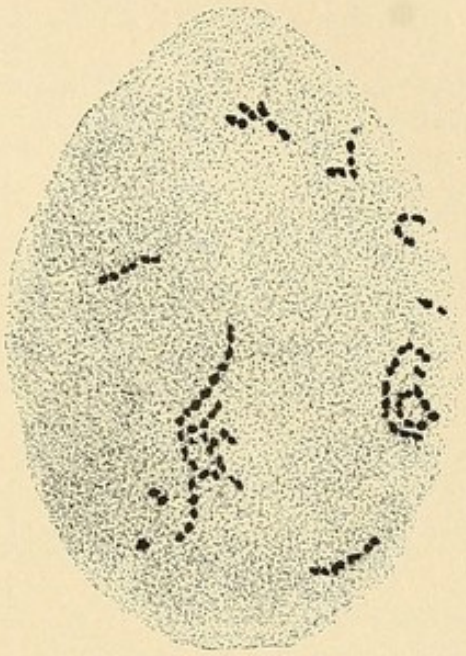

FIG. 802.—Streptococcus pyogenes in large hyaline epithelium of urethra.

Several species of diplococci so closely resemble Neisser's gonococcus in shape and in staining qualities that in making a diagnosis of specific urethritis it is necessary not only to recognize the shoals of diplococci crowding the pus corpuscles, epithelial cells, and floating free in the discharge, but to associate these with the general and grosser symptoms of *true* gonorrhœa.

A simple and rapid method of demonstrating the gonococcus of Neisser is as follows: Place a small drop of the discharge upon a cover-glass and smear by rubbing two cover-glasses together; dry it by passing one of the cover-glasses with pus side upward through a spirit flame two or three times; immerse this at once in a solution of methyl blue; wash off the excess of coloring matter by holding it under clear running water or by dipping the glass several times into clear water; dry the stained pus well by pressing with blotting paper; then cover it with a small drop of cedar oil; put on a thin cover-glass and examine with a lens magnifying from 700 to 1000 diameters. The peculiar double bean-shaped arrangement of the diplococci will be seen within the protoplasm of the pus corpuscle and epithelium.[1]

When the discharge is scanty it may be obtained on a film of cotton wrapped about a probe and introduced into the urethra. When the microscope is not

[1] Gram's method, which may be used in doubtful cases, is more complicated. To fresh aniline water (aniline oil shaken well with water and filtered through moistened filter paper) a concentrated alcoholic solution of gentian violet is added, drop by drop, up to the point of saturation—i. e., until the liquid loses its transparency. The cover-glass prepared as above is allowed to float on this solution for ten minutes. It is then washed with water, and placed for five minutes in a solution of iodine (one part), iodide of potassium (two parts), distilled water (three hundred parts), and from there put in absolute alcohol, where it remains until no more color is extracted. After a renewed washing, the preparation is subjected for half a minute to a second process of staining in a weak (light-brown) watery solution of Bismarck brown or vesuvine, washed again with water, and examined as before in water or Canada balsam. If a preparation treated in this manner shows blue diplococci, it is sure that they are not gonococci; but in case of brown diplococci, no absolute certainty is reached. For the bacterioscopic examination of gonorrhœal or urethral discharges a good microscope with Abbe's condenser and highly magnifying lens is needed. Dry objective lenses are not to be recommended except Zeiss' new apochromatic system, while a one-twelfth-inch homogeneous immersion lens and an ocular No. 2 and No. 3 will answer the purpose very well. (Lustgarten.)

employed the diagnosis will be emphasized by the history of exposure, the time elapsing between contact and the appearance of the discharge, the peculiar, irritating character of the discharge, and the progressive increase of the same during the first five or six days.

Symptoms.—When the virus is brought in contact with the mucous surface of the urethra, the period of time which elapses before local symptoms of inflammation appear varies greatly in different individuals, and even in the same individual in different inoculations. It is very probable that the condition of the mucous membrane at the time of contact, as well as the variations in the normal resistance of the patient's tissues, have a great deal to do with the rapid progress of the inflammation, and it may be that the virus in some instances is more intensely infective than in others. Thus the period of incubation varies from a few hours to several days, and in very rare instances as much as two weeks have elapsed between the contact and the recognition of the inflammatory process. The limit, however, between twenty-four hours and three days will include the large majority of cases of specific urethritis. Usually the earliest symptom is a burning sensation at the meatus, which is more severe as the urine is escaping. The lips of the meatus soon become swollen, usually everted, prominent, and red. When carefully separated, a thin film of muco-pus will be seen coating the mucous membrane. The *first stage* of the disease may be considered as beginning at the moment of contact, and ending with the first appearance of suppuration. The average duration is from two to ten days. From this period, *in neglected cases*, the inflammatory symptoms increase for from four days to as much as two weeks. The quantity of pus discharged varies from a few drops to several drams in the twenty-four hours. It is increased by exercise, by unnecessary exposure to cold and wet, the use of alcoholic stimulants, any form of dissipation, and improper diet. The color of the discharge varies from the bluish-white hue of the first few drops to the yellow and yellowish-green tinge of that discharged during the height of the inflammatory process. In some instances it becomes stained with blood as a result of rupture of the capillaries in the engorged mucous membrane.

The *second stage*, that of increasing inflammation and suppuration (in cases not treated), lasts about twelve days. It is followed by the *third stage*, that of decreasing inflammation, the duration of which is from three to six weeks. In addition to the purulent discharge and the pain which characterizes the second stage of the disease, there is a diminution in the size of the stream of urine, due to the swollen and puffy condition of the mucous membrane of the urethra. In the milder forms of gonorrhœa there are no other symptoms present in the second stage. In many neglected cases, however, the inflammatory process extends into the membranous and prostatic urethra, thence along the seminal ducts, oftentimes into the bladder, epididymis, and testicle, producing serious consequences. In the female it may produce endometritis and salpingitis, resulting either from infection of the specific germ or from a mixed infection with other pyogenic organisms, which find their way into the Fallopian tubes, causing abscesses, producing sterility in the vast majority of cases, and ultimately leading to the necessity of surgical interference. In males, infiltration of the vascular erectile tissue of the corpus spongiosum occurs in a varied degree, and occasionally the exudation extends into the corpora cavernosa. A more frequent complication of gonorrhœa is inflammation of the glans penis (balanitis) and of the prepuce (posthitis), due not only to mechanical irritation of the part, but to direct infection. As a result of such extensive inflammation, the penis is liable to various deformities, painful in an extreme degree, and not without danger to its integrity. *Chordee*, or bowing of the organ, is a common symptom. It becomes in part or wholly erect, and, on account of the infiltration of the vascular spaces of the spongiosum with the embryonic inflammatory tissue, it fails to expand with the corpora cavernosa.

Pathology.—Strictly speaking, the morbid process is an inflammation of the mucous membrane of the urethra and the submucous connective tissue with or without extension to other organs. It commences at the meatus and travels backward. The epithelium is swollen, there is marked hyperæmia of the submucous tissue, with the escape of leucocytes, the production of pus, and the formation of

the common embryonic tissue of inflammation. In milder cases the products of inflammation undergo retrogressive changes and are absorbed, while in other instances connective-tissue development is precipitated, ending in cicatrization and the formation of *stricture*. The organic elements of gonorrhœal pus are leucocytes, embryonic cells, epithelia, and blood corpuscles.

In a certain proportion of cases the virus of gonorrhœa becomes absorbed and metastasis occurs in the *joints*, producing also *endocarditis* at times, the gonococcus being found in these secondary lesions as in other metastatic abscesses.

Treatment.—It is essential to begin treatment at the earliest possible moment, and it is a wise precaution to consider every case as specific or virulent until its character can be determined. Although difficult to achieve, the first aim is to prevent the gonococcus from reaching the deep urethra. In rare instances it may be possible to accomplish this by Lyon's method,[1] especially when only a few hours have elapsed from the date of contact.

After the patient has urinated for the purpose of cleansing the canal, and is in the recumbent posture, the operator injects into the meatus with an ordinary funnel-pointed rubber syringe one dram of a four-per-cent solution of nitrate of silver. This is held in the urethra for from two to three minutes by the watch. There is little pain at the time and not a severe smarting on urination during the next twenty-four hours, at which time the treatment is repeated, provided that on careful examination of the discharge gonococci are found; if not, no further treatment is necessary. A two-per-cent solution should be used for the second injection, and for a third if gonococci are still present.

In these acute specific cases, especially in a first attack, Prof. Charles H. Chetwood recommends an injection of a ten-per-cent argyrol solution which fills the urethra, with moderate distention, and is held in contact with the mucous membrane for ten minutes by closure of the anterior urethra. This is used three times daily for from one week to ten days. When, under the influence of this agent, the acute symptoms subside, irrigation with $\frac{1}{4000}$ permanganate of potash for ten minutes, two or three times a day, is substituted. The irrigator should have an elevation as high as the head of the patient standing.

A double, short glass pipette, to which is attached an inlet and outlet rubber tube, is introduced into the first half inch of the urethra. Digital pressure is now made over the membranous portion in order to guard against deeper infection. As the solution fills the urethra and is running out, frequently interrupted closure of the outlet tube should be made in order to distend the urethra.

In non-specific or mild urethritis the argyrol solution is not employed, permanganate of potash being used from the commencement of the attack.

Irrigation with the potash solution by means of a single soft-rubber catheter with a free opening at the lower end, which is carried down as far as the deep urethra, may be substituted. A continuous flow from behind, forward, can thus be secured, and hyperdistention is effected by compression of the anterior part of the urethra.

With any suggestion of involvement of the membranous and prostatic urethra the argyrol solution should be carried into this portion of the urethra by kneading or milking, or by the catheter.

In gonorrhœa in the female, the treatment should be applied to the vagina as well as the urethra.

The patient should be advised as to the necessity of strict antisepsis in order to prevent the inoculation of the conjunctiva. Disinfection of the hands with a 1–500 mercuric-chloride solution is of great value, and all instruments and material infected should be thoroughly boiled.

An important adjunct in treatment is rest, regulation of diet and of the manner of living. The diet should be simple and nutritious, and all stimulating beverages, such as alcohol, coffee, and tea, avoided. The bowels should be kept open daily. In the first week of this disease citrate of potash, twenty grains, four or five times a day, decreases the irritating effect of the urine by its diuretic effects. The hip bath in warm water every night and morning not only insures

[1] "N. Y. Medical Record," vol. xlvii, p. 549.

a degree of cleanliness, but is of value as an antiphlogistic. The free discharge of pus from the urethra, vagina, and prepuce is essential. An absorbent dressing or bag of oil silk or rubber tissue made to fit without pressure may be held in place by strings fastened to a belt around the waist. Absorbent cotton is useful in taking up the discharge.

Chronic or recurring urethritis is one of the most distressing of the genito-urinary diseases. Gonococci or other pathogenic organisms once lodged in the follicles of the prostate, or in the mucous and submucous tissues of the deep urethra or vesiculæ seminales, are practically beyond the reach of local applications. While these should be thoroughly employed for the destruction of such organisms as may be reached, the chief reliance must be in building up the patient's resistance and aiding phagocytosis by careful nourishment.

Balanitis and *posthitis* (inflammations of the glans and prepuce) are conditions existing in a varying degree in almost all cases of specific urethritis, the acrid discharge readily affecting the epithelial covering of these organs. When the foreskin becomes swollen, tense, and painful, the annoying condition of *phimosis* results, and in some cases *paraphimosis* ensues, and may require operative interference to prevent sloughing. In phimosis it is often necessary to irrigate the glans beneath a tight foreskin with the permanganate solution, either with a specially constructed syringe with a delicate nozzle or with a common fountain syringe. If these milder measures do not suffice, an incision through the prepuce along the middle line of the dorsum should be made to expose the excoriated surfaces or to relieve tension.

Non-specific Urethritis.—This form of urethritis is due to infection of the mucous membrane of this canal by pyogenic organisms independent of the gonococci. Traumatism due to external violence, or excessive sexual indulgence, the introduction of unclean instruments, foreign substances, calculi, etc., produce conditions favorable for the lodgment and proliferation of pus-making organisms and the development of a purulent discharge. It is usually of short duration, mild in character, and involves only a limited portion of the canal. The *diagnosis* may be made from the absence of the *gonococci* in large numbers and within the pus cells and epithelia, as given in specific urethritis, and from the absence of the symptoms of a violent infection. The *treatment* is rest, the removal of any cause of irritation, the dilution and sterilization of the urine, and irrigation, as in gonorrhœa.

Syphilis is an infectious disease affecting the nutrition of all the tissues. It is believed to be due to the presence in the blood of a specific micro-organism, the Spirochæte pallida.

It may be acquired or inherited. Acquired syphilis ensues when the specific germ is carried into the lymph or blood channels of a human being. It is believed that an abrasion of the skin or mucous membrane is essential to inoculation. The germ is conveyed in the fluid which transudes from the surface of the initial ulcer (chancre) and from mucous patches. The blood of a syphilitic patient carries the poison if injected into or inoculated upon the tissues of a non-immune. The same is true of the liquid from the cutaneous lesions of the secondary stage of syphilis. It is not admitted that the lesions of tertiary syphilis are capable of reproducing the disease.

The normal secretions from a syphilitic subject will not produce the disease when unmixed with the discharge from mucous patches or the initial ulcer. Milk from a woman in any stage of the disease will not produce it when injected into the tissues or ingested as food.

Transudation from a fissure in the nipple of a syphilitic nurse brought in contact with an abrasion upon the lip, tongue, or buccal wall of a child will produce this disease in a non-immune subject. On the other hand, a syphilitic child may inoculate a healthy nurse. It is claimed that the pus from a vaccine pustule on a syphilitic subject does not convey the virus, even when the vaccination has been successful; but if blood be mingled with the pus, syphilis may result.

Inoculation occurs most frequently upon the genital organs, but it may occur on any part of the body. Physicians are frequently inoculated on the finger in

examining patients, and in like manner they may transfer the virus to others. If rubber gloves were worn, this accident could not occur. Dentists and barbers may also convey the virus from a syphilitic to a non-immune subject. The germs from an ulcer on the lip or of mucous patches, lodged upon a drinking vessel, may inoculate an abrasion on the lip of a non-syphilitic subject.

The clinical history of a typical case of acquired syphilis which runs its course may be divided in three stages: primary, secondary, and tertiary. In cases recognized in their incipiency and properly treated, the later manifestations may be entirely eliminated.

The primary stage includes: (1) the entrance of the specific organism; (2) the ulcer; (3) local lymphangitis and adenitis.

To the second stage belong the cutaneous eruptions, mucous patches, fever, arteritis, condylomata, alopecia, iritis, and general adenitis. In the tertiary stage the pathological changes are confined chiefly to the arteries, viscera, bones, the integument, and the subcutaneous and submucous connective tissue. This is the period of gummy tumors, connective-tissue formations, arterial occlusion, and deep-seated ulcers of the skin and mucous membrane.

The first stage lasts from six to nine weeks. Secondary symptoms may, however, appear at the fifth or sixth week from the date of the inoculation. In rare instances they may be delayed from three to six months.

The second stage lasts generally from the fifth or sixth week after the inoculation to about the end of the first year.

The tertiary stage begins at the end of the preceding stage, and may last indefinitely.

When the specific germs are lodged in an abrasion the changes while absorption is taking place may be so slight as not to attract attention. If, as is usually the case, pyogenic organisms also lodge in this abrasion, a mixed infection takes place, causing an ulcer more or less phagedenic in character.

Absorption takes place chiefly through the lymphatic channels. There is usually a period of three weeks from the lodgment of the virus until the local inflammatory process is recognized, but before this is seen the poison has already passed into the lymph channels, to be temporarily arrested in the nearest group of glands. From the inoculation to the appearance of the ulcer the time is about three weeks, never less than ten days; occasionally it is delayed as many weeks. The duration of the sore varies from two to ten weeks, at times longer. It often begins as a small papule, from the covering of which a clear serum escapes, or from the beginning it may exist as an erosion. There is usually one, although there may be several points inoculated simultaneously.

An uncomplicated initial lesion does not tend to ulcerate. It is usually circular or oval in outline, is shallow, increasing gradually in depth from the periphery toward the center, and its surface is covered with a yellow serous transudation.

Grasped between the thumb and finger, it is found to be indurated but not painful. The induration is closely limited to the sore, and terminates rather abruptly, not fading off gradually in a wide infiltration of the skin.

When a syphilitic ulcer becomes infected with pyogenic bacteria it loses its specific character and becomes in appearance and behavior a phagedenic or soft chancre.

If the sore is well on one side of the penis or vulva, the glands of that side are usually first affected. When situated in the median line, or if ulcers exist on both sides, the adenitis is apt to be bilateral. In very exceptional cases ulcer of one side is followed by unilateral adenitis on the opposite side of the body. Dating from the appearance of the sore, from eight to fourteen days usually elapse before enlargement of the inguinal glands is noticed. Less frequently, three or four weeks intervene.

From one to seven distinct glandular nodules may be felt. They are hard, yet slightly elastic to the touch, not painful under ordinary pressure, and freely movable beneath the skin. They vary in size from those that are so small as scarcely to be recognized up to half an inch or more in diameter. There is no periadenitis, and unless an acute or phagedenic inflammatory process is super-

added, the glands do not become matted together in one hard, painful lump, nor does the integument become red and sensitive, as in the adenitis of phagedenic ulcer or gonorrhœa. The primary adenitis continues into the second stage, in which induration of the glands is general. When the ulcer is situated upon the lips, tongue, or mouth, the submaxillary plexus becomes enlarged. Adenitis of the epitrochlear and axillary glands follows inoculation upon the fingers, hand, or forearm.

Second Stage.—In this stage cutaneous and mucous lesions occur with falling of the hair, fever, headache, arteritis, lymphangitis, adenitis, iritis, and osteitis.

The skin lesions (syphilides) may be macular, papular, vesicular, pustular, and tubercular.

The macular syphilide appears as an indistinct spot or stain, not elevated, varying from a light red to a slate or copper color. It is frequently seen at the end of the first stage, about the sixth or seventh week after the ulcer appears, but may come later. The maculæ are usually first observed upon the abdomen, and may spread over the entire body. They vary in size from a pin-head to round or oval spots a half inch or more in diameter.

The papular syphilide occurs in several forms, which may be present in the secondary or tertiary period. Not only the skin, but the mucous surfaces may be affected, and the papulæ may be preceded or accompanied by maculæ. Some may be small and pointed, others broader at the base and flat on top, like a truncated cone. Upon mucous surfaces the papular character of the eruption may be observed if seen early, but on account of the moisture the papules soon disappear, leaving mucous patches which may be elevated or depressed. When recent, these patches are red in color, but later become covered with a whitish-gray film.

The papular syphilide, which occurs near the junction of the skin and mucous surfaces, as those below the mammary glands in women, and between the thighs and gluteal regions in either sex, often as result of uncleanliness and irritation, becomes developed into a papillary or watery growth known as condylomata.

The papular eruption of syphilis may cover the entire body, and is often well marked upon the palms and soles, while at times the trunk alone is occupied, the face, hands, and feet escaping. They are well defined, vary in size, and are darker in color than the maculæ. The eruption disappears by absorption of the cells which have infiltrated the papillæ and corium, and this may occur with or without desiccation. The scaling syphilide, or psoriasis syphilitica, is at times with difficulty differentiated from true psoriasis, especially when the inoculation is denied.

The vesicular syphilide is peculiar to the second stage, and is seldom observed. The vesicles may be small, pointed, and gathered in clusters as in herpes, or scattered at various intervals over the body. Commencing as vesicles, they sometimes become pustules, which, as evaporation occurs, are covered with small crusts or scabs.

The pustular syphilide, while almost always associated with the hair follicles, may be met with on all parts of the body. It is most common in the secondary and not infrequently seen in the tertiary period. In the later manifestations they have wide bases, and may spread extensively.

Scabbing, with underlying ulceration, is the common history of all pustular syphilides, although extensive molecular death of tissue is less apt to occur in the secondary than in the tertiary stage. The color of the crusts varies from black to a brownish-copper color. If the scab is removed the walls of the ulcer will be seen to be precipitate and curvilinear in outline, while the floor is covered with a varying amount of serum and detritus.

The tubercular syphilide is so rarely a lesion of secondary syphilis that it will be described with the symptoms of the third stage.

It is exceedingly rare to find all of the foregoing syphilides in any one individual. The macular and papular frequently come together, while the pustular form usually occurs alone.

Alopecia occurs in varying degree in most cases of well-marked syphilis. Though observed chiefly in the scalp and beard, all the hairy portions of the body may be involved. Except in the case of the pustular syphilide, the hair

follicles are rarely destroyed, so that as the violence of the attack is diminished the hairs are reproduced. Falling of the hair from general seborrhœa is one of the later manifestations of syphilis.

Fever.—Elevation of temperature occurs in the second stage of syphilis in a large proportion of cases. It may be so mild as not to be observed, but as a rule the thermometer will register from one to three degrees above the normal. Febrile movement usually begins when the virus has passed through the first network of lymphatics. It may precede the eruption or occur with it, and in general continues after the eruption disappears.

Headache, usually referred to the frontal region, at times to the vertex or base, occurs during the period of fever, and is generally proportionate to the intensity of the febrile movement.

Arteritis, lymphangitis, and general adenitis occur in the secondary stage and in neglected cases, continue into the third stage. Iritis is not uncommon in secondary syphilis, is usually unilateral, and is recognized by immobility of the iris, photophobia, and by the red injection of the membrane.

Pathological changes in the bones do not occur, as a rule, in the early stages of syphilis. Pain, mild in character, is present in some cases in the second stage, but lesions of the osseous structures belong to the last stage of this disease.

Third Stage.—The lesions of tertiary syphilis rarely manifest themselves earlier than the second year. They may continue for a while and disappear, and in neglected cases return at varying intervals during the life of the individual. No tissue or organ is exempt from the grave pathological changes induced by the syphilitic virus in this stage.

Skin.—Nodules resulting from cell proliferation and accumulation in the deeper layers, and at times in the subcutaneous tissues (gummata), appear, and after existing for a considerable period, may lead to molecular death of the adjacent tissues, or, failing in this, undergo fatty metamorphosis and absorption. The syphilitic ulcer of this stage is round, oval, or curvilinear, with regular edges, not ragged or indented. When granular degeneration occurs the skin immediately over the tubercle has a stretched or glazed appearance, and is slightly discolored.

A not infrequent pustular cutaneous lesion of the third stage is known as rupia syphilitica. In very rare instances a pustular syphilide, similar in appearance and with difficulty differentiated from rupia, occurs as a secondary lesion. The rupia pustules are circular or oval in shape, appear as slight elevations or blebs, which soon break open. The seropurulent contents ooze out; evaporation and scabbing occur; these crusts, by reason of new deposits underneath, are gradually lifted, and give to the scab a laminated, rough, oyster-shell appearance. These crusts are dark brown or slightly greenish in color. When the late cutaneous lesions of syphilis attack the fingers, the nail or matrix is affected (paronychia), causing a roughened condition of the nail and a swollen matrix, leading at times to temporary and occasionally to permanent loss of the nail. In like manner, permanent alopecia may occur from destruction of the hair follicles.

Nervous System: Brain.—Paralysis is one of the most frequent lesions of tertiary syphilis. It may be caused by pressure of a gumma developed within the brain substance, or upon the meninges; pressure from exostoses; destruction of brain cells by connective-tissue hyperplasia in the neuroglia, with consequent cicatrization and contraction; and by more or less complete occlusion of the arteries (endarteritis obliterans).

Hemiplegia, partial or complete, is the rule. Occasionally the center of language is alone affected. Dementia may ensue as the result of softening or pressure, and epilepsy may be classed among the late manifestations of this disease.

Chronic meningitis is an occasional symptom of late syphilis. It is accompanied by headache, dull and persisting in character, impairment of intellect, interference with the functions of one or more of the cranial nerves by extension of the morbid process, resulting at times in ptosis, strabismus, or impairment of vision, hearing, taste, smell, etc. The more serious cases progress gradually to coma and death. There is in all an elevation of temperature, loss or impairment of appetite, and derangement of the entire digestive apparatus.

The spinal cord and its membranes are less frequently attacked. Paraplegia, more or less complete, may ensue, involving at times the bladder and rectum. In milder cases coördination is disturbed, with varying loss of muscular power. Pain may be present, referred to the spine, or along the distribution of the sensory nerves, with or without loss of sensation.

One or more of the nerves, sensory or motor, may be affected by pressure from gummata, or connective-tissue changes in the neurilemma, or the presence of exostoses or other neoplasms.

Bones.—Periostitis and ostitis is observed more frequently in the bones of the skull, along the spine of the tibia, and in the clavicle, than in other parts of the osseous system. The enlargements are in some instances extensive, and pain on palpation may be elicited.

Gummata are developed upon or beneath the periosteum, forming soft, semi-fluctuating swellings, elliptical or circular in shape, and from half an inch to an inch or more in diameter. These nodules, while not painful under ordinary pressure, are the seat of exacerbations of pain which are usually experienced at night. They frequently break down in ulceration which involves necrosis of the underlying bone.

When the inflammatory process is violent, extensive destruction may occur. A peculiar type of bone disease is known as osteitis rarefaciens, in which there is no suppuration or exfoliation, a portion of the bone substance undergoing absorption, giving to the part involved a porous or worm-eaten appearance.

In certain cases of syphilitic hypertrophy of the bones the entire cancellous portion may be replaced by a dense eburnated structure.

Joints.—Synovitis, with thickening of the membrane and ligaments, may occur with impairment of motion and pain of a dull character. In severer cases the cartilages and bones may become involved, leading to osteo-arthritis and destruction of the joint.

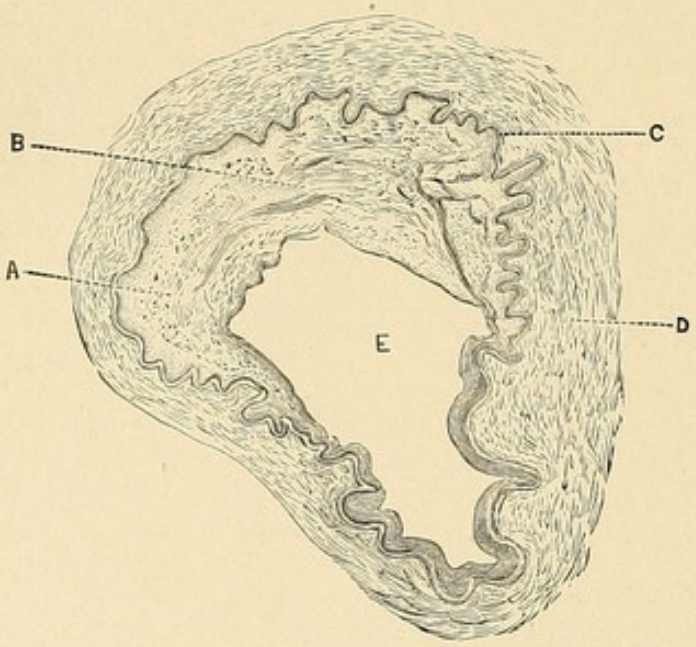

Fig. 803.—Syphilitic arteritis. Section of basilar; E, lumen of vessel about two thirds filled with new formation at A B; C, media; D, muscular layer and adventitia. From a patient dead from syphilis. (Specimen of the author's, drawn by Dr. Wardwell. Magnified about 40 diameters.)

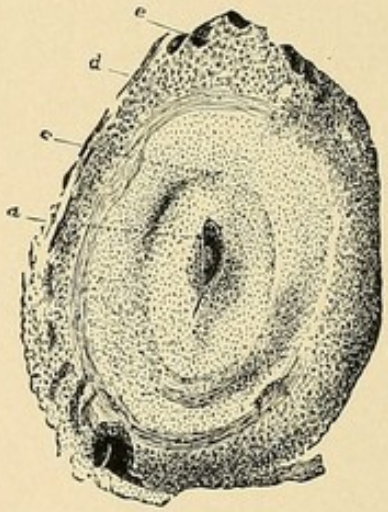

Fig. 804.—Syphilitic arteritis. Section of small artery of cerebellum, magnified 30 diameters. *a*, lumen of vessel; *c*, thickened inner coat; *d*, muscular coat; *e*, outer coat. (After Greenfield.)

Heart and Vessels.—Fatty degeneration of the heart muscle following syphilitic myocarditis and the formation of gummata upon the pericardium or within the muscular walls, are the chief lesions of this organ in the tertiary period. The pericardium may also be affected, and in like manner the endocardium, which may undergo atheromatous degeneration or give rise to vegetations. The capillaries, always affected in the first and second stages, are, as a rule, not so seriously involved in the later stages as the arteries. The veins are rarely affected. Arteritis, espe-

cially of the variety known as endarteritis obliterans, is one of the most common and grave lesions of chronic syphilis (Figs. 803, 804). While the larger trunks are involved, the more characteristic changes occur in the terminal arteries and arterioles. The cerebral vessels are especially susceptible.

Lymphatics.—Gummatous deposits occasionally take place in the lymphatic glands in the tertiary period. The superficial set may break down and discharge their contents. The deep glands undergo granular degeneration with absorption or the gummatous material undergoes caseous or calcareous degeneration.

Respiratory System: Nose.—The mucous membrane may be thickened, or may be more or less destroyed by ulceration. The cartilage and bony framework are not infrequently destroyed, and in neglected cases lead to marked sinking in of this organ with great deformity.

Larynx.—The mucous membrane of the larynx may be thickened or the seat of ulcers or vegetations. Chondritis and perichondritis are not infrequent, and stricture, more or less complete, may occur from cicatricial contraction. The larynx is occasionally the seat of gummata, while the trachea and bronchi are subject to similar lesions inducing stricture.

In the lungs the principal lesions are chronic interstitial or fibrous pneumonia, and more or less widely disseminated gummatous deposits, usually in the lower portions of these organs.

Digestive System: Mouth.—Superficial ulcers of the walls of the buccal cavity are frequent. Deep, destructive ulcers are rare. In the palate, as result of gummatous deposits or general infiltration, at times rapid and irreparable destruction of tissue may occur. The curtain of the soft palate may be destroyed, the bony septum between the mouth and nose perforated, while in extreme cases the pillars of the fauces and the pharynx may be involved.

Tongue.—Gummatous deposits may occur in any portion of this organ, where they tend to break down, giving rise to ulcers varying in size and depth.

The other principal lesion of the tongue in the tertiary period is more or less widely diffused connective-tissue hyperplasia, giving rise to a varying degree of enlargement. As the new-formed tissue contracts it gives to the organ a lobulated appearance, the boundaries of the lobules being well-marked fissures in the line of the contracting bands.

Œsophagus.—Stricture of the œsophagus may occur from connective-tissue hyperplasia, or cicatricial contraction following ulcer; from mechanical obstruction caused by gummatous deposits; by pressure from exostoses, aneurisms, enlarged glands, etc. Syphilitic ulcers of the stomach and bowels have been observed, though rarely. Gummata form here, however, with a certain degree of frequency, and stricture of the pylorus and alimentary canal near the rectum is known to occur in a fair proportion of cases. The rectum is especially liable to become seriously involved in the late manifestation of syphilis. Of the solid viscera, the liver is most seriously affected. The pathological changes are: connective-tissue hyperplasia, or chronic interstitial hepatitis, or syphilitic cirrhosis, which may be general or local; gummata in any portion of the organ; and waxy degeneration from long-continued general sepsis.

The spleen may undergo similar changes while the pancreas is rarely affected.

Genito-urinary System.—Amyloid degeneration of the kidneys occurs as a result of the long-continued sepsis of syphilis. The fibrous stroma of this organ becomes thickened, with consequent atrophy of the excretory or glandular elements (chronic interstitial nephritis).

Gummata of the kidney is not as common as in other viscera.

Orchitis, rarely met with in the secondary stage, is essentially a late manifestation of this disease. Syphilitic orchitis should be suspected in all cases of tumor of this organ in which there is a history of specific infection. It is apt to occur in both organs about the same time. The enlargement is smooth and spherical, and when lifted conveys the sense of unusual weight. It is not painful beyond the sense of dragging. Slight hydrocele not infrequently accompanies this form of orchitis.

The testicles are not exempted from gummatous deposits. In rare instances

these break down, causing more or less destruction of the substance of these organs.

The Eye.—Syphilitic iritis occurring in the second stage may also occur as a later manifestation. Inflammation of the sclera, choroid and ciliary bodies, lens and capsule, retina, and, though rarely, of the optic nerve, are of varying frequency in the tertiary period.

Lesions of the muscles may be due to connective-tissue new formations between the fasciculi, resulting in granular degeneration of the muscle substance and contraction of the new tissue. It may occur in the second as well as in the third stage of this disease. Gummata are rarely met with. Inflammation in the tendons and their sheaths may also occur.

The fingers and toes, during the tertiary period, in a certain proportion of cases become the seat of gummatous deposits; the skin and subcutaneous tissues may be infiltrated, or the bones and cartilages may be involved. When confined to the soft parts, the entire organ will appear swollen, and purple or reddish in color. When the bone is the seat of the deposit, it may be limited to a single phalanx or invade all the bones of the finger (Fig. 805). The process terminates in ulcer, necrosis, or granular degeneration of the cells of the new tissue, and absorption.

Pathology of Syphilis.—The chief feature in the pathology of syphilis in all of its stages is the proliferation of an embryonic tissue, usually of a type so low that it is not capable of organization into a definite tissue. From the initial lesion and the primary lymphangitis and adenitis to the final involvement of the viscera, this cell proliferation continues. The accumulation of these so-called lymphoid cells in and around the capillary loops of the cutaneous papillæ, which produce a macular or papular syphilide in one individual whose tissues are resistant, will produce a squamous or vesicular eruption in another, or a pustular syphilide in a weaker subject who has the unfortunate inheritance of a gouty, scrofulous, or tubercular dyscrasia. Or a papular lesion of the first stage in a patient in good nutrition may be superseded by a rupia in the tertiary period when assimilation is impaired.

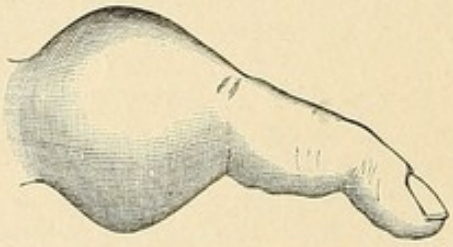

Fig. 805.—Syphilitic dactylitis. (After Bergh and Bumstead.)

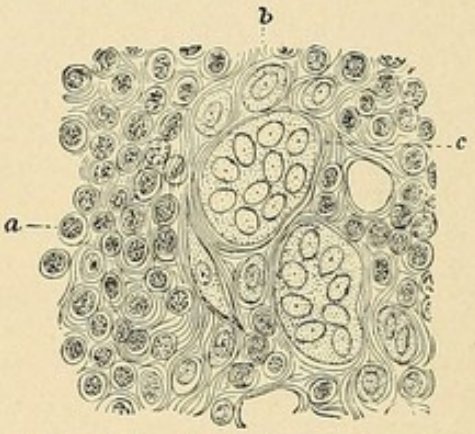

Fig. 806.—Section through a hard chancre; *a*, round-celled infiltration; *b*, large mononuclear cells; and *c*, polynuclear giant cells. Hæmatoxylin staining. × 300.

If the initial lesion of syphilis is excised and examined with the microscope, the following conditions will be observed: The epidermis in the immediate vicinity of the ulcer is more or less completely destroyed. The membrane which covers the floor of the ulcer is composed of pus cells, fragments of epidermal cells, cells of the Malpighian layer, and fragments of connective tissue and other detritus. These elements vary in proportion as the process of necrobiosis is limited or extensive. In the deeper portions of the Malpighian layer, and in and around the papillæ where these layers are not wholly destroyed, and in the connective-tissue layer of the skin, there is a general infiltration with the embryonic cells of the syphilitic process.

The arterioles, veins, and capillaries are more or less completely occluded. The cell proliferation is especially marked in the arterioles, the adventitia and intima are thickened, the thickening being more marked in the latter, while the lumen

of the vessel is more or less encroached upon by the new-formed tissue. The venules undergo analogous changes. The walls of the lymph channels are thickened, and many of these vessels are crowded with cells. The infiltration is, however, limited to the immediate borders of the ulcer, and the line between this and the uninvaded tissue is sharply defined. As the mass of cells gradually obstruct the vessels, the nutrition of the new tissue is interfered with, and it either undergoes granular metamorphosis or breaks down more rapidly as a slough. The absence of pain in the chancre is also explained by the gradual pressure upon the terminal nerves and the comparative dryness of the typical sore by the arterial occlusion.

The *lymphatics* immediately around the ulcer, and those leading from it to the nearest glands, are more or less filled with the new cells, and their walls appear thicker than normal.

The changes which occur in the glands in the earlier stages of syphilis consist in a hyperplasia of the connective-tissue cells of the stroma and thickening of the fibrous framework, together with an increase in the cell elements of the gland substance proper.

The *cutaneous* lesions of secondary syphilis result from the more or less complete obstruction of the capillary loops of the papillæ by the cells of this indifferent tissue. The walls of the capillaries undergo degeneration; the coloring matter of the blood escapes, causing the peculiar staining of the syphilides. In the macular syphilide the abnormal cell accumulation is less than in the papular eruption. The changes which occur in mucous patches differ very slightly from those described in the cutaneous lesions. The epidermis soon breaks down; the Malpighian layer and papillæ are infiltrated with the cell elements; while the capillaries, arterioles, and lymphatic vessels undergo changes almost identical with those described in the initial lesion.

In the later or tertiary lesions of the skin in syphilis the infiltration is deeper. Cutaneous gummata consist of aggregations of the cell elements heretofore described, which are crowded into the subcutaneous areolar tissue, into the connective tissue of the true skin, in the walls of and just outside the vessels, while the endothelia of these vessels undergo proliferation and aid in their occlusion. Ulceration ensues from the rapid arrest of nutrition, and the process of necrobiosis is aided by the depressed condition of the tissues which usually exists in the tertiary stage of syphilis. The tertiary lesions of the mucous surfaces are analogous to those of the integument.

The pathology of visceral syphilis presents two distinct morbid processes: (1) the hyperplasia of the connective-tissue stroma of the organs (cirrhosis); and (2) the aggregation of the syphilitic embryonic cells (gumma). The character of these changes in the different organs has been given.

Diagnosis.—In a typical case of acquired syphilis a diagnosis may be made upon the following symptoms: 1, an ulcer in appearance and behavior like that described as belonging to the initial lesion of this disease, the sore occurring not less than ten days, and usually about the twentieth day, after an exposure; 2, induration and enlargement of the nearest lymphatic glands occurring in from eight to fourteen days after the appearance of the ulcer; 3, after from two to four weeks of seeming arrest of the infection, the development of headache, pain in the back, slight febrile movement, with an eruption (sixth to seventh week after the appearance of the sore) over all or a portion of the body, accompanied with an unusual sense of dryness or soreness of the mouth, pharynx, or fauces; 4, following or occurring with these symptoms, general adenitis.

In the majority of cases, excluding even those in which the sore is concealed, as in the urethra, etc., on account of mixed infection little value can be placed upon the appearance of the ulcer at the point of inoculation. The classical "initial lesion" of syphilis, with its well-defined margin of induration, feeling like a "split pea" or piece of cartilage when grasped between the thumb and finger; the absence of pain and peripheral inflammation; the peculiar "scooped-out" concavity of the sore, the surface of which is covered with a scanty, serous transudation, is so frequently absent in cases in which the later and unmistakable signs of this disease are developed, that it alone can scarcely be relied upon in arriving at a

diagnosis. As stated heretofore, the syphilitic virus may be lodged in and absorbed from a phagedenic ulcer in which not a single feature of the specific sore is present. The same is true of the herpetic ulcer, or that resulting from traumatism or the inoculation of any form of virus. All of these ulcers are grouped under the heading of "mixed sores" or mixed infection.

Induration of the glands is more reliable in a diagnostic sense. When the typical initial lesion is present, the ensuing adenitis is also typical. In the inguinal region one gland of the group after another is enlarged and becomes indurated. The process is slow and deliberate. There is no periadenitis, the glands do not adhere to each other and the intervening tissues, nor to the integument. Each body may be distinctly made out by palpation and moved beneath the skin independently. There is no tenderness, and the gland is leathery to the touch. Even when the sore is *mixed*, if the phagedenic or inflammatory process is not severe, the adenitis is more apt to be specific than inflammatory, and will possess the features of syphilitic bubo in a sufficient degree to admit of recognition. When the specific infection is complicated with a typical phagedenic ulcer or gonorrhœa, the resulting bubo does not possess a single appreciable feature of syphilitic adenitis.

The eruption of syphilis is, of all the symptoms of this disease, the most reliable. When the sore is mixed, and the character of the adenitis doubtful, the early cutaneous and mucous lesions are, in the vast majority of cases, appreciable and unmistakable. Headache, rise in temperature, pains in the back, etc., are confirmatory symptoms, but independently of no value. The same may be said of dryness or soreness of the mouth, pharynx, and fauces. Lastly, general adenitis, which occurs in a varying degree in all cases of syphilis in which mercurialization has not been affected at a very early date, is a strong confirmatory symptom, and of great value in diagnosis if all the other lesions have escaped observation. The greatest importance is attached to induration of the epitrochlear, and to the occipital and post-mastoid glands. The former can scarcely be recognized in their normal state. In general adenitis a single body, feeling like a small bean in shape, may be recognized at the inner aspect of the arm just above the elbow, where it lies superficial, and internal to the basilic vein. When any inflammatory process exists in the member beyond the elbow, the enlarged gland possesses no specific diagnostic value. In like manner lesions of the scalp, face, or mouth may cause enlargement of the occipital or mastoid lymphatic glands.

A diagnosis of syphilis in the tertiary period must depend upon a careful study of the history of the case and the presence of one or more of the lesions which belong to this stage, and which have been fully described.

The importance of commencing treatment at the earliest possible moment cannot be overestimated. With a characteristic chancre present, the surgeon should administer mercury without waiting for adenitis or the cutaneous lesions. If the initial lesion shows a mixed infection, the most careful scrutiny should be made, if possible, into the source of the inoculation in order to determine the diagnosis at once and justify vigorous measures. Even in cases of doubt, it would be a wise precaution to lean to the side of treatment, since this insures safety and can do no harm if properly managed. If delayed until the characteristic cutaneous lesions are present, the process of infection is so far advanced that it cannot be so readily checked, nor the poison so easily neutralized and eliminated as when the treatment is instituted at an earlier date.

Prognosis.—A favorable prognosis in syphilis will depend upon (1) the physical condition of the individual affected at the time of inoculation; (2) the early recognition of the disease and the prompt institution of treatment; (3) the faithful and energetic coöperation of the physician and patient in carrying out the measures indicated.

That syphilis is a curable disease there can be no doubt. Under favorable conditions the symptoms disappear, leaving little or no trace of the infection. Its severe results are seen in individuals with an inherited or acquired dyscrasia, with impaired nutrition, and in neglected cases.

Even in the worst class of cases, the prognosis is not wholly unfavorable if proper treatment is instituted and maintained.

When the initial lesion is early seen and recognized and treatment at once instituted, late secondary and tertiary manifestations need not appear. Even when, by reason of the uncertain character of the early lesion, a positive diagnosis cannot be made until the eruption is seen, a favorable prognosis may be given.

Treatment.—The treatment of syphilis may be divided into (1) measures which tend to destroy the potency of the virus and aid in the absorption of the inflammatory products of this disease, and (2) those which tend to improve the nutrition of the tissues. Both are essential to the successful management of this formidable disease.

Nothing is more satisfactorily demonstrated than the power of mercury to neutralize and destroy the virus of syphilis.

The management of a case of syphilis should be carried on for a period of at least two years. The person affected should be impressed with the gravity of the situation, and the certainty of disaster if the rules laid down are not strictly obeyed. All excesses should be prohibited. In certain cases, where digestion and assimilation are impaired, a small quantity of whisky, claret, or sherry may be taken with the meals. Sexual indulgence, if from no other than humanitarian motives, should cease for at least a year from the appearance of the initial lesion. The child of parents, either of whom is within the first year of syphilitic inoculation, becomes the victim of a dyscrasia which, if not fatal to life, is fatal to the perfect usefulness of its possessor.

In addition to the danger of direct inoculation during the prevalence of the chancre, is that of infection to the mother from the fœtus *in utero* or the child in the act of parturition. A patient under treatment for syphilis should retire early, avoid excessive use of the eyes, especially at night, sudden changes in temperature, and all articles of diet which are not readily digestible.

Of the preparations of mercury, preference should be given to the protoiodide. It is convenient to administer this in pills of one quarter grain each. One of these pills should be given three times a day, an hour after eating.

The indications for a diminution of the quantity are pain of a cramplike nature in the stomach or bowels, with or without diarrhœa, and any symptom of salivation. Clinical experience teaches that salivation does not occur with the protoiodide until after a colicky diarrhœa, which should be a timely warning for diminishing the dose. If diarrhœa results, it is advisable to administer about one quarter of a grain of opium, or to reduce the number of pills. In certain conditions inunctions with mercuric ointment are of great value.

Salivation may be guarded against by careful observation of the gums. At the earliest indications of tenderness felt when the teeth are firmly pressed together, or when direct pressure is made upon the alveolus, the dose should be diminished, or, if necessary, discontinued for a few days.

It will usually suffice to administer one quarter grain of protoiodide three times a day for the first month, and at the expiration of this time to increase to one grain. It will rarely be necessary to give more than this quantity, although in some cases the full beneficial effects of the remedy may not be realized until a larger dose is given. The mercury should be continued without interruption—excepting for the reasons just given—for the first six months. At the expiration of this period it is a good plan to discontinue the protoiodide for two weeks, and then administer the iodide of potassium three times a day for one month. This should then be stopped and the pills resumed for a period of two months, and so on, alternating these two remedies to the end of the first year. For the first six months of the second year the alternations should be equal—i. e., one month of the potassium salt and the next of the protoiodide. For the last six months of treatment the iodide of potassium should alone be given.

In addition to the foregoing it is of great importance that tonics should be administered from the commencement of treatment, and especially in delicate patients. When protoiodide of mercury cannot be obtained, the biniodide in $\frac{1}{16}$ to $\frac{1}{12}$ gr. may be substituted.

When mercuric inunctions are indicated, proceed as follows: Take about a teaspoonful of mercuric ointment and rub it well into the skin of the groin and under

the arms. Or spread the ointment on lint and apply it to these parts, holding it in place by lightly fitting clothes or bandages. It should be used only at night, and removed upon rising by washing with warm water and soap.

The hypodermic injection of corrosive sublimate in the treatment of syphilis, while objectionable on account of the annoyance produced by the insertion of the solution beneath the skin, may become necessary in certain patients who cannot be brought under its influence in any other manner.

The injections should be made under the skin of the back, and with most careful asepsis. From $\frac{1}{16}$ to $\frac{1}{8}$ gr. of corrosive sublimate may be used once or twice a day, watching the effect closely. A few minims of two-per-cent cocaine preceding the mercury will lessen the pain.

Within recent years very remarkable success in the treatment of syphilis has been claimed by well-known specialists from the intramuscular injection of a ten-per-cent suspension of the salicylate of mercury in liquid petroleum. According to Gottheil, who recommends the following formula, it never produces abscess[1]:

℞ Hydrargyri salicylatis ..... 5 gm. or c.c.
Petrolati liquidi ..... 50 gm. or c.c.

M. Sig.: For hypodermic injection.
½ c.c. = .05 gm. of the mercury.
10 ♏ = 1 grain of the mercury.
5 ♏ = ½ grain of the mercury.

This must be thoroughly shaken before using. Of the above mixture, 10 minims are equal to one grain of the salicylate, containing $\frac{4.5}{100}$ grain of metallic mercury.

These injections are given at intervals of four days or more and the greatest aseptic care should be taken. The solution is rapidly absorbed. Gottheil holds that it is not necessary to sterilize the injection fluid, provided ordinary care is taken to prevent it from contamination. The needles should be about 21 gauge. The site of injection should be about half-way between the intergluteal fold and a line running parallel to it and dividing the buttocks into halves. It should be made on alternate sides, dividing each half of the area into three injection sites, so that the unindurated tissue may be used for each separate injection.

The first injection should be 5 minims (½ grain, .03 gm.). Two days later this should be increased to 7 minims; four days later, 10 minims; and from this time on the average case requires about 1 grain every seven days. Some require more than others, but the dosage must be determined by a careful study of the effect.

In view of Dr. Gottheil's large experience and the results reported by him, this method of treatment strongly commends itself.

In the treatment of the tertiary lesions of syphilis practically the same rule of practice should be adopted as just given for the second year following the appearance of the initial lesion. The employment of iodide of potassium in full doses hastens the absorption of the inflammatory products of this stage, while the protoiodide destroys the potency of the virus. Both remedies should be administered in doses as large as can be borne without interfering with the functions of the digestive organs or producing any serious constitutional disturbances.

In the treatment of gumma and the destructive cutaneous tertiary lesions met with in neglected cases large doses of iodide of potassium are imperative. The dose should be gradually increased until either the symptoms of iodism are present or the lesions disappear. As much as 960 grains a day have been employed with curative effect.

Inherited Syphilis.—The fœtus may become syphilitic from a syphilitic father or mother. If pregnancy occurs within the first year, and especially in the first six months of the disease in the mother, the child becomes inoculated, either dying *in utero*, or, if carried to term, usually perishes within a few weeks after its birth. If, however, the disease is recognized and proper treatment instituted, a more favorable prognosis may be made.

[1] "International Clinics," Vol. III, Fourteenth Series. "New York Medical Journal," June 30, 1906. "Journal of the American Medical Association," August 3, 1907.

In the second year after infection, if properly treated, a mother may bear a non-syphilitic child, although the chances are against complete immunity. During the third and each succeeding year, under judicious management, the prognosis is still more favorable.

A female patient should be advised of the great danger of pregnancy within the two years immediately following inoculation. When she has been under constant and proper treatment for this length of time, and has been perfectly free from symptoms for one year, the gravity of the danger is diminished. If she has not been treated, she should under no circumstances be made liable to pregnancy. In case such a woman becomes pregnant, she should be treated carefully for syphilis, and in this way the infection of the child may be modified, if not prevented.

It is stated that the virus of syphilis may be conveyed by the spermatic elements, and the embryo thus become inoculated.[1] The prognosis is more favorable in proportion to the length of time which has elapsed after the initial lesion, and to the thoroughness of the treatment instituted. A syphilitic man should not beget a child within two years after the initial sore, nor at any later period unless thorough treatment has been instituted and one year has elapsed since the disappearance of all symptoms of the disease.

Symptoms.—The symptoms of specific infection in the child manifest themselves usually within the first eight or twelve weeks after birth. Occasionally the disease is latent, and the symptoms do not appear until a variable period has elapsed. Even puberty may be reached before it is evident. Excepting the chancre, the local lymphangitis and adenitis, the evolution of the symptoms of inherited syphilis is not unlike those of the acquired form. The lesions are cutaneous, mucous, and visceral.

The macular or papular syphilide occurs in most cases, and may be distributed over the general surface or confined to certain limits. It is usually first seen upon the abdomen, and from this starting point it becomes more or less widely distributed. At the muco-cutaneous margins, and in the folds of the skin where irritation is greater and moisture exists, condylomata are not infrequent, and are often persistent. Vascular, pustular, and tubercular syphilides occur in a certain proportion of cases. The tubercular form is rare. The pustular form (syphilitic pemphigus) indicates a low order of tissue vitality, and justifies an unfavorable prognosis.

Lesions of the mucous surfaces occur either before or with the cutaneous lesions. Papules and excoriations (mucous patches) are found in the buccal cavity, on the tongue, fauces, and pharynx. Fissures of the lips are not uncommon, and especially in the angles of the mouth. The infection of the mucous membrane of the nose and air passages leads to the distressing coryza and cough so often noticed in syphilitic infants. Gummata of the skin and of all organs occur in the same manner and with the same pathological significance as in the acquired form.

Treatment.—The preparations of mercury antagonize the virus in this as in the acquired form of syphilis. The careful mercurialization of the mother during pregnancy is important in preventing the development of the disease in its severer forms. Inunction with the ointment of mercury should be first faithfully tried in the treatment of syphilis in the newly born. One dram of mercury to one ounce of lard is the proportion recommended by Brodie. This is spread upon a soft flannel belt and worn continuously around the patient's waist. The ointment should be renewed as needed. If the beneficial effects of the mercury are not secured by this method, the internal administration or the intramuscular injections may be tried.

[1] As heretofore stated, a non-syphilitic mother may be inoculated from a syphilitic child in the act of parturition. That the mother is also subjected to the influence of this virus from carrying the offspring of a syphilitic father is proved by *Colles' law*, which is, that a previously healthy mother of such a child can nurse it without danger of chancre of the nipple and syphilitic infection, while a non-syphilitic nurse will become inoculated.

CHAPTER XXXVIII

BURNS—SCALDS—SKIN-GRAFTING—FROSTBITE—FURUNCLE—CARBUNCLE—ULCERS—GANGRENE

Burns and *scalds* are classified in degrees varying from the mildest form, which produces a simple inflammation of the epidermis, to the most severe form, which destroys all the tissues or organs of a part. The gravity of the prognosis is usually in proportion to the extent of surface of the integument destroyed rather than to the depth of the destructive process. Burns of the head and face are most dangerous; those of the extremities least grave. Recovery is exceptional after destruction of one third of the cutaneous surface. Death may result from shock, ulcer of the duodenum, or exhaustion from prolonged suppuration and septic absorption.

The history of a slight burn or scald involving only a limited area of the integument, and not extending beyond the skin, is simply one of local disturbance. When, however, a considerable extent of tissue is involved, symptoms of profound constitutional disturbance rapidly supervene. The patient is seized with chills or rigors, suffers excruciating pain, betrays in his expression the extreme anxiety felt as to his condition, and sinks into a condition of collapse, which is often the prelude to a fatal issue. When not rapidly fatal, the duration of this stage is from six to thirty-six hours. It is followed by the stage of reaction and inflammation. The character of the febrile movement depends upon the extent of the destruction of the tissues, and upon the concurrence of certain lesions of the thoracic and abdominal viscera. Inflammation of the duodenal glands, and the formation of ulcer with perforation, is not of infrequent occurrence during the second week after the accident. Peritonitis, pleuritis, or pneumonitis may add to the gravity of the prognosis. Laryngitis and bronchitis are apt to follow the efforts at inspiration in the presence of scalding steam.

Treatment.—The immediate indication is to relieve pain by the administration of morphia hypodermically, or by some form of opium by the rectum or stomach. Locally, the most generally convenient remedy is a saturated solution of baking soda in water, with submersion of the burned surface, if possible, or a mixture of bicarbonate of soda and corn starch, each one teaspoonful to a quart of water. This should be applied freely to the burned area and the dressing kept wet with the solution. This should be followed, after five or six hours, by applying freely the following mixture:

Ichthyol	℥ss.;
Cotton-seed (or olive) oil	O.ss.;
Limewater	O.ss.

Mix into an emulsion.

This should be continuously applied for the first three to five days during the stage of acute inflammation. In order to bring about a rapid repair of the skin, employ the following:

Ichthyol	℥j;
Diachylon ointment, White vaseline, āā	℥iij.

This should be mixed thoroughly. If these remedies are not convenient, the following may be substituted with equal benefit:

Lead plaster, Liquid albolene, Lanolin, Vaseline,	āā	..... ℥j.

Melt together, and, when cooling, add 40 minims of ichthyol.

Either of these ointments should be applied thickly on the soft linty side of canton flannel, surgeon's lint, or on several layers of sterile gauze. The application should be repeated daily at first, having previously opened all blebs and being careful not to remove the epidermis of the bleb, as this may be revitalized and greatly accelerate the healing process. In changing the dressing it is very important not to disturb the new granulations, but simply to wipe around the edges of the wound for cleansing purposes, and not wipe over the granulations. Healing is seriously delayed by mistaken zeal in mopping these surfaces. After healing is well under way, the dressing should not be changed oftener than every second or third day.

When the new skin becomes white and spongy, a two-per-cent ointment of resorcin should be used.[1]

In the treatment of the depression or shock which often follows severe burns, stimulation with whisky or brandy, by enema or by the mouth, is indicated, as well as the hypodermic injection of morphia. Normal salt solution by the colon, or injected into the areolar tissue, is of great value when the burn is extensive and the shock profound. The use of opium and alcohol should be made with a certain degree of caution to avoid a too profound narcosis with the former, while alcohol in excess may add to the fever of reaction which follows when the patient rallies from the shock. The clothing should be carefully removed and the burned surface shielded from the atmosphere by immersion, when possible, in a strong solution of bicarbonate of soda.

In an emergency, when the foregoing remedies may not be obtained, a coating of ordinary white lead, as mixed for use in painting dwellings, is an efficient protection when poured over the burn. Flour sprinkled over until all the excoriated surface is well hidden is a method of treatment applicable in almost any emergency. Rubber-tissue protective or oil silk, sterilized and laid over the raw surface, with cotton batting applied on top of this but never directly upon the burned surface, is equally efficient. Lint, or a soft cloth dipped in two-per-cent carbolized oil, may be employed directly on the burn. In holding these various dressings in place, no pressure should be exercised. In the not infrequent form of injury in which the back and posterior aspects of the extremities are chiefly involved, the prone position is of necessity maintained.

Skin-grafting.—When the destruction of integument has been so extensive that in the process of cicatrization the granulating surface is not re-covered by skin, transplantation must of necessity be practiced. The various methods are by sliding, grafting, or transplantation *en masse*. In all the operative surgery of the skin, no method gives such perfect satisfaction as that of sliding, in which a flap of skin is dissected up, leaving a pedicle sufficiently broad to insure its blood supply. The loosened skin is shifted to its new position and carefully stitched in place. While the loose flap may be quite considerably stretched and made to cover a surface larger than it originally occupied, *no tension whatever should be made upon the pedicle*. In severe burns of the face it is often possible to cover in very extensive defects after a thorough removal of all cicatricial tissue by sliding a series of large flaps from the neck.

Illustrative Case.—As the result of a burn the integument upon the under and anterior surface of the chin had been destroyed so that in the process of cicatrization the corner of the mouth was drawn down to the lower border of the

[1] Prof. Thurston G. Lusk.

inferior maxilla, exposing the teeth and gums, and permitting a continuous leakage of saliva. The vermilion border of the lip and the orbicularis oris muscle were not destroyed. Thoroughly removing all the cicatricial tissue, the orbicular muscle and the lip were brought back to their normal position, leaving an exposed surface from the middle line of the chin and lip downward two and a half inches wide, extending backward to near the angle of the jaw. The area exposed by this dissection measured two and a half by four inches. By making careful measurements and cutting a pattern of sterile sheet-rubber, an incision parallel with the lower margin of this wound and three inches below was made across the neck, the flap so shaped being long enough when dissected loose, *and all the subcutaneous fat carefully removed*, to be swung upward and fill in the most distant angle of the raw surface. In stitching this into place, fine silkworm-gut sutures were used, and the normal elasticity of the skin was taken advantage of to stretch the flap carefully from one suture to another, at the same time making a very careful apposition of the edges. A second flap of similar shape was cut still farther below and carried upward to fill in the deficiency made by the removal of the first flap, and in like manner a third was made to take the place of the second, until the incision was finally carried below the collar line, where it would not be visible. The disfigurement of the face was very satisfactorily relieved.

By taking advantage of the skin's elasticity and viability a gain of about one-half inch was made with each flap, leaving only a narrow cicatrix below the collar.

The dressing applied should make no pressure over the flaps or pedicles, and the position assumed should be such as to prevent strain or tension.

In restoring the integrity of the lower eyelid in ectropion, or the *ala nasi* after syphilitic ulceration, this sliding procedure may be utilized to great advantage.

When there is not sufficient integument immediately about the uncovered surface to supply the want, the flap may be secured from some other portion of the body. Thus in extensive ulcer with destruction of the integument on the front of the leg, the author has succeeded in covering in the surface by turning a flap from the posterior aspect of the opposite leg, leaving a wide pedicle, and fastening the two members in an immovable position with plaster of Paris, so that the flap remained in its proper place and free from strain. After about ten days the pedicle may be divided. In the case of a boy who had been seriously burned at the wrist and where the cicatricial contraction displaced the fingers, deformed the hand, and threatened amputation of the member by obstruction of the radial and ulnar, the following operation was done with success: All the cicatricial tissue of the wrist and arm was dissected off down to the tendons and bones, which were in good condition. Two parallel incisions, six or seven inches long and four inches apart, were then made from the ensiform cartilage down to the umbilicus, and the strip of skin dissected up in the middle and left attached at both ends. When the small amount of bleeding had been arrested, the hand was slid beneath this flap, the under surface of which was held in contact with the raw surface by stitching the edges together with silk. A sterile dressing was applied, and the hand and arm held immovable by adhesive plaster (Fig. 807). On the tenth day the strip of skin was divided above and below, and the cuff of skin folded around the wrist and stitched in position. This procedure has been repeated in a number of cases, and always with gratifying success. In all cases of transplanting skin no more of the subcutaneous tissue should be lifted with the integument than is necessary for the vitality of the flap. In short flaps a very thin dissection may be made. Near the pedicle a good deal of tissue should be left to insure the safety of the blood vessels.

When sliding cannot be made, the method next in order of preference is transplantation *en masse*. In removing a piece of integument either from the patient's own body or from that of another person, it is advisable not to attempt the transfer of a large piece unless the skin to be transplanted has been removed in the course of an operation. In covering over large denuded areas after operation for the removal of cancer of the breast, or in repairing the injury resulting from extensive burns, the superfluous skin removed from healthy subjects in operations for herniæ, circumcisions, etc., may be successfully utilized as grafts. As soon as removed,

the pieces should be placed in warm normal salt solution (110° F.) until they are laid upon the raw or granulating surface. As a rule, pieces about an inch square give the greatest satisfaction, although smaller bits may be employed. The piece to be transferred should be stretched over the finger in the salt solution and every vestige of fat or loose connective tissue trimmed off with a curved scissors or sharp knife until it is so thin that little remains but the epidermis, the Malpighian layer, and a film of the corium or connective-tissue substratum. The

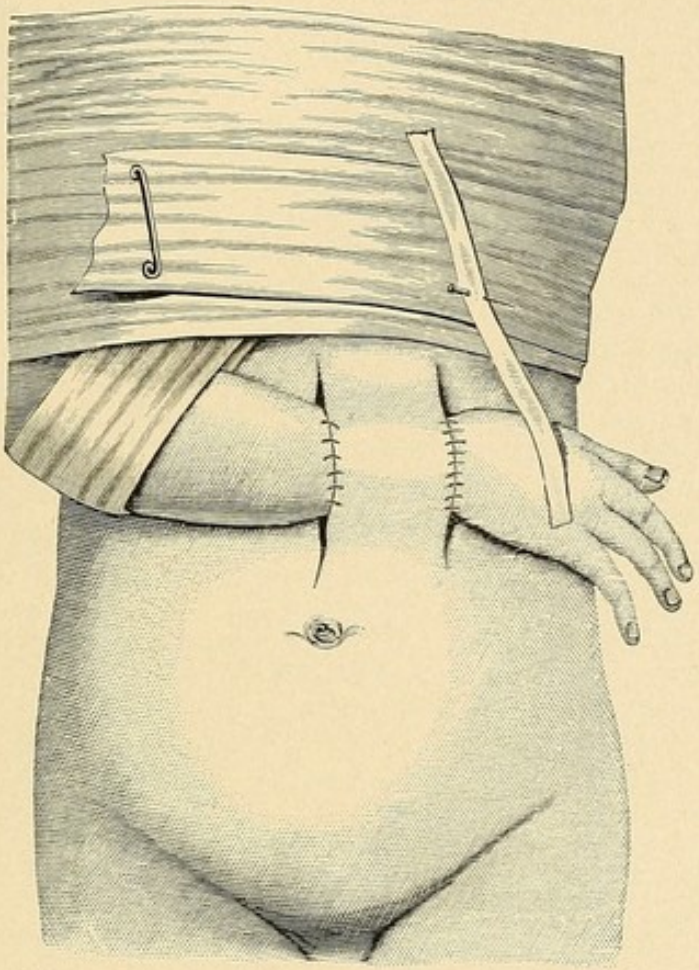

FIG. 807.—One of the author's cases of transplantation from the abdomen to the arm.

surface upon which the graft is to be laid should be rendered *aseptic and dry*, and if there are granulations, and these are rich and exuberant, they should be trimmed with the scissors twenty-four hours before the transplantation is made, and treated with a one-per-cent solution of picric acid. This application may have to be made several times before the surface is in proper condition. When the larger transplanted sections are applied, three or four fine chromicized catgut sutures should be inserted in order to hold them immovably in place, since any shifting of position is fatal to success. When the skin is intentionally removed for transplanting, it should be sliced off with a razor or dissected in thin sections.

Dr. J. H. Girdner has demonstrated that pieces of skin taken from a healthy subject six hours after death by accident, "cut into a great many small pieces and laid upon a healthy granulating surface, will become revitalized."

Prof. Ernest Laplace recommends the following modification of the method of Thiersch[1]: The exposed surface covered with granulations is treated with a one-per-cent solution of picric acid for a day or two, until it assumes a thoroughly healthy red and dry condition. Grafts are then transplanted to it, covering it completely after Thiersch's method. A single layer of gauze is applied carefully over the parts, projecting about an inch beyond the granulating surface. It is

[1] "Am. Jr. of Clin. Med.," March, 1907.

maintained in position by plaster straps along the edges of the wound. This gauze protects the wound, but does not interfere in the least with the evaporation of the serum, which must necessarily exude from the surface. As a result, a little scab forms about the edges of the grafts, no secretion results, and the grafts adhere and take root in the granulating surface. Care must be taken, however, that nothing comes in contact with the surface for fear of dislodging the grafts.

"A shield must be improvised of such size and construction as to prevent any possibility of the sheet or binder touching the affected parts.

"It is remarkable how little secretion takes place under these circumstances; and therefore how little the development of the growth of the graft is interfered with."

The method of Thiersch is as follows: The surface from which the skin-grafts are to be taken should be thoroughly shaved, scrubbed with soap and water, the skin follicles cleansed with ether, then thoroughly mopped with a 1–500 mercuric-chloride solution, and again with normal salt solution[1] to remove the mercury, and the place covered with a dressing wet with the salt solution. In some instances, such as superficial burns or ulcers, especially where careful treatment has kept the granulating surfaces aseptic, and even in cases which have become foul and then thoroughly cleansed, the grafts may take hold and live, but it is advisable to remove with the curette, or preferably with the knife, the edges of the ulcer down to the healthy skin, together with the granulations which are shaved off with the knife, or scraped if the sharp spoon is employed. The bleeding surface should be carefully sterilized by normal salt solution, which should be boiled just before using, and hæmorrhage stopped by pressure with sterilized gauze for the double reason that the escaping blood would lift the grafts up from the prepared bed, while a coagulum would invite infection. Grafts or flakes of skin, including chiefly the epithelial layers, are shaved off with a very sharp, broad-bladed knife, long enough to permit a free sawing movement, which facilitates the cutting of thin sections. Moisten the blade in salt solution, make the skin tense, and remove large, thin flakes. From half an inch to an inch in width and from two to three inches or more in length is a convenient size for lifting and transplanting. These grafts include the epithelia and the papillary layer; even a film of the connective-tissue stroma of the corium will not interfere with growth. Keep the graft moist all the time with salt solution and carry it directly to the surface to be covered, sliding it from the razor to its proper place on the wound, bottom side down. As the tendency of these grafts is always to roll toward their raw surface, each should be gently unfolded with dull forceps or a probe and laid flat down. Piece after piece should be applied and carefully adjusted along the edges of the wound and to each other like paving stones until the entire surface is floored. The whole is then covered over with thin strips of rubber tissue about half an inch in width. The rubber tissue should be sterilized in mercuric-chloride solution, washed off in salt solution, and shaken before being applied. It is well enough in applying these strips to leave here and there a little crevice or crack, through which any transudation may escape. Directly over the strips a layer of sterile gauze, absorbent cotton, a large piece of rubber tissue, and over all a bandage with light compression.

In from thirty-six to forty-eight hours the dressing may be removed, not disturbing the protective, however, for from one to two weeks. Upon removing the protective, it should be carefully taken off so as not to lift the grafts; if suppuration has occurred, the fluid should be absorbed with gauze mops or cotton wet with salt solution, the parts being touched very lightly.

When the condition demands, several thicknesses of grafts may be laid, one over the other, at the original or a subsequent operation. Some operators employ Esmarch's bloodless method when an extremity is involved, as it prevents bleeding and saves time in operating. The constriction is not removed until the operation is completed and the dressing applied, the compression of the final roller preventing oozing.

The more remote changes in Thiersch skin-grafts have been studied by Goldmann ("Annals of Surgery," vol. xix, 1894), who says that cell proliferation in

[1] Normal salt solution, six tenths of one per cent, approximately gr. ijss. to water ℥j.

the middle layer of the epidermis is vigorous, and this continues two or three months; the outer layer is cast off more rapidly than in normal skin, due to the novel and insufficient nutrition, the exfoliation ceasing when the new vessels are sufficiently formed beneath the skin. Mobility of the new skin in case of small defects was noticed in about eight weeks, longer in larger wounds. He also demonstrated in skin thus developed elastic fibers and connective tissue; sensation is restored slowly, traveling from the periphery to the center, showing that the new skin from Thiersch grafts requires from two to eight months to become fully formed. It is a matter of importance that all dense cicatricial tissue, as after deep burns, should be dissected away, since grafts do not yield satisfactory results when planted upon scar tissue.

Dr. Z. J. Lusk [1] reports the successful use of the epithelium raised by blisters in successfully covering in large granulating surfaces after burns.

Defects of hairy surfaces can be covered with grafts of hair-growing skin. Dr. P. A. Morrow has successfully planted grafts which included the entire thickness of the skin and scalp, using a punch or trephine to cut out buttons of material and accurately fitting them to depressions or beds in the scar tissue. In some instances the hairs reappeared, though not as luxurious in growth as before.

Destruction of the skin by acids or alkalies require no special consideration beyond the adoption of measures to neutralize the escharotic action in the parts involved. For covering the denuded area the method just given for ordinary burns and scalds is employed. Carbolic acid is best neutralized by the application of alcohol, while the acids and alkalies are in general antagonized for chemical neutralization.

Frostbite.—The effect of prolonged and extreme cold upon the animal tissues is to cause occlusion of the capillaries, loss of sensation, and death by gangrene. The *treatment* is to attempt a gradual restoration of the circulation by friction in a low temperature. A part of the body benumbed by cold should never be submitted suddenly to a high temperature, but should be bathed and rubbed in snow or cold water, the temperature of which is slowly elevated. When gangrene results, amputation is demanded after the line of demarcation is established.

Furuncle.—A boil is a circumscribed infection, commencing usually in the hair follicles and sebaceous glands, and extending to the subcutaneous tissues. It is caused by the lodgment in a suitable nidus of pyogenic bacteria. The proliferation of this organism produces inflammation, and suppuration with localized necrosis. A boil may be differentiated from a carbuncle by the more acute inflammatory process of the furuncle, with almost always a single point of suppuration, well-defined, limited redness, and the acute character of the pain. In carbuncle the inflammation extends more widely and deeper, the induration is greater, there are several points of suppuration, and the febrile symptoms more appreciable. The *treatment* looks to an early relief from tension in the integument, and the separation and discharge of the slough and pus. Incision should be performed at once. The judicious use of cocaine hypodermically will prevent pain, and much suffering will be avoided by prompt action. The application of cold or heat is at times useful. Poultices are almost universally employed to soften the skin and hasten the discharge of the dead tissue. It is in general not advisable to wait for so slow a process. After incision a warm, moist sublimate flaxseed poultice or dressing should be applied, and continued until a cure is effected.

The constitutional treatment should be directed to the correction of any existing dyscrasia. The preparations of iron and mercury are the best general remedies. Tonics, good food, regulation of the alimentary apparatus, and good hygiene are essential. Sulphide of calcium (gr. $\frac{1}{10}$ to $\frac{1}{4}$ three or four times a day), arsenic, the iodides, cod-liver oil, with the hypophosphites of lime and soda, are among the remedies most recommended.

Carbuncle.—This disease—which, as Prof. A. R. Robinson [2] remarks, has been misnamed "*anthrax*"—is an infectious inflammatory process of a low order, involving chiefly the skin and the connective tissues immediately beneath it, and in

[1] "Medical Record," December 7, 1895.
[2] "Manual of Dermatology," 1884.

some instances extending into the deeper organs. Anthrax or *malignant pustule* is not in its incipiency a suppurative disease; carbuncle is always so. The process is akin to that of furuncle, though indicative of a more depraved condition of the tissues. While the infection in furuncle is single, as a rule, in carbuncle there are two or many centers of infection with pyogenic bacteria, which may or may not gradually coalesce in one wide area of inflammation and necrosis. When this occurs the inflamed area breaks down in several places, giving discharge to pus (usually in small quantity), as well as to dead tissue. It is apt to occur as a complication of the same diseases with which furuncles are seen—diabetes mellitus, tuberculosis, etc.—and in parts of the economy subjected to more than ordinary irritation, as the back of the neck, where the collar presses, and in the gluteal region.

The *symptoms* of this affection are a sense of malaise, loss of appetite, headache, fever, varying in intensity, which is followed by or accompanied with a deep-seated and severe pain in and about the local expression of the disease. The skin at this point becomes tense, injected, doughy to the touch, throbbing, and painful; the epidermis becomes lifted at various spots in the inflamed area, vesicles form, localized gangrene occurs, and the dead matter sloughs away. Not infrequently the necrotic process rapidly extends through the areolar tissue beneath the skin some time before the integument breaks down. The extent of necrosis varies under different conditions, and may be general or limited. The constitutional symptoms are determined by the amount of septic absorption and the degree of pain experienced.

The process of repair is by granulation, the development of an embryonic tissue which advances from the sides and bottom of the cavity as the slough is carried away. As to the length of time carbuncle may last, nothing positive can be stated. Usually from three to seven weeks; at times, when the process is subacute, several months.

The *prognosis* depends upon the condition of the patient, the age, the location and extent of the lesion, and the ability of the capillaries and lymphatics to resist septic absorption. Occurring in diabetes or any dangerous malady, it hastens a fatal issue. Situated upon the face, the gravity of the prognosis is increased. This is in great part due to the intense pain which follows an invasion of that part of the body in which the trifacial nerve is distributed. When located on the thorax, the pleura may become involved, thereby causing a grave complication.

The *treatment* should look to the immediate improvement of the patient's vitality by all available means. The local treatment should be directed to the removal of the entire area of infection at an early date. In this way alone can the great danger of septicæmia be averted, or the relief of tension by incisions, and the discharge of septic matter.

Poultices, if employed, should be made with 1–5000 sublimate solution, as heretofore directed.

Ulcers.—An ulcer is the result of molecular death in the integument or mucous membrane, and the underlying areolar or submucous tissue, and is due to the presence of one or several varieties of pathogenic bacteria. The arrest of nutrition which these organisms produce may be local, as in the ulcer of chancroid, or general, as in the late manifestations of syphilis, scorbutus, etc. Occurring with a dyscrasia, ulcers are even then more apt to occur in parts of the body subjected to abnormal interference with the circulation.

Specific ulcers will be considered with the diseases of which they form a part. *Ulcers* may be divided into two clinical groups—the *active* and *indolent*. In one, the material for repair is in excess; in the other it is deficient. One of the most frequent seats of ulcer is upon the anterior aspect of the tibia at its middle and lower portions. They occur usually in the aged, and chiefly among the poorly fed and laboring classes, where the erect posture is of necessity maintained for many successive hours. Varicosities of the veins of the lower extremities must be put down as a common cause of non-specific ulcers.

The *treatment* of ulcers must be directed to the cause of the tissue destruction. In varicosities the integrity of the circulation should be restored by supporting the

vessels by mechanical means, or relieving the overpressure by position. For the former the elastic stocking, properly adjusted, is invaluable. Martin's elastic bandage is an excellent apparatus, but requires considerable care in its even and skillful application. When neither of these methods is available, pressure may be successfully employed by means of flannel or muslin bandages. An elevated position of the foot and leg should be maintained in all ulcers of the lower extremities.

An *indolent* ulcer demands stimulation. This may be effected by irrigation from a fountain syringe sufficiently elevated to give strong pressure, with normal salt solution at 120° F., for ten or fifteen minutes twice daily. A wet gauze dressing and tight roller should be applied. Supporting the edges of the sore with well-adjusted strips of diachylon plaster is also a commendable practice. The strips should be cut about three fourths of an inch wide, and crossed in a spiral manner (Fig. 808).

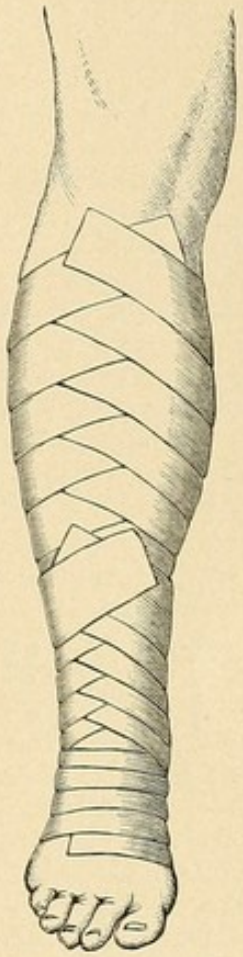

Fig. 808.

Irritable ulcers require rest and soothing applications. One of the most satisfactory preparations for the treatment of all forms of ulcers, granulating surfaces, incised accumulations of pus, septic wounds of all kinds, burns, etc., where absorption of moisture is desired, is the *balsam-oil* mixture first employed by Prof. W. W. Van Arsdale in 1884. It forms an excellent, slightly astringent, and unirritating dressing. For ordinary use it suffices to cover the surface with a mat of absorbent gauze, painting it over thickly with a brush. Enough gauze should be used to absorb the quantity of exudate for the time it is to be left on. Over the absorbent gauze, cotton batting is laid, over this rubber tissue or oil-silk protective, and a light bandage over all. When it can be obtained, the sterile preparation should be used. It is made by submitting castor oil for at least two hours to a temperature of 160° C. (320° F.). A special chemical thermometer is necessary for this purpose. The sterilized oil should then be poured into bottles taken out of boiling water, immediately corked with rubber stoppers similarly sterilized. The sterile oil will suffice without the addition of the Peruvian balsam, but I usually prefer to add this, and this must be done as the oil is poured out at the time of using. Balsam cannot be heated without destroying its value. Twenty minims of balsam to the ounce of castor oil is the proportion. For infected wounds, while the aseptic preparation is always to be preferred, yet, when it cannot be obtained, the ordinary cold-pressed castor oil can be used, and the balsam added in the same proportion as given. The constitutional treatment of all patients suffering from ulcers is of first importance. Ulcers which have destroyed large areas of integument cannot be cured without the transplantation of skin.

Gangrene is death of a part of the body from the gradual or sudden arrest of its nutrition. The term is usually applied to the process of mortification in the softer structures. The analogous condition of bone is called *necrosis*. Animal tissues have two modes of dying—the one is *molecular*, or death by granular metamorphosis, in which no trace of the anatomical or histological properties of the tissues remains; the other is death *in bulk*, in which, although the tissues deprived of life undergo rapid decomposition and ultimate disintegration, they retain for a time something of their original form. It is to denote this last variety of tissue death that the term *gangrene* is employed.

There are three varieties—namely, the *acute*, or *moist*; the *chronic*, *senile*, or *dry*; and the *contagious*, *phagedenic*, or *hospital* gangrene.

Acute Gangrene.—The chief cause of moist gangrene is the sudden obstruction of the afferent or efferent vessels of a part. Whether the artery is alone occluded, as by an embolus, the ligature, or an accidental solution of its continuity; or

whether the venous current is arrested while the artery is permeable; or whether the arrest in both systems is simultaneous, as by the constriction of a finger with a ring, or in the case of a strangulated hernia—the part beyond the lesion is charged with blood which, arrested in its flow, loses its vitality and takes an early part in the work of decomposition which ensues.

When an *artery* is obliterated, the vitality of the tissues on the peripheral side of the occlusion depends upon the integrity of the collateral circulation. If the occlusion is gradual, the enlargement of the collateral branches is usually sufficient to carry the necessary supply of blood. There is scarcely a point in the arterial system where a collateral route may not be established, provided the process of obliteration is not too sudden, and the blood has not, by reason of constitutional disturbance, been deprived of its nutritive properties. When these conditions do not prevail, mortification ensues with a rapidity proportionate to the partial or total arrest of nutrition. Pallor is the immediate and earliest symptom of arterial obstruction, followed by coldness of the skin and pain, which is usually not acute. Beginning in the parts farthest removed from the heart, the phenomena of death extend toward the center until the border line is reached between the living and dying tissues. Congestion and swelling are not marked features of arterial gangrene. The normal contractility of the tissues, an elevated position, and the influence of the return current in veins with which those of the part involved communicate, tend to empty the vessels beyond the seat of obstruction. Of necessity, however, a considerable quantity of blood remains, and when its flow is arrested its function is lost, and its elements join in the general decomposition which ensues. In the putrefactive process, gases, notably sulphuretted hydrogen and those resulting from decomposition of the fatty tissue, are evolved, and the coloring matter of the blood is liberated. Myosin, the albuminous principle of muscle, coagulates, giving a temporary sense of rigidity, and the serum which remained in the vessels undergoes transudation, and is generally distributed among the tissues. Cutaneous sensibility is soon lost, and the momentary pallor gives way to a grayish hue, which deepens into a greenish-black color. Though not so marked as in the condition resulting from venous occlusion, the skin and subcutaneous tissues become infiltrated with fluid and gases, giving a doughy feel upon pressure, and at times the peculiar crackling of emphysema. Serum and hydrogen, in the effort to escape, may at various points be caught under the impervious epidermis, which is lifted up into blisters. In resisting gangrene, certain tissues retain their anatomical features longer than others. Bone and tendon are slow to disappear, and at times the arteries will resist destructive change, when the tissues through which they pass have been entirely destroyed.

When once inaugurated, mortification extends to a point where nutritive changes in the tissues are sufficiently active to resist death. The line between this zone and the blackened slough is called the *line of demarcation.*

The line of demarcation is, as a rule, irregular in extent. When a part has been constricted until death ensues, the line of separation may be a well-defined circumference; but in arterial occlusion this is a rare exception.

Accompanying the phenomena above detailed, shoals of organisms proliferate in the tissues involved, and rapid putrefactive changes occur; the soft parts drop away in offensive sloughs, leaving the bone projecting from the stump of this *natural amputation.*

The symptoms of gangrene from *venous* obstruction differ in some essential features from mortification after *arterial* occlusion.

Engorgement is more marked, since the cardiac and arterial forces are at work overdistending the tissues beyond the obstruction with blood. The skin is of purplish hue from the start, pain is intense, the swelling great, and, until coagulation is accomplished, there is a sense of throbbing in the affected part. There is at first an elevation of temperature, which, however, is of short duration. Blisters are more numerous, and putrefaction occurs more rapidly.

Gangrene from combined arterial and venous occlusion has its type in a strangulated hernia, or in mortification of a finger which has been constricted by a ring. In this variety, arrest of the circulation and coagulation of the blood are more

abrupt. The remaining features of this form of mortification do not differ materially from those heretofore described.

Treatment of Moist Gangrene.—When an artery is obstructed, the first indication is to remove the obstruction. Failing in this, to promote the establishment of a collateral circulation, and to maintain the temperature of the part affected. The position of the limb should be such that pressure upon the structures through which the anastomotic branches run should be avoided. Cotton batting should be carefully wrapped about the part to the thickness of several inches, and oil silk or rubber-tissue protective wrapped around this. No pressure by bandages should be employed. The application of hot water, directly or by bottles, is to be deprecated, for heat is now known to produce capillary contraction. The extremity may be slightly lowered, in order to invite the flow of blood, although care should be taken to prevent obstruction of the veins.

While these *local* measures are being adopted, certain *constitutional* remedies may be indicated. These relate primarily to cardiac stimulation, opium to relieve pain and palliate shock, and to an early improvement in the nutritive quality of the blood; the administration of alcohol and beef juice, and the careful combination of those articles of food which are acceptable to the patient, and are known to be rich in nitrogen. Any intercurrent disease or complication will indicate a modification of the treatment to suit the emergency. As death progresses and the sloughing begins, all structures which can be removed easily and without pain should be cut away with dressing forceps and scissors. Iodoform, freely sprinkled over the sloughs, will prove a good deodorizer, or the dead part may be kept wrapped in sublimate gauze, soaked in 1–2000 solution, and kept moist by protective.

Hæmorrhage is rare in this variety of gangrene, yet when it does occur it demands the ligature or compression.

The treatment of gangrene where the vein alone is obstructed, in which, as has been stated, the condition of engorgement is extreme, demands the elevation of the part in order to facilitate the escape of blood through the venous channels. The tension of the part may at times demand incisions through the deep fascia. The same precautions as to temperature must be taken here. The constitutional treatment will be less stimulating, yet supporting, and the local management of the dead part will be the same as given.

When all the vessels are subjected to pressure, it is essential to relieve the constriction as early as possible. However, the vitality of an organ seemingly dead should not be despaired of, since restoration of function after prolonged strangulation is occasionally witnessed. When, as in phlegmonous or other inflammation, the tension is so extreme that gangrene is threatened by pressure of the exudation upon the capillaries or larger vessels, free incisions should be made, parallel with the general direction of the vessels, and of sufficient depth and number to relieve the tension. When, as in threatened gangrene of a finger, the swelling is severe, increasing, as it does, the tension of the organ and its own destruction, incisions are also demanded, and may prevent mortification before the constricting body is removed.

Dry or *senile gangrene* is a disease of malnutrition, the immediate cause of which is a gradual diminution of an already impoverished blood supply, due to a more or less complete occlusion of the terminal arterioles. With the extremely rare exceptions caused by toxic ingesta (ergot of rye, etc.), it is a disease of old age, and the chronic arteritis which ultimately causes the death of tissue follows in the train of syphilis, rheumatism, gout, alcoholism, and nephritis. In all probability alcohol, syphilis, and diabetes are the chief factors.

The inflammatory changes in the blood vessels which conduce to senile gangrene are connected with the *intima*, which, as a result of cell proliferation, together with the incidental deposit of fibrin upon the roughened surfaces of the lining membrane, becomes greatly thickened, impinges upon the lumen of the vessel, and finally occludes it. In syphilis the changes in the vessels are more rapid than in alcoholic arteritis, and are usually first observed in the brain, and in this condition calcification is not so apt to occur as in the endarteritis which is a part of the

alcoholic, rheumatic, or gouty diathesis.[1] The process of occlusion is almost always gradual, and the signs of commencing death are usually first noticed in the lower extremities, where, by reason of gravitation and remoteness from the heart, the circulation is naturally retarded. The occlusion is at times hastened by traumatism or some accidental inflammatory process established in a limited area of the wall of an artery already the seat of chronic arteritis.

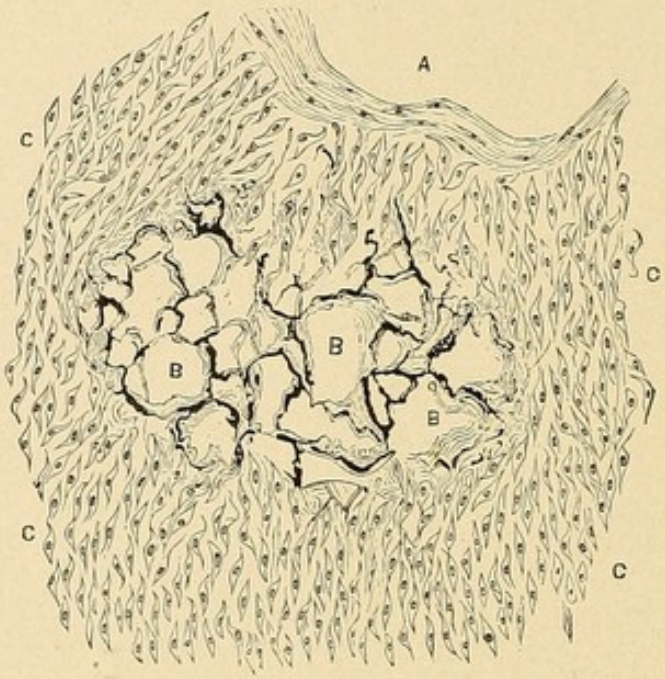

FIG. 809.—Arteritis with primary calcification. Section from human radial artery, showing at B primary calcification of the media, C. A, the intima comparatively unchanged. (Drawn from specimens prepared by Dr. W. L. Wardwell, at Conheim's Laboratory. Magnified about 350 diameters.)

Treatment.—The part affected should be enveloped in cotton batting, covered with oil silk or protected and placed in the position of least discomfort to the patient. The pressure upon the limb as it rests in bed should be equably distributed. The general condition of nutrition should be given strict attention. Tonics, mild stimulation, and the most nourishing articles of diet, taking care to keep the alimentary canal empty. No operative procedure is justifiable until a well-defined line of demarcation is established, unless septic absorption threatens the life of the patient, or unless pain is so severe as to be unendurable. In performing amputation, in order to insure asepsis the operation should be done several inches away from the line of demarcation, and the least possible traumatism should be inflicted. No tourniquet should be applied. The circulation can be controlled by gravitation, aided by digital pressure upon the main artery at a point remote from the line of amputation. When calcification of the arteries is present it will be advisable to include in the grasp of the ligature a certain amount of muscular or other connective tissue, since the ligature is apt to break or cut through. The flap should be closed with silkworm-gut sutures, not nearer than one half inch from each other, with little wisps of catgut inserted, so as to insure drainage. On account of the low resistance of these tissues infection is apt to occur, followed by gangrene of the flaps.

[1] The late Dr. W. L. Wardwell, of New York City, in Conheim's Laboratory. His experience includes examinations made from twenty-five cases at the request of Conheim, who approved his conclusions. Dr. Wardwell says all authorities recognize a morbid change in the arteries known as calcification, and the majority look upon it as a change secondary to atheroma or endarteritis. Few of these recognize a primary calcification not dependent upon a preceding inflammation. This condition is, however, the chief change in the senile calcification of arteries. The microscopic appearances of primary calcification are well shown in Fig. 809.

Conheim states that in senile aterial calcification sometimes the media, sometimes the interna (its outermost layer), is affected, and that in them the lime salts are deposited.

CHAPTER XXXIX

THE BLOOD

Hæmatology.—A careful study of the blood, especially as to the percentage of hæmoglobin which is present, and the condition of the various corpuscular elements and their numerical proportion to each other, is of importance in the treatment of many surgical lesions, and should enable the surgeon to detect not only any form of anæmia, but to determine whether it is a type of blood impoverishment which can be corrected, or whether it is of the graver or more pernicious forms which would either preclude an operation or, if this is absolutely necessary, would enable him to announce the gravity of the prognosis.

In ordinary practice it is not always essential to differentiate between a pernicious anæmia or a leukæmia, or whether this latter condition is present in the lymphatic or splenic-myelogenous form, for the reason that all of these graver varieties call a halt to operative measures when these may be avoided. But the anæmia which comes from malnutrition or malaria or chlorosis can be positively diagnosticated by a careful blood technic.

In general, the resistance of the tissues may be measured by the nearness of the hæmoglobin ratio to the normal.

Normal blood contains approximately 13.5 of hæmoglobin, but for convenience the normal amount is reckoned at 100 per cent.

A simple method of determining this proportion is by means of the Tallquist hæmoglobin scale, which is sufficiently accurate for ordinary purposes, and has the advantage of being made quickly and without artificial light. It consists of sheets of absorbent paper which, when stained with a drop of blood, the redness or richness of the stain is determined by comparison with a fixed scale of colors.

A low percentage of hæmoglobin contra-indicates the shock or exhaustion of an anæsthetic and an operation. It suggests the aid of the microscope in a further examination as to the condition of the corpuscular elements of the blood. It is advised by Mikulicz never to operate when the register of the hæmometer shows less than 35, and it would probably be safer to place the standard 10 or 15 points higher.[1]

Under the microscope there are observed the red corpuscles (erythrocytes), the white corpuscles (leucocytes), and the blood platelets.

[1] A more accurate method is that employed with von Fleischl's hæmometer, which consists of a metal stand resembling the stage, pillar, and base of a microscope. In the center of the stage is a circular opening, which receives a circular cell or tube with a glass bottom and which is divided into two equal compartments by a partition. Beneath the stage is a plaster-of-Paris disk, not unlike the mirror of a microscope both as regards its shape and position. In a sliding groove beneath the stage a metal frame is fitted, which supports a colored glass prism, wedge-shaped and accordingly deeper in color at one end than at the other. By means of a milled screw the prism can be moved back and forth, and at will any portion of its length can be brought into view through the opening in the stage. When the cell is in its place on the stage, the prism can be seen through one of its compartments, while the white surface of the plaster disk is seen through the other. For use, both these compartments are filled with water, and to that compartment which appears white a certain measured quantity of blood is added and thoroughly mixed with the water. If the room is now darkened and a candle is placed in front of the apparatus and the glass prism moved back and forth, there will be a time when both compartments will appear to have the same color. A reading taken from the scale on the back of the stage, when both compartments are alike, expresses the percentage of hæmoglobin.

The blood is measured by means of small capillary pipettes fixed in metal handles. These are so small that if they are thoroughly clean they will immediately become filled by capillary attraction if one end is touched to a drop of blood, obtained in the usual way. Three or four of

The red corpuscles are normally about 5,000,000 to the cubic millimetre). They are circular biconcave disks, homogeneous in structure, and devoid of nuclei. Their average diameter is $\frac{1}{3500}$ of an inch (seven to nine micro-millimetres). By transmitted light they have a faint amber color and are fairly transparent. The margins are smooth in general, but they sometimes appear with broken or serrated edges, due to contact with the air. This condition, known as crenation, differs from poikilocytosis, a distortion of the cells due to a diseased condition to be considered later.

At times when the red cells are numerically near the normal (5 mm. to the cubic millimetre) they still show certain characteristic deformities of the individual cells (poikilocytosis), as well as variations in size in the presence of microcytes and macrocytes which appear in the field and are not seen in the normal blood. Red corpuscles which are paler than normal, and which readily undergo crenation and do not form rouleaux, are evidences of anæmia. The danger signals are still further in evidence when nucleated red cells (erythroblasts) appear, and to these are added the giant red cells (megalocytes) or the abnormally small microcytes, the conditions are still more serious, since these corpuscles never exist in the normal blood.

The leucocytes vary in number from 4,000 to 10,000 to the cubic millimetre, the average being about 7,000, and in size from 10 to 25 μ or more. They may be divided for clinical study into five principal types—the polynuclear neutrophiles, lymphocytes, eosinophiles, transitionals, and myelocytes. The polynuclear neutrophiles vary in size from 6 to 15 μ. They consist of a nucleus and protoplasm, which latter is thickly studded with fine, irregular granulations and is readily stained with neutral dyes. The nucleus is partly or wholly divided into fragments, usually three in number. In a combination of eosin and methylene blue the nucleus is stained blue and the protoplasm pink, with red granulations. In the normal blood from sixty to eighty per cent of the white cells is of the polynuclear variety, while in disease they may constitute as low as five per cent or as high as ninety-five per cent.

The lymphocytes measure from 9 to 15 μ in diameter. They have a single nucleus, and with the eosin and methylene blue combination stain both nucleus and protoplasm are colored blue. They are divided into large and small types. The protoplasm is rarely observed as granular. The nucleus is either round or oval, and stains much more markedly than the protoplasm. This type of cell constitutes from twenty to forty per cent of the white count, but in disease it may also vary from less than five to more than ninety-five per cent.

The eosinophile leucocytes greatly resemble the polynuclear neutrophiles, but their protoplasm is studded with large, distinct, well-marked spherical granules, which are highly refractive and which are deeply stained with eosin. Ordinarily but two fragments to the nucleus are observed. They constitute from one to four per cent of the white count, but in lesions may reach forty per cent.

The transitional leucocytes are about the size of the polynuclear, but are mononucleated with their nuclei in some modification of a horseshoe in shape. The nuclei and protoplasm are stained blue with the eosin and methylene blue combination. There are no granules in the protoplasm.

The relative number of leucocytes in any quantity of blood and their proportion to the red corpuscles can be readily determined by the use of the Thoma-Zeiss apparatus, which consists of two pipettes, one for the red and one for the white cells, with a well-outlined slide or counting apparatus. It is employed with the ordinary one-sixth laboratory objective. It may be well to state that at the sea level the average number of red cells per c.m. is 5,000,000 in men and 4,500,000 in women,

these are furnished with each instrument, and it is well to know that the number stamped on their metal handles must correspond with that stamped on the pillar of the stand. They must be kept scrupulously clean, as, when otherwise, they cannot be filled.

When measuring the blood the pipette should be evenly filled and none should adhere to its end or outer surface. As soon as filled, it should be placed in the half-filled cell of the apparatus, and with the accompanying glass pipette washed clean of all trace of blood. Both compartments must be filled even with the top, taking care that the fluid of one side does not mix with that of the other. The practiced eye will without difficulty recognize the blending of the colors and may then read off the hæmoglobin percentage on the apparatus.

and 6,000,000 in the young and more vigorous adults, while the white cells average about 7,500 per c.m. for each sex. The proportion of red cells is, in general, increased with the altitude.

To obtain blood for examination, cleanse the lobe of the ear or the tip of the finger, and with a clean small lance make a puncture just deep enough to cause the blood to flow without forcing it out by pressure. Have three or four perfectly clean slides and cover-slips in readiness, and when the first drop appears wipe it away with gauze and quickly touch the tip of the new drop with the slide and immediately cover the blood with a cover-slip. Secure three or four such specimens, and one of them is likely to be so thin that the corpuscles will not overlay each other. If the slide has not been too cold this preparation will last for half an hour, and may be examined during that time with a $\frac{1}{12}$ oil immersion objective.

To prepare a stained specimen the blood must be thinly and evenly spread over the surface of the glass. To do this the drop of blood is placed on the slide near one end, and as quickly as possible the end of another slide is lightly drawn over the drop along the slide. Practice will enable one to prepare a thin, even, and broad smear in which the corpuscles will be evenly distributed and not overlay. The more quickly the smear is dried, the less crenation will occur and the better will be the result. A number may be prepared at the bedside for examination at leisure. If kept free from dust, they may be preserved for study for several days.

For staining purposes two separate solutions are kept on hand: Grübler's eosin, one half gram, pure methyl alcohol, one hundred cubic centimetres, and a saturated aqueous solution of methylene blue. Pour a small quantity of the eosin solution over the dried smear, add a little water, and then wash off with water. It is now covered with the methylene blue solution and allowed to stand for a minute or so, washed with water, and dried thoroughly, when it is ready for examination.

In the study of the stained specimen of blood the following points are to be considered: The size, uniformity, shape, and color of the erythrocytes (hæmoglobin), the presence or absence of erythroblasts or of malarial parasites; also the number and varieties of leucocytes, and their relative proportions.

Leucocytes.—An increase in the number of white corpuscles occurs under certain conditions which are practically normal. *Leucocytosis* is present during digestion from two to four hours after eating; it follows severe and prolonged muscular exercise, may even be temporarily observed in the reaction from a cold bath, and is always coincident with the late months of pregnancy. While under these conditions the number of leucocytes is increased, there remains the normal proportion of the various cell elements to each other, the whole count rarely going beyond 10,000.

In a pathological leucocytosis, while there is almost always an increase in the number of white cells, this is not absolutely essential, the true condition of leucocytosis being an increased percentage of one or another type of cell, usually the polynuclear neutrophile. There are also conditions in which the eosinophiles are proportionately increased, while in others this holds true of the lymphocytes.

Leucocytosis occurs in all infectious fevers except malaria, measles, mumps, tuberculosis, influenza, and typhoid fever, in all of which there is more likely to be a diminution (leucopenia). Leucocytosis is the rule in hæmorrhage, diarrhœa, vomiting, and acute abscess, and it follows the administration of certain drugs, such as potassium chlorate, phenacetine, arsenic, oil of turpentine, antipyrine, antifebrin, chloroform, ether, quinine, salicylates, and tuberculin.

In the differential diagnosis between a neoplasm of the breast and an abscess the increased leucocyte count would indicate the septic process.

An hour and for several hours after hæmorrhage the white cells are increased in number. Cabot gives an instance of hæmorrhage of the brain which was diagnosed by the presence of leucocytosis otherwise unaccounted for. As between concussion and cerebral hæmorrhage, the leucocyte count is in favor of the latter.

In general a white blood count above 10,000 may be considered as a leucocytosis. In an acute infective process (as in appendicitis) it will rise in proportion to the resistance of the tissues. This rise does not add to the gravity of the prognosis, but it does indicate an increasing infection.

In the present condition of our knowledge the following conclusions may be accepted:

A slight polynuclear increase with a pronounced leucocyte increase indicates slight infection and good resistance.

When the polynuclear and leucocyte increase are both pronounced, there is severe infection and good resistance.

A pronounced polynuclear increase, with little or no leucocyte increase, indicates severe infection and good resistance.

When the polynuclear percentage is increased with a decrease in the number of leucocytes, the indications are increasing infection and decreasing body resistance.

A decreasing polynuclear count and a diminishing leucocyte count indicates improvement.

Using the leucocyte count as an aid in diagnosis, all physiological leucocytoses must be carefully excluded. In the differentiation between incipient appendicitis and a developing typhoid, a leucocytosis would point strongly to appendicitis. The count is here of great value for the reason that it can be made before Widal's reaction is present.

When the resistance is approximately normal, all acute septic infections are accompanied by a more or less well-pronounced increase in the number of leucocytes.

A lowering of the leucocyte count, with improvement in the general symptoms, justifies a favorable prognosis, while a smaller count with increased general symptoms is unfavorable.

"When a spreading peritonitis is diagnosed from the clinical evidence, the leucocyte count is of great value as an indication of the patient's resistance. Operation upon a patient with a swollen tympanitic abdomen, high fever, rapid pulse, and a low leucocyte count is but to court disaster." (Deaver.)

In the differentiation of ulcer of the stomach from carcinoma of this organ, there is more apt to be a marked anæmia with the latter than the former. In pelvic infection, puerperal sepsis, salpingitis, ruptured tubal pregnancy, and menorrhagia, leucocytosis is the rule. It is not the rule in the gonorrhœal infections.

While under some septic conditions there may be slight or no increase of leucocytes, there may be noticed a diminution of the red corpuscles, accompanied by a corresponding fall in the hæmoglobin percentage. A red cell count below 3,500,000, with diminished hæmoglobin, may be considered as of decidedly unfavorable import.

Meningitis is accompanied by leucocytosis even when of tubercular origin, and this is claimed to be the only tubercular lesion accompanied by an increase of the white cells.

Pleural, pericardial, and peritoneal infections are accompanied by leucocytosis.

The white cells are rapidly increased in intestinal obstruction, there being a comparatively higher count with total than with partial occlusion. When gangrene ensues, the leucocyte count falls.

In differentiation between cancer of the stomach and pernicious anæmia, the following points are advised to be taken into consideration by Professor Jeffries:

In cancer, the color index is low; in pernicious anæmia, high. The number of white cells is increased in the former, diminished in the latter, and the same is true of the lymphocytes. The red cells are diminished in size in cancer and increased in pernicious anæmia, and there will be found in the former normoblasts, with megaloblasts in the latter. While the red cells may vary in shape in cancer, in pernicious anæmia there is a general tendency to assume an oval form.

Whenever a leucocytosis accompanies a tumor, it suggests the malignant nature of the neoplasm.

Anæmia.—The fact that pallor does not always indicate anæmia emphasizes the necessity for a careful study of the blood to detect its exact condition.

Secondary anæmia, a condition which occurs with and follows protracted fevers, practically all forms of infection or neoplasms which interfere in any way with

nutrition (cancer of the stomach), hæmorrhage, parasitic diseases, starvation, bad hygiene, and the prolonged action of certain chemical poisons, is of especial interest to the surgeon. The blood is paler in color than normal, the red disks will be found to vary in size and shape with an average increase in diameter, while the hæmoglobin will range from fifty to seventy per cent. The red cells average from 3,000,000 to 4,000,000 to the c.m., and as a rule there will exist a leucocytosis.

Chlorosis.—In chlorosis, which occurs usually in young girls about puberty and from which young men are not entirely exempt, the average red cell count varies from 4,000,000 to 2,000,000, rarely falling so low as 1,000,000, with from thirty to fifty per cent of hæmoglobin. While the red cells vary in shape, size, and color as given for secondary anæmia, there is in chlorosis, as a rule, no leucocytosis, while the erythroblasts are more common.

In *pernicious* anæmia the average diameter of red cells is increased, and the count as given by Cabot will average 1,000,000 per c.m. The white cells are also fewer, varying from 4,200 to so low a count as 500, with lymphocytosis as a prominent feature. Megaloblasts are plentiful in pernicious anæmia, and are rarely met with in chlorosis. The cause of pernicious anæmia is as yet undiscovered. It has been observed that it is usually associated with a change in bone marrow.

In *leukæmia* there is a marked increase of leucocytes with a largely disproportionate increase of the mononuclear cells. The lymph glands and spleen are enlarged, and there are marked changes in the bone marrow. The two varieties of leukæmia are the *lymphatic* and the *myelogenous*. In *lymphatic* leukæmia the erythrocyte count is diminished, usually to about 3,000,000. All forms of erythroblasts are common and the hæmoglobin is diminished. The average leucocyte count is 100,000, and about ninety per cent are lymphocytes. Myelocytes are infrequent. In *myelogenous* leukæmia the erythrocyte count is about 3,000,000. Erythroblasts [1] of all forms are abundant and the hæmoglobin is diminished. The average leucocyte count is 400,000; lymphocytes about seven per cent; polynuclears about fifty per cent; eosinophiles, four per cent, and myelocytes about thirty-five per cent. The large ratio of myelocytes is very characteristic. Myelocytes vary in size from 15 to 25 μ. They are mononucleated, with an indistinct, pale, oval nucleus which is generally excentrically located. The protoplasm is abundant, and is possessed of neutrophile granules in one type and eosinophile granules in another. The cell is not found in the normal peripheral blood, but is found normally in bone marrow. It appears in the circulation in certain pathologic conditions.

Leukæmia should be differentiated from Hodgkin's disease, tubercular adenitis, sarcoma, and malaria. Tuberculosis and sarcoma are easily recognized from the physical signs, while malaria may be determined by a blood examination.

In Hodgkin's disease the changes in the blood are so slight when compared with those given for leukæmia that the differentiation is not difficult.

Bacteria.—For bacterial examination the blood is best obtained from a vein in the bend of the elbow. Under careful asepsis, ten to twenty-five cubic centimetres should be withdrawn with a sterile aspirating needle or, preferably, glass tube. It should at once be subdivided in culture tubes for various dilutions, and these are placed in the incubator for development and identification.

The following organisms may be recognized: Typhoid and paratyphoid bacillus, colon bacillus, staphylococcus, streptococcus, gonococcus, pneumococcus, meningococcus, anthrax, glanders, and bubonic plague.

The tubercle bacillus has been repeatedly found in the blood, but is more readily found twenty-four hours after the administration of tuberculin.

[1] Concerning blood platelets, the third variety of corpuscle, little is known and at present they are of no aid in diagnosis. They are small bodies about half the diameter of erythrocytes, possess an indistinct nucleus and a homogeneous protoplasm. They number from 200,000 to 400,000 to the centimetre and have a marked tendency to gather in clumps. They may be mistaken for malarial parasites.

The spirochæte pallida may be demonstrated in the blood and serum at all stages of syphilitic infection, but is more readily found in mucous patches and at the edges of the initial lesion. To obtain the material the surface should be scarified till the blood flows, and smears are prepared as already directed. The dried smear is then stained with Goldhorn's spirochæte stain for a few seconds, then dipped in clean water with the smear downward, and finally washed and dried. The parasite may then be detected by aid of a $\frac{1}{12}$-inch objective.

APPENDIX

A COMPARISON of the Standards of Weights and Measures, taken by permission from Dorland's American Illustrated Medical Dictionary.[1]

TABLE OF WEIGHTS AND MEASURES

APOTHECARIES' WEIGHT

Troy grains.		Scruples.		Drams.		Troy ounces.		Pound.		Metric equivalents. Grams.
gr. 20	=	℈ 1							=	1.295
60	=	3	=	ʒ 1					=	3.885
480	=	24	=	8	=	℥ 1			=	31.08
5760	=	288	=	96	=	12	=	℔ 1	=	372.96

AVOIRDUPOIS WEIGHT

Troy grains.		Drams.		Ounces.		Pound.		Metric equivalents. Grams.
gr. 27.34375	=	dr. 1					=	1.7705
437.5	=	16	=	oz. 1			=	28.328
7000	=	256	=	16	=	℔ 1	=	453.25

TROY WEIGHT

Grains.		Pennyweights.		Ounces.		Pound.
24	=	dwt. 1				
480	=	20	=	oz. 1		
5760	=	240	=	12	=	℔ 1

APOTHECARIES' (WINE) MEASURE

Minims.		Fluidrams.		Fluidounces.		Pints.		Gallons.
♏ 60	=	f ʒ 1						
480	=	8	=	f ℥ 1				
7680	=	128	=	16	=	O 1		
61440	=	1024	=	128	=	8	=	C. 1

RELATION OF MEASURES OF U. S. PHARMACOPEIA TO CUBIC MEASURE

1 gallon	=	231.0	cubic inches.
1 pint	=	28.875	cubic inches.
1 fluidounce	=	1.80468	cubic inches.
1 fluidram	=	0.22558	cubic inch.
1 minim	=	0.00375	cubic inch.

IMPERIAL MEASURE

Minims.		Fluidrams.		Fluidounces.		Pints.		Gallon.
60	=	1						
480	=	8	=	1				
9600	=	160	=	20	=	1		
76800	=	1280	=	160	=	8	=	1

[1] W. B. Saunders and Company, Philadelphia, Pa.

TABLE FOR CONVERTING APOTHECARIES' INTO IMPERIAL MEASURE

APOTHECARIES' MEASURE.		IMPERIAL MEASURE.			
		Pints.	Fluidounces.	Fluidrams.	Minims.
1 minim	=				1.04
1 fluidram	=			1	2.5
1 fluidounce	=		1	0	20
1 pint	=		16	5	18
1 gallon	=	6	13	2	23

TABLE FOR CONVERTING IMPERIAL INTO APOTHECARIES' MEASURE

IMPERIAL MEASURE.		APOTHECARIES' MEASURE.				
		Gallon.	Pint.	Fluidounces.	Fluidrams.	Minims.
1 minim	=					0.96
1 fluidram	=					58
1 fluidounce	=				7	41
1 pint	=		1	3	1	38
1 gallon	=	1	1	9	5	8

RELATION OF WEIGHTS AND MEASURES OF U. S. PHARMACOPEIA

1 pound	=	0.7900031	pint	= 6067.2238
1 ounce	=	1.0533376	fluidounces	= 505.6019
1 dram	=	1.0533376	fluidrams	= 63.2002
1 scruple				= 21.0667
1 grain				= 1.0533
1 gallon	=	10.1265427	pounds	= 58328.8862
1 pint	=	1.2658178	pounds	= 7291.1107
1 fluidounce	=	0.9493633	ounce	= 455.6944
1 fluidram	=	0.9493633	dram	= 56.9618
1 minim				= 0.9493

APPROXIMATE VALUE OF DOMESTIC MEASURES

Tea-cup	=	f℥iv.	Tablespoon	=	f℥ss.
Wine-glass	=	f℥ij.	Teaspoon	=	f℥j.

LINEAR MEASURE

Lines.		Inches.		Feet.		Yards.		Fathoms.		Perches.		Furlongs.		Mile.
1	=	0.833	=	0.00696										
		12	=	1										
		36	=	**3**	=	1								
		72	=	6	=	2	=	1						
		198	=	16.5	=	**5.5**	=	2.75	=	1				
		7920	=	660	=	220	=	110	=	**40**	=	1		
		63360	=	5280	=	1760	=	880	=	320	=	**8**	=	1

SQUARE MEASURE

Square inches.		Square feet.		Square yards.		Square perches.		Rods.		Acre.
144	=	1								
1296	=	**9**	=	1						
39204	=	272.25	=	**30.25**	=	1				
1568160	=	10890	=	1210	=	**40**	=	1		
6272640	=	43560	=	4840	=	160	=	**4**	=	1

SOLID MEASURE

Cubic inches.		Cubic feet.		Cubic yard.
1728	=	1		
46656	=	**27**	=	1

DRY MEASURE

Pints.		Quarts.		Gallons.		Pecks.		Bushels.		Quarter.
2	=	1								
8	=	**4**	=	1						
16	=	8	=	**2**	=	1				
64	=	32	=	8	=	**4**	=	1		
512	=	256	=	64	=	32	=	**8**	=	1

METRIC WEIGHTS AND MEASURES

The *meter*, or unit of length, at 32° F., = 39.370432 inches.
The *liter*, or unit of capacity, = 33.816 fluidounces.
The *gram*, or unit of weight, = 15.43234874 troy grains.

METRIC MEASURES OF LENGTH

1 myriameter = 10000 meters.
1 kilometer = 1000 meters.
1 hectometer = 100 meters.
1 decameter = 10 meters.
1 meter = ten-millionth part of a quarter of a meridian of the earth.
1 decimeter = tenth part of 1 meter, or 0.1 meter.
1 centimeter = hundredth part of 1 meter, or 0.01 meter.
1 millimeter = thousandth part of 1 meter, or 0.001 meter.

		English inches.
Millimeter (mm.)	=	.03937
Centimeter (cm.)	=	.39370
Decimeter (dm.)	=	3.93704
Meter (m.)	=	39.37043
Decameter (Dm.)	=	393.70432
Hectometer (Hm.)	=	3937.04320
Kilometer (Km.)	=	39370.43200
Myriameter (Mm.)	=	393704.32000

		Miles.	Rods.	Yards.	Feet.	Inches.
	=			1	0	3.370
	=			10	2	9.704
	=			109	1	1.043
	=		160	213	1	10.432
	=	6	40	156	0	8.320

METRIC MEASURES OF CAPACITY

1 myrialiter = 10 cubic meters, or the measure of 10 milliliters of water.
1 kiloliter = 1 cubic meter, or the measure of 1 milliliter of water.
1 hectoliter = 100 cubic decimeters, or the measure of one quintal of water.
1 decaliter = 10 cubic decimeters, or the measure of 1 myriagram of water.
1 liter = 1 cubic decimeter, or the measure of 1 kilogram of water.
1 deciliter = 100 cubic centimeters, or the measure of 1 hectogram of water.
1 centiliter = 10 cubic centimeters, or the measure of 1 decagram of water.
1 milliliter = 1 cubic centimeter, or the measure of 1 gram of water.

		English Cubic Inches.	Apothecaries' Measure.	English.			
Milliliter (c.c.)	=	.061028	= 16.2318 minims.				
Centiliter (cl.)	=	.610280	= 2.7053 fluidrams.				
Deciliter (dl.)	=	6.102800	= 3.3816 fluidounces.	Tons.	Hhd.	Wine Gals.	Pints.
Liter (l.)	=	61.028000	= 2.1135 pints.				2.1133
Decaliter (Dl.)	=	610.280000	= 2.6419 gallons.			2	5.1352
Hectoliter (Hl.)	=	6102.800000	=			26.419	
Kiloliter (Kl.)	=	61028.000000	=	1	0	12.19	
Myrialiter (Ml.)	=	610280.000000	=	10	1	58.9	

METRIC WEIGHTS

1 myriagram = 10000 grams.
1 kilogram = 1000 grams.
1 hectogram = 100 grams.
1 decagram = 10 grams.
1 gram = weight of 1 cubic centimeter of water.
1 decigram = tenth part of 1 gram, or 0.1 gram.
1 centigram = hundredth part of 1 gram, or 0.01 gram.
1 milligram = thousandth part of 1 gram, or 0.001 gram.

		Troy grains.
Milligram (mg.)	=	.0154
Centigram (cg.)	=	.1543
Decigram (dg.)	=	1.5432
Gram (Gm.)	=	15.4323
Decagram (Dg.)	=	154.3234
Hectogram (Hg.)	=	1543.2348
Kilogram (Kg.)	=	15432.3487
Myriagram (Mg.)	=	154323.4874

	lb (troy).	℥	ʒ	Gr.
			2	34.3
		3	1	43.2
=	2	8	1	12.3
=	26	9	4	3.4

VALUE OF AVOIRDUPOIS WEIGHTS AND IMPERIAL MEASURES IN METRIC WEIGHTS AND MEASURES

Avoirdupois Weights.		Metric Weights.	Imperial Measures.		Metric Measures.
1 pound	=	453.5925 grams.	1 gallon	=	4.543487 liters.
1 ounce	=	28.3495 grams.	1 pint	=	0.567936 liter.
1 grain	=	0.0648 gram.	1 fluidounce	=	0.028396 liter.
			1 fluidram	=	0.003549 liter.
			1 minim	=	0.000059 liter.

COMPARATIVE VALUES OF STANDARD AND METRIC MEASURES OF LENGTH

Inches.		Centimeters.	Inches.		Centimeters.	Inches.		Millimeters.	Inches.		Millimeters.
12	=	30.48	6	=	15.24	$\frac{1}{25}$	=	1.00	$\frac{5}{8}$	=	15.85
11	=	27.94	5	=	12.70	$\frac{1}{12}$	=	2.11	$\frac{2}{3}$	=	16.92
10	=	25.40	4	=	10.16	$\frac{1}{8}$	=	3.17	$\frac{3}{4}$	=	19.05
9	=	22.86	3	=	7.62	$\frac{1}{4}$	=	6.35	$\frac{5}{6}$	=	21.15
8	=	20.32	2	=	5.08	$\frac{1}{3}$	=	8.46	$\frac{7}{8}$	=	22.19
7	=	17.78	1	=	2.54	$\frac{1}{2}$	=	12.70	$1\frac{1}{2}$	=	23.28

COMPARATIVE VALUES OF APOTHECARIES' AND METRIC FLUID MEASURES

Minims.		Cubic Centimeters.	Minims.		Cubic Centimeters.	Fluid-ounces.		Cubic Centimeters.	Fluid-ounces.		Cubic Centimeters.
1	=	0.06	25	=	1.54	**1**	=	**30.00**[1]	21	=	621.00
2	=	0.12	**30**	=	**1.90**	2	=	59.20	22	=	650.00
3	=	0.18	35	=	2.16	3	=	89.00	23	=	680.00
4	=	0.24	40	=	2.50	4	=	118.40	24	=	710.00
5	=	0.30	45	=	2.80	5	=	148.00	25	=	740.00
6	=	0.36	50	=	3.08	6	=	178.00	26	=	769.00
7	=	0.42	55	=	3.40	7	=	207.00	27	=	798.50
8	=	0.50	Fluidrams.			8	=	236.00	28	=	828.00
9	=	0.55	1	=	**3.75**	9	=	266.00	29	=	858.00
10	=	0.60	$1\frac{1}{4}$	=	4.65	10	=	295.70	30	=	887.25
11	=	0.68	$1\frac{1}{2}$	=	5.60	11	=	325.25	31	=	917.00
12	=	0.74	$1\frac{3}{4}$	=	6.51	12	=	355.00	32	=	946.00
13	=	0.80	2	=	7.50	13	=	385.00	48	=	1419.00
14	=	0.85	3	=	11.25	14	=	414.00	56	=	1655.00
15	=	0.92	4	=	15.00	15	=	444.00	64	=	1892.00
16	=	1.00	5	=	18.50	**16**	=	**473.11**	72	=	2128.00
17	=	1.05	6	=	22.50	17	=	503.00	80	=	2365.00
18	=	1.12	7	=	26.00	18	=	532.00	96	=	2839.00
19	=	1.17				19	=	562.00	112	=	3312.00
20	=	1.25				20	=	591.50	**128**	=	**3785.00**

COMPARATIVE VALUES OF METRIC FLUID AND APOTHECARIES' MEASURES

Cubic Centimeters.		Fluid-ounces.	Cubic Centimeters.		Fluid-ounces.	Cubic Centimeters.		Fluidrams.	Cubic Centimeters.		Minims.
1000	=	33.81	400	=	13.53	25	=	6.76	4	=	64.8
900	=	30.43	300	=	10.14	10	=	2.71	3	=	48.6
800	=	27.05	200	=	6.76	9	=	2.43	2	=	32.4
700	=	23.67	100	=	3.38	8	=	2.16	**1**	=	**16.00**[3]
600	=	20.29	75	=	2.53	7	=	1.89	0.09	=	1.46
500	=	16.90	50	=	1.69	6	=	1.62	0.07	=	1.14
473	=	16.00	30	=	1.00[2]	5	=	1.35	0.05	=	0.81

[1] More accurately, 29.57 c.c. [2] More accurately, 1.01. [3] More accurately, 16.23.

COMPARATIVE VALUES OF METRIC AND APOTHECARIES' WEIGHTS

Grams.		Grains.	Grams.		Grains.	Grams.		Grains.	Grams.		Grains.
0.0010	=	1/64	0.065	=	1.003	1	=	15.43	100	=	1543.23
0.0020	=	1/32	0.100	=	1.543	2	=	30.86	125	=	1929.04
0.0040	=	1/16	0.130	=	2.006	3	=	46.30	150	=	2314.85
0.0065	=	1/10	0.150	=	2.315	4	=	61.73	175	=	2700.65
0.0081	=	1/8	0.180	=	2.778	5	=	77.16	450	=	6944.55
0.0108	=	1/6	0.200	=	3.086	6	=	92.60	550	=	8487.78
0.0162	=	1/4	0.300	=	4.630	7	=	108.01	650	=	10031.01
0.0324	=	1/2	0.500	=	7.716	8	=	123.46	750	=	11574.26
0.0486	=	3/4	0.700	=	10.803	9	=	138.90	850	=	13117.49
0.0567	=	7/8	0.900	=	13.890	10	=	154.32	1000	=	15432.35

COMPARATIVE VALUES OF APOTHECARIES' AND METRIC WEIGHTS

Grains.		Grams.	Grains.		Grams.	Grains.		Grams.	Drams.		Grams.
1/100	=	0.00065	1	=	0.065	24	=	1.55	1	=	3.90
1/64	=	0.00101	2	=	0.130	25	=	1.62	2	=	7.80
1/60	=	0.00108	3	=	0.195	26	=	1.70	3	=	11.65
1/50	=	0.00130	4	=	0.260	27	=	1.75	4	=	15.50
1/48	=	0.00135	5	=	0.324	28	=	1.82	5	=	19.40
1/40	=	0.00162	6	=	0.400	29	=	1.87	6	=	23.30
1/36	=	0.00180	7	=	0.460	30	=	1.95	7	=	27.20
1/32	=	0.00202	8	=	0.520	31	=	2.00	Ounces.		
1/30	=	0.00216	9	=	0.600	32	=	2.10	**1**	=	**31.10**[2]
1/25	=	0.00259	10	=	0.650	33	=	2.16	2	=	62.20
1/24	=	0.00270	11	=	0.715	34	=	2.20	3	=	93.30
1/20	=	0.00324	12	=	0.780	35	=	2.25	4	=	124.40
1/18	=	0.00360	13	=	0.845	36	=	2.30	5	=	155.50
1/16	=	0.00405	14	=	0.907	37	=	2.40	6	=	186.60
1/15	=	0.00432	15	=	0.972	38	=	2.47	7	=	217.70
1/12	=	0.00540	**15.5**[1]	=	**1.000**	39	=	2.55	8	=	248.80
1/10	=	0.00648	16	=	1.040	40	=	2.60	9	=	280.00
1/8	=	0.00810	17	=	1.102	42	=	2.73	10	=	311.00
1/6	=	0.01080	18	=	1.160	44	=	2.86	11	=	342.14
1/5	=	0.01296	19	=	1.240	48	=	3.00	12	=	373.23
1/4	=	0.01620	20	=	1.300	50	=	3.25	14	=	435.50
1/3	=	0.2160	21	=	1.360	52	=	3.40	16	=	497.60
1/2	=	0.03240	22	=	1.425	56	=	3.65	24	=	746.40
2/3	=	0.04860	23	=	1.460	58	=	3.75	48	=	1492.80
									100	=	3110.40

COMPARATIVE VALUES OF AVOIRDUPOIS AND METRIC WEIGHTS

Avoir. Ounces.		Grams.	Avoir. Ounces.		Grams.	Avoir. Ounces.		Grams.	Avoir. Pounds.		Grams.
1/16	=	1.772	5	=	141.75	13	=	368.54	3	=	1360.78
1/8	=	3.544	6	=	170.10	14	=	396.90	4	=	1814.37
1/4	=	7.088	7	=	198.45	15	=	425.25	5	=	2267.96
1/2	=	14.175	8	=	226.80	Avoir.			6	=	2727.55
1	=	28.350	9	=	255.15	Pounds.			7	=	3175.14
2	=	56.700	10	=	283.50	1	=	453.60	8	=	3628.74
3	=	85.050	11	=	311.84	2	=	907.18	9	=	4082.33
4	=	113.400	12	=	340.22	2.2	=	1000.00	10	=	4535.92

[1] More accurately, 15.432+gr. = 1 gram.

[2] More accurately, 31.10349 grams.

COMPARATIVE VALUES OF METRIC AND AVOIRDUPOIS WEIGHTS

Grams.	Oz.	Gr.	Grams.	Oz.	Gr.	Grams.	Oz.	Gr.	Grams.	Oz.	Gr.
28.35 =	1		38 =	1	149	125 =	4	179	600 =	21	72
29 =	1	10	39 =	1	164	150 =	5	127	650 =	22	405
30 =	1	25	40 =	1	180	200 =	7	24	700 =	24	303
31 =	1	41	50 =	1	334	250 =	8	358	750 =	26	198
32 =	1	56	60 =	2	50	300 =	10	255	800 =	28	96
33 =	1	72	70 =	2	205	350 =	12	152	850 =	29	429
34 =	1	87	80 =	2	360	400 =	14	48	900 =	31	326
35 =	1	103	85 =	3		450 =	15	382	950 =	33	222
36 =	1	118	90 =	3	76	500 =	17	279	1000 =	35	120
37 =	1	133	100 =	3	230	550 =	19	175			

TABLE OF EQUIVALENTS OF CENTIGRADE AND FAHRENHEIT THERMOMETRIC SCALES

Cent.	Fahr.	Cent.	Fahr.	Cent.	Fahr.
Degrees.	Degrees.	Degrees.	Degrees.	Degrees.	Degrees.
−40	−40.0	9	48.2	57	134.6
−39	−38.2	10	50.0	58	136.4
−38	−36.4	11	51.8	59	138.2
−37	−34.6	12	53.6	60	140.0
−36	−32.8	13	55.4	61	141.8
−35	−31.0	14	57.2	62	143.6
−34	−29.2	15	59.0	63	145.4
−33	−27.4	16	60.8	64	147.2
−32	−25.6	17	62.6	65	149.0
−31	−23.8	18	64.4	66	150.8
−30	−22.0	19	66.2	67	152.6
−29	−20.2	20	68.0	68	154.4
−28	−18.4	21	69.8	69	156.2
−27	−16.6	22	71.6	70	158 0
−26	−14.8	23	73.4	71	159.8
−25	−13.0	24	75.2	72	161.6
−24	−11.2	25	77.0	73	163.4
−23	− 9.4	26	78.8	74	165.2
−22	− 7.6	27	80.6	75	167.0
−21	− 5.8	28	82.4	76	168.8
−20	− 4.0	29	84.2	77	170.6
−19	− 2.2	30	86.0	78	172.4
−18	− 0.4	31	87.8	79	174.2
−17	+ 1.4	32	89.6	80	176.0
−16	3.2	33	91.4	81	177.8
−15	5.0	34	93.2	82	179.6
−14	6.8	35	95.0	83	181.4
−13	8.6	36	96.8	84	183.2
−12	10.4	37	98.6	85	185.0
−11	12.2	38	100.4	86	186.8
−10	14.0	39	102.2	87	188.6
−9	15.8	40	104.0	88	190.4
−8	17.6	41	105.8	89	192.2
−7	19.4	42	107.6	90	194.0
−6	21.2	43	109.4	91	195.8
−5	23.0	44	111.2	92	197.6
−4	24.8	45	113.0	93	199.4
−3	26.6	46	114.8	94	201.2
−2	28.4	47	116.6	95	203.0
−1	30.2	48	118.4	96	204.8
0	32.0	49	120.2	97	206.6
+1	33.8	50	122.0	98	208.4
2	35.6	51	123.8	99	210.2
3	37.4	52	125.6	100	212.0
4	39.2	53	127.4	101	213.8
5	41.0	54	129.2	102	215.6
6	42.8	55	131.0	103	217.4
7	44.6	56	132.8	104	219.2
8	46.4				

A simple rule for the conversion of Centigrade to Fahrenheit, and vice versa: 212° F. — 32 × 5 ÷ 9 = 100° C.; 100° C. × 9 ÷ 5 + 32 = 212° F.

Example:

212° F.	100° C.
32	9
180	5)900
5	180
9)900	32
100° C.	212° F.

Local Anæsthesia

Further experience in the employment of endermic and hypodermic injections of the hydrochloride of quinia and urea as a local anæsthetic has demonstrated in several instances that the stronger solution (two per cent) is capable of producing a necrosis of the skin along the lines of the incision. This result has in no instance followed the employment of a one-per-cent solution, and the local anæsthesia obtained has been as satisfactory with this weaker as with the stronger solution.

In the present state of our knowledge concerning this newer agent, the author is of the opinion that the weak solutions of cocaine, as given in the text, will be found preferable in the large majority of operative cases where local anæsthesia is to be preferred, and that the quinia and urea solutions will be valuable in subjects who develop an idiosyncrasy which contra-indicates cocaine. It is advised that in using the quinia solution, free infiltration be made beneath the skin, waiting fifteen or twenty minutes for the full anæsthetic effect, and that the endermic method be either not employed, or, if used, the weaker solution be injected.

The following formula may be used to advantage as an adjunct to the local anæsthesia of cocaine. It is especially recommended by Dr. A. T. Bristow, who has employed it extensively, and so far without a symptom to contra-indicate its use, especially in the removal of thyroid enlargements:

℞ Hyoscine hydrobromide ..... $\frac{1}{100}$ gr.
Atropine ..... $\frac{1}{200}$ "
Morphine sulphate ..... $\frac{1}{4}$ " [1]

One half of a tablet is given hypodermically three hours before operation. One and one half hours later this dose is repeated, and again just before the operation is begun. The skin incision is made after the usual endermic injection of a one-half-of-one-per-cent solution of cocaine. Usually the subcutaneous dissection may be made without further infiltration, but, when necessary, the same cocaine solution may be employed.

OPERATION FOR THE RADICAL CURE OF INGUINAL HERNIA IN THE MALE

Prof. W. S. Halsted, who independently of Bassini's investigations was one of the originators of the plastic operation for the radical cure of inguinal hernia (generally known as the Bassini operation), has since 1890 practiced in a large number of operations *non-transplantation* of the spermatic cord. His success leads the author to conclude that transplantation is not necessary in inguinal herniæ of comparatively small size and of short duration. When the hernial opening is very large, with attrition of the tissues from the pressure of a truss, and when a well-marked varicocele exists, in addition to the partial removal of the enlarged veins for the cure of the varicocele, transplantation of the cord should be preferred. When the internal oblique and transversalis muscles, reënforced by the cremasteric fibers, are stitched to Poupart's ligament, the cord rests beneath the line of sutures. The procedure is simplified and the cord is left practically in its normal relation. This operation also does away with the possible danger of overcompression of the

[1] This formula is prepared as a single tablet by Parke, Davis & Company.

cord, which sometimes follows—at least temporarily—when transplantation has been practiced.

In the milder cases, where the opening is small, and especially in cases of incomplete herniæ, in addition to non-transplantation, simple deligation of the neck of the sac at the peritoneal level will also suffice, leaving the more radical procedure of Macewen in the treatment of the sac to the larger herniæ.

Formula for Harrington's (Antiseptic) Solution

℞ Commercial alcohol (ninety-four per cent pure)	600	c.c.
Strong hydrochloric acid	60	"
Water	300	"
Bichloride of mercury	8	grams.

Many operators of large experience prefer this preparation for cleansing the hands, which should first be put through the ordinary routine of washing and brushing in hot, clean soap and water and then immersing for two minutes in this solution. It is also recommended as a disinfectant for abscess cavities from which the drainage is free, and where any excess can be removed by immediate irrigation with normal salt solution.

INDEX

Abbe's treatment of œsophageal strictures, 354.
Abdomen, wounds of, 374; hysterectomy, 631.
Abdominal injuries in general, 373; aorta, aneurism of, 106; aorta, ligation of, 136, 137; section for intestinal occlusion, 419; irrigator, Blake's, 449.
Abscess, extra-dural, 293; of jaw, 309; of antrum of Highmore, 309; chronic alveolar, 309; of palate, 317; of mammary gland, 357; of thoracic walls, 364; of Brodie, 145; of tongue, 325; of tonsil, 329; of neck, 331; retro-pharyngeal, 331, 647, 736; from foreign bodies in air passages, 344; of scalp, 230; of frontal sinuses, 230; of brain, 239; diagnosis of, 243; of cornea, 261; vulvo-vaginal, 603; of the vagina, 623; of the liver, hepatic, 401; subphrenic, 401, 402; of the spleen, 411.
Absence of vagina, 623.
Absorbent dressings, 13.
Aconite, in tonsillitis, 329.
Acquired tumors, of scalp, 229.
Acromegaly, 146.
Acromion process, fracture of, 155.
Actinomycosis, 146, 753.
Actual cautery, for occlusion of arteries and veins, 110.
Acupuncture, for aneurisms, 98.
Acute, osteomyelitis, 144; periostitis, 144.
Adenitis, acute infective, 85; symptoms, 85; treatment, 85; cervical, 85; catarrhal pharyngitis as cause, 85; tuberculous, 85; inguinal, 562.
Adenoid vegetations, 298.
Adenoma, of lips, 304; testis, 599, 712; of mammary gland, 357.
Adhesions, of auricle of ear to scalp, 283; between pericardium and pleura, 369; of stomach, 390; of the clitoris, 605.
Adrenalin, in hæmorrhage from nose, 294.
Advancement of insertion of eye muscles, 273.
After-care of gastrectomy, 398.
Agnew's canalicula knife, 257.
Air, entrance in veins of neck, 331.
Air tumor, of scalp, 230.
Alcohol, injection for trifacial neuralgia, 245; as cause of atrophy of optic nerve, 281.
Alimentary canal, obstruction of, 414; clearing of, 1.
Alimentation, colon, 349, 350.
Allis', inhaler, 25; operation for congenital dislocation of hip, 656; method of treating fractures at elbows, 160.
Alveolar abscess, chronic, 309.
Amaurosis, 271.
Amblyopia, 271.
Ametropia, 273.
Amputation, shoulder-joint, 59; through humerus, 60, 61; shoulder-joint, 61, 62; of upper extremity, 63; amputations, 48; retraction in, 51; catgut ligatures, 51; catgut drainage, 51; sutures in, 51; dressing, 51; at knee, 73; of Stephen Smith, 70, 73, 74; hip-joint, 75, 76, 77, 78; rubber tubing in, 77; at carpo-radial joint, 55; at elbow-joint, 58, 59; tarso-metatarsal, 64; at tibio-tarsal joint, 68; mediotarsal, 66; of Chopart, 66; of Esmarch, 53; of middle finger, 53; of Forbes, 66; of Pirogoff, 66; of Hey, 66; of Lisfranc, 66; of Lee, 71; of Teale, 71; of Sedillot, 71; of Malgaigne, 67; of Syme, 68; of Wyeth, 61, 75; prognosis in, 48; primary, 48; secondary, 48; special, 51; infusion in, 49; by circular skin flaps, 50; by circular solid flaps, 50; by modified circular flaps, 50; Estes' views on, 48; of Gritti, 74; of the penis, Humphrey, 583; of the cervix, 626; of the finger, 692; at ankle-joint, 68; time, 48; Esmarch's bandage in, 48; transfixion pins, 44; shock, 49; nitrous oxide, 49; for malignant neoplasms, 49; point of selection, 49; operation, 49; tourniquet, 50; Trendelenburg posture, 50; flap, 50; combination skin and muscular flap, 50; in diabetics, 50; in senile gangrene, 50; circular flap in, 50; modified circular flap, 50; of toes, 63, 64; through tarsus, 66; prognosis, 48; classification of, 48; injury to skin, 48; of hand and fingers, 51; interphalangeal, 52; at posterior phalangeal joint, 52; metacarpo-phalangeal joint of thumb, 53; of index-finger, 53, 54; of ring-finger, 54; of little finger, 54, 55; calcaneo-astragaloid joint, 67; at metacarpus, 55; carpo-metacarpal, 55; of thumb, 55.
Anæmia, 788.
Anæsthesia, 15; ether, 18; chloroform, 22 nitrous oxide, 23; cocaine, 25; rectal, 28 selection of, 16; in alcoholics, 16; in fat subjects, 16; gastric lavage, 16; tracheotomy, 21; whisky, 22; artificial respiration, 21, 22; local, with herniotomy, 465; local, 797.
Anastomosis, of the ureter, 510; intestinal, 420; end-to-end, 421; lateral intestinal, 427.
Anatomy of arteries, of internal carotid artery, 120; of external carotid artery, 121; of femoral, 139; of the innominate, 113; of common carotids, 114; of superior thyroid, 123; of lingual, 123; of facial artery, 125; of ascending pharyngeal, 126; of occipital arteries, 126; of posterior auricular, 126; of temporal, 126; of internal maxillary, 126; of subclavian, 127; of axillary, 132; of brachial, 133; of intercostals, 136; of abdominal aorta, 136; of common iliac, 137; of internal iliac, 138; of external iliac, 138.
Ancient dislocation, 185.
Anel, deligation in aneurism, 96; syringe, 258.
Aneurism, classification of, 93; spherical, 93; fusiform, 93, 94; dissecting, 93, 94; true, 93; false, 93, 94; pathology of, 93, 94; of arch of

aorta, 93; of aorta, 100; popliteal, 93, 108; varicose, 93, 94; of axillary artery, 106; of brachial artery, 106; of radial artery, 106; of ulnar artery, 106; of internal mammary artery, 106; of abdominal aorta, 106; of common iliac artery, 107; of innominate artery, 100, 102; of thoracic aorta, 99, 102; of aorto-innominate, 102; of common carotid, 102; of vertebral artery, 103; of external carotid, 103; of internal carotid, 104; of ophthalmic artery, 104; of subclavian artery, 104; of ascending aorta, 99, 100; calcareous deposits in, 94; cirsoid aneurism, 94; prognosis of aneurism, 94; gangrene in, 94, 95; symptoms of, 95; diagnosis of, 95; sacculated, 99; treatment, 95; by acupuncture, 98; by compression with fingers, 96; by flexion, 99; by iodide of potassium, 95; by mercury, 95; method of Macewen, 98; Wyeth's method, 98; method of Valsalva, 95; of Hunter, 96; of Anel, 96; of Brasdor, 96; of Wardrop, 96; of Antyllus, 96; special aneurisms, 99; of descending aorta, 106; arterio-venous, 108; of gluteal artery, 107; of sciatic artery, 107; of femoral artery, 107; of anterior and posterior tibials, 108; of dorsalis pedis, 108; method of Matas, 108; aspiration of, 107; of heart, 369.
Aneurismal varix, 93, 94.
Angeioma, of ear, 283; of scrotum, 588; 716; of lips, 304; of tongue, 325; venous, 88; of heart, 369; of nipple, 356; arterial, 87; capillary, 89; Wyeth's treatment of, 88; of lower jaw, 312.
Angeiotribe, for crushing arteries, 111.
Angle of jaw, fracture of, 153.
Angular depressions of nose, 298.
Ani, pruritus, 478–501.
Ankle-joint, exsection of, 221; diseases of, 215; synovitis of, 215; osteo-arthritis of, 216; dislocation of, 200.
Ankylosis, of inferior maxilla, 315; at the knee, 665; of the shoulder, 681.
Anteflexion of the uterus, 611.
Anterior tibial artery, ligation of, 143; curvature of the spine, 644, 645; polar cataract, 267; synechia, 263.
Anthrax, 753, 779.
Antisepsis, 3.
Antiseptic solution, 798.
Antrum, of Highmore, abscess of, 309; drainage of, 310; diseases of, 310; tumor of, 310; of mastoid, location of, 291.
Antyllus, deligation in aneurism, 96.
Anus, absence of, 476; eczema of, 478; herpes of, 478; fistula, 479; erythema of, 478; pityriasis versicolor, 478; atresia of, 477; foreign bodies in, 479; neoplasms of, 486; fissure, 482; syphilitic chancre of, 483, 484; artificial, 433; imperforate, 438.
Aorta, thoracic, aneurism of, 99, 102; aneurism of abdominal, 107; ligation of, for iliac aneurism, 107.
Aorto-innominate aneurism, 102.
Appendectomy, 443.
Appendicitis, 440.
Arcus senilis, 263.
Arterial angeioma, 87; capillary, 89; venous, 88; Wyeth's treatment of, 88.
Arterioplasty, reconstructive, 97, 98.
Arteriorrhaphy, operative, 98.
Arteritis, 87; etiology of, 87; sequelæ of, 87; thrombosis and embolism in, 87; syphilitic, 766.
Artery, ligation of external carotid, 121, 122; of internal carotid, 120; of superior thyroid, 123; of lingual, 123; of facial, 125; of ascending pharyngeal, 126; of anterior tibial, 143; ligation of occipital, 126; of internal mammary, 131; of posterior tibial, 142; of femoral, 139; wounds of, 109; suture of, 109; of profunda femoris, 141; of popliteal, 141, 142; of intercostal, 136; of abdominal aorta, 136, 137; of common iliac, 138; of internal iliac, 138; of external iliac, 138; of gluteal, 138; of sciatic, 138; of internal pudic, 139; of subclavian, 130, 131; of vertebral, 131; of axillary, 132; of brachial, 133; of ulnar, 133, 134; of radial, 133, 134; of innominate, 113, 114; of common carotid, 114; inflammation of, 87; of carotid at root of neck, 118; of posterior auricular, 126; of temporal, 126; of internal maxillary, 126; of dorsalis pedis, 143; occlusion of arteries, 110.
Arthritis, 202; of ankle-joint, 215; of hip-joint, 203.
Artificial, respiration, Sylvester's method, 21, 22; anus, 433; limb, time to apply, 71; eye, time to wear, 265; respiration, in wounds of the neck, 331.
Ascarides, 479.
Ascending aorta, aneurism of, 99, 100; pharyngeal artery, anatomy of, 126; ligation of, 126.
Ascites, 400; operation for relief of, 402, 403.
Asepsis, 2, 3, 4.
Aseptic wounds, healing of, 42.
Ashurst, John, remarks on hip-joint amputation, 75.
Aspermatism, 557.
Aspiration of knee-joint, 212; of ankle-joint, 215; of shoulder-joint, 216; of the ventricles of brain, 243, 244; of pleura, 365; in abscess of neck, 332.
Asthenopia, 275.
Astigmatism, 276.
Astragalus, fracture of, 181.
Atresia of rectum and anus, 477.
Atrophy of optic nerve, 281.
Atropine in iritis, 264; in refraction, 275.
Auricle of ear, 283.
Avulsion of trifacial nerve for neuralgia, 247; of neoplasms in larynx, 347.
Axillary artery, aneurism of, 106; ligation of, 132.

Bacteria, 732; in the blood, 789.
Bainbridge, spinal analgesia, 28.
Balanitis, 560, 762.
Bandage, Velpeau's, in fracture of clavicle, 186; in fracture of coracoid process, 156; figure-of-8, for hand, 33; for shoulder and upper extremity, 33; hip and abdominal spica, 48; single and double spica, for groin, 34; spica, 34; Velpeau's, for fracture of clavicle, 186; plaster of Paris, 29; simple spiral, 30; of fingers, 31; roller, 29; reverse spiral, 30, 31; simple figure-of-8, 30; Esmarch, 12; figure-of-8, reverse, 31; Wyeth's hand, thumb, and finger, 31; of hands and fingers, 32; of forearm, arm, and shoulder, 32; of toes, foot, and thigh, 33; for head and face, 35, 36, 37; four-tailed, 37; four-tailed cap, 38; head and face hood, 38; skull-net, for holding ice-bag, 38; four-tailed, for chin and lower jaw, 38; T bandage, 39; Esmarch's, 29; Martin's rubber, 29; for mammary gland, 34, 35; hood, 35; for head and chin, 36; for fracture of lower

jaw, 36; for hæmorrhage, 36; knotted, 36; for eye and upper lip, 37.
Bandaging, 29; material for, 29.
Bands, constriction by, 417.
Banks, E. A., filiform bougies, 568, 569.
Barker, exophthalmic goître, 336.
Barnes' dilator, 2.
Bartlett, Willard, preparation of catgut, 5; method of treatment for wounds of the ureter, 509; case of hernia, 475.
Baruch, Simon, case of appendicitis, 440.
Basedow's disease, 336.
Bassini's operation for radical cure of inguinal hernia, 461.
Beck, Carl, operation to prevent cerebral hernia, 242; congenital malformations of urethra, 579.
Beebe, S. P., parathyroid bodies, 334; serum in goître, 340.
Beef juice for colon alimentation, 350.
Beer's keratome, 265; straight needle, 270.
Benign tumors, differentiation between malignant and, 719–720.
Bevan, A. D., lateral curved incision, 398.
Bichloride (see mercury) in lymphangitis, 85.
Bier, A., method of treatment of tuberculosis, 756; treatment by hyperæmia, 757.
Bier, Edwin, intrahepatic cholelithiasis, 407.
Bigelow, dislocation of the hip, 195; method of reducing, 197, 198.
Billroth's disease, 86, 333.
Bilharzia hæmatobia, 533.
Biliary calculi in gall duct, 408–409; 414.
Bistouries, 9.
Bite, dog, 751.
Bladder, 515; exstrophy of, 516; hernia of, 517; cystocele, 517; wounds of, 517; rupture of, 517; gunshot wounds of, 519; neoplasms of, 526; stone in, 533; calculus in, 534; cystotomy, suprapubic, 540; female, stone in, 545; foreign bodies in, 546.
Blake, J. A., abdominal irrigator, 449; hernia, 468–472.
Blasius' operation on lower lip, 306.
Blepharitis, 252; ciliaris, 252; acute, 252; chronic ciliary, 252.
Blepharophimosis, 252.
Blepharoptosis, 252.
Blepharospasm, 252.
Blood-letting in iritis, 264.
Blood, pus in, 531, 785; vessels, 766; bacteria in, 789.
Bodine, temporary artificial anus, 377; cocaine infiltration, 26; formula, 26; abdominal section for intestinal occlusion, 420; operation for lateral anastomosis, 438; case of hernia, 465.
Boils, 779.
Bone, surgery and surgical diseases of, 144; caries, of, 144; osteomyelitis, of, 144, 145; tuberculous inflammation, of, 145; caries sicca, of, 145; special fractures, 150; hydatid cysts, of, 146; syphilitic lesions, of, 146; exostoses, of, 146; Paget's disease, of, 146; actinomycosis, of, 146; acromegaly, of, 146; osteomalacia, of, 145; rachitis, 146; process of, repair in, 728, 766.
Bony new growths of ear, 286.
Boric acid in gonorrhœal ophthalmia, 259; in blepharitis, 252.
Bougies, Banks' filiform, 568; flexible, 572–573; urethral, 573.
Bowleg, 664.
Bow-saw, 10.
Brace for spine, Taylor's, 654.
Brachial artery, aneurism of, 96; ligation of, 133; cysts, 333.
Bradford and Lovett, hip-disease, 206.
Brain, compression by tumors of, 237.
Brain, exploration of, 238, 765; penetrating wounds of, 232; centers, localization of, 233, 234; abscess of, diagnosis of, 239, 243.
Brandy, 19, 22.
Brasdor's operation for aneurism, 96.
Breast, *vide* mammary gland, 356; tuberculosis of, 359; carcinoma of, 359; sarcoma of, 359; encephaloid cancer of, 360; epithelioma of, 360; tumors of, 357; removal of, 360.
Brewer, George E., pancreas, 412.
Brickner, W. M., malposition of testicle, 600.
Bristle prong for removing foreign bodies in œsophagus, 348.
Bristow, A. T., local anæsthesia, 797.
Brodie's abscess, 145.
Bronchi, surgery of, 365; foreign bodies in, 343.
Bronchitis from foreign bodies in air passages, 344.
Bronchotomy, 367.
Brophy, Truman W., operation for cleft palate, 318, 319; needles, 318; periosteotomes, 10, 320.
Brown, E., gas-oxygen apparatus, 24.
Brown, F. Tilden, suprapubic apparatus for bladder drainage, 555.
Bruit in aneurism, 95, 99.
Bryant's test for fracture in neck of femur, 169.
Bubo, 562.
Buchanan, operation for rupture of quadriceps extensor, 227.
Buck's method of treating fracture of acetabulum, 169; extension in facture of thigh, 174; extension after dislocation of knee, 199.
Bunions, 679.
Burns, 774.
Bursitis of hip-joint, 205.
Butlin, epithelioma of tongue, 326.
Button, J. B. Murphy's, 410, 421.

Caffein in shock, 49.
Calcaneus, talipes, 667.
Calcareous degeneration in tubercular adenitis, 86; deposits in aneurism, 94.
Calculi, nasal, 295; of Steno's duct, 307; urinary, 533; in urethra, 408–409, 414, 573.
Calculus in the bladder, 534; of the pancreas, 413.
Calomel, value of, 1.
Camphor in shock, 49.
Cancer of œsophagus, 354, 700.
Canthoplasty in gonorrhœal ophthalmia, 259; in diphtheritic conjunctivitis, 260; in trachoma, 259.
Canthotomy in phlyctenular keratitis, 263.
Canula for trachea, 342.
Capillary angeioma, 89, 90; location of, 90.
Capsular cataract, 267.
Carbuncle, 780.
Carcinoma of tonsils, 329; of thyroid body, 335; of parotid gland, 308; of the prostate, 557; of the uterus, 628, 700; of larynx, 346; of œsophagus, 354; of antrum of Highmore, 310; of the liver, 400, 413; of the colon, 430; of lung, 367; of stomach, 392; of heart, 369; of mammary land, 359; of meninges, 231.
Cardioclasia, 367.

Cardiomorphia, 367.
Cargile membrane in adhesions of stomach, 390.
Caries of bone, 144; sicca, 145.
Carotid, arteries, common, aneurism of, 102; of internal carotid, 104; relation of the veins to, 120; body, hypertrophy of, 333.
Carpus, fracture of, 165.
Cartilage, repair of, 731.
Caruncle of urethra, 623.
Case, Meigs, suspension apparatus, 655.
Caseous degeneration in tubercular adenitis, 86.
Castor oil, value of, 1.
Cataract, varieties of, 266; removal of, 268.
Catarrh, nasopharyngeal, 298.
Catarrhal pharyngitis causing adenitis, 85; inflammation of rectum, 500.
Catgut in amputations, 50; for drain, in compound fractures, 182; in scalp wounds, 151; for ligature, 41; preparation of, 45; for drainage, 14.
Catherization of ureter, Kelly's method, 512, 513; Pawlik's method, 513, 514.
Catheter, Eustachian, 286; introduction of, 287.
Cauda equina, tumors of, 694.
Cautery, actual, for occlusion of arteries and veins, 110; in hæmorrhoids, 499.
Cavernous nævus, 87, 88.
Cavus, talipes, 675.
Celiotomy, 327.
Centers of brain, 233.
Centigrade, 796.
Centipede, 46.
Central cataract, 267.
Cephalic vein, 45.
Cerebral hæmorrhage, 242.
Cervical glands, tumors of, 332; adenitis, 85; superficial, infection of, 332.
Cervix, uteri, 606; inflammation of, 606; lacerations of, 625; amputation of, 626.
Chair, Martin's, 431.
Chalazion, 251.
Chappell, Walter F., pharyngotomy, 341.
Chaps of lips, 304.
Charcot disease of knee-joint, 215.
Cheeks, lupus of, 303.
Chest, wounds of, 365.
Cheyne-Stokes respiration in cerebral hæmorrhage, 242.
Chin and head support, 654.
Chipault localization of brain centers, 233, 234.
Chisels, 10.
Chloroform, 22; selection of, 16; heart, 16; in children, 16; in parturition, 16; mortality, 16; skin, 22; tissues, 15; secretions, 17; test for purity, 22; morphia, 22; warming of, 23; technic, 23; cause of death, 23; inhaler, 23.
Chlorosis, 789.
Cholecystectomy, 403, 404–407.
Cholecystenterostomy, 410.
Cholecystotomy, 403.
Choledochotomy, 407–409.
Cholelithiasis, intrahepatic, 407.
Chondroma, 717; fibro-, 718.
Chopart's amputation through tarsus, 66.
Choroiditis, 264, 282.
Chromic acid in benign tumors of larynx, 347.
Chronic urethritis, follicular, 563.
Circular skin flaps, 50; skin and muscle flaps, 50.
Cirsoid aneurism, 87.
Clamp, Smith's, in hæmorrhoids, 499; Roosevelt's, 427; Michels, 5.
Classification of tumors, 698.
Clavicle, fracture of, 154; dressing for, 154, 155; dislocation of, 186.
Cleft palate, 317; acquired, 317; time to operate, 318; operation for, 318, 319.
Clitoris, adhesions of, 605.
Clubfoot, 665.
Clubhand, 683.
Coagulation in hæmorrhage, 42.
Cobra, 45.
Cocaine, in removal of thyroid body, 333, 340; in hæmorrhage from nose, 294; in operations upon external auditory meatus, 285; on auricle of ear, 283; in eye, 25; shock, 26; in amputation of fingers, 52; cure of hernia, 26; preparation, 26; in fracture of patella, 176; in removal of cysts, 229; Bodine's formula, 26; morphia, 27; tourniquet, 27; small incisions, 90; thyroidectomy, 27; in removal of cataract, 268; in ophthalmoscopy, 280; in deligation of arteries, 106; in gonorrheal ophthalmia, 259; in excision of moles, etc., 90; in removal of varicose veins, 91; in refraction, 275.
Coccyx, dislocation of, 201; fracture of, 167.
Cod-liver oil in ununited fractures, 182.
Coffee in syncope, 45.
Coley, toxines in sarcoma of parotid gland, 309; mixed toxines in sarcoma of stomach, 398; remarks on lymphosarcoma, 86.
Colles' fracture, 164; diagnosis from dislocation, 193; dressing for, 165; Pilcher's method of reducing, 165.
Colon alimentation, in removal of tongue, 327; flexure of, 429; carcinoma, 430; in wounds of œsophagus, 331, 349, 350.
Color-blindness, 271.
Colostomy, 433–437.
Common carotid artery, aneurism of, 102; ligation of, 114; at root of neck, 118.
Common iliac artery, aneurism of, 107; ligation of, 137, 138.
Complete dislocation, 185.
Complicated dislocation, 185.
Compound dislocation, 185.
Compression of the brain, 151; by tumors, 237.
Concretions, prostatic, 557.
Concussion of the brain, 151; of the spine, 693.
Condyle of jaw, fracture of, 153.
Congenital, malformations of urethra, 577; lesions of nose, 301; dislocation of knee-joint, 199; fistulæ, 439; tumors of scalp, 229; dislocation of hip, 195, 656; dislocation at shoulder, 681; deformities of forearm, 682; deformities of fingers, 684; deformities of hands, 684.
Conical, stump, in amputations of humerus, 61; cornea, 263.
Conjunctiva, lupus of, 260; epithelioma of, 260; cystic tumors of, 260; xerosis of, 260; phlyctenulæ of, 262, 258.
Conjunctivitis, acute, 258; chronic, 258; circumscribed, 258; diffuse, 258; simple, 258; granular, 258; follicular, 258; croupous, 260; diphtheritic, 260.
Connective tissue, 726; formation of, 726.
Connell or buttonhole suture, in gastro-jejunostomy, 387; in end-to-end anastomosis, 422–423.
Constriction of intestine, by bands, 414, 417; by diverticula, 417.
Contraction, of the mouth, 306; Dupuytren's, 686.
Contused wound, 42; of scalp, 232.
Contusions of the abdomen, 374; of the spine, 693.
Coracoid process, fracture of, 156.

Cornea, 261; foreign bodies and wounds of, 261; abscess of, 261; ulcer of, 262; herpetic vesicles of, 262; phlyctenulæ of, 262; staphyloma of, 263.
Corneitis, 261.
Coronoid process of jaw, fracture of, 153; of ulna, 163.
Cortical cataract, 266.
Corns, 679.
Cosmoline in treatment of blepharitis, 252.
Cotton, absorbent, 13; sterilization of, 4.
Coxitis, 203.
Cranial defects, 242.
Cranium, fractures of, 150.
Crepitus in fracture of bones, 147.
Crinoline for bandage, 29.
Critchett's operation for staphyloma, 263.
Croupous conjunctivitis, 260.
Crushing for occlusion of arteries and veins, 110, 111.
Crystalline lens, 266.
Curettage of the uterus, 627.
Curvature of the spine, 638; lateral, 638; rotary lateral, 638, 641.
Cushing, H. W., mattress suture, 382; suture in gastrectomy, 397, 424.
Cushing, Harvey, exploration of brain, 238; fracture of base of skull, 241; operation for excision of Gasserian ganglion, 247.
Cyclitis, 265.
Cyphosis, 638.
Cystic goitre, 335; drainage of, 337; tumors of neck, 333; tumors of tongue, 325; tumors of tonsils, 329; tumors of larynx, 346; tumors of conjunctiva, 260; formations of lower jaw, 312; tumors of lips, 304.
Cysticercus of tongue, 325.
Cystitis, 520–523.
Cystocele, 517.
Cystoma of parotid gland, 308.
Cystotome, 269.
Cystotomy, suprapubic, 540.
Cysts, congenital of scalp, 229; dermoids, 229; multilocular, 229; sebaceous, 229; of mammary gland, 359; of nipple, 356; brachial, 333; dentigerous, 316; of eyelids, 251; of kidney, 506; of scrotum, 588; of ovary, dermoid, 636, 713; of spleen, 412; hydatid of liver, 401; mucous, 714; serous, 714.

Dacryo-cystitis, 257.
Dacryoadenitis, 257.
Dacryoliths, 257.
Daviels' curette, 261; spoon, 269.
Davis, D. B., case of splenectomy, 412.
Davy's lever in aneurism of external iliac artery, 107.
Dawbarn's sequestration, 16, 17, 20, 28; in removal of thyroid body, 334, 337; in gunshot wounds of skull and brain, 233; in removal of parotid gland, 308; in formidable operations about mouth, 314; in complete removal of external carotid artery, 330.
Deaver, J. B., method of treatment for wounds of the ureter, 509; case of appendicitis, 440, 445; abdominal incision, 373.
Defects, cranial, 242.
Deformities, of the uterus, 611; of the spinal column, 638; of the lower extremity, 656; of the knee, 660, 661; of the toes, 676–677; of upper extremity, 681; congenital, of the forearm, 682; congenital, of the fingers, 684; congenital, of the hands, 684.
Degrees, 796.
Deligation of arteries (*vide* ligation) for aneurism, 96.
Deltoid, paralysis of, 681.
Dench, introduction of Eustachian catheter, 287; myringotomy, 289; location of mastoid antrum, 291; removal of adenoids, 298.
Dental forceps, 315.
Dentigerous cysts, 316.
Dermoid cysts, of mammary gland, 359; of ovary, 636; of scalp, 229.
Deschamp's needles, 320.
Desmarres' retractors, 261.
Destructive osteo-arthritis of knee-joint, 213.
Detachment of retina, 271.
Detmold's method of controlling hæmorrhage, 40, 47.
De Vilbiss, forceps in trephining, 236; bone forceps, 11.
Diagnosis of syphilis, 769.
Diaphragm, hernia of, 456.
Dieffenbach, hip-joint amputation, 75.
Diet list, 2.
Differentiation between benign and malignant tumors, 719–720.
Diffuse keratitis, 261.
Dilating urethrotome (Otis'), 567.
Diphtheria, 745, 747.
Diphtheritic conjunctivitis, 260.
Diplopia, 278.
Disarticulation, at tarso-metatarsal joint, 64; at tibio-tarsal joint, 68, 69; of finger phalanges, 52; of toes, 63; at elbow-joint, 58, 59; at metacarpo-phalangeal joint, 54; at carpo-radial joint, 55, 56; at astragalus, 67; at calcaneus, 67; at hip-joint, 75, 76, 77; at knee, 73, 74; at metatarsal joint, 64; at shoulder-joint, 61, 62; carpo-metacarpal joint, 55.
Discission of cataract, 270.
Diseases, of ankle-joint, 215; of knee-joint, 212; of shoulder-joint, 216; of hip-joint, 203; of bone, 144; of special joints, 203; of joints, 202; of lips, 302; of fingers, 688; surgical, 721; of foot, 755; of mouth, 755; venereal, 758.
Dislocations, traumatic, 185; pathological, 185; congenital, 185; complete, 185; simple, 185; complicated, 185; compound, 185; recent, 185; ancient, 185; primitive, 185; secondary, 185.
Dislocation, of ankle-joint, 200; of tibio-tarsal, 200; of patella, 200; of hip, 194–198; of phalanges of fingers, 193; of knee-joint, 199; of inferior maxilla, 185; at elbow, 190–192; of head of radius, 186; of radius and ulna at elbow, 191–193; of wrist-joint, 193; of metacarpal bones, 193; of clavicle, 186; at shoulder-joint, 186; subglenoid, 186; subcoracoid, 186; subclavicular, 186; subspinous, 186; subacromial, 190; of vertebræ, 201; of condyles of occipital bone, 201; of ribs, 201; of pelvis, 201; of coccyx, 201; of tibia at lower end, 200; of fibula, 201; of bones of tarsus, 201; of astragalus, 201; of phalanges of toes, 201; of metatarsal bones, 201; congenital, of hip, 656; at the shoulder, 681; of the spine, 693.
Displacement, of the uterus, 611; of the spleen, 412; of the liver, 402.
Dissecting aneurism, 93, 94.
Distichiasis, 256.
Diverticula, of œsophagus, 354; constriction by, 417.
Divulsion of urethral stricture, 567.

Dobell's solution in ozæna, 296.
Dog-bite, 751.
Dorsalis pedis artery, ligation of, 143; aneurism of, 108.
Double, harelip, 324; penis, 515, 516; Wood's method of treatment of, 517.
Dowd, cysts of mesentery, 413.
Downey's op. table, 6, 8; in fracture of femur, 170.
Doyen, holding clamps, 386.
Drain, 14; in compound fracture, 182; in scalp wounds, 153.
Drainage, of cystic goître, 337; of gall bladder, 404; in amputations, 51; of wounds, 43.
Dressing, for fracture of clavicle, 154, 155; for Colles' fracture, 165.
Drills, 11; in exsection of knee-joint, 221; of ankle-joint, 222; Wyeth's, 168.
Drooping of ears, 283.
Drum, for testing edge of instruments, 266; of ear, perforation of, 289.
Dry synovitis, 203.
Duct, parotid, 306.
Dugas, diagnosis of dislocated humerus, 187; differentiation between fracture and dislocation of humerus, 156.
Duodeno-gastroplasty, 390.
Duodenum, surgery of, 398; ulcer of, 398; perforations of, 399.
Duplay, congenital malformations of urethra, 577.
Dupuytren's contraction, 686.
Dura mater, sarcoma of, 231; carcinoma of, 231.

Ear, 283; foreign bodies in, 285; double hook for, 284; forceps, 284; probe, 284; external auditory canal, 284; intertrigo of, 283; lesions of, 285; vegetable parasites, 285; impacted cerumen, 285; drooping of, 283; auricle of, 283; adhesions to scalp, 283; benign neoplasms of, 283; angeioma of, 283; epithelioma of, 283; hypertrophy of, 283.
Earle, method of treatment of hæmorrhoids, 499.
Écraseur in ablation of tongue, 327.
Ectocardia, 367.
Ectopic gestation and pregnancy, 637.
Ectropion, 253.
Eczema, of rectum and anus, 478; of the scrotum, 588; of nipple, 356; of eyelids, 256.
Effusion into knee-joint, 212.
Eggs for colon alimentation, 350.
Elbow, fractures at, 147.
Elbow-joint, amputation at, 58, 59; disarticulation at, 58, 59; synovitis of, 217; dislocation of, 190–192; prognosis of, 191.
Electric saw, 236; trephine, 236.
Elephantiasis of scrotum, 588, 605.
Emmetropia, 273.
Encephaloid cancer of breast, 359.
Encephalocele, 231.
Enchondroma, of lower jaw, 312; of larynx, 346; of tongue, 326; of parotid gland, 308; of mammary gland, 358; testis, 599, 717.
Encysted fibroma of lower jaw, 312.
Endarteritis, 87.
Endo-aneurismorrhaphy, 97.
Endocervicitis, 606; tuberculous, 606.
Endometritis, 607; puerperal, 608.
Endo-phlebitis, 86.
Endoscope, in gastric ulcer, 382; Klotz urethral, 564.
Endostitis, 144.
End-to-end anastomosis, 421.
Enteroliths, 414.
Entropion, 255.
Enucleation of eye, 265.
Epicanthus, 256.
Epididymis, tuberculosis of, 596, 598.
Epididymitis, 561, 596.
Epilation of eyelashes, 252.
Epilepsy, surgical treatment of, 244.
Epiphora, 257.
Epistaxis, 294.
Epithelioma, diagnosis from lupus vulgaris, 304; of eyelids, 251; of ear, 283; of nose, 296; of breast, 359; of nipple, 356; of scrotum, 589, 702; of conjunctiva, 260; of œsophagus, 354; of lips, 302; of tongue, 326.
Equina (cauda), 694.
Equinus, talipes, 665.
Erdmann, J. F., case of appendicitis, 441.
Erysipelas of scrotum, 588, 744.
Erythema of rectum and anus, 478.
Eserine after excision of cataract, 269.
Esmarch's, bandage, 12, 29, 31; in osteomyelitis, 145; in fractures about elbow, 158; for reducing swelling, 160; in aneurism, 107, 108; screen, 20, 23; bandage for eye and upper lip, 37; head and face hood, 38; in hæmorrhage, 40; bandage in exsection of shoulder-joint, 224; splint for exsection of wrist, 226; in amputations, 48, 49; in exarticulation at shoulder-joint, 63; method of amputating at carpo-metacarpal joint, 55; bandage in amputation at hip-joint, 76; in exsection of, 224.
Esophoria, 278.
Ether, 18; with nitrous oxide, 16, 25; morphia, 16; in children, 16; mortality, 16; selection of, 16; heart, 21; drop method, 19, 20; warming, 18; effect on temperature, 18; administration of, 18, 25; nervous system, 18; inhaler, 18; in brain surgery, 234.
Eustachian catheter, 286; introduction of, 287.
Eve, F. S., shortening gastrohepatic omentum, 391.
Everbusch, operation for ptosis, 253.
Examination of patient, 2.
Excision (*vide* exsection), of Gasserian ganglion, 245, 247; of uvula, 317; of knee-joint, 199; of the intestine, 420.
Exophoria, 278.
Exophthalmic goître, 336.
Exostoses, 146; of the skull, 146; after fractures, 146.
Exostosis of skull, 231.
Exploration of brain, 238.
Exsection (*vide* excision), of wrist-joint, 225; of shoulder-joint, 222; of knee-joint, 219; of hip-joint, 217; of elbow, 224; of ankle-joint, 221; of metacarpo-phalangeal joints, 227; of inter-phalangeal joints, 227; of joints, 217.
Exstrophy of the bladder, 516.
External auditory canal, 286; lesions of, 285; carotid artery, branches of, 121; anatomy of, 121; ligation of, 121, 122; aneurism of, 103; iliac artery, anatomy of, 138; ligation of, 138; urethrotomy, 566; modified, 570.
Extraction of teeth, 315.
Extremity, deformities of lower, 656; deformities of upper, 681.
Eye, wounds of lids, 251; contusions about, 251; new formations, 251; capillary angeioma, 251, 768.
Eyelashes, epilation of, 252.
Eyelids, affections of, 251; restoration of, 256.

Face, contusions of, 302; lacerated wounds of, 302; punctured wounds of, 302; shot wounds of, 302; incised wounds of, 302; horns of, 229.
Facial artery, ligation of, 125; paralysis, 249.
Fahrenheit, 796.
Fallopian tubes, infection of, 610.
False, aneurism, 93, 94; knot, 41.
Fascia palmar, 686.
Fecal fistula, 438.
Females, gonorrhœa in, 563, 603; genito-urinary organs in, 602.
Femoral artery, anatomy of, 139; ligation of, 139, 140; aneurism of, 107; hernia, 456, 465–468.
Femur, fracture of, 168.
Ferguson, crushing clamps, 394.
Fibroma, of antrum of Highmore, 310; of tonsils, 329, 714; of nipple, 356; of mammary gland, 358; of heart, 369; of lower jaw, 312; of tongue, 326; of parotid gland, 308; of lips, 304.
Fibro-chondroma, 718.
Fibroids of the uterus, 628.
Fibromata, of larynx, 346; of nose, 295.
Fibro-myxoma of larynx, 312.
Fibula, dislocation of, 201; fracture of, 178.
Filaria sanguinis hominis, 86.
Filiform bougies, Banks', 568.
Fingers, amputation of, 51, 52; disarticulation of, 52; bandage for, 31, 32; web-, 685; snap-, 687; jerk-, 687; lesions of, 687; tendon suture of, 687; real diseases of, 688; phlegmon of, 689; amputation of, 692.
Fischer's double spica bandage, 35; for breast, 35.
Fissure, of lips, 304; of nipple, 356; of nares, 295; of anus, 482.
Fistula, of the anus, 479; fecal, 438; operation for, 480–481; urinary, 574; urethral, 574; urethro-perineal, operation for, 575, 576; vesico-vaginal, 623–624; of œsophagus, 354; salivary, 306.
Fistulæ, of scrotum, 589; congenital, 439; brachial, 333.
Fitz, R. H., appendicitis, 440.
Flap, modified circular skin, 50; circular skin and muscle, 61; circular, 50, 57; modified circular in amputation of leg, 70; long plantar and short dorsal, 56; flap in amputation at knee, 73; in hip-joint amputation, 78, 79; combination skin and muscle flap, 50; long plantar in amputation of toes, 63.
Flat-foot, 674.
Flaxseed poultice in lymphangitis, 85.
Flexible bougies, 572–573.
Flexure of the colon, 429.
Fluhrer, W. F., swing, 740.
Fluoroscope in dislocation at elbow, 191.
Follicular conjunctivitis, 258.
Foot disease, 755.
Forbes, amputation at tarsus, 66.
Forceps, for removing foreign bodies from the trachea, 345; dental, 315; hæmostatic, 12; dissecting, 12; rongeur, 11; suture, 12; sequestrum, 12; for iris, 268.
Forearm, fracture of, 161; congenital deformities of, 682.
Foreign bodies, in œsophagus, 347; in pharynx, 347; in cornea, 261; in the ear, 285; in the nose, 294; in bladder, 546; in urethra, 573; in intestines, 414; in stomach, 379.
Formalin in pleural empyema, 366.
Formation of connective tissue, 726.
Foster's, cataract, 267.
Fowler solution in Billroth's disease, 333; posture in traumatic affections of viscera, 377.
Fracture, 146; of sternum, 165; of ribs, 165; of vertebræ, 166; of sacrum, 167; of coccyx, 167; of os innominatum, 167; of ulna, 161; of radius, 163; Colles', 164; of cranium, 150; of base of skull, 152; of nasal bones, 152; of malars, 152; plaster-of-Paris dressing for, 148; process of repair in, 148; special, 150; partial, 146; green-stick, 147; complete, 147; transverse, 147; oblique, 147; longitudinal, 147; single, 147; double, 147; multiple, 147; simple, 147; comminuted, 147; compound, 147, 183; complicated, 147; impacted, 147; ununited, 147, 181; from direct violence, 147; from indirect violence, 147; symptoms and diagnosis of, 147; prognosis of, 147; at the elbow, 147; of coronoid process of ulna, 163; box, 180; of the spine, 693; classification of, 146; review of, 161; of neck of femur, 168; of patella, 175; of leg, 178; of tibia, 178; of fibula, 178; Pott's fracture, 178; of tarsus, 181; of os calcis, 181; of astragalus, 181; of metatarsal bones, 181; of phalanges of foot, 181; of zygoma, 152; of superior maxilla, 152; of lower jaw, 153; of angle of jaw, 153; of ramus of jaw, 153; of coronoid process of jaw, 153; of larynx, 153; of hyoid bone, 154; of clavicle, 154; of scapula, 155; of acromion process, 155; of coracoid process, 156; of glenoid process, 156; of humerus, 156; of carpus, 165; of metacarpus, 165; of phalanges of hand, 165.
Frank, gastrostomy, 352.
Friction knot, 41.
Frontal sinuses, abscess of, 230.
Frostbite as cause of epithelioma of ear, 283, 779.
Fuller, Eugene, treatment of chronic vesiculitis, 559.
Functional disturbances of thyroid body, 336.
Fundus of eye, examination of, 280.
Furuncle, 779.
Fusiform aneurism, 93, 94; reconstructive arterioplasty in, 97; cataract, 267.

Gall bladder, 403; drainage of, 404; Rockey's valvular method of closing, 404.
Gall ducts, 403; removal of stone from, 408; biliary calculi in, 408–409.
Galt's trephine, 12, 151.
Ganglion, 691, 692.
Gangrene from foreign bodies in air passages, 344; hospital, 753, 781; senile, 783; pulmonary, 366.
Gant's, incision for ablation of tongue, 327; treatment of fissure of anus, 482.
Gas-oxygen inhaler, 24; gas-ether inhaler, 18.
Gasserian ganglion, excision of, 245, 247.
Gastrectomy, 393.
Gastric, ulcer, 381; perforations, 399; lavage, 2.
Gastro-duodenostomy, 389.
Gastro-enterostomy, 389.
Gastro-jejunostomy, 383; landmarks of, 384; operation, 384.
Gastroplication, 391.
Gastroptosis, 390.
Gastro-pylorectomy, 390.
Gastrostomy, Sebanijew and Frank, for stricture of œsophagus, 352.
Gastrotomy for removal of foreign bodies in stomach, 379.
General suppurative peritonitis, 449.

Genito-urinary organs, 502; in females, 602.
Genu, valgum, 660–661; varum, 660, 664; Macewen's operation for, 663.
Giant-cell sarcoma, 707.
Gibney, Pott's disease, 656.
Gigli, wire saw, 10; in exsection of hip-joint, 218.
Gila monster, 46.
Girdner, J. H., skin-grafting, 777.
Gland, parotid, removal of, 307; lachrymal, 257; parotid, 306; submaxillary, 309; lymphatic, infection of, 85; tuberculosis of, 85.
Glanders, 754.
Glass cylinder, Sims', 607.
Glaucoma, 265; simplex, 282; iridectomy for, 266.
Gleet, 563.
Glénoid process, fracture of, 156.
Glossitis, 325.
Glottis, spasm of, in aneurism, 94.
Gloves, hop-pickers, 3; rubber, 3.
Glüge, granular corpuscles in goître, 335.
Gluteal artery, ligation of, 138; aneurism of, 107; hernia, 456.
Goître, 333; cystic, 335; simple, 334; solid form, 334; semi-solid, 335.
Gonorrhœa in females, 563, 603, 758–761.
Gonorrœhal, infection of the rectum, 500; proctitis, 562; ophthalmia, 259, 562; rheumatism, 562.
Goodwillie's mouth-gag, 19.
Graefe's, speculum, 268; fixation forceps, 268; linear knife, 268.
Grafting, skin-, 775–777.
Graham, ulcer of duodenum, 398.
Grant, H. H., enterotome, 438.
Grant, W. W., case of appendicitis, 440.
Granular conjunctivitis, 258.
Grave's disease, 336.
Green, goître, 340.
Gritti, amputation at knee, 74.
Groin, inguinal adenitis of, 562.
Groove director, 12.
Gross' speculum oris, 19.
Growths, new classification of, 698.
Gruening's depilating forceps, 256.
Guitéras, Ramon, dislocation of testicle, 601.
Gumma of heart, 369.
Gunshot wounds, of the bladder, 46; A. C. Walker's operation for, 519; treatment of, 47; of skull and brain, 232; of neck, 331; of joints, 203.
Gwathmey's, ether inhaler, 18; warm vapor apparatus, 18.

Hæmatobia, Bilharzia, 533.
Hæmatology, 785.
Hæmatoma of scrotum, 589.
Hæmorrhage, 40; classification, 40; primary, 40; secondary, 40; arrest of, 40; Esmarch's bandage, 40; method of Detmold, 40; hot and cold applications in, 40; torsion, 40, 41; ligature, 40, 41; artery forceps, 40; retraction, 41; catgut, silk and linen, 41; lateral ligature in, 41; reef knot, 41; false knot, 41; friction knot, 41; aneurism needle, 42; coagulation, syncope in, 45; in removal of arterial angeioma, 87; after, internal urethrotomy, 568; of the spine, 693–694; arrest of, in major injuries, 48; as cause of shock, 49; in hip-joint amputation, 75; in fracture of nasal bones, 152; cerebral, 242; from nose, 294.
Hæmorrhoids, 495; Whitehead's operation for, 497; L. S. Pilcher's method of treatment of, 498, 499; Earle's method of treatment of, 499; A. B. Mitchell's method, 499; clamp and cautery, operation for, 499.
Hagedorn needle, 45.
Hair on lips, 304.
Hall, Richard, case of appendicitis, 440.
Hallux valgus, 677; varus, 677.
Halstead, A. E., case of hernia, 455.
Halsted, W. S., case of hernia, 463; inguinal hernia, 797.
Hamilton's long splint in fracture of thigh, 174; bandage for fracture of lower jaw, 153; olecranon splint, 162; splint for patella, 177; long splint in hip disease, 207.
Hancock, T. H., apparatus for applying plaster, 170.
Hand, amputation of, 51, 56; bandages for, 31, 32; disinfection of, 3; congenital deformities of, 684; phlegmon of, 689; tuberculosis of, 691; cleansing of, 798.
Harelip, 321; double, 324; operation for, 321.
Harrington's solution, 798.
Harris, tooth forceps, 316.
Hartley, operation for excision of Gasserian ganglion, 247; apparatus for trephining, 236.
Head and chin support, 654.
Heart, aneurism of, 369; tumors of, 369; foreign bodies in, 369; wounds of, 367; surgery of, 367; stab wounds of, 368; massage of, 22; paralysis of, 16, 766.
Hemeralopia, 271.
Hemianopsia, 271.
Hepatic abscess of the liver, 401.
Hernia, 452, 455; inguino-properitoneal, 455; infantile, 455; femoral, 465–468, 486; ventral, 456; diaphragmatic 456; gluteal, 456; obturator, 456, 474; lumbar, 456, 474; vaginal, 456, 474; perineal, 458; pudenal, 458, 474; inguinal, 485; Bassini's operation for radical cure of, 461; strangulated inguinal, 464; umbilical, 456; Mayo's operation for, 472–473; of bladder, 517; of labium, 604; of ovary, 604; of spleen, 412; cerebri, 231; of stomach, 391.
Herniotomy with local anæsthesia, 465.
Herpes of penis, 585.
Heterophoria, 278.
Hey, modification of Lisfranc's amputation of foot, 66.
Highmore, antrum of, affections of, 309.
Hill, L. L., stab wound of heart, 368.
Hip, congenital dislocation of, 656; osteotomy at, 658.
Hip-joint, Sayre's exsection of, 217; arthritis of, 203; causes of, 204; dislocation of, 194, 195, 196, 197; prognosis of, 199; disease of, 203; amputation at, Wyeth, 75, 76, 77.
Hodgkin's disease, 86.
Holding straps, 20.
Holmes' elastic ball for compression in aneurism, 107.
Holmgren's colored woolen threads, 271.
Holt, L. Emmet, intussusception, 415.
Homatropine hydrobromate, in refraction, 275; in ophthalmoscopy, 280.
Hop-picker's gloves, 3.
Hordeolum, 251.
Horns of scalp, 229; of face, 229.
Horsehair, for suture, 4; sutures in wounds of face, 302.
Horsley's sterile wax in trephining, 236.
Hospital gangrene, 753.
Hour-glass stomach, 389.

Humerus, fracture of surgical neck of, 156; of shaft, 157; at elbow, 158; fracture of external condyle, 159; of internal condyle, 159; paralysis from fracture of, 147; dislocation of, 186; general considerations of, 190; section at anatomical neck, 60.
Humphrey's operation for amputation of penis, 583.
Hunter's method of ligating in aneurism, 96.
Hyalitis, 270.
Hydatid cysts, of mammary gland, 359; of thyroid body, 341; in bone, 146.
Hydrocele, 590, 591; Volkmann's operation for, 592; tunica funiculi of, 592; Levis' operation for, 591.
Hydrocephalus, 231.
Hydronephrosis, 503, 504.
Hydrophobia, 751.
Hyoid bone, fracture of, 154.
Hyperæmia, Bier's method of treatment of, 756.
Hypermetropia, 273.
Hyperostosis of skull, 231.
Hyperphoria, 278.
Hypertrophy, of tongue, 325; of lips, 304; of mammary gland, 357; of prostate, 547–549; treatment of, 549, 550; of auricle of ear, 283; of thyroid body, 334.
Hyperthyroidism, 336.
Hypophosphites of lime and soda in ununited fractures, 182; in hip-disease, 210.
Hypopyon, 261.
Hypospadias, 577; operation for, 578, 579.
Hysterectomy, abdominal, 631; during pregnancy, 633; vaginal, 634.
Hysterotomy, 631.

Idiopathic choroiditis, 264.
Imperforate, hymen, 623; anus, 438.
Incised wound, 42; of neck, 331.
Incision, in exsection of knee-joint, 219; of hip-joint, 217; of ankle-joint, 221; of Shrapnell's membrane, 289.
Incontinence of urine, 525; H. Marion-Sims' treatment of, 525.
Index-finger, amputation of, 53.
Infantile hernia, 455.
Infection, of mastoid bone, 291; of Fallopian tubes, 610.
Inferior dental nerve, resection of, 114.
Inferior maxilla, 312; fracture of, 153; ankylosis of, 115; dislocation of, 185; reduction of dislocation of, 186.
Inflammation, 503; of joints, 202; of kidneys, 503; of cervix uteri, 606, 621.
Inflation, of tympanum, 286.
Ingrowing nail, 679, 680.
Inguinal, adenitis of groin, 562; hernia, 458; Bassini's operation for radical cure of, 461.
Inguino-properitoneal hernia, 455.
Inhaler, for ether, 18; for chloroform, 23; of Ormsby, 19; of Allis, 25; for gas-ether, 18; for gas-oxygen, 24; sterilization of, 22.
Inherited syphilis, 772.
Injection of alcohol for trifacial neuralgia, 245.
Innominate artery, aneurism of, 100, 102; anatomy of, 113; ligation of, 113, 114.
Instruments, surgical, 8–13; sterilization of, 13.
Intercostal arteries, anatomy of, 136; ligation of, 136.
Internal, iliac artery, anatomy of, 138; ligation of, 138; carotid artery, aneurism of, 104; anatomy of, 120; ligation of, 120; rectus muscle, tenotomy of, 272; pudic artery, ligation of, 139; mammary artery, aneurism of, 106; relations of, 129; ligation of, 131; maxillary artery, anatomy of, 126; ligation of, 126.
Internal, urethrotomy, 566; hæmorrhage after, 568; modified, 569; œsophagotomy, 351; jugular veins, ligation of, 126.
Interphalangeal, amputations of fingers, 52; joints, exsection of, 227.
Intertrigo of ear, 283.
Intestinal perforations, closure of, 376; obstruction, 414; anastomosis, 420.
Intestines, foreign bodies in, 414; intussusception, 415; strangulation and occlusion, abdominal section for, 419; obstruction of, 414; condition of, 417; neoplasms of, 418; stricture of, 418; excision of, 420; resection of, 421–424; carcinoma of, 430.
Intrahepatic cholelithiasis, 407.
Intravenous infusion, in syncope, 45; apparatus for, 44, 45; salt solution for, 45.
Intussusception, 415.
Inversion of the uterus, 627.
Involucrum, 144.
Iodide of potassium in treatment of aneurism, 95.
Iridectomy, for glaucoma, 266; for staphyloma, 263, 269.
Iris, forceps, 265; scissors for, 266.
Iritis, 264.
Irrigator, Blake's abdominal, 449.

Jackson's exploring dilator in abscess of the brain, 239.
Jacobi, A., gastric ulcer, 381.
Jaeger's angular keratome, 265; test-types, 277.
Jarvis' snare, 295; wire loop in neoplasms of larynx, 347.
Jaw, 309; upper, removal of, 311.
Jerk-finger, 687.
Joints, dislocation of, 185; diseases of, 202; inflammation of, 202; tuberculosis of, 202; of hip, 203; exsection of, 217; 766; shoulder, dislocation of, 186, 190; wrist, dislocation at, 193; hip, dislocation at, 194, 197.
Jones, Wharton, operation for ectropion, 254.
Jugular vein, ligation of, 114.

Kangaroo tendon, 4, 6.
Keen, W. W., aspiration of ventricles of brain, 243.
Kelly, H. A., method of ureteral catherization, 512, 513; treatment of lacerations of vagina and perinæum, 613; complete rupture of recto-vaginal septum, 615–618; caruncle, 623.
Keloid, 719.
Keratitis, 261; traumatic, 261; diffuse, 261.
Keratome, Jaeger, 265.
Keyes', stylet, 524; case of urinary fistula communicating with urethra, 576.
Keyhole saw, 10.
Kidneys, wounds of, 502; inflammation of, 503; pyelitis, pyelonephritis, hydronephrosis, 503, 504; nephrolithiasis, stone in, 505; cysts of, 506; tumors of, 506; movable, 506, 507; floating, 506, 507; nephrectomy, 508, 767.
Klotz's urethral endoscope, 564.
Knapp's entropion forceps, 255.
Knee, deformities of, 660, 661; knock-, 660–663; ankylosis at, 665.
Knee-joint, amputation at, 73; exsection of, 219; acute synovitis of, 212; chronic effusion into, 212; Charcot's disease of, 215; dislocation of, 199.
Knives, 9.

Knock-knee, 660–63.
Knot, reef, 41; false, 41; friction, 41.
Knott, Van Buren, appendectomy, 445.
Kocher, death-rate in thyroidectomy, 340; thyroid body, 333; transverse incision for removal of goitre, 337, 338; operation for removal of tongue, 327; method of treating dislocation of humerus, 187.
Kölliker, osteoclasts, 150.
Krause, operation for excision of Gasserian ganglion, 247.
Kredal's steel plates in brain surgery, 235.
Kronlein, gangrene of transverse colon, 395; case of appendicitis, 440.

Labium, hernia of, 604.
Lacerated wounds, 42; of neck, 331; of scalp, 232.
Lacerations, of lobule of ear, 283; of vagina, 612; of perinæum, 612; of cervix uteri, 625.
Lachrymal gland, 257.
Lagophthalmos, 252.
Lamellar cataract, 267.
Laminectomy, 166.
Lange, treatment of œsophageal strictures, 354.
Langenbeck's incision in exsection of the wrist, 226.
Lannelongue, operation for microcephalus, 232.
Lanphear, hip-joint amputation, 83.
Laplace, Ernest, avulsion for trifacial neuralgia, 247; skin-grafting, 777.
Laryngeal tube, 343.
Laryngectomy, complete, 345; partial, 346.
Laryngotomy, 342.
Laryngo-tracheotomy, 342.
Larynx, 341; neoplasms of, removal of, 346; foreign bodies in, 343, 767; fracture of, 153.
Lateral ventricle, aspiration of, 243, 244; curvature of the spine, 638; intestinal anastomosis, 427.
Lawrence's, strabismometer, 272.
Le Conte, paracentesis of pericardium, 369.
Lee, amputation of leg, 71.
Leg, amputation of, 70; artificial, time to wear, 71; bandage for, 33; fracture of, 178; varicose veins of, 90, 91.
Lembert, suture in closing perforations of bowels, 376; method of suturing veins, 110.
Lenormant, cardiac suture, 368.
Leprosy, 757.
Lesions, of external auditory meatus, 285; of the palm, 686; of the fingers, 687.
Leucocytes, 787.
Leucocytosis, 787.
Leucoma, 263.
Leukæmia, 789.
Levis' operation for hydrocele, 591.
Levy and Baudouin, injection of trifacial nerve, 245.
Lewis' method of treatment for double penis, 516.
Ligamentum teres, rupture of, in hip dislocation, 194; patellæ, rupture of, 228.
Ligation, of arteries; of innominate artery, 113, 114; of common carotid arteries, 114; of carotid at root of neck, 118; of internal carotid artery, 120; of external carotid, 121, 122; of lingual, 123; of facial, 125; of ascending pharyngeal, 126; of internal mammary, 131; of occipital, 126; of posterior auricular, 126; of femoral, 139; of profunda femoris, 141; of popliteal, 141, 142; of posterior tibial, 141, 142; of subclavian, 130, 131; of vertebral, 131; of axillary artery, 132; of brachial, 133; of radial, 133, 134; of ulnar, 133, 134; of intercostals, 136; of abdominal aorta, 136, 137; of common iliac, 138; of internal iliac, 138; of external iliac, 138; of gluteal, 138; of sciatic, 138; of internal pudic, 139; of anterior tibial, 143; of dorsalis pedis, 143; of temporal, 126; of internal maxillary, 126; of superior thyroid, 123; for occlusion of arteries and veins, 110; in continuity, 112; of extremities in hæmorrhage from nose, 294.
Ligature, 4; in hæmorrhage, 40, 41; forceps for, 42; aneurism needle, 42.
Light for ear examination, 284.
Linen for lateral ligature, 5, 41, 110.
Lingual artery, ligation of, 123.
Lipoma, of heart, 369; of lips, 304; of tongue, 326, 714; of scalp, 229.
Lips, angeioma, moles, papilloma, lipoma, adenoma and fibroma, 304; fissures and phlegmon, 304; lupus of, 303; hypertrophy of, 304; hair on, 304; reparative surgery of, 304; diseases of, 302.
Lisfranc, amputation at tarsus, 65.
Liston's method of reducing dislocation at elbow, 192.
Lithiasis, conjunctival, 261.
Lithotomy, 540; perineal, 543.
Lithotrity, 537–40.
Little finger, amputation of, 54; disarticulation of, at carpo-metacarpal joint, 54.
Little's lithotomy staff, 543.
Liver, 400; neoplasms of, 400; carcinoma, 400; sarcoma, 401; cysts of, 401; abscess of, 401; displacement of, 402; wounds of, 402; gunshot wounds of, 47.
Lobule of ear, lacerations of, 283.
Local anæsthesia, 18; cocaine in, 25; quinia and urea in, 27; in alcoholics, 16; in herniotomy, 465, 797.
Local death of bone, 144.
Lockjaw, 748.
Long, J. W., case of typhoid ulcer, 428.
Lorenz, operation for congenital dislocation of hip, 656.
Lower, jaw, fracture of, 153; lip, 305; extremity, deformities of, 686.
Luckett, W. H., paraffin, 299.
Ludwig's angina, 332.
Lumbar hernia, 456, 474.
Lungs, malignant neoplasms of, 367; surgery of, 365.
Lupus of lips, 303; nose and cheeks, 303; vulgaris, 303; diagnosis of, 304; of scalp, 230; of conjunctiva, 260.
Lusk, Z. J., skin-grafting, 779.
Luxations (*vide* Dislocations), 185.
Lymphadenoma, 704, 717.
Lymphangeioma, 717.
Lymphangitis, acute, 84; symptoms of, 84; treatment of, 84, 85.
Lymphatic glands, 85, 767; vessels, 84; infection of, 84; varicosities in, 85; cystic dilatation in, 85.
Lymphoma, of tonsils, 329; of neck, 332.

MacCallum, W. G., exophthalmic goitre, 336; examination of parathyroids, 334.
Macewen's operation, for genu valgum, 663; for hernia, 462.
Mackenzie, tonsillotome, 329.
Macnamara, drilling in morbus coxæ, 212.
Macula, 263.
Malar bones, fracture of, 152.
Malformations, congenital, of urethra, 577.

Malgaigne, disarticulation at calcaneo-astragaloid joint, 67.
Malignant tumors, differentiation between benign and, 719, 720; œdema, 754.
Mallet, 10.
Malposition of the testicle, 600.
Mammary gland, 356; congenital defects of, 356; abscess of, 357; hypertrophy of, 357; tumors of, 357; adenoma of, 357; myxoma of, 358; fibroma of, 358; enchondroma of, 358; cysts of, 359; tuberculosis of, 359; sarcoma of, 359; carcinoma of, 359; encephaloid cancer, 360; epithelioma of, 360; removal of, 361; bandage for, 35.
Mammary artery, internal, ligation of, 131; aneurism of, 106.
Mandelbaum, F. S., classification of new growths of the bladder, 526.
Marion Sims, H., treatment of incontinence of urine, 525.
Marsden's paste, in epithelioma of ear, 283; in epithelioma of nose, 296; in epithelioma of nipple, 356; in epithelioma of eyelids, 251.
Martin's rubber bandage, 29; for varicose veins, 91; chair, 431.
Masland's saw in trephining, 235, 236.
Mason, Lewis D., fracture of nasal bones, 152.
Massage of heart, 22.
Mastitis, 356.
Mastoid cells, 291; bone, infection of, 291.
Matas', Rudolph, method of treating aneurism, 108; endo-aneurismorraphy, 97; fracture of zygoma, treatment, 152.
Mathews, neoplasms of rectum and anus, 487; villous papilloma, 492.
Mattress suture, 43.
Maxilla, superior, 309.
Maxillary artery, internal, ligation of, 126.
Maydl, treatment of œsophageal stricture, 354.
Mayo, C. H. and W. J., 487; case of lateral intestinal anastomosis, 427; case of lateral anastomosis, 421; case of carcinoma, 431; case of urethra, 578; case of gall ducts, 411; operation for umbilical hernia, 472, 473; gastro-jejunostomy, 383; vein enucleator, 91; method of removing veins, 91, 92; gastrectomy, 393; line, 382; suture in gastrectomy, 396; catgut suture in excision of stomach ulcers, 382.
Mayo-Cushing suture in gastrectomy, 379, 382, 384, 396, 424.
McBurney, Charles, operation for fracture of neck of humerus, 177; method of hip-joint amputation, 83; operation for fracture of neck of humerus, 190; abdominal incision, 372; gall ducts, 411; appendicitis, 440; abdominal section for intestinal occlusion, 419.
Measures, 791.
Meatotomy, 566.
Median nerve, injury to, in dislocation at elbow, 192; basilic vein, 45.
Meibomian glands, obstruction of ducts of, 251.
Membrana tympani, wounds of, 286; flaccida, 285.
Meninges, carcinoma of, 231; sarcoma of, 231.
Meningocele, 231.
Mental foramen, 314.
Mercuric chloride in osteomyelitis, 145.
Mercury, bichloride of, in major injuries, 38, 39; in treatment of aneurism, 95.
Mesarteritis, 87.
Mesentery, 413; strangulation through slits in, 417.
Meso-phlebitis, 86.
Metacarpo-phalangeal joints, exsection of, 227.
Metacarpus, fracture of, 165.
Metastases with septicæmia, 742.
Metatarsal bones, fracture of, 181; dislocation of, 201.
Metatarsus, synovitis in joints of, 216.
Metric system, 793, 794.
Meyer, Willy, hernia of stomach, 391; costoplastic operation, 380.
Michel, metallic clamps, 5; metal clips, 44.
Microcephalus, 232.
Micropsia, 271.
Milk, for colon alimentation, 349; quantity given, 350.
Mitchell, A. B., method of treatment of hæmorrhoids, 499.
Mobilization of lesser curvature of stomach, 394.
Modified, circular flaps, 50; in amputation of leg, 70; internal urethrotomy, 569; external urethrotomy, 570.
Moles, 90; dangers of, 90; treatment of, 90; of lips, 304.
Mollities ossium, 145.
Monks, G. H., abdominal section for intestinal occlusion, 419.
Moore, dressing for fracture of clavicle, 155.
Morbus coxæ, 203.
Morphia, before anæsthesia, 20, 22, 25; in laryngectomy, 346.
Morgagni, cataract, 267.
Morris, stab wound of heart, 368.
Morrow, P. A., skin-grafting, 779.
Morton, T. G., case of appendicitis, 440.
Moschcowitz, A. V., preparation of catgut, 4, 5; method for cure of femoral hernia, 469.
Mouth, contusion of, 306; disease of, 755, 767.
Mouth-gag, 19.
Movable kidney, 506, 507.
Mucocele, 257.
Mucous cysts, 714.
Multilocular cysts of scalp, 229.
Mumps, 309.
Murphy, J. B., oblong button and key, 389; button forceps, 389; gastro-enterostomy, 389; button, 377; anastomosis of facial and spinal accessory nerves, 249; operation for resection of rectum in women, 490, 491; case of puerperal sepsis, 608; case of gall ducts, 410; button, 421, 425, 426; suppurative peritonitis, 451; fracture of olecranon, 162; adhesions between pericardium and pleura, 369; pleural empyema, 366; button in gastrectomy, 396.
Muscæ volitantes, 271.
Muscles, diseases of, 227, 696; repair of, 726.
Muscular rheumatism, of shoulder-joint, 216; of hip, 205.
Musculo-spiral nerve, injury to, in dislocation at elbow, 192; injury to, in fracture of humerus, 158.
Mydriatics, 275.
Myoma of the uterus, 628, 715.
Myopia, 273, 275.
Myositis, 638.
Myringotomy, 289.
Myxoma, of mammary gland, 358, 715; of nose, 295.
Myxomata, of parotid gland, 308; of antrum of Highmore, 310.

Nævi of scalp, 229.
Nævus pigmentosus, 90; treatment of, 90.
Nail, ingrowing, 679, 680.

Narcosis, chloroform, 22, 23; ether, 18–22; morphia in, 20, 22; nitrous oxide, 23–25; whisky in, 19, 22.
Nasal, bones, fracture of, 152; calculi, 295; pin, 296.
Nasopharyngeal catarrh, 298.
Nachet, trial glasses for testing vision, 276.
Nebula, 263.
Neck, abscess of, 331; Billroth's disease of, 333; brachial cysts of, 333; cystic tumors of, 333; gunshot wounds of, 331; phlegmon of, 332; tubercular lymphoma of, 332; tumors of, 332; wounds of, 331.
Necrosis, in adenitis, 85; of palate, 317.
Needle-holder, 12.
Nelaton's, test in fracture at neck of femur, 169.
Neoplasms, of thyroid body, 335; of pharynx, 347; of larynx, 346; avulsion of, 347; of trachea, 346; of liver, 400; of the rectum and anus, 486; of the bladder, 526; of the urethra, 580; of the vagina, 623; of the spine, 694; to classification of, 698; non-malignant, 712; of bladder, 400; of the intestines, 418; benign, of auricle of ear, 283; of nose, 295.
Nephrectomy, 508.
Nephrolithiasis, 505.
Nerves, 695; inferior dental, exsection of, 314; repair of, 727; stretching of, 696; suture of, 696.
Nervous system, 765.
Nettleship, trachoma, 259; pannus, 262.
Neuralgia, from aneurism, 94; of prostate, 558; of rectum, 493; trifacial, 245; of shoulder-joint, 216; of hip-joint, 206.
Neuritis, optic, 271, 281.
Neuroma, 716.
New growths, classification of, 698.
Niles, H. D., ulcer of sigmoid, 430.
Nipple, angeioma of, 356; cysts of, 356; eczema or fissure of, 356; epithelioma of, 356; inflammation of, 356; papilloma of, 356; fibroma of, 356.
Nitrate of silver, in neoplasms of larynx, 347; in ulcers of tongue, 326.
Nitric acid, in gonorrhœal ophthalmia, 259; in phlyctenular keratitis, 263; in polyp of nose, 295.
Nitrous oxide, 23; with oxygen, 17–25; with morphia, 25; with ether, 24, 25; in extraction of teeth, 315; sequestration in, 17; mortality, 17; administration of, 24; duration of, 23; in fracture at elbow, 161; in removal of varicose veins, 91.
Non-malignant neoplasms, 712.
Non-specific, urethritis, 563, 762; ulcers, 585.
Nose, 294; adenoid vegetations in, 298; angular depressions of, 298; congenital lesions of, 301; fibromata of, 295; fissures of nares, 295; foreign bodies in, 294; hæmorrhage from, 294; loss of substance of, 299; lupus of, 303, 767; neoplasms, 295; rhinitis, 295; tampon of, 294.
Nostrils, papillomata of, 295.
Nuclear cataract, 266.
Nyctalopia, 271.

Obstruction of the intestines, 414.
Obturator hernia, 456, 474.
Occipital artery, ligation of, 126.
Occlusion of arteries and veins, 110; intestinal, 419.
Ochsner, A. J., case of appendicitis, 446, 447.
O'Dwyer, laryngeal tube, 343.
Œdema of scrotum, 588; malignant, 754.
Œsophagectomy, 352.
Œsophagotome, Sands, 351.
Œsophagotomy, internal, 351; for removal of foreign bodies, 348.
Œsophagus, rupture of, 347; foreign bodies in, 347; sound, 347; stricture of, 350; new formations in, 354; fistula of, 352, 767.
Oiled silk, 13.
Oleate of mercury in lupus, 303.
Olecranon, fracture of, 161.
Omentum, 413; strangulation through slits in, 417.
Opacity, of lens, 266; of cornea, 263.
Operating room, 7, 8; table, 6, 8.
Operation on mastoid bone, 291; for sinus thrombosis, 292; for relief of ascites, 402, 403.
Operative arteriorrhaphy, 98.
Ophthalmia, gonorrhœal, 259, 562.
Ophthalmic artery, aneurism of, 104.
Ophthalmitis, sympathetic, 265.
Ophthalmoscope, in cataract, 267; in choroiditis, 264.
Ophthalmoscopy, 280.
Optic nerve, atrophy of, 281; neuritis of, 271, 281.
Oral screw, 19.
Orbicularis palpebrarum muscle, spasm of, 252.
Orchitis, 562; testicle, enlargement of, 562, 596; in mumps, 309.
Organs, genito-urinary, in females, 602.
Ormsby inhaler, 19.
Os innominatum, fracture of, 167; hyoides, fracture of, 154; calcis, fracture of, 181.
Osteo-arthritis, of ankle-joint, 216; of knee-joint, 213; of joints, 202.
Osteoma, 718; of skull, 231.
Osteomalacia, 145; in ununited fractures, 181.
Osteomyelitis, acute, 144; tuberculous, 145.
Osteotome, 10.
Osteotomy at the hip, 658.
Ostitis, in ununited fractures, 182; varieties of, 144; tuberculous, 145; deformans, 146; interna caseosa, 145; of hip, 205, 206; of skull, 230; periostitis of ribs as cause of sub-axillary abscess, 357; of upper jaw, 309; of lower jaw, 312.
Otis, F. N., dilating urethrotome, 567.
Otitis media, 290.
Ovariotomy, 631.
Ovaritis, 611.
Ovary, hernia of, 604; tumors of, 631, 636; cysts of, 636; dermoid cysts, 636.
Ozæna, 295.

Pagenstecher, celluloid linen, 388.
Palate, affections of, 317; cleft of, 317; operation for cleft of, 318.
Pallida, spirochæte, 790.
Palm, fascia of, 686; lesions of, 686.
Pancreas, 412; tuberculosis of, 413; calculus of, 413.
Pannus, 261.
Panopeptone for colon alimentation, 350.
Papilloma, of tongue, 326; of lips, 304; of larynx, 329; of rectum, 492, 712; of antrum of Highmore, 310.
Papillomata, of nostrils, 295; of scalp, 229; of larynx, 346.
Paraffin, Luckett, 299.
Paralysis, from fracture of humerus, 147; of deltoid, 681; facial, 249.
Paraphimosis, 762.
Parasites in the urine, 533.

Parathyroid bodies, 334; acute tetany from removal of, 334.
Paronychia, 688.
Parotid gland, removal of, 307, 308; tumors of, 306, 308; duct, 306.
Parotitis, 309.
Parovarium, tumors of, 636.
Parrish, B. F., muscle tendon grafting, 228.
Partial laryngectomy, 346; rhinoplasty, 301.
Patella, rupture of ligament of, 228; dislocation of, 200; fracture of, 175; removal of, in knee-joint amputation, 73, 74.
Pathological dislocation, 185; at hip, 195; at knee-joint, 199.
Pathology of syphilis, 768.
Patient, examination of, 2; preparation of, 1, 2.
Pawlik's method of urethral catheterization, 513, 514.
Pelvis, dislocation of, 201.
Penetrating wounds, of abdomen, 375; of skull and brain, 232.
Penis, double, 515, 516; wounds of, 580; Humphrey's operation for amputation of, 582; carcinoma of, 581; herpes of, 585; phagedenic ulcer of, 586, 587; sarcoma of, 583; ulcer of, 585.
Peptonized, milk, for colon alimentation, 349, 350; for food, 349, 350.
Perforation of stomach, 399.
Periarteritis, 87; phlebitis, 86.
Periarticular inflammation of hip, 205.
Pericardium, adhesions of, 369; dropsy of, 369.
Perichondroma, 717.
Perineal, lithotomy, 543; hernia, 458; prostatectomy, Young's operation for, 550–553.
Perinæum, laceration of, 612; rupture of and operation for, 613, 623.
Periosteotomes, Brophy, 320.
Periosteum, 728; process of repair, in, 728.
Periostitis, serous, 144; non-suppurative or fibrous, 144; acute, 144; tuberculous, 144; of jaw, 309; of skull, 230.
Peritonitis, from perforation of stomach, 399; general suppurative, 449; tuberculous, 451.
Petit's fracture box, 180.
Phagedenic ulcer of penis, 586, 587.
Phalangeal joints, disarticulation of, 52, 53.
Phalanges, of toes, dislocation of, 201; of fingers, dislocation of, 193; reduction of, 194, 195; of hand, fracture of, 165; of foot, fracture of, 181.
Pharyngotomy in neoplasms of larynx, 341, 347.
Pharynx, neoplasms of, 347; foreign bodies in, 347.
Phimosis, 584, 585, 762.
Phlebitis, 86; symptoms of, 87; treatment of, 87; dangers of, 87.
Phlegmon, of lips, 304; of neck, 332; of hands, 689; of fingers, 689.
Phlyctenulæ, of conjunctiva, 262; of cornea, 262.
Pilcher, L. S., method of treatment of hæmorrhoids, 498, 499; method of reducing Colles' fracture, 165.
Pinguecula, 260.
Pityriasis versicolor, of rectum and anus, 478.
Planus, talipes, 676.
Plaster-of-Paris bandage, in fracture of humerus, 156; in Colles' fracture, 165; in fracture of acromion process, 155; in fracture of patella, 176; in fracture of thigh, 173; in fracture of leg, 179; in ununited fractures, 182; in treatment of fractures, 148; in Pott's fracture, 180; Sayre's, for Pott's disease, 649; bandage, 29; bandage in sprains, 202; in hip disease, 210.
Pleura, surgery of, 365.
Pleuritis, 365.
Plugging of nares, 294.
Pneumonectomy, 366.
Pneumonia from foreign bodies in air passages, 344.
Pneumo-thorax, 365.
Pneumonotomy, 366.
Pneumorrhaphy, 366.
Politzer's perforator, 285; inflation of tympanum, 286, 288.
Polydactylus, 676, 685.
Polypoid growths of heart, 369.
Polypus, of conjunctiva, 260; of rectum, 491, 492; of nose, 295.
Poole, E. H., parathyroids, 334.
Popliteal artery, aneurism of, 93, 108; ligation of, 141, 142.
Porter, M. F., cysts of mesentery, 413.
Port-wine marks of scalp, 229.
Position, Sims', 602.
Posterior tibial artery, ligation of, 142; auricular artery, ligation of, 126; curvature of the spine, 644, 645; synechia, 264.
Posthitis, 560, 762.
Potassium permanganate in snake bite, 46.
Pott's disease of the spine, 645; suspension apparatus for applying Sayre's plaster-of-Paris jacket, 145, 649; fracture, 178, 179.
Pregnancy, hysterectomy during, 633.
Preparation of patient for operation, 1, 2.
Presbyopia, 278.
Primitive dislocation, 185.
Prince's forceps, 259.
Probes, 12.
Process of repair, in the periosteum, 728; in bone, 728.
Proctitis, gonorrhœal, 562.
Profunda femoris artery, ligation of, 141.
Prolapse of the rectum, 493.
Prostate, 547; carcinoma of, 557; tuberculosis of, 557; neuralgia of, 558; treatment for hypertrophy of, 549, 550.
Prostatectomy, 550, 551; perineal, Young's operation for, 550–553.
Prostatic hypertrophy, changes in contour of, 554, 555; sarcoma, 557; concretions, 557.
Prostatorrhœa, 555.
Pruritus, ani, 478–501; vulvæ, 604.
Pryor, W. R., operation for puerperal septicæmia, 609; lock forceps, 635; operation for vaginal hysterectomy, 635.
Pterygium, 260.
Ptosis, 252.
Pudendal hernia, 458, 474.
Puerperal endometritis, 608; septicæmia, Pryor's operation for, 608, 609.
Pulmonary gangrene, 366.
Punctured wound, 42; wounds of neck, 331.
Pus in blood, 531, 737.
Pyelitis, 503, 504.
Pyelonephritis, 503, 504.
Pyæmia, 742.
Pyrogallic acid in lupus vulgaris, 304.

Quadriceps extensor muscle, rupture of, 227.
Quénu's operation for resection of rectum, Tuttle's modification of, 487–489.
Quill suture, 43.
Quinia and urea hydrochloride, 797; Thibault, 27; preparation, 27; ingredients, 28; for

curetting ulcers, 28; mucous surfaces, 28, 797.
Quinine in tonsillitis, 329.

Rabies, 751.
Rachitis, 146, 182.
Radial artery, ligation of, 133. 134; aneurism of, 106.
Radius, dislocation of head of, 191; reduction of, 191; dislocation of radius and ulna, 191–193; fracture of, 163; of shaft, 164; Colles' fracture of, 164.
Ramus of jaw, fracture of, 153.
Ranula, 328.
Rassieur, Lewis, excision of a portion of the lung, 366.
Rattle-snake, 45.
Razors, 13.
Recent dislocation, 185.
Reconstructive arterioplasty, 97, 98.
Rectal anæsthesia, 28.
Recto-vaginal septum, 613; rupture of, 613.
Rectum, absence of, 476; foreign bodies in, 479; erythema of, 478; stricture of, 484, 485; neoplasms of, 486; herpes of, 478; pityriasis versicolor, 478; atresia of, 477; eczema of, 478; ulcers of, 482; syphilitic chancre of, 483, 484; resection of 431–433, 487; polypus, 491, 492; papilloma of, 492; prolapse of, 493; neuralgia of, 493; catarrhal inflammation of, 500; tuberculosis of, 500; gonorrhœal infection of, 500.
Reef knot, 41; in tying arteries, 111.
Reeves, operation on the ear, 283.
Refraction of eye, 273.
Relaxation of vulvo-vaginal outlet, 617; operation for, 618–621.
Repair, of skin, 726; of muscles, 726; of tendons, 726; of nerves, 727; in bone, 728; in periosteum, 728; of cartilage, 731.
Reparative surgery on the lips, 304.
Resection, of the rectum, 431–433, 487; Murphy's operation for (in women), 490, 491; of the intestines, 421–424; of inferior dental nerve, 114.
Retention of urine, 561.
Restoration of eyelids, 256.
Retina, 271.
Retinitis, 281; pigmentosa, 271.
Retractors, 10; silk or linen, 370.
Retropharyngeal abscess, 331; diagnosis of, 332, 647.
Retroversion of the uterus, 612.
Reversed Trendelenburg posture in removal of thyroid body, 334; in removal of parotid gland, 308.
Review of fractures about elbow, 161.
Rheumatism, as cause of strabismus, 273; gonorrhœal, 562.
Rhinitis, hypertrophic, 296; atrophic, 297.
Rhinolites, 295.
Rhinoplasty, from forehead, 300; partial, 301.
Riberi, operation of Steno's duct, 307.
Ribs, fracture of, 166; dislocation of, 201.
Rickets in ununited fractures, 146, 182.
Ricketts, pneumorrhaphy, 366; suture of heart, 366.
Ring-finger, amputation of, 54.
Roberts, John B., deflected septum, 296; nasal pin, 296.
Robin myeloplaxes, 149, 150.
Robinson, A. R., lupus, 303; carbuncle, 779.
Rockey, valvular method of closing gall bladder, 404.
Rodman, W. L., resection of stomach, 383.
Roentgen ray, in fracture of humerus, 156, 157; in fracture about elbow, 158; in fractures, 147, 148; in dislocations, 185.
Rogers, serum in goître, 340.
Rokitansky, diverticula of œsophagus, 352.
Roller for bandage, 29.
Rongeur forceps, 11.
Roosevelt's clamp, 427.
Rotary-lateral curvature of the spine, 638, 641.
Round-cell sarcoma, 706.
Royster, H. A., case of appendicitis, 441.
Rubber, tubing, in hip-joint amputation, 77; tissue, 13, 14; gloves, 3.
Rupture, of the bladder, 517; of the recto-vaginal septum, 613; of the perinæum, 613; of œsophagus, 347.
Russell, R. Hamilton, hypospadias, 577.

Sacculated aneurism, 99.
Sacrum, fracture of, 167.
Saline solution, for intravenous injection, 45; in major injuries, 48.
Salivary fistula, 306.
Salpingitis, 610.
Salt solution for intravenous infusion, 45.
Sands, œsophagotome, 351.
Sarcoma, of œsophagus, 354; of upper and lower jaw, prognosis of, 313; of thyroid body, 335; of heart, 369; of mammary gland, 359; of lung, 367; of stomach, 398; of dura mater, 231; of parotid gland, 308; of tonsils, 329; toxines for, 309; of antrum of Highmore, 310; prostatic, 557; of the penis, 583; of the testicle, 599; of the uterus, 630, 705; round-cell, 706; spindle-cell, 706; giant-cell, 707; treatment of, 710, 711; of the liver, 401.
Saw, 10; electric, in trephining, 235, 236.
Sayre, exsection of hip-joint, 217; apparatus for fractured clavicle, 186; elevator in exsection of ankle-joint, 221; wire breeches, 211; muscular torticollis, 639; dressing for fractured clavicle, 155; periosteal knife, 11; elevator, 19; suspension apparatus for applying plaster-of-Paris jacket for Pott's disease, 649.
Scalds, 774.
Scale, United States, 571.
Scalp, lipomata of, 229; nævi of, 229; papillomata of, 229; ulcers of, 230; tuberculosis of, 230; elephantiasis of, 230; hæmatoma of, 230; abscess of, 230; pneumatocele of, 230; tumors of, 229; cysts of, 229; dermoids of, 229; sebaceous cyst, 229; horns of, 229; wounds of, 232.
Scalpels for eyelid, 255.
Scapula, fracture of, 155.
Schaede's operation for varicose veins, 92.
Sciatic artery, ligation of, 138; aneurism of, 107.
Scirrhus carcinoma of heart, 359.
Scissors for iris, 12, 266.
Scleritis, 264.
Sclerotic, 264.
Scoliosis, 638.
Scorpion, 46.
Scrotum, wounds of, 588; œdema of, 588; eczema of, 588; cysts of, 588; erysipelas of, 588; elephantiasis of, 588; angeioma of, 588; epithelioma of, 589; fistulæ of, 589; hæmatoma of, 589.
Scudder, stomach clamp, 396.
Sebaceous cysts of scalp, 229.
Sebanijew, gastrostomy, 352.
Secondary dislocation, 185.

Sedillot, amputation of leg, 71.
Seminal vesicles, 558.
Senile cataract, 267; gangrene, 783.
Senn, abdominal section for intestinal occlusion, 419.
Separation of the pyloric end of the stomach, 394.
Septicæmia, puerperal, Pryor's operation for, 608, 609, 741; with metastases, 742.
Sequestration, Dawbarn, in formidable operations about mouth, 314; in removal of thyroid body, 334; in removal of parotid gland, 308; in removal of tongue, 327; in removal of goître, 337; in gunshot wounds of skull and brain, 16, 17, 20, 28, 233.
Sequestrum, 144; forceps, 12.
Serous cysts, 714.
Sexton's probe, 284; ear forceps, 284; ear-hook, 284; snare, 285.
Shaffer's abduction hip apparatus, 209; knee-splint, 214; rotary-lateral curvature apparatus, 644; head and chin support, 654.
Shock, caffein and camphor in, 49; in amputations, 49; cause of, 49; anæsthesia in, 49; syncope in, 49; psychical, 49; hæmorrhagic, 49; in brain surgery, 233; in penetrating wounds of abdomen, 375.
Shoulder, ankylosis of, 681; congenital dislocation at, 681.
Shoulder-joint, exsection of, 222; dislocation of, 186; general considerations, 190; synovitis of, 216; tuberculous osteo-arthritis of, 217.
Shrapnell's membrane, 285; incision of, 289.
Sigmoid colon, catarrhal inflammation of, 500.
Silk, 41; retractors, 370; for lateral ligatures, 110.
Silkworm gut, 5, 44.
Silver wire, 5.
Simple, conjunctivitis, 258; dislocation, 185; goître, 334.
Sims, J. Marion, rectal speculum, 479; position, 602; glass cylinder of, 607; operation for vesico-vaginal fistula, 623; speculum, 625; removal of lower jaw, 313.
Sinus, thrombosis, 292.
Skin, repair of, 726; syphilis of, 765; grafting, 775–77; injury of, in amputations, 48.
Skull, ostitis of, 230; periostitis of, 230; osteoma or exostosis of, 231; trephine of, 234; penetrating wounds of, 232; fractures of, 150.
Small intestine, lesions of, 374.
Smith's clamp, 499.
Smith, Stephen, amputation of leg, 70; at knee, 73, 74.
Snake-bite, 45; antidote for, 46; bromine, iodine, sodium and potassium hydrate and potassium permanganate in, 46; symptoms, 46; duration of, 46; treatment, 46; toxicity of, 45; prognosis, 45; tourniquet in, 46.
Snap-finger, 687.
Snellen's test-types, 277; operation for entropion, 255.
Sound for œsophagus, 348, 571.
Spasm, of ciliary muscle, 275; of the vagina, 606.
Special joints, diseases of, 203; dislocations, 185; aneurisms, 99.
Speculum oris, 19; Sims' rectal, 479, 625.
Spermatic cord, transplantation of, 797.
Spermatorrhœa, 557.
Spherical aneurism, 93.
Spina bifida, 694.
Spinal accessory nerve, anastomosis with facial nerve, 249; column, deformities of, 638; cord, 693; analgesia, 28; usage, 28; Bainbridge's method, 28.
Spindle-cell sarcoma, 706.
Spine, deformities of, 638; curvature of, 638; rotary-lateral curvature of, 638, 641; lateral curvature of, 638; anterior curvature of, 644, 645; posterior curvature of, 644, 645; Pott's disease of, 645; Taylor's brace, 654; concussion of, 693; contusion of, 693; penetrating wounds of, 693; hæmorrhage, 693, 694; dislocation of, 693; fractures of, 693; neoplasms of, 694.
Spirochæte pallida, 790.
Spleen, 411; abscess of, 411; displacement of, 412; cysts of, 412; hernia of, 412; gunshot wounds of, 47.
Splenectomy, 412.
Spondylitis, 645.
Spoons, sharp, 11.
Sprain, 202.
Stab wound of heart, 368.
Staff, Little's lithotomy, 543.
Staphyloma corneæ, 263.
Steno's duct, calculi of, 307.
Sterilization, of patient, 2; of hands, 3; of gauze, cotton, towels, sheets, etc., 4; of instruments, 13.
Sterilizer, 4.
Sternum, fracture of, 165.
Stevens, Geo. T., phorometer, 278.
Stimson, L. A., method of reducing hip-joint dislocation, 197, 198.
Stings, of bees, 46; of wasps, 46; of hornets, 46.
Stomach, 379; hernia of, 391; carcinoma of, 392; perforation of, 399; sarcoma of, 398; foreign bodies in, 379; wounds of, 379; ulcers of, 381; hour-glass, 389; adhesions of, 390; mobilization of the lesser curvature of, 393; separation of the pyloric end of, 394; freeing the greater curvature of, 395; removal of diseased structures of, 396.
Stone, in bladder, 533; in kidneys, 505; in female bladder, 545.
Strabismometer, 272.
Strabismus, 272; scissors, 272.
Strangulated inguinal hernia, 464.
Strangulation through slits in mesentery, 417; in omentum, 417.
Stretching of nerves, 696.
Stricture of the rectum, 484–485; of the ureter, 509; of the male urethra, 563; of the intestines, 418; divulsion of urethral, 567; of the vagina, 607; of œsophagus, 350; gastrostomy for, 352.
Stylet, Keyes', 524.
Subacromial dislocation, reduction of, 190.
Subclavian artery, ligation, 130; anatomy of, 127; aneurism of, 104, 105.
Subclavicular, dislocation, 186, 187.
Subcoracoid dislocation, 186, 187.
Subcutaneous suture, 44.
Subcuticular suture, 44.
Subglenoid dislocation, 186, 189, 190.
Sublimate for irrigation in exsection of hip-joint, 218.
Subluxation of head of radius, 191.
Submaxillary gland, 309.
Subphrenic abscess, 401, 402.
Subspinous dislocation, 187, 190.
Suction for cataract, 270; for snake-bites, 46.
Sugar in urine, 530.
Sulphate of copper in follicular conjunctivitis, 258.
Sulphide of calcium in hordeolum, 251.

Superior intercostal artery, origin of, 130; thyroid artery, ligation of, 123.
Superior maxilla, 309; removal of, 311; fracture of, 152; *vide* jaw.
Suppression of the urine, 526.
Suppuration, in lymphangitis, 84; in adenitis, 85; in tubercular adenitis, 86, 736.
Suppurative peritonitis, general, 449.
Suprapubic cystotomy, 540.
Supra-scapular artery, relations of, 129.
Surgery of pleura, 365; of lungs, 365; of bronchi, 365; of heart, 367; of bones, 144.
Surgical, operation, 1; dressings, 13; instruments, 8, 9, 10, 11, 12; occlusion of arteries and veins, 110; diseases of bones, 144, 721.
Suspension apparatus, for applying Sayre's plaster-of-Paris jacket, 649; Meigs case, 655.
Suture, 4; of wounds, 43; alternating deep and superficial, 43; interrupted, 43; continuous, 43; mattress, 43; quill or lead-plate, 43; silver-wire, 43; silkworm gut, 44; subcuticular, 44; needles for, 45; of gastric stump, 396; Mayo-Cushing in gastrectomy, 379; in closing perforations of bowels, 376; of arteries, 109–111; of veins, 109–111; tendon of fingers, 687; of nerves, 696.
Swanzy conjunctivitis, 258.
Symblepharon, 253.
Syme amputation at tibio-tarsal joint, 68.
Sympathetic ophthalmitis, 265.
Symphyseotomy, 633.
Synchisis, 270.
Syncope, in shock, 49; in hæmorrhage, 45.
Syndactylus, 676, 685.
Syndesmitis of joints, 202.
Synechia, anterior, 263; posterior, 264.
Synovitis, in articulations of tarsus, 216; of metatarsus, 216; of knee-joint, 212; of shoulder-joint, 216; of joints, 202; of elbow-joint, 217; of wrist-joint, 217; of metacarpal joints, 217; of phalangeal joints, 217; of hip-joint, 205.
Synovo-arthritis, 203.
Syphilis, 758, 762–767; of the skin, 765; pathology of, 768; diagnosis of, 769; treatment of, 771, 772; inherited, 772; in ununited fractures, 182.
Syphilitic, ostitis, 146; periostitis, 146; arteritis, 766; chancre of rectum and anus, 483, 484.
System, nervous, 765; metric, 793, 794.

Table, operating, 6, 8.
Talipes, 665; equinus, 665; calcaneus, 667; varus, 668; valgus, 673; cavus, 675; planus, 676.
Tarantula, 46.
Tarsorrhaphy, 252.
Tarsotomy, 672.
Tarsus, synovitis in joints of, 216; fractures of, 181; dislocation of, 201.
Taylor's brace for spine, 654.
Teale, amputation of leg, 71; operation for symblepharon, 253.
Teeth, extraction of, 315.
Telangiectasis of larynx, 346.
Temporal artery, ligation of, 126.
Tendo Achillis, division of, 668.
Tendons, 696; repair of, 726; diseases of, 227; tuberculosis of, 227.
Tenotomy, for strabismus, 272; of internal rectus muscle, 272, 691.
Testicle, 596; tuberculosis of, 598; enchondroma of, 599; adenoma of, 599; carcinoma, 599; sarcoma, 599; malposition of, 600, 767; atrophy of, in mumps, 309; abscess of, 309.
Testing vision for glasses, 277.
Test-types, of Jaeger, 277; of Snellen, 277.
Tetanus, 748.
Thecitis at ankle-joint, 215.
Theobold's lachrymal probe, 257.
Thermal inhaler, 19.
Thermometric scales, 796.
Thibault's method, quinia and urea, 27.
Thigh, amputation through, 75; bandage for, 33.
Thomas' method of treating hip disease, 209; hip splint, 209.
Thompson, W. Gilman, carcinoma of stomach, 392.
Thoracic aorta, aneurism of, 99, 102.
Thread-worms, 479.
Thrombosis of sinus, 292.
Thumb, dislocation of metacarpal bone of, 193; amputation of, 53; disarticulation of, 53; metacarpal joint, 55.
Thyroid body, 333; neoplasms of, 335; sarcoma of, 335; carcinoma of, 335; functional disturbances of, 336; removal of, 337; infection of, 334; cachexia from removal of, 334; hypertrophies of, 334; hydatid cysts of, 341; wounds of, 334; artery, ligation of, 123; axis, relations of, 129.
Thyroidectomy, 337.
Thyrotomy in neoplasms of larynx, 342, 347.
Tibia, fracture of, 178; dislocation of, 199.
Tibial arteries, aneurism of, 108.
Tibio-tarsal, amputation, 68; preservation of vascular supply, 68; dislocation, 200.
Tiemann, tonsillotome, 330.
Tissue, connective, 726.
Toad, 46.
Tobacco as cause of atrophy of optic nerve, 281.
Toes, deformities of, 676, 677.
Tongue, controlling hæmorrhage of, 325; hypertrophy of, 325; cystic tumors of, 325; atrophy of, 325; angeioma of, 325; abscess of, 325; ulcers of, 326; epithelioma of, 326; adhesion of, 328; bifid, 328; excision of, by Gant's method, 327; excision by Kocher's method, 327; forceps, 19, 767; removal of, 327; wounds of, 325; tie, 328.
Tonsillitis, cause of adenitis, 85; acute, 328.
Tonsillotome of Mackenzie, 329; of Tiemann, 330.
Tonsillotomy, 329.
Tonsils, 328; abscess of, 329; chronic hypertrophy of, 329; removal of, 329; sarcoma of, 329; carcinoma of, 329; cystic tumors of, 329; fibroma of, 329; lymphoma, 329; as factor in tubercular adenitis, 85.
Torsion in hæmorrhage, 40, 41, 110, 111.
Torticollis, 638.
Tourniquet in snake-bite, 46.
Toxines, Coley, in sarcoma of parotid gland, 309.
Trachea, 341; canula for, 342; neoplasms of, 346; foreign bodies in, 343.
Tracheotomy for foreign bodies, 342, 345; for removal of tumors of laryngo-pharynx, 342.
Trachitis from foreign bodies in air passages, 344.
Trachoma, 258.
Transplantation of spermatic cord, 797.
Transversalis coli artery, relations of, 129.
Traumatic dislocation, 185; at hip, 195; synovo-arthritis, 202; at knee, 199; endarteritis, 41; keratitis, 261; mastitis, 356.

Treatment of hypertrophy of the prostate, 549, 550; of syphilis, 771, 772.
Trephine, electric, 236; Galt, 151, 12.
Trichiasis, 256.
Trifacial neuralgia, 245.
True aneurism, 93.
Tube for trachea, 342.
Tubercular, osteo-arthritis in dislocation, 185; lymphoma, of cervical glands, 332.
Tuberculosis, of joints, 202; of tendons, 227; of hip-joint, 203; of mammary gland, 359; in ununited fractures, 182; of rectum, 500; of colon, 500; of prostate, 557; Bier's method of treatment of, 756; of pancreas, 413; of testis, 598; of epididymis, 598, 755; of scalp, 229.
Tuberculous inflammation of bone, 145; osteomyelitis, 145; ostitis, 145; periostitis, 144; synovitis of ankle-joint, 215; osteo-arthritis of shoulder-joint, 217; of elbow-joint, 217; of wrist-joint, 217; adenitis, 85; symptoms of, treatment of, 86; endocervicitis, 606; peritonitis, 451.
Tufnell method of treating aneurism, 95, 101.
Tumors, of laryngo-pharynx, removal of, 341; of neck, 332; of cervical glands, 332; of palate, 317; of parotid gland, 308; of kidney, 506; of heart, 369; of breast, 357; of brain, removal of, 235; of scalp, 229; of eyelids, 251; of brain, 237; of ovary, 631, 636; of parovarium, 636; of hand, 691; of cauda equina, classification of, 698; differentiation between benign and malignant, 719, 720.
Tunica funiculi hydrocele of, 592.
Tuttle, J. P., modification of Quénu's operation, 487–489; position, 429; case of carcinoma, 431; case of artificial anus, 434, 435.
Tympanum, inflation of, 286.
Typhoid ulcer, 428.

Ulcer, of rectum, 482; of penis, 585; non-specific, 585; of herpes, 585; phagedenic, of penis, 586, 587; of vulva, 604, 780; typhoid, 428; of stomach, 381; location of, 382; treatment of, 382; of duodenum, 398; of scalp, 230; of cornea, 262; of tongue, 326.
Ulceration of palate, 317.
Ulcus serpens, 262; cornea, 262.
Ulna, fracture of, 161; of shaft, 163; of coronoid process, 163; dislocation of, at elbow, 191–193; injury to, in dislocation at elbow, 192.
Ulnar artery, aneurism of, 106; ligation of, 133, 134.
Umbilical hernia, 456, 471; Mayo's operation for, 472, 473.
Umbo of tympanum, 285.
Ununited fracture, 181.
Upper extremity, deformities of, 681.
Ureters, 508, 509, 510, 511, 512, 513; stricture of, 509; anastomosis of, 510; Deaver's method, 509; Bartlett's method, 509; Van Hook's method, 510; catheterization of, 512; Kelly's method, 512, 513; Pawlik's method, 513, 514.
Urethra, changes in contour due to hypertrophy, 554, 555; neoplasms of, 580; congenital malformations of, 577; calculi in, 573; foreign bodies in, 573; caruncle of, 623; stricture of the male, 563.
Urethral, endoscope, Klotz, 564; divulsion of stricture, 567; fistula, 574; sounds, 572; bougies, 573.
Urethritis, non-specific, 563, 762; chronic, 563; chronic follicular, 563, 758.
Urethro-perineal fistula, operation for, 575, 576.
Urethrotome, Otis' dilating, 567.
Urethrotomy, internal, 566; external, 566; hæmorrhage after internal, 568; internal modified, 569; external modified, 570.
Urinary, calculi, 533; fistula, 574.
Urine, 528, 529; incontinence of, 525; suppression of, 526; sugar in, 530; parasites in, 533; retention of, 561.
Uterus, deformities of, 611; displacements of, 611; anteflexion of, 611; retroversion of, 612; carcinoma of, 628; fibroids of, 628; curettage of, 627; inversion of, 627; myoma of, 628; sarcoma of, 630.
Uvula, 317; excision of, 317.

Vagina, spasm of, 606; hernia of, 456, 474; stricture of, 607; lacerations of, 612; absence of, 623; hysterectomy, operation for, 635; neoplasms of, 623; abscess of, 623.
Vaginismus, 606.
Vaginitis, 605.
Valentine's meat juice for colon alimentation, 350.
Valgum, genu, 660, 661.
Valgus, talipes, 673; hallux, 677.
Valsalva's method of treating aneurism, 95, 101.
Van Arsdale, W. W., reduction of dislocated humerus, 191.
Vance corset, 210; osteotome, 10.
Van Hook, operation for wounds of ureter, 510; method of forming new meatus, 578.
Van Horn and Sawtell catgut, 5.
Varicocele, 594, 595.
Varicose veins, or venous varix, etiology, 90; dangers of, 91; treatment of, 91, 92; with occlusion of popliteal or femoral veins, 91; Babcock's operation for removal of, 92; Mayo's method, 91, 92; Schaede's method, 92; aneurism, 93, 94.
Varum, genu, 660, 664.
Varus, talipes, 668; hallux, 677.
Vascular tumors, 87; classification of, 87.
Vegetable parasites in ear, 285.
Veins, wounds of, 109; suture of, 109; Lembert's method of suturing, 110; ligation of internal jugulars, 126; phlebitis, 86; pathology of, 86; varix of, 90; median basilic, 45; for intravenous injection of, 45; cephalic, 45.
Velpeau's bandage, for fractured clavicle, 155, 186; for fracture of coracoid process, 156.
Venereal diseases, 758.
Venom of snakes, 45.
Venous, angeioma, 88; Wyeth's treatment of, 88; technic, 89; dangers of, 89; varix, see varicose veins, 90.
Ventral hernia, 456.
Ventricles of brain, aspiration of, 243.
Vertebræ, dislocation of, 201; fracture of, 166.
Vertebral artery, aneurism of, 103; relations of, 129; ligation of, 131.
Vesico-vaginal fistula, 623, 624.
Vessels, lymphatic infection of, 85.
Vitreous, 270.
Volkmann's spoons, 11; sliding foot piece, 175; operation for hydrocele, 592; anterior splint, 222.
Volvulus, 416.
Von Graefe's strabismus hook, 272; operation for conical cornea, 263.
Vulva, ulcers of, 604; wounds of, 605.
Vulvæ, pruritus, 604.
Vulvitis, 603.
Vulvo-vaginal, abscess, 603; outlet, relaxation of, 617; operation for, 618–621.

Walker, A. C., operation for gunshot wound, 519.
Wardrop's method of treating aneurism, 96.
Wardwell, W. L., gangrene, 784.
Warren, John Collins, completed healing of wounds, 371; removal of breast, 361.
Warts, of eyelids, 251; of nostrils, 295; of scalp, 229.
Wasserman, Melville, epithelioma of urethra, 580.
Web-finger, 685.
Webster, David, pannus, 262; treatment of hordeolum, 251.
Weights, 791; and measures, 791.
Weir, Robert, platinum support for nose, 301.
Wens of scalp, 229.
Whey for colon alimentation, 350.
Whisky, in snake-bite, 46; in syncope, 45.
Whitehead, operation for hæmorrhoids, 495.
Whitlow, 689.
Whitman, Royal, fracture of neck of femur, 171; congenital dislocation, 681.
Wiener, Jos., Jr., case of hernia, 475.
Wilms, massage of heart, 368.
Wire, breeches of Sayre, 211, 218; screen, 175.
Wolff operation for ptosis, 253.
Wolverton's tooth forceps, 316.
Wood, method of treatment of double penis, 517.
Wounds, 42; classification of, 42; incised, 42; punctured, 42; lacerated, 42; contused, 42; leucocytes, 42; aseptic, 42; treatment of, 42; suture of, 43; clot, serum and dead tissue in, 43; drainage, 43; upon face, 43; three-cornered, 44; metal clips in, 44; poisoned wounds, 45; gunshot, 46, 47; of liver, 47; of thyroid body, 334; of neck, 331; of tongue, 335; of kidneys, 502; of bladder, 517; of penis, 580; of scrotum, 588; of vulva, 605; of liver, 402; of stomach, 379; of heart, 367; of abdomen, 374; of chest, 365; of eyelids, 251; of arteries, 109; of veins, 109; of cornea, 261; of scalp, 232; of membrana tympani, 286; of auricle of ear, 283.
Wrist-joint, dislocation of, 193; exsection of, 225; thecitis of, 217.
Wry-neck, 638.
Wyeth's treatment of vascular tumors, 88, 89, 90; operation for arterial angeioma (cirsoid aneurism), 88; for venous angeioma, 88; for capillary angeioma, 89, 90; hot water syringe, 88; shoulder-joint amputation, 61; hip-joint amputation, 75; pins, 76; conclusions as to arterial occlusion after ligation, 42; ligature forceps, 42; deligation of external carotid, 103; bandage for hand, thumb, and fingers, 31; foot bandage, 34; drills in exsection of knee-joint, 221; of ankle-joint, 222; exsector, 19, 22, 218; operation for large tumors of antrum of Highmore, 310; operation for microcephalus, 232; operation for excision of lower jaw, 313; conclusions as to arterial occlusion after ligation, 111; drills, 168.

X-ray in fracture of glenoid process, 156; about elbow, 157; of humerus, 156; in fractures, 147, 148; of coronoid process, 163; in gunshot wounds of skull and brain, 233; in lupus vulgaris, 304; for foreign bodies in air passages, 344.

Y fracture at elbow, 158.
Young, Hugh H., operation for perineal prostatectomy, 550, 553.

Zygomatic process, fracture of, 152.

THE END