

The diseases of children's teeth, their prevention and treatment : a manual for medical practitioners and students.

Contributors

Pedley, R. Denison.
University of Toronto

Publication/Creation

London : J. P. Segg & Co., 1895.

Persistent URL

<https://wellcomecollection.org/works/nz9s7cvm>

License and attribution

This material has been provided by This material has been provided by the University of Toronto, Harry A Abbott Dentistry Library, through the Medical Heritage Library. The original may be consulted at the Harry A Abbott Dentistry Library, University of Toronto. where the originals may be consulted.

This work has been identified as being free of known restrictions under copyright law, including all related and neighbouring rights and is being made available under the Creative Commons, Public Domain Mark.

You can copy, modify, distribute and perform the work, even for commercial purposes, without asking permission.



Wellcome Collection
183 Euston Road
London NW1 2BE UK
T +44 (0)20 7611 8722
E library@wellcomecollection.org
<https://wellcomecollection.org>

THE DISEASES
OF
CHILDREN'S TEETH:
THEIR
PREVENTION & TREATMENT.

R. DENISON PEDLEY,


P3 $\frac{4}{8}$




Society of Apothecaries.

PRESENTED BY

Date





THE SOCIETY OF APOTHECARIES
OF LONDON.

THE DISEASES OF CHILDREN'S TEETH,
THEIR PREVENTION AND TREATMENT.



THE SOCIETY OF APOTHECARIES
OF LONDON.

THE
DISEASES OF CHILDREN'S TEETH,
THEIR
PREVENTION AND TREATMENT.

A MANUAL
FOR MEDICAL PRACTITIONERS AND STUDENTS.

BY
R. DENISON PEDLEY, M.R.C.S., L.D.S. Eng.
F.R.C.S. Edin.

*Dental Surgeon to the Evelina Hospital for Sick Children,
Southwark, London.*


With numerous Illustrations.

¹ PUBLISHED IN LONDON BY
J. P. SEGG & CO., 289 & 291, REGENT STREET, W.

IN AMERICA BY THE
S. S. WHITE DENTAL MFG. CO.,
CHESTNUT STREET, PHILADELPHIA, PA., U.S.A.

All Rights Reserved.

[1895]



AS A TRIBUTE OF ESTEEM

AND AFFECTIONATE

REGARD,

I DEDICATE THIS BOOK TO MY FATHER,

GEORGE PEDLEY,

FROM WHOSE RIPE EXPERIENCE

I HAVE LEARNED

MORE THAN I CAN TELL.



CORRIGENDA.

- PAGE 6, LINE 10—*For* 18 per cent., *read* 28 per cent.
- „ 73 „ 23 „ Mr. Moore „ Mr. Moon.
- „ 76 „ 23 „ such teeth are rarely found, *read* such
teeth are *now* rarely found.
- „ 77 „ 1 „ Gemmination, *read* Geminatation.
- „ 93 „ 7 „ perpetration „ perpetuation.
- „ 94 „ 6 „ overlock „ interlock.
- „ 144 „ 19 „ Between the ages of 6 and 12, *read* Be-
tween the ages of 5 and 12.
- „ 145 Column 5, Line 3, *for* 157, *read* 175.
- „ 145 „ 9 „ 15 „ 10795, „ 10695.
- „ 149 „ 4 „ „ „ „
- „ 176 Lines 21 and 22, *for* an average of nearly 5 teeth, *read*
an average of nearly 6 teeth.



CONTENTS.

	PAGE
INTRODUCTION	1
CHAPTER I.	
STRUCTURE	5
CHAPTER II.	
ERUPTION	15
CHAPTER III.	
CARIES	33
CHAPTER IV.	
INFLAMMATION OF THE PULP. PULPITIS	45
CHAPTER V.	
INFLAMMATION OF THE PERIODONTAL MEMBRANE, PERIODONTITIS, ALVEOLAR ABSCESS, NECRO- SIS, AND OTHER SEQUELÆ	51
CHAPTER VI.	
IRREGULARITIES OF THE TEETH	67
<i>a.</i> Irregularities of Structure in Temporary and Perma- nent Teeth	68
<i>b.</i> Irregularities of Form in Temporary and Permanent Teeth	77
<i>c.</i> Irregularities of Number in Temporary and Perma- nent Teeth	79
<i>d.</i> Irregularities of Position in Temporary and Perma- nent Teeth	84
<i>e.</i> Overcrowding of the Teeth and Its Treatment	115

CHAPTER VII.


THE HYGIENE OF THE MOUTH—

In the Home	133
In the School	143
In the Hospital.	The Relationship between Dental and						
other Diseases	150

CHAPTER VIII.

TREATMENT—

<i>a.</i> Examination of the Patient	184
<i>b.</i> The Instruments Required	185,	234
<i>c.</i> Toothache in Temporary and Permanent Teeth				186,	194
<i>d.</i> Stopping or Filling of					
(i) Temporary Teeth	205
(ii) Permanent Teeth	214
<i>e.</i> Extraction of Temporary and Permanent Teeth				...	235
<i>f.</i> Injuries of the Teeth	254
<i>g.</i> Tartar and Its Removal	259



PREFACE.

SO numerous are the subjects to which the attention of the Student of Medicine is necessarily directed while passing through a Hospital training, that, in most instances, the Dental Department is neglected. It is when settling down in the country, where the area of practice is wide, and the opportunities of obtaining skilled dental assistance are few, that the Practitioner of Medicine finds much reason to regret the absence of a knowledge of Diseases of the Teeth, and the means by which they may be prevented.

As children form so large a proportion of the patients he is called upon to treat, I am not without hope that the General Practitioner

may find in the following pages some facts worthy of his consideration.

If I may venture—from a Dental Practitioner's point of view—to offer a word of advice to the Student of Medicine, it is that he should supplement his reading by a brief course of practical work in the Dental Department of his own hospital, where he may possibly learn how teeth are saved as well as lost.

In the chapter on Treatment much will be found that is as applicable to adults as to children, for Caries of the Teeth is essentially the same in both.

Although writing particularly for the Student and Practitioner of Medicine, I have endeavoured to embody in these pages information which, I hope, may prove of service to the Student and Practitioner of Dentistry.

In the preparation of this Manual, I am deeply indebted to Mr. SIDNEY SPOKES, Dental Surgeon to University College Hospital, for material assistance.

TO DR. ARTHUR NEWSHOLME, Medical Officer of Health for Brighton, I am also indebted for his kindness in correcting and approving the chapter on "The Hygiene of the Mouth."

The Illustrations from Models and Photographs have been drawn by Mr. ALFRED BEAUCHAMP. My thanks are tendered to Messrs. ASH & SONS, of Broad Street, Golden Square, W., for placing at my disposal most of the illustrations of instruments.

RICHARD DENISON PEDLEY.

LONDON, *October*, 1895.



INTRODUCTION.

IN order to claim attention for a consideration of the connection between Disease in children and abnormal dental conditions, it is only necessary to refer to the large proportion of cases occurring during Infancy and Childhood, in which the digestive tract is at fault. And if it be true, as some have taught, that failure of the digestive tract is increasing, it also appears true that dental caries is accompanying it with equal step. Indeed it may rather be suggested that the prevalence of dental disease has been preparing the way for the manifestation of other departures from a normal performance of the function of nutrition. Although from time to time the matter has been referred to by physicians writing upon such subjects, it is scarcely too much to say that only within recent years has the importance of the teeth in

connection with the maintenance of good health, received anything like proper consideration at the hands of medical practitioners, and that even now there is need for further recognition. The departure from a normal standard becomes, perhaps, of still greater importance in those pathological conditions in which the organs of digestion are essentially at fault. Situated as the teeth are, at the very entrance of the alimentary tract, and concerned, as they are, in the function of nutrition, it becomes a matter of vital importance that their preservation in a state of functional integrity should be the first care of those who are consulted upon, or find themselves charged with, the management of cases in which there is faulty assimilation. Recent investigations in bacteriology have not only explained the way in which the teeth themselves are destroyed, thus influencing more or less directly the general condition of health, but they have also been the means of suggesting a hitherto unrecognised factor in the causation of various diseases, the origin of which has frequently been looked for elsewhere outside the body. It is now evident that the mouth, besides containing normally some six or

eight kinds of micro-organisms, forms an excellent incubator for the cultivation of many other forms of bacteria, and when in addition to its natural advantages, unhealthy teeth are present, themselves the foci of decomposition and microphytes, it becomes manifest that it may be necessary to look in the mouth for a possible source of infection in such instances as when pneumonia or actinomycosis attack a patient without appreciable cause. These points are considered later on, but are alluded to as showing the necessity of recognising that a diseased condition of the teeth may be an indirect cause of constitutional complaints of an infective nature, and also help to directly induce and maintain an abnormal condition in the function of nutrition. It is proposed to present, in the following pages, a short account of the most important of those points of dental pathology and treatment occurring in children, which the fully trained medical practitioner should be cognisant of.

In the first place it may be well to remind the reader, briefly, of the origin and structure of the tooth tissues, as these have an important bearing upon what follows, both from a

prophylactic and restorative point of view.

In order to emphasize the importance and value of preventive treatment, the *Hygiene of the Mouth* in the Home, in the School, and in the Hospital ward has been fully considered. An attempt has also been made to prove the relationship which exists between dental and other diseases.

CHAPTER I.

STRUCTURE.

FOR the purposes of description each tooth consists of a "crown," the part exposed in the mouth, and which is separated from one or more "roots" (implanted in the jaw) by the constricted portion called the "neck." The surface of a crown nearest to an imaginary median line at the front of the mouth is called the "mesial," that farthest away the "distal;" whilst the aspect opposite the lips and cheeks has been named "labial" or "buccal" according to whether the tooth is at the front or at the side of the mouth; and the terms "palatal" or "lingual" suffice to describe the inner surfaces. Although the hard parts of a tooth remind one of bone it is to be remembered that the teeth do not belong to the skeleton. The dentine and cementum more closely resemble bone in formation, whilst the other tissue, enamel, is of epiblastic origin.

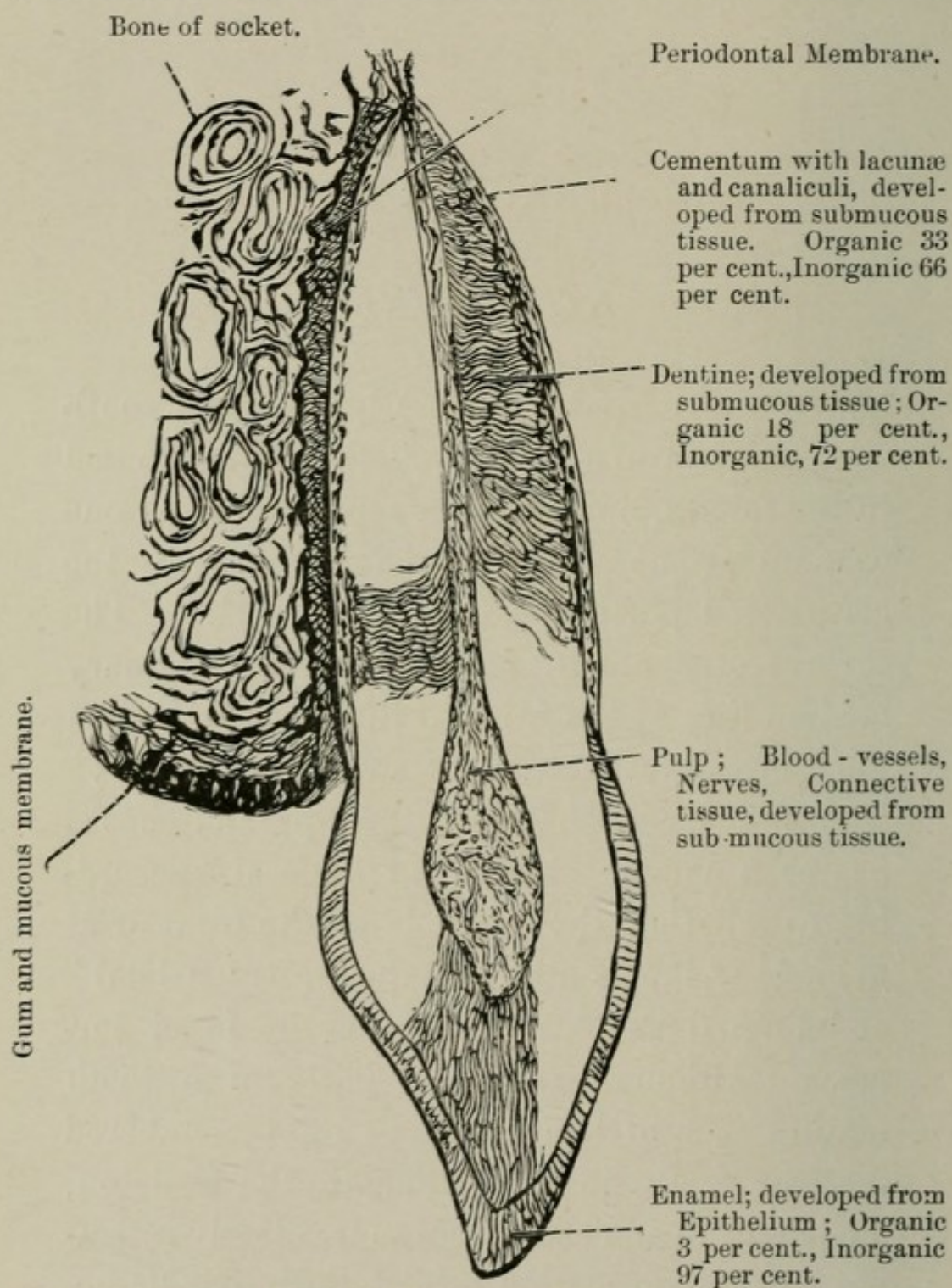


Fig. 1.—DIAGRAM OF A VERTICAL SECTION OF A TOOTH AND ITS ATTACHMENT.

One side only of the socket is represented and part only of the Dentine.

Enamel.—In enamel we have the hardest tissue in the human body ; it covers the whole of the crown or exposed part of a tooth, being thicker where there are cusps and terminating at the neck by a thin edge which is slightly overlapped by cementum. It is composed of prisms, closely joined together and placed at right angles to the surfaces of the crown, and, according to the generally accepted theory, it represents in a calcified condition the original soft columnar epithelial cells of the embryonic tooth germ. Where well-developed and intact, enamel presents a pearly lustre and protects the tissue beneath, for the very small percentage of organic matter present does not afford sufficient pabulum for microbes. On the other hand, the surfaces of the crown of a tooth are not plane and the elevations of enamel necessitate the existence of corresponding depressions, or pits and fissures, in which retained particles of food undergo fermentation with the formation of acid. Although enamel is hard enough to turn the edge of dental instruments, it occasionally becomes chipped through the improper use of a tooth. In cases of faulty development, where possibly a deficiency of lime-salts has

prevented a complete calcification, the enamel will present a chalky aspect, and this can also be noticed where, the tissue having been perhaps originally good, the process of decalcification has commenced. In other cases in which the proportion of organic matter present is still larger, the enamel may be observed to be brownish in colour. In the deciduous dentition the colour is generally lighter although the density is supposed to be less.

Dentine. This tissue, which makes up the large mass of tooth substance, consists of a hard matrix penetrated throughout by a system of minute tubules running spirally from the centre towards the periphery, and each containing a dentinal fibril—a fine process from the cells upon the surface of the pulp. The tubules divide and give off branches, and, in the root portion of the tooth, terminate beneath the cementum in what is termed “the granular layer” of dentine, a system of uncalcified loculi by means of which the protoplasmic elements of the two tissues are brought into relationship. With regard to the matrix, recent observations show a much closer analogy to bone than has hitherto been supposed. According to the

latest views* the matrix consists "of a reticulum of fine fibres of connective tissue modified by calcification, and where that process is complete, entirely hidden by the densely deposited lime-salts." It is proposed to call these "odonto-genic fibres," not that they are regarded, any more than the osteogenic fibres of bone, as the actual material of which the tissue is composed, but merely as the scaffolding upon which it may be built up. There are also reasons for supposing that there exists a lamination of the matrix concentric with the pulp. It may be detected in newly-formed dentine but is hidden when the calcification is perfect. Although the dentinal fibril has generally been entrusted with the function of sensation in dentine, the matter cannot be said to have been satisfactorily explained, as a demonstration of the ultimate ending of the nerve fibres of the pulp is yet wanting.

The dentine is formed upon the surface of the pulp by a process of calcification and, where this is incomplete, loculi with rounded contours

* *Some points in the Structure and Development of Dentine* by J. Howard Mummery, M.R.C.S., L.D.S., (Philosoph. Trans. 1891.)

are to be found in the substance of the tissue. These are known as "interglobular areas" and they form an element of weakness should the tooth be attacked by caries.

Cementum. In the human tooth, cementum is confined to the surface of the root, or implanted portion of the tooth, slightly overlapping the enamel at the neck by a very thin margin. It closely resembles bone in its composition as well as in structure, but it is not thick enough to contain Haversian systems and blood-vessels. Lacunæ and canaliculi, however, are present, the former arranged in the longitudinal layers of cementum which are applied to the surface of the dentine. Sharpey's fibres are also to be found running transversely to the lamellæ. The lacunæ contain "bone-cells" and, from these, fine processes are prolonged into the canaliculi communicating with one another, whilst some of those in the innermost layer penetrate the "granular layer" of the dentine. The two structures are therefore, closely connected. The outer surface of the cementum is covered by the periodontal, or alveolo-dental, membrane, from which the hard tissue itself is developed by a process of calcifi-

cation, and there is reason to believe that the thickness of the deposit of cementum increases during the life-time of the tooth.

The Pulp Chamber and its Contents. The centre of a tooth is occupied by a soft mass, surrounded everywhere by dentine and composed of connective-tissue, cells, blood-vessels, and nerves. This is called the pulp, or more popularly and insufficiently the "nerve" of the tooth. The shape of the central chamber, and its contained pulp, corresponds with the external aspect of the crown of the tooth, cornua of the pulp being present beneath the cusps, whilst below there are prolongations into the root-canals. The pulp is the remaining soft portion of the original formative organ, a large part of which is represented by the dentine in the more or less completed tooth. There is reason, however, to believe that the formation of dentine goes on slowly during the rest of the life-time of the tooth, the chamber gradually becoming smaller until at last, in some instances, it may be obliterated and the pulp, as such, is no longer present. It appears also as if the pulp may be stimulated into a quickened formative activity by the approach

of caries, and a protective layer, or barrier, of dentine is then formed beneath the increasing cavity of decay. The row of cells upon the surface of the pulp are larger and otherwise differentiated during the active formation of dentine. They are termed "odontoblasts," and from the distal margin one or more processes (dentinal fibrils) pass into the dentinal tubes. The blood-vessels and nerves enter at the apex of the root and breaking up into branches form plexuses beneath the odontoblasts. No lymphatics have hitherto been demonstrated.

The Alveolo-dental, or periodontal, membrane. This important structure intervenes between the bone of the socket and the root of the tooth, and serves to maintain an intimate and living relationship between the two. Connective tissue fibres run from one to the other in a slightly oblique direction thus allowing a limited mobility of the tooth. The fibres at the neck blend with the fibrous structure of the periosteum of the jaw and of the gum, and both in this situation and at the apex of the root the membrane is somewhat thicker, whilst some of the fibres can be traced into the bone

on the one side, and the cementum on the other to persist as Sharpey's fibres. In the meshes next the cementum are seen the osteoblasts concerned in the calcification of that tissue whilst blood-vessels and nerves ramify in the membrane, some of them being derived from trunks which also supply the pulp. This common origin of some of the vessels and nerves of the pulp and the periodontal membrane may have a certain significance in the diseased conditions affecting either structure. Lymphatics and some elastic fibres have also been described, (Black). By some this membrane has been regarded as a ligament, but apart from its serving as an attachment for the tooth, its function is important not only as a formative organ for the production of cementum, but also as a means of keeping up a living connection for a "dead" tooth, when the sensitive and vascular pulp has been destroyed by operation or disease. For, in consequence of the communication existing between the termination of the dentinal fibrils and the contents of the canaliculi of the cementum, either by means of direct contact, or by way of the granular layer, the dentine may be

supposed to be brought into connection to some extent, with the periodontal membrane. At all events so long as this latter is intact, the pulpless tooth is not regarded by the rest of the organism as altogether a foreign body but frequently, with proper care, does duty for many years. In this manner we are confronted with an apparent paradox of a "dead" tooth still alive!

CHAPTER II.

THE ERUPTION OF TEETH.

AS is common amongst Mammalia, Man is provided with two sets of teeth, the first to serve from infancy through a part of childhood, whilst the second set, which is nearly complete at puberty, is intended to last the rest of the life-time

There are many points of anatomical interest connected with the eruption of these two sets of teeth and the change from one to the other, but the physiological aspects are of more practical importance in consideration of the necessity which exists, at this body-building period of life, for the proper action of all the organs concerned in nutrition.

The temporary or milk teeth are twenty in number, ten in each jaw, five on each side, right and left, viz., two incisors, a "central" and "lateral," one canine, and two molars, "1st and 2nd temporary molars." In those

cases where parents are anxious for, or capable of, instruction on such matters it may be useful for the practitioner to remind them of the analogy, in numbers, of the temporary teeth with the fingers and toes, the digits of the right and left hands being compared with the teeth on each side of the upper jaw, those of the feet

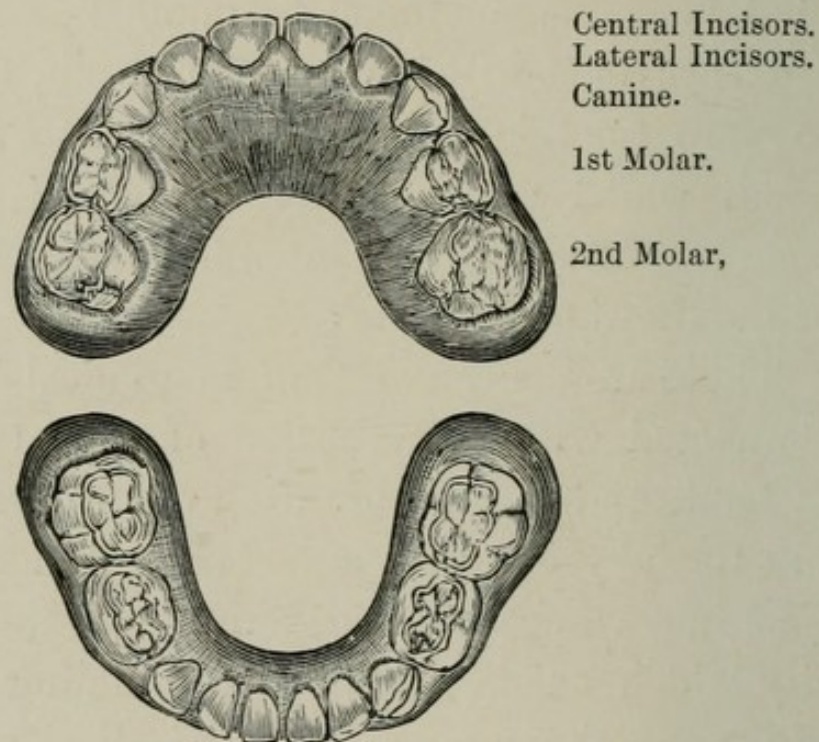
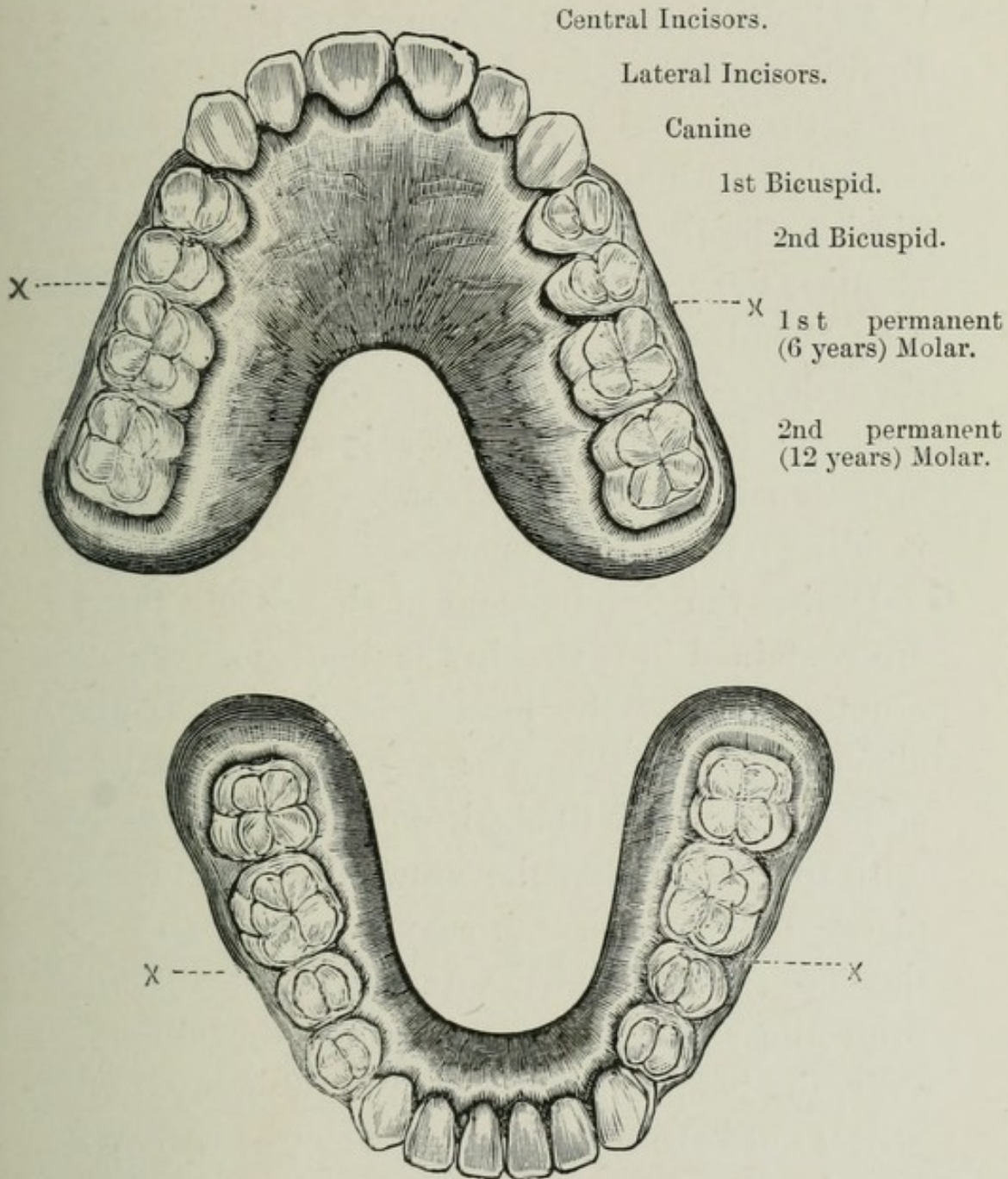


Fig. 2 and 3.—MODELS OF UPPER AND LOWER JAWS.
Showing Temporary Teeth complete. From a child aged 3 years.

with the teeth in the lower jaw. Intelligent watching and counting will often prevent a permanent tooth being mistaken for a temporary one by those who are unable to recognise the individual anatomical peculiarities.



Figs. 4 and 5.—MODELS OF UPPER AND LOWER JAW.
Showing Permanent Teeth complete. From a child aged 13 years.

X These lines indicate the former position of the 2nd temporary molars now replaced by the 2nd bicuspid teeth.

As is well known, the temporary teeth make their appearance above the gums at different ages, the central incisors about the sixth or seventh month after birth, the laterals from the ninth to tenth, the first molars about twelve months, the canine about eighteen months, and the second molar about two years. Whilst these dates are variable, it is generally stated that the teeth in the lower jaw make their appearance slightly in advance of the corresponding ones in the upper.

During the development of these teeth they are contained in crypts in the bone, and when eruption occurs the crowns of the teeth are alone complete; the roots are only gradually added, and the individual tooth is not finished until some time after the crown has taken its place. So that although we may expect to see the crowns of all the temporary teeth on inspecting the mouth at the end of the second year, the temporary dentition is probably not *perfect* until the fourth or fifth year, or perhaps even later.

As the implantation of the teeth at their eruption is not complete their arrangement in proper line is more easily determined by the

action of the lips and cheeks upon the outer surfaces, and the pressure of the tongue upon the inner side. In the front of the mouth the cutting edges of the upper teeth overlap those of the lower, whilst at the sides the outer cusps of the upper molars close outside those of the lower.

There are two stages in the eruption of the temporary teeth ; first, the absorption of the crypt, and secondly the absorption of the gum. The bony crypt is from the first widely open at the top, but not sufficiently so to allow the crown to pass through without removal of some of the osseous tissue. The whole process is, normally, a physiological one, and should be accomplished without the manifestation of any constitutional disturbance. If any reflex irritation may be expected to occur during absorption and the escape of the tooth, it is reduced to a minimum from the fact that the teeth are cut in groups with intervals of rest in between, instead of all coming through about the same time. This arrangement is decidedly in favour of the child, but it is also beneficial from the point of view of the development of the jaw. If the back teeth were erupted at the

same time as the front, such is the form of the jaw at six months, that the back teeth in each jaw alone would come into contact, leaving an "open bite" in front. But the incisors by being first erupted separate the jaws in front, and the interval of six months which follows, before the appearance of the first molars, allows the development of the jaw to progress in the normal directions, and, by an elongation of the ramus, to provide room for the full eruption and regular apposition of the back teeth.

But whatever the cause may be, whether due to heredity or some evolutionary process working in a new direction, it is well known that in some cases it not unfrequently happens that the period of "teething" is accompanied by a train of symptoms which marks the passage of a physiological process into a pathological condition. In addition to the increased secretion which is associated with the commencement of functional activity in the salivary glands, there may be noticed, as abnormal conditions, the usual indications of irritation in the rest of the digestive tract, viz.:—colic, diarrhoea and vomiting, and if the nervous system (at this age in an unstable condition,

and liable to respond readily to morbid stimuli) becomes involved, convulsions may also ensue. It is often an open question how far such symptoms may be caused by irritation due to teething. The fact that they occur at other moments of infantile life, in consequence of improper feeding or exposure to cold, may account sometimes for their presence, accidentally so to speak, during the eruption of a tooth. Still, when we find that these symptoms coincide with a turgid, swollen gum, a hot mouth, and that the speechless child directs attention to the spot by trying to overcome tension by pressure, we may reasonably conclude that the *fons et origo* is the tooth, more especially as when the latter escapes all the symptoms, both direct and reflex, quickly disappear. In connection with this condition arises the question as to the use of the gum lancet. Although still condemned by some, its employment, in suitable cases, appears reasonable. Most practitioners have at some time been called to a child cutting a tooth who, after keeping the household awake for several nights, has, perhaps, been seized with convulsions. The crown of a tooth has been easily

recognised beneath a swollen, more or less tense gum, and a simple incision in the case of an incisor or canine, or, as is more frequently demanded, a crucial incision over a molar, has resulted in cessation of all symptoms, and a good night's rest for all concerned. Such treatment in such a recognised pathological condition is infinitely better practice than the administration of so-called "teething powders" which, when they contain preparations of mercury, as is too often the case, can only be alluded to here for the purpose of condemnation. The possible occurrence of undue hæmorrhage and septic infection may with proper care be ignored, whilst the formation of a cicatrix, which is said to retard the advance of the tooth, can only take place where the incision has been prematurely made, and even in such a case the more lowly organised tissue may be expected to give way without trouble. As a possible explanation of the conduction and radiation of nervous stimulation from an erupting tooth we may refer again to the incomplete condition of the tooth itself. At this period the edge of the open, forming root will be in intimate relation with the pulp

tissue, and if there is pressure by resisting gum (*vis a fronte*) the irritation may give rise to relatively the same degree of stimulus received in the case of a large exposure of pulp in an adult tooth affected with caries.

It has been stated that the crowns of the twenty temporary teeth are normally present in the mouth by the end of the second year. Each of these on being shed will be replaced by a tooth of the permanent series, and in addition there will be twelve molars which come up behind, three on each side, above and below. In the table on the following page the dates must be understood as being merely approximate.

As is the case with those of the temporary set, the permanent teeth are incomplete when the crowns appear through the gum, and thus any obstruction caused by retained temporary teeth, or their roots will easily direct the permanent tooth into a wrong position and as the bone of the alveolar process is built up round the neck of the erupting tooth in whatever situation it may assume, the completion of the root will perpetuate the irregularity unless an opportunity is afforded for rectification.

TABLE OF ERUPTION OF TEETH.									
TEMPORARY, 20.					PERMANENT, 32.				
Central Incisor ...	erupted about 6—9 months.	Succeeded by Central Incisor ...	about 7th year.						
Lateral Incisor...	"	" 7—10	"	"	" Lateral Incisor	...	"	8th	"
First Molar ...	"	" 12	"	"	" 1st Bicuspid	...	"	9th	"
Canine ...	"	" 18	"	"	" Canine	...	"	11—12	"
Second Molar ...	"	" 2 years.	"	"	" 2nd Bicuspid	...	"	10th	"
No Predecessors {					1st Permanent Molar	6th	"
					2nd	"	...	12th	"
					3rd	"	...	17—25	"

The actual shedding of the temporary teeth sets in somewhere about the seventh year, the incisors being lost first, but the process which thus physiologically brings to a close the life of a temporary tooth will have commenced some time before the tooth actually disappears. The cementum covering the root is first gradually absorbed, and then the dentine, until finally perhaps nothing remains but a cap of enamel resting upon the gum. Caries may, of course, cause the destruction of temporary teeth, or by the production of pain lead to their removal by extraction.

One of the principal signs which indicate the approaching loss of the temporary teeth may readily be noticed without subjecting the little patient to a searching examination of the mouth. Whilst the temporary teeth have been fulfilling their function the permanent teeth have been developing behind them in the jaws, and these latter have also been increasing in size. The result is that the temporary teeth instead of remaining shoulder to shoulder now become separated, and are, so to speak, spread around the margin of the jaws. The spaces between the teeth are characteristic of the

approaching change. On the loss by absorption of a temporary tooth, the respective permanent tooth is generally found ready to take its place, but in those cases where the temporary molars have been removed for pain caused by caries, it may be some time before the corresponding successor is erupted, and thus a prolonged reduction of the surfaces for mastication results. It is well also to remember that the first of the permanent teeth to make their appearance are the first molars, which should be erupted behind, and next to, the second temporary molars about the sixth year, and before the temporary incisors disappear. This arrangement provides masticating surfaces at the back of the mouth, whilst the temporary molars are being replaced by the bicuspid; and in those cases where the temporary molars are prematurely lost by neglect, the first permanent molars, if not themselves neglected, are the only teeth to be relied upon to provide some surface for mastication, and to prevent the wearing out of the incisors by attrition, which would otherwise result.

Occasionally the temporary teeth are not lost at the proper time, and instances are

recorded of a retention of temporary molars at the ages of 63* and 65 years†. Whilst it is generally best that such teeth should not be retained long after puberty, it must be remembered that the corresponding bicuspid may be absent through non-development, and that at a more advanced age the gap caused by the extraction will not so readily be filled up by the approach of the adjoining teeth towards each other.

The temporary canine tooth should be the last of the milk dentition to disappear. It serves the useful purpose of preserving the necessary room for the permanent canine to take its place between the lateral and the first bicuspid. The crypts in which the two latter teeth are developed, are placed side by side, whilst that of the canine is more deeply placed in the jaw, so that the premature loss of the temporary canine allows the permanent tooth on each side to approach the other with the result that the aftercoming permanent canine assumes a position outside the dental arch. This, however, as will be shown later on, is not the only

* J. Ackery, Trans. Odontological Society, 1891.

† Salter, Dental Pathology and Surgery, p. 196.

cause which produces "outstanding canines."

The anterior permanent teeth, at all events in the upper jaw, are inclined somewhat obliquely forwards instead of taking a vertical position as did the temporary ones. This spreading arrangement allows the larger crowns of the permanent teeth to adapt themselves round a segment of a larger circle at the front of the jaws, the canine also sharing, normally, in the regularity of position, side by side with the neighbouring teeth.

It is often a matter of importance for the practitioner to be able to recognise the members of the temporary and permanent dentitions, and when a systematic watching and record has not been observed by those in charge of the child, it is, occasionally, not an easy matter for one without special experience to determine what teeth are present in the mouth and to differentiate between, say, a temporary and a permanent canine; or perhaps, a carious condition of the crown of a temporary molar, still firmly implanted and unduly retained, might possibly prevent the due recognition of an unerupted, or perhaps, misplaced, bicuspid.

Any individual front tooth of the temporary

series is smaller than its representative of the permanent dentition. As regards the temporary molars, they are larger teeth than the bicuspid, but the characteristic shape of the crowns of the latter when intact, especially those of the upper jaw, enable them to be easily recognised. The crowns of the temporary teeth are usually lighter in colour, and instead of the enamel being bevelled to a thin edge at the neck, as occurs in a permanent tooth, the temporary teeth have a thickened rounded rim marking the boundary of the crown. Internally, the pulp and its prolongations into the roots are perhaps relatively larger than in a completed permanent tooth, but this will depend to some extent upon the age of the tooth, and, although of importance in other directions, does not offer assistance in distinguishing a temporary from a permanent tooth whilst in the mouth.

Parents, however, occasionally appeal to the general practitioner with regard to an extracted molar, and an inspection of the roots alone, will enable a decision to be easily made. In the case of a temporary tooth there will generally be some, frequently to a large extent, signs of absorption; but the roots, or the remains of

them are always widely separated to allow for the reception of the crypts beneath, in which the permanent teeth (bicuspid) are developing. A point in connection with this relationship is alluded to under "Extraction of Teeth."

The first upper temporary molar has three cusps, two external, and one internal; the first lower has four cusps, two external and two internal; whilst the second temporary molars present a similar appearance on the crown to that of the permanent molars behind them. The two cusps of the lower bicuspid are not so marked as in the case of the upper ones and the depression between them is bridged over by a ridge of enamel. Indeed the inner cusp of a first lower bicuspid is often but feebly marked, and as the outer, or labial, surface of the crown is rounded vertically, the tooth may approach the shape presented by the tooth in front of, and next to it, namely the lower canine. The inner cusp of the second lower bicuspid is much more pronounced, and assists in forming a squarish surface.

The practical importance of distinguishing temporary from permanent teeth is evidenced,

if in no other way, by the necessity which arises for determining whether some particular tooth should be saved by treatment, or whether it may be extracted; in the case of the former the appropriate filling must be decided upon, as the methods and composition employed are somewhat different for temporary and permanent teeth. On the other hand, the fact that a temporary tooth has, normally, a distinctly limited lifetime, renders, in certain cases, a waste of time and labour in filling unnecessary, and an extraction advisable or justifiable. This question will be alluded to later on in connection with the extraction of temporary teeth, but it may be well to refer here to the great danger which exists in connection with the first permanent molars. The general arrangement of the crown is similar to that of the second temporary molar, and from the fact that it is erupted before any of the temporary teeth are lost, and that it has no predecessor, the first permanent molar is commonly regarded as being itself a temporary tooth, the loss of which is to be expected before long. From its position at the back of the mouth it does not get its proper share of inspection and atten-

tion, even if its presence is recognised, and the result is that its decay and loss are too frequently ignored to the great injury of a complete dentition. It should ever be borne in mind that, instead of being the last teeth of the temporary set, the six-year-old molars are the first of the permanent set, and most important teeth, not only for size and masticating function, but also on account of the position they hold in the jaws and in the series of teeth making up a full set. After their eruption the temporary teeth are gradually replaced by the corresponding members of the permanent dentition, and at twelve years, and not until then, the second permanent molars may be expected. It is, therefore, most important that at all events up to that age or period, the six-year, or first permanent, molars should be preserved as presenting the only constant masticating surfaces during the change which is taking place between the temporary and permanent teeth.

CHAPTER III.

CARIOES.

THE condition which is undoubtedly accountable for, by far, the largest proportion of dental diseases consists in the destruction of the hard tissues of a tooth, and although it has received the name of Caries, it must be borne in mind that it is not a similar process to that which takes place in bone. It invariably commences on the external aspect, and is due to external agents, and although the process is more or less gradual, and the destruction what may be termed molecular, yet it must always be remembered that the tissues concerned are non-vascular.

In order to understand the causation of caries, as it affects the teeth, it may be desirable to remind the reader that the teeth owe their density of structure to lime salts which are deposited in the process of development. Weak acids are capable of dissolving out the

lime salts, leaving behind a gelatinous matrix in the case of the dentine. Such acids are constantly found in the mouth. The secretion from the mucous membrane of the gums is sometimes said to be acid, but in conditions of health this acid secretion is neutralised at once by the constant flow of saliva from the salivary glands. Where the mouth is in an unhealthy condition, it is not at all uncommon to find the saliva acid, and then we have an important factor in the production of caries.

The principal source from which acids are formed in the mouth is found in particles of food remaining in the neighbourhood of the gums and teeth, or, in brief, on those surfaces which the tongue does not sweep. In such positions the food undergoes fermentative changes.

It is a well established fact that to microscopic organisms we owe such processes as fermentation. In order that these may be carried out successfully, material is necessary, and also a chamber kept constantly moist, at a sufficiently high temperature, with free access to the air. The mouth is such an ideal chamber with all the conditions favourable for

the action and propagation of micro-organisms, and the particles of food left upon, or in the neighbourhood of the teeth, are the material essential for cultivation. It is now well recognised that the production of caries in teeth depends entirely upon the presence of micro-organisms in the mouth; thirty species of these were isolated and cultivated by Miller of Berlin, twelve of them being characterised by the formation of lactic acid.

There are two stages in the process which results in the loss of a tooth by decay or caries. In the first the protective covering of enamel is affected to such an extent that the dentine beneath becomes accessible. In the second, sufficient destruction of the dentine takes place to subject the pulp to irritation and subsequent inflammation. The amount of tissue removed, and the rate at which the process progresses vary in individual cases, whilst the age of the tooth and the consequent size and condition of the pulp also influence the course of the disease. The activity of the agents concerned is modified by the changes in their environment, or life-relations, brought about by local hygienic conditions, and also by the extent to

which the tissues involved are well, or badly, developed. The action of germs upon particles of food (carbo-hydrates)* retained in the fissures and interstices of the teeth results in fermentation, and the production of acid, and when this remains sufficiently long in contact with the enamel, and has been frequently enough renewed, the lime salts in the tissue are dissolved and a *nidus* is formed in which the bacteria and sugar are even better protected, and in which the fermentative process can proceed still more rapidly. It is said that the lactic acid produced combines with the lime-salts set free, and that thus the organisms remain unaffected. So soon as the process of decalcification has brought the dentine within range, the bacteria are able to travel along the dentinal tubules, and to extend the destructive action into the surrounding matrix. Whether this destruction depends upon a continuance of the decalcification merely, or whether the albuminous dental cartilage is dissolved by certain germs which have the power of peptonising it, the result is readily apparent, and owing to the exposed

* Converted into some form of sugar by ptyalin, the active principle of saliva.

conditions of the teeth the physical signs of caries, or decay, are easily observed.

The first change is seen in the enamel, which loses its semi-translucent appearance at one spot, and is discoloured and rough, the colour varying from white to a darkish brown. The tissue is porous and can easily be perforated by a steel point, or cut into with a fine chisel. When sufficient enamel is removed, the dentine immediately beneath is found softened and discoloured, this condition extending on all sides beneath the still sound enamel which forms the margin of the cavity. The carious dentine varies both in colour and consistence. The colour may be a light yellow, or a dark brown, nearly black, the former generally presenting in cases where the progress of caries has been rapid, the latter where the course has been slow and chronic. These two forms are sometimes distinguished by the terms "soft" and "hard" caries; for the dentine may be of a cheesy consistence, or, in some cases, a pasty mass with a putrid odour, whilst in others where the tissue is very dark, it would almost seem as if the advance of the destructive process had been checked.

The direction of the decay may be superficial or deep, as the extent of caries varies not only in different teeth but in the different tissues of an individual tooth. The structure of the enamel and dentine differs very much in density, and this fact largely accounts for the slowness, or rapidity of caries; the tissue with the greatest amount of organic material is more rapidly disorganised, so that it is not uncommon to find, in preparing a cavity for filling, that a comparatively small hole in the enamel leads down to a large unexpected, or at all events previously unknown, excavation in the dentine. In some cases the decay is so rapid that the first intimation is the collapse of a large portion of the crown, when the dentine below may be found to be a caseous mass. In others, caries has spread superficially over the whole surface, the enamel is gone and the dentine is of brownish colour reduced in quantity and burnished.

As the enamel and dentine are entirely devoid of blood-vessels there is no such thing as "vital" or inflammatory action present in caries of these structures. Experiments have shown conclusively that a precisely similar

condition can be produced in teeth long removed from the mouth, and where natural teeth and ivory blocks have been worn as artificial substitutes, caries has been found just as active in them as in living teeth in the same mouth. It is, perhaps, scarcely necessary to remind the reader that artificial teeth are now made of porcelain and that ivory is no longer used.

Not only has it been demonstrated that, by imitating the usual surroundings, artificial caries can be produced in an extracted tooth, which cannot be distinguished from natural caries, even by the microscope, but it has also been proved that without the presence of micro-organisms caries cannot occur.

Having thus considered the actual, or exciting causes of dental caries, it may be well to allude briefly to those conditions which predispose the tooth tissues to this disease. They may be readily mentioned under two headings:

- a.* Abnormal conditions of the tooth itself.
- b.* Abnormal conditions of its environment.

Defective tooth structure is an important factor of caries. It has already been mentioned that teeth vary in density, and

every dental surgeon is familiar with this fact owing to the cutting operations necessary to remove carious tissue. The difference is due to imperfect calcification, and microscopic sections show this both in enamel and dentine. In the latter it is more apparent in what have been described as "Interglobular areas."

Imperfect enamel, such as one finds of constant occurrence in what are called "honey-combed" teeth, is also due to a deficiency of lime-salts. The tissue is pitted all over the crown, and is sometimes absent in certain spots, or else is deeply furrowed. This latter condition, especially, is found in the permanent incisors. In addition to the intrinsic defects there may be external faults. Wherever there is an irregularity on the crown of a tooth, or any departure from the smooth and beautifully polished surface of the enamel, food is apt to collect, and caries is the result. It is not at all uncommon to find chinks or crevices in the crowns of molars and bicuspid just where the folds of enamel meet, leading down to dentine which is also defective. In such cases acid secretions prepare the way, and softening takes place assisting the inroads of true caries.

Another cause depending upon the teeth themselves is due to an irregular position being assumed. From what has already been stated it will be apparent that any arrangement tending to favour the retention of food particles in the neighbourhood of the teeth will conduce to caries. So, when a tooth does not range properly side by side with its fellows in the alveolar arch, angles are necessarily formed which the tongue finds it difficult to sweep, and the *debris* collected in the recesses jeopardises not only the misplaced tooth but its innocent neighbours.

In this latter case we see a predisposing cause depending upon surrounding circumstances, and it may be said, generally, that a crowded condition of the teeth, and any similar impediment to the maintenance of a hygienic state of the mouth, will constitute such a cause. There seems to be reason to believe that caries affects the modern tooth to a much greater extent than obtained in bygone times, and the absence of this destruction which is apparent upon inspection of ancient skulls, and also the immunity enjoyed by many existing savage races, would point in the

direction that amongst the concomitant effects of civilization must be enumerated a liability to caries of teeth. The extent to which cooking and other preparation of food is practised and possibly the nature of the food itself, may have a great deal to do with this. There are also indications that some members of the dental series are undergoing suppression, the individual teeth showing the greatest tendency to non-appearance being the lateral incisors and third molars. In conjunction with this gradual withdrawal, on the part of Nature, of organs which are no longer necessary, we may consider the interference with the ordinary rules governing natural selection which is taking place in the human race *pari passu*, and in proportion to, the progress of what is recognized as civilization; and we thus perceive how the standard of the actual tooth structure may become lowered in consequence of outside influences.

The effect too, of certain drugs seems likely to be overlooked; the administration of mercury in congenital syphilis, or in the form of "teething powders," has a prejudicial effect upon the formation of the teeth undergoing de-

velopment and appears to modify the process of calcification.

One result of the lessened use of a tooth is observed when, the principal opposing tooth being lost, the surface is no longer kept clean by mastication, but remains subject to accumulation of food with subsequent caries. And although the tartar which tends to collect upon the sides of such a tooth may not itself produce caries, it may lead to irritation of the gum and unhealthy secretion, thus imitating another predisposing condition to which attention must be drawn. We allude to the sordes which form around the teeth during the exanthemata and other constitutional febrile attacks, which in this respect are quite as noxious, although frequently overlooked, as the equally common results associated with such local affections as the different forms of stomatitis.

The retention of the diseased temporary teeth, or the existence of a cavity in the next tooth will also predispose a well-formed tooth to attack by caries.

By taking a comprehensive view it will be seen that these two classes of predisposing causes can re-act one upon the other, for bad

structure may lead to loss of teeth, imperfect nutrition and, as a more remote effect, debased offspring ; whilst on the other hand it becomes

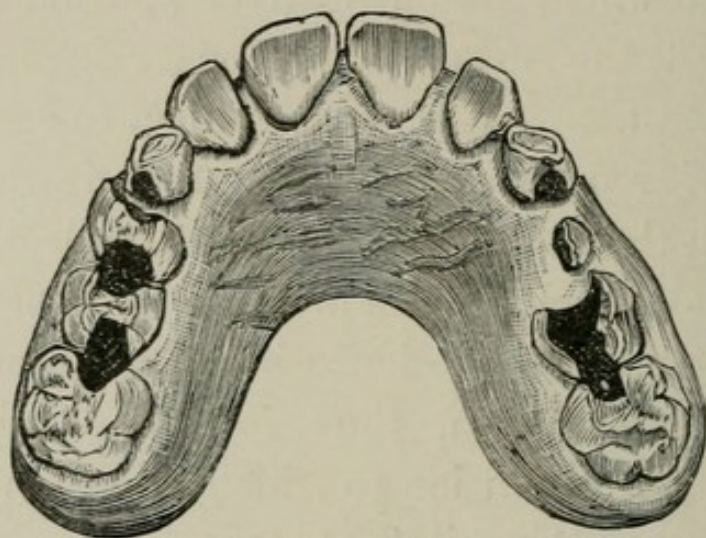


FIG. 6.—MODEL OF UPPER JAW.

Showing caries in temporary molars by which the permanent molars have been affected. From a child aged 9 years.

manifest that an artificial interference with the survival of the fittest may result in depraved structure of the teeth in succeeding generations.

CHAPTER IV.

INFLAMMATION OF THE PULP.
PULPITIS.

COMPARATIVELY few in number are the individuals, whether children or adults, who do not know that dentine when exposed by decay is sensitive, and that the sensation is the reverse of pleasant; and although at present no satisfactory explanation is forthcoming, even as some sort of solatium, of the actual method by which the external stimuli are conveyed to the dental pulp, yet the presence in the dentinal tubes of processes from its cells and the close relationship which the soft tissue bears to the hard, together with the existence of numerous nerves in the former, make it sufficiently easy to understand how an impression is conveyed to the sensorium that a new and unfavourable set of conditions is affecting the

vasculo-nervous mass in the pulp chamber, and threatening to abolish its vitality.

A post-mortem examination of a tooth shows, in some instances, that an attempt to resist the approach of caries is manifested by an increased activity of the dentine-forming function of the pulp, a barrier of calcified tissue being constructed at that portion of the pulp chamber which is nearest to the carious cavity.

But when once a direct communication is made (exposure of the pulp) the outside influences come more powerfully into play, including the admission of micro-organisms; the pain is increased, and the other usual pathological states accompanying inflammation are followed by suppuration. Another variation of this ordinary sequence of events in what is called acute pulpitis, and which not uncommonly happens, is exemplified when the pulp is acutely inflamed (by transmission of irritation?) before an exposure actually occurs, and then, owing to the confined space in which it is situated, severe pain is experienced, probably followed by gangrene of the pulp.

Besides that due to caries the pulp is liable to inflammation caused in other ways. Fracture

of a tooth (afterwards alluded to) may either absolutely expose the pulp, or lay bare the dentine so close to it as to subject it to irritation, whilst other forms of violence may so interfere with the vascular and nerve supply entering the apical foramen as to cause inflammation or gangrene.

Sometimes, however, exposure does not result in a more or less immediate destruction of the whole pulp, and the inflammatory action pursues a more chronic course, so that occasionally a secreting, or ulcerating, surface is to be found; or perhaps, if the case is seen at a still later stage, the granulations have given place to a fibrous polypoid growth and, in rare cases, calcification has been noted.

During the physiological absorption which takes place in temporary teeth, and principally in their roots, although the pulp and its prolongations seem frequently protected by special formation of dentine, yet the root canals leading to the pulp chamber do become opened and the soft mass may be destroyed. But this is not necessarily the case, and there would seem to be some process by which a line of demarcation is kept between the advancing area of

absorption and the still living remnant of the pulp.

Another condition affecting the pulp is not essentially concomitant with an exposure, or even with caries. Many cases have been

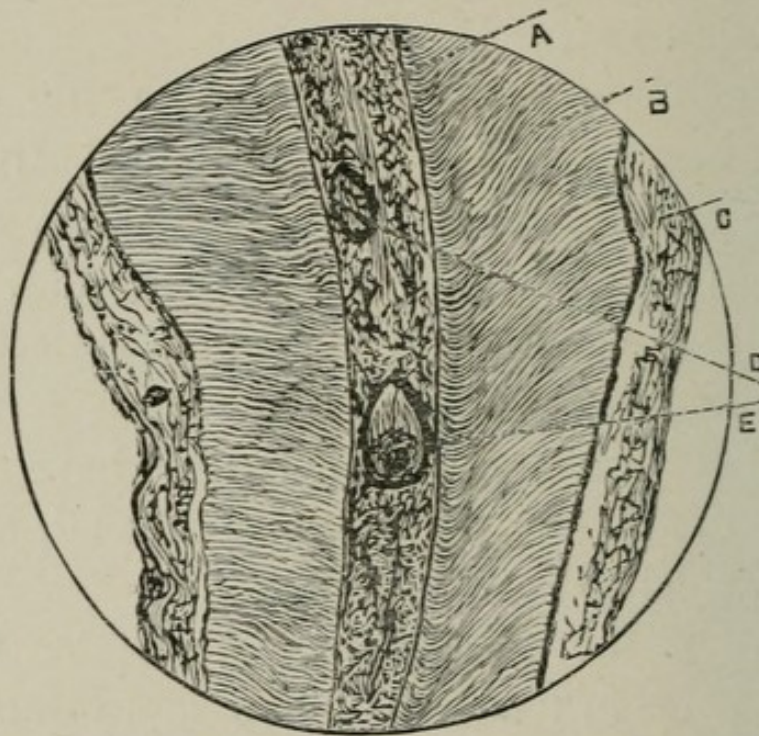


Fig. 7—LONGITUDINAL SECTION OF ROOT OF BICUSPID.

Stained with Carmine, and prepared by the Weil method.

From Mr. Spokes' Collection. $\frac{2}{3}$ inch Objective.

A.—Pulp. B.—Dentine. C.—Cementum. D.—“Pulp Stones.”

recorded where in consequence of pain a tooth has been extracted and on examination of the pulp rounded or oval masses of calcified tissue have been discovered embedded in its substance.

When these are large, or numerous enough it is easy to see how irritation of the nerves is produced by pressure. (Fig. 7.)

On the other hand, the pulp in some old teeth undergoes such an extended solidification that scarcely any soft tissue is to be found; in still others none at all, and this without a history of pain. Perhaps in these cases there has been a concurrent degeneration of the nerve elements, and both together may be regarded, physiologically, as a senile condition of the tooth.

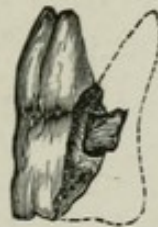


Fig. 8.—UPPER MOLAR TOOTH (Split into two pieces.)
Showing complete calcification of the Pulp.

If, as indeed happens in some cases, the pulp always succumbed without the occurrence of sequelæ due to septic infection of adjacent tissues, a pulpless tooth might be regarded, in a certain sense, with relief, even if impaired for mastication. But the experience of dental surgeons forbids such an expectation, for whilst

a tooth in such a condition may not be absolutely a foreign body (being, as already elsewhere pointed out, kept in some sort of relationship with the rest of the organism by means of the periodontal membrane) yet the putrid remains of the pulp exposed to the atmosphere through the mouth, will not only render this cavity unpleasant and unwholesome, and possibly affect neighbouring teeth, but also will constitute a source of danger to the tissues at the bottom of the socket, especially if the external outlet in the crown of the tooth become blocked by food or other substances. It is for these reasons that "dead" teeth, if allowed to remain in the mouth, should first be treated *secundum artem* by the dentist.

CHAPTER V.

*INFLAMMATION
OF THE PERIODONTAL MEMBRANE,
PERIODONTITIS, ALVEOLAR
ABSCESS, NECROSIS, AND OTHER
SEQUELÆ.*

When one considers how intimately the periosteum of a tooth (the periodontal membrane) is connected with the blood vessels and nerves of the pulp, it is scarcely a matter of surprise that inflammation of this fibro-vascular membrane arises for the most part as a continuation of pathological changes which have already affected the crown. In its simplest form such inflammation may commence as follows:—A cavity of decay in some surface of a tooth has laid bare the dentine. The access of salt or sugar, and of hot and cold water, sends a thrill of pain through the tooth. This

may pass away within a few minutes, to be succeeded a few hours later by symptoms of inflammation in the periodontal membrane. There is an uneasy sensation, the tooth is tender to bite upon, seems raised above its fellows, and is somewhat loose in its socket. In a day or two the symptoms may subside, and the tooth is as firm and as useful as ever.

Such transient irritation *may* happen to the soundest of teeth, and one is justified in concluding that it is due to direct communication of nervous irritation from the pulp to the periodontal membrane. Far more frequently, however, acute inflammation of a septic character occurs as a direct consequence of inoculation from the pulp chamber. It has been mentioned (*vide* Pulpitis) that exposure of a pulp is often followed by gangrene. The acute pain which usually accompanies this condition has subsided, and mastication proceeds as usual. The necrotic condition of the pulp very soon extends through the whole length of the fangs. So long as the open cavity in the crown of the tooth remains patent the products of decomposition will escape into the mouth ; but as soon as this is closed, by the

accumulation of food, it is squeezed down by mastication into the tooth, septic material is forced through the open ends of the fangs (apical foramen) into the surrounding tissue, and acute inflammation is usually the result. A throbbing, aching, pain is referred to the tooth and gum around it. The gum is acutely inflamed, and the tissues beneath become

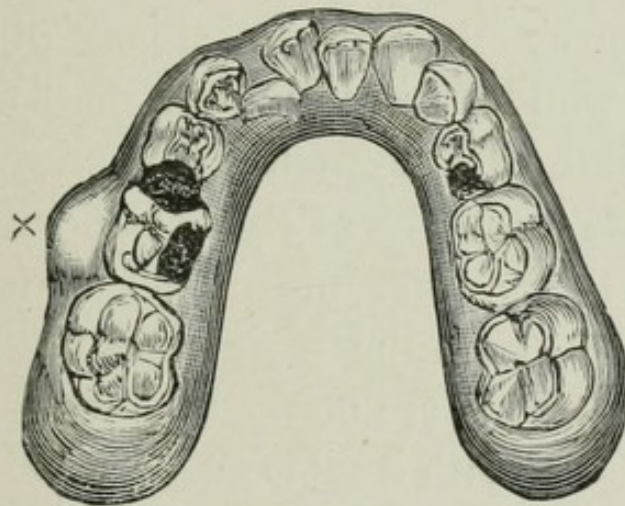


Fig. 9.

Model of lower jaw of a child aged 7 years, showing alveolar abscess on the left side, caused by a second temporary molar tooth.

infiltrated and swollen with inflammatory products. The tooth is raised above its fellows and though at first relief is found by biting, it very soon becomes so acutely sensitive that any pressure is impossible, and the mouth cannot be closed. If at this stage the offender is

extracted, the periosteum which clothes the fangs will be found thickened and quite red in colour. Later, this membrane will be stripped from the ends of the fangs, and pus is poured out between it and the tooth, expanding and dissolving the porous bony and fibrous tissue, making its way to the surface either round the neck of the tooth (Fig. 9) or through the alveolar plate and gum. Occasionally the pus finds its way through the inner (lingual or palatal) wall of the alveolus, but more frequently it opens through the buccal wall. In either case it may be expected to finally burrow through the mucous membrane which covers the alveolus. At the same time the constitutional symptoms are marked by an elevation of temperature, with headache, a coated tongue, and general malaise.

With the exit of pus all the acute symptoms subside, and the tooth gradually sinks down again into its socket, leaving a small sinus on the gum through which pus is more or less continually discharged.

This swelling and discharge is often spoken of as an *alveolar abscess*, or, more popularly, is called a gum-boil.

The consequences of such inflammation are somewhat different in temporary and permanent teeth.

It has been pointed out in a previous chapter that the fangs of a temporary tooth are no sooner formed, than a process is commenced by which they are eaten away, in order to make room for the erupting permanent tooth. The little mound of tissue crowded with the so-called osteoclasts (large multi-nucleated cells) lies immediately beneath the open end of the fangs. This is essentially a vital process, and should the fangs remain healthy not only will they be removed, but the whole of the inside of the crown will be eaten out, so that the tooth may be tilted off the gum with the finger nail. An examination of such teeth shows little pits and cavities all over the inside of what is left. If caries has attacked any portion of the tooth, the dentine will be eaten out all the way round it, leaving the carious portion standing alone.

When the exposure of a pulp occurs, followed by death and the forcing of septic matter through the fangs, the absorption papillæ are entirely destroyed. The periodontal mem-

brane is separated from the roots at the apex, and as pus accumulates this separation may—and for the most part does—extend right up to the neck. The alveolar wall is gradually dissolved away, leaving the fangs of a dusty brown or greyish colour protruding through the outer wall and perforating the adjoining cheek or lips. (Fig. 10.) The normal method

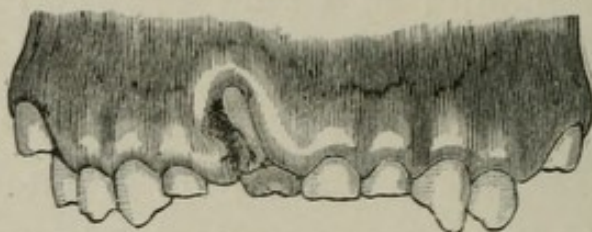


Fig. 10. Model, showing necrotic root of an upper temporary central incisor tooth.

of removal of the tooth to make way for its successor has ceased and it becomes a veritable foreign body. In cases where the periosteal covering has been removed from the lower portion of the fangs only, the tooth may remain firm in its socket, dark in colour with a small sinus through the alveolus discharging pus, showing that the apex of the fangs are necrotic. Septic inflammation of the periodontal membrane often extends to the crypts of the permanent teeth. This is more likely to occur in the region of the temporary molars.

Lying immediately beneath or above them (according as one speaks of the lower or upper jaw) are the permanent bicuspid, the crowns of which are the only part of them at all fully formed; and it is no unusual occurrence when removing a temporary molar, the fangs of which are bathed in pus, to find the crown of the bicuspid lying loose below it dark in colour, in a necrotic condition and the formative tissue of the fangs entirely destroyed.

The fangs of the permanent teeth are larger than those of their predecessors and more deeply implanted in the jaw. The alveolar process is of denser structure so that when septic periodontitis affects them the symptoms are more acute owing to the greater difficulty in the escape of pus. When, however, pus has escaped and the tooth becomes firm in its socket once more, the vitality of the periodontal membrane is for the most part retained and the tooth will still receive some nourishment through the cementum. At the apex of the fang (or fangs) it will be destroyed, the termination of the fang will be necrosed and a fistulous tract established between it and the point of exit.

The pathology of acute periodontitis followed

by alveolar abscess is similar to that occurring in other bony tissues. The membrane surrounding the tooth becomes swollen and congested—hence the tooth is raised from the socket. Proliferation of cells from the fibrous tissue and the capillaries, with exudation of inflammatory lymph follows. Thrombosis of the blood vessels and a rapid liquefaction of inflammatory products into pus is a consequence of the poison introduced to the tissues, viz., micro-organisms and their chemical products. As pus accumulates, the inner layer of the periodontal membrane is more or less stripped from the cementum of the tooth. In chronic cases it is not unusual to find this layer expanded and thickened so that when the tooth is removed a small sac is found at the extremity of a fang. This stripping of the membrane from the tooth would take place more frequently were it not for the fact that pus readily finds a way into the cancellous bone of the jaw. Expansion and erosion take place simultaneously. The throbbing, aching pain which occurs while these changes are taking place, at once ceases when pus has escaped through the bone into the fibro-cellular tissues.

In acute alveolar abscess the inflammatory œdema is considerable. It is especially noticeable in the upper jaw. Children often present themselves with their faces puffed and eyelids so swollen as to be almost closed. Just as if they had received a severe blow or injury to the face without breach of tissue.

In weak or unhealthy children pus is likely to burrow deeply into the tissues of the jaw, destroying other teeth it may come in contact with, or making its way out on the face or beneath the jaw. This may occur in connection with either temporary or permanent teeth, though it is frequently associated with the first permanent or six-year molar.

A. F. A girl, æt. five years, of pallid complexion, complains of a sore on her face. Had toothache some months ago; three weeks since the face suddenly swelled up causing much pain. It was well poulticed by the mother. The child had an unhealthy looking sore on the left cheek opposite the molar region of the lower jaw. It was small in size, circumscribed, and on its summit there was a small papilla from which pus was oozing. Careful probing showed a direct connection with the roots of a lower temporary molar which was found deeply carious, but firm in its socket. This was removed, and in one week the scar alone remained.

As in this instance, advice is often sought when the mischief is done. It also illustrates a method of treatment frequently adopted by

the ignorant, viz., that of poulticing swellings upon the face, which, if nothing else happens, may leave a life-long scar. (Fig. 11.)



Fig. 11.—DRAWN FROM A PHOTOGRAPH.

Showing papilla on the face from which pus was oozing. Caused by a neglected six-year molar. The swelling had been incised several times from the outside,

Another case:—

Annie Knight, aged 13, five or six months ago had toothache on the right side. Seven weeks ago face began to swell, and hot fomentations were applied. It was then lanced, and has been poulticed since.

On the right side, beneath the lower jaw was a small papilla, around it the skin was puckered and adherent to the bone. A carious permanent molar was found quite firm in its socket. The pulp was putrid. The tooth was extracted, and adhering to the posterior fang was a small sac. In a week the sinus beneath the jaw had ceased to discharge.

When upper teeth are affected pus may find its way into the palate, or open into the floor of the nose, or into the antrum.

M. E., aged eight years. Measles three years ago, since which there has been a constant discharge from both ears. Five weeks ago left cheek began to ache and swell. A doctor removed a tooth and matter came away. A week later a lump was noticed below the left eye. The face being swollen and red, hot fomentations were applied. The patient was a well nourished-child, with fair hair and blue eyes. The face was considerably swollen on the left side involving mostly the cheek, the latter being red and brawny. There was a fluctuating swelling below, and external to the inner canthus of the left eye, and at its summit pus was oozing from beneath a thick yellow crust. The crust being removed, examination with a probe showed that the fistulous opening was in connection with the antral cavity. On inspection of the mouth, a scarcely healed wound was seen between the temporary incisor and molar tooth, indicating clearly that the temporary canine had been removed. The hard palate on the affected side was quite normal, but viewed from outside the anterior wall of the left antrum was more prominent than the right. No fluctuation could be obtained through the antral wall. The child was placed under chloroform, and with an ordinary gimlet, previously rendered aseptic, the orifice through the canine socket was enlarged. The developing permanent canine, lying quite loose and in front of the opening, was removed. A probe was then thrust into the antrum and out on to the cheek. The cavity of the antrum was carefully explored at the same time, the walls appearing healthy, except anteriorly. The sinus on the cheek was dressed with boracic ointment, and a pad placed over it. The antrum was syringed out with warm boracic lotion through the perforation of the jaw. The mother was directed to syringe it frequently with this lotion. The sinus on the cheek healed in a few days, and ten days later the wound in the mouth was closed up.

A collection of pus in the antrum in connection with temporary teeth is of rare occurrence.

Owing to the small size of this cavity the temporary teeth lie well outside its walls, which are comparatively thick. In this case pus from an alveolar abscess at the root of a temporary canine had burrowed deeply beneath the permanent canine, and, finding its way into the antrum, had pointed through the anterior wall and opened out on to the cheek. Far more serious injury is likely to occur as the result of periodontitis. Numerous cases are recorded by Tomes* and Salter† where pyæmia and death have occurred.

Mr. Arbuthnot Lane, of Guy's Hospital, records the following case, an abstract of which is given.

ALVEOLAR ABSCESS. PYÆMIA.

EXCISION OF THROMBOSED VEINS.

H. R., æt. four years. Suffering from a swelling over the left half of the lower jaw, which commenced with toothache about a week before. Five days previously an abscess burst into the mouth. Temperature on admission, 105·4. There was an alveolar abscess in connection with a second temporary molar. This was removed, and the abscess cavity scraped and thoroughly cleansed out under an anæsthetic. The boy became jaundiced, and suffered from recurring rigors. Mr. Lane excised the thrombosed veins, the external jugular, and branches of the facial. The abscess cavity and bone were cleansed thoroughly and packed with iodoform gauze. Many inflamed lymphatic glands were removed. This operation

* *Manual of Dental Surgery.*

† *Dental Surgery and Pathology.*

was followed by disappearance of the jaundice; but subsequently the child died, and it was found that there were a number of abscesses in the liver and lungs. These were produced by septic emboli before the operation took place.—*Lancet*, Nov. 5, 1892.

The case is instructive not only in showing how pyæmia may be caused by a tooth, but as showing that the removal of thrombosed veins is effectual in staying the pyæmic process while yet local and uncomplicated.

It is really a matter of surprise, considering the frequency of such septic inflammation, that fatal cases do not more frequently occur. It is by no means an uncommon occurrence in examining the mouths of children to find several sinuses or fistulæ in the mouth, each one connected with a separate tooth, duly discharging its share of pus which is daily mixed with the food and saliva and swallowed. In connection with these teeth, or their roots, septic matter has escaped into the alveolus, periodontitis has followed; with the swelling, formation of pus, its escape through the alveolus, and the subsidence of all symptoms. Many such cases are of a passive type, passing through all the stages of inflammation and suppuration with very little pain and consequent distress, though it by

no means follows that the results are less serious, as the following case will show :—

A. B., a boy æt. five years, brought to the hospital because he had a sore mouth and bad breath. The mother stated that a few weeks ago the boy had a swelling on the side of his cheek.

The patient, a puny child of dark complexion, had a foul breath and coughed incessantly. On examination all the temporary molars were found deeply carious. On the right side in the upper jaw both upper molars were loose, the gum was dark red, and round the necks of the teeth there was a greyish slough. Pus was oozing out opposite the apex of the roots. On removing the teeth, the fangs were quite dark in colour and necrosed. A good sized portion of the alveolus was found lying loose. This was removed, and also the crowns of two bicuspid which were offensive and almost black. The cavity was well mopped out with a solution of carbolic acid 1 in 10. The mother was directed to syringe the cavity, and to wash the mouth out frequently with a solution of Pot. Permang. Internally quinine and iron were prescribed.

This child had suffered very little pain indeed, so little that it was the child's breath alone which attracted attention.

Children who are wrongly fed, starved, or suffering from constitutional diseases, such as tuberculosis, rickets, or syphilis, are the subjects of periodontitis. It generally commences with marginal ulceration of the gums, affecting carious and non-carious teeth alike. Many teeth may be involved or one tooth alone. Sometimes it is symmetrical as in the following case :—

T. V., age 3 years. A delicate boy with well-marked Rickets. The mother says "food passes through him as soon as he eats it." The child cannot masticate because of loose teeth. On examination the teeth are seen to be well-formed, none are carious. The lower and upper canines are much raised above the other teeth, and are somewhat loose. The patient cannot close his mouth properly as only the canines meet. The gum is ulcerated round the necks of the teeth; the alveolus is expanded beneath the R. lower, and above the R. upper canine. Pus is oozing from sinuses. On removal of the teeth the periosteal covering was found much thickened. The teeth however, were neither carious nor discoloured.

Exfoliation of the alveolar plates following periodontitis is of frequent occurrence after scarlet fever and measles; and though it is in many cases intimately connected with carious teeth and roots, this is not necessarily the case. When associated with carious teeth or necrotic roots it would appear that the starting point may be through the fang of a tooth, or external to the teeth. The inflammation in the latter case spreads from a purulent gum margin which surrounds them. This latter condition is especially noticeable where the teeth are quite sound. The continuity of gum with periodontal membrane and the connection of the latter with the periosteum of the jaw, will serve to explain the means by which septic inflammation, either occurring within or outside may involve the deeper tissues of the jaw; the symptoms in

both cases are the same. The inflammation is of a passive type. A child is brought up for a swelling of the face, generally a foul breath and a discharge from the mouth, but very little pain. On examining the affected side the gums will be found puffy, swollen, and deeply ulcerated round the necks of the teeth, leaving bare the alveolus. The teeth will be found quite loose, and pus oozing from the gum margins. Beyond removing loose and carious teeth, and seeing that the mouth is constantly cleaned, no treatment is required. In a month or six weeks the sequestrum will become quite loose and can then be easily removed.

CHAPTER VI.

IRREGULARITIES OF THE TEETH.

IRREGULARITIES OF STRUCTURE IN TEMPORARY AND
PERMANENT TEETH.

IRREGULARITIES OF FORM IN TEMPORARY AND PERMA-
NENT TEETH.

IRREGULARITIES OF NUMBER IN TEMPORARY AND
PERMANENT TEETH.

IRREGULARITIES OF POSITION IN TEMPORARY AND
PERMANENT TEETH.

OVERCROWDING OF THE TEETH AND ITS TREATMENT.

IRREGULARITIES OF STRUCTURE.

Temporary Teeth. That there is an intimate connection between defective teeth and Rickets, would seem obvious, judging by the references which are found in most text books of Medicine and Surgery where rickets is discussed. Thus one writer says, "Dentition is late and irregular. . . . The teeth themselves are imperfectly formed, their enamel is defective; in a year or two they turn black and break off or fall out."* Another writer says: "Dentition is much delayed in rickets . . . the enamel of rachitic teeth is bad, rocky, or pitted in its disposition, the teeth are notched, or have horizontal ridges, and break away down to the gum, where they appear as black and jagged stumps. These conditions are not peculiar to rickets."† Another remarks, "Dentition is much delayed and the teeth when cut are

* Fagge, third edition, vol. II., page 736-7.

† Goodhart, fourth edition, page 646.

deficient in dental enamel, so that they decay rapidly.”* Another says, “The teeth are late in appearing; the teeth, moreover, are specially apt to decay and become loose.”† Another observes “The teeth appear very late . . . while they also rapidly decay or fall out, being deficient in enamel.”‡ Others again state that modifications of dentition vary according to the period at which the active phase of rickets becomes manifest. If it be early, there are three ways in which the modifications may occur. 1.—The teeth are late in their eruption. 2.—The teeth are cut cross—that is, they appear in wrong order. 3.—They soon become carious and are often shed early.†† Other authors might be quoted, but perhaps more than sufficient extracts have been given to show that there is a consensus of opinion among medical writers. 1.—That in Rickets there is delayed dentition. 2.—That the enamel is

* Quain's "*Dictionary of Medicine*," article "Rickets," (Eustace Smith), p. 1373.

† Bristowe, seventh edition, p. 930.

‡ Roberts, seventh edition, p. 285.

†† Keating's "*Encyclopædia*" *Diseases of Children*, article, "Rickets": Barlow and Berry, vol. II., p. 226.

rocky, pitted, or deficient. 3.—That the teeth rapidly decay and fall out.

That the eruption of the temporary teeth is delayed in Rickets is undoubtedly a fact, and the author believes it to be one of the diagnostic signs of this disease.

That the enamel is defective, or honey-combed—a condition so often found among teeth of the permanent set and to be described later—does not accord with his experience.

In order that the surface of the enamel should be defective it is necessary that the teeth should be influenced by this disease when in a soft condition and during the process of calcification.

Calcification of the enamel commences in the temporary teeth about the seventeenth or eighteenth week of intra-uterine life. From this time forward it is continuous; and at birth parts of the crowns are fully formed, though it is still doubtful whether the enamel has received its *full* impregnation of lime-salts.

If *fœtal rickets* were a common disease, we should expect to find some modification in structure of the upper parts of the crowns of

the temporary teeth. It is, however, comparatively rare, and when present is associated with such profound changes in the skeleton, as to bear only a superficial resemblance to true Rickets, "and is more appropriately called *foetal cretinism*."*

On the other hand, if Rickets were common within the first three months after a child is born, we should expect to find some alteration in appearance on the lower portion of the crowns of the temporary teeth. This again is comparatively rare, for most authors are agreed that Rickets is developed after the first three months of life, and is essentially a diet disease due to the administration of starchy food.

As however some eminent authorities believe that Rickets is not uncommonly inherited, and that its manifestations are by no means rare at (or immediately after) birth, a brief comparison may be drawn (so far as the temporary teeth are concerned) between it and syphilis, a disease in which there can be no question as to hereditary transmission. The author has ex-

* Heath's *Dictionary of Practical Surgery*, "Rickets," by R. W. Parker.

amined from time to time a large number of syphilitic children, and has found that in the vast majority the temporary teeth were perfect in form. When, however, there has been any defect in the enamel, it has been seen round the necks or lower portions of the crowns of the canine teeth, or that portion of the crown which is least developed at birth, and in such cases it is quite certain that mercury had been given in consequence of early symptoms of syphilis. It may be well to remember that such an eminent observer as Mr. Jonathan Hutchinson attributes such markings to the administration of the drug and not to the disease.

It cannot be supposed that the quotations made above are devoid of foundation, for the writers are all careful observers. The mistake (if it can be considered such) has arisen in the following way. Medical men have noted that delayed dentition is one of the features of Rickets, therefore an examination of the teeth is a necessary part of diagnosis, and becomes a matter of routine practice.

As the teeth of such children are very prone to decay, and as caries is frequently seen on

the labial surfaces, it has led to the supposition that honeycombed, pitted, or rocky enamel is of frequent occurrence among teeth of the temporary set.

Dr. G. A. Carpenter,* and the author, have examined some 500 children with well marked Rickets in the out-patient department of the Evelina Hospital, and found in the majority of cases the teeth were perfect in form.

Permanent Teeth. Though structural alterations in the crowns of teeth are rare among the temporary set, it is by no means so among those of the permanent dentition. “*Honeycombed*” or “*ridged*” are terms used to describe the enamel surface of such defective teeth, and they are of frequent occurrence. They have no highly polished surfaces, the teeth are yellow in colour, and a variable portion of the crown appears as if it had when soft been pricked, or pushed into with a blunt pin.

Mr. Hutchinson believes this is due in a large number of cases to the administration of mercury, and Mr. Moore has traced it to

* Primary Dentition in its Relation to Rickets, *The Lancet* June, 1892.

teething, or soothing, powders which contain mercury.

The crowns of the teeth most affected are the six-year-old (or first permanent) molars, the cusps of which are frequently pointed; they appear to be stunted in growth, often showing a marked absence of enamel. The incisors also are affected in various ways,

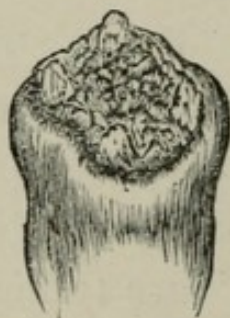

Fig. 12. HONEYCOMBED PERMANENT MOLAR.

From a child aged six years. (Enlarged.)

sometimes the whole of the front or labial surface is pitted, sometimes the whole crown, but mostly that portion of the tooth nearest the cutting edge.

It is not at all uncommon to see a line of good and then one of defective enamel (*ridged*).

Frequently the lower half of the incisors are defective and the tips of the canines, this according with the development of the teeth

at the time they were affected. Such alterations in enamel structure point to a profound disturbance in nutrition during the first two

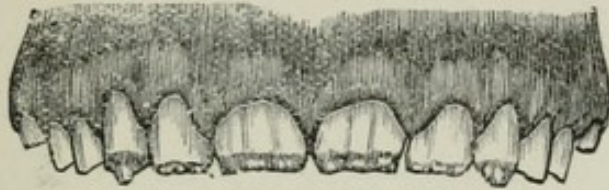


Fig. 13. MODEL OF UPPER JAW.

Showing honeycombed teeth. From a child aged 12 years.

years of life, and may be traceable to rickets, convulsions, and exanthematous fevers. As

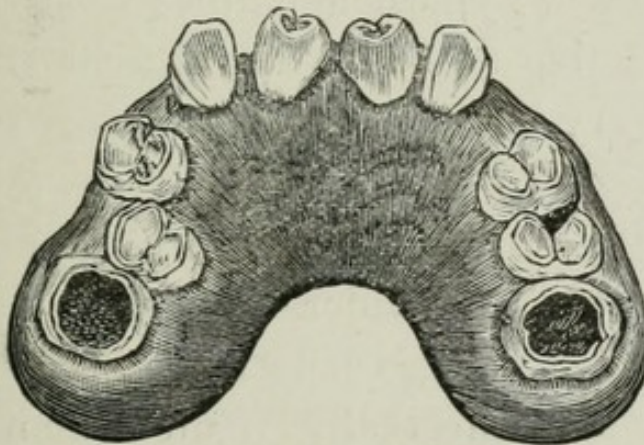


Fig. 14. MODEL OF UPPER JAW.

Showing syphilitic central incisors and molars—the latter extensively carious. From a child aged 12 years. The lateral incisors are absent.

pointed out by Mr. Tomes,* “transverse markings, resulting from alternations in the developmental process, find an exact parallel

* *Dental Surgery*, p. 133.

in the striæ produced by similar causes on the nails."

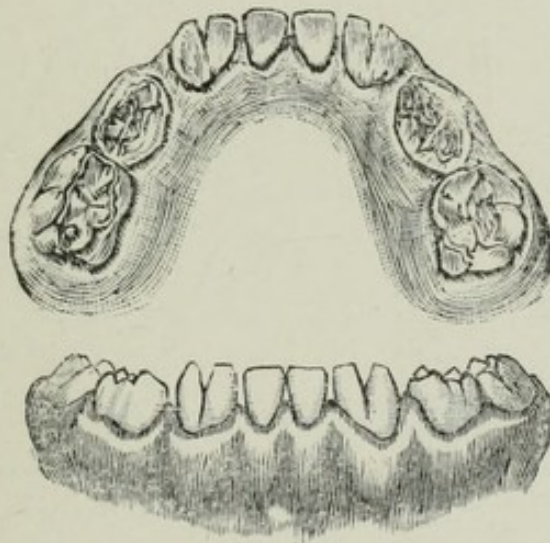
True syphilitic teeth (or Hutchinsonian, as they have been called after the distinguished writer who first described them) are generally found to be the upper central incisors (test teeth).

These are dwarfed teeth, peg-shaped, narrow at the cutting edge, with a crescentic margin on that border. The molar teeth, and the lower incisors are small and honeycombed in appearance. Typical syphilitic teeth are not only defective in form, but also in structure, and are very liable to become rapidly carious.

Whether we regard syphilis as a narrow and muddy stream, becoming clearer as it is diffused through wider channels, or as a disease which, being easily recognised, is more promptly and effectually treated than it was some thirty years ago, when Mr. Hutchinson noted and described the test teeth in association with its congenital form, it is nevertheless a fact that such teeth are rarely found among syphilitic children. When seen they are quite unmistakeable.

IRREGULARITIES OF FORM.

Gemmination.—The union of two teeth is, among those of the temporary dentition, confined to the incisors and canines, either of the upper or lower jaw; and may be described as



Figs. 15 and 16. MODEL OF THE LOWER JAW OF A CHILD
AGED $3\frac{1}{2}$ YEARS.

Showing union of canines and lateral incisor teeth, as seen from
the lingual and the labial aspects.

congenital. It is brought about by the confluence of two pulps while in an early stage of development. The cementum, dentine, and enamel form a common investment.

The union of teeth in the permanent set is found among the incisors and the molars. At the back of the mouth, union, by cementum, of the roots of neighbouring teeth is occasionally met with. There may be a complete union of two teeth throughout their entire length in the incisor region. Or there may

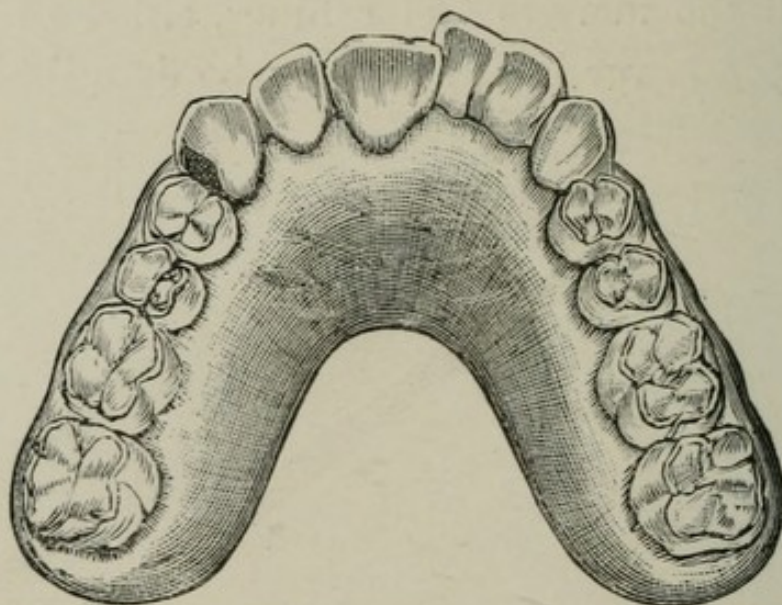


Fig. 17. MODEL OF UPPER JAW OF A BOY AGED 13 YEARS.

Showing union of central and lateral incisor teeth on left side.

be a union of the crowns, the fangs being quite separate, and having two separate pulps.

It is well to be acquainted with the fact that such teeth exist, in view of the necessity for extraction. Unless they are a source of irritation they should not be interfered with.

A *modification* in the form of the teeth is sometimes seen, as in the following illustration, taken from the healthy mouth of a child aged three years, where the lower incisors are all pointed and simulate somewhat the canines.

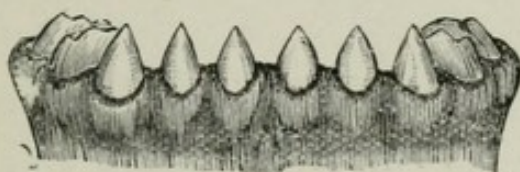


Fig. 18.

IRREGULARITIES IN NUMBER.

It is very rare to find *less* than the normal number of temporary teeth—viz., ten in each jaw, when eruption is completed between the ages of two and three years. The absence of permanent teeth is by no means uncommon, and that generally in the incisor region. Sometimes one or both lateral incisors are absent, occasionally one or both canines. Unless carefully looked for, such cases generally pass unnoticed, because the gaps are filled up by

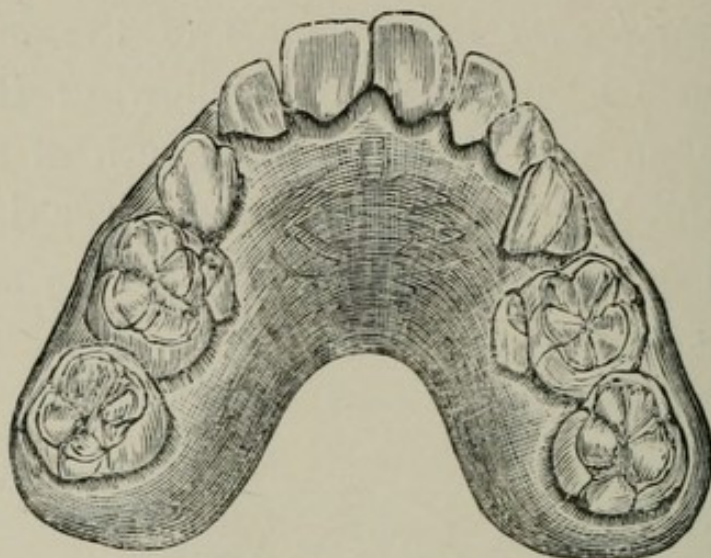


Fig. 19. MODEL OF UPPER JAW.

The bicuspid have not erupted. A temporary canine on the left side is persistent. From a boy aged 18 years.

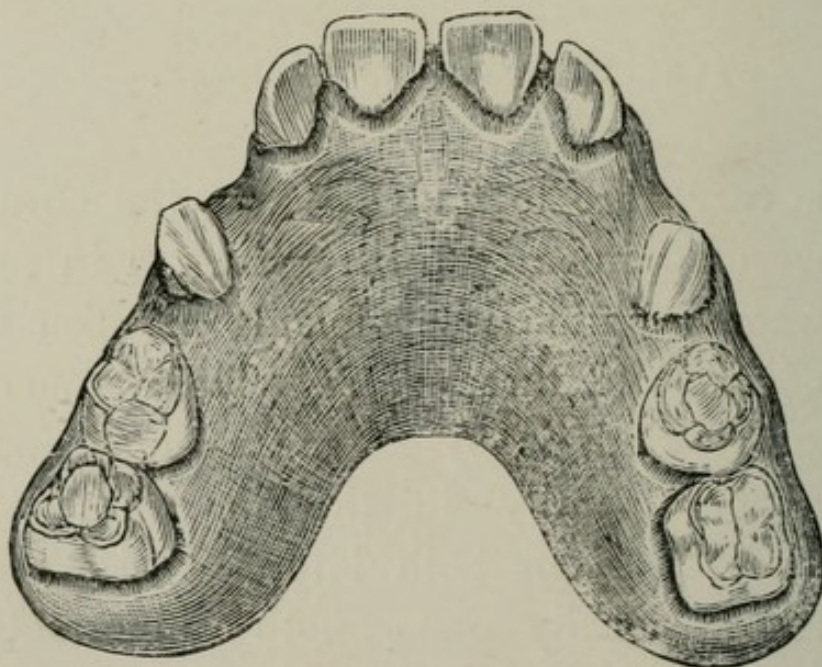


Fig. 20. MODEL OF UPPER JAW.

Showing spaces owing to non-eruption of the bicuspid teeth.
From an adult.

the neighbouring teeth. Rarely one finds the bicuspid absent in the upper or lower jaw. Figs. 19, 20 illustrate this condition. In Fig. 19 the molar teeth and canine have approximated, on the left side is a temporary canine. In Fig. 20 the molars have remained stationary; the canines, however, have wandered from their normal position and have approached the molars.

SUPPLEMENTAL OR SUPERNUMERARY TEETH.

Additions to the normal number are found both among temporary and permanent teeth. Supplemental teeth differ very little from the series of teeth near which they are found. Fig. 21 shows a supplemental canine tooth in a child of six years. This tooth is situated between the upper temporary central and lateral. It has the appearance of a permanent tooth. It was erupted at three years, and being outside the range of the lower teeth

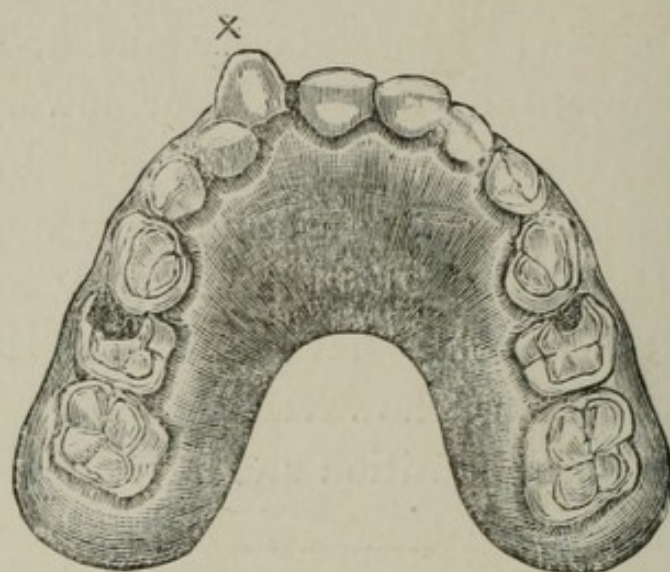


Fig. 21. MODEL OF UPPER JAW.

Showing supplemental temporary canine. From a child aged 6 years. The last molar on each side is a permanent tooth.

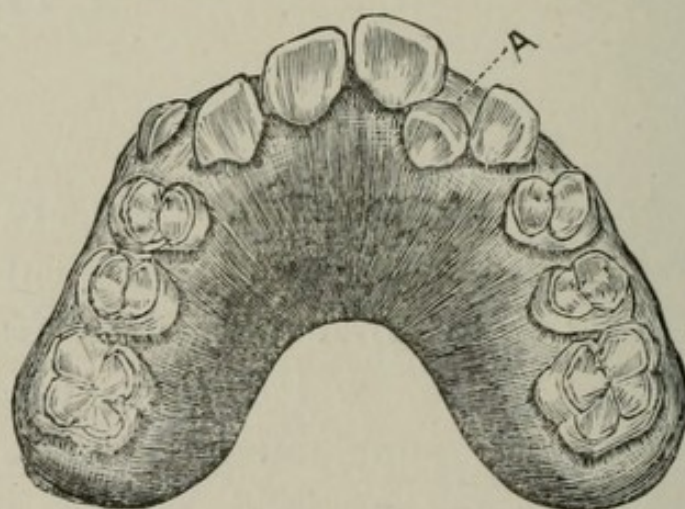


Fig. 22.

is not worn down by mastication as the others are. Figs. 22, 23, are from models lent by Mr. Sidney Spokes.

At A (Fig. 22) is a supplemental lateral between the left upper permanent central and lateral teeth. In Fig. 23 this has been removed and silk ligatures, connected on the

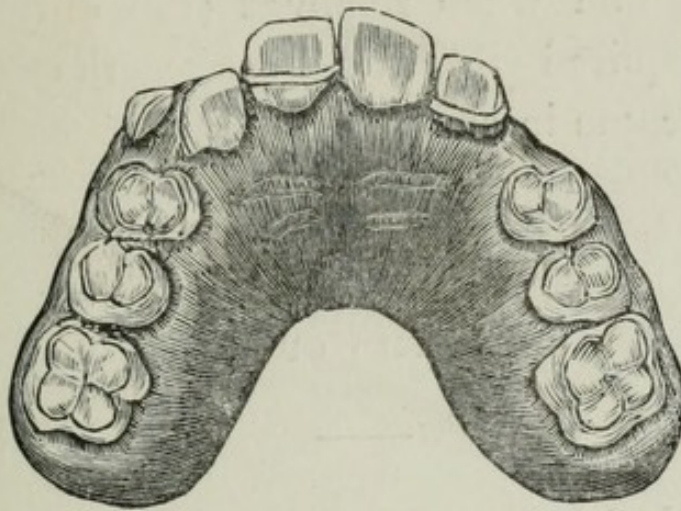


Fig. 23.

outside by a rubber band, have been used to draw the true lateral tooth into its proper

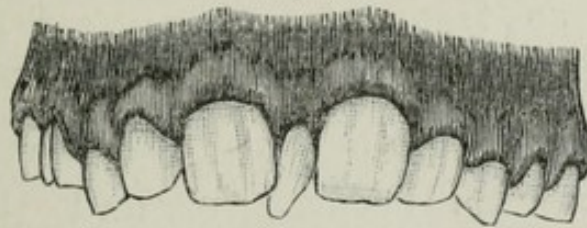

Fig. 24.

position. Both permanent canines were commencing to erupt.

Supernumerary teeth are generally conical in form, and may appear among any of the teeth

of the permanent set. Fig. 24, also from a model lent by Mr. Sidney Spokes, illustrates an ordinary form of supernumerary tooth. This was between the two upper permanent centrals, and when removed (the only treatment required in such cases) the central incisors came in close apposition,

IRREGULARITIES OF POSITION.

Irregularities in position of the temporary teeth are only of importance in so far as they interfere with their successors.

Irregularities in position of the permanent teeth are so frequent, and assume so many varieties, that it is only possible, in a work of this kind, to point out those forms which are of common occurrence, and the usual treatment adopted by the dental surgeon.

One of the most frequent causes of such irregularities is the retention of temporary teeth, or the remains of them, past the normal period at which they should be shed. It is,

therefore, important to know approximately the times when permanent teeth are likely to erupt. Although in the chapter on ERUPTION this matter has been mentioned, some repetition is essential in order that irregularities may receive the attention they deserve. Illustrative cases will be given with a view of helping the practitioner to discern where treatment may be necessary, and (what is of equal importance) where the policy of *laissez faire* may be adopted. It has been stated that at six years of age the first permanent molars make their appearance *behind* the temporary molars, *not in place of them*, four in number, one on each side, in the upper and lower jaws. This fact cannot be too emphatically stated or borne in mind, because they are so frequently mistaken for temporary teeth, and they are so prone to decay. Parents frequently dispute this point, on the assumption that as no temporary teeth have been lost, no permanent teeth can have erupted. A reference to Fig. 25 will show these teeth in position. The developing crowns of the bicuspid are embraced by the fangs of the temporary molars.

The second permanent molars are erupted

at or about twelve years. In Fig. 25 the cap of one of these teeth is seen in the lower jaw behind the first permanent tooth. So regular, in point of time, is the eruption of the first and second permanent molars, that in dental

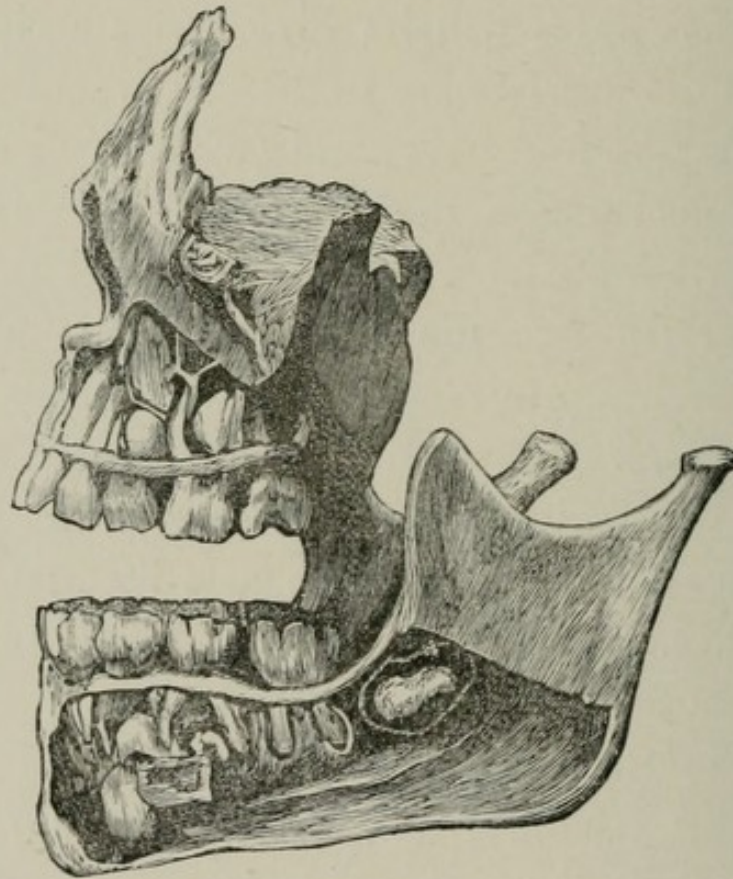


Fig. 25. SIDE VIEW OF UPPER AND LOWER JAWS.
The alveolar plate has been removed to show the developing permanent teeth. From a child aged 6 years.

language they are sometimes spoken of as the "six-year old molar" and "twelve-year old molar." After the eruption of the first

permanent molars, and before the eruption of the second permanent molars (that is, between six and twelve years), all the temporary teeth should be replaced by their permanent successors.

Thus at or about twelve years a child should have fourteen teeth in each jaw, 28 in all, forming a complete set if we exclude the four

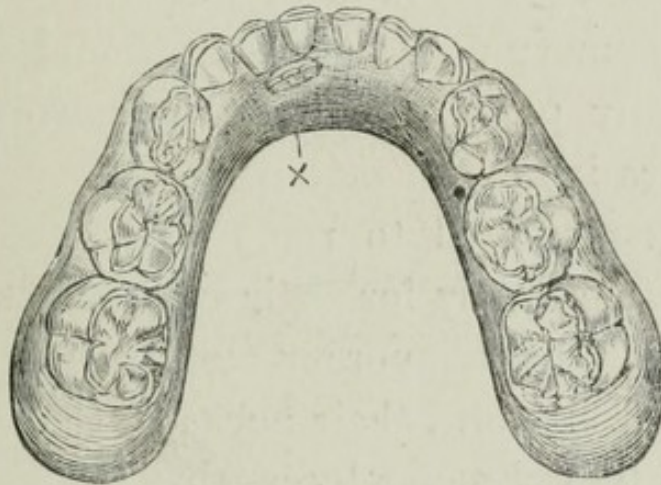


Fig 26. MODEL OF LOWER JAW.

Showing eruption of central incisor on the left side behind the temporary teeth. From a child aged 7 years.

wisdom teeth which are erupted at maturity between 17 and 25 years.

About the 7th year the permanent central incisors will appear through the gum in the *lower jaw*. If the temporary teeth have been shed they will generally come up in the spaces

left vacant. More often the fangs of the temporary teeth are not yet completely absorbed; and while still in their sockets the permanent teeth come up *behind* them, one tooth appearing before its fellow.

They are therefore out of sight; but the child's attention will be directed to them by the tongue. The cutting edge is surmounted by three small tubercles, giving the teeth an irregular margin. These are found in teeth structurally perfect; but are soon worn down in mastication.

One is tempted to remove the temporary teeth to make way for their successors. However, while the temporary teeth are firm it is better to wait until their normal attachment is lost, and they become loose, thus showing that absorption of their fangs is almost accomplished. They can then be removed without giving a child unnecessary pain.*

Nothing is lost by waiting a reasonable time as the tongue will push the teeth forward into proper position.

* An exception to this rule will be mentioned later in connection with "persistent" temporary teeth.

The eruption of the lower central incisors is followed in two or three months by the eruption of the upper central incisors. These sometimes appear in front of the temporary teeth: but more frequently *behind* them. When in the

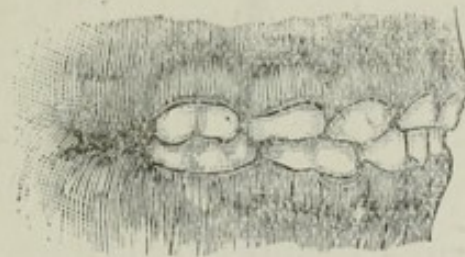


Fig. 27.

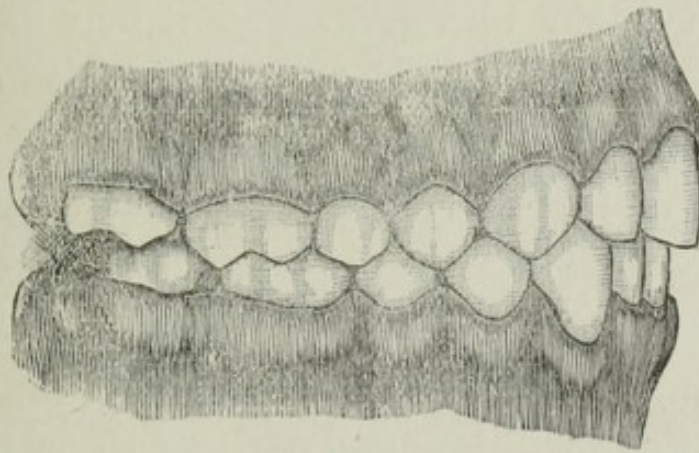


Fig. 28.

Models showing position of the temporary teeth and the permanent teeth when the jaws are closed. From children aged $3\frac{1}{2}$ and 13 years.

latter position the question of removing the temporary teeth (however firm in their sockets) assumes a different aspect to that of teeth in the lower jaw. On the examination of normal

articulations, (Figs. 27 and 28,) it will be seen that the teeth of the upper jaw overlap those of the lower when the jaws are closed. In temporary teeth this position is almost invariable. The exception is found in those rare cases where inheritance plays a part and one or both parents have prominent lower jaws. Should it be noticed that the lower temporary incisors bite *in front* of the upper teeth, extra care should be taken in watching the eruption of the permanent teeth as this deformity may to a great extent be corrected.

As a rule the incisors and canines of the upper jaw come down in front of the lower incisors and canines, while the outer cusps of the bicuspid and the molars above extend outside those of the teeth below.* The teeth are arranged around a wider curve in the upper than in the lower jaw and each tooth meets two on either side. The effect of such an arrangement is two-fold ; perfect mastication is ensured and the lower jaw is kept in its proper position.

While the lower jaw is freely movable, the upper jaw is fixed, so far as mastication is

* For an excellent description of the relationship of the upper and lower teeth, *vide* Tomes' *Dental Anatomy*.

concerned. Should the incisor teeth of both jaws meet edge to edge, or should the lower teeth bite outside the upper teeth when the jaws are closed, there is a constant inclination for the lower jaw to slide forward producing what is described as an "underhung jaw" or "underhung bite." This condition of jaw, which alters the character of the face and is therefore more or less a deformity, may be *inherited* or *acquired*. It may be due to a lack of development of the maxilla, or to an undue lengthening of the mandible. It is, however, the acquired protrusion of the lower jaw, we propose to discuss. Sometimes it arises from a habit in childhood of protruding the lower jaw, which for want of a better name, may be described as a "nervous habit" closely allied to that of blinking the eyes or biting the nails.

During the period of eruption of the permanent teeth there is a tendency for the upper incisors in many jaws to come down inside the normal arch of the upper jaw, so that, when the teeth are closed, the upper ones bite *behind* the lower. When the temporary teeth are gone or only a temporary root is persistent this may soon be noticed, as in Fig. 29, but while the

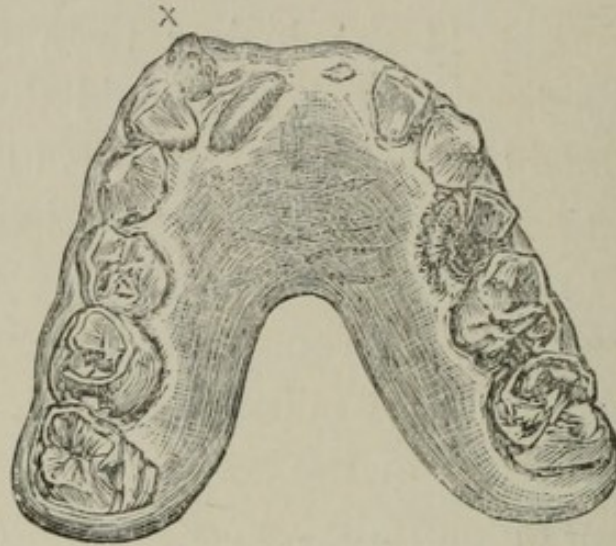


Fig. 29.

Model showing eruption of a permanent central in an abnormal position owing to the retention of a temporary incisor root. From a boy aged 7 years.

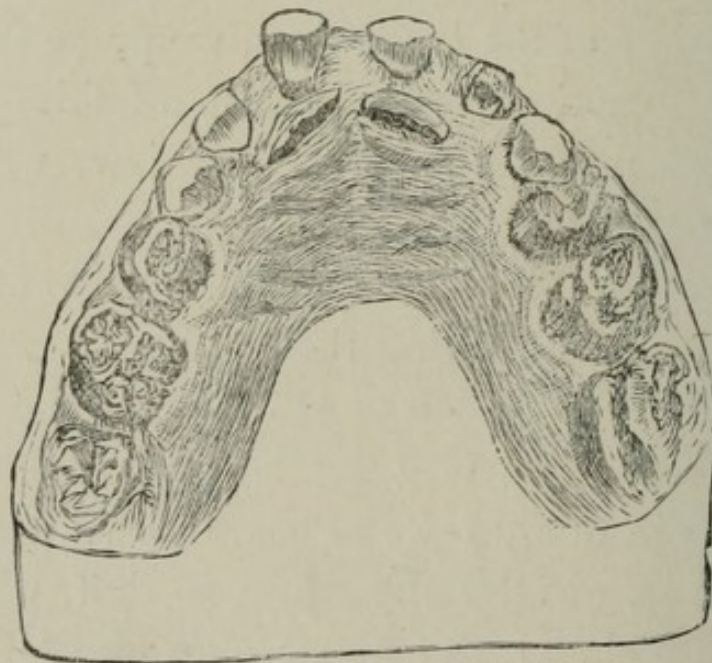


Fig. 30. MODEL OF UPPER JAW.

Showing eruption of central incisors inside the arch owing to retention of temporary incisors. From a boy aged 7 years, 6 months.

former are present the permanent teeth may remain unnoticed, until they are well through the gum, and are prevented from coming forward by interlocking with the lower teeth. Should they be allowed to remain in this position, the first step is reached toward the perpetration of an "underhung bite."

Fig. 30 illustrates the position assumed by the permanent central incisors owing to the retention of the temporary teeth.

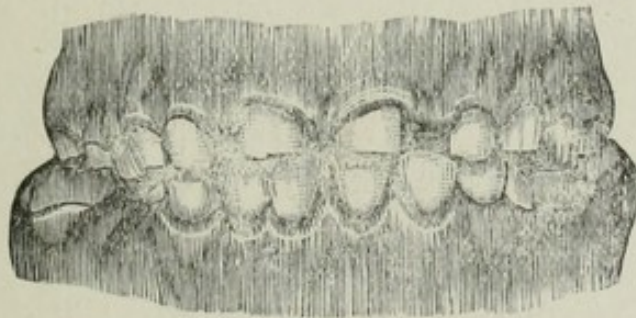


Fig. 31.

Front view of the same with the lower jaw in position.

The inclination of the crowns of the permanent teeth was such, that when the jaws were closed the lower incisors came just between the temporary and permanent teeth, the temporary teeth being in front and outside the lower incisors, and the permanent teeth behind as shown in Fig. 31, where the permanent centrals are completely hidden.

In such cases, it is necessary to use some mechanical means in order to push the permanent teeth forward, after extracting the temporary teeth. It is obvious that this cannot be accomplished so long as the teeth are allowed to overlock. A plate of metal or vulcanite—generally the latter—is therefore

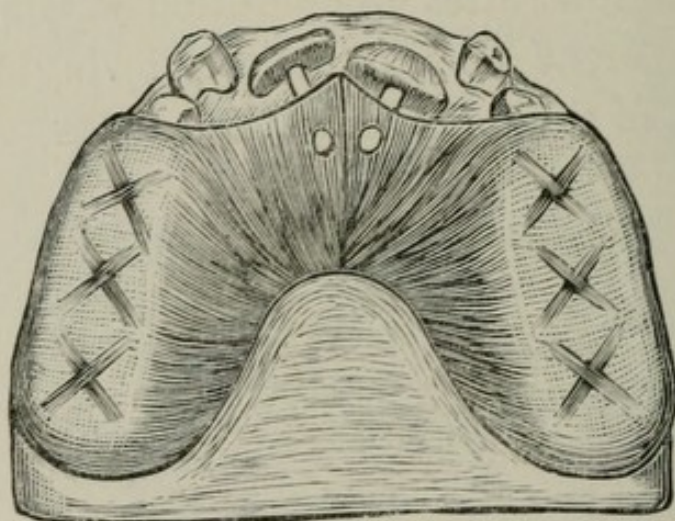


Fig. 32.

The same Model showing position of plate to press forward the permanent incisor teeth. The temporary incisors have been removed.

made on a model of the upper jaw, well covering the back teeth while the front are left exposed. This plate serves two purposes. It opens the bite or prevents the teeth from closing. It also forms a fixed point from which pressure is made.

In order to obtain such pressure two small holes are drilled into the plate (Fig. 32) just behind the teeth. Hickory, or orange, wood pegs are inserted of such a length, as to rest against the teeth, so that when the jaws are closed, sufficient force is exerted to press the teeth slightly forward. As the teeth are moved, longer pegs may be inserted, until the teeth are moved the required distance. Instead of pegs of wood, fresh vulcanite may be added to the plate, or springs of piano wire formed in a simple loop, are often inserted in the plate with the same object in view.

It is necessary for the patient to wear this apparatus night and day, eating and sleeping. Though uncomfortable at first, a child soon becomes accustomed to it. The plate should, however, be removed after each meal and carefully cleansed with soap and water. The neglect of such a simple measure will result in more damage being done to the teeth, than any good the regulation may accomplish. A certain amount of food is sure to find its way between the teeth and the plate. Putrefactive changes will go on, and caries of the teeth will rapidly ensue.

Irregularities of this character may be confined to one or involve all the upper incisor teeth. Occasionally it is met with in canines, which, however, from their position above generally erupt well outside the arch. In each case the method is practically the same, having for its object the placing of the upper teeth outside (or in front of) the lower teeth. It is only necessary to push the teeth far enough forward to accomplish this purpose; then treatment ceases.

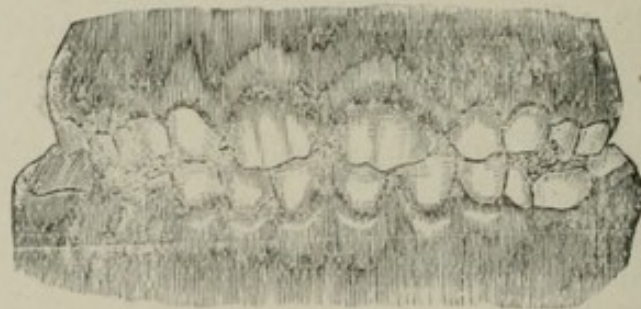


Fig. 33.

Models showing the result of treatment. The permanent incisors are now in proper position.

Fig. 33 shows the effect of such treatment with the permanent teeth in their normal position. The earlier this is done, the better, as the sockets of young teeth are large, the roots are not fully formed, and they are easily moved. If left until the alveolar plate is well

built up around them, a new socket has to be formed and the process is consequently slow.

On reference to Fig. 34 it will be seen that the permanent upper incisors are fully erupted and they appear to be in good position.

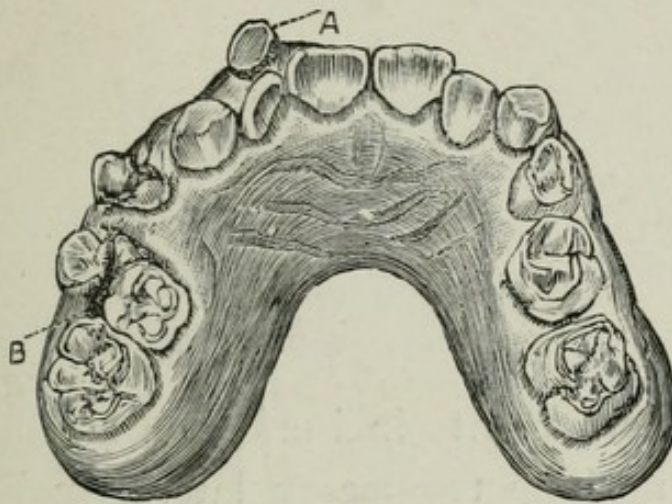


Fig. 34. MODEL OF UPPER JAW.

Showing persistent temporary lateral and molar teeth, with permanent incisors apparently in good position. From a boy aged 10 years.

At "A" is a temporary lateral tooth, which though quite firm could scarcely be mistaken for a permanent tooth, because of its small size, and the evident wearing down or attrition on its masticating surface. At "B" is a temporary molar which is gradually being pushed out of place by the eruption of its successor, the second bicuspid tooth. It is desirable, however, to direct attention to the position of the upper

incisors when the jaws are closed, and in Fig. 35 it is seen that these teeth all bite behind the

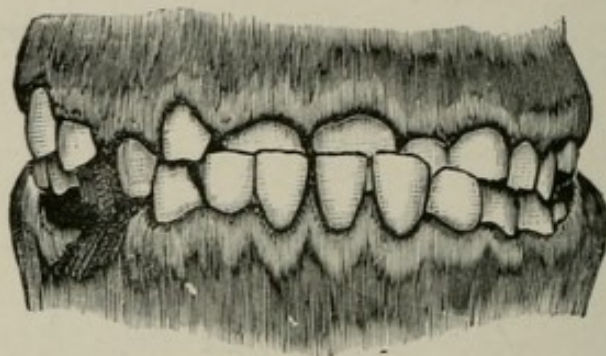


Fig. 35.

Front view of above with lower jaw in position, showing abnormal position of incisors.

lower permanent incisors in an abnormal position. The temporary lateral incisor tooth hides its successor. From the position of the temporary tooth it seems obvious that all the permanent incisors have erupted behind the temporary. Had the patient received attention at the right time, the deformity need not have existed; and the difficulty of pushing the teeth forward would have been a far easier matter at 8 than at 10 years.

As a readier method of treatment, than that of making a plate to push upper teeth into their proper position, it has been suggested that more forcible means should be taken to

effect the purpose*. Mr. Sidney Spokes, from whose collection the following illustrations are taken, has in suitable cases adopted a plan which seems likely to answer well. The temporary teeth are first removed. Then with a pair of forceps, the jaws of which are lined with

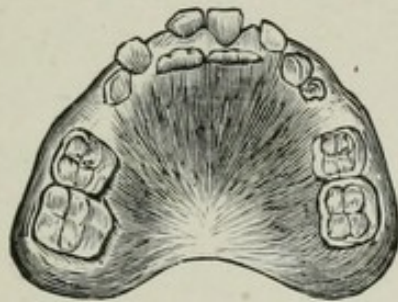


Fig. 36.

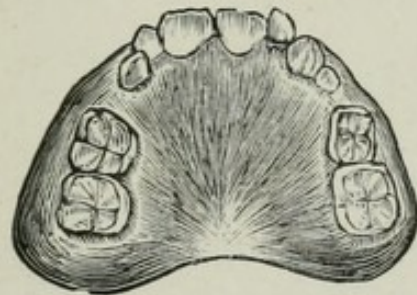


Fig. 37.

leather or rubber tubing, to prevent crushing or slipping, the permanent teeth are grasped, and forcibly brought into position. A thin silver wire is interlaced between them and the neighbouring teeth for the comfort of the

* Transactions of the Odontological Society, June, 1895.

patient. Fig. 36 and 37 illustrate the "immediate treatment."

Fig. 36 shows the persistent temporary centrals in the upper jaw, with permanent

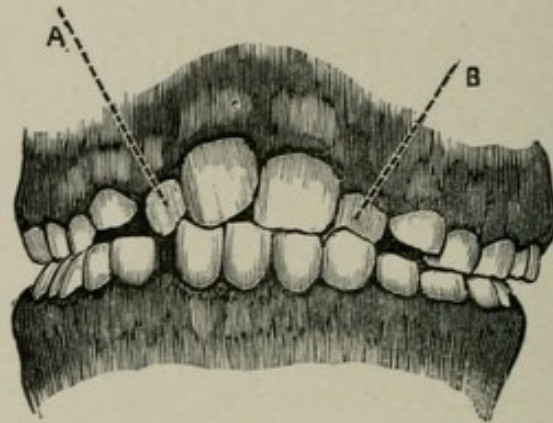


Fig. 38.

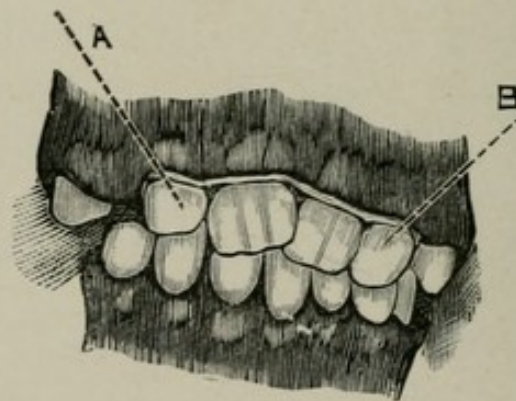


Fig. 39.

teeth erupting behind them, Fig. 37, the permanent centrals in position.

In Figs. 38, 39, the letters A and B indicate the position of the permanent laterals before and after treatment. A silver wire was passed

round the two teeth, after they were moved, and made to join over the central incisors. It is too early yet to express a definite opinion upon this small operation, although Mr. Spokes has had no record of failure with six laterals and five centrals. The risks of *immediate treatment* seem to be:—The possible extraction of the tooth operated upon; injury and destruction of the developing pulp. Healthy subjects should be chosen and treatment should be adopted before the fangs are fully grown and the alveolus has become very firm.

Mr. Charles Tomes, F.R.S,* quoting Dr. Pierce† gives approximately the times of completion of the roots of the permanent teeth; as follows:—

Central Incisors	10 years.
Lateral Incisors	a little later.
Bicuspid	12 years.
Canines	a little later.
6-year Molar	9 or 10 years.
12-year Molar	16 or 17 years.

In Fig. 40 a central incisor will be seen erupting outside the arch and in front of the temporary roots.

* *Dental Anatomy*, p. 202.

† *Dental Cosmos*, 1884.

The only treatment needed in such a case is the removal of the necrotic stump. The

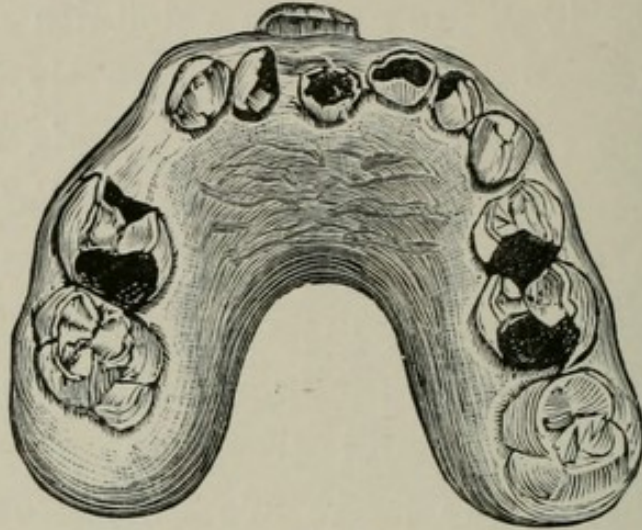


Fig. 40.

Model showing effect of retention of roots of temporary incisor.
From a boy aged 9 years 3 months.

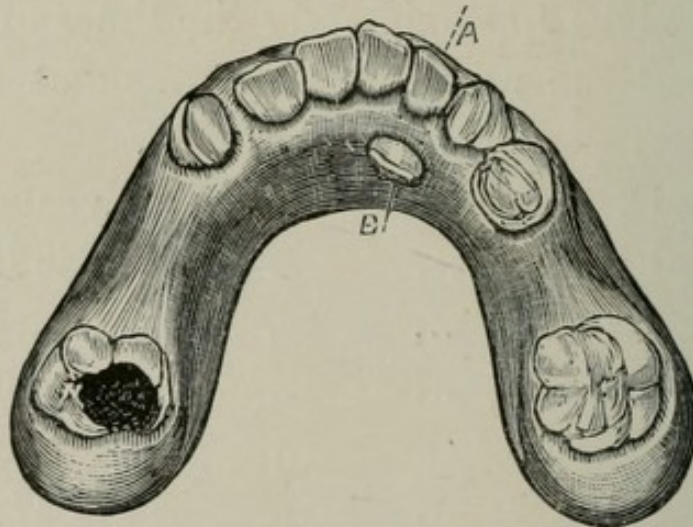


Fig. 41. MODEL OF LOWER JAW.

Showing eruption of permanent lateral in an abnormal position
From a girl aged 8 years 3 months.

pressure of the upper lip will be sufficient to
push the tooth into position.

About the eighth year the lateral incisors of the lower jaw will come up either in place of, or behind the temporary teeth.

Fig. 41 illustrates both. The permanent lateral is in position on the left side. B shows the eruption of the right lateral in an abnormal position, owing to the retention of the temporary tooth at A. In this case the temporary lateral was quite loose and was therefore extracted; but as already mentioned, in speak-

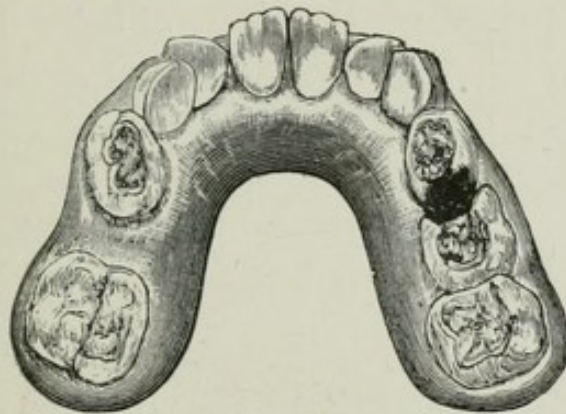


Fig. 42.

Model showing the irregularity of permanent incisors owing to the retention of temporary canines. The latter should not be removed.

of *lower* central incisors when the temporary teeth are firm there is no necessity to remove them until a reasonable time has been allowed for absorption of their fangs.

In some jaws when the incisor teeth are in proper position they are crowded (Fig 42).

The laterals will impinge upon the temporary canines. The latter *should not be removed* to give more room unless they are carious on the side nearest to the permanent laterals (and thus form receptacles for food, which cause the permanent teeth to decay). It is not until 3 years later that the permanent canines come up to take their place, and in the meantime they may be crowded out by the other teeth. This, however, will be referred to later on.

The eruption of the lower lateral teeth is followed in a few months by the eruption of the upper lateral teeth. These may erupt outside the temporary teeth (Fig. 43) and beneath the lip.

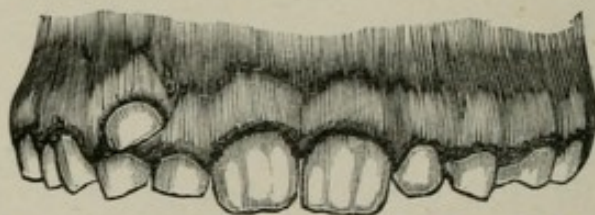


Fig. 43. MODEL OF UPPER JAW.

Showing eruption of a permanent lateral incisor, above and outside the arch. From a girl aged 9 years.

In this case the temporary lateral was not carious and was very firm. It was therefore allowed to remain until absorption of the fang had taken place to some extent, and the tooth

more easily removed. Fig. 44 shows a not unusual position on eruption of the upper lateral incisors.

Apart from the fact that the temporary teeth A and B were carious, it was absolutely necessary to remove them because the permanent teeth, if allowed to remain and come further through the gum would have been

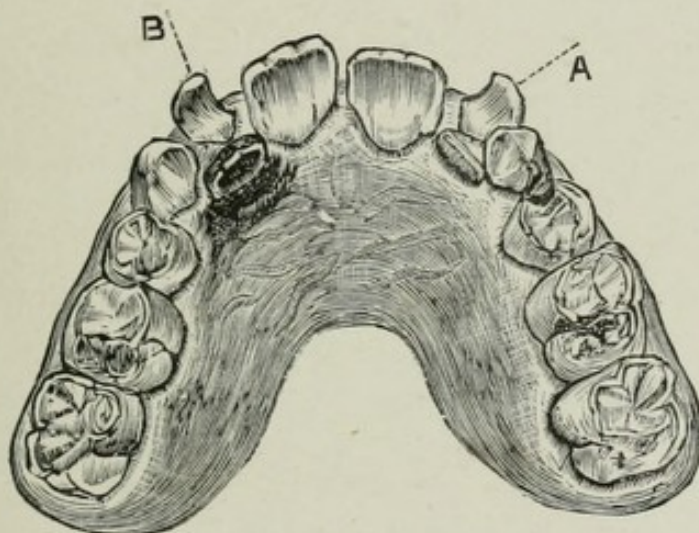


Fig. 44. MODEL OF UPPER JAW.

Showing eruption of lateral incisors inside the arch owing to the retention of temporary laterals. From a boy aged 8 years 6 months.

overlapped by the lower permanent teeth and a plate to push them forward would have been as necessary as in the upper centrals already referred to in Figs. 30 and 35.

Between the ninth and tenth year the

bicuspids of the lower jaw followed by those of the upper jaw, may be expected to make their appearance. If sound, the roots of the temporary molars will become absorbed and loose, and they can readily be removed without trouble, the bicuspid appearing just beneath them. Frequently, however, the bicuspids are turned aside from their normal position by the

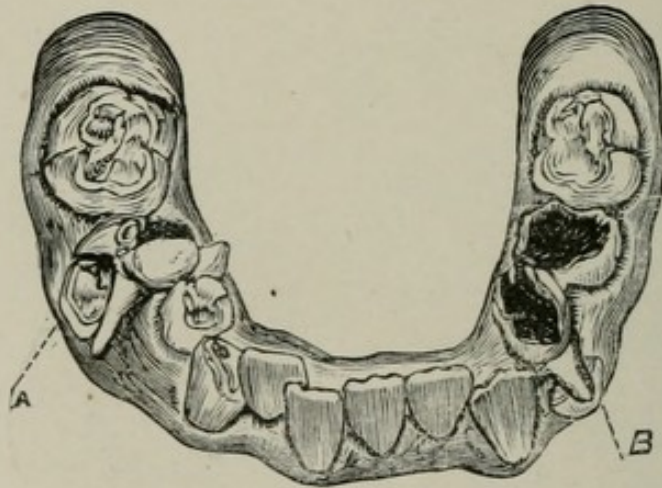


Fig. 45. MODEL OF LOWER JAW.

Showing eruption of bicuspids, the carious temporary teeth retained. From a boy aged 9 years 6 months.

necrotic fangs of temporary molars. This is well shown in Fig. 45, where on the left side of the jaw at B is seen the crown of the first bicuspid pushing its way through the gum. On it rests the fang of a carious temporary molar.

At A on the right side the second bicuspid is erupting in an abnormal position owing to the retention of a carious temporary molar the fangs of which embrace its crown. The force of an erupting tooth is sufficient sometimes (notwithstanding the fact that its position may be to some extent abnormal) to push a temporary molar almost out of its socket. To some extent this is shown in Fig. 45, but

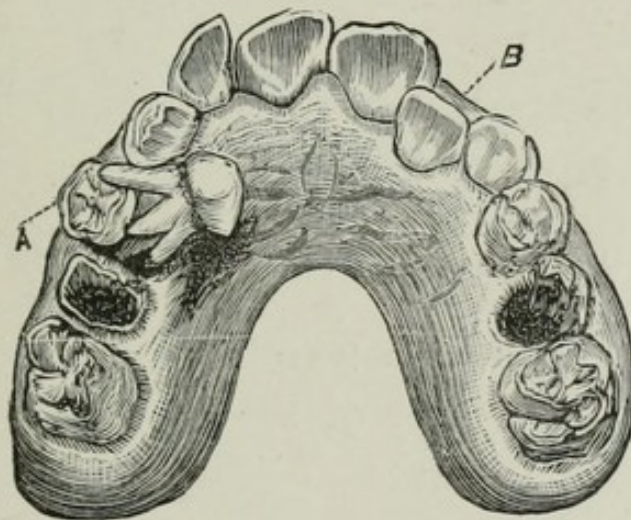


Fig. 46. MODEL OF UPPER JAW.

Showing eruption of first bicuspid (A), and the tilting over of the temporary molar. B is the permanent lateral inside the arch.

From a girl aged 9 years 6 months.

it is more evident in Fig. 46, where a temporary molar is seen lying on the gum, completely tilted over, with its crown looking toward the middle line of the palate, and its

fangs resting with their apices on the crown of the bicuspid. The side of the temporary tooth was firmly attached to the gum.

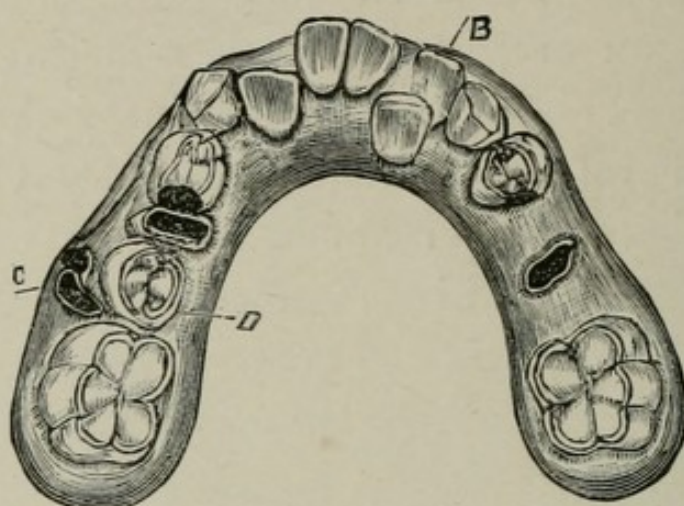


Fig. 47. MODEL OF LOWER JAW.

Showing necrotic roots C, a bicuspid D, and B is a temporary lateral, "persistent." From a boy aged 10 years.

No better illustration could be found of the facts that the vitality of the absorptive papillæ is destroyed when temporary teeth become necrotic, and that absorption therefore ceases. For in each case the teeth were carious, and as their pulps had long been dead, they were necrotic and dark brown in colour.

Between eleven and twelve years of age the lower, and then the upper, canines are erupted. The lower canines cause little anxiety as they generally appear outside the temporary canines.

When these are removed there is as a rule no difficulty in their successors assuming their *normal* position in the jaw. The eruption of the canine teeth of the upper jaw is a constant source of irregularity owing to the fact that they appear beneath the lip, high up, and outside the line of the permanent teeth and immediately above the temporary teeth.

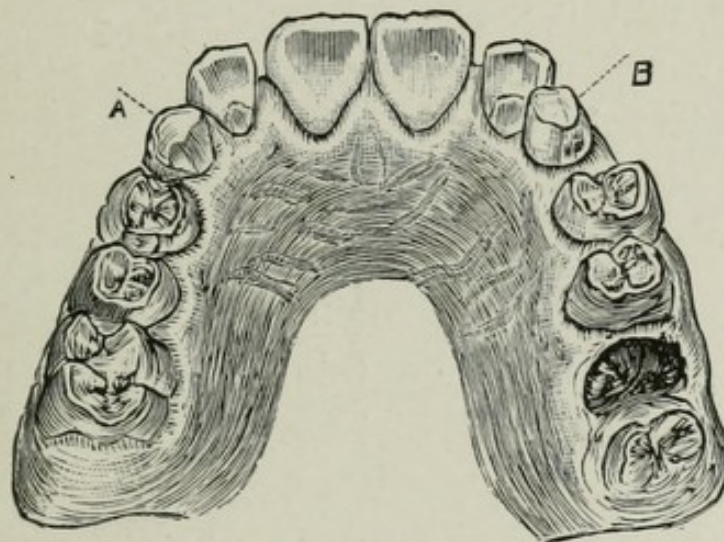


Fig. 48. MODEL OF UPPER JAW.

Showing permanent teeth in position except canines. A and B are the temporary canines. From a boy aged 11 years 3 months.

They look like "tusks" coming through the gum, and advice is frequently sought by parents in order that something may be done. As recommended with *lower* temporary teeth, when permanent teeth erupt *behind* them, or

with upper temporary teeth when their successors appear *above and in front of them*, while sound and firm, the temporary canines should not be extracted until a reasonable time has been allowed for the removal of their fangs by natural means.

Fig. 48 shows the position of the temporary canines A B, when all the permanent teeth are in position excepting their successors. They keep a space between the lateral incisor and first bicuspid for the permanent teeth to come into position. If prematurely removed the lateral and first bicuspid will come close together and the permanent canine is shut out. Great care must be taken not to remove a permanent *lateral* incisor by mistake for a temporary canine. We have seen this done more than once, and it is another reason why a tooth should not be removed in a hurry. A reference to Fig. 48 will show that the temporary canines on both sides show unmistakable signs of being worn down by mastication. In other words the pointed tips have gone. Looked at from the front such teeth simulate permanent lateral teeth. Careful examination with a reflecting mirror will enable the

Practitioner to discriminate between the two.

As pointed out by Tomes,* the absorption of the fangs of temporary teeth is not of necessity continuous, even in those unaffected by caries.

Under certain conditions the multi-nucleated cells of the absorptive papillæ, seem capable of eating out the cementum or bony portion

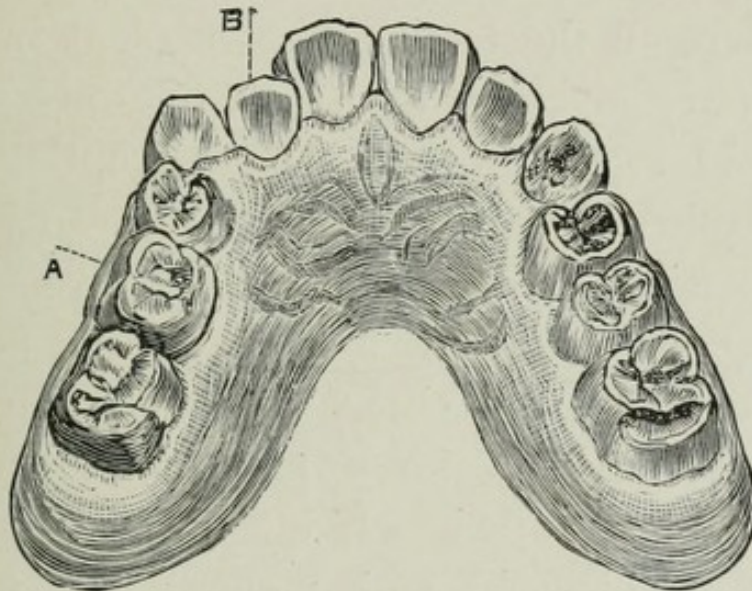


Fig. 49. MODEL OF UPPER JAW.

Showing persistent temporary molar. From a child aged 10 years.

of the tooth and then becoming calcified in the excavations.

This may be due to some irritation of the pulp or periodontal membrane, as in permanent teeth inflammatory conditions often lead

* *Dental Anatomy*, p. 197, *et seq.*

to a calcification of pulp tissue, or a fresh bony deposit is added to the fangs.

As a consequence of this alternate excavation and deposition of cementum, a tooth with half its fangs absorbed may become and remain firmly fixed in its socket. The permanent tooth will then be prevented from coming into position either good or bad.

Where all the teeth are permanent but the temporary molars (Fig. 49 A), not only is the bicuspid tooth prevented from erupting, but the teeth are overcrowded on the same side. The persistent tooth in this case was removed; it was very firm, though the major portion of the fangs was absorbed. The bicuspid erupted quickly, and a plate was made to push the lateral incisor B into proper position, the first bicuspid and molar teeth falling back into their places.

Should "persistent" molar teeth not be seen or removed until maturity is reached, they may become wedged in between the permanent tooth on either side, as in Fig. 50, where the overhanging margins of the first bicuspid and six-year molars to a certain extent conceal the crowns of the persistent temporary

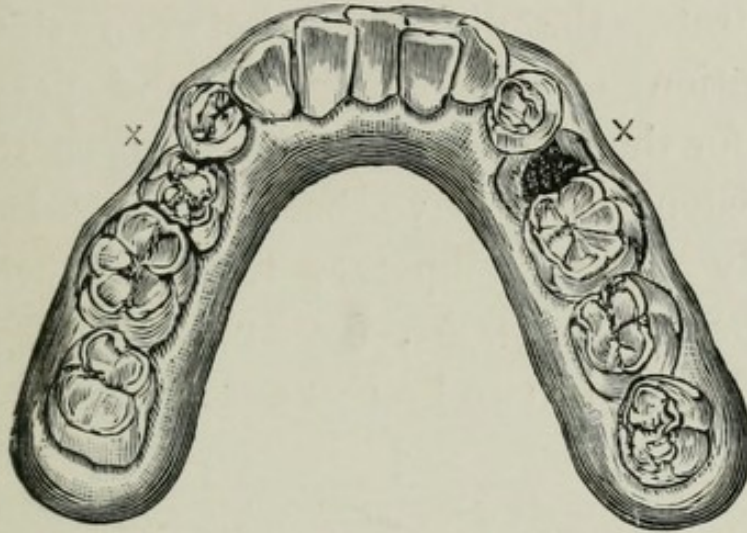


Fig. 50. MODEL OF LOWER JAW.
Showing persistent temporary molars, in an adult.

molars. It is quite possible in such a case that the second bicuspid which should have succeeded the temporary molars are absent from the jaw, but it would have been better

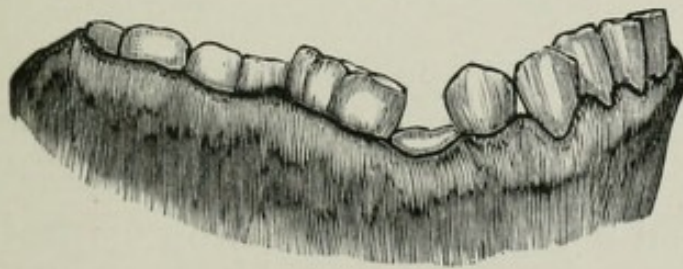


Fig. 51.
Side view of above.

to remove the molars to prevent overcrowding. Fig. 51 is a side view of the same jaw which not only shows the wedging of the persistent temporary between the permanent teeth, but

illustrates the difference between the usual elevation of the temporary and permanent set, for there is no reason to suppose that the persistent teeth have been depressed. Very rarely all the temporary teeth are *persistent*, as seen in Figs. 52, 53, and taken from the upper jaws of two brothers. Fig. 52 is from a

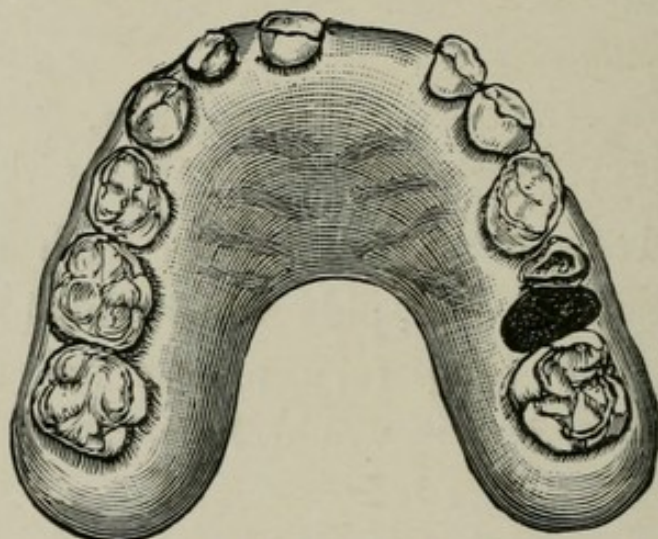


Fig. 52. MODEL OF UPPER JAW.

From a boy aged 9 years. Showing "persistent" temporary teeth.

boy aged 9 years. The missing central incisor was knocked out. One molar was lost through caries, the roots alone remaining.

Fig. 53 is from a boy aged 12 years. All the temporary teeth were persistent with the exception of one molar. The crown was lost through caries, the roots remain.

In front is a permanent incisor not yet through the gum. The incisor teeth were removed in this case, though quite firm in

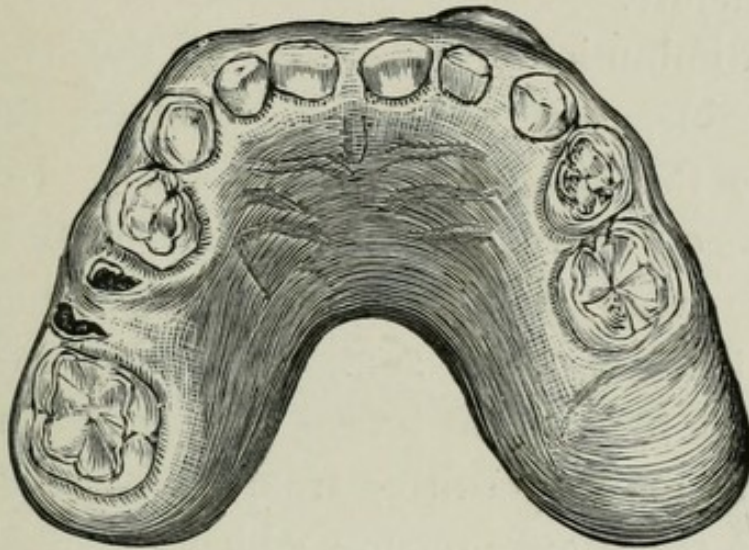


Fig. 53. MODEL OF UPPER JAW.

From a boy aged 12 years. Showing persistent temporary teeth.

their sockets in order that their successors might erupt. The fulness of the gum above the other teeth showed that the permanent ones were present.

OVERCROWDING OF THE PERMANENT TEETH.

Probably owing to diminished exercise, and hereditary influences, the jaws of civilised races (as compared with ancestral types) are

becoming smaller. It would also appear that an alteration has taken place in the teeth which is one partly of dimension and partly of structure.

A diminution in the size of the teeth is noticeable, but not (we believe) corresponding to the diminution in the jaws. In consequence, many jaws are overcrowded with fragile teeth, and these are so close together that there is only sufficient space for the *debris* of food to be forced between them, and into the angles resulting from crowding.

The enormous pressure which the teeth are subjected to in mastication is, to some extent, compensated for by their *giving* slightly in all directions. A certain amount of lateral movement ensures a rubbing between the crowns of the teeth when in close apposition, and were all teeth dense in structure this might be ignored; but when frail, wearing of the enamel is the result, and at such weak points softening and caries follow.

One tooth may be alone affected at first, but its next door neighbour is soon involved by continuity of tissue. A breaking down of the enamel during mastication, or a sudden

pain from an exposed pulp, is generally the first intimation that two teeth are threatened with destruction instead of one.

The remedy for overcrowding is judicious and timely extraction. This should be carried out between the ages of 12 and 16 years. The earlier the better, before the alveolus is built up firmly around the teeth. The movements which take place in the teeth during mastication (always in the lines of least resistance) will ensure the rapid filling up of gaps thus made. To remove one alone is not, however, sufficient. On referring to Fig. 28 of a normal articulation in permanent teeth, it will be seen that the bicuspid and molars interlock when the jaws are closed. The effect of removing one of these teeth alone, an upper bicuspid or molar tooth, for instance, is, that the lower teeth effectually prevent the tooth on either side of the space above from approaching one another, and a gap remains. Should, however, the tooth above and its principle opponent below (as in the case of first permanent molars) be removed, within a year's time the teeth on that side of the mouth will all have moved, the back teeth forward,

and perhaps the front teeth backwards, leaving an interval between each tooth. Further, if two teeth on one side of the mouth are alone removed, the front teeth will show a tendency to move toward that same side, and a vertical line drawn between the two upper central teeth will show a deviation from the middle of the face, which though it may not at once be apparent, will give a one-sided appearance to the teeth when the lip is raised, as in smiling.

For these reasons it is advisable when removing teeth for general overcrowding, that this should be done symmetrically, one from the upper and lower jaws, on each side of the mouth.

Generally speaking marked *overcrowding* shows itself in the region of the canines which, as mentioned before, in erupting may be very prominent and appear as "tusks" beneath the lip on each side. Those cases we refer to are seen in children whose temporary teeth have been lost in the normal course, and the spaces between the first bicuspid and lateral incisor have closed so far as to prevent the canine teeth from assuming their proper position within the arch.

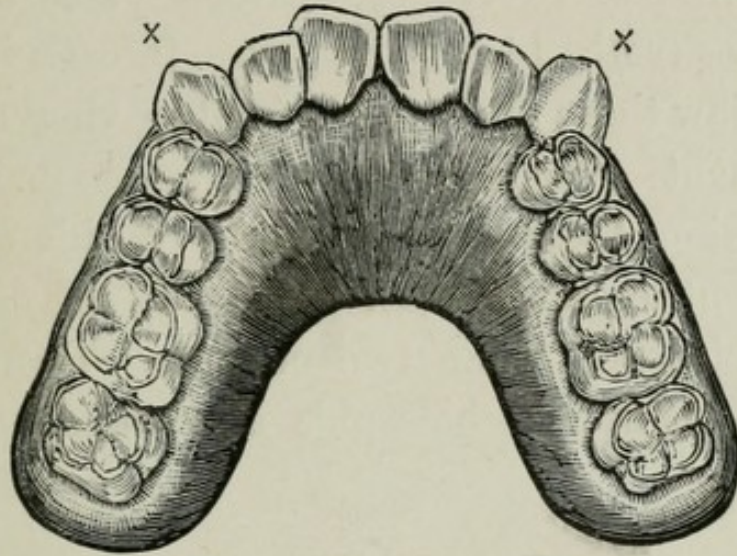


Fig. 54. MODEL OF UPPER JAW.

Showing overcrowding of the teeth, and outstanding canines, from a boy aged 16 years.

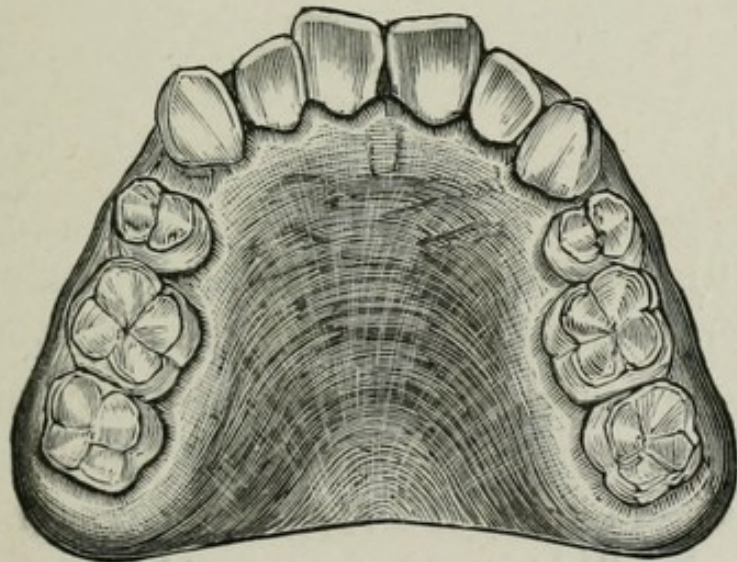


Fig. 55.—MODEL OF THE SAME JAW,

A few months later, showing the results of symmetrical extraction of the first bicuspid teeth.

A child of twelve or thirteen years should have 28 teeth, 14 in each jaw. In each half of each jaw there are 7 teeth (and in view of the treatment recommended, viz., symmetrical extraction, these facts are worth consideration). One central and one lateral incisor, one canine, two bicuspid and two molars. There are duplicates in the bicuspid and molars alone.

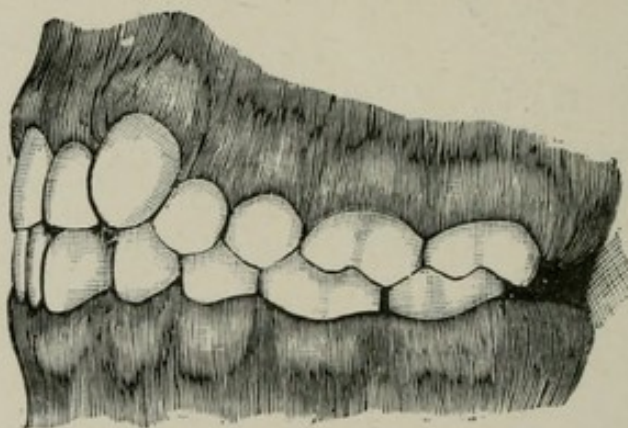


Fig. 56.—Side view of above before treatment, with the lower jaw in position.

(Fig. 56). Should one, two, or three of the first permanent (6-year) molars be carious, the four molars may be extracted with advantage; but if all the teeth are sound, the middle tooth of the seven ought, as a rule, to be chosen, and that tooth will be the first bicuspid just behind the canine.

Should the overcrowding (as in outstanding

canines) be confined to the upper jaw, the removal of the first bicuspid on each side may be all that is requisite. Generally speaking, however, both jaws are involved, then it is wiser to extract symmetrically as in the case illustrated.

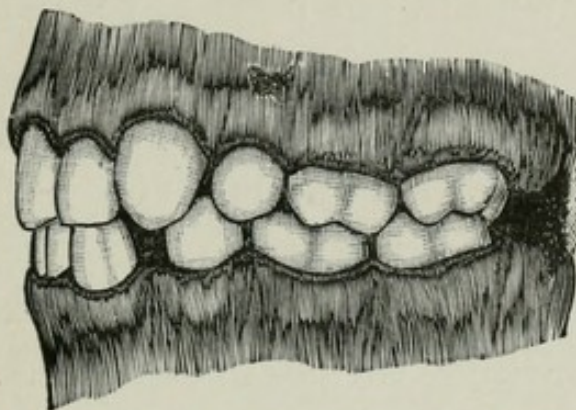


Fig. 57.—Side view of above after treatment.

The advantages to be obtained by the extraction of the first bicuspid teeth are as follows :—The spaces left will soon fill up. The remaining bicuspids and molars in each jaw will slightly advance, thus leaving room for the wisdom teeth to erupt in later years. This is a by no means undesirable object, as their eruption in crowded mouths is often attended by severe and prolonged pain. The canines instead of being unduly prominent will sink into their proper position. If they are already in position, they, with the lateral and central

incisors, will move slightly backwards, and perhaps an interval will be thus left between each tooth.

As an alternative to symmetrical extraction, the separation of teeth by wedging, or by removing a portion of each tooth with files or corundum wheels, has been advocated. There are, however, obvious objections to such methods. Wedging the teeth apart enlarges the normal arches, and may render the patient unsightly. The removal of portions of the teeth at once weakens them, by taking away their protecting surfaces of enamel. Such objections would appear to be fatal apart from the facts that the patient would be subjected to much pain, and the operator to an unnecessary amount of trouble.

There are a number of cases where instead of presenting the normal arch the teeth are arranged so as to give the appearance of a wedge, the apex being formed by the centrals, the base by a line drawn between the two last molars. There are others where a contraction takes place in the bicuspid region. These are sometimes treated by extraction of certain teeth (depending largely upon the deformity which exists)

but generally by expansion, by means of vulcanite or metal plates. The "Coffin" or split plate is the one generally used.

Sometimes it is advisable to remove incisors in order to relieve overcrowding as in Fig. 58, where the canines have taken up their position close to the centrals. The laterals A and B are shut in behind and should be removed.

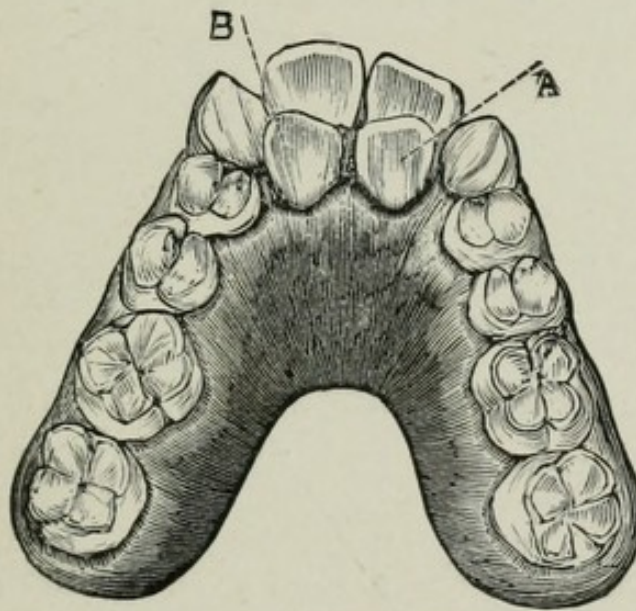


Fig. 58.--MODEL OF UPPER JAW.

Showing permanent laterals A B immediately behind the central incisor teeth.

Fig. 59 is a good illustration of a neglected mouth in an adult, and shows the effect of overcrowding in the incisor region of the lower jaw.

A B passes through the central incisors, and

thus indicates the divergence from the middle line of the jaw.

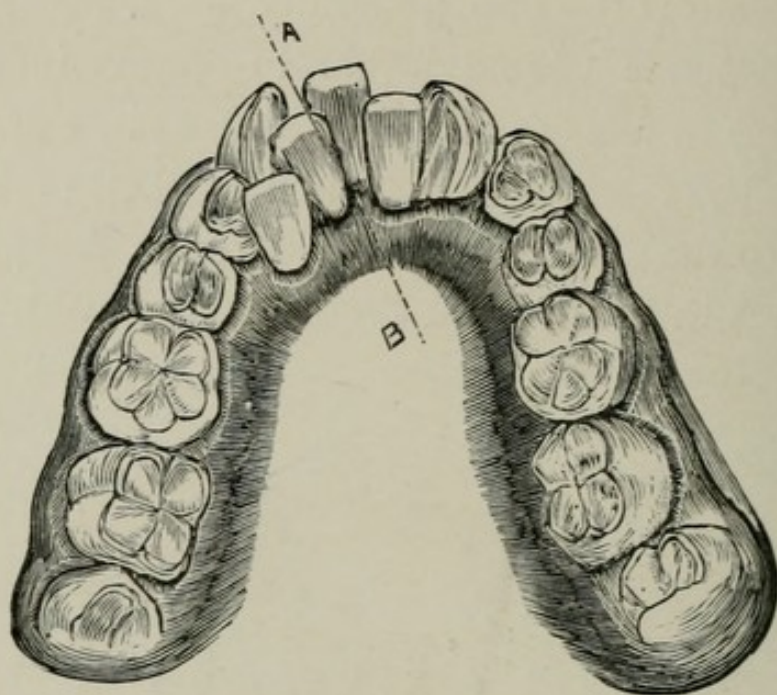


Fig. 59.

The central and lateral on the left side lie behind the canine and first bicuspid respectively.

Such cases as the above give occasion to the popular impression of "double rows" of teeth, which, literally, means the eruption of more teeth than is normal.

Canine teeth should never be extracted to relieve overcrowding. They are deeply rooted. They help to form the angles of the mouth, and give expression to the face. The canine

eminences in the superior maxillæ are very prominent; and should these teeth be removed on either side the eminence disappears. This is well shown in Fig. 60, where the left upper canine has been removed (instead of the first bicuspid) because it "stuck out." The consequence was a marked sinking in, at the angle of the mouth, a depression above the upper lip, and a deviation of central incisors toward the

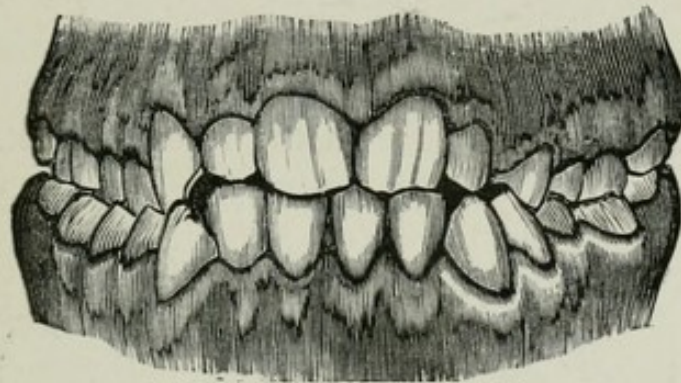


Fig. 60.—MODEL SHOWING JAWS OF A GIRL AGED 17 YEARS.

The left upper canine has been removed and the central incisors have deviated towards the left side.

left side, which by no means improved the personal appearance of the patient.

Protrusion of the upper front teeth is a condition which arises early in life, and is for the most part hereditary. It is the antithesis of the "underhung jaw," is extremely difficult to treat and very unsightly.

Figs. 61 and 62 are taken from a brother and sister. The mother and two aunts had projecting teeth. On comparing these illustrations

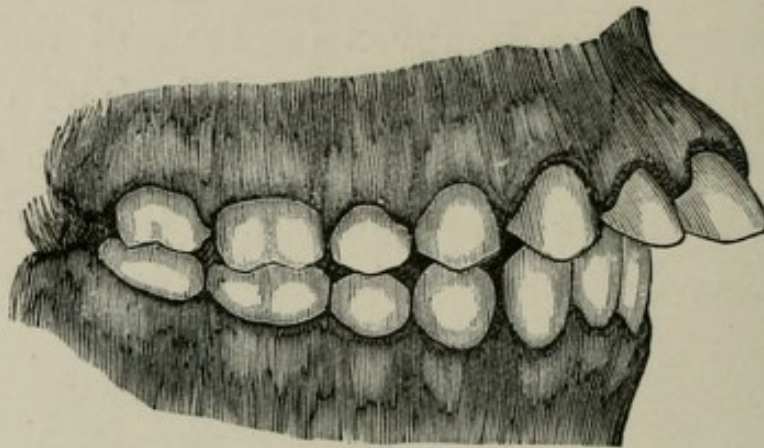


Fig. 61.—MODELS FROM A GIRL AGED 16 YEARS.

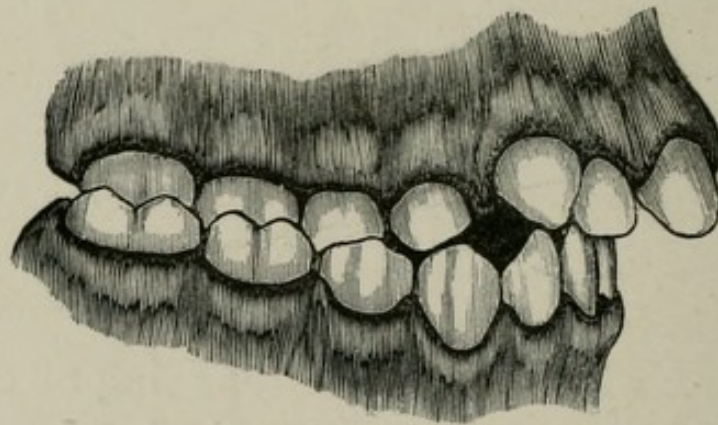


Fig. 62.—MODELS FROM A BOY AGED 12 YEARS.

with Fig. 28 of a normal articulation it will be noticed that in Figs. 61 and 62 no *interlocking* of the molars and bicuspid takes place. Instead of each upper tooth overlapping and

articulating with two lower teeth, one tooth alone meets its fellow in the lower jaw.

The canines also cover one tooth instead of two.

In adult life one often sees a protrusion of the upper incisors induced by the loss of the molar and bicuspid teeth. In consequence of mastication being performed by the front teeth, the upper teeth are forced outwards, and the pressure of the lower incisors against their inclined planes tends to perpetuate the deformity.

Judging by the above illustrations it would appear that the upper jaw is more forward, or else the lower jaw is more backward than is normal.

As pointed out by Tomes,* in many of these cases the ramus of the inferior maxilla is rectangular instead of oblique.

This would account for the retraction of the lower jaw. Undoubtedly, however, there is an undue development of bone in the pre-maxillary region. When first this deformity was noticed (Fig. 62) the boy could close his lips with comfort, and nothing but an undue

* *Dental Surgery.* Page 177.

prominence above the lip was to be seen. With the girl (Fig. 61) it was different, the upper teeth projected so much that the lower lip passed between them and the lower teeth. The pressure exerted by the lower lip forces the upper teeth further out, and the upper lip resting on half the upper teeth, leaves the lower half exposed. The treatment adopted will vary, of course, as to the peculiarity of the case. The dental surgeon generally extracts the first bicuspid tooth from each side of the upper jaw, the bite is raised in order to prevent the lower incisors from touching the backs of the upper teeth, and then an attempt is made to draw the upper teeth into a normal position by means of a regulation plate and bands passing round the front teeth.

Deviations from the normal type of jaw are innumerable. As each face differs from another, so no two mouths will be found alike. Would space permit there are many points which might be dealt with in respect to irregularities of the teeth and their treatment, which, however, will be found in the text books on Dental Surgery.

In concluding this chapter, it is advisable

for the practitioner to remember that the facial muscles of the cheeks, the lips, the tongue, and those of mastication are always exerting certain, though it may be unnoticed, pressure to mould the teeth and jaws into shape.

In dealing with cases of irregularity it is a good plan to take impressions of the mouth, so that models may be made from them. Careful notice should be taken of the position of the jaws when closed, that the models may be so placed afterwards. These should then be studied at leisure; by so doing, treatment will not be too hastily carried out.

If there is any doubt as to the course of treatment the patient should be sent to a dental practitioner. Should this not be possible, the impression or models might be forwarded to a dentist in the nearest town, and his advice sought as to the requirements of the case.

In order to take an impression of the mouth it is necessary to have modelling composition and a few "trays." These are metal shapes of various sizes with handles attached (Fig. 63) to fit loosely over the teeth of either jaw, and to hold the composition. Modelling composi-

tion* is made in cakes, and has the property of softening in hot water.

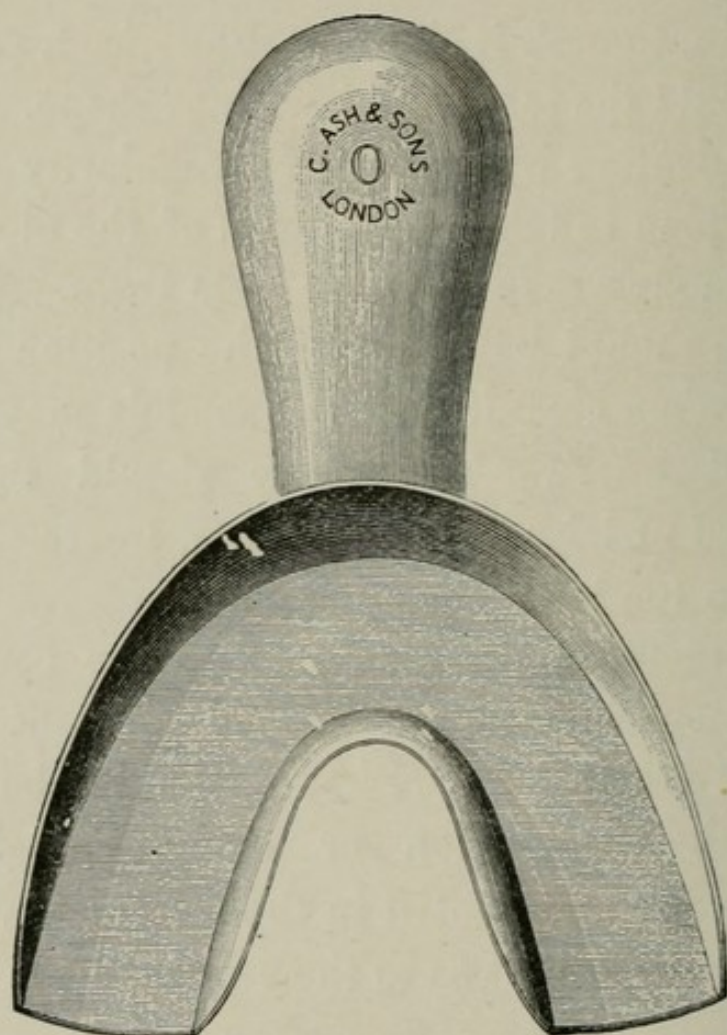


Fig. 63. IMPRESSION TRAY.

To take a mould or impression. A tray of the requisite size should first be found, and then a cake of composition should be placed in a basin of hot water—not boiling—until quite soft.

* Generally made of Kowrie Gum, Stearine, and French Chalk.

The tray should then be dipped in the water in order to make the composition adhere. Sufficient composition should be moulded into the "tray" with the fingers so as to fill it level with the edges, and the surface may be lightly rubbed over with vaseline or oil.

This should then be placed in the mouth, and gently but firmly pressed up round the teeth, care being taken not to have the composition, or the tray, hot enough to burn the patient's mouth. To guard against this the water need be of no higher temperature than the fingers of the operator will bear, and a further test may be applied by touching the back of the hand with the surface of the composition before rubbing vaseline over it.

In two or three minutes the composition will have set sufficiently hard. It should then be gently withdrawn, easing first one side and then the other, not *pulling* it out of the mouth.

In order to make a cast of the jaw from this, a table-spoonful or two of plaster* should be mixed in a basin with sufficient water to make it the consistency of thick cream. This

* Sulphate of Calcium, or Plaster of Paris, supplied in small air-tight canisters.

should be slowly run into the mould and while so doing the mould should be gently tapped against the edge of the basin or table to drive air bubbles out. When the mould is full, more plaster should be quickly mixed, but much thicker; this should be placed on a sheet of paper, and the mould turned upside down on to it; so that the plaster in the mould and that on the paper may cohere. In a few hours the plaster will have set quite hard. The whole should then be immersed in hot water—the composition and tray can be thus removed, leaving the model of the teeth in plaster.

CHAPTER VII.

HYGIENE OF THE MOUTH.

Various surmises have been made as to the contributory or more remote causes of decay in teeth, such as an advanced civilization, with its accompaniments of overcrowding in our cities, the continuous nervous strain with the ever-increasing struggle of life, the alteration of food with its methods of preparation which give less work for the jaws, or a general deterioration of tissue. Whatever opinion is held on these points, there are well-established facts which show that to micro-organisms are due the immediate—or rather the direct—destruction of the teeth. In the chapter on Caries this fact has been fully emphasized (see page 39), but we may again mention that dental caries commences from the outside.

Food and its *debris* allowed to remain between the teeth undergo acid fermentation due to bacteria, and when, by means of this acid, lime-salts are dissolved out of the teeth, bacteria find an excellent pabulum upon which to work. At a later stage, disintegration and destruction of the tissues follow with the concomitant evils of exposed pulp, &c.

In dental, as in other diseases, the clear recognition of causation is the surest guide to rational treatment, and in this respect the dental surgeon is not slow to avail himself of every aid to his art.

We must look, however, to preventive measures for amelioration of a large amount of unnecessary suffering, the result of dental disease.

Personal cleanliness is recognized as a valuable aid, both in the treatment and prevention of many diseases. It is, nevertheless, a curious fact, that in very few works on medicine is mention made of the necessity for keeping the mouth in a healthy condition during childhood, though careful directions are given as to personal hygiene from infancy onward, of other parts of the body. Yet we have in dental

caries a disease which is wider spread among children than any other disorder which can be mentioned. It attacks the rich as well as the poor, children who are surrounded by the comfort and the necessities of a healthy existence, such as pure air, efficient sanitation and excellent food, as well as those who eke out a miserable existence in the streets and courts of our towns.

While the educated among all classes of the community are very well aware of the necessity and the comfort of personal cleanliness, the utmost ignorance prevails as to the need of keeping the mouths of children in a healthy condition in order to prevent the decay of teeth.

The constant reply to the question "Is this child taught to clean its teeth?" is "Oh! I did not think the first teeth needed cleaning," or "Oh, yes! always *in the morning*."

There can be no doubt that the friction of the food and the use of the tongue in a healthy animal should be sufficient to effectually cleanse the teeth, but there are important factors which must not be lost sight of.

Children receive no encouragement to masti-

cate for the sake of the proper development of their jaws. The ceaseless activity of the young is as clearly shown in the desire to use the muscles of mastication as the muscles of locomotion, and as soon as a child has teeth so soon will it be nibbling, and (if allowed) masticating every substance within reach.

Instead of encouraging this natural habit by giving the child hard biscuits of wholesome material, at suitable times, with other foods which require chewing, a tender solicitude for the child's welfare prompts both parents and nurse to provide material of soft consistency, so that the young stomach may receive food which they consider easy of digestion; and in order to suppress a suspicion of vulgarity, the larger bones which would afford both nourishment and exercise are carefully removed and given to the dog.

The selection of foods which can be most easily digested, does not end with the children, it affects the parents who seek the same for themselves, being ignorant of the fact that even the muscular coats of the stomach require a reasonable amount of exercise. The amount of food stuffs offered to the public having the

same undesirable end in view, adds to the indictment. This may give the idea to some future generation that we were either a race of invalids, or, if healthy, as wise as he who would ride *always* in a carriage in order to develop his legs.

Thus by precept, and example, children are early led to acquire a taste for the softest food, and grumble if a piece of steak is tough, or bread is crusty or stale. They often seek relief from such opportunities for exercise, by indiscriminate drinking before the mouth is empty, preventing both teeth and saliva from performing their proper physiological functions. Another important consideration is the slow but very marked decrease in the size of the jaws which is believed to be in progress. If the teeth followed suit it would be less serious, but the overcrowding of teeth among the young is the best evidence we have that this is not so. Overcrowded teeth lead to portions of food being lodged in such positions, that it is neither possible for the tongue to remove, nor the fluid taken to wash away such accumulations.

The efficient and careful cleansing of the teeth of the young should be commenced so

soon as there are teeth through the gum. This will be about the 7th or 9th month, and at such an age, a smooth piece of wet flannel or the corner of a towel can be used by the nurse to wipe away any particles of food.

Later, when the child is capable of using a toothbrush this should be allowed. At first only water with the tooth-brush is necessary ; when, however, a child has sufficiently advanced to be able to spit out water instead of swallowing it, the toothbrush may be previously rubbed on a piece of curd soap. Later still, precipitated chalk should be added. The toothbrush should then be moistened, rubbed on the soap, and afterwards dipped in the powder. The teeth must be cleansed all over. The labial surfaces are to be brushed not only from side to side, but up and down, *i.e.*, the motion should be vertical as well as horizontal, in order that food may be removed from *between* the teeth. This may seem of trivial importance, but a simple diagram will show that the arches made by the teeth have many recesses which are all resting places for food, and brushing from side to side alone does not always reach them. The soap will remove

the mucous secretion which exudes from the gums, and the impalpable chalk gives substance for cleaning the polished surface of enamel. Both are alkaline and serve to check fermentation.

They may be used in the solid form, as a powder or paste

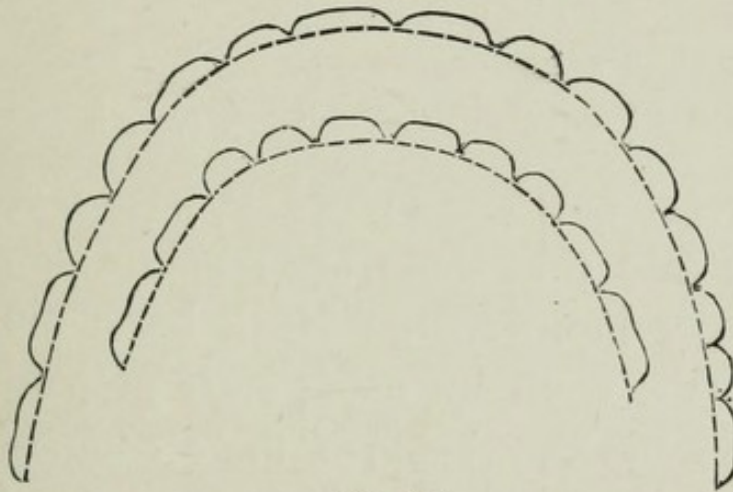


Fig. 63.

The following formulæ may be found useful:—

- | | | | | |
|----|--------------------------|-----|-----|-----------------|
| 1. | Precipitated Chalk ... | ... | ... | 4 ounces. |
| | Curd Soap, in powder | ... | ... | $\frac{1}{2}$ " |
| | Carbolic Acid | ... | ... | 20 minims. |
| | Otto of Roses | ... | ... | 5 " |
| 2. | Precipitated Chalk ... | ... | ... | 2 ounces. |
| | Boric Acid... | ... | ... | 2 drachms. |
| | Orris root, in powder... | ... | ... | 2 " |
| | Curd Soap | ... | ... | 2 " |
| | Oil of Peppermint, or | ... | ... | |
| | Oil of Geranium | ... | ... | 2 minims. |

3.	Prepared or Precipitated Chalk	...	2 ounces.
	Chlorinated Lime (dry)	10 grains.
	Oil of Cassia	5 minims.
4.	Camphor	1 ounce.
	Precipitated Chalk	3 to 7 ozs.
5.	Powdered Castile Soap	2 drachms.
	„ Orris Root	$\frac{1}{2}$ ounce.
	„ Boracic Acid	2 drachms.
	Precipitated Chalk	2 ounces.
	Carbolic Acid	30 minims.
	Oil of Eucalyptus	$\frac{1}{2}$ drachm.

Of proprietary tooth powders, pastes, &c., it may be said that some are good, others bad and many indifferent. Much harm may be done to the teeth by using such preparations without some knowledge of their composition. Those so often advertised and “warranted” to “whiten the enamel” may very effectually do so and help destroy it.

The receipt of a tooth powder, called “Parmena,” has been placed before the writer, and he has no hesitation in recommending it as an excellent dentifrice. It is antiseptic, very agreeable to use, and can be obtained from all chemists.

Cleansing the mouth should be done after

every meal with the same regularity with which the child gets a daily bath, and washing of the face and hands. Especially is the tooth toilet necessary after the last meal of the day, because more mischief is done in the night, while the tongue and jaws are at rest, than at any other period. This is an obvious fact, notwithstanding the popular impression that a brush round in the morning is all that is necessary, even among those who are in the habit of cleansing their teeth.

A quill toothpick should always be at the service of a child to remove stray particles of food jammed between the teeth. Metal toothpicks, as a rule, should be avoided, being apt to injure the enamel.

In answer to the question, "Why should temporary teeth be taken so much care of?" it is only necessary to point out that the temporary teeth serve the purposes of mastication during the most important period of a child's existence. It has already been mentioned that carious temporary teeth often spoil their successors, or frequently interfere with their eruption. There are other reasons spoken of elsewhere; but above all, there is the fact that

when the *debris* of food is removed caries cannot take place; as without it there is no material for acid fermentation, and therefore no softening of dental tissue. Such a habit of cleanliness early impressed both by precept and example is seldom lost through life, and a child will be as uncomfortable later on in years when his teeth remain uncleansed as when he is unwashed.

When children leave the parental roof to reside in schools they should be carefully looked after. It may be mentioned that the Hygiene of the Mouth does not yet form a necessary part of the curriculum; and children often return to their homes, through the neglect of simple precautions, with more caries in their teeth at the end of a few school terms than can be remedied in a life time.

So far, we have considered the Hygiene of the Mouth in the home, and here the General Practitioner has far more power and influence than the Dental Surgeon.

In order to find out with what frequency dental disease affects children who are otherwise healthy, it is necessary to step outside the ordinary routine of practice and to examine

them in large numbers. For this purpose children in schools are best; as it is easy to investigate them with regularity and without risk of repetition.

On the initiative of Mr. Fisher, of Dundee, and Dr. Cunningham, of Cambridge, such an investigation is being carried out in various parts of the United Kingdom, by members of the British Dental Association. Children in Parochial Schools, Industrial Homes, and National Schools are being examined, and valuable statistics will (it is to be hoped) be forthcoming, as the condition of each child's mouth is being permanently recorded, and every tooth is taken note of. For our present purpose a few facts with regard to some statistics obtained by the writer, and Mr. S. Spokes, are sufficient. A table showing figures has been drawn up that the reader may see at a glance the relative frequency of dental disease at various ages.

The dental condition of three thousand eight hundred (3,800) boys and girls whose ages range from three years to sixteen years is recorded.

In the second column the number of children

at a definite age is mentioned, thus 37 children aged 3 years, 110 children aged 4 years, 160 children aged 5 years and so on.

Temporary Teeth.—There were 3,187 temporary teeth which required filling among 1,786 children whose ages varied from 3 to 10 years. Deducting from the number of children those whose dentitions were “sound,” that is, whose teeth were free from caries, viz., 326—*vide* last column—1,460 had 3,187 saveable teeth. The number of teeth, or the remains of them, requiring extraction was 2,491, either being too carious to save, or unduly retained (to the detriment of their successors) beyond the normal period.

Permanent Teeth.—It will be seen that 3,511 permanent teeth required filling, and 1,506 were so carious as to require extraction. Between the ages of 6 and 12 there were 2,178 teeth which required filling, and these, for the most part, were 6-year, or first permanent, molars.

Under the heading *Sound Dentitions* are enumerated those cases in which there was an absence of diseased teeth. Many of these were passing through the transitional period

Age.	No.	Temporary Teeth requiring Filling.	Temporary Teeth requiring Extracting.	Permanent Teeth requiring Filling.	Permanent Teeth requiring Extracting.	Tempo- rary Total.	Perma- nent Total.	Unsound Teeth.	Sound Denti- tions.
3	37	57	5			57		57	20
4	110	290	35	18		295	18	295	41
5	160	411	114	57		446	57	464	44
6	222	561	202	157		675	175	732	27
7	282	633	221	163	2	835	165	1010	41
8	201	366	221	163	8	587	165	752	28
9	340	468	302	365	68	770	373	1143	46
10	434	401	334	435	117	735	503	1238	79
11	434		478	439	321	478	556	1034	110
12	501		385	544	321	385	865	1250	129
13	477		236	513	337	236	850	1086	130
14	359		128	457	374	128	831	959	86
15	212		40	291	247	40	538	578	43
16	31		11	54	32	11	86	97	4
	3800	3187	2491	3511	1506	5678	5017	10795	828

between the first and second dentitions. Some children required merely the easy extraction of temporary teeth to place them in a satisfactory state, but it is a fact which merits careful consideration that out of 3,800 children's mouths inspected, there were only 828 in which neither fillings nor extractions were required.

The facts above mentioned show very clearly that the hygiene of the mouth requires some consideration from another point of view—viz, as it affects the community. The children examined belonged to the poorer classes.

The schools* were situated within 20 miles of London in extensive grounds, where the inmates have all the advantage of good air and healthy exercise. They are gathered from various parishes in London. They are clothed, housed, fed, and educated at the public expense.

In connection with each school is a large staff of teachers, with band and drilling masters, and they are all under expert medical supervision.

These points are only mentioned in order to

* Southall, Hanwell, Sutton, and Feltham.

show that the environment was generally good, and the children were living under healthy conditions; yet, notwithstanding all this, a vast amount of preventible disease existed among them.

The boys in such schools are either taught a trade, or enter the army and navy.

The girls are trained for domestic service.

According to the report of the Army Medical Department for 1890—published in 1892—55,673 recruits were examined; 21,712 were considered unfit for service. Out of these, 506 recruits were rejected on account of “loss and decay of many teeth,” and although the rejections were by no means so numerous as from other diseases, yet this is an interesting statement, and not only points to the prevalence of bad teeth among the working classes, but shows clearly how lads from rate-supported schools may be disqualified from a lack of cleanliness.

458 girls from pauper schools of the metropolis *alone*, entered domestic service in one year.

Five-sixths of that number had never known the use of a tooth-brush. The troubles of a

domestic servant suffering from neglected teeth need little imagination to picture, but disordered digestion, irritability of temper, and inability to perform the allotted duties are some of the most obvious results which may appeal to employers.

There is an increasing recognition of the importance of systematic care of the teeth. In the case of children, who during the growth of the body have not merely to maintain nutrition, it is surely a matter of urgency that all the organs of digestion should be kept in a state of functional integrity; and if, as seems to be the case, disease of the digestive tract is increasing, it is evident that any departure from the normal dentition places the child and future adult at a disadvantage.

Instead of waiting until a child suffers pain and thus directs attention to a carious tooth, it is far better, both for patient and operator, that the earliest appearance of caries should be noted, and its progress prevented by a regulated system of inspection and prompt treatment. Under such circumstances dental disease and the necessity for painful operations become reduced to a minimum; and at the same

time the function of mastication is retained.

Referring once more to the table of figures, it will be seen that 2,972 children had among them 10,795 carious teeth.

In one school of 661 boys, according to the medical officer's report, 135 were admitted to the Infirmary during one year for dyspepsia alone.

In none of the schools were tooth-brushes used.

With the Medical Practitioners will rest, to a large extent, the responsibility of pointing out to all who are concerned with the care of children, the need for constant dental supervision, whether it be poor law guardians who stand *in loco parentis*, or the managers of private and public schools.

A clearer recognition is needed of the fact that a knowledge of his own body, and how to treat it well, is an essential factor in a child's education; also that a tooth-brush drill is as needful as any gymnastic exercise for the preservation of health.

Having considered this important subject as it concerns children who are living under the ordinary conditions of health; it now remains to discuss the Hygiene of the Mouth as it

affects children who are suffering from disease.

That diseases of the teeth are more frequent in those who are sick, than in those who are well, is a matter of common observation; and dental surgeons know well by experience, how rapidly teeth have become carious after a serious illness. While considering somewhat in detail the reasons of such alterations in the dental tissues, it is desirable to place on record some facts with regard to the condition of sick children's mouths; and then to see what conclusions can be drawn from them; at the same time supporting such conclusions, as far as may be, by illustrative cases drawn from clinical experience and gathered from various sources.

A careful tabulation has been made of 306 boys and girls suffering from various diseases in the wards of the Evelina Hospital for sick children, Southwark. These cases were tabulated only where there was no complaint of toothache, or other sign of dental trouble; and which, therefore, under ordinary circumstances, would escape attention and treatment. A record was made on somewhat similar lines to those already mentioned in connection with the poor-law and industrial schools.

Some results of an examination of 306 boys and girls whose average age was 6 years 6 months in the wards of the Evelina Hospital for sick children, Southwark.

Diseases.	Number of Children.	Carious Teeth.		Total Number.	Sound Dentition.
		Temporary.	Permanent.		
Rickets	56	174	13	187	15
Diseases of the Nervous System ...	31	140	54	194	3
Diseases of the Alimentary Canal ...	24	98	16	114	4
Diseases of the Bones and Joints ...	107	411	95	506	19
Diseases of the Respiratory Organs ...	69	355	28	383	14
General Tuberculosis ...	19	111	28	139	—
	306	1289	234	1523	55

In the first column will be found a list of those diseases which may be considered as fairly including the large majority of cases admitted to a children's hospital.

Rickets. — 56 children had well-marked rickets, and among them 15 were entirely free from caries of the teeth. The average age was 4 years, and there were 174 carious temporary teeth, and 13 carious permanent teeth; a total number of 187 among 41 children. In very many cases the dentition was considerably delayed. In only 3 children out of 56 were the temporary teeth defective in structure—so far as naked-eye appearances can tell,—thus bearing out what has been previously stated* by Dr. G. A. Carpenter and the author that in rickety children there is, as a rule, no deficiency of enamel. This question of defective tooth-structure is, however, fully discussed in the chapter on Irregularities.

Delayed dentition is the only reliable test so far as the teeth are concerned, and an examination of a child's mouth will often lead to a recognition of rickets long before the appear-

* *The Lancet*, June, 1892. *Primary Dentition in its relation to Rickets.*

ance of other symptoms, such as beading of the ribs, enlargement of wrists and ankle bones, &c.

There is no evidence to prove that caries is more frequent among rickety children than among those who are suffering from other diseases.

Diseases of the Nervous System.—31 children were suffering from diseases of the nervous system. 3 had healthy mouths, 28 children had 140 carious temporary teeth, and 54 carious permanent teeth, 194 in all. While the *disorders* associated with the *eruption* of temporary teeth have been well recognised and often exaggerated from the time of Hunter to the present day, the disorders connected with *caries* of the temporary teeth have as yet been scarcely realised.

Carious teeth are a source of irritation from which the nervous system may be readily affected, more especially in young and growing children where its condition is unstable, and readily responds to abnormal stimulus.

As a direct source of irritation, pain in the affected tooth may occur, or pain on the same

side of the face and head. Both headache* and earache†—so common among children apart from any organic disease—are frequently due to, and kept up by the same cause.

In such cases attention should soon be directed to the origin of the trouble, but it is well to remember that pain is only *one* symptom of carious teeth, and all the evidence here obtained proves that it is one of small significance, for, as mentioned above, not one patient in more than 300 complained of toothache.

The earliest manifestations of *reflex* irritation in connection with temporary teeth are well known in retarded eruption, where the occurrence of even general convulsions is by no means rare. Later, the signs of reflex irritation from carious teeth are not always recognised, but they do exist, and it is necessary for the Practitioner to be aware of the fact. Mr. Coleman, F.R.C.S.,‡ states that “true cases of epilepsy do occur, the result of irritation

* Lauder Brunton. *Disorders of Digestion*, pp. 48, 76.

† Campbell. *Headaches and other morbid cephalic sensations*. p. 30.

‡ *Manual of Dental Surgery and Pathology*, p. 331.

set up by diseased temporary teeth; some of these have come under the notice of the writer, in which there could be no doubt as to cause and effect."

To Dr. Morgan, of Seaford, I am indebted for the following notes of a case in his practice.

Q. Bennett, aged 9 years. A delicate-looking girl very anæmic. Four years ago she had a severe fit, after which she was unconscious for about an hour. From that time she used to have slight fits in the morning about twice a week, lasting from one to two minutes. The child was seen in June, 1894, and being very thin and emaciated, was ordered Syr. Ferri. Iodid. and Ol. Morrhuæ. She had some very carious teeth on both sides of the mouth. Chloroform was administered, and 6 carious molars were removed from the upper and lower jaws on June 13th. Since then the child has greatly improved in health, and has not had one fit. There was no history of epilepsy in the family. She had no convulsions as an infant.

Mr. Tomes* and Mr. Salter† place on record well authenticated cases of nervous disorders as the result of reflex irritation from carious teeth. One case from the latter writer, is worth quoting, of Dr. Ramskill's patient.‡

A boy, æt. 13, has had frequent attacks of epilepsy for the last eighteen months. Latterly his mother has noticed that some days he rubs his left cheek, complaining of face-ache, after which the fit follows. On examining the mouth, there is to be seen a molar tooth considerably decayed, with a swollen gum around it,

* *Dental Surgery and Pathology*, p. 255 et seq.

† *Dental Surgery*, pp. 564, 579.

‡ *Medical Times and Gazette*, 1862.

and partly growing into the cavity. It is not very tender to the touch, and the examination does not give rise to toothache. On questioning, I find the sensation which the boy experiences before a fit does not seem to be one of pain, but rather of an indefinite uneasiness. He always has a fit the night this comes on. Has never felt it during the day, it is always about seven or eight o'clock. I desired the mother to have the tooth extracted, and ordered a simple saline with a quarter of a grain of belladonna to be taken twice daily. This was in June. The tooth was extracted next day. I saw this boy once a fortnight from that time for four months, but he has had no recurrence of the fit.

Among the 31 children referred to under the heading of nervous diseases, 16 had well-marked symptoms of chorea, and only one child was free from carious teeth.

The following is a typical case from those mentioned.

A. W. A boy, aged 8 years, has 2 permanent teeth, and 8 temporary teeth, carious. Of this number 2 temporary molars in the upper jaw, 3 temporary molars in the lower jaw, and 1 temporary canine were extensively decayed and necrotic. *These required removal.* Mouth foul.

The causation of chorea is by no means settled. It is well-known that the symptoms arise in children of a neurotic type. The symptoms appear to lie dormant for a time, and then be set up by very trivial causes.

Given a neurotic subject, any source of irritation may be cited as a primary cause, or as a means of keeping up the peculiar movements

so typical of the disease. Though often associated with rheumatism, chorea appears to be the expression of a nervous system goaded to desperation by accumulated ills. Removal of one evil alone does not effect a cure. It is only as each one is sought out, and removed, that the symptoms disappear. That a fruitful source of irritation may be found in carious teeth, is well illustrated by the following cases: and those above mentioned at any rate point to the teeth as an important factor, if not in causation, in the maintenance of the disease.

The first is from the out-patient department of my colleague, Dr. Soltan Fenwick.

The second is from notes taken by Dr. Wainwright, the patient being under the care of my colleague, Dr. Willcocks.

The third is from the practice of Dr. Morgan, of Seaford.

1. September 18th, 1894. Maria Heath, 8 years, has had Chorea for 3 months. Headache, palpitation, twitchings of hands and face. Treated with Liq. Arsenicalis and Pot. Bromidum. This was only followed by sickness.

September 25th. Child's mouth examined, 8 carious temporary teeth were present, also 2 carious permanent molars. Two necrotic teeth removed.

October 2nd. Headache much worse. Much pain at night. The pulp of a lower permanent molar was exposed and acutely painful—pulpitis. The tooth was removed.

October 13th. Patient quite well, all choreic symptoms have disappeared.

January 29th, 1895. Quite well, no return of chorea.

2. Harriet Buxton, aged 8 years. Chorea of 7 weeks' standing. She did not improve at all during the first 2 weeks in the hospital. A painful stump was removed. In four days all movements ceased and did not recur.

3. A little girl, aged 9 years, suffering from well marked chorea, was brought to me by her mother for advice. The mother said that the child had had twitching of the head and face and hands for 2 months past. She was getting worse, and punishment did no good! I gave her arsenic first, but found no beneficial results follow its use. I then tried zinc sulphate for a time, but the child was no better. One day, as she complained of toothache, my assistant, Dr. Murphy, removed a largely decayed permanent molar from the lower jaw. Almost from that moment the child became free from choreic movements, and she has not had a symptom of their return since (now 3 months).

The following are from notes furnished by Mr. Senior, while House Physician at the East London Hospital for children, Shadwell. They are intended to illustrate the effects of dental treatment upon children in the wards, and are published by the courtesy of the Physicians under whose care the children were at the time.

4. October 16th, 1894. Eva Cott, age 6 years. Chorea of 5 weeks' duration. 3 carious temporary teeth removed. *Result*—a marked improvement.

5. Edith Venn, age 10 years. Chorea at 3 years and 5 years. Present attack commenced 7 weeks ago. A severe case, unable to walk or even stand. She has improved since admission. Has 6

carious molars. Two were removed. The others treated with nitrate of silver. *Result*—has improved rapidly. She can now knit with ease and celerity. Jerks still in walking. There is some loss of power in lower limbs still she improves daily.

6. Mary Ann King, age 7 years. Chorea for 2 years. Since admission has varied: but not improved. 6 hopelessly bad teeth removed. Four molars and two incisors. *Result*.—October 23rd discharged quite well.

7. Arthur Johnson, age 9 years. Chorea at $7\frac{1}{2}$ years. Present attack commenced 8 weeks ago. On the whole there has been no improvement since admission. 4 carious molars removed. 2 temporary, 2 permanent. *Result*.—The boy improved rapidly. October 24th, discharged quite well.

Diseases of the Alimentary Canal.—An examination of 24 children suffering from diseases of the alimentary canal, showed that 4 had healthy mouths. Among 20 children there were 98 carious temporary teeth, and 16 carious permanent teeth, with a total of 114. In disorders of the digestive tract the saliva is altered in character and consistency. Typical cases are seen in catarrhal inflammation of the mouth and fauces, where there is at first a distinct diminution of secretions, followed by a profuse flow of saliva. At first thin and watery; later, thick, tenacious, and ropy. In such conditions acid fermentation proceeds rapidly. As the saliva tends to cling about the necks of the teeth, and mastication of food

becomes painful, softening and disintegration of tooth-structure is a necessary consequence.

Inflammation of the mucous membrane of the mouth is most frequently seen among the children of the poor, and may be induced by improper feeding and impure air. In such children, who may be said to be constitutionally weak, it is often associated with carious teeth.

Dr. Bristowe* says "Catarrhal inflammation of the mouth more frequently and seriously affects those who suffer from bad teeth, than those whose teeth are sound, and reveals itself mainly by pain, tenderness and swelling of the gums, and particularly of the periosteum of the sockets of the teeth. The teeth consequently become loose and tender; and neuralgic pains, often most severe at night-time flicker about the gums; and sometimes extend to the periosteum of the jaws and along the superficial branches of the fifth pair." This statement is entirely true with regard to children; and the out-patient department of a Children's Hospital affords numerous examples. It not only applies to the simple catarrhal affections, but to

* *Theory and Practice of Medicine*, p. 626, 2nd edition.

the specific affections of the mouth generally described as "ulcerative stomatitis." In addition to the fetid breath, marginal necrosis of gum tissue round the necks of teeth, and unhealthy ulcerated patches on the tongue, and cheeks, one frequently finds necrotic roots of teeth or carious cavities in molars with sharp edges. These not only keep up the irritation, but intensify the ulceration and sloughing of adjoining tissue both of gum and cheek which rests against them; furnishing a plentiful supply of putrid material while mastication is reduced to a minimum.

The ulceration of the cheek is often so extensive, the inflammatory thickening so great, and constitutional symptoms so grave as often to give rise to the suspicion of Noma. Many such cases of ulcerative stomatitis are started and kept up by carious teeth*; and it is remarkable how quickly many heal up on the removal of carious teeth without even the aid of such a specific remedy as Chlorate of Potash. The connection between ulcerative stomatitis and carious teeth is well illustrated by the following:—

* Salter *Dental Pathology and Surgery*, page 188, *et seq.*

M. D., age 7 years. A pale, fairly well nourished girl complains of faceache. Had toothache 7 days ago on the right side, which gradually became worse until the face began to swell.

On examination, the right cheek was found to be much inflamed and thickened. The glands beneath the jaw enlarged. Breath fetid. A blood-stained discharge from the mouth, and great difficulty in swallowing. The upper and lower central incisor teeth were carious and loose. In the lower jaw, on the right side, were two carious temporary molars. In the upper jaw, on the same side, were two temporary molars in a necrotic condition, and through the alveolar plate above pus was oozing from two sinuses on the inside of right cheek; opposite to the temporary molars an unhealthy ulceration of mucous membrane extended as far as the soft palate. On the same side there was a large ulcer on the tongue.

Treatment.—The temporary molars were removed. The ulcers were dusted over with iodoform. A chlorate of potash mixture was ordered, and milk diet. The patient rapidly recovered.

Carious teeth *re-act* upon the digestive system by preventing proper mastication of food, by reflex nervous irritation, and by the accumulation of the products of putrefaction within the mouth.

Among the patients examined, three were suffering from diarrhœa, uncomplicated and without symptoms of tubercular disease.

E. G. A girl, aged 3 years 11 months, had 5 carious molars.

C. B. A boy „ 7 „ „ 2 „ „

T. M. A boy „ 10 „ 9 „ „ 2 „ temporary molars and 2 carious permanent molars.

The causes of diarrhœa seem to be innumerable: but there are two which seem to be worthy of mention in relation to the teeth.

That the peristaltic action of the intestines and the increased secretion of the intestinal glands may be profoundly influenced through the nervous system in young children, is recognised by the Physician; hence the term "Nervous Diarrhœa." The commonest example of this is to be found in delicate nervous children as the result of fright, anxiety or mental excitement. Any source of nerve irritation is liable to bring on such attacks. Painful or difficult dentition has long been considered a cause, and the writer has seen several cases where nerve irritation from carious molars was the only traceable cause for such a condition. The diarrhœa ceased when the teeth were removed or otherwise treated.

A far more frequent source of this complaint is to be found as the result of the introduction of poisonous products to the alimentary canal. Foul emanations from sewers, decomposing food and bad water are amongst those most frequently mentioned. There are, however, conditions often existing in the mouths of children which are quite sufficient to give rise to systemic disorders of which diarrhœa is only one symptom.

Inability to masticate food favours the deposition of lime salts (tartar) upon the teeth, also the retention of particles of food which rapidly undergo decomposition. Apart from these evils an untreated carious tooth is in most cases a receptacle for food which furnishes material for bacteria. Especially is this the case when the cavity contains the portion of a pulp no longer living. It has been mentioned—*vide* Structure—that the nerve cavity, or pulp chamber, contains a mass of soft material consisting of connective tissue, cells, blood-vessels and nerve fibres. When caries has reached the “nerve” and the pulp is affected and exposed, after a variable period of inflammation the pulp generally dies and putrefactive changes take place owing to the entrance of the fluids of the mouth, air, and bacteria. The pulp chamber and its contents are relatively large in young teeth, hence exposure and death are more rapid.

Such a tooth contains a small mass of putrid material which is added to by the *debris* of food. Where several teeth in this condition are found in the mouth (as in the patients above mentioned) the products of putrefaction are daily mixed up with the food and swallowed in

addition to small quantities of pus which oozes out through the alveolus.

In order to prove the presence of such material it is only necessary to remove the contents of a necrotic tooth and examine it. It has the most fetid odour and is crammed with micro-organisms and their products. Dr. Miller, of Berlin, in his interesting and instructive book* gives an account of experiments performed by him as to the effect of micro-organisms on the digestive tract to which we would refer the reader. He points out "that the micro-organisms in an unclean mouth, quite independently of those introduced with food and drink, suffice to produce intense fermentative processes, chronic dyspepsia etc.," in the stomach.

The following cases are from notes supplied by Dr. Wainwright, the resident House Surgeon at the Evelina Hospital, as to patients under the care of Dr. Tirard and Dr. Willcocks.

1. Mary Banton, æt. $7\frac{1}{2}$. Stomatitis and diarrhœa of 5 weeks' standing. Nearly all the teeth were carious and very foul. Four were removed, and a mouth-wash of Pot. Permang. was ordered, and was also used with the tooth-brush. The mouth became clean, and the diarrhœa ceased in one week.

* *The Micro-Organisms of the Mouth.*

2. Ada Halliday, æt. 10. Pertussis and constant offensive diarrhœa. 5 carious teeth were removed. The same mouth-wash was ordered. The diarrhœa ceased almost at once.

3. Charles Burnet, æt. 8. Aortic valve disease. Chronic diarrhœa. 5 teeth and roots extracted. The diarrhœa ceased in 4 days.

4. Harry Morgan, æt. 4 years 6 months. 4 teeth removed after 2 weeks. The diarrhœa ceased in 6 days.

5. Mary Ann Haines, æt. 7. Chronic diarrhœa. A feeble emaciated child. Weight 2 stone 6 lbs. Motions 3 per diem, very offensive. Three very foul stumps were removed on May 11th, and the child given full diet. On May 18th her weight was 2 stone 9 lbs., and the diarrhœa had ceased. On June 2nd the weight was 3 stone 5 lbs., and her general appearance was very good.

6. Horace Few, æt. $3\frac{1}{2}$. Broncho-pneumonia and chronic diarrhœa. The child did not improve for 5 weeks. Then the carious and purulent remains of 5 front teeth were removed. Both bronchitis and diarrhœa ceased. The weight rose from 1 stone $5\frac{1}{2}$ lbs. to 1 stone $11\frac{1}{2}$ lbs. and he left the hospital in 14 days quite well.

7. Elizabeth Brand, æt. 8 years. Chronic tubercular peritonitis with very offensive diarrhœa. This continued for 9 days, when 3 stumps were removed, freeing a lot of pus. Though the diarrhœa continued, its offensive character ceased at once.

8. Edith Blackwell, æt. 6. Corneal ulcers 18 months, bad *stomatitis* and diarrhœa. Was constantly sick and would eat nothing. 6 teeth and stumps were removed. The appetite returned, the diarrhœa ceased; and as nutrition improved the corneal ulcers disappeared and have not recurred.

9. Alice Webb, æt. 6. Broncho-pneumonia and diarrhœa. The latter has been constant for 10 weeks. On admission 4 carious teeth were removed and a mouth-wash ordered. The diarrhœa ceased in a week, and the bronchitis cleared up rapidly.

10. Caroline Willcocks, æt. 3. Extreme *stomatitis* and diarrhœa with great emaciation. Pus was oozing from all the teeth which were carious. They were removed. The child became quite well at once, grew fat and is still so, though toothless.

11. Ellen Burns, æt. $6\frac{1}{2}$. *Broncho-pneumonia and diarrhœa.* 3 lower molars were removed, one opening up an abscess cavity. The diarrhœa ceased, and in 4 weeks the child's weight increased from 2 stone 3 lbs. to 3 stone $4\frac{1}{2}$ lbs.

The diarrhœa in all these cases was of the same nature. About 3 motions each day, which were frothy and intensely offensive. In most cases the offensive character disappeared for some days before the diarrhœa ceased.

The effects of swallowing quantities of putrid material are associated with other symptoms besides those of disturbance of the alimentary canal.

When the toxines are taken up by the lymphatics of the stomach and intestines, they pass into the blood-stream. Headache, nausea, and vomiting follow, showing a disturbance of the nervous system. These symptoms are generally accompanied with slight fever. The temperature rises from 101 deg. to 103 F., and anæmia follows. Such a form of septic poisoning is known as *sapræmia*,* and is "due to the absorption of a chemical substance, and is in no sense of the word an infective condition." This is proved by the rapid disappear-

* *Sapræmia*, by Victor Horsley, F.R.S. Heath's *Dictionary of Practical Surgery*.

ance of all symptoms when the source of supply is stopped.

Modified forms of sapræmia from foul mouths are of frequent occurrence among both adults and children.

The following cases are illustrative of this condition. The first is from notes supplied by Mr. Senior; the second from notes furnished by Dr. Wainwright.

1. October 16th, 1894. Clara Pollington, age 6 years. Had measles at $2\frac{1}{2}$ years. Whooping cough at 4 years. Always delicate. Highly neurotic. Anæmic. Has suffered from pains in the head on and off for 6 months, with occasional attacks of vomiting.

This child had 13 carious temporary teeth, 3 were extracted; the others treated with nitrate of silver every morning. She rapidly improved, regained appetite and flesh. October 20th, was discharged quite well.

2. Jessie Hamilton, age 11. Admitted as tubercular meningitis. Emaciation extreme, marked anæmia, constant vomiting. Breath most offensive. The child seemed almost moribund. The mouth was cleansed with Pot. Permang. for 3 days, then 7 teeth were removed. She was given full diet. In 8 weeks her weight increased from 2 stone 11 lbs. to 4 stone 8 lbs. Seven months later she weighed 5 stone 11 lbs.

Dr. Wainwright believes these symptoms were due entirely to the swallowing of pus.

Diseases of the Respiratory Organs.—Sixty-nine children were examined who were suffering from various diseases of the respiratory

organs, pneumonia, bronchitis, broncho-pneumonia and phthisis. Among them were found 14 healthy mouths; 355 carious temporary teeth, and 28 carious permanent teeth were present. A total of 383 carious teeth in 55 children with unhealthy mouths. Nearly 7 to each child.

The high temperature, in addition to digestive disturbance, which accompanies diseases of the respiratory organs has a marked effect in rendering the mouth unhealthy. The tongue is furred, and the secretions of the salivary glands are scanty, and sordes accumulate on the teeth. Hence caries of the teeth is accelerated,

There were 17 patients with pneumonia, and only one of these had sound teeth. A typical case was :—

T. P., a boy aged 5 years. Croupous pneumonia. 4 upper incisors quite loose, but not carious. 2 upper temporary molars carious. 3 lower temporary molars carious, and in a necrotic condition. From sinuses connected with two of these molars pus was oozing at the apex of the roots on the outer side of the alveolar plate. Mouth foul. Marginal ulceration of gums.

That it is possible to establish any connection between the condition of this patient's teeth and the disease from which he was suffering, we do not pretend. But there are

interesting facts in connection with bacteria frequently found in the mouth and with Pneumonia which deserve mention.

Croupous pneumonia is now looked upon by many physicians and pathologists as being due indirectly to a specific organism. Among the pathogenic organisms found in the mouth is the micrococcus of sputum septicæmia. This when introduced into the bodies of animals in many cases produces the symptoms of acute septicæmia. It is found in the mouths of those suffering from pneumonia, also in the mouths of healthy persons.

1. Dr. Emil Schreier, as mentioned by Kirk,* examined some twenty cases of apical inflammation in the roots of teeth, and found this organism (which is indetical with that of A. Fraenkel's diplococcus pneumonica) in every one of them.

Dr. Sims Woodhead† suggests that this micrococcus may remain in the mouth for some time without giving rise to any symptoms. Finding its way into healthy lung tissue it will have no effect; but if there is slight inflamma-

* *British Journal of Dental Science.* Nov. 1, 94.

† *Bacteria and their Products.* Vide p. 344.

tion or congestion, it "is enabled to grow on the exuded fluid constituents of the blood, and to set up at once those intense inflammatory changes characteristic of croupous pneumonia or acute inflammation of the lungs."

2. The micrococcus of septicæmia has also been found in diseases of the middle ear and in meningitis; thus suggesting the transmission of this organism from the mouth to the pharynx where it may find its way along the Eustachian tube, setting up acute inflammatory mischief which may extend to the membranes of the brain.

That there is a connection between conditions of the mouth and lungs is often seen in cases of septic pneumonia which occur after operations about the mouth. Whether such cases are due to direct transmission of organisms to the lungs or are simply a local manifestation of a general poisoning of the system, cannot with certainty be stated. It is however, evident that the presence of necrotic teeth and discharging sinuses tends to lower the vitality of a patient, and favours the accumulation of organisms which in a healthy mouth would find no encouragement to thrive.

General Tuberculosis. Nineteen children had 111 carious temporary teeth, 28 carious permanent teeth ; a total of 139 carious teeth and not one healthy mouth.

A. B., a girl, aged 8 years, with tubercular glands in the neck and in the axilla. This patient has 8 carious temporary molars, and 1 carious permanent molar.

This case is mentioned in order to direct attention to a favourite site of gland infection.

Researches made by Bacteriologists in comparatively recent times furnish abundant evidence that tubercular disease is due to the entrance and multiplication in the system of a micro-organism, the tubercle bacillus.

The sources of supply are to be found in particles of dust in the air we breathe, and in milk and the meat of tuberculous cattle. The chief channels of infection are the respiratory passages and the alimentary canal. Once a fertile soil has been found the bacillus multiplies and spreads through the tissues, there producing those changes which lead to the various manifestations of this disease. This in brief is the Bacteriologists' view.* Clinical evidence tends to show that when the lungs are attacked as in

* *Vide* Dr. Sims Woodhead's *Bacteria and their Products*.

Phthisis, the meninges of the brain as in Tubercular Meningitis, or the glands of the intestine as in Tubercular Peritonitis, these are but local manifestations of systemic disease.

Where, however, the glands of the skin are attacked, tubercular material may be found *only* in those glands; and their prompt and thorough removal is looked upon by many surgeons as a means of arresting the spreading of this disease to other glands by "continuity of tissue."

One of the commonest sites, if not the most common, for tubercle to develop in such glands is about the neck and beneath the lower jaw; in those lymphatics which drain the surfaces of the head and face, in fact those parts most liable to irritation.

Enlargement of the lymphatic glands in the neck is due to the absorption of inflammatory products through the lymph canals of the skin, or mucous membrane. Inflammatory affections of the scalp, the ear, and the mouth, are the ordinary sources of such irritation.

Mr. Owen, the Senior Surgeon to the Children's Hospital, Great Ormond Street, W., has

directed attention* to the fact that *septic* infection of the glands beneath the jaw frequently takes place in children through carious teeth. This view accords with the experience of many dental surgeons and practitioners. Such septic infection generally takes place through the open pulp chamber of a tooth, where the pulp is in a putrefactive condition.

It may be simple and transitory, disappearing when the site of infection has been removed, but it may be tubercular, and, spreading to other glands, infect the whole body.

Diseases of Bones and Joints.—Out of 107 children examined there were found only 19 healthy mouths. 88 children had 411 carious temporary teeth, and 95 carious permanent teeth, a total of 506 carious teeth.

The following is a typical case :

J. S., a boy, aged 7 years 9 months, with hip-joint disease. This patient has 4 permanent molars carious, and 8 temporary molars carious.

The total number of children examined was 306. There were 55 healthy mouths, and the total number of carious teeth was 1,523.

The facts are interesting as showing what

* *Odontological Society's Transactions*, June, 1894.

an amount of disease may exist in the mouths of children without causing any obvious suffering. They also prove what one has been led to expect, that carious teeth are more prevalent among sick children than among those who are healthy.

It is also interesting to note that what is often described as a disease of one organ of the body, is but a local manifestation of general weakness of tissue, either inherited or acquired. For instance, a child with hip joint disease may be syphilitic; another who is the subject of empyema may be rickety; another with pneumonia may be tubercular; and so on. The facts are recognised by surgeons and physicians alike, and apart from any special treatment adopted for sick children—whether it be an operation for the removal of diseased bone, the evacuation of pus from an abscess, the administration of some special drug to lessen the irritation of a cough or ameliorate the sufferings of a patient—there is a general course of treatment adopted in all cases which has for its main object the careful nutrition of the whole body. Briefly, this general treatment consists of the removal of

all sources of irritation to procure rest, perfect cleanliness, nutritious food, and pure air. On such hygienic conditions do the surgeon and physician rely for the cure of disease, rather than upon any other method of treatment. Whether we believe with Metschnikoff that the leucocytes of the blood and tissues devour pathogenic bacteria when the body is in health, and that this resisting power is lost when nutrition is impaired, the evidence—accumulating almost daily—of the origin and causation of diseases seems to point to a time when empirical measures will surely pass away, and the administration of special drugs for the curation of the numerous “ills the flesh is heir to” will be replaced by the more sure and certain improvement of the general conditions under which we live.

That carious teeth are a source of irritation, no one will dispute; and the fact that in 251 sick children, out of 306 examined, an average of nearly 5 such teeth were present in every mouth, would seem to show that of all sources of irritation this is the most important because of its vast preponderance over all others.

That more work shall not be thrown upon

the stomach than it is able or fitted to perform, it is necessary that a child shall be able to masticate its food. How much *more needful* then (nutritious as that food may be) in cases where the stomach is already enfeebled by disease.

That mouths are rendered foul by the presence of carious teeth in health, gives additional point to the urgent necessity of adopting measures of cleanliness in sickness; for however wholesome is the diet, and pure the air before entering the body, once having passed the portals of a chamber crammed with bacteria and their products, they are wholesome and pure no longer. Further, it may be pointed out that while food passes on to the alimentary canal leaving only remnants to form a veritable feast for the micro-organisms of the mouth, the air is returned and may prove a source of danger to others. That this statement is not entirely fanciful is abundantly proved by the evidence we have in cases of such diseases as whooping cough, measles, scarlatina and diphtheria, where the infection is carried by the breath; and isolated cases of infectious diseases which occasionally arise in

the medical and surgical wards of a Children's Hospital are of sufficient importance to direct attention to the mouths of patients as a source whence the air may be vitiated.

It seems reasonable therefore, to conclude that while the conditions of the oral cavity in sick children are left untouched or are ignored, no small part of that general hygiene so necessary for restoration to health remains unfulfilled.

Summarizing what has already been stated with regard to the examination of the sick children, we may say there is no distinct proof of a connection between dental and other diseases as cause and effect; but there is strong reason to suspect, and even to believe that many of the diseases of the nervous system, diseases of the respiratory organs, diseases of the alimentary canal may be due, in some cases directly, in others indirectly, to the fact that the masticatory organs have been neglected.

Carious teeth besides causing nervous irritation may prove the starting point of putrefaction and its allied processes, and, acting as an infective focus, materially influence diseases of the respiratory organs and of the alimentary

canal. Or, apart from loss of function, they may produce general *malaise*, followed by malnutrition, thus paving the way for diseases which often seem to lie in wait until a favourable opportunity is afforded of exercising a malign influence on their youthful victims.

Special treatment will be found elsewhere. It is only necessary here to point out general remedial measures to be adopted in sickness, as we have already indicated preventive measures in health.

A careful examination should be made of the mouth in every case of illness. This should be a matter of routine, and where clinical reports are made, as in Hospital practice, a note should be entered as to the condition of the teeth and gums, with the same regularity as the condition of the tongue is mentioned. It is often found that a clean tongue is present where there is a mouthful of carious teeth, so often, in fact, as to lead one to suppose that the condition of the digestive organs may be far more surely indicated by an examination of the latter than of the former.

A cursory glance at the teeth in front of the mouth alone, should not be relied upon.

In the records of the children above mentioned, by far the larger proportion of defective teeth were found in the molar region. However good the incisor teeth may be, it is in this region that search should be made. The mouth should be carefully cleansed morning and evening, with some antiseptic solution. Where a child is too ill, and therefore feeble, this cleansing must be carried out by the nurse. In such cases a mackintosh sheet may be placed round the child's neck, the head turned to one side, so that no fluid may be swallowed. Small pieces of lint rolled up are very useful; one of these should be securely fastened in the claws of a clean sponge holder and dipped into the solution. The nurse having previously washed her hands, should with the forefinger and the thumb of the left hand, gently part the lips and with the right introduce the pledget of lint and wipe over the surfaces of the teeth, thus removing all vitiated secretions or *débris* of food.

Another method which may be adopted in such cases, is the use of a clean glass or india-rubber syringe with a fine nozzle. Having filled this with a solution, the mouth can be

thoroughly washed out. The syringing is especially needed where the mucous membrane of the lips and mouth is ulcerated. Where the mouth is easily opened a stream may be directed against the back of the pharynx. If the mouth be closed the stream may be directed against the necks of the teeth in front and at each side.

Whenever a child is sufficiently well it should be taught to brush the teeth after every meal.

For all ordinary purposes a quarter per cent. solution, or one grain to the ounce of permanganate of potash will answer, and the water should be warm.

Chloride of sodium (ordinary table salt) 4 to 8 grains to the ounce of water is an excellent mouth-wash.

Boracic Acid, Chlorinated lime water, Aqua menth. pip. and Chlorate of Potash are useful.

Or the following formulæ may be used :—

- | | | | |
|-----------------------|-----|-----|----------|
| 1. R.—Carbolic Acid | ... | ... | 1 ounce. |
| Glycerine | ... | ... | 1½ „ |
| Methylated Chloroform | ... | ... | ½ „ |
- 5 to 10 drops in a wineglass full of water.

DR. MILLER'S ANTISEPTIC MOUTH WASH.

2.	R.—Thymol	0.25
	Benzoic Acid	3.00
	Tincture of Eucalyptus	15.00
	Alcohol	100.00
	Oil of Peppermint	0.50

A tablespoonful to a tumbler of water.

SALICYLIC ACID MOUTH WASH.

3.	R.—Acid Salicylic	100 grains.
	Ess. Menth. pip....	1½ drachms.
	Tinct. Lavand. Co.	4 „
	Sacch. Ust.	15 minims.
	Sp. Vini rect.	6½ ounces.
	Aquæ ad.	10 „

A teaspoonful to a tumbler of water.

In conclusion it may be pointed out, that all who are in attendance on sick children, should be scrupulously careful as to the condition of their own mouths, both for themselves and their patients.

The atmosphere of a sick room or a Hospital is not conducive to sound teeth. The writer has elsewhere* pointed out the possibility of direct infection being conveyed from the mouth; and an examination of a very large number of nurses forces the conviction that the hygiene of the mouth requires more consideration in nursing institutions than it at present receives.

* *Puerperal Fever, Lancet*, December 21st, 1889.

CHAPTER VIII.

TREATMENT.

THE question of preventive treatment of dental caries has been fully discussed in the chapter on "Hygiene of the Mouth"; we now propose to offer some practical suggestions as to the remedial measures which may be adopted by the medical practitioner in the various phases of tooth disease which may come under his notice in cases of urgency. In order to make this information as useful as possible we shall endeavour to describe :

1. EXAMINATION OF THE PATIENT.
2. THE INSTRUMENTS REQUIRED.
3. TREATMENT OF TOOTHACHE IN TEMPORARY TEETH.
" " " " PERMANENT "
4. STOPPING, OR FILLING, OF
 - (a) TEMPORARY TEETH.
 - (b) PERMANENT TEETH.

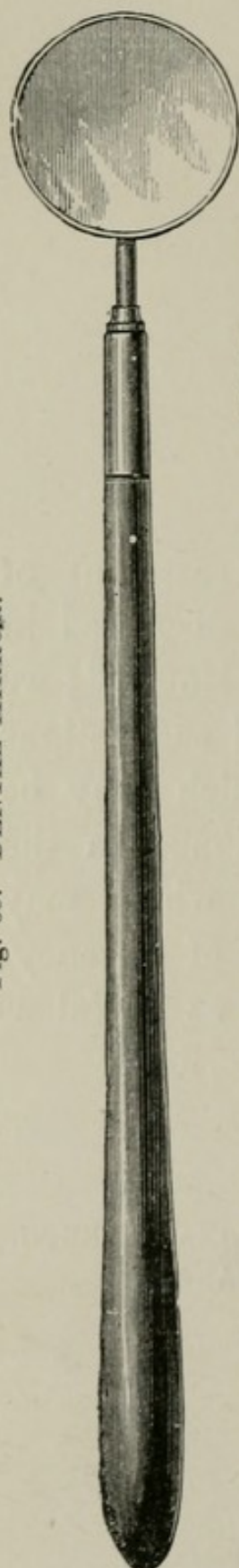


Fig. 65. DENTAL MIRROR.




5. EXTRACTION OF THE TEMPORARY AND PERMANENT TEETH.
6. INJURIES OF THE TEETH.
7. TARTAR AND ITS REMOVAL.

A good light is essential for examining the mouth, daylight by preference, and the patient should be placed in front of a window with a N. aspect; this avoids the possibility of direct sunlight, awkward both for patient and operator.

If the child is very young it may be placed on the nurse's right knee, her right arm round its waist; the left hand if necessary, should hold the patient's hands. If the child be old enough, it should be placed in a high-seated chair. The practitioner should stand on the right side and rather behind the patient, so that his left arm may encircle

Fig. 66.—DENTAL PROBE.



the head when necessary. In examining the upper jaw the head should be slightly tilted backward. In examining the lower jaw the head should be forward, the chin depressed. Two instruments are essential for a proper examination of the mouth. The first and most important is a dental mirror (a small laryngeal mirror will do if the former is not at hand), warmed in the usual way to prevent condensation. It is well to accustom oneself to the use of this instrument. It reflects the light on to the teeth, enables the operator to examine the upper teeth, by reflection, without the necessity of bending his neck to examine the upper jaw, or the patient's head far enough back to inconvenience or frighten him, and, as it is slightly concave, magnifies the reflected image. The introduction of a mirror into a child's mouth is sufficient to cause a reasonable amount of fear, and, on this ground alone, the child may be shown the "looking-glass" as a means of assurance. The mirror may be dispensed with in examining the mouths of infants; but where there are teeth to

examine in a child say from 3 years upwards it is indispensable, for in addition to its other advantages it enables the discovery of decay in teeth to be made, where no cavity is observable, showing up opaque spots on the surface of the enamel, which is semi-translucent in sound teeth. Especially is this the case where teeth are crowded together and caries has commenced between them.

The dental probe, the other necessary instrument, is made of steel with fine and curved points, and while the mirror is held between the thumb and forefinger of the left hand the probe should be held in the right. This latter enables the operator to find out small cavities of decay and with very slight pressure will show whether a tooth is loose or not. It should never be used to test a possible exposure of pulp.

Odontalgia, or Toothache, in Temporary Teeth.

Probably the first intimation the Practitioner will have that a child's teeth need attention is the application for relief from pain. Of course the easiest way out of the difficulty is to extract the tooth. Before proceeding to such a drastic remedy, it is advisable to ask a few questions. How old is the child? The character of the

pain? Its severity? Does it keep the child awake at night? Much may be learnt before an examination is made. If the patient is *under* 6 years, we have to deal with a temporary tooth. Probably the tooth is a temporary molar. In 9 cases out of 10 this is the case. If the pain comes on after meals, and goes off in an hour's time it is most likely a case of simple caries with exposure of dentine.

If the pain is paroxysmal, and more or less severe, we have to deal with a carious tooth in which the nerve-pulp is *exposed*. If the pain in addition to being paroxysmal, keeps the patient awake at night the nerve is not only exposed, but acutely inflamed (*vide* Pulpitis). Should the pain be dull and throbbing and persistent, and accompanied by some swelling of the alveolus, then it is a case of inflammation of the periosteum of the tooth, and alveolus. The pulp previously exposed has passed through the stages of inflammation, gangrene and putrefaction. Septic material (*vide* Periodontitis) has forced its way through the apex of the fangs.

On examination, the carious cavity either in the crown of a tooth or between two teeth (interstitial) will be found filled with *débris*; this

should be carefully removed either with a probe or better still by a stream of warm water from a fine-pointed syringe with a removable nozzle and with a ball of 2 oz. capacity.

Cases of simple caries differ in this respect. One tooth may be faulty or many. On examining the teeth of a child complaining of toothache after meals, it is often found that superficial

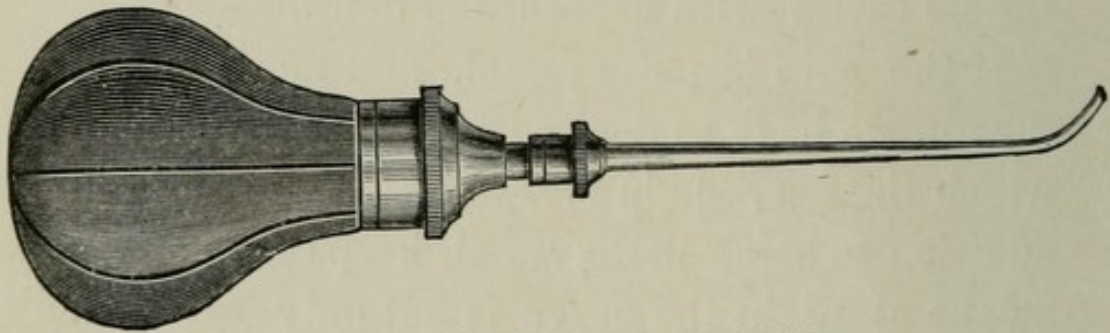


Fig. 67. DENTAL SYRINGE.

caries has attacked many teeth. There are no actual cavities: but the teeth seem to be denuded of their enamel. Sometimes it is confined to the front teeth, perhaps all are involved. In children of weakly constitution, or of weakly parentage, this is likely to occur. Also in tolerably healthy children who are allowed to have biscuits or a piece of bread to keep them quiet in bed of a night. Such children often complain of headache and dread to eat because of pain.

The following case is instructive in showing what may be done by general treatment.

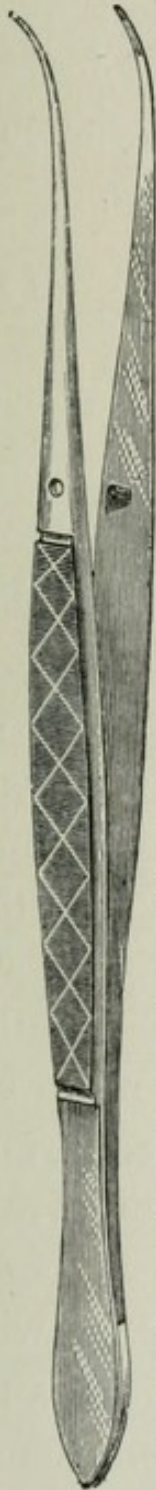
Charles G., aged 5 years 6 months. Complains of pain in his teeth at night time, cannot eat well. No localised pain. Child anæmic, dainty. Discharge from left ear since a baby. Superficial caries affecting 12 teeth.

Treatment. R.—Mist. Ferri Perchlor (Evelina), 1 drachm ter die. Patient seen once a week for a month. Does not complain of toothache, nor has he done so since he has had the medicine.

In a case of simple caries, whether it be of one tooth or many, and where there is no great depth of decay, much relief will be given by painting the carious surfaces over with lunar caustic, or liniment of iodine.

After all *débris* of food has been washed away, a small pledget of absorbent cotton, or blotting paper held in a pair of tweezers, should be rubbed lightly over the surface to remove superfluous moisture. The simplest and safest way of applying the lunar caustic is to wind a wisp of cotton wool round the uninflamm-

Fig. 68.—DENTAL TWEEZERS.



able end of a match, slightly moisten it with water, rub it on the caustic, and then over the surface of the tooth. Liniment of iodine may be used with the same simple instrument or painted on with a camel's hairbrush.

Tommy F., 5 years 6 months, brought by a sister, who says he "keeps mother up of a night." Teeth seldom hurt him after eating. On examination there are two lower molars, one on each side of the mouth, with saucer-like cavities of decay. No exposure of the pulp in either tooth.

Treatment.—Surfaces painted with liniment of iodine. The child was seen a week later, and has had no further trouble.

The application of lunar caustic is valuable, not only for removing that sensitive condition so often found where the enamel is defective, but in arresting caries where it is superficial. The use of this drug has only one disadvantage — viz., that of discolouring the tooth. This, however, is a matter of no concern where teeth are at the back of the mouth. For front teeth liniment of iodine may be used. It is just as useful so far as rendering the dentine insensitive, but does not arrest decay.

If caries has reached the pulp the pain will be variable. It may come on after meals and last for an hour or two. It may be continuous

or come on in paroxysms and be agonizing. If there is no swelling of the alveolus, and the tooth seems to be fairly firm in the socket (this may be easily tested by slight pressure on a sound portion of the crown with the probe, or by gently grasping the crown of the tooth between the thumb and forefinger) it is tolerably certain that our diagnosis is confirmed. The first efforts should be directed to stopping the pain. For this purpose no better preparation can be used than "carbolyzed resin." This is a preparation that the practitioner should always have at hand.

In most cases where pulpitis or acute inflammation of the pulp exists—and they form a very large proportion of those who seek relief from the toothache—the effect of its application is instantaneous relief. It consists of Resin (in coarse powder) one ounce, Carbolic Acid one ounce, Chloroform half an ounce. If cloudy, filter through cotton wool.

Superfluous moisture should be removed from the carious cavity—as in the application of lunar caustic—great care being taken not to press heavily on the exposed pulp. A wisp of absorbent cotton wool should be rolled up

between the finger and thumb about the size of the cavity, taken up by the tweezers, dipped into the "carbolyzed resin," and then inserted gently into the tooth.

Should the pain be caused by periodontitis, the carious tooth will be raised above its fellows, so that the child cannot close the jaws without the greatest discomfort. The alveolus will be more or less expanded, and the tooth loose in its socket.

These cases usually terminate with an alveolar abscess—"gum-boil"—and vary in severity. In 19 cases out of 20, swellings about the mouth or cheeks of children are due to periodontitis followed by an abscess in the alveolar plate, and a glance at the patient is often quite sufficient to realise the cause. Instead of a carious tooth it may be only the remains broken down, one or two roots level with the gum. It is often at first sight difficult to say which is the offender, especially if on the same side as the swelling most of the teeth are carious. Gentle pressure on the crown or root of each tooth with the blunt end of the probe will be quite sufficient, as a rule, to cause immediate pain.

Lillie Whitfield, aged 5 years, has complained of toothache for the past 3 weeks. Came on at meals, lasted for an hour two and kept her awake at night. On Saturday last complained of pain all day. At night the face began to swell, and she has had no pain since. Inflammatory swelling on left cheek extending to eyelids, which are nearly closed, on the same side. On examining the teeth of the upper jaw the temporary molars on the same side as the swelling are found to be carious. The cavity of decay is between the two teeth. The crown of the second molar is darker in colour than the first, looser in its socket, and more painful when pressed upon. This tooth was extracted, the periodontal membrane was thickened and flocculent. The pulp of the tooth was putrid.

There is only one form of treatment necessary in such cases; and that is immediate extraction. The tooth, or root, acts as a foreign body. By its removal the pus will have free exit, and in most cases the swelling will quickly subside. As the patient will be suffering from general *malaise* with a furred tongue, it is generally advisable to give a mild aperient followed by a tonic. If the child is old enough to spit out a mouth-wash instead of swallowing it, warm water and salt (10 grains to the ounce) or a weak solution of Pot. Permang. should be used freely.

There seems to be an impression among the public and among some members of the medical profession (if the repeated assertion "The doctor said so," is to be believed) that a carious tooth or root should not be extracted "until

the swelling is gone down." We have often tried to find a reason for this idea, but have never yet succeeded. If an attempt is made to find an exit for pus, this may be made as in dealing with some permanent teeth, by running a small bistoury into the gum and through the expanded alveolar plate just over the apex of the fang. This, however, is usually quite unnecessary with temporary teeth or roots. In most cases the pus will find an exit for itself through alveolus and gum. Then the necessity for immediate extraction is no longer present, although the suffering entailed by the patient is often very great. As previously stated the retention of a temporary tooth or root (which is the cause of an abscess) often leads to the destruction of the forming crown of its permanent successor, and may lead to general poisoning. To wait until the swelling disappears before extracting a tooth, seems somewhat equivalent to having a thorn in the hand, and keeping it there until the discomfort it occasions has passed away. In other words retaining the cause until the effect has ceased.

Toothache in Permanent Teeth. If a child is more than 6 years of age probably the pain is

caused by a first permanent molar, and these should be sought for. Much has been said about recognising these teeth and their great liability to decay. Here we may mention that so far as toothache is concerned, six years may be taken for all practical purposes as the dividing line between the temporary and permanent teeth. Out of 9 children over 6 years who seek relief from toothache at the Evelina Hospital, 7 will be suffering from a carious first permanent (or 6-year old) molar.

Of course it must be remembered that trouble may arise from a temporary tooth; but all the temporary teeth should be lost before 12 years, therefore the necessity for saving them is not so great after 6 years as before that age is reached.

On examination, the *size* of the crown, and the presence of the two temporary molars in front of it, (or their successors the bicuspid) will be the best guide to recognition. Should both be absent, a space between the tooth and the canine may be noted.

The removal of *débris* with warm water from a syringe will help the practitioner to realise whether he has to deal with decay which *appears*

to be only superficial, or with a cavity of more or less extent.

We say *appears*; such appearances, however, are very deceptive. It may be stated generally, that if caries is superficial on the crown of a tooth it extends over a large surface. This is especially true of the first permanent molars, because they are particularly liable to be erupted with defective enamel, showing that when in the soft condition these teeth have undergone a change in their nutrition which results in arrested calcification. In many teeth of this class the whole of the masticating surface will be discoloured, the dentine seems to have become carious and then hardened ("arrested decay"). Neuralgic pains are apt to arise in consequence of such bare surfaces of dentine. Salt or sugar, hot or cold water, readily convey transient impressions to the pulp which may be kept in a chronic state of irritation. The application of caustic to these teeth will often relieve pain.

There may be a very small centre of decay in the crown of a well-formed tooth, only sufficient to admit the point of a probe or excavator; and *such* an appearance is often

deceptive, for as the dentine is much softer than the enamel, when once admission has been gained (*vide* Caries) to this softer tissue, extensive decay may have gone on. As, however, our present purpose is *to relieve pain* whether the cavity be large or small, the insertion of some carbolised resin, on cotton wool, will at once relieve the patient whether it be due to chronic irritation or acute inflammation of the pulp, with or without exposure.

The fact of a permanent tooth being slightly loose, showing an extension of the inflammation to the periodontal membrane, does not militate against the use of this drug and the relief it gives. It is quite possible that the pulp of the tooth may (through long exposure) have become gangrenous, and the pain be due to the pent-up products of putrefaction, then no relief will follow the application of any drug. Here we have a distinction and a difference between temporary and permanent teeth. Inflammation of the pulp in temporary teeth is rapidly followed by death and putrefaction, owing to the small size of the roots; septic periodontitis sooner or later follows with expansion and perforation of the thin alveolar wall,

and all the accompanying signs of alveolar abscess.

Inflammation of the pulp in a permanent tooth is, as a rule, followed more slowly by necrosis and putrefaction; the fangs are longer, therefore more deeply situated and the alveolus or cancellous bone which grows up around the neck of the tooth is each year denser, until maturity is reached. For these reasons the remains of the necrotic pulp are not so readily pushed through the apex of the fangs; expansion of the alveolus does not so readily occur. How (it may be asked) is it possible to distinguish for the purposes of relieving pain, between a tooth with an inflamed pulp and a necrotic pulp, if the tooth in each case will be loose? The past history of the case, and the character of the pain may help us. What has been previously stated with regard to temporary teeth will equally apply to permanent. Acute pain, paroxysmal in character, darting into the ear on the same side, if it be a lower tooth, or up over the side of the head if it be an upper tooth, and often wandering from the source of trouble, is mostly due to inflammation of the pulp. A dull heavy throbbing confined to the neighbour-

hood of the tooth itself, with a past history of great pain in the tooth which gradually subsided (showing a previous inflammation of the pulp and subsequent death) is very significant of pent-up pus, or gases, in the pulp chamber. An examination, however, is the final test. *If the pulp is dead* the crown of the tooth will have lost its translucent appearance, and have become darkened in colour. On carefully scraping away the carious dentine, no pain will be caused by approaching the pulp chamber, though moving the tooth bodily will produce it. On the other hand *if the pulp be alive* scraping of the dentine in the neighbourhood of the pulp is acutely painful. Should the Practitioner decide that the pain arises from a pent up discharge or gases of putrefaction, in what the Dentist calls a "dead tooth," a careful attempt should be made to remove the carious dentine until the pulp chamber is reached, and these are liberated. If this can be done, relief will rapidly follow, and a small pledget of absorbent cotton can be placed loosely in the cavity sufficient to take up any discharge and prevent food from blocking it up.

Should, however, the symptoms be more pro-

nounced, the alveolar plate expanded, the patient's face swollen and tense, and the tooth quite loose in its socket, in fact, with all the signs of an acute alveolar abscess, it is better to extract the tooth at once. This may be stated as a general rule, though it is an absolute necessity where pus threatens to perforate the tissues of the cheek or make its way out beneath the lower jaw. Just as with temporary teeth, the necrotic fangs of a permanent tooth may, and often do, cause an alveolar abscess and in every case such roots should be extracted. The lack of an elementary knowledge of what a carious tooth or root is capable of doing, may lead the Practitioner to treat the patient for necrosis of the jaw, when pus has found its way out on to the face. Whereas on the timely removal of a carious tooth, or root, the sinus would cease to exist.

So far we have been considering the first permanent molar, taking it as a type of the permanent set, because of its greater frequency of decay. All we have said as to relieving pain, may be said to apply to all the permanent teeth with an exception to the general rule spoken of above, viz., extraction for an alveolar

abscess. Many cases occur where the tissues of the face are not threatened with perforation by pus, yet there may be a general swelling of the cheek. Though it might be quite justifiable to extract a six-year-old molar, where there is no chance of obtaining assistance from a dentist, it would not be so if the tooth be one in front of the mouth, say a central incisor or canine. On gently raising the upper lip fluctuation may or may not be found over the apex of the loose tooth. An attempt should be made to give vent to the pus by passing a small abscess knife (bistoury) through the gum and expanded alveolus to give immediate relief. Such teeth may be saved for years if the case handed over to a Dental Surgeon for further treatment. Should the crown of the tooth be gone and the fang alone left, this may be extracted.

It is quite possible to find that with all the signs of an alveolar abscess the teeth may be free from caries. Examination with reflected light—by the aid of the mirror—will often enable the Practitioner to notice a change in colour of one tooth near the swelling, this, in addition to the fact that the tooth is exquisitely painful when pressed upon, will help to decide the source of trouble.

STOPPING OR FILLING TEETH.

A long mechanical training, no small amount of manipulative skill, and a wide experience, are the chief essentials required of the Dental Surgeon in order that he may perform, with efficiency and ease, the varied operations of filling teeth. Although to an observer it may very well appear that the methods are extremely complicated, and that the instruments required are innumerable, it is nevertheless desirable that the Medical Practitioner should make himself acquainted with the principles and some of the methods adopted, so that when occasion requires he may be enabled to carry out in practice such operations in their simplest form, when skilled assistance is not to be obtained, or as a temporary means of saving teeth until the patient can be handed over to the dentist.

The objects sought to be attained in filling teeth are briefly as follows:—To remove carious enamel and dentine. To replace the lost tissue with a stopping, which shall exclude moisture, prevent further decay, and cause no after-pain.

In order to obtain the best results it is needful to keep in mind two or three important facts. The earlier a tooth is treated, when caries has once attacked it, the better for both patient and operator, for the patient will suffer less pain, and the operator will have less difficulty in stopping the tooth.

Were it possible to fill teeth without regard to the *nerve pulps* which they contain, most of the difficulties and complications which beset one's path in the performance of such duties, would at once be swept away. Unfortunately this cannot be; when once caries has passed into the dentine it approaches the pulp. It may be slowly, but surely, with pain or without.

When once the pulp chamber is reached and the contents are exposed to bacteria and fluids of the mouth, the best time for filling that tooth, and the best opportunity of saving it, so that it may become useful once more, have passed away. A carious tooth may be likened to a simple fracture of a limb; when the pulp is exposed, the simple fracture becomes compound, and not only is treatment far more complicated, but the chances of saving it are very

much lessened. Moreover, complications are apt to arise which otherwise would not be thought of, or at any rate need not be taken into account.

Parents are extremely ignorant or careless of such matters and require constant reminders. They bring their children to have teeth stopped. "Did you know that this child's teeth were decaying?" you may ask. "Oh, yes! but the child had no pain, and I thought it did not matter," is the constant reply.

Then one finds that the stopping resolves itself into relieving pain. For if a filling is introduced into an aching tooth, it simply means adding to the pain and the tooth will have to be removed.

In addition to the instruments already mentioned, it will be necessary for the Practitioner to be provided with several chisels, as illustrated below. These are used for cutting away overhanging edges of enamel, which if left will break down after the tooth is filled; at the same time they form obstructions which conceal decay beneath.

A dozen excavators of various shapes are required; those illustrated will be found the most

useful. These instruments are made of the finest steel, hardened and carefully tempered at their cutting edges. The "excavators" as their name implies, are used for scooping out, or preferably cutting away the soft and carious dentine.

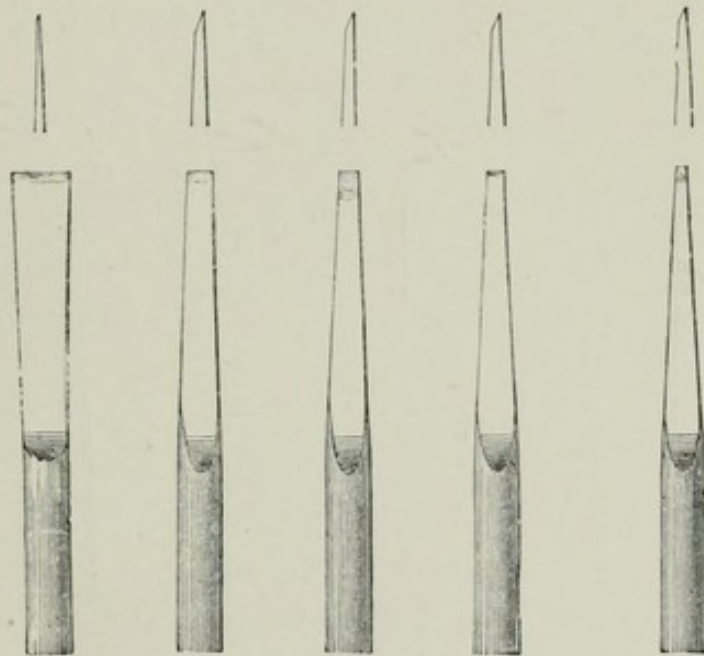


Fig. 69. CHISELS.

Stopping Temporary Teeth.

Wherever possible, temporary teeth should be saved by filling, in order that they may be preserved until their successors are due. This is especially true of the molar teeth which are required for approximately 7 years,

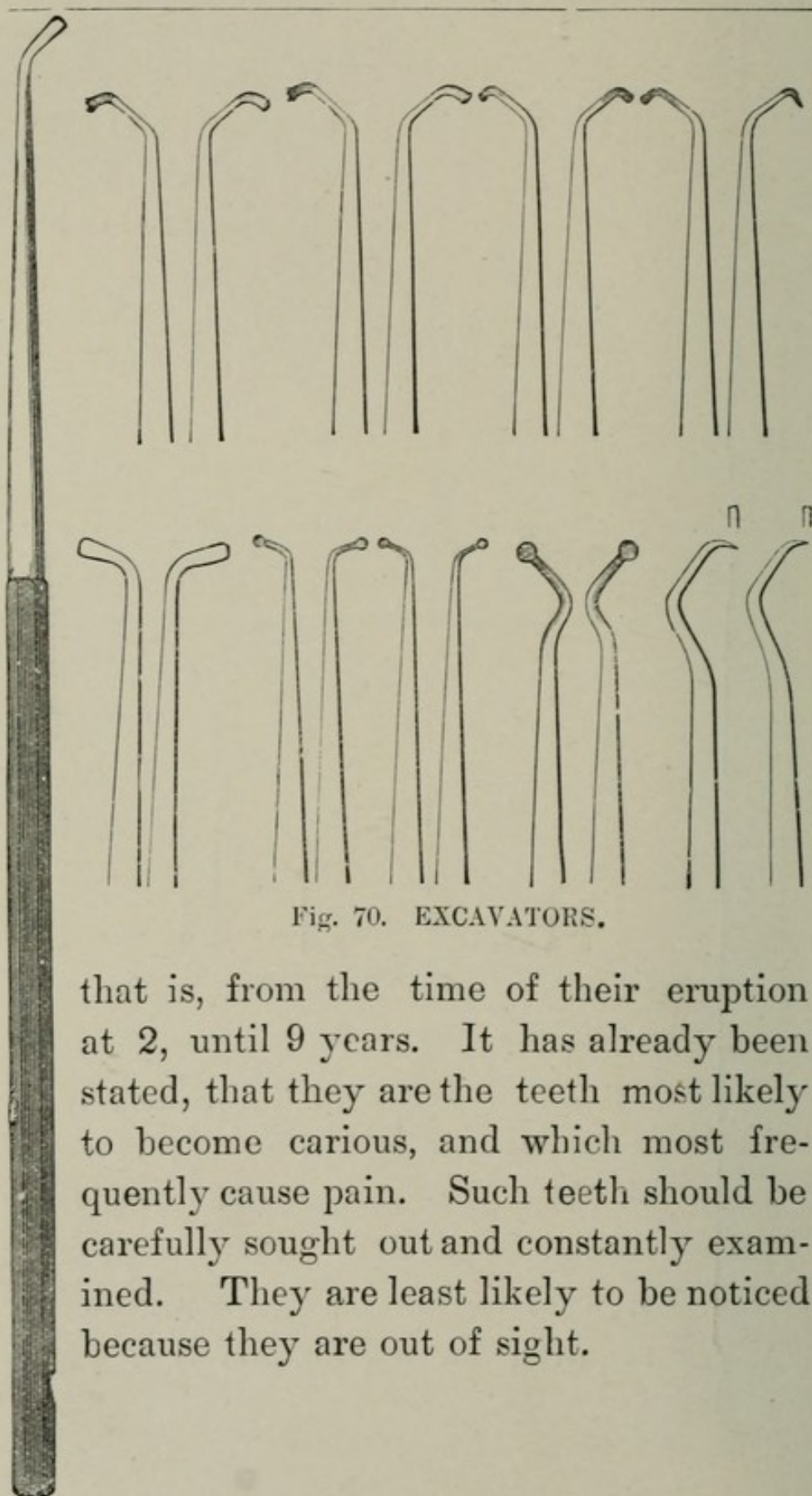


Fig. 70. EXCAVATORS.

that is, from the time of their eruption at 2, until 9 years. It has already been stated, that they are the teeth most likely to become carious, and which most frequently cause pain. Such teeth should be carefully sought out and constantly examined. They are least likely to be noticed because they are out of sight.

Caries in a temporary molar is either found in the centre of the crown or between two teeth (interstitial). Fig. 71, is a diagrammatic representation of a lower tooth with caries commencing in the centre of the crown. It

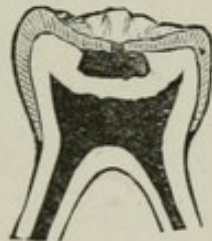


Fig. 71. Section of a temporary molar showing caries on the masticating surface.

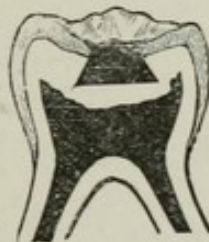

Fig. 72. Section of temporary molar showing cavity shaped for filling,

will be seen that the amount of enamel attacked is small compared with that of the dentine beneath. In order to expose the carious dentine, the frail edges of the enamel should be carefully cut away with a chisel round the margins of the cavity. If this margin be left, it constitutes a source of danger after the tooth

is filled. Great care must be exercised to avoid the possible slipping of the instrument into the cavity. This can best be accomplished while operating on teeth of the lower jaw, by holding the chisel somewhat in the same manner as a pen is held, with the second finger near the cutting edge, its tip resting on the margin of the crown of the same, or the next, tooth. For teeth of the upper jaw the chisel may be grasped in the palm of the hand by the four fingers, with the cutting edge upwards guarded by the thumb, much in the position of a pen-knife when sharpening a pencil.

Fig. 72 is intended to show an ideal cavity with enamel margins cut away. When this is done, the *débris* should be washed away with warm water from the syringe. Before proceeding to remove the carious dentine it is well to ascertain if possible whether caries has reached the pulp. Enquiry should be made as to whether the patient has suffered pain? If so, whether the pain has been acute or not, or has been felt in the night. If not, we have presumptive evidence that the pulp has not been reached. This however, is insufficient, as abundant proof is forthcoming that caries may reach a

pulp and that it may be destroyed without a sign of pain. In order to test the matter further, a wisp of cotton wool should be rolled up, between the thumb and finger, of sufficient size to fill the cavity, and then conveyed with a pair of tweezers, to the tooth. This pledget of wool should then be *gently* pressed into the cavity. The process should be repeated as the child is apt to flinch with fear. If pain is entirely absent, further evidence is given of the caries not having reached the pulp.

The really painful part of tooth-stopping commences with the removal of carious dentine. In order to reduce this to a minimum the application of lunar caustic as previously recommended (*vide* Toothache) is advisable. This not only renders the carious dentine insensitive but acts as a powerful antiseptic. The latter quality is of great importance in the stopping of temporary teeth, as the removal of caries by excavators should be almost entirely confined to the edges of the cavity. Owing to the large size of the pulp chamber, there is great danger of an exposure if much of the carious dentine is removed from the floor. There will be no bad results by leaving it there,

and (unless the dentine is so thoroughly disintegrated as to be soft—powdery if dry, pasty if wet), the caustic will coagulate the albumen and turn it into a leathery mass. It is round the margins of the cavity that caries is likely to recur, and care should be taken to remove this so that the cavity is shaped as near like Fig. 72 as possible, the floor of the cavity slightly larger than the exit, in order to retain a stopping.

It frequently happens that caries is found between two teeth, the front (or mesial surface) of one tooth, and the back (or distal surface) of another.

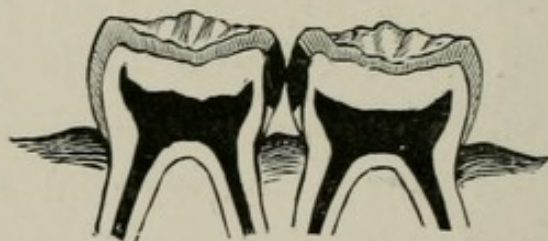

Fig. 73.—SECTIONS OF TEMPORARY MOLARS.
Showing interstitial cavities.

In temporary teeth, and in temporary teeth alone, it is quite justifiable to treat such cases as one cavity. The same precautions should be taken to cut away frail edges of enamel, to ascertain whether the pulps are exposed, and in

the removal of carious dentine. The proximity of the pulp should be kept in mind. The base of the cavity may be the gum and it is at the sides where pulp exposure is likely to occur, the pulps of two teeth being exposed instead of one. In the cavities, both of crown centre and between two teeth, the filling may be of amalgam or gutta percha. These fillings will be described fully when speaking of permanent teeth.

If on enquiry one is told that the child has had acute or persistent pain, and on examination it is found that a pledget of cotton when pressed into the cavity gives rise to immediate pain in the tooth, it is tolerably certain that caries has reached the pulp. Very careful removal of carious dentine will probably confirm this by the pain it occasions. The cavity should be washed with warm water from the syringe and dried with absorbent cotton.

A small roll of cotton wool or a piece of Amadou* should be soaked in carbolized resin and placed in the cavity. This may be changed every other day until all tenderness from the

* Soft Amadou or German Tinder—a fungoid growth—is supplied in sheets or pellets by the Dental depots.

pulp has passed away. The carbolic acid and chloroform will in time destroy what vitality remains in the exposed pulp. They are, however, soon washed away by the fluids of the mouth.

The resin will remain in the meshes of the cotton or amadou to form an efficient covering.

Dentists sometimes apply a trace of arsenic to the exposed pulp in order to destroy its vitality. So far as *temporary teeth* are concerned this is unnecessary. It often occasions

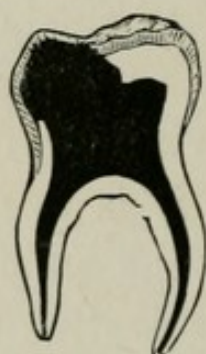


Fig. 74.—SECTION OF TEMPORARY MOLAR.

Showing caries in the crown which has extended to pulp chamber. much pain and the same results may be obtained without it. Should the tooth remain sensitive after several applications of carbolized resin, lunar caustic should be applied. The cavity should be thoroughly excavated and the *contents of the pulp chamber* should be removed.

No attempt should be made to remove the

pulp from the fangs. A wisp of cotton or pellet of amadou should be dipped into Iodoform or moistened with a drop or two of Oil of Cassia and placed in the pulp chamber, over this should be placed a disc of card, cork, or tin, and over this again a gutta percha or metal stopping.

The Iodoform or Oil of Cassia will prevent putrefaction taking place in any portions of the pulp remaining.

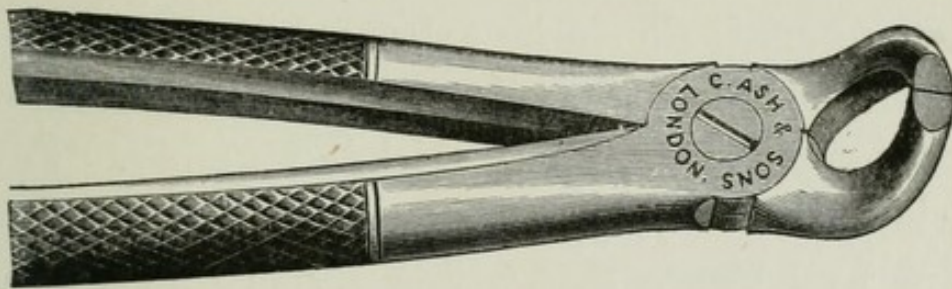


Fig. 75.—EXCISING FORCEPS.

Should caries have reached the pulp chamber the pulp being quite insensitive, and the tooth discoloured, it will be evident that the pulp is dead and probably putrid. If cotton is introduced into the cavity and has a putrid odour on removal, this amounts to a certainty. To stop such a tooth is dangerous, for the products of putrefaction will if pent up be driven through the apex of the fangs, If left alone the tooth

will form a receptacle for decomposing food. What then should be done? If the tooth is firm in its socket, it should be cut down level with the gum. This may be done with a pair of excising forceps, and without pain. One blade of the instrument should be pushed into the cavity, the other on the outside of the crown. In most cases on closing the forceps the whole crown comes away. Should it not do so, it must be removed in pieces.

If the tooth, however, be loose and painful to bite upon, it should be extracted at once.

Stopping permanent Teeth. In the stopping of permanent teeth much skill is required. For while in the stopping of temporary teeth we are well aware that within a short time they will be lost, the object of filling permanent teeth is to save them for many years. They *should* last the life-time of the owner, and although it is a fact that a carious tooth is liable again to become carious, it is nevertheless true that when care is exercised teeth filled may be useful for one or forty years.

The Practitioner who has had the opportunity of watching and treating the temporary teeth of a child should very carefully examine

the 6-year old permanent molar from time to time. Reflected light should be thrown on to each tooth with the mirror; and the fine probe should search the centre of the surface for commencing caries. A cavity may be only of sufficient size to admit the point of the probe, either in the centre of the tooth or some part of the grooves, or fissures, which separate the cusps. Wherever the probe sinks in by careful pressure, the surface of the tooth should be wiped dry with absorbent cotton, and on closer examination, it will be seen at the point of entry that the enamel is dark, or semi-opaque, on all sides of the cavity. The enamel should be cut away, as mentioned when dealing with caries of a temporary tooth only *far more thoroughly*, with chisels. It will be found convenient to commence with a narrow blade, and as the cavity becomes larger to use broader ones. So long as a reasonable amount of care be taken there need be no risk of driving the chisel into the softened dentine. Fig. 76 is intended to represent the crown of a molar with commencing caries in the centre and in the fissures. Fig. 77 shows the same tooth when enamel has been cut away so that frail edges are removed and

the carious dentine can be reached thoroughly.

After washing all *débris* from the cavity the softened dentine must be carefully taken away.

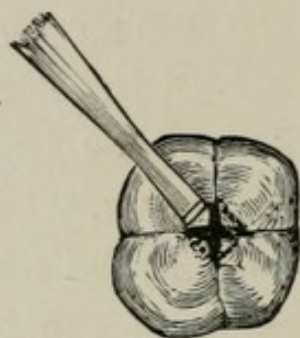


Fig. 76 —CROWN OF A MOLAR TOOTH.

Showing the method of using a chisel.

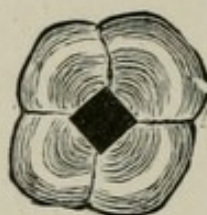


Fig. 77. CROWN OF A MOLAR TOOTH.

With the frail edges of enamel removed.

There is not so much danger of exposing the pulp as in a temporary tooth, though sufficient care is needed in removing the carious tissue from the floor of the cavity, that the pulp is not too nearly approached. It would be well for the Practitioner to cut in halves, or break in a small vice, such teeth as he is obliged to extract in order to become well acquainted with the

position of the pulp chamber. A few such *post mortem* examinations will be valuable in more ways than one. He will also learn the condition of the pulp, where acutely inflamed, gangrenous &c. A certain amount of discoloured

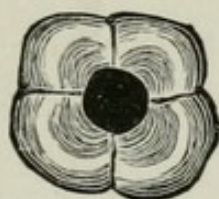

Fig. 78. CROWN OF A MOLAR TOOTH.
Showing orifice of cavity shaped with a drill.

dentine may be left on the floor of the cavity ; but great care should be exercised in removing all sign of such round the walls and especially just beneath the enamel.

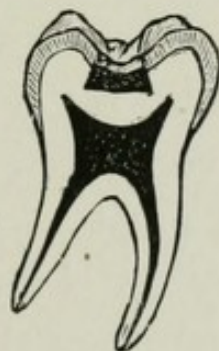


Fig. 79. SECTION OF A PERMANENT MOLAR.
Showing cavity shaped for filling.

With the excavators already illustrated all parts of the cavity can easily be reached. Smaller instruments may be used at first (as

with chisels) and larger later, as the cavity will admit of them.

Although in Figs. 72 and 79, ideal cavities have been shown, it is not to be supposed that all can be shaped in this way. Where caries is slight a saucer-like hollow is seen when all disorganised tissue is removed. It will be necessary to cut away (and this can be done with sharp instruments) sufficient of the sound dentine to make the base of the cavity broader than the orifice, or no filling can be retained. This simple fact should be remembered in the shaping of all cavities for the retention of fillings whatever the teeth may be.

For the removal of caries and the shaping of cavities the Dentist uses a dental engine. This is an upright stand, with a long arm containing a spiral spring. By means of a band round a fly wheel and connected with a treadle, this may be driven at great speed while kept under perfect control by hand and foot. Drills of 3 inches in length of every shape and size can be attached to such a machine and by a simple mechanism can be locked and unlocked in the free end of the arm.

This is a formidable instrument in the hands

of a novice and requires special training for its use. As a substitute for simple cavities, a crutch drill handle may be used, into which the different drills may be fitted. Some of the

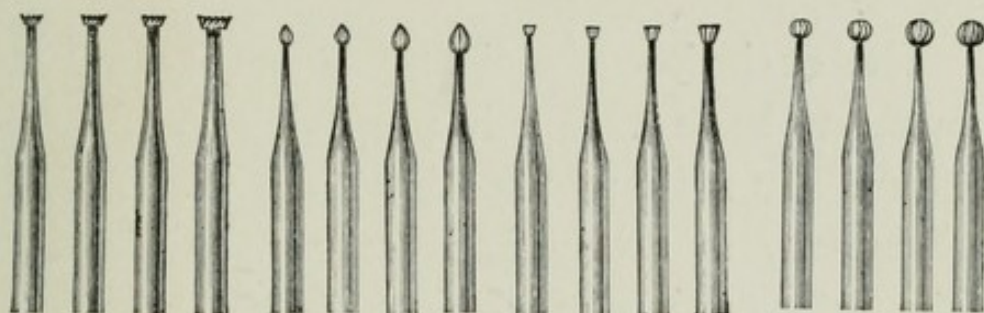


Fig. 80.—DRILLS.

most useful shapes are shown and it is advisable to have duplicates. The rotatory motion is given by the thumb and forefinger, which grasp the instrument, the crutch resting on the soft tissue between them.




Fig. 81.—CRUTCH HANDLE.

In order to lessen the pain of drilling, the cavity should be constantly moistened with carbolic acid, or chloroform, after wiping away all moisture. It is not advisable to use lunar

caustic in excavating small cavities in permanent teeth, as the staining which rapidly takes place is apt to prevent the operator from distinguishing between healthy and unhealthy tissue.

The exclusion of moisture is one of the difficulties to be overcome in preparing cavities for filling. In some mouths this is easy of accomplishment, in others it is extremely difficult. The introduction of an instrument, or even a finger, into the mouth is often sufficient to excite an increased flow of saliva; and the necessary cutting of a tooth is often sufficient to flood the tooth and the cavity. In the upper jaw the chief supply is from the Parotid gland through Steno's duct inside the cheek opposite to the second permanent molar. In the lower jaw from the sublingual and submaxillary glands.

To exclude moisture the Dentist generally uses a thin sheet of rubber, about 4 inches square; 3 small holes are punched out the size of a pin's head, for the tooth to be operated upon, and one on each side of it. The rubber is then stretched over the crowns of the teeth and tightly encircles their necks.

For all ordinary purposes a soft table napkin will answer the purpose. One corner of this should be rolled up, and placed beneath the upper lip, or tucked up between the gum and the cheek, according to whether teeth are being treated in the front or back of the mouth.

The necessary position for stopping teeth of the upper jaw (with the head well back in order to obtain light) makes the exclusion of the saliva a comparatively easy matter as it gravitates towards the back of the mouth. With the lower jaw it is difficult; the chin being depressed the saliva gravitates toward the front of the mouth. In mouths where the saliva flows freely it is well for the Practitioner to accustom himself to excavating under water, occasionally mopping the cavity to find out how far unhealthy tissue is being cut away. When the cavity is prepared for filling it is well to have all the instruments ready and the stopping prepared close at hand on a small table, so that each may be reached with the right hand, without the necessity of leaving the patient's side.

Supposing a *lower* molar tooth on the *left* side is to be filled. A pledget of cotton wool

should be rolled up and placed between the cheek and gum, in the upper jaw on the left side, to control the flow of saliva from Steno's duct. Another pledget should be introduced

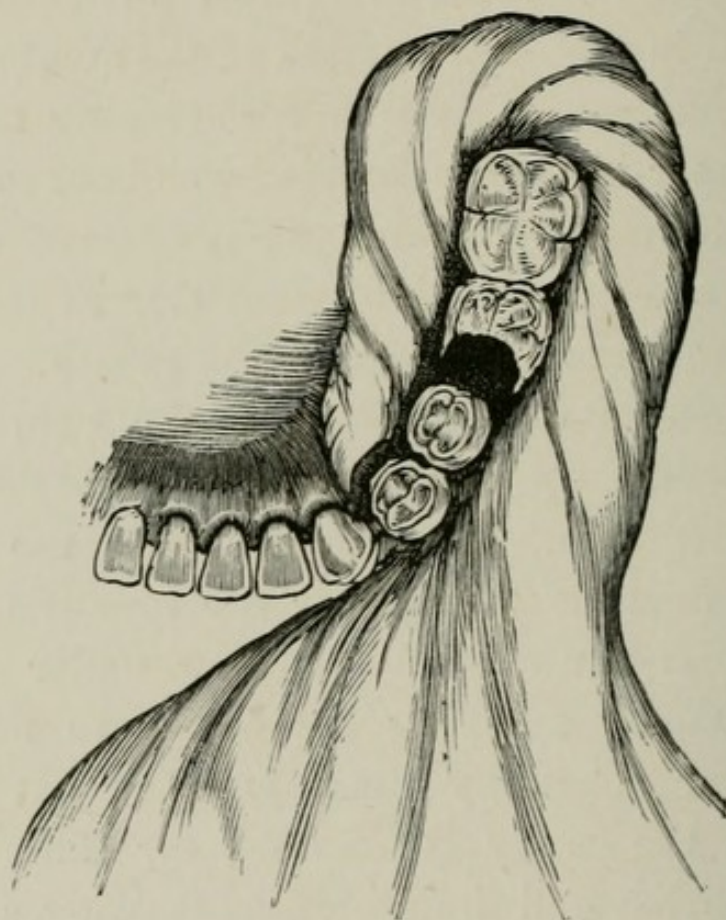


Fig. 82.

Showing Napkin in position on the lower jaw of the left side.

just under the side of the tongue on the floor of the mouth on the left side, no attempt being made to press the tongue down. A roll of the napkin should then be placed in the sulcus

between the gums and lip on the same side, with its free end long enough to be brought round the last molar tooth and forward, so as to cover the cotton wool. (Fig. 82.) This may be kept in position by the thumb and fore-fingers of the left hand of the operator (who should be standing on the R. side of the patient, the L. arm being brought round the head) or if the patient is old and intelligent enough, by two fingers of the patient, one finger on the outside, the other on the inside of the tooth or teeth to be kept dry.

The cavity being prepared for filling, it is desirable to know what stopping may with safety be put into it, and how it is to be done.

If the tooth has not previously ached, and the cavity is of moderate size with no exposure of the pulp, no stopping will answer better at the back of the mouth than an amalgam. Amalgams are mixtures of a metal, or metals, with mercury. They are used while soft and set hard within an hour. When a good amalgam is introduced under favourable conditions, it will last for many years on a masticating surface.

The simplest method of making an amalgam

is to file down a silver coin. Place the filings in the palm of the left hand, add a small quantity of mercury, and rub them together, with the forefinger of the right hand into a paste.

This should then be placed in a small piece of wash leather and squeezed until all superfluous mercury is removed.

A far better amalgam for filling young and delicate teeth is that known as *Sullivan's*. It is a mixture of pure copper and mercury. This is sold in pellets of suitable size already mixed; and differs from other amalgams in this respect, that it can be melted up over and over again without adding fresh mercury. A pellet is

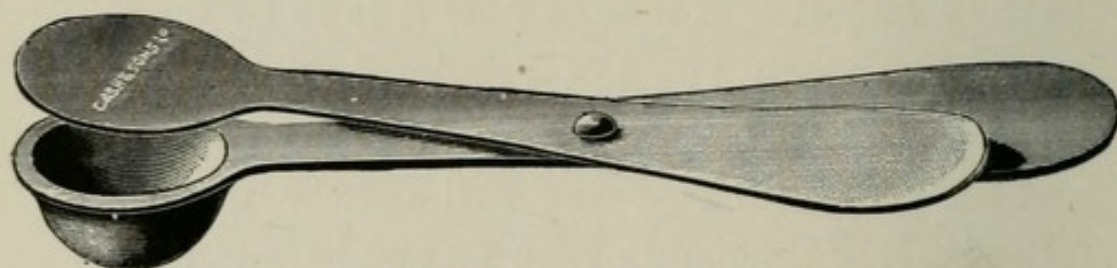


Fig. 83.—AMALGAM SPOON.

placed in an amalgam spoon (Fig. 83) and is held over the flame of a spirit lamp until beads of mercury are seen to exude from the surface. It is then dropped into a small mortar made for the purpose—Fig. 84—and with a pestle is ground up into a powder or paste.

Both coin silver and copper amalgam turn quite black in the mouth. Copper amalgam stains the tooth tissue; but it has the advantage of being the only filling as yet known which is antiseptic in its action.


In addition to changing colour amalgams have other disadvantages. They contract more or less and thermal changes are rapidly felt.

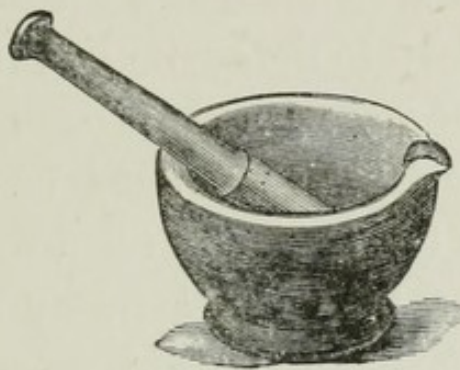

Fig. 84.—PESTLE AND MORTAR FOR AMALGAM.

Therefore, they should not be put into a cavity where there is a suspicion of nerve exposure, where the tooth has ached or where there is only a thin layer of dentine covering the pulp. The pulp may be irritated, and this will certainly be the case if a stopping is placed over it when exposed. Acute inflammation will follow; and the tooth will be more easily removed than the stopping. With care, however, this need not happen.


Fig. 85.—CUP AND BALL AMALGAM FILLER.



When the cavity is prepared and dried, the amalgam may be conveyed in small pieces to the tooth between the points of a pair of tweezers, or better still with an instrument, which is round or oval shaped at one end and has a small cup at the other. (Fig. 85.) A small piece may be taken up in the cup placed into the cavity and thoroughly pressed with the round end into all parts. This must be repeated until the cavity is filled to the surface of the enamel. Any superfluous amalgam should be wiped off with cotton wool and the surface made quite smooth with the ball-ended plugger, or spatula. (Fig. 86).

Should caries attack the posterior (distal) surface of one tooth and the anterior (mesial) surface of another, each tooth should be treated and filled separately, and a piece of tape, or ribbon, be passed between them to remove fragments

Fig. 86.—BALL AND SPATULA.



of a stopping. Teeth are always more or less movable, and the effect of joining two teeth by one amalgam plug, is that the latter will sure to be loosened in at least one of the cavities.

Instead of a small cavity in the crown which has to be enlarged, caries may have extended so far beneath the enamel as to thoroughly undermine a portion of the biting surface. This may (and often does) proceed until, on masticating, the frail wall of enamel is broken down, the patient for the first time becoming aware of the fact that a cavity exists. More caution will be necessary to prevent an exposure of the pulp. Should the dentine be extremely sensitive it will be advisable to fill the cavity with a permanent filling, which shall prevent further decay, and at the same time act as a non-conductor. A hard gutta percha filling will for this purpose be most suitable.

Gutta Percha fillings are of the greatest value for stopping children's teeth. They are easily introduced and should trouble arise can be readily removed. They expand slightly, thus preventing the access of moisture round the margins of cavities, and the renewal of decay.

The greatest failing is that of wearing rapidly on a masticating surface, though they are insoluble in the secretions of the mouth and do not change colour. In consequence G. P. may be used as freely in the front as at the back of the mouth,

It is desirable to have two kinds, *hard* and *soft*, and they may be made as follows :

Into a Wedge-wood mortar of good size 3 drachms of china clay and 4 drachms of Oxide of Zinc should be thoroughly mixed with the pestle and then turned out on a sheet of paper. The mortar and pestle should then be gradually warmed over a small gas burner or paraffin lamp, a piece of wire gauze being placed between the flame and the mortar to prevent the latter cracking. 2 drachms of pure Gutta Percha — tissue answers well — should be cut up small and put in the mortar until quite softened *without burning*. The oxide of zinc and china clay should be gradually added, and thoroughly incorporated with the G. P. into a mass. While warm, this should be cut in pieces and rolled down into sticks, between two pieces of wood or glass, and when cold, cut into pellets.

A *soft* G.P. stopping may be made in exactly the same manner of the following ingredients.

China Clay	...	3	drachms.
Oxide of Zinc	...	2	„
Gutta Percha	...	1	„
White Wax	1	„
Carmine	...	2	grains.

To introduce a gutta percha filling, the cavity should be prepared and dried as above mentioned.

The instruments required are three or four spatulas and pluggers of various sizes. The most useful are those with a plugger at one end and a spatula at the other.—Fig. 87. The plugger should be heated gently in the flame of a spirit lamp and pressed upon a small pellet of G.P. so that it adheres. The instrument with the pellet attached should be passed to and fro over the flame until it is softened, care being taken that it is not burnt. It should then be conveyed to the cavity, gentle pressure being exerted to spread it out upon the floor. Fresh pieces should then be added and pressed into all parts of the cavity until it is filled. Any superfluous material may be cut away with a warmed

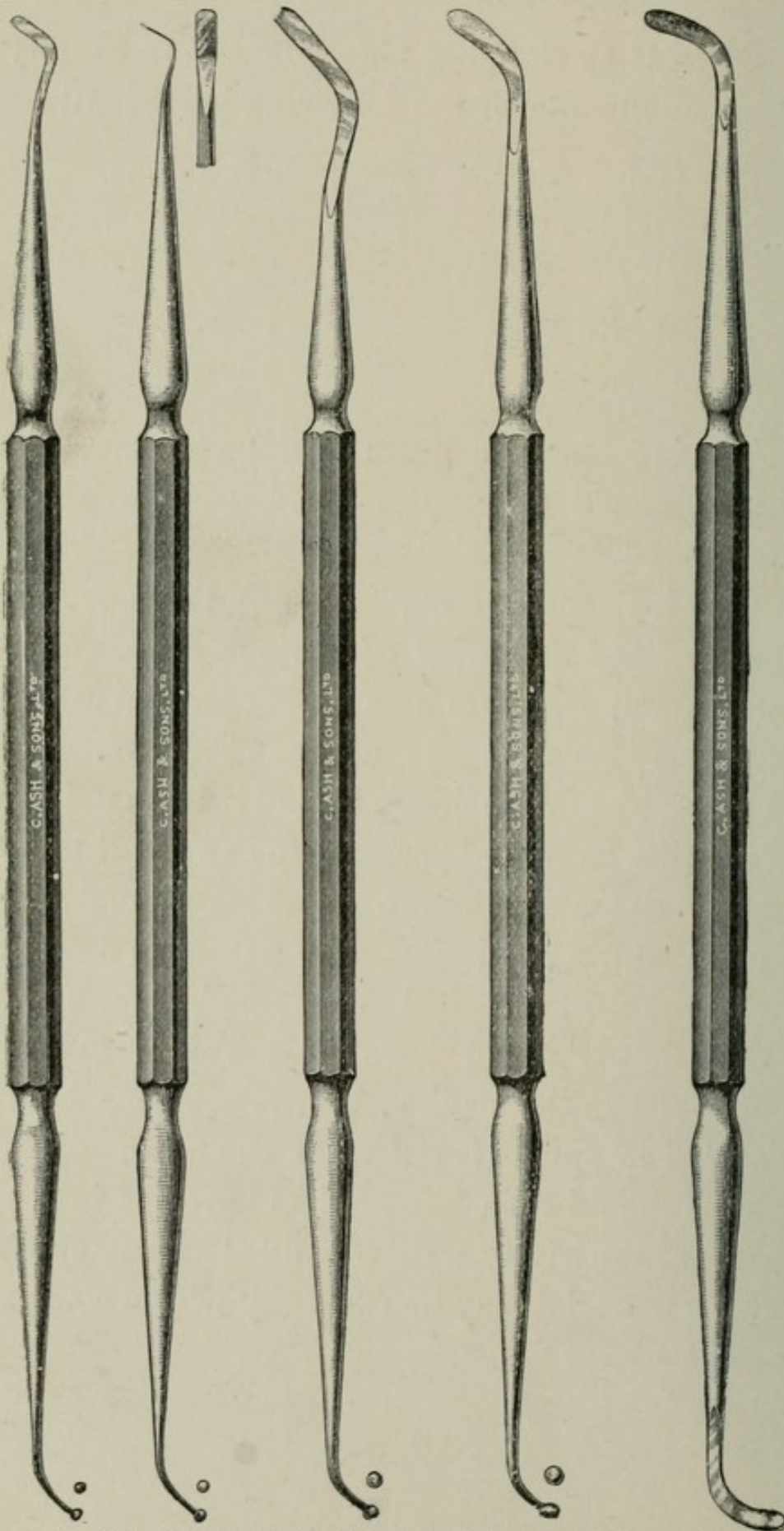


Fig 87. GUTTA PERCHA FILLING INSTRUMENTS.

spatula and the filling smoothed over with cotton wool moistened with chloroform or Eucalyptus oil. A hard filling of G. P. thus carefully introduced, will often last for years, and can when worn down be renewed or a more permanent stopping may be used.

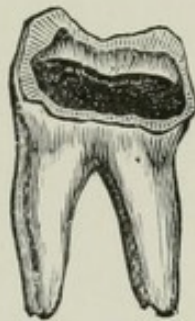

Fig 88.

In large cavities where more or less pain had been experienced (thus showing that the pulp is in an irritable condition), gentle pressure with a pledget of cotton wool—as above mentioned—will almost always be enough to show whether the pulp is exposed, as well as irritated. Should pain not follow the pressure of cotton wool, Lunar caustic should be applied, and the cavity (after drying) should be filled with a *soft G. P.* Should the introduction of this stopping give rise to pain, it may be removed and carbolised resin on cotton wool, or amadou,

should be placed in the tooth and changed each day until all tenderness has ceased, when the G. P. filling may again be tried.

It will far too frequently happen that patients will come in an agony of pain; on examining the tooth a cavity varying in size will be found and whether the pulp is actually exposed or septic matter have reached the pulp through the disorganized dentine, the pulp will be acutely inflamed. We have already stated above that

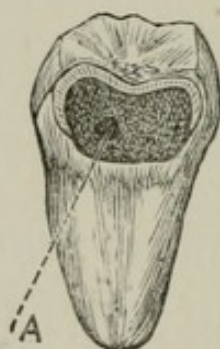


Fig 89.—FRONT VIEW OF LOWER MOLAR TOOTH.

Showing exposure of the Pulp at A.

the application of carbolized resin arrests the pain: but now the question will naturally arise, is it possible to save the tooth so that it may be useful to the patient in after life? In young children when such trouble arises (as it will in the majority of cases) in a six-year-old, or first permanent, molar, we believe it is better to

extract the tooth at once. The repeated application of carbolized resin although stopping pain, will not allow of the patient eating with comfort on that side of the mouth. Especially is it advisable to extract such teeth if the child be delicate, and under 8 or 9 years of age, while the fangs of the teeth are not yet completely formed. Should it be considered desirable to save a permanent molar, or a front tooth with a pulp exposed, it will be far better to seek skilled assistance.

The method of procedure adopted by the Dental Surgeon will be to apply a trace of arsenic on cotton wool to the exposed pulp in order to destroy its vitality. Remove the contents of the pulp chamber, and as much from the fangs as is possible, with barbed instruments called nerve extractors. Fill them with an antiseptic root-filling and then stop the tooth. In children of robust health and above 10 years of age this operation is frequently performed with success. In adults such operations are the most successful and teeth when properly filled last for some years.

If, in excavating a large cavity of a molar tooth, it is found that the pulp is gangrenous,

the tooth quite firm in its socket, and not painful, it is better to cut the crown off level with the gum as advised with regard to temporary teeth, than to attempt to fill it and run the risk of shutting up septic material, or leave the tooth to become a receptacle for the *débris* of food.

Summary of Instruments, Drugs, and Stop-pings, etc., as mentioned above :

Instruments.

Dental Mirror and Probe,
Dental syringe,
A pair of tweezers,
Chisels 4,
Excavators 12,
Excising forceps,
Crutch handle and 12 drills,
Amalgam spoon,
Pestle and mortar,
Cup and ball plugger } for amalgam fillings,
Ball and spatula }
Pluggers and spatulas for G.P. fillings.

Drugs, etc.

Lunar caustic,
Liniment of iodine
Carbolized resin,

Oil of cassia
Iodoform,
Absorbent cotton,
Amadou.

Stoppings.

Sullivan's amalgam,
Hard G. P.
Soft G. P.

THE EXTRACTION OF TEETH.

In former pages it has been pointed out where treatment by extraction is absolutely essential. There will, however, occur to the Practitioner—as so often happen to the Dentist—cases about which he may have some doubt whether the removal of one or more teeth is justifiable or not? Especially if, as has been urged, a careful examination of the mouth be made in the case of every child for whom medical advice is sought.

The condition of a child's mouth is often unknown until it is found upon a bed of sickness, and in many cases it will be impossible—

and that for obvious reasons—to do more than to see that the mouth is repeatedly washed out with some antiseptic lotion. When the patient is sufficiently well, all loose carious teeth, necrotic roots, and carious teeth or fangs from which pus is oozing through the alveolus, should be extracted.

These will be found, for the most part, among temporary teeth. They not only prevent the child from eating, but poison the alimentary canal and form infective foci for the spread of disease to other tissues of the body.

Whenever teeth can be saved, they should be treated according to directions already given. Should any doubt exist as to the removal of a permanent tooth, it is wiser to seek the aid of a Dentist than to remove a tooth, which by careful stopping might be made useful in the future.

What the Practitioner should do, however, is to give his patient a clean and healthy mouth ; and where no efficient dental aid is to be obtained he must determine for himself whether mastication is performed with comfort or not. Even though a tooth be filled, unless a child can eat upon it, more harm than good will be done by keeping such a tooth in the jaw.

In order to properly extract a tooth it is essential that the practitioner should provide himself with a set of forceps. These are made of the best steel, are of light construction and are so formed that their blades accurately fit the necks of the teeth.

The blades are wedge-shaped, the outer surfaces smooth and polished, the inner surfaces finely serrated in order that the tooth may not slip. The handles are roughened on their outer surfaces and their extremities blunt, and sometimes curved, in order to afford sufficient hold when grasped, and that upward pressure may be used from the palm of the hand when needful.

In removing a tooth it is necessary that the gum and the alveolar process should be injured as little as possible. The cutting edges of the forceps are made sharp, so that they may be introduced beneath the gum, and between it and the tooth.

No more force should be used than is absolutely necessary. It is not by pulling, but by twisting, or lateral movements, that a tooth can be removed skilfully. In grasping a tooth, sufficient care must be exercised that it shall

not be crushed within the blades of the forceps.

The movement must be very deliberate and sure.

When the tooth is grasped, it should never be lost sight of until it is removed from the mouth. Any sudden movement, such as a jerk, or a pull, may result in a fracture of the tooth within the socket. If successful so far as the extraction is concerned, the tooth may be accompanied by a portion of the alveolar plate and gum.

The forceps should be kept scrupulously clean. It is best to dip them in boiling water before using. After being used, the jaws may be dipped in a strong solution of Carbolic Acid, and then wiped dry. It is necessary to see that no moisture remains between the joints. This seems a small matter; but where such instruments are not in frequent request, it is annoying to find the jaws rusted, and not freely movable, a contingency easily avoided by the application of a drop of oil, before the forceps are put on one side.

There are two points in the extraction of teeth which require special attention. 1. The application of the blades of the instrument to

the tooth. 2. The separation of the tooth from its socket and its removal from the mouth.

1. The handles should be opened sufficiently wide for the blades to pass well over the crown of the tooth. They should then be closed lightly, just enough to feel that the tooth is grasped; the blades should then be pushed well up (in extracting an upper tooth) or (in extracting a lower tooth) well down *between the gum and the neck of the tooth, and, if possible, within the alveolus.*

An exception to this will of course be made in extracting loose temporary teeth from the front of the mouth where the alveolus has practically disappeared, but whenever a tooth is at all firm in its socket it is essential to obtain a sufficient hold of the sound portion of a tooth without crushing.

If this is not very carefully carried out, and sufficient force is used to remove the tooth, the blades will simply break into a carious crown or root; and should the pulp be still alive, the result will be for the patient an agony of pain and for the operator great discouragement.

2.—Having grasped the neck or sound portion of the tooth, the handles should be held sufficiently tight to steadily force—not pull—it

from its socket. The movements required to complete this part of the operation will depend upon the form and the position of the tooth in the jaw.

Later, the extraction of individual teeth will be mentioned, but in general terms it may be stated that teeth at the back of the mouth require a rocking or lateral movement from side to side, in front of the mouth in the upper jaw a slight rotatory motion, in front of the mouth in the lower jaw an outward and upward movement.

Teeth are separated from their surroundings in the lines of least resistance. It is by no means necessary that the alveolus should be fractured, though in some cases where the alveolar plate is very thin, or closely adherent to the fangs of the teeth such fractures are unavoidable. Apart from these possibilities, it is well to bear in mind that by forcible expansion alone, most teeth are removed from their sockets, and that it is the external plate of the alveolar process which most readily yields.

Extraction of Teeth from the Upper Jaw. The patient, when seated, should face a good light with the head well back, and, where a choice

is possible, the seat of the chair should be high.

The operator standing on the right side of the patient, with his left arm encircling the patient's head, will be in the best position for controlling involuntary movements. Of course it is assumed that the patient is seated on an ordinary chair. The fingers of the left hand may be used to keep the lips apart, and when extracting a front tooth one finger should be placed in front of, and another behind the alveolus above the tooth.

When extracting teeth at the back of the mouth this is usually impossible, as the fingers will obstruct the light.

Although forceps are made to fit the necks of the teeth, it is unnecessary to have a set for the permanent, and another for the temporary teeth. Those which have been chosen and illustrated are well adapted for both.

The fangs of *Upper Incisors* are conical. When the blades of the forceps are fitted on to the neck, a slight semi-rotary motion, or twisting of the tooth in its socket, is necessary to sever it from its attachments. Then it can be pulled downwards and slightly outwards.

Should the crown of the tooth have been lost

and decay have left little else than a hollow cone, the cavity, (all *débris* having been washed away) may be packed with cotton wool, and the forceps pressed well up between the gum and the root until a sound portion is reached.

The *Canines* are slightly flattened from side to side. It will, therefore, be necessary, when the forceps are applied, to force the tooth backwards and then forwards, before pulling downwards and outwards.

Bicuspids. These teeth, it is well to remember, are not present in the temporary set. They succeed the temporary molars, in the permanent dentition. Their roots are flattened and the first bicuspid has generally two fangs. When the tooth is grasped it should be forced inwards, then outwards and downwards.

The forceps required for the extraction of Upper Incisors, Canines, and Bicuspids have straight handles and narrow beaks, as shown in Fig. 90.

Upper molars. These teeth have three fangs, one internal, or palatal, and two external. It is necessary to have two pairs of forceps, one for each side. The external blade is triangular at its edge, and the apex or terminal point

should be applied to the division between the two external fangs, the inner blade fitting close

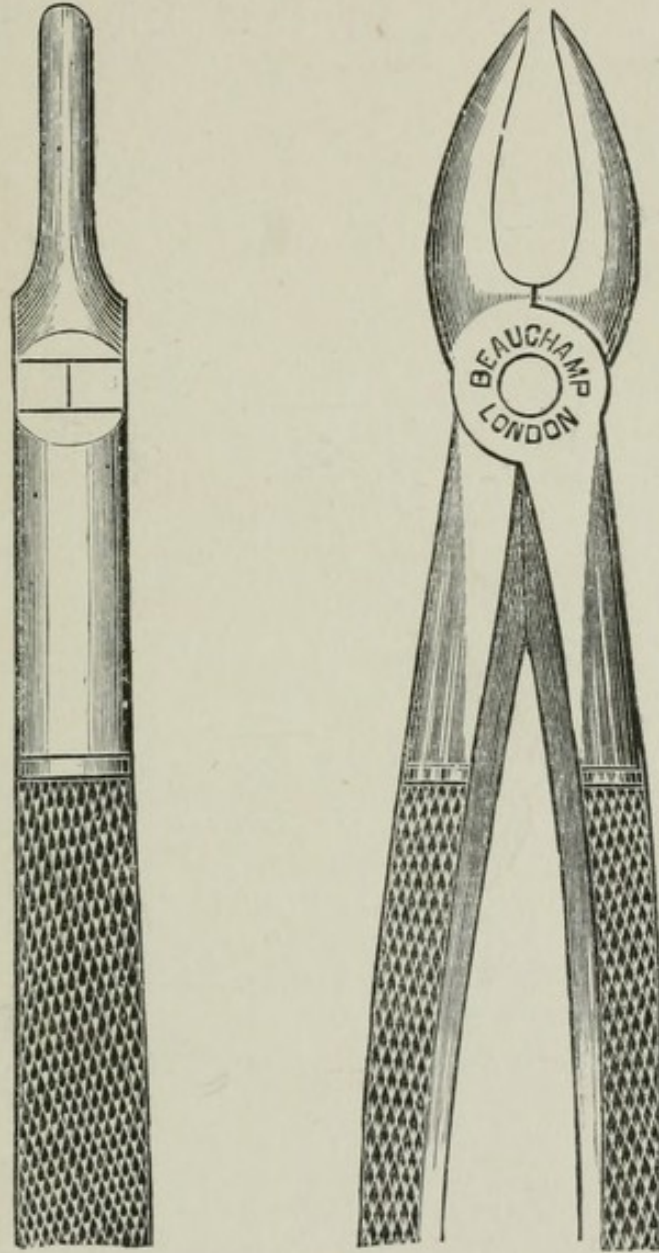


Fig. 90.—UPPER INCISOR FORCEPS.

against the neck of the palatal root. It is, generally speaking, advisable in extracting

upper teeth from the back of the mouth to apply the internal blade first and then the external. The blades must be pushed well up before

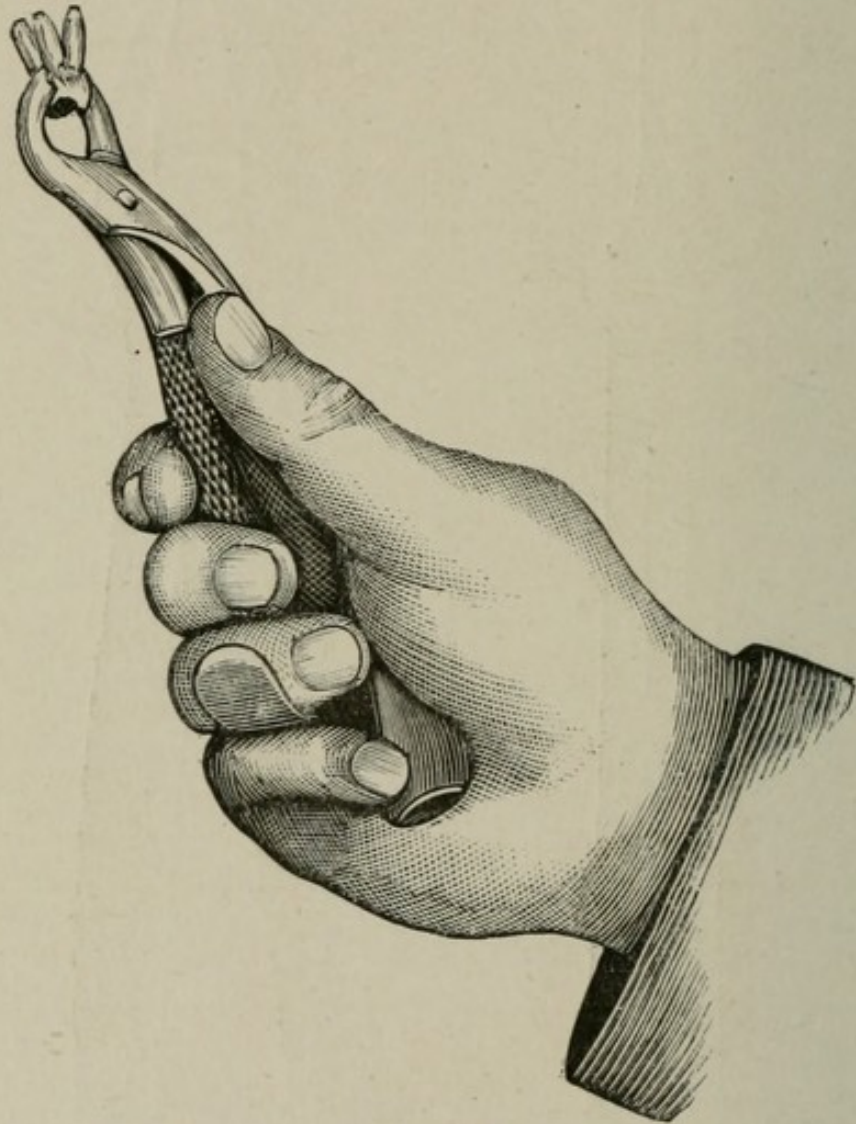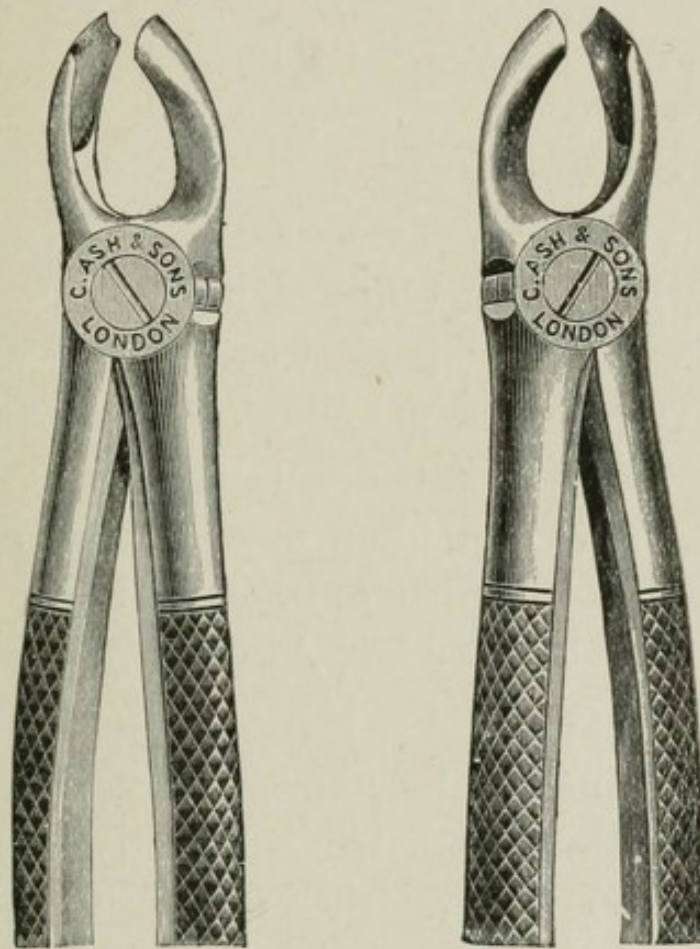


Fig. 91.

Showing position of the hand and forceps in the extraction of an Upper Molar Tooth.

attempting to extract the tooth. In order to regulate the force required in grasping the

handles, the pulp of the thumb should lie between the handles as they are closed. If the tooth is squeezed hastily the crown will probably be crushed. Should it not be held



Figs. 92 and 93.—UPPER MOLAR FORCEPS.
Right and Left.

sufficiently tight, the inner blade may slip over the edge of the crown. When the tooth is carefully grasped, it should be moved slightly inwards (to disengage the two external fangs) and

then steadily, and firmly, outwards and downwards, the external plate of the alveolus giving way.

It is very necessary for the practitioner to determine beforehand whether the molar he proposes to remove belongs to the temporary or permanent dentition. Temporary molars often require a great deal of force to extract them owing to their divergent fangs; but a permanent molar requires much more force, and the older the patient is, the firmer will be the alveolus round the fangs.

Fracture through the crown or neck of a tooth, may, and often does, occur, however careful the attempt to extract, or however skilful the operator may be. As already mentioned, this will happen if the blades of the instrument are not pushed up far enough to secure a sound portion of the neck. Often it is the result of a sudden movement, either on the part of the patient or the operator. The removal of a tooth causes an agony of pain, and not the least painful is the first part of the procedure, due to the necessary pressure of the blades of the forceps in order to secure a sufficient hold of the tooth. The patient will probably

move away, unless a counter force is used, and the head kept well under control, On the other hand, the screams of a child will, at times, require all the calmness one is possessed of, in

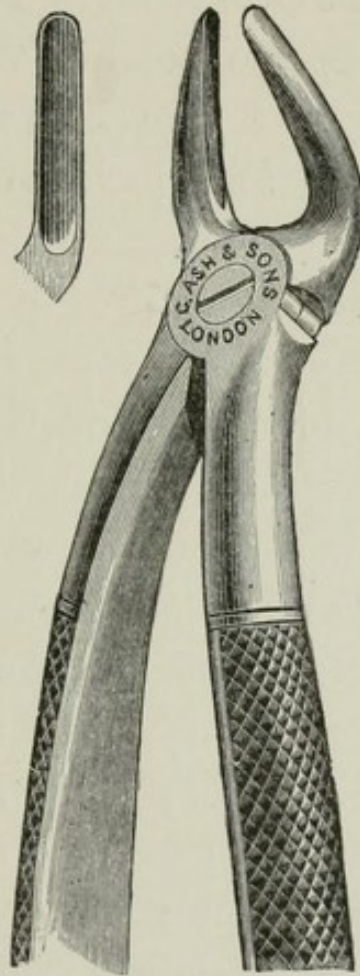


Fig. 94—UPPER STUMP FORCEPS.

order to complete the operation without undue rapidity of action.

Carious molars are very deceptive in appearance; the walls may look to be comparatively

sound, but when the forceps is applied the crown may collapse, and it will then be found that caries has extended far up the neck of the tooth almost to the fangs. Carious and necrotic teeth are often very brittle and break off at the slightest attempt to remove them. This is most frequently the case with temporary teeth which break up and have to be removed in pieces.

Whenever the crown of a molar tooth is sufficiently decayed as to appear likely to break, the full molar forceps should be discarded, and a pair of upper stump forceps should be used.

The inner blade should be pressed up so that the palatal fang may be grasped, and the outer blade should grasp the anterior external fang. If these two roots are removed there will be no difficulty in extracting the remaining root either at the same time or at a later date.

Upper Stumps. For the removal of stumps in the front of the mouth the incisor forceps (Fig. 90) may be used with advantage, but at the back of the mouth as the position differs so will the forceps. Although the blades of the forceps are similar in both cases, those used to extract molar roots are somewhat curved for-

ward, so that they can be used without touching the lower teeth. If the position in the jaw is remembered there is little difficulty in removing a stump of an upper molar tooth, when once grasped. A slight lateral, or side to side, movement will loosen it from the its socket. The real difficulty is when the fangs are united at the neck of the tooth. The blades of the forceps must be passed up rather high and then by squeezing the handles the divergent fangs will be forced together and can be removed singly.

Extraction of Teeth from the Lower Jaw. The patient may be seated, as in extracting teeth from the upper jaw, but instead of placing the head well back, it should be inclined slightly forward, that is, instead of raising the chin it should be depressed. It is necessary that this be mentioned, as in both cases, the head and body must rest against the back of the chair.

For the removal of a tooth on the right side, the operator should stand *behind* so that he may stoop over the patient. The left arm should encircle the patient's head, and the wrist be bent so that the thumb may press down the tongue while the forefinger keeps back the lip,

three fingers passing under the jaw to give support.

When extracting teeth from the front of the mouth, or on the left side, the operator should stand on the right side, and facing the patient.

The forefinger of the left hand being placed on the outer side of the alveolus, removing the lip, the second finger, on the inner side, depresses the tongue, while the thumb is naturally passed under the jaw to support it. The jaw is thus grasped between the fingers and thumb. In many cases it will not be possible to put the fingers into the mouth of a small child, but the jaw should always be supported. When it is possible it is always advisable to introduce the instrument before placing the fingers in the mouth, or the latter may be bitten by the frightened child.

The extraction of lower teeth on the left side will necessitate the operator reaching across the patient. This is a little awkward at first, but it is better than standing in front, for by so doing the operator will intercept the light, and have less control over the patient.

Lower Incisors and Canines. The fangs of these teeth are compressed laterally, and when a

tooth is grasped, it must first be forced outward and then upwards and outwards

*Lower Bicuspid*s have cone-shaped roots, and in order to displace them, a slight semi-rotary or twisting movement is necessary.

The forceps required for the extraction of lower incisors and bicuspid have fine blades at right angles to the handles.

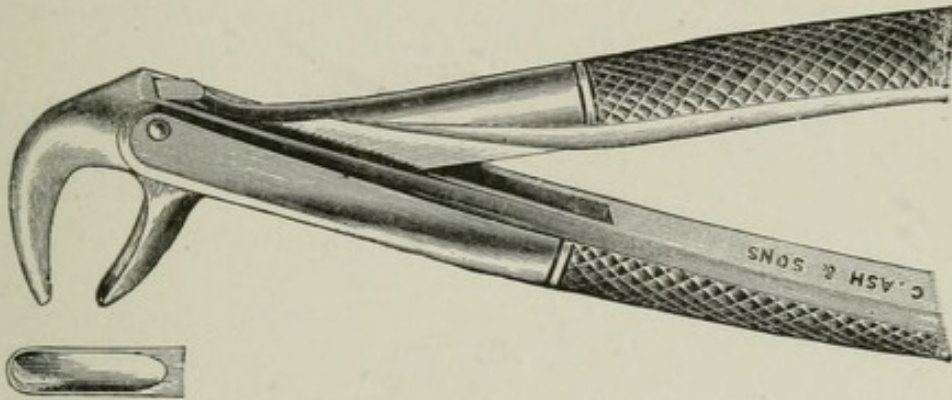


Fig. 95.—LOWER STUMP FORCEPS.

Lower Molars. The lower molars have two fangs, an anterior and a posterior. When extracting it is well to remember that the crowns of the permanent teeth are inclined slightly inwards. The blades of the forceps at their edges are triangular. When fitted on to a tooth the apex of the triangle should pass between the fangs.

The handles of the forceps should be opened

sufficiently wide just to pass over the centre of the crown, the inner blade being applied first and then the outer. The forceps must be well pressed down, the thumb of the left hand being used to exert pressure, if necessary, though care must be taken that the tooth is not hidden from sight.

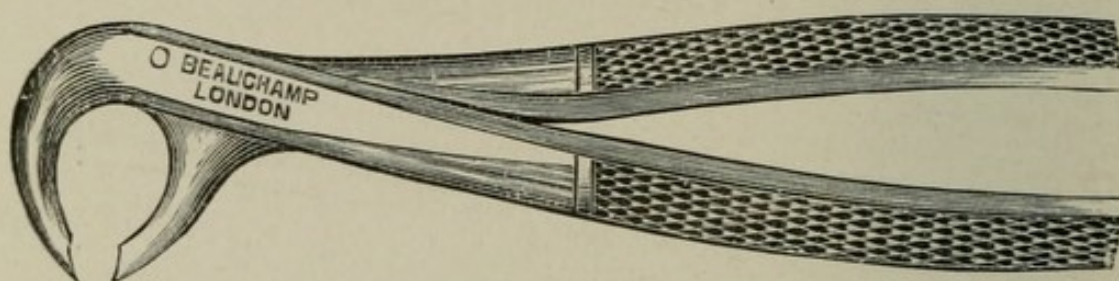


Fig. 96.—LOWER MOLAR FORCEPS.

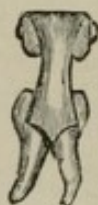

Fig. 97.

Should the crown of the tooth be very deeply carious, it is better to use the incisor and bicuspid forceps. (Fig. 95.) Choosing the anterior or posterior part of the tooth, whichever appears to be the most sound, the blades of the forceps are passed well down so that one fang may be grasped. In most cases the other

will follow: but if not it can be removed after bleeding has almost ceased.

The movements required for the extraction of a lower molar are slightly inwards, and then outwards. The handles of the forceps are first raised; and then are forcibly depressed, the tooth being then lifted from its socket. One pair of forceps for either side is all that is needful.

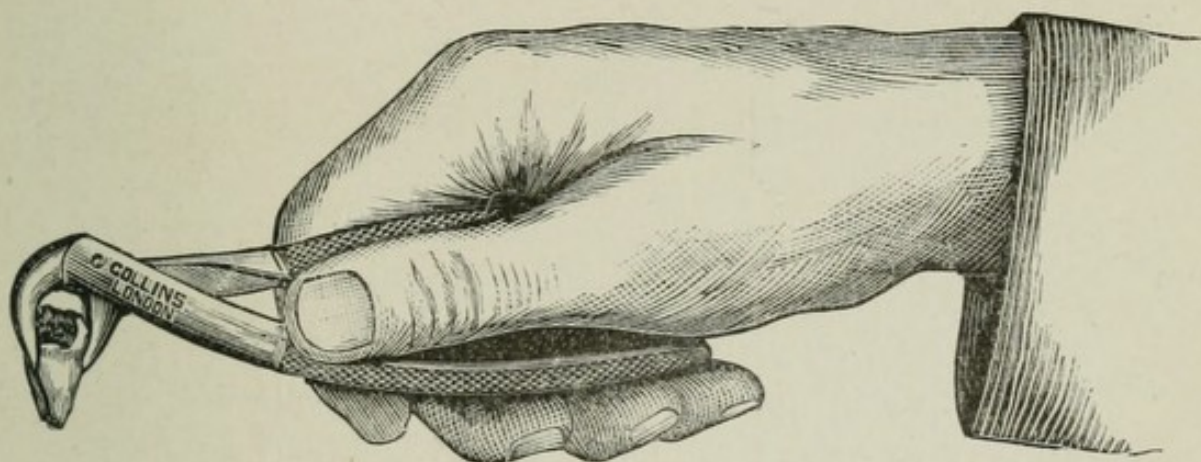


Fig. 98.

The Elevator. This instrument is extremely useful for removing roots of teeth, both temporary and permanent. It has a straight handle with a curved or straight blade. The one figured tapers to an edge, one side is serrated and flat, the other side is polished and round. In using, it should be held firmly in the palm of the hand and the blade should be guarded by

the thumb or forefinger to within an inch of its termination. Thus it will be prevented from injuring the tissues of the jaw should it slip, as it is liable to do. It is a simple lever, the fulcrum being a neighbouring tooth, the alveolar process, or the fingers of the left hand of the operator; the latter method is necessary in the removal of temporary roots, where the alveolus has disappeared.




Fig. 99.—ELEVATOR.

The point of the blade must be pushed well down between the root and the gum, with the flat side against the tooth. The handle should then be twisted and the root prized, or lifted out of its socket.

INJURIES OF THE TEETH.

Falling over a carpet, or stool, tumbling downstairs, or a blow on the mouth while at play, are the usual accidents which cause an injury to the teeth. Those of the upper jaw

are most likely to suffer, and, as a rule, the central incisors are affected. Amongst poor children, the habit of drinking from a water tap is common, and the front teeth are often injured by the child, in the act of drinking, being pushed from behind.

The effects, of necessity, will vary as the force of contact, whether the mouth is open or closed, and will also partly depend upon the condition of the patient's health at the time.

Such injuries may be briefly described for the sake of convenience under the headings,—Concussion, Displacement, and Fracture.

Concussion. A tap or blow upon a tooth, biting upon a piece of bone, or other hard substance in the food, is usually followed by periodontitis.

The tooth becomes loose in its socket, and tender to bite upon for a few days. Should the blow be severe, or the child in delicate health, the periodontitis may be preceded, or followed, by acute inflammation of the pulp (pulpitis). A dull aching, or, if there be pulpitis, acute pain, with exquisite sensitiveness of the tooth on biting, will prevent the patient from eating, and later, an alveolar

abscess may point opposite to the apex of the fang.

If concussion of a temporary tooth causes much pain, and an alveolar abscess is threatened, it is advisable to remove the tooth. If left, pus may find its way to the developing permanent teeth and injure them. A permanent tooth should be left alone. Should an alveolar abscess form beneath the lip this should be opened through the gum with a small abscess knife. As a rule such teeth become quite firm in their sockets

Displacement or *Dislocation* of a tooth may be complete or partial. A tooth may be forced out of, or driven up into, its socket. The absence of a tooth from its socket, and which cannot be found after an injury, should always lead to a careful examination of the alveolus.

A temporary tooth which has been driven up into its socket, should at once be removed with a pair of incisor forceps. In some cases a permanent tooth may be drawn gently down and ligatured.

The question of restoring a tooth to its former position only arises with regard to permanent teeth. Should the patient be

healthy, and the fang of the tooth fully grown, (and this with the incisors is between the 10th and 11th years) the tooth should be carefully cleansed and replaced in its socket.

The death of the pulp is almost inevitable; but such teeth have been known to remain firm (though discoloured) from 5 to 15 years, even though they had been out of the mouth for two or three days.* A ligature of silk attached to adjoining teeth will suffice to keep the displaced tooth in position. Should two teeth have been displaced and restored, a small gutta-percha cap may be moulded over them including a tooth on each side. This will effectually protect the injured teeth from being bitten upon.

Fracture. Fractures of the teeth are of frequent occurrence, and are generally confined to those of the permanent dentition. Sufficient force to break a permanent tooth will, as a rule, completely displace a temporary tooth. The fracture may be in almost any direction.

Where the corner of a tooth is broken off, as so frequently happens with incisor teeth, the

* A tooth freshly extracted from the socket, and immediately replaced may not even become discoloured, and, stranger still, may even be found to be sensitive afterwards.

dentine will be exposed and the tooth become sensitive. The surface should be painted over with caustic, and any sharp edges should be smoothed down with a file. Should the fracture extend to the pulp, leaving it exposed as an exquisitely sensitive spot, such exposure will, if left alone, be followed by pulpitis, and later, if the opening become blocked by food particles or other foreign body, by periodontitis with alveolar abscess.

Such teeth should at once be extracted if the child is under 12 years of age, because the fangs will not be completed. Beyond 12 years of age there may be a reasonable hope of saving the root of the tooth, and placing an artificial crown on it which may last many years.

If the fracture is transverse through the crown, so that the fang of the tooth is not injured, it is often possible to save the fang by destroying the pulp and crowning the tooth artificially. It is, however, necessary that the root of the tooth should be fully developed. If a child is more than 12 years of age the Dental Surgeon would adopt this treatment and such a crowned tooth will last for many years. Under 12 years of age the tooth should be extracted. The gap

thus made will be readily filled up by the approximation of the other teeth.

TARTAR ; AND ITS REMOVAL.

The Saliva holds in solution a certain proportion of lime salts, chiefly Calcium Carbonate and Phosphate. Under certain conditions these are deposited upon the teeth; and the deposit is known as Tartar.

According to Miller* the lime salts are held in solution by the presence of carbonic acid; and when this escapes the salts are precipitated.

In the absence of carious teeth, the friction which occurs during mastication, and the cleansing of the surfaces of the teeth with the tooth brush tend to remove any trace of Tartar.

A favourite site for its formation is the outer surfaces of the molar teeth, where the saliva from the parotid gland is poured out of Steno's duct.

In adults, even in the healthiest mouths, Tartar is apt to accumulate behind the lower

* *Micro-Organisms of the Mouth*, p. 100.

incisors and may be very hard. With children this is very rare.

Tartar when formed on the teeth of children is usually very soft, contains a large admixture of the *débris* of food; and has an offensive odour.

One of the diagnostic signs of imperfect mastication is the deposition of Tartar, generally on one side of the mouth, sometimes on both sides, and occasionally in front. Whenever such a deposit is found it may be taken for granted that on the same side, one or more tender or carious teeth are present, and the patient is unable to eat with comfort. The teeth may be so covered as to entirely obscure a carious cavity. The child's breath is generally offensive.

All tartar must be carefully removed, and the operation is known to Dentists as *Scaling*. This can be done with sharp excavators, and especial care should be taken to remove it from the necks of the teeth, where it rests upon the soft tissue. As the gum surrounding the teeth will be very tender a 5 per cent solution of Cocaine may be painted over its surface.

If tartar is allowed to remain, a further

deposition takes place, and ulceration of gum tissue with a sanious or purulent discharge is followed by absorption of the alveolus and the loss of the teeth.


Amy J. H., aged 6 years 3 months. The mother says the child's mouth has been bad for the last 9 months. She has constant headache. Cries every morning "about her forehead." The teeth on the left side of the mouth are coated with a soft brownish deposit of tartar and *débris* of food. The gum margin round the necks of the teeth is deeply ulcerated where the tartar rests. The ulcerated surfaces are surmounted with greyish slough. The discharge is profuse, and very foul, staining the pillow and night gown "shocking."

Treatment.—Removal of all tartar, also a deeply carious molar. A mouth-wash of Pot. Permang. ordered and

R. Mist. Pot. Chlor. c Acid. (Evelina.)

This child was quite well in 7 days.





INDEX.

	PAGE		PAGE
ABSORPTION of bone ...	19	Carbolized resin 191, 197, 211, 231	
" " cementum ...	25	Caries ...	33
" " dentine ...	25	" arrested ...	196
" " gum ...	19	" artificial ...	39
" " temporary		" cause of ...	35
teeth ...	47, 88, 108, 111	" and civilization 42, 133	
Actinomycosis ...	3	" colours of ..	34
Alimentary canal, diseases of	159	" and domestic servants 148	
Alveolar abscess 51, 62, 192, 200,		" forms of ...	37
201, 258		" in Hospital patients... 150	
Alveolar process 23, 192, 237, 240		" and mastication 162, 177	
Amadou ...	211	" and micro - organ-	
Amalgam ...	211, 223, 225	isms ...	39, 133
" method of using... 226		" and nervous diseases 153	
" spoon ...	224	" predisposing causes 39, 43	
" Sullivan's ...	224	" prevention of ...	134
Antrum ...	61	" and recruits ...	147
Arrested decay ...	196	" and sick children ...	175
Arsenic ...	212, 233	" stages of, ...	35
Articulation of teeth ...	90	" superficial, 38, 188, 196	
Attrition ...	26	" in temporary teeth 207	
BACTERIOLOGY ...	2	" and tuberculosis ...	172
Bicuspid 17, 26, 30, 57, 81, 85, 106		Carious Dentine, removal of 209,	
" absence of ...	27	211	
Bones, diseases of ...	174	" teeth, and infec-	
Boracic Acid... ..	181	tious diseases ...	177
Bristowe, Dr., catarrhal in-		" teeth and various	
flammation and dental		diseases ...	178
caries ...	160	Cassia, Oil of, use of, in cari-	
Brushing the teeth ...	181	ous temporary teeth 213	
CALCIFICATION ... 9, 13, 46, 70		Cavities, deceptive ...	196
" of pulp ...	47	" interstitial ...	210
Canines, outstanding 27, 118		" saucer-shaped ...	218
" treatment of ...	121, 124	Cavity, shaping for filling	
		207, 210, 218	

	PAGE		PAGE
Cementum	10, 25	Enamel, "ridged"	73
Chisels, dental	204	" of temporary teeth	29
Chisels, dental, use of	208, 215	Engine, the dental...	218
Chlorate of potash	181	Epilepsy	154
Chloride of sodium, as a		Eruption of teeth	15, 85
mouth-wash	181, 193	" " dates of	24
Chlorinated lime water ...	181	" " faulty	93
Chorea	156	Examination of the mouth	179, 184
Cleansing the mouth	135, 180	Exanthemata	75
Cocaine	260	Excavators	204
Coleman, Mr., Epilepsy and		Excising forceps	215
diseased teeth	154	Exfoliation	65
Colic	20	Expansion of the dental arch	123
Concussion of teeth	255	Extraction of teeth	235
Convulsions	21, 75, 154	" of first permanent	
Crutch-handle, for drills ...	219	molar	233
DECALCIFICATION	36	" fracture during	239, 246
Decay, "arrested"	196	" general rules of	237 <i>et seq.</i>
Dental chisels	204	" of hollow molars	248
" " use of	208, 215	" of incomplete	
" Engine, The	219	teeth... ..	258
" Mirror, The	185	" of lower bicus-	
" Probe, The	186	pids and molars	251
" Syringe, The	188, 195	" of lower incisors	
" Tweezers	189	and canines	250
Dentinal Fibril, The	9, 12, 13	" for overcrowding	117
Dentine,	8, 25	" position of oper-	
" sensation in	9	ator and patient	241, 249
" "sensitive"	190, 196, 227	" symmetrical	118
Dentition, delayed	68, 152	" of upper bicus-	
" difficult	163	pids	242
Development of jaw	19	" of upper canines	242
" of teeth	18, 25	" " incisors	241
Diarrhoea	20, 162	" " molars	242
Diseases of alimentary canal	159	" " stumps	248
" bones and joints	174	Extractors, nerve	233
" nervous system	153	FERMENTATION in the mouth	
" respiratory or-		7, 34, 36, 134, 142, 159	
gans	168	Fistula, dental	57, 63
Dislocation of teeth	256	Food, selection of	136
"Double Rows" of teeth ...	124	Forceps, dental, 237, 241 <i>et seq.</i>	
Drills, dental	219	" cleaning	238
Drugs for treating teeth ...	234	Fracture of teeth	246, 257, 239
ELEVATOR, The	253	Fraenkel's pneumococcus	170
Enamel	7, 25		
" colour of	8		
" defective	196		
" opaque	186		

	PAGE		PAGE
GEMINATION	77	Iodine, use of, in toothache	189
General tuberculosis ...	172	Iodoform in carious tempo-	
Granular layer of dentine	8, 10, 13	rary teeth	213
Gum-boil	54, 192	Irregularity of Teeth	23, 41, 67
Gum-lancet, use of, ...	21	" " in structure	68
Gums, ulceration of ...	64, 66	" " in form	77
" irritation of, by tartar	43	Irregularity of teeth in number	79
Gutta Percha	211, 227 <i>et seq.</i>	" " in position	84
" " Method of using	229	Irritation, reflex, from erup-	
HÆMORRHAGE	22	tion	19, <i>et seq.</i> 154
Heredity	20	Irritation, reflex, in diarrhœa	
Honey-combed teeth	40, 70, 73	from carious teeth ...	163
Hutchinson, Mr. J., and mer-		Irritation of carious teeth	
curial teeth	72, 73	in children	176
"Hutchinsonian" teeth	76	Irritation of the gum by tartar	43
Hygiene of the Mouth ...	133	Irritation of the pulp ...	52
ILLUSTRATIVE CASES—		LACTIC Acid in the mouth	35, 36
Alveolar Abscess	64, 193	Lancet, the gum	21
"Pyæmia" and		Lane's, Mr. Arbuthnot, case	
Chorea	157	of pyæmia	62
Diarrhœa and carious		Lunar caustic	189, 196, 209, 220
Teeth	165		231, 258
Fistula on cheek	59, 61	Lymphatic glands and cari-	
" beneath jaw ...	60	ous teeth	173
General treatment for		MASTICATION during change	
toothache	189	of dentitions	26, 32
Iodine, Use of, for tooth-		Mastication and children's	
ache	190	food	136
Pneumonia and carious		Mastication, The distribu-	
teeth	169	tion of pressure in ...	116
Symmetrical Periodon-		Mastication with the front	
titis	65	teeth	127
Tartar	261	Mastication and stomatitis	161
Tuberculosis	172	" and the accumu-	
Ulcerative Stomatitis ...	162	lation of tartar	43, 164, 2
Immediate treatment of		Mastication and the tempo-	
Irregular teeth	100	rary teeth	141
Impression of the mouth for		Mastication as an indication	
models	129	in treatment	236
Incisors, extraction of upper	241	Mercury, effect upon develop-	
" " lower	250	ing teeth	72
Injuries of teeth	254	Micro-organisms of the mouth	
Instruments for stopping			3, 34, 46, 165
teeth	234	" and septic pneumonia	171
Interglobular areas in den-		Micro-organisms of the mouth	
tine	10, 40	and Meningitis ..	171
Interstitial cavities ...	188		

	PAGE		PAGE
Miller, Dr., on micro-organisms	164	Overcrowding of teeth, treatment of	121
Miller, Dr., prescription for antiseptic mouth-wash	182	Owen, Mr. E., septic infection and carious teeth ...	173
Milk-teeth (<i>vide</i> temporary teeth)	15	Periodontal membrane, The ...	10, 12, 14, 50
Modelling composition ...	129	Periodontitis ...	51, 64, 187, 192
Models, plaster of Paris ...	131	" symmetrical ...	65
Moisture, exclusion of, from cavities	220	Permanent molars, the first ...	31, 59, 74, 195, 232
Molars, temporary	15, 18	" " the second ...	32, 85
" The first permanent ...	31, 59, 74, 85, 200	Permanganate of potash, as a mouth wash ...	181, 193
" The second permanent ...	32, 85	Persistent temporary teeth ...	112, 114
Moon, Mr. F., and mercurial teeth	73	Pneumonia, croupous, and carious teeth ...	169
Morgan, Dr., case of epilepsy ...	155	Position of patient in stopping upper teeth ...	221
" " " of chorea ...	158	Protrusion of teeth ...	125
Mouth, The examination of the	179, 184	Pulp, The dental ...	11, 35, 45, 203
Mouth-washes ...	181, 193, 261	" " calcification of ...	47
Mummery, Mr. J. H., on the structure of dentine ...	9	" " cornua of ...	11
Necrosis ...	51, 57, 65, 198, 200	" " degeneration of ...	49
Nervous system, diseases of the, and carious teeth ...	153	Pulp, the dental, death of ...	164
Nitrate of silver, use of, ...	189, 196, 209, 220, 231, 258	" " exposure of ...	46, 187, 225, 227
Odontalgia, in Temporary teeth	186	" " gangrene of ...	46, 197, 233
Odontalgia in permanent teeth	194	" " polypus of ...	47
Œdema in alveolar abscess ...	59	" " putrefaction of ...	174
Oil of Cassia, use of, in carious Temporary teeth ...	213	Pulp chamber, The ...	11, 164
"Open bite"	20	" " of Temporary teeth ...	209
Oral Hygiene	133	Pulpitis ...	45, 187, 191, 232, 258
" " and sick children	178	" diagnosis of ...	198, 231
Oral Hygiene and nurses ...	182	Pulp-stones	48
Osteoblasts	13	Putrefaction of the mouth ...	164
Osteoclasts	55	Pyæmia	62
Outstanding canines ...	27, 118	REFLEX irritation ...	19, 154
" " Treatment of	121	Regulation plate	94
Overcrowding of teeth ...	115, 137	Respiratory organs, diseases of the	151
		Retention of teeth	43
		Rickets	64, 68, 75, 152

	PAGE		PAGE
Roots of teeth, completion of	101	Teeth, development of	18
" " as foreign		" difference between	
bodies	193	Temporary and Perma-	
Rubber-dam, The	220	nent	29, 57, 195, 197
SALICYLIC ACID, mouth-wash	182	Teeth, difference between Tem-	
Saliva 137, 159, 220, 221, 259		porary and Permanent,	
" acid, cause of, ...	34	importance of	31, 246
Salivary glands, 20, 34, 169, 220		Teeth, discolouration of	37, 257
Sapræmia	167	" dislocation of	256
Sapræmia, cases of	168	" "double rows" of	124
Scaling	260	Teeth, eruption of	15, 24
School children's teeth	143	" extraction of... ..	235
Schreier, Dr. Emil; the diplo-		" fracture of 46, 246, 257, 239	
coccus pneumonica	170	" "hone-combed" 40, 70, 73	
Senior, Mr., cases of sapræ-		" injuries of	254
mia	168	" irregularity of	41
Senior, Mr., cases of chorea	158	" post-mortem examina-	
Sensitive dentine 190, 196, 227		tion of	217
Separation of teeth... ..	122	" protrusion of... ..	125
Septic infection 22, 49, 55, 63, 174		" " treatment	
Sharpey's fibres	10, 13	of	128
Sinus	60, 63	" ridged	73, 74
Sockets of teeth	96	" School-children's	142
Sordes,	43, 169	" separation of	122
Sound dentitions	144	" shedding of	25
Stopping, or filling, teeth ...	202	" size of	116
" " " position of		" stopping, or filling of	202
patients	221	" structure of	5
Stopping temporary teeth... ..	205	" suppression of	42
" permanent "	214	" surfaces of	5, 7
Structure of teeth	5	" symmetrical extraction	
" irregularities of	68	of... ..	118
Superficial caries ... 38, 188, 196		" temporary 15, 18, 141, 144	
Supernumerary teeth	83	" " persistent 112, 114	
Supplemental teeth... ..	81	" " premature loss	
Surfaces of teeth	5, 7	of	27
Survival of the fittest	44	" " retention of 27, 43,	
Syphilis	64, 72	84, 93, 194	
Syphilitic teeth	76	" " roots of	88
Syringe, the dental... ..	188	" " spacing of	25
Syringing the mouth	180	Teething	20
TARTAR	43, 164, 259	" Powders 22, 42, 74	
Teeth, articulation of	19, 117	Temporary canines	104, 110
" canine... ..	124	" molars 15, 205	
" and civilization	42	" " caries in 207	
" cleansing of	137	" " retention	
" concussion of	255	of	27
" crowding of 41, 103, 115		" " shedding of 106	

	PAGE		PAGE
Thrombosed veins ...	60	ULCERATION of cheek ...	161
Toothache ...	186, 194	" of gum ...	64, 66, 161
Toothbrush, The use of the	138.	Ulcerative stomatitis ...	161
	147, 181	Underhung jaw ...	91
Tooth, a "dead,"	13, 14, 49, 50,	VOMITING in teething ...	20
	199	WAINWRIGHT, Dr., cases of	
Tooth, a, as a foreign body	193	diarrhoea ...	165
Toothpick, The use of the	141	Wainwright, Dr., case of	
Tooth powders ...	139	sapræmia ...	168
Treatment ...	183	Wisdom teeth ...	87
Treatment, importance of early	203	Woodhead, Dr. Sims; the	
" immediate, of irre-		diplococcus pneumonia	170
gular teeth ...	100	Woodhead, Dr. Sims; croup-	
Tuberculosis ...	64	ous pneumonia... ..	171

7721

