

**Cleft palate and harelip.**

**Contributors**

University of Toronto

**Publication/Creation**

1908

**Persistent URL**

<https://wellcomecollection.org/works/aga4dfsu>

**License and attribution**

This material has been provided by This material has been provided by the University of Toronto, Harry A Abbott Dentistry Library, through the Medical Heritage Library. The original may be consulted at the Harry A Abbott Dentistry Library, University of Toronto. where the originals may be consulted.

This work has been identified as being free of known restrictions under copyright law, including all related and neighbouring rights and is being made available under the Creative Commons, Public Domain Mark.

You can copy, modify, distribute and perform the work, even for commercial purposes, without asking permission.



Wellcome Collection  
183 Euston Road  
London NW1 2BE UK  
T +44 (0)20 7611 8722  
E [library@wellcomecollection.org](mailto:library@wellcomecollection.org)  
<https://wellcomecollection.org>

MS  
S

Starr, F.N.G.

Cleft palate and harelip.

467703





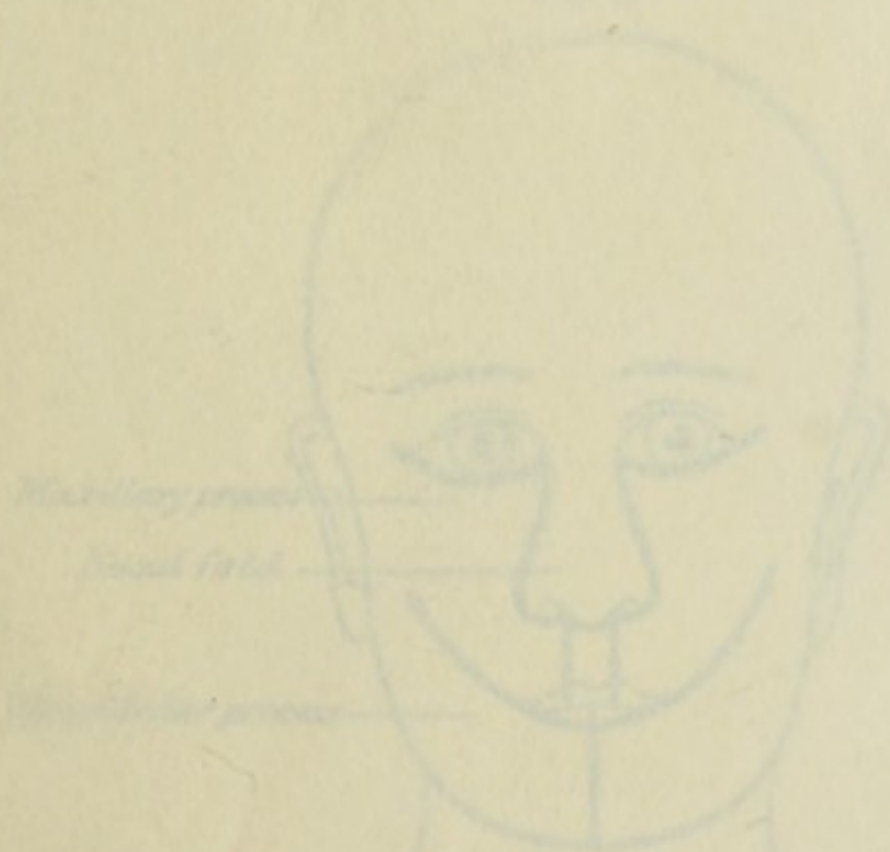
# Orthognathia

## Upper Jaw and Lip

W. H. C. T. M. M. (TOR)


Professor of Orthognathia, University of Toronto, Ontario  
Fellow of the Royal Society, Fellow of the Royal Society of Medicine  
Fellow of the Royal Society of Medicine, Fellow of the Royal Society of Medicine

The orthognathia of the upper jaw is a condition of the jaw which is characterized by a protrusion of the upper jaw and lip. We have here a case of orthognathia of the upper jaw and lip. The condition is characterized by a protrusion of the upper jaw and lip. The condition is characterized by a protrusion of the upper jaw and lip.



The condition is characterized by a protrusion of the upper jaw and lip. The condition is characterized by a protrusion of the upper jaw and lip. The condition is characterized by a protrusion of the upper jaw and lip. The condition is characterized by a protrusion of the upper jaw and lip.





# (Orthopædics)

467703  
6-11-47

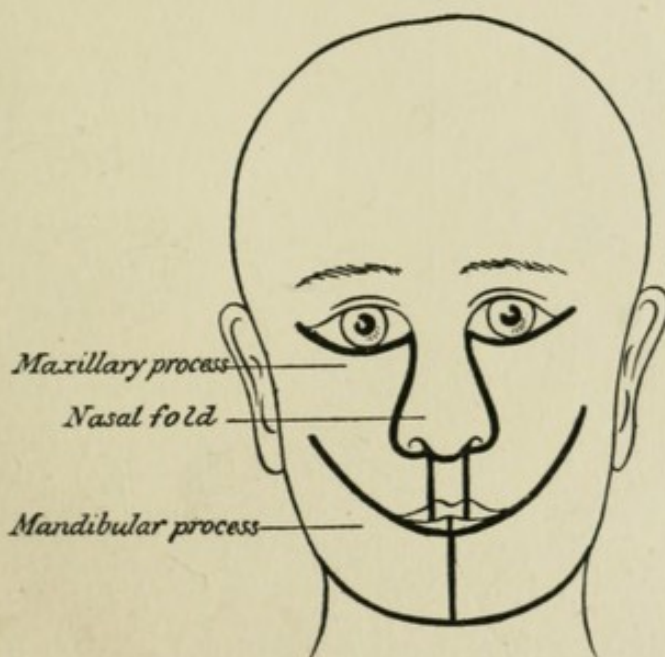
## CLEFT PALATE AND HARELIP

BY F. N. G. STARR, M.B. (TOR.)

Associate Professor of Clinical Surgery, University of Toronto; Associate Surgeon, Hospital for Sick Children; Senior Assistant Surgeon, Toronto General Hospital

To understand fully the requirements of treatment in cleft palate and harelip it is essential that one should understand something of the development of the face. We have been taught, that during the latter half of the first month of fetal life five processes

FIG. 1.



begin to show, springing from the base of the primitive cerebral capsule,—the nasal, two maxillary, and two mandibular (Fig. 1).

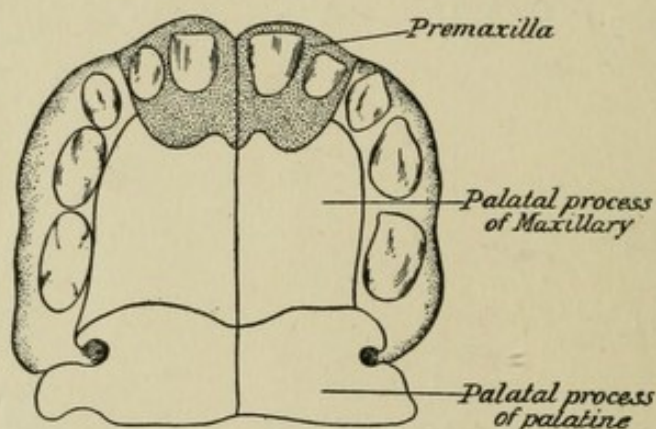
If the nasal and maxillary processes fail to fuse—because of amniotic adhesions—as they should do by the end of the second month of fetal life, the condition known as “harelip” is the result,



and if the failure occurs between the deep parts of these processes the condition known as "cleft palate" supervenes. From the mesial nasal processes are formed, by fusion, the premaxillæ and the nasal septum. In the premaxillæ are the sockets of the upper incisors. The premaxilla fuses with the maxillary process (superior maxilla), the latter overlapping and almost excluding it from the face (Fig. 2).

"The hard palate,—with the exception of the premaxillary part,—and the soft palate and its muscles with the uvula, are formed by a horizontal plate (palatal process), which grows inwards from the maxillary process and fuses with the plate of the opposite side beneath the septum of the nose, with which the horizontal plates also unite. The palatal processes separate the buccal

FIG. 2.



Showing (Keith) hard palate at birth. The premaxillary part is formed from the mesial nasal process; the remainder by the palatal plates in the maxillary process.

from the nasal cavities, forming the roof of the one and the floor of the other. The horizontal palatal processes meet first in front, the process of fusion spreads backward, and by the end of the second month it is complete."<sup>1</sup>

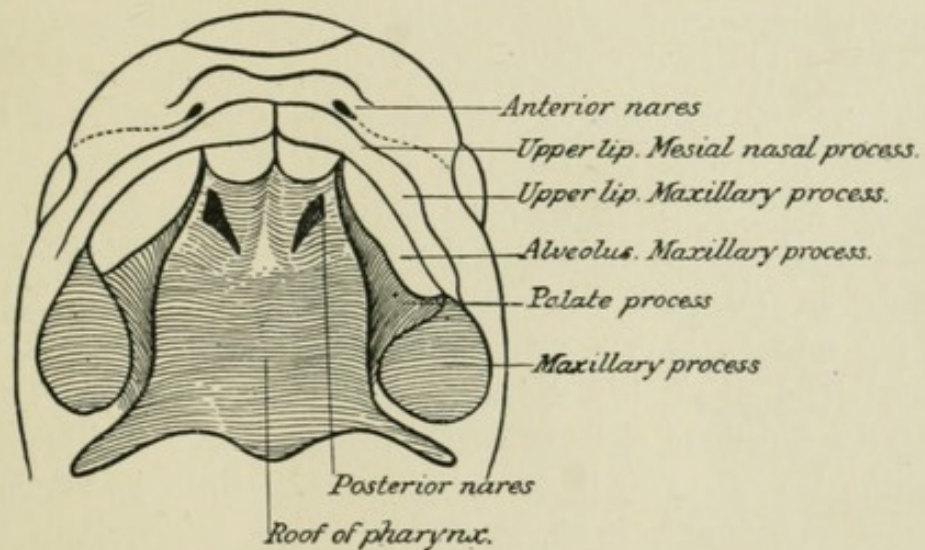
It will readily be seen then that the condition of cleft palate is due to a complete or a partial failure of fusion (Fig. 3).

If fusion of these processes should occur at the second month of fetal life, and fails, then surely the proper time to bring about artificial fusion is as soon after birth as possible, for during the early postnatal developmental period, repair is very rapid, and healing takes place with but little reaction. The unfortunate in-



fant has not had time to become unhealthy from improper feeding; it is practically free from the possibility of bacterial autoinfection; there is no catarrh present, as in older children; there is rarely any sickness after the anæsthetic and the patient is able to take nourishment as soon as the anæsthesia is over. There is little or no evidence of suffering, and in my experience, the risk from hæmorrhage—sometimes so serious in older children—is practically nil. A further advantage is, that owing to the mere fact of having made nasal respiration possible, the nose, the fauces, the palate and mouth are more uniformly developed. The flattening of the nose, with its wide bridge and the accompanying breadth of face between

FIG. 3.



the eyes will be entirely overcome by early operation from the effect of the entrance and exit of the respired air. The greatest advantage of all, however, is that the child will learn to articulate without the so-called nasal speech, because when he learns to talk, the cleft has already been closed. The nasal and mouth cavities are separate, with a good air-chamber for the passage of air through the nose and through the resonating air-chambers which give rise to the normal intonation.

The question then arises, How early should an attempt at repair be made? To which I would answer, that I have successfully operated at the age of three days, and, if opportunity offers,



and I can get a competent anæsthetist with some nerve, I shall not hesitate to attempt the repair on a child *three hours old*.

It is true that this doctrine differs essentially from the usual text-book teaching, as will be seen from the following quotations: Lexer,<sup>2</sup> in Von Bergmann's System of Practical Surgery, says: "In what year of life may the operation for cleft palate be best performed? The conditions here are somewhat different from those in the operation for harelip, but here not only the closure of the cleft formation is to be considered, but also above all things the subsequent functional activity of the soft palate. On this account, as Gutzmann rightly advised, it is best immediately after the healing of the operated cleft to begin with systematic exercise of the palate muscles by means of instruction in a language. This can be begun, according to Gutzmann's experiences, in the fifth year of life at the earliest. At this age under ordinary circumstances and with strong children there is no danger to life in the operation itself; according to Kuster, absolutely no such danger exists after the third year. If in addition the fact, important for the psychical condition of the children, is considered that they must be free from this strange congenital deformity before beginning school, the present standpoint of most surgeons is readily explained when they place the best time for uranostaphyloplasty in the fourth to sixth or fifth to seventh year of life. From the author's experience in Von Bergmann's clinic, he cannot see that it is necessary to perform the operation on principle before the third year, although Wolff has shown that the operation may be performed still earlier, even in the first month of fetal life, without necessarily having to fear a lack of development in the transverse direction of the superior maxilla, as Ehrmann described as a consequence of the early operation.

"In complete labial maxillary palatal cleft the harelip operation, if necessary combined with the reposition of the intermaxilla, always precedes union of the palate. This, as mentioned above, causes not only an improvement in the nutrition, but also a diminution of the uranoschisma."

Treves,<sup>3</sup> in his System of Surgery, says: "Whenever possible, operative treatment, having for its object the complete and permanent closure of the cleft, should be undertaken. In this



connection several points present themselves for consideration. Of prime importance is the question, At what age should the operation be performed? It may, I think, be laid down that, whilst it is never wise to operate upon a child under three years of age, the time of election is from this age up to six years. However severe and complicated the case may be, no advantage can accrue from postponing the operation longer than the sixth, or at the very outside limit, the eighth year."

Cheyne and Burghard,<sup>4</sup> in their Manual of Surgical Treatment, put the matter in the following way: "The age at which uncomplicated harelips may be operated upon depends to a large extent upon the size of the gap. In slight, simple cases the operation may be done within a few weeks or even a few days of birth. If, on the other hand, the cleft is wide, extends up into the nostril and entails a long operation and a free separation of the soft parts from the bone with a considerable loss of blood, the operation should be delayed until the child is at least three months old. This must certainly always be the case in double harelip. In all cases, however, unless there be some very strong contraindication, such as marked marasmus, the operation should be performed before the occurrence of dentition."

"When cleft palate complicates harelip, the question whether the operations for uniting the harelip and the cleft palate should be done at the same time or separately has to be considered. It is a generally accepted rule, and one with which we are in the main disposed to agree, that the harelip should be closed as soon as possible, whether the operation on the palate be deferred to a later period or not. This is advisable, because the development of the parts improves directly the lip is united, the cleft in the palate, and especially in the alveolus, apparently tends to diminish and the nutrition of the child becomes better."

From a study of the last sentence here quoted note that they claim that, "the development of the parts improves directly the lip is united." If that is the case in the lip, why not in the palate?

It looks to the writer as if some one of the Early Fathers in Surgery had laid down a law as to the age at which the operation should be done—perhaps hoping that death from *malnutrition* might occur during the period of waiting—and that most writers since



have followed this lead with perhaps the same end in view, or because it never seemed worth while to think otherwise. But surely it is worth while when the child's ability to speak without nasal intonation depends upon the early operation.

It is often urged that if the lip is done first, the cleft in the palate narrows materially, and a less extensive operation will be required for its closure. While it is quite true that the cleft becomes less wide under such circumstances, yet to my mind it does not lessen the extent of the operation, for I think it may be laid down as an axiom that the older the child, the more grave is any operation that may be undertaken upon its palate. There is greater danger from hemorrhage, from infection and from shock.

Lane<sup>5</sup> makes out a good case for operation upon the palate before the deformity in the lip is touched, and in most instances I agree with him. If the palate is done first access to the field of operation is easier, and the surgeon has better control of his technic. As a rule the cleft in the lip may be attended to at the same operation, with the one anæsthetic.

The flap operation as outlined by Lane is a most excellent one, and in his hands has given gratifying results. It seems to me, however, that unless the operation is done within the first few days of life, there is a serious risk of doing damage to the temporary teeth when it is necessary to go outside the alveolar margin for a large flap. Then, too, in older children one cannot go outside the alveolar margin because of the erupted teeth, and as it will probably be another half century before the profession really becomes alive to the advantages of early operation, I feel prone to recommend a modification of an operation already described by the writer.<sup>6</sup>

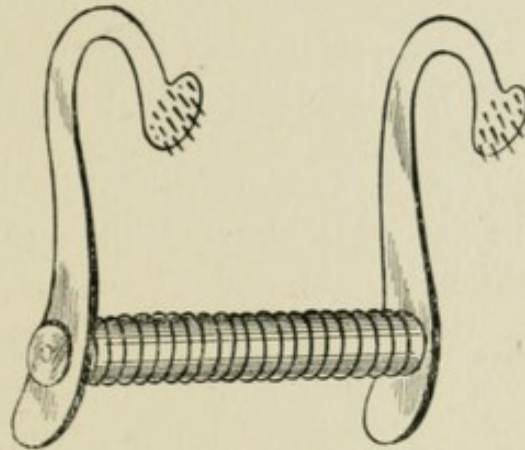
The patient is placed on its back with a small sandbag under the shoulders, and the occiput resting on the edge of the table. The anæsthetist is on one side, and should be prepared to administer oxygen at any moment in conjunction with ether or chloroform, whichever may be selected as the anæsthetic.

As a preliminary step to the operation the tongue is drawn well forward and a stout silk suture passed through it. The ends of this suture are then caught in a pair of artery forceps which in turn are clipped into one of the towels over the patient's chest and thus fixed, saving one hand of an assistant. A pair of Lane's gags



(Fig. 4) are now placed in position. The use of these gives splendid access to the field of operation; they do not interfere with the operator's movements, and the prongs readily fasten into the toothless gums. An incision is then made into the mucoperiosteum of the hard palate well out to the alveolar margin extending forward

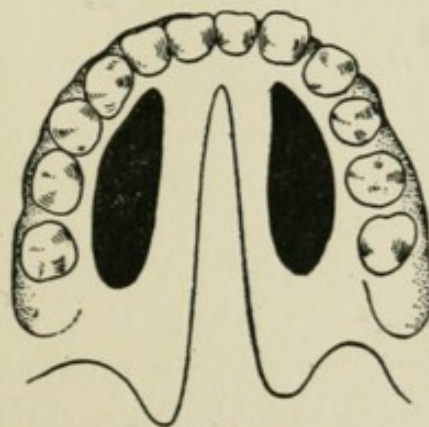
FIG. 4.



Lane's Gag.

beyond the anterior extremity of the cleft,—if this does not extend through the alveolar margin,—and backward to a point just behind the posterior border of the hard palate. With a periosteal elevator, suited to the case, the mucoperiosteum is quickly denuded from this

FIG. 5.



Showing primary lateral incisions.

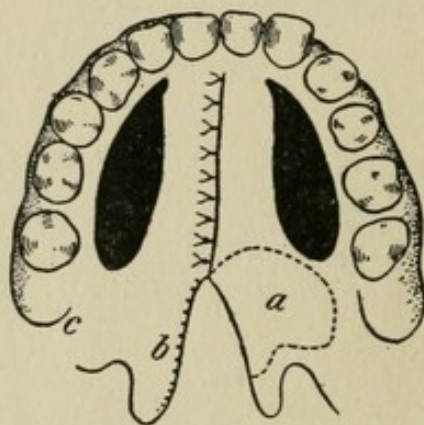
side, when, with a pair of sharply curved scissors the palate aponeurosis is snipped from the posterior margin of the hard palate, thus freeing the flap from its bony attachment. This incision is now packed with a piece of sea sponge, and the surgeon proceeds to deal with the opposite side in the same manner. The



first packing may now be removed, when one, as a rule, finds that all hemorrhage has ceased. Returning to this flap again, the edges forming the sides of the cleft are carefully pared with a small tenotomy knife, cutting as thin a slice as possible, at the same time making certain to include the whole thickness of the flap margin. The denudation should begin posteriorly within the soft palate, but need not include the uvula. By the time the edges are pared on the one side, the packing may be removed from the lateral incision on the other, and the edges of that flap pared in a similar way. (Fig. 5.)

While the newly-pared edges are still oozing, and before there is time for them to become glazed over with mucus, the sutures are introduced. Horsehair is used, and the sutures are passed about

FIG. 6.



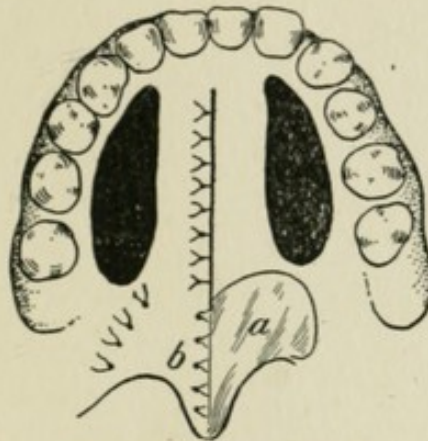
Showing sutures in anterior portion of cleft and outline for posterior flap.

one-eighth of an inch from the margin, and about a quarter of an inch apart, beginning at the anterior angle. When the required number of sutures have been passed they are tied, care being taken that the raw edges are carefully approximated, and that the stitches are not tied with too great tension.

A flap is now outlined upon the soft palate (see Fig. 6, *a*). If need be, one may encroach upon the cheek to make sure that there will be no tension upon this flap. This is dissected up, superficial to the tensor palati, making as it were a hinge at the free margin of the soft palate. An incision is then made along the free margin of the cleft on the opposite side (Fig. 6, *b*) and a flap is here undermined. Into this flap (Fig. 6, *c*), at its base, a suture is passed, carried over and through from the raw surface to

the mucous surface of the flap of the opposite side not far from its margin, back again through the second flap, and is brought out close to the point of entrance, thus completing a mattress suture. Two or three of such will be required, and these, when drawn up


FIG. 7.



Showing sutures complete.

and tied, will bring the edge of the overturned flap well under the flap on the opposite side, opposing raw surface to raw surface. Two or three sutures are now passed as indicated at *b* in Fig. 7. In the same figure *a* represents raw surface left to granulate.

FIG. 8.



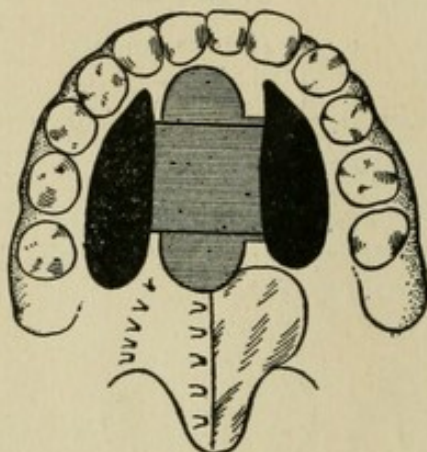
A piece of aluminum, gauge No. 36, is now selected and prepared as indicated in Fig. 8 with a flange at one end. At *a*, Fig. 8, this is bent at a right angle. The smaller end, *b*, is now



passed up through one lateral incision, then, by passing a pair of curved forceps into the opposite lateral incision, the free end is grasped and drawn down into the mouth again, until the angle *a*, Fig. 8, comes in contact with the newly-formed palate. The flange is still further bent over until it lies flat against the sutured margin (Fig. 9). The free end is then flattened over the top of the flange and the excess of aluminum is cut away, leaving about one quarter of an inch more than seems necessary. This free margin is now snipped in two places with a pair of scissors and each of the three pieces is carefully clamped with a pair of artery forceps over the edge of the first layer of aluminum.

The advantages of the aluminum seem to me to be threefold; it prevents tension upon the flaps, and also prevents—till union of

FIG. 9.



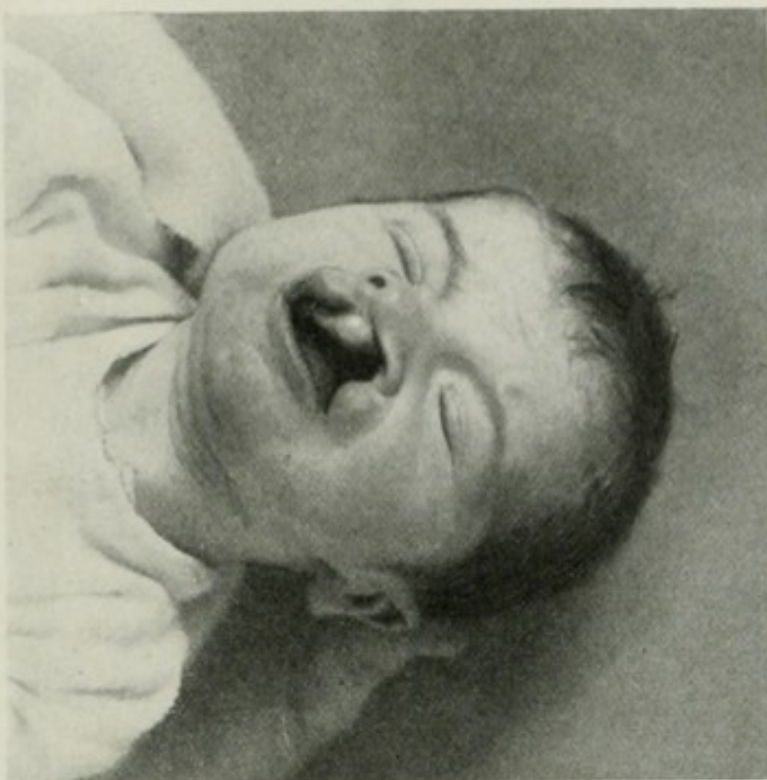Aluminum strip in place.

the edges had occurred—adhesions between the mucoperiosteum and the bone of the hard palate. I am satisfied that scores of cases in which the Langenback operation, or some modification of it has been done, have gone bad because of union taking place rapidly between the mucoperiosteum and the hard palate, thus giving rise to tension on the flaps that was not present upon the completion of the operation. Then the aluminum plate prevents the child sucking the stitches, which I have no doubt is a very common cause of failure.

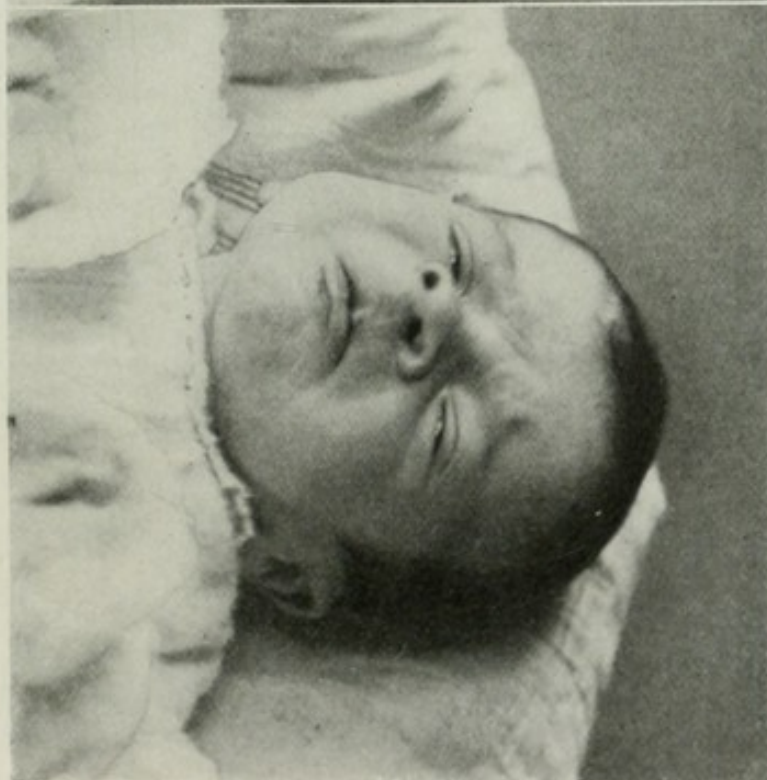It has been urged as an objection to the aluminum splint that the food will collect under it, but to that objection I would reply, that as yet I have never seen such a thing occur.

The aluminum may be left in for 8 or 10 days, when it is

FIG. 10.



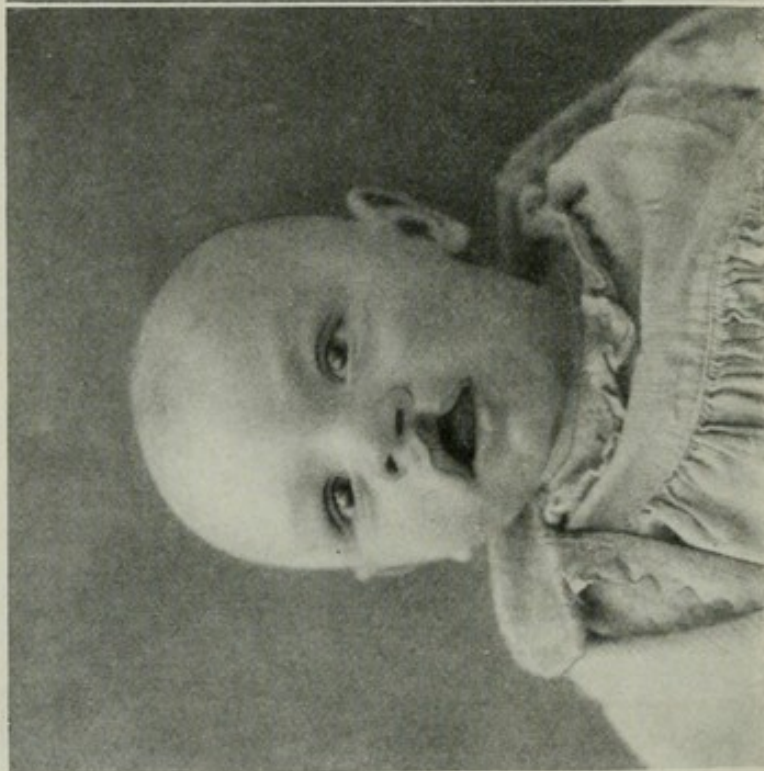
Before.



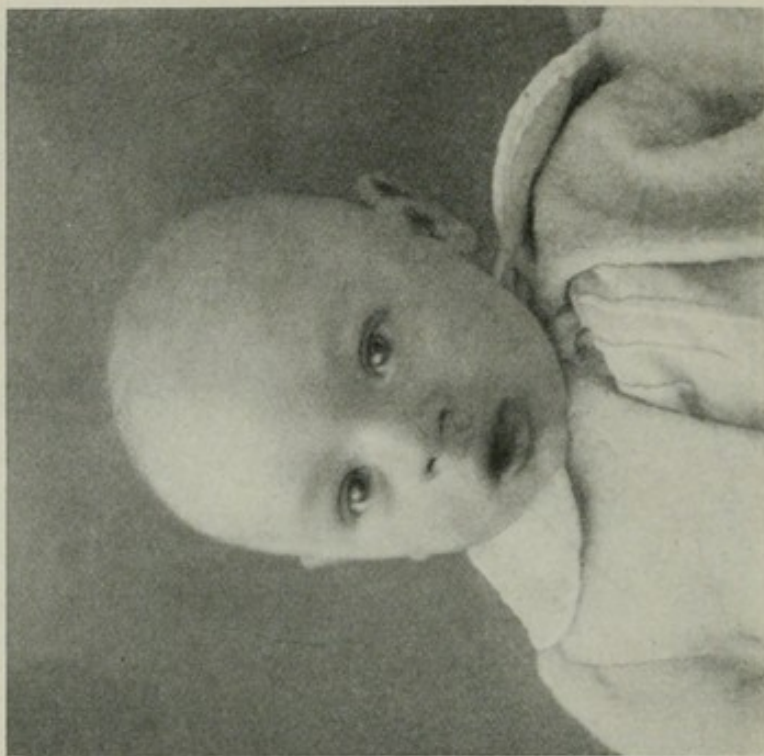
After.



Fig. 11.

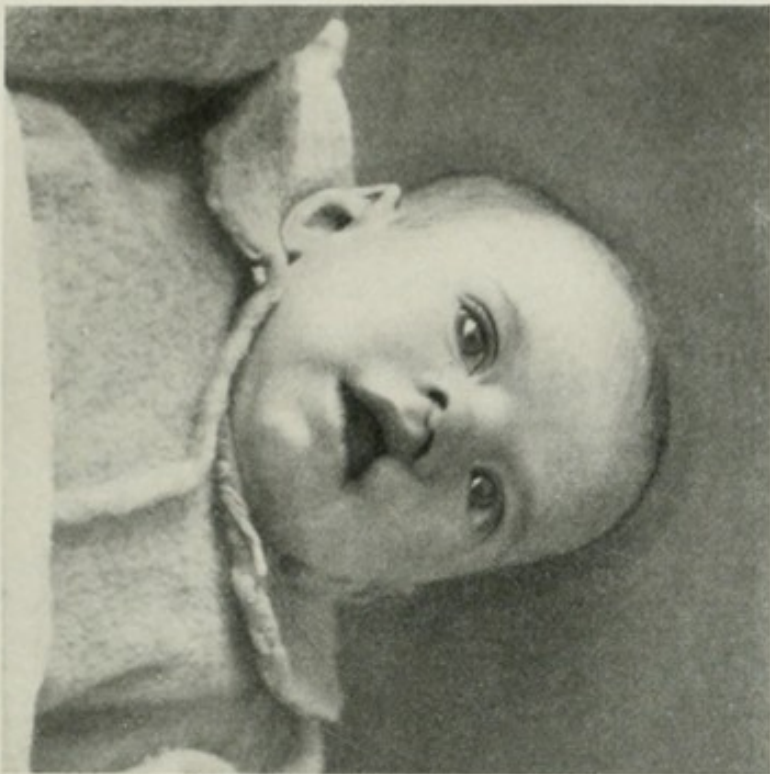


Before.

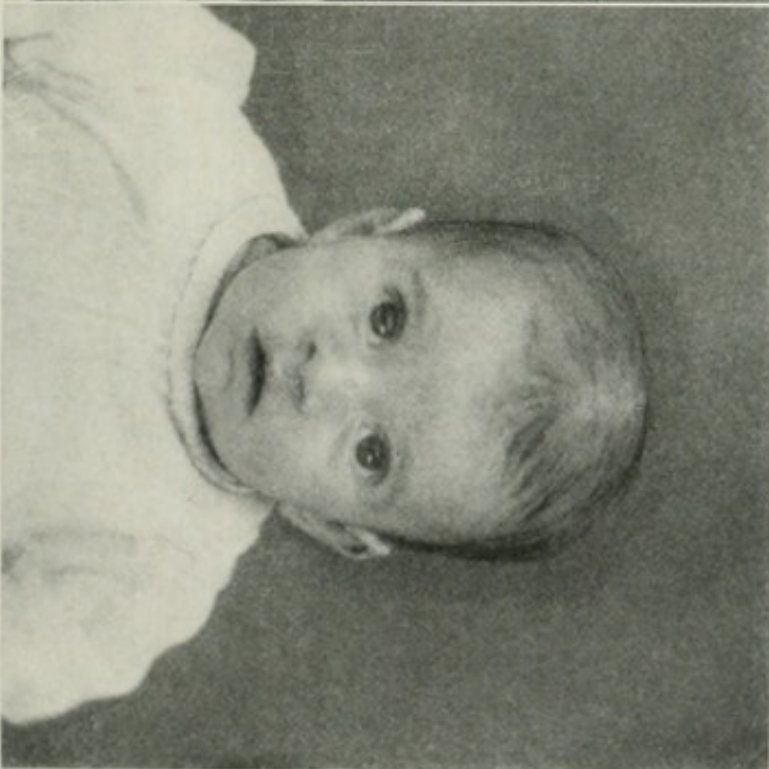

After.

FIG. 12.




Before.



After.





easily removed by cutting it across with a pair of scissors curved on the edge, close to one lateral incision. These lateral openings rapidly granulate in and the patient is often able to leave the hospital, cured, in from ten days to two weeks after the operation. The child is fed regularly according to the requirements of its age. For nursing babies I have the nourishment dropped into the mouth by means of an eye dropper. During the process of healing the mouth is sprayed with a boracic solution containing 10 per cent. of alcohol, to ensure cleanliness.

In those cases in which the cleft extends through the alveolar margin, and in the case of double cleft, a flap may be turned up from the alveolar margin in the one, or from the back of the premaxilla in the other, and the lateral flaps sutured over the top, thus bringing raw surface to raw surface.

The operation up to this point has consumed from half an hour to an hour, and as the harelip can be completed in another ten or fifteen minutes, it is as well to complete the surgical procedure at the one sitting.

In my experience the secret of success in the repair of harelip is to make certain that there is no tension on the flaps, that horsehair is used as the suture material, and that no dressing is applied. If there is subsequent tension it matters not how accurately one gets the edges approximated, the sutures will cut out somewhere and leave an unsightly scar. If there is no tension the horsehair is quite sufficient to keep the parts together, and afterwards it leaves no sign of the unsightly suture scars that one so often sees in cases of repaired harelip. Under such circumstances the wound is certain to heal well, whereas if a dressing is applied it absorbs all the nasal discharge that may pour out, and sooner or later will lead to infection of the line of suture.

In approaching a case of harelip one should first evert the lips and then cut through the frenum close to the superior maxillary bone and as much of the mucous membrane as seems necessary. In cases where the nostril is flattened or deformed in any way the nostril and the surface of the face for some distance external to it, should be undermined. I often undermine up to the orbital margin to make sure of doing enough. If the case is one of double harelip, this is done on both sides. A few strands of gauze are



now packed up under the lip to check hemorrhage, and one approximates the uncut margins of the cleft in the lip to estimate the extent it may be necessary to denude the edges. It is very necessary to estimate carefully the amount of vermillion border available, and in most cases it is well to have the edges at the newly-formed junction pout a little to allow for the contraction of the scar. I have succeeded on more than one occasion in presenting the mother with a child with a veritable "Cupid's bow" of a mouth in exchange for the distressing monstrosity that came to the Children's Hospital. On several occasions mothers have been loath to believe that they were getting their own child back again.

Besides getting over all possibility of tension by undermining extensively, there is another advantage that I must mention, namely, the exudation that takes place in the face is sufficient to make the face absolutely rigid, so that if the child cries there is no movement whatever of the upper lip, and therefore, even if the child were to cry day and night, there would be no possibility of the lip being pulled apart.

In cases of double harelip with a projecting premaxilla, the lip should be freed from the premaxilla, and this bone used to fill in the space in the alveolar margin before the lip is dealt with. The small portion of skin attached to the premaxilla may then be utilized in the repair of the lip.

After operation it is well to keep the lower lip retracted and the lower jaw depressed for a few days by a piece of adhesive plaster, lest the child, accustomed to a large space for respiration, becomes suffocated before it has learned the use of its new nasal cavity.

It is well, too, after all such operations, to apply to the arms some light splint sufficient to prevent flexion of the elbow-joint and thus prevent the child's hands reaching the site of operation with perhaps disastrous results.

#### BIBLIOGRAPHY.

- <sup>1</sup> Arthur Keith, *Human Embryology and Morphology*.
- <sup>2</sup> Von Bergmann's *System of Practical Surgery*, vol. 1, page 457.
- <sup>3</sup> Treves' *System of Surgery*, vol. 2, page 465.
- <sup>4</sup> Cheyne and Burghard, *Manual of Surgical Treatment*, part 5, page 162.
- <sup>5</sup> *Cleft Palate and Harelip*, W. Arbuthnot Lane,—A Monograph.
- <sup>6</sup> New Method of Dealing with Cleft Palate, F. N. G. Starr, *British Medical Journal*, June 29th, 1907.

University of Toronto  
Library

44713

DO NOT

REMOVE

FROM

THIS

BOOK

DOCKET





This book must be returned to  
the Dental Library by the last  
date stamped below. It may  
be renewed if there is no  
reservation for it.

Nov. 12

Jan

Dec 5

Jan 10

Dec 10

DEC 18 1959

270-347-1 M

467703

Starr, F. N. G.

Cleft palate and harelip.

University of Toronto  
Library

*Dent*  
467703

DO NOT  
REMOVE  
THE  
CARD  
FROM  
THIS  
POCKET





